

Chapter 48 – Vertical Partial Laryngectomy

David E. Eibling

The technique of vertical partial laryngectomy (VPL) was popularized in the United States by Ogura's group in the 1970s.^[1,2] VPL is performed for early glottic carcinoma and entails the removal of a portion of one or both vocal cords with or without the anterior commissure, together with the thyroid cartilage as the deep margin. The resection may be as simple as excision of one vocal cord or may involve resection of up to three fourths or five eighths of the glottic larynx. The term *hemilaryngectomy* or VPL is generically used to include removal of one half of the larynx, as well as any one of the aforementioned variations. The introduction of transoral endoscopic laser surgery, supracricoid laryngectomy, and improved techniques of radiation therapy, especially when combined with concomitant chemotherapy, has decreased the use of VPL for the treatment of glottic cancer.

PATIENT SELECTION

VPL is ideally suited for primary treatment of glottic cancers that are not likely to be satisfactorily managed with endoscopic laser excision or radiotherapy.^[3] These lesions typically include bulky T1 cancer of the true vocal cord (TVC) involving the anterior commissure or the vocal process of the arytenoids, cancer of the TVC with invasion of the vocalis muscle but not the thyroid cartilage, or T2 cancers that extend above or below the level of the TVC.^[4] It should be noted that large tumor volume correlates with the likelihood of radiation failure in early-stage vocal cord cancer.^[5] The procedure is also appropriate for surgical salvage of selected patients with persistent carcinoma of the vocal cord after initial treatment with radiotherapy, for early glottic cancer in patients who wish to avoid radiotherapy, and for patients with verrucous carcinoma.

The most commonly performed procedure is a vertical frontolateral partial laryngectomy (Fig. 48-1). Many surgeons now perform supracricoid partial laryngectomy (SPL) with cricohyoidoepiglottomy to manage more extensive cancer involving both vocal cords, the anterior commissure, and the paraglottic space.^[6] These procedures rely on very different paradigms of reconstruction, so decisions to use one or the other technique must be made before surgery.

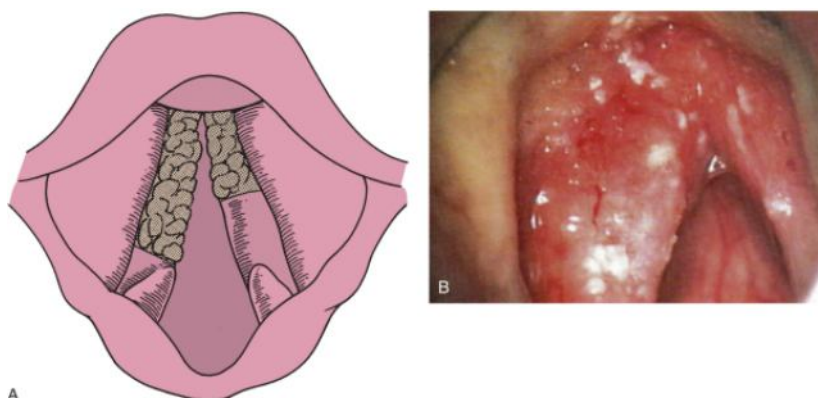


Figure 48-1 A, Maximal size of a cancer that can be removed by frontolateral hemilaryngectomy. B, Bulky lesion involving the vocal cord and anterior commissure.

(A, Redrawn from Pearson BW, Donald PJ: *Larynx*. In Donald PJ [ed]: *Head and Neck Cancer: Management of the Difficult Case*. Philadelphia, WB Saunders, 1984, pp 93-148.)

Cancer involving the cricoid cartilage is a contraindication to hemilaryngectomy and a relative contraindication to SPL. Recently, Laccourreye and colleagues^[7] reported excision of the superior aspect of the cricoid cartilage in patients with extensive subglottic extension. Therefore, the cancer should ideally not extend more than 1 cm subglottically at the anterior commissure and no more than 5 mm subglottically posteriorly. Cancer extending onto the arytenoid cartilage is theoretically resectable by SPL as long as there is a sufficient margin of resection in the posterior commissure and the contralateral arytenoid can be left intact. Cancers with vocal cord fixation or those that extend through the ventricle up onto the false vocal cord (*transglottic*) are not suitable for VPL. These cancers may be pathologically T4 because of proximity of the laryngeal ventricle to thyroid cartilage with resultant cartilage invasion and may spread by way of the rich lymphatic drainage into the cervical lymph nodes.^[8,9] Because thyroid cartilage is resected by SPL, some of these cancers may be candidates for supracricoid resection if the cricoarytenoid joint is free of involvement (see Chapter 47).^[7]

Extended frontolateral partial laryngectomy with epiglottomy is feasible and in the past was considered a standard procedure for larger tumors involving both vocal cords. However, this procedure results in glottic dysfunction and has largely been supplanted by SPL.

Decisions regarding resection of thyroid cartilage and methods of reconstruction after VPL remain controversial. If the thyroid ala is left in situ, a soft tissue flap, typically strap muscle, may be used to fill the void.^[9] Brasnu and coauthors reported the use of a false vocal cord (if uninvolved) flap for reconstruction.^[10] We routinely resect the ipsilateral thyroid ala to permit the adjacent soft tissue to fall into the void created by tumor resection, which results in acceptable voice postoperatively. Patients with cancer involving the anterior commissure are good candidates for VPL because the results of treatment with radiation therapy and laser surgery are poor.^[11]

PREOPERATIVE PLANNING

The most critical part of planning is preoperative performance of suspension microlaryngoscopy to adequately evaluate and stage the tumor. Esophagoscopy should be carried out simultaneously to rule out second primary cancers. Subglottic extension up to 1 cm below the margin of the false vocal cord is staged T1, so most cancers suitable for VPL are, in actuality, T1.^[12,13] Examination of the subglottic airway with 30-degree telescopes is invaluable in assessing the extent of subglottic involvement and should be routine. In the past, as many as one third of T2 cancers were actually T4 on pathologic examination^[13]; however, with modern imaging techniques such as the use of thin-cut computed tomography scans, understaging should be encountered only rarely. Accurate preoperative assessment of these tumors is feasible because of the overall small size of tumors amenable to resection by VPL. With accurate preoperative tumor assessment, the likelihood that an unexpected intraoperative finding would require conversion to total laryngectomy is low (Fig. 48-2). However, surgeons should routinely obtain consent for total laryngectomy.

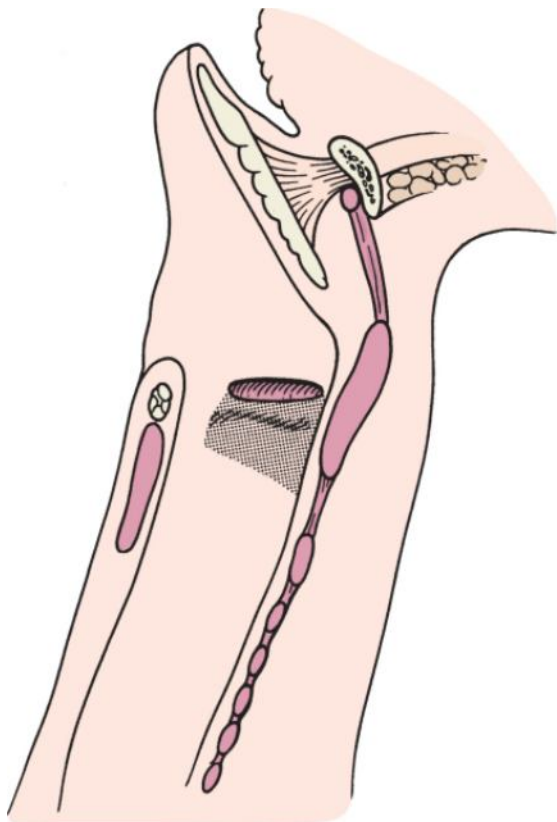


Figure 48-2 Sagittal incision through the larynx demonstrating the limit of resectability for subglottic extension. A cancer that extends more than 1 cm subglottically at the anterior commissure may be a contraindication to partial laryngectomy.

TECHNIQUE

The steps in the procedure are presented in Table 48-1. The technique illustrated is that of thyroid cartilage resection, which is our preferred technique.

Table 48-1 -- STEPS IN HEMILARYNGECTOMY

Indications and Contraindications
Ideal for bulky lesions of the membranous true vocal cord
Normal or slightly impaired vocal cord mobility
No involvement of the supraglottis
Tumor may extend as far as the apex of the ventricle
Subglottic extension of no more than 5 mm posteriorly (10 mm anteriorly)
The body of the arytenoid is a contraindication, although the vocal process is not
No more than one third of the contralateral vocal cord involved (consider supracricoid partial laryngectomy)
Technical Points
Administer perioperative antibiotics
Re-endoscope the patient
Perform a preliminary tracheostomy
Make a horizontal skin incision over the thyroid ala
Raise the flaps superiorly and inferiorly while avoiding the tracheostomy incision
Incise the perichondrium from the thyroid notch down the midline over the cricothyroid membrane
Elevate the perichondrium with the attached overlying strap muscles
Mark the cartilage incisions while retaining a 3-mm-wide posterior strip
Cut with a sagittal saw
Use a headlight
Incise the perichondrium along the superior border of the thyroid ala. Incise across the petiole of the epiglottis. This will provide a panoramic view of the larynx
Incise the cricothyroid membrane along the superior aspect of the cricoid cartilage
Using a no. 15 blade, cut down to the true vocal cord and examine and cut through the true vocal cord either in the midline or, in lesions that cross the anterior commissure, 2 to 3 mm behind the visible tumor. Be careful
Using hooks, open the thyroid alae like a book
STOP. Carefully evaluate the lesion and determine the area to be excised
Excise the tumor by incising along the apex of the aryepiglottic fold down around the arytenoid or through the vocal process of the arytenoid, depending on the posterior extent of the tumor
Orient and examine the surgical specimen and select sites for frozen section examination of the margins
Obtain hemostasis
Suture the contralateral cord to the anterior end of the remaining cartilage or to the external perichondrium
An epiglottopexy must be performed in cases of extended vertical partial laryngectomy
Insert a nasogastric tube for feeding
Close the perichondrium with absorbable suture
Inferiorly based or bipedicle muscle flaps may be used to reconstruct the glottis but are probably not necessary
A cricopharyngeal myotomy is not required
Close the wound in layers over a drain
Apply a neck dressing
Postoperative Care
Antibiotics are continued for 24 hours postoperatively
Nasogastric feedings can begin as soon as the patient has bowel sounds
The tracheotomy tube can be deflated more rapidly than after supraglottic laryngectomy

Swallowing is characteristically delayed until the tracheostoma has closed
--

The larynx will appear abnormal for an extended period, so it is wise to delay biopsies until re-epithelialization has occurred, usually in 6 to 8 weeks
--

Perioperative antibiotics are routinely administered to reduce the incidence of postoperative wound infections, as in all other procedures that enter the aerodigestive tract. The side of the tumor should be marked on the skin of the neck before induction of anesthesia and confirmed again at endoscopy.

The patient should undergo endoscopy again before starting the procedure, especially if the initial examination was performed elsewhere. Preliminary endoscopy permits reconfirmation of the side with the tumor, the limits of tumor extension, and the margins of the intended resection. We routinely use a microscope to visualize the vocal cords and make an incision in the vocal cord at the point where we will excise the tumor when the larynx is open. This technique makes the surgery very precise.

A tracheotomy is performed at the beginning of the procedure in all patients. It should be noted that Laccourreye's group has not routinely used a tracheostomy and has reported no untoward consequences in a 25-year experience, although their surgical technique differs.^[7] Brumund and associates reported their experience with frontolateral partial laryngectomy without tracheotomy for invasive squamous cell carcinoma of the TVC and found that this technique has a very favorable outcome.^[11] The tracheotomy should be placed sufficiently low to avoid contamination of the surgical wound with tracheal secretions during the postoperative period. If the tracheostomy wound communicates with the surgical wound, it must be separated with several absorbable sutures between the strap muscles and the subcutaneous tissue at the completion of the procedure to avoid contamination of the cervical wound.

A horizontal skin incision is made through the skin crease over the thyroid ala (Fig. 48-3). An apron incision is not generally used in VPL because the likelihood of extending the procedure to a total laryngectomy is exceedingly low. Subplatysmal flaps are elevated superiorly and inferiorly while avoiding entry into the tracheotomy incision. The fascia is incised in the midline between the strap muscles and carried down to the level of the thyroid cartilage and inferiorly over the cricoid cartilage. The perichondrium is incised along the superior margin of the thyroid cartilage (Fig. 48-4). The perichondrium is elevated with the attached overlying strap muscles to the posterior margin of the thyroid ala on the side of the tumor (Fig. 48-5). The perichondrium will need to be incised along its attachment to the inferior portion of the thyroid ala to permit elevation laterally. Every attempt should be made to preserve the perichondrium because it will become an important component of the reconstruction.

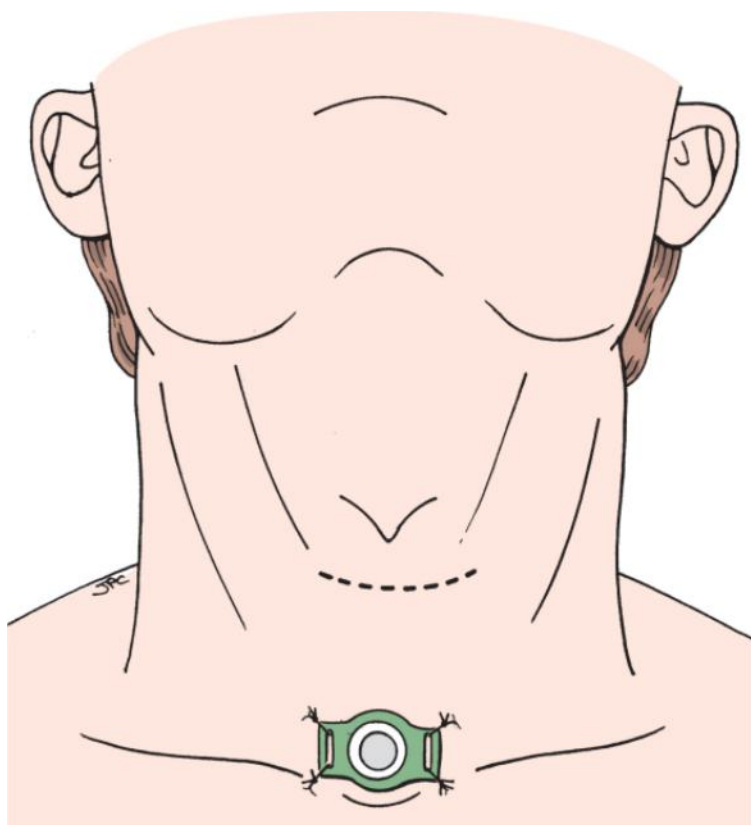


Figure 48-3 Incision for vertical partial laryngectomy. Care should be taken to ensure separation of the tracheostomy incision from that required for the partial laryngectomy.

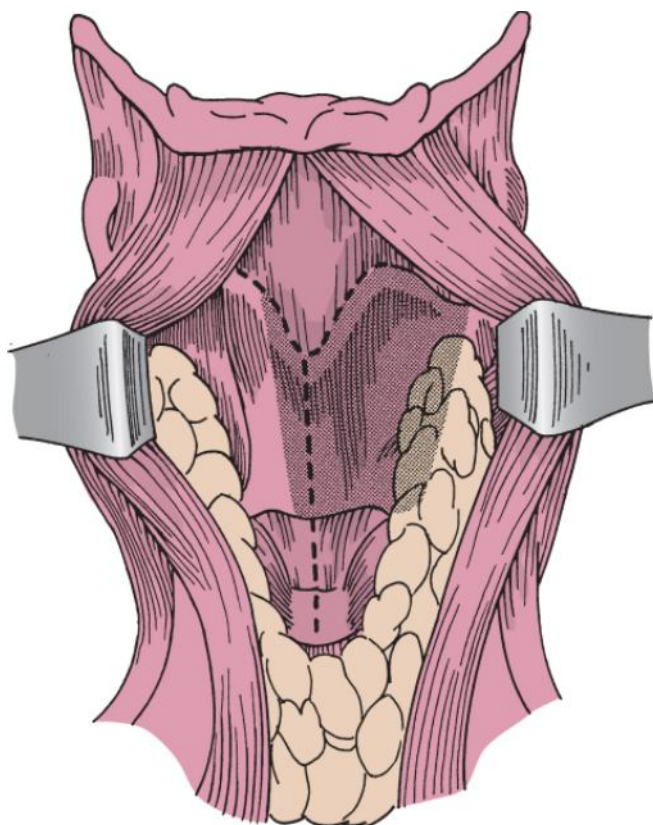


Figure 48-4 Incision of the perichondrium to expose the thyroid ala.

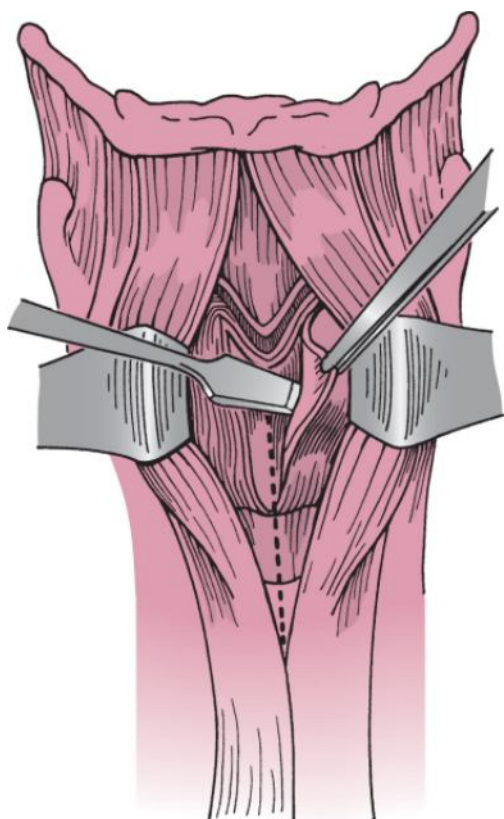


Figure 48-5 Elevation of the perichondrium with the overlying strap muscles.

The cancer usually extends to the midline, so the cartilage incision must be made just lateral to the midline to ensure adequate resection of the anterior commissure with the specimen.^[14] A posterior vertical cartilage cut is made as well, and a 3- to 5-mm-wide strip of cartilage is retained to connect the inferior and superior cornua of the thyroid cartilage (Fig. 48-6). The incision should be made through cartilage only and not through the underlying mucosa at this time. An oscillating saw with a small right-angled blade is ideal for this procedure, particularly because the larynx is usually ossified in patients in the older age group.

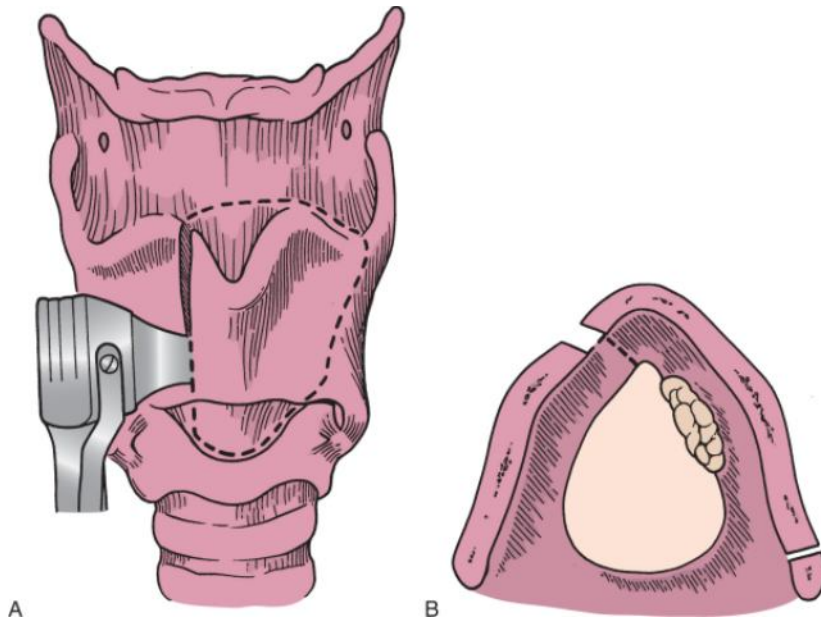


Figure 48-6 A and B, Incision of cartilage for a left frontolateral hemilaryngectomy and the planned incision in the vocal cord. To remove the entire anterior commissure, note the incision in the cartilage just to the right of the midline. A 3- to 5-cm-wide strip of cartilage is maintained posteriorly.
(Redrawn from Pearson BW, Donald PJ: *Larynx*. In Donald PJ [ed]: *Head and Neck Cancer: Management of the Difficult Case*. Philadelphia, WB Saunders, 1984, pp 93-148.)

The larynx is entered by cutting across the petiole of the epiglottis, which facilitates visualization of the entire glottis and the incisions in the vocal cords made at endoscopy to mark the limits of resection (Fig. 48-7). The cricothyroid membrane is then incised just above the cricoid cartilage (Fig. 48-8). The TVC is transected with care to ensure that the cord is cut at right angles (Fig. 48-9A) and not at a different angle (Fig. 48-9B). Once the contralateral vocal cord or the anterior commissure has been divided, the cartilage halves are spread open like a book, and the incision is extended across the false vocal cord on the involved side with scissors. This is done by placing one blade of the scissors within the lumen and above the ipsilateral thyroid ala; several incisions are made to open the larynx for visualization of the posterior extent of the cancer (Fig. 48-10). The incisions are continued along the superior margin of the cricoid cartilage on the side of the cancer while taking care to ensure that an adequate margin below the carcinoma is obtained.

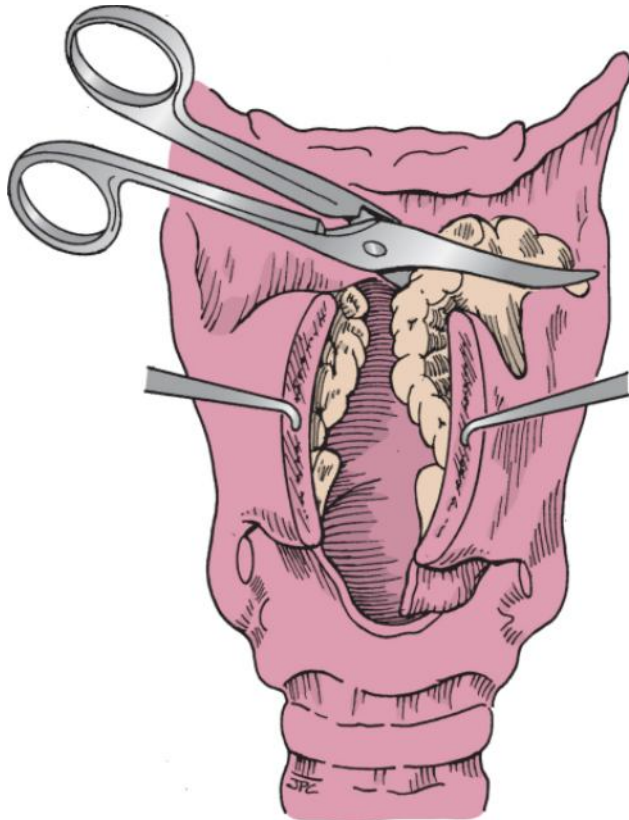


Figure 48-7 Scissors are used to extend the incision across the preepiglottic space and the false vocal cord to expose the cancer.

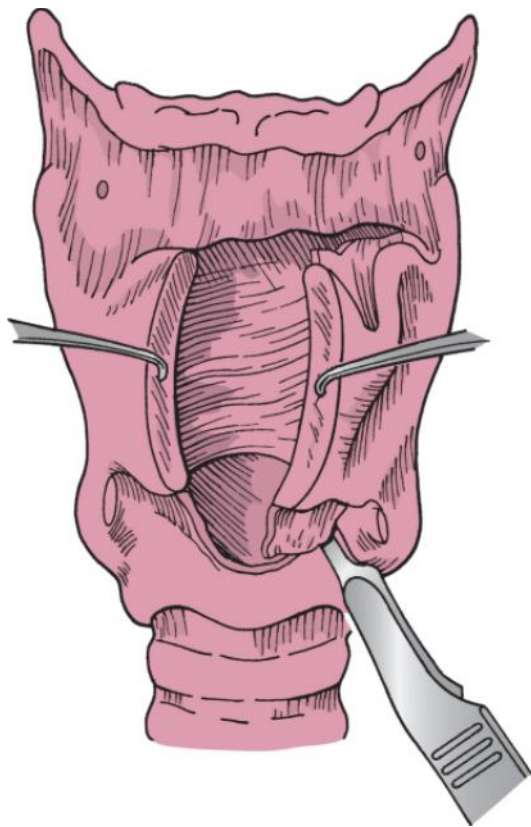


Figure 48-8 The cricothyroid membrane is opened just superior to the cricoid cartilage to verify that the cricoid is not involved.

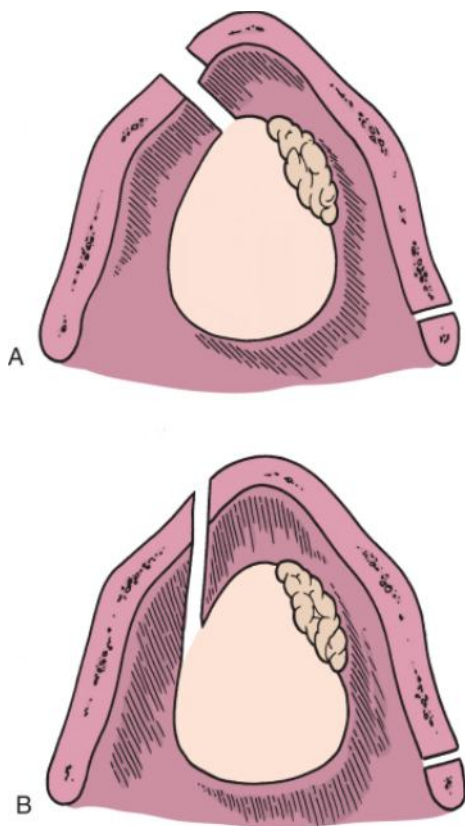


Figure 48-9 Proper (A) and improper (B) angles of the cut through the vocal cord. Note the excess sacrifice of tissue caused by improper angulation of the incision through the vocal cord.

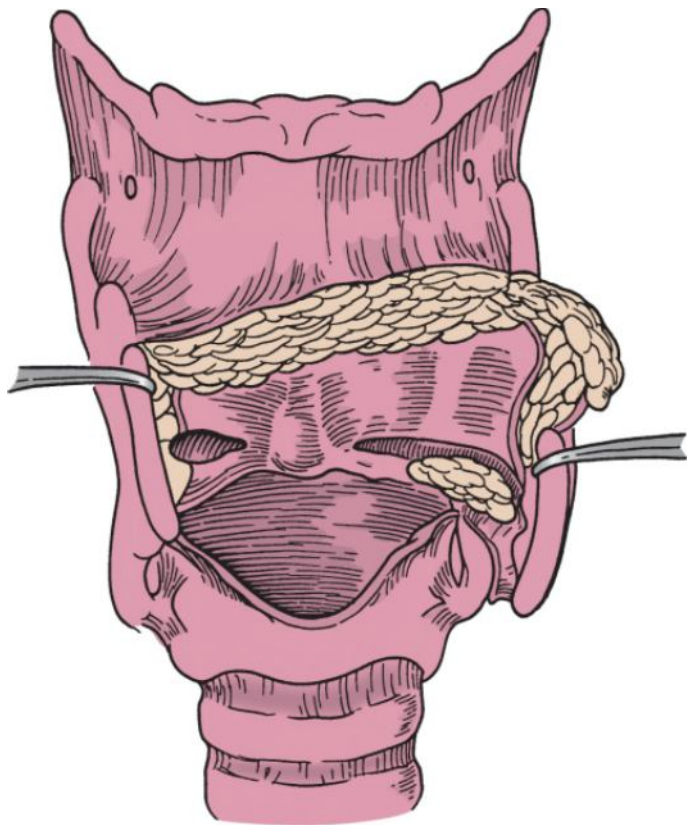


Figure 48-10 View of the posterior aspect of the cancer after the superior incision is completed.

The incisions are extended posteriorly, and the specimen is reviewed. The entire arytenoid may need to be included with the resection (Fig. 48-11). There will be some bleeding in this part of the procedure, and it is important to achieve hemostasis for complete visualization of the lesion to avoid leaving cancer.

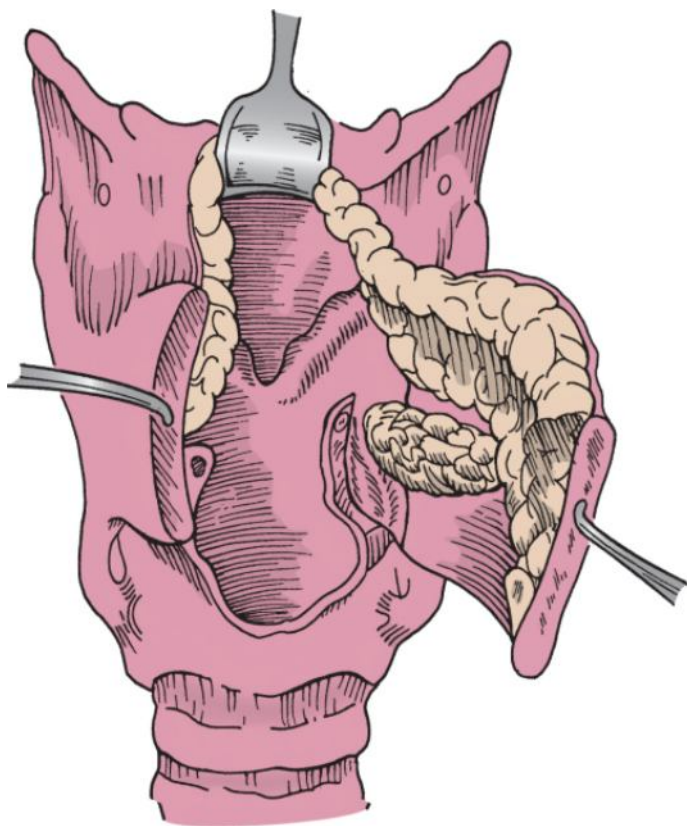


Figure 48-11 Resection of the cancer by continuing the incision superiorly through the vocal process and vocal cord posterior to the cancer. The arytenoid may be taken at this step.

At the completion of the resection, hemostasis is obtained and the specimen is carefully oriented and examined (Fig. 48-12). Frozen section analysis of the margins is performed. It is necessary to obtain a new margin for frozen section evaluation if any doubt about margins exists.

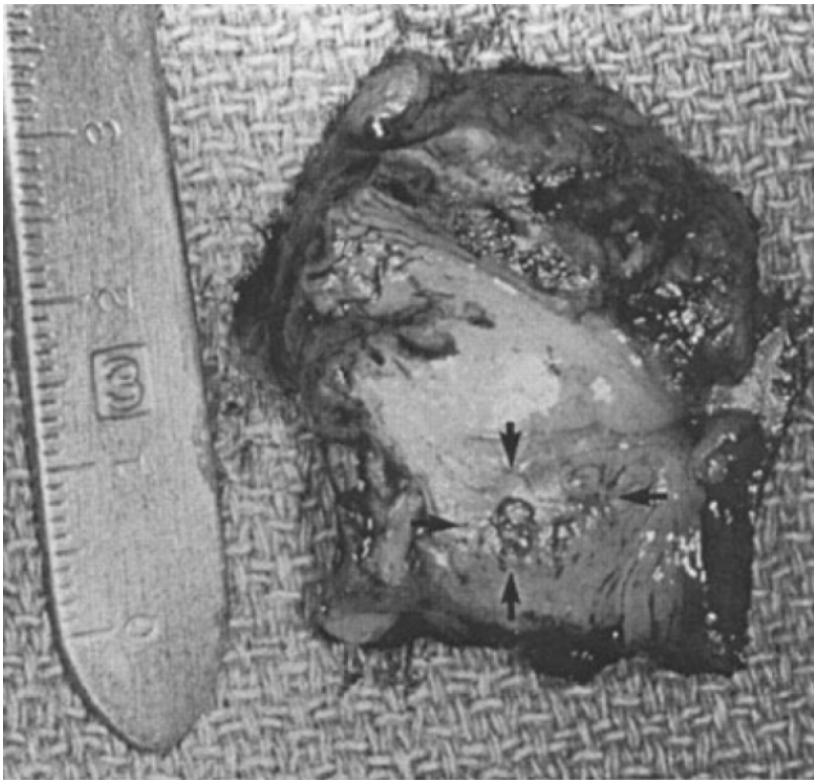


Figure 48-12 Hemilaryngectomy specimen. Anterior is toward the left. The tumor is indicated with arrows. Note the close margins feasible with this procedure.

Piriform mucosa can be advanced over the posterior portion of the cricoid to resurface the posterior larynx, particularly if the arytenoid has been resected. The contralateral TVC must be reattached to the anterior surface of the cartilage with nonabsorbable suture, except in the unlikely situation in which the ligamentous attachment of the contralateral anterior commissure has been left intact (Fig. 48-13).

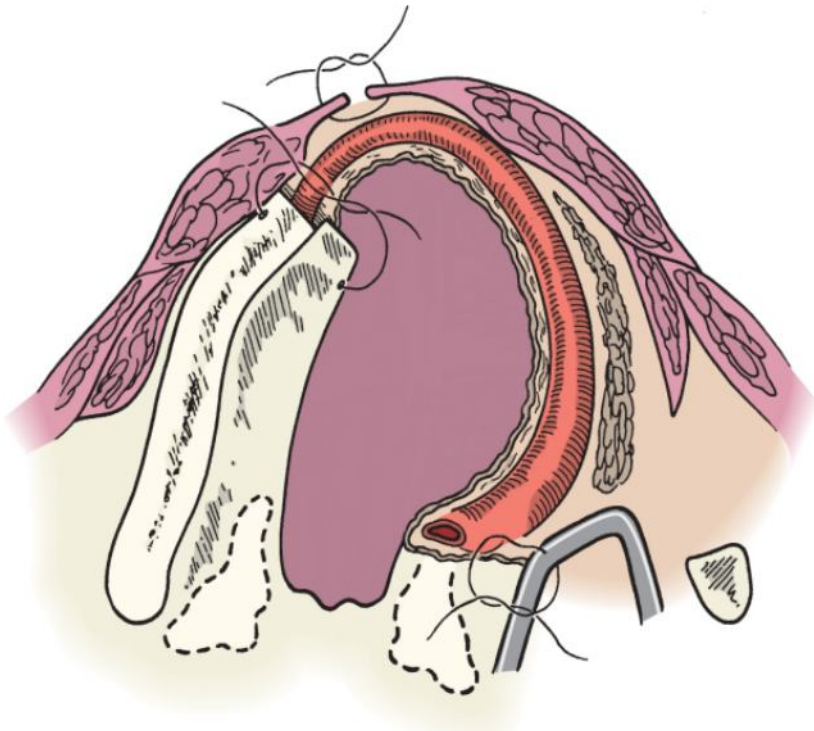


Figure 48-13 Reattachment of the vocal cord remnant to the thyroid ala.

If it is apparent that much of the least involved vocal cord was resected, the surgeon has a number of options. One is to convert the procedure to an SPL (see Chapter 47). Another option is to use the epiglottis to reconstruct the larynx (epiglottopexy) (Fig. 48-14). The mucosa of the laryngeal surface of the epiglottis provides immediate epithelialization of the interior of the larynx. The epiglottic cartilage provides structural support to prevent glottic stenosis. This preserves an adequate glottic airway but leads to an open anterior glottis with a resultant breathy voice.

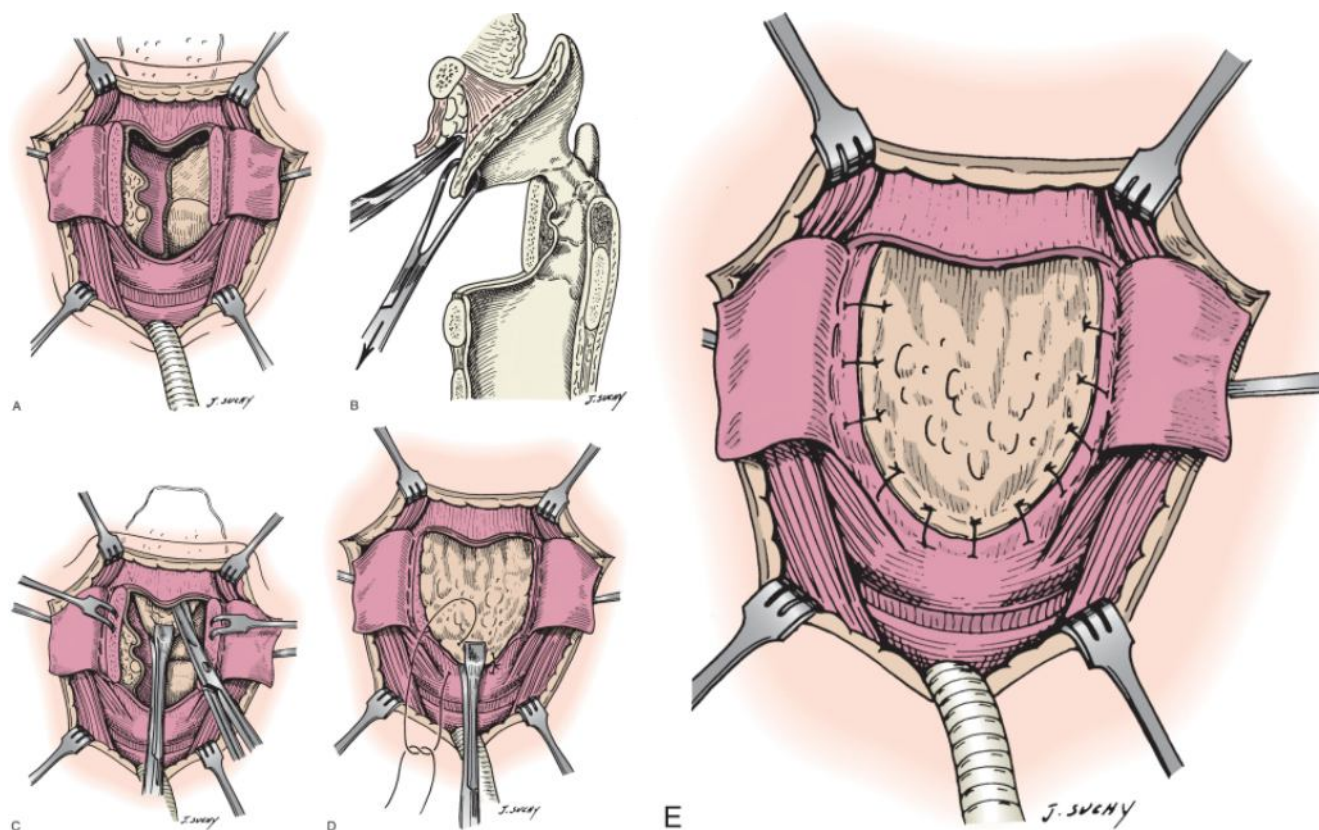


Figure 48-14 Epiglottopexy. **A**, The remaining larynx after the specimen has been removed. **B**, The lingual surface of the epiglottic cartilage is undermined in the subperichondrial plane. **C**, The epiglottis is pulled inferiorly. **D**, The epiglottis is sutured to the cricoid cartilage to reconstruct the lumen of the larynx. **E**, The reconstruction is completed.

A nasogastric tube is inserted and secured for postoperative feeding. The anterior perichondrium and the strap muscles are closed with absorbable suture. A Hemovac drain is placed subcutaneously. The neck incision is closed, with care taken to ensure that the wound does not communicate with the tracheostomy incision.

POSTOPERATIVE CARE

Antibiotics are continued for 24 hours postoperatively. Nasogastric feeding is usually begun when bowel sounds are audible. After approximately 10 days, decannulation can commence because aspiration is not generally a problem in this patient population. Decannulation is begun by deflating the cuff of the tracheostomy tube and, if tolerated, downsizing to a smaller (usually a no. 4 Shiley) uncuffed tube. The patient is decannulated when able to tolerate plugging of the uncuffed tube for 24 hours. Once decannulation has occurred, the nasogastric tube can be removed and oral feeding resumed. Patients who have failed previous radiation therapy may have more edema, and decannulation may require several weeks.

Visualization of the larynx will be quite abnormal for several weeks postoperatively. Remarkably, once healing has occurred, the excised vocal cord is replaced by a scar band that often resembles a TVC.

PEARLS

- Vertical partial laryngectomy is a procedure ideally suited for patients who have cancer of the vocal cord that is too large for laser excision and not extensive enough for total laryngectomy.
- Preoperative endoscopy is necessary to evaluate the tumor before surgery.
- Imaging may help identify cartilage invasion and subglottic extension.
- Meticulous surgical technique is critical in ensuring complete excision of the tumor and a functional larynx.
- Glottic stenosis after extended vertical partial laryngectomy can be prevented with an epiglottopexy.

PITFALLS

- Re-endoscopy in patients in whom the diagnosis has been made elsewhere and who were referred for surgery will help verify the diagnosis and avoid understaging.
- Inaccurate staging may result in excessive vocal cord excision that can lead to glottic stenosis, prolonged tracheostomy dependence, unanticipated total laryngectomy, or early recurrence of the cancer.
- Extensive excision of the contralateral vocal cord will result in glottic stenosis unless an epiglottopexy is performed.
- Failure to reconstruct the posterior glottis after arytenoid resection will lead to aspiration.
- Resection of one arytenoid cartilage will cause aspiration, which can usually be overcome by intensive swallowing therapy.