

## Chapter 114 – Ossicular Chain Reconstruction

Barry E. Hirsch

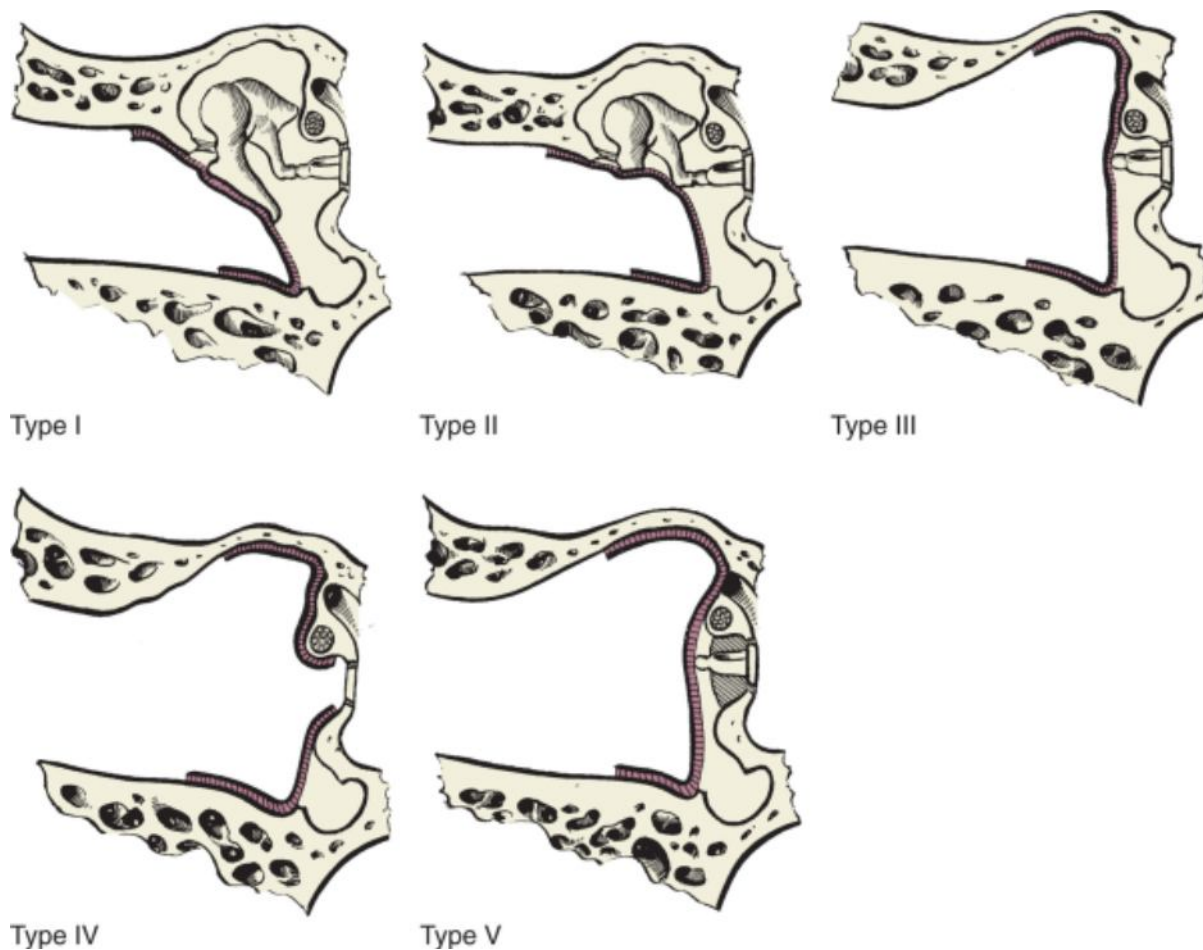
Conductive hearing loss results from restriction of sound wave energy in displacing the basilar membrane of the organ of Corti. Conductive hearing loss not of middle ear or tympanic membrane origin can result from obstruction in the external auditory canal and possibly from fluid distention within the inner ear, such as that seen in early Meniere's disease. Inner ear conductive hearing loss also occurs when a "third window" exists in the otic capsule. Dehiscence of the superior semicircular canal provides a site for expansion of inner ear fluid, which prevents the fluid wave from providing full stimulation to the basilar membrane of the cochlea. This may result in conductive hearing loss even though acoustic reflexes will still be present.

Conductive hearing loss of middle ear origin may be congenital or acquired and results from ossicular chain fixation, erosion, dislocation, or fracture. Ossicular chain reconstruction (OCR) re-establishes the sound-transforming mechanism to provide a mobile connection from the tympanic membrane through an aerated middle ear space to the perilymph. This chapter focuses on the surgical techniques for OCR. Tympanic membrane grafting, surgery for stapes fixation secondary to otosclerosis, and chronic otitis media with cholesteatoma are addressed in other chapters.

The term *tympanoplasty* describes procedures that address the status of the middle ear from the tympanic membrane to the vestibule. OCR is frequently performed in conjunction with tympanic membrane grafting for eliminating middle ear and mastoid disease. Zollner and Wullstein were early pioneers in the concepts of middle ear reconstructive surgery.<sup>[1,2]</sup> Wullstein provided a classification system consisting of five types (I to V) of tympanoplasty that focus on reconstruction with the remaining ossicular chain. Each type refers to the most lateral intact structure that remains connected to the inner ear on which the tympanic membrane is grafted or the ossicular chain reconstructed. Type I tympanoplasty indicates that all three ossicles are present and mobile. Thus, OCR is not needed. In type II tympanoplasty, the tympanic membrane is grafted to an intact incus and stapes. In practice, the need for type II tympanoplasty is rarely encountered. According to Wullstein, a type III tympanoplasty exists when an intact mobile stapes superstructure is present and the tympanic membrane or graft remains directly on the stapes superstructure. Type IV tympanoplasty describes an absent or eroded superstructure with the graft or tympanic membrane overlying a mobile stapes footplate. Type V tympanoplasty refers to a fenestration created in the horizontal semicircular canal (Fig. 114-1).

Use of this classification system was subsequently encouraged by Farris,<sup>[3]</sup> who clarified the terminology by basing the type of OCR on the pathologic anatomy at the completion of surgery rather than the method of reconstruction used. According to Farris, type III tympanoplasty refers to establishing continuity of the stapes to the more lateral tympanic membrane or malleus by interposing a sculpted ossicle, bone, or other alloplastic material. A type IV tympanoplasty denotes reconstruction of the ossicular chain from a mobile stapes footplate to the malleus, tympanic membrane, graft, or rarely, the incus. Type V tympanoplasty has been subdivided into types Va and Vb. Type Va designates a true fenestration procedure into the horizontal canal, whereas type Vb implies that the footplate is fixed or absent. After the vestibule is sealed with a tissue graft, continuity is restored from the oval window to the incus, malleus, tympanic membrane, or graft. Technically, stapedectomy would be characterized as a type Vb tympanoplasty, but this terminology is not proposed for otosclerosis surgery.

This classification system is supplemented by describing the method of reconstruction used for each case. This is applied particularly to type III tympanoplasty. The most common type III tympanoplasty performed is an incus interposition with the patient's own incus (autograft). We had used homograft (cadaver) ossicles in the past, but concern regarding possible infection or contamination with viral or prion particles has eliminated their use. A type III tympanoplasty with stapes augmentation entails increasing the height of the stapes above the fallopian canal when a canal wall-down mastoidectomy is performed and the malleus is absent. This technique frequently uses the body of the incus, the head of the malleus, or a cortical bone graft. We use the term *partial ossicular replacement prosthesis* (PORP) when a synthetic biocompatible prosthesis is positioned from the stapes superstructure to the tympanic membrane, graft, or malleus. Types IV and Vb tympanoplasty are performed with either a *total ossicular replacement prosthesis* (TORP) or the patient's own incus from the footplate or grafted oval window to the malleus, tympanic membrane, or graft.



**Figure 114-1** The Wullstein classification of types of tympanoplasty.

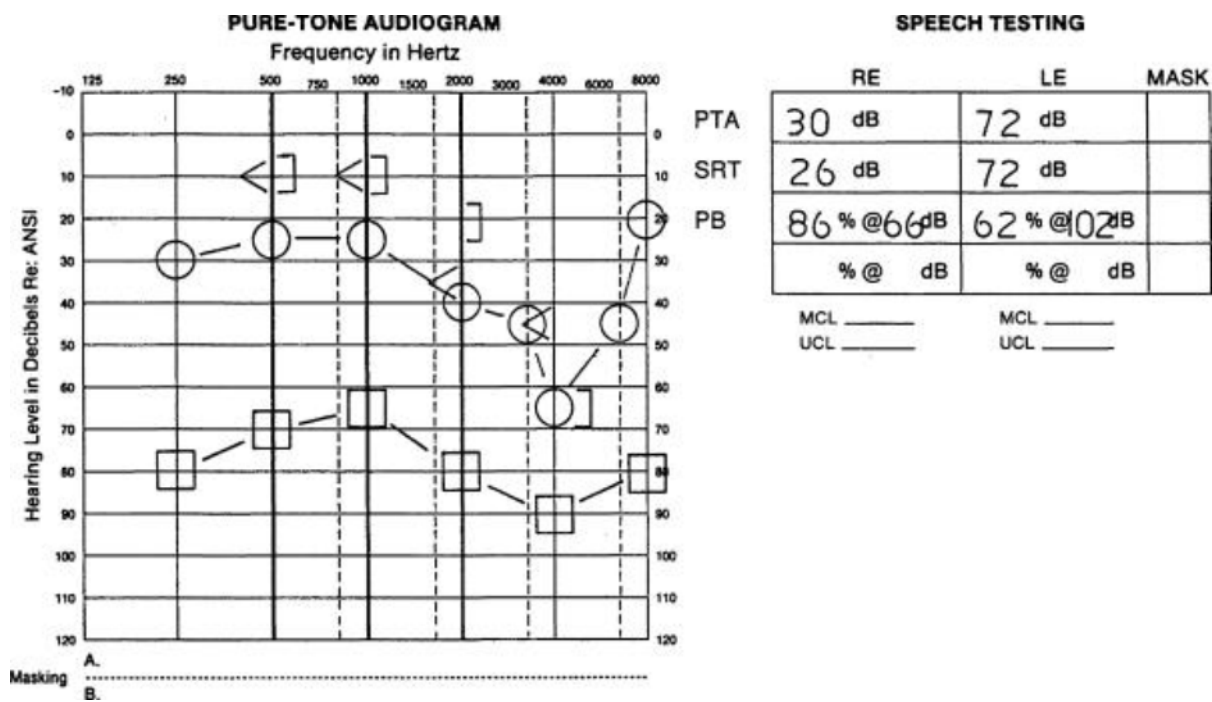
(From Kley W: *Surgical treatment of chronic otitis media and its immediate consequences*. In Naumann HH [ed]: *Head and Neck Surgery*, vol 3: *Ear*. Stuttgart, Germany, Georg Thieme, 1982, p 221.)

## PATIENT SELECTION

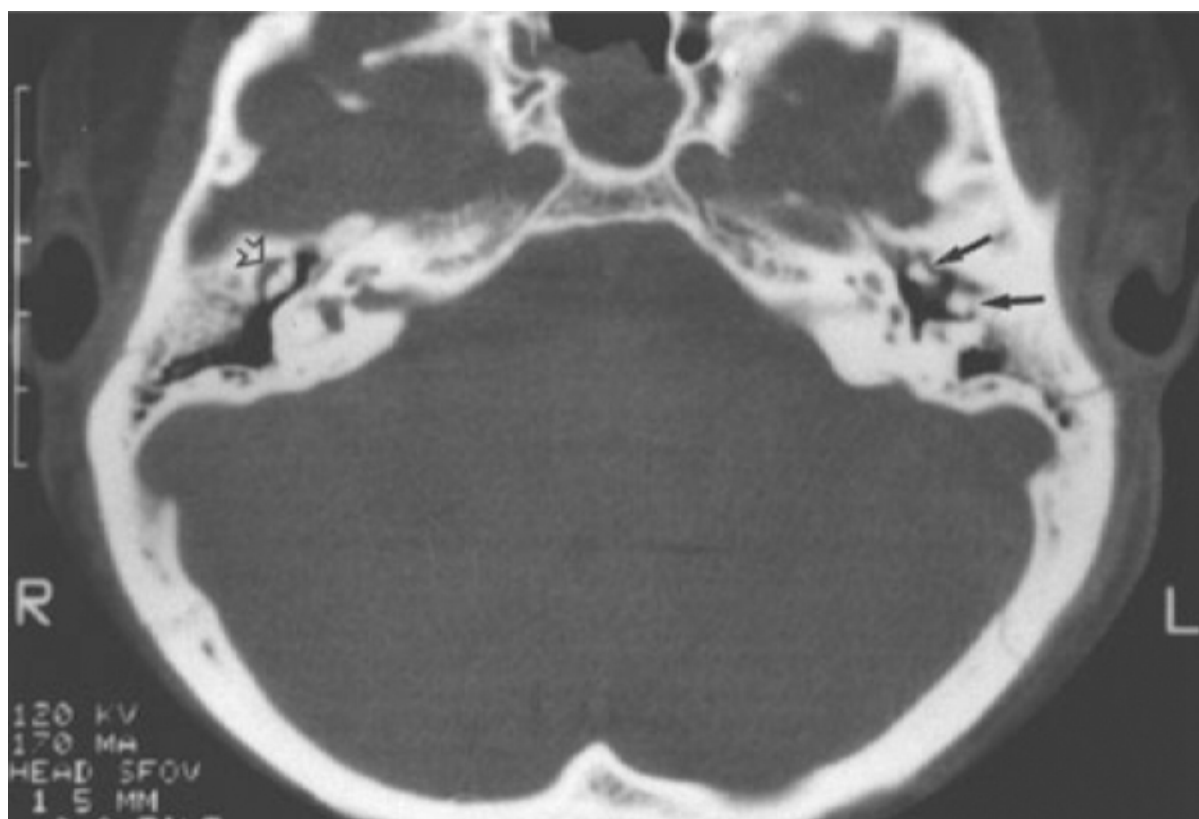
OCR is performed for conductive hearing loss or when the ossicular chain must be disarticulated for access to other middle ear pathology. A chief complaint of hearing loss may result from trauma, chronic eustachian tube dysfunction, congenital anomalies, chronic otitis media, tumors of the middle ear space, or ossicular chain fixation resulting from tympanosclerosis. Physical examination may demonstrate an intact or perforated tympanic membrane. It is important to examine the contralateral ear, which provides a means of predicting the likelihood of successful tympanoplasty and OCR when eustachian tube function is compromised.

Patients sustaining head trauma with fractures involving the temporal bone may present with a conductive, sensorineural, or mixed hearing loss. Hemotympanum often occurs but is usually resorbed in 4 to 6 weeks. This time frame is necessary to determine the type and degree of residual hearing loss after return of middle ear aeration. The anatomy of the external canal should be examined along with the integrity of the tympanic membrane. Pneumatic otoscopy is useful for confirming a small tympanic membrane perforation by demonstrating lack of mobility. Myringosclerosis can also restrict movement of the tympanic membrane. In contrast, hypermobility suggests a flaccid membrane or possible fracture of the malleus handle. Tuning forks are used to both confirm the presence and estimate the magnitude of a conductive hearing loss.

Pure-tone audiometry is performed to determine the degree of conductive hearing loss and the quality of cochlear function. A persistent conductive hearing loss typically indicates ossicular chain disruption. This may be repaired electively or rehabilitated by aural amplification. Patients demonstrating a large mixed hearing loss should be considered surgical candidates for OCR (Fig. 114-2). In patients with significant mixed hearing loss, bone-windowed thin-cut computed tomography (CT) helps define the status of the cochlea, ossicles, and middle ear space. Disruption of the ossicular chain can be demonstrated in these scans (Fig. 114-3). Patients with severe to profound mixed hearing loss may have hearing aid tolerance problems. Closing the air-bone gap restores hearing thresholds to levels at which routine hearing aid amplification is more feasible. OCR may not be warranted in patients with cochlear concussion and poor speech discrimination.



**Figure 114-2** The audiogram shows a left moderate to severe mixed hearing loss with fair word recognition. Options for rehabilitation include amplification or ossicular chain reconstruction. ANSI, American National Standards Institute; LE, left ear; MCL, most comfortable loudness level; PB, phonetic balance; PTA, pure-tone average; RE, right ear; SRT, speech reception threshold; UCL, uncomfortable loudness level.



**Figure 114-3** Computed tomography scan demonstrating temporal bone trauma with disruption of the ossicular chain. The normal incudomalleus complex is indicated with the *open arrow*. The *solid arrows* identify the separated malleus and incus.

Patients undergoing tympanoplasty with or without mastoidectomy and are found to have significant middle ear mucosal disease may not be ideal candidates for immediate reconstruction. On occasion, the procedure is staged in anticipation of achieving an aerated middle ear space with healthier mucosa. Our philosophy on staging the procedure has evolved over the past 2 decades. It was our routine approach to remove pathologic disease,

reconstruct the ossicular chain, and graft the tympanic membrane in one procedure. We believed that recurrent or persistent disease would become evident by the findings of subsequent progressive conductive hearing loss, recurrent otorrhea, or evidence of cholesteatoma in an ear with cholesteatoma as the original pathology. Our approach has been modified slightly based on the findings in the middle ear and the age of the patient. In initial procedures or operations performed on young people in whom taking the canal wall down would minimize the likelihood of persistent disease, we would attempt total removal of the disease and keep the canal wall intact but plan to re-explore the ear in 6 to 12 months.

A staged procedure is performed when cholesteatoma is mixed within granulation tissue around the stapes footplate and superstructure and cannot be completely removed. Another situation follows removal of thickened hyperplastic inflamed mucosa from the promontory and eustachian tube orifice when a large graft to the tympanic membrane is necessary. If the incus or head of the malleus is available and free of disease (cholesteatoma), it is removed and banked for planned subsequent reconstruction. A piece of sculpted Silastic sheeting (0.02 to 0.04 inch) with a rounded tip extending into epitympanum is placed over the promontory. The video shows a disc of reinforced Silastic sheeting being placed on the promontory and medial to the malleus ([see Video 114-1](#)). A

fascia graft is positioned lateral to the Silastic and rests on the bony annulus ([see Video 114-2](#)

). Placement of the Silastic block over a mobile stapes superstructure occasionally provides an effective columellar connection between the stapes and the tympanic membrane and results in near closure of the air-bone gap. If good hearing has been achieved with the initial procedure, re-exploration is not mandatory unless concern exists about residual or recurrent disease.

On rare occasion, reconstruction at a subsequent staged procedure may not require access through the external auditory canal and tympanic membrane. If the original tympanomastoidectomy procedure entailed opening the facial recess, it is possible to reconstruct the ossicular chain from the postauricular approach. Endoscopes may be necessary to fully evaluate the attic and mesotympanum. This technique allows improvement in hearing and avoids canal incisions, middle ear packing, and restrictions from water exposure.[4]

In keeping with otologic principles, the surgeon is cautioned about operating on the better-hearing ear. As with all rules, there are exceptions. Surgical intervention could be considered in a better-hearing ear if other pathologic findings are present, such as cholesteatoma in the involved ear. However, the status of the contralateral ear is most important to consider.

Age does not impose a limitation for tympanoplasty and OCR. In children who do not have a recent history of recurrent episodes of otitis media and demonstrate a dry ipsilateral perforation and normal contralateral ear on physical examination, it can be assumed that eustachian tube function is competent and they are candidates for tympanoplasty. Similarly, elderly patients in good health have the option of amplification or middle ear reconstruction.

The decision regarding elective reconstruction for conductive hearing loss remains with the patient. If there is no evidence of active infection, potential tumor, or cholesteatoma, the option of hearing aid amplification should be discussed. If a patient has chronic otitis media with perforation and it is believed that a hearing aid would exacerbate the underlying disease and promote drainage, appropriate counseling should be given.

Patients with a large conductive loss in the involved ear and normal hearing in the contralateral ear require further counseling. Despite a technically successful operation, complete closure of the air-bone gap is frequently not achieved in some type III and more complicated reconstructive procedures. Although hearing can be improved substantially, a residual difference between the two ears may be perceived by the patient as being an unsuccessful result. Realistic expectations must be conveyed when discussing anticipated goals of the procedure.

It may be difficult to decide what to recommend to patients with residual conductive hearing loss who have undergone previous attempts at OCR. Although previous operative dictations are occasionally unreliable, in this situation it is often helpful to review them. Nearly complete closure of the air-bone gap should be anticipated with a type I tympanoplasty. Patients with a type III or IV tympanoplasty and residual conductive hearing loss of 15 to 20 dB with normal hearing on the contralateral side may desire further improvement. Surgeons must have an appreciation of the hearing results before contemplating revision surgery.

## **PREOPERATIVE PLANNING**

Physical examination of the external auditory canal and tympanic membrane is important in determining the status of the ear. Primary inflammation of the skin of the external canal or inflammation secondary to disease from the middle ear requires medical management to optimize postoperative healing. A few weeks of topical and systemic

antibiotics may be necessary. The integrity of the tympanic membrane and middle ear space is noted. Tuning fork testing with 256-, 512-, and 1024-Hz forks is performed to determine whether a conductive hearing loss is present and to estimate the degree of loss. The most commonly used frequency is 512 Hz. Obtaining an audiogram is mandatory to establish the nature and degree of the conductive hearing loss and cochlear function. Patients with an intact tympanic membrane, no history of chronic ear disease, and progressive conductive hearing loss most likely have otosclerosis. Fixation of the lateral ossicular chain is relatively uncommon. An astute clinician may detect decreased mobility of the malleus during pneumatic otoscopy. It is typically diagnosed at the time of exploratory tympanotomy. The cause may be congenital. Delayed lateral chain fixation is probably due to tympanosclerosis secondary to chronic inflammation of the middle ear. Acoustic reflexes should be absent in the setting of conductive hearing loss caused by pathology within the middle ear. Dehiscence of the superior semicircular canal may give findings of conductive hearing loss of inner ear origin. Acoustic reflexes are characteristically present in this form of conductive hearing loss. We now request acoustic reflex testing of patients with conductive hearing loss and an intact tympanic membrane.

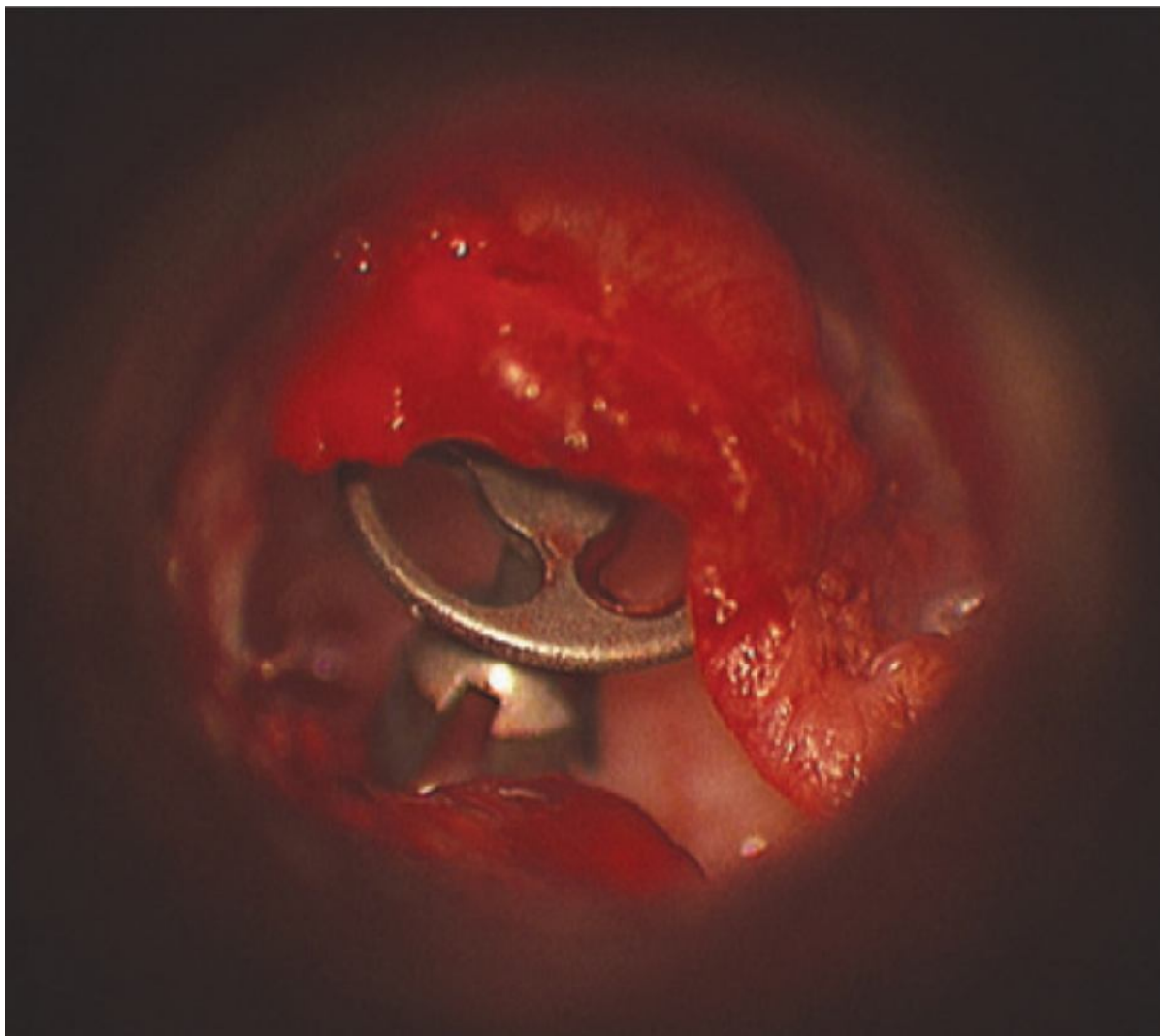
CT is not routinely performed unless symptoms or signs of complications of chronic otitis media and cholesteatoma are present, including asymmetrical cochlear function, dizziness, severe headaches, facial paresis, or cerebrospinal fluid otorrhea. Repair of congenital atresia also requires CT scanning to define the otic capsule, middle ear space, ossicular chain, bony plate, and course of the facial nerve. This topic is covered more thoroughly in Chapter 111.

The method for providing anesthesia is dictated by the status of the tympanic membrane, the presumed status of the ossicular chain, the presence or absence of inflammatory middle ear disease, the anticipated approach, the patient's tolerance for a procedure under sedation, and the experience of the surgeon. Patients with an intact tympanic membrane and conductive hearing loss can undergo an endaural approach under local anesthesia and intravenous sedation. General anesthesia is recommended for children and patients with a tympanic membrane perforation who require a postauricular approach. Facial nerve monitoring is not used for routine tympanoplasty procedures; however, monitoring is indicated for patients with evidence of facial nerve signs of weakness, fasciculations, or spasm and during procedures for repair of congenital aural atresia. Antibiotics are not given perioperatively. As with all procedures, the patient is informed of the risks, benefits, and alternative treatments.

## **PROSTHESIS OPTIONS AND ADJUNCTIVE TECHNIQUES**

Over the past 60 years there have been significant advances in the development and application of new materials available for reconstruction of the ossicular chain. In a poll of members of the American Otologic Society published in 2001, hydroxyapatite was the preferred alloplastic material because it provided biocompatibility, rigidity for sound transmission, durability, longevity, ease of use, and good hearing results.<sup>[5]</sup> Plastipore prostheses, which had been widely used in the latter part of the past century, were reported to have the lowest satisfaction rate, of all prostheses.

The newest material currently available is titanium, which is lightweight, has great tensile strength, and is rigid yet slightly malleable. It requires a cartilage interface between the prosthesis and the tympanic membrane. The design for partial prostheses incorporated a bell-shaped configuration that fits over the stapes superstructure (Fig. 114-4). Jackson and colleagues compared titanium with synthetic non-titanium-based prostheses and showed improved hearing outcomes with titanium prostheses but thought that there was a minimal learning curve needed to successfully achieve closure of the air-bone gap.<sup>[6]</sup> A consortium of otologists from different regions of the United States were similarly in favor of titanium prostheses given their good hearing results and low rate of extrusion.<sup>[7]</sup> Our only reservation with using this material is the requirement for a cartilage graft under the tympanic membrane. This inhibits visual monitoring of the middle ear for recurrent cholesteatoma after surgery for that pathology.



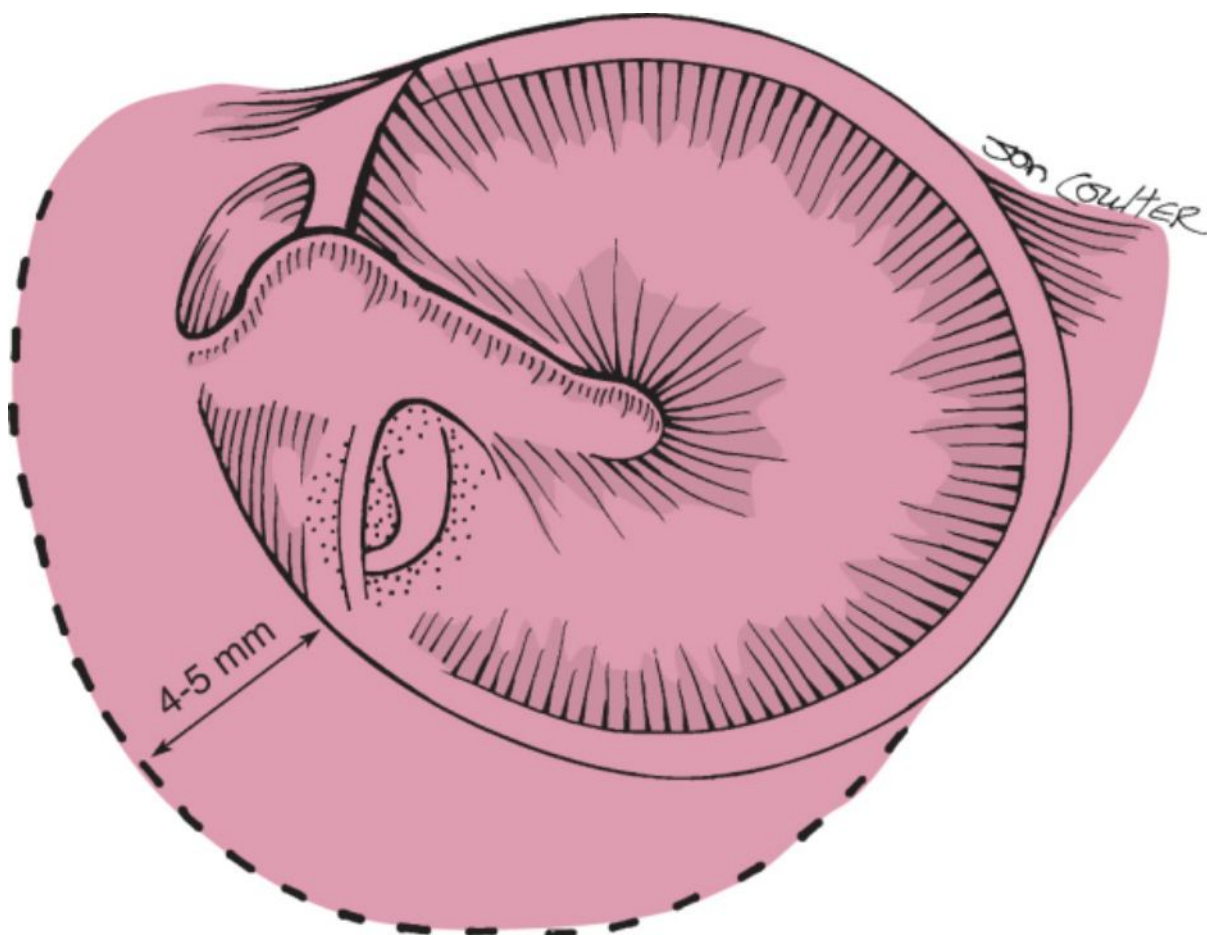
**Figure 114-4** Titanium partial ossicular replacement prosthesis with a cage or bell that fits over the stapes superstructure.

The use of bone cement in skull base surgery and cranioplasty has led to applications in otology and reconstruction of the ossicular chain. The chemical composition of these products includes hydroxyapatite, cyanoacrylates, polymethyl methacrylates, and glass ionomers. Great care must be taken with the latter product to avoid contact with any neural tissue because of the severe neurologic complications that can occur from aluminum being leached from the product. A study using SerenoCem (Corinthian Laboratory, Nottingham, UK) for repair of an eroded incus confirmed that the product was not exothermic when reconstituted but required at least 20 minutes to harden in a dry operative field.<sup>[8]</sup>

Hydroxyapatite bone cement is available from numerous manufacturers. It too is minimally exothermic, is malleable for a few minutes, sets in 4 to 6 minutes, and undergoes osteointegration over time. It can provide an adjunct or alternative to ossiculoplasty with preformed prostheses. Goebel and Jacob reported successful use of hydroxyapatite bone cement in challenging cases with difficult ossicular reconstruction.<sup>[9]</sup> The products currently available include Mimix (Walter Lorenz Surgical, Jacksonville, FL), BoneSource (Stryker Leibinger, Portage, MI), and Norian (Synthes USA, Paoli, PA).

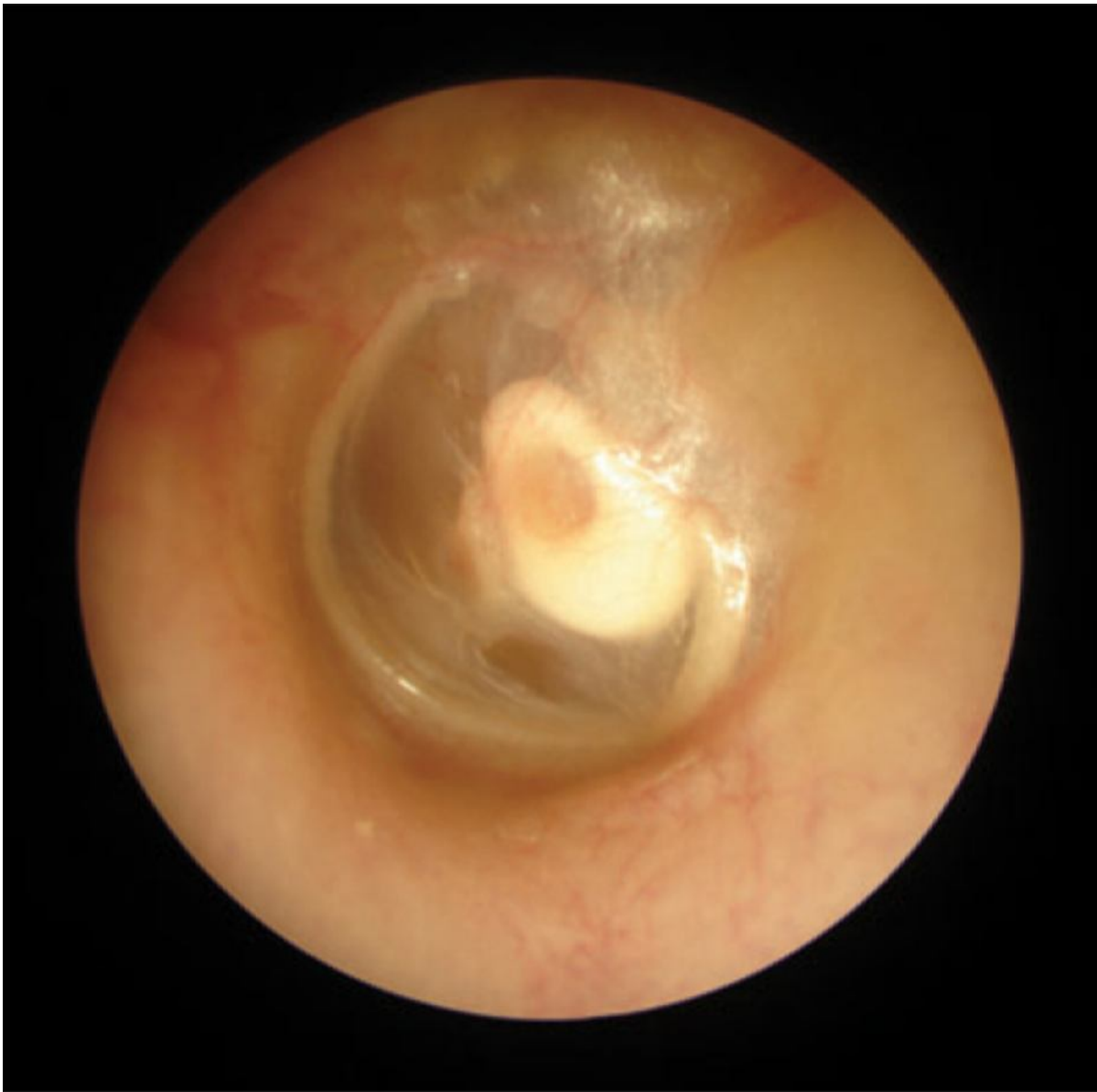### ***SURGICAL TECHNIQUES***

The approaches to and methods for tympanic membrane grafting are reviewed in Chapter 113. Frequently, the preoperative status of the ossicular chain is unknown when correction of conductive hearing loss is attempted. The surgeon must be prepared to have access to the entire ossicular chain. When elevating a tympanomeatal flap, the superior limb of the incision should be superior to the pars flaccida and approximately 4 to 5 mm from the posterosuperior annulus (Fig. 114-5). This longer flap permits removal of bone from this area to provide exposure of the malleus neck and the entire stapes footplate and to gain access for removal of the body of the incus, if necessary.



**Figure 114-5** The tympanomeatal incision for exploratory tympanotomy should be 4 to 5 mm away from the posterosuperior annulus.

Reconstruction of the tympanic membrane and ossicular chain demands a precise and stable connection between the drum and the stapes or footplate. The reconstructed ossicle or prosthesis should not make direct contact with the surrounding tympanic ring, which would restrict transmission of sound to the cochlea. A prosthesis that is too short will have a tendency to fall or become displaced. On the other hand, excessive length and poor eustachian tube dysfunction set the stage for extrusion of the prosthesis. The prosthesis should not only touch the tympanic membrane but should also be under slight tension to create minimal tenting of the tympanic membrane over the prosthesis (Fig. 114-6). The following text focuses on isolated problems encountered in OCR and the methods and techniques for reconstruction.

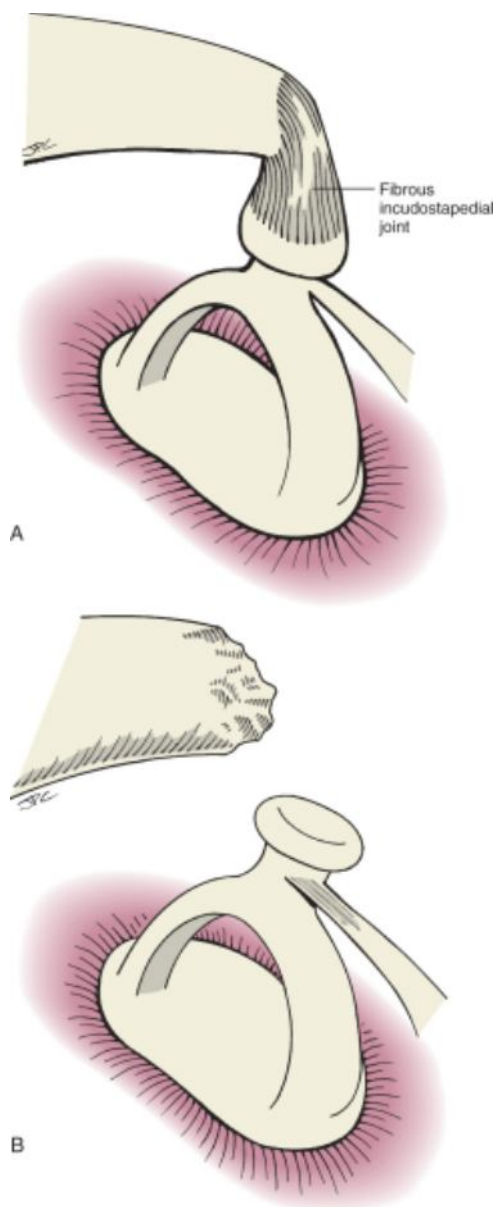


**Figure 114-6** Hydroxyapatite partial ossicular replacement prosthesis making direct contact with the tympanic membrane. Note the very slight tenting over the prosthesis.

### Problems with the Incus



The most commonly encountered abnormality in the ossicular chain involves the incus. Rarely, it is manifested as incudomalleal fusion or fixation. More commonly, the long process and lenticular process of the incus are eroded or connected by a fibrous union (Fig. 114-7). In patients with an intact mobile malleus and stapes, incus interposition is the most commonly used method for OCR. This technique has been used for the past 50 years. A variety of techniques are available for modification of the incus to provide a mobile yet firm connection from the stapes superstructure to the malleus. The surgeon should note the status of the middle ear mucosa and the relationship of the malleus to the stapes.

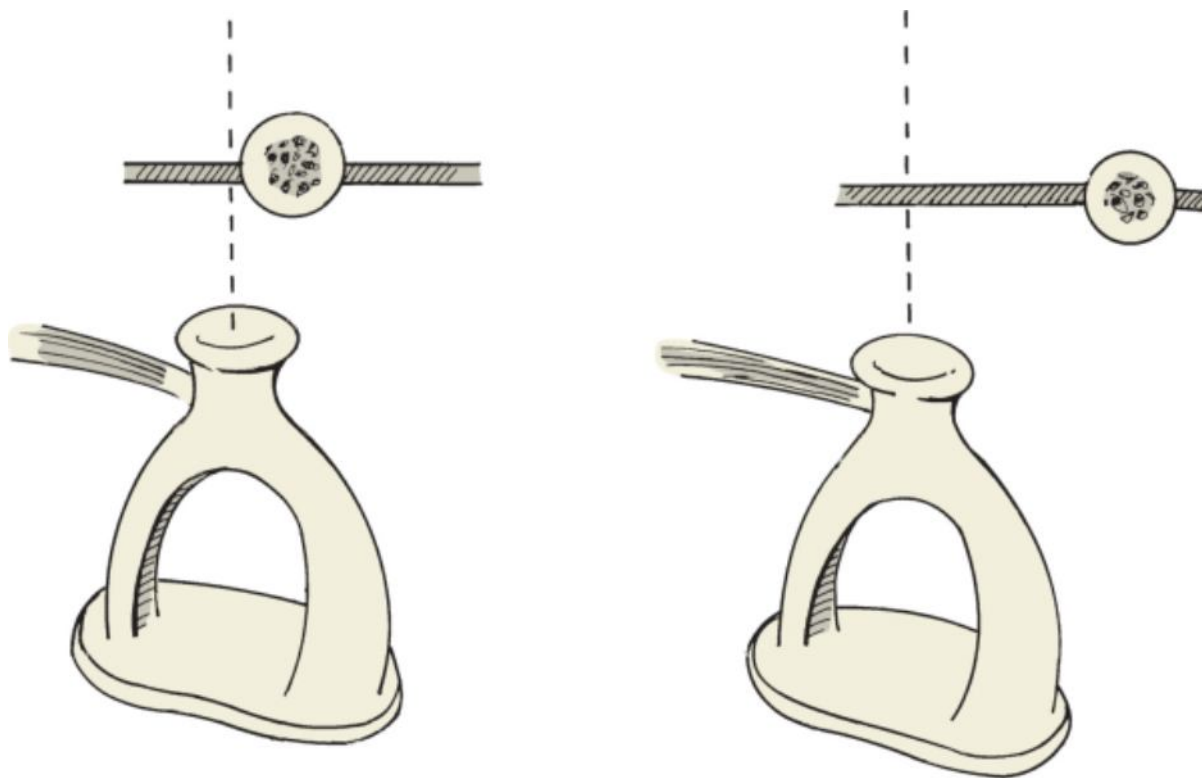




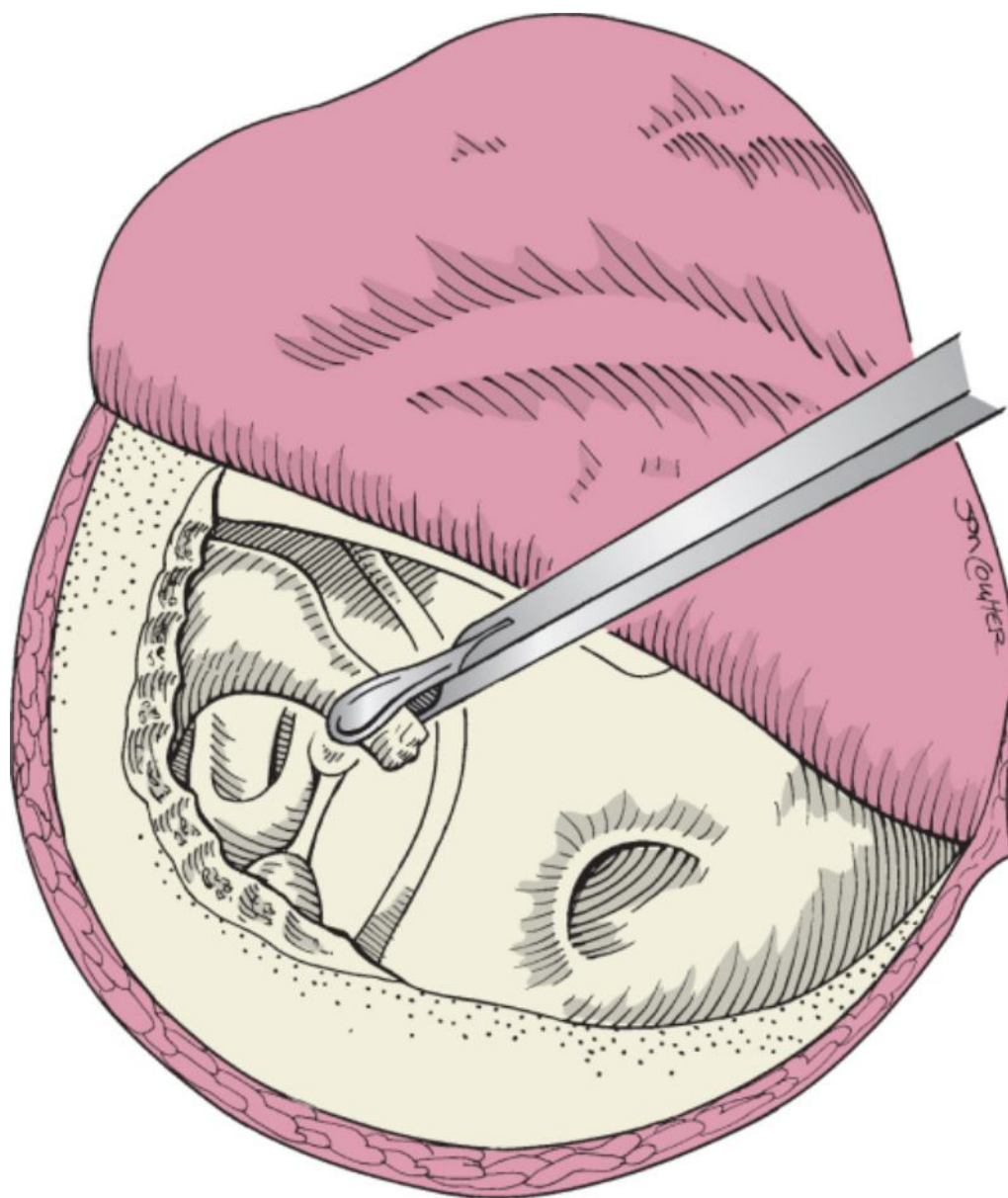
**Figure 114-7** A, Erosion of the lenticular process with a residual fibrous joint. B, Erosion of the long process of the incus.

The stapes may be located directly medial to the handle of the malleus. The other anatomic variation occurs when the malleus is located anterior to the vertical plane of the stapes. This relationship is important in determining how the incus will be sculpted so that it can be interposed between the stapes and the malleus (Fig. 114-8). In addition, the height of the stapes relative to the promontory and facial nerve is noted. This is more of an issue when disease in the middle ear and mastoid requires a canal wall-down mastoidectomy. The patient's incus (autograft) is usually available for reconstruction, but it may be necessary to remove additional bone from the posterosuperior canal to extract the incus. A right-angled hook or curved needle is used to disarticulate any remaining attachments of the incus body to the malleus head. Cup forceps are used to grasp the proximal long process of the incus. With a rotating downward maneuver the surgeon extracts the incus from the epitympanum entering into the middle ear

(Fig. 114-9)  (see [Video 114-3](#) ). Care is taken to avoid displacement of the stapes superstructure and injury to the chorda tympani nerve.



**Figure 114-8** The position of the malleus relative to the stapes determines how the incus will be sculpted to perform an interposition. **Left**, The malleus is located lateral to the stapes. **Right**, Reconstruction requires augmenting the vertical height of the stapes and its anterior span to the malleus.



**Figure 114-9** The incus body is disarticulated from the malleus head and extracted with cup forceps.

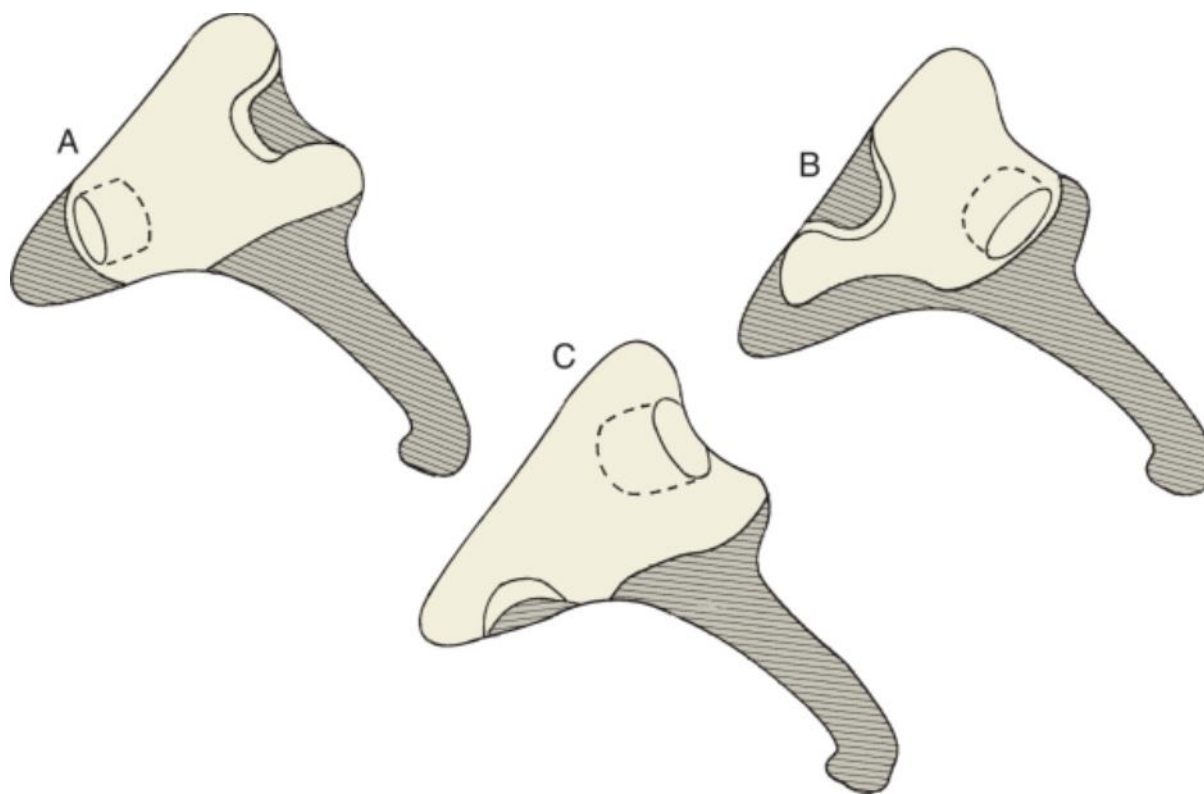
Various designs for sculpting an incus for interpositioning between the stapes and the malleus are demonstrated in Figure 114-10. The incus should be held with an instrument such as a fine hemostat or forceps designed for holding ossicles (Fig. 114-11). Should the incus be inadequate because of significant erosion or infiltration by cholesteatoma, we had used a homograft incus in the past but now use a synthetic PORP prosthesis. If a mastoidectomy had been performed, the same variable high-speed drill is used for incus sculpting. Otherwise, a

battery-powered microdrill is used




([see Video 114-4](#) ).



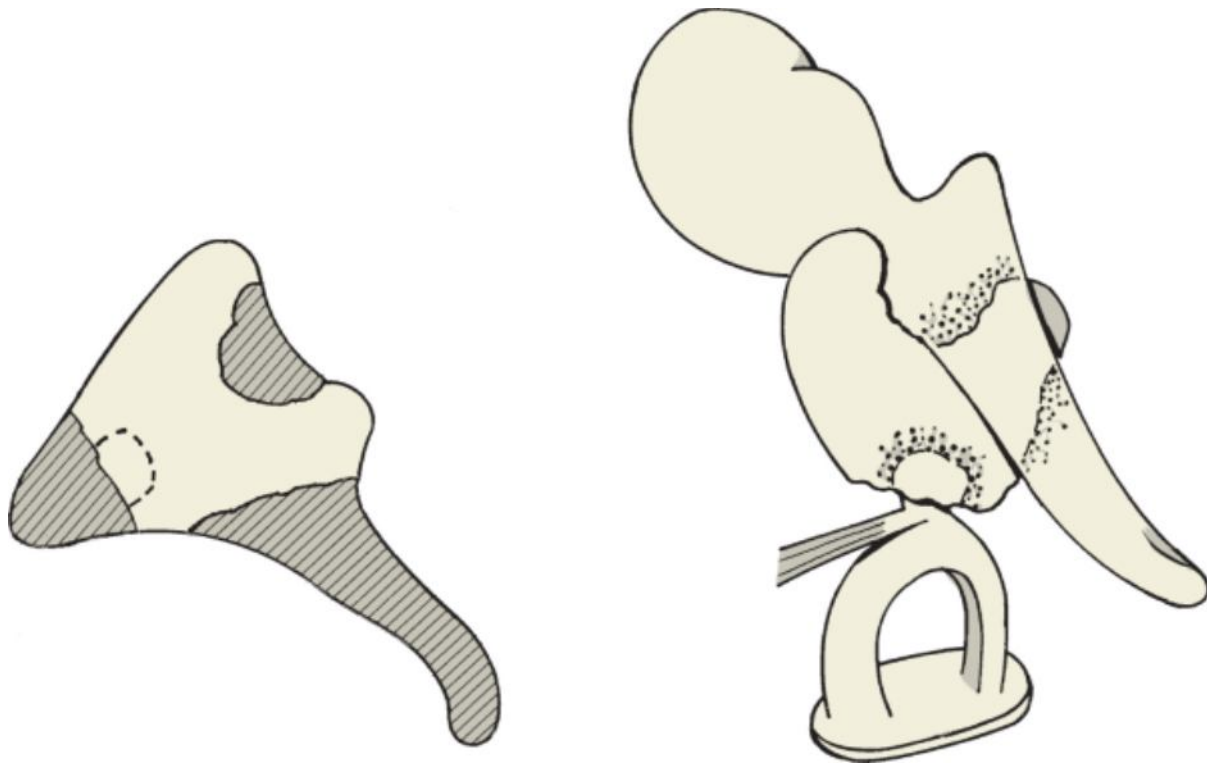


**Figure 114-10** The incus body can be sculpted in a variety of forms to accommodate each particular relationship between the malleus and stapes. **A**, Gains vertical height. **B**, Gains some vertical height and mostly horizontal span. **C**, Gains mostly vertical height and some horizontal span.

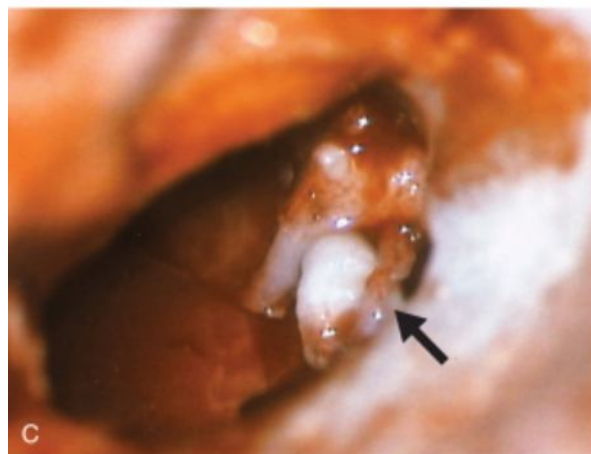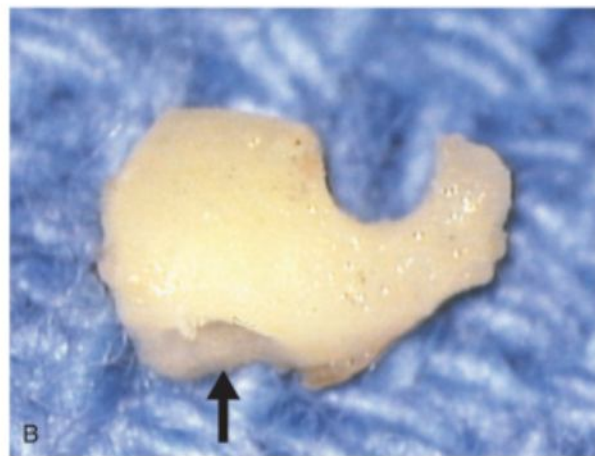
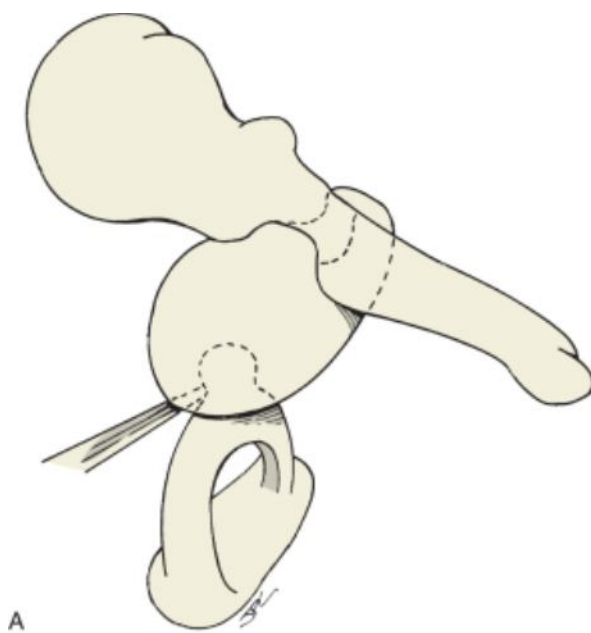


**Figure 114-11** Ossicle holder firmly grasping a sculpted incus.

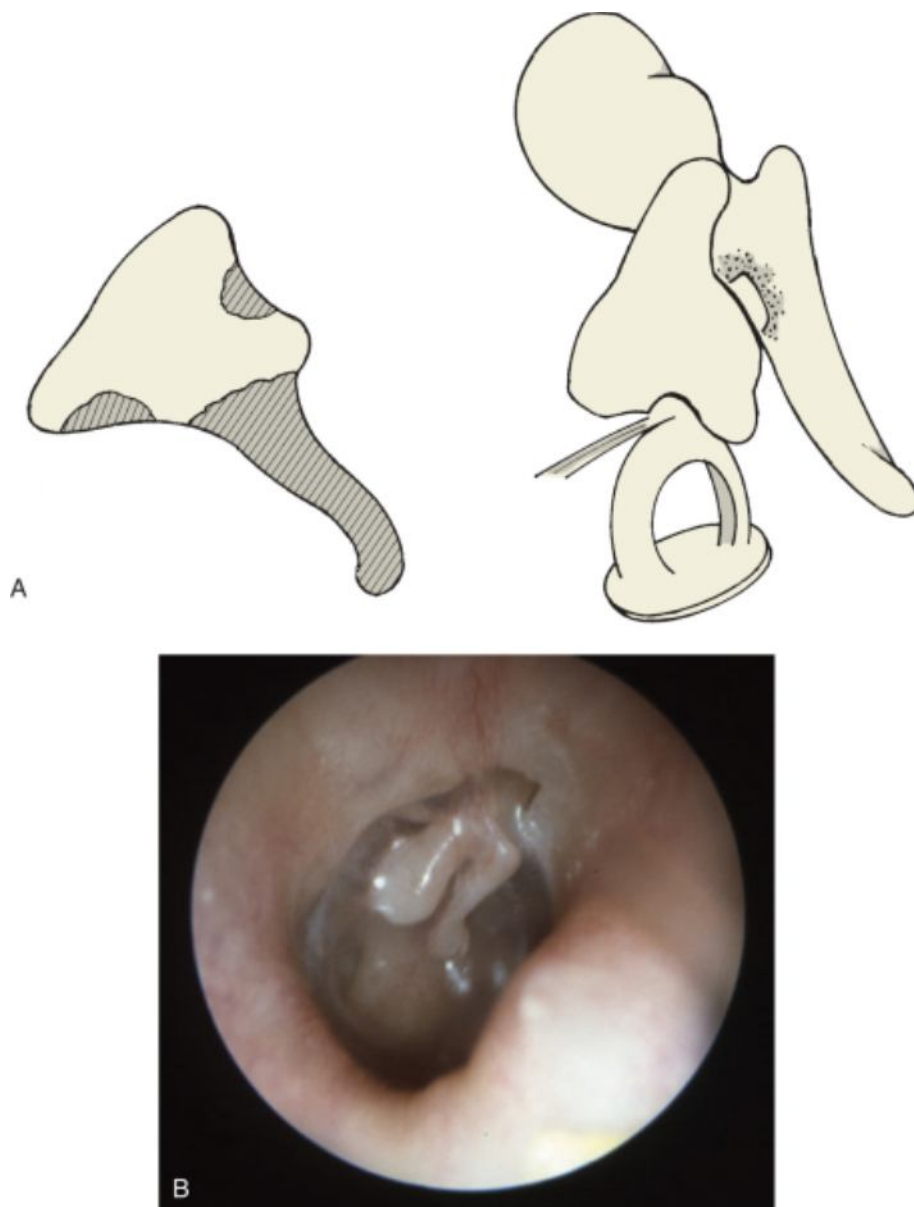
When the stapes and malleus are in a nearly vertical plane, height is needed to connect the two ossicles. The acetabulum for the stapes head is drilled into the short process of the incus. A groove for the malleus handle is created in the articulating surface of the incus body. This is initially positioned underneath the malleus handle, and the malleus-incus complex is lifted and rolled onto the stapes (Fig. 114-12). A very common configuration is one used to gain some height and horizontal span. The acetabulum for the stapes is created in the body of the incus near its junction with the long process (Fig. 114-13A). A more oval aperture is drilled to accommodate the shoulder of the crura (see Fig. 114-13B). Care must be taken to ensure that the undersurface of the short process of the incus is not resting on the promontory of the cochlea. With all interpositioning techniques, placement of the incus superior or inferior to the chorda tympani nerve can provide further support to the sculpted ossicle (see Fig. 114-13C). When considerable height is needed to be bridged, the incus is configured as shown in Figure 114-14A. This relationship can be appreciated when the tympanic membrane is atrophic and translucent (see Fig. 114-14B).



**Figure 114-12** Incus interposition to gain height from the stapes to the malleus.



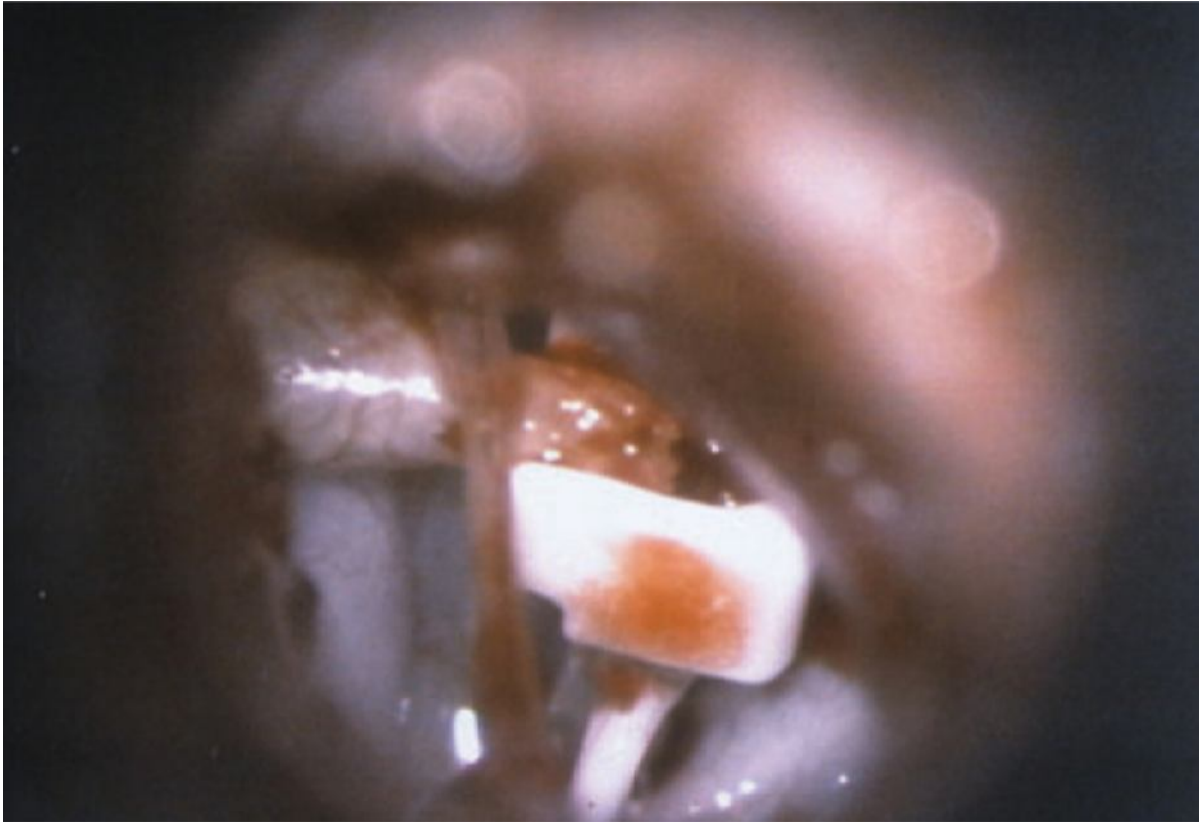**Figure 114-13** **A**, Incus interpositioning to gain some height and mostly horizontal span. **B**, The sculpted incus has an oval aperture that fits snugly on the stapes (*arrow*). **C**, In a left ear, the incus has been positioned superior to the stapes and medial to the malleus handle. The chorda tympani nerve provides additional support (*arrow*).



**Figure 114-14** **A**, Incus interposition to gain mostly vertical height and some horizontal span. **B**, Postoperative photograph of a right ear with a translucent tympanic membrane. A groove was drilled into the short process of the incus so that it can rest against the neck of the malleus.



Occasionally, the incus is eroded just at the incudostapedial joint (see Fig. 114-7). Rather than removing the incus, an alternative method for reconstructing this joint is to use an Applebaum hydroxyapatite prosthesis. This prosthesis fits on the stapes superstructure and supports the remaining long process of the incus (Fig. 114-15)

(see [Video 114-5](#) ).   

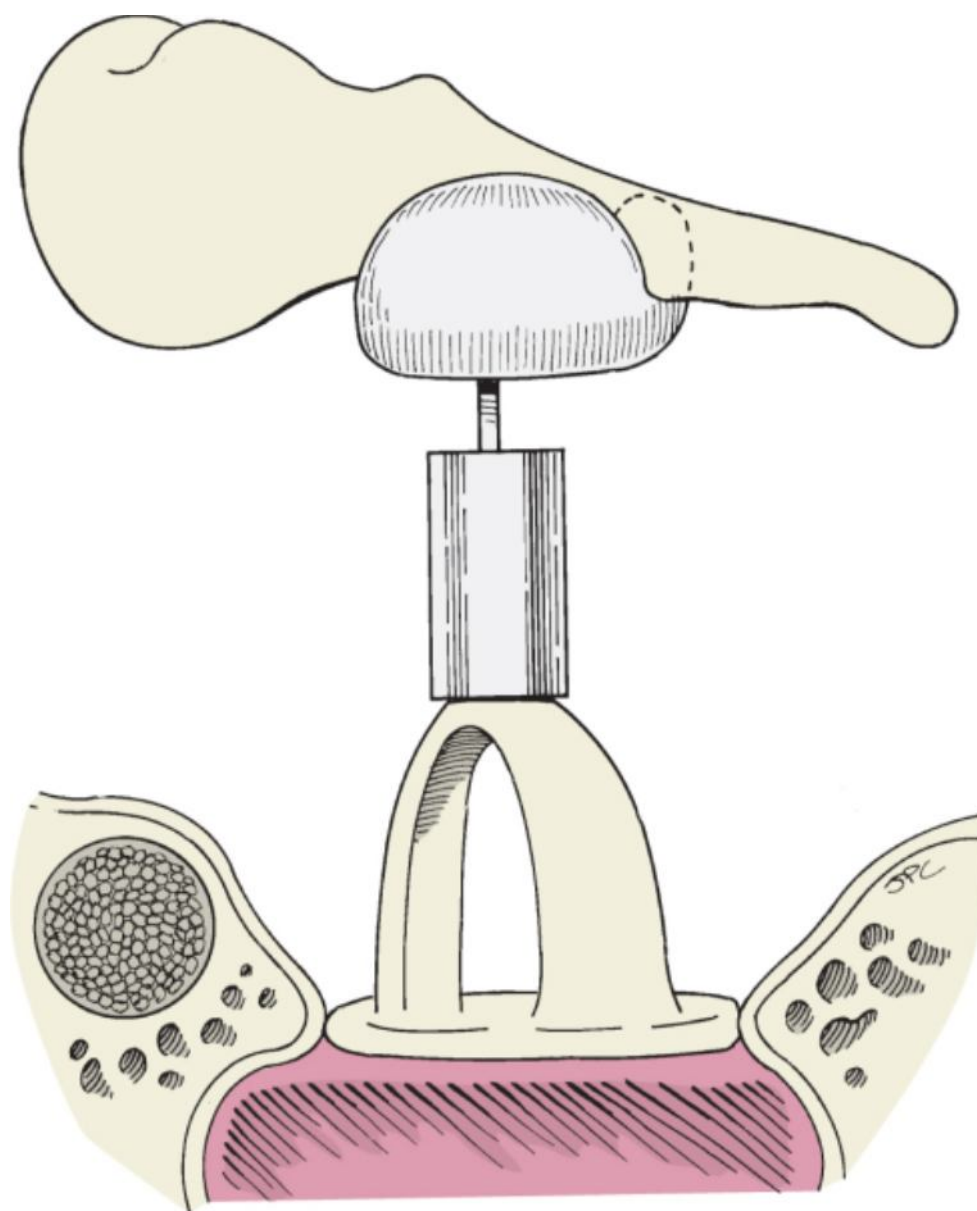


**Figure 114-15** Intraoperative photograph of an Applebaum prosthesis placed between the stapes and an eroded long process of the incus.

Type III tympanoplasty is also performed with synthetic prostheses. Products containing hydroxyapatite are well tolerated. A cartilage interface between the dense hydroxyapatite prosthetic head and the tympanic membrane or graft is not needed. The shafts are made of a combination of hydroxyapatite and polyethylene or fluoroplastic. In a technique similar to that used for incus interpositioning, a PORP can be positioned from the stapes to the mobile

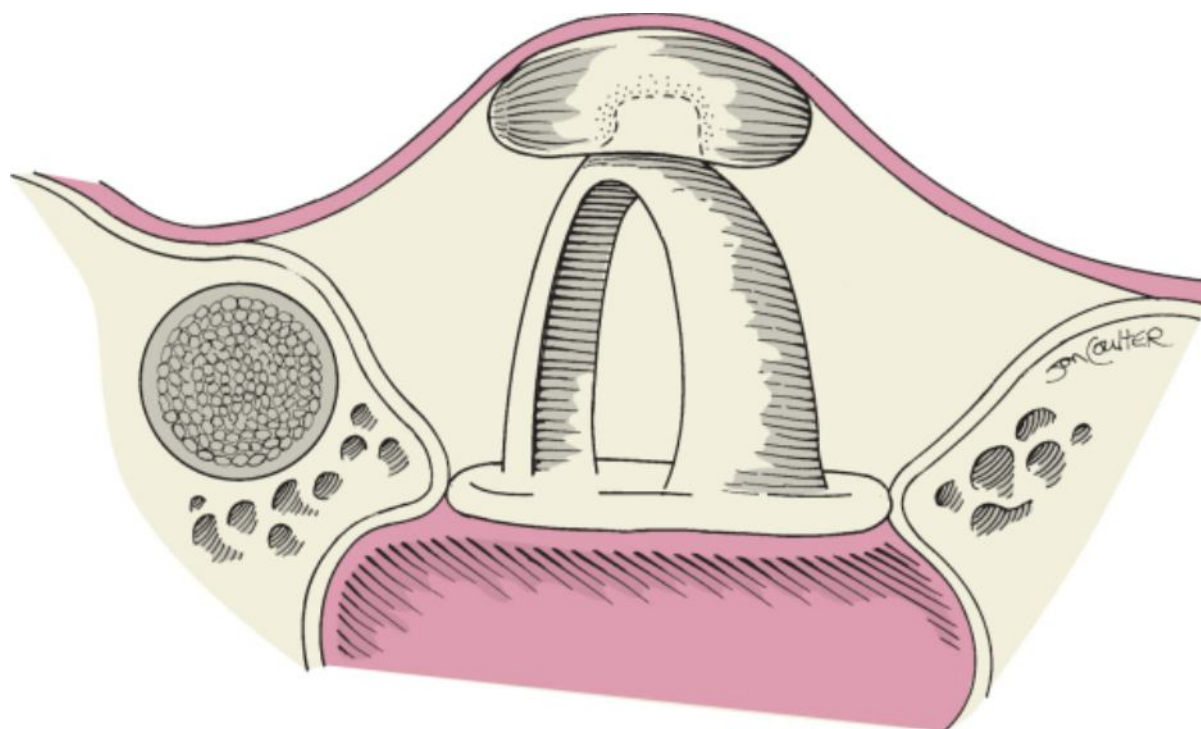
membrane  (Fig. 114-16). It can easily be shortened to provide the appropriate distance from the stapes to the malleus handle and tympanic membrane ([see Video 114-6](#) ). We do not strictly apply the terms *PORP* and *TORP* to indicate ossicular reconstruction directly to the tympanic membrane or its graft. We use the terms *PORP* and *TORP* synonymously with *incus replacement prosthesis* and *incus-stapes replacement prosthesis*, respectively. The malleus may be present and can provide further support for the prosthesis.





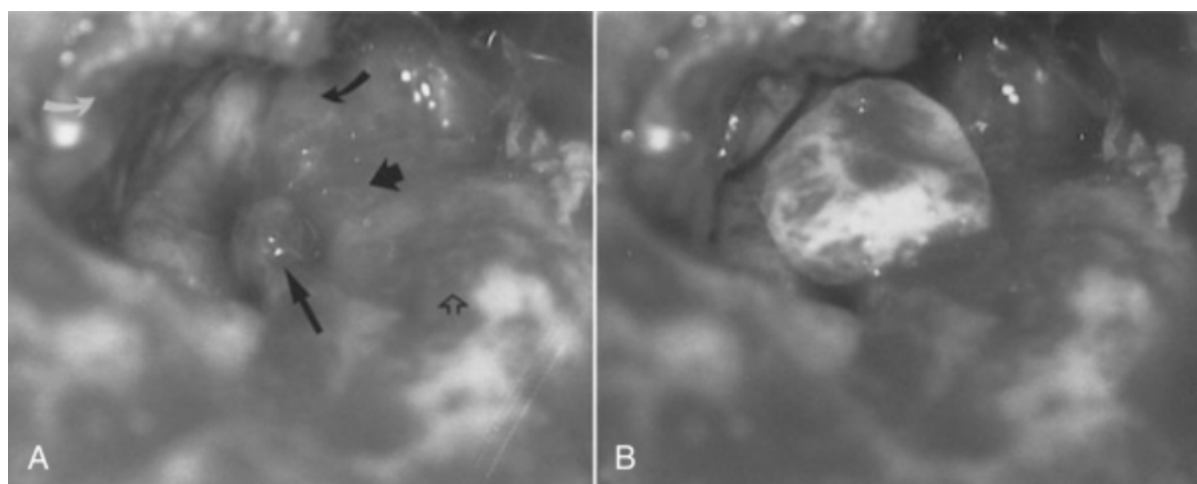
**Figure 114-16** A partial ossicular replacement prosthesis is positioned between the stapes and the malleus handle. It can be placed directly onto the medial surface of the tympanic membrane or graft without intervening cartilage when the dome of the prosthesis is made of hydroxyapatite.

Reconstruction of the ossicular chain in patients undergoing a canal wall-down mastoidectomy may also require a type III tympanoplasty. After the head of the malleus is removed, a connection from the stapes to the malleus handle is necessary. This can be accomplished with incus interposition techniques or with a synthetic prosthesis. When the level of the tympanic membrane is displaced medially because of an absent malleus, minimal height is needed for the stapes to reach the tympanic membrane. The membrane could be grafted directly onto the stapes superstructure as described by Wullstein. However, greater surface contact is achieved when an ossicular graft is placed on the stapes. The body of the incus, the head of the malleus, or a small cortical bone graft harvested from the root of the zygoma or the outer table of the squamosa portion of the temporal bone can be drilled to form a dome for the stapes superstructure (Fig. 114-17).



**Figure 114-17** Ossicular chain reconstruction in a canal wall-down cavity. The stapes has a greater area of contact with the tympanic membrane or graft. This is a type III tympanoplasty with stapes augmentation.

Under high magnification, the relationship of the facial nerve and horizontal semicircular canal to the height of the stapes can be appreciated. When the tympanic membrane or graft is returned to cover the middle ear, it is supported laterally by the horizontal semicircular canal and the facial ridge. The height of the stapes must be augmented to make better contact with the tympanic membrane (Fig. 114-18). The vertical height of a PORP is too great in this situation. It cannot be trimmed sufficiently to provide the necessary height of 2 to 3 mm.




**Figure 114-18** **A**, Left ear, canal wall-down mastoidectomy in preparation for ossicular chain reconstruction. Note that the stapes head (*long arrow*) is at the level of the tympanic segment of the facial nerve (*short arrow*). The tympanic membrane (*curved white arrow*) will rest on the facial ridge and the horizontal semicircular canal (*open arrow*). The cochleariform process is identified (*curved black arrow*). **B**, A sculpted cortical bone graft is placed as a dome over the stapes. This augments the height of the stapes and provides greater surface contact with the tympanic membrane.


On rare occasion, the malleus can be directly attached to the stapes superstructure. This situation occurs in a canal wall-down procedure when the incus is absent and the stapes superstructure is intact. If the malleus remains attached to the tympanic membrane along the distal handle and umbo, its attachment to the tensor tympani tendon can be divided and the malleus rotated posteriorly and placed on top of the stapes.

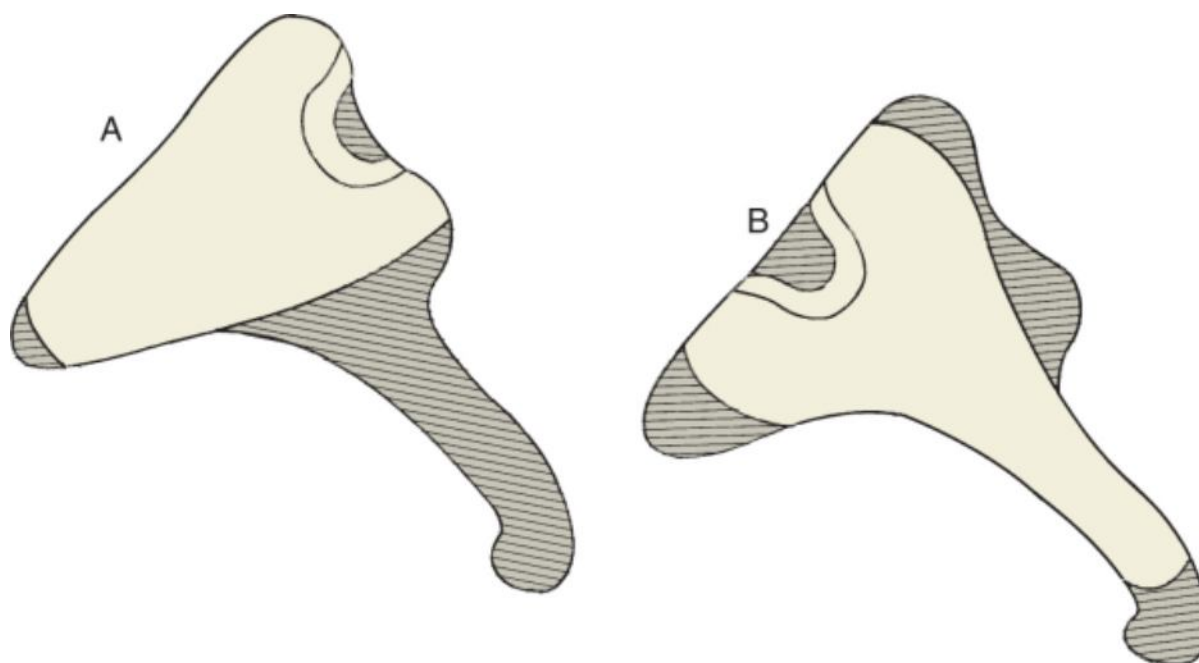
### Problems with the Stapes

If the stapes superstructure is partially eroded, interposing an ossicle or prosthesis from the stapes arch or one of its crura will probably fail. Reconstruction from the undersurface of the malleus to the mobile stapes footplate provides a more secure connection of the ossicular chain.

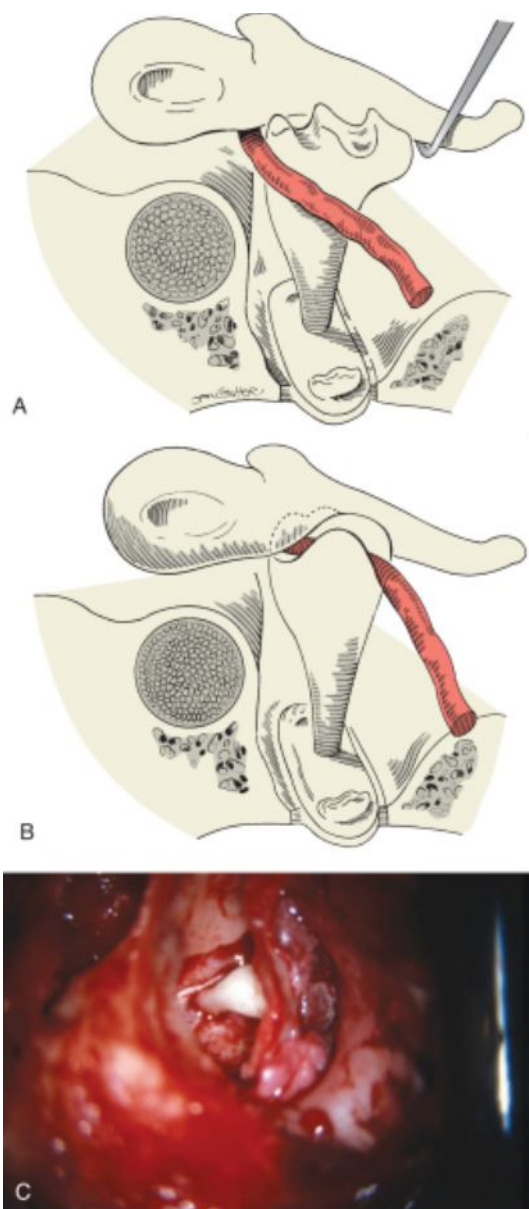
An autograft incus occasionally provides adequate length to meet these requirements. The distance should be measured before sculpting the incus. The size of the incus from the short process to its articulating surface often satisfies the length needed from the footplate to the undersurface of the malleus.

The incus is sculpted by flattening the short process to rest on the stapes footplate. A groove in the articulating surface of the incus is further defined to secure the incus to the medial surface of the malleus (Fig. 114-19A). Additional length is available when the long process of the incus remains. The lenticular process is removed, and the groove for the malleus is drilled on the superior surface of the incus (see Fig. 114-19B) (see [Video 114-7](#) ).

The sculpted ossicle is placed on the  footplate between the remaining crura. While the malleus handle is lifted, the incus is rotated into position (Fig. 114-20). The chorda tympani nerve can be positioned to further secure the ossicular assembly.



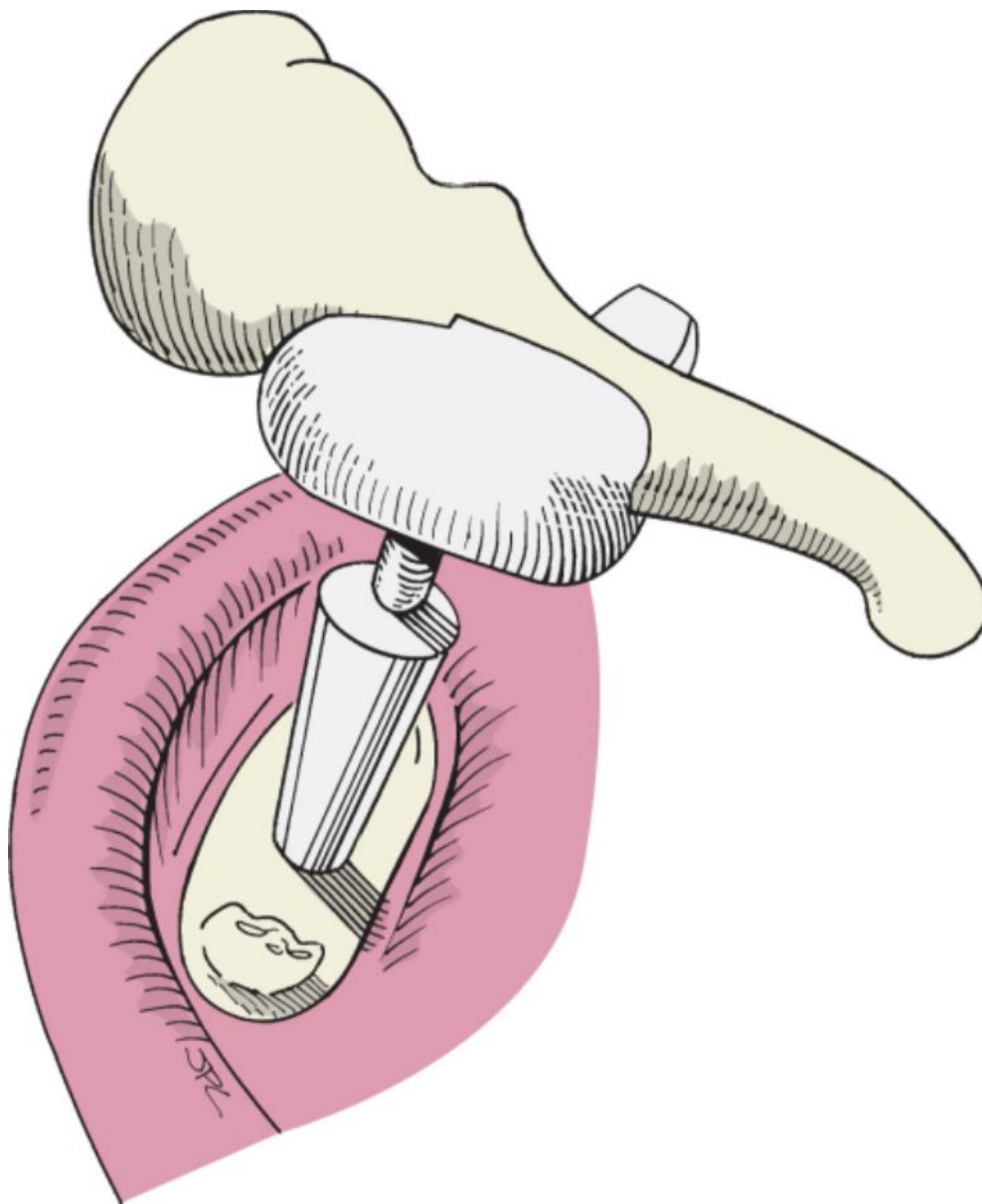
**Figure 114-19** Techniques for sculpting the incus for a type IV tympanoplasty. **A**, The short process of the incus is flattened. The long process is removed and a groove drilled for the malleus handle. **B**, The long process is flattened, and the notch for the malleus handle is on the superior surface of the incus.



**Figure 114-20** Type IV tympanoplasty with incus. **A**, The sculpted short process of the incus is placed on the stapes footplate. Note the small groove created for the chorda tympani nerve (shown in red). The malleus is lifted laterally to permit the incus to be rotated into position. **B**, The incus is secured between the footplate and the proximal malleus handle. The chorda tympani nerve provides additional support. **C**, Intraoperative photograph of a type IV tympanoplasty using the incus.

When the oval window niche is narrow and deep, a wide incus body may have to be thinned to fit between the promontory and the facial nerve. More often, a synthetic prosthesis is necessary. The principle for reconstruction is connection of the malleus to the footplate. Any columella-type prosthesis can be used. In the past, a stainless steel wire incus replacement prosthesis was fashioned from the neck of the malleus to the footplate. However, placement of this prosthesis was technically difficult and occasionally resulted in extrusion. Materials such as polytetrafluoroethylene, titanium, Polycel with wire, and prefabricated prostheses of hydroxyapatite are currently available.

We currently use either a titanium prosthesis or one with a dense hydroxyapatite dome attached to a shaft that can be trimmed easily. This is the same composition as the PORPs previously described. The TORP is secured from the stapes footplate to the malleus in a manner similar to that for a type IV tympanoplasty with an incus (Fig. 114-21). A straight strut of hydroxyapatite from the stapes footplate to the malleus neck has also been used. The length must be shortened appropriately to permit placement of this prosthesis. We have experienced problems when the shaft was made of dense hydroxyapatite. This ceramic material had a tendency to shatter or crack when the length was shortened. This problem can be remedied by holding the prosthesis firmly between one's thumb and forefinger. The shaft can then be shortened with a fine diamond burr drill and drip irrigation. The shaft of the prostheses that we currently use is a combination of hydroxyapatite and polytetrafluoroethylene (Teflon). It is readily trimmable and does not osteointegrate when there is direct contact with the promontory.



**Figure 114-21** Type IV tympanoplasty from the footplate to the malleus with an incus-stapes replacement prosthesis (total ossicular replacement prosthesis).

Titanium prostheses are available in fixed lengths or with a trimmable shaft. A sizing set is used to determine the proper length needed. The video demonstrates use of a 5-mm sizing prosthesis to verify the appropriate length

needed for the prosthesis implanted ([see Video 114-8](#) ).



Type IV tympanoplasty often requires temporary support of the prosthesis. Wet Gelfoam is placed around the shaft base up to the level of the facial nerve if the malleus handle is present. When the prosthesis is in direct contact with the tympanic membrane, as will be described,

the level of the tympanic membrane ([see Video 114-9](#) ).



### Problems with the Malleus

A relatively uncommon source of conductive hearing loss is fixation of the malleus and incus, also known as lateral chain fixation. This may entail ankylosis of the head of the malleus and body of the incus to the scutum, immobility of the incudomalleal joint, or calcification of the anterior malleus ligament restricting its movement.

A recently described technique for liberating the lateral ossicular chain addressed both the head of the malleus and the body of the incus in the epitympanum. A tympanomeatal flap is elevated beginning anterior to the malleus and extended more superiorly to provide access to the scutum. A laser was used to release the areas of bony fixation

anterior to the malleus head and the superior body of the incus. A small drill provided greater space between the ossicles and surrounding bone, and a small piece of thin Silastic sheeting was placed to prevent refixation.<sup>[10]</sup> A problem with this technique is the possibility of contacting the ossicular chain with the drill and causing sensorineural hearing loss. Exposure of the epitympanum by removal of the scutum may also result in retraction of the pars flaccida and acquired cholesteatoma.

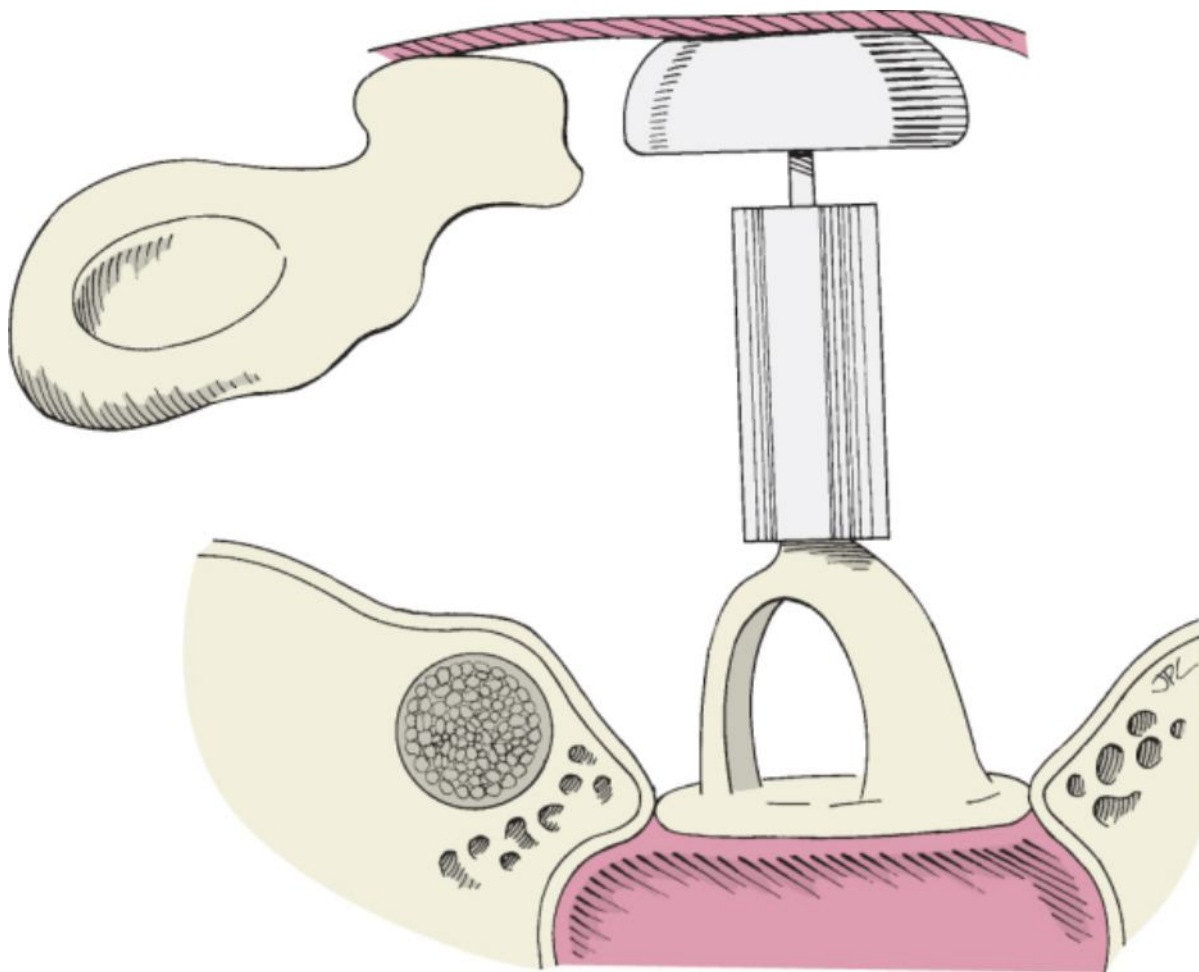
Our method for handling lateral chain fixation does not require as much exposure of the epitympanum, but the tympanomeatal flap must be designed to be superior to the pars flaccida. The flap is elevated anterior to the neck of the malleus. Palpation of the malleus confirms immobility of the lateral chain. It is necessary to separate the incudostapedial joint to ensure that limitation of movement is not being caused by otosclerosis. The joint between the malleus and incus is disarticulated with a curved pick to allow the entire incus to be removed ([see Video](#)

[114-10](#) ). 

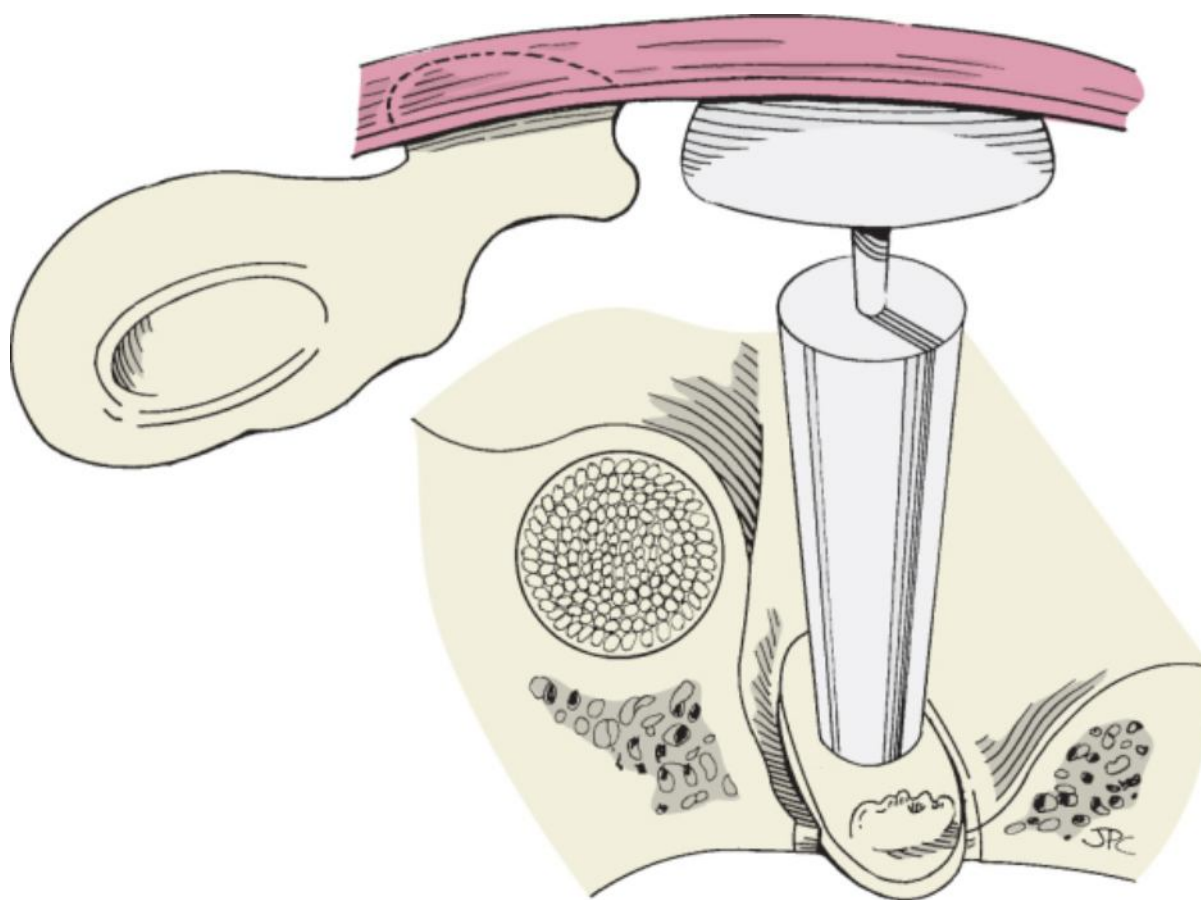
Typically, fixation of the malleus persists. A 1-mm microdrill is used to divide the head of the malleus from its handle at the neck of the malleus. Care must be taken to avoid injury to the chorda tympani nerve, which runs just medial to the neck of the malleus. This technique creates a malleus handle that is mobile and supported by its attachment to the tympanic membrane and tensor tympani tendon. At this point the incus is sculpted and interposed between the head of the stapes and the handle of the malleus.

On rare occasion, the malleus handle alone may be absent or deficient. Difficulty arises in situations in which the malleus handle is shortened and the surgeon must decide whether its length is adequate to use for reconstruction. As a general rule, shortening beyond a third of its length will probably preclude satisfactory closure of the air-bone gap. This is a more difficult decision and a problem for reconstruction. Again, an incus interposition can be performed. However, the incus should be sculpted to maintain sufficient height for connecting the stapes superstructure to the grafted tympanic membrane. Improved transmission of tympanic membrane vibration is achieved by directing the position of the short process of the incus toward the center of the membrane.

When the malleus handle is absent, we more frequently use a synthetic prosthesis. In canal wall-up procedures, the remaining malleus head can be ignored. If the stapes superstructure is present, a PORP is used (Fig. 114-22). If the stapes superstructure is absent but the footplate is present and mobile, a TORP is placed (Fig. 114-23).



**Figure 114-22** Type III tympanoplasty with a partial ossicular replacement prosthesis when the malleus is absent (stapes to the tympanic membrane or graft).



**Figure 114-23** Type IV tympanoplasty with a total ossicular replacement prosthesis when the malleus handle is absent (stapes footplate to the tympanic membrane or graft).

A unique situation arises when there is a total or near-total perforation of the tympanic membrane and all the ossicles are gone except for a mobile footplate. The options for reconstruction are grafting the tympanic membrane and placing a TORP from the footplate to the graft or placing a thick piece of Silastic sheeting (0.04 inch) in the middle ear, grafting the tympanic membrane, and staging the procedure. A problem with the first method is that the final position of the grafted tympanic membrane is not known. It may heal in a more lateral or, more likely, a more medial position. This creates potential uncertainty about how to choose the appropriate length when placing the prosthesis. The second method of staging will circumvent this problem, but the patient is committed to two procedures. Unless there is minimal disease in the middle ear and the ossicular reconstruction can achieve the appropriate connection to the grafted tympanic membrane, we opt for performing the grafting and reconstruction in two stages.

On rare occasion, the malleus handle may be fractured. Preoperative physical examination with pneumatic otoscopy can show hypermobility of the tympanic membrane and malleus. If exploration and palpation of the malleus can verify this pathologic condition, reconstruction is performed either by incus interposition or with a



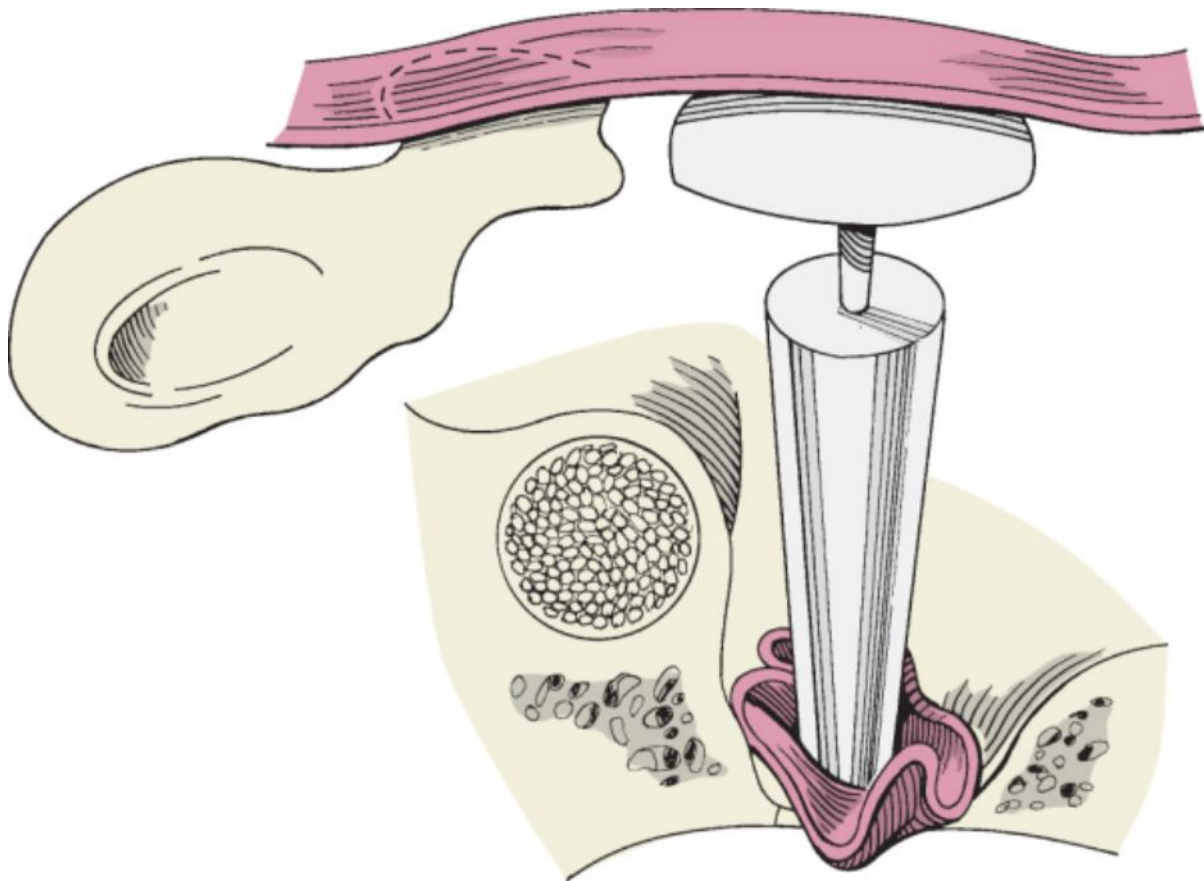
PORP (see [Video 114-11](#) ).

### Problems with the Footplate

The most common cause of stapes footplate fixation is otosclerosis. If a fixed footplate is identified while repairing a perforation of the tympanic membrane, it is best to stage the reconstruction to avoid opening the vestibule to a potentially contaminated middle ear space. The same philosophy applies to extensive tympanosclerosis of the footplate when a tympanic membrane perforation or chronic otitis media is present. Tympanosclerosis describes deposition of sclerotic plaque after recurrent acute or chronic otitis media. This brittle calcification can restrict the tympanic membrane and ossicular chain. Movement of the stapes footplate can also be restricted by

tympansclerosis, which can be confirmed by gentle palpation of the stapes while observing for a round window reflex. If the tympanic membrane is perforated, it should be repaired and the operation staged for a subsequent procedure. Healing is typically complete within 4 to 6 months, at which time the footplate can be safely addressed. There is controversy about how to best manage the stapes when it becomes fixed by this process. Options include not intervening surgically and providing amplification, performing stapes mobilization, or removing the footplate (stapedectomy) and placing a prosthesis. The concern for mobilization is based on the possibility of re-fixation of the stapes by new plaque formation. If the status of the ear disease is stable, both short- and long-term hearing results are similar, thus indicating that re-fixation is unlikely to occur after mobilization. It has also been shown when tympansclerosis affects the footplate, stapedectomy in a sterile middle ear is a safe and effective procedure.[11]

In cases of chronic otitis media with cholesteatoma, the stapes footplate may be eroded. If the vestibule is opened inadvertently or by disease, OCR is warranted at that time. It is rare to have such extensive disease yet still have an intact incus. Therefore, reconstruction is frequently done from the vestibule to the malleus, tympanic membrane, or graft (type Vb tympanoplasty). The vestibule is covered with a thin but strong graft that will support a prosthesis. The grafted tympanic membrane may heal in a more medial position when exposed to the negative pressure of the middle ear space. This puts further demand on the support needed from the oval window graft. If there is concern that the prosthesis may subluxe into the vestibule, a perichondrial graft is harvested from the posterior conchal cartilage or the tragus. Otherwise, true fascia is obtained from the temporalis muscle. The graft is air-dried, cut to approximately 3 × 4 mm, and placed over the vestibule. The shaft of the prosthesis is placed in the center of the graft and the cap or dome is positioned under the malleus handle or directly to the grafted tympanic membrane (Fig. 114-24).



**Figure 114-24** Type Vb tympanoplasty with a total ossicular replacement prosthesis. A graft covers the vestibule on which the shaft of the prosthesis is embedded. The dome of the prosthesis tents the grafted tympanic membrane. The malleus handle is absent.

## POSTOPERATIVE MANAGEMENT

The principles of care and instructions given to patients postoperatively are similar to those after tympanoplasty. Patients are instructed to keep the ear free of water and avoid blowing the nose or other forms of Valsalva maneuvers. It is also recommended that significant changes in barometric pressure, such as during an air flight, be avoided for several weeks postoperatively. Although difficult to enforce, attempts are made to minimize vigorous head movement in the postoperative period. Parents are encouraged to restrict pediatric patients from engaging in gymnastic or other excessive physical activities.



Less caution is needed for patients undergoing OCR with an intact tympanic membrane. In this situation, significantly compromised eustachian tube dysfunction is less likely to be present, so middle ear aeration is more predictable. Patients with tympanic membrane perforations more likely have compromised eustachian tube function or middle ear disease that must also be taken into consideration.

Patients with an intact tympanic membrane who are undergoing OCR have silk packing placed supported by small cotton balls or Gelfoam. The packing is removed 7 to 10 days postoperatively. If inflammation exists, topical ear drops are used for 1 week. The patient is seen again in 4 weeks for examination of the ear and audiometry testing. Patients requiring lateral graft tympanoplasty (tympanic membrane reconstruction) usually have double-silk rosebud packing in place. The outer pack is removed in 1 week and topical eardrops are prescribed. Postauricular Steri-Strips are removed from the tympanic membrane graft donor site. The second medial pack is removed 1 week later. Topical drops are continued twice daily for 2 weeks. Patients are seen a few weeks later to assess healing of the canal and tympanic membrane. When the tympanic membrane inflammation has resolved and the membrane is thin and mobile, audiometric testing is performed (see Chapter 113).

#### PEARLS

- The surgeon should be prepared to manage all reconstructive problems within the middle ear by being familiar with the various techniques for OCR should unanticipated problems arise.
- Careful palpation plus inspection of the tympanic membrane and all ossicles is critical to decide whether myringosclerosis and tympanosclerosis, separately or in combination, have caused the conductive hearing loss.
- To avoid restriction of movement, an interposed ossicle or prosthesis should not be placed so that it makes direct contact with the surrounding tympanic ring or rests on the cochlear promontory.
- Reconstruction of the tympanic membrane and ossicular chain demands a precise connection between the drum and the stapes or footplate.
- In the postoperative period, should significant retraction of a tympanic membrane cause to it drape over a prosthesis, placement of a myringotomy tube may prevent extrusion.

#### PITFALLS

- Normal mobility must be confirmed by palpation of the malleus and incus because lateral ossicular chain fixation may be missed by an inexperienced surgeon.
- Reconstruction with a partially eroded stapes (type III tympanoplasty) may not provide adequate support of a partial ossicular replacement prosthesis, and the reconstruction may need to be taken medially to the footplate.
- Excessive manipulation of the stapes when tympanosclerosis is present on the footplate may result in fracture or unanticipated removal of the stapes.
- A prosthesis will become displaced unless there is adequate tension between its medial site of contact (footplate or stapes) and the tympanic membrane or intervening cartilage.
- Excessive removal of the scutum without the support of a block of cartilage may result in retraction of the attic and cholesteatoma.

Copyright © 2009 Elsevier Inc. All rights reserved. Read our Terms and Conditions of Use and our Privacy Policy.  
For problems or suggestions concerning this service, please contact: [online.help@elsevier.com](mailto:online.help@elsevier.com)