

## Chapter 64 – Masses in the Buccal Space

Eugene N. Myers

A mass appearing within the substance of the cheek is unusual and suggests a tumor of the buccal space or the accessory lobe of the parotid gland. The buccal space is a compartment within the masticator space that was described by Kostrubala in 1945.<sup>[1]</sup> There are a number of reports of buccal space masses, and many surgical approaches have been suggested in the literature.<sup>[1–9]</sup> Lesions in the buccal space are readily apparent because they are easily palpated just beneath the buccal mucosa or the skin of the cheek.<sup>[10]</sup> Definitive diagnosis of a mass in the buccal space is made by excision of the mass and histopathologic evaluation.

Understanding the anatomy of the buccal space is necessary for proper management.<sup>[4,5]</sup> The medial wall is formed by the buccinator muscle and its overlying fascia, which extends from the mandible inferiorly to the zygomatic arch superiorly (Fig. 64-1). The deep portion of the lateral wall is formed by the muscles of facial expression (risorius, zygomaticus major, and levator labii superioris) and their fascia. More superficial to these muscles lie the superficial fascia and skin. The anterior border of the buccal space is formed by the orbicularis oris muscle. The posterior border is the anterior border of the masseter muscle and the parotid gland. Posterior to the buccal space is the parotid gland and the masticator space. The superior and inferior limits are formed as the fascia attaches to the periosteum of the zygomatic arch and mandible, respectively. Anatomic structures found in the buccal space include Stensen's duct medially, the facial artery and vein, lymphatic channels, minor salivary glands, accessory parotid lobules, and most laterally, the buccal branches of the facial nerve. These nerve branches enter the medial surface of the muscles of facial expression. Most of the buccal space is filled with adipose tissue, referred to as the buccal fat pad, and lymph nodes.

The accessory lobe of the parotid gland is an island of salivary gland tissue found anterior to and separate from the main parotid gland. Frommer demonstrated in cadaver studies that an accessory lobe of the parotid gland is found in approximately 21% of the population.<sup>[11]</sup> He described the accessory lobe as being clearly separate from the main parotid gland by an average of 6 mm, as opposed to the anterior facial process of the parotid gland, which is an anterior extension of the main gland. The accessory lobe of the parotid gland is usually located in the soft part of the cheek along Stensen's duct. The lobe drains through one or more ducts into nearby Stensen's duct and is usually closely related to the buccal and zygomatic branches of the facial nerve.<sup>[12]</sup> The normal size of an accessory lobe of the parotid gland, when present, is approximately 0.5 to 2.5 cm in diameter. One percent to 7% of all parotid neoplasms arise within the accessory lobe of the parotid gland, depending on inclusion criteria<sup>[12,13]</sup> (Table 64-1). These neoplasms are similar in histology to those found in the parotid gland, although up to 50% can be malignant, a rate higher than that in the parotid gland itself.<sup>[13]</sup> Most malignant tumors of the accessory lobe of the parotid gland are primary salivary gland cancers. However, there are a few case reports of metastases to this area from primary tumors in the head and neck or distant site.<sup>[16]</sup> We recently described a case of metastasis to the accessory lobe of the parotid gland from renal cell carcinoma (Fig. 64-2).<sup>[17]</sup>

The typical history encountered in patients with a mass in the buccal space is that of a slowly growing, painless mass in the cheek. If the mass is more deeply seated, it tends to lie more medial and the patient may be able to feel the intraoral mass with the tongue. When the mass is located in the oral cavity, patients are often seen initially by their dentist or an oral maxillofacial surgeon. Physical examination provides information that is useful in establishing a working diagnosis and usually reveals a mobile mass within the substance of the cheek that can be seen in the oral cavity and can clearly be demonstrated by bimanual palpation (Fig. 64-3). The differential diagnosis of a mass in the buccal space includes lesions originating from each of the tissue components in the space. Table 64-1 lists the lesions that have been found in the buccal space.<sup>[2–4,13,15,18–31]</sup>

Imaging studies can often provide useful information about a mass in the buccal space. The purpose of a computed tomography (CT) scan is primarily to determine the type and extent of the lesion for planning surgical treatment. This may be particularly helpful in deciding whether the mass is benign or malignant. Kurabayashi and coworkers evaluated the CT features of buccal space masses in 53 patients.<sup>[6]</sup> CT images were assessed to determine the number, location, internal architecture, and margins of lesions and their relationship to surrounding structures. Their series included 44 tumors (33 benign and 11 malignant) and 9 masses that were not tumors. Tumors of the buccal space were found adjacent to the outer surface of the buccinator muscle, in contrast to epidermoid cysts and tumors of the accessory lobe of the parotid gland, which were completely separate from it. None of the cases in their series were tumors of the accessory lobe of the parotid gland. Tumors of the accessory lobe of the parotid gland, epidermoid cysts, lipomas, and lymphoma could be differentiated from other lesions in this series. In all other cases, the CT features were nonspecific. Hemangiomas were characterized by multiple

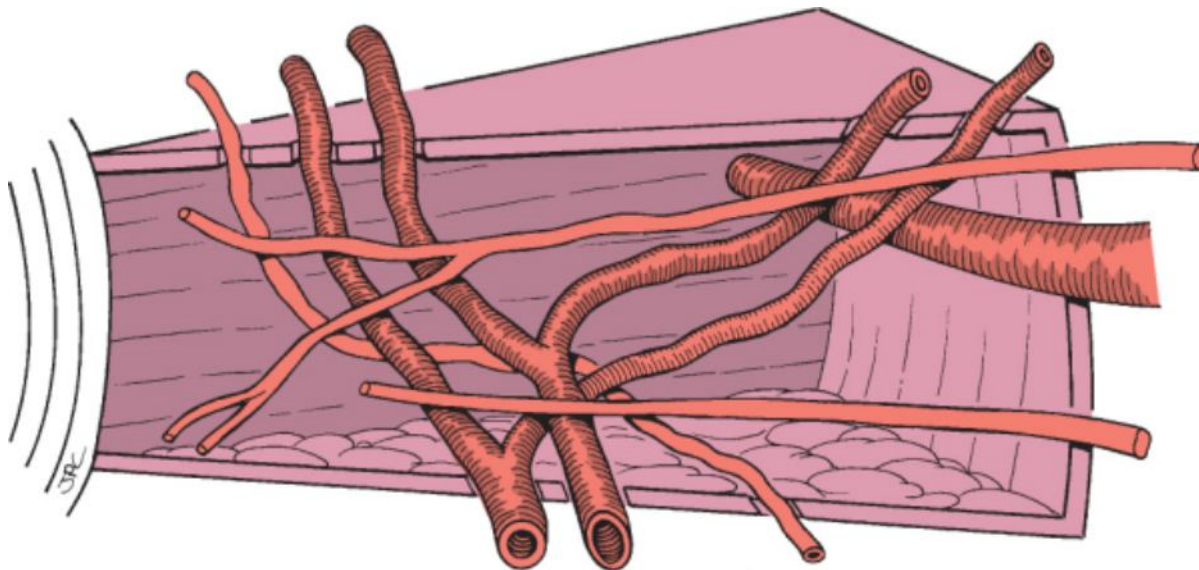
masses and the presence of phleboliths. When ill-defined margins, violation of fascial planes, and aggressive bone destruction were used as the criteria for malignancy, only seven malignant tumors were correctly diagnosed preoperatively. The authors concluded that CT was useful in demonstrating the presence and location of masses in the buccal space and sometimes in the differential diagnosis, and that the value of CT in differentiating malignant from benign buccal space lesions is limited.

Kurabayashi and colleagues also studied 30 patients with benign and malignant lesions in the buccal space with magnetic resonance imaging (MRI).[7] The authors evaluated the MRI characteristics of lesions in the buccal space and concluded that MRI was useful in demonstrating the extent of lesions in the buccal space but that its diagnostic value in predicting malignancy was very limited. This was especially true for malignant tumors of minor salivary gland origin, which were typically seen as well-defined masses without infiltration into surrounding structures on MRI.

Neoplasms of the salivary glands are uncommon and account for only 2% of all tumors. Of these, 85% are found in the parotid glands, with most of the remainder occurring in the submandibular glands. A small proportion are found in the sublingual and minor salivary glands. Tumors of minor salivary gland origin are most commonly located on the palate, with the tongue and buccal space being the next most common locations.[32]

Tumors of the minor salivary glands are more likely to be malignant (>50%) than tumors of the major salivary glands (20%). Tumors of the minor salivary glands, even when malignant, tend to progress slowly. Regardless of whether the tumor is benign or malignant, patients usually have a nontender, mobile palpable mass that has been present for 1 to 5 years. At the time of diagnosis, most tumors range from 2 to 6 cm in diameter. Patients with a malignant tumor can exhibit pain, numbness, paresthesia, or facial paralysis. These tumors rarely infiltrate into adjacent structures.[32]

Most neoplasms in the buccal space are tumors of minor salivary gland origin. Benign tumors are most often pleomorphic adenoma, monomorphic adenoma, or Warthin's tumor. Malignant tumors in the buccal space include adenocarcinoma; adenoid cystic, mucoepidermoid, acinic cell, anaplastic, and small cell carcinoma; carcinoma ex pleomorphic adenoma; polymorphous low-grade adenocarcinoma; and metastasis from other sites.[14,33,34] Other less common primary tumors include fibroma, fibrosarcoma, lipoma, lymphoma, melanoma, nerve sheath tumor, and hemangioma. For tumors other than lipoma, biopsy is necessary because no clinical or radiographic criteria are reliable in establishing a histologic diagnosis.



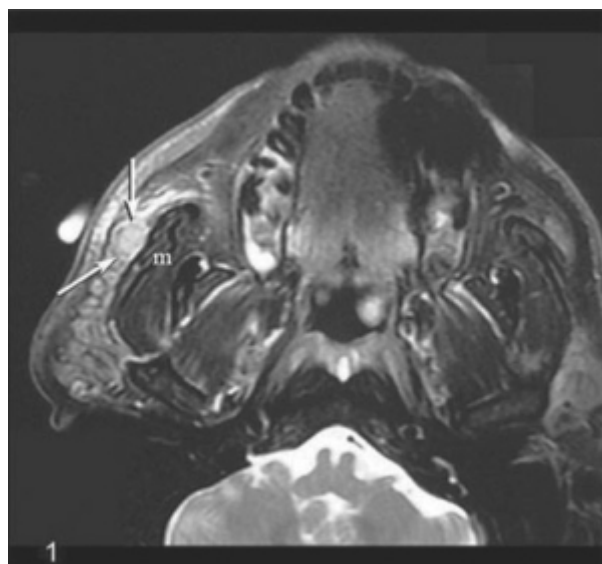
**Figure 64-1** The left buccal space and its contents.

**Table 64-1 -- REPORTED BUCCAL SPACE LESIONS**

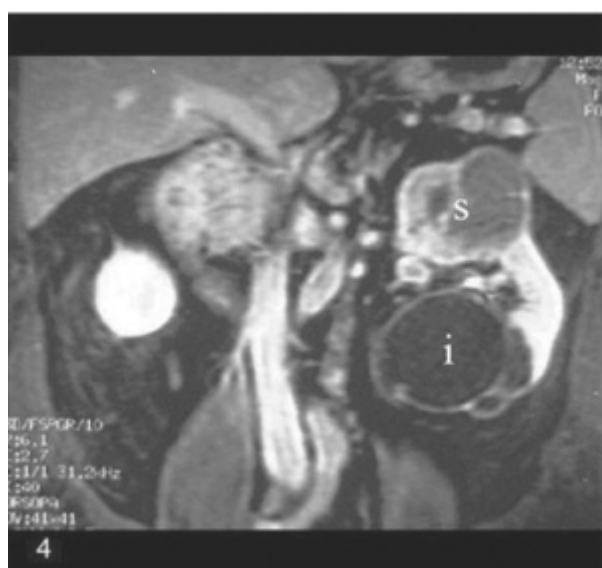
<b>Glandular</b>
Accessory parotid or aberrant salivary gland tumors
Mixed tumor (benign <sup>[*]</sup> and malignant)
Mucoepidermoid carcinoma (low and high grades)
Acinic cell carcinoma
Adenoid cystic carcinoma <sup>[7]</sup>

Carcinoma ex pleomorphic adenoma
Metastatic clear cell carcinoma
Chronic sialadenitis[*]
Oncocytoma[*]
Papillary cystadenoma lymphomatosum
Sebaceous adenoma[*]
Parotid duct tumor or calculus
Minor salivary gland calculus
<b>Lymph Node</b>
Calcified node
Benign reactive node
Lymphoma[*]
Lymphosarcoma
Metastatic nodal involvement
Lymphangioma
<b>Neural</b>
Neurofibroma
Neuroma
<b>Vascular</b>
Hyalinized thrombus[*]
False aneurysm
Hemangioma
Hemangioendothelioma
Hemangiopericytoma
<b>Connective</b>
Fibromatosis
Lipoma
Liposarcoma
Spindle cell lipoma[*]
Fibroma
Fibrosarcoma
Rhabdomyosarcoma
Nodular fasciitis[*]
<b>Muscular</b>
Myositis ossificans
Masseteric hypertrophy
<b>Inflammatory</b>
Abscess formation
Bacterial abscess
Aspergilloma
Sarcoidosis[*]
Polymorphic low-grade adenocarcinoma <sup>[14]</sup>
Tuberculous granuloma and adenoid cystic carcinoma manifested as a single buccal space mass <sup>[15]</sup>
Clear cell carcinoma metastatic from the kidney

\* Identifies the diagnoses of 10 patients treated between 1975 and 1987.

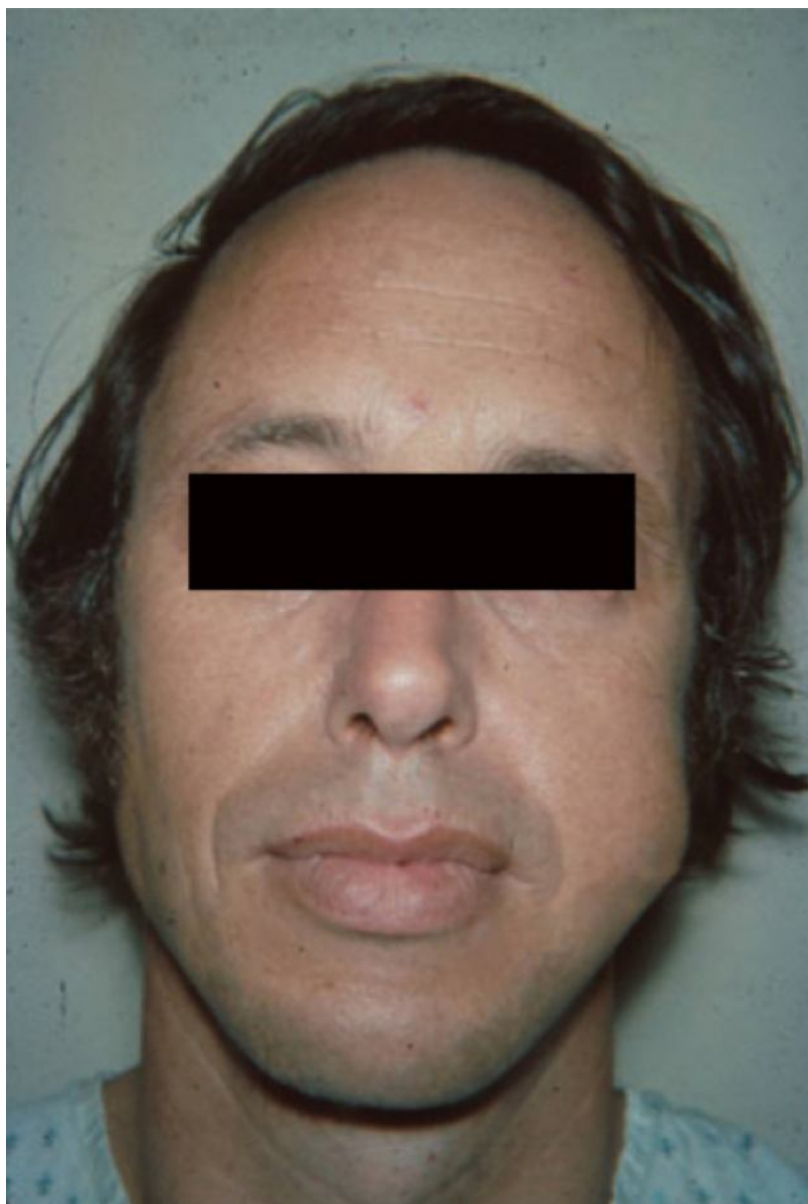

A



B

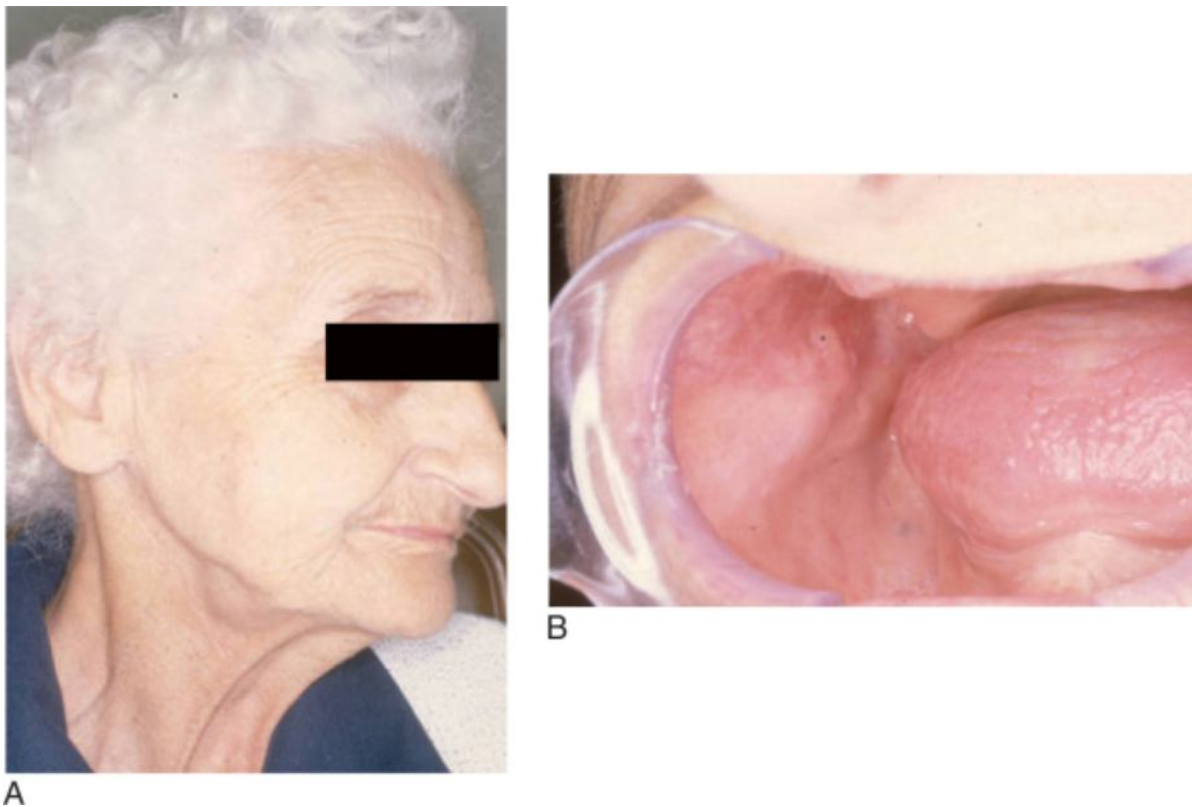
**Figure 64-2** **A**, T2-weighted axial magnetic resonance imaging (MRI) through the parotid gland demonstrating a round 10-mm mass (*arrows*) overlying the masseter muscle (*m*). The mass has a signal intensity slightly higher than the adjacent gland, but not high enough to be definitive for pleomorphic adenoma. It proved to be renal cell carcinoma metastatic to the accessory lobe. **B**, Sagittal post-contrast-enhanced spoiled-gradient MRI of the abdomen with T1 weighting shows two distinct masses in the left kidney. The superior mass (*s*) has cystic and solid components. The inferior mass (*i*) is predominantly cystic and has extensive septations. This renal cell carcinoma was the primary tumor.



**Figure 64-3** Preoperative frontal view illustrating swelling in the cheek.

### ***SURGICAL APPROACHES***

Several surgical approaches to the buccal space have been described. The approach used most commonly is a direct transmucosal intraoral incision with dissection and removal of the mass. This approach is appealing, because the bulging of the tumor into the intraoral area appears to lend itself to easy excision and of course eliminates a skin incision with its inevitable scar (Fig. 64-4). Despite this apparent advantage, the intraoral approach may not provide adequate exposure. While removing these tumors through the external approach I have observed that the buccal branches of the facial nerve are always closely associated with or actually incorporated into the capsule on the *lateral* aspect of the tumor, which cannot be visualized through the intraoral approach. Stensen's duct is also closely associated with these tumors. Without proper exposure, these vital structures are at risk for injury, which could produce facial paralysis and sialocele. Although the direct transcutaneous approach is also appealing because of the apparent advantage of requiring less time and dissection and no need to raise skin flaps, thereby avoiding the possibility of flap necrosis, it is not recommended, however, because of the highly visible scar. This approach also makes it difficult to use local tissue to fill in the depressed area left by removal of the tumor.



**Figure 64-4** A, External view of a right buccal space mass. B, Internal view. Note the intraoral bulge produced by the mass.

### Preoperative Planning

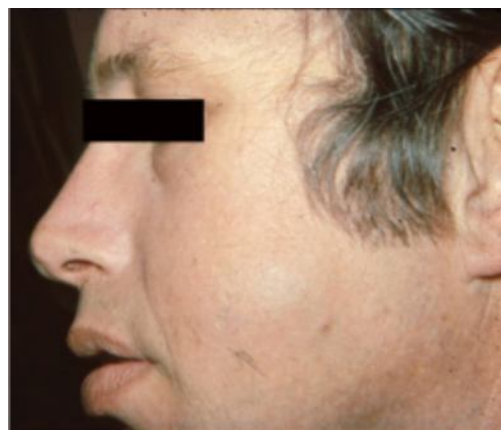
The history, physical characteristics of the mass, and select imaging studies may suggest a specific diagnosis. Fine-needle aspiration biopsy may be used to obtain information for planning treatment while recognizing that this procedure poses a potential risk to the facial nerve. Such injury, however, is often elusive, and removal of the mass is required for histologic evaluation.

I designed the extended parotid-submandibular incision for removal of tumors in the buccal space because it provides excellent exposure and minimizes the risk of complications such as injury to Stensen's duct or the facial nerve during excision of these tumors.<sup>[4,5]</sup> I have found that this technique also provides an excellent cosmetic result. Patients are counseled that the buccal branch of the facial nerve will be dissected and elevated off the tumor and is therefore vulnerable to intraoperative injury and postoperative weakness as a result of dissection and stretching of the nerve. I have also successfully used the rhytidectomy approach for removal of these tumors. Use of this technique for tumors of the buccal space has been very well described by Madorsky and Allison.<sup>[6]</sup> These two techniques will now be described.

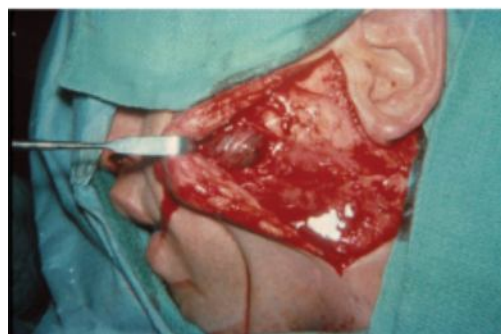
### Surgical Technique

#### *Extended Parotid-Submandibular Incision*

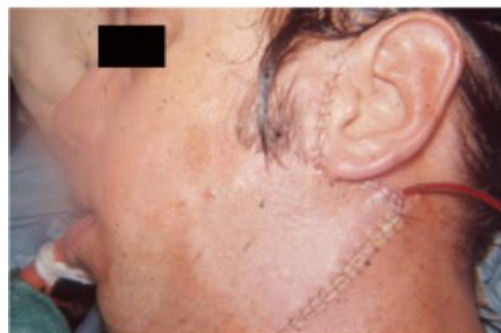The incision is a modification of the standard parotidectomy incision (Fig. 64-5). Extension of the preauricular incision somewhat superiorly and extension of the cervical incision into a submandibular space skin crease allow wide undermining of the flap, which is necessary to gain exposure anterior to the parotid gland for visualization of the tumor. It is not necessary to carry out a formal parotidectomy or to identify the facial nerve at the stylomastoid foramen, because the tumor is anterior to the anterior border of the parotid gland and therefore only the buccal branches of the nerve are anatomically associated with these tumors.



A



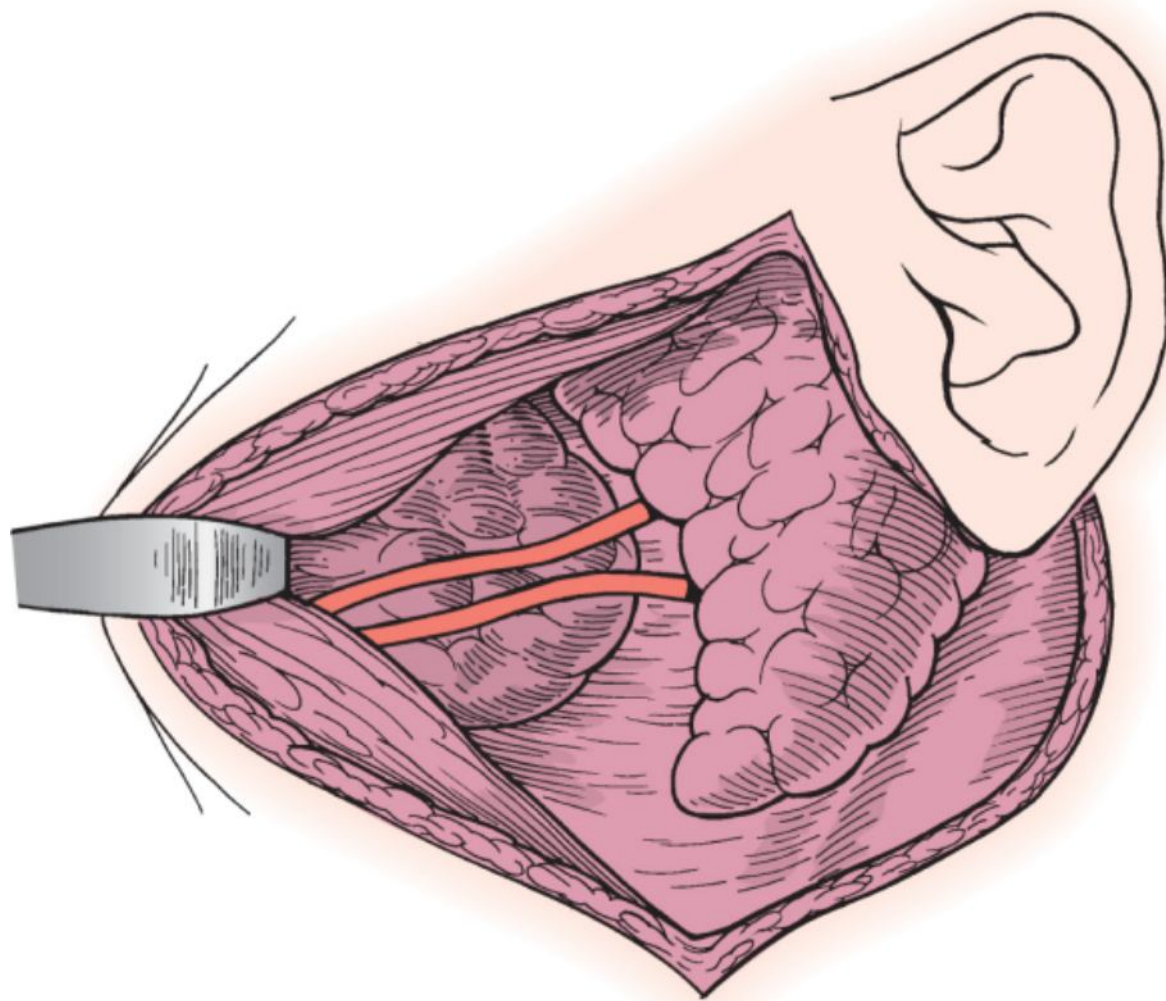
B



C

**Figure 64-5** A, Lateral view of a mass in the buccal space. B, Surgical exposure of the mass. C, Surgical closure over closed-suction drains.

The skin flap is elevated anterior to the anterior border of the parotid gland where the mass is encountered. Further elevation of the flap provides exposure of the entire mass. The location of the buccal branches of the facial nerve is easily identified, usually during blunt dissection of the mass, and confirmed with a facial nerve stimulator (Fig. 64-6). Stensen's duct is usually also identified during this phase of the dissection. Dissection of the branches of the nerves somewhat anterior and posterior to the mass itself will allow undermining and mobilization of the nerve. A small nerve retractor is then used to retract the branches of the nerve away from the mass. Once dissected, the nerves may be marked with arterial loops. The mass itself is then removed by sharp and blunt dissection. After removal of the mass, the nerves are returned to their normal anatomic position. Removal of the tumor leaves a noticeable defect in the facial contour that is eliminated by approximating the superficial musculoaponeurotic system (SMAS).



**Figure 64-6** Surgical exposure of a buccal space tumor demonstrating the facial nerve branches adherent to the lateral aspect of the mass.

Hemostasis is obtained, the wound is irrigated, and a Hemovac drain is inserted under the skin flap and brought out through a separate stab wound posterior to the incision. The skin flap is closed with subcutaneous chromic catgut suture and then continuous closure with 6-0 plain catgut suture. Steri-Strips and a pressure dressing are applied. The patient is allowed to recover from anesthesia. Within 24 hours the drainage has usually stopped, the pressure dressing and drain are removed, and the patient is discharged.

### *Rhytidectomy Approach*

Mitz and Peyronie in 1976 described the rhytidectomy approach and how this technique allows reconstruction of the contour defect associated with tumor extirpation by SMAS interposition.<sup>[9]</sup> They used this technique in five patients: two tumors of the accessory lobe of the parotid gland, one parotid cyst, one case of nodular fasciitis of the anterior masseter muscle, and one lymphoma.

The incision used in these cases is the one used for rhytidectomy. The incision begins at the temple and continues in a preauricular crease and then post-tragally. The incision is carried inferior to the ear lobe, up to the level of the posterior auricularis muscle posteriorly, and posteriorly into the hairline. The skin is undermined anterior to the tumor, mobilized, and retracted away from the tumor. The tumor is then excised as described earlier. After removal of the tumor, the SMAS is closed directly to give sufficient support to the cheek to avoid deformity. Rotation of a flap of SMAS has been recommended for defects that are too large for direct closure or advancement closure. This technique distributes the volume defect over a wider area and converts the depression to a gradual transition that is less noticeable.

Madorsky and Allison relied on their extensive experience with the rhytidectomy approach in managing 126 patients who had a tumor of the parotid gland and adjacent structures.<sup>[8]</sup> They described the relationship of the SMAS as being superficial to the facial nerve. If too much tension is placed on the SMAS closure, the SMAS is mobilized by dissecting the facial nerve branches underlying it and advancing it for closure.



## POSTOPERATIVE MANAGEMENT

The only complication that I have encountered in my series is a hematoma in a patient who had histiocytic lymphoma. It is unclear why the hematoma occurred, but I assume that it was due to inadequate hemostasis rather than the underlying disease. Injury to the facial nerve is avoided by early identification of the nerve and gentle retraction and dissection.

Care must be taken when undermining the superior aspect of the flap because the zygomatic branch of the upper division of the facial nerve is superficial in this area and the branch could be injured with resultant facial nerve paralysis.

## COMPLICATIONS

Complications are minimized with this procedure, which is exactly why I use it systematically for tumors in this space. The experience of caring for a patient who had a mass previously removed through an incision in the buccal mucosa, during which an injury to the facial nerve was sustained and a sialocele developed in the buccal space because of inadvertent injury to Stensen's duct, was the incentive to design the extended parotid-submandibular incision. The need to identify Stensen's duct and the branches of the facial nerve are the fundamental advantages of the transcutaneous approach. The general principles of surgery are never better demonstrated than in this procedure, which include (1) adequate exposure, (2) potential to extend the surgery should it be necessary, and (3) an acceptable cosmetic result.

### PEARLS

- Evaluate the patient with fine-needle aspiration biopsy and imaging before surgery to enhance planning for the surgical procedure and patient counseling.
- Evaluate the patient's needs regarding cosmetic appearance. The modified parotid incision leaves a visible scar, so for a female patient, a rhytidectomy approach should be used, whereas the incision in a male patient is usually hidden in the beard line and is acceptable.
- Undermine in the plane between the subcutaneous tissue and the SMAS.
- Begin to look for divisions of the buccal branch of the facial nerve once the soft tissues have been undermined as far as the anterior border of the parotid gland.
- Identify the branches of the facial nerve with the nerve stimulator and dissect them off the tumor.
- Retract the branches of the nerve away from the tumor to excise it without nerve injury.
- Closing the SMAS either primarily or with a flap will prevent an unsightly depression in the cheek.

### PITFALLS

- Failure to select the proper incision based on the patient's perceived needs can leave visible scars.
- Failure to identify and preserve the important structures contained in the buccal space, especially the facial nerve, can lead to complications.
- Failure to close the SMAS properly will result in an unsightly depression in the cheek.

Copyright © 2009 Elsevier Inc. All rights reserved. Read our Terms and Conditions of Use and our Privacy Policy.  
For problems or suggestions concerning this service, please contact: [online.help@elsevier.com](mailto:online.help@elsevier.com)