

## Chapter 69 – Laryngotracheal Separation

### Eugene N. Myers

The three major functions of the larynx include airway protection, airway maintenance, and phonation. When airway protection is compromised to the extent of intractable aspiration, patients can no longer nourish themselves by oral alimentation and are also subject to recurrent and potentially fatal aspiration pneumonia.

Chronic aspiration can result from any condition that affects the ability of the larynx to perform one of its primary functions, that of airway protection.<sup>[1]</sup> Patients at risk for chronic aspiration and aspiration pneumonia include those with (1) chronic debilitating central nervous system disease, including stroke; (2) esophageal dysfunction<sup>[2]</sup>; (3) myopathies<sup>[2]</sup>; and (4) advanced cancer of the larynx and oropharynx in patients who require combined therapy.<sup>[1]</sup>

Takamizawa and coauthors<sup>[3]</sup> reported a series of 11 children ranging in age from 3 months to 16 years who had intractable aspiration pneumonia. These patients all had chronic, severe neurologic disorders. None of the patients had verbal communication. Yamana and coworkers<sup>[4]</sup> reported a series of nine patients with intractable aspiration pneumonia. The patients ranged in age from 4 to 71 years. A tracheostomy was previously placed in six patients; however, the use of a cuffed tracheostomy tube did not prevent aspiration. Three of these patients also had severe gastroesophageal reflux disorder.

Broniatowski and associates<sup>[5]</sup> pointed out that an estimated 500,000 patients per year in the United States are affected by stroke-related dysphagia. Approximately half of these patients experience aspiration that can lead to pneumonia and death. Aspiration may result from many factors, including late transport of the bolus, faulty laryngeal elevation, and poor coordination or inappropriate timing of vocal cord closure.

Most patients with intractable aspiration will have already had a tracheostomy. Many of the patients will respond to conservative measures such as dietary modification, postural changes, compensatory maneuvers, and the use of prosthetic devices.<sup>[1]</sup>

When conservative measures fail to control the aspiration or when the aspiration pneumonia becomes intractable, adjunctive surgical procedures may be used, including<sup>[6]</sup>

- Tracheostomy
- Cricopharyngeal myotomy
- Gastrostomy
- Jejunostomy
- Injection of the vocal cords
- Thyroplasty for vocal cord medialization

Unfortunately, these adjunctive procedures will not usually be sufficient to prevent intractable aspiration pneumonia.

Multiple laryngeal closure procedures have been described with varying degrees of success<sup>[6]</sup>:

- Laryngeal stenting
- Supraglottic closure
- Glottic closure
- Tracheoesophageal diversion—Lindeman's procedure
- Laryngotracheal separation
- Laryngectomy

The laryngeal diversion technique (LDT) was first described by Lindeman in 1975 (Fig. 69-1).<sup>[7]</sup> Modifications of this technique led to development of the laryngotracheal separation (LTS) technique.<sup>[8,9]</sup>

Snyderman and Johnson<sup>[10]</sup> described the characteristics that they believed to be ideal for the surgical treatment of chronic aspiration:

- Simplicity
- Low morbidity
- Effectiveness

- Reliability
- Preservation of vocal and swallowing function
- Reversibility

LTS meets all these criteria except for preservation of vocal function. LTS is usually favored over LDT because of ease of performance. The condition of patients with intractable aspiration pneumonia is usually poor. LTS requires less time to perform because tracheoesophageal diversion is not necessary. It is also possible to perform LTS under local anesthesia, which is a significant advantage for patients with impaired respiratory function.<sup>[4]</sup>

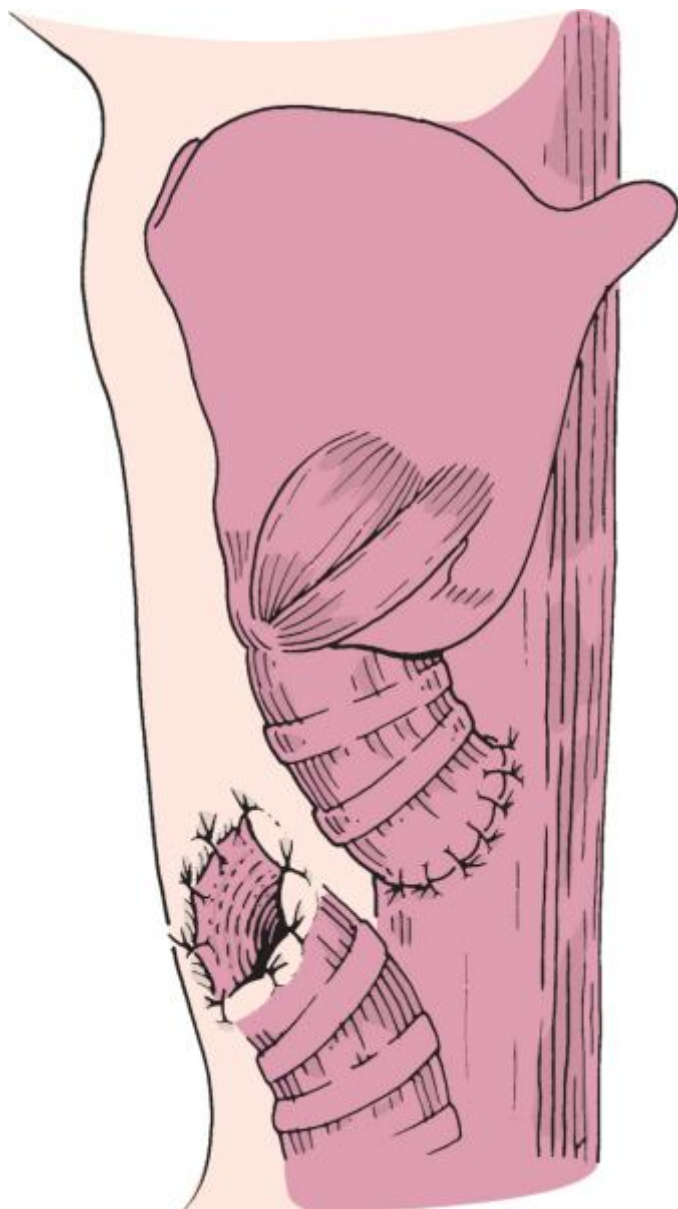
Eibling and associates<sup>[11]</sup> endorsed the success of LTS. More recently, Takamizawa and coauthors<sup>[3]</sup> carried out LTS in a series of 11 children with severe neurologic disorders. LTS decreased the frequency of performing suction from an average of once every 30 minutes to once every 4.5 hours in all patients. Pneumonia was eliminated completely in 10 of 11 patients. The remaining patient only had one episode of pneumonia postoperatively. Two of the patients who were not able to eat before LTS could eat table food postoperatively. Yamana and colleagues<sup>[4]</sup> reported a series of 9 patients with intractable aspiration pneumonia who underwent LTS. None of the patients had aspiration pneumonia postoperatively.

I recently performed LTS successfully in an elderly woman with complete oropharyngeal stenosis as a result of attempting suicide by the ingestion of a caustic substance. The patient had chronic aspiration pneumonia before LTS, but no aspiration or pneumonia occurred after LTS.

Broniatowski and coworkers<sup>[5]</sup> reported their experience with “dynamic laryngotracheal closure” for aspiration. They studied two stroke patients with chronic aspiration diagnosed on modified barium swallow. They used a device (Huntington Medical Research Institute Bipolar Helical Electrodes) linked to a NeuroControl Implantable Receiver-Stimulator on the left recurrent laryngeal nerve. The device was successfully triggered intraoperatively and postoperatively, which demonstrated that aspiration is systematically arrested with low levels of electrical stimulation. This pioneering work has shown that aspiration can be controlled without airway damage in a wide population of neurologically impaired patients because it is more physiologic than surgical treatment.

Unfortunately, both LTS and LDT disconnect the vocal cords from their pulmonary power source.<sup>[1]</sup> Therefore, patients and their surgeons often have to make the difficult decision of oral nutrition versus the pulmonary power source. Usually, the decision is based on the life-threatening reality of death from intractable aspiration pneumonia.

Darrow and colleagues<sup>[12]</sup> performed tracheoesophageal puncture after LTS in a select group of patients. Apparently, they had success in this group of patients, who then continued to not aspirate and were able to phonate. Lombard and Carrault<sup>[1]</sup> in 2001 described a tracheotracheal puncture. This technique followed LTS and had the advantage of protection against aspiration and yet allowed laryngeal communication.



**Figure 69-1** Lindeman's procedure. The proximal trachea is diverted into the esophagus.

(From Eibling DE, Bacon GW, Snyderman CH: *Surgical management of chronic aspiration*. *Adv Otolaryngol Head Neck Surg* 6:107, 1992.)

## PATIENT SELECTION

Recurrent aspiration pneumonia, which can be fatal, may develop in patients with central nervous system disorders or structural abnormalities of the oral cavity or oropharynx. Management of these patients with intractable aspiration is difficult, partly because of the wide variety of manifestations, underlying illnesses, and levels of residual pharyngeal function (Table 69-1). A wide assortment of useful therapeutic modalities, both surgical and nonsurgical, are feasible (Tables 69-2 and 69-3). When conservative treatment of chronic aspiration fails, surgery is indicated. The surgery must be designed to eliminate communication between the pharynx and larynx.

**Table 69-1 -- PATHOLOGIC STATES ASSOCIATED WITH ASPIRATION**

Surgical
Skull base
Head and neck
Thyroid carcinoma
Supraglottic laryngectomy
Major oropharyngeal resection
Carotid endarterectomy

Anterior spinal fusion
<b>Reduced Consciousness</b>
Alcohol or sedative drug overdose
Head injury
General anesthesia
<b>Gastrointestinal Disease</b>
Zenker's diverticulum
Esophageal neoplasm
<b>Neurologic and Neuromuscular Disease</b>
Cerebrovascular accident
Intracranial tumors
Amyotrophic lateral sclerosis
Parkinson's disease
Myasthenia gravis
Polymyositis/dermatomyositis
Guillain-Barré syndrome
Dystonia/tardive dyskinesia
Vocal cord paralysis
Progressive muscular dystrophy
Meningitis

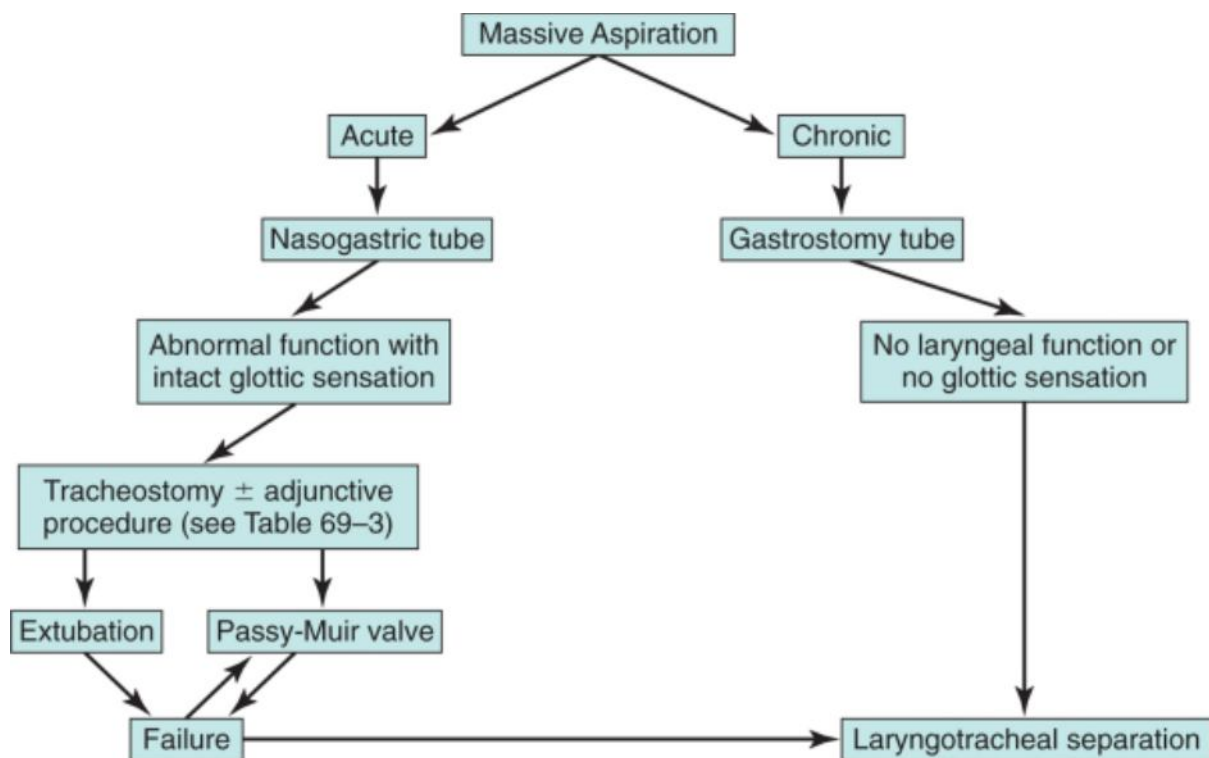
**Table 69-2 -- NONSURGICAL TREATMENT OF ASPIRATION**

Nothing by mouth
Nasoenteric feeding or gastrostomy
Swallowing therapy
Postural feeding technique

**Table 69-3 -- SURGICAL TREATMENT OF ASPIRATION**

<b>Adjunctive Procedures</b>
Tracheostomy
Cricopharyngeal myotomy
Gastrostomy/feeding jejunostomy
Thyroplasty for vocal cord medialization
<b>Definitive Procedures</b>
Laryngeal stenting
Supraglottic closure
Glottic closure
Tracheoesophageal diversion——Lindeman's procedure
Laryngotracheal separation
Laryngectomy

Patients who are candidates for LTS have either acute or chronic aspiration that does not permit oral alimentation and may also produce life-threatening aspiration pneumonia. The decision to perform LTS is complex because of the anxiety produced by contemplating the loss of voice. After successful LTS patients may regain their ability to swallow without aspiration. Some of the developments listed earlier, such as dynamic laryngotracheal closure and tracheotracheal puncture, may be able to allow patients not only to swallow without aspiration but also to phonate. However, patients should be counseled that such treatment is impossible in some cases, particularly in patients who are relatively alert or who may have had an acute exacerbation of laryngeal dysfunction and aspiration and may be expected to recover, such as a patient whom we treated some years ago who had an exacerbation of her multiple sclerosis with severe aspiration. The patient was treated by LTS when tracheostomy failed to control the aspiration. She went into remission and was able to have the LTS taken down and a tracheal anastomosis carried out. A useful algorithm is presented in Figure 69-2.



**Figure 69-2** Algorithm for the evaluation and management of the aspirating patient.

(From Snyderman CH, Johnson JT, Eibling DE: *Laryngotracheal diversion and separation in the treatment of massive aspiration*. *Curr Opin Otolaryngol Head Neck Surg* 2:66, 1994.)

## PREOPERATIVE PLANNING

Ideally, LTS should be performed before a tracheostomy. Unfortunately, this is not usually feasible because the underlying aspiration or associated neuromuscular process has already led to the performance of a tracheostomy. Moreover, the severity of aspiration and its role in the disease process are often not suspected until after tracheostomy, when copious tracheal secretions become obvious. LTS after tracheostomy is technically more difficult and results in the creation of a shorter proximal stump. This will make reconstruction, if clinically indicated later, technically more difficult.

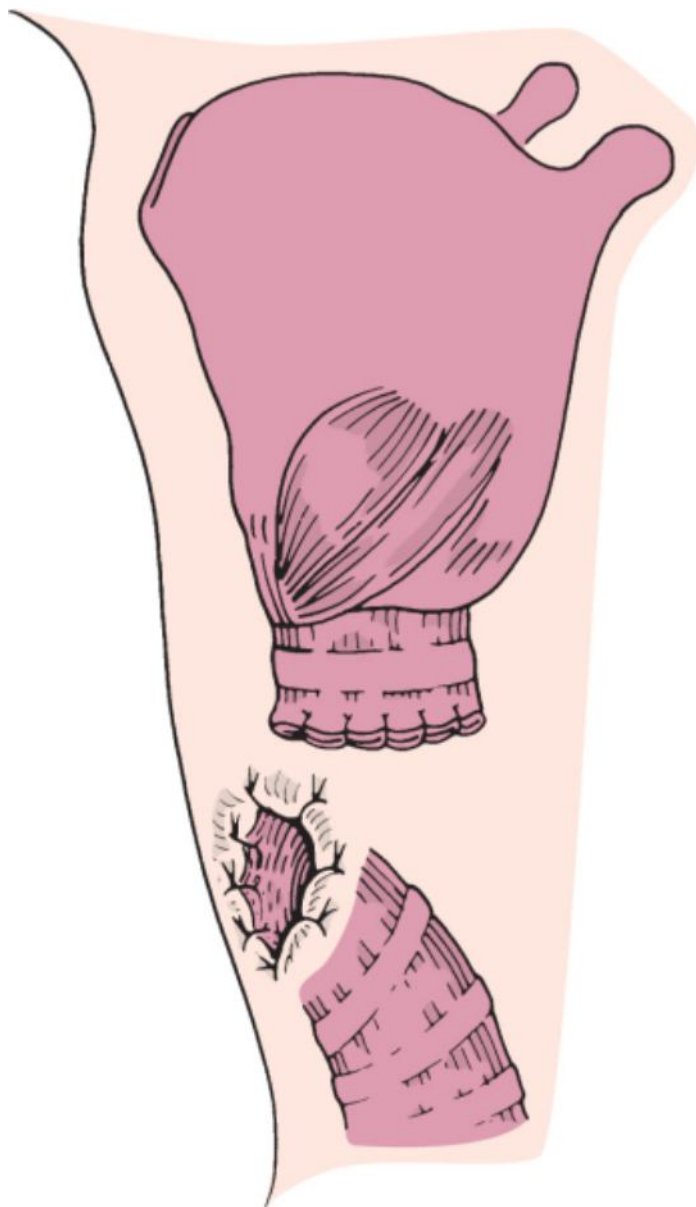
Antibiotics are administered perioperatively, although patients are usually ill and normally in an intensive care unit. Generally, they have been given multiple antibiotics and are frequently colonized by multiple organisms. As a result, the efficacy of perioperative antibiotics is open to question. During family counseling it is important to not make too many promises regarding the ability of the patient to swallow after the procedure. Less than half the patients in the University of Pittsburgh series<sup>[11]</sup> were able to subsist without enteral feeding after LTS. Moreover, the family and patient must understand that there is nearly a one in three risk of a fistula developing from the proximal stump.<sup>[13]</sup>

## PROCEDURE

The patient is positioned and draped as for a tracheostomy. If a tracheostomy has previously been performed, the incision is widened laterally, and the previous tracheostomy scar and granulation tissue are excised from the skin down to the level of the trachea. Patients who have not undergone tracheostomy previously are approached as they would be for a routine tracheostomy—via a horizontal incision with dissection through subcutaneous tissue and splitting of the strap muscles to expose the trachea. Division of the thyroid isthmus may also be necessary to gain adequate exposure for closure of the proximal stump of the trachea in patients who have previously undergone tracheostomy.

The location for the separation is identified at the site of the previous tracheostomy or at the interspace of the third or fourth tracheal ring. In older patients with an increased anteroposterior dimension of the chest, the larynx may be located more inferiorly and be resistant to retraction superiorly. In these patients the trachea may need to be divided more superiorly, at the second interspace. The higher levels of tracheal division may make the procedure easier; however, the short stump dramatically increases the difficulty of reanastomosis if attempted later. In most patients who have previously undergone tracheostomy, the proximal trachea will usually consist of only one or two rings above the level of the stoma.

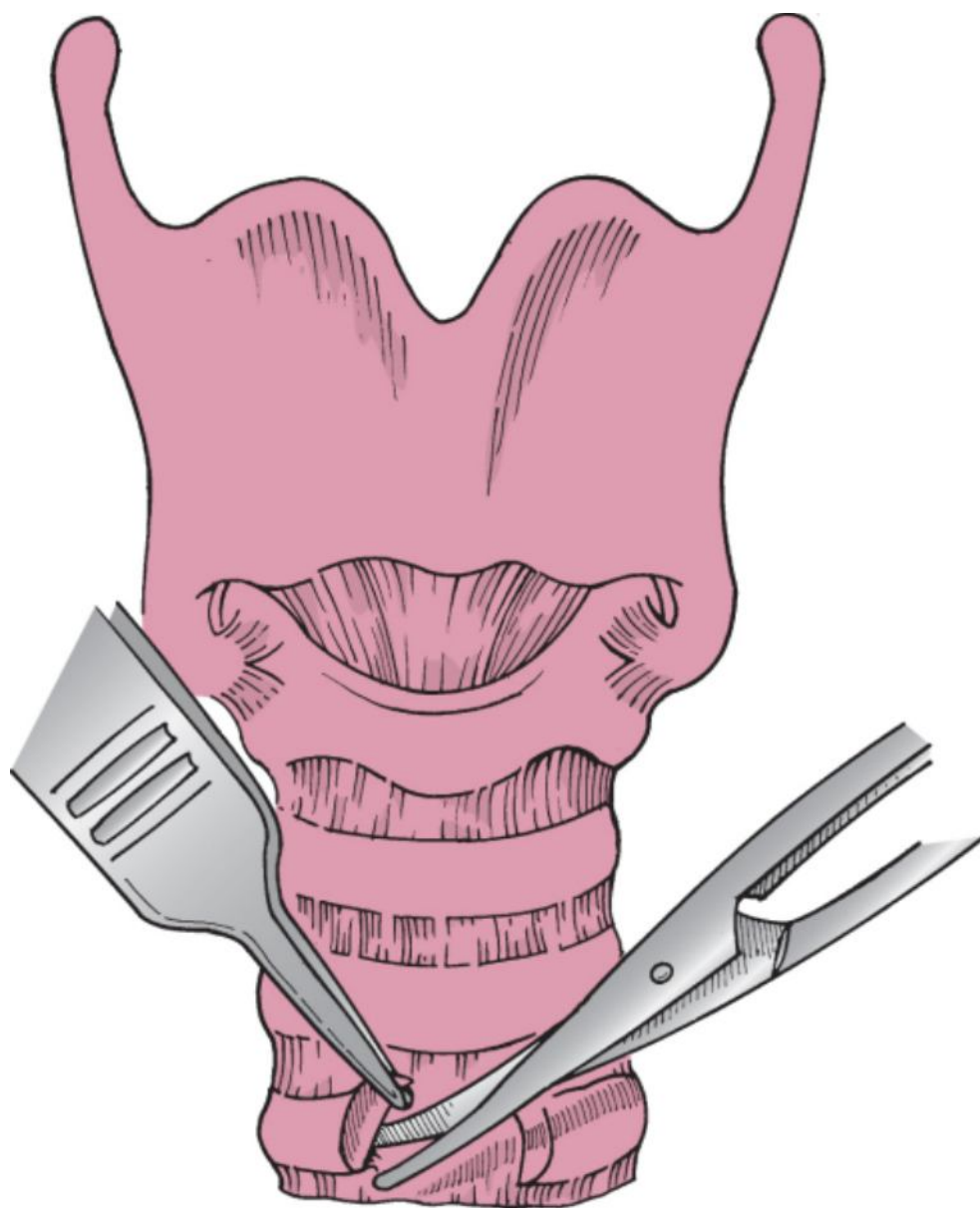
When the trachea has been identified, dissection is carried laterally around the trachea at the site of the stoma. If the patient does not have an indwelling tracheostomy, an endotracheal tube must be passed through the wound into the distal trachea for ventilation throughout the remainder of the procedure. The trachea is then transected, with care taken to maintain the dissection next to the wall of the trachea to avoid injury to the recurrent laryngeal nerves. The posterior wall is then transected with care taken to not enter the esophagus. This can be performed by either bluntly dissecting posterior to the trachea or continuing the incisions through the lateral walls bilaterally and across the posterior wall until they meet. Care should be taken to maintain this line of transection in a straight transverse plane to avoid tapering superiorly such that closure of the proximal stump becomes problematic (Fig. 69-3).



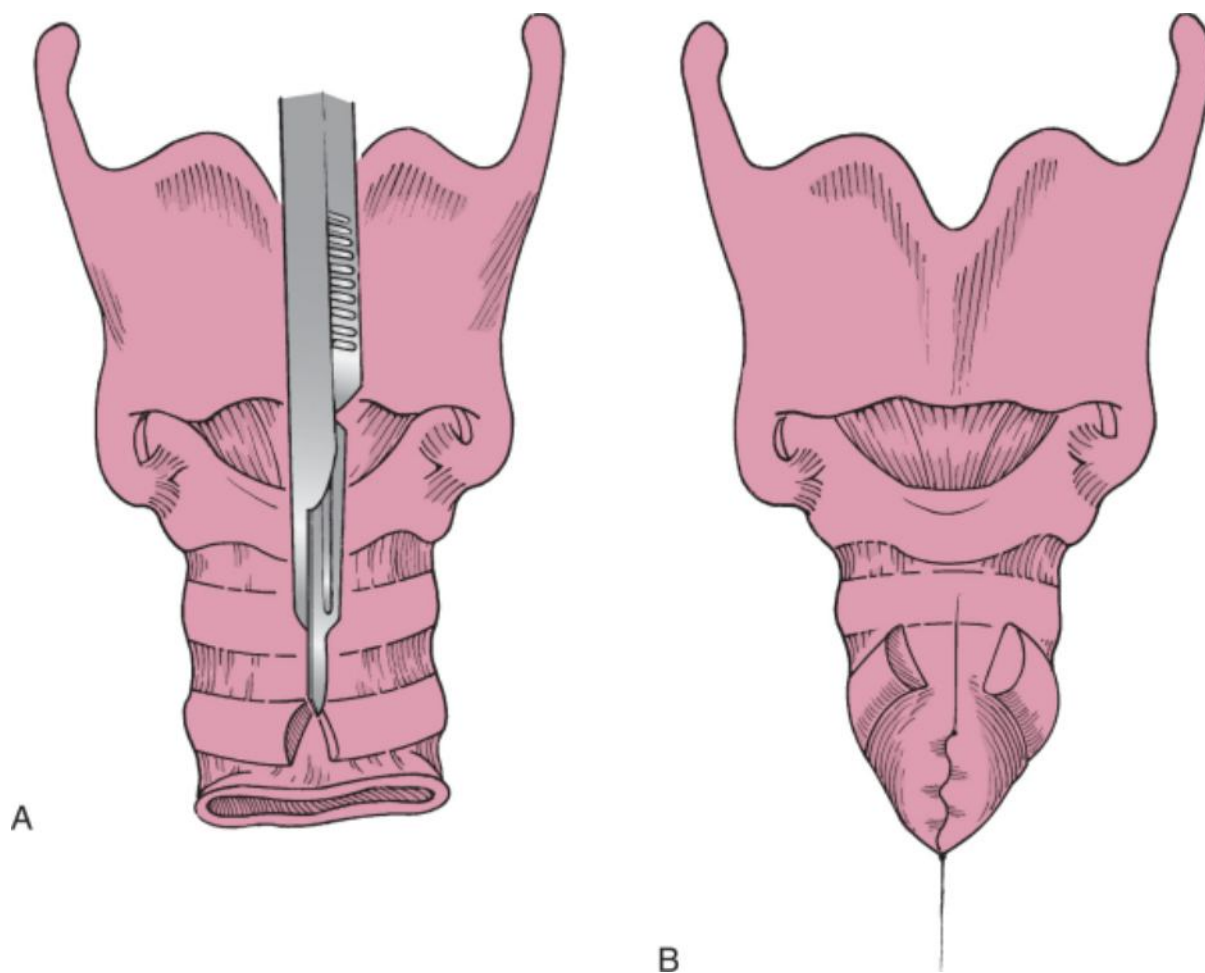
**Figure 69-3** Laryngotracheal separation. The proximal trachea is closed as a blind pouch.

(From Eibling DE, Bacon GW, Snyderman CH: *Surgical management of chronic aspiration. Adv Otolaryngol Head Neck Surg* 6:108, 1992.)

Once the trachea has been divided, it is dissected free in both a superior and an inferior direction. Care should be taken to avoid extending the dissection too far into the soft tissues laterally to prevent recurrent laryngeal nerve injury. An incision is made in the fascia to expose the inferior-most ring in the upper stump. The ring is then dissected free with a small periosteal elevator. Care should be taken to avoid injury to the underlying mucosa. Removing this ring frees the internal mucoperichondrium and permits mucosal closure (Fig. 69-4). So that collapse of the upper stump is fully accomplished, the second to the last ring (usually the first or second tracheal ring) is divided anteriorly to allow the ring to collapse on itself and reduce tension on the mucosal closure (Fig. 69-5).



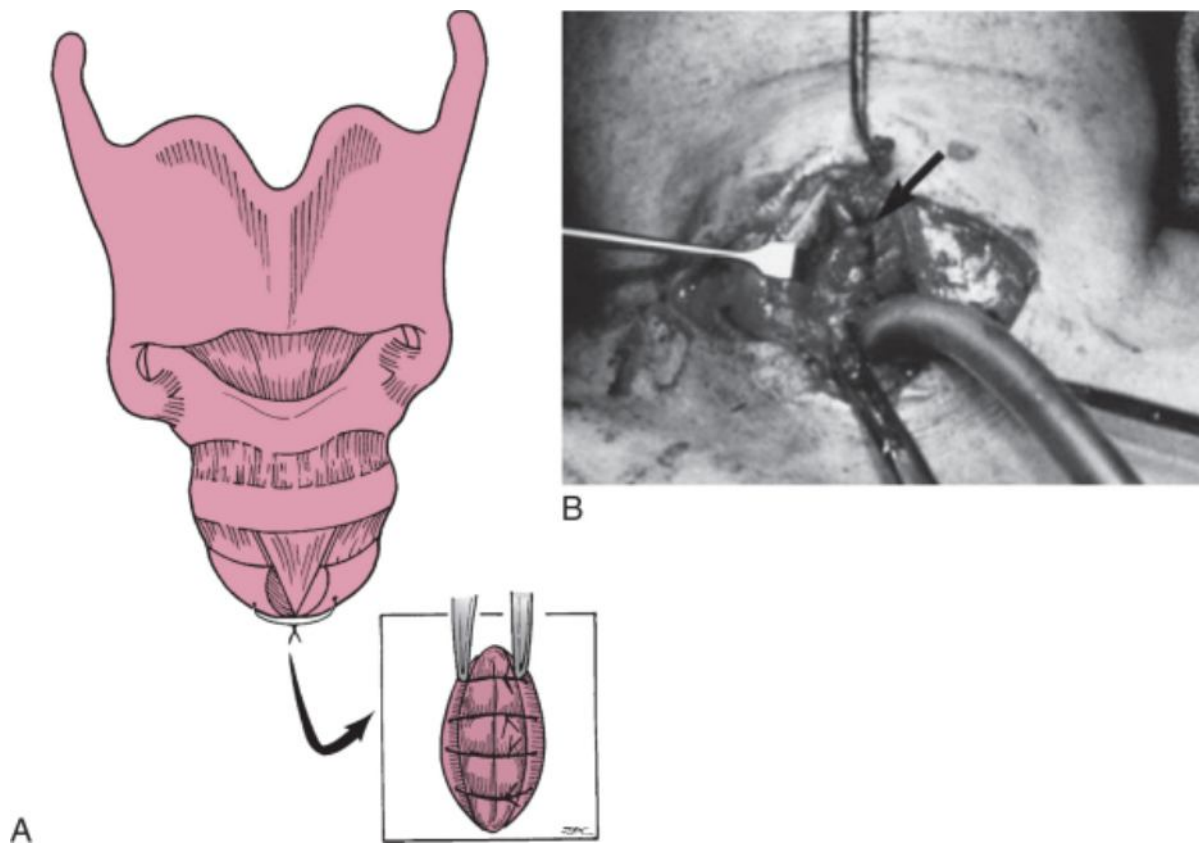
**Figure 69-4** After the trachea is divided, a ring is removed by dissecting the cartilage away from the mucosa. This provides mucosa for closure.



**Figure 69-5** Stump closure. The next ring above is then divided (A), and the mucosa is closed in watertight fashion with inverting continuous suture (B).

The mucosa is then closed in a running inverting fashion similar to a pharyngeal closure (see Fig. 69-5). The mucosal closure is reinforced by additional interrupted sutures placed through the remaining, but divided tracheal ring. This effectively reinforces the closure and helps prevent postoperative leaks (Fig. 69-6).

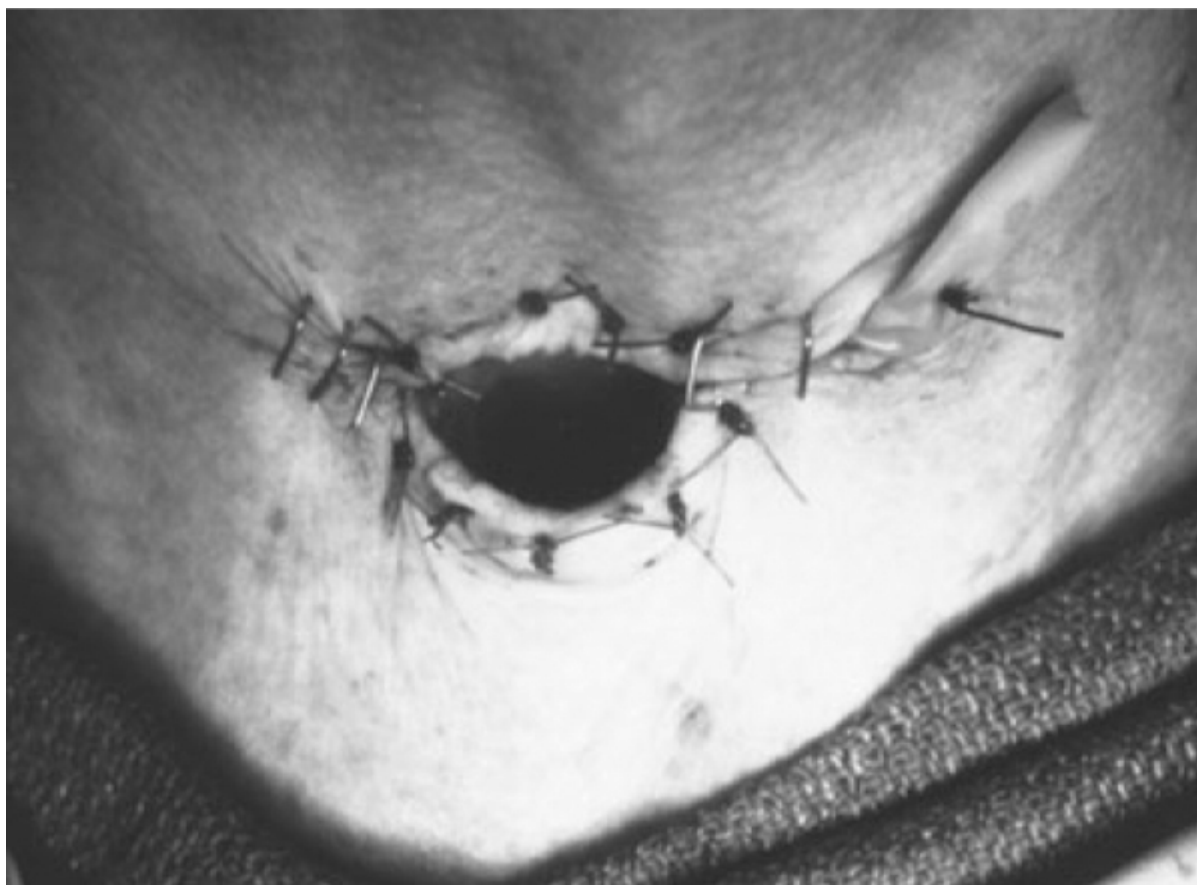



**Figure 69-6** Reinforcement of the closure. **A**, The ring that was divided is then collapsed with a clamp, and an additional layer of reinforcing sutures is placed to reinforce the closure. **B**, Operative photograph of closure of a subglottic tracheal stump (*arrow*).

Some surgeons routinely reinforce the closure with a flap of strap muscle sewn below the proximal tracheal closure. Unfortunately, this maneuver does not always prevent a fistula. An adequate inverting mucosal closure performed without tension appears to be the most critical step in this part of the procedure.

The distal trachea is then brought to the skin, and a stoma is formed in a manner identical to that for a laryngectomy stoma. Half-mattress sutures are used to advance skin from the lateral to the medial aspect as would occur in a total laryngectomy (Fig. 69-7). A small Penrose drain is brought out one corner of the wound, and any remaining skin lateral to the tracheostoma is then closed. A cuffed tracheostomy tube is inserted to help prevent aspiration of any wound drainage that seeps from the skin edges.



**Figure 69-7** After closure. Note the Penrose drain left in place for 24 hours to avoid subcutaneous collection of fluid.

## **POSTOPERATIVE CARE**

The Penrose drain is generally removed the next day, and the cuffed tracheostomy tube can often be replaced with a laryngectomy tube in 2 to 3 days. Feeding can be started as early as 3 to 5 days, depending on the metabolic condition of the patient, the degree of aspiration preoperatively, the patient's ability to tolerate an oral diet, and perceived adequate healing of the wound. Postoperative care is similar to that for a laryngectomy, and routine stomal care will be required.

## **COMPLICATIONS**

One of the factors to be considered in postoperative management is the importance of relaying to other care providers the procedure that was actually performed. There is less anterior neck deformity after LTS than after laryngectomy; hence, those unfamiliar with the procedure might assume that this stoma represents a routine tracheostomy with persistent communication with the pharynx. Such assumptions can lead to inappropriate airway management, such as insertion of an expiratory speaking valve or attempts to intubate the patient through the larynx. It may be worthwhile to have a sign placed above the patient's bed describing the procedure that has been performed, particularly if the patient is transferred to another facility.

In the series of patients treated at the University of Pittsburgh, transient fistulas occurred in approximately a third of the patients undergoing separation procedures.<sup>[13]</sup> Postoperative fistula has occurred more commonly in patients who have previously undergone tracheostomy and is usually secondary to technical difficulties in closing the mucosa of the proximal trachea stump.

Less than half of patients treated by LTS at the University of Pittsburgh were able to swallow after surgery.<sup>[13]</sup> The lack of swallowing was due to the underlying neurologic disease that necessitated the procedure and was not a complication of the procedure. The major difficulty in the procedure is selection of patients for it, not the procedure itself.

## **PITFALLS**

- Despite technically successful LTS, some patients will not be able to swallow because of their underlying neurologic condition.
- If LTS is not carried out correctly, poor healing with fistula formation may occur.
- Reversing LTS in patients not fully recovered from their underlying condition will result in resumption of chronic aspiration.
- Relying on a cuffed tracheotomy tube in a patient with severe chronic aspiration will lead to recurrent aspiration pneumonia.
- Patients who are highly anxious about the loss of their voice may not be suitable candidates for LTS.

#### PEARLS

- LTS can be a lifesaving procedure in patients with chronic aspiration.
- LTS can be reversed if the cause of the aspiration is overcome (e.g., a patient with an exacerbation of multiple sclerosis going into remission).
- Tracheoesophageal puncture can be performed in some patients to restore their ability to speak.
- LTS can be performed under local anesthesia in patients whose general condition will not allow general anesthesia.
- Patients whose underlying condition permits may resume swallowing a few days after LTS.

Copyright © 2009 [Elsevier](#) Inc. All rights reserved. Read our Terms and Conditions of Use and our Privacy Policy.  
For problems or suggestions concerning this service, please contact: [online.help@elsevier.com](mailto:online.help@elsevier.com)