

Chapter 94 – Fractures of the Orbit

S. Tonya Stefko

Because the orbit is made up in part by two of the horizontal beams of facial structure and two of the vertical buttresses, orbital fractures are common, and proper repair of such fractures is key to restoring normal facial appearance and function. Complicating evaluation and treatment are the vital and complex structures contained within: the eye and optic nerve, extraocular muscles, and the lacrimal secretory and excretory systems. Understanding the classes of fractures involving the orbit is critical to their evaluation and prediction of other possible associated injuries. These categories will suggest a systematic approach to their treatment and repair.

The bony orbit is shaped like a pyramid with its apex directed posteromedially (Figs. 94-1 and 94-2). The medial walls are approximately parallel, and the lateral walls diverge at roughly 90 degrees. The normal volume of an adult orbit is 30 mL. The periosteum of the orbit is also known as the periorbita, and it surrounds the orbital contents in a continuous sheet except over the various foramina and fissures.

Most fractures involving the bones of the orbit occur as a consequence of blunt trauma to the face. Penetrating trauma, such as that caused by a projectile, is less common. Consideration of the probable velocity (momentum and direction) of the inciting object will often give clues to the likely location and severity of the bony involvement. For example, true blowout fractures are frequently the result of low-velocity trauma to the orbit, such as a thrown baseball, whereas a motor vehicle collision or being struck by a baseball bat in the face (high-velocity trauma) may cause a displaced zygomaticofacial complex (ZMC) or Le Fort–type fracture.

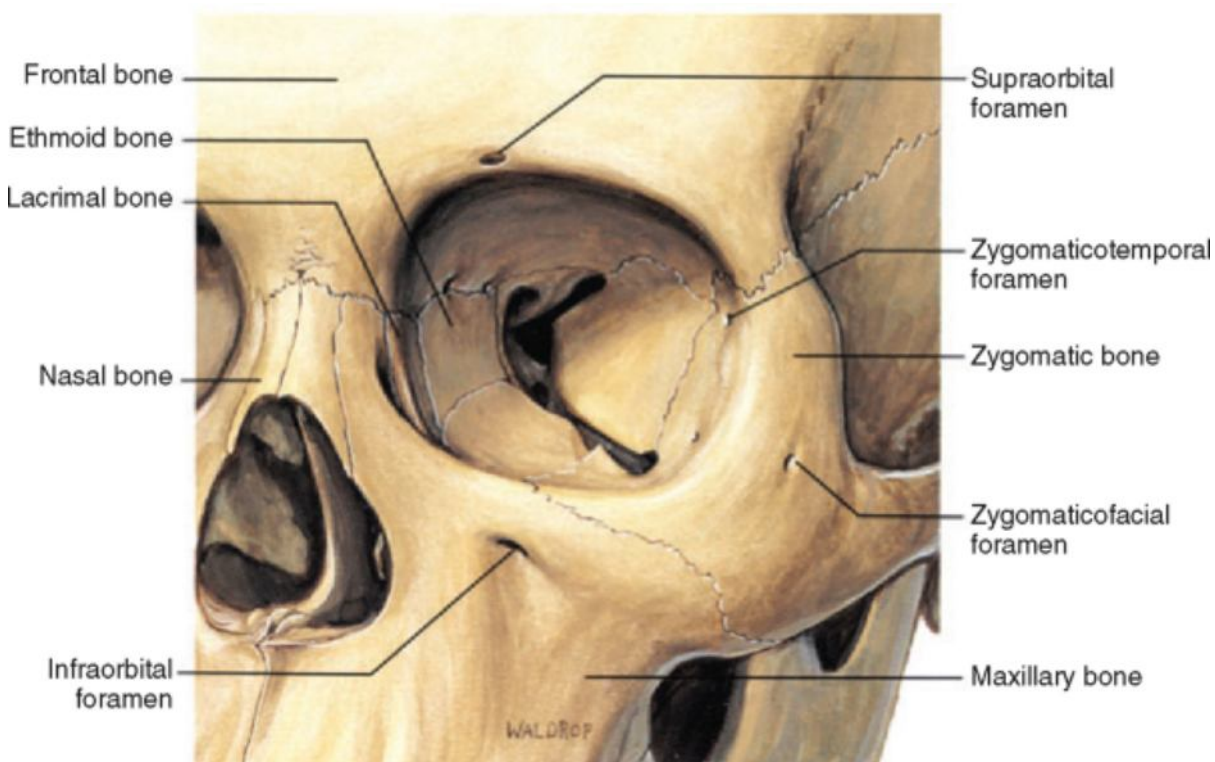


Figure 94-1 Orbital bones, frontal view.

(From Dutton JJ: *Atlas of Clinical and Surgical Orbital Anatomy*. Philadelphia, WB Saunders, 1994.)

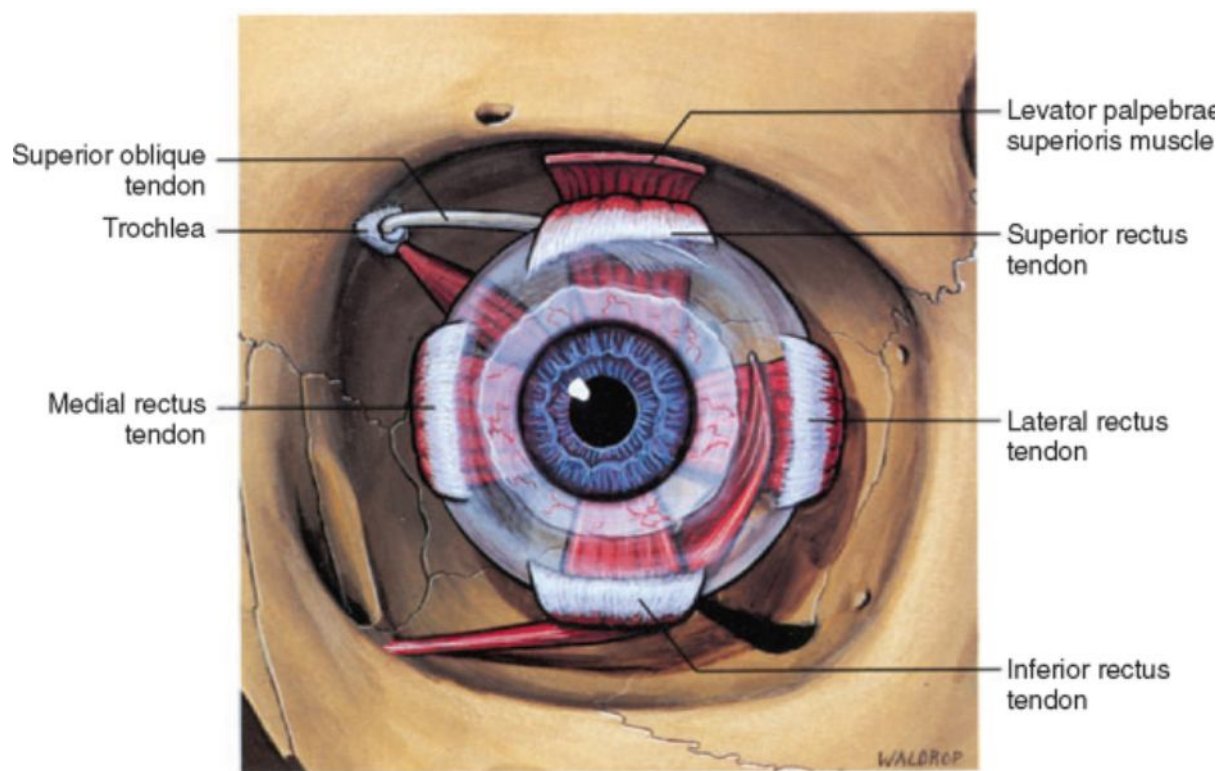


Figure 94-2 Extraocular muscles, frontal composite view.

(From Dutton JJ: *Atlas of Clinical and Surgical Orbital Anatomy*. Philadelphia, WB Saunders, 1994.)

PATIENT SELECTION

Most orbital fracture repairs can be delayed for 7 to 10 days, so consideration of the status of the rest of the patient must be undertaken immediately. The usual trauma evaluation, including establishment of the airway, breathing, and circulation, is performed first. A secondary survey will then uncover less urgent issues, including facial fractures. Delayed repair allows stabilization of the patient, full evaluation of the impact of the injury, and attention to more urgent issues (e.g., decompression craniotomy). However, in some instances fracture repair will be undertaken more urgently because of intercurrent issues, such as an intractable cerebrospinal fluid leak.

Evaluation of the severity of the fracture must include attention to the orbital contents. A basic eye examination can be performed on even a comatose patient by using a penlight and pair of toothed forceps. In most major trauma centers, an ophthalmologist is available on call to evaluate the eye and periorbital area, the safest way to ensure that no occult injury is overlooked. In other emergency rooms, the otolaryngologist will need to document at least vision, if possible, pupillary reactions, eye movements, and appearance of the eye.

Types of Orbital Fractures

Force applied to the lower midface region produces variations of the classic fracture patterns described by Le Fort. Rarely do Le Fort fractures occur precisely as he described or symmetrically; however, these divisions help guide repair and provide an orderly and predictable approach. Le Fort II fractures, discussed in more detail in Chapter 93, traverse the maxillary sinus, orbital floor, medial wall, and nasal bones. Le Fort III fractures, also called craniofacial dysjunction, involve the zygomatic bones in the lateral orbital walls, the floor and medial orbital walls, and the nasal bones. Although an air-fluid level noted on computed tomography (CT) in one maxillary sinus suggests a sinus or orbital fracture, when this sign is present in both maxillary sinuses, one must assume a Le Fort II or III fracture until careful examination has proved otherwise. All Le Fort fractures also cause some measure of malocclusion.

Application of significant force to the upper midface area can lead to telescoping nasal fractures and naso-orbito-ethmoidal fractures. The hallmark of these injuries is traumatic telecanthus, with the normal intercanthal distance being about 35 mm or less. Fracture lines generally travel posteriorly through the medial orbital walls. The most urgent issues with these fractures involve possible leakage of cerebrospinal fluid with associated meningitis and trauma to the brain, as well as the possibility of involvement of the optic canals posteriorly. Careful consideration must be given to the urgent need for decompression. When repairing these fractures, it will also be necessary to re-establish the normal anatomic relationships of the medial canthi. These injuries are discussed further in Chapter

93.

ZMC fractures involve force directed posteriorly over the malar eminence or zygomatic arch. They were formerly referred to as "tripod" fractures, but this term is not entirely accurate because this bone articulates in five places, even though two of the five generally do not require fixation during reduction. The characteristic facial deformity of a displaced ZMC fracture is flattening of the malar eminence, with or without apparent enophthalmos, and difficulty opening the mouth completely.

The remaining fractures involving the orbit are referred to as blowout fractures. They were first described by Smith and Regan in 1957^[1] after observing a patient who had been hit in the periorbital area by a hurling ball. With a Waters view on plain films, the characteristic opacification of the maxillary sinus was observed, and the patient complained of diplopia. Surgical exploration via a Caldwell-Luc approach allowed visualization of the inferiorly displaced orbital floor (maxillary sinus roof) and prolapse of the orbital contents. Repair was undertaken by packing of the maxillary sinus to elevate its roof, and further cadaver experiments were carried out by the authors.

A classification of orbital fractures was described in 1967 and consisted of separating the fractures into "pure" blowout and "impure" blowout fractures.^[2] Impure blowout fractures referred to those associated with other orbital rim fractures, mainly those mentioned earlier and the occasional unclassifiable rim fracture with a floor component. The term was expanded to include fractures of the orbital roof unassociated with frontal sinus fractures, which occur almost exclusively in children. The definition of a blowout fracture has come to mean an orbital floor, medial wall, or roof fracture not associated with a rim fracture.

The hydraulic theory suggests that the orbital contents are deformable and that a blow to the soft tissues causes rapid expansion beyond what the elastic modulus of the surrounding bone can tolerate. Thus, the weakest areas of the orbital structures fracture outward, often lacerating the periorbita and intraorbital tissues, and allow prolapse into the adjacent sinus. Younger patients merit special consideration because they often suffer greenstick-type orbital wall fractures, during which the orbital contents can herniate and become trapped by rapid recoil of the partially fractured orbital wall (so-called trapdoor fractures). A second explanation, the "buckling" theory, instead explains fracture of the orbital walls by the application of a load to the thick orbital rim, which deforms somewhat and causes the orbital wall posterior to it to bend.^[3] As the tougher orbital rim returns to its original position, the thin and brittle bones of the associated wall have less elasticity and consequently break. It is likely that some combination of these mechanisms explains most blowout fractures.

Determination of Need for Repair

The initial symptoms of the patient will provide the first clue to the need for and timing of repair. Many patients with ZMC fractures complain of pain or numbness in the cheek (or both) and notice deformity of their cheek. The deformity may be obscured in the early stages by edema. If the zygomatic arch is involved, the patient may have symptoms of pain with attempted opening of the mouth. Because this fracture only rarely causes significant orbital injury or airway compromise, the approach to repair is most often elective and based on the amount of cosmetic deformity or the presence of symptomatic bony fragments in the temporomandibular joint space. Earlier repair is preferable to obviate the need for osteotomy. If the fragments are nondisplaced and stable, surgery is unnecessary.

Patients with blowout fractures of the floor may have the classic triad of enophthalmos, hypoesthesia of the cheek, and a deficit of upgaze. Hypoesthesia of the cheek is common to most patients with blowout fractures of the floor because the fracture occurs medial to the infraorbital canal and often involves it. Young patients with significant deficiency of upgaze, particularly if accompanied by nausea and vomiting,^[4] require careful evaluation to determine whether a trapped inferior rectus muscle is present. These so-called white-eyed blowout fractures are the most critical, and repair should proceed within 24 hours if possible.

Clues to muscle entrapment include age of the patient, small fracture size, severe pain on attempted duction, severe limitation of upgaze, and nausea and vomiting (Figs. 94-3 to 94-5). Traction on the inferior rectus is thought to activate the oculocardiac reflex (bradycardia, hypotension, and vomiting) and could theoretically be fatal. In addition, the muscle is compressed and quickly becomes ischemic, thereby rapidly leading to irreversible scarring and permanent double vision.^[5]

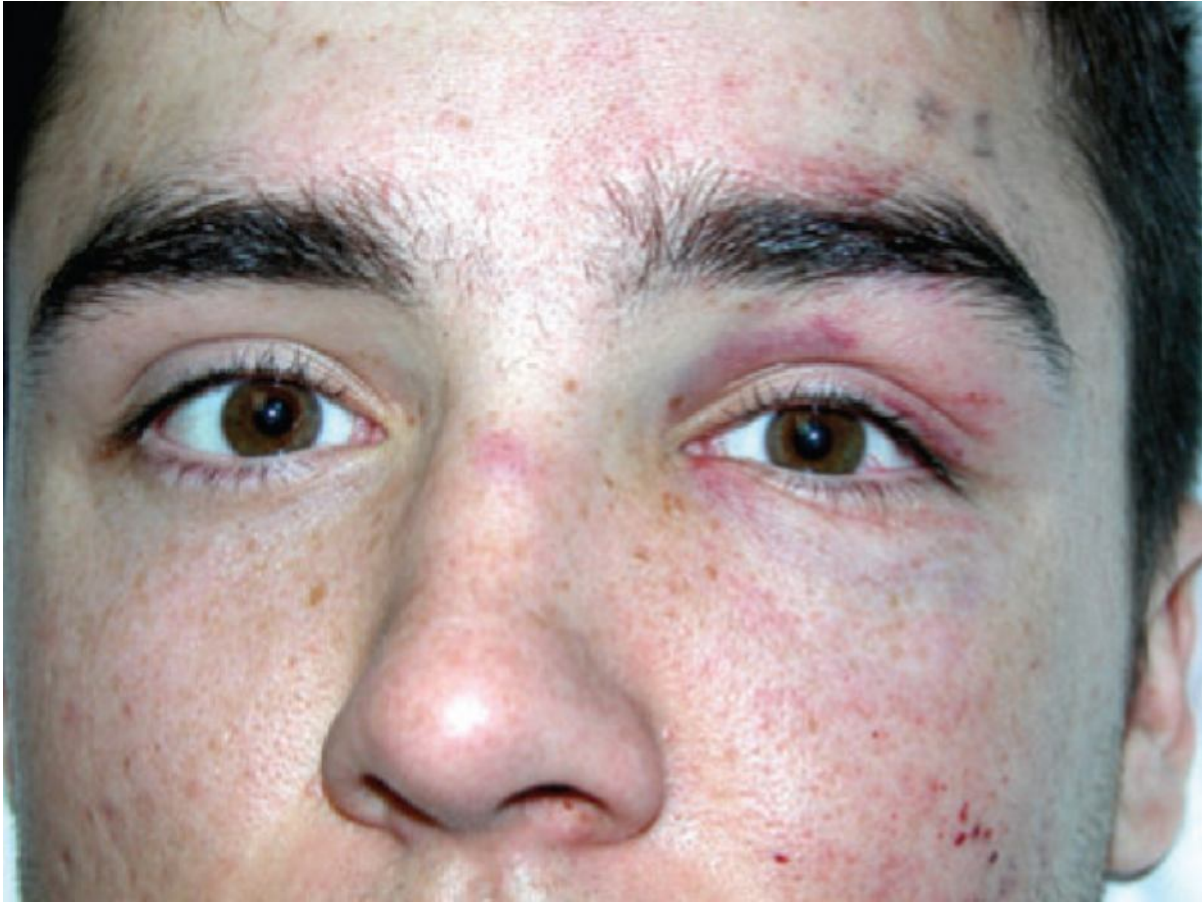

Figure 94-3 Patient 1: 16-year-old with a blowout fracture of the left orbit.

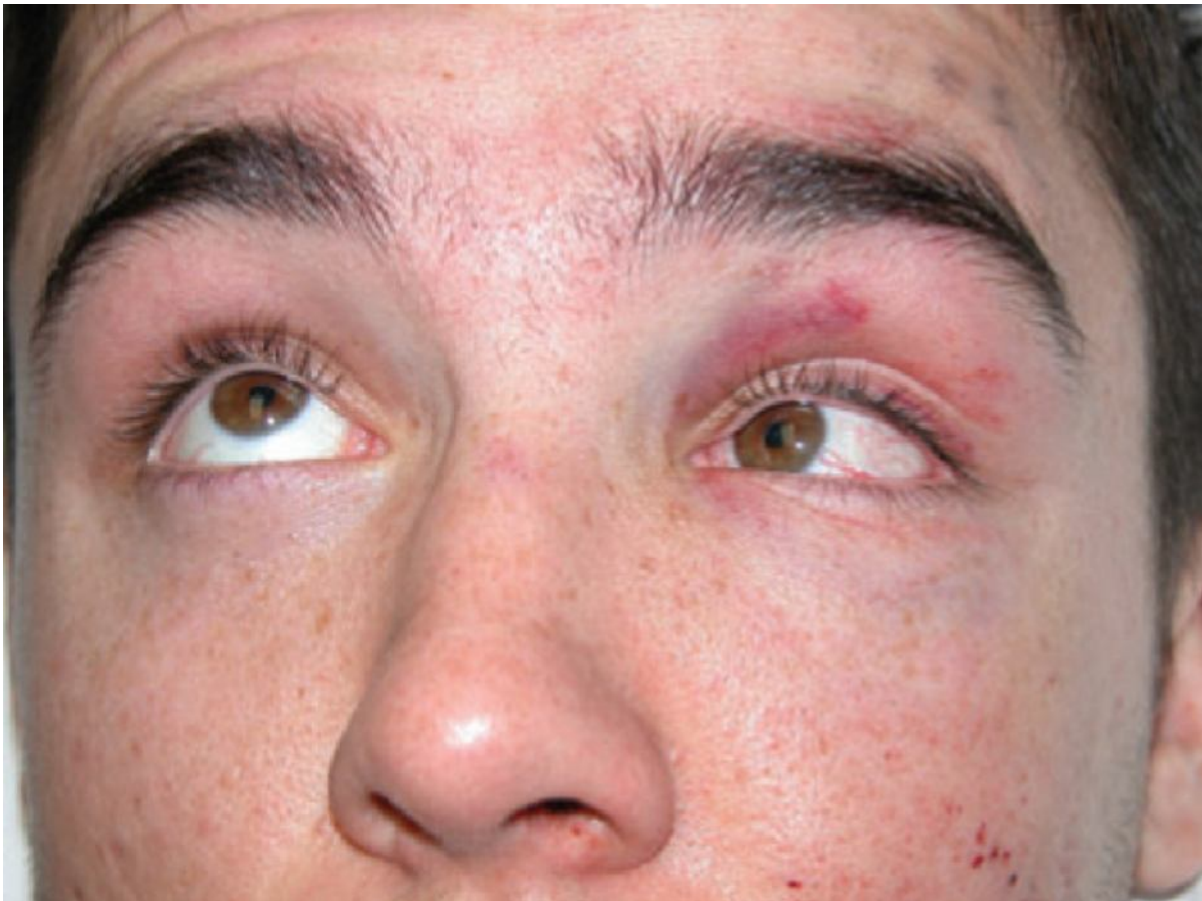

Figure 94-4 Patient 1: attempted upgaze.

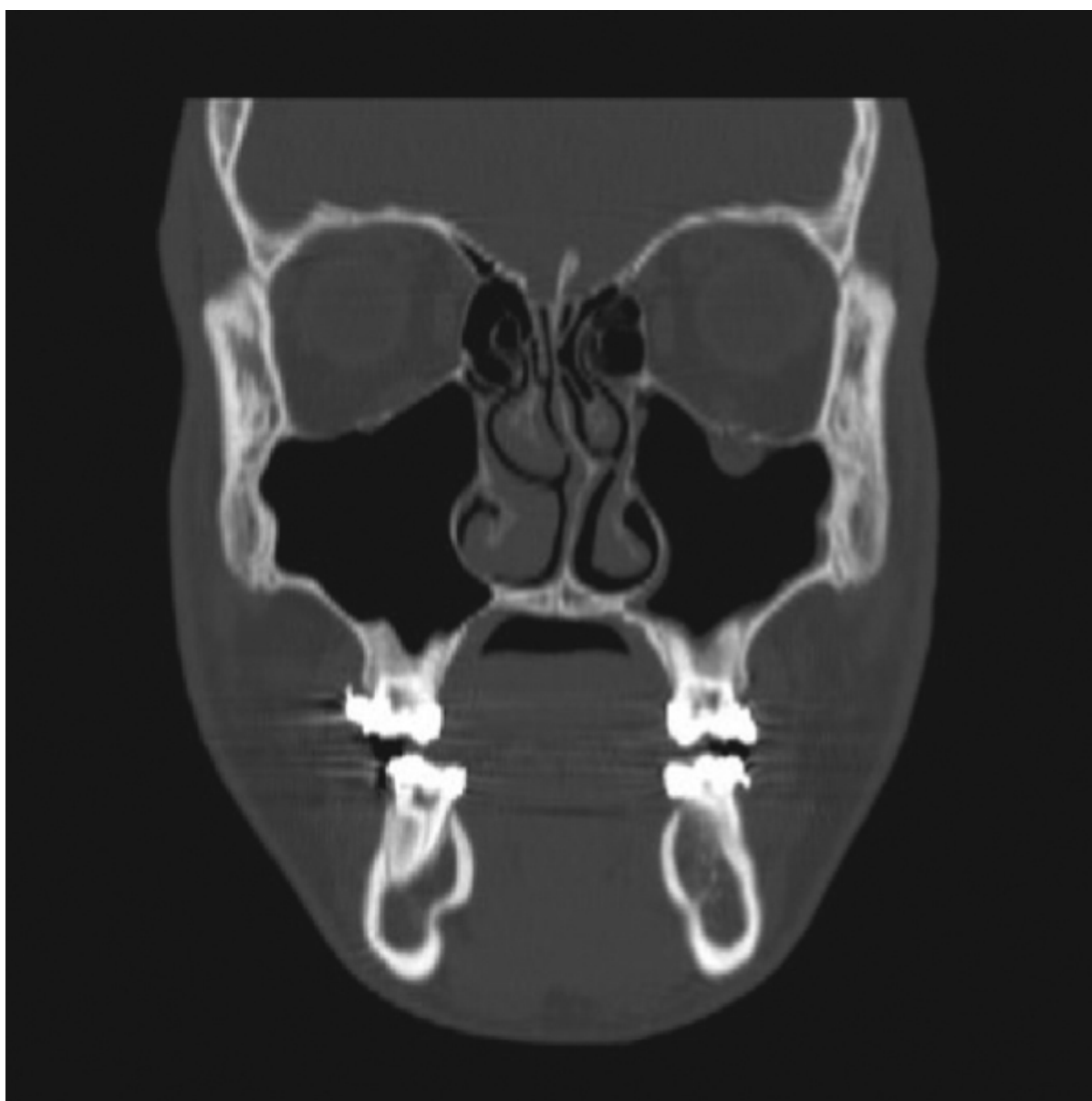

Figure 94-5 Coronal scan of a trapdoor fracture of the left eye; note the "hanging drop" sign and small, nondisplaced fracture.

Decisions regarding the suitability and timing of repair of other blowout fractures may be undertaken with less urgency. Factors affecting such decisions include the size of the fracture, injury to other adjacent structures, associated symptoms, and characteristics of the particular patient.

Symptoms associated with blowout fractures most commonly include pain, hypoesthesia of the cheek, diplopia, and enophthalmos. The former two nearly always resolve without intervention, and thus only diplopia and enophthalmos remain as possible indications for repair. Putterman and colleagues^[6] showed that the natural history of most uncomplicated blowout fractures (i.e., those without entrapped muscle) is resolution of the diplopia over a period of days to weeks. Early enophthalmos (immediate or within the first week) bodes poorly for cosmetic outcome because this sign generally portends a large and displaced fracture. With the advent of CT scanning and more precise measurement of the size and location of these injuries, it became possible to predict which patients will suffer long-term consequences, including cosmetic deformity and permanent double vision.

It is generally accepted that fractures involving more than 50% of the orbital floor are likely to cause later enophthalmos. Displaced fractures with an area of 2 cm² or greater are most significant: approximately 1 cm² produces about 1 mm of enophthalmos,^[7] and at a 2-mm or greater difference in projection of the globes, an aesthetic defect is noticed. The area of the medial wall fractured must be accounted for when making this rough

calculation; although the medial wall is repaired less frequently, it contributes to later enophthalmos (Figs. 94-6 to 94-8).

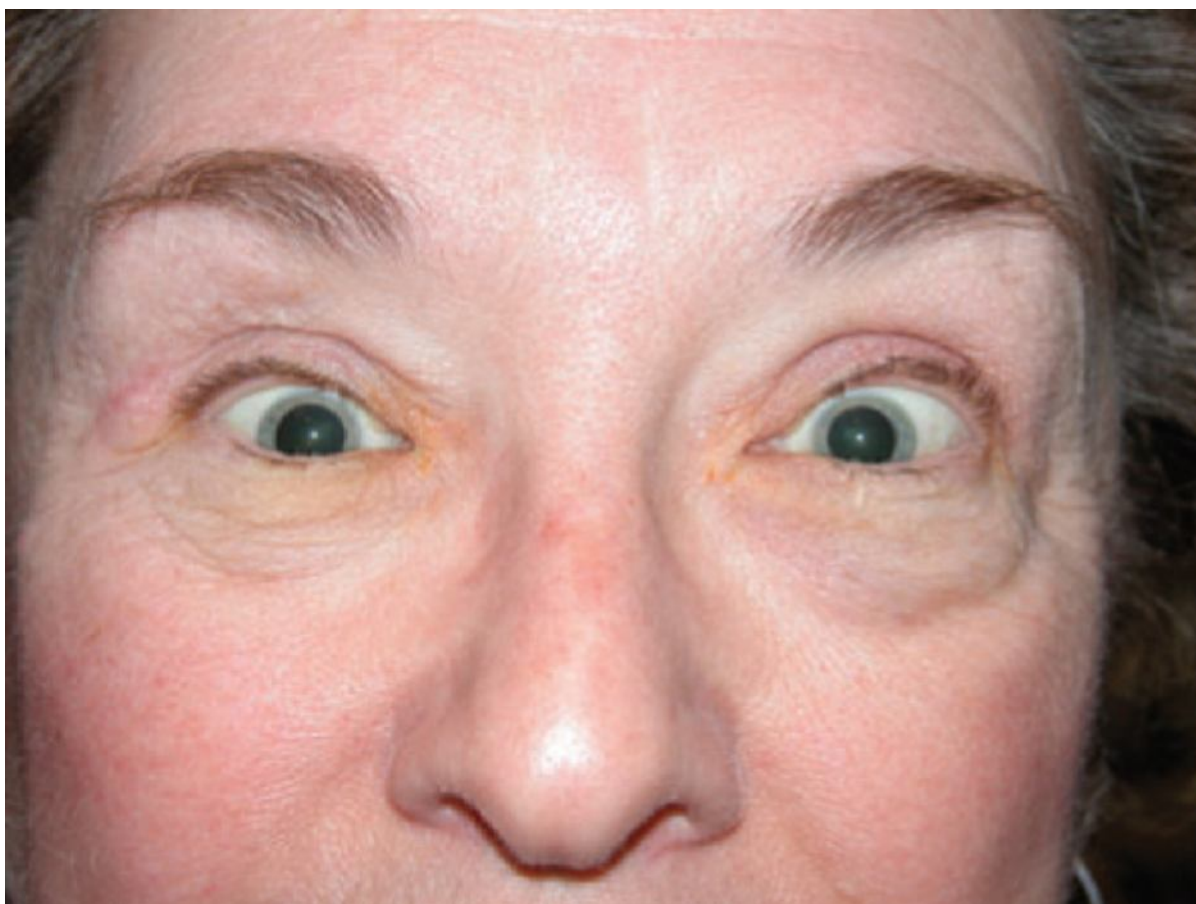

Figure 94-6 Patient 2: 4½ months after fracture of the orbital floor and medial wall. Diplopia and 6 mm of enophthalmos are evident in the right eye.

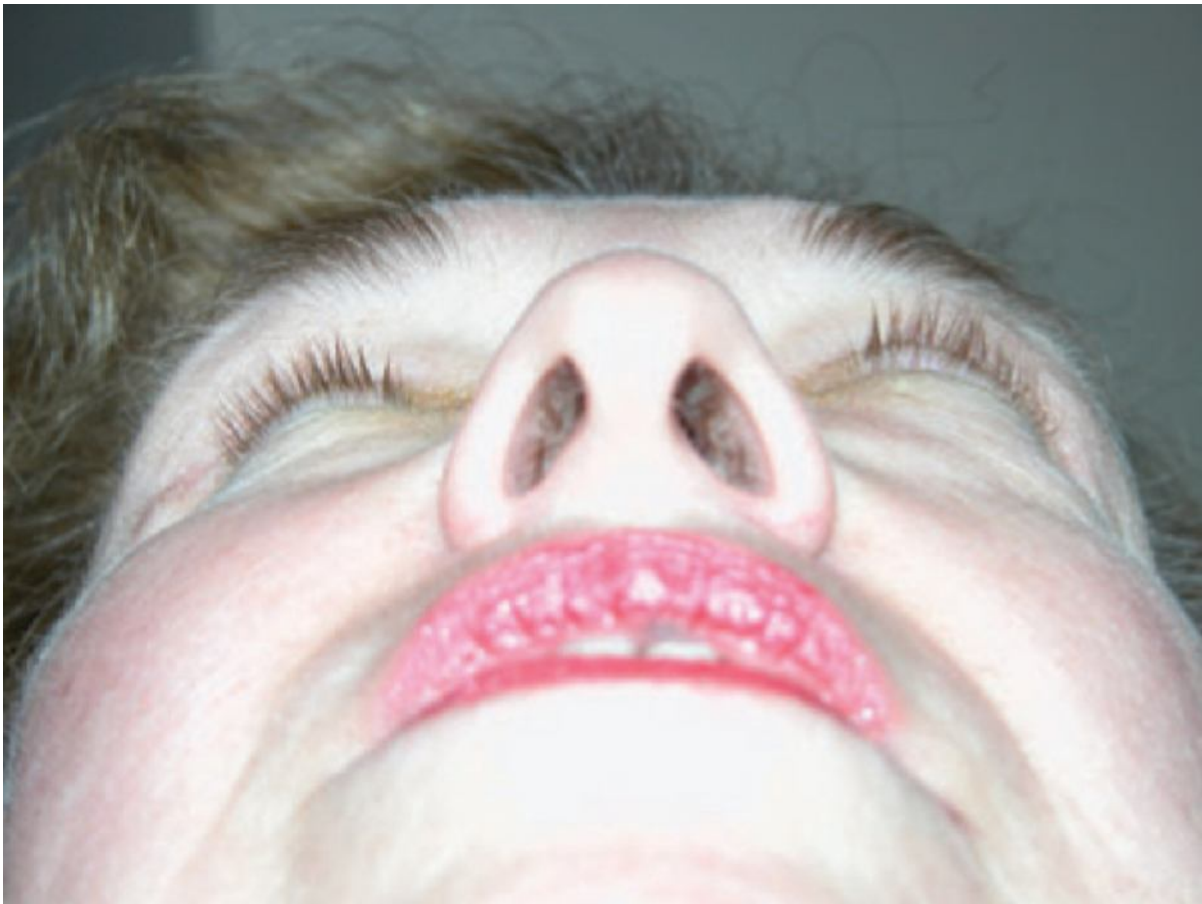

Figure 94-7 Patient 2: 4½ months after a blowout fracture.

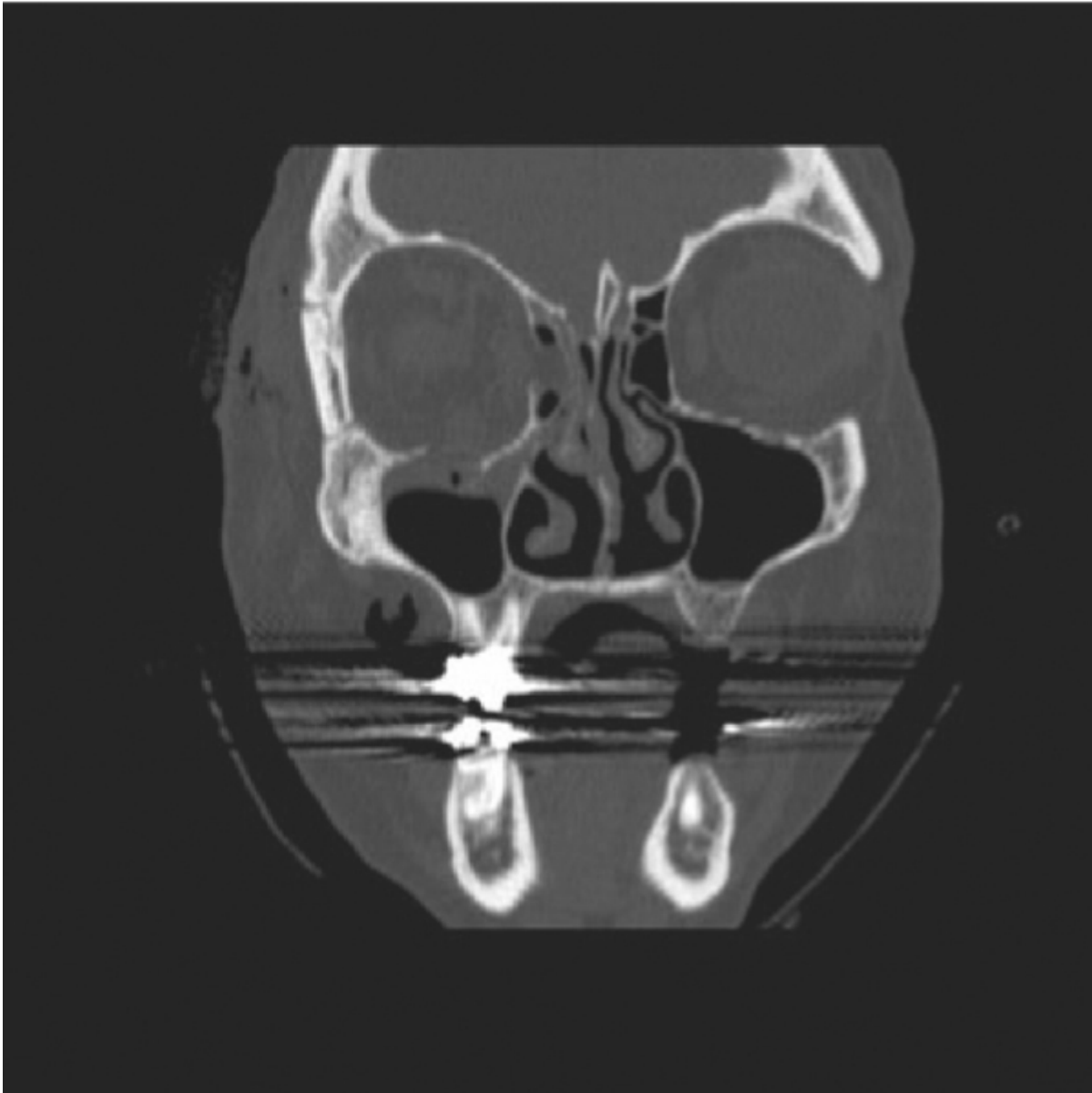

Figure 94-8 Blowout fracture of the floor and medial wall of the orbit.

The risk of diplopia after repair of a blowout fracture is difficult to quantify without a randomized, controlled prospective trial. A small retrospective trial of 54 patients who underwent surgical repair found that approximately a third of the patients continued to have diplopia more than 6 months after repair.^[8] However, approximately two thirds of these patients had combined floor and medial wall fractures, thus making the risk greater than after floor fracture alone, for which it is about 10% to 12%.

In considering the general health of the patient, it is best to frankly discuss with the patient that the repair to be undertaken is for aesthetic reconstruction and occasionally to prevent double vision, not to treat abnormal cheek sensation or pain. Nor, in most instances, is it necessary to undergo surgery to prevent double vision from persisting. Thus, a patient in her 80s in a nursing home would be a less likely candidate for intervention than a 22-year-old student with a similar-appearing fracture.

PREOPERATIVE EVALUATION

Evaluation of Orbital Contents

The most complete evaluation of a patient with an orbital fracture occurs when the otolaryngologist and ophthalmologist work together to manage the case. Ensuring the integrity of the eye is of utmost importance. Open globe injuries, particularly in the case of penetrating trauma, are occasionally seen in association with orbital fractures. A high index of suspicion must be maintained in patients with decreased vision, obvious globe deformity, opacification of areas of the cornea, an irregularly shaped pupil, and areas of hemorrhagic conjunctival chemosis. Although subconjunctival hemorrhage is common in the setting of any orbital fracture, chemosis (significant edema

of the conjunctiva) associated with hemorrhage is quite worrisome for occult rupture. In such instances, structural integrity of the eye must be established first, with repair of any significant orbital fracture undertaken with caution at a much later time. A retrospective study of open globe injuries recently found 26% to be associated with orbital or adnexal trauma (or both), and conversely, a review of orbital injuries found approximately the same proportion with significant injury to the globe.^[9,10]

The second instance in which orbital fracture repair ought not be undertaken immediately is in patients with traumatic optic neuropathy. The sine qua non of this injury is a relative afferent pupillary defect, except in those with bilateral neuropathy. A relative afferent pupillary defect (Marcus Gunn pupil) is observed by noting a difference in the reactivity of one pupil versus the other by transferring a bright light rapidly from one eye to the other. It is important that the patient not focus on the examiner during the examination because this will cause constriction of both pupils and render the examination more difficult. The patient should be asked to focus on a distant object such as a light switch. The patient will usually note that the light is brighter in the unaffected eye than in the affected one. Several caveats attend this examination: a decrease in reactivity of a pupil can also be caused by third nerve injury, accompanied by ptosis of the upper eyelid and deficit of upgaze, downgaze, and adduction, or by direct pupillary trauma, in which case hyphema will often be present.

If the patient is thought to have traumatic optic neuropathy, consideration should be given to surgical decompression of the optic nerve, particularly when bony fragments are obviously present in the canal or posterior orbit on CT scan. Associated findings are frontal sinus fractures, blood in the posterior ethmoid air cells and sphenoid sinus, and sphenoid sinus fractures. No established treatment of traumatic optic neuropathy exists. The International Optic Nerve Trauma Study attempted to determine whether observation, treatment with corticosteroids, or surgical intervention made any difference in outcome for patients with indirect (i.e., nonpenetrating) trauma to the optic nerve.^[11] The trial was changed to an observational one because of low enrollment, and no clear benefit was found for either treatment.

Small case series have suggested that unroofing the bony canal may be of benefit. Complicating factors in these reports have been a lack of standardization of timing or technique of surgery, lack of definition of visual "improvement," and poor understanding of the natural history of the disease (a significant number of patients will improve without treatment). In any case, repair of orbital fracture in this setting is fraught with uncertainty and could presumably make the situation worse.

The third contraindication to early exploration of orbital fractures is the presence of hyphema (bleeding into the anterior chamber of the eye). Hyphema is often visible grossly as a red layer between the cornea and iris, but more subtle cases may go undetected without slit-lamp examination. The highest chance of rebleeding in these patients occurs during the first 5 days after injury, during which the patient must remain at bed rest and keep the eye shielded. Any further trauma to the eye (e.g., retraction of the orbital contents during surgery) is to be strictly avoided. If the hyphema is small and resolves entirely within the 5-day period, it is probably safe to proceed with repair of the fracture the following week. If the hyphema is large and remains unresolved, it is most prudent to defer surgery on the orbit until a later date.

Examination of ocular motility is easily done by asking the patient to move the eyes to all extremes of gaze. Edema of muscle or periorbital or patient discomfort is a very common cause of limitation of duction, so in instances in which there is doubt about the nature of the limitation, forced ductions should be performed. This is done by instilling anesthetic drops into the eye and then holding a cotton-tipped applicator soaked in these drops over the conjunctiva at the 6-o'clock position for at least 90 seconds. Toothed forceps can then be used to firmly grasp the conjunctiva and underlying connective tissue and rotate the eye in each direction. Resistance to forced movement suggests either entrapment of tissues in a fracture site or decreased compliance of the extraocular muscle (e.g., by hematoma).

If possible, a dilated fundus examination should be performed to rule out or document any intraocular hemorrhage or retinal pathology before exploration of the fracture.

Associated Soft Tissue Injuries

Any associated soft tissue injuries should be noted at the time of initial examination. This will guide repair of any lid or lacrimal injury, and a preexisting laceration can often be used for good surgical access. If the repairs are to be performed at the same surgery, the fractures should be repaired before any eyelid repair to avoid undoing the reconstruction already performed. However, during exploration and repair, the tissue must be kept hydrated and treated as gently as possible to avoid further damage. A laceration, no matter how small, between the lacrimal punctum and medial canthus usually means avulsion of the canalicular system and should be repaired within 72 hours with a silicon stent. Most injuries, excluding dog bites and motor vehicle collisions with sharp laceration, leave the bulk of the periorbital tissue intact. The blood supply in this area is excellent, so every attempt should be made to complete the original repair with the available tissue. Extreme caution should be exercised during any attempt at débridement of apparently devitalized soft tissue in the area. A laceration at the orbital rim is particularly helpful to

the surgeon because it provides direct access to the ZMC and orbital floor.

Imaging

CT scanning with fine cuts through the orbit and direct coronal projections if possible is the best study for evaluation of orbital fractures. Most modern coronal reconstructions are more than adequate for evaluation of the size of the fracture and the orbital contents. Intravenous contrast material is not necessary, and magnetic resonance imaging of the orbits is of little use in the evaluation of bony injury.

When evaluating an orbital fracture, attention must be paid to the size of the fracture. Tiny trapdoor fractures may be missed on an initial look by radiology, so if clinically suspected, scrutiny of the film for the position and size of the inferior rectus and surrounding tissue is important. The rough area of the fracture may be calculated by measuring its width and length on the scan while keeping in mind that a fracture approximately 1 cm² will produce about 1 mm of enophthalmos. The normal aesthetics of the orbit allow up to a 2-mm difference in the projection of the eyes.

Access to the scans during surgery, if at all possible, can be extremely helpful in orientation within the orbit.

SURGICAL APPROACHES

Zygomaxillary Complex Fractures

By combining the approaches described later with a buccal sulcus incision, most ZMC fractures can be reduced and plated. If the arch is involved and displaced medially, a Gillies maneuver may suffice for repair. If, however, the arch is badly comminuted and displaced outward, it is likely that a coronal incision will be required. This is described in more detail in Chapter 93.

When reduction plus fixation of the zygomatic and maxillary bones has been accomplished, it is necessary to examine the state of the orbital floor. Most often, repair of the floor will also be required lest a large defect be left and place the patient at risk for a suboptimal cosmetic result.

Blowout Fractures of the Orbital Floor

Surgical access for repair of blowout fractures depends on the patient's associated injuries. If a laceration is present along the inferior orbital rim, it is acceptable to expose the fracture site by way of this laceration. Most frequently, however, there is no associated laceration, and blowout fractures of the floor should be approached via a transconjunctival incision. Subciliary, mid eyelid, and rim incisions all provide good exposure but leave the patient with a risk of eyelid malposition because of scarring within the delicate lamellae of the lower eyelid. A transconjunctival incision as described here is rapid and provides wide access to the floor and very little risk of entropion or ectropion (Fig. 94-9). This incision can also be combined with a lateral canthotomy for access to the zygomaticofrontal suture and lateral wall and with a transcaruncular incision for access to the medial wall.

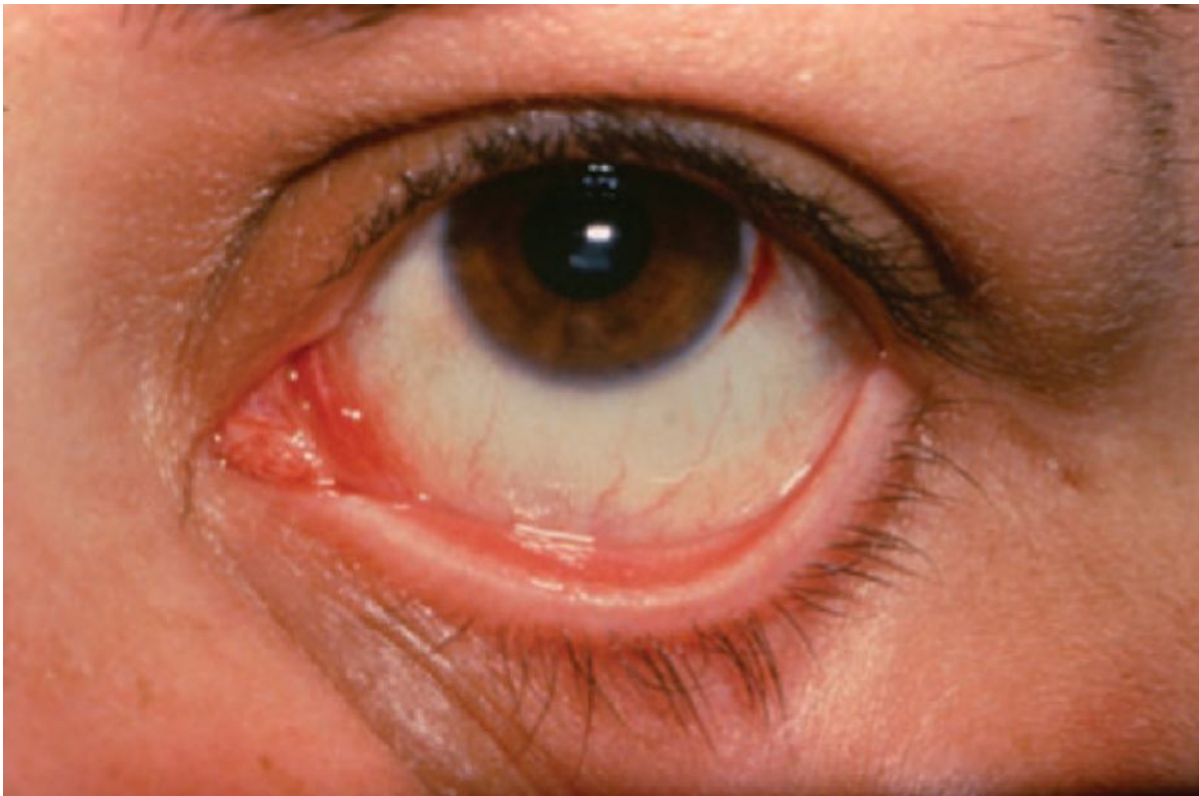

Figure 94-9 Inferior conjunctival fornix 3 weeks after repair of a blowout fracture via a transconjunctival approach.

The patient is placed under general anesthesia for the surgery. An antibiotic such as cephalexin and a steroid such as dexamethasone should be administered intravenously during surgery. The opposite eye usually need not be left exposed in the surgical field unless late repair of enophthalmos is being performed and comparison of projection is necessary.

Before placement of a lubricated corneal protective lens, forced ductions should be performed with toothed forceps and any limitation noted (Fig. 94-10). Although the goal of the surgery is to improve any limitation of duction, at the end of surgery the excursion of the eye must be at least as good as at the beginning.

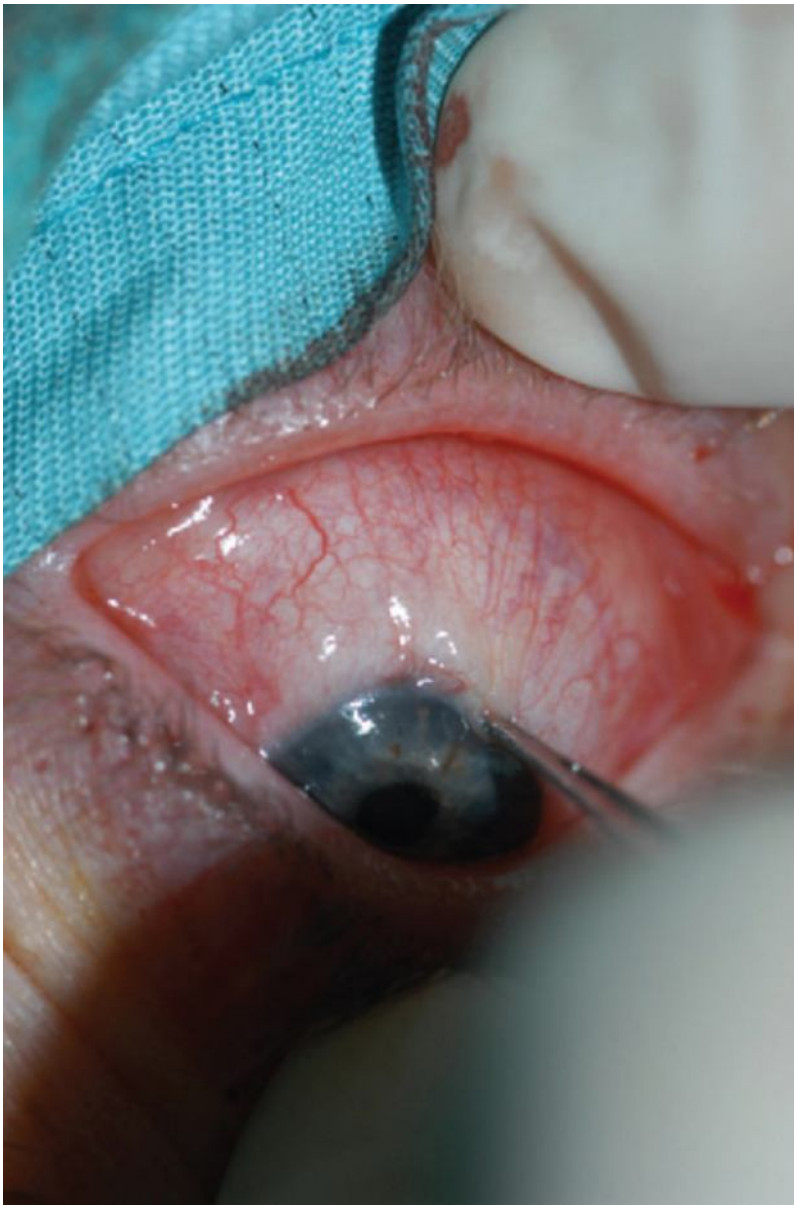

Figure 94-10 Forced duction.

An assistant uses a Desmarres or similar retractor to reflect the lower eyelid down anterior to the rim, and a malleable retractor is used to hold the orbital contents back, with both retractors compressing the tissue somewhat over the rim (Fig. 94-11). A Colorado needletipped Bovie or similar insulated electrocautery device is used to palpate the rim of the orbit and then cut down directly on it. This will place the incision roughly in the inferior conjunctival fornix, well below the lower extent of the tarsus and well away from the globe (Fig. 94-12). If it is necessary to carry the incision fairly far medially, care should be taken to stay anterior to the origin of the inferior oblique muscle and avoid the lacrimal system.

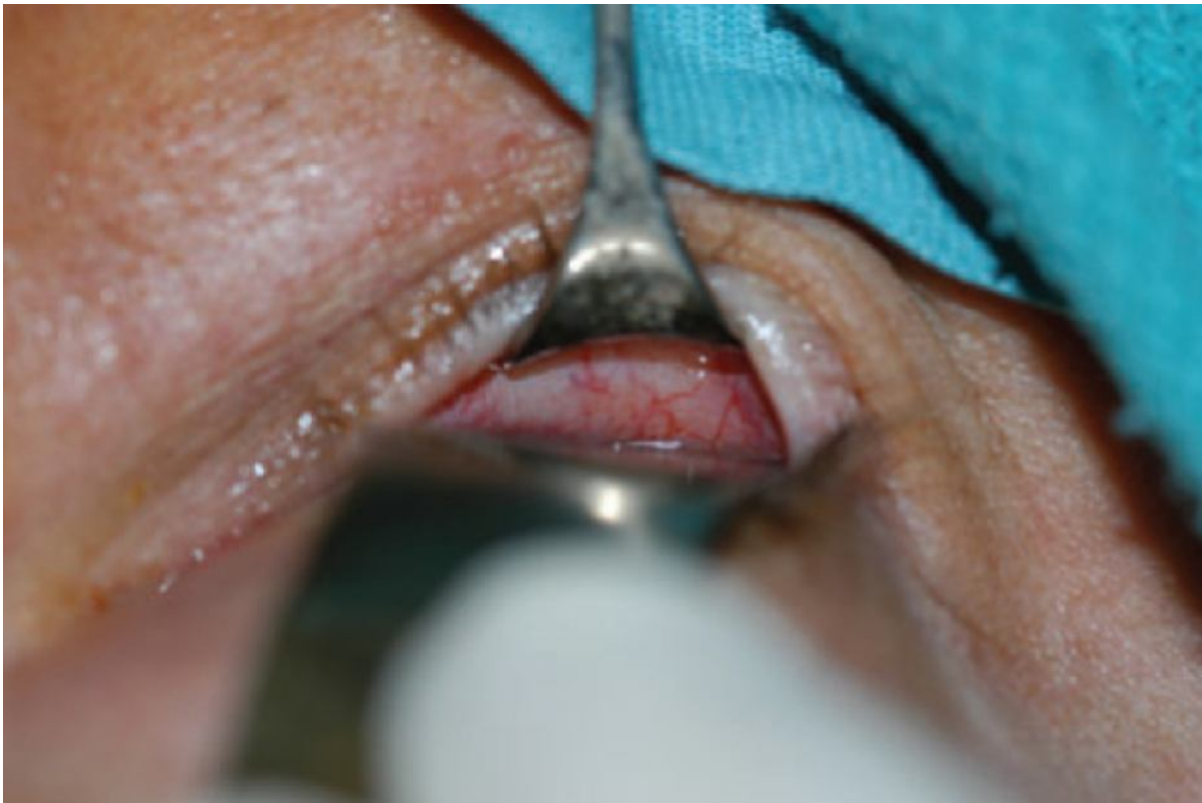

Figure 94-11 Retraction of the lower eyelid and orbital contents.

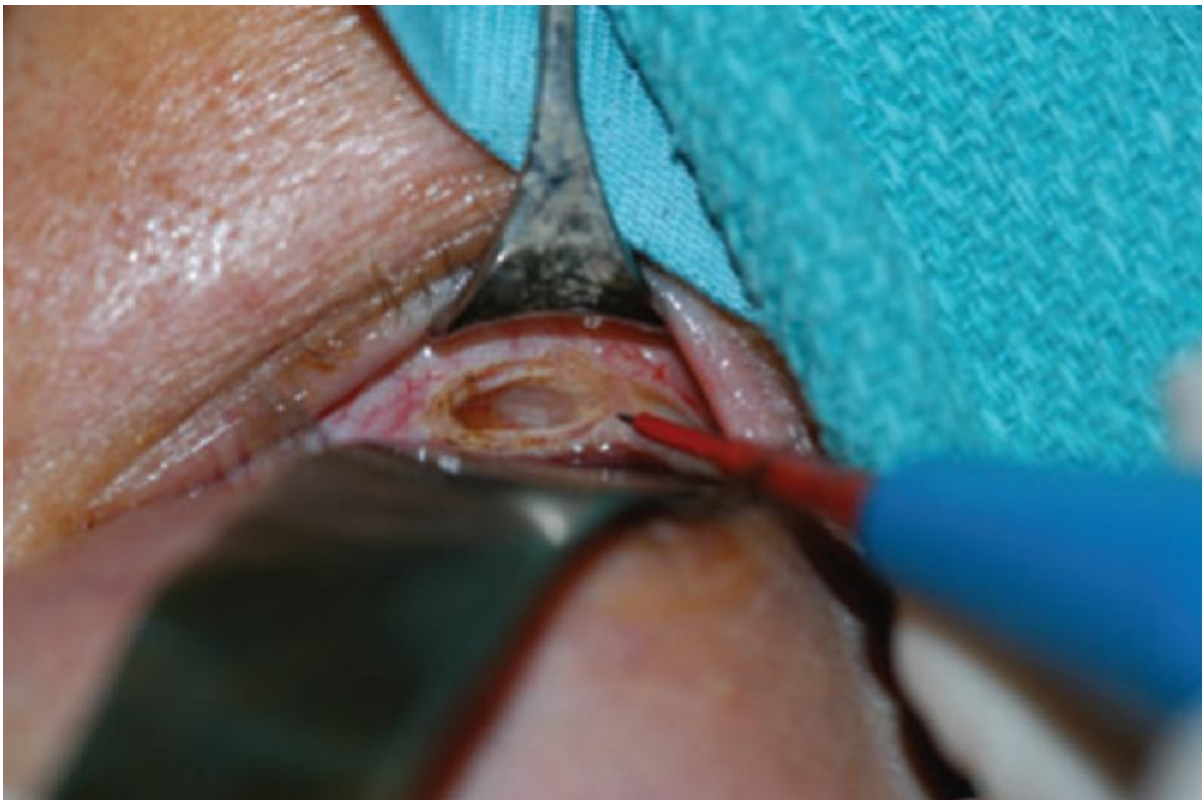

Figure 94-12 Transconjunctival incision with a Colorado needle.

A Cottle or similar small sharpened periosteal elevator is then used to cut the periosteum of the rim and lift the periorbital in one continuous layer back to the fracture site (Fig. 94-13). The medial shelf of the fracture, the lateral shelf, and later, the posterior shelf must all be accessible and free of periosteum for proper implant placement. As the fracture site is exposed, gentle elevation of the orbital contents from the maxillary sinus should proceed in a

hand-over-hand manner by using the elevator and malleable retractor (Fig. 94-14). The maxillary sinus may be débrided of bone fragments and clot. Care is taken to disturb the infraorbital neurovascular bundle as little as possible. A small orbital branch of the infraorbital vessels may be encountered and should be divided with cautery.

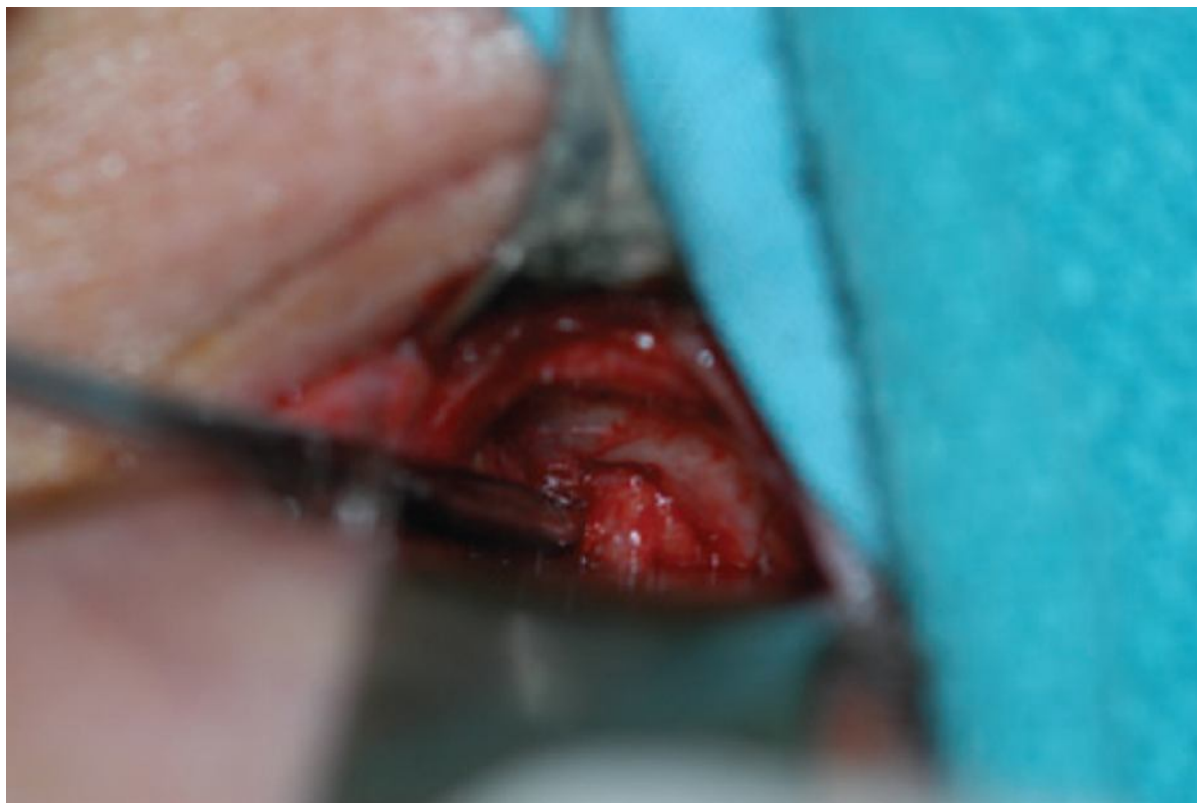

Figure 94-13 Anterior extent of the fracture with herniation of orbital fat into the sinus.

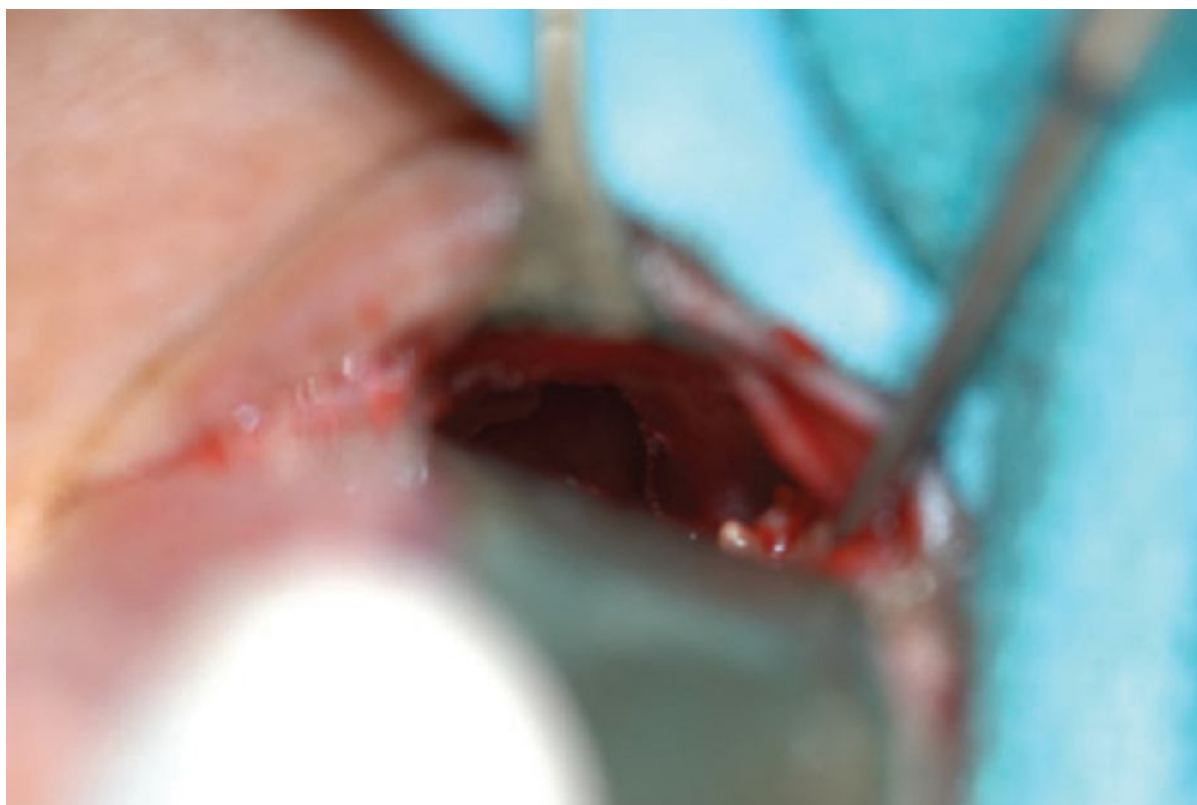

Figure 94-14 Exposure of the floor fracture.

When all orbital tissue has been freed and brought superiorly, the posterior limit of the fracture should be located. This is done by bringing the elevator around from the medial or lateral fixed bone or, in some cases, by drawing the elevator superiorly along the posterior wall of the sinus until the upper aspect is reached.

At intervals of several minutes during the surgery, it is wise to withdraw the retractors from the orbit and allow the tissues to reperfuse.

A suitable implant is now cut to size, dipped in antibiotic solution, and placed in the orbit to support the tissue (Fig. 94-15). It is critical that the implant rest firmly on the posterior edge of the fixed bone around the fracture or the fracture will remain incompletely reduced. A small unrepaired area at the anterior extension of the fracture is acceptable if necessary. When the implant is properly placed, it will remain in position when the retractors are gently removed. It must be placed several millimeters posterior to the rim or it will be palpable postoperatively. Inspection of the tissue surrounding the implant ensures that no orbital contents are trapped beneath the plate, and forced ductions are again performed to confirm the absence of trapping.




Figure 94-15 Measurement of a nylon implant.

A small pilot hole is drilled in the anteromedial corner of the implant, and the plate is fixed with a titanium microscrew (Fig. 94-16). It is not necessary that the screw be perpendicular to the implant because it is not providing structural support (placement of the implant firmly on the medial, lateral, and posterior shelves ensures support), but it does prevent rotation or migration of the material. If insufficient bone is present medially, the plate may be fixed with hardware placed laterally, but great care must be taken to not place the screw through the infraorbital canal. Usually, one point of fixation is sufficient.

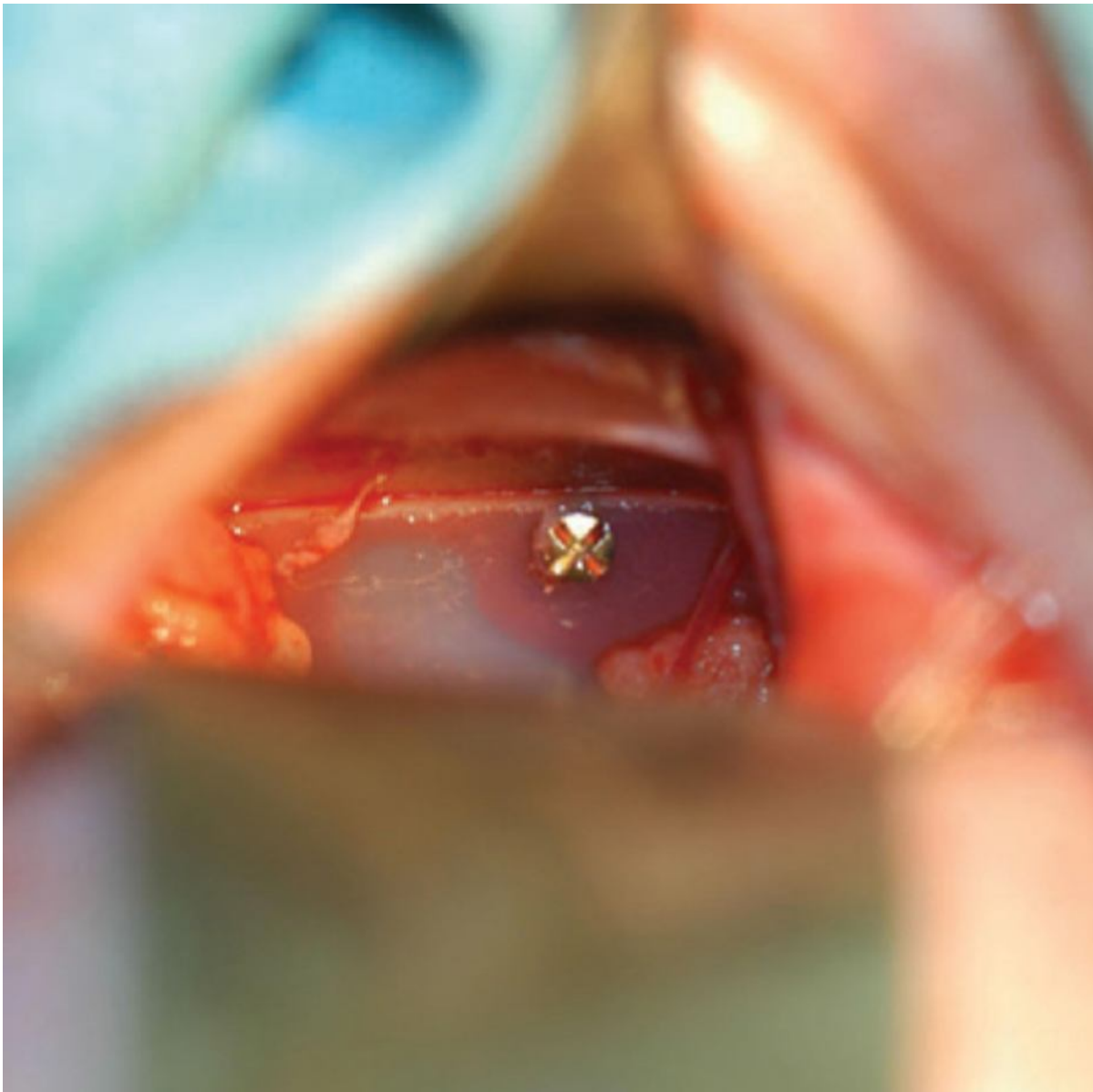


Figure 94-16 Fixation of the nylon implant with a titanium screw.

A Penrose or similar drain may be placed in the wound to emerge at its lateral extreme. The drain is placed superior to the implant and sutured to the lid with a 5-0 nylon loose drain stitch. The end is cut to approximately 5 mm beyond the lid margin. A 5-0 nylon modified Frost stitch is then placed through the skin and orbicularis in the center of the lid just inferior to the lashes. It is taped to the brow under tension and serves to extend the conjunctival edges and obviate the need for closure of the wound (Fig. 94-17). The stitch and drain are removed the following morning before the patient is discharged home. Before closure of the lid, ophthalmic antibiotic-steroid ointment is placed on the eye. A light absorbent dressing is placed so that perception of light may be checked by the nursing staff through the patch.

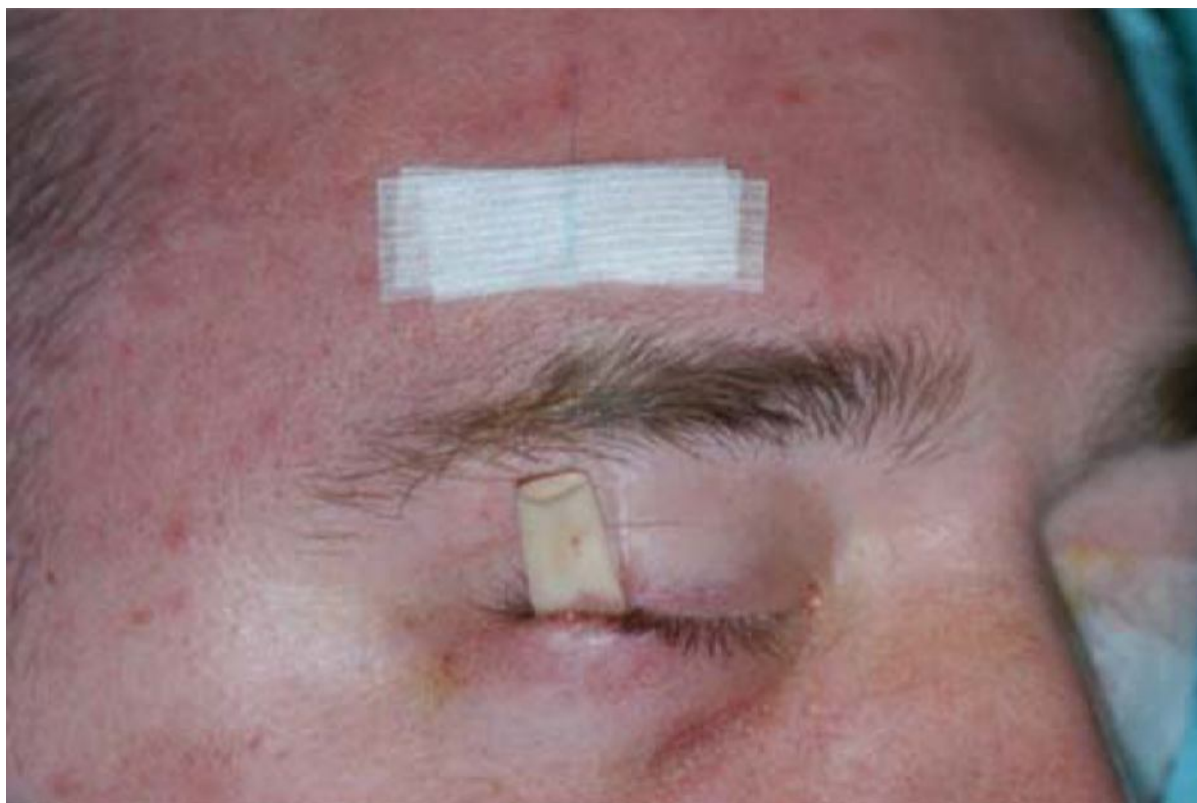

Figure 94-17 Postoperative view of a patient with a drain and traction stitch in place.

Blowout Fractures of the Medial Wall of the Orbit

Repair of medial blowout fractures is similar in principle, but the incision used is either a Lynch incision or a conjunctival incision placed between the plica semilunaris and the caruncle.^[12] A Desmarres retractor is used to retract the caruncle medially, and a Colorado needle again makes the incision through the conjunctiva, with the eye protected by a narrow malleable retractor and corneal shield. Tissue is then gently divided with blunt Stevens scissors in a posteromedial direction to avoid the lacrimal system. The periosteum is again incised and elevated posteriorly to expose the fracture site. It is likely that at least the anterior and, possibly, the posterior ethmoid arteries will require cautery and division. If the posterior ethmoid artery is reached, dissection must proceed with great care because the optic foramen will be found 3 to 8 mm posterior to this artery. Frequently, a less robust allograft is needed, such as 0.4-mm nylon. Caution is required to avoid driving the fixation screw above the frontoethmoidal suture.

The incisions may be joined to provide wide exposure of the floor and medial wall.

Fractures of the Roof of the Orbit

Fractures of the roof of the orbit associated with intracranial injury may be approached via a coronal incision to provide wide access for examination and repair of possible dural injury. Other fractures without intracranial involvement may be exposed endoscopically by way of the frontal sinus. The bony fragment may be reduced and, if necessary, fixated. If associated outer table fractures are to be repaired, they may then be plated through the same sub-brow incision while taking care to preserve the supraorbital neurovascular bundle. Most commonly, however, roof fractures that need to be repaired require neurosurgical consultation and a combined approach.

Choice of Implant Material

In the current era, alloplastic materials have advanced enough that surgeons can often avoid the use of autografts, thereby precluding donor site morbidity and resorption. Titanium mesh has been a common choice for reconstruction of the orbit because it is readily shaped and cut. However, tissue adheres strongly to this mesh, thus making it less desirable in such situations.

A variety of plastic materials have been designed for reconstructive use. Silicon is an older implant that causes no adhesions but is quite soft. Porous polyethylene is a popular choice for floor and medial wall fractures and is particularly useful when barrier coated on the side facing the orbit. It is available in numerous sizes and shapes and is easily shaped with scissors or scalpel. Although no fixation is theoretically required, the periosteum over the

implant must be closed with interrupted sutures.

Our group uses nylon foil implants. This material is easily shaped, has some memory, and rarely becomes infected. The 0.6-mm thickness is malleable enough to bend for insertion but stiff enough to support the orbital contents. A 0.4-mm thickness is useful for repair of medial wall fractures, where less strength is necessary and the ability to temporarily deform the plate is desirable. No tissue adhesion occurs, and because the implant is fixed to bone, closure of periosteum is unnecessary.

A relatively new alloplastic material has also been found to be well suited to repair of these fractures: a titanium mesh–reinforced thin porous polyethylene sheet. It has the advantages of tissue ingrowth and excellent memory with easy intraoperative shaping, and the barrier coating on the side placed toward the orbit prevents adherence of tissue.

POSTOPERATIVE MANAGEMENT

Our group admits patients overnight for observation and pain control after fracture repair. If orbital hemorrhage occurs, the most serious complication of the surgery, it will be noted quickly and may be drained as soon as possible. Placement of a drain and lack of conjunctival closure are intended to help prevent buildup of significant orbital pressure in the event of bleeding, but occasionally, opening of the wound, evacuation of hematoma, and possibly removal of hardware may be necessary. Oral narcotic/acetaminophen combinations generally suffice for control of pain. The patient rests with the head of the bed elevated and is instructed to not bend below the waist, lift greater than 5 lb, or strain for 3 days. Nose blowing is not allowed for the following 4 weeks. Nausea is treated with an antiemetic because vomiting might cause a severe increase in orbital pressure. An antibiotic such as cephalexin and a steroid are administered intravenously while in the hospital. Antibiotics are taken orally for 7 days postoperatively to prevent infection of the allograft, along with rapidly tapering doses of oral steroid.

The patient is seen in the office 1 week and 1 month postoperatively and as needed after that. In the event of entrapped muscle, it is wise to prepare the patient and family for the probable subsequent temporary paresis of the involved muscle and to reassure them that when the patch is removed, the abnormal eye position is expected and almost certainly temporary (Figs. 94-18 to 94-21).

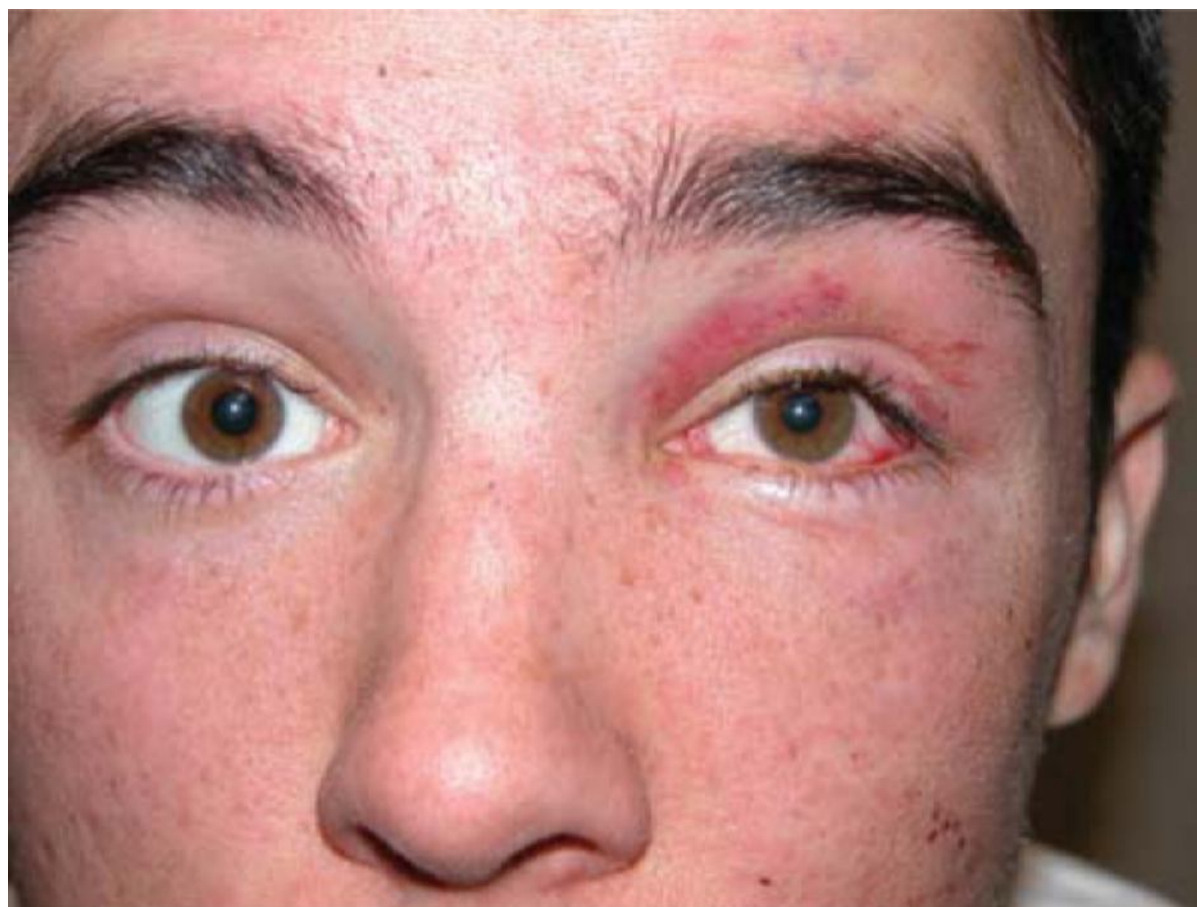

Figure 94-18 Trapdoor fracture of the left eye 24 hours after repair.

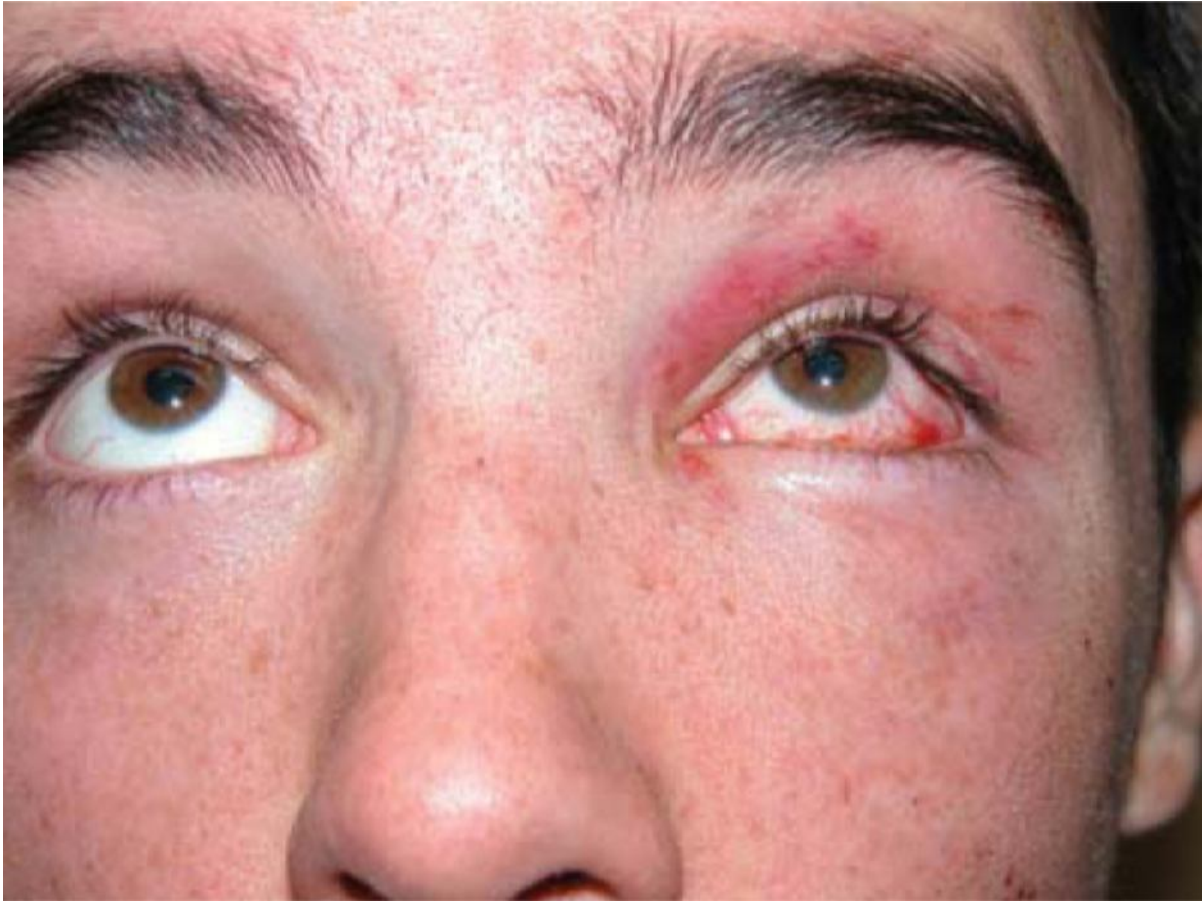

Figure 94-19 Upgaze.

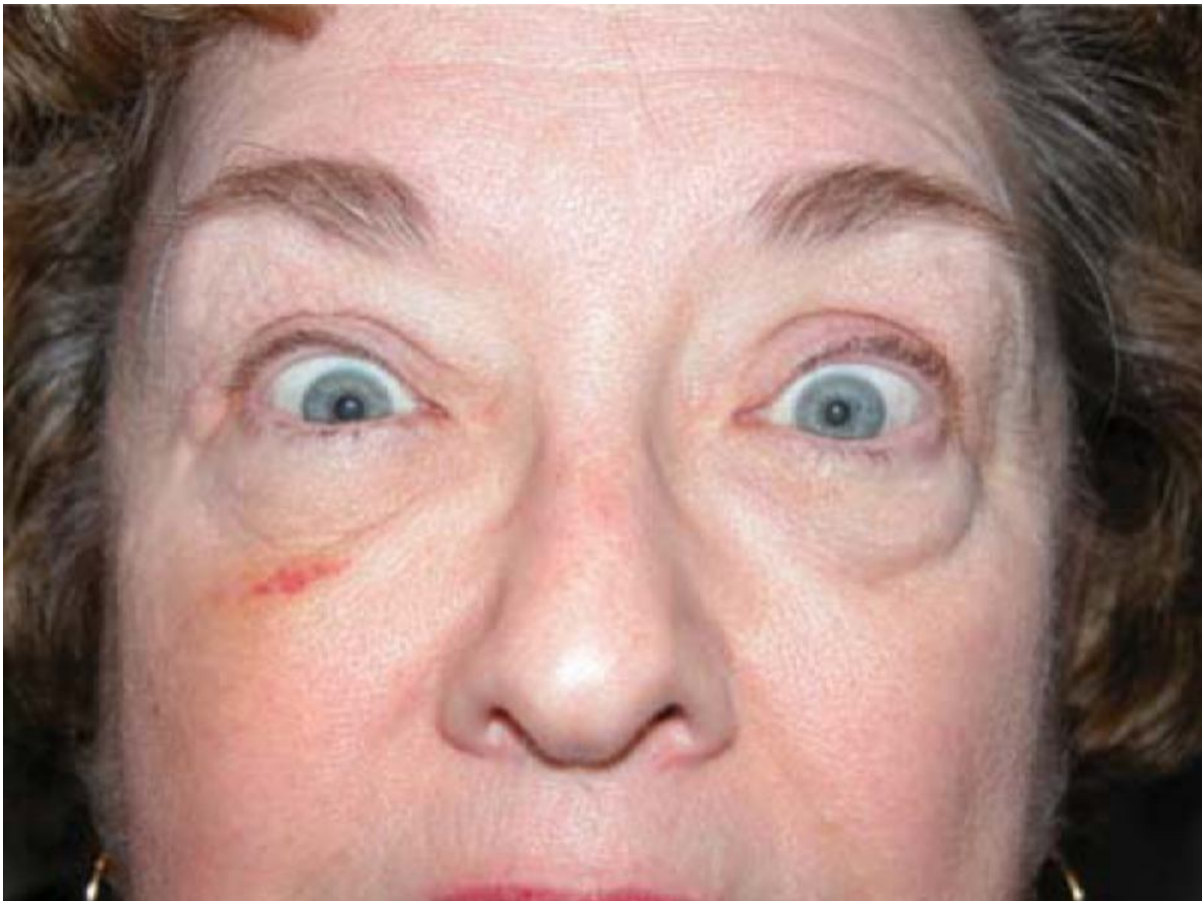

Figure 94-20 Patient 2, 1 week postoperatively—the diplopia has resolved.

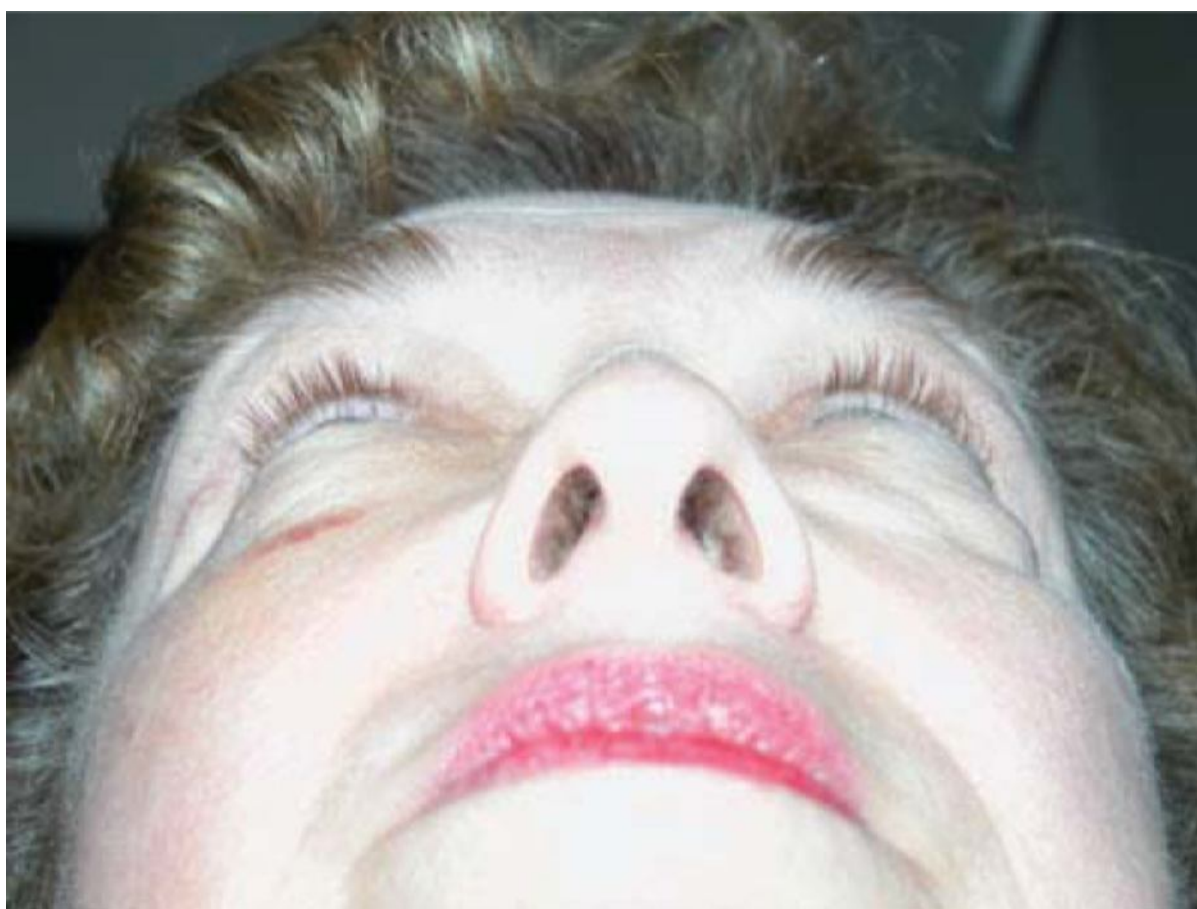


Figure 94-21 Patient 2, 1 week postoperatively.

PEARLS

- Documentation of the condition of the eye before and after surgery is critical.
- Young patients with small floor fractures, particularly when experiencing severe pain or nausea, must be suspected of having an entrapped inferior rectus muscle.
- Muscle entrapment does not occur in large fractures, but muscle herniation (not an emergency) does.
- Floor implants should be placed far enough posterior to the orbital rim that they are not palpable.
- Approximately 1 cm² of fracture will allow the eye to move posteriorly about 1 mm.

PITFALLS

- Failure of the implant to rest on the posterior shelf of bone may cause continued enophthalmos.
- Manipulation of the orbit in the presence of significant globe injury or traumatic optic neuropathy must be avoided.
- Failure to check and document that forced ductions at the conclusion of the procedure are as free as or better than those at the beginning may allow orbital tissue trapped under the implant to go unnoticed.