

Chapter 108 – Foreign Bodies of the External Auditory Canal

Barry E. Hirsch

A foreign body of the external auditory canal can pose a real challenge to otolaryngologists. Foreign bodies are more commonly seen in the pediatric population but they do occur in adults. Insects, vegetable matter, and inorganic material are the objects seen most frequently. Removal of the material is important not only for relieving acute symptoms of pain, pressure, and hearing loss but also to avoid potential sequelae of infection, canal stenosis, and further hearing loss.

PATIENT SELECTION

The acute event resulting from entrapment of a foreign body in the ear canal will bring most patients to the attention of a physician. Such patients also include adults, who become immediately aware that an object that they were using to clean or manipulate the ear becomes dislodged and is left in the external auditory canal. The most common inorganic object creating this problem is the end of a cotton-tipped applicator. After ear cleaning, people may realize that the cotton tip is no longer attached to the end of the applicator. Similarly, other materials, such as facial tissue and paper, can be rolled in an elongated fashion and used to probe the ear. Institutionalized adults and children may also use these materials for ear cleaning or packing. In this population, if drainage, infection, or odor has not developed, such material may be found only on routine physical examination.

Along with using instrumentation to clean their ears, adults also place objects in the ear canal for protection, including devices to minimize water exposure because of recurrent otitis externa or perforation of the tympanic membrane. Material used for hearing protection can become lodged or break off and remain in the external canal. Examples of such products include silicone putty used for sound or water protection and Silastic occlusive plugs or foam inserts for sound protection. Again, patients become acutely aware of broken off material remaining in the ear canal.

The list of objects that children can put in their ears is endless. Unless a witness observes a child placing a foreign body in the canal, its presence may not be discovered until routine physical examination detects the object or problems arise because of its presence. Objects that occlude the ear canal could produce hearing loss. This is a common chief complaint in an aware child or adult. Inflammation caused by the foreign object may result in infection and drainage. Localized aural discharge, cellulitis of the concha and external meatus, or serosanguineous otorrhea would prompt further evaluation. Certain materials pose more of a challenge to extract from the canal. Once water enters the external canal, vegetable materials such as beans and peas can swell and cause obstruction, pain, and maceration. Other materials that have been found in the ear canal include small toys, beads, erasers, crayons, pits from fruit, disc batteries, nuts, and stones. Disc batteries should be removed as soon as possible to avoid the liquefaction necrosis that results when moisture and secretions permit flow of electrons.[1] Irrigation of the ear canal should be avoided to minimize the risk of generating an electric current. Similarly, unsuccessful attempts at removal of the battery that result in trauma and bleeding in the ear canal would also allow flow of current and therefore further tissue destruction.

Insects occasionally find their way into the ear canals of children and adults alike. These are usually flying insects, but crawling insects may also enter the canal, especially when people are asleep. Patients become acutely aware of their presence because of the insect's noise and the induced pain. Management in this situation becomes more urgent than that needed for inanimate objects.

PREOPERATIVE PLANNING

In most situations, removal of a foreign body is an elective event. This permits planning in terms of the appropriate instrumentation, lighting, the need for and type of anesthesia, and the method of extraction. Adult or pediatric patients with otorrhea, hearing loss, and obstruction or occlusion of the ear canal who fail to respond to topical and systemic therapy may have pathology of the middle ear and mastoid or foreign bodies causing their symptoms and findings. If medical therapy fails to reduce the inflammation that limits visualization of the medial canal and tympanic membrane, computed tomography is appropriate to assess the status of the external canal, middle ear, and mastoid.

Management of insects in the ear canal requires additional material. A live insect can be difficult and painful to extract. Various solutions, including ether, isopropyl alcohol, and mineral oil, are effective in drowning and killing the

insect before flushing or extraction. Topical tetracaine (Pontocaine) or lidocaine (Xylocaine) solution can also be used to submerge and paralyze the insect in the ear canal.^[2] This is readily available in all emergency room settings.

Foreign bodies can be categorized not only by their chemical composition but also by their shape and consistency. Understanding the physical properties of a foreign body facilitates the choice of method for removal. Soft and wet objects similar to cerumen can be suctioned or flushed from the canal. Firm or hard foreign bodies require specific instruments for extraction. Round objects may get wedged at the bony isthmus or the cartilaginous-bony junction. Small foreign bodies may shift to the medial canal and get caught in the anteroinferior sulcus between the tympanic membrane and the bony canal.

Another classification system categorizes the foreign bodies into two groups: objects with smooth surfaces and not easily grasped (nongraspable) and objects with irregularly shaped surfaces and easily grasped. In a study of pediatric patients treated in emergency departments for foreign bodies in the ear canal, it was noted that beads were the most common objects. When the foreign bodies were group by nongraspable and graspable, the success rate for removal of a graspable object was 64% with a 14% complication rate. In contrast, successful removal of a nongraspable object occurred in only 45% of cases with a 70% complication rate. It was concluded that skilled emergency department personnel could handle pediatric patients with graspable foreign bodies in the ear canal with low complication rates. Nongraspable foreign objects should be referred to an otolaryngologist early in the course of their management.^[3]

A variety of instruments need to be available before extracting a foreign body in the ear canal. Otologic examination of the external auditory meatus (or mastoid cavity) identifies the presence of the foreign object. Its shape and consistency are noted. Small objects can readily be removed with a hand-held otoscope and operating head.

In a series of 698 pediatric patients with foreign bodies in the external auditory canal, Schulze and colleagues proposed indications for referral for otomicroscopy-guided removal. These indications were categorized by the type of foreign body (spherical or sharp-edged shape, disc batteries, and vegetable matter), location of the foreign body (adjacent to the tympanic membrane), time in the ear (>24 hours), patient description (<4 years of age with difficulty visualizing the foreign object, agitation, or both), and a history of previous attempts at removal.^[4]

Objects with an unusual shape that are wedged in the ear canal often require maximal lighting and more dexterous manipulation. An operating microscope provides the necessary light and the means for bimanual removal. Some of the instruments that should be available include various-sized ear specula; a water irrigation kit; small, medium, and large suction devices; ring and wire loop curettes; right-angled hooks; and picks. If necessary, the use of progressively larger specula facilitates exposure and dilatation of the canal. Injectable local anesthetics such as lidocaine with epinephrine should be available when manipulation and extraction are potentially painful.

It is important to determine whether the foreign object has penetrated the tympanic membrane or middle ear. Patients with acute hearing loss and dizziness should be suspected of injury transmitted to the inner ear. If available, an audiogram should be obtained to determine the nature and degree of the hearing loss. Exploration of the ear under intravenous sedation or general anesthesia should be considered for patients in whom damage to the ossicular chain or inner ear is suspected. General anesthesia will probably be necessary for most children and anxious, uncooperative adults.

SURGICAL TECHNIQUES

Removal of Insects

Flying or crawling insects that enter the external canal typically need to be removed urgently. Live insects can cause pain and ongoing irritation because of their movement and potential trauma to the tympanic membrane. The noise and disturbing sensation created by live insects drive patients to seek urgent medical attention. The ear canal and tympanic membrane are inspected to identify the species of insect and the trauma it may have caused. The presence of loose appendages such as wings or legs should be noted. The patient is placed supine with the involved ear facing up. The ear canal is filled with one of the previously mentioned solutions (ether, isopropyl alcohol, mineral oil, tetracaine, or lidocaine). This may incur a flurry of activity as the insect drowns. Should the patient have severe pain, the skin of the external canal can be infiltrated with local anesthetic. The insect is extracted from the canal with suction, which also removes the excess solution. Ideally, the insect is removed with the suction tip as well. It may be necessary to remove the insect with alligator forceps. Once the insect is removed, the canal is carefully inspected for residual body parts, which are carefully removed with forceps or a fine, cotton-tipped applicator. The integrity of the ear canal skin and tympanic membrane is verified.

Removal of Vegetable Material

Foreign bodies such as peas, beans, nuts, and corn have the potential to swell as a result of oil secretions from the canal, water from swimming or showering, or attempts at flushing the ear. If the object is relatively dry and intact, extraction with suctioning may simply remove the material. It may be necessary to place a small, right-angled hook behind the object to manipulate it into the lateral canal. Flushing these objects out is not recommended to avoid swelling, maceration, and disruption of the integrity of the object. However, if the object is soft, crumbling, and friable and cannot be extracted with suction, irrigation may be necessary. Warm tap water typically suffices for such irrigation. Mixing hydrogen peroxide with an equal volume of water mechanically facilitates aural flushing. An irrigating system such as that shown in Figure 108-1 is most effective. Other systems would include a large-gauge angiocatheter attached to a syringe. Large metal ear syringes are also available for this purpose. Care is taken to avoid directing excessive pressure at the tympanic membrane.



Figure 108-1 A DeVilbiss irrigating system (syringe and bottle DV177) connected to a positive pressure air source is used to flush soft material from the external auditory canal.

Management of foreign bodies in children is particularly challenging. One must assess the nature of the foreign body and the anticipated degree of technical difficulty that will be necessary to extract it. If the object is relatively intact and can be removed with suction or just a few passes of a right-angled instrument, effort should be made to extract it without general anesthesia, which may require that the child be restrained by the parents or an assistant or be wrapped in a sheet like a papoose. If the foreign body is impacted, it is usually necessary to take the child to the operating room and, under masked general anesthesia, extract the object.

Objects that are wedged in the ear canal medial to the cartilaginous-bony junction pose a significant challenge. By using sequentially larger ear specula, attempts are made to dilate the lateral external auditory meatus to facilitate extraction. A large-gauge suction placed on the object may remove it from the canal. Care must be taken to avoid further impaction and medialization with this technique (Fig. 108-2). If this method is unsuccessful, a right-angled hook (Fig. 108-3) is passed beyond the object and withdrawn laterally. Passing the instrument in the anterior inferior canal should be avoided because of the thin skin and sensitivity of the canal. The superior and posterior quadrants have thicker skin that is more readily compressed. If manipulation of the ear is uncomfortable, a local anesthetic can be injected into the canal skin. A small volume should be used to minimize further edema from the injected solution. After adequate anesthesia has been achieved, extraction can proceed in a more relaxed setting.

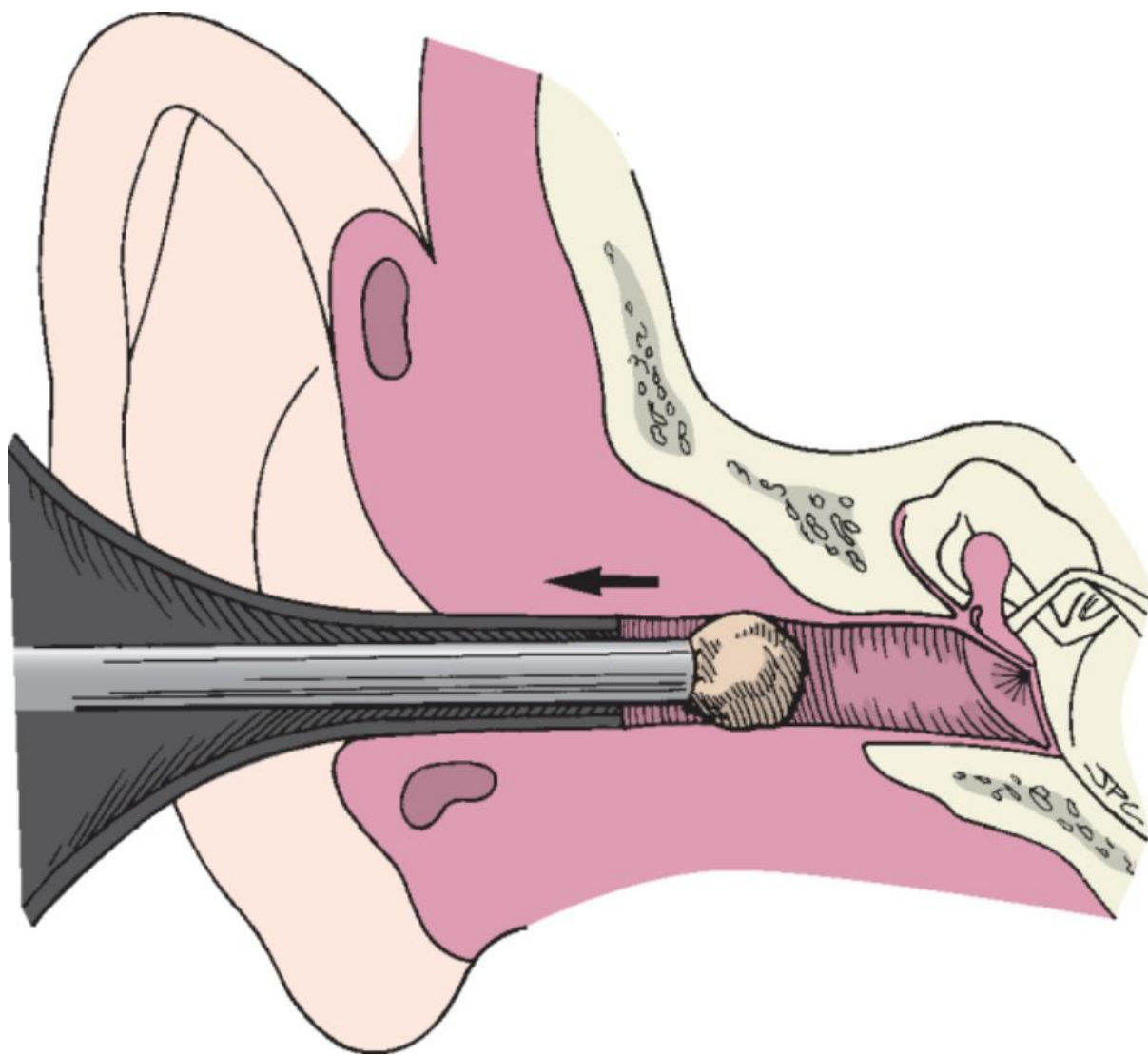


Figure 108-2 A large-gauge suction is usually successful in removing most objects from the external auditory canal. Care must be taken to not push the foreign body more medially.

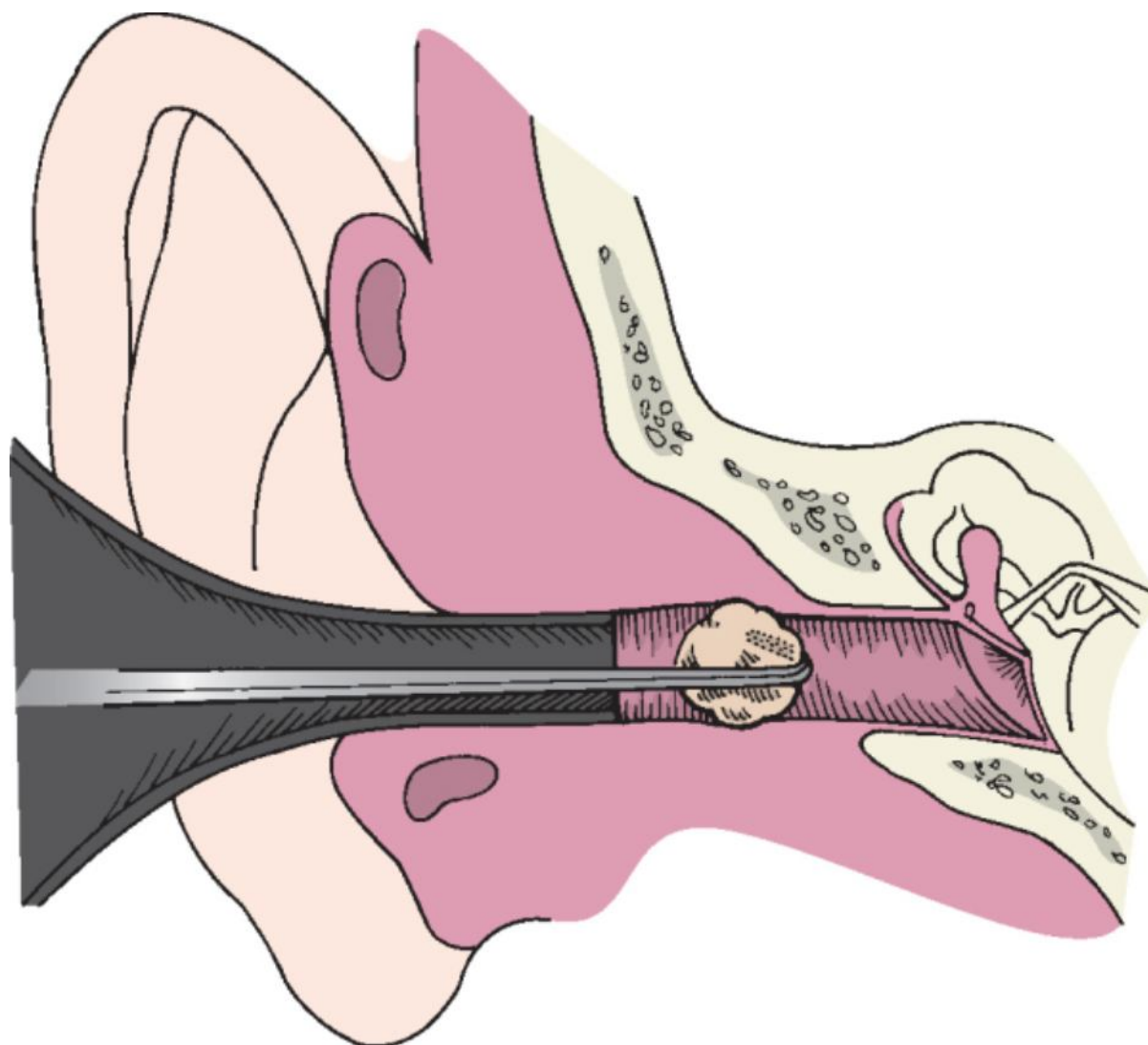


Figure 108-3 A right-angled hook is passed beyond the object, which is then extracted laterally.

A novel idea for removing an object that is difficult to extract is to attach an anchor to the foreign body. Isaacson described applying a quick-setting epoxy adhesive to a foreign body that is spherical in shape with a smooth surface and impacted medially in the canal. This was done in a two-step procedure by applying the first layer of glue to the foreign body in the clinic 1 to 2 days in advance. After 10 minutes, a second layer was applied to a small metal anchor (a no. 8 machine screw with a fashioned concave surface), which was then attached to the foreign object. The child was taken to the operating room 2 days later, at which time a firm grasp on the anchor permitted extraction through the ear canal.^[5]

On rare occasions, larger objects cannot be extracted despite the techniques previously described. This usually occurs when the foreign body has been wedged medially beyond the cartilaginous meatus. Children and rarely adults may require general anesthesia for more complete foreign body removal. The ear canal and postauricular area are prepared and draped in sterile manner. The largest ear speculum that fits into the external auditory meatus is placed into the meatus. If a hook cannot be advanced beyond the object, it may be necessary to open the incisura with an incision made at the 12-o'clock position down to the bony canal. This permits further dilatation of the external canal and facilitates advancement of an instrument (Fig. 108-4).

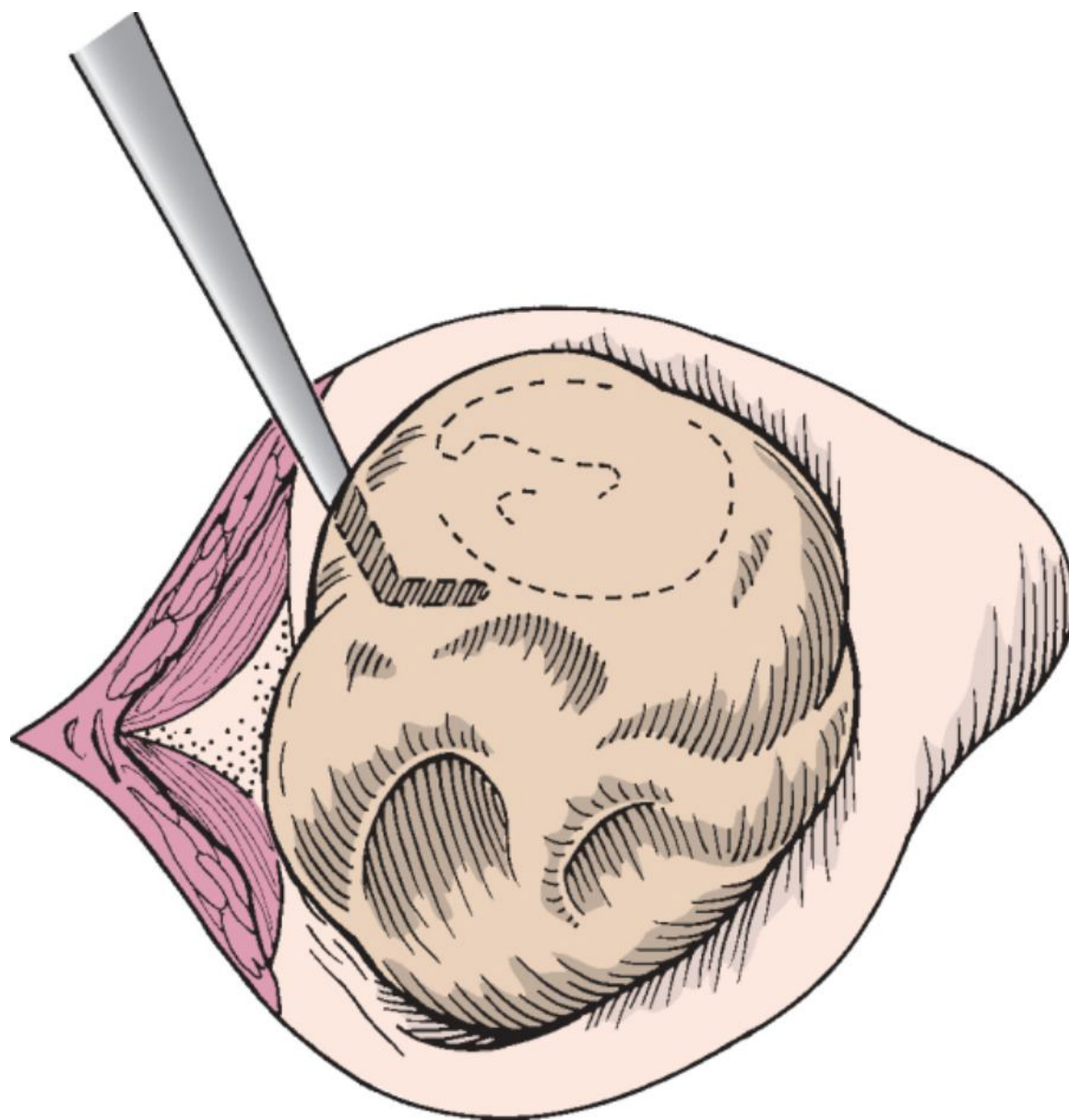


Figure 108-4 An incision is made in the incisura (12-o'clock position) of the external auditory meatus to widen the meatus and permit an instrument to be passed medial to the foreign body.

Perforation of the tympanic membrane with possible disruption of the ossicular chain may occur as a result of a foreign object placed in the ear. The penetrating object, such as a cotton-tipped applicator, pencil, bobby pin, stick, or knitting needle, is usually long and narrow. It is often removed or readily extracted at the time of injury.

Intravenous sedation or general anesthesia is preferred for patients in whom perforation of the tympanic membrane is suspected. After removal of the foreign body, the tympanic membrane is carefully inspected. Small central perforations or lacerations are repaired with Gelfoam placed in the middle ear medial to the tympanic membrane defect or with a paper patch applied to the lateral surface of the tympanic membrane (see Chapter 113). Patients with significant conductive or sensorineural hearing loss should undergo exploratory tympanotomy for evaluation of the integrity of the ossicular chain and the round and oval windows. Details regarding repair of the ossicular chain and oval window can be found in Chapters 114 and 117, respectively.

Occasionally, it may be necessary to undertake a postauricular approach. In such cases, a postauricular incision is made down to the posterior wall of the bony external auditory canal, similar to the postauricular approach for exostoses of the external auditory canal (see Chapter 109). A lateral conchal flap is incised through the ear canal. A postauricular incision is made and connected with the conchal flap, and tracheostomy tape and a self-retaining retractor are positioned to reflect the auricle anteriorly for postauricular exposure of the meatus lateral to the foreign body (Fig. 108-5). A right-angled hook can be passed anterosuperiorly beyond the object and extracted laterally. If excessive trauma and laceration of canal skin are anticipated with extraction of the object, a flap of canal skin pedicled inferiorly is raised. The foreign body is removed, and the canal skin and auricle are returned to their original positions. The ear canal should be stented to immobilize any skin flaps and avoid stenosis. Care is

taken to avoid trapping of epithelium by unrolling folded edges and reapproximating skin flaps to the best fit. Methods for packing the ear canal include the use of Gelfoam, a Merocel ear pack, or a rosebud packing made of silk strips and cotton balls (see Chapter 113).

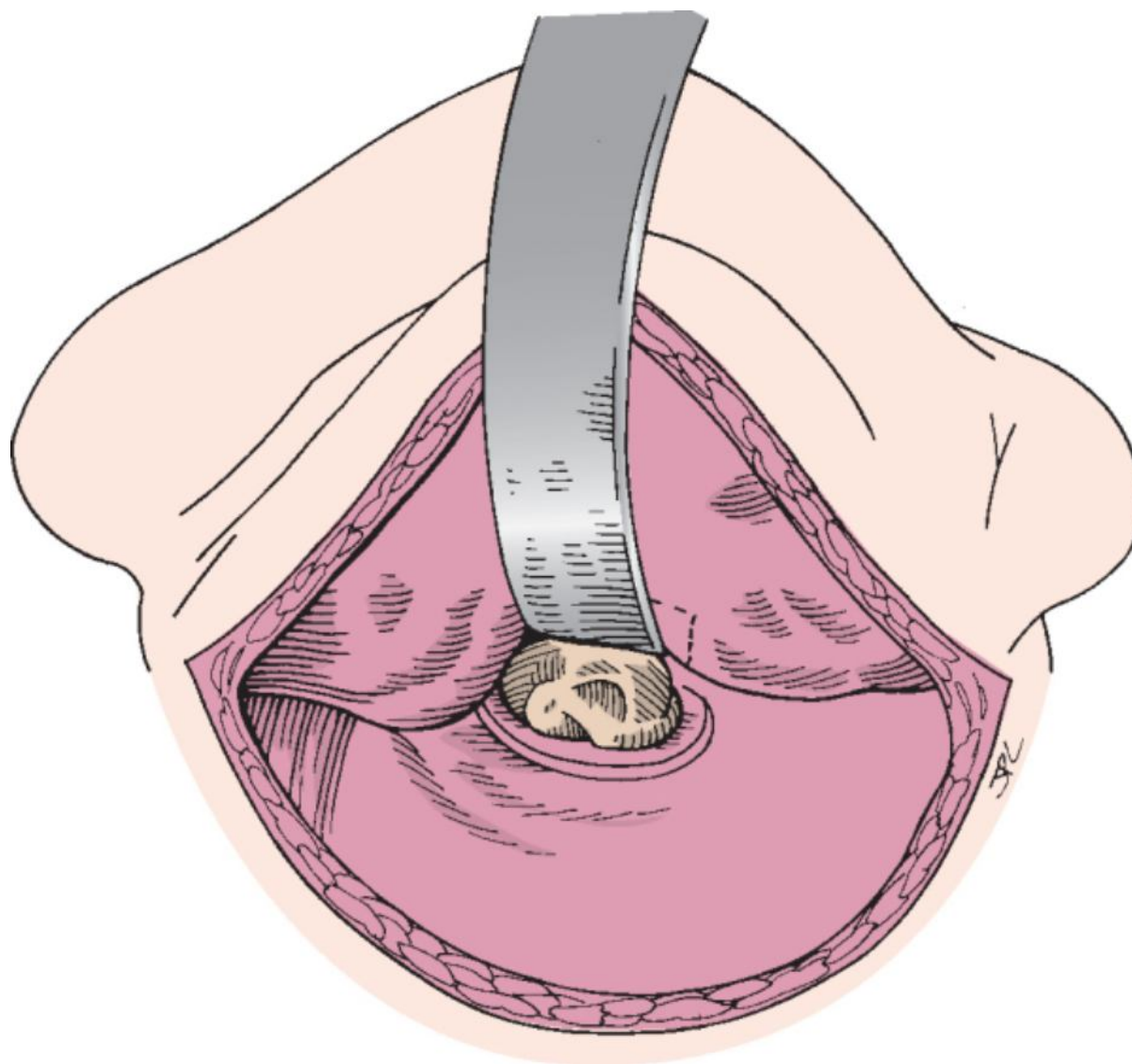


Figure 108-5 The ear has been reflected anteriorly to expose the lodged foreign object medially.

POSTOPERATIVE MANAGEMENT

Patients having foreign bodies extracted from the ear canal who incur minimal trauma and have no associated inflammation require no further treatment. Should maceration or cellulitis preexist or laceration and inflammation occur during extraction, topical eardrops are advised. Otological antibiotics, usually containing steroids, are instilled twice daily, depending on the severity of inflammation. The patient is instructed to avoid further water contamination by keeping the ear free of swimming pool or shower water. Vaseline applied to a cotton ball is usually effective in keeping the ear canal dry.

If significant cellulitis has developed or the patient is diabetic, the use of systemic antibiotics may be necessary. *Staphylococcus aureus* and *Pseudomonas aeruginosa* are the organisms most likely to be involved. Oral ciprofloxacin should be effective in treating external canal cellulitis.

Patients who require external canal stenting or packing are also treated with topical antibiotic drops. The Gelfoam, canal pack, or rosebud pack serves as a wick for delivering the topical drops. Wicks meant to be placed for a short time, such as a Pope otowick, are generally removed after 3 days unless there is severe inflammation or laceration of the canal skin. The wick then remains for 1 week. The patient removes the wick and continues applying topical drops. Patients in whom a Merocel ear pack or rosebud pack is placed are seen in approximately 1 week. The packing is removed and the canal inspected. Topical drops are continued for a few more days. The patient continues to keep the ear free of water exposure for a few weeks, at which time examination of the ear

canal is performed to confirm complete healing.

PITFALLS

- Instrumental removal of a live insect without drowning it can intensify the pain and stimulation experienced by the patient.
- Instrumentation directed medially along the posterior ear canal may contact and traumatize the tympanic membrane.
- Aggressive manipulation may result in more medial impaction and possible injury to the tympanic membrane and ossicular chain.
- Failure to recognize and properly reapproximate lacerated canal skin may lead to trapped epithelium and the development of canal cholesteatoma.
- Repeated unsuccessful attempts at foreign body removal will result in canal trauma, further obstruction, and an uncooperative patient.

PEARLS

- Aural irrigation to remove foreign bodies (other than insects) in the external auditory canal should be avoided because the object is rarely flushed out and skin maceration often results.
- Live insects can be drowned with alcohol, mineral oil, or topical anesthetics (Pontocaine, Xylocaine).
- A large nasal suction (9F) device may make sufficient contact with the object to remove it from the canal.
- Passing a right-angled hook parallel to the object and then beyond it allows optimal placement of instruments for extraction.
- Injection of a local anesthetic followed by canal dilatation with progressively larger specula may facilitate removal of the foreign body.

Copyright © 2009 Elsevier Inc. All rights reserved. Read our Terms and Conditions of Use and our Privacy Policy.
For problems or suggestions concerning this service, please contact: online.help@elsevier.com