



Expert Consult: Online and Print

Chapter 118 – Bone-Anchored Hearing Devices

Yael Raz

Conductive and mixed hearing loss can often be treated surgically or with conventional hearing aids. However, certain patients are not candidates for standard surgical approaches or traditional amplification—for example, those whose external auditory meatus has been closed off during lateral temporal bone resection, mastoid cavities that continue to drain despite surgical treatment, or congenital aural atresia not favorable for repair.

Bone-anchored hearing devices conduct sound via bone vibration, thereby effectively bypassing the middle ear conductive apparatus, and represent a viable alternative for this subset of patients. Although conventional bone-conducting hearing aids can also provide amplification in such cases, these devices can cause discomfort and possible skin erosion as a result of pressure from the headband. Bone-anchored devices are osseointegrated and thus do not place pressure on the surrounding skin. Bone-anchored hearing devices are also an appealing alternative to the CROS (contralateral routing of offside signal) aid in the treatment of single-sided deafness. Sound from the deafened side is transmitted to the intact contralateral cochlea with little attenuation. Multiple studies suggest that the Baha is better accepted than amplification with the CROS aid.^[1,2]

Coupling of a bone vibrator to an osseointegrated implant was initiated in Sweden in the early 1970s.^[3] Several companies have marketed bone-anchored hearing aids in the past; however, at present there is one dominant device in the marketplace, the Baha (manufactured by Cochlear Corporation, which recently acquired Entific Corporation). The Baha consists of three parts: an implanted titanium flange fixture, a sound processor, and an external abutment that couples the titanium fixture to the sound processor (Fig. 118-1). Successful placement of the Baha depends on the creation of a healthy, permanent percutaneous connection. Osseointegration of the flange fixture is a critical factor. The implant is made of titanium, a metal that is highly biocompatible and corrosion free. The microstructure of the implant has been designed with a rough surface containing micropits that enhance interaction between osteocytes and the implant, thus maximizing osseointegration.^[4] The fixture is threaded to maximize contact with the surrounding bone and enhance stability. The implant is inserted with a high-torque drill at slow speed to avoid thermal damage to the surrounding osteocytes. Disposable drill bits ensure a sharp bit for each step, and irrigation prevents thermal damage. Another critical factor in ensuring the health of the percutaneous connection is avoidance of infection or inflammation. Modeled after the natural interface between fingernails, talons, or teeth and the surrounding skin or gingival bed, the skin at the fixture penetration site must be free of hair and immobile.^[5] Movement of skin at the implant-skin interface or the presence of hair follicles can provide an entry point for bacterial infection or inflammation. Meticulous attention to technique in the soft tissue work is critical for stabilization of the surrounding skin. Insertion of the titanium device requires a specialized handpiece that is fitted with multiple adaptors to elevate the skin graft, establish a guide hole, and countersink and insert the fixture. Attention to detail such as handling the titanium components with titanium forceps, using appropriate drill speeds, and irrigation can be critical in ensuring osseointegration of the device and a healthy percutaneous connection. Complications with the Baha consist primarily of adverse soft tissue reaction surrounding the fixture and failure of osseointegration.^[6,7]



Figure 118-1 The Baha system includes a flange fixture, an external abutment, and a sound processor that snaps on to the external abutment. In adults undergoing a single-stage procedure, the flange fixture is preattached to the external abutment, and both pieces are inserted as a unit. (Permission granted from Cochlear Corporation.)

PATIENT SELECTION

When the Baha is being considered for mixed or conductive hearing loss, the bone line should be better than 45-dB pure-tone average (PTA; 0.5, 1, 2, 3 kHz) in the affected ear, and word recognition should be greater than

60%. When bone conduction is worse than 45 dB, a body-level sound processor is more suitable. For single-sided deafness, the contralateral ear should have a PTA air conduction threshold better than 20 dB. Insertion of the titanium flange fixture is a relatively safe and quick procedure that can be performed under local anesthesia, and there are relatively few contraindications. The patient must be comfortable with the concept of having a device protruding from the scalp. Certain patients actually prefer the aesthetic appearance of the Baha as opposed to a conventional hearing aid because it can be hidden with certain hairstyles. It is important to communicate to patients that it is necessary to permanently remove the hair follicles surrounding the abutment and that the scalp will be concave at the site of the implant to immobilize the surrounding skin. Extensive preoperative counseling with photographs enhances patient satisfaction. A test band coupled to the sound processor can provide a simulation of the sound input achieved with the Baha; however, sound fidelity is not as high as with the actual implanted device because of soft tissue attenuation.

The patient's ability to care for the implant site must be taken into consideration in selection for this procedure. Patients with certain psychiatric or other disorders that impair the ability to maintain proper hygiene may not be able to perform the appropriate local skin care required to keep the implant site healthy. Patients with a history of external beam irradiation to the scalp, diabetes, or dermatologic conditions such as psoriasis may be more prone to adverse skin reactions and need to be monitored closely, but these conditions have not been found to increase the risk of implant loss.^[8] Before surgery, the patient meets with an audiologist to select the sound processor.

PREOPERATIVE EVALUATION

In children, a computed tomography (CT) scan of the temporal bone can be helpful, particularly in the presence of developmental abnormalities that affect the thickness of the skull. In adults, there is no indication for imaging studies. One potentially frustrating aspect of the preoperative evaluation is the preauthorization process. The Baha device falls in the gray zone between cochlear implants, which are routinely covered by insurance, and hearing aids, which are not generally covered. Insurance policies regarding the Baha seem to vary from state to state and among various companies. It is critical to address this issue before surgery and to clarify whether the insurance company will cover the cost of the sound processor in addition to placement of the flange fixture. On occasion, coverage can be obtained with physician advocacy on the patient's behalf in the form of a letter indicating that the patient is not a candidate for conventional amplification and explaining how the device differs from a conventional hearing aid.

SURGICAL APPROACH

We prefer to insert the titanium flange fixture under general anesthesia. However, when there are concerns regarding a patient's ability to withstand general anesthesia, the procedure can be performed under intravenous sedation with local anesthesia or even with local anesthesia alone. In adults, insertion of the device is performed in a single-stage procedure in which the flange fixture is inserted with the abutment preattached. Once the site has healed and osseointegration has occurred, the sound processor is attached to the abutment. In children or in adults with irradiated skin or poor bone quality, the flange fixture is inserted at the first stage and the abutment is placed at a second stage once osseointegration has occurred.

Planning the Flap

We typically use an inferiorly based skin flap. A mock device is useful in outlining the size of the skin flap. However, We have found that the fixture is ideally placed at the center of the skin flap and not at its superior aspect, as marked in the present generation of mock devices. If the fixture site is marked too superiorly within the outline of the mock device, gravity often results in a superior overhang of tissue that makes contact with the sound processor. The implant site should be 5 to 5.5 cm away from the ear canal to prevent the sound processor from contacting the pinna (Fig. 118-2). Placing the fixture in the region of the temporal line will make it most likely that adequately thick cortical bone will be encountered. It is our preference to use the dermatome because it is rapid and consistently results in an even, thin skin flap (0.6-mm thickness, 24-mm width). However, equally thin flaps can also be achieved manually. When two-stage surgery is performed, if the cover screw projects from the skin surface, the dermatome can tear at this site and therefore manual elevation plus thinning of the flap is recommended.

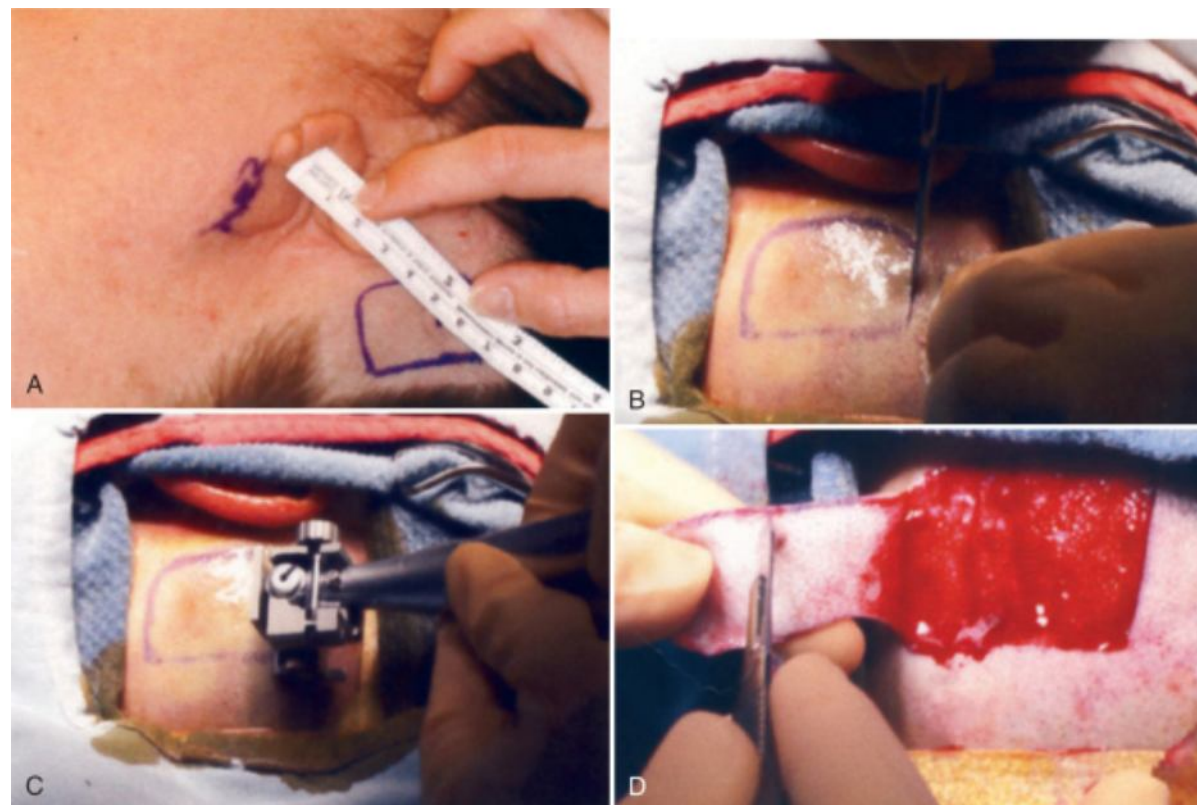


Figure 118-2 A, A mock device is used to plan the size of the skin flap. The implant should be placed 5.0 to 5.5 cm from the ear canal to ensure that the sound processor will not contact the auricle. B, The skin is incised superficially to allow the dermatome to engage the skin. C, The Baha dermatome is used to elevate an inferiorly based skin flap. D, Hair follicles are removed from the undersurface of the skin flap.

The postauricular region is shaved and topical anesthetic is infiltrated at the planned flap site. If using the dermatome, the local anesthetic should be massaged into the skin so that the skin surface is smooth before harvesting the graft. A superficial skin incision at the superior aspect of the planned flap is helpful in allowing the dermatome to engage the skin. Use of mineral oil and application of pressure with a tongue depressor in advance of the dermatome is helpful in developing the skin graft. Steady downward pressure and slow, even progress ensure an intact graft that remains attached to the scalp inferiorly. If constant downward pressure is not maintained until the dermatome has been stopped, the skin graft may be severed at the base. The graft can still be used; it should be maintained in moist gauze and sutured as a free graft over the implant site. Once the flap has been elevated, its undersurface is freed of hair follicles with a horizontal sweeping motion of the scalpel (Fig. 118-2). Even for thin flaps elevated with the dermatome, this step is helpful in keeping the percutaneous connection clean and infection free. The skin graft is then reflected inferiorly and covered with moist gauze.

Drilling the Fixture Site

The soft tissue is incised superiorly, anteriorly, and posteriorly; elevated off the underlying periosteum; and reflected inferiorly. The inferior attachment is not divided until adequate cortical thickness has been established by drilling the guide hole. Thus, if the drill site needs to be altered significantly, the soft tissue can be replaced while avoiding unnecessarily large and unsightly defects. This area of the mastoid cortex is denuded of periosteum in an amount sufficient to accept the countersink. Once the initial drilling steps (guide hole and countersinking) establish adequate cortical depth, more extensive removal of soft tissue can be performed.

Drilling of the guide hole is performed at high speed with irrigation and use of the guide drill and a plastic spacer to ensure that depth of drilling is not greater than 3 mm (Fig. 118-3). It is critical that this step and all subsequent drilling steps be carried out precisely perpendicular to the mastoid cortex. Acute angles during the early drilling steps will result in angling of the flange fixture, which will lead to contact between the sound processor and the surrounding tissue and may result in discomfort or acoustic feedback. A drill indicator attachment is available to facilitate visualization of the drill's trajectory (see Fig. 118-3). The guide hole is examined to ensure that the sigmoid sinus, dura, and mastoid air cells have not been violated. The plastic spacer is then removed and drilling continues to a depth of 4 mm, again using copious irrigation. Some authors have recommended proceeding with implantation in the event of violation of the dura or sigmoid sinus because the flange fixture effectively stops leakage of cerebrospinal fluid or bleeding. However, a cerebral abscess has been reported with the Baha system.^[9] Additionally, osseointegration may be impaired by the absence of bone at the deep surface of the

fixture. If multiple attempts do not reveal bone depth sufficient to handle a 4-mm fixture, the surgeon may elect to proceed with a 3-mm fixture, although it is somewhat more prone to failure of osseointegration.[10] In a young child with a thin skull, exposure of the dura is often unavoidable, thus frequently necessitating use of the 3-mm fixture.[11]

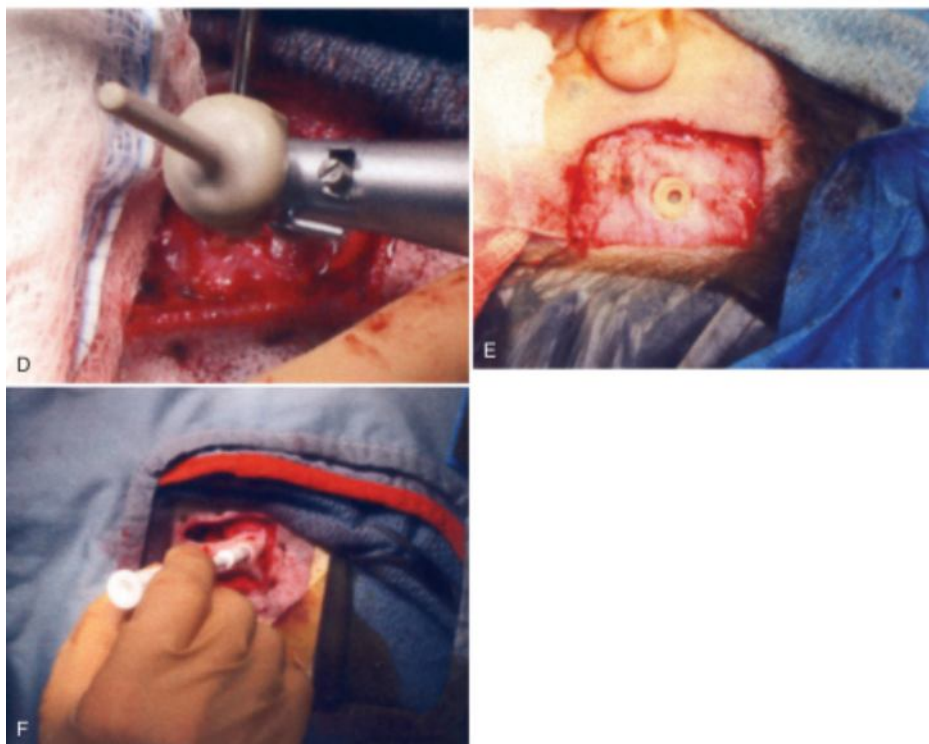
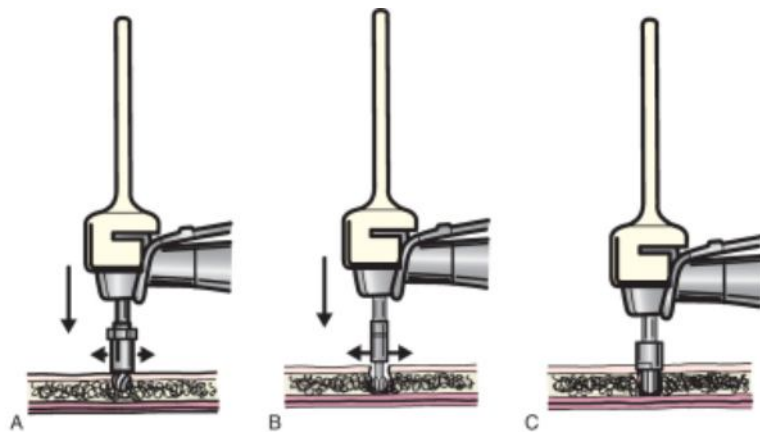


Figure 118-3 A, Drilling commences with use of the guide drill and a plastic spacer to ensure a depth no greater than 3 mm. B, The spacer is then removed and the guide hole is drilled to a depth of 4 mm if cortical bone thickness is sufficient. C, The appropriately sized countersink is then used. Drilling of the guide hole and countersink is performed under high speed (≈ 2000 rpm) with copious irrigation. D, The drill indicator facilitates visualization of the drill's trajectory. E, If the countersink has been drilled precisely perpendicular to the cortex, a concentric ring should be visible surrounding the guide hole. F, A 4-mm biopsy punch is used to remove skin directly overlying the drill site.

Once the guide hole has been established, the appropriately sized countersink drill bit is attached to the handpiece (3 or 4 mm, depending on the depth of the guide hole). The drilling motion for making the countersink and the guide hole should be up and down rather than plunging the drill in a single downward trajectory. This allows irrigation fluid to enter the drilled area and protects against thermal damage. The countersink drill widens the guide hole to an appropriate diameter and creates an even surface for the flange, thereby enhancing contact between the fixture and the surrounding bone. Care should be taken to remove bone from the threads of the drill. If drilling has been performed directly perpendicular to the cortex, a concentric countersink should be visible surrounding the drill hole. A cruciate incision is then made in the skin graft overlying the drill site. Alternatively, a 4-mm biopsy punch can be used (see Fig. 118-3).

Soft Tissue Removal

After drilling of the guide hole and countersink, the inferior attachment of the soft tissue underlying the skin flap is

divided. The periosteum is left intact except for the area of the countersink. Absence of soft tissue between the skin graft and the periosteum is essential to ensure fixation of the skin surrounding the flange fixture and prevent infection and inflammation. The margins surrounding the graft site are then retracted with double skin hooks, and the soft tissue surrounding the graft site is removed anteriorly, posteriorly, and superiorly (Fig. 118-4). The result is a beveled, gentle slope onto the skin flap and implant site. Individuals who are obese or have a particularly thick scalp are more prone to the development of this superior soft tissue overhang. Beveling of the margins is particularly important in this population to avoid contact between this superior shelf of skin and the sound processor.

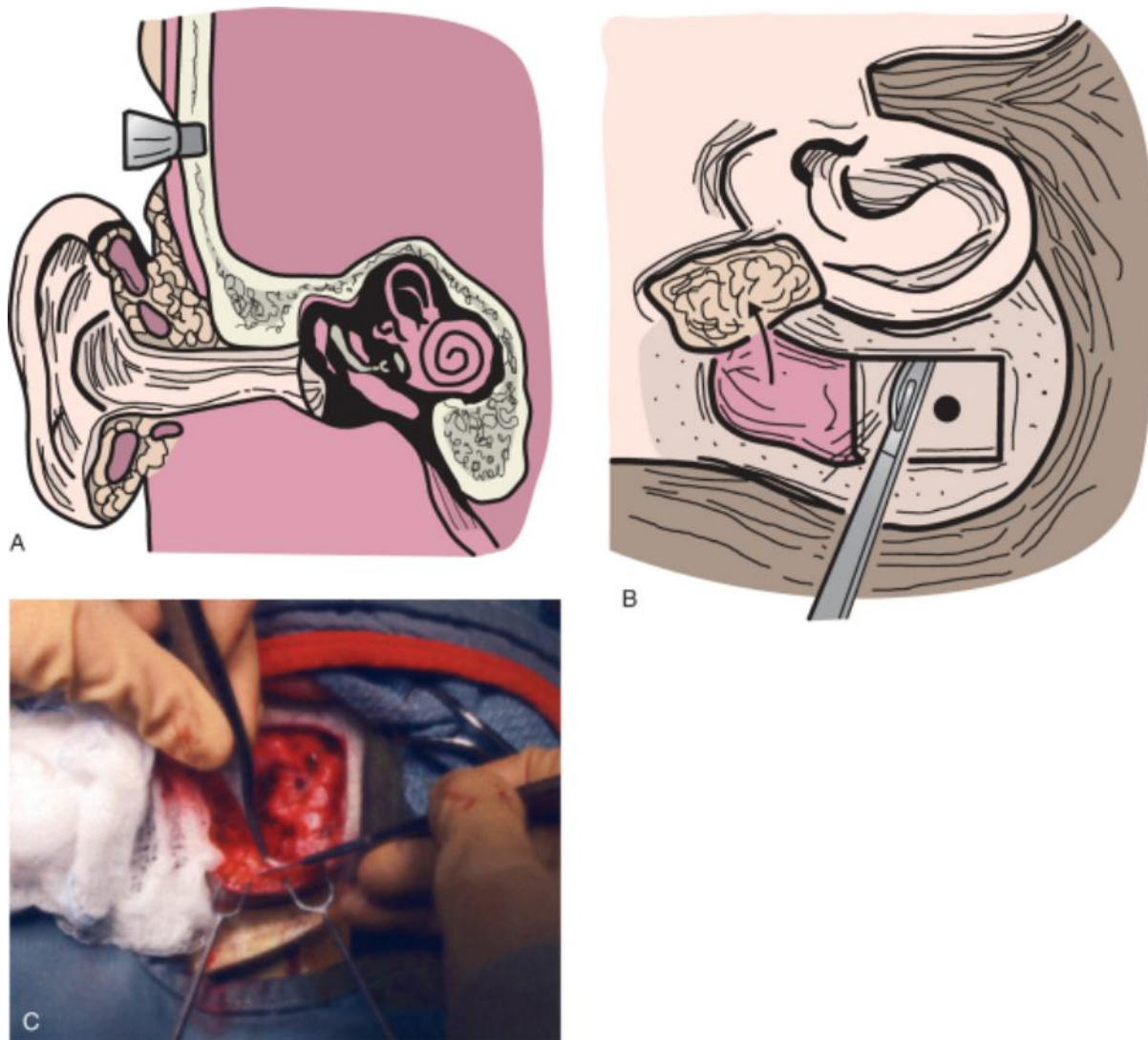


Figure 118-4 **A**, The bone underneath the skin graft site is covered only by periosteum. Note the absence of soft tissue. **B** and **C**, The tissue surrounding the graft site is also thinned aggressively to allow the skin margins surrounding the graft to slope gently toward the graft site.

Insertion of the Device

For adults undergoing a planned single-stage insertion, the abutment is packaged preattached to the titanium fixture (Fig. 118-5). An abutment inserter attachment is used to pick up the implant, which is inserted at low speed. The fixture is self tapping. Irrigation should be avoided until the first threads have engaged so that fluid is not trapped between the screw and bone. No pressure is necessary at this stage, and the fixture should be allowed to find its own way. The final turns can be performed manually to ensure a tight fit; however, care must be taken to not tighten the screw excessively and damage the surrounding bone. The implant must be stable once inserted or connective tissue will form at the bone-screw interface and prevent osseointegration of the fixture. If a biopsy punch was used previously, a small incision may be necessary to enlarge the opening sufficiently to accept the abutment. Alternatively, a small cruciate incision can be made in the skin overlying the abutment and the abutment delivered through the skin.

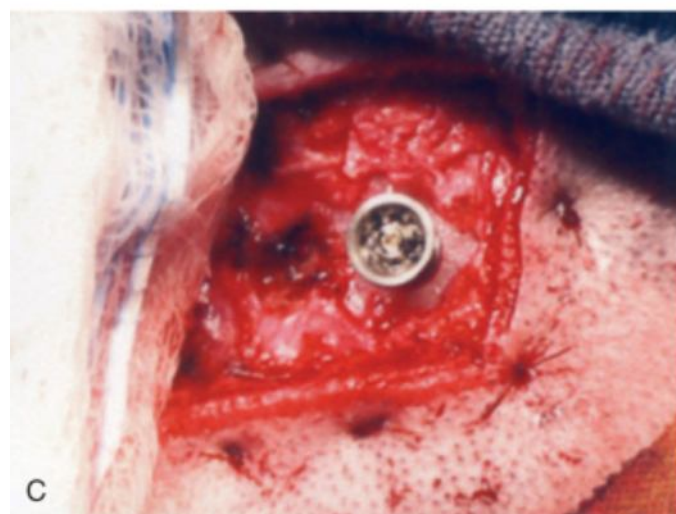
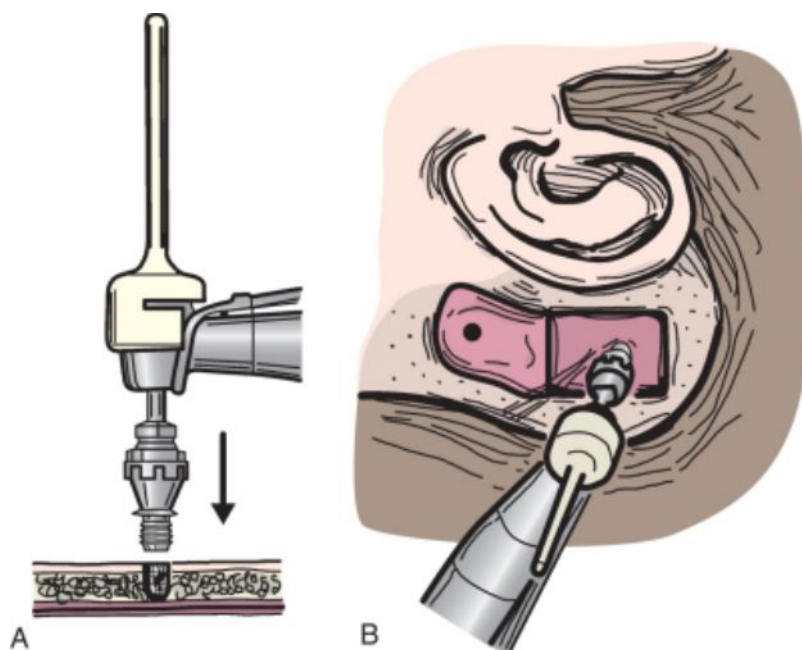


Figure 118-5 **A**, The abutment adaptor is placed on the drill and used to pick up the flange fixture with the preattached abutment. **B**, The fixture is inserted at slow speed. **C**, The flange fixture is self tapping, and the drill stops automatically once complete insertion has been achieved.

Shrinkage of the skin graft, as well as the added surface area created by beveling of the margins, sometimes makes the closure tight. Tension can be diminished by tacking the margins surrounding the skin flap to the periosteum, particularly at the corners. It is better to leave some of the beveled margin to granulate than to approximate the graft under tension. The incision is closed with interrupted chromic suture. Alternate sutures incorporate the underlying periosteum (Fig. 118-6). Tacking sutures, particularly at the base of the flap, and small incisions in the center of the graft prevent hematoma formation and subsequent separation of the skin graft from the periosteum. A healing cap is snapped onto the abutment. An inverted Y-shaped incision is made at one edge of a folded Xeroform sheet, which is placed under the healing cap. A mastoid dressing is applied and left in place for 1 to 2 days.

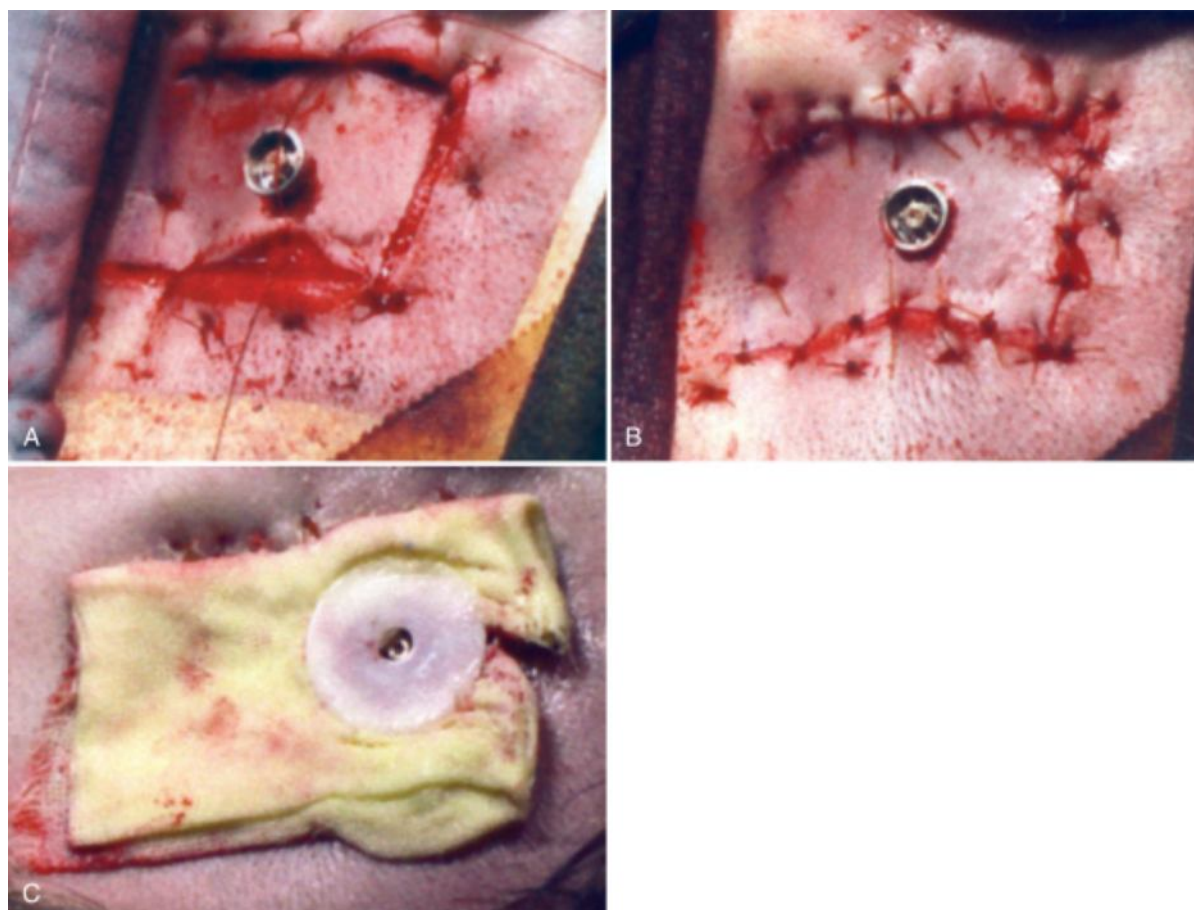


Figure 118-6 **A**, The abutment is delivered through the skin flap and draped over the underlying periosteum. The skin margins surrounding the graft site have been tacked to the periosteum at the two superior corners and inferiorly. For closure, simple sutures are alternated with sutures incorporating the underlying periosteum. **B**, The completed closure is free of tension. **C**, A healing cap is snapped onto the external abutment, and a large sheet of folded Xeroform with an inverted Y incision at one edge is tucked under the healing cap. The Xeroform keeps the skin graft secure against the underlying periosteum.

Special Considerations in the Pediatric Population

The Baha has been approved by the U.S. Food and Drug Administration for children 5 years of age and older, although reports from outside the United States suggest that the first stage can be performed successfully in younger children.^[12] The optimal age for Baha insertion depends on the thickness of the skull, which correlates with height more than with age. The procedure should be staged in young children, particularly if the calvaria is less than 3 mm thick. A longer period—between 6 and 12 months—should be allotted for osseointegration. The procedure can be performed in a single stage between 9 and 12 years of age. If a staged procedure is planned, a cover screw is threaded into the inner threads of the fixture to maintain its patency for later attachment of the abutment. At the second stage this screw is removed and the abutment is attached and externalized. The sound processor may be coupled to the abutment 4 weeks after the second stage. In children, the thickness of the skull may limit the fixture to 3 mm instead of the 4-mm implant typically used in adults.

Children with craniofacial anomalies, such as Treacher Collins syndrome or microcephaly, are more likely to have thin cortical bone or a low-hanging middle fossa tegmen. In this population, preoperative CT scanning can be useful for assessing the thickness of the skull and determining the position of the middle fossa relative to the mastoid. Techniques have been described for building up the bone surrounding the fixture with the use of a Gore-Tex membrane.^[13]

Children who are too young for insertion of the Baha may be fitted with a Baha soft band, which maintains the sound processor over the mastoid with light pressure. Infants with unilateral hearing loss often do not allow the band to remain in place for long; however, children with bilateral conductive hearing loss enjoy the sound and thus tolerate the soft band quite well. When the hearing loss is due to microtia or anotia, insertion of the Baha must be coordinated with reconstructive efforts. Special planning and perhaps more posterior placement of the device might be required to keep the device from contacting the anticipated helical rim of the reconstructed auricle and avoid disruption of the vascular supply to the temporoparietal skin flap used for its coverage. Alternatively, osseointegrated flange fixtures can be used to affix a prosthetic auricle. The location of these fixtures must be coordinated with an experienced prosthetist. In children, consideration should be given to the insertion of a

“sleeper” fixture. This additional fixture is maintained under the skin flap with an internal cover screw and serves as a backup in case of failure of osseointegration or secondary trauma with loss of the initial fixture.

POSTOPERATIVE MANAGEMENT

One week postoperatively, the folded Xeroform is replaced. Two weeks after surgery, if the site has healed satisfactorily, the healing cap can be removed. The patient is instructed to clean the site with soap and water. The sound processor is coupled to the abutment after allowing 3 months for osseointegration to take place (Fig. 118-7). Premature loading of the abutment can result in failure of osseointegration. The patient is then monitored at 6-month intervals to ensure stability of the abutment.

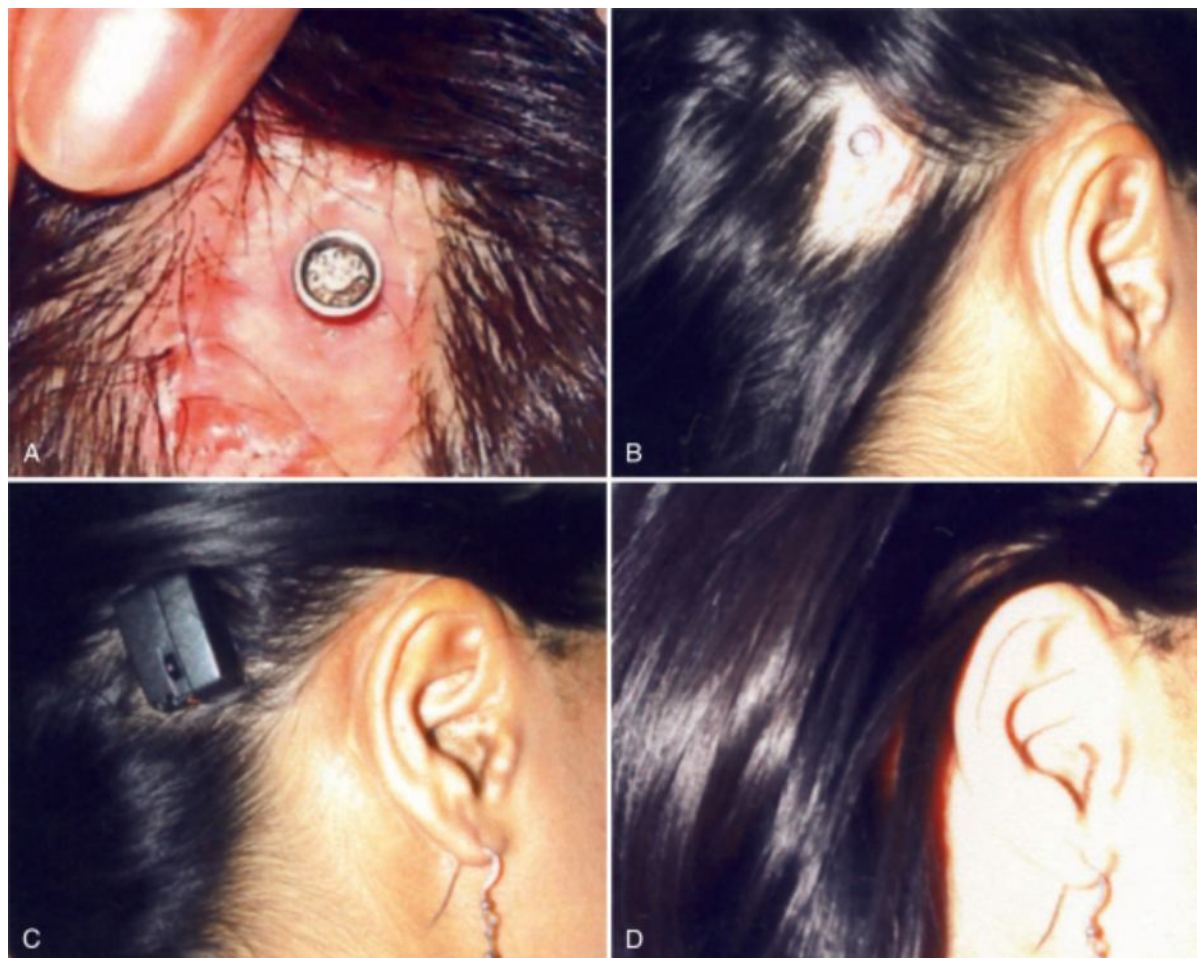

Figure 118-7 **A**, The graft site with external abutment 3 months postoperatively. Note the absence of hair follicles, a key factor in preventing infection at the percutaneous connection. **B**, The graft site 1 year postoperatively. **C**, The sound processor has been coupled to the external abutment. **D**, With certain hairstyles, the BAHA can be quite inconspicuous.

PEARLS

- The planned fixture site should be marked at the center of the skin flap rather than superiorly, as indicated by the marker hole in the present generation of mock devices.
- Successful osseointegration depends on copious irrigation and maintenance of the appropriate drill speed when establishing the guide hole and countersink, as well as insertion of the flange fixture.
- Removal of surrounding hair follicles, a thin skin graft, and excision of soft tissue underlying the skin graft will ensure a reaction-free penetration site.
- The mastoid cortex is thickest at the temporal line, thus making it an optimal site for the flange fixture.
- Extra care must be taken to ensure that all drilling steps are performed perpendicular to the mastoid cortex.
- Maintenance of the periosteum surrounding the drill site is vital for ensuring a satisfactory blood supply to the skin flap.

PITFALLS

- A skin graft that has inadvertently been severed at the base can still be used; it should be maintained in moist gauze and sutured as a free graft over the implant site.
- Inadequate removal of tissue at the margins of the skin graft, particularly superiorly, can result in a soft tissue overhang that makes contact with the sound processor.
- Skin growth over the external abutment can usually be managed by excision of the skin in the office, followed by silver nitrate cautery, injection of triamcinolone (Kenalog), and application of the healing cap.
- When the Baha is selected for patients with microtia, the fixture must not violate the blood supply to the skin flaps used for construction of the auricle.
- Tension on the suture line can be diminished by tacking the margins surrounding the skin flap to the underlying periosteum.
- In children with thin skin undergoing a second-stage procedure, consideration should be given to raising the skin flap manually because the internal hexagonal screw may catch on the dermatome and cause a tear in the flap.

Copyright © 2009 [Elsevier](#) Inc. All rights reserved. Read our Terms and Conditions of Use and our Privacy Policy.
For problems or suggestions concerning this service, please contact: online.help@elsevier.com