

## Chapter 90 – Blepharoplasty

**Grant S. Gillman**

As our population continues to grow older, society's emphasis on a more youthful appearance continues to increase and has led to rising interest in reversing the visible signs of aging. The periorbital region is usually the first area of the face to show significant signs of aging. Correction of this imperfection can significantly “turn back the clock” of aging and has thus led to the popularity of aesthetic surgery on the eyelids.

### **PATIENT SELECTION**

Appropriate candidates for upper eyelid blepharoplasty are patients who objectively have redundant skin of the upper eyelids (dermatochalasis). Although in most cases the motivation is purely cosmetic, other patients with more significant excess skin and hooding of the upper lids may have functional visual field restriction. In the latter patients, automated visual field testing is necessary for proper documentation to justify the medical necessity so that reimbursement by third-party payers is facilitated.

Appropriate candidates for lower eyelid blepharoplasty will generally have pseudo-herniation of the orbital fat (“bags”), either with or without a vertical excess of skin.

In all cases patients must be well motivated and have realistic expectations regarding the surgical outcome.

### **PREOPERATIVE PLANNING**

All patients are asked to describe their particular area of concern. A thorough history of any ocular problems is then elicited, including any history of periorbital surgery, previous blepharoplasty, visual difficulties, glaucoma, and “dry eye” symptoms such as frequent blinking, tearing, dryness, red eyes, itching, burning, or crusting of the lid margins.

A medical history is obtained and should cover all past medical problems with special emphasis on hypertension, diabetes, thyroid disease, facial muscle weakness, cardiovascular disorders, and the use of any anticoagulant medications (including aspirin products, warfarin, nonsteroidal anti-inflammatory drugs, vitamin E, multivitamins, and over-the-counter oral herbal preparations). If the surgeon has any concerns regarding other ophthalmic conditions (e.g., dry eyes, glaucoma, ptosis), the patient should be evaluated preoperatively by an ophthalmologist for clearance before making plans for surgery.

Whether one is planning upper or lower eyelid surgery, the surgeon must be familiar with the anatomy of the eyelid and periorbital area<sup>[1]</sup> to make the best preoperative decisions, in addition to performing well-executed surgery.

In assessing the upper eyelid area, the position of the brow is first evaluated to determine the extent to which brow ptosis might be contributing to the apparent skin excess of the upper eyelids. In men, a youthful brow position rests at the level of the superior orbital rim, whereas in women, the brow should rest at a level about 1 cm above the orbital rim. Significant brow ptosis should prompt a conversation with the patient about the merits of a brow-lift or a combination of brow-lift and blepharoplasty.

The size, shape, and configuration of the bony orbit, as well as the size, shape, and symmetry of the palpebral aperture, are then evaluated. Complete eye closure preoperatively is naturally critical—any preexisting lagophthalmos is a definite contraindication to upper eyelid blepharoplasty because it will undoubtedly increase if upper lid surgery is performed. It is important to look at the position and symmetry of the upper lid folds and supratarsal creases, the amount of scleral show, and the position of the globe in the orbit. Any asymmetry should be pointed out to the patient preoperatively. A patient with eyelid ptosis must understand that blepharoplasty alone will not correct eyelid ptosis and that ptosis repair is necessary in addition.

The appearance of aging in the periorbital area can be due to an excess of periorbital skin, protuberant fat, and hypertrophic orbicularis muscle. It is important to correctly diagnose and record the contribution of each to the patient's deformity. One should record the degree of excess skin in each eyelid and fat in each fat compartment (upper medial and central; lower medial, central, and lateral). Any orbicularis oculi muscle hypertrophy is also recorded.

The patient is asked to look straight at the surgeon with the eyes open, then with the eyes closed, and finally in

upward gaze without moving the head. During these maneuvers, the upper and lower eyelids are closely evaluated for the relative amount of excess skin and fat. The excess fat in the lower lid compartments is highlighted in the upward gaze position. Applying pressure to the patient's globe while the eyelids are closed helps exaggerate and delineate the locations of excess fat in both the upper and lower eyelid compartments.

Lower eyelid tone is assessed with a "snap test" (also called the lid distraction test) whereby the lid is drawn anteriorly outward from the globe with the thumb and forefinger. More than 10-mm movement of the lid margin is considered abnormally lax. In addition, one watches how long it takes for the lower lid to return to its pretest position. A normal, youthful lid will snap back immediately. In the lid retraction test, the lower lid is drawn inferiorly toward the orbital rim, and once again one observes for abnormally slow return of the lid to its normal position. Poor lower lid tone should lead the surgeon to consider alternative techniques to standard skin-muscle lower lid blepharoplasty or a concomitant canthoplasty or canthopexy.

Finally, the visual acuity of each eye should be tested individually with an eye chart or by having the patient read fine print with one eye.

Preoperative photographs are important for documentation and planning. A complete set would include a full facial view (vertically oriented, 1:7 or 1:8 ratio) and close-up (1:4 ratio, horizontally oriented) frontal, oblique, and lateral views of the eyes. The close-up frontal view should include a photo with the eyes closed and one with the eyes gazing upward. Consistent preoperative and postoperative focal length, lighting, background, patient positioning, and subject-to-lens distance are essential.

The patient and physician must decide together on the most appropriate anesthetic for each patient. Local anesthesia, supplemented by intravenous sedation, is usually adequate for all aesthetic surgical procedures on the eyelids. Patients who require only resection of skin of the upper eyelids often do well with local anesthesia alone. In some cases the patient or anesthesiologist may feel most comfortable with general anesthesia. Patient comfort should be the ultimate goal for maximal surgical safety.

## **SURGICAL TECHNIQUES**

### **Upper Lid Blepharoplasty**

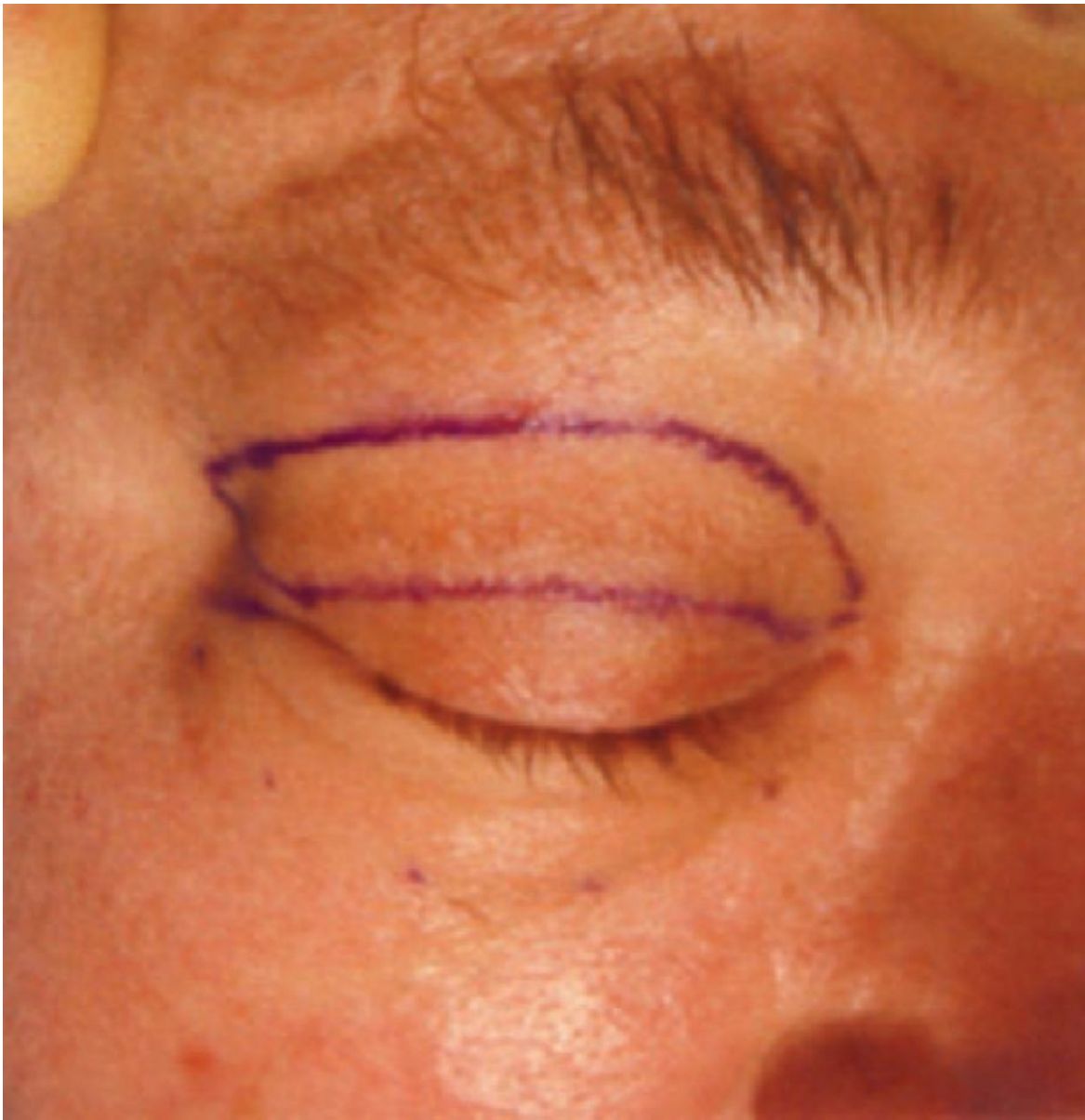For upper eyelid blepharoplasty, the amount of skin resected depends on the amount of excess as determined by preoperative examination.<sup>[2]</sup> It is again emphasized that one should ensure that the brow is not ptotic and that it is held in correct position during marking of the upper eyelid resection.

#### **Markings**

The incisions are marked preoperatively with the patient in the sitting position and the brow held in proper position before injection of local anesthetic. The level of the inferior incision is usually between 8 and 12 mm from the lash line in the midpupillary line and 5 to 6 mm above the medial and lateral canthi. The inferior incision is generally marked in the patient's natural upper eyelid crease, which lies at the upper edge of the tarsal plate, unless the crease is less than 8 mm from the lash line centrally. In such cases the central marking should be measured to lie 8 to 10 mm above the lashes. The incision is planned such that it lies in the upper eyelid crease and the skin resected is from the preseptal region, not the pretarsal area. The natural supratarsal crease may or may not be symmetrical from one side to another. One can choose to use the patient's natural crease regardless or adjust one side to ensure sym-metry. This decision is best made with the patient preoperatively.

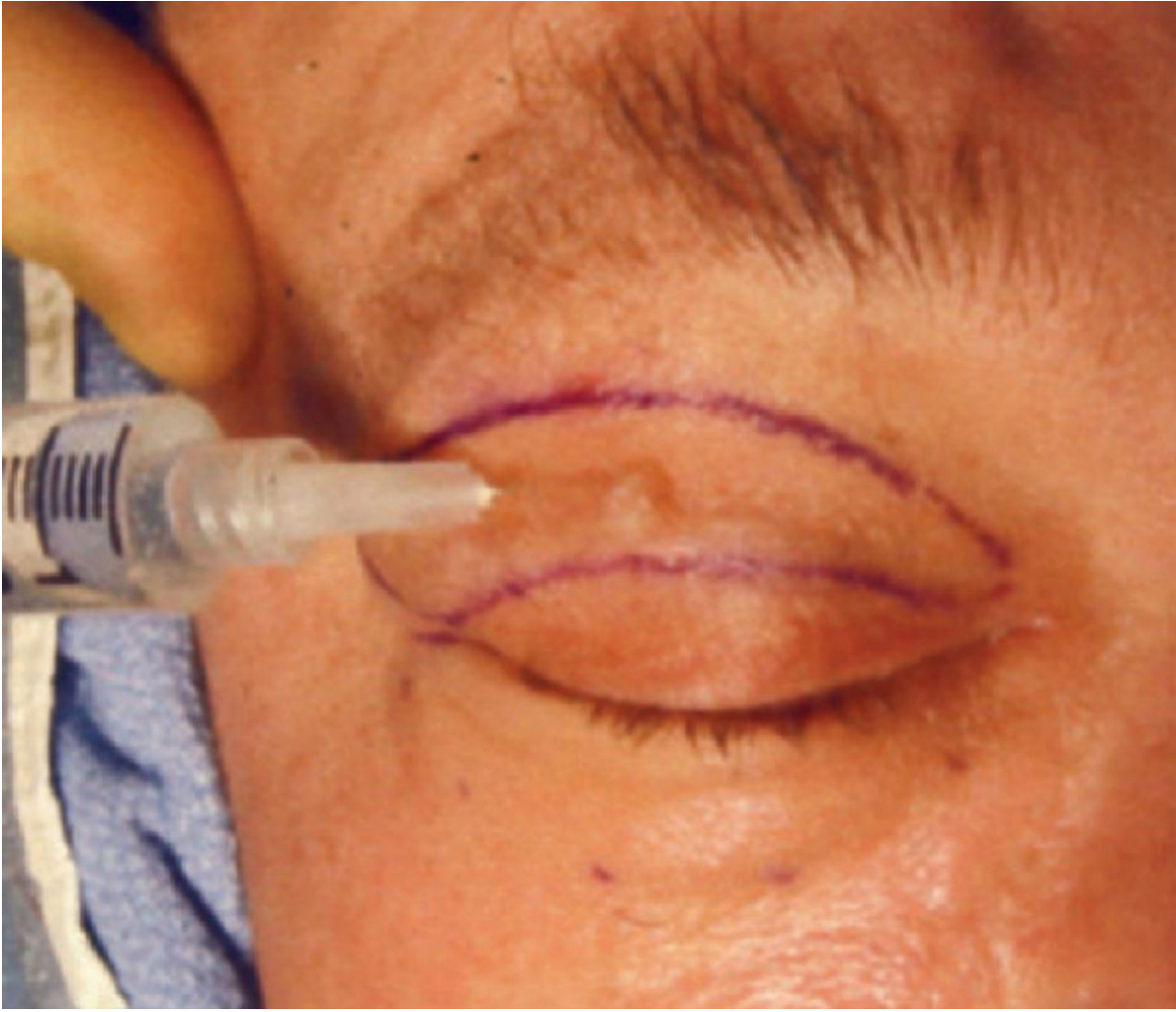At the lateral canthus the marking should sweep gently laterally and upward toward the tail of the brow, as much as needed to excise the skin that accounts for any lateral hooding. It rarely needs to extend beyond the lateral aspect of the lateral orbital rim. Medially, the incision marking should not extend more than 1 to 2 mm beyond the punctum of the eyelid. Extending the incision too far nasally into the concavity at the medial orbit increases the risk of creating a webbed scar across this area. In patients with significant excess skin, the medial extension is curved upward in a W pattern to avoid a dog-ear and keep the scar from coinciding with the epicanthal fold.

It is important to hold the patient's brow in its correct anatomic position when determining the amount of skin to be resected from the upper lid. A "skin pinch" technique is then used to determine the amount of excess skin to be resected. Conservatism is always recommended. The middle of the excess skin is gently grasped with fine forceps and lifted until slight eversion of the lashes occurs. The upper incision is marked at the point where the lower incision meets the upper limit of the excess skin. This is done in at least four positions across the upper eyelid. The marks are then connected to outline the upper incision line (Fig. 90-1). This resection is tested at multiple levels by pinching the upper and lower incision lines together (before injecting the local anesthetic) and checking for excess eversion of the lid margin.



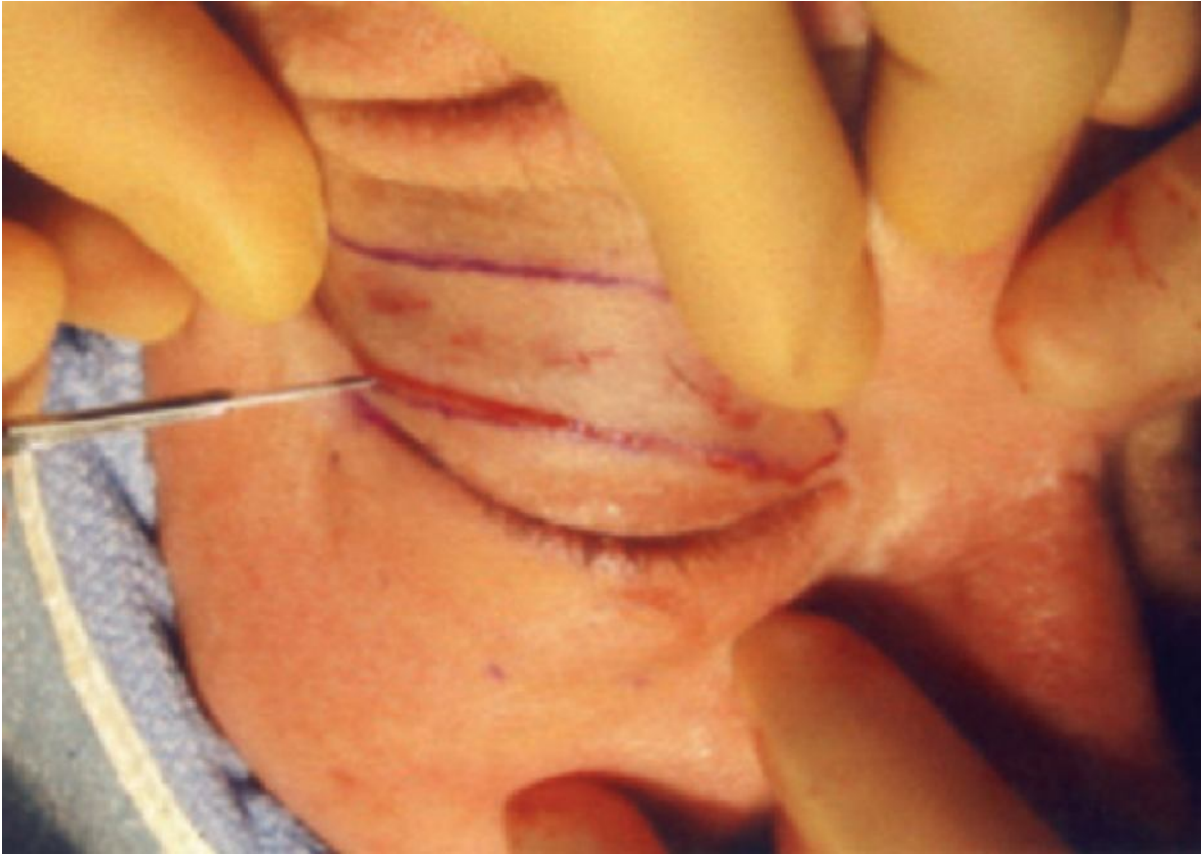
**Figure 90-1** Outline of an upper eyelid blepharoplasty incision.

Infiltration of the local anesthetic is accomplished with a 30-gauge, 1½-inch needle (Fig. 90-2). Injecting just below the skin and superficial to the underlying orbicularis oculi will minimize hematoma formation. Total volume per lid is generally about 1 to 1.5 mL. After allowing adequate time for the hemostatic effect of the local anesthetic to commence, the skin is incised along the markings (Fig. 90-3). A skin-only resection is first performed with either a no. 15 scalpel, a needle-tipped cautery, or sharp scissors (Fig. 90-4). Hemostasis is obtained with a needle-tipped electrocautery (Fig. 90-5).

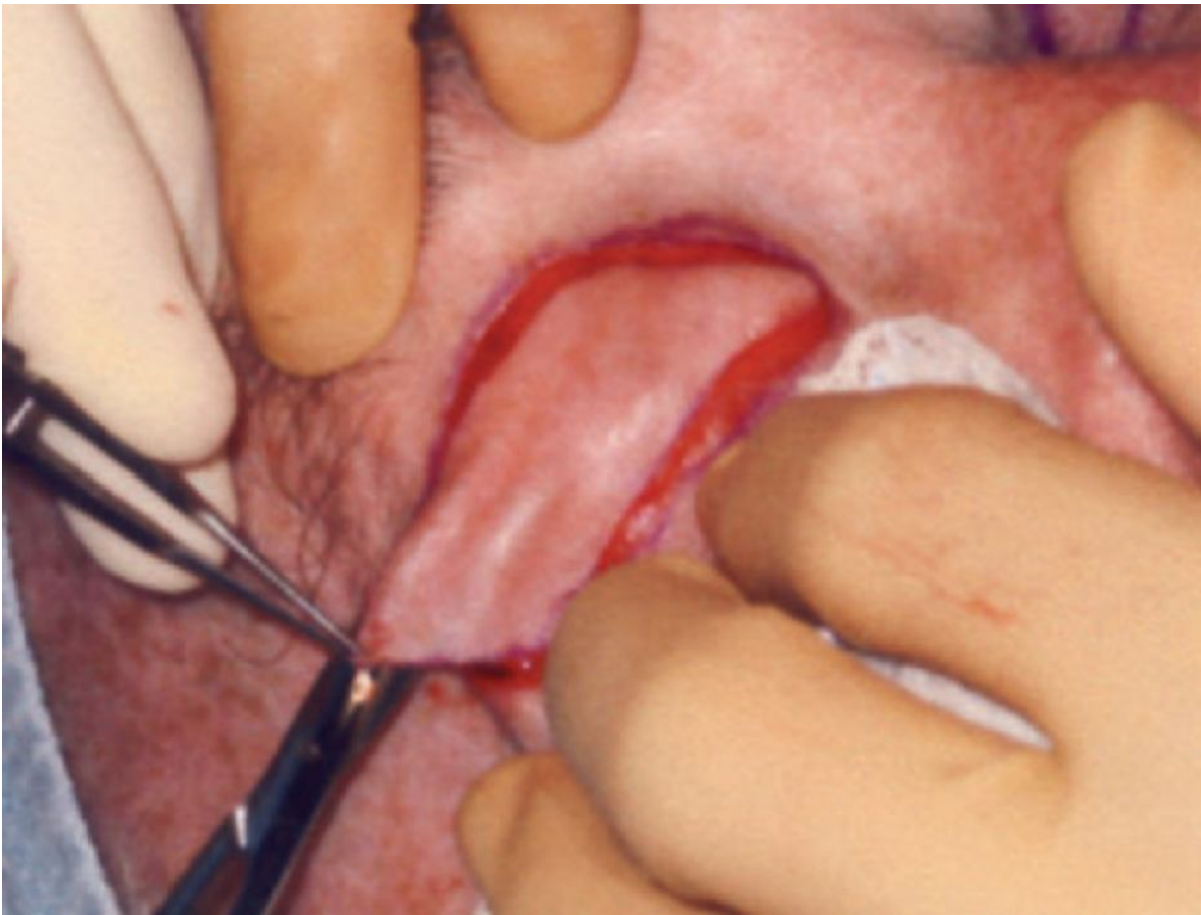


**Figure 90-2** Injection of local anesthetic.

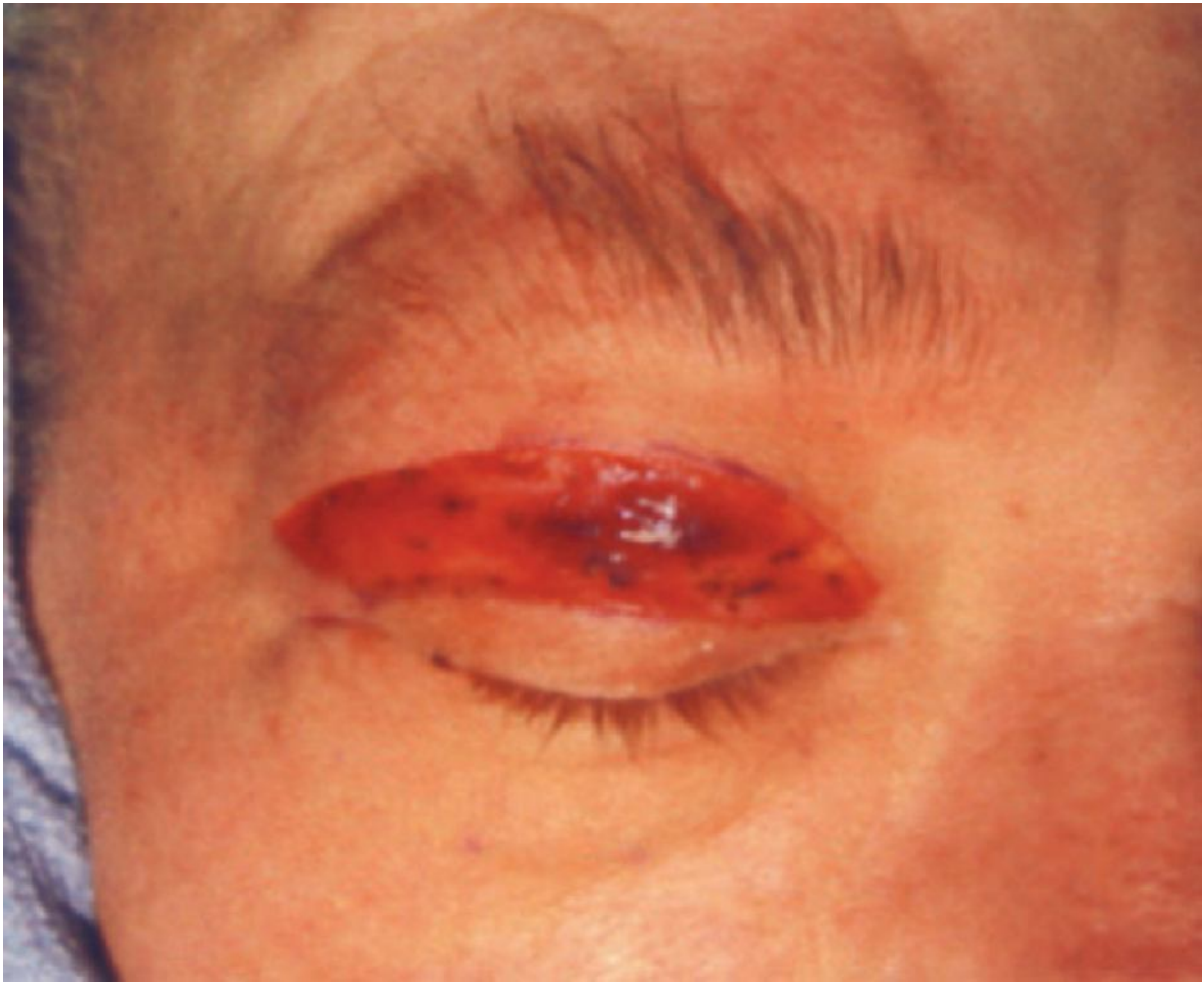



**Figure 90-3** Skin incision with a no. 15 blade for upper eyelid blepharoplasty.

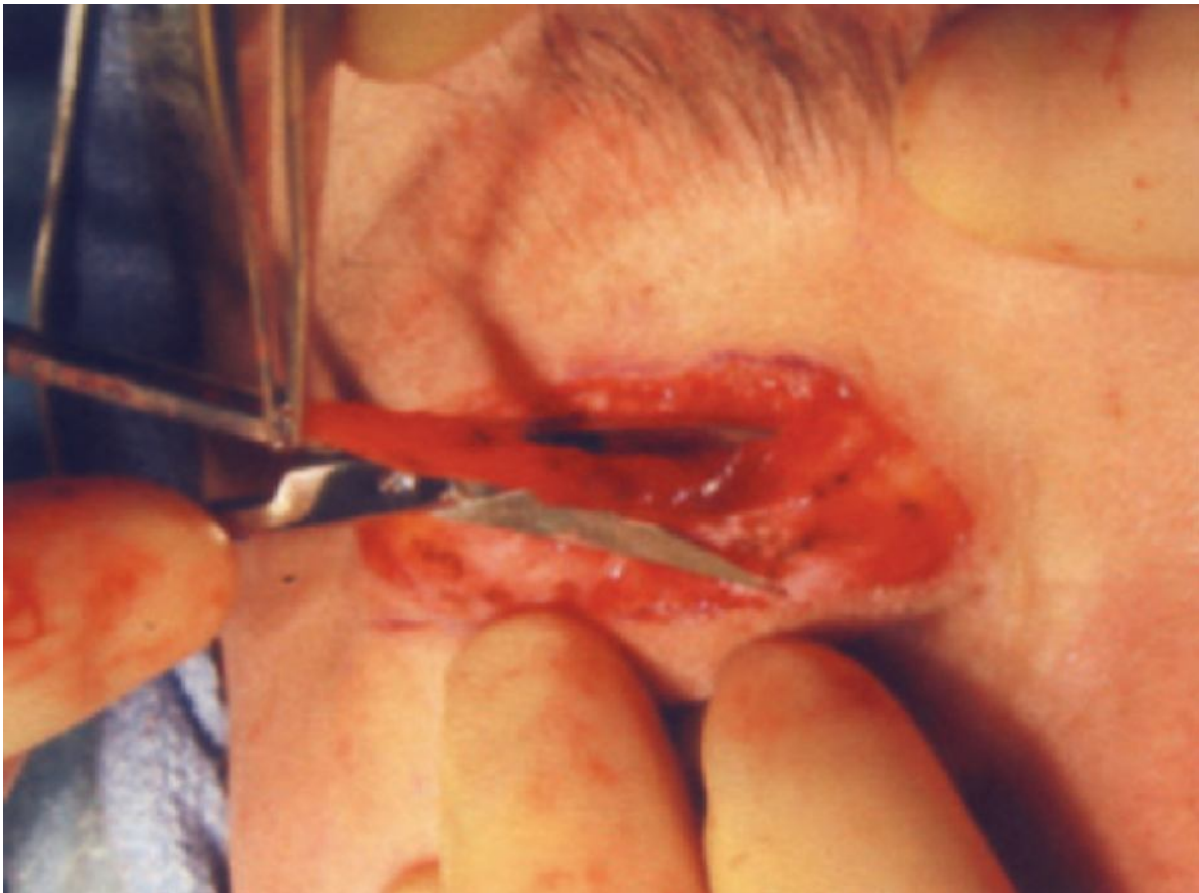


**Figure 90-4** Skin excision with scissors undermining superficial to the orbicularis oculi.



**Figure 90-5** Hemostasis achieved after skin excision.

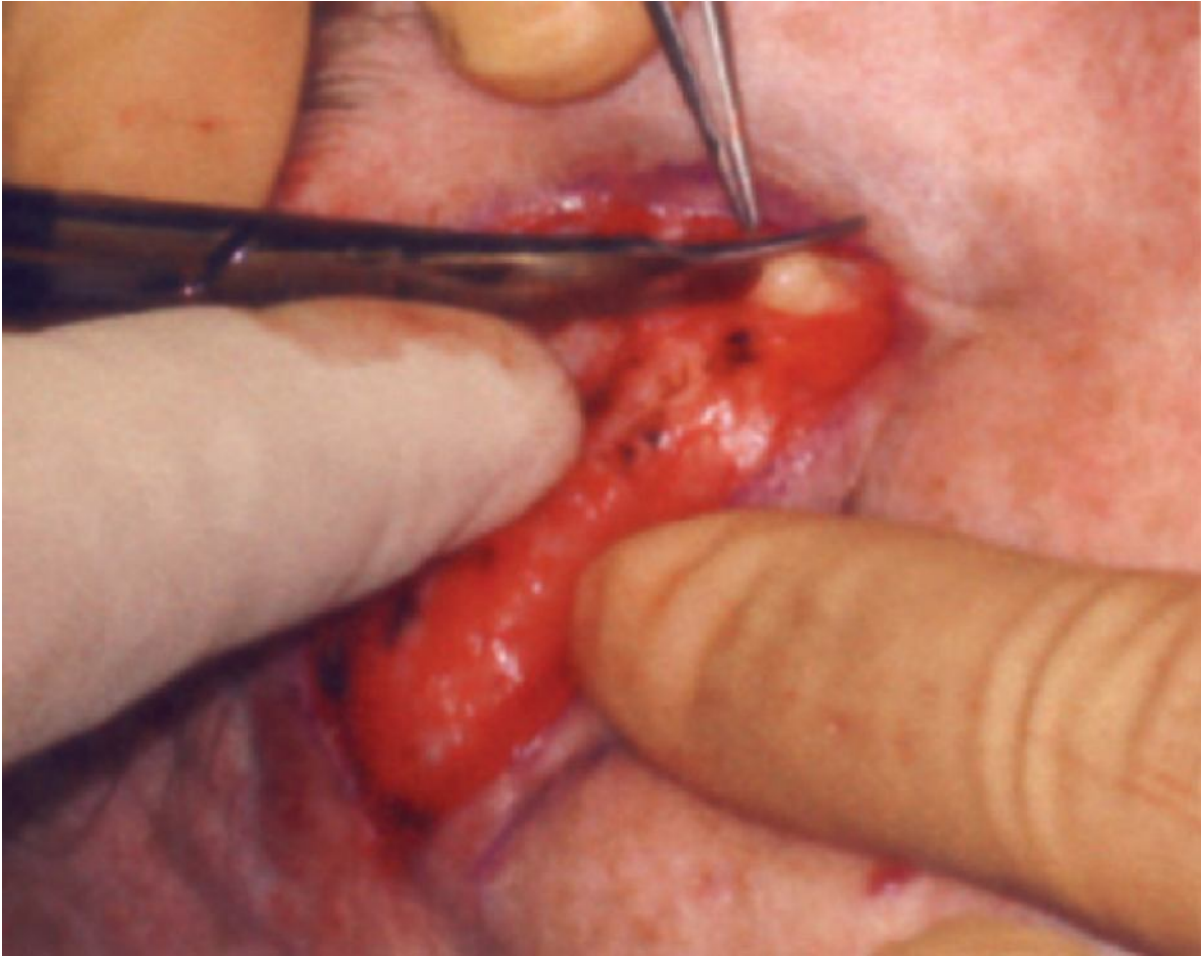
In patients in whom the supratarsal crease needs to be accentuated, excision of a 3-mm strip of orbicularis muscle is done separately with fine forceps and fine, sharp, curved scissors in the midportion of the wound (Fig. 90-6).



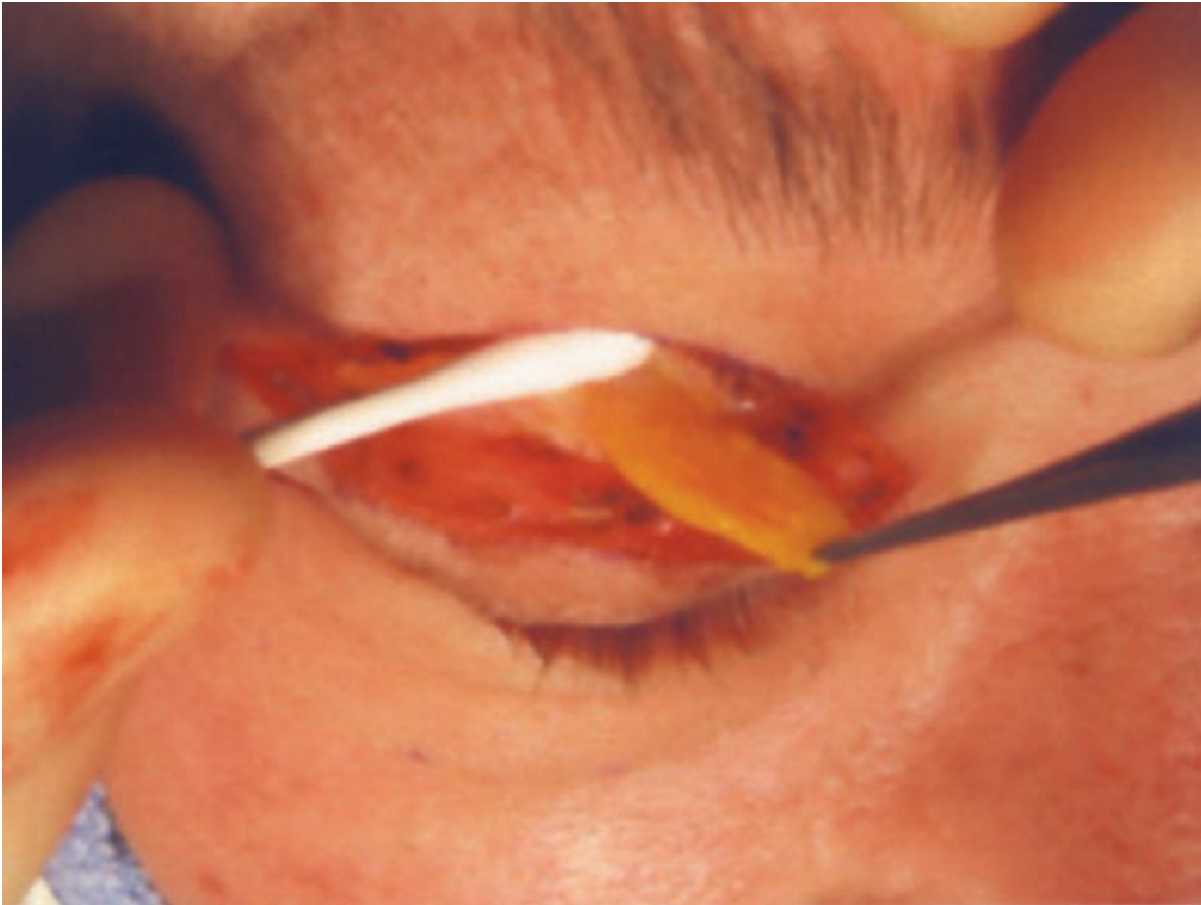**Figure 90-6** Excision of a thin strip of orbicularis oculi muscle in the midportion of the upper eyelid wound.

If it was determined preoperatively that excision of orbital fat is necessary, one proceeds with that step at this time. Preoperative evaluation of each compartment will help one determine the amount of excess fat to be excised and avoid under-resection. With finger pressure on the globe, the excess fat in the orbital compartments can be seen bulging through the orbital septum. A small opening is made through the orbital septum over the top of the fat compartments to be addressed (Fig. 90-7). The excess fat is then teased through the opening in the septum with fine forceps and a cotton swab (Fig. 90-8).





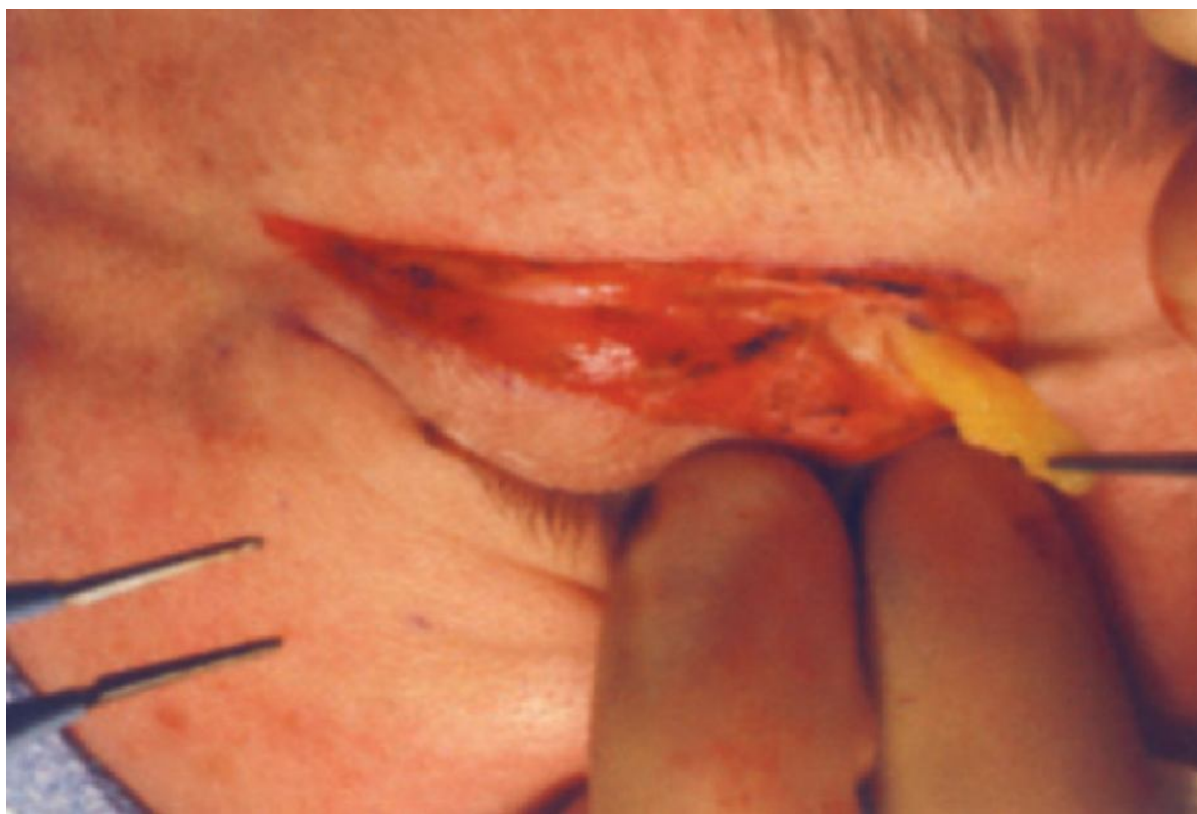**Figure 90-7** Opening of the orbital septum over the medial upper eyelid fat compartment.





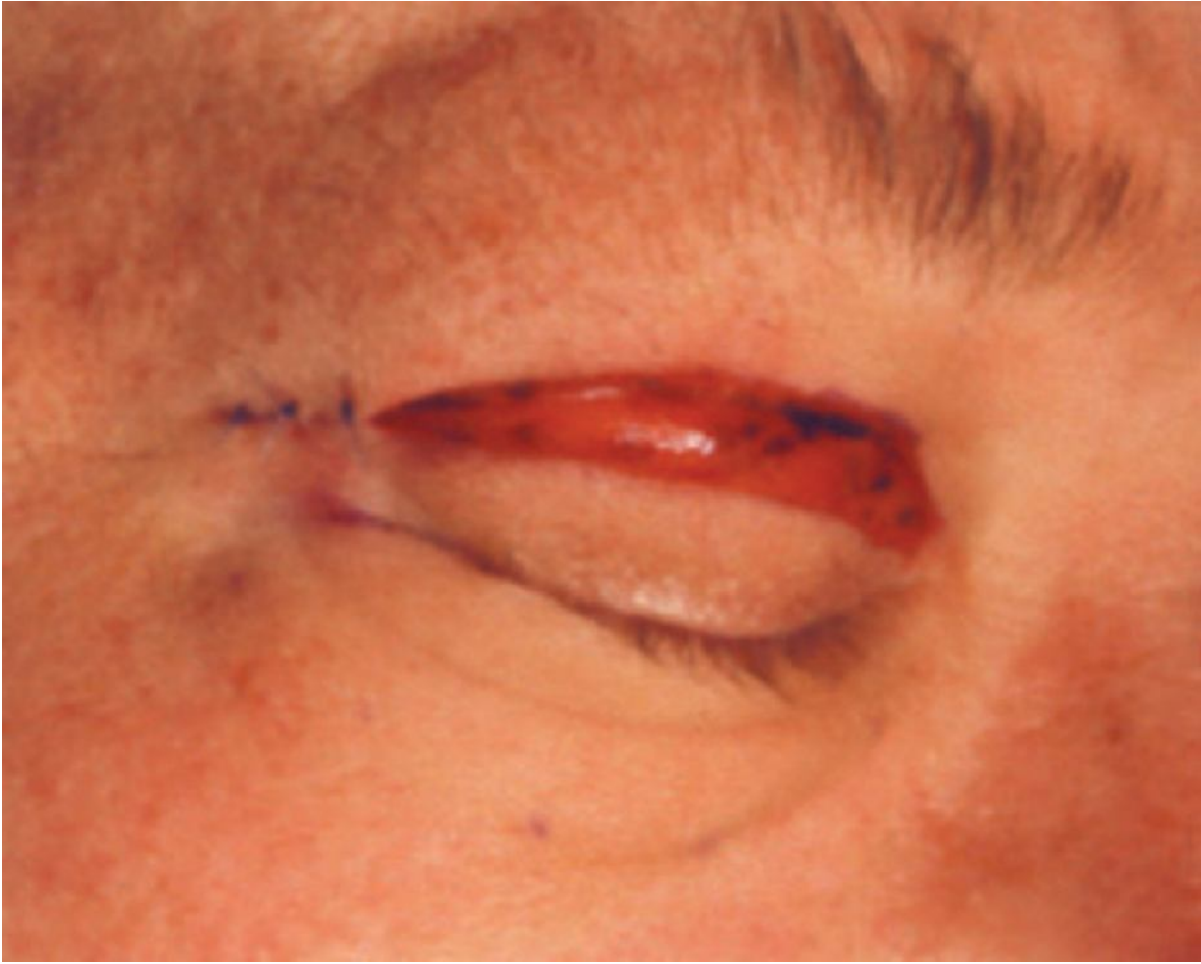**Figure 90-8** Teasing orbital fat through the orbital septum (upper eyelid lateral compartment).

Before fat excision, a small amount of local anesthetic should be injected into the base of the fat pedicle because the excision can be uncomfortable for the patient. A small, curved hemostat is then placed at the base of the excess fat to be removed. To avoid over-resection, excess traction is not placed on the fat, and only the fat that is *easily* delivered through the orbital septum is resected. Small, curved scissors are used to excise the fat while leaving a small cuff above the hemostat. The cut edge is cauterized before releasing the hemostat. As an alternative, one can slowly cauterize across the base of the fat (bipolar cautery) *without* clamping across the base of the pedicle (Fig. 90-9), thereby minimizing the risk of excess traction on the posterior orbital vessels that might result from manipulation of the hemostat.

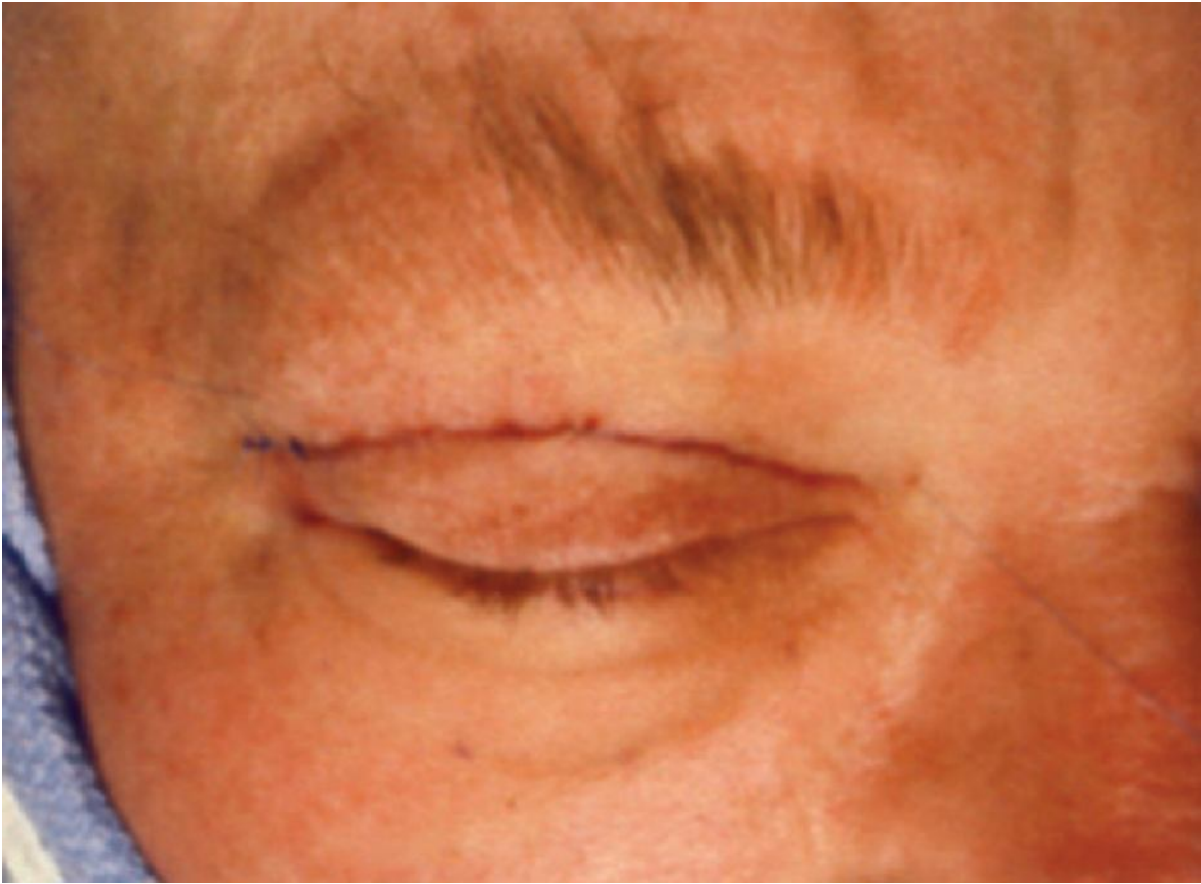


**Figure 90-9** Bipolar cautery (seen at the corner of the photo) is used to cauterize across the base of the fat pad, which is then carefully excised.

Simple interrupted sutures can be placed in the incision lateral to the lateral canthus (Fig. 90-10) to better manage tension at the closure line in this part of the wound. The remainder of the upper lid incision is closed with running 6-0 monofilament pullout subcuticular suture (Fig. 90-11). Any gaps in the closure should be addressed with an additional simple stitch of interrupted 6-0 fast-absorbing gut suture. Mastisol and small Steri-Strips are used to anchor the medial and lateral extent of the suture.



**Figure 90-10** Interrupted stitches are used to close the wound lateral to the lateral canthus.



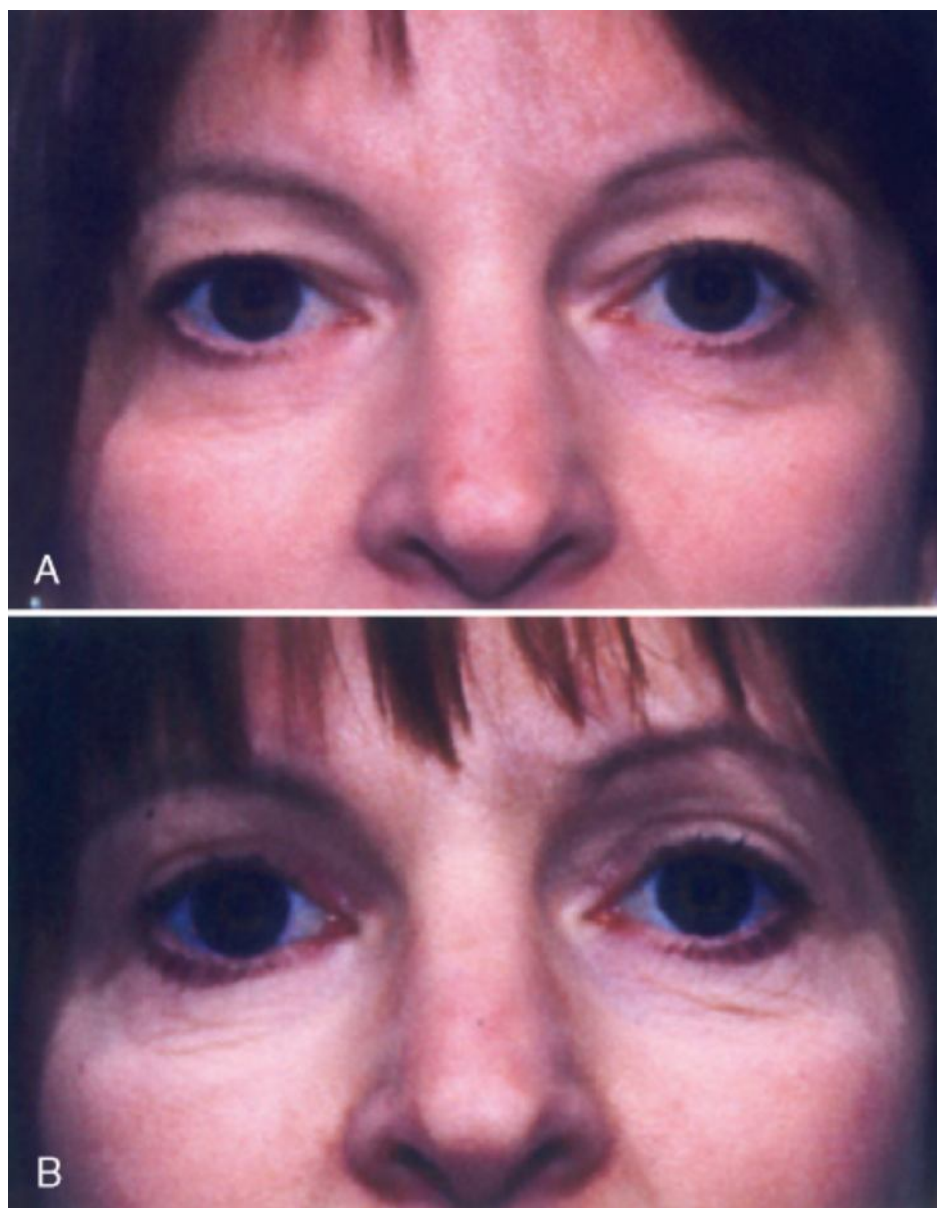
**Figure 90-11** Closure of the remaining incision with a subcuticular stitch.

### *Postoperative Management*

The patient applies ice-cool compresses to the eyes during the first 24 to 48 hours. Many patients have found small bags of frozen peas to be an excellent source of cool compresses. The frozen peas are in plastic bags, they conform well to the face and eyes, and they hold the cool temperature for a prolonged period. In addition, they can be refrozen and reused for this purpose.

Patients are told preoperatively that their eyes will swell and bruise during the first few days postoperatively. Liquid tears are used for daytime dryness of the eyes if needed, and Lacri-Lube ointment can likewise be used for nighttime protection if required. An ophthalmic antibiotic ointment is applied over the incisions three times daily after gently cleaning the incisions with a cotton swab soaked in hydrogen peroxide.

The subcuticular suture is removed at a follow-up appointment about 5 days postoperatively. A representative preoperative patient photo and postoperative result are seen in Figure 90-12.



**Figure 90-12** Preoperative (A) and postoperative (B) views of an upper eyelid blepharoplasty patient.

### *Lower Lid Blepharoplasty*



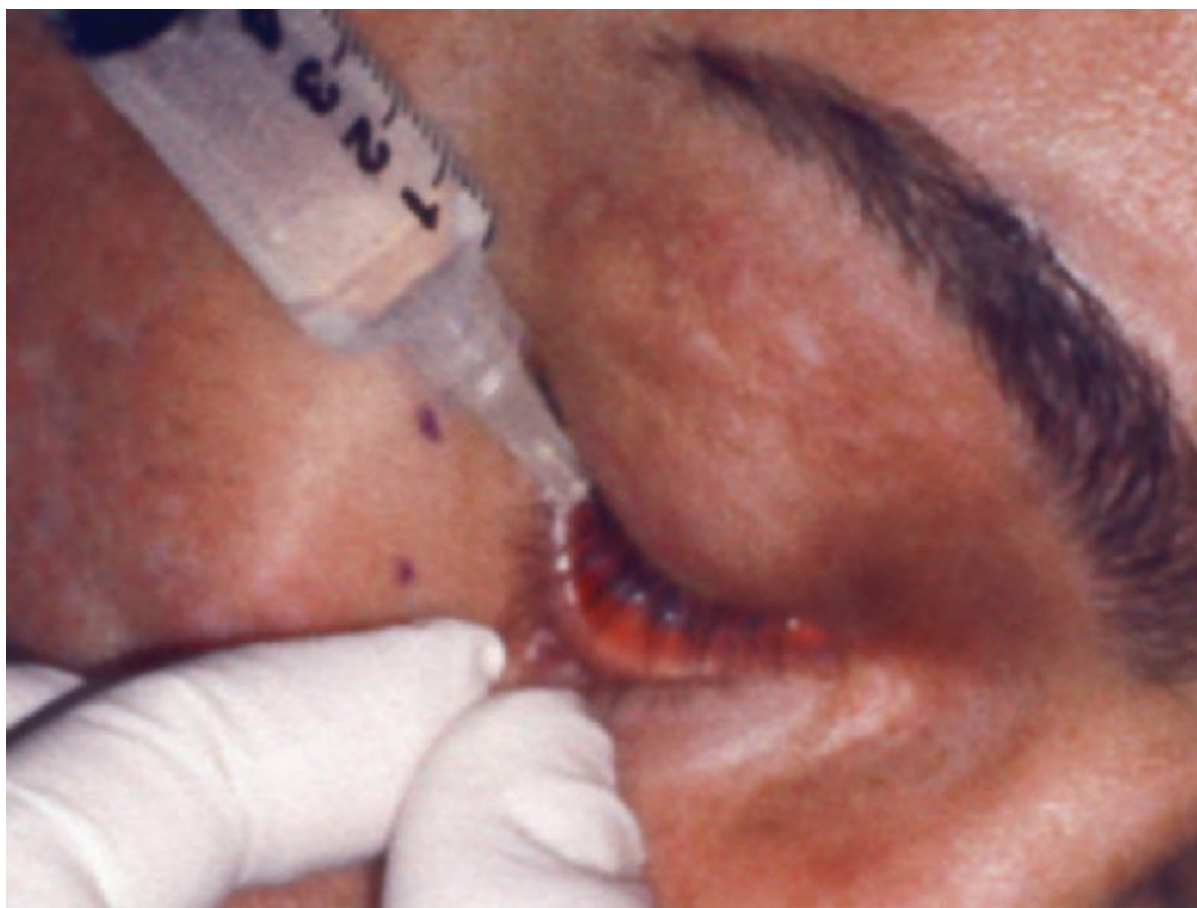Preoperative evaluation of the lower lids is essential in determining the type of operation most appropriate for each patient. One should evaluate and record the amount of excess fat in each of the lower lid compartments (medial, central, and lateral), the amount of excess skin of the lower lids, the presence or absence of orbicularis hypertrophy, the extent of fine skin wrinkling, and the degree of lower lid laxity.

In patients with minimal excess skin, the transconjunctival approach<sup>[3]</sup> to the lower lids is preferred. The transconjunctival approach eliminates the “rounding” deformity often found in the lateral aspect of the lower lid after the traditional transcutaneous approach. It also minimizes the chance of lower eyelid retraction developing (scleral show and frank ectropion). A mild trichloroacetic acid (TCA) chemical peel can be used as an adjunct to transconjunctival blepharoplasty. In patients with significant excess skin of the lower lid or those who already have lower lid deformities secondary to lid laxity that require correction, a transcutaneous approach<sup>[4]</sup> is used with a subciliary incision and elevation of a skin-muscle flap.

### *Transconjunctival Approach*

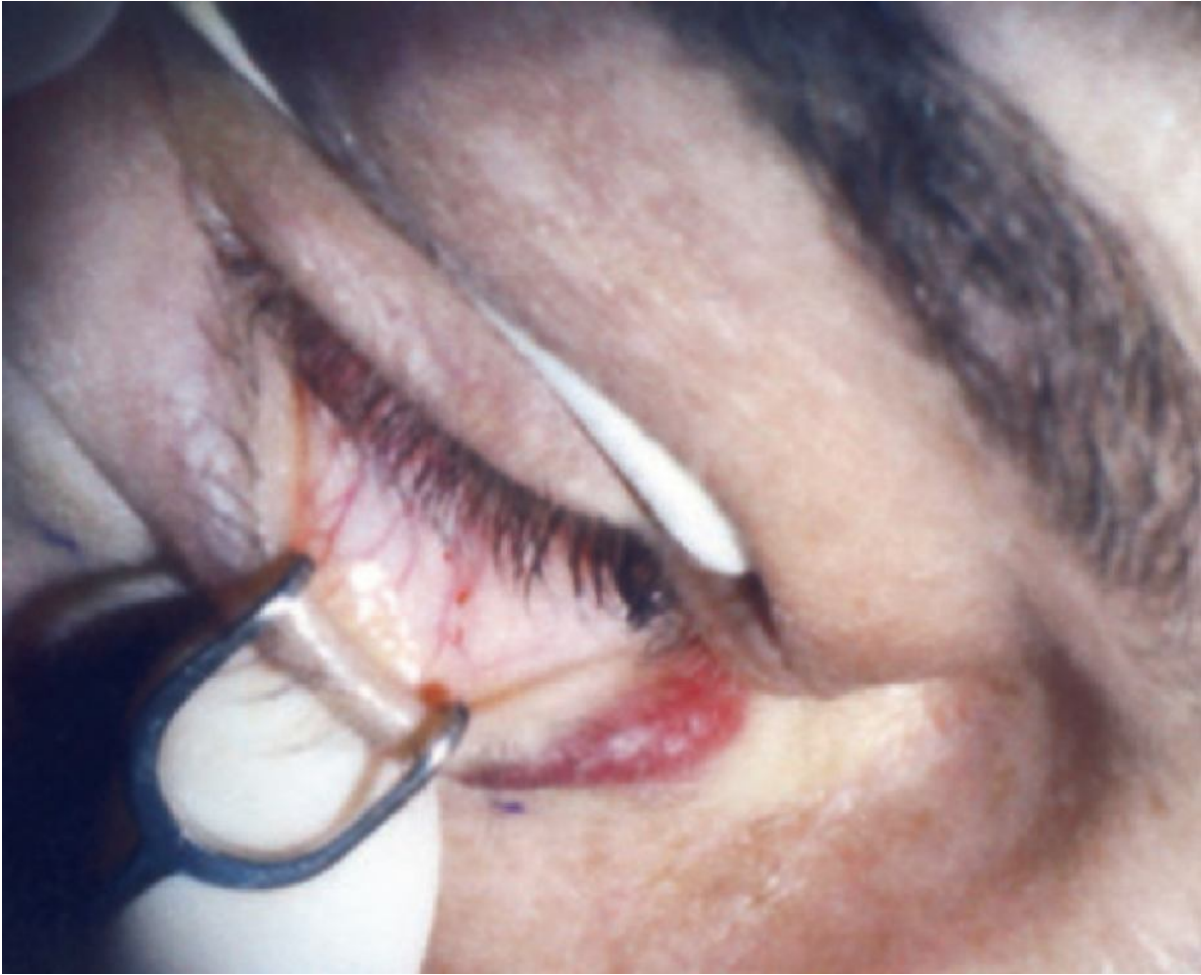Although this operation can be done under general anesthesia, it is typically performed under local anesthesia with intravenous sedation. Once the depth of sedation is adequate, the conjunctivae are anesthetized with 0.5% topical ophthalmic tetracaine or proparacaine hydrochloride solution, and corneal shields (green contacts) are lubricated with ophthalmic ointment and used to protect the cornea.

Lidocaine (1%) with 1 : 100,000 epinephrine is injected via a 27- or 30-gauge needle in the conjunctiva beneath the planned incision (Fig. 90-13) and percutaneously deep to the orbicularis overlying the orbital septum of the lower lid to anesthetize and hydrodissect the plane of dissection.

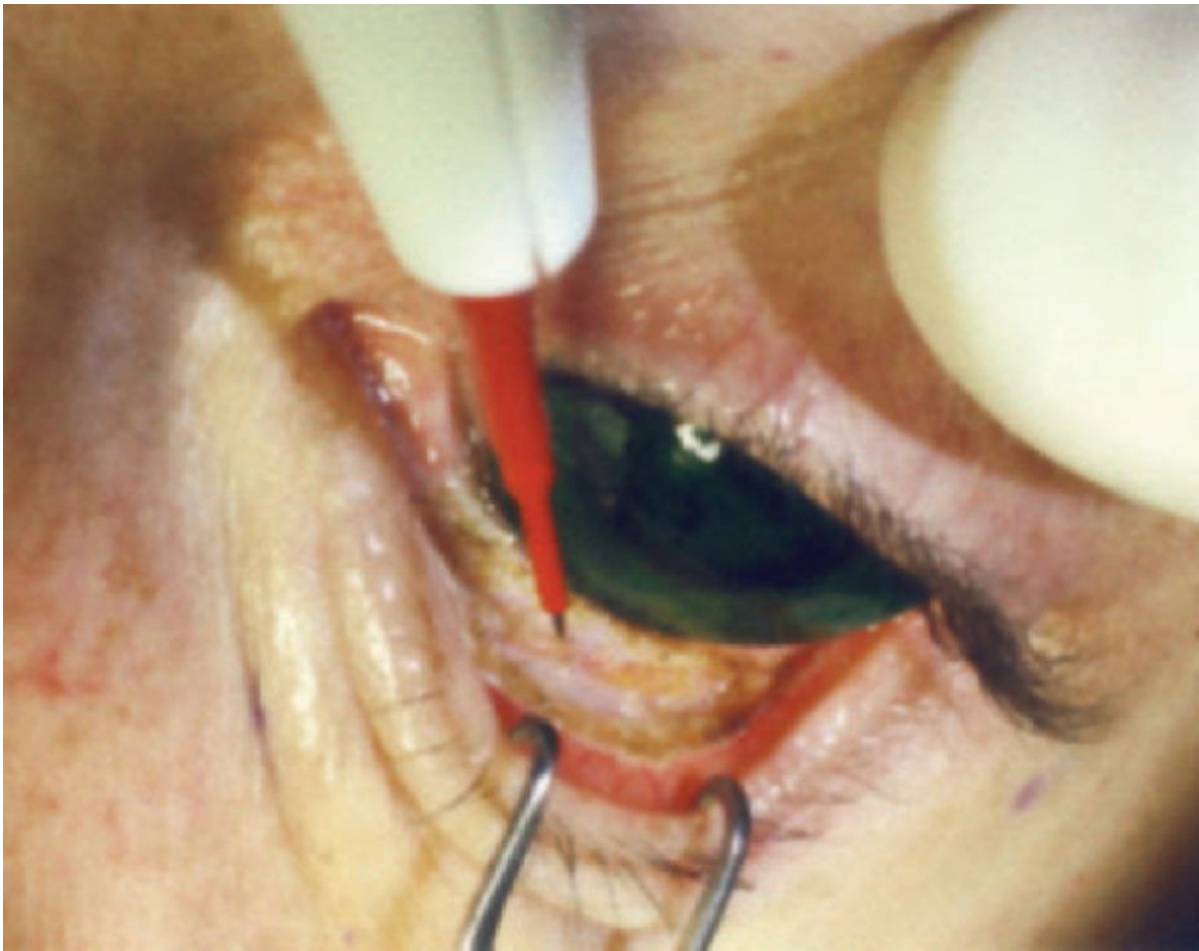


**Figure 90-13** Injection of the lower eyelid conjunctiva (right eye).

A wide double hook is then used to retract the lower lid margin (Fig. 90-14). A conjunctival incision is made with a needle-tipped cautery at a level 1 to 2 mm below the tarsal plate (Fig. 90-15) and deepened to divide the attachment of the lower lid retractors to the inferior tarsus. Medially, the incision should stop short of the punctum of the lacrimal duct to avoid inadvertent injury to the lacrimal canaliculi, and laterally the incision is carried as far as necessary to provide adequate exposure of the lower lid fat compartments.



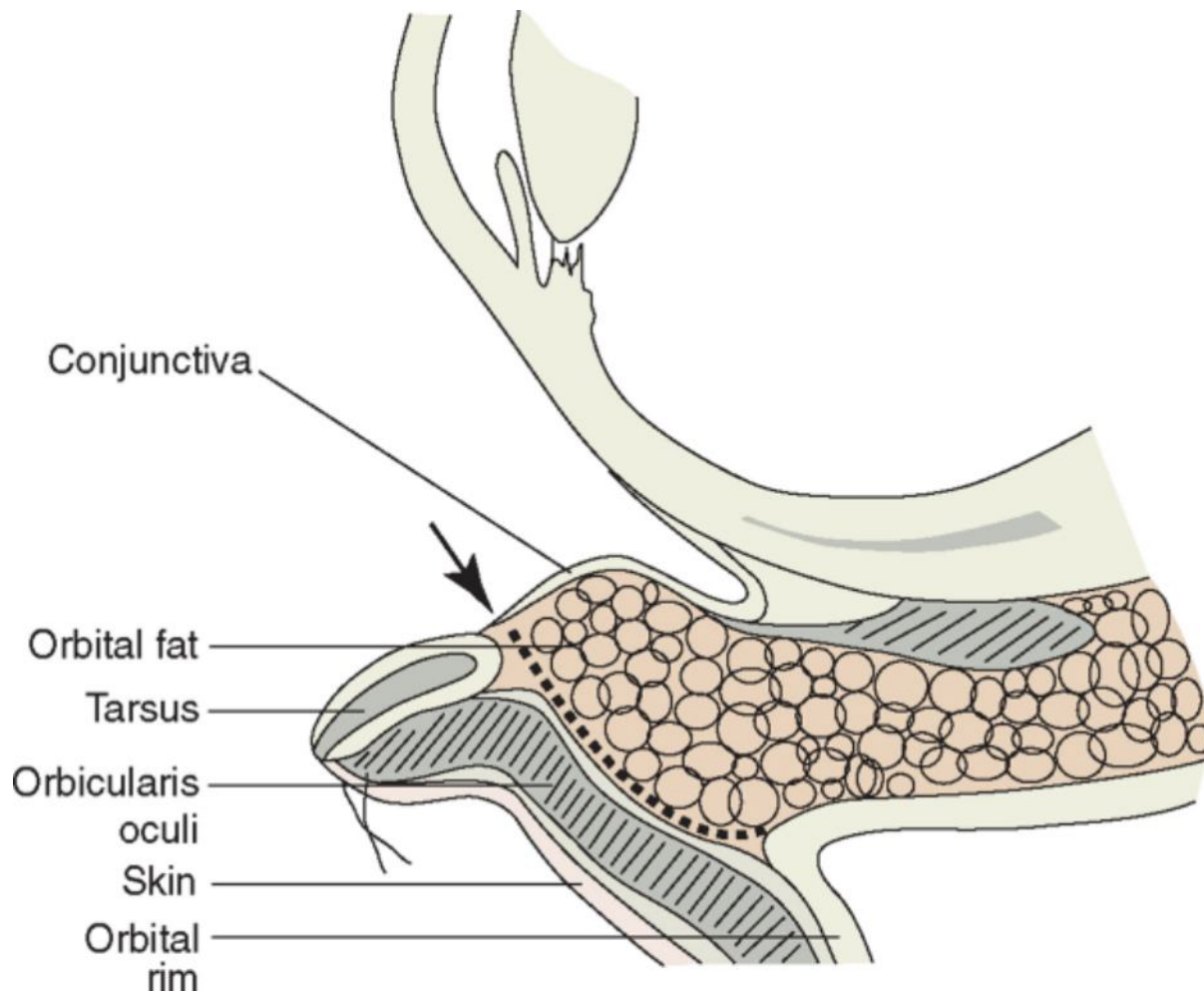
**Figure 90-14** Eversion of the lower eyelid with a blunt double hook to expose the conjunctiva before making an incision (right eye).



**Figure 90-15** Conjunctival incision (with needle-tipped electrocautery) just below the inferior edge of the tarsal plate (left eye). Note the corneal protector in place.

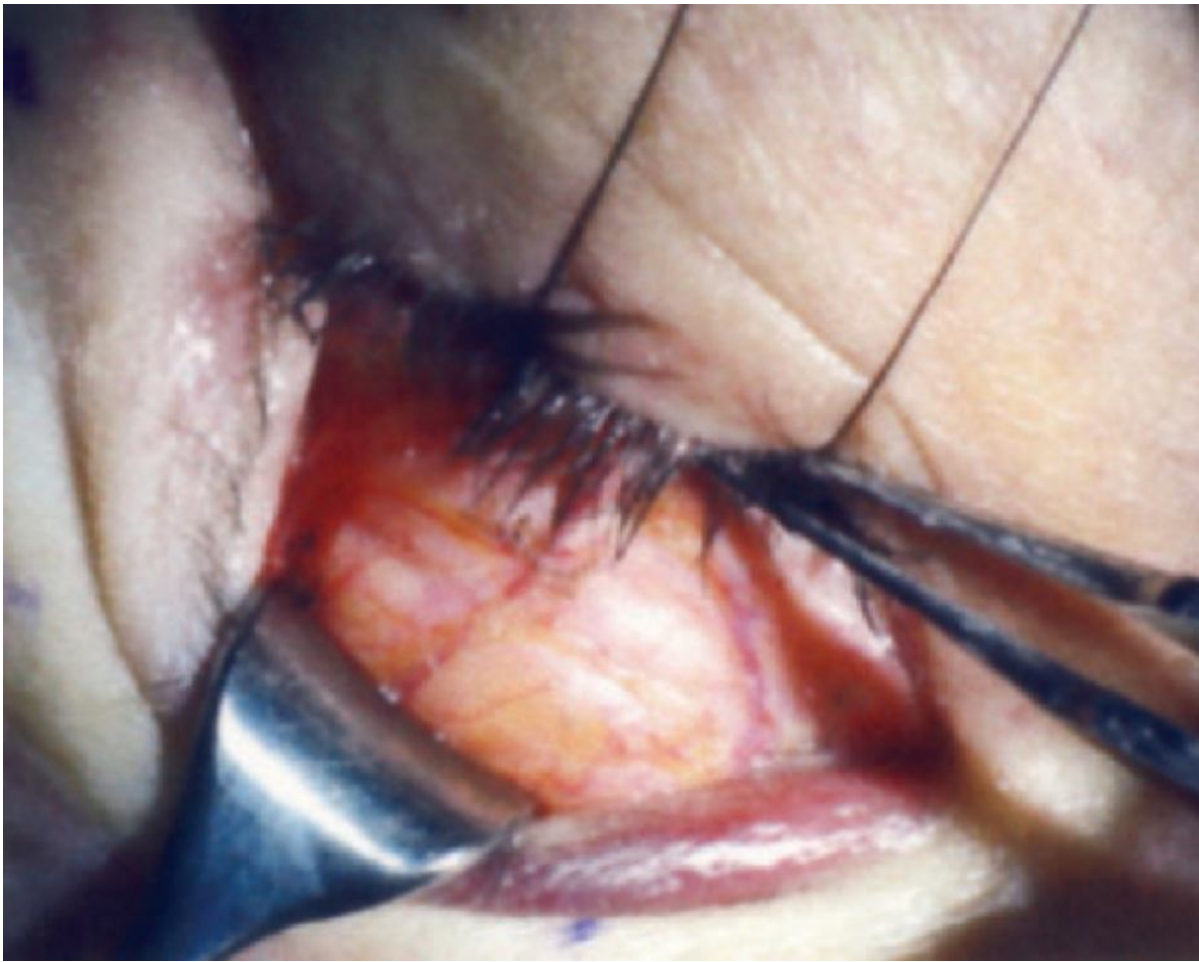A 5-0 silk or nylon traction suture is then placed through the inferior conjunctival incision margin, with a hemostat on the free ends of the suture. The hemostat is passed over the patient's forehead to retract the conjunctiva and inferior retractors up over the cornea. This provides countertraction for the dissection and protects the underlying cornea as well. An assistant then uses a wide double hook or a Desmarres retractor to retract the lid side of the conjunctival incision (the superior incision margin). Preseptal dissection (Fig. 90-16) is then carried out to elevate the overlying skin and muscle off the orbital septum down to the orbital rim with a combination of sharp and blunt dissection. The orbicularis can easily be separated from the septum by pushing the muscle anteriorly and inferiorly with a cotton swab. The dissection should be relatively quick and avascular.





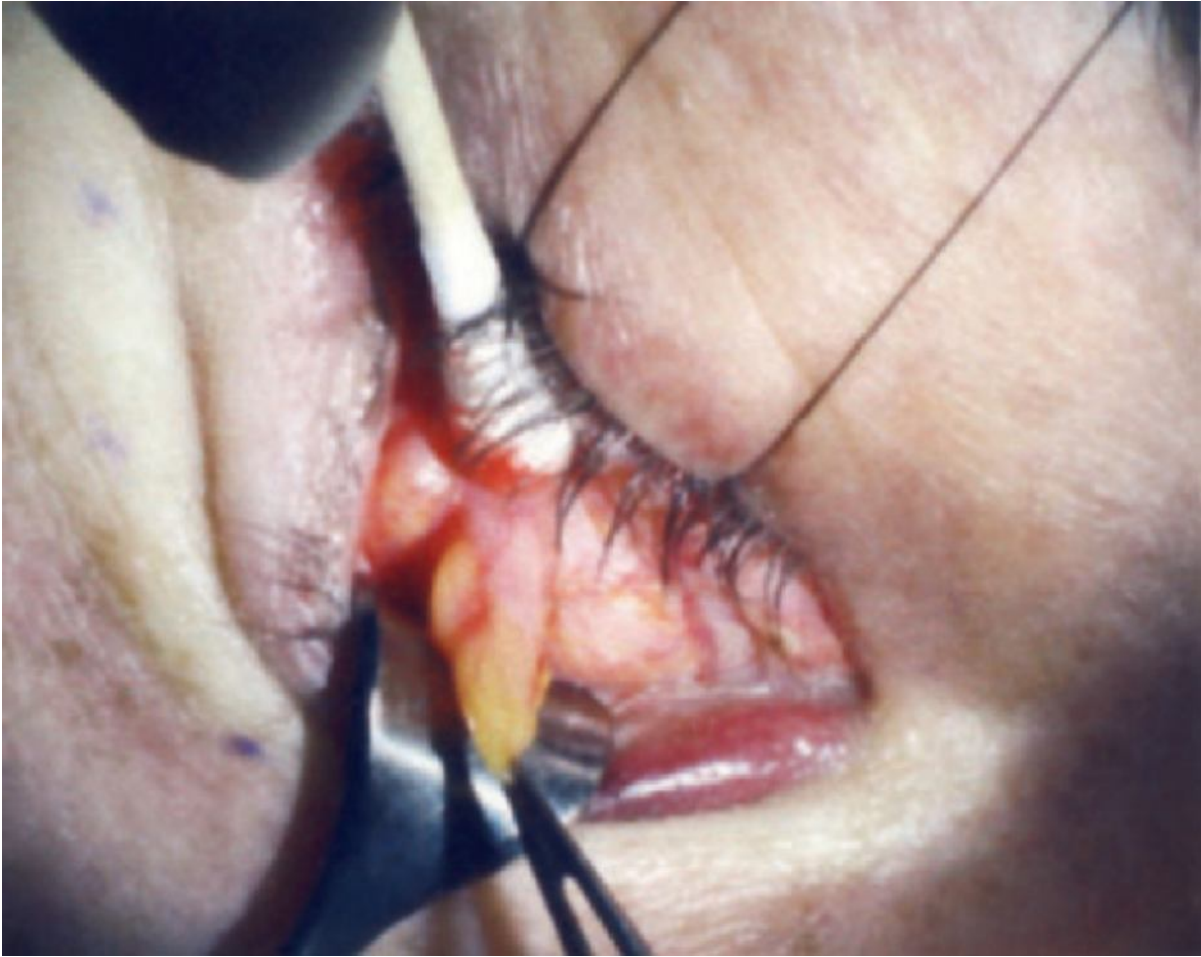
**Figure 90-16** Sagittal schematic view of the plane of dissection for preseptal transconjunctival blepharoplasty. The *arrow* indicates the level of the conjunctival incision, just below the inferior edge of the tarsal plate. The dissection then proceeds (*dashed line*) toward the inferior orbital rim in the plane between the orbicularis oculi and the orbital septum overlying the orbital fat compartments.

Once the flap is elevated, orbital fat should be readily apparent behind the orbital septum (Fig. 90-17). Pressure on the globe will cause the orbital fat to bulge forward; a small opening is then made in the septum overlying the fat compartments to be addressed.



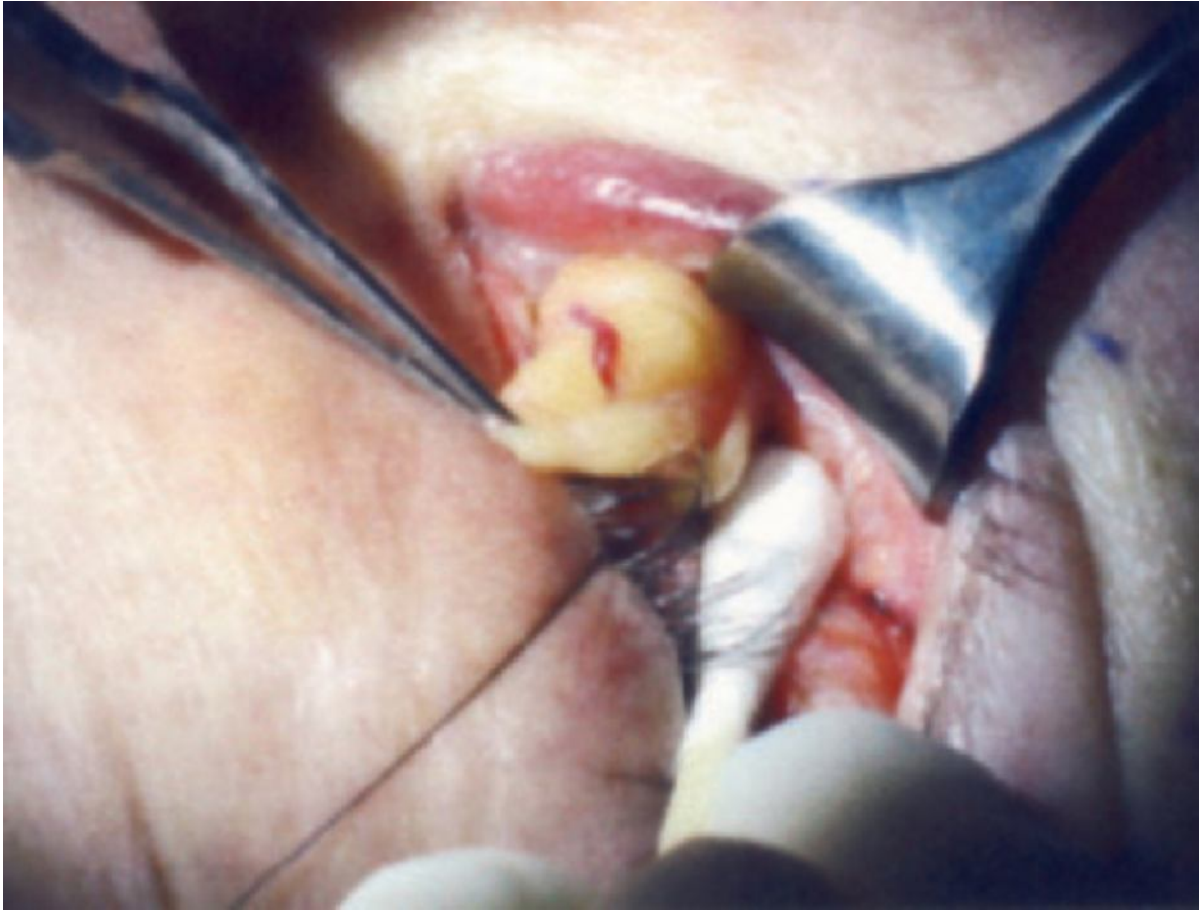
**Figure 90-17** After preseptal dissection in the plane between the orbicularis oculi and the orbital septum, a Desmarres retractor placed deep to the muscle exposes the orbital septum, through which one can see the underlying orbital fat compartments (right eye). A bridle suture is in place to retract the conjunctiva superiorly for corneal protection.

The fat from each compartment is dealt with separately. The fat is teased free from the surrounding fascia and attachments with fine forceps in one hand and a cotton-tipped swab in the other (Figs. 90-18 and 90-19; lateral fat dissection not shown). Once the orbital fat has been mobilized, one can resect the excess fat. As with upper lid fat removal, a small amount of local anesthetic should be injected into the base of the fat pedicle before excision.



**Figure 90-18** Central compartment fat being teased through an opening in the orbital septum with the aid of a cotton-tipped applicator (right eye).



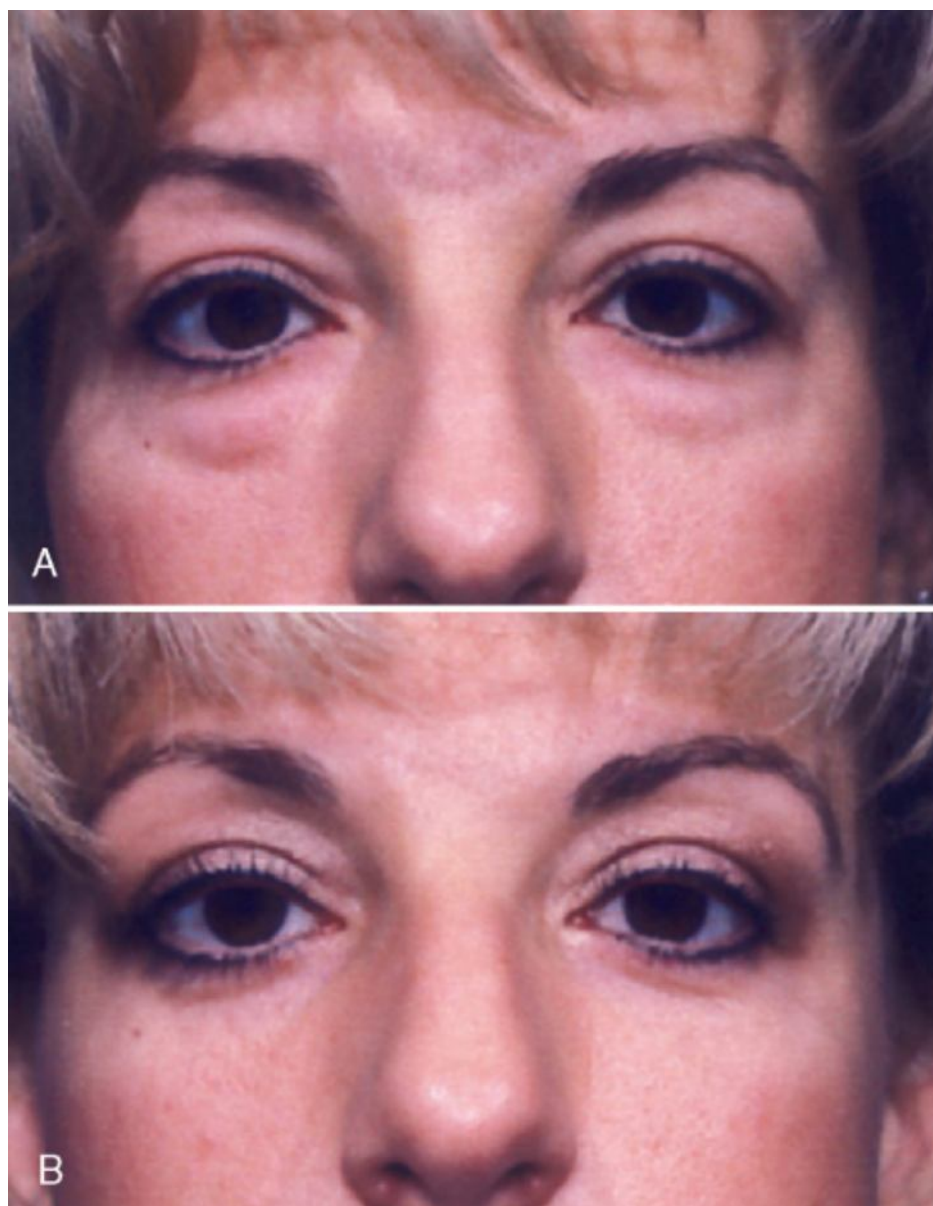


**Figure 90-19** Medial compartment fat teased through an opening in the orbital septum before removal (right eye).

A fine curved hemostat is placed at the base of the mobilized fat, and small curved scissors are used for sharp resection while leaving a small cuff of fat above the hemostat. A cautery device is then used to coagulate the cut edge of the fat. Alternatively, one can use bipolar cautery across the base of the fat without a hemostat and fine scissors to incise the cauterized stump and excise the fat. With this technique one works slowly and incrementally across the base of the fat to maximize control and minimize the risk of bleeding. Adequate resection is achieved by removing only the fat that extends above the plane of the inferior orbital rim without traction; at this level one minimizes the risk of injuring the inferior oblique muscle, which lies between the medial and central fat compartments.

It is important to address each compartment individually to avoid missing any of the fat pads. The medial fat pad is distinguished from central or lateral fat by its paler color. After adequate resection has been performed, one should evaluate the resection by replacing the lower lid in its anatomic position and examining the lower lid with and without pressure on the globe. It is important to re-explore any area that continues to look prominent and to pay particular attention to bilateral symmetry. With the patient in the supine position, a slight concavity of the overall contour of the lid will generally ensure a good result.

It is not absolutely necessary to close the conjunctival incision. It will heal without problem even if left unsutured. Alternatively, a single suture can be placed in the incision to properly align the conjunctival wound, but it should be placed lateral or medial to the corneal limbus (corneal-scleral junction) to avoid any direct corneal irritation from the suture. Fast-absorbing 6-0 catgut suture is used with an inverted buried knot. Preoperative and postoperative photos of a lower eyelid transconjunctival blepharoplasty patient are seen in Figure 90-20.



**Figure 90-20** Preoperative (A) and postoperative (B) views of a lower eyelid transconjunctival blepharoplasty patient.

As one becomes more comfortable with the procedure, small amounts of excess skin can be removed by subciliary “pinch” excision at the same time if only a minor amount of skin resection is needed, or a mild 35% TCA peel of the periorbital area can be used to treat fine wrinkles.

### *Transcutaneous Approach*

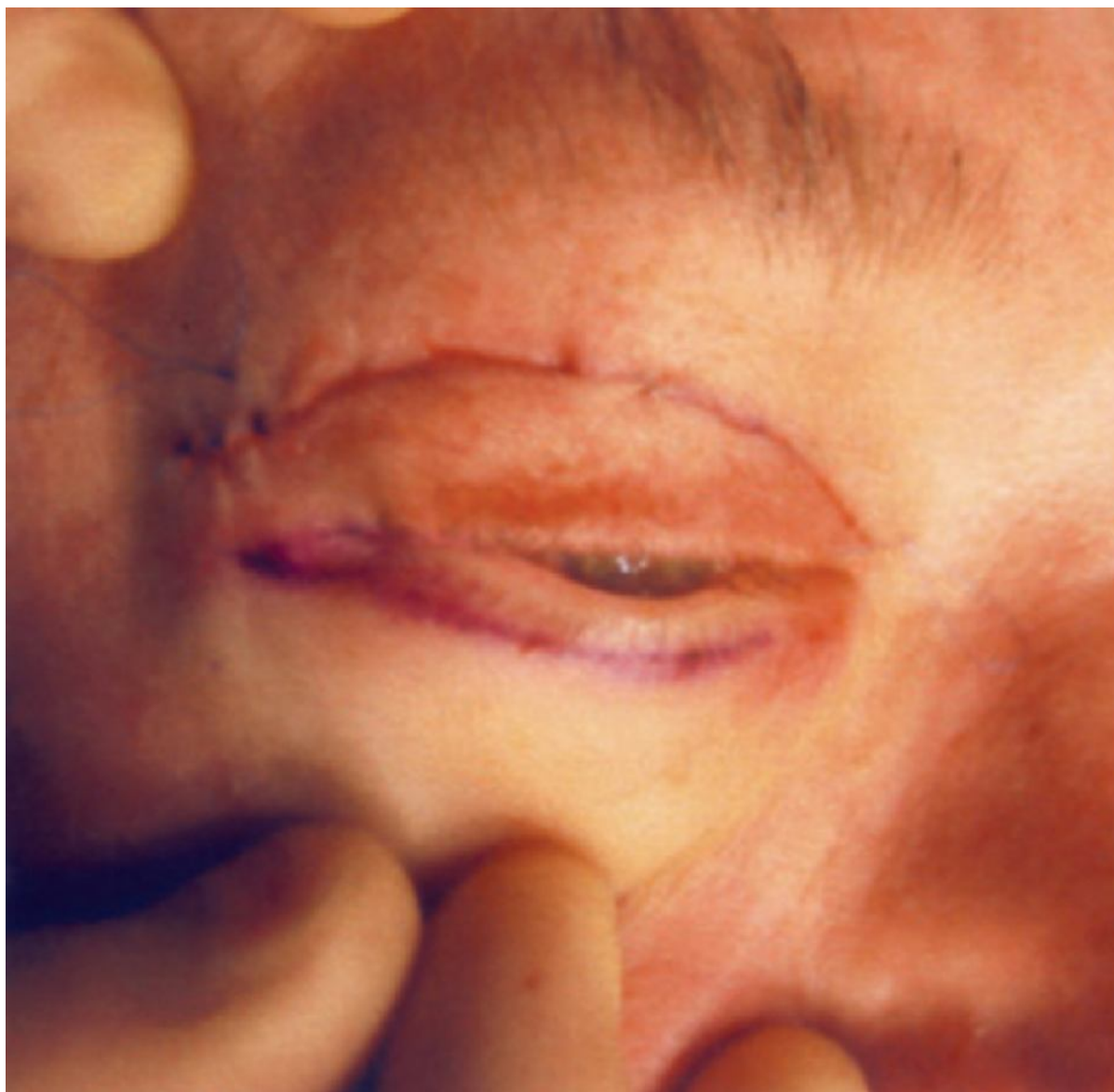Transcutaneous lower lid blepharoplasty is reserved for patients with large amounts of excess skin or hypertrophy of the orbicularis muscle that needs to be addressed, as well as those with lower lid deformities secondary to laxity that would benefit from a lower lid suspension procedure.

In patients with a significant disparity in the amount of excess skin and muscle, separate skin and muscle flaps are raised to the level of the infraorbital rims, and the appropriate excesses are dealt with individually. This is less common and probably accounts for no more than 2% to 3% of all blepharoplasty patients. All other transcutaneous blepharoplasty patients are treated with the standard skin-muscle flap technique that is described later.

### *Markings*

The lower eyelid incision parallels the lash line and is placed 1.5 to 2 mm below it (Fig. 90-21). Adequate access can often be achieved with an incision extending medially only as far as the medial limbus of the cornea and lengthening the incision further only if need be. Beyond the lateral canthus, the incision angles slightly downward and lateral, parallel to or in a lateral periorbital skin crease (crow's foot), and extends about 5 to 7 mm. It is important to make this extension only as long as needed to remove the redundant skin. The distance between the

designed lateral extents of the upper and lower incisions should be at least 5 to 7 mm.



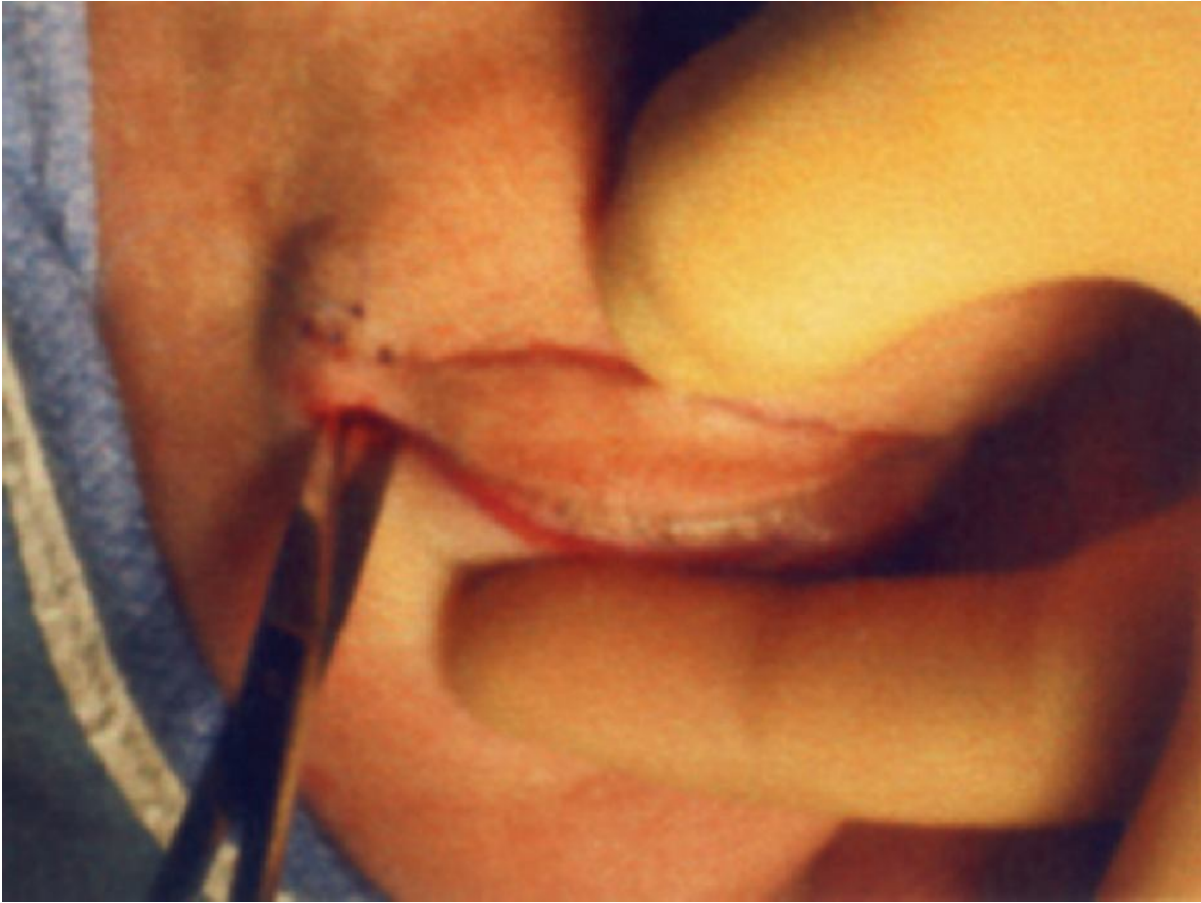**Figure 90-21** The subciliary incision is marked approximately 2 mm below the lash margin and extends 5 to 7 mm beyond the lateral canthus.

### *Procedure*

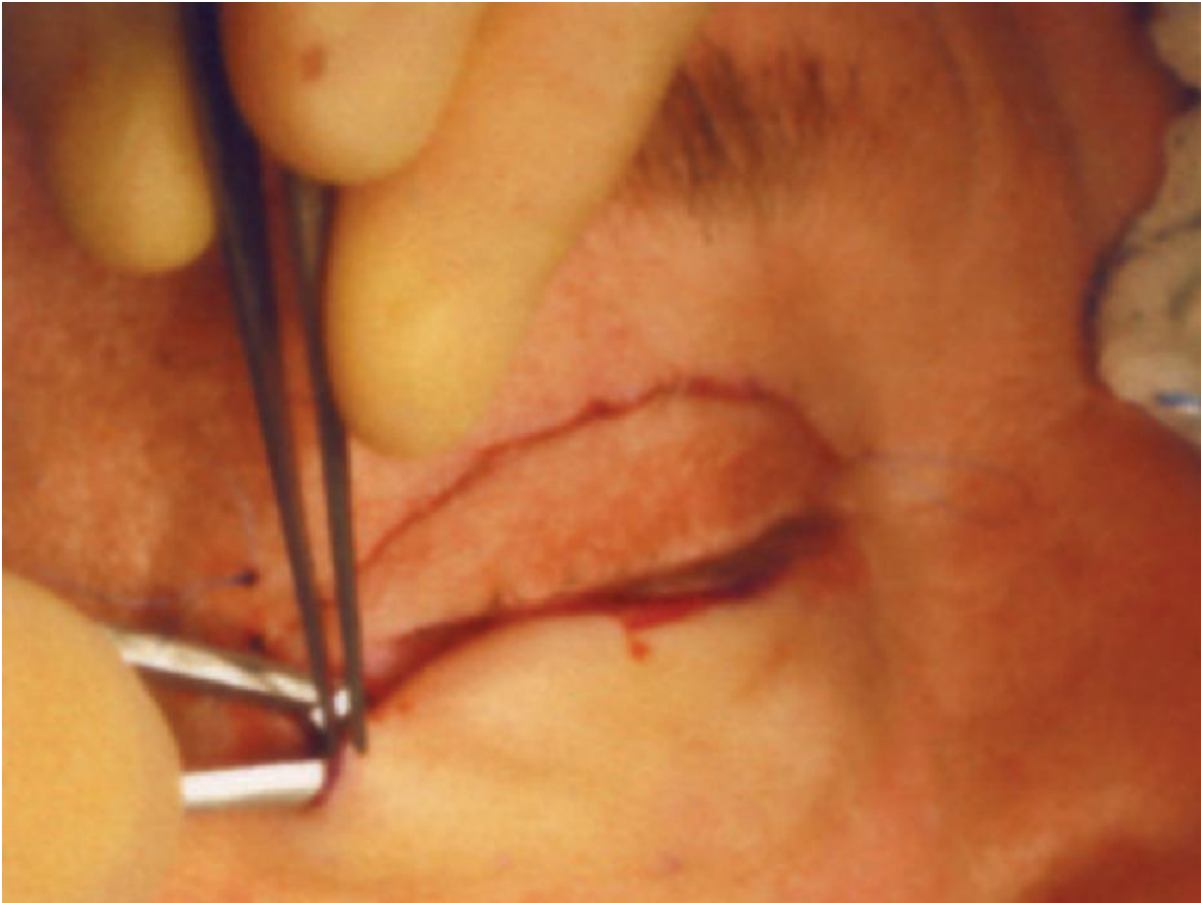
Although this operation can be done under general anesthesia, it is typically performed under local anesthesia with intravenous sedation. Once the depth of sedation is adequate, the eyes are lubricated with ophthalmic ointment. Lidocaine (1%) with 1:100,000 epinephrine is injected along the proposed incision, as well as deep to the preseptal orbicularis oculi, with a 27-gauge, 1½-inch needle.

A no. 15 blade is then used to incise through the skin of the small extension beyond the lateral canthus or along the entire subciliary incision, through skin only. The incision lateral to the canthus is next deepened to a submuscular (preseptal) plane (Fig. 90-22). One can then blindly predissect or elevate inferiorly and medially down to the orbital rim deep to the muscle to separate the muscle from the septum beneath it with fine scissors in a blunt spreading motion (Fig. 90-23). Small, sharp curved scissors are then tunneled medially under the skin in the pretarsal area, superficial to the orbicularis oculi, and the subciliary incision is completed through skin only.





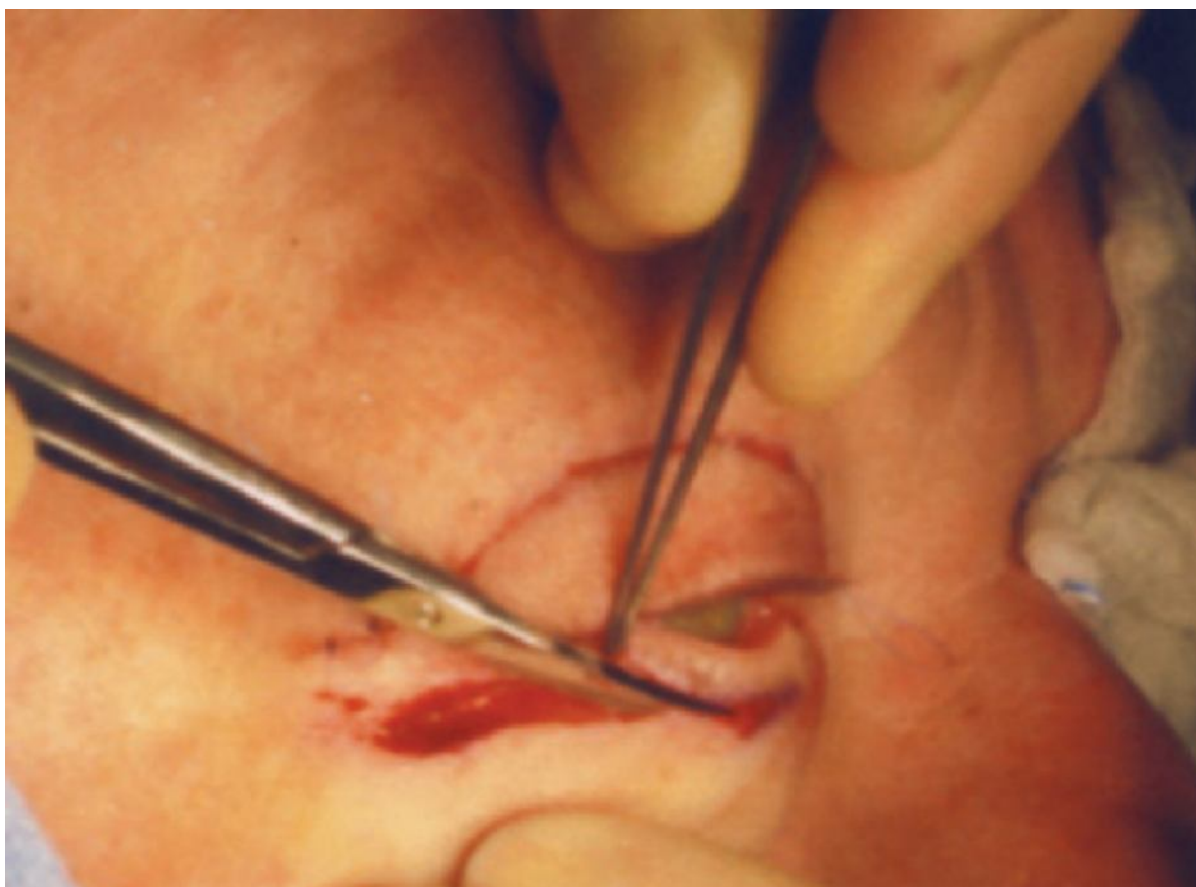
**Figure 90-22** On completion of the subciliary skin-only incision, the segment beyond the lateral canthus is deepened to a submuscular plane.



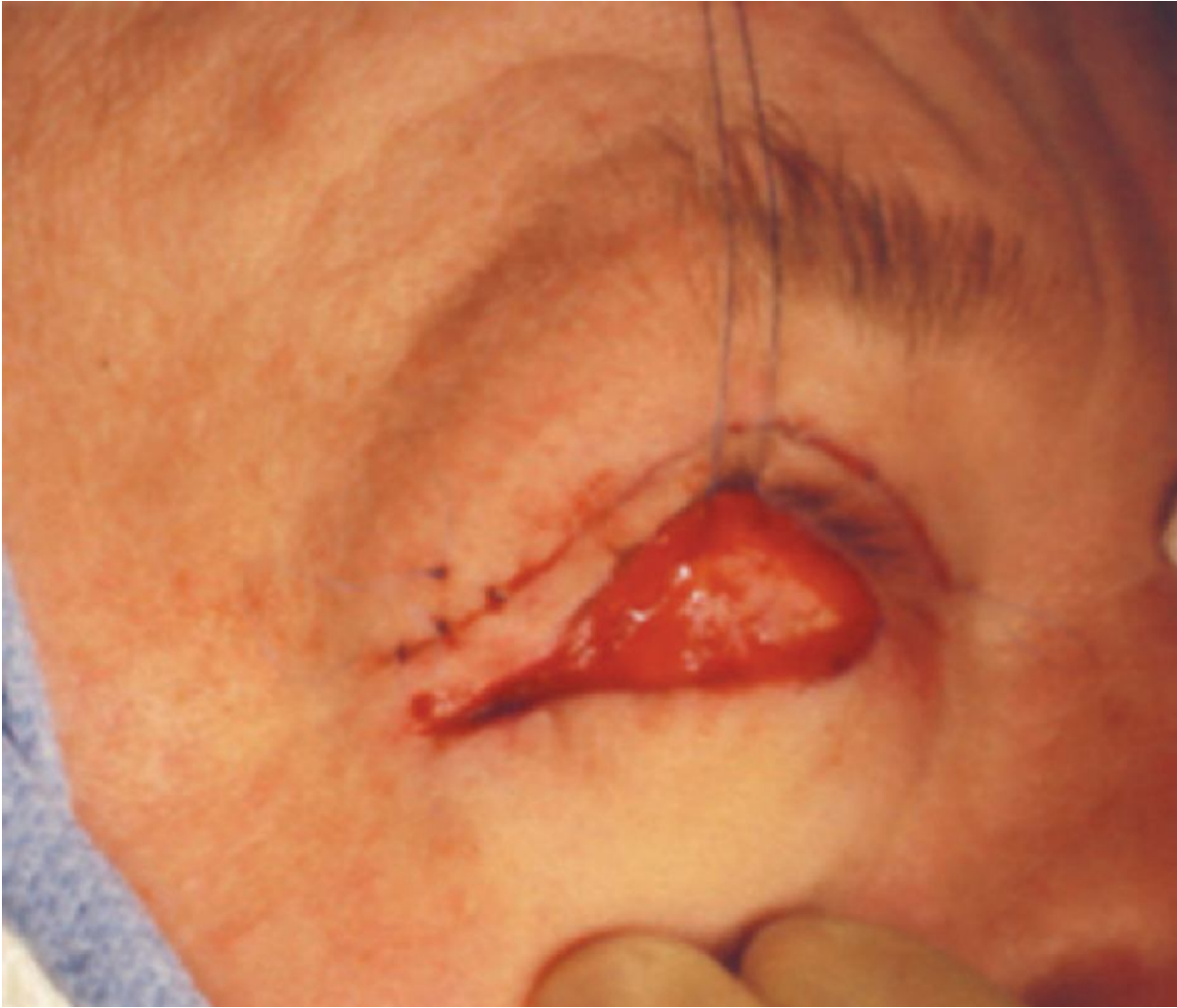**Figure 90-23** The initial blind submuscular dissection should proceed easily, without encountering any resistance, through the relatively avascular plane between the orbicularis oculi and the orbital septum deep to it. The dissection is carried toward the inferior orbital rim.

At this point the dissection has involved skin only in the pretarsal area, and the pretarsal orbicularis muscle is left intact and not elevated. It is important to leave the pretarsal orbicularis muscle intact to act as a hammock and help support the lower lid to decrease the likelihood of ectropion. The dissection in the preseptal area has thus far been deep to the orbicularis.

The planes of the skin-only elevation (pretarsal) and the skin-muscle flap dissection (preseptal) are then connected by incising the muscle below the tarsus, approximately 3 to 5 mm from the lash line (Fig. 90-24). A bridle suture is placed through the superior incision margin or the gray line to retract the conjunctivacephalically for corneal protection (Fig. 90-25). The skin-muscle flap is then elevated down to the level of the infraorbital rim, and the entire orbital septum is exposed. The flap can be retracted by an assistant with a wide blunt double-ball hook (Fig. 90-26).

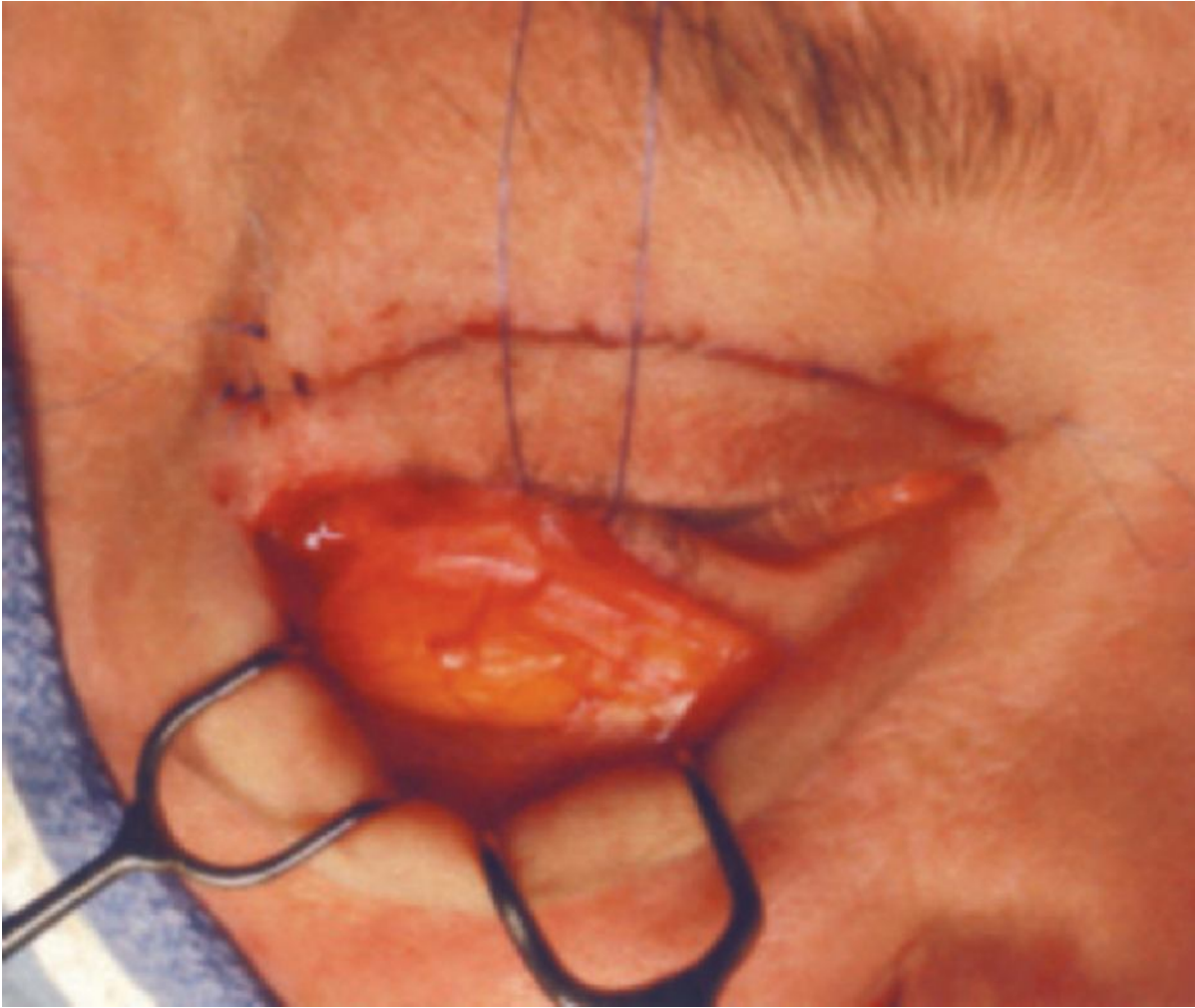


**Figure 90-24** The muscle is incised below the level of the subciliary incision with a “blade-in, blade-out” maneuver to connect the skin-only pretarsal dissection with the submuscular elevation below the tarsus.



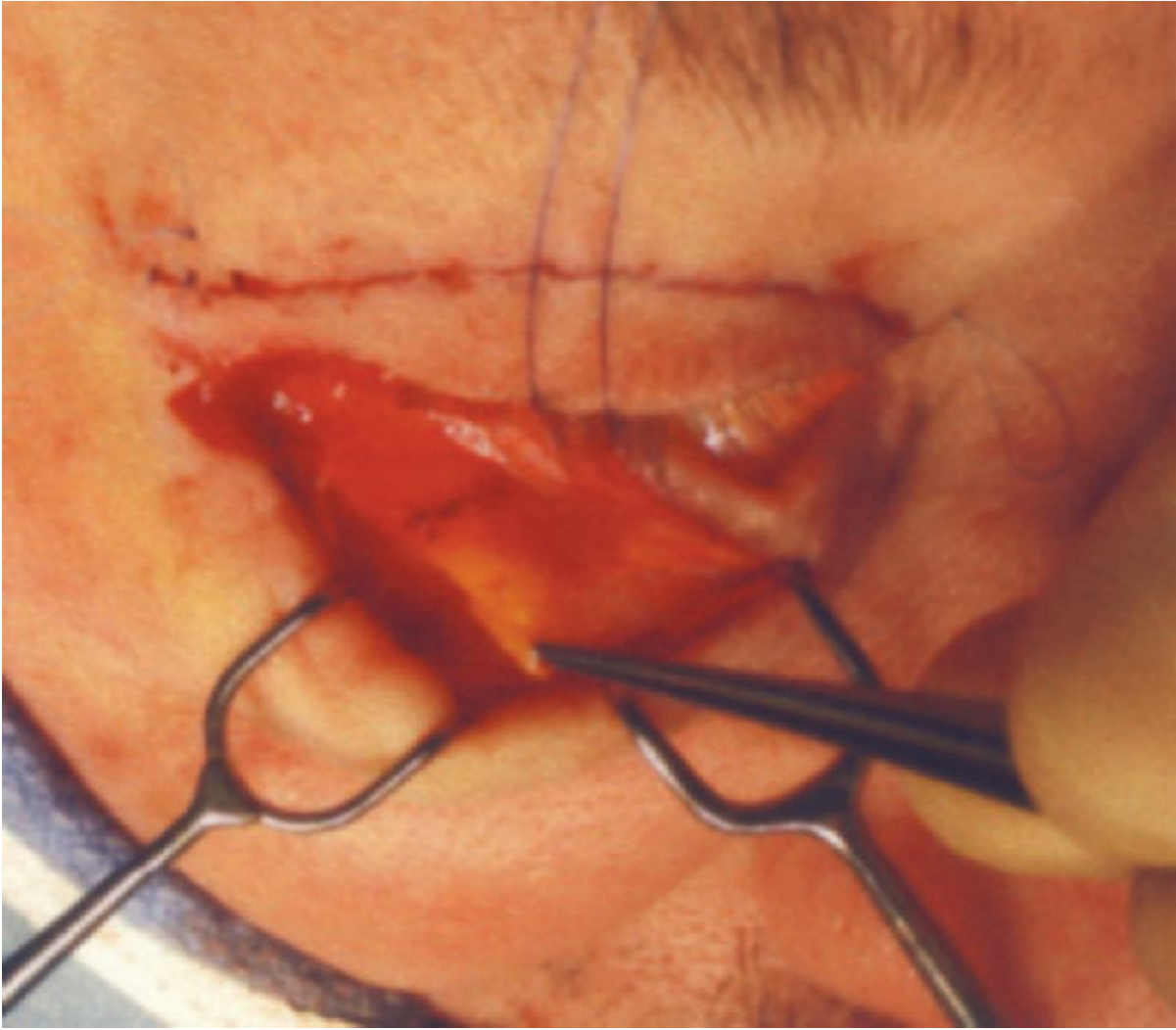
**Figure 90-25** A bridle suture is placed to retract the tarsus and conjunctiva superiorly for corneal protection.



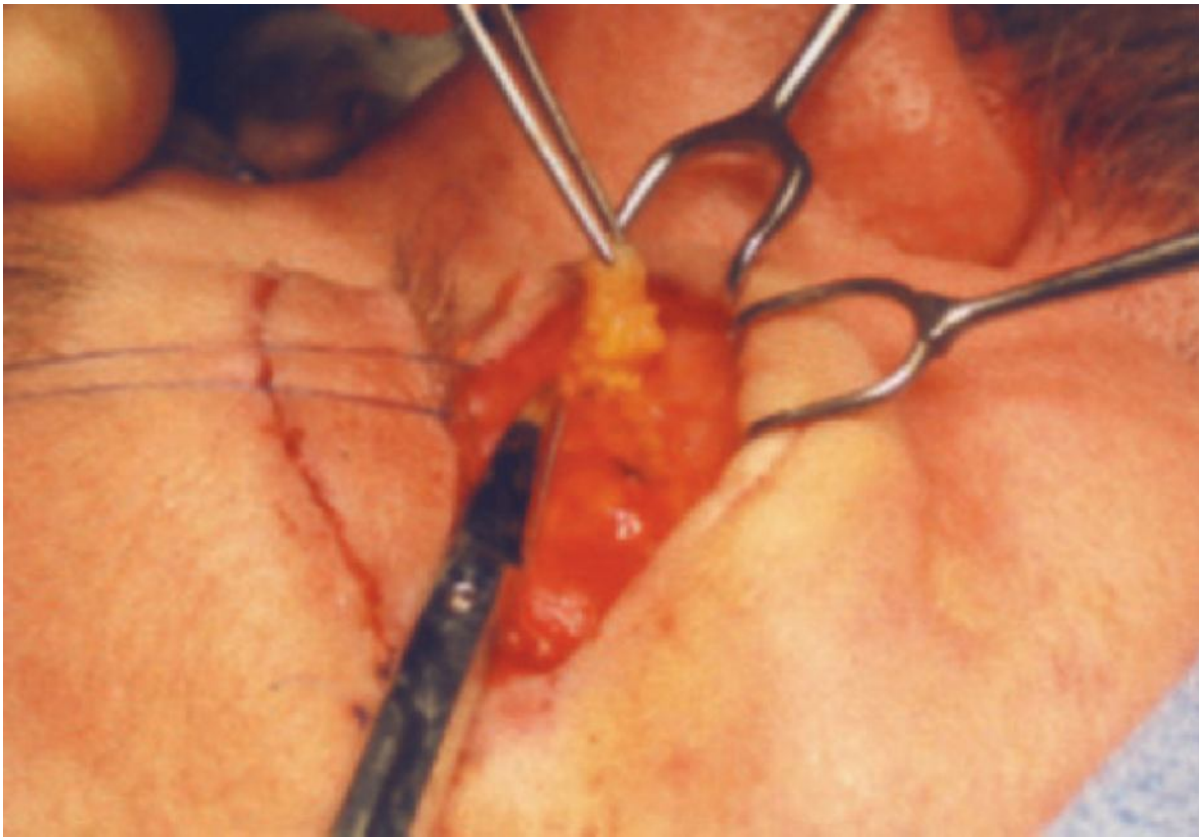


**Figure 90-26** The skin-muscle flap is elevated and retracted toward the inferior orbital rim to expose the orbital septum and the underlying orbital fat compartments.

Small openings are made through the orbital septum to facilitate dissection of fat from each compartment (central, medial, and lateral) as needed (Figs. 90-27 and 90-28 show removal of fat from the central and medial compartments, respectively). Fat removal proceeds as previously described for preseptal transconjunctival lower lid blepharoplasty.



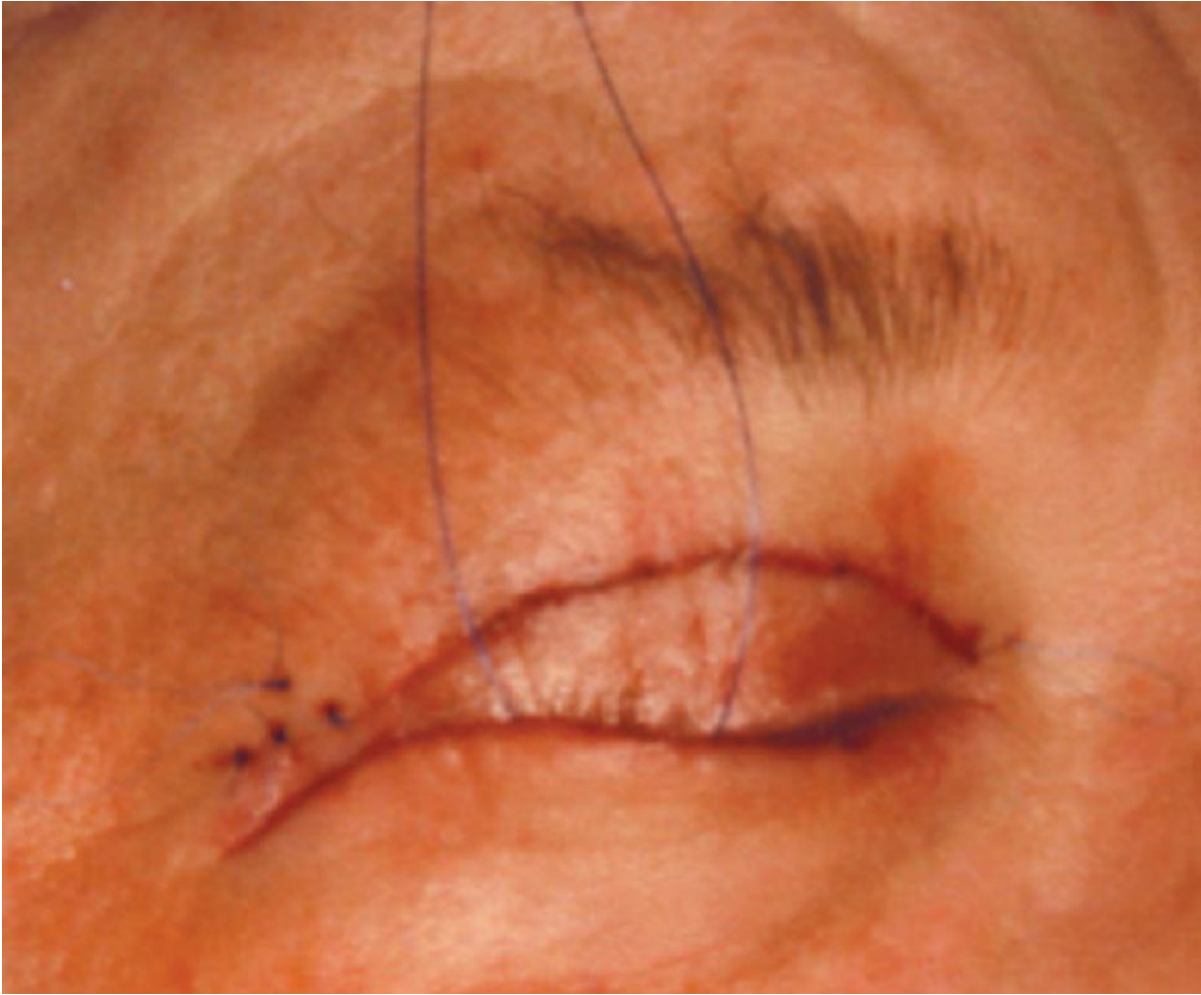
**Figure 90-27** Delivery of fat from the central compartment.



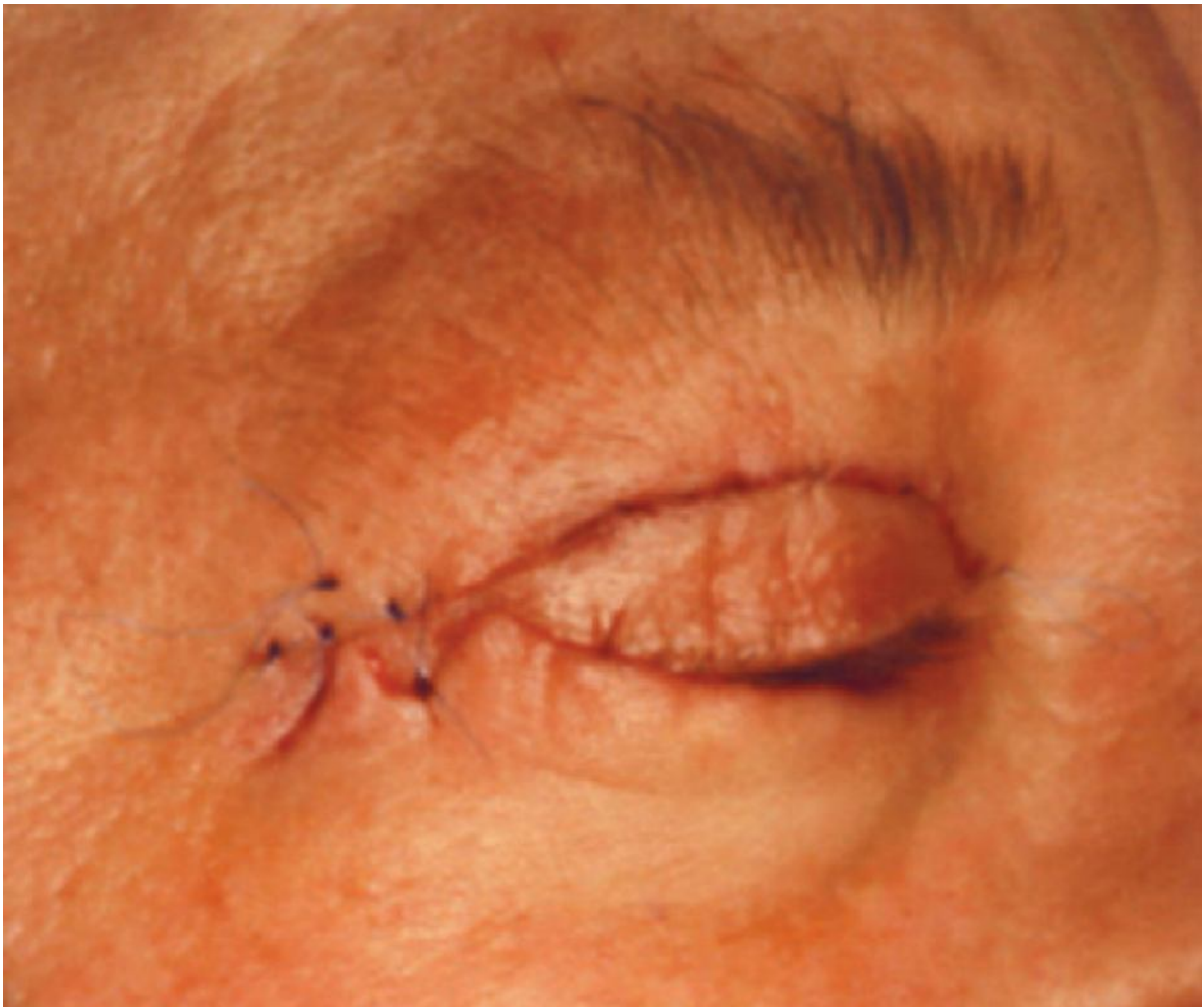**Figure 90-28** Delivery of fat from the medial compartment.

The skin-muscle flap is then redraped over the lower lid lashes in an upward and slightly lateral direction (Fig. 90-29). If sufficiently responsive at this point, the patient is asked to open the mouth and to look toward the top of the head. A cut is then made in the skin-muscle flap at the level of the lateral canthus to the point at which the excess skin meets the cut edge of the infraciliary margin. That point is sutured with 6-0 Prolene, and the excess skin is effectively divided into two triangles of excess skin—one medial and one lateral to the canthus (Fig. 90-30). The surgeon next excises the extra skin, first the lateral triangle (Fig. 90-31) and then the medial triangle (Fig. 90-32), so that there is no tension on the skin closure. It is imperative that the surgeon be conservative with skin excision from the lower eyelid to minimize the risk of lid malposition. A strip of orbicularis (several millimeters) is then excised from beneath the upper margin of the skin-muscle flap (Fig. 90-33)—failure to do so would result in overlapping of this muscle over the pretarsal orbicularis that was not elevated.

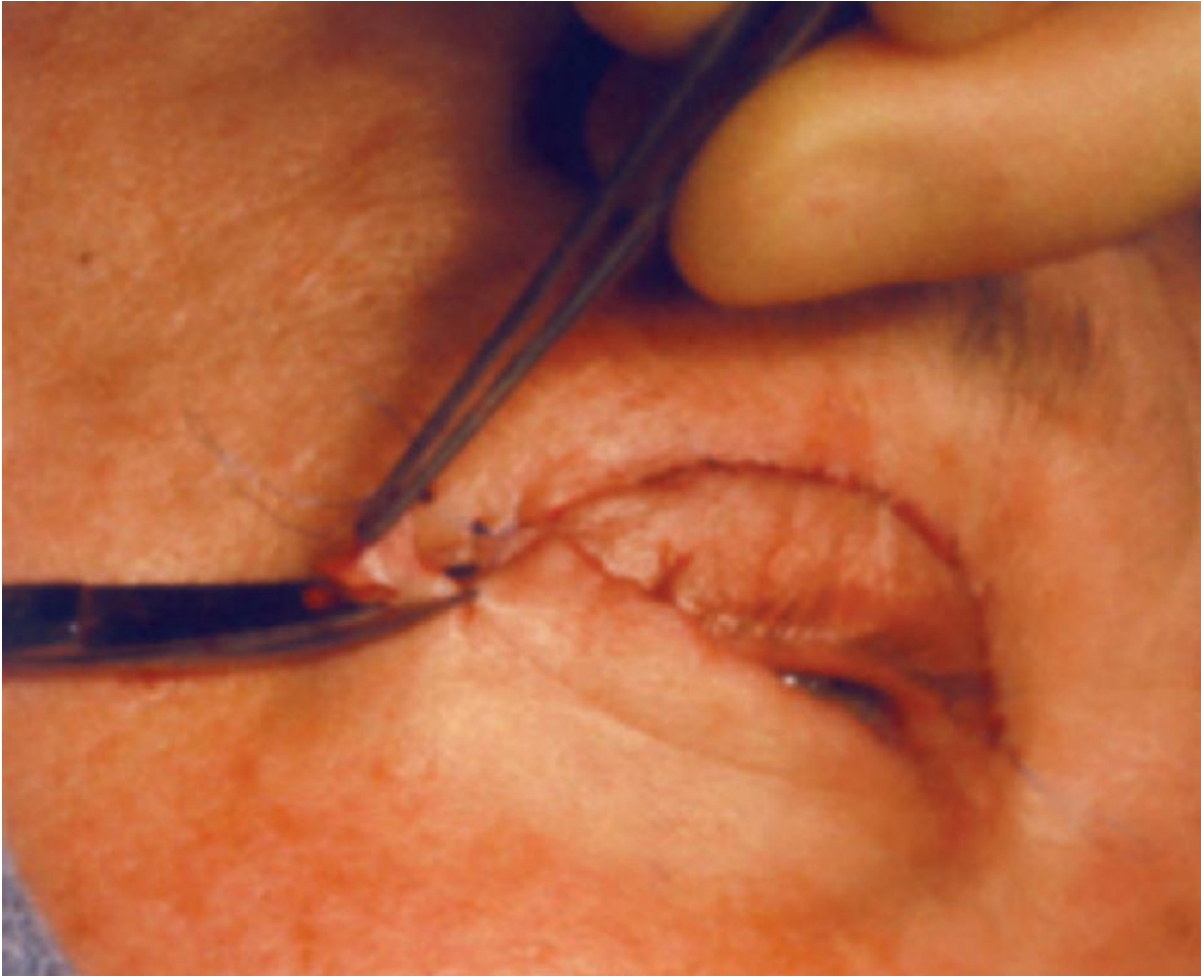




**Figure 90-29** The skin-muscle flap is redraped over the infraciliary incision.

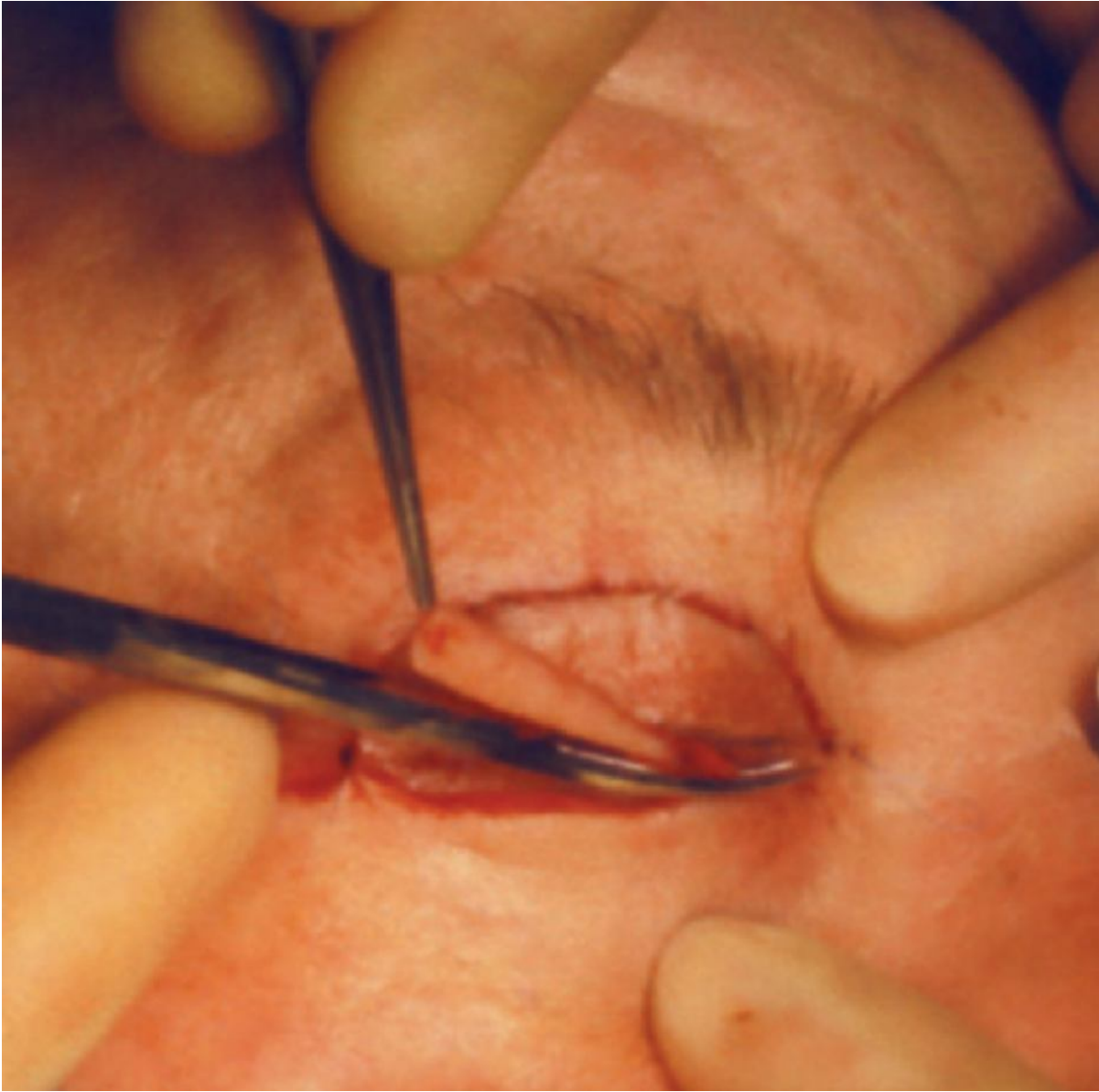


**Figure 90-30** An incision is made in the flap at the lateral canthus as far as the edge of the infraciliary incision, and that point is secured with 6-0 Prolene suture, thereby effectively dividing the skin excess into two separate triangles—one medial and one lateral to the canthus.

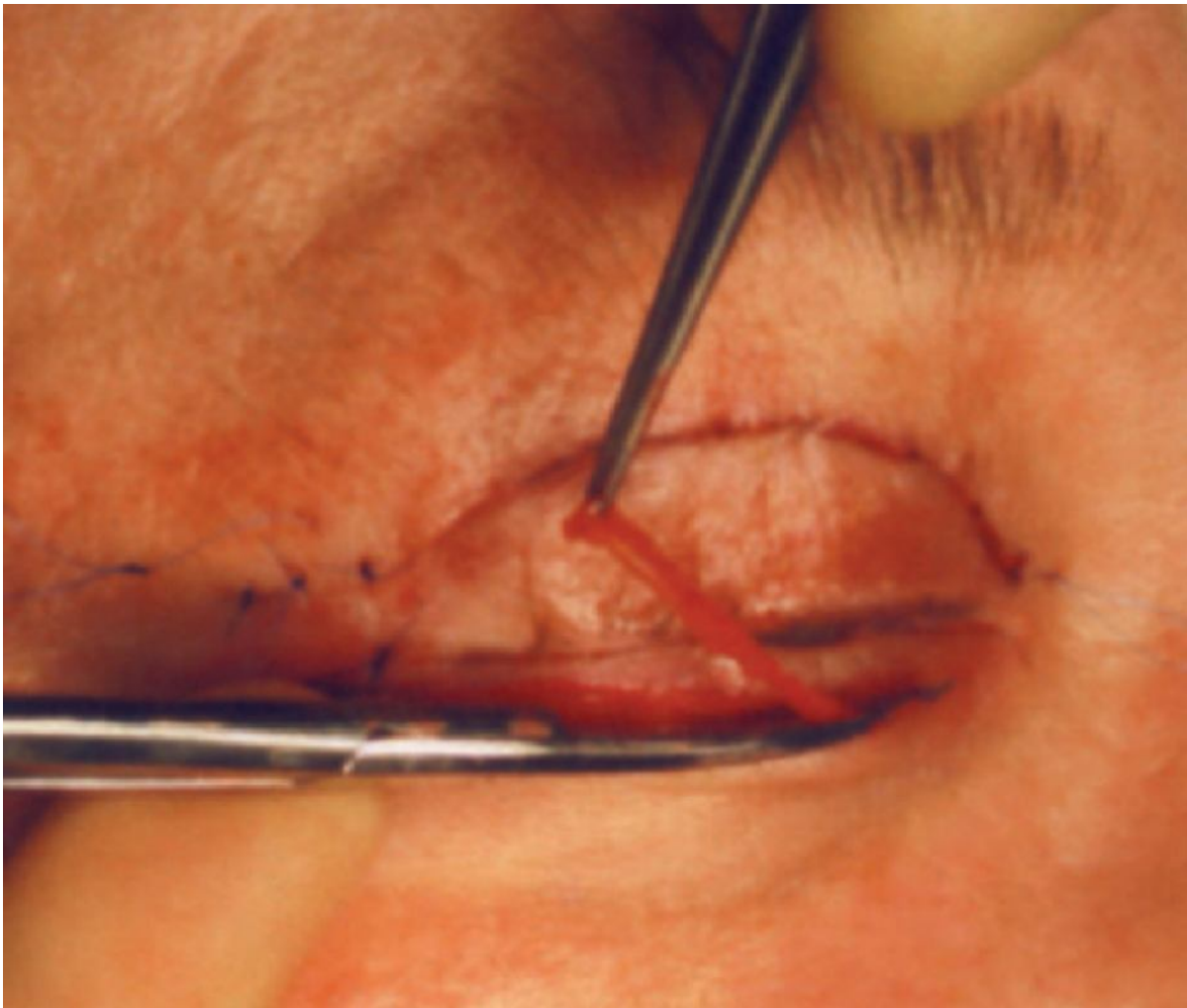


**Figure 90-31** Excision of excess skin lateral to the lateral canthus.



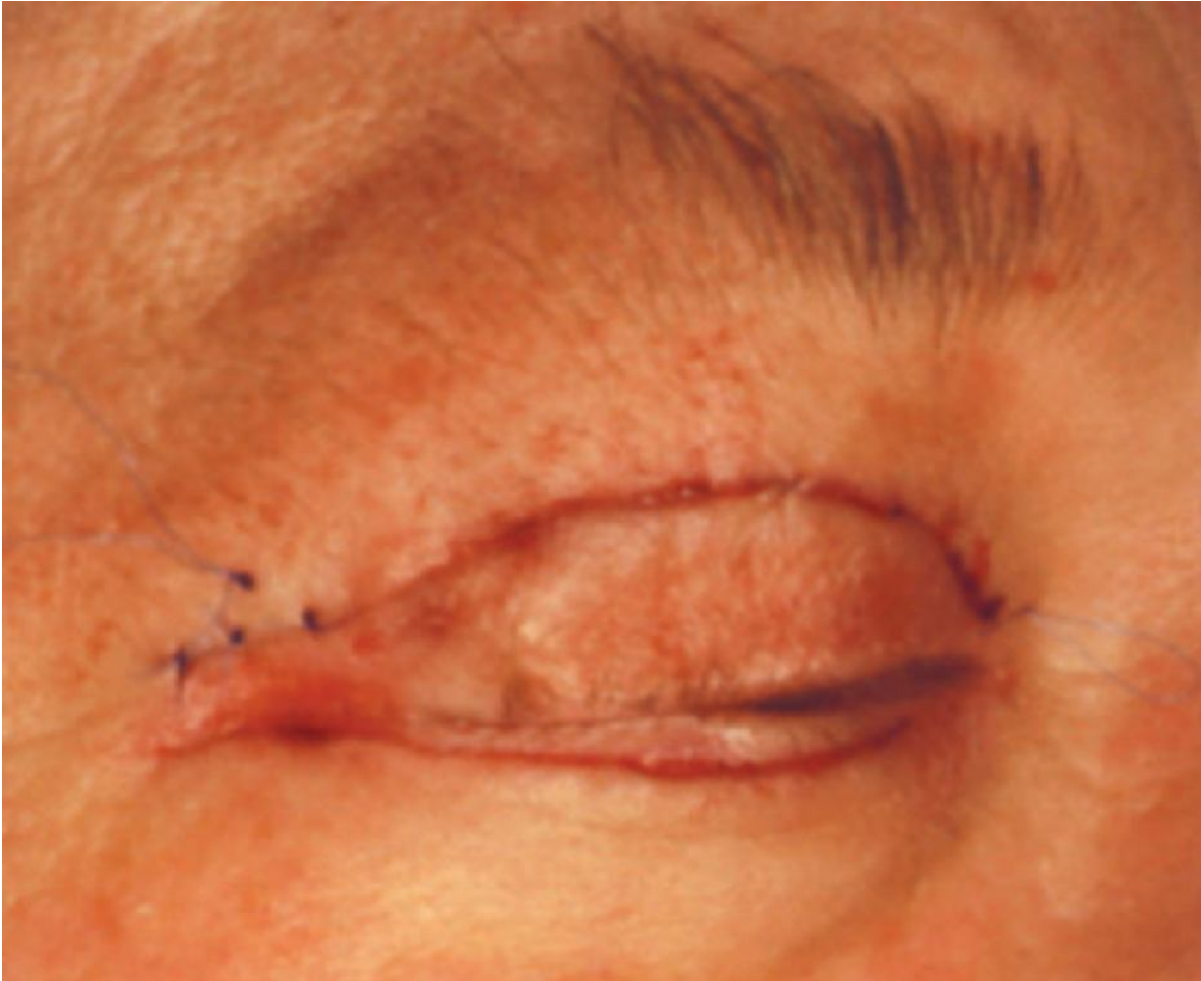


**Figure 90-32** Excision of the excess triangular skin medially.



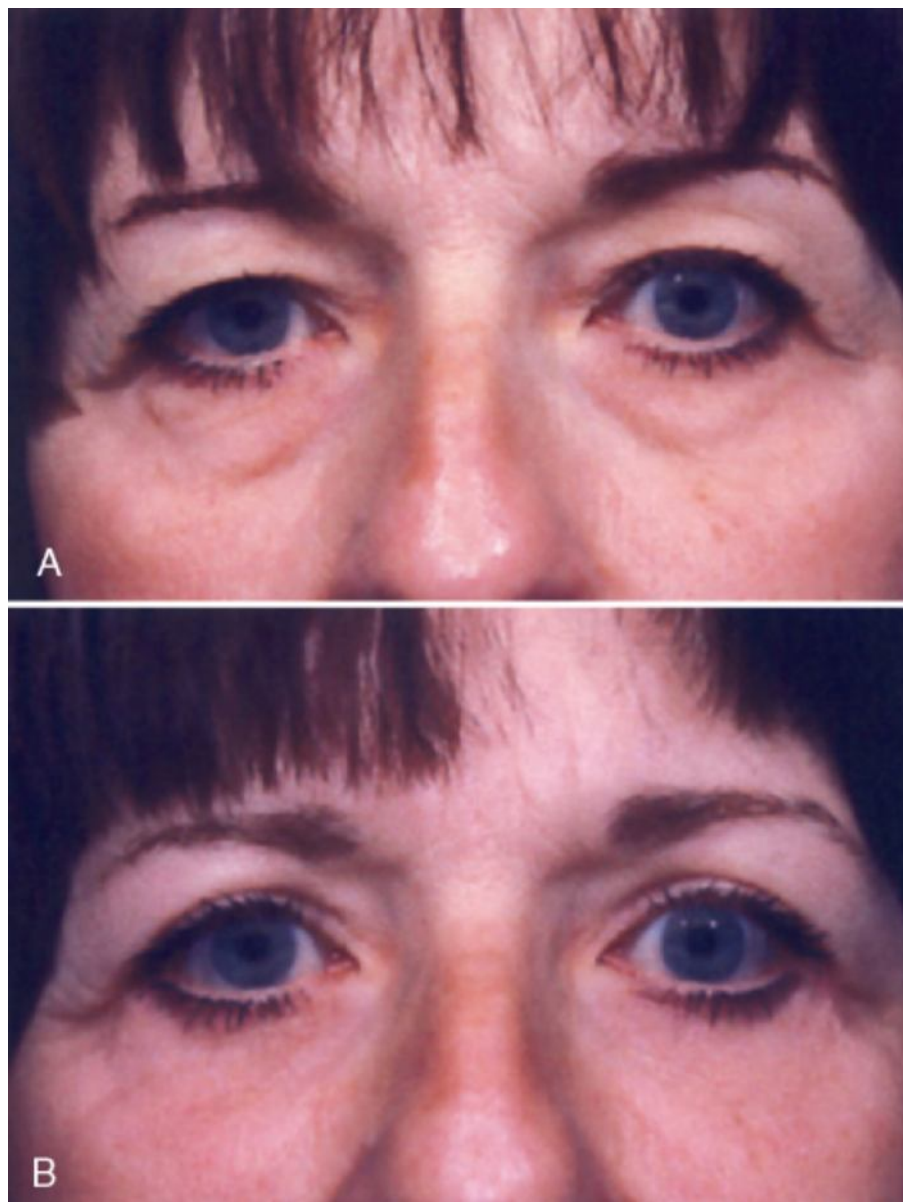
**Figure 90-33** Excision of a thin strip of orbicularis muscle from beneath the skin-muscle flap edge to prevent muscle beneath the flap from overlapping the pretarsal muscle, which was preserved.

After hemostasis is verified, a flap suspension suture of 5-0 PDS is placed to support the position of the lower lid through the healing period.<sup>[5]</sup> The orbicularis under the skin-muscle flap is grasped medial to and below the lateral orbital tubercle (Whitnall's tubercle) and suspended with a buried inverted suture to the periosteum at the lateral orbital tubercle. It is important to get a good bite of periosteum and also to ensure sufficient purchase on the muscle *without* dimpling the overlying skin. The skin edges at this point should lie in easy approximation (Fig. 90-34) to allow closure without tension. The wounds are then closed with interrupted 7-0 Prolene suture lateral to the canthal angle and interrupted or running 6-0 fast-absorbing gut suture along the subciliary portion of the incision. Preoperative and 4-month postoperative photos of a patient who underwent a lower eyelid skin-muscle flap blepharoplasty are seen in Figure 90-35.



**Figure 90-34** Skin-muscle flap blepharoplasty, just before skin closure with easy tension-free approximation of skin edges.





**Figure 90-35** Preoperative (A) and postoperative (B) views of a lower eyelid skin-muscle flap blepharoplasty patient.

### *Postoperative Management*

Postoperative management of a patient after lower lid blepharoplasty is similar whether done via the transconjunctival or the transcutaneous approach and not unlike that of the upper lids. The only difference is that if a transconjunctival approach is used for the lower lids, an ophthalmic antibiotic drop with steroid (e.g., TobraDex) is applied for the first 5 days postoperatively. Patients are instructed to not wear contact lenses for at least 1 week after surgery.

### **COMPLICATIONS[6]**

#### *Corneal Injury*

The best treatment of corneal injuries is prevention. Lubrication should be placed in the eyes to prevent desiccation during surgery. Shields can be worn during blepharoplasty to protect the cornea, and the surgeon should be cautious about the use of abrasive gauze near the cornea.

Pain in the eye is a warning sign of a corneal injury. If any concern exists postoperatively regarding possible corneal injury, evaluation by an ophthalmologist is recommended. Fluorescein staining can be used for diagnosis, and treatment includes ophthalmic antibiotic ointment and maintenance of the eye at rest with an occlusive dressing until healing is complete.

#### *Wound Separation*

Sutures are typically removed on or before the fifth postoperative day. Infrequently, the lateral aspect of the wound may begin to separate, and this should be corrected with Steri-Strips or the wound should be resutured if necessary.

### Asymmetries

Not uncommonly, postoperative asymmetries will reflect unrecognized preoperative asymmetries in excess lid skin or asymmetric preoperative brow position. Noting such asymmetries and discussing them with the patient *preoperatively* will often make minor postoperative asymmetries acceptable. If a brow procedure is not indicated, asymmetric skin excision may be necessary in an attempt to avoid postoperative differences between the two sides. Asymmetry in fat excision can also be apparent postoperatively. Again, attention to detail intraoperatively will help avoid such problems. If asymmetry persists after several months postoperatively, revision surgery will be necessary.

### Dry Eyes

Possible causes of dry eyes include an unrecognized preoperative condition, injury to the lacrimal gland (uncommon), excessive skin resection, and edema. By far postoperative edema is the most common cause and should settle over a 1- to 3-week period postoperatively. The interim use of artificial tears and lubricating ointments is important to help prevent keratitis. Excessive skin resection will ultimately require repair with a full-thickness skin graft replacement.

### Epiphora

Excess tearing from the eyes is common during the first 48 hours postoperatively. It is usually due to edema of the skin or temporary muscular atony, which can then impair the function of the tear drainage system. The epiphora usually resolves as the swelling subsides. Intermittent episodes may persist with changes in weather. Other possible causes include eversion of the punctum (secondary to either edema or ectropion—see later) or, less commonly, injury to the canaliculus.

### Lagophthalmos

Patients are often unable to completely close their eyes because of edema in the immediate postoperative period. Most commonly, lagophthalmos is due to immediate postoperative edema. It is treated with lubricating ointments and time. If this condition is secondary to over-resection of upper lid skin, desiccation can lead to corneal injury. In such cases, release of the upper lid along with skin grafting must be considered. Again, the best treatment is prevention, which is why it is imperative to measure the amount of skin to be resected (via the aforementioned pinch technique) several times before making any skin incisions.

### Ptosis

Temporary “pseudoptosis” secondary to swelling is not uncommon in the first postoperative week. Persistent ptosis suggests injury to the levator expansion during opening of the orbital septum. The levator apparatus is most at risk in the inferior portion of the wound where the surgeon is closest to the upper border of the tarsal plate, the point at which the levator fuses with the orbital septum. Any excision of muscle or opening of the septum is safest if one stays away from the lower portion of the wound after excision of skin. Persistent ptosis should be corrected by reinsertion of the levator into the tarsus or dermis.

### Extraocular Muscle Injury

The inferior oblique muscle lies in a vulnerable position between the medial and central fat compartments of the lower lid. It should be looked for in every case, although it is not always seen. Being alert to the location of the muscle, however, will help avoid inadvertent injury. Care must be taken to avoid clamp, Bovie, or sharp injury to this muscle during fat dissection and resection. If immediately identified, the transected ends should be approximated. Diplopia on upward lateral gaze is indicative of injury to the muscle. Persistent postoperative diplopia that lasts longer than 1 or 2 weeks should be evaluated by an oculoplastic surgeon for appropriate care.

### Lower Lid Malposition

Temporary excess “scleral show” in the immediate postoperative period may be due to edema and temporary paresis of the orbicularis oculi muscle. It will often resolve in the perioperative period as the edema lessens and the muscle reinnervates. Treatment of any chemosis includes topical steroids and prevention of exposure keratitis. Massage of the lower lid in an upward and outward direction will also help. Often, tape support of the lower lid during the early postoperative period will lessen the degree of scleral show.

Unrecognized preoperative lower lid laxity may also contribute to postoperative ectropion. In such cases,

secondary canthopexy or canthoplasty may be required. If the ectropion is due to overaggressive skin resection, secondary surgery to correct the deformity with scar release and full-thickness skin grafting may be necessary after several months of observation and conservative management.

The best means of treatment is prevention. The transconjunctival approach avoids the contraction associated with healing of the skin and muscle incisions used for the infraciliary approach. In addition, patients with any degree of laxity who require skin excision via an infraciliary approach should be considered for prophylactic lateral canthopexy.

### Retrobulbar Hematoma/Visual Loss

Retrobulbar hematoma is the most feared complication after routine blepharoplasty. The most likely cause is a vascular injury with retraction of the bleeding vessel into the retrobulbar space. The eye becomes firm, chemotic, and progressively more proptotic. The lids cannot close as the globe continues to bulge outward. Progressively increasing intraocular pressure can lead to ophthalmoplegia, ischemia of the optic nerve, and visual loss. A retrobulbar hematoma generally develops within the first 4 to 6 hours postoperatively, and prompt diagnosis and management are critical to prevent permanent visual loss.

Initial treatment involves opening of incisions; iced saline compresses; 20% mannitol (2 g/kg) as an osmotic agent to decrease intraocular pressure; acetazolamide (Diamox) 500 mg intravenously; dexamethasone (Decadron) 10 mg intravenously; control of hypertension (if present); head elevation; and correction of any coagulopathies. Visual acuity should be evaluated frequently.

Any deterioration in visual acuity is an urgent sign and, when coupled with elevated intraocular pressure, signifies potential optic nerve ischemia. In this situation, in addition to removal of all external sutures, lateral canthotomy and inferior cantholysis are indicated on an emergency basis to facilitate orbital decompression. Emergency ophthalmic consultation is necessary but should not delay performance of canthotomy and cantholysis if faced with visual compromise.

#### PEARLS

- A well-considered preoperative evaluation of the upper and lower eyelids, including assessment of orbital fat, skin, lid laxity/tone, and brow position, and a general medical and ophthalmic history are essential for guiding decisions regarding the surgical approach and extent of surgery.
- Conservatism is always warranted with eyelid surgery. It is always easier to do more at a later date if necessary, but complications resulting from overaggressive eyelid surgery can be very difficult to correct.
- For upper eyelid surgery, preoperative skin markings should be checked and rechecked to avoid excessive excision of skin.
- Absolute hemostasis is necessary to minimize the possibility of postoperative retrobulbar hematoma.
- The risk of lower eyelid malposition is much lower with a transconjunctival approach.

#### PITFALLS

- Failure to consider brow position as it relates to any apparent excess of upper eyelid skin may still leave patients with a somewhat hooded appearance or “crowded” upper periorbital region. In patients in whom the primary problem is brow ptosis, it should be addressed either instead of or in addition to upper blepharoplasty.
- Opening the orbital septum low toward the tarsal plate in the upper eyelid increases the risk for injury to the levator aponeurosis and iatrogenic ptosis.
- Overaggressive surgery or fat removal, whether from the upper or lower eyelids, can create a hollowed, gaunt appearance in addition to functional complications such as lagophthalmos and eyelid malposition.
- Patients with a very prominent, protrusive globe (“pseudoproptosis”) in which the corneal plane lies anterior to the inferior orbital rim on lateral view—the so-called negative vector—are at high risk for postoperative eyelid malposition with lower lid transcutaneous approaches.
- Lack of attention to hemostasis through every step of the operation may result in injury to important structures (e.g., levator aponeurosis, lacrimal gland, tarsal plate, inferior oblique muscle) or worse, retrobulbar hematoma.