

Chapter 89 – Face Lift (Rhytidectomy)

Grant S. Gillman

Society places a high premium on a youthful appearance, yet there is no way to stop the natural effects of gravity, sun exposure, and dermal atrophy associated with aging on one's appearance. These facts have led to a growing demand for reversal of the visible effects of aging. Furthermore, these requests now come from younger and younger patients—both male and female. In addition, there is ever-increasing interest in preventive measures, minimally invasive procedures, shorter recovery times, reduced risk, and a more natural postoperative appearance.

Although the fundamental goals of face-lift surgery are similar in most patients, there exists a wide array of surgical techniques and many procedural variations among surgeons. Issues to be considered include placement of the incision, the length of the incision (short scar or limited incision face lift versus traditional incision face lift), the extent of skin undermining, the depth of dissection, management of the superficial musculoaponeurotic system (SMAS), treatment of the neck and vector of the SMAS, and skin redraping, to name a few. Indeed, if a single technique were clearly superior, it would be adopted by all surgeons. In all cases, preoperative analysis, clinical judgment, and individualizing care based on the patient's present state of aging, expectations, and ability to tolerate and accept each contemplated procedure and its postoperative recovery and potential complications should be combined to direct surgical choices.

PREOPERATIVE PLANNING

Preoperative evaluation begins by having patients highlight their specific areas of concern and outlining for the surgeon what bothers them most. In this way not only can one begin to formulate a surgical plan, but equally important, one can also begin to get a sense of how realistic the patient's expectations are, as well as the motivation for having surgery. Proper patient selection cannot be overstated as an important determinant of postoperative patient satisfaction.

A medical history is obtained and should cover all past medical problems, with special emphasis on hypertension, diabetes, thyroid disease, facial muscle weakness, previous facial surgery, cardiovascular disorders, smoking, and the use of any anticoagulant medications (including products containing warfarin [Coumadin], aspirin, or ibuprofen and any herbal products). A general medical consultation is obtained if there is any concern about the patient's past or present state of health. Smokers must be forewarned of the increased risk of complications such as hematoma, skin sloughing, and poor healing. Ideally, they should stop smoking at least 2 weeks before surgery and for 2 weeks afterward.

A complete physical evaluation of the patient's entire head and neck is performed. For most patients considering facial rejuvenation surgery, this will require attention to forehead rhytides, brow position, and the upper and lower eyelids, in addition to issues relevant to face-lift surgery in particular.

For face-lift surgery, physical evaluation begins with an overall assessment of the facial structure, shape, and contour. Patients with good underlying bone structure, prominent facial features, and a thin face are likely to have more dramatic improvement and are therefore better candidates for a face-lift than those with poor facial skeletal structure and a rounder heavy face.

Skin texture—the quality, thickness, laxity, and degree of wrinkling of the patient's skin—is noted and recorded. Older, thicker, less elastic skin with more obvious actinic changes cannot be expected to hold the contour as well as younger, thinner, more elastic skin with less sun damage.

The examination continues with an evaluation of the degree of sagging in the midface and cheek, jowls, and submental region. The neck is examined for overall contour, laxity of the platysma, and the presence or absence of platysmal bands. One should ask the patient to clench the teeth tightly to accentuate the platysmal bands. Chin position should be assessed as well because relative microgenia may be an indication for chin augmentation, which will help facilitate improvement in overall neck definition.

The hairline is evaluated to enable decisions regarding placement of incisions.^[1] Whereas a patient with a low sideburn or temporal tuft may tolerate some superior shift of the hairline (and therefore a temporal incision that extends upward from the helical root), a patient with a high sideburn or temporal hairline will not tolerate any hairline shift (and should therefore have an incision that follows the temporal hairline).

Decisions also need to be made regarding a pretragal or post-tragal incision. Although a post-tragal incision is better camouflaged, it is balanced against the risk of a tragus that then looks unnatural postoperatively. In patients with a deep preauricular crease, a pretragal incision in front of the ear is a reasonable option. In general, a pretragal incision is preferred in men to avoid moving hair-bearing skin (the beard) all the way back to the posterior edge of the tragus, as would happen with a post-tragal incision. It is wise to discuss all incision options and the rationale for the various choices with the patient preoperatively and to engage the patient in the decision-making process.

A thorough discussion with the patient should follow regarding realistic expectations for outcome, the typical intraoperative and postoperative course, and potential complications and their relative frequency.

A complete set of photographs is important for documentation and planning. At a minimum, frontal, right and left oblique, and lateral views should be included. Additional views that are frequently helpful include three-quarter views from each side and a frontal view with the patient's teeth clenched to highlight platysmal banding.

Anesthesia

The patient and physician must decide together on the most appropriate anesthesia for that particular patient. Local anesthesia, supplemented by intravenous sedation, is adequate for many aesthetic surgical procedures on the face. The choice of intravenous sedation with local anesthesia versus general anesthesia should take into consideration the surgeon's comfort level, the patient's preference, the anesthesiologist's preference, the duration of the procedure, and any tendency or predisposition of the patient to obstruction of the airway when sedated. Even with a general anesthetic, local anesthesia with epinephrine is used for its hemostatic effect and postoperative pain relief. Limiting the combined operative procedures to be performed on the same day to a maximum of 6 hours will lead to fewer complications and will be better tolerated by the patient and surgeon.

When intravenous sedation is chosen, in all circumstances it should be managed by the anesthesiologist/nurse anesthetist rather than the operating surgeon to maximize safety and allow the surgeon to focus only on the procedure at hand. During infiltration of the local anesthetic the sedation is deepened, and then patients can be allowed to "come up" from the sedation and it can be titrated to a level at which they can respond to commands, breathe on their own, and express any discomfort.

Injections of local anesthetic are not performed until all markings have been made. A mix of 50 mL of 1% lidocaine with 1 : 100,000 epinephrine combined with 30 mL of 0.5% bupivacaine (Marcaine) with 1 : 200,000 epinephrine is used for the face and neck. Typically, the neck is injected together with one side of the face at the outset. The other side of the face is injected when the first operative side is being closed. In this way one can distribute the total amount of lidocaine and Marcaine injected over a longer interval to avoid toxicity.

Markings

Skin markings are made with the patient in a semi-upright or sitting position preoperatively. Markings include those for skin incisions, the planned extent of undermining, the topographic location of the facial nerve (a line from 0.5 cm below the inferior attachment of the earlobe to 1.5 cm above lateral brow), the inferior border of the mandible, the angle of the mandible, the specific location of the sagittal jowls, and platysmal banding when present.

In the temporal area, if the patient's sideburn is low enough to tolerate some hairline shift without looking unnatural, the planned incision can extend superiorly from the helical root in curvilinear fashion into the temporal hair, where it will be well camouflaged (Fig. 89-1). If any doubt exists about whether the patient can tolerate a shift of the sideburn tuft or if the patient already has a higher sideburn, the temporal incision is designed to follow the hairline, several millimeters within the hair, extends anteriorly from the helical root, and then curves superiorly along the hairline for an additional 1 to 2 cm (Fig. 89-2). By placing this incision several millimeters within the hairline one can bevel the incision to preserve the hair follicles below the incision. Over time hair will then grow back through the incision and render it less conspicuous.

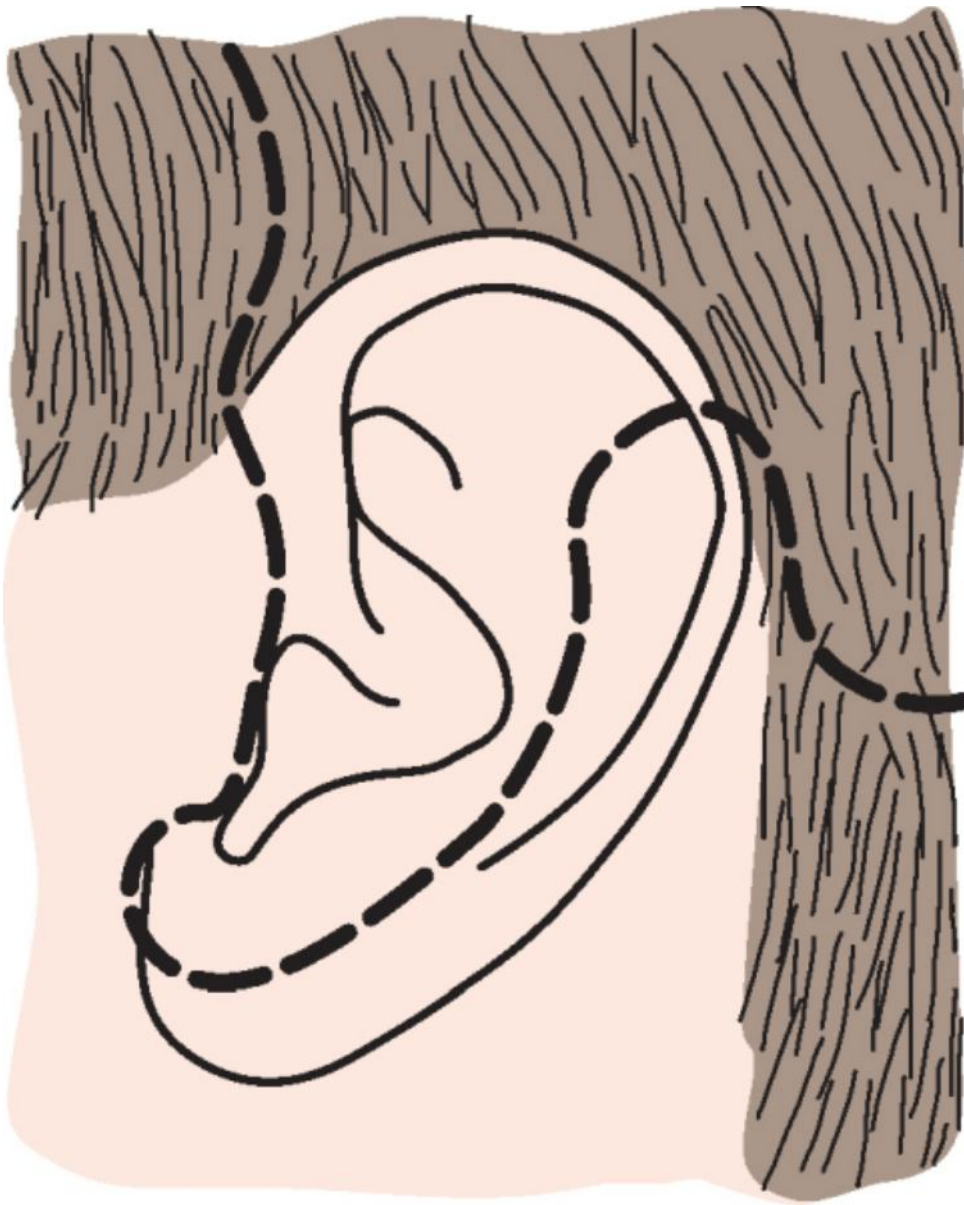


Figure 89-1 Schematic of a face-lift incision extending superiorly from the helical root into the temporal hair anteriorly. It can be used in patients with a low temporal hairline tuft and extended posteriorly behind the ear into the occipital hair.

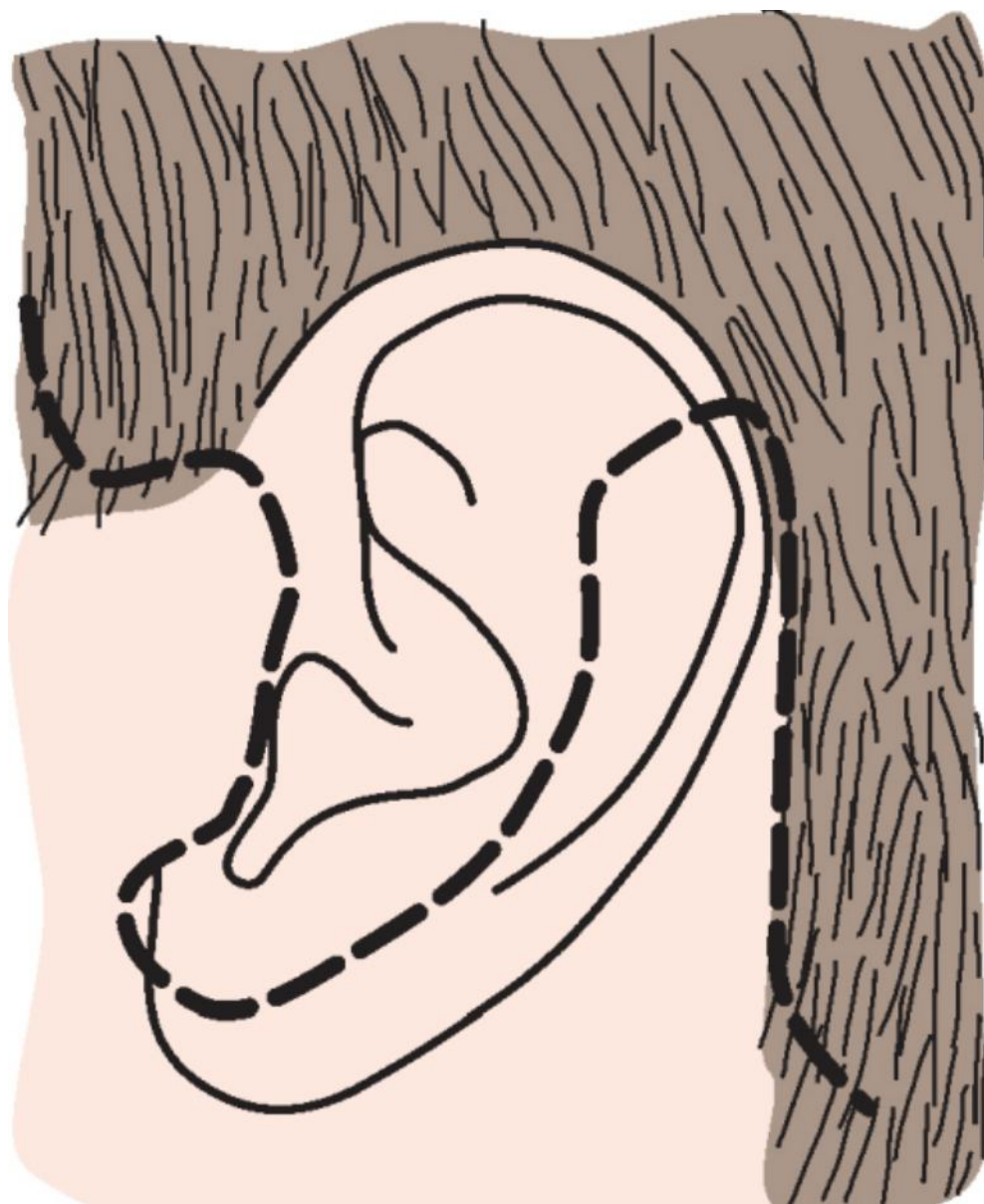


Figure 89-2 Schematic of a face-lift incision extending anteriorly within the temporal hairline. This incision is preferred in patients with a low temporal hairline to prevent posterior shift of the hairline. Posteriorly, an incision along the occipital hairline is illustrated.

A pretragal or post-tragal continuation of the incision is marked as determined preoperatively. A post-tragal incision is made right along the free posterior margin of the tragus. A pretragal incision follows the crus of the helix into the incisura anteriorly before it curves slightly forward in front of the tragus and travels inferiorly in a natural skin crease to the base of the earlobe.

In a female the incision is designed to curve around the earlobe at its junction with the cheek, whereas in males, a small cuff (several millimeters) of skin is maintained below the earlobe to prevent advancing bearded skin right into the junction of the earlobe with the cheek. The incision continues along the posterior auricle, where it is carried 2 to 3 mm onto the posterior surface of the conchal cartilage (i.e., lateral to the postauricular sulcus) because this incision will ultimately generally settle into the sulcus rather than drift onto a more visible area of postauricular skin. As with the infralobular incision, in men the postauricular incision is made either in or several millimeters behind the postauricular sulcus to avoid drawing bearded skin up onto the auricle.

The postauricular incision is drawn superiorly to a point where the helical rim crosses the hairline (usually 1 to 1.5 cm above the level of the tragus) before turning horizontally and posteriorly. From here the incision may extend back into the occipital hair for several centimeters (see Fig. 89-1) or may follow the hairline inferiorly (several millimeters within the hairline) and gently curve further into the hair for 1.5 to 2 cm at its inferior extent (Fig. 89-2). The length of this incision depends on the amount of redundant skin that is to be excised; it must be long enough to allow the skin to redrape without leaving a posterior scalp "dog-ear" or a fold in the neck. Placing the incision along the hairline will make it easier to prevent any step-off deformity along the postauricular hairline, particularly if one anticipates removing a significant amount of skin in this region as the skin of the neck is lifted and redraped. An

example of intraoperative skin markings is presented in Figure 89-3.

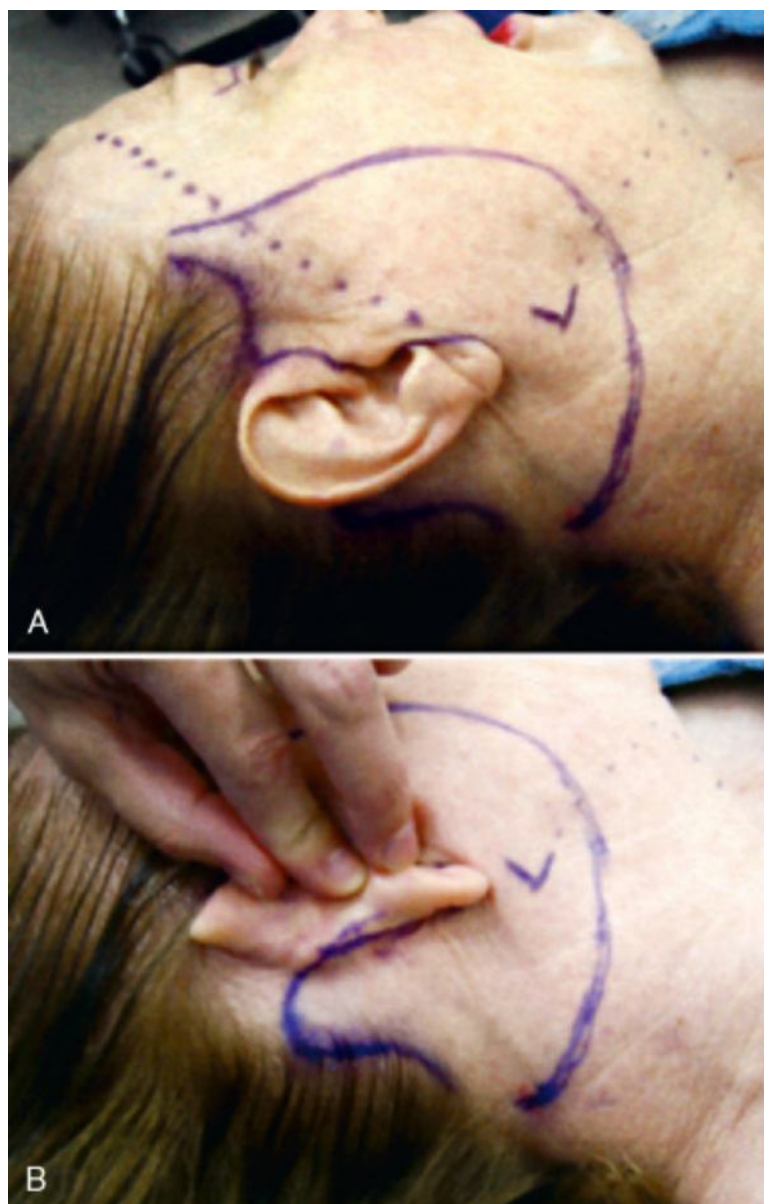


Figure 89-3 **A**, Preoperative skin markings along the temporal hairline and post-tragally. The topographic location of the facial nerve is outlined (*dashed line*), as is the extent of the proposed undermining, the angle, and inferior border of the mandible. **B**, The postauricular markings, which extend superiorly on the posterior auricle several millimeters from the postauricular sulcus, traverse the scalp above the level of the tragus, and extend inferiorly just within the occipital hairline.

It is not necessary to shave or cut the patient's hair, but after parting the hair, segments of twisted hair in front and behind the planned incisions are wrapped with rubber bands or paper tape. Lacri-Lube ointment is combed into the hair on each side of the part to further prevent hair from interfering with the wound closure.

Once all markings are complete, injections of local anesthetic are carried out with a 22- or 25-gauge spinal needle in the subcutaneous dissection plane. Appropriate infiltration facilitates subsequent dissection. To prevent injection of excessive amounts of lidocaine/bupivacaine, only the first region to be dissected is injected at the outset of the operation, with each successive region injected intraoperatively 10 to 15 minutes before transitioning to that part of the surgery.

SURGICAL TECHNIQUE

As alluded to earlier, there are multiple variations on face-lift surgery—a skin-only lift, skin dissection with some modification of the SMAS,^[2–6] deep-plane face-lifts,^[7] composite face-lifts,^[8] subperiosteal face-lifts,^[9] and others.^[10,11] In general, the more extensive the dissection or the deeper the plane of dissection, the greater the risk of postoperative complications and facial nerve injury. Furthermore, from surgeon to surgeon there will be differences in incision preference, degree of liposuction, extent of undermining, and methods of treating the SMAS and

platysma. With that in mind, what is described herein is an outline of a safe, basic, generic procedure with elaboration of some variations.

Preoperative evaluation of the neck and platysmal banding will help identify patients who will require direct submental fat resection, liposuction, or medial plication of the platysmal bands. In a patient with a good cervicomental angle without excessive submental fat or platysmal banding it may not be necessary to do any direct submental dissection or flap elevation at all. If it is thought that liposuction is warranted (a particularly heavy neck with excessive subcutaneous fat) or there are platysmal bands that need to be addressed, this part of the surgery is done first.

The operation begins with infiltration of local anesthetic into the neck. The incision is placed in the submental area several millimeters behind (posterior to) the submental crease (Fig. 89-4). This incision provides the access necessary for submental liposuction if planned or, alternatively, for elevation of neck skin flaps for better redraping or platysmal plication. Bear in mind that the surgery will draw this incision anteriorly and superiorly, so consideration must be given to ensuring that it remains well concealed in the submental region. If only liposuction is planned, a smaller incision is sufficient (0.5 to 1 cm), whereas if a skin flap is to be elevated and the platysma plicated, a slightly longer incision will be needed for optimal visualization.

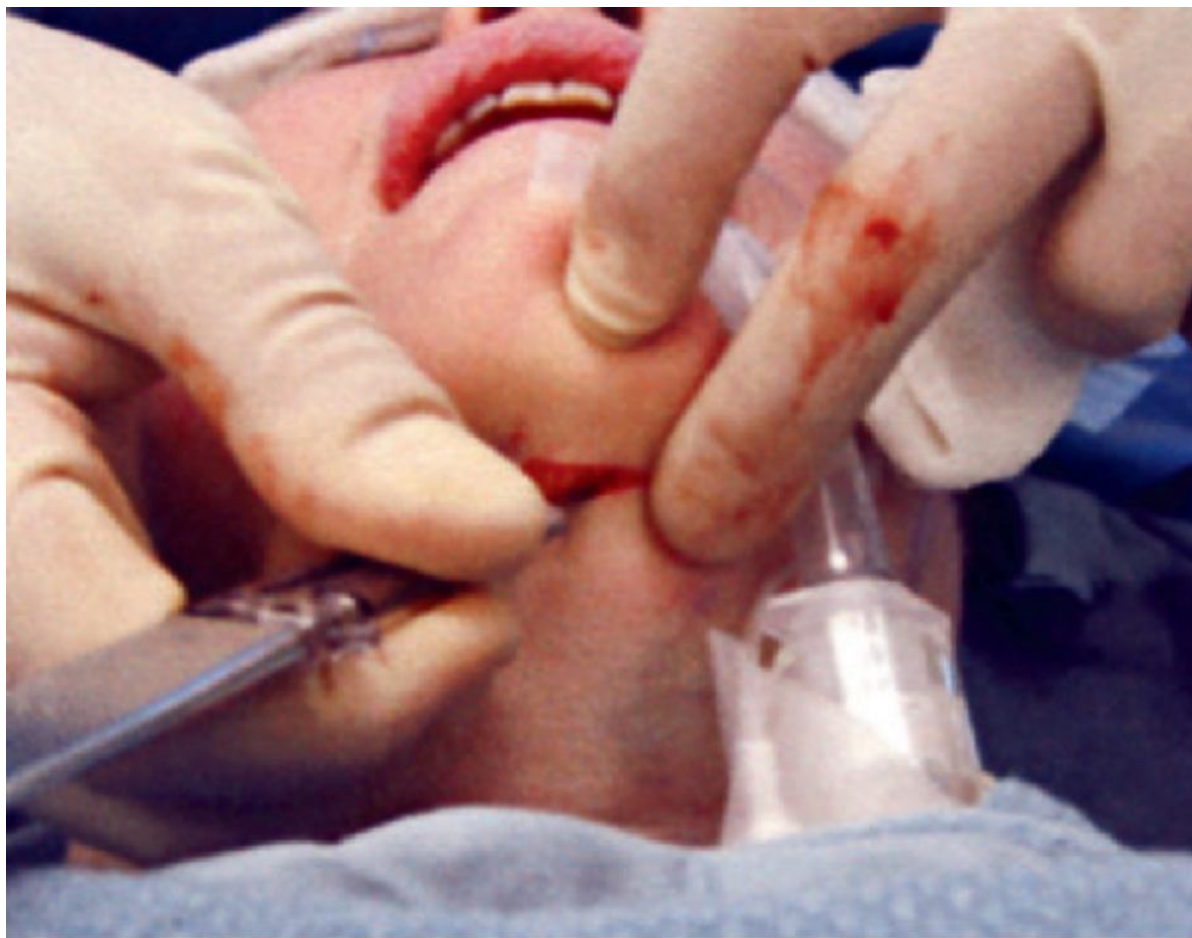

Figure 89-4 The submental incision used for access to elevate the neck skin flap.

For liposuction, one can pretunnel with the liposuction cannula off suction to initiate elevation of the neck skin flap.^[12] A 3- or 4-mm three-hole blunt bullet-tipped cannula is used initially while taking care at all times to keep the aperture in the cannula directed deep, away from the overlying skin, to prevent injury to the dermis and minimize the potential for postoperative irregularities or unevenness in the skin. The cannula is then attached to suction and the liposuction is carried out with care taken to maintain an even contour (to palpation) across the entire area suctioned.

An alternative is to elevate the skin flap over the neck first with face-lift scissors and maintain an even 2- to 3-mm cuff of fat on the undersurface of the skin. "Open" liposuction is then conducted under more direct vision. Boundaries for safe liposuction extend from the inferior border of the mandible down to the thyroid cartilage while remaining between the anterior borders of the sternocleidomastoid muscles from either side.

After using the 3- to 4-mm blunt cannula, a 5- to 6-mm single-hole spatula-tipped cannula is passed over the same area to smooth out, sculpt, and contour the area. Care is taken to avoid overaggressive resection, which may lead to cutaneous depressions and contour irregularities postoperatively.

At this point it is helpful to inject local anesthetic into the first side of the face to be operated on. Next, if not already done, the skin flap is elevated through the submental incision over the neck (Fig. 89-5). Dissection across the entire neck is needed in patients who require substantial fat excision or redraping of significant excesses of skin. Plication of the medial borders of the platysma is then carried out if indicated for platysmal banding. Either a lighted retractor is placed in the submental incision or two Senn retractors can be used with headlight illumination. The medial edge of the platysma muscle from either side is identified. The medial edges are then sutured together from the level of the thyroid notch up to the incision with buried 3-0 or 4-0 Vicryl or PDS suture. In selected cases in which it is thought that there is a great redundancy of platysma muscle, it may be necessary to resect a strip of the medial margin of muscle from either side before suturing the medial borders to one another. Hemostasis should be ensured beneath the neck flaps before moving to the next step.

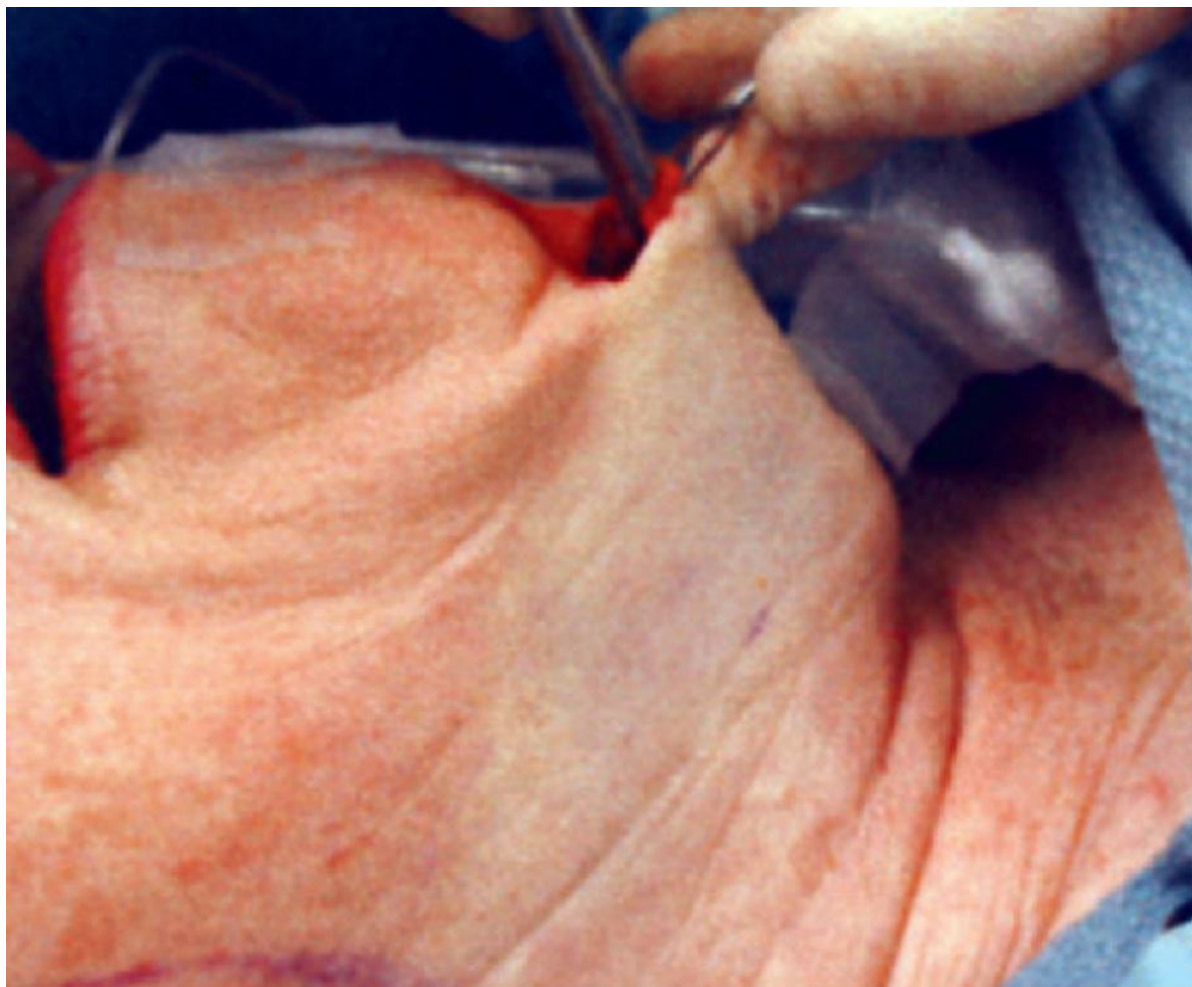


Figure 89-5 Elevation of the neck skin flap.

The postauricular and occipital incisions are then made and the flaps elevated with scalpel dissection for the first 2 to 3 cm (Fig. 89-6). Care is required initially to maintain a thick flap over the mastoid region (because this is some of the thinnest skin elevated in the entire operation and therefore most at risk for necrosis or skin sloughing). As one transitions down into the neck below the mastoid, the flap must be superficial to the fascia overlying the sternocleidomastoid muscle to protect the integrity of the greater auricular nerve as it crosses the midportion of the muscle 6.5 cm below the external auditory meatus. Once beyond the mastoid region, further dissection is carried out with face-lift scissors, and the flap is retracted with one or two sharp double hooks and counter-traction provided by the assistant distal to the point of elevation. The dissection is carried forward within the plane of the subcutaneous fat until one joins the dissection of the neck skin already elevated (Fig. 89-7).

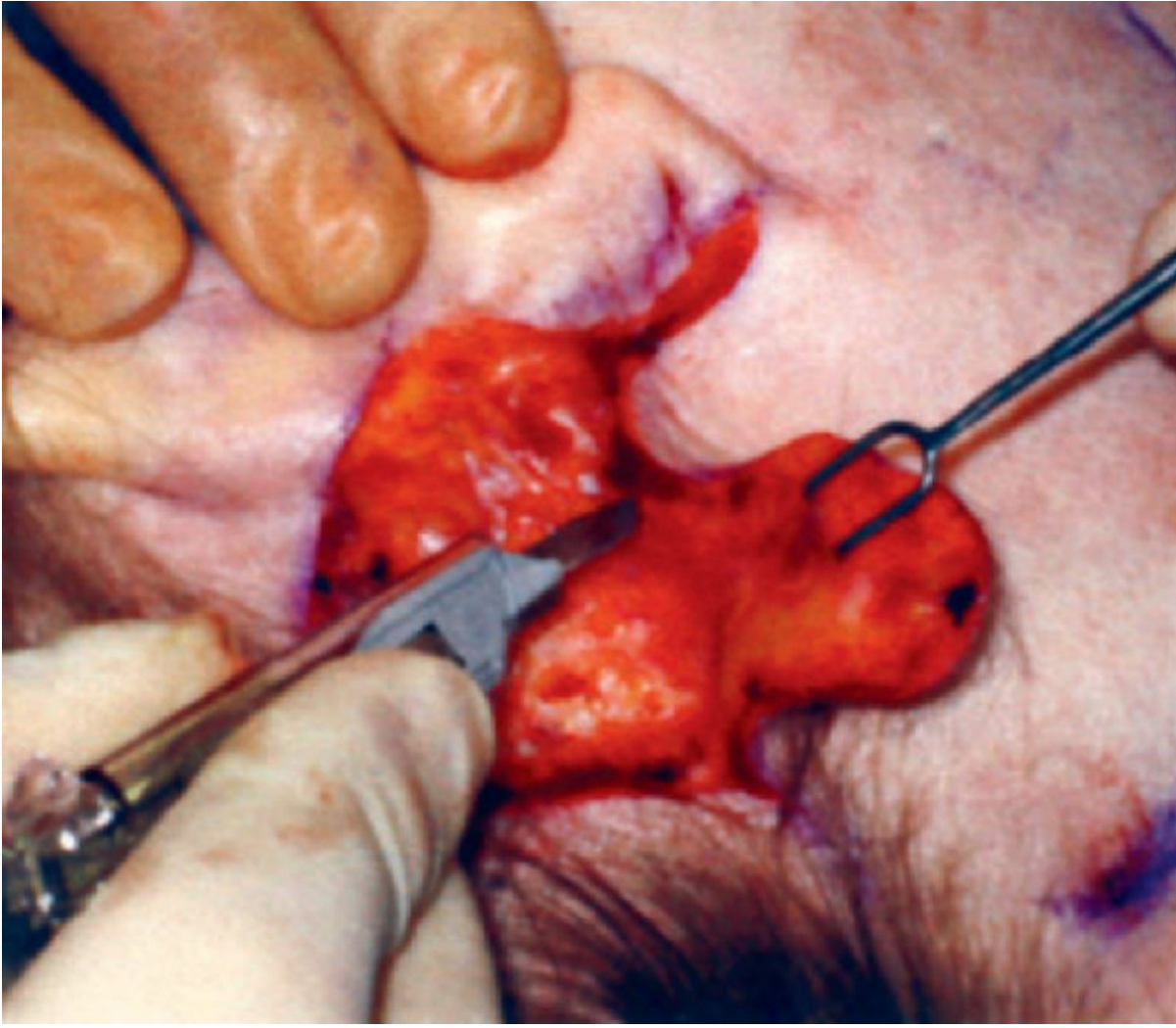


Figure 89-6 Initial sharp elevation of the postauricular skin flap.

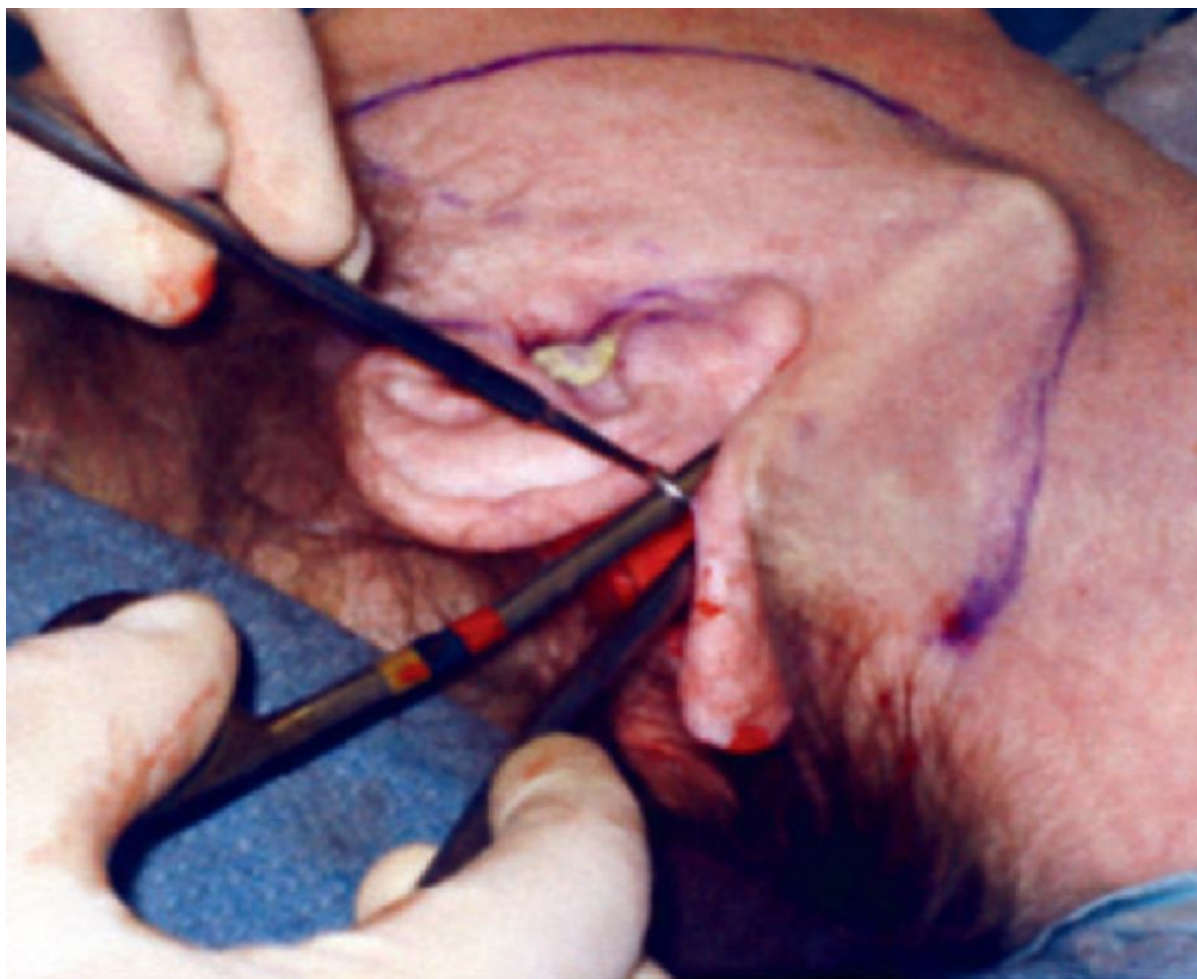


Figure 89-7 Anterior extension of the postauricular dissection to join the neck flap dissection.

Attention is then turned to elevation of the facial skin flaps. The incision is begun in the temporal region along the predetermined markings and continues to the base of the earlobe (Fig. 89-8). Dissection in the temporal region can be either in the subcutaneous plane or right on the deep temporal fascia—the former being superficial to the frontal branch of the facial nerve, the latter deep to the nerve. In either case, awareness of the depth of dissection relative to the facial nerve is critical to prevent injury.^[13]

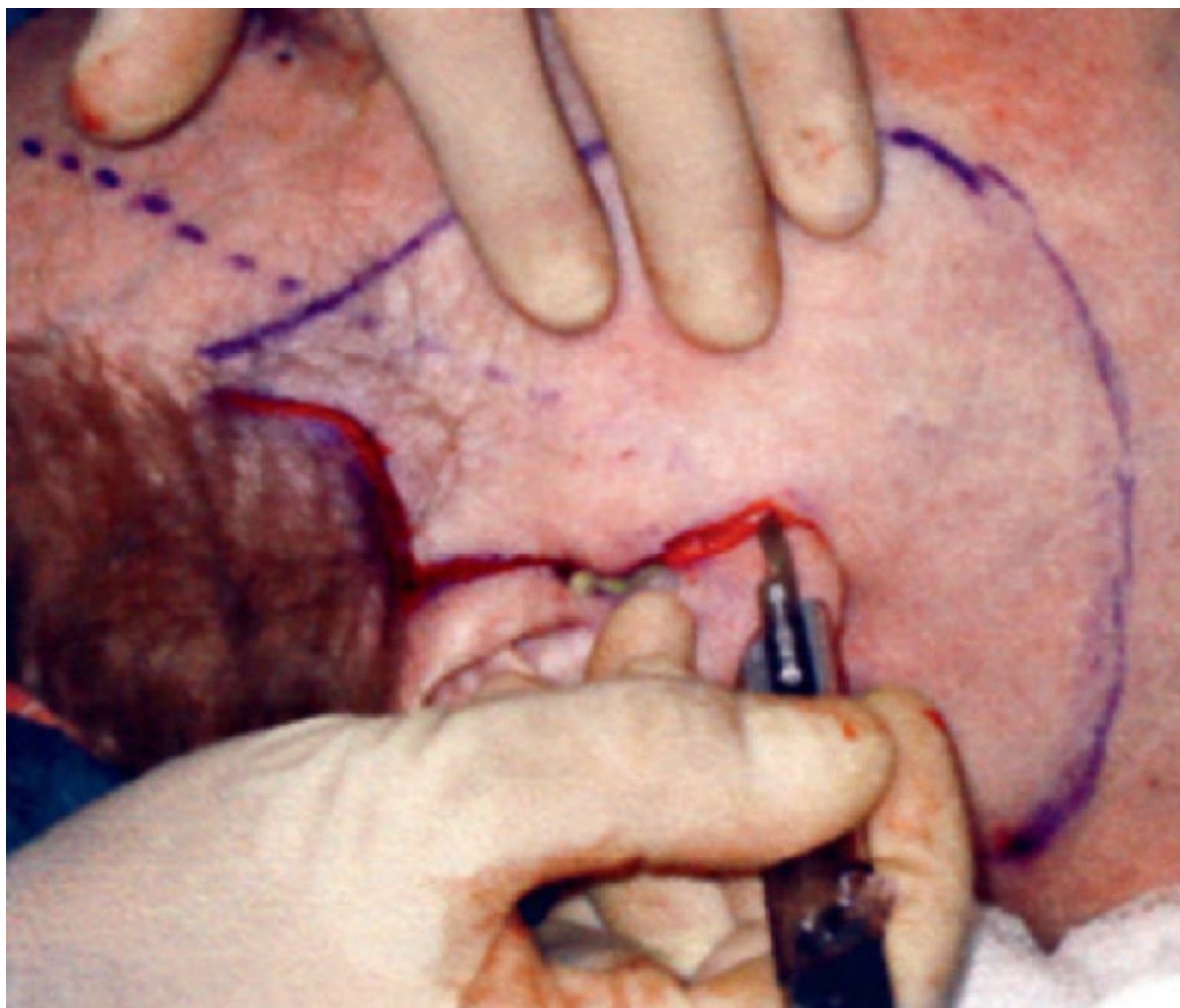


Figure 89-8 The preauricular skin incision.

Having completed the incision with a no. 15 blade, dissection along the deep temporal fascia can generally be done quickly and bluntly with the back end of the knife handle or even with finger dissection to the level of the lateral orbital rim and the lateral aspect of the forehead while always staying above the level of the zygomatic arch. It is important to recognize that a subcutaneous soft tissue bridge or mesentery from the deeper tissues up to the skin must be preserved at the level of the zygomatic arch and lateral canthus to separate the deeper temporal dissection from the subcutaneous dissection of the preauricular cheek skin flap because the frontal branch of the facial nerve lies in this soft tissue. When the temporal dissection is in the subcutaneous plane (as opposed to being right on the deep temporal fascia), it is contiguous with the plane in which the facial skin is elevated and superficial to the nerve at all levels. In this case it is not necessary to preserve a soft tissue bridge at the level of the zygomatic arch.

Subcutaneous dissection of the facial skin (and temporal skin when that plane is chosen) is initiated with either a no. 15 blade or sharp serrated iris scissors and a sharp double-hook retractor for the first 1 to 2 cm because the deep tissues in this region are more adherent to the overlying skin than the skin further forward over the cheek.

Once the proper plane of dissection is identified, after the first 1 to 2 cm, subsequent elevation of the preauricular facial skin flap is performed with face-lift scissors under direct vision (Fig. 89-9). The flap should be elevated while leaving a thin, even layer of fat on the undersurface of the skin to protect the subdermal plexus. Having the assistant apply constant countertraction on the skin medially and using the operating room lights to backlight or transilluminate the flap will help one identify and maintain the proper plane of dissection and an even thickness of the skin flap. The flap is undermined out to the limits that were marked preoperatively (usually about 5 to 6 cm). Preliminary hemostasis is achieved at this point with bipolar cautery for maximal safety. A moist sponge can then be placed beneath the flap as attention is turned to the postauricular area.

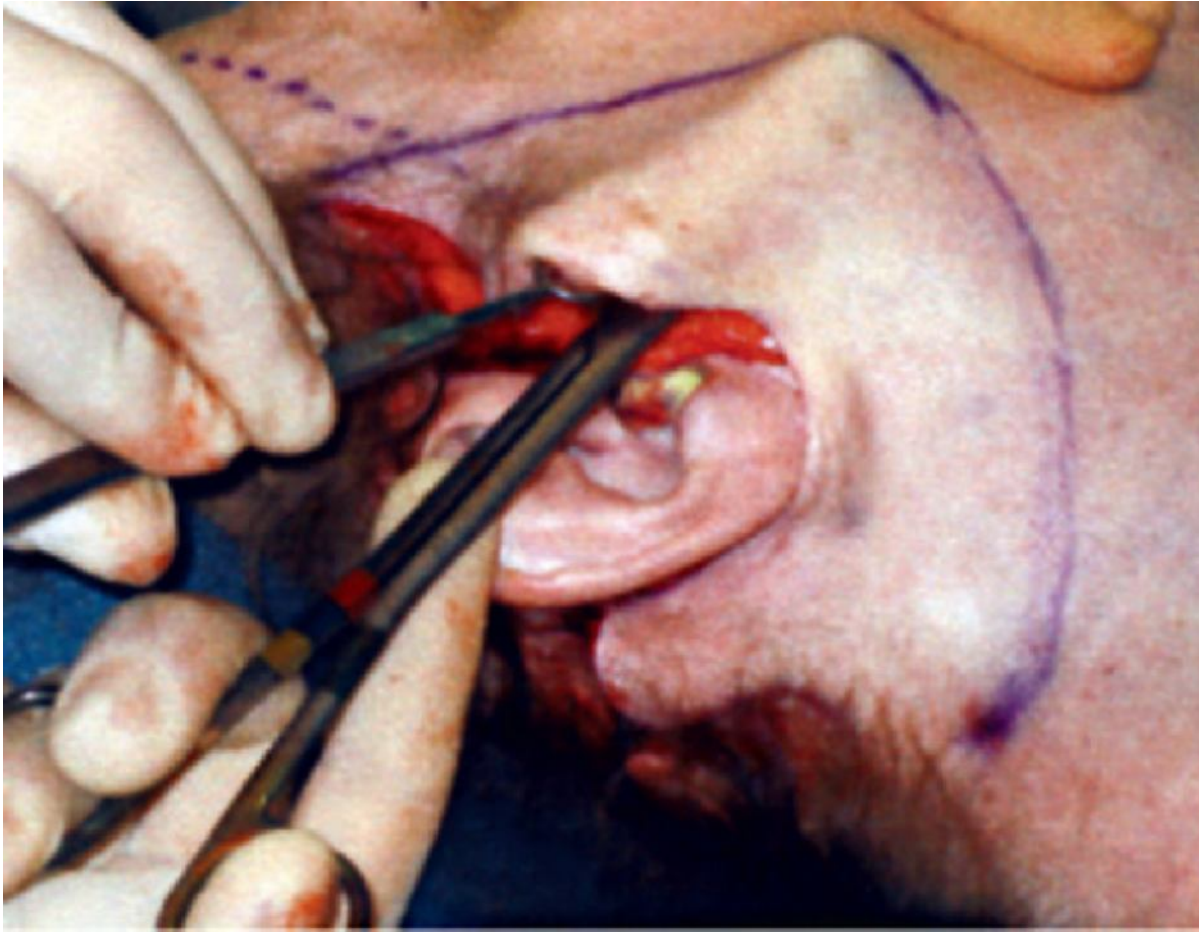

Figure 89-9 Elevation of the cheek flap with face-lift scissors.

Once the preauricular cheek flap is elevated, the dissection is connected with the postauricular skin flap and continues into the neck to bring this flap into continuity with the neck skin previously undermined (Fig. 89-10). With the neck and cheek skin thus elevated, hemostasis is once again addressed.

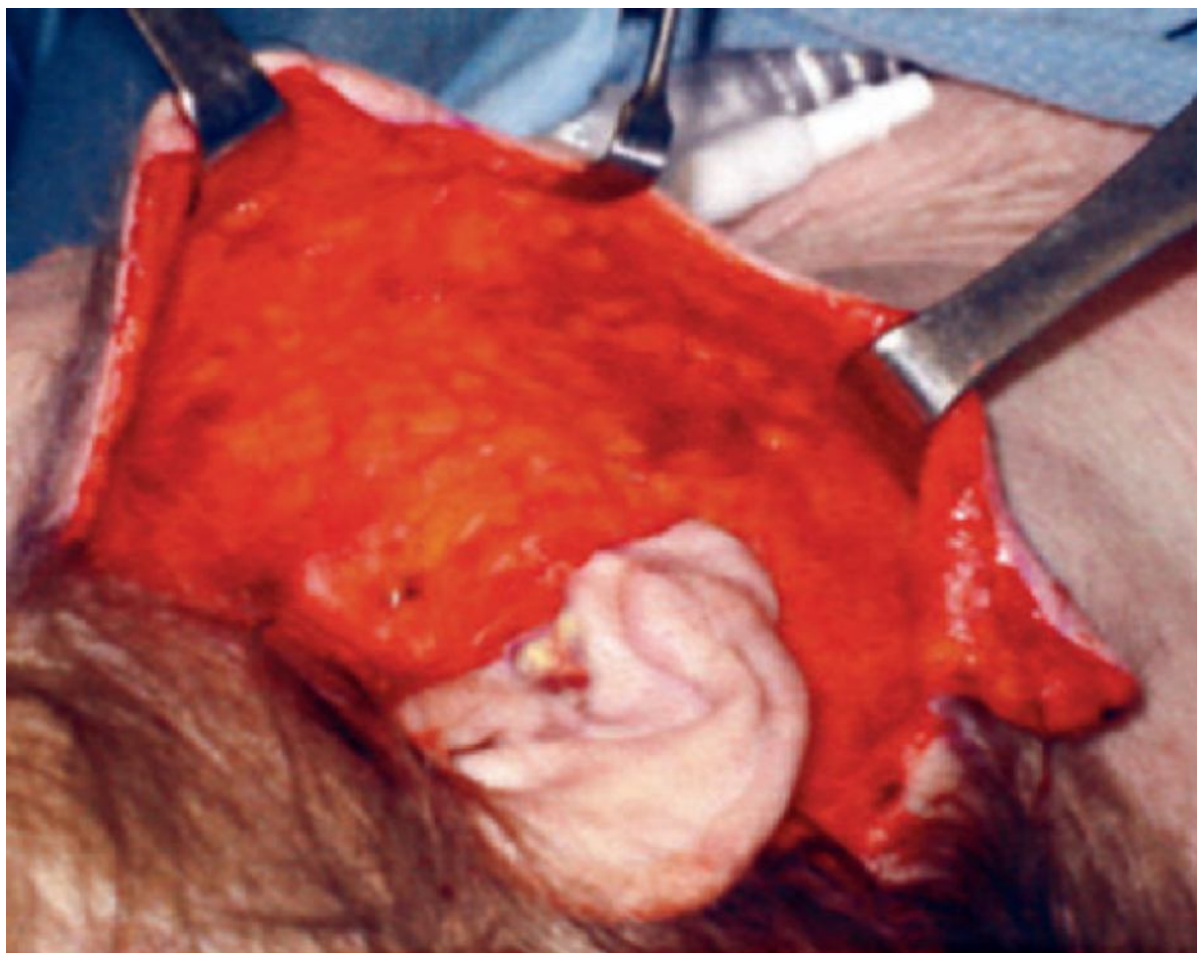

Figure 89-10 Facial, occipital, and neck skin flaps elevated and joined in continuity.

SMAS suspension is carried out next. Suspension may be in the form of SMAS plication (suture suspension whereby the SMAS is folded on itself) or imbrication (either as a lateral SMAS-ectomy or by elevation and trimming of a SMAS flap, with suture fixation of the margins of the excision). Because SMAS plication can lead to bunching of soft tissue beneath the skin, SMAS imbrication is favored and will be discussed here.

One method of SMAS imbrication involves formal SMAS flap elevation,^[2] redraping of the SMAS along a superolateral vector, trimming of the excess, and suspension with 3-0 PDS or Vicryl suture to reapproximate the edges after excision of redundant SMAS. Alternatively, SMAS imbrication can be carried out by way of a lateral SMAS-ectomy (without actual elevation of the SMAS flap).^[5,6,12] In the latter method, a J-shaped, 1.5- to 2-cm strip of SMAS is excised (the "SMAS-ectomy") in the preauricular area down to the parotid fascia (Fig. 89-11), with extension superiorly and anteriorly from below the lobule of the ear up toward the malar eminence (Fig. 89-12). The SMAS excision should not go higher than the zygomatic arch to prevent injury to the frontal branch of the facial nerve.

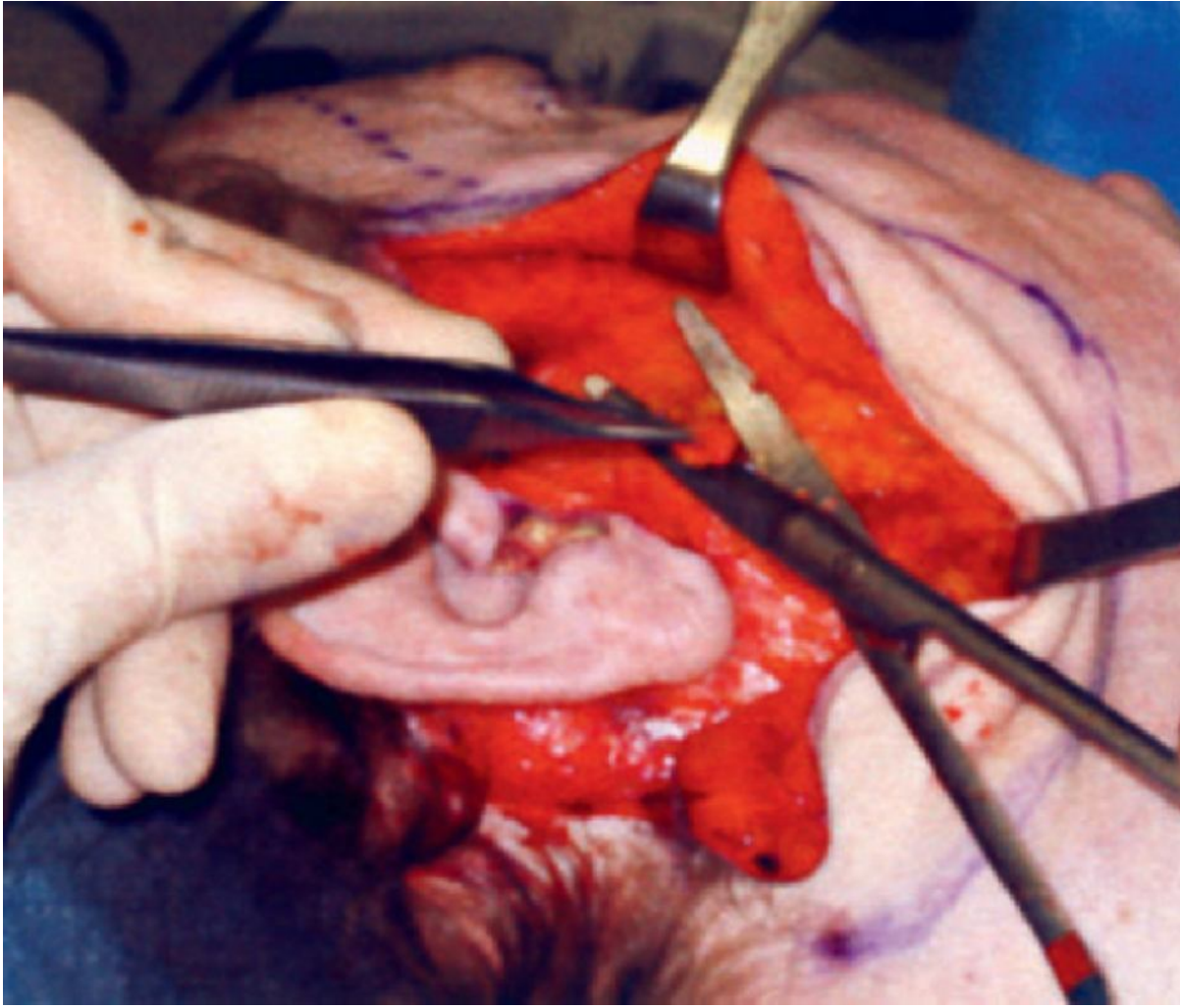


Figure 89-11 Initiation of the SMAS-ectomy by gently retracting the SMAS while engaging the face-lift scissors to resect the SMAS tissue down to the parotid fascia.

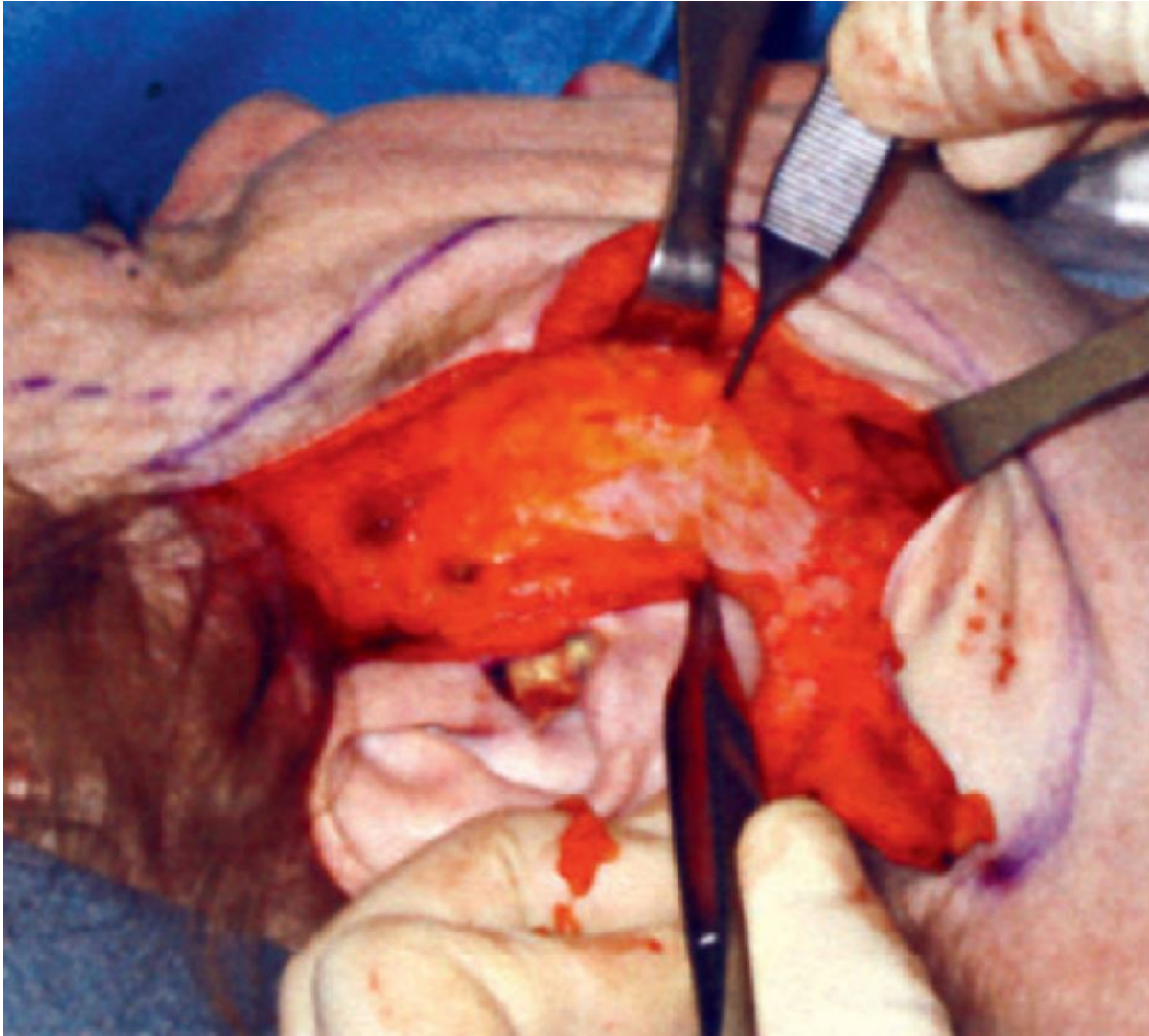


Figure 89-12 The completed SMAS-ectomy. Parotid fascia is visible between the edges of the SMAS defect, which are being grasped with forceps.

Approximation of the edges of the SMAS defect that results from SMAS-ectomy will create the SMAS suspension needed to elevate the jowl, neck, and nasolabial fold. The direction of SMAS suspension is not simply posterior, but rather primarily superior and slightly posterior. Multiple 3-0 PDS or Vicryl sutures are used to close the two exposed edges of the SMAS-ectomy defect (Fig. 89-13).

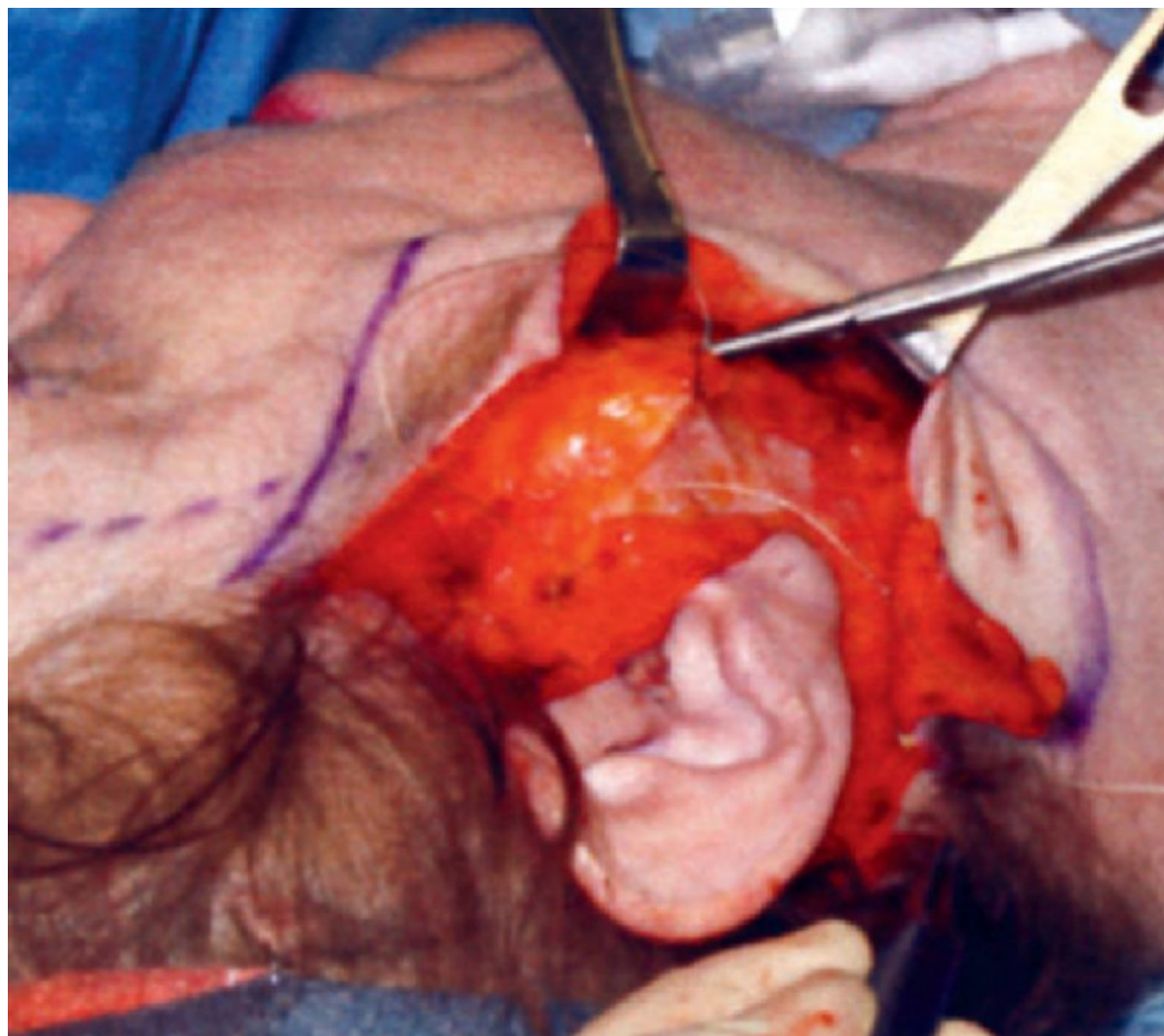


Figure 89-13 Initiation of imbrication of the edges of the SMAS defect with 3-0 Vicryl. The tension placed on the SMAS closure relieves the tension on the skin closure.

The advantage of SMAS-ectomy over SMAS flap dissection is that it can be done quickly and with less risk to the facial nerve if one remains over the parotid fascia. Furthermore, less tissue elevation/dissection should theoretically help reduce the risk for postoperative hematoma.

Once the SMAS suspension is complete, the redundant skin will be overlapping the ear. Redraping and excision of the excess skin follow. If there are any irregularities, dimpling, or bunching of skin as a result of the SMAS suspension, further undermining of the skin flap will resolve these problems and is carried out before the skin excision.

For skin redraping, the anterior (preauricular) skin flap is retracted along a superior and slightly posterior vector while the posterior (postauricular) skin flap is drawn superiorly and slightly anteriorly (if the postauricular incision extends straight back into the hair) to enable one to realign the hairline and thus avoid any step-off in that area. If the postauricular incision was designed to follow the hairline, the skin flap can be redraped in a more superior and posterior direction.

The flap is tailored with two key tension sutures. The key sutures placed during closure of a face-lift assume the greatest degree of tension on the closure and also serve as guides for the direction of pull of the facial skin. The anterior skin flap (preauricular cheek skin) is first "lifted" in a superior and posterior direction (Fig. 89-14). An incision is made in the flap down to the helical root (Fig. 89-15). The first tension or tacking suture of 4-0 Prolene (or staple) is placed at this point to effectively separate the temporal skin excess from the preauricular skin excess (Fig. 89-16). The excess temporal skin above the first tension suture is then excised. Skin closure in this area is achieved with staples if in the hair or with 5-0 or 6-0 Prolene if along the temporal hairline. If much tension is encountered, a deep layer of 5-0 PDS sutures is used.

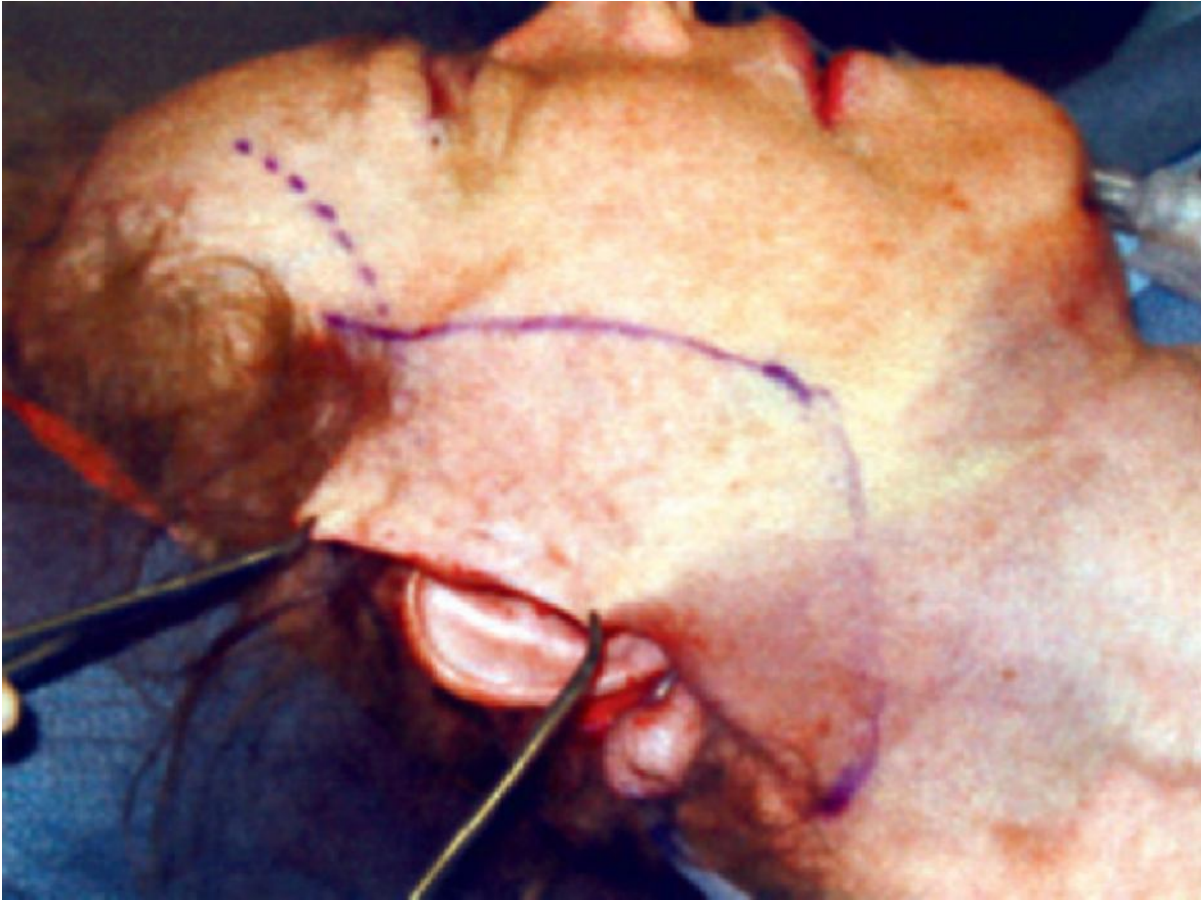


Figure 89-14 Redraping of the cheek flap along a posterior superior vector.

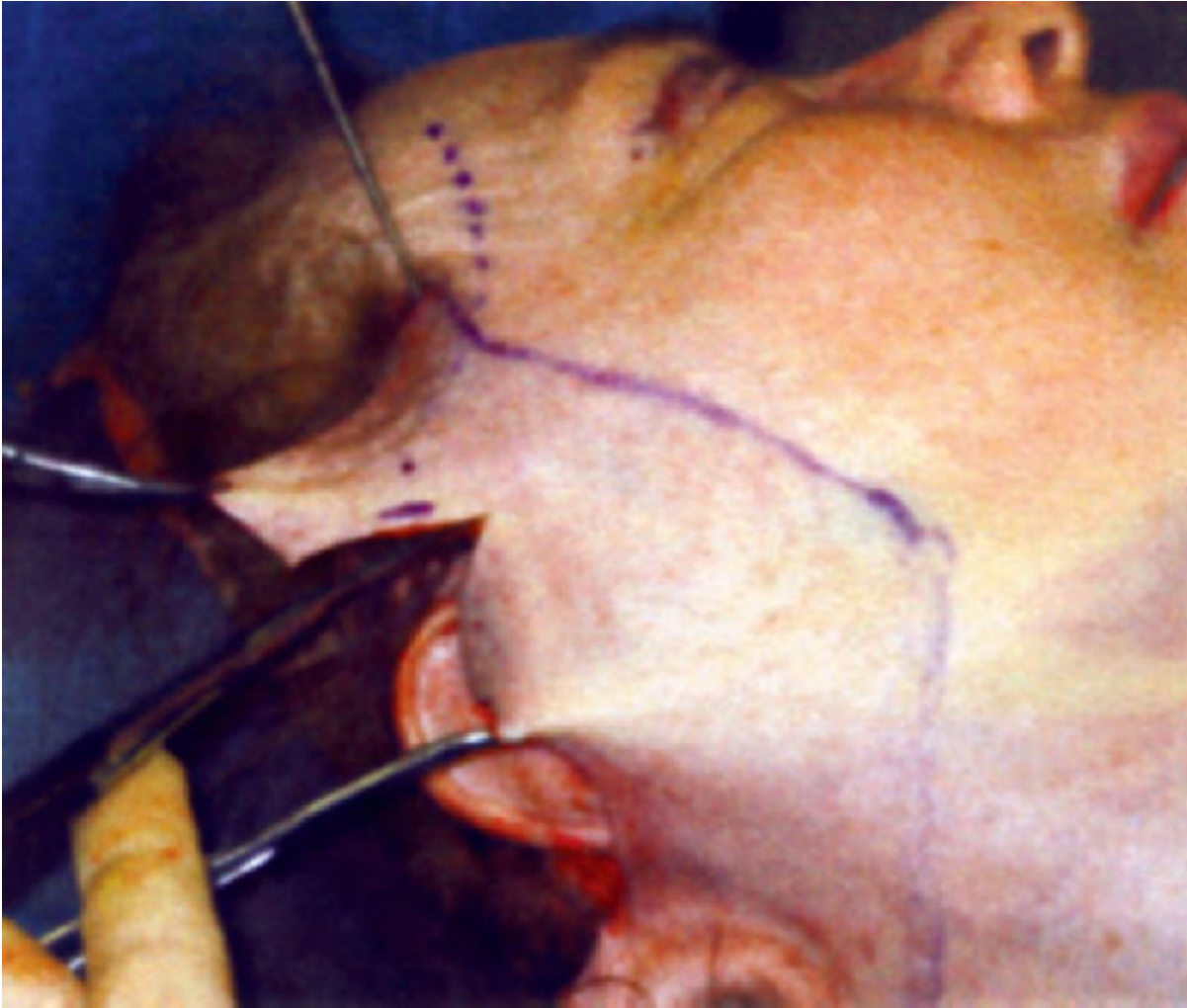


Figure 89-15 Incision in the facial flap down to the helical root.

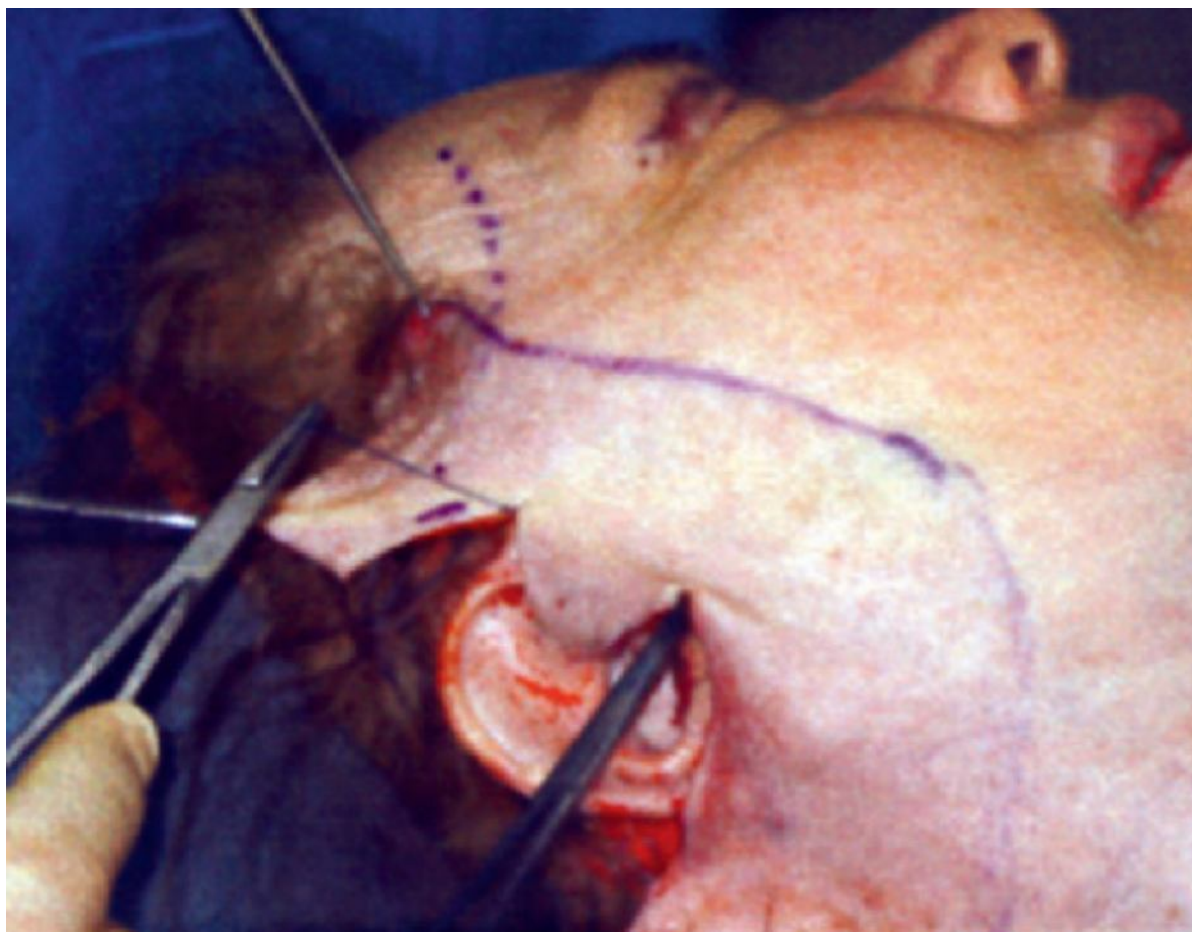


Figure 89-16 Tacking suture placed to separate the temporal skin excess from the cheek skin excess.

The postauricular skin flap is then redraped (Fig. 89-17). The second tension suture is next placed in the postauricular incision at the level of the postauricular hairline by cutting into the flap posteriorly at the point where the hairline needs to be realigned. This effectively separates the occipital portion of the skin flap from the more immediate postauricular portion of the flap.

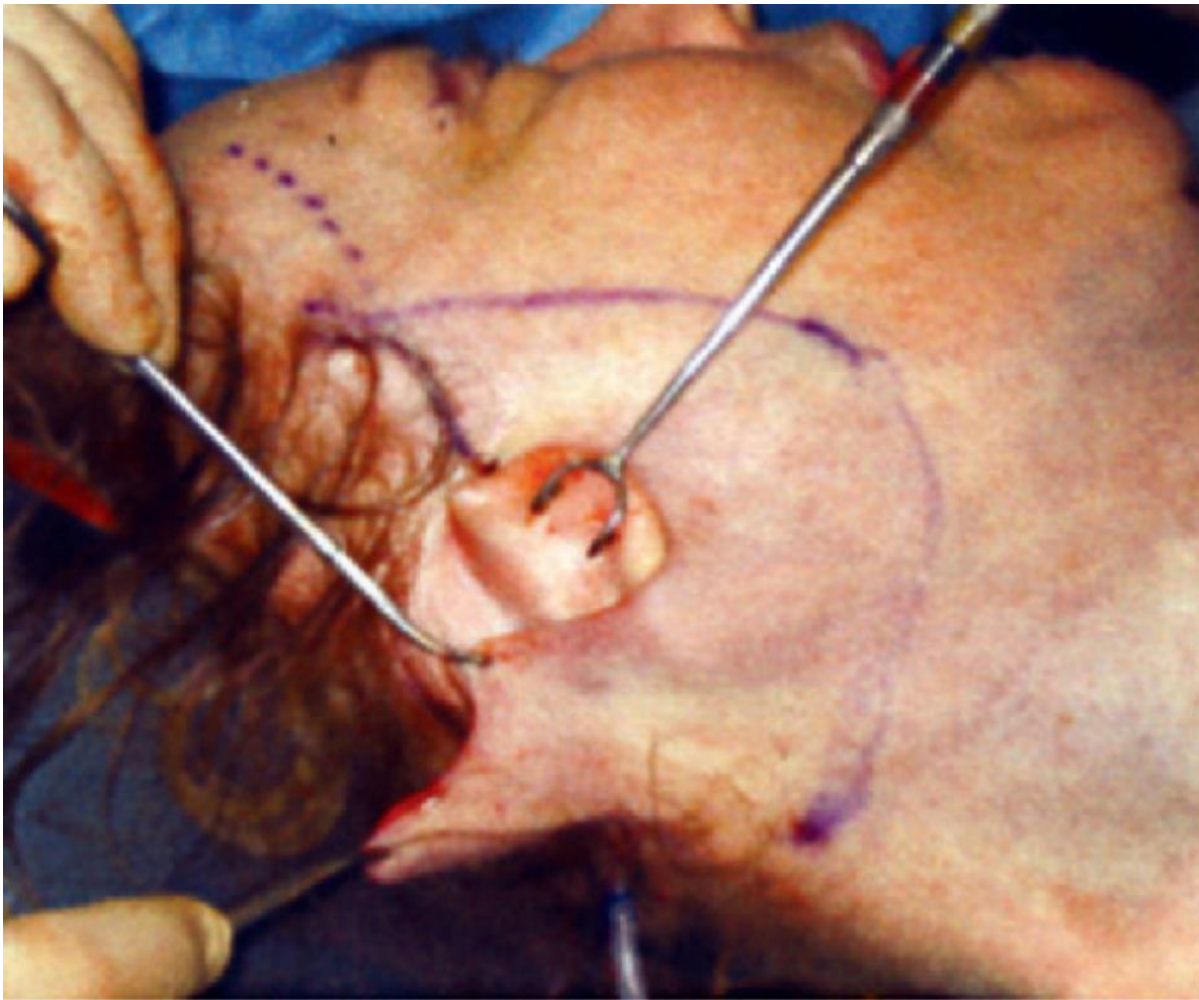


Figure 89-17 The postauricular skin flap is redraped to facilitate skin excision and closure without tension. In this case, because the incision was just inside the hairline, the skin flap is retracted along a posterior and superior vector. Note also that the anterior temporal skin excess has been excised and sutured without tension.

The excess occipital skin behind the second tension suture can then be excised and closure carried out in a fashion similar to that in the temporal area—staples if the occipital incision heads into the hair or running 5-0 or 6-0 Prolene or staples if the incision follows the hairline (Fig. 89-18). A flat closed suction drain is brought out through a separate stab wound in the occipital hair (behind the incision) and laid in the neck before closing the occipital incision.

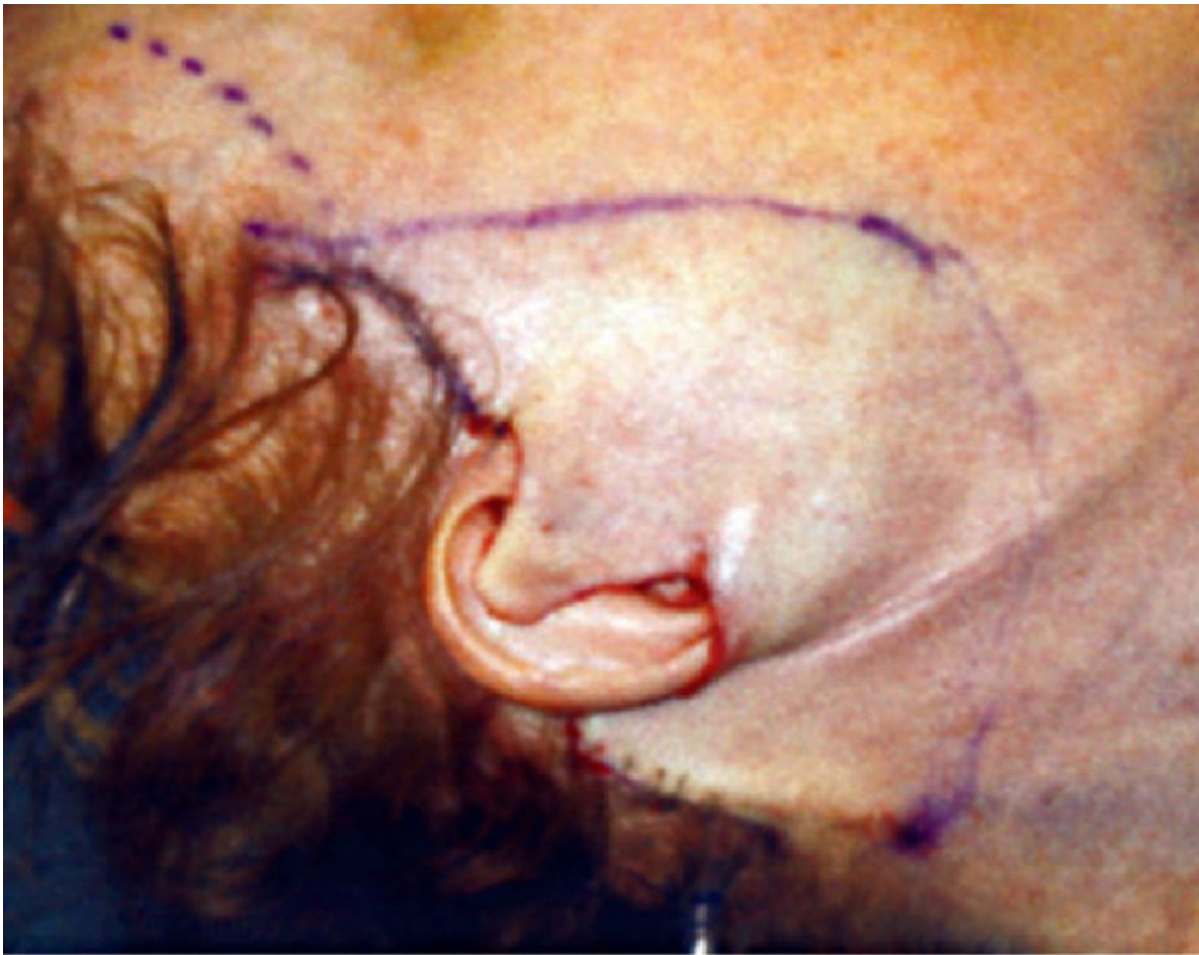

Figure 89-18 Completion of the closure along the occipital hairline leaves only the skin excess that cradles the auricle.

Moving from the hairline over the preauricular skin to the superior aspect of the incision along the postauricular sulcus, the redundant skin is trimmed and the skin edges closed with 5-0 plain or fast-absorbing catgut suture.

Skin now overlies the ear and only the trim around the ear remains to be completed. Scissors are used to cut the skin overlying the ear down toward the earlobe along a line parallel to the auricular helix or postauricular sulcus (Fig. 89-19). The incision should not come all the way down to the lower pole of the earlobe but rather stop approximately 0.5 to 1 cm above the base of the earlobe. This preserves more skin below the earlobe to cradle the earlobe at closure rather than risking closure under tension and inferior retraction of the earlobe with healing. The earlobe is then sutured in place (Fig. 89-20), and any excess skin overlying the postauricular sulcus incision line is trimmed. Postauricular closure is with 5-0 plain or fast-absorbing catgut.

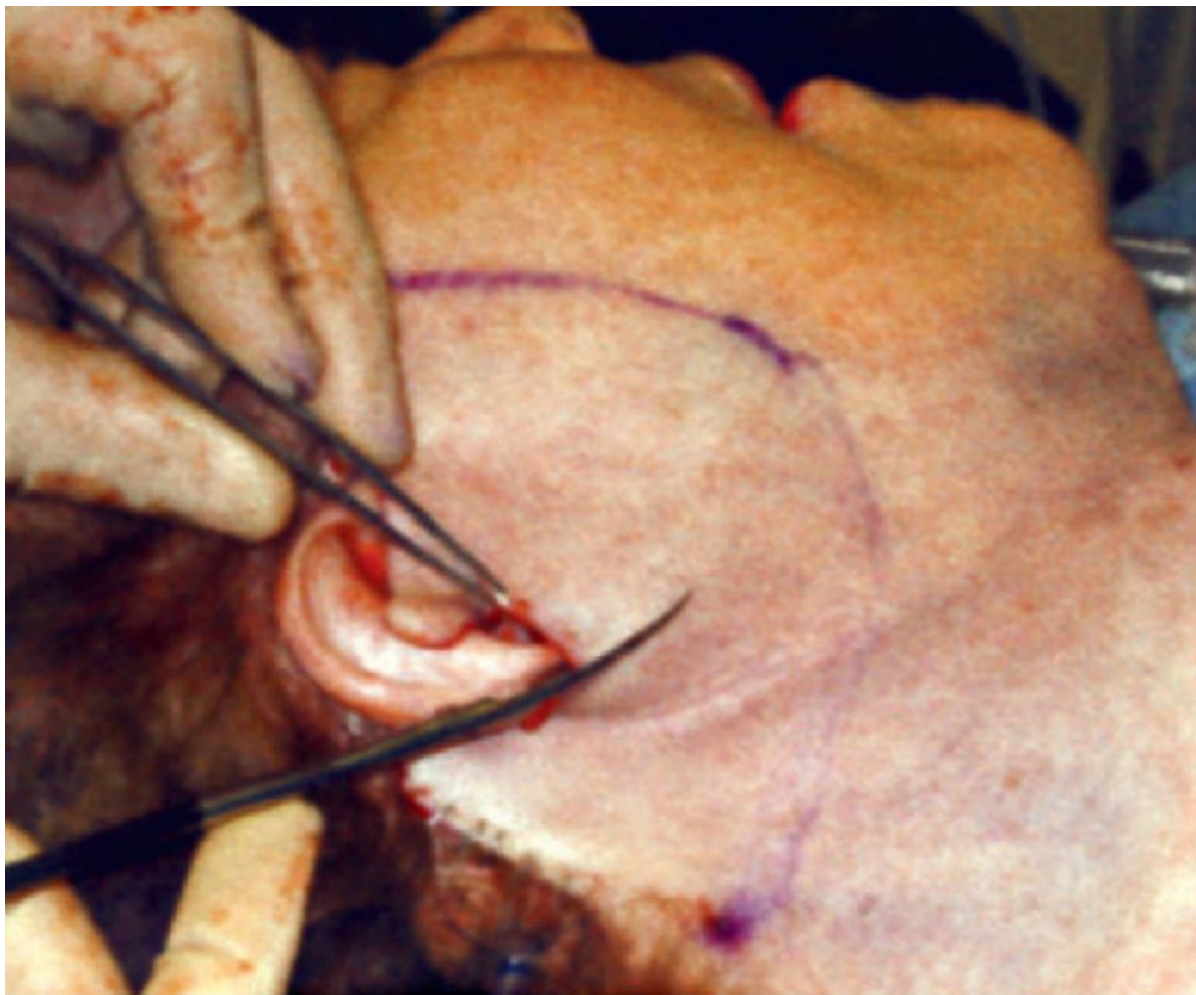


Figure 89-19 Skin is incised along the line of the auricular helix toward the lower pole of the ear; the incision stops 0.5 to 1 cm above the base of the earlobe to allow the skin to be tucked under the earlobe without any inferior pull or tension at closure.

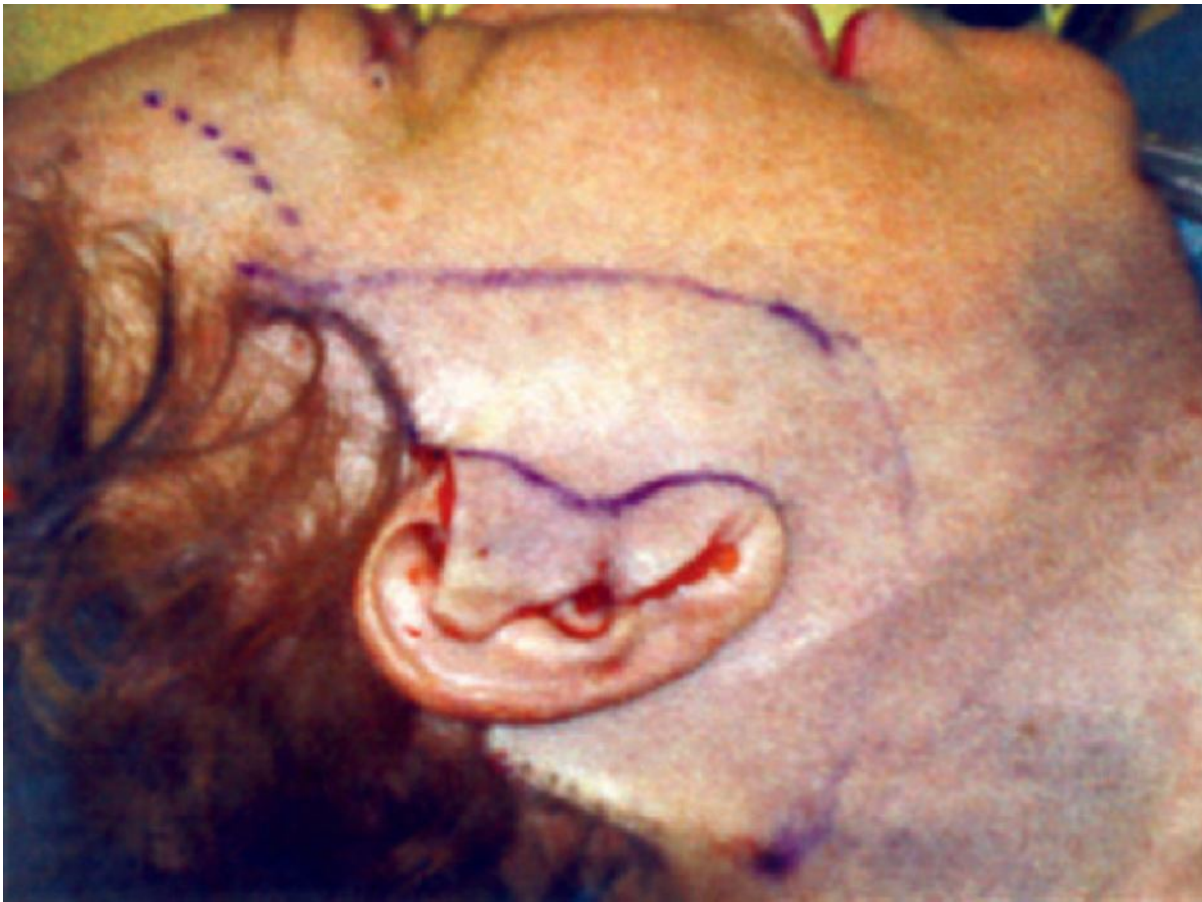

Figure 89-20 The earlobe position has been secured and the excess skin along the postauricular sulcus excised and closed.

The excess preauricular skin is then tailored to facilitate an exacting tension-free closure (Fig. 89-21) with running 6-0 Prolene (Fig. 89-22).

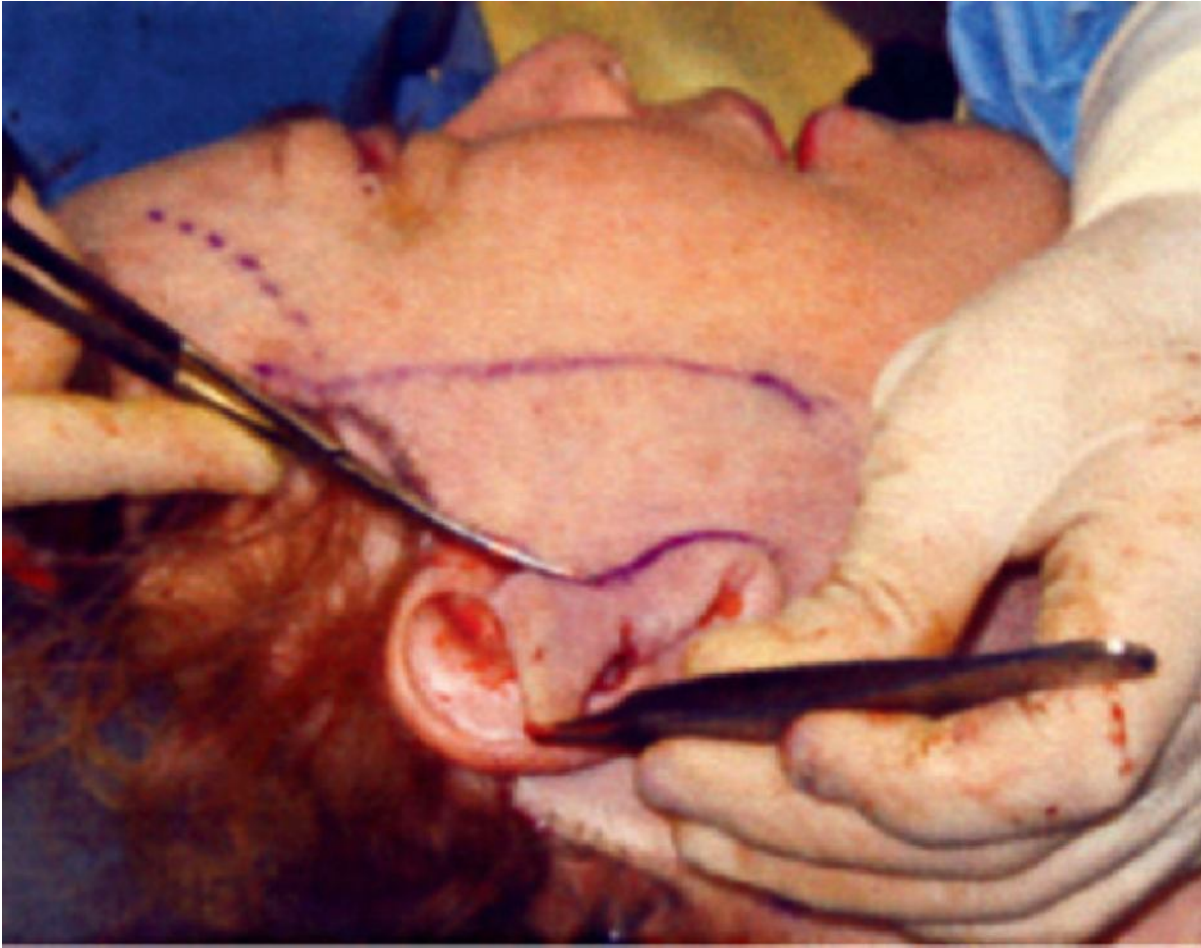


Figure 89-21 Excision of the anterior (cheek) skin redundancy.

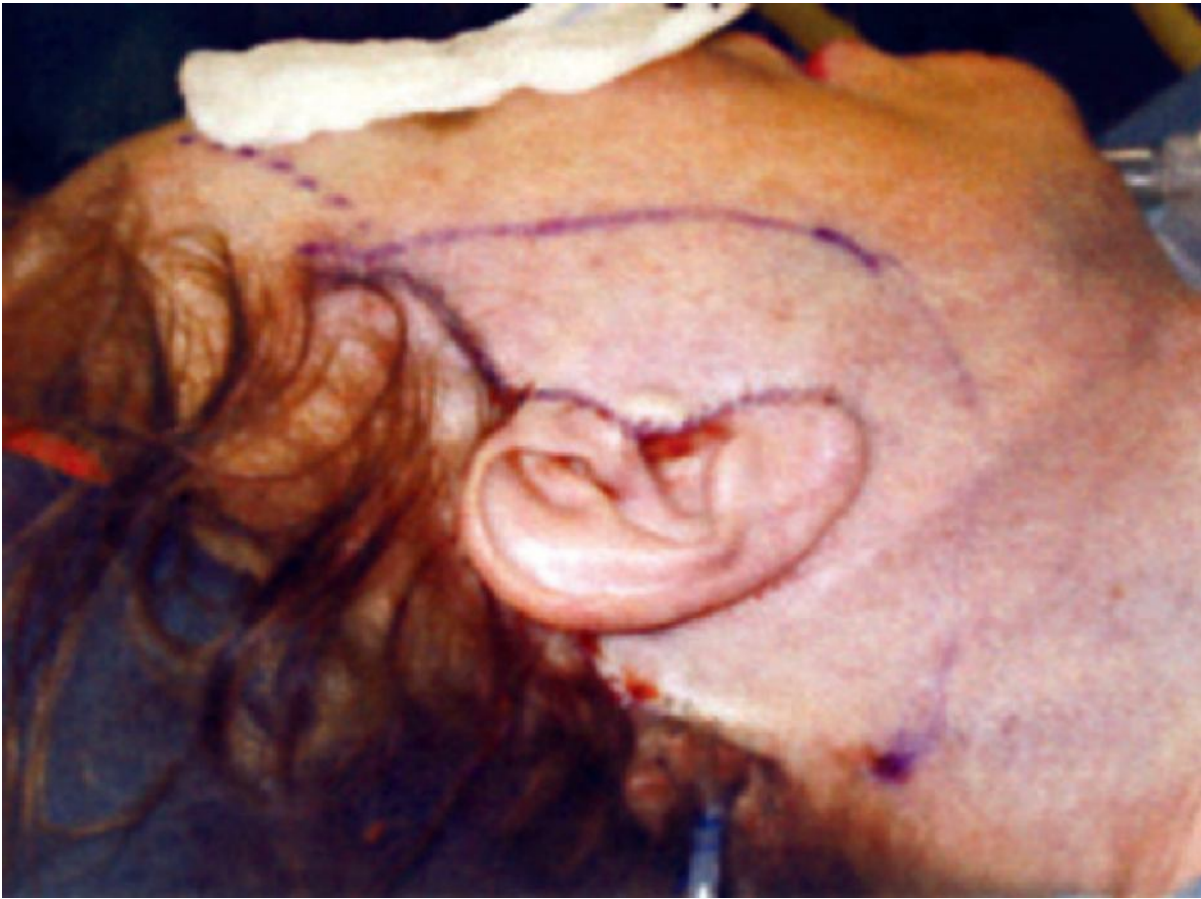

Figure 89-22 Appearance on completion of skin closure.

Ten to fifteen minutes before completing closure on the first side, the second side of the face should be injected with local anesthetic. The second side of the face-lift proceeds in the same way as the first side. The submental incision is closed at the completion of surgery with either 5-0 fast-absorbing gut or 6-0 Prolene suture.

Dressings

The end of the operation is the best time to comfortably clean the patient's hair. Saline and a large-toothed comb are used to remove all loose hair, dried blood, and debris. Bacitracin ointment is next applied to all incisions, which are then covered with either Xeroform gauze or a nonadherent dressing (Telfa).

A lightly compressive dressing of open fluffed 4 × 4-inch gauze is applied to provide padding over the periauricular area, around the lower part of the face, and over the neck. The dressing is then secured with a 3- or 4-inch Kerlix gauze wrap and either an elastic bandage or a 3-inch roll of Coban self-adhesive tape to hold the dressing in place. The goal is a snug but comfortable dressing.

POSTOPERATIVE MANAGEMENT

The patient is instructed to keep the head of the bed elevated 30 degrees, avoid bending over, and not undertake strenuous activities for the first week. Most patients are kept overnight in a unit capable of caring for face-lift patients unless they have made appropriate arrangements for home care. Ice-cool compresses are applied to the face during the first 24 to 48 hours. Many patients have found small bags of frozen peas to be an excellent source of cool compresses over these moist dressings. The peas are in plastic bags, conform well to the face and eyes, and hold the cool temperature for a prolonged period. In addition, they can be refrozen and reused for this purpose. Patients are told preoperatively that they will swell and bruise during the first few postoperative days.

Patients are evaluated on the first postoperative morning for any evidence of hematoma and to test the integrity of the facial nerve. The drains are removed, and a clean, lighter dressing is secured. Patients are told to remove the dressing the following day (postoperative day 2) and may then begin to gently wash their hair and care for their own face. They are instructed to be careful with the temperature of the water and their blow dryer because of temporary alterations in scalp and facial sensation. In addition, patients should wait 3 to 4 weeks before undergoing hair coloring or a permanent. A nylon or spandex elasticized facial support dressing is supplied to the patient, who wears it full-time (aside from bathing) for the first week. Patients are told to gently clean the visible incisions with hydrogen peroxide and then reapply an antibacterial ointment three times daily.

The preauricular sutures are removed on the fifth or sixth postoperative day. Scalp staples are removed 7 to 10 days postoperatively. The absorbable postauricular sulcus stitch is allowed to dissolve.

Representative preoperative and postoperative patient photos are seen in Figure 89-23.

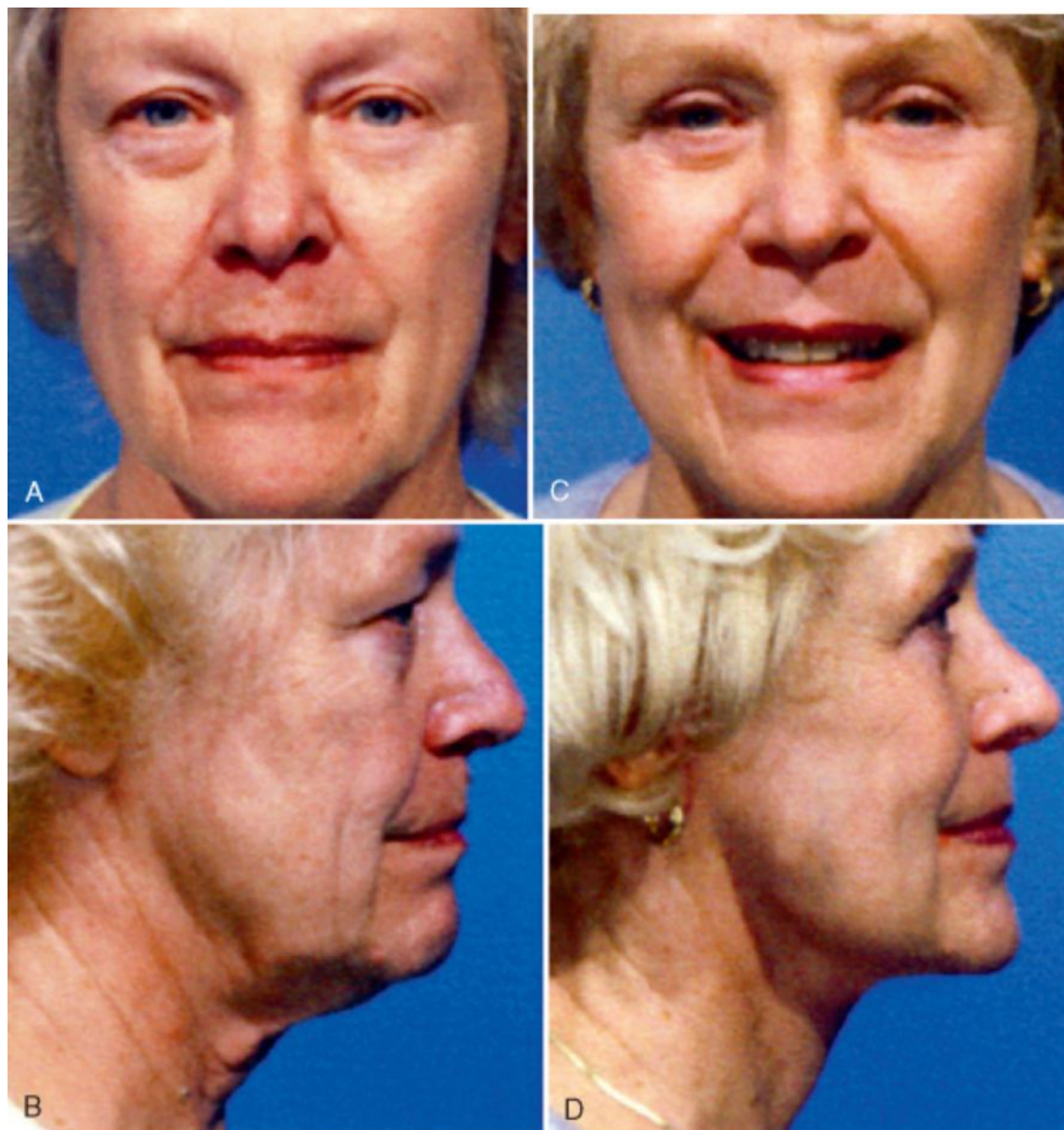

Figure 89-23 A and B, Preoperative frontal and lateral views of a patient before a face-lift and blepharoplasty. C and D, Postoperative frontal and lateral views of the patient who underwent a face-lift and blepharoplasty.

COMPLICATIONS[14–16]

Hematoma

Small hematomas are one of the most common and troublesome complications. If identified immediately postoperatively, they can often be aspirated with an 18-gauge needle. However, when a small hematoma is camouflaged by swelling, one must wait 7 to 14 days before the hematoma will liquefy and allow removal by aspiration. Residual hematomas may cause some dimpling and firmness beneath the facial skin. Larger hematomas (incidence of approximately 3% in females and up to 9% in males) are generally apparent within the first 24 hours and mandate return to the operating room for evacuation, hemostasis, and reclosure. Failure to identify or address a more substantial hematoma puts the patient at increased risk for skin necrosis, infection, and dimpling or irregularities in the overlying skin.

Facial Nerve Injury

Most immediate postoperative facial nerve paralysis will resolve spontaneously within 6 weeks and is due to the effects of the local anesthetic, stretch, local crush injury, inflammation, or compression by a support suture. Occasionally, permanent paralysis will occur as a result of complete transection of the frontal, marginal mandibular, or buccal branch or injury induced by electrocautery. If the injury is identified intraoperatively, immediate repair is indicated; otherwise, treatment is expectant in the hope that the deficit will resolve or diminish. Ultimately, prevention of such injuries is paramount, and if the dissection is maintained in the proper plane and the

surgeon is cognizant of the depth of the facial nerve relative to the depth of dissection, facial nerve injuries are avoidable.

Skin Necrosis

The incidence of significant skin necrosis is between 1% and 3%. It is most common in the mastoid region because the skin flap is the thinnest there, tension is greatest, and it is farthest away from the blood supply. The usual causes of more extensive skin necrosis are some combination of the following: delayed recognition of a significant hematoma, excess tension on the closure, excessive superficial dissection (overly thin skin flaps), a history of impaired circulation secondary to smoking or diabetes, excessive pressure from the dressing, infection, or traumatic handling of tissues. All sloughing should be treated by observation, reassurance, and wound care. A lot of personal attention is required to help these patients deal psychologically with this unexpected sequela. An eschar will eventually form at sites with full-thickness skin loss, and the scars are usually satisfactory. Scars that heal unacceptably can be revised later.

PEARLS

- Attention to detail in the preoperative evaluation will help establish realistic patient expectations and guide decisions to optimize surgical results.
- Careful consideration should be paid to the position of the hairline, and incisions should be chosen to avoid excessive shift or misalignment of the hairline, which can result in telltale signs of surgery.
- Incisions in males should be modified to avoid shifting bearded skin all the way back to the posterior margin of the tragus or right up to the attachment of the earlobe.
- The surgeon should always be conscious of the location and depth of the facial nerve relative to the plane of dissection to avoid inadvertent injury.
- Suspension of the SMAS, whether by plication, imbrication, or SMAS-ectomy, is fundamental to minimize skin closure tension and improve the longevity of the face-lift.

PITFALLS

- Tobacco smokers are at much higher risk for complications and must be counseled appropriately preoperatively; heavy smokers should not be considered candidates for this procedure.
- Dissection deep to the fascia overlying the sternocleidomastoid muscle in the neck may injure the greater auricular nerve.
- Overaggressive surgery must be avoided to prevent an unnatural, pulled, "surgical" look.
- Excessive tension on the skin closure will increase the risk for skin necrosis and widened scars, both of which are largely preventable.
- Disproportionate, particularly unilateral facial pain may be indicative of a hematoma and mandates immediate examination of the patient.

Copyright © 2009 Elsevier Inc. All rights reserved. Read our Terms and Conditions of Use and our Privacy Policy.
For problems or suggestions concerning this service, please contact: online.help@elsevier.com