

- A
- A alpha fibers, 822, 823t
- Abbe-Estlander flap, 366, 664, 665
- Abbe flap, 664f
- Abdomen
- children, 528
 - examination of
 - in trauma patient, 352–353
 - fat graft harvest, 501, 501f
- A beta fibers, 822, 823t
- ABG, 28
- Ablative skin resurfacing
- classification of, 1420t
- Abnormal flexor activity, 346
- Abnormal posturing, 346
- Abrasions, 360, 396–397. *See also* Dermabrasion; Microdermabrasion
- corneal, 470f, 1402
- Abscess
- pharyngeal space, 282f
 - pterygomandibular space, 282f
 - subperiosteal, 304
- Abutment fracture, 270
- Abutment transfer impression
- closed-tray technique, 258f
- Accelerated fractionation, 636
- Access flap, 205–206
- Accessory muscles
- ribs, 103
- Accessory ostia, 298
- ACE distraction dental implant system, 184
- ACE inhibitors. *See* Angiotensin-converting enzyme (ACE) inhibitors
- Acellular dermal matrix (AlloDerm), 220–221, 221f
- Acetaminophen
- for fever, 287
- Acetazolamide
- for OSA, 1302
- Acetylcholinesterase
- reversal doses of, 99t
- Acetylsalicylic acid
- inhibiting platelet function, 78
- Acid-base analysis, 53–54
- Acid-base disturbances, 53–54
- Acid-etch splints, 396f, 397t
- Acquired anomalies, 1205
- Acquired immunodeficiency disease (AIDS).
- See also* Human immunodeficiency virus (HIV)
 - immunocompromised, 283
- Acral-lentiginous melanoma, 684, 703
- Acromegaly, 76
- Acrylic resin, 505
- Acrylic splint therapy
- mandibular fractures
 - children, 425
- ACTH, 34
- Actinic cheilitis, 662f, 663f
- lower lip, 618f
- Actinic keratosis, 698, 699f
- Active jaw exercise
- for TMJ, 955
- Acupressure
- for TMJ, 957
- Acupuncture
- for TMJ, 957
- Acyclovir, 687
- Adalimumab
- for rheumatoid arthritis, 36
- Addison's disease, 61, 682
- A delta fibers, 822–823, 823t
- Adenocarcinoma
- metastasizing to condyle, 945
 - polymorphous
 - low-grade, 672
 - recurrent low-grade, 674f
- Adenoids
- children, 103
 - cystic carcinoma, 672
 - hypertrophy, 298
- Adenoma. *See* Pleomorphic adenoma
- Adenomatoid odontogenic tumors, 593f, 594f
- ADHD
- anesthesia with, 119
- Adjuvant chemotherapy, 639
- Adnexal tumors, 697
- Adolescents
- dentoalveolar injuries, 383–384
 - midface advancement surgery
 - timing of, 1269–1270
 - pregnancy testing, 107
 - psychological assessment, 105
- Adrenal crisis, 61
- Adrenal glands
- assessment of, 61, 74
 - disorders of, 34
- Adrenal insufficiency, 34
- Adrenocorticotrophic hormone (ACTH), 34
- Adult respiratory distress syndrome (ARDS), 348, 354
- Advanced Trauma Life Support (ATLS), 330
- Advancement flaps, 712–713, 772, 772f
- buccal, 772f
 - double, 771f
- Advancement genioplasty
- soft tissue changes associated with, 1232t
- AEV-12 hand engine, 1430
- Affective disorders, 38–39
- African Americans
- hypertension, 49
 - oral cancer, 617
- AFS, 301, 304f
- Afterload, 22, 26, 49
- Age
- determining preoperative risk, 18
 - wound healing, 12
- Aggressive mesenchymal tumors
- children, 602
- Agonist drugs, 84
- AIC, 52–53
- AIDS. *See also* Human immunodeficiency virus (HIV)
- immunocompromised, 283
- Air bags, 529
- Air leak test, 290, 291f
- Airways, 404
- assessment of, 28, 73–74
 - in asthma, 29
 - BSSO, 1161
 - children, 103, 528
 - craniofacial dysostosis syndrome, 902–903
 - gunshot wounds, 515–516
 - management of difficult, 75f
 - obstruction of
 - in odontogenic infection, 281
 - oral cancer, 635
 - panfacial fractures, 552
 - security of, 284
 - trauma patient, 330
- Alabaster skin, 1428

- Alanine aminotransferase (ALAT), 35, 77
- Alar base
alterations in, 1256
cinch suture, 1237f
reduction, 1363f
- Alar cinch, 1236, 1441f
with V-Y closure, 1236–1237
- Alar width
rhinoplasty, 1353
- ALAT, 35, 77
- Albright's syndrome, 597, 682
- Albumin, 34
- Albuterol
for asthma, 29
- Alcohol abuse, 39, 281, 1298
anesthesia with, 121
immunocompromised, 283
squamous cell carcinoma, 617
- Alcohol withdrawal
oral cancer, 635
- Alfentanil
chemical structure of, 88f
end-stage TMJ disease, 1017
pharmacology of, 89
- Alignment, 795f
- Allen's test
abnormal, 808f
- Allergic fungal sinusitis (AFS), 301, 304f
- Allergic rhinitis, 106–107, 299
- Allevyn spray, 718
- AlloDerm, 220–221, 221f
- Allogenic bone implants, 166
- Allografts, 786t, 787
- Alloplastic chin implants
soft tissue changes associated with, 1232t
- Alloplastic esthetic facial augmentation,
1435–1447
- Alloplastic graft, 787
- Alloplastic materials, 1008
- Alopecia, 1403
- Alpha-blockers
for hypertension, 32
- Alpha-glucosidase inhibitors
mechanism of action, 60t
- Alpha-hydroxy acid, 1422
- Alpha-interferon
for central giant cell granuloma, 604
- Aluminum oxide, 1008
cemented abutment
with all-ceramic crown, 257f
- Alveolar and dental fractures
etiology of, 383–384
hard tissue and pulp, 387–397
historic perspectives of, 383
incidence of, 383–384
management of, 383–399
maxillofacial examination, 384–386
patient history, 384
physical examination, 384
radiographic examination, 386–387
- Alveolar artery, 1248
- Alveolar bone
in edentulous patient
characteristics of, 157–158
injuries
diagram of, 390f
loss, 263f
preservation of, 167–171
- Alveolar cleft
grafting, 859–869
allogenic bone and bone substitutes,
863–864
bilateral, 865f
calvarial bone, 863
central incisor, 861
dental vs. chronologic age, 861
lateral incisor, 861
late secondary, 862
maxillary central incisor, 865f
multidisciplinary team, 862
outcomes, 859
pre-vs. postsurgical orthodontics, 864–865
primary, 860
rationale for, 859
secondary, 860–862
social issues, 861
source of bone graft, 862–864, 863t
sulcular incision, 866f
surgical technique, 865–866
timing, 859–862, 860t, 861t
unilateral, 862f, 864f
reconstruction
occlusal radiograph, 868f, 869f
reconstruction of, 859–869
- Alveolar distraction devices, 1293f
- Alveolar distraction osteogenesis, 183–185,
230–231
dental implants, 1290–1293
- Alveolar distractors, 1291f
- Alveolar mucosa
treatment, 396–397
- Alveolar osteitis, 149, 151
- Alveolar process
anterior, 1182
fractures
treatment, 395–396
growth of, 1063
- Alveolar ridge
cancer, 621
survival, 645
reconstructive surgery of, 180–181
squamous cell carcinoma, 621f
- Alveoloplasty, 168–169
- Alveolus
squamous cell carcinoma, 644–645
- Ameloblastic carcinoma, 588–589
- Ameloblastic fibroma, 590f
- Ameloblastic fibro-odontoma, 590, 590f
- Ameloblastoma, 583–588
benign, 588f, 589f
malignant metastasizing, 588
mural unicystic, 586
peripheral, 587–588
solid or multicystic, 583–585, 584f, 585f
unicystic, 585–586, 586f, 587f
- American College of Cardiology
cardiovascular risk factors, 19–20, 20t
perioperative evaluation for noncardiac
surgery, 47
- American M-16, 512
- American Society of Anesthesiologists (ASA)
Classification of Physical Status,
66, 66t
- Amide
avoiding in malignant hyperthermia, 38
- Amifostine, 638
- Aminocaproic acid, 473
- Aminosteroids
pharmacology of, 98
properties, 99t
- Amitriptyline
end-stage TMJ disease, 1022, 1023
- Amoxicillin
for bites, 362
for infectious endocarditis prophylaxis, 24t
for odontogenic infection, 289
for rhinosinusitis, 305, 502
for sinus infection, 305
- Amphetamine abuse
anesthesia with, 121
- Amphotericin B
for fungal sinusitis, 307
- Ampicillin, 944
for COPD, 30
for infectious endocarditis prophylaxis, 24t
- Amyloidosis, 38
- Anakinra
for rheumatoid arthritis, 36
- Ancient Egypt, 189
- Andreasen classification, 387
- Anemia, 30–31
- Anemia of chronic disease, 38
- Anesthesia
general
risk after myocardial infarction, 20

- inhalation
 - pharmacology of, 93–97
 - properties of, 94t
- local
 - TMJ, 953
- outpatient
 - distribution of, 84–85
 - pharmacodynamics of, 83–85
 - pharmacokinetics of, 84–85
 - pharmacology of, 83–100
- regional
 - end-stage TMJ disease, 1017
- Aneurysmal bone cyst, 605, 606f
- Aneurysms
 - maxillary fractures, 442
- Angina, 19, 48–49, 66–67
 - Ludwig's, 284
- Angiogenesis, 5, 8
- Angiography
 - for neck injuries, 518
- Angiotensin-converting enzyme (ACE)
 - inhibitors
 - for aortic regurgitation, 25
 - for congestive heart failure, 22, 26
 - for hypertension, 32
- Angiotensin receptor blockers (ARB)
 - for hypertension, 32
- Angle fractures, 409
 - Champy method, 373f
 - load-sharing fixation, 375
 - widening mandible, 381f
- Angle regions
 - bimanual pressure over, 406f
- Animal bites, 362
- Ankylosed maxillary cuspid
 - partially submerged, 1116f
- Ankylosed permanent tooth, 1131–1132
- Ankylosed primary tooth, 1131
- Ankylosed teeth, 1115, 1131
 - orthodontics, 1132
- Ankylosing spondylitis, 37, 1036, 1037
- Ankylosis, 390–391, 460, 1289
 - after prosthesis placement, 1038
 - bilateral bony, 1039f–1040f
 - computed tomography, 428f
 - of condyle, 1040
 - extra articular, 1035
 - and mandibular fractures, 428–429
 - of TMJ, 1035f, 1041f–1043f
 - and traumatically induced effusions, 412
 - of zygomatic arch coronoid, 460
- Anodontia, 238f
- Anomalies. *See also* Congenital anomalies; Developmental anomalies
 - acquired, 1205
 - Kleeblattschädel, 925–926, 926f
- Anorexia nervosa, 39
- Anosmia, 503
- Antagonist drugs, 84
- Anterior capsular release, 975
- Anterior dislocation, 410–411
- Anterior ethmoidal artery, 465
- Anterior ethmoidal nerve, 1349
- Anterior mandible
 - FPD, 262
- Anterior maxillary congenital deformities, 1287f
- Anterior maxillary defect
 - interpositional grafting, 230f
- Anterior maxillary osteotomy, 1193–1196
- Anterior maxillary segmental osteotomies, 1123, 1123f
- Anterior nasal spine, 436
 - reduction
 - maxillary osteotomy, 1241f
 - poor esthetic outcome, 1241f
- Anterior open bite, 1262–1263, 1291f
- Anterior segmental setback osteotomy
 - soft tissue changes associated with, 1226t
- Anteroposterior arch asymmetry, 1129
- Anteroposterior orthopedic treatment, 1073–1076, 1076–1077
- Anticholinergic medications
 - effects of, 100t
 - with ketamine, 111
 - pharmacology of, 99–100
 - reversal doses of, 99t
- Anticholinesterase
 - pharmacology of, 98–99
- Anticytokines
 - for rheumatoid arthritis, 36
- Antidepressants, 953t
 - for TMJ, 952–953
- Antiemetic medications, 100–101
- Antihistamines
 - adverse effects of, 307
 - children, 115
 - for TMJ, 952
- Antileukotriene drugs
 - for asthma, 29
- Antineoplastic drugs
 - and wound healing, 11
- Antioxidants, 1421
- Antiphospholipid antibodies, 37
- Anxiolytics
 - for TMJ, 952
- AO/ASIF
 - compression plates, 402
 - fracture management biomechanical principles, 373
- Aortic regurgitation, 24–25, 68
- Aortic stenosis, 25, 68
- Apert syndrome, 527, 915, 917f–922f, 922f–923f
 - cranial vault expansion, 915
 - lower facial esthetic reconstruction, 915
 - primary cranio-orbital decompression, 915
 - total midface deformity, 915
- Apthous stomatitis, 692f
- Apthous ulcers, 691–692
- Apical repositioned flap
 - canine teeth labially impacted, 135f
- Apnea, 58
- Apoptosis
 - vs. proliferation, 576f
- Approximation, 832
- Arachidonic acid, 1019f
- ARB
 - for hypertension, 32
- Arch, 1386f
 - creating space in, 1121–1122
 - length, 1111–1132, 1112f
 - load, 403f
 - width, 1113
- Arch bars, 372f, 415, 439f
 - isolated mandibular body fracture, 377f
- Archigenes, 383
- Arcus marginalis, 466
- ARDS, 348, 354
- Aripiprazole
 - for psychotic disorders, 39
- Arnold's nerve, 1451
- Arrhythmias, 51–52
- Arterial blood gases (ABG), 28
- Arterial oxygen tension, 332
- Arthrocentesis
 - TMJ, 963–987
- Arthroplasty
 - condyle, 1003f
- Arthroscope
 - TMJ, 969
- Arthroscopic knives, 1000f, 1006f
- Arthroscopic osteoplasty, 978f
- Arthroscopy
 - TMJ, 963–987
 - contraindications for, 967–968
 - development of, 964–965
 - history, 965–966
 - imaging, 966
 - indications for, 966–967
 - instruments, 968–971, 985–986
 - patient selection, 965–966
 - physical examination, 965–966
- Articular apparatus
 - nonfracture injuries of, 410–411, 410t

- Articular cartilage, 934, 935f
 Articular disk
 TMJ, 935–936
 Articular eminence
 endaural view, 973f
 Articular tubercle
 disk impingement, 972f
 ASA Classification of Physical Status, 66, 66t
 Ascending ramus fracture, 409
 Aseptic necrosis, 1250, 1250f
 Asian lid crease reformation, 1334f
 Asian upper eyelid, 1320
 blepharoplasty, 1334
 Aspart
 onset, peak and duration, 61t
 Aspartate aminotransferase (AST), 77
Aspergillus flavus, 301
Aspergillus fumigatus, 300–301
Aspergillus sinusitis, 304f
 Aspiration, 106
 Aspirin
 for cerebrovascular disease, 37
 determining preoperative risk, 18
 for fever, 287
 Aspirin-sensitivity triad, 299
 AST, 77
 Asthma, 28–29, 299
 bronchial, 72–73
 pulmonary assessment, 54–55
 questions about, 29t
 Asymmetric hybrid functional appliance, 1073f
 Asymmetric skull
 CT, 1209f
 Asymmetry. *See also* Facial asymmetry
 anteroposterior arch, 1129
 zygomatic arch fractures, 457
 Asymptomatic patients
 screening tests for, 79
 Atenolol
 avoidance in liver disease, 35
 ATLS, 330
 Atracurium
 properties, 99t
 Atrial dysrhythmias, 27
 Atrial fibrillation, 24, 27, 51
 Atrial flutter, 27
 Atrioventricular blocks, 27–28
 Atrophic mandible, 185f
 augmentation, 195–197
 gingival graft, 211
 iliac crest corticocancellous block graft augmentation, 196f
 implants without grafting, 197
 plane radiograph, 196f
 wishboning, 380, 380f
 Atrophic maxilla
 gingival graft, 211
 Atropine, 99, 106, 473
 with ketamine, 111
 Attention deficit hyperactivity disorder (ADHD)
 anesthesia with, 119
 Auditory canal
 external
 sectioned, 995f
 Auricle. *See* Ear
 Auriculotemporal nerve, 1390
 Auriculotemporal syndrome, 1263
 Austin-Flint murmur, 25
 Autism
 anesthesia with, 119–120
 Autogenous bone grafts
 sites for, 787–792
 Autogenous conchal cartilage, 1008
 Autogenous fascia interpositional grafts, 1007
 Autogenous grafts, 168
 Autoimmune disease, 690–691
 implants, 252
 Autologous fat injection, 1413–1414, 1414f
 Autologous fat transfer, 1412–1415
 complications, 1414–1415
 Automatic implantable cardioverter
 defibrillators (AIC), 52–53
 Avulsions, 361–362, 393–394
 ear, 368f
 lip, 369f
 maxillary fractures, 441
 splints, 395, 396t
 temporary storage of, 393
 treatment, 393–394, 395t
 Axial frontonasal flaps, 772, 773f
 Axial pattern flaps, 716–717
 Azathiaprine
 for rheumatoid arthritis, 36
 Azithromycin
 for infectious endocarditis prophylaxis, 24t
 for rhinosinusitis, 502
- B**
 Babinski sign, 346
Bacteroides (Porphyromonas), 140, 426
 Baker-Gordon phenol peel, 1427–1428
 complications from, 1428f
 formula of, 1428t
 freezing from, 1429f
 Ballistics, 510
 Balloon catheters
 nasal packing, 517f
 Bands of Büngner, 824
 Bar attachment, 264, 265f
 overdenture, 264f
 Barbiturates
 pharmacology of, 89–91
 Barbituric acid
 chemical structure of, 90f
 Bar-clip attachments, 265
 Bardach two-flap palatoplasty, 852
 Barium swallow
 vs. esophagoscopy
 for neck gunshot injuries, 518
 Barlow's syndrome, 69
 Barosinusitis, 299
 Bar-retained denture, 264f
 Barton dressing, 287f
 Basal cell cancer
 nasal, 707f
 Basal cell carcinoma, 700, 706f, 712f
 indiscreet temple, 716f
 of left temple, 714f
 Mohs' micrographic surgery removal, 717f
 NMCS, 697
 nodulo-ulcerative, 701f
 resection, 719f
 superficial, 718f
 Basal cell nevus syndrome, 698
 clinical features of, 570t
 Basaloid squamous cell carcinoma, 632
 Base alar reduction
 nasal, 1363
 Basic fibroblast growth factor (bFGF), 193
 Basic multicellular unit (BMU), 7
 Basilar skull fractures, 471
 Battle's sign, 346, 429, 471
 Beaking, 974, 977f
 Beck's triad, 338
 Behçet's syndrome, 692
 Bekhterev's disease, 1036
 Belfast Study Group, 139, 140
 Bell hand engine, 1430
 Bell's phenomenon, 1330
 Benign fibro-osseous disease, 597–600
 cemento-osseous dysplasia, 598–599
 fibrous dysplasia, 597–598
 Benign mucosa membrane pemphigoid (BMMP), 690–691
 Benign ventricular ectopy, 52
 Benzamides
 children, 117
 Benzodiazepines, 952t, 953t
 for delirium tremens, 39, 635
 for depression, 39
 in elderly, 41
 with ketamine, 111
 pharmacology of, 85–87

- for TMJ, 952
- Benzylisoquinolines
 - pharmacology of, 98
 - properties, 99t
- Bernard flap, 666, 666f
- Beta-agonists
 - for asthma, 29
- Beta-antagonist
 - for hyperthyroidism, 34
- Beta blockers, 20, 23
 - for atrial fibrillation, 24
 - for hypertension, 32
- Beta carotene, 641
- Beta-lactam
 - for odontogenic infection, 289
- Beta-sympathetic antagonists
 - reduction in liver disease, 35
- bFGF, 193
- Bicoronal flap, 551
- Bicortical screws, 1259f
- Bicuspid
 - mandible
 - impacted, 136
 - progressive soft tissue recession, 212f
- Biguanides
 - mechanism of action, 60t
- Bilateral alar base wedge, 1243f
- Bilateral body osteotomy, 1125f
- Bilateral sagittal split osteotomy (BSSO), 1137
 - bleeding, 1160
 - complications of, 1155–1156
 - indications for, 1150
 - of mandible, 1214
 - for mandibular horizontal deficiency, 1153f–1154f
 - modification, 1155
 - technique, 1150–1155
 - illustrated, 1152f
 - of vertical ramus, 1150–1161, 1277
- Bilevel positive airway pressure (Bi-PAP)
 - OSA, 1304
- Bilobed flap of Zitelli
 - nasal, 714
- Bilobed flaps, 771f, 773–774
- Bimanual examination, 496, 496f
- Biofeedback
 - for TMJ, 957
- Biologic creep, 712
- Biopsy forceps
 - TMJ arthroscopy, 970
- Bi-PAP
 - OSA, 1304
- Bipolar (manic-depressive) disorders, 39
- Bite appliances, 1009
- Bite depth, 1106
- Black necrotic eschars, 301
- Blade implants, 190f
- Blair, Vilray, 840
- Blair's horizontal osteotomy of vertical ramus, 1135, 1136f
- Blanch test, 338
- Bleeding
 - BSSO, 1160
 - control of, 339–340
 - flaps, 720
 - gunshot wounds, 516–517
 - with impacted teeth removal, 150
 - internal sites of, 341
 - Le Fort level fractures, 438
 - lower eyelid blepharoplasty, 1341
 - mandible, 1249
 - maxilla, 1247–1249
 - maxillary fractures, 442
 - TMJ
 - internal derangement, 1010
 - upper eyelid blepharoplasty, 1340
- Bleeding disorders
 - assessment of, 78
- Bleomycin, 682
- Blepharoplasty, 1317–1342
 - adjunctive procedures, 1341–1342
 - anatomy, 1317–1326
 - anesthesia, 1331
 - chief concern, 1326–1327
 - complications, 1339–1341
 - lower eyelids, 1334–1337
 - patient evaluation, 1326–1331
 - photographic documentation, 1331
 - physical examination, 1328–1330
 - postoperative management of, 1337–1339
 - upper eyelids, 1331–1334
- Blind finger dissection, 1397f
- Blindness, 464
 - maxillary fractures, 442
- Blood clot, 4, 4f, 8
- Blood pressure
 - children, 105, 528
 - in trauma patient, 337
- Blow-in fractures, 467, 472
 - children, 536–537
- Blown pupil, 347
- Blow-out fractures, 457f, 477, 485
 - bilateral, 536f
 - children, 536–537
 - of left orbital floor, 538f
 - orbital, 484
- Blue bloater, 73
- BMMP, 690–691
- BMP, 13, 785, 787
- BMU, 7
- Boat tail bullet, 514
- Body fracture, 409
- Body temperature
 - restoration and maintenance of, 343
- Bolton's analysis, 1112–1113, 1113f
- Bonded orthodontic bracket, 134
- Bone
 - allogenic implants, 166
 - biology of, 785–786
 - healing
 - osseointegration, 192–193
 - secondary, 373f, 374f
 - indirect healing, 6, 373f, 374f
 - loss
 - secondary, 159
 - maturation stages of, 167f
 - regeneration of, 6
 - principles of, 162–164
 - remodeling, 7
 - tension-stress, 164
 - volume
 - implant prosthodontics, 252
 - inadequate posterior, 236f
 - wound healing, 6–7
- Bone grafts, 165–167, 786t
 - autogenous
 - sites for, 787–792
 - benefits of, 1268–1269
 - biology of, 786–787
 - cleft maxilla/palate, 1269f
 - timing and sequencing, 1268–1269
 - cranial, 788, 788f, 789f, 790f
 - cranial onlay
 - maxilla, 263f
 - guided
 - augmentation, 223
 - harvesting, 196
 - iliac crest, 268f, 789–791, 862–863
 - inlay, 179–180
 - intraoral, 787–788
 - donor site, 787f
 - onlay, 177–179, 1274f
 - orbital floor
 - zygomatic arch fractures, 457
 - panfacial fractures, 551–552, 552f
 - sinus, 232–234, 241f
 - tibial, 791–792, 792f
 - vertical alveolar augmentation, 223–234
- Bone marrow needle, 108, 108f
- Bone morphogenetic proteins (BMP), 13, 785, 787
- Bone plates, 372f, 378f, 439
 - biomechanical effectiveness of, 377f
 - device, 185
 - fatigue, 379–380

- vs. lag screws, 379
- Le Fort I level fracture, 375f
- load-bearing fixation, 375f
- strong, 380f
- symphysis fracture, 382f
- Bone tunnel fixation, 1399f, 1400
- Booster seats, 529
- Botulinum toxin A, 1329
- Botulinum toxin-assisted brow lift, 1401
- Bowman-Birk inhibitor, 641
- Bowstring test, 496, 496f
- Brachycephaly, 889f, 895f, 908f
- Brachytherapy, 637
- Brackets, 1130f
- Bradycardia, 25
 - with hypertension, 345
- Brain
 - damage caused by hypertension, 32
 - growth
 - craniofacial dysostosis syndrome, 901–902
 - limitations, 887–888
- Brånemark drilling system, 191
- Brånemark protocol, 201
- Breast-feeding
 - cleft lip/palate, 844
- Breast-feeding mothers, 42
 - medications for, 42t
- Breath-holding test, 28
- Breathing
 - trauma patient, 332–337
- Bridging fixation. *See* Load-bearing fixation
- Bronchi
 - children, 103
- Bronchial asthma, 72
- Bronchiectasis, 73
- Bronchitis, 73
- Bronchoscope
 - rigid, 624
- Bronchospasm, 29
- Bronstein and Merrill arthroscopic staging
 - IJD, 968t
- Brophy, Truman, 840
- Brow
 - youthful, 1384f
- Brow incision
 - lateral, 452, 482
- Brow lift, 1383–1403, 1395
 - bony landmarks, 1384–1389
 - complications, 1402–1403
 - endoscopic view, 1391–1393, 1396–1400, 1396f
 - muscle and fascial anatomy, 1385–1386
 - positions, 1383f
 - postoperative care, 1402
 - preoperative evaluation, 1393–1395
 - skin care and micropigmentation, 1401–1402
 - vessel and nerve anatomy, 1389–1391
- Brown dermatome, 718
- Brown technique, 423f
- Bruxism
 - drug-induced, 1023
 - implants, 252
- BSSO. *See* Bilateral sagittal split osteotomy (BSSO)
- Buccal advancement flaps, 772f
- Buccal artery, 144
- Buccal flaps
 - full-thickness mucoperiosteal, 866
- Buccal fragment
 - after osteotomy, 180f
- Buccal mucosa
 - flap, 1270f
 - squamous cell carcinoma, 621f, 642, 642f
 - verrucous carcinoma, 631f
- Buccal object rule, 133
- Buccal segment, 1257f
- Buccal space
 - borders of, 278t
 - infection, 279t
- Buccinator, 1184
- Buckshot, 513
- Bulimia, 39
- Bullets
 - diameter, 511
 - fragmentation, 511
 - kinetic energy, 510–511
 - velocity, 511
 - wounding power, 510–511
- Bullous pemphigoid, 691
- Bundle branch blocks, 28
- Büngner's band, 6
- Bupivacaine
 - for blepharoplasty, 1331
 - end-stage TMJ disease, 1017
- Burns, 1248f
 - TMJ
 - arthroscopy, 986
- Burow's triangle, 367f, 665f, 772
- Buser periosteal elevator, 213, 218
- Busulfan, 682
- Buttress, 547–548
- Butyrophenones
 - for psychotic disorders, 39
- C
- Cadaveric mandible tray
 - atrophic mandible, 182f
- Cadaveric mandibular adjustment, 183
- Calcified sialoliths, 674
- Calcifying epithelial odontogenic tumors, 592
- Calcifying odontogenic cysts (COC), 582, 583f
- Calcitonin
 - for central giant cell granuloma, 604
- Calcium channel blockers
 - for aortic regurgitation, 25
 - for hypertension, 32
- Calcium hydroxide paste, 388
- Caldwell-Luc procedure, 152, 232–234, 308, 309f
- Caldwell's view
 - zygomatic complex fractures, 448
- Caliber, 512
- Caloric response, 347, 347f
- Calvaria
 - bone formation in, 192–193
- Canaliculus, 364, 365f
- Cancellous grafts, 165
- Cancer chemotherapy
 - adjuvant, 639
 - immunocompromised, 283
 - induction, 639
 - neoadjuvant, 639
 - nonmelanoma skin cancer, 708
 - oral cancer, 638–640
 - palliative, 639
- Candida*, 680
- Candidosis, 680–681, 692
 - HIV, 689
 - oral, 680f, 681f
- Canine teeth
 - labially impacted
 - apical repositioned flap, 135f
 - removal of, 136
 - palatal impacted
 - removal of, 136
- Cannula, 1408–1409, 1409f
 - TMJ arthroscopy, 970
- Canthal ligament
 - lateral, 1321–1322
- Canthal ligaments, 1322f
- Canthal tendons, 446
- Canthotomy
 - lateral, 453
- Cantilevered fixed partial denture, 263, 263f
 - extension of, 265
- Cantilevering, 256f
- Capillary filling time, 338
- Capnography, 59
- Capsaicin
 - end-stage TMJ disease, 1017
- Capsular ligament, 936, 936f
- Capsular tightening procedure, 1005f
- Carbamazepine, 691

- Carbon dioxide lasers
photoaging, 1431
- Carbon dioxide snow, 386
- Carboplatin, 639, 640
- Cardiac assessment, 47–53
algorithm, 72f
arrhythmias, 51–52
automatic implantable cardioverter
defibrillators, 52–53
chest pain suggesting myocardial
infarction, 50
decompensated congestive heart failure, 50
myocardial ischemia, 48–49
recent myocardial infarction, 49–50
- Cardiac disease, 18–28
assessment of, 66–70, 107
cardiac dysrhythmias, 26–28
congestive heart failure, 26
coronary artery disease, 18–22
mitral valve prolapse, 24–25
- Cardiac dysrhythmias, 26–28
- Cardiac output
age-related changes, 41
children, 104–105
- Cardiac risk
index of, 67t
morbidity and mortality based on, 48t
- Cardiac tamponade, 338, 339
- Cardiomyopathy, 69
- Cardiovascular system
nicotine effect on, 57
normal function, 105t
- C-arm fluoroscopy unit, 499
- Carotid artery, 1248
- Carotid stenosis, 37
- Carpenter syndrome, 903
- Carroll-Girard screw, 451, 452f
- Cartilage. *See also* specific cartilage
nasal septum, 1357f
nose, 1347–1348
TMJ, 934–935
- Cartridges, 512
muzzle energy, 511t
velocities, 511t
- Cast cap splints, 415
- Cataplexy, 1298
- Cataract surgery, 472
- Cat bites, 362f
- Catecholamines, 338
- Cavernous sinus thrombosis, 278, 304
- Cavity, 511
- CCR, 30
- Cefazolin
for infectious endocarditis prophylaxis, 24t
- Cefotaxime, 944
- Cefpodoxime
for rhinosinusitis, 502
- Cefprozil
for rhinosinusitis, 502
- Cefuroxime
for rhinosinusitis, 502
- Celecoxib
for rheumatoid arthritis, 36
- Cell cycle, 576f
- Cellulitis, 282f
- Cemento-osseous dysplasia, 598–599
- Cement retention
vs. screw retention, 260t
- Central anticholinergic syndrome, 99–100
- Central giant cell granuloma, 603–605, 603f, 604f
- Central sleep apnea, 1298
- Cephalometric analysis, 1113f
craniofacial dysostosis syndrome, 905
- Cephalometric films
alveolar ridge, 163f
edentulous mandible, 194
implants, 253, 253f
lateral
facial asymmetry, 1209
for preprosthetic and reconstructive
surgery, 161
- Cephalometric radiographs
lateral
facial asymmetry, 1209
posteroanterior
facial asymmetry, 1209
- Cephalosporin
avoided with renal patients, 31
for rhinosinusitis, 305
for TMJ arthroscopy, 984
- Cerebral. *See* Brain
- Cerebral palsy, 1207
anesthesia with, 119
- Cerebrospinal fluid (CSF)
normal values of, 495t
- Cerebrovascular disease, 37
- Cervical incisions, 551
- Cervical lymphadenectomy
lip cancer, 666
- Cervical lymph nodes
levels, 619–620
squamous cell carcinoma, 646–648
- Cervical spine
injuries, 350–351
radiograph, 351, 351f
trauma patient, 330
- Cervical wire, 134
- Cervicofacial liposuction, 1407–1411
anesthesia, 1409
complications, 1411
history, 1407
indications for, 1407–1408
instrumentation, 1408–1409
patient evaluation, 1408
technique, 1410–1411
- Champy method, 373f
- Champy miniplate technique, 376
- Charcot-Leyden crystals, 301, 303
- Chase method, 40
- Cheek
augmentation, 1443–1446, 1445f
stabilization, 1444f
undermining, 1444f
high-velocity entrance wound, 520f
- Cheever, David, 435
- Chemexfoliation, 1341–1342
- Chemical peeling, 1341–1342, 1421–1422
deep, 1427–1429
medium-depth, 1424–1427, 1424t, 1425f, 1426f, 1431f
superficial, 1422–1423
- Chemoreceptor trigger zone, 100, 100f
- Chemotherapy. *See* Cancer chemotherapy
- Cherubism, 604–605, 605f
- Chest
examination of
in trauma patient, 348–349
normal radiography of, 348f
- Chest tube
for pneumothorax, 333, 334f
- Chest wall
children, 528
inspection of, 332
- Chewing, 405
- Child abuse, 384, 529
- Children, 42
abdomen, 528
adenoids, 103
aggressive mesenchymal tumors, 602
airways, 103, 528
anatomic considerations, 528–529
blood pressure, 105, 528
blow-in fractures, 536–537
blow-out fracture, 536–537
bronchi, 103
cardiac output, 104–105
cardiovascular system, 104–105
chest wall, 528
condylar process, 529
condyle fracture
open reduction, 539
cranial vault fractures, 532
craniomaxillofacial fractures, 527–542
complications, 531–532

- diagnosis of, 529–530
 - epidemiology of, 530–532
 - historic perspectives, 527–528
 - mechanism of, 530t
 - patterns of, 530, 532–542
 - prevention of, 529
 - by region, 530t, 531t
 - treatment, 531t
 - dentoalveolar injuries, 383–384, 397–398, 398t, 541–542
 - emergency treatment on full stomach, 106
 - endotracheal intubation, 104
 - facial trauma, 540f
 - fluid requirements for, 42t
 - FRC, 104
 - frontal sinus fractures, 532–534
 - hypothermia, 528
 - impacted teeth, 144
 - impacted tooth removal, 142–143
 - Le Fort (midface) fractures, 534
 - mandible, 529
 - mandibular condyle fractures, 538–539
 - mandibular fractures, 424–425, 538–542
 - mandibular subcondyle fractures, 538–539
 - maxillary fractures, 441
 - nasal air passages, 528
 - nasal fractures, 537–538
 - naso-orbitoethmoid fractures, 532–534
 - neural innervation, 105
 - paranasal sinuses, 529
 - parasymphyseal fractures, 541
 - periosteum, 529
 - permanent tooth buds, 529
 - resorbable fixation materials, 542
 - ribs, 103
 - sedation, 103–123
 - anatomic and physiologic considerations, 103–105
 - perioperative complications, 115–116
 - pharmacologic agents, 110–115
 - preoperative evaluation, 105–106
 - routes of administration, 107–110
 - techniques for, 107–115
 - substance abuse, 120–123
 - supraorbital ridge fractures, 532
 - tongue, 103
 - tonsils, 103
 - trachea, 103, 104
 - upper respiratory infection, 106–107
 - urine output in, 42t
 - ventilation, 103
 - zygomatic complex fractures, 534–537
- Chin**
- alloplastic augmentation, 1435–1437
 - alloplastic implants
 - soft tissue changes associated with, 1232t
 - augmentation, 1438f
 - liposuction, 1412
 - poor esthetic results, 1241
 - ptosis, 1242, 1243f
- Chin cup, 1077f**
- Chinese gunpowder, 509**
- Chin-lift procedure, 330, 332f**
- Chin-neck anatomy, 1100**
- Chin point deviation**
- distraction, 1280f
- Chisel, 1248f**
- Chloral hydrate**
- children, 115
- Chlordiazepoxide**
- reduction in liver disease, 35
- Chlorhexidine**
- for alveolar osteitis, 151
- Cholesterol, 19**
- Chondrocytes, 934**
- Chondroitin**
- TMJ, 942
- Chondroma, 601, 602f**
- Chronic obstructive pulmonary disease (COPD), 29–30**
- Chronic renal disease**
- immunocompromised, 283
- Chuck changer, 242f**
- Chyle leak, 519f**
- Cicatricial pemphigoid, 690–691, 690f, 691f**
- Cigarette smoking, 300**
- involuntary exposure
 - risks of, 58
 - lip cancer, 659
 - perioperative effects of, 56–58
 - preoperative cessation of, 30
- Cilia, 297, 298f**
- Ciliary nerve, 1326**
- Cimetidine, 106**
- Cinch suture**
- alar base, 1237f
- Ciprofloxacin**
- for odontogenic infection, 289
- Circle of knowledge and caution, 1373–1374, 1375f**
- Circulation**
- trauma patient, 337–344
- Circumoral tissue**
- collapsed, 182f
- Circumvestibular incision, 1271, 1271f**
- intraoral mucosal, 534
- Cisatracurium**
- properties, 99t
- Cisplatin, 639, 640**
- Clarithromycin**
- for infectious endocarditis prophylaxis, 24t
 - for rhinosinusitis, 502
- Clavicle**
- bone formation in, 192–193
- Clear cell odontogenic carcinoma, 589**
- Cleft lip/palate, 839–855, 842f, 1206**
- bilateral repair, 847–849, 850f, 851f, 852f
 - bone graft reconstruction, 881
 - breast-feeding, 844
 - classification, 842, 843f
 - complex facial clefting, 853–855
 - dental and prosthetic rehabilitation, 883–884, 883f, 884f
 - embryology, 841
 - etiology, 841–842
 - feeding, 843–844
 - fistula closure, 872–875
 - indications for, 872–873
 - operative technique, 873–875, 873f, 874f
 - genetics, 841–842
 - historical perspective of, 840–841
 - incidence of, 1267
 - lip adhesion, 847
 - midfacial deficiency
 - orthognathic surgery, 881
 - nasal deformity reconstruction, 881–882
 - orthognathic surgery, 1267–1275
 - bone grafting with maxillary advancement, 1272–1273
 - presurgical counseling, 1270–1271
 - outcome, 855
 - prenatal counseling, 842–843
 - presurgical taping and orthopedics, 846–853
 - reconstruction stages, 871t
 - repair, 849–853
 - revisional surgery, 881–883
 - scar revision surgery, 882–883
 - secondary procedures, 871–884
 - staged reconstruction of, 845t
 - submucous, 880–881
 - treatment planning and timing, 844–846
 - unilateral repair, 847, 848f, 849f, 853f
 - velopharyngeal dysfunction, 875–880, 875f
 - complications, 879–880
 - operative technique, 878–879
 - timing, 877–878
 - Z-type repair, 849f
- Cleft maxilla/palate**
- bone grafting, 1269f
 - timing and sequencing, 1268–1269
- Cleidocranial dysplasia**
- multiple impacted teeth in, 132f
- Click-murmur syndrome, 69**
- Clindamycin**

- for infectious endocarditis prophylaxis, 24t
 - for sinus infection, 305
- Clinical and dental model diagnosis, 1111–1118
- Clinical diagnosis, 564
- Clinical examination, 565–566
- Clinical impression, 564
- Clinical neurosensory testing (CNT), 825–826, 826t
 - algorithm, 827f
- Clinician
 - neophyte *vs.* expert clinician case study, 567–568
- Clip overdenture retention
 - two-implant bar, 194f
- Clonidine
 - for hypertension, 32
 - for hypertensive crisis, 50t
 - for opioid withdrawal, 39–40
- Closed lock phenomenon, 990
- Closed pneumothorax, 333, 335f
- Closed reduction, 401
 - mandibular fracture, 413–414
- Closed technique
 - subepithelial connective tissue grafting implants
 - recipient-site surgery, 214–215, 215
- Cloverleaf skull anomaly, 925–926, 926f
- CNT, 825–826, 826t
 - algorithm, 827f
- Coaptation, 832–833
- Cobalt
 - effect on wound healing, 12
- COC, 582, 583f
- Cocaine, 40
 - anesthesia with, 121
- Coil springs, 1126f
- Cold
 - common, 299
- Cold therapy
 - for TMJ, 956
- Collateral (diskal) ligaments, 936
- Colonial America, 189
- Combes' formula, 1422t
- Commando's operation, 645
- Comminuted fractures, 409f, 410
 - grossly, 410
 - mandible
 - fixation, 375
- Commissure height, 1090
- Common cold, 299
- Competitive antagonists, 84
- Complete strip technique, 1362f
- Complex fractures, 410
- Compliance, 22
- Complicated fractures, 410
- Composite grafts, 719
- Compound fracture, 409–410, 409f
- Compression (Raney) clips, 483
- Compression plates, 372f, 378f
 - AO/ASIF, 402
 - osteosynthesis
 - vs.* noncompression plate osteosynthesis, 378
- Computed tomography (CT), 569
 - abdominal injuries, 352, 354t
 - ankylosis, 428f
 - asymmetric skull, 1209f
 - cervical lymph nodes, 647, 647f
 - cervical spine injuries, 351
 - condyle mechanical displacement, 1159
 - craniofacial dysostosis syndrome, 905
 - edentulous mandible, 194
 - facial asymmetry, 1209
 - frontal sinus
 - anterior table fractures, 499
 - posterior table fractures, 499
 - head trauma, 345, 346f
 - implants, 253, 270f
 - intracerebral hemorrhage, 346f
 - mandibular cancer, 645–646
 - mandibular fracture, 407
 - mandibular fragmentation
 - gunshot wounds, 520f
 - maxillary fractures, 439f
 - maxillary sinuses, 163f
 - NOE fracture, 496, 497f
 - oral cancer, 625, 625f
 - orbital fractures, 468, 470
 - OSA, 1301
 - osteomeatal complex, 303f
 - osteomyelitis, 315
 - panfacial fractures, 550–551, 550f, 551f
 - paranasal sinuses, 304f
 - pediatric craniomaxillofacial fractures, 529–530
 - preprosthetic and reconstructive surgery, 161
 - sinus infection, 302–303
 - subarachnoid hemorrhage, 346f
 - TMJ, 977f
 - zygomatic complex fractures, 447–448, 448, 449f, 450f, 454f
- Computer-databasing program, 1090f
- Computer-generated scanner, 1431
- Computerized cephalometric prediction, 1107–1108
- Concha bullosa, 298
- Conchal cartilage
 - autogenous, 1008
- Conchal hypertrophy, 1453
- Concussion, 391, 503
- Conduit nerve repair, 833f, 834t
- Condylectomy, 1009
- Condyles, 783–784
 - adenocarcinoma metastasizing to, 945
 - arthroplasty, 1003f
 - asymmetry
 - panoramic radiography of, 1208f
 - children, 529
 - classification of, 408
 - dislocation, 411f
 - fractures, 409, 1035f
 - abnormal growth from, 1208f
 - children
 - open reduction, 539
 - closed treatment, 382f
 - complications, 429–430
 - endoscopic management of, 421f
 - IMF, 415
 - mandibular hypoplasia, 427f
 - with midsymphysis fracture, 381
 - open reduction, 418–420
 - indications for, 419–420, 419t
 - panoramic films, 407, 407f
 - range of motion, 406
 - stabilization of, 422f–423f
 - surgery, 420
 - inappropriate positioning of, 1189f
 - mandible, 934f
 - mechanical displacement of, 1159
 - remodeling, 978f
 - resorption
 - idiopathic, 1291f
 - spontaneous resorption of, 1160
 - trauma, 1208
- Condylotomy, 1009
- Conformal radiation, 636–637
- Congenital agenesis
 - premaxilla, 1285
- Congenital anomalies, 1205, 1206–1207
 - altered anatomy in, 104
 - cleft lip/palate, 1206
 - congenital hemifacial hyperplasia, 1207
 - hemifacial microsomia, 1206, 1206f
 - plagiocephaly, 1206–1207
- Congenital hemifacial hyperplasia, 1207
- Congestive heart failure, 26, 67–68
 - decompensated, 50
 - ECG, 22
 - symptoms of, 22
- Connective tissue disorders, 36
 - implants, 252
- Conscious sedation, 93
- Contact sports, 383

- Contemporary orthognathic treatment
 planning, 1087–1088, 1088f
- Context-sensitive half-time, 85, 86f
- Continuous passive motion (CPM), 540
 device, 1044f
- Continuous positive airway pressure (CPAP)
 OSA, 1304
- Continuous wire loop technique, 415
- Contractility, 49
- Contusions, 360, 397
- Converse-Wood-Smith technique, 1452–1453
- COPD, 29–30
- Copper
 effect on wound healing, 12
- Cornea
 abrasions, 470f, 1402
 laceration, 472f
 reflex, 347
- Coronal forehead lift, 1395
- Coronal incision, 483, 497
- Coronal synostosis
 bilateral, 889
 craniofacial skeleton, 904f
 unilateral, 888–889
- Coronary artery disease, 18–22, 66–67
 echocardiography, 19
 history, 19
 left ventricular dysfunction, 22–23
 physical examination, 19
 postoperative ECG, 20–22
- Cor pulmonale, 73
- Corrugator supercillii, 1387, 1389f, 1392
- Cortical grafts, 165
- Corticosteroids, 62t
 for TMJ, 951–952
- Cortisol, 34
- Cortisporin
 for TMJ arthroscopy, 984
- Cosmetic surgery
 history of, 1317
- Cost
 gunshot wounds, 510
- C osteotomy, 1136, 1137f, 1146–1150
 different forms of, 1149f
- Costochondral grafts, 788–789
- Cottle elevator, 1357f
- Cover screws, 244f
- Cowley, R.A., 527
- COX-2. *See* Cyclooxygenase-2 (COX-2)
 inhibitors
- CPAP
 OSA, 1304
- CPM, 540
 device, 1044f
- Cranial base
 development of, 1060
 malformations, 1065–1066
 neonatal, 1061f
- Cranial bone grafts, 788, 788f, 789f, 790f
- Cranial nerves
 peripheral, 357
- Cranial nerve VII, 1325
 anatomy of, 1325f
 marginal mandibular branch of, 1139–1140
- Cranial onlay bone grafts
 maxilla, 263f
- Cranial vault, 897f
 development of, 1059–1060
 fractures
 children, 532
- Craniofacial defects
 maxillofacial prostheses, 268–269
- Craniofacial dysostosis syndrome
 airway, 902–903
 anthropometric surface measurements, 905
 Apert syndrome, 915
 brain growth, 901–902
 Carpenter syndrome, 923
 cephalometric analysis, 905
 cranial vault dead space, 906–907
 Crouzon syndrome, 907–915
 CT, 905
 dentition, 903
 extremities, 903
 frontoforehead esthetic unit, 903
 hearing, 903
 hydrocephalus, 902
 ICP, 901–902
 incision placement, 906
 intervention timing, 906
 maxillary-nasal base esthetic unit, 904
 morphologic considerations, 903
 occlusion, 903
 orbitonasozygomatic esthetic unit, 903–904
 Pfeiffer syndrome, 922–923
 posterior cranial vault esthetic unit, 903
 quantitative assessment, 904
 reconstruction staging, 901–927
 Saethre-Chatzen syndrome, 923–925
 soft tissue, 907
 surgery
 historic perspectives, 905–906
 vision, 902
- Craniofacial fibrous dysplasia, 597
- Craniofacial growth and development,
 1051–1080
 during adulthood, 1064
 dental development, 1063
 embryonic period, 1051–1056
 facial development, 1063–1064
 factors influencing, 1064–1070
 fetal period, 1056–1058
 orthodontic camouflage, 1079–1080
 orthopedic and orthodontic considerations,
 1070–1080
 postnatal, 1058–1064
 postnatal factors, 1068–1070
 prenatal factors, 1065–1068
 skeleton, 1058–1063
- Craniofacial malformations, 1065–1066
- Craniofacial skeleton
 growth and remodeling field of, 165f
- Craniomaxillofacial fractures
 children, 527–542
 complications, 531–532
 diagnosis of, 529–530
 epidemiology of, 530–532
 historic perspectives, 527–528
 mechanism of, 530t
 patterns of, 530, 532–542
 prevention of, 529
 by region, 530t, 531t
 treatment, 531t
- Craniosynostosis. *See* Nonsyndromic cranio-
 synostosis
- Crawford tube, 364, 365f, 503
- C-reactive protein (CRP), 314
- Creatinine, 77
- Creatinine clearance (CCR), 30
- Crestal incision, 242
 edentulous mandible, 194
 for mylohyoid ridge reduction, 171
- Cribiform plate, 465
- Cricothyroidotomy, 281, 516
- Cricothyrotomy
 children, 116
- Cromolyn sodium
 for asthma, 56
- Cross-hair incision, 996
- Cross-lip mucosal flaps, 662, 665f
- Crouzon syndrome, 104, 907–915, 909f
 and Le Fort III osteotomy, 527
 and Le Fort I osteotomy, 916f
 lower facial esthetic reconstruction,
 912–915
 management of, 905
 pediatric cranio-orbital procedure,
 910f–912f
 primary cranio-orbital decompression,
 907–908
 repeat craniotomy, 908–909
 total midface deformity, 909–912
- Crown
 fracture
 with pulp involvement, 389

- without pulp involvement, 388–389, 390f
 - height, 1090
 - infracture, 387
 - splints, 224
 - Crown-root fracture, 389
 - Crow's feet, 1329, 1401
 - CRP, 314
 - Crural excision, 1362f
 - Cryer, Matthew, 840
 - Cryer elevator, 146
 - Cryotherapy
 - for TMJ, 956
 - CSF
 - normal values of, 495t
 - CT. *See* Computed tomography (CT)
 - Culture
 - odontogenic infection, 286–287
 - Curve of Spee, 1107, 1126–1129, 1211
 - in maxillary arch, 1130
 - measurement for, 1107
 - and subapical osteotomy, 1128f
 - Curve of Wilson, 1115, 1115f
 - Curvilinear incision
 - partial-thickness, 213
 - Cushing's disease, 34
 - Cushing's phenomenon, 345
 - Cuspid-molar position, 1115f
 - Cutaneous horns, 698
 - Cutback incisions, 219
 - Cutting forceps
 - TMJ arthroscopy, 970
 - Cyclooxygenase-2 (COX-2) inhibitors, 641
 - end-stage TMJ disease, 1019
 - for rheumatoid arthritis, 36
 - for TMJ, 951
 - Cyclophosphamide, 682
 - Cyclosporine
 - for rheumatoid arthritis, 36
 - CYP-450, 85
 - Cystic fibrosis, 301–302
 - Cytochrome P-450 (CYP-450), 85
 - Cytokines
 - TMJ, 942
 - Cytomegalovirus, 686
- D
- Dacryocystorhinostomy, 364, 503–504
 - DalPont's modification of sagittal osteotomy, 1137f, 1153
 - Dantrolene, 38, 95
 - for malignant hyperthermia, 62–63
 - Database acquisition and treatment planning, 1087–1109
 - Data collection, 1088–1092
 - conventional records, 1088–1089
 - direct measurement, 1089–1090
 - Davis, Christopher, 964
 - Davis method, 1453–1454, 1453f, 1455f
 - Débridement, 795f
 - Deciduous teeth
 - impacted, 131
 - Decongestants, 502
 - Decortication, 1164f
 - Deep bite, 1095f
 - Deep heat
 - for TMJ, 956
 - Deep spaces
 - head and neck
 - borders of, 278t
 - infections, 279t
 - severity score for, 278
 - Deep temporal
 - infection, 279t
 - Deep vein thrombosis
 - oral cancer, 635
 - Defect fracture, 321f, 375
 - Definitive restoration, 237f
 - Deformities, 1205
 - Degenerative joint disease, 1208
 - Degree of dislocation, 408
 - Degree of displacement, 408
 - Delay, 710
 - Delayed union
 - mandible, 425–426, 1251
 - maxilla, 1250–1251
 - Delirium tremens, 635
 - Deltpectoral flap, 778
 - Dental arches, 548–549
 - Dental caries
 - prevention of, 141
 - Dental examination, 1105–1107
 - Dental follicle, 575
 - Dental fractures. *See* Alveolar and dental fractures
 - Dental implants
 - alveolar distraction osteogenesis, 1290–1293
 - history of, 189–190
 - Dental models
 - facial asymmetry, 1215f
 - Dental papilla, 575
 - Dental tissue injuries
 - diagram of, 388f
 - DentaScan software, 645–646
 - Dentate patients
 - intermaxillary techniques in, 415–417
 - Dentigerous cyst, 576–578, 577f, 578f
 - vs. enlarged dental follicle, 577
 - prognosis, 577–578
 - treatment, 577–578
- Dentition
 - craniofacial dysostosis syndrome, 903
- Dentoalveolar fracture, 409
- Dentoalveolar injuries, 383–399, 384f
 - adolescents, 383–384
 - children, 383–384, 397–398, 398t, 541–542
 - classification of, 387–388
 - etiology of, 383–384
 - hard tissue and pulp, 387–397
 - historic perspectives of, 383
 - incidence of, 383–384
 - maxillofacial examination, 384–386
 - patient history, 384
 - physical examination, 384
 - radiographic examination, 386–387
- Dentoalveolar trauma record, 386, 386f
- Dentofacial deformity
 - macroesthetic examination of, 1092–1102
 - miniesthetic examination of, 1102–1104
 - systematic clinical examination of, 1092–1107
- Dentures
 - bar-retained, 264f
 - conditioning material, 245f
 - fixed partial, 236f, 258
 - hybrid
 - implant, 254
 - mandibular hybrid, 265f
- Denture-sore mouth, 680
- Depression, 38, 1298
- Depressor muscle, 1394f, 1398f
- Depressors, 1385–1386
- Depressor supercillii, 1387
- Depth gauge, 242f
- Dermaabrasion
 - full-face, 1432f
 - motorized, 1430–1432, 1431t
- Dermal fat grafts, 1414, 1414f
- Dermal graft, 1004f, 1006
- Dermal substitutes
 - wound healing, 13–14
- Derma sanding
 - manual, 1429–1430, 1430f, 1430t
- Dermatofibrosarcoma protuberans, 697
- Dermis, 709
- Desflurane, 95
 - chemical structure of, 96f
 - children, 115
 - pharmacology of, 97
- Desmoplastic fibroma, 602f, 603f
- Developmental anomalies, 1205, 1207
 - intrinsic jaw-growth deformities, 1207
 - secondary growth deformities, 1207
- Deviated septum, 1256f

- Dexamethasone, 100
 impacted teeth removal, 149
- Diabetes, 281, 282, 424
 effect on wound healing, 10
 implants, 252
- Diabetes insipidus, 607
- Diabetes mellitus, 32–33, 59–61, 76–77
 insulin, 60
 type 2, 33
 diet only, 60
 oral hypoglycemic agents, 60
- Diabetic ketoacidosis (DKA), 32, 77
- Diagnostic list, 1118
- Diagnostic peritoneal lavage (DPL), 352, 354t
- Diagnostic process, 564–566, 564f
- Diamond fraise, 1430
- Diastolic decompensation, 23
- Diazepam
 chemical structure of, 86f
 end-stage TMJ disease, 1022
 with ketamine, 111
 pharmacology of, 86–87
 reduction in liver disease, 35
- Diazoxide
 for hypertensive crisis, 50t
- Diet
 TMJ, 950
- Dietary supplements
 determining preoperative risk, 17–18
- Differential diagnosis
 developing, 566–568
 to final diagnosis
 case study, 564
 microscopic, 571–572
- Differential osteotomy
 knife-edge ridges, 1294f
- Digital videography, 1092, 1093f
- Digoxin
 for congestive heart failure, 22–23, 26
- Dingman, Reed, 840
- Diplopia, 468, 474–475, 503, 1330
 lower eyelid blepharoplasty, 1341
 persistent posttraumatic, 474
 upper eyelid blepharoplasty, 1340
 zygomatic arch fractures, 458–459, 458f, 459f
- Dipyridamole
 for cerebrovascular disease, 37
- Direct bone healing, 6, 7f
- Direct bone union, 371
- Direct brow lift, 1400
- Direct fixation, 401
- Direct fracture, 409f
- Direct wiring, 415
- Discoid lupus erythematosus (DLE), 691f
- Disk
 horizontal incision, 996
 partial displacement, 1000f, 1001f
- Diskal ligaments, 936
- Disk dancing, 1279, 1279f
- Dislocated fracture, 410
- Displaced fracture, 410
- Displaced tooth, 1115f
- Displaced zygomatic complex
 elderly, 486f–487f
- Displacements, 391
- Dissector, 1368f
- Distal root
 overdevelopment of, 140
- Distoangular impaction, 143
 bone removal, 146
 removal of, 148f
- Distoangular teeth
 eruption, 140
- Distraction approach, 906
- Distraction devices
 disadvantages of, 1292
- Distraction osteogenesis, 1277–1294, 1293f
 alveolar, 183–185, 230–231
 dental implants, 1290–1293
 bony edge separation, 1277f
 complications of, 1293–1294
 mandibular symphysis, 1124–1125, 1125f
 mandibular widening, 1280–1281
 protocol, 1278t
 and regenerate chamber, 1278f, 1279f
 simultaneous maxillary and mandibular, 1281–1282
 soft tissue changes associated with, 1233, 1234t
 transport, 1286–1289, 1289f
 neocondyle, 1289–1290
- Distractor, 1281f
- DKA, 32, 77
- DLE, 691f
- Dog bites, 362
- Dog-ears, 715f
- Doll's eye reflex, 347, 347f
- Donor tissue
 soft tissue grafts, 209
- Dorsal hump
 removal of, 1358f
- Dorsal nasal artery, 1346
- Dorsal reduction, 1359f
- Double advancement flap, 771f
- Double-ring sign, 533
- Double vision, 469f
- Double V-Y closure, 1239–1241, 1242f
- Down syndrome, 74, 1066
 anesthesia with, 119–120
- Doxacurium
 properties, 99t
- DPL, 352, 354t
- Draining sinus tract, 292f
- Dressing plate, 613f
- Drug dependence, 1298
- Dry eye
 upper eyelid blepharoplasty, 1340
- Dry socket. *See* Alveolar osteitis
- D-tubocurarine
 properties, 99t
- Dual-incision approach
 subepithelial connective tissue graft
 harvesting, 212–213, 214
 subepithelial connective tissue grafting, 213f
- Dual-suture alar cinch technique, 1239f
- Duchenne's disease
 anesthesia with, 120
- Duchenne's muscular dystrophy, 1207
- Dufourtmental flap, 714–716
- Duke University Activity Status Index, 70, 71t
- Dying patient
 avoidance of, 652–653
- Dynamic sphincter pharyngoplasty, 878
- Dysplastic nevi, 683
- E
- Ear, 1451. *See also* Protruding ear
 avulsive injuries, 368f
 blood supply, 1450–1451, 1452f
 defect conversion, 367f
 deformities, 1451–1452
 development of, 1450f
 embryology of, 1449
 hematomas, 365–366
 injuries, 365–366, 366f
 nerve supply, 1451
 osseointegration implants, 368f
 surgical anatomy of, 1449–1450
- Earlobe
 protruding
 correction of, 1456
- EB. *See* Epidermolysis bullosa (EB)
- EBV, 686, 688
- Ecchymosis, 405f, 437, 447, 494, 685
 upper eyelid blepharoplasty, 1340
- Economically disadvantaged
 maxillofacial trauma, 384
- Ecstasy
 anesthesia with, 121–123
- Ectodermal dysplasia, 238f
- Edentulism
 functional effects of, 158–159
- Edentulous fractures
 mandibular fracture, 423–425

- Edentulous mandible, 193–197
 flap design for implant placement, 207f
 incision design, 194
 osseointegration, 193–197
 physical examination, 194
 prepared for bone graft, 224f
 radiologic examination, 194
 simultaneous gingival grafting, 212f
- Edentulous maxilla, 197–199, 197f, 226f–227f, 228f
 atrophy, 236f
 flap design for implant placement, 207f
 Parel's classification of, 197
 with severe atrophy, 232f
- Edentulous patients
 alveolar bone characteristics, 157–158
 closed reduction, 417
- Edentulous restorations, 263–264
 FDP, 265–266
 implant-retained overdentures, 263–264
 implant-supported overdentures, 264–265
- Edinger-Westphal nucleus, 347
- EDTA, 944
- Eight-ball hyphema, 472–473
- Elastic fibers, 709
- Elderly, 40–42
 displaced zygomatic complex, 486f–487f
 drug modifications in, 41–42
 hypertension, 49
 impacted teeth, 142–143, 144, 149
 maxillary fractures, 441
 orbital injuries, 481
 wound healing, 12
- Elective lymph node dissection, 667
- Elective neck dissection (END), 647, 648
 vs. elective neck irradiation, 650
- Electric drill, 145
- Electrolytes and acid-base disturbances, 53–54
- Electrometric test, 386
- Elevators, 1385–1386
 Buser periosteal, 213, 218
 Cottle, 1357f
 Cryer, 146
 J-shaped, 1438, 1438f
 curved hook, 450
 periosteal, 866, 1387f
 TMJ arthroscopy, 970, 971f
- Elevator technique, 136
- Elliptic incision
 for frenum attachment excision, 173
- Ellis classification, 387, 387f
- Ellis technique, 423f
- Embryo, 1052f
 amnion, 1053f
 lateral view, 1053f
 scanning electron micrograph, 1055f
- Emergence delirium, 93
- Emergency treatment on full stomach
 children, 106
- Eminectomy, 1046
- Emphysema, 73
- Enalaprilat
 for hypertension, 32
 for hypertensive crisis, 50t
- Enamel fractures, 387
- Enamel organ, 575, 575f
- END, 647, 648
 vs. elective neck irradiation, 650
- Endocarditis
 cardiac conditions associated with, 23t
 prophylaxis if, 24t
- Endochondral bones
 formation of, 192–193
- Endocrine disorders, 32–34, 59–61, 74–77
 diabetes, 281, 282, 424
 effect on wound healing, 10
 implants, 252
 diabetes insipidus, 607
 diabetes mellitus, 32–33, 59–61, 76–77
 insulin, 60
 type 2, 33, 60
 hyperglycemia, 60–61
 hypoglycemia, 60–61
 thyroid disorders, 33–34
- Endonasal rhinoplasty
 surgical sequence for, 1356t
- Endoscopic lens system
 TMJ
 arthroscopy, 970f
- Endoscopy
 sinus infection, 302–303
 complications of, 309
- Endosseous implants, 191–192, 270f
 long-term
 first, 189
- Endotracheal intubation
 children, 104
 for flail chest, 337
- Endotracheal tube stabilizer pad, 980f
- End-stage renal disease (ESRD), 31, 77
- End-to-side anastomosis, 805f
- Enflurane
 avoided with renal patients, 31
 chemical structure of, 96f
- England, 189
- Enophthalmos, 468, 479
 zygomatic arch fractures, 457–458, 458f
- Entubulation (conduit) nerve repair, 833f, 834t
- Entubulation techniques, 833–834
- Envelope flap, 144, 146f
- Envelope incision, 144, 145f
- Environment
 craniofacial growth and development, 1068–1070
 craniofacial malformations, 1066–1068
- Enzyme induction, 85
- Ephelides, 683
- Epidermis, 709
- Epidermodysplasia verruciformis, 698
- Epidermolysis bullosa (EB), 685–686
 atrophicans generalisata gravis Herlitz type, 686
 bullosa acquisita, 686
 Cockayne-Touraine type, 686
 dystrophica Hallopeau-Siemens, 686
 simplex Koebner type, 686
- Epidural hemorrhage, 345f
- Epilepsy, 78
- Epinephrine, 95, 338, 340
 for arrhythmias, 52
 for blepharoplasty, 1331
- Epiphora, 364, 1263, 1327
- Epistat, 438
- Epistaxis, 437
- Epithelialized palatal graft technique
 implants, 210–111
- Epstein-Barr virus (EBV), 686, 688
- ePTFE, 223
- Erich arch bars, 415f
- Erythema multiforme, 693–694, 694f
- Erythematous lesions, 685–686
- Erythrocyte sedimentation rate (ESR), 314
- Erythromycin
 for COPD, 30
- Erythroplakia, 618, 619, 619f
- Esmolol
 for hypertensive crisis, 50t
- Esophagoscopy, 624
 vs. barium swallow
 for neck gunshot injuries, 518
- ESR, 314
- ESRD, 31, 77
- Essential hypertension, 31–32, 37
- Esthetic facial augmentation
 alloplastic, 1435–1447
- Esthetic flaps, 710
- Esthetic implants
 flaps, 207f
- Esthetic ridge defect
 large-volume combination hard and soft
 tissue
 reconstruction of, 219f
- Esthetic tooth wax-up, 200
- Estlander flap, 664

- Etanercept
for rheumatoid arthritis, 36
- Ethanol, 35
- Ethmoid bone, 437, 465
- Ethmoid bulla
anatomy and physiology of, 297
- Ethmoid fracture, 535f
- Ethmoid sinus, 494f
anatomy and physiology of, 297
- Ethylenediaminetetraacetic acid (EDTA), 944
- Etomidate
chemical structure of, 92f
pharmacology of, 92
- Exarticulations, 393–394
- Excisional biopsy, 570, 704
- Exercise therapy
for TMJ, 954–955
- Exercise tolerance
assessment of, 70–71
determining preoperative risk, 17
- Exfoliative cytology, 569–570
- Exophthalmos, 468, 495, 607
- Exostoses, 169
- Expanded polytetrafluoroethylene (ePTFE), 223
- Extended neck dissection, 649
- External auditory canal
sectioned, 995f
- External ballistics, 510
- External ear
anatomy of, 1451f
- External fixator, 796f
- External neurolysis, 830–831
- External pin fixation, 416
- External rhinoplasty
surgical sequence for, 1356t
- Extraction
vs. nonextraction, 1130
- Extraction wounds, 7–8
- Extraoral inverted L osteotomy, 1147f, 1148f
- Extraoral vertical subcondylar osteotomy, 1145f
- Extraosseous devices, 184–185
- Extravasated blood
lesions, 685
- Extravasation
with TMJ arthroscopy, 984–985
- Extremities
craniofacial dysostosis syndrome, 903
examination of
in trauma patient, 353–354
- Extrusive luxation, 392
- Eyebrows
anatomy, 1318
examination of, 1328
- fat pad, 1318
- female position, 1318f
- male position, 1318f
- reconstruction of, 363
- Eyelids. *See also* Lower eyelids; Upper eyelids
aging skin changes, 1319
- arteries, 1324
- avulsive injuries of, 362f
- cheek contour, 1318
- connective tissue, 1321
- crease reformation, 1332–1334
- cross-section, 1319f
- fat pads, 1323
- innervation, 1325–1326
- laceration, 470f, 475, 476f
- layers of, 466t
- lymphatics, 1324–1325
- musculature, 1322–1323
- normal position of, 1320f
- reconstruction
history of, 1317
- resection of, 364f
- skin thickness, 1319
- soft tissue injuries, 364–365
- surgical repair of, 364f
- topography, 1319–1320
- vasculature, 1324
- veins, 1324
- Eyes
adnexa, 1319–1326
- examination of, 447
- injuries, 471–476
- sagittal view of, 455f
- surface evaluation, 1330
- F
- Face
asymmetry, 412f
- bones, 192–193
- and reconstruction, 164
- buttresses, 547–548
- developing, 1054f
- esthetic augmentation
alloplastic, 1435–1447
- examination of, 404–405
- expression muscles, 445
- fractures
evaluation of, 405
- frontal view of, 1057f
- gunshot wounds, 363, 363f
blind clamping, 516f
- hemiatrophy, 1207, 1207f
- horizontal buttresses of, 548f
- liposuction
postoperative instructions, 1418
- lower
for macroesthetic examination, 1100, 1101
- macroesthetic examination, 1100, 1101
- profiles, 1101
Dedo classification of, 1367f, 1367t
- prosthesis, 270f
- scars, 1263
- skeleton
surgical approach to, 551, 551f
- trauma
children, 540f
psychosocial issues, 384
- vertical buttresses of, 548f
- wounds, 357
grazing gunshot, 523f
- Face-bow transfer, 1215f
- Face lift
dressing, 1373f
skin incision, 1376f
- Facemask, 1078f
- Facial artery, 1346, 1389
- Facial asymmetry, 1205–1217, 1267
acquired, 1208
condylar trauma, 1208
degenerative joint disease, 1208
juvenile idiopathic arthritis, 1208
- basal view, 1214f
- clinical assessment of, 1208–1209
- delayed treatment, 1210
- etiology, 1205
- frontal view, 1217f
- lateral and frontal view, 1216f
- midface deficiency, 1213f
- orthodontic considerations, 1210–1212
- radiography, 1209
- surgery, 1209–1216
techniques, 1212–1216
- TMJ function, 1210
- Facial nerve, 357, 483, 992, 1325, 1390
anatomy of, 358f
zone of arborization, 358f
- gunshot wound, 522
- landmarks, 993f
- Facial primordia
development of, 1053–1054
- Falls, 383, 530
- Familial gigantiform cementoma, 599
- Fasting, 105–106
- Fat debulking, 1332
- Fat embolism syndrome, 341f, 354
- Fat grafts, 1401
abdominal
harvest of, 501, 501f
- dermal, 1414, 1414f

- Fat injection
autologous, 1413–1414, 1414f
- Fat pads, 1322f
- Fat transfer
autologous, 1412–1415
complications, 1414–1415
- Femur
fracture of, 341f, 353
- Fenoldopam
for hypertensive crisis, 50t
- Fentanyl
chemical structure of, 88f
children, 115
end-stage TMJ disease, 1022
pharmacology of, 88–89
- Fernandez technique, 423f
- Fetus
changing body proportions, 1059f
- FEV1, 56f
- Fever
odontogenic infection, 283, 287–288
with osteomyelitis, 314
- FFP, 343
- Fiberoptic laryngoscopy
children, 528
- Fiberoptic nasal examination, 295
- Fibrin clots, 8
- Fibroblasts, 5, 786
- Fibroma
mandible, 313f
- Fibromyalgia, 941
- Fibro-osseous disease
benign, 597–600
cemento-osseous dysplasia, 598–599
fibrous dysplasia, 597–598
- Fibro-osseous neoplasms
juvenile aggressive ossifying fibroma, 600
ossifying fibroma, 599–600
- Fibrous dysplasia, 597–598, 597f, 598f
- Fibrous inflammatory hyperplasia, 172
- Fibular grafts, 268
- Field of vision
TMJ
arthroscopy, 970f
- Figure-eight alar cinch suture technique, 1238f
- Figure-of-eight wire, 421, 424f
- Final diagnosis
determining, 568–569
- Fine-needle aspiration biopsy (FNAB), 570, 704
parotid gland tumors, 672
- Firearms
terminology of, 512–514
- First molars
progressive soft tissue recession, 212f
- Fissure bur, 146f, 242, 242f
- Fistulas, 1252–1253
residual oronasal, 1271
- Fitzpatrick skin types, 697, 698t
- Fixed crown-and-bridge restoration, 197, 197f, 198
- Fixed partial denture (FPD), 236f, 258, 260–263, 263, 263f
anterior mandible, 262
cantilevered, 263, 263f
esthetic zone, 261–262
extension of, 265
mandibular, 268f
posterior mandible, 262–263
posterior maxilla, 262
- Flail chest, 332, 335–336, 336f
- Flaps, 710–711. *See also* specific flaps
blood supply, 770
complications, 780–781
configuration, 770
design, 712–716, 771–772
implants, 205–208, 206f, 207f
lateral advancement, 208, 208f
location, 770
necrosis, 709
nomenclature, 770–771
principles, 769–771
superiorly based, 779f
tissue content, 770
transfer method, 770–771
types of, 772–780
undermining, 712
- Flavopiridol, 640
- Flexor
abnormal activity, 346
- Floating forehead technique, 905
- Floating teeth, 607, 608f
- Floor of mouth
cancer, 621–622, 622f, 644
examination of, 406
lowering procedures, 175, 179f
squamous cell carcinoma, 644f
- Florid cemento-osseous dysplasia, 599, 599f
- Fluctuance, 280
- Fluid
management
oral cancer, 635
requirements in children, 42t
- Flumazenil, 86
chemical structure of, 86f
pharmacology of, 87
- Fluorescein dye, 470, 499
- Fluoroquinolone
for rhinosinusitis, 305
- 5-fluorouracil, 639, 640
- Fluoxetine (Prozac)
TMJ, 953
- FNAB, 570, 704
parotid gland tumors, 672
- Focal cemento-osseous dysplasia, 599
- Foley catheter
contraindications for in trauma patients, 343f
- Follicular sac
dentigerous cyst in, 141
odontogenic tumor in, 141
- Fontana-Masson stain, 683–684
- Fontanelles
neonatal skull, 1060f
- Forced expiratory volume in 1 second (FEV1), 56f
- Forced vital capacity (FVC), 56f
- Forceps, 308f
- Forehead, 1383–1403
anatomy, 1318, 1384–1389
bony landmarks, 1384–1389
endoscopic view, 1390f, 1391–1393, 1391f
esthetic considerations, 1384–1389
flaps, 774
lift
complications, 1402–1403
endoscopic, 1396–1400, 1396f
postoperative care, 1402
skin care and micropigmentation, 1401–1402
muscle and fascial anatomy, 1385–1386
positions, 1383f
preoperative evaluation, 1393–1395
soft tissue injuries, 363–364
vessel and nerve anatomy, 1389–1391
youthful, 1384
- FPD, 263, 263f. *See also* Fixed partial denture (FPD)
extension of, 265
- Fractionation, 636
- Fractured teeth
assessment of, 385
- Fracture lines, 408
- Fractures. *See also* specific fractures
bone healing after, 6
- Frank-Starling curve, 24
- FRC
children, 104
- Free autogenous grafts, 786t
- Free fibula flap, 811–814, 814f
anatomic considerations, 811–813, 811f
elevation, 813f
morbidity following, 813–814
technique, 812–813
- Free flaps. *See also* Radial forearm free flaps
iliac crest osteomyocutaneous, 814–815

- microvascular, 792
- radial forearm, 804–811
- Free gingival grafts, 210
- Free tissue transfer
 - head and neck, 803
 - versatility of, 815–816
- Frenectomy, 172–174
- Frenum attachments
 - excision of, 173, 173f, 174f
 - exposure of, 173f
 - wide-based, 174
- Fresh frozen plasma (FFP), 343
- Frey's syndrome, 1263
- Fricke, Johann Karl George, 1317
- Frontal bone, 491, 492f, 1384
 - fracture, 535f
 - injuries
 - complications of, 503
 - ossification of, 491
 - osteology of, 492–493
 - posttraumatic deformity correction, 504–505
- Frontalis muscle, 1318, 1385–1386, 1387f
- Frontal recess
 - anatomy and physiology of, 297
- Frontal sinus, 492f, 494f
 - anatomy and physiology of, 491–494
 - anterior table fractures, 499
 - depressed injury, 495
 - development of, 491
 - embryology of, 491
 - fractures, 495f
 - children, 532–534
 - classification of, 496–497
 - clinical findings, 494–497
 - patient evaluation, 494–497
 - surgery, 497–502
 - neovascular structures, 493
 - osteology of, 492f
 - physiology of, 491–492
 - posterior table fractures, 499–500
- Frontoforehead esthetic unit
 - craniofacial dysostosis syndrome, 903
- Frown lines
 - glabella, 1389f
- Frozen section specimens, 634f
- Full-arch ceramometal restoration, 265, 266f
- Full histologic periosteal refixation, 1399
- Full-jacketed bullet, 514f
- Full-metal jacket, 514
- Full-thickness mucoperiosteal buccal flaps, 866
- Full-thickness skin grafts, 8, 717–718
- Functional appliances, 1075f
- Functionally stable fixation, 371–372, 373
- Functional matrix concept, 164
- Functional residual capacity (FRC)
 - children, 104
- Fungal balls
 - maxillary sinus, 303f
- Fungal disease
 - oral cavity, 680–681
- Fungal sinusitis, 303–304
- Furlow double opposing Z-plasty procedure, 876
- Furnas technique, 1452
- Furosemide
 - for congestive heart failure, 22
- Fusobacterium*, 140, 288
- FVC, 56f
- G
- GABAergics, 1024
- Gabapentin
 - for seizure disorders, 37
- GABA receptor, 84
- Galeal tissue, 1399
- Galen, 383
- Gamma-aminobutyric acid (GABA)
 - receptor, 84
- Ganglion cysts
 - TMJ, 945
- Gap arthroplasty, 1038, 1290f
- Gastritis, 35
- Gastroesophageal reflux disease (GERD), 300, 1298
- Gauge, 512
- GCS. *See* Glasgow Coma Scale (GCS)
- General anesthesia
 - risk after myocardial infarction, 20
- Gene therapy
 - wound healing, 13
- Genetics
 - craniofacial growth and development, 1068
 - craniofacial malformations, 1065–1066
- Genial advancement
 - with hyoid myotomy and suspension
 - OSA, 1307–1308
 - OSA, 1307
- Genial segment surgical procedures
 - anterior repositioning, 1229–1232
 - posterior repositioning, 1232–1233
 - soft tissue changes associated with, 1229–1233
 - vertical repositioning, 1233
- Genial tubercle
 - advancement, 1307f
 - reduction, 169–170
- Genioglossus attachment, 175
- Genioglossus muscle, 169
- Genioplasty
 - advancement
 - soft tissue changes associated with, 1232t
 - reduction
 - soft tissue changes associated with, 1233t
 - setback
 - soft tissue changes associated with, 1233t
- Genitourinary tract
 - examination of
 - in trauma patient, 353
- GERD, 300, 1298
- Geriatric patients. *See* Elderly
- German measles, 689
- Germinated tooth, 136f
- Germ layer formation, 1051
- GFR, 30
- Ghost cell tumor
 - malignant epithelial odontogenic, 589
- Giant cell granuloma
 - central, 603–605, 603f, 604f
- Giant cell tumor, 604
- Gilles's approach, 451f
- Gillies, H., 527
- Gillies and Harrison total midface advancement, 527
- Gingiva
 - examination of, 406
 - excess display on smile, 1102–1103, 1103f
 - grafts
 - dental implants, 210–211, 210f
 - indications for, 211
 - edentulous mandibular site, 212f
 - melanin pigmentation
 - smoking, 682
 - squamous cell carcinoma, 644–645
 - trauma
 - treatment, 396–397
- Ginglymoarthrodial, 933
- Ginglymoid, 933
- Glabella
 - crease, 1393
 - frown lines, 1389f
 - lacerations, 494
 - vertical rhytids, 1398
- Glargine
 - onset, peak and duration, 61t
- Glasgow Coma Scale (GCS), 78, 78t, 329t
 - development of, 328
 - for grading consciousness, 346
 - and head injuries, 348
- Glenoid fossa
 - coronal section, 992f
 - horizontal incision, 996
- Gliding hole, 379
- Globes

- evaluation of, 468
- penetrating injury, 472
- perforated, 516f
- Globulomaxillary lesion, 608, 609f
- Glogau's classification
 - photoaging, 1419, 1419t
- Glomerular filtration rate (GFR), 30
- Glossectomy, 643
- Glucocorticoids
 - for asthma, 56
 - for rheumatoid arthritis, 36
 - for TMJ, 951
- Gluconeogenesis, 35
- Glutamine, 12
- Glycogen storage, 35
- Glycolic acid, 1341
 - resorbable plating system, 441–442
- Glycopyrrolate, 99, 106
 - with ketamine, 111
- Goiter, 76
- Goldenhar's syndrome, 74, 104
- Goldman Index, 66
- Gold salts
 - for rheumatoid arthritis, 36
- Gold wire splinting
 - Lebanon, 383f
- Gompertzian kinetics, 638
- Gonial arc, 1140f
- Gonorrhea, 682
- Goode method, 1353, 1353f
- Gorham's disease, 612, 612f
- Gorlin's syndrome, 698
- Grafts, 710. *See also* specific graft
- Granulation tissue, 5
- Grasping forceps
 - TMJ arthroscopy, 970
- Graves' disease, 76
- Grayson nasoalveolar molding appliance, 846f
- Greater auricular nerve, 1371f
 - cable graft, 833f
- Greenstick fracture, 410
- Grossly comminuted fractures, 410
- Ground substance, 709, 934, 935
- Group A Coxsackievirus, 688
- Growth
 - factors
 - effect on wound healing, 12–13
 - mandibular fracture, 426
 - modification
 - orthopedic treatment for, 1070–1079
- Growth deformities
 - secondary, 1207
- Guided bone grafts
 - augmentation, 223
- Gullwing incision, 497
- Gummy smile, 1097f
- Gunning's splints, 440–441, 441
- Gunshot wounds, 509–524
 - bone grafting, 523–524
 - classification of, 514–515
 - closed vs. open management, 522–527
 - contamination, 522
 - cost, 510
 - delayed vs. early management, 522–527
 - demographics, 509–510
 - face, 363, 363f
 - blind clamping, 516f
 - hemorrhage, 516–517
 - history, 509
 - incidence, 509–510
 - late reconstruction, 524
 - mandible, 795f
 - mouth, 521f
 - neck, 517–519
 - decision tree, 519f
 - surgery, 520–522
 - treatment, 515–522
- Gustatory sweating, 1263
- H
- Haemophilus influenzae*, 300, 305
 - TMJ, 944
- Hageman factor, 4
- Hairy leukoplakia, 689
- Haller cell, 298
- Halothane, 95f
 - for asthma, 56
 - chemical structure of, 96f
 - children, 114
 - pharmacology of, 93, 96
- Hamartomatous fibro-osseous disease, 597
- Handguns, 512
- Hank's balanced salt solution, 393, 393f
- Hard palate
 - cancer, 622, 622f
- Hardy, Michael, 964
- Harness restraints, 529
- Haversian remodeling, 371
- Head
 - assessment of
 - in trauma patient, 345–346
 - examination of, 357
- Headache, 1299
 - frontal sinus, 503
- Head and neck
 - assessment
 - odontogenic infection, 277–278
 - cancer, 697–720
 - inoperable, 652
 - survival, 652
 - treatment failure, 652
 - deep spaces of
 - borders of, 278t
 - infections, 279t
 - severity score for, 278, 280t
 - free tissue transfer, 803
 - infections of
 - drainage of, 285f
 - radiation
 - implants, 252
- Headgear, 1074f, 1076f, 1078f
- Healing by secondary intention, 710–711
- Hearing
 - craniofacial dysostosis syndrome, 903
- Heart
 - age-related changes, 41
 - of infants, 42
- Heart blocks, 27–28
- Heat therapy
 - for TMJ, 956
- Hemangioendothelioma
 - salivary gland, 672
- Hemangiomas, 684
- Hematomas, 685
 - in bone healing, 6
 - cervicofacial liposuction, 1411
 - ear, 365–366
 - flaps, 780
 - maxillary fractures, 442
 - nasal septum, 364
 - protruding ear, 1457
 - upper eyelid blepharoplasty, 1340
 - in wound healing, 10
- Hematuria, 353
- Hemifacial hyperplasia
 - congenital, 1207
- Hemifacial microsomia, 104, 1206, 1206f
- Hemimandibular hyperplasia/elongation, 1207
- Hemorrhage. *See* Bleeding
- Hemostasis, 10, 357
- Hemothorax, 334–335
- Hemotympanum, 346
- Heparin
 - DVT, 635
 - in spinal cord disorders, 38
- Hepatitis, 35
- Hepatitis A, 35
- Hepatitis B, 35
- Hepatitis C, 35
- Hepatogastrointestinal disorders, 34–36
 - liver disease, 34–35
 - peptic ulcer disease, 35–37
- Herbal supplements
 - determining preoperative risk, 18
- Herbst appliance, 1303

- Hereditary diseases, 685–686
- Herpes
 cytology, 687f
 Herpes simplex infection, 1432
 Herpes simplex virus (HSV), 686
 Herpes zoster, 688f
 Herpetic
 gingivostomatitis, 686f
 Herpetic gingivostomatitis, 686f
 Herpetic whitlow, 687, 687f
 Hertwig's root sheath, 575
 Hexed implant, 256f
 High-flow vascular malformation, 606f, 607f
 High-velocity accident, 350
 High-voltage stimulation
 for TMJ, 956
- Hilum
 calcified stone
 sialogram, 675f
 stones, 675–676
- Hippocrates, 383
- Hirudo medicinalis*, 780
- Histamine antagonists
 children, 117
- HIV. *See* Human immunodeficiency virus (HIV)
- Hofer's subapical osteotomy, 1138f
- Holmium:YAG (HO:YAG) lasers
 TMJ arthroscopy, 971
- Hooding, 1393
- Hooked probe
 TMJ arthroscopy, 970
- Horizontal glabellar lines, 1398
- Horizontal impaction, 143, 147f
 bone removal, 145–146
- Horizontal osteotomy
 for horizontal chin deficiency, 1172f
 for horizontal chin excess, 1171f
 of the symphysis, 1168–1173, 1168f
 complications, 1173
 indications for, 1168
 technique, 1168–1173
 various forms of, 1169f–1170f
- Horizontal osteotomy of vertical ramus
 Blair's, 1135, 1136f
- Horizontal ramus
 sagittal osteotomy, 1164
- Horizontal tightening, 1335
- Hoshino, Kazumasa, 964
- Hospice, 653
- HO:YAG lasers
 TMJ arthroscopy, 971
- HPV
 squamous cell carcinoma, 617
- HSV, 686
- Hullihen's mandibular subapical osteotomy,
 1135, 1135f
- Human bites, 362
- Human immunodeficiency virus (HIV),
 11, 689
 immunocompromised, 283
 implants, 252
- Human papilloma virus (HPV)
 squamous cell carcinoma, 617
- Hunsuck modification, 1254
- Hyaluronidase
 for blepharoplasty, 1331
- Hybrid dentures
 implant, 254
- Hydantoin, 682
- Hydralazine, 691
- Hydration
 for fever, 287
- Hydrocephalus
 craniofacial dysostosis syndrome, 902
- Hydrocodone
 for TMJ, 951
- Hydrogen peroxide, 360
- Hydroxy acids, 1421
- Hydroxychloroquine
 for rheumatoid arthritis, 36
- Hydroxylapatite coatings
 implants, 190, 192
- Hyoid myotomy, 1308f
- Hyoid suspension, 1308
- Hyperbaric oxygen therapy
 flaps, 780–781
 implants, 252
 jaws, 794
 odontogenic infection, 281
 osteomyelitis, 317
 osteoradionecrosis, 320
 wound healing, 11–12
- Hyperdivergent faces, 1211
- Hyperfractionation, 636
- Hyperglycemia, 60–61, 77, 344
 effect on wound healing, 10
- Hyperkalemia, 31
- Hypermobility tissue, 172
- Hyperparathyroidism, 603, 604, 605f
- Hyperpigmentation, 1425f
- Hypersomnolence, 1298
- Hypersplenism, 35
- Hypertension, 31–32, 49, 1299
 African Americans, 49
 with bradycardia, 345
 elderly, 49
 essential, 31–32, 37
 and preoperative patient assessment, 69–70
 risk factors for, 70
- Hypertensive crisis
 medications for, 50t
- Hypertensive urgency, 49
- Hyperthyroidism, 33–34, 61–62, 76
- Hypertrophic cardiomyopathy, 69
- Hypertrophic scars, 9, 359
 protruding ear, 1458
- Hypertrophic subaortic stenosis
 idiopathic, 69
- Hyphema, 470, 472, 473f
- Hypnagogic hallucinations, 1298
- Hypodivergent faces, 1211
- Hypoglycemia, 59, 60–61, 344
- Hypokalemia, 53
- Hypo-ophthalmos, 479
- Hypopnea, 58
- Hypotension, 70
 with tachycardia, 345
- Hypothermia
 children, 528
- Hypothyroidism, 34, 62, 74
- Hypovolemia, 338
- Hypovolemic shock
 estimated blood loss, 342t
 estimated fluid loss, 342t
 with multisystem injuries, 341–344
 treatment, 343–344
- Hypoxia, 345
- I
- Ibuprofen
 for rheumatoid arthritis, 36
- ICP
 craniofacial dysostosis syndrome, 901–902
- Ideal face, 1094f
- Idiopathic condylar resorption, 1291f
- Idiopathic hypertrophic subaortic stenosis
 (IHSS), 69
- Idiopathic vesiculoulcerative disease, 691–692
- IGF-I, 76
- IHSS, 69
- IJD, 967, 967t, 968t
- Iliac corticocancellous graft, 231–232
- Iliac crest
 bone grafts, 268f, 789–791, 862–863
 corticocancellous block graft augmentation
 atrophic mandible, 196f
 osteomyocutaneous free flap, 814–815
 harvesting, 815f
 morbidity following, 815
- Ilizarov, 164
- Illicit drug abusers, 39–40
- Imaging, 568–569
 gunshot wounds
 neck, 519–520

- panfacial fractures, 550–551
 - Imbrication, 1371, 1372f
 - vs. plication, 1372f
 - IMF. *See* Internal maxillary fixation (IMF)
 - Imipramine
 - end-stage TMJ disease, 1022
 - Imiquimod, 698, 708
 - Immunocompromised
 - effect on wound healing, 10–11
 - factors associated with, 282t
 - odontogenic infection, 282–283
 - Impacted fractures, 410
 - Impacted teeth, 139–153
 - age, 144
 - angulation of, 143
 - bone removal, 145
 - children, 144
 - debridement, 146
 - defined, 132
 - depth of impaction, 143
 - etiology, 132–133, 132f
 - evaluation of, 133
 - incidence of, 131–132
 - management of, 131–136
 - multiple, 131f, 132f
 - perioperative care, 143–149
 - relationship to ramus anterior border, 143
 - removal of, 146f
 - age, 142–143
 - antibiotics, 147–149
 - bleeding, 150
 - children, 142–143
 - complications of, 149
 - compromised medical status, 143
 - contraindications for, 142–143
 - for dental caries prevention, 141
 - indications for, 140–142
 - irrigation, 147
 - for odontogenic cyst and tumor prevention, 141
 - orthodontic considerations, 141
 - pain, 142, 150
 - for pericoronitis, 140–141
 - postoperative course, 149–150
 - to prevent jaw fractures, 142
 - root resorption, 142
 - steroids, 149
 - stiffness, 150
 - surgical damage to adjacent structures, 143
 - swelling, 150
 - roots, 144
 - surgery of, 133, 135, 143–149
 - alveolar osteitis, 151
 - complications of, 150
 - determining difficulty of, 143–144
 - fracture, 151
 - irrigation, 151
 - nerve disturbances, 151
 - rare complications, 152
 - technique, 144–147
 - surgical exposure, 133–134
 - vs. unerupted teeth, 140
 - uprighting, 135–136
 - Impingement lesions
 - progressive stages, 973t
 - Implant driver, 242f
 - Implant level transfer impression
 - open-tray technique, 258f
 - Implant prosthodontics, 251–271, 254
 - biomechanical considerations, 251–252
 - crown-to-implant ratio, 254–255, 255f
 - full-arch restoration, 255, 255f
 - implant selection, 255–256
 - occlusion, 255
 - patient factors, 251–252
 - periimplant biology, 251
 - radiographic evaluation, 252–253
 - complications of, 269–270
 - abutment fracture, 270
 - porcelain fracture, 270
 - radiographic bone loss, 270
 - resin base fracture, 270
 - screw loosening, 270
 - soft tissue, 269–270
 - contemporary techniques, 266–267
 - immediate load, 267
 - immediate placement, 266
 - immediate restoration, 266–267
 - maxillofacial prostheses, 267–268
 - surgical installation stability, 266
 - edentulous restorations, 263–264
 - FPD, 260–263
 - maintenance of, 270–271
 - single-tooth replacement, 258–260
 - cemented single units, 259–260
 - esthetic zone, 259
 - nonrestorable tooth, 258–259
 - screw-retained single units, 260
 - success criteria, 271
- Implant-retained obturator, 269f
- Implant-retained overdentures, 264
- Implants. *See also* specific implants
 - advances in, 167–171
 - angulation, 200
 - bone healing around, 193
 - depth, 200–201
 - four or more, 195
 - placed too far facially, 260f
 - presurgical planning for placement, 252f
 - soft tissue, 205–221
 - with acellular dermal matrix, 220–221
 - augmentation guidelines, 209
 - epithelialized palatal graft technique, 210–211, 210–211
 - flaps, 205–208, 206f, 207f
 - grafts, 208–209
 - nonsubmerged placement, 206
 - subepithelial connective tissue grafting, 212–215
 - submerged placement, 205–206
 - vascularized interpositional periosteal connective tissue flap, 217–220
 - two, 195
 - without grafting
 - atrophic mandible, 197
- Implant-supported overdentures
 - attachment mechanisms for, 265
- Incisional biopsy, 570, 704
- Incisions. *See also* specific incisions
 - brow lift, 1400f
- Incisors
 - altering axial inclination of, 1122
 - angulation, 1113
 - implant
 - preoperative view of, 213f
 - progressive soft tissue recession, 212f
 - mandibular
 - apical fractures, 390f
 - correct underangulated, 1126
 - crowding of, 141
 - impacted, 132f
 - maxillary
 - altering mesiodistal angulation of, 1122
 - correct underangulated, 1125–1126
 - extraction of, 1122
 - subluxation, 392f
 - position in facial asymmetry, 1212
- Indalones
 - for psychotic disorders, 39
- Indirect bone healing, 6, 373f, 374f
- Indirect fixation, 401
- Indirect fracture, 409f, 410
- Induction agents
 - children, 113–114
- Induction chemotherapy, 639
- Infants, 42
 - seat belts, 529
- Infection
 - cervicofacial liposuction, 1411
 - flaps, 720
 - with impacted teeth removal, 150
 - lip cancer, 659
 - mandibular fracture, 426
 - maxillary fractures, 442

- nasofrontal duct, 503
 - TMJ
 - arthroscopy, 986
 - internal derangement, 1010
 - Infectious endocarditis
 - cardiac conditions associated with, 23t
 - prophylaxis if, 24t
 - Infectious hepatitis, 35
 - Inferior alveolar canal
 - potential tooth proximity to, 820t
 - Inferior alveolar injuries, 820
 - Inferior alveolar nerve
 - anesthesia, 149, 151
 - damage, 1254
 - BSSO, 1157
 - numbness, 405
 - Inferior border augmentation, 182–183
 - Inferior lid
 - cross-section of, 481f
 - Inferiorly based pharyngeal flap, 878
 - Inferior mandibular osteotomy, 1308f
 - Inferior meatus
 - anatomy and physiology of, 297
 - Inferior orbital fissure, 464
 - Inferior orbital rim, 485f
 - Inferior suspensory ligament
 - Lockwood's, 466
 - Inflammation cascade, 951f, 954
 - Inflammatory papillary hyperplasia, 172
 - Inflammatory resorption, 391
 - Infliximab
 - for rheumatoid arthritis, 36
 - Informed consent
 - suction-assisted lipectomy, 1416–1417
 - Infrahyoid muscles, 938
 - Inframandibular muscles, 940, 940f
 - Infraorbital nerve, 437, 445, 464
 - and external nasal branch, 1349
 - and lower eyelid conjunctiva, 1326
 - Infraorbital paresthesia
 - zygomatic arch fractures, 457
 - Infraorbital rim
 - internal fixation of, 456
 - surgery
 - pitfalls in, 453–455
 - Infraorbital space
 - borders of, 278t
 - infection, 279t
 - Infratemporal space
 - infection, 279t
 - Infundibulum
 - anatomy and physiology of, 297
 - Inhalation agents, 96–98, 114t
 - chemical structure of, 96f
 - children, 114–115
 - Inhalational substance abuse
 - anesthesia with, 122
 - Inhalation anesthetics
 - pharmacology of, 93–97
 - properties of, 94t
 - Inhalation induction
 - disadvantages of, 109
 - Injury severity scores, 329–330
 - mortality rates for
 - by age, 330t
 - Inlay bone grafts, 179–180
 - Inoculation, 8
 - Insulin, 60
 - onset, peak and duration, 61t
 - Insulin-like growth factor (IGF-I), 76
 - Intercanthal region, 550
 - Intercartilaginous incision, 1349f
 - rhinoplasty, 1354–1355, 1356f
 - Interdental eyelet wiring, 415
 - Interdental osteotomies, 1130f
 - Interferon
 - nonmelanoma skin cancer, 709
 - Interlabial gap, 1090
 - Intermaxillary fixation, 439f
 - Internal ballistics, 510
 - Internal fixation
 - biomechanic studies vs. clinical outcomes, 374–375
 - selection of, 374
 - zygomatic arch fractures, 455–456
 - Internal inflammatory resorption, 391
 - Internal joint derangement (IJD), 967, 967t, 968t
 - Internal maxillary artery, 1346
 - Internal maxillary fixation (IMF), 402
 - for condylar fractures
 - length of, 415
 - for mandibular fractures
 - length of, 415
 - screws, 415, 416f
 - Internal nasal nerve, 1349
 - Internal neurolysis, 831–832, 832f
 - Internal replacement resorption, 391
 - Internal wire fixation
 - symphysis fracture, 373f
 - Interorbital space, 493
 - Interpolation flaps, 774–775
 - Interpositional grafts, 179, 183
 - anterior maxillary defect, 230f
 - vertical alveolar augmentation, 230
 - Interproximal tooth size reduction, 1121
 - Interrupted strip technique, 1363f
 - Interstitial radiotherapy, 637
 - Intrabony tumors
 - salivary gland, 674
 - Intracartilaginous incision
 - rhinoplasty, 1355
 - Intracerebral hemorrhage, 345f
 - CT, 346f
 - Intracranial hypertension, 887
 - Intracranial pressure (ICP)
 - craniofacial dysostosis syndrome, 901–902
 - Intramuscular sedation, 109
 - Intranasal sedation, 109
 - Intraoperative stereotactic navigation, 308f
 - Intraoral approach
 - to zygomatic arch, 450
 - Intraoral bone grafts, 787–788
 - donor site, 787f
 - Intraoral incisions
 - atrophic mandible, 196
 - Intraoral vertical subcondylar osteotomy (IVSO), 1145, 1250
 - Intraosseous infusions, 108, 108f
 - Intraosteal wiring
 - mandibular fracture, 421
 - Intravenous resuscitation fluid, 342
 - Intravenous tubing
 - maxillary distractors, 1285f
 - Intrinsic jaw-growth deformities, 1207
 - Intrusive luxation, 392
 - Inverted L osteotomy, 1136, 1146–1150
 - extraoral, 1147f, 1148f
 - Ionizing radiation, 699
 - Iontophoresis
 - for TMJ, 956–957
 - Irrigation system
 - TMJ
 - arthroscopy, 968–969
 - Ischemic heart disease, 66–67
 - Isoflurane, 95
 - chemical structure of, 96f
 - pharmacology of, 96–97
 - Isolated mandibular body fracture
 - arch bars and miniplate, 377f
 - Isometric jaw exercise
 - for TMJ, 955
 - Issue ischemia, 10
 - IVSO, 1145, 1250
 - Ivy, Robert, 840
 - Ivy loops, 416f
 - wiring, 415
- J**
- Jacketed bullets, 514
 - Jackson Pratt drain, 285, 286f
 - Jaws
 - aneurysmal bone cyst, 605
 - benign fibro-osseous disease, 597–600
 - benign nonodontogenic lesions, 597–613

- bony reconstruction of, 783–798
 - anatomic considerations, 783–787
 - limitations of, 785
 - chondroma, 601
 - drug-induced clenching, 1023
 - examination of, 404–405
 - exercise therapy
 - for TMJ, 955
 - fractures of
 - prevention of, 142
 - Langerhans cell histiocytosis, 607–608
 - lesions with giant cells, 603–605
 - neurogenic tumors, 610–611
 - nonodontogenic cysts, 608–610
 - osteoblastoma, 600
 - osteochondroma, 601–602
 - osteoid osteoma, 600
 - osteoma, 601
 - pediatric aggressive mesenchymal tumors, 602
 - rotational mechanics, 972f
 - synovial chondromatosis, 601–602
 - vascular malformations, 605–607
 - Jaw thrust procedure, 330, 332f
 - Jessner's solution, 1422t, 1423, 1426f, 1427f
 - Joe Hall Morris external fixator, 417f
 - Johnson, Lanny, 964
 - Joint disorders, 36
 - Joyce, John, 964
 - J-shaped curved hook elevator, 450
 - J-shaped elevator, 1438, 1438f
 - J stripper, 1188f
 - Jug-handle view
 - zygomatic complex fractures, 448
 - Juvenile aggressive ossifying fibroma, 600
 - Juvenile idiopathic arthritis, 1208
 - Juvenile rheumatoid arthritis, 1037
- K**
- Kaban protocol, 1038
 - Kaminishi, Ronald, 964
 - Kaposi's sarcoma, 685
 - Karapandzic flap, 366, 663, 664, 664f, 665
 - Kartagener's triad, 302
 - Kazanjian, V.H., 527
 - Kazanjian flap vestibuloplasty, 178f
 - Kelly clamp
 - for pneumothorax, 333
 - Keloids, 9
 - protruding ear, 1458
 - Keratinized gingiva, 192
 - Keratitis sicca, 1330f
 - Ketamine, 110–112
 - avoiding in malignant hyperthermia, 38
 - cardiovascular effect, 111
 - chemical structure of, 93f
 - children, 111
 - disadvantages of, 111
 - pharmacology of, 92–93
 - Ketorolac
 - end-stage TMJ disease, 1017
 - pharmacology of, 97
 - KGF-2, 13
 - Ki-67, 653
 - Kidneys
 - age-related changes, 41
 - disease, 30–31
 - assessment of, 77–78
 - caused by hypertension, 32
 - chronic
 - immunocompromised, 283
 - end-stage, 31, 77
 - insufficiency, 54
 - chronic, 30–31
 - normal architecture of, 55f
 - Kiesselbach's plexus, 1347
 - Killian incision
 - rhinoplasty, 1354
 - Kitayama technique, 423f
 - Klearway titratable appliance, 1303, 1304f
 - Klebsiella*, 300
 - Klebsiella pneumoniae*, 287
 - Kleeblattschadel anomaly, 925–926, 926f
 - Klein's tumescent technique, 1409
 - Klippel-Feil, 74
 - Knife-edge ridges, 1292
 - differential osteotomy, 1294f
 - Kobert technique, 422f
 - Kole's subapical osteotomy, 1138f
 - Kolle, Frederick, 1317
 - Kussmaul's sign, 338
- L**
- Labetalol
 - for hypertension, 32
 - for hypertensive crisis, 50t
 - Labial frenectomy, 172–174
 - Labial mucosal advancement flaps, 662
 - Labial pedicle
 - for anterior maxillary osteotomy, 1195f, 1196f
 - Labial splint, 416
 - Labial structures
 - maxillary surgical procedures, 1225, 1225f
 - Labii superioris, 445
 - Labiomental sulcus, 1229
 - Lacerations, 360–361, 437
 - under chin, 405
 - closure of, 362f
 - and facial injuries, 397
 - glabella, 494
 - maxillary fractures, 442
 - Lacrimal apparatus, 465, 493–494
 - Lacrimal glands, 364, 1326
 - prolapse, 1332
 - Lacrimal injuries, 475
 - Lacrimal probe, 365f
 - Lacrimal sac, 484
 - incision of, 504f
 - Lacrimal secretion, 1330
 - Lacrimal system, 466, 1326, 1326f
 - Lactating mothers, 42
 - medications for, 42t
 - Lag screws, 372f, 375, 379f, 1154
 - vs. bone plates, 379
 - fixation technique, 379, 401
 - placement of, 380f
 - Lambdoid synostosis
 - unilateral, 890
 - Lamellar bone, 193
 - Lamotrigine
 - for seizure disorders, 37
 - LAN. *See* Lingual nerve (LAN)
 - Lane's osteotomy, 1137f
 - Langerhans cell, 709
 - histiocytosis, 607–608
 - Lanz, Otto, 435
 - Lap belts, 529
 - Laryngoscope, 624
 - Laryngoscopy
 - fiberoptic
 - children, 528
 - Laryngospasm
 - children, 115–116
 - Laser ablation, 641
 - leukoplakia, 632
 - Laser-assisted uvulopalatoplasty
 - OSA, 1306–1307
 - Laser Doppler flowmetry (LDF), 386
 - Lasers
 - skin resurfacing, 1342
 - TMJ arthroscopy, 970–971
 - vestibuloplasty, 175
 - Lateral brow incision, 452, 482
 - Lateral canthal ligament, 1321–1322
 - Lateral canthotomy, 453
 - Lateral capsular prolapse, 973
 - Lateral cartilage
 - lower
 - anatomy of, 1349f
 - Lateral cephalometric radiographs
 - facial asymmetry, 1209
 - Lateral crural steal, 1360f
 - Lateral dislocation, 411
 - Lateral luxation, 392

- Lateral maxillary osteotomy, 1273f
- Lateral pharyngeal space
borders of, 278t
infection, 279t
- Lateral pterygoid muscle, 784
- Lateral tarsal strip procedure, 1335
- Lateral temporomandibular ligaments, 936
- Lateral tuberculectomy, 1003f
- Latissimus dorsi myocutaneous flaps, 780
- LDF, 386
- Lebanon
gold wire splinting, 383f
- LeClerc procedure, 1046f
- Leeches
medicinal, 780
- Le Fort, René, 435, 527, 1179
- Le Fort classification system
maxillary fractures, 435–436, 435f
- Le Fort fractures, 405f
bone plates, 375f
children, 534
hemorrhage, 438
orbital fractures with, 477
- Le Fort III osteotomy, 527
- Le Fort I maxillary osteotomy
delayed hemorrhage, 1248
- Le Fort I island
maxillary tumor, 645f
- Left medial canthus
reattachment, 477f
- Left ventricular dysfunction, 22–23
- Lens
discoloration, 473
- Lentigo maligna, 703f
- Lentigo maligna melanoma, 684, 703
- Lentigo simplex, 683
- Leukocytes, 4, 6, 8
- Leukoplakia, 618f, 619, 632–633
proliferative verrucous variant
gingiva, 618f
transformation to squamous cell carcinoma, 632
treatment
Cochrane review, 632
ventral tongue, 632f
- Leukotrienes
end-stage TMJ disease, 1019
- Levator aponeurosis
cross-sectional view of, 1320f
- Levator palpebrae superioris muscle, 466, 1323, 1325, 1328
- Levofloxacin
for rhinosinusitis, 502
- Lichen planus, 692–693, 692f, 693f
- Lidocaine, 359
for blepharoplasty, 1331
reduction in liver disease, 35
- Lid retractor, 468
- Lifting, 710
- Ligaments
TMJ, 936–937
- Limberg flaps, 773
- Lincomycin
for alveolar osteitis, 151
- Linear fracture
load-sharing fixation, 375
orbital, 484
- Linear tomography, 254f
implants, 253
- Lingual frenectomy, 174
- Lingual frenum attachment, 174f
- Lingual nerve (LAN), 821
blocks
for genial tubercle reduction, 169
for mylohyoid ridge reduction, 171
exposure technique, 831f
injuries, 820, 822, 1254
- Lingual splint, 416, 416f, 1259f
- Lipexeresis, 1407
- Liposculpting, 1407–1418
- Liposuction. *See also* Cervicofacial liposuction
as adjunctive procedure, 1411–1412
facial
postoperative instructions, 1418
syringe system, 1409f
- Liposuction-assisted rhytidectomy, 1412, 1413f
- Lipping, 974, 977f
- Lips
avulsive injuries, 369f
cancer, 659–667, 662–663
anatomic considerations, 659–660
cervical lymphadenectomy, 666
cervical metastasis from, 660
epidemiology, 659–660
etiology, 659–660
neglected, 620f
oral, 641–645
staging, 661t
surgery, 661–662
treatment, 660–661
results, 666–667
tumor node metastasis system, 661t
excision, 662, 662f
injuries, 366
lower
actinic cheilitis, 618f
changes with orthodontic incisor retraction, 1224
lymphatic drainage, 660
metastasis from, 660
squamous cell carcinoma, 661f, 663f
ultraviolet lip, 618
W excision, 662, 662f
mucosa, 175f
squamous cell carcinoma, 641–645, 642f
vermilion injuries, 360
- Lip shave, 641, 662
- Lip-splitting approach
incision for, 646f
- Lipswitch flap, 775
- Lipswitch vestibuloplasty, 175, 194
- Lip-tooth-gingival relationship
direct measurement of, 1091f
- Lispro
onset, peak and duration, 61t
- Lithium carbonate
for affective disorders, 39
for bipolar disorders, 39
- Lithotripsy
for parotid gland sialoliths, 676
- Little's area, 1347
- Liver disease, 34–35
assessment of, 77
- L-lactic acid resorbable plating system, 441–442
- Load-bearing fixation
bone plate, 375f
vs. load-sharing fixation, 375–376
- Load-sharing fixation
vs. load-bearing fixation, 375–376
- Local anesthetics
TMJ, 953
- Local flaps, 769–781, 772–776
- Localized pigmented lesions, 682–685
- Locking plate-screw systems, 378–379, 379f
- Lockwood's ligament, 446, 466, 1322
- Long dolichocephalic faces, 159
- Long drills, 242
- Long-term endosseous implant
first, 189
- Loracarbef
for rhinosinusitis, 502
- Lorazepam
chemical structure of, 86f
for delirium tremens, 39, 635
pharmacology of, 87
- L osteotomy, 1137f, 1294f
inverted, 1136, 1146–1150, 1147f, 1148f
reverse, 1290f
- Lower eyelids
blepharoplasty, 1334–1337
complications of, 1340–1341
ectropion, 1341
fat removal, 1341
lateral canthopexy, 1337
midfacial rejuvenation, 1337

- retraction, 1340–1341
- skin pinch excision, 1337
- transconjunctival approach, 1335–1336, 1338f
- transcutaneous approach, 1335, 1336f
- crease, 1320
- examination of, 1329
- fat pads, 1324
- retractors, 1323
- LSD
 - anesthesia with, 122
- L-shaped incision, 996
- Ludwig's angina, 284
- Luhr, Hans, 527
- Lumbar puncture, 347
- Lunchtime peels, 1423
- Lungs
 - age-related changes, 41
 - assessment of, 28
 - volume, 59f
- Lupus anticoagulant, 37
- Lupus erythematosus, 691
- Luxation injury
 - permanent dentition malformation, 399f
- Lymphocytes, 11
- Lyons, Chalmers, 840
- Lyophilized dura, 1008
- Lysergic acid diethylamide (LSD)
 - anesthesia with, 122
- M
- Macroesthetic examination
 - oblique view, 1100
 - profile view, 1101
- Macroglossia, 1117f
- Macrolides
 - for rhinosinusitis, 305
- Macrophages, 4, 6, 193
- Macular lesions, 565, 566f
- Magnetic resonance imaging (MRI), 569
 - closed lock phenomenon, 990
 - dislocated disk, 991f
 - oral cancer, 625
 - orbital fractures, 470
 - osteomyelitis, 315
 - TMJ, 975, 976f
 - tongue, 643f
- Major Trauma Outcome Study, 329
- Malignancy
 - HIV, 689
 - masquerading as osteomyelitis, 320f
- Malignant epithelial odontogenic ghost cell tumor, 589
- Malignant hyperthermia, 37–38, 62–63, 95
- Mallampati classification, 74, 76f
- Mallampati test, 281–282
- Malnutrition
 - immunocompromised, 283
- Malocclusion, 405
- Malunion
 - mandibular fracture, 426
 - maxillary fractures, 442
 - zygomatic arch fractures, 457
- Mandible. *See also* Atrophic mandible; Edentulous mandible
 - ablative defect
 - delayed reconstruction of, 796, 797f
 - advancement, 1251f
 - OSA, 1307
 - posterior airway, 1301f
 - sagittal split osteotomy, 1283f
 - soft tissue changes associated with, 1230t
 - alveolus, 784
 - anatomy of, 934
 - angle
 - functional forces acting across, 376f
 - inferior border augmentation, 1437–1439, 1440f
 - anterior
 - FPD, 262
 - anterior segmental osteotomy
 - soft tissue changes associated with, 1229t
 - anterior teeth
 - anterior osteotomies, 1124
 - bilateral mandibular body osteotomies, 1124
 - crowded, 1123–1125
 - distalize posterior teeth, 1124
 - extraction and retraction, 1124
 - slenderizing and retraction, 1124
 - atrophy of, 158f
 - augmentation of, 181–183
 - autorotation
 - soft tissue changes associated with, 1231t
 - bicuspid
 - impacted, 136
 - progressive soft tissue recession, 212f
 - bimanual manipulation, 1045f
 - block autografts, 223–224, 228
 - body of, 784
 - bone
 - formation n, 192–193
 - loss, 162
 - buttress, 548
 - children, 529
 - comminuted fractures
 - fixation, 375
 - condyle, 934f
 - condyle fractures
 - children, 538–539
 - contour irregularities, 162f
 - defects, 785
 - maxillofacial prostheses, 267–268
 - deformation, 1205
 - delayed union, 1251
 - development of, 1062–1063, 1062f
 - distraction, 1279–1280
 - fibroma, 313f
 - FPD, 268f
 - fracture, 149, 152, 549
 - anatomic location, 409
 - binding teeth together, 383
 - biomechanical considerations, 402–404
 - children, 424–425, 538–542
 - classification of, 407–412
 - clinical examination, 405–406
 - complex facial fractures, 418
 - complications, 425–429
 - concurrent condylar fracture, 418
 - delay in treating, 418
 - dentures, 406f
 - edentulous sites, 423–425, 424f
 - evaluation of, 404–407
 - gunshot wounds, 517f
 - intermaxillary techniques, 415–417
 - intraoral examination, 406
 - intraosteal wiring, 421
 - medically compromised patients, 418
 - nonreduced, 549f
 - one-point vs. two-point fixation, 377
 - open reduction, 417–418
 - pattern of, 409–410
 - penicillin, 425
 - postoperative management, 429–430
 - radiographic evaluation, 406–407, 407f
 - right angle and left body, 381f
 - rigid fixation for, 372f, 423
 - single vs. multiple, 380–381
 - sinus tract, 426f
 - site distribution, 413f
 - teeth in line of fracture, 425
 - treatment, 401–430
 - goals, 413–414
 - types of, 409f
 - unfavorable or unstable fracture, 417–418
 - gunshot wounds, 795f
 - fragmentation, 520f
 - hemorrhage, 1249
 - hybrid denture, 265f
 - hypoplasia
 - condylar fractures, 427f
 - implants, 263f
 - incisors
 - apical fractures, 390f

- correct underangulated, 1126
 - crowding of, 141
 - impacted, 132f
- with insufficient supracanal height, 268f
- large traumatic defect
 - reconstruction of, 795–796
- manipulation
 - for TMJ, 955, 955t
- molars
 - lack of eruption, 131
- muscular attachments, 162f
- nonunion, 1251
- occlusal view, 407
- oral cancer, 645–646
- orthognathic surgery
 - anatomic and physiologic considerations, 1138–1141
 - historical development of, 1135–1138
 - muscles, 1140–1141
 - nerves, 1139–1140
 - osteotomy techniques, 1141–1173
 - principles of, 1135–1173
 - vascular supply, 1138–1139
- osteotomy fractures
 - lingual segment fracture, 1258–1259
 - proximal segment, mandible intact, 1257
 - proximal segment split complete, 1257–1258
 - unanticipated, 1257–1259
- palpation of, 405f
- posterior
 - FPD, 262–263
- ramus
 - position in facial asymmetry, 1213
 - radiolucency, 577f
- reconstruction of, 794–795
- regions, 783, 784f
- relapse of, 1262
- ridge extension procedures, 174–175
- second molars
 - impacted
 - repositioning of, 135
- sensory injuries in, 1253–1254
- setback
 - OSA, 1310–1311
 - soft tissue changes associated with, 1231t
- subapical osteotomy
 - Hullihen's, 1135, 1135f
- subcondyle fractures
 - children, 538–539
- surgery
 - anterior repositioning, 1226–1227
 - anterior segmental posterior repositioning, 1226
 - autorotation, 1228
 - poor esthetic results, 1241
 - posterior repositioning, 1227–1228
 - soft tissue changes associated with, 1226–1228
- swelling, 317f
- symphysis distraction osteogenesis, 1124–1125, 1125f
- teeth
 - eruption of, 1063
- third molars
 - development of, 139–140
 - impacted, 131
 - partial eruption, 140
- titanium reconstruction plate, 796f
- tori, 172f
 - removal of, 170–171
- vascularized fibular graft to implants, 268f
- vestibular incision, 551
- vestibuloplasty, 175
- widening
 - with angle fracture, 381f
 - with distraction osteogenesis, 1280–1281
 - with symphysis fracture, 382f
- Mandibulectomy, 644, 646, 646f
- Mandrel and cover screw drivers, 242f
- Manic-depressive disorders, 39
- MAOI
 - for affective disorders, 39
 - for TMJ, 952–953
- Marginal incision
 - rhinoplasty, 1356f
- Margin reflex distance, 1328f, 1329
- Marijuana
 - anesthesia with, 122
- Marsupialization
 - for dentigerous cyst, 577, 578f
- Mask-induction techniques, 115
- Masseter muscle, 445, 938, 939f
- MAST, 339
- Masticatory myalgia, 940–941
- Masticatory space, 278
- Matrix metalloproteinases (MMP), 6
- Maxilla, 784–785
 - advancement
 - posterior airway, 1301f
 - soft tissue changes associated with, 1227t
 - anatomy of, 437f
 - anterior segmentalization of, 1179
 - anterior teeth
 - extraction, 1122–1123
 - missing, 261f
 - overangulated or crowded, 1122–1123
 - retraction, 1122
 - slenderizing, 1122
 - antroostomy, 307–308
 - arch, 1126–1127
 - width of, 1114t, 1130–1131
 - augmentation, 175–180
 - bicuspid
 - impacted, 131, 136
 - bone loss, 162
 - buttress, 548
 - canine teeth
 - impacted, 131, 132
 - panoramic films, 133, 133f
 - unerupted, 134f
 - cranial onlay bone graft, 263f
 - cross-section, 1183f
 - defects, 237–238, 785
 - maxillofacial prostheses, 268
 - delayed union, 1250–1251
 - distraction, 1282–1284
 - maxillary hypoplasia, 1286f
 - distractors
 - intravenous tubing, 1285f
 - four implants, 198
 - fractures
 - anatomy, 436–437
 - avulsive injuries, 441
 - children, 441
 - clinical examination, 437–438
 - complications, 439, 441–442, 442t
 - computed tomography, 439f
 - diagnosis, 437–438
 - elderly, 441
 - examination, 438f
 - history, 435
 - imaging, 438
 - Le Fort classification system, 435–436, 435f
 - rigid internal fixation, 439
 - surgical splints, 440–441
 - treatment, 435–442, 438–439
 - unanticipated, 1261
 - Water's radiography, 438f
 - hemorrhage, 1247–1249
 - horizontal measurements of, 160f
 - hypoplasia
 - maxillary distraction, 1286f
 - impaction
 - soft tissue changes associated with, 1228t
 - impaction osteotomy
 - septal reduction during, 1242f
 - incisors
 - altering mesiodistal angulation of, 1122
 - correct underangulated, 1125–1126
 - extraction of, 1122
 - subluxation, 392f
 - inferiorly positioned, 1251f

- interpositional iliac crest grafts, 181f
mesiodistal teeth diameter, 1112t
model, 1182f
molars
 impacted, 132f
multiple implant-borne restorations, 199–200
nonunion, 1250–1251
orthognathic surgery, 1179–1201
 anterior repositioning, 1192
 historical development of, 1179
 inferior repositioning, 1192
 intraoperative positioning, 1180–1181
 models marked for, 1181f
 osseous structures, 1181–1183
 posterior repositioning, 1192–1193
 reference marks for, 1180–1181
 soft tissue envelope, 1184–1185
 superior repositioning, 1192
 surgical anatomy, 1181–1185
 surgical techniques, 1185–1193
 vascular structures, 1183–1184
orthopedic expansion appliances, 1071f
osteoradionecrosis, 322f
osteotomy
 anterior nasal spine reduction, 1241f
 first American report of, 1179
 lateral, 1273f
 stable fixation for, 1193
palatal cuspid
 impacted, 134
paresthesia, 1253
posterior segmentalization of, 1179
premolar replacement, 199f
reconstruction of, 795–798, 798f
 case studies, 795–798
regions, 784f
ridge extension procedures, 174–175
segmental distraction, 1284–1286
sensory injury in, 1253
setback
 soft tissue changes associated with, 1228t
severe atrophy, 237f
single-unit restorations, 200
sinus, 464, 1181
 CT, 163f
 fungal balls, 303f
 Water's radiography, 470f
sinusitis, 299
submucosal vestibuloplasty, 176f
surgery, 1185–1190
 anterior repositioning, 1226
 anterior segmental repositioning, 1225
 inferior repositioning, 1226
 labial structures, 1225, 1225f
 multidirectional maxillary movements, 1226
 nasal structures, 1224–1225, 1225f, 1225t
 poor esthetic results with, 1234, 1235f
 posterior repositioning, 1226
 postoperative hemorrhage, 1248
 soft tissue, 1224–1229, 1234
 superior repositioning, 1226
teeth
 bone removal, 145
 eruption of, 1063
 extraction, 201t
third molars
 impacted, 131
 delivery of, 149f
tori, 171f
 removal of, 170–171
transverse tilting of, 1099f
tuberosities, 1062, 1183
tumor
 Le Fort I island, 645f
 vestibular incision, 551
 vestibuloplasty, 175
Maxillary-nasal base esthetic unit
 craniofacial dysostosis syndrome, 904
Maxillectomy, 254f
Maxillofacial area
 in trauma patient, 349
Maxillofacial examination
 dentoalveolar injuries, 384–386
Maxillofacial imaging
 osteomyelitis, 315
Maxillofacial injuries, 349
Maxillofacial prostheses, 267–268
 craniofacial defects, 268–269
 mandible defects, 267–268
 maxillary defects, 268
 radiotherapy, 269
Maxillomandibular advancement
 OSA, 1308–1310, 1311t
Maxillomandibular complex
 manual positioning of, 1188f
Maxillomandibular discontinuities, 239f
Maxillomandibular fixation
 skeletal fixation, 1141f
Maxillomandibular fixation (MMF), 371, 1281–1282
McCain, Joseph, 964
McGill Pain Questionnaire (MPQ), 825
MDMA
 anesthesia with, 121–122
Measles, 688–689
Meatus
 narrowed, 1458
MEC, 672
Mechanical creep, 712
Mechanical stimulation, 386
Medial canthal ligament, 1321–1322
Medial canthal tendon, 465, 484, 493
 instability, 496
Medial canthus
 left
 reattachment, 477f
Medial lid lacerations, 477f
Medial zygomaticotemporal vein, 1389
Median mandibular cyst, 608
Median rhomboid glossitis, 680–681, 681f
Medically compromised patients
 mandibular fracture
 open reduction, 418
Medications
 to avoid during pregnancy, 42t
 for breast-feeding mothers, 42t
 determining preoperative risk, 17–18
 history
 blepharoplasty, 1327–1328
Medicinal leeches, 780
Meglumine diatrizoate, 518
Meissner's corpuscles, 709
Melanin pigmentation
 smoking
 gingiva, 682
Melanocytes, 709
Melanocytic lesions, 683
Melanoma in situ, 703
Melanomas, 683–684, 684f, 701–714
 acral-lentiginous, 684, 703
 biopsy, 704t
 description, 702–704
 lentigo maligna, 684
 nodular, 684, 703
 risk factors, 701–702
 superficial spreading, 684
 survival rates, 704t
Membrane-placement instrument, 213, 215
Membranous bone
 formation of, 192–193
Meningitis, 500
Mental foramina
 radiography, 253f
Mental status
 of trauma patient, 338
Menton
 osseous deposition at, 1232f
Meperidine
 chemical structure of, 88f
 in elderly, 41
 overdose of, 344
 pharmacology of, 88

- reduction in liver disease, 35
- Merkel cell, 709
 - tumor, 697
- Meroceal packing, 438
- Mesenchyme, 583
- Mesioangular impaction, 143, 147f
 - bone removal, 145
- Mesocephalic facial type, 1094f
- Messer technique, 422f
- MET, 48, 70
 - for common activities, 48t
- Metabolic acidosis, 53, 77
- Metabolic equivalents (MET), 48, 70
 - for common activities, 48t
- Metered-dose inhalers
 - for asthma, 29
- Methadone, 39
- Methohexital
 - chemical structure of, 90f
 - children, 113
 - pharmacology of, 91
- Methotrexate, 639
 - for rheumatoid arthritis, 36
- Methyl dopa, 691
- Methylene blue dye, 499
- 3,4-methylenedioxyamphetamine (MDMA)
 - anesthesia with, 121–122
- Methylprednisolone, 473
 - impacted teeth removal, 149
 - for sinus infection, 305
- Metoclopramide, 106
- Metopic synostosis, 889–890
- Metronidazole
 - for odontogenic infection, 289
- Microdermabrasion, 1429, 1429f
- Microesthetic examination, 1107
- Micrognathia, 1280
- Microhyphemas, 473
- Microliths, 674
- Microneurosurgery, 819–834
 - demographics, 819–820
 - exposure, 830
 - medicolegal issues, 834
 - postsurgical management, 834
 - referral indications, 828t
 - treatment algorithms, 828–830
- Micropigmentation, 1401–1402
- Microsomia, 1282f
- Microvascular anastomosis, 803–804
- Microvascular flaps, 320
- Microvascular free flaps, 792
- Microvascular free tissue transfer, 803–816
- Midazolam
 - chemical structure of, 86f
- children, 112–113
 - with ketamine, 111
 - pharmacology of, 87
- Middle meatus
 - anatomy and physiology of, 297
 - discharge from, 302f
 - polyp of, 302f
- Midface
 - advancement surgery
 - timing of, 1269–1270
 - anatomy, 1318–1319
 - architecture, 1329–1330
 - for macroesthetic examination, 1100
 - superficial fascia, 1184
- Midforehead lift, 1400
- Midline palatal incision, 1198f
 - total maxillary alveolar osteotomy, 1191f
- Midline ridging, 890f
- Midsagittal osteotomy of inferior fragment, 1168
- Midsymphyseal osteotomy, 1155
- Midsymphysis
 - fracture
 - with condylar process fracture, 381
 - measurement of, 1099f
- Military antishock trousers (MAST), 339
- Millard, Ralph, 840
- Milled-bar attachments, 265
- Miller, Charles Conrad, 1317
- Minié ball, 513f, 514
- Miniplates, 373f, 380f, 402, 549f
 - isolated mandibular body fracture, 377f
- Minocycline, 682
- Minorities
 - maxillofacial trauma, 384
- Minor salivary glands
 - tumors, 673–674
- Missing teeth, 1131
- Mitral insufficiency, 69
- Mitral regurgitation, 24
- Mitral stenosis, 23–24, 68–69
- Mitral valve prolapse, 24–25, 69
- Mivacurium
 - pharmacology of, 98
 - properties, 99t
- Mixed sleep apnea, 1298
- MMF, 371, 1281–1282
- MMP, 6
- Mobitz type I (Wenckebach), 28
- Möbius sequence, 104
- Modified Cawood and Howell classification of resorption, 161f
- Modified channel retractor, 226
- Modified Le Fort osteotomies, 1201–1202, 1201f
- Modified radical neck dissection, 648
- Modiolus, 1184
- Mohs' micrographic surgery
 - nonmelanoma skin cancer, 705–708
- Molars
 - impacted
 - neoplastic change around, 141
 - mandibular
 - lack of eruption, 131
 - restoration, 199
- Monheit-Fulton index of photoaging skin, 1421t
- Monoamine oxidase inhibitors (MAOI)
 - for affective disorders, 39
 - for TMJ, 952–953
- Monocortical miniplate osteosynthesis, 423
- Monocortical plate, 1262f
- Monostotic fibrous dysplasia, 597
- Moraxella catarrhalis*, 300
- Morbid obesity, 58
- Morphine
 - in elderly, 41
 - end-stage TMJ disease, 1017, 1021
 - pharmacology of, 88
 - reduction in liver disease, 35
- Morse taper, 256
 - internal connection, 257f
- Moses, Jeffrey, 964
- Moses' release elevator, 971f
- Motor function
 - in trauma patient, 346
- Mouth
 - gunshot wound, 521f
- Moxifloxacin
 - for odontogenic infection, 289
- MPD, 941
- MRI, 569. *See also* Magnetic resonance imaging (MRI)
- Mucoceles, 503, 676–677
- Mucoepidermoid carcinoma (MEC), 672
- Mucolytics, 502
- Mucoperichondrium
 - elevation of, 1357f
- Mucoperiosteal flap, 144
- Mucosa. *See also* Oral mucosa
 - advancement flaps
 - labial, 662
 - flaps
 - buccal, 1270f
 - cross-lip, 662, 665f
 - lip cancer, 620–621
 - membrane pemphigoid
 - benign, 690–691
 - substitutes
 - wound healing, 13–14
- Muller's muscle, 466, 1323

- Multiple trauma algorithm, 331f
 - Murakami, Ken-Ischiro, 964
 - Murmurs, 107
 - Muscarinic receptor antagonists
 - children, 117
 - Muscle injections
 - for TMJ, 957
 - Muscle relaxants, 954t
 - TMJ, 953
 - Muscular dystrophy
 - anesthesia with, 120
 - Musculoaponeurotic system incision, 1376f
 - Musculocutaneous arteries, 710
 - Mustarde technique, 1453f, 1454–1456, 1456f
 - Muzzleloaders, 513
 - Myelin sheaths, 824
 - Mylohyoid attachment, 175
 - Mylohyoid ridge reduction, 171
 - Myocardial infarction, 49–50
 - general anesthesia risk after, 20
 - Myocardial ischemia, 18, 19, 48–49
 - Myocutaneous flaps, 770f
 - latissimus dorsi, 780
 - pectoralis major, 777–778
 - trapezium, 779–780
 - Myofascial pain and dysfunction (MPD), 941
 - Myositis ossificans progressiva, 941, 1035f
 - Myotonic dystrophy, 941
- N
- Nalbuphine
 - pharmacology of, 89
 - Naloxone
 - pharmacology of, 89
 - Narcolepsy, 1298, 1299
 - Narcotics
 - avoidance in COPD, 30
 - Nasal cavity
 - lateral wall of, 340f
 - packing of, 340, 340f
 - Nasal dorsum, 1352f, 1358–1359
 - augmentation, 1358–1359
 - reduction, 1358
 - rhinoplasty, 1352, 1353
 - Nasal septum, 437
 - abnormalities of, 298
 - alterations in, 1255
 - anatomy of, 437f, 1349f
 - anterior aspect of, 1189f
 - arteries, 1348f
 - cartilage resection, 1357f
 - hematomas, 364
 - repositioning, 1357f
 - sensory nerves, 1351f
 - suturing to anterior nasal spine, 1190f
 - Nasal tip
 - defect, 366f
 - definition, 1352f
 - rhinoplasty, 1352
 - projection
 - rhinoplasty, 1352–1353
 - rhinoplasty, 1359–1363
 - rotation
 - rhinoplasty, 1353
 - Nasal valve, 1350
 - alterations in, 1256
 - Nasal wall
 - anatomy and physiology of, 297, 297f
 - Nasoantral window, 298
 - Nasociliary nerve, 1325
 - Nasofrontal angle
 - rhinoplasty, 1351–1352
 - Nasofrontal duct, 497f
 - evaluation of, 499f
 - identifying, 499f
 - intraoperative evaluation of, 498–499
 - obstruction, 500–501
 - patency, 496
 - Nasofrontal suture line, 1385
 - Nasolabial cysts, 608, 609f
 - Nasolabial flap, 774–775, 776f
 - Nasolacrimal apparatus
 - soft tissue injuries, 364–365
 - Nasolacrimal duct
 - ostium, 437
 - Nasolacrimal system
 - anatomy of, 365f
 - Nasomaxilla
 - development of, 1060–1061
 - intramembranous growth, 1061f
 - malformations, 1065–1066
 - Naso-orbitoethmoid (NOE) fractures,
 - 467, 488, 495f
 - children, 532–534
 - classification, 496, 498f
 - imaging, 496
 - osseous recovery, 498
 - reconstruction, 501–502
 - Nasopalatine duct cyst, 608–609, 609f
 - Nasopharyngeal carcinoma, 1036f
 - Nasotracheal intubation, 439
 - Nausea, 1299
 - Neck. *See also* Head and neck
 - dissection
 - in-continuity *vs.* discontinuity, 650
 - examination of, 357
 - gunshot wounds, 517–519
 - decision tree, 519f
 - surgery, 520–522
 - injuries, 366–367
 - inspection of in trauma patient, 349
 - levels, 667f
 - lymph node levels of, 619f
 - oral cavity
 - squamous cell carcinoma, 648f
 - palpation of, 625
 - in trauma patient, 349
 - Necrotizing fasciitis, 281, 281f
 - Necrotizing ulcerative gingivitis, 681
 - Needle decompression, 284
 - Neisseria gonorrhoeae*, 682
 - TMJ, 944
 - Neoadjuvant chemotherapy, 639
 - Neocondyle
 - transport distraction osteogenesis, 1289–1290
 - Neonate
 - cranial base, 1061f
 - skull
 - fontanelles, 1060f
 - sutures, 1060f
 - Neonates, 42
 - Neophyte clinician
 - vs.* expert clinician
 - case study, 567–568
 - Neovascularization, 8
 - Nephrosclerosis, 32
 - Nerve growth factor (NGF), 13
 - Nerves
 - damage
 - BSSO, 1156–1158
 - grafts, 833
 - donor size, 833t
 - injuries, 1253–1255
 - classification of, 824–825, 824f
 - Seddon *vs.* Sunderland, 825t
 - mandibular fracture, 426–427
 - peripheral, 827–828, 828t
 - layer formation, 1051–1052
 - stump preparation, 832, 832f
 - treatment algorithms, 829f
 - wound healing, 6
 - Neural complications
 - horizontal ramus osteotomies, 1164
 - Neural crest migration, 1053f
 - Neural damage
 - VSO, 1146
 - Neural fascicular patterns, 822, 823f
 - Neural innervation
 - children, 105
 - Neural wound healing, 823f
 - Neurocranium
 - formation of, 1055
 - Neurofibroma, 610–611, 610f
 - Neurofibromatosis, 682
 - Neuroleptic malignant syndrome (NMS), 63

- Neurologic disorders
assessment of, 78–79
cerebrovascular disease, 37
epilepsy, 78
malignant hyperthermia, 37–38
spinal cord disorders, 38
stroke, 37, 78
caused by hypertension, 32, 79
TIA, 37, 78–79
- Neuroma, 6, 611f
traumatic, 611
types of, 824f
- Neuromuscular-blocking medications
pharmacology of, 97
properties, 99t
- Neuromuscular disorders, 37–38
assessment of, 78–79
seizure disorders, 37
- Neuropeptides, 300
- Neuropraxia, 6
- Neuropsychiatric disorders, 888
- Neurorrhaphy, 833, 833f
- Neurotmesis, 6
- Neutrophils, 4, 193
- Nevi, 683
- Nevoid basal cell carcinoma syndrome,
580–581, 580f
- Nevus sebaceus of Jadassohn, 698, 699f
- Newborns. *See* Neonates
- New York Heart Association cardiac patient
classification, 67–68, 67t
- NGF, 13
- Nicardipine
for hypertension, 32
for hypertensive crisis, 50t
- Nicotine
effect on cardiovascular system, 57
- Nikolsky's sign, 690
- Nitroglycerin, 67
- Nitroprusside
for hypertensive crisis, 50t
- Nitrous oxide
avoidance in COPD, 30
chemical structure of, 96f
children, 114
pharmacology of, 93, 95–96
properties of, 94t
- NLP, 472
- NMS, 63
- Nobecutane spray, 718
- Nobel Biocare implants, 243
- Nocturnal myoclonus
sleep-related, 1298
- Nodes of Ranvier, 823
- Nodular melanomas, 684, 703
- NOE. *See* Naso-orbitoethmoid (NOE)
fractures
- Noel, Suzanne, 1317
- No light perception (NLP), 472
- Noncompetitive antagonists, 84
- Noncompression plate osteosynthesis
vs. compression plate osteosynthesis, 378
- Nondepolarizing agents
pharmacology of, 98
- Nondilated cardiomyopathy, 69
- Non-Hodgkin's lymphoma, 689–690
- Nonischemic heart disease, 68–69
- Nonmelanoma skin cancer, 697–700
applied skin anatomy, 709–710
chemotherapy, 708
cryosurgery, 708
curettage, 708
electrodesiccation, 708
epidemiology, 697
etiology, 697–698
excision, 705
flaps, 710–711
interferon, 709
lasers, 708–709
Mohs' micrographic surgery, 705–708
photodynamic therapy, 709
prevention, 699–700
radiation therapy, 708
retinoids, 709
treatment, 704–705
- Nonopioid analgesics
end-stage TMJ disease, 1018–1019
- Nonrestorable tooth
orthodontic extrusion of, 266f
replaced with immediate implant, 267f
- Nonrigid internal fixation, 371–373
vs. rigid internal fixation, 371–382
- Nonsteroidal anti-inflammatory drugs
(NSAID), 641, 952t
avoidance
in liver disease, 35
in renal patients, 31
ideal properties, 952t
inhibiting platelet function, 78
periarticular ectopic bone formation, 1027
for rheumatoid arthritis, 36
for TMJ, 951
- Nonsyndromic craniosynostosis, 887–899
bilateral coronal synostosis, 892–895, 895f
classification, 888–889
diagnosis, 888
functional considerations, 887–888
management, 891–899
metopic synostosis, 896f–897f
sagittal synostosis, 896–897, 898f
unilateral coronal synostosis, 891–895, 892f
unilateral lambdoid synostosis, 899
- Nonunion
mandible, 1251
mandibular fracture, 425–426
maxilla, 1250–1251
maxillary fractures, 442
- Norepinephrine, 338
- Normal radiography of
chest, 348f
- Normochromic anemia, 30–31
- Normocytic anemia, 30–31
- Nose
air passages
children, 528
anatomy, 1345–1360
anatomy and physiology of, 297
basal cell cancer, 707f
base alar reduction, 1363
bilobed flap of Zitelli, 714
blood supply, 1346–1347
bones, 437, 1347–1348
anatomy of, 437f
cartilage, 1347–1348
chemicals irritating, 300
continuous positive airway pressure
for OSA, 1302
endoscope, 308f
examination
fiberoptic, 295
external
arteries of, 1347f
sensory nerves, 1350f
fractures
children, 537–538
incidence, 488
gull in flight contour, 1098f
laceration, 476f
lateral wall
arteries of, 1347f
musculature, 1346, 1346f
nerves, 1348–1350
packing
balloon catheters, 517f
polyps, 298
projection, 1353f
secretions
normal values of, 495t
skin, 1345–1346
soft tissue, 1345–1346
injuries, 364–365
structures
maxillary surgical procedures,
1224–1225, 1225f, 1225t
surface anatomy, 1345, 1345t

- surgery
OSA, 1305
- Novum restoration, 267f
- NSAID. *See* Nonsteroidal anti-inflammatory drugs (NSAID)
- Nutrition
- gunshot wounds
 - neck, 519
 - oral cancer, 635–636
 - wound healing, 12
- Nystatin
- for fungal sinusitis, 307
- O
- Obesity, 40, 58
- drug pharmacokinetics, 40
 - pulmonary problems, 40
 - thrombophlebitis, 40
- Obstructive disk blockade, 975
- Obstructive pulmonary disease
- physical examination of, 71–72
- Obstructive sleep apnea (OSA), 1297–1311, 1298, 1309f, 1310f
- bimaxillary advancement surgery for
 - soft tissue changes associated with, 1233–1234
 - Bi-PAP, 1304
 - cephalometric examination, 1300–1301, 1300f
 - clinical manifestations of, 1299
 - CPAP, 1304
 - CT, 1301
 - diagnosis, 1300–1302
 - history of, 1299
 - laser-assisted uvulopalatoplasty, 1306–1307
 - maxillomandibular advancement
 - soft tissue changes associated with, 1233
 - medical treatment, 1302–1304
 - obstruction site, 1301–1302
 - oral appliances, 1302–1304, 1303f
 - orthognathic surgery procedures, 1307–1311
 - physical examination, 1300
 - physical findings, 1299
 - polysomnography, 1301
 - surgery, 1304–1311
- Obturator
- TMJ arthroscopy, 970
- Obwegeser's osteotomies of the ramus, 1150, 1150f, 1179
- Obwegeser's technique, 415, 421
- Occlusal adjustment
- for TMJ, 959
- Occlusal radiographs
- alveolar and dental fractures, 386–387
 - alveolar cleft reconstruction, 868f, 869f
 - implants, 252
- Occlusal splint, 267f
- for TMJ arthroscopy, 984
- Occlusion
- craniofacial dysostosis syndrome, 903
- Occult neck metastasis, 644
- OCIF/OPG
- TMJ, 943
- O'Conner, Richard, 963
- Octylcyanoacrylate, 360
- Ocular. *See* Eyes
- Oculocephalic maneuver, 347, 347f
- Oculocephalic response, 347f
- Oculovestibular response test, 347
- Odontogenic carcinoma
- classification of, 588t
 - clear cell, 589
- Odontogenic cysts, 576–582
- classification of, 577f
 - dentigerous cyst, 576–578
 - glandular, 581–582, 582f
 - odontogenic keratocyst, 578–581
 - prevention of, 141
- Odontogenic infection, 277–292
- airway compromise, 281–282
 - anatomic location, 277–278
 - antibiotics, 288–290, 288t
 - care setting, 283–284
 - hospital admission
 - indications for, 283t
 - host defenses, 282–283
 - medical support, 287–288
 - operating room procedures for
 - indications for, 284, 284f
 - patient evaluation, 290–292
 - rate of progression, 280–281
 - severity of, 277–282
 - stages of, 280, 280t
 - surgery, 284–287
 - surgical drainage, 284–286, 285f
 - treatment failure
 - causes of, 290t
- Odontogenic keratocysts, 579f, 580f, 699f
- Odontogenic myxoma, 591f
- Odontogenic tumors, 583–594
- adenomatoid, 593, 593f
 - ameloblastic fibroma, 589–590
 - ameloblastic fibro-odontoma, 590
 - ameloblastoma, 583–588
 - calcifying epithelial, 592
 - classification of, 583t
 - incidence, 584t
 - malignant, 588–594
 - ameloblastic carcinoma, 588–589
 - clear cell odontogenic carcinoma, 589
 - epithelial ghost cell tumor, 589
 - metastasizing ameloblastoma, 588
 - primary intraosseous squamous cell carcinoma, 589
 - myxoma, 591–592
 - odontoma, 590–591, 591f
- Odontoma, 590–591, 591f
- Ohngren's line, 645
- Ohnishi, Masatoshi, 964
- Olfactory bulb
- esthesioneuroblastoma
 - radiotherapy, 637f
- One-point fixation
- vs.* two-point fixation, 377
- One-stage protocol, 201–202
- Onlay bone grafts, 177–179, 1274f
- Open arthrotomy
- TMJ
 - indications for, 943
- Open bites, 1261–1263, 1263f
- Open fractures, 410
- Open pneumothorax, 332–334
- Open reduction and internal fixation (ORIF), 401f, 532
- Open sky
- approach, 497
 - incision, 996
- Open submucosal vestibuloplasty, 177f
- Open technique
- subepithelial connective tissue grafting
 - implants
 - recipient-site surgery, 215–217, 216f
- Ophthalmic artery, 1346
- Opiates, 87
- overdose of, 344
- Opioids
- abusers, 39–40
 - addiction, 1023
 - end-stage TMJ disease, 1017, 1020–1021
 - pharmacology of, 87–89
 - risk of addiction to, 1021
 - side effects of, 87–88
- Optic nerve, 493
- injury, 473
- Optic neuropathy
- traumatic
 - zygomatic arch fractures, 459
- Optimized problem list, 1108–1109
- Oral appliances
- OSA, 1302–1304, 1303f
- Oral burning sensation, 680
- Oral cancer, 617–622
- biopsy, 627
 - cervical lymphadenectomy, 666
 - cervical lymph node levels, 619–620

- chemoprevention, 640–641
 - chemotherapy, 638–640
 - clinical correlation by site, 620–623
 - diagnosis, 626–627
 - distant metastasis, 626
 - histology, 631–632
 - lip, 641–645
 - perioperative issues, 635–636
 - pre-malignant disease, 618–619
 - treatment, 632–633
 - primary lesion assessment, 623–624
 - primary tumors, 623t
 - radiation, 636–637
 - recurrence, 651–653
 - regional lymph nodes, 623t
 - regional metastasis, 624–626
 - sentinel node biopsy, 650–651
 - squamous cell carcinoma, 617–618
 - staging, 623
 - surgery, 633–636
 - complications, 636
 - therapeutic neck dissection, 651
 - treatment, 631–653
 - future, 653
 - panendoscopy, 633
 - selection, 633
 - Oral candidosis, 680f, 681f
 - Oral cavity
 - fungus disease, 680–681
 - inspection of in trauma patient, 349
 - squamous cell carcinoma
 - neck dissection, 648–650, 648f
 - Oral decongestants
 - for sinus infection, 305
 - Oral disease
 - differential diagnosis, 564–572
 - Oral hypoglycemic agents, 60
 - Oral melanotic macules, 683
 - Oral mucosa
 - bacterial infections, 681–682
 - generalized pigmentation, 682, 682f
 - pigmented lesions, 682–685
 - Oral sedation, 109
 - Oral submucous fibrosis, 619
 - Orbicularis oculi, 1322–1323, 1387f
 - Orbicularis oris, 1184
 - Orbit, 445, 464f
 - anatomy of, 463
 - anterior boundary of, 466
 - apex, 445
 - arterial blood, 1324f
 - fat
 - aging changes, 1324
 - fissures, 464t
 - floor, 445, 463, 464
 - fractures, 480f
 - zygomatic arch fractures, 456–457
 - fractures
 - acute repair of, 484–488
 - anatomy of, 463–464
 - clinical examination, 467–470
 - configurations, 467
 - imaging, 470–471
 - medial orbital approach, 483–484
 - nonoperative management of, 476–479
 - surgery, 479–488, 480–484
 - indications, 479–480
 - inferior and lateral orbital approach, 480–482
 - superior and medial orbital approaches, 482–483
 - injuries
 - surgery, 477
 - surgery vs. observation, 478
 - lateral wall of, 464–465
 - ligament, 1386
 - lobe, 466
 - potential sites for traumatic injuries, 463f
 - rim, 1385, 1398f
 - anatomy of, 463
 - roof, 445, 464
 - reconstruction, 500
 - septum, 466, 1321, 1321f
 - structures distance from bony landmarks, 465t
 - upper trauma, 533f
 - walls
 - anatomy of, 463
 - Orbitonasal fracture, 535f
 - ORIF, 401f, 532
 - Oronasal communication, 1252f
 - Orthodontic appliances
 - with surgical exposure
 - of impacted teeth, 134
 - Orthodontic band pusher, 866
 - Orthodontics, 1111–1134
 - diagnostic list, 1118
 - initial surgical treatment objective, 1118–1119
 - treatment, 1120–1133
 - Orthodontic tooth movement
 - soft tissue changes associated with, 1225
 - Orthodontic treatment
 - obstruction of, 141
 - Orthognathic surgery
 - cleft palate, 1267–1275
 - bone grafting with maxillary advancement, 1272–1273
 - presurgical counseling, 1270–1271
 - cleft palate/maxilla
 - bone grafting, 1273–1274
 - complications of, 1247–1263
 - dental and periodontal injuries, 1251–1252
 - excessive lateral displacement, 1259
 - genial segment surgical procedures
 - soft tissue changes associated with, 1229–1233
 - historical perspective, 1221
 - interference with, 141
 - liposuction, 1411–1412
 - mandibular surgical procedures
 - soft tissue changes associated with, 1226–1228
 - maxillary surgical procedures
 - soft tissue changes with, 1224–1229
 - medial displacement, 1259
 - motor nerve injuries, 1254–1255
 - nasal and sinus considerations, 1255–1256
 - OSA, 1307–1311
 - poor esthetic results
 - secondary revision of, 1243
 - proximal segment rotation, 1259–1260
 - soft tissue changes associated with, 1221–1243, 1222t
 - cephalometric considerations, 1222–1223, 1224f
 - orthodontic considerations, 1222
 - orthodontic incisor retraction, 1223–1224
 - TMJ dysfunction, 1260–1261
 - unanticipated maxillary fractures, 1261
 - vascular complications, 1247–1250
 - velopharyngeal considerations, 1274–1275
- Orthognathic treatment planning
 - contemporary, 1087–1088, 1088f
- Orthopantomaxillary view
 - osteomyelitis, 315, 315f, 316f, 318f
- Orthotic splints, 966
- OSA. *See* Obstructive sleep apnea (OSA)
- Osada surgical handpiece, 1430
- Osseointegration, 189–202
 - atrophic mandible augmentation, 195–197
 - defined, 192
 - edentulous mandible, 193–197
 - incision design, 194
 - physical examination, 194
 - radiologic examination, 194
 - edentulous maxilla, 197–199
 - eight implants without graft, 198
 - eight implants with sinus grafts, 198–199
 - esthetic sites
 - incisions, 200
 - failure of, 191–192
 - four or more implants, 195
 - implants materials, 189–190
 - one-stage protocol, 201–202

- placement without trauma, 190–191
 restorations, 199–200
 surgical protocol, 190–192
 time for, 191
 two implants, 195
 wound healing, 192–193
- Osseointegration implants, 251f
 ear, 368f
- Osseous surgery, 1186–1187
- Ossification, 1055
- Ossifying fibroma, 599–600, 599f
- Osteoarthritis, 941
- Osteoblastoma, 600, 600f
- Osteoblasts, 7, 165, 192–193, 371
- Osteochondroma, 601–602, 602f
- Osteoclastogenesis inhibitory factor/
 osteoprotegerin (OCIF/OPG)
 TMJ, 943
- Osteoclasts, 8, 166, 786
- Osteoid
 bone formation in, 192–193
- Osteoid osteoma, 600
- Osteoma, 601, 601f
- Osteomeatal complex
 CT, 303f
 diagram of, 296f
- Osteomyelitis, 313–318, 500
 classification of, 314
 clinical characteristics, 314–315
 malignancy masquerading as, 320f
 mandibular fracture, 426
 microbiology of, 314
 pathogenesis of, 313–314
 surgery, 317–318
 treatment, 316–317
- Osteons, 371
- Osteopenia, 307
- Osteoplasty
 arthroscopic, 978f
 ridge split, 176–177
- Osteoporosis, 41, 252, 307, 424
- Osteoprogenitor cells, 164
- Osteoradionecrosis, 318–322
 maxilla, 322f
- Osteotomes, 200, 233f
 and condylar arthroplasty, 1003f
 and lateral nasal wall, 1272f
 and nasal septum separation, 1187f
- Osteotomy, 645–646, 1161–1164. *See also*
 specific osteotomy
 Lane's, 1137f
 lateral wall, 1187f
 of ramus
 Obwegeser's, 1150, 1150f, 1179
- Ostium
 nasolacrimal duct, 437
- Outpatient anesthesia medications
 distribution of, 84–85
 pharmacodynamics of, 83–85
 pharmacokinetics of, 84–85
 pharmacology of, 83–100
- Overdentures
 bar attachment, 264f
 bar splint, 237f
 implant-retained, 264
 implant-supported, 254
 attachment mechanisms for, 265
 long-term overuse, 238f
 precision detachable, 265f
- Oxazepam
 for DT, 39
- Oxidative stress
 TMJ, 942
- Oxycodone
 for TMJ, 951
- Oxygenation
 trauma patient, 336–337
- Oxygen dissociation curve, 57f
- Oxygen therapy
 for OSA, 1302
- Oxymetazoline
 for sinus infection, 305
- Oxymetazoline hydrochloride, 502
- P**
- Pacinian corpuscles, 709
- Paclitaxel, 640
- Paget's disease, 611–612, 611f, 612f
- Pain, 405, 494
 frontal sinus, 503
 with impacted teeth removal, 150
 with osteomyelitis, 314
 with TMJ end-stage disease, 1016–1018,
 1016t
 unexplained, 142
- Palate, 1182
 distraction appliance, 1073f
 flaps, 866, 867f
 rotated, 772
 incisions, 218
 mucosa, 1184–1185
 pedicle
 for anterior maxillary osteotomy, 1195f,
 1196f
 pleomorphic adenoma, 673f
 recurrent low-grade polymorphous adeno-
 carcinoma, 674f
 salivary gland tumors, 673–674
 squamous cell carcinoma, 645
- Palatine arteries, 1183f, 1184f, 1248
- Palatine bone, 437, 1188f
 bone removal from, 1197f
- Palatoplasty
 Bardach two-flap, 852
 two-flap, 874f
- Palliative chemotherapy, 639
- Palpebral lobe, 466
- Pancuronium
 pharmacology of, 98
 properties, 99t
- Panendoscopy, 624
- Panfacial fractures, 547–557, 556f–557f
 anatomic considerations, 547–548
 bone grafts, 551–552, 552f
 complications, 555
 etiology, 547
 historical perspective, 547
 soft tissue resuspension, 551–552
 treatment sequence, 552–555, 553f, 554f, 555t
- Panoramic radiograph
 zygoma implants, 244f
- Panoramic radiographs
 alveolar ridge, 163f
 condylar neck fracture, 407, 407f
 condyles asymmetry, 1208f
 edentulous mandible, 194
 facial asymmetry, 1209
 implants, 253
 maxillary canine teeth, 133, 133f
 for preprosthetic and reconstructive
 surgery, 160
- Panorex
 intrusion, 392f
- Papilla
 creating/preserving, 252t
- Papillary epithelial lesion
 asymptomatic, 565f
- Paraformaldehyde-containing paste, 299
- Parallel walled screw, 256
- Paranasal sinuses
 anatomy and physiology of, 297
 children, 529
 CT, 304f
 development of, 1057
- Paraplegia, 38
- Parasymphyseal fractures, 541f
 children, 541
- Parasymphysis fractures, 409
- Pare, Ambroise, 509
- Parel's classification of edentulous maxilla, 197
- Parents
 presence during sedative administration, 105
- Paresthesia
 maxilla, 1253
 with osteomyelitis, 314
- Parotidomasseteric fascia, 994f

- Parotid gland, 358f, 671
ducts
sialogram, 676f
injuries, 358–359, 359f
pleomorphic adenoma, 673f
posterior duct stones, 676
squamous cell carcinoma, 642
stones, 676
terminal duct stones, 676
tumors, 672–673
- Paroxysmal atrial tachycardia (PAT), 27
- Paroxysmal supraventricular tachycardias (PSVT), 51
- Parry-Romberg syndrome, 1207
- Partial-thickness curvilinear incision, 213
- Partial-thickness pedicle flaps
subepithelial connective tissue graft, 212
- Partial transfixion, 1348f
- PASG, 339
- Passive jaw exercise
for TMJ, 955, 955f, 1025
- Pasteurella multocida*, 362f
- PAT, 27
- Pathologic fracture, 410
- Patient follow-up, 572, 572t
- Patient history, 564–565
- PCP
anesthesia with, 122–123
- PDGF-BB, 13, 225
- PDT
leukoplakia, 632–633
- Peck graft, 1361f
- Pectoralis major myocutaneous flaps, 777–778, 777f
harvesting, 796f
- Pediatric patients. *See* Children
- Pedicle grafts, 183
- Pedicle flaps
partial-thickness
subepithelial connective tissue graft, 212
split-thickness
subepithelial connective tissue graft, 212
- Pedicles
passive adaptation of, 207
- Pelvic fracture, 341f, 353
- Pemphigus, 690
antibodies, 690f
- Penicillamine, 691
for rheumatoid arthritis, 36
- Penicillin
avoided with renal patients, 31
mandibular fracture, 425
for rhinosinusitis, 305, 502
- Penicillin V
for odontogenic infection, 289
- Penrose drain, 285
- Pentazocine
avoidance in liver disease, 35
- Pentobarbital
chemical structure of, 90f
pharmacology of, 91
- Peptic ulcer disease, 35–36
- Peptostreptococcus*, 140
- Percussion sensitivity, 385
- Periapical cemento-osseous dysplasia, 598–599, 599f
- Periapical occlusal method, 133
- Periapical radiographs
alveolar and dental fractures, 386–387
implants, 252
- Periarticular ectopic bone formation, 1025–1027
- Pericardial aspiration, 339
- Pericardiocentesis, 339f
- Perichondritis
protruding ear, 1457–1458
- Perichondrium
identification, 1357f
- Pericoronitis
prevention of, 140
- Pericrestal incisions, 206, 206f
- Periimplant soft tissue
papilla regeneration, 207–208, 208f
resective contouring, 207, 208f
surgical maneuvers, 206–208
- Perimandibular space, 278
- Perinasal incision, 551
- Periodontal concussion, 389f
- Periodontal disease
HIV, 689
implants, 252
- Periodontal healing
after replantation, 395f
- Periodontal injuries
classification of, 391–392
- Periodontal ligament
cell metabolites
solutions to replenish, 394t
injury, 385
- Periodontal problems
total alveolar osteotomy, 1167–1168
- Periodontal subluxation, 389f
- Periodontal tissue injuries, 390–395
- Perioperative analgesic medications
pharmacology of, 97
- Perioperative antibiotics
oral cancer, 635
- Perioperative cardiovascular evaluation
algorithm, 70–71
- Perioperative considerations, 47–63
cardiac assessment, 47–53
cigarette smoking, 56–58
electrolytes and acid-base disturbances, 53–54
endocrine assessment, 59–61
malignant hyperthermia, 62–63
pulmonary assessment, 54–55
renal insufficiency, 54
- Perioperative morbidity
risk factors associated with, 47t
- Perioperative risks
determinants of, 17
- Perioral-periorbital carbon dioxide laser
resurfacing, 1426f
- Periorbital ecchymosis, 437, 494
- Periorbital incision sites, 455f
- Periosteum
cells, 373f
children, 529
elevator, 866, 1387f
incision, 452
stripping, 1290
- Peripheral cranial nerves, 357
- Peripheral nerve injuries
pharmacologic management, 827–828, 828t
- Peritoneal lavage fluid
evaluation of, 352t
- Permanent cavity, 511
- Permanent teeth
developing buds, 398f
children, 529
impacted, 132
- PET. *See* Positron emission tomography (PET)
- Petechiae, 685
- Petzel technique, 422f
- Peutz-Jeghers syndrome, 682
- Pfannenstiel's incision, 501
- Pfeiffer syndrome, 903, 924f, 925f
- Pharyngeal flaps, 1274–1275
inferiorly based, 878
superiorly based, 878
- Pharyngeal space
abscess, 282f
computed tomography of, 291f
drainage of, 285f
lateral
borders of, 278t
infection, 279t
- Phenobarbital
chemical structure of, 90f
- Phenol, 1341
- Phenothiazines
children, 117
for psychotic disorders, 39
- Phentolamine
for hypertensive crisis, 50t

- Phenylephrine
for sinus infection, 305
- Phenytoin, 691
- Philtrum height, 1089
- Phonophoresis
for TMJ, 956
- Photoaging
Glogau's classification, 1419, 1419t
medical care of, 1420–1421
- Photodynamic therapy (PDT)
leukoplakia, 632–633
- Pierre Robin, 74, 104
- Piezoelectric sinus window, 233f
- Piezoelectric surgery, 233
- Pigmented lesions, 704f
localized, 682–685
oral mucosa, 682–685
- Pilot drill, 242f
- Pindborg tumor, 592, 593f
- Pink puffers, 73
- Pipercuronium
properties, 99t
- Pipe smoking
lip cancer, 659
- Pituitary gland, 76
- Plagiocephaly
description of, 1206–1207
frontal and superior views, 888f
and nasal bridge, 889f
positional, 891f
right anterior, 893f–894f
- Plain radiographs, 568
abdominal trauma, 352
atrophic mandible, 196f
zygomatic complex fractures, 448
- Plantar pitting, 581f
- Plaques, 18, 19
- Plastic skin, 1428
- Platelet-derived growth factor-BB (PDGF-BB), 13
- Platelet release, 224–225
- Platelet-rich plasma (PRP), 221, 792–794, 793f
- Platysmal plication, 1370f
- Playground injuries, 383
- Pleomorphic adenoma
palate, 673f
parotid gland, 673f
salivary gland, 671
- Plication, 1045, 1045f, 1371, 1372f
vs. imbrication, 1372f
- Plunger attachments, 265
- PMI, 22
- Pneumatic antishock garments (PASG), 339
- Pneumonia, 38
- Pneumothorax, 333f
closed, 333
tension, 332, 334, 335f
- Pocket principle, 366
- Pogonion
osseous resorption at, 1232f
- Point of maximal impulse (PMI), 22
- Pollutants, 300
- Polyethylene-tipped instruments, 271f
- Polymeric silicone catheter, 359
- Polymeric silicone implant, 1009f
- Polymeric silicone tubes, 364, 365f
placement of, 505f
- Polymorphous adenocarcinoma
low-grade, 672
recurrent low-grade
palate, 674f
- Polymyxin B sulfate, 359
- Polyostotic fibrous dysplasia, 597
- Polyps
recurrent, 310
- Polytetrafluoroethylene (PTFE), 1008
- Ponderal index, 40
- PONV, 100
children, 117–118
- Porcelain fracture, 270
- Porcelain-fused-to-metal, 239f
- Porous polyethylene implants, 1201f
- Porphyromonas*, 140, 288, 426
- Positron emission tomography (PET), 569
cervical lymph nodes, 647, 648f
oral cancer, 626, 626f
- Postauricular coronal (scalp) incision, 907
- Posterior cranial vault esthetic unit
craniofacial dysostosis syndrome, 903
- Posterior ethmoidal foramen, 465
- Posterior ethmoid artery, 1346
- Posterior maxilla
FPD, 262
- Posterior maxillary osteotomy, 1196–1197, 1196f
- Posterior plagiocephaly, 890
- Posterior teeth
distalizing, 1123
- Posteroanterior cephalometric radiographs
facial asymmetry, 1209
- Postnatal skull
changing proportions, 1059f
- Postoperative instructions
facial liposuction, 1418
- Postoperative nausea and vomiting (PONV), 100
children, 117–118
- Postoperative occlusal discrepancies, 1261
- Postorthodontic models, 549f
- Posturing
abnormal, 346
- Preauricular incision, 993f
- Precession, 514
- Predistraction hyperbaric oxygen therapy, 1289
- Prednisone
for sinus infection, 305
and wound healing, 11
- Preemptive analgesia
end-stage TMJ disease, 1016–1018
- Pregnancy, 42
medications to avoid during, 42t
testing
adolescents, 107
- Preload, 22, 26, 49
- Premachined abutment
for cement-retained restorations, 257f
for screw-retained restorations, 257f
- Premature ventricular contraction (PVC), 27
- Premaxilla
bone grafts, 1274f
congenital agenesis, 1285
traumatic avulsion, 1287f
- Premolars
impacted, 133–134
replacement
maxilla, 199f
restoration, 199
- Prenatal craniofacial development, 1051–1058
- Preoperative patient, 65–79
bleeding disorders, 78
cardiovascular disease assessment, 21f, 66–70, 107
endocrine assessment, 74–77
fasting, 105–106
liver disease, 77
neurologic disorders, 78–79
neuromuscular disorders, 78–79
psychological, 105
pulmonary assessment, 71–73
questionnaire, 17t
renal disease, 77–78
screening tests for asymptomatic patients, 79
- Preprosthetic and reconstructive surgery, 157–185
alveolar distraction osteogenesis, 183–185
bone
regeneration, 162–164
exostoses, 169
fibrous inflammatory hyperplasia, 172
genial tubercle reduction, 169–170
grafts, 165–167
hard tissue
augmentation, 175–180
recontouring, 167–171
hypermobile tissue, 172
inflammatory papillary hyperplasia, 172

- labial and lingual frenum, 172–174
 medical considerations, 159–161
 hard and soft tissue, 159–160
 radiographic evaluation, 160–161
 mylohyoid ridge reduction, 171
 ridge extension procedures, 174–175
 skeletal and alveolar ridge discrepancies,
 180–181
 soft tissue recontouring, 171–173
 tori removal, 170–171
 treatment planning, 161–162
 tuberosity reduction, 169, 170f
- Preseptal cellulitis, 304
 Press-fit cylinder-type implant, 256f
 Presurgical orthodontics, 1119–1120
 goals, 1118, 1119f
 Presurgical orthopedic (PSO) appliances, 846
 Pretracheal space
 borders of, 278t
 Pretrichial forehead lift, 1395–1396
Prevotella, 288
 Primary bone
 healing, 373f
 loss, 159
 union, 371
 Primary intraosseous squamous cell
 carcinoma, 589
 Primary retention, 132
 Primary teeth
 incomplete eruption of, 1116f
 lack of eruption, 131
 Primidone, 691
 Principle of favorableness, 408
 Procainamide, 691
 Procera titanium framework
 zygoma implants, 248f
 Procerus, 1387f
 Profile view
 macroesthetic examination, 1101
 Proliferation
 vs. apoptosis, 576f
 Propofol, 100
 chemical structure of, 91f
 children, 113
 pharmacology of, 91–93
 Propofol-infusion syndrome, 113
 Propoxyphene
 reduction in liver disease, 35
 for TMJ, 951
 Proptosis, 495
 ProRoot, 394
 Prosthetic Fox plane, 1215f
 Prosthetic heart valves, 25
 mitral valve prolapse, 25
Proteus, 300
- Prothrombin, 77
 Protriptyline
 for OSA, 1302
 Protruding ear, 1098f, 1449–1458
 complications, 1456–1458
 surgical correction of, 1452–1456
 Protruding earlobe
 correction of, 1456
 Prozac
 TMJ, 953
 PRP, 221, 792–794, 793f
 Pseudoaneurysms, 517
 maxillary fractures, 442
 Pseudoephedrine, 502
 for sinus infection, 305
Pseudomonas, 301
Pseudomonas aeruginosa
 TMJ, 944
 Pseudoshave biopsy, 704
 PSO appliances, 846
 PSVT, 51
 Psychiatric disorders, 38–40
 affective disorders, 38–39
 Psychological assessment, 105
 Psychotherapy
 for TMJ, 957–958
 Psychotic disorders, 39
 illicit drug abusers, 39–40
 opioid abusers, 39–40
 substance abuse, 39–40
 Pterygoid fovea, 934
 Pterygoid muscle, 938–939, 939, 939f
 lateral, 784
 Pterygoid plates, 644
 Pterygoid space
 squamous cell carcinoma, 642
 Pterygomandibular space, 278
 abscess, 282f
 computed tomography of, 291f
 borders of, 278t
 infection, 279t
 Pterygomaxilla
 fissure grafts, 1179
 junction, 1183f
 separation, 1187f
 Pterygomaxillary
 suture, 437
 PTFE, 1008
 Ptosis, 495, 1329f, 1385f, 1394f
 chin, 1242
 upper eyelid blepharoplasty, 1339–1340
 Pulmonary assessment, 54–55, 71–73
 bronchitis, 73
 capnography, 59
 emphysema, 73
 obesity, 58
 ventilation, 59
 Pulmonary contusions, 348
 Pulmonary edema, 24
 Pulmonary function
 age-related changes, 41
 testing, 28
 Pulp
 healing
 after replantation, 394f
 injuries
 diagram of, 388f
 testing, 385
 viability, 385
 Pulseless ventricular tachycardia, 52
 Pulse oximeter, 57, 282
 sources of error in, 58t
 Pulse rate, 338
 Pulsus paradoxus, 338
 Punch biopsy, 704
 Pupillary light
 reactivity, 468
 reflex, 347
 PVC, 27
- Q
 Quad-helix, 1072f
 Quadrant defects, 468
 Questionnaire
 preoperative patient, 17t
 Quetiapine
 for psychotic disorders, 39
- R
 Radial forearm free flaps, 804–811, 806f, 810f
 anatomic considerations, 807–809
 blood supply, 807
 complications, 808–809
 development, 805–807
 technique, 809–811
 vascular abnormalities, 807–808
 Radiation injury
 and wound healing, 11
 Radiation therapy
 periarticular ectopic bone formation,
 1025–1027, 1026f
 Radical neck dissection, 648, 649f
 Radiographs. *See also* Panoramic radiographs
 alveolar and dental fractures, 386–387
 cervical spine, 351, 351f
 dentoalveolar injuries, 386–387
 facial asymmetry, 1209
 implant prosthodontics
 biomechanical considerations, 252–253
 complications of, 270

- lateral cephalometric
 facial asymmetry, 1209
- mandible fracture, 406–407, 407f
- mental foramina, 253f
- occlusal
 alveolar and dental fractures, 386–387
 implants, 252
- periapical
 alveolar and dental fractures, 386–387
 implants, 252
- plain, 568
 of abdominal trauma, 352
 atrophic mandible, 196f
 zygomatic complex fractures, 448
- posteroanterior cephalometric
 facial asymmetry, 1209
- Water's
 maxillary fractures, 438f
 maxillary sinus, 470f
 zygoma implants, 240, 245f
 zygomatic complex fractures, 447–448
- Radionuclide imaging, 569
- Radioprotectants, 638
- Radiosensitizers, 638
- RADPLAT protocol, 640
- Ramus, 784
 fracture
 ascending, 409
- Ramus buccal shelf block graft harvest,
 225–230, 228–229
 case studies, 226–230
 recipient site morbidity, 229
- Randall-Tennison repair, 847
- Raney clips, 483
- Ranulas, 676–677, 677f
- Rare earth magnets, 134
- Reactive airway disease, 55
 treatment of, 55–56
- Reapproximation, 795f
- Recipient site
 soft tissue grafts, 209
- Recombinant human bone morphogenetic
 protein-2 (rhBMP-2), 13, 162
- Recombinant human bone morphogenetic
 protein-7 (rhBMP-7), 13
- Recombinant human keratinocyte growth
 factor 2 (KGF-2), 13
- Reconstructive surgery. *See* Preprosthetic and
 reconstructive surgery
- Rectal sedation, 110
- Reduced enamel epithelium, 576
- Reed-Sternberg cells, 688
- Reepithelialization, 5
- Regeneration, 3
- Regional anesthesia
 end-stage TMJ disease, 1017
- Regional dynamic forces, 376–377
- Regional flaps, 769–781
- Reiche, Charles Frederick William, 435
- Relaxation
 for TMJ, 957
- Relaxed skin tension lines (RSTL), 769
- Releasing incisions, 218, 242
- Remifentanyl
 chemical structure of, 88f
 pharmacology of, 89
- Removable anterior repositioning splints
 OSA, 1303
- Removable overdenture-type prosthesis, 198
- Removable prostheses
 success of, 259
- Removal, 136
- Renal. *See* Kidneys
- Repair, 3
- Repositioning appliances
 for TMJ, 958–959, 958t, 959f
- Residual ridge form, 159
- Resin base fracture, 270
- Resorbable fixation materials
 children, 542
- Resorbable plate, 425f
- Resorbable screws, 1154
- Resorption
 modified Cawood and Howell classification
 of, 161f
- Respiradone
 for psychotic disorders, 39
- Respiratory acidosis, 53
- Respiratory arrest
 algorithm for, 57f
- Respiratory problems, 28–30
 airway and lung assessment, 28
 asthma, 28–29
 chronic obstructive pulmonary disease,
 29–30
- Restrictive cardiomyopathy, 69
- Retinoids, 632, 641, 1421
 nonmelanoma skin cancer, 709
- Retrobulbar hematoma, 472, 472f
- Retrobulbar hemorrhage
 zygomatic arch fractures, 459, 459f
- Retrograde knives
 TMJ arthroscopy, 970
- Retromolar fossa, 674
- Retromolar gingiva cancer, 621
- Retromolar trigone
 cancer, 621
 oral cancer, 642
 squamous cell carcinoma, 642f
 ulcerative carcinoma, 622f
- Retropharyngeal space
 borders of, 278t
- Revised Trauma Score, 328–329
 variables, 329t
 predicting mortality, 329t
- rhBMP-2, 13, 162
- RhBMP-7, 13
- Rhegmatogenous retinal detachment, 473
- Rheumatoid arthritis, 36, 1037, 1037f
- Rhinitis
 allergic, 106–107
- Rhinitis medicamentosa, 305
- Rhinoplasty, 1345–1363
 anesthesia, 1354
 cosmetic evaluation, 1350–1354
 endonasal
 surgical sequence for, 1356t
 external
 surgical sequence for, 1356t
 facial analysis, 1351
 functional considerations, 1354
 incisions, 1354–1355
 nasal analysis, 1351
 nasal anatomy, 1345–1360
 nasal base alar reduction, 1363
 nasal dorsum, 1358–1359
 nasal tip, 1359–1363
 osteotomies, 1359
 photographs, 1354
 postoperative, 1352f, 1363
 preoperative, 1351f
 psychiatric stability, 1351
 tip projection, 1360–1361
 tip rotation, 1361–1362
 tip shape, 1362
 turbinectomy, 1358
- Rhinorocket, 438
- Rhinosinusitis, 296, 502
 factors associated with history of, 296t
 treatment, 305
- Rhombic flaps, 773, 774f
- Rhytidectomy, 1365–1379
 with complementing procedures, 1375f
 deep plane, 1373–1378
 flap development, 1371–1372, 1371f
 generations of, 1366t
 historical development, 1365–1366
 incision, 1369f, 1370f
 liposuction-assisted, 1412, 1413f
 patient evaluation, 1366–1368
 requirements, 1366t
 skin closure, 1372–1373
 superficial plane, 1368–1373, 1374f
 surgical technique, 1368–1378
 trocar sites, 1368f

- Rhytids, 1329
- Ribs
 accessory muscles, 103
 children, 103
- Ridge split osteoplasty, 176–177
- Rifle cartridges, 512f
- Rifles, 512
- Rifling, 513
- Rigid bronchoscope, 624
- Rigid fixation
 mandibular fracture, 423
- Rigid internal fixation
 mandibular fracture, 372f
 maxillary fractures, 439
 vs. nonrigid internal fixation, 371–382
- Rimfire, 514
- Rim/marginal incision
 rhinoplasty, 1355
- Ring sign, 348
- Risdon incision, 421
- Robinson Inter-OSS alveolar device, 184
- Robinson technique, 422f
- Rocuronium
 pharmacology of, 98
 properties, 99t
- Rofecoxib
 for rheumatoid arthritis, 36
- Root canal resorption, 391
- Roots
 adjacent to interdental surgical sites
 divergence of, 1129–1130
 fracture, 389–390
 in third molar removal, 151
 impacted teeth, 144
 injured surface, 1252f
 resorption
 classification of, 390
 surface resorption, 390–391
- Rotary trough, 172f
- Rotated flaps, 1270f
- Rotated palatal flaps, 772
- Rotated teeth, 1131
- Rotational flaps, 713–714, 771f, 772
- Round bur, 242f
- Rounds, 512
- Rowe disimpaction forceps, 440, 440f
- RSTL, 769
- Rubella, 689
- Rule of 10's, 844
- S
- SAARD
 for rheumatoid arthritis, 36
- Saddle nose, 364
- Saethre-Chotzen syndrome, 923–925
- Sagittal osteotomy, 1136–1137
 of horizontal ramus, 1164
 of vertical ramus
 mandibular range of motion, 1159–1160
- Sagittal split osteotomy, 1153, 1215. *See also*
 Bilateral sagittal split osteotomy
 (BSSO)
 aseptic necrosis, 1250
 facial nerve injury, 1255f
 hemorrhage, 1249
 mandibular advancement, 1283f
 sensory injuries, 1253–1254
- Sagittal synostosis, 890
- Salicylates
 for TMJ, 950–951
- Salicylic acid peels, 1423, 1423f
- Salivary-cutaneous fistula, 523f
- Salivary ducts
 gunshot wound, 522
- Salivary glands
 injuries, 1263–1264
 minor
 tumors, 673–674
 obstructive disease, 674–675
 tumors, 671–677
 benign, 671–672
 histopathology, 671–672
 malignant, 672
 site, 672–673
- Sanders, Bruce, 964
- Sandwich osteotomy, 183f
- Sandwich-visor osteotomy, 184f
- SARPE. *See* Surgically assisted rapid palatal
 expansion (SARPE)
- Save-A-Tooth, 393
- SCALP, 1386
- Scalp
 defects, 713f
 laps, 773f
 soft tissue injuries, 363–364
 squamous cell carcinoma, 711f
- Scalp incision, 907
- Scapha buckling, 1458
- Scaphocephaly, 890f
- Schwann cells, 6, 823
- Schwannoma, 610
- Scissors, 1371f
 TMJ arthroscopy, 970
- Scleral rupture, 472
- Scleroderma, 1034f, 1037
- Scopolamine, 99, 473
- Screening tests
 for asymptomatic patients, 79
- Screw-retained prosthesis, 262f
- Screw-retained restorations, 261
- Screw retention
 vs. cement retention, 260t
- Screws, 439
 loosening of, 270
- Scroll
 configurations of, 1348f
- Seat belts, 529
- Secobarbital
 chemical structure of, 90f
- Secondary bone healing, 373f, 374f
- Secondary bone loss, 159
- Secondary growth deformities, 1207
- Second molars
 impacted, 132, 135f
- Sedation, 93, 109
 children, 103–123
- Sedatives
 parents' presence during administration of,
 105
- Seddon classification, 824f
- Segmentalization, 1186f, 1190–1191
 loss of vascularity, 1249–1250
- Seizure disorders, 37
- Selective neck dissection, 649
- Selective serotonin reuptake inhibitors
 for affective disorders, 38
- Selective serotonin reuptake inhibitors (SSRI)
 for TMJ, 952–953
- Semilunar incision, 501
- Senile keratosis, 698
- Senn retractor, 1188f
- Sensitivity testing
 odontogenic infection, 286–287
- Sensory nerve, 445, 1325–1326, 1451
- Sensory recovery
 classification of, 830t
- Sentinel node biopsy, 650–651, 650f
- Sentinel vein, 1389
- Septocutaneous arteries, 710
- Septoplasty, 1238, 1355–1358
- Serine proteases, 6
- Seromas
 cervicofacial liposuction, 1411
- Serotonin receptor antagonists
 children, 117–118
- Serum
 normal values of, 495t
- Serum albumin, 77
- Serum aspartate transaminase, 35
- Serum prealbumin, 12
- Setback genioplasty
 soft tissue changes associated with, 1233t
- 702L tapered fissure bur, 225
- Severe maxillary vertical deficiency, 231f
- Sevoflurane, 95

- chemical structure of, 96f
- children, 114, 115
- pharmacology of, 97
- Shave biopsy, 704
- Shield graft, 1361f
- Shock
 - assessment of, 337
- Shock trauma center
 - University of Maryland, 527
- Short subcondylar osteotomy, 1252f
- Shot
 - classification of, 513
- Shotguns, 512
 - shells, 513f
 - wounds, 515
- Sialography, 568
- Sialoliths
 - calcified, 674
- Sigmoid notch
 - excessive flaring at, 1259f
- Silicone elastomer, 1008
- Silverman technique, 422f
- Simon's method, 1353
- Simple fracture, 409, 409f
- Single-incision approach
 - subepithelial connective tissue graft
 - harvesting, 212–213, 214
- Single-stage gold implant, 189
- Single-tooth osteotomy, 1132, 1132f
- Sinonasal mucosa
 - histology of, 298f
- Sinonasal polyps, 298
- Sinonasal tumors, 298
- Sinus. *See also* Frontal sinus
 - bone grafts, 232–234, 241f
 - dysrhythmia, 1299
 - ethmoid, 494f
 - anatomy and physiology of, 297
 - grafts, 192, 198–199
 - infection, 295–310
 - anatomic factors, 298–299
 - clinical characteristics of, 296–297
 - diagnosis of, 302–305
 - etiology, 297–302
 - fungi, 300–301
 - genetic disorders, 301–302
 - inflammatory conditions, 299–300
 - treatment, 305–310
 - medical management, 305–307
 - surgery, 307–310
 - lifts, 179–180, 181f
 - obliteration, 501, 502f
 - postoperative medical therapy, 502–503
 - postoperative symptoms, 1256–1257
 - tachycardia, 25, 27
 - window, 243f
- Sinusitis, 295, 299f, 442, 500. *See also* Rhino-sinusitis
 - allergic fungal, 301, 304f
 - Aspergillus*, 304f
 - bacteriology of, 300–301
 - complications of, 304
 - etiology, 299t
 - fungal, 303–304
 - intracranial complications of, 305f
 - maxillary, 299
 - orbital complications of, 305f
- Sinus slot technique
 - zygoma implants, 243f
- Sjögren's syndrome, 37
- Skeleton
 - craniofacial
 - growth and remodeling field of, 165f
 - nasal base, 1439–1443
- Skin
 - aging, 709
 - biomechanics, 711–712
 - blood supply, 710
 - cross-section of, 1420f
 - laser resurfacing, 1342
 - perfusion
 - in trauma patient, 337–338
 - rejuvenation, 1419–1432
 - mechanical resurfacing procedures, 1429–1432
 - resurfacing
 - ablative, 1420t
 - postoperative complications, 1432t
 - rhinoplasty, 1351
- Skin cancer. *See* Nonmelanoma skin cancer
- Skin grafts, 8, 716–717
 - age-related changes, 41
 - full-thickness, 8, 717–718
 - reinnervation of, 8
 - split-thickness, 8, 718–719
- Skin-muscle flap, 481
 - excision of, 1332
- Skoog's technique, 1365
- Skulls
 - by age, 539f
 - assessment of
 - in trauma patient, 345–346
 - fractures
 - basilar, 471
- SLE, 36–37, 691
- Sleep
 - normal stages of, 1297
- Sleep apnea
 - craniofacial dysostosis syndrome, 902–903
- Sleep apnea syndrome, 1297–1300
 - classification of, 1298
 - differential diagnosis, 1298–1299
- Sleep paralysis, 1298
- Sleep-related abnormal swallowing syndrome, 1298
- Sleep-related nocturnal myoclonus, 1298
- Slenderizing teeth, 1121, 1121f
- Sliding, 710
- Sliding buccal gingival flap, 1270f
- Slit-lamp examination, 468, 470
- Slow-acting antirheumatic drugs (SAARD)
 - for rheumatoid arthritis, 36
- SMAS. *See* Superficial musculoaponeurotic system (SMAS)
- Smile
 - gummy, 1097f
- Smile arc, 1090–1091, 1104, 1105f
- Smoking, 71, 252, 719
 - melanin pigmentation
 - gingiva, 682
 - orbital injuries, 481
 - squamous cell carcinoma, 617
 - and wound healing, 10
- Sniffing position, 281
- Sodium bicarbonate
 - for blepharoplasty, 1331
- Sodium citrate, 106
- Soft endotracheal tube
 - children, 528
- Soft eye, 470
- Soft palate
 - squamous cell carcinoma, 645f
- Soft tissue
 - craniofacial dysostosis syndrome, 907
 - grafts, 209–217
 - implants, 208–209, 220–221
 - incision
 - maxillary surgery, 1185f
 - injuries, 349
 - cleansing, 359
 - closing, 360
 - ear, 365–366
 - eyelids, 364–365
 - forehead, 363–364
 - lip, 366
 - management of, 357–358
 - nasolacrimal apparatus, 364–365
 - neck, 366–367
 - nose, 364–365
 - postoperative care, 368–369
 - repair of, 359–360
 - scalp, 363–364
 - types of, 360–363
 - integration, 205
 - management
 - implants, 205–221

- resuspension
 - panfacial fractures, 551–552
- Solar keratosis, 698
- South America, 189
- Soviet AK-47, 512
- Spade drill, 191
- Spark erosion, 265
- Spatial descriptors, 1346f
- Specimens, 570–571
- Speckled erythroplakia, 619
- Spectacle incision, 497
- Sphenoid bone, 437
- Sphenopalatine artery, 1346
- Sphenopalatine foramen, 1183
- Sphenozygomatic suture, 549–550, 550f
- Sphincteroplasty procedure, 880f
- Spinal accessory nerve
 - dissection, 649f
- Spinal cord disorders, 38
 - neurologic examination of, 350
 - physical examination of, 350
 - in trauma patient, 349–352
- Spiral drill, 191
- Spirometry, 28
- Spline implants, 228
- Splints. *See also* specific splints
 - avulsed tooth, 395, 396f
 - crowns, 224
- Split-thickness flaps
 - supraperiosteal dissection, 214
- Split-thickness pedicle flaps
 - subepithelial connective tissue graft, 212
- Split-thickness skin grafts, 8, 718–719
- Sports, 530
 - contact, 383
- Squamous cell carcinoma, 321f–322f
 - alveolar ridge, 621f
 - alveolus, 644–645
 - basaloid, 632
 - buccal mucosa, 621f, 642, 642f
 - cervical lymph nodes, 646–648
 - description of, 700–701
 - floor of mouth, 644f
 - gingiva, 644–645
 - lip, 641–645, 642f
 - lower lip, 661f, 663f
 - on midforehead, 714f
 - nasal defect after excision, 775f
 - on nasal tip, 702f
 - and NMSC, 697
 - oral cavity
 - neck dissection, 648–650
 - risk factors for, 617–618
 - palate, 645
 - primary intraosseous, 589
 - retromolar trigone, 642f
 - scalp, 711f
 - soft palate, 645f
 - tongue, 643–644, 644f
 - well-differentiated
 - lip, 660–661
- Squamous papilloma, 565f
- SSRI
 - for TMJ, 952–953
- Stability
 - BSSO, 1155–1156
 - horizontal ramus osteotomies, 1164
 - total alveolar osteotomy, 1167
 - VSO, 1145–1146
- Stabilization appliances
 - for TMJ, 958, 958f, 958t
- Stafne’s bone defect, 609–610, 610f
- Staphylococcus*, 362f
- Staphylococcus aureus*, 287, 300
 - TMJ, 944
- Steiger bur, 1191f
- Steinmann pin, 1214
- Stensen’s papilla, 676
- Stents, 253f, 254f, 261f, 270f
 - implants, 253–254
- Stephenson technique, 422f
- Step osteotomy, 1162f, 1163f
- Stereolithographic modeling
 - facial asymmetry, 1209
- Sternocleidomastoid flap, 779, 780f
- Sternocleidomastoid muscle
 - blood supply to, 779f
- Sternocleidomastoid torticollis, 1207
- Steroids, 424
 - for adrenal gland disorders, 34
 - for asthma, 29
 - immunocompromised, 283
 - impacted teeth removal, 149
- Stevens-Johnson syndrome, 693
- Stickler’s syndrome, 842
- Stiffness, 281
 - with impacted teeth removal, 150
 - with osteomyelitis, 314
 - zygomatic arch fractures, 459–460
- Stout’s method, 415
- Strauman system, 201
- Streptococcus*, 288, 362f, 426
- Streptococcus pneumoniae*, 300
- Streptococcus pyogenes*, 300
- Streptococcus viridans*, 289
- Stress relaxation, 712
- Stroke, 37
 - caused by hypertension, 32
- Stud-retained overdenture, 263f
- Subapical osteotomies, 1164–1166
 - anterior, 1164–1165, 1164f
 - Kole’s, 1138f
 - posterior, 1165–1166, 1166f
- Subarachnoid hemorrhage
 - CT, 346f
- Subciliary incision, 453f, 481, 551
- Subcondylar fracture, 405
 - mandible series, 408f
- Subcondylar osteotomy, 1135
- Subconjunctival hemorrhage, 469f
- Subcutaneous dissection, 1376f
- Subcutaneous fat atrophy
 - TMJ
 - arthroscopy, 986
- Subdural hemorrhage, 345f
 - CT, 346f
- Subepithelial connective tissue grafting
 - harvesting from premolar region, 212–213
 - implants
 - donor-site surgery, 212–213, 214f
 - recipient-site surgery, 214–215
- Sublingual ecchymosis, 406
 - floor of mouth, 385
- Sublingual gland, 671
 - tumors, 674
- Sublingual space
 - borders of, 278t
- Subluxation, 391–392, 391f
 - maxillary central incisor, 392f
- Submandibular gland, 671, 674f
 - anterior duct stone, 675
 - posterior duct, 675
 - retraction of, 675f
 - tumors, 673
- Submandibular space
 - borders of, 278t
 - infection, 279t
 - through-and-through drain, 286f
- Submasseteric space, 278
 - borders of, 278t
 - infection, 279t
- Submental intubation, 439f
- Submental space
 - borders of, 278t
 - infection, 279t
- Submentovertebral view
 - zygomatic complex fractures, 448
- Submerged implants
 - ready for abutment connection, 211f
- Submerged teeth, 131
- Submergible threaded cylindrical implant, 189
- Submucous vestibuloplasty, 174
- Subperiosteal abscess, 304, 305f
- Subperiosteal dissection, 465
- Subscleral hemorrhage, 346

- Substance abuse, 39–40
 children, 120–123
 inhalational
 anesthesia with, 122
 maxillofacial trauma, 384
 Substance P, 300
 Succinylcholine
 avoiding in malignant hyperthermia, 38
 children, 116
 pharmacology of, 98
 properties, 99t
 Suction-assisted lipectomy
 informed consent, 1416–1417
 Suction device, 1409
 Sufentanil
 chemical structure of, 88f
 pharmacology of, 89
 Suicide
 shotgun wounds, 515, 515f
 Sulbactam, 944
 Sulcular incision, 225
 Sulfa
 avoided with renal patients, 31
 Sulfasalazine
 for rheumatoid arthritis, 36
 Sulfonyleureas
 mechanism of action, 60t
 Sunder classification, 824, 824f
 Sunscreens, 700
 Superficial chemical peeling, 1422–1423
 Superficial fascia, 992
 Superficial musculoaponeurotic system
 (SMAS), 1318, 1374–1378
 description of, 1318
 and manipulation, 1371
 and rhytidectomy, 1365
 and subcutaneous dissection, 1374, 1376f,
 1377f
 Superficial spreading melanoma, 684
 Superficial temporal
 infection, 279t
 Superficial temporal artery, 1389
 Superior dislocation, 411
 Superior joint space, 996f
 Superiorly based pharyngeal flaps, 878, 879f
 Superior meatus
 anatomy and physiology of, 297
 Superior oblique muscle pulley, 465
 Superior orbital fissure syndrome, 472
 zygomatic arch fractures, 459
 Superior orbital rim, 464
 Suprahyoid muscles, 938, 1141
 Supramandibular muscles, 938
 Supraomohyoid neck dissection, 649f
 Supraorbital bar reconstruction, 500
 Supraorbital nerves, 465, 1325, 1389, 1393f
 Supraorbital notch, 464
 Supraorbital ridge fractures
 children, 532
 Supraorbital vessels, 1393f
 Supratarsal fold incision, 452, 453f
 Supratrochlear nerve, 1389, 1390
 Supraventricular tachycardias, 25
 Surgeons
 experience and training of, 149
 Surgical guides, 1288f
 Surgically assisted rapid palatal expansion
 (SARPE), 1197–1198
 arch length discrepancy, 1198
 arch morphology, 1198
 history, 1197–1198
 surgical technique, 1198–1200, 1199f, 1200f
 vertical dimension, 1198
 Surgical microscope
 historical development of, 803
 Surgical mobilization
 position in facial asymmetry, 1213
 Surgical patient
 medical management of, 17–42
 Surgical splints
 maxillary fractures, 440–441
 Surgical stent
 for implant placement, 164f
 Suture milia
 upper eyelid blepharoplasty, 1339
 Sutures
 neonatal skull, 1060f
 Sweat test, 301
 Swelling
 with impacted teeth removal, 150
 Swiss Association for the Study of Internal
 Fixation (AO/ASIF)
 compression plates, 402
 fracture management biomechanical prin-
 ciples, 373
 Swiss screw, 201
 Switching stick, 1187f
 TMJ arthroscopy, 971f
 Swivel latches, 266f
 Symmetry
 rhinoplasty, 1351–1352
 Symphysis
 block graft harvest, 225
 donor site morbidity, 228
 force, 404f
 fracture, 405, 409
 bone plate, 382f
 internal wire fixation, 373f
 posteroanterior mandibular view, 414f
 reconstruction, 1288
 Syncope, 68
 Synechiae, 309
 Synovial chondromatosis, 601–602
 TMJ, 945
 Synovial disorders
 classification of, 941t
 Synovium
 TMJ, 934–935
 Syphilis, 681–682
 Syringe liposuction system, 1409f
 Systemic lupus erythematosus (SLE), 36–37,
 691
 Systemic reserve
 odontogenic infection, 283
 T
 T3, 33
 T4, 33
 Tachycardia, 338
 with hypotension, 345
 Tagaki, Kenji, 963
 Tanning, 697
 Tapered fissure bur
 702L, 225
 Tapered-wall screw implant, 256f
 Tarsal plate, 466
 Tarsus, 1321, 1322f
 Tattoo deformity, 10
 Tattooing, 359, 360, 685
 TCA, 1341
 peels, 1427t
 Tear film, 1326
 composition, 1326
 Technetium 99m
 facial asymmetry, 1209
 osteomyelitis, 315
 Teeth
 arch symmetry, 1115, 1115f
 missing, 1131
 permanent
 developing buds, 398f
 children, 529
 impacted, 132
 sectioning, 145
 selling for transplantation, 189
 size, 1112–1113
 discrepancy, 1120–1122
 vitality, 385
 Telecanthus, 476
 Telephone ear deformity, 1458
 Telescoped fractures, 410
 Temporal incisions, 450, 1398
 Temporalis fascia, 446
 Temporalis flap, 778–779, 778f
 Temporalis muscle, 938, 938f, 1007

- flap, 778f
- graft
 - disk replacement, 1007f
- Temporalis myofascial flap, 1007
- Temporal space, 278
- Temporary bridge
 - demonstrating vertical deficiency, 230f
- Temporary cavity, 511
- Temporomandibular ankylosis, 1038
- Temporomandibular joint (TMJ)
 - anatomy and physiology of, 933–946
 - arthrocentesis, 963–987
 - arthroscopy, 963–987
 - anesthesia, 971
 - anesthetic complications, 986
 - anterolateral approach, 980
 - appliance therapy, 984
 - approaches, 979, 979f
 - articular pathology, 971–975
 - cannula, 970
 - capsular stretch procedures, 980
 - complications, 984–986
 - contraindications for, 967–968
 - development of, 964–965
 - elevators, 970
 - endaural approach, 980
 - entry errors, 980–981
 - equipment hookup sequence, 971f
 - history, 965–966
 - imaging, 966
 - indications for, 966–967
 - instrument breakage, 985–986
 - instruments, 968–971
 - intra-articular injury, 985
 - joint entry techniques, 975–982
 - lateral eminence release, 984f
 - neurologic injury, 985
 - obturators, 970
 - otologic complications, 986
 - patient selection, 965–966
 - physical examination, 965–966
 - physical therapy, 984
 - posterolateral approaches, 979
 - postoperative management, 982–983
 - postoperative medications, 984
 - preoperative management, 982
 - puncture anatomy and landmarks, 977–979
 - superior posterolateral approaches, 979
 - superoposterior lateral approach, 980
 - trocarr puncture technique, 980, 982f
 - trocars, 970
 - vascular injury, 985
 - visible fields, 983f
 - articular disk, 935–936
 - articular disorders, 941–942
 - benign tumors, 945
 - biologic mechanisms, 942–943
 - bony structures, 933–934
 - capsular herniation, 979f
 - cartilage, 934–935
 - classification, 933
 - coronal view, 934f
 - CPM, 541
 - diet, 950
 - disk immobility, 974f
 - disk migration, 974f
 - disk placement, 975f
 - dysfunction, 1260–1261
 - BSSO, 1158–1160
 - VSO, 1146
 - effusion, 411
 - endaural arthroscopic approach, 981–982, 981f, 982f
 - end-stage disease, 1015–1027
 - pain control, 1016–1018
 - periarticular ectopic bone formation, 1025–1027
 - perioperative management, 1016
 - physical therapy, 1024–1025
 - postsurgical pain management, 1018–1024
 - preemptive analgesia, 1016–1018
 - sympathetically maintained pain, 1024
 - hemarthrosis, 411–412
 - hypermobility, 1044–1047
 - classification, 1044
 - etiology, 1044, 1045t
 - treatment, 1045–1046
 - hypomobility, 1033–1044
 - classification, 1033
 - clinical characteristics, 1033–1034
 - complications, 1040–1044
 - etiology, 1033, 1034t
 - following orthognathic surgery, 1037
 - following radiation therapy, 1036
 - imaging, 1034
 - inflammatory and rheumatologic causes, 1036–1037
 - postcraniotomy, 1036
 - postinfectious, 1035–1036
 - postoperative physical therapy, 1044
 - posttraumatic, 1034–1035
 - treatment, 1037–1040
 - infection, 943–944
 - innervation, 937
 - internal derangement, 989–1010
 - capsular incisions, 995–997, 997f
 - complications, 1010
 - diagnosis, 989–991
 - diskectomy without replacement, 1006
 - disk reapproximation, 1002f
 - disk-removal procedures, 1002–1006
 - disk replacements, 1006–1008
 - disk repositioning, 1003f
 - disk-repositioning procedures, 998–1000, 998f, 999f
 - endaural approach, 994–995, 994f
 - operative procedures, 997–1000
 - partial diskectomy, 1002–1004, 1004f
 - perforated posterior attachment, 1000–1002, 1001f
 - postauricular approach, 995, 995f
 - postoperative management, 1009–1010
 - preauricular approach, 992–994
 - surgical anatomy, 991–992
 - surgical approaches, 991–1008
 - surgical goals, 991
 - total diskectomy, 1004–1005, 1006f
 - internal derangement of, 427–428
 - lateral view, 936f, 937f
 - ligaments, 936–937
 - malignant tumors, 945–946
 - mandibular fracture, 426–429
 - medial view, 937f
 - movement biomechanics, 940
 - musculature, 937–940
 - neoplastic disease, 945
 - nonarticular disorders, 940–941
 - nonsurgical management, 949–959
 - occlusal appliances, 958–959
 - orthopedic development history, 963–964
 - pathology of, 940
 - perforated disk, 942f
 - pharmacotherapy, 950–953
 - physical therapy, 953–957, 954t
 - retrodiskal tissue, 936
 - stress reduction, 957–958
 - synovial tumors, 945
 - synovium, 934–935
 - vascular supply, 937
 - Wilkes staging classification, 967t
 - Temporomandibular (lateral) ligaments, 936
 - TENS
 - for TMJ, 956
 - Tension pneumothorax, 332, 334, 335f
 - Tension-stress
 - bone, 164
 - Tentative diagnosis, 564
 - Tent pole bone screws, 224f
 - Teratogens, 1067f
 - Terminal ballistics, 510
 - Terminally ill
 - avoidance of, 652–653
 - Tessier no. 7 left facial cleft, 855f

- Tetanus-prone wounds, 357
Tetanus prophylaxis, 385t
Tetracycline, 168
 for alveolar osteitis, 151
 avoidance in liver disease, 35
Tetraplegia, 350
TGF, 225, 785
Theophylline
 for asthma, 29, 56
 reduction in liver disease, 35
TheraBite Jaw Motion Rehabilitation System, 955, 955f
Therapeutic neck dissection
 oral cancer, 651
Thermal agents
 for TMJ, 956
Thermal injury
 lip cancer, 659
Thermal test, 386
Thiamylal
 chemical structure of, 90f
Thiazolidinediones
 mechanism of action, 60t
Thiopental
 chemical structure of, 90f
 pharmacology of, 90–91
Thiouracil, 691
Thioxanthenes
 for psychotic disorders, 39
Third Molar Project, 150
Third molars
 antibiotics, 148
 failure to erupt, 140
 impacted
 removal contraindications, 152
 removal of, 149
 mandibular
 development of, 139–140
 impacted, 131
 partial eruption, 140
 in path of second molars eruption, 135, 135f
 removal of
 root fracture, 151
 retarded maturation of, 140
 surgery
 periodontal healing after, 152–153
Thoma technique, 422f
Thoracic vascular injury
 chest radiographs, 349f
Threaded cobalt-chrome-molybdenum screw, 189
Thrombin, 340
Thrombocytes, 4
Thromboembolism, 38
Thrombophlebitis
 obesity, 40
Through-and-through drain
 submandibular space, 286f
Thyroid
 assessment, 61–62
 assessment of, 74
 disorders, 33–34
 orbitopathy, 1327f
Thyroxine (T3), 33
TIA, 37, 78–79
Tiagibine
 for seizure disorders, 37
Ti-6Al-4V, 189
Tibial bone grafts, 791–792, 792f
Tip
 support, 1350t
 rhinoplasty, 1353
Tissue
 oxygenation
 evaluation of, 337
 smoking effect on, 10
 perfusion, 10
 evaluation of, 337
 shaver, 309f
 trauma
 minimizing, 9
Titanium, 439–440
 mesh, 441f, 485, 500, 500f
 microscrews, 500
 plasma-sprayed surface, 190f
 reconstruction plate
 mandible, 796f
 screws, 1439f
Titanium alloy (Ti-6Al-4V), 189
TMJ. *See* Temporomandibular joint (TMJ)
Tobacco. *See* Cigarette smoking
Tobramycin, 944
Toluidine blue, 626–627
Tongue
 cancer, 622–623, 622f
 children, 103
 edema, 516f
 flaps, 662, 775–776, 777f
 leukoplakia, 632f
 magnetic resonance imaging, 643f
 radial forearm flap, 643f
 squamous cell carcinoma, 643–644, 644f
 traction of, 624f
Tongue-retaining device (TRD)
 OSA, 1303
Tonometry, 468
Tonsils
 children, 103
 surgical specimen of, 1306f
Topical 5-FU, 708
Topiramate
 for seizure disorders, 37
Tori, 612–613
 mandibular, 172f
Torus mandibularis, 613
Torus palatinus, 612, 612f, 613f
Total alveolar osteotomy, 1166–1168, 1167f
Total maxillary alveolar osteotomy, 1193
 midline palatal incision, 1191f
 vertical incision, 1191f
Total pulp necrosis, 386
Toxic epidermal necrolysis, 693, 694
Trachea
 children, 103, 104
 injuries
 signs of, 518
Tracheostomy, 516
 OSA, 1304–1305
Tracheotomy, 281
Track Plus System, 184
Traffic accidents, 530
Transantral osteotomy, 1197f
Transblepharoplasty, 1401
Transcolumellar incision
 rhinoplasty, 1355
Transconjunctival incision, 455f, 482, 483, 551
Transconjunctival upper lid blepharoplasty, 1334
Transcutaneous nerve stimulation (TENS)
 for TMJ, 956
Transforming growth factor (TGF), 225, 785
Transfusion
 oral cancer, 635
Transient ischemic attacks (TIA), 37, 78–79
Transmucosal sedation, 109
Transnasal wiring, 501–502
Transosseous circum-mandibular wiring, 421, 424f
Transpalpebral procedure, 1401
Transplantation, 136
Transport diagnosis, 1288f
Transport distraction osteogenesis, 1286–1289, 1289f
 neocondyle, 1289–1290
Transpositional flaps, 178f, 714, 773–774
Transverse characteristics, 1103–1104, 1107f
Transverse compensations, 1107
Transverse facial proportion, 1096–1098
Transverse orthopedic treatment, 1071–1072
Transverse smile, 1104f
Trapezium myocutaneous flaps, 779–780
Trauma patient
 airway maintenance, 330
 breathing, 332–337
 cervical spine, 330

- circulation, 337–344
 initial management of, 327–354
 injury severity assessment, 327–330
 neurologic examination of, 344–345
 primary survey, 330–344, 344f
 secondary assessment of, 344–345
 stabilization of, 349f
 triage decision scheme, 328f
 Trauma Score, 328
 Traumatic avulsion
 premaxillary segment, 1287f
 Traumatic bone cyst, 609, 610f
 Traumatic hyphema
 zygomatic arch fractures, 459
 Traumatic loop deformity, 776f
 Traumatic neuroma, 611
 Traumatic optic neuropathy
 zygomatic arch fractures, 459
 Trauner, 1150
 TRD
 OSA, 1303
 Treacher Collins, 74, 104
Treponema pallidum, 681
 Triage decision scheme
 trauma patient, 328f
 Triamcinolone acetone, 475
 Triazolam
 pharmacology of, 87
 Tricalcium phosphate, 168
 Trichloroacetic acid (TCA), 1341
 peels, 1427t
 Trichophytic forehead lift, 1395–1396
 Tricyclic antidepressants
 for affective disorders, 38–39
 for TMJ, 952–953
 Trigeminal nerve, 1325
 anatomy and physiology, 822–824, 822f
 fibers, 823t
 injuries, 821
 demographics, 819–820
 third division of, 1139–1140
 Trigger points
 for TMJ, 957
 Trigonoccephaly, 890f, 896f
 Triiodothyronine (T₃), 33
 Trimethadione, 691
 Trimethaphan camsylate
 for hypertensive crisis, 50t
 Trimethoprim
 for COPD, 30
 Trimethoprim/sulfamethoxazole
 for rhinosinusitis, 305, 502
 for sinus infection, 305
 Triple endoscopy, 624
 Trismus (stiffness), 281
 with impacted teeth removal, 150
 with osteomyelitis, 314
 zygomatic arch fractures, 459–460
 Trocars
 rhytidectomy, 1368f
 TMJ arthroscopy, 970, 971f
 Trochlea, 464
 T-shaped incision, 996
 Tuberculectomy
 lateral, 1003f
 Tuberosity reduction, 169, 170f
 Tube shift method, 133
 Tumescence solution, 1410t
 Tumescence technique, 1368f
 Klein's, 1409
 Turbinate pneumatization, 298
 Turbinectomy
 rhinoplasty, 1358
 Turner syndrome, 1066
 Twist drill, 242f
 Two-flap palatoplasty, 874f
 Bardach, 852
 Two-implant bar
 clip overdenture retention, 194f
 Two-point fixation
 one-point fixation, 377
 Two-staged titanium implants, 189

 U
 Ulcerated lesions, 685–686
 Ulcers, 565
 Ultrasonography, 569
 abdominal injuries, 352–353, 354t
 cervical lymph nodes, 647
 oral cancer, 625–626
 TMJ, 956
 Ultraviolet damage, 1420
 Umbrella graft, 1361f
 Uncinate
 anatomy and physiology of, 297
 Unconjugated bilirubin, 77
 Unerupted teeth
 vs. impacted teeth, 140
 localizing, 133
 University of Maryland
 shock trauma center, 527
 Upper blepharoplasty incision, 482–483
 Upper eyelid
 crease, 1328
 crease incision, 551
 Upper eyelids
 blepharoplasty, 1331–1334
 complications, 1339–1340
 fat removal, 1339
 high lid crease, 1339
 lid crease asymmetry, 1339
 preoperative concerns, 1331–1333
 skin excision, 1339
 examination of, 1328
 fat pads, 1324
 laxity, 1394f
 transcutaneous blepharoplasty, 1333f
 Upper lips
 augmentation, 1443f
 changes with orthodontic incisor
 retraction, 1223–1224
 developing, 660f
 Upper respiratory infection
 children, 106–107
 UPPP, 1305f
 OSA, 1305–1306
 Urethral meatus
 blood at, 343f, 353
 Urinalysis, 353
 Urinary tract disease, 30
 Urine
 output in children, 42t
 Uvula
 surgical specimen of, 1306f
 Uvulopalatopharyngoplasty (UPPP), 1305f
 OSA, 1305–1306

 V
 Vagus nerve, 1451
 Valacyclovir, 688
 Valdecoxib
 for rheumatoid arthritis, 36
 Valvular heart disease, 23–24, 68
 mitral regurgitation, 24
 mitral stenosis, 23–24
 Vancomycin
 for odontogenic infection, 289
 Van Graefe, Carl Ferdinand, 435
 Varicella-zoster virus, 686, 687–688
 Varix, 684–685
 Vascular compromise
 management of tissue after, 1253–1254
 Vascularity
 loss of, 1249–1250
 Vascularized fibular graft to mandible
 implants, 268f
 Vascularized interpositional periosteal
 connective tissue flap (VIP-CT),
 217–220, 217f, 218f, 220f
 surgical technique, 217–218
 Vascular lesions, 684–685
 Vascular malformation
 high-flow, 606f, 607f
 Vasopressin
 for arrhythmias, 52

- Vector control devices, 1292f
- Vecuronium
properties, 99t
- Velopharyngeal insufficiency (VPI), 845
- Velopharyngeal mechanism
anatomy of, 876f
muscle groups contributing to, 876t
- Velopharyngeal port
catheter passed through, 1272f
- Ventilation, 59
children, 103
- Ventricular ectopy
benign, 52
- Ventricular fibrillation, 52
- Ventricular tachycardia, 27
- Verapamil
reduction in liver disease, 35
- Vermilionectomy, 641, 641f, 662
- Verrucous carcinoma, 631
buccal mucosa, 631f
- Vertical alveolar augmentation
bone grafts, 223–234
alveolar distraction osteogenesis, 230–231
guided, 223
iliac corticocancellous, 231–232
interpositional, 230
mandibular block autografts, 223–224
sinus, 232–234
symphysis block graft harvest, 225
ramus buccal shelf block graft harvest,
225–230
- Vertical augmentation or reduction
genioplasty
soft tissue changes associated with, 1233t
- Vertical dystopia, 468
- Vertical facial proportions, 1093–1096
- Vertical impaction, 143
bone removal, 146
removal of, 148f
- Vertical incision, 996–997
total maxillary alveolar osteotomy, 1191f
- Vertical orthopedic treatment, 1077–1079
- Vertical ramus
osteotomies, 1141–1142
sagittal osteotomy
mandibular range of motion, 1159–1160
- Vertical rhytids
glabella, 1398
- Vertical subcondylar osteotomy (VSO),
1142–1146, 1142f, 1143f, 1144f
complications of, 1145–1146
indications for, 1142
techniques for, 1142–1145
- Vesicular lesions, 685–686
- Vesiculoulcerative disease
idiopathic, 691–692
- Vestibular incisions, 1185, 1186f
atrophic mandible, 196
- Vestibuloplasty
lasers, 175
- ViaSpan, 393, 393f
- Video monitoring cart
TMJ
arthroscopy, 969f
- Video monitoring equipment
TMJ
arthroscopy, 968
- VIP-CT. *See* Vascularized interpositional
periosteal connective tissue flap
(VIP-CT)
- Viral infection, 686–687
- Viscerocranium
formation of, 1055
- Vision
craniofacial dysostosis syndrome, 902
loss
lower eyelid blepharoplasty, 1341
upper eyelid blepharoplasty, 1340
- Visor osteotomy, 183f
- Visual acuity, 468, 1330
- Visual analog scale, 826f
- Visual field evaluation, 1330–1331
- Visual fields, 468
TMJ
arthroscopy, 969–970
- Visual impairment, 472–474, 887
- Vital signs, 404
- Vitamin A
effect on wound healing, 12
- Vitamin B
effect on wound healing, 12
- Vitamin C
effect on wound healing, 12
- Vitamin E, 641
- Vitreous hemorrhage, 473
- Volkman's contracture, 475, 477
- Von Eiselberg's step osteotomy, 1138f
- Von Graefe, Ferdinand, 1317
- Von Langenbeck procedure, 874, 874f
- Von Willebrand's factor, 78
- VPI, 845
- Vs. unerupted teeth, 140
- VSO. *See* Vertical subcondylar osteotomy (VSO)
- V-Y closure, 1235–1236, 1236f, 1240f, 1442f
alar cinch with, 1236–1237
double, 1239–1241, 1242f
- V-Y flap, 772
- W
- Wadcutters, 514
- Wallerian degeneration, 828
- Warthin's tumors
salivary gland, 671–672
- Watanabe, Masaki, 963
- Water's radiographs
maxillary fractures, 438f
maxillary sinus, 470f
maxilla sinus, 470f
zygomatic complex fractures, 448
- Wedge excision, 641
- Weight loss
for OSA, 1302
- Weir's excision, 1363f
- Well-differentiated squamous cell carcinoma
lip, 660–661
- Wenckebach, 28
- Wharton's duct
calcified sialolith, 675f
- White blood cell count
odontogenic infection, 283
- Whitenall's ligament, 1322, 1322f
- Whitenall's tubercle, 446, 465, 466
- Whitlow
herpetic, 687, 687f
- Wickham's striae, 692
- Wide-eyed look, 466
- Wilkes staging classification, 942t
IJD, 967t
- Wire brush, 1430
- Wiring techniques, 424f
- Witch's chin, 1242, 1243f
- Wolff-Parkinson-White syndrome, 51, 52f
- Wood's lamp, 470
- Working diagnosis, 564
- Wound care
advances in, 12–14
- Wound debridement, 10
- Wound dehiscence, 9
upper eyelid blepharoplasty, 1339
- Wound healing, 3–24
age, 12
bone, 6–7
complications of, 8–9
dermal substitutes, 13–14
extraction wounds, 7–8
gene therapy, 13
hyperbaric oxygen therapy, 11–12
inflammatory phase, 4–5, 193
maturation phase, 193
mucosal substitutes, 13–14
nerves, 6
nutrition, 12
optimizing, 9–12
osseointegration, 192–193
phases of, 193

- process, 3
- proliferative phase, 5, 5f, 193
- proliferative scarring, 9
- remodeling phase, 5–6
- response, 3–6
- skin grafts, 8
- specialized, 6–8
- stages of, 361f
- Wound hypoxia, 9
- Woven bone, 193

- X
- Xenograft, 168
- Xeroderma pigmentosa, 698
- Xerostomia, 638

- Y
- Yaw, 514
- Young's syndrome, 302
- Youthful brow, 1384f
- Youthful forehead, 1384
- Yperman, Jehan, 840

- Z
- Zinc
 - effect on wound healing, 12
- Zinc oxide-eugenol cement, 388
- Ziprasidone
 - for psychotic disorders, 39
- Zone of fixation, 1391
- Z-plasty incision, 772
- Z-plasty technique
 - for frenum attachment excision, 173
- Z-shaped osteotomy, 1192f, 1193f
- Zygoma
 - anatomy of, 437f
- Zygoma fixture placement, 243f, 437
- Zygoma implants, 235–248, 238f, 242f, 270f
 - abutment platform, 243
 - abutments, 245f
 - armamentarium, 242f
 - border molding, 245f
 - buccal index, 247f
 - cast framework, 247f
 - casting technique, 247f
 - clinical assessment, 240
 - complications of, 239–240
 - contraindications for, 238–239
 - final impressions, 246f
 - fixtures, 198, 235f
 - fully inserted, 244f
 - hybrid denture tooth processing, 248f
 - immediate loading, 240f
 - impression coping, 241f
 - indications for, 236–238
 - acquired and congenital defects, 237–238
 - atrophy, 236
 - immediate loading, 238
 - inadequate posterior support, 236
 - partial edentulism, 238
 - syndromes, 236–237
 - master cast, 246f
 - milled bar structure, 247f
 - milling process, 248f
 - mounted casts, 246f
 - panoramic radiograph, 244f
 - presurgical assessment, 240
 - procelain-fused-to-metal fixed partial denture, 248f
 - procera technology, 247f, 248f
 - procera titanium framework, 248f
 - prosthetic procedure, 244–248
 - final construction, 245–246
 - healing phase, 244
 - protective splinting, 244–245
 - protective splint, 246f
 - radiographic assessment, 240, 245f
 - record bases, 246f
 - screw access holes, 247f
 - sinus slot technique, 243f
 - soft tissue conditioning material, 246f
 - stage II surgery, 245f
 - surgical cast, 246f
 - surgical protocol, 242–243
 - waxed teeth, 247f
- Zygoma retractor, 242, 243f
- Zygomatic arch, 445
 - coronal section, 992f
 - fractures
 - incidence, 488
 - internal fixation, 455–456
 - orbital floor, 456–457
 - orbital fractures with, 477
 - reduction of, 451f
 - surgery, 457–460
 - treatment, 450–451
 - internal fixation of, 456
 - surgical approach to, 455
- Zygomatic buttress, 548
- Zygomatic complex
 - displaced
 - elderly, 486f–487f
 - fractures, 445–460, 446f, 447f, 448f, 467
 - children, 534–537
 - classification of, 448–449
 - computed tomography, 454f
 - diagnosis, 447–448
 - high-energy, 451–455
 - history, 447
 - low-energy, 451
 - middle-energy, 451
 - physical examination, 447
 - radiographic evaluation, 447–448
 - surgical anatomy, 445–446
 - treatment, 449–457, 451–456
 - without need for internal orbit reconstruction, 452f
- Zygomatic nerve, 1326
- Zygomaticofrontal buttress, 451
 - internal fixation of, 456
 - surgery, 452–453
- Zygomaticofrontal suture
 - palpation of, 447
- Zygomaticomaxillary buttress
 - fracture
 - fixation, 453f
 - subciliary incision, 453f
 - supratarsal fold incision, 453f
 - internal fixation of, 456
 - surgery, 452
- Zygomatic osteotomy, 1200–1201
- Zygomatic retractor, 242f
- Zygomaticus major, 445

INDEX

- A
A alpha fibers, 822, 823t
Abbe-Estlander flap, 366, 664, 665
Abbe flap, 664f
Abdomen
 children, 528
 examination of
 in trauma patient, 352–353
 fat graft harvest, 501, 501f
A beta fibers, 822, 823t
ABG, 28
Ablative skin resurfacing
 classification of, 1420t
Abnormal flexor activity, 346
Abnormal posturing, 346
Abrasions, 360, 396–397. *See also* Dermabrasion; Microdermabrasion
 corneal, 470f, 1402
Abscess
 pharyngeal space, 282f
 pterygomandibular space, 282f
 subperiosteal, 304
Abutment fracture, 270
Abutment transfer impression
 closed-tray technique, 258f
Accelerated fractionation, 636
Access flap, 205–206
Accessory muscles
 ribs, 103
Accessory ostia, 298
ACE distraction dental implant system, 184
ACE inhibitors. *See* Angiotensin-converting enzyme (ACE) inhibitors
Acellular dermal matrix (AlloDerm), 220–221, 221f
Acetaminophen
 for fever, 287
Acetazolamide
 for OSA, 1302
Acetylcholinesterase
 reversal doses of, 99t
Acetylsalicylic acid
 inhibiting platelet function, 78
Acid-base analysis, 53–54
Acid-base disturbances, 53–54
Acid-etch splints, 396f, 397t
Acquired anomalies, 1205
Acquired immunodeficiency disease (AIDS).
 See also Human immunodeficiency virus (HIV)
 immunocompromised, 283
Acral-lentiginous melanoma, 684, 703
Acromegaly, 76
Acrylic resin, 505
Acrylic splint therapy
 mandibular fractures
 children, 425
ACTH, 34
Actinic cheilitis, 662f, 663f
 lower lip, 618f
Actinic keratosis, 698, 699f
Active jaw exercise
 for TMJ, 955
Acupressure
 for TMJ, 957
Acupuncture
 for TMJ, 957
Acyclovir, 687
Adalimumab
 for rheumatoid arthritis, 36
Addison's disease, 61, 682
A delta fibers, 822–823, 823t
Adenocarcinoma
 metastasizing to condyle, 945
 polymorphous
 low-grade, 672
 recurrent low-grade, 674f
Adenoids
 children, 103
 cystic carcinoma, 672
 hypertrophy, 298
Adenoma. *See* Pleomorphic adenoma
Adenomatoid odontogenic tumors, 593f, 594f
ADHD
 anesthesia with, 119
Adjuvant chemotherapy, 639
Adnexal tumors, 697
Adolescents
 dentoalveolar injuries, 383–384
 midface advancement surgery
 timing of, 1269–1270
 pregnancy testing, 107
 psychological assessment, 105
Adrenal crisis, 61
Adrenal glands
 assessment of, 61, 74
 disorders of, 34
Adrenal insufficiency, 34
Adrenocorticotrophic hormone (ACTH), 34
Adult respiratory distress syndrome (ARDS), 348, 354
Advanced Trauma Life Support (ATLS), 330
Advancement flaps, 712–713, 772, 772f
 buccal, 772f
 double, 771f
Advancement genioplasty
 soft tissue changes associated with, 1232t
AEV-12 hand engine, 1430
Affective disorders, 38–39
African Americans
 hypertension, 49
 oral cancer, 617
AFS, 301, 304f
Afterload, 22, 26, 49
Age
 determining preoperative risk, 18
 wound healing, 12
Aggressive mesenchymal tumors
 children, 602
Agonist drugs, 84
AIC, 52–53
AIDS. *See also* Human immunodeficiency virus (HIV)
 immunocompromised, 283
Air bags, 529
Air leak test, 290, 291f
Airways, 404
 assessment of, 28, 73–74
 in asthma, 29
 BSSO, 1161
 children, 103, 528
 craniofacial dysostosis syndrome, 902–903
 gunshot wounds, 515–516
 management of difficult, 75f
 obstruction of
 in odontogenic infection, 281
 oral cancer, 635
 panfacial fractures, 552
 security of, 284
 trauma patient, 330
Alabaster skin, 1428

- Alanine aminotransferase (ALAT), 35, 77
- Alar base
alterations in, 1256
cinch suture, 1237f
reduction, 1363f
- Alar cinch, 1236, 1441f
with V-Y closure, 1236–1237
- Alar width
rhinoplasty, 1353
- ALAT, 35, 77
- Albright's syndrome, 597, 682
- Albumin, 34
- Albuterol
for asthma, 29
- Alcohol abuse, 39, 281, 1298
anesthesia with, 121
immunocompromised, 283
squamous cell carcinoma, 617
- Alcohol withdrawal
oral cancer, 635
- Alfentanil
chemical structure of, 88f
end-stage TMJ disease, 1017
pharmacology of, 89
- Alignment, 795f
- Allen's test
abnormal, 808f
- Allergic fungal sinusitis (AFS), 301, 304f
- Allergic rhinitis, 106–107, 299
- Allewyn spray, 718
- AlloDerm, 220–221, 221f
- Allogenic bone implants, 166
- Allografts, 786t, 787
- Alloplastic chin implants
soft tissue changes associated with, 1232t
- Alloplastic esthetic facial augmentation,
1435–1447
- Alloplastic graft, 787
- Alloplastic materials, 1008
- Alopecia, 1403
- Alpha-blockers
for hypertension, 32
- Alpha-glucosidase inhibitors
mechanism of action, 60t
- Alpha-hydroxy acid, 1422
- Alpha-interferon
for central giant cell granuloma, 604
- Aluminum oxide, 1008
cemented abutment
with all-ceramic crown, 257f
- Alveolar and dental fractures
etiology of, 383–384
hard tissue and pulp, 387–397
historic perspectives of, 383
incidence of, 383–384
management of, 383–399
maxillofacial examination, 384–386
patient history, 384
physical examination, 384
radiographic examination, 386–387
- Alveolar artery, 1248
- Alveolar bone
in edentulous patient
characteristics of, 157–158
injuries
diagram of, 390f
loss, 263f
preservation of, 167–171
- Alveolar cleft
grafting, 859–869
allogenic bone and bone substitutes,
863–864
bilateral, 865f
calvarial bone, 863
central incisor, 861
dental vs. chronologic age, 861
lateral incisor, 861
late secondary, 862
maxillary central incisor, 865f
multidisciplinary team, 862
outcomes, 859
pre-vs. postsurgical orthodontics, 864–865
primary, 860
rationale for, 859
secondary, 860–862
social issues, 861
source of bone graft, 862–864, 863t
sulcular incision, 866f
surgical technique, 865–866
timing, 859–862, 860t, 861t
unilateral, 862f, 864f
reconstruction
occlusal radiograph, 868f, 869f
reconstruction of, 859–869
- Alveolar distraction devices, 1293f
- Alveolar distraction osteogenesis, 183–185,
230–231
dental implants, 1290–1293
- Alveolar distractors, 1291f
- Alveolar mucosa
treatment, 396–397
- Alveolar osteitis, 149, 151
- Alveolar process
anterior, 1182
fractures
treatment, 395–396
growth of, 1063
- Alveolar ridge
cancer, 621
survival, 645
reconstructive surgery of, 180–181
squamous cell carcinoma, 621f
- Alveoloplasty, 168–169
- Alveolus
squamous cell carcinoma, 644–645
- Ameloblastic carcinoma, 588–589
- Ameloblastic fibroma, 590f
- Ameloblastic fibro-odontoma, 590, 590f
- Ameloblastoma, 583–588
benign, 588f, 589f
malignant metastasizing, 588
mural unicystic, 586
peripheral, 587–588
solid or multicystic, 583–585, 584f, 585f
unicystic, 585–586, 586f, 587f
- American College of Cardiology
cardiovascular risk factors, 19–20, 20t
perioperative evaluation for noncardiac
surgery, 47
- American M-16, 512
- American Society of Anesthesiologists (ASA)
Classification of Physical Status,
66, 66t
- Amide
avoiding in malignant hyperthermia, 38
- Amifostine, 638
- Aminocaproic acid, 473
- Aminosteroids
pharmacology of, 98
properties, 99t
- Amitriptyline
end-stage TMJ disease, 1022, 1023
- Amoxicillin
for bites, 362
for infectious endocarditis prophylaxis, 24t
for odontogenic infection, 289
for rhinosinusitis, 305, 502
for sinus infection, 305
- Amphetamine abuse
anesthesia with, 121
- Amphotericin B
for fungal sinusitis, 307
- Ampicillin, 944
for COPD, 30
for infectious endocarditis prophylaxis, 24t
- Amyloidosis, 38
- Anakinra
for rheumatoid arthritis, 36
- Ancient Egypt, 189
- Andreasen classification, 387
- Anemia, 30–31
- Anemia of chronic disease, 38
- Anesthesia
general
risk after myocardial infarction, 20
inhalation
pharmacology of, 93–97
properties of, 94t
local
TMJ, 953
outpatient
distribution of, 84–85
pharmacodynamics of, 83–85
pharmacokinetics of, 84–85

- pharmacology of, 83–100
 - regional
 - end-stage TMJ disease, 1017
- Aneurysmal bone cyst, 605, 606f
- Aneurysms
 - maxillary fractures, 442
- Angina, 19, 48–49, 66–67
 - Ludwig's, 284
- Angiogenesis, 5, 8
- Angiography
 - for neck injuries, 518
- Angiotensin-converting enzyme (ACE)
 - inhibitors
 - for aortic regurgitation, 25
 - for congestive heart failure, 22, 26
 - for hypertension, 32
- Angiotensin receptor blockers (ARB)
 - for hypertension, 32
- Angle fractures, 409
 - Champy method, 373f
 - load-sharing fixation, 375
 - widening mandible, 381f
- Angle regions
 - bimanual pressure over, 406f
- Animal bites, 362
- Ankylosed maxillary cuspid
 - partially submerged, 1116f
- Ankylosed permanent tooth, 1131–1132
- Ankylosed primary tooth, 1131
- Ankylosed teeth, 1115, 1131
 - orthodontics, 1132
- Ankylosing spondylitis, 37, 1036, 1037
- Ankylosis, 390–391, 460, 1289
 - after prosthesis placement, 1038
 - bilateral bony, 1039f–1040f
 - computed tomography, 428f
 - of condyle, 1040
 - extra articular, 1035
 - and mandibular fractures, 428–429
 - of TMJ, 1035f, 1041f–1043f
 - and traumatically induced effusions, 412
 - of zygomatic arch coronoid, 460
- Anodontia, 238f
- Anomalies. *See also* Congenital anomalies; Developmental anomalies
 - acquired, 1205
 - Kleeblattschädel, 925–926, 926f
- Anorexia nervosa, 39
- Anosmia, 503
- Antagonist drugs, 84
- Anterior capsular release, 975
- Anterior dislocation, 410–411
- Anterior ethmoidal artery, 465
- Anterior ethmoidal nerve, 1349
- Anterior mandible
 - FPD, 262
- Anterior maxillary congenital deformities, 1287f
- Anterior maxillary defect
 - interpositional grafting, 230f
- Anterior maxillary osteotomy, 1193–1196
- Anterior maxillary segmental osteotomies, 1123, 1123f
- Anterior nasal spine, 436
 - reduction
 - maxillary osteotomy, 1241f
 - poor esthetic outcome, 1241f
- Anterior open bite, 1262–1263, 1291f
- Anterior segmental setback osteotomy
 - soft tissue changes associated with, 1226t
- Anteroposterior arch asymmetry, 1129
- Anteroposterior orthopedic treatment, 1073–1076, 1076–1077
- Anticholinergic medications
 - effects of, 100t
 - with ketamine, 111
 - pharmacology of, 99–100
 - reversal doses of, 99t
- Anticholinesterase
 - pharmacology of, 98–99
- Anticytokines
 - for rheumatoid arthritis, 36
- Antidepressants, 953t
 - for TMJ, 952–953
- Antiemetic medications, 100–101
- Antihistamines
 - adverse effects of, 307
 - children, 115
 - for TMJ, 952
- Antileukotriene drugs
 - for asthma, 29
- Antineoplastic drugs
 - and wound healing, 11
- Antioxidants, 1421
- Antiphospholipid antibodies, 37
- Anxiolytics
 - for TMJ, 952
- AO/ASIF
 - compression plates, 402
 - fracture management biomechanical principles, 373
- Aortic regurgitation, 24–25, 68
- Aortic stenosis, 25, 68
- Apert syndrome, 527, 915, 917f–922f, 922f–923f
 - cranial vault expansion, 915
 - lower facial esthetic reconstruction, 915
 - primary cranio-orbital decompression, 915
 - total midface deformity, 915
- Apthous stomatitis, 692f
- Apthous ulcers, 691–692
- Apical repositioned flap
 - canine teeth labially impacted, 135f
- Apnea, 58
- Apoptosis
 - vs. proliferation, 576f
- Approximation, 832
- Arachidonic acid, 1019f
- ARB
 - for hypertension, 32
- Arch, 1386f
 - creating space in, 1121–1122
 - length, 1111–1132, 1112f
 - load, 403f
 - width, 1113
- Arch bars, 372f, 415, 439f
 - isolated mandibular body fracture, 377f
- Archigenes, 383
- Arcus marginalis, 466
- ARDS, 348, 354
- Aripiprazole
 - for psychotic disorders, 39
- Arnold's nerve, 1451
- Arrhythmias, 51–52
- Arterial blood gases (ABG), 28
- Arterial oxygen tension, 332
- Arthrocentesis
 - TMJ, 963–987
- Arthroplasty
 - condyle, 1003f
- Arthroscope
 - TMJ, 969
- Arthroscopic knives, 1000f, 1006f
- Arthroscopic osteoplasty, 978f
- Arthroscopy
 - TMJ, 963–987
 - contraindications for, 967–968
 - development of, 964–965
 - history, 965–966
 - imaging, 966
 - indications for, 966–967
 - instruments, 968–971, 985–986
 - patient selection, 965–966
 - physical examination, 965–966
- Articular apparatus
 - nonfracture injuries of, 410–411, 410t
- Articular cartilage, 934, 935f
- Articular disk
 - TMJ, 935–936
- Articular eminence
 - endaural view, 973f
- Articular tubercle
 - disk impingement, 972f
- ASA Classification of Physical Status, 66, 66t
- Ascending ramus fracture, 409
- Aseptic necrosis, 1250, 1250f
- Asian lid crease reformation, 1334f
- Asian upper eyelid, 1320
 - blepharoplasty, 1334
- Aspart
 - onset, peak and duration, 61t
- Aspartate aminotransferase (AST), 77
- Aspergillus flavus*, 301
- Aspergillus fumigatus*, 300–301

- Aspergillus* sinusitis, 304f
 Aspiration, 106
 Aspirin
 for cerebrovascular disease, 37
 determining preoperative risk, 18
 for fever, 287
 Aspirin-sensitivity triad, 299
 AST, 77
 Asthma, 28–29, 299
 bronchial, 72–73
 pulmonary assessment, 54–55
 questions about, 29t
 Asymmetric hybrid functional appliance, 1073f
 Asymmetric skull
 CT, 1209f
 Asymmetry. *See also* Facial asymmetry
 anteroposterior arch, 1129
 zygomatic arch fractures, 457
 Asymptomatic patients
 screening tests for, 79
 Atenolol
 avoidance in liver disease, 35
 ATLS, 330
 Atracurium
 properties, 99t
 Atrial dysrhythmias, 27
 Atrial fibrillation, 24, 27, 51
 Atrial flutter, 27
 Atrioventricular blocks, 27–28
 Atrophic mandible, 185f
 augmentation, 195–197
 gingival graft, 211
 iliac crest corticocancellous block graft augmentation, 196f
 implants without grafting, 197
 plane radiograph, 196f
 wishboning, 380, 380f
 Atrophic maxilla
 gingival graft, 211
 Atropine, 99, 106, 473
 with ketamine, 111
 Attention deficit hyperactivity disorder (ADHD)
 anesthesia with, 119
 Auditory canal
 external
 sectioned, 995f
 Auricle. *See* Ear
 Auriculotemporal nerve, 1390
 Auriculotemporal syndrome, 1263
 Austin-Flint murmur, 25
 Autism
 anesthesia with, 119–120
 Autogenous bone grafts
 sites for, 787–792
 Autogenous conchal cartilage, 1008
 Autogenous fascia interpositional grafts, 1007
 Autogenous grafts, 168
 Autoimmune disease, 690–691
 implants, 252
 Autologous fat injection, 1413–1414, 1414f
 Autologous fat transfer, 1412–1415
 complications, 1414–1415
 Automatic implantable cardioverter
 defibrillators (AIC), 52–53
 Avulsions, 361–362, 393–394
 ear, 368f
 lip, 369f
 maxillary fractures, 441
 splints, 395, 396t
 temporary storage of, 393
 treatment, 393–394, 395t
 Axial frontonasal flaps, 772, 773f
 Axial pattern flaps, 716–717
 Azathioprine
 for rheumatoid arthritis, 36
 Azithromycin
 for infectious endocarditis prophylaxis, 24t
 for rhinosinusitis, 502
 B
 Babinski sign, 346
Bacteroides (Porphyromonas), 140, 426
 Baker-Gordon phenol peel, 1427–1428
 complications from, 1428f
 formula of, 1428t
 frosting from, 1429f
 Ballistics, 510
 Balloon catheters
 nasal packing, 517f
 Bands of Büngner, 824
 Bar attachment, 264, 265f
 overdenture, 264f
 Barbiturates
 pharmacology of, 89–91
 Barbituric acid
 chemical structure of, 90f
 Bar-clip attachments, 265
 Bardach two-flap palatoplasty, 852
 Barium swallow
 vs. esophagoscopy
 for neck gunshot injuries, 518
 Barlow's syndrome, 69
 Barosinusitis, 299
 Bar-retained denture, 264f
 Barton dressing, 287f
 Basal cell cancer
 nasal, 707f
 Basal cell carcinoma, 700, 706f, 712f
 indiscreet temple, 716f
 of left temple, 714f
 Mohs' micrographic surgery removal, 717f
 NMCS, 697
 nodulo-ulcerative, 701f
 resection, 719f
 superficial, 718f
 Basal cell nevus syndrome, 698
 clinical features of, 570t
 Basaloid squamous cell carcinoma, 632
 Base alar reduction
 nasal, 1363
 Basic fibroblast growth factor (bFGF), 193
 Basic multicellular unit (BMU), 7
 Basilar skull fractures, 471
 Battle's sign, 346, 429, 471
 Beaking, 974, 977f
 Beck's triad, 338
 Behçet's syndrome, 692
 Bekhterev's disease, 1036
 Belfast Study Group, 139, 140
 Bell hand engine, 1430
 Bell's phenomenon, 1330
 Benign fibro-osseous disease, 597–600
 cemento-osseous dysplasia, 598–599
 fibrous dysplasia, 597–598
 Benign mucosa membrane pemphigoid (BMMP), 690–691
 Benign ventricular ectopy, 52
 Benzamides
 children, 117
 Benzodiazepines, 952t, 953t
 for delirium tremens, 39, 635
 for depression, 39
 in elderly, 41
 with ketamine, 111
 pharmacology of, 85–87
 for TMJ, 952
 Benzylisoquinolines
 pharmacology of, 98
 properties, 99t
 Bernard flap, 666, 666f
 Beta-agonists
 for asthma, 29
 Beta-antagonist
 for hyperthyroidism, 34
 Beta blockers, 20, 23
 for atrial fibrillation, 24
 for hypertension, 32
 Beta carotene, 641
 Beta-lactam
 for odontogenic infection, 289
 Beta-sympathetic antagonists
 reduction in liver disease, 35
 bFGF, 193
 Bicornal flap, 551
 Bicortical screws, 1259f
 Bicuspid
 mandible
 impacted, 136
 progressive soft tissue recession, 212f
 Biguanides
 mechanism of action, 60t
 Bilateral alar base wedge, 1243f

- Bilateral body osteotomy, 1125f
 Bilateral sagittal split osteotomy (BSSO), 1137
 bleeding, 1160
 complications of, 1155–1156
 indications for, 1150
 of mandible, 1214
 for mandibular horizontal deficiency, 1153f–1154f
 modification, 1155
 technique, 1150–1155
 illustrated, 1152f
 of vertical ramus, 1150–1161, 1277
 Bilevel positive airway pressure (Bi-PAP)
 OSA, 1304
 Bilobed flap of Zitelli
 nasal, 714
 Bilobed flaps, 771f, 773–774
 Bimanual examination, 496, 496f
 Biofeedback
 for TMJ, 957
 Biologic creep, 712
 Biopsy forceps
 TMJ arthroscopy, 970
 Bi-PAP
 OSA, 1304
 Bipolar (manic-depressive) disorders, 39
 Bite appliances, 1009
 Bite depth, 1106
 Black necrotic eschars, 301
 Blade implants, 190f
 Blair, Vilray, 840
 Blair's horizontal osteotomy of vertical ramus, 1135, 1136f
 Blanch test, 338
 Bleeding
 BSSO, 1160
 control of, 339–340
 flaps, 720
 gunshot wounds, 516–517
 with impacted teeth removal, 150
 internal sites of, 341
 Le Fort level fractures, 438
 lower eyelid blepharoplasty, 1341
 mandible, 1249
 maxilla, 1247–1249
 maxillary fractures, 442
 TMJ
 internal derangement, 1010
 upper eyelid blepharoplasty, 1340
 Bleeding disorders
 assessment of, 78
 Bleomycin, 682
 Blepharoplasty, 1317–1342
 adjunctive procedures, 1341–1342
 anatomy, 1317–1326
 anesthesia, 1331
 chief concern, 1326–1327
 complications, 1339–1341
 lower eyelids, 1334–1337
 patient evaluation, 1326–1331
 photographic documentation, 1331
 physical examination, 1328–1330
 postoperative management of, 1337–1339
 upper eyelids, 1331–1334
 Blind finger dissection, 1397f
 Blindness, 464
 maxillary fractures, 442
 Blood clot, 4, 4f, 8
 Blood pressure
 children, 105, 528
 in trauma patient, 337
 Blow-in fractures, 467, 472
 children, 536–537
 Blown pupil, 347
 Blow-out fractures, 457f, 477, 485
 bilateral, 536f
 children, 536–537
 of left orbital floor, 538f
 orbital, 484
 Blue bloater, 73
 BMMP, 690–691
 BMP, 13, 785, 787
 BMU, 7
 Boat tail bullet, 514
 Body fracture, 409
 Body temperature
 restoration and maintenance of, 343
 Bolton's analysis, 1112–1113, 1113f
 Bonded orthodontic bracket, 134
 Bone
 allogenic implants, 166
 biology of, 785–786
 healing
 osseointegration, 192–193
 secondary, 373f, 374f
 indirect healing, 6, 373f, 374f
 loss
 secondary, 159
 maturation stages of, 167f
 regeneration of, 6
 principles of, 162–164
 remodeling, 7
 tension-stress, 164
 volume
 implant prosthodontics, 252
 inadequate posterior, 236f
 wound healing, 6–7
 Bone grafts, 165–167, 786t
 autogenous
 sites for, 787–792
 benefits of, 1268–1269
 biology of, 786–787
 cleft maxilla/palate, 1269f
 timing and sequencing, 1268–1269
 cranial, 788, 788f, 789f, 790f
 cranial onlay
 maxilla, 263f
 guided
 augmentation, 223
 harvesting, 196
 iliac crest, 268f, 789–791, 862–863
 inlay, 179–180
 intraoral, 787–788
 donor site, 787f
 onlay, 177–179, 1274f
 orbital floor
 zygomatic arch fractures, 457
 panfacial fractures, 551–552, 552f
 sinus, 232–234, 241f
 tibial, 791–792, 792f
 vertical alveolar augmentation, 223–234
 Bone marrow needle, 108, 108f
 Bone morphogenetic proteins (BMP), 13, 785, 787
 Bone plates, 372f, 378f, 439
 biomechanical effectiveness of, 377f
 device, 185
 fatigue, 379–380
 vs. lag screws, 379
 Le Fort I level fracture, 375f
 load-bearing fixation, 375f
 strong, 380f
 symphysis fracture, 382f
 Bone tunnel fixation, 1399f, 1400
 Booster seats, 529
 Botulinum toxin A, 1329
 Botulinum toxin-assisted brow lift, 1401
 Bowman-Birk inhibitor, 641
 Bowstring test, 496, 496f
 Brachycephaly, 889f, 895f, 908f
 Brachytherapy, 637
 Brackets, 1130f
 Bradycardia, 25
 with hypertension, 345
 Brain
 damage caused by hypertension, 32
 growth
 craniofacial dysostosis syndrome, 901–902
 limitations, 887–888
 Brånemark drilling system, 191
 Brånemark protocol, 201
 Breast-feeding
 cleft lip/palate, 844
 Breast-feeding mothers, 42
 medications for, 42t
 Breath-holding test, 28
 Breathing
 trauma patient, 332–337
 Bridging fixation. *See* Load-bearing fixation
 Bronchi
 children, 103
 Bronchial asthma, 72
 Bronchiectasis, 73

- Bronchitis, 73
 Bronchoscope
 rigid, 624
 Bronchospasm, 29
 Bronstein and Merrill arthroscopic staging
 IJD, 968t
 Brophy, Truman, 840
 Brow
 youthful, 1384f
 Brow incision
 lateral, 452, 482
 Brow lift, 1383–1403, 1395
 bony landmarks, 1384–1389
 complications, 1402–1403
 endoscopic view, 1391–1393, 1396–1400,
 1396f
 muscle and fascial anatomy, 1385–1386
 positions, 1383f
 postoperative care, 1402
 preoperative evaluation, 1393–1395
 skin care and micropigmentation, 1401–1402
 vessel and nerve anatomy, 1389–1391
 Brown dermatome, 718
 Brown technique, 423f
 Bruxism
 drug-induced, 1023
 implants, 252
 BSSO. *See* Bilateral sagittal split osteotomy
 (BSSO)
 Buccal advancement flaps, 772f
 Buccal artery, 144
 Buccal flaps
 full-thickness mucoperiosteal, 866
 Buccal fragment
 after osteotomy, 180f
 Buccal mucosa
 flap, 1270f
 squamous cell carcinoma, 621f, 642, 642f
 verrucous carcinoma, 631f
 Buccal object rule, 133
 Buccal segment, 1257f
 Buccal space
 borders of, 278t
 infection, 279t
 Buccinator, 1184
 Buckshot, 513
 Bulimia, 39
 Bullets
 diameter, 511
 fragmentation, 511
 kinetic energy, 510–511
 velocity, 511
 wounding power, 510–511
 Bullous pemphigoid, 691
 Bundle branch blocks, 28
 Büngner's band, 6
 Bupivacaine
 for blepharoplasty, 1331
 end-stage TMJ disease, 1017
 Burns, 1248f
 TMJ
 arthroscopy, 986
 Burow's triangle, 367f, 665f, 772
 Buser periosteal elevator, 213, 218
 Busulfan, 682
 Buttress, 547–548
 Butyrophenones
 for psychotic disorders, 39
 C
 Cadaveric mandible tray
 atrophic mandible, 182f
 Cadaveric mandibular adjustment, 183
 Calcified sialoliths, 674
 Calcifying epithelial odontogenic tumors, 592
 Calcifying odontogenic cysts (COC), 582, 583f
 Calcitonin
 for central giant cell granuloma, 604
 Calcium channel blockers
 for aortic regurgitation, 25
 for hypertension, 32
 Calcium hydroxide paste, 388
 Caldwell-Luc procedure, 152, 232–234, 308,
 309f
 Caldwell's view
 zygomatic complex fractures, 448
 Caliber, 512
 Caloric response, 347, 347f
 Calvaria
 bone formation in, 192–193
 Canaliculus, 364, 365f
 Cancellous grafts, 165
 Cancer chemotherapy
 adjuvant, 639
 immunocompromised, 283
 induction, 639
 neoadjuvant, 639
 nonmelanoma skin cancer, 708
 oral cancer, 638–640
 palliative, 639
Candida, 680
 Candidosis, 680–681, 692
 HIV, 689
 oral, 680f, 681f
 Canine teeth
 labially impacted
 apical repositioned flap, 135f
 removal of, 136
 palatal impacted
 removal of, 136
 Cannula, 1408–1409, 1409f
 TMJ arthroscopy, 970
 Canthal ligament
 lateral, 1321–1322
 Canthal ligaments, 1322f
 Canthal tendons, 446
 Canthotomy
 lateral, 453
 Cantilevered fixed partial denture, 263, 263f
 extension of, 265
 Cantilevering, 256f
 Capillary filling time, 338
 Capnography, 59
 Capsaicin
 end-stage TMJ disease, 1017
 Capsular ligament, 936, 936f
 Capsular tightening procedure, 1005f
 Carbamazepine, 691
 Carbon dioxide lasers
 photoaging, 1431
 Carbon dioxide snow, 386
 Carboplatin, 639, 640
 Cardiac assessment, 47–53
 algorithm, 72f
 arrhythmias, 51–52
 automatic implantable cardioverter
 defibrillators, 52–53
 chest pain suggesting myocardial
 infarction, 50
 decompensated congestive heart failure, 50
 myocardial ischemia, 48–49
 recent myocardial infarction, 49–50
 Cardiac disease, 18–28
 assessment of, 66–70, 107
 cardiac dysrhythmias, 26–28
 congestive heart failure, 26
 coronary artery disease, 18–22
 mitral valve prolapse, 24–25
 Cardiac dysrhythmias, 26–28
 Cardiac output
 age-related changes, 41
 children, 104–105
 Cardiac risk
 index of, 67t
 morbidity and mortality based on, 48t
 Cardiac tamponade, 338, 339
 Cardiomyopathy, 69
 Cardiovascular system
 nicotine effect on, 57
 normal function, 105t
 C-arm fluoroscopy unit, 499
 Carotid artery, 1248
 Carotid stenosis, 37
 Carpenter syndrome, 903
 Carroll-Girard screw, 451, 452f
 Cartilage. *See also* specific cartilage
 nasal septum, 1357f
 nose, 1347–1348
 TMJ, 934–935
 Cartridges, 512
 muzzle energy, 511t
 velocities, 511t
 Cast cap splints, 415
 Cataplexy, 1298

- Cataract surgery, 472
 Cat bites, 362f
 Catecholamines, 338
 Cavernous sinus thrombosis, 278, 304
 Cavity, 511
 CCR, 30
 Cefazolin
 for infectious endocarditis prophylaxis, 24t
 Cefotaxime, 944
 Cefpodoxime
 for rhinosinusitis, 502
 Cefprozil
 for rhinosinusitis, 502
 Cefuroxime
 for rhinosinusitis, 502
 Celecoxib
 for rheumatoid arthritis, 36
 Cell cycle, 576f
 Cellulitis, 282f
 Cemento-osseous dysplasia, 598–599
 Cement retention
 vs. screw retention, 260t
 Central anticholinergic syndrome, 99–100
 Central giant cell granuloma, 603–605, 603f, 604f
 Central sleep apnea, 1298
 Cephalometric analysis, 1113f
 craniofacial dysostosis syndrome, 905
 Cephalometric films
 alveolar ridge, 163f
 edentulous mandible, 194
 implants, 253, 253f
 lateral
 facial asymmetry, 1209
 for preprosthetic and reconstructive surgery, 161
 Cephalometric radiographs
 lateral
 facial asymmetry, 1209
 posteroanterior
 facial asymmetry, 1209
 Cephalosporin
 avoided with renal patients, 31
 for rhinosinusitis, 305
 for TMJ arthroscopy, 984
 Cerebral. *See* Brain
 Cerebral palsy, 1207
 anesthesia with, 119
 Cerebrospinal fluid (CSF)
 normal values of, 495t
 Cerebrovascular disease, 37
 Cervical incisions, 551
 Cervical lymphadenectomy
 lip cancer, 666
 Cervical lymph nodes
 levels, 619–620
 squamous cell carcinoma, 646–648
 Cervical spine
 injuries, 350–351
 radiograph, 351, 351f
 trauma patient, 330
 Cervical wire, 134
 Cervicofacial liposuction, 1407–1411
 anesthesia, 1409
 complications, 1411
 history, 1407
 indications for, 1407–1408
 instrumentation, 1408–1409
 patient evaluation, 1408
 technique, 1410–1411
 Champy method, 373f
 Champy miniplate technique, 376
 Charcot-Leyden crystals, 301, 303
 Chase method, 40
 Cheek
 augmentation, 1443–1446, 1445f
 stabilization, 1444f
 undermining, 1444f
 high-velocity entrance wound, 520f
 Cheever, David, 435
 Chemexfoliation, 1341–1342
 Chemical peeling, 1341–1342, 1421–1422
 deep, 1427–1429
 medium-depth, 1424–1427, 1424t, 1425f, 1426f, 1431f
 superficial, 1422–1423
 Chemoreceptor trigger zone, 100, 100f
 Chemotherapy. *See* Cancer chemotherapy
 Cherubism, 604–605, 605f
 Chest
 examination of
 in trauma patient, 348–349
 normal radiography of, 348f
 Chest tube
 for pneumothorax, 333, 334f
 Chest wall
 children, 528
 inspection of, 332
 Chewing, 405
 Child abuse, 384, 529
 Children, 42
 abdomen, 528
 adenoids, 103
 aggressive mesenchymal tumors, 602
 airways, 103, 528
 anatomic considerations, 528–529
 blood pressure, 105, 528
 blow-in fractures, 536–537
 blow-out fracture, 536–537
 bronchi, 103
 cardiac output, 104–105
 cardiovascular system, 104–105
 chest wall, 528
 condylar process, 529
 condyle fracture
 open reduction, 539
 cranial vault fractures, 532
 craniomaxillofacial fractures, 527–542
 complications, 531–532
 diagnosis of, 529–530
 epidemiology of, 530–532
 historic perspectives, 527–528
 mechanism of, 530t
 patterns of, 530, 532–542
 prevention of, 529
 by region, 530t, 531t
 treatment, 531t
 dentoalveolar injuries, 383–384, 397–398, 398t, 541–542
 emergency treatment on full stomach, 106
 endotracheal intubation, 104
 facial trauma, 540f
 fluid requirements for, 42t
 FRC, 104
 frontal sinus fractures, 532–534
 hypothermia, 528
 impacted teeth, 144
 impacted tooth removal, 142–143
 Le Fort (midface) fractures, 534
 mandible, 529
 mandibular condyle fractures, 538–539
 mandibular fractures, 424–425, 538–542
 mandibular subcondyle fractures, 538–539
 maxillary fractures, 441
 nasal air passages, 528
 nasal fractures, 537–538
 naso-orbitoethmoid fractures, 532–534
 neural innervation, 105
 paranasal sinuses, 529
 parasymphyseal fractures, 541
 periosteum, 529
 permanent tooth buds, 529
 resorbable fixation materials, 542
 ribs, 103
 sedation, 103–123
 anatomic and physiologic considerations, 103–105
 perioperative complications, 115–116
 pharmacologic agents, 110–115
 preoperative evaluation, 105–106
 routes of administration, 107–110
 techniques for, 107–115
 substance abuse, 120–123
 supraorbital ridge fractures, 532
 tongue, 103
 tonsils, 103
 trachea, 103, 104
 upper respiratory infection, 106–107
 urine output in, 42t
 ventilation, 103
 zygomatic complex fractures, 534–537
 Chin
 alloplastic augmentation, 1435–1437
 alloplastic implants

- soft tissue changes associated with, 1232t
- augmentation, 1438f
 - liposuction, 1412
- poor esthetic results, 1241
- ptosis, 1242, 1243f
- Chin cup, 1077f
- Chinese gunpowder, 509
- Chin-lift procedure, 330, 332f
- Chin-neck anatomy, 1100
- Chin point deviation
 - distraction, 1280f
- Chisel, 1248f
- Chloral hydrate
 - children, 115
- Chlordiazepoxide
 - reduction in liver disease, 35
- Chlorhexidine
 - for alveolar osteitis, 151
- Cholesterol, 19
- Chondrocytes, 934
- Chondroitin
 - TMJ, 942
- Chondroma, 601, 602f
- Chronic obstructive pulmonary disease (COPD), 29–30
- Chronic renal disease
 - immunocompromised, 283
- Chuck changer, 242f
- Chyle leak, 519f
- Cicatricial pemphigoid, 690–691, 690f, 691f
- Cigarette smoking, 300
 - involuntary exposure
 - risks of, 58
 - lip cancer, 659
 - perioperative effects of, 56–58
 - preoperative cessation of, 30
- Cilia, 297, 298f
- Ciliary nerve, 1326
- Cimetidine, 106
- Cinch suture
 - alar base, 1237f
- Ciprofloxacin
 - for odontogenic infection, 289
- Circle of knowledge and caution, 1373–1374, 1375f
- Circulation
 - trauma patient, 337–344
- Circumoral tissue
 - collapsed, 182f
- Circumvestibular incision, 1271, 1271f
 - intraoral mucosal, 534
- Cisatracurium
 - properties, 99t
- Cisplatin, 639, 640
- Clarithromycin
 - for infectious endocarditis prophylaxis, 24t
 - for rhinosinusitis, 502
- Clavicle
 - bone formation in, 192–193
- Clear cell odontogenic carcinoma, 589
- Cleft lip/palate, 839–855, 842f, 1206
 - bilateral repair, 847–849, 850f, 851f, 852f
 - bone graft reconstruction, 881
 - breast-feeding, 844
 - classification, 842, 843f
 - complex facial clefting, 853–855
 - dental and prosthetic rehabilitation, 883–884, 883f, 884f
 - embryology, 841
 - etiology, 841–842
 - feeding, 843–844
 - fistula closure, 872–875
 - indications for, 872–873
 - operative technique, 873–875, 873f, 874f
 - genetics, 841–842
 - historical perspective of, 840–841
 - incidence of, 1267
 - lip adhesion, 847
 - midfacial deficiency
 - orthognathic surgery, 881
 - nasal deformity reconstruction, 881–882
 - orthognathic surgery, 1267–1275
 - bone grafting with maxillary advancement, 1272–1273
 - presurgical counseling, 1270–1271
 - outcome, 855
 - prenatal counseling, 842–843
 - presurgical taping and orthopedics, 846–853
 - reconstruction stages, 871t
 - repair, 849–853
 - revisional surgery, 881–883
 - scar revision surgery, 882–883
 - secondary procedures, 871–884
 - staged reconstruction of, 845t
 - submucous, 880–881
 - treatment planning and timing, 844–846
 - unilateral repair, 847, 848f, 849f, 853f
 - velopharyngeal dysfunction, 875–880, 875f
 - complications, 879–880
 - operative technique, 878–879
 - timing, 877–878
 - Z-type repair, 849f
- Cleft maxilla/palate
 - bone grafting, 1269f
 - timing and sequencing, 1268–1269
- Cleidocranial dysplasia
 - multiple impacted teeth in, 132f
- Click-murmur syndrome, 69
- Clindamycin
 - for infectious endocarditis prophylaxis, 24t
 - for sinus infection, 305
- Clinical and dental model diagnosis, 1111–1118
- Clinical diagnosis, 564
- Clinical examination, 565–566
- Clinical impression, 564
- Clinical neurosensory testing (CNT), 825–826, 826t
 - algorithm, 827f
- Clinician
 - neophyte *vs.* expert clinician
 - case study, 567–568
- Clip overdenture retention
 - two-implant bar, 194f
- Clonidine
 - for hypertension, 32
 - for hypertensive crisis, 50t
 - for opioid withdrawal, 39–40
- Closed lock phenomenon, 990
- Closed pneumothorax, 333, 335f
- Closed reduction, 401
 - mandibular fracture, 413–414
- Closed technique
 - subepithelial connective tissue grafting
 - implants
 - recipient-site surgery, 214–215, 215
- Cloverleaf skull anomaly, 925–926, 926f
- CNT, 825–826, 826t
 - algorithm, 827f
- Coaptation, 832–833
- Cobalt
 - effect on wound healing, 12
- COC, 582, 583f
- Cocaine, 40
 - anesthesia with, 121
- Coil springs, 1126f
- Cold
 - common, 299
- Cold therapy
 - for TMJ, 956
- Collateral (diskal) ligaments, 936
- Colonial America, 189
- Combes' formula, 1422t
- Commando's operation, 645
- Comminuted fractures, 409f, 410
 - grossly, 410
 - mandible
 - fixation, 375
- Commissure height, 1090
- Common cold, 299
- Competitive antagonists, 84
- Complete strip technique, 1362f
- Complex fractures, 410
- Compliance, 22
- Complicated fractures, 410
- Composite grafts, 719
- Compound fracture, 409–410, 409f
- Compression (Raney) clips, 483
- Compression plates, 372f, 378f
 - AO/ASIF, 402
 - osteosynthesis
 - vs.* noncompression plate osteosynthesis, 378

- Computed tomography (CT), 569
 abdominal injuries, 352, 354t
 ankylosis, 428f
 asymmetric skull, 1209f
 cervical lymph nodes, 647, 647f
 cervical spine injuries, 351
 condyle mechanical displacement, 1159
 craniofacial dysostosis syndrome, 905
 edentulous mandible, 194
 facial asymmetry, 1209
 frontal sinus
 anterior table fractures, 499
 posterior table fractures, 499
 head trauma, 345, 346f
 implants, 253, 270f
 intracerebral hemorrhage, 346f
 mandibular cancer, 645–646
 mandibular fracture, 407
 mandibular fragmentation
 gunshot wounds, 520f
 maxillary fractures, 439f
 maxillary sinuses, 163f
 NOE fracture, 496, 497f
 oral cancer, 625, 625f
 orbital fractures, 468, 470
 OSA, 1301
 osteomeatal complex, 303f
 osteomyelitis, 315
 panfacial fractures, 550–551, 550f, 551f
 paranasal sinuses, 304f
 pediatric craniomaxillofacial fractures,
 529–530
 preprosthetic and reconstructive surgery,
 161
 sinus infection, 302–303
 subarachnoid hemorrhage, 346f
 TMJ, 977f
 zygomatic complex fractures, 447–448, 448,
 449f, 450f, 454f
- Computer-databasing program, 1090f
 Computer-generated scanner, 1431
 Computerized cephalometric prediction,
 1107–1108
- Concha bullosa, 298
 Conchal cartilage
 autogenous, 1008
 Conchal hypertrophy, 1453
 Concussion, 391, 503
 Conduit nerve repair, 833f, 834t
 Condylectomy, 1009
 Condyles, 783–784
 adenocarcinoma metastasizing to, 945
 arthroplasty, 1003f
 asymmetry
 panoramic radiography of, 1208f
 children, 529
 classification of, 408
 dislocation, 411f
 fractures, 409, 1035f
 abnormal growth from, 1208f
 children
 open reduction, 539
 closed treatment, 382f
 complications, 429–430
 endoscopic management of, 421f
 IMF, 415
 mandibular hypoplasia, 427f
 with midsymphysis fracture, 381
 open reduction, 418–420
 indications for, 419–420, 419t
 panoramic films, 407, 407f
 range of motion, 406
 stabilization of, 422f–423f
 surgery, 420
 inappropriate positioning of, 1189f
 mandible, 934f
 mechanical displacement of, 1159
 remodeling, 978f
 resorption
 idiopathic, 1291f
 spontaneous resorption of, 1160
 trauma, 1208
- Condylotomy, 1009
 Conformal radiation, 636–637
 Congenital agenesis
 premaxilla, 1285
 Congenital anomalies, 1205, 1206–1207
 altered anatomy in, 104
 cleft lip/palate, 1206
 congenital hemifacial hyperplasia, 1207
 hemifacial microsomia, 1206, 1206f
 plagiocephaly, 1206–1207
 Congenital hemifacial hyperplasia, 1207
 Congestive heart failure, 26, 67–68
 decompensated, 50
 ECG, 22
 symptoms of, 22
 Connective tissue disorders, 36
 implants, 252
 Conscious sedation, 93
 Contact sports, 383
 Contemporary orthognathic treatment
 planning, 1087–1088, 1088f
 Context-sensitive half-time, 85, 86f
 Continuous passive motion (CPM), 540
 device, 1044f
 Continuous positive airway pressure (CPAP)
 OSA, 1304
 Continuous wire loop technique, 415
 Contractility, 49
 Contusions, 360, 397
 Converse-Wood-Smith technique, 1452–1453
 COPD, 29–30
 Copper
 effect on wound healing, 12
 Cornea
 abrasions, 470f, 1402
 laceration, 472f
 reflex, 347
 Coronal forehead lift, 1395
 Coronal incision, 483, 497
 Coronal synostosis
 bilateral, 889
 craniofacial skeleton, 904f
 unilateral, 888–889
 Coronary artery disease, 18–22, 66–67
 echocardiography, 19
 history, 19
 left ventricular dysfunction, 22–23
 physical examination, 19
 postoperative ECG, 20–22
 Cor pulmonale, 73
 Corrugator supercilii, 1387, 1389f, 1392
 Cortical grafts, 165
 Corticosteroids, 62t
 for TMJ, 951–952
 Cortisol, 34
 Cortisporin
 for TMJ arthroscopy, 984
 Cosmetic surgery
 history of, 1317
 Cost
 gunshot wounds, 510
 C osteotomy, 1136, 1137f, 1146–1150
 different forms of, 1149f
 Costochondral grafts, 788–789
 Cottle elevator, 1357f
 Cover screws, 244f
 Cowley, R.A., 527
 COX-2. *See* Cyclooxygenase-2 (COX-2)
 inhibitors
- CPAP
 OSA, 1304
 CPM, 540
 device, 1044f
 Cranial base
 development of, 1060
 malformations, 1065–1066
 neonatal, 1061f
 Cranial bone grafts, 788, 788f, 789f, 790f
 Cranial nerves
 peripheral, 357
 Cranial nerve VII, 1325
 anatomy of, 1325f
 marginal mandibular branch of, 1139–1140
 Cranial onlay bone grafts
 maxilla, 263f
 Cranial vault, 897f
 development of, 1059–1060
 fractures
 children, 532
 Craniofacial defects
 maxillofacial prostheses, 268–269
 Craniofacial dysostosis syndrome

- airway, 902–903
anthropometric surface measurements, 905
Apert syndrome, 915
brain growth, 901–902
Carpenter syndrome, 923
cephalometric analysis, 905
cranial vault dead space, 906–907
Crouzon syndrome, 907–915
CT, 905
dentition, 903
extremities, 903
frontoforehead esthetic unit, 903
hearing, 903
hydrocephalus, 902
ICP, 901–902
incision placement, 906
intervention timing, 906
maxillary-nasal base esthetic unit, 904
morphologic considerations, 903
occlusion, 903
orbitonasozygomatic esthetic unit, 903–904
Pfeiffer syndrome, 922–923
posterior cranial vault esthetic unit, 903
quantitative assessment, 904
reconstruction staging, 901–927
Saethre-Chotzen syndrome, 923–925
soft tissue, 907
surgery
 historic perspectives, 905–906
 vision, 902
Craniofacial fibrous dysplasia, 597
Craniofacial growth and development,
 1051–1080
 during adulthood, 1064
 dental development, 1063
 embryonic period, 1051–1056
 facial development, 1063–1064
 factors influencing, 1064–1070
 fetal period, 1056–1058
 orthodontic camouflage, 1079–1080
 orthopedic and orthodontic considerations,
 1070–1080
 postnatal, 1058–1064
 postnatal factors, 1068–1070
 prenatal factors, 1065–1068
 skeleton, 1058–1063
Craniofacial malformations, 1065–1066
Craniofacial skeleton
 growth and remodeling field of, 165f
Craniomaxillofacial fractures
 children, 527–542
 complications, 531–532
 diagnosis of, 529–530
 epidemiology of, 530–532
 historic perspectives, 527–528
 mechanism of, 530t
 patterns of, 530, 532–542
 prevention of, 529
 by region, 530t, 531t
 treatment, 531t
Craniosynostosis. *See* Nonsyndromic cranio-
 synostosis
Crawford tube, 364, 365f, 503
C-reactive protein (CRP), 314
Creatinine, 77
Creatinine clearance (CCR), 30
Crestal incision, 242
 edentulous mandible, 194
 for mylohyoid ridge reduction, 171
Cribriform plate, 465
Cricothyroidotomy, 281, 516
Cricothyrotomy
 children, 116
Cromolyn sodium
 for asthma, 56
Cross-hair incision, 996
Cross-lip mucosal flaps, 662, 665f
Crouzon syndrome, 104, 907–915, 909f
 and Le Fort III osteotomy, 527
 and Le Fort I osteotomy, 916f
 lower facial esthetic reconstruction,
 912–915
 management of, 905
 pediatric cranio-orbital procedure,
 910f–912f
 primary cranio-orbital decompression,
 907–908
 repeat craniotomy, 908–909
 total midface deformity, 909–912
Crown
 fracture
 with pulp involvement, 389
 without pulp involvement, 388–389,
 390f
 height, 1090
 infraction, 387
 splints, 224
Crown-root fracture, 389
Crow's feet, 1329, 1401
CRP, 314
Crural excision, 1362f
Cryer, Matthew, 840
Cryer elevator, 146
Cryotherapy
 for TMJ, 956
CSF
 normal values of, 495t
CT. *See* Computed tomography (CT)
Culture
 odontogenic infection, 286–287
Curve of Spee, 1107, 1126–1129, 1211
 in maxillary arch, 1130
 measurement for, 1107
 and subapical osteotomy, 1128f
Curve of Wilson, 1115, 1115f
Curvilinear incision
 partial-thickness, 213
Cushing's disease, 34
Cushing's phenomenon, 345
Cuspid-molar position, 1115f
Cutaneous horns, 698
Cutback incisions, 219
Cutting forceps
 TMJ arthroscopy, 970
Cyclooxygenase-2 (COX-2) inhibitors, 641
 end-stage TMJ disease, 1019
 for rheumatoid arthritis, 36
 for TMJ, 951
Cyclophosphamide, 682
Cyclosporine
 for rheumatoid arthritis, 36
CYP-450, 85
Cystic fibrosis, 301–302
Cytochrome P-450 (CYP-450), 85
Cytokines
 TMJ, 942
Cytomegalovirus, 686
D
Dacryocystorhinostomy, 364, 503–504
DalPont's modification of sagittal osteotomy,
 1137f, 1153
Dantrolene, 38, 95
 for malignant hyperthermia, 62–63
Database acquisition and treatment planning,
 1087–1109
Data collection, 1088–1092
 conventional records, 1088–1089
 direct measurement, 1089–1090
Davis, Christopher, 964
Davis method, 1453–1454, 1453f, 1455f
Débridement, 795f
Deciduous teeth
 impacted, 131
Decongestants, 502
Decortication, 1164f
Deep bite, 1095f
Deep heat
 for TMJ, 956
Deep spaces
 head and neck
 borders of, 278t
 infections, 279t
 severity score for, 278
Deep temporal
 infection, 279t
Deep vein thrombosis
 oral cancer, 635
Defect fracture, 321f, 375
Definitive restoration, 237f
Deformities, 1205
Degenerative joint disease, 1208
Degree of dislocation, 408
Degree of displacement, 408

- Delay, 710
 Delayed union
 mandible, 425–426, 1251
 maxilla, 1250–1251
 Delirium tremens, 635
 Deltopectoral flap, 778
 Dental arches, 548–549
 Dental caries
 prevention of, 141
 Dental examination, 1105–1107
 Dental follicle, 575
 Dental fractures. *See* Alveolar and dental fractures
 Dental implants
 alveolar distraction osteogenesis, 1290–1293
 history of, 189–190
 Dental models
 facial asymmetry, 1215f
 Dental papilla, 575
 Dental tissue injuries
 diagram of, 388f
 DentaScan software, 645–646
 Dentate patients
 intermaxillary techniques in, 415–417
 Dentigerous cyst, 576–578, 577f, 578f
 vs. enlarged dental follicle, 577
 prognosis, 577–578
 treatment, 577–578
 Dentition
 craniofacial dysostosis syndrome, 903
 Dentoalveolar fracture, 409
 Dentoalveolar injuries, 383–399, 384f
 adolescents, 383–384
 children, 383–384, 397–398, 398t, 541–542
 classification of, 387–388
 etiology of, 383–384
 hard tissue and pulp, 387–397
 historic perspectives of, 383
 incidence of, 383–384
 maxillofacial examination, 384–386
 patient history, 384
 physical examination, 384
 radiographic examination, 386–387
 Dentoalveolar trauma record, 386, 386f
 Dentofacial deformity
 macroesthetic examination of, 1092–1102
 miniesthetic examination of, 1102–1104
 systematic clinical examination of, 1092–1107
 Dentures
 bar-retained, 264f
 conditioning material, 245f
 fixed partial, 236f, 258
 hybrid
 implant, 254
 mandibular hybrid, 265f
 Denture-sore mouth, 680
 Depression, 38, 1298
 Depressor muscle, 1394f, 1398f
 Depressors, 1385–1386
 Depressor supercillii, 1387
 Depth gauge, 242f
 Dermabrasion
 full-face, 1432f
 motorized, 1430–1432, 1431t
 Dermal fat grafts, 1414, 1414f
 Dermal graft, 1004f, 1006
 Dermal substitutes
 wound healing, 13–14
 Dermasanding
 manual, 1429–1430, 1430f, 1430t
 Dermatofibrosarcoma protuberans, 697
 Dermis, 709
 Desflurane, 95
 chemical structure of, 96f
 children, 115
 pharmacology of, 97
 Desmoplastic fibroma, 602f, 603f
 Developmental anomalies, 1205, 1207
 intrinsic jaw-growth deformities, 1207
 secondary growth deformities, 1207
 Deviated septum, 1256f
 Dexamethasone, 100
 impacted teeth removal, 149
 Diabetes, 281, 282, 424
 effect on wound healing, 10
 implants, 252
 Diabetes insipidus, 607
 Diabetes mellitus, 32–33, 59–61, 76–77
 insulin, 60
 type 2, 33
 diet only, 60
 oral hypoglycemic agents, 60
 Diabetic ketoacidosis (DKA), 32, 77
 Diagnostic list, 1118
 Diagnostic peritoneal lavage (DPL), 352, 354t
 Diagnostic process, 564–566, 564f
 Diamond fraise, 1430
 Diastolic decompensation, 23
 Diazepam
 chemical structure of, 86f
 end-stage TMJ disease, 1022
 with ketamine, 111
 pharmacology of, 86–87
 reduction in liver disease, 35
 Diazoxide
 for hypertensive crisis, 50t
 Diet
 TMJ, 950
 Dietary supplements
 determining preoperative risk, 17–18
 Differential diagnosis
 developing, 566–568
 to final diagnosis
 case study, 564
 microscopic, 571–572
 Differential osteotomy
 knife-edge ridges, 1294f
 Digital videography, 1092, 1093f
 Digoxin
 for congestive heart failure, 22–23, 26
 Dingman, Reed, 840
 Diplopia, 468, 474–475, 503, 1330
 lower eyelid blepharoplasty, 1341
 persistent posttraumatic, 474
 upper eyelid blepharoplasty, 1340
 zygomatic arch fractures, 458–459, 458f, 459f
 Dipyrindamole
 for cerebrovascular disease, 37
 Direct bone healing, 6, 7f
 Direct bone union, 371
 Direct brow lift, 1400
 Direct fixation, 401
 Direct fracture, 409f
 Direct wiring, 415
 Discoid lupus erythematosus (DLE), 691f
 Disk
 horizontal incision, 996
 partial displacement, 1000f, 1001f
 Diskal ligaments, 936
 Disk dancing, 1279, 1279f
 Dislocated fracture, 410
 Displaced fracture, 410
 Displaced tooth, 1115f
 Displaced zygomatic complex
 elderly, 486f–487f
 Displacements, 391
 Dissector, 1368f
 Distal root
 overdevelopment of, 140
 Distoangular impaction, 143
 bone removal, 146
 removal of, 148f
 Distoangular teeth
 eruption, 140
 Distraction approach, 906
 Distraction devices
 disadvantages of, 1292
 Distraction osteogenesis, 1277–1294, 1293f
 alveolar, 183–185, 230–231
 dental implants, 1290–1293
 bony edge separation, 1277f
 complications of, 1293–1294
 mandibular symphysis, 1124–1125, 1125f
 mandibular widening, 1280–1281
 protocol, 1278t
 and regenerate chamber, 1278f, 1279f
 simultaneous maxillary and mandibular, 1281–1282
 soft tissue changes associated with, 1233, 1234t
 transport, 1286–1289, 1289f

- neocondyle, 1289–1290
- Distractor, 1281f
- DKA, 32, 77
- DLE, 691f
- Dog bites, 362
- Dog-ears, 715f
- Doll's eye reflex, 347, 347f
- Donor tissue
soft tissue grafts, 209
- Dorsal hump
removal of, 1358f
- Dorsal nasal artery, 1346
- Dorsal reduction, 1359f
- Double advancement flap, 771f
- Double-ring sign, 533
- Double vision, 469f
- Double V-Y closure, 1239–1241, 1242f
- Down syndrome, 74, 1066
anesthesia with, 119–120
- Doxacurium
properties, 99t
- DPL, 352, 354t
- Draining sinus tract, 292f
- Dressing plate, 613f
- Drug dependence, 1298
- Dry eye
upper eyelid blepharoplasty, 1340
- Dry socket. *See* Alveolar osteitis
- D-tubocurarine
properties, 99t
- Dual-incision approach
subepithelial connective tissue graft
harvesting, 212–213, 214
subepithelial connective tissue grafting, 213f
- Dual-suture alar cinch technique, 1239f
- Duchenne's disease
anesthesia with, 120
- Duchenne's muscular dystrophy, 1207
- Dufourtmental flap, 714–716
- Duke University Activity Status Index, 70, 71t
- Dying patient
avoidance of, 652–653
- Dynamic sphincter pharyngoplasty, 878
- Dysplastic nevi, 683
- E**
- Ear, 1451. *See also* Protruding ear
avulsive injuries, 368f
blood supply, 1450–1451, 1452f
defect conversion, 367f
deformities, 1451–1452
development of, 1450f
embryology of, 1449
hematomas, 365–366
injuries, 365–366, 366f
nerve supply, 1451
osseointegration implants, 368f
surgical anatomy of, 1449–1450
- Earlobe
protruding
correction of, 1456
- EB. *See* Epidermolysis bullosa (EB)
- EBV, 686, 688
- Ecchymosis, 405f, 437, 447, 494, 685
upper eyelid blepharoplasty, 1340
- Economically disadvantaged
maxillofacial trauma, 384
- Ecstasy
anesthesia with, 121–123
- Ectodermal dysplasia, 238f
- Edentulism
functional effects of, 158–159
- Edentulous fractures
mandibular fracture, 423–425
- Edentulous mandible, 193–197
flap design for implant placement, 207f
incision design, 194
osseointegration, 193–197
physical examination, 194
prepared for bone graft, 224f
radiologic examination, 194
simultaneous gingival grafting, 212f
- Edentulous maxilla, 197–199, 197f, 226f–227f, 228f
atrophy, 236f
flap design for implant placement, 207f
Parel's classification of, 197
with severe atrophy, 232f
- Edentulous patients
alveolar bone characteristics, 157–158
closed reduction, 417
- Edentulous restorations, 263–264
FDP, 265–266
implant-retained overdentures, 263–264
implant-supported overdentures, 264–265
- Edinger-Westphal nucleus, 347
- EDTA, 944
- Eight-ball hyphema, 472–473
- Elastic fibers, 709
- Elderly, 40–42
displaced zygomatic complex, 486f–487f
drug modifications in, 41–42
hypertension, 49
impacted teeth, 142–143, 144, 149
maxillary fractures, 441
orbital injuries, 481
wound healing, 12
- Elective lymph node dissection, 667
- Elective neck dissection (END), 647, 648
vs. elective neck irradiation, 650
- Electric drill, 145
- Electrolytes and acid-base disturbances, 53–54
- Electrometric test, 386
- Elevators, 1385–1386
Buser periosteal, 213, 218
Cottle, 1357f
- Cryer, 146
J-shaped, 1438, 1438f
curved hook, 450
periosteal, 866, 1387f
TMJ arthroscopy, 970, 971f
- Elevator technique, 136
- Elliptic incision
for frenum attachment excision, 173
- Ellis classification, 387, 387f
- Ellis technique, 423f
- Embryo, 1052f
amnion, 1053f
lateral view, 1053f
scanning electron micrograph, 1055f
- Emergence delirium, 93
- Emergency treatment on full stomach
children, 106
- Eminectomy, 1046
- Emphysema, 73
- Enalaprilat
for hypertension, 32
for hypertensive crisis, 50t
- Enamel fractures, 387
- Enamel organ, 575, 575f
- END, 647, 648
vs. elective neck irradiation, 650
- Endocarditis
cardiac conditions associated with, 23t
prophylaxis if, 24t
- Endochondral bones
formation of, 192–193
- Endocrine disorders, 32–34, 59–61, 74–77
diabetes, 281, 282, 424
effect on wound healing, 10
implants, 252
diabetes insipidus, 607
diabetes mellitus, 32–33, 59–61, 76–77
insulin, 60
type 2, 33, 60
hyperglycemia, 60–61
hypoglycemia, 60–61
thyroid disorders, 33–34
- Endonasal rhinoplasty
surgical sequence for, 1356t
- Endoscopic lens system
TMJ
arthroscopy, 970f
- Endoscopy
sinus infection, 302–303
complications of, 309
- Endosseous implants, 191–192, 270f
long-term
first, 189
- Endotracheal intubation
children, 104
for flail chest, 337
- Endotracheal tube stabilizer pad, 980f
- End-stage renal disease (ESRD), 31, 77

- End-to-side anastomosis, 805f
- Enflurane
 - avoided with renal patients, 31
 - chemical structure of, 96f
- England, 189
- Enophthalmos, 468, 479
 - zygomatic arch fractures, 457–458, 458f
- Entubulation (conduit) nerve repair, 833f, 834t
- Entubulation techniques, 833–834
- Envelope flap, 144, 146f
- Envelope incision, 144, 145f
- Environment
 - craniofacial growth and development, 1068–1070
 - craniofacial malformations, 1066–1068
- Enzyme induction, 85
- Ephelides, 683
- Epidermis, 709
- Epidermodysplasia verruciformis, 698
- Epidermolysis bullosa (EB), 685–686
 - atrophicans generalisata gravis Herlitz type, 686
 - bullosa acquisita, 686
 - Cockayne-Touraine type, 686
 - dystrophica Hallopeau-Siemens, 686
 - simplex Koebner type, 686
- Epidural hemorrhage, 345f
- Epilepsy, 78
- Epinephrine, 95, 338, 340
 - for arrhythmias, 52
 - for blepharoplasty, 1331
- Epiphora, 364, 1263, 1327
- Epistat, 438
- Epistaxis, 437
- Epithelialized palatal graft technique
 - implants, 210–211
- Epstein-Barr virus (EBV), 686, 688
- ePTFE, 223
- Erich arch bars, 415f
- Erythema multiforme, 693–694, 694f
- Erythematous lesions, 685–686
- Erythrocyte sedimentation rate (ESR), 314
- Erythromycin
 - for COPD, 30
- Erythroplakia, 618, 619, 619f
- Esmolol
 - for hypertensive crisis, 50t
- Esophagoscopy, 624
 - vs. barium swallow
 - for neck gunshot injuries, 518
- ESR, 314
- ESRD, 31, 77
- Essential hypertension, 31–32, 37
- Esthetic facial augmentation
 - alloplastic, 1435–1447
- Esthetic flaps, 710
- Esthetic implants
 - flaps, 207f
- Esthetic ridge defect
 - large-volume combination hard and soft tissue
 - reconstruction of, 219f
- Esthetic tooth wax-up, 200
- Estlander flap, 664
- Etanercept
 - for rheumatoid arthritis, 36
- Ethanol, 35
- Ethmoid bone, 437, 465
- Ethmoid bulla
 - anatomy and physiology of, 297
- Ethmoid fracture, 535f
- Ethmoid sinus, 494f
 - anatomy and physiology of, 297
- Ethylenediaminetetraacetic acid (EDTA), 944
- Etomidate
 - chemical structure of, 92f
 - pharmacology of, 92
- Exarticulations, 393–394
- Excisional biopsy, 570, 704
- Exercise therapy
 - for TMJ, 954–955
- Exercise tolerance
 - assessment of, 70–71
 - determining preoperative risk, 17
- Exfoliative cytology, 569–570
- Exophthalmos, 468, 495, 607
- Exostoses, 169
- Expanded polytetrafluoroethylene (ePTFE), 223
- Extended neck dissection, 649
- External auditory canal
 - sectioned, 995f
- External ballistics, 510
- External ear
 - anatomy of, 1451f
- External fixator, 796f
- External neurolysis, 830–831
- External pin fixation, 416
- External rhinoplasty
 - surgical sequence for, 1356t
- Extraction
 - vs. nonextraction, 1130
- Extraction wounds, 7–8
- Extraoral inverted L osteotomy, 1147f, 1148f
- Extraoral vertical subcondylar osteotomy, 1145f
- Extraosseous devices, 184–185
- Extravasated blood
 - lesions, 685
- Extravasation
 - with TMJ arthroscopy, 984–985
- Extremities
 - craniofacial dysostosis syndrome, 903
 - examination of
 - in trauma patient, 353–354
- Extrusive luxation, 392
- Eyebrows
 - anatomy, 1318
 - examination of, 1328
 - fat pad, 1318
 - female position, 1318f
 - male position, 1318f
 - reconstruction of, 363
- Eyelids. *See also* Lower eyelids; Upper eyelids
 - aging skin changes, 1319
 - arteries, 1324
 - avulsive injuries of, 362f
 - cheek contour, 1318
 - connective tissue, 1321
 - crease reformation, 1332–1334
 - cross-section, 1319f
 - fat pads, 1323
 - innervation, 1325–1326
 - laceration, 470f, 475, 476f
 - layers of, 466t
 - lymphatics, 1324–1325
 - musculature, 1322–1323
 - normal position of, 1320f
 - reconstruction
 - history of, 1317
 - resection of, 364f
 - skin thickness, 1319
 - soft tissue injuries, 364–365
 - surgical repair of, 364f
 - topography, 1319–1320
 - vasculature, 1324
 - veins, 1324
- Eyes
 - adnexa, 1319–1326
 - examination of, 447
 - injuries, 471–476
 - sagittal view of, 455f
 - surface evaluation, 1330
- F
- Face
 - asymmetry, 412f
 - bones, 192–193
 - and reconstruction, 164
 - buttresses, 547–548
 - developing, 1054f
 - esthetic augmentation
 - alloplastic, 1435–1447
 - examination of, 404–405
 - expression muscles, 445
 - fractures
 - evaluation of, 405
 - frontal view of, 1057f
 - gunshot wounds, 363, 363f
 - blind clamping, 516f
 - hemiatrophy, 1207, 1207f
 - horizontal buttresses of, 548f
 - liposuction

- postoperative instructions, 1418
- lower
 - for macroesthetic examination, 1100, 1101
- macroesthetic examination, 1100, 1101
- profiles, 1101
 - Dedo classification of, 1367f, 1367t
- prosthesis, 270f
- scars, 1263
- skeleton
 - surgical approach to, 551, 551f
- trauma
 - children, 540f
 - psychosocial issues, 384
- vertical buttresses of, 548f
- wounds, 357
 - grazing gunshot, 523f
- Face-bow transfer, 1215f
- Face lift
 - dressing, 1373f
 - skin incision, 1376f
- Facemask, 1078f
- Facial artery, 1346, 1389
- Facial asymmetry, 1205–1217, 1267
 - acquired, 1208
 - condylar trauma, 1208
 - degenerative joint disease, 1208
 - juvenile idiopathic arthritis, 1208
 - basal view, 1214f
 - clinical assessment of, 1208–1209
 - delayed treatment, 1210
 - etiology, 1205
 - frontal view, 1217f
 - lateral and frontal view, 1216f
 - midface deficiency, 1213f
 - orthodontic considerations, 1210–1212
 - radiography, 1209
 - surgery, 1209–1216
 - techniques, 1212–1216
 - TMJ function, 1210
- Facial nerve, 357, 483, 992, 1325, 1390
 - anatomy of, 358f
 - zone of arborization, 358f
 - gunshot wound, 522
 - landmarks, 993f
- Facial primordia
 - development of, 1053–1054
- Falls, 383, 530
- Familial gigantiform cementoma, 599
- Fasting, 105–106
- Fat debulking, 1332
- Fat embolism syndrome, 341f, 354
- Fat grafts, 1401
 - abdominal
 - harvest of, 501, 501f
 - dermal, 1414, 1414f
- Fat injection
 - autologous, 1413–1414, 1414f
- Fat pads, 1322f
- Fat transfer
 - autologous, 1412–1415
 - complications, 1414–1415
- Femur
 - fracture of, 341f, 353
- Fenoldopam
 - for hypertensive crisis, 50t
- Fentanyl
 - chemical structure of, 88f
 - children, 115
 - end-stage TMJ disease, 1022
 - pharmacology of, 88–89
- Fernandez technique, 423f
- Fetus
 - changing body proportions, 1059f
- FEV1, 56f
- Fever
 - odontogenic infection, 283, 287–288
 - with osteomyelitis, 314
- FFP, 343
- Fiberoptic laryngoscopy
 - children, 528
- Fiberoptic nasal examination, 295
- Fibrin clots, 8
- Fibroblasts, 5, 786
- Fibroma
 - mandible, 313f
- Fibromyalgia, 941
- Fibro-osseous disease
 - benign, 597–600
 - cemento-osseous dysplasia, 598–599
 - fibrous dysplasia, 597–598
- Fibro-osseous neoplasms
 - juvenile aggressive ossifying fibroma, 600
 - ossifying fibroma, 599–600
- Fibrous dysplasia, 597–598, 597f, 598f
- Fibrous inflammatory hyperplasia, 172
- Fibular grafts, 268
- Field of vision
 - TMJ
 - arthroscopy, 970f
- Figure-eight alar cinch suture technique, 1238f
- Figure-of-eight wire, 421, 424f
- Final diagnosis
 - determining, 568–569
- Fine-needle aspiration biopsy (FNAB), 570, 704
 - parotid gland tumors, 672
- Firearms
 - terminology of, 512–514
- First molars
 - progressive soft tissue recession, 212f
- Fissure bur, 146f, 242, 242f
- Fistulas, 1252–1253
 - residual oronasal, 1271
- Fitzpatrick skin types, 697, 698t
- Fixed crown-and-bridge restoration, 197, 197f, 198
- Fixed partial denture (FPD), 236f, 258, 260–263, 263, 263f
 - anterior mandible, 262
 - cantilevered, 263, 263f
 - esthetic zone, 261–262
 - extension of, 265
 - mandibular, 268f
 - posterior mandible, 262–263
 - posterior maxilla, 262
- Flail chest, 332, 335–336, 336f
- Flaps, 710–711. *See also* specific flaps
 - blood supply, 770
 - complications, 780–781
 - configuration, 770
 - design, 712–716, 771–772
 - implants, 205–208, 206f, 207f
 - lateral advancement, 208, 208f
 - location, 770
 - necrosis, 709
 - nomenclature, 770–771
 - principles, 769–771
 - superiorly based, 779f
 - tissue content, 770
 - transfer method, 770–771
 - types of, 772–780
 - undermining, 712
- Flavopiridol, 640
- Flexor
 - abnormal activity, 346
- Floating forehead technique, 905
- Floating teeth, 607, 608f
- Floor of mouth
 - cancer, 621–622, 622f, 644
 - examination of, 406
 - lowering procedures, 175, 179f
 - squamous cell carcinoma, 644f
- Florid cemento-osseous dysplasia, 599, 599f
- Fluctuance, 280
- Fluid
 - management
 - oral cancer, 635
 - requirements in children, 42t
- Flumazenil, 86
 - chemical structure of, 86f
 - pharmacology of, 87
- Fluorescein dye, 470, 499
- Fluoroquinolone
 - for rhinosinusitis, 305
- 5-fluorouracil, 639, 640
- Fluoxetine (Prozac)
 - TMJ, 953
- FNAB, 570, 704
 - parotid gland tumors, 672
- Focal cemento-osseous dysplasia, 599
- Foley catheter
 - contraindications for in trauma patients, 343f
- Follicular sac
 - dentigerous cyst in, 141

- odontogenic tumor in, 141
- Fontana-Masson stain, 683–684
- Fontanelles
 - neonatal skull, 1060f
- Forced expiratory volume in 1 second (FEV1), 56f
- Forced vital capacity (FVC), 56f
- Forceps, 308f
- Forehead, 1383–1403
 - anatomy, 1318, 1384–1389
 - bony landmarks, 1384–1389
 - endoscopic view, 1390f, 1391–1393, 1391f
 - esthetic considerations, 1384–1389
 - flaps, 774
 - lift
 - complications, 1402–1403
 - endoscopic, 1396–1400, 1396f
 - postoperative care, 1402
 - skin care and micropigmentation, 1401–1402
 - muscle and fascial anatomy, 1385–1386
 - positions, 1383f
 - preoperative evaluation, 1393–1395
 - soft tissue injuries, 363–364
 - vessel and nerve anatomy, 1389–1391
 - youthful, 1384
- FPD, 263, 263f. *See also* Fixed partial denture (FPD)
 - extension of, 265
- Fractionation, 636
- Fractured teeth
 - assessment of, 385
- Fracture lines, 408
- Fractures. *See also* specific fractures
 - bone healing after, 6
- Frank-Starling curve, 24
- FRC
 - children, 104
- Free autogenous grafts, 786f
- Free fibula flap, 811–814, 814f
 - anatomic considerations, 811–813, 811f
 - elevation, 813f
 - morbidity following, 813–814
 - technique, 812–813
- Free flaps. *See also* Radial forearm free flaps
 - iliac crest osteomyocutaneous, 814–815
 - microvascular, 792
 - radial forearm, 804–811
- Free gingival grafts, 210
- Free tissue transfer
 - head and neck, 803
 - versatility of, 815–816
- Frenectomy, 172–174
- Frenum attachments
 - excision of, 173, 173f, 174f
 - exposure of, 173f
 - wide-based, 174
- Fresh frozen plasma (FFP), 343
- Frey's syndrome, 1263
- Fricke, Johann Karl George, 1317
- Frontal bone, 491, 492f, 1384
 - fracture, 535f
 - injuries
 - complications of, 503
 - ossification of, 491
 - osteology of, 492–493
 - posttraumatic deformity correction, 504–505
- Frontalis muscle, 1318, 1385–1386, 1387f
- Frontal recess
 - anatomy and physiology of, 297
- Frontal sinus, 492f, 494f
 - anatomy and physiology of, 491–494
 - anterior table fractures, 499
 - depressed injury, 495
 - development of, 491
 - embryology of, 491
 - fractures, 495f
 - children, 532–534
 - classification of, 496–497
 - clinical findings, 494–497
 - patient evaluation, 494–497
 - surgery, 497–502
 - neovascular structures, 493
 - osteology of, 492f
 - physiology of, 491–492
 - posterior table fractures, 499–500
- Frontoforehead esthetic unit
 - craniofacial dysostosis syndrome, 903
- Frown lines
 - glabella, 1389f
- Frozen section specimens, 634f
- Full-arch ceramometal restoration, 265, 266f
- Full histologic periosteal refixation, 1399
- Full-jacketed bullet, 514f
- Full-metal jacket, 514
- Full-thickness mucoperiosteal buccal flaps, 866
- Full-thickness skin grafts, 8, 717–718
- Functional appliances, 1075f
- Functionally stable fixation, 371–372, 373
- Functional matrix concept, 164
- Functional residual capacity (FRC)
 - children, 104
- Fungal balls
 - maxillary sinus, 303f
- Fungal disease
 - oral cavity, 680–681
- Fungal sinusitis, 303–304
- Furlow double opposing Z-plasty procedure, 876
- Furnas technique, 1452
- Furosemide
 - for congestive heart failure, 22
- Fusobacterium*, 140, 288
- FVC, 56f
- G
- GABAergics, 1024
- Gabapentin
 - for seizure disorders, 37
- GABA receptor, 84
- Galeal tissue, 1399
- Galen, 383
- Gamma-aminobutyric acid (GABA)
 - receptor, 84
- Ganglion cysts
 - TMJ, 945
- Gap arthroplasty, 1038, 1290f
- Gastritis, 35
- Gastroesophageal reflux disease (GERD), 300, 1298
- Gauge, 512
- GCS. *See* Glasgow Coma Scale (GCS)
- General anesthesia
 - risk after myocardial infarction, 20
- Gene therapy
 - wound healing, 13
- Genetics
 - craniofacial growth and development, 1068
 - craniofacial malformations, 1065–1066
- Genial advancement
 - with hyoid myotomy and suspension
 - OSA, 1307–1308
 - OSA, 1307
- Genial segment surgical procedures
 - anterior repositioning, 1229–1232
 - posterior repositioning, 1232–1233
 - soft tissue changes associated with, 1229–1233
 - vertical repositioning, 1233
- Genial tubercle
 - advancement, 1307f
 - reduction, 169–170
- Genioglossus attachment, 175
- Genioglossus muscle, 169
- Genioplasty
 - advancement
 - soft tissue changes associated with, 1232t
 - reduction
 - soft tissue changes associated with, 1233t
 - setback
 - soft tissue changes associated with, 1233t
- Genitourinary tract
 - examination of
 - in trauma patient, 353
- GERD, 300, 1298
- Geriatric patients. *See* Elderly
- German measles, 689
- Germinated tooth, 136f
- Germ layer formation, 1051
- GFR, 30
- Ghost cell tumor
 - malignant epithelial odontogenic, 589
- Giant cell granuloma

- central, 603–605, 603f, 604f
 Giant cell tumor, 604
 Gilles's approach, 451f
 Gillies, H., 527
 Gillies and Harrison total midface advancement, 527
 Gingiva
 examination of, 406
 excess display on smile, 1102–1103, 1103f
 grafts
 dental implants, 210–211, 210f
 indications for, 211
 edentulous mandibular site, 212f
 melanin pigmentation
 smoking, 682
 squamous cell carcinoma, 644–645
 trauma
 treatment, 396–397
 Ginglymoarthrodial, 933
 Ginglymoid, 933
 Glabella
 crease, 1393
 frown lines, 1389f
 lacerations, 494
 vertical rhytids, 1398
 Glargine
 onset, peak and duration, 61t
 Glasgow Coma Scale (GCS), 78, 78t, 329t
 development of, 328
 for grading consciousness, 346
 and head injuries, 348
 Glenoid fossa
 coronal section, 992f
 horizontal incision, 996
 Gliding hole, 379
 Globes
 evaluation of, 468
 penetrating injury, 472
 perforated, 516f
 Globulomaxillary lesion, 608, 609f
 Glogau's classification
 photoaging, 1419, 1419t
 Glomerular filtration rate (GFR), 30
 Glossectomy, 643
 Glucocorticoids
 for asthma, 56
 for rheumatoid arthritis, 36
 for TMJ, 951
 Gluconeogenesis, 35
 Glutamine, 12
 Glycogen storage, 35
 Glycolic acid, 1341
 resorbable plating system, 441–442
 Glycopyrrolate, 99, 106
 with ketamine, 111
 Goiter, 76
 Goldenhar's syndrome, 74, 104
 Goldman Index, 66
 Gold salts
 for rheumatoid arthritis, 36
 Gold wire splinting
 Lebanon, 383f
 Gompertzian kinetics, 638
 Gonial arc, 1140f
 Gonorrhea, 682
 Goode method, 1353, 1353f
 Gorham's disease, 612, 612f
 Gorlin's syndrome, 698
 Grafts, 710. *See also* specific graft
 Granulation tissue, 5
 Grasping forceps
 TMJ arthroscopy, 970
 Graves' disease, 76
 Grayson nasoalveolar molding appliance, 846f
 Greater auricular nerve, 1371f
 cable graft, 833f
 Greenstick fracture, 410
 Grossly comminuted fractures, 410
 Ground substance, 709, 934, 935
 Group A Coxsackievirus, 688
 Growth
 factors
 effect on wound healing, 12–13
 mandibular fracture, 426
 modification
 orthopedic treatment for, 1070–1079
 Growth deformities
 secondary, 1207
 Guided bone grafts
 augmentation, 223
 Gullwing incision, 497
 Gummy smile, 1097f
 Gunning's splints, 440–441, 441
 Gunshot wounds, 509–524
 bone grafting, 523–524
 classification of, 514–515
 closed vs. open management, 522–527
 contamination, 522
 cost, 510
 delayed vs. early management, 522–527
 demographics, 509–510
 face, 363, 363f
 blind clamping, 516f
 hemorrhage, 516–517
 history, 509
 incidence, 509–510
 late reconstruction, 524
 mandible, 795f
 mouth, 521f
 neck, 517–519
 decision tree, 519f
 surgery, 520–522
 treatment, 515–522
 Gustatory sweating, 1263
 H
Haemophilus influenzae, 300, 305
 TMJ, 944
 Hageman factor, 4
 Hairy leukoplakia, 689
 Haller cell, 298
 Halothane, 95f
 for asthma, 56
 chemical structure of, 96f
 children, 114
 pharmacology of, 93, 96
 Hamartomatous fibro-osseous disease, 597
 Handguns, 512
 Hank's balanced salt solution, 393, 393f
 Hard palate
 cancer, 622, 622f
 Hardy, Michael, 964
 Harness restraints, 529
 Haversian remodeling, 371
 Head
 assessment of
 in trauma patient, 345–346
 examination of, 357
 Headache, 1299
 frontal sinus, 503
 Head and neck
 assessment
 odontogenic infection, 277–278
 cancer, 697–720
 inoperable, 652
 survival, 652
 treatment failure, 652
 deep spaces of
 borders of, 278t
 infections, 279t
 severity score for, 278, 280t
 free tissue transfer, 803
 infections of
 drainage of, 285f
 radiation
 implants, 252
 Headgear, 1074f, 1076f, 1078f
 Healing by secondary intention, 710–711
 Hearing
 craniofacial dysostosis syndrome, 903
 Heart
 age-related changes, 41
 of infants, 42
 Heart blocks, 27–28
 Heat therapy
 for TMJ, 956
 Hemangioendothelioma
 salivary gland, 672
 Hemangiomas, 684
 Hematomas, 685
 in bone healing, 6
 cervicofacial liposuction, 1411
 ear, 365–366
 flaps, 780
 maxillary fractures, 442

- nasal septum, 364
 - protruding ear, 1457
 - upper eyelid blepharoplasty, 1340
 - in wound healing, 10
 - Hematuria, 353
 - Hemifacial hyperplasia
 - congenital, 1207
 - Hemifacial microsomia, 104, 1206, 1206f
 - Hemimandibular hyperplasia/elongation, 1207
 - Hemorrhage. *See* Bleeding
 - Hemostasis, 10, 357
 - Hemothorax, 334–335
 - Hemotympanum, 346
 - Heparin
 - DVT, 635
 - in spinal cord disorders, 38
 - Hepatitis, 35
 - Hepatitis A, 35
 - Hepatitis B, 35
 - Hepatitis C, 35
 - Hepatogastrointestinal disorders, 34–36
 - liver disease, 34–35
 - peptic ulcer disease, 35–37
 - Herbal supplements
 - determining preoperative risk, 18
 - Herbst appliance, 1303
 - Hereditary diseases, 685–686
 - Herpes
 - cytology, 687f
 - Herpes simplex infection, 1432
 - Herpes simplex virus (HSV), 686
 - Herpes zoster, 688f
 - Herpetic
 - gingivostomatitis, 686f
 - Herpetic gingivostomatitis, 686f
 - Herpetic whitlow, 687, 687f
 - Hertwig's root sheath, 575
 - Hexed implant, 256f
 - High-flow vascular malformation, 606f, 607f
 - High-velocity accident, 350
 - High-voltage stimulation
 - for TMJ, 956
 - Hilum
 - calcified stone
 - sialogram, 675f
 - stones, 675–676
 - Hippocrates, 383
 - Hirudo medicinalis*, 780
 - Histamine antagonists
 - children, 117
 - HIV. *See* Human immunodeficiency virus (HIV)
 - Hofer's subapical osteotomy, 1138f
 - Holmium:YAG (HO:YAG) lasers
 - TMJ arthroscopy, 971
 - Hooding, 1393
 - Hooked probe
 - TMJ arthroscopy, 970
 - Horizontal glabellar lines, 1398
 - Horizontal impaction, 143, 147f
 - bone removal, 145–146
 - Horizontal osteotomy
 - for horizontal chin deficiency, 1172f
 - for horizontal chin excess, 1171f
 - of the symphysis, 1168–1173, 1168f
 - complications, 1173
 - indications for, 1168
 - technique, 1168–1173
 - various forms of, 1169f–1170f
 - Horizontal osteotomy of vertical ramus
 - Blair's, 1135, 1136f
 - Horizontal ramus
 - sagittal osteotomy, 1164
 - Horizontal tightening, 1335
 - Hoshino, Kazumasa, 964
 - Hospice, 653
 - HO:YAG lasers
 - TMJ arthroscopy, 971
 - HPV
 - squamous cell carcinoma, 617
 - HSV, 686
 - Hullihen's mandibular subapical osteotomy, 1135, 1135f
 - Human bites, 362
 - Human immunodeficiency virus (HIV), 11, 689
 - immunocompromised, 283
 - implants, 252
 - Human papilloma virus (HPV)
 - squamous cell carcinoma, 617
 - Hunsuck modification, 1254
 - Hyaluronidase
 - for blepharoplasty, 1331
 - Hybrid dentures
 - implant, 254
 - Hydantoin, 682
 - Hydralazine, 691
 - Hydration
 - for fever, 287
 - Hydrocephalus
 - craniofacial dysostosis syndrome, 902
 - Hydrocodone
 - for TMJ, 951
 - Hydrogen peroxide, 360
 - Hydroxy acids, 1421
 - Hydroxychloroquine
 - for rheumatoid arthritis, 36
 - Hydroxylapatite coatings
 - implants, 190, 192
 - Hyoid myotomy, 1308f
 - Hyoid suspension, 1308
 - Hyperbaric oxygen therapy
 - flaps, 780–781
 - implants, 252
 - jaws, 794
 - odontogenic infection, 281
 - osteomyelitis, 317
 - osteoradionecrosis, 320
 - wound healing, 11–12
 - Hyperdivergent faces, 1211
 - Hyperfractionation, 636
 - Hyperglycemia, 60–61, 77, 344
 - effect on wound healing, 10
 - Hyperkalemia, 31
 - Hypermobile tissue, 172
 - Hyperparathyroidism, 603, 604, 605f
 - Hyperpigmentation, 1425f
 - Hypersomnolence, 1298
 - Hypersplenism, 35
 - Hypertension, 31–32, 49, 1299
 - African Americans, 49
 - with bradycardia, 345
 - elderly, 49
 - essential, 31–32, 37
 - and preoperative patient assessment, 69–70
 - risk factors for, 70
 - Hypertensive crisis
 - medications for, 50t
 - Hypertensive urgency, 49
 - Hyperthyroidism, 33–34, 61–62, 76
 - Hypertrophic cardiomyopathy, 69
 - Hypertrophic scars, 9, 359
 - protruding ear, 1458
 - Hypertrophic subaortic stenosis
 - idiopathic, 69
 - Hyphema, 470, 472, 473f
 - Hypnagogic hallucinations, 1298
 - Hypodivergent faces, 1211
 - Hypoglycemia, 59, 60–61, 344
 - Hypokalemia, 53
 - Hypo-ophthalmos, 479
 - Hypopnea, 58
 - Hypotension, 70
 - with tachycardia, 345
 - Hypothermia
 - children, 528
 - Hypothyroidism, 34, 62, 74
 - Hypovolemia, 338
 - Hypovolemic shock
 - estimated blood loss, 342t
 - estimated fluid loss, 342t
 - with multisystem injuries, 341–344
 - treatment, 343–344
 - Hypoxia, 345
- I
- Ibuprofen
 - for rheumatoid arthritis, 36
 - ICP
 - craniofacial dysostosis syndrome, 901–902
 - Ideal face, 1094f
 - Idiopathic condylar resorption, 1291f
 - Idiopathic hypertrophic subaortic stenosis (IHSS), 69

- Idiopathic vesiculoulcerative disease, 691–692
 IGF-I, 76
 IHSS, 69
 IJD, 967, 967t, 968t
 Iliac corticocancellous graft, 231–232
 Iliac crest
 bone grafts, 268f, 789–791, 862–863
 corticocancellous block graft augmentation
 atrophic mandible, 196f
 osteomyocutaneous free flap, 814–815
 harvesting, 815f
 morbidity following, 815
 Ilizarov, 164
 Illicit drug abusers, 39–40
 Imaging, 568–569
 gunshot wounds
 neck, 519–520
 panfacial fractures, 550–551
 Imbrication, 1371, 1372f
 vs. plication, 1372f
 IMF. *See* Internal maxillary fixation (IMF)
 Imipramine
 end-stage TMJ disease, 1022
 Imiquimod, 698, 708
 Immunocompromised
 effect on wound healing, 10–11
 factors associated with, 282t
 odontogenic infection, 282–283
 Impacted fractures, 410
 Impacted teeth, 139–153
 age, 144
 angulation of, 143
 bone removal, 145
 children, 144
 debridement, 146
 defined, 132
 depth of impaction, 143
 etiology, 132–133, 132f
 evaluation of, 133
 incidence of, 131–132
 management of, 131–136
 multiple, 131f, 132f
 perioperative care, 143–149
 relationship to ramus anterior border, 143
 removal of, 146f
 age, 142–143
 antibiotics, 147–149
 bleeding, 150
 children, 142–143
 complications of, 149
 compromised medical status, 143
 contraindications for, 142–143
 for dental caries prevention, 141
 indications for, 140–142
 irrigation, 147
 for odontogenic cyst and tumor
 prevention, 141
 orthodontic considerations, 141
 pain, 142, 150
 for pericoronitis, 140–141
 postoperative course, 149–150
 to prevent jaw fractures, 142
 root resorption, 142
 steroids, 149
 stiffness, 150
 surgical damage to adjacent structures,
 143
 swelling, 150
 roots, 144
 surgery of, 133, 135, 143–149
 alveolar osteitis, 151
 complications of, 150
 determining difficulty of, 143–144
 fracture, 151
 irrigation, 151
 nerve disturbances, 151
 rare complications, 152
 technique, 144–147
 surgical exposure, 133–134
 vs. unerupted teeth, 140
 uprighting, 135–136
 Impingement lesions
 progressive stages, 973t
 Implant driver, 242f
 Implant level transfer impression
 open-tray technique, 258f
 Implant prosthodontics, 251–271, 254
 biomechanical considerations, 251–252
 crown-to-implant ratio, 254–255, 255f
 full-arch restoration, 255, 255f
 implant selection, 255–256
 occlusion, 255
 patient factors, 251–252
 periimplant biology, 251
 radiographic evaluation, 252–253
 complications of, 269–270
 abutment fracture, 270
 porcelain fracture, 270
 radiographic bone loss, 270
 resin base fracture, 270
 screw loosening, 270
 soft tissue, 269–270
 contemporary techniques, 266–267
 immediate load, 267
 immediate placement, 266
 immediate restoration, 266–267
 maxillofacial prostheses, 267–268
 surgical installation stability, 266
 edentulous restorations, 263–264
 FPD, 260–263
 maintenance of, 270–271
 single-tooth replacement, 258–260
 cemented single units, 259–260
 esthetic zone, 259
 nonrestorable tooth, 258–259
 screw-retained single units, 260
 success criteria, 271
 Implant-retained obturator, 269f
 Implant-retained overdentures, 264
 Implants. *See also* specific implants
 advances in, 167–171
 angulation, 200
 bone healing around, 193
 depth, 200–201
 four or more, 195
 placed too far facially, 260f
 presurgical planning for placement, 252f
 soft tissue, 205–221
 with acellular dermal matrix, 220–221
 augmentation guidelines, 209
 epithelialized palatal graft technique,
 210–111, 210–211
 flaps, 205–208, 206f, 207f
 grafts, 208–209
 nonsubmerged placement, 206
 subepithelial connective tissue grafting,
 212–215
 submerged placement, 205–206
 vascularized interpositional periosteal
 connective tissue flap, 217–220
 two, 195
 without grafting
 atrophic mandible, 197
 Implant-supported overdentures
 attachment mechanisms for, 265
 Incisional biopsy, 570, 704
 Incisions. *See also* specific incisions
 brow lift, 1400f
 Incisors
 altering axial inclination of, 1122
 angulation, 1113
 implant
 preoperative view of, 213f
 progressive soft tissue recession, 212f
 mandibular
 apical fractures, 390f
 correct underangulated, 1126
 crowding of, 141
 impacted, 132f
 maxillary
 altering mesiodistal angulation of, 1122
 correct underangulated, 1125–1126
 extraction of, 1122
 subluxation, 392f
 position in facial asymmetry, 1212
 Indalones
 for psychotic disorders, 39
 Indirect bone healing, 6, 373f, 374f
 Indirect fixation, 401
 Indirect fracture, 409f, 410
 Induction agents
 children, 113–114
 Induction chemotherapy, 639
 Infants, 42

- seat belts, 529
- Infection
 - cervicofacial liposuction, 1411
 - flaps, 720
 - with impacted teeth removal, 150
 - lip cancer, 659
 - mandibular fracture, 426
 - maxillary fractures, 442
 - nasofrontal duct, 503
 - TMJ
 - arthroscopy, 986
 - internal derangement, 1010
- Infectious endocarditis
 - cardiac conditions associated with, 23t
 - prophylaxis if, 24t
- Infectious hepatitis, 35
- Inferior alveolar canal
 - potential tooth proximity to, 820t
- Inferior alveolar injuries, 820
- Inferior alveolar nerve
 - anesthesia, 149, 151
 - damage, 1254
 - BSSO, 1157
 - numbness, 405
- Inferior border augmentation, 182–183
- Inferior lid
 - cross-section of, 481f
- Inferiorly based pharyngeal flap, 878
- Inferior mandibular osteotomy, 1308f
- Inferior meatus
 - anatomy and physiology of, 297
- Inferior orbital fissure, 464
- Inferior orbital rim, 485f
- Inferior suspensory ligament
 - Lockwood's, 466
- Inflammation cascade, 951f, 954
- Inflammatory papillary hyperplasia, 172
- Inflammatory resorption, 391
- Infliximab
 - for rheumatoid arthritis, 36
- Informed consent
 - suction-assisted lipectomy, 1416–1417
- Infrahyoid muscles, 938
- Inframandibular muscles, 940, 940f
- Infraorbital nerve, 437, 445, 464
 - and external nasal branch, 1349
 - and lower eyelid conjunctiva, 1326
- Infraorbital paresthesia
 - zygomatic arch fractures, 457
- Infraorbital rim
 - internal fixation of, 456
 - surgery
 - pitfalls in, 453–455
- Infraorbital space
 - borders of, 278t
 - infection, 279t
- Infratemporal space
 - infection, 279t
- Infundibulum
 - anatomy and physiology of, 297
- Inhalation agents, 96–98, 114t
 - chemical structure of, 96f
 - children, 114–115
- Inhalational substance abuse
 - anesthesia with, 122
- Inhalation anesthetics
 - pharmacology of, 93–97
 - properties of, 94t
- Inhalation induction
 - disadvantages of, 109
- Injury severity scores, 329–330
 - mortality rates for
 - by age, 330t
- Inlay bone grafts, 179–180
- Inoculation, 8
- Insulin, 60
 - onset, peak and duration, 61t
- Insulin-like growth factor (IGF-I), 76
- Intercanthal region, 550
- Intercartilaginous incision, 1349f
 - rhinoplasty, 1354–1355, 1356f
- Interdental eyelet wiring, 415
- Interdental osteotomies, 1130f
- Interferon
 - nonmelanoma skin cancer, 709
- Interlabial gap, 1090
- Intermaxillary fixation, 439f
- Internal ballistics, 510
- Internal fixation
 - biomechanic studies vs. clinical outcomes, 374–375
 - selection of, 374
 - zygomatic arch fractures, 455–456
- Internal inflammatory resorption, 391
- Internal joint derangement (IJD), 967, 967t, 968t
- Internal maxillary artery, 1346
- Internal maxillary fixation (IMF), 402
 - for condylar fractures
 - length of, 415
 - for mandibular fractures
 - length of, 415
 - screws, 415, 416f
- Internal nasal nerve, 1349
- Internal neurolysis, 831–832, 832f
- Internal replacement resorption, 391
- Internal wire fixation
 - symphysis fracture, 373f
- Interorbital space, 493
- Interpolation flaps, 774–775
- Interpositional grafts, 179, 183
 - anterior maxillary defect, 230f
 - vertical alveolar augmentation, 230
- Interproximal tooth size reduction, 1121
- Interrupted strip technique, 1363f
- Interstitial radiotherapy, 637
- Intrabony tumors
 - salivary gland, 674
- Intracartilaginous incision
 - rhinoplasty, 1355
- Intracerebral hemorrhage, 345f
 - CT, 346f
- Intracranial hypertension, 887
- Intracranial pressure (ICP)
 - craniofacial dysostosis syndrome, 901–902
- Intramuscular sedation, 109
- Intranasal sedation, 109
- Intraoperative stereotactic navigation, 308f
- Intraoral approach
 - to zygomatic arch, 450
- Intraoral bone grafts, 787–788
 - donor site, 787f
- Intraoral incisions
 - atrophic mandible, 196
- Intraoral vertical subcondylar osteotomy (IVSO), 1145, 1250
- Intraosseous infusions, 108, 108f
- Intraosteal wiring
 - mandibular fracture, 421
- Intravenous resuscitation fluid, 342
- Intravenous tubing
 - maxillary distractors, 1285f
- Intrinsic jaw-growth deformities, 1207
- Intrusive luxation, 392
- Inverted L osteotomy, 1136, 1146–1150
 - extraoral, 1147f, 1148f
- Ionizing radiation, 699
- Iontophoresis
 - for TMJ, 956–957
- Irrigation system
 - TMJ
 - arthroscopy, 968–969
- Ischemic heart disease, 66–67
- Isoflurane, 95
 - chemical structure of, 96f
 - pharmacology of, 96–97
- Isolated mandibular body fracture
 - arch bars and miniplate, 377f
- Isometric jaw exercise
 - for TMJ, 955
- Issue ischemia, 10
- IVSO, 1145, 1250
- Ivy, Robert, 840
- Ivy loops, 416f
 - wiring, 415
- J
- Jacketed bullets, 514
- Jackson Pratt drain, 285, 286f
- Jaws
 - aneurysmal bone cyst, 605
 - benign fibro-osseous disease, 597–600
 - benign nonodontogenic lesions, 597–613
 - bony reconstruction of, 783–798

- anatomic considerations, 783–787
 - limitations of, 785
 - chondroma, 601
 - drug-induced clenching, 1023
 - examination of, 404–405
 - exercise therapy
 - for TMJ, 955
 - fractures of
 - prevention of, 142
 - Langerhans cell histiocytosis, 607–608
 - lesions with giant cells, 603–605
 - neurogenic tumors, 610–611
 - nonodontogenic cysts, 608–610
 - osteoblastoma, 600
 - osteochondroma, 601–602
 - osteoid osteoma, 600
 - osteoma, 601
 - pediatric aggressive mesenchymal tumors, 602
 - rotational mechanics, 972f
 - synovial chondromatosis, 601–602
 - vascular malformations, 605–607
- Jaw thrust procedure, 330, 332f
- Jessner's solution, 1422t, 1423, 1426f, 1427f
- Joe Hall Morris external fixator, 417f
- Johnson, Lanny, 964
- Joint disorders, 36
- Joyce, John, 964
- J-shaped curved hook elevator, 450
- J-shaped elevator, 1438, 1438f
- J stripper, 1188f
- Jug-handle view
 - zygomatic complex fractures, 448
- Juvenile aggressive ossifying fibroma, 600
- Juvenile idiopathic arthritis, 1208
- Juvenile rheumatoid arthritis, 1037
- K**
- Kaban protocol, 1038
- Kaminishi, Ronald, 964
- Kaposi's sarcoma, 685
- Karapandzic flap, 366, 663, 664, 664f, 665
- Kartagener's triad, 302
- Kazanjian, V.H., 527
- Kazanjian flap vestibuloplasty, 178f
- Kelly clamp
 - for pneumothorax, 333
- Keloids, 9
 - protruding ear, 1458
- Keratinized gingiva, 192
- Keratitis sicca, 1330f
- Ketamine, 110–112
 - avoiding in malignant hyperthermia, 38
 - cardiovascular effect, 111
 - chemical structure of, 93f
 - children, 111
 - disadvantages of, 111
 - pharmacology of, 92–93
- Ketorolac
 - end-stage TMJ disease, 1017
 - pharmacology of, 97
- KGF-2, 13
- Ki-67, 653
- Kidneys
 - age-related changes, 41
 - disease, 30–31
 - assessment of, 77–78
 - caused by hypertension, 32
 - chronic
 - immunocompromised, 283
 - end-stage, 31, 77
 - insufficiency, 54
 - chronic, 30–31
 - normal architecture of, 55f
- Kiesselbach's plexus, 1347
- Killian incision
 - rhinoplasty, 1354
- Kitayama technique, 423f
- Klearway titratable appliance, 1303, 1304f
- Klebsiella*, 300
- Klebsiella pneumoniae*, 287
- Kleeblattschadel anomaly, 925–926, 926f
- Klein's tumescent technique, 1409
- Klippel-Feil, 74
- Knife-edge ridges, 1292
 - differential osteotomy, 1294f
- Kobert technique, 422f
- Kole's subapical osteotomy, 1138f
- Kolle, Frederick, 1317
- Kussmaul's sign, 338
- L**
- Labetalol
 - for hypertension, 32
 - for hypertensive crisis, 50t
- Labial frenectomy, 172–174
- Labial mucosal advancement flaps, 662
- Labial pedicle
 - for anterior maxillary osteotomy, 1195f, 1196f
- Labial splint, 416
- Labial structures
 - maxillary surgical procedures, 1225, 1225f
- Labii superioris, 445
- Labiomental sulcus, 1229
- Lacerations, 360–361, 437
 - under chin, 405
 - closure of, 362f
 - and facial injuries, 397
 - glabella, 494
 - maxillary fractures, 442
- Lacrimal apparatus, 465, 493–494
- Lacrimal glands, 364, 1326
 - prolapse, 1332
- Lacrimal injuries, 475
- Lacrimal probe, 365f
- Lacrimal sac, 484
 - incision of, 504f
- Lacrimal secretion, 1330
- Lacrimal system, 466, 1326, 1326f
- Lactating mothers, 42
 - medications for, 42t
- Lag screws, 372f, 375, 379f, 1154
 - vs. bone plates, 379
 - fixation technique, 379, 401
 - placement of, 380f
- Lambdoid synostosis
 - unilateral, 890
- Lamellar bone, 193
- Lamotrigine
 - for seizure disorders, 37
- LAN. *See* Lingual nerve (LAN)
- Lane's osteotomy, 1137f
- Langerhans cell, 709
 - histiocytosis, 607–608
- Lanz, Otto, 435
- Lap belts, 529
- Laryngoscope, 624
- Laryngoscopy
 - fiberoptic
 - children, 528
- Laryngospasm
 - children, 115–116
- Laser ablation, 641
 - leukoplakia, 632
- Laser-assisted uvulopalatoplasty
 - OSA, 1306–1307
- Laser Doppler flowmetry (LDF), 386
- Lasers
 - skin resurfacing, 1342
 - TMJ arthroscopy, 970–971
 - vestibuloplasty, 175
- Lateral brow incision, 452, 482
- Lateral canthal ligament, 1321–1322
- Lateral canthotomy, 453
- Lateral capsular prolapse, 973
- Lateral cartilage
 - lower
 - anatomy of, 1349f
- Lateral cephalometric radiographs
 - facial asymmetry, 1209
- Lateral crural steal, 1360f
- Lateral dislocation, 411
- Lateral luxation, 392
- Lateral maxillary osteotomy, 1273f
- Lateral pharyngeal space
 - borders of, 278t
 - infection, 279t
- Lateral pterygoid muscle, 784
- Lateral tarsal strip procedure, 1335
- Lateral temporomandibular ligaments, 936
- Lateral tuberculectomy, 1003f
- Latissimus dorsi myocutaneous flaps, 780
- LDF, 386

- Lebanon
 gold wire splinting, 383f
- LeClerc procedure, 1046f
- Leeches
 medicinal, 780
- Le Fort, René, 435, 527, 1179
- Le Fort classification system
 maxillary fractures, 435–436, 435f
- Le Fort fractures, 405f
 bone plates, 375f
 children, 534
 hemorrhage, 438
 orbital fractures with, 477
- Le Fort III osteotomy, 527
- Le Fort I maxillary osteotomy
 delayed hemorrhage, 1248
- Le Fort I island
 maxillary tumor, 645f
- Left medial canthus
 reattachment, 477f
- Left ventricular dysfunction, 22–23
- Lens
 discoloration, 473
- Lentigo maligna, 703f
- Lentigo maligna melanoma, 684, 703
- Lentigo simplex, 683
- Leukocytes, 4, 6, 8
- Leukoplakia, 618f, 619, 632–633
 proliferative verrucous variant
 gingiva, 618f
 transformation to squamous cell
 carcinoma, 632
 treatment
 Cochrane review, 632
 ventral tongue, 632f
- Leukotrienes
 end-stage TMJ disease, 1019
- Levator aponeurosis
 cross-sectional view of, 1320f
- Levator palpebrae superioris muscle, 466,
 1323, 1325, 1328
- Levofloxacin
 for rhinosinusitis, 502
- Lichen planus, 692–693, 692f, 693f
- Lidocaine, 359
 for blepharoplasty, 1331
 reduction in liver disease, 35
- Lid retractor, 468
- Lifting, 710
- Ligaments
 TMJ, 936–937
- Limberg flaps, 773
- Lincomycin
 for alveolar osteitis, 151
- Linear fracture
 load-sharing fixation, 375
 orbital, 484
- Linear tomography, 254f
- implants, 253
- Lingual frenectomy, 174
- Lingual frenum attachment, 174f
- Lingual nerve (LAN), 821
 blocks
 for genial tubercle reduction, 169
 for mylohyoid ridge reduction, 171
 exposure technique, 831f
 injuries, 820, 822, 1254
- Lingual splint, 416, 416f, 1259f
- Lipexeresis, 1407
- Liposculpting, 1407–1418
- Liposuction. *See also* Cervicofacial liposuction
 as adjunctive procedure, 1411–1412
 facial
 postoperative instructions, 1418
 syringe system, 1409f
- Liposuction-assisted rhytidectomy, 1412, 1413f
- Lipping, 974, 977f
- Lips
 avulsive injuries, 369f
 cancer, 659–667, 662–663
 anatomic considerations, 659–660
 cervical lymphadenectomy, 666
 cervical metastasis from, 660
 epidemiology, 659–660
 etiology, 659–660
 neglected, 620f
 oral, 641–645
 staging, 661t
 surgery, 661–662
 treatment, 660–661
 results, 666–667
 tumor node metastasis system, 661t
 excision, 662, 662f
 injuries, 366
 lower
 actinic cheilitis, 618f
 changes with orthodontic incisor
 retraction, 1224
 lymphatic drainage, 660
 metastasis from, 660
 squamous cell carcinoma, 661f, 663f
 ultraviolet lip, 618
 W excision, 662, 662f
 mucosa, 175f
 squamous cell carcinoma, 641–645, 642f
 vermillion injuries, 360
- Lip shave, 641, 662
- Lip-splitting approach
 incision for, 646f
- Lipswitch flap, 775
- Lipswitch vestibuloplasty, 175, 194
- Lip-tooth-gingival relationship
 direct measurement of, 1091f
- Lispro
 onset, peak and duration, 61t
- Lithium carbonate
 for affective disorders, 39
 for bipolar disorders, 39
- Lithotripsy
 for parotid gland sialoliths, 676
- Little's area, 1347
- Liver disease, 34–35
 assessment of, 77
- L-lactic acid resorbable plating system, 441–442
- Load-bearing fixation
 bone plate, 375f
 vs. load-sharing fixation, 375–376
- Load-sharing fixation
 vs. load-bearing fixation, 375–376
- Local anesthetics
 TMJ, 953
- Local flaps, 769–781, 772–776
- Localized pigmented lesions, 682–685
- Locking plate-screw systems, 378–379, 379f
- Lockwood's ligament, 446, 466, 1322
- Long dolichocephalic faces, 159
- Long drills, 242
- Long-term endosseous implant
 first, 189
- Loracarbef
 for rhinosinusitis, 502
- Lorazepam
 chemical structure of, 86f
 for delirium tremens, 39, 635
 pharmacology of, 87
- L osteotomy, 1137f, 1294f
 inverted, 1136, 1146–1150, 1147f, 1148f
 reverse, 1290f
- Lower eyelids
 blepharoplasty, 1334–1337
 complications of, 1340–1341
 ectropion, 1341
 fat removal, 1341
 lateral canthopexy, 1337
 midfacial rejuvenation, 1337
 retraction, 1340–1341
 skin pinch excision, 1337
 transconjunctival approach, 1335–1336,
 1338f
 transcutaneous approach, 1335, 1336f
 crease, 1320
 examination of, 1329
 fat pads, 1324
 retractors, 1323
- LSD
 anesthesia with, 122
- L-shaped incision, 996
- Ludwig's angina, 284
- Luhr, Hans, 527
- Lumbar puncture, 347
- Lunchtime peels, 1423
- Lungs
 age-related changes, 41
 assessment of, 28

- volume, 59f
- Lupus anticoagulant, 37
- Lupus erythematosus, 691
- Luxation injury
 - permanent dentition malformation, 399f
- Lymphocytes, 11
- Lyons, Chalmers, 840
- Lyophilized dura, 1008
- Lysergic acid diethylamide (LSD)
 - anesthesia with, 122
- M
- Macroesthetic examination
 - oblique view, 1100
 - profile view, 1101
- Macroglossia, 1117f
- Macrolides
 - for rhinosinusitis, 305
- Macrophages, 4, 6, 193
- Macular lesions, 565, 566f
- Magnetic resonance imaging (MRI), 569
 - closed lock phenomenon, 990
 - dislocated disk, 991f
 - oral cancer, 625
 - orbital fractures, 470
 - osteomyelitis, 315
 - TMJ, 975, 976f
 - tongue, 643f
- Major Trauma Outcome Study, 329
- Malignancy
 - HIV, 689
 - masquerading as osteomyelitis, 320f
- Malignant epithelial odontogenic ghost cell tumor, 589
- Malignant hyperthermia, 37–38, 62–63, 95
- Mallampati classification, 74, 76f
- Mallampati test, 281–282
- Malnutrition
 - immunocompromised, 283
- Malocclusion, 405
- Malunion
 - mandibular fracture, 426
 - maxillary fractures, 442
 - zygomatic arch fractures, 457
- Mandible. *See also* Atrophic mandible; Edentulous mandible
 - ablative defect
 - delayed reconstruction of, 796, 797f
 - advancement, 1251f
 - OSA, 1307
 - posterior airway, 1301f
 - sagittal split osteotomy, 1283f
 - soft tissue changes associated with, 1230t
 - alveolus, 784
 - anatomy of, 934
 - angle
 - functional forces acting across, 376f
 - inferior border augmentation, 1437–1439, 1440f
 - anterior
 - FPD, 262
 - anterior segmental osteotomy
 - soft tissue changes associated with, 1229t
 - anterior teeth
 - anterior osteotomies, 1124
 - bilateral mandibular body osteotomies, 1124
 - crowded, 1123–1125
 - distalize posterior teeth, 1124
 - extraction and retraction, 1124
 - slenderizing and retraction, 1124
 - atrophy of, 158f
 - augmentation of, 181–183
 - autorotation
 - soft tissue changes associated with, 1231t
 - bicuspid
 - impacted, 136
 - progressive soft tissue recession, 212f
 - bimanual manipulation, 1045f
 - block autografts, 223–224, 228
 - body of, 784
 - bone
 - formation n, 192–193
 - loss, 162
 - buttress, 548
 - children, 529
 - comminuted fractures
 - fixation, 375
 - condyle, 934f
 - condyle fractures
 - children, 538–539
 - contour irregularities, 162f
 - defects, 785
 - maxillofacial prostheses, 267–268
 - deformation, 1205
 - delayed union, 1251
 - development of, 1062–1063, 1062f
 - distraction, 1279–1280
 - fibroma, 313f
 - FPD, 268f
 - fracture, 149, 152, 549
 - anatomic location, 409
 - binding teeth together, 383
 - biomechanical considerations, 402–404
 - children, 424–425, 538–542
 - classification of, 407–412
 - clinical examination, 405–406
 - complex facial fractures, 418
 - complications, 425–429
 - concurrent condylar fracture, 418
 - delay in treating, 418
 - dentures, 406f
 - edentulous sites, 423–425, 424f
 - evaluation of, 404–407
 - gunshot wounds, 517f
 - intermaxillary techniques, 415–417
 - intraoral examination, 406
 - intraosteal wiring, 421
 - medically compromised patients, 418
 - nonreduced, 549f
 - one-point vs. two-point fixation, 377
 - open reduction, 417–418
 - pattern of, 409–410
 - penicillin, 425
 - postoperative management, 429–430
 - radiographic evaluation, 406–407, 407f
 - right angle and left body, 381f
 - rigid fixation for, 372f, 423
 - single vs. multiple, 380–381
 - sinus tract, 426f
 - site distribution, 413f
 - teeth in line of fracture, 425
 - treatment, 401–430
 - goals, 413–414
 - types of, 409f
 - unfavorable or unstable fracture, 417–418
 - gunshot wounds, 795f
 - fragmentation, 520f
 - hemorrhage, 1249
 - hybrid denture, 265f
 - hypoplasia
 - condylar fractures, 427f
 - implants, 263f
 - incisors
 - apical fractures, 390f
 - correct underangulated, 1126
 - crowding of, 141
 - impacted, 132f
 - with insufficient supracanal height, 268f
 - large traumatic defect
 - reconstruction of, 795–796
 - manipulation
 - for TMJ, 955, 955t
 - molars
 - lack of eruption, 131
 - muscular attachments, 162f
 - nonunion, 1251
 - occlusal view, 407
 - oral cancer, 645–646
 - orthognathic surgery
 - anatomic and physiologic considerations, 1138–1141
 - historical development of, 1135–1138
 - muscles, 1140–1141
 - nerves, 1139–1140
 - osteotomy techniques, 1141–1173
 - principles of, 1135–1173
 - vascular supply, 1138–1139
 - osteotomy fractures
 - lingual segment fracture, 1258–1259
 - proximal segment, mandible intact, 1257
 - proximal segment split complete, 1257–1258
 - unanticipated, 1257–1259

- palpation of, 405f
 posterior
 FPD, 262–263
 ramus
 position in facial asymmetry, 1213
 radiolucency, 577f
 reconstruction of, 794–795
 regions, 783, 784f
 relapse of, 1262
 ridge extension procedures, 174–175
 second molars
 impacted
 repositioning of, 135
 sensory injuries in, 1253–1254
 setback
 OSA, 1310–1311
 soft tissue changes associated with, 1231t
 subapical osteotomy
 Hullihen's, 1135, 1135f
 subcondyle fractures
 children, 538–539
 surgery
 anterior repositioning, 1226–1227
 anterior segmental posterior repositioning, 1226
 autorotation, 1228
 poor esthetic results, 1241
 posterior repositioning, 1227–1228
 soft tissue changes associated with, 1226–1228
 swelling, 317f
 symphysis distraction osteogenesis, 1124–1125, 1125f
 teeth
 eruption of, 1063
 third molars
 development of, 139–140
 impacted, 131
 partial eruption, 140
 titanium reconstruction plate, 796f
 tori, 172f
 removal of, 170–171
 vascularized fibular graft to implants, 268f
 vestibular incision, 551
 vestibuloplasty, 175
 widening
 with angle fracture, 381f
 with distraction osteogenesis, 1280–1281
 with symphysis fracture, 382f
 Mandibulectomy, 644, 646, 646f
 Mandrel and cover screw drivers, 242f
 Manic-depressive disorders, 39
 MAOI
 for affective disorders, 39
 for TMJ, 952–953
 Marginal incision
 rhinoplasty, 1356f
 Margin reflex distance, 1328f, 1329
 Marijuana
 anesthesia with, 122
 Marsupialization
 for dentigerous cyst, 577, 578f
 Mask-induction techniques, 115
 Masseter muscle, 445, 938, 939f
 MAST, 339
 Masticatory myalgia, 940–941
 Masticatory space, 278
 Matrix metalloproteinases (MMP), 6
 Maxilla, 784–785
 advancement
 posterior airway, 1301f
 soft tissue changes associated with, 1227t
 anatomy of, 437f
 anterior segmentalization of, 1179
 anterior teeth
 extraction, 1122–1123
 missing, 261f
 overangulated or crowded, 1122–1123
 retraction, 1122
 slenderizing, 1122
 antroostomy, 307–308
 arch, 1126–1127
 width of, 1114t, 1130–1131
 augmentation, 175–180
 bicuspid
 impacted, 131, 136
 bone loss, 162
 buttress, 548
 canine teeth
 impacted, 131, 132
 panoramic films, 133, 133f
 unerupted, 134f
 cranial onlay bone graft, 263f
 cross-section, 1183f
 defects, 237–238, 785
 maxillofacial prostheses, 268
 delayed union, 1250–1251
 distraction, 1282–1284
 maxillary hypoplasia, 1286f
 distractors
 intravenous tubing, 1285f
 four implants, 198
 fractures
 anatomy, 436–437
 avulsive injuries, 441
 children, 441
 clinical examination, 437–438
 complications, 439, 441–442, 442t
 computed tomography, 439f
 diagnosis, 437–438
 elderly, 441
 examination, 438f
 history, 435
 imaging, 438
 Le Fort classification system, 435–436, 435f
 rigid internal fixation, 439
 surgical splints, 440–441
 treatment, 435–442, 438–439
 unanticipated, 1261
 Water's radiography, 438f
 hemorrhage, 1247–1249
 horizontal measurements of, 160f
 hypoplasia
 maxillary distraction, 1286f
 impaction
 soft tissue changes associated with, 1228t
 impaction osteotomy
 septal reduction during, 1242f
 incisors
 altering mesiodistal angulation of, 1122
 correct underangulated, 1125–1126
 extraction of, 1122
 subluxation, 392f
 inferiorly positioned, 1251f
 interpositional iliac crest grafts, 181f
 mesiodistal teeth diameter, 1112t
 model, 1182f
 molars
 impacted, 132f
 multiple implant-borne restorations, 199–200
 nonunion, 1250–1251
 orthognathic surgery, 1179–1201
 anterior repositioning, 1192
 historical development of, 1179
 inferior repositioning, 1192
 intraoperative positioning, 1180–1181
 models marked for, 1181f
 osseous structures, 1181–1183
 posterior repositioning, 1192–1193
 reference marks for, 1180–1181
 soft tissue envelope, 1184–1185
 superior repositioning, 1192
 surgical anatomy, 1181–1185
 surgical techniques, 1185–1193
 vascular structures, 1183–1184
 orthopedic expansion appliances, 1071f
 osteoradionecrosis, 322f
 osteotomy
 anterior nasal spine reduction, 1241f
 first American report of, 1179
 lateral, 1273f
 stable fixation for, 1193
 palatal cuspid
 impacted, 134
 paresthesia, 1253
 posterior segmentalization of, 1179
 premolar replacement, 199f
 reconstruction of, 795–798, 798f
 case studies, 795–798
 regions, 784f

- ridge extension procedures, 174–175
segmental distraction, 1284–1286
sensory injury in, 1253
setback
 soft tissue changes associated with, 1228t
severe atrophy, 237f
single-unit restorations, 200
sinus, 464, 1181
 CT, 163f
 fungal balls, 303f
 Water's radiography, 470f
sinusitis, 299
submucosal vestibuloplasty, 176f
surgery, 1185–1190
 anterior repositioning, 1226
 anterior segmental repositioning, 1225
 inferior repositioning, 1226
 labial structures, 1225, 1225f
 multidirectional maxillary movements, 1226
 nasal structures, 1224–1225, 1225f, 1225t
 poor esthetic results with, 1234, 1235f
 posterior repositioning, 1226
 postoperative hemorrhage, 1248
 soft tissue, 1224–1229, 1234
 superior repositioning, 1226
teeth
 bone removal, 145
 eruption of, 1063
 extraction, 201t
third molars
 impacted, 131
 delivery of, 149f
tori, 171f
 removal of, 170–171
transverse tilting of, 1099f
tuberosities, 1062, 1183
tumor
 Le Fort I island, 645f
 vestibular incision, 551
 vestibuloplasty, 175
Maxillary-nasal base esthetic unit
 craniofacial dysostosis syndrome, 904
Maxillectomy, 254f
Maxillofacial area
 in trauma patient, 349
Maxillofacial examination
 dentoalveolar injuries, 384–386
Maxillofacial imaging
 osteomyelitis, 315
Maxillofacial injuries, 349
Maxillofacial prostheses, 267–268
 craniofacial defects, 268–269
 mandible defects, 267–268
 maxillary defects, 268
 radiotherapy, 269
Maxillomandibular advancement
 OSA, 1308–1310, 1311t
Maxillomandibular complex
 manual positioning of, 1188f
Maxillomandibular discontinuities, 239f
Maxillomandibular fixation
 skeletal fixation, 1141f
Maxillomandibular fixation (MMF), 371, 1281–1282
McCain, Joseph, 964
McGill Pain Questionnaire (MPQ), 825
MDMA
 anesthesia with, 121–122
Measles, 688–689
Meatus
 narrowed, 1458
MEC, 672
Mechanical creep, 712
Mechanical stimulation, 386
Medial canthal ligament, 1321–1322
Medial canthal tendon, 465, 484, 493
 instability, 496
Medial canthus
 left
 reattachment, 477f
Medial lid lacerations, 477f
Medial zygomaticotemporal vein, 1389
Median mandibular cyst, 608
Median rhomboid glossitis, 680–681, 681f
Medically compromised patients
 mandibular fracture
 open reduction, 418
Medications
 to avoid during pregnancy, 42t
 for breast-feeding mothers, 42t
 determining preoperative risk, 17–18
 history
 blepharoplasty, 1327–1328
Medicinal leeches, 780
Meglumine diatrizoate, 518
Meissner's corpuscles, 709
Melanin pigmentation
 smoking
 gingiva, 682
Melanocytes, 709
Melanocytic lesions, 683
Melanoma in situ, 703
Melanomas, 683–684, 684f, 701–714
 acral-lentiginous, 684, 703
 biopsy, 704t
 description, 702–704
 lentigo maligna, 684
 nodular, 684, 703
 risk factors, 701–702
 superficial spreading, 684
 survival rates, 704t
Membrane-placement instrument, 213, 215
Membranous bone
 formation of, 192–193
Meningitis, 500
Mental foramina
 radiography, 253f
Mental status
 of trauma patient, 338
Menton
 osseous deposition at, 1232f
Meperidine
 chemical structure of, 88f
 in elderly, 41
 overdose of, 344
 pharmacology of, 88
 reduction in liver disease, 35
Merkel cell, 709
 tumor, 697
Meroceol packing, 438
Mesenchyme, 583
Mesioangular impaction, 143, 147f
 bone removal, 145
Mesocephalic facial type, 1094f
Messer technique, 422f
MET, 48, 70
 for common activities, 48t
Metabolic acidosis, 53, 77
Metabolic equivalents (MET), 48, 70
 for common activities, 48t
Metered-dose inhalers
 for asthma, 29
Methadone, 39
Methohexital
 chemical structure of, 90f
 children, 113
 pharmacology of, 91
Methotrexate, 639
 for rheumatoid arthritis, 36
Methyldopa, 691
Methylene blue dye, 499
3,4-methylenedioxymethamphetamine (MDMA)
 anesthesia with, 121–122
Methylprednisolone, 473
 impacted teeth removal, 149
 for sinus infection, 305
Metoclopramide, 106
Metopic synostosis, 889–890
Metronidazole
 for odontogenic infection, 289
Microdermabrasion, 1429, 1429f
Microesthetic examination, 1107
Micrognathia, 1280
Microhyphemas, 473
Microliths, 674
Microneurosurgery, 819–834
 demographics, 819–820
 exposure, 830
 medicolegal issues, 834
 postsurgical management, 834
 referral indications, 828t

- treatment algorithms, 828–830
 Micropigmentation, 1401–1402
 Microsomia, 1282f
 Microvascular anastomosis, 803–804
 Microvascular flaps, 320
 Microvascular free flaps, 792
 Microvascular free tissue transfer, 803–816
 Midazolam
 chemical structure of, 86f
 children, 112–113
 with ketamine, 111
 pharmacology of, 87
 Middle meatus
 anatomy and physiology of, 297
 discharge from, 302f
 polyp of, 302f
 Midface
 advancement surgery
 timing of, 1269–1270
 anatomy, 1318–1319
 architecture, 1329–1330
 for macroesthetic examination, 1100
 superficial fascia, 1184
 Midforehead lift, 1400
 Midline palatal incision, 1198f
 total maxillary alveolar osteotomy, 1191f
 Midline ridging, 890f
 Midsagittal osteotomy of inferior fragment, 1168
 Midsymphyseal osteotomy, 1155
 Midsymphysis
 fracture
 with condylar process fracture, 381
 measurement of, 1099f
 Military antishock trousers (MAST), 339
 Millard, Ralph, 840
 Milled-bar attachments, 265
 Miller, Charles Conrad, 1317
 Minié ball, 513f, 514
 Miniplates, 373f, 380f, 402, 549f
 isolated mandibular body fracture, 377f
 Minocycline, 682
 Minorities
 maxillofacial trauma, 384
 Minor salivary glands
 tumors, 673–674
 Missing teeth, 1131
 Mitral insufficiency, 69
 Mitral regurgitation, 24
 Mitral stenosis, 23–24, 68–69
 Mitral valve prolapse, 24–25, 69
 Mivacurium
 pharmacology of, 98
 properties, 99t
 Mixed sleep apnea, 1298
 MME, 371, 1281–1282
 MMP, 6
 Mobitz type I (Wenckebach), 28
 Möbius sequence, 104
 Modified Cawood and Howell classification of resorption, 161f
 Modified channel retractor, 226
 Modified Le Fort osteotomies, 1201–1202, 1201f
 Modified radical neck dissection, 648
 Modiolus, 1184
 Mohs' micrographic surgery
 nonmelanoma skin cancer, 705–708
 Molars
 impacted
 neoplastic change around, 141
 mandibular
 lack of eruption, 131
 restoration, 199
 Monheit-Fulton index of photoaging skin, 1421t
 Monoamine oxidase inhibitors (MAOI)
 for affective disorders, 39
 for TMJ, 952–953
 Monocortical miniplate osteosynthesis, 423
 Monocortical plate, 1262f
 Monostotic fibrous dysplasia, 597
Moraxella catarrhalis, 300
 Morbid obesity, 58
 Morphine
 in elderly, 41
 end-stage TMJ disease, 1017, 1021
 pharmacology of, 88
 reduction in liver disease, 35
 Morse taper, 256
 internal connection, 257f
 Moses, Jeffrey, 964
 Moses' release elevator, 971f
 Motor function
 in trauma patient, 346
 Mouth
 gunshot wound, 521f
 Moxifloxacin
 for odontogenic infection, 289
 MPD, 941
 MRI, 569. *See also* Magnetic resonance imaging (MRI)
 Mucocoeles, 503, 676–677
 Mucoepidermoid carcinoma (MEC), 672
 Mucolytics, 502
 Mucoperichondrium
 elevation of, 1357f
 Mucoperiosteal flap, 144
 Mucosa. *See also* Oral mucosa
 advancement flaps
 labial, 662
 flaps
 buccal, 1270f
 cross-lip, 662, 665f
 lip cancer, 620–621
 membrane pemphigoid
 benign, 690–691
 substitutes
 wound healing, 13–14
 Muller's muscle, 466, 1323
 Multiple trauma algorithm, 331f
 Murakami, Ken-Ischiro, 964
 Murmurs, 107
 Muscarinic receptor antagonists
 children, 117
 Muscle injections
 for TMJ, 957
 Muscle relaxants, 954t
 TMJ, 953
 Muscular dystrophy
 anesthesia with, 120
 Musculoaponeurotic system incision, 1376f
 Musculocutaneous arteries, 710
 Mustarde technique, 1453f, 1454–1456, 1456f
 Muzzleloaders, 513
 Myelin sheaths, 824
 Mylohyoid attachment, 175
 Mylohyoid ridge reduction, 171
 Myocardial infarction, 49–50
 general anesthesia risk after, 20
 Myocardial ischemia, 18, 19, 48–49
 Myocutaneous flaps, 770f
 latissimus dorsi, 780
 pectoralis major, 777–778
 trapezium, 779–780
 Myofascial pain and dysfunction (MPD), 941
 Myositis ossificans progressiva, 941, 1035f
 Myotonic dystrophy, 941

 N
 Nalbuphine
 pharmacology of, 89
 Naloxone
 pharmacology of, 89
 Narcolepsy, 1298, 1299
 Narcotics
 avoidance in COPD, 30
 Nasal cavity
 lateral wall of, 340f
 packing of, 340, 340f
 Nasal dorsum, 1352f, 1358–1359
 augmentation, 1358–1359
 reduction, 1358
 rhinoplasty, 1352, 1353
 Nasal septum, 437
 abnormalities of, 298
 alterations in, 1255
 anatomy of, 437f, 1349f
 anterior aspect of, 1189f
 arteries, 1348f
 cartilage resection, 1357f
 hematomas, 364
 repositioning, 1357f
 sensory nerves, 1351f
 suturing to anterior nasal spine, 1190f

- Nasal tip
 defect, 366f
 definition, 1352f
 rhinoplasty, 1352
 projection
 rhinoplasty, 1352–1353
 rhinoplasty, 1359–1363
 rotation
 rhinoplasty, 1353
- Nasal valve, 1350
 alterations in, 1256
- Nasal wall
 anatomy and physiology of, 297, 297f
- Nasoantral window, 298
- Nasociliary nerve, 1325
- Nasofrontal angle
 rhinoplasty, 1351–1352
- Nasofrontal duct, 497f
 evaluation of, 499f
 identifying, 499f
 intraoperative evaluation of, 498–499
 obstruction, 500–501
 patency, 496
- Nasofrontal suture line, 1385
- Nasolabial cysts, 608, 609f
- Nasolabial flap, 774–775, 776f
- Nasolacrimal apparatus
 soft tissue injuries, 364–365
- Nasolacrimal duct
 ostium, 437
- Nasolacrimal system
 anatomy of, 365f
- Nasomaxilla
 development of, 1060–1061
 intramembranous growth, 1061f
 malformations, 1065–1066
- Naso-orbitoethmoid (NOE) fractures,
 467, 488, 495f
 children, 532–534
 classification, 496, 498f
 imaging, 496
 osseous recovery, 498
 reconstruction, 501–502
- Nasopalatine duct cyst, 608–609, 609f
- Nasopharyngeal carcinoma, 1036f
- Nasotracheal intubation, 439
- Nausea, 1299
- Neck. *See also* Head and neck
 dissection
 in-continuity *vs.* discontinuity, 650
 examination of, 357
 gunshot wounds, 517–519
 decision tree, 519f
 surgery, 520–522
 injuries, 366–367
 inspection of in trauma patient, 349
 levels, 667f
 lymph node levels of, 619f
 oral cavity
 squamous cell carcinoma, 648f
 palpation of, 625
 in trauma patient, 349
- Necrotizing fasciitis, 281, 281f
- Necrotizing ulcerative gingivitis, 681
- Needle decompression, 284
- Neisseria gonorrhoeae*, 682
 TMJ, 944
- Neoadjuvant chemotherapy, 639
- Neochondyle
 transport distraction osteogenesis, 1289–1290
- Neonate
 cranial base, 1061f
 skull
 fontanelles, 1060f
 sutures, 1060f
- Neonates, 42
- Neophyte clinician
vs. expert clinician
 case study, 567–568
- Neovascularization, 8
- Nephrosclerosis, 32
- Nerve growth factor (NGF), 13
- Nerves
 damage
 BSSO, 1156–1158
 grafts, 833
 donor size, 833t
 injuries, 1253–1255
 classification of, 824–825, 824f
 Seddon *vs.* Sunderland, 825t
 mandibular fracture, 426–427
 peripheral, 827–828, 828t
 layer formation, 1051–1052
 stump preparation, 832, 832f
 treatment algorithms, 829f
 wound healing, 6
- Neural complications
 horizontal ramus osteotomies, 1164
- Neural crest migration, 1053f
- Neural damage
 VSO, 1146
- Neural fascicular patterns, 822, 823f
- Neural innervation
 children, 105
- Neural wound healing, 823f
- Neurocranium
 formation of, 1055
- Neurofibroma, 610–611, 610f
- Neurofibromatosis, 682
- Neuroleptic malignant syndrome (NMS), 63
- Neurologic disorders
 assessment of, 78–79
 cerebrovascular disease, 37
 epilepsy, 78
 malignant hyperthermia, 37–38
 spinal cord disorders, 38
 stroke, 37, 78
 caused by hypertension, 32, 79
 TIA, 37, 78–79
- Neuroma, 6, 611f
 traumatic, 611
 types of, 824f
- Neuromuscular-blocking medications
 pharmacology of, 97
 properties, 99t
- Neuromuscular disorders, 37–38
 assessment of, 78–79
 seizure disorders, 37
- Neuropeptides, 300
- Neuropraxia, 6
- Neuropsychiatric disorders, 888
- Neurorrhaphy, 833, 833f
- Neurotmesis, 6
- Neutrophils, 4, 193
- Nevi, 683
- Nevoid basal cell carcinoma syndrome,
 580–581, 580f
- Nevus sebaceus of Jadassohn, 698, 699f
- Newborns. *See* Neonates
- New York Heart Association cardiac patient
 classification, 67–68, 67t
- NGF, 13
- Nicardipine
 for hypertension, 32
 for hypertensive crisis, 50t
- Nicotine
 effect on cardiovascular system, 57
- Nikolsky's sign, 690
- Nitroglycerin, 67
- Nitroprusside
 for hypertensive crisis, 50t
- Nitrous oxide
 avoidance in COPD, 30
 chemical structure of, 96f
 children, 114
 pharmacology of, 93, 95–96
 properties of, 94t
- NLP, 472
- NMS, 63
- Nobecutane spray, 718
- Nobel Biocare implants, 243
- Nocturnal myoclonus
 sleep-related, 1298
- Nodes of Ranvier, 823
- Nodular melanomas, 684, 703
- NOE. *See* Naso-orbitoethmoid (NOE)
 fractures
- Noel, Suzanne, 1317
- No light perception (NLP), 472
- Noncompetitive antagonists, 84
- Noncompression plate osteosynthesis
vs. compression plate osteosynthesis, 378
- Nondepolarizing agents
 pharmacology of, 98

- Nondilated cardiomyopathy, 69
 Non-Hodgkin's lymphoma, 689–690
 Nonischemic heart disease, 68–69
 Nonmelanoma skin cancer, 697–700
 applied skin anatomy, 709–710
 chemotherapy, 708
 cryosurgery, 708
 curettage, 708
 electrodesiccation, 708
 epidemiology, 697
 etiology, 697–698
 excision, 705
 flaps, 710–711
 interferon, 709
 lasers, 708–709
 Mohs' micrographic surgery, 705–708
 photodynamic therapy, 709
 prevention, 699–700
 radiation therapy, 708
 retinoids, 709
 treatment, 704–705
 Nonopioid analgesics
 end-stage TMJ disease, 1018–1019
 Nonrestorable tooth
 orthodontic extrusion of, 266f
 replaced with immediate implant, 267f
 Nonrigid internal fixation, 371–373
 vs. rigid internal fixation, 371–382
 Nonsteroidal anti-inflammatory drugs
 (NSAID), 641, 952t
 avoidance
 in liver disease, 35
 in renal patients, 31
 ideal properties, 952t
 inhibiting platelet function, 78
 periarticular ectopic bone formation, 1027
 for rheumatoid arthritis, 36
 for TMJ, 951
 Nonsyndromic craniosynostosis, 887–899
 bilateral coronal synostosis, 892–895, 895f
 classification, 888–889
 diagnosis, 888
 functional considerations, 887–888
 management, 891–899
 metopic synostosis, 896f–897f
 sagittal synostosis, 896–897, 898f
 unilateral coronal synostosis, 891–895, 892f
 unilateral lambdoid synostosis, 899
 Nonunion
 mandible, 1251
 mandibular fracture, 425–426
 maxilla, 1250–1251
 maxillary fractures, 442
 Norepinephrine, 338
 Normal radiography of
 chest, 348f
 Normochromic anemia, 30–31
 Normocytic anemia, 30–31
 Nose
 air passages
 children, 528
 anatomy, 1345–1360
 anatomy and physiology of, 297
 basal cell cancer, 707f
 base alar reduction, 1363
 bilobed flap of Zitelli, 714
 blood supply, 1346–1347
 bones, 437, 1347–1348
 anatomy of, 437f
 cartilage, 1347–1348
 chemicals irritating, 300
 continuous positive airway pressure
 for OSA, 1302
 endoscope, 308f
 examination
 fiberoptic, 295
 external
 arteries of, 1347f
 sensory nerves, 1350f
 fractures
 children, 537–538
 incidence, 488
 gull in flight contour, 1098f
 laceration, 476f
 lateral wall
 arteries of, 1347f
 musculature, 1346, 1346f
 nerves, 1348–1350
 packing
 balloon catheters, 517f
 polyps, 298
 projection, 1353f
 secretions
 normal values of, 495t
 skin, 1345–1346
 soft tissue, 1345–1346
 injuries, 364–365
 structures
 maxillary surgical procedures,
 1224–1225, 1225f, 1225t
 surface anatomy, 1345, 1345t
 surgery
 OSA, 1305
 Novum restoration, 267f
 NSAID. *See* Nonsteroidal anti-inflammatory
 drugs (NSAID)
 Nutrition
 gunshot wounds
 neck, 519
 oral cancer, 635–636
 wound healing, 12
 Nystatin
 for fungal sinusitis, 307
 O
 Obesity, 40, 58
 drug pharmacokinetics, 40
 pulmonary problems, 40
 thrombophlebitis, 40
 Obstructive disk blockade, 975
 Obstructive pulmonary disease
 physical examination of, 71–72
 Obstructive sleep apnea (OSA), 1297–1311,
 1298, 1309f, 1310f
 bimaxillary advancement surgery for
 soft tissue changes associated with,
 1233–1234
 Bi-PAP, 1304
 cephalometric examination, 1300–1301, 1300f
 clinical manifestations of, 1299
 CPAP, 1304
 CT, 1301
 diagnosis, 1300–1302
 history of, 1299
 laser-assisted uvulopalatoplasty, 1306–1307
 maxillomandibular advancement
 soft tissue changes associated with, 1233
 medical treatment, 1302–1304
 obstruction site, 1301–1302
 oral appliances, 1302–1304, 1303f
 orthognathic surgery procedures,
 1307–1311
 physical examination, 1300
 physical findings, 1299
 polysomnography, 1301
 surgery, 1304–1311
 Obturators
 TMJ arthroscopy, 970
 Obwegeser's osteotomies of the ramus, 1150,
 1150f, 1179
 Obwegeser's technique, 415, 421
 Occlusal adjustment
 for TMJ, 959
 Occlusal radiographs
 alveolar and dental fractures, 386–387
 alveolar cleft reconstruction, 868f, 869f
 implants, 252
 Occlusal splint, 267f
 for TMJ arthroscopy, 984
 Occlusion
 craniofacial dysostosis syndrome, 903
 Occult neck metastasis, 644
 OCIF/OPG
 TMJ, 943
 O'Conner, Richard, 963
 Octylcyanoacrylate, 360
 Ocular. *See* Eyes
 Oculocephalic maneuver, 347, 347f
 Oculocephalic response, 347f
 Oculovestibular response test, 347
 Odontogenic carcinoma
 classification of, 588t
 clear cell, 589
 Odontogenic cysts, 576–582
 classification of, 577f

- dentigerous cyst, 576–578
- glandular, 581–582, 582f
- odontogenic keratocyst, 578–581
- prevention of, 141
- Odontogenic infection, 277–292
 - airway compromise, 281–282
 - anatomic location, 277–278
 - antibiotics, 288–290, 288t
 - care setting, 283–284
 - hospital admission
 - indications for, 283t
 - host defenses, 282–283
 - medical support, 287–288
 - operating room procedures for
 - indications for, 284, 284f
 - patient evaluation, 290–292
 - rate of progression, 280–281
 - severity of, 277–282
 - stages of, 280, 280t
 - surgery, 284–287
 - surgical drainage, 284–286, 285f
 - treatment failure
 - causes of, 290t
- Odontogenic keratocysts, 579f, 580f, 699f
- Odontogenic myxoma, 591f
- Odontogenic tumors, 583–594
 - adenomatoid, 593, 593f
 - ameloblastic fibroma, 589–590
 - ameloblastic fibro-odontoma, 590
 - ameloblastoma, 583–588
 - calcifying epithelial, 592
 - classification of, 583t
 - incidence, 584t
 - malignant, 588–594
 - ameloblastic carcinoma, 588–589
 - clear cell odontogenic carcinoma, 589
 - epithelial ghost cell tumor, 589
 - metastasizing ameloblastoma, 588
 - primary intraosseous squamous cell carcinoma, 589
 - myxoma, 591–592
 - odontoma, 590–591, 591f
- Odontoma, 590–591, 591f
- Ohngren's line, 645
- Ohnishi, Masatoshi, 964
- Olfactory bulb
 - esthesioneuroblastoma
 - radiotherapy, 637f
- One-point fixation
 - vs. two-point fixation, 377
- One-stage protocol, 201–202
- Onlay bone grafts, 177–179, 1274f
- Open arthrotoomy
 - TMJ
 - indications for, 943
- Open bites, 1261–1263, 1263f
- Open fractures, 410
- Open pneumothorax, 332–334
- Open reduction and internal fixation (ORIF),
 - 401f, 532
- Open sky
 - approach, 497
 - incision, 996
- Open submucosal vestibuloplasty, 177f
- Open technique
 - subepithelial connective tissue grafting implants
 - recipient-site surgery, 215–217, 216f
- Ophthalmic artery, 1346
- Opiates, 87
 - overdose of, 344
- Opioids
 - abusers, 39–40
 - addiction, 1023
 - end-stage TMJ disease, 1017, 1020–1021
 - pharmacology of, 87–89
 - risk of addiction to, 1021
 - side effects of, 87–88
- Optic nerve, 493
 - injury, 473
- Optic neuropathy
 - traumatic
 - zygomatic arch fractures, 459
- Optimized problem list, 1108–1109
- Oral appliances
 - OSA, 1302–1304, 1303f
- Oral burning sensation, 680
- Oral cancer, 617–622
 - biopsy, 627
 - cervical lymphadenectomy, 666
 - cervical lymph node levels, 619–620
 - chemoprevention, 640–641
 - chemotherapy, 638–640
 - clinical correlation by site, 620–623
 - diagnosis, 626–627
 - distant metastasis, 626
 - histology, 631–632
 - lip, 641–645
 - perioperative issues, 635–636
 - pre-malignant disease, 618–619
 - treatment, 632–633
 - primary lesion assessment, 623–624
 - primary tumors, 623t
 - radiation, 636–637
 - recurrence, 651–653
 - regional lymph nodes, 623t
 - regional metastasis, 624–626
 - sentinel node biopsy, 650–651
 - squamous cell carcinoma, 617–618
 - staging, 623
 - surgery, 633–636
 - complications, 636
 - therapeutic neck dissection, 651
 - treatment, 631–653
 - future, 653
 - panendoscopy, 633
 - selection, 633
- Oral candidosis, 680f, 681f
- Oral cavity
 - fungal disease, 680–681
 - inspection of in trauma patient, 349
 - squamous cell carcinoma
 - neck dissection, 648–650, 648f
- Oral decongestants
 - for sinus infection, 305
- Oral disease
 - differential diagnosis, 564–572
- Oral hypoglycemic agents, 60
- Oral melanotic macules, 683
- Oral mucosa
 - bacterial infections, 681–682
 - generalized pigmentation, 682, 682f
 - pigmented lesions, 682–685
- Oral sedation, 109
- Oral submucous fibrosis, 619
- Orbicularis oculi, 1322–1323, 1387f
- Orbicularis oris, 1184
- Orbit, 445, 464f
 - anatomy of, 463
 - anterior boundary of, 466
 - apex, 445
 - arterial blood, 1324f
 - fat
 - aging changes, 1324
 - fissures, 464t
 - floor, 445, 463, 464
 - fractures, 480f
 - zygomatic arch fractures, 456–457
 - fractures
 - acute repair of, 484–488
 - anatomy of, 463–464
 - clinical examination, 467–470
 - configurations, 467
 - imaging, 470–471
 - medial orbital approach, 483–484
 - nonoperative management of, 476–479
 - surgery, 479–488, 480–484
 - indications, 479–480
 - inferior and lateral orbital approach, 480–482
 - superior and medial orbital approaches, 482–483
 - injuries
 - surgery, 477
 - surgery vs. observation, 478
 - lateral wall of, 464–465
 - ligament, 1386
 - lobe, 466
 - potential sites for traumatic injuries, 463f
 - rim, 1385, 1398f
 - anatomy of, 463
 - roof, 445, 464
 - reconstruction, 500
 - septum, 466, 1321, 1321f

- structures distance from bony landmarks, 465t
- upper trauma, 533f
- walls
 - anatomy of, 463
- Orbitonasal fracture, 535f
- ORIF, 401f, 532
- Oronasal communication, 1252f
- Orthodontic appliances
 - with surgical exposure
 - of impacted teeth, 134
- Orthodontic band pusher, 866
- Orthodontics, 1111–1134
 - diagnostic list, 1118
 - initial surgical treatment objective, 1118–1119
 - treatment, 1120–1133
- Orthodontic tooth movement
 - soft tissue changes associated with, 1225
- Orthodontic treatment
 - obstruction of, 141
- Orthognathic surgery
 - cleft palate, 1267–1275
 - bone grafting with maxillary advancement, 1272–1273
 - presurgical counseling, 1270–1271
 - cleft palate/maxilla
 - bone grafting, 1273–1274
 - complications of, 1247–1263
 - dental and periodontal injuries, 1251–1252
 - excessive lateral displacement, 1259
 - genial segment surgical procedures
 - soft tissue changes associated with, 1229–1233
 - historical perspective, 1221
 - interference with, 141
 - liposuction, 1411–1412
 - mandibular surgical procedures
 - soft tissue changes associated with, 1226–1228
 - maxillary surgical procedures
 - soft tissue changes with, 1224–1229
 - medial displacement, 1259
 - motor nerve injuries, 1254–1255
 - nasal and sinus considerations, 1255–1256
 - OSA, 1307–1311
 - poor esthetic results
 - secondary revision of, 1243
 - proximal segment rotation, 1259–1260
 - soft tissue changes associated with, 1221–1243, 1222t
 - cephalometric considerations, 1222–1223, 1224f
 - orthodontic considerations, 1222
 - orthodontic incisor retraction, 1223–1224
 - TMJ dysfunction, 1260–1261
 - unanticipated maxillary fractures, 1261
 - vascular complications, 1247–1250
 - velopharyngeal considerations, 1274–1275
- Orthognathic treatment planning
 - contemporary, 1087–1088, 1088f
- Orthopantomaxillary view
 - osteomyelitis, 315, 315f, 316f, 318f
- Orthotic splints, 966
- OSA. *See* Obstructive sleep apnea (OSA)
- Osada surgical handpiece, 1430
- Osseointegration, 189–202
 - atrophic mandible augmentation, 195–197
 - defined, 192
 - edentulous mandible, 193–197
 - incision design, 194
 - physical examination, 194
 - radiologic examination, 194
 - edentulous maxilla, 197–199
 - eight implants without graft, 198
 - eight implants with sinus grafts, 198–199
 - esthetic sites
 - incisions, 200
 - failure of, 191–192
 - four or more implants, 195
 - implants materials, 189–190
 - one-stage protocol, 201–202
 - placement without trauma, 190–191
 - restorations, 199–200
 - surgical protocol, 190–192
 - time for, 191
 - two implants, 195
 - wound healing, 192–193
- Osseointegration implants, 251f
- ear, 368f
- Osseous surgery, 1186–1187
- Ossification, 1055
- Ossifying fibroma, 599–600, 599f
- Osteoarthritis, 941
- Osteoblastoma, 600, 600f
- Osteoblasts, 7, 165, 192–193, 371
- Osteochondroma, 601–602, 602f
- Osteoclastogenesis inhibitory factor/osteoprotegerin (OCIF/OPG)
 - TMJ, 943
- Osteoclasts, 8, 166, 786
- Osteoid
 - bone formation in, 192–193
- Osteoid osteoma, 600
- Osteoma, 601, 601f
- Osteomeatal complex
 - CT, 303f
 - diagram of, 296f
- Osteomyelitis, 313–318, 500
 - classification of, 314
 - clinical characteristics, 314–315
 - malignancy masquerading as, 320f
 - mandibular fracture, 426
 - microbiology of, 314
 - pathogenesis of, 313–314
 - surgery, 317–318
 - treatment, 316–317
- Osteons, 371
- Osteopenia, 307
- Osteoplasty
 - arthroscopic, 978f
 - ridge split, 176–177
- Osteoporosis, 41, 252, 307, 424
- Osteoprogenitor cells, 164
- Osteoradionecrosis, 318–322
 - maxilla, 322f
- Osteotomes, 200, 233f
 - and condylar arthroplasty, 1003f
 - and lateral nasal wall, 1272f
 - and nasal septum separation, 1187f
- Osteotomy, 645–646, 1161–1164. *See also* specific osteotomy
 - Lane's, 1137f
 - lateral wall, 1187f
 - of ramus
 - Obwegeser's, 1150, 1150f, 1179
- Ostium
 - nasolacrimal duct, 437
- Outpatient anesthesia medications
 - distribution of, 84–85
 - pharmacodynamics of, 83–85
 - pharmacokinetics of, 84–85
 - pharmacology of, 83–100
- Overdentures
 - bar attachment, 264f
 - bar splint, 237f
 - implant-retained, 264
 - implant-supported, 254
 - attachment mechanisms for, 265
 - long-term overuse, 238f
 - precision detachable, 265f
- Oxazepam
 - for DT, 39
- Oxidative stress
 - TMJ, 942
- Oxycodone
 - for TMJ, 951
- Oxygenation
 - trauma patient, 336–337
- Oxygen dissociation curve, 57f
- Oxygen therapy
 - for OSA, 1302
- Oxymetazoline
 - for sinus infection, 305
- Oxymetazoline hydrochloride, 502
- P
- Pacinian corpuscles, 709
- Paclitaxel, 640
- Paget's disease, 611–612, 611f, 612f
- Pain, 405, 494
 - frontal sinus, 503
 - with impacted teeth removal, 150
 - with osteomyelitis, 314

- with TMJ end-stage disease, 1016–1018, 1016t
- unexplained, 142
- Palate, 1182
 - distraction appliance, 1073f
 - flaps, 866, 867f
 - rotated, 772
 - incisions, 218
 - mucosa, 1184–1185
 - pedicle
 - for anterior maxillary osteotomy, 1195f, 1196f
 - pleomorphic adenoma, 673f
 - recurrent low-grade polymorphous adenocarcinoma, 674f
 - salivary gland tumors, 673–674
 - squamous cell carcinoma, 645
- Palatine arteries, 1183f, 1184f, 1248
- Palatine bone, 437, 1188f
 - bone removal from, 1197f
- Palatoplasty
 - Bardach two-flap, 852
 - two-flap, 874f
- Palliative chemotherapy, 639
- Palpebral lobe, 466
- Pancuronium
 - pharmacology of, 98
 - properties, 99t
- Panendoscopy, 624
- Panfacial fractures, 547–557, 556f–557f
 - anatomic considerations, 547–548
 - bone grafts, 551–552, 552f
 - complications, 555
 - etiology, 547
 - historical perspective, 547
 - soft tissue resuspension, 551–552
 - treatment sequence, 552–555, 553f, 554f, 555t
- Panoramic radiograph
 - zygoma implants, 244f
- Panoramic radiographs
 - alveolar ridge, 163f
 - condylar neck fracture, 407, 407f
 - condyles asymmetry, 1208f
 - edentulous mandible, 194
 - facial asymmetry, 1209
 - implants, 253
 - maxillary canine teeth, 133, 133f
 - for preprosthetic and reconstructive surgery, 160
- Panorex
 - intrusion, 392f
- Papilla
 - creating/preserving, 252t
- Papillary epithelial lesion
 - asymptomatic, 565f
- Paraformaldehyde-containing paste, 299
- Parallel walled screw, 256
- Paranasal sinuses
 - anatomy and physiology of, 297
 - children, 529
 - CT, 304f
 - development of, 1057
- Paraplegia, 38
- Parasymphseal fractures, 541f
 - children, 541
- Parasymphysis fractures, 409
- Pare, Ambroise, 509
- Pare's classification of edentulous maxilla, 197
- Parents
 - presence during sedative administration, 105
- Paresthesia
 - maxilla, 1253
 - with osteomyelitis, 314
- Parotideomasseteric fascia, 994f
- Parotid gland, 358f, 671
 - ducts
 - sialogram, 676f
 - injuries, 358–359, 359f
 - pleomorphic adenoma, 673f
 - posterior duct stones, 676
 - squamous cell carcinoma, 642
 - stones, 676
 - terminal duct stones, 676
 - tumors, 672–673
- Paroxysmal atrial tachycardia (PAT), 27
- Paroxysmal supraventricular tachycardias (PSVT), 51
- Parry-Romberg syndrome, 1207
- Partial-thickness curvilinear incision, 213
- Partial-thickness pedicle flaps
 - subepithelial connective tissue graft, 212
- Partial transfixion, 1348f
- PASG, 339
- Passive jaw exercise
 - for TMJ, 955, 955f, 1025
- Pasteurella multocida*, 362f
- PAT, 27
- Pathologic fracture, 410
- Patient follow-up, 572, 572t
- Patient history, 564–565
- PCP
 - anesthesia with, 122–123
- PDGF-BB, 13, 225
- PDT
 - leukoplakia, 632–633
- Peck graft, 1361f
- Pectoralis major myocutaneous flaps, 777–778, 777f
 - harvesting, 796f
- Pediatric patients. *See* Children
- Pedicated grafts, 183
- Pedicle flaps
 - partial-thickness
 - subepithelial connective tissue graft, 212
 - split-thickness
 - subepithelial connective tissue graft, 212
- Pedicles
 - passive adaptation of, 207
- Pelvic fracture, 341f, 353
- Pemphigus, 690
 - antibodies, 690f
- Penicillamine, 691
 - for rheumatoid arthritis, 36
- Penicillin
 - avoided with renal patients, 31
 - mandibular fracture, 425
 - for rhinosinusitis, 305, 502
- Penicillin V
 - for odontogenic infection, 289
- Penrose drain, 285
- Pentazocine
 - avoidance in liver disease, 35
- Pentobarbital
 - chemical structure of, 90f
 - pharmacology of, 91
- Peptic ulcer disease, 35–36
- Peptostreptococcus*, 140
- Percussion sensitivity, 385
- Periapical cemento-osseous dysplasia, 598–599, 599f
- Periapical occlusal method, 133
- Periapical radiographs
 - alveolar and dental fractures, 386–387
 - implants, 252
- Periarticular ectopic bone formation, 1025–1027
- Pericardial aspiration, 339
- Pericardiocentesis, 339f
- Perichondritis
 - protruding ear, 1457–1458
- Perichondrium
 - identification, 1357f
- Pericoronitis
 - prevention of, 140
- Pericrestal incisions, 206, 206f
- Periimplant soft tissue
 - papilla regeneration, 207–208, 208f
 - resective contouring, 207, 208f
 - surgical maneuvers, 206–208
- Perimandibular space, 278
- Perinasal incision, 551
- Periodontal concussion, 389f
- Periodontal disease
 - HIV, 689
 - implants, 252
- Periodontal healing
 - after replantation, 395f
- Periodontal injuries
 - classification of, 391–392
- Periodontal ligament
 - cell metabolites
 - solutions to replenish, 394t
 - injury, 385
- Periodontal problems

- total alveolar osteotomy, 1167–1168
- Periodontal subluxation, 389f
- Periodontal tissue injuries, 390–395
- Perioperative analgesic medications
pharmacology of, 97
- Perioperative antibiotics
oral cancer, 635
- Perioperative cardiovascular evaluation
algorithm, 70–71
- Perioperative considerations, 47–63
cardiac assessment, 47–53
cigarette smoking, 56–58
electrolytes and acid-base disturbances, 53–54
endocrine assessment, 59–61
malignant hyperthermia, 62–63
pulmonary assessment, 54–55
renal insufficiency, 54
- Perioperative morbidity
risk factors associated with, 47t
- Perioperative risks
determinants of, 17
- Perioral-periorbital carbon dioxide laser
resurfacing, 1426f
- Periorbital ecchymosis, 437, 494
- Periorbital incision sites, 455f
- Periosteum
cells, 373f
children, 529
elevator, 866, 1387f
incision, 452
stripping, 1290
- Peripheral cranial nerves, 357
- Peripheral nerve injuries
pharmacologic management, 827–828, 828t
- Peritoneal lavage fluid
evaluation of, 352t
- Permanent cavity, 511
- Permanent teeth
developing buds, 398f
children, 529
impacted, 132
- PET. *See* Positron emission tomography (PET)
- Petechiae, 685
- Petzel technique, 422f
- Peutz-Jeghers syndrome, 682
- Pfannenstiel's incision, 501
- Pfeiffer syndrome, 903, 924f, 925f
- Pharyngeal flaps, 1274–1275
inferiorly based, 878
superiorly based, 878
- Pharyngeal space
abscess, 282f
computed tomography of, 291f
drainage of, 285f
lateral
borders of, 278t
infection, 279t
- Phenobarbital
chemical structure of, 90f
- Phenol, 1341
- Phenothiazines
children, 117
for psychotic disorders, 39
- Phentolamine
for hypertensive crisis, 50t
- Phenylephrine
for sinus infection, 305
- Phenytoin, 691
- Philtrum height, 1089
- Phonophoresis
for TMJ, 956
- Photoaging
Glogau's classification, 1419, 1419t
medical care of, 1420–1421
- Photodynamic therapy (PDT)
leukoplakia, 632–633
- Pierre Robin, 74, 104
- Piezoelectric sinus window, 233f
- Piezoelectric surgery, 233
- Pigmented lesions, 704f
localized, 682–685
oral mucosa, 682–685
- Pilot drill, 242f
- Pindborg tumor, 592, 593f
- Pink puffers, 73
- Pipercuronium
properties, 99t
- Pipe smoking
lip cancer, 659
- Pituitary gland, 76
- Plagiocephaly
description of, 1206–1207
frontal and superior views, 888f
and nasal bridge, 889f
positional, 891f
right anterior, 893f–894f
- Plain radiographs, 568
abdominal trauma, 352
atrophic mandible, 196f
zygomatic complex fractures, 448
- Plantar pitting, 581f
- Plaques, 18, 19
- Plastic skin, 1428
- Platelet-derived growth factor-BB (PDGF-BB),
13
- Platelet release, 224–225
- Platelet-rich plasma (PRP), 221, 792–794, 793f
- Platysmal plication, 1370f
- Playground injuries, 383
- Pleomorphic adenoma
palate, 673f
parotid gland, 673f
salivary gland, 671
- Plication, 1045, 1045f, 1371, 1372f
vs. imbrication, 1372f
- Plunger attachments, 265
- PMI, 22
- Pneumatic antishock garments (PASG), 339
- Pneumonia, 38
- Pneumothorax, 333f
closed, 333
tension, 332, 334, 335f
- Pocket principle, 366
- Pogonion
osseous resorption at, 1232f
- Point of maximal impulse (PMI), 22
- Pollutants, 300
- Polyethylene-tipped instruments, 271f
- Polymeric silicone catheter, 359
- Polymeric silicone implant, 1009f
- Polymeric silicone tubes, 364, 365f
placement of, 505f
- Polymorphous adenocarcinoma
low-grade, 672
recurrent low-grade
palate, 674f
- Polymyxin B sulfate, 359
- Polyostotic fibrous dysplasia, 597
- Polyps
recurrent, 310
- Polytetrafluoroethylene (PTFE), 1008
- Ponderal index, 40
- PONV, 100
children, 117–118
- Porcelain fracture, 270
- Porcelain-fused-to-metal, 239f
- Porous polyethylene implants, 1201f
- Porphyromonas*, 140, 288, 426
- Positron emission tomography (PET), 569
cervical lymph nodes, 647, 648f
oral cancer, 626, 626f
- Postauricular coronal (scalp) incision, 907
- Posterior cranial vault esthetic unit
craniofacial dysostosis syndrome, 903
- Posterior ethmoidal foramen, 465
- Posterior ethmoid artery, 1346
- Posterior maxilla
FPD, 262
- Posterior maxillary osteotomy, 1196–1197, 1196f
- Posterior plagiocephaly, 890
- Posterior teeth
distalizing, 1123
- Posteroanterior cephalometric radiographs
facial asymmetry, 1209
- Postnatal skull
changing proportions, 1059f
- Postoperative instructions
facial liposuction, 1418
- Postoperative nausea and vomiting (PONV),
100
children, 117–118
- Postoperative occlusal discrepancies, 1261
- Postorthodontic models, 549f
- Posturing

- abnormal, 346
- Preauricular incision, 993f
- Precession, 514
- Predistraction hyperbaric oxygen therapy, 1289
- Prednisone
 - for sinus infection, 305
 - and wound healing, 11
- Preemptive analgesia
 - end-stage TMJ disease, 1016–1018
- Pregnancy, 42
 - medications to avoid during, 42t
 - testing
 - adolescents, 107
- Preload, 22, 26, 49
- Premachined abutment
 - for cement-retained restorations, 257f
 - for screw-retained restorations, 257f
- Premature ventricular contraction (PVC), 27
- Premaxilla
 - bone grafts, 1274f
 - congenital agenesis, 1285
 - traumatic avulsion, 1287f
- Premolars
 - impacted, 133–134
 - replacement
 - maxilla, 199f
 - restoration, 199
- Prenatal craniofacial development, 1051–1058
- Preoperative patient, 65–79
 - bleeding disorders, 78
 - cardiovascular disease assessment, 21f, 66–70, 107
 - endocrine assessment, 74–77
 - fasting, 105–106
 - liver disease, 77
 - neurologic disorders, 78–79
 - neuromuscular disorders, 78–79
 - psychological, 105
 - pulmonary assessment, 71–73
 - questionnaire, 17t
 - renal disease, 77–78
 - screening tests for asymptomatic patients, 79
- Preprosthetic and reconstructive surgery, 157–185
 - alveolar distraction osteogenesis, 183–185
 - bone
 - regeneration, 162–164
 - exostoses, 169
 - fibrous inflammatory hyperplasia, 172
 - genial tubercle reduction, 169–170
 - grafts, 165–167
 - hard tissue
 - augmentation, 175–180
 - recontouring, 167–171
 - hypermobile tissue, 172
 - inflammatory papillary hyperplasia, 172
 - labial and lingual frenum, 172–174
 - medical considerations, 159–161
 - hard and soft tissue, 159–160
 - radiographic evaluation, 160–161
 - mylohyoid ridge reduction, 171
 - ridge extension procedures, 174–175
 - skeletal and alveolar ridge discrepancies, 180–181
 - soft tissue recontouring, 171–173
 - tori removal, 170–171
 - treatment planning, 161–162
 - tuberosity reduction, 169, 170f
- Preseptal cellulitis, 304
- Press-fit cylinder-type implant, 256f
- Presurgical orthodontics, 1119–1120
 - goals, 1118, 1119f
- Presurgical orthopedic (PSO) appliances, 846
- Pretracheal space
 - borders of, 278t
- Pretrichial forehead lift, 1395–1396
- Prevotella*, 288
- Primary bone
 - healing, 373f
 - loss, 159
 - union, 371
- Primary intraosseous squamous cell carcinoma, 589
- Primary retention, 132
- Primary teeth
 - incomplete eruption of, 1116f
 - lack of eruption, 131
- Primidone, 691
- Principle of favorableness, 408
- Procainamide, 691
- Procera titanium framework
 - zygoma implants, 248f
- Procerus, 1387f
- Profile view
 - macroesthetic examination, 1101
- Proliferation
 - vs. apoptosis, 576f
- Propofol, 100
 - chemical structure of, 91f
 - children, 113
 - pharmacology of, 91–93
- Propofol-infusion syndrome, 113
- Propoxyphene
 - reduction in liver disease, 35
 - for TMJ, 951
- Proptosis, 495
- ProRoot, 394
- Prosthetic Fox plane, 1215f
- Prosthetic heart valves, 25
 - mitral valve prolapse, 25
- Proteus*, 300
- Prothrombin, 77
- Protriptyline
 - for OSA, 1302
- Protruding ear, 1098f, 1449–1458
 - complications, 1456–1458
 - surgical correction of, 1452–1456
- Protruding earlobe
 - correction of, 1456
- Prozac
 - TMJ, 953
- PRP, 221, 792–794, 793f
- Pseudoaneurysms, 517
 - maxillary fractures, 442
- Pseudoephedrine, 502
 - for sinus infection, 305
- Pseudomonas*, 301
- Pseudomonas aeruginosa*
 - TMJ, 944
- Pseudoshave biopsy, 704
- PSO appliances, 846
- PSVT, 51
- Psychiatric disorders, 38–40
 - affective disorders, 38–39
- Psychological assessment, 105
- Psychotherapy
 - for TMJ, 957–958
- Psychotic disorders, 39
 - illicit drug abusers, 39–40
 - opioid abusers, 39–40
 - substance abuse, 39–40
- Pterygoid fovea, 934
- Pterygoid muscle, 938–939, 939, 939f
 - lateral, 784
- Pterygoid plates, 644
- Pterygoid space
 - squamous cell carcinoma, 642
- Pterygomandibular space, 278
 - abscess, 282f
 - computed tomography of, 291f
 - borders of, 278t
 - infection, 279t
- Pterygomaxilla
 - fissure grafts, 1179
 - junction, 1183f
 - separation, 1187f
- Pterygomaxillary
 - suture, 437
- PTFE, 1008
- Ptosis, 495, 1329f, 1385f, 1394f
 - chin, 1242
 - upper eyelid blepharoplasty, 1339–1340
- Pulmonary assessment, 54–55, 71–73
 - bronchitis, 73
 - capnography, 59
 - emphysema, 73
 - obesity, 58
 - ventilation, 59
- Pulmonary contusions, 348
- Pulmonary edema, 24
- Pulmonary function
 - age-related changes, 41
 - testing, 28

- Pulp
 healing
 after replantation, 394f
 injuries
 diagram of, 388f
 testing, 385
 viability, 385
- Pulseless ventricular tachycardia, 52
- Pulse oximeter, 57, 282
 sources of error in, 58t
- Pulse rate, 338
- Pulsus paradoxus, 338
- Punch biopsy, 704
- Pupillary light
 reactivity, 468
 reflex, 347
- PVC, 27
- Q
- Quad-helix, 1072f
- Quadrant defects, 468
- Questionnaire
 preoperative patient, 17t
- Quetiapine
 for psychotic disorders, 39
- R
- Radial forearm free flaps, 804–811, 806f, 810f
 anatomic considerations, 807–809
 blood supply, 807
 complications, 808–809
 development, 805–807
 technique, 809–811
 vascular abnormalities, 807–808
- Radiation injury
 and wound healing, 11
- Radiation therapy
 periarticular ectopic bone formation,
 1025–1027, 1026f
- Radical neck dissection, 648, 649f
- Radiographs. *See also* Panoramic radiographs
 alveolar and dental fractures, 386–387
 cervical spine, 351, 351f
 dentoalveolar injuries, 386–387
 facial asymmetry, 1209
 implant prosthodontics
 biomechanical considerations, 252–253
 complications of, 270
 lateral cephalometric
 facial asymmetry, 1209
 mandible fracture, 406–407, 407f
 mental foramina, 253f
 occlusal
 alveolar and dental fractures, 386–387
 implants, 252
 periapical
 alveolar and dental fractures, 386–387
 implants, 252
- plain, 568
 of abdominal trauma, 352
 atrophic mandible, 196f
 zygomatic complex fractures, 448
 posteroanterior cephalometric
 facial asymmetry, 1209
- Water's
 maxillary fractures, 438f
 maxillary sinus, 470f
 zygoma implants, 240, 245f
 zygomatic complex fractures, 447–448
- Radionuclide imaging, 569
- Radioprotectants, 638
- Radiosensitizers, 638
- RADPLAT protocol, 640
- Ramus, 784
 fracture
 ascending, 409
- Ramus buccal shelf block graft harvest,
 225–230, 228–229
 case studies, 226–230
 recipient site morbidity, 229
- Randall-Tennison repair, 847
- Raney clips, 483
- Ranulas, 676–677, 677f
- Rare earth magnets, 134
- Reactive airway disease, 55
 treatment of, 55–56
- Reapproximation, 795f
- Recipient site
 soft tissue grafts, 209
- Recombinant human bone morphogenetic
 protein-2 (rhBMP-2), 13, 162
- Recombinant human bone morphogenetic
 protein-7 (rhBMP-7), 13
- Recombinant human keratinocyte growth
 factor 2 (KGF-2), 13
- Reconstructive surgery. *See* Preprosthetic and
 reconstructive surgery
- Rectal sedation, 110
- Reduced enamel epithelium, 576
- Reed-Sternberg cells, 688
- Reepithelialization, 5
- Regeneration, 3
- Regional anesthesia
 end-stage TMJ disease, 1017
- Regional dynamic forces, 376–377
- Regional flaps, 769–781
- Reiche, Charles Frederick William, 435
- Relaxation
 for TMJ, 957
- Relaxed skin tension lines (RSTL), 769
- Releasing incisions, 218, 242
- Remifentanyl
 chemical structure of, 88f
 pharmacology of, 89
- Removable anterior repositioning splints
 OSA, 1303
- Removable overdenture-type prosthesis, 198
- Removable prostheses
 success of, 259
- Removal, 136
- Renal. *See* Kidneys
- Repair, 3
- Repositioning appliances
 for TMJ, 958–959, 958t, 959f
- Residual ridge form, 159
- Resin base fracture, 270
- Resorbable fixation materials
 children, 542
- Resorbable plate, 425f
- Resorbable screws, 1154
- Resorption
 modified Cawood and Howell classification
 of, 161f
- Respiradone
 for psychotic disorders, 39
- Respiratory acidosis, 53
- Respiratory arrest
 algorithm for, 57f
- Respiratory problems, 28–30
 airway and lung assessment, 28
 asthma, 28–29
 chronic obstructive pulmonary disease,
 29–30
- Restrictive cardiomyopathy, 69
- Retinoids, 632, 641, 1421
 nonmelanoma skin cancer, 709
- Retrobulbar hematoma, 472, 472f
- Retrobulbar hemorrhage
 zygomatic arch fractures, 459, 459f
- Retrograde knives
 TMJ arthroscopy, 970
- Retromolar fossa, 674
- Retromolar gingiva cancer, 621
- Retromolar trigone
 cancer, 621
 oral cancer, 642
 squamous cell carcinoma, 642f
 ulcerative carcinoma, 622f
- Retropharyngeal space
 borders of, 278t
- Revised Trauma Score, 328–329
 variables, 329t
 predicting mortality, 329t
- rhBMP-2, 13, 162
- RhBMP-7, 13
- Rhegmatogenous retinal detachment, 473
- Rheumatoid arthritis, 36, 1037, 1037f
- Rhinitis
 allergic, 106–107
- Rhinitis medicamentosa, 305
- Rhinoplasty, 1345–1363
 anesthesia, 1354
 cosmetic evaluation, 1350–1354

- endonasal
 - surgical sequence for, 1356t
- external
 - surgical sequence for, 1356t
- facial analysis, 1351
- functional considerations, 1354
- incisions, 1354–1355
- nasal analysis, 1351
- nasal anatomy, 1345–1360
- nasal base alar reduction, 1363
- nasal dorsum, 1358–1359
- nasal tip, 1359–1363
- osteotomies, 1359
- photographs, 1354
- postoperative, 1352f, 1363
- preoperative, 1351f
- psychiatric stability, 1351
- tip projection, 1360–1361
- tip rotation, 1361–1362
- tip shape, 1362
- turbinectomy, 1358
- Rhinorocket, 438
- Rhinosinusitis, 296, 502
 - factors associated with history of, 296t
 - treatment, 305
- Rhombic flaps, 773, 774f
- Rhytidectomy, 1365–1379
 - with complementing procedures, 1375f
 - deep plane, 1373–1378
 - flap development, 1371–1372, 1371f
 - generations of, 1366t
 - historical development, 1365–1366
 - incision, 1369f, 1370f
 - liposuction-assisted, 1412, 1413f
 - patient evaluation, 1366–1368
 - requirements, 1366t
 - skin closure, 1372–1373
 - superficial plane, 1368–1373, 1374f
 - surgical technique, 1368–1378
 - trocax sites, 1368f
- Rhytids, 1329
- Ribs
 - accessory muscles, 103
 - children, 103
- Ridge split osteoplasty, 176–177
- Rifle cartridges, 512f
- Rifles, 512
- Rifling, 513
- Rigid bronchoscope, 624
- Rigid fixation
 - mandibular fracture, 423
- Rigid internal fixation
 - mandibular fracture, 372f
 - maxillary fractures, 439
 - vs. nonrigid internal fixation, 371–382
- Rimfire, 514
- Rim/marginal incision
 - rhinoplasty, 1355
- Ring sign, 348
- Risdon incision, 421
- Robinson Inter-OSS alveolar device, 184
- Robinson technique, 422f
- Rocuronium
 - pharmacology of, 98
 - properties, 99t
- Rofecoxib
 - for rheumatoid arthritis, 36
- Root canal resorption, 391
- Roots
 - adjacent to interdental surgical sites
 - divergence of, 1129–1130
 - fracture, 389–390
 - in third molar removal, 151
 - impacted teeth, 144
 - injured surface, 1252f
 - resorption
 - classification of, 390
 - surface resorption, 390–391
- Rotary trough, 172f
- Rotated flaps, 1270f
- Rotated palatal flaps, 772
- Rotated teeth, 1131
- Rotational flaps, 713–714, 771f, 772
- Round bur, 242f
- Rounds, 512
- Rowe disimpaction forceps, 440, 440f
- RSTL, 769
- Rubella, 689
- Rule of 10's, 844
- S
- SAARD
 - for rheumatoid arthritis, 36
- Saddle nose, 364
- Saethre-Chotzen syndrome, 923–925
- Sagittal osteotomy, 1136–1137
 - of horizontal ramus, 1164
 - of vertical ramus
 - mandibular range of motion, 1159–1160
- Sagittal split osteotomy, 1153, 1215. *See also*
 - Bilateral sagittal split osteotomy (BSSO)
 - aseptic necrosis, 1250
 - facial nerve injury, 1255f
 - hemorrhage, 1249
 - mandibular advancement, 1283f
 - sensory injuries, 1253–1254
- Sagittal synostosis, 890
- Salicylates
 - for TMJ, 950–951
- Salicylic acid peels, 1423, 1423f
- Salivary-cutaneous fistula, 523f
- Salivary ducts
 - gunshot wound, 522
- Salivary glands
 - injuries, 1263–1264
- minor
 - tumors, 673–674
- obstructive disease, 674–675
- tumors, 671–677
 - benign, 671–672
 - histopathology, 671–672
 - malignant, 672
 - site, 672–673
- Sanders, Bruce, 964
- Sandwich osteotomy, 183f
- Sandwich-visor osteotomy, 184f
- SARPE. *See* Surgically assisted rapid palatal expansion (SARPE)
- Save-A-Tooth, 393
- SCALP, 1386
- Scalp
 - defects, 713f
 - laps, 773f
 - soft tissue injuries, 363–364
 - squamous cell carcinoma, 711f
- Scalp incision, 907
- Scapha buckling, 1458
- Scaphocephaly, 890f
- Schwann cells, 6, 823
- Schwannoma, 610
- Scissors, 1371f
 - TMJ arthroscopy, 970
- Scleral rupture, 472
- Scleroderma, 1034f, 1037
- Scopolamine, 99, 473
- Screening tests
 - for asymptomatic patients, 79
- Screw-retained prosthesis, 262f
- Screw-retained restorations, 261
- Screw retention
 - vs. cement retention, 260t
- Screws, 439
 - loosening of, 270
- Scroll
 - configurations of, 1348f
- Seat belts, 529
- Secobarbital
 - chemical structure of, 90f
- Secondary bone healing, 373f, 374f
- Secondary bone loss, 159
- Secondary growth deformities, 1207
- Second molars
 - impacted, 132, 135f
- Sedation, 93, 109
 - children, 103–123
- Sedatives
 - parents' presence during administration of, 105
- Seddon classification, 824f
- Segmentalization, 1186f, 1190–1191
 - loss of vascularity, 1249–1250
- Seizure disorders, 37
- Selective neck dissection, 649

- Selective serotonin reuptake inhibitors
for affective disorders, 38
- Selective serotonin reuptake inhibitors (SSRI)
for TMJ, 952–953
- Semilunar incision, 501
- Senile keratosis, 698
- Senn retractor, 1188f
- Sensitivity testing
odontogenic infection, 286–287
- Sensory nerve, 445, 1325–1326, 1451
- Sensory recovery
classification of, 830t
- Sentinel node biopsy, 650–651, 650f
- Sentinel vein, 1389
- Septocutaneous arteries, 710
- Septoplasty, 1238, 1355–1358
- Serine proteases, 6
- Seromas
cervicofacial liposuction, 1411
- Serotonin receptor antagonists
children, 117–118
- Serum
normal values of, 495t
- Serum albumin, 77
- Serum aspartate transaminase, 35
- Serum prealbumin, 12
- Setback genioplasty
soft tissue changes associated with, 1233t
- 702L tapered fissure bur, 225
- Severe maxillary vertical deficiency, 231f
- Sevoflurane, 95
chemical structure of, 96f
children, 114, 115
pharmacology of, 97
- Shave biopsy, 704
- Shield graft, 1361f
- Shock
assessment of, 337
- Shock trauma center
University of Maryland, 527
- Short subcondylar osteotomy, 1252f
- Shot
classification of, 513
- Shotguns, 512
shells, 513f
wounds, 515
- Sialography, 568
- Sialoliths
calcified, 674
- Sigmoid notch
excessive flaring at, 1259f
- Silicone elastomer, 1008
- Silverman technique, 422f
- Simon's method, 1353
- Simple fracture, 409, 409f
- Single-incision approach
subepithelial connective tissue graft
harvesting, 212–213, 214
- Single-stage gold implant, 189
- Single-tooth osteotomy, 1132, 1132f
- Sinonasal mucosa
histology of, 298f
- Sinonasal polyps, 298
- Sinonasal tumors, 298
- Sinus. *See also* Frontal sinus
bone grafts, 232–234, 241f
dysrhythmia, 1299
ethmoid, 494f
anatomy and physiology of, 297
grafts, 192, 198–199
infection, 295–310
anatomic factors, 298–299
clinical characteristics of, 296–297
diagnosis of, 302–305
etiology, 297–302
fungi, 300–301
genetic disorders, 301–302
inflammatory conditions, 299–300
treatment, 305–310
medical management, 305–307
surgery, 307–310
- lifts, 179–180, 181f
obliteration, 501, 502f
postoperative medical therapy, 502–503
postoperative symptoms, 1256–1257
tachycardia, 25, 27
window, 243f
- Sinusitis, 295, 299f, 442, 500. *See also* Rhino-sinusitis
allergic fungal, 301, 304f
Aspergillus, 304f
bacteriology of, 300–301
complications of, 304
etiology, 299t
fungal, 303–304
intracranial complications of, 305f
maxillary, 299
orbital complications of, 305f
- Sinus slot technique
zygoma implants, 243f
- Sjögren's syndrome, 37
- Skeleton
craniofacial
growth and remodeling field of, 165f
nasal base, 1439–1443
- Skin
aging, 709
biomechanics, 711–712
blood supply, 710
cross-section of, 1420f
laser resurfacing, 1342
perfusion
in trauma patient, 337–338
rejuvenation, 1419–1432
mechanical resurfacing procedures,
1429–1432
- resurfacing
ablative, 1420t
postoperative complications, 1432t
rhinoplasty, 1351
- Skin cancer. *See* Nonmelanoma skin cancer
- Skin grafts, 8, 716–717
age-related changes, 41
full-thickness, 8, 717–718
reinnervation of, 8
split-thickness, 8, 718–719
- Skin-muscle flap, 481
excision of, 1332
- Skoog's technique, 1365
- Skulls
by age, 539f
assessment of
in trauma patient, 345–346
fractures
basilar, 471
- SLE, 36–37, 691
- Sleep
normal stages of, 1297
- Sleep apnea
craniofacial dysostosis syndrome, 902–903
- Sleep apnea syndrome, 1297–1300
classification of, 1298
differential diagnosis, 1298–1299
- Sleep paralysis, 1298
- Sleep-related abnormal swallowing syndrome,
1298
- Sleep-related nocturnal myoclonus, 1298
- Slenderizing teeth, 1121, 1121f
- Sliding, 710
- Sliding buccal gingival flap, 1270f
- Slit-lamp examination, 468, 470
- Slow-acting antirheumatic drugs (SAARD)
for rheumatoid arthritis, 36
- SMAS. *See* Superficial musculoaponeurotic
system (SMAS)
- Smile
gummy, 1097f
- Smile arc, 1090–1091, 1104, 1105f
- Smoking, 71, 252, 719
melanin pigmentation
gingiva, 682
orbital injuries, 481
squamous cell carcinoma, 617
and wound healing, 10
- Sniffing position, 281
- Sodium bicarbonate
for blepharoplasty, 1331
- Sodium citrate, 106
- Soft endotracheal tube
children, 528
- Soft eye, 470
- Soft palate
squamous cell carcinoma, 645f
- Soft tissue

- craniofacial dysostosis syndrome, 907
grafts, 209–217
 implants, 208–209, 220–221
incision
 maxillary surgery, 1185f
injuries, 349
 cleansing, 359
 closing, 360
 ear, 365–366
 eyelids, 364–365
 forehead, 363–364
 lip, 366
 management of, 357–358
 nasolacrimal apparatus, 364–365
 neck, 366–367
 nose, 364–365
 postoperative care, 368–369
 repair of, 359–360
 scalp, 363–364
 types of, 360–363
integration, 205
management
 implants, 205–221
resuspension
 panfacial fractures, 551–552
Solar keratosis, 698
South America, 189
Soviet AK-47, 512
Spade drill, 191
Spark erosion, 265
Spatial descriptors, 1346f
Specimens, 570–571
Speckled erythroplakia, 619
Spectacle incision, 497
Sphenoid bone, 437
Sphenopalatine artery, 1346
Sphenopalatine foramen, 1183
Sphenozygomatic suture, 549–550, 550f
Sphincteroplasty procedure, 880f
Spinal accessory nerve
 dissection, 649f
Spinal cord disorders, 38
 neurologic examination of, 350
 physical examination of, 350
 in trauma patient, 349–352
Spiral drill, 191
Spirometry, 28
Spline implants, 228
Splints. *See also* specific splints
 avulsed tooth, 395, 396f
 crowns, 224
Split-thickness flaps
 supraperiosteal dissection, 214
Split-thickness pedicle flaps
 subepithelial connective tissue graft, 212
Split-thickness skin grafts, 8, 718–719
Sports, 530
 contact, 383
Squamous cell carcinoma, 321f–322f
 alveolar ridge, 621f
 alveolus, 644–645
 basaloid, 632
 buccal mucosa, 621f, 642, 642f
 cervical lymph nodes, 646–648
 description of, 700–701
 floor of mouth, 644f
 gingiva, 644–645
 lip, 641–645, 642f
 lower lip, 661f, 663f
 on midforehead, 714f
 nasal defect after excision, 775f
 on nasal tip, 702f
 and NMSC, 697
 oral cavity
 neck dissection, 648–650
 risk factors for, 617–618
 palate, 645
 primary intraosseous, 589
 retromolar trigone, 642f
 scalp, 711f
 soft palate, 645f
 tongue, 643–644, 644f
 well-differentiated
 lip, 660–661
Squamous papilloma, 565f
SSRI
 for TMJ, 952–953
Stability
 BSSO, 1155–1156
 horizontal ramus osteotomies, 1164
 total alveolar osteotomy, 1167
 VSO, 1145–1146
Stabilization appliances
 for TMJ, 958, 958f, 958t
Stafne’s bone defect, 609–610, 610f
Staphylococcus, 362f
Staphylococcus aureus, 287, 300
 TMJ, 944
Steiger bur, 1191f
Steinmann pin, 1214
Stensen’s papilla, 676
Stents, 253f, 254f, 261f, 270f
 implants, 253–254
Stephenson technique, 422f
Step osteotomy, 1162f, 1163f
Stereolithographic modeling
 facial asymmetry, 1209
Sternocleidomastoid flap, 779, 780f
Sternocleidomastoid muscle
 blood supply to, 779f
Sternocleidomastoid torticollis, 1207
Steroids, 424
 for adrenal gland disorders, 34
 for asthma, 29
 immunocompromised, 283
 impacted teeth removal, 149
Stevens-Johnson syndrome, 693
Stickler’s syndrome, 842
Stiffness, 281
 with impacted teeth removal, 150
 with osteomyelitis, 314
 zygomatic arch fractures, 459–460
Stout’s method, 415
Strauman system, 201
Streptococcus, 288, 362f, 426
Streptococcus pneumoniae, 300
Streptococcus pyogenes, 300
Streptococcus viridans, 289
Stress relaxation, 712
Stroke, 37
 caused by hypertension, 32
Stud-retained overdenture, 263f
Subapical osteotomies, 1164–1166
 anterior, 1164–1165, 1164f
 Kole’s, 1138f
 posterior, 1165–1166, 1166f
Subarachnoid hemorrhage
 CT, 346f
Subciliary incision, 453f, 481, 551
Subcondylar fracture, 405
 mandible series, 408f
Subcondylar osteotomy, 1135
Subconjunctival hemorrhage, 469f
Subcutaneous dissection, 1376f
Subcutaneous fat atrophy
 TMJ
 arthroscopy, 986
Subdural hemorrhage, 345f
 CT, 346f
Subepithelial connective tissue grafting
 harvesting from premolar region, 212–213
 implants
 donor-site surgery, 212–213, 214f
 recipient-site surgery, 214–215
Sublingual ecchymosis, 406
 floor of mouth, 385
Sublingual gland, 671
 tumors, 674
Sublingual space
 borders of, 278t
Subluxation, 391–392, 391f
 maxillary central incisor, 392f
Submandibular gland, 671, 674f
 anterior duct stone, 675
 posterior duct, 675
 retraction of, 675f
 tumors, 673
Submandibular space
 borders of, 278t
 infection, 279t
 through-and-through drain, 286f
Submasseteric space, 278
 borders of, 278t
 infection, 279t

- Submental intubation, 439f
- Submental space
 borders of, 278t
 infection, 279t
- Submentovertebral view
 zygomatic complex fractures, 448
- Submerged implants
 ready for abutment connection, 211f
- Submerged teeth, 131
- Submersible threaded cylindrical implant, 189
- Submucous vestibuloplasty, 174
- Subperiosteal abscess, 304, 305f
- Subperiosteal dissection, 465
- Subscleral hemorrhage, 346
- Substance abuse, 39–40
 children, 120–123
 inhalational
 anesthesia with, 122
 maxillofacial trauma, 384
- Substance P, 300
- Succinylcholine
 avoiding in malignant hyperthermia, 38
 children, 116
 pharmacology of, 98
 properties, 99t
- Suction-assisted lipectomy
 informed consent, 1416–1417
- Suction device, 1409
- Sufentanil
 chemical structure of, 88f
 pharmacology of, 89
- Suicide
 shotgun wounds, 515, 515f
- Sulbactam, 944
- Sulcular incision, 225
- Sulfa
 avoided with renal patients, 31
- Sulfasalazine
 for rheumatoid arthritis, 36
- Sulfonyleureas
 mechanism of action, 60t
- Sunder classification, 824, 824f
- Sunscreens, 700
- Superficial chemical peeling, 1422–1423
- Superficial fascia, 992
- Superficial musculoaponeurotic system (SMAS), 1318, 1374–1378
 description of, 1318
 and manipulation, 1371
 and rhytidectomy, 1365
 and subcutaneous dissection, 1374, 1376f, 1377f
- Superficial spreading melanoma, 684
- Superficial temporal
 infection, 279t
- Superficial temporal artery, 1389
- Superior dislocation, 411
- Superior joint space, 996f
- Superiorly based pharyngeal flaps, 878, 879f
- Superior meatus
 anatomy and physiology of, 297
- Superior oblique muscle pulley, 465
- Superior orbital fissure syndrome, 472
 zygomatic arch fractures, 459
- Superior orbital rim, 464
- Suprahyoid muscles, 938, 1141
- Supramandibular muscles, 938
- Supraomohyoid neck dissection, 649f
- Supraorbital bar reconstruction, 500
- Supraorbital nerves, 465, 1325, 1389, 1393f
- Supraorbital notch, 464
- Supraorbital ridge fractures
 children, 532
- Supraorbital vessels, 1393f
- Supratarsal fold incision, 452, 453f
- Supratrochlear nerve, 1389, 1390
- Supraventricular tachycardias, 25
- Surgeons
 experience and training of, 149
- Surgical guides, 1288f
- Surgically assisted rapid palatal expansion (SARPE), 1197–1198
 arch length discrepancy, 1198
 arch morphology, 1198
 history, 1197–1198
 surgical technique, 1198–1200, 1199f, 1200f
 vertical dimension, 1198
- Surgical microscope
 historical development of, 803
- Surgical mobilization
 position in facial asymmetry, 1213
- Surgical patient
 medical management of, 17–42
- Surgical splints
 maxillary fractures, 440–441
- Surgical stent
 for implant placement, 164f
- Suture milia
 upper eyelid blepharoplasty, 1339
- Sutures
 neonatal skull, 1060f
- Sweat test, 301
- Swelling
 with impacted teeth removal, 150
- Swiss Association for the Study of Internal Fixation (AO/ASIF)
 compression plates, 402
 fracture management biomechanical principles, 373
- Swiss screw, 201
- Switching stick, 1187f
 TMJ arthroscopy, 971f
- Swivel latches, 266f
- Symmetry
 rhinoplasty, 1351–1352
- Symphysis
 block graft harvest, 225
 donor site morbidity, 228
 force, 404f
 fracture, 405, 409
 bone plate, 382f
 internal wire fixation, 373f
 posteroanterior mandibular view, 414f
 reconstruction, 1288
- Syncope, 68
- Synechia, 309
- Synovial chondromatosis, 601–602
 TMJ, 945
- Synovial disorders
 classification of, 941t
- Synovium
 TMJ, 934–935
- Syphilis, 681–682
- Syringe liposuction system, 1409f
- Systemic lupus erythematosus (SLE), 36–37, 691
- Systemic reserve
 odontogenic infection, 283
- T
- T3, 33
- T4, 33
- Tachycardia, 338
 with hypotension, 345
- Tagaki, Kenji, 963
- Tanning, 697
- Tapered fissure bur
 702L, 225
- Tapered-wall screw implant, 256f
- Tarsal plate, 466
- Tarsus, 1321, 1322f
- Tattoo deformity, 10
- Tattooing, 359, 360, 685
- TCA, 1341
 peels, 1427t
- Tear film, 1326
 composition, 1326
- Technetium 99m
 facial asymmetry, 1209
 osteomyelitis, 315
- Teeth
 arch symmetry, 1115, 1115f
 missing, 1131
 permanent
 developing buds, 398f
 children, 529
 impacted, 132
 sectioning, 145
 selling for transplantation, 189
 size, 1112–1113
 discrepancy, 1120–1122
 vitality, 385
- Telecanthus, 476
- Telephone ear deformity, 1458

- Telescoped fractures, 410
- Temporal incisions, 450, 1398
- Temporals fascia, 446
- Temporals flap, 778–779, 778f
- Temporals muscle, 938, 938f, 1007
- flap, 778f
 - graft
 - disk replacement, 1007f
- Temporals myofascial flap, 1007
- Temporal space, 278
- Temporary bridge
 - demonstrating vertical deficiency, 230f
- Temporary cavity, 511
- Temporomandibular ankylosis, 1038
- Temporomandibular joint (TMJ)
 - anatomy and physiology of, 933–946
 - arthrocentesis, 963–987
 - arthroscopy, 963–987
 - anesthesia, 971
 - anesthetic complications, 986
 - anterolateral approach, 980
 - appliance therapy, 984
 - approaches, 979, 979f
 - articular pathology, 971–975
 - cannula, 970
 - capsular stretch procedures, 980
 - complications, 984–986
 - contraindications for, 967–968
 - development of, 964–965
 - elevators, 970
 - endaural approach, 980
 - entry errors, 980–981
 - equipment hookup sequence, 971f
 - history, 965–966
 - imaging, 966
 - indications for, 966–967
 - instrument breakage, 985–986
 - instruments, 968–971
 - intra-articular injury, 985
 - joint entry techniques, 975–982
 - lateral eminence release, 984f
 - neurologic injury, 985
 - obturators, 970
 - otologic complications, 986
 - patient selection, 965–966
 - physical examination, 965–966
 - physical therapy, 984
 - posterolateral approaches, 979
 - postoperative management, 982–983
 - postoperative medications, 984
 - preoperative management, 982
 - puncture anatomy and landmarks, 977–979
 - superior posterolateral approaches, 979
 - superoposterior lateral approach, 980
 - trocars, 970
 - vascular injury, 985
 - visible fields, 983f

articular disk, 935–936

articular disorders, 941–942

benign tumors, 945

biologic mechanisms, 942–943

bony structures, 933–934

capsular herniation, 979f

cartilage, 934–935

classification, 933

coronal view, 934f

CPM, 541

diet, 950

disk immobility, 974f

disk migration, 974f

disk placement, 975f

dysfunction, 1260–1261

 - BSSO, 1158–1160
 - VSO, 1146

effusion, 411

endaural arthroscopic approach, 981–982, 981f, 982f

end-stage disease, 1015–1027

 - pain control, 1016–1018
 - periarticular ectopic bone formation, 1025–1027
 - perioperative management, 1016
 - physical therapy, 1024–1025
 - postsurgical pain management, 1018–1024
 - preemptive analgesia, 1016–1018
 - sympathetically maintained pain, 1024

hemarthrosis, 411–412

hypermobility, 1044–1047

 - classification, 1044
 - etiology, 1044, 1045t
 - treatment, 1045–1046

hypomobility, 1033–1044

 - classification, 1033
 - clinical characteristics, 1033–1034
 - complications, 1040–1044
 - etiology, 1033, 1034t
 - following orthognathic surgery, 1037
 - following radiation therapy, 1036
 - imaging, 1034
 - inflammatory and rheumatologic causes, 1036–1037
 - postcraniotomy, 1036
 - postinfectious, 1035–1036
 - postoperative physical therapy, 1044
 - posttraumatic, 1034–1035
 - treatment, 1037–1040

infection, 943–944

innervation, 937

internal derangement, 989–1010

 - capsular incisions, 995–997, 997f
 - complications, 1010
 - diagnosis, 989–991
 - diskectomy without replacement, 1006
 - disk reapproximation, 1002f
 - disk-removal procedures, 1002–1006
 - disk replacements, 1006–1008
 - disk repositioning, 1003f
 - disk-repositioning procedures, 998–1000, 998f, 999f
 - endaural approach, 994–995, 994f
 - operative procedures, 997–1000
 - partial diskectomy, 1002–1004, 1004f
 - perforated posterior attachment, 1000–1002, 1001f
 - postauricular approach, 995, 995f
 - postoperative management, 1009–1010
 - preauricular approach, 992–994
 - surgical anatomy, 991–992
 - surgical approaches, 991–1008
 - surgical goals, 991
 - total diskectomy, 1004–1005, 1006f

internal derangement of, 427–428

lateral view, 936f, 937f

ligaments, 936–937

malignant tumors, 945–946

mandibular fracture, 426–429

medial view, 937f

movement biomechanics, 940

musculature, 937–940

neoplastic disease, 945

nonarticular disorders, 940–941

nonsurgical management, 949–959

occlusal appliances, 958–959

orthopedic development history, 963–964

pathology of, 940

perforated disk, 942f

pharmacotherapy, 950–953

physical therapy, 953–957, 954t

retrodiskal tissue, 936

stress reduction, 957–958

synovial tumors, 945

synovium, 934–935

vascular supply, 937

Wilkes staging classification, 967t

Temporomandibular (lateral) ligaments, 936

TENS

 - for TMJ, 956

Tension pneumothorax, 332, 334, 335f

Tension-stress

 - bone, 164

Tentative diagnosis, 564

Tent pole bone screws, 224f

Teratogens, 1067f

Terminal ballistics, 510

Terminally ill

 - avoidance of, 652–653

Tessier no. 7 left facial cleft, 855f

Tetanus-prone wounds, 357

Tetanus prophylaxis, 385t

Tetracycline, 168

 - for alveolar osteitis, 151

- avoidance in liver disease, 35
- Tetraplegia, 350
- TGF, 225, 785
- Theophylline
for asthma, 29, 56
reduction in liver disease, 35
- TheraBite Jaw Motion Rehabilitation System,
955, 955f
- Therapeutic neck dissection
oral cancer, 651
- Thermal agents
for TMJ, 956
- Thermal injury
lip cancer, 659
- Thermal test, 386
- Thiamylal
chemical structure of, 90f
- Thiazolidinediones
mechanism of action, 60t
- Thiopental
chemical structure of, 90f
pharmacology of, 90–91
- Thiouracil, 691
- Thioxanthenes
for psychotic disorders, 39
- Third Molar Project, 150
- Third molars
antibiotics, 148
failure to erupt, 140
impacted
removal contraindications, 152
removal of, 149
mandibular
development of, 139–140
impacted, 131
partial eruption, 140
in path of second molars eruption,
135, 135f
removal of
root fracture, 151
retarded maturation of, 140
surgery
periodontal healing after, 152–153
- Thoma technique, 422f
- Thoracic vascular injury
chest radiographs, 349f
- Threaded cobalt-chrome-molybdenum screw,
189
- Thrombin, 340
- Thrombocytes, 4
- Thromboembolism, 38
- Thrombophlebitis
obesity, 40
- Through-and-through drain
submandibular space, 286f
- Thyroid
assessment, 61–62
assessment of, 74
disorders, 33–34
orbitopathy, 1327f
- Thyroxine (T3), 33
- TIA, 37, 78–79
- Tiagibine
for seizure disorders, 37
- Ti-6Al-4V, 189
- Tibial bone grafts, 791–792, 792f
- Tip
support, 1350t
rhinoplasty, 1353
- Tissue
oxygenation
evaluation of, 337
smoking effect on, 10
perfusion, 10
evaluation of, 337
shaver, 309f
trauma
minimizing, 9
- Titanium, 439–440
mesh, 441f, 485, 500, 500f
microscrews, 500
plasma-sprayed surface, 190f
reconstruction plate
mandible, 796f
screws, 1439f
- Titanium alloy (Ti-6Al-4V), 189
- TMJ. *See* Temporomandibular joint (TMJ)
- Tobacco. *See* Cigarette smoking
- Tobramycin, 944
- Toluidine blue, 626–627
- Tongue
cancer, 622–623, 622f
children, 103
edema, 516f
flaps, 662, 775–776, 777f
leukoplakia, 632f
magnetic resonance imaging, 643f
radial forearm flap, 643f
squamous cell carcinoma, 643–644, 644f
traction of, 624f
- Tongue-retaining device (TRD)
OSA, 1303
- Tonometry, 468
- Tonsils
children, 103
surgical specimen of, 1306f
- Topical 5-FU, 708
- Topiramate
for seizure disorders, 37
- Tori, 612–613
mandibular, 172f
- Torus mandibularis, 613
- Torus palatinus, 612, 612f, 613f
- Total alveolar osteotomy, 1166–1168, 1167f
- Total maxillary alveolar osteotomy, 1193
midline palatal incision, 1191f
vertical incision, 1191f
- Total pulp necrosis, 386
- Toxic epidermal necrolysis, 693, 694
- Trachea
children, 103, 104
injuries
signs of, 518
- Tracheostomy, 516
OSA, 1304–1305
- Tracheotomy, 281
- Track Plus System, 184
- Traffic accidents, 530
- Transantral osteotomy, 1197f
- Transblepharoplasty, 1401
- Transcolumellar incision
rhinoplasty, 1355
- Transconjunctival incision, 455f, 482, 483, 551
- Transconjunctival upper lid blepharoplasty, 1334
- Transcutaneous nerve stimulation (TENS)
for TMJ, 956
- Transforming growth factor (TGF), 225, 785
- Transfusion
oral cancer, 635
- Transient ischemic attacks (TIA), 37, 78–79
- Transmucosal sedation, 109
- Transnasal wiring, 501–502
- Transosseous circum-mandibular wiring, 421,
424f
- Transpalpebral procedure, 1401
- Transplantation, 136
- Transport diagnosis, 1288f
- Transport distraction osteogenesis, 1286–1289,
1289f
neocondyle, 1289–1290
- Transpositional flaps, 178f, 714, 773–774
- Transverse characteristics, 1103–1104, 1107f
- Transverse compensations, 1107
- Transverse facial proportion, 1096–1098
- Transverse orthopedic treatment, 1071–1072
- Transverse smile, 1104f
- Trapezium myocutaneous flaps, 779–780
- Trauma patient
airway maintenance, 330
breathing, 332–337
cervical spine, 330
circulation, 337–344
initial management of, 327–354
injury severity assessment, 327–330
neurologic examination of, 344–345
primary survey, 330–344, 344f
secondary assessment of, 344–345
stabilization of, 349f
triage decision scheme, 328f
- Trauma Score, 328
- Traumatic avulsion
premaxillary segment, 1287f
- Traumatic bone cyst, 609, 610f
- Traumatic hyphema

- zygomatic arch fractures, 459
- Traumatic loop deformity, 776f
- Traumatic neuroma, 611
- Traumatic optic neuropathy
 - zygomatic arch fractures, 459
- Trauner, 1150
- TRD
 - OSA, 1303
- Treacher Collins, 74, 104
- Treponema pallidum*, 681
- Triage decision scheme
 - trauma patient, 328f
- Triamcinolone acetone, 475
- Triazolam
 - pharmacology of, 87
- Tricalcium phosphate, 168
- Trichloroacetic acid (TCA), 1341
 - peels, 1427t
- Trichophytic forehead lift, 1395–1396
- Tricyclic antidepressants
 - for affective disorders, 38–39
 - for TMJ, 952–953
- Trigeminal nerve, 1325
 - anatomy and physiology, 822–824, 822f
 - fibers, 823t
 - injuries, 821
 - demographics, 819–820
 - third division of, 1139–1140
- Trigger points
 - for TMJ, 957
- Trigonocephaly, 890f, 896f
- Triiodothyronine (T4), 33
- Trimethadione, 691
- Trimethaphan camsylate
 - for hypertensive crisis, 50t
- Trimethoprim
 - for COPD, 30
- Trimethoprim/sulfamethoxazole
 - for rhinosinusitis, 305, 502
 - for sinus infection, 305
- Triple endoscopy, 624
- Trismus (stiffness), 281
 - with impacted teeth removal, 150
 - with osteomyelitis, 314
 - zygomatic arch fractures, 459–460
- Trocars
 - rhytidectomy, 1368f
 - TMJ arthroscopy, 970, 971f
- Trochlea, 464
- T-shaped incision, 996
- Tuberculectomy
 - lateral, 1003f
- Tuberosity reduction, 169, 170f
- Tube shift method, 133
- Tumescent solution, 1410t
- Tumescent technique, 1368f
 - Klein's, 1409
- Turbinate pneumatization, 298
- Turbinectomy
 - rhinoplasty, 1358
- Turner syndrome, 1066
- Twist drill, 242f
- Two-flap palatoplasty, 874f
 - Bardach, 852
- Two-implant bar
 - clip overdenture retention, 194f
- Two-point fixation
 - one-point fixation, 377
- Two-staged titanium implants, 189
- U
- Ulcerated lesions, 685–686
- Ulcers, 565
- Ultrasonography, 569
 - abdominal injuries, 352–353, 354t
 - cervical lymph nodes, 647
 - oral cancer, 625–626
 - TMJ, 956
- Ultraviolet damage, 1420
- Umbrella graft, 1361f
- Uncinate
 - anatomy and physiology of, 297
- Unconjugated bilirubin, 77
- Unerupted teeth
 - vs. impacted teeth, 140
 - localizing, 133
- University of Maryland
 - shock trauma center, 527
- Upper blepharoplasty incision, 482–483
- Upper eyelid
 - crease, 1328
 - crease incision, 551
- Upper eyelids
 - blepharoplasty, 1331–1334
 - complications, 1339–1340
 - fat removal, 1339
 - high lid crease, 1339
 - lid crease asymmetry, 1339
 - preoperative concerns, 1331–1333
 - skin excision, 1339
 - examination of, 1328
 - fat pads, 1324
 - laxity, 1394f
 - transcutaneous blepharoplasty, 1333f
- Upper lips
 - augmentation, 1443f
 - changes with orthodontic incisor retraction, 1223–1224
 - developing, 660f
- Upper respiratory infection
 - children, 106–107
- UPPP, 1305f
 - OSA, 1305–1306
- Urethral meatus
 - blood at, 343f, 353
- Urinalysis, 353
- Urinary tract disease, 30
- Urine
 - output in children, 42t
- Uvula
 - surgical specimen of, 1306f
- Uvulopalatopharyngoplasty (UPPP), 1305f
 - OSA, 1305–1306
- V
- Vagus nerve, 1451
- Valacyclovir, 688
- Valdecoxib
 - for rheumatoid arthritis, 36
- Valvular heart disease, 23–24, 68
 - mitral regurgitation, 24
 - mitral stenosis, 23–24
- Vancomycin
 - for odontogenic infection, 289
- Van Graefe, Carl Ferdinand, 435
- Varicella-zoster virus, 686, 687–688
- Varix, 684–685
- Vascular compromise
 - management of tissue after, 1253–1254
- Vascularity
 - loss of, 1249–1250
- Vascularized fibular graft to mandible
 - implants, 268f
- Vascularized interpositional periosteal
 - connective tissue flap (VIP-CT), 217–220, 217f, 218f, 220f
 - surgical technique, 217–218
- Vascular lesions, 684–685
- Vascular malformation
 - high-flow, 606f, 607f
- Vasopressin
 - for arrhythmias, 52
- Vector control devices, 1292f
- Vecuronium
 - properties, 99t
- Velopharyngeal insufficiency (VPI), 845
- Velopharyngeal mechanism
 - anatomy of, 876f
 - muscle groups contributing to, 876t
- Velopharyngeal port
 - catheter passed through, 1272f
- Ventilation, 59
 - children, 103
- Ventricular ectopy
 - benign, 52
- Ventricular fibrillation, 52
- Ventricular tachycardia, 27
- Verapamil
 - reduction in liver disease, 35
- Vermilionectomy, 641, 641f, 662
- Verrucous carcinoma, 631
 - buccal mucosa, 631f
- Vertical alveolar augmentation
 - bone grafts, 223–234

- alveolar distraction osteogenesis, 230–231
 - guided, 223
 - iliac corticocancellous, 231–232
 - interpositional, 230
 - mandibular block autografts, 223–224
 - sinus, 232–234
 - symphysis block graft harvest, 225
 - ramus buccal shelf block graft harvest, 225–230
- Vertical augmentation or reduction
 - genioplasty
 - soft tissue changes associated with, 1233t
- Vertical dystopia, 468
- Vertical facial proportions, 1093–1096
- Vertical impaction, 143
 - bone removal, 146
 - removal of, 148f
- Vertical incision, 996–997
 - total maxillary alveolar osteotomy, 1191f
- Vertical orthopedic treatment, 1077–1079
- Vertical ramus
 - osteotomies, 1141–1142
 - sagittal osteotomy
 - mandibular range of motion, 1159–1160
- Vertical rhytids
 - glabella, 1398
- Vertical subcondylar osteotomy (VSO), 1142–1146, 1142f, 1143f, 1144f
 - complications of, 1145–1146
 - indications for, 1142
 - techniques for, 1142–1145
- Vesicular lesions, 685–686
- Vesiculoulcerative disease
 - idiopathic, 691–692
- Vestibular incisions, 1185, 1186f
 - atrophic mandible, 196
- Vestibuloplasty
 - lasers, 175
- ViaSpan, 393, 393f
- Video monitoring cart
 - TMJ
 - arthroscopy, 969f
- Video monitoring equipment
 - TMJ
 - arthroscopy, 968
- VIP-CT. *See* Vascularized interpositional periosteal connective tissue flap (VIP-CT)
- Viral infection, 686–687
- Viscerocranium
 - formation of, 1055
- Vision
 - craniofacial dysostosis syndrome, 902
 - loss
 - lower eyelid blepharoplasty, 1341
 - upper eyelid blepharoplasty, 1340
- Visor osteotomy, 183f
- Visual acuity, 468, 1330
- Visual analog scale, 826f
- Visual field evaluation, 1330–1331
- Visual fields, 468
 - TMJ
 - arthroscopy, 969–970
- Visual impairment, 472–474, 887
- Vital signs, 404
- Vitamin A
 - effect on wound healing, 12
- Vitamin B
 - effect on wound healing, 12
- Vitamin C
 - effect on wound healing, 12
- Vitamin E, 641
- Vitreous hemorrhage, 473
- Volkman's contracture, 475, 477
- Von Eiselberg's step osteotomy, 1138f
- Von Graefe, Ferdinand, 1317
- Von Langenbeck procedure, 874, 874f
- Von Willebrand's factor, 78
- VPI, 845
- Vs. unerupted teeth, 140
- VSO. *See* Vertical subcondylar osteotomy (VSO)
- V-Y closure, 1235–1236, 1236f, 1240f, 1442f
 - alar cinch with, 1236–1237
 - double, 1239–1241, 1242f
- V-Y flap, 772
- W
- Wadcutters, 514
- Wallerian degeneration, 828
- Warthin's tumors
 - salivary gland, 671–672
- Watanabe, Masaki, 963
- Water's radiographs
 - maxillary fractures, 438f
 - maxillary sinus, 470f
 - maxilla sinus, 470f
 - zygomatic complex fractures, 448
- Wedge excision, 641
- Weight loss
 - for OSA, 1302
- Weir's excision, 1363f
- Well-differentiated squamous cell carcinoma
 - lip, 660–661
- Wenckebach, 28
- Wharton's duct
 - calcified sialolith, 675f
- White blood cell count
 - odontogenic infection, 283
- Whitenall's ligament, 1322, 1322f
- Whitenall's tubercle, 446, 465, 466
- Whitlow
 - herpetic, 687, 687f
- Wickham's striae, 692
- Wide-eyed look, 466
- Wilkes staging classification, 942t
 - IJD, 967t
- Wire brush, 1430
- Wiring techniques, 424f
- Witch's chin, 1242, 1243f
- Wolff-Parkinson-White syndrome, 51, 52f
- Wood's lamp, 470
- Working diagnosis, 564
- Wound care
 - advances in, 12–14
- Wound debridement, 10
- Wound dehiscence, 9
 - upper eyelid blepharoplasty, 1339
- Wound healing, 3–24
 - age, 12
 - bone, 6–7
 - complications of, 8–9
 - dermal substitutes, 13–14
 - extraction wounds, 7–8
 - gene therapy, 13
 - hyperbaric oxygen therapy, 11–12
 - inflammatory phase, 4–5, 193
 - maturation phase, 193
 - mucosal substitutes, 13–14
 - nerves, 6
 - nutrition, 12
 - optimizing, 9–12
 - osseointegration, 192–193
 - phases of, 193
 - process, 3
 - proliferative phase, 5, 5f, 193
 - proliferative scarring, 9
 - remodeling phase, 5–6
 - response, 3–6
 - skin grafts, 8
 - specialized, 6–8
 - stages of, 361f
- Wound hypoxia, 9
- Woven bone, 193
- X
- Xenograft, 168
- Xeroderma pigmentosa, 698
- Xerostomia, 638
- Y
- Yaw, 514
- Young's syndrome, 302
- Youthful brow, 1384f
- Youthful forehead, 1384
- Yperman, Jehan, 840
- Z
- Zinc
 - effect on wound healing, 12
- Zinc oxide-eugenol cement, 388
- Ziprasidone
 - for psychotic disorders, 39
- Zone of fixation, 1391
- Z-plasty incision, 772

- Z-plasty technique
 - for frenum attachment excision, 173
- Z-shaped osteotomy, 1192f, 1193f
- Zygoma
 - anatomy of, 437f
- Zygoma fixture placement, 243f, 437
- Zygoma implants, 235–248, 238f, 242f, 270f
 - abutment platform, 243
 - abutments, 245f
 - armamentarium, 242f
 - border molding, 245f
 - buccal index, 247f
 - cast framework, 247f
 - casting technique, 247f
 - clinical assessment, 240
 - complications of, 239–240
 - contraindications for, 238–239
 - final impressions, 246f
 - fixtures, 198, 235f
 - fully inserted, 244f
 - hybrid denture tooth processing, 248f
 - immediate loading, 240f
 - impression coping, 241f
 - indications for, 236–238
 - acquired and congenital defects, 237–238
 - atrophy, 236
 - immediate loading, 238
 - inadequate posterior support, 236
 - partial edentulism, 238
 - syndromes, 236–237
 - master cast, 246f
 - milled bar structure, 247f
 - milling process, 248f
 - mounted casts, 246f
 - panoramic radiograph, 244f
 - presurgical assessment, 240
 - procelain-fused-to-metal fixed partial denture, 248f
 - procera technology, 247f, 248f
 - procera titanium framework, 248f
 - prosthetic procedure, 244–248
 - final construction, 245–246
 - healing phase, 244
 - protective splinting, 244–245
 - protective splint, 246f
 - radiographic assessment, 240, 245f
 - record bases, 246f
 - screw access holes, 247f
 - sinus slot technique, 243f
 - soft tissue conditioning material, 246f
 - stage II surgery, 245f
 - surgical cast, 246f
 - surgical protocol, 242–243
 - waxed teeth, 247f
- Zygoma retractor, 242, 243f
- Zygomatic arch, 445
 - coronal section, 992f
 - fractures
 - incidence, 488
 - internal fixation, 455–456
 - orbital floor, 456–457
 - orbital fractures with, 477
 - reduction of, 451f
 - surgery, 457–460
 - treatment, 450–451
 - internal fixation of, 456
 - surgical approach to, 455
- Zygomatic buttress, 548
- Zygomatic complex
 - displaced
 - elderly, 486f–487f
 - fractures, 445–460, 446f, 447f, 448f, 467
 - children, 534–537
 - classification of, 448–449
 - computed tomography, 454f
 - diagnosis, 447–448
 - high-energy, 451–455
 - history, 447
 - low-energy, 451
 - middle-energy, 451
 - physical examination, 447
 - radiographic evaluation, 447–448
 - surgical anatomy, 445–446
 - treatment, 449–457, 451–456
 - without need for internal orbit reconstruction, 452f
- Zygomatic nerve, 1326
- Zygomaticofrontal buttress, 451
 - internal fixation of, 456
 - surgery, 452–453
- Zygomaticofrontal suture
 - palpation of, 447
- Zygomaticomaxillary buttress
 - fracture
 - fixation, 453f
 - subciliary incision, 453f
 - supratarsal fold incision, 453f
 - internal fixation of, 456
 - surgery, 452
- Zygomatic osteotomy, 1200–1201
- Zygomatic retractor, 242f
- Zygomaticus major, 445

Part 1

**PRINCIPLES OF MEDICINE,
SURGERY, AND ANESTHESIA**

Wound Healing

Vivek Shetty, DDS, Dr.Med.Dent.

Charles N. Bertolami, DDS, D.Med.Sc.

The healing wound is an overt expression of an intricate and tightly choreographed sequence of cellular and biochemical responses directed toward restoring tissue integrity and functional capacity following injury. Although healing culminates uneventfully in most instances, a variety of intrinsic and extrinsic factors can impede or facilitate the process. Understanding wound healing at multiple levels—biochemical, physiologic, cellular, and molecular—provides the surgeon with a framework for basing clinical decisions aimed at optimizing the healing response. Equally important it allows the surgeon to critically appraise and selectively use the growing array of biologic approaches that seek to assist healing by favorably modulating the wound microenvironment.

The Healing Process

The restoration of tissue integrity, whether initiated by trauma or surgery, is a phylogenetically primitive but essential defense response. Injured organisms survive only if they can repair themselves quickly and effectively. The healing response depends primarily on the type of tissue involved and the nature of the tissue disruption. When restitution occurs by means of tissue that is structurally and functionally indistinguishable from native tissue, *regeneration* has taken place. However, if tissue integrity is reestablished primarily through the formation of fibrotic scar tis-

sue, then *repair* has occurred. Repair by scarring is the body's version of a spot weld and the replacement tissue is coarse and has a lower cellular content than native tissue. With the exception of bone and liver, tissue disruption invariably results in repair rather than regeneration.

At the cellular level the rate and quality of tissue healing depends on whether the constitutive cells are labile, stable, or permanent. Labile cells, including the keratinocytes of the epidermis and epithelial cells of the oral mucosa, divide throughout their life span. Stable cells such as fibroblasts exhibit a low rate of duplication but can undergo rapid proliferation in response to injury. For example, bone injury causes pluripotential mesenchymal cells to speedily differentiate into osteoblasts and osteoclasts. On the other hand permanent cells such as specialized nerve and cardiac muscle cells do not divide in postnatal life. The surgeon's expectation of "normal healing" should be correspondingly realistic and based on the inherent capabilities of the injured tissue. Whereas a fibrous scar is normal for skin wounds, it is suboptimal in the context of bone healing.

At a more macro level the quality of the healing response is influenced by the nature of the tissue disruption and the circumstances surrounding wound closure. Healing by first intention occurs when a clean laceration or surgical incision is

closed primarily with sutures or other means and healing proceeds rapidly with no dehiscence and minimal scar formation. If conditions are less favorable, wound healing is more complicated and occurs through a protracted filling of the tissue defect with granulation and connective tissue. This process is called healing by second intention and is commonly associated with avulsive injury, local infection, or inadequate closure of the wound. For more complex wounds, the surgeon may attempt healing by third intention through a staged procedure that combines secondary healing with delayed primary closure. The avulsive or contaminated wound is débrided and allowed to granulate and heal by second intention for 5 to 7 days. Once adequate granulation tissue has formed and the risk of infection appears minimal, the wound is sutured close to heal by first intention.

Wound Healing Response

Injury of any kind sets into motion a complex series of closely orchestrated and temporally overlapping processes directed toward restoring the integrity of the involved tissue. The reparative processes are most commonly modeled in skin¹; however, similar patterns of biochemical and cellular events occur in virtually every other tissue.² To facilitate description, the healing continuum of coagulation, inflammation, reepithelialization, granulation

tissue, and matrix and tissue remodeling is typically broken down into three distinct overlapping phases: inflammatory, proliferative, and remodeling.^{3,4}

Inflammatory Phase

The inflammatory phase presages the body's reparative response and usually lasts for 3 to 5 days. Vasoconstriction of the injured vasculature is the spontaneous tissue reaction to staunch bleeding. Tissue trauma and local bleeding activate factor XII (Hageman factor), which initiates the various effectors of the healing cascade including the complement, plasminogen, kinin, and clotting systems. Circulating platelets (thrombocytes) rapidly aggregate at the injury site and adhere to each other and the exposed vascular subendothelial collagen to form a primary platelet plug organized within a fibrin matrix. The clot secures hemostasis and provides a provisional matrix through which cells can migrate during the repair process. Additionally the clot serves as a reservoir of the cytokines and growth factors that are released as activated platelets degranulate (Figure 1-1). The bolus of secreted proteins, including interleukins, transforming growth factor β (TGF- β), platelet-derived growth factor (PDGF), and vascular endothelial growth factor (VEGF), maintain the wound milieu and regulate subsequent healing.¹

Once hemostasis is secured the reactive vasoconstriction is replaced by a more persistent period of vasodilation that is mediated by histamine, prostaglandins, kinins, and leukotrienes. Increasing vascular permeability allows blood plasma and other cellular mediators of healing to pass through the vessel walls by diapedesis and populate the extravascular space. Corresponding clinical manifestations include swelling, redness, heat, and pain. Cytokines released into the wound provide the chemotactic cues that sequentially recruit the neutrophils and monocytes to the site of injury. Neutrophils normally

begin arriving at the wound site within minutes of injury and rapidly establish themselves as the predominant cells. Migrating through the scaffolding provided by the fibrin-enriched clot, the short-lived leukocytes flood the site with proteases and cytokines to help cleanse the wound of contaminating bacteria, devitalized tissue, and degraded matrix components. Neutrophil activity is accentuated by opsonic antibodies leaking into the wound from the altered vasculature. Unless a wound is grossly infected, neutrophil infiltration ceases after a few days. However, the proinflammatory cytokines released by perishing neutrophils, including tumor necrosis factor α (TNF- α) and interleukins (IL-1a, IL-1b), continue to stimulate the inflammatory response for extended periods.⁵

Deployment of bloodborne monocytes to the site of injury starts peaking as the levels of neutrophils decline. Activated monocytes, now termed macrophages,

continue with the wound microdebridement initiated by the neutrophils. They secrete collagenases and elastases to break down injured tissue and phagocytose bacteria and cell debris. Beyond their scavenging role the macrophages also serve as the primary source of healing mediators. Once activated, macrophages release a battery of growth factors and cytokines (TGF- α , TGF- β 1, PDGF, insulin-like growth factor [IGF]-I and -II, TNF- α , and IL-1) at the wound site, further amplifying and perpetuating the action of the chemical and cellular mediators released previously by degranulating platelets and neutrophils.⁶ Macrophages influence all phases of early wound healing by regulating local tissue remodeling by proteolytic enzymes (eg, matrix metalloproteases and collagenases), inducing formation of new extracellular matrix, and modulating angiogenesis and fibroplasia through local production of cytokines such as thrombospondin-1 and IL-1b. The centrality of

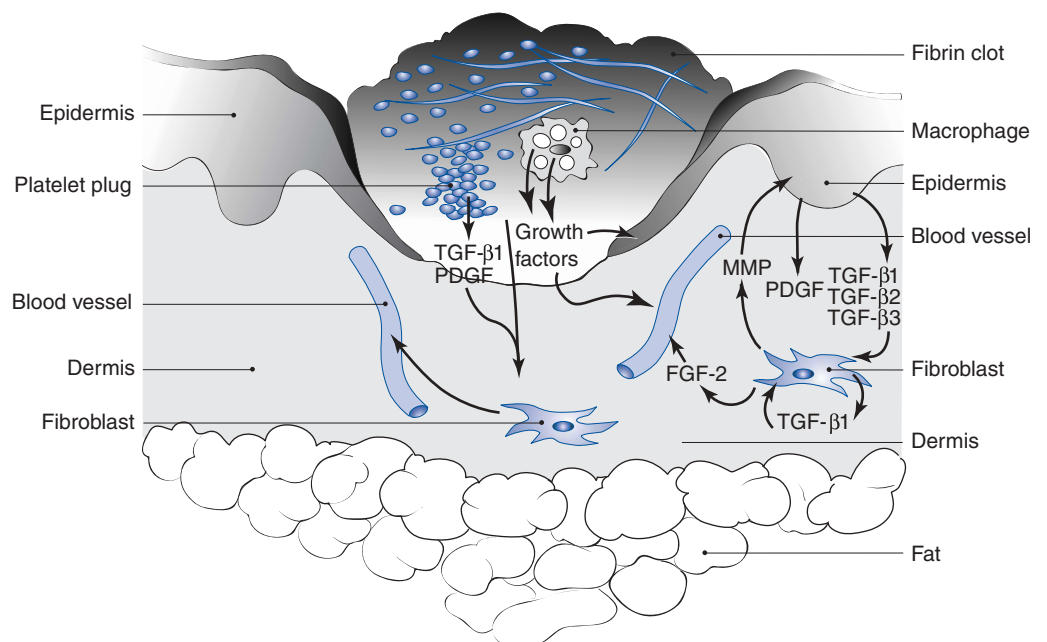


FIGURE 1-1 Immediately following wounding, platelets facilitate the formation of a blood clot that secures hemostasis and provides a temporary matrix for cell migration. Cytokines released by activated macrophages and fibroblasts initiate the formation of granulation tissue by degrading extracellular matrix and promoting development of new blood vessels. Cellular interactions are potentiated by reciprocal signaling between the epidermis and dermal fibroblasts through growth factors, MMPs, and members of the TGF- β family. FGF = fibroblast growth factor; MMP = matrix metalloproteinase; PDGF = platelet-derived growth factor; TGF- β = transforming growth factor beta. Adapted from Bissell MJ and Radisky D.⁷⁰

macrophage function to early wound healing is underscored by the consistent finding that macrophage-depleted animal wounds demonstrate diminished fibroplasia and defective repair. Although the numbers and activity of the macrophages taper off by the fifth post injury day, they continue to modulate the wound healing process until repair is complete.

Proliferative Phase

The cytokines and growth factors secreted during the inflammatory phase stimulate the succeeding proliferative phase (Figure 1-2).⁷ Starting as early as the third day post injury and lasting up to 3 weeks, the proliferative phase is distinguished by the formation of pink granular tissue (granulation tissue) containing inflammatory cells, fibroblasts, and budding vasculature enclosed in a loose matrix. An essential first step is the establishment of a local microcirculation to supply the oxygen and nutrients necessary for the elevated metabolic needs of regenerating tissues. The generation of new capillary blood vessels (angiogenesis) from the interrupted vasculature is driven by wound hypoxia as well as with native growth factors, particularly VEGF, fibroblast growth factor 2 (FGF-2), and TNF- β (see Figure 1-2). Around the same time, matrix-generating fibroblasts migrate into the wound in response to the cytokines and growth factors released by inflammatory cells and wounded tissue. The fibroblasts start synthesizing new extracellular matrix (ECM) and immature collagen (Type III). The scaffold of collagen fibers serves to support the newly formed blood vessels supplying the wound. Stimulated fibroblasts also secrete a range of growth factors, thereby producing a feedback loop and sustaining the repair process. Collagen deposition rapidly increases the tensile strength of the wound and decreases the reliance on closure material to hold the wound edges together. Once adequate collagen and ECM have been generated,

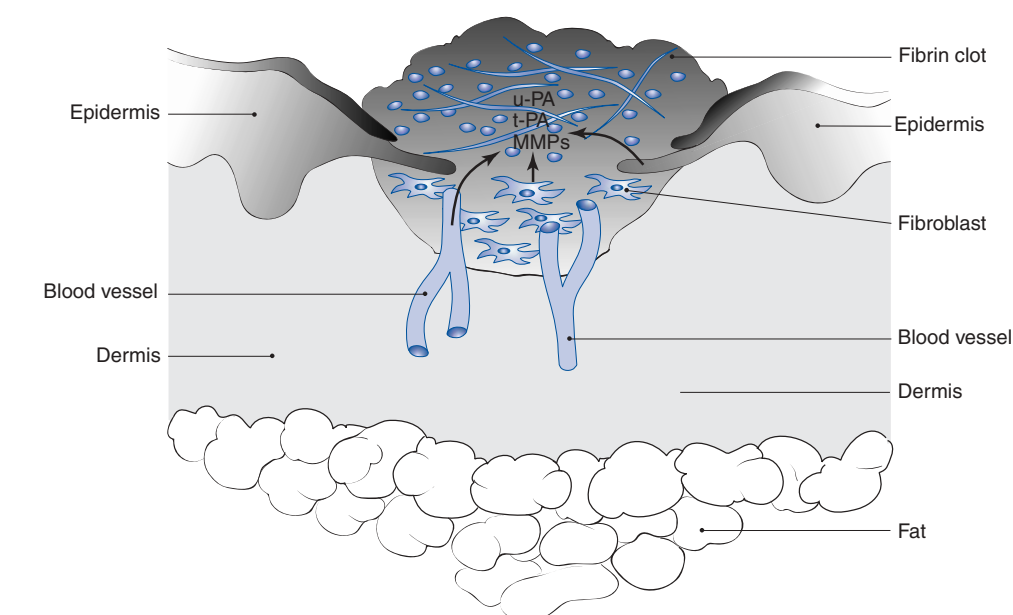


FIGURE 1-2 The cytokine cascade mediates the succeeding proliferative phase. This phase is distinguished by the establishment of local microcirculation and formation of extracellular matrix and immature collagen. Epidermal cells migrate laterally below the fibrin clot, and granulation tissue begins to organize below the epithelium. MMPs = matrix metalloproteinases; t-PA = tissue plasminogen activator; u-PA = urinary plasminogen activator. Adapted from Bissell MJ and Radisky D.⁷⁰

matrix synthesis dissipates, evidencing the highly precise spatial and temporal regulation of normal healing.

At the surface of the dermal wound new epithelium forms to seal off the denuded wound surface. Epidermal cells originating from the wound margins undergo a proliferative burst and begin to resurface the wound above the basement membrane. The process of reepithelialization progresses more rapidly in oral mucosal wounds in contrast to the skin. In a mucosal wound the epithelial cells migrate directly onto the moist exposed surface of the fibrin clot instead of under the dry exudate (scab) of the dermis. Once the epithelial edges meet, contact inhibition halts further lateral proliferation. Reepithelialization is facilitated by underlying contractile connective tissue, which shrinks in size to draw the wound margins toward one another. Wound contraction is driven by a proportion of the fibroblasts that transform into myofibroblasts and generate strong contractile forces. The extent of wound contraction

depends on the depth of the wound and its location. In some instances the forces of wound contracture are capable of deforming osseous structures.

Remodeling Phase

The proliferative phase is progressively replaced by an extended period of progressive remodeling and strengthening of the immature scar tissue. The remodeling/maturation phase can last for several years and involves a finely choreographed balance between matrix degradation and formation. As the metabolic demands of the healing wound decrease, the rich network of capillaries begins to regress. Under the general direction of the cytokines and growth factors, the collagenous matrix is continually degraded, resynthesized, reorganized, and stabilized by molecular crosslinking into a scar. The fibroblasts start to disappear and the collagen Type III deposited during the granulation phase is gradually replaced by stronger Type I collagen. Correspondingly the tensile strength of the scar tissue

gradually increases and eventually approaches about 80% of the original strength. Homeostasis of scar collagen and ECM is regulated to a large extent by serine proteases and matrix metalloproteinases (MMPs) under the control of the regulatory cytokines. Tissue inhibitors of the MMPs afford a natural counterbalance to the MMPs and provide tight control of proteolytic activity within the scar. Any disruption of this orderly balance can lead to excess or inadequate matrix degradation and result in either an exuberant scar or wound dehiscence.

Specialized Healing

Nerve

Injury to the nerves innervating the orofacial region may range from simple contusion to complete interruption of the nerve. The healing response depends on injury severity and extent of the injury.⁸⁻¹⁰ Neuropraxia represents the mildest form of nerve injury and is a transient interruption of nerve conduction without loss of axonal continuity. The continuity of the epineurial sheath and the axons is maintained and morphologic alterations are minor. Recovery of the functional deficit is spontaneous and usually complete within 3 to 4 weeks. If there is a physical disruption of one or more axons without injury to stromal tissue, the injury is described as axonotmesis. Whereas individual axons are severed, the investing Schwann cells and connective tissue elements remain intact. The nature and extent of the ensuing sensory or motor deficit relates to the number and type of injured axons. Morphologic changes are manifest as degeneration of the axoplasm and associated structures distal to the site of injury and partly proximal to the injury. Recovery of the functional deficit depends on the degree of the damage.

Complete transection of the nerve trunk is referred to as neurotmesis and spontaneous recovery from this type of

injury is rare. Histologically, changes of degeneration are evident in all axons adjacent to the site of injury.¹¹ Shortly after nerve severance, the investing Schwann cells begin to undergo a series of cellular changes called wallerian degeneration. The degeneration is evident in all axons of the distal nerve segment and in a few nodes of the proximal segment. Within 78 hours injured axons start breaking up and are phagocytosed by adjacent Schwann cells and by macrophages that migrate into the zone of injury. Once the axonal debris has been cleared, Schwann cell outgrowths attempt to connect the proximal stump with the distal nerve stump. Surviving Schwann cells proliferate to form a band (Bünger's band) that will accept regenerating axonal sprouts from the proximal stump. The proliferating Schwann cells also promote nerve regeneration by secreting numerous neurotrophic factors that coordinate cellular repair as well as cell adhesion molecules that direct axonal growth. In the absence of surgical realignment or approximation of the nerve stumps, proliferating Schwann cells and outgrowing axonal sprouts may align within the randomly organized fibrin clot to form a disorganized mass termed *neuroma*.

The rate and extent of nerve regeneration depend on several factors including type of injury, age, state of tissue nutrition, and the nerves involved. Although the regeneration rate for peripheral nerves varies considerably, it is generally considered to approximate 1 mm/d. The regeneration phase lasts up to 3 months and ends on contact with the end-organ by a thin myelinated axon. In the concluding maturation phase both the diameter and performance of the regenerating nerve fiber increase.

Bone

The process of bone healing after a fracture has many features similar to that of skin healing except that it also involves calcifica-

tion of the connective tissue matrix. Bone is a biologically privileged tissue in that it heals by regeneration rather than repair. Left alone, fractured bone is capable of restoring itself spontaneously through sequential tissue formation and differentiation, a process also referred to as *indirect healing*. As in skin the interfragmentary thrombus that forms shortly after injury staunches bleeding from ruptured vessels in the haversian canals, marrow, and periosteum. Necrotic material at the fracture site elicits an immediate and intense acute inflammatory response which attracts the polymorphonuclear leukocytes and subsequently macrophages to the fracture site. The organizing hematoma serves as a fibrin scaffold over which reparative cells can migrate and perform their function. Invading inflammatory cells and the succeeding pluripotential mesenchymal cells begin to rapidly produce a soft fracture callus that fills up interfragmentary gaps. Comprised of fibrous tissue, cartilage, and young immature fiber bone, the soft compliant callus acts as a biologic splint by binding the severed bone segments and damping interfragmentary motion. An orderly progression of tissue differentiation and maturation eventually leads to fracture consolidation and restoration of bone continuity.

More commonly the surgeon chooses to facilitate an abbreviated callus-free bone healing termed *direct healing* (Figure 1-3). The displaced bone segments are surgically manipulated into an acceptable alignment and rigidly stabilized through the use of internal fixation devices. The resulting anatomic reduction is usually a combination of small interfragmentary gaps separated by contact areas. Ingrowth of mesenchymal cells and blood vessels starts shortly thereafter, and activated osteoblasts start depositing osteoid on the surface of the fragment ends. In contact zones where the fracture ends are closely apposed, the fracture line is filled concentrically by lamellar bone. Larger gaps are filled through a succession of fibrous

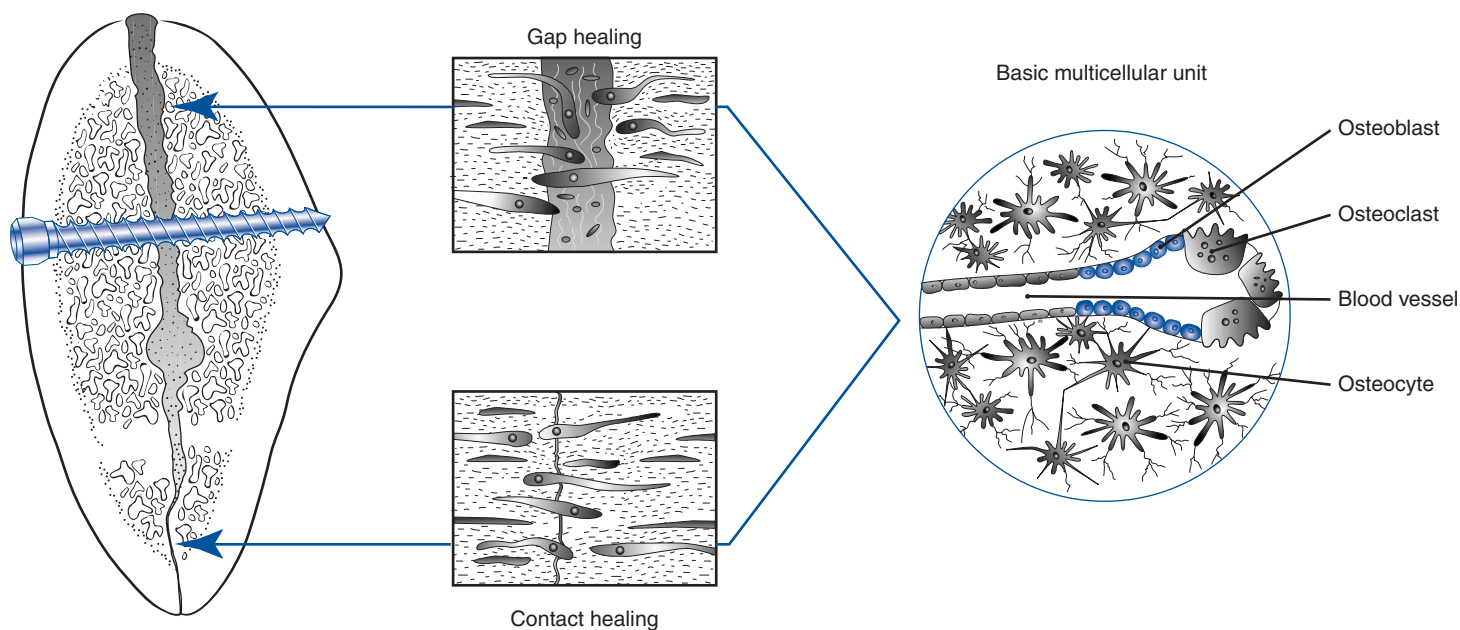


FIGURE 1-3 Direct bone healing facilitated by a lag screw. The fracture site shows both gap healing and contact healing. The internal architecture of bone is restored eventually by the action of basic multicellular units.

tissue, fibrocartilage, and woven bone. In the absence of any microinstability at the fracture site, direct healing takes place without any callus formation.

Subsequent bone remodeling eventually restores the original shape and internal architecture of the fractured bone. Functional sculpting and remodeling of the primitive bone tissue is carried out by a temporary team of juxtaposed osteoclasts and osteoblasts called the basic multicellular unit (BMU). The osteoblasts develop from pluripotent mesenchymal stem cells whereas multicellular osteoclasts arise from a monocyte/macrophage lineage.¹² The development and differentiation of the BMUs are controlled by locally secreted growth factors, cytokines, and mechanical signals. As osteoclasts at the leading edge of the BMUs excavate bone through proteolytic digestion, active osteoblasts move in, secreting layers of osteoid and slowly refilling the cavity. The osteoid begins to mineralize when it is about 6 μm thick. Osteoclasts reaching the end of their lifespan of 2 weeks die and are removed by phagocytes. The majority (up to 65%) of the remodeling osteoblasts also die within 3 months

and the remainder are entombed inside the mineralized matrix as osteocytes.

While the primitive bone mineralizes, remodeling BMUs cut their way through the reparative tissue and replace it with mature bone. The “grain” of the new bone tissue starts paralleling local compression and tension strains. Consequently the shape and strength of the reparative bone tissue changes to accommodate greater functional loading. Tissue-level strains produced by functional loading play an important role in the remodeling of the regenerate bone. Whereas low levels of tissue strain ($\sim 2,000$ microstrains) are considered physiologic and necessary for cell differentiation and callus remodeling, high strain levels ($> 2,000$ microstrains) begin to adversely affect osteoblastic differentiation and bone matrix formation.^{13,14} If there is excess interfragmentary motion, bone regenerates primarily through endochondral ossification or the formation of a cartilaginous callus that is gradually replaced by new bone. In contrast osseous healing across stabilized fracture segments occurs primarily through intramembranous ossification. Major fac-

tors determining the mechanical milieu of a healing fracture include the fracture configuration, the accuracy of fracture reduction, the stability afforded by the selected fixation device, and the degree and nature of microstrains provoked by function. If a fracture fixation device is incapable of stabilizing the fracture, the interfragmentary microinstability provokes osteoclastic resorption of the fracture surfaces and results in a widening of the fracture gap. Although bone union may be ultimately achieved through secondary healing by callus production and endochondral ossification, the healing is protracted. Fibrous healing and nonunions are clinical manifestations of excessive microstrains interfering with the cellular healing process.

Extraction Wounds

The healing of an extraction socket is a specialized example of healing by second intention.¹⁵ Immediately after the removal of the tooth from the socket, blood fills the extraction site. Both intrinsic and extrinsic pathways of the clotting cascade are activated. The resultant fibrin meshwork containing entrapped red blood cells seals off the

torn blood vessels and reduces the size of the extraction wound. Organization of the clot begins within the first 24 to 48 hours with engorgement and dilation of blood vessels within the periodontal ligament remnants, followed by leukocytic migration and formation of a fibrin layer. In the first week the clot forms a temporary scaffold upon which inflammatory cells migrate. Epithelium at the wound periphery grows over the surface of the organizing clot. Osteoclasts accumulate along the alveolar bone crest setting the stage for active crestal resorption. Angiogenesis proceeds in the remnants of the periodontal ligaments. In the second week the clot continues to get organized through fibroplasia and new blood vessels that begin to penetrate towards the center of the clot. Trabeculae of osteoid slowly extend into the clot from the alveolus, and osteoclastic resorption of the cortical margin of the alveolar socket is more distinct. By the third week the extraction socket is filled with granulation tissue and poorly calcified bone forms at the wound perimeter. The surface of the wound is completely reepithelialized with minimal or no scar formation. Active bone remodeling by deposition and resorption continues for several more weeks. Radiographic evidence of bone formation does not become apparent until the sixth to eighth weeks following tooth extraction. Due to the ongoing process of bone remodeling the final healing product of the extraction site may not be discernible on radiographs after 4 to 6 months.

Occasionally the blood clot fails to form or may disintegrate, causing a localized alveolar osteitis. In such instances healing is delayed considerably and the socket fills gradually. In the absence of a healthy granulation tissue matrix, the apposition of regenerate bone to remaining alveolar bone takes place at a much slower rate. Compared to a normal socket the infected socket remains open or partially covered with hyperplastic epithelium for extended periods.

Skin Grafts

Skin grafts may be either full thickness or split thickness.¹⁶ A full-thickness graft is composed of epidermis and the entire dermis; a split-thickness graft is composed of the epidermis and varying amounts of dermis. Depending on the amount of underlying dermis included, split-thickness grafts are described as thin, intermediate, or thick.¹⁷ Following grafting, nutritional support for a free skin graft is initially provided by plasma that exudes from the dilated capillaries of the host bed. A fibrin clot forms at the graft-host interface, fixing the graft to the host bed. Host leukocytes infiltrate into the graft through the lower layers of the graft. Graft survival depends on the ingrowth of blood vessels from the host into the graft (neovascularization) and direct anastomoses between the graft and the host vasculature (inosculation). Endothelial capillary buds from the host site invade the graft, reaching the dermoepidermal junction by 48 hours. Concomitantly vascular connections are established between host and graft vessels. However, only a few of the ingrowing capillaries succeed in developing a functional anastomosis. Formation of vascular connections between the recipient bed and transplant is signaled by the pink appearance of the graft, which appears between the third and fifth day postgrafting. Fibroblasts from the recipient bed begin to invade the layer of fibrin and leukocytes by the fourth day after transplantation. The fibrin clot is slowly resorbed and organized as fibroblastic infiltration continues. By the ninth day the new blood vessels and fibroblasts have achieved a firm union, anchoring the deep layers of the graft to the host bed.

Reinnervation of the skin graft occurs by nerve fibers entering the graft through its base and sides. The fibers follow the vacated neurilemmal cell sheaths to reconstruct the innervation pattern of the donor skin. Recovery of sensation usually begins within 2 months after transplanta-

tion. Grafts rarely attain the sensory qualities of normal skin, because the extent of re-innervation depends on how accessible the neurilemmal sheaths are to the entering nerve fibers. The clinical performance of the grafts depends on their relative thickness. As split-thickness grafts are thinner than full-thickness grafts, they are susceptible to trauma and undergo considerable contraction; however, they have greater survival rates clinically. Full-thickness skin grafts do not “take” as well and are slow to revascularize. Nevertheless full-thickness grafts are less susceptible to trauma and undergo minimal shrinkage.

Wound Healing Complications

Healing in the orofacial region is often considered a natural and uneventful process and seldom intrudes into the surgeon’s consciousness. However, this changes when complications arise and encumber the wound healing continuum. Most wound healing complications manifest in the early postsurgical period although some may manifest much later. The two problems most commonly encountered by the surgeon are wound infection and dehiscence; proliferative healing is less typical.

Wound Infection

Infections complicating surgical outcomes usually result from gross bacterial contamination of susceptible wounds. All wounds are intrinsically contaminated by bacteria; however, this must be distinguished from true wound infection where the bacterial burden of replicating microorganisms actually impairs healing.¹⁸ Experimental studies have demonstrated that regardless of the type of infecting microorganism, wound infection occurs when there are more than 1×10^5 organisms per gram of tissue.^{19,20} Beyond relative numbers, the pathogenicity of the infecting microorganisms as well as host response factors determine whether wound healing is impaired.

The continual presence of a bacterial infection stimulates the host immune defenses leading to the production of inflammatory mediators, such as prostaglandins and thromboxane. Neutrophils migrating into the wound release cytotoxic enzymes and free oxygen radicals. Thrombosis and vasoconstrictive metabolites cause wound hypoxia, leading to enhanced bacterial proliferation and continued tissue damage. Bacteria destroyed by host defense mechanisms provoke varying degrees of inflammation by releasing neutrophil proteases and endotoxins. Newly formed cells and their collagen matrix are vulnerable to these breakdown products of wound infection, and the resulting cell and collagen lysis contribute to impaired healing. Clinical manifestations of wound infection include the classic signs and symptoms of local infection: erythema, warmth, swelling, pain, and accompanying odor and pus.

Inadequate tissue perfusion and oxygenation of the wound further compromise healing by allowing bacteria to proliferate and establish infection. Failure to follow aseptic technique is a frequent reason for the introduction of virulent microorganisms into the wound. Transformation of contaminated wounds into infected wounds is also facilitated by excessive tissue trauma, remnant necrotic tissue, foreign bodies, or compromised host defenses. The most important factor in minimizing the risk of infection is meticulous surgical technique, including thorough débridement, adequate hemostasis, and elimination of dead space. Careful technique must be augmented by proper postoperative care, with an emphasis on keeping the wound site clean and protecting it from trauma.

Wound Dehiscence

Partial or total separation of the wound margins may manifest within the first week after surgery. Most instances of wound dehiscence result from tissue fail-

ure rather than improper suturing techniques. The dehisced wound may be closed again or left to heal by secondary intention, depending upon the extent of the disruption and the surgeon's assessment of the clinical situation.

Proliferative Scarring

Some patients may go on to develop aberrant scar tissue at the site of their skin injury. The two common forms of hyperproliferative healing, hypertrophic scars and keloids, are characterized by hypervascularity and hypercellularity. Distinctive features include excessive scarring, persistent inflammation, and an overproduction of extracellular matrix components, including glycosaminoglycans and collagen Type I.²¹ Despite their overt resemblance, hypertrophic scars and keloids do have some clinical dissimilarities. In general, hypertrophic scars arise shortly after the injury, tend to be circumscribed within the boundaries of the wound, and eventually recede. Keloids, on the other hand, manifest months after the injury, grow beyond the wound boundaries, and rarely subside. There is a clear familial and racial predilection for keloid formation, and susceptible individuals usually develop keloids on their face, ear lobes, and anterior chest.

Although processes leading to hypertrophic scar and keloid formation are not yet clarified, altered apoptotic behavior is believed to be a significant factor. Ordinarily, apoptosis or programmed cell death is responsible for the removal of inflammatory cells as healing proceeds and for the evolution of granulation tissue into scar. Dysregulation in apoptosis results in excessive scarring, inflammation, and an overproduction of extracellular matrix components. Both keloids and hypertrophic scars demonstrate sustained elevation of growth factors including TGF- β , platelet-derived growth factor, IL-1, and IGF-I.²² The growth factors, in turn, increase the numbers of local fibroblasts and prompt exces-

sive production of collagen and extracellular matrix. Additionally, proliferative scar tissue exhibits increased numbers of neoangiogenesis-promoting vasoactive mediators as well as histamine-secreting mast cells capable of stimulating fibrous tissue growth. Although there is no effective therapy for keloids, the more common methods for preventing or treating these lesions focus on inhibiting protein synthesis. These agents, primarily corticosteroids, are injected into the scar to decrease fibroblast proliferation, decrease angiogenesis, and inhibit collagen synthesis and extracellular matrix protein synthesis.

Optimizing Wound Healing

At its very essence the wound represents an extreme disruption of the cellular microenvironment. Restoration of constant internal conditions or homeostasis at the cellular level is a constant undertow of the healing response. A variety of local and systemic factors can impede healing, and the informed surgeon can anticipate and, where possible, proactively address these barriers to healing so that wound repair can progress normally.²³

Tissue Trauma

Minimizing surgical trauma to the tissues helps promote faster healing and should be a central consideration at every stage of the surgical procedure, from placement of the incision to suturing of the wound. Properly planned, the surgical incision is just long enough to allow optimum exposure and adequate operating space. The incision should be made with one clean consistent stroke of evenly applied pressure. Sharp tissue dissection and carefully placed retractors further minimize tissue injury. Sutures are useful for holding the severed tissues in apposition until the wound has healed enough. However, sutures should be used judiciously as they have the ability to add to the risk of infection and are capable of strangulating the tissues if applied too tightly.

Hemostasis and Wound Débridement

Bleeding from a transected vessel or diffuse oozing from the denuded surfaces interfere with the surgeon's view of underlying structures. Achieving complete hemostasis before wound closure helps prevent the formation of a hematoma postoperatively. The collection of blood or serum at the wound site provides an ideal medium for the growth of microorganisms that cause infection. Additionally, hematomas can result in necrosis of overlying flaps. However, hemostatic techniques must not be used too aggressively during surgery as the resulting tissue damage can prolong healing time. Postoperatively the surgeon may insert a drain or apply a pressure dressing to help eliminate dead space in the wound.

Devitalized tissue and foreign bodies in a healing wound act as a haven for bacteria and shield them from the body's defenses.²³ The dead cells and cellular debris of necrotic tissue have been shown to reduce host immune defenses and encourage active infection. A necrotic burden allowed to persist in the wound can prolong the inflammatory response, mechanically obstruct the process of wound healing, and impede reepithelialization. Dirt and tar located in traumatic wounds not only jeopardize healing but may result in a "tattoo" deformity. By removing dead and devitalized tissue, and any foreign material from a wound, débridement helps to reduce the number of microbes, toxins, and other substances that inhibit healing. The surgeon should also keep in mind that prosthetic grafts and implants, despite refinements in biocompatibility, can incite varying degrees of foreign body reaction and adversely impact the healing process.

Tissue Perfusion

Poor tissue perfusion is one of the main barriers to healing inasmuch as tissue

oxygen tension drives the healing response.^{24,25} Oxygen is necessary for hydroxylation of proline and lysine, the polymerization and cross-linking of procollagen strands, collagen transport, fibroblast and endothelial cell replication, effective leukocyte killing, angiogenesis, and many other processes. Relative hypoxia in the region of injury stimulates a fibroblastic response and helps mobilize other cellular elements of repair.²⁶ However, very low oxygen levels act together with the lactic acid produced by infecting bacteria to lower tissue pH and contribute to tissue breakdown. Cell lysis follows, with releases of proteases and glycosidases and subsequent digestion of extracellular matrix.²⁷ Impaired local circulation also hinders delivery of nutrients, oxygen, and antibodies to the wound. Neutrophils are affected because they require a minimal level of oxygen tension to exert their bactericidal effect. Delayed movement of neutrophils, opsonins, and the other mediators of inflammation to the wound site further diminishes the effectiveness of the phagocytic defense system and allows colonizing bacteria to proliferate. Collagen synthesis is dependent on oxygen delivery to the site, which in turn affects wound tensile strength. Most healing problems associated with diabetes mellitus, irradiation, small vessel atherosclerosis, chronic infection, and altered cardiopulmonary status can be attributed to local tissue ischemia.

Wound microcirculation after surgery determines the wound's ability to resist the inevitable bacterial contamination.²⁸ Tissue rendered ischemic by rough handling, or desiccated by cautery or prolonged air drying, tends to be poorly perfused and susceptible to infection. Similarly, tissue ischemia produced by tight or improperly placed sutures, poorly designed flaps, hypovolemia, anemia, and peripheral vascular disease, all adversely affect wound healing. Smoking is a common contributor to decreased tissue oxygenation.²⁹ After every

cigarette the peripheral vasoconstriction can last up to an hour; thus, a pack-a-day smoker remains tissue hypoxic for most part of each day. Smoking also increases carboxyhemoglobin, increases platelet aggregation, increases blood viscosity, decreases collagen deposition, and decreases prostacyclin formation, all of which negatively affect wound healing. Patient optimization, in the case of smokers, may require that the patient abstain from smoking for a minimum of 1 week before and after surgical procedures. Another way of improving tissue oxygenation is the use of systemic hyperbaric oxygen (HBO) therapy to induce the growth of new blood vessels and facilitate increased flow of oxygenated blood to the wound.

Diabetes

Numerous studies have demonstrated that the higher incidence of wound infection associated with diabetes has less to do with the patient having diabetes and more to do with hyperglycemia. Simply put, a patient with well-controlled diabetes may not be at a greater risk for wound healing problems than a nondiabetic patient. Tissue hyperglycemia impacts every aspect of wound healing by adversely affecting the immune system including neutrophil and lymphocyte function, chemotaxis, and phagocytosis.³⁰ Uncontrolled blood glucose hinders red blood cell permeability and impairs blood flow through the critical small vessels at the wound surface. The hemoglobin release of oxygen is impaired, resulting in oxygen and nutrient deficiency in the healing wound. The wound ischemia and impaired recruitment of cells resulting from the small vessel occlusive disease renders the wound vulnerable to bacterial and fungal infections.

Immunocompromise

The immune response directs the healing response and protects the wound from infection. In the absence of an adequate immune response, surgical outcomes are

often compromised. An important assessment parameter is total lymphocyte count. A mild deficit is a lymphocytic level between 1,200 and 1,800, and levels below 800 are considered severe total lymphocyte deficits. Patients with debilitated immune response include human immunodeficiency virus (HIV)-infected patients in advanced stages of the disease, patients on immunosuppressive therapy, and those taking high-dose steroids for extended periods.³¹ Studies indicate that HIV-infected patients with CD4 counts of less than 50 cells/mm³ are at significant risk of poor wound outcome.³² Although newer immunosuppressive drugs, such as cyclosporine, have no apparent effect on wound healing, other medications can retard the healing process both in rate and quality by altering both the inflammatory reaction and the cell metabolism.

The use of steroids, such as prednisone, is a typical example of how suppression of the innate inflammatory process also increases wound healing complications. Exogenous corticosteroids diminish prolyl hydroxylase and lysyl oxidase activity, depressing fibroplasias, collagen formation, and neovascularity.³³ Fibroblasts reach the site in a delayed fashion and wound strength is decreased by as much as 30%. Epithelialization and wound contraction are also impaired. The inhibitory effects of glucocorticosteroids can be attenuated to some extent by vitamin A given concurrently.

Most antineoplastic agents exert their cytotoxic effect by interfering with DNA or RNA production. The reduction in protein synthesis or cell division reveals itself as impaired proliferation of fibroblasts and collagen formation. Attendant neutropenia also predisposes to wound infection by prolonging the inflammatory phase of wound healing. Because of their deleterious effect on wound healing, administration of antineoplastic drugs should be restricted, when possible, until such time that the potential for healing complications has passed.

Radiation Injury

Therapeutic radiation for head and neck tumors inevitably produces collateral damage in adjacent tissue and reduces its capacity for regeneration and repair. The pathologic processes of radiation injury start right away; however, the clinical and histologic features may not become apparent for weeks, months, or even years after treatment.³⁴ The cellular and molecular responses to tissue irradiation are immediate, dose dependent, and can cause both early and late consequences.³⁵ DNA damage from ionizing radiation leads to mitotic cell death in the first cell division after irradiation or within the first few divisions. Early acute changes are observed within a few weeks of treatment and primarily involve cells with a high turnover rate. The common symptoms of oral mucositis and dermatitis result from loss of functional cells and temporary lack of replacement from the pools of rapidly proliferating cells. The inflammatory response is largely mediated by cytokines activated by the radiation injury. Overall the response has the features of wound healing; waves of cytokines are produced in an attempt to heal the radiation injury. The cytokines lead to an adaptive response in the surrounding tissue, cause cellular infiltration, and promote collagen deposition. Damage to local vasculature is exacerbated by leukocyte adhesion to endothelial cells and the formation of thrombi that block the vascular lumen, further depriving the cells that depend on the vessels.

The acute symptoms eventually start to subside as the constitutive cells gradually recover their proliferative abilities. However, these early symptoms may not be apparent in some tissues such as bone, where cumulative progressive effects of radiation can precipitate acute breakdown of tissue many years after therapy. The late effects of radiation are permanent and directly related to higher doses.³⁶ Collagen hyalinizes and the tissues become increas-

ingly fibrotic and hypoxic due to obliterative vasculitis, and the tissue susceptibility to infection increases correspondingly. Once these changes occur they are irreversible and do not change with time. Hence, the surgeon must always anticipate the possibility of a complicated healing following surgery or traumatic injury in irradiated tissue. Wound dehiscence is common and the wound heals slowly or incompletely. Even minor trauma may result in ulceration and colonization by opportunistic bacteria. If the patient cannot mount an effective inflammatory response, progressive necrosis of the tissues may follow. Healing can be achieved only by excising all nonvital tissue and covering the bed with a well-vascularized graft. Due to the relative hypoxia at the irradiated site, tissue with intact blood supply needs to be brought in to provide both oxygen and the cells necessary for inflammation and healing. The progressive obliteration of blood vessels makes bone particularly vulnerable. Following trauma or disintegration of the soft tissue cover due to inflammatory reaction, healing does not occur because irradiated marrow cannot form granulation tissue. In such instances the avascular bone needs to be removed down to the healthy portion to allow healing to proceed.

Hyperbaric Oxygen Therapy

HBO therapy is based on the concept that low tissue oxygen tension, typically a partial pressure of oxygen (P_{O₂}) of 5 to 20 mm Hg, leads to anaerobic cellular metabolism, increase in tissue lactate, and a decrease in pH, all of which inhibit wound healing.⁶⁴ HBO therapy entails the patient lying in a hyperbaric chamber and breathing 100% oxygen at 2.0 to 2.4 atmospheres for 1 to 2 hours. The HBO therapy is repeated daily for 3 to 10 weeks. HBO increases the quantity of dissolved oxygen and the driving pressure for oxygen diffusion into the tissue. Correspondingly the oxygen diffusion distance

is increased threefold to fourfold, and wound PO_2 ultimately reaches 800 to 1,100 mm Hg. The therapy stimulates the growth of fibroblasts and vascular endothelial cells, increases tissue vascularization, enhances the killing ability of leukocytes, and is lethal for anaerobic bacteria. Clinical studies suggest that HBO therapy can be an effective adjunct in the management of diabetic wounds.⁶⁵ Animal studies indicate that HBO therapy could be beneficial in the treatment of osteomyelitis and soft tissue infections.^{66,67} Adverse effects of HBO therapy are barotraumas of the ear, seizure, and pulmonary oxygen toxicity. However, in the absence of controlled scientific studies with well-defined end points, HBO therapy remains a controversial aspect of surgical practice.^{68,69}

Age

In general wound healing is faster in the young and protracted in the elderly. The decline in healing response results from the gradual reduction of tissue metabolism as one ages, which may itself be a manifestation of decreased circulatory efficiency. The major components of the healing response in aging skin or mucosa are deficient or damaged with progressive injuries.³⁷ As a result, free oxidative radicals continue to accumulate and are harmful to the dermal enzymes responsible for the integrity of the dermal or mucosal composition. In addition the regional vascular support may be subjected to extrinsic deterioration and systemic disease decompensation, resulting in poor perfusion capability.³⁸ However, in the absence of compromising systemic conditions, differences in healing as a function of age seem to be small.

Nutrition

Adequate nutrition is important for normal repair.³⁹ In malnourished patients fibroplasia is delayed, angiogenesis decreased, and wound healing and remodeling prolonged. Dietary protein has

received special emphasis with respect to healing. Amino acids are critical for wound healing with methionine, histidine, and arginine playing important roles. Nutritional deficiencies severe enough to lower serum albumin to < 2 g/dL are associated with a prolonged inflammatory phase, decreased fibroplasia, and impaired neovascularization, collagen synthesis, and wound remodeling. As long as a state of protein catabolism exists, the wound will be very slow to heal. Methionine appears to be the key amino acid in wound healing. It is metabolized to cysteine, which plays a vital role in the inflammatory, proliferative, and remodeling phases of wound healing.

Serum prealbumin is commonly used as an assessment parameter for protein.^{40,41} Contrary to serum albumin, which has a very long half-life of about 20 days, prealbumin has a shorter half-life of only 2 days. As such it provides a more rapid assessment ability. Normal serum prealbumin is about 22.5 mg/dL, a level below 17 mg/dL is considered a mild deficit, and a severe deficit would be below 11 mg/dL. As part of the perioperative optimization process, malnourished patients may be provided with solutions that have been supplemented with amino acids such as glutamine to promote improved mucosal structure and function and to enhance whole-body nitrogen kinetics. An absence of essential building blocks obviously thwarts normal repair, but the reverse is not necessarily true. Whereas a minimum protein intake is important for healing, a high protein diet does not shorten the time required for healing.

Several vitamins and trace minerals play a significant role in wound healing.⁴² Vitamin A stimulates fibroplasia, collagen cross-linking, and epithelialization, and will restimulate these processes in the steroid-retarded wound. Vitamin C deficiency impairs collagen synthesis by fibroblasts, because it is an important cofactor, along with α -ketoglutarate and ferrous iron, in

the hydroxylation process of proline and lysine. Healing wounds appear to be more sensitive to ascorbate deficiency than uninjured tissue. Increased rates of collagen turnover persist for a long time, and healed wounds may rupture when the individual becomes scorbutic. Local antibacterial defenses are also impaired because ascorbic acid is also necessary for neutrophil superoxide production. The B-complex vitamins and cobalt are essential cofactors in antibody formation, white blood cell function, and bacterial resistance. Depleted serum levels of micronutrients, including magnesium, copper, calcium, iron, and zinc, affect collagen synthesis.⁴³ Copper is essential for covalent cross-linking of collagen whereas calcium is required for the normal function of granulocyte collagenase and other collagenases at the wound milieu. Zinc deficiency retards both fibroplasia and reepithelialization; cells migrate normally but do not undergo mitosis.⁴⁴ Numerous enzymes are zinc dependent, particularly DNA polymerase and reverse transcriptase. On the other hand, exceeding the zinc levels can exert a distinctly harmful effect on healing by inhibiting macrophage migration and interfering with collagen cross-linking.

Advances in Wound Care

An increased understanding of the wound healing processes has generated heightened interest in manipulating the wound microenvironment to facilitate healing. Traditional passive ways of treating surgical wounds are rapidly giving way to approaches that actively modulate wound healing. Therapeutic interventions range from treatments that selectively jumpstart the wound into the healing cascade, to methods that mechanically protect the wound or increase oxygenation and perfusion of the local tissues.^{45,46}

Growth Factors

Through their central ability to orchestrate the various cellular activities that underscore inflammation and healing,

cytokines have profound effects on cell proliferation, migration, and extracellular matrix synthesis.⁴⁷ Accordingly newer interventions seek to control or modulate the wound healing process by selectively inhibiting or enhancing the tissue levels of the appropriate cytokines.

The more common clinical approach has been to apply exogenous growth factors, such as PDGF, angiogenesis factor, epidermal growth factor (EGF), TGF, bFGF, and IL-1, directly to the wound. However, the potential of these extrinsic agents has not yet been realized clinically and may relate to figuring out which growth factors to put into the wound, and when and at what dose. To date only a single growth factor, recombinant human platelet-derived growth factor-BB (PDGF-BB), has been approved by the United States Food and Drug Administration for the treatment of cutaneous ulcers, specifically diabetic foot ulcers. Results from several controlled clinical trials show that PDGF-BB gel was effective in healing diabetic ulcers in lower extremities and significantly decreased healing time when compared to the placebo group.^{48,49} More recently, recombinant human keratinocyte growth factor 2 (KGF-2) has been shown to accelerate wound healing in experimental animal models. It enhanced both the formation of granulation tissue in rabbits and wound closure of the human meshed skin graft explanted on athymic nude rats.^{50,51} Experimental studies suggest potential for the use of growth factors in facilitating peripheral nerve healing. Several growth factors belonging to the neurotrophin family have been implicated in the maintenance and repair of nerves. Nerve growth factor (NGF), synthesized by Schwann cells distal to the site of injury, aids in the survival and development of sensory nerves. This finding has led some investigators to suggest that exogenous NGF application may assist in peripheral nerve regeneration following injury.⁵² Newer neurotrophins such as brain-derived neurotrophic factor and neurotrophin-3 as

well as ciliary neurotrophic factor appear to support the growth of sensory, sympathetic, and motor neurons in vitro.⁵³⁻⁵⁵ Insulin-like growth factors have demonstrated similar neurotrophic properties.⁵⁶ Although most of the investigations hitherto have been experimental, increasing sophistication in the dosing, combinations, and delivery of neurotrophic growth factors will lead to greater clinical application.

Osteoinductive growth factors hold special appeal to surgeons for their ability to promote the formation of new bone. Of the multiple osteoinductive cytokines, the bone morphogenetic proteins (BMPs) belonging to the TGF- β superfamily have received the greatest attention. Advances in recombinant DNA techniques now allow the production of these biomolecules in quantities large enough for routine clinical applications. In particular, recombinant human bone morphogenetic protein-2 (rhBMP-2) and rhBMP-7 have been studied extensively for their ability to induce undifferentiated mesenchymal cells to differentiate into osteoblasts (osteoinduction). Yasko and colleagues used a rat segmental femoral defect model to show that rhBMP-2 can produce 100% union rates when combined with bone marrow.⁵⁷ The union rate achieved with the combination approach was three times higher than that achieved with autologous cancellous bone graft alone. Similarly, Toriumi and colleagues showed that rhBMP-2 could heal mandibular defects with bone formed by the intramembranous pathway.⁵⁸ The widespread application of osteoinductive cytokines depends in large part on a better understanding of the complex interaction of growth factors and the concentrations necessary to achieve specific effects.

Gene Therapy

The application of gene therapy to wound healing has been driven by the desire to selectively express a growth factor for controlled periods of time at the site of tissue injury.⁵⁹ Unlike the diffuse effects of a

bolus of exogenously applied growth factor, gene transfer permits targeted, consistent, local delivery of peptides in high concentrations to the wound environment. Genes encoding for select growth factors are delivered to the site of injury using a variety of viral, chemical, electrical, or mechanical methods.⁶⁰ Cellular expression of the proteins encoded by the nucleic acids help modulate healing by regulating local events such as cell proliferation, cell migration, and the formation of extracellular matrix. The more popular methods for transfecting wounds involve the in vivo use of adenoviral vectors. Existing gene therapy technology is capable of expressing a number of modulatory proteins at the physiologic or supraphysiologic range for up to 2 weeks.

Numerous experimental studies have demonstrated the use of gene therapy in stimulating bone formation and regeneration. Mesenchymal cells transfected with adenovirus-hBMP-2 cDNA have been shown to be capable of forming bone when injected intramuscularly in the thighs of rodents.^{61,62} Similarly bone marrow cells transfected ex vivo with hBMP-2 cDNA have been shown to heal femoral defects.⁶³ Using osteoprogenitor cells for the expression of bone-promoting osteogenic factors enables the cells to not only express bone growth promoting factors, but also to respond, differentiate, and participate in the bone formation process. These early studies suggest that advances in gene therapy technology can be used to facilitate healing of bone and other tissues and may lead to better and less invasive reconstructive procedures in the near future.

Dermal and Mucosal Substitutes

Immediate wound coverage is critical for accelerated wound healing. The coverage protects the wound from water loss, drying, and mechanical injury. Although autologous grafts remain the standard for replacing dermal mucosal surfaces, a number of bioengineered substitutes are finding their

way into mainstream surgical practice. The human skin substitutes available are grouped into three major types and serve as excellent alternatives to autografts. The first type consists of grafts of cultured epidermal cells with no dermal components. The second type has only dermal components. The third type consists of a bilayer of both dermal and epidermal elements. The chief effect of most skin replacements is to promote wound healing by stimulating the recipient host to produce a variety of wound healing cytokines. The use of cultured skin to cover wounds is particularly attractive inasmuch as the living cells already know how to produce growth factors at the right time and in the right amounts. The ultimate goal of bioengineers is to develop engineered skin that contains all of the components necessary to modulate healing and allow for wound healing with a surrogate that replicates native tissue and limits scar formation.

References

- Singer AJ, Clark RA. Cutaneous wound healing. *N Engl J Med*. 1999;341:738–46.
- Hackam DJ, Ford HR. Cellular, biochemical, and clinical aspects of wound healing. *Surg Infect (Larchmt)* 2002;3 Suppl 1:S23–35.
- Clark RAF. Biology of dermal wound repair. *Dermatol Clin* 1993;11:647–66.
- Steed DL. Wound-healing trajectories. *Surg Clin North Am* 2003;83:547–55.
- Werner S, Grose R. Regulation of wound healing by growth factors and cytokines. *Physiol Rev* 2003;83:835–70.
- McCartney-Francis NL, Wahl SM. TGF-beta and macrophages in the rise and fall of inflammation. In: Breit SN, Wahl SM, editors. *TGF-beta and related cytokines in inflammation*. Basel: Birkhauser; 2001. p. 65–90.
- Niesler CU, Ferguson MWJ. TGF-beta superfamily cytokines in wound healing. In: Breit SN, Wahl SM, editors. *TGF-beta and related cytokines in inflammation*. Basel: Birkhauser; 2001. p. 173–98.
- Thanos PK, Okajima S, Terzis JK. Ultrastructure and cellular biology of nerve regeneration. *J Reconstr Microsurg* 1998;14:423–36.
- Sunderland S. A classification of peripheral nerve injuries producing loss of function. *Brain* 1951;74:491–7.
- Sunderland S. Factors influencing the course of regeneration and the quality of the recovery after nerve suture. *Brain* 1952;75:19–25.
- Fu SY, Gordon T. The cellular and molecular basis of peripheral nerve regeneration. *Mol Neurobiol* 1997;14(1–2):67–116.
- Jilka RL. Biology of the basic multicellular unit and the pathophysiology of osteoporosis. *Med Pediatr Oncol* 2003;41:182–5.
- Frost HM. A brief review for orthopedic surgeons: fatigue damage (microdamage) in bone (its determinants and clinical implications). *J Orthop Sci* 1998;3:272–81.
- Frost HM. From Wolff's law to the Utah paradigm: insights about bone physiology and its clinical applications. *Anat Rec* 2001;262:398–419.
- Huebsch RE, Hansen LS. A histopathologic study of extraction wounds in dogs. *Oral Surg Oral Med Oral Pathol* 1969;28:187–96.
- Muller W. Split skin and full-thickness skin grafts. *Mund Kiefer Gesichtschir* 2000;4 Suppl 1:S314–21.
- Branham GH, Thomas JR. Skin grafts. *Otolaryngol Clin North Am* 1990;23:889–97.
- Kingsley A. The wound infection continuum and its application to clinical practice. *Ostomy Wound Manage* 2003;49 Suppl 7A:1–7.
- Robson MC, Krizek TK, Heggers JP. Biology of surgical infection. In: Ravitch MM, editor. *Current problems in surgery*. Chicago (IL): Yearbook Medical Publishers; 1973. p. 1–62.
- Bowler PG. The 10⁵ bacterial growth guideline: reassessing its clinical relevance in wound healing. *Ostomy Wound Manage* 2003;49(1):44–53.
- Rahban SR, Garner WL. Fibroproliferative scars. *Clin Plast Surg* 2003;30(1):77–89.
- Urioste SS, Arndt KA, Dover JS. Keloids and hypertrophic scars: review and treatment strategies. *Semin Cutan Med Surg* 1999;18:159–71.
- Burns JL, Mancoll JS, Phillips LG. Impairments to wound healing. *Clin Plast Surg* 2003;30:47–56.
- Bowler PG. Wound pathophysiology, infection and therapeutic options. *Ann Med* 2002;34:419–27.
- Hunt TK, Hopf H, Hussain Z. Physiology of wound healing. *Adv Skin Wound Care* 2000;13 Suppl 2:6–11.
- Hunt TK, Conolly WB, Aronson SB, et al. Anaerobic metabolism and wound healing: a hypothesis for the initiation and cessation of collagen synthesis in wounds. *Am J Surg* 1978;135:328–32.
- Jonsson K, Jensen JA, Goodson WH, et al. Tissue oxygenation, anemia, and perfusion in relation to wound healing in surgical patients. *Ann Surg* 1991;214:605–13.
- Gottrup F. Oxygen, wound healing and the development of infection. Present status. *Eur J Surg* 2002;168:260–3.
- Krueger JK, Rohrich RJ. Clearing the smoke: the scientific rationale for tobacco abstinence with plastic surgery. *Plast Reconstr Surg* 2001;108:1063–73; discussion 1074–7.
- Goodson WH III, Hunt TK. Wound healing in well-controlled diabetic men. *Surg Forum* 1984;35:614–6.
- Burns J, Pieper B. HIV/AIDS: impact on healing. *Ostomy Wound Manage* 2000;46(3):30–40.
- Davis PA, Corless DJ, Gazzard BG, Wastell C. Increased risk of wound complications and poor healing following laparotomy in HIV-seropositive and AIDS patients. *Dig Surg* 1999;16:60–7.
- Anstead GM. Steroids, retinoids, and wound healing. *Adv Wound Care* 1998;11:277–85.
- Stone HB, Coleman CN, Anscher MS, McBride WH. Effects of radiation on normal tissue: consequences and mechanisms. *Lancet Oncol* 2003;4:529–36.
- Denham JW, Hauer-Jensen M. The radiotherapeutic injury—a complex 'wound'. *Radiother Oncol* 2002; 63:129–45.
- Tibbs MK. Wound healing following radiation therapy: a review. *Radiother Oncol* 1997;42:99–106.
- Reed MJ, Koike T, Puolakkainen P. Wound repair in aging. A review. *Methods Mol Med* 2003;78:217–37.
- Fenske NA, Lober CW. Structural and functional changes of normal aging skin. *J Am Acad Dermatol* 1986;15(4 Pt 1):571–85.
- Badwal RS, Bennett J. Nutritional considerations in the surgical patient. *Dent Clin North Am* 2003;47:373–93.
- Cartwright A. Nutritional assessment as part of wound management. *Nurs Times* 2002; 98(44):62–3.
- Collins N. The difference between albumin and prealbumin. *Adv Skin Wound Care* 2001;14:235–6.
- Ayello EA, Thomas DR, Litchford MA. Nutritional aspects of wound healing. *Home Healthc Nurse Manag* 1999;17:719–29.
- Scholl D, Langkamp-Henken B. Nutrient recommendations for wound healing. *J Intra-ven Nurs* 2001; 24(2):124–32.
- Tengrup I, Ahonen J, Zederfeldt B. Granulation tissue formation in zinc-treated rats. *Acta Chir Scand* 1980;146:1–4.
- Krishnamoorthy L, Morris HL, Harding KG. A dynamic regulator: the role of growth factors in tissue repair. *J Wound Care* 2001;10(4):99–101.

46. Sefton MV, Woodhouse KA. Tissue engineering. *J Cutan Med Surg* 1998;3 Suppl 1:S1–23.
47. Rumalla VK, Borah GL. Cytokines, growth factors, and plastic surgery. *Plast Reconstr Surg* 2001;108:719–33.
48. Wieman TJ, Smiell JM, Su Y. Efficacy and safety of a topical gel formulation of recombinant human platelet-derived growth factor-BB (Becaplermin) in patients with non healing diabetic ulcers: a phase III, randomized, placebo-controlled, double-blind study. *Diabetes Care* 1998;21:822–7.
49. Steed DL. Clinical evaluation of recombinant human platelet-derived growth factor for the treatment of lower extremity diabetic ulcers. Diabetic Ulcer Study Group. *J Vasc Surg* 1995;21:71–81.
50. Xia YP, Shao Y, Marcus J, et al. Effects of keratinocyte growth factor-2 (KGF-2) on wound healing in an ischemia-impaired rabbit ear model and on scar formation. *J Pathol* 1999;188:431–8.
51. Soler PM, Wright TE, Smith PD, et al. In vivo characterization of keratinocyte growth factor-2 as a potential wound healing agent. *Wound Repair Regen* 1999;7:172–8.
52. He C, Chen Z, Chen Z. Enhancement of motor neuron regeneration by nerve growth factor. *Microsurgery* 1992;13:151–4.
53. Utley D, Lewin S, Cheng E, et al. Brain derived neurotrophic factor and collagen tubulization enhance functional recovery after peripheral nerve transection and repair. *Arch Head Neck Surg* 1996;122:407–13.
54. Lohof A, Ip N, Poo M. Potentiation of developing neuromuscular synapses by the neurotrophins NT-3 and BDNF. *Nature* 1993;363:350–2.
55. Lewin S, Utley D, Cheng E, et al. Simultaneous treatment with BDNF and CNTF after peripheral nerve transection and repair enhances rate of functional recovery compared with BDNF treatment alone. *Laryngoscope* 1997;107:992–9.
56. Glazner G, Lupien S, Miller J, Ishii D. Insulin-like growth factor II correlates the rate of sciatic nerve regeneration in rats. *Neuroscience* 1993;54:791–7.
57. Yasko AW, Lane JM, Fellingner EJ, et al. The healing of segmental bone defects, induced by recombinant human bone morphogenetic protein (rhBMP-2): a radiographic, histological, and biomechanical study in rats. *J Bone Joint Surg* 1992;74A:659–70.
58. Toriumi DM, Kotler HS, Luxenberg DP, et al. Mandibular reconstruction with a recombinant bone-inducing factor: functional, histologic, and biomechanical evaluation. *Arch Otolaryngol Head Neck Surg* 1991;117:1101–12.
59. Braun-Falco M. Gene therapy concepts for promoting wound healing. *Hautarzt* 2002;53(4):238–43.
60. Hoeller D, Petrie N, Yao F, Eriksson E. Gene therapy in soft tissue reconstruction. *Cells Tissues Organs* 2002;172(2):118–25.
61. Lieberman JR, Le LQ, Wu L, et al. Regional gene therapy with a BMP-2-producing murine stromal cell line induces heterotopic and orthotopic bone formation in rodents. *J Orthop Res* 1998;16:330–9.
62. Lou J, Xu F, Merkel K, et al. Gene therapy: adenovirus-mediated human bone morphogenetic protein-2 gene transfer induces mesenchymal progenitor cell proliferation and differentiation in vitro and bone formation in vivo. *J Orthop Res* 1999;17:43–50.
63. Lieberman JR, Daluiski A, Stevenson S, et al. The effect of regional gene therapy with bone morphogenetic protein-2-producing bone-marrow cells on the repair of segmental femoral defects in rats. *J Bone Joint Surg* 1999;81A:905–17.
64. Broussard CL. Hyperbaric oxygenation and wound healing. *J Wound Ostomy Continence Nurs* 2003;30:210–6.
65. Faglia E, Favales F, Aldeghi A, et al. Adjunctive systemic hyperbaric oxygen therapy in treatment of severe prevalently ischemic diabetic foot ulcer. A randomized study. *Diabetes Care* 1996;19:1338–43.
66. Bakker DJ. Hyperbaric oxygen therapy and the diabetic foot. *Diabetes Metab Res Rev* 2000;16 Suppl 1:S55–8.
67. Mader JT, Guckian JC, Glass DL, Reinartz JA. Therapy with hyperbaric oxygen for experimental osteomyelitis due to *Staphylococcus aureus* in rabbits. *J Infect Dis* 1978;138:312–8.
68. Guo S, Counte MA, Romeis JC. Hyperbaric oxygen technology: an overview of its applications, efficacy, and cost-effectiveness. *Int J Technol Assess Health Care* 2003;19:339–46.
69. Coulthard P, Esposito M, Worthington HV, Jokstad A. Therapeutic use of hyperbaric oxygen for irradiated dental implant patients: a systematic review. *J Dent Educ* 2003;67(1):64–8.
70. Bissell MJ, Radisky D. Putting tumors in context. *Nature Rev Canc* 2001;1:46–54.

Medical Management of the Surgical Patient

James R. Hupp, DMD, MD, JD, MBA

David N. Duddleston, MD

Oral-maxillofacial surgery frequently causes temporary but clinically significant alteration of the anatomy and physiology of the upper aerodigestive tract, but has minor direct impact on vital organ systems. Therefore, the surgery itself is generally safe to perform even on relatively unhealthy individuals. However, the physiologic stresses produced by surgery and the anesthetic techniques necessary for these procedures can lead to serious morbidity and mortality. This is especially true in patients with various organs on the brink of decompensation due to disease or comorbid conditions.

This chapter presents the common medical situations that can compromise the successful outcome of oral or maxillofacial surgery. Emphasis is given to the means of detecting health problems preoperatively and preparing patients with various medical disorders so that complications in the perioperative period are avoided or minimized. The liberal use of medical consultations is highly recommended for all situations in which a surgeon has concerns for the medical well-being of a surgical patient.

Most commonly oral-maxillofacial surgery is performed on healthy patients. A quick screen of health conditions may give additional data in the evaluation of

the healthy patient. A preoperative patient questionnaire has been used in determining whether any further risk should be ascertained.¹ The questions in Table 2-1 have been valuable in preoperative patient evaluation.

In addition to this group of questions, other questionnaire-type screening tools can be valuable. Exercise capacity, such as the 6-minute walk test, use of medications and herbal supplements, and age can be important determinants of perioperative risks.² Exercise tolerance has been shown to predict long-term mortality as well as short-term perioperative risks.³ All patients

should be questioned regarding their exercise tolerance with a question such as, “If I asked you to walk as far as you could, how far would that be?” This may be answered as a function of time or distance. It is helpful to ask, “When was the last time you walked that far?” If there is a limitation of exercise, then ask, “What is the reason for the limitation?” It may be due to orthopedic or other musculoskeletal problems that limit exercise, or cardiac or pulmonary insufficiency.

Medication use is important, and with the use of a plethora of over-the-counter medications and dietary supplements,

Table 2-1 Preoperative Patient Questionnaire

1. Do you feel unwell?
2. Have you ever had any serious illnesses in the past?
3. Do you get any more short of breath on exertion than other people of your age?
4. Do you have any coughing?
5. Do you have any wheezing?
6. Do you have any chest discomfort on exertion?
7. Do you have any ankle swelling?
8. Have you taken any medicine or pills in the past 3 months (including excess alcohol)?
9. Do you have any allergies?
10. Have you had an anesthetic in the past 2 months?
11. Have you or your relatives had any problems with a previous anesthetic?
12. What is the date of your last menstrual period?
13. Do you observe any serious abnormality from “end of bed” that might affect anesthetic? (Clinician’s observation)

specific questioning is in order. Aspirin or other nonsteroidal anti-inflammatory drug use may exacerbate bleeding during major surgery. Some herbal supplements are known to increase the risk of bleeding as well.⁴

Finally age can be used as a surrogate for underlying disease or decreased reserve. There are no absolute cutoffs for age in estimation of risk; age of 70 years is used as a benchmark for a separate risk factor in surgical mortality. Laboratory testing may be helpful in a small subset of patients. Routine testing requirements may vary from operative center, office, or hospital, but in general there is often overtesting and under-review of the results. If guidelines at a particular center have been established, it is important to use a checklist of the tests, including their results. Many of these tests are arbitrary and not supported by evidence-based research. However, it is not unreasonable to establish a schedule of routine testing in unselected patients. While most young and apparently healthy patients do not need any preoperative laboratory testing, unselected adults over the age of 40 years may benefit from a preoperative hematocrit and tests of renal function and blood glucose. A blood count may reveal anemia or serve as a benchmark when excessive blood loss or anemia is found after surgery. Glucose determination is helpful in those patients with diabetes or obesity, and serves as a useful screening tool for diabetes in the general population.⁵

The preoperative evaluation of healthy patients should include the following^{6,7}:

1. A screening questionnaire for all patients (see Table 2-1)
2. A history of exercise tolerance for all patients
3. Blood pressure and pulse for all patients
4. History and physical examination if one of the above is abnormal, in patients over 60 years, or in those undergoing major surgery
5. Pregnancy test for women who may be pregnant
6. Hematocrit for surgery with expected major blood loss
7. Serum creatinine concentration if undergoing major surgery, hypotension is expected, nephrotoxic drugs will be used, or the patient is over age 50 years
8. Electrocardiogram (ECG) recommendations as above, unless obtained within the previous month
9. Chest radiograph for patients over 60 years, or for those with suspected cardiac or pulmonary disease, if such imaging has not been performed within the past 6 months
10. Other tests only if the clinical evaluation suggests a likelihood of disease

Cardiac Disease

Cardiac disease is common in the North American and other populations, and the patient is usually well aware of any existing cardiac problem. Thus, it is essential to screen for cardiovascular disease, and recent interventions have shown the ability to greatly reduce perioperative risks in patients with known or suspected cardiac disease.

Preservation of cardiac health is an essential element of any perioperative protocol. The proper match of oxygen supply to oxygen use in myocardial tissue is the key to maintaining normal contractility and electrical activity. In the patient with a healthy heart and lungs, the myocardium is protected in the perioperative period by avoiding hypovolemia, ensuring adequate oxygen-carrying capacity of the blood, keeping serum electrolytes within physiologic limits, and supplying the lungs with adequate oxygen. Cardiac output also depends on properly functioning valves. Finally the load against which the ventricles must work should stay within reasonable limits to preserve optimal myocardial function.

Several cardiac conditions can exist preoperatively that have the potential to

compromise the heart's ability to maintain adequate blood pressure intra- or postoperatively. These conditions include coronary artery disease, valvular disease, various processes predisposing the heart to congestive failure, and abnormalities of electrical impulse generation or conduction. In the discussion of the four conditions that follows, emphasis is on the means of assessing the degree of cardiac compromise and reserve, of improving the situation preoperatively, and of managing the condition perioperatively.

Coronary Artery Disease

The two principal processes that cause an insufficient blood supply to the myocardium are coronary artery obstruction and spasm. Myocardial ischemia will occur when the supply of oxygen is inadequate to meet the demand for oxygen. Myocardial oxygen need is increased when the heart has increased rate or mass, or is forced to work against an increased afterload that increases end-diastolic wall tension. In these situations symptoms of ischemia will occur if oxygen supply to the myocardium cannot be increased because the coronary arteries are critically narrowed by fixed atheromatous lesions and/or spasm; clinically this is manifested by exercise-induced angina pectoris.

Coronary artery disease is one of the most studied diseases in humans. Over the past several years new paradigms regarding coronary artery disease have emerged and have been validated. The idea of a hard plaque slowly encircling the lumen of a coronary artery until occlusion has occurred has been replaced by the concept of plaque rupture. Many plaques in the lumen of the coronary vessels are considered to be soft, with a membrane or thin cell layer covering a highly thrombogenic lipid core. This membrane may rupture even in small lesions, exposing thrombogenic materials into the blood. This sets up an immediate clotting cascade resulting in thrombus formation, occluding the vessel

and precipitating myocardial infarction or unstable angina.^{8,9}

Coronary artery disease includes the progression of an endothelial lesion from a fatty streak to an occlusive lesion or plaque rupture as noted above. Several risk factors for coronary artery disease have been identified, including family history of early coronary disease (under age 65 yr), male gender, diabetes mellitus, and elevated cholesterol, including total cholesterol and/or low-density lipoprotein (LDL) cholesterol. High levels of LDL cholesterol, low levels of high-density lipoprotein cholesterol, hypertension, and cigarette smoking are the most predictive risk factors of coronary artery disease. Additional risk factors such as elevated levels of homocysteine, C-reactive protein, myeloperoxidase and others are being evaluated.¹⁰ Interestingly a large percentage of patients with first-time myocardial infarction do not have known risk factors for coronary artery disease.^{11,12}

As noted above, a plaque may progress to cause a limitation of flow of blood through the coronary artery to the myocardial tissue. Myocardial ischemia produces decreased myocardial contractility rapidly leading to systemic hypotension and pulmonary vascular congestion. The limitation of flow leads to the symptom of angina. Patients may complain of a squeezing, choking, or tight feeling in the substernal region radiating to the throat, jaw, shoulders, or arms. The patient may also experience dyspnea, diaphoresis, and nausea. Anginal symptoms will dissipate soon after the provoking activity ceases or after transmucosal nitroglycerin is administered. Infarction symptoms will usually persist despite nitroglycerin use or rest.

It is important to ask patients suspected of having coronary artery disease if they have discomfort with exertion, rather than focusing on pain. A patient may give a history of dyspnea and chest tightness, among other symptoms, after exertion, eating a heavy meal, or entering a cold environment.

Typically these symptoms are reproducible. Patients who have angina symptoms that are progressive with less precipitating forces, angina with increasing frequency, or angina at rest are considered to have unstable angina and require evaluation by a qualified cardiovascular specialist.

There are no standard physical signs of coronary artery insufficiency so preoperative screening relies on historic information and electrocardiography. A cardiovascular examination may show evidence of vascular or valvular disease, or some degree of cardiac decompensation. Symptoms of compromised coronary or carotid arteries should be sought preoperatively in all adult males, as well as in menopausal and postmenopausal females.

Physical Examination The physical examination in patients with coronary artery disease is frequently unrevealing. The history is the most important determinant of risk. However, a cardiovascular examination may show evidence of vascular disease, valvular disease, or evidence of cardiac decompensation.

Patients with findings of peripheral vascular disease should be considered at high risk for underlying coronary artery disease. On heart examination an S_4 may be present, reflecting reduced compliance in an ischemic myocardium. Auscultation of the neck, periumbilical area of the abdomen, and inguinal areas should be used to detect bruits. In addition, pedal pulses and inguinal pulses should be checked. Diminished or absent pulses, cool feet, and skin changes such as hair loss in the ankles and feet may indicate peripheral vascular disease. Specific questioning about problems occurring during physical activity or postprandially should be included. It must be remembered that many patients with first time myocardial infarction have no known risk factors.

A resting ECG should be done within a month of a planned elective general anesthetic and surgery in all males age

35 years and older, all females age 45 years and older, and all other patients with a history suggestive of cardiac disease.¹³ More elaborate routine cardiac testing is unwarranted. Although it is unlikely to see resting ECG changes suggestive of acute ischemia, old silent infarcts (representing 20 to 60% of all infarctions) or conduction blocks due to coronary disease may be detected.¹⁴ It should be noted that 30% of patients with a history of myocardial infarction have a normal resting ECG.¹⁵ ECG after controlled treadmill exercise is a more sensitive means of detecting ischemic tendencies as evidenced by ST depression or T-wave inversion. Patients with a past history of cardiac disease should have preoperative posteroanterior and lateral chest radiographs to detect early signs of congestive heart failure. Finally a thallium stress test can be used, but only in the case of an equivocal treadmill test, or coronary angiography can be performed to identify areas of narrowing, which predispose the patient to perioperative myocardial ischemia if clinical indications for angiography are present.

All patients with a documented history of angina may have an increased risk of perioperative infarction. This risk varies with the severity of the coronary disease and the degree of physiologic stress in the perioperative period. Patients with stable angina have only a slightly raised risk during anesthesia and surgery compared to the normal population. Angina that is worsening with respect to frequency, duration, response to medication, or ease of production is, by definition, unstable angina. Surgery in such a situation should only proceed if required emergently. Patients with stable but poorly controlled angina need medical intervention to improve their cardiac status before most elective surgery.

The American College of Cardiology has produced a listing of major, intermediate and minor cardiovascular risk factors and matched these with a listing of higher-risk operations. These risks are then entered

into a straightforward algorithm directed to decisions on invasive testing, noninvasive testing, intervention or progression to surgery (Table 2-2 and Figure 2-1).¹⁶ Risk reduction strategies have also evolved, with reduced emphasis on preoperative testing. The newest risk reduction strategy includes the use of β -blockade in patients with known coronary artery disease or with risk factors for coronary artery disease.¹⁷

Patients with stable, well-controlled angina, or who have delayed surgery after an uncomplicated myocardial infarction for a period dictated by their cardiologist, can usually undergo elective maxillofacial procedures safely if intraoperative hyper-

hypotension is avoided. Although some studies indicate the risk of infarction increases with the duration of surgery, this has only been well documented in the case of major thoracic or upper abdominal procedures.^{18,19} In general, nonurgent surgery should be postponed for at least 6 weeks after myocardial infarction. Patients who need nonurgent surgery in this 6-week window should be co-managed by a cardiologist. Modern day general anesthesia may actually be protective of the myocardium, because supraphysiologic levels of oxygen are administered and cardiac work is minimized through maintenance of muscle relaxation, sympathetic nervous system

antagonism, blood pressure control, and prompt dysrhythmia recognition and management. To assist with these goals consideration should be given to radial artery cannulation for blood gas and pH measurement and precise blood pressure monitoring. The presence of signs of chronic congestive failure following a myocardial infarction increases operative risk, as is discussed later in this chapter.

The risk of general anesthesia after a recent myocardial infarction is due to possible extension of the earlier myocardial infarction and the development of cardiac dysrhythmias. A target-like zone is described in myocardial infarction, with the center being infarcted tissue. It is a zone surrounding this infarcted tissue that is considered to be stunned or vulnerable. This zone is the area into which the myocardial infarction may extend and from which dysrhythmias can be generated. After the 6-week window has passed, the patient can be evaluated as any other coronary artery disease patient.²⁰

Patients with coronary artery disease have their greatest risk of cardiac problems in the early postoperative period. The cardiorespiratory system is no longer controlled by general anesthesia, and the normal stresses that occur in the early recovery period exist. There is usually a need for increased cardiac output, which the diseased heart may not be able to deliver or tolerate, and ischemia can result. Therefore, these patients need frequent cardiopulmonary physical examinations and close monitoring of vital signs, urine output, jugular venous pressure, and electrolytes. An immediate postoperative ECG should be obtained in patients with a history of coronary artery disease, particularly if they have any of the following:

- Unexplained hypotensive or syncopal episode
- Signs of heart failure
- Dysrhythmias
- Angina

Table 2-2 Clinical Predictors of Increased Perioperative Cardiovascular Risk (Myocardial Infarction, Heart Failure, Death)

<i>Major</i>
Unstable coronary syndromes Acute or recent myocardial infarction* with evidence of important ischemic risk by clinical symptoms or noninvasive study Unstable or severe† angina (Canadian Class III or IV) ¹³³ Decompensated heart failure Significant dysrhythmias High-grade atrioventricular block Symptomatic ventricular dysrhythmias in the presence of underlying heart disease Supraventricular arrhythmias with uncontrolled ventricular rate Severe valvular disease
<i>Intermediate</i>
Mild angina pectoris (Canadian Class I or II) Previous myocardial infarction by history or pathological Q waves Compensated or prior heart failure Diabetes mellitus (particularly insulin-dependent) Renal insufficiency
<i>Minor</i>
Advanced age Abnormal electrocardiogram (left ventricular hypertrophy, left bundle-branch block, ST-T abnormalities) Rhythm other than sinus (eg, atrial fibrillation) Low functional capacity (eg, inability to climb one flight of stairs with a bag of groceries) History of stroke Uncontrolled systemic hypertension
<small>*The American College of Cardiology National Database Library defines recent myocardial infarction as greater than 7 days but less than or equal to 1 month (30 days); acute myocardial infarction is within 7 days. †May include “stable” angina in patients who are unusually sedentary. Adapted from Eagle KA et al.¹⁶</small>

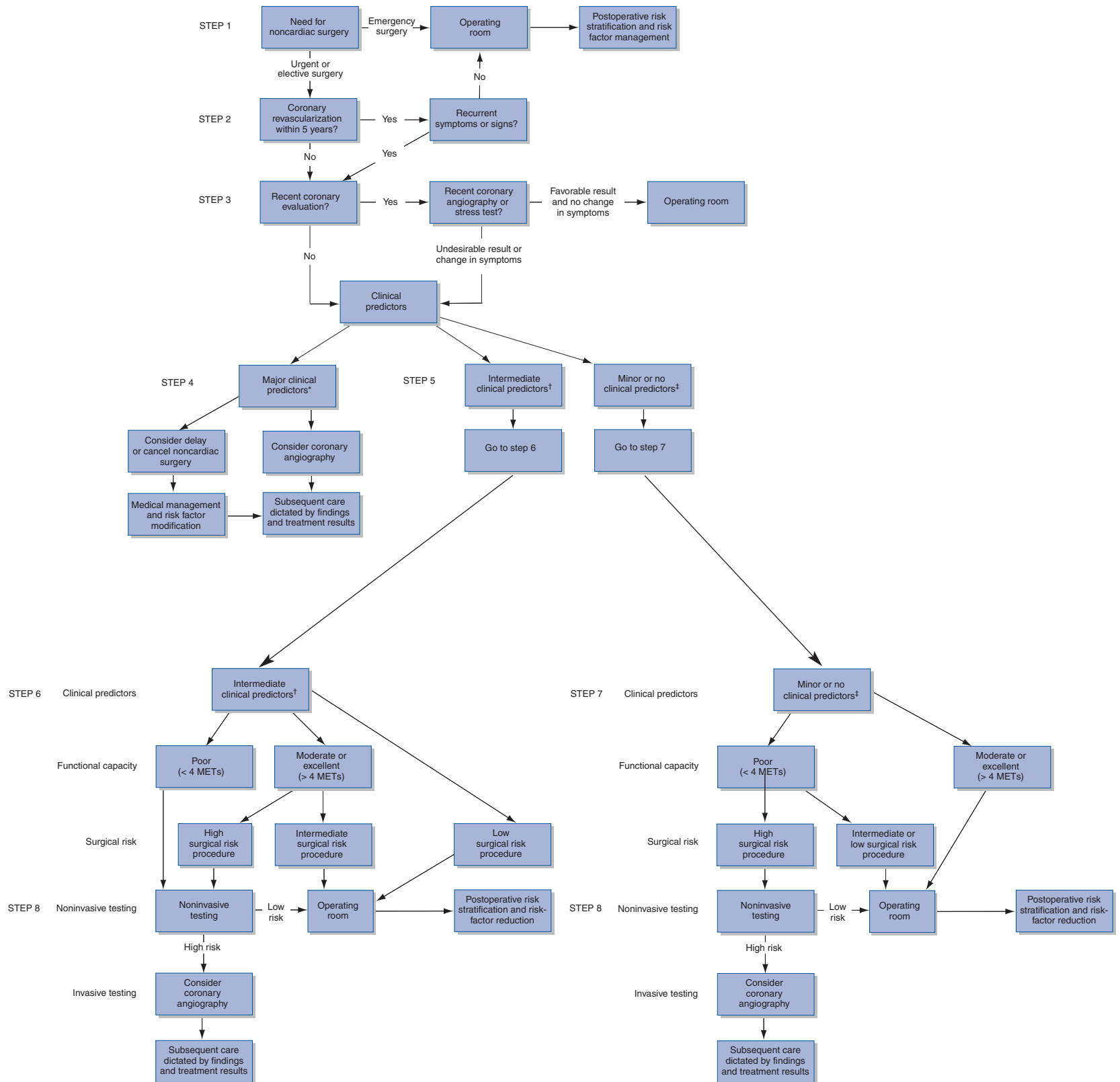


FIGURE 2-1 Stepwise approach to preoperative cardiac assessment. Steps are discussed in the text. Note that subsequent care may include cancellation or delay of surgery, coronary revascularization followed by noncardiac surgery, or intensified care. MET = metabolic equivalent. *Major clinical predictors include unstable coronary syndromes, decompensated congestive heart failure, significant dysrhythmias, and severe valvular disease. †Intermediate clinical predictors include mild angina pectoris, prior myocardial infarction, compensated or prior congestive heart failure, diabetes mellitus, and renal insufficiency. ‡Minor clinical predictors include advanced age, abnormal electrocardiogram, rhythm other than sinus, low functional capacity, history of stroke, and uncontrolled systemic hypertension. Adapted from Eagle KA et al.¹⁶

Care in the postoperative period should be taken to maintain normal intravascular volume, avoid hyper- or hypotension, keep serum electrolytes in their physiologically normal ranges, manage patient anxiety and pain, give supplemental oxygen when needed, and resume preoperative cardiac medications. Signs of infections or pulmonary problems should be pursued aggressively.

Left Ventricular Dysfunction Left ventricular dysfunction can result from myocardial infarction or primary cardiomyopathy. Left ventricular dysfunction can be separated into systolic or diastolic dysfunction. Systolic dysfunction occurs after myocardial infarction or other direct muscle injury, causing either wall motion abnormalities or decreased cardiac output. Diastolic dysfunction results from stiffness or reduced compliance of the left ventricle.²¹

Concepts of preload, afterload, and compliance are useful to know when discussing left ventricular dysfunction. Preload is thought of as volume being presented to the right heart. The right heart is a low-pressure chamber, handling the influx of blood via the right atrium. Excess volume may be presented to the pulmonary vasculature, resulting in pulmonary congestion or pulmonary edema. Preload problems can occur from left heart failure causing fluid to back up into the pulmonary arterial tree, or may also be due to reduced compliance in the left ventricle. Rarely isolated right-sided ventricular failure occurs, such as from pulmonary hypertension or right ventricular infarction. Excess preload is usually managed with diuretic therapy or fluid restriction.

Afterload refers to the pressure in the aorta against which the left ventricle must pump. This arterial resistance or afterload may be increased in hypertension and aortic stenosis. Afterload may also be relative to the pumping capacity of the left ventricle; hence normal blood pressures may impair a failing heart. Afterload reduction

using vasodilators, especially angiotensin-converting enzyme (ACE) inhibitors, is an important treatment in heart failure, certain valvular abnormalities, and hypertension. For instance, afterload reduction in systolic dysfunction reduces the work of the left ventricle against the normal arterial pressure. This reduces demand on the heart. *Compliance* refers to the ability of the heart to distend. Reduced compliance in the left ventricle is described as a stiffness or alteration in the diastolic filling of the left ventricle. If the left ventricle does not fill properly during the cardiac cycle, pulmonary congestion can occur, even though the apparent forward flow of blood is not impaired.

Left ventricular systolic dysfunction can be tolerated within the reserve capacity of the individual, or may manifest itself as congestive heart failure. As noted above it can be due to insults, such as myocardial infarction, viral myocarditis, or direct trauma to the heart. In addition there may be global dysfunction due to more widespread ischemia, idiopathic cardiomyopathy, or valvular abnormalities.

Symptoms suggesting congestive heart failure include dyspnea on exertion, paroxysmal nocturnal dyspnea (PND), nighttime cough, and ankle swelling. Patients with PND may sit up on the side of the bed for a moment and then get up to drink a glass of water. Patients with severe heart failure may sleep in a sitting position or slumped against a countertop. On physical examination of the heart there may be an S₃ gallop rhythm and the point of maximal impulse (PMI) may be shifted laterally and inferiorly. In addition a diffuse PMI may be present. A murmur of mitral insufficiency may be present due to dilated annulus of the heart. The neck veins, which should be flat with the patient's chest being elevated 30°, may be distended. On lung examination rales may be present from pulmonary congestion and there may be dullness to percussion from pleural effusions.

Diagnostic testing for patients with heart failure includes an ECG, which may show Q waves of a previous myocardial infarction, elevated QRS amplitude of left ventricular hypertrophy, or low QRS amplitude in some patients with severe myocardial dysfunction. An echocardiogram may show evidence of diastolic dysfunction through measurements of compliance, or may show wall motion abnormalities and reduced ejection fraction.

Management of congestive heart failure is indicated when evidence of decompensation is present. Decompensation is manifested by increased symptoms of dyspnea on exertion or PND, the presence of an S₃ gallop rhythm, distended neck veins, or an increase in peripheral edema.²² The decision is then made whether or not to admit the patient to the hospital for treatment or to advanced treatment as an outpatient. This is determined more by the severity of the heart failure than the urgency of the surgery. In either case the management includes starting or increasing diuretic therapy, reducing afterload, and in some cases, increasing contractility of the heart. If a diuretic has not been prescribed, furosemide 20 mg daily for 3 to 4 days should suffice in reducing total body salt and water. If a diuretic has already been prescribed, doubling of the dose is indicated. Rarely a second diuretic such as metolazone would be added to boost the loop diuretic.

Afterload reduction is a key tenet in the treatment of congestive heart failure.²³ An ACE inhibitor is first-line treatment for congestive heart failure and would be added or increased in dose during an episode of decompensated congestive heart failure. Typically the systolic blood pressure is lowered to between 90 and 110 mm Hg unless significant hypertension was involved in the decompensation. After appropriate diuretic therapy and ACE inhibition, attention may be turned to systolic contractility. In cases of dilated cardiomyopathy the addition of digoxin can be helpful. Its

applicability in other types of heart failure is questionable. Digoxin therapy should be guided by serum digoxin levels. In addition, treatment of decompensated congestive heart failure should include monitoring of electrolytes. If a patient's known congestive heart failure is compensated, the patient's surgical risk is greatly reduced toward normal.²⁴ If the patient has reasonable functional capacity, for instance is able to walk two blocks or more without shortness of breath, the risk factor of heart failure can be discounted, and the patient can come to surgery. In summary a patient with decompensated heart failure is at high risk for major cardiac events, but this risk can be greatly reduced with appropriate management, including diuretic therapy, afterload reduction, and digoxin therapy when needed. Diastolic decompensation is usually treated acutely with diuretic therapy alone, using afterload reduction and the use of β -blockers if hypertension is present or further treatment is needed. While β -blockers are often used in dilated cardiomyopathy, acute use in the treatment of decompensation is not recommended.

Valvular Heart Disease

Most patients with valvular heart disease who have few symptoms or limitations of activity can safely undergo most elective maxillofacial surgery. Diseased cardiac valves pose two general risks: precipitation of cardiac failure and susceptibility to infective endocarditis. The likelihood of causing failure or worsening preexisting cardiac failure is dependent on the location and severity of valve pathology. Prophylactic antibiotics should be used for all patients with a cardiac valve abnormality with a resultant murmur who undergo maxillofacial procedures in which bleeding occurs (Tables 2-3 and 2-4).

Mitral Stenosis Mitral stenosis is almost always a sequela of childhood rheumatic heart disease, although a definite history can be obtained in only half of such cases.

Fortunately the incidence of new cases of this problem has decreased substantially since the use of antibiotics to manage streptococcal infections became common practice. The rheumatic disease process causes valve fibrosis, fusion, and calcification. These changes limit valve motion, thus restricting the flow of blood into the left ventricle. The latency period is usually 15 to 20 years. Once valve obstruction occurs the patient will begin to suffer gradually worsening exertional dyspnea and fatigue due to pulmonary vascular congestion and progressive right heart failure. Left arterial enlargement may lead

to the appearance of atrial fibrillation (AF) with possible atrial thrombus formation and systemic arterial embolization.^{25,26}

Examination of the patient with clinically significant mitral stenosis may reveal an early diastolic opening snap followed by a low-pitched murmur and a loud first heart sound. Patients in AF will characteristically have an irregularly irregular pulse. A chest radiograph will reveal an enlarged left atrium, pulmonary vascular enlargement, and in more severe cases right ventricular hypertrophy. An ECG may reveal AF, left atrial enlargement, and right ventricular hypertrophy. Echocardiography is

Table 2-3 Cardiac Conditions Associated with Infectious Endocarditis

High-Risk Category: Prophylaxis Recommended

Prosthetic cardiac valves
Previous infectious endocarditis
Complex cyanotic congenital heart disease

Moderate-Risk Category: Prophylaxis Recommended

Most other congenital malformations
Acquired valvular dysfunction
Hypertrophic cardiomyopathy
Mitral valve prolapse with valvular regurgitation

Negligible-Risk Category: Prophylaxis NOT Recommended

Coronary artery bypass graft
Mitral valve prolapse without regurgitation
Physiologic, functional, or innocent heart murmur
Isolated secundum atrial septal defect
Surgical repair of atrial septal defect; patent ductus arteriosus
Previous rheumatic fever without valvular dysfunction

Oral Procedures in which Prophylaxis is Recommended

Dental extractions and biopsies
Periodontal procedures
Dental implant placement
Periapical endodontic procedures
Intraligamentary local anesthetic injections
Dental prophylaxis when bleeding is expected
Other procedures causing intraoral bleeding

Oral Procedures in which Prophylaxis is NOT Recommended

Routine local anesthetic injection
Intracanal endodontic therapy
Suture removal
Taking impressions

Table 2-4 Antibiotic Regimen for Prophylaxis of Infectious Endocarditis

Situation	Antibiotic	Regimen
Standard prophylaxis	Amoxicillin	Adults: 2 g orally 1 h before procedure Children: 50 mg/kg orally 1 h before procedure*
Penicillin allergic	Clindamycin or azithromycin or clarithromycin	Adults: 600 mg orally 1 h before procedure Children: 20 mg/kg orally 1 h before procedure* Adults: 500 mg orally 1 h before procedure Children: 15 mg/kg orally 1 h before procedure* Adults: 500 mg orally 1 h before procedure Children: 15 mg/kg orally 1 h before procedure*
Unable to take oral medication	Ampicillin	Adults: 2 g IM or IV within 30 min before procedure Children: 20 mg/kg IV within 30 min before procedure*
Unable to take oral medication and penicillin allergic	Clindamycin or cefazolin	Adults: 600 mg IV within 30 min before procedure Children: 20 mg/kg IV within 30 min before procedure* Adults: 1 g IM or IV within 30 min before procedure Children: 25 mg/kg IM or IV within 30 min before procedure*

IM = intramuscularly; IV = intravenously.
*Total children's dose should not exceed adult dose.

usually the definitive test used to detect and characterize mitral stenosis.

Patients with severe mitral stenosis who require elective surgery may need preoperative mitral valve commissurotomy or valve replacement. AF may be managed by preoperative digitalization or β -sympathetic blockade; pulmonary congestion is treated with diuretic therapy. Patients with a known or suspected atrial thrombus are usually on chronic anticoagulant therapy, which may need temporary alteration. Surgeons should note the compromised cardiac output of patients with mitral stenosis.

Acute pulmonary edema is not uncommon following noncardiac surgery on patients with significant mitral stenosis, particularly if excess fluid replacement was given. An additional problem facing these patients is diminished pulmonary compliance that may require postoperative mechanical ventilation longer than is usually necessary.

Mitral Regurgitation Mitral regurgitation or insufficiency is most commonly the result of damage or dysfunction due to coronary artery disease or from prior rheumatic heart disease. The incompetent valve prompts left ventricular enlargements as the heart works and expands to maintain cardiac output. Symptoms of congestive failure appear as regurgitation worsens and the enlarging heart transitions to the decompensation (right) side of the Frank-Starling curve.

Physical examination of the patient with significant mitral regurgitation will reveal an apical point of maximal impact displaced inferolaterally, an apical, high-pitched, holosystolic murmur, and a third heart sound (gallop rhythm). Left ventricular hypertrophy and AF may appear on an ECG. Echocardiography will help define the extent of valve disease and, with a measurement of end-systolic left ventricular dimension, the prognosis can be determined (a

dimension of more than 55 mm indicates left ventricular dysfunction). Doppler studies or cardiac angiography can be used to determine the severity of dysfunction.

Patients with failure secondary to initial regurgitation are medically managed with sodium restriction, digoxin, diuretics, and preload- and afterload-reducing vasodilators. Eventually surgical valve repair or replacement may be necessary.

There is little increased risk during maxillofacial surgery for patients with well-controlled mitral regurgitation. The surgeon and anesthesiologist must guard against the pulmonary edema to which these patients are prone. Monitoring of pulmonary capillary wedge pressure will help guide therapy.

Mitral Valve Prolapse

Mitral valve prolapse is a common form of mitral regurgitation, most frequently seen in young women, in which one or both of the mitral valve leaflets prolapse into the left atrium during systole, allowing varying degrees of regurgitation to occur. It is characterized by a midsystolic click followed by a late systolic murmur. Symptoms include palpitations and chronic fatigue, but it can be asymptomatic; echocardiography is diagnostic. The prevalence of mitral valve prolapse in women and the general population has been overestimated, with more recent study showing a prevalence of about 3%, equally distributed among men and women; symptoms have been overestimated as well.²⁷ Mitral valve prolapse is usually managed symptomatically, using β -sympathetic antagonists to control palpitations.²⁸

As with other causes of mitral regurgitation, with medical management there is little increased risk for anesthesia and surgery. Patients should have ECG monitoring to detect intraoperative dysrhythmias, and those with a murmur should be given antibiotics to prevent infective endocarditis.

Aortic Regurgitation Aortic regurgitation or insufficiency occurs when the

aortic valve becomes partially incompetent, resulting in a backflow of aortic blood into the left ventricle during diastole. This causes left ventricular volume overload resulting in hypertrophy and increased wall thickness, both of which increase myocardial oxygen requirements.

Patients with clinically significant aortic regurgitation will report unusual awareness of their heartbeat, prominent neck pulsations, and symptoms of pulmonary congestion at rest that resolve during exercise. Examination reveals a widened pulse pressure, a bisferious (bifid) carotid pulse, an inferolaterally displaced and prolonged apical PMI, and diastolic decrescendo murmur at the base. In severe cases there may be a third heart sound and apical low-pitched diastolic (Austin Flint) murmur.

The ECG will reveal left ventricular hypertrophy, and a chest radiograph will show left ventricular and aortic root enlargement. Echocardiography with or without a Doppler is used to diagnose and characterize aortic regurgitation. Patients with significant aortic regurgitation will be treated with vasodilators such as calcium channel blockers or ACE inhibitors. β -Blockers should be avoided since they can prolong diastole, increasing the regurgitant flow. Eventually aortic valve replacement may be necessary. Low-risk patients have a near-normal sized left ventricular cavity, while high-risk patients nearing the time for aortic valve replacement show enlargement of end-systolic left ventricular dimensions, corrected for body surface area.^{29,30}

Typically bradycardia or vasodilation cannot be tolerated; thus measures to prevent these changes should be used. The ECG lead V_5 should be monitored perioperatively for signs of subendocardial ischemia. Pulmonary artery catheterization is useful in the perioperative period for measuring left-sided pressure and cardiac output. Afterload reduction may be helpful in patients with normal left ventricular function by reducing the regurgitant frac-

tion, increasing stroke volume, and decreasing left ventricular end-diastolic volume and pressure. Care must be taken when using afterload reducers to not allow aortic diastolic pressure to drop so low as to compromise coronary perfusion.

Aortic Stenosis Aortic stenosis can involve the valve itself or be supra- or infravalvular. Valve stenosis is most often due to either a congenitally bicuspid valve (which occurs in about 2% of the population) or an aging-related degeneration of a normal trileaflet valve. In either situation valve fibrosis and calcification occur and cause varying degrees of left ventricular outflow obstruction.

Symptoms classically include exertional angina, syncope, or dyspnea. However, many patients can be asymptomatic until surgical stress unmasks problems. Physical examination of the patient with significant aortic stenosis will typically reveal a weak pulse, narrow pulse pressure, and a nondisplaced but accentuated and prolonged PMI. A diamond-shaped systolic murmur is heard at the base while a fourth heart sound is heard at the apex. Patients typically have little pulmonary hypertension so that many of the classic noncardiac symptoms and signs of heart failure are not present. But because the left ventricle depends on the end-diastolic boost from the left atrium, the development of AF can be catastrophic and should be suspected in a patient with aortic stenosis who suddenly deteriorates.

An ECG shows left ventricular hypertrophy, while the chest radiograph reveals left ventricular and ascending aortic enlargement and calcification. Echocardiography can be used to define the valvular pathology, and cardiac angiography is used to determine the pressure gradient across the valve and to check the status of the coronary arteries. Severely stenotic valves may require surgical replacement.

Patients with mild-to-moderate dysfunction requiring maxillofacial surgery typically require little modification in sur-

gical or anesthetic management. The aortic valve opening must be narrowed to 75% of its normal size before obstructive signs occur. If aortic and mitral stenoses coexist, the problems due to mitral stenosis will predominate. Perioperative risks in patients with isolated aortic stenosis are highest if the history includes exertional dizziness, syncope, or angina and the presence of coronary artery disease.

The preservation of sinus rhythm is important in these patients. Tachydysrhythmias must be avoided since the atrial “kick” supplies needed left ventricular filling. Supraventricular tachycardias should be treated immediately with direct current cardioversion. Sinus tachycardia may require administration of a β -sympathetic antagonist. Bradycardia is also harmful, and rates below 45 bpm should be increased with atropine. Anesthetics that cause myocardial depression should be used cautiously, if at all, and systemic vascular resistance should be maintained. The ECG lead V_5 should be monitored for signs of ischemia; if detected, coronary obstruction must be differentiated from insufficient coronary filling pressure due to aortic stenosis.

Prosthetic Heart Valves Patients with prosthetic heart valves represent a special situation in which properly functioning valves have essentially normal cardiac function but may have new problems directly related to the artificial valve itself. These patients are susceptible to endocarditis (particularly staphylococcal), red cell destruction by the valve, prosthetic valve obstruction by thrombosis or pannus formation, and paravalvular regurgitation. Serum bilirubin, lactate dehydrogenase, and reticulocytes should be measured to detect occult hemolysis. Patients with mechanical (not bioprosthetic) valves are on chronic anticoagulant therapy that needs perioperative management. Patients with prosthetic valves should be given antibiotics to prevent infective endocarditis.

Congestive Heart Failure

The normal myocardium responds to increased physiologic demands by increasing the frequency of contractions and by dilating through the Frank-Starling mechanism, which increases contractility (the end-diastolic wall tension). Heart failure occurs when the heart's compensatory mechanisms fail to handle the hemodynamic load, causing blood to back up into the pulmonary vasculature, right heart, and major venous beds such as the portal system.

Failure can be produced in two basic ways. First, the heart can be overwhelmed by excessive loads, such as elevated preload (venous return; eg, by hypervolemia) or increased afterload (resistance to ejection; eg, by elevated total peripheral resistance or aortic stenosis). Second, the heart's ability to compensate for increased demands can be compromised, such as by myocardial infarction or cardiomyopathy.

Long-term management requires that both excessive preload and afterload be modulated. Preload is lessened by limiting intravascular volume through the use of dietary sodium restriction and diuretics, and by venodilation with drugs such as nitrates. Afterload is reduced through the administration of vasodilators. Cardiac contractility is augmented by digoxin. Angiotensin-converting enzyme inhibitors are another common therapeutic drug for failure. Finally, physiologic demands on the heart are controlled by advising the patient to get adequate rest and avoid strenuous exercise.

A failing heart produces many signs and symptoms that vary according to the severity of the decompensation. Dilation of the heart as it tries to compensate can be detected on a posteroanterior chest radiograph. The chest film will also show increased pulmonary vascular markings that occur as pressure forces fluid into interstitial spaces and alveoli, producing pulmonary edema. The signs of rales and decreased breath sounds in dependent portions of the lungs, and symptoms such

as dyspnea at rest or on exertion, paroxysmal nocturnal dyspnea, and orthopnea commonly occur. Failure of the heart to propel blood out of the systemic venous system can produce increased interstitial fluid in the lower legs which is revealed as pitting edema of the feet, ankles, and even shins, increased central venous pressure giving jugular venous distention, and portal hypertension causing hepatomegaly.

When surgery is contemplated for a patient with a history of congestive heart failure, preoperative steps should be taken to optimize the patient's physical status. The patient should be questioned about the amount of exertion necessary to produce dyspnea and about how many pillows are necessary while sleeping to prevent orthopnea, in order to quantitate the severity of the cardiac disability. Nocturnal cough and restlessness and easy fatigability can be early symptoms of problems. Signs of congestive failure include jugular venous distention, presence of a third heart sound (gallop rhythm), pulsus alternans, basilar rales, and pitting edema. A chest radiograph and ECG should be used to measure heart size, to visualize the lung fields, and to help detect AF. If poorly compensated failure is detected, the risk of postoperative pulmonary edema is raised by 25%.³¹

Patients prone to failure can be improved by increased attention to sodium and water restriction and to their compliance with medications such as diuretics, digoxin, and preload and afterload reducers. Potassium levels should be normalized. Mild preoperative hypokalemia can be managed by oral replacement therapy or intravenous administration at a rate of up to 10 mEq/h in concentrations up to 30 mEq/L. Patients taking digoxin should have serum levels measured. Signs and symptoms of digoxin toxicity such as nausea, diarrhea, anorexia, and new dysrhythmias should prompt postponement of surgery until levels are normalized. Consideration should be given to placement of a central venous line for monitoring peri-

operative central venous pressure or for placing a Swan-Ganz catheter. An indwelling arterial line can also be useful for monitoring mean arterial pressure and for obtaining samples for blood gas analysis. After intubation the patient's lung compliance should be monitored closely, because decreased compliance is an early sign of pulmonary edema. Mini-dose heparin and elastic stockings can be used postoperatively to decrease the likelihood of deep vein thrombosis and pulmonary embolization. Passive leg exercises and early ambulation postoperatively also help prevent these problems. An early postoperative chest radiograph can reveal early signs of pulmonary edema, as does an elevation of pulmonary capillary wedge pressures. During recovery the patient's physical activity and emotional stress should be kept low to reduce unnecessary demands on the heart.

Cardiac Dysrhythmias

Patients with diagnosed or occult cardiac rhythm disturbances present a management challenge to the surgeon and anesthesiologist in the perioperative period. Dysrhythmias can compromise cardiac output leading to myocardial ischemia, cerebral ischemia, congestive failure, or shock. In addition, dysrhythmias can predispose towards the formation of intracardiac thrombi and subsequent systemic embolization.

Patients with significant dysrhythmias may or may not have symptoms. The tendency of dysrhythmias to compromise cardiac function frequently depends on overall cardiac health. For example, an otherwise healthy individual can easily tolerate heart rates at the extremes of the range of 40 to 180, whereas someone with a diseased heart would be less tolerant.

Anesthesia and surgery are capable of unmasking a tendency toward dysrhythmias through vagal stimulation, stress-related release of catecholamines, drug-induced histamine release, dysrhythmogenic drugs such

as inhalational anesthetics, and hypoxia due to inadequate ventilation. Statistically, perioperative dysrhythmias, particularly during intubation, are most common in patients with preexisting dysrhythmias or heart disease, or who are on digoxin medication or undergo surgery and anesthesia for longer than 3 hours. In addition, surgery near the carotid sinus can cause atrioventricular conduction disturbances due to the stimulation of intercostal nerves.

The presence of significant cardiac dysrhythmias can often be detected based on symptoms reported during a medical history, such as intermittent palpitations, unexplained syncopal episodes, and transient ischemic attacks. Determination of pulse rate and rhythm should be obtained during the physical examination. An ECG should be obtained in all patients with either suspected or diagnosed dysrhythmias.

Atrial Dysrhythmias The most common dysrhythmia is sinus tachycardia with a heart rate of 100 to 180. Such an elevated rate compromises cardiac output by lessening diastolic filling time and increasing myocardial oxygen consumption. Sinus tachycardia can have many etiologies including fever, hypovolemia, anemia, hypoxia, drug use, and hyperthyroidism. Therapy is directed at the underlying cause.³²

Paroxysmal Atrial Tachycardia Paroxysmal atrial tachycardia (PAT) is a frequent dysrhythmia with an atrial rate of 140 to 240 and a lower ventricular response rate. PAT can be due to digoxin toxicity or myocardial ischemia, but is usually due to reentrant pathways between the atria and ventricles.

The rhythm is unstable, reverting back to sinus in almost all cases. Risk of surgical procedures is not elevated with a history of PAT; however, if there have been frequent or recent episodes of PAT, a β -blocker may help prevent tachycardia. Ablation of reentrant pathways via electrophysiology procedures is the treatment of choice and is usually curative.³³

Atrial Flutter Atrial flutter (rate 250–300) commonly appears with a 2:1 block producing a ventricular rate of 125 to 150. Patients in atrial flutter who undergo surgery have a 50% mortality rate. It is therefore incumbent on the surgeon to identify and seek correction of this dysrhythmia preoperatively, with direct-current low-energy (25 to 50 watt-seconds) cardioversion.

Atrial Fibrillation Atrial fibrillation is the second most common cardiac dysrhythmia. It is commonly asymptomatic but characteristically produces an irregularly irregular pulse rhythm and a fibrillation pattern on ECG. The atrial rate is greater than 350, whereas the ventricular rate varies from 140 to 180 bpm. Etiologies include any cause of left atrial hypertrophy, thyrotoxicosis, and coronary artery disease, and may result from the excessive use of caffeine, cocaine, ethanol, diet pills, or nicotine, even in healthy hearts.

The physiologic compromise produced by AF depends on the ventricular response, myocardial health, and duration of the dysrhythmia. A rapid ventricular response increases perioperative mortality by about 15%. Congestive heart failure or myocardial ischemia can appear abruptly in susceptible patients going into AF. Long-standing AF can allow the formation of an atrial thrombus and subsequent thromboembolic complications.

Preoperative management of patients with a history of AF should include consideration of digitalization that by itself may convert AF to a normal sinus rhythm. Intravenous verapamil can also be used but is less successful in converting AF. Both digoxin and calcium channel antagonists decrease chronotropy, thus helping to slow the ventricular response rate to more physiologic levels. Amiodarone has been shown to have prophylactic value.³⁴ Care should be taken to not allow the ventricular rate to fall below 70. Acute onset of AF is most effectively managed with direct current cardioversion starting at about

200 watt-seconds. Patients with chronic AF should be on anticoagulants, which must be adjusted perioperatively.

Premature Ventricular Contractions Premature ventricular contractions (PVCs) can be due to many causes including fever, hypoxia, drugs (including digoxin, aminophylline, and inhalational anesthetics), pulmonary artery catheters, electrolyte disturbances, and myocardial ischemia, or they may be idiopathic. The significance of PVC activity, including more complex ectopic ventricular disturbances such as nonsustained ventricular tachycardia, is controversial. Long-term mortality is not reduced in PVC patients without apparent heart disease, but PVCs postmyocardial infarction or with cardiomyopathy do carry increased risk. This is more a function of underlying cardiomyopathy rather than the dysrhythmia itself.

The discovery of significant PVC activity on a preoperative ECG warrants a complete cardiac evaluation, and identified causes of PVCs should be corrected preoperatively. Development of PVCs or runs of ventricular tachycardia during surgery may signal cardiac ischemia or electrolyte abnormalities, which should be investigated and corrected.^{35,36} The cause of PVCs should be sought and corrected, but note that lidocaine is no longer used to suppress ectopic activity.

Ventricular Tachycardia The appearance of three or more PVCs in a row is defined as ventricular tachycardia. It has a variety of etiologies including hypoxia, acidosis, myocardial ischemia, digoxin toxicity, hyper- or hypokalemia, and hypercalcemia. Prompt therapy consists of intravenous lidocaine or low-energy direct-current cardioversion.^{37,38}

Heart Blocks Atrioventricular blocks take several forms. A P–R interval greater than 20 ms constitutes a first degree atrioventricular block and is of little significance perioperatively in the absence of

other cardiac abnormalities. In second degree block, some atrial impulses are not conducted into the ventricles. The Mobitz type I (Wenckebach) second degree block has a P–R interval that progressively lengthens until a nonconducted P wave occurs and the cycle begins again. Mobitz type I rhythms are usually due to digoxin excess, myocardial ischemia, or degeneration of cardiac conduction tissue. Treatment with atropine is necessary only for excessively slow ventricular rates. Mobitz type II second degree blocks have a constant P–R interval but frequent P waves without a ventricular response. This is a worrisome dysrhythmia and perioperative ventricular pacing should be considered.³⁹

Third degree atrioventricular blocks imply a complete block of atrial impulses into the ventricle. The ventricles therefore beat at their low intrinsic rate of about 45. Therapy usually requires the use of a pacemaker.

Bundle branch blocks present no direct contraindication to anesthesia and surgery but usually signal some underlying cardiac disease. Pacing for bundle branch blocks is necessary only if symptomatic bradycardia or complete heart block occurs.

Patients who have permanent cardiac pacemakers pose little increased risk during surgery over and above the underlying cardiac problem. If electrocautery is necessary special care should be taken to ensure that it is properly grounded. A magnet to convert a demand pacemaker to the fixed rate mode should be available in the operating suite.

Surgery in the Patient with Respiratory Problems

General Assessment of Airway and Lungs

Maxillofacial surgery itself has minimal effect on pulmonary function compared with general thoracic or abdominal surgery, except when tissue is being transferred from the thorax to the maxillofacial

region. However, maxillofacial surgery does sometimes involve prolonged general anesthesia, and procedures can compromise the upper airways. Therefore, it is important to discover and treat airway and lung abnormalities preoperatively or, when not possible, make necessary compensations in surgical and anesthetic plans.

The medical history should ascertain the following about the status of the ventilatory system: the presence of symptoms such as wheezing, productive cough, and low exercise tolerance; the use of pulmonary medications; cigarette smoking; prior thoracic surgery or trauma; and previously diagnosed pulmonary diseases including asthma, pneumonia, chronic obstructive pulmonary disease (COPD), or tuberculosis. In physical examination, points of significance to the assessment of the respiratory system include a careful inspection of the nasal airways, auscultation of lung fields for abnormal sounds, inspection of mucosa and nail beds for signs of cyanosis or clubbing, and measurement of the respiratory rate.^{40,41}

A plain chest radiograph is useful for detecting diffuse or localized parenchymal disease, pulmonary edema, hyperinflation, and consolidations such as pneumonia or neoplasms. However, the yield from routine preoperative chest radiographs is low in patients without a history or examination suggestive of pulmonary disease.

Some pulmonary function testing can be performed at bedside, such as the breath-holding test. The breath-holding test involves having a patient make a maximum inspiration and then hold the breath for as long as possible. Inability to hold one's breath for at least 15 seconds is indicative of significant pulmonary problems. Spirometry is another useful bedside test for assessing pulmonary function although a delay in surgery is usually unwarranted. Surgeons should request formal pulmonary function testing (PFT) for all patients in whom lung disease is suspected. PFTs help gauge respiratory

reserve and measure the potential response to measures taken to improve lung function.^{42,43}

Measurement of arterial blood gases (ABGs) is frequently a part of pulmonary function testing. ABG determination serves both as a baseline for intra- and postoperative measurements, and helps assess the status of pulmonary gas exchange. A low partial pressure of oxygen (PaO₂) may be due to hypoventilation, diffusion impairment, shunting, or a ventilation-perfusion inequality, the last being the most common cause. An elevated partial pressure of carbon dioxide (PaCO₂) is a sign of hypoventilation either due to an inadequate respiratory rate or depth, or to a ventilation-perfusion inequality. Intraoperative capnography and intra- and postoperative oximetry have reduced the need for frequent ABG sampling. Oximetry is also beneficial during the first few hours after maxillofacial surgery, when respiratory insufficiency is most likely to occur.⁴⁴

Asthma

Asthma is characterized by episodes of wheezing, cough, and production of mucous plugs. It is more common in children, although some adults will have new or relapsed asthma later in life. Chronic uncontrolled asthma can lead to COPD, and asthma complicated by cigarette smoking can lead to COPD as well. Questions regarding history of asthma, frequent or nocturnal coughing, shortness of breath, dyspnea on exertion, and production of mucous plugs are helpful in diagnosing asthma. Physical examination may show wheezing, particularly with forced expiration.^{45,46}

Well-controlled asthma does not pose a significant perioperative risk. Patients with well-controlled asthma should have a dose of albuterol by inhaler or nebulization prior to general anesthesia to prevent intraoperative bronchospasm or laryngospasm.^{47,48}

The patient with a recent history of problematic asthma is at significant risk

when having general anesthesia and surgery. The bronchospasm that characterizes asthma can develop precipitously and compromise ventilation, even with positive pressure, and may be difficult to reverse in time to prevent complications. As with most conditions of this nature, recognition and prevention are the best management strategies.

The airway narrowing in asthma is due to smooth muscle contraction, edema in airway walls, or mucous plugging of airways. Whereas bronchospasm is rapidly reversible with muscle relaxants, edema and plugging are not.

The likelihood of an asthmatic episode occurring during surgery can be judged by a few pieces of historic information. The frequency, severity, duration, and response to therapy of recent asthma attacks will help gauge how well an individual's asthma is controlled and therefore the safety of proceeding with surgical plans.

When questioning a patient with asthma, key factors are the frequency and nature of attacks, current medication use, last use of steroids, and an indication of the severity of asthma. A history of multiple emergency room visits for asthma, hospitalization for asthma, history of mechanical ventilation for asthma, and steroid dependency are indicators of severe asthma (Table 2-5).

For many years aminophylline-like treatment was the mainstay of asthma and COPD treatment. Several medications have replaced aminophylline and theophylline treatment. For acute treatment albuterol by inhaler or nebulized administration is used. The usual dose is 1 to 2 actuations of a metered-dose inhaler or a nebulization treatment every 4 to 6 hours as needed, although hospitalized patients may receive dosing more frequently. In addition, oral or parenteral steroid treatment is used more liberally than in past years. Patients who are wheezing and are to undergo surgical treatment are usually given steroids to reduce wheezing and the

chance of anesthesia-induced laryngospasm and bronchospasm. Steroids are then rapidly tapered and discontinued over 3 to 7 days postoperatively.⁴⁹

Maintenance therapy in asthma has also broadened to include inhaled steroids, long-acting β -agonists, antileukotriene drugs, and theophylline.⁵⁰⁻⁵² Inhaled steroids using metered-dose inhalers or dry-powder inhalation devices are given on a regular dosing schedule and are not absorbed, preventing systemic complications of steroid use.

Prolonged corticosteroid use carries its own risks as is discussed later in this chapter. The surgeon should confer with the physician managing a patient's asthma to ensure that the patient has recently been evaluated and that the steroid regimen provides the least amount of drug that is still effective. If possible the patient may benefit from a switch to inhaled corticosteroid use through metered-dose inhalers that may help minimize systemic effects.

Intra- and postoperatively asthmatic patients should be monitored for the appearance of increased airway resistance, wheezing, pulsus paradoxus, tachycardia, fever, hypoxemia, hypercapnia, and acidosis. Atelectasis is common in asthmatics and causes an increased risk of bacterial pneumonia, which is why thorough pulmonary examinations must be given at frequent intervals during recovery.⁴⁹

Chronic Obstructive Pulmonary Disease

Chronic obstructive pulmonary disease (COPD) is an all-encompassing term for lung diseases characterized by loss of lung tissue and its surface area. It includes chronic bronchitis, emphysema, and other conditions, but these distinctions are rather vague and do not result in differing management. Alveolar loss from destruction in COPD results in less surface area to exchange gases and in lower smooth muscle tone of the bronchioles. Emphysematous blebs may replace normal lung tissue. Mid-

dle- and large-sized bronchi have lost their cilia and muscle tone, and exude excess mucus, causing pooling of secretions and reduced clearance of dust, smoke, and bacteria. Symptoms and signs of COPD include chronic cough, sputum production, shortness of breath, decreased exercise tolerance, wheezing, and increased anteroposterior thoracic diameter. Patients with advanced disease may purse their lips to increase intrathoracic pressure during exhalation, thus holding open airways that would otherwise close prematurely.⁵³

A chest radiograph may show hyperlucency, kyphosis, and depressed and flattened diaphragms. Pulmonary function tests show a reduced forced expiratory volume in the first second of exhalation (FEV₁) and a reduced forced vital capacity/FEV₁ ratio. FEV₁ is compared to age, gender, and racial norms, and an FEV₁ of less than 80% of predicted normal is abnormal, with readings of less than 60 indicating severe obstructive disease. Arterial blood gases may show a loss of oxygenation and elevated carbon dioxide, due to reduced gas exchange and an alteration in the usual respiratory drive. As the term implies, bronchospasm in COPD may be less responsive to bronchodilators than in asthma.

Surgery and anesthesia for patients with significant COPD usually brings few intraoperative risks due to the lung disease itself. However, the likelihood of postoperative pulmonary complications is high in COPD patients. Therefore, proper preoperative identification and preparation are important.

Preparing COPD patients for surgery usually involves reversing pathology able to be altered medically. Hydration to

Table 2-5 Questions for Asthma Patients

Frequency and nature of attacks
Use of oral steroids
Emergency room visits
Hospitalization
Mechanical ventilation

mobilize mucus secretions, inhaled β -agonists by metered-dose inhaler or nebulization, and inhaled ipratropium are used to optimize preoperative therapy. Oral or parenteral steroids are used if wheezing is detected prior to surgery.

Production of mucopurulent sputum may indicate the need for preoperative antibiotics to help improve COPD symptoms. Ampicillin, trimethoprim/sulfa combinations, or erythromycin are used most commonly and are given in 7- to 10-day courses.⁵⁴

Cigarette smoking is the most common cause of COPD and further exacerbates symptoms if continued after irreversible lung pathology occurs. Reversible problems that smoking causes include the release of nicotine, production of carbon monoxide, mucus hypersecretion, impaired ciliary function, and impaired local lung immunity. Preoperative cessation of smoking for 24 hours allows a significant decline in plasma carboxyhemoglobin and nicotine levels, but the rate of pulmonary complications due to smoking takes weeks to fall after smoking is stopped. In the case of coronary artery bypass grafting, the percentage of postoperative pulmonary complications in former smokers does not begin to approach the rate seen in nonsmokers until after at least 8 weeks of abstinence from smoking.⁵⁵

Other preoperative measures that can prevent postoperative problems in patients with COPD include good nutrition and correction of hypokalemia to improve respiratory muscle strength and familiarization of the patient with incentive spirometry. Preoperative teaching in the use of incentive spirometry, cough/deep breathing exercises, and early ambulation help the patient prepare for recovery before the pain and recovery period from anesthesia occur.

There are several anesthetic considerations for patients with COPD. Volatile anesthetics provide bronchodilatory effects and thus are useful. Nitrous oxide, on the other hand, may cause problems due to its accumulation in bullae potenti-

ating rupture and production of pneumothorax. The respiratory depressive effects of narcotics makes their use in COPD patients hazardous, especially if it is likely that their effects will outlast the duration of needed anesthesia.

The techniques of controlled ventilation must be altered in patients with obstructive airway disease. Ventilatory rates need to be slow enough (typically 6 to 10 per minute) to allow sufficient exhalation time and to compensate for slower diffusion of gases across membranes. Care should be taken to avoid high pressures to lessen the potential of ruptured bullae. Generally COPD patients do best with large tidal volumes at slow rates and do not need positive end-expiratory pressure.⁵⁶

Surgery in the Patient with Renal and Urinary Tract Disease

The kidneys play several roles in helping maintain physiologic normalcy; they are therefore important for continuing or regaining homeostasis during and after surgery and anesthesia. The renal system is necessary to support the processes of fluid, electrolyte, and acid-base balance, drug metabolism and elimination, blood pressure control through the renin-angiotensin system, red blood cell production through erythropoietin production, and vitamin D hydroxylation.

There are several diseases that can affect one or more aspects of kidney function. However, for the maxillofacial surgeon a better gauge of the degree to which the patient's ability to tolerate anesthesia and surgery is compromised is the adequacy of renal function. The glomerular filtration rate (GFR), normally 100 to 125 mL/min per 1.73 m² of body surface area in an adult, is the single most useful measure of renal health. The GFR is measured clinically by determining the clearance of endogenous creatinine. The body's serum creatinine (SC) load is highly dependent on muscle mass, and the clearance of creatinine from the serum depends on the number of func-

tioning glomeruli, a number that gradually decreases with age. Also, SC varies inversely with creatinine clearance (CCR). Thus, an estimation of the CCR in males involves obtaining the level of SC and then multiplying its reciprocal by factors that are correct for muscle mass and age.

$$\text{CCR} = \frac{(140 - \text{Age in yr}) (\text{Weight in kg})}{(\text{SC}) (72 \text{ kg})}$$

For females, the above result is multiplied by 0.85. Although much less accurate, measurement of SC (normal is < 1.5 mg/dL) can be used to help gauge renal function. Although measurement of blood urea nitrogen is used commonly to test renal health, it is a crude measure and may be misleading, especially in patients with poor nutrition or who have been bleeding into the intestinal tract.

Serum electrolyte abnormalities can signal significant renal disease. Poor renal function will often result in decreased secretion of potassium causing hyperkalemia or a concentrating defect leading to urinary sodium wasting and hydrogen ion retention with resultant hyperchloremic metabolic acidosis. Other indications of renal problems include proteinuria, pyuria, and hematuria, all detectable on routine urinalysis.

Chronic Renal Insufficiency

The risks of anesthesia and surgery in the patient with known renal insufficiency vary according to the severity of renal compromise. Patients with mild to moderate renal insufficiency (GFR of 25–50 mL/min) usually tolerate the perioperative period well if properly managed. When renal function is severely impaired (GFR of 10–25 mL/min) or frank failure is present (GFR < 10 mL/min), complications of renal origin are much more likely. Patients with severe renal insufficiency have a 60% increase in perioperative morbidity and a 2 to 4% increased mortality compared to healthy patients.⁵⁷

Extrarenal problems can be produced by renal insufficiency. Normochromic or

normocytic anemia frequently occurs due to several factors, including decreased erythropoietin, decreased red cell survival time, and bone marrow depression. In addition, uremia can also cause decreased platelet aggregating ability and depressed platelet factor 3 release.⁵⁸

Pericardial inflammation or effusion is commonly associated with chronic uremia or hemodialysis, as is myocardial dysfunction. End-stage renal disease is almost always complicated by systemic hypertension. Patients with renal insufficiency have impairment of their immune systems with heightened susceptibility to bacterial, viral, and fungal infections. The cause seems to be faulty neutrophil and lymphocyte production and function. Many of the other problems caused by renal dysfunction affect the gastrointestinal tract. Symptoms of nausea, vomiting, diarrhea, and anorexia frequently accompany uremia. Acute stomatitis and salivary adenitis can occur, as can pancreatitis. The stomach and intestine linings may undergo inflammatory changes. Hepatitis C is present in about 19% of dialysis patients.⁵⁹

Excessive water retention is most easily managed by fluid restriction, which usually helps improve the hypo-osmolar state, and sodium and hydrogen ion balance. Hyperkalemia before elective surgery can be managed with dietary potassium restriction and potassium-wasting diuretics. More acute potassium control may necessitate the use of cation-exchange resins, strategies to drive potassium intracellularly, or dialysis. Hypertension and fluid retention may necessitate diuretic use preoperatively. In cases of renal failure, hemodialysis is recommended to reverse fluid, electrolyte, and acid-base problems, as well as extrarenal disorders such as uremic immunodepression. Dialysis should be performed no more than 24 hours preoperatively. Platelet counts are helpful to identify heparin-induced thrombocytopenia.⁶⁰ The lower heparin requirements in newer dialysis techniques prevent many of

the residual anticoagulation problems of the past. However, surgeons should remember the capability of heparin to induce thrombocytopenia. Preoperative chest radiographs and an ECG can be used to detect myocardial dysfunction or pericardial problems due to uremia or chronic fluid overload. Plans should include the use of prophylactic antibiotics even for minimally invasive procedures.⁶¹⁻⁶³

Intraoperative management of the patient with severe renal insufficiency should include careful cardiac monitoring for dysrhythmias and fluid overload. Intravenous fluids should be administered in quantities only sufficient to replace insensible fluid and blood losses, and be free of potassium. If a hemodialysis vascular access (shunt) is in place, it should be protected from trauma. Intraoperative hemostasis should be especially meticulous if the patient will be dialyzed immediately after surgery.^{64,65}

After surgery, steps should be taken to maintain proper fluid and electrolyte balance, particularly until dialysis can be done. Most surgeons delay postoperative hemodialysis for at least 2 to 3 days to lessen the chance of wound bleeding during heparinization. However, patients with oral or nasal procedures commonly swallow a significant amount of blood, which increases the blood's nitrogen load and may prompt earlier dialysis than would otherwise be necessary. Extended nasogastric suctioning may help prevent blood swallowing when the likelihood of swallowing large amounts is high.

A significant problem that the anesthesiologist and surgeon face when managing a patient with renal insufficiency is drug elimination and the toxic effects of some drugs on the kidney. Drugs commonly used during maxillofacial surgery that need to be avoided or used with care in the patient with renal compromise include cephalosporins, penicillin, and sulfa antibiotics, nonsteroidal anti-inflammatory drugs, nondepolarizing muscle relaxants,

and enflurane. Many references are available that list drugs and dosing modifications needed in renal failure patients.

Hypertension

Essential hypertension is one of the most common disorders of adults, so it is not surprising that a large percentage of adult patients who require surgery have hypertension. With more people aware of the hazards of untreated hypertension, many patients seeking the type of care offered by specialty surgeons have had their hypertensive status evaluated and a management regimen prescribed.

Two basic problems can arise in the hypertensive patient requiring anesthesia and surgery. The first is that untreated chronic hypertension can damage many organ systems, particularly the heart, kidneys, and brain. The damaged organs may be less able to tolerate demands placed on them during the perioperative period. The second problem is that for many hypertensive patients, the medications prescribed for controlling hypertension may dull some of the natural responses the body uses to counteract anesthetic and surgical challenges.⁶⁶

Statistically there is no increase in the incidence of adverse effects from untreated hypertension as long as the diastolic pressure is less than 110 mm Hg and no concurrent medical problems exist. When conferring with a patient the surgeon can usually gain an idea of the likelihood of hypertensive organ damage by attempting to learn of the patient's compliance with antihypertensive regimens. The patient's physician can often supply this information. Target organ damage can also be detected by various physical and laboratory examinations. Cardiac damage usually manifests initially with left ventricular hypertrophy (LVH). This causes a prolonged and displaced point of maximal impact of the heart apex on palpation. In addition LVH shows on ECG, chest radiographs, and echocardiograms. With time,

signs and symptoms of congestive heart failure arise predisposing the heart to dysrhythmias, ischemia, and the appearance of pulmonary edema.^{67,68}

The renal damage caused by chronic high blood pressure usually consists of nephrosclerosis. This may be detectable by routine urinalysis, on which proteinuria, hematuria, or pyuria is seen. Renal damage may also cause serum creatinine levels to rise.

Cerebral damage due to hypertension usually manifests later in life with an increased incidence of stroke. In addition the cerebral vascular system's ability to autoregulate is impaired so that a greater perfusion pressure must be maintained than would otherwise be necessary. Some clinicians also believe chronic hypertension promotes the progress of carotid atherosclerosis and therefore recommend that the surgeon auscultate for carotid bruits.

Many of the vascular changes that occur because of chronic hypertension can easily be seen in the one site where the small vessels are visible; that is, the fundus of the eye. Hemorrhages and exudates seen on fundoscopic examination typically indicate similar changes in other vascular beds.⁶⁹

There is a variety of treatment options available for hypertensive patients, including diuretics, ACE inhibitors, angiotensin receptor blockers (ARBs), β -blockers, calcium channel blockers, selective α_1 -blockers, and central α -blockers. The surgeon should be familiar with these drugs and their side effects and risks in surgery.⁷⁰⁻⁷²

Diuretics can cause hypokalemia and hyponatremia, necessitating screening of electrolytes prior to surgery. ACE inhibitors and, less likely, ARBs can cause hyperkalemia and decreased renal perfusion. β -Blockers reduce heart rate and contractility, although beneficial effects of decreased myocardial demand and preservation of normal sinus rhythm generally outweigh perioperative risks of use. Calci-

um channel blockers may cause bradycardia but are usually well tolerated. Selective α -blockers may cause first-dose hypotension, but are also usually well tolerated. Central α -blockers may cause drowsiness, depression, and dry mouth.^{73,74}

For the patient with poorly controlled hypertension (systolic pressure over 200 mm Hg, diastolic pressure over 110 mm Hg), the surgeon should defer elective surgery until better control is obtained and any end-organ damage is detected; appropriate compensations should be made in the treatment plan. Acute treatment of hypertension can include clonidine given in 0.1 mg increments, or intravenous antihypertensives such as enalaprilat, labetalol, or nicardipine infusion. Sublingual nifedipine should not be used.

Patients whose blood pressure is well controlled preoperatively usually exhibit large swings in their blood pressure during and after surgery. Hypotension usually responds to fluid administration. Hypertension can usually be tolerated if it does not reach severe levels. Excessive increases in blood pressure can be managed with short courses of additional antihypertensive medications until anesthetic drugs or surgery-related stresses have stopped, allowing patients to return to their preoperative status.⁷⁵

Surgery in the Patient with Endocrine Disorders

Diabetes Mellitus

The impact of diabetes mellitus on the anesthetic and surgical management of a patient is highly dependent on the type, severity, and degree of control of the diabetes. Type 1 (insulin-dependent) diabetes mellitus is due to impaired production by or an insufficient mass of pancreatic islet β -cells. Type 2 (non-insulin-dependent) diabetes mellitus occurs due to an altered number and affinity of peripheral insulin receptors. Total insulin production may also be depressed but might be elevated.⁷⁶

The usual daily production of insulin by a lean adult is 33 U; approximately 3 to 5 U are needed for each meal while the basal insulin requirement is about 1 U/h. The ketosis-prone diabetic patient produces less than 10% of the average daily insulin requirement, but the typical type 2 diabetic patient produces an average of 15 U/24 h.

Type 1 diabetes presents the more significant challenge to the well-being of a surgical patient. Patients are usually lean and have had this disease since their youth. Those with long-standing type 1 diabetes cannot go without their insulin for more than 48 hours without diabetic ketoacidosis (DKA) occurring. Hormones that increase during periods of physiologic stress, including cortisol, catecholamines, and glucagon, act to counter the effects of insulin, producing a stress-induced glucose intolerance, even in many healthy nondiabetic patients. This is why type 1 patients who depend on exogenous administration of their insulin commonly have increased insulin requirements from preoperative emotional stress, intraoperative anesthetic stress, and postoperative wound, physiologic, and emotional stress. Studies have shown that elevated blood glucose not only impairs wound healing, but can also depress leukocyte and pancreatic β -cell function. These are reasons, in addition to prevention of DKA, for appropriate insulin supplementation during and after surgery.^{43,77}

Type 1 patients, in contrast to type 2 diabetics, have a high rate of systemic problems. Peripheral neuropathies are common, predisposing these individuals to chronic lower leg and foot lesions, which should be detected and noted preoperatively and prevented perioperatively. Long-standing diabetics are also at increased risk for coronary artery disease and may suffer silent (painless) ischemic episodes due to myocardial neuropathy.⁷⁸ Insulin-dependent diabetics, particularly those with poor control, handle infections poorly. Therefore, vigilance should be

especially high for breaks in aseptic techniques and consideration given to the use of prophylactic antibiotics. Type 1 patients also have enhanced platelet stickiness that may promote unwanted clotting in surgical flaps. The formation of glycosylated hemoglobin A_{1C} interferes with oxygen release into tissues.⁷⁹

A rational approach to management of diabetes assists in maintaining glycemic control perioperatively. Care should be given to avoid hypoglycemia at any time during surgery, and to prevent severe hyperglycemia as well. The general range of adequate control is between 120 and 200 mg/dL. This would involve decreasing the usual morning insulin by one-half to allow plasma glucose to rise during the surgery, but providing enough basal insulin to prevent DKA.^{80,81}

If a patient is to have relatively short-duration ambulatory surgery and is required to consume nothing by mouth the morning of surgery, only half the usual morning dose of insulin should be given at the time when intravenous access is gained. Surgery should be early in the morning and intravenous glucose should be given intraoperatively. During surgery the clinician should watch for signs of hypoglycemia such as tachycardia and diaphoresis. The patient should then be encouraged to consume some calorie source by mouth within 3 hours after surgery is completed. Portable glucose monitoring is useful for intra- and postoperative serum glucose monitoring.⁸²

Patients requiring more major surgery and longer duration general anesthesia are usually best managed in a setting in which an anesthesiologist can monitor blood glucose levels in the operating room and administer insulin on an as-needed basis. The morning insulin should be withheld until intravenous glucose is available; then one-half to three-quarters of the usual dose can be administered and supplemented intraoperatively by the anesthesiologist.^{83,84}

When patients are unlikely to enterally receive their usual caloric supply postoperatively, their insulin should be given based on periodic (every 6 h) plasma glucose sampling. Insulin doses should be gauged to keep the plasma glucose at 150 to 250 mg/dL until normal dietary habits and activity levels return. The patient's primary care physician can help guide dietary decisions.

Type 2 patients usually have fewer systemic abnormalities due to diabetes and are less likely to suffer perioperative complications. But when major surgery and general anesthesia are performed, these patients usually become hyperglycemic. Not uncommonly patients who are well managed on diet and oral hypoglycemics will need temporary insulin supplementation in the intra- and postoperative periods. As in type 1 patients, blood glucose should be kept at 150 to 250 mg/dL, with insulin supplementation based on periodic sampling.⁸⁵

Thyroid Disorders

The need for normal levels of thyroid hormones to maintain the function of many of the body's physiologic functions makes proper thyroid gland function important to the surgeon. The gland is composed of follicles, each of which is a lumen filled with thyroglobulin, which is produced by a single layer of epithelial cells lining the follicle. Thyroid hormones, thyroxine (T₃) and triiodothyronine (T₄), are produced and stored in the gland in a ratio of 10 to 15:1 (T₃:T₄) and are released on stimulation by thyroid-stimulating hormone, an anterior pituitary hormone. Between the follicles parafollicular cells exist which secrete calcitonin, whose function is to help lower serum calcium by blocking its release from bone.

The majority of T₃ and T₄ released from the gland are bound to various carrier proteins. Most circulating T₃ is produced by conversion from T₄ in the liver and kidney. T₃ is much more potent than

T₄, but only the unbound form of either hormone is active, and in the case of T₃ an inactive form called reverse T₃ (rT₃) can be formed. In normal states 35% of T₄ is converted to T₃ and 40% to rT₃. However, in times of physical illness or emotional stress, or if certain drugs (such as corticosteroids) are used, a higher percentage of T₃ conversion to rT₃ can occur.

The most common laboratory tests of thyroid function are (1) measurements of total thyroid hormone (T) levels by radioimmunoassay (normal is 5,012 pg/dL), in which high values indicate hyperthyroidism and low values indicate hypothyroidism; and (2) T₃ resin uptake, in which unoccupied thyroid hormone binding sites on thyroid-binding globulin are measured. High values of T₃ resin uptake are associated with hypothyroidism, whereas low values are consistent with hyperthyroidism.⁸⁶

Hyperthyroidism Symptoms of hyperthyroidism include weight loss, palpitations, and restlessness. Exophthalmos occurs in more severe cases owing to increased amounts of retro-orbital fat. Once diagnosed, therapy usually begins with antithyroid drugs such as propylthiouracil or methimazole. β -adrenergic antagonists can be used to control symptoms until thyroid hormone levels decrease. Autoimmune thyrotoxicosis can be allowed time to resolve spontaneously, or treatment with radioactive iodine can ablate the gland. Total thyroidectomy is seldom indicated, except for adenomas or malignancy.^{87,88}

Surgery in the face of hyperthyroidism carries high risks of cardiac dysrhythmias or failure, and the potential for causing a thyroid crisis. Therefore, elective surgery should be deferred until thyroid hormone levels are properly managed. If emergency surgery is necessary on a patient with poorly controlled hyperthyroidism, β -sympathetic antagonists can be used to help control the effects of thyroid

hormones on the heart while intravenous sodium iodide (1 g) can be administered to help block hormone release from the thyroid gland. The β -antagonist should be continued postoperatively until the administered antithyroid drugs have taken effect. Palpation of the thyroid gland should be gentle in patients with known hyperthyroidism to avoid increasing hormone release, and infections should be aggressively managed because they too may precipitate a thyroid crisis.⁸⁹⁻⁹¹

Hypothyroidism The hypothyroid patient presents a lesser surgical and anesthetic risk when compared with the hyperthyroid patient. The insufficiency of thyroid hormones causes cardiac depression, respiratory depression with weakening of the muscles of respiration, hyponatremia, constipation, neurologic problems with memory loss and depression, and several other metabolic problems. Signs of hypothyroidism include weight gain, periorbital edema, bradycardia, slowed deep tendon reflexes, generalized muscle weakness, and hair loss.

The potential surgical problems in a patient with untreated hypothyroidism include intra- or postoperative heart failure, hypotension, ileus, mental confusion, and delayed wound healing. Therefore, thyroid replacement therapy is advisable prior to elective surgery. In an emergency the surgeon must remain alert to potential problems due to the hypothyroidism and compensate for them if they occur.⁹²

Adrenal Gland Disorders

The adrenal gland, responsible for the production of a variety of hormones including cortisol, aldosterone, and androgens, plays a central role in regulating many metabolic processes. The gland usually comes to the attention of surgeons because of abnormalities in cortisol production. The average daily secretion of cortisol in the adult is 15 to 17 mg (range 8–28 mg). Secretion follows a diurnal pattern, peaking at about 3:00 or 4:00 am, and falling to

low levels at about 8:00 or 9:00 pm. Release of cortisol is regulated by adrenocorticotrophic hormone (ACTH) secreted by the pituitary, with ACTH release normally increased in time of physiologic stress. It is not unusual for plasma cortisol levels to remain elevated for up to 19 days after major surgery.

Excessive release of cortisol from the adrenal cortex (Cushing's disease) is rare. These patients show truncal obesity, hypertension, thin skin that heals poorly, and glucose intolerance. These problems can also be seen in patients on long-term therapeutic corticosteroids for problems such as inflammatory joint or bowel disease. Increased surgical risks faced by patients with hypercortisolism include delayed wound healing and a tendency for infections. Delay of elective surgery is warranted until excessive cortisol levels are under control. If surgery cannot wait, techniques designed to compensate for poor wound healing such as better vascularized flaps and the use of prophylactic antibiotics will be helpful.

Adrenal insufficiency is more commonly seen due to exogenous therapeutic steroid administration than to primary adrenal glandular disease. Exogenous corticosteroids will inhibit ACTH release. Current concepts of steroid supplementation for surgery hold that brief periods of steroid use, low-dose steroid use, and alternate-day steroid use do not suppress the hypothalamic-pituitary axis. Thus, if steroids have been used for less than 3 consecutive weeks within the past year, the dose of chronic steroids is 5 mg of prednisone or less, or if alternate-day steroid administration is used, no supplemental (stress-dose) steroids are needed.⁹³ Once adrenal suppression has occurred, a patient is at great risk for problems during major surgery due to their inability to mount a significant cortisol response to the stress. This may precipitate an adrenal crisis, signaled by the onset of lethargy, tachycardia, flank or abdominal pain,

vomiting, fever, restlessness, delirium, hypotension, or coma. Because mineralocorticoid production is not controlled by ACTH, its levels remain normal.

Prevention of problems remains the focus of management of patients prone to adrenal insufficiency. For those patients requiring higher doses of steroids, it is prudent to use stress-dose steroids perioperatively. A typical dose is hydrocortisone 100 mg intravenously on call to the operating room, followed by 50 mg every 8 hours for 48 hours postoperatively. The usual dose of oral steroids or its equivalent intravenous dose can then be resumed. Note that more minor procedures usually do not require steroid supplementation.^{94,95}

Surgery in the Patient with Hepatogastrointestinal Disorders

Liver Disease

Surgeons are well aware of the liver's vital roles in processing nutrients, synthesizing protein, and metabolizing drugs. Fortunately the liver has a tremendous reserve capacity for maintaining function in the face of even severe hepatic pathology.

Protein synthesis is one of the principal liver activities. Of proteins produced, the ones of particular concern to surgeons and anesthesiologists are albumin and several of the clotting factors. Hepatic production of albumin is in the range of 10 to 15 g daily. Albumin helps maintain the oncotic force necessary to restrict excessive loss of intravascular fluid into the interstitium. Albumin also has a large number of reactive sites and can therefore reversibly bind to most drugs. If albumin production slows sufficiently that serum levels fall below 2.5 g/dL, then edema, ascites, and an elevation in the free-to-bound ratio of administered drugs can result.

The vitamin K-dependent coagulation factors II, VII, IX, and X are made in the liver. A significant fall in their levels can be seen with either severe hepatocellular dis-

ease or with impaired vitamin K absorption due to biliary problems.

The liver is responsible for the proper function of several enzyme systems that help to limit drug actions. Plasma cholinesterase is produced by the liver; by breaking ester linkages it inactivates drugs such as succinylcholine and ester-type local anesthetics. The hepatic microsomal enzyme system converts lipid soluble drugs into more water soluble ones that can be excreted by the kidney. Agents such as some benzodiazepines, lidocaine, meperidine, morphine, and alfentanil depend on this system for elimination.

The most common insults to the liver that affect the performance of maxillofacial surgery are ethanol and infectious hepatitis. In the first case many liver functions can be compromised, whereas in the second case, not only is proper liver function jeopardized, the surgeon must also help prevent the spread of the infection to others.⁹⁶

Other important consequences of liver disease include impaired glycogen storage and gluconeogenesis; hypersplenism due to obstructed portal blood flow, causing thrombocytopenia; and poor handling of large gastrointestinal nitrogen loads such as swallowed blood, which alters the level of consciousness in patients with severe liver dysfunction.

Significant liver problems cause a large number of signs and symptoms so that detection is usually straightforward. Laboratory tests of liver function tend to be nonspecific indicators of tissue damage but are commonly used to evaluate patients with suspected liver disease. Serum aspartate transaminase levels rise because of damage to either liver, heart, kidney, or skeletal muscles. Changes in serum alanine aminotransferase (ALAT) levels, on the other hand, are more specific for hepatocellular disease. Lactate dehydrogenase is commonly measured but is another nonspecific indicator of tissue damage, although its isoenzyme-5 fraction is believed to be more specific for liver

damage. Elevations in serum alkaline phosphatase indicate obstructed bile ducts. Measurement of serum albumin helps gauge the severity of liver disease, with levels of less than 2.5 g/dL being significant; however, malnutrition can also cause hypoalbuminemia. Severe liver disease is indicated by a prolonged prothrombin time (PT) and a decreased platelet count. Suspicion of an infectious cause of hepatic disease mandates the use of immunologic tests for signals of viral disease. Hepatitis A, typically due to fecal contamination of food and water, is evidenced by hepatitis A antibodies. Acute hepatitis B, transmitted parenterally or venereally, will stimulate production of surface and core antigen antibodies; the chronic form is revealed by the presence of only surface antigen antibodies. Non-A, non-B hepatitis, caused by several different viruses and usually transmitted by infected blood products, causes elevated ALAT but no hepatitis A or B antibodies. Finally, hepatitis C (δ -agent), seen most commonly in illicit drug users and multiply transfused patients, causes the appearance of δ -agent antibodies and in its acute form coexists with hepatitis B.⁹⁷⁻⁹⁹

Maxillofacial surgery in the patient with mild to moderate liver disease usually presents few problems because of hepatic reserve. Borderline severe cases require special perioperative attention to prevent complications or a deterioration of liver function. Liver function tests, especially serum ALAT measurement, are useful. A PT and platelet count are necessary to detect a potential coagulopathy. Intravenous vitamin K (5 to 10 mg over 3 to 5 min) can be administered if a deficiency is suspected and will shorten an abnormal PT in 4 to 12 hours. Fresh frozen plasma can be used temporarily to make up for a vitamin K deficiency until the parenterally administered vitamin is effective.

Because patients with severe liver disease have problems with improper gluconeogenesis, the surgeon should closely

monitor serum glucose levels. Patients likely to handle nitrogen poorly, particularly those with a history of hepatic encephalopathy, should be placed on dietary protein restriction. If it is likely that blood will be swallowed, the patient may need measures to reduce nitrogen absorption in the intestines, such as administration of nonabsorbable antibiotics or the use of a cathartic such as lactulose; consciousness should be closely monitored.

Drugs used for anesthesia and analgesia may need to be modified in the patient with hepatic disease. Drugs to avoid in patients with severe liver disease include all nonsteroidal anti-inflammatory drugs, tetracyclines, pentazocine, and atenolol. Drugs for which dosages need to be reduced include diazepam, chlordiazepoxide, meperidine, morphine, propoxyphene, theophylline, lidocaine, verapamil, and most β -sympathetic antagonists. Most anesthetics are generally safe to use in patients with hepatic disease, although some feel halothane, fentanyl, and nitrous oxide should be avoided because of their potential for causing liver toxicity.

Peptic Ulcer Disease

Peptic ulcers and gastritis are two of the most common afflictions of adults, but they are usually easily controlled with H₂ receptor antagonists, which reduce acid secretion, or sucralfate that forms a protective coat over lesions shielding them from the effects of pepsin and acid. Although many patients still use antacids, side effects such as diarrhea (in magnesium-based antacids), constipation (in aluminum-based antacids), and sodium overload make them less desirable.

Signs of active gastrointestinal bleeding include unexplained anemia and a guaiac-positive stools, but the process is usually diagnosed based on the presence of epigastric pain temporarily relieved by food or antacids. Endoscopy is used to confirm clinical suspicions.

Before maxillofacial surgery can be performed in patients with a history of gastritis or peptic ulcer disease or predisposed to these problems due to prolonged physiologic stress, the surgeon must ensure that the patient's gastrointestinal problem is being addressed properly. The clinician should verify that the patient is compliant with either their H₂ receptor antagonist regimen (cimetidine, 800 mg hs; ranitidine, 150 mg bid; or famotidine, 40 mg hs) or with sucralfate (1 g qid). When the patient is unable to take oral medication, cimetidine (300 mg q8h), ranitidine (50 mg q8h), or famotidine (20 mg q12h) can be given intravenously or intramuscularly.

Patients with a predisposition to gastritis or peptic ulcer disease should not be given non-steroidal anti-inflammatory drugs (NSAIDs). The use of corticosteroids in these patients is controversial. There is no strong scientific evidence that corticosteroids can cause peptic ulcers in most patients, but many clinicians avoid their use in these patients.

Surgery in the Patient with Disorders of Connective Tissue and Joints

Rheumatoid Arthritis

Rheumatoid arthritis (RA) is a chronic disease causing not only polyarthritis but also problems in serosal surfaces, blood vessels, muscle, skin, and bone marrow. Maxillofacial surgery in patients with RA requires careful evaluation to discover the extent of the patient's abnormalities and to attempt to have those problems under reasonable control. Classic signs and symptoms of RA include morning stiffness of involved joints, symmetric involvement of proximal hand joints, subcutaneous (rheumatoid) nodules over bony prominences or extensor surfaces, elevated serum rheumatoid factor, and marked bony erosions visible on radiographs.

Nonarticular problems seen with RA include pericarditis, pleuritis, pneumonitis, myopathies, vasculitis, bone marrow depression, and skin ulcers.

Rheumatoid arthritis patients are treated with five classes of drugs: analgesics (NSAIDs), glucocorticoids, slow-acting antirheumatic drugs (SAARDs), or disease-modifying antirheumatic drugs (DMARDs), and anticytokines. Analgesics include acetaminophen, tramadol, and narcotics. NSAIDs range from over-the-counter ibuprofen to newer selective cyclooxygenase-2 (COX-2) inhibitors such as celecoxib, rofecoxib, and valdecoxib. NSAIDs relieve pain and reduce inflammation but do not alter the course of rheumatoid arthritis. COX-2 inhibitors do not have any inherent benefit over older NSAIDs other than less gastrointestinal toxicity. Glucocorticoids effectively suppress inflammation, often at low doses, but carry their own substantial risks. SAARDs and DMARDs include hydroxychloroquine, sulfasalazine, methotrexate, and leflunomide. Methotrexate is now considered to be first-line treatment for active rheumatoid arthritis. Penicillamine, azathioprine, cyclosporine, and gold salts are seldom used. Anticytokines include etanercept, infliximab, adalimumab, and anakinra. These drug classes are often used in combination to control inflammation and slow the progression of the disease.^{100–103}

Patients with RA who require endotracheal intubation should be evaluated preoperatively for their ability to extend at the neck, open their mandible, and move their cricoarytenoid joints.

An early symptom of neck involvement in RA is neck pain with radiation to the occiput. Preoperative cervical spine films should be considered to evaluate for subluxation of the cervical spine.¹⁰⁴ The surgeon needs to remain more vigilant than usual to prevent long periods of overextension or flexion of involved joints. Patients with Raynaud's phenomenon need their fingers and toes kept warm

intraoperatively. Patients with Sjögren's syndrome will require special care to prevent eye desiccation. The skin of RA patients is commonly thin and easily damaged, so additional padding of pressure points is indicated. Preoperative PT and partial thromboplastin time (PTT) measurement will help detect circulating anticoagulants due to the RA. Early postoperative ambulation, heat treatments, and possibly physical therapy of affected joints will help prevent prolonged stiffness.

Other Connective Tissue Disorders

The patient coming to surgery may have other connective tissue disorders such as systemic lupus erythematosus (SLE), psoriatic arthritis, ankylosing spondylitis, dermatomyositis, and scleroderma, which have similar perioperative concerns.

Preoperative assessment of patients with SLE and other connective tissue disorders should include a thorough history and physical examination, a urinalysis, electrolyte panel including blood urea nitrogen and creatinine, a complete blood count, and a PT and PTT. Blood typing or screening should be done in advance of surgery to evaluate for blood compatibility. A chest radiograph and ECG are indicated for evidence of pleural or pericardial disease.¹⁰⁵

Patients who have taken glucocorticoid therapy should be screened for use of stress-dose steroids, as noted above. Consider stopping NSAID therapy, if possible, to allow return of platelet function. The time needed for this varies from 7 to 10 days for aspirin to 1 day for ibuprofen. Generally NSAIDs other than aspirin should be stopped 3 to 4 days preoperatively, and acetaminophen or narcotics can be used to control pain during this time. There is no evidence that stopping SAARDs or DMARDs prior to surgery conveys any benefit. Anticytokines can limit immune response in severe infections, and in maxillofacial surgery these drugs should be discontinued

1 week before surgery and resumed 2 weeks postoperatively.

Sjögren's syndrome patients should have artificial tears or lubricating gel placed in the eyes during anesthesia. Pilocarpine, if used, should be held to avoid confusion over anesthetic complications of bronchospasm, bradycardia, and tremor.

Patients with ankylosing spondylitis have similar spine concerns as RA patients. Scleroderma patients may have limited mandibular movement as a consequence of their disease, causing difficulty with endotracheal intubation. SLE patients may have low platelets, which is generally well tolerated without excessive bleeding. For counts less than 50,000, intravenous immunoglobulin may be used to improve the platelet count. SLE patients may also have evidence of the lupus anticoagulant, manifest by an elevated PTT. The lupus anticoagulant, also referred to as antiphospholipid antibodies, can produce thromboembolism. Patients may be treated with aspirin if antibodies are present and there have been no previous thromboembolic events, or may be fully anticoagulated, requiring adjustment perioperatively.¹⁰⁶

Surgery in the Patient with Neurologic and Neuromuscular Disorders

Seizure Disorders

Seizures are typically recurrent transient paroxysms of hyperactive brain function, which can appear as impaired consciousness, involuntary movement, autonomic disturbance, or psychic experiences. They can result from known causes such as fever, ethanol withdrawal, hypoglycemia, hypoxia, or brain damage, or be idiopathic. Most investigators feel the fundamental site of pathology is in the cerebral cortex, which can be detected on an electroencephalogram (EEG).

The reconstructive maxillofacial surgeon is likely to encounter patients who suffer seizures secondary to head trauma

(Chronic recurrent seizures occur in 30% of patients with cerebral hematomas, 15% of those with depressed skull fractures, and 5% of patients hospitalized with closed head injuries). Chronic posthead trauma seizures usually do not occur until 6 to 12 months from the time of injury.

Patients providing a past history of any form of seizure disorder (except perhaps febrile seizures in childhood) should be under the care of or evaluated by a neurologist before undergoing major elective surgery.¹⁰⁷ Patients with well-documented seizures and who are under good control can safely have general anesthesia and surgery. Control is usually obtained by the use of antiseizure medications such as dilantin, phenobarbital, valproic acid, carbamazepine, ethosuximide, and clobazepam. Most of these drugs can cause sedation, which can be additive with anesthetic drugs. Side effects of carbamazepine and dilantin include nausea, dizziness, diplopia, and rarely bone marrow depression. Valproic acid can inhibit liver enzymes, potentially causing oversedation with barbiturates.

Newer drugs include lamotrigine, gabapentin, tiagabine, and topiramate. Most of these drugs can cause sedation, which can be additive with anesthetic drugs. Other side effects vary with each drug.

When evaluating a patient with a seizure disorder for surgery, the clinician should learn of the frequency, type, duration, and sequelae of seizures to gauge the degree to which control of the seizures has been obtained. Serum drug levels of these agents can be obtained to help check compliance and predict the appearance of seizures, if subtherapeutic, or possible toxic reactions.

Cerebrovascular Disease

Patients with a history of cerebrovascular accidents, such as transient ischemic attacks (TIAs) or strokes, requiring maxillofacial surgery need evaluation by their primary physician before surgery. In most

cases little can be done preoperatively to diminish the risk of a stroke during surgery. A careful neurologic examination should be performed preoperatively to document residual damage, and again postoperatively to detect evidence of intraoperative problems.¹⁰⁸

Two situations in which preoperative improvement may be possible are in the patient with either poorly controlled hypertension or severe carotid stenosis. Essential hypertension is a known risk factor for the development of a stroke; therefore, institution of successful antihypertensive therapy before elective surgery is recommended. The preoperative management of patients with carotid lesions is controversial. Part of the problem is that the finding of a carotid bruit by itself does not correlate with the degree or even presence of carotid stenosis. Thus, angiography is necessary if stenosis is suspected, to document the severity of the process. The question is whether to perform a carotid endarterectomy only if a TIA occurs or if carotid artery occlusion is greater than 70%.¹⁰⁹

Patients with a history of stroke or TIA frequently harbor coronary artery disease as well. A thorough assessment of the risk for coronary disease is indicated, as noted in the above section.

Patients with a history of cerebrovascular disease are often placed on inhibitors of platelet aggregation such as aspirin or dipyridamole. Most physicians will permit these drugs to be stopped at least 1 week preoperatively to prevent bleeding problems perioperatively. Stroke patients may also have trouble clearing secretions or controlling saliva.

Malignant Hyperthermia

Malignant hyperthermia is the leading cause of unexpected anesthetic deaths in North America. It is a rare genetic disorder that manifests following treatment with anesthetic agents, most commonly succinylcholine and halothane. The onset of malignant hyperthermia is usually within

an hour of the administration of general anesthesia but rarely may be delayed as long as 11 hours.

Approximately one-half of cases appear to be inherited in an autosomal-dominant fashion; the remainder of cases are inherited in different patterns.

Susceptible patients with autosomal-dominant disease have any one of eight distinct mutations in the ryanodine receptor. This receptor is a homotetrameric calcium channel found in the sarcoplasmic reticulum of skeletal muscle.

In the presence of anesthetic agents, alterations in the hydrophilic, amino-terminal portion of the ryanodine receptor result in uncontrolled efflux of calcium from the sarcoplasmic reticulum with subsequent tetany, increased skeletal muscle metabolism, and heat production. For unclear reasons, overexpression of the wild-type ryanodine receptor does not ablate abnormal myocyte responses to halothane, although overexpression of a mutated ryanodine receptor can induce the malignant hyperthermia phenotype in myocytes from normal individuals.

Typically malignant hyperthermia presents soon after induction of anesthesia with a rapid rise in body temperature and muscle rigidity. Difficulty in ventilating the patient or opening the mandible for intubation are common early manifestations. Other signs include diaphoresis, tachypnea, tachycardia, hyperkalemia, hypocalcemia, elevated temperature and carbon dioxide content of expired air, and cardiac dysrhythmias. Renal failure can occur due to rhabdomyolysis and myoglobinuria.¹¹⁰ Consumptive coagulopathy can also be triggered. Mortality in patients in which the disorder was not suspected before anesthesia ranges from 63 to 73%.

A predisposition to malignant hyperthermia should be suspected in patients with the following characteristics:

- Unusual muscle hypertrophy
- Ptosis, ophthalmoplegia, strabismus

- Pectus deformities or kyphoscoliosis
- Limb girdle weakness
- Hip dislocation, dislocated patella, malaligned feet
- Known central core myopathy
- Young males with previously described appearance
- Any history of myopathy of unknown etiology

Patients with a known or suspected tendency should be considered for local or regional anesthetic techniques. If general anesthesia is necessary a technique that uses nitrous oxide, barbiturates, benzodiazepines, narcotics, or neuroleptic drugs is advisable. Nondepolarizing muscle relaxants should be used if necessary. Drugs such as succinylcholine, amide local anesthetics, ketamine, and volatile anesthetics should be avoided. Premedication with dantrolene (1 mg/kg) orally the day before surgery or as an intravenous bolus the day of surgery is appropriate when malignant hyperthermia is a high probability. In addition a set protocol for its management, should it occur, should be in place before starting anesthesia for patients at risk for malignant hyperthermia.^{111,112}

Spinal Cord Disorders

Paraplegia due to spinal cord damage can cause a number of problems of which the surgeon needs to be cognizant. Abnormal bladder emptying predisposes these patients to urinary tract infections and chronic pyelonephritis. Paraplegia affecting the diaphragm can lead to pneumonia, and inability to exercise the lower extremities and pelvic region setting up a situation in which thromboembolism to the lungs is common. Inability to move can also cause the development of decubitus ulcers. Renal and adrenal functions are often impaired due to amyloidosis, and anemia of chronic disease is frequent in paraplegics.

Maxillofacial surgery for these individuals can be accomplished safely with

good patient preparation. Preoperative checks of pulmonary and renal function will reveal patients at high risk for perioperative complications. The sputum and urine should be checked for evidence of infection and blood count obtained to discover if anemia is present. Special care needs to be taken to properly position and pad vulnerable parts of the body during and after surgery. Minidose heparin will help prevent pulmonary embolism, as will keeping the legs elevated during surgery and providing proper physical therapy after surgery. Physical therapy is also necessary to the upper extremities to prevent contractures. Continuous urinary catheterization is needed during surgery, returning to the intermittent bladder catheterization regimen (in place preoperatively) as soon as possible after surgery.

Surgery in the Patient with a Psychiatric Disorder

Affective Disorders

Affective disorders such as depression are common problems in modern society. Patients with this disorder need special care during any surgical treatment.

Major depression is characterized by a depressed mood and an inability to enjoy life. Symptoms include sleep disturbance such as early morning waking, appetite disturbance, fatigue, decreased libido, low self-esteem, and a feeling of hopelessness. Many patients are able to mask or deny their symptoms when under no undue stress, but facing a surgical procedure will usually uncover hidden symptoms of depression.

In addition to the emotional problems that patients with depression incur in the perioperative period, problematic drug interactions can occur between anesthetic agents and many of the agents used to control depression. Selective serotonin reuptake inhibitors are in widespread use for depression, anxiety, and panic disorder, and are well tolerated perioperatively. Tricyclic antidepressants are in common use

for depression, chronic pain, and sleep disorders. They can carry unwanted anticholinergic and hypotensive side effects, which should be remembered when anesthesia is given. An additional problem with tricyclic antidepressants is their tendency to cause increased conduction delays in patients with preexisting heart blocks.

Monoamine oxidase inhibitors (MAOIs) are also used to manage depressive symptoms. They also have anticholinergic and orthostatic hypotensive effects. Drugs with sympathomimetic action should be avoided in patients on MAOIs.

Lithium carbonate is used for patients with bipolar (manic-depressive) disorders. It induces the characteristic ECG changes of inverted and flattened T waves. It can also produce sinus node dysfunction and ventricular irritability. Serum levels should be checked preoperatively in these patients.

Benzodiazepines used for depression pose little risk for safe anesthesia as long as the anesthesiologist is aware of their use. Abrupt discontinuation should be avoided to prevent the appearance of a withdrawal phenomenon.

Conditions such as anorexia nervosa and bulimia should be addressed prior to major surgical procedures due to the impairment to nutritional health and electrolyte balance they produce.¹¹³

Psychotic Disorders

Psychotic disorders are characterized by delusions and hallucinations. Psychotic patients are usually easily recognized by the results of a comprehensive mental status examination. Antipsychotic drugs such as phenothiazines, thioxanthenes, butyrophenones, and indalones control many of the symptoms of psychosis and cause little increased risk of problems with anesthesia. They do have the tendency to cause sedation and extrapyramidal symptoms in many patients. Introduction of atypical antipsychotic medications has resulted in a large number of patients being converted to these drugs, including risperidone,

olanzapine, quetiapine, ziprasidone, and aripiprazole. These medications have many drug-drug interactions, and consultation with a drug reference manual or pharmacist would be prudent to avoid such complications.

Surgery in psychotic patients carries no increased risk of complications as long as the disorder is well controlled.

Acute psychosis, combativeness, and agitation can be disruptive as well as unsafe for the patient and medical staff. After ruling out serious medical complications such as hypoxia, drug or alcohol withdrawal, serious infection, and myocardial infarction, administration of lorazepam 1 to 2 mg PO or IV, or haloperidol 1 to 2 mg PO, IM, or IV, can be used for control of symptoms acutely. Haloperidol also comes in a flavorless liquid formula.

Substance Abuse

Alcoholism Patients who regularly consume large amounts of ethanol must be allowed to withdraw from the effects of the alcohol before they undergo elective surgery and anesthesia. Failure to follow this strategy risks the appearance of minor alcohol withdrawal syndrome, with its compensatory neuronal excitability and catecholamine release, or the severe syndrome delirium tremens (DT) with hallucinosis, hyperpyrexia, hypertension, and life-threatening cardiac dysrhythmias and seizures.^{114,115}

The following four questions have a high sensitivity and specificity for detecting alcoholism.¹¹⁶

- Have you ever felt the need to cut down on drinking?
- Have you ever felt annoyed by criticism of your drinking?
- Have you ever had guilty feelings about your drinking?
- Have you ever taken a morning eye opener?

Previous history of DT and drinking a morning “eye opener” denote a high risk of alcohol withdrawal.

Two strategies are available for the alcoholic patient coming to surgery: continuation of alcohol perioperatively, or avoidance of alcohol with vigilance for withdrawal syndromes. While it seems counterintuitive to continue alcohol use in a hospital or postoperative setting, this strategy can prevent withdrawal; most patients will resume drinking as soon as they can anyway. For patients newly abstaining, those with a prior history of DT may be given scheduled benzodiazepines, such as lorazepam 1 to 2 mg every 8 hours, but most patients should be observed for evidence of DT and treated based on symptoms. Early symptoms include restlessness and tremulousness, followed by agitation, combativeness, fever, and seizures. Symptoms should be treated as soon as they emerge, with oxazepam 15 to 30 mg PO every 6 to 8 hours as needed, or lorazepam 1 to 2 mg PO, IV, or IM every 6 to 8 hours as needed.

Most of the anesthetic hazards in the sober alcoholic patient are due to ethanol-induced hepatic changes (see “Liver Disease”). Chronic ethanol use increases anesthetic requirements for halothane and isoflurane. Clearance of benzodiazepines is also increased, so that larger doses may be necessary in alcoholic patients. Patients with ethanol-induced liver disease are prone to hypoglycemia and need frequent serum glucose determinations during and after surgery.

Opioid and Illicit Drug Abusers If surgery is urgently necessary in opioid-dependent patients, it is usually prudent for the surgeon to avoid precipitating the withdrawal syndrome by substituting methadone (2.5 mg equals 10 mg of morphine) for the abused opioid. Usually 20 to 40 mg of methadone is needed daily, administered orally or intramuscularly in 4 to 6 divided doses. Clonidine has also

been found useful for helping prevent symptoms of opioid withdrawal.¹¹⁷

Hypotension is a common problem in opioid abusers during the perioperative period. They also are likely to have difficult veins in which to gain access, necessitating placement of central lines. Intravenous illicit drug abusers also have a high incidence of hepatitis B and C and human immunodeficiency virus positivity.

Cocaine use potentiates problems such as coronary vasospasm, myocardial ischemia/infarction, and dysrhythmias. The rapid metabolism of cocaine in a patient's system prior to presenting for surgery makes it unlikely that acutely intoxicated patients will be placed under sedation or general anesthesia.^{118,119}

Surgery in the Special Patient

Obese Patients

Obesity is a common affliction in modern society due to a combination of poor dietary habits and general lack of physical activity. The excessive weight in an obese individual is due to an overabundance of adipose tissue. Morbid obesity is defined as when a patient is 100% over ideal body weight due to fat accumulation. Calculation of the body mass index (BMI) assists in the diagnosis of obesity, with a BMI of 30 kg/m² and above defining obesity.

$$\text{BMI} = \frac{\text{Body weight in kg}}{\text{Square of stature (height in m)}}$$

Obesity by itself does not increase surgical mortality until it becomes severe, but then the risk rises exponentially. The ponderal index has been used to quantitate the increased risk faced by obese individuals. The index is calculated by dividing an individual's height in inches by the cube root of their weight in pounds. A result greater than 12.5 correlates highly with a significantly heightened risk of complications in the perioperative period. The

Chase method is another means of gauging risk in obese individuals in which surgical risk is determined by the ratio of weight versus height.

Pulmonary problems are the most frequent complications in the perioperative period in obese patients. These include pulmonary embolism, bronchospasm, atelectasis, and pneumonia. Obesity creates a form of restrictive lung disease, especially when these patients are supine, due to excessive weight on the thorax and abdomen that restricts full inspiration.

Before elective surgery in obese patients a careful history and physical examination are necessary to determine how the obesity may affect anesthesia and to detect a concurrent disease. Specific questions about a history of daytime somnolence and snoring are needed to find if a patient's airway is easily compromised. Past history of lung disease, heart problems, thrombophlebitis, or pulmonary embolism should also be elicited. Obese patients should also be asked about any previous problems in the establishment of venous access. The usefulness of physical examination of the chest and abdomen is commonly limited in obese patients. Therefore, ancillary examination techniques such as PFTs, ECG, and plain chest radiography are usually warranted.

Because obese patients have heightened risks of pulmonary problems, those who smoke should be helped to quit, hopefully for as long as possible before surgery. A reasonable program of weight reduction should also be recommended. Many patients may benefit from a consultation about potential gastrointestinal surgery for weight control.

When planning surgery the possibility of regional anesthesia should be considered. Deep sedation should be avoided if the airway is likely to be difficult to maintain. If general anesthesia is selected as the method of pain and anxiety control, the patient can be given preoperative instruc-

tion in incentive spirometry techniques. The increased risk of thrombophlebitis in these patients can be lessened by the use of a minidose heparin or enoxaparin regimen. Finally, a lowered threshold is appropriate for placement of invasive monitors such as a central venous pressure line or a Swan-Ganz catheter.

Obese patients are difficult anesthetic cases. They are typically more of a problem to mask ventilate during the induction of anesthesia. This should be anticipated by being ready to quickly intubate the patient if necessary even though intubation itself can be challenging.¹²⁰ The excess weight usually decreases pulmonary compliance and the functional residual and vital capacities. It should be kept in mind that squeezing the bag connected to the endotracheal tube will not give an accurate feel of pulmonary compliance due to the weight of the chest wall. Furthermore, the lowered lung capacities will cause an increased shunt fraction, which should be monitored by frequent measurements of arterial blood gases. Chest weight effects on the lungs can be lessened by elevating the upper body 15 to 20° from the horizontal.

The pharmacokinetics of drugs differ in obese versus lean individuals. The washout of fat-soluble anesthetic agents needs to begin earlier in the surgery to allow the patient to be awakened when desired. When calculating the dose of water-soluble drugs, the estimated lean body mass of the obese individual should be used.

Postoperative management of obese patients should include elevation of the head of the bed, early ambulation, incentive spirometry, deep venous thrombosis prophylaxis, and frequent physical examination for signs of pulmonary problems or deep vein thrombophlebitis.

Geriatric Patients

Although many clinicians are concerned that there will be medical complications when treating elderly patients, studies sub-

stantiate the fact that most elective surgery is safe in healthy geriatric patients. However, geriatric patients with chronic diseases such as COPD, diabetes, and coronary artery disease are certainly susceptible to the same problems as younger individuals with these same processes. Therefore, when older patients have chronic diseases, preoperative preparation should include efforts to minimize the detrimental effect of the disease process on the patient's physiology.¹²¹

Even though elderly patients can appear frail and sick, a large percentage are actually well. Conversely the appearance of health can be deceiving, because all older individuals experience various changes in physiologic function that can affect their response to the stress of an operation.

Statistically the most common complications that follow major surgery in the elderly are pulmonary embolism, myocardial infarction, pneumonia, and congestive heart failure. The surgeon should be especially vigilant for a past history or perioperative signs of these problems. Furthermore, although geriatric patients usually are able to withstand the initial physiologic stresses of surgery, if a complication occurs, they have less reserve to aid with recovery.

The heart undergoes age-related changes that decrease the maximal heart rate ($220 - \text{age in yr}$). Cardiac output falls (about 1% each year after age 20 yr) because of increased afterload and decreased elasticity of arteries secondary to atherosclerosis. This decreased elasticity also causes any small increase in blood volume to result in sharp increases in blood pressure. Total circulation time at age 20 years is 48 seconds; this rises to 65 seconds at age 70 years. The cardiovascular system also loses much of its responsiveness to catecholamines with age, so that postural hypotension is common. Maximum coronary flow capacity in the elderly is about 65% of that in teenagers.

Pulmonary function also falls as people get older. Loss of lung elasticity and

increased stiffness of the chest wall predispose lungs to atelectasis and ventilation-perfusion imbalances, as does the increased residual volume in older lungs. Whereas the PaO₂ on room air at age 30 years averages about 94 mm Hg, it normally falls to about 74 mm Hg above age 60 years. Vital capacity and expiratory flow rate begin to fall when individuals reach age 30. Muscle weakness prevents forceful coughing, and degeneration of bronchial epithelium leads to less efficient lung cleansing. All of these changes help to account for the relatively high incidence of pulmonary complications following surgery in older patients.

Renal function decreases 20 to 30% between the ages of 30 and 80 years because of natural loss of glomeruli and fibrosis of interstitial tissue. Creatinine clearance falls, but because lean body mass also decreases there is usually no change in measured serum creatinine. An approximation of expected age-related changes in renal function can be gained by the following equation:

$$\text{Creatinine clearance (mL/min)} = 133 - (0.84 \times \text{Age})$$

This formula can be used to judge dosages of drugs dependent on renal clearance. Geriatric patients also suffer a loss of renal concentrating and diluting abilities as tubules become less responsive to antidiuretic hormone. For that reason they can easily have intravascular volume disturbances and electrolyte abnormalities. Thirst perception also becomes a problem and thirst cannot be relied on to help gauge fluid requirements in these patients. Prostatic hypertrophy occurs in 80% of men with age, causing urinary problems that are commonly worsened by general anesthesia.^{122,123}

The loss of muscle mass and plasma volume with age may affect drug actions and necessitate changes in drug doses. Older white females are also predisposed to loss of bone strength owing to osteoporosis;

extra care should be taken when transporting these patients to and from the operating table. Thinning of skin in older patients also makes them more susceptible to pressure damage, heightening the need for proper intraoperative padding.

Geriatric patients tend to mount poor fever responses to pyrogens. Therefore, other signs of problems such as malaise or altered states of consciousness may need to be used to detect infections. The hearing and visual problems of older patients predispose them to states of confusion owing to sensory deprivation; providing appropriate sensory stimulation helps prevent this problem. A decrease in gastrointestinal motility leads to frequent constipation, and aging often causes impaired glucose tolerance.

Evaluation of elderly patients before elective maxillofacial surgery should begin with a careful medical history. Old records and consultation with the patient's primary care provider are usually excellent sources of needed information. During the physical examination specific note should be made of the patient's state of hydration, signs of age-related problems such as carotid or aortic stenosis, and any pulmonary and mental status problems. An ECG and chest radiograph are useful for detecting occult problems and provide a baseline for later comparisons.^{124,125}

Intraoperatively the patient should be kept from excessive loss of heat and over- or underhydration. Postoperatively, the clinician should be alert to possible respiratory depression due to narcotics and signs of myocardial damage such as sudden dyspnea or worsening of congestive heart failure.

Drug modifications in the elderly include reducing benzodiazepine dosages by at least 50%, recognizing the dysrhythmogenic potential of atropine, and being aware that narcotics such as morphine and meperidine have prolonged duration of action, and that water-soluble drugs will have a heightened pharmacologic effect

while lipid-soluble drugs such as barbiturates will have a long elimination time.¹²³

Pediatric Patients

The surgical challenges in pediatric patients are usually due to their small size. However, it is hazardous to consider children as just small adults when considering their anesthetic needs for surgery.

The physiology of pediatric patients is what makes them differ from adults in their response to drugs and anesthesia. Newborns and infants are obligate mouth breathers. Children have relatively small nasal airways, large tongues, small mandibles, short necks, and an abundance of pharyngeal lymphoid tissue; all of these serve to create an airway that is easily compromised. Dead space in children is about 2 mL/kg, and tidal volume is about three times the dead space.

The heart of infants has a fixed stroke volume, so that cardiac output is entirely dependent on heart rate. Blood volume in relation to body weight is high in infants, but ratio decreases with age. Fluid requirements of children vary with weight as shown in Table 2-6. Normal urine output also varies (Table 2-7).

Children have relatively large surface areas that can quickly allow excessive heat loss if they are left uncovered in an operating room.

Table 2-6 Fluid Requirements for Children

Weight (kg)	Fluid Requirements
1–10	100 mL/kg daily
10–20	1,000 mL + 50 mL/kg over 10 kg daily
20	1,500 mL + 20 mL/kg over 20 kg daily

Table 2-7 Urine Output

Age (yr)	Urine Output
0–2	3 mL/kg/h
2–5	2 mL/kg/h
5 to adult	1 mL/kg/h

Table 2-8 Medication to Avoid during Pregnancy*

Aspirin and other nonsteroidal anti-inflammatory agents
Carbamazepine
Chloral hydrate (if chronically used)
Chlordiazepoxide
Corticosteroids
Diazepam and other benzodiazepines
Diphenhydramine hydrochloride
Morphine
Nitrous oxide (if exposure greater than 9 hours per week)
Pentazocine hydrochloride
Phenobarbital
Promethazine
Propoxyphene
Tetracyclines

*All medications should be used with care in pregnant patients. The patient's obstetrician should be consulted if there is any question concerning the safety of a drug for a pregnant patient or the fetus.

Dosing of drugs to children is usually best decided based on the manufacturer's recommendations.¹²⁶

Pregnant and Lactating Patients

Pregnancy and lactation are relative contraindications to elective maxillofacial surgery because of the negative effects on the mother and developing child of various drugs, irradiation from imaging studies, and psychological stress associated with surgery.^{127–129}

If surgery cannot be deferred, the patient's obstetrician should be consulted for guidance with respect to safe drugs to use (Table 2-8). When feasible the surgery should be conducted under local anesthesia. Steps to minimize anxiety are also appropriate. During later stages of pregnancy, patients cannot tolerate long procedures without being allowed to empty their bladder. In addition, pressure from the uterus compromises venous return to the heart by placing pressure on the vena cava when patients are in a supine position.¹³⁰ Therefore, allowing patients to assume a more left lateral position is nec-

Table 2-9 Medications for Breast-Feeding Mothers

Safe	Potentially Harmful
Acetaminophen	Ampicillin
Antihistamines	Aspirin
Cephalexin	Barbiturates
Codeine	Chloral hydrate
Erythromycin	Corticosteroids
Fluoride	Diazepam
Lidocaine	Metronidazole
Meperidine	Penicillin
Oxacillin	Propoxyphene
Pentazocine	Tetracyclines

essary. A late-term pregnant patient's blood pressure or urinary protein must be carefully monitored to detect any early sign of preeclampsia.^{131,132}

Lactating patients need to avoid the use of drugs capable of passing into breast milk and potentially harming the infant (Table 2-9).

References

- Hilditch WG, Asbury AJ, Crawford JM. Preoperative screening: criteria for referring to anesthetists. *Anesthesiology* 2003;58:117–27.
- Wu G, Sanderson B, Bittner V. The 6-minute walk test: how important is the learning effect? *Am Heart J* 2003;146:129–33.
- Reilly DF, McNeely MJ, Doerner D, et al. Self-reported exercise tolerance and the risk of serious perioperative complications. *Arch Intern Med* 1999;159:2185–92.
- Ang-Lee MK, Moss J, Yuan C. Herbal medicine and perioperative care. *JAMA* 2001;286:208–16.
- Mukherjee D, Eagle KA. Perioperative cardiac assessment for noncardiac surgery. *Circulation* 2003;107:2771–4.
- Smetana, Up To Date; 2003.
- Linton MF, Fazio S. A practical approach to risk assessment to prevent coronary artery disease and its complications. *Am J Cardiol* 2003;92 Suppl:19i–26i.
- Falk E, Shah PK, Fuster V. Coronary plaque disruption. *Circulation* 1995;92:657–61.
- Cannon CP, Turpie AG. Unstable angina and non-ST-elevation myocardial infarction. *Circulation* 2003;107:2640–5.
- Dibra A, Mehelli J, Braun S, et al. Association between C-reactive protein level and subsequent cardiac events among patients with

- stable angina treated with coronary artery stenting. *Am J Med* 2003; 114:715–22.
11. Greenland MD, Knoll MD, Stomler T, et al. Major risk factors as antecedents of fatal and nonfatal coronary heart disease events. *JAMA* 2003;290:891–7.
 12. Khot UN, Khot MB, Bajyer CT, et al. Prevalence of conventional risk factors in patients with coronary heart disease. *JAMA* 2003;290:898–904.
 13. Felner JM, Arensberg D. Perioperative management of the cardiac patient. In: Lubin MF, Walker HK, Smith RB, editors. *Medical management of the surgical patient*. 2nd Ed. Boston (MA): Butterworths; 1988. p. 91.
 14. Miller R, Silvoy G, Lumb PD. Anesthesia, surgery and myocardial infarction: a review. *Anesth Rev* 1979;6:14.
 15. Mauney FM, Ebert PA, Salistan DC. Postoperative myocardial infarction. A study of predisposing factors, diagnosis and mortality in a high-risk group of surgical patients. *Ann Surg* 1970;172:497–503.
 16. Eagle KA, Berger PB, Calkins H, et al. ACC/AHA guideline update for perioperative cardiovascular evaluation for noncardiac surgery update: a report of the American College of Cardiology/American Heart Association Task Force on Practice Guidelines. Committee to Update the 1996 Guidelines on Perioperative Cardiovascular Evaluation for Noncardiac Surgery 2002; American College of Cardiology Web site. Available at: http://www.acc.org/clinical/guidelines/perio/update/pdf/perio_update.pdf (accessed November 18, 2003).
 17. Auerbach A, Goldman L. Beta-blockers and reduction of cardiac events in noncardiac surgery: scientific review. *JAMA* 2002; 287:1435–44.
 18. Goldman L, Caldera DL, Southwick FS, et al. Multi-factorial index of cardiac risk in noncardiac surgical procedures. *N Engl J Med* 1977;297:845–50.
 19. Hupp JR. Myocardial infarction: current management strategies. *J Oral Maxillofac Surg* 1989;47:1070–3.
 20. Tschopp MD, Sorin J, Brener MD. Complications of acute myocardial infarction. *Cleve Clin Dis Manage Proj*. Available at: www.clevelandclinicmed.com (accessed June 23, 2003).
 21. Hochman JS. Cardiogenic shock complicating acute myocardial infarction. *Circulation* 2003;107: 2998–3002.
 22. Drazner MH, Rome JE, Dries DL. Third heart sound and elected jugular venous pressure as markers of the subsequent development of heart failure in patients with asymptomatic left ventricular dysfunctions. *Am J Med* 2003;114:431–7.
 23. Ranjan A, Tarigopula L, Srivastara RK, et al. Effectiveness of the clinical pathway in the management of congestive heart failure. *South Med J* 2003;96:661–3.
 24. Schiff GD, Fung S, Speroff T, et al. Decompensated heart failure: symptoms, patterns of onset, and contributing factors. *Am J Med* 2003;114:625–30.
 25. Cohn JN. The management of chronic heart failure. *N Engl J Med* 1996;335:490–8.
 26. Rackley CE, Edwards JE, Karp RB. Mitral valve disease. In: Hurst JW, editor. *The heart*. 7th Ed. New York (NY): McGraw-Hill; 1990. p. 820.
 27. Freed LA, Levy D, Levine RA, et al. Prevalence and clinical outcome of mitral valve prolapse. *N Engl J Med* 1999;341:1–7.
 28. Cheitlin MD, Byrd RC. Prolapsed mitral valve. *Curr Probl Cardiol Dis* 1984;8:1–51.
 29. Dujardin KS, Enriquez-Sarano M, Schaff HV, et al. Mortality and morbidity of aortic regurgitation in clinical practice. *Circulation* 1999;99:1851–7.
 30. Iung B, Gohlke-Barwolf C, Tornos P, et al. Recommendations on the management of the asymptomatic patient with valvular heart disease. *Eur Heart J* 2002;23:1253–66.
 31. Felner JM. Congestive heart failure. In: Lubin MF, Walker HK, Smith RB, editors. *Medical management of the surgical patient*. 2nd Ed. Boston (MA): Butterworths; 1988. p. 133.
 32. Kaufman L. Unforeseen complications encountered during dental anesthesia. *Proc R Soc Med* 1966;59:731–40.
 33. Calkins H, Sousa J, el-Atassi R, et al. Diagnosis and cure of the Wolff-Parkinson-White syndrome or paroxysmal supraventricular tachycardias during a single electrophysiologic test. *N Engl J Med* 1991;324:1612–8.
 34. Roy D. Amiodarone to prevent recurrence of full atrial fibrillation. *N Engl J Med* 2000;342:913–20.
 35. Kennedy HL, Whitlock JA, Sprague MK, et al. Long-term follow-up of asymptomatic healthy subjects with frequent and complex ventricular ectopy. *N Engl J Med* 1985; 312:193–7.
 36. Bigger JT Jr, Fleiss JL, Kleiger R, et al. The relationships among ventricular arrhythmias, left ventricular dysfunction, and mortality in the 2 years after myocardial infarction. *Circulation* 1984;69(2):250–8.
 37. Lown B, Grayboys TB. Management of patients with malignant ventricular dysrhythmias. *Am J Cardiol* 1977;39:910–8.
 38. Wyse DG. Pharmacologic therapy in patients with ventricular tachyarrhythmias. *Cardiol Clin* 1993;11: 65–83.
 39. Belocci F, Sontarelli P, Di Gennaro M, et al. The risk of cardiac complications in surgical patients with bifascicular block. *Chest* 1980;77:343–8.
 40. Hodgkin JD. Preoperative assessment of respiratory function. *Respir Care* 1984;29:496–505.
 41. Tisi GM. Preoperative identification and evaluation of the patient with lung disease. *Med Clin North Am* 1987;71:399–412.
 42. Ford GT, Guenter CA. Toward prevention of postoperative pulmonary complications. *Am Rev Respir Dis* 1984;130:4–5.
 43. Gass GD, Olsen GN. Preoperative pulmonary function testing to predict postoperative morbidity and mortality. *Chest* 1986;89:127.
 44. Crapo RO. Pulmonary-function testing. *N Engl J Med* 1994;331:25.
 45. McFadden ER Jr. Asthma. In: Braunwald E, Fauci AS, Kasper DL, et al, editors. *Harrison's principles of internal medicine*. 15th Ed. New York (NY): McGraw-Hill; 2001.
 46. Star RA. Treatment of acute renal failure. *Kidney Int* 1998;54:1817–31.
 47. Van den Toorn LM, Overbeek SE, Prins J, et al. Asthma remission: does it exist? *Curr Opin Pulm Med* 2003;9:15–20.
 48. Bishop MJ, Cheney FW. Anesthesia for patients with asthma: low risk but not no risk. *Anesthesiology* 1996;85:455–6.
 49. Warner DO, Warner MA, Barnes RD, et al. Perioperative respiratory complications in patients with asthma. *Anesthesiology* 1996;85:460–7.
 50. Chervinsky P, Bronsky EA, Dockhorn R, et al. Fluticasone propionate aerosol for the treatment of adults with mild to moderate asthma. *J Allerg Clin Immunol* 1994;94:676–83.
 51. Kavuru M, Melomed J, Gross G, et al. Salmeterol and fluticasone propionate combined in a new powder inhalation device for the treatment of asthma. *Allerg Clin Immunol* 2000;105:1108–16.
 52. Suissa S, Dennis R, Ernst P, et al. Effectiveness of the leukotriene receptor antagonist zafirlukast for mild-to-moderate asthma. *Ann Intern Med* 1977;126: 177–83.
 53. Celli B. Standards for the diagnosis and care of patients with chronic obstructive pulmonary disease. *Am J Respir Crit Care Med* 1995;152:S77–83.
 54. Soto FJ, Varkey B. Evidence-based approach to acute exacerbations of COPD. *Curr Opin Pulm Med* 2003;9:117–24.
 55. Sethi JM, Rochester CL. Smoking and chronic obstructive pulmonary disease. *Clin Chest Med* 2000;21:67–86.
 56. Rehder K, Sessler AD, Marsh HM. General

- anesthesia and the lung. *Am Rev Respir Dis* 1975;112:541–63.
57. Kellerman PS. Perioperative care of the renal patient. *Arch Intern Med* 1994;154:1674–88.
 58. Anagnostou A, Kurtzman NA. The anemia of chronic renal failure. *Semin Nephrol* 1985;5:115–27.
 59. de Medina M, Ashby M, Schluter V, et al. Prevalence of hepatitis C and G virus infection in chronic hemodialysis patients. *Am J Kidney Dis* 1998;31:224–6.
 60. Alberio L, Kimmerle S, Baumann A, et al. Rapid determination of anti-heparin/platelet factor 4 antibody titers in the diagnosis of heparin-induced thrombocytopenia. *Am J Med* 2003;114:528–36.
 61. Brenowitz JB, Williams CD, Edwards WS. Major surgery in patients with chronic renal failure. *Am J Surg* 1977;134:765–9.
 62. Burke GR, Gulyassy PF. Surgery in the patient with renal disease and related electrolyte disorders. *Med Clin North Am* 1979;63:1191–62.
 63. Ifudu O. Care of patients undergoing hemodialysis. *N Engl J Med* 1998;339:1054–62.
 64. Thodhani R. Acute renal failure. *N Engl J Med* 1996;334:1448–60.
 65. Deutsch S. Anesthetic management of patients with chronic renal disease. *South Med J* 1975;68:65–9.
 66. Oparil S, Calhoun DA. High blood pressure. *Sci Am Med* 2000;1–6.
 67. Edwards WJ. Preanesthetic management of the hypertensive patient. *N Engl J Med* 1979;301:158–9.
 68. Goldman L, Caldera DL. Risks of general anesthesia and elective operation in the hypertensive patient. *Anesthesiology* 1979;50:285–92.
 69. Ropper AH, Wechsler LR, Wilson LS. Carotid bruit and the risk of stroke in elective surgery. *N Engl J Med* 1982;307:1388–90.
 70. Puschett JB. Diuretics and the therapy of hypertension. *Am J Med Sci* 2000;319:1–9.
 71. Conlin PH, Williams GH. Use of calcium blockers in hypertension. *Adv Intern Med* 1998;43:533–62.
 72. Thurman JM, Schrier RW. Comparative effects of angiotensin-converting enzyme inhibitors and angiotensin blockers on blood pressure and the kidney. *Am J Med* 2003;114:588–98.
 73. Colson P, Ryckwaert F, Coriat P. Renin-angiotensin system antagonists and anesthesia. *Anesth Analg* 1999;89: 1143–55.
 74. Bertrand M, Godet G, Meerschaert K, et al. Should the angiotensin II antagonists be discontinued before surgery? *Anesth Analg* 2001;92:26–30.
 75. Martin DE, Kommerer WS. The hypertensive surgical patient. *Surg Clin North Am* 1983;63:1017–33.
 76. Alberti KG, Zimmet PZ. Definition, diagnosis and classification of diabetes mellitus and its complications. *Diabet Med* 1997;15:539–53.
 77. Fletcher J, Langman MS, Kellock TD. Effect of surgery on blood sugar levels in diabetes mellitus. *Lancet* 1965;2:52–4.
 78. O'Sullivan JJ, Conroy RM, Macdonald K, et al. Silent ischaemia in diabetic men with autonomic neuropathy. *Br Heart J* 1991;66:313–5.
 79. Rayfield EJ, Ault MJ, Keusch GT, et al. Infection and diabetes. *Am J Med* 1982;72:439–50.
 80. Jacober SJ, Sowers JR. An update on perioperative management of diabetes. *Arch Intern Med* 1999;159:2405–11.
 81. McAnulty GR, Robertshaw HJ, Hall GM. Anesthetic management of patients with diabetes mellitus. *Br J Anaesth* 2000;85:80–90.
 82. Clark CM, Lee DA. Prevention and treatment of the complications of diabetes mellitus. *N Engl J Med* 1995;332:1210–7.
 83. Thomas DJ, Platt HS, Alberti KG. Insulin-dependent diabetes: an assessment of continuous glucose-insulin potassium infusion, and traditional treatment. *Anesthesiology* 1984;39:629–37.
 84. Jacober SJ, Sowers JR. An update on perioperative management of diabetes. *Arch Intern Med* 1999;159: 2405–11.
 85. DeFronzo RA. Pharmacologic therapy for type 2 diabetes mellitus. *Ann Intern Med* 1999;131:281–303.
 86. Roizen MT, Hensel P, Lichter JL, et al. Patients with disorders of thyroid function. *Anesth Clin North Am* 1987;5:277–86.
 87. Streetman DD, Khanderia V. Diagnosis and treatment of Graves disease. *Ann Pharmacother* 2003;37:1100–9.
 88. Franklyn JA. The management of hyperthyroidism. *N Engl J Med* 1994;330:1731–8.
 89. Goldman DR. Surgery in patients with endocrine dysfunction. *Med Clin North Am* 1987;71:499–509.
 90. Leech NJ, Dayan CM. Controversies in the management of Graves' disease. *Clin Endocrinol* 1998;49:27–80.
 91. Singer PA, et al. Treatment guidelines for patients with hyperthyroidism and hypothyroidism. *JAMA* 1995;273:808–12.
 92. Lindsay RS, Toft AD. Hypothyroidism. *Lancet* 1997; 349:413–7.
 93. Schlaghecke R, Korneby E, Santen RT, et al. The effect of long-term glucocorticoid therapy on pituitary-adrenal responses to exogenous corticotropin-releasing hormone. *N Engl J Med* 1992;326:226–30.
 94. Salem M, Tinsch RE, Bromberg J, et al. Perioperative glucocorticoid coverage: a reassessment 42 years after emergence of a problem. *Ann Surg* 1994;219:416–25.
 95. Weatherill D, Spence AA. Anaesthesia and disorders of the adrenal cortex. *Br J Anaesth* 1984;56:741–9.
 96. Arteil G, Marsano L, Mendez C, et al. Advances in alcoholic liver disease. *Clin Gastroenterol* 2003;17:625–47.
 97. Keefe EB. Cirrhosis of the liver. *Sci Am Med* 1998;1–13.
 98. Barrera JM, Bruguera M, Ercilla MG, et al. Persistent hepatitis C viremia after acute self-limiting posttransfusion hepatitis C. *Hepatology* 1995;21:639–44.
 99. Liang TJ, Rehermann B, Seeff LB, et al. Pathogenesis, natural history, treatment, and prevention of hepatitis C. *Ann Intern Med* 2000;132:296–305.
 100. Adalimumab (Humira) for rheumatoid arthritis. *Med Lett* 2003;45:25.
 101. Bombardier C, Laikne L, Reicin A, et al. Comparison of upper gastrointestinal toxicity of rofecoxib and naproxen in patients with rheumatoid arthritis. *N Engl J Med* 2000; 343:1520–8.
 102. Lee DM, Weinblatt ME. Rheumatoid arthritis. *Lancet* 2001;358:903–11.
 103. O'Dell JR. Combination DMARD therapy for rheumatoid arthritis. *Ann Rheum Dis* 1996;55:781–3.
 104. Kwek TK, Lew TW, Thoo FL. The role of preoperative cervical spine X-rays in rheumatoid arthritis. *Anesth Intern Care* 1998; 26:636–41.
 105. Mills JA. Systemic lupus erythematosus. *N Engl J Med* 1994;330:1871–9.
 106. Preoperative evaluation and perioperative management of patients with rheumatic diseases. *Up-to-Date*; 2003. Available at: [http://www.uptodateonline.com/application/topic.asp?file=rheumati/46608](http://www.uptodateonline.com/application/topic.asp?fi le=rheumati/46608) (accessed Jan 1, 2004).
 107. Shneker BF, Fountain NB. Epilepsy. *Dis Month* 2003;49:426–78.
 108. Morgenstern LB, Kasner SE. Cerebrovascular disorders. *Sci Am Med* 2000;1–15.
 109. Kistler JP, Furie KL. Carotid endarterectomy revisited. *N Engl J Med* 2000;342:1743–5.
 110. Peters KR, Nance P, Wingard DW. Malignant hyperthyroidism or malignant hyperthermia? *Anesth Analg* 1981;60:613–5.
 111. Wackym PA, Dubrow TJ, Abdul-Rasool IH, et al. Malignant hyperthermia in plastic surgery. *Plast Reconstr Surg* 1988;82:878–82.
 112. Hopkins PM. Malignant hyperthermia: advances in clinical management and diagnosis. *Br J Anaesth* 2000;85:118–28.
 113. Sellar CA, Ravalia A. Anesthetic implications of anorexia nervosa. *Anaesthesia* 2003;58: 437–43.

114. Rimm Ed, Giovannucci EL, Willett WC, et al. Prospective study of alcohol consumption and risk of coronary disease in men. *Lancet* 1991;338:464–68.
115. Spies CD, Rommelspacher H. Alcohol withdrawal in the surgical patient: prevention and treatment. *Anesth Analg* 1999;88:946–54.
116. Bush B, Shaw S, Cleary P, et al. Screening for alcohol abuse using the CAGE questionnaire. *Am J Med* 1987;82:231–5.
117. Jenkins LC. Anaesthetic problems due to drug abuse and dependence. *Can Anaesth Soc J* 1972;19:461–77.
118. Cregler L, Mark H. Medical complications of cocaine abuse. *N Engl J Med* 1986;315:1495–1500.
119. Bernards CM, Teijeiro A. Illicit cocaine ingestion during anesthesia. *Anesthesiology* 1996;84:218–20.
120. Juvin P, Lavaut E, Dupont H, et al. Difficult tracheal intubation is more common in obese than in lean patients. *Anesth Analg* 2003;97:595–600.
121. Ershler WB, Longo DL. The biology of aging. *Cancer* 1997;80:1284–93.
122. Greenblatt DJ, Sellers EM, Shader RI. Drug disposition in old age. *N Engl J Med* 1982;306:1081–8.
123. Vestal R. Aging and pharmacology. *Cancer* 1997;80:1302–10.
124. Parikh SS, Chung F. Postoperative delirium in the elderly. *Anesth Analg* 1995;80:1223–32.
125. Peibe H-J. The aged cardiovascular risk patient. *Br J Anaesth* 2000;85:763–78.
126. Campbell RL, Weiner M, Stewart LM. General anesthesia for the pediatric patient. *J Oral Maxillofac Surg* 1982;40:497–506.
127. Bremme KA. Haemostatic changes in pregnancy. *Clin Haematol* 2003;16:153–68.
128. Santos AC, Pedersen H. Current controversies in obstetric anesthesia. *Anesth Analg* 1994;78:753–60.
129. Koren G, Pastuszak A, Ito S. Drugs in pregnancy. *N Engl J Med* 1998;338:1128–37.
130. Bamber JH, Dresner M. Aortocaval compression in pregnancy: the effect of changing the degree and directions of lateral tilt on maternal cardiac output. *Anesth Analg* 2003;97:256–8.
131. Lipstein H, Lee CC, Crupi RS. A current concept of eclampsia. *Am J Emerg Med* 2003;21:223–6.
132. Cunningham FG, Lindheimer MD. Hypertension in pregnancy. *N Engl J Med* 1992;326:927–32.

Perioperative Considerations

Noah A. Sandler, DMD, MD

Many factors need to be considered when evaluating a patient prior to oral and maxillofacial procedures. Whether a surgery is being performed in an office or operating room, the practitioner must acknowledge the impact of the surgery and the stress the perioperative period potentially entails. In addition, the pathophysiology of concomitant medical ailments that may modify therapy needs to be considered. Preoperative assessment, intraoperative monitoring, and postoperative care need to be modified based on individual patient requirements. The following discussion does not attempt to answer all questions regarding perioperative patient care. Common clinical scenarios and disease processes are presented. Despite our best efforts to prevent problems through assessment and monitoring, problems or emergencies can arise; therefore, this chapter also addresses patient monitoring and emergency management of common clinical situations.

Cardiac Assessment

Since the 1970s risk assessment has been performed in an attempt to identify individuals who may encounter a significant cardiac event (ie, myocardial infarction [MI] or death) in the perioperative period. In their often-referenced article, Goldman and colleagues identified nine independent factors associated with increased perioperative cardiac risk (Table 3-1).¹

These were assigned a point system based on their relative contribution to cardiac risk. The more points, the higher the risk of significant morbidity or mortality, primarily in the immediate postoperative period (Table 3-2).

Since 1980 the American College of Cardiology in association with the American Heart Association (ACC/AHA) has produced guidelines for the management of cardiovascular disease. In 1996 a committee was developed to assess guidelines in the perioperative evaluation for noncardiac surgery. Expanding on the factors identified by Goldman and colleagues,

patient daily function and surgical risk were also considered.

Recent evidence based on 4,315 patients over the age of 50 years undergoing elective noncardiac procedures suggests six major risk factors exist. These are included in a revised cardiac risk index: high-risk type of surgery, history of ischemic heart disease, congestive heart failure, cerebrovascular disease, preoperative treatment with insulin, and preoperative serum creatinine > 2.0 mg/dL.² Based on these findings as well as support from similar studies and recent technologic advances in coronary testing and therapies, the ACC/AHA

Table 3-1 Risk Factors Commonly Associated with Perioperative Morbidity and Their Point Value*

<i>Risk Factor</i>	<i>Point Value</i>
Third heart sound or jugular venous distention	11
Recent myocardial infarction	10
Rhythm other than sinus or premature atrial contractions on last echocardiogram	7
> 5 premature ventricular contractions per minute at any time	7
Intraperitoneal, intrathoracic, or aortic operation	3
Age > 70 yr	5
Important aortic stenosis	3
Emergent operation	4
Poor general medical condition	3
Partial pressure of oxygen < 60 or of carbon dioxide > 50 mm Hg	
K < 30 mEq/L	
Creatinine > 3 mg/dL or blood urea nitrogen > 50 mg/dL	
Chronic liver disease	
Bedridden from noncardiac causes	

*As determined in Goldman L et al.¹ Adapted with permission from Goldman L et al.¹

Table 3-2 Assessment of Morbidity and Mortality Based on Cardiac Risk Factors*

Class	Point Total	No or Minor Complications [†] (n = 943)(%)	Life-Threatening Complications [†] (n = 39)(%)	Cardiac Deaths (n = 19)(%)
I (n = 537)	0–5	532 (99)	4 (0.7)	1 (0)
II (n = 316)	6–12	295 (93)	16 (5)	5 (2)
III (n = 130)	13–25	112 (86)	15 (11)	3 (2)
IV (n = 18)	> 26	4 (22)	4 (22)	10 (56)

*As determined in Goldman L et al.¹
[†]Documented intraoperative or postoperative myocardial infarction, pulmonary edema, or ventricular tachycardia.
 Adapted with permission from Goldman L et al.¹

practice guidelines were updated in 2002.³ As part of these guidelines, consideration is given to cardiac testing for individuals determined to be at risk for a perioperative event. The following factors are assessed:

- Is the surgery urgent? If delay of the surgery may be detrimental, cardiac assessment may need to be performed at a later time.
- Has the patient undergone coronary revascularization in the past 5 years or percutaneous coronary intervention from 6 months to 5 years previously? If the patient has remained free from symptoms of ischemia, the risk of perioperative cardiac death or MI is extremely low.
- Has the patient undergone a coronary evaluation in the past 2 years? If invasive or noninvasive testing was negative and the person has remained symptom free, no further perioperative testing is indicated.
- Does the individual have an unstable cardiac condition or major clinical predictor of risk? These include acute (within 7 d) or recent (7–30 d) MI, unstable or severe angina, decompensated heart failure, significant arrhythmias, and severe valve disease. These conditions warrant delay of the procedure when possible, and usually coronary angiography is performed.
- Are there intermediate clinical predictors of risk? These include angina pec-

toris, prior MI as indicated by history or electrocardiography, compensated or prior heart failure, preoperative creatinine > 2 mg/dL (ie, renal insufficiency), and diabetes mellitus (DM), particularly insulin-dependent DM. In addition to these risks, the functional capacity of the individual is determined. This is recorded in metabolic equivalents (METs), where 1 MET is the oxygen consumption of a 70 kg 40-year-old man at rest. Functional capacity is classified as excellent (> 10 METs), good (7–10 METs), moderate (4–7 METs), poor (< 4 METs) (Table 3-3).

- What are the specific risks of the surgery? Considerations include the type of surgery (eg, vascular surgery is high risk) and hemodynamic changes that occur with certain surgeries (eg, significant bleeding or hypotension). Most oral and maxillofacial surgery procedures are considered to be of intermediate risk.

In general, patients with no major and few intermediate predictors of clinical risk and moderate or excellent functional capacity can undergo oral and maxillofacial surgery procedures with little risk of perioperative death or MI. On the other hand, individuals with poor functional capacity who are to undergo higher-risk surgery (eg, head and neck cancer resection) are often considered for further non-

invasive testing (eg, stress test, echocardiography). This approach has been demonstrated in recent studies to be efficacious and cost-effective.^{4–7}

Since most oral and maxillofacial surgical procedures are considered to be intermediate risk, the primary cardiac risk factor is the existence of one or more of the major clinical predictors of risk (ie, recent MI, unstable or severe angina, decompensated heart failure, significant dysrhythmias, and severe valve disease). The primary method of initial identification of these factors is a history taking and physical examination. Patients with identifiable risks warrant deferment of surgery with a referral for consideration for a thorough cardiac evaluation.

Myocardial Ischemia/Angina

The stress of elective surgery begins well before the incision is made. Activation of the hypothalamic-pituitary-adrenal axis is initiated by just scheduling the procedure and persists through the surgical period until at least a week after the surgery. Concomitant with the release of cortisol is stimulation of the adrenal medulla and the activation of the sympathetic nervous system with catecholamine release. These responses may have served an evolutionary purpose and/or aid in aspects of healing; however, they can be detrimental in a debilitated patient with poor reserve. Surgery, itself, necessitates myocardial work. Patients with atherosclerosis and coronary artery disease with narrowing of

Table 3-3 Metabolic Equivalents for Common Activities

Functional Capacity	Metabolic Equivalents
Take care of yourself	1
Walk a block or two	
Climb a flight of stairs	4
Heavy work	
Moderate recreation	>10
Strenuous sports	

the coronary vessels may be unable to meet this increased demand. Myocardial ischemia within 48 hours of surgery results in a ninefold increase in the risk of unstable angina (defined as angina at rest or increasing angina symptoms) and/or MI.

Myocardial work is primarily determined by four factors related to myocardial oxygen demand: heart rate, preload, afterload, and contractility. *Preload* represents all factors that contribute to passive ventricular wall stress (tension) at the end of diastole. It is approximately equal to end-diastolic volume or pressure (ie, the volume of blood left in the heart after diastole). Preload is generally a reflection of the volume status of a patient. It is measured via the central venous pressure or the pulmonary capillary wedge pressure. Additionally, the left ventricular end-diastolic volume determines the cardiac output according to Starling's law. Clinically, this means increasing precontraction muscle fiber length by increasing left ventricular end-diastolic volume through volume administration leads to an increase in the force of contraction. *Afterload*, in turn, represents all of the factors that contribute to total ventricular wall stress (tension) during systole. The primary determinants of afterload are the total peripheral resistance against which the heart muscle must pump and changes in intrathoracic pressure. Afterload is indirectly measured through blood pressure and mean arterial pressure. *Contractility* is the ability of the heart muscle to shorten itself in the face of appropriate stimuli.⁸ Of these factors, heart rate and afterload are the major contributors to cardiac work and myocardial oxygen consumption. Elevated heart rate is also potentially harmful in that it decreases the time that oxygen and nutrients can be delivered to the myocardial cells (diastolic perfusion time). This is the basis for the goal of maintaining the blood pressure and pulse within 10% of the preoperative value during anesthesia.⁹

Patients with coronary artery disease often have a history of hypertension. Blood pressure is measured using the proper cuff size with patients quiet and comfortable (with back support, if seated) for at least 5 minutes prior to measurement. *Hypertension* is defined as two elevated blood pressure readings separated by at least 2 minutes of $\geq 140/90$ mm Hg on two or more separate visits. Healthy patients with persistent elevated pressures $\geq 160/100$ mm Hg and those considered to be at high risk (diabetics or patients with clinical cardiovascular disease) should be considered for antihypertensive therapy.¹⁰

Preoperatively, elevated blood pressure should be managed by deferring treatment for elective procedures. Intraoperative or postoperative hypertension rarely requires treatment. Hypertensive crisis or emergency is a sudden increase in systolic and diastolic blood pressure associated with end-organ damage of the central nervous system, heart, or kidneys. Headache, altered level of consciousness, and less severe manifestations of central nervous system dysfunction are classic findings in hypertensive encephalopathy. Advanced retinopathy with arteriolar changes, hemorrhages, and exudates as well as papilledema are seen on fundoscopic examination. Angina, acute MI, or signs of heart failure can be present in hypertensive crisis. Renal failure with oliguria and/or hematuria is present with damage to the kidneys. Less than 1% of patients with a diagnosis of hypertension experience a crisis. In the United States the incidence is higher among African Americans and the elderly. The majority have previously been diagnosed with hypertension and many have been prescribed antihypertensive therapy but with poor control. The incidence of postoperative hypertensive crisis varies depending on the population studied and has been reported in 4 to 35% of patients. Reduction of blood pressure in a hypertensive

crisis should be performed with intra-arterial blood pressure monitoring.

The term *hypertensive urgency* is characterized by severely elevated blood pressure without acute end-organ damage. Postoperative hypertension has been defined arbitrarily as systolic blood pressure > 190 mm Hg and/or diastolic blood pressure ≥ 100 mm Hg. It should be appreciated that most patients with severely elevated blood pressure (diastolic > 110 mm Hg) have no acute end-organ damage. The elevated blood pressure should be treated in a controlled fashion in an intensive care unit. The use of sublingual nifedipine is strongly discouraged as this may result in a precipitous fall in blood pressure. Similarly, intravenous hydralazine may result in severe uncontrolled hypotension. Rapid and uncontrolled reduction of blood pressure may result in cerebral, myocardial, and renal ischemia or infarction. Table 3-4 describes commonly recommended medications and dosages should it be determined that reduction of blood pressure is necessary.¹¹

Recent Myocardial Infarction

It is important to attempt to avoid the stress of surgery if the patient is experiencing acute ischemia or has a history of recent infarction. Traditionally a 6-month interval between the initial incidence of MI and elective noncardiac surgery has been advocated to avoid stress and the risk of re-infarction. However, recently the importance of this time interval has been called into question. The use of thrombolytics, angioplasty, and risk stratification after an acute MI has been the impetus for this change. Although some patients may continue to have myocardium at risk with subsequent ischemic episodes, others may have critical stenosis converted to widely patent vessels. The AHA/ACC Task Force on Perioperative Evaluation of the Noncardiac Surgery has advocated that the group at highest risk is those who have had an MI within 6 weeks;

Table 3-4 Common Antihypertensive Agents Used to Actively Lower Blood Pressure in Hypertensive Crisis

Drug	Mechanism	Dosage	Comments
Clonidine	Central α_2 -agonist	0.1 mg PO q20min	Useful in hypertensive urgency; gradually decreases BP
Diazoxide	Smooth muscle relaxant	1–3 mg/kg IV, maximum single dose of 150 mg	Causes rapid BP decrease
Enalaprilat	Angiotensin converting enzyme inhibitor	1.25 mg over 5 min q6h	Blocks angiotensin II
Esmolol	β_1 -selective blocker	0.5 mg/kg followed by infusion of 25–300 μ g/kg/min	Rapid onset (60 s), short duration (10–20 min)
Fenoldopam	Dopamine agonist	Initial dose 0.1 μ g/kg/min titrate; maximum 1.6 μ g/kg/min	Short acting, increases renal perfusion
Labetalol	α - and β -blocker (α : β = 1:7)	Loading dose of 20 mg followed by 20–80 mg dose at 10 min intervals or 1–2 mg/min infusion	Avoid larger bolus doses; can cause hypotension
Nicardipine	Ca channel blocker	5 mg/h increasing 2.5 mg/h q5min (maximum 15 mg/h)	Useful for cardiac and cerebral ischemia; dose independent of weight
Nitroprusside	Arterial/venous dilatation	Infusion; usually < 2 μ g/kg/min	Rapidly decreases BP; risk of cyanide toxicity
Phentolamine	α -blocker	IV 1–5 mg boluses	Can cause tachyarrhythmias, angina
Trimethaphan camsylate	Nondepolarizing ganglionic block	IV infusion 0.5–1 mg/min; maximum 15 mg/min	Adrenergic block is therapeutic effect; cholinergic block of side effects

BP = blood pressure.

after this period risk stratification is based on the presentation of the disease (ie, those with persistent symptoms consistent with active ischemia remain at the highest risk level).¹²

During severe ischemic episodes the release of intracellular potassium from injured cells may result in partial repolarization of the surviving cardiac cells, particularly along the infarct border. These cells may then initiate areas of ectopia, potentially leading to arrhythmias, especially with concurrent sympathetic stimulation, electrolyte abnormalities, and ventricular hypertrophy. β -Blockers, nitroglycerin, and amiodarone as well as high vagal tone can be protective in this circumstance. In addition, intra-aortic balloon pumps, ventricular assist devices, coronary angioplasty, and revascularization may be indicated.

Acute Episode of Chest Pain Suggestive of Myocardial Ischemia/Infarction

Immediate intervention includes the assessment of vital signs and the administration of oxygen and nitroglycerin tablets or spray at 0.4 mg/dose (to be repeated in 5 min intervals for three doses or until the pain is eliminated). If the pain is persistent, intravenous morphine (2–5 mg q5min or until pain relief is achieved) and aspirin 325 mg should be given. The local Emergency Medical Service should be contacted early as the protocol calls for the performance of an early 12-lead echocardiography (preferably by Emergency Medical Service personnel) and screening of the patient for an antifibrinolytic or reperfusion (ie, an angioplasty with stent placement or coronary artery bypass graft) procedure.¹³

Decompensated Congestive Heart Failure

A history of worsening shortness of breath (dyspnea), difficult ventilation when assuming the supine position (orthopnea), or gasping for oxygen when assuming the supine position when asleep (paroxysmal nocturnal dyspnea) should alert the practitioner to the possibility of acute congestive heart failure. Signs of cardiac failure include raised jugular venous pressure, added heart sounds (S₃ [the presence of a third heart sound], in particular), pulmonary crackles (indicating pulmonary edema), hepatomegaly, and peripheral edema. The presence of any of these signs or symptoms warrants a complete cardiac evaluation prior to initiating any elective procedure.^{1,3}

Arrhythmias

The normal pattern of electric transmission of the heart starts with the initiation of the impulse in the sinoatrial (SA) node, spreading through the atria with a convergence of the impulse at the atrioventricular (AV) node. There is a delay of conduction through the AV node, accounting for the P–R interval on the echocardiogram (ECG; 100 ms). This interval is prolonged by parasympathetic (vagal) stimulation and shortened by sympathetic activity. Activation of the ventricles starts on the left side of the interventricular septum, crossing over to the right at the midpoint of the septum. The impulse spreads through the Purkinje system to the apex. The wave of depolarization then moves along the walls of the ventricles from the endocardium to the epicardium to reach the AV groove.

Perioperative cardiac arrhythmias are caused by abnormalities of cardiac impulse formation, impulse conduction, or a combination of both. There is a higher incidence of arrhythmias in the perioperative setting, and anesthetic agents are known to alter cardiac impulse generation and conduction. Perioperative catecholamines owing to exogenous administration or endogenous release in the presence of ischemia set the stage for new arrhythmia during this period.^{14,15}

Volatile agents directly decrease SA and AV node automaticity, but increasing extracellular calcium can antagonize this phenomenon. A common occurrence with the use of volatile agents is isorhythmic AV dissociation, in which the AV node generates the pacemaker at a modestly higher rate than the SA node. This is a result of direct depression of the SA node by the volatile agent and some stimulation of the AV node by sympathetic activity. Serious hemodynamic consequences are not usually seen in healthy individuals but are a concern with ventricular noncompliance such as ventricular hypertrophy as a result of atherosclerosis of the aorta or

peripheral vessels. Inhalation agents in general are not otherwise arrhythmogenic, but arrhythmias can be produced in the presence of triggering agents and clinical situations that generate a high catecholamine state. This includes light anesthesia levels (with hypertension and tachycardia), hypoxemia, hypercarbia, and the use of exogenous epinephrine or aminophylline (the latter of which indirectly causes the release of endogenous catecholamines). The arrhythmogenic dose in micrograms per kilogram of epinephrine administered by infiltration with various inhaled agents are 2.1 with halothane, 3.7 with halothane and lidocaine, 6.7 with isoflurane, and 10.9 with enflurane.¹⁶

Paroxysmal supraventricular tachycardias (PSVTs) arise from the SA or AV node, atrium, or an accessory AV connection. They are common arrhythmias that are usually seen in cardiac surgical patients (20–40%) but can develop in patients undergoing noncardiac surgery (usually major vascular, cancer, or orthopedic procedures). The onset and termination of these rhythms are usually abrupt, with rates between 120 and 300 beats per minute (bpm). The ECG typically identifies the area of origin of the ectopic conduction with a positive P wave being present in SA-node reentry PSVTs, absent or inverted P waves in AV-node origin PSVTs, and altered P wave morphology in intra-atrial reentry PSVTs.

The most common PSVT is atrial fibrillation (> 90% of SVTs in the postoperative period). It can occur as the result of cardiac disease, such as mitral valve disease, congestive heart failure, coronary artery disease, or pericarditis. It can also be the result of systemic processes such as thyrotoxicosis, pulmonary embolus, chronic obstructive pulmonary disease (COPD), alcohol or caffeine excess, or electrolyte disturbances. Changes seen on the ECG are most evident in lead II as an irregular rhythm.

Untreated PSVT can result in ventricular rates that exceed 120 to 200 bpm, which can cause significant hemodynamic insta-

bility. If uncontrolled ventricular rates occur acutely in the perioperative period, prompt treatment is necessary. Rate control is achieved with verapamil (a calcium channel blocker noted for decreasing conduction at the AV node), digoxin, or esmolol (a β_1 -selective blocker). If patients do not convert to sinus rhythm with these agents, electrocardioversion with prior anticoagulation is attempted.

It is interesting to note that a recently performed meta-analysis has demonstrated that β -blockers reduce the incidence of postoperative atrial fibrillation, whereas digoxin and verapamil have no effect. If a PSVT is detected upon routine monitoring, patients should be referred for further evaluation. Acute evaluation is required if the individual is symptomatic and/or the rate is poorly controlled. A complete discussion of the causes and treatment protocols of PSVTs is beyond the scope of this chapter. The reader is hereby referred to the most recent advanced cardiac life support protocols released by the American Heart Association.¹³

Abnormal conduction pathways can present as an irregular rhythm. Wolff-Parkinson-White syndrome is a condition in which such a pathway connects the atria to the ventricles, bypassing the AV junction through the bundles of Kent. As a result of impulses traveling through this accessory pathway, the electrocardiogram demonstrates a shortened P–R interval (< 0.12 s), a wide QRS complex (> 0.10 s), and a characteristic slurring of the upstroke of the R wave (called a delta wave) (Figure 3-1). This extra or accessory electric pathway is present in approximately 1.5 per 1,000 people. It runs in families in < 1% of cases. In the majority of individuals, it is completely silent and is only detected on a routine ECG. In a small proportion of patients, the extra electric pathway generates an electric circuit that produces a very rapid heart rate. Most patients tolerate this well, but some experience very troublesome palpitations,

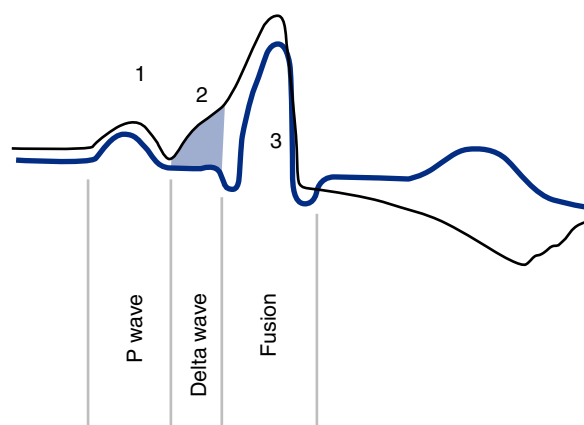


FIGURE 3-1 Demonstration of the delta wave in Wolff-Parkinson-White syndrome.

light-headedness, and blackouts. A very small minority of patients may die suddenly from ventricular fibrillation. The ideal treatment in patients with symptoms is to destroy the extra electric pathway using radiofrequency ablation. Younger patients (< 25 yr) are most at risk of sudden death and require further tests to assess their possibility of developing life-threatening electric disturbances. This is best done with an exercise test under the supervision of a cardiologist. The abrupt disappearance of the delta wave on the ECG as the heart rate increases is a good sign, obviating the need for further investigation. If this does not happen, further electrophysiologic testing is recommended.¹⁷

Ventricular arrhythmias can be classified as benign, potentially malignant, and malignant. Benign ventricular ectopy (ie, premature ventricular contraction) occurs in a normal heart with or without a previous history of arrhythmias, is asymptomatic, and generally does not warrant treatment unless hemodynamic perturbations are noted. Nonspecific cardiac challenges such as hypoxemia, hypercarbia, acidemia, sympathetic surge, drug effects, and electrolyte disturbances should be investigated and treated as necessary. A recently completed study demonstrated a 6.3% incidence of pre-

ature ventricular beats, but only 0.62% suffered severe adverse outcomes, which, according to the author, may have been related more to the aggressive treatment employed in these cases. More than six premature ventricular contractions per minute, especially if they are multifocal, are considered to be ventricular tachycardia and should be treated accordingly.¹⁶ Ventricular tachycardia with a pulse is treated using cardioversion or antiarrhythmia medication in a controlled monitored setting. Pulseless ventricular tachycardia is managed in the same manner as ventricular fibrillation, as described below. After assessing an unconscious victim for responsiveness, breathing, and a pulse, the airway should be opened, two rescue breaths given, and cardiopulmonary resuscitation initiated until a defibrillator is obtained. The rhythm should be assessed, and if ventricular tachycardia without a pulse or ventricular fibrillation is detected, progressive electric shocks should be administered at 200 J, 200 to 300 J, and 360 J using a conventional defibrillator or an automatic external defibrillator. Less energy is needed for a biphasic defibrillator (eg, 120 J, 150 J, and 200 J). If the rhythm is persistent, epinephrine in 1 mg doses every 3 to 5 minutes or vasopressin as a single 40-unit dose should be administered. Defibrillation at maximum dose (360 J or the biphasic equivalent) should be repeated after the catecholamine (epinephrine or vasopressin dose). If unsuccessful, doses of amiodarone, lidocaine, procainamide, or magnesium may be attempted followed by defibrillation at a maximal dose. For the most part, these drugs have only preventive roles in case of recurrence of the arrhythmia.^{13,17}

Automatic Implantable Cardioverter Defibrillators and Pacemakers

The first automatic implantable cardioverter defibrillator (AICD) was placed in 1980

and became commercially available in 1986. In recent years the use of AICDs has become widespread and has significantly reduced cardiac death in this susceptible population from 40 to 60% to < 2 to 3% over a 3-year postimplantation period. They are primarily used in cases of ventricular ectopy or spontaneous/recurrent episodes of ventricular tachycardia/fibrillation despite drug therapies. For the practitioner treating an individual with an AICD, it is important to realize that basic and advanced cardiac resuscitation should proceed as if the individual does not have the device. The shock delivered by the appliance may be discernible but does not pose any risk to the caregiver. The proper functioning of the device should be checked after resuscitation. In addition, the use of magnetic resonance imaging (MRI) is contraindicated when the device is in place. Since electrocautery can cause the device to administer an inappropriate shock, the device should be inactivated prior to using any electrosurgical equipment.

Presently there are over 1,500 types of pacemakers working in over two million individuals. In general, they are used for bradycardia and to prevent resultant low-cardiac output states. Modern devices adapt the rate to the metabolic needs of the patient. Sensors of oxygen saturation, right ventricular pressure, central venous blood temperature, and body movements help to adapt the rate. No pacemaker beats are observed if the intrinsic rate is greater than the threshold of the pacemaker. If the pacemaker is functioning, there should be a pacemaker spike on the down slope of the R wave, ST segment, or T wave with a QRS complex following in a one-to-one relationship. Pacemaker failure in the perioperative period can occur as a result of hypokalemia, hypo- or hyperventilation, or acute ischemia. Some pacemaker generators can be affected by electrocautery. It is advisable to use bipolar cautery with the lowest possible current and to avoid using cautery within 13 cm of the

pacemaker (usually located in the subpectoral region or “beltline” of the anterior abdominal wall). Avoidance of the use of MRI is advisable as well. A discussion with the patient’s cardiologist prior to surgery is prudent.¹⁷

Electrolytes and Acid-Base Disturbances

With any arrhythmia, coexisting acid base and electrolyte disturbances should be identified and corrected. Part of the perioperative assessment of hypoxia is the maintenance of acid-base balance. Normal pH of arterial blood is 7.4 and is maintained to within 0.05 (ie, the normal pH range of the blood is 7.35 to 7.45). The main buffering of acids occurs through the lungs (through the conversion of carbonic acid [H_2CO_3] to CO_2 and H_2O) and the kidney (through the base bicarbonate [NaHCO_3]).

Respiratory acidosis occurs when the lungs are not exhaling CO_2 adequately. This can occur with emphysema or respiratory depressive states such as oversedation, respiratory insufficiency, and arrest. Conversely, respiratory alkalosis occurs when too much CO_2 is expelled as in hyperventilation, neurogenic disorders, and salicylate toxicity (which, interestingly, is accompanied by metabolic acidosis).

Metabolic acidosis is caused by a deficit of the base bicarbonate. Normally there is an H_2CO_3 -to- NaHCO_3 ratio of 1:20. H^+ is excreted in the urine, and bicarbonate is reabsorbed into the renal tubules to maintain this ratio. With the presence of excess acid, the bicarbonate combines with this source of H^+ , is excreted, and is therefore no longer available for its usual buffering role. This results in an upset of the 1:20 ratio and acidosis. Lactic acid from muscle activity or anaerobic conditions, diabetic ketoacidosis, renal failure, or exogenous sources such as methanol, ethanol, or paraldehyde can all serve as the alternative acid source. A method to determine whether metabolic acidosis is pre-

sent is to calculate an anion gap (if information on electrolytes is available):

$$\text{Anion gap} = \text{Na}^+ - ([\text{Cl}^-] + [\text{HCO}_3^-])$$

A normal range is 10 to 14 mEq/L.

Metabolic alkalosis is caused by a relative increase in bicarbonate. Only rarely is this caused by the exogenous administration of bicarbonate since the kidney normally excretes excess bicarbonate in an individual who is well hydrated and has good kidney function. More commonly this condition occurs owing to electrolyte disturbances such as occur as a result of vomiting, nasogastric suctioning, or diuretic use. Primarily this can occur through shifts in intracellular potassium.

Hypokalemia increases the excitability and automaticity of cardiac muscle, increasing the possibility of arrhythmias. Hypomagnesemia can potentiate this effect by decreasing the extrusion of intracellular calcium, which is also arrhythmogenic in cardiac conduction cells. Assessment of electrolytes and their correction is therefore warranted in acid-base perturbations.

Examples of Acid-Base Analysis

1. Note the pH value: $\text{pH} < 7.35$ = acidosis; $\text{pH} > 7.45$ = alkalosis.
2. Note the value of partial pressure of carbon dioxide in arterial blood (PaCO_2 value).

If it is the same sign as the pH, the condition is metabolic in nature. If it is the opposite in sign, the condition is respiratory. Therefore, $\text{pH} < 7.35$ and $\text{PaCO}_2 < 40$ mm Hg indicate metabolic acidosis; $\text{pH} < 7.35$ and $\text{PaCO}_2 > 40$ mm Hg signify respiratory acidosis.

This represents a method of analysis that is easy to remember. The basis involves the underlying cause of each condition. Respiratory acidosis is primarily caused by an elevation of CO_2 , causing a compensatory elevation of carbonic acid in the lung with

a resultant decreased pH. Metabolic acidosis is caused by the addition of an acid source to the normal acid-base buffering system. This acid source lowers the pH. One of the methods of buffering this acid is the carbonic acid system in the lung. Respiration rate and depth increase in an attempt to eliminate the additional CO_2 produced, lowering the CO_2 . Ultimately, however, this system cannot eliminate all of the additional acid and maintain the normal acid-base ratio.¹⁸

The cause of alkalosis can be determined in a similar manner: $\text{pH} > 7.45$ and $\text{PaCO}_2 > 40$ mm Hg indicate a metabolic condition; $\text{pH} > 7.45$ and $\text{PaCO}_2 < 40$ mm Hg signify respiratory alkalosis.

3. Confirm the acid-base relationship through analysis of the bicarbonate level (assuming normal kidney compensations are present).

In respiratory acidosis the kidney should retain bicarbonate and reestablish the normal 1:20 acid-to-base ratio (ie, the bicarbonate level should remain at its normal value of 24 mEq/L). In metabolic acidosis there is usually a bicarbonate deficit (ie, bicarbonate level < 24 mEq/L).

Case Example 1 A 54-year-old man is referred for lethargy. A review of systems reveals polydipsia, polyphagia, and polyuria. His laboratory results are as follows: arterial blood gases reveal a pH of 7.22, PaCO_2 of 24 mm Hg, and HCO_3^- of 12 mEq/L. Serum chemistries reveal $\text{Na} = 130$ mEq/L, $\text{Cl}^- = 94$ mEq/L, $\text{K} = 4.5$ mEq/L, and glucose = 600 mg/dL.

In this example, the pH is < 7.35 ; therefore, it is a case of acidosis. The PaCO_2 is < 40 mm Hg; therefore, the process is metabolic acidosis. The bicarbonate level (12 mEq/L) confirms a relative bicarbonate deficiency consistent with metabolic acidosis. An anion gap analysis is as follows:

$$\text{Na}^+ - ([\text{Cl}^-] + [\text{HCO}_3^-]) \\ 130 - (12 + 94) = 31.5$$

This reveals the presence of an anion gap metabolic acidosis, consistent with diabetic ketoacidosis based on the clinical presentation and elevated glucose level (600 mg/dL).

Case Example 2 A 75-year-old woman was recently started on furosemide to treat pedal edema. She describes a loss of energy and a light-headed sensation when arising from a seated position. Her arterial blood gases indicate a pH of 7.53, PaCO₂ of 52 mm Hg, and HCO₃⁻ of 32 mEq/L. Serum chemistries show the following levels: Na = 129 mEq/L, Cl⁻ = 90 mEq/L, K = 3.0 mEq/L, and glucose = 120 mg/dL.

In this case, the pH (7.53) and PaCO₂ (52 mm Hg) reveal the presence of an alkalotic state. This is confirmed by the bicarbonate level (32 mEq/L). Metabolic alkalosis is often caused by secondary volume depletion with resultant electrolyte shifts. The loss of intracellular potassium can cause the shift of protons (H⁺) into the cell to maintain neutrality.

Renal Insufficiency

It is interesting to note that an elevated creatinine is presently included as a factor in risk assessment for surgery.² Acute renal failure is primarily a result of intraoperative renal hypoperfusion. It is usually seen in cardiopulmonary bypass procedures and thoracoabdominal and abdominal aortic aneurysm repairs, where its incidence is reported to be as high as 15%, 25%, and 5.4%, respectively.^{19–21} In addition to surgical type, preoperative renal insufficiency is the single consistent predictor of postoperative renal failure.¹⁹ Additional insults that may further predispose a patient to perioperative kidney failure are the presence of an already ischemic state caused by renal artery stenosis, volume depletion, and diabetes, or a recent acute ischemic event caused by hemor-

rhage or exposure to radiocontrast agents. Many other conditions can predispose the kidneys to ischemic injury, including sepsis, cirrhosis, jaundice, hepatorenal syndrome, congestive heart failure, shock, malignant hypertension, preeclampsia, sickle cell anemia, collagen vascular diseases, and multiple myeloma. Many drugs also potentiate the risk of ischemic renal injury through alterations in intrarenal hemodynamics, including angiotensin-converting enzyme inhibitors, nonsteroidal anti-inflammatory drugs, cyclosporine, tacrolimus, and amphotericin B.^{19,22}

The most susceptible area to ischemic injury is the tubular cells of the thick ascending loop of Henle and a portion of the proximal convoluted tubules located in the renal medulla (Figure 3-2). The cells in this region are rich in mitochondria and are responsible primarily for chloride ion absorption. A combination of low blood flow (compared with that in the renal cortex) and high metabolic demand accounts for this susceptibility. Initially there is a loss of urine-concentrating ability as the normal medullary gradient dissipates, followed by a decline in urine output as tubules become obstructed and denuded.

Traditionally, the management of acute renal failure has been the maintenance of urine output through the use of intravenous hydration and diuretics such as furosemide and mannitol in addition to low-dose dopamine to maintain renal perfusion. Recently this practice has come into question since increasing renal blood flow elevates the oxygen demand at the medulla and may lead to further injury.¹⁹ Present research is directed at regulating renal vasoactive substances discovered in animal models including prostaglandins (especially prostaglandin E₂), angiotensin II, nitric oxide, endothelin, and adenosine.²³

Since volume depletion and hypotension are risk factors for the development of acute renal failure, preoperative testing of blood urea nitrogen and creatinine should be conducted in patients with a known his-

tory of renal insufficiency or a disease mechanism (eg, diabetes mellitus) in which kidney damage may be present and significant volume loss or hypotension may occur. In addition, the use of intraoperative invasive monitoring (ie, central venous pressure or pulmonary capillary wedge pressure) may be warranted in these cases.¹⁹

Pulmonary Assessment

Asthma

Asthma is a disease characterized by an episodic variable airflow obstruction with increased airway reactivity. Recently the importance of submucosal inflammation and its control in managing asthma has been stressed. Bronchoconstriction in asthmatics is triggered by a stimulus such as an antigen, exercise, or exposure to cold. The trigger elicits an acute inflammatory cascade, characterized by degranulation of mast cells and activation of eosinophils and macrophages in the airway. Released leukotrienes, histamines, and bradykinins increase vascular permeability and resultant edema. The airways fill with mucus and inflammatory cells, and smooth muscles contract as a response to released mediators and an increased cholinergic tone.^{24,25}

Heightened airway responsiveness can increase the likelihood or severity of bronchospasm under anesthesia. Aspects of the patient's history that may indicate the potential for problems to arise include frequent nocturnal awakenings from bronchospasm, increased necessity for inhaler use, recent hospitalizations or emergency department visits, a change in the amount or quality of secretions, or a recent viral illness or cold symptoms. Spirometry is helpful in the initial diagnosis and chronic management of reactive airway disease. Its routine use adds little information to the preoperative assessment that cannot be ascertained by the recent history and physical examination. Repeat assessments over time can be helpful, however, as subtle changes in flow rates can be detected by spirometry before they

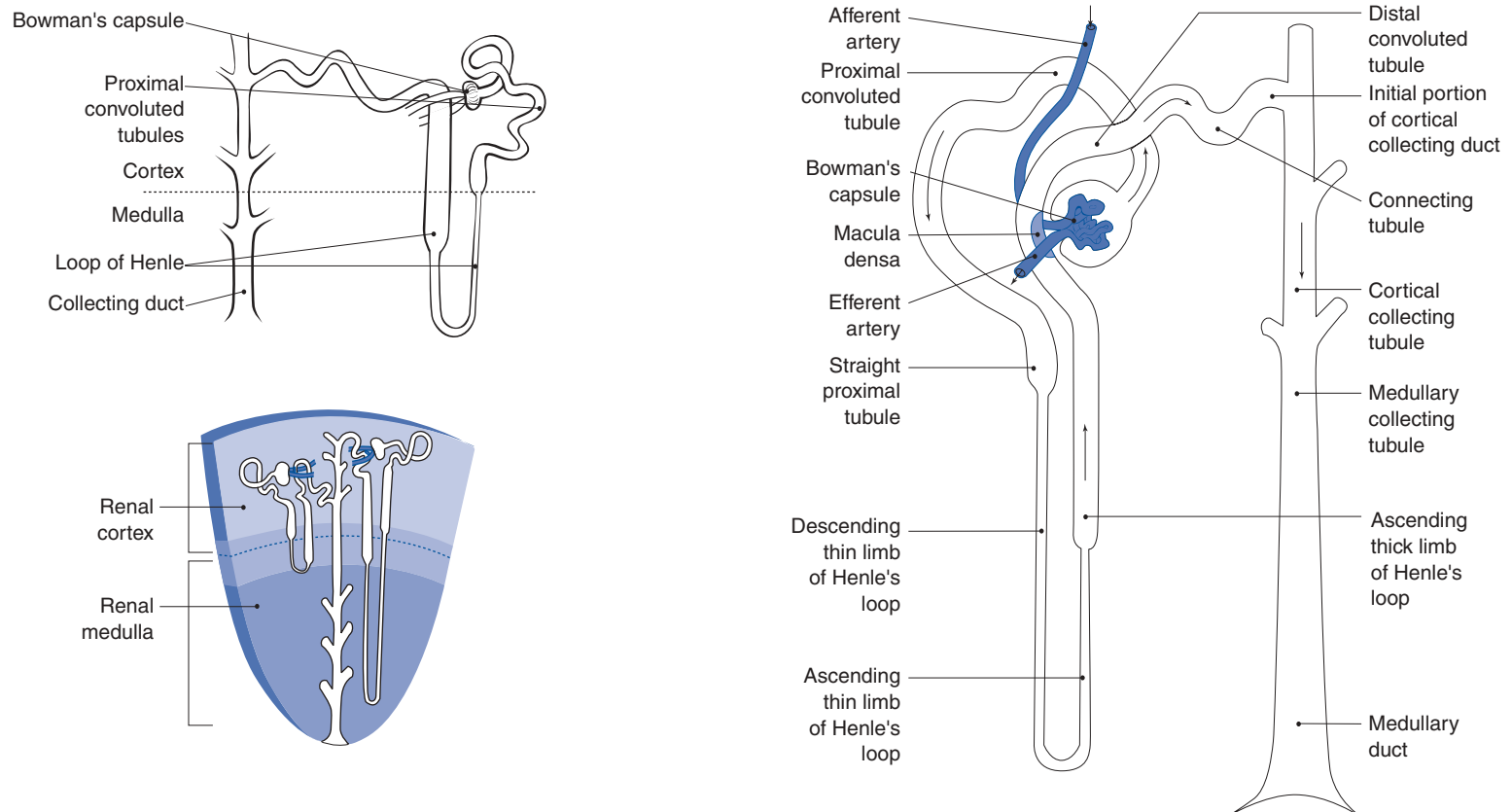


FIGURE 3-2 Normal renal architecture.

become symptomatic; this allows preventive treatment to be initiated.

The most common parameters that are assessed over time are the forced expiratory volume generated in the first second of exhalation and the peak expiratory flow rate (Figure 3-3).²⁶ These parameters can be measured with inexpensive handheld devices. A 20% variation in peak expiratory flow rates is normal. Rates that fall to 50 to 80% below normal are considered a moderate exacerbation. Flow rates < 50% of baseline are considered severe and require prompt medical attention.

The term *reactive airway disease* is considered by some individuals to be synonymous with *asthma*. However, airway reactivity is also increased owing to allergic rhinitis, bronchitis, emphysema, and respiratory viral infections. Bronchospasm is a physical sign of acute increased airway resistance. It is associated with tachypnea, wheezing, air trapping, and worsened gas

exchange. Under anesthesia wheezing and bronchospasm can occur with or without a prior history of reactive airway disease. Most wheezing is self-limited and requires no intervention, but it can indicate the initiation of a more severe bronchospasm. Patients with symptoms of bronchospasm preoperatively should have elective procedures postponed.²⁶

Whereas asthmatics have chronic hyperactivity of the airways, patients with upper respiratory tract infections (URIs) have acute airway reactivity that can last up to 6 weeks after recovery from the initial infection. Airway hyperactivity in URIs is neurally mediated with an increase in vagal-mediated bronchoconstriction. Children with a concomitant URI are especially susceptible to bronchospasm. These children are two to seven times more likely to have adverse events in the perioperative period, and there is an increased risk of postoperative desaturation in these

patients. The risks are highest in those patients undergoing endotracheal intubation (in whom there is an 11-fold increase in perioperative respiratory complications). Definitive criteria for canceling a surgery to be performed under sedation or general anesthesia have not been established, and the decision is often subjective. Suggested criteria for cancellation include the necessity of endotracheal intubation, parental observation that the child is acutely ill the day of surgery, the presence of nasal congestion and cough, concomitant exposure to passive smoke, and active sputum production. Most surgeons agree that the planned surgery, if elective, should be postponed until after the acute symptoms have resolved and have not recurred for a 3-week period after the initial evaluation.²⁷

Treatment of a Reactive Airway

Inhaled short-acting β_2 -adrenergic agonists are the drug of first choice for the treatment

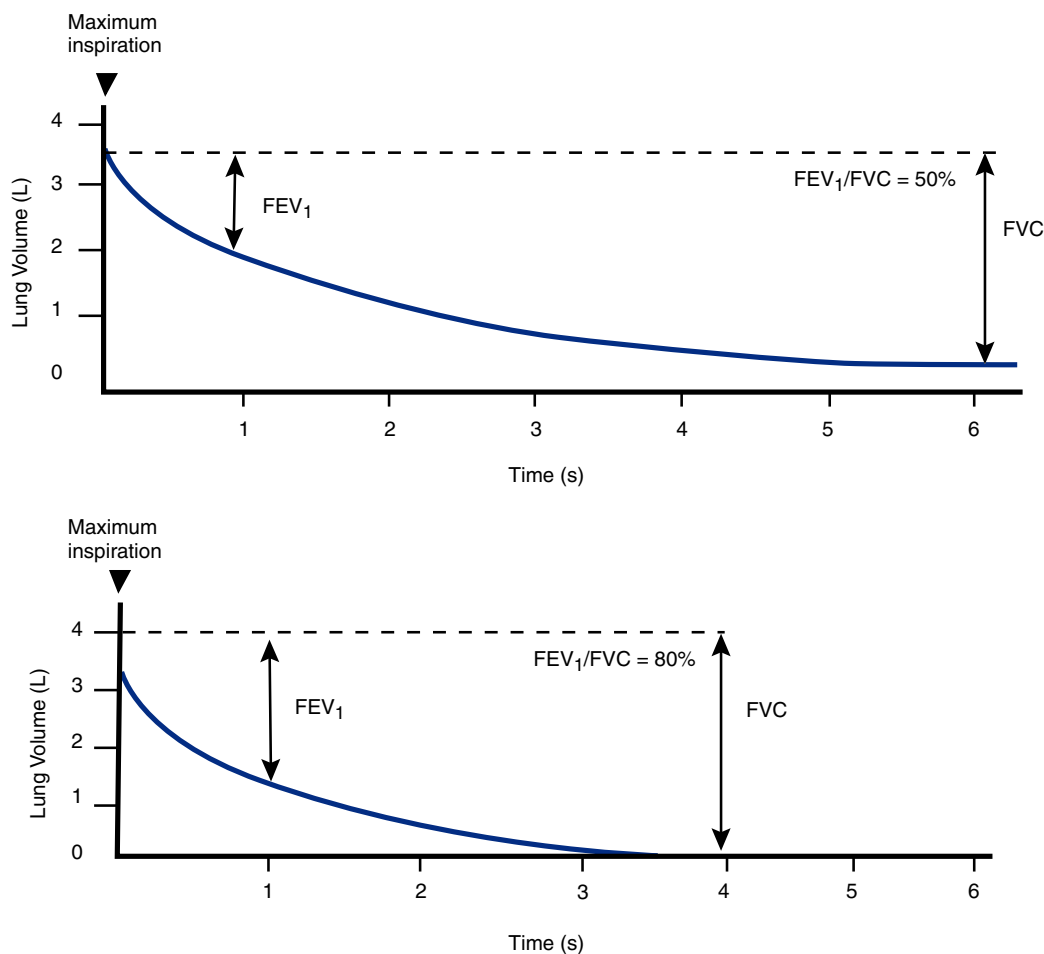


FIGURE 3-3 Comparison of forced expiratory volume in 1 second (FEV_1) and forced vital capacity (FVC) in a patient with obstructive lung disease (A) and a normal individual (B).

of acute bronchospasm. β_2 -Agonists directly relax smooth muscle, aid in the stabilization of mast cells, and inhibit the release of acetylcholine from postganglionic cholinergic nerves. The inhibition of the cholinergic response is important because bronchospasm during a surgery is often mediated by a vagal response. Doses should be limited by side effects rather than by an arbitrary number of inhalations. In general, intubated patients require twice the drug dose since the delivery of drug through the endotracheal tube is inefficient. If the patient is unconscious, the β_2 -agonist can be delivered subcutaneously or intravenously, usually as epinephrine. Intravenous epinephrine can be used safely in low doses, but dysrhythmias and other undesirable effects may occur in older individuals.

Glucocorticoids are useful in asthma in patients who have not adequately responded to β_2 -agonists. Their reported benefits include reduction of inflammation, histamine, and arachidonic acid metabolites. Anticholinergic drugs such as ipratropium cause bronchodilation directly and blunt bronchoconstriction from cholinergic-mediated triggers. Both steroids and anticholinergic agents enhance the activity of β_2 -agonists but are not indicated for acute exacerbations of bronchospasm.

In the past theophylline was frequently recommended for acute exacerbations of bronchospasm; however, this has been encouraged less in recent years since its potency as a bronchodilator is less than the β_2 -agonists and it frequently produces toxicity and undesirable side

effects including dysrhythmias. In some patients with chronic asthma or COPD, theophylline can decrease the severity and frequency of attacks and decrease steroid requirements. Its mechanism of action also has been questioned recently. Although it does increase concentrations of cyclic nucleotides (ie, cyclic adenosine monophosphate) in airway smooth muscle and inflammatory cells by inhibiting the phosphodiesterase isozyme, it also has been demonstrated in dogs to produce bronchodilation by increasing the release of endogenous catecholamines. (Halothane appears to block this effect.) The drug also acts as an adenosine-receptor antagonist, which may help to mediate its effects on ventilation and mediator release.²⁸ Cromolyn sodium reduces the degranulation of mast cells, inhibiting the release of histamine and leukotrienes. As such, it is useful as a prophylaxis against acute attacks in patients with asthma. It has no beneficial value in the management of acute bronchoconstriction. The latest approach in reactive airway management is to block the conversion of arachidonic acid to leukotrienes. Similar to other measures that are directed at reduction of the inflammatory response, these medications prevent acute exacerbations of asthma or bronchospasm but are not appropriate for acute attacks. An example of a leukotriene inhibitor is montelukast sodium, which specifically blocks the leukotriene D₄ receptor.

Respiratory arrest in the perioperative period is commonly caused by airway obstruction, laryngospasm, or a foreign body in the airway. A further differential diagnosis and treatment algorithm is provided in Figure 3-4.^{29,30}

Perioperative Effects of Tobacco Smoking

Cigarette smoke contains over 3,000 constituents, some of which are toxic or tumorigenic. Carbon monoxide, produced as an end product of burning tobacco, has

a 200 times greater affinity than oxygen for the hemoglobin (Hb) molecule. Carboxyhemoglobin, which can be as high as 15%, predisposes a patient to perioperative hypoxia. Pulse oximetry fails to recognize the presence of carboxyhemoglobin (COHb) as distinct from oxyhemoglobin. Therefore, a patient with 10% COHb may display a saturation of 100% when, in fact, the actual saturation may be closer to 90%. In addition, carboxyhemoglobin has the effect of shifting the oxygen dissociation curve to the left (ie, less oxygen is delivered to tissues; Figure 3-5). The relative hypoxia detected by the body (more specifically, the kidneys) results in an increased release of erythropoietin with a resultant thrombocytosis. In addition, carbon monoxide has a direct effect on the myocardium with increased automaticity and a lower threshold for ventricular fibrillation.³¹

The pulse oximeter functions by positioning a pulsating arterial bed between a two-wavelength light-emitting diode and a detector (photodiode). One wavelength is 660 nm (red), and the other is 940 nm (infrared). Oxygenated hemoglobin absorbs more of the 940 nm wavelength than does reduced hemoglobin, which, in turn, absorbs more of the 660 nm wavelength. The percent saturation reading (SpO₂%) is determined from the ratio of oxygenated hemoglobin to the total hemoglobin. A common difficulty in determining SpO₂ occurs secondary to changes in the strength of the arterial pulse or patient movement, resulting in either no signal or artificially low readings. Causes of these errors include hypothermia, hypotension, the use of vasopressors, electrocautery, artificial or opaque nail finishes, and additional monitors such as an automatic blood pressure cuff or arterial line on the same arm. The effects of other potential sources of error in SpO₂ measurement are given in Table 3-5.³²

Nicotine as a vasoconstrictor can have a significant effect on the cardiovascular system. Similar to other vasoconstrictors,

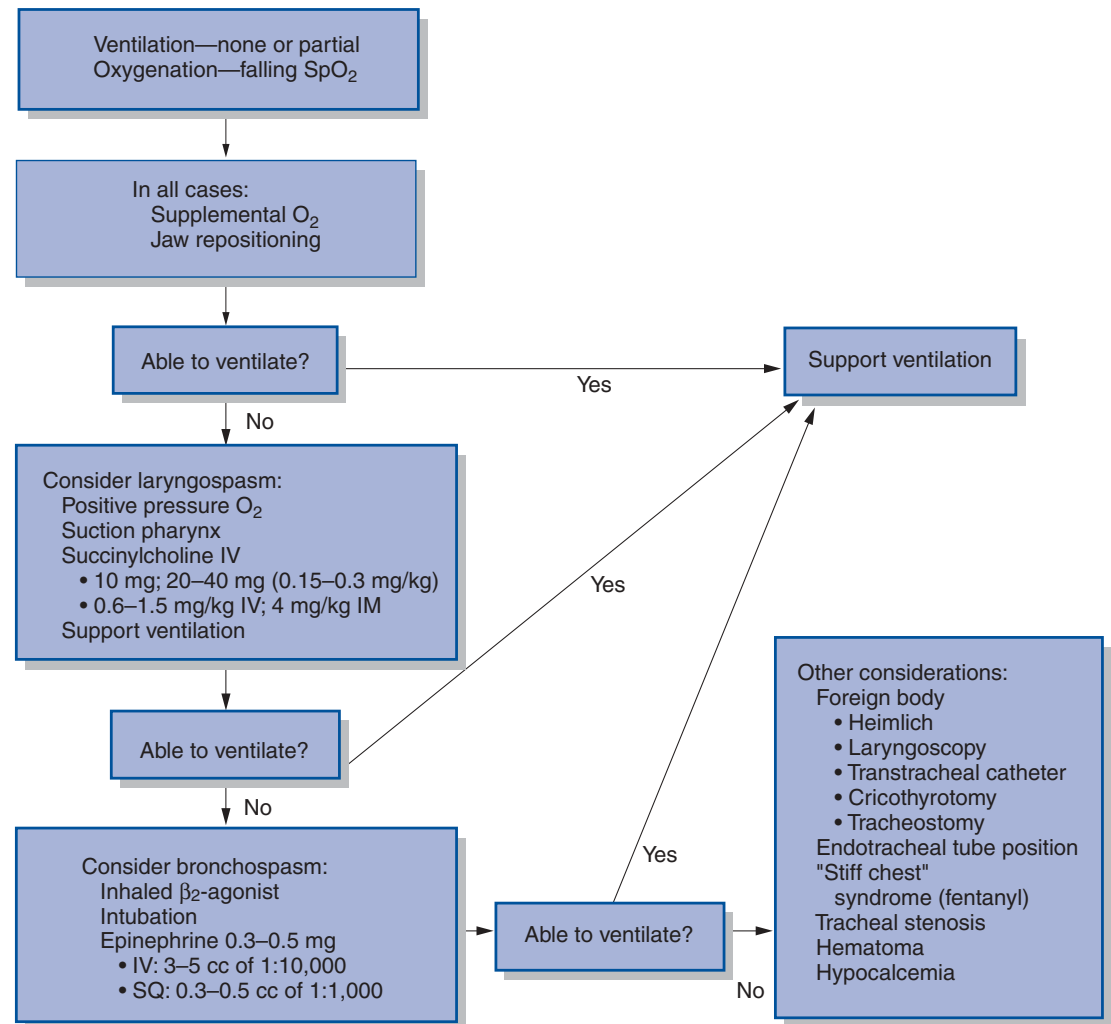


FIGURE 3-4 Respiratory arrest algorithm. Adapted from American Association of Oral and Maxillofacial Surgeons²⁹; American Heart Association.³⁰

increases in heart rate, blood pressure, and peripheral vascular resistance are seen secondary to the activation of the sympathetic nervous system and the release of catecholamines from the adrenal medulla. This effect persists for 30 minutes after smoking a cigarette. Coronary artery vascular resistance is similarly affected, potentially leading to further limited blood flow in areas predisposed to ischemia. Nicotine can also lower the threshold for ventricular fibrillation. Carbon monoxide and nicotine have a relatively short half-life (carbon monoxide $t_{1/2}$ = 4 h; nicotine $t_{1/2}$ = 30–60 min). With regard to potential cardiac complications, there is a direct benefit of abstinence from smoking for 12 to 24 hours.

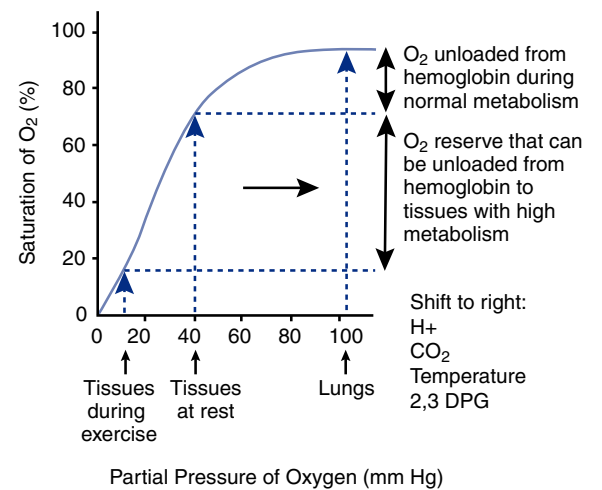


FIGURE 3-5 Oxygen dissociation curve. DPG = 2,3-diphosphoglycerate.

Table 3-5 Some Sources of Error in Pulse Oximetry

Source	Effect on SpO ₂	Action
Carboxyhemoglobinemia	Falsely high SpO ₂	Increase ventilation, eliminate rebreathing
Methemoglobinemia	Falsely low readings, approaching 85%	Administer methylene blue
Hyperbilirubinemia, hyperalbuminemia, hyperlipidemia	Overestimation of SpO ₂ owing to interference of light transmission	Eliminate causative agent
Venous pulsations	Falsely low SpO ₂	Change site

SpO₂ = percent saturation of oxygen.
 © 1992. Reproduced with permission of Alliance Communication Group, a division of Allen Press, Inc., from Mardirossan G and Schneider RE.³²

Unfortunately, detrimental effects on ciliary function and mucus overproduction by respiratory mucosa as a response to tobacco can last for months after smoking cessation. Additional detrimental effects include increased bronchial reactivity, macrophage dysfunction, and changes in pulmonary surfactant. Assuming a smoker has not had long-term deleterious effects related to COPD, these changes require 6 to 8 weeks for complete reversal. Postoperative pulmonary complications including atelectasis, pneumonia, and bronchospasm are much more likely to occur in individuals who smoke.

Interestingly, increased pulmonary complications have been demonstrated when a patient ceases smoking < 8 weeks prior to a planned surgery. Therefore, recommendations to the smoking patient should include at least a 12- to 24-hour smoking “fast” or, more desirably, a cessation of smoking for 8 weeks or more. Patients should be counseled that cessation for periods < 8 weeks may actually predispose the individual to increased pulmonary complications.³³

In recent studies the effects of second-hand or passive smoke have been analyzed. The risks of chronic bronchitis, asthma, and wheezing were all higher in patients exposed to involuntary tobacco exposure, especially in the workplace with a daily exposure of > 8 h/d. The exposure

levels in the workplace have been estimated to be higher than at home, and the time spent at work is usually longer. It is prudent to determine secondhand smoke exposure in the perioperative management of the surgical patient.³⁴

Obesity

The difference between normality and obesity is arbitrary, but an individual with increased fat tissue to such an extent that physical and mental health are affected and life expectancy is reduced should be considered obese. Body mass index (BMI) is widely used in clinical and epidemiologic studies. It is the ratio of body weight (in kilograms) to height (in meters squared). A patient with a BMI of < 25 kg/m² is considered normal. A patient with a BMI of 25 to 30 kg/m² is overweight but at relatively low risk for serious medical complications; one with a BMI of > 30 kg/m² is obese with a higher risk of morbidity and mortality. Morbidly obese individuals have an increased risk of death from cardiorespiratory and cerebrovascular disorders, diabetes mellitus, and certain forms of cancer in addition to many other diseases. These risks are proportional to the duration of obesity. Weight loss reduces the risks but only over time; weight reduction immediately prior to surgery has not been shown to reduce perioperative risk.^{35,36}

Approximately 5% of obese individuals have obstructive sleep apnea (OSA),

which is characterized by episodes of apnea or hypopnea during sleep. Obstructive apnea is characterized by apnea despite a continuous respiratory effort against a closed airway. Central apnea is characterized by the loss of ventilatory effort. Many patients diagnosed with OSA can have periods of central apnea during sleep as well. *Apnea* is typically defined as 10 seconds or more of total cessation of airflow. *Hypopnea* is defined as a reduction in airflow (typically 30–50%) or a reduction sufficient to lead to a 4% decrease in arterial oxygen saturation. The number of apneic or hypopneic episodes believed to be significant is five or more per hour. The exact number is arbitrary, as are the definitions of apnea and hypopnea used by various sleep laboratories. Often individuals with OSA are noted to have nocturnal snoring and daytime hypersomnolence. OSA can lead to hypercapnia, systemic and pulmonary hypertension, and cardiac arrhythmias.

In the perioperative period, episodes of OSA are most frequent during rapid eye movement sleep, the extent of which is relatively low in the initial postoperative period but in excess on the third to fifth postoperative nights. Caution should therefore be exercised any time anesthetic agents are used in a patient with a history or signs and symptoms consistent with OSA. In addition, the continued use of medical therapies including continuous positive airway pressure should be stressed in the perioperative period.³⁷

Morbid obesity is characterized by reductions in functional residual capacity (the volume remaining in the lungs after a normal quiet expiration), expiratory reserve volume (the volume of air that can forcefully be expired after a normal resting expiration), and total lung capacity. These changes have been attributed to mass loading and splinting of the diaphragm (Figure 3-6). Anesthesia compounds these problems and impairs the ability of the obese to tolerate periods of apnea.^{30,31}

Ventilation and Capnography

Capnography is defined as the measurement and display of exhaled carbon dioxide. Increases in end-tidal CO₂ combined with decreases in the respiratory rate of the individual have been demonstrated to be an effective way to detect hypoventilation and respiratory depression. Pulse oximetry, in contrast, indirectly measures oxygenation (partial pressure of oxygen in arterial blood). Based on the oxygen-hemoglobin dissociation curve (see Figure 3-5), there can be a significant decline in oxygen saturation that can go initially undetected by the pulse oximeter. Capnography, by detecting hypoventilation, may be used to prevent hypoxia; upon noting hypoventilation, the practitioner can take measures to improve patient ventilation. Proponents of capnography for non intubated sedation advocate its use over other forms of ventilatory monitors that can experience interference from operator noise, clothing, or surgical drapes. These methods include observation of chest wall movements, plethysmography, auscultation of breath sounds (precordial stethoscope), or palpation or movement of the reservoir bag.

Opponents to the use of capnography for nonintubated sedation cite sampling errors, particularly in individuals who are mouth breathing when nasal sampling is being used.³⁸⁻⁴⁰

Endocrine Assessment

Diabetes Mellitus

Perioperative care of the diabetic patient depends on identification and assessment of the current status of end-organ disease. Long-standing diabetics frequently have compromise in one or more organ system. Commonly associated diseases include atherosclerosis, coronary artery disease, hypertension, cardiomyopathy, cerebrovascular disease, peripheral vascular disease, peripheral and autonomic neuropathy, and/or renal insufficiency. Preoperative evaluation should focus on these concerns, and events of prior surgeries should be reviewed. For more complex procedures, laboratory values that may be reviewed include blood glucose, blood urea nitrogen, creatinine, urinalysis (for glucose, ketones, and proteins), and glycosylated hemoglobin (Hb A_{1c}) levels. Hb A_{1c} levels

reflect the adequacy of glucose control during the previous 1 to 3 months. Levels in nondiabetics range from 5 to 7% of hemoglobin. Levels in diabetics with poor long-term glucose control exceed 8%.⁴¹

With more procedures being performed on an outpatient basis and the length of hospital stays being shortened dramatically, perioperative management of the diabetic patient has become more complicated. Many factors are present that determine the glycemic response, including insulin secretion, insulin sensitivity, overall metabolism, and nutritional intake in addition to the stress and length of the procedure. Surgical stress and some general anesthetic agents, themselves, are associated with increases in the counter-regulatory hormones epinephrine, norepinephrine, glucagon, growth hormone, and cortisol. The effect of these hormones is to elevate insulin resistance, which increases hepatic glucose production and decreases peripheral glucose use. Patients receiving pharmacologic therapy to control their diabetes may also be susceptible to hypoglycemia, especially when fasting preoperatively. Although hypoglycemia can cause significant morbidity, marked hyperglycemia should also be avoided since it can lead to dehydration and electrolyte disturbances and impaired wound healing and predispose to infection or diabetic ketoacidosis in the patient with type 1 DM. This is not to say that patients with historically poor control of their disease should be rapidly normalized presurgically; little evidence supports this approach. In general, the goal for glucose control during surgery should be between 150 and 200 mg/dL. The more unstable the diabetes, the more frequently this level should be assessed in the perioperative period.

As in all patients, underlying cardiac, pulmonary, renal, and electrolyte disturbances and anemia should be evaluated. Assessment should include a focus on the microvascular (ie, renal insufficiency,

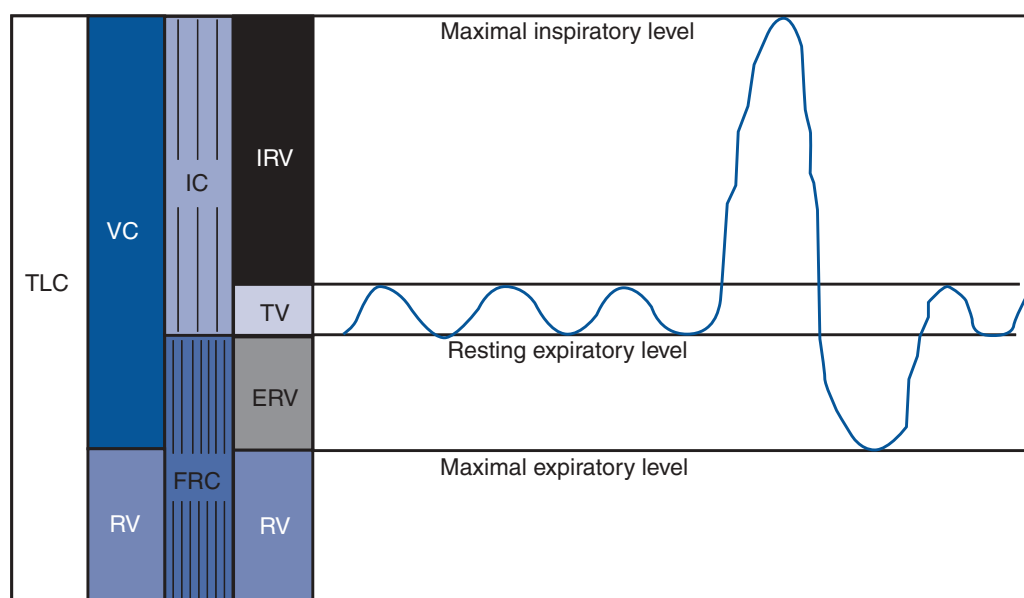


FIGURE 3-6 Summary of lung volumes and capacities. ERV = expiratory reserve volume; FRC = functional residual capacity; IC = inspiratory capacity; IRV = inspiratory reserve volume; RV = residual volume; TLC = total lung capacity; TV = tidal volume; VC = vital capacity.

retinopathy), macrovascular (including atherosclerosis, coronary artery disease, hypertension), and neuropathic signs related to poor diabetes control. Medication use and insulin regimen should be recorded. Management of the patient should be coordinated with the individual who manages the patient's daily protocol. The following are recommended guidelines in the management of patients with diabetes who require a period of nothing by mouth prior to their planned procedure.

Type 2 DM Controlled by Diet Only Measurement of blood glucose should be considered prior to the procedure, after the procedure, and intraoperatively for longer surgeries. Hyperglycemia is treated with short-acting insulin (regular or lispro), usually administered subcutaneously. It is prudent to remind patients prior to discharge of the signs and symptoms of hyperglycemia (discussed below) and to reinforce guidelines for contacting their physician.

Type 2 DM Treated with Oral Hypoglycemic Agents Oral hypoglycemic agents are generally administered the day prior to surgery and withheld the day of surgery. If patients manifest marked hyperglycemia, supplemental insulin may be indicated; the surgery may be performed if electrolyte levels are acceptable. Table 3-6 provides information on common oral hypoglycemic agents.

Types 1 and 2 DM Treated with Insulin For individuals who take long-acting insulin (ie, extended zinc suspension or glargine; Table 3-7), a switch to an intermediate-acting type is initiated a day or two prior to surgery. The regulation of intermediate insulin is then adjusted based on the likelihood of the patient eating lunch. If the likelihood of oral intake at lunch time is high, two-thirds of the normal intermediate dose is given on the morning of the procedure. If the patient is treated with a twice-daily dose of insulin, then one-half of the total morning dose of insulin (including short-acting) should be administered in the morning as intermediate insulin. If the likelihood of consuming lunch is low, one-half of the total morning dose of insulin (including short-acting) should be administered as intermediate-acting insulin for the patient treated with a single insulin dose and one-third for those on a twice-daily regimen. For the patient taking multiple doses of short-acting insulin, one-third of the pre-meal dose of short-acting insulin is administered. Patients treated with continuous insulin infusion therapy (with an insulin pump) are treated with their usual basal infusion rate.

Individual modifications of insulin therapy may be required, and it is advisable to discuss the management with the patient's physician. Procedures scheduled later in the day can be more complex to manage, and intravenous glucose infusion and/or supplemental short-acting insulin may be necessary. Long complex operative

procedures may require intravenous insulin regimens. Table 3-7 reviews the common types of insulin and their onset, peak activity, and duration.

Hypoglycemia and Hyperglycemia: Identification and Management

Direct neurologic symptoms and an adrenergic response characterize the manifestations of hypoglycemia. Neuroglycopenia generally begins with confusion, irritability, fatigue, headache, and somnolence. Prolonged severe hypoglycemia can cause seizures and even focal neurologic deficits, coma, and death. Therefore, any new neurologic symptom in the postoperative period should be investigated for hypoglycemia because prolonged deficit of glucose can result in irreversible neurologic deficits. The adrenergic symptoms include anxiety, restlessness, diaphoresis, tachycardia, hypertension, arrhythmias, and angina owing to catecholamine release in response to hypoglycemia. Recognition of perioperative hypoglycemia can be difficult initially because presenting symptoms can be altered or absent as a result of the effects of anesthetic agents, analgesics, and sympatholytic agents. In addition, diabetics with autonomic neuropathy have blunting of the adrenergic response associated with hypoglycemia.

Hypoglycemia is defined as glucose < 50 mg/dL in adults and < 40 mg/dL in

Table 3-6 Mechanism of Action of Common Oral Hypoglycemic Agents

<i>Drug Class</i>	<i>Example(s)</i>	<i>Mechanism</i>	<i>Notes</i>
α -Glucosidase inhibitors	Acarbose, miglitol	Inhibit intestinal brush border oligo- and disaccharidases	No efficacy until patient is eating
Biguanides	Metformin	Sensitize target tissue (muscle, fat) to insulin action	May potentiate the risk of developing lactic acidosis perioperatively
Thiazolidinediones	Pioglitazone, rosiglitazone, troglitazone	Improve peripheral glucose uptake	No increased incidence of lactic acidosis
Sulfonylureas	Glipizide, chlorpropamide	Stimulate insulin secretion	Higher potential for developing perioperative hypoglycemia

Table 3-7 Onset, Peak, and Duration of Common Insulin Preparations

Type of Insulin	Example	Onset	Peak	Duration
Rapid-acting	Lispro	5–15 min	30–75 min	2–4 h
	Aspart	5–15 min	1–2 h	3–6 h
Short-acting	Regular	30–45 min	2–3 h	4–8 h
Intermediate-acting	NPH	2–4 h	4–8 h	10–16 h
	Zinc suspension	2–4 h	4–8 h	10–16 h
Prolonged intermediate-acting	Extended zinc suspension	3–5 h	8–12 h	18–20 h
Long-acting	Glargine	4–8 h	No peak	24 h
Premixed combination insulin	70/30 or 50/50 (NPH/regular)	30–60 min	Early–late peak: 2–12 h	About 18 h

children. Its treatment is a glucose source if oral intake is possible; however, to avoid the risk of aspiration and delay in absorption, 50 mL of 50% (25 g) of glucose should be administered intravenously. Each milliliter of D50 raises the blood glucose approximately 2 mg/dL. Glucagon (1–2 mg), diazoxide, and octreotide have been used but are typically reserved for sulfonyl urea–induced hypoglycemia.

Perioperatively many regulatory hormones that oppose insulin action are released. Catecholamines, glucocorticoids, growth hormone, and glucagons can cause plasma glucose levels of > 180 mg/dL, exceeding the capacity of the kidney and resulting in glycosuria. Glucose-induced diuresis can occur, resulting in dehydration or the formation of ketone bodies, which, in turn, results in diabetic ketoacidosis. Treatment includes the use of intravenous insulin and appropriate rehydration. One unit of regular insulin typically lowers the glucose 25 to 30 mg/dL in a 70 kg individual. Subcuticular injection should be avoided in the perioperative period owing to unpredictable cutaneous blood flow.⁴²

Adrenal Assessment

Adrenal insufficiency is classified as either primary, owing to disease of the adrenal

glands themselves, or secondary, owing to decreased adrenocorticotrophic hormone (ACTH) because of pituitary or hypothalamus disorders. Primary adrenal insufficiency is also known as Addison’s disease and is thought to be the result of an autoimmune process. Other causes of primary adrenal insufficiency include chronic granulomatous disease including tuberculosis.

Secondary adrenal insufficiency is most commonly seen in patients on chronic glucocorticoid therapy. Patients on steroid therapy may have ACTH suppression a full year after steroid therapy. Symptoms include fatigue, weakness, anorexia, nausea and vomiting, and weight loss. Only in primary adrenal insufficiency is ACTH elevated, indirectly resulting in increased skin pigmentation, especially in skinfolds. In primary adrenal insufficiency, aldosterone levels are low, resulting in dehydration with hyponatremia and hyperkalemia since the role of aldosterone in the kidney is resorption of sodium (and water) and excretion of potassium. In secondary adrenal insufficiency, there are often other endocrine abnormalities present.

In individuals with an intact hypothalamic-pituitary-adrenal axis undergoing a stressful event such as a surgical procedure, the adrenal glands increase their baseline secretion of cortisol. Increasing

cortisol helps maintain hemodynamic stability in the face of stress. Patients with long-term exogenous steroid use have a blunted response to surgical stress compared to that of normal controls, with resultant lower cortisol levels.

Adrenal crisis is usually seen in patients with adrenal suppression and is precipitated by a stressor, typically surgery, trauma, or sepsis. Patients may experience intractable nausea and vomiting, abdominal pain, fever, lethargy, and coma. Hypotension and a narrow pulse pressure (the difference between systolic and diastolic pressure) are evident as shock ensues. Based on these potential risks and anecdotal reports published, supraphysiologic corticosteroid regimens have been recommended for patients on exogenous steroids.

Recent evidence suggests that patients on long-term steroids who receive no perioperative coverage suffer a 1 to 2% risk of incurring a hypotensive crisis. Studies support maintaining patients on their daily steroid dosage throughout the perioperative period or providing smaller steroid dosages rather than the supraphysiologic dosages once routinely recommended. An exception to this practice is the critically ill patient, in whom supraphysiologic dosages are often administered. An example of a suggested steroid regimen based on the degree of stress is provided in Table 3-8.^{43,44}

Thyroid Assessment

Hyperthyroidism primarily affects women, with a female-to-male ratio of approximately 8:1. Common causes of hyperthyroidism include Graves’ disease (a toxic diffuse goiter secondary to an autoimmune reaction caused by stimulatory antibodies to the thyroid-stimulating hormone receptor), toxic nodular goiter, exogenous thyroid hormone (iatrogenic), and iodine administration. The effects of excess thyroid hormone include tachycardia, atrial fibrillation, premature ventricular contractions, worsening of angina pectoris, and high-output cardiac failure

owing to increased β -receptor sensitivity. Respiratory complications include impairment and weakness of respiratory muscles with associated tachypnea, and hypercarbia owing to the associated hypermetabolic state. Patients may be hypovolemic secondary to diarrhea and hyperthermia. Exophthalmos secondary to fatty infiltrate and edema can occur (ie, Graves' orbitopathy) and, if severe, can lead to blindness. Bone resorption with secondary hypercalcemia may occur as well.

It is important to assess the degree of thyroid control through a history taking and physical examination (and confirmatory laboratory examination, if needed). There is a direct correlation between the severity of hyperthyroidism and intraoperative risk. Patients scheduled for elective surgery should be made euthyroid before surgery (this usually requires weeks), and cardiovascular control, as demonstrated by stable vital signs, should be confirmed. If the surgery cannot be delayed and the patient is hyperthyroid, β -blockers are used to slow the heart rate and decrease the potential for arrhythmia. β -Blockers also inhibit the deiodination of thyroxine to the more active triiodothyronine. This latter effect also occurs with the use of propylthiouracil, which additionally inhibits the synthesis of thyroid hormones. Iodine inhibits the release of thyroid hormones but is only given after antithyroid drugs to avoid a thyroid hormone surge.

Failure to recognize that a patient has uncontrolled hyperthyroidism can result in a thyroid storm, which can manifest either during the procedure or in the postoperative period. It is characterized by marked tachycardia, hyperthermia, weakness, and an altered level of consciousness. Untreated, the result can be congestive heart failure and/or cardiovascular collapse. Treatment includes airway and ventilatory support with increased minute ventilation to control excessive CO_2 production. Body temperature should be aggressively managed with cool intravenous fluids, cooling blankets, and decreased ambient temperature. β -Blocker administration should be started immediately to interrupt the adrenergic response. Traditionally, a nonselective β -blocker, propranolol, has been used. More recently the use of esmolol, a shorter-acting β_1 -selective blocker has been advocated. Patients with COPD, asthma, and congestive heart failure are more likely to tolerate therapy with a β_1 -selective agent. Hemodynamic monitoring and the correction of fluid and electrolyte imbalances should be performed. The differential diagnosis of a thyroid storm includes malignant hyperthermia (MH; see below), neuroleptic malignant syndrome, and pheochromocytoma.

Women are ten times more likely to develop hypothyroidism than are men. The most common cause is iatrogenic, secondary to surgical resection or radioactive ablation of the thyroid gland. Hashimoto's thyroiditis, an autoimmune disorder characterized by the presence of antimicrobial antibodies, is the most common noniatrogenic cause of hypothyroidism.

Hypothyroidism is usually insidious in onset and often goes unrecognized despite multisystem effects. The most common signs and symptoms include lethargy, constipation, cold intolerance, weight gain, and anorexia. Although severe hypothyroidism can result in increased morbidity

and mortality, most experts agree that mild to moderate hypothyroidism poses no increased surgical risk. Elective surgery should be postponed in hypothyroid patients until adequate replacement therapy is administered. Usually this can be accomplished by oral thyroxine supplementation. Two weeks are required before the patient has symptomatic improvement. Triiodothyronine, which is the active hormone, can be administered for a more acute response, but it usually takes more than 2 weeks until the thyroid-stimulating hormone, the marker for adequate thyroid function, normalizes.⁴²

Malignant Hyperthermia

MH is a rare autosomal dominant trait in which individuals inherit hypersensitivity to specific trigger agents that cause the rapid accumulation of calcium into the sarcoplasmic reticulum of skeletal muscle. This causes sudden hypermetabolic reactions, leading to hyperthermia and massive rhabdomyolysis. Trigger agents include potent volatile anesthetic agents and succinylcholine (a depolarizing muscle relaxant). Halothane has traditionally been described as a causative agent and forms the basis of the diagnostic test to confirm MH. However, all volatile agents, including sevoflurane according to recent reports, can induce MH.⁴⁵

The reaction that typically occurs is abrupt and severe, requiring immediate attention. Elevation of end-tidal CO_2 is an early sign, prior to temperature elevation. The main treatment is dantrolene, a non-specific muscle relaxant. Its mechanism is likely the blockade of the release of calcium from the sarcoplasmic reticulum. In an acute episode of MH, a supply of at least 36 vials of dantrolene should be available for immediate use; this corresponds to a maximum dose of 10 mg/kg in a 70 kg adult. In an acute attack dantrolene is administered repeatedly in 2 to 3 mg/kg doses every 5 to 10 minutes. Each vial needs to be reconstituted with 60 mL of

Table 3-8 Suggested Preoperative Surgical Steroid Coverage in Patients on Chronic Corticosteroid Regimens

<i>Surgical Stress</i>	<i>Steroid (Hydrocortisone) Dose</i>
Low	25 mg on day of surgery
Moderate	50–75 mg on day of surgery, 1 or 2 d taper
Major	100–150 mg on day of surgery, 1 or 2 d taper

Adapted from Salem M et al.⁴⁴

sterile water. Although the use of dantrolene has reduced the mortality risk from 50% prior to its use, there still is approximately a 10% mortality rate.

There is an estimated occurrence of MH in 1 of 15,000 children and 1 of 50,000 adults. Those at risk for an attack include survivors of an MH reaction and individuals with muscular dystrophy. The clinical sign of masseter muscle spasm during anesthesia with halothane or succinylcholine may also indicate a susceptibility to MH. The *in vitro* caffeine halothane contracture test is used to evaluate individuals susceptible to developing MH when exposed to triggering agents. Diagnostic tests based on deoxyribonucleic acid are currently available for MH-susceptible individuals. In addition to trigger agents, phenothiazines (such as prochlorperazine) should be avoided since there is a possible association between MH and neuroleptic malignant syndrome (NMS). NMS is a rare, occasionally lethal, idiosyncratic complication associated with neuroleptic antipsychotic drugs. NMS is characterized by high temperature and muscle rigidity. Anxiety and agents with sympathomimetic activity, especially α -agonists, have been demonstrated to aggravate MH experimentally. Agents that some authors have recommended to be avoided owing to sympathomimetic effects include ketamine and atropine. The use of dantrolene prophylaxis in MH patients is uncommon in view of the low likelihood (0–0.62%) of an MH reaction when a trigger-free anesthetic regimen is used. Dantrolene is associated with a high frequency of muscle weakness and postoperative nausea. In the past, outpatient surgery was discouraged. It is now recommended that careful postoperative monitoring be continued for at least 4 hours. However, most oral and maxillofacial surgeons likely avoid performing outpatient sedation for someone with a personal or family history of malignant hyperthermia owing to the factors described.^{45,46}

References

- Goldman L, Caldera DL, Nussbaum SR, et al. Multifactorial index of cardiac risk in noncardiac surgical procedures. *N Engl J Med* 1977;297:845–50.
- Lee TH, Marcantonio ER, Mangione CM, et al. Derivation and prospective validation of a simple index for prediction of cardiac risk of major noncardiac surgery. *Circulation* 1999;100:1043–9.
- Eagle KA, Berger PB, Calkins H, et al. ACC/AHA guideline update for perioperative cardiovascular evaluation for noncardiac surgery—executive summary a report of the American College of Cardiology/American Heart Association Task Force on Practice Guidelines (committee to update the 1996 guidelines on perioperative cardiovascular evaluation for noncardiac surgery). *Circulation* 2002;105:1257–67.
- Bartels C, Bechtel JF, Hossman V, Horsch S. Cardiac risk stratification for high-risk vascular surgery. *Circulation* 1997;95:2473–5.
- Glance LG. Selective preoperative cardiac screening improves five-year survival in patients undergoing major vascular surgery: a cost-effective analysis. *J Cardiothorac Vasc Anesth* 1999;13:265–71.
- Rubin DN, Ballal RS, Marwick TH. Outcomes and cost implications of a clinical-based algorithm to guide the discriminate use of stress imaging before noncardiac surgery. *Am Heart J* 1997;134:83–92.
- Shaw LJ, Hachamovitch R, Cohen M, et al. Cost implications of selective preoperative risk screening in the care of candidates for peripheral vascular operations. *Am J Manag Care* 1997;3:1817–27.
- Norton JM. Toward consistent definitions of preload and afterload. *Adv Physiol Educ* 2001;25:53–61.
- Selzman CH, Miller SA, Zimmerman MA, Harken AH. The case for [beta]-adrenergic blockade as prophylaxis against perioperative cardiovascular morbidity and mortality. *Arch Surg* 2001;136:286–90.
- Garg J, Messerli A, Bakris G. Evaluation and treatment of patients with systemic hypertension. *Circulation* 2002;105(1):2458–61.
- Varon J, Marik P. The diagnosis and management of hypertensive crisis. *Chest* 2000; 118(1):214–27.
- Fleisher L. Evaluation of the patient with cardiac disease undergoing noncardiac surgery: an update on the original AHA/ACC guidelines. *Int Anesthesiol Clin* 2002;40(2):109–120.
- Cummins RO, editor. *Advanced cardiac life support*. Dallas (TX): American Heart Association; 1997.
- Forrest J, Cahalan M, Rehder K, et al. Multicenter study of general anesthesia II. Results. *Anesthesiology* 1990;72:262–8.
- Forrest J, Rehder K, Cahalan M, Goldsmith C. Multicenter of general anesthesia III. Predictors of severe perioperative adverse outcomes. *Anesthesiology* 1992;76:3–15.
- Elamana V. Anesthetic considerations in patients with cardiac arrhythmias, pacemakers and AICDs. *Int Anesthesiol Clin* 2001;39(4):21–42.
- Al-Khatib SM, Pritchett EL. Clinical features of Wolff-Parkinson-White syndrome. *Am Heart J* 1999;138(3 Pt 1):403–13.
- Horne C, Derrico D. Mastering ABGs. *Am J Nurs* 1999;99(8):26–32.
- Sadovnikoff N. Perioperative acute renal failure. *Int Anesthesiol Clin* 2001;39(1):95–109.
- Godet G, Fléron MH, Vicaut E, et al. Risk factors for acute postoperative renal failure in thoracic or thoracoabdominal aortic surgery: a prospective study. *Anesth Analg* 1997;85:1227–32.
- Johnston KW. Multicenter prospective study of nonruptured abdominal aortic aneurysm: part II. Variables predicting morbidity and mortality. *J Vasc Surg* 1989;9:437–47.
- Thadvani R, Pascual M, Bonventre JV. Acute renal failure. *N Engl J Med* 1996;334: 1449–60.
- Solomon R. Radiocontrast-induced nephropathy. *Semin Nephrol* 1998;18:505–18.
- Moudgil G. The patient with reactive airways disease. *Can J Anaesth* 1997;44(5):R77–83.
- Kersjens H, Groen HJ, van der Bij W. Respiratory medicine. *BMJ* 2001;323:1349–53.
- Hurford WE. The bronchospastic patient. *Int Anesthesiol Clin* 2000;38(1):77–90.
- Ferrari L. Do children need a preoperative assessment that is different from adults? *Int Anesthesiol Clin* 1992;40(2):167–86.
- Tobias JD, Kubos KL, Hirshman CA. Aminophylline does not attenuate histamine-induced airway constriction during halothane anesthesia. *Anesthesiology* 1989; 1:723–9.
- American Association of Oral and Maxillofacial Surgeons. *Office anesthesia evaluation manual*. 6th ed. Rosemont (IL): American Association of Oral and Maxillofacial Surgeons; 2000.
- American Heart Association. *Guidelines 2000 for cardiopulmonary resuscitation and emergency cardiovascular care*. *Circulation* 2000;102 Suppl 1:143–308.
- Woehlck HJ, Connolly LA, Cinquegrani MP, et al. Acute smoking increases ST depression in humans during general anesthesia. *Anesth Analg* 1999;89:856–63.

32. Mardirossan G, Schneider RE. Limitations of pulse oximetry. *Anesth Prog* 1992;39:194–6.
33. Kotani N, Kushikata T, Hashimoto H, et al. Recovery of intraoperative microbicidal and inflammatory functions of alveolar immune cells after a tobacco smoke-free period. *Anesthesiology* 2001;94: 999–1006.
34. Radon K, Busching K, Heinrich J, et al. Passive smoking exposure: a risk factor for chronic bronchitis and asthma in adults? *Chest* 2002;122:1086–90.
35. Shenkman Z, Shir Y, Brodsky JB. Perioperative management of the obese patient. *Br J Anaesth* 1993;70: 349–59.
36. Adams JP, Murphy PG. Obesity in anesthesia and intensive care. *Br J Anaesth* 2000; 85:91–108.
37. Benumof JL. Obstructive sleep apnea in the adult obese patient. *J Clin Anesth* 2001; 13:144–56.
38. Bennett J, Petersen T, Burleson JA. Capnography and ventilatory assessment during ambulatory dentoalveolar surgery. *J Oral Maxillofac Surg* 1997;55:921–5.
39. Vascello LA. A case for capnographic monitoring as a standard of care. *J Oral Maxillofac Surg* 1999;57: 1342–7.
40. Bennett J. A case against capnographic monitoring as a standard of care. *J Oral Maxillofac Surg* 1999;57: 1348–52.
41. Jacober SJ, Sowers J. An update on perioperative management of diabetes. *Arch Intern Med* 1999;159:2405–11.
42. Graham GW, Unger BP, Coursin DB. Perioperative management of selected endocrine disorders. *Int Anesthesiol Clin* 2000; 38(4):31–67.
43. Brown CJ, Buie WD. Perioperative stress dose steroids: do they make a difference? *J Am Coll Surg* 2001;193:678–86.
44. Salem M, Tainish RE, Bromberg J, et al. Perioperative glucocorticoid coverage: a reassessment 42 years after emergence of a problem. *Ann Surg* 1994;219:416–25.
45. Ducart A, Adnet P, Renaud B, et al. Malignant hyperthermia during sevoflurane administration. *Anesth Analg* 1995;80:609–11.
46. Abraham RB, Cahana A, Krivosic-Horber RM, Perel A. Malignant hyperthermia susceptibility: anesthetic implications and risk stratification. *QJM* 1997; 90(1):13–8.

Preoperative Patient Assessment

Joel M. Weaver, DDS, PhD

The primary purpose of preoperative patient assessment is to provide sufficient information to the surgical and anesthetic team members to permit them to formulate the most appropriate surgical and anesthetic plans. The same process should be used for both office and hospitalized patients, including trauma victims; medically, mentally, or physically compromised patients; and healthy patients having elective surgery with either local anesthesia alone, conscious sedation, deep sedation, or general anesthesia. Depending on the variables discovered in the assessment, modifications to the usual surgical and anesthetic regimens may be necessary to improve the chances of attaining a satisfactory outcome.

The components of the preoperative assessment are (1) a review of the previous medical records if available, including all medical, surgical, and medication information; (2) a personal interview with the patient or knowledgeable guardian to obtain additional past medical and surgical histories; (3) a focused physical and psychological examination of the patient, with emphasis on the cardiovascular and respiratory systems and the adequacy of the airway in regard to the potential for difficulty in attaining and maintaining its patency during deep sedation or general anesthesia; (4) a review of results of the medical tests and referral for consultation if needed; (5) a determination of the patient's periopera-

tive risk; and (6) a thorough explanation of the various treatment options in discussion with the patient or guardian to assist with their treatment decisions and to obtain their informed consent.

Information such as current medications, drug allergies, the likelihood of pregnancy, family history of malignant hyperthermia, a significant medical or surgical history, and, if the procedure is scheduled at the time of evaluation, an assessment of fluid or food ingestion may influence the surgeon's choice on how to proceed.

A review of the previous medical records can provide a wealth of information that the patient may not know or be able to relate during their interview. For example, if there is previous documentation of a "difficult airway" whereby an anesthesiologist had significant difficulty with mask ventilation and needed multiple attempts to intubate a severely retrognathic patient, an oral surgeon might not choose to administer deep sedation or light general anesthesia to that patient in the office. Better alternatives might include light conscious sedation in the office with only those drugs for which pharmacologic antagonists exist, or possibly an awake fiberoptic intubation in the office, surgicenter, or hospital prior to the induction of general anesthesia. For patients who are poor historians, previous medical records may be the sole source of information concerning previous surg-

eries and medical problems. Unfortunately, timely access to previous medical records may be difficult or impossible.

Usually, information concerning the patient's past medical, surgical, and anesthetic history can be gathered by a personal or telephone interview. Although completion of a health questionnaire or medical history form by the patient may be a starting point for the interview, it alone does not meet the important goal of establishing a personal dialogue with the patient to ensure that this information is as complete and accurate as possible. The true value of the medical history form is to alert the interviewer as to which areas need further explanation. For example, a positive indication of asthma by the patient on a health screening questionnaire is relatively worthless information by itself; it must be followed up with further questioning concerning the frequency of attacks, its precipitating factors, successful measures for treatment, the most recent attack, and the degree of severity of symptoms, including previous emergency room treatments for severe asthmatic episodes, hospital admissions, or even endotracheal intubation in the intensive care unit for status asthmaticus. Only after appropriate questioning has been completed for each positive item on the past medical history form can the patient's past medical, surgical, and anesthetic history be considered adequate.

Obviously, the additional information gleaned from the patient must be written on the form for review at the time of the procedure as well as for proper medicolegal documentation.

Once the information is gathered, the surgeon should categorize the surgical patient according to the American Society of Anesthesiologists (ASA) Classification of Physical Status (Table 4-1), even if only local anesthesia is to be used. ASA PS-1 patients would be expected to have a lower risk of perioperative complications than ASA PS-4 patients. Despite a lack of absolute precision in accurately classifying the perioperative risk for all patients, this index is, nevertheless, commonly used to help identify certain risk factors so that modifications in the treatment plan can be accomplished. For instance, ambulatory general anesthesia in a dental office for ASA PS-1 and many ASA PS-2 patients is considered safe and cost effective, whereas ASA PS-4 patients would only receive local anesthesia and perhaps light levels of anxiety in an office setting.

Assessment of Cardiovascular Disease

Cardiac Disease

Cardiac disease can be subdivided into ischemic and nonischemic disease. Ischemic disease includes atherosclerotic heart disease, angina pectoris, and previous myocardial infarction. Nonischemic disease includes a wide variety of etiologies, such as

vascular (polyarteritis nodosa), congenital (tetralogy of Fallot), infectious (bacterial endocarditis), inflammatory/autoimmune (scleroderma), traumatic (cardiac contusion), toxic (alcoholic cardiomyopathy), pulmonary (cor pulmonale), metabolic (obesity), neoplastic (carcinoid), and endocrine (hyperthyroidism).

In a landmark article, Goldman and colleagues developed a multifactorial index to assess cardiac risk associated with a variety of noncardiac procedures such as orthopedic and general surgery.¹ This prospective study followed 1,001 patients older than 40 years at Massachusetts General Hospital until discharge and recorded all complications. Various potential risk factors for cardiac complications were correlated with actual complications, and a risk index based on a points system was subsequently formed. Of the 537 Class I patients, with 0 to 5 points, only 0.7% had life-threatening complications and 0.2% experienced cardiac death. Patients with 6 to 12 points were placed into Class II, whereas those with 13 to 25 points comprised Class III. Class IV patients, with 26 or more points, had a 22% incidence of life-threatening complications and 56% experienced cardiac death. Of all these factors, a previous history of congestive heart disease was the most predictive of complications, followed by a myocardial infarction within the previous 6 months.

Detsky and colleagues modified the Goldman Index by including unstable angina and remote myocardial infarction

as additional risk factors for perioperative cardiac complications in vascular surgery patients.² They simplified the scoring system of Goldman and colleagues into three classes, improving predictive accuracy. Table 4-2 represents Goldman and colleagues' and Detsky and colleagues' factors for perioperative cardiac risk.

Although anesthetic and surgical care have markedly improved in the last 25 years and risks may be less in some areas, Kenchaiah and colleagues recently reported that in both men and women who are obese, the risk of heart failure was doubled.³ With the increasingly high prevalence of obesity in the United States, this risk factor, among others, will prove more important in determining the risk of poor outcomes in the future.

Ischemic Heart Disease Angina Pectoris and Coronary Artery Disease Angina pectoris is typically a substernal chest pain or pressure that may radiate to either arm, the neck, or the mandible that is initiated by exercise, mental stress, pain, or other factors that produce increased myocardial oxygen demand in the presence of reduced oxygen delivery to the myocardium. It is most often caused by coronary artery disease, although other precipitating factors include severe anemia, hypotension, vasoconstrictor overdose, and coronary artery spasm. Angina pectoris may be classified as stable, unstable, or variant.

Unfortunately, the symptoms of angina pectoris may be confused with mitral valve prolapse, esophageal reflux, esophageal spasm, peptic ulcer disease, biliary disease, hyperventilation, musculoskeletal disease, and pulmonary disease. The diagnosis of angina pectoris is therefore not necessarily easy for the clinician to establish.

Stable angina pectoris is diagnosed when there is minimal change over 2 months regarding precipitating factors, frequency, intensity, duration, and treatments for successful termination of the attacks. Unstable angina pectoris relates to

Table 4-1 American Society of Anesthesiologists Physical Status Classification

Classification	Description
PS-1	Normal healthy patient
PS-2	Patient with mild systemic disease
PS-3	Patient with severe systemic disease
PS-4	Patient with severe systemic disease and a constant life threat
PS-5	Moribund patient who is not expected to survive without the operation
PS-6	Declared brain-dead donor patient for organ harvest

Adapted from American Society of Anesthesiologists. Relative value guide, 2003. Park Ridge (IL): American Society of Anesthesiologists; 2003.

Table 4-2 Index of Cardiac Risk

Condition	Goldman et al ¹	Detsky et al ²
Myocardial infarction		
< 6 mo	10	10
> 6 mo	—	5
Angina pectoris		
Unstable angina < 3 mo	—	10
Class III angina	—	10
Class IV	—	20
Symptoms of congestive heart failure	11	—
< 1 wk prior	—	10
> 1 wk prior	—	5
Dysrhythmia		
Preventricular contractions > 5/min	7	5
Rhythm other than sinus rhythm	7	5
Valvular disease: significant/critical aortic stenosis	3	20
Miscellaneous		
Age > 70 yr	5	5
Emergency operation	4	10
Major invasive surgery	3	—
Poor general health: obstructive pulmonary disease, major electrolyte disturbance, renal failure, liver disease, nonambulatory	3	5

Adapted from Goldman L et al¹; Detsky A et al.²

recent changes in some or all the above factors. Thus, unstable angina is defined by chest pain encountered during less than the usual exercise, or that lasts longer, is more intense, more frequent, or requires more than normal measures to terminate it. Unstable angina is also termed preinfarction angina since it may be the harbinger of an impending myocardial infarction. Variant angina, also known as Prinzmetal's angina, may occur in patients who have no detectable coronary artery disease but in whom coronary vasospasm occurs periodically, even at rest or with ordinary exercise. Cardiac dysrhythmias are frequently present during such spasms. These patients are frequently prescribed calcium channel antagonists prophylactically.

Patients who elicit a history of angina pectoris must be thoroughly interviewed to permit the practitioner to properly

place them into the appropriate category. Patients who are judged to have reasonable cardiac reserve and are considered stable are certainly good candidates for relatively simple office procedures while being carefully monitored. Light to moderate levels of conscious sedation may prove beneficial in preventing an angina attack, particularly in the anxious patient, by reducing the stress of the procedure and decreasing myocardial oxygen demand. Using profound local anesthesia with no more than 40 µg of epinephrine has been recommended by Malamed for medically compromised dental patients.⁴ These patients should be told to take their usual prophylactic medications such as β₁-adrenergic antagonists perioperatively, and to bring their nitroglycerin sublingual tablets or spray on the day of surgery to abort an attack if it were to occur.

Common risk factors for coronary artery disease include advanced age, diabetes mellitus, hypertension, peripheral vascular disease, hypercholesterolemia, obesity, cigarette smoking, sedentary lifestyle, and family history of coronary artery disease. According to Tarhan and colleagues, the perioperative risk of an acute myocardial infarction in patients without a history of myocardial infarction is 0.13%.⁵

Numerous retrospective studies involving large groups of patients indicate that the risk of a second myocardial infarction in the perioperative period seems to stabilize at approximately 6% after 6 months from the initial infarction.⁵⁻⁸ However, the 6% re-infarction rate is considerably higher than the 0.13% incidence of perioperative infarction for the same procedures in patients without previous myocardial infarction.

Congestive Heart Disease Multiple studies indicate that the presence of congestive failure is the single most important risk factor for perioperative cardiac morbidity independent of the presence of dysrhythmias, cardiomyopathy, valvular disease, or coronary artery disease.^{1,9,10} Appropriate strategies for perioperative management include optimization with careful attention to fluid management and maximizing therapies such as inotropes, diuretics, vasodilators, and antidysrhythmics.

The New York Heart Association (NYHA) functional classification of patients with heart disease (Table 4-3) is useful in categorizing patients who have

Table 4-3 New York Heart Association Classification of Cardiac Patients

Class	Symptoms
I	Asymptomatic cardiac disease
II	Symptomatic with ordinary activity, comfortable at rest
III	Symptomatic with minimal activity, comfortable at rest
IV	Symptomatic at rest

heart failure. It has been shown to be predictive of cardiac morbidity and mortality in the perioperative period. In Goldman and colleagues' study, NYHA Class I patients (asymptomatic cardiac disease) had a 3% risk of developing perioperative pulmonary edema, whereas the risk increased to 25% in NYHA Class IV patients (symptomatic at rest).¹⁰ Similarly, patients with signs of congestive heart failure by examination or radiograph were more likely to develop pulmonary edema than those without such signs.

Identification of swollen ankles, ascites, and distended neck veins during physical examination may help identify right-sided heart failure, whereas a persistent cough, three-pillow orthopnea, and rales on auscultation of the chest may be significant signs and symptoms of left-sided failure.

Nonischemic Heart Disease *Valvular Disease* When valvular heart disease is recognized through history or physical examination, the surgeon must judge the potential impact that this condition might have in relation to the proposed procedure and the need for antibiotic prophylaxis to help prevent endocarditis. The extent to which the patient's physical activity is limited by the cardiac condition usually serves as a useful guide to determine whether further consultation or testing is needed. The surgeon must understand the potential cardiac risks associated with the specific problem and know the physiologic consequences associated with changes in cardiac rate, rhythm, blood pressure, preload, afterload, and inotropy that anesthesia and surgery may produce.

Aortic Stenosis Aortic stenosis is recognized by its characteristic systolic murmur in the second intercostal space. A chest radiograph may demonstrate a prominent ascending aorta owing to poststenotic dilatation. Symptoms include angina pectoris, dyspnea on exertion, and a history of

syncope episodes. Although syncope can be caused by central nervous system pathology (epilepsy, stroke, or transient ischemic attack), metabolic pathology (hyperventilation or hypoglycemia), or autonomic pathology (orthostatic hypotension, carotid sinus hypersensitivity, or micturition syncope), episodes of syncope in the presence of cardiac pathology such as heart block, ventricular tachycardia, and aortic stenosis are an ominous sign. The incidence of sudden death is increased with aortic stenosis.

Of all the valvular conditions encountered in practice, aortic stenosis appears to be the most significant. Goldman and colleagues recognized critical aortic stenosis as an independent risk factor for poor outcome. It increased the risk of perioperative cardiac death by a factor of 14.^{1,10} Critical aortic stenosis is generally defined as an orifice of $< 0.75 \text{ cm}^2$ and/or $> 50 \text{ mm Hg}$ gradient across the valve during normal cardiac output. This markedly increases the resistance to normal aortic flow, and the increased load on the left ventricle causes a concentric left ventricular hypertrophy and decreased compliance. Myocardial oxygen demand is therefore markedly increased, and ischemia-related chest pain can occur even without coronary artery disease. These patients do not tolerate increases in heart rate because of decreased ejection time, filling time, and diastolic coronary artery perfusion time of the left ventricle. Thus, β -adrenergic agonists, anticholinergics, vasodilators, hypovolemia, pain, and anxiety are poorly tolerated, particularly for patients whose end-stage disease involves angina, syncope, and congestive heart failure.

The consulting cardiologist should define the disease and the degree of hemodynamic significance and optimize the patient prior to surgery. Echocardiography can be a useful tool to demonstrate abnormal valve leaflets and a constricted orifice. The amount of flow reduction and the valvular area can be calculated with Doppler

echocardiography. Although an invasive procedure, cardiac catheterization is more accurate in assessing aortic stenosis and has a dual advantage of assessing coexisting coronary artery disease. Therefore, it is most important to carefully assess the significance of aortic stenosis for a patient who presents with this diagnosis or in whom the practitioner suspects it may exist.

Aortic Regurgitation Aortic regurgitation produces a diastolic murmur heard best in the right second intercostal space and is associated with a widened pulse pressure, decreased diastolic pressure, and bounding peripheral pulses. It is often seen in combination with left ventricular hypertrophy on a chest radiograph and electrocardiogram. Aortic regurgitation associated with chronic aortic insufficiency is not associated with increased perioperative cardiac death according to Goldman and colleagues.¹ However, aortic insufficiency increases the perioperative risk of congestive heart failure, which may result from factors that decrease the forward flow of blood. The use of vasoconstrictors and the presence of anxiety, pain, and poorly controlled hypertension may increase peripheral vascular resistance and contribute to pulmonary congestion. Reduced inotropy and bradycardia increase diastolic filling from aortic regurgitation, whereas tachycardia and vasodilation help maintain forward flow.

Mitral Stenosis Mitral stenosis is usually the result of fusion of the valve leaflets at the commissures during the healing process from rheumatic fever. A normal-sized orifice is 4 to 6 cm^2 , but the patient becomes symptomatic when the area decreases by 50%. The condition produces an opening snap early in diastole and a rumbling diastolic murmur heard best at the cardiac apex. It may be associated with left atrial enlargement on a chest radiograph and notched P waves on the electrocardiogram.

Mitral stenosis without regurgitation causes left atrial enlargement and ultimately congestive heart failure. Critical mitral stenosis is usually defined as an area $< 1 \text{ cm}^2$. Because the atrial outflow is reduced, tachycardia reduces the flow into the left ventricle, which increases pulmonary congestion and decreases cardiac output. Thus, heart rate must remain reasonably normal, and the atrial “kick” associated with sinus rhythm may be necessary for maintaining cardiovascular stability.

Mitral Insufficiency Mitral insufficiency is frequently associated with mitral stenosis as the result of rheumatic heart disease. It produces a holosystolic blowing murmur heard best at the apex. It is often tolerated until the patient begins to develop signs and symptoms of congestive heart failure. Mitral insufficiency is associated with an increased mortality rate if present with other risk factors such as congestive heart failure or recent myocardial infarction.^{1,10} As in aortic insufficiency, attention must be given to preventing excessive fluid administration and to maintaining forward blood flow with moderate increases in heart rate and vasodilation.

Mitral Valve Prolapse Mitral valve prolapse, or Barlow’s syndrome, is associated with a bulging or prolapse of the mitral valve leaflets into the left atrium during systole. Typically, it produces a nonejection click cardiac murmur, often called “click-murmur syndrome,” heard best at the cardiac apex and may be associated with a regurgitant murmur. The diagnosis is normally confirmed with echocardiography. Although not a benign condition, it is less likely to be problematic than many of the above valvular diseases. It is often associated with a history of chest pain, anxiety attacks, dizziness, supraventricular tachycardia, and palpitations. These patients are at risk of paroxysmal tachydysrhythmias and sudden death. Occasionally, mitral valve prolapse is associated

with significant regurgitation and endocarditis. Appropriate care includes measures to prevent significant positive inotropic and chronotropic responses to stress by adequate control of anxiety and pain, judicious use of β -adrenergic agonists such as epinephrine, and careful monitoring of cardiovascular parameters during surgery.

Cardiomyopathy Cardiomyopathy may result from a variety of causes not related to valvular or coronary disease, such as systemic disease, infection, or drug and alcohol abuse. The degree of cardiac impairment can be estimated by invasive or noninvasive measurement of the cardiac ejection fraction (percent EF); this is the percentage of left ventricular blood volume ejected into the aorta during each contraction. The normal value is approximately 70% and should increase with exercise or stress, whereas an EF of 30% is usually associated with decreased exercise tolerance. Patients with an EF of 15% or less have significant physiologic impairment and may be candidates for cardiac transplantation.

There are three classes of cardiomyopathy: dilated, nondilated, and hypertrophic. The typical findings associated with dilated cardiomyopathy include a marked increase in left ventricular end-diastolic volume. The perioperative implications of dilated cardiomyopathy include optimization of function including careful fluid management and maximizing therapies such as inotropes, diuretics, vasodilators, and antidysrhythmics, as in the management of congestive heart failure.

Patients with nondilated cardiomyopathy, also known as restrictive cardiomyopathy, present with rigid ventricles that impair diastolic filling, although the contractile function may remain somewhat intact. Right ventricular failure and elevated venous pressures are common. Dysrhythmias are a common cause of death in these patients; therefore, careful monitoring of

cardiovascular parameters is essential to facilitate rapid recognition, diagnosis, and treatment of life-threatening dysrhythmias during any surgical procedure.

Hypertrophic cardiomyopathy, also known as idiopathic hypertrophic subaortic stenosis (IHSS), is usually an inherited autosomal dominant characteristic, although it can also be a result of long-standing hypertension. The intraventricular septum may be greatly thickened in asymmetric septal hypertrophy, or the hypertrophy may be concentric. Depending on the area of hypertrophy, left ventricular outflow obstruction may occur during systole. Furthermore, the septal leaflet of the mitral valve may not function properly owing to the hypertrophy of the septum, and mitral regurgitation may result. Fatal ventricular dysrhythmias may result in sudden death even in apparently healthy teenagers with undiagnosed hypertrophic cardiomyopathy. Ischemia within the hypertrophic segment may also result in myocardial infarction. Preparation for surgery would include careful monitoring of vital signs and minimization of those factors associated with increases in cardiac inotropy and rate, such as hypotension, vasodilation, β -adrenergic drugs, pain, and anxiety. Preoperative β_1 -blockade, adequate hydration, and local anesthetics without epinephrine, unless absolutely necessary, are the usual components of good operative planning.

Hypertension

Hypertension is a very common disease. Although it can occur secondarily as a result of a definable cause such as hyperthyroidism or pheochromocytoma, it is most often a multifactorial primary disease of poorly understood origin, termed essential hypertension.¹¹ In their seventh report, the Joint National Committee on Prevention, Detection, Evaluation and Treatment of High Blood Pressure recently revised their definition of hypertension

from previous reports, recognizing that early detection and treatment of prehypertension and hypertension is important and ultimately reduces risk. Important key messages in the joint committee's latest report are as follows: (1) for patients < 50 years of age, systolic blood pressure > 140 mm Hg is a much more important risk factor for cardiovascular disease than is diastolic pressure elevation; (2) beginning with a pressure of 115/75 mm Hg, the risk of cardiovascular disease doubles with every incremental increase of 20/10 mm Hg; and (3) a systolic pressure of between 120 and 139 mm Hg or a diastolic pressure of between 80 and 89 mm Hg is prehypertension, and lifestyle modifications are recommended to prevent cardiovascular disease (Table 4-4).¹¹

Major risk factors for hypertension include smoking, dyslipidemia, diabetes mellitus, age > 60 years, gender (men and postmenopausal women), and family history of cardiovascular disease in women > 65 and men > 55 years. If untreated, it commonly causes coronary artery disease, cardiomegaly, congestive heart failure, and end-organ damage to vital tissues such as the heart, kidneys, retina, and brain. Elevated systolic blood pressure in the elderly appears to be a better predictor than elevated diastolic blood pressure of terminal end-organ damage, such as coronary artery/cardiovascular disease, stroke, renal failure, postoperative myocardial ischemia, and overall death.^{11,12}

Because the increased peripheral vascular resistance produces a contracted intravascular volume, hypertensive patients are highly susceptible to the vasodilator effects of sedative and anesthetic agents that may result in a relative or absolute severe hypotensive episode.

Prolonged excessive hypotension in a patient with significant peripheral vascular disease who needs a relatively high pressure to perfuse vital organs may be more detrimental during surgery than permitting a modest degree of hypertension to continue. For patients planning for elective surgery who are found to be significantly hypertensive at the preoperative assessment, it is best to postpone the procedure until their physician can optimize their pressure and volume status. It is recommended that surgery be delayed, if possible, for poorly controlled hypertensive patients with blood pressure above the mild to moderate range (> 180/110 mm Hg).^{11,13}

Acute treatment of hypertension at the time of elective surgery may produce blood pressure numbers that initially make the practitioner more comfortable before starting anesthesia and the procedure, but the less-than-optimized patient is much more likely to have significant labile hypertensive and/or hypotensive episodes during the course, and this may increase their risk of morbidity or mortality. As a general rule, patients with hypertension should take all of their normal antihypertensive medications at their normal times with a sip of water prior to surgery. Indeed, patients who skip a dose

of drugs such as clonidine or propranolol may develop severe rebound hypertension, tachycardia, and angina pectoris. Maintaining pharmacologic homeostasis, with only a few exceptions, such as holding or halving the usual dose of insulin if the patient is fasting preoperatively, is just as important on the day of surgery as for any other day.

Assessment of Exercise Tolerance

The Duke University Activity Status Index (Table 4-5) uses the rate of oxygen consumption necessary to accomplish various physical tasks to quantify the degree of physical activity performed.¹⁴ One metabolic equivalent (MET) consumes 3.5 mL/kg/min of oxygen. Hollenberg indicated that patients who could undergo > 7 METs had excellent functional capacity, whereas those able to perform only 4 to 7 METs had only moderate capacity. Patients who could do < 4 METs had poor functional capacity.¹⁵

Experienced clinicians usually relate that they have confidence in judging a patient's overall capacity to safely undergo anesthesia and surgery by inquiring about the degree of exercise that the patient is able to accomplish. Those who can walk up several flights of steps without stopping to rest are much less worrisome than are those who can manage only a few steps without developing severe dyspnea or chest pain.

Perioperative Cardiovascular Evaluation Algorithm

The most recent update of perioperative cardiovascular evaluation guidelines by the American College of Cardiology and the American Heart Association provides a framework for determining the need for additional cardiac consultation for patients with cardiovascular disease, depending on the presence of various predictors of risk for perioperative cardiac death and nonfatal myocardial

Table 4-4 Classification of Hypertension

Systolic BP		Diastolic BP	Category
< 120	and	< 80	Normal
120–139	or	80–89	Prehypertension
140–159	or	90–99	Stage 1 hypertension (mild)
> 160	or	> 100	Stage 2 hypertension (moderate)

Adapted from the seventh report of the Joint National Committee on Prevention, Detection, Evaluation and Treatment of High Blood Pressure.¹¹
BP = blood pressure.

Table 4-5 Duke Activity Status Index

Activity	METs	Functional Capacity
Walk in house	1.75	Poor
Personal care (dress, bath, toilet)	2.75	Poor
Walk 1–2 blocks	2.75	Poor
Light work: dusting, washing dishes	2.7	Poor
Moderate work: vacuuming	3.5	Poor
Yard work: raking, mowing	4.5	Moderate
Sexual relations	5.25	Moderate
Climb stairs	5.5	Moderate
Golf, bowling	6	Moderate
Swim, basketball, ski	7.5	Excellent
Run	8	Excellent

Adapted from Hlatky MA et al¹⁴; Hollenberg SM.¹⁵
MET = metabolic equivalent; 1 MET = 3.5 mL/kg/min oxygen use.

infarction and the risk stratification for various noncardiac surgical procedures.¹³ Using these guidelines, the oral and maxillofacial surgeon can estimate the cardiac risks associated with the surgical procedure and decide whether the patient's medical condition warrants further cardiac consultation. For instance, according to the algorithm in Figure 4-1, a cardiac patient with intermediate predictors of cardiac risk (mild angina or controlled congestive heart failure) with good exercise tolerance (equal to or greater than 4 METs) who is scheduled for a low-risk surgery (tooth extraction or tori removal) should not need an extensive cardiac work-up. However, that same patient scheduled for hemimandibulectomy, partial pharyngectomy, laryngectomy, or radical neck dissection with flap reconstruction that would entail large fluid shifts while under anesthesia for many hours (high surgical risk) and who has poor exercise tolerance (< 4 METs) should receive cardiac testing prior to surgery. Likewise, a patient with minor predictors of cardiac risk (advanced age or previous stroke) scheduled for the above high-risk surgery would not need cardiac consultation if his or her exercise tolerance was good but should be referred if the exercise tolerance was poor.

Although the guidelines in Figure 4-1 do not specifically define the surgical risk category of the most common oral surgical procedures, the surgeon should attempt to compare the severity of their proposed surgery with that of the examples provided. Perhaps a Le Fort III fracture would be similar in risk to an intermediate-risk acetabular fracture, whereas a dental implant would be considered a low-risk superficial procedure.

Assessment of Pulmonary Disease

Patients with pulmonary disease must be carefully assessed preoperatively because even healthy patients may develop pulmonary complications as a direct result of surgery and anesthesia. Pulmonary disease can be classified as either restrictive or obstructive. Restrictive disease may be the result of, for instance, severe scoliosis or morbid obesity and results in a decrease in all measured lung volumes. Obstructive disease is usually the result of smoking or asthma and may be characterized by marked increases in residual volume and functional residual capacity. A thorough past medical history and physical examination related to the pulmonary system prior to sedation or general anesthesia is mandatory. Unfortu-

nately, many patients, particularly smokers, are not aware that they have significant pulmonary compromise until it is very advanced.

As first reported by Morton in 1944, smoking is a risk factor for postoperative pulmonary complications, even among smokers without signs or symptoms of chronic obstructive pulmonary disease.^{16,17} The risk declines from 33 to 14.5% after only 8 weeks following cessation of smoking, whereas those who stop smoking for < 8 weeks have a higher risk of complications than do current smokers.¹⁸

The assessment should start with questions regarding dyspnea on exertion and functional level of physical activity that can be accomplished, such as how many flights of stairs can be managed without rest. Patients with mild or only occasional symptoms usually need no further investigation, whereas those with frequent or severe symptoms may need further evaluation and management prior to surgery. Although physical limitations may also be indicative of cardiovascular disease or pulmonary disease, they often present simultaneously because smoking is a major risk factor for cardiovascular disease.

Physical examination of the patient with obstructive pulmonary disease may reveal an increased anteroposterior diameter of the chest, a depressed diaphragm, a hyperresonant thorax on percussion, and wheezing, particularly during expiration. The chest radiograph may demonstrate hyperinflated lungs. The forced expiratory volume in 1 second (FEV₁) is usually < 80% of the vital capacity. Obstructive disease may be reversible, as in bronchial asthma, or it might have a reversible component. Common irreversible diseases include emphysema, chronic bronchitis, and bronchiectasis. However, antibiotics and bronchodilator therapy may reverse at least some of the components of acute symptoms of chronic bronchitis.

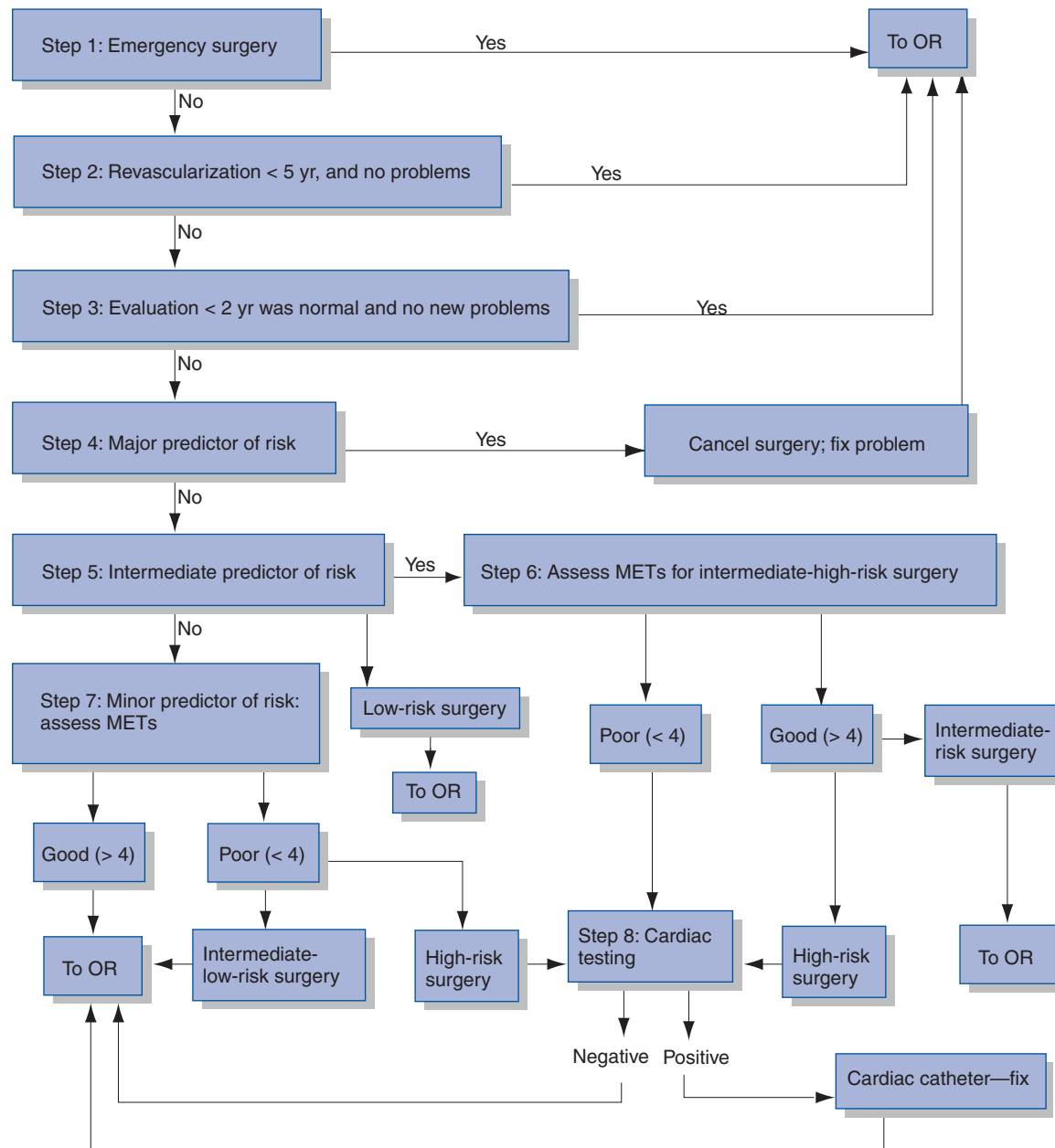


FIGURE 4-1 Preoperative cardiac assessment algorithm for surgical risk of cardiac death/nonfatal myocardial infarction. Major predictors of risk: unstable angina, decompensated heart failure, significant dysrhythmias, and severe valvular disease; intermediate predictors of risk: mild angina, prior myocardial infarction, controlled heart failure, diabetes, and renal insufficiency; minor predictors of risk: advanced age, abnormal electrocardiogram, nonsinus rhythm, poor functional capacity, prior stroke, and uncontrolled hypertension. High-risk surgeries: emergent major surgery, major vascular surgery, and prolonged cases/major blood loss/fluid shifts; intermediate-risk surgeries: carotid endarterectomy, head and neck, intraperitoneal, intrathoracic, orthopedic, and prostate; low-risk surgeries: endoscopic, superficial, cataract, and breast. METs = metabolic equivalents; OR = operating room. Adapted from Eagle K et al.¹³

Asthma

Bronchial asthma is a common pulmonary condition that must be respected for its potential to cause life-threatening complications during surgery and anes-

thesia. In addition to taking a careful history with regard to asthmatic triggers, frequency, severity, emergency room visits, and hospitalizations, one can also assess the potential for an acute event by noting

the number of different asthma medications required to control symptoms and the frequency and efficacy of their use. Wheezing from asthma immediately prior to the induction of anesthesia and surgery

is an ominous sign and is reason to postpone all but the most urgent procedures.

Emphysema

Emphysema is characterized by irreversible enlargement of the alveolar air ducts and by destruction of the walls of these air spaces. The loss of elasticity of these structures permits collapse of the airways during exhalation, resulting in increased airway resistance. To keep their airways from collapsing, patients with severe emphysema can be observed to purse their lips during exhalation to attain positive end-expiratory pressure in their airways. The chest radiograph typically demonstrates low flat diaphragms and extremely hyperlucent lung fields, consistent with gas trapping and loss of lung parenchyma.

Preoperative management may decrease the incidence of postoperative pulmonary complications.¹⁹ Those with suspected significant obstructive disease may be candidates for preoperative pulmonary function testing and analysis of arterial blood gases. Many emphysema patients, commonly known as “pink puffers,” have reasonably normal arterial blood gases as they are able to increase their minute ventilation and cardiac output to compensate for increased airway resistance. With increasing pulmonary artery pressures above a mean of 20 mm Hg, cor pulmonale develops as the right ventricle begins to fail, resulting in hypoxemia, venous congestion, and systemic edema.

Measurement of the ratio of FEV₁ to forced vital capacity (FVC) may help to discern the severity of the disease and predict the chance for respiratory failure if the ratio is < 50%.²⁰ Carbon dioxide retention typically occurs when the FEV₁:FVC ratio is < 35%.

Chronic Bronchitis

Chronic bronchitis, characterized by a chronic excess of mucus in the bronchioles, is due to enlarged mucous glands

that reduce the luminal diameter of the airways and increase resistance to airflow. Chronic bacterial infections are common and produce inflammation and fibrosis that further contribute to increased resistance. Patients with chronic bronchitis develop hypoxemia and carbon dioxide retention relatively early in the course of the disease compared with emphysema patients. Cor pulmonale, manifested by hepatjugular reflux and peripheral edema, also develops comparatively early and results in the patient being termed a “blue bloater.” The preoperative evaluation and management of chronic bronchitis is similar to that for emphysema.

Bronchiectasis

Bronchiectasis occurs when there is an abnormal enlargement of the bronchi that are frequently filled with purulent sputum and highly vascularized granulation tissue. There is risk of significant hemoptysis and an increased risk of pulmonary edema, pulmonary hypertension, and cor pulmonale.

Summary

The surgeon must complete a careful and thorough past medical history and physical examination to assess the risk of pulmonary disease. Recognition of poor exercise tolerance, clubbing of the fingertips, chronic cough and dyspnea with minimal exertion, decreased breath sounds, wheezes, rhonchi, and excessive expiratory effort are ominous signs of significant pulmonary disease that may warrant further evaluation and treatment prior to surgery and anesthesia.

Many patients with severe pulmonary disease require continual administration of supplemental oxygen via a nasal cannula at home. This should be continued during dental treatment. In the event of a medical emergency such as chest pain, giving of 100% oxygen by face mask and monitoring of the respiratory rate are highly recommended for all such

patients. Should the respiratory rate of a patient who is a chronic carbon dioxide retainer decrease because of loss of respiratory drive caused by the additional oxygen, the practitioner may simply need to remind the conscious patient to breathe, or manually ventilate the unconscious patient with positive pressure oxygen. Only if a severely compromised pulmonary patient is left unmonitored while breathing 100% oxygen by face mask would there be danger of oxygen causing hypoventilation in the dental office that is properly equipped with airway adjuncts needed for artificial ventilation.

Assessment of the Airway

Assessment of the airway is one of the most important facets of the preanesthesia evaluation process because the inability to maintain a patent airway and provide adequate ventilation and oxygenation is frequently responsible for anesthesia-related morbidity and mortality. In a closed claims study by the American Society of Anesthesiologists, Caplan and colleagues reported that 34% of 1,541 liability claims were for adverse respiratory events.²¹ This was the largest source of adverse outcomes in their study. Of these cases approximately 75% were related to either inadequate ventilation (38%), esophageal intubation (18%), and difficult intubation (17%). Although the current universal use of the pulse oximeter and end-tidal carbon dioxide monitoring have undoubtedly decreased some of these events, at least some of the difficult intubations could have been situations in which the anesthesiologist could neither intubate nor mask ventilate an apneic patient. Thus, the oral and maxillofacial surgeon must carefully assess the potential for this type of catastrophic failure to maintain the airway during any sedation or anesthesia administered in the office or other surgical venue and be prepared to properly manage that circumstance should it occur despite careful assessment and planning to avoid it.

The American Society of Anesthesiologists has developed and updated an algorithm for management of the difficult airway.²² As seen in Figure 4-2, these guidelines enable anesthesiologists, nurse anesthetists, dentist anesthesiologists, and oral and maxillofacial surgeons to have a detailed series of plans and alternatives to facilitate the management of the difficult airway. This reduces the likelihood of adverse outcomes such as death, brain death, myocardial injury, and airway trauma. These guidelines recommend that a careful airway history and examination be conducted prior to the induction of anesthesia to detect medical, surgical, and anesthetic factors including previous anesthetic records, if available, that may identify the difficult airway.

Congenital and acquired diseases or conditions, for instance, may alter the airway anatomy to such an extent that attaining and maintaining a patent airway during anesthesia may be difficult or impossible. Congenital conditions such as Pierre Robin, Treacher Collins, Goldenhar's, Klippel-Feil, and Down syndromes are associated with abnormalities such as restricted movement of the neck and mandible, micrognathia, maxillary and mandibular hypoplasia, and macroglossia. Examples of acquired conditions include obesity, oropharyngeal space infections, epiglottitis, tonsillitis, rheumatoid arthritis, tumors, temporomandibular joint disorders, head and neck cancer surgery, and oropharyngeal radiation therapy.

A careful physical examination of the airway must be accomplished. Anatomic characteristics associated with difficult intubation include a short large-diameter neck, retrognathia with obtuse mandibular angles, protruding maxillary incisors, decreased mobility of the temporomandibular joint, and a high-arched palate.

Although there is no airway rating system that can accurately predict a difficult airway with high sensitivity and specificity, the modified Mallampati classification

is widely used.²³ The hypothesis of Mallampati and colleagues is that the base of the tongue in certain individuals is disproportionately large, which makes direct laryngoscopy difficult. The tongue base is therefore compared with other anatomic features that it may obscure. To perform this test correctly, the patient should be sitting or standing upright and asked to open their mouth as widely as possible without phonating. In Class I patients the uvula, faucial pillars, and soft palate are visible. In Class II patients only the faucial pillars and soft palate are visible, whereas in the Class III patients, only the soft palate is observed. Class I patients are expected to have normal airways, whereas patients in Class II are somewhat more likely to be difficult to intubate. Intubation in Class III patients is even more likely to be difficult.

Samsoon and Young later added a fourth category to the original Mallampati classification.²⁴ Their fourth class included visualization of the hard palate but not the soft palate or other structures. Class IV patients have the highest risk for a difficult intubation (Figure 4-3).

Although difficult intubation does not always coincide with difficult mask ventilation, one must recognize that patients in modified Mallampati Classes III and IV pose an increased risk of loss of a patent airway during nonintubated deep sedation or general anesthesia. When compounded with other risk factors such as mandibular retrognathia, obesity, or postradiation therapy, the practitioner may elect to administer only light conscious sedation with drugs that are pharmacologically reversible or to secure the airway via awake fiberoptic intubation prior to induction of general anesthesia.

In certain instances additional evaluation of the airway may be prudent. For example, fiberoptic pharyngoscopy, soft tissue radiography, computerized tomography, and magnetic resonance imaging may be helpful in identifying the extent of

airway compromise and tracheal deviation associated with severe dentofacial and neck infections. Patients with a severe infection and significant trismus, orthopnea, dysphagia, drooling, and dyspnea may easily lose the patency of their tenuous airway with even modest doses of sedative, anxiolytic, or opioid analgesic medications given prior to attempted fiberoptic intubation. Preparations for an immediate surgical airway must be made well in advance.

Assessment of Endocrine Disease

Any of the major endocrine disorders can impact the course of anesthesia and surgery and should be considered in the preoperative assessment.

Adrenal Gland

A lack of adrenal cortical activity, as in Addison's disease, may decrease the production of cortisol and aldosterone and alter cardiovascular stability. Patients who take supplemental glucocorticosteroids may have a suppression of adrenocorticotropic hormone from their pituitary gland and may need preoperative supplementation of cortisol. An overproduction of epinephrine and norepinephrine in the adrenal medulla from a pheochromocytoma may create a hypertensive-tachycardiac crisis intraoperatively.

Thyroid Gland

Hypothyroidism Hypothyroidism has many potential causes and is usually determined by an assessment of levels of thyroid stimulating hormone (TSH), triiodothyronine (T_3), and thyroxine (T_4). Patients who complain of fatigue and intolerance to cold and who are hypotensive may suffer from myxedema. Theoretically, myxedematous patients may be more susceptible to the depressant effects of anesthetics and less responsive to adrenergic vasopressors and cardiac inotropes. However, a retrospective study demonstrated no significant difference

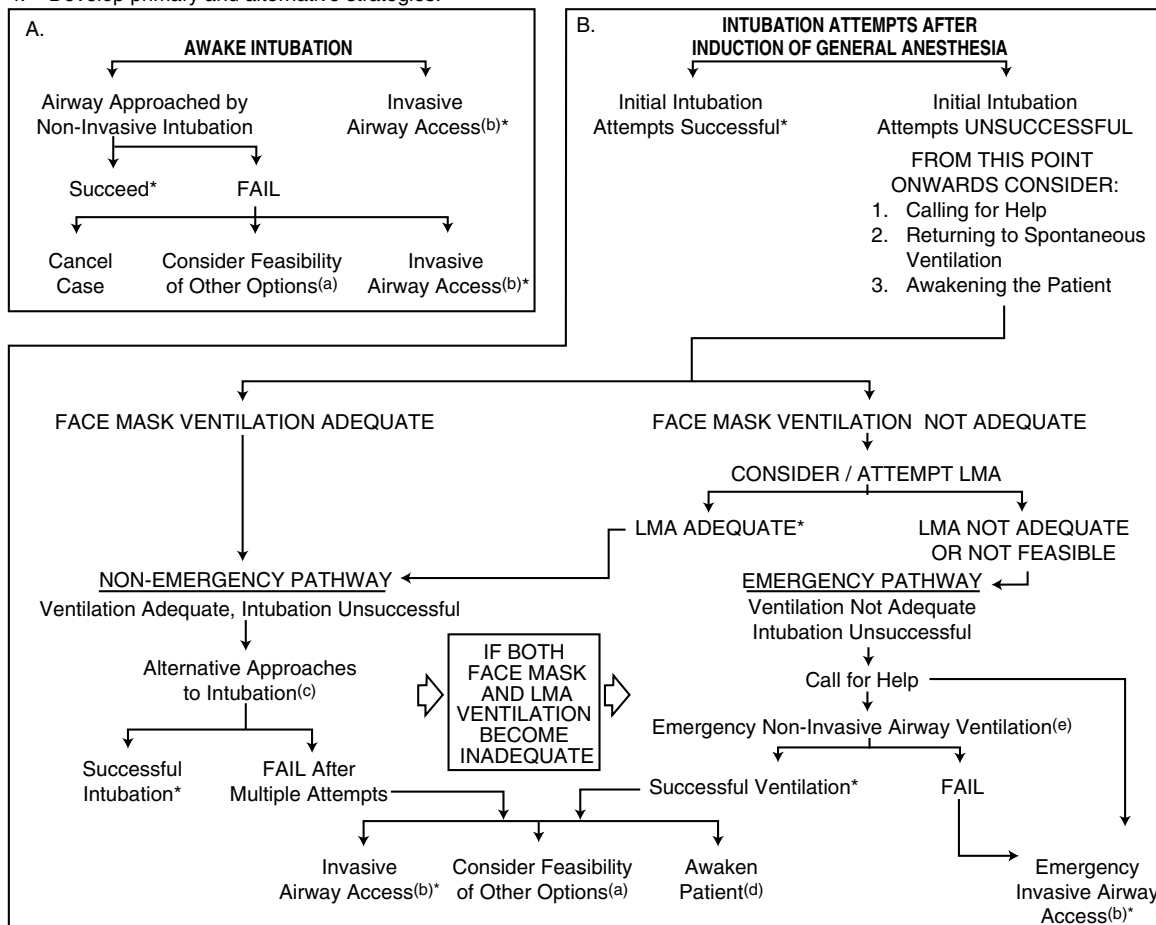


DIFFICULT AIRWAY ALGORITHM

- Assess the likelihood and clinical impact of basic management problems:
 - Difficult Ventilation
 - Difficult Intubation
 - Difficulty with Patient Cooperation or Consent
 - Difficult Tracheostomy
- Actively pursue opportunities to deliver supplemental oxygen throughout the process of difficult airway management.
- Consider the relative merits and feasibility of basic management choices:

- Awake Intubation vs. Intubation Attempts After Induction of General Anesthesia
- Non-Invasive Technique for Initial Approach to Intubation vs. Invasive Technique for Initial Approach to Intubation
- Preservation of Spontaneous Ventilation vs. Ablation of Spontaneous Ventilation

- Develop primary and alternative strategies:



* Confirm ventilation, tracheal intubation, or LMA placement with exhaled CO₂

a. Other options include (but are not limited to): surgery utilizing face mask or LMA anesthesia, local anesthesia infiltration or regional nerve blockade. Pursuit of these options usually implies that mask ventilation will not be problematic. Therefore, these options may be of limited value if this step in the algorithm has been reached via the Emergency Pathway.

b. Invasive airway access includes surgical or percutaneous tracheostomy or cricothyrotomy.

c. Alternative non-invasive approaches to difficult intubation include (but are not limited to): use of different laryngoscope blades, LMA as an intubation conduit (with or without fiberoptic guidance), fiberoptic intubation, intubating stylet or tube changer, light wand, retrograde intubation and blind oral or nasal intubation.

d. Consider re-preparation of the patient for awake intubation or canceling surgery.

e. Options for emergency non-invasive airway ventilation include (but are not limited to): rigid bronchoscope, esophageal-tracheal combitube ventilation, or transtracheal jet ventilation.

FIGURE 4-2 Algorithm for management of a difficult airway. LMA = laryngeal mask airway. Reproduced with permission from the American Society of Anesthesiologists.²²

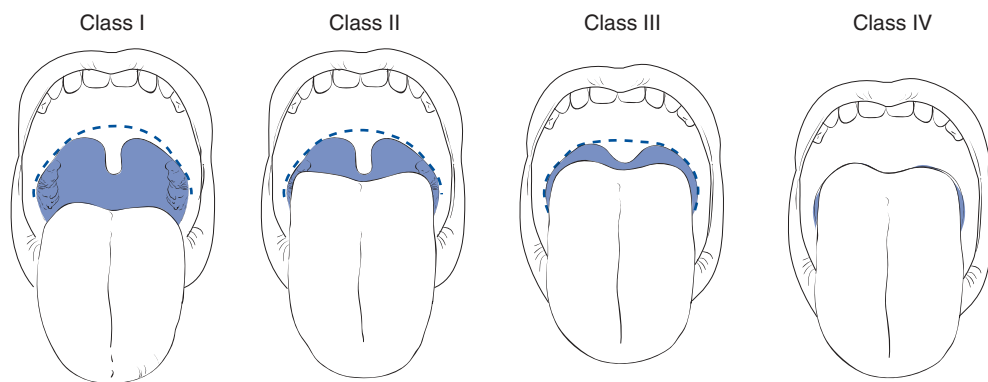


FIGURE 4-3 Mallampati classification. Adapted from Samsoon GLT and Young JRB.²⁴

in hemodynamic instability, imbalance in fluid and electrolytes, necessity for vasopressors, myocardial infarction, sepsis, bleeding, extubation time, or time to discharge compared with matched controls.²⁵ The conclusion of the study was that mild hypothyroidism is not a contraindication for surgery. However, severe myxedema can lead to coma, cardiovascular collapse, and heart failure and necessitates a postponement of surgery until it can be corrected.²⁶

Hyperthyroidism Graves' disease is the most common type of primary hyperthyroidism. Symptoms include hyperexcitability, weight loss, hypertension, and tachycardia. Thyroid storm during anesthesia can resemble malignant hyperthermia. Propylthiouracil or methimazole is frequently prescribed to reduce thyroxin secretion prior to surgery, and β -adrenergic antagonists are used to stabilize the adrenergic activity prior to and during surgery.

Goiter Enlargement of the thyroid gland may adversely influence the patency of the airway. Substernal goiter may be difficult to recognize on physical examination without a chest radiograph, but it may produce symptoms of dyspnea and dysphagia. Large superficial goiters may increase the difficulty of endotracheal intubation.

Pituitary Gland

The pituitary gland has a wide influence on many glands and organs. Increased pro-

duction of hypophyseal pituitary tropic hormones can produce secondary hyperthyroidism (TSH), secondary Cushing's syndrome (adrenocorticotrophic hormone), and acromegaly (growth hormone).

Acromegaly predisposes the patient to cardiomyopathy, dysrhythmias, and sudden death.^{27,28} The excessive growth hormone increases the production of insulin-like growth factor I (IGF-I) by the liver and other tissues. Excessive levels of IGF-I can produce headaches, profuse sweating, joint disorders, soft tissue swelling, and overgrowth of the hands, feet, mandible, and viscera. The patient with acromegaly may therefore present with a difficult airway, particularly for endotracheal intubation.

Diabetes Mellitus

Diabetes mellitus is a common disease with far-reaching implications, primarily owing to the microangiopathy-related impairment of normal blood flow and subsequent end-organ damage. Patients diagnosed with insulin-dependent diabetes at a young age are less commonly seen than those diagnosed with non-insulin-dependent diabetes later in life, who are generally able to control it with oral hypoglycemic agents. Insulin-dependent diabetics generally have more severe signs and symptoms related to their diabetes and have increased potential to suffer the consequences for a longer period of time than non-insulin-dependent diabetics. Preoperative evaluation of all

diabetics includes an assessment of the degree of blood glucose control and a search for evidence of end-organ damage. As the degree of end-organ damage progresses, the likelihood of perioperative complications, often cardiovascular in nature, increases.

Blood sugar is usually measured several times a day when insulin therapy is needed. Although blood sugar concentrations can vary widely throughout the day, a measurement at the preoperative assessment appointment can give the practitioner an idea of the degree of control that the patient might have at that time. The practitioner may also discern that the patient is in optimal control by measuring the glycosylated fraction of adult hemoglobin (HbA_{1c}) for a long-term picture of overall control. Hemoglobin A₁ binds with glucose to form HbA_{1c}, which is a relatively stable complex that provides more of an average blood glucose level over a period of 1.5 to 2 months. Thus, taken together, these two measurements provide the practitioner with information on both short- and long-term control.

A well-controlled diabetic is expected to have fewer perioperative complications including reduced incidences of wound infection and diabetic ketoacidosis. Although long-term tight control should reduce end-organ damage, tight control in the immediate perioperative period may predispose the patient to hypoglycemia, which can result in central nervous system damage.

A rational approach to properly managing diabetic patients is based on knowledge of the type of diabetes present, the degree of its control by the patient, the stress associated with the surgical procedure, and the likelihood of the patient quickly resuming a normal diet and hypoglycemia medication postoperatively.²⁹ Short-term control by the sliding scale may be best in the perioperative period for many patients; however, others may do well administering their insulin after surgery in

their usual manner, as if surgery never happened. An individualized approach to diabetic management is essential.

End-organ damage from diabetes may result in problems that directly affect surgery and anesthesia. Renal failure may be the result of diabetic nephropathy, which may alter fluid and electrolyte balance and drug elimination. The lack of erythropoietin production by the kidney may result in significant anemia. Diabetic sensory neuropathy may permit myocardial ischemia and silent myocardial infarction to go unrecognized by the patient and is an independent predictor of perioperative cardiac morbidity.³⁰ Diabetic autonomic neuropathy may also increase the risk of aspiration of gastric contents during deep sedation or general anesthesia by delaying gastric emptying. In addition, it may cause unpredictable cardiovascular responses to anesthetic drugs and to other cardiovascular-active drugs.

Metabolic acidosis with hyperglycemia > 300 mg/dL in the diabetic defines ketoacidosis. Insulin-resistance owing to trauma, surgery, or infection may be a contributing factor. The conversion of fatty acids to acetoacetic acid, β -hydroxybutyrate, and acetone in the absence of insulin produces metabolic acidosis and the fruity smell on the breath that may be recognized during the preoperative assessment. Extracellular potassium increases as it leaves the cells, and this results in intracellular depletion of potassium in the presence of hyperkalemia. Significant hypovolemia results from the osmotic diuretic effect of glucose in the urine. All of these deviations must be corrected with insulin, fluid, and electrolytes before proceeding with all but the most urgent surgery.

Assessment of Liver Disease

Preoperative assessment for liver disease is particularly important for those individuals with cirrhosis or acute hepatitis because morbidity and mortality rates with these diseases are markedly increased.

When the practitioner suspects liver disease during the perioperative assessment, several screening tests are available. Acute or chronic hepatocellular damage is indicated with elevations of aspartate aminotransferase (AST) and alanine aminotransferase (ALT). Acute damage can produce very high enzyme elevations, whereas chronic damage may produce only mildly elevated levels. ALT is more specific to hepatocytes.

Unconjugated bilirubin from normal red cell destruction may increase in the presence of severe liver disease if the hepatocytes cannot conjugate it with glucuronide. Elevated serum bilirubin is responsible for the yellow jaundiced appearance.

Serum albumin and nearly all of the clotting factors such as prothrombin are produced in the liver. Severe liver disease can decrease the synthesis of many important proteins, as reflected in decreased serum albumin levels. Additionally, because many anesthetic drugs are normally highly bound to albumin, reduced serum albumin levels over a period of many weeks may permit unusually high levels of free drug to exist in the plasma, which could produce a markedly enhanced effect from a relatively small dose. Reduced prothrombin levels would be reflected in an increased prothrombin time (PT) and International Normalized Ratio (INR) and serve as additional markers for the severity of hepatic disease. Because significant liver disease influences so many bodily functions, only necessary simple procedures under local anesthesia and perhaps nitrous oxide–oxygen conscious sedation should be attempted in an office setting for those patients with significant hepatic compromise.

Assessment of Renal Disease

Renal disease has a great impact on perioperative morbidity and mortality. The mortality rate associated with acute renal failure ranges from 42 to 88%.³¹ Levy and colleagues demonstrated that acute renal

failure is an independent risk factor for mortality, regardless of other risk factors.³² He also noted that because the mortality of contrast medium–associated acute renal failure is above 30%, elective surgery should be postponed if possible until renal function returns to baseline in these patients. Although newer less toxic contrast agents are now available, acute renal failure can still occur.

As previously discussed, renal failure is often a consequence of diabetes and long-standing hypertension. It can be responsible for congestive heart failure, fluid and electrolyte imbalance, anemia, hypertension, and azotemia. When renal disease is suspected from the history and physical examination, several tests can be completed to assess its presence and the degree of impairment. Because urea and creatinine are excreted by glomerular filtration and their blood levels are therefore inversely proportional to the glomerular filtration rate, blood urea nitrogen and serum creatinine levels are commonly obtained to initially assess renal function. Creatinine serum levels are normally in the range of 0.6 to 1.5 mg/dL. Approximately a 50% loss in kidney function is indicated by a creatinine level > 2.0, whereas a 75% loss of function would be indicated by a creatinine level > 4.8. Creatinine levels > 10.0 are consistent with end-stage renal disease (ESRD).

Patients with ESRD who depend on hemodialysis often present for perioperative assessment in either a hypervolemic or hypovolemic state, depending on whether they need dialysis soon or have just completed it. Chronic hyperkalemia and anemia are commonly seen. Patients on hemodialysis are usually treated on the day after dialysis, when they have somewhat stabilized their physiology and when the effects of their dialysis-associated heparin are no longer present. Many of these patients are quite sensitive to small doses of sedatives and anxiolytics; therefore, slow careful intravenous titration of

these drugs prior to dental procedures is highly recommended.

Assessment of Bleeding Disorders

A careful history regarding bleeding problems is essential prior to surgery. Excessive bleeding may result from a variety of causes. For instance, drugs such as acetylsalicylic acid and other nonselective nonsteroidal anti-inflammatory analgesics may inhibit platelet function. Liver disease may decrease the production of clotting factors. A family history of bleeding may be the result of autosomal dominant transmission of von Willebrand's disease to males and females, whereas hemophilia A and B are both inherited as sex-linked recessive traits. These patients may be taking various factors to bring their levels to the normal range or may have had a history of intravenous desmopressin administration to acutely elevate levels of factor VIII and von Willebrand's factor prior to surgery. A decreased ristocetin cofactor activity is the most sensitive and specific screening test for von Willebrand's disease because large multimers of von Willebrand's factor are important in ristocetin-induced platelet aggregation.

To help uncover previously unrecognized bleeding disorders prior to major dental surgery, Holtzman and colleagues recommend preoperative laboratory assessment of hemostasis prior to orthognathic surgery.³³ However, there are a large number of studies that generally concur that routine hemostatic testing of asymptomatic patients does not significantly alter treatment and is not cost-effective for the low yield.³⁴⁻³⁹

Wahl reviewed more than 950 patients continuously receiving anticoagulants who underwent more than 2,400 dental surgical procedures, and only 12 (< 1.3%) required more than local measures to control bleeding.⁴⁰ Conversely, of the 526 patients who stopped their anticoagulant therapy, 5 suffered serious embolic complications and 4 of the 5 died. Wahl rec-

ommends that most dental surgery patients should remain at therapeutic levels of their anticoagulant during the perioperative period.

When a bleeding disorder is suspected, the usual screening tests include the PT or INR to test the activity of the extrinsic and final common pathways and the activated partial thromboplastin time to test the intrinsic and final common pathways. Platelet counts may be important when thrombocytopenia is suspected and bleeding time is prolonged.

Assessment of Neurologic and Neuromuscular Disorders

The oral and maxillofacial surgeon may encounter a variety of patients with neurologic disorders. Neurologic examination may reveal important findings that may alter treatment planning. For instance, head-injured trauma patients are classified according to the Glasgow Coma Scale (Table 4-6).⁴¹

Protection of the airway without increasing the chances of worsening any existing neurologic impairment is of prime importance in severely traumatized patients. The preoperative assessment of some of these patients may be, by necessity, quite limited during resuscitative procedures. Nevertheless, it is absolutely necessary to accomplish to whatever degree is possible.

Neuromuscular disorders such as Parkinson's disease or multiple sclerosis may increase the risks of ventilatory insufficiency during spontaneous breathing and aspiration during sedation or anesthesia when the airway is relatively unprotected. Duchenne's muscular dystrophy may be a risk factor for development of malignant hyperthermia or neuroleptic malignant syndrome in response to various anesthetic drugs.

Epilepsy

Epilepsy is a common neurologic disorder that requires careful assessment. Patients

with a history of seizure should maintain their antiseizure therapy during the perioperative period. The practitioner should be aware of the frequency and duration of the seizures, including the most recent one, and what to expect should a seizure occur. Despite maximal doses of multiple medications, some patients remain poorly controlled, and the surgeon must then determine the most appropriate venue for surgical treatment, while considering that the risks of pulmonary aspiration and respiratory insufficiency during seizure episodes are increased.

Transient Ischemic Attack and Stroke

Patients with a history of transient ischemic attacks (TIAs) or stroke should be evaluated in the same manner as those with angina pectoris and myocardial infarction. Those who are deemed to have unstable TIAs or who have had a stroke within the previous 6 months are managed

Table 4-6 Glasgow Coma Scale

Action	Score
Eye opening	
Spontaneously	4
To speech	3
To pain	2
None	1
Motor response	
Obeys	6
Localizes pain	5
Withdraws from pain	4
Flexion to pain	3
Extension to pain	2
None	1
Verbal response	
Oriented	5
Confused	4
Inappropriate	3
Incomprehensible	2
None	1

Adapted from Teasdale G, Jennett B.⁴¹

Patient's score determines category of neurologic impairment: 15 = normal; 13 or 14 = mild injury; 9-12 = moderate injury; 3-8 = severe injury.

similarly to those with unstable angina and recent myocardial infarction, respectively. The hypercoagulable state associated with the stress of surgery is more likely to manifest itself in patients with preexisting disease in coronary and cerebral arteries.

Preoperative Screening Tests for Asymptomatic Patients

With the advent of high-tech automated equipment in the past several decades that can quickly complete a large number of preoperative screening tests, practitioners who wished to gather as much information as possible about their patient to optimize care and reduce poor outcomes began to order “universal testing,” even for apparently healthy asymptomatic patients, in a futile attempt to “leave no stone unturned.” Unfortunately, the indiscriminate ordering of multiple laboratory tests has many drawbacks and usually does not uncover diseases that normally should be discovered by other means such as a thorough history and physical examination. For instance, Rabkin and Horne identified 165 patients who had been diagnosed as having “new electrocardiographic changes.”⁴² However, of that number, 163 were identified as having changes consistent with their history and physical examination, so these changes were not unexpected. Of the 2 patients whose new electrocardiographic changes were not consistent with the basic information recorded in their chart, 1 patient was found to be in atrial fibrillation, which should most likely have been discovered by palpation of an irregular pulse during the examination process. The other patient had no physical examination performed. Thus, this study indicated that a thorough history and physical examination should be the key to determining whether the practitioner should look for new electrocardiographic changes.

Domoto and colleagues performed 19 screening tests in 70 asymptomatic elderly patients whose mean age was > 80 years.⁴³

Most abnormalities were minimally outside normal ranges, and only 0.1% of the patients had a resulting change in treatment. Most importantly, no patient received an important benefit from the tests. Likewise, Dzankic found that the prevalence of abnormal preoperative electrolyte values and thrombocytopenia was small and had a low predictive value in elderly surgical patients.⁴⁴ Although more prevalent, abnormal hemoglobin, creatinine, and glucose values were also not predictive of postoperative adverse outcomes. Thus, the routine preoperative testing in geriatric patients for hemoglobin, creatinine, glucose, and electrolytes on the basis of age alone may not be indicated. Selective laboratory testing, as indicated by history and physical examination, determines a patient’s comorbidities and surgical risk.

Narr and colleagues studied 3,000 ASA PS-1 and PS-2 patients who received elective surgery and found no benefit from the tests.⁴⁵ Archer and colleagues completed a meta-analysis of over 14,000 patients and concluded that the practice of obtaining routine preoperative chest radiographs should be abandoned.⁴⁶

It is important to understand that the “normal values” of various tests are often set around a normal distribution that would include values of perhaps 95% of a healthy population. However, some healthy individuals may fall above or below the normal range yet still be without disease. When one considers the variable selectivity of individual tests, it is not unreasonable to expect that from a large battery of tests, at least one may reveal a falsely positive result. Such a result may prompt the clinician to seek additional information from more invasive tests, which may result in a severe complication. Therefore, indiscriminate testing can actually do more damage than the potential harm of some unrecognized disease that it is designed to discover. Additionally, in an era of cost containment, testing asymptomatic patients in hopes of improving out-

comes is generally not cost-effective for the resulting low yield.^{47–50} Although many patients with significant diseases such as diabetes and coronary artery disease, as well as women of child-bearing age who are not sure of their pregnancy status, need certain laboratory testing preoperatively, routine testing of healthy asymptomatic patients with no complicating factors is unwarranted.^{51–53}

A carefully taken medical history and a thorough physical examination remain the most important aspects of optimal patient care when supplemented by specific tests that are indicated by this information.

Summary

Having obtained and evaluated all of the appropriate information from the above sources, the oral and maxillofacial surgeon must, in the end, judge whether the benefit-to-risk ratio of completing a procedure for a particular patient, using a particular sedative/anesthesia technique in a specific venue (office, ambulatory surgical center, or hospital), is acceptable. For some medically, physically, or mentally complex patients, an alternative surgical procedure, surgeon, anesthesia provider, anesthesia technique, and/or venue may be deemed more appropriate than for those same variables with the healthy patient. Sound professional judgment of the surgeon is the hallmark of successful oral surgical practice, and a complete preoperative assessment of each patient provides an opportunity to influence that judgment for a safe and successful operation. The oft-mentioned statement “never treat a stranger” is indeed profound.

References

1. Goldman L, Caldera D, Nussbaum SR, et al. Multifactorial index of cardiac risk in non-cardiac surgical procedures. *N Engl J Med* 1977;297:845–50.
2. Detsky A, Abrams H, McLaughlin J, et al. Predicting cardiac complications in patients undergoing non-cardiac surgery. *J Gen Intern Med* 1986;1:211–9.

3. Kenchaiah S, Evans J, Levy D, et al. Obesity and the risk of heart failure. *N Engl J Med* 2002;347:305–13.
4. Malamed S. *Handbook of local anesthesia*. 4th ed. St Louis (Mo): Mosby-Year Book Inc; 1997.
5. Tarhan S, Moffitt E, Taylor W, Giuliani E. Myocardial infarction after general anesthesia. *Anesth Analg* 1977;56:455–61.
6. Steen P, Tinker J, Tarhan S. Myocardial reinfarction after anesthesia and surgery. *JAMA* 1978;239:2566–70.
7. Rao T, Jacobs K, El-Etr A. Reinfarction following anesthesia in patients with myocardial infarction. *Anesthesiology* 1983;59:499–505.
8. Shah K, Kleinman B, Sami H, et al. Reevaluation of perioperative myocardial infarction in patients with prior myocardial infarction undergoing noncardiac operations. *Anesth Analg* 1990;71:231–5.
9. Goldman L, Hashimoto B, Cook E, et al. Comparative reproducibility and validity of systems for assessing cardiovascular functional class: advantages of a specific activity scale. *Circulation* 1981;64:1227–34.
10. Goldman L, Caldera D, Southwick F, et al. Cardiac risk factors and complications in noncardiac surgery. *Medicine* 1978;57:359–70.
11. The seventh report of the Joint National Committee on Prevention, Detection, Evaluation and Treatment of High Blood Pressure. Bethesda (MD): National Institute of Health; National Heart, Lung and Blood Institute; 2003. NIH Publication No.: 03-5233.
12. Howell S, Hemming A, Allman K, et al. Predictors of postoperative myocardial ischemia. The role of intercurrent arterial hypertension and other cardiovascular risk factors. *Anaesthesia* 1997;52:107–11.
13. Eagle K, Berger P, Calkins H, et al. ACC/AHA guideline for the perioperative cardiovascular evaluation for noncardiac surgery—executive summary. A report of the American College of Cardiology/American Heart Association Task Force on Practice Guidelines (committee to update the 1996 guidelines on perioperative cardiovascular evaluation for non-cardiac surgery). *Anesth Analg* 2002;94:1052–64.
14. Hlatky MA, Boineau RE, Higginbotham MB, et al. A brief self-administered questionnaire to determine the functional capacity (the Duke Activity Status Index). *Am J Cardiol* 1989;64:651–4.
15. Hollenberg SM. Preoperative cardiac risk assessment. *Chest* 1999;115:51s–7s.
16. Morton HJV. Tobacco smoking and pulmonary complications after surgery. *Lancet* 1944;1:368–70.
17. Wightman JA. A prospective survey of the incidence of postoperative pulmonary complications. *Br J Surg* 1968;55:85–91.
18. Warner MA, Offord KP, Warner ME, et al. Role of preoperative cessation of smoking and other factors in postoperative pulmonary complications: a blinded prospective study of coronary artery bypass patients. *Mayo Clin Proc* 1989;64:609–16.
19. Tarhan S, Moffitt E, Sessler A, et al. Risk of anesthesia and surgery in patients with chronic bronchitis and chronic obstructive pulmonary disease. *Surgery* 1973;74:720–6.
20. Stein M, Cassara E. Preoperative pulmonary evaluation and therapy for surgery patients. *JAMA* 1970;211:787–90.
21. Caplan RA, Posner KL, Ward RJ, et al. Adverse respiratory events in anesthesia: a closed claims analysis. *Anesthesiology* 1990;72:828–33.
22. American Society of Anesthesiologists. Practice guidelines for management of the difficult airway: an updated report by the American Society of Anesthesiologists Task Force on Management of the Difficult Airway. *Anesthesiology* 2003;98:1269–77.
23. Mallampati SR, Gatt SP, Gugino LD, et al. A clinical sign to predict difficult tracheal intubation. A prospective study. *Can Anaesth Soc J* 1985;32:429–34.
24. Samssoon GLT, Young JRB. Difficult tracheal intubation: a retrospective study. *Anaesthesia* 1987;42:487–90.
25. Weinberg A, Brennan M, Gorman C, et al. Outcome of anesthesia and surgery in hypothyroid patients. *Arch Intern Med* 1983;143:893–7.
26. Weinberg A, Ehrenwerth J. Anesthetic considerations and perioperative management of patients with hypothyroidism. *Adv Anesthesiol* 1987;4:185–212.
27. Rossi L, Thiene G, Caragara L, et al. Dysrhythmias and sudden death in acromegalic heart disease: a clinicopathologic study. *Chest* 1977;72:495–8.
28. Martins J, Kerber R, Sherman M, et al. Cardiac size and function in acromegaly. *Circulation* 1977;56:863–9.
29. Hirsch I, McGill J, Cryer P, et al. Perioperative management of surgical patients with diabetes mellitus. *Anesthesiology* 1991;74:346–59.
30. Eagle K, Coley C, Newell J, et al. Combining clinical and thallium data optimizes preoperative assessment of cardiac risk before major vascular surgery. *Ann Intern Med* 1989;110:859–66.
31. Gelman S. Preserving renal function during surgery. *Anesth Analg* 1992;74:88–92.
32. Levy E, Viscoli C, Horwitz R. The effect of acute renal failure on mortality: a cohort analysis. *JAMA* 1996;275:1489–94.
33. Holtzman L, Burns E, Kraut R. Preoperative laboratory assessment of hemostasis for orthognathic surgery. *Oral Surg Oral Med Oral Pathol* 1992;73:403–6.
34. Eisenberg J, Clarke J, Sussman S. Prothrombin and partial thromboplastin times as preoperative coagulation tests. *Arch Surg* 1982;117:48–51.
35. Roher M, Michelotti M, Nahrweald D. A prospective evaluation of the efficacy of preoperative coagulation testing. *Ann Surg* 1988;208:554–7.
36. Barber A, Green D, Galluzzo T, T'sao C. The bleeding time as a preoperative test. *Am J Med* 1985;78:761–4.
37. Myers E, Clarke-Pearson D, Olt G, et al. Preoperative coagulation testing on a gynecologic oncology service. *Obstet Gynecol* 1994;83:438–44.
38. MacPherson C, Jacobs P, Dent D. Abnormal perioperative hemorrhage in asymptomatic patients is not predicted by laboratory testing. *S Afr Med J* 1993;83:106–8.
39. Close H, Kryzer T, Nowlin J, Alving B. Hemostatic assessment of patients before tonsillectomy: prospective study. *Otolaryngol Head Neck Surg* 1994;111:733–8.
40. Wahl M. Myths of dental surgery in patients receiving anticoagulant therapy. *J Am Dent Assoc* 2000;131:77–81.
41. Teasdale G, Jennett B. Assessment of coma and impaired consciousness: a practical scale. *Lancet* 1974;2:81–4.
42. Rabkin S, Horne J. Preoperative electrocardiography: effect of new abnormalities on clinical decisions. *Can Med Assoc J* 1983;128:146–7.
43. Domoto K, Ben R, Wei JY, et al. Yield of routine annual laboratory screening in the institutionalized elderly. *Am J Public Health* 1985;75:243–5.
44. Dzankic S, Pastor D, Gonzalez C, et al. The prevalence and predictive value of abnormal preoperative laboratory tests in elderly surgical patients. *Anesth Analg* 2001;93:301–8.
45. Narr BJ, Hansen TR, Warner MA. Preoperative laboratory screening in healthy Mayo patients: cost-effective elimination of tests and unchanged outcomes. *Mayo Clin Proc* 1991;66:155–9.
46. Archer C, Levy AR, McGregor M. Value of routine preoperative chest x-rays: meta analysis. *Can J Anaesth* 1993;40:1022–7.
47. Roizen MF, Kaplan EB, Schreider BD, et al. The relative roles of the history and physical examination, and laboratory testing in

- preoperative evaluation for outpatient surgery: the "Starling" curve of preoperative laboratory testing. *Anesthesiol Clin North Am* 1987;5:15–34.
48. Johnson H, Knee-Ioli S, Butler TA, et al. Are routine preoperative laboratory screening tests necessary to evaluate ambulatory surgery patients? *Surgery* 1988;104:639–45.
 49. Turnbull JM, Buck C. The value of preoperative screening investigations in otherwise healthy individuals. *Arch Intern Med* 1987;147:1101–5.
 50. Perez A, Planell J, Bacardaz C, et al. Value of routine preoperative tests: a multicenter study in four general hospitals. *Br J Anaesth* 1995;74:250–6.
 51. Lind LJ. Anesthetic management. *Oral Maxillofac Surg Clin North Am* 1996;8:235–44.
 52. Roizen MF. Routine preoperative testing. In: Miller RD, editor. *Anesthesia*. 2nd ed. New York: Churchill Livingstone; 1986. p. 225–53.
 53. Kaplan EB, Sheier LB, Boeckmann MS, et al. The usefulness of preoperative laboratory screening. *JAMA* 1985;253:3576–81.

Pharmacology of Outpatient Anesthesia Medications

M. Cynthia Fukami, DMD, MS

Steven I. Ganzberg, DMD, MS

Intravenous sedation has a long history of use in oral surgery practice. Oral surgeons have been the historical leaders in the development of office-based ambulatory anesthesia practice. The development of newer intravenous agents and techniques have led to the increased acceptance of these practices as being safe and cost effective. Currently, the vast majority (> 70%) of surgical procedures are performed on an ambulatory basis, and at least 20% of surgical procedures are performed with office-based sedation or general anesthesia.

While it is neither possible nor the intention of the authors to present the full scope of anesthetic medications including emergency medications in this chapter, we will review the pharmacology of many agents used in office-based sedation and general anesthesia practice. Where applicable the use of these agents in oral surgical practice is highlighted.

Pharmacodynamics and Pharmacokinetics

Pharmacodynamics

Pharmacodynamics is the study of the pharmacologic actions and clinical effects of a drug in the body.¹ The clinical response of most anesthetic and sedative

medications derives from their actions in the central nervous system (CNS).

At a cellular level the most frequent mechanism by which drugs exert their pharmacologic effects is through interactions with specific protein receptors embedded in cell membranes, which then initiate a specific set of intracellular actions. These protein receptors can be characterized as ion channels or transmembrane receptors. Ion channels allow the passage of specific ions into or out of the cell, including chloride, potassium, sodium, and calcium. Alterations in the intracellular concentration of these ions initiate characteristic cellular effects such as depolarization of a cell membrane or movement of storage vesicles. Opening of ion channels may be triggered by either changes in membrane voltage or binding by a specific ligand. Voltage-sensitive ion channels open and close depending on cell membrane voltage, whereas a ligand-gated ion channel undergoes conformational changes when a drug or natural ligand binds to it, altering ion channel opening and closing. The γ -aminobutyric acid (GABA) receptor is an example of a ligand-gated chloride ion receptor.

Transmembrane receptors are also ligand regulated and typically rely on second messenger systems to carry out the phar-

macodynamic effect. When a specific ligand binds to the extracellular portion of these transmembrane receptors, a conformational change in the domain of the receptor exposed towards the cytoplasm activates either a specific enzyme or a second messenger system. Second messenger systems, such as G proteins and cyclic adenosine monophosphate, are complex cascades of signaling proteins that, once triggered, will produce the intended effect. An example of an enzyme-activated system is insulin, which binds to its specific receptor, activating an intracellular enzyme called tyrosine kinase, resulting in increased glucose uptake. Muscarinic acetylcholine (ACh) receptors also use a second messenger cascade involving intracellular calcium.

Some lipid-soluble drugs do not engage membrane receptors, but instead exert their pharmacodynamic effect intracellularly via receptors found in the cytoplasm. Hormones and steroid medications cross the cell membrane and bind to cytoplasmic receptors, which then alter cellular functions such as gene transcription. A small number of medications may also alter enzyme activity outside of cells, such as anticholinesterase drugs that block the activity of acetylcholinesterase.

Drugs are commonly classified as either agonists or antagonists for a specific

receptor. *Agonist* drugs function to exert the normal property associated with receptor activation. GABA A agonists like benzodiazepines activate GABA receptors, allowing an influx of chloride, hyperpolarizing the cell, and reducing neuronal activity, thus promoting the normal activity associated with GABA activation. *Antagonist* drugs exert the opposite effect of the natural ligand or agonist drug activity. *Competitive antagonists* bind at the normal ligand-binding site but exert no pharmacologic effect. Instead the antagonist “takes up space” at the binding site, thus blocking agonist drug activity. The higher the concentration of antagonist, the greater the blocking effect. Agonist activity returns once the antagonist concentration decreases or if additional agonist is administered to overcome the antagonist concentration. Nondepolarizing neuromuscular blockers are competitive antagonists for the acetylcholine receptor. *Noncompetitive antagonists* do not bind at the ligand site but instead attach to a different location on the receptor, altering the configuration of the binding site and preventing normal ligand binding. Administration of an additional agonist does not affect noncompetitive antagonist activity, as they do not compete for the same binding site. Many pesticides are an example of noncompetitive antagonist agents.

Pharmacokinetics

Pharmacokinetics is the study of the factors that affect the plasma concentration of a drug in the body, encompassing the processes of absorption, distribution, metabolism, and elimination.¹ Commonly identified by the route of administration, such as per oral (PO), intravenous (IV), intramuscular (IM), or inhalation, absorption describes the point of entry of the drug into the body. Orally administered agents undergo *first-pass metabolism*; PO medications are absorbed by the intestinal mucosa and carried via the portal circulation to the liver where they

undergo partial metabolism prior to entrance into the central circulation. This process potentially reduces the plasma concentration of drug that reaches the effector site, such as the CNS. Since the degree of gastrointestinal absorption and first-pass metabolism is unpredictable, PO sedative drugs can have less reliable clinical effects. Most anesthetic agents used in oral surgical practice are delivered intravenously, intramuscularly, or by inhalation. In contrast to oral agents these routes of administration do not undergo first-pass metabolism. Both intravenous and inhalation administration provide direct entry into the central circulation, reaching peak plasma concentration very quickly following drug administration. Inhalation pharmacokinetics will be discussed in the following section “Inhalation Anesthetics.”

Distribution describes the movement of the drug between body compartments. The main factors influencing distribution include the allocation of blood flow to a specific compartment, the concentration gradient of the drug between compartments, the chemical structure of the drug, and plasma protein binding of the drug. Following administration the majority of the drug initially redistributes to the vessel-rich compartments. This vessel-rich group includes the brain, heart, kidney, and liver, representing 10% of total body mass but 75% of cardiac output. Since the major site of anesthetic agent activity is the brain, early distribution to the CNS results in early anesthetic effects.

The transfer of the drug from the central circulation to the brain is also determined by the concentration gradient between the two compartments. A lower concentration in one compartment favors the transfer from a region of higher concentration. Following initial intravenous administration the initial drug concentration in the brain is low relative to the plasma concentration; thus, the drug will rapidly transfer into the brain based on this differential concentration gradient. As

the plasma concentration falls by continued redistribution to other vessel-rich organs, and later to less vessel-rich organs such as skeletal muscle (approximately 20% of cardiac output), anesthetic drug not bound to receptors in the brain will transfer back into the central circulation for further redistribution to other tissue sites. As the brain concentration of sedative agent falls, the clinical effects of sedation also decrease.

Characteristics of the drug itself affect its distribution throughout the body. Lipophilic drugs readily cross the blood-brain barrier and cellular membranes, and generally exert their effects rapidly. Likewise lipophilic drugs can quickly exit the CNS, shortening the duration of their effects. Hydrophilic medications either cross very slowly or must be transported by specific mechanisms. The size or molecular weight of the drug molecules influences movement across capillary walls; smaller molecules will cross more readily. The degree to which the drug binds to plasma proteins such as albumin and α_1 -acid glycoprotein will affect the amount of free drug available to cross into the brain. Most sedative agents are highly plasma-protein bound. For example, initial doses of diazepam are 98% bound to plasma protein and unavailable to cross into the CNS. As the free drug plasma concentration decreases through further redistribution, and later metabolism and elimination, plasma-protein-bound drug is released back into the plasma as free drug and is able to cross the blood-brain barrier. In this way drug bound to plasma protein may be thought of as a reservoir of drug that may contribute to prolonged sedative effects. Once plasma-protein binding sites have been filled, an additional consequence is that further administration of small quantities of drug can have profound effects as the majority of the additional administered agent will be free drug that is able to cross the blood-brain barrier. Careful titration of intravenous

agents, especially after initial administration and filling of protein binding sites, is important to avoid oversedation due to this mechanism. Hypoproteinemia secondary to advanced age or severe liver failure can also dramatically increase the concentration of free drug, and dose reduction may be required.

As redistribution continues, a fraction of the plasma concentration is delivered to the liver, the primary organ of drug metabolism, undergoing transformation from a lipid-soluble entity to a water-soluble form. There are four main pathways of hepatic metabolism: oxidation, reduction, hydrolysis, and conjugation. Phase I reactions include the first three pathways, converting the drug into a water-soluble metabolite or intermediate form. Phase II reactions involve most forms of conjugation, in which an additional group is added onto the metabolite in order to increase its polarity. Subsequent elimination via the kidney, the main excretory organ, requires hydrophilicity to avoid reabsorption of the excreted drug. Water-soluble drugs and metabolites are eliminated chiefly by the kidney, but also via the bile, lungs, skin, and other organs.

Phase I hepatic reactions, including the cytochrome P-450 (CYP-450) group of enzymes which carry out the oxidation and reduction reactions, occur in the hepatic smooth endoplasmic reticulum (hepatic microsomal enzymes). The CYP-450 group of enzymes has been characterized into several isoforms, including CYP-3A4, CYP-2D6, and CYP-1A2. The conjugation reaction of glucuronidation is also conducted by the hepatic microsomal enzymes. The hepatic microsomal enzymes are unique in that certain chemicals and drugs, including those used in anesthesia, can stimulate their activity. This is termed *enzyme induction* and generally requires chronic exposure of the drug to the enzyme system for at least several days or weeks. An isolated exposure to anesthetic agents is unlikely to induce

hepatic enzyme activity. However, if the patient's daily medications induce hepatic enzymes, then increased metabolism of additional medications is possible. Induction is isoform specific; a coadministered drug will only be affected by enzyme induction if both drugs are metabolized by the same enzyme system. Hepatic microsomal enzymes can also be inhibited by certain drugs, thus reducing metabolism of drugs by a specific enzyme system. For example, patients taking cimetidine for treatment of gastric ulcers may experience prolonged residual CNS effects from diazepam, as cimetidine inhibits the hepatic enzymes that normally metabolize diazepam. Various tables have been published which list drugs that are substrates, inducers, and inhibitors of the various cytochrome enzyme systems.

Nonhepatic forms of metabolism are important for certain anesthetic medications, and are useful in patients with significant liver or kidney disease. Drugs susceptible to Hofmann elimination spontaneously degrade at body pH and temperature. Ester hydrolysis by nonspecific and specific (eg, pseudocholinesterase) esterases is also less dependent on renal and hepatic functions.

Redistribution, metabolism, and elimination reduce the plasma concentration of the drug, increasing the transfer of drug from tissue sites (eg, brain) back into the central circulation for further redistribution, metabolism, and elimination. Different mathematical models involving these processes have been developed that describe the offset of activity of anesthetic agents. The fall of 50% of the plasma concentration of the drug secondary to redistribution is termed the *alpha half-life*. The removal of 50% of the drug from the body due to metabolism and/or elimination is termed the *beta half-life*, or elimination half-life. Offset of clinical effects and awakening from a bolus of an IV anesthetic agent is more dependent on redistribution of the drug away from the brain and is therefore better approximated by the

alpha half-life than the beta half-life. In some cases residual CNS effects can be predicted by a long elimination half-life. The beta half-life has more use for orally administered agents and particularly describes central compartment concentration in a one-compartment model.

The pharmacokinetics of a continuous infusion of intravenous anesthetic agents may be better described by the *context-sensitive half-time*. This value represents the time necessary for the plasma drug concentration to decrease by 50% after discontinuing a continuous infusion, depending on how long the anesthetic agent has been administered.² Figure 5-1 describes the context-sensitive half-time for a number of common anesthetic agents. Currently computer-controlled pumps administer continuous infusions based on a specific amount of drug per time, but the newest infusion pumps can be programmed to calculate and provide target plasma concentrations of an agent to a specified anesthetic or analgesic level. In the future these pumps will likely be integrated with concurrent electroencephalogram consciousness monitoring to individualize anesthetic drug delivery.

Benzodiazepines

Benzodiazepines are the most commonly used sedative and anxiolytic medications in oral surgery. Their relatively high margin of safety as compared to other sedative-hypnotic medications, in addition to the availability of an effective reversal agent, makes their use attractive during operator-anesthetist procedures in an outpatient setting.

Benzodiazepines are composed of a benzene and diazepine ring fused together.³ Agonist agents contain a 5-aryl substitution which is not present on the antagonist reversal agent (Figure 5-2). This structure binds to inhibitory GABA receptors found throughout the brain, particularly in the cerebral cortex. Binding to the GABA A subunit increases the frequency of pore

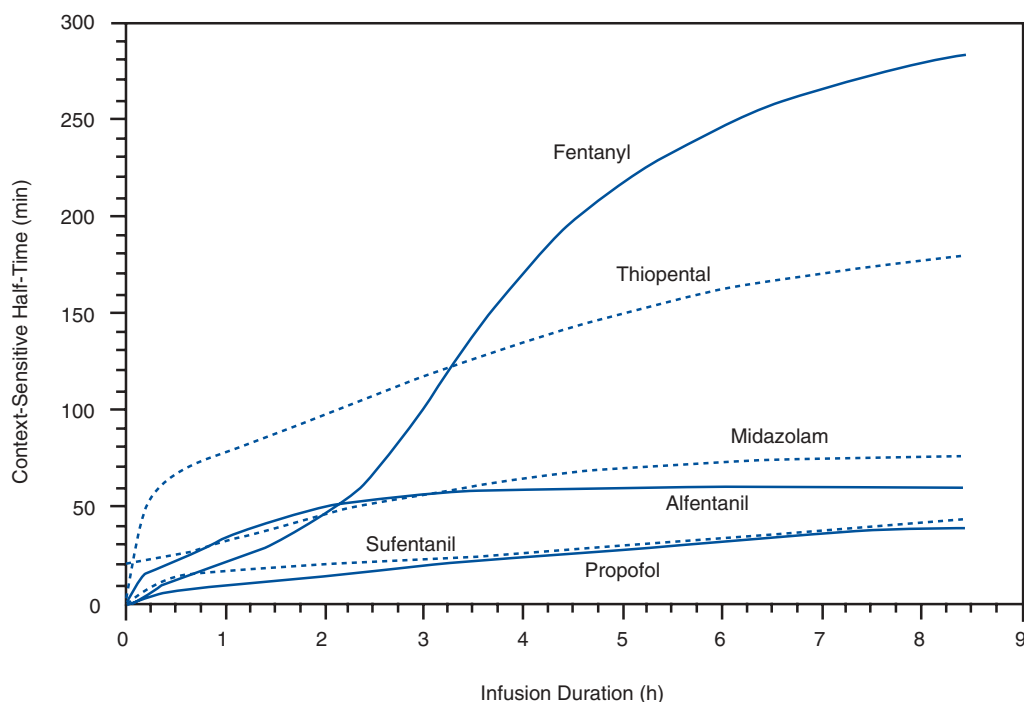


FIGURE 5-1 Context-sensitive half-time of a number of anesthetic agents. Adapted from Hughes MA et al.²

opening in the chloride-gated channel, thus increasing inward chloride flow, hyperpolarizing cell membranes, and reducing neuronal transmission.

Characteristics shared by benzodiazepines include sedation, anxiolysis, anterograde amnesia, muscle-relaxing properties, and anticonvulsant activity. Indeed, any intravenous benzodiazepine agonist may be used to suppress acute seizure activity. These drugs do not produce analgesia.

Benzodiazepines are commonly used for preoperative sedation both immedi-

ately prior to the procedure and as a sleep adjunct the night before surgery. In clinical practice they are also used for conscious sedation, and at higher doses can produce deep sedation and even general anesthesia.

In a nervous patient anxiolysis from benzodiazepines can produce noticeable reduction in blood pressure and heart rate, but these medications have little direct effect on cardiovascular parameters. Given alone in slowly titrated doses, benzodiazepines also have minimal effects on ventilation. Large bolus doses will,

however, induce unconsciousness and apnea. Additionally, even smaller doses when given in combination with an opioid can synergistically enhance opioid-induced respiratory depression.

Benzodiazepines are metabolized by hepatic enzymes into hydrophilic forms. These metabolites are then excreted by the kidney in urine.

Side effects of benzodiazepines are few, but paradoxical excitement, in which patients may become overly disinhibited and disoriented, is a possible complication. Flumazenil is useful in the reversal of paradoxical excitement and benzodiazepine-related respiratory depression.

Diazepam

Diazepam is lipid soluble and is carried in an organic solvent such as propylene glycol or a soybean oil emulsion. Intravenous injection can be painful, although injecting into a larger vein or pre-administration of lidocaine or an opioid can reduce discomfort. Intramuscular injection is painful and absorption can be unpredictable.

Diazepam is still used for intravenous conscious sedation, given in 2.5 to 5 mg increments every few minutes. Onset of sedation occurs in several minutes and recovery from clinical sedation by diazepam is similar compared to midazolam. However, the much longer elimination time of diazepam may contribute to lingering sedative effects. Diazepam can also be given orally (5 to 10 mg) for preoperative anxiolysis and mild sedation.

This highly lipid-soluble drug accumulates in fat tissues with slow reentry of very small quantities into the central circulation, leading to an elimination half-life of 24 to 96 hours. Diazepam is also metabolized into two pharmacologically active metabolites, desmethyldiazepam and oxazepam, each with long elimination half-lives as well. The active metabolites and parent drug are partially eliminated in bile and can result in

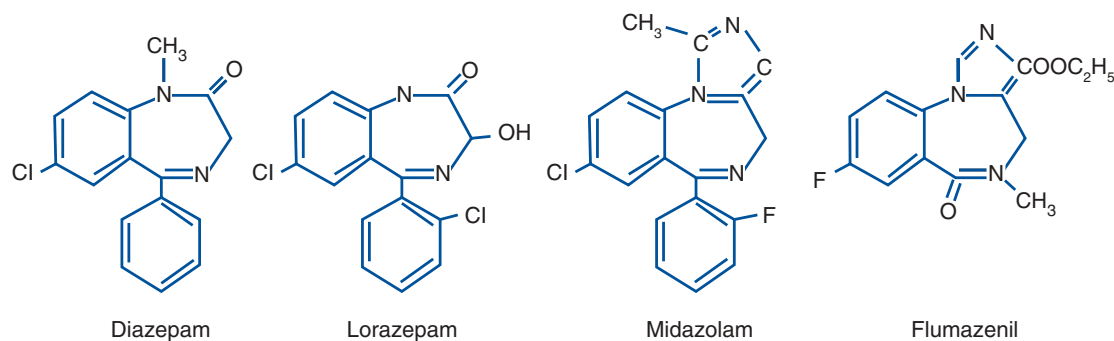


FIGURE 5-2 Chemical structure of benzodiazepine agonists and antagonist.

reemergence of sedation several hours after completion of the procedure, due to enterohepatic metabolism. Upon ingestion of a fat-rich meal, bile is released into the gut, and active drug components in the bile are reabsorbed by the intestinal mucosa and undergo first-pass metabolism. These still active drugs are then re-introduced into the central circulation and into the CNS, resulting in possible resedation.

Midazolam

Midazolam has an imidazole ring attached to its diazepine ring. The imidazole ring is open, rendering the compound water soluble at pH less than 4, but the ring closes at physiologic pH producing the lipid-soluble benzodiazepine. Midazolam can therefore be delivered in an aqueous solution, rather than propylene glycol, resulting in less pain on intravenous and intramuscular injection.⁴ It is 2 to 3 times as potent as diazepam, with a faster onset, much faster elimination, and shorter duration of lingering effects. Its active metabolites are not thought to produce significant sedative effects. Respiratory depression is more of a concern with midazolam than diazepam after bolus intravenous administration.

Midazolam is currently more popular than diazepam for intravenous sedation for short oral surgical procedures. For conscious sedation 0.05 to 0.15 mg/kg IV in divided doses is titrated to effect, typically given in 1 or 2 mg boluses every few minutes. Peak effect is seen in approximately 5 minutes. Dosage should be adjusted downward when given concurrently with other medications such as opioids or propofol. An intramuscular injection of 0.5 mg/kg to a maximum of 10 to 15 mg depending on patient age is also possible. As an alternative midazolam may be given orally at 0.5 to 1 mg/kg (maximum 15 mg), usually mixed into a flavored syrup or in a commercially available premixed product; this route may be better accepted by pediatric patients.⁵ Clinical effect from PO adminis-

tration will be seen after 15 to 20 minutes in the pediatric patient.

Lorazepam

Lorazepam is a long-acting benzodiazepine with a slow onset. Its use for PO and IV sedation is therefore limited but is an option for oral preoperative anxiolysis, particularly the night before surgery or for long operative appointments. Dosage for an adult is 0.05 mg/kg, not to exceed 4 mg total.

Triazolam

Triazolam is only available in an oral formulation as 0.125 mg and 0.25 mg tablets. This sleep adjunct can be used off-label for anxiolysis and sedation at a dose of 0.25 to 0.5 mg for an adult. It is a very short-acting benzodiazepine and its effects are observed in 30 to 45 minutes with clinically effective sedation lasting from 30 to 90 minutes.

Flumazenil

Flumazenil is a highly specific competitive antagonist for the benzodiazepine receptor and is used as a reversal agent for benzodiazepine agonists.⁶ It will reverse benzodiazepine sedation, excessive disinhibition, and the additive ventilatory depression related to benzodiazepines when combined with opioids. Flumazenil is given 0.2 mg IV initially, followed by 0.1 mg at 1-minute intervals as necessary, to a total of 1 mg. In emergency situations, 0.5 to 1 mg or more may be administered in a bolus dose. Reversal effects may take several minutes to manifest. The effect of flumazenil will last 30 to 60 minutes and may require redosing since agonist drug activity may outlast the reversal effects. Flumazenil should not be administered to epileptic patients using benzodiazepines for seizure control and should be used cautiously with other epileptic patients.

Opioids

Opioid medications are used in oral surgery primarily for analgesia and mild

sedation or euphoria. It is important to note that narcotic medications do not produce amnesia or classic sedation, nor do they induce loss of consciousness or sensation of touch at clinically relevant doses. Patients given opioid medications alone will retain awareness and memory. Instead, opioids are often used in combination with sedative-hypnotic medications such as benzodiazepines and barbiturates to provide analgesia and augment the desired level of anesthesia.

While the term *opiate* refers to any drug derived from opium, *opioid* medications include all substances, natural and synthetic, which bind to the opioid receptors.⁷ Common opioid medications are shown in Figure 5-3. Endogenous opioids such as endorphins and enkephalins, and administered opioid medications like morphine, bind to opioid receptors located in presynaptic and postsynaptic neurons throughout the CNS as well as in peripheral afferent nerves. Agonist activity at these receptors either modifies or decreases neuronal transmission of pain signals. Several subtypes of opioid receptors (eg, μ , κ , δ) with differential effects have been identified. The μ and κ receptors are predominantly responsible for analgesia, and most clinically used opioids are agonists for the μ receptor. A subset of opioids, termed *agonist-antagonist* opioids, are agonists at κ receptors and antagonists at μ receptors. Thus agonist-antagonist opioids are contraindicated for patients on long-term opioids, such as those using these agents for chronic pain or those on methadone maintenance for treatment of opioid substance abuse.

Respiratory depression is the most common and pronounced side effect of μ receptor agonists as used in anesthetic practice. This effect can be significantly exacerbated with concurrent administration of other medications such as benzodiazepines, barbiturates, propofol, and other opioids. Respiratory depression is dose dependent, resulting from a decrease in

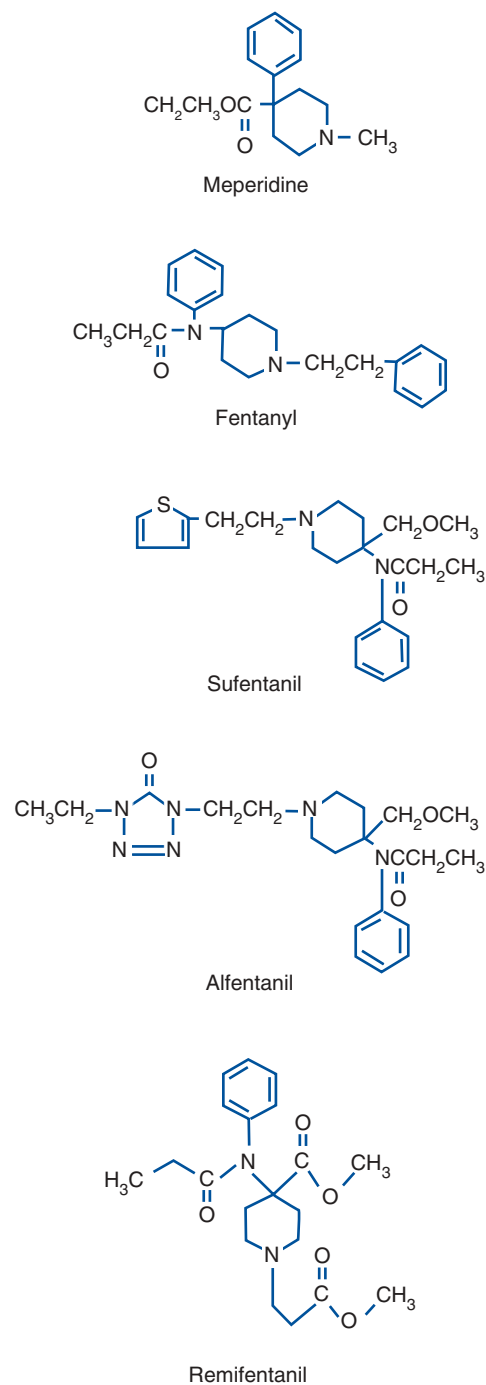


FIGURE 5-3 Chemical structure of synthetic opioid agonists.

the respiratory response to arterial carbon dioxide (CO₂) levels in the brainstem respiratory centers. Decreased respiratory rate and arterial hypoxemia may result without supplemental oxygen (O₂) and appropriate monitoring (eg, pulse oximetry). Opioids are often titrated incrementally to balance the analgesic effect against respiratory depression.

Bradycardia as a direct effect is more apparent with high doses of opioids and is due to centrally mediated vagal response. This effect is common with opioids such as morphine, fentanyl, and the synthetic derivatives, but less common with meperidine. A mild decrease or stabilization of the heart rate may be desirable in patients with cardiovascular disease.

Most opioids are metabolized by hepatic enzymes and excreted into the urine and bile. The exception is remifentanyl, which is metabolized by plasma esterases.

Opioids suppress the cough reflex and are a common ingredient in cough medicines. These antitussive effects can be beneficial during sedation, especially when used in patients with hyperreactive airways (eg, smokers). However, several opioids can cause the release of histamine and caution should be used when histamine-triggering opioids are administered to an asthmatic patient. Other manifestations of histamine release include a decrease in blood pressure secondary to vasodilation, and pruritus and erythema, especially at the site of injection.

Other adverse effects such as nausea and vomiting, constipation, urinary retention, and biliary tract spasm may increase patient discomfort postoperatively, particularly with repeated oral or neuraxial administration. These reactions are frequently misinterpreted by the patient and other health care providers as an “allergic” reaction.

Morphine

Morphine is the standard agent by which other opioids are compared. It has poor lipid solubility and therefore has a slow onset. Peak effect following IV administration occurs in 15 to 30 minutes and the analgesic effect lasts approximately 4 hours. Because of its slow onset and longer duration of activity, it is commonly used in anesthesia for postoperative pain management rather than intravenous sedation. Morphine is normally given in 1 to 2 mg IV increments for postoperative analgesia.

Morphine has several notable characteristics. Histamine release from morphine can result in skin flushing and a decrease in blood pressure and may be of concern in an asthmatic patient. Morphine is metabolized by hepatic enzymes into two metabolites that are subsequently eliminated by the kidney. One of these metabolites, morphine-6-glucuronide, is more potent than morphine itself, and prolonged opioid effects in patients with renal failure can be significant.

Meperidine

Meperidine is a synthetic opioid with a relatively rapid onset time and duration of action between 2 and 3 hours. It is used for both intravenous sedation and postoperative pain control. Meperidine is usually given in 12.5 to 25 mg IV increments titrated to effect.

The drug has several identifying characteristics. Like morphine, it also has an active metabolite, normeperidine, which is half the potency of meperidine. When mixed with monoamine oxidase inhibitors, meperidine administration may produce a dangerous excitatory hyperthermic reaction. With repeated dosing, particularly in renally compromised patients, accumulation of normeperidine may lead to seizures. Meperidine is also associated with the release of histamine; thus, appropriate precautions should be taken. Unlike the other opioids it is not associated with bradycardia; its structure resembles atropine and it possesses mild anticholinergic effects such as a mild increase in heart rate (offset by direct vagal stimulation) and xerostomia. Meperidine is commonly used to reduce shivering postoperatively, an action likely associated with partial agonist activity at the κ receptor.

Fentanyl

Fentanyl is a synthetic opioid, and its high lipid solubility leads to its high potency, rapid onset (1 min), and shorter duration of action (10 to 20 min). With

such characteristics fentanyl is a frequent choice for intravenous conscious sedation for short office-based procedures. It is typically given in 25 to 50 μg increments towards a total dose of approximately 1 to 2 $\mu\text{g}/\text{kg}$. It is also given during induction of general anesthesia, both for analgesia and attenuation of airway reflexes during intubation.

Fentanyl does not induce histamine release and is therefore not associated with vasodilatory or bronchospastic effects. However, at higher doses, it can cause more pronounced bradycardia than morphine. Fentanyl is a potent respiratory depressant. At high doses and with rapid bolus administration, fentanyl and other synthetic derivatives have been associated with chest wall and glottic rigidity, making ventilation impossible; there are reports that even lower doses (eg, 100 μg) can trigger this centrally mediated effect. Fentanyl-associated chest wall rigidity is treated with either naloxone or succinylcholine (SCh), and positive pressure O_2 and other resuscitation equipment should be immediately available. The incidence of fentanyl rigidity is reduced by a preceding dose of a benzodiazepine or other hypnotic drug.

Remifentanyl, Sufentanil, and Alfentanil

Remifentanyl, sufentanil, and alfentanil are synthetic fentanyl derivatives used primarily for analgesia during general anesthesia. Remifentanyl in particular is associated with a rapid onset and extremely short duration of action, resulting in a significantly shorter recovery time. Metabolized by nonspecific plasma esterases, its clearance is very rapid and independent of both hepatic and renal functions. It has a very short context-sensitive half-time of 4 minutes with virtually no cumulative effect, even following hours of continuous infusion. These features make remifentanyl ideal for use in a titratable continuous infusion. Of note is the fact that because the actions of this medication are so short-

lived, postoperative pain will not be addressed by intraoperative remifentanyl, and alternative pain control with another narcotic such as a nonsteroidal anti-inflammatory drug (NSAID) or local anesthesia should be considered towards the end of the procedure.

Remifentanyl is used in a total intravenous infusion anesthetic technique to maintain anesthesia during dental surgery, often in combination with propofol. For analgesia during general anesthesia it is used at 0.25 to 1 $\mu\text{g}/\text{kg}$ or 0.5 to 2 $\mu\text{g}/\text{kg}/\text{min}$. During sedation the dose ranges from 0.05 to 0.10 $\mu\text{g}/\text{kg}/\text{min}$.

Remifentanyl, like fentanyl, can cause chest wall rigidity and caution should be used during bolus administration. It is also a highly potent respiratory depressant, and even at lower doses, apnea may be pronounced. If spontaneous ventilation is desired the remifentanyl infusion is usually titrated to maintain an adequate respiratory rate. None of these synthetic derivatives cause the release of histamine.

Sufentanil and alfentanil are shorter-acting agents than fentanyl but not as rapid in offset as remifentanyl. These agents are commonly used as a continuous infusion adjunct for intubated general anesthesia during cardiac or prolonged surgery, particularly when residual opioid effects are desirable postoperatively. They are not as commonly used for office-based oral surgical anesthesia.

Nalbuphine

Nalbuphine is the most frequently used intravenous agonist-antagonist opioid. It has a relatively short onset and duration of action of 2 to 4 hours at sedation doses of 5 to 10 mg for the adult patient. Although nalbuphine and other agonist-antagonist opioids do possess a ceiling effect for respiratory depression at higher doses, at equianalgesic and clinically relevant sedation doses, the respiratory depressant effects are similar to μ agonist opioids. Nalbuphine does not release histamine.

Unlike all the other agents noted above which are US Drug Enforcement Agency Schedule II controlled substances, nalbuphine is not currently a scheduled controlled substance and does not require state and federal documentation of use.

Naloxone

Naloxone is a pure opioid antagonist that is active at all opioid receptor subtypes. It will reverse both the ventilatory depressive and analgesic effects of opioids. It can also be used to reverse chest wall or glottic rigidity from fentanyl and its derivatives. In patients taking opioids chronically (eg, chronic pain management, illicit opioid users, methadone therapy for opioid abuse), naloxone must be used with caution as the antagonist effect may precipitate acute opioid withdrawal and acute congestive heart failure may result.

The initial dose is 0.4 to 2 mg IV for acute reversal. Naloxone can also be titrated in 0.04 mg increments when gradual adjustment of mild respiratory depression is required. Because the duration of naloxone activity is 30 to 45 minutes, reemergence of respiratory depression may occur and additional dosing may be needed.

Barbiturates

Barbiturates are sedative-hypnotic medications that have long been employed as induction agents of general anesthesia. Barbiturates produce sedation, loss of consciousness, and amnesia. These drugs do not provide analgesia and may actually reduce pain threshold at lower doses. Several barbiturates such as IV pentobarbital and oral phenobarbital are commonly used as anticonvulsants for both prevention and treatment of seizures. High doses of any intravenous barbiturate can also suppress acute seizure activity.

Barbiturates are derivatives of barbituric acid (Figure 5-4). The characteristics of the individual barbiturate are determined by the side chains attached to the barbiturate ring (Figure 5-5). For example,

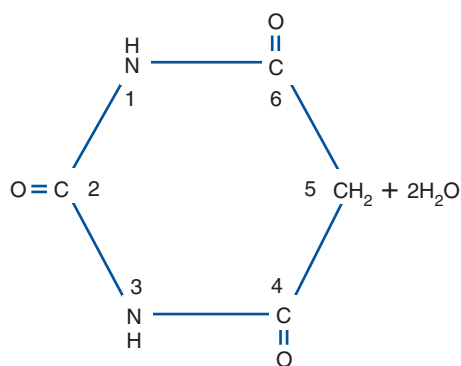


FIGURE 5-4 Chemical structure of barbituric acid.

sulfur substitution on the no. 2 carbon in thiobarbiturates increases the lipid solubility of these drugs and hence decreases onset of action and duration of activity. The methyl group attached to the nitrogen atom of the ring in methohexital results in a more rapid onset for this oxybarbiturate and increased susceptibility to cleavage, producing a shorter duration than other oxybarbiturates.

Barbiturates act on GABA receptors at a specific binding site (different from ben-

zodiazepines), causing the chloride channel to remain open for a longer duration. The increased negative inward flow hyperpolarizes the membrane, decreasing neuronal transmission.

Awakening from intravenous barbiturates is dependent on redistribution from the brain. These medications are metabolized by hepatic enzymes without the formation of active metabolites and are then cleared renally. Because these drugs are highly protein-bound, hypoproteinemia secondary to liver failure or malnutrition increases the plasma concentration of free drug. Chronic use of barbiturates can cause induction of liver enzymes. Barbiturates are also contraindicated in patients with acute intermittent porphyria as they may precipitate an attack.

Barbiturates are associated with a dose-dependent decrease in respiratory rate and tidal volume with apnea observed at higher doses. Centrally mediated peripheral vasodilation leads to a transient drop of 10 to 30% in systemic blood pres-

sure, particularly when a full induction dose is administered. This is partially attenuated by a compensatory increase in heart rate as baroreceptor reflexes remain intact. Hypotension is more evident in the elderly or medically compromised, hypovolemic patients. Thiopental can cause histamine release, which is clinically insignificant with methohexital.

Intra-arterial injection of barbiturates causes painful spasm of the vessel from precipitation of barbiturate crystals, which damage the endothelium and may result in occlusion of the artery. At worst, decreased distal perfusion may result in tissue necrosis of a limb or nerve damage and must be addressed immediately. The intravenous catheter should be left in place, IV cardiac lidocaine or procaine (without epinephrine) administered, and the patient should be transported to an emergency department where medications or regional blockade may be given to relieve the spasm and reduce the occlusion. Although also uncommon, venous irritation and thrombosis secondary to crystal formation is also possible with concentrations of barbiturates above 1% methohexital and 2.5% thiopental.

These medications are stored in powder form and reconstituted in saline prior to use as sodium salts. The alkalinity of the solutions prevents bacterial growth and ensures a longer refrigerated shelf life of up to 2 weeks for thiopental and 6 weeks for methohexital.

Thiopental

Thiopental is an ultrashort-acting barbiturate that is commonly used at 3 to 5 mg/kg IV to induce loss of consciousness for general anesthesia prior to endotracheal intubation. It is associated with a longer recovery than methohexital due to its decreased plasma clearance and is generally not used as a continuous infusion to maintain anesthesia due to significant storage in multiple drug compartments. A 2.5% solution of thiopental is less

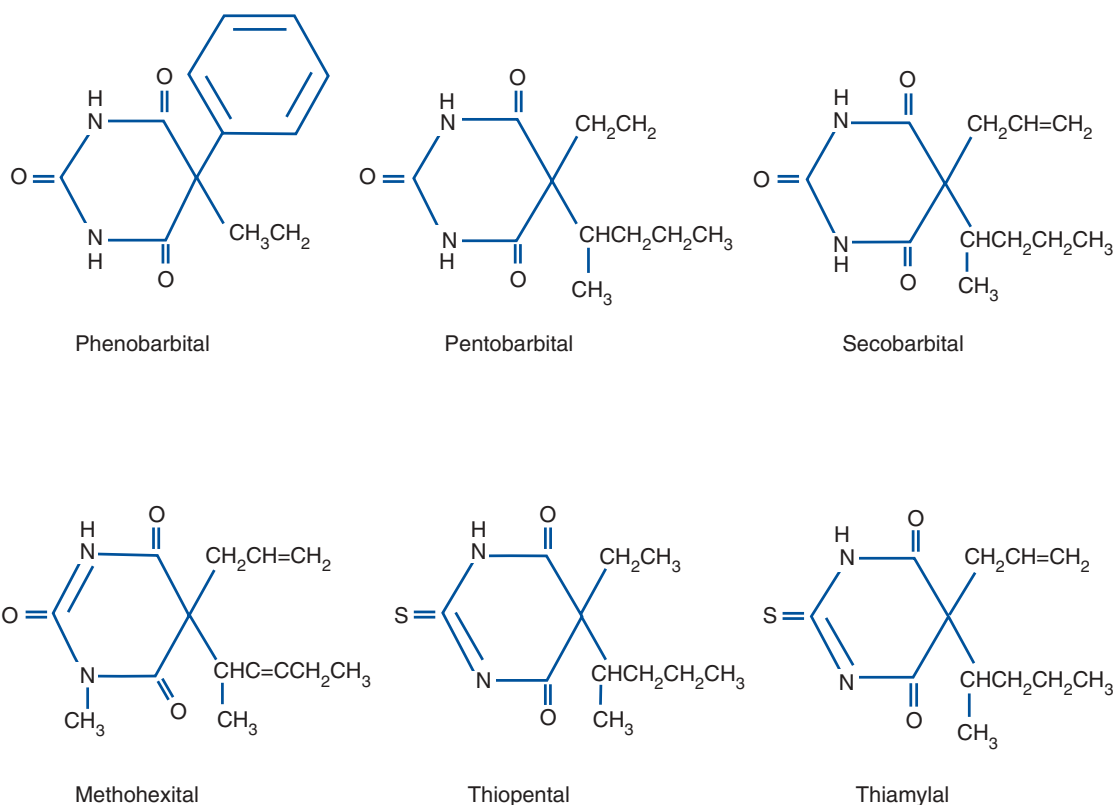


FIGURE 5-5 Chemical structure of barbiturates.

expensive than other induction agents, but when rapid recovery is desired during outpatient anesthesia, other agents such as methohexital and propofol have proven more popular. Thiopental can release histamine, which is a concern in asthmatic patients.

Methohexital

Methohexital is an ultrashort-acting barbiturate that is commonly employed for outpatient oral surgical procedures, primarily for its more rapid recovery compared to thiopental and its lower cost compared to propofol. As an oxybarbiturate, methohexital is less lipid soluble than thiopental but is associated with a more rapid awakening because of its increased hepatic clearance.⁸ Psychomotor function returns more quickly with methohexital than thiopental, allowing for earlier discharge following an outpatient procedure.

Methohexital is reconstituted into a 1% solution and given at 1.5 to 2 mg/kg IV for induction of general anesthesia. With these doses blood pressure may drop by up to 35% and heart rate increases up to 40% of baseline. In a common deep sedation technique used in oral surgical practice, 10 to 30 mg increments of methohexital are periodically administered after obtaining baseline conscious sedation with a benzodiazepine and opioid to produce a state of deep sedation for local anesthetic administration and other stimulating portions of dentoalveolar surgery.

Methohexital is associated with involuntary movements such as myoclonus and hiccuping. These excitatory phenomena are dose dependent and may be reduced by prior administration of opioids. Low doses of methohexital can activate seizure foci and should be used cautiously, if at all, for epileptic patients. Shivering upon awakening is also common following methohexital anesthesia. Methohexital exhibits clinically insignificant histamine release.

Pentobarbital

Pentobarbital is an intravenous short-acting barbiturate with a duration of action of 2 to 4 hours. It is generally used for conscious sedation in doses of 100 to 300 mg, combined with opioids and possibly benzodiazepines, for longer operative procedures. Cardiovascular effects are more modest than the ultrashort-acting agents.

Nonbarbiturate Induction Agents

Other medications are available for sedation and induction of general anesthesia. These include propofol, etomidate, and ketamine, all of which can produce unconsciousness but with several differing characteristics from barbiturate medications.

Propofol

Propofol has become one of the most popular sedative-hypnotic drugs used for ambulatory surgery. Propofol, 2,6-diisopropylphenol (Figure 5-6), is highly lipid soluble and available as a milky white 1% suspension in soybean oil, glycerol, and egg phosphatide. Like benzodiazepines and barbiturates, propofol is thought to interact with the GABA receptor, causing increased chloride conductance and hyperpolarization of neurons. At higher doses propofol can produce amnesia and loss of consciousness. It is also an anticonvulsant, although spontaneous excitatory movements may be noted following administration.⁹

Depending on the dose and technique, propofol is used for all levels of sedation and general anesthesia. For induction of general anesthesia a bolus of 1.5 to 2.5 mg/kg IV produces unconsciousness within 30 seconds. In the intermittent bolus technique frequently used for deep sedation in oral surgery, small increments of propofol (10 to 30 mg) are periodically administered after a baseline conscious sedation with a benzodiazepine and opioid is obtained, in order to produce a state of deep sedation for local anesthetic adminis-

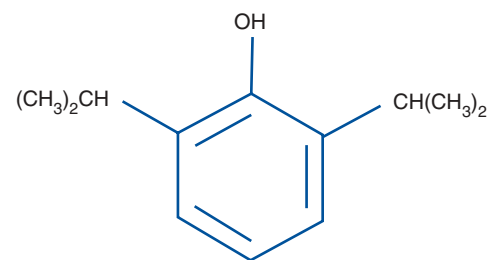


FIGURE 5-6 Chemical structure of propofol.

tration and other stimulating portions of dentoalveolar surgery. Propofol can also be used as a continuous intravenous infusion.¹⁰ The dosages for conscious sedation range from 25 to 100 $\mu\text{g}/\text{kg}/\text{min}$, deep sedation from 75 to 150 $\mu\text{g}/\text{kg}/\text{min}$, and general anesthesia from 100 to 300 $\mu\text{g}/\text{kg}/\text{min}$ depending on the use of intubation. The overlap of dose ranges, from conscious sedation to general anesthesia, highlights the lower margin of safety of this drug, especially if the intended level of sedation is conscious sedation. US Food and Drug Administration labeling prohibits use of propofol by those involved in the conduct of the surgical or diagnostic procedure.

Propofol is extensively metabolized by hepatic enzymes. In addition, extensive redistribution and other mechanisms of metabolism and elimination most likely occur, as the rate of propofol clearance from the plasma exceeds hepatic blood flow. This rapid plasma clearance may account for the decreased cumulative effect of this drug in the body, contributing to rapid awakening. The context-sensitive half-time for this drug is short, reaching a maximum of 40 minutes even after 2 to 6 hours of continuous infusion. Context-sensitive half-times are even shorter with brief infusions.

Propofol decreases systemic blood pressure by as much as 20 to 40% from baseline through centrally mediated vasodilation. Propofol also blocks sympathetic tone and allows parasympathetic vagal responses to predominate, thereby blunting the reflex tachycardia that would

normally be associated with such a drop in blood pressure. Hypotension may therefore be very significant following bolus administration of propofol, particularly in the elderly, medically compromised, and hypovolemic patients.

Propofol also leads to dose-dependent respiratory depression and can produce apnea at higher doses. It is not associated with histamine release and has bronchodilatory properties.

Recovery from anesthesia with propofol has several unique characteristics. Compared to other induction agents propofol is associated with a more rapid awakening and recovery, with less residual CNS effects. Many patients also experience mild euphoria on awakening, which enhances reported satisfaction with the anesthesia postoperatively. Even at subhypnotic doses propofol is associated with decreased postoperative nausea and vomiting.⁹ All these features make propofol an attractive choice for outpatient procedures where decreased time to discharge is desirable.

Even with an available generic formulation the higher cost compared to barbiturates is still apparent. The increased cost can overshadow the advantages of using propofol infusions, especially if the surgical time is long (> 2 h), or if quick discharge is not required.

Several considerations should be taken when using propofol. The solution can cause significant pain on injection, especially in smaller vessels. This may be attenuated with pre-administration of opioids or 1% cardiac lidocaine. Unlike barbiturates, however, it does not cause vasospasm when inadvertently injected into an artery.

Anaphylaxis is rare but has been reported in patients with a history of allergic reactions to other medications, especially neuromuscular blocking drugs. A history of egg allergy does not necessarily preclude the use of propofol, as the egg protein contained in the suspension is lecithin, whereas most egg allergies con-

sist of a reaction to egg albumin. The original proprietary agent, Diprivan, uses ethylenediaminetetraacetic acid as an antibacterial agent, whereas the generic version contains a sulfite. Although this generic agent should not be used in patients with known sulfite sensitivity, it appears that allergic reactions and bronchospasm are very unlikely, although not completely unheard of, in other patients including asthmatics. Both drug suspensions are pH neutral and can support bacterial growth; therefore, the observation of sterile technique and discarding of an opened vial or filled syringe after 6 hours are recommended. Cracked glass containers or discolored contents should be discarded, as sepsis is a possibility.

Etomidate

Like midazolam, etomidate contains an imidazole structure (Figure 5-7). It is water soluble but available in a 0.2% solution in propylene glycol. In the same way as the other induction medications, etomidate interacts at the GABA receptor.

Etomidate is used primarily as an induction agent for general anesthesia at 0.2 to 0.4 mg/kg IV. Its main advantage over barbiturates and propofol is cardiovascular stability. Although systemic blood pressure can decrease by up to 15% with etomidate, changes in heart rate are minimal. It also does not depress myocardial contractility. Etomidate is usually reserved for patients with unstable cardiac disease because it is more expensive than other induction agents.

Spontaneous respiration may be maintained. Respiratory depression is less pronounced with etomidate compared to barbiturates, although apnea is still possible with higher doses.

Etomidate is metabolized by both hepatic enzymes and plasma esterases. This rapid clearance leads to awakening and recovery that is faster than with thiopental but slower than with methohexital or propofol.

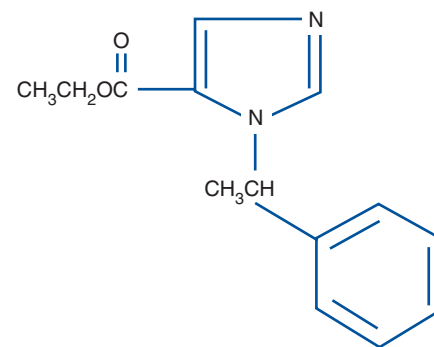


FIGURE 5-7 Chemical structure of etomidate.

Myoclonus is common in over 50% of patients and may be partially prevented with pre-administration of a benzodiazepine or opioid. Many patients experience pain on injection secondary to the propylene glycol. Etomidate has been associated with adrenocortical suppression but this is less profound when only a single induction dose is administered.

Ketamine

Ketamine is a phencyclidine derivative (Figure 5-8) that induces a state of “dissociative anesthesia.” This is characterized as a “dissociation” between the thalamocortical and limbic systems, producing a cataleptic state during which the patient may appear awake but does not respond to commands.¹¹ The eyes may be open and nystagmic. Ketamine does produce anterograde amnesia, and unlike other induction agents, it can produce intense analgesia.

Unlike other hypnotic agents ketamine does not interact with GABA receptors. The exact mechanism of action is unclear but ketamine is a nonselective antagonist of supraspinal *N*-methyl-D-aspartate receptors, which involve the excitatory neurotransmitter glutamate. Inhibition of these receptors decreases neuronal signaling and is likely responsible for some analgesic effects. Ketamine may also interact with pain receptors in the spinal cord as well as opioid receptors, which may also account for analgesia.¹²

Ketamine is highly lipid soluble and redistributes quickly, which accounts for

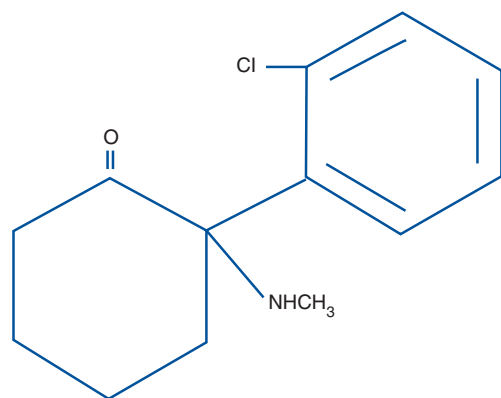


FIGURE 5-8 Chemical structure of ketamine.

its rapid onset of action and relatively short duration. It is metabolized by hepatic enzymes and has an active metabolite, norketamine. Ketamine does have a significant abuse potential and chronic use can lead to enzyme induction.

The cardiovascular effects of ketamine reflect its indirect activation of the sympathetic nervous system. Ketamine causes an increase in norepinephrine by inhibiting reuptake at postganglionic sympathetic neurons. Sympathetic stimulation increases heart rate and systemic blood pressure. Ketamine should therefore be used with caution in patients with uncontrolled hypertension or in whom tachycardia should be avoided. However, ketamine may be chosen for induction of general anesthesia at 1 to 2 mg/kg IV when cardiovascular stimulatory effects are desired, as in emergent trauma surgery. Practitioners should note that ketamine is actually a direct myocardial depressant, an effect normally masked by the indirect sympathetic stimulation. In severely compromised patients, however, catecholamine stores may be exhausted and hypotension secondary to myocardial depression can become significant.

Respiratory depression is not significant with ketamine, although apnea will occur with rapid bolus administration. Upper airway reflexes remain largely but not reliably intact; aspiration is still possible, especially as ketamine increases sali-

vary secretions and postoperative nausea and vomiting. Ketamine does not cause histamine release and is a potent bronchodilator secondary to sympathetic activation as well as direct bronchial smooth muscle relaxation.

In oral surgical practice a primary indication for ketamine is intramuscular injection for uncooperative adult patients, such as the mentally challenged or those with severe psychiatric illness, or for children who will not tolerate IV placement. The intramuscular dose for induction of general anesthesia is 3 to 7 mg/kg, whereas 2 to 3 mg/kg is usually sufficient to obtain adequate control for IV placement. A water-soluble benzodiazepine like midazolam is commonly added to reduce the possibility of uncomfortable dreaming associated with ketamine. An anticholinergic medication like glycopyrrolate is also given to reduce the production of salivary secretions secondary to ketamine. Glycopyrrolate may be preferred over atropine or scopolamine for its superior antisialagogue effects, less pronounced cardiac effects, and poor CNS penetration.

The other main use in oral surgical practice is in an IV deep-sedation technique. Conscious sedation is first achieved with a benzodiazepine, followed by subanesthetic doses of 10 to 30 mg of ketamine until a state that is similar to deep sedation is achieved. Although ketamine is quite analgesic some surgeons also add an opioid in the baseline sedation. Alternatively, if a standard deep-sedation technique with methohexital has been applied (see “Methohexital,” above) and large doses of the barbiturate become necessary to achieve adequate sedation, or unwanted patient movement persists despite high methohexital doses, the addition of small boluses of ketamine can often enhance the quality of sedation.

“Emergence delirium” can occur during awakening. The patient may experience visual and auditory hallucinations that can be perceived as either pleasant

(euphoria) or unpleasant (dysphoria), lasting for up to several hours. Delirium occurrence is less common in children and with doses less than 2 mg/kg IV. It may be attenuated with prior or concurrent administration of benzodiazepines, which should be routine when intravenous sedation techniques are used.

Inhalation Anesthetics

Inhalation anesthetics include nitrous oxide (N_2O) as well as the potent volatile halogenated agents, such as halothane, isoflurane, sevoflurane, and desflurane. N_2O alone is commonly used in dental offices for anxiolysis and mild sedation, but it is also used in combination with other medications to induce and maintain both sedation and general anesthesia. The halogenated agents are extremely potent and are used for induction and maintenance of general anesthesia.

The pharmacokinetics of these anesthetic agents differ from those of intravenous medications. These drugs are inhaled and cross from the alveoli into the pulmonary vasculature, entering the general circulation. They are able to cross the blood-brain barrier and exert anesthetic effects within the brain. Except for halothane most of these agents are minimally metabolized and are subsequently excreted unchanged back into the alveoli. Once exhaled these gases are deposited into the anesthesia circuit and eventually scavenged.

Plasma concentrations of the inhaled anesthetics are dependent on the concentration of the gas within the alveoli, solubility characteristics of the individual gases, and cardiac output.^{13,14} Cardiac output influences the rate of uptake from the alveoli. Main factors affecting alveolar gas concentration include the inspired concentration of gas, alveolar ventilation, and the total gas flow rate. Administering a higher concentration of gas will increase intra-alveolar concentration, whereas altering the total gas inflow or alveolar

ventilation (respiratory rate, tidal volume) will affect how quickly the concentration of gas within the alveoli changes.

Each agent varies in its solubility in blood and other tissues such as the brain and fat, and these characteristics determine the ease with which the gas crosses into the different tissues. Of these, the blood:gas solubility coefficient (Table 5-1) is the most useful in describing the onset and offset of action of an anesthetic gas. The blood:gas solubility coefficient expresses the extent to which the anesthetic gas molecules from the alveolar spaces will dissolve into plasma before the plasma solution becomes saturated. Conceptually, a lower coefficient means that the gas is less soluble in blood and will saturate the plasma compartment quickly. Additional “overflow” molecules will then be free to move into other highly vascular tissues such as the brain, where the CNS anesthetic effect takes place. A lower blood:gas coefficient therefore translates into faster onset of action at the brain. Once the gas is discontinued and the alveolar and plasma concentrations decrease, the gas molecules move down their concentration gradient from the tissues back into the blood stream and then into the alveoli. Gases with lower blood:gas coefficients will likewise “offload” from the blood stream into alveoli more quickly and can translate into a faster offset of action.

Unlike intravenous medications these inhaled drugs are not administered in doses of mg/kg. The equivalent of the effective dose (ED₅₀) of inhaled anesthetic agent is the minimum alveolar concentration (MAC). The MAC value of any given agent is the inhaled concentration (volume %) of that agent required to prevent movement in 50% of patients to a surgical stimulus. MAC values for different agents are given in Table 5-1. MAC values provide a useful dosage guide for anesthetic gases. In adults a level of 1.3 MAC will prevent movement in 95% of patients, whereas 1.5 MAC (MAC-BAR) will block an adrenergic response in 95% of patients. Below 0.3 MAC (MAC-Awake), patient awareness is more likely. MAC values are additive; for example, if 0.5 MAC of N₂O and 1.0 MAC of isoflurane are given simultaneously, the total MAC of anesthetic agent administered to the patient is 1.5 MAC. It should be noted that MAC values are general guidelines, and individual anesthetic requirements can be influenced by a variety of factors such as age or medical status. Neonates have the lowest MAC requirement, whereas children have the highest requirement. MAC requirements subsequently decrease in the elderly patient. MAC values are typically listed for adult (30- to 35-year-old) patients at 1 atm pressure and 20°C.

The exact mechanism of action of inhaled anesthetic agents at the CNS is still controversial. Earlier theories have suggested that anesthetic molecules insert into and disrupt the lipid bilayer of neuronal cell membranes, thus interfering with the cellular function. More current theories suggest that anesthetic molecules may instead directly interact with cellular proteins, possibly with membrane ion channels or even specific receptors.

Whereas N₂O has mild or minimal sympathomimetic effects, all of the halogenated agents produce generalized cardiovascular depressant effects. The potent volatile agents block peripheral vasoconstriction thus lowering mean arterial blood pressure. At lower doses below 1 MAC the baroreceptor sympathetic reflex is activated, which leads to a compensatory increase in heart rate. The exception is halothane, which in addition to directly depressing myocardial contractility, blocks the baroreceptor reflex. This resulting decrease in cardiac output can lead to a precipitous drop in systemic blood pressure with higher doses of halothane.

Halothane also has the highest association with cardiac dysrhythmias. Halothane induction commonly suppresses sinoatrial node activity, leading to the development of junctional rhythms. It also sensitizes the myocardium to catecholamine-related

Table 5-1 Different Properties of Nitrous Oxide and Potent Volatile Agents

General Properties of Inhalation Anesthetics – Adults						
	<i>Nitrous Oxide</i>	<i>Isoflurane</i>	<i>Enflurane</i>	<i>Halothane</i>	<i>Desflurane</i>	<i>Sevoflurane</i>
Molecular weight	44	184.5	184.5	197.4	168	218
Vapor pressure 20°C	Gas	238	172	243	664	160
MAC in O ₂	105	1.2	1.6	0.77	6.0	2.0
% recovered metabolites	0	0.2	2.4	20	0.02	3
Partition Coefficients at 37°C						
Blood:gas	0.47	1.46	1.91	2.5	0.42	0.69
Brain:blood	1.1	1.6	1.4	1.9	1.3	1.7
Muscle:blood	1.2	2.9	1.7	3.4	2	3.1
Fat:blood	2.3	45	36	51	27	48

MAC = minimum alveolar concentration.

ventricular dysrhythmias (Figure 5-9), particularly under conditions of hypercarbia.¹⁵ Isoflurane, sevoflurane, and desflurane are not significantly associated with an increased incidence of epinephrine-associated dysrhythmias. Epinephrine contained in local anesthetic solutions should be limited to a maximum dose of 1 to 2 $\mu\text{g}/\text{kg}$ during halothane anesthesia whereas up to 3 to 4.5 $\mu\text{g}/\text{kg}$ is considered safe with the other three agents. Under halothane anesthesia, administration of 1.0 to 1.5 mg/kg cardiac lidocaine IV immediately prior to intubation reduces the incidence of ventricular dysrhythmias during this stimulating period when endogenous epinephrine release may occur. Hypoxia and hypercarbia also lower the threshold for dysrhythmias and should be especially avoided with halothane anesthesia. Treatment of the presenting dysrhythmia should be managed as required, including hyperventilation, deepening of anesthetic level and, if indicated, discontinuation of halothane with administration of an alternative anesthetic agent.

At usual doses N_2O does not appreciably affect respiration. However, the

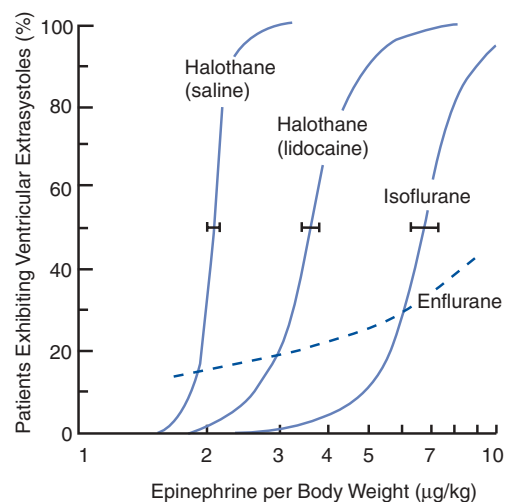


FIGURE 5-9 *Halothane sensitizes the myocardium to dysrhythmias following administration of epinephrine in saline. Addition of 0.5% lidocaine to the epinephrine solution decreases the incidence of dysrhythmias, but the incidence is still higher than during isoflurane use. Adapted from Johnston RR et al.¹⁵*

halogenated agents produce a characteristic “rapid and shallow” spontaneous breathing pattern. A decrease in tidal volume is accompanied by an increase in the frequency of breaths, but the faster respiratory rate does not fully compensate for the smaller tidal volumes. Therefore, minute ventilation is reduced and arterial CO_2 levels will be elevated in patients spontaneously breathing while under general anesthesia with these agents. The halogenated agents also cause a dose-dependent decrease in airway resistance and produce bronchodilation. Hypoxic pulmonary vasoconstriction is attenuated at 0.1 MAC for all volatile agents.

Although hepatic blood flow decreases with these agents, hepatic damage, if any, resulting from hypoxia is usually subclinical and transient. Hepatotoxicity is more of a concern with halothane administration. Renal blood flow and urine output are reduced secondary to the decreased mean arterial pressure. The release of fluoride from the halogenated gases does not appear to cause clinically significant damage to renal tissues. With sevoflurane, fresh gas flows should be at least 2 L/min to minimize compound A accumulation in the CO_2 absorber which can lead to very rare hepatic or renal damage.

Malignant hyperthermia (MH) is another rare but very dangerous reaction triggered by the halogenated agents as well as SCh. N_2O , nondepolarizing neuromuscular blockers, opioids, benzodiazepines, and other intravenous anesthetic agents do not trigger MH. Exposure to these medications causes an abnormal receptor in skeletal muscle cells to release excessive intracellular calcium, leading to uncontrolled muscle contractions. As a result CO_2 production increases quickly and exhaled CO_2 rises sharply. Initial signs include tachycardia and tachypnea, along with muscle stiffness. Metabolic acidosis and hyperkalemia develop next and cardiac arrest is a possibility. Increasing body temperature is a relatively late sign. The

halogenated agent must be discontinued at once and 100% O_2 given, preferably through a different circuit and machine. Dantrolene at 2.5 to 10 mg/kg IV must be given as soon as possible. Cooling measures including cooled IV fluids should be instituted. Emergency help must be obtained immediately and the patient will require medical management and monitoring for at least 24 hours following the episode. Reemergence of the reaction is common, requiring re-administration of dantrolene, and acute renal failure is the most common morbidity secondary to myoglobinemia. A mortality rate of 10% is associated with an acute MH episode, even with immediate proper management.

Nitrous Oxide

N_2O is commonly administered in dental offices for anxiolysis and mild sedation. It is a colorless and odorless gas, available in blue cylinders. In the dental setting it is commonly administered with a nasal hood and appropriate scavenger system. Concentration ratios of $\text{N}_2\text{O}:\text{O}_2$ range up to 70:30 on most N_2O and anesthesia machines. High levels of $\text{N}_2\text{O}:\text{O}_2$ alone can produce sedation and significant analgesia. Unexpected respiratory depression or airway obstruction can occur when N_2O is added to other sedative agents.

N_2O in O_2 is likely the most commonly used sedative agent in dental offices and enjoys the unique advantage of not requiring an escort after completion of the procedure provided adequate recovery time has elapsed. The drug can be titrated, usually starting at 20% N_2O and gradually increasing to 50% as needed. Doses above that level are associated with increased nausea and dysphoria, although the brief application of doses higher than 50% is useful during local anesthetic administration and other short stimulating surgical episodes. At the conclusion of N_2O sedation, 3 to 5 minutes of 100% O_2 is administered to prevent diffusion hypoxia; if room air O_2 is given instead, the rapidly exiting N_2O can

dilute the O₂ concentration in the alveoli to hypoxic levels during recovery.

With a low blood:gas solubility coefficient of 0.47, N₂O has a very quick onset and recovery. While N₂O lacks the potency of the halogenated agents at a MAC value of 105, it also lacks the respiratory and cardiovascular side effects. During general anesthesia it is often administered to an intubated patient in combination with other medications such as halogenated gases and opioids. Using this combination can reduce the dose required of each drug if given singly and will lessen the incidence of potential side effects. N₂O is also inexpensive and can reduce the total cost of administered drugs.

There are a few contraindications for the use of N₂O. It can enter closed spaces faster than nitrogen can exit, leading to distention of the closed space.¹³ In oral surgical practice the implication of this property is to avoid N₂O use in patients with current otitis media and sinus infections and with emphysema (blebs). Other contraindications of N₂O use include current respiratory disease and a history of severe postoperative nausea.

Several precautions should be exercised when using N₂O. It has been implicated in producing sexual hallucinations in some patients, predominantly young women. An additional person such as an assistant should always be present when this gas is being administered. Patients with preexisting psychiatric disorders may experience exacerbated symptoms while undergoing N₂O sedation. Because low levels of N₂O in room air have been demonstrated to increase spontaneous abortion rates in pregnant anesthesia providers, proper scavenging is essential to minimize room air levels so that surgical personnel are not at increased risk. Frequent recreational use of N₂O has been reported to lead to peripheral neuropathy and other deleterious effects. As with all anesthetic agents anesthesia providers must never use these drugs for personal

use and should be alert to potential misuse by other providers of these drugs.

Potent Inhalation Agents

The halogenated inhalation agents commonly in use today in the United States include halothane, isoflurane, sevoflurane, and desflurane. As seen in Figure 5-10, all are derivatives of ether except for halothane. Unlike the original anesthetic gas, diethyl ether, these agents are halogenated and nonflammable. The newer halogenated agents, sevoflurane and desflurane, are unique in that all of the side chain halogen atoms are fluorine. The gases are stored and released by gas-specific vaporizers that control the concentration (volume %) allowed into the anesthesia circuits and into the patient. They must also be scavenged effectively so that room air levels do not affect health care personnel.

Halothane Halothane has a sweet non-pungent odor that does not irritate the airway mucosa to the extent of isoflurane and desflurane, and is therefore useful for inhalation induction of general anesthesia. Halothane is very potent, with a MAC value at 0.75 but a relatively high blood:gas solubility of 2.54. Therefore, halothane will have a slow onset of inhalation induction unless high doses are used. Recovery from anesthesia will

be slower than with other agents with lower solubility coefficients.

Halothane is the oldest and most inexpensive of currently available potent gases but presents with the most deleterious side effects. As noted above, halothane is associated with significant cardiovascular changes and dysrhythmias. These should be monitored closely during induction and epinephrine administration, such as with local anesthesia, when dysrhythmias are more commonly encountered. Unlike the other agents, at least 15% of the halothane molecules are metabolized by the liver, and hepatotoxicity is more significant with halothane, especially after repeated and prolonged administration. Halothane hepatitis is very rare but can result in hepatic necrosis and death. Of all the halogenated agents it also appears to be the most potent trigger for MH.

Isoflurane Isoflurane is more pungent than halothane and is not a good choice for inhalation induction. It has an intermediate potency (MAC 1.2) and blood:gas partition coefficient (1.46). This agent is a common choice for maintenance of anesthesia, as recovery time is in the intermediate range and shorter than halothane. Isoflurane is also much more cost-effective for longer periods of anesthesia compared to two other popular agents, sevoflurane

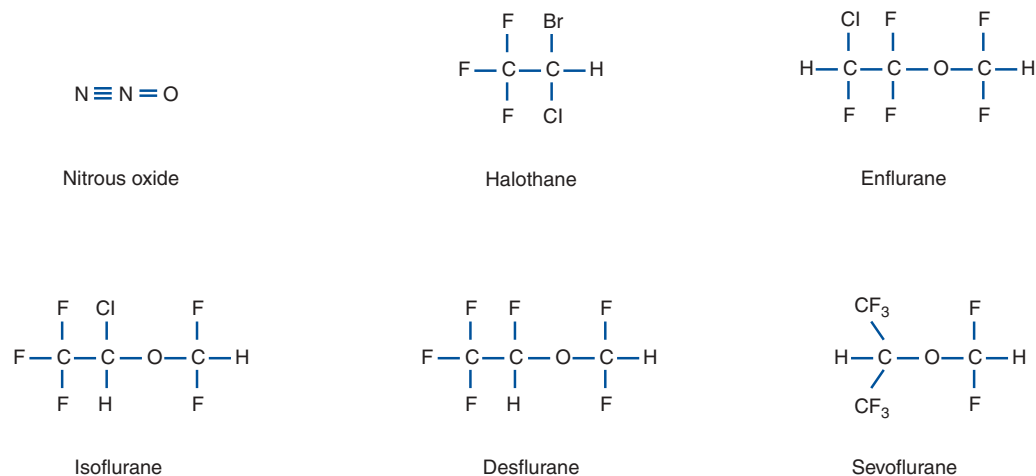


FIGURE 5-10 Chemical structure of inhalation agents.

and desflurane; its cost per bottle is significantly lower and the total amount used is less due to the lower MAC.

Isflurane may be associated with an increase in coronary steal phenomena, leading some practitioners to avoid using this anesthetic in patients with significant atherosclerotic cardiac disease. Otherwise, contraindications for using isoflurane are few.

Sevoflurane Sevoflurane is nonpungent and a common choice for inhalation induction. It has an intermediate potency (MAC 2.0), and at higher doses, induction will be rapid. Recovery from sevoflurane following a short anesthetic (< 1 h) is more rapid than either isoflurane or halothane due to the lower blood:gas solubility coefficient (0.69). For longer procedures, however, the advantage of faster recovery is offset by the much greater cost of sevoflurane compared to isoflurane. The recovery time is also not significantly improved compared to isoflurane, as both gases similarly redistribute into fat during longer anesthesia periods, and offset of these gases from fat storage is not different.

All of the side chain halogen atoms in sevoflurane are fluorine, contributing to its low blood:gas solubility and recovery profile. Unlike earlier inhaled agents the small amount of inorganic fluorine released during sevoflurane use has not been associated with renal damage.¹⁶ Sevoflurane and CO₂ absorbers (soda lime, barium lime) produce a degradation product called compound A, an olefin, which is nephrotoxic in rats but has not been associated with significant permanent renal damage in humans. Regardless, sevoflurane is not usually the agent of choice for patients with renal disease. Even in healthy patients many practitioners recommend limiting sevoflurane use to less than 2 hours and maintaining a total gas flow of at least 2 L/min, to reduce the production of compound A.

Desflurane Desflurane is extremely pungent and can be so irritating to nonanes-

thetized airways that it may precipitate coughing and laryngospasm. It is to be avoided for inhalation inductions. During initial administration of desflurane, tachycardia can also occur until deeper levels of anesthesia are realized.

Desflurane is delivered from specially heated vaporizers as its vapor pressure is close to atmospheric pressure. It also possesses only fluorine substitutions which, like sevoflurane, confer a low blood:gas solubility. In fact, desflurane has the lowest blood:gas solubility coefficient (0.43) of any inhalation agent, lower than even N₂O. This confers a quick onset and offset, and recovery can be very rapid following a short anesthetic with desflurane. Like sevoflurane, desflurane is more expensive than the other gases, and considering its higher MAC value (6.0), much more of the gas will be used per minute, resulting in a significantly higher cost if desflurane is used for a longer procedure.

Perioperative Analgesic Medications

Opioid medications, which have been discussed previously, are the classic intraoperative and postoperative analgesic medications. In the operating room opioids are often given concurrently with other anesthetic agents in a balanced technique to supplement intraoperative analgesia. An opioid with a long duration of action like morphine or hydromorphone is commonly administered by the practitioner prior to the end of the procedure, in anticipation of postoperative pain. During the initial phase of postoperative care these medications may be given either by the nursing staff or patient, administered via computer-aided patient-controlled analgesia pumps.

Another option is ketorolac tromethamine, currently the only available intravenous NSAID medication in the United States. This agent can provide effective analgesia for many dentoalveolar procedures at IV and IM doses of 30 to 60 mg or 0.5 to 1.0 mg/kg. Onset time is 10 to 15 minutes,

with an analgesic duration of approximately 6 hours. Ketorolac 30 mg IM is the analgesic equivalent of 10 mg of parenteral morphine and does not produce opioid-related respiratory depression, nausea, or sedation.³ NSAID use does have several cautions, however. Because of possible NSAID-induced inhibition of platelet aggregation, the drug is normally administered after bleeding has been controlled, and should be avoided for surgeries associated with postoperative hemorrhage. Patients with bleeding-related disorders (gastrointestinal ulcers, inflammatory bowel disease, blood dyscrasias, liver failure, etc) should not be given ketorolac. Life-threatening bronchospasm can also occur with NSAIDs, particularly in those with a history of asthma or aspirin allergy. Because NSAIDs block prostaglandin production, patients who depend on renal prostaglandins for adequate renal function should be administered ketorolac cautiously. Patients with congestive heart failure, hypovolemia, or cirrhosis, and those taking angiotensin-converting enzyme inhibitors or angiotensin II receptor antagonists, may require renal perfusion to maintain adequate renal perfusion, and NSAID administration can result in acute fluid retention. This drug is also associated with a higher cost than other analgesic medications.

The most commonly used agents for postoperative pain control in oral surgery are likely the local anesthetics. Long-acting local anesthetics, like bupivacaine and etidocaine, provide several hours of analgesia for inferior alveolar nerve block anesthesia as well as soft tissue anesthesia in the maxilla. Lidocaine with epinephrine given intraoperatively can also provide adequate analgesic duration until postoperative oral NSAIDs or opioid/acetaminophen combinations can achieve reliable plasma levels for generally predictable postoperative pain control.

Neuromuscular-Blocking Medications

Skeletal muscle relaxation is often required during surgery when patient movement

interferes with procedures involving anesthesia or surgery. For example, paralysis may be required to facilitate tracheal intubation, relax abdominal wall muscles for access during gastrointestinal surgery, or completely inhibit patient movement during ocular surgery. Whereas relaxation can be achieved with deeper anesthetic levels or appropriate peripheral neural blockade, neuromuscular-blocking agents are commonly used to provide the necessary amount and duration of relaxation.

The potential of these drugs during anesthesia and surgery was not recognized until the middle of the twentieth century. Many of the current neuromuscular-blocking agents used are derivatives of curare, one of the oldest paralyzing agents, used by ancient hunters to paralyze prey. All are competitive antagonists that bind to the nicotinic ACh receptors located at the postsynaptic membrane of the neuromuscular junction of skeletal muscle, thus interfering with proper contraction of the muscle.

Neuromuscular-blocking agents can be classified as either depolarizing or nondepolarizing, and within the latter group can be divided based on structure, speed of onset, duration of action, and metabolism.

Succinylcholine

SCh, two joined ACh molecules, was introduced for surgical muscle relaxation in the 1950s and is the only depolarizing agent used today. Once SCh binds to the ACh receptor, the postsynaptic membrane depolarizes, an action potential is generated, and the muscle contracts. Subsequent muscle contractions are delayed until SCh dissociates from the receptor and is metabolized by pseudocholinesterase.

SCh has the fastest onset (30–60 s) and shortest duration (5–10 min) of the neuromuscular-blocking agents and is typically used to treat laryngospasm not relieved with positive pressure (20 to 40 mg, or 0.1 to 0.2 mg/kg). It is also given to facilitate tracheal intubation (1 to 1.5 mg/kg IV) or when

emergent tracheal intubation is required to treat laryngospasm. It is no longer used to maintain intraoperative paralysis.

SCh has several notable side effects. Tachycardia can result upon initial administration but sinus bradycardia may develop, especially with repeated administration. Widespread muscle contractions can result in postoperative myalgia, which can at times be prevented by prior administration of a small dose of a nondepolarizing muscle blocker. The contractions may increase intraocular and intragastric pressure and can also cause a transient elevation in plasma potassium levels by 0.5 mEq/L. Plasma potassium levels may rise even higher than 0.5 mEq/L in patients with certain neuromuscular disorders, stroke, spinal cord injury, or significant burn injury. SCh is therefore contraindicated in these patients, along with patients in renal failure. SCh is a trigger for MH (see section on malignant hyperthermia). Its use should also be avoided in patients with pseudocholinesterase abnormalities, as the recovery from this drug will be prolonged.

Nondepolarizing Agents

All of the remaining neuromuscular blocking agents are nondepolarizing and do not initiate muscle contraction upon administration. The chemical structures of these drugs fall into two classes: benzyloquinolines and aminosteroids.¹³ Characteristics of currently available nondepolarizing muscle relaxants are outlined in Table 5-2.

Although it is not as rapid in onset as SCh, rocuronium has the fastest onset of the nondepolarizing agents, with paralysis occurring at approximately 1 minute with higher doses. It is often chosen for facilitating intubation when SCh cannot be used, particularly in an emergent situation. Onset time for most other agents is approximately 3 minutes.

Drug selection for maintenance of muscle relaxation is often based upon the anticipated need for continued paralysis.

Pancuronium has the longest duration, whereas mivacurium has the shortest. With any of these agents paralysis will last longer than that produced with SCh and controlled ventilation must be provided. Return of skeletal muscle function is usually monitored by a nerve stimulator, and the degree of paralysis is gauged by the number of twitches produced by stimulation of specific muscles, such as adductor pollicis and orbicularis oris. Paralysis may need to be reversed by an anticholinesterase to ensure adequate recovery of airway and respiratory muscle function prior to extubation.

Adverse effects may also affect the choice of neuromuscular-blocking agent and can be categorized by structure. The benzyloquinoline compounds may trigger histamine release thus causing flushing and peripheral vasodilation. Aminosteroid structures may block vagal activity, causing a noticeable increase in heart rate. Histamine release may be undesirable in asthmatic patients. Increased heart rate can be problematic in patients with cardiovascular disease.

Most of the nondepolarizing agents are metabolized by the liver and excreted by the kidney. Three of these are less dependent on hepatic or renal function. Mivacurium, like SCh, is metabolized by pseudocholinesterase and is affected by its deficiency. Atracurium and cisatracurium are removed by Hofmann elimination, whereby the drug spontaneously degrades at body pH and temperature.

Anticholinesterases

Anticholinesterases, or anti-acetylcholinesterases, block the action of acetylcholinesterase, the enzyme that breaks down ACh. In anesthesia, anticholinesterases such as neostigmine, edrophonium, and pyridostigmine are used to reverse the effects of nondepolarizing muscle relaxants once partial muscle function has returned and paralysis is no longer necessary, usually at the conclusion of surgery. By increasing

Table 5-2 Common Neuromuscular-Blocking Medications and Their Properties

<i>TSI Characteristics of Commonly Used Neuromuscular-Blocking Agents</i>	<i>Intubating Dose (mg/kg)</i>	<i>Time to Intubate (min)</i>	<i>25% Twitch Recovery (min)</i>	<i>Metabolism and Elimination</i>	<i>Histamine Release</i>	<i>Vagolysis</i>
<i>Depolarizing</i>						
Succinylcholine	1	1	5–10	Plasma cholinesterase	±	0
<i>Nondepolarizing</i>						
<i>Aminosteroids</i>						
Rocuronium	0.6–1.2	1–1.5	40–150	Liver; kidney	0	0
Vecuronium	0.1–0.12	2–3	25–30	Liver; kidney	0	0
Pancuronium	0.08–0.1	3–5	80–100	Liver; kidney	0	+
Pipecuronium	0.07–0.085	3–5	50–120	Liver; kidney	0	±
<i>Benzylisoquinolines</i>						
Mivacurium	0.15–0.25	1.5–2.0	16–20	Plasma cholinesterase	+	0
Atracurium	0.4–0.5	2–3	25–30	Hofmann elimination	+	0
Cisatracurium	0.15–0.2	1.5–2	50–60	Hofmann elimination	0	0
Doxacurium	0.05–0.08	4–5	100–160	Liver; kidney	0	0
d-Tubocurarine	0.5–0.6	3–5	80–100	Liver; kidney	++	0

the amount of ACh available at the neuromuscular junction, more of the neurotransmitter can bind to nicotinic ACh receptors, overcoming the competitive inhibition of the neuromuscular blocker and aiding in the return of muscle function.

Increased ACh will also bind to muscarinic ACh receptors at the heart, lungs, salivary glands, and smooth muscle. This can lead to undesirable side effects including bradycardia, bronchospasm, abdominal cramping, and excessive salivation.¹⁷ To prevent these effects anticholinergic medications such as atropine or glycopyrrolate, which block muscarinic but not nicotinic ACh receptors, are given together with anticholinesterases. The anticholinesterase

and anticholinergic medications are paired according to similar time of onset and duration. Glycopyrrolate is generally administered with neostigmine, whereas atropine is more commonly used with edrophonium. Doses of these agents are listed in Table 5-3.

Anticholinergic Medications

ACh is a neurotransmitter that binds to two types of receptors. Nicotinic receptors are located at autonomic ganglia and the neuromuscular junctions of skeletal muscle. Muscarinic receptors are found at postganglionic sites of the parasympathetic nervous system at the heart, salivary glands, and smooth muscle. Anticholiner-

gic medications specifically block muscarinic receptors but do not affect nicotinic receptors.

Clinical uses in anesthesia of atropine, glycopyrrolate, and scopolamine are defined by their varied effect at the muscarinic receptor sites of different organs (Table 5-4). Atropine has the fastest onset of increasing heart rate by blocking vagal nerve receptors at the heart and is used to treat emergent bradycardia. Both atropine and glycopyrrolate are used to counteract bradycardia secondary to anticholinesterase use during reversal of muscle relaxation. All three anticholinergic medications decrease salivary secretions. Glycopyrrolate is a quaternary ammonium compound, which cannot cross the blood-brain barrier. Atropine and scopolamine, both tertiary amines, can cross the blood-brain barrier and cause sedation. Scopolamine is also used for management of nausea and prevention of motion sickness.

Central anticholinergic syndrome is a concern with higher doses of centrally acting anticholinergic medications, manifesting as restlessness and confusion. It may be reversed by physostigmine, an

Table 5-3 Reversal Doses of Acetylcholinesterase and Anticholinergic Medications

<i>Cholinesterase</i>	<i>Cholinesterase Dose (mg/kg)</i>	<i>Anticholinergic</i>	<i>Anticholinergic Dose (mg/mg of cholinesterase)</i>
Neostigmine	0.4–0.8	Glycopyrrolate	0.2
Edrophonium	0.5–1.0	Atropine	0.014

The two most commonly used acetylcholinesterase medications are listed. Acetylcholinesterase and anticholinergic medications are given in recommended combinations according to similar onset time and duration of action of the two types of drugs. The maximum dose of cholinesterase is not always necessary, but should be given based on the degree of recovery from muscle relaxation. The dose of the anticholinergic drug is determined by the amount of cholinesterase given.

Table 5-4 Varied Effects of Anticholinergic Medications

	Anticholinergic Medication Characteristics			
	Tachycardia	Bronchodilation	Sedation	Antisialagogue
Atropine	###	##	≠	##
Glycopyrrolate	##	##	0	###
Scopolamine	≠	≠	###	###

≠ = mild effect; ## = moderate effect; ### = strong effect.

anticholinesterase that can cross the blood-brain barrier.

Antiemetic Medications

Postoperative nausea and vomiting (PONV) is one of the most common complaints following surgery. Certain groups of patients (female, obese, previous history of nausea and vomiting) appear to be more susceptible. Certain surgeries (ear, ocular, tonsillar, gynecologic) are likewise associated with increased PONV. Nausea and vomiting after oral surgery is not uncommon. Swallowed blood and secretions stimulate the gag reflex and are potent gastric irritants. Drugs used during sedation and anesthesia, such as N₂O, opioids, and ketamine, may trigger nausea postoperatively. Other “nonchemical” triggers of nausea include smell, gastric distention, motion, and even stress.

Chemical triggers in the bloodstream come into contact with an area in the medulla lacking an intact blood-brain barrier called the chemoreceptor trigger zone (CTZ).¹⁸ The CTZ (Figure 5-11) contains receptors for serotonin, histamine, muscarinic ACh, and dopamine. Opioids, toxins, and chemotherapy agents, as well as input from the middle ear, also stimulate this area. Stimulation of the CTZ will activate vomiting.

Many antiemetic medications act by blocking these receptors at the CTZ. Medications that block the dopamine receptor include phenothiazines (eg, prochlorperazine), and butyrophenones (eg, droperidol). They effectively reduce PONV but

are associated with adverse effects such as sedation and extrapyramidal reactions. 5-HT₃ antagonists including ondansetron and dolasetron are expensive, but produce less sedation and other adverse effects than the dopamine antagonists. Antihistamines such as promethazine (which also possesses a phenothiazine structure) and diphenhydramine can cause significant sedation. Anticholinergic medications (eg, scopolamine) are rarely used for PONV,

although the antihistamines promethazine and diphenhydramine also possess anticholinergic effects.

Recently, dexamethasone has been shown to decrease the incidence of PONV when given shortly after induction of general anesthesia. A minimum adult dose of 8 mg IV appears to be required for this effect to be realized.¹⁹

Selection of anesthetic agents may help prevent PONV. Propofol appears to have antiemetic effects as well, particularly when administered for maintenance of anesthesia. Additional antiemetic treatment may be unnecessary following the use of propofol infusions, even in patients with a previous history of PONV. Avoidance of known nausea triggering agents such as N₂O, ketamine, and longer-acting opioid medications may also reduce PONV.

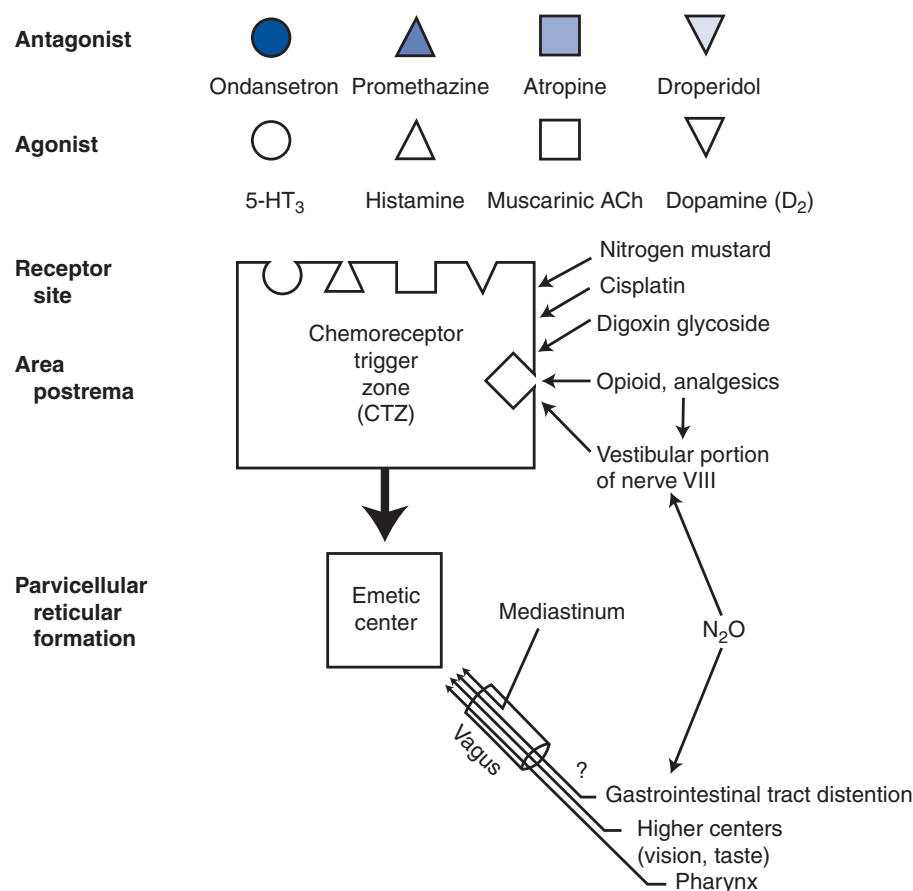


FIGURE 5-11 Diagrammatic representation of the chemoreceptor trigger zone (CTZ). Adapted from Watcha MF and White PF.¹⁸ 5-HT₃ = 5-hydroxytryptamine (serotonin); N₂O = nitrous oxide.

References

1. Katzung BG. Basic and clinical pharmacology. 8th Ed. New York: McGraw-Hill; 2000.
2. Hughes MA, Glass PSA, Jacobs JR. Context-sensitive half-time in multicompartment pharmacokinetic models for intravenous anesthetic drugs. *Anesthesiology* 1992;76:334–41.
3. Stoelting RK. Pharmacology and physiology in anesthetic practice. 3rd ed. Philadelphia (PA): Lippincott; 1999.
4. Reves JG, Fragen RJ, Vinik R, Greenblatt DJ. Midazolam: pharmacology and uses. *Anesthesiology* 1985; 62:310–24.
5. McMillan CO, Spahr-Schopfer LA, Sikich N, et al. Premedication of children with oral midazolam. *Can J Anaesth* 1992;39:545–50.
6. Brogden RN, Goa KL. Flumazenil: a reappraisal of its pharmacological properties and therapeutic efficacy as a benzodiazepine antagonist. *Drugs* 1991;42:1061–89.
7. Cherny NI. Opioid analgesics: comparative features and prescribing guidelines. *Drugs* 1996;51:713–37.
8. Hudson RJ, Stanski DR, Burch PG. Pharmacokinetics of methohexital and thiopental in surgical patients. *Anesthesiology* 1983;59:215–9.
9. Borgeat A, Wilder-Smith OHG, Suter PM. The nonhypnotic therapeutic applications of propofol. *Anesthesiology* 1994;80:642–56.
10. Smith I, White PF, Nathanson M, Gouldson R. Propofol: an update on its clinical use. *Anesthesiology* 1994;81:1005–43.
11. Reich DL, Silvey G. Ketamine: an update on the first twenty-five years of clinical experience. *Can J Anaesth* 1989;36:186–97.
12. Hirota K, Lambert DG. Ketamine: its mechanism(s) of action and unusual clinical uses. *Br J Anaesth* 1996; 77:441–4.
13. Faust RJ, Cucchiara RF, Wass CT. *Anesthesiology review*. 3rd Ed. New York: Churchill Livingstone; 2002.
14. Eger EI. New inhaled anesthetics. *Anesthesiology* 1994;80:906–22.
15. Johnston RR, Eger EI, Wilson C. A comparative interaction of epinephrine with enflurane, isoflurane, halothane in man. *Anesth Analg* 1976;55:709–12.
16. Eger EI, Koblin DD, Bowland T, et al. Nephrotoxicity of sevoflurane versus desflurane anesthesia in volunteers. *Anesth Analg* 1997;84:160–8.
17. Morgan GE, Mikhail MS, Murray MJ. *Clinical anesthesiology*. 3rd ed. New York: McGraw-Hill; 2002.
18. Watcha MF, White PF. Postoperative nausea and vomiting. *Anesthesiology* 1992;77: 162–84.
19. Henzi I, Walder B, Tramer MR. Dexamethasone for the prevention of postoperative nausea and vomiting: a quantitative systematic review. *Anesth Analg* 2002;90:186–94.

Pediatric Sedation

Jeffrey D. Bennett, DMD

Jeffrey B. Dembo, DDS, MS

Kevin J. Butterfield, DDS, MD

The anesthetic management of the pediatric patient presents the oral and maxillofacial surgeon with unique and different challenges from those with an adult patient. The surgeon must be aware of anatomic and physiologic differences, different pharmacokinetics and pharmacodynamics of most medications, and the unique psychological development of the child and his or her corresponding ability to cope with the stress of the surgical experience. As the child matures, changes in these parameters occur; therefore, an understanding of the growth and maturation of the pediatric patient dictates the selection of the anesthetic technique and medications used in the patient's management.

Anatomic and Physiologic Considerations

Respiratory System

Much of the uniqueness regarding anesthetic management of children in oral and maxillofacial surgery is focused on anesthesia delivered during intraoral procedures in which the patient is not intubated. Intraoral surgery in the anesthetized nonintubated patient presents a formidable and unique challenge. The foremost concern is that the surgical site—the oral cavity—is in close proxim-

ity to the pharynx, thereby rendering the patient susceptible to airway obstruction and irritation. These factors can result in a significant degree of hypoxia.^{1,2} Such effects can be exacerbated by a decreased minute ventilation and airway tone secondary to sedative medication used during the anesthetic administration.

There are anatomic differences unique to the pediatric upper airway that increase the risk of airway obstruction. In the young child the tongue is large relative to the size of the oral cavity. It is positioned higher in the oral cavity impinging on the soft palate secondary to the rostrally positioned larynx. Lymphoid hypertrophy with enlargement of the tonsils and adenoids between the ages of 4 and 10 years can also contribute to upper airway obstruction.

The lower airway, consisting of the trachea, bronchi, and alveoli, also differs between pediatric and adult patients. The trachea and bronchi are conduits in which gas is transported from the environment to the alveoli. The pediatric airway diameter is relatively smaller than that of the adult. Since resistance is inversely proportional to the radius of the lumen to the fourth power, there is an increased resistance. Narrowing of the airway secondary to secretions or edema will have a more profound adverse effect on airway

exchange. The pediatric trachea is also more compliant. The increased compliance makes the airway susceptible to collapse secondary to increased negative inspiratory pressure. This is significant because of the potential for airway obstruction in the nonintubated patient. When patients become obstructed they attempt to overcome the obstruction by increasing the respiratory effort. In the child an attempt to compensate for upper airway obstruction with increasing respiratory effort can cause collapse of the trachea and bronchial passages, which may paradoxically worsen the obstruction. The frightened child may already be at risk for airway collapse since crying tends to increase negative inspiratory pressure.

Anatomic differences between pediatric and adult patients diminish the efficacy of ventilation. In the child each rib is angled more horizontally relative to the vertebral column; adults' ribs have a caudal slant.³ Additionally, the accessory muscles are less developed in the child. This results in a less effective thoracic expansion and a greater dependence on diaphragmatic breathing. Upper airway obstruction in the young child occurring with sedation can result in a paradoxical chest wall movement, characterized by an inward movement of the chest opposing the expansile downward movement of the diaphragm. Greater

energy is required, which can lead to fatigue and subsequent hypoxia.

Exchange of gas takes place within the alveoli. Closing volume, which is the volume of the lung at which dependent airways begin to close, is greater in the pediatric patient. The increased closing volume in the pediatric patient results in increased dead space ventilation. Thus, more energy must be expended to adequately ventilate the alveoli. The alveoli are also both smaller and fewer in number in the pediatric patient than in the adult. The alveoli increase in number until around 8 years of life and continue to increase in size until full adult growth is reached. The number of alveoli may increase more than 10-fold from infancy to adulthood, with a resultant increase in surface area that can be as great as 60-fold.⁴⁻⁶

Functional residual capacity (FRC) is the volume of gas in the lung after a normal expiration and is related to the surface area of the lung. The pediatric patient has a diminished FRC expressed on a basis of weight.⁷ This is illustrated by a minute ventilation to FRC ratio of approximately 5:1 in a 3 year old and 8:1 in a 5 year old compared to approximately 2:1 in an adult.⁷ FRC decreases further in the sedated patient. The FRC provides a pulmonary oxygen reserve.⁸ Because children have a higher metabolic demand and greater oxygen consumption, the decreased FRC results in a more rapid desaturation of hemoglobin during periods of respiratory depression.⁹⁻¹¹ One model comparing the child to the adult concluded that an apneic period of 41 seconds in the pediatric patient would result in an arterial oxyhemoglobin saturation of 85%, compared with an apneic period of 84 seconds in the adult.¹²

Endotracheal Intubation There are also anatomic differences between the pediatric and adult airways that influence intubation. A large tongue, rostral larynx, and long and narrow epiglottis make laryn-

gосcopy and visualization of the glottic opening more difficult in the pediatric patient. Adenoidal hypertrophy can also result in hemorrhage or obstruction of an endotracheal tube, particularly during nasal intubation.

The narrowest part of the trachea in the pediatric patient is the cricoid cartilage, in contrast with the glottis in the adult. It is not until the age of approximately 10 to 12 years that the pediatric airway matures to that of the adult. In the pediatric patient care must be taken when placing and securing an endotracheal tube to prevent impingement of the tip of the tube on the narrow subglottic region. Such impingement of the endotracheal tube on the tracheal mucosa can result in edema and tracheal narrowing causing increased airway resistance post extubation. Uncuffed tubes are used by most anesthesiologists for patients less than 8 to 10 years of age.¹³ The arguments against cuffed tubes are that they increase the risk of airway mucosal injury and that an appropriately sized uncuffed endotracheal tube can provide an adequate seal at the level of the cricoid cartilage. Formulas exist for calculating the appropriate size of endotracheal tube ($[\text{age (yr)} + 16]/4$) and the appropriate length of endotracheal insertion ($[\text{age (yr)}/2 + 12]$).¹⁴ However, 28% of the time the initially selected uncuffed endotracheal tube does not provide an adequate seal, and re-intubation may be necessary.¹⁵ An additional benefit in using the uncuffed tube is that a larger tube may be inserted, which causes less airway resistance and less breathing work. The argument for a cuffed endotracheal tube is that the fit can be adjusted and it can protect against aspiration. Ensuring that the cuff pressure does not exceed 25 cm H₂O, which is believed to be the mucosal capillary pressure, can minimize injury to the mucosa. When using an uncuffed tube, an air leak of 25 cm H₂O should be allowed.

The trachea is also shorter in the pediatric patient. It is not uncommon that head position is frequently changed during an oral and maxillofacial surgery procedure; this can cause the tube to become displaced out of the trachea or pass further into the trachea and impinge on the mucosa overlying the cricoid cartilage. Change in head position, use of an endotracheal tube that is too large, and patient age between 1 and 4 years are three factors contributing to the reported 1% incidence of postintubation croup.¹⁶

Certain congenital anomalies are well recognized for their altered anatomy. Some of the most commonly encountered disorders are Crouzon syndrome (hypoplastic maxilla—obligate mouth breather), Goldenhar's syndrome (micrognathia, vertebral anomalies), hemifacial microsomia (hypoplasia of mandibular condyle and ramus), Möbius sequence (micrognathia and limited mandibular movement), Pierre Robin's anomalad (micrognathia, glossoptosis), and Treacher Collins syndrome (mandibular hypoplasia). These craniofacial anomalies may complicate ventilation and/or endotracheal intubation. For example, maxillary or mandibular hypoplasia may increase the difficulty in achieving a satisfactory mask fit. Anatomic differences in the nasal cavity may impair nasal ventilation. This can potentiate respiratory obstruction during an intraoral procedure in which a pharyngeal curtain is placed and the patient is dependent on nasal respiration. The tongue may be displaced posteriorly by either maxillary or mandibular hypoplasia, increasing the potential for obstruction.

Cardiovascular System

The pediatric cardiovascular system has some significant differences compared with that of the adult. Each relevant physiologic difference is outlined below.

Cardiac Output Perfusion is dependent on cardiac output and peripheral resis-

tance. Cardiac output is dependent on heart rate and stroke volume. The pediatric heart has less compliance than that of the adult, with minimal ability to alter stroke volume. Thus, pediatric cardiac output is largely dependent on heart rate (Table 6-1).

Neural Innervation The myocardium is innervated by both the sympathetic and parasympathetic nervous systems, with the parasympathetic nervous system having a greater influence in the pediatric patient than in the adult. In one retrospective study the incidence of bradycardia during anesthesia was reported to be age related. The incidence of bradycardia was approximately threefold less in the 3- to 4-year-old compared with the 2- to 3-year-old.¹⁷

Blood Pressure Blood pressure is the product of cardiac output and peripheral vascular resistance. The pediatric patient has less ability to alter peripheral vascular resistance; therefore, blood pressure is largely dependent on cardiac output. A bradycardia with resultant decreased cardiac output thus results in a decrease in blood pressure since the child cannot compensate by increasing peripheral vascular resistance.

Summary

These fundamental concepts clearly illustrate the increased potential risks associated with sedating the pediatric patient:

- The airway is more susceptible to obstruction, and the patient has less ventilatory reserve; these result in a more rapid oxygen desaturation (and hypoxia causes bradycardia).

- The pediatric patient has increased parasympathetic innervation, resulting in a more rapid onset of bradycardia (which may be influenced indirectly by respiratory impairment or directly by the sedative drugs).
- There is less cardiovascular compensatory ability, which results in hemodynamic instability.

Preoperative Evaluation of the Patient

The purpose of a preoperative evaluation is to compile information about the patient to establish the most optimal treatment plan. One needs to assess the psychological and behavioral development of the patient, obtain a medical history that identifies both acute and chronic disease processes, and determine the patient's preparation for surgery (eg, cardiovascular status), while performing an appropriate physical examination dictated largely by the patient's medical history.

Psychological Assessment

The perioperative period can be very stressful for a child. The child is confronted with an unfamiliar environment, unfamiliar people, apprehension about the unknown, and loss of control. The child fears separation from the parents, the threat of needles, the perception of impending pain, and the fear of mutilation. Younger children frequently cannot verbalize these concerns. Behavioral manifestations of perioperative anxiety may include hyperventilation, trembling, crying, agitation, and/or physical resistance. Children < 6 years of age frequently cannot

comprehend the need for or benefits of the surgical procedure. Children > 6 years old or those who have better-developed social skills (eg, acquired from daycare programs) may be more capable of understanding the situation and expressing their concerns.¹⁸ If possible, an older child should be allowed to participate in determining the anesthetic treatment and should be exposed to the various induction techniques: intravenous, intramuscular, oral, and inhalation.

Adolescents may be more capable of comprehending the planned surgery and anesthetic management. However, they are not adults. They have the ability to demonstrate myriad behaviors and rapid mood changes. A paradoxical reaction to sedation in which the adolescent appears to become agitated after the administration of anxiolytic medication may necessitate a deeper level of anesthesia than what may have originally been planned. Another concern in the adolescent patient is the use of illicit substances. This has reached epidemic proportions with an estimated 10.8% of 12- to 17-year-old youths reported to be current illicit drug users in 2001.¹⁹

The presence of parents during the administration of the sedative agent may reduce the stress of the procedure and improve the child's cooperation. Conversely, a parent's anxiety may be sensed by the child, further exacerbating the child's own level of anxiety.²⁰ Clear, simple, and succinct explanations appropriate for the age of the child may minimize adverse behavior.

Preoperative Fasting

The risk of pulmonary aspiration of gastric contents in the pediatric patient during anesthesia is reported to be up to 10 incidents per 10,000 cases.²¹⁻²³ Morbidity secondary to aspiration includes obstruction from particulate material as well as aspiration pneumonitis that is dependent on both the quantity and

Table 6-1 Means and Ranges of Normal Cardiovascular Function

Function	Age (yr)		
	2-6	7-13	14-18
Heart rate (beats/min)	100 (80-120)	90 (70-110)	80 (55-95)
Systemic arterial pressure (mm Hg)	75-115/50-75	95-125/60-80	105-140/65-85
Cardiac output (mL/kg/min)	150-170	100-140	90-115

acidity of the aspirate. Establishing parameters that minimize the risk of particulate gastric contents as well as decrease the quantity and acidity of residual gastric fluids can decrease the incidence of this morbidity.

Gastric emptying of solids is variable. A 6- to 8-hour fast from solids is recommended to allow gastric emptying and minimize the risk of particulate aspiration. Alternatively, gastric emptying time for clear liquids is approximately 10 to 15 minutes. After a 1-hour fast of clear liquids, approximately 80% of the consumed liquid is usually absorbed from the stomach. Numerous studies have shown that consumption of unlimited volumes of clear liquids by pediatric patients up to 2 hours prior to surgery does not significantly increase the quantity of gastric volume or gastric acidity.^{24–28} Guidelines have thus been established for healthy pediatric patients that allow unlimited amounts of clear liquids to be consumed up to 2 to 3 hours prior to surgery. This recommendation avoids the need for an extended fast, which has the potential to make the patient irritable and uncomfortable and to increase the incidence of hypotension secondary to dehydration. However, in most cases it still may be simplest to state that the child should have nothing by mouth (NPO) after midnight and to schedule the procedure as the first case in the morning. Children who are scheduled in the afternoon may have a light breakfast at least 6 hours prior to the surgery.

Emergency Treatment: Full Stomach

Patients may present to the office or emergency room requiring urgent care. The injury or the patient's ability to cooperate may be such that the necessary treatment cannot be completed on the patient while he or she is awake and non-medicated, despite the fact that the patient is not NPO. The duration

between the last food ingestion and the injury is the critical time period that is important in assessing a patient's risk of gastric aspiration. Each patient and situation must be assessed individually. If sedation or general anesthesia is required, patient management may necessitate the placement of an endotracheal tube to minimize the risk of gastric aspiration.

The following interventions may minimize the risk of aspiration and/or the ensuing injury that may result from gastric aspiration: an H₂-antagonist such as cimetidine to decrease gastric acidity, a clear antacid such as sodium citrate to decrease gastric acidity, and metoclopramide to promote gastric emptying and increase the tone of the lower esophageal sphincter. Glycopyrrolate also reduces the acidity and volume of gastric contents.²⁹ Atropine, alternatively, decreases the tone of the lower esophageal sphincter and predisposes to gastroesophageal reflux of stomach contents.

Upper Respiratory Infection

It is not uncommon for children to present for surgery with a runny nose. Reports of children presenting to surgery with or having recently had such symptoms state incidences as high as 22.3% and 45.8%, respectively.³⁰ Rhinitis is not a contraindication to general anesthesia. Alternatively, a child with a severe upper respiratory infection (URI; symptoms include a productive cough, fever, and mucopurulent discharge) should not be anesthetized. However, it is unclear whether a child with a mild URI or a child recovering from a URI should be anesthetized; therefore, it is important to differentiate between the diagnosis of rhinitis and an infective process.

Pathophysiologic changes in the pulmonary system secondary to a URI include increased nasal and lower airway secretions, increased airway edema and inflammation, and increased airway tachykinins. These pathophysiologic changes can result in laryngospasm, bron-

chospasm, severe coughing, airway hyperactivity, breath holding, diminished diffusion capacity, increased closing volumes, atelectasis, and postintubation croup.^{31–34} The elevated hyperactivity with associated bronchoconstriction and the increased closing volume compounded by a greater oxygen uptake (secondary to the inflammatory response of the infection) and a decreased FRC (which normally occurs with general anesthesia) increases the risk of hypoxemia.^{35–42} Oxygen desaturation can occur both intraoperatively and postoperatively; the latter indicates the need for continued postoperative monitoring. URIs have also been demonstrated to cause respiratory muscle weakness that can persist for up to 12 days.⁴³ The pathophysiologic changes that contribute to these adverse respiratory events can persist for 4 to 6 weeks after the URI.

Traditional office-based ambulatory anesthesia in oral and maxillofacial surgery is dependent on spontaneous ventilation in the nonintubated patient. This is significant since the incidence of adverse respiratory events is less in a patient anesthetized with a face mask or laryngeal mask airway than in those with an endotracheal tube. However, surgery involving the airway has been shown to increase the risk of adverse respiratory events. Although intraoral surgery is not truly airway surgery, it encroaches on the airway and can cause airway irritability. The nonintubated patient undergoing oral or maxillofacial surgery is also susceptible to periods of hypoventilation and apnea, which cannot be corrected without interrupting the surgery. Kinouchi and colleagues demonstrated that a patient with an active or recent URI requires approximately 30% less apneic time to desaturate than does a healthy patient.⁴⁴

In conclusion, the patient who presents for elective surgery with allergic rhinitis or a mild URI that is not of acute onset may be anesthetized in the office without an endotracheal tube. If the

patient has a significant URI, the procedure should be rescheduled. Traditional guidelines suggest that the procedure should be rescheduled for 4 to 6 weeks later if the patient is to be intubated, but because many children have several URIs per year, trying to reschedule the surgery for a date when the child is without symptoms may be difficult.⁴⁵ Considering the above, a delay of 2 weeks is probably acceptable before performing a short office-based minor dentoalveolar procedure in which the patient is not intubated.

Cardiovascular Evaluation

The child who presents for surgery with a previously undiagnosed cardiac murmur poses a diagnostic challenge. Innocent murmurs are heard in up to 50% of normal pediatric patients at some point during childhood. The cause of these murmurs is usually turbulent blood flow through any of the great vessels. Features that commonly identify innocent murmurs include those that are crescendo-decrescendo and of short duration and low intensity, and those that occur early in systole. All diastolic murmurs are pathologic. The patient's history may also suggest signs and symptoms of cardiac pathology. These may include limited exercise tolerance, pale color, frequent respiratory problems, hypoxemia, palpitations, or dysrhythmias. A murmur in an asymptomatic child is frequently not pathologic, and no special anesthetic considerations are required. However, if there is uncertainty regarding the significance of a murmur, a consultation with a cardiologist is recommended. For patients with congenital heart disease, prophylaxis against bacterial endocarditis is necessary.

Pregnancy Testing in the Adolescent Patient

The incidence of pregnancy detected by routine universal testing in the ambulatory surgical adolescent between 12 and 21 years

of age has been reported to be approximately 0.5%.⁴⁶ Because of the severity of the potential consequences of anesthetizing a pregnant patient, it is important to reliably detect a pregnancy. An accurate and reliable history in the educated patient can be effective.⁴⁷ However, many patients in this age group may not provide an accurate history, especially in the presence of their family. This is not an acceptable rationale for routine testing. If routine testing is implemented, there is the potential for a false-positive test result, which may have significant emotional consequences. The issue remains controversial.

Sedative Techniques

It is generally agreed that managing the anxious, uncomfortable, and uncooperative pediatric patient is one of the more difficult anesthetic tasks. The primary goals in the management of the pediatric patient include reducing anxiety, establishing cooperation, ensuring comfort, establishing amnesia and analgesia, and ensuring hemodynamic stability. Although the goals of sedation are similar for both the child and the adult, reducing anxiety in the adult may enhance cooperation, whereas in the child it may not. To achieve a satisfactory result and facilitate completion of the planned surgical procedure, the child may require a greater depth of sedation.

Sedation should be accomplished in as nonthreatening a manner as possible. Because some children may be intensely afraid of needles, establishing intravenous access may not be possible. The surgeon must be familiar with alternative techniques that allow for a safe satisfactory induction and recovery from anesthesia. Each case must be considered individually to select both the most appropriate drug and the route of administration. The surgeon must take into consideration the following factors in developing the anesthetic plan: (1) the age of the patient, (2) the level of anxiety and ability to cooperate with

medical/dental staff, (3) the medical history of the patient, (4) the patient's prior surgical or anesthetic experience, (5) the infringement of the procedure on the airway, and (6) the duration of procedure. The selected technique should ideally be painless, be accepted by the patient and parents, be rapid in onset, be appropriate in duration with rapid recovery, and have minimal side effects and a broad margin of safety. If drug administration is associated with pain or adverse memories, the benefit of the sedation may be decreased. The anesthetic must also provide an environment in which the procedure can be completed. In certain clinical situations a moderate degree of movement may be acceptable, whereas in other situations no movement is acceptable. Also, the induction agent may establish a depth such that the treatment may be completed, but in other cases the goal of the induction agent may be to establish sufficient sedation to allow intravenous access and maintenance of anesthesia with intravenous agents. Lastly, and of extreme importance, one is cautioned not to sedate a young child who will be transported in a car seat prior to arrival in the office. The respiratory depressant effect of the medication combined with the positioning of the unattended child in the car can result in unrecognized upper airway obstruction or respiratory impairment, with resultant death or significant neurologic impairment.⁴⁸

Routes of Administration

Sedative medication may be administered by many routes, including oral, intranasal, transmucosal, rectal, intramuscular, inhalational, and intravenous.⁴⁹ The advantage of the intravenous route is that it results in the most rapid onset, rapid offset, and predictable effect. The disadvantage is that it entails establishing intravenous access. A percentage of children do not cooperate and allow an intravenous catheter to be inserted. Many children

report the needle puncture from either intravenous placement or intramuscular injection as the worst part of their care.

Even with a cooperative or an anesthetized child, gaining peripheral intravenous access can present a challenge. Proper knowledge of venous anatomy with a controlled organized approach gives the best chance for success. Commonly accepted sites for venous cannulation include the dorsum of the hand, volar aspect of the wrist, antecubital fossa, and greater saphenous vein. Even when an alternative route (eg, inhalation or intramuscular) is used to induce the anesthetic, we recommend the establishment of intravenous access. This can be achieved once the child is sedated. Even if the procedure can be accomplished without the administration of an intravenous agent, an established intravenous line can be used to administer intravenous agents if needed to augment the initial anesthetic agent or to prolong the duration of the anesthesia. The line can additionally be used to administer other medications required to manage adverse events.

In an emergent situation, if the traditional peripheral cannulation technique is not successful, the clinician has two possible access sites that allow for a high degree of predictability. These sites are the femoral vein and intraosseous access, which are associated with a higher incidence of morbidity. The femoral vein usually requires a 20-gauge or 22-gauge angiocatheter. The intraosseous needle is recommended primarily for children < 6 years of age because they still have red bone marrow (Figure 6-1). In this technique a bone marrow needle or a no. 14 through 18 Cook intraosseous infusion needle is percutaneously inserted into the flat portion of the proximal tibia. Entry is made in the tibial plateau 1.5 cm below the knee joint and 2 cm medial to the tibial tuberosity. The special bone marrow-stilette needle is inserted with a rotary motion into the bone until the cavity is

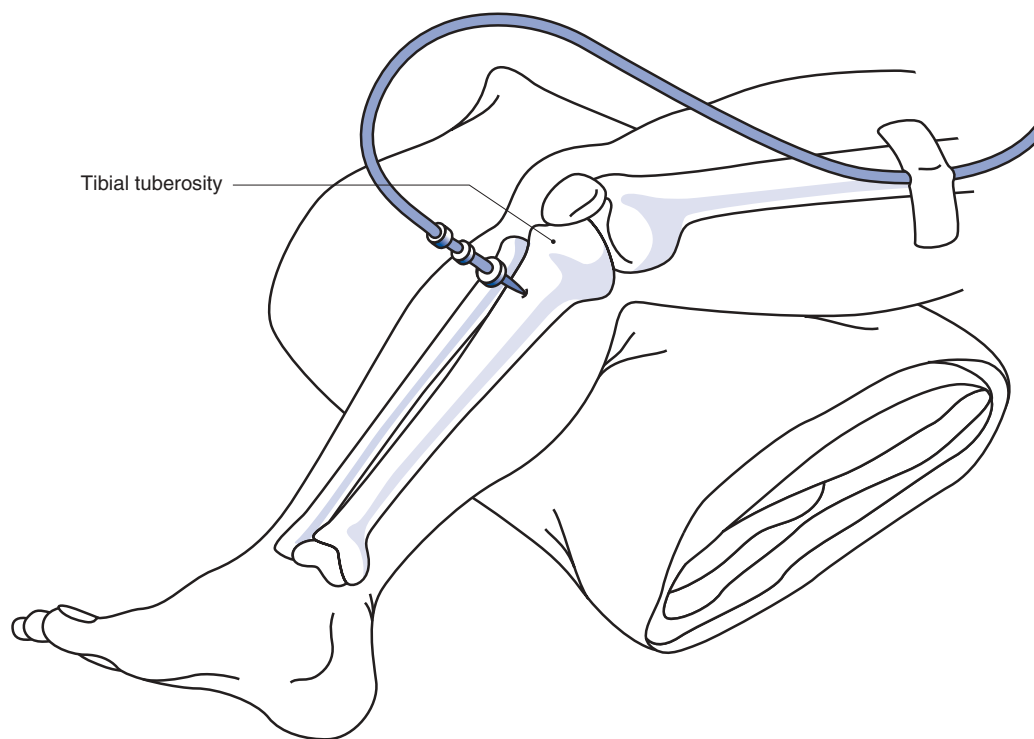


FIGURE 6-1 For intraosseous infusions a bone marrow needle or specially made intraosseous needle is inserted into the tibial plateau (just medial and down from the tibial tuberosity). The catheter is then secured and intravenous solutions and medications may be administered. Adapted from American Heart Association. *Textbook of pediatric advanced life support*. Dallas: American Heart Association; 1994.

reached. The depth of the needle insertion should be planned. If it is advanced too far, the needle penetrates the posterior cortex and does not allow infusion. The needle should be firmly set in the bone. Often bone marrow may be aspirated to confirm the placement. A syringe or intravenous line can be attached; if it runs easily, placement is confirmed. Slight extravasation around the placement site should not prevent the use of the needle. The catheter can serve as a conduit for all intravenous fluids and drugs.

The inhalational induction of anesthesia with a potent anesthetic agent also provides rapid onset, rapid offset, and a predictable effect. The advantage of this technique, similar to the intravenous route, is the option to use short-acting agents enabling the anesthetic state to be rapidly terminated at the end of the procedure.

The traditional inhalation induction is accomplished by administering oxygen or

a mixture of oxygen (minimum concentration of 30%) and nitrous oxide using a full face mask. Induction can be achieved using one of two techniques. The potent vapor agent can be increased gradually every few breaths until the induction is complete. Alternatively, the patient may be immediately administered a high concentration of the potent inhalational agent. A modification of the latter technique is to ask the patient to exhale completely and then take a deep inspiration of the vapor agent and hold his or her breath. Induction will be achieved with a single breath, and spontaneous ventilation will resume once a state of general anesthesia is achieved. For brief procedures (eg, extraction of a deciduous tooth), once general anesthesia is achieved, the face mask can be removed, the procedure performed, the face mask reapplied, and the patient allowed to awaken breathing 100% oxygen. Some clinicians advocate maintaining the general anesthesia by con-

tinuing the administration of the potent vapor agent via a traditional nasal hood. This can result in the delivery of a diluted concentration of anesthetic agent to the alveoli, resulting in a lightening of the patient's anesthetic depth. Such an occurrence would necessitate the interruption of the procedure to replace the full face mask to increase the alveolar concentration of the inhalational agent. Although the continued administration of the vapor agent via a nasal hood is not contraindicated, it may result in excessive environmental pollution, even with a scavenger device that is a component of the nasal hood. A circuit that scavenges the vapor agent must also be used with the face mask. To avoid these potential problems, especially for longer procedures, the establishment of intravenous access is recommended. The vasodilatory effects of the potent agent may optimize conditions for establishing intravenous access. Once access is set, anesthetic depth can be maintained with intravenous anesthetic agents.

There are a few disadvantages to inhalation induction. The vapor agent has a scent that may be objectionable to some. Applying a scent (eg, scented lip gloss) selected by the child to the face mask may alter the odor of the agent. The odor may also be minimized if the child breathes through the nose as opposed to the mouth.¹⁸ In addition, inhalation induction is also dependent on the child accepting the face mask. Techniques such as asking the child to inflate a balloon may be employed to distract the child. Any need for mild restraint should be explained to the parent and may be used to facilitate induction in the younger child. However, in older children or extremely uncooperative children, the technique is dependent on the child's acceptance of the face mask. If excessive physical restraint is necessary, an alternative technique should be considered.

The intramuscular route of administration approximates the rapidity and predictability of onset of intravenous admin-

istration. Its primary disadvantage is the discomfort associated with the injection. However, for the uncooperative child, it may be the least traumatic method of inducing anesthesia. Four anatomic regions are used for intramuscular administration of drugs: the deltoid muscle, the vastus lateralis muscle, the ventrogluteal area, and the superior lateral aspect of the gluteus maximus muscle. These sites have been identified because they have minimal numbers of nerves and large blood vessels, as well as adequate bulk to accommodate the volume of the injected medication. The rapidity of onset of the drug is dependent upon the perfusion of the muscle. Absorption and onset are also affected by the ionization of the drug and the vehicle in which it is dissolved.

Oral administration is considered by many to be the least-threatening induction technique. Children are generally familiar with and readily accept oral medications. Oral administration also is generally well accepted by the mentally impaired or autistic patient. However, oral techniques have limitations. In one study of children between the age of 20 and 48 months, one-third of the children required that the medication be administered into the back of their throat with a needle-free syringe.⁵⁰ Although frequently used as a sole sedative agent by many surgeons, an oral sedative agent can be used as a premedicant prior to establishing intravenous access or inducing general anesthesia by a different route (eg, inhalation or intramuscular). The limited volume of fluid administered with the oral medication is not associated with an increased risk for aspiration pneumonitis.⁵¹

The primary disadvantages of oral sedation are the slow onset, variable response, and prolonged recovery. Injecting a sedative agent into the back of the throat with a needle-free syringe (when the child does not otherwise accept the medication) has also been associated with adverse consequences. It has been theorized that the drug intended for orogastric

administration can be inadvertently aspirated by the crying child. Bronchial absorption can result in an excessive plasma level of drug.

The intranasal route was initially proposed for pediatric sedation because it was felt to avoid first-pass degradation, be rapid in onset, and be less traumatic than the other routes that possessed these same benefits.⁵² Medications administered intranasally do result in a rapid rise in the plasma level of a drug. This occurs because the nasal cavity, which functions to warm and cleanse nasal respirations, has a relatively extensive surface area with a thin nasal mucosa and an abundance of capillaries that facilitate the absorption of drug. The nasal mucosa also provides a direct connection to the central nervous system (CNS) through the cribriform plate. Medication may be absorbed through the cribriform plate directly into the CNS through the capillary beds or the olfactory neurons, or directly into the cerebrospinal fluid.⁵³ Rhinitis or a URI may impair the absorption of a drug via this route.⁵⁴

The intranasal route, although initially felt to be less traumatic than alternative routes, is frequently not well accepted by children.^{55,56} The volume of medication used frequently results in a portion passing into the pharynx and being swallowed. Therefore, the unpleasant taste of the medication is not avoided, and the drug is subject to first-pass hepatic degradation. Midazolam is the most commonly intranasally administered medication, but the acidic pH is irritating to the nasal mucosa.

Transmucosal absorption has also been considered. The oral epithelium is thin with a rich vascular supply. The minimum epidermal barrier and the vascular supply provide an environment that promotes relatively rapid absorption of drugs. Oral transmucosal administration of a drug also has the advantage of avoiding hepatic first-pass degradation. Transmucosal administration requires cooperation of the patient to keep the drug in contact

with the oral mucosa. The medication may be administered as a solution placed sublingually or as a lozenge. At the present time the only available lozenge that has an acceptable flavor and is commercially available is fentanyl citrate. Other sedative medications are bitter. Palatability can be improved by mixing these medications with a flavored solution that increases their volume; thus, the solution will be bitter or the volume will be excessive, neither of which is advantageous for the transmucosal administration of a liquid/solution. Many, if not most, pediatric patients expectorate the medication or prematurely swallow the liquid medication that is placed within the oral cavity as opposed to keeping it there.

Rectal drug administration has been used for the administration of antiemetics, antipyretics, and analgesics to both adults and pediatric patients. Many sedative drugs that are usually administered IV, IM, or orally can be administered rectally. Rectal administration may also be used in the management of emergencies. For example, rectal administration of diazepam is an acceptable route for the treatment of seizures.^{57,58}

The rectum is a flat organ that is usually empty. Its blood supply is derived from the inferior rectal arteries and is drained via the superior, middle, and inferior rectal veins. The superior rectal vein drains into the hepatic portal circulation via the inferior mesenteric vein. The middle and inferior rectal veins drain into the internal iliac vein. The internal iliac vein drains into the vena cava, thus bypassing the hepatic-portal circulation and avoiding first-pass metabolism by the liver.

The absorption of a drug that is administered per rectum is affected by several factors. The variable absorption of the drug may be partially influenced by the venous drainage of the rectum. Therefore, some individuals feel that absorption and subsequent peak plasma level of medication is dependent on the location of deposition of

drug within the rectum. However, there are significant anastomoses between the three rectal veins, and peak drug blood level has not clearly been shown to be dependent on the location of agent deposition within the rectum. Solutions are absorbed more rapidly than are suppositories. A more dilute solution with greater volume provides more rapid onset and prolonged duration.⁵⁹ Stool within the rectal vault as well as expulsion of an unmeasurable quantity of drug results in delayed or decreased absorption. Alteration in the integrity of the mucosa or the presence of hemorrhoids results in greater absorption. If a child is uncooperative, he or she may tightly close the anal sphincter during any aspect of the administration process. Excessive force both in placing or removing the catheter may result in a laceration of the mucosa and cause a greater absorption of drug.

Pharmacologic Agents

The objective in selecting a pharmacologic agent is to choose an agent that establishes an appropriate environment to complete the surgical procedure. The effects sought in the pediatric patient include anxiolysis, amnesia, analgesia, immobilization, sedation, and hypnosis. There are numerous agents that are currently used by oral and maxillofacial surgeons and other practitioners. In this section we discuss what we feel to be the most appropriate anesthetic agents and the routes by which they should be delivered.

Ketamine Ketamine is a pharmacologic agent that induces a distinct anesthetic state that resembles catalepsy. The patient appears awake but is noncommunicative. Nonpurposeful movements may occur but are not disruptive. The eyes are commonly open with a blank stare and intact corneal and light reflexes.⁶⁰ A lateral nystagmus is also very characteristic. Ketamine also produces amnesia and analgesia.

The clinical effect created by ketamine results from a dissociation between the

thalamoneocortical and limbic systems, which disrupts the brain from interpreting visual, auditory, and painful stimuli.⁶¹ The analgesic effect, which occurs at subanesthesia plasma levels, is partially mediated by ketamine binding to the μ -opioid and NMDA receptors. This is significant because the effect persists into the postoperative period and may decrease the need for postoperative analgesia.⁶²

Ketamine is also unique in its effects on the respiratory system. In clinical doses commonly used in oral and maxillofacial surgery, ketamine usually preserves upper airway musculature tone, spontaneous respirations, and FRC. This minimizes the incidence of upper airway obstruction and hypopneas/apneas, and maintains the pulmonary oxygen reserve.^{63,64} In contrast, most other anesthetics contribute to a decrease in muscular tone, respirations, and FRC. In addition to maintaining upper airway muscular tone, ketamine tends to better maintain the pharyngeal and laryngeal airway reflexes. This allows the patient to maintain the ability to swallow and cough, which minimizes the risk of pulmonary aspiration. Ketamine has also been shown to relax bronchial smooth muscle and cause bronchial dilatation. It has been used in the management of wheezing during anesthesia.⁶⁵

Despite these benefits the practitioner must respect the inherent dangers associated with the anesthetic management of a patient. Respiratory depression characterized by a decrease in respiratory rate and tidal volume can occur with ketamine. Respiratory arrest has been reported in a 4-year-old child following the intramuscular administration of ketamine 4 mg/kg.⁶⁶ However, respiratory depression is not common, and the occurrence of apnea is more likely to occur in infants or with the rapid intravenous infusion of an induction dose greater than 2 mg/kg. Slow intravenous infusion over 30 to 60 seconds of doses between 0.5 mg/kg and 1 mg/kg should minimize the incidence of signifi-

cant respiratory depression. Aspiration of gastric contents can also occur despite the fact that ketamine better preserves the protective airway reflexes allowing a patient the ability to swallow and cough.^{67,68} The protective reflexes, although less impaired than with other drugs, are diminished. We feel that a patient who is considered not to have an empty stomach should not be sedated, and disagree with those who feel that preservation of the airway reflexes justifies sedating such patients.⁶⁹ The preservation of the laryngeal reflexes is a protective mechanism; this may also contribute to airway complications. Ketamine produces an increase in salivary and tracheobronchial secretions, and the preservation of the laryngeal reflexes may predispose the patient to laryngospasm.

Ketamine has both direct and indirect effects on the cardiovascular system. The direct myocardial depressant effects are generally not seen in the healthy patient anesthetized in the office. The indirect effects, which are a result of a sympathetic stimulation, produce an increase in heart rate and blood pressure. The former may be more common in the pediatric patient. These effects are well tolerated in the healthy pediatric patient. These hemodynamic changes may be reduced when ketamine is combined with an anesthetic agent that tends to blunt sympathetic stimulation (eg, benzodiazepines, propofol).

A disadvantage of ketamine is its stimulation of dreams and hallucinations described as “out of body” experiences, sensations of floating, and delirium.⁷⁰ Although the incidence is less in children < 16 years of age, the incidence may be as high as 10%.^{71,72} Ketamine is also contraindicated in patients who may have a globe or intracranial injury as ketamine increases both intraocular and intracranial pressure.

Ketamine can be administered IV, IM, orally, intranasally, and rectally. We discuss only the intravenous, intramuscular, and oral administrations of ketamine.

The advantage of intramuscular administration is that it does not require patient cooperation. The mild distress associated with the injection is brief as the drug has a rapid onset, within 3 to 5 minutes. Dosing recommendations up to 10 mg/kg IM have been described in various papers and texts. The larger dose clearly produces a general anesthetic state. For office-based or emergency-department procedures performed by oral and maxillofacial surgeons, however, a dose of 4 to 5 mg/kg IM should provide effective dissociation. One investigation prospectively assessed pediatric patients requiring sedation for minor procedures in an emergency department and found that a 4 mg/kg dose provided effective sedation and immobilization for 86.1% of the children. A satisfactory quality of sedation was achieved with adjunctive local anesthesia for 97.2% of these patients, although 3.7% required mild restraint despite adequate sedation and an absent withdrawal response to pain. Only 2.8% of the patients required a repeat dose secondary to inadequate sedation.⁷³ Local anesthesia is an important component of any sedative technique used by oral and maxillofacial surgeons. Although this study demonstrated that it is not always required, incorporation of local anesthesia into the anesthetic plan minimizes the amount of other anesthetic agents required. The working time achieved from a 4 mg/kg dose of ketamine was 15 to 30 minutes. A disadvantage of intramuscular ketamine is that recovery is variable and can be quite long. Although the mean recovery time in the above study was 82 minutes, recovery from injection to discharge at times took up to 3 hours.

Benzodiazepines can be administered concomitantly with ketamine. The purpose for coadministering a benzodiazepine is to reduce the amount of ketamine administered, reduce the incidence of ketamine-induced hallucinations, attenuate the cardiovascular effects of ketamine, and provide additional amnesia.⁷⁴ Coadminis-

tration of a benzodiazepine with ketamine may prolong recovery.⁷⁵ Midazolam produces a better reduction in unpleasant dreams than does diazepam.⁷⁶ The favorable pharmacokinetics of midazolam compared with diazepam also provide a more rapid recovery. In a prospective investigation, ketamine 3 mg/kg with midazolam 0.5 mg/kg was administered to pediatric patients requiring sedation for minor surgical procedures in the emergency department.⁷⁷ Although 30% of the patients who received this regimen manifested “intermittent crying,” only 14% required additional medication to establish a satisfactory anesthetic state to allow completion of the planned treatment. Recovery for this regimen was at times prolonged.

The level of sedation and immobilization is dependent on the planned procedure. Although the intent is to provide an atraumatic experience for the child, a mildly dissociative sedative and analgesic state compared with a deeper dissociative anesthetic state may be acceptable for a brief dentoalveolar procedure. The intent is to modify the patient’s perception of the procedure. In this situation the patient is not profoundly sedated and the practitioner has to tolerate some movement and possibly some vocalization. Ketamine 2 mg/kg to 3 mg/kg IM should provide this desirable sedative depth. The lower dose of 2 mg/kg is advantageous in that recovery from injection to discharge approximates 60 minutes. For many children the low intramuscular dose of ketamine provides a depth of sedation that allows the placement of an intravenous line. If necessary, the depth of sedation can then be modified using intravenous medications. Incremental doses of ketamine 5 to 10 mg IV can be administered to the sedated patient, with onset occurring within 30 to 60 seconds. The duration of sedation is 10 to 15 minutes. Although we have found that ketamine 2 mg/kg generally facilitates intravenous placement, one study reported that 31% of the children resisted intra-

venous placement with a dose of 3 mg/kg.⁷⁸ For the patient who remains combative and for whom intravenous access cannot be established, an additional dose of ketamine 1 to 2 mg/kg IM can be administered. If the child allows placement of an intravenous catheter (without any premedicant), a dose of ketamine 0.5 to 1 mg/kg IV administered over 30 to 60 seconds will establish dissociation.

An anticholinergic agent (eg, glycopyrrolate or atropine) is frequently coadministered with ketamine to decrease hypersalivation. Tachycardia and postoperative psychomimetic effects are problems associated with ketamine. Atropine, when combined with ketamine, produces a significantly higher heart rate compared with the effect of glycopyrrolate. As a tertiary amine, atropine crosses the blood-brain barrier and can, itself, produce postoperative delirium. A higher incidence of adverse emergence phenomenon, however, was not identified in studies comparing glycopyrrolate with atropine.^{79,80} Both drugs can be mixed in the same syringe with ketamine for an intramuscular injection. The peak effect of intramuscular glycopyrrolate occurs within 30 minutes, at which time the procedure is frequently completed and the patient is in the recovery phase of treatment. If an intravenous line is to be established after the onset of sedation, glycopyrrolate can be administered IV with a peak effect in approximately 1 minute. The dose of atropine is 0.1 to 0.2 mg/kg, with a minimum dose of 0.1 mg and a maximum dose of 0.6 mg. Glycopyrrolate is twice as potent as atropine. The dose is the same for both drugs, regardless of the route of administration.

Ketamine can also be administered orally.⁸¹ Bioavailability is approximately 17% following oral administration compared with 93% after intramuscular administration.^{82,83} Onset of sedation occurs in approximately 20 minutes. Although doses reported have ranged from

3 to 10 mg/kg, a more consistent effect is achieved with doses > 6 mg/kg. In one investigation oral ketamine 6 mg/kg was administered for sedating anxious pediatric dental patients with a mean duration of sedation of 36 minutes.⁸⁴ The quality of sedation was reported as good for 65% of the patients, and 100% of the treatment was completed. Mean recovery time was 56 minutes with one child sleeping for 3 hours. Creating a state of deep sedation is dependent on using larger doses of medications. Ketamine 10 mg/kg PO was used as a premedicant in the management of pediatric patients undergoing invasive oncologic procedures. Approximately 50% of the patients were unresponsive at 60 minutes. This dose was ineffective in < 10% of the patients.⁸⁵ Recovery, however, generally took 2 to 4 hours, with 20% of the patients being deeply sedated at 120 minutes post administration. Several authors have shown that the anxiolytic and sedative properties of midazolam 0.5 mg/kg result in a more clinically effective sedation than does ketamine 5 or 6 mg/kg.^{86,87}

The combination of oral midazolam and ketamine has also been described. This drug combination may provide effective sedation when oral midazolam has been ineffective. One study that demonstrated a greater efficacy with this combination used ketamine 4 mg/kg with midazolam 0.4 mg/kg.⁸⁸ The reported dosing regimens have varied from ketamine 4 to 10 mg/kg with midazolam 0.25 to 0.5 mg/kg.

Situations may occur in the management of a mentally impaired, autistic, or older child in whom an intravenous line or an intramuscular injection cannot be administered without harm to the patient or the healthcare provider, and who will not accept a face mask. Oral ketamine alone or combined with oral midazolam can be used to establish a cataleptic state, facilitating treatment of the combative patient.^{89,90} It may be helpful to solicit assistance from the patient's caregiver or parent, as these individuals may be aware

of strategies to ensure that the full oral dose is taken. Atropine or glycopyrrolate can be orally administered with ketamine; however, the time to peak decrease in salivation is 2 hours.⁹¹

Regardless of the route of administration, ketamine can establish a clinical effect described as a "chemical straight-jacket." The catatonic state created by ketamine is different from that with other general anesthetic agents; ketamine, when used at the doses discussed above, may not be considered to be a true general anesthetic. However, the anesthetic depth created by ketamine is not consistent with conscious sedation, and airway problems can occur. Therefore, appropriate anesthetic standards for deep sedation or general anesthesia must be followed.

Midazolam Midazolam is a water-soluble short-acting benzodiazepine. As a class of agents, the benzodiazepines provide anxiolysis, sedation, and amnesia. Midazolam can be administered IV, IM, orally, sublingually, intranasally, or rectally. Because of its water solubility, intramuscular injection of midazolam is pain free, and absorption is predictable. Unlike ketamine, however, as a single agent there is no unique anesthetic benefit to the intramuscular administration of midazolam.

Intranasal administration of midazolam was popular in the past. It was once the most common intranasally administered medication. However, because of an acidic pH, it produces irritation to the nasal mucosa. The medication if administered slowly is discomforting and if administered rapidly passes through the nose into the nasal pharynx and is swallowed. In a study that compared oral to intranasal administration of midazolam, children were found to be less tolerant of the intranasal administration.⁹²

Oral midazolam is probably the most widely used premedicant in children. The recommended dose of midazolam is 0.5 to 1.0 mg/kg to a maximum of 20 mg. Mida-

zolam 0.5 mg/kg achieves anxiolysis in 70 to 80% of patients. The anesthetic depth may be potentiated by the administration of nitrous oxide. The combined administration of 40% nitrous oxide with midazolam 0.5 mg/kg has produced deep sedation in 12% of patients.⁹³

Unlike ketamine, midazolam causes loss of airway muscle tone. Although airway obstruction is not common with doses of 0.5 to 1.0 mg/kg, airway obstruction has been reported after 0.5 mg/kg oral midazolam.⁹⁴ The incidence of airway obstruction may increase with the administration of nitrous oxide. In one study the combined administration of 50% nitrous oxide and 0.5 mg/kg oral midazolam resulted in a 56% incidence of upper airway obstruction in children with enlarged tonsils.⁹⁵ With maintenance of airway patency, however, oral midazolam doses of 0.5 to 0.75 mg/kg generally do not result in a change in oxygen saturation, heart rate, or blood pressure.⁹⁶

The onset of effect of oral midazolam is within 20 minutes, and the duration of sedation is 20 to 40 minutes. Patients can generally be discharged within 60 to 90 minutes from the time at which the medication is administered.

Midazolam is metabolized by the cytochrome oxidase system. Oral midazolam is subject to hepatic first-pass metabolism. Erythromycin, clarithromycin, protease inhibitors,azole antifungal medications, fluvoxamine maleate, and grapefruit juice alter this cytochrome oxidase system and result in a higher and a more sustained midazolam plasma level.^{97,98}

Higher doses of oral midazolam (0.75 to 1.0 mg/kg) are associated with a greater incidence of side effects. These include loss of head control, blurred vision, and/or dysphoria. A paradoxical reaction may also occur in which the patient becomes more excited as opposed to sedated. This is more common in children and adolescents.⁹⁹

Induction Agents Methohexital and propofol are rapid-onset short-acting agents that are effective for induction and maintenance of anesthesia. These are the primary anesthetic agents for general anesthesia in oral and maxillofacial surgery performed in an office. The pharmacology of these agents is discussed in Chapter 5, "Pharmacology of Outpatient Anesthesia Medications." There are some important points to make relative to their use in the pediatric patient.

Methohexital is an ultrashort-acting oxybarbiturate. It can be administered rectally, IM, and IV. The advantage to the rectal administration of methohexital is that the drug is administered in the presence of the parents, and, thus, the child is asleep prior to parental separation. Rectal administration, however, can be distressing, as discussed above. Methohexital can also be administered intramuscularly. Administration is quite painful, and there is no advantage to its use in office-based anesthesia compared with other available intramuscular agents. Neither rectal nor intramuscular administration is generally employed in ambulatory oral and maxillofacial surgery offices. Most frequently methohexital is administered IV. Interestingly, despite years of safe administration in this environment, the manufacturer's package insert states that the use of methohexital in the pediatric patient is not adequately studied and thus not recommended.

Propofol is an alkylphenol. Its characteristics include rapid onset and short duration of clinical effect, similar to methohexital. Its high clearance rate and minimal tendency for drug accumulation make it a more ideal anesthetic agent for ambulatory surgery in both adult and pediatric patients. In one study comparing propofol to methohexital for anesthesia in pediatric patients undergoing procedures in a dental chair, propofol was associated with a 9% incidence of ventricular arrhythmias compared with a 32% incidence associated with methohexital.¹⁰⁰

Clinical trials and case series have demonstrated propofol's efficacy in pediatric patients.^{101–107} The proprietary formulation of propofol (Diprivan) is licensed by the US Food and Drug Administration (FDA) for use in children > 3 years of age in the surgical setting.

Transient pain at the site of injection is reported in approximately 10 to 20% of patients given propofol. In the pediatric patient this discomfort may result in gradations of movement, which may require restraint of the patient until induction is fully achieved. Propofol may also cause hypotension and bradycardia. The incidence is reported to be higher in the pediatric patient (17%) compared with that in the adult patient (3–10%). This usually is not detected in the adult oral and maxillofacial surgery patient when a relatively low initial dose (< 1 mg/kg) is typically used to achieve deep sedation or general anesthesia. Pediatric patients frequently need to be more profoundly anesthetized. This requires the administration of a greater dose of propofol, which may result in a higher occurrence of hypotension or bradycardia in pediatric oral and maxillofacial surgery patients. Propofol may also cause excitatory movement or myoclonus, the incidence of which is greater in the pediatric patient (17% vs 3–10%).

The greatest potential concern with the use of propofol in the pediatric patient is that cases of fatal metabolic acidosis and cardiac failure, termed *propofol-infusion syndrome*, have been reported in over a dozen children.^{108–112} These incidents have all been associated with prolonged intubation and propofol infusions. A review by the FDA concluded that propofol had not been shown to have a direct link to any pediatric deaths.¹¹³ Although the causal relationship between propofol and metabolic acidosis remains unproven, clinicians should be aware of the risk for this reaction in children and limit the dose and duration of propofol therapy accordingly.

Inhalational Agents The origin of anesthesia is rooted within dentistry. The first anesthetic was nitrous oxide. Nitrous oxide has anxiolytic, analgesic, amnesic, and sedative effects.^{114,115} Although not a potent anesthetic agent, nitrous oxide possesses a wide margin of safety and has few (if any) residual side effects. Another advantage of nitrous oxide is its low solubility. An anesthetic agent that has low solubility has rapid equilibration between the alveoli and the blood, and the blood and the brain. This results in both rapid onset and anesthetic emergence. Also, nitrous oxide may be combined with other anesthetic agents. A deep sedative or general anesthetic state may be established with the coadministration of nitrous oxide and an oral or parenteral agent. This may result in respiratory impairment. Although nitrous oxide may potentiate the effect of another agent, the discontinuance of it can, likewise, reverse the anesthetic depth and promote a more rapid emergence.^{116–118}

Although nitrous oxide lacks sufficient potency to solely induce general anesthesia, halothane, sevoflurane, desflurane, and isoflurane have sufficient potency to induce and maintain general anesthesia (Table 6-2). The primary benefit of an inhalational agent is for mask induction, and of the potent inhalational agents, only halothane and sevoflurane are nonpungent. These agents can be administered to an awake patient with minimal respiratory complications (eg, coughing, breath hold-

ing, laryngospasm), whereas desflurane and isoflurane tend to irritate the airway if used for mask induction.^{119–121}

The blood and tissue solubility of an inhalational agent is also important. These properties influence the speed of induction and emergence from anesthesia. Agents that have a low solubility in blood have a more rapid induction and shorter emergence time. The blood gas solubility coefficients of desflurane, nitrous oxide, sevoflurane, isoflurane, and halothane are 0.42, 0.47, 0.6, 1.4, and 2.3, respectively. These figures imply a more rapid onset and emergence for desflurane, sevoflurane, and nitrous oxide.

Since all anesthetic agents affect the pulmonary and cardiovascular systems, it is important to understand these effects. All potent inhalational agents depress minute ventilation in a dose-dependent manner, with a resulting increase in partial pressure of carbon dioxide in arterial blood (PaCO_2). Clinically the practitioner will observe a decrease in tidal volume and a slight increase in respiratory rate. Although acceptable respiratory parameters can be maintained during spontaneous ventilations, of the two agents used for mask induction, halothane produces less respiratory depression than does sevoflurane.¹²² Not all respiratory effects are detrimental. All inhalational agents are beneficial in that they produce bronchial dilatation and are advantageous in the management of the patient with bron-

chospastic disease. All potent inhalational agents have myocardial depressant effects. The cardiovascular depressant effects are greatest with halothane use, which can result in hypotension and bradycardia. However, of greater significance is the ability of halothane to sensitize the heart to catecholamines with resultant dysrhythmias. One study reported that 48% of pediatric patients anesthetized with halothane had arrhythmias compared with 16% of those induced with 8% sevoflurane. Patients who had an incremental induction of sevoflurane had even fewer arrhythmias. Furthermore, of the arrhythmias associated with halothane, 40% were ventricular arrhythmias (consisting of ventricular tachycardia, bigeminy, and couplets); with sevoflurane, only 1% were ventricular arrhythmias (consisting of single ventricular ectopic beats).¹²³ The occurrence of these arrhythmias may also be associated with the administration of local anesthetics containing epinephrine. Halothane is the only inhalational agent that is associated with arrhythmias with clinical doses of epinephrine. A limit of 1 $\mu\text{g}/\text{kg}$ of epinephrine in patients receiving halothane is recommended.^{124–126}

Use of inhalational agents is advantageous in the oral and maxillofacial surgeon's office because they provide a general anesthetic state without intravenous access. Therefore, only agents that are pleasant and nonirritating to the airway can be used. Halothane has traditionally been the agent used by both anesthesiologists in the operating room and oral and maxillofacial surgeons in their offices. Sevoflurane appears to have the characteristics that most approximate the ideal inhalational agent, in that it is of sufficient potency, is nonpungent, has a low blood and tissue solubility, and has limited cardiorespiratory effects. Sevoflurane has replaced halothane in the operating rooms.

There are several variations in mask-induction techniques. First, the inhalational agent may be administered with a

Table 6-2 Inhalational Anesthetic Agents

Agent	Blood Gas Solubility	Maximum Acceptable Concentration (%)	
		1–12 yr	Adult
Nitrous oxide	0.47	—	105.00
Halothane	2.40	0.87	0.76
Sevoflurane	0.69	2.5	1.70
Desflurane	0.42	7.98–8.72	7.30
Isoflurane	1.40	1.60	1.20

Adapted from Cauldwell CB. Induction, maintenance and emergence. In: Gregory GA, editor. Pediatric anesthesia. 2nd ed. New York: Churchill Livingstone; 1989.

combination of nitrous oxide and oxygen or 100% oxygen. The combination of nitrous oxide with the potent vapor agent decreases the percentage of vapor agent required to achieve an anesthetic depth. The decrease in minimum alveolar concentration (MAC) for halothane is significantly clinically greater for halothane than for sevoflurane. This most likely is related to the difference in solubility of the two potent inhalational agents. Another variation in mask induction pertains to the concentration of inhalational agent administered. The practitioner may administer an incrementally increasing concentration of an agent (eg, increasing an agent by 0.5–1% after a few breaths) or a high initial concentration of an agent (eg, sevoflurane 8%). Although one would expect that sevoflurane would have a more rapid speed of induction, the differences between sevoflurane and halothane have not been consistently demonstrated.^{121,127} The difference in speed of induction appears to be less distinguishable when a high concentration of halothane is used.

Similar to speed of induction, anesthetic emergence is dependent on several variables. Agents that have a low blood solubility coefficient should have a shorter emergence time. Several studies have shown that desflurane, which has the lowest blood solubility coefficient, has a very rapid anesthetic emergence (5–7 min), and halothane, which has the highest blood solubility coefficient, has a more prolonged recovery (10–21 min).^{128–132} Sevoflurane has been shown, although not consistently, to have a more rapid anesthetic emergence for intermediate- and long-duration anesthetics compared with halothane. However, typically the required state of anesthesia for a pediatric dental procedure in the office is brief, lasting < 10 minutes. Recovery from anesthesia is also dependent on the duration of the anesthesia. Clinical studies comparing sevoflurane and halothane for pediatric

dental extractions lasting between 4 and 6 minutes have not demonstrated a more rapid recovery with sevoflurane.¹³³ In one study, in which children were subject to a 4-minute anesthesia, time to eye opening was 102 seconds with halothane and 167 seconds with sevoflurane.¹³⁴

The last factor that needs to be considered both in comparing sevoflurane and halothane and in selecting an anesthetic agent for the office is the toxicity of each drug. Halothane is metabolized in the liver to a trifluoroacetylated product, which binds liver proteins promoting an immunologic response that can result in hepatic injury.^{135,136} The incidence, which may be as high as 1 in 6,000 cases of anesthesia in adults, is significantly lower in the pediatric population. Sevoflurane, although not associated with liver toxicity, has been associated with the potential for renal toxicity.^{137,138} The drug undergoes hepatic metabolism, which produces inorganic fluoride. However, the rapid elimination of sevoflurane minimizes the renal fluoride exposure, which probably accounts for the lack of clinical renal dysfunction, despite some reports of serum fluoride levels > 50 μmol . Renal injury has also been associated with the formation of compound A, which is a product of the reaction between sevoflurane and CO_2 absorbents. Most of the data, however, suggest that compound A does not induce renal toxicity in humans.

Other Medications Chloral hydrate is an alcohol-based sedative. It produces a sleep from which one is easily roused, in which the cardiorespiratory effects are consistent with those that occur with natural sleep. The onset of chloral hydrate is slow (30–60 min), its duration is variable (2–5 h), and it lacks the anxiolytic effects of benzodiazepines. The sedative effect of chloral hydrate does not produce as favorable a work environment as the anxiolytic effect of a benzodiazepine.⁵⁰ Another disadvantage of chloral hydrate

is that it is a gastric irritant and is associated with nausea and vomiting.

Antihistamines are commonly used in medicine and dentistry for their antipruritic and antiemetic effects. When used for these conditions, sedation is frequently an unwanted side effect. However, the sedative effects can be used to advantage, and antihistamines such as promethazine and hydroxyzine are frequently combined with other drugs such as chloral hydrate and meperidine to potentiate the sedative effect of the primary anesthetic agent and to provide antiemetic effects. The sedative effects of antihistamines may last between 3 and 6 hours, and when used alone do not provide anxiolysis.

The oral transmucosal administration of a sedative medication is appealing. Fentanyl citrate is available as a lozenge on a stick. The recommended dose is between 10 and 20 $\mu\text{g}/\text{kg}$. Bioavailability is between 33% in children and 50% in adults.¹³⁹

The difference in bioavailability results from the amount of drug that is swallowed and the amount of drug that is absorbed through the oral mucosa. The drug provides both analgesia and sedation. Onset of analgesia precedes the onset of sedation. Analgesia also lasts for 2 to 3 hours, providing some postoperative pain control. Adverse side effects associated with the fentanyl lozenge include a high incidence of nausea and vomiting, and pruritus. The major adverse effect associated with the use of fentanyl citrate is a higher incidence of respiratory depression than that seen with other sedative medications. The respiratory depression associated with the fentanyl lozenge may last beyond the sedative effect.¹⁴⁰

Perioperative Complications

Laryngospasm

Intraoral surgery in the anesthetized non-intubated patient renders the patient susceptible to airway obstruction and airway irritation. Such irritation can result in a

laryngospasm, which is the apposition of the supraglottic folds, the false vocal cords, and the true vocal cords. The laryngospasm may be sustained and may become progressively worse as the supraglottic tissues fold over the vocal cords during forceful inspiratory efforts. The incidence of laryngospasm is 8.7 per 1,000 patients in the total population and 17.4 per 1,000 in patients < 9 years of age.³⁹

The treatment of laryngospasm depends on whether the airway obstruction is complete or incomplete. The single diagnostic feature that distinguishes complete from incomplete airway obstruction is simply the absence or presence of sound. If there are inspiratory or expiratory squeaks, sounds, grunts, or whistles, then chances are the child has incomplete airway obstruction. Airway obstruction of either type requires initial treatment with a patency-preserving maneuver such as the jaw-thrust/chin-lift maneuver.

Because incomplete airway obstruction may rapidly become complete, signs and symptoms of obstruction (eg, tracheal tug, paradoxical respiration) should be treated aggressively. The first maneuver is to apply gentle continuous positive airway pressure with 100% O₂ by face mask. An effective technique to deliver gentle positive pressure is to “flutter the bag.” In this technique the reservoir bag is very rapidly squeezed and released in a staccato rhythm, similar to what one would see with an atrial flutter of the heart. In essence, one performs a manual high-frequency oscillatory ventilation with this technique. If the patient improves, anesthesia and normal ventilation may be resumed. Overuse of the high-pressure flush valve to fill the breathing circuit and anesthetic bag may dilute potent anesthetic gases (if being used) and lead to a lighter plane of anesthesia in the child. In addition, high pressure applied to the airway may force gas down the esophagus and into the stomach, reducing ventilation even more. Pos-

itive airway pressure cannot “break” laryngospasm in the presence of complete airway obstruction and may, in fact, worsen laryngospasm by forcing supraglottic tissues downward to occlude the glottic opening.

For the laryngospasm that is refractory to continuous positive airway pressure, a neuromuscular blocking agent should be administered. The ideal agent should have rapid onset. For the nonintubated patient, rapid recovery is also desirable. Succinylcholine is the only neuromuscular blocking agent that provides these effects.

Succinylcholine

If intravenous access is available, succinylcholine 0.5 to 1.0 mg/kg is administered. If the child is hypoxemic, atropine 0.02 mg/kg should precede the administration of the succinylcholine to prevent a bradycardia secondary to the muscarinic effect of succinylcholine. If intravenous access is not available, succinylcholine may be administered intralingually or IM (succinylcholine 4 mg/kg).¹⁴¹

There are several potential complications associated with the use of succinylcholine. These include myalgias, malignant hyperthermia, masseter muscle rigidity, and hyperkalemic cardiac arrest in patients with undiagnosed myopathies. In some children the administration of succinylcholine can result in masseter muscle spasm. Masseter muscle spasm may indicate a susceptibility to malignant hyperthermia, but it can also be isolated and not progress to malignant hyperthermia. The anesthetic team needs to differentiate between an isolated spasm and a prodromal sign of an impending emergency to make a decision regarding the continuation of the anesthetic and surgical course. In a tertiary environment with appropriate monitoring, the anesthesia may be continued with observation for the development of other systemic signs reflective of the hypermetabolic state of malignant hyperthermia. Tachycardia is usually the earliest sign,

whereas end-tidal CO₂ is the most sensitive sign of malignant hyperthermia.^{142,143}

Another potential life-threatening complication following the administration of succinylcholine is hyperkalemic cardiac arrest. Hyperkalemic cardiac arrest follows the administration of succinylcholine in patients with undiagnosed myopathies; succinylcholine induces rhabdomyolysis, which causes hyperkalemia leading to bradycardia/asystolic rhythm. Several case reports have appeared in the literature emphasizing this potential risk in the pediatric patient, which exists because Duchenne’s and Becker’s muscular dystrophies may go undiagnosed until the ages of 6 and 12 years, respectively.^{144,145}

Alternative neuromuscular agents have been developed that can provide rapid onset and should be used for elective situations. Rocuronium may be used when succinylcholine is contraindicated. Its onset is rapid, however, with a considerably longer duration. The administration of lidocaine topically to the vocal cords may also be effective. Succinylcholine remains the most ideal drug for the management of laryngospasm and emergent tracheal intubation and is the essential drug for managing laryngospasm in the oral and maxillofacial surgery office.

Cricothyrotomy

Three approaches to emergency surgical opening of the airway are mentioned in the literature: emergency tracheotomy, emergency cricothyrotomy, and emergency transtracheal ventilation.¹⁴⁶ In the experience of most, emergency tracheotomy cannot be performed rapidly enough in dire situations. Likewise, transtracheal jet ventilation is extremely hazardous in children because barotrauma may occur owing to the restricted egress of ventilatory gas. Therefore, when endotracheal intubation cannot be accomplished, the most rapid method for oxygenating the patient in an emergency situation is cricothyrotomy.¹⁴⁷

Nausea and Vomiting

Postoperative nausea and vomiting (PONV) is a cause of morbidity in pediatric patients. Even mild PONV is associated with delayed discharge, decreased parental satisfaction, and increased use of resources. More severe complications associated with PONV include dehydration and electrolyte disturbances, or hypoxemia secondary to airway obstruction or aspiration. PONV occurs in 6 to 42% of all pediatric surgical patients. The incidence is variable depending on age of the patient, the sex of the patient (there is a greater incidence in females > 13 yr), the anesthetic agents used, and the surgical procedure. Fortunately, severe or intractable PONV is less common, occurring in 1 to 3% of pediatric patients.¹⁴⁸

Anesthetic drug selection can have an effect on the incidence of PONV. Preoperative midazolam has been associated with reduced PONV in children.¹⁴⁹ Subsedative doses of propofol also provide antiemetic effects. This contrasts with methohexital, which is associated with a higher incidence of PONV than is propofol in adults. Studies are lacking comparing the incidence of PONV of these two agents in a pediatric population. Premedication with opioid analgesics increases the risk of PONV. Oral transmucosal fentanyl citrate in doses of 5 to 20 µg/kg is associated with PONV in almost all patients.¹⁴⁰ As discussed above, ketamine is an excellent agent for pediatric sedation. An unfortunate adverse effect associated with ketamine is a reported incidence of PONV that is as high as 50%. Nitrous oxide also has emetic effects. However, concentrations < 40% are less likely to cause PONV.

Vomiting is a complicated response mediated by the emetic center located in the lateral reticular formation of the medulla. This center receives input from several areas within the CNS, including the chemoreceptor trigger zone, vestibular apparatus, cerebellum, higher cortical and

brainstem centers, and solitary tract nucleus. These structures are rich in dopaminergic, muscarinic, serotonergic, histaminic, and opioid receptors. Blockade of these receptors is the mechanism of the antiemetic action of drugs. At the present time there are no drugs known that act directly on the emetic center.

Routine administration of antiemetic agents to all children undergoing surgery is not justifiable as the majority do not experience PONV or have, at most, one or two episodes. The agents used are the same as those used to manage PONV in the adult. The following discussion identifies points significant to the management of PONV in the pediatric patient.

Phenothiazines The phenothiazines are believed to exert their antiemetic effects primarily by antagonism of central dopaminergic receptors in the chemoreceptor trigger zone. Low doses of chlorpromazine, promethazine, and perphenazine are effective in preventing and controlling PONV. These drugs are frequently combined with opioids (when administered orally by pediatric dentists) to decrease the emetic effect of the opioid. All phenothiazines are capable of producing extrapyramidal symptoms and sedation, which may complicate postoperative care. The degree of sedation varies between phenothiazines, with little sedation produced by perphenazine compared with the other phenothiazines.¹⁵⁰

Benzamides The benzamide derivative metoclopramide has antiemetic and prokinetic effects and is the most effective antiemetic of this class. Its antiemetic effects are mediated by antagonism of central dopaminergic receptors, and at high doses it also antagonizes serotonin-3 receptors. In the gastrointestinal tract metoclopramide has significant dopaminergic and cholinergic actions and increases motility from the distal esophagus to the ileocecal valve. High doses of metoclo-

pramide are well tolerated by adults, but children are prone to dystonic reactions. For this reason, metoclopramide is combined frequently with diphenhydramine to decrease this incidence. Although metoclopramide has been used successfully to reduce the incidence of PONV in high-risk children, it is not as effective as droperidol or the newer serotonin antagonists.^{151,152}

Histamine Antagonists The histamine receptor antagonists are weakly antiemetic drugs with profound sedative effects, which make them less suitable for use in postoperative patients. They are frequently combined with other anesthetic agents in an oral cocktail for their sedative and antiemetic effects. These drugs may be useful for controlling emesis resulting from vestibular stimulation, as occurs in patients with motion sickness or after middle ear surgery. They also counteract the extrapyramidal effects of the more efficacious dopamine receptor antagonists.

Muscarinic Receptor Antagonists The vestibular apparatus and the nucleus of the tractus solitarius are rich in muscarinic and histaminic receptors. Muscarinic receptor antagonism is effective in preventing emesis related to vestibular stimulation, which may be the mechanism of morphine-induced PONV. In adults the use of glycopyrrolate, a drug that does not cross the blood-brain barrier, has been associated with three times the need for rescue antiemetic therapy compared with atropine.¹⁵³ Transdermal scopolamine has been used successfully to reduce PONV in children receiving morphine but is associated with a significant increase in sedation and dry mouth.¹⁵⁴ Other potential side effects include dysphoria, confusion, disorientation, hallucinations, and visual disturbances.

Serotonin Receptor Antagonists Serotonin antagonists were discovered serendipitously when compounds struc-

turally related to metoclopramide were found to have significant antiemetic effects but lacked dopamine receptor affinity. These drugs produce pure antagonism of the serotonin-3 receptor. Ondansetron was the first drug of this class to become available for clinical use in 1991. Since that time granisetron, and dolasetron have been introduced. This class of pure serotonin-3 receptor antagonists is not associated with the side effects of dopamine, muscarinic, or histamine receptor antagonists. The most serious side effects of ondansetron are rare hypersensitivity reactions.¹⁵⁵ Gastric emptying and small bowel transit time were not affected by ondansetron. Asymptomatic brief prolongation of the P–R interval and the QRS complex of the electrocardiogram have been reported in adults, but rapid intravenous infusion of ondansetron in children was not associated with changes in heart rate, arterial pressure, or oxyhemoglobin saturation.¹⁵⁶ Psychomotor and respiratory function were unaffected by ondansetron. Prophylactic ondansetron 0.05 to 0.15 mg/kg IV or orally reduced the incidence of PONV in children after a variety of surgical procedures.¹⁵⁷

Glucocorticoids (dexamethasone, methylprednisolone) exert antiemetic properties by a mechanism as yet unknown. These drugs have been used successfully in the postoperative setting to prevent PONV. Dexamethasone in doses up to 1 mg/kg IV (maximum dose 25 mg) was effective in reducing postoperative vomiting in children after tonsillectomy.¹⁵⁸ However, low-dose dexamethasone 0.15 mg/kg IV was not as effective as perphenazine 70 µg/kg IV in preventing emesis after tonsillectomy in children.¹⁵⁹ This class of drugs is better used in combination with another antiemetic than as the sole agent to prevent PONV.

Special Considerations

Oral and maxillofacial surgeons treat a diverse group of patients. Simplistically, the pediatric patient differs from the adult

patient anatomically, physiologically, and behaviorally. Beyond these differences the pediatric population is a diverse group within itself. Oral and maxillofacial surgeons are involved with the management of patients with craniofacial syndromes as well as other physical or mental impairments. The craniofacial syndromes may result in anatomic and physiologic alterations as well as mental disabilities. Potential airway abnormalities include macroglossia, micrognathia, choanal atresia, limited mouth opening, kyphoscoliosis, or cervical spine abnormalities. These abnormalities may make the patient more susceptible to upper airway obstruction and compromise spontaneous ventilation, oxygenation, mask ventilation, or laryngoscopy and intubation. Many of these patients may have significant cardiovascular disease associated with their syndrome. Mental impairment may also be associated with several congenital syndromes. Alternatively, physical disabilities are not always associated with mental impairments. The health care provider must avoid treating these patients as if they were mentally impaired because of their inability to communicate normally. Lastly, substance abuse among children and teens has reached epidemic proportions.

This section reviews the clinical presentation and anesthetic management of some patients with special considerations.

Attention Deficit Hyperactivity Disorder

Attention deficit hyperactivity disorder (ADHD) is defined as a persistent severe pattern of inattention or hyperactivity-impulsivity symptoms compared with other children at a comparable developmental level. Three subtypes of ADHD are identified: a predominantly hyperactive-impulsive type, a predominantly inattentive type, and a combined type. It is estimated to affect up to 5% of children.

Medical therapy frequently includes psychostimulants such as methyl-

phenidate, dextroamphetamine, or pemoline. Methylphenidate is the most commonly prescribed drug for ADHD. In addition to its use in the management of ADHD, 1 to 2% of the US high-school population without a diagnosed medical condition is reported to abuse this drug.¹⁶⁰ These drugs increase the bioavailability of neurotransmitters. The drugs tend to cause an increase in blood pressure and heart rate. Adverse effects are similar to that of other sympathomimetic agents. CNS effects include restlessness, dizziness, tremor, hyperactive reflexes, weakness, insomnia, delirium, and psychosis. Cardiovascular effects may include headaches, palpitations, arrhythmias, hypertension followed by hypotension, and circulatory collapse.¹⁶¹

Perioperative management of a patient on a psychostimulant (such as methylphenidate) includes recognizing signs and symptoms suggestive of inappropriate use. If there is a suggestion regarding overdose of the medication, the surgery should be postponed. However, when the medication is used appropriately, it is generally well tolerated. If there are no indications of adverse events, the medication should be continued throughout the perioperative period. Chronic use of the medication may decrease anesthetic requirements.

The anesthetic management of these patients is dependent on the level of cooperation of the patient. Preoperative sedatives may be used. Many of these individuals allow the placement of an intravenous catheter. However, for the patient in whom intravenous access cannot be established, ketamine (with or without midazolam) administered orally or IM is effective and not contraindicated owing to the chronic use of a psychostimulant.

Autism

Autism is a complex developmental disability that typically appears during the first 3 years of life. The result of a neurologic disorder that affects the functioning

of the brain, autism is the third most common developmental disability in the United States and occurs in approximately 2 to 4 per 10,000 live births.¹⁶² Autism is four times more prevalent in boys than in girls and knows no racial, ethnic, or social boundaries. Family income, lifestyle, and educational levels do not affect the chance of autism's occurrence.

Autism impacts the normal development of the brain in the areas of social interaction and communication skills. Children and adults with autism typically have difficulties in verbal and nonverbal communication, social interactions, and leisure or play activities. The disorder makes it difficult for them to communicate with others and relate to the outside world.^{163,164} In some cases aggressive and/or self-injurious behavior may be present. Persons with autism may exhibit repeated body movements (hand flapping, rocking), unusual responses to people, or attachments to objects and resistance to changes in routines. Children with autistic disorders may include a subgroup of individuals with associated psychiatric symptoms, including aggression, self-abusive behavior, and violent tantrums, and often-times necessitate the use of psychiatric medications; antipsychotics are the most prevalently prescribed medications in this group.¹⁶⁵ The autistic patient may also be prescribed medications similar to those prescribed for ADHD.

Management of these patients in the oral and maxillofacial surgery setting requires respect for the autistic child's need for ritualistic behavior, which may result in tantrum-like rages with any disruptions of routine. Providing a calm environment with minimal stimulation and consideration of all associated pharmacologic influences aids in the management of these patients. Premedication with a benzodiazepine may be beneficial. However, establishing an intravenous access still may not be possible, and an alternative technique may be required. A mask induction

with a potent vapor agent or intramuscular ketamine may be considered; however, the individual may be too physically strong and combative for these techniques. An alternative that should be considered (even in the noncombative individual) is oral administration of a premedicant of ketamine or ketamine and midazolam.⁸⁹ Alterations in management must be carried over into the postoperative period, in which many patients with behavioral or mental impairments are more agitated. Restraint may be necessary to prevent premature removal of the intravenous line, wound disturbance, or self-injury.

Cerebral Palsy

Cerebral palsy is a group of neurologic disorders that are characterized by impaired control of movement. The clinical manifestations are variable and are dependent on the site and extent of injury. There are four classifications: spastic, athetoid, ataxic, and mixed. Spastic cerebral palsy is the most common form and affects up to 80% of the patients. Patients with spastic cerebral palsy present with muscle hypertonicity, hyperreflexia, muscle contractures, muscle rigidity, and muscle weakness. The pattern of dysfunction can be further classified into monoplegia (one limb), diplegia (both arms or both legs), hemiplegia (unilateral), triplegia (three limbs), and quadriplegia (all limbs). The severity of the contractures may result in spinal deformities such as scoliosis. Athetoid or dyskinetic cerebral palsy is characterized by choreiform, tremor, dystonia, and hypotonia. The involuntary movements seen with athetoid cerebral palsy often increase with emotional stress. Ataxic cerebral palsy is characterized by poor coordination and jerky movements.

Associated medical conditions include mental retardation, speech abnormalities, seizures, drooling, dysphagia, and gastroesophageal reflux.¹⁶⁶ Mental impairment is most common in patients with spastic cerebral palsy. It is important to recognize

that > 50% of patients with cerebral palsy do not demonstrate mental impairment. Dysarthria or speech abnormalities secondary to a lack of coordination in muscle movement of the mouth can be seen in athetoid cerebral palsy. This muscle abnormality should not be confused with mental impairment. Seizures are seen in up to 35% of patients with spastic cerebral palsy. The lack of muscle coordination contributes to drooling and dysphagia. The inability to handle the secretions and the incompetent pharyngeal swallow reflex increase the risk of laryngospasm. Individuals with impaired neurologic function may also have an increased incidence of gastroesophageal reflux.

Several factors must be taken into consideration in treating these patients. The spasticity and lack of coordination can contribute to a hyperactive gag reflex. Anxiety can aggravate the involuntary movements. Nitrous oxide sedation may be effective in reducing these responses.¹⁶⁷ Severe contractures may make positioning the patient difficult. Contractures, which may result in scoliosis, can result in a restrictive lung disorder. The patient's hypotonia may necessitate stabilization of the head (even for the nonsedated patient). If the patient is to be sedated, muscle weakness may predispose the patient to impaired respirations. This may be compounded by medications prescribed to control the spasticity or seizure disorder. Conscious sedation may be contraindicated because of the inability to handle oral secretions and the risk of gastroesophageal reflux. It may be necessary to protect the airway with the placement of an endotracheal tube. In the event that the airway requires emergent intubation, the use of succinylcholine is not contraindicated.¹⁶⁸

Down Syndrome

Down syndrome, or trisomy 21, is a common chromosomal disorder occurring at a rate of 1.5 per 1,000 live births and is usually characterized by mild to moderate

mental retardation, cardiovascular abnormalities, and craniofacial abnormalities. Craniofacial abnormalities that have an impact on the anesthetic management of these patients include macroglossia, micrognathia, and a short neck, putting these patients at increased risk for airway obstruction during sedation. Enlargement of the lymphoid tissue may also place these patients at risk for upper airway obstruction. In addition, these patients have generalized joint laxity that may be associated with subluxation of the temporomandibular joint during airway manipulation. Intubation is usually not difficult, but subglottic stenosis, which is present in up to 25% of Down syndrome individuals, may necessitate a smaller-diameter endotracheal tube.

Atlantoaxial instability occurs in approximately 20% of patients with Down syndrome, and airway maneuvers, such as neck positioning during anesthesia for airway opening or intubation, may induce a serious cervical injury (C1-2 subluxation). This cervical spine instability is a contraindication for routine treatment until both the patient and the treatment risks are fully evaluated. Sequelae to neurologic injury are usually characterized by significant symptoms or declining neurologic function without other neurologic disorder. Specific symptoms may include a positive Babinski sign, hyperactive deep tendon reflexes, ankle clonus, neck discomfort, and gait abnormalities.

Down syndrome is associated with congenital heart disease in approximately 40% of its patients, and consideration of these abnormalities (endocardial cushion defect, ventricular septal defect, tetralogy of Fallot, patent ductus arteriosus, and atrial septal defect) in conjunction with their primary care physician is mandatory prior to proceeding with a surgical procedure.

Muscular Dystrophy

Muscular dystrophy is a group of diseases of genetic origin, characterized by the pro-

gressive loss of skeletal muscle function. There are nine types of muscular dystrophies, the most common and dramatic being Duchenne's disease (pseudohypertrophic muscular dystrophy). Symptoms typically begin between the ages of 2 to 5 years, often with the patient becoming wheelchair-bound by age 12 years. Death usually occurs between ages 15 and 25 years, usually secondary to pneumonia or congestive heart failure. Becker's muscular dystrophy is the next most common form of muscular dystrophy. Its manifestations are similar, although milder, to those of Duchenne's disease. Its onset is later, and the progression of the disease is slower. Time to onset of disease, being wheelchair-bound, and death are 12, 30, and 42 years, respectively.¹⁶⁹

The anesthetic management of these patients is complicated by muscle weakness contributing to poor respiratory function. Atrophy of the paraspinal muscles also leads to kyphoscoliosis (restrictive lung disease), which further restricts respiratory function. Pulmonary function tests should be considered as part of the preoperative assessment. Patients with functional vital capacities < 35% of normal are at increased risk. Muscle weakness also contributes to obtunded laryngeal reflexes and an inability to clear tracheobronchial secretions. Patients are at increased risk for aspiration secondary to the obtunded laryngeal reflexes and delayed gastric emptying.

Patients with muscular dystrophy may also have cardiovascular disorders. These include degenerative cardiomyopathy, cardiac arrhythmias, and mitral valve prolapse. It is frequently difficult to assess cardiovascular function in these patients because they are usually wheelchair-bound and not sufficiently stressed. However, cardiac compromise must be considered, especially in an older individual. Anesthetic considerations must take into consideration the potential for underlying respiratory and cardiovascular disease. Succinyl-

choline is contraindicated because it can cause rhabdomyolysis with a resultant hyperkalemia. Although all patients may have a slight increase in extracellular potassium after the administration of succinylcholine, the increase in a patient with muscular dystrophy can cause hyperkalemic cardiac arrest. The avoidance of succinylcholine and volatile inhalational agents is also recommended because of the association of Duchenne's disease with increased malignant hyperthermia. Nondepolarizing muscle relaxants may be used; however, a prolonged recovery time is seen in patients with muscular dystrophy. The response to reversal agents is also variable. Additionally, patients are susceptible to an unexplained late respiratory depression. Ambulatory surgery may be unadvisable but at a minimum requires prolonged observation prior to discharge.¹⁷⁰

Substance Abuse

Substance abuse amongst children and teens has reached epidemic proportions, regardless of socioeconomic status. In 2001 an estimated 15.9 million Americans ages 12 or older were current illicit drug users, meaning they had used an illicit drug during the month prior to the survey interview. This estimate represents 7.1% of the population ages 12 years old or older. Among youths ages 12 to 17 years, approximately 10% were current illicit drug users. Data from 1999 to 2001 identify marijuana as the most popular abused drug, with a use approximating 7% of this population. Other abused substances included psychotherapeutic agents (approximately 3%), cocaine (approximately 0.5%), hallucinogens (approximately 1%), and inhalants (approximately 1%). An adequate history taking prior to anesthesia regarding substance use and abuse is therefore mandatory with all patients. This history allows for a safer selection of anesthetic agents and improved management of any perioperative complications.

Alcohol Alcohol is the most commonly used and abused substance among teenagers. Most alcohol use by US teenagers is in the form of binge drinking. Most long-term systemic effects of chronic alcohol abuse, including hepatic injury, pancytopenia, and the neurotoxic effects (seizures, Wernicke-Korsakoff syndrome) are not present in the pre-adult abuser. Nonetheless, laboratory examinations may reveal elevation of γ -glutamyltransferase, which is usually the first liver enzyme to increase as a result of heavy ethanol ingestion. Hepatic damage owing to alcohol frequently results in an aspartate transaminase-to-alanine aminotransferase ratio > 1 . A mean corpuscular volume > 100 is strong confirmatory evidence of alcoholism.

Aspiration risk is significantly increased in the chronic alcoholic as alcohol stimulates gastric acid secretion and delays gastric emptying time. In addition, the alcoholic patient may consume alcohol the morning of the procedure to quell the signs of withdrawal, thus negating the NPO status. Cardiovascular changes associated with chronic alcohol abuse result in alcoholic cardiomyopathy, with resultant tachycardia and unexplained atrial or ventricular ectopy.

Alcohol abuse influences the choice of anesthetic agents used in an outpatient setting. Tolerance to anesthetic agents appears to develop in the chronic alcoholic. Altered liver function results in an increased toxicity with anesthetic agents that undergo hepatic metabolism. Prolonged activity and increased serum levels of both succinylcholine and local anesthetic agents are the result of decreased activity of plasma cholinesterase. Nondepolarizing paralytics are also prolonged in chronic alcohol abuse secondary to an increased level of acetylcholine. Intravenous agents should also include a benzodiazepine that compensates for the lack of γ -aminobutyric acid (GABA)-ergic stimulation.

Amphetamine Amphetamine, a racemic mixture of β -phenylisopropylamine, is an indirect sympathomimetic drug. It is a powerful CNS stimulant with peripheral α and β actions. The CNS mechanism of amphetamine appears dependent on the local release of biogenic amines such as norepinephrine from storage sites in nerve terminals. Acute amphetamine use dramatically increases anesthetic requirement and has been implicated in a case of severe intraoperative intracranial hypertension.^{171,172} Chronic amphetamine use is associated with a markedly diminished anesthetic requirement.¹⁷³ This results from chronic stimulation of adrenergic nerve terminals in the peripheral nervous system and CNS that depletes CNS catecholamines. Refractory hypotension can result both intra- and postoperatively, requiring prompt pharmacologic intervention. There can be a diminished pressor response to ephedrine after chronic amphetamine use. This is due to catecholamine depletion in central and peripheral adrenergic neurons.

Cocaine Cocaine is an alkaloid derived from the leaves of a South American shrub. The drug is snorted (intranasal), injected (intravenous), or smoked (inhaled). Its administration provides an intense euphoria. Cocaine use amongst 12- to 17-year-olds in the United States is approximately 0.8%.¹⁷⁴

The medical effects from cocaine result from both acute intoxication as well as chronic use. CNS stimulation, hypervigilance, anxiety, and agitation are common in the acutely intoxicated individual. Cardiovascular effects may include tachycardia, arrhythmias, hypertension, and ischemia. Ischemic myocardial injury may occur, even in the young patient. These effects result from the inhibition of neural reuptake of dopamine, serotonin, and tryptophan; increased adrenergic activity; and blockade of the sodium conduction channels. Chronic cocaine abuse has been

associated with ventricular hypertrophy, myocardial depression, and cardiomyopathy. Long-term use may also lead to contraction band necrosis. This phenomenon is associated with hypermetabolic conditions, such as cocaine abuse, hyperthyroidism, and pheochromocytoma resulting from continuous catecholamine concentration elevation. This condition predisposes the patient to dysrhythmias.¹⁷⁵

Patients may also manifest neurologic effects. A decrease in seizure threshold has been demonstrated in young adults. Ischemic cerebral vascular accidents may result from the hypertensive crisis potentiated by the cerebral vasoconstriction resulting from the increased serotonin levels.

Respiratory complications associated with intranasal administration include sneezing, sniffing, and acute rhinitis. Pulmonary complications associated with inhalational administration include cocaine-induced asthma, chronic cough, pulmonary edema, and pneumopericardium. Acute intoxication may result in hypoxia owing to pulmonary vasculature vasoconstriction.

High levels of cocaine may persist for 6 hours after nasal administration. Elective anesthetic management should be deferred for at least 24 hours after the patient has last used cocaine. Electrocardiographic monitoring is recommended in all patients owing to the potential for silent ischemia and arrhythmias. Anesthetic management may include control of preoperative anxiety with benzodiazepines. Consideration should be given to avoiding adrenergic stimulants such as ketamine and epinephrine-containing local anesthetics.

“Ecstasy” 3,4-Methylenedioxymethamphetamine (MDMA) is a stimulant that has psychedelic effects that can last for 4 to 6 hours and is usually taken orally in pill form. The psychological effects of MDMA include confusion, depression, anxiety, sleeplessness, drug craving, and paranoia.

Adverse physical effects include muscle tension, involuntary teeth clenching, nausea, blurred vision, feeling faint, tremors, rapid eye movement, and sweating or chills. There is also an added risk involved with MDMA ingestion by people with circulatory problems or heart disease because of MDMA's ability to increase heart rate and blood pressure.

In 2001 an estimated 8.1 million (3.6%) of Americans ages 12 or older had tried ecstasy at least once in their lifetime. The principle constituent of ecstasy (MDMA) can produce robust deleterious effects on serotonergic functioning in animals, including serotonin depletion and the degeneration of serotonergic nerve terminals.¹⁷⁶ Although MDMA has been characterized as a hallucinogenic amphetamine because of its structural similarity to mescaline and amphetamine, it rarely induces hallucinatory experiences, nor is it as potent a psychostimulant as amphetamine. Whether neurotoxicity also occurs in humans is unknown, but emerging evidence indicates that repeated ecstasy exposure results in performance decrements in neurocognitive function, which may be a manifestation of neurotoxicity.^{177,178}

Most ecstasy tablets contain MDMA; other commonly identified ingredients include ketamine, methylenedioxyamphetamine, amphetamine, dextromethorphan, and combinations of these drugs. Some tablets contain inert ingredients, whereas others contain phencyclidine hydrochloride (PCP).

Perioperative management may involve addressing several complications, the most common being syndrome of inappropriate antidiuretic hormone, and hyperthermia. Other less common but well-known potential complications include tachycardia, agitation, and nausea and vomiting. Monitoring for the stigmata of hyponatremia and hyperthermia supplements a well-performed preoperative history to determine which patients are at risk.

Inhalational Substances Inhalation substance abuse is a problem usually associated with young patients including preteens. The 1997 Monitoring the Future nationwide survey reported that inhalant use is most common in the eighth grade, in which 5.6% of students used inhalants on a past-month basis and 11.8% on a past-year basis.¹⁷⁹ They may present with photophobia, eye irritation, diplopia, tinnitus, sneezing, anorexia, chest pain, and dysrhythmia. Before administering anesthesia one must take into consideration hepatic, renal, bone marrow, and other organ pathology caused by halogenated and impure chemicals.

Lysergic Acid Diethylamide Approximately 1% of 16-year-olds in the United States used lysergic acid diethylamide (LSD) in 2001. LSD, also known as "acid," is odorless and colorless, has a slightly bitter taste, and is usually taken by mouth. Often LSD is added to absorbent paper such as blotter paper and divided into small decorated squares, with each square representing one dose. The effects of LSD are unpredictable. They depend on the amount taken; the user's personality, mood, and expectations; and the surroundings in which the drug is used. Usually the user feels the first effects of the drug 30 to 90 minutes after taking it. Physical manifestations include mydriasis, hyperthermia, tachycardia, hypertension, diaphoresis, anorexia, and tremors. Extreme emotional variability may occur, with extreme delusions and visual hallucinations. LSD effects are prolonged, typically lasting for > 12 hours. "Flashbacks" with auditory and visual hallucinations may recur suddenly without reuse of the drug and may occur within a few days or more than a year after LSD use. Flashbacks usually occur in people who have used hallucinogens chronically or who have an underlying personality problem. However, otherwise healthy people who use LSD may also experience flashbacks. Long-term effects of chronic LSD include psychiatric disorders (schizophre-

nia, severe depression). It is difficult to determine the extent and mechanism of the LSD involvement in these illnesses. Perioperative anesthetic practice involves recognition of the potential psychiatric effects of LSD on patients and avoidance of potentially aggravating agents.

Marijuana Marijuana is the most commonly used nonalcohol illicit drug for people < 18 years old. In 2001 it was used by 76% of current illicit drug users. Approximately 56% of current illicit drug users consumed only marijuana, 20% used marijuana and another illicit drug, and the remaining 24% used an illicit drug but not marijuana in the past month. Patients who use marijuana may present with anxiety, panic attacks, and sympathetic discharge.

Adverse effects of marijuana include immunodeficiency and upper airway hyperreactivity. Cases of laryngospasms within 36 hours of its use have been reported.¹⁸⁰ A β_2 -adrenergic agonist such as albuterol may be considered to treat this increased airway reactivity. Other perioperative considerations include that marijuana potentiates opioid-induced respiratory depression, and barbiturate and ketamine recovery time may be prolonged. Myocardial depression can occur, and the threshold for sympathomimetic-induced dysrhythmias is lowered.

PCP PCP is a dissociative anesthetic that originally was synthesized for intravenous use. Because of its postoperative emergence reactions (ie, hallucinations, prolonged abnormal level of consciousness, agitation), it fell out of favor, and its use as an anesthetic in humans was discontinued in 1963. PCP subsequently emerged as an oral drug of abuse. PCP is a commonly abused street drug that is sold under many different names and in various forms. It may be sold on the street in tablet or capsule form, as a powder, or as a solution. The PCP content in each form differs widely, commonly from 10 to 30%. "Angel

dust,” the powdered form of PCP, generally has a higher PCP content, occasionally reaching 100%. Angel dust may be sniffed, smoked, ingested, or injected IV. Percutaneous absorption also has been reported to occur in individuals handling PCP (eg, law enforcement officers). Smoking remains the desired method of use; the substance commonly is sprinkled onto dried leaf material (eg, marijuana, tobacco, oregano, mint) and then smoked.

Perioperative anesthetic considerations include its sympathomimetic effects, similar to its congener, ketamine, with the potential for tachycardia, tachyarrhythmias, and a true hypertensive emergency. Maintaining normotension and avoiding sympathomimetics, which may exacerbate PCP's effects, are the standard for anesthetic management.

Summary

Ambulatory anesthesia in the pediatric patient can be safely achieved in the oral and maxillofacial surgery office. The surgeon has an array of techniques that are available. A technique has to be selected that is appropriate for the patient, the planned procedure, and the specific office.

References

- Allen NA, Rowbotham DJ, Nimmo WS. Hypoxemia during outpatient anaesthesia. *Anaesthesia* 1989;44:509–11.
- Bone ME, Galler D, Flynn PJ. Arterial oxygen saturation during general anaesthesia for paediatric dental extractions. *Anaesthesia* 1987;42:879–82.
- Takahashi E, Atsumi H. Age differences in thoracic form as indicated by thoracic index. *Hum Biol* 1955;27:65.
- Davies G, Reid L. Growth of the alveoli and pulmonary arteries in childhood. *Thorax* 1970;25:669–81.
- Dunnill MS. Postnatal growth of the lung. *Thorax* 1962;17:329.
- Thurlbeck WM. Postnatal human lung growth. *Thorax* 1982;37:564–71.
- Gerhardt T, Reifenberg L, Hehre D, et al. Functional residual capacity in normal neonates and children up to 5 years of age determined by a N₂ washout method. *Pediatr Res* 1986;20:668–71.
- Todres ID, Cronin JH. Growth and development. In: Cote, Todres, Goudsouzian, Ryan, editors. *A practice of anesthesia for infants and children*. 3rd ed. Philadelphia: W.B. Saunders; 2001. p. 12.
- Benumof JL, Dagg R, Benumof R. Critical hemoglobin desaturation will occur before return to an unparalyzed state following 1 mg/kg intravenous succinylcholine. *Anesthesiology* 1997;87:979–82.
- Kinouchi K, Fukumitsu K, Tashiro C, et al. Duration of apnoea in anaesthetized children required for desaturation of haemoglobin to 95%: comparison of three different breathing gases. *Pediatr Anaesth* 1995;5:115–9.
- Xue FS, Luo LK, Tong Sy, et al. Study of the safe threshold of apneic period in children during anesthesia induction. *J Clin Anesth* 1996;8:568–74.
- Farmery AD, Roe PG. A model to describe the rate of oxyhaemoglobin desaturation during apnoea. *Br J Anaesth* 1996;76:284–91.
- Veyckemans F. New developments in the management of the paediatric airway: cuffed or uncuffed tracheal tubes, laryngeal mask airway, cuffed oropharyngeal airway, tracheostomy and one-lung ventilation devices. *Curr Opin Anaesthesiol* 1999;12:315.
- King BR, Baker MD, Braitman LE, et al. Endotracheal tube selection in children: a comparison of four methods. *Ann Emerg Med* 1993;22:530–4.
- Mostafa SM. Variation in subglottic size in children. *Proc R Soc Med* 1976;69:793–5.
- Litman RS, Keon TP. Postintubation croup in children. *Anesthesiology* 1991;75:1122–3.
- Keenan RL, Shapiro JH, Kane FR, et al. Bradycardia during anesthesia in infants: an epidemiologic study. *Anesthesiology* 1994; 80:976–82.
- Pang LM, Liu LMP, Cote CJ. Premedication and induction of anesthesia. In: Cote, Todres, Goudsouzian, Ryan, editors. *A practice of anesthesia for infants and children*. 3rd ed. Philadelphia: W.B. Saunders; 2001. p. 173.
- US Department of Health and Human Services. 2001 national household survey on drug abuse. Available at: <http://www.samhsa.gov/oas/nhsda/2k1nhsda/vol1/chapter2.htm#2.age> (accessed Sept 25, 2003).
- Kain ZN, Mayes LC, O'Connor TZ, et al. Preoperative anxiety in children: predictors and outcomes. *Arch Pediatr Adolesc Med* 1996;150:1238–45.
- Borland LM, Sereika SM, Woelfel SK, et al. Aspiration in pediatric patients during general anesthesia: incidence and outcome. *J Clin Anesth* 1998;10:95–102.
- Olsson GL, Hallen B, Hambraeus-Jonzon K. Aspiration during anesthesia: a computer aided study of 185,358 anesthetics. *Acta Anaesthesiol Scand* 1986; 30:84–92.
- Tiret L, Nivoche Y, Hatton F, et al. Complications related to anaesthesia in infants and children: a prospective survey of 40,240 anaesthetics. *Br J Anaesth* 1988;61:263–9.
- Maekawa N, Mikawa K, Yaku H, et al. Effects of two-, four-, and twelve-hour fasting intervals on preoperative gastric fluid pH and volume, and plasma glucose and lipid homeostasis in children. *Acta Anaesthesiol Scand* 1993;37:783–7.
- Splinter WM, Stewart JA, Muir JG. The effect of preoperative apple juice on gastric contents, thirst, and hunger in children. *Can J Anaesth* 1989;36:55–8.
- Splinter WM, Stewart JA, Muir JG. Large volumes of apple juice preoperatively do not affect gastric pH and volume in children. *Can J Anaesth* 1990;37:36–9.
- Splinter WM, Schaefer JD, Zunder IH. Clear fluids three hours before surgery do not affect the gastric fluid contents of children. *Can J Anaesth* 1990;37:498–501.
- Splinter WM, Schaefer JD. Ingestion of clear fluids is safe for adolescents up to three hours before anesthesia. *Br J Anaesth* 1991;66:48–52.
- Salem MR, Wong AY, Mani M, et al. Premedication drugs and gastric juice pH and volume in pediatric patients. *Anesthesiology* 1976;44:216–9.
- Parnis SJ, Barker DS, Van Der Walt JH. Clinical predictors of anaesthetic complications in children with respiratory tract infections. *Paediatr Anaesth* 2001;11:29–40.
- Bailey AG, Badgwell JM. Common and uncommon co-existing diseases that complicate pediatric anesthesia. In: Badgwell JM, editor. *Clinical pediatric anesthesia*. 1st ed. Philadelphia: Lippincott-Raven; 1997.
- Cate TR, Roberts TS, Russ MA, et al. Effect of common cold on pulmonary function. *Am Rev Respir Dis* 1973;108:858–65.
- Fridy WW Jr, Ingram RH Jr, Hierholzer JC, et al. Airway function during mild viral respiratory illnesses. *Ann Intern Med* 1974; 80:150–5.
- Horner GJ, Gray FD Jr. Effect of uncomplicated, presumptive influenza on the diffusion capacity of the lung. *Am Rev Respir Dis* 1973;108:866–9.
- Cohen MM, Cameron CB. Should you cancel the operation when a child has an upper respiratory tract infection? *Anesth Analg* 1991;72:282–8.
- Dueck R, Prutow R, Richman D. Effect of

- parainfluenza infection on gas exchange and FRC response to anesthesia in sheep. *Anesthesiology* 1991;74:1044–51.
37. DeSoto H, Patel RI, Soliman IE, et al. Changes in oxygen saturation following general anesthesia in children with upper respiratory infection signs and symptoms undergoing otolaryngological procedures. *Anesthesiology* 1988;68:276–9.
 38. Levy L, Pandit UA, Randel GI, et al. Upper respiratory tract infections and general anaesthesia in children: peri-operative complications and oxygen saturation. *Anaesthesia* 1992;47:678–82.
 39. Olsson GL, Hallen B. Laryngospasm during anesthesia: a computer-aided incidence study in 136,929 patients. *Acta Anaesthesiol Scand* 1984;28:567–75.
 40. Olsson GL. Bronchospasm during anesthesia: a computer aided incidence study of 136,929 patients. *Acta Anaesthesiol Scand* 1987;31:244–52.
 41. Tait AR, Reynolds PI, Gutstein HB. Factors that influence an anesthesiologist's decision to cancel elective surgery for the child with an upper respiratory tract infection. *J Clin Anesth* 1995;7:491–9.
 42. Tait AR, Malviya S, Voepel-Lewis T, et al. Risk factors for perioperative adverse respiratory events in children with upper respiratory tract infections. *Anesthesiology* 2001;95:299–306.
 43. Mier-Jedrzejowicz A, Brophy C, Green M. Respiratory muscle weakness during upper respiratory tract infections. *Am Rev Respir Dis* 1988;138:5–7.
 44. Kinouchi K, Tanigami H, Tashiro C, et al. Duration of apnea in anesthetized infants and children required for desaturation of hemoglobin to 95%. *Anesthesiology* 1992;77:1105–7.
 45. Martin LD. Anesthetic implications of an upper respiratory infection in children. *Pediatr Clin North Am* 1994;41:121–30.
 46. Pierre N, Moy L, Redd S, et al. Evaluation of a pregnancy-testing protocol in adolescents undergoing surgery. *J Pediatr Adolesc Gynecol* 1998;11:139–41.
 47. Malviya S, D'Errico C, Reynolds P, et al. Should pregnancy testing be routine in adolescent patients prior to surgery? *Anesth Analg* 1996;83:854–8.
 48. Cote CJ, Notterman DA, Karl HW, et al. Adverse sedation events in pediatrics: a critical incidence analysis of contributing factors. *Pediatrics* 2000;105:1494.
 49. Committee on Drugs, American Academy of Pediatrics. Alternate routes of drug administration: advantages and disadvantages. *Pediatrics* 1997;100:143–52.
 50. Badalaty MM, Houpt MI, Koenigsberg SR, et al. A comparison of chloral hydrate and diazepam sedation in young children. *Pediatr Dent* 1990;12:33–7.
 51. Brzustowicz RM, Nelson DA, Betts EK, et al. Efficacy of oral premedication for pediatric outpatient surgery. *Anesthesiology* 1984;60:475–7.
 52. Malinovsky J-M, Populaire C, Cozian A, et al. Premedication with midazolam in children. Effect of intranasal, rectal, and oral routes on plasma midazolam concentrations. *Anaesthesia* 1995;50:351–4.
 53. Hilger PA. *Fundamentals of otolaryngology: a textbook of ear, nose, and throat disease*. 6th ed. Philadelphia: WB Saunders Co; 1989.
 54. Walbergh EJ, Wills RJ, Eckhart J. Plasma concentrations of midazolam in children following intranasal administration. *Anesthesiology* 1991;74:233–5.
 55. Fishbein M, Lugo RA, Woodland J, et al. Evaluation of intranasal midazolam in children undergoing esophagogastroduodenoscopy. *J Pediatr Gastroenterol Nutr* 1997;25:261–6.
 56. Lejus C, Renaudin M, Testa S, et al. Midazolam for premedication in children: nasal vs. rectal administration. *Eur J Anaesthesiol* 1997;14:244–9.
 57. Graves NM, Kreil RL. Rectal administration of antiepileptic drugs in children. *Pediatr Neurol* 1987;3:321–6.
 58. Knudsen FU. Rectal administration of diazepam in solution in the acute treatment of convulsions in infants and children. *Arch Dis Child* 1979;54:855–7.
 59. Forbes RB, Vanderwalker GE. Comparison of two and ten per cent rectal methoxitone for induction of anaesthesia in children. *Can J Anaesth* 1988;35:345–9.
 60. White PF, Way WL, Trevor AJ. Ketamine—its pharmacology and therapeutic uses. *Anesthesiology* 1982;56:116–36.
 61. Kitahata LM, Taub A, Kosaka Y. Lamina specific suppression of dorsal-horn unit activity by ketamine hydrochloride. *Anesthesiology* 1973;38:4–11.
 62. Smith DJ, Bouchal RL, deSanctic CA, et al. Properties of the interaction between ketamine and opiate binding sites in vivo and in vitro. *Neuropharmacology* 1987;26:1253–60.
 63. Drummond GB. Comparison of sedation with midazolam and ketamine: effects on airway muscle activity. *Br J Anaesth* 1996;76:663–7.
 64. Shulman D, Beardsmore CS, Aronson HB, et al. The effect of ketamine on the functional residual capacity in young children. *Anesthesiology* 1985;62:551–6.
 65. Corssen G, Gutierrez J, Reves JG, et al. Ketamine in the anesthetic management of asthmatic patients. *Anesth Analg* 1972;51:588–96.
 66. Smith JA, Santer LJ. Respiratory arrest following intramuscular ketamine injection in a 4 year-old child. *Ann Emerg Med* 1993;22:613–5.
 67. Carson IW, Moore J, Balmer JP, et al. Laryngeal competence with ketamine and other drugs. *Anesthesiology* 1973;38:128–33.
 68. Penrose BH. Aspiration pneumonitis following ketamine induction for general anesthesia. *Anesth Analg* 1972;51:41–3.
 69. Green SM, Johnson NE. Ketamine sedation for pediatric procedures: part 2, review and implications. *Ann Emerg Med* 1990;19:1033–46.
 70. White PF, Ham J, Way WL. Pharmacology of ketamine isomers in surgical patients. *Anesthesiology* 1980;52:231–9.
 71. Hollister GR, Burn JMB. Side effects of ketamine in pediatric-anesthesia. *Anesth Analg* 1974;53:264–7.
 72. Meyers EF, Charles P. Prolonged adverse reactions to ketamine in children. *Anesthesiology* 1978;49: 39–40.
 73. Green SM, Nakamura R, Johnson NE. Ketamine sedation for pediatric procedures: part 1, a prospective study. *Ann Emerg Med* 1990;19:1024–32.
 74. Jackson APF, Dhadphale PR, Callaghan ML. Haemodynamic studies during induction of anaesthesia for open-heart surgery using diazepam and ketamine. *Br J Anaesth* 1978;50:375–8.
 75. Reich DL, Silvey G. Ketamine: an update on the first twenty-five years of clinical experience. *Can J Anaesth* 1989;35:186–97.
 76. Cartwright PD, Pingel SM. Midazolam and diazepam in ketamine anaesthesia. *Anaesthesia* 1984;39:439–42.
 77. Pruitt JW, Goldwasser MS, Sabol SR, et al. Intramuscular ketamine, midazolam, and glycopyrrolate for pediatric sedation in the emergency department. *J Oral Maxillofac Surg* 1995;53:13–7.
 78. Ryhanen P, Kangas T, Rantakla S. Premedication for outpatient adenoidectomy: comparison between ketamine and pethidine. *Laryngoscope* 1980;90:494–500.
 79. Mogensen F, Muller D, Valentin N. Glycopyrrolate during ketamine/diazepam anaesthesia: a double-blind comparison with atropine. *Acta Anaesthesiol Scand* 1986;30:332–6.
 80. Toft P, Romer UD. Glycopyrrolate compared with atropine in association with ketamine anaesthesia. *Acta Anaesthesiol Scand* 1987;31:438–40.
 81. Qureshi FA, Mellis PT, McFadden MA. Efficacy of oral ketamine for providing sedation and analgesia to children requiring laceration repair. *Pediatr Emerg Care* 1995;11:93–7.
 82. Grant IS, Nimmo WS, McNichol LR, et al. Ket-

- amine disposition in children and adults. *Br J Anaesth* 1983;55:1107–11.
83. Grant IS, Nimmo WS, Clements JA. Pharmacokinetics and analgesic effect of IM and oral ketamine. *Br J Anaesth* 1981;53:805–10.
84. Alfonso-Echeverri EC, Berg JH, Wild TW, et al. Oral ketamine for pediatric dental surgery sedation. *Pediatr Dent* 1993;15:182–5.
85. Tobias JD, Phipps S, Smith B, et al. Oral ketamine premedication to alleviate the distress of invasive procedures in pediatric oncology patients. *Pediatrics* 1992;90:537–41.
86. Alderson PJ, Lerman J. Oral premedication for paediatric ambulatory anaesthesia: a comparison of midazolam and ketamine. *Can J Anaesth* 1994;41:221–6.
87. Funk W, Jakob W, Riedl T, et al. Oral preanesthetic medication for children: double-blind randomized study of a combination of midazolam and ketamine vs. midazolam or ketamine alone. *Br J Anaesth* 2000;84:335–40.
88. Warner DL, Cabaret J, Velling D. Ketamine plus midazolam, a most effective paediatric oral premedicant. *Paediatr Anaesth* 1995;2:293–5.
89. Rosenberg M. Oral ketamine for deep sedation of difficult-to-manage children who are mentally handicapped: case report. *Pediatr Dent* 1991;13:221–3.
90. Rainey L, van der Walt JH. The anaesthetic management of autistic children. *Anaesth Intensive Care* 1998;26:682–6.
91. Mirakhor RK. Comparative study of the effects of oral and I.M. atropine and hyoscine in volunteers. *Br J Anaesth* 1978;50:591–8.
92. Connors K, Terndrup TE. Nasal versus oral midazolam for sedation of anxious children undergoing laceration repair. *Ann Emerg Med* 1994;24:1074–9.
93. Litman RS, Kottra JA, Berkowitz RJ, et al. Breathing patterns and levels of consciousness in children during administration of nitrous oxide after oral midazolam premedication. *J Oral Maxillofac Surg* 1997;55: 1372–7.
94. Litman RS. Airway obstruction after oral midazolam. *Anesthesiology* 1996;85:1217–8.
95. Litman RS, Kottra JA, Berkowitz RJ, et al. Upper airway obstruction during midazolam/nitrous oxide sedation in children with enlarged tonsils. *Pediatr Dent* 1998; 20:318–20.
96. McMillan CO, Spahr SI, Sikich N, et al. Premedication of children with oral midazolam. *Can J Anaesth* 1992;39:545–50.
97. Hiller A, Olkkola KT, Isohanni P, et al. Unconsciousness associated with midazolam and erythromycin. *Br J Anaesth* 1994;65:826–8.
98. Bailey DG, Malcolm J, Arnold O, et al. Grapefruit juice-drug interactions. *Br J Clin Pharmacol* 1998;46: 101–10.
99. van der Bijl P, Roelofse JA. Disinhibitory reactions to benzodiazepines: a review. *J Oral Maxillofac Surg* 1991;49:519–23.
100. Ewah B, Carr C. A comparison of propofol and methohexitone for dental chair anaesthesia in children. *Anaesthesia* 1993;48:260–2.
101. Borgeat A, Popovic V, Meier D, et al. Comparison of propofol and thiopental/halothane for short-duration ENT surgical procedures in children. *Anesth Analg* 1990;71:511–5.
102. Havel CJ Jr, Strait RT, Hennes H. A clinical trial of propofol vs midazolam for procedural sedation in a pediatric emergency department. *Acad Emerg Med* 1999;6:989–97.
103. Hertzog JH, Campbell JK, Dalton HJ, et al. Propofol anesthesia for invasive procedures in ambulatory and hospitalized children: experience in the pediatric intensive care unit. *Pediatrics* 1999;103(3):E30.
104. Lebovic S, Reich DL, Steinberg LG, et al. Comparison of propofol versus ketamine for anesthesia in pediatric patients undergoing cardiac catheterization. *Anesth Analg* 1992;74:490–4.
105. Martin TM, Nicolson SC, Bargas MS. Propofol anesthesia reduces emesis and airway obstruction in pediatric outpatients. *Anesth Analg* 1993;76:144–8.
106. Norreslet J, Wahlgreen C. Propofol infusion for sedation of children. *Crit Care Med* 1990;18:890–2.
107. Reed MD, Yamashita TS, Marx CM, et al. A pharmacokinetically based propofol dosing strategy for sedation of the critically ill, mechanically ventilated pediatric patient. *Crit Care Med* 1996;24:1473–81.
108. Macrae D, James I. Propofol infusion in children. *BMJ* 1992;305:953–4.
109. Bray RJ. Fatal myocardial failure associated with a propofol infusion in a child. *Anaesthesia* 1995;50(1):94.
110. Cray SH, Robinson BH, Cox PN. Lactic acidemia and bradyarrhythmia in a child sedated with propofol. *Crit Care Med* 1998;26:2087–92.
111. Parke TJ, Stevens JE, Rice AS, et al. Metabolic acidosis and fatal myocardial failure after propofol infusion in children: five case reports. *BMJ* 1992;305:613–6.
112. Strickland RA, Murray MJ. Fatal metabolic acidosis in a pediatric patient receiving an infusion of propofol in the intensive care unit: is there a relationship? *Crit Care Med* 1995;23:405–9.
113. FDC Reports. US Food and Drug Administration; 1992 Sep 7;54:14.
114. Jastak JT, Donaldson D. Nitrous oxide. *Anesth Prog* 1991;38:142–53.
115. Kaufman E, Chastain DC, Gaughan AM, et al. Staircase assessment of the magnitude and time course of 50% nitrous oxide analgesia. *J Dent Res* 1992;71: 1598–603.
116. Litman RS, Berkowitz RJ, Ward DS. Levels of consciousness and ventilatory parameters in young children during sedation with oral midazolam and nitrous oxide. *Arch Pediatr Adolesc Med* 1996;150:671–5.
117. Litman RS, Kottra JA, Berkowitz RJ, et al. Breathing patterns and levels of consciousness in children during administration of nitrous oxide after oral midazolam premedication. *J Oral Maxillofac Surg* 1997;55: 1372–7.
118. Litman RS, Kottra JA, Verga KA, et al. Chloral hydrate sedation: the additive sedative and respiratory depressant effects of nitrous oxide. *Anesth Analg* 1998;86:724–8.
119. Epstein RH, Stein AL, Marr AT, et al. High concentration versus incremental induction of anesthesia with sevoflurane in children: a comparison of induction times, vital signs, and complications. *J Clin Anesth* 1998 ;10:41–5.
120. Kern C, Erb T, Frei FJ. Haemodynamic responses to sevoflurane compared with halothane during inhalational induction in children. *Paediatr Anaesth* 1997;7:439–44.
121. Sigston PE, Jenkins AM, Jackson EC, et al. Rapid inhalation induction in children: 8% sevoflurane compared to 5% halothane. *Br J Anaesth* 1997;78:362–5.
122. Doi M, Ikeda K. Respiratory effects of sevoflurane used in conjunction with nitrous oxide & surgical stimulation. *J Clin Anesth* 1994;6:1–4.
123. Blayney MR, Malins AF, Cooper GM. Cardiac arrhythmias in children during outpatient general anaesthesia: a prospective randomized trial. *Lancet* 1999;354:1864–6.
124. Johnston RR, Eger EI Jr, Wilson C. A comparative interaction of epinephrine with enflurane, isoflurane, and halothane in man. *Anesth Analg* 1976;55:709–12.
125. Moore MA, Weiskopf RB, Eger EI Jr, et al. Arrhythmogenic doses of epinephrine are similar during desflurane or isoflurane anesthesia in humans. *Anesthesiology* 1993;79:943–7.
126. Navarro R, Weiskopf RB, Morre MA, et al. Humans anesthetized with sevoflurane or isoflurane have similar arrhythmogenic response to epinephrine. *Anesthesiology* 1994;80:545–9.
127. Simmons M, Miller CD, Cummings GC, et al. Outpatient pediatric dental anesthesia: a comparison of halothane, enflurane, and isoflurane. *Anaesthesia* 1989;44:735–8.
128. Campbell C, Nahrwold ML, Miller DD. Clini-

- cal comparison of sevoflurane and isoflurane when administered with nitrous oxide for surgical procedures of intermediate duration. *Can J Anaesth* 1995;42:884–90.
129. Davis PJ, Cohen IT, McGowan FX, et al. Recovery characteristics of desflurane versus halothane for maintenance of anesthesia in pediatric ambulatory patients. *Anesthesiology* 1994;80:298–302.
 130. Epstein RH, Mendel HG, Guarnieri KM, et al. Sevoflurane versus halothane for general anesthesia in pediatric patients: a comparative study of vital signs, induction and emergence. *J Clin Anesth* 1995;7:237–44.
 131. Nathanson MH, Fredman B, Smith I, et al. Sevoflurane versus desflurane for outpatient anesthesia: a comparison of maintenance and recovery profiles. *Anesth Analg* 1995;81:1186–90.
 132. Welborn LG, Hannallah RS, Norden JM, et al. Comparison of emergence and recovery characteristics of sevoflurane, desflurane, and halothane in pediatric ambulatory patients. *Anesth Analg* 1996;83:917–20.
 133. Ariffin SA, Whyte JA, Malins AF, et al. Comparison of induction and recovery between sevoflurane and halothane supplementation of anaesthesia in children undergoing outpatient dental extractions. *Br J Anaesth* 1997;78:157–9.
 134. Paris ST, Cafferkey M, Tarling M, et al. Comparison of sevoflurane and halothane for outpatient dental anaesthesia in children. *Br J Anaesth* 1997;79:280–4.
 135. Kenna JG, Jones RM. The organ toxicity of inhaled anesthetics. *Anesth Analg* 1995; 81:S51–66.
 136. Njoku D, Laster MJ, Gong DH, et al. Biotransformation of halothane, enflurane, isoflurane, and desflurane to trifluoroacetylated liver proteins: association between protein acylation and hepatic injury. *Anesth Analg* 1997;84:173–8.
 137. Malan TP Jr. Sevoflurane and renal function. *Anesth Analg* 1995;81:S39–45.
 138. Ebert TJ, Messana LD, Uhrich TD, et al. Absence of renal and hepatic toxicity after 1.25 minimum alveolar anesthetic concentration sevoflurane anesthesia in volunteers. *Anesth Analg* 1998;86:662–7.
 139. Dsida RM, Wheeler M, Birmingham PK, et al. Premedication of pediatric tonsillectomy patients with oral transmucosal fentanyl citrate. *Anesth Analg* 1998;86:66–70.
 140. Epstein RH, Mendel HG, Witkowski TA, et al. The safety and efficacy of oral transmucosal fentanyl citrate for preoperative sedation in young children. *Anesth Analg* 1996;83:1200–5.
 141. Liu LM, DeCook TH, Goudsouzian NG, et al. Dose response to intramuscular succinylcholine in children. *Anesthesiology* 1981; 55:599–602.
 142. Lazzell VA, Carr AS, Lerman J, et al. The incidence of masseter muscle rigidity after succinylcholine in infants and children. *Can J Anaesth* 1994;41:475–9.
 143. Littleford JA, Patel LR, Bose D, et al. Masseter muscle spasm in children: implications of continuing the triggering anesthetic. *Anesth Analg* 1991;72:151–60.
 144. Sullivan M, Thompson WK, Hill GD. Succinylcholine induced cardiac arrest in children with undiagnosed myopathy. *Can J Anaesth* 1994;41:497–501.
 145. Kerr TP, Durward A, Hodgson SV, et al. Hyperkalaemic cardiac arrest in a manifesting carrier of Duchenne muscular dystrophy following general anaesthesia. *Eur J Paediatr* 2001;160:579–80.
 146. deLisser EA, Muravchick S. Emergency transtracheal ventilation. *Anesthesiology* 1981;55:606–7.
 147. Peak DA, Roy S. Needle cricothyroidotomy revisited. *Pediatr Emerg Care* 1999;15:224–6.
 148. Cohen MM, Cameron CB, Duncan PG. Pediatric anesthesia morbidity and mortality in the perioperative period. *Anesth Analg* 1990;70:160–7.
 149. Splinter WM, MacNeill HB, Menard EA, et al. Midazolam reduces vomiting after tonsillectomy in children. *Can J Anaesth* 1995;42:201–3.
 150. Splinter WM, Roberts DJ. Perphenazine decreases vomiting by children after tonsillectomy. *Can J Anaesth* 1997;44:1308–10.
 151. Ferrari LR, Donlon JV. Metoclopramide reduces the incidence of vomiting after tonsillectomy in children. *Anesth Analg* 1992;75:351–4.
 152. Fujii Y, Toyooka H, Tanak H. Antiemetic efficacy of granisetron and metoclopramide in children undergoing ophthalmic or ENT surgery. *Can J Anaesth* 1996;43:1095–9.
 153. Salmenpera M, Kuoppamaki R, Salmenpera A. Do anticholinergic agents affect the occurrence of postanaesthetic nausea? *Acta Anaesthesiol Scand* 1992;36:445–8.
 154. Doyle E, Byers G, McNicol LR, Morton NS. Prevention of postoperative nausea and vomiting with transdermal hyoscine in children using patient-controlled analgesia. *Br J Anaesth* 1994;72:72–6.
 155. Smith RN. Safety of ondansetron. *Eur J Cancer Clin Oncol* 1989;25 Suppl 1:S47–50.
 156. Rose JB, McCloskey JJ. Rapid intravenous administration of ondansetron or metoclopramide is not associated with cardiovascular compromise in children. *Paediatr Anaesth* 1995;5:121–4.
 157. Furst SR, Sullivan LJ, Soriano SG, et al. Effects of ondansetron on emesis in the first 24 hours after craniotomy in children. *Anesth Analg* 1996;83:325–8.
 158. Morton NS, Camu F, Dorman T, et al. Ondansetron reduces nausea and vomiting after paediatric adenotonsillectomy. *Paediatr Anaesth* 1997;7:37–45.
 159. Pappas ALS, Sukhani R, Hotaling AJ, et al. The effect of preoperative dexamethasone on the immediate and delayed postoperative morbidity in children undergoing adenotonsillectomy. *Anesth Analg* 1998;87:57–61.
 160. US Department of Health and Human Services. 1999–2000 National household survey on drug abuse. Available at: http://www.samhsa.gov/oas/nhsda/2kdetailedtabs/Vol_1_Part_1/sect1v1.htm#1.109b (accessed Sept 25, 2003).
 161. Huss M, Lehmkuhl U. Methylphenidate and substance abuse: a review of pharmacology, animal, and clinical studies. *J Atten Disord* 2002;6 Suppl 1:S65–71.
 162. Frith U. Autism. *Sci Am* 1993;268:108–14.
 163. Bauer S. Autism and the pervasive developmental disorders: part 1. *Pediatr Rev* 1995; 16(4):130–60.
 164. Bauer S. Autism and the pervasive developmental disorders: part 2. *Pediatr Rev* 1995;16(5):168–76.
 165. Behrman RE, Kliegman RM, Arvin AM, editors. *Nelson textbook of pediatrics*. 16th ed. Philadelphia: WB Saunders; 2000. p. 87–8.
 166. Stoelting RK, Dierdorf SF. Diseases common to the pediatric patient. In: Stoelting RK, Dierdorf SF, editors. *Anesthesia and co-existing diseases*. 3rd ed. Edinburgh: Churchill Livingstone; 1993. p. 579.
 167. Kaufman E, Meyer S, Wolnerman JS, et al. Transient suppression of involuntary movements in cerebral palsy patients during dental treatment. *Anesth Progr* 1991;38:200–5.
 168. Theroux MC, Brandom BW, Zagnoev M, et al. Dose response of succinylcholine at the adductor pollicis of children with cerebral palsy during propofol and nitrous oxide anesthesia. *Anesth Analg* 1994;79:761–5.
 169. Engel AG. Diseases of muscles (myopathies) and neuromuscular junction. In: Bennett JC, Plum F, editors. *Cecil textbook of medicine*. 20th ed. Philadelphia: WB Saunders; 1996. p. 2161.
 170. Tonkovic-Capin M, Cheng EY. Perioperative management of the patient with muscular dystrophy. In: Altee JL, editor. *Complications in anesthesia*. Philadelphia: WB Saunders; 1999. p. 486.

171. Foex P, Prys-Robert D. Anesthesia and the hypertensive patient. *Br J Anaesth* 1974;46:575–88.
172. Michel R, Adams AP. Acute amphetamine abuse. Problems during general anaesthesia for neurosurgery. *Anaesthesia* 1979;34:1016–9.
173. Johnston RR, Way WL, Millard RD. Alteration of anesthetic requirement by amphetamine. *Anesthesiology* 1972;36:357–63.
174. US Department of Health and Human Services. Summary of findings from the 1998 national household survey on drug abuse. Available at: http://www.samhsa.gov/oas/nhsda/98SummHtml/NHSDA98Summ-05.htm#P369_29947 (accessed Sept 25, 2003).
175. Laposata EA. Cocaine-induced heart disease: mechanisms and pathology. *J Thorac Imaging* 1991;6:68–75.
176. Ricaurte GA, Yuan J, McCann UD. (+/-)3,4-Methylenedioxyamphetamine ('Ecstasy')-induced serotonin neurotoxicity: studies in animals. *Neuropsychobiology* 2001;42:5–10.
177. Morgan JF. Ecstasy use and neuropathology. *Br J Psychiatry* 1999;175:589.
178. Rodgers J. Cognitive performance amongst recreational users of "ecstasy." *Psychopharmacology (Berl)* 2000;151:19–24.
179. US Department of Health and Human Services. 1998 national drug control strategy. Available at: <http://www.health.org.ndcs98/ii.html>, 1999.
180. White SM. Cannabis abuse and laryngospasm. *Anaesthesia* 2002;57:622–3.

Part 2

DENTOALVEOLAR SURGERY

Management of Impacted Teeth Other than Third Molars

Deborah L. Zeitler, DDS, MS

The management of impacted teeth is a basic component of most oral and maxillofacial surgery practices. Although the majority of impacted teeth are third molars, any other tooth may be impacted. The usual care for impacted third molars is removal; however, the care for impacted teeth other than third molars may include exposure (with or without attachment of an orthodontic bracket), uprighting, transplantation, or removal. These teeth often pose challenges in treatment planning and surgical care. This chapter includes information on incidence, etiology, evaluation, and surgical treatment options.

Incidence

The incidence of impacted permanent teeth has been addressed in several studies. Grover and Lorton examined 5,000 army recruits and found a high frequency of impacted teeth (Figure 7-1).¹ Although maxillary and mandibular third molars were the teeth most commonly impacted, 212 teeth excluding third and fourth molars were impacted. This study identified the maxillary canine as the tooth most likely to be impacted following maxillary and mandibular third molars. Impactions of every permanent tooth were identified except the mandibular incisors and first molars. Thilander and

Myrberg examined more than 6,000 Swedish school children and found a 5.4% prevalence of impacted teeth excluding third molars.² In an evaluation of 3,874 full-mouth radiographs, Dachi and Howell found the incidence of impacted canines in the maxilla to be 0.92% and of other non-third molar teeth to be 0.38%.³ This study also identified maxillary canines as the most commonly impacted teeth after maxillary and mandibular third molars. In a study of middle-aged and older Swedish women, Grondahl found approximately 25 non-third molar impacted teeth in 1,418 women evaluated.⁴ Again, the canine tooth was the most frequent non-third molar impaction identified, followed by premolars and second molars. This study examined an older population than did most of the other studies and had a lower incidence of non-third molar impacted teeth. Presumably symptomatic teeth and those with pathologic findings were removed at earlier ages in this population.⁴ These studies are all similar in identifying the maxillary canine as the tooth most likely to be impacted following third molars. The next most likely teeth to be impacted are mandibular bicuspid, followed by maxillary bicuspid and second molars. Impactions of first molars and incisors are relatively uncommon (Figure 7-2).⁵

Although impaction of permanent teeth is a relatively common finding, the lack of eruption of a primary tooth is apparently quite rare. When it occurs it is almost always a mandibular molar. Submerged teeth are common in the primary dentition but generally reflect teeth that erupted into a normal position and later became ankylosed and secondarily submerged. Bianchi and Rocuzzo have identified 10 cases in the literature of the past 20 years that appear to illustrate primary impaction of deciduous teeth.⁶ A recent review suggests that primary tooth impaction is usually associated with defects in the development and eruption of the permanent successor, suggesting the need for long-term follow-up.⁷

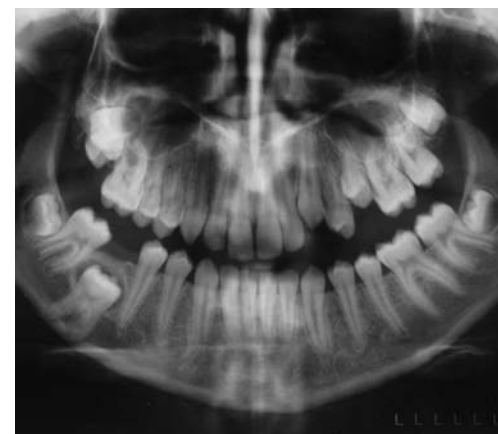

FIGURE 7-1 Multiple impacted teeth.

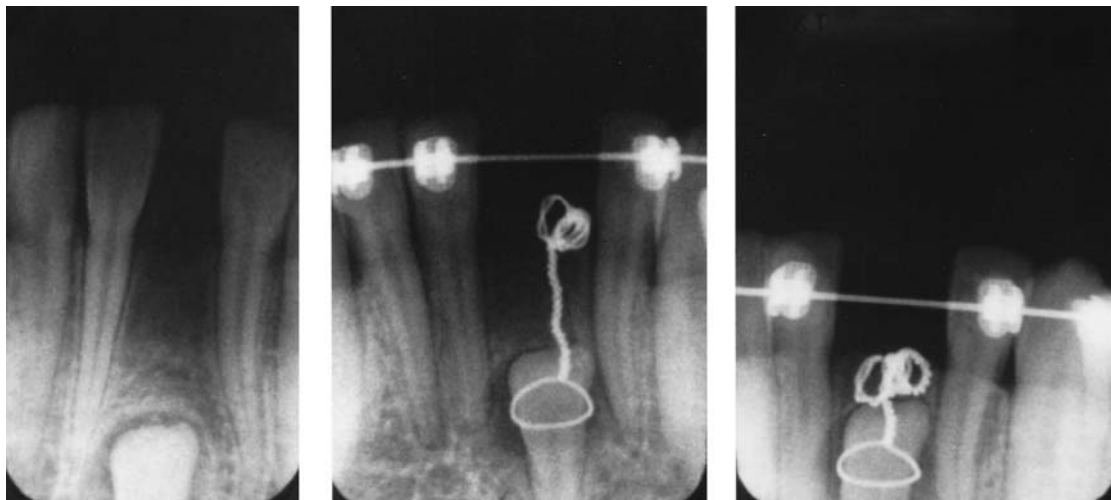


FIGURE 7-2 Unusual case of an impacted mandibular incisor. Reproduced with permission from Zeitler D. *Management of impacted teeth other than third molars. Oral Maxillofac Surg Clin North Am* 1993;5:95–103.

Etiology

The definition of an impacted tooth is “a tooth that can not, or will not, erupt into its normal functioning positions, and is, therefore, pathologic and requires treatment.”⁸ Causes of impacted permanent teeth include systemic and local factors. Impaction of teeth in the hereditary syndrome of cleidocranial dysplasia (Figure 7-3) is more properly termed *primary retention*.⁵ Endocrine deficiencies (hypothyroidism and hypopituitarism), febrile diseases, Down syndrome, and irradiation are other systemic factors that may influence impaction of permanent teeth.^{9,10} In all of these systemic conditions, multiple teeth are generally involved. More commonly local factors are the cause of permanent tooth impaction. These factors include prolonged deciduous tooth retention, malposed tooth germs, arch-length deficiency, supernumerary teeth, odontogenic tumors abnormal eruption path, and cleft lip and palate.^{5,11,12}

Because the maxillary canine is relatively commonly impacted, it has been studied to identify the causes of this tooth impaction. Jacoby separates labially unerupted maxillary canines from palatally impacted canines in his evaluation of the cause of failure of eruption of these teeth.¹¹ Labially unerupted canines tend to

show a degree of arch-length deficiency, whereas palatally impacted canines do not. He stated that a canine might appear in a palatal position if extra space is available in the maxillary bone owing to either excessive growth, agenesis, or peg shape of the lateral incisor, or stimulated eruption of a lateral incisor or first premolar.¹¹ In a review of impacted maxillary canines, Bishara stated that the presence of the lateral incisor root with normal length at the normal time is important to guide the canine in a proper eruptive direction.⁹

Impacted second molars have been studied to determine the cause of these

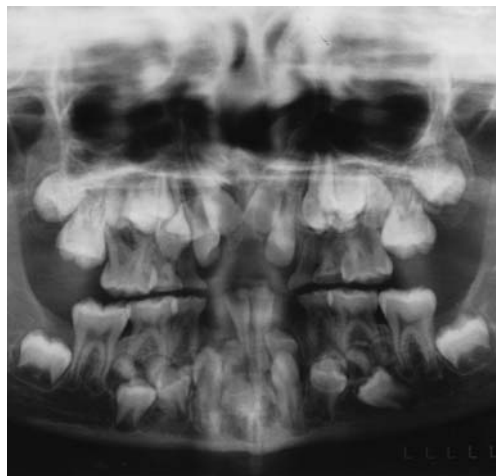


FIGURE 7-3 Multiple impacted teeth in a case of cleidocranial dysplasia.

impactions. Although maxillary second permanent molars are infrequently impacted, in a study of these impactions, Ranta found that the third molar was generally positioned occlusally and palatally in relation to the second molar, acting as an obstruction (Figure 7-4).¹³ In a similar study Levy and Regan identified the most probable cause of impaction of developing second molars as malposition of the tooth germs of the maxillary third molars.¹⁰ A typical finding was deformation of the mesial surfaces of the crowns and roots of the third molars. Raghoobar and colleagues stated that impaction of first molars is often diagnosed as ectopic eruption, whereas impaction of second molars is usually associated with arch-length deficiency.⁵

Clinical problems have been identified associated with impacted permanent teeth. Failure of teeth to erupt into their normal position in the arch may result in problems that include malocclusion, loss of arch length, migration or loss of neighboring teeth, periodontal disease, root resorption of adjacent teeth, resorption (internal or external) of the impacted

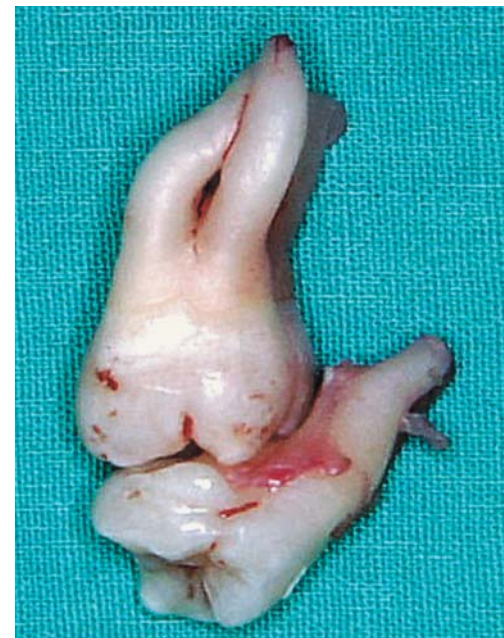

FIGURE 7-4 Impacted maxillary second and third molars.

tooth, dentigerous cysts or odontogenic tumors, and pericoronitis.^{5,9}

Evaluation

Clinical diagnosis of impacted permanent teeth is straightforward, involving clinical inspection that discloses the absence of the tooth in its normal position combined with the radiographic assessment showing the unerupted position of the tooth.

Radiographic assessment of the impacted teeth is important in the preparation for surgical or orthodontic treatment. Most techniques for localization of an impacted tooth have been studied primarily with maxillary canines. These techniques, however, can be generalized to other teeth in the oral cavity. Ericson and Kurol have studied the radiographic appearance of ectopically erupting maxillary canines and have found that a palpable canine generally erupts in a relatively normal position.¹⁴ Most canines can be evaluated with accuracy from conventional periapical films. Axial or panoramic films were less useful.¹⁴ When polytomograms were used, root resorption was diagnosed with greater accuracy. This study indicated that the optimal age for evaluating an ectopically positioned canine was 10 to 13 years, depending on individual development.¹⁵ A study comparing plain film radiography with computed tomography (CT) showed CT to be superior in showing tooth and root shape, crown-root relationship, and tooth inclination.¹⁶ However, the higher cost and radiation dose of CT limits its use to impacted teeth in unusual positions or in proximity to vital structures.

Standard radiographic techniques may be used to localize the unerupted teeth. These include the tube shift method, buccal object rule, and periapical occlusal method.¹⁷ The tube shift method uses two periapical radiographs, shifting the tube horizontally between exposures. If the unerupted tooth moves in the same direction in which the tube is shifted, it is local-

ized on the lingual or palatal side. A facial or buccally located tooth moves in the opposite direction to the tube shift.¹⁷ The buccal object rule uses two radiographs taken with different vertical angulations of the x-ray beam. An object located on the buccal side moves inferiorly with the beam directed inferiorly, whereas an object located in a lingual or palatal position moves superiorly. The periapical occlusal method uses the periapical radiograph taken with a standard technique and an occlusal radiograph to give two different views of the impacted tooth.¹⁷

Panoramic films can be used to assess maxillary canine position (Figure 7-5).¹⁸ This technique uses the property that an object closer to the tube (palatal) is relatively magnified, and is most accurate when the tooth is close to the alveolar crest. A study comparing magnification from a panoramic radiograph with a vertical parallax from occlusal and panoramic films showed a slight superiority for the vertical parallax method. Both methods were better at localizing palatal cuspids than labial cuspids.¹⁹

Surgical Treatment

Treatment of impacted permanent teeth must be based on clinical and radiographic evaluation as well as a determination of future risks. Clearly, teeth that are symptomatic, have caused infection in the surrounding tissues, or have radiographic evidence of development of changes (cyst formation, resorption of adjacent teeth, or root resorption of the impacted teeth) require surgical treatment. Treatment of the asymptomatic tooth must take into account many factors, including age, specific prevalence of pathologic conditions, severity of potential pathology associated with impacted teeth, progression of untreated conditions, frequency and severity of potential complications of treatment, potential patient discomfort and inconvenience associated with either treatment or nontreatment, and economic

consequences of treatment.⁴ Methods of treatment of impacted permanent teeth include orthodontic assistance through surgical exposure with or without attachment of the tooth, surgical uprighting, transplantation, and surgical removal.

Exposure

Surgical exposure is a procedure that allows natural eruption of impacted teeth.^{9,20} Öhman and Öhman studied 542 impacted teeth in 389 patients.²⁰ In this study the crowns of the teeth were surgically exposed with removal of tissues in the direction most appropriate for crown movement. The wounds were packed until they were totally epithelialized. The teeth were allowed to erupt for up to 24 months or until the greatest diameter of the crown reached the level of the mucosal surface. Of 542 teeth only 16 were failures (failure to erupt after 24 mo or with other complications). This study found that the teeth tended to show a change of inclination of the longitudinal axis by rotation along the root. Age did not appear to be a factor in success, although most patients were < age 19 years.²⁰

In a study of impacted premolars, Thilander and Thilander showed that surgical exposure alone resulted in eruption, provided that space was present in the arch.²¹ However, mesially tipped premolars had a poor prognosis and required orthodontic

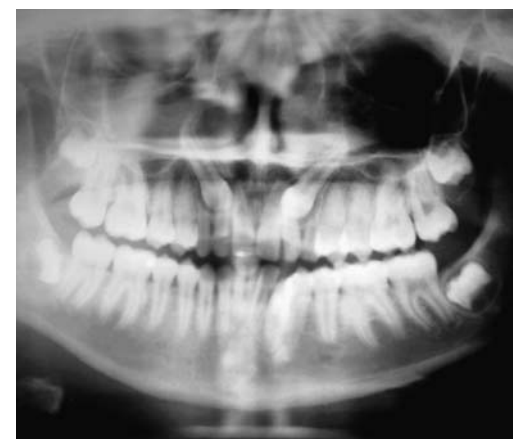

FIGURE 7-5 Panoramic films can be used to localize maxillary canines.

guidance. Laskin and Peskin believe that if exposure of teeth is to result in successful spontaneous eruption, it should be done as soon as it is determined that the tooth is not going to erupt spontaneously.²²

More commonly, the technique of surgical exposure is combined with attachment of an orthodontic appliance to the tooth, allowing active guidance of the impacted tooth into an ideal position. Important factors in this technique are prior orthodontic treatment to provide adequate space within the dental arch for the impacted tooth, and anchorage. Many appliances have been advocated, including polycarbonate crowns and pins inserted into the structure of the tooth. Both of these techniques are used rarely because of the problems of availability of bonded orthodontic brackets/buttons.

Wires placed around the cervical line of the tooth have been a common method of orthodontic guidance; however, this technique has been regarded as relatively invasive. A clinical report in 1981 identified external resorption as a possible sequela of the wide exposure at the cemento-enamel junction (CEJ) that is necessary for placement of a cervical wire.²³ This complication was studied by Kohavi and colleagues in 1984 in 23 patients who had surgical exposure and attachment of a cervical wire to the tooth.²⁴ The teeth were separated into two groups; one had “light exposure” for placement of a band not exposing the CEJ, and the second had “heavy exposure” involving the removal of bone, complete removal of the follicular sac, and full exposure of the CEJ. This study showed significantly more damaging effects of the heavy exposure technique, and the authors recommended avoiding exposure of the neck of the tooth for placement of a cervical wire.²⁴

Although the use of attachments such as rare earth magnets has been advised for the movement of teeth, the most common method is the placement of a bonded orthodontic bracket.²⁵ This can usually be

done with a conservative exposure of the tooth, removing only enough soft tissue and bone to place the bonded bracket, and avoiding exposure of the CEJ.⁹

Studies have compared simple exposure with packing to maintain a gingival path for eruption, with exposure and bonding of a bracket. Iramaneerat and colleagues found that there was no difference in total orthodontic treatment time for the two techniques.²⁶ Pearson and colleagues found that bracketing was more costly and more likely to require reoperation.²⁷ Nonetheless, placing a bracket is the more popular technique, perhaps owing to orthodontist preference and patient comfort.

For the most common type of non-third molar impaction, the maxillary palatal cuspid, the typical surgical exposure involves reflection of the full-thickness palatal flap, conservative exposure of the tooth, and bonding of a bracket to its palatal surface (Figure 7-6). If the tooth is near the free edge of the flap, soft tissue may be removed to leave the crown exposed; the wound is then packed gently during the initial healing period. If the tooth is deeply impacted, it may be more appropriate to replace the soft tissue flap, bringing a wire attached to the bonded bracket through the soft tissues near the crest of the ridge. The technique of replacing the flap has been examined for its periodontal consequences. The clinical outcomes show minimal effects of the closed eruption technique on the periodontium.²⁸

Management of the cuspid that is impacted on the labial side follows the same general principles as for the palatally impacted cuspid. A position in the arch must be established by preliminary orthodontic treatment prior to cuspid exposure. An additional important factor for the labially impacted cuspid is preservation of attached mucosa adjacent to the cervical line of this tooth. Generally the most appropriate technique is to begin with a full-thickness mucoperiosteal flap to iden-

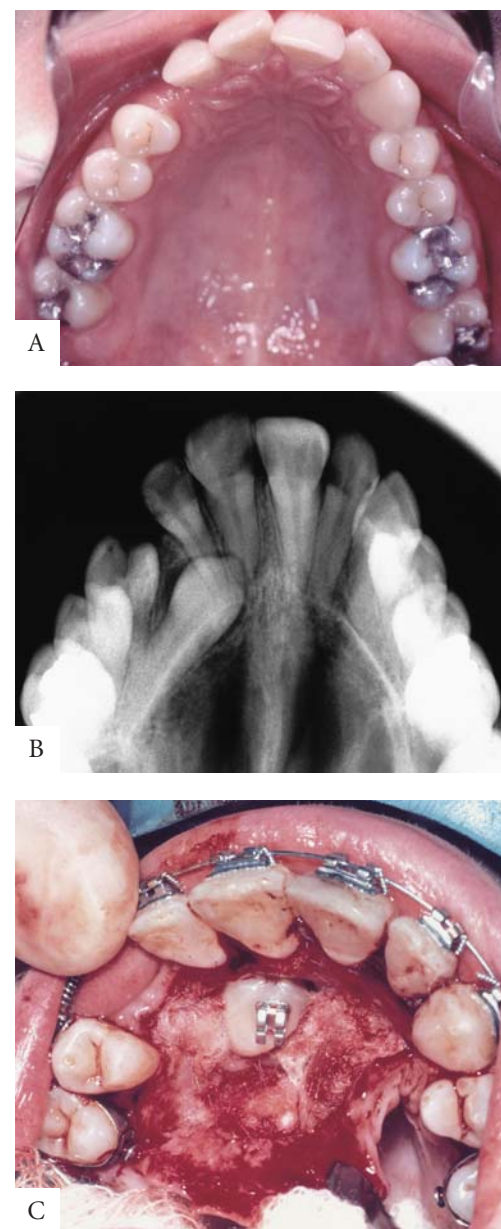


FIGURE 7-6 A, Right maxillary canine is unerupted. B, Radiograph showing impacted canine. C, Bracket placed. Reproduced with permission from Zeitler D. Management of impacted teeth other than third molars. *Oral Maxillofac Surg Clin North Am* 1993;5:95–103.

tify the position of the impacted tooth. The crown of the tooth is conservatively uncovered, and a bonded bracket is attached; then vertical releasing incisions are made to provide a broadly based flap that is superiorly repositioned to cover the CEJ of the tooth. The bonded bracket helps to support the attached gingiva in this apical relationship (Figure 7-7). As the

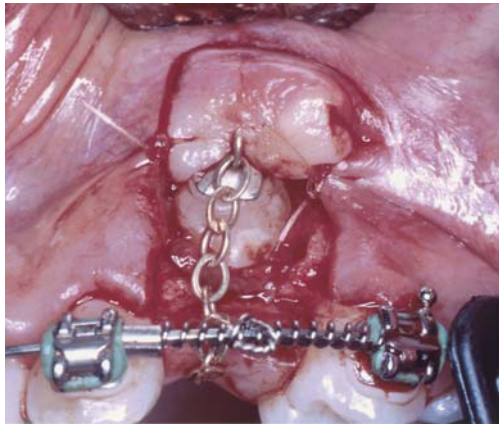


FIGURE 7-7 Labially impacted canine exposed using an apically repositioned flap.

tooth is orthodontically moved into position, an adequate band of keratinized gingiva is present. Techniques that involve removal of the attached gingiva, leaving alveolar mucosa surrounding the cervical area of the tooth, are to be avoided.

These basic principles of exposure of canines can be generalized to many other impacted teeth. Exposure and orthodontic attachment of maxillary and mandibular bicuspid can be similar to those for maxillary canines. Often mandibular bicuspid are located relatively centrally in the alveolar process. This may also be true of mandibular molars. When this is the case, exposure from the coronal aspect of the tooth may be indicated. A bonded bracket may be placed on the occlusal surface of the tooth and orthodontic forces applied in a relatively vertical direction until the tooth is exposed sufficiently to place the orthodontic bracket in a more traditional position.

Uprighting

Surgical uprighting of teeth has been applied most commonly to impacted molars. Reynolds identifies several reasons for uprighting lower molar teeth, including providing occlusion with opposing teeth and proximal contacts with adjacent teeth, minimizing the risk of caries and periodontal disease, and assisting in orthodontic treatment.²⁹ Paleczny adds

that avoiding treatment of unerupted or submerged teeth may result in occlusal and periodontal problems for adjacent and opposing teeth.³⁰

An important factor in the treatment of impacted molars is removal of the third molars that prevent the second molars' normal eruption (Figure 7-8). Ranta stated that it is typical for impacted second molars to erupt normally when the offending third molar is removed.¹³ Although removal of the second molar to allow eruption of the third molar into the second molar position may occasionally have a satisfactory outcome in the maxilla, this is not likely to happen in the mandible.³¹ Vig also recommends routine removal of the third molar when a second molar is impacted.³²

Consequently, surgical repositioning of impacted mandibular second molar teeth and occasionally first molars is the usual treatment of choice. When impaction of a second molar is identified, consideration should be given to correcting the impaction before the roots are fully formed.³¹ The optimal time for uprighting a molar tooth is when two-thirds of the root has formed; molars with fully formed roots have a poor prognosis.⁵ The technique for second molar uprighting begins with the removal of the third molar (Figure 7-9). This generally creates the necessary space for posterior tipping of the second molar. If no third molar is present, it will likely be necessary to remove bone

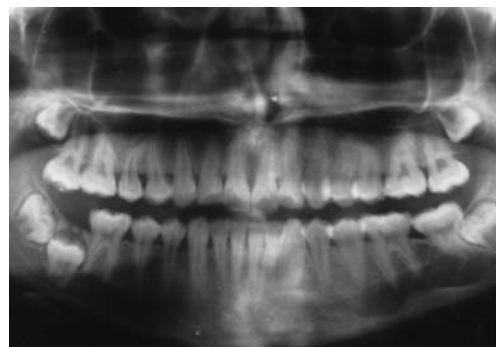

FIGURE 7-8 Third molar in path of second molar eruption.

posterior to the second molar. When doing so, it is important to avoid damage to the CEJ of the second molar. After adequate distal space is obtained, the second molar may be gently lifted superiorly and posteriorly to clear the height of contact of the adjacent first molar.

Most second molars are relatively stable after being lifted past the height of contour of the first molar. Usually it is not necessary to fix the tooth into position (see Figure 7-9B). An extremely important part of this surgical procedure

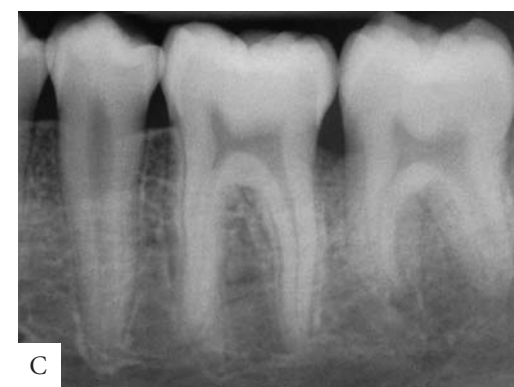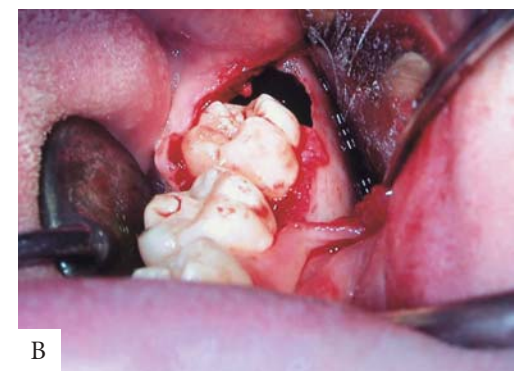

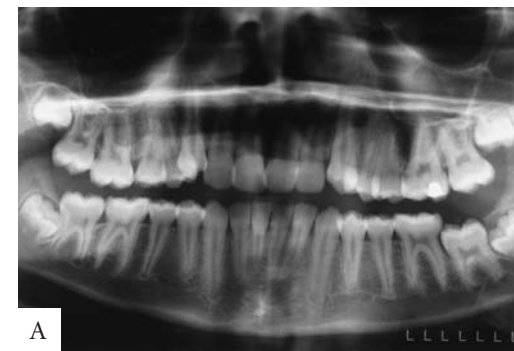
FIGURE 7-9 A, Impacted second molar. B, Second molar lifted into position. C, Six-month follow-up radiograph of repositioned second molar.

is ensuring that there are no occlusal forces on the repositioned second molar. This generally does not require equilibration on the opposing tooth, but an occlusal adjustment can be performed if necessary. Antibiotics are prescribed following this procedure.

An endodontic evaluation should be performed 3 weeks following the uprighting of the tooth. When a tooth with fully developed roots is repositioned, endodontic treatment, if indicated, should be undertaken approximately 6 to 8 weeks following the surgery. Radiographs should be taken at 6-month intervals for 2 years to evaluate the postoperative course (see Figure 7-9C).³¹

Transplantation

Transplantation of teeth has been advocated as an alternative to other methods of treatment of impacted teeth. It may be appropriate for the adult patient who cannot undergo conventional orthodontic movement of a canine or premolar. Sagne

and Thilander studied 47 patients with 56 canines that were surgically transplanted.³³ The advocated technique is a careful wide exposure of the impacted tooth. The tooth is then moved into its position within the dental arch and stabilized with a segmental orthodontic appliance. Endodontic treatment begins with calcium hydroxide paste 6 to 8 weeks after the surgical procedure. Conventional root canal filling is performed at 1 year following surgery. This study showed a successful outcome in 54 of 56 transplanted canines. Their concluding recommendation is to perform conventional orthodontic treatment for impacted canines in children and young individuals. However, when extraction would otherwise be performed, they recommend transalveolar transplantation as a sound alternative (Figure 7-10).³³

Removal

Surgical removal of impacted permanent teeth may be performed when other methods of treatment are unavailable. Basic

surgical principles of radiographic assessment and careful surgical technique must be followed. Conservation of bone through conservative exposure and removal with sectioning of the tooth should be considered. Impacted canines should be approached from the surface of the maxilla with which they are most closely associated. Labially impacted canines are frequently removed with an elevator technique, but palatal canines generally require removal of the crown followed by sectioning of the root. Longitudinal sectioning of the root of the palatal canine often is useful and may conserve bone. When a large palatal flap has been reflected, maintaining a palatal splint to support the soft tissues for several days prevents hematoma formation.

Impacted maxillary bicuspids may be removed much like canines. Mandibular bicuspids are generally approached from the labial surface of the mandible. Care must be taken to preserve the integrity of the mental nerve when the impacted tooth is nearby. When the impacted lower bicuspid is lingually positioned, it is sometimes useful to identify the tooth through a lingual exposure; a labial flap then may be raised and a small hole placed in the labial surface of the bone to allow the bicuspid to be pushed through to the lingual. Removal of impacted molars is similar to removal of impacted third molars.

Summary

Impacted teeth other than third molars are relatively common findings. Much can be done to preserve these teeth and allow their functional positioning within the dental arch. Surgical exposure with or without orthodontic guidance, surgical uprighting, and transplantation of teeth are valuable techniques that can be mastered by oral and maxillofacial surgeons. Although some studies have indicated that routine removal of impacted teeth is not necessary, removal is indicated in many different situations.

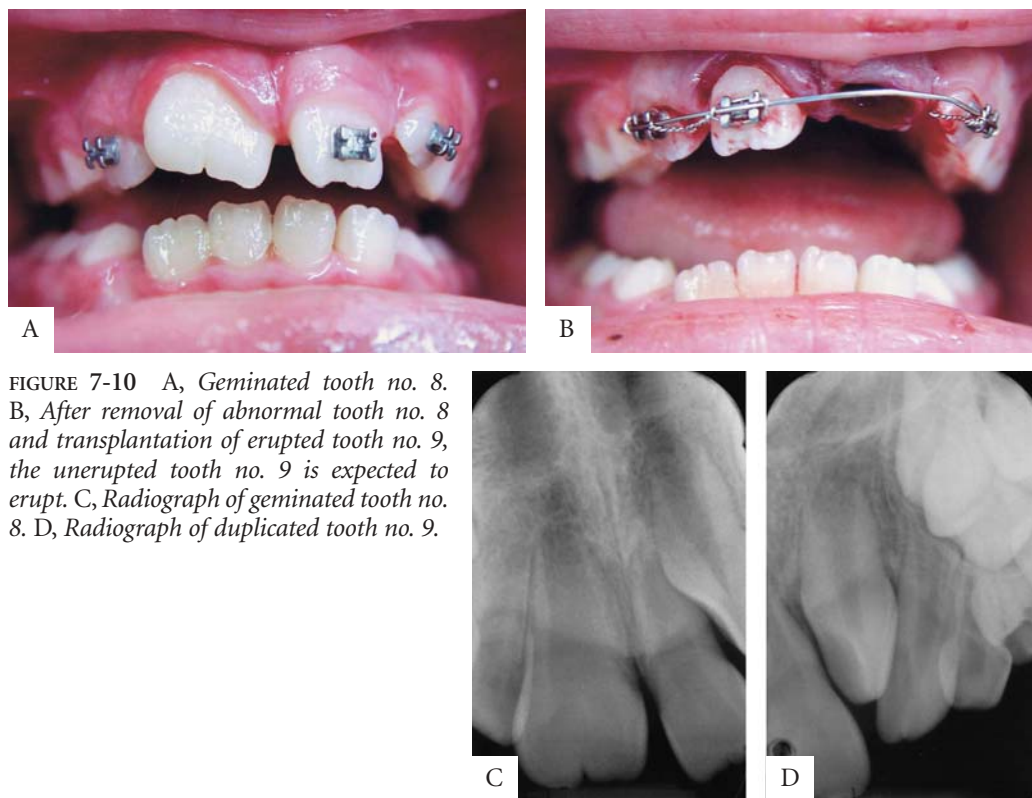


FIGURE 7-10 A, Geminated tooth no. 8. B, After removal of abnormal tooth no. 8 and transplantation of erupted tooth no. 9, the unerupted tooth no. 9 is expected to erupt. C, Radiograph of geminated tooth no. 8. D, Radiograph of duplicated tooth no. 9.

References

1. Grover PS, Lorton L. The incidence of unerupted permanent teeth and related clinical cases. *Oral Surg Oral Med Oral Pathol* 1985;59:420–5.
2. Thilander B, Myrberg N. The prevalence of malocclusion in Swedish schoolchildren. *Scand J Dent Res* 1973;81:12–20.
3. Dachi SF, Howell FV. A survey of 3,874 routine full-mouth radiographs: II. A study of impacted teeth. *Oral Surg Oral Med Oral Pathol* 1961;14:1165–9.
4. Grondahl AM. Prevalence of impacted teeth and associated pathology in middle-aged and older Swedish women. *Community Dent Oral Epidemiol* 1991;19:116–9.
5. Raghoebar GM, Boering G, Vissink A, Steenga B. Eruption disturbances of permanent molars: a review. *J Oral Pathol Med* 1991; 20:159–66.
6. Bianchi SD, Rocuzzo M. Primary impaction of primary teeth: a review and report of three cases. *J Clin Pediatr Dent* 1991;15:165–8.
7. Ostuka Y, Mitomi T, Tomizawa M, Noda T. A review of clinical features in 13 cases of impacted primary teeth. *Int J Paediatr Dent* 2001;11:57–63.
8. American Association of Oral and Maxillofacial Surgery. Impacted teeth. *Oral Health* 1998;88:31–2.
9. Bishara SE. Impacted maxillary canines: a review. *Am J Orthod Dentofacial Orthop* 1992;101:159–71.
10. Levy I, Regan D. Impaction of maxillary permanent second molars by the third molars. *J Paediatr Dent* 1989;5:31–4.
11. Jacoby H. The etiology of maxillary canine impaction. *Am J Orthod* 1983;84:125–32.
12. Moyres RE. *Handbook of orthodontics*. 4th ed. Chicago: Year Book Medical Publishers; 1988. p. 387.
13. Ranta R. Impacted maxillary second permanent molars. *J Dent Child* 1985;52:48–51.
14. Ericson S, Kurol J. Radiographic assessment of maxillary canine eruption in children with clinical signs of eruption disturbance. *Eur J Orthod* 1986;8:133–40.
15. Ericson S, Kurol J. Radiographic examination of ectopically erupting maxillary canines. *Am J Orthod Dentofacial Orthop* 1987;91:483–92.
16. Bodner L, Bar-Ziv J, Becker A. Image accuracy of plain film radiography and computerized tomography in assessing morphological abnormality of impacted teeth. *Am J Orthod Dentofacial Orthop* 2001;120:623–8.
17. Langland OE, Sippy FH, Langlais RP. *Textbook of dental radiology*. 2nd ed. Springfield (IL): Charles C Thomas; 1973.
18. Chaushu S, Chaushu G, Becker A. The use of panoramic radiographs to localize displaced maxillary canines. *Oral Surg Oral Med Oral Pathol Oral Radiol Endod* 1999;88:511–6.
19. Mason C, Papadakou P, Roberts GJ. The radiographic localization of impacted maxillary canines: a comparison of methods. *Eur J Orthod* 2001;23:25–34.
20. Öhman I, Öhman A. The eruption tendency and changes of direction of impacted teeth following surgical exposure. *Oral Surg Oral Med Oral Pathol* 1980;49:383–9.
21. Thilander B, Thilander H. Impacted premolars. In: *Transactions of the European Orthodontic Society*. Gothenburg, Sweden: European Orthodontic Society; 1976. p. 167–75.
22. Laskin DM, Peskin S. Surgical aids in orthodontics. *Dent Clin North Am* 1968; July:509–24.
23. Shapiro Y, Katine MM. Treatment of impacted cuspids: the hazard lasso. *Angle Orthod* 1981;51:203–7.
24. Kohavi D, Becker A, Silverman Y. Surgical exposure, orthodontic movement, and final tooth position as factors in periodontal breakdown of treated palatally impacted canines. *Am J Orthod* 1984;85:72–7.
25. Vardimon AD, Graber TM, Drescher D, Bourauel C. Rare earth magnets and impaction. *Am J Orthod Dentofacial Orthop* 1991;100:494–512.
26. Iramaneerat S, Cunningham S, Horrocks E. The effect of two alternative methods of canine exposure upon subsequent duration of orthodontic treatment. *Int J Paediatr Dent* 1998;8:123–9.
27. Pearson MH, Robinson SN, Reed R, et al. Management of palatally impacted canines: the findings of a collaborative study. *Eur J Orthod* 1997;19:511–5.
28. Becker A, Brim I, Ben-Basset Y, et al. Closed eruption surgical technique for impacted maxillary incisors: a post-orthodontic periodontal evaluation. *Am J Orthod Dentofacial Orthop* 2002;122:9–14.
29. Reynolds LM. Uprighting lower molar teeth. *Br J Orthod* 1976;3:45–51.
30. Paleczny G. Treatment of the ankylosed mandibular permanent first molar: a case study. *J Can Dent Assoc* 1991;57:717–9.
31. Johnson JV, Quirk GP. Surgical repositioning of impacted mandibular second molar teeth: case report. *Am J Orthod Dentofacial Orthop* 1987;91:242–51.
32. Vig KW. Some methods of uprighting lower second molars—II. *Br J Orthod* 1976;3:39–44.
33. Sagne S, Thilander B. Transalveolar transplantation of maxillary canines. A follow-up study. *Eur J Orthod* 1990;12:140–7.

Impacted Teeth

Gregory M. Ness, DDS

Larry J. Peterson, DDS, MS†

Removal of impacted teeth is one of the most common surgical procedures performed by oral and maxillofacial surgeons, and most surgeons cite third molar removal as the operation most likely to humble them. Extensive training, skill, and experience are necessary to perform this procedure with minimal trauma. When the surgeon is untrained and/or inexperienced, the incidence of complications rises significantly.¹⁻³ Determining the need for removal of asymptomatic teeth is no less problematic. In many situations this decision is made based on clinical experience and professional judgment; in others the decision is clear cut based on available scientific data. Contemporary medical and dental practices demand evidence-based decision-making, and the surgeon is called on more and more frequently to justify surgical procedures, including the removal of third molars.

This chapter reviews and discusses the indications and contraindications for the removal of impacted teeth, the classification of impacted teeth and the determination of the degree of difficulty of surgery, the parameters of perioperative patient care, and the likely complications and their management following third molar surgery.

Development of the Mandibular Third Molar

The mandibular third molar is the most commonly impacted tooth. It also presents the greatest surgical challenge and invites the greatest controversy when indications for removal are considered. When the surgeon is determining whether a specific third molar will become impacted and whether it should be removed, he or she needs to have a clear understanding of the development and movement of the third molar between the ages of 7 and 25 years.

A number of longitudinal studies have clearly defined the development and eruption pattern of the third molar.⁴⁻⁷ The mandibular third molar tooth germ is usually visible radiographically by age 9 years, and cusp mineralization is completed approximately 2 years later. At age 11 years, the tooth is located within the anterior border of the ramus with its occlusal surface facing almost directly anteriorly. The level of the tooth germ is approximately at the occlusal plane of the erupted dentition. Crown formation is usually complete by age 14 years, and the roots are approximately 50% formed by age 16 years. During this time the body of the mandible grows in length at the expense of resorption of the anterior border of the ramus. As this process occurs the position of the third molar relative to the adjacent teeth changes, with the third

molar assuming a position at approximately the root level of the adjacent second molar. The angulation of the crown becomes more horizontal also. Usually the roots are completely formed with an open apex by age 18 years. By age 24 years 95% of all third molars that will erupt have completed their eruption.

The change in orientation of the occlusal surface from a straight anterior inclination to a straight vertical inclination occurs primarily during root formation. During this time the tooth rotates from horizontal to mesioangular to vertical. Therefore, the normal development and eruption pattern, assuming the tooth has sufficient room to erupt, brings the tooth into its final position by age 20 years.

Most third molars do not follow this typical eruption sequence and, instead, become impacted teeth. Approximately half do not assume the vertical position and remain as mesioangular impactions. There are several possible explanations for this. The Belfast Study Group claims that there may be differential root growth between the mesial and distal roots, which causes the tooth to either remain mesially inclined or rotate to a vertical position depending on the amount of root development.^{7,8} In their studies they have found that underdevelopment of the mesial root results in a mesioangular impaction. Overdevelopment of the same root results in over-rotation of the third molar into a distoangular

†Deceased.

impaction. Overdevelopment of the distal root, commonly with a mesial curve, is responsible for severe mesioangular or horizontal impaction. The Belfast Group has noted that, whereas the expected normal rotation is from horizontal to mesioangular to vertical, failure of rotation from the mesioangular to the vertical position is also common. To a lesser extent, they documented worsening of the angulation from mesioangular to horizontal impaction and over-rotation from mesioangular to distoangular. These over-rotations from mesioangular to horizontal and from mesioangular to distoangular occur during the terminal portion of root development.

A second major reason for the failure of the third molar to rotate into a vertical position and erupt involves the relation of the bony arch length to the sum of the mesiodistal widths of the teeth in the arch. Several studies have demonstrated that when there is inadequate bony length, there is a higher proportion of impacted teeth.^{6,9,10} In general, patients with impacted teeth almost invariably have larger-sized teeth than do those without impactions.¹⁰ Even when the tooth-bone relationship is favorable, a lower third molar that is positioned lateral to the normal position almost always fails to erupt.⁶ This may also be the result of the dense bone present in the external oblique ridge.

A final factor that seems to be associated with an increased incidence of tooth impaction is retarded maturation of the third molar. When dental development of the tooth lags behind the skeletal growth and maturation of the jaws, there is an increased incidence of impaction. This is most likely a result of a decreased influence of the tooth on the growth pattern and resorption of the mandible. This phenomenon results in the rather counterintuitive observation that in a 20-year-old, an impacted third molar with partially developed roots is less likely to erupt than a similarly positioned tooth with fully developed roots.

Impacted versus Unerupted Teeth

Not all unerupted teeth are impacted. A tooth is considered impacted when it has failed to fully erupt into the oral cavity within its expected developmental time period and can no longer reasonably be expected to do so. Consequently, diagnosing an impaction demands a clear understanding of the usual chronology of eruption, as well the factors that influence eruption potential.

It is important to remember that eruption of lower third molars is complete at the average age of 20 years but that it can occur up to age 24 years. A tooth that appears impacted at age 18 years may have as much as a 30 to 50% chance of erupting fully by age 25 years, according to several longitudinal studies.^{11–13} It is fairly well established that the position of retained third molars does not change substantially after age 25 years,¹⁴ although there is some evidence of continued movement as late as the fourth decade.¹¹ Many patients are evaluated for third molar removal in their late teens, and the surgeon must therefore attempt to discern the probable outcome of the eruption process based on more than tooth position alone.

Numerous studies have evaluated the influence of various factors on the eruption potential of a lower third molar. Two factors consistently emerge as most prognostic: angulation of the third molar and space available for its emergence.^{15–19} By age 18 to 20 years, lower third molars that are horizontal or strongly mesioangular have much less eruption potential than do those that are oriented more vertically. Distoangular teeth are intermediate in their likelihood to erupt fully. However, the strongest hope of future eruption lies with those third molars that can be seen radiographically to have space at least as wide as their crown between the distal of the second molar and the ascending mandibular ramus. At age 20 years, unerupted lower third molars that are

nearly vertical and have adequate horizontal space are more likely to erupt than to remain impacted. However, if the crown-to-space ratio is > 1 or if the tooth orientation diverges substantially from vertical, the tooth is unlikely ever to erupt fully.

Indications for Removal of an Impacted Tooth

An impacted tooth can cause the patient mild to serious problems if it remains in the unerupted state. Not every impacted tooth causes a problem of clinical significance, but each does have that potential. A body of information has been collected based on extensive clinical experience and clinical studies from which indications for removal of impacted teeth have been developed. For some indications, there is lack of evidence-based data gained from long-term prospective longitudinal studies.

Pericoronitis Prevention or Treatment

When a third molar, usually the mandibular third molar, partially erupts through the oral mucosa, the potential for the establishment of a mild to moderate inflammatory response similar to gingivitis and periodontitis exists. In certain situations the patient may actually experience a severe infection, which may require vigorous medical and surgical treatment. The bacteria that are most commonly associated with pericoronitis are *Peptostreptococcus*, *Fusobacterium*, and *Bacteroides (Porphyromonas)*.^{20–22} Initial treatment of pericoronitis is usually aimed at débridement of the periodontal pocket by irrigation or by mechanical means, disinfection of the pocket with an irrigation solution such as hydrogen peroxide or chlorhexidine, and surgical management by extraction of the opposing maxillary third molar and, occasionally, of the offending mandibular third molar. Severe cases of pericoronitis with systemic symptoms may warrant antibiotic therapy.

Prevention of recurrent pericoronitis is usually achieved by removal of the involved mandibular third molar. Although operculectomy has been recommended for management of this problem, the soft tissue redundancy usually recurs owing to the relationship between the anterior border of the ramus and the fully or partially erupted mandibular third molar. Pericoronitis can occur whenever the involved tooth is partially exposed through the mucosa, but it occurs most commonly around mandibular third molars that have soft or hard tissue lying over the posterior aspect of the crown.²³

Approximately 25 to 30% of impacted mandibular third molars are extracted because of pericoronitis or recurrent pericoronitis.^{14,24–27} Pericoronitis is the most common reason for removal of impacted third molars after age 20 years. With increasing age, the incidence of pericoronitis as an indication for removal of impacted teeth also increases.

Prevention of Dental Disease

Dental caries can occur in the mandibular third molar or in the adjacent second molar, most commonly at the cervical line. Owing to the patient's inability to effectively clean this area and because the third molar is inaccessible to the restorative dentist, caries in the second and third molars are responsible for extraction of impacted third molars in approximately 15% of patients.^{14,24–27} As with pericoronitis, the presence of caries and eventual pulpal necrosis are responsible for an increasing percentage of extractions with age.

The presence of the partially impacted third molar and the patient's inability to clean the area thoroughly may result in early advanced periodontal disease. This is the primary reason for removal of approximately 5% of impacted third molars.^{14,24–27} Even young patients in otherwise good general periodontal health have a significant increase in periodontal pocketing, attachment loss, pathogen activity, and inflamma-

tory markers at the distal of the second molar and around the third molar.^{28–30} In patients whose dental health is poor and who have partially erupted third molars, the periodontal condition around the second molar and partially erupted third molar can become extremely severe at an early age.

Orthodontic Considerations

The presence of the impacted third molar, especially in the mandible, may be responsible for several orthodontic problems. These problems fall into three general areas, which are outlined below.

Crowding of Mandibular Incisors Perhaps one of the most controversial issues regarding mandibular third molars has been the issue of their influence on anterior crowding of mandibular incisor teeth, especially after orthodontic therapy. A variety of studies have been reported that support both sides of the controversy. Many of these studies have been reviews of small numbers of patients or of anecdotal information.^{31,32} More recent literature includes longitudinal reviews of orthodontically treated patients in larger numbers,^{33,34} and the preponderance of evidence now suggests that impacted third molars are not a significant cause of post-orthodontic anterior crowding. In fact, anterior incisor crowding is associated with deficient arch length rather than the mere presence of impacted teeth.

Obstruction of Orthodontic Treatment

In some situations the orthodontist attempts to move the molar teeth distally, but the presence of an impacted third molar may inhibit or even prevent this procedure. Therefore, if the orthodontist is attempting to move the buccal segments posteriorly, removal of the impacted third molar may facilitate treatment and allow predictable outcomes.

Interference with Orthognathic Surgery When maxillary or mandibular osteotomies

are planned, presurgical removal of the impacted teeth may facilitate the orthognathic procedure. Delaying removal of third molars until mandibular osteotomy, especially in mandibular advancement surgery, substantially reduces the thickness and quality of lingual bone at the proximal aspect of the distal segment, where fixation screws are usually applied. If third molars are to be removed in advance, sufficient time must be allowed for the extraction site to fill with mature bone. On the other hand, following maxillary down-fracture a deeply impacted upper third molar is often easily approached superiorly through the maxillary sinus and may be safely removed in this manner without compromising the soft tissue vascular pedicle of the maxilla. Although these circumstances involve a small percentage of all impacted third molars, the surgeon must plan well in advance (6–12 mo) for patients undergoing these procedures.

Prevention of Odontogenic Cysts and Tumors

In the impacted third molar that is left intact in the jaw, the follicular sac that was responsible for the formation of the crown may undergo cystic degeneration and form a dentigerous cyst. The follicular sac may also develop an odontogenic tumor or, in quite rare cases, a malignancy. These possibilities have frequently been cited as a reason for removal of asymptomatic teeth; although rare, when pathology occurs, it may pose a serious health threat.³⁵ The general incidence of neoplastic change around impacted molars has been estimated to be about 3%.^{36,37} In retrospective surveys of large numbers of patients, between 1 and 2% of all third molars that are extracted are removed because of the presence of odontogenic cysts and tumors.^{14,24–27} These pathologic entities are usually seen in patients under age 40 years, suggesting that the risk of neoplastic change around impacted third molars may decrease with age.

Root Resorption of Adjacent Teeth

Third molars in the process of eruption may cause root resorption of adjacent teeth. The general view is that misaligned erupting teeth may resorb the roots of adjacent teeth, just as succedaneous teeth resorb the roots of primary teeth during their normal eruption sequence. The actual occurrence of significant root resorption of adjacent teeth is not clear, although it may be as high as 7%.³⁸ If root resorption is noted on adjacent teeth, the surgeon should consider removing the third molar as soon as it is convenient. In most cases the adjacent tooth repairs itself with the deposition of a layer of cementum over the resorbed area and the formation of secondary dentin. However, if resorption is severe and the mandibular third molar displaces significantly into the roots of the second molar, both teeth may require removal.

Teeth under Dental Prostheses

Before construction of a removable or fixed prosthesis, the dentist should make sure that there are no impacted teeth in the edentulous area that is being restored. If such teeth are present, the general recommendation is that they be removed before the final placement of the prosthesis. Teeth that are completely covered with bone, that show no pathologic changes, and that are in patients more than 40 years old are unlikely to develop problems on their own. However, if a removable tissue-borne prosthesis is to be constructed on a ridge where an impacted tooth is covered by only soft tissue or 1 or 2 mm of bone, it is highly likely that in time the overlying bone will be resorbed, the mucosa will perforate, and the area will become painful and often inflamed. If this occurs, the impacted tooth will often need to be removed and the dental prosthesis either altered or refabricated.

Each situation must be viewed individually, and the risks and benefits of removing the impacted tooth must be given care-

ful consideration. In older patients with tooth- or implant-borne fixed prostheses, asymptomatic deeply impacted teeth can be safely left in place. However, if a removable prosthesis is to be made and the bone overlying the impacted tooth is thin, the tooth should probably be removed before the final prosthesis is constructed.

Prevention of Jaw Fracture

Patients who engage in contact sports, such as football, rugby, martial arts, and some so-called noncontact sports such as basketball, should consider having their impacted third molars removed to prevent jaw fracture during competition. An impacted third molar presents an area of lowered resistance to fracture in the mandible and is therefore a common site for fracture.³⁹⁻⁴¹ Additionally, the presence of an impacted third molar in the line of fracture may cause increased complications in the treatment of the fracture.

Management of Unexplained Pain

Occasionally patients complain of jaw pain in the area of an impacted third molar that has neither clinical nor radiographic signs of pathology. In these situations removal of the impacted third molar frequently results in resolution of this pain. At this time there is no plausible explanation as to why this relief of pain occurs. Approximately 1 to 2% of mandibular third molars that are extracted are removed for this reason.^{14,24-27}

When a patient presents with this type of complaint, the surgeon must make sure that all other sources of pain are ruled out before suggesting surgical removal of the third molar. In addition, the patient must be informed that removal of the third molar may not relieve the pain completely.

Summary

The preceding discussion has dealt with the indications for removal of symptomatic impacted third molars. Most clini-

cians agree that if a patient presents with one or more of the above pathologic problems or symptoms, the involved teeth should be removed. It is much less clear what should be done prophylactically with teeth that are impacted before they cause these problems. Most of the symptomatic pathologic problems that result from third molars occur as a result of a partially erupted tooth. There is a lower incidence of problems associated with a complete bony impaction.

Contradictions for Removal of Impacted Teeth

The decision to remove a given impacted tooth must be based on a careful evaluation of the potential benefits versus risks. In situations in which pathology exists, the decision to remove the tooth is uncomplicated because it is necessary to treat the disease process. Likewise, there are situations in which removal of impacted teeth is contraindicated because the surgical complications and sequelae outweigh the potential benefits. The general contraindications for removal of impacted teeth can be grouped into three primary areas: advanced patient age, poor health, and surgical damage to adjacent structures.⁴²

Extremes of Age

Healing generally occurs more rapidly and more completely in younger patients; however, surgical removal of unerupted third molars in the very young is contraindicated. Although some clinicians report that removal of the tooth bud of the developing third molar at age 8 or 9 years can be accomplished with minimal surgical morbidity,⁴³ the general consensus is that this is not a prudent approach. The original view was based on the belief that accurate growth predictions could be made and, therefore, that an accurate determination could be established regarding whether a given tooth would be impacted. If such a determination were the case, then the tooth bud could be removed

relatively atraumatically in the very young patient. The evidence at this time, however, is contradictory to that opinion, and the general consensus is that removal of the tooth bud at this stage may, in fact, be unnecessary because the involved third molar may erupt into proper position.

As a patient becomes older there is decreased healing response,⁴⁴ which may result in a greater bony defect postoperatively than was present because of the impacted tooth. Additionally, the surgical procedure grows more and more difficult as the patient ages owing to more densely calcified bone, which is less flexible and more likely to fracture. As a patient ages, the response to surgical insult is tolerated less easily and the recuperation period grows longer. There is overwhelming clinical evidence to support the fact that the number of days missed from work and other normal activity following third molar extraction is much higher in the patient over age 40 years compared with patients under age 18 years.

As a general rule, if a patient has a fully impacted third molar that is completely covered with bone, has no obvious potential source of communication with the oral cavity, and has no signs of pathology such as an enlarged follicular sac, and if the patient is over age 40, the tooth probably should not be removed. Long-term follow-up by the patient's dentist should be performed periodically, with radiography performed every several years to ensure that no adverse sequelae are occurring. If signs of pathology develop, the tooth should be removed. If the overlying bone is very thin and a removable denture is to be placed over that tooth, the tooth should probably be removed before the final prosthesis is constructed.

Compromised Medical Status

Patients who have impacted teeth may have some compromise in their health status, especially if they are elderly. As age increases, so does the incidence of moderate to severe cardiovascular disease, pul-

monary disease, and other health problems. Thus, the combination of advanced age and compromised health status may contraindicate the removal of impacted teeth that have no pathologic processes.

Other factors may compromise the health status of younger people, such as congenital coagulopathies, asthma, and epilepsy. In this group of patients, it may be necessary to remove impacted teeth before the incipient pathologic process becomes fulminant. Thus, not only in the older compromised patient but also the younger compromised patient, the surgeon occasionally needs to remove symptomatic as well as asymptomatic third molars. The compromised medical status becomes a relative contraindication and may require the surgeon to work closely with the patient's physician to manage the patient's medical problems.

Surgical Damage to Adjacent Structures

Occasionally an impacted tooth is positioned such that its removal may seriously compromise adjacent nerves, teeth, and other vital structures (eg, sinus), making it prudent to leave the impacted tooth in situ. The potential complications must be weighed against the potential benefits of surgical removal of the tooth. When fully developed, totally bone-impacted third molars are present around the inferior alveolar nerve; it may be best to leave that impacted tooth in place and not risk permanent anesthesia of the inferior alveolar nerve. In such situations the potential risk of development of pathologic problems would be relatively small, and, therefore, the advantage of removal of such a tooth would not outweigh the potential risks. Surgical extraction of impacted third molars can result in significant bony defects that may not heal adequately in older patients and, in fact, may result in the loss of adjacent teeth rather than the improvement or preservation of periodontal health. This also would be viewed

as a contraindication to removal of the impacted tooth.

Surgery and Perioperative Care

Determining Surgical Difficulty

Preoperative evaluation of the third molar, both clinically and radiographically, is a critical step in the surgical procedure for removal of impacted teeth. The surgeon pays particular attention to the variety of factors known to make the impaction surgery more or less difficult. A variety of classification systems have been developed to aid in the determination of difficulty. The three most widely used are angulation of the impacted tooth, the relationship of the impacted tooth to the anterior border of the ramus and the second molar, and the depth of the impaction and the type of tissue overlying the impacted tooth.

It is generally acknowledged that the mesioangular impaction, which accounts for approximately 45% of all impacted mandibular third molars, is the least difficult to remove. The vertical impaction (40% of all impactions) and the horizontal impaction (10%) are intermediate in difficulty, whereas the distoangular impaction (5%) is the most difficult.

The relationship of the impacted tooth to the anterior border of the ramus is a reflection of the amount of room available for the tooth eruption as well as the planned extraction. If the length of the alveolar process anterior to the anterior border of the ramus is sufficient to allow tooth eruption, the tooth is generally less difficult to remove. Conversely, teeth that are essentially buried in the ramus of the mandible are more difficult to remove.

The depth of the impaction under the hard and soft tissues is likewise an important consideration in determining the degree of difficulty. The most commonly used scheme for determining difficulty involves consideration of the soft tissues and partial or complete bony impaction. It is widely employed in part because it may be the most useful

indicator of the time required for surgery and, perhaps even more importantly, because it is the system required to classify and code impaction procedures to all commercial insurance carriers. Surprisingly, factors such as the angulation of impaction, the relationship of the tooth to the anterior border of the ramus, and the root morphology may have little influence on the time that surgery requires.⁴⁵

Other factors have been implicated in making the extraction process more difficult. Roots can be either conical and fused roots or separate and divergent, with the latter being more difficult to manage. A large follicular sac around the crown of the tooth provides more room for access to the tooth, making it less difficult to extract than one with essentially no space around the crown of the tooth.

Another important determinant of difficulty of extraction is the age of the patient. When impacted teeth are removed before age 20 years, the surgery is almost always less difficult to perform. The roots are usually incompletely formed and thus less bone removal is required for tooth extraction. There is usually a broader pericoronal space formed by the follicle of the tooth, which provides additional access for tooth extraction without bone removal. Because the roots of the impacted teeth are incompletely formed, they are usually separated from the inferior alveolar nerve.

In contradistinction, removal of impacted teeth in patients of older age groups is almost always more difficult. The roots are usually completely formed and are thus longer, which requires more bone removal, and closer to the inferior alveolar canal, which increases the risk of postsurgical anesthesia and paresthesia. The follicular sac almost always degenerates with age, which makes the pericoronal space thinner; as a result, more bone must be removed for access to the crown of the tooth. Finally, there is increasing density and decreasing elasticity in the bone,

necessitating greater bone removal to deliver the tooth from its socket.

In summary, the degree of difficulty of the surgery to remove an impacted tooth is determined primarily by two major factors: (1) the depth of impaction and type of overlying tissue and (2) the age of the patient. Full bony impactions are always more difficult to remove than are soft tissue impactions and, given two impactions of the same depth, the impaction in the older patient is always more difficult than the one in the younger patient.

A corollary of surgical difficulty is difficulty of recovery from the surgery. As a general rule, a more challenging and time-consuming surgical procedure results in a more troublesome and prolonged postoperative recovery. It is more difficult to perform surgery in the older individual, and it is harder for these patients to recover from the surgical procedure.

Technique

The technique for removal of impacted third molars is one that must be learned on a theoretic basis and then performed repeatedly to gain adequate experience. There is more variety in presentation of the surgical situation of impacted third molars than in any other dental surgical procedure. Therefore, extensive experience is required to master their removal. A variety of textbooks are available that describe in detail the technique for removal of the different types of impactions.^{46,47}

In general, the surgeon's approach must gain adequate access to the underlying bone and tooth through a properly designed and reflected soft tissue flap. Bone must be removed in an atraumatic, aseptic, and non-heat-producing technique, with as little bone removed and damaged as possible. The tooth is then divided into sections and delivered with elevators, using judicious amounts of force to prevent complications. Finally, the wound must be thoroughly débrided mechanically and by irrigation to provide

the best possible healing environment in the postoperative period.

The initial step in removing impacted teeth is to reflect a mucoperiosteal flap, which is adequate in size to permit access. The most commonly used flap is the envelope flap, which extends from just posterior to the position of the impacted tooth anteriorly to approximately the level of the first molar (Figure 8-1A and B). If the surgeon requires greater access to remove a deeply impacted tooth, the envelope flap may not be sufficient. In that case, a release incision is done on the anterior aspect of the incision, creating a three-cornered flap (Figure 8-1C and D). The envelope incision is usually associated with fewer complications and tends to heal more rapidly and with less pain than the three-cornered flap. The buccal artery is sometimes encountered when creating the releasing incision, and this may be bothersome during the early portion of the surgery.

The posterior extension of the incision must extend to the lateral aspect of the anterior border of the mandibular ramus. The incision should not continue posteriorly in a straight line because the mandibular ramus diverges laterally. If the incision were to be extended straight, the blade might damage the lingual nerve. High-resolution magnetic resonance imaging has demonstrated that the lingual nerve may be intimately associated with the lingual cortical plate in the third molar region in 25% of cases and be above the lingual crest in 10%.⁴⁸ The mucoperiosteal flap is reflected laterally to the external oblique ridge with a periosteal elevator and held in this position with a retractor such as an Austin or Minnesota.

The most commonly used incision used for the maxillary third molar is also an envelope incision (Figure 8-2A and B). It extends posteriorly from the distobuccal line angle of the second molar and anteriorly to the first molar. A releasing incision is rarely necessary for the maxillary third molar (Figure 8-2C and D), although it

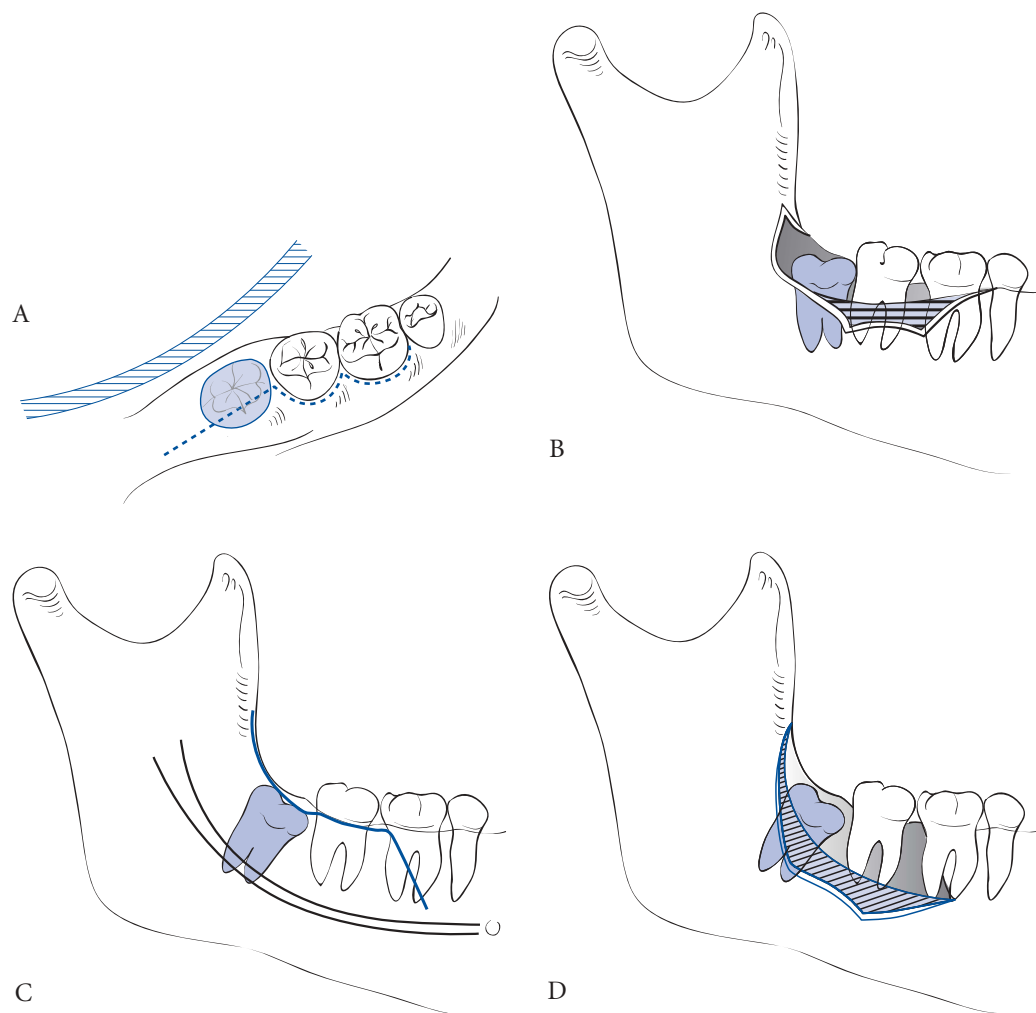


FIGURE 8-1 A, The envelope incision is most commonly used to reflect the soft tissue of the mandible for removal of an impacted third molar. Posterior extension of the incision should diverge laterally to avoid injury to the lingual nerve. B, The envelope incision is reflected laterally to expose bone overlying impacted tooth. C, When a three-cornered flap is used, the release incision is made at the mesial aspect of the second molar. D, When the soft tissue flap is reflected by means of a release incision, greater visibility is possible, especially at the apical aspect of the surgical field. Adapted from Peterson LJ. Principles of management of impacted teeth. In: Peterson LJ, Ellis E III, Hupp JR, Tucker MR, editors. Contemporary oral and maxillofacial surgery. 4th ed. St Louis: CV Mosby; 2003. p. 184–213.

may be useful when the occlusal surface of the third molar is at or superior to the midportion of the second molar root.

The second major step is bone removal from around the impacted tooth. Most surgeons use a high-speed low-torque air-driven handpiece, although a few surgeons still choose to use a chisel for bone removal. The most recent advance is the relatively high-speed high-torque electric drill, which has some significant advantages in reducing the time required for bone removal and tooth sectioning. It is

essential that the handpiece exhaust the air pressure away from the surgical site to prevent tissue emphysema or air embolism, and that the handpiece can be sterilized completely, usually in a steam autoclave.

The bone on the occlusal, buccal, and cautiously on the distal aspects of the impacted tooth is removed down to the cervical line. The amount of bone that must be removed varies with the depth of the impaction. It is advisable not to remove any bone on the lingual aspect because of the likelihood of damage to the

lingual nerve (Figure 8-3). A variety of burs can be used to remove bone, but the most commonly used are the no. 8 round bur and the 703 fissure bur.

For maxillary teeth, bone removal is done primarily on the lateral aspect of the tooth down to the cervical line to expose the entire clinical crown. Frequently, the bone on the buccal aspect is thin enough that it can be removed with a periosteal elevator or a chisel using manual digital pressure.

Once the tooth has been sufficiently exposed, it is sectioned into appropriate pieces so that it can be delivered from the socket. The direction in which the impacted tooth is divided is dependent on the angulation of the impaction. Tooth sectioning is performed either with a bur or chisel, but with the advent of high-speed drills, the bur is most commonly used because it provides a more predictable plane of sectioning. The tooth is usually divided three-quarters of the way through to the lingual aspect and then split the remainder of the way with a straight elevator or a similar instrument. This prevents injury to the lingual cortical plate and reduces the possibility of damage to the lingual nerve.

The mesioangular impaction is usually the least difficult to remove. After sufficient bone has been removed, the distal half of the crown is sectioned off from the buccal groove to just below the cervical line on the distal aspect of the tooth. This portion of the tooth is delivered, and the remainder of the tooth is removed with a small straight elevator placed at a purchase point on the mesial aspect of the cervical line (Figure 8-4). An alternative is to prepare a purchase point in the tooth with the drill and use a crane pick or a Cryer elevator in the purchase point to deliver the tooth.

The horizontal impaction usually requires the removal of more bone than does the mesioangular impaction. The crown of the tooth is usually sectioned from the roots and delivered with a Cryer

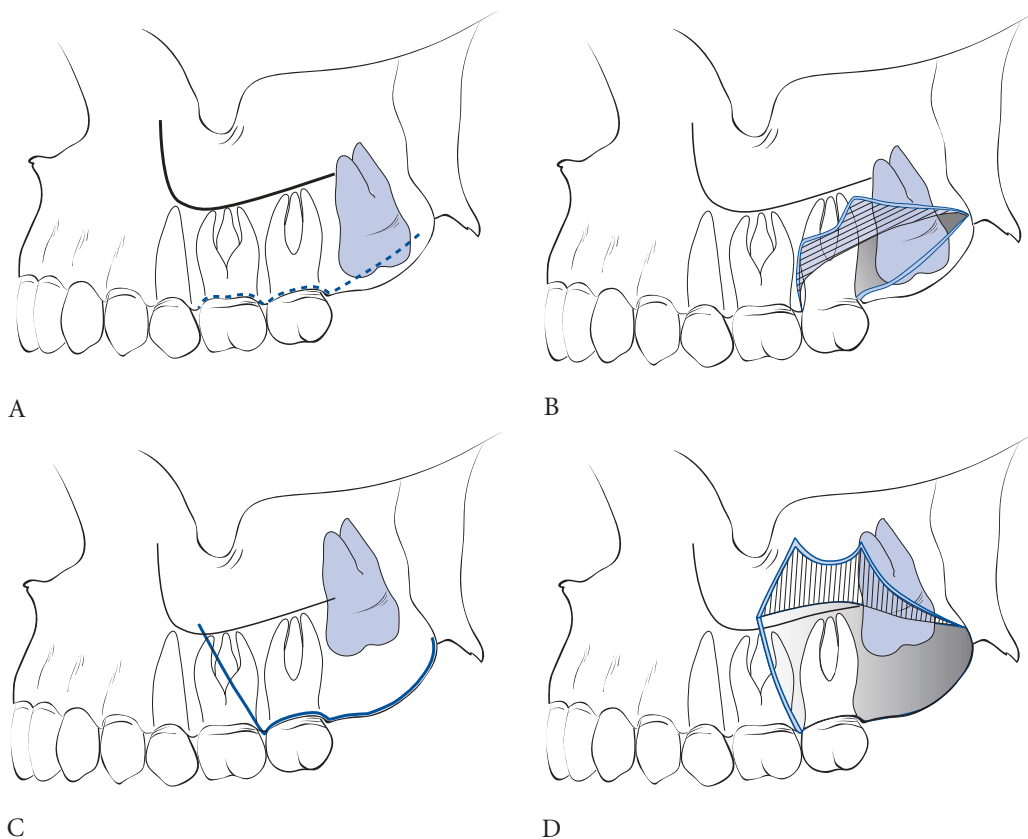


FIGURE 8-2 A, The envelope flap is the most commonly used flap for the removal of maxillary impacted teeth. B, When soft tissue is reflected, the bone overlying the third molar is easily visualized. C, If tooth is deeply impacted, a release incision can be used to gain greater access. D, When the three-cornered flap is reflected, there is greater visibility of bone's more apical portions. Adapted from Peterson LJ, Ellis E III, Hupp JR, Tucker MR, editors. *Contemporary oral and maxillofacial surgery*. 4th ed. St Louis: CV Mosby; 2003.

elevator. The roots are then displaced into the socket that was previously occupied by the crown and are delivered into the mouth. Occasionally, they may need to be sectioned into separate portions and delivered independently (Figure 8-5).

The vertical impaction is one of the more difficult ones to remove, especially if it is deeply impacted. The procedure for bone removal and sectioning is similar to that for the mesioangular impaction in that occlusal, buccal, and judicious distal bone is removed first. The distal half of the crown is sectioned and removed, and the tooth is elevated by applying a small straight elevator at the mesial aspect of the cervical line (Figure 8-6). The option of preparing a purchase point in the tooth is also frequently used, as for the mesioangular impaction.

The most difficult tooth to remove is one with a distoangular impaction. After the removal of bone, the crown is usually

sectioned from the roots just above the cervical line and delivered with a Cryer elevator. A purchase point is then prepared in the tooth, and the roots are delivered together or sectioned and delivered independently with a Cryer elevator (Figure 8-7). Extraction of this impaction is more difficult because more distal bone must be removed and the tooth tends to be elevated posteriorly into the ramus portion of the mandible.

Impacted maxillary third molars are rarely sectioned because the overlying bone is thin and relatively elastic. In patients with thicker bone, the extraction is usually accomplished by removing additional bone rather than by sectioning the tooth. The tooth should never be sectioned with a chisel because it may be displaced into the maxillary sinus or infratemporal fossa when struck with the chisel (Figure 8-8).

Once the impacted tooth is delivered from the alveolar process, the surgeon must pay strict attention to débriding the wound of all particular bone chips and other debris. The best method to accomplish this is to mechanically débride the socket and the area under the flap with a periapical curette. A bone file should be used to smooth any rough sharp edges of the bone. A mosquito hemostat is usually used carefully to remove any remnant of

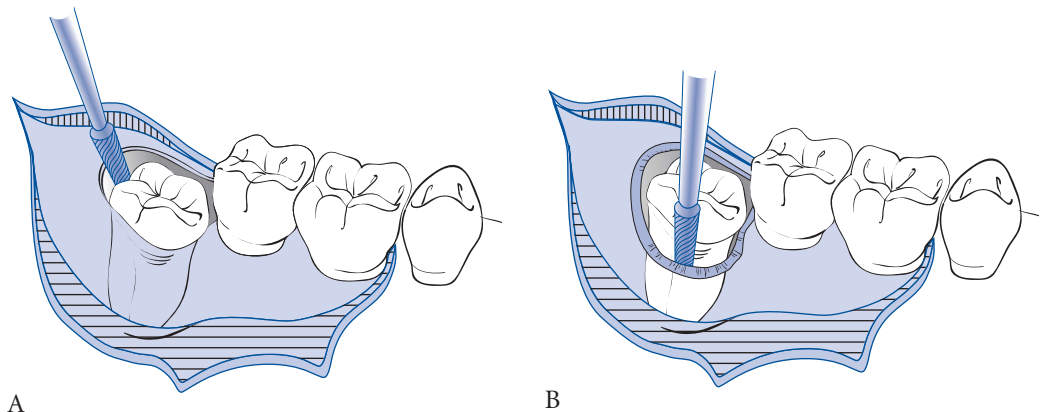


FIGURE 8-3 A, After the soft tissue has been reflected, the bone overlying the occlusal surface of tooth is removed with a fissure bur. B, Bone on the buccal and distal aspects of impacted tooth is then removed with bur. Adapted from Peterson LJ, Ellis E III, Hupp JR, Tucker MR, editors. *Contemporary oral and maxillofacial surgery*. 4th ed. St Louis: CV Mosby; 2003.

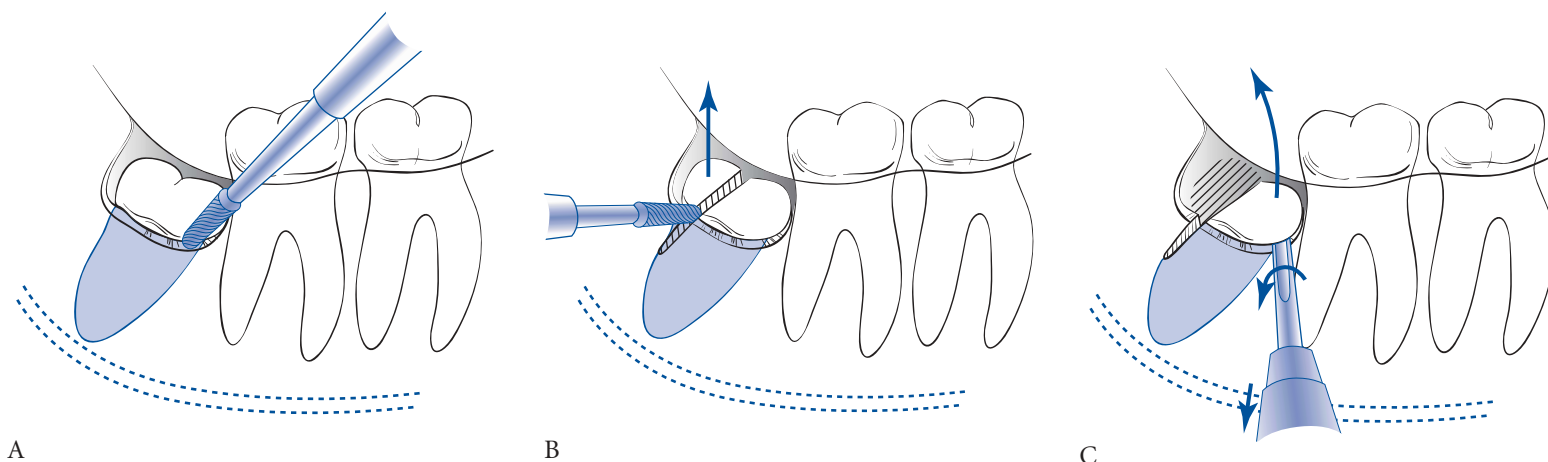


FIGURE 8-4 A, When removing a mesioangular impaction, buccal and distal bone are removed to expose crown of tooth to its cervical line. B, The distal aspect of the crown is then sectioned from tooth. Occasionally it is necessary to section the entire tooth into two portions rather than to section the distal portion of crown only. C, After the distal portion of crown has been delivered, a small straight elevator is inserted into the purchase point on mesial aspect of third molar, and the tooth is delivered with a rotational and level motion of elevator. Adapted from Peterson LJ, Ellis E III, Hupp JR, Tucker MR, editors. *Contemporary oral and maxillofacial surgery*. 4th ed. St Louis: CV Mosby; 2003.

the dental follicle. Finally, the socket and wound should be thoroughly irrigated with saline or sterile water (30 to 50 mL is optimal).⁴⁹ Within certain limitations, the more irrigation that is used, the less likely the patient is to have a dry socket, delayed healing, or other complications.

The incision should usually be closed by primary intention. The flap is returned to its original position, and the initial resorbable suture is placed at the posterior aspect of the second molar. Additional sutures are placed as necessary.

Use of Perioperative Systemic Antibiotics

One of the primary goals of the surgeon in performing any surgical procedure is to prevent postoperative infection as a result of surgery. To achieve this goal, prophylactic antibiotics are necessary in some surgical procedures. Most of these procedures fall into the clean-contaminated or contaminated categories of surgery. The incidence of postoperative infections in a clean surgery is related more to operator technique than to the use of prophylactic antibiotics.

Surgery for the removal of impacted third molars clearly fits into the category of clean-contaminated surgery; however, the

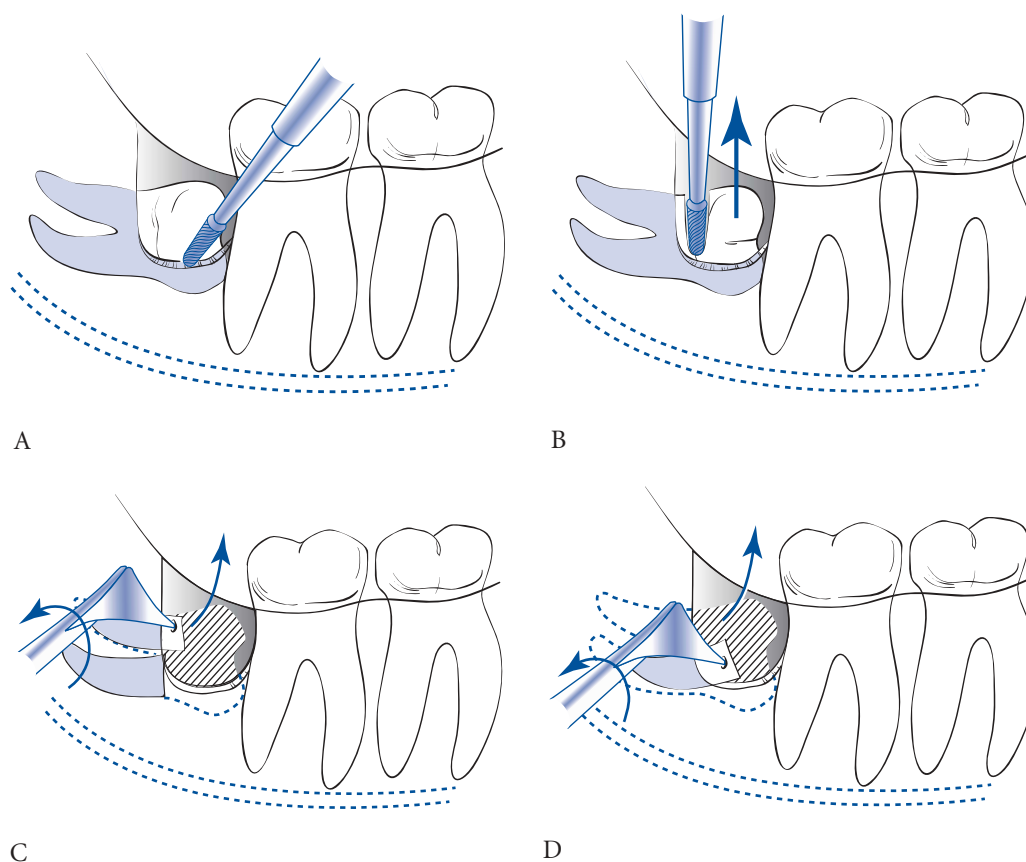


FIGURE 8-5 A, During the removal of a horizontal impaction, the bone overlying the tooth—that is, the bone on the distal and buccal aspects of tooth—is removed with a bur. B, The crown is sectioned from the roots of the tooth and is delivered from socket. C, The roots are delivered together or independently with a Cryer elevator used with a rotational motion. The roots may need to be separated into two parts: occasionally the purchase point is made in the root to allow the Cryer elevator to engage it. D, The mesial root of the tooth is elevated in similar fashion. Adapted from Peterson LJ, Ellis E III, Hupp JR, Tucker MR, editors. *Contemporary oral and maxillofacial surgery*. 4th ed. St Louis: CV Mosby; 2003.

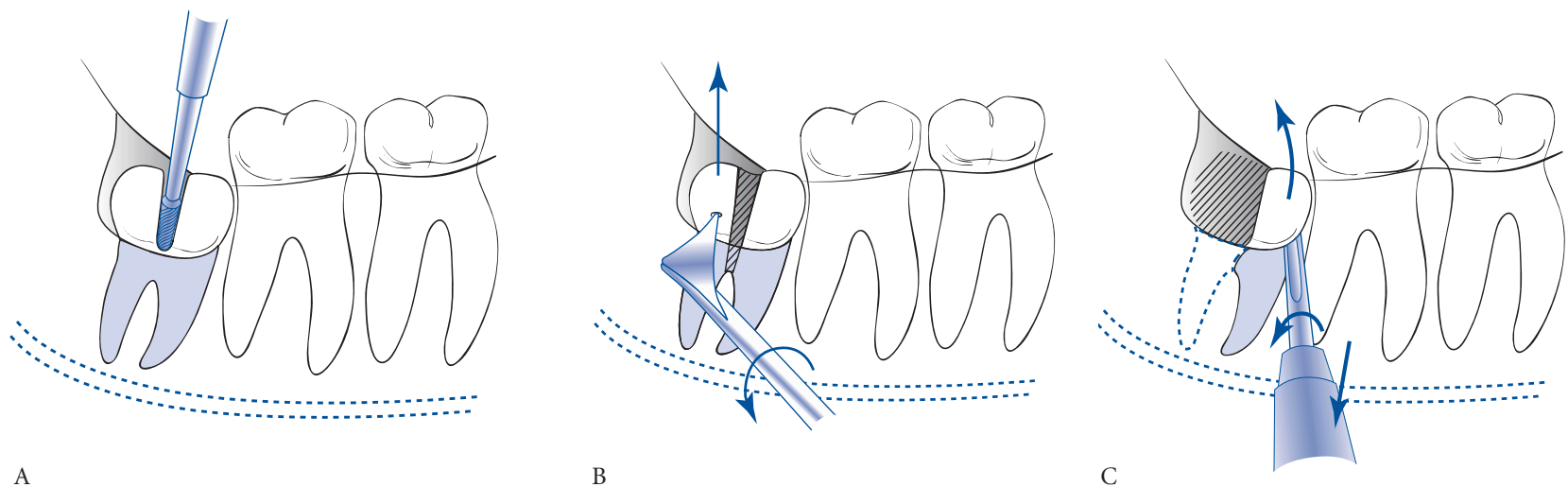


FIGURE 8-6 A, When removing a vertical impaction, the bone on the occlusal, buccal, and distal aspects of the crown is removed, and the tooth is sectioned into mesial and distal portions. If the tooth has a fused single root, the distal portion of the crown is sectioned off in a manner similar to that depicted for a mesioangular impaction. B, The posterior aspect of the crown is elevated first with a Cryer elevator inserted into a small purchase point in the distal portion of the tooth. C, A small straight no. 301 elevator is then used to lift the mesial aspect of the tooth with a rotary and levering motion. Adapted from Peterson LJ, Ellis E III, Hupp JR, Tucker MR, editors. *Contemporary oral and maxillofacial surgery*. 4th ed. St Louis: CV Mosby; 2003.

exact incidence of postoperative infection is unknown. In the usual sense of the word, infection probably is a rare occurrence following third molar surgery. This means that it is unusual to see pain, swelling, and a production of purulence that requires incision and drainage or antibiotic therapy. The incidence of such infections is very low for most surgeons. In general, a competent

experienced surgeon would expect to have an infection rate in the range of 1 to 5% for all third molar procedures.⁵⁰ It is difficult, and probably impossible, to reduce infection rates below 5% with the use of prophylactic antibiotics. Therefore, it is unnecessary to use prophylactic antibiotics in third molar surgery to prevent postoperative infection in the normal healthy

patient. Although the literature contains many articles that discuss the use of prophylactic perioperative antibiotics, there is essentially no report of their usefulness in the prevention of infection following third molar surgery.^{51,52}

A more subtle type of wound healing problem that occurs after the surgical removal of the impacted mandibular third

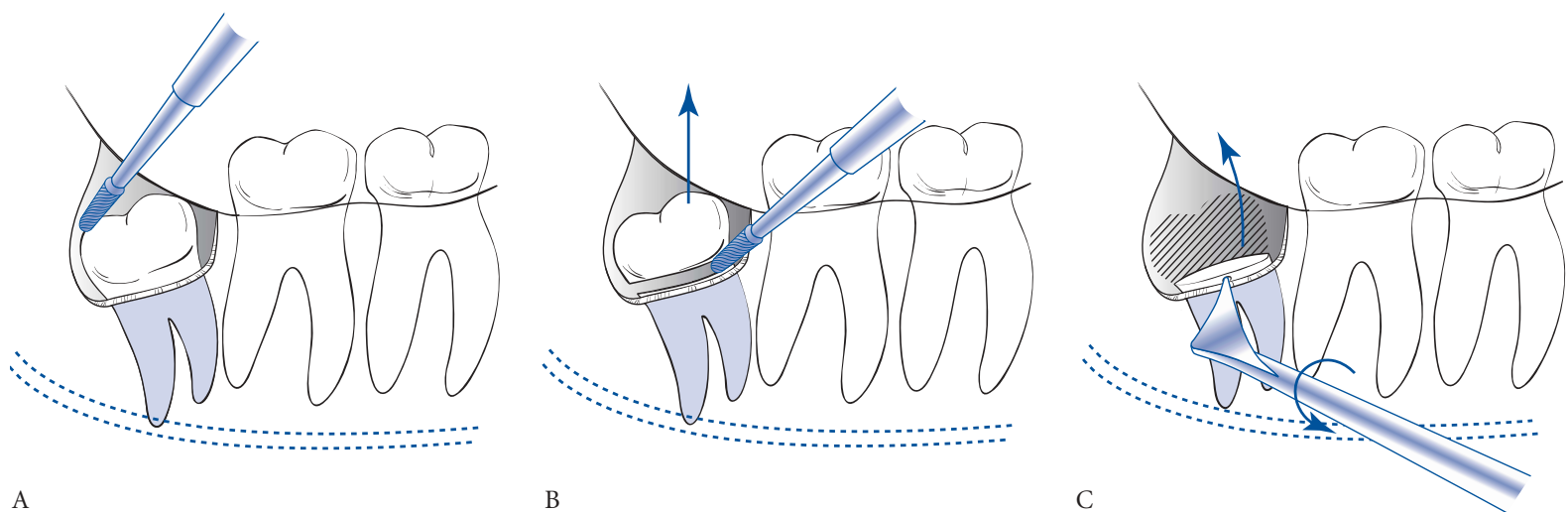


FIGURE 8-7 A, For a distoangular impaction, the occlusal, buccal, and distal bone is removed with a bur. It is important to remember that more distal bone must be taken off than for a vertical or mesioangular impaction. B, The crown of the tooth is sectioned off with a bur and is delivered with straight elevator. C, The purchase point is put into the remaining root portion of the tooth, and the roots are delivered by a Cryer elevator with a wheel-and-axle motion. If the roots diverge, it may be necessary in some cases to split them into independent portions. Adapted from Peterson LJ, Ellis E III, Hupp JR, Tucker MR, editors. *Contemporary oral and maxillofacial surgery*. 4th ed. St Louis: CV Mosby; 2003.

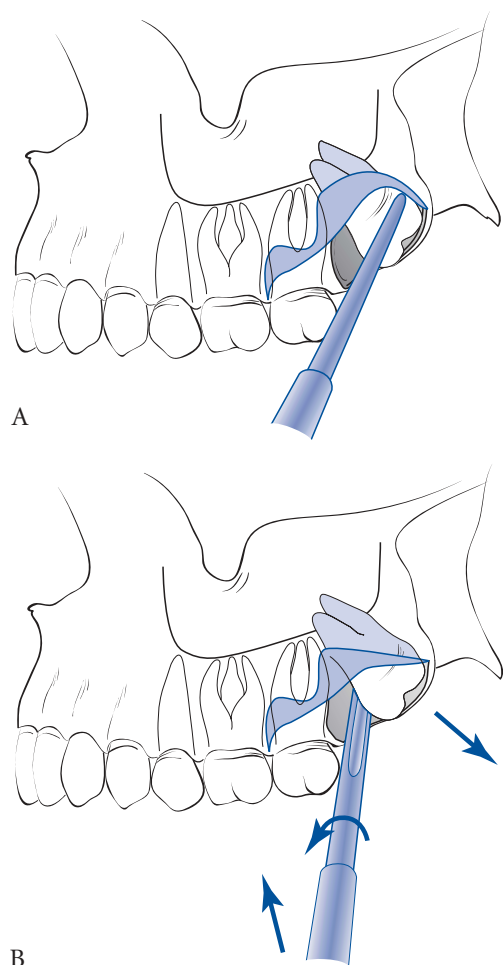


FIGURE 8-8 Delivery of an impacted maxillary third molar. A, Once the soft tissue has been reflected, a small amount of buccal bone is removed with a bur or a hand chisel. B, The tooth is then delivered by a small straight elevator with rotational and lever types of motion. The tooth is delivered in the distobuccal and occlusal direction. Adapted from Peterson LJ, Ellis E III, Hupp JR, Tucker MR, editors. *Contemporary oral and maxillofacial surgery*. 4th ed. St Louis: CV Mosby; 2003.

molar is so-called alveolar osteitis or dry socket. This disturbance in wound healing is most likely caused by the combination of saliva and anaerobic bacteria. The use of prophylactic antibiotics in third molar surgery does, in fact, reduce the incidence of dry socket. Other techniques that reduce bacterial contamination of the socket, such as copious irrigation, preoperative rinses with chlorhexidine, and placement of antibiotics in the extraction socket, are also effective.⁵³⁻⁶⁰ Once again, the issue of risks

versus benefits becomes important. Although systemic antibiotics are effective in the reduction of postoperative dry socket, they are no more effective than are local measures. The increase of antibiotic-related complications, such as allergy, resistant bacteria, gastrointestinal side effects, and secondary infections, is not outweighed by the benefits. Therefore, the use of perioperative systemic antibiotic administration does not seem to be valid.

Use of Perioperative Steroids

Just as the oral and maxillofacial surgeon desires to minimize the incidence of infection following third molar surgery, he or she also has a major interest in reducing the perioperative morbidity. The use of corticosteroids to help minimize swelling, trismus, and pain has gained wide acceptance in the oral and maxillofacial surgery community. The method of usage, however, is extremely variable, and the most effective therapeutic regimen has yet to be clearly delineated.

There is little doubt that an initial intravenous dose of steroid at the time of surgery has a major clinical impact on swelling and trismus in the early postoperative period. However, if the initial intravenous dose is not followed up with additional doses of steroids, this early advantage disappears by the second or third postoperative day. Maximum control of swelling requires that additional steroids be given for 1 or 2 days following surgery. The two most widely used steroids are dexamethasone and methylprednisolone. Both of these are almost pure glucocorticoids, with little mineralocorticoid effect. Additionally, these two appear to have the least depressing effect on leukocyte chemotaxis. Common dosages of dexamethasone are 4 to 12 mg IV at the time of surgery. Additional oral dosages of 4 to 8 mg bid on the day of surgery and for two days afterward result in the maximum relief of swelling, trismus, and pain. Methylprednisolone is most commonly

given 125 mg IV at the time of surgery followed by significantly lower doses, usually 40 mg PO tid or qid, later on the day of surgery and for two days after surgery.

High-dose short-term steroid use is associated with minimal side effects. It is contraindicated in the patient with gastric ulcer disease, active infection, and certain types of psychosis. The administration of perioperative steroids may increase the incidence of alveolar osteitis after third molar surgery, but the data are lacking as to the precise degree of increase.⁶¹⁻⁶⁵

Expected Postoperative Course

Surgical removal of impacted third molars is associated with a moderate incidence of complications, around 10%.^{66,67} These complications range from the expected and predictable outcomes, such as swelling, pain, stiffness, and mild bleeding, to more severe and permanent complications, such as inferior alveolar nerve anesthesia and fracture of the mandible. The overall incidence of complication and the severity of these complications are associated most directly with the depth of impaction, that is, whether it is a complete bony impaction, and to the age of the patient.⁶⁸⁻⁷⁰ Because of factors already discussed, removal of impacted teeth in the older patient is associated with a higher incidence of postoperative complications, especially alveolar osteitis, infections, mandible fracture, and inferior alveolar nerve anesthesia. The removal of complete bony impactions is likewise associated with increased postoperative pain and morbidity and an increase in the incidence of inferior alveolar nerve anesthesia.

Another determinant of the incidence of complications of third molar surgery is the relative experience and training of the surgeon. The less experienced surgeon will have a significantly higher incidence of complications than the trained experienced surgeon.^{1,2} After the surgical removal of an impacted third molar, certain normal physiologic responses occur. These include

such things as mild bleeding, swelling, stiffness, and pain. All of these are interpreted by the patient as being unpleasant and should therefore be minimized as much as possible.

With experience, most oral and maxillofacial surgeons develop a clear understanding of third molar surgery's impact on their patients' lives. However, despite its extreme importance, this topic has received little significant study. Several authorities have published data on the short-term impact of third molar removal on quality of life.^{71,72} As expected, third molar removal often has a profoundly negative impact for the first 4 to 7 days after surgery, but longer follow-up reveals improved quality of life, mostly resulting from the elimination of chronic pain and inflammation (usually pericoronitis). A large multicenter prospective study, the Third Molar Project, has recently produced detailed data on the postoperative quality of life in patients who undergo third molar removal.⁷³ The performing surgeon must be intimately familiar with this information if he or she is to provide proper preoperative counseling.

Bleeding

Bleeding can be minimized by using a good surgical technique and by avoiding the tearing of flaps or excessive trauma to the overlying soft tissue. When a vessel is cut, the bleeding should be stopped to prevent secondary hemorrhage following surgery. The most effective way to achieve hemostasis following surgery is to apply a moist gauze pack directly over the site of the surgery with adequate pressure. This is usually done by having the patient bite down on a moist gauze pad. In some patients, immediate postoperative hemostasis is difficult. In such situations a variety of techniques can be employed to help secure local hemostasis, including oversuturing and the application of topical thrombin on a small piece of absorbable gelatin sponge into the extraction socket.

The socket can also be packed with oxidized cellulose. Unlike the gelatin sponge, oxidized cellulose can be packed into the socket under pressure. In some situations microfibrillar collagen can be used to promote platelet plug formation. Patients who have known acquired or congenital coagulopathies require extensive preparation and preoperative planning (eg, determination of International Normalized Ratio, factor replacement, hematology consultation) before third molars are removed surgically.

Swelling

Postsurgical edema or swelling is an expected sequela of third molar surgery. As discussed earlier, the parenteral administration of corticosteroids is frequently employed to help minimize the swelling that occurs. The application of ice packs to the face may make the patient feel more comfortable but has no effect on the magnitude of edema.⁷⁴ The swelling usually reaches its peak by the end of the second postoperative day and is usually resolved by the fifth to seventh day.

Stiffness

Trismus is a normal and expected outcome following third molar surgery. Patients who are administered steroids for the control of edema also tend to have less trismus. Like edema, jaw stiffness usually reaches its peak on the second day and resolves by the end of the first week.

Pain

Another postsurgical morbidity expected after third molar surgery is pain. The postsurgical pain begins when the effects of the local anesthesia subside and reaches its maximum intensity during the first 12 hours postoperatively.⁷⁵ A large variety of analgesics are available for management of postsurgical pain. The most common ones are combinations of acetylsalicylic acid or acetaminophen with codeine and its congeners, and the nonsteroidal anti-inflammatory analgesics. Women may be

more sensitive to postoperative pain than men⁷⁶; thus, they require more analgesics. Analgesics should be given before the effect of the local anesthesia subsides. In this manner, the pain is usually easier to control, requires less drug, and may require a less potent analgesic. The administration of nonsteroidal analgesics before surgery may be beneficial in aiding in the control of postoperative pain.

The most important determinant of the amount of postoperative pain that occurs is the length of the operation. Neither swelling nor trismus correlate with the length of time of the surgery. There is, however, a strong correlation between postoperative pain and trismus, indicating that pain may be one of the principal reasons for the limitation of opening after the removal of impacted third molars.⁷⁷

Complications of Impaction Surgery

Infection

An uncommon postsurgical complication related to the removal of impacted third molars is infection. The incidence of infection following the removal of third molars is very low, ranging from 1.7 to 2.7%.⁷⁸ Infection after removal of mandibular third molars is almost always a minor complication. About 50% of infections are localized subperiosteal abscess-type infections, which occur 2 to 4 weeks after a previously uneventful postoperative course. These are usually attributed to debris that is left under the mucoperiosteal flap and are easily treated by surgical débridement and drainage. Of the remaining 50%, few postoperative infections are significant enough to warrant surgery, antibiotics, and hospitalization. Infections occur in the first postoperative week after third molar surgery approximately 0.5 to 1% of the time. This is an acceptable infection rate and would not be decreased with the administration of prophylactic antibiotics.

Fracture

One of the most frequent problems encountered in removing third molars is the fracture of a portion of the root, which may be difficult to retrieve. In these situations the root fragment may be displaced into the submandibular space, the inferior alveolar canal, or the maxillary sinus. Uninfected roots left within the alveolar bone have been shown to remain in place without postoperative complications.⁷⁹ The pulpal tissues undergo fibrosis, and the root becomes totally incorporated within the alveolar bone. Aggressive and destructive attempts to remove portions of roots that are in precarious positions seem to be unwarranted and may cause more damage than benefit. Radiographic follow-up may be all that is required.

Alveolar Osteitis

The incidence of alveolar osteitis or dry socket following the removal of impacted mandibular third molars varies between 3 and 25%. Most of the variation is most likely a result of the definition of the syndrome. When *dry socket* is defined in terms of pain that requires the patient to return to the surgeon's office, the incidence is probably in the range of 20 to 25%.^{2,80-87}

The pathogenesis of alveolar osteitis has not been clearly defined, but the condition is most likely the result of lysis of a fully formed blood clot before the clot is replaced with granulation tissue. This fibrinolysis occurs during the third and fourth days and results in symptoms of pain and malodor after the third day or so following extraction. The source of the fibrinolytic agents may be tissue, saliva, or bacteria.⁸⁰ The role of bacteria in this process can be confirmed empirically based on the fact that systemic and topical antibiotic prophylaxis reduces the incidence of dry socket by approximately 50 to 75%. The periodontal ligament may also play a role in the development of alveolar osteitis.

The incidence of dry socket seems to be higher in patients who smoke and in

female patients who take oral contraceptives.^{81,82} Its occurrence can be reduced by several techniques, most of which are aimed at reducing the bacterial contamination of the surgical site. Presurgical irrigation with antimicrobial agents such as chlorhexidine reduces the incidence of dry socket by up to 50%.² Copious irrigation of the surgical site with large volumes of saline is also effective in reducing dry socket.⁴⁹ Topical placement of small amounts of antibiotics such as tetracycline or lincomycin may also decrease the incidence of alveolar osteitis.⁸³⁻⁸⁶

The goal of treatment of dry socket is to relieve the patient's pain during the delayed healing process. This is usually accomplished by irrigation of the involved socket, gentle mechanical débridement, and placement of an obtundent dressing, which usually contains eugenol. The dressing may need to be changed on a daily basis for several days and then less frequently after that. The pain syndrome usually resolves within 3 to 5 days, although it may take as long as 10 to 14 days in some patients. There is some evidence that topical antibiotics such as metronidazole may hasten resolution of the dry socket.⁸⁷

In summary, alveolar osteitis is a disturbance in healing that occurs after the formation of a mature blood clot but before the blood clot is replaced with granulation tissue. The primary etiology appears to be one of excess fibrinolysis, with bacteria playing an important but yet ill-defined role. Antimicrobial agents delivered by perioperative mouthrinses, topically placed in the socket, or administered systemically all help to reduce the incidence of dry socket. Mechanical débridement and copious saline irrigation of the surgical wound also are effective in reducing the incidence of dry socket. A rational approach may be to provide preoperative chlorhexidine rinses for approximately 1 week before surgery, irrigate the wound thoroughly with normal saline at the con-

clusion of surgery, place a small square of gelatin sponge saturated with tetracycline in the socket, and continue chlorhexidine rinses for 1 additional week. This combination approach should substantially reduce the incidence of dry socket.

Nerve Disturbances

Surgical removal of mandibular third molars places both the lingual and inferior alveolar branches of the third division of the trigeminal nerve at risk for injury. The lingual nerve is most often injured during soft tissue flap reflection, whereas the inferior alveolar nerve is injured when the roots of the teeth are manipulated and elevated from the socket. The generally accepted incidence of injury to the inferior alveolar and lingual nerves following third molar surgery is about 3%.^{66-69,88-90} Only a small proportion of these anesthesia and paresthesia problems remain permanent. However, there is a significant incidence of some minor alterations of sensation after injury caused by third molar surgery. As many as 45% of nerve compression injuries, which are typical in third molar surgery, result in a permanent neurosensory abnormality.⁹¹

Inferior alveolar nerve injury is most likely to occur in specific situations. The first and most commonly reported predisposing factor is complete bony impaction of mandibular third molars. The angulation classifications most commonly involved are usually mesioangular and vertical impaction. In some cases, nerve proximity to the root is indicated by an apparent narrowing of the inferior alveolar canal as it crosses the root or severe root dilaceration adjacent to the canal. Other well-documented radiographic signs are diversion of the path of the canal by the tooth, darkening of the apical end of the root indicating that it is included within the canal, and interruption of the radiopaque white line of the canal.⁹² In surgically verified inferior alveolar nerve injuries, the presence of more than one of

these signs was highly sensitive but not highly specific for the risk of injury, whereas the absence of all of these signs had a strong negative predictive value.⁹³ When they are noted on a preoperative evaluation of the radiograph, the surgeon should take extraordinary precautions to avoid injury to the nerve, such as additional bone removal or sectioning of the tooth into extra pieces, and the patient should be counseled in advance regarding his or her increased risk of nerve injury.

When an injury to the lingual or inferior alveolar nerve is diagnosed in the postoperative period, the surgeon should begin long-term planning for its management including consideration of referral to a neurologist and/or microneurosurgeon. These issues are dealt with elsewhere in this textbook.

Rare Complications

The complications already discussed are the more common occurrences, accounting for the great majority of complications in surgery to remove impacted third molars. Several additional complications occur only rarely and are mentioned briefly.

Maxillary third molars that are deeply impacted may have only thin layers of bone posteriorly separating them from the infratemporal fossa, or anteriorly separating them from the maxillary sinus. Small amounts of pressure in an errant direction can result in displacement of the maxillary third molar into these adjacent spaces. When a maxillary third molar is displaced posteriorly into the infratemporal fossa, the surgeon should try to manipulate the tooth back into the socket with finger pressure placed high in the buccal vestibule near the pterygoid plates. If this is unsuccessful, the surgeon can attempt to recover the tooth by placing the suction tip into the socket and aiming it posteriorly. If both of these maneuvers are unsuccessful in recovering the tooth, the most effective technique is to allow the tooth to undergo fibrosis and to return 2 to 4 weeks later to remove it. If the tooth is

asymptomatic, is not causing any restriction in jaw movement, and is not causing pain, the surgeon should consider leaving the tooth in place. If the decision is made to remove the tooth, three-dimensional localization of the tooth should be made before surgery is initiated.

If the tooth is displaced into the maxillary sinus, retrieval is usually done by a Caldwell-Luc procedure at the same appointment. The surgeon should localize the tooth with at least a one-dimensional radiographic view and preferably a three-dimensional study before performing the retrieval surgery.⁹⁴

Fracture of the mandible during the removal of impacted mandibular third molars is a rare occurrence. The typical situation is a deeply impacted third molar, most commonly in an older individual with dense bone. The surgeon places excessive pressure on the tooth with an elevator in an attempt to deliver the tooth or tooth section into the mouth; the fracture occurs, and the remaining portion of the tooth is easily retrieved. The surgeon should then perform an immediate reduction and fixation of the fracture. If the surgeon has the experience and the armamentarium available, rigid internal fixation with miniplates is an excellent choice in this unfortunate situation. Wire fixation and application of intermaxillary fixation is an acceptable alternative. Late mandible fractures usually occur 4 to 6 weeks following extraction in patients over age 40 years.

Periodontal Healing after Third Molar Surgery

Two of the important reasons for removing impacted third molars is to preserve periodontal health or, in some situations, to treat a periodontitis that already exists.²³ A relative contraindication to the removal of impacted third molars is a situation in which there is good periodontal health and a complete bony impaction in an older patient. Removal is contraindicat-

ed because the healing response in older patients would likely result in a large persistent postsurgical defect.

After third molar surgery, the bone height distal to the second molar usually remains at the preoperative level,⁹⁵⁻⁹⁷ although some studies have indicated a net gain in bone level after surgery.⁹⁸ If the bone level on the distal aspect of the mandibular second molar is compromised by the presence of the third molar, it usually remains at that level following the healing of the bone. There is universal agreement that bone healing is better if surgery is done before the third molar resorbs the bone on the distal aspect of the second molar and while the patient is young.⁹⁹⁻¹⁰¹ The greatest bony defect occurs in situations in which the third molar has resorbed extensive amounts of bone from the second molar in an older patient, which compromises bony repair and bone healing.

The other periodontal parameter of importance is attachment level or, less accurately, sulcus or pocket depth. As with bone levels, if the preoperative pocket depth is great, the postoperative pocket depth is likely to be similar. In most studies the attachment level has been found to be at essentially the same level as it is preoperatively.^{95,102,103} In older patients with complete bony impactions, pocket depth and attachment levels may be significantly lower than preoperative levels. However, in patients younger than age 19 years, removal of complete bony impactions results in no compromise in attachment level or pocket depth. Initial healing after third molar surgery usually results in a reduction in pocket depth in young patients.⁹⁷ The long-term healing in this group continues for up to 4 years after surgery, with continuing reduction in probable pocket depths.¹⁰⁰ However, long-term follow-up of older patients clearly demonstrates that this long-term healing does not occur.^{98,100} Usually, the surgeon makes an attempt to mechanically débride the distal aspect of the second molar root area with a curette to encourage

improved bone regeneration following third molar extraction.

In summary, periodontal healing following third molar surgery is clearly best when the impacted tooth is removed before it becomes exposed in the mouth, before it resorbs bone on the distal aspect of the second molar, and when the patient is as young as possible.^{95–100,102,103} If the third molar is partially impacted and is partially exposed in the mouth, it should be removed as soon as possible. The reason for this is that there is already a deep and potentially destructive periodontal lesion that is difficult for the patient to maintain hygienically. Even if the patient is asymptomatic, the impacted tooth should be removed as soon as possible to allow the best periodontal healing after surgery as possible. In these situations the periodontal healing is compromised because of the fact that there was already a destructive lesion caused by the presence of the partially impacted third molar.

The completely impacted third molar in a patient older than age 35 years should be left undisturbed unless some pathology develops. Removal of asymptomatic completely impacted third molars in these older patients results in pocket depths that are significant and the potential loss of alveolar bone on the posterior aspect of the second molar.

Summary

The issue of whether to remove impacted third molars has generated much controversy over the past three decades. The reason for this controversy has been the lack of long-term prospective studies that have followed up large groups of patients with impacted teeth to determine the eventual outcome of leaving impactions in situ. Recently there has been intense interest in establishing clear scientifically valid evidence regarding the role of third molar removal in patient health care, especially with respect to predicting the likelihood of eruption or the risk of future pathology in

asymptomatic patients. Ongoing studies are already greatly improving our knowledge in these areas, and significant advances may be expected to appear in the scientific literature for the next several years.

Clearly, impacted third molars associated with or contributing to adjacent pathology require removal as early as is reasonably possible. The major controversy regarding proper care centers around asymptomatic unerupted third molars. It is clear that although incompletely erupted mandibular third molars will continue to erupt beyond age 18 or 20 years, in the vast majority of these situations, there will be a soft tissue or bone tissue flap over the distal aspect of the erupted third molar, which has the potential to cause recurrent pericoronitis. In fact, the tooth that is most likely to be involved in pericoronitis is the erupted vertically positioned third molar with a soft tissue flap (operculum) over the distal aspect of the tooth. Although most attempts at very early prediction of impaction and removal of tooth buds at age 8 or 9 years have now been generally abandoned, it is reasonable that by age 17 or 18 years the dentist and surgeon can reasonably predict whether there will be adequate room for the tooth to erupt with sufficient clearance of the anterior ramus to prevent soft tissue overgrowth (as in patients with large arch length and relatively small teeth).

Soft tissue and bone tissue healing will occur at a maximum level if the surgery to remove impacted third molars is done as early as possible. By age 17 years, if the diagnosis of inadequate room for functional eruption can be made, then the asymptomatic third molar should be removed. Even though the tooth may be completely covered with soft and hard tissue, removing the third molar at that age will eliminate the future pathologic potential and maximize the periodontal health of the second molar; these are important goals of the oral and maxillofacial surgeon.

References

1. Sisk AL, Hammer WB, Shelton DW, Joy ED Jr. Complications following removal of impacted third molars: the role of the experience of the surgeon. *J Oral Maxillofac Surg* 1986;44:855–9.
2. Larsen PE. The effect of chlorhexidine rinse on the incidence of alveolar osteitis following the surgical removal of impacted mandibular third molars. *J Oral Maxillofac Surg* 1991;49:932–7.
3. Capuzzi P, Montebugnoli L, Vaccaro MA. Extraction of impacted 3rd molars—a longitudinal prospective study on factors that affect postoperative recovery. *Oral Surg Oral Med Oral Pathol* 1994;77:341–3.
4. Rantanen AV. The age of eruption of the third molar teeth. *Acta Odontol Scand* 1967;25 Suppl 1:48.
5. Engstrom C, Engstrom H, Sagne S. Lower third molar development in relation to skeletal maturity and chronological age. *Angle Orthod* 1983;53:97–106.
6. Richardson ER, Malhotra SK, Semenva K. Longitudinal study of three views of mandibular third molar eruption in males. *Am J Orthod* 1984;86:119–29.
7. Richardson ME. The effect of mandibular first premolar extraction on third molar space. *Angle Orthod* 1989;59:291–4.
8. Richardson ME. Pre-eruptive movements of the mandibular third molar. *Angle Orthod* 1978; 48:187–93.
9. Ng F, Bums M, Ken WJS. The impacted lower third molar and its relationship to tooth size and arch form. *Eur J Orthod* 1986;8:254–8.
10. Forsberg CM. Tooth size, spacing, and crowding in relation to eruption or impaction of third molars. *Am J Orthod Dentofacial Orthop* 1988;94:57–62.
11. Kruger E, Thomson WM, Konthasinghe P. Third molar outcomes from age 18 to 26: findings from a population-based New Zealand longitudinal study. *Oral Surg Oral Med Oral Pathol Oral Radiol Endod* 2001;92:150–5.
12. Venta I, Turtola L, Ylipaavalniemi P. Radiographic follow-up of impacted third molars from age 20 to 32 years. *Int J Oral Maxillofac Surg* 2001;30:54–7.
13. Hattab FN. Positional changes and eruption of impacted mandibular third molars in young adults—a radiographic 4-year follow-up study. *Oral Surg Oral Med Oral Pathol Oral Radiol Endod* 1997;84:604–8.
14. Lysell L, Rohlin M. A study of indications used for removal of the mandibular third molar. *Int J Oral Maxillofac Surg* 1988;17:161–4.

15. Hattab FN, Abu Alhaja ESJ. Radiographic evaluation of third molar eruption space. *Oral Surg Oral Med Oral Pathol Oral Radiol Endod* 1999;88:285–91.
16. Venta I, Murtomaa H, Ylipaavalniemi P. A device to predict lower third molar eruption. *Oral Surg Oral Med Oral Pathol Oral Radiol Endod* 1997;84:598–603.
17. Venta I. Predictive model for impaction of lower third molars. *Oral Surg Oral Med Oral Pathol* 1993; 76:699–703.
18. Mollaoglu N, Cetiner S, Gungor K. Patterns of third molar impaction in a group of volunteers in Turkey. *Clin Oral Investig* 2002;6:109–13.
19. Venta I, Schou S. Accuracy of the third molar eruption predictor in predicting eruption. *Oral Surg Oral Med Oral Pathol Oral Radiol Endod* 2001;91:638–42.
20. Heimdahl A, Nord CE. Treatment of orofacial infections of odontogenic origin. *Scand J Infect Dis* 1985;46 Suppl:101–5.
21. Van Winkelhoff AJ, Carlee AW, deGraaff J. *Bacteroides endodontalis* and other black-pigmented *Bacteroides* species in odontogenic abscesses. *Infect Immun* 1985;49:494–7.
22. Mombelli A, Buser D, Lang NP, Berthold H. Suspected periodontopathogens in erupting third molar sites of periodontally healthy individuals. *J Clin Periodontol* 1990;17:48–54.
23. Leone SA, Edenfield MJ, Cohen ME. Correlation of acute pericoronitis and the position of the mandibular third molar. *Oral Surg* 1986;62:245–50.
24. Nordenram A, Hultin M, Kjellman O, Ramstrom G. Indications for surgical removal of the mandibular third molar. *Swed Dent J* 1987;2:23–9.
25. Stanley HR, Alattar M, Collett WE, et al. Pathological sequelae of “neglected” impacted third molars. *J Oral Pathol* 1988;17:113–7.
26. von Wowern N, Nielsen HO. The fate of impacted lower third molars after the age of 20. *Int J Oral Maxillofac Surg* 1989;18:277–80.
27. Schroeder DC, Cecil JC III, Cohen ME. Retention and extraction of third molars in naval personnel. *Mil Med* 1983;148:50–3.
28. Blakey GH, Marciani RD, Haug RH, et al. Periodontal pathology associated with asymptomatic third molars. *J Oral Maxillofac Surg* 2002;60:1227–33.
29. White RP, Madianos PN, Offenbacher S, et al. Microbial complexes detected in the second/third molar region in patients with asymptomatic third molars. *J Oral Maxillofac Surg* 2002;60:1234–40.
30. White, RP, Offenbacher S, Phillips C, et al. Inflammatory mediators and periodontitis in patients with asymptomatic third molars. *J Oral Maxillofac Surg* 2002;60:1241–5.
31. Ades AG, Joondeph DR, Little RM, Chapko MK. A long-term study of the relationship of third molars to changes in the mandibular dental arch. *Am J Orthod Dentofacial Orthop* 1990;97:323–35.
32. Bishara SE, Andreasen G. Third molars: a review. *Am J Orthod* 1983;83:131.
33. Richardson ME. The etiology of late lower arch crowding alternative to mesially directed forces: a review. *Am J Orthod Dentofacial Orthop* 1994;105:592–7.
34. Kahl B, Gerlach L, Hilgers RD. A long-term, follow-up, radiographic evaluation of asymptomatic impacted third molars in orthodontically treated patients. *Int J Oral Maxillofac Surg* 1994;23:279–85.
35. Curran AE, Damm DD, Drummond JF. Pathologically significant pericoronitis lesions in adults: histopathologic evaluation. *J Oral Maxillofac Surg* 2002;60: 613–7.
36. Guven O, Keskin A, Akal UK. The incidence of cysts and tumors around impacted third molars. *Int J Oral Maxillofac Surg* 2000; 29:131–5.
37. Berge TI. Incidence of large third-molar-associated cystic lesions requiring hospitalization. *Acta Odontol Scand* 1996;54:327–31.
38. Nitzan D, Keren T, Marmary Y. Does an impacted tooth cause root resorption of the adjacent one? *Oral Surg* 1981;51:221–4.
39. Yamada T, Sawaki Y, Tohna I, et al. A study of sports-related mandibular angle fracture: relation to the position of the third molars. *Scand J Med Sci Sports* 1998;8:116–9.
40. Safdar N, Meechan JG. Relationship between fractures of the mandibular angle and the presence and state of eruption of the lower 3rd molar. *Oral Surg Oral Med Oral Pathol Oral Radiol Endod* 1995;79:680–4.
41. Tevepaugh DB, Dodson TB. Are mandibular third molars a risk factor for angle fractures? A retrospective cohort study. *J Oral Maxillofac Surg* 1995;53:646–9.
42. Peterson LJ. Principles of management of impacted teeth. In: Peterson LJ, Ellis E III, Hupp JR, Tucker MR, editors. *Contemporary oral and maxillofacial surgery*. 4th ed. St Louis: CV Mosby; 2003. p. 184–213.
43. Ricketts RM. Studies leading to the practice of abortion of lower third molars. *Dent Clin North Am* 1979; 23:393–411.
44. Amler MH. The age factor in human extraction wound healing. *J Oral Surg* 1977;35:193–7.
45. Larsen PE, Mesieha ZS, Peterson LJ, Beck FM. Impacted third molars: radiographic features used to predict extraction difficulty. *J Dent Res* 1991;70:551–7.
46. Waite DE, editor. *Textbook of practical oral and maxillofacial surgery*, 3rd ed. Philadelphia: Lea & Febinger; 1987.
47. Andreasen JO, Petersen JK, Laskin D. *Textbook and color atlas of tooth impactions: diagnosis, treatment, and prevention*. Oxford: Munksgaard; 1998.
48. Miloro M, Halkias LE, Slone HW, Chakeres DW. Assessment of the lingual nerve in the third molar region using magnetic resonance imaging. *J Oral Maxillofac Surg* 1997;52:134–7.
49. Sweet JB, Butler DP, Drager JL. Effects of lavage techniques with third molar surgery. *Oral Surg* 1976;42:152–68.
50. Loukota RA. The incidence of infection after third molar removal. *Br J Oral Maxillofac Surg* 1991; 29:336–7.
51. Happonen RP, Backstrom AC, Ylipaavalniemi P. Prophylactic use of phenoxymethylpenicillin and tinidazole in mandibular third molar surgery, a comparative placebo controlled clinical trial. *Br J Oral Maxillofac Surg* 1990;28:12–5.
52. Bystedt H, Nord CE. Effect of antibiotic treatment on postoperative infections after surgical removal of mandibular third molars. *Swed Dent J* 1980;4:27–38.
53. Bystedt H, von Konow L, Nord CE. Effect of tinidazole on postoperative complications after surgical removal of impacted mandibular third molars. *Scand J Infect Dis* 1981;26 Suppl:135–9.
54. Hellem S, Nordenra A. Prevention of postoperative symptoms by general antibiotic treatment and local bandage in removal of mandibular third molars. *Int J Oral Surg* 1973;2:273–8.
55. Kariro GSN. Metronidazole (Flagyl) and *Arnica montana* in the prevention of post-surgical complications; a comparative placebo controlled clinical trial. *Br J Oral Maxillofac Surg* 1984;22:42–9.
56. Krekmanov L, Nordenram A. Postoperative complications after surgical removal of mandibular third molars. *Int J Oral Maxillofac Surg* 1986;15:25–9.
57. Krekmanov L, Hallander HO. Relationship between bacterial contamination and alveolitis after third molar surgery. *Int J Oral Surg* 1950;9:274–80.
58. Krekmanov L. Alveolitis after operative removal of third molars in the mandible. *Int J Oral Surg* 1981;10:173–9.
59. Macgregor AJ, Addy A. Value of penicillin in the prevention of pain, swelling and trismus following the removal of ectopic mandibular third molars. *Int J Oral Surg* 1980;9:166–72.

60. Rood JP, Murgatroyd JM. Metronidazole in the prevention of "dry socket." *Br J Oral Surg* 1979;17:62-70.
61. Hooley JR, Francis FH. Betamethasone in traumatic oral surgery. *J Oral Surg* 1969;27:398-403.
62. Huffman GG. Use of methylprednisolone sodium succinate to reduce postoperative edema after removal of impacted third molars. *J Oral Surg* 1977;35:198-9.
63. Pedersen A. Decadron phosphate in the relief of complaints after third molar surgery. *Int J Oral Surg* 1985;14:235-40.
64. Beirne OH, Hollander B. The effect of methylprednisolone on pain, trismus, and swelling after removal of third molars. *Oral Surg* 1986;61:134-8.
65. Bustedt H, Nordenram A. Effect of methylprednisolone on complications after removal of impacted mandibular third molars. *Swed Dent J* 1985;9:65-9.
66. Nordenram A. Postoperative complications in oral surgery. *Swed Dent J* 1983;7:109-14.
67. Goldberg MH, Nemarich AN, Marco WP. Complications after mandibular third molar surgery: a statistical analysis of 500 consecutive procedures in private practice. *J Am Dent Assoc* 1985;111:277-9.
68. Bruce RA, Frederickson GC, Small CS. Age of patients and morbidity associated with mandibular third molar surgery. *J Am Dent Assoc* 1980;101:240-5.
69. Osborn TP, Frederickson C, Small IA, Torgerson TS. A prospective study of complications related to mandibular third molar surgery. *J Oral Maxillofac Surg* 1985;43:767-9.
70. Hinds EC, Frey KF. Hazards of retained third molars in older persons: report of 15 cases. *J Am Dent Assoc* 1980;101:246-50.
71. McGrath C, Comfort MB, Lo ECM, Luo Y. Changes in life quality following third molar surgery—the immediate postoperative period. *Br Dent J* 2003;194:265-8.
72. Shafer DM, Frank ME, Gent JF, Fischer ME. Gustatory function after third molar extraction. *Oral Surg Oral Med Oral Pathol Oral Radiol Endod* 1999;87:419-28.
73. White RP, Shugars DA, Shafer DM, et al. Recovery after third molar surgery: clinical and health-related quality of life outcomes. *J Oral Maxillofac Surg* 2003;61:535-44.
74. Forsgren H, Heimdahl AN, Johansson B, Krekmanov L. Effect of application of cold dressings on the postoperative course in oral surgery. *Int J Oral Surg* 1985;14:223-8.
75. Seymour RA, Blair GS, Wyatt FAR. Postoperative dental pain and analgesic efficacy. *Br J Oral Surg* 1983;23:298-303.
76. Seymour RA, Meechan JG, Blair GS. An investigation into post-operative pain after third molar surgery under local analgesia. *Br J Oral Maxillofac Surg* 1985;23:410-8.
77. Pedersen A. Interrelation of complaints after removal of impacted mandibular third molars. *Int J Oral Surg* 1985;14:241-4.
78. Nordenram A, Grave S. Alveolitis sicca dolorosa after removal of impacted mandibular third molars. *Int J Oral Surg* 1983;12:226-31.
79. Knutsson K, Lysell L, Rohlin M. Postoperative status after partial removal of the mandibular third molar. *Swed Dent J* 1989;13:15-22.
80. Nitzan DNW. On the genesis of "dry socket." *J Oral Maxillofac Surg* 1983;41:706-10.
81. Sweet JB, Butler DP. The relationship of smoking to localized osteitis. *J Oral Surg* 1979;37:732-5.
82. Meechan JG, MacGregor IDM, Rogers SN, et al. The effect of smoking on immediate post-extraction socket filling with blood and the incidence of painful socket. *Br J Oral Maxillofac Surg* 1988;26:402-9.
83. Swanson AE. A double-blind study on the effectiveness of tetracycline in reducing the incidence of fibrinolytic alveolitis. *J Oral Maxillofac Surg* 1989;47:165-7.
84. Nordenram A, Sydens G, Odegaard J. Neomycin-bacitracin cones in impacted third molar sockets. *Int J Oral Surg* 1973;2:279-83.
85. Goldman DR, Kilgore DS, Panzer JD, Atkinson WH. Prevention of dry socket by local application of lincomycin in Gelfoam. *Oral Surg* 1973;35:472-4.
86. Hall HD, Bildman BS, Hand CD. Prevention of dry socket with local application of tetracycline. *J Oral Surg* 1971;29:35-7.
87. Mitchell L. Topical metronidazole in the treatment of "dry socket." *Br Dent J* 1984;156:132-4.
88. Kipp DP, Goldstein BH, Weiss WW Jr. Dysesthesia after mandibular third molar surgery: a retrospective study and analysis of 1,377 surgical procedures. *J Am Dent Assoc* 1980;100:185-92.
89. Wofford DT, Miller RI. Prospective study of dysesthesia following odontectomy of impacted mandibular third molars. *J Oral Maxillofac Surg* 1987;45:15-9.
90. Mason DA. Lingual nerve damage following lower third molar surgery. *Int J Oral Maxillofac Surg* 1988; 17:290-4.
91. Robinson PP. Observations on the recovery of sensation following inferior alveolar nerve injuries. *Br J Oral Maxillofac Surg* 1988; 26:177-89.
92. Rood JP. The radiological prediction of inferior alveolar nerve injury during third molar surgery. *Br J Oral Maxillofac Surg* 1990;28:20-5.
93. Blaeser BF, August MA, Donoff RB, et al. Panoramic radiographic risk factors for inferior alveolar nerve injury after third molar extraction. *J Oral Maxillofac Surg* 2003;61:417-21.
94. Oberman M, Horowitz I, Ramon Y. Accidental displacement of impacted maxillary third molars. *Int J Oral Maxillofac Surg* 1986;15:756-8.
95. Osborne WH, Snyder AJ, Tempel TR. Attachment levels and crevicular depths at the distal of mandibular second molars following removal of adjacent third molars. *J Periodontol* 1982;53:93-5.
96. Meister F Jr, Nery EB, Angell DM, Meister RC. Periodontal assessment following surgical removal of mandibular third molars. *Gen Dent* 1986; 34-Apr:120-3.
97. Kugelberg CF, Ahlstrom U, Ericson S, Hugoson A. Periodontal healing after impacted lower third molar surgery. *Int J Oral Surg* 1985;14:29-40.
98. Marmary Y, Brayer L, Tzukert A, Feller L. Alveolar bone repair following extraction of impacted mandibular third molars. *Oral Surg* 1985;60:324.
99. Ash MM Jr, Costich ER, Hayward JR. A study of periodontal hazards of third molars. *J Periodontol* 1962;33:209-19.
100. Kugelberg CF. Periodontal healing two and four years after impacted lower third molar surgery. *Int J Oral Maxillofac Surg* 1990;19:341-5.
101. Kugelberg CF, Ahlstrom U, Ericson S, et al. The influence of anatomical, pathophysiological and other factors on periodontal healing after impacted lower 3rd molar surgery a multiple-regression analysis. *J Clin Periodontol* 1991;18:37-43.
102. Grondahl HG, Lekholm U. Influence of mandibular third molars on related supporting tissues. *Int J Oral Surg* 1973; 2:137-42.
103. Chin Quee TA, Gosselin D, Miller EP, Stamm JW. Surgical removal of the fully impacted mandibular third molar. *J Periodontol* 1985;56:625-30.

Preprosthetic and Reconstructive Surgery

Daniel B. Spagnoli, DDS, PhD

Steven G. Gollehon, DDS, MD

Dale J. Misiek, DMD

Preprosthetic surgery in the 1970s and early 1980s involved methods to prepare or improve a patient's ability to wear complete or partial dentures. Most procedures were centered around soft tissue corrections that allowed prosthetic devices to fit more securely and function more comfortably. In severe cases bony augmentation was incorporated and included such procedures as cartilage grafts, rib grafts, alloplastic augmentation, visor osteotomies, and sandwich grafts. Patients who were poor candidates for surgery were often left with less-than-satisfactory results both functionally and esthetically.

In the late 1970s Brånemark and colleagues demonstrated the safety and efficacy of the implant-borne prosthesis.¹ In the 1990s implantology, distraction osteogenesis, and guided tissue regeneration significantly expanded the capabilities of today's reconstructive and preprosthetic surgeon. Genetically engineered growth factors will soon revolutionize our thoughts about reconstructive procedures. As a result, more patients are able to tolerate procedures because they are given increased freedom and satisfaction with regard to their prosthetic devices and, in many cases, undergo less-invasive techniques.

In spite of the fact that routine dental care has improved over the past century, approximately 10% of the population is either partially or completely edentulous and > 30% of patients older than 65 years are completely edentulous.² Although these figures are predicted to decrease over the next several decades, the treatment of partial and total edentulism will never be completely eliminated from the oral and maxillofacial surgeon's armamentarium.

Since the primary goal in preprosthetic reconstructive surgery is to eliminate the condition of edentulism, one must consider the etiology of the edentulous state when evaluating patients and planning treatment. In many cases the etiology of a patient's edentulism has a major bearing on the reconstructive and restorative plan. Edentulism arising from neglect of the dentition and/or periodontal disease often poses different reconstructive challenges than does that resulting from trauma, ablative surgery, or congenital defects. Although restoration of a functional dentition is the common goal, each specific etiology poses its own unique set of challenges. The goal of preprosthetic and reconstructive surgery in the twenty-first century is to establish a functional biolog-

ic platform for supportive or retentive mechanisms that will maintain or support prosthetic rehabilitation without contributing to further bone or tissue loss. This environment will allow for a prosthesis that restores function, is stable and retentive, preserves the associated structures, and satisfies esthetics.³

Characteristics of Alveolar Bone in the Edentulous Patient

Native alveolar bone responds to the functional effects (or lack thereof) caused by edentulism. Increased resorption owing to traditional methods of oral rehabilitation with complete and partial dentures often results in an overall acceleration of the resorptive process. The mandible is affected to a greater degree than the maxilla owing to muscle attachments and functional surface area.⁴ As a result, there is proportionally a qualitative and quantitative loss of tissue, resulting in adverse skeletal relationships in essentially all spatial dimensions (Figure 9-1).

General systemic factors, such as osteoporosis, endocrine abnormalities, renal dysfunction, and nutritional deficiencies, play a role in the overall rate of alveolar atrophy. Local factors, including

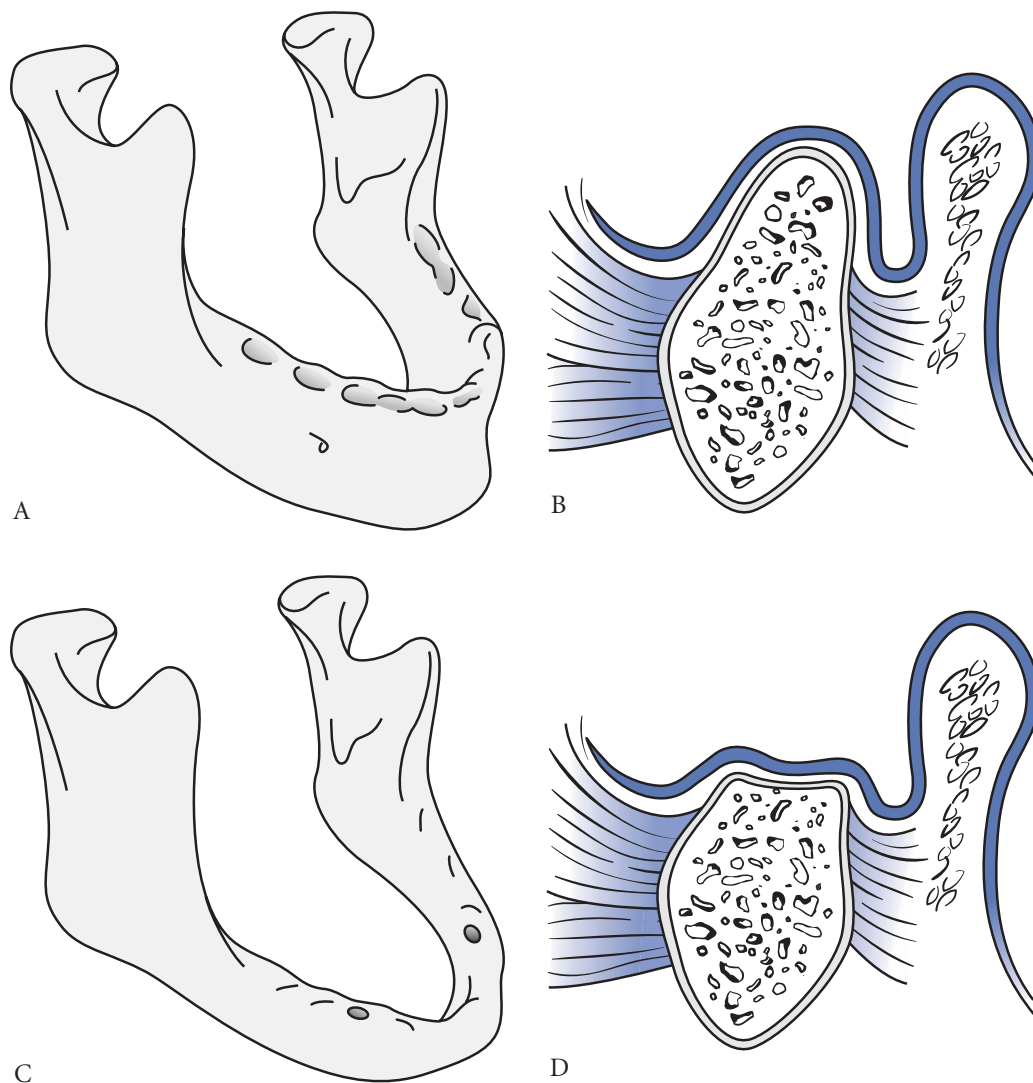


FIGURE 9-1 The diagrams show patterns and varying degrees of severity of mandibular atrophy. A, Mandible shows minimal alveolar bone resorption. B, Cross-section of large alveolar ridge including mucosal and muscular attachments. C, Mandible shows severe loss of alveolar bone that has resulted in residual basal bone only. D, Cross-section shows resorbed alveolar ridge, with muscular attachments. Adapted from Tucker MR. *Ambulatory preprosthetic reconstructive surgery*. In: Peterson LJ, Indresano AT, Marciani RD, Roser SM. *Principles of oral and maxillofacial surgery*. Vol 2. Philadelphia (PA): JB Lippincott Company; 1992. p. 1104.

jaw function, vascular changes, increased physical demands owing to decreased mandibular plane angle, adverse prosthetic loading, mucosal inflammation, vascular changes, and the number and extent of previous surgeries involving mucoperiosteal elevation, also contribute to progressive alveolar bone loss.⁵

Although the factors contributing to bone loss and the resulting patterns are well understood, the rate of bone loss

varies significantly from individual to individual. The consistent factor is the overall duration of the patient's edentulous state.

Functional Effects of Edentulism

The maxillomandibular relationship is altered in all spatial dimensions as a result of the loss of physiologic function and teeth. There is a progression toward

decreased overall lower facial height, leading to the typical overclosed appearance, decreased alveolar support for traditional prostheses, encroachment of muscle and tissue attachments to the alveolar crest resulting in progressive instability of conventional soft tissue–borne prosthetic devices, neurosensory changes secondary to atrophy, and an overall reduction in size and form in all three dimensions. These changes result in an overall decrease in fit and increase in patient discomfort with the use of conventional dentures. The prolonged effects of edentulism compounded with systemic factors and functional physical demands from prosthetic loading produce atrophy that, in severe cases, places the patient at significant risk for pathologic fracture. As a result of the above effects, a goal-oriented approach to treatment is the most appropriate. The overall objectives include the following⁶: (1) to eliminate pre-existent or recurrent pathology; (2) to rehabilitate infected or inflamed tissue; (3) to reestablish maxillomandibular relationships in all spatial dimensions; (4) to preserve or restore alveolar ridge dimensions (height, width, shape, and consistency) conducive to prosthetic restoration; (5) to achieve keratinized tissue coverage over all load-bearing areas; (6) to relieve bony and soft tissue undercuts; (7) to establish proper vestibular depth and repositioning of attachments to allow for prosthetic flange extension if necessary; (8) to establish proper notching of the posterior maxilla and palatal vault proportions; (9) to prevent or manage pathologic fracture of the atrophic mandible; (10) to prepare the alveolar ridge by onlay grafting, corticocancellous augmentation, sinus lift, or distraction osteogenesis for subsequent implant placement; and (11) to satisfy facial esthetics, speech requirements, and masticatory challenges. To satisfy these goals, a treatment plan directly addressing each existing condition is indicated. Such a plan should include correction of maxillomandibular relationship, restoration of ridge form and

soft tissue relationship including histologic type and condition, bone and/or soft tissue grafting/repositioning, options regarding implant-supported or -stabilized prosthetic treatment, immediate versus delayed implant placement, preservation of existing alveolar bone with implants, and correction or minimization of the effects of combination syndrome in cases involving partially edentulous patients.

Prior to developing a plan one must consider the amount and source of bone loss. Common causes of primary bone loss include trauma, pathology such as periodontal disease, destructive cysts or tumors, and bone loss associated with extraction and alveoloplasty. Secondary bone loss, if not prevented, can follow all of the primary types listed above. Secondary maxillary/mandibular bone loss is an insidious regressive remodeling of alveolar and even basal bone that is a sequela of tooth loss. This secondary process is referred to as edentulous bone loss and varies in degree based on a number of factors. The pathophysiology of edentulous bone loss relates to an individual's characteristic anatomy, metabolic state, jaw function, and prior use of and type of prosthesis. Anatomically, individuals with long dolichocephalic faces typically have greater vertical ridge dimensions than do those with short brachycephalic faces. In addition, those with shorter faces are capable of a higher bite force. Metabolic disorders can have a significant impact on a patient's potential to benefit from osseous reconstructive surgery. Nutritional or endocrine disorders and any associated osteopenia, osteoporosis, and especially osteomalacia must be addressed prior beginning bone reconstruction.⁵ Mechanical influences on the maxilla and mandible have a variable effect on the preservation of bone. The normal nonregressive remodeling of bone essentially represents a balance between breakdown and repair that

maintains bone osteons, the functional unit of bone, and consequently the viability of bone shape and form. Bone requires stimulation often referred to as "the minimum essential strain" to maintain itself. Both insufficient strain and excessive loads can lead to regressive remodeling of bone, with the classic example being denture compression leading to an anterior-posterior and transverse deficient maxilla opposing a wide mandible that is excessive in its anterior-posterior dimension.

Residual ridge form has been described and classified by Cawood and Howell⁷ (Figures 9-2 and 9-3) as follows:

- Class I—dentate
- Class II—postextraction
- Class III—convex ridge form, with adequate height and width of alveolar process
- Class IV—knife-edge form with adequate height but inadequate width of alveolar process
- Class V—flat-ridge form with loss of alveolar process
- Class VI—loss of basal bone that may be extensive but follows no predictable pattern

Modifications to this classification that may be relevant to contemporary reconstructive methods include subclassifications in II and VI: Class II—no defect, buccal wall defect, or multiwall defect or deficiency; and Class VI—marginal resection defect or continuity defect.

Medical Considerations

During the patient evaluation process, particular attention to the patient's chief complaint and concerns is imperative; a thorough understanding of the past medical history is mandatory in the treatment and evaluation of any patient. A current or previous history regarding the patient's success or failure at maintaining previous prosthetic devices is also necessary. Careful attention to patient's func-

tional, cognitive, and physical ability to participate with the reconstructive plan is crucial to the success of future restorations and overall patient satisfaction. The evaluation process should include a comprehensive work-up of the patient's predilection for metabolic disease, including serum calcium, phosphate, albumin, alkaline phosphatase, and calcitonin levels.⁵ Decreased renal function and the presence of a vitamin D deficiency should also be ruled out. The maintenance of bone mass requires a balanced calcium metabolism, a functional endocrine system, and physiologic loading of bone tissue. Secondary medical complications affecting edentulous patients include candidiasis, hyperkeratosis, fibrous inflammatory hyperplasia, dysplasia, papillomatosis, breathing changes, and diet compromise away from natural foods high in fiber and toward an increase in processed foods.

Hard and Soft Tissue Examination

A problem-oriented physical examination should include evaluation of the maxillo-mandibular relationship; existing alveolar contour, height, and width; soft tissue attachments; pathology; tissue health; palatal vault dimension; hamular notching; and vestibular depth. Identification of both soft tissue and underlying bone characteristics and/or deficiencies is essential to formulate a successful reconstructive plan. This plan should be defined and presented to the patient both to educate the patient and to allow him or her to play a role in the overall decision-making process with all members of the dental team.

The soft tissue evaluation should involve careful visualization, palpation, and functional examination of the overlying soft tissue and associated muscle attachments (Figure 9-4). Retraction of the upper and lower lips help one identify muscle and frenum attachments buccally. A mouth mirror can be used lingually to

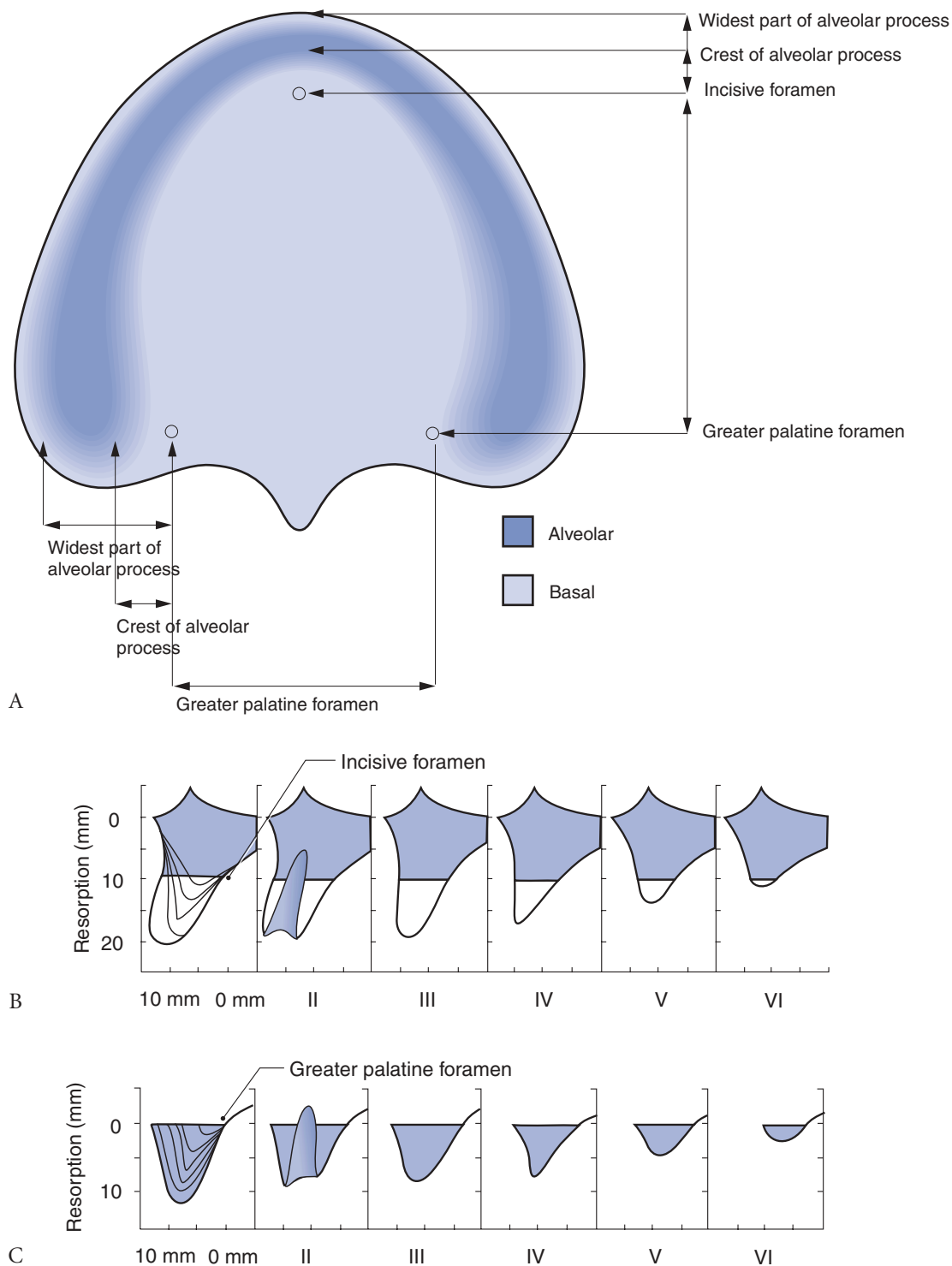


FIGURE 9-2 Maxillary horizontal measurements (A). Classification of resorption of maxillary alveolar ridge: anterior (B) and posterior (C). Adapted from Cawood JI, Howell RA.⁷

tent the floor of mouth to evaluate the mylohyoid–alveolar ridge relationship. Careful palpation with manipulation of both upper and lower alveolar ridges is the best diagnostic determinant of loose and

excessive soft tissue. One must be aware of occult bony abnormalities obscured by soft tissue excess, especially in cases where adequate alveolar ridge height and width is imperative for implant placement (Figure

9-5). Such abnormalities can lead to embarrassing and unexpected changes in the restorative plan at the time of mucoperiosteal reflection of the overlying soft tissue. If conventional prosthetic restorations are planned, attention to bony and soft tissue undercuts that oppose the prosthetic path of insertion must be addressed. Critical attention should be given to deficiencies in the palatal vault or buccal/lingual vestibule, defects in the alveolar ridge, and the presence of buccal, palatal, or lingual exostoses. During this evaluation process, final decisions should be made regarding the prognosis of any existing teeth and their role in the overall rehabilitation and contribution to the long-term success of the treatment plan. Finally, careful neurosensory evaluation of the patient with severe regressive remodeling may play a significant role in the determination of future grafting or repositioning procedures aimed at maintaining proper neurosensory function in conjunction with prosthetic rehabilitation.

Radiographic Evaluation

To date, the panoramic radiograph provides the best screening source for the overall evaluation and survey of bony structures and pathology in the maxillofacial skeleton. From examination radiographs, one can identify and evaluate pathology, estimate anatomic variations and pneumatization of the maxillary sinus, locate impacted teeth or retained root tips, and gain an overall appreciation of the contour, location, and height of the basal bone, alveolar ridge, and associated inferior alveolar neurovascular canal and mental foramina.⁸

Calibration of radiographs for magnification is necessary to determine the spatial dimensions needed to plan implant restorations adjacent to neurovascular structures or the maxillary sinus, to determine defect size and shape in distraction osteogenesis, and to predict the necessary dimensions of planned augmentation materials.

Posteroanterior and lateral cephalometric radiographs can be used to evaluate interarch space, relative and absolute skeletal excesses or deficiencies existing in the maxilla or mandible, and the orientation of the alveolar ridge between arches. These are exceptionally useful when the presence of skeletal discrepancies may necessitate orthognathic correction to provide acceptable functional relationships for prosthetic rehabilitation. Cephalometric analysis in combination with mounted dental models helps one establish the planned path of insertion of future prosthetic devices as well as identify discrepancies in interarch relationships that affect the restorative plan (Figure 9-6).⁹

In recent years computed tomography (CT) has played an increased role in the treatment planning of complex cases. Detailed evaluation of alveolar contour, neurovascular position, and sinus anatomy is available for the subsequent planning of advanced implant applications. Zygomatic implants that obviate the need for sinus lifting can be used in cases involving edentulous atrophic maxillary sinuses (Figure 9-7). Careful evaluation of the path of insertion is easily accomplished using coronal CT examination of the maxillary sinuses. CT can also provide the clinician with information regarding bone quantity and volume as well as density (Figure 9-8).

In many cases the combination of imaging modalities and mounted models with diagnostic wax-ups can be helpful in determining the reconstructive plan. These elements are also useful in the fabrication of surgical stents guiding implant placement or grafting procedures. Surgical stents fabricated from CT-based models combine esthetic and surgical considerations; bridge the gap between the model surgery and the operation; and allow cooperation between the surgeon, laboratory technician, periodontist, prosthodontist, and orthodontist, which results in a cost-effective prosthetic reconstruction with improved esthetic

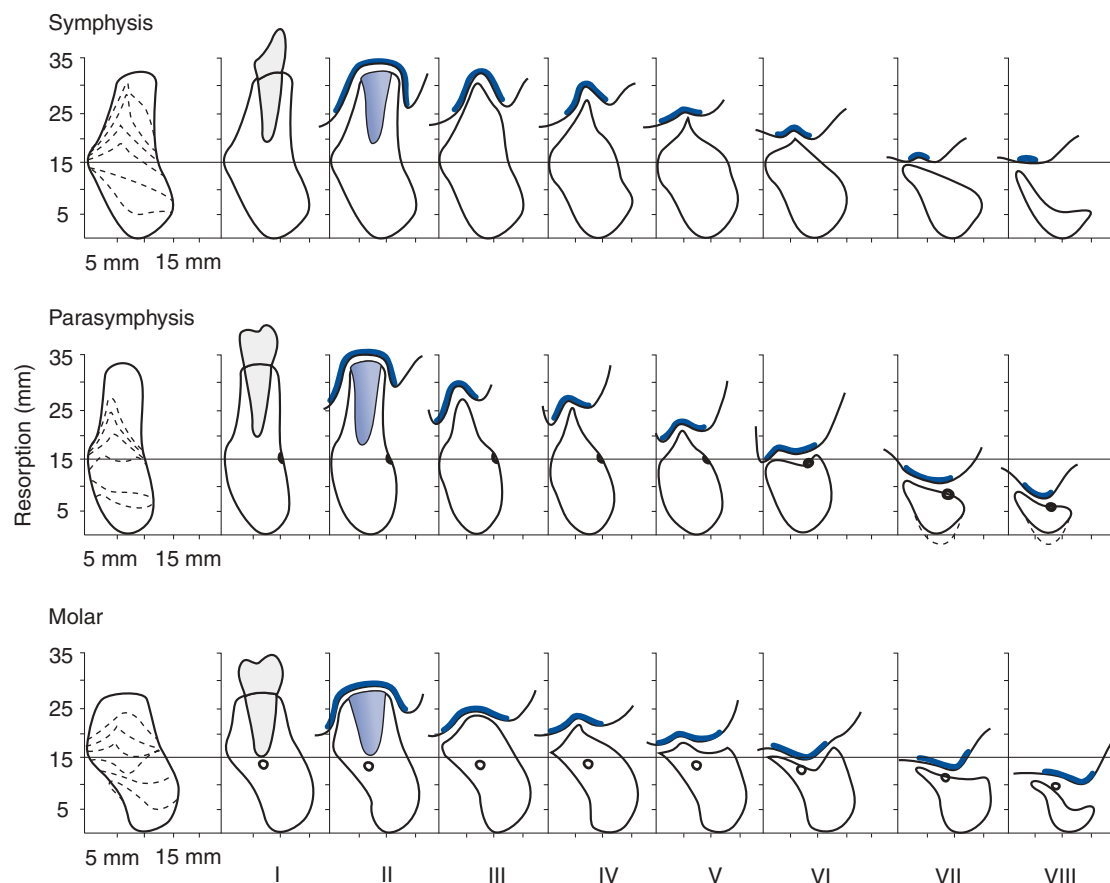


FIGURE 9-3 Modified Cawood and Howell classification of resorption. The thicker line illustrates the amount of attached mucosa, which decreases with progressive resorption. Adapted from Cawood JI, Howell RA.⁷

results (Figure 9-9). In addition, accuracy of the surgical procedure can be greatly increased with an overall decrease in the duration of the procedure.

Treatment Planning Considerations

The conventional tissue-borne prosthesis has given way to implant-borne devices that have proven superior in providing increased patient function, confidence, and esthetics. Preprosthetic surgical preparation of areas directly involved with device support and stability are of primary importance and should be addressed early in the treatment plan.

Overlying soft tissue procedures need not be attempted until satisfactory positioning of underlying bony tissues is complete. As a general rule, one should always maintain excessive soft tissue coverage

where available until the final bony augmentation is complete. Complications such as dehiscence, loss of keratinized mucosa, and obliteration of vestibular depth can be avoided if respect is given to overlying soft tissue. Once bony healing is complete, if the overlying tissue is clearly excessive, removal of the excess soft tissue can proceed without complication. Using the classification of edentulous jaws according to Cawood and Howell,⁷ the reconstructive surgeon can plan treatment for his or her patients accordingly.

Many excellent reconstructive plans achieve less-than-satisfactory results because of inadequate anesthetic management of the patient during the procedure. Although many procedures can be accomplished under local anesthesia or sedation, the clinician must have a low threshold to provide general anesthesia in a controlled

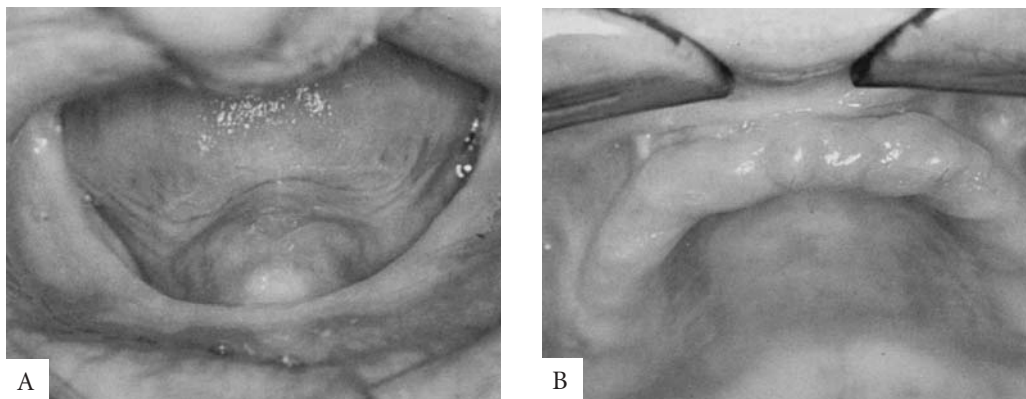


FIGURE 9-4 A, Example of mandible with muscular attachments at or near the crest of the ridge. Also note the absence of fixed keratinized tissue over the alveolar ridge area. B, Example of maxilla with inadequate vestibular depth anteriorly, frenal attachments near the crest of the alveolar ridge, and flabby soft tissue over the alveolar ridge crest. Reproduced with permission from Tucker MR. Ambulatory preprosthetic reconstructive surgery. In: Peterson LJ, Indresano AT, Marciani RD, Roser SM. Principles of oral and maxillofacial surgery. Vol 2. Philadelphia (PA): JB Lippincott Company; 1992. p. 1107.

operative setting to allow for appropriate manipulation of the surgical site to achieve the necessary goals of the surgical procedure. Patient desires, health issues, surgeon comfort, and the magnitude of the deformity should all be considered when making decisions regarding anesthetic type.

The loss of maxillary and mandibular bone can have mild to severe effects on an individual's well-being. Interestingly, the size of the defect does not always correlate with the level of debilitation perceived by the patient. Individuals missing a single anterior tooth with an associated buccal wall defect can feel quite compromised, whereas, although it is rare, we have encountered totally edentulous patients who live and function without even a removable denture. This variability underscores the need for the dental team to understand the patient's chief complaint and desired restorative goals. After obtaining a medical dental history and diagnostic database, time spent educating the patient about his or her problem may help the patient refine goals and make it easier to develop a satisfactory treatment plan. Since acceptable prosthetic reconstruction can be achieved with a variety of treatments that vary in complexity, invasiveness, time to completion, simplicity of

maintenance, functional attributes, esthetic attributes, and cost, it is reasonable to develop more than one treatment plan that can address the patient's needs.

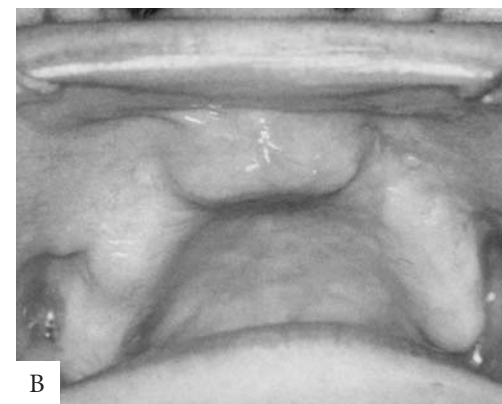
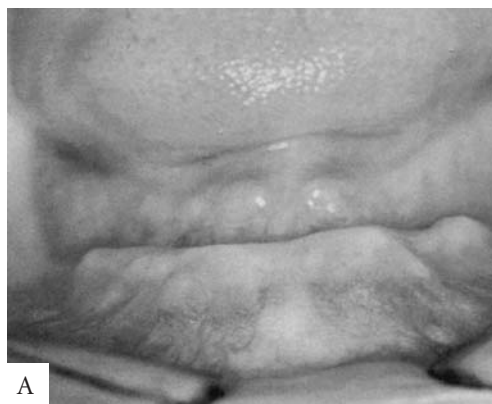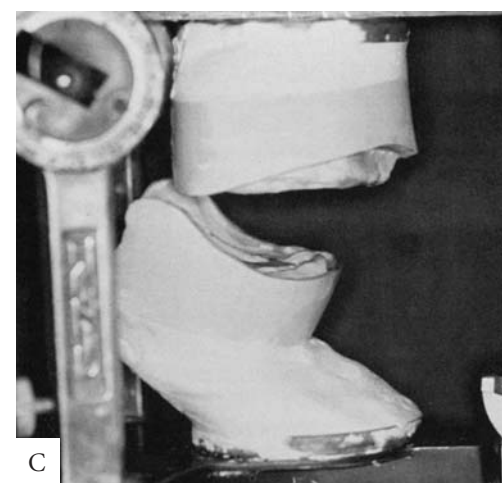


FIGURE 9-5 A, Evaluation of the bone in the mandible reveals contour irregularities of the anterior region and a vertical alveolar deficiency in the posterior mandible area bilaterally. B, Gross irregularities are evident along the maxillary alveolar ridge, with bilateral contour defects in the canine-premolar area. C, Mounted casts are used to evaluate mandibular alveolar ridge deficiency and anteroposterior skeletal deficiency of the mandible. Reproduced with permission from Tucker MR. Ambulatory preprosthetic reconstructive surgery. In: Peterson LJ, Indresano AT, Marciani RD, Roser SM. Principles of oral and maxillofacial surgery. Vol 2. Philadelphia (PA): JB Lippincott Company; 1992. p. 1106.



The patient's overall health status, compliance potential, patience, and ability to maintain the final prosthesis/prostheses must be considered when planning reconstructive preprosthetic surgical procedures as well as future prosthetic rehabilitation. Moreover, a multidisciplinary approach involving the patient's input is imperative for long-term success and patient satisfaction.³

Principles of Bone Regeneration

There are many approaches available for reconstructing a deficiency or defective osseous anatomy of the alveolar portions of the facial skeleton. These include biologically viable autogenous bone grafts, nonviable homologous allogeneic or heterogeneic bone implants, recombinant human bone morphogenetic protein-2 (rhBMP-2), and tissue regeneration by distraction histogenesis. These techniques can be used alone or in combination and

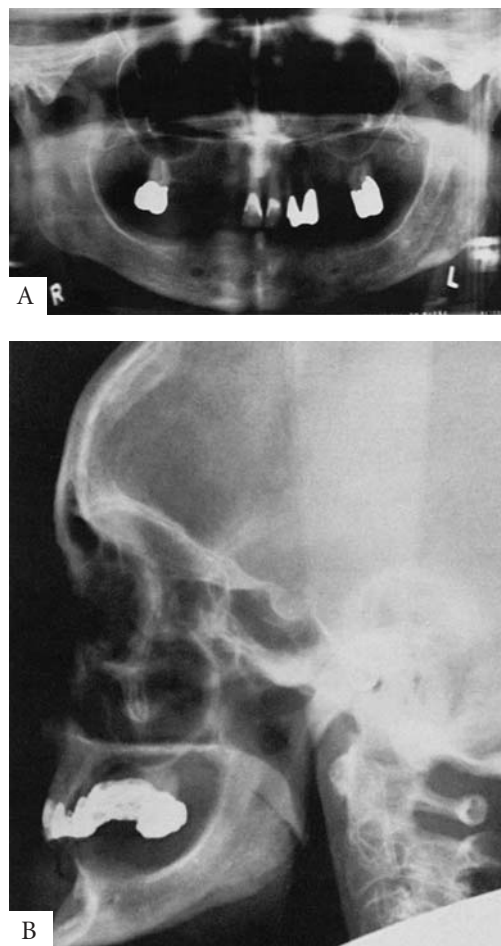


FIGURE 9-6 A, Panoramic radiograph shows an apparently adequate alveolar ridge height. B, Lateral cephalometric radiograph of the same patient shows a concavity in the anterior area of the alveolar ridge, which produces a knife-edge ridge crest. This type of alveolar ridge deformity cannot be fully appreciated except on a cephalometric radiograph. Reproduced with permission from Tucker MR. *Ambulatory preprosthetic reconstructive surgery*. In: Peterson LJ, Indresano AT, Marciani RD, Roser SM. *Principles of oral and maxillofacial surgery*. Vol 2. Philadelphia (PA): JB Lippincott Company; 1992. p. 1107.

often are enhanced by the application of adjunct procedures such as rigid fixation and guided bone regeneration. The choice of a reconstructive technique is influenced by many variables, including the location, ridge relationships, dimensions of the defect, dimensions of underlying bone stock, soft tissue availability and viability, and esthetic goals.

Beyond choosing a reconstructive technique, one must also consider inher-

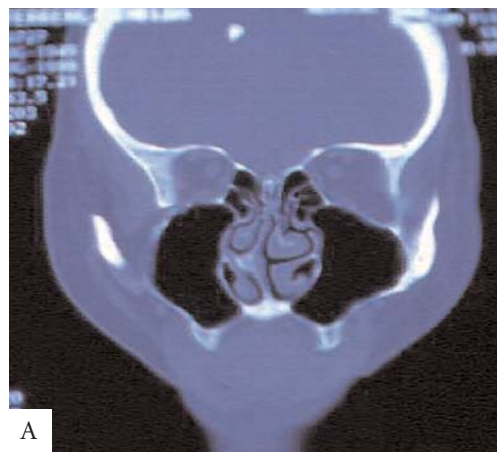


FIGURE 9-7 A, Preoperative computed tomography (CT) scan of the maxillary sinuses to allow for angulation and size measurement of a transantral implant restoration. B, The information gained from the CT evaluation is applied to the surgical placement of implants. C, Postoperative panoramic radiograph of the implant placement traversing the maxillary sinus.

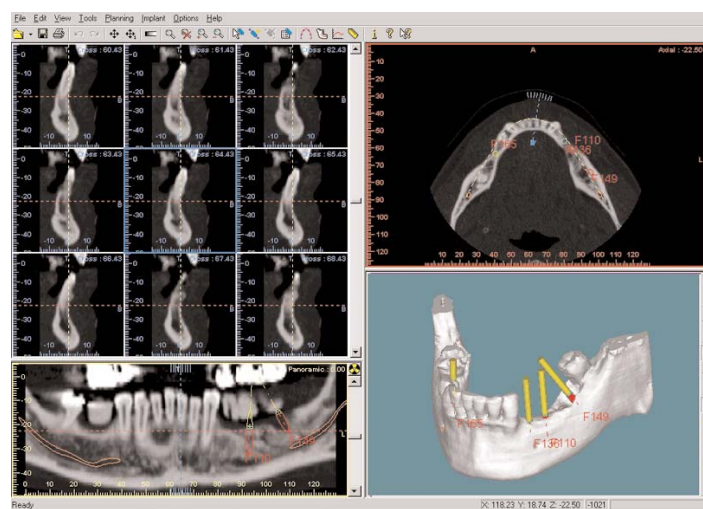
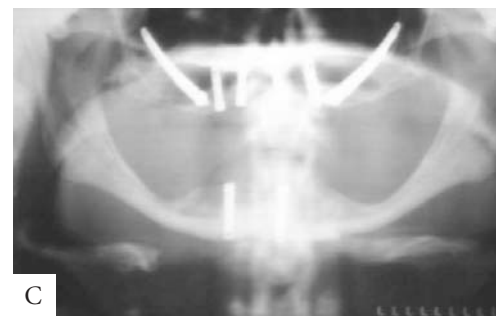
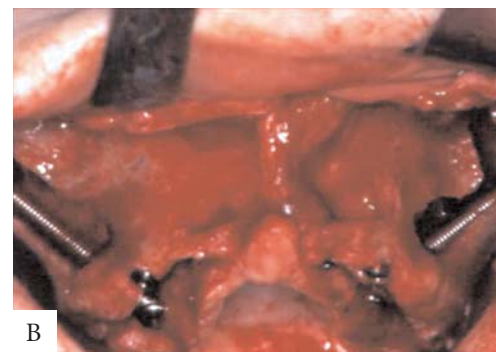
FIGURE 9-8 Computed tomography-based imaging used to evaluate bone density, quality, contour, and volume. This information, which has cross-sectional tomographic and three-dimensional components, can be used to plan treatments for complex cases of implant placement. (Courtesy of SimPlant Technologies)

ent properties of facial bone and its natural growth and remodeling characteristics. For bone to grow or regenerate in direct pressure areas, it must go through an endochondral replacement process such as that in active long bones or the mandibular condyle. Areas of the skeleton that are under pressure must be covered by cartilage—a tissue adapted to this function

because it grows interstitially; is minimally calcified, avascular, turgid, and nourished by diffusion; and does not require a membrane for nutrition. In contrast, bone cannot withstand significant pressure because of compression closure of the vascular bed in the periosteum. Because bone matrix is calcified, it must be vascularized to grow, regenerate, or be sustained. In

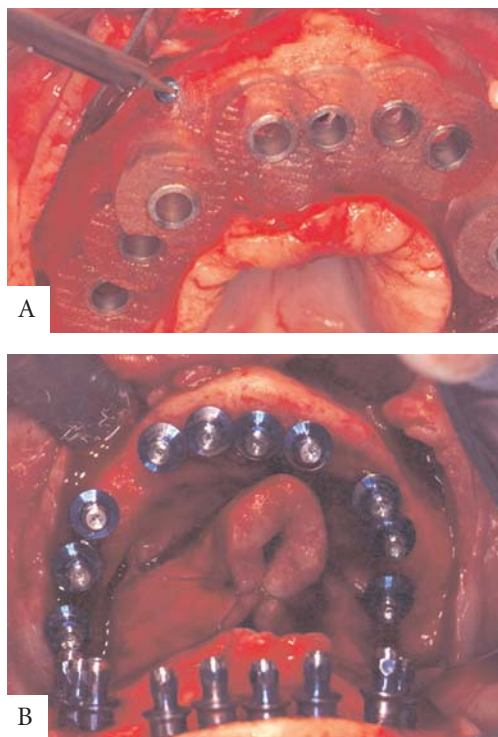


FIGURE 9-9 A, Computer-generated surgical stent for implant placement. B, Clinical photograph of implants placed with the use of a computer-generated surgical stent.

addition, calcification of the matrix precludes interstitial growth, so bone can only grow by the appositional activity of its membranes. Periosteum has a dense connective tissue component and is structurally adapted to transfer tensile forces that are generated by muscles, tendons, and ligaments to bone.

The majority of the facial skeleton is not under load during development; thus it does not require an endochondral phase, so it develops by an intramembranous process. In the natural state, alveolar bone is protected from load by the dentition and is actually stimulated by strain forces transferred to the alveolus via the periodontal ligament. Although technology to date has not been able to exactly replicate this interface, osseointegrated implants have a similar protective effect on underlying bone, native or reconstructed, and thus should be a component of all alveolar bone reconstructive plans.

Another aspect of facial bone growth and development relevant to reconstruction that needs to be clearly understood is the regional differences in periosteum activity that exist in association with facial bones. It is a misconception that the cortices of growing facial bones are produced only by periosteum. In fact, at least half of the facial bone tissue is formed by endosteum, the inner membrane lining the medullary cavity. Of great significance to the placement of alveolar ridge or alveolar defect bone grafts are the findings that about half of the periosteal surfaces of facial bones are resorptive in nature and half are depository. These properties exist because facial growth is a complex balance between deposition and resorption that adds to the size and shape of a bone while it is being displaced to achieve its final position and relationships to the bones of the facial cranial skeleton. One can study the works and diagrams of Enlow and colleagues to gain a better understanding of these concepts and the regional variations of naturally resorptive and depository surfaces of the facial skeleton.¹⁰ This understanding should help one better determine the most efficacious location for graft placement. For example, the anterior surface of the maxillary and mandibular alveolar ridges are resorptive and thus are best treated by the placement of interpositional grafts in association with the endosteal aspects of these bones, as seen in Figure 9-10. Interestingly, the periosteal lining of the maxillary sinus is also mostly resorptive. Successful bone grafting via the sinus lift technique has been demonstrated by numerous authors using a variety of graft techniques. It has been our experience that sinus lift grafts of autogenous cancellous bone, and bone induced to grow by rhBMP-2, secondarily treated with osseointegrated implants remodel over time. A follow-up of > 5 years of some of our patients has shown that the grafts become scalloped over the surfaces of the implants, similar to the relationship seen when natural roots extend above the floor of a pneu-

matized sinus. This finding suggests that the capacity for remodeling by the periosteal membrane exists even after the face is mature, and that viable bone established by autogenous grafts or rhBMP-2-mediated induction responds to this process.¹¹

Another concept of facial growth that bears relevance to contemporary methods of reconstruction is the functional matrix concept that has largely been described by Moss.¹² This concept states that bone, itself, does not regulate the rate of bone growth. Instead, it is the functional soft tissue matrix related to bone that actually directs and determines the skeletal growth process. The vector and extent of bone growth are secondarily dependent on the growth of associated soft tissue. Bone, by virtue of its matrix maturity, gives feedback to this process by either inhibiting it or allowing it to accelerate. Thus, the volume of bone generated is based on genetic properties of the soft tissue and a mechanical equilibration between bone and its soft tissue matrix. These principles are visited when distraction forces are applied to osteotomized bone.

In 1989 Ilizarov forwarded the theory of tension-stress applied to bone as a mechanism of lengthening bone.^{13,14} He stated that controlled mechanically applied tension-stress allows bone and soft tissue to regenerate in a controlled, reliable, and reproducible manner. During the latency phase of distraction, there is a periosteal and medullary revascularization and recovery. Simultaneously a relatively hypovascular fibrous interzone develops that is rich in osteoprogenitor cells and serves as a pseudo-growth plate. Adjacent and connected to the interzone are areas of hypervascular trabeculae aligned in the direction of the distraction. Osteoprogenitor cells in the interzone differentiate into osteoblasts and line the trabeculae. As distraction progresses, appositional bone growth enlarges the trabeculae. This underscores the idea that mechanical

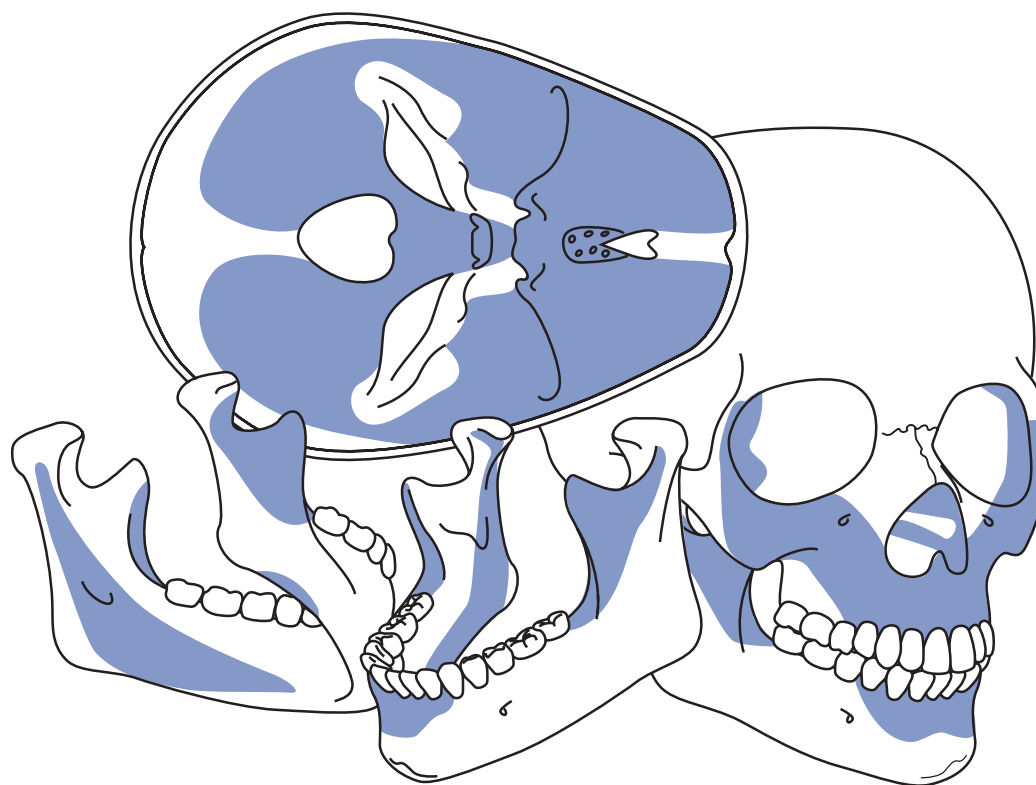


FIGURE 9-10 Growth and remodeling field of the craniofacial skeleton. Resorptive fields are shaded and depository fields are free of shading.

stress applied to the soft tissue matrix of osteotomized bone can reactivate these native growth processes.

It is interesting to note that if the distraction device lacks sufficient mechanical stability or if the rate of distraction progresses too rapidly, the tissue established may mature very slowly or not at all. On the other hand, if distraction progresses too slowly, the regenerate may mature prematurely or there may be increased pain during the procedure. We have found that if there is recurrent pain associated with the activation of a distractor, a slight increase in the rate of distraction usually reduces the pain. In many ways distraction histogenesis recapitulates the process of native bone growth directed by the influence of the soft tissue matrix. Premature maturation of the matrix increases resistance to distraction necessitating increased distraction force and the perception of pain by the patient. This suggests that even the feedback role of the bone matrix is active during this process. In most

cases the net result of distraction histogenesis is the formation of a bone ossicle that is vascular and rich in osteolysis, has a shape similar to the native bone, and has an appropriate soft tissue envelope. Often distraction histogenesis alone is sufficient to regenerate deficient alveolar ridge anatomy. In other cases distraction can be used in association with bone grafting, especially when the associated bone stock is of less-than-ideal shape or volume. In some cases, particularly in the posterior mandible, the distraction osteotomy can be extended beyond the area of intended implants so that the distraction process actually grows the bone needed for the graft. Bone grafts placed adjacent to regenerate typically mature very rapidly owing to the vascularity, cellularity, and high concentration of natural BMP in regenerate.

Bone Grafts

Bone graft principles are discussed in Chapters 12, “Bone Grafting Strategies for

Vertical Alveolar Augmentation,” 39, “Bony Reconstruction of the Jaws,” 40, “Microvascular Free Tissue Transfer,” and 43, “Reconstruction of the Alveolar Cleft.” Nonetheless, some of the characteristics of grafts and bone implants pertinent to preprosthetic surgery are examined here. By far the most common graft type is the free autogenous viable bone graft. Since these grafts are from the patient, they do not elicit an immune-rejection response. Common areas for procurement include the maxilla, mandible, cranium, tibial plateau, iliac crest, and rib. The shape, form, and volume of the graft procured are linked to the defect to be reconstructed. These grafts are used as corticocancellous blocks or particulate cancellous grafts compacted and shaped by various membranes or trays. In many instances purely cancellous blocks or cancellous particulate bone is used again with membranes or trays or sandwiched in unloaded osteotomies or defects. A third form includes purely cortical grafts, primarily used to form a wall or strut in association with a defect that is simultaneously packed with particulate cancellous bone. Cortical grafts revascularize very slowly and have minimal to no cell survival; thus, they are not ideal for implant placement.¹⁵

Cancellous grafts have the greatest concentration of osteogenic cells, and the particulate form of these grafts has the greatest cell survival owing to better diffusion and rapid revascularization. These grafts must completely undergo a two-phase mechanism of graft healing.¹⁶ Osteoblasts that survive transplantation proliferate and form osteoid. This process is active in the first 2 to 4 weeks, and the definitive amount of bone formed is related to the quantity of osteoid formed in phase one. Phase two starts around the second week after grafting, and although it peaks in intensity at approximately 4 to 6 weeks, it continues until the graft matures. The initiation of phase two is marked by osteoclastic cell activity within

the graft. Osteoclasts remove mineral, forming Howship's lacunae along the trabeculae. This resorptive process exposes the extracellular matrix of bone, which is the natural location of the bone-inductive glycoprotein BMP. Exposure of BMP initiates an inductive process characterized by chemotaxis of mesenchymal stem cells, proliferation of cells in response to mitogenic signals, and differentiation of cells into osteoblasts.¹⁷ Inducible cell populations may be local or distant from the graft site. Examples of local cell populations that may contribute to the graft include osteoprogenitor cells in the graft endosteum, stem cells of the transplanted marrow, or cells in the cambium layer of adjacent periosteum. Additional inducible pluripotent cells may arrive at the graft site with budding blood vessels. During phase two there is progressive osteoclastic resorption of phase one osteoid and nonviable graft trabeculae; this continues to expose BMP, which perpetuates the differentiation of osteoblasts, leading to the formation of mature vascular osteocyte-rich bone.

This two-phase bone graft healing process is the one that most reliably and quickly can regenerate bone with characteristics suitable for implant placement. When choosing a bone graft, one must consider its ultimate purpose; since most grafts associated with preprosthetic surgery are designed to support implants, these grafts must provide the biologic environment necessary for osseointegration. Osseointegration is a biologic process, and its long-term success requires vascular osteocyte-rich bone.

Another adjunct to preprosthetic bone reconstruction is the use of allogeneic bone. Since these grafts are nonviable, they are technically implants. Allogeneic bone is procured in a fresh sterile manner from cadavers of genetically unrelated individuals. American Association of Tissue Bank standards require that all donors be screened, serologic tests be performed, and all specimens be sterilized

and verified by culture prior to release. Processing of allogeneic bone is designed to achieve sterility and reduce immunogenicity. Bone cell membranes have both class I and II major histocompatibility complexes on their surfaces. These are the main sources of immunogenicity within allogeneic bone grafts. Allogeneic bone implants are processed to remove the organic matrix and only retain the mineral components; architecture is generally considered to be nonimmunogenic. Implants retaining both mineral and organic components or demineralized implants with only the organic component are washed and then lyophilized to reduce immunogenicity. In most cases this process reduces the immune response to clinically insignificant levels. In addition to this treatment, allogeneic bank bone is irradiated with γ -rays, a process that assures sterility and further reduces antigenicity. Unfortunately, this requires 2 to 3 Mrad per radiation dose, which destroys BMP and thus the ability of these implants to be osteoinductive.¹⁸

Common applications of allogeneic bone implants for preprosthetic surgery include mandibles, iliac crest segments, and calcified or decalcified ribs that can be prepared and used as biologic trays for the placement and retention of cancellous bone grafts. Additional uses include mineral matrix or demineralized particulate implants used as osteoconductive graft extenders or for extraction-site shape and form preservation. Research on particle size suggests that particles in the range of 250 to 850 μm are the most useful. Although the current carrier system used for rhBMP-2 bone induction is a collagen membrane, Becker and colleagues showed that BMP extracted from the bone can be added to particulate 200 to 500 μm demineralized freeze-dried bone allografts obtained from four American tissue banks; this resulted in the transformation of noninductive particles to particles with osteoinductive properties.¹⁹ Heterogeneous bone grafts, or xenografts, are specimens trans-

ferred from one species to another. Implants of this type contain an organic component that would elicit a strong immune response; thus, they are not used in contemporary practice. Bovine implants that have undergone complete deproteinization to remove the organic component have been shown to be nonimmunogenic. These implants remain as an inorganic mineral scaffold that can be used for their osteoconductive properties as graft extenders or for extraction-site preservation.

The above discussion has identified two reconstructive methods that can reliably restore bone with the characteristics necessary for maintaining osseointegrated implants. These methods include autogenous cancellous bone grafts and distraction histogenesis alone or with graft supplementation. A third approach alluded to above is the use of rhBMP-2.²⁰ rhBMP-2 has been studied extensively in animal models, and human clinical trials in the areas of orthopedic surgery, spine surgery, and maxillofacial surgery have been ongoing during the past decade. rhBMP-2/ACS, which is the clinical combination of BMP with an absorbable collagen sponge carrier placed with a metal cage, received US Food and Drug Administration (FDA) approval for spine fusion surgery in 2002. To date, US human clinical trials related to maxillofacial reconstruction include complete feasibility studies, safety and efficacy studies, and dose-response studies involving either alveolar ridge buccal wall defects or posterior maxillary alveolar bone deficiency at sinus lift bone sites. Safety has been established, and a dose of 1.5 mg/mL, the same dose used for spine fusion, was chosen for maxillofacial applications after completion of a sinus lift dose-response study. A 20-center study of pivotal sinus lifts is near completion; its dual end points include the evaluation of bone regeneration at end point one and the evaluation of 2-year loaded implant data at end point two. To date, a time frame for submitting this data for FDA approval has not been established.

At our center 9 patients were enrolled in the pivotal study, with 21 evaluated sinus lifts sites. All study sites were confirmed before treatment by CT scan to have 5 mm or less of natural bone. Six months after graft placement, comparative CT scans were obtained from all study sites and the presence of graft and graft dimensions were assessed. All sites had enough bone for placement of implants at least 4 mm in diameter and 12 mm high. Trephine-procured biopsy specimens obtained at the time of implant placement were used to verify the presence of homogeneous vascular osteocyte-rich bone with a normal trabecular and marrow-space architecture. At our center all 21 implants have remained functionally loaded for at least 36 months. These results are preliminary and may not reflect the findings of all centers. Similar to natural BMP, rhBMP-2/ACS has been shown to stimulate the cascade of bone-regeneration events, including chemotaxis, induction of pluripotent cells, and proliferation. Our results to date show that this technique has the potential to significantly enhance patient care by providing an unlimited supply of nonimmunogenic sterile protein that can induce de novo

bone formation. Bone regenerated by this process has characteristics of bone desirable for implant placement (Figure 9-11).

Hopefully, the discussion of host properties and regenerative or graft techniques in this section will aid one in determining the best graft for sites to be reconstructed as part of a preprosthetic surgical treatment plan.

Hard Tissue Recontouring

Current Trends in Alveolar Preservation

As dental implants continue to grow in popularity and play a major role in prosthetic reconstruction, the need for traditional bony recontouring at the time of extraction has been de-emphasized. Current trends tend to lean toward preservation of alveolar bone and overlying periosteal blood supply, which enhances and preserves future bone volume. Alternatives to traditional alveoloplasty have emerged in an effort to maintain bone height and volume for the placement of implants to provide a stable platform for prosthetic reconstruction. Such alternatives include orthodontic guided tooth/root

extraction, conservative extraction techniques using periosteotomes to maintain alveolar continuity, immediate grafting of extraction sites, relief of undercuts using bone grafts or hydroxylapatite (HA) augmentation, and guided tissue regeneration. In cases where bony abnormalities or undercuts require attention, selective alveolar recontouring is indicated.

Advances in implant technology have placed a greater emphasis on planning for alveolar ridge preservation. Beginning at the initial consultation, all extraction sites should be considered for implant reconstruction. Regardless of the reason for extraction (ie, pulpal disease, periodontal disease, or trauma), every effort should be made to maintain alveolar bone, particularly buccal (labial) and lingual (palatal) walls. However, even with alveolar bone maintenance, there can be unpredictable resorption in a short period of time.²¹ Multiple adjacent extractions may also contribute to extensive alveolar bone loss precluding implant reconstruction.

Historically, techniques for alveolar ridge preservation were developed to facilitate conventional denture prostheses. HA materials were the first materials not

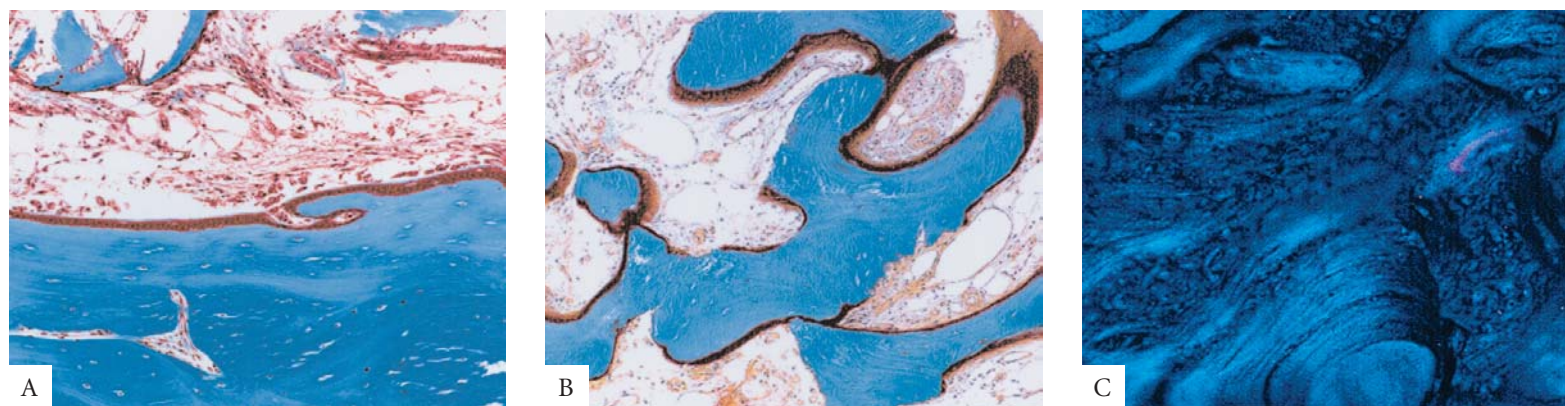


FIGURE 9-11 Stages of bone maturation are evident in these photomicrographs of autogenous bone grafts, autogenous grafts with bone morphogenetic protein (BMP), and distraction-regenerate. A, Autogenous tibial plateau with no filler was placed in this sinus lift site with < 5 mm of native bone, procured by trephine, and sampled at 6 months after the graft. Viable osteocyte-rich bone trabeculae are evident with normal marrow spaces with a few residual foci of nonviable graft ($\times 100$ original magnification; hematoxylin and eosin stain). B, BMP was placed in an identical site to that shown in Figure A ($\times 75$ original magnification; hematoxylin and eosin stain). This specimen reveals viable trabeculae with normal haversian canals, de novo bone growth, and no nonviable components. C, Regenerate was procured at the time of the distractor removal at this mandibular distraction site. The regenerated growth represents woven bone with some mature haversian systems ($\times 128$ original magnification; hematoxylin and eosin stain).

plagued by host rejection and fibrous encapsulation. Previously, the use of polymethyl methacrylate, vitreous carbon, and aluminum oxide had led to poor results. Root form and particulate HA both were adapted and successful in preserving alveolar ridge form.²² The obvious limitation with nonresorbable materials is that they preclude later implant reconstruction. Tricalcium phosphate is a resorbable ceramic that was originally thought would solve this problem, but it proved not to be truly osteoconductive as it promoted giant cell rather than osteoclastic resorption.²³ This resulted in limited osteogenic potential. Another alloplast that has been used for this purpose is bioactive glass, which consists of calcium, phosphorus, silicone, and sodium, but, again, the biologic behavior of the replacement bone was never felt to be satisfactory for implant reconstruction.²⁴

The gold standard for use for bony reconstruction anywhere has always been autogenous grafts. The dilemma with autogenous grafts involves donor site morbidity: whether from an intraoral or extraoral source, the additional surgery and inconvenience to the patient has precluded its general use. To avoid the use of a donor site, various allogeneic bone preparations have been advocated. Stringent tissue bank regulations have provided the public with greater confidence in the use of these materials. Anorganic bone has most recently been adapted for use in alveolar ridge preparation. Two products are currently available commercially. The first is a xenograft derived from a bovine source. The main advantage of this type of material is that it is available in an almost unlimited supply and is chemically and biologically almost identical to human bone. Minimal immune response is elicited because of the absence of protein; however, the resorption rate of bovine cortical bone is slow. In both animal and human studies, remnants of nonvital cortical bone have been shown to be present 18 months or

longer in the grafted site.²⁵ A second product, derived from human bone, is processed by solvent extraction and dehydration. Animal studies have shown that there is near-complete remodeling with little or no remnant of the human anorganic bone left in the specimen.²⁶

Both the deproteinized bovine bone and the solvent dehydrated mineralized human bone appear to have great potential in alveolar ridge preservation. These materials take a long time to resorb, so a ridge form is maintained over an extended period of time, and are resorbed and remodeled via an osteoclastic process that results in bone ideally suited for implant placement.

The technique for alveolar ridge preservation at the time of extraction has been described by Sclar.²⁷ Atraumatic extraction is essential. Preservation of buccal or labial bone may be facilitated by the use of microosteotomes, and, whenever possible, buccal or labial mucoperiosteal elevation is to be avoided or limited. The socket should be gently curetted and irrigated, and in the presence of periodontal infection, topical antibiotics may be helpful. Tetracycline powder mixed with the deproteinized bovine bone or the solvent dehydrated mineralized human bone may allow for the use of either of these types of bone in almost any clinical situation. It is not essential that the graft have complete watertight mucosal coverage. Collagen membrane is used to prevent spillage of the material from the socket, particularly in maxillary extractions. When temporary restorations are employed at the time of surgery, an ovate pontic provisional restoration helps to support the adjacent mucosa during soft tissue maturation. In selected instances immediate placement of implants in the extraction site can be done in conjunction with the use of these deproteinized bone preparations. Because of the slow resorptive nature of both of these bone preparations, they may be ideally suited for buccal or labial defects that would otherwise be grafted with autogenous cortical bone.

Alveoloplasty

Often hard and soft tissues of the oral region need to undergo recontouring to provide a healthy and stable environment for future prosthetic restorations. Simple alveolar recontouring after extractions consists of compression and in-fracture of the socket; however, one must avoid over-compression and over-reduction of irregularities. Current trends endorse a selective stent-guided approach to site-specific bony recontouring, eliminating bony abnormalities that interfere with prosthetic reconstruction or insertion. Multiple irregularities produce undercuts that are obstructions to the path of insertion for conventional prosthetic appliances. These obstructions need a more complex alveoloplasty to achieve desired results. In many cases the elevation of mucoperiosteal flaps using a crestal incision with vertical releases is necessary to prevent tears and to produce the best access to the alveolar ridge. During mucoperiosteal flap resection, periosteal and Woodson elevators are the most appropriate tools to prevent excess flap reflection, devitalization, and sequestrum formation. These conditions increase pain and discomfort for the patient and increase the duration needed before prosthetic restoration can proceed. The use of a rongeur or file for advanced recontouring is preferred to rotary instruments to prevent over-reduction. For large bony defects, rotary instrument recontouring is preferred. Normal saline irrigation is used to keep bony temperatures < 47°C to maintain bone viability.

Owing to the physiology of bone and current restorative options available, interseptal alveoloplasty is rarely indicated. The main disadvantage of this procedure is the overall decrease in ridge thickness, which results in a ridge that may be too thin to accommodate future implant placement.⁹ Removal of interseptal bone eliminates endosteal growth potential, which is necessary for ridge preservation. Therefore, if this technique is to be used,

one must be cognizant of ridge thickness and reduce the labial dimension only enough to lessen or eliminate undercuts in areas where implants are not anticipated.

After hard tissue recontouring, excessive soft tissue is removed to relieve mobile tissue that decreases the fit and functional characteristics of the final prosthesis. Closure with a resorbable running/lock-stitch suture is preferred because fewer knots are less irritating for the patient.

Treatment of Exostoses

Undercuts and exostoses are more common in the maxilla than in the mandible. In areas requiring bony reduction, local anesthetic should be infiltrated. This produces adequate anesthesia for the patient as well as an aid in hydrodissection of the overlying tissues, which facilitates flap elevation. In the mandible an inferior alveolar neurovascular block may also be necessary. A crestal incision extending approximately 1.5 cm beyond each end of the area requiring contour should be completed. A full mucoperiosteal flap is reflected to expose all the areas of bony protuberance. Vertical releasing incisions may be necessary if adequate exposure cannot be obtained since trauma of the soft tissue flap may occur. Recontouring of exostoses may require the use of a rotary instrument in large areas or a hand rasp or file in minor areas. Once removal of the bony protuberance is complete and visualization confirms that no irregularities or undercuts exist, suturing may be performed to close the soft tissue incision. If nonresorbable sutures are used, they should be removed in approximately 7 days.

In areas likely to be restored with implants or implant-supported prostheses, irregularities and undercuts are best treated using corticocancellous grafts from an autogenous or alloplastic source. This can be done using a vertical incision only adjacent to the proposed area of grafting. A subperiosteal dissection is used to create a pocket for placement of the graft material. Visual inspection and palpation of the

area should be done at the conclusion of the procedure to verify the relief of the defect. The incision can be closed with resorbable sutures. In areas that require a large amount of graft material, scoring of the periosteum can assist in closure of soft tissue defects. In addition, the use of a resorbable collagen membrane can be used to prevent tissue ingrowth into the surgical site.

Tuberosity Reduction

Excesses in the maxillary tuberosity may consist of soft tissue, bone, or both. Sounding, which is performed with a needle, can differentiate between the causes with a local anesthetic needle or by panoramic radiograph. Bony irregularities may be identified, and variations in anatomy as well as the level of the maxillary sinuses can be ascertained. Excesses in the area of the maxillary tuberosity may encroach on the interarch space and decrease the overall freeway space needed for proper prosthetic function. Access to the tuberosity area can be obtained easily using a crestal incision beginning in the area of the posterior tuberosity and progressing forward to the edge of the defect using a no. 12 scalpel blade. Periosteal dissection then ensues exposing the underlying bony anatomy. Excesses in bony anatomy are removed using a side-cutting rongeur. Careful evaluation of the level of the maxillary sinus must be done before bony recontouring is attempted in the area of the tuberosity. Sharp undermining of the overlying soft tissue may be performed in a wedge-shaped fashion beginning at the edge of a crestal incision to thin the overall soft tissue bulk overlying the bony tuberosity. Excess overlying soft tissue may be trimmed in an elliptical fashion from edges of the crestal incision to allow a tension-free passive closure (Figure 9-12). Closure is performed using a nonresorbable suture in a running fashion. Small sinus perforations require no treatment as long as the membrane remains intact. Large perforations must be treated with a tension-free tight closure as well as antibiotics,

preferably a penicillinase-resistant penicillin such as an amoxicillin/clavulanate potassium preparation or a second-generation cephalosporin. The patient is instructed to take sinus medications including antihistamines and decongestants for approximately 10 to 14 days and not to create excessive transmural pressure across the incision site by blowing his or her nose or sucking through straws.

Genial Tubercle Reduction

The genioglossus muscle attaches to the lingual aspect of the anterior mandible. As the edentulous mandible resorbs, this tubercle may become significantly pronounced. In cases in which anterior mandibular augmentation is indicated, leaving this bony projection as a base for subsequent grafting facilitates augmentation of mandibular height. During conventional mandibular denture fabrication, this bony tuberosity as well as its associated muscle attachments may create displacement issues with the overlying prostheses. In these cases it should be relieved. Floor-of-mouth lowering procedures should also be considered in cases in which genioglossus and mylohyoid muscle attachments interfere with stability and function of conventional mandibular prostheses.

Bilateral lingual nerve blocks in the floor of the mouth are necessary to achieve adequate anesthesia in this area. A crestal incision from the midbody of the mandible to the midline bilaterally is necessary for proper exposure. A subperiosteal dissection exposes the tubercle and its adjacent muscle attachment. Sharp excision of the muscle from its bony attachment may be performed with electrocautery, with careful attention to hemostasis. A subsequent hematoma in the floor of the mouth may lead to airway embarrassment and life-threatening consequences if left unchecked. Once the muscle is detached, the bony tubercle may then be relieved using rotary instrumentation or a rongeur. Closure is performed using a resorbable suture in a

running fashion. The genioglossus muscle is left to reattach independently.

Tori Removal

The etiology of maxillary and mandibular tori is unknown; however, they have an incidence of 40% in males and 20% in females.²⁸ Tori may appear as a single or multilobulated bony mass in the palate or on the lingual aspect of the anterior mandible either unilaterally or bilaterally. In the dentate patient they are rarely indicated for removal. Nevertheless, repeated overlying mucosal trauma and interference with normal speech and masticatory patterns may necessitate treatment. In the patient requiring complete or partial conventional prosthetic restoration, they may be a significant obstruction to insertion or interfere with the overall comfort, fit, and function of the planned prosthesis.

In the maxilla, bilateral greater palatine and incisive blocks are performed to achieve adequate anesthesia. Local infiltration of the overlying mucosa helps with hemostasis and hydrodissection that facilitates flap elevation. A linear midline incision with posterior and anterior vertical releases or a U-shaped incision in the palate followed by a subperiosteal dissection is used to expose the defect. Rotary instrumentation with a round acrylic bur may be used for small areas; however, for large tori, the treatment of choice is sectioning with a cross-cut fissure bur. Once sectioned into several pieces, the torus is easily removed with an osteotome. Care must be taken not to over-reduce the palate and expose the floor of the nose. Final contouring may be done with an egg-shaped recontouring bur (Figure 9-13). Copious irrigation is necessary throughout the pro-

cedure. Closure is performed with a resorbable suture. Presurgical fabrication of a thermoplastic stent, made from dental models with the defect removed, in combination with a tissue conditioner helps to eliminate resulting dead space, increase patient comfort, and facilitate healing in cases in which communication occurs with the nasal floor. Soft tissue breakdown is not uncommon over a midline incision; however, meticulous hygiene, irrigation, and tissue conditioners help to minimize these complications.

Mandibular tori are accessed using bilateral inferior alveolar and lingual nerve blocks as well as local infiltration to facilitate dissection. A generous crestal incision with subsequent mucoperiosteal flap elevation is performed. Maintenance of the periosteal attachment in the midline reduces hematoma formation and maintains vestibular depth. Nevertheless, when large tori encroach on the midline, maintenance of this midline periosteal attachment is impossible. Careful flap elevation with attention to the thin friable overlying mucosa is necessary as this tissue is easily damaged. Small protuberances can be sheared away with a mallet and osteotome. Large tori are divided superiorly from the adjacent bone with a fissure bur parallel to the medial axis of the mandible and are out-fractured away from the mandible by an osteotome, which provides leverage (Figure 9-14). The residual bony fragment inferiorly may then be relieved with a hand rasp or bone file. It is not imperative that the entire protuberance be removed as long as the goals of the procedure are achieved. Copious irrigation during this procedure is imperative, and closure is completed using a resorbable suture in a running fashion. Temporary denture delivery or gauze packing lingually may be used to prevent hematoma formation and should be maintained for approximately 1 day postoperatively. Wound dehiscence and breakdown with exposure

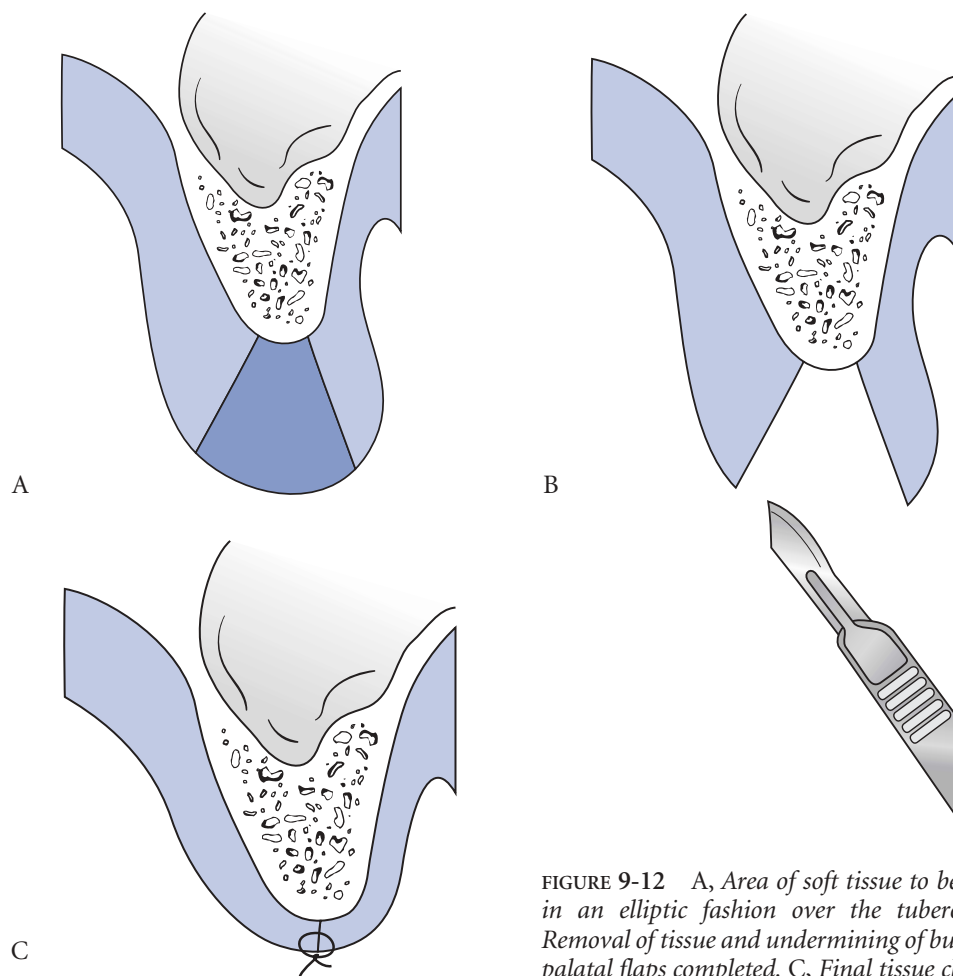


FIGURE 9-12 A, Area of soft tissue to be excised in an elliptic fashion over the tuberosity. B, Removal of tissue and undermining of buccal and palatal flaps completed. C, Final tissue closure.

of underlying bone is not uncommon and should be treated with local irrigation with normal saline.

Mylohyoid Ridge Reduction

In cases of mandibular atrophy, the mylohyoid muscle contributes significantly to the displacement of conventional dentures. With the availability of advanced grafting techniques and dental implants, there are fewer indications for the reduction of the mylohyoid ridge. In severe cases of mandibular atrophy, the external oblique and mylohyoid ridges may be the height of contour of the posterior mandible. In these cases the bony ridge may be a significant source of discomfort as the overlying mucosa is thin and easily irritated by denture flanges extending into the posterior floor of the mouth. As a result, reduction of the mylohyoid ridge may accompany grafting techniques to provide greater relief and comfort for subsequent restorations. Historically, this procedure has been combined with lowering of the floor of the mouth; however, with the advanced armamentarium available today, there are few, if any, indications for these procedures alone or in combination.

Anesthesia is achieved with buccal, inferior alveolar, and lingual nerve blocks. A crestal incision over the height of contour is made, erring toward the buccal aspect to protect the lingual nerve. Subperiosteal dissection along the medial aspect of the mandible reveals the attachment of the mylohyoid muscle to the adjacent ridge. This can be sharply separated with electrocautery to minimize muscle bleeding. Once the overlying muscle is relieved, a reciprocating rasp or bone file can be used to smooth the remaining ridge. Copious irrigation and closure with particular attention to hemostasis is completed. Placement of a stent or existing denture may also aid in hemostasis as well as inferiorly repositioning the attachment. Again, these procedures are rarely indicated and are

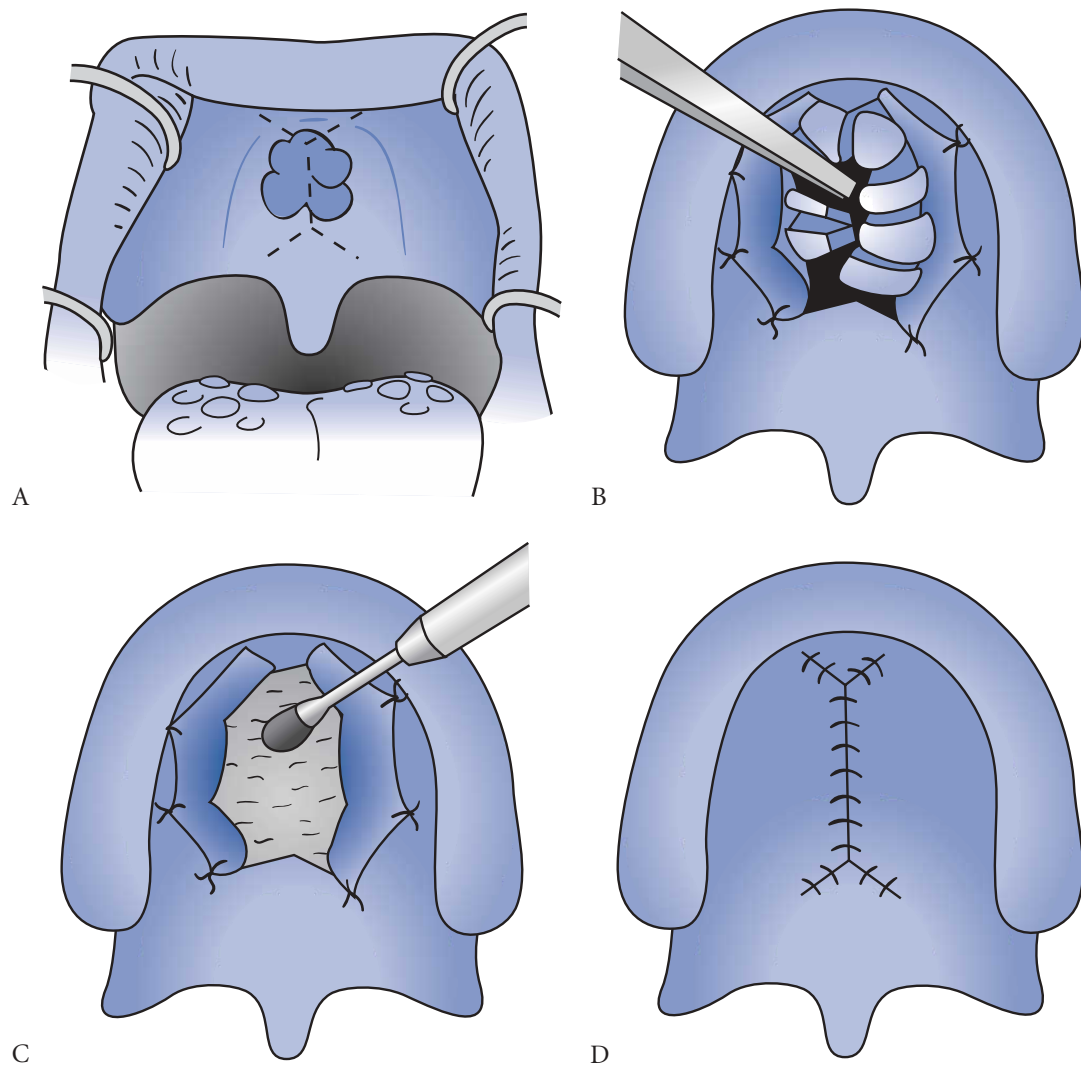


FIGURE 9-13 A, Preoperative view of a maxillary torus with the midline incision indicated (dashed line). B, Removal of sectioned elements of the torus with an osteotome. C, Final smoothing of irregularities with a rotary bur. D, Final closure.

included here essentially for historic reference, not for routine use.

Soft Tissue Recontouring

With the eventual bony remodeling that follows tooth loss, muscle and frenum attachments that initially were not in a problematic position begin to create complications in prosthetic reconstruction and to pose an increasing problem with regard to prosthetic comfort, stability, and fit. Often these attachments must be altered before conventional restoration can be attempted. As dental implants become commonplace in the restoration of partially and totally edentulous patients, sur-

gical alteration of these attachments is indicated less often. Nevertheless, inflammatory conditions such as inflammatory fibrous hyperplasia of the vestibule or epulis, and inflammatory hyperplasia of the palate must be addressed before any type of prosthetic reconstruction can proceed. Obviously, any lesion presenting pathologic consequences should undergo biopsy and be treated accordingly before reconstruction commences. In keeping with reconstructive surgery protocol, soft tissue excesses should be respected and should not be discarded until the final bony augmentation is complete. Excess tissue thought to be unnecessary may be

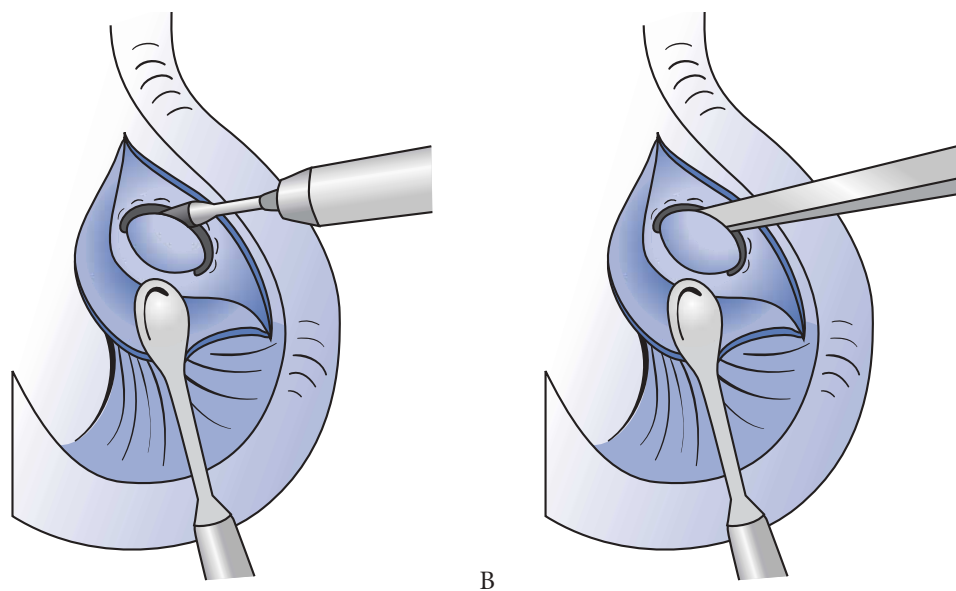


FIGURE 9-14 A, Rotary trough exposes a mandibular torus and creates a cleavage plane between the torus and mandible. B, Osteotome shears the remaining attachment of the torus from mandible.

valuable after grafting or augmentation procedures are performed to increase the overall bony volume.

Hypermobile Tissue

When excess mobile unsupported tissue remains after successful alveolar ridge restoration, or when mobile tissue exists in the presence of a preserved alveolar ridge, removal of this tissue is the treatment of choice. Usually infiltrative local anesthesia can be performed in selected areas. Sharp excision parallel to the defect in a supraperiosteal fashion allows for removal of mobile tissue to an acceptable level. Beveled incisions may be needed to blend the excision with surrounding adjacent tissues and maintain continuity to the surrounding soft tissue. Closure with resorbable suture then approximates residual tissues. Impressions for prosthesis fabrication should proceed after a 3- to 4-week period to allow for adequate soft tissue remodeling. In cases in which denture flange extension is anticipated, the clinician must be careful to preserve the vestibule when undermining for soft tissue closure. Granulation is a better alternative if residual tissues cannot be approximated because

it maintains the vestibule and increases the width of the attached keratinized mucosa.

Fibrous Inflammatory Hyperplasia

Fibrous inflammatory hyperplasia is often the result of an ill-fitting denture that produces underlying inflammation of the mucosa and eventual fibrous proliferation resulting in patient discomfort and a decreased fit of the overlying prosthesis. Early management consists mainly of adjustment of the offending denture flange with an associated soft reline of the prosthesis. When there is little chance of eliminating the fibrous component, surgical excision is necessary. In most cases laser ablation with a carbon dioxide laser is the method of choice. When the treatment of large lesions would result in significant scarring and obliteration of the vestibule, sharp excision with undermining of the adjacent mucosa and reapproximation of the tissues is preferred. Again, maintenance of a supraperiosteal plane with repositioning of mucosal edges allowing for subsequent granulation is preferred over approximation of wound edges that results in the alteration of

vestibular depth. This is accomplished with local anesthetic infiltrated into the proposed tissue bed, which is closed only if necessary with resorbable sutures.

Inflammatory Papillary Hyperplasia

Once thought to be a neoplastic process, inflammatory papillary hyperplasia occurs mainly in patients with existing prosthetic appliances.²⁹ An underlying fungal etiology most often is the source of the inflammatory process and appears to coincide with mechanical irritation and poor hygiene practices. The lesion appears as multiple proliferative nodules underlying a mandibular prosthesis likely colonized with *Candida*. Early stages are easily treated by an improvement of hygiene practices and by the use of antifungal therapy such as nystatin tid alternating with clotrimazole troches intermittently. Nocturnal soaking of the prosthesis in an antifungal solution or in an extremely dilute solution of sodium hypochlorite helps decrease the overall colonization of the prosthesis.

In proliferative cases necessitating surgical treatment, excision in a supraperiosteal plane is the method of choice. Many methods are acceptable, including sharp excision with a scalpel, rotary débridement, loop electrocautery as described by Guernsey, and laser ablation with a carbon dioxide laser.³⁰⁻³² Because of the awkward access needed to remove the lesions, laser ablation is the method we employ. Treatment proceeds supraperiosteally to prevent exposure of underlying palatal bone. Subsequently, placement of a tissue conditioner and a denture reline is helpful to minimize patient discomfort.

Treatment of the Labial and Lingual Frenum

Labial Frenectomy

Labial frenum attachments consist of thin bands of fibrous tissue covered with

mucosa extending from the lip and cheek to the alveolar periosteum. The height of this attachment varies from individual to individual; however, in dentate individuals frenum attachments rarely cause a problem. In edentulous individuals frenum attachments may interfere with fit and stability, produce discomfort, and dislodge the overlying prostheses.

Several surgical methods are effective in excising these attachments. Simple excision and Z-plasty are effective for narrow frenum attachments (Figures 9-15 and 9-16). Vestibuloplasty is often indicated for frenum attachments with a wide base.

Local anesthetic infiltration is performed in a regional fashion that avoids direct infiltration into the frenum itself; such an infiltration distorts the anatomy and leads to misidentification of the frenum. Eversion of the lip also helps one identify the anatomic frenum and assists with the excision. An elliptic incision around the proposed frenum is completed in a supraperiosteal fashion. Sharp dissection of the frenum using curved scissors removes mucosa and underlying connective tissue leading to a broad base of periosteum attached to the underlying bone. Once tissue margins are undermined and wound edges are approximated, closure can proceed with resorbable sutures in an interrupted fashion. Sutures should encounter the periosteum, especially at the depth of the vestibule to maintain alveolar ridge height. This also reduces hematoma formation and allows for the preservation of alveolar anatomy.

In the Z-plasty technique, excision of the connective tissue is done similar to that described previously. Two releasing incisions creating a Z shape precede undermining of the flaps. The two flaps are eventually undermined and rotated to close the initial vertical incision horizontally. By using the transposition flaps, this technique virtually increases vestibular depth and should be used when alveolar height is in question.

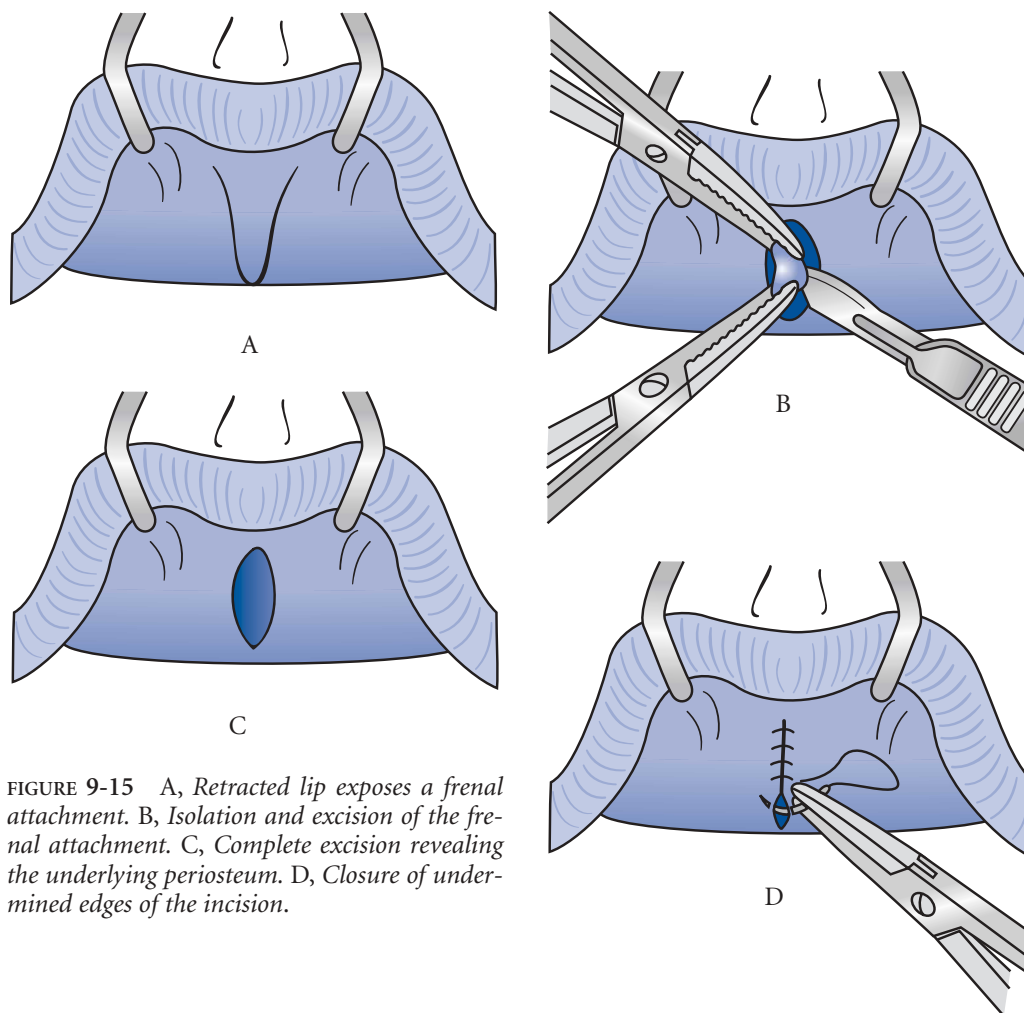


FIGURE 9-15 A, Retracted lip exposes a frenal attachment. B, Isolation and excision of the frenal attachment. C, Complete excision revealing the underlying periosteum. D, Closure of undermined edges of the incision.

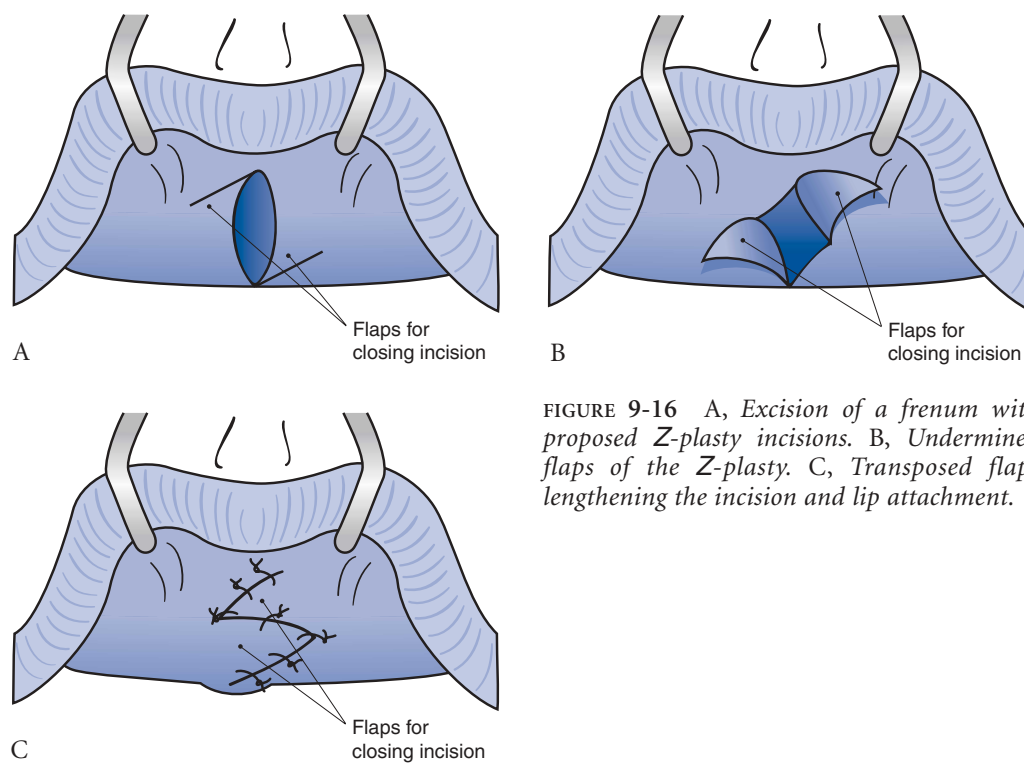


FIGURE 9-16 A, Excision of a frenum with proposed Z-plasty incisions. B, Undermined flaps of the Z-plasty. C, Transposed flaps lengthening the incision and lip attachment.

Wide-based frenum attachments may best be treated with a localized vestibuloplasty technique. A supraperiosteal dissection is used to expose the underlying periosteum. Superior repositioning of the mucosa is completed, and the wound margin is sutured to the underlying periosteum at the depth of the vestibule. Healing proceeds by secondary intention. A preexisting denture or stent may be used for patient comfort in the initial postoperative period.

Lingual Frenectomy

High lingual frenum attachments may consist of different tissue types including mucosa, connective tissue, and superficial genioglossus muscle fibers. This attachment can interfere with denture stability, speech, and the tongue's range of motion. Bilateral lingual blocks and local infiltration in the anterior mandible provide adequate anesthesia for the lingual frenum excision. To provide adequate traction, a suture is placed through the tip of the tongue. Surgical release of the lingual frenum requires dividing the attachment of the fibrous connective tissue at the base of the tongue in a transverse fashion, followed by closure in a linear direction, which completely releases the ventral aspect of the tongue from the alveolar ridge (Figure 9-17). Electrocautery or a

hemostat can be used to minimize blood loss and improve visibility. After removal of the hemostat, an incision is created through the area previously closed within the hemostat. Careful attention must be given to Wharton's ducts and superficial blood vessels in the floor of the mouth and ventral tongue. The edges of the incision are undermined, and the wound edges are approximated and closed with a running resorbable suture, burying the knots to minimize patient discomfort.

Ridge Extension Procedures in the Maxilla and Mandible

Submucous Vestibuloplasty

In 1959 Obwegeser described the submucous vestibuloplasty to extend fixed alveolar ridge tissue in the maxilla.³³ This procedure is particularly useful in patients who have undergone alveolar ridge resorption with an encroachment of attachments to the crest of the ridge. Submucous vestibuloplasty is ideal when the remainder of the maxilla is anatomically conducive to prosthetic reconstruction. Adequate mucosal length must be available for this procedure to be successful without disproportionate alteration of the upper lip. If a tongue blade or mouth mirror is placed to the height of the max-

illary vestibule without distortion or inversion of the upper lip, adequate labiovestibular depth is present (Figure 9-18).⁹ If distortion occurs then maxillary vestibuloplasty using split-thickness skin grafts or laser vestibuloplasty is the appropriate procedure.

Submucous vestibuloplasty can be performed in the office setting under outpatient general anesthesia or deep sedation. A midline incision is placed through the mucosa in the maxilla, followed by mucosal undermining bilaterally. A supraperiosteal separation of the intermediate muscle and soft tissue attachments is completed. Sharp incision of this intermediate tissue plane is made at its attachment near the crest of the maxillary alveolus. This tissue layer may then be excised or superiorly repositioned (Figure 9-19). Closure of the incision and placement of a postsurgical stent or denture rigidly screwed to the palate is necessary to maintain the new position of the soft tissue attachments. Removal of the denture or stent is performed 2 weeks postoperatively. During the healing period, mucosal tissue adheres to the underlying periosteum, creating an extension of fixed tissue covering the maxillary alveolus. A final relines of the patient's denture may proceed at approximately 1 month postoperatively.

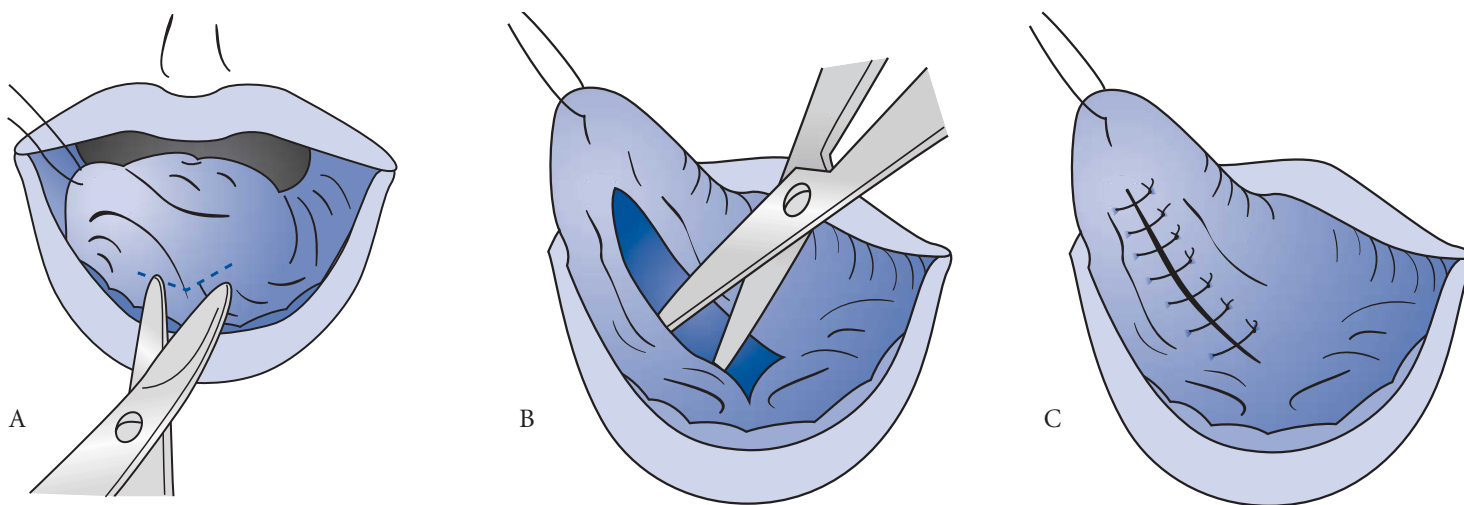


FIGURE 9-17 A, Lingual frenum attachment encroaching on an atrophic mandibular alveolus. B, Excision of the frenum with undermining of mucosal edges. Note: Care must be taken to avoid causing damage to Wharton's ducts. C, Final closure of mucosal edges.

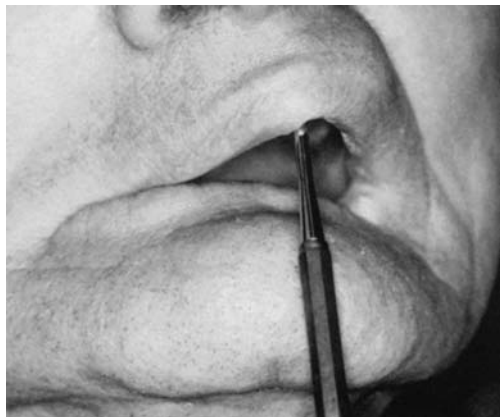

FIGURE 9-18 A mirror presses the vestibular mucosa to the desired height to evaluate the adequacy of lip mucosa. In this example, extension of the vestibular mucosa superiorly on the alveolar ridge does not result in thinning or intrusion of the lip. Reproduced with permission from Tucker MR. *Ambulatory preprosthetic reconstructive surgery*. In: Peterson LJ, Indresano AT, Marciani RD, Roser SM. *Principles of oral and maxillofacial surgery*. Vol 2. Philadelphia (PA): JB Lippincott Company; 1992. p. 1126.

Maxillary Vestibuloplasty

When a submucous vestibuloplasty is contraindicated, mucosa pedicled from the upper lip may be repositioned at the depth of the vestibule in a supraperiosteal fashion. The exposed periosteum can then be left to epithelialize secondarily. Split-thickness skin grafts may be used to help shorten the healing period. In addition, placement of a relined denture may minimize patient discomfort and help to mold and adapt underlying soft tissues and/or skin grafts.

Another option in this situation is laser vestibuloplasty. A carbon dioxide laser is used to resect tissue in a supraperiosteal plane to the depth of the proposed vestibule. A denture with a soft reline is then placed to maintain vestibular depth. Removal of the denture in 2 to 3 weeks reveals a nicely epithelialized vestibule that extends to the desired depth (Figure 9-20).

Lip-Switch Vestibuloplasty

Both lingually based and labially based vestibuloplasties have been described.^{34,35} In the former an incision in the lower lip

and submucosa undermining to the alveolus is followed by a supraperiosteal dissection to the depth of the vestibule (Figure 9-21). The mucosal flap is then sutured to the depth of the vestibule and stabilized with a stent or denture. The labial denuded tissue is allowed to epithelialize secondarily.

In the transpositional vestibuloplasty, the periosteum is incised at the crest of the alveolus and transposed and sutured to the denuded labial submucosa. The elevated mucosal flap is then positioned over the exposed bone and sutured to the depth of the vestibule (Figure 9-22).

These procedures provide satisfactory results provided that adequate mandibular height exists preoperatively. A minimum of 15 mm is acceptable for the above procedures. Disadvantages include unpredictable results, scarring, and relapse.

Mandibular Vestibuloplasty and Floor-of-Mouth Lowering Procedures

As with labial muscle attachments and soft tissue in the buccal vestibule, the mylohyoid and genioglossus attachments can preclude denture flange placement lingually. In a combination of the procedures described by Trauner as well as Obwegeser and MacIntosh, both labial and lingual extension procedures can be performed to effectively lower the floor of the mouth (Figure 9-23).³⁶⁻³⁸ This procedure eliminates the components involved in the displacement of conventional dentures and provides a broad base of fixed tissue for prosthetic support. Again, adequate mandibular height of at least 15 mm is required. Split-thickness skin grafting is used to cover the denuded periosteum and facilitate healing.

Today, with the incorporation of endosteal implants and the fabrication of implant-borne prostheses, lingual and buccolabial flange extensions to stabilize mandibular prostheses are not necessary. Consequently, attention is directed toward preservation or preparation of the alveolus for implants rather than extension of the

fixed tissue attachments. As a result, these procedures are rarely used today.

Hard Tissue Augmentation

As stated previously, the overall goals of reconstructive preprosthetic surgery are to provide an environment for the prosthesis that will restore function, create stability and retention, and service associated structures as well as satisfy esthetics and prevent minor sensory loss. There are many classification systems of rigid deficiencies associated with many treatment options; nevertheless, each patient must be evaluated individually. When atrophy of the alveolus necessitates bony augmentation, undercuts, exostoses, and inappropriate tissue attachments should be identified and included in the overall surgical plan prior to prosthetic fabrication.

Maxillary Augmentation

In the past, vestibuloplasties were the procedure of choice to accentuate the alveolus in the atrophic maxilla. Unfortunately, poor quality and quantity of bone combined with excessive occlusal loading by conventional prostheses continued to accelerate the resorptive process. Either augmentation or transantral implant cross-arch stabilization must be considered when anatomic encroachment of the palatal vault or zygomatic buttress and loss of tuberosity height affect overall fit and function of a conventional prosthesis. This section discusses conventional augmentation procedures of the maxilla to restore acceptable alveolar form and dimensions.

There is a fourfold increase in resorption in the mandible compared with that in the maxilla, combination syndromes notwithstanding. When severe resorption results in severely atrophic ridges (Cawood and Howell Classes IV–VI), some form of augmentation is indicated. Onlay, interpositional, or inlay grafting are the procedures of choice to reestablish acceptable maxillary dimensions.

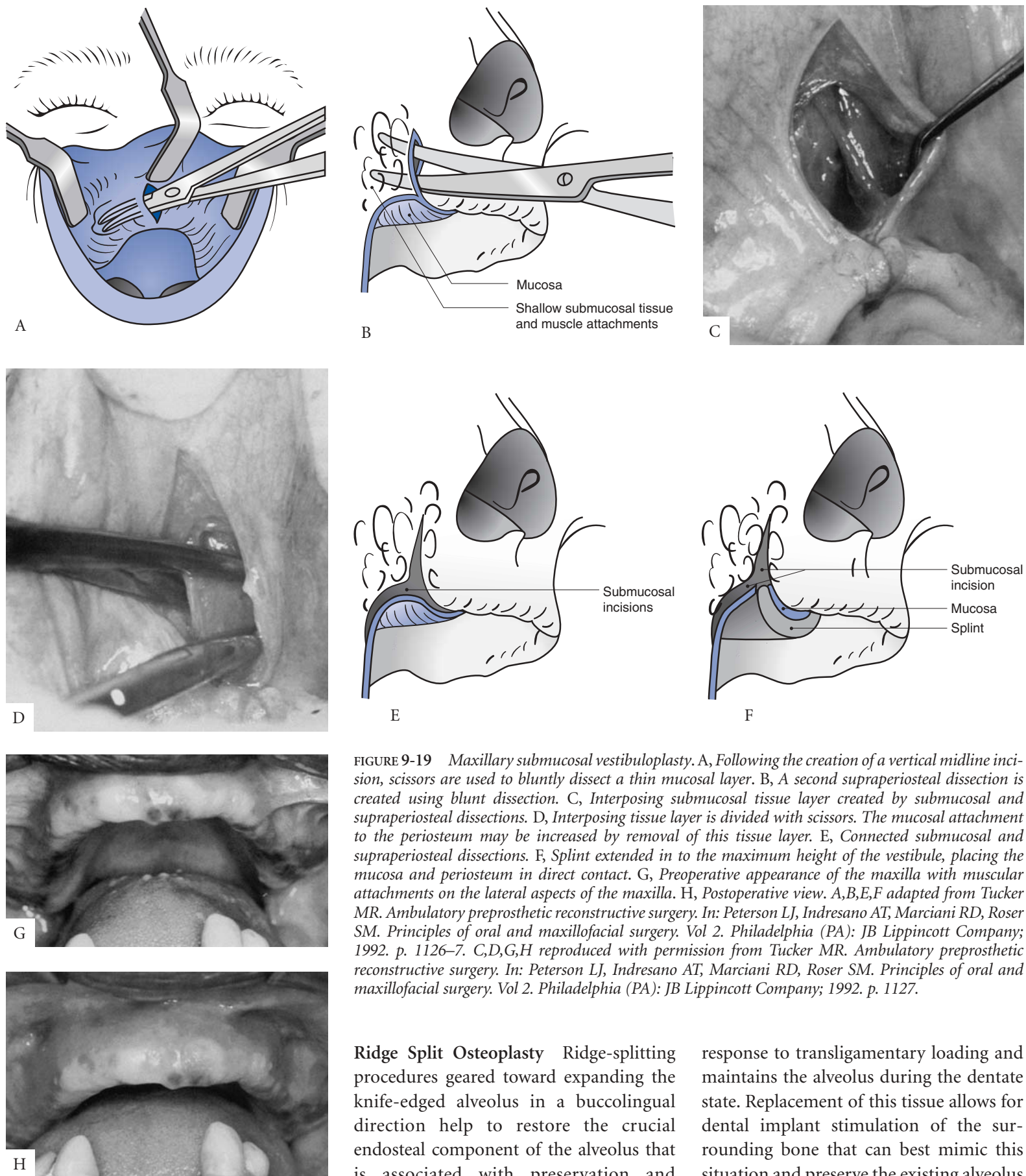
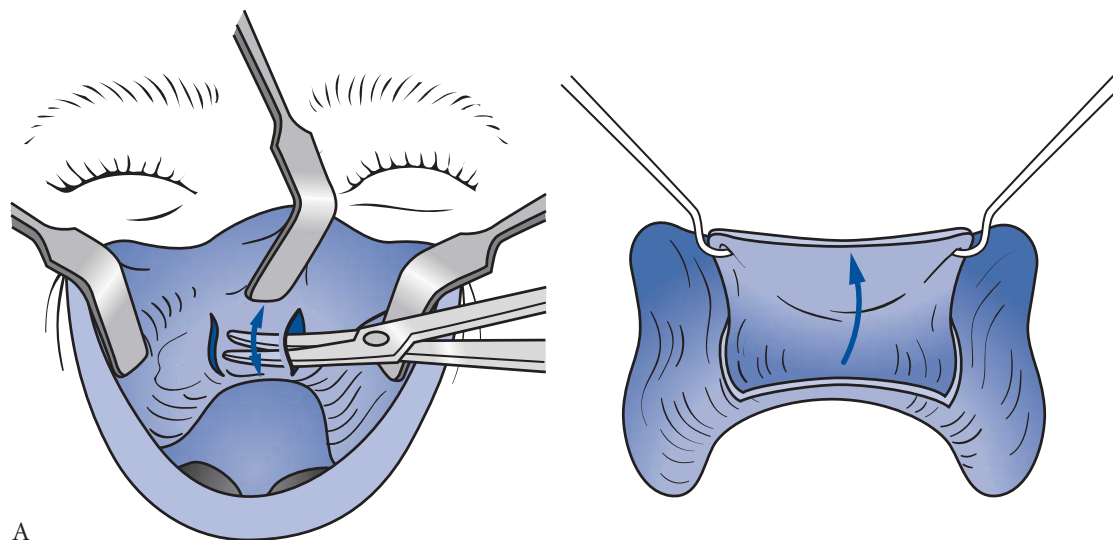


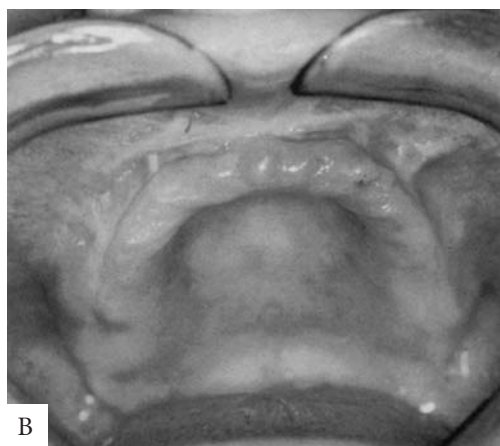FIGURE 9-19 Maxillary submucosal vestibuloplasty. A, Following the creation of a vertical midline incision, scissors are used to bluntly dissect a thin mucosal layer. B, A second supraperiosteal dissection is created using blunt dissection. C, Interposing submucosal tissue layer created by submucosal and supraperiosteal dissections. D, Interposing tissue layer is divided with scissors. The mucosal attachment to the periosteum may be increased by removal of this tissue layer. E, Connected submucosal and supraperiosteal dissections. F, Splint extended in to the maximum height of the vestibule, placing the mucosa and periosteum in direct contact. G, Preoperative appearance of the maxilla with muscular attachments on the lateral aspects of the maxilla. H, Postoperative view. A,B,E,F adapted from Tucker MR. Ambulatory preprosthetic reconstructive surgery. In: Peterson LJ, Indresano AT, Marciani RD, Roser SM. *Principles of oral and maxillofacial surgery*. Vol 2. Philadelphia (PA): JB Lippincott Company; 1992. p. 1126–7. C,D,G,H reproduced with permission from Tucker MR. Ambulatory preprosthetic reconstructive surgery. In: Peterson LJ, Indresano AT, Marciani RD, Roser SM. *Principles of oral and maxillofacial surgery*. Vol 2. Philadelphia (PA): JB Lippincott Company; 1992. p. 1127.

Ridge Split Osteoplasty Ridge-splitting procedures geared toward expanding the knife-edged alveolus in a buccolingual direction help to restore the crucial endosteal component of the alveolus that is associated with preservation and

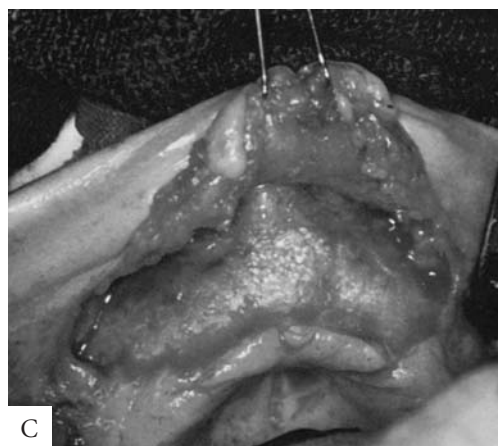response to transligamentary loading and maintains the alveolus during the dentate state. Replacement of this tissue allows for dental implant stimulation of the surrounding bone that can best mimic this situation and preserve the existing alveolus



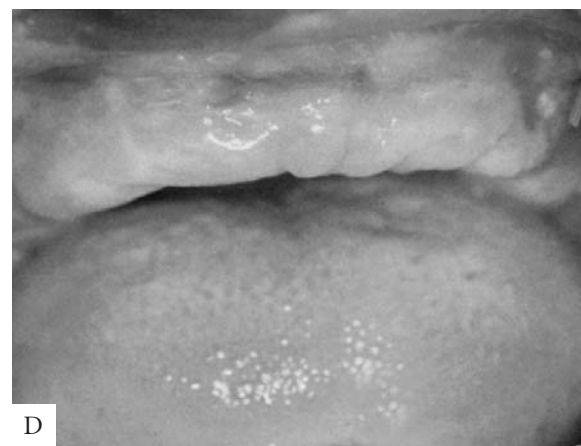A



B



C



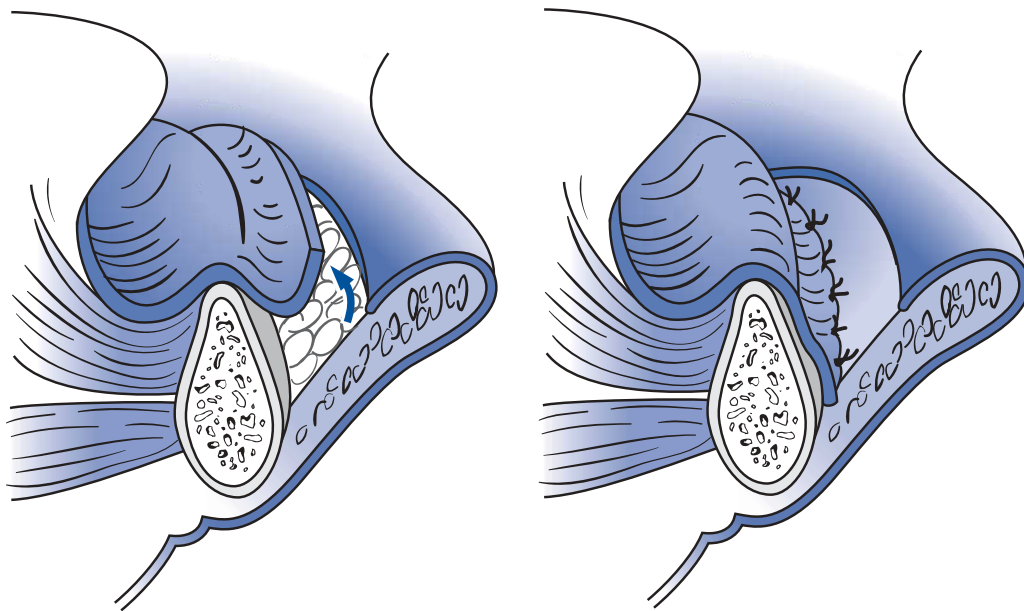
D

FIGURE 9-20 Open submucosal vestibuloplasty. A, Submucosal dissection between two anterior vertical incisions followed by an incision on the crest of the alveolar ridge. B, Preoperative appearance of the maxilla; hydroxylapatite augmentation had been performed but resulted in inadequate vestibular depth. C, Intraoperative photograph after elevation of the mucosal flap and removal of submucosal tissue. D, Appearance at the time of splint removal. A adapted from and B–D reproduced with permission from Tucker MR. Ambulatory preprosthetic reconstructive surgery. In: Peterson LJ, Indresano AT, Marciani RD, Roser SM. Principles of oral and maxillofacial surgery. Vol 2. Philadelphia (PA): JB Lippincott Company; 1992. p. 1128.

and possibly stimulate future bone growth. Adequate dimensions, however, should exist that allow for a midcrestal osteotomy to separate the buccal and lingual cortices (Figures 9-24 and 9-25). A labial incision originates just lateral to the vestibule and continues supraperiosteally to a few millimeters below the crest of the alveolus. A subperiosteal flap then originates exposing the underlying crest. Copious irrigation accompanies an osteotomy circumferentially anterior to the maxillary sinus from one side to the other. Mobilization of the labial segment can be achieved

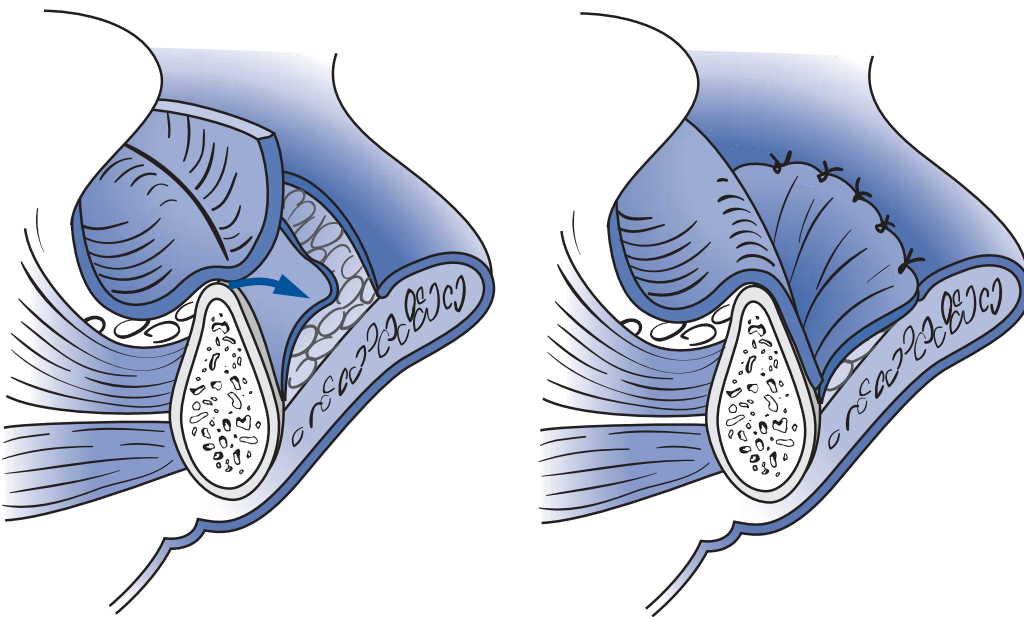
with careful manipulation with an osteotome, taking care to maintain the labial periosteal attachment. An interpositional cancellous graft can then be placed in the resulting defect, replacing the lost bony mass. Closure of the incision is away from the graft site and usually requires suturing of the flap edge to the periosteum with subsequent granulation of the remainder of the exposed tissue bed. Endosteal implants can be placed approximately 3 to 4 months later; waiting this length of time has been shown to increase overall long-term implant success.

Onlay Grafts When clinical loss of the alveolar ridge and palatal vault occur (Cawood and Howell Class V), vertical onlay augmentation of the maxilla is indicated. Initial attempts at alveolar restoration involved the use of autogenous rib grafts; however, currently corticocancellous blocks of iliac crest are the source of choice.^{39,40} In a similar approach to that described above, the crest of the alveolus is exposed and grafts are secured with 1.5 to 2.0 mm screws. Studies show increased success with implant placement in a second-stage procedure rather than using them as



A

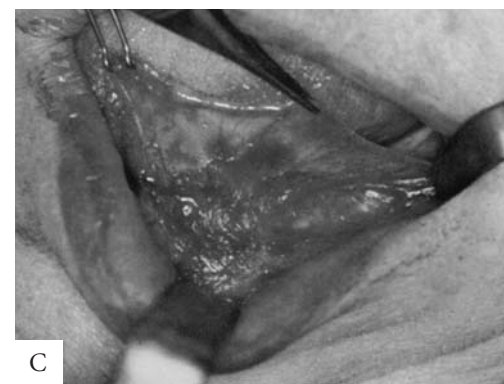B



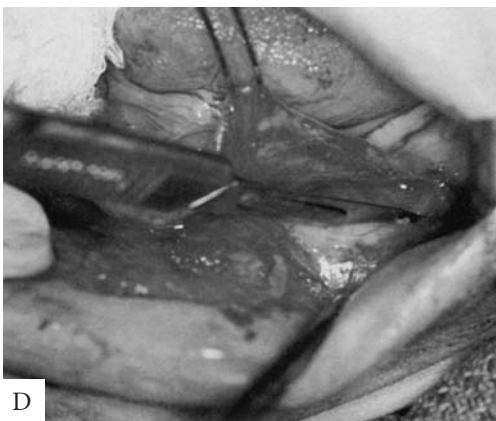
A

B

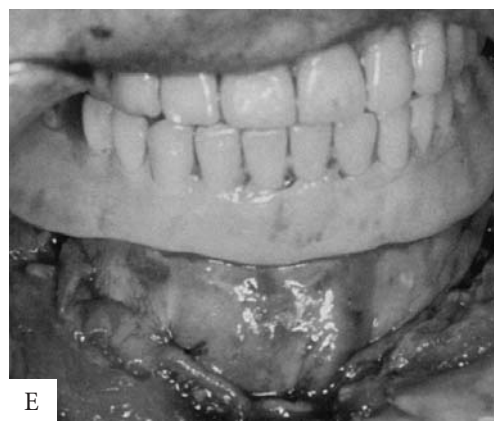
FIGURE 9-21 Kazanjian flap vestibuloplasty. A, An incision is made in the labial mucosa, and a thin mucosal flap is dissected from the underlying tissue. A supraperiosteal dissection is performed on the anterior aspect of the mandible. B, The labial mucosal flap is sutured to the depth of the vestibule. The anterior aspect of the labial vestibule heals by secondary intention. Adapted from Tucker MR. Ambulatory preprosthetic reconstructive surgery. In: Peterson LJ, Indresano AT, Marciani RD, Roser SM. Principles of oral and maxillofacial surgery. Vol 2. Philadelphia (PA): JB Lippincott Company; 1992. p. 1120.



C



D



E

FIGURE 9-22 Transpositional flap (lip-switch) vestibuloplasty. A, After elevation of the mucosal flap, the periosteum is incised at the crest of the alveolar ridge and a subperiosteal dissection is completed on the anterior aspect of the mandible. B, The periosteum is then sutured to the anterior aspect of the labial vestibule, and the mucosal flap is sutured to the vestibular depth at the area of the periosteal attachment. C, Elevation of the mucosal flap. D, Periosteal incision along the crest of the alveolar ridge. E, Mucosa is sutured to the vestibular depth at the area of the periosteal attachment. Note amount of vestibular depth extension compared with the old vestibular depth, which is marked by the previous denture flange. A, B adapted from and C–E reproduced from Tucker MR. Ambulatory preprosthetic reconstructive surgery. In: Peterson LJ, Indresano AT, Marciani RD, Roser SM. Principles of oral and maxillofacial surgery. Vol 2. Philadelphia (PA): JB Lippincott Company; 1992. p. 1121.

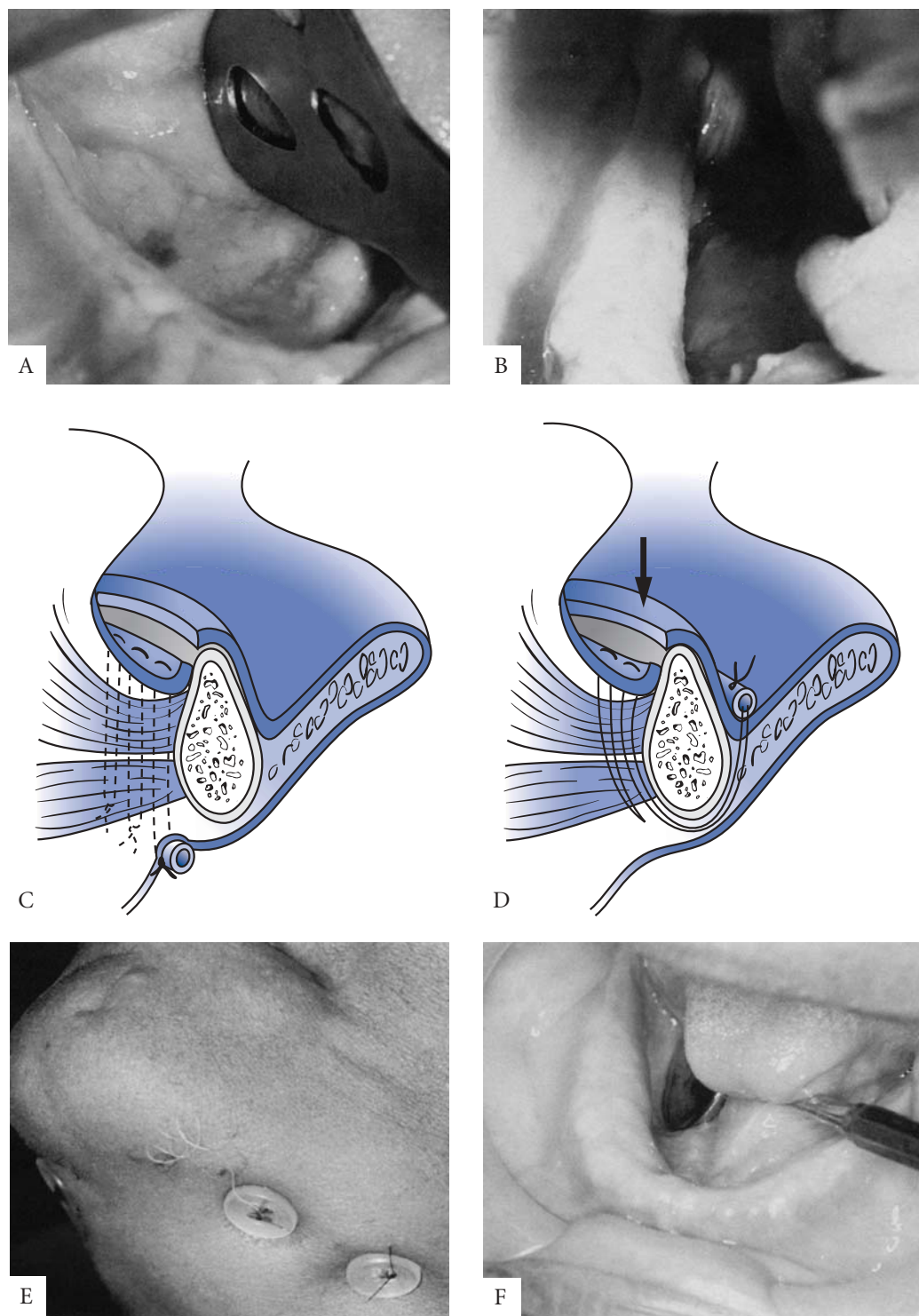


FIGURE 9-23 Floor-of-mouth lowering. A, Mucosal and muscular attachments near the crest of the alveolar ridge. B, Inferior repositioning of the mucosal flap after the mucosal incision and sectioning of mylohyoid muscle have been performed. C, Bolsters placed percutaneously to secure the flap inferiorly. D, Inferior mandibular “sling” sutures provide inferior traction on the mucosal flap. E, Buttons secure the mucosal flap sutures. F, Postoperative appearance of the floor-of-mouth extension. A,B,E,F reproduced with permission from Tucker MR. *Ambulatory preprosthetic reconstructive surgery*. In: Peterson LJ, Indresano AT, Marciani RD, Roser SM. *Principles of oral and maxillofacial surgery*. Vol 2. Philadelphia (PA): JB Lippincott Company; 1992. p. 1122–3. C,D adapted from Tucker MR. *Ambulatory preprosthetic reconstructive surgery*. In: Peterson LJ, Indresano AT, Marciani RD, Roser SM. *Principles of oral and maxillofacial surgery*. Vol 2. Philadelphia (PA): JB Lippincott Company; 1992. p. 1122.

sources of retention and stabilization of the graft and alveolus at the time of augmentation. Implant success ranges from > 90% initially and falls to 75% and 50%, respectively, at 3 and 5 years postoperatively.^{41–45} Implant success may be directly proportional to the degree of graft maturation and incorporation at the time of implant placement. As a result, 4 to 6 months of healing is an acceptable waiting period when long-term implant success may be affected.

Interpositional Grafts Interpositional grafts are indicated when adequate palatal vault height exists in the face of severe alveolar atrophy (Cawood and Howell Class VI) posteriorly, resulting in an increased interarch space. Because this method involves a Le Fort I osteotomy, true skeletal discrepancies between the maxilla and mandible can be corrected at the time of surgery. The improvement of maxillary dimensions as a result of interpositional grafts may obviate the need for future soft tissue recontouring to provide adequate relief for prosthetic rehabilitation (Figure 9-26). Although early studies entertained the simultaneous placement of dental implants at the time of augmentation, recently several authors have demonstrated better success rates for implants placed in a second-stage procedure; this alleviates the need for excessive tissue reflection for implant placement and allows for a more accurate placement at a later date.⁴¹ A relapse of 1 to 2 mm has been demonstrated in interpositional grafts using the Le Fort I technique with rigid fixation.^{46–50} More data are needed to determine long-term overall success and relapse with these procedures.

Sinus Lifts and Inlay Bone Grafts Sinus lift procedures and inlay bone grafting play a valuable role in the subsequent implant restoration of a maxilla that has atrophied posteriorly and is unable to accommodate implant placement owing to the proximity of the maxillary sinus to

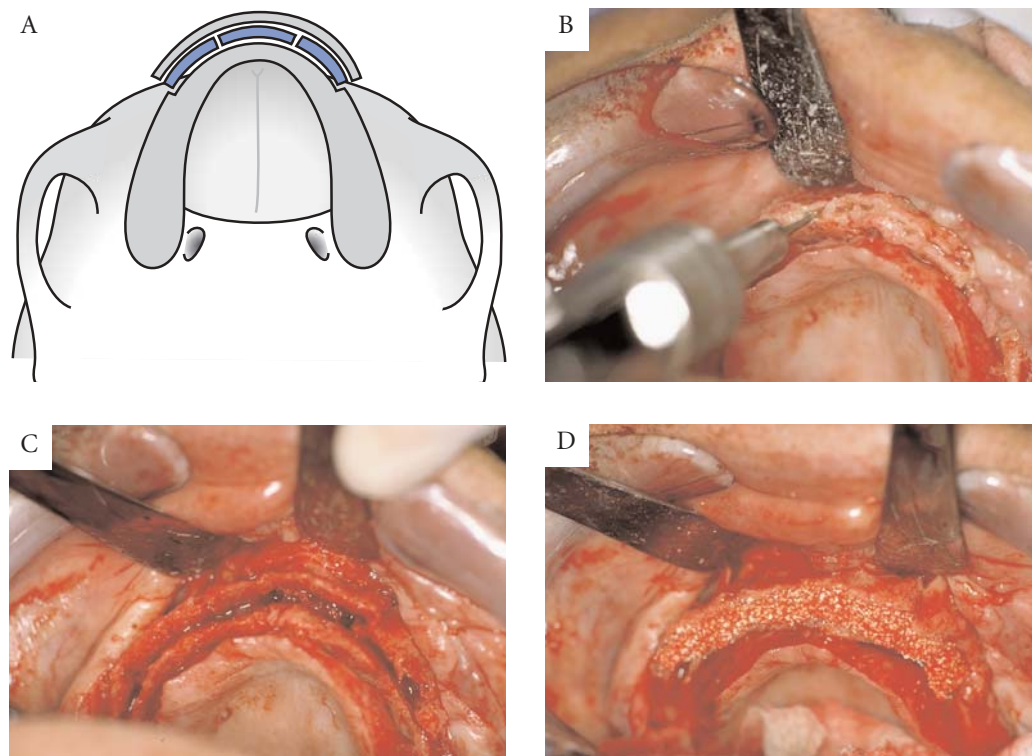


FIGURE 9-24 A, Diagram shows bone cuts and the position of the buccal fragment after the osteotomy. The bone grafts are already in position. Adapted from Stoeltinga PJW.⁶¹ B, Handpiece in position with small crosscut fissure bur performing osteotomy along the crest of the alveolar ridge. C, Osteotomy completed and buccal plate outfractured to complete ridge split. The defect is now ready for interpositional graft to maintain the increased buccolingual width. D, Completed ridge split with interpositional corticocancellous and allogeneic bone used to fill the defect and maintain the increased buccolingual dimension.

the alveolar crest. Incisions just palatal to the alveolar crest are created, followed by subperiosteal exposure of the anterior maxilla. A cortical window 2 to 3 mm above the sinus floor is created with the use of a round diamond bur down to the membrane of the sinus. Careful infraction of the window with dissection of the sinus membrane off the sinus floor creates the space necessary for graft placement; the lateral maxillary wall is the ceiling for the subsequent graft (Figure 9-27). Cortico-cancellous blocks or particulate bone may be placed in the resulting defect. Tears in the membrane may necessitate coverage with collagen tape to prevent extrusion and migration of particulate grafts through the perforations. Although implant placement can proceed simultaneously when 4 to 5 mm of native alveolus exists, we have found few cases where the

alveolus meets these requirements and therefore elect to place implants approximately 6 months later. Block and Kent have reported an 87% success rate with

sinus-grafting procedures. They also have stated that in the literature there is an overall success rate ranging from 75 to 100%.^{51,52} As these procedures gain popularity and are routinely incorporated into mainstream preprosthetic surgery treatment plans, more accurate data and long-term follow-up will be available.

Treatment of Skeletal and Alveolar Ridge Discrepancies

Supraeruption of teeth and associated alveolar bone into opposing edentulous spaces in partially edentulous patients precludes prosthetic rehabilitation owing to functional loss of freeway space and the fact that the opposing arch cannot be restored without the extraction of the offending supraerupted dentition. With segmental alveolar surgery, these teeth can be repositioned to achieve a more appropriate relationship with the adjacent dentition and to increase the interarch space to allow for proper prosthetic restoration of the opposing dentition. A preoperative work-up should include a thorough extraoral and intraoral examination. Cephalometric analysis and study models should be obtained. Close communication with the restorative dentist is necessary to determine expectations regarding the final position of the tooth-bearing segment postoperatively. Mounted

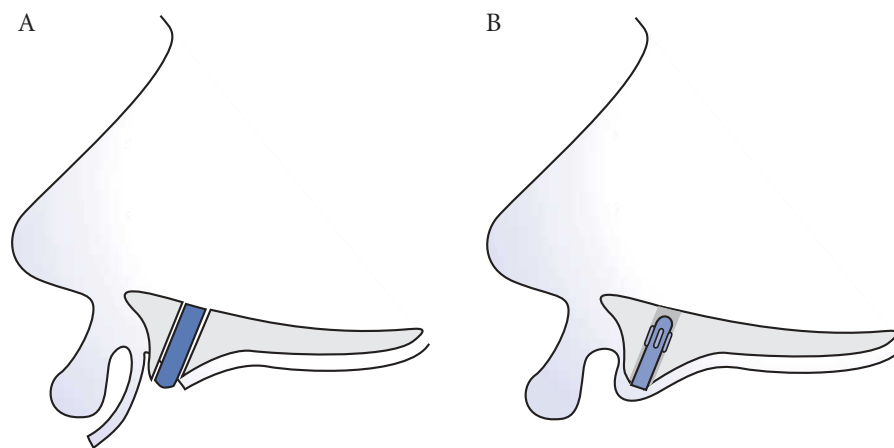


FIGURE 9-25 A, Schematic drawing of the bone graft position in relation to the nasal floor. Note the reflected buccal periosteum after palatal incisions. B, Position of endosteal implants after the bone graft has healed. Adapted from Stoeltinga PJW.⁶¹

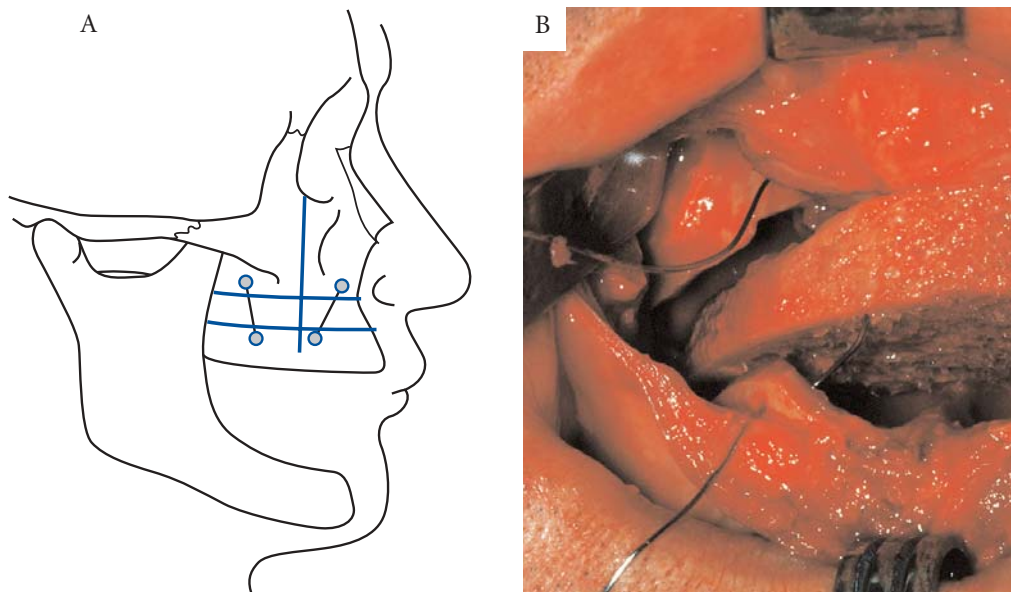


FIGURE 9-26 Graphic (A) and clinical presentation (B) of interpositional iliac crest grafts to the maxilla.

models, model surgery to reposition the segment, and diagnostic wax-ups of the proposed opposing dentition help one to verify the feasibility and success of the future prosthetic reconstruction. Surgical splint fabrication is necessary to support and stabilize the segment postoperatively. Increased stability is obtained if as many teeth as possible are included in the splint to help stabilize the teeth in the repositioned segment. The splint can be thickened to the opposing edentulous alveolar ridge to prevent relapse and to maintain the new vertical alignment of the repositioned segment. Techniques for segmental surgery are discussed Chapter 57, “Maxillary Orthognathic Surgery,” and in other texts. An adequate healing period of approximately 6 to 8 weeks should precede prosthetic rehabilitation.

In totally edentulous patients with skeletal abnormalities that prevent successful prosthetic reconstruction owing to an incompatibility of the alveolar arches, orthognathic surgical procedures may create a more compatible skeletal and alveolar ridge relationship. This can aid the restorative dentist in the fabrication of functional and esthetic restorations (Fig-

ure 9-28).⁴⁶ During the evaluation and treatment planning stage, the restorative dentist should play a major role in determining the final position of the maxillary and mandibular arches. Clinical examination, radiographic and cephalometric examinations, and articulated models should be attained to determine appropri-

ate presurgical vertical and horizontal dimensions. This information should be combined with a cephalometric prediction analysis to determine the overall problem list and surgical treatment plan. Indexed surgical splints that can be rigidly fixed to the edentulous arches should be fabricated preoperatively at the time of model surgery; these splints aid in surgical repositioning of the maxilla, mandible, or both. Surgical procedures describing repositioning of the maxilla and mandible with rigid fixation are discussed in Chapter 56, “Principles of Mandibular Orthognathic Surgery” and Chapter 57, “Maxillary Orthognathic Surgery.” Prosthetic reconstruction can usually proceed at 6 to 8 weeks postoperatively.

Mandibular Augmentation

One of the most challenging procedures in reconstructive surgery remains the reconstruction of the severely atrophic mandible (Cawood and Howell Classes V and VI). Patients exhibiting these deficits are characteristically overclosed, which creates an aged appearance, are usually severely debilitated from a functional perspective, and

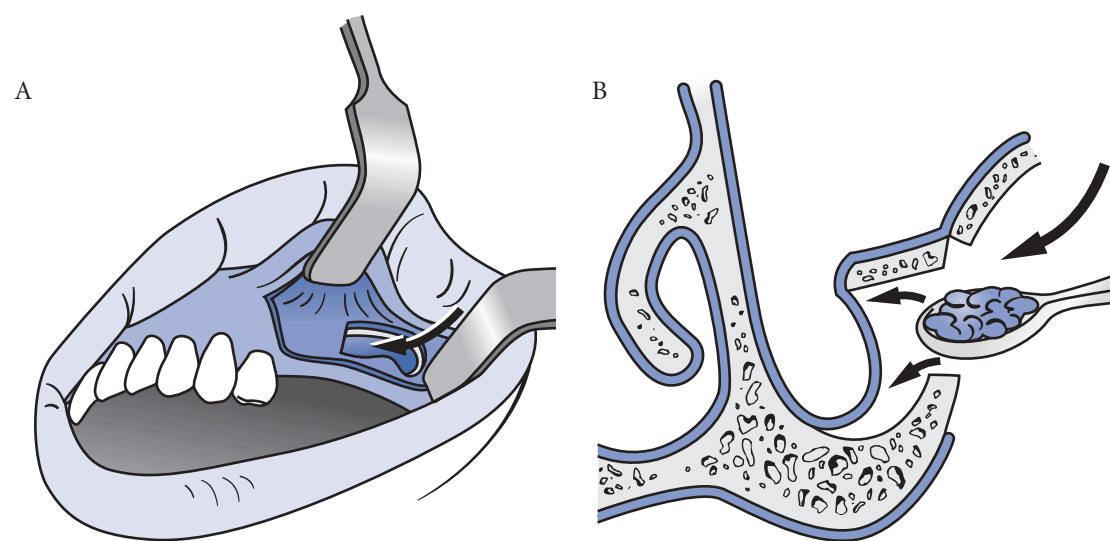


FIGURE 9-27 A, Sinus lift procedure with an inward trapdoor fracture of lateral sinus wall. B, Graft material is placed on the floor of the sinus. The sinus lining should not be perforated during the elevation of the bone. Adapted from Beirne OR. Osseointegrated implant systems. In: Peterson LJ, Indresano AT, Marciani RD, Roser SM. Principles of oral and maxillofacial surgery. Vol 2. Philadelphia (PA): JB Lippincott Company; 1992. p. 1146.

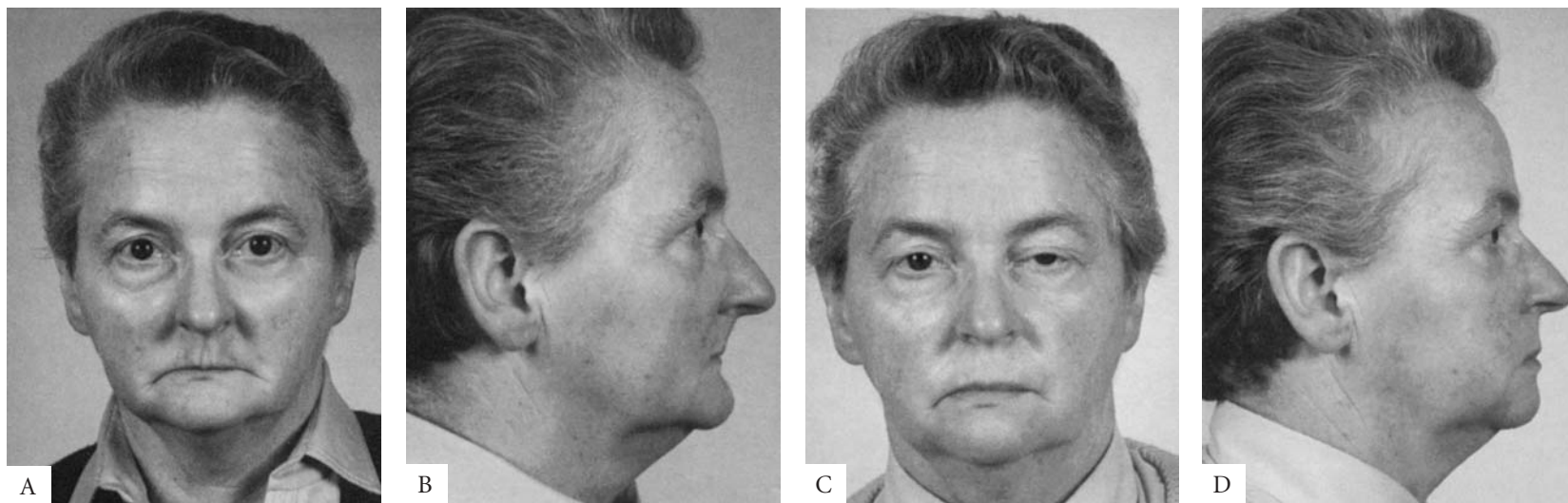


FIGURE 9-28 A and B, Preoperative views of a 52-year-old patient show severely collapsed circumoral tissues. C and D, The same patient 6 months postoperatively. Note the improvement of the sagging chin and support for circumoral muscles. Better support for the lower lip also favorably affects the position of the upper lip. The patient is not wearing dentures in any of the photographs. Reproduced with permission from Stoelting PJW.⁶¹

often present with significant risk for pathologic fracture of the mandible. Because the ideal graft should be vascularized and eventually incorporated into the host bone through a combination of osteoconduction and induction, autogenous bone grafts consistently meet these requirements and offer the most advantages to the reconstructive plan. Unfortunately, graft resorption and unpredictable remodeling have complicated grafting procedures; however, rigid fixation and later incorporation of dental implants have allowed for the needed stability postoperatively with regard to resorption and have promoted beneficial stimulation to preserve existing graft volume. Initially, mandibular augmentation with autogenous rib and ileum enjoyed little long-term success. However, recent incorporation of rigid fixation, delayed implant placement 6 months after grafting (allowing for the initial stage of graft resorption), guided tissue regeneration, and BMP have all contributed to increased success rates in onlay augmentation of the mandible.⁵³⁻⁵⁷

Inferior Border Augmentation Inferior border augmentation has been demonstrated using autogenous rib or composite

cadaveric mandibles combined with autogenous cancellous bone (Figure 9-29).⁵⁸⁻⁶⁰ The following describes our technique for inferior augmentation of the atrophic mandible using the latter method.

Incisions are placed as inconspicuous as possible from one mandibular angle to the other and proceed circumferentially

3 to 4 mm below the inferior border of the mandible and anteriorly to the contralateral side. The superficial layer of the deep cervical fascia is sharply dissected. The fascia is then incorporated in the reflection; a nerve tester is used to perform a careful evaluation for the marginal mandibular branch of the facial nerve. Reflection

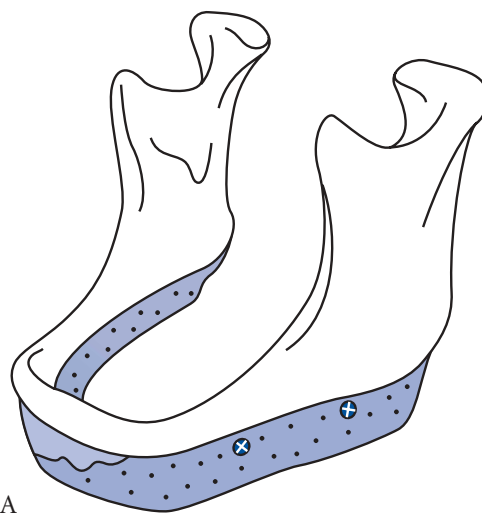
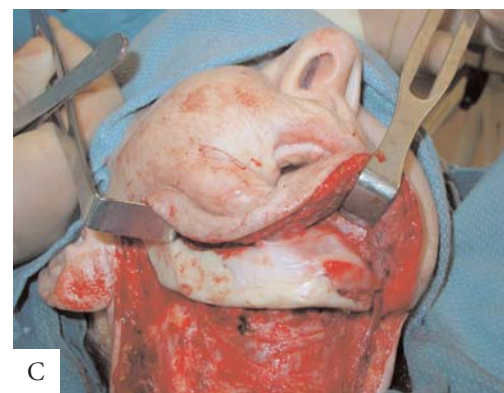
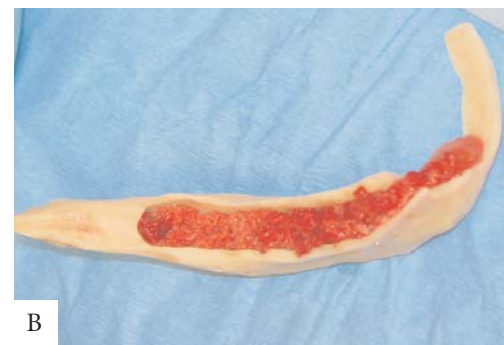

FIGURE 9-29 A, Cadaveric mandible tray rigidly fixed to an atrophic mandible with autogenous cancellous bone sandwiched between native and cadaveric bone. Note that bur holes have been created to facilitate the revascularization of the graft. B, Cadaveric tray filled with autogenous bone before inseting. C, Graft and cadaveric tray inset for inferior border augmentation.



superficial to the capsule of the submandibular gland allows dissection to the inferior border. Facial blood vessels are located and managed with surgical ties accordingly. The inferior border is exposed in a subperiosteal dissection with great care to avoid intraoral exposure. Cadaveric mandibular adjustment involves relieving the condyles and superior rami, thinning the bone to a uniform thickness of approximately 2 to 3 mm, and creating a scalloped tray to incorporate the autogenous bone. Repeated try-ins are necessary to evaluate the overall adaptation to the native mandible. Osseous interfaces as well as form and symmetry as they relate to the overall maxillomandibular relationship are evaluated. Once appropriate dimensions have been reached, the atrophic mandible fits securely inside the cadaveric specimen without creating a Class III appearance, and flap closure is attainable, bur holes are drilled throughout the specimen to facilitate vascularization. Autogenous bone is then obtained from the ileum, morselized, and placed in the cadaveric specimen. BMP soaked in collagen is placed in the recipient bed as well as in a layered fashion over the autogenous graft. The entire specimen is fixed rigidly to the native mandible using screw fixation posterior to the area of future implant placement and in the mandibular midline, where implants are usually not placed. Postoperatively patients can function with their preexisting prosthesis and enjoy increased stabilization of the mandible. When combined with implant placement at 4 to 6 months, this procedure results in an overall resorption rate of < 5% and is associated with low rates of infection and dehiscence intraorally owing to the maintenance of mucosal barriers during reconstruction.

Pediced and Interpositional Grafts
Placement of pediced or interpositional grafts in the mandible is based on the maintenance of the lingual periosteum.

The lingual periosteum maintains ridge form and its presence results in minimal resorption of the transpositioned basalar bone, as described by Stoelinga.⁶¹ Peterson and Slade as well as Harle described the visor osteotomy in the late 1970s (Figure 9-30).^{62,63} Unfortunately, labial bone grafting of the superiorly repositioned lingual segment was necessary to reproduce alveolar dimensions that were compatible with prosthesis use. Schettler and Holtermann and then Stoelinga and Tideman described a horizontal osteotomy with interpositional grafts to augment mandibular height, with repositioning of the inferior alveolar neurovascular bundle (Figures 9-31 and 9-32).^{64,65} Unfortunately, neurosensory complications and collapse of the lingual segment became significant disadvantages to this technique. With the incorporation of mandibular implants and the success of full mandibular prostheses that are supported by four or five anterior implants between mental foramina, many of these pediced and interpositional procedures are in decline today.

Alveolar Distraction Osteogenesis

As alluded to previously, growing bone via the application of tension or stress has been

shown to be a viable solution to defects of the long bone, mandible, and midface. Application to alveolar bone has been limited only by technologic advancement in appliances—the principles are still the same. Alveolar distraction offers some distinct advantages over traditional bone-grafting techniques. No donor site morbidity is involved, and the actual distraction process from the latency period through active distraction and consolidation is actually shorter than Phase I and Phase II bone remodeling and maturation. The quality of the bone grown in response to this tension/stress application is ideal for implant placement. The vascularity and cellularity of the bone promote osseointegration of dental implants. The greatest successes are related to the achievement of vertical graft stability. One of the biggest problems in alveolar bone grafting historically has been maintaining vertical augmentation of bone graft sites. When distraction is used, the transported alveolar segment does not undergo any significant resorptive process because it maintains its own viability through an intact periosteal blood supply. The intermediate regenerate quickly transforms into immature woven bone and matures through the normal processes of active bone remodeling. The sequencing of

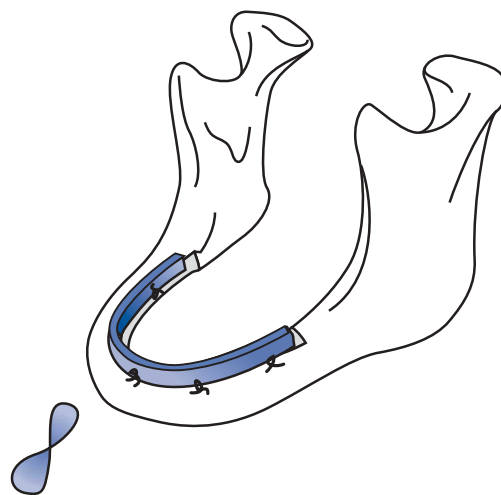


FIGURE 9-30 *Visor osteotomy devised by Harle F. Adapted from Stoelinga PJW⁶¹ and Harle F.⁶³*

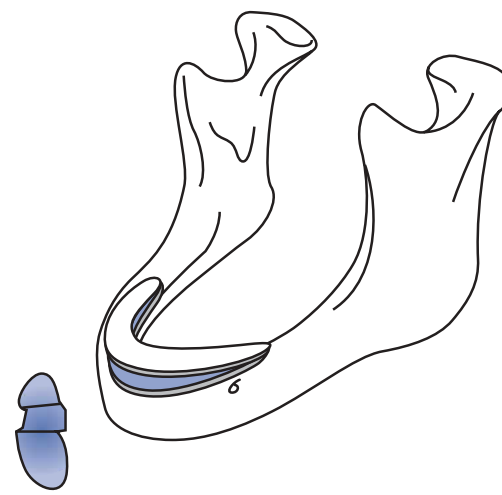


FIGURE 9-31 *Sandwich osteotomy designed by Schettler and Holtermann. Adapted from Stoelinga PJW⁶¹ and Schettler D and Holtermann W.⁶⁴*

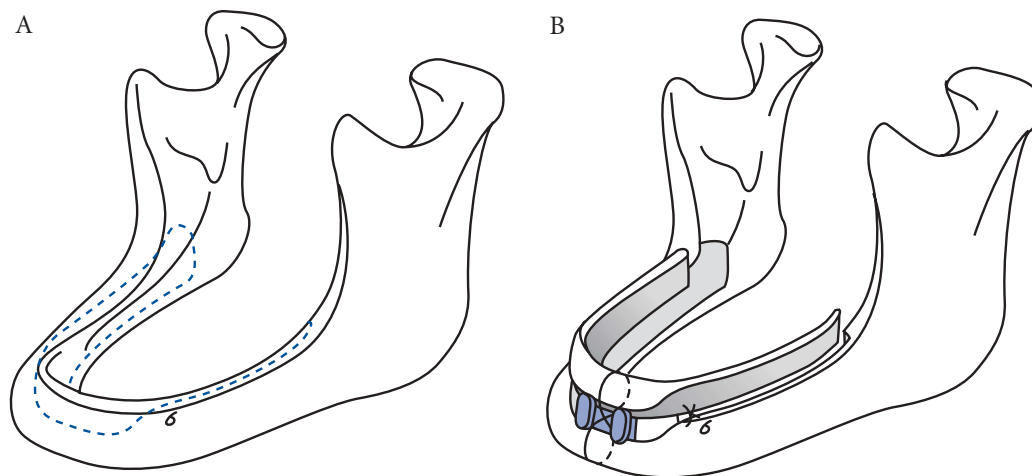


FIGURE 9-32 Sandwich-visor osteotomy according to Stoelinga and Tideman. A, Bone cut is outlined (dotted line). B, Cranial fragment is lifted, supported by bone struts, and secured by a wire tied in a figure of eight. Adapted from Stoelinga PJW⁶¹ and Schettler D and Holtermann W.⁶⁴

events is crucial to maintaining the newly augmented bone and is definitely applicable in cases in which the alternatives are limited.

Diagnosis and treatment planning of a typical case for alveolar distraction osteogenesis involves good clinical and radiographic examinations, primarily using panoramic radiographs. Anatomic structures such as adjacent teeth, the sinus floor, the nasal floor, and the inferior alveolar canal are all easily identifiable in these situations. It is rare that CT or other more sophisticated imaging studies are required. The prosthetic work-up for these cases is also important. The ideal placement of the new alveolar crest both vertically and buccolingually determines the success of the distraction. The final position of the alveolus determines the exact alignment of the transport device and how it should be positioned in the bone.

The shape of the residual alveolar bone is also important to identify. Often vertical bone defects are accompanied by a significant horizontal bone loss. This bone loss must be dealt with either by further reduction of the vertical height to achieve adequate horizontal width or by some type of pre- or postdistraction bone graft augmentation to achieve an adequate width.

Although the success rates with alveolar distraction are very high when cases are

properly planned, there are surgical pitfalls to be avoided to ensure that alveolar distraction succeeds. First and foremost is maintenance of the blood supply of the distracted or transported segment. Many times this is difficult when access to the osteotomies is limited. Although there is no minimum height or width for the transport segment, it should not exceed the distance across which the segment is being transported. Mistakes are often made related to the application of the distraction appliances. In the posterior mandible, the appliances are often inclined too far lingually for implant reconstruction. Similarly, in the anterior maxilla, an adequate labial projection of bone is difficult to achieve unless the appliance is proclined to transport the alveolus inferiorly and labially. Additionally, care must be taken when handling soft tissues at alveolar ridge distraction sites. Mucosal flaps maintained with a substantial vascular supply are necessary to achieve predictable wound healing. In addition, we recommend both periosteal and mucosal closure to prevent segmental dehiscence during the distraction process.

There are both intraosseous and extraosseous devices that have been designed for alveolar distraction. The Lead R System device designed by Chin is a simple one

consisting of two bone plates and a distraction rod.⁶⁶ A horizontal osteotomy is created, and the distraction rod is inserted from a crestal direction. The transport bone plate is then engaged and positioned on the transport section with a bone screw; the basal bone plate is engaged and likewise supported on the bone with a screw. There are some limitations with this device because the distraction rod may limit its use in areas where the vertical dimension of occlusion is compromised. The rod is also visible anteriorly, which may be an esthetic issue. Finally, the rod may interfere with future implant placement unless the implant can be placed directly into the site vacated by the rod.

The Robinson Inter-Oss alveolar device was designed to be used in a one-stage procedure in which the transport appliance actually becomes the implant when the regenerate has matured. Anatomic limitations require a fairly significant crestal bone height and width for use. A similar device, the ACE distraction dental implant system, allows for a distractor that can be placed and then replaced with a dental implant once the distraction has been completed. Again, this is a simple and easy implant to be placed, but anatomic constraints limit its use to certain situations. Both the ACE device and the Robinson Inter-Oss device have limitations in that they must be externally directed or the distraction may veer off course. Other devices available commercially that are similar to those above are the DISSIS distraction implant and the Veriplant. The Lead device mentioned above provides relatively rigid stabilization of the transport segment, but these other devices may violate one of the prime requirements of successful alveolar distraction, namely, rigid fixation of the transport segments.

Extraosseous devices are much more successful and practical for distraction and rigid fixation of the segments. The Track Plus System manufactured by KLS Martin

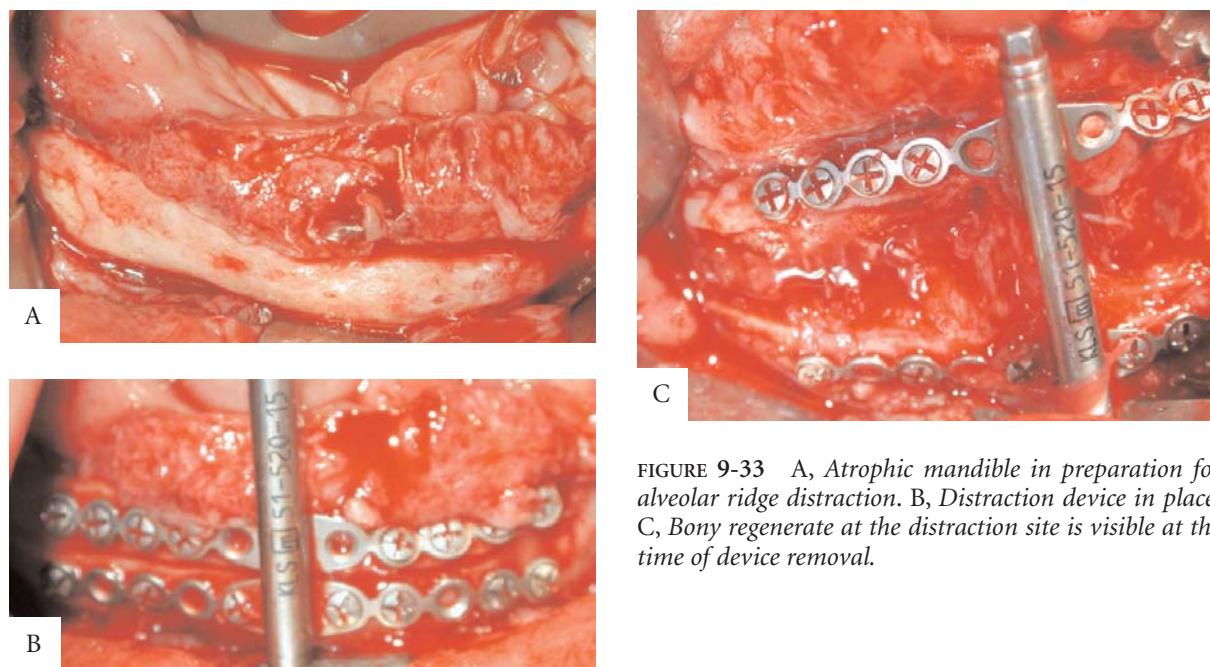


FIGURE 9-33 A, Atrophic mandible in preparation for alveolar ridge distraction. B, Distraction device in place. C, Bony regenerate at the distraction site is visible at the time of device removal.

and the bone plate device manufactured by Walter Lorenz Surgical are two devices that adhere to the principles of distraction and rigid fixation (Figure 9-33).

After placement of a distraction device, a latency period must be observed, the duration of which is 4 to 7 days, depending on the age of the patient and the quality of tissue at the transport site. The latter is significant in patients who have previously undergone irradiation, multiple surgical procedures, or trauma, resulting in scar tissue and compromised blood supply. The active distraction period varies depending on the distance the segment is transported. Standard principles must be followed. The rate and rhythm of transport is 1 mm/d in divided segments—0.25 mm four times a day is the most practical for appliances as well as the patient. The consolidation phase commences when the distraction is complete. Generally the consolidation period should be three times the length of the distraction period. The extrasosseous appliances provide rigid fixation to promote faster maturation of the regenerated bone. At the conclusion of the consolidation phase, the appliance can be removed. Rather than

waiting for full mineralization of the regenerate, one can place the implants, which then provide further rigidity to the transport segment and allow for healing of both the implant and the immature regenerate simultaneously. The total treatment time is thus much shorter than with conventional bone grafting with either autogenous or allogeneic bone, and in most cases the appliance does not interfere with day-to-day function. Other than the inability to wear a transitional prosthesis, there is minimal disruption of the normal activity and diet. Morbidity is generally minimal and is related strictly to management of soft tissue flaps, maintenance of adequate transport segment blood supply, and proper positioning of osteotomies.

Conclusion

With the evolution and success of dental implant technology, guided tissue regeneration, and genetically engineered growth factors such as BMP, current indications for grafting and augmentation are usually related to facilitation of implant placement. Time-honored reconstructive procedures including bone grafting and augmentation are also evolving to create the

ideal environment for implant-supported and -stabilized prosthetic reconstruction.

References

1. Brånemark PI, Hansson B, Adell R, et al. Osseointegrated implants in the treatment of the edentulous jaw. Experience from a 10-year period. *Scand J Plast Reconstr Surg Suppl* 1977;16:1–132.
2. Weintraub JA, Burt BA. Oral health status in the United States: tooth loss and edentulism. *J Dent Educ* 1985;49:368–78.
3. Cawood JI, Stoelinga JPW, et al. International research group on reconstructive preprosthetic surgery—consensus report. *Int J Oral Maxillofac Surg* 2000;29:139–62.
4. Tallgren A. The continuing reduction of residual alveolar ridges in complete denture wearers: mixed longitudinal study covering 25 years. *J Prosthet Dent* 1972;27:120–32.
5. Bays RA. The pathophysiology and anatomy of edentulous bone loss. In: Fonseca R, Davis W, editors. *Reconstructive preprosthetic oral and maxillofacial surgery*. Philadelphia: W.B. Saunders; 1985. p 19–41.
6. Starshak TJ. Oral anatomy and physiology. In: Starshak TJ, Saunders B, editors. *Preprosthetic oral and maxillofacial surgery*. St. Louis: Mosby; 1980.
7. Cawood JI, Howell RA. A classification of the edentulous jaws. *Int J Oral Maxillofac Surg* 1988;17:232–6.
8. Crandal CE, Trueblood SN. Roentgenographic

- findings in edentulous areas. *Oral Surg* 1960;13:1342.
9. Ochs MW, Tucker MR. Preprosthetic surgery. In: Peterson LJ, Ellis E, Hupp J, Tucker M, editors. *Contemporary oral and maxillofacial surgery*. 4th ed. St Louis: Mosby; 2003. p. 248–304.
 10. Enlow DH, Kuroda T, Lewis AB. The morphological and morphogenetic basis for craniofacial form and pattern. *Angle Orthod* 1971;41:161–88.
 11. Wozney JM. The bone morphogenetic protein family and osteogenesis. *Mol Reprod Dev* 1992;31:160–7.
 12. Moss ML. The primary role of functional matrices in facial growth. *Am J Orthod* 1969;55:566–77.
 13. Ilizarov GA. The tension-stress effect on the genesis and growth of tissues. *Clin Orthop* 1989;238:249–81.
 14. Ilizarov GA, editor. *Transosseous osteosynthesis*. Germany: Springer-Verlag; 1992.
 15. Sullivan WG, Szwajkun PR. Revascularization of cranial versus iliac crest bone grafts in the rat. *Plast Reconstr Surg* 1991;87:1105–8.
 16. Burchardt H. The biology of bone graft repair. *Clin Orthop* 1983;174:28–42.
 17. Reddi AH, Weintraub S, Muthukumaran N. *Biologic principles of bone induction*. *Orthop Clin North Am* 1987;18:207–12.
 18. Hosney M. Recent concepts in bone grafting and banking. *J Craniomandib Pract* 1987; 5:170–82.
 19. Becker WM, Urist M, Tucker L. Human demineralized freeze-dried bone: inadequate induced bone formation in athymic mice. A preliminary report. *J Periodontol* 1995;66:822–8.
 20. Wozney JM, Rosen V, Celeste A, et al. Novel regulators of bone formation: molecular clones and activities. *Science* 1998;42:1528–34.
 21. Dean OT. Surgery for the denture patient. *J Am Dent Assoc* 1936;23:124–32.
 22. Kent JN, Jarcho M. Reconstruction of the alveolar ridge with hydroxyapatite. In: Fonseca R, Davis W, editors. *Reconstructive preprosthetic oral and maxillofacial surgery*. Philadelphia: WB Saunders; 1985. p. 853–936.
 23. Wiltfang J, Schlegel K, Schultze-Mosgau S, et al. Sinus floor augmentation with beta-tricalciumphosphate (beta-TCP): does platelet-rich plasma promote its osseous integration and degradation? *Clin Oral Implants Res* 2003;14:213–8.
 24. Stvrtecky R, Gorustovich A, Perio C, Guglielmotti MB. A histologic study of bone response to bioactive glass particles used before implant placement: a clinical report. *J Prosthet Dent* 2003;90:424–8.
 25. Taylor JC, Cuff SE, Leger JP, et al. In vitro osteoclast resorption of bone substitute biomaterials used for implant site augmentation: a pilot study. *Int J Oral Maxillofac Implants* 2002;17:321–30.
 26. Alexopoulou M, Semergidis T, Sereti M. Allogenic bone grafting of small and medium defects of the jaws. Presented at the XIV congress of the European Association for Cranio-Maxillofacial Surgery. 1998 September 1–5; Helsinki, Finland.
 27. Sclar AG. Preserving alveolar ridge anatomy following tooth removal in conjunction with immediate implant placement. The Bio-Col technique. *Atlas Oral Maxillofac Surg Clin North Am* 1999;7(2):39–59.
 28. Kalas S. The occurrence of torus palatinus and torus mandibularis in 2,478 dental patients. *Oral Surg* 1953;6:1134–43.
 29. Bhaskar SN. *Synopsis of oral pathology*. 7th ed. St. Louis: Mosby; 1986.
 30. Guernsey LH. Reactive inflammatory papillary hyperplasia of the palate. *Oral Surg* 1965;20:814–27.
 31. Starshak TJ. Corrective soft tissue surgery. In: Starshak TJ, Saunders B, editors. *Preprosthetic oral and maxillofacial surgery*. St. Louis: Mosby; 1980.
 32. Hartwell CN Jr. *Syllabus of complete dentures*. Philadelphia: Lea & Febiger; 1968.
 33. Obwegeser H. Die Submukose Vestibulumplastik. *Dtsch Zahnarzt Z* 1959;14:629–38.
 34. Kazanjian VH. Surgical operations as related to satisfactory dentures. *Dent Cosmos* 1924;66:387–91.
 35. Keithley JL, Gamble JW. The lip-switch: a modification of Kazanjian's labial vestibuloplasty. *J Oral Surg* 1978;36:701–07.
 36. Trauner R. Alveoloplasty with ridge extensions on the lingual side of the lower jaw to solve the problem of a lower dental prosthesis. *Oral Surg* 1952;5:340–8.
 37. MacIntosh RB, Obwegeser HL. Preprosthetic surgery: a scheme for its effective employment. *J Oral Surg* 1967;25:397–415.
 38. Richardson D, Cawood JI. Anterior maxillary osteoplasty to broaden the narrow maxillary ridge. *Int J Oral Maxillofac Surg* 1991;20:343–8.
 39. Terry BC, Albright JE, Baker RD. Alveolar ridge augmentation in the edentulous maxilla with the use of autogenous ribs. *J Oral Surg* 1974;32:429–34.
 40. Terry BC. Subperiosteal onlay grafts. In: Stoelting PJW, editor. *Proceedings Consensus Conference: 8th International Congress Conference in Oral Surgery*. Chicago: Quintessence International; 1984.
 41. Nystrom E, Ahlqvist J, Kahnberg KE, Ronsenquist JB. Autogenous onlay bone grafts fixed with screw implants for the treatment of severely resorbed maxillae. Radiographic evaluation of preoperative bone dimensions, postoperative bone loss, and changes in soft tissue profile. *Int J Oral Maxillofac Surg* 1996;25:351–9.
 42. Vermeeren JI, Wismeijer D, van Wass MA. One-step reconstruction of the severely resorbed mandible with onlay bone grafts and endosteal implants. A 5-year follow-up. *Int J Oral Maxillofac Surg* 1996;25:112–5.
 43. Nystrom E, Lundgren S, Gonne J, Nilson H. Interpositional bone grafting in LeFort I osteotomy for reconstruction of the atrophic edentulous maxilla. A two stage technique. *Int J Oral Maxillofac Surg* 1997;26:423–7.
 44. Keller EE, Eckerd SE, Tolman DE. Maxillary antral and nasal one stage inlay composite bone graft. A preliminary report on 30 recipient sites. *J Oral Maxillofac Surg* 1994;52:438–48.
 45. Astrand P, Nord PG, Brånemark PI. Titanium implants and onlay bone grafts to the atrophic edentulous maxilla. A three year longitudinal study. *Int J Oral Maxillofac Surg* 1996;25:25–9.
 46. Bell WH, Profit WR, White RP Jr. Surgical correction of dentofacial deformities. Philadelphia: W.B. Saunders; 1980.
 47. Piecuch J, Segal D, Grasso J. Augmentation of the atrophic maxilla with interpositional autogenous bone grafts. *J Maxillofac Surg* 1984;12:133–6.
 48. Cawood JI, Stoelting PJW, Brouns, JJ. A reconstruction of the severely resorbed, Class VI in maxilla. A two step procedure. *Int J Oral Maxillofac Surg* 1994;23:219–25.
 49. Piecuch JF, Silverstein K, Quinn PD. Bone grafts in preprosthetic surgery. *Oral Maxillofacial Surgery Knowledge Update, Vol II*. Chicago (IL): American Association of Oral and Maxillofacial Surgeons; 1998. p. 11–31
 50. Locher MC, Sailer HF. Results after a LeFort I osteotomy in combination with titanium implants: sinus inlay method. *Oral Maxillofac Surg Clin North Am* 1994;6:679–88.
 51. Block MS, Kent JN. Sinus augmentation for dental implants: the use of autogenous bone. *J Oral Maxillofac Surg* 1997;55:1281–6.
 52. Thoma KH, Holland DJ. Atrophy of the mandible. *Oral Surg* 1951;4:1477–81.
 53. Curtis T, Ware W. Autogenous bone graft procedures for atrophic edentulous mandibles. *J Prosthet Dent* 1977;38:366–79.
 54. Saunders B, Cox R. Inferior border rib grafting for augmentation of the atrophic edentulous mandible. *J Oral Surg* 1976;34:897–900.
 55. Davis WH, Delo RI, Ward WB, et al. Long term

- ridge augmentation with rib graft. *J Maxillofac Surg* 1975; 3:103–6.
56. Bell WH, Buche W, Kennedy J III, et al. Surgical correction of the atrophic alveolar ridge: a preliminary report on a new concept of treatment. *Oral Surg* 1977;43:485–98.
57. Baker RD, Connole PW. Preprosthetic augmentation grafting: autogenous bone. *J Oral Surg* 1977;35:541–51.
58. Quinn PD. The atrophic mandible: an alternative to superior border grafting. In: Worthington P, Evans J, editors. *Controversies in oral and maxillofacial surgery*. Philadelphia: W.B. Saunders; 1994. p. 460–6.
59. Quinn PD, Kent JN, MacAfee KA. Reconstructing the atrophic mandible with inferior border grafting and implants: a preliminary report. *Int J Oral Maxillofac Implants* 1992;7:87–93.
60. Miloro M, Quinn PD. Prevention of recurrent pathologic fracture of the atrophic mandible using inferior border grafting: report of two cases. *J Oral Maxillofac Surg* 1994;52:414–20.
61. Stoelinga PJW. Preprosthetic reconstructive surgery. In: Peterson LJ, Indresano AT, Marciani RD, Roser SM, editors. *Principles of oral and maxillofacial surgery*. Philadelphia: JB Lippincott Co; 1992. p. 1169–207.
62. Peterson LJ, Slade E. Mandibular ridge augmentation by a modified visor osteotomy: a preliminary report. *J Oral Surg* 1977;35:999–1004.
63. Harle F. A follow up investigation of surgical correction of the atrophied alveolar ridge with visor osteotomy. *J Maxillofac Surg* 1979;7:283–93.
64. Schettler D, Holtermann W. Clinical and experimental results of a sandwich-technique for mandibular alveolar ridge augmentation. *J Maxillofac Surg* 1977;5:199–202.
65. Stoelinga PJW, Tideman H. Interpositional bone graft augmentation of the atrophic mandible: a preliminary report. *J Oral Surg* 1978;36:30–2.
66. Chin M. Alveolar distraction osteogenesis. In: Samchucov ML, Cope JB, Cherkashin AM, editors. *Craniofacial distraction osteogenesis*. St. Louis: Mosby; 2001. p. 387–92.

Osseointegration

Michael S. Block, DMD

Ronald M. Achong, DMD, MD

History of Dental Implants

Replacement of lost dentition has been traced to ancient Egyptian and South American civilizations.¹ In ancient Egyptian writings implanted animal and carved ivory teeth were the oldest examples of primitive implantology. In eighteenth and nineteenth century England and colonial America, poor individuals sold their teeth for extraction and transplantation to wealthy recipients.² The clinical outcomes of these transplanted dentitions were either ankylosis or root resorption. Continued research prolonged allotransplant survival but did not appreciably improve predictability.

In 1809 Maggiolo placed an immediate single-stage gold implant in a fresh extraction site with the coronal aspect of the fixture protruding just above the gingiva.³ Postoperative complications included severe pain and gingival inflammation. Since then various implant materials were used ranging from roughened lead roots holding a platinum post to tubes of gold and iridium.³⁻⁶ Adams in 1937 patented a submergible threaded cylindrical implant with a ball head screwed to the root for retention for an overdenture in a fashion similar to that done today.⁷

Up to this point implant success was marginal with a maximum longevity of only a few years. Strock placed the first long-term endosseous implant at Harvard in 1938.⁸ This implant was a threaded cobalt-

chrome-molybdenum screw with a cone-shaped head for the cementation of a jacket crown. The implant remained stable and asymptomatic until 1955, at which time the patient died in a car accident. Strock wrote, "The histological sections of implants in the dog study showed remarkable complete tolerance of the dental implant and the pathologist report so indicated to our gratification." Strock demonstrated for the first time that metallic endosteal dental implants were tolerated in humans, with a survival rate of up to 17 years.⁸

Due to inadequate alveolar bone height in certain sites of the jaws, subperiosteal implants were developed. In 1943 Dahl placed a metal structure on the maxillary alveolar crest with four projecting posts.⁹ Multiple variations to this initial design were fabricated but these devices often resulted in wound dehiscence. Blade implants were introduced by Linkow and by Roberts and Roberts.^{10,11} There were numerous configurations with broad applications, and the implants became the most widely used device in implantology in the United States and abroad (Figure 10-1).

A two-staged threaded titanium root-form implant was first presented in North America by Brånemark in 1978.¹² He showed that titanium oculars, placed in the femurs of rabbits, osseointegrated in the femurs of rabbits after a period of healing. Two-staged titanium implants

were first placed in patients in 1965 and studies showed prolonged survival, free-standing function, bone maintenance, and significant improvement in benefit-to-risk ratio over all previous implants.¹³ This breakthrough has revolutionized maxillofacial reconstruction. Subsequently, various implant designs have been manufactured and research in implantology has grown exponentially. The frontiers of implantology are rapidly being advanced and esthetics continue to be an integral part of this progress.

Implant Materials and Surface

Implant materials have undergone a number of different modifications and developments over the past 40 years. Commercially pure titanium has excellent biocompatibility and mechanical properties. When titanium is exposed to air, a 2 to 10 nm thick oxide layer is formed immediately on its surface.¹⁴ This layer is bioinert. However, strength issues with pure titanium have led manufacturers to use a titanium alloy to enhance strength of the implant. Most abutments are made of titanium alloy. The use of alloy significantly increases strength, which can be an issue with small-diameter and internal connections. Titanium alloy (Ti-6Al-4V) is becoming the metal of choice for endosseous dental implants.

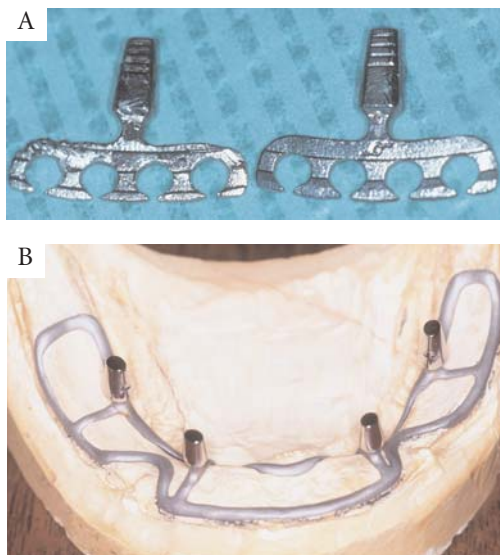


FIGURE 10-1 A, Blade implants. B, Subperiosteal implant. C, Threaded implants with smooth titanium or hydroxylapatite-coated surface.



contact values at 5 weeks of 72.4% for the acid-etched surface, 56.8% for TPS, 54.8% for grit-blasted, and 48.6% for machined surface implants.¹⁹ Reduced healing times have been documented which are believed to result in the need for less time from implantation to loading and better results in poorer-quality bone.²⁰

Despite the success with machined smooth titanium implants, the use of a roughened surface has been substituted by all manufacturers and clinicians as the current surface of choice. With rare exceptions most endosseous implants have a roughened surface texture.

Surgical Protocol Generic for All Implants

Placement without Trauma to the Soft and Hard Tissues

Heat generation during rotary cutting is one of the important factors influencing the development of osseointegration. It is widely accepted that heat increases in proportion to drill speed, and that by extension,

Several attempts have been made to improve implant anchorage in bone by modifying the surface characteristics of titanium implants (Figure 10-2). In order to enhance the bone connection to the implant, a thin coating of hydroxylapatite (HA) has been plasma-sprayed onto a roughened and prepared titanium implant. HA coatings usually range from 50 to 70 μm and are applied to the implant surface with plasma-spray technology.¹⁵ A pressurized hydrothermal postplasma-spray increases the crystalline HA content from 77 to 96%, with an amorphous content of 4%. This coating offers an improved bone adhesion as shown in several studies.^{16,17}

Because of the success in orthopedics with roughened titanium surfaces for endosteal appliances, dental implant manufacturers have modified the titanium surface either by adding titanium to the surface through plasma-spray technology or by reduction procedures involving etching and blasting the surface. The titanium plasma-sprayed surface was the first rough titanium surface introduced into implant dentistry. The titanium plasma-sprayed (TPS) surface process is characterized by high-velocity molten drops of metal being sprayed onto the implant body to a thickness of 10 to 40 μm .¹⁸ Its original intent was to obtain a greater surface area for

bone attachment. TPS implants demonstrated satisfying long-term results in fully and partially edentulous patients.

Roughened titanium surfaces can also be produced by reduction techniques such as sand- or grit-blasting, titanium oxide blasting, acid etching, or combinations of these techniques. In 2000 Cordoli and colleagues reported mean bone-to-implant

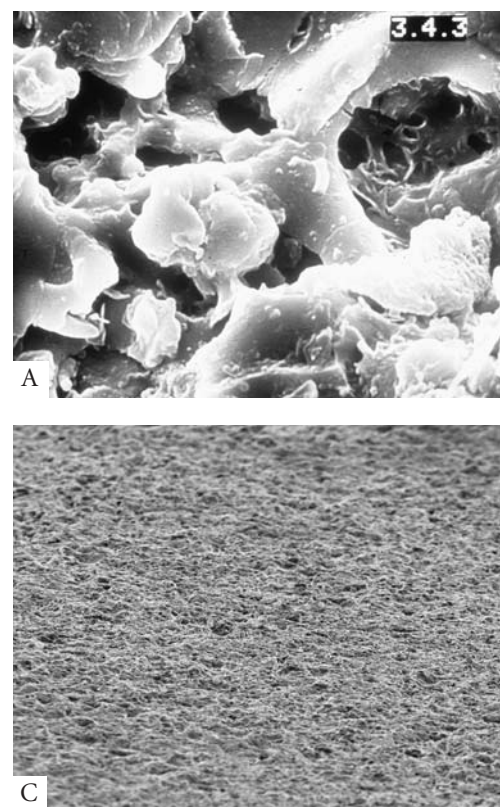


FIGURE 10-2 A, Titanium plasma-sprayed surface at high magnification. B, Acid-etched titanium surface at low magnification. C, Hydroxylapatite-coated surface at low magnification.

high-speed drilling causes physiologic damage to bone. In 1983 Eriksson and Albrektsson demonstrated the occurrence of irreversible histologic damage in the rabbit tibia when heat exposure at a temperature of 47°C was longer than 1 minute.²¹ An even greater injury occurred after heating the bone to 53°C for 1 minute, and heating to temperatures of 60°C or more resulted in permanent cessation of blood flow and obvious necrosis that showed no sign of repair over follow-up period of 100 days.²¹

Minimal heat during implant site preparation has been recommended to achieve optimal healing conditions. Although the relationship between speed and heat generation is still under debate, the consensus has been to recommend speeds of less than 2,000 rpm with copious irrigation for preparation of implant sites.²¹ In 1986 Eriksson and Adell showed that the Brånemark drilling system had a mean maximum temperature of 30.3°C during drilling, with a maximum temperature of 33.8°C.²² The duration of maximum temperature never exceeded 5 seconds.

Watanabe and colleagues measured heat distribution to the surrounding bone with three different implant drill systems, in 1992.²³ Generation of heat in the presence or absence of irrigation when drilling with spiral or spade-type drills was observed in the pig rib via thermography. The maximum temperature generated without irrigation was significantly greater than with irrigation for each drill. The heat generated continuously spread to the surrounding bone even after the bur or drill was removed from the bone, and the original temperature returned in about 60 seconds. The spiral drill required the longest time to generate heat, with gradual increase of temperature. The round bur and cannon or spade drill could finish cutting in a short time, with rapid generation of heat. Maximum temperature without irrigation was higher than with irrigation for any drill. With irrigation at proper speed, minimal

heat was generated. When cortical bone was prepared using the spiral drill, irrigation decreased the maximum temperature by 10°C or more. It is recommended by all manufacturers that the bur be moved up and down while preparing the implant site, to allow accessibility of irrigation to the cutting edges of the bur, neutralizing heat generation and removing bone debris.

Time for Integration

Historically a nonloading healing period of machined-surfaced dental implants has been 4 to 6 months for the mandible and 6 months for the maxilla.²⁴ The 4- to 6-month recommendations were made to prevent the development of a fibrous encapsulation of the implant fixtures that occurs with premature loading. These early recommendations for implant surgical protocol were developed based on clinical observations and not necessarily based on an understanding of the biologic principles of implant integration. The original Brånemark protocol has been greatly modified due to the advances in implant microtopographic surfaces and design. In recent years histologic and experimental studies have shown that specifically designed microtopographic implant surfaces can result in increased bone-to-implant contact at earlier healing times than obtained with machined-surface implants. Over the years histologic and clinical studies investigating early and immediate implant loading revealed that implants can be placed into function earlier than previously recommended. In 1998 Lazzara and colleagues evaluated the efficacy of loading Osseotite dental implants at 2 months to determine the effect of early loading on implant performance and survival.²⁵ The cumulative implant survival rate was 98.5% at 12.6 months. The cumulative postloading implant survival rate was 99.8% at 10.5 months. Testori and colleagues investigated the clinical outcome of 2 months of loaded Osseotite implants placed in the posterior jaws, with

a follow-up period of 3 years.²⁶ The overall cumulative implant survival rate after functional loading was 97.7% in the mandible and 98.4% in the maxilla. Cooper and colleagues investigated the early loaded implants in clinical function without risking the result of osseointegration.²⁷ They demonstrated a 96.2% implant survival rate with loaded unsplinted maxillary anterior single-tooth implants 3 weeks after one-stage surgical placement.²⁷ The majority of the tapered threaded implants were placed in type 3 bone with a minimal length of 11 mm. The mean change in marginal bone level was 0.4 mm with a mean gain in papilla length of 0.61 mm at 12 months. In a recent report unsplinted implants placed by a single-stage procedure were successful when loaded by a mandibular overdenture prosthesis.²⁸ Further developments in implant surfaces will greatly reduce integration time (Figure 10-3).

Key Reasons for Failure

Endosseous dental implants have been used successfully throughout the past few decades. Unfortunately implants are not always successful. Improper implant placement can result in a framework design that compromises esthetics and distribution of force on implants. Endosseous implants distribute occlusal load best in an axial direction, but if the occlusal load is in a lateral direction, many damaging stresses, including shear stresses, are generated directly at the crest of bone. Lazzara proposed that off-angle implant positioning requiring over 25° of angle correction will cause an implant to fail.²⁹ Overheating bone during placement will result in a fibrous tissue against the implant surface rather than the bone. Placing implants into bone of poor quality without consideration to the mechanical forces of loading can result in early or late failure. Lack of bone contact at the time of placement is also a factor leading to lack of integration or marginal

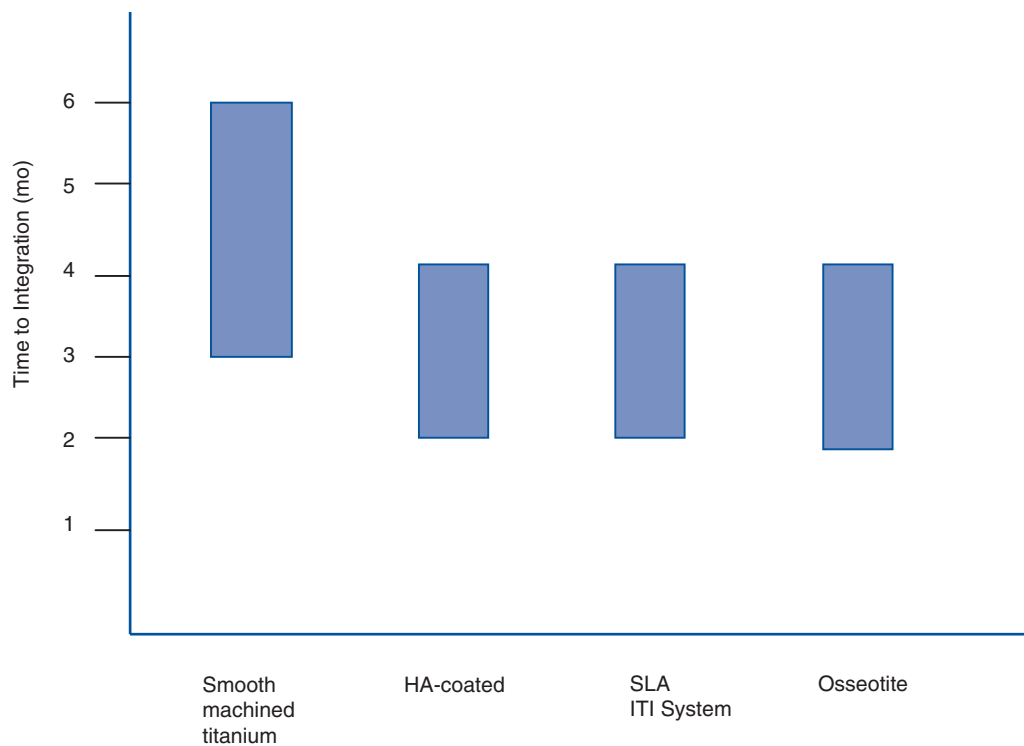


FIGURE 10-3 Chart showing relative healing times for different implant surfaces. HA = hydroxylapatite; SLA type = sandblasted and acid-etched.

integration. The presence of infection when placing an implant can lead to sub-optimal healing and eventual lack of integration, infection within a week of placement, or lack of bone formation that results in early failure after loading.

Keratinized gingiva has been shown to promote soft tissue health around teeth. However, around dental implants, the presence of keratinized gingiva may or may not be important for preservation of crestal bone. Krekeler and colleagues suggested that there is a strong correlation of keratinized gingiva with implant failure and the absence of an adequate band of keratinized mucosa surrounding the abutment.³⁰ This suggested relationship was based on the ability of the keratinized mucosa to withstand bacterial insult and ingress, which can lead to periimplantitis.

Clinical trials with HA-coated implants indicate that the presence of keratinized gingiva is important for long-term success of endosseous implants. There was a significant relationship

between implant survival and crestal bone level maintenance with posterior mandible implants in the presence of a 1 to 2 mm thick band of attached keratinized gingiva.³¹ The early Brånemark reports indicate that crestal bone levels were not affected by the presence of keratinized gingiva in the anterior mandible, although the presence of transient gingivitis was increased in patients without the protective effect of keratinized gingiva. Thus, keratinized gingiva is important for overall periimplant health.³¹ Procedures to create and preserve keratinized gingiva are recommended when placing and exposing implants. When placing a one-stage implant, incision design should result in keratinized gingiva labial to the implant.

The most important factors for implant success, identified by Block and Kent in 1990, are surgery without compromise in technique, placing implants into sound bone, avoiding thin bone or implant dehiscence at the time of implant placement, established balance restoration, and ensur-

ing appropriate follow-up hygiene care.³¹ Implants placed into thin ridges or that had dehiscence of their surface did not uniformly gain bone attachment levels during the healing period. Labial bone implant defects should be grafted with particulate hydroxylapatite. In the posterior maxilla, vertical bone loss seems to be due to excessive cantilever-type forces placed on the implants. The use of sinus grafting is recommended to provide adequate bone support in the atrophic posterior maxilla. The presence of keratinized gingiva strongly correlated with bone maintenance in the posterior mandible. Consequently, implant surgical techniques should preserve all keratinized gingiva. Most patients who receive implants for dental restorations have lost teeth due to caries or periodontal disease. Patients need to maintain meticulous oral hygiene. If pocket probing greater than 3 mm around the implant occurs, additional antibacterial solution application or pocket elimination is recommended for hygiene purposes.

Wound Healing

Bone healing is a physiologic cascade of events in which complex regenerative processes restore original skeletal structure and function. Bone is generated by two separate mechanisms: endochondral and membranous bone formation. Endochondral bone formation occurs at the epiphyseal plates in long bones and condylar head of the mandible and accounts for growth in length.³² It entails the laying down of a preformed cartilaginous template, which is gradually resorbed and replaced by bone. Membranous bone formation or primary bone healing requires differentiation of mesenchymal cells into osteoblasts, which produces osteoid. The osteoid is then mineralized to form bone.³² This type of bone formation occurs in the calvaria, most facial bones, the clavicle, and the mandible. Osseointegration belongs to the category of primary bone healing. The word *osseointegration* was defined as “a direct structural and functional connection

between ordered, living bone and the surface of a load carrying implant.²⁴

Wound healing consists of three fundamental phases: inflammation, proliferation, and maturation. The induction of bone formation at surgical interfaces reflects a major alteration in cellular environment. These crucial events involve an inflammatory phase, a proliferative phase, and a maturation phase.

Phase One: Inflammatory Phase

Bone healing around implants results in a well-defined progression of tissue responses that are designed to remove tissue debris, to reestablish vascular supply and produce a new skeletal matrix. Platelet contact with implant surfaces causes liberation of intracellular granules that, when released, are involved in the early events associated with tissue injury.³³ Release of adenosine diphosphate, serotonin, prostaglandins, and thromboxane A₂ promotes platelet aggregation, resulting in a hemostatic plug. Platelets continue to degranulate during the formation of the hemostatic plug and release constituents that increase vascular permeability (serotonin, kinins, and prostaglandins) and contribute to the inflammatory response accompanying tissue injury.³³

Acute wound healing consists of a cellular inflammatory response dominated mainly by neutrophils. Migration of the neutrophils to the site of injury generally peaks during the first 3 to 4 days following surgery.³⁴ These cells are attracted to the local area by chemotactic stimuli and then migrate from the intravascular space to the interstitial space by diapedesis. The role of these cells is primarily phagocytosis and digestion of debris and damaged tissue. Digestion of tissue is feasible via the release of digestive enzymes such as collagenase, elastase, and cathepsin.³⁴ By the fifth day macrophages predominate and remain until the reparative sequence is completed.³² These cells are derived from circulating monocytes that originate from

the bone marrow via monoblast differentiation. Macrophages can be activated by products of activated lymphocytes and the complement system. Macrophages have the ability to ingest inflammatory debris by phagocytosis and to digest such particles by releasing hydrolytic enzymes.³²

Phase Two: Proliferative Phase

Microvascular ingrowth from the adjacent bony tissues during this phase is called neovascularization.³⁵ Cellular differentiation, proliferation, and activation result in the production of an immature connective tissue matrix that is later remodeled. The local inflammatory cells (fibroblasts, osteoblasts, and progenitor cells) proliferate within the wound and begin to lay down collagen.³⁶ This combination of collagen and a rich capillary network forms granulation tissue with a low oxygen tension. This hypoxic state, combined with certain cytokines such as basic fibroblast growth factor (bFGF) and platelet-derived growth factor, is responsible for stimulating angiogenesis. bFGF seems to activate hydrolytic enzymes, such as stromelysin, collagenase, and plasminogen, which help to dissolve the basement membranes of local blood vessels.³² Reestablishment of local microcirculation improves tissue oxygen tension and provides essential nutrients necessary for connective tissue regeneration.

Local mesenchymal cells begin to differentiate into fibroblasts, osteoblasts, and chondroblasts in response to local hypoxia and cytokines released from platelets, macrophages, and other cellular elements.³² These cells begin to lay down an extracellular matrix composed of collagen, glycosaminoglycans, glycoproteins, and glycolipids. The initial fibrous tissue and ground substance that are laid down eventually form into a fibrocartilaginous callus. The initial bone laid down is randomly arranged (woven type) bone.³⁶ Woven bone formation clearly dominates wound healing at this point for the first 4 to 6 weeks after surgery.

Phase Three: Maturation Phase

After the establishment of a well-vascularized immature connective tissue, osteogenesis continues by the recruitment, proliferation, and differentiation of osteoblastic cells.³² Differentiated osteoblasts secrete a collagenous matrix and contribute to its mineralization. Osteoid-type bone within a vascularized connective tissue matrix becomes deposited at dental implant surgical interfaces.¹⁶ Eventually this matrix envelops the osteoblastic cells and is subsequently mineralized. This cell-rich and unorganized bone is called woven bone. Loading of the dental implant stimulates the transformation of woven bone to lamellar bone.¹⁶ Lamellar bone is an organized bone displaying a haversian architecture. Bone remodeling occurs around an implant in response to loading forces transmitted through the implant to the surrounding bone. The lamellae around the implant are remodeled according to the exposed load, which with passage of time, shows a characteristic pattern of well-organized concentric lamellae with formation of osteons in the traditional manner.¹⁶

Under normal circumstances healing of implants is usually associated with a reduction in the height of alveolar marginal bone. Approximately 0.5 to 1.5 mm of vertical bone loss occurs during the first year after implant insertion.³⁵ The rapid initial bone loss is attributed to the generalized healing response resulting from the inevitable surgical trauma, such as periosteal elevation, removal of marginal bone, and bone damage caused by drilling.

Options for the Edentulous Mandible

Options for patients with an edentulous mandible include a conventional denture, a tissue-borne implant-supported prosthesis, or an implant-supported prosthesis (Figure 10-4).

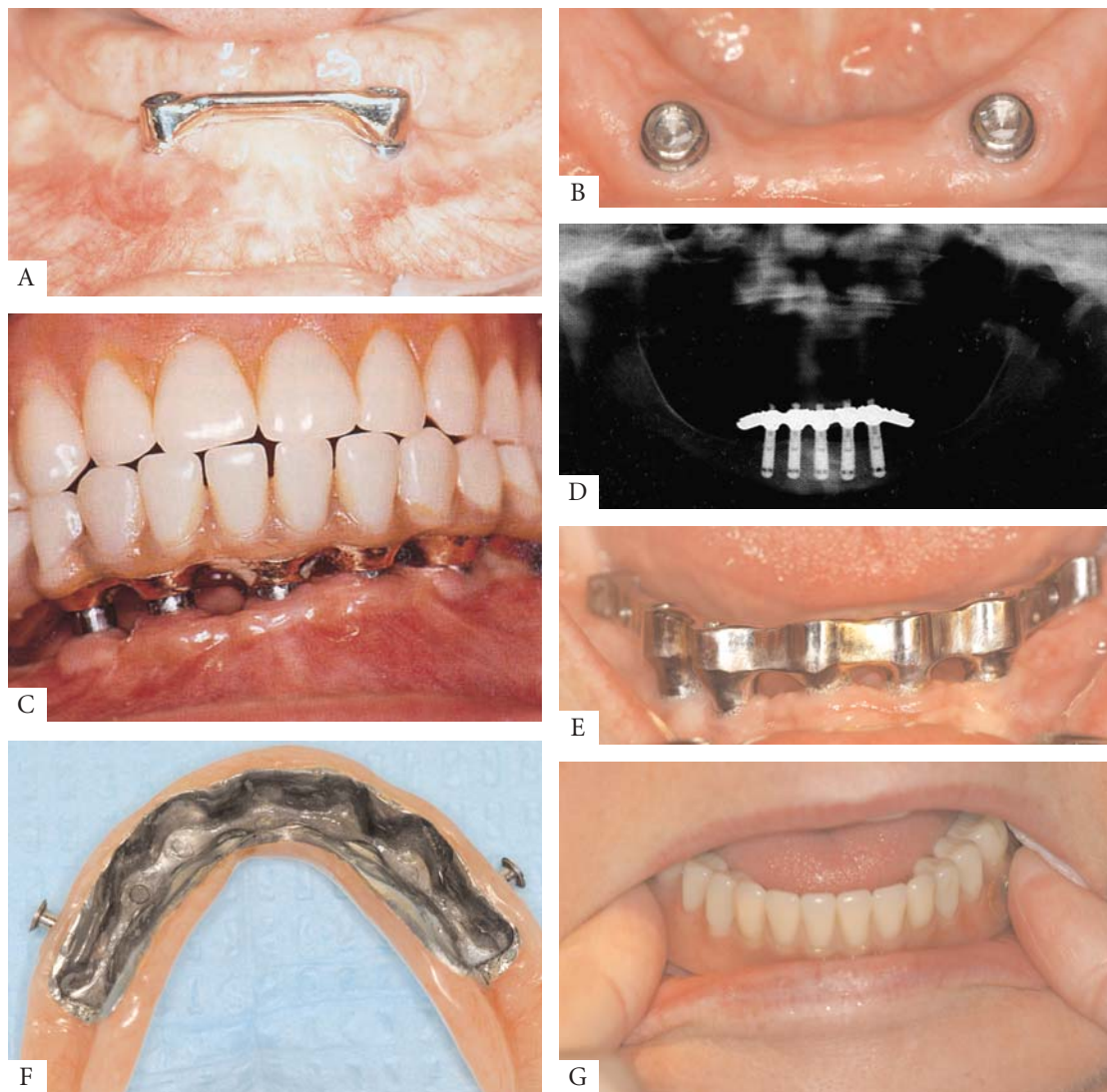


FIGURE 10-4 A, Two-implant bar for clip overdenture retention. B, Two-implant locator for overdenture retention. C, Hybrid prosthesis retained by five implants. D, Panoramic radiograph showing position of five implants for hybrid prosthesis. E, Milled bar for fixed/removable prosthesis. F, Inner aspect of prosthesis showing metal substructure with plunger attachments. G, The patient pushes the plunger attachments to engage the milled bar and thus retains the prosthesis to the bar. C, D reproduced with permission from Block MS. *Color atlas of dental implant surgery*. Philadelphia (PA): W.B. Saunders Company, 2001. p. 5.

Physical Examination of the Edentulous Patient

The depth of the vestibule and the mentalis muscle attachments are noted to determine the necessity of a vestibuloplasty. The width of keratinized gingiva on the alveolar crest and the distance from the alveolar crest to the junction of the attached and unattached mucosa are noted. Identification of the mental foramen by digital palpation is useful to deter-

mine subsequent implant location. In a relaxed vertical position of the jaws, the relationship of the anterior mandible to the maxilla is observed to determine the benefits of positioning the implants to correct or mask a Class II or Class III skeletal jaw relationship. Alveolar ridge palpation will determine the slopes of the labial and lingual cortices and the alveolar height. The location of the genial tubercles should also be noted.

Radiologic Examination of the Edentulous Patient

Radiologic evaluation of the patient prior to placing implants is focused on the determination of vertical height and the slopes of the cortices in relation to the opposite arch. A panoramic radiograph is the baseline radiograph used to evaluate the implant patient. The lateral cephalogram is useful to demonstrate the slopes of the cortices of the anterior mandible and the skeletal ridge relationships of the mandible to the maxilla, and to provide a simple and inexpensive radiographic assessment of anterior alveolar height. Additional radiographic techniques include the use of complex motion tomography or reformatted computed tomography (CT) scans. CT has a less than 0.5 mm error when reformatted cross-sectional images are examined. As clinical experience increases most surgeons agree that there is less need for these more expensive radiographic techniques for preparation of placing implants. CT scans are becoming popular in combination with models of the bone for accurate treatment planning and the fabrication of final prostheses prior to the actual surgical procedure.

Incision Design Considerations

Based on the location of the muscle attachments and the height of the mandible, the surgeon makes the decision regarding which incision to use to expose the bone and subsequently place implants into the edentulous mandible. If the attachment of the mentalis muscle is 3 mm or more labial to the location of the attached gingiva on the alveolar crest, a crestal incision can be used. If the mentalis muscle is in close proximity to the alveolar crest, resulting in mobile unattached gingiva directly against the implant abutment, a "lipswitch" vestibuloplasty is performed to inferiorly reposition the muscle attachments.

Two Implants

In general, when placing two implants for an overdenture, one should take into consideration the potential need for additional implants at a later time. Some patients enjoy the overdenture prosthesis but may complain of food getting caught under the denture, mobility of the prosthesis when speaking, swallowing, or chewing, and a desire to eliminate changing clips, O rings, or locator-type attachments. These patients may then desire the retention of a fixed or fixed-removable prosthesis. For these patients three additional implants may be placed to result in a total of five implants in the anterior mandible, which is sufficient to support an implant-borne prosthesis. Taking this into consideration when placing two implants into the anterior mandible, locating the implants 20 mm apart, each 10 mm from the midline of the mandible, allows for later implant placement if needed.

Implant placement at the correct height in relation to the alveolar crest is crucial. If the implant is placed such that the cover screw is superficial to the adjacent bone, a chance of incisional dehiscence or mucosal breakdown may occur. It is advantageous to countersink implants in the anterior mandible sufficiently (1 to 2 mm depending on the type of external or internal connection of the specific implant used) to allow the height of the cover screw to be in a flush relationship with the adjacent alveolar bone. The surgeon should follow the guidelines for the specific implant system being used. For one-stage implants temporary healing abutments are placed as recommended by the manufacturer. Accidental loading from poorly relined dentures can lead to trauma to the implants and eventual loss. Thus it is prudent to excessively relieve and use appropriate soft liners for the transitional denture during the healing period.

The anterior mandible may have a dense cortical plate with an abundant

marrow space, or it may have very minimal marrow with an abundance of cortical bone. The smaller the mandible, the more cortical bone and less cancellous bone is available. When encountering very dense bone it is important to periodically clean the drill bits to keep the cutting surfaces clean of debris during the preparation of the implant site. For coated implants a threadformer type of bur is used to create threads in the bone. For self-tapping implants the surgeon may need to use a slightly larger bur than is customarily used in other areas of the mouth. For example, rather than using a 3.0 mm bur prior to self tapping a 3.75 mm implant, a 3.25 mm diameter drill may be necessary to allow for ease of implant insertion into very dense bone.

Four or More Implants

Four or more implants are placed when considering an implant-borne prosthesis. Implant-borne prostheses include hybrid screwed-retained, crown-and-bridge type, or fixed/removable with milled bars and retentive devices (see Figure 10-4). The incision design is similar for placement of four or more implants into the anterior mandible. The subperiosteal reflection should be sufficient to expose the lingual and labial cortices and the mental foramen bilaterally. After the periosteal reflection is completed, the surgeon has an excellent view of the operative site, the contours of the bone, and the location of the mental foramen. A caliper is used to mark the alveolar ridge at no less than 5 mm anterior to the mental foramen. This distance is usually the anterior extent of the nerve, as it loops forward in the bone prior to exiting the bone at the mental foramen. A small round bur is used to place a depression in the bone to locate the implant site on one side of the mandible. A similar mark is placed on the opposite side of the mandible, no less than five mm anterior to the mental foramen. The caliper is then set to 7 or 8 mm and the next implant loca-

tions are marked in a similar manner anterior to the two distal locations. If a fifth implant is to be used, then a mark is made in the midline of the mandible. By using the caliper, the implant bodies are placed a sufficient distance apart to ensure adequate space for restoration and hygiene. The use of CT-generated models of the mandible can result in surgical templates that can be secured to the jaws with pins or the implants themselves, resulting in precise implant location by preoperative planning. As the planning process matures with CT-generated applications and templates, incisions will be needed less often.

After the implant locations are identified, the first drill in the implant drilling sequence is used. If available a surgical stent is placed in order to correctly locate the implants in relation to the teeth. For Class III mandibles the implants can be angled slightly lingually, for Class II mandibles the implants can be angled slightly anteriorly, and for Class I mandibles the implants are placed vertically in relation to the inferior border of the mandible. Regardless of the angulation of the implants, the crestal location of the implants is the same, with the implants exiting the crest midcrestally without excessive labial or lingual location.

Augmentation of the Atrophic Mandible

If the patient is in satisfactory health for a bone graft harvest procedure, the indication for bone augmentation of the anterior mandible is a patient with less than 6 mm of bone height. Patients with greater than 6 mm of bone height can do well with implants without bone augmentation.³⁷ Most clinicians will use iliac crest corticocancellous blocks to augment the height in an atrophic mandible. The procedure can be performed through either an intraoral or an extraoral incision, depending on clinician preference (Figure 10-5). The placement of implants at the time of bone graft placement is also

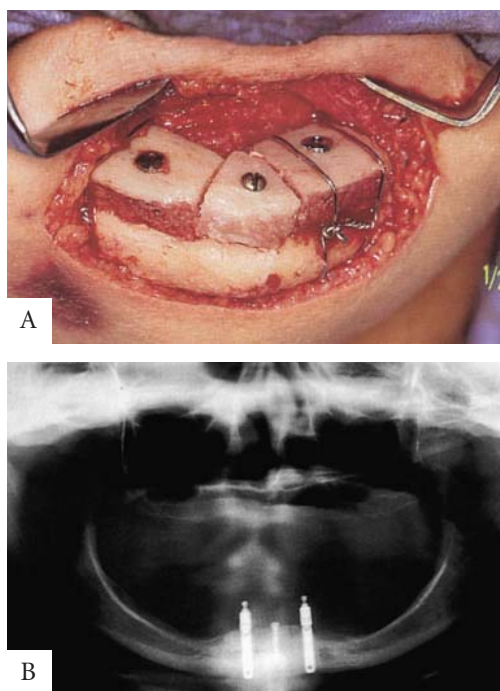


FIGURE 10-5 A, Iliac crest corticocancellous block graft augmentation of the atrophic mandible, through an extraoral approach with simultaneous placement of two implants. B, Panoramic radiograph of final prosthesis retained by two overdenture attachments. Reproduced with permission from Block MS. *Color atlas of dental implant surgery*. Philadelphia (PA): W.B. Saunders Company, 2001. p. 28.

clinician dependent. If implants are placed at the time of bone graft placement, then the patient's time to restoration is decreased, the graft can be secured to the mandible with threaded implants, and the shorter time to functional loading may prevent graft resorption. The disadvantages of placing implants at the time of bone graft placement include possible partial resorption of the graft and exposed portions of the implants, which is difficult to treat, malposition of the implants due to lack of proper angulation at placement, which can be technically challenging from an extraoral approach, and potential lack of integration secondary to poor graft remodeling. Technically the graft procedures are similar, with the exception of the surgical preparation of the sites for the implants.

Intraoral incisions for placement of blocks of bone can be made either crestal-

ly or within the vestibule. The crestal incision places the incision over the bone graft, but it also allows the surgeon to have the best chance to avoid incisional dehiscence secondary to vascular insufficiency. A vestibular incision places the incision away from the bone graft; however, blood supply to the edge of the vestibular incision travels through the dense fibrous tissue over the crest and thus may be prone to breakdown secondary to vascular insufficiency. Both of the intraoral incisions and their subsequent release will result in obliteration of the vestibule, which will require secondary soft tissue grafting. One should note that the mental foramen is often palpable on the alveolar crest, with some portion of the inferior alveolar nerve dehiscenced from the mandible secondary to resorption of the alveolar crest bone.

The bone grafts are harvested and trimmed as necessary. The goal of the graft should be to restore the mandible to approximately 15 mm of vertical height; however, for a 3 mm mandible, gaining this amount of bone may be excessive. For the extremely small 1 to 5 mm tall mandible, restoring the mandible to 10 to 13 mm is considered a great success. Two or three pieces of corticocancellous bone blocks are trimmed and placed over the superior aspect of the mandible. The edges are smoothed and the grafts are stabilized in position with screws placed through the grafts, engaging the inferior border of the mandible. If implants are placed at the time of graft placement, the clinician must weigh the possibility of partial graft resorption and subsequent implant failure. Implants can be placed 4 months after the graft was performed, and combined with a simultaneous vestibuloplasty.

The disadvantage of using an extraoral approach is the scar that results and difficulty placing implants at the time of graft placement. Most implants, when placed into a bone graft performed through an extraoral incision, are flared to the labial aspect. The advantages of using an extrao-

ral approach to graft the atrophic mandible include avoidance of intraoral incision breakdown, avoidance of an intraoral communication with the bone graft and potential infection, maintenance of the vestibular attachments, which may eliminate the need for vestibuloplasty, and ease of reflection of the inferior alveolar nerve from the alveolar crest without incising over the nerve (Figure 10-6). These advantages often are significant and offer the patient the least chance of incisional dehiscence; hence, this approach is the method of choice for these authors. From this approach bone grafts can be placed in either block or particulate form, with implants used as "tent poles" to maintain space over the graft.³⁸

Most clinicians will allow at least 4 months to healing of the iliac crest corticocancellous bone graft prior to placing implants. Iliac crest corticocancellous

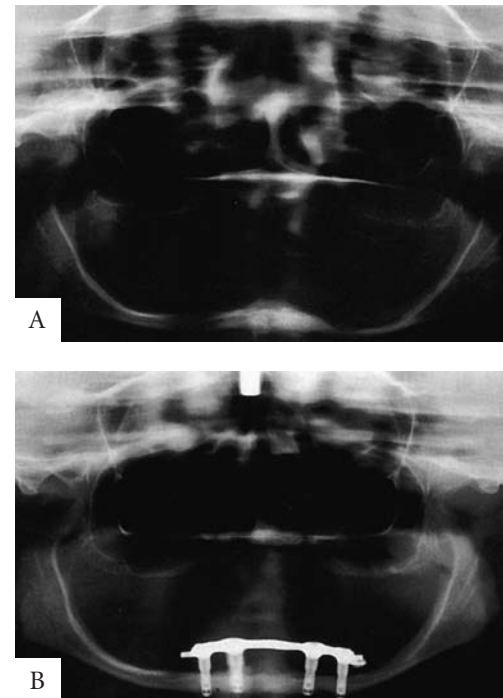


FIGURE 10-6 A, Atrophic mandible in a 75-year-old female. B, A 5-year follow-up radiograph of 10 mm long implants placed without bone graft. Reproduced with permission from Block MS. *Color atlas of dental implant surgery*. Philadelphia (PA): W.B. Saunders Company, 2001. p. 29–30.

grafts heal well but start resorbing after 3 to 4 months, so the surgeon may need to place the implants at 3 months, depending on consolidation and remodeling of the bone graft, which is determined radiographically. If necessary a split-thickness dissection can be made intraorally and a palatal or split-thickness dermis or skin graft can be placed to restore some semblance of vestibule. At the time of vestibuloplasty, rigid fixation screws can be removed and implants placed, engaging the inferior border of the mandible. When simultaneously performing a vestibuloplasty with implant placement, one should countersink the implants below the level of the periosteum so that the graft can lay flush and not be tented up off the host tissue bed by the dome-like prominence of the cover screws of implants.

Placement of Implants into Atrophic Mandibles without Grafting

The majority of patients with atrophic mandible with less than 10 mm of bone height and at least 5 to 6 mm of height are not good candidates for bone grafting secondary to health-related issues. For these patients four implants can be placed, with 1 to 2 mm of the implant through the inferior border of the mandible, and 1 to 2 mm supracrestal as necessary. It is important to gently prepare the bone with new sharp drills and prelap these bones since they can be brittle and have minimal blood supply. The implants should be placed to avoid labial protrusion (see Figure 10-6).³⁷

Options for the Edentulous Maxilla

Treatment planning for the edentulous maxilla is usually initiated at the restorative dentist's office. This includes establishment of the patient's goals of what he/she desires at the completion of implant therapy. Once these goals are established the surgeon is seen and an assessment of bone availability is performed.

A panoramic radiograph and a physical examination are often all that are required to delineate satisfactory bone bulk for the placement of implants into the maxilla. From the panoramic radiograph one can estimate the amount of vertical bone available throughout the entire maxilla. Occasionally a reformatted CT scan is obtained to confirm the presence of bone prior to implant placement. If cross-sectional radiography is planned, using a radiopaque stent at the time of the radiography significantly increases the amount of information gathered. The teeth in the patient's prosthesis are made radiopaque by using a radiopaque material, typically 20 to 30% barium sulfate combined with clear acrylic so that the teeth are included in the cross-sectional image. This provides information concerning the relationship of the bone to the desired teeth.

Parel's classification of the edentulous maxilla is useful for conceptualization of the prosthetic plan (personal communication, 1991). The Class I maxilla involves the patient who seems to be missing only the maxillary teeth, but has retained the alveolar bone almost to its original level (Figure 10-7). The Class II maxilla has lost the teeth and some of the alveolar bone, and the Class III maxilla has lost the teeth and most of the alveolar bone to the basal level.

For the Class I patient a fixed restoration, borne by implants, can be fabricated because the patient has adequate alveolar bone for support of the soft tissues and is missing only the teeth. There is usually greater than 10 mm of bone height in both the anterior and posterior maxilla. For a fixed crown-and-bridge restoration, implants need to be placed within the confines of the teeth of the planned restoration. The implants should be

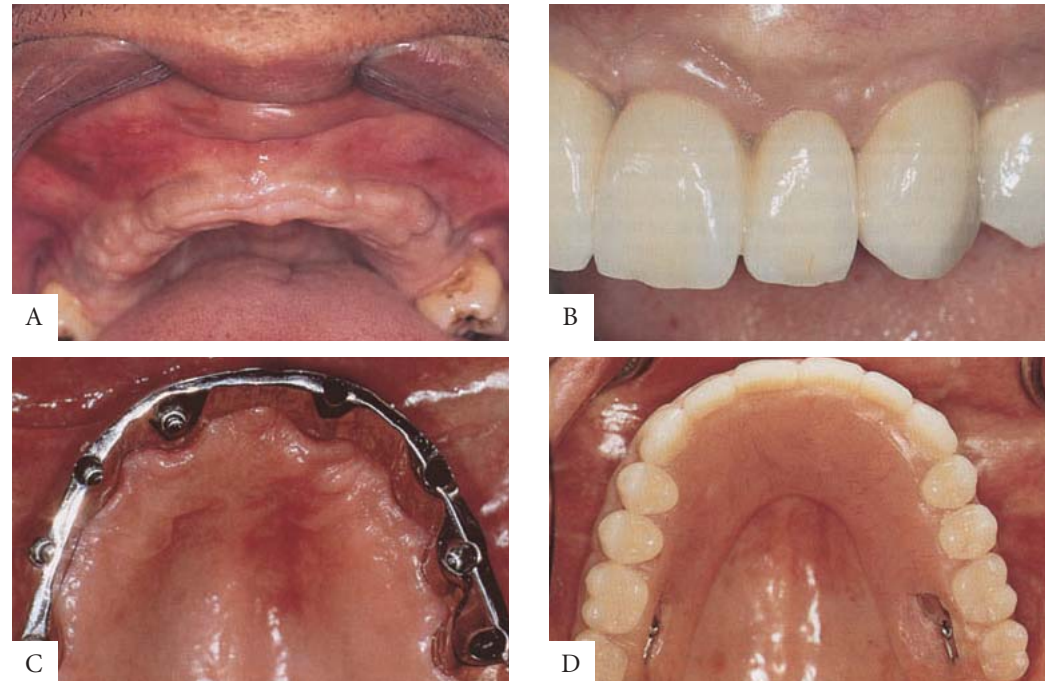


FIGURE 10-7 A, Edentulous Class I maxilla treatment planned for fixed crown-and-bridge maxillary prosthesis. Reproduced with permission from Block MS. Color atlas of dental implant surgery. Philadelphia: W.B. Saunders Company, 2001. p. 65. B, Final anterior dentition demonstrating excellent gingival contours on implants in the edentulous maxillary patient. Reproduced with permission from Block MS. Color atlas of dental implant surgery. Philadelphia (PA): W.B. Saunders Company, 2001. p. 66. C, Milled bar for implant-retained fixed/removable prosthesis. D, Fixed/removable prosthesis retained by "swing-lock" attachments to the milled bar. Reproduced with permission from Block MS. Color atlas of dental implant surgery. Philadelphia (PA): W.B. Saunders Company, 2001. p. 19.

placed to avoid the embrasure regions in order to promote esthetics and oral hygiene. For a fixed crown-and-bridge restoration, the implants should be placed 3 mm apical to the gingival margin of the planned restoration in order to allow the restorative dentist to develop a natural emergence of the crowns from the gingiva. If the Class I patient desires a tissue-borne overdenture on four implants because of financial constraints, then the design of the overdenture bar must be such as to avoid excessive space-occupying designs, since the patient is missing only their teeth, not the alveolus.

The Class II patients rarely can be esthetically managed with a fixed crown-and-bridge prosthesis since they require the labial flange of the maxillary prosthesis to support the nasal-labial soft tissues. In order to distinguish the need for acrylic to support the soft tissues, it is useful to duplicate their maxillary dentures and remove the labial flange, leaving only the teeth. The resultant soft tissue profile with the modified duplicated maxillary denture will easily help the implant team and patient decide on a treatment plan. If the patients look good without the flange of their denture, indicating sufficient nasal-labial support, a fixed crown-and-bridge restoration can be fabricated using pink porcelain or acrylic to decrease apical gaps from lost alveolar bone. In addition the deficiency of alveolar bone necessitates placing the implants more apical than is ideal, resulting in excessively long teeth, teeth with pink acrylic, a removable lip “plumper,” or a hybrid-type prosthesis with space between the prosthesis and the implants.

A fixed crown-and-bridge, fixed/removable (spark erosion or milled prosthesis), or removable overdenture-type prosthesis may be prescribed. The implant-borne fixed and fixed-removable prostheses require at least six, or preferably eight, endosseous implants to adequately support a maxillary implant-borne prosthesis. The

exception is the use of the Zygomaticus implant fixtures. These prostheses require posterior maxillary vertical height of bone for implants placed in the first molar region. The removable prosthesis requires two to four implants placed into the anterior maxilla to support a bar that has retentive vertical stress-breaking attachments. Edentulous maxillary prostheses are usually fabricated with cross-arch stabilization of the left and right implants. Cross-arch stabilization significantly increases implant survival long term.

Placement of Four Implants into the Anterior Maxilla

For the patient with adequate anterior vertical bone height, and for whom a treatment plan has been made for anterior implants for overdenture support, four implants can be placed. It is recommended to place at least four implants for a tissue-supported overdenture in the maxilla. Four implants in the anterior maxilla are used to support a rigid bar, often combined with vertical stress-broken attachments placed at the distal aspects. Implants for overdentures are typically placed with their centers slightly palatal to the crest to avoid dehiscence and thin bone over the facial aspect of the implants. The incisive canal should be avoided as a site for implant placement. Specifically, implants for overdentures are placed in the canine and premolar locations, dependent on the availability of bone. An implant can be placed in the lateral incisor position if necessary. However, implants placed in the central incisor locations complicate the prosthetic rehabilitation since the presence of the abutments and a bar near the midline may result in excessive palatal bulk in the denture, which may be bothersome to the patient.

Placement of Eight Implants without a Graft

If the goals of the patients are to have a denture or prosthesis that will enable them to have a palateless prosthesis and allow them

to chew all textured foods without the prosthesis depending on the tissues for support, then a sufficient number of implants is required to resist the forces of mastication. For these patients it is recommended to use six to eight implants for an implant-supported fixed or fixed/removable prosthesis, with an adequate number of implants located posteriorly to support the molars.

Eight implants in the anterior and posterior maxilla are used to support a suprastructure for a totally implant-borne restoration with tissue contact only for speech. If a bar-type structure is planned, the implants should be placed within the confines of the borders of the planned prosthesis, and not labial or outside the borders of the teeth. The implants should be placed to avoid impingement of the teeth in the overdenture and to allow space for the fabrication of the bar. For many of these implant-borne cases, implants are placed from the canine region extending posteriorly, with a minimal number of implants placed into the incisal region. This pattern of placement makes the design of the anterior portion of the prosthesis easier.

The implants for fixed/removable overdentures are typically placed with their centers slightly palatal to the crest in order to avoid dehiscence and thin bone over the facial aspect of the implants. The implants can be positioned from second molar to central incisor; however, most restorative dentists prefer to avoid of the central incisor and second molar sites. The second molar site can be used in select cases, but it does make the placement of screws, abutments, and transfer copings difficult. In addition the bars may need the space of the second molar site for attachments, depending on the prosthetic design of the retentive bar.

Placement of Eight Implants with Sinus Grafts

Patients who have received a treatment plan or an implant-borne restoration but who

have insufficient vertical bone for the placement of implants in the maxilla posterior to the canines are considered for a combination of sinus grafting and implant placement. The sinus grafts can be performed as one surgery, followed 6 to 12 months later with implant placement, or the sinus graft can be performed and the implants placed at the time of the sinus graft. If the sinus graft is performed prior to implant placement, the surgeon should verify that bone has formed within the graft.

We and our colleagues perform sinus grafting with immediate placement of implants. Currently, the recommended sinus graft material is autogenous bone, harvested from the jaws, tibia, or iliac crest. If necessary the autogenous bone volume can be augmented with demineralized bone in a ratio not to exceed 1:1. Hydroxylapatite-coated implants are used for immediate placement into sinus grafts.

Single- and Multiple-Unit Restorations

There are different surgical concerns when placing single- or multiunit restorations in the anterior maxilla or other areas where esthetics are less of a concern. Placement of implants into premolar and molar locations can usually be performed with less concerns of papilla and root eminence morphology (Figure 10-8).

Premolar or Molar Restorations

Diagnosis and treatment planning will indicate whether there is sufficient space and bone available for implant placement. Periapical radiographs are necessary for single-tooth restorations to confirm that the roots of the adjacent teeth do not impinge in the space that will be used by the implant. If root angulation is a problem, then preoperative orthodontics will need to be performed prior to implant placement, or a fixed bridge can be made rather than placement of an implant.

Careful attention should be directed to the final restorations and the mechan-

ical loading that the restoration and hence implants will feel. Canine guidance or group function is usually present and can affect the position of the implants. Canine discursion is recommended when placing posterior implants for fixed restorations. The ideal single premolar or molar restoration has a balanced occlusion that will result in atraumatic forces upon the implant. Single-tooth implants should be placed such that the implant is under the working cusp of the tooth, to avoid excessive cantilever forces. Maximal length implants should be used whenever possible. Short implants in the posterior jaws tend to have less long-term survival than longer implants. The crown-to-root ratio needs to be addressed. Complete treatment planning, which includes knowledge of the final restoration, will increase success and limit complications.

The surgical incision is made slightly palatal to the crest, with vertical releasing incisions flaring into the vestibule in order to keep the base of the flap wider than the crestal incision width. Full-thickness subperiosteal labial and palatal flaps are reflected to expose the crest and to provide visualization of the vertical cortices of bone. The implant should be placed with its axis parallel to the occlusal forces, with the emergence of the implant angling to meet the buccal cusps of the mandibular teeth.

Multiple Implant–Borne Restorations for the Posterior Maxilla

Since these restorations commonly involve the distal teeth, assessment of the availability of bone in relation to the sinus is critical. If 10 mm of bone is not available, then a sinus augmentation is indicated. If two long implants can be

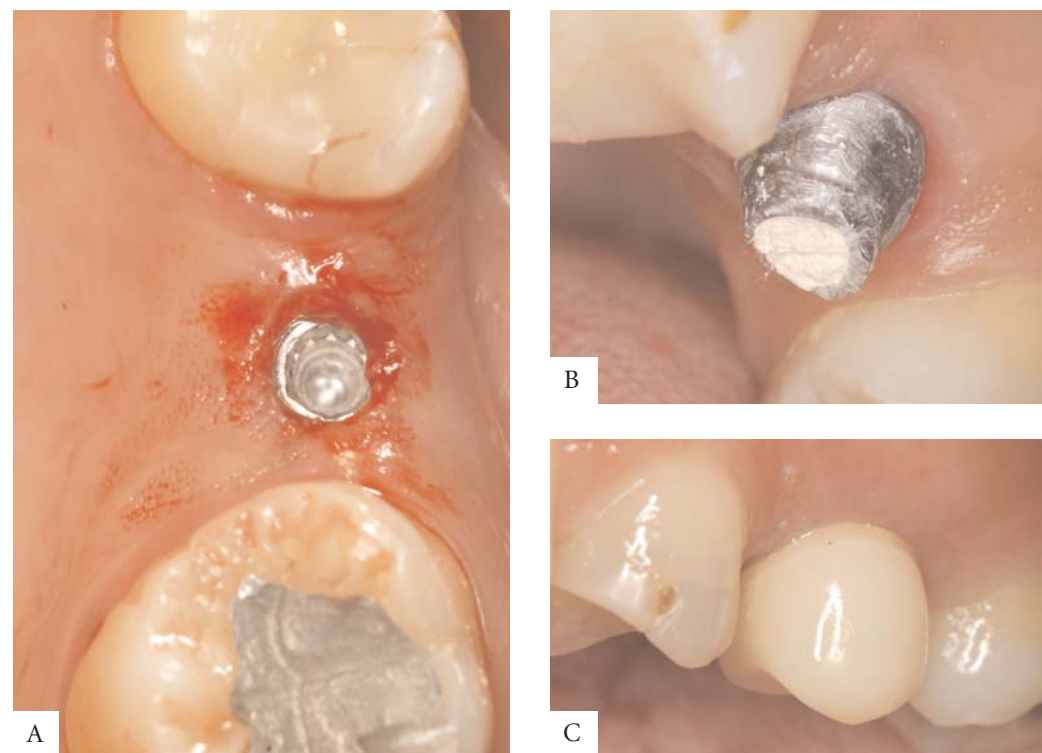


FIGURE 10-8 A, This patient required a single implant for replacement of a premolar in the maxilla. A tissue punch was used to access the crestal bone. The implant site was prepared and the implant placed through this circular soft tissue hole. This implant has an internal connection. B, A fixed abutment was placed immediately into the implant and prepared. A provisional crown, not in occlusion, was fabricated. C, This is the final crown. Note the excellent soft tissue reaction to the crown, abutment, implant complex.

placed without the need for a sinus graft, along with sinus elevation of a third site by the use of osteotomes, then 8 mm of bone for the third implant is acceptable. However, the use of osteotomes to elevate the sinus floor by 2 mm is not a procedure that has abundant scientific validation. Therefore the patient must be apprised of the risks and potential failure. When in doubt a sinus elevation is performed. The mechanics of the final restoration need to be taken into consideration when placing multiple implants for a full quadrant restoration.

There are patients who have sufficient vertical bone but are deficient in the width projection of the bone. After maxillary teeth are extracted for a variety of reasons, facial bone resorption can occur, leaving the palatal bone intact, with the alveolus thin and deficient. Placing the implant in the ideal position may result in facial bone dehiscence. For the thin ridge in the posterior maxilla, with sufficient bone height, several surgical options are available. These include the use of particulate bone grafting with membrane coverage, the use of onlay bone grafts harvested from the symphysis or ramus, and ridge expansion using osteotomes or osteotomies.

Restorative Options for Single-Unit Restorations in the Anterior Maxilla

Esthetic implant restorations represent a challenge to reproduce normal-appearing restorations with normal-appearing soft tissue profile and integrity. Most implant sites that require esthetics have deficiencies in the ideal bone and overlying soft tissue, and must be enhanced with a variety of surgical techniques. A tooth may be missing because of lack of tooth development, caries, external or internal resorption of teeth following trauma, root canal complications, bone loss from periodontal disease, or recent dentoalveolar trauma. Each of these etiologies has secondary

effects on the proposed implant site. It is common to find a deficiency in labial bone with loss of the previous root eminence form of the ridge. In addition, the overlying soft tissue at the level of the alveolar crest may be thin, resulting in a lack of stippling, variations in gingival color, and increased translucency resulting in parts of the implant and abutment showing through the gingiva.

The majority of anterior maxillary single-tooth sites present with inadequate bone and soft tissue, requiring both bone and soft tissue augmentation. The height of the papilla reflects the underlying crestal bone height on the adjacent teeth.³⁷ Careful assessment of the bone levels on the adjacent teeth enables the surgeon and restorative dentist to inform patients of the realistic expectations of retaining or creating papilla for an esthetic single-tooth restoration.

The presurgical assessment, using the esthetic tooth wax-up, results in the ability of the surgeon to estimate the height and width of a bone graft, if one is indicated. For severe bone deficiency, which prevents implant stabilization, a bone graft should be placed at least 4 months prior to implant placement, allowing future implant placement in the ideal location horizontally and vertically. When the deficit of the bone is such that the implant can be placed and is mechanically stable, with a portion of its surface exposed through the bone, then a hard tissue particulate graft is placed at the same time as the placement of the implant. The material used for grafting depends on the extent of the implant bone fenestration. Autogenous bone is used for larger fenestrations, with a gradual increase in hydroxylapatite used as the implant bone dehiscence decreases in size.

Incision Considerations for Esthetic Sites

When placing an implant in the central incisor location, careful attention to the

detail of gaining access to the underlying bone is critical for obtaining a perfect result, without ablation of the papilla or vertical scars from poor incision design and technique. If there is 5 mm from the contact point of the teeth to the crestal bone of the adjacent tooth, then the use of sulcular incisions is indicated. If there are papillae present but the teeth are long, with an excess of 5 mm between the contact point to the crestal bone of the adjacent tooth, then the patient needs to be warned that papillae may not be present after implant placement. When necessary, vertical incisions should be beveled to allow for esthetic scar healing. When the bone anatomy permits, the use of a tissue punch and avoidance of incisions will allow for no scars and no loss of papilla.

Angulation of the implant should result in the axis of the implant being oriented to emerge slightly palatal to the incisive edge of the planned restoration. If placed at or anterior to the incisive edge of the tooth, there may be difficulty in developing the emergence profile of the restoration. If the implant is placed too far labial, with the anterior edge of the implant at the edge of the gingival margin of the planned tooth, then with addition of the abutment and porcelain, the gingival contour will be excessive and gingival recession results. As the platform (ie, diameter of the implant) increases, the clinician must be cautious to ensure that the labial edge of the implant is not excessively labial, or emergence of the crown will be compromised and will result in an obese crown form. Most restorations require more than 1 mm of clearance from the labial surface of the implant to the eventual clinical crown, secondary to development of the emergence profile of the restoration from the subgingival portion of the implant restoration.

The depth of the implant in relation to the planned gingival margin is also critical. If the implant is placed too shallow, with 2 mm or less from the top of the implant to the gingival margin, then several adverse

events can occur. The metal from the implant may be visible through the gingival margin. Because the distance from the top of the implant to the gingival margin is minimal, metal showing through the gingiva is difficult to camouflage. A minimal distance between the gingival margin and the top of the implant may also result in difficulty in adjusting the margins of the abutment, with porcelain extending to the implant itself. It is then difficult to develop a natural appearance since the gingival margin region of the restoration is excessively bulked or round in shape. The use of ceramic abutments may help in these adverse situations. However, proper implant placement is a simple means to avoid these problems.

Immediate Loading and One-Stage Protocol

The evolution of implant-related therapies in the modern era was based on the work of Brånemark and colleagues, who scientifically validated the process of placing an implant into bone, waiting a period of time for bone to heal to the implant, followed by long-term functional loading.¹³ During the 1970s and early 1980s a one-stage threaded titanium plasma-coated implant was used for overdenture retention with immediate loading. The “Swiss screw” was placed into the anterior mandible and had excellent long-term success. Other one-stage implant systems were slow to develop, but as they have emerged with data to support a one-stage process (ie, with no need for exposure surgery), the concept of a one-stage

endosseous implant therapy has gained credibility. The Strauman system has long-term data indicating that a one-stage unloaded implant system can work in all areas of the mouth, in distinction to the Swiss screw and the Brånemark protocols.¹⁴ Recently, more interest has arisen for placement of implants into the esthetic zone of the maxilla, with either immediate loading or the use of a healing abutment that mimics the natural shape of the tooth. The hypothesis is that by placing a healing abutment with natural contours, the soft tissue response will be enhanced, potentially resulting in a more esthetic final restoration.

Treatment planning for a one-stage or immediately temporized anterior maxillary restoration begins with a list of contraindications. If a tooth is present and needs to be extracted, a one-stage exposed implant placement at the time of extraction will require the following:

- No purulent drainage or exudate from the site
- Excellent gingival tissue quality without excessive granulation tissue
- Lack of periapical, uncontrolled radiolucency
- Adequate bone levels circumferentially without the need for additional soft or hard tissue grafting

The clinician has several options (Table 10-1). At the time of tooth extraction, if there are any of the contraindications present as described above, either a graft can be placed into the extraction socket, or no

graft is placed. The decision to avoid a graft is based on the thickness of the labial bone and the prior healing patterns of the patient, if known. However, in our institution, an anterior extraction site without a socket graft is more prone to labial bone resorption and hence less-than-ideal bone is available at the time of implant placement. If a graft is placed into the socket, then after 3 to 6 months, depending on the material placed, the implant can usually be placed in an ideal location.

If there is ideal bone and soft tissue present at the time of extraction, an implant can be placed at the time of extraction. The clinician should decide prior to extraction if a provisional restoration is to be placed at the time of implant placement, or if the implant is to have a healing abutment placed for a one-stage protocol, or submerged for a two-stage protocol.

Preoperative planning for immediate temporization after implant placement involves fabrication of a surgical guide that precisely locates the implant in one position. The surgeon must work closely with the restorative dentist to ensure that the planned placement of the implant will indeed be able to be performed. The restorative dentist should be available during surgery to guide the surgical placement and be able to adapt the temporary restoration after implant placement.

After the implant is placed and the orientation approved by the restorative dentist, the abutment is placed, and removed as necessary so that changes in its height and contours can be accomplished outside

Table 10-1 Options When Extracting Anterior Maxillary Tooth

<i>Procedure</i>	<i>Adjunctive Treatments</i>	<i>Advantage</i>	<i>Disadvantage</i>
Extract tooth	No graft; wait 8 wk	Short time to implant placement	Labial bone loss and need for adjunctive tissue grafts
Extract tooth	Immediate placement of implant	Less time for overall treatment	Increased chance for infection; may not have ideal bone support upon placement
Extract tooth	Graft extraction site; wait 4 mo for implant placement	Provides ideal placement site	Extended time for treatment

of the mouth. The abutment and temporary crown may be prepared on a model prior to surgery in selected cases. The abutment is placed and tightened to the implant and the temporary crown completed. The occlusion should be relieved to avoid loading the implant during the healing period. In some patients who may be prone to loading the implant because of athletics, weight lifting, or their occlusion, an anatomic healing abutment or a custom healing abutment can be placed in order to preserve the morphology of the gingiva, without the presence of a tooth form.

Procedures performed during the integration or healing period are delayed until implant integration has occurred, in order to avoid disturbance of this critical aspect of implant success. Approximately 2 months after the implants have been placed, the patients are seen by the restorative dentist and surgeon to decide, based on the esthetic set-up, whether the implant site requires additional augmentation of the ridge. The goal is to achieve a convex ridge profile and develop the site's shape to allow for the restoration to emerge from the gingiva, similar to a natural tooth. Our experience indicates that 70% of the implant sites that required hard tissue grafts also benefited from subepithelial connective tissue grafts placed 3½ months after implant placement.

Summary

The successful restoration of the patient with dental implants can result in a change in dental function and health, with a happy patient. The basis for the use of dental implants is initiated by the normal sequence of wound healing, the translation of surface engineering to implant design, and evidence-based trials that verify and confirm efficacy of treatment methods.

References

1. Lemons J, Natiella J. Biomaterials, biocompatibility and peri-implant considerations. *Dent Clin North Am* 1986;30:3–23.

2. Shulman LB. Transplantation and replantation of teeth. Laskin: Oral and maxillofacial surgery. Vol 2. St. Louis (MO): C.V. Mosby Co.; 1985. p. 132–6.
3. Driskell TD. History of implants. *J Calif Dent Assoc* 1987;15:16–25.
4. Bonwell, AC. First District Dental Society. In: Greenfield EG, editor. Implantation of artificial bridge abutments. *Dent Cosmos* 1913;55:364.
5. Greenfield EJ. Implantation of artificial crown and bridge abutments. *Dent Cosmos* 1913;55:364.
6. Harris SM. An artificial tooth. *Dent Cosmos* 1887;55:433.
7. Adams PB, inventor. Anchoring means for false teeth. US patent 2,112,007. 1938 March 22.
8. Strock EA. Experimental work on a method for the replacement of missing teeth by direct implantation of a metal support into the alveolus. *Am J Orthodont Oral Surg* 1939;25:457–72.
9. Dahl GSA. Om impijligheten for implantation i Keken au metaliskelett som has eller rention for fastoc eller avatagbara protesor. *J Odontol Tidskr* 1943;51:440.
10. Linkow LI. The blade-vent: a new dimension in endosseous implants. *Dent Concepts* 1968;11:3–12.
11. Roberts HD, Roberts RA. The ramus endosseous implants. *J South Calif Dent Assoc* 1970;38:571–7.
12. Proceedings of the Toronto Consensus Development Conference on Dental Implants. *J Prosthet Dent* 1983;49:50.
13. Brånemark PI. Introduction to osseointegration. In: Brånemark PI, et al, editors. *Tissue integrated prostheses*. Chicago (IL): Quintessence Publishing Co. Inc.; 1985. p. 29.
14. Schenk RK, Buser D. Osseointegration: a reality. *Periodontology*. 2000;17:22–35.
15. Sykaras N, Iacopino A, Marker V, et al. Implant materials, design and surface topographies: their effect on osseointegration [review]. *Int J Oral Maxillofac Implants* 2000; 15:675–90.
16. Buser D, Schenk RK, Steinemann S, et al. Influence of surface characteristics on bone integration of titanium implants. A histometric study in miniature pigs. *J Biomed Mater Res* 1991;25:889–902.
17. Thomas KA, Kay JF, Cook SD, Jarcho M. The effect of surface macrotexture and hydroxylapatite coating on the mechanical strengths and histologic profiles of titanium implant materials. *J Biomed Mater Res* 1987;21:1395–414.
18. Brunski JB, Puleo DA, Nanci A. Biomaterials and biomechanics of oral and maxillofacial implants: current status and future developments. *Int J Oral Maxillofac Implants*. 2000;15:15–46.
19. Cordioli G, Zajzoub Z, Piatelli A, Scarano A. Removal torque and histomorphometric study of four different titanium surfaces. *Int J Oral Maxillofac Implants* 2000;15:668–74.
20. Cochran DL, Buser D, ten Bruggenkate C, et al. The use of reduced healing times on ITI implants with a sandblasted and acid-etched (SLA) surface: early results from clinical trials on ITI SLA implants. *Clin Oral Implants Res* 2002;13:144–53.
21. Eriksson RA, Albrektsson T. Temperature threshold levels for heat-induced bone tissue injury: a vital-microscopic study in the rabbit. *J Prosthet Dent* 1983;50:101.
22. Eriksson RA, Adell R. Temperatures during drilling for placement of implants using the osseointegration technique. *J Oral Maxillofac Surg* 1986;44:4–7.
23. Watanabe F, Tawanda Y, Komatsu S, Hata Y. Heat distribution in bone during preparation of implant sites: heat analysis by real-time thermography. *Int J Oral Maxillofac Implants* 1992;7:212–9.
24. Adell R, Lekholm U, Brånemark PI. Surgical procedures. In: Brånemark PI, Zarb GA, Albrektsson T, editors. *Tissue integrated prostheses: osseointegration in clinical dentistry*. Chicago (IL): Quintessence Publishing Co. Inc.; 1985. p. 211–32.
25. Lazzara R, Porter S, Testori T, et al. A prospective multicenter evaluation loading of Osseotite implants two months after placement: one-year results. *J Esthet Dent* 1998;10(6):280–9.
26. Testori T, DelFabbro CH, Feldman S, et al. A multicenter prospective evaluation of 2-months loaded Osseotite implants placed in the posterior jaws: 3 year follow-up results. *Clin Oral Implants Res* 2001;12:1–7.
27. Cooper L, Felton D, Kugelberg C, et al. A multicenter 12 month evaluation of single-tooth implants restored 3 weeks after 1 stage surgery. *Int J Oral Maxillofac Implants* 2001;16:182–92.
28. Cooper LF, Scurria MS, Lang LA, et al. Treatment of edentulism using Astra Tech implants and ball abutments to retain mandibular overdentures. *Int J Oral Maxillofac Implants* 1999;14:646–53.
29. Lazzara RJ. Esthetic and restorative benefits of non-axillary loaded implants. *Implant Dent* 1995;4:282–3.
30. Krekeler G, Schilli W, Diemer J. Should the exit of the artificial abutment tooth be positioned in the region on attached gingival? *Int J Oral Surg* 1985; 14:504–8.

31. Block MS, Kent JN. Factors associated with soft and hard tissue compromise of endosseous implants. *J Oral Maxillofac Surg* 1990; 48:1153–60.
32. Feinberg SE, Steinberg B, Helman J. Healing of traumatic injuries. In: Fonseca RJ, Walker RV, Betts NJ, Barber HD, editors. *Oral and maxillofacial trauma*. Vol 1. 2nd Ed. Philadelphia (PA): WB Saunders Co.; 1997. p. 13–59.
33. Shetty V, Bertolami CN. The physiology of wound healing. In: Peterson LJ, Indresano AT, Marciani RD, Roser SM, editors. *Principles of oral and maxillofacial surgery*. Philadelphia (PA): JB Lippincott; 1992. p. 3–18.
34. Black J. Reaction of biological molecules with biomechanical surfaces. In: Black J, editor. *Biologic performance of materials. Fundamentals of biocompatibility*. New York (NY): Marcel Dekker; 1981. p. 45.
35. Adell R. A 15 year study of osseointegrated implants in the treatment of the edentulous jaw. *Int J Oral Surg* 1981;10:387–416.
36. Cooper LF. Biologic determinants of bone formation for osseointegration: clues for future clinical improvements. *J Prosthet Dent* 1998;80:439–49.
37. Higuchi KW, Block MS. Current trends in implant reconstruction. *J Oral Maxillofac Surg* 1995;Suppl 1:7–19.
38. Marx RE, Shellenberger T, Winsatt J, Correra P. Severely resorbed mandible: predictable reconstruction with soft tissue matrix expansion (Tent Pole) grafts. *J Oral Maxillofac Surg* 2002;60:878–88.

Soft Tissue Management in Implant Therapy

Anthony G. Sclar, DMD

Soft Tissue Integration

The term *soft tissue integration* describes the biologic processes that occur during the formation and maturation of the structural relationship between the soft tissues (connective tissue and epithelium) and the transmucosal portion of an implant. Although experimental and clinical research have only recently begun to focus on improving our understanding of the factors that can affect this soft tissue environment, our current knowledge indicates that the maintenance of a healthy soft tissue barrier is as important as osseointegration itself for the long-term success of an implant-supported prosthesis. As such, the implant surgeon must be well acquainted with various surgical techniques and approaches for successfully managing peri-implant soft tissues in commonly encountered clinical situations. Furthermore, when an inadequate quantity or quality of soft tissue is available to secure a stable periimplant environment, the implant surgeon must know the principles and techniques to successfully reconstruct these components. This chapter focuses on basic principles and surgical techniques to manage and, when indicated, reconstruct peri-implant soft tissues to enhance the long-term predictability and esthetic outcomes achieved in implant therapy.

Flap Management Considerations

The primary goal of implant soft tissue management is to establish a healthy peri-implant soft tissue environment. This goal is accomplished by obtaining circumferential adaptation of attached tissues around the transmucosal implant structures, thereby providing the connective tissue and epithelium needed for the formation of a protective soft tissue seal.¹ In addition, when implant therapy is performed in esthetic areas, re-creating natural-appearing soft tissue architecture and topography at the prosthetic recipient site is often necessary. To achieve these goals, the surgeon must carefully preserve and manipulate existing soft tissues at the implant site and perform soft tissue augmentation, when indicated. The quantity, quality, and positioning of the existing attached tissues relative to the planned implant emergence should be evaluated prior to implant surgery. The flap should be designed to ensure that an adequate band of attached, good-quality tissue is always available lingual or palatal to the planned implant emergence. Designing the flap in this fashion is practical because subsequent correction of soft tissue problems occurring in lingual and palatal areas is difficult. Preoperative evaluation using a surgical template helps the

surgeon visualize whether adequate tissue quality and volume are available in the area critical for prosthetic emergence. The surgeon can then decide where the incisions will have to be made or how the existing soft tissues must be manipulated with specific surgical maneuvers to establish a stable periimplant soft tissue environment in each individual case.

Design for Submerged Implant Placement

When placing a submerged implant, the buccal flap must be designed to preserve both the blood supply to the implant site and the topography of the alveolar ridge and mucobuccal fold. The access flap is outlined by a pericrestal incision and one or more linear or curvilinear vertical releasing incisions that extend onto the buccal aspect of the alveolar ridge. The pericrestal incision is beveled to the lingual or palatal aspects (Figure 11-1). The incision is initiated over the lingual or palatal aspects of the ridge crest, and the scalpel blade is angled to make contact with the underlying bone. Typically, linear vertical releasing incisions are used in edentulous situations and curvilinear beveled incisions are used in partially edentulous situations. In either case, reflection of the buccal flap exposes the

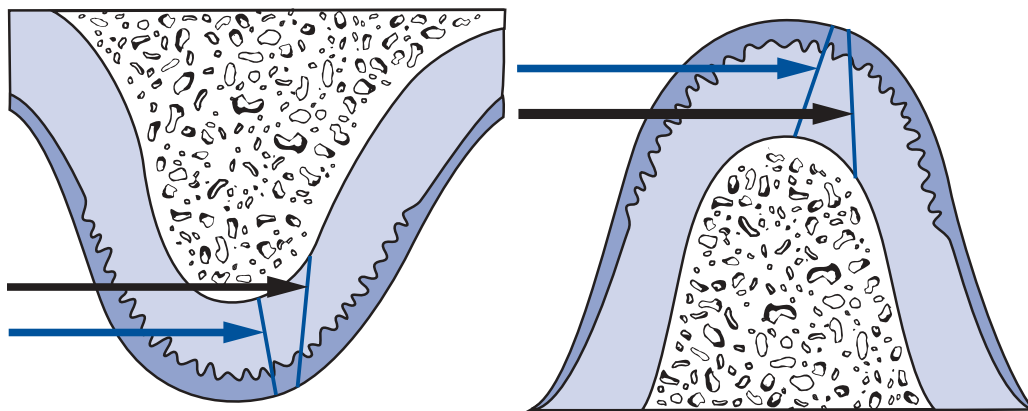


FIGURE 11-1 *Beveled pericrestal incisions: the black arrows represent the path of the palatal and lingual beveled pericrestal incisions recommended for submerged implant placement in the maxilla and mandible. The blue arrows represent the buccal beveled incisions recommended for abutment connection and nonsubmerged implant placement in the maxilla and mandible. Adapted from Sclar A.³*

entire ridge crest and provides ample access for implant instrumentation. This is accomplished with minimal lingual or palatal flap elevation, thus preserving periosteal circulation and providing attached tissue to anchor the buccal flap during subsequent wound closure. The stability of the postoperative wound complex is improved, and the topography of the alveolar ridge and mucobuccal fold is preserved. As a result, wound dehiscence is decreased and the use of a provisional prosthesis during the osseointegration period is facilitated.

Design for Abutment Connection and Nonsubmerged Implant Placement

Except for the location and bevel of the pericrestal incisions, the same flap design is used for an abutment connection to submerged implants as for placement of nonsubmerged implants (see Figure 11-1). The pericrestal incision is initiated in a position that ensures the maintenance of approximately a 3 mm apicocoronal dimension of attached lingual tissue or good-quality palatal mucosa (free of rugae) for re-adaptation around the emerging implant structures. The quantity and position of the existing soft tissues guide the location of the incision. In gen-

eral, this incision is located closer to the midcrestal position than the one made for submerged implant placement. The scalpel blade is held so as to create a buccal bevel to facilitate abutment connection and implant placement while preserving periosteal blood supply by minimizing the need for a lingual or palatal flap reflection. Additionally, the buccal bevel maximizes the amount of attached tissue reflected with the buccal flap (see Figure 11-1).

As suggested above, by adjusting the location and bevel of pericrestal incisions and precisely locating linear or curvilinear vertical releasing incisions, the implant surgeon is equipped with practical flap designs for submerged implant placement, abutment connection, and nonsubmerged implant placement in edentulous and partially edentulous and esthetic case types (Figures 11-2–11-6).

Surgical Maneuvers for Management of Periimplant Soft Tissues

Once the flap has been outlined in a manner that ensures an optimal lingual and palatal soft tissue environment, the surgical maneuvers that are used for managing the resulting buccal flap during abutment connection and nonsubmerged implant placement can be determined, for the

most part, by the apicocoronal dimension of the attached tissue remaining on the buccal flap margin. There are three distinct soft tissue surgical maneuvers that are commonly used during abutment connection or nonsubmerged implant placement to achieve the desired outcome of obtaining primary closure with circumferential adaptation of attached tissues around emerging implant structures: resective contouring, papilla regeneration, and lateral flap advancement.

Although the minimum width of attached tissue necessary to establish a stable periimplant soft tissue environment has yet to be established, the following guidelines for using each of the soft tissue maneuvers provide consistent results in most clinical situations. It is important to note that the use of a specific maneuver is based primarily on the apicocoronal dimension of the attached tissue remaining along the buccal flap margin at each implant site. A combination of these surgical maneuvers is often indicated because the width of attached

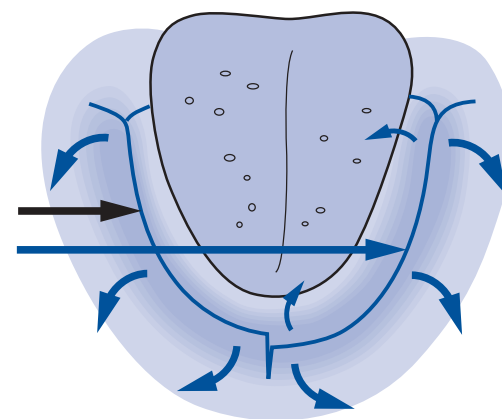


FIGURE 11-2 *The flap design for implant placement in the edentulous mandible incorporates a midline vertical releasing incision and distal vertical releasing incisions made well beyond the area planned for the implant placement. The black arrow indicates the location of the pericrestal incision used for submerged implant placement. The location of the incision used for abutment connection and nonsubmerged implant placement is indicated by the straight blue arrow. Adapted from Sclar A.³*

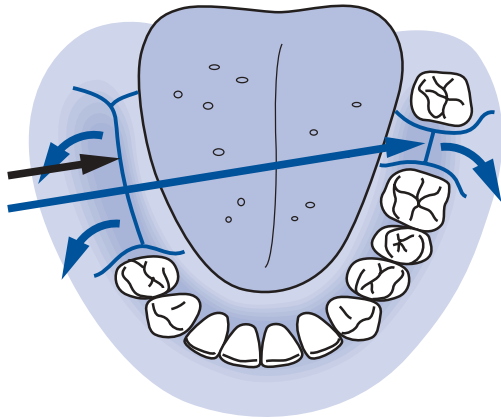


FIGURE 11-3 The flap design for implant placement in the partially edentulous mandible is outlined by pericrestal and curvilinear beveled vertical releasing incisions. The black arrow indicates the location of the pericrestal incision used for submerged implant placement. The location of the incision used for abutment connection and nonsubmerged implant placement is indicated by the straight blue arrow. Adapted from Sclar A.³

tissue remaining on the buccal flap varies as a result of necessary adjustments made in the path of the crestal incision to maintain an adequate width of attached tissue on the lingual or palatal flap.

Resective Contouring When the width of the gingival tissues remaining on the buccal flap is 5 to 6 mm, resective contouring facilitates circumferential adaptation of the soft tissues around the emerging implant structures. A fine scalpel blade held in a round handle is used to perform a gingivectomy on the buccal flap corresponding in shape and position to the anterior-most abutment or nonsubmerged implant neck. After resective contouring the tissue is adapted around the emerging implant structure; this process is then repeated sequentially around each implant (Figure 11-7). The contoured flap is then repositioned apically and secured around the abutments with a suture passing through each interimplant area, and additional sutures are placed to close the curvilinear releasing incisions.

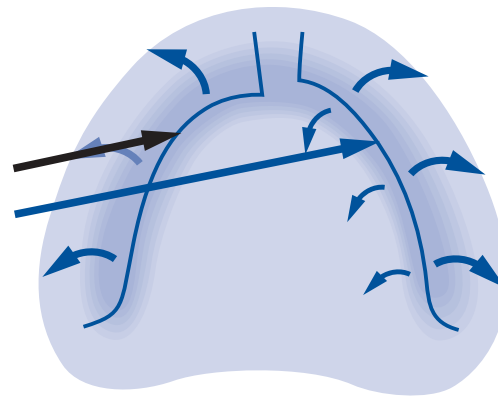


FIGURE 11-4 The flap design for implant placement in the edentulous maxilla incorporates paramidline vertical releasing incisions and distal vertical releasing incisions made well beyond the area planned for the implant placement. The black arrow indicates the location of the pericrestal incision used for submerged implant placement. The location of the incision used for abutment connection and nonsubmerged implant placement are indicated by the straight blue arrow. Adapted from Sclar A.³

Papilla Regeneration When the width of the gingival tissues remaining on the buccal flap is 4 to 5 mm, use of the papilla regeneration maneuver is indicated. Advocated by Palacci and colleagues,² this

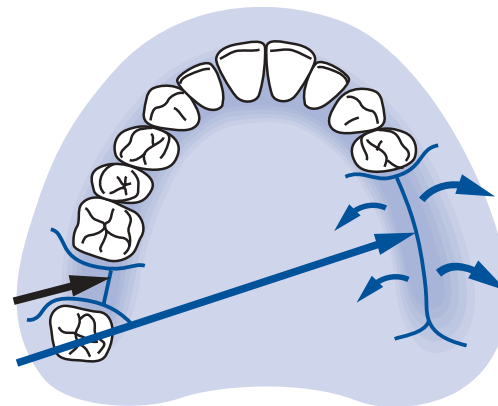


FIGURE 11-5 The flap design for an implant placement in the partially edentulous maxilla is outlined by pericrestal and curvilinear beveled vertical releasing incisions. The black arrow indicates the location of the pericrestal incision used for submerged implant placement. The location of the incision used for abutment connection and nonsubmerged implant placement is indicated by the straight blue arrow. Adapted from Sclar A.³

maneuver facilitates primary closure and circumferential adaptation around the transmucosal implant structures while preserving an adequate band of attached tissue around the emerging implant structures. In addition, attached mucosa is taken from the top of the ridge and moved in a buccal direction while approximately 3 mm of attached lingual or palatal tissues is preserved. A fine scalpel is subsequently used to sharply dissect the tissues to create pedicles in the buccal flap, which are passively rotated to fill the interimplant spaces (Figure 11-8). Passive adaptation of the pedicles in the interimplant space may require reverse cutback incisions made away from the base of the pedicle. The tissues are sutured, avoiding tension within the pedicles, usually using a figure-of-eight horizontal mattress suture. Alternatively, a simple interrupted suture passed through the buccal flap in a fashion that

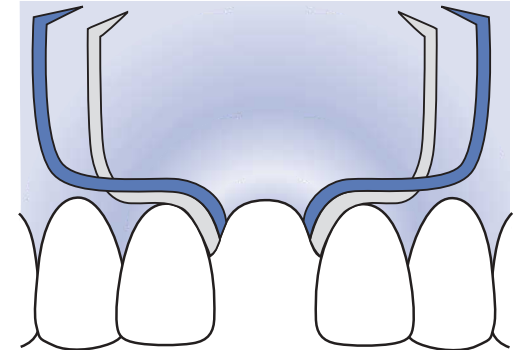


FIGURE 11-6 The flap design for esthetic implant therapy is outlined by pericrestal and curvilinear beveled releasing incisions. The vertical legs of the releasing incisions are made in the adjacent interdental areas, thereby providing the opportunity to camouflage within interdental grooves and the mucogingival junction. This flap design incorporates greater amounts of mucosal tissues, improving the overall elasticity of the flap. When combined with tension-releasing cutback incisions, coronal advancement is facilitated without an embarrassment of circulation to the flap margin. The flap design is exaggerated by moving the releasing incisions farther away from the site when reconstruction of large-volume esthetic ridge defects is necessary or for implant placement at sites where vestibular depth is inadequate. Adapted from Sclar A.³

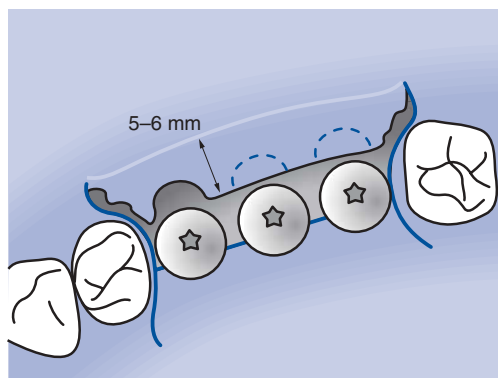


FIGURE 11-7 Resective contouring maneuver. When the apicocoronary dimension of the attached tissue remaining on the buccal flap used for the abutment connection or a nonsubmerged implant placement is between 5 and 6 mm, resective contouring is used to facilitate circumferential adaptation of the soft tissues around the emerging implant structures. Adapted from Sclar A.³

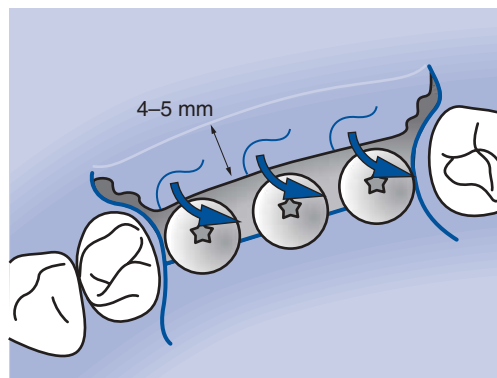


FIGURE 11-8 Papilla regeneration maneuver. When the apicocoronary dimension of the attached tissue remaining on the buccal flap used for an abutment connection or a nonsubmerged implant placement is between 4 and 5 mm, the papilla regeneration maneuver is used to facilitate circumferential adaptation of the soft tissues around the emerging implant structures. Adapted from Sclar A.³

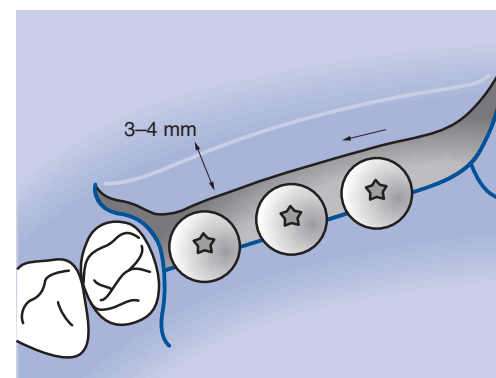


FIGURE 11-9 Lateral flap advancement maneuver. When the apicocoronary dimension of the attached tissue remaining on the buccal flap used for an abutment connection or a nonsubmerged implant placement is between 3 and 4 mm, lateral flap advancement is used to facilitate circumferential adaptation of the soft tissues around the emerging implant structures. Adapted from Sclar A.³

passively advances the pedicle into the interimplant space is effective in many situations. Care must be taken to avoid placement of the suture through the pedicle as this would reduce circulation to the pedicle. Another variation of this technique uses pedicles created in the palatal flap, which can also be rotated to fill the interimplant spaces, and is especially useful in maxillary situations where thick palatal tissues exist.³

Lateral Flap Advancement When the width of the gingival tissues remaining on the buccal flap is 3 to 4 mm, the use of the lateral flap advancement maneuver facilitates primary closure and circumferential adaptation of attached tissues around the emerging implant structures (Figure 11-9).³ This maneuver is especially suited for completely edentulous or posterior partially edentulous implant case types, where an adequate band of attached tissue exists adjacent to the implant site. Attached tissues available from adjacent areas are simply repositioned to obtain primary closure with attached tissues around the emerging implant structures.

This maneuver requires that the flap be designed to extend beyond the area of

implant placement to include the attached tissues present in adjacent edentulous areas. As the closure progresses, the flap advances, resulting in primary closure around the implants and the creation of a denuded area that will heal by secondary intention at the distal extent of the dissection. This surgical maneuver is useful in edentulous situations and in Kennedy Class I and II partially edentulous situations.

Rationale for Soft Tissue Grafting with Implants

The rationale for soft tissue augmentation around dental implants is related to the need for soft tissue around natural dentition. In general, experienced clinicians agree that an adequate zone of attached tissue around a natural tooth or implant prosthesis is desirable to better withstand the functional stresses resulting from mastication and oral hygiene. Moreover, a certain amount of attached tissue is needed to withstand the potential mechanical and bacterial challenges presented by esthetic restorations that extend below the free gingival margin. Potential mechanical challenges include tooth preparation, soft tissue retraction, impression procedures,

cementation of provisional and permanent restorations, removal of implant healing abutments, replacement of healing abutments with permanent abutments, taking of implant-level impressions, and placement of provisional and permanent implant restorations.

After the final restoration the intra-crevicular esthetic restorative margins may continue to present a permanent inflammatory challenge to the surrounding soft tissue attachment apparatus. Some implant practitioners believe that the microgap at the site of the abutment connection to two-piece implants may present a similar challenge. Whether these challenges result in an initial apical displacement of the marginal tissues or possibly even progressive loss of attachment depends on multiple factors, including the following³:

- Age of the patient
- General health of the patient
- Host resistance factors
- Effects of systemic medications
- Periodontal phenotype
- Technique and effectiveness of oral hygiene
- Frequency and technique of professional oral hygiene care

- Operative technique
- Choice of restorative materials
- Initial location of restorative margin vis-à-vis circumferential biologic width requirements
- Prominence of the implant position in the alveolus
- Pre-existing bony dehiscence
- Design and surface characteristics of the implant
- Depth of implant placement
- Thickness and apicocoronal dimension of the attached tissue

Because multiple factors influence the health of the marginal tissues, prospective or retrospective experimental or clinical studies are difficult to design and conduct, much less interpret. Certainly, studies that primarily consider the apicocoronal dimension of attached tissue and its effect on marginal soft tissue health, without considering the other factors, are inconclusive at best. Therefore, the rationale for soft tissue augmentation around natural dentition or a dental implant prosthesis should be based on clinical experience rather than on results from experimental or clinical studies.³

Clinical Guidelines for Soft Tissue Augmentation

When the apicocoronal dimension of attached tissue remaining on the buccal flap will be < 3 mm, the surgeon should consider soft tissue augmentation. Other factors to consider include tissue thickness, tissue quality, the presence of soft tissue inflammation or pathology, the type of implant restoration planned, and the esthetic importance of the site. In a nonesthetic area the surgeon can use the various surgical maneuvers described above to obtain primary closure and then reevaluate the need for soft tissue grafting based on the health and volume of periimplant attached tissues obtained after initial healing. In contrast, when the total width of attached tissue present is < 3 mm in an

esthetic area, soft tissue augmentation is indicated prior to implant placement. In most instances this can be accomplished with an epithelialized palatal mucosal graft, which quickly provides an improvement in the quality of the soft tissues.

Similarly, in esthetic areas, small-volume soft tissue esthetic ridge defects can be corrected simultaneously with submerged or nonsubmerged implant placement with subepithelial connective tissue grafting, whereas large-volume soft tissue esthetic ridge defects are most predictably reconstructed prior to implant placement with a series of subepithelial connective tissue grafts. Large-volume soft tissue defects can also be corrected with the use of a vascularized interpositional periosteal connective tissue (VIP-CT) flap, which, in ideal circumstances, allows for predictable reconstruction synchronous with implant placement.

Principles of Oral Soft Tissue Grafting

The first principle of oral soft tissue grafting is that the recipient site must provide for graft vascularization. It is understood that free grafts initially survive by plasmatic diffusion and are subsequently vascularized as capillaries and arterioles form a vascular network providing the permanent circulation for the graft. When a recipient site is partially avascular (eg, a denuded root surface, an exposed implant abutment, or an area recently reconstructed with a block bone graft), the dissection should be extended to provide a peripheral source of circulation to support the free graft over the avascular or poorly vascularized areas. Although pedicle grafts and flaps maintain their blood supply, it is also good surgical practice to prepare a recipient site that can contribute circulation to ensure optimal results in the event of a reduction of circulation to a portion (most commonly, the margin) of the pedicle graft or flap.

The second principle of oral soft tissue grafting is that the recipient site must pro-

vide a means for rigid immobilization of the graft tissue. Initial graft survival requires that the graft be immobilized and intimately adapted to the recipient site. Mobility of the graft during initial healing can interfere with its early nourishment through plasmatic diffusion or can disrupt the newly forming circulatory supply to the graft, resulting in excessive shrinkage or sloughing of the graft.

The third principle is that adequate hemostasis must be obtained at the recipient site. Active hemorrhage at the site prevents the intimate adaptation of the graft to the recipient site. Hemorrhage also interferes with the maintenance of the thin layer of fibrin between the graft and recipient site, which serves to physically attach the graft to the recipient site and provides for the plasmatic diffusion that initially nourishes the graft before its vascularization. Preparation of a recipient site with a uniform surface enhances the intimate adaptation with the graft. The periosteum is generally considered to be an excellent recipient site for oral soft tissue grafts because it fulfills all of the requirements discussed above. In addition, decorticated alveolar bone can support and nourish a free soft tissue graft, although immobilizing the graft at the site is more troublesome.

The fourth principle of oral soft tissue grafting involves the size and thickness of the donor tissue. The donor tissue must be large enough to facilitate immobilization at the recipient site and to take advantage of peripheral circulation when root or abutment coverage is the goal. The graft also must be large enough and thick enough to achieve the desired volume augmentation after secondary contraction has occurred. In addition, the donor tissue should be harvested to ensure a uniform graft surface that facilitates intimate adaptation to the recipient site. Thicker grafts (> 1.25 mm) are especially useful for root and abutment coverage when graft healing over the central portion of the avascular surface is characterized by necrosis. The

necrotic graft is gradually overtaken by granulation tissue from the periphery and ultimately forms a scar. Thicker grafts are better able to maintain their physical integrity during this process, which can take as long as 4 to 6 weeks. In summary, harvesting a graft that is too small or too thin should be avoided by evaluating the donor site prior to surgery and by applying the foregoing principles during recipient- and donor-site surgery.

Although failure to adhere to these surgical principles may not result in the loss of the soft tissue graft, increased complications such as inadequate volume yield, graft sloughing, wound breakdown, infection, and patient discomfort can be expected.

Epithelialized Palatal Graft Technique for Dental Implants

General Considerations

The use of an epithelialized palatal graft for the treatment of a mucogingival defect has enjoyed a long history of predictable success.⁴⁻⁶ This versatile technique can be used not only to increase the dimensions of attached tissue around the natural dentition and dental implants but also as a predictable method for covering denuded root or abutment surfaces. Although the term *free gingival graft* is a misnomer, it is commonly used to describe the transfer of epithelialized tissue harvested from the palate. When the contemporary surgical technique is used as described below, thick split-thickness grafts (> 1.25 mm) or full-thickness grafts are preferred around both natural dentition and dental implants.

Contemporary Surgical Technique

The surgical technique for gingival grafting around dental implants is essentially the same as the technique used around natural dentition.³⁻⁷ When gingival grafting is performed after implant abutment connection or delivery of the final restoration, a hori-

zontal incision is made through the inter-implant papilla coronal to the desired final tissue position. This facilitates abutment coverage with the gingival graft. When gingival grafting is performed at second-stage surgery or simultaneously with nonsubmerged implant placement, the horizontal incision is made at the mucogingival junction, and any existing gingival tissues are

repositioned to the lingual or palatal aspect of the implants (Figure 11-10A). This step is extremely important when implants are placed in the mandible because subsequent lingual soft tissue defects in this area are difficult to correct. A split-thickness dissection is then carried apically to create a uniform periosteal site. In the edentulous mandible, care must be taken to avoid damage to the

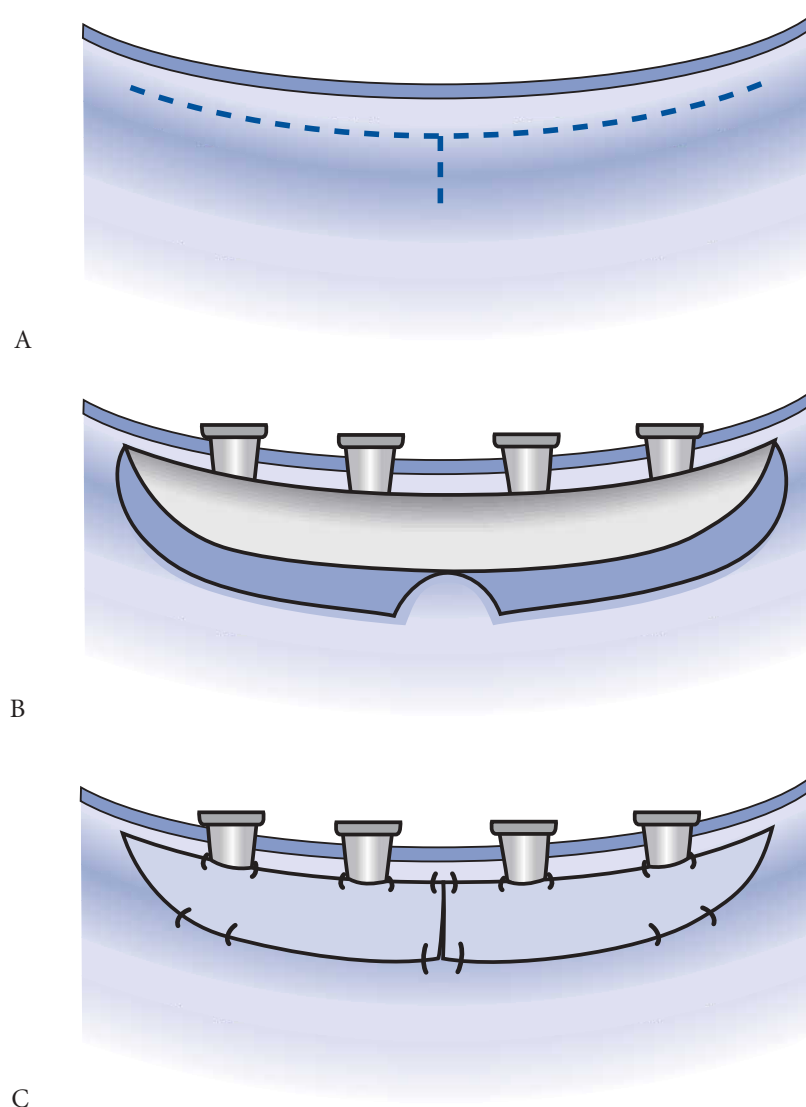


FIGURE 11-10 Surgical technique for gingival grafting simultaneous with abutment connection or nonsubmerged implant placement. A, A full-thickness horizontal incision is made at the mucogingival junction, and a partial-thickness vertical releasing incision is made at the midline. B, Full-thickness elevation of the flap lingually exposes the ridge crest and allows repositioning of the keratinized tissues lingually for abutment connection or nonsubmerged implant placement. C, Split-thickness dissection on the buccal aspect of the alveolar ridge provides a recipient site for rigid immobilization of the donor graft, which is adapted around the emerging implant structures and secured to the lingual tissues and to the periosteum peripherally. The dissection is limited distally to avoid unwanted injury to the mental nerve. Adapted from Sclar A.³

mental nerve with the vertical releasing incisions that typically outline the mesial and distal extents of the recipient site in the dentate patient. Instead, in these instances a midline vertical releasing incision and sharp dissection are used to create an adequate recipient site (> 5 mm apicocoronal dimension) with a half-moon shape, as shown in Figure 11-10B. Subsequently, the mucosal flaps are excised and residual elastic or muscular tissue are removed with tissue scissors or nippers. When working in a severely atrophic mandible, the mucosal flaps are preserved and sutured to the periosteum at the base of the dissection. The technique for graft immobilization is the same regardless of whether gingival grafting is performed around natural dentition, at second-stage surgery for submerged implants, or at the time of nonsubmerged implant placement. The graft is sutured to each papilla or interimplant area coronally

and then to the periosteum peripherally to rigidly immobilize the graft at the recipient site (Figures 11-10C, 11-11, and 11-12). The following graft immobilization pressure is applied with a moistened saline gauze for 10 minutes. Although a periodontal dressing is not necessary for the recipient site, a protective dressing for the donor site is recommended.

Gingival grafting is indicated prior to implant placement in the severely atrophic maxilla or mandible that is < 10 mm in height and has < 3 mm of attached tissue. In this clinical situation the surgeon should avoid significant dissection of the palatal or lingual tissues. Instead, a large recipient bed is created on the buccal aspect of the site, extending far enough apically from the midcrest to re-create the buccal vestibular fold. The graft is then harvested and rigidly immobilized with sutures placed approximately 5 mm apart to avoid unne-

cessary trauma and hematoma formation at the periphery. During subsequent implant surgery, a 3 mm or greater portion of the mature grafted tissue is repositioned lingually, providing good-quality gingival tissue for wound closure over submerged implants and circumferential adaptation of attached tissue around emerging implant abutments or nonsubmerged implants.

Subepithelial Connective Tissue Grafting for Dental Implants

General Considerations

The subepithelial connective tissue graft is an extremely versatile procedure that can be used to enhance soft tissue contours around the natural dentition and dental implants (Figures 11-13–11-15). The procedure combines the use of a free soft tissue autograft harvested from the palate

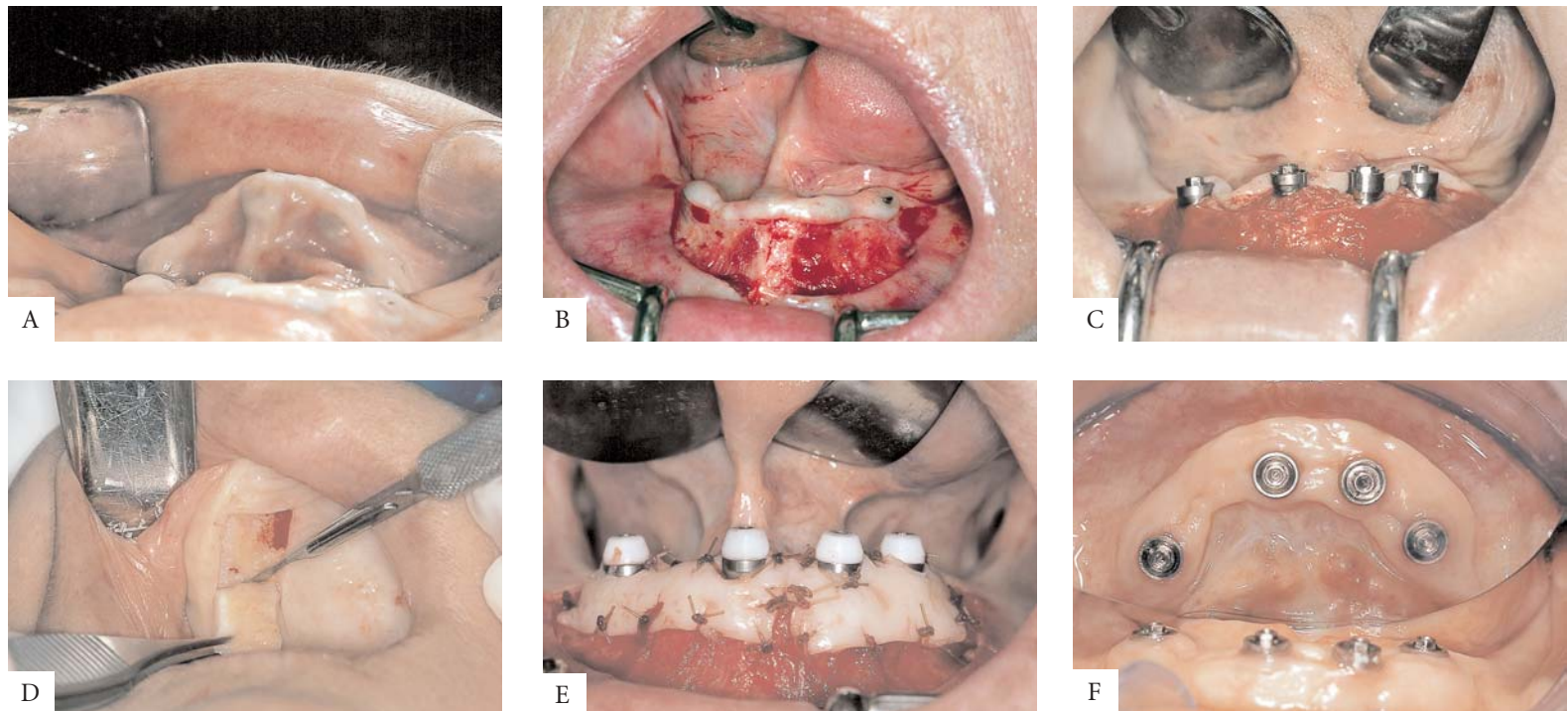


FIGURE 11-11 A, Preoperative view of four submerged implants ready for abutment connection. The amount of attached tissue is inadequate to ensure a stable periimplant soft tissue environment. B, Split-thickness dissection is performed to create a uniform periosteal recipient site. C, Full-thickness elevation of the attached tissues exposes the implants for abutment connection; the existing keratinized tissue has been repositioned to the lingual aspect of the emerging abutments. D, A palatal mucosal graft (gingival graft) is harvested from each side of the palate. E, The grafts have been contoured for precise adaptation around the abutments and secured to the lingual tissues and periosteum peripherally. F, This 2-month postoperative view demonstrates a tremendous volume yield from the gingival grafting procedure. A stable periimplant soft tissue environment has been obtained. Reproduced with permission from Sclar A.³

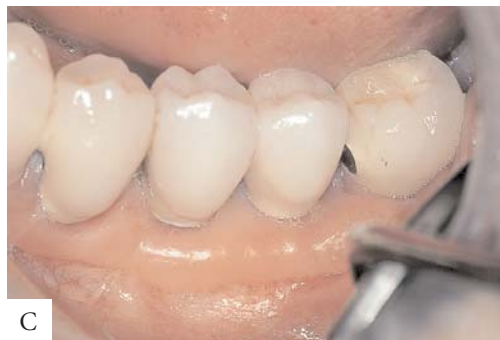
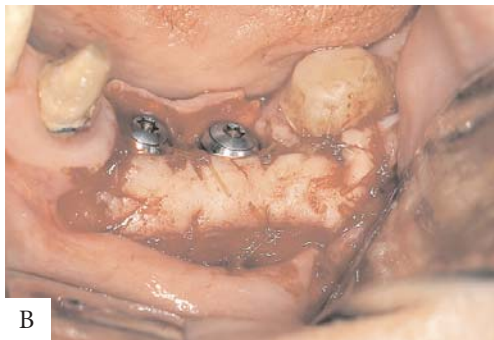
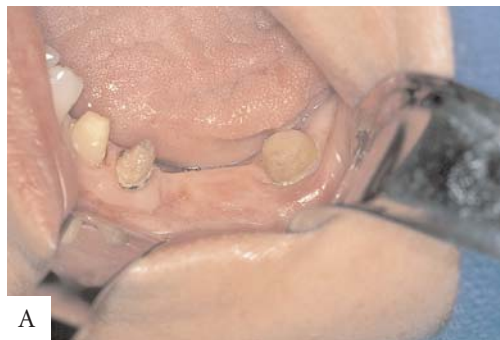FIGURE 11-12 A, Preoperative view of a partially edentulous mandibular site planned for simultaneous gingival grafting with the placement of nonsubmerged implants. B, Gingival graft adapted around the transmucosal portion of nonsubmerged implants and secured to the lingual tissues and the periosteum peripherally. C, Final restoration in place. Note that a healthy periimplant soft tissue environment has been created. Reproduced with permission from Sclar A.³

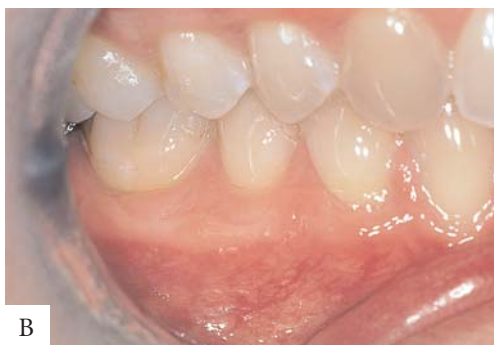
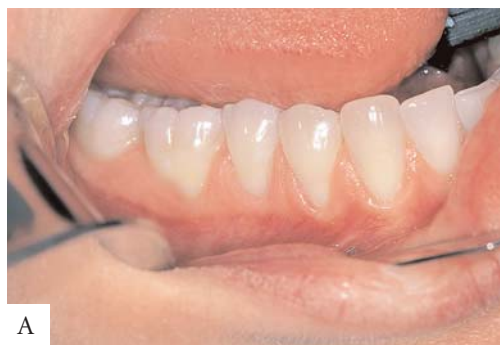
FIGURE 11-13 A and B, Progressive soft tissue recession involving the mandibular bicuspid and a first molar tooth was successfully corrected with a root coverage procedure using a subepithelial connective tissue graft. Reproduced with permission from Sclar A.³

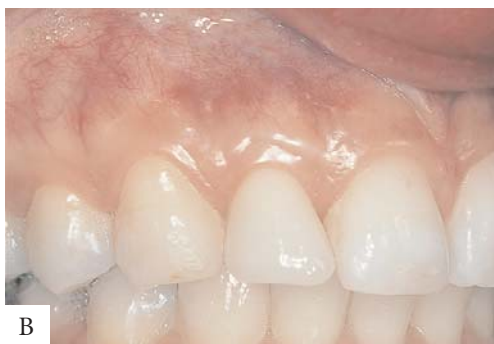
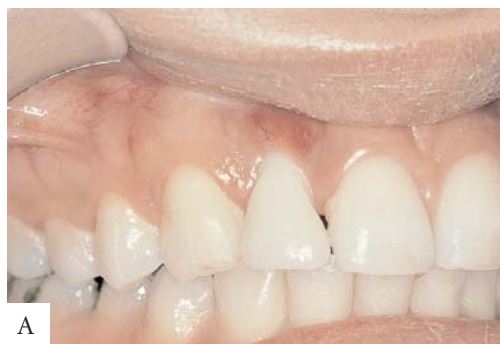
FIGURE 11-14 A, The progressive soft tissue recession around this lateral incisor implant restoration jeopardized its long-term success. B, A subepithelial connective tissue graft was performed via a closed pouch recipient site, resulting in the restoration of soft tissue esthetics and stability for this patient with a thin scalloped periodontium. Prophylactic soft tissue grafting would have prevented the recession from occurring and is indicated when intracrevicular restorations are planned for patients who present with thin periodontal tissues. Reproduced with permission from Sclar A.³

that is interposed beneath a partial-thickness pedicle flap at the recipient site (ie, open approach). Alternatively, the graft can be secured in a split-thickness pouch prepared at the recipient site (ie, closed approach). The graft is harvested internally from the palate, resulting in a partial-thickness donor-site pouch that allows for primary closure and thus a more comfortable palatal wound. Because the graft is positioned between the periosteum and a partial-thickness cover flap or pouch at the recipient site, it enjoys the advantage of a dual blood supply to support graft revascularization. Because of the abundant blood supply available for healing, the connective tissue graft is less technique sensitive, easier to perform, and more predictable than the gingival graft. The connective tissue graft also results in superior color matching and esthetic blending at the recipient site. The subepithelial connective tissue graft can be used during initial implant-site development prior to implant placement or simultaneous with submerged implant placement for the correction of small-volume soft tissue esthetic ridge defects. Similarly, the connective tissue graft can be performed simultaneous with an abutment connection or nonsubmerged implant placement to reconstruct these small-volume soft tissue defects or for the correction of soft tissue recession defects that develop in the recall period. Finally, whenever a large-volume soft tissue esthetic ridge defect is present, a series of connective tissue grafts is usually required for reconstruction of these esthetic ridge defects prior to implant placement.³

Surgical Technique: Donor-Site Surgery

The technique for harvesting subepithelial connective tissue grafts from the premolar region of the palate has two variations: the single-incision approach and the dual-incision approach.^{7,8} In either case, the donor-site surgery begins with a full-thickness curvilinear incision made

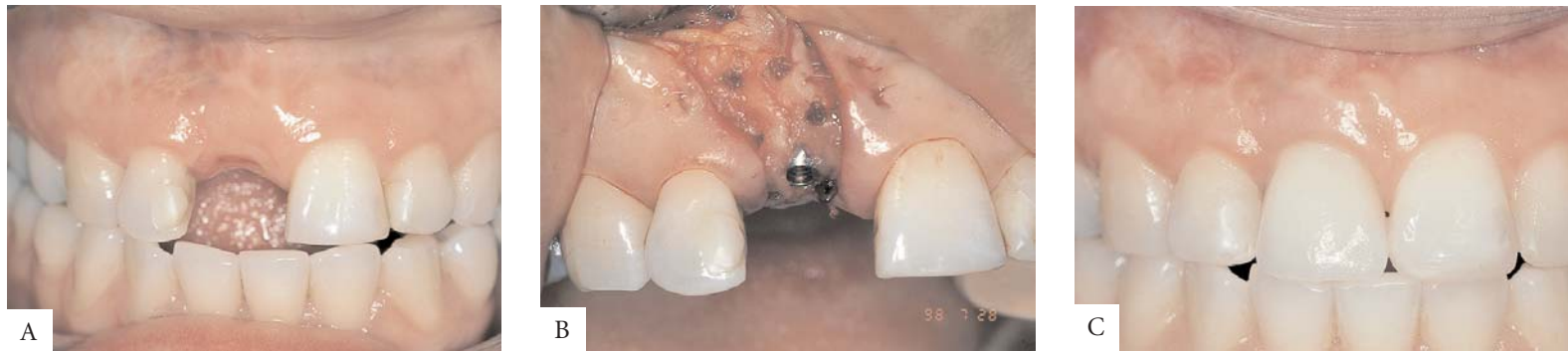

FIGURE 11-15 A, Preoperative view of central incisor implant site with a small-volume soft tissue esthetic ridge defect. B, An open flap approach involving full thickness dissection at the ridge crest and partial thickness dissection on the buccal aspect of the alveolar ridge was used for the implant placement and synchronous subepithelial connective tissue grafting. Coronal advancement of the cover flap enabled further soft tissue volume enhancement via submersion of the one-piece nonsubmerged implant, thus expanding the “soft tissue envelope.” C, Following conservative exposure and insertion of a custom abutment and provisional restoration, the soft tissues were allowed to stabilize prior to the delivery of the final restoration, which demonstrates pleasing soft tissue esthetics. Reproduced with permission from Sclar A.³

through the palatal tissues approximately 2 to 3 mm apical to the gingival margin of the premolars (Figure 11-16A). This incision can be made perpendicular to the surface of the palatal tissue, or it can be slightly beveled. When it is made perpendicular to the palatal tissues, the thickness of the coronal portion of the graft is maximized; however, this usually prevents passive primary closure. In contrast, beveling the first incision limits the thickness of the coronal portion of the graft but, in many cases, enables a passive primary closure.

When using the dual-incision approach, a partial-thickness curvilinear incision is then made approximately 2 mm apical to the first incision to complete an ellipse (Figure 11-16B). This incision defines the thickness of the subepithelial connective tissue graft to be harvested. The incision should be approximately 1 mm deep to ensure adequate thickness of the remaining cover tissue and to minimize the incidence of sloughing at the donor site. The scalpel is then oriented parallel to the surface of the palatal tissue, and sharp dissection is used to create a rectangular pouch. The apical extent of the dissection is determined by the height of the palate. The mesiodistal extent of the dissection is determined by the length of the first and second incisions, which, in turn, are

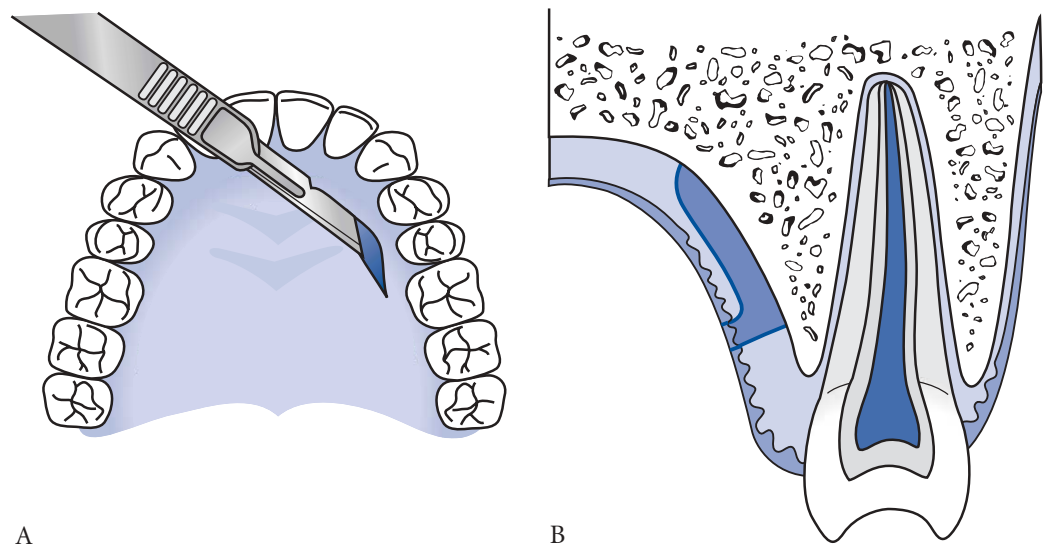


FIGURE 11-16 Subepithelial connective tissue grafting donor-site surgery via a dual-incision approach. A, The occlusal view demonstrates the location and orientation of the full-thickness and partial-thickness incisions. B, The cross-sectional view demonstrates the pathways of the incisions for donor-site harvest via the dual-incision approach. The shaded area represents the resultant donor graft, consisting of both connective tissue and periosteum. Adapted from Sclar A.³

determined by the overall size of the palate and the width of the premolars. The scalpel blade is then used to complete the outline of the donor connective tissue graft with incisions that pass through the underlying connective tissue and periosteum just short of the mesial and distal extent of the pocket. Unnecessary trauma to the overlying palatal tissues is thus avoided when the scalpel is turned perpendicular to the surface of the

donor tissue. A Buser periosteal elevator and membrane-placement instrument are then used to carefully begin subperiosteal elevation of donor tissue at the coronal aspect of the dissection. Once the coronal aspect of the graft has been elevated, it is carefully supported with tissue forceps and the subperiosteal elevation is extended to the apical portion of the pouch. Next, gentle traction is placed on the elevated tissue with forceps,

and a horizontal incision is made through the apical aspect of the donor tissue from within the pouch. The harvested tissue, which contains epithelium, connective tissue, and periosteum, is then transferred with tissue forceps to the recipient site or temporarily placed on sterile gauze moistened with saline. If the graft is submerged under the recipient's site flap, curved Iris tissue scissors should be used to remove the epithelial tissue. Hemostasis is then obtained at the donor site by placing an absorbable collagen dressing, such as CollaPlug, and applying pressure with saline-moistened gauze. The donor site is closed using interrupted 4-0 chromic gut sutures on a P3 needle passed through the interproximal areas.

The single-incision technique differs in that only one incision is used to establish access to both the subperiosteal and subepithelial planes of dissection. This approach begins with a full-thickness curvilinear incision, as described above. Next, the scalpel is reoriented within the incision until it is parallel to the surface of the palatal tissue. Subepithelial dissection that parallels the external surface of the palatal tissue is accomplished to create a rectangular pouch. After making the first incision, the surgeon may find it useful to perform subperiosteal elevation coronally. This improves visualization of available soft tissue thickness (Figure 11-17), thereby aiding the surgeon to establish the appropriate subepithelial plane of dissection. The remainder of the surgical procedure is identical to the procedure described above for the dual-incision technique.

The advantage of the dual-incision approach is that it is easier to perform. Since the thickness of the donor tissue is defined by the second incision, the result is the harvesting of a graft of uniform thickness. The disadvantage of this approach is that primary closure is seldom possible, and, therefore, the palatal wound can be uncomfortable. Nevertheless, this approach is usually recommended for the novice surgeon. Although harvesting a donor graft of

uniform thickness is technically more challenging when the single-incision approach is used, primary closure of the palatal wound results in greater patient comfort. As a result, most experienced surgeons prefer this approach.

Surgical Technique: Recipient-Site Surgery

Preparation of the recipient site involves either the elevation of a split-thickness flap through supraperiosteal dissection (open technique) or a supraperiosteal dissection, which avoids vertical releasing incisions to create an envelope or pouch (closed technique). The decision of which technique to use when grafting around a natural tooth or an implant restoration depends on several factors. The open technique allows direct visualization during dissection, which ensures the preparation of a uniform recipient site. This approach also allows for significant coronal advancement when vertical soft tissue augmentation is needed over an exposed root or abutment surface. The vertical releasing incisions used in the open technique sacrifice some circulation. However, the use of a curvilinear beveled flap with tension-releasing cutback incisions avoids embarrassment of circulation to the flap margin and allows for greater coronal flap advancement than do traditional trapezoidal flaps that require periosteal releasing incisions to allow even limited coronal advancement.

In contrast, the closed technique avoids the need for vertical incisions, thus preserving the blood supply to the site and optimizing esthetic results. However, as a "blind" technique, it can be technically more demanding. Also, because it does not allow for significant coronal advancement of the cover flap, this technique is of limited use when significant vertical soft tissue augmentation is needed, and it is contraindicated whenever vestibular depth limits the preparation of an adequately sized recipient site. In general, the closed recipient site is preferred when the abut-

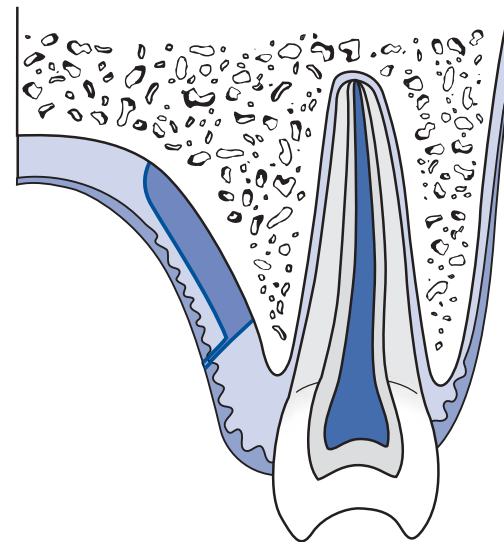


FIGURE 11-17 *Subepithelial connective tissue grafting donor-site surgery via the single-incision approach. The cross-sectional view demonstrates the pathways of the incision and the dissection for the donor-site harvest. The shaded area represents the resultant donor graft consisting of both connective tissue and periosteum. Adapted from Sclar A.³*

ment or root exposure is < 4 mm apico-coronally or when there is a significant risk of sloughing of the cover flap because of poor vascularity at the site.

Closed Technique The technique for closed recipient-site preparation is the same whether it is performed around a natural tooth or an implant restoration. A horizontal incision is extended to the mesial and distal aspects of the soft tissue defect just coronal to the level of the root or abutment coverage desired (Figure 11-18). Using a no. 15C scalpel, the surgeon makes this incision at a right angle to the epithelium at a depth of approximately 1 mm. The horizontal incisions not only mark the graft's final coronal position but also facilitate the pouch dissection and subsequent immobilization of the graft.

Next, the scalpel is oriented parallel to the tissue surface, and the horizontal incisions are extended into the sulcus to create the entrance to the recipient site. The split-thickness dissection is extended apically beyond the mucogingival junction at the

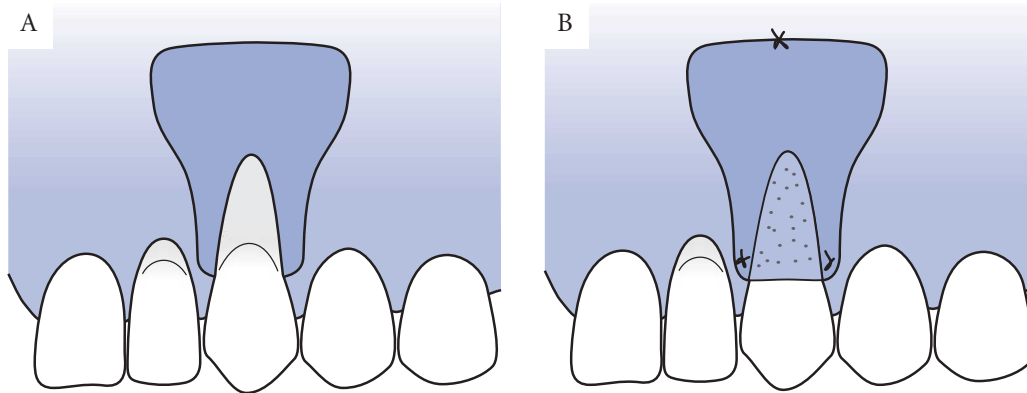


FIGURE 11-18 Closed “pouch” technique for the preparation of a recipient site for a subepithelial connective tissue graft to improve soft tissue contours around a natural tooth or an implant restoration. A, Split-thickness dissection (shaded area). B, Graft mobilization apically and coronally. Adapted from Sclar A.³

mesial and distal aspects of the site before crossing the midline. To ensure that the recipient site can contribute adequate peripheral blood supply to sustain the graft, the dissection must extend well beyond the width of the soft tissue defect being corrected. As a general rule, the width of the recipient site should be three times that of the exposed root or abutment, which can be accomplished by extending the defect mesially and distally. The surgeon must take care to avoid perforating or tearing the overlying tissues with the scalpel; a meticulous technique is required to ensure a uniform recipient-site surface.

The blunt end of a membrane-placement instrument is then used to probe the resultant pouch and confirm that the dissection is complete. Occasionally, strands or webs of tissue extending from the overlying tissues to the periosteum are detected in the apical extent of the dissection. If not released with sharp dissection, these tissue strands prevent proper positioning and passive adaptation of the connective tissue graft within the pouch. A periodontal probe is then used to measure the dimensions of the recipient pouch and to guide the surgeon in the donor harvest, and pressure is applied with saline-moistened gauze to obtain hemostasis.

Once the recipient site has been prepared and the donor tissue has been har-

vested, the donor tissue should be intimately adapted and rigidly immobilized at the recipient site. When a closed recipient site is used, the dimensions of the donor connective tissue should closely match those of the recipient-site pouch. Curved Iris tissue scissors are used to size the graft prior to securing it in the pouch. The graft should always be oriented so that the periosteal side faces down at the recipient site. A 4-0 chromic suture on a P3 or FS2 needle is used to place a horizontal mattress suture that enters the apical portion of the recipient pouch, engages the graft, and exits the pouch apically. This suture is used to gently “pull” the graft into the recipient pouch and secure the graft apically, thereby resisting subsequent coronal displacement. First, the suture needle is passed through the vestibular mucosa into the recipient pouch and retrieved with forceps. The suture needle is then passed through the connective tissue side of the graft and back through the periosteal side of the graft. Next, the membrane-placement instrument is used to identify the apical extent of the recipient site, and the suture needle is passed back through the mucosal tissue to exit the pouch several millimeters lateral of where it entered. A fine hemostat is clamped across equal lengths (approximately 7.5 cm) of the suture material, and suture scissors are used to cut away the remaining suture and needle.

Subsequently, the surgeon uses the clamped suture material to slowly pull the graft into the recipient pouch, taking care not to tear the overlying tissue. The paddle end of the membrane-placement instrument is used like a shoehorn to guide the graft into the entrance of the recipient pouch. The flat portion of the instrument is moistened with saline and placed between the graft and the overlying tissue as the graft is gently pulled into the pouch. This technique prevents bunching of the graft at the entrance of the recipient pouch as well as excessive stretching of, and damage to, the overlying tissues. The spiked end of the membrane-placement instrument is then used to gently “push” the graft further into the pouch entrance, while the clamped suture material is used to “pull” the graft apically. A triple tie secures the graft in the pouch.

The graft is secured coronally, either with interrupted sutures that pass through the graft and interproximal tissues (see Figure 11-18) or with a sling suture. Interrupted sutures in the papillary area are then used to secure the cover tissue pouch. Additional sutures can be carefully placed to approximate the coronal margins of the pouch in an effort to cover more of the exposed graft. Nevertheless, because significant coronal advancement of the overlying tissues is not possible, a portion of the graft will remain uncovered. Whenever possible, it is recommended that two-thirds or more of the graft be secured within the recipient-site pouch. Gentle pressure is applied over the graft site with saline-moistened gauze for a minimum of 10 minutes.

Open Technique Again, the technique for open recipient-site preparation is the essentially the same whether it is performed around a natural tooth or an implant restoration, or to improve soft tissue contours during implant-site development. This approach is useful for a moderate amount of vertical soft tissue augmentation, making it applicable for abutment coverage

procedures and for improving soft tissue contours during implant-site development or when performed over a submerged implant (Figure 11-19). The dissection begins by outlining the recipient site with partial-thickness horizontal and vertical incisions using a no. 15C scalpel blade on a round handle. The horizontal incision, which is performed first, extends mesial and distal to the soft tissue defect at a level just coronal to the final soft tissue position desired after augmentation. Exaggerated curvilinear beveled incisions with tension-releasing cutback incisions are then initiated apically well beyond the mucogingival junction to outline the cover flap. Next, sharp dissection is used to elevate a split-thickness

flap. The dissection is initiated coronally with a no. 15C scalpel blade. Flap elevation is continued apically under direct vision with sharp dissection under tension, which is carefully maintained with the use of micro-Adson tissue forceps. The goal is to maximize the thickness of the overlying tissue flap, leaving only a thin layer of immobile periosteum. When coronal advancement of the cover flap is performed, the adjacent papillary areas are de-epithelialized with a fresh no. 15C scalpel. This further extends the wound margin, thereby reducing flap retraction and greatly enhancing incision line esthetics. It also eliminates the possibility that the undersurface of the coronally advanced flap will be coapted over

an epithelial surface, which would prevent initial wound healing and could result in dehiscence along the incision. The dimensions of the recipient site are then measured with a periodontal probe, and hemostasis is obtained by applying gentle pressure with saline-moistened gauze.

Once the donor graft has been harvested, it is usually trimmed to be slightly smaller than the open recipient site. This facilitates immobilization of the graft and suturing of the cover flap into position without unwanted engagement of the underlying graft, which can cause graft dislodgment secondary to swelling or retraction of the cover flap. Whether grafting around natural dentition or an implant restoration(s), the graft is first secured coronally with sutures passed through the adjacent papillary areas using a 4-0 chromic gut suture on a P3 needle. Alternatively, sling sutures can be used for this purpose. Next, the graft is secured laterally and apically to the periosteum with additional sutures. The goal is to gently stretch the tissue, thus improving its adaptation to the recipient site.

Next, the cover flap is secured coronally with interrupted sutures passing through the papillae. These sutures should pass through the facial flap and the de-epithelialized papillary tissue and then return under the contact points, where they are tied facially. Alternatively, a sling suture can be used. In this case, the suture passes through the flap and the papillary tissue on the first pass; it then passes under the contact points as it returns to the facial aspect, where it is tied. Depending on the thickness of the cover flap tissue, 4-0 or 5-0 chromic gut suture on a P3 needle is used. Next, the cover flap is secured laterally. The use of exaggerated curvilinear beveled incisions to outline the cover flap not only extends the recipient site, providing additional circulation to sustain the graft, it also facilitates immobilization of the graft and closure of the cover flap.

The suture needle should be perpendicular to the beveled incision as it passes

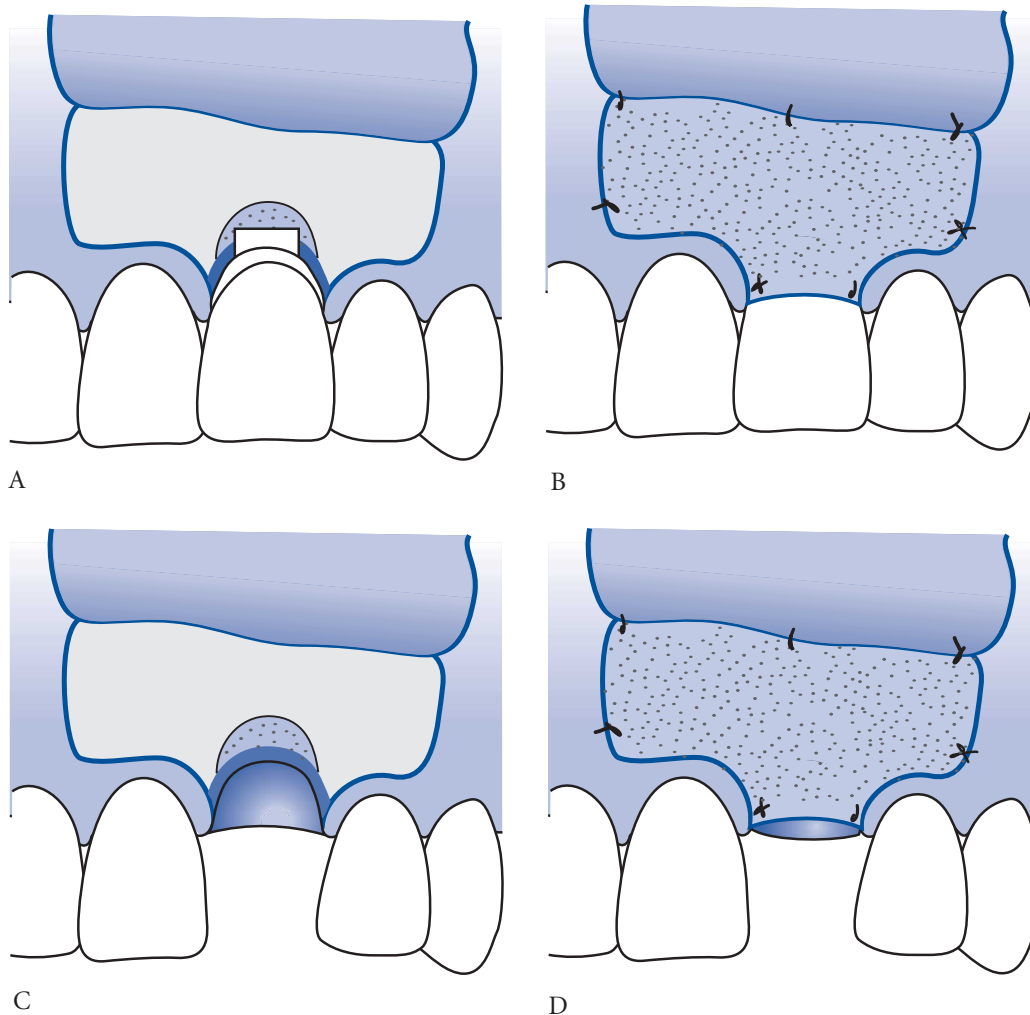


FIGURE 11-19 Open flap technique for the preparation of a recipient site for a subepithelial connective tissue graft to improve soft tissue contours at an implant site. This approach is useful at the time of abutment connection (A and B) and over a submerged implant (C and D). Adapted from Sclar A.³

through the tissue. It also should be oriented in an apicocoronal direction as it is passed through the flap and adjacent tissue. A single pass is recommended to ensure precise positioning of the cover flap. The attached tissue contained in the flap is first precisely repositioned and secured with sutures placed laterally. The sutures then are placed apical to the mucogingival junction. When performed as part of implant-site development or when grafting over a submerged implant, the recipient site is extended further onto the palatal or lingual surface of the alveolar ridge via split-thickness dissection, and the graft is secured in a similar fashion before closing the cover flaps, as described above. Moistened saline gauze is used to apply gentle pressure at the site for 10 minutes; a periodontal dressing is not usually needed.

Vascularized Interpositional Periosteal Connective Tissue Flap

General Considerations

The vascularized interpositional periosteal connective tissue flap (VIP-CT) flap is an innovative technique that provides for reconstruction of large-volume soft tissue esthetic ridge defects with a single procedure.³ In addition, the pedicled blood sup-

ply derived from the connective tissue–periosteal plexus within the flap provides the biologic basis for predictable simultaneous hard and soft tissue grafting procedures during esthetic implant-site development, even at compromised sites. Additional advantages of the technique include negligible postoperative soft tissue shrinkage; enhanced results realized from hard tissue grafting procedures owing to the supplemental source of circulation and the contribution to phase-two bone graft healing provided by the mesenchymal cells transferred with the flap; and, when hard and soft tissue site-development procedures are necessary, a reduction in treatment time and patient inconvenience.

Although the amount of horizontal soft tissue augmentation obtained with the VIP-CT flap is consistently greater than that obtained with free soft tissue grafting techniques, the amount of vertical soft tissue augmentation typically obtained exceeds that obtainable even when several free soft tissue grafts are performed, which has allowed the re-creation of positive gingival architecture, even in situations where previous hard and soft tissue site development techniques have fallen short. This technique has also proven useful in the treatment of compromised sites in which existing soft tissues were poor in quality

and severely scarred, rendering them inadequate to support required hard tissue implant-site development (Figure 11-20). It is a predictable means of resubmerging an implant in the anterior area when an unexpected soft tissue dehiscence compromises the final esthetic result.

The volume of tissue transfer routinely obtained with the VIP-CT flap has also allowed the camouflaging of small-volume combination hard and soft tissue ridge defects, as well as the correction of large-volume soft tissue defects simultaneously with implant placement (Figures 11-21 and 11-22), as previously discussed.

Of greatest significance, this technique provides the implant surgeon with a proven technique for predictable simultaneous hard and soft tissue esthetic implant-site development at compromised anterior sites with large-volume combination esthetic ridge defects (Figure 11-23). These enhanced results are directly related to maintenance of intact circulation to the flap and decreased postsurgical contraction.

Surgical Technique

As in the previously described techniques, the surgeon begins by outlining and preparing the recipient site and then proceeds to donor-site preparation. An exaggerated

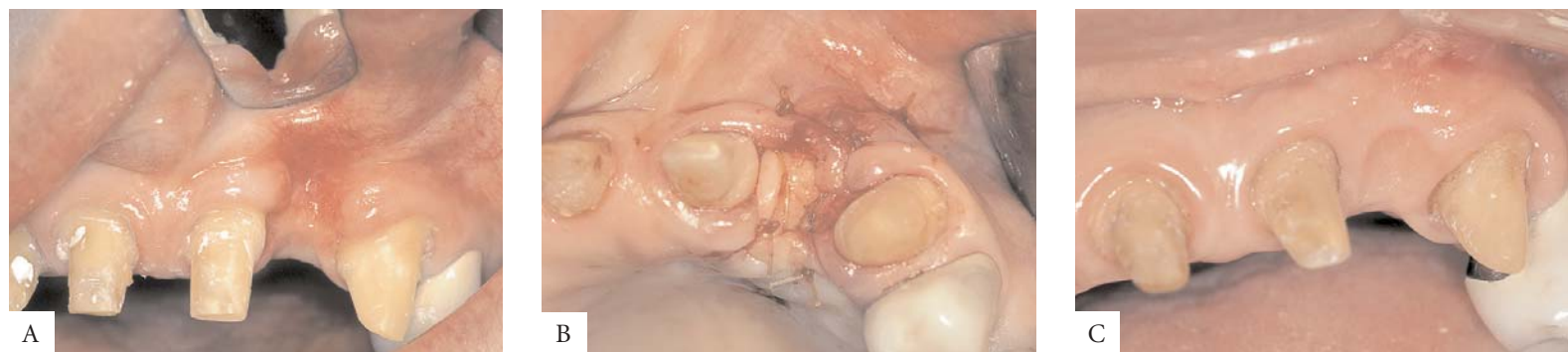

FIGURE 11-20 Use of the vascularized interpositional periosteal connective tissue (VIP-CT) flap to restore soft tissue volume and health at a severely compromised site. A, Preoperative view of a severely compromised lateral incisor site following a failed bone graft that resulted in the loss of col and papilla on the adjacent central incisor and severely scarred and inelastic soft tissue cover at the site. B, A VIP-CT flap was performed to provide sufficient volume of good-quality tissue to support the subsequent bone graft. C, The final result after subsequent bone grafting demonstrates the complete reconstruction of natural ridge contours and the successful restoration of the adjacent col and papilla, a remarkable result that is not always obtainable even with the VIP-CT flap. Reproduced with permission from Sclar A.³

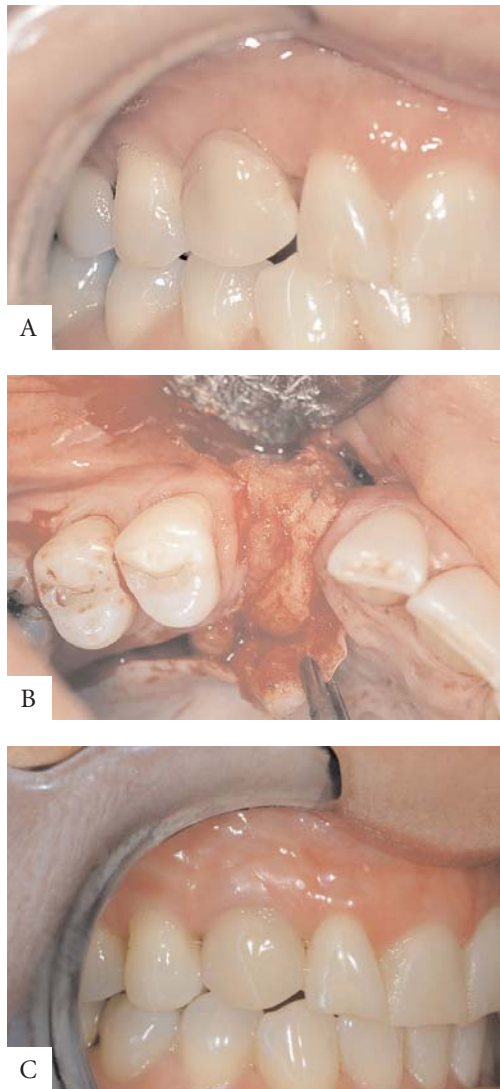


FIGURE 11-21 Use of the vascularized interpositional periosteal connective tissue (VIP-CT) flap for the correction of a small-volume combination hard and soft tissue esthetic ridge defect. A, Preoperative view of a maxillary canine site with a ridge lap pontic attempting to disguise an obvious ridge contour defect. B, After implant placement, a VIP-CT flap is rotated and interposed underneath the donor- and recipient-site flaps, which are closed primarily. C, The final restoration demonstrates a natural esthetic emergence and successful camouflaging of the small-volume combination esthetic ridge defect. Reproduced with permission from Sclar A.³

curvilinear beveled flap design is used at the recipient site. Abbreviated vertical releasing incisions are extended over the alveolar crest onto the palatal surface at both the mesial and distal aspects of the recipient site. This allows full exposure of the ridge crest for

hard tissue grafting or implant placement. The palatal incision at the distal aspect of the recipient site parallels the gingival margin on the oral aspect of the adjacent tooth (Figure 11-24A).

After recipient-site preparation, donor-site preparation begins by extending this incision horizontally to the distal aspect of the second premolar. To facilitate subsequent closure of the donor site, the orientation of this incision should be slightly beveled and follow a path approximately 2 mm apical to the free gingival margins of the canine and premolar teeth (see Figure 11-24A). Sharp dissection is then used internally to create a split-thickness palatal flap in the premolar area. The subepithelial dissection is carried mesially toward the distal aspect of the canine. The surgeon should be careful to maintain an adequate thickness of the palatal cover flap to avoid sloughing. In most cases the dissection has to be deeper in the area of the palatal rugae to avoid perforating the cover flap. Next, a vertical incision is made internally through the connective tissue and periosteum at the distal extent of the subepithelial dissection, as far apically as is possible without damaging the greater palatine neurovascular structures. This incision defines the margin of the flap. Using a Buser periosteal elevator and a membrane-placement instrument, the surgeon then carefully elevates the resultant periosteal–connective tissue layer, beginning in the second premolar area and working toward the anterior extent of the dissection. Usually, this careful subperiosteal dissection yields intact periosteum on the undersurface of the pedicle, which aids in subsequent rigid immobilization of the graft. Furthermore, intact periosteum potentially provides osteoblastic activity if applied over a bone graft when simultaneous hard and soft tissue site development is performed. A second incision is then initiated under tension internally at the apical extent of the previous vertical incision and extended horizontally anterior to

the distal aspect of the canine. The outline of the periosteal–connective tissue pedicle is now complete. Limiting the incisions to the anatomic landmarks given ensures that the margin of the pedicle is safely harvested from the palatal area, where the thickest amount of connective tissue is available, without risk of damage to adjacent neurovascular structures. Next, a Buser periosteal elevator is used to carefully elevate the periosteal–connective tissue pedicle and undermine the full thickness of the palatal mucosa and periosteum at the base of the pedicle, just beyond the midline of the palate (Figure 11-24B). This subperiosteal elevation or undermining

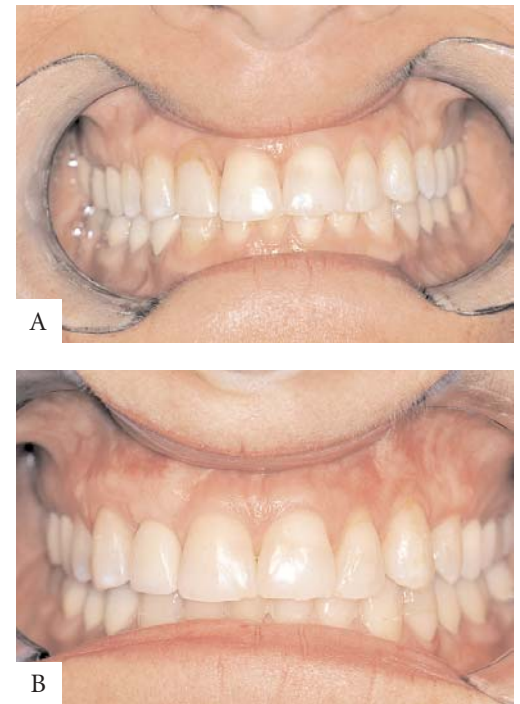


FIGURE 11-22 Use of the vascularized interpositional periosteal connective tissue (VIP-CT) flap for the correction of a large-volume soft tissue esthetic ridge defect simultaneous with a submerged implant placement. A, Preoperative view of a lateral incisor implant site with removable partial denture with a tissue-colored flange used to disguise the large-volume soft tissue defect at the site. B, The final restoration demonstrates a natural emergence and soft tissue esthetics following the implant placement and synchronous use of the VIP-CT flap. Typically, several free soft tissue grafts are necessary to restore a large-volume soft tissue defect. Reproduced with permission from Sclar A.³

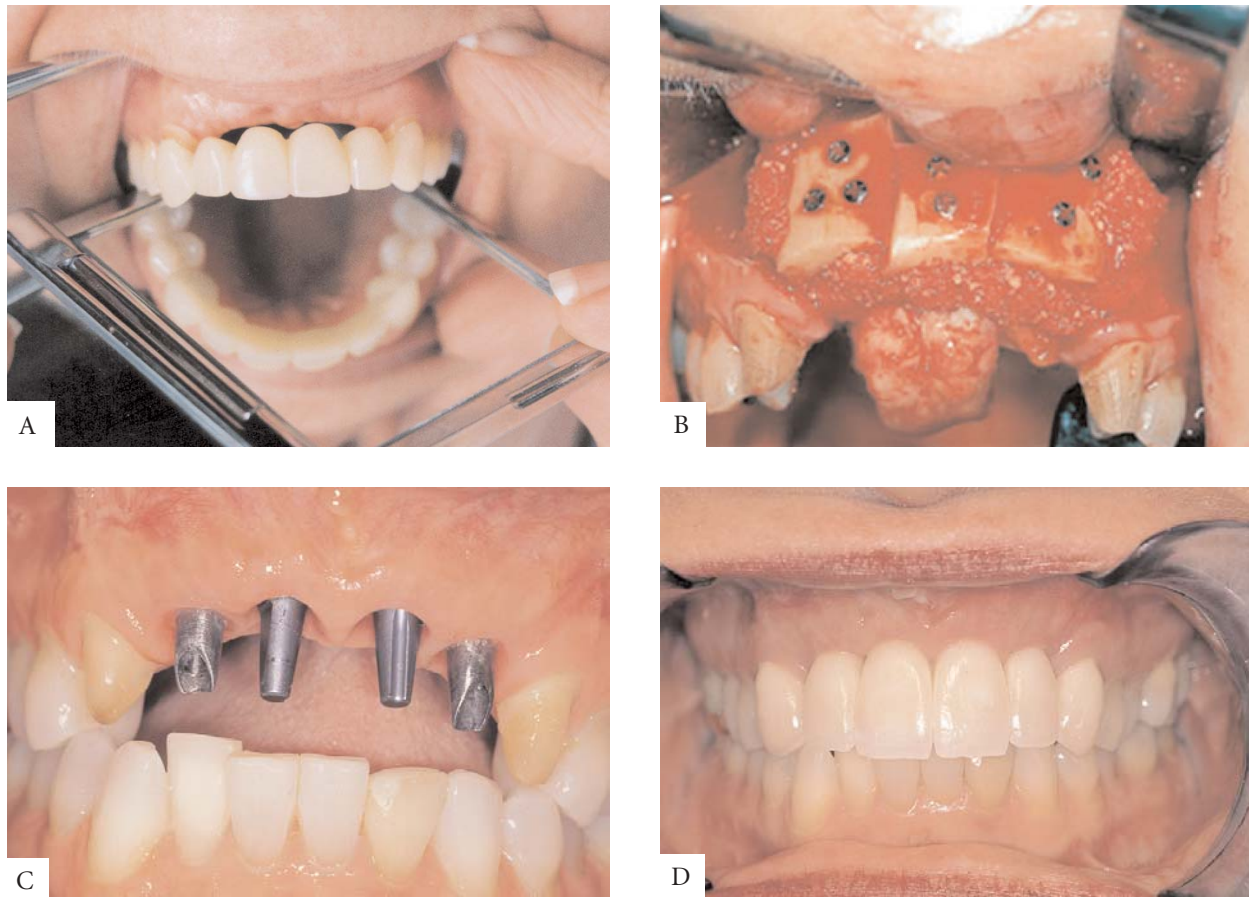


FIGURE 11-23 Simultaneous reconstruction of a large-volume combination hard and soft tissue esthetic ridge defect for the replacement of four maxillary incisors. A, Preoperative view of the compromised site secondary to multiple interventions leading to tooth loss and a previously failed attempt at bone graft reconstruction. B, Intraoperative view following rigid fixation of corticocancellous block bone grafts and condensation of particulate bone graft material. The vascularized interpositional periosteal connective tissue (VIP-CT) flaps have been prepared and are ready for rotation over the block bone graft, thereby improving the volume of the soft tissue in the areas critical for prosthetic emergence and supplementing the circulation of the soft tissue cover for enhanced bone graft healing. C, Nonsubmerged central and lateral incisor implants were placed after 4 months of healing with customized tooth-form healing abutments. The final restorative abutments, pictured in this clinical photograph, were delivered after an additional 4 months. Note that use of the VIP-CT flap simultaneous with the block bone grafting procedure resulted in a significant vertical soft tissue augmentation and the restoration of the natural soft tissue architecture at the site. D, The final restorations are harmonious in appearance, and pleasing gingival esthetics are evident. Reproduced with permission from Sclar A.³

begins at the distal aspect of the dissection in the area of the second premolar and is carried anteriorly toward but short of the incisive foramen so as to avoid compromise to the neurovascular structures in this area. Doing so provides additional elasticity at the base of the pedicle to allow passive rotation to the recipient site without the need for a tension-releasing cutback incision. Essentially, the two distinct planes of dissection performed define the interpositional periosteal-connective tissue pedicle flap without disrupting its cir-

culcation. The subepithelial plane is superficial to the greater palatine vessels but deep enough to avoid sloughing of the palatal cover flap. The subperiosteal plane is deep to the greater palatine vessels and is limited anteriorly and posteriorly to avoid damage to the neurovascular structures as they course through the palate.

Tension-releasing cutback incisions extended into the base of the pedicle flap are rarely necessary when subperiosteal undermining is performed. When unavoidable, these relaxing incisions are initi-

ated at the pivot point of flap rotation along the line of greatest tension. Although the line of greatest tension is the radius of the rotation arc created by the apical horizontal incision, the pivot point may not coincide with the termination of that incision. This is because the periosteal undermining causes a favorable displacement of the flap's pivot point and in most cases allows for tension-free rotation of the flap into the maxillary anterior area without the need for a tension-releasing cutback incision. Nevertheless, when a tension-

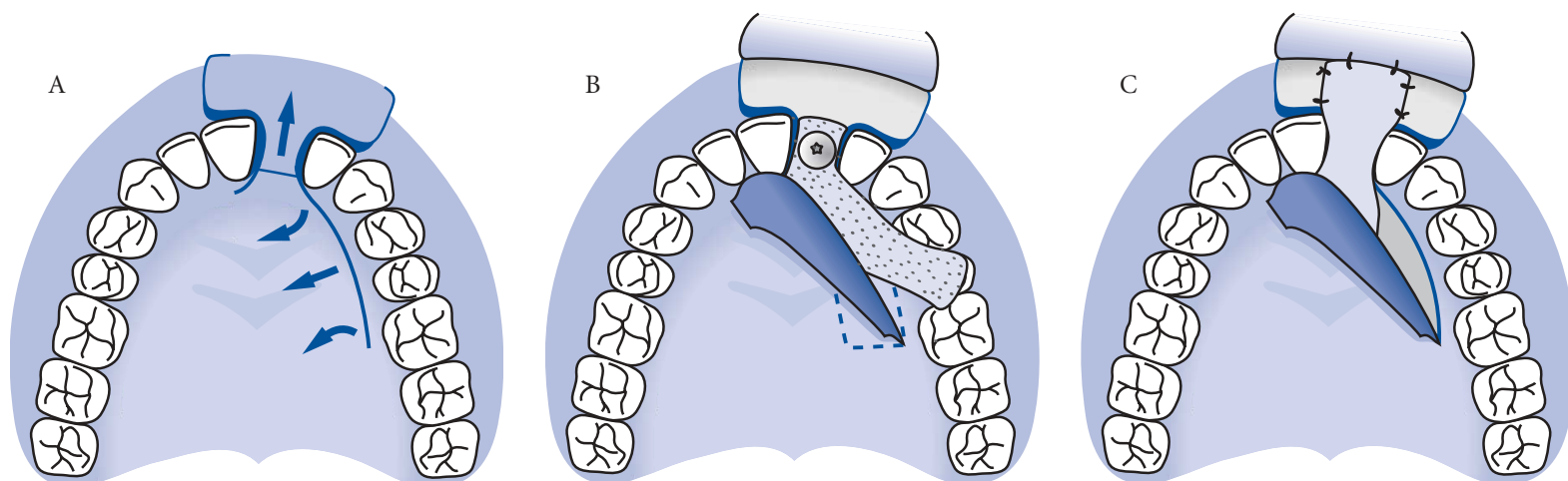


FIGURE 11-24 Surgical technique for the vascularized interpositional periosteal connective tissue (VIP-CT) flap. A, Occlusal view of incisions that outline the donor and recipient sites. Note that the preparation of the recipient site involves de-epithelialization of the adjacent col and papillary areas. B, After split-thickness recipient-site preparation, de-epithelialization of the attached tissue on the buccal aspect of the ridge as well as the adjacent col and papillary areas is performed, and implant placement is completed. Subsequently, the VIP-CT flap is developed via subepithelial and subperiosteal dissections performed within the bicuspid region of the palate. C, Subperiosteal undermining is extended to the midline, allowing the flap to passively rotate to the midline, where it is secured to the de-epithelialized areas and periosteum at a split-thickness recipient site, or over a block bone graft when simultaneous reconstruction is performed. Adapted from Sclar A.³

releasing cutback incision is necessary despite undermining, the surgeon must be careful to limit the length of the incision to avoid embarrassing the circulation. An intraoperative assessment of the area of greatest tension will guide the placement of releasing incisions. Next, the flap is rotated into the recipient site and rigidly immobilized with sutures placed apically and/or laterally (Figure 11-24C). Alternatively, the flap can be secured directly to a block bone graft using sutures passed through transosseous perforations in the bone graft. An absorbable collagen dressing, such as CollaPlug, is used as an aid to hemostasis and to eliminate dead space in the donor harvest area. Finally, the donor and recipient sites are closed primarily with absorbable sutures, and gentle pressure is applied with saline-moistened gauze for 10 minutes.

Oral Soft Tissue Grafting with Acellular Dermal Matrix

General Considerations

Acellular dermal matrix (AlloDerm) has been used as an alternative to harvesting autogenous epithelialized palatal grafts and

subepithelial connective tissue grafts in periodontal surgery since 1996. AlloDerm grafts are composed of freeze-dried allograft skin processed to remove all immunogenic cellular components (epidermis and dermal cells), leaving a useful acellular dermal matrix for soft tissue augmentation. AlloDerm can be used to increase the width of attached tissue around the natural dentition and implants, obtain root or abutment coverage, and correct small-volume soft tissue ridge defects. The advantages of using AlloDerm include the elimination of donor-site surgery for greater patient comfort, unlimited tissue supply, excellent handling characteristics, and decreased surgical time. Disadvantages include greater secondary shrinkage and slower healing at the recipient sites when used as an onlay graft or when complete coverage of an interpositional AlloDerm graft is not obtainable. Predictable root or abutment coverage requires coverage of the AlloDerm graft with good-quality cover flap tissue.

Surgical Technique

The surgical technique for using AlloDerm is essentially the same as that described

above for the gingival and subepithelial connective tissue grafts. The AlloDerm graft must be rehydrated for 10 minutes before use. Two distinct sides of the AlloDerm graft are identified by applying the patient's blood to each surface and rinsing with sterile saline. The connective tissue side will retain the red coloration, whereas the basement membrane side will appear white. The connective tissue side contains preexisting vascular channels that allow for cellular infiltration and revascularization. When used as an onlay graft to increase the width of attached tissues, the connective tissue side should be oriented toward and intimately adapted to the recipient site (Figure 11-25). When used for root or abutment coverage, the basement membrane side of the graft should be oriented toward the exposed root or abutment (Figure 11-26). The basement membrane side of the AlloDerm graft facilitates epithelial cell migration and attachment. Wherever possible, the author recommends preparing a larger recipient site (6–8 mm apicocoronal dimension) and immobilizing a larger AlloDerm graft compared to what is used when an autogenous gingival graft is performed.

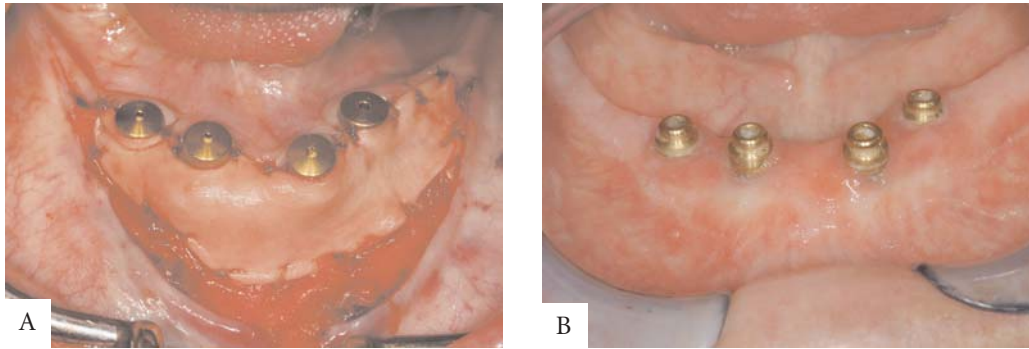


FIGURE 11-25 Use of AlloDerm (a freeze-dried allograft skin processed to remove all immunogenic cellular components [epidermis and dermal cells]) to increase the width of attached tissue around an implant restoration. A, Intraoperative view of the use of an AlloDerm graft simultaneous with the placement of four nonsubmerged implants in an edentulous mandible to improve the periimplant soft tissue environment and to eliminate mobile mucosal tissues in the area, while increasing vestibular depth. B, The 2-month postoperative view demonstrates a sufficient area of attached nonmobile peri-implant soft tissues to ensure a healthy soft tissue environment and ample access for oral hygiene maintenance. Reproduced with permission from Sclar A.³

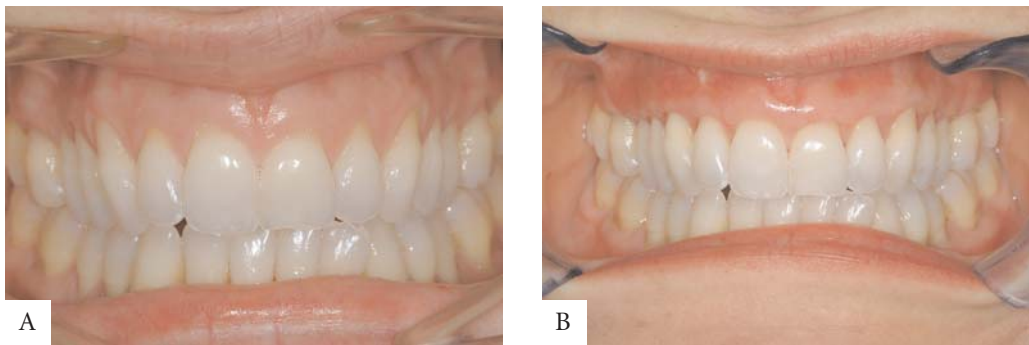


FIGURE 11-26 Use of AlloDerm (a freeze-dried allograft skin processed to remove all immunogenic cellular components [epidermis and dermal cells]) for root- or abutment-coverage procedures. A, Preoperative view of generalized progressive periodontal soft tissue recession treated with AlloDerm grafts. B, The postoperative view demonstrates successful root coverage at sites amenable to such a result and an increased width of attached tissue at those sites not amenable to complete root coverage.

This offsets the additional shrinkage observed with AlloDerm onlay grafts.

Improvement has been observed in the rate of incorporation of AlloDerm onlay and interpositional grafts when platelet-rich plasma (PRP) is incorporated into the surgical protocol.³ In these instances the AlloDerm graft is first rehydrated in non-activated anticoagulated PRP solution

prior to its immobilization at the recipient site. Subsequently, activated PRP is used topically at the recipient site as a growth factor-enriched wound dressing. Whenever PRP is used with AlloDerm or autogenous soft tissue grafts, care must be taken to avoid the formation of a PRP blood clot between the soft tissue graft and the periosteal recipient site or the cover flap.³

Conclusion

This chapter provides the implant surgeon with the basic information necessary for successful management of periimplant soft tissues in the most common clinical scenarios. In addition, it presents principles of oral soft tissue grafting and surgical details of the most commonly used oral soft tissue grafting techniques. However, as limited information concerning the indications, advantages, and expected outcomes of the individual surgical approaches and techniques has been presented, further study by the reader is encouraged.

References

- Schroeder A, van der Zypen E, Stich H, Sutter F. The reaction to bone, connective tissue, and epithelium to endosteal implants with titanium-sprayed surfaces. *J Maxillofac Surg* 1981;9:15–25.
- Palacci P, Ericsson I, Engstrand P, Rangert B. Optimal implant positioning and soft tissue management for the Brånemark System. Chicago: Quintessence Publishing Co.; 1995. p. 59–70.
- Sclar A. Soft tissue and esthetic considerations in implant therapy. Chicago: Quintessence; 2003. p. 52–54.
- Sullivan HC, Atkins JH. Free autogenous gingival grafts, I. Principles of successful grafting. *Periodontics* 1968;6:121–9.
- Gordon HP, Sullivan HC, Atkins JH. Free autogenous gingival grafts, II. Supplemental findings—histology of the graft site. *Periodontics* 1968;6:130–3.
- Sullivan HC, Atkins JH. Free autogenous gingival grafts, III. Utilization of grafts in the treatment of gingival recession. *Periodontics* 1968;6:152–60.
- Langer B, Calagna L. The subepithelial connective tissue graft: a new approach to the enhancement of anterior cosmetics. *Int J Periodontics Restorative Dent* 1982; 2(2):23–34.
- Reiser C, Bruno JF, Mahan PE, Larkin LH. The subepithelial connective tissue graft palatal donor site: anatomic considerations for surgeons. *Int J Periodontics Restorative Dent* 1996;16:131–7.

Bone Grafting Strategies for Vertical Alveolar Augmentation

Ole T. Jensen, DDS, MS

Michael A. Pikos, DDS

Massimo Simion, DDS

Tomaso Vercellotti, MD, DDS

Strategies to increase alveolar vertical dimension fall into six general categories: (1) guided bone graft augmentation, (2) onlay block grafting, (3) interposition alveolar bone graft, (4) alveolar distraction osteogenesis, (5) iliac corticocancellous augmentation bone graft, and (6) the sinus bone graft.

The difficulty in gaining and maintaining alveolar vertical augmentation is well established in the literature, but the various procedures that have been used have been complicated by relapse and resorption.¹⁻³ Augmentations without the placement of implants generally resorb unless a nonresorbable grafting material such as hydroxylapatite is used.⁴⁻⁶

This chapter reviews the indications and contraindications for the above procedures, all of which have found their niche in oral and maxillofacial surgery reconstruction using osseointegrated implants.

Alveolar vertical defects have been classified according to the size of the defect.⁷ Deficiencies can range from 1 or 2 mm to more than 20 mm in height. In general monocortical grafts or guided bone graft augmentations are useful for smaller augmentations. Interpositional grafts work

well for moderate-sized defects, whereas distraction osteogenesis is reserved for more extensive alveolar defects. Large bone mass deficiencies, where there is not enough bone to distract, require iliac bone graft reconstruction, though a vertical gain of 10 mm is difficult to achieve in these settings. Finally, there is the sinus bone graft, which functions as an “endosteal” expansion of alveolar vertical bone mass.

Guided Bone Graft Augmentation

Vertical bone augmentation of deficient alveolar ridges can be obtained with guided bone regeneration techniques. These techniques allow vertical augmentation of up to 10 mm both in the posterior and anterior maxilla and mandible. A barrier membrane is placed and stabilized with tacks or screws in order to protect an autogenous bone graft usually harvested from the retromolar area in the mandible. The membrane is maintained in the site completely covered by the soft tissues for a period of at least 6 months.

The implants can be placed either at the time of bone regeneration or at the membrane removal surgery.

Figure 12-1 illustrates a posterior mandible atrophy in which 7 mm of vertical bone height is required. After full thickness flap elevation, a couple of 10 mm long tenting screws have been placed in order to avoid the membrane collapse toward the bone ridge. The cortical bone has been perforated with a round bur (see Figure 12-1A). Autogenous bone chips have been placed and covered with a titanium-reinforced expanded polytetrafluoroethylene (ePTFE) membrane (see Figure 12-1B). After 6 months of uneventful healing, a mucoperiosteal flap has been elevated (see Figure 12-1C), and the membrane has been removed to expose the regenerated bone (see Figure 12-1D). Two Brånemark implants have been placed (see Figure 12-1E). Figure 12-1F and 12-1G show the final porcelain-fused-to-metal prosthesis and the periapical x-ray after 3 years of occlusal loading.

Mandibular Block Autografts for Localized Vertical Ridge Augmentation

Mandibular block autografts have been used extensively for alveolar ridge augmentation with great success and include

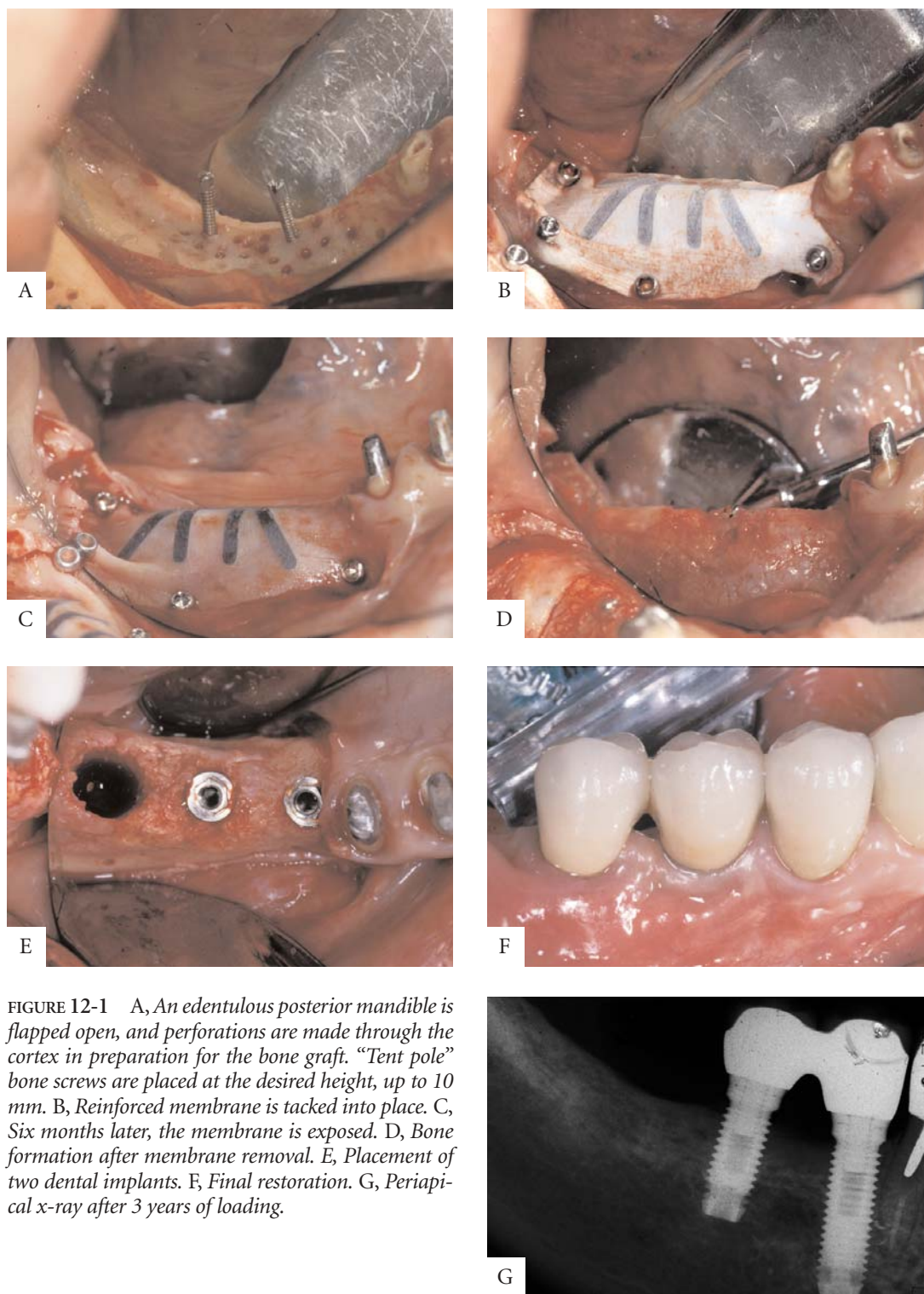


FIGURE 12-1 A, An edentulous posterior mandible is flapped open, and perforations are made through the cortex in preparation for the bone graft. “Tent pole” bone screws are placed at the desired height, up to 10 mm. B, Reinforced membrane is tacked into place. C, Six months later, the membrane is exposed. D, Bone formation after membrane removal. E, Placement of two dental implants. F, Final restoration. G, Periapical x-ray after 3 years of loading.

the symphysis and ramus buccal shelf as donor sites.⁸⁻¹⁶ The vertically deficient ridge presents the greatest challenge for reconstruction, and success with these grafts can be achieved with defects of up to 6 mm. The posterior maxilla and mandible are the most common areas of

the mouth where this type of deficiency occurs. This section focuses on posterior maxillary and mandibular reconstruction in a staged manner prior to implant placement. Implants are placed in a submerged or nonsubmerged mode after appropriate healing time with the block grafts.

Typically, there is loss of alveolar bone height in the posterior maxilla and mandible secondary to periodontal disease and after tooth removal. Tooth loss results in buccal plate compromise and a reduction in alveolar width. This bone resorption process continues in a medial direction until a knife-edged ridge forms. This may then result in a deficiency of alveolar height that would preclude implant placement. The cortical plate may be minimal or absent, further complicating implant placement. Finally, occlusal forces are greater in the posterior than in the anterior area of the mouth, necessitating appropriate surgical and prosthetic treatment planning for long-term implant success.

Treatment planning in these areas must include solutions to reduce stress. A primary plan includes increasing the number of implants. No pontics are used, so one implant per buccal root is the treatment planned for each case. In addition, no cantilevers are allowed. Splinting of all crowns is also indicated for biomechanical force distribution. Occlusal considerations include eliminating lateral interferences during any excursive movements. The final factors involved in decreasing undesirable stress to the implants are interrelated. They include increasing the bone density and maximizing the diameter of implants. These two goals are accomplished with mandibular block grafts. The quality of bone from the ramus buccal shelf is typically type 1, and the symphysis normally exhibits type 2 and occasionally type 1 quality bone. These grafts create areas for the use of larger diameter implants that increase the surface area over which the stresses of occlusal forces are distributed.^{17,18}

There are four key principles that should be followed for mandibular block graft success. First, recipient site preparation must be done to allow access for trabecular bone blood vessels and osteogenic cells, which is critical for predictable bone incorporation. Also, platelet release from

damaged blood vessels produces platelet-derived growth factor and transforming growth factor (TGF- β), which accelerate wound healing. Site preparation facilitates intimate adaptation of the graft to its underlying bony bed. Second, two-point fixation of each block is important to prevent microrotation of the graft resulting in incomplete bone incorporation. Low-profile self-tapping screws are recommended. Third, primary closure without tension of the wound site is critical to prevent dehiscence, which is the primary complication of monocortical block grafts. Careful attention to undermining the flap will allow for complete relaxation prior to closure. Prosthesis contact with the ridge is not allowed for the entire duration of healing. Finally, implant placement must follow graft incorporation and should never be done simultaneously. This staging provides predictable bone volume and optimal bone density to be created prior to stage 1 surgery.

The symphysis can provide a range of dense cortical cancellous bone ranging from 4 to 11 mm, in contrast to a typical ramus buccal shelf block graft that is 3 to 4 mm. These grafts can be used for predictable horizontal augmentation of 5 to 7 mm and vertical augmentation of up to and including 6 mm.

Symphysis Block Graft Harvest

A sulcular incision design is preferred for the symphysis block graft harvest as opposed to the more conventional vestibular design. This approach can be safely used if the periodontium is healthy and no crowns are present in the anterior dentition. Also, a highly scalloped thin gingival biotype is contraindicated.

The incision begins in the sulcus from second bicuspid to second bicuspid. An oblique releasing incision is made at the mesial buccal line angle of these teeth and continues into the depth of the buccal vestibule. A full thickness mucoperiosteal flap is reflected to the inferior

border of the mandible. This allows for good visualization of the entire symphysis, including both mental neurovascular bundles. It also provides easy retraction at the inferior border and results in a relatively dry field. Contrast this with the vestibular approach, which results in more limited access, incomplete visualization of the mental neurovascular bundles, and more difficulty in superior and inferior retraction of the flap margins. Also, there is typically bleeding secondary to the mentalis muscle incision resulting in the need for hemostasis. Finally, wound dehiscence from the sulcular approach is rare. The vestibular incision can result in wound dehiscence and scar band formation.

A 702L tapered fissure bur in a straight handpiece is used to penetrate the symphysis cortex via a series of holes that outline the graft. It is important to not encroach within 5 mm of the apices of the incisor and canine teeth as well as the mental neurovascular bundles. Also, the inferior osteotomy is made no closer than 4 mm from the inferior border. All holes are then connected to a depth of at least the full extent of the bur flutes (7 mm). The graft is then harvested using straight and curved osteotomes or modified bone spreaders. The donor site is packed with gauze soaked in either saline or platelet-poor plasma. Closure of the site is done after graft fixation and includes a particulate graft. This graft is not critical to the esthetic outcome; however, grafting of the donor site to allow for a secondary block harvest can be done.

Ramus Buccal Shelf Block Graft Harvest

A full thickness mucoperiosteal incision is made distal to the most posterior tooth in the mandible and continues to the retro-molar pad and ascending ramus. An oblique release incision can be made into the buccinator muscle at the posterior extent of this incision. The incision con-

tinues in the buccal sulcus opposite the first bicuspid where an oblique release is made to the depth of the vestibule. A full thickness mucoperiosteal flap is then reflected to the inferior border allowing for visualization of the external oblique ridge, buccal shelf, lateral ramus and body, and mental neurovascular bundle. The flap is further elevated superiorly from the ascending ramus and includes stripping of the temporalis muscle attachment.

There are three complete osteotomies and one bone groove that need to be prepared prior to graft harvest. A superior osteotomy is created with a 702L fissure bur in a straight handpiece. It begins opposite the mandibular second molar and continues posteriorly to the ascending ramus approximately 4 to 5 mm medial to the external oblique ridge. The length of this osteotomy depends on the graft size. The anterior extent of this bone cut can approach the distal aspect of the first molar, depending on the anterior location of the buccal shelf. A modified channel retractor is used for ideal access to the lateral ramus body area to allow for two vertical bone cuts. The osteotomies begin at each end of the superior bone cut and continue inferiorly approximately 12 mm. All osteotomies just barely penetrate cortical bone. Finally, a no. 8 round bur is used to create a groove connecting the inferior aspect of each vertical osteotomy. The graft is then harvested using modified bone spreaders that are malleted along the superior osteotomy. The graft will fracture along the inferior groove and should be carefully harvested so as to avoid injury to the inferior alveolar neurovascular bundle. The sharp ledge that is created at the superior extent of the ascending ramus is then smoothed with a large round fissure bur. Gauze moistened with either saline or platelet-poor plasma is then packed into the wound site. Closure of the donor site can be done after graft fixation.

Case 1

A healthy 59-year-old white female was referred for implant evaluation. Clinical and radiographic examination revealed a missing right maxillary second bicuspid and all molars (Figure 12-2A). The edentulous space exhibited a deficiency in alveolar height of approximately 4 mm, along with minimal sinus pneumatization precluding the need for sinus grafting (Figure 12-2B and C). The treatment plan included vertical bone augmentation using a right ramus buccal shelf block graft prior to implant placement for a three-unit fixed bridge.

The recipient site was exposed via a full thickness buccal flap reflection (Figure 12-2D). Site preparation included slight decortication and perforation prior to block grafting (Figure 12-2E). A right ramus buccal shelf graft was harvested in the conventional manner (Figure 12-2F–H) and contoured to size (Figure 12-2I and 12-2J). Platelet-rich plasma was then placed on the recipient site prior to block graft fixation (Figure 12-2K and L). Particulate demineralized freeze-dried bone allograft was mortised free superior to the graft (Figure 12-2M), and

additional platelet-rich plasma was placed over the graft complex (Figure 12-2N). Primary closure without tension was accomplished prior to particulate grafting and administration of platelet-rich plasma. A posterior vertical release incision was also made to allow for advancement of the full thickness flap (Figure 12-2O and P). Five months later the site was reentered revealing excellent block incorporation (Figure 12-2Q). Implants were placed in a nonsubmerged mode because of the excellent type 1 quality bone (Figure 12-2R and S).

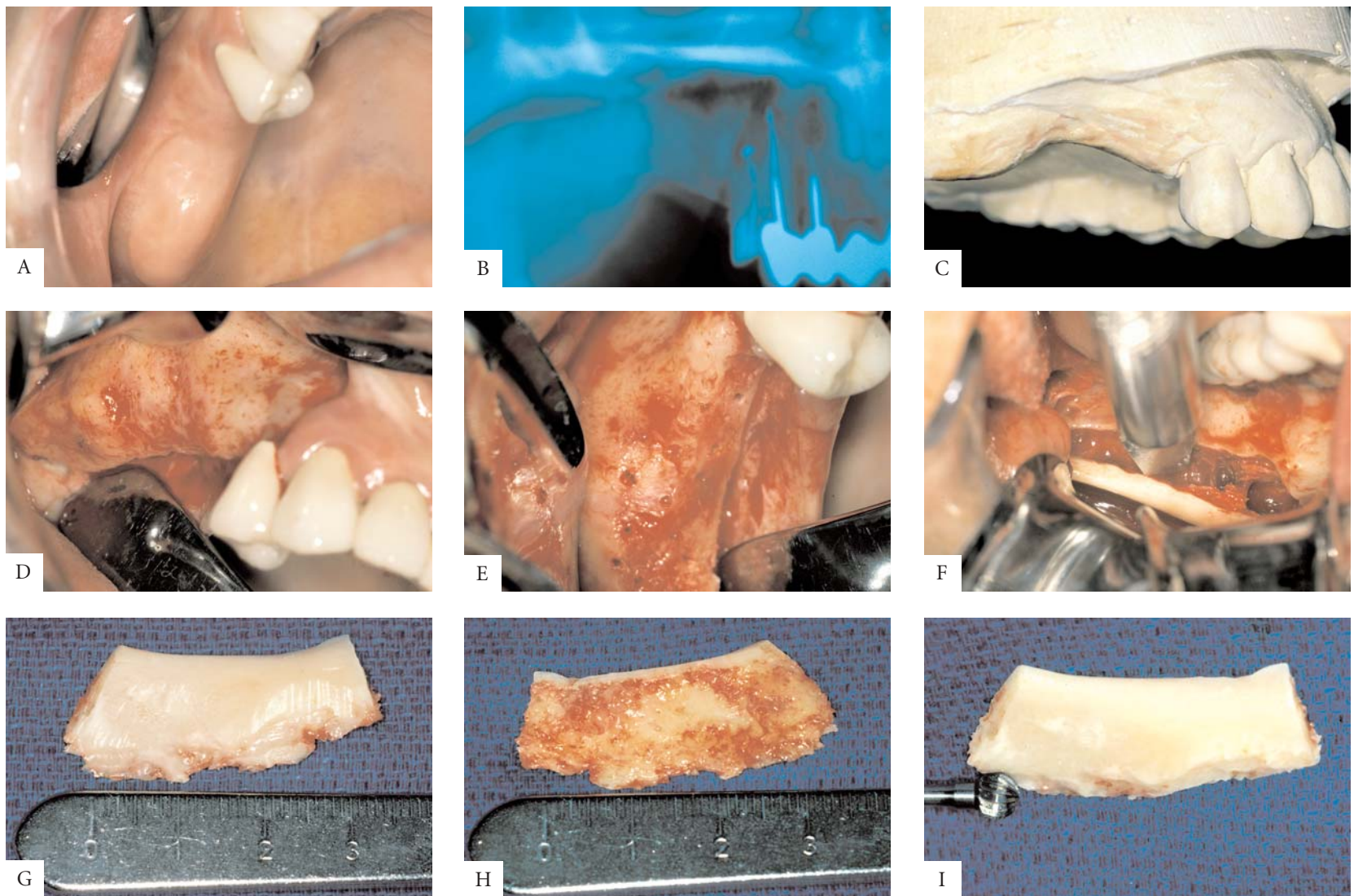


FIGURE 12-2 A, Clinical photograph indicating edentulous right posterior maxilla. B, Radiograph depicting vertical deficiency and minimal sinus pneumatization. C, Model depicting vertical alveolar deficiency. D, Full thickness buccal flap reflection. E, Site preparation including decortication and perforation. F, Right ramus buccal shelf block graft harvest. G, Ramus buccal shelf graft—cortical surface. H, Ramus buccal shelf graft—marrow surface. I, Contouring of block graft. (CONTINUED ON NEXT PAGE)

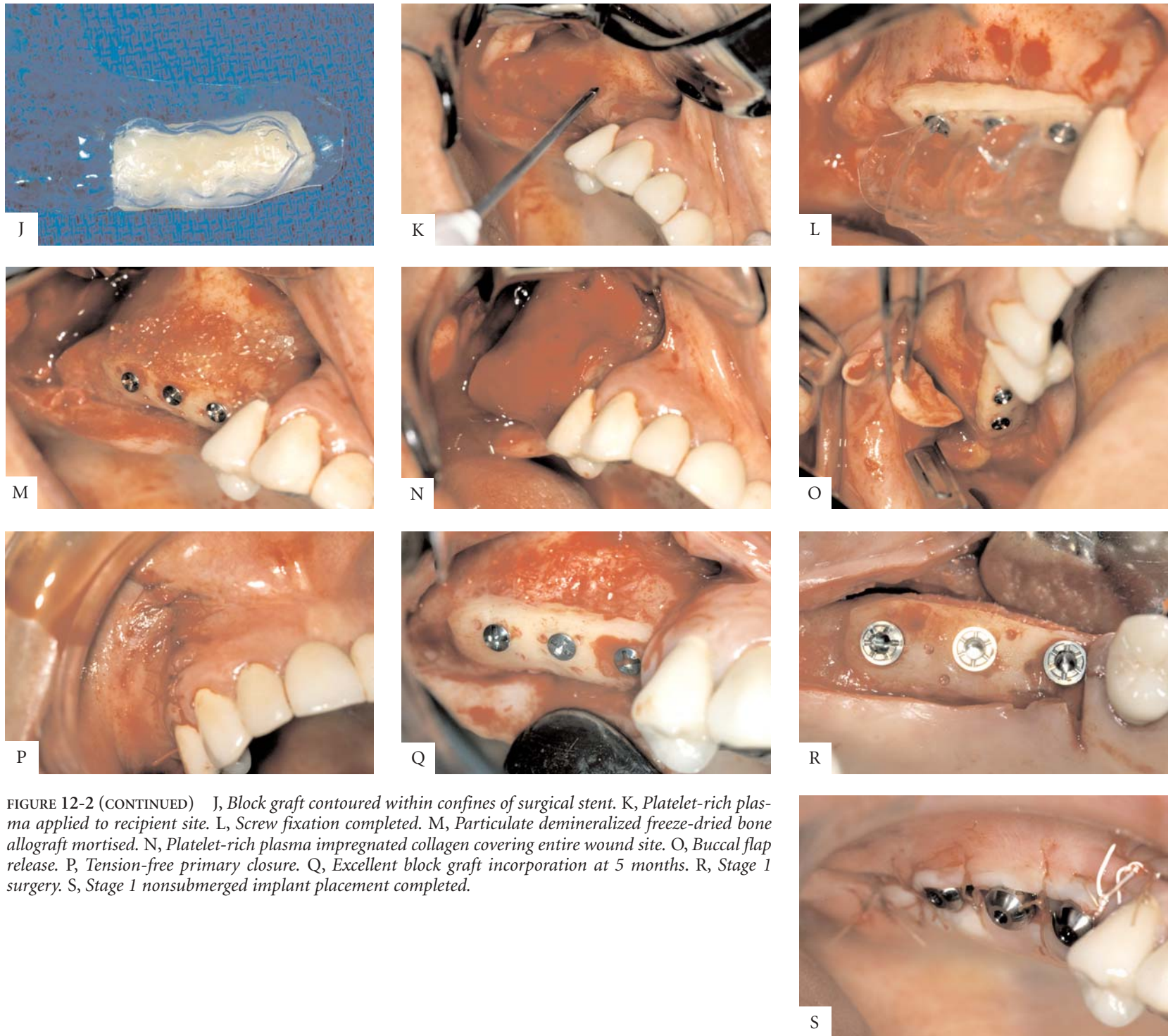


FIGURE 12-2 (CONTINUED) J, Block graft contoured within confines of surgical stent. K, Platelet-rich plasma applied to recipient site. L, Screw fixation completed. M, Particulate demineralized freeze-dried bone allograft mortised. N, Platelet-rich plasma impregnated collagen covering entire wound site. O, Buccal flap release. P, Tension-free primary closure. Q, Excellent block graft incorporation at 5 months. R, Stage 1 surgery. S, Stage 1 nonsubmerged implant placement completed.

Case 2

A healthy 62-year-old white female was referred for implant evaluation. This patient was unhappy with her existing bilateral distal extension partial denture and desired fixed prosthetic work in both edentulous areas (Figure 12-3A and

B). Clinical and radiographic examination revealed missing mandibular molars bilaterally (Figure 12-3A–C). Also noted was a vertical deficiency of more than 5 mm in the right posterior mandible and 4 mm in the left posterior mandible. The treatment

plan included vertical ridge augmentation of the right side with a symphysis graft and of the left side with a right ramus buccal shelf block graft.

The right edentulous site was exposed, appropriate crestal decortication and perforation was done, and a symphysis block

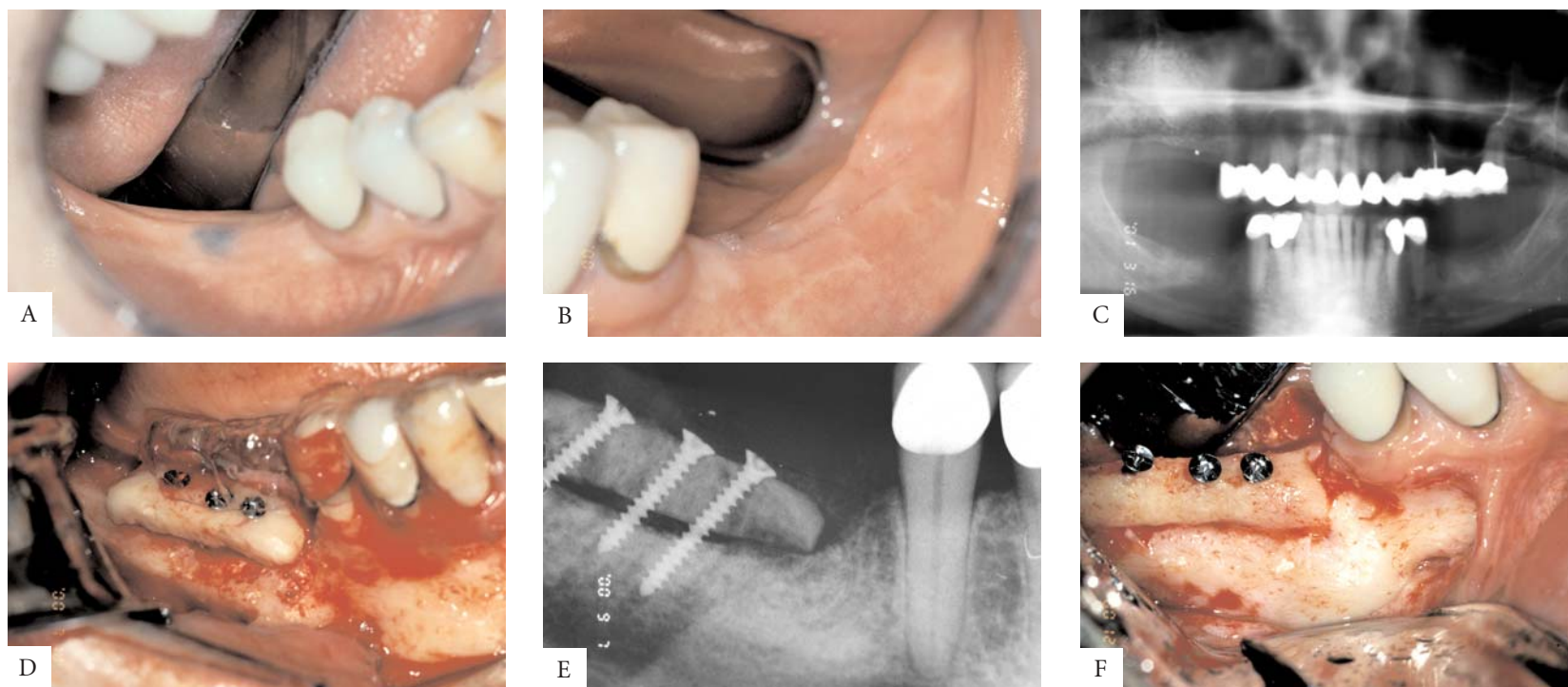


FIGURE 12-3 A, Right posterior edentulous mandible. B, Left posterior edentulous mandible. C, Radiograph indicating bilateral posterior mandibular vertical deficiency. D, Block graft fixation with platelet-rich plasma application. E, Block graft fixation. Note butt joint at anterior recipient donor interface. F, Excellent block graft incorporation at 5 months. (CONTINUED ON NEXT PAGE)

graft was fixated to the crest (Figure 12-3D and E). Platelet-rich plasma was applied to the recipient site prior to graft fixation. Five months later both sites were reentered and revealed no evidence of bone resorption (Figure 12-3F and G). The right side revealed vertical augmentation of 5 mm. Three threaded Spline implants were placed in a nonsubmerged mode because of the excellent type 1 quality bone (Figure 12-3H and I). The left edentulous space was augmented 4 mm with a right ramus buccal shelf block graft in the same fashion and three threaded implants were also placed nonsubmerged (Figure 12-3J–L). Both sites were ultimately grafted with epithelial palatal tissue for enhanced keratinized gingiva (Figure 12-3M and N), and three-unit fixed bridgework was fabricated for each site (Figure 12-3O).

Mandibular block autografts for vertical alveolar ridge augmentation are predictable and offer many advantages. These grafts are primarily cortical in nature, exhibit minimal resorption, and tend to

incorporate exceptionally well with recipient bone in a relatively short time. They also maintain post-implant placement bone volume and retain their radiographic density to the augmented site. Despite the many advantages block grafts offer for alveolar ridge augmentation, there are complications with posterior mandibular autografts when used for horizontal and vertical augmentation. Morbidity with this grafting protocol is associated with both donor and recipient sites. This includes experience with 434 grafts harvested between August 1991 and December 2002: 208 symphysis grafts and 226 ramus buccal shelf grafts.

Symphysis donor site morbidity includes intraoperative complications such as bleeding; mental nerve injury; soft tissue injury of cheeks, lips, and tongue; block graft fracture; and potential bicortical harvest. Bleeding episodes are intrabony and can be taken care of with cautery, local anesthesia, and collagen plugs. Injury to the mental neurovascular

bundle is avoidable with proper surgical technique, especially in the use of the sulcular approach for bone harvest. Block fracture and bicortical block harvest can also be prevented by following good surgical technique. Pain, swelling, and bruising occur as normal postoperative sequelae and are not excessive in nature. Use of platelet-rich plasma has decreased overall soft tissue morbidity. Infection rate is minimal (< 1%). Neurosensory deficits include altered sensation of the lower lip, chin (temporary 19%; permanent < 1%), and dysesthesia of the anterior mandibular dentition (transient 53%; permanent < 1%). No evidence of dehiscence was seen using the sulcular approach.

The ramus buccal shelf harvest can also result in intraoperative complications including bleeding, nerve injury, soft tissue injury, block fracture, and mandible fracture. Intrabony bleeding and soft tissue bleeding can be handled with cautery. Injury to the inferior alveolar neurovascular bundle and the lingual neurovascular

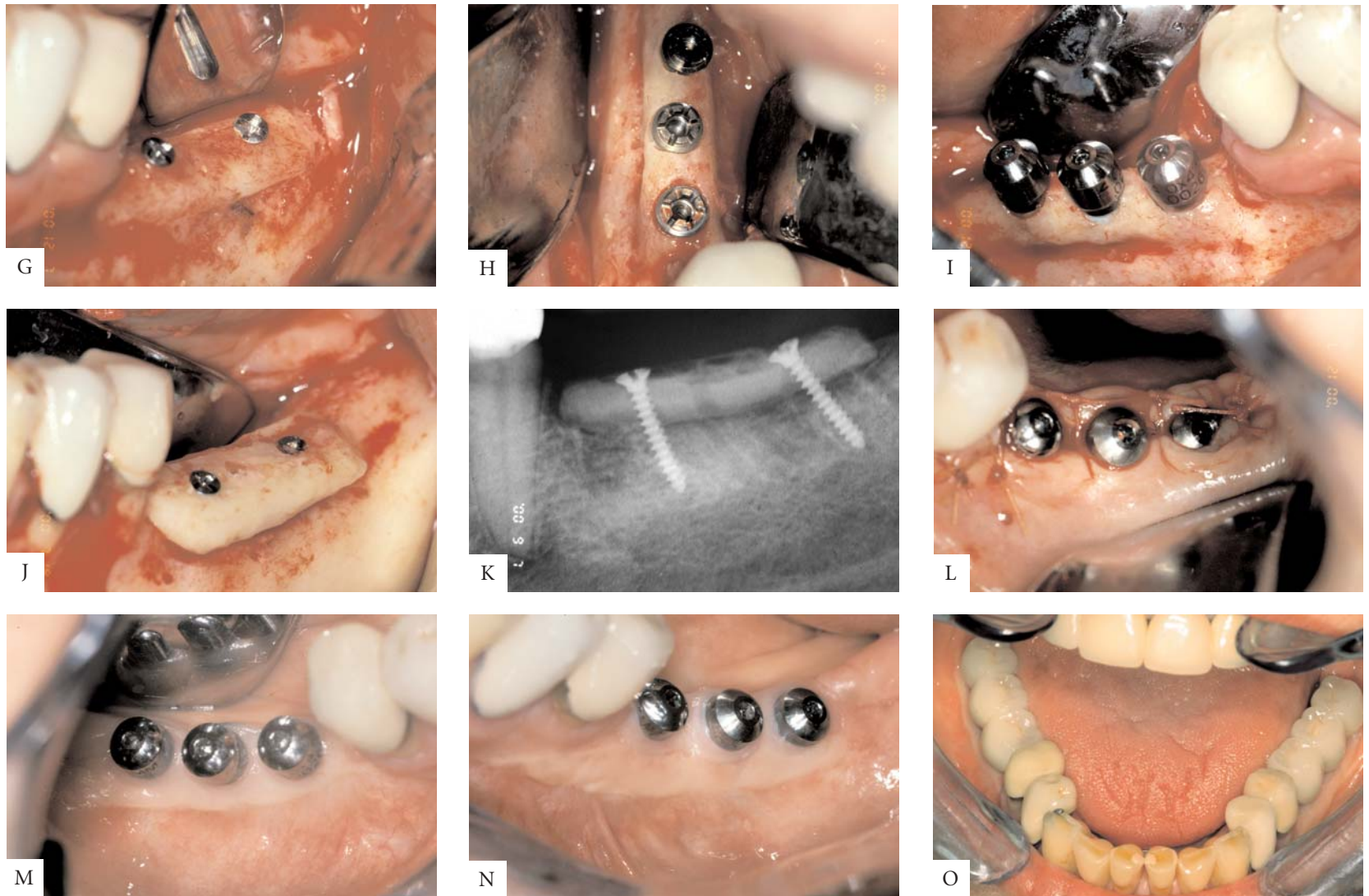


FIGURE 12-3 (CONTINUED) G, Excellent block graft incorporation at 5 months. H, Stage 1 implant surgery. I, Nonsubmerged implant placement. J, Ramus buccal shelf block graft with fixation. K, Radiograph indicating block graft in fixation. L, Completed stage 1 nonsubmerged implant placement. M, N, Completed epithelial palatal graft. O, Completed restorations.

bundle can be avoided with proper soft tissue manipulation and meticulous osteotomy preparation. Block fracture is also an avoidable problem with proper surgical technique. Postoperative morbidity includes trismus (approximately 34%) but is certainly transient and can take up to 2 weeks to resolve. Pain, swelling, and bruising are typically mild to moderate and, again, are minimal with use of platelet-rich plasma. Infection rate is less than 1%. Altered sensation of the lower lip or chin occurs approximately 8% of the time, with less than 1% being permanent. Altered sensation of the lingual nerve has also been reported but has been transient

only. No incidence of altered sensation of mandibular dentition has been found. Infection rate is less than 1%.

Recipient site morbidity includes trismus, bleeding, pain, swelling, bruising, infection, neurosensory deficits, bone resorption, dehiscence, and graft failure. Trismus can be expected, as the surgical protocol for reconstruction of the posterior mandible includes manipulation of the posterior mandibular musculature. Incidence is less than 40% and is transient. Bleeding of the recipient bed is intentional secondary to meticulous site preparation (decortication and perforation), but excessive bleeding, although rare, can occur sec-

ondary to both intrabony and soft tissue vessel transection. Pain, swelling, and bruising are mild to moderate and are minimized with platelet-rich plasma. Infection rate is less than 1% and is usually secondary to graft exposure. Nerve neurosensory deficits can occur secondary to site preparation and block fixation because normal anatomy is violated. Dehiscence and graft failure (approximately 2.5%) are seen secondary to soft tissue closure with tension or prosthesis contact with the graft site. (Strong recommendation: avoid the use of any type of prosthesis secondary to posterior mandibular block graft reconstruction.) Finally, block graft resorption at

stage 1 surgery is minimal (0 to 1.5 mm) but can be excessive if dehiscence of the graft occurs. In summary, overall morbidity of mandibular block autografts for atrophic posterior mandibular reconstruction is minimal. Most complications are preventable. Those that occur can be handled predictably with minimal adverse effects to the patient.

Interpositional Bone Graft

The interpositional bone graft is placed between a mobilized segmental osteotomy and the basal bone. A typical vertical gain is 4 or 5 mm in the maxilla but 5 to 10 mm in the mandible. The indication for the procedure is an alveolar defect where there is insufficient vertical height for placement

of implants such as in the anterior maxilla or in the posterior mandible when a stable vertical augmentation is required, usually over a three- or four-tooth segment.

Figure 12-4A to C illustrates an anterior maxillary defect treated with interpositional grafting. Figure 12-4D shows a posterior mandibular deficiency with 6 mm of bone available above the inferior alveolar nerve. An osteotomy was done (Figure 12-4E) through a vestibular incision to maintain both lingual and crestal blood supply. An interpositional cortical bone graft harvested from the ramus was placed at the osteotomy site, raising the alveolus about 7 mm (Figure 12-4F). The raised segment rotated slightly lingually, but this was compensated for by using a bone plate to

establish both the final vertical height and the crestal axis of the osteotomized segment (Figures 12-4G and H).

Alveolar Distraction Osteogenesis

A deficient alveolus can be distracted to improve vertical dimension for implant placement. Sufficient width (5 mm) and vertical height (8 to 10 mm) of a distraction site are needed in order to ensure sufficient (5×5 mm) bone mass of the segment to be translated.

Figure 12-5A to G illustrates a case where severe atrophy of both soft and hard tissues left a significant alveolar retrognathia and a vertical defect of at least 10 mm (see Figure 12-5A and B). Using a

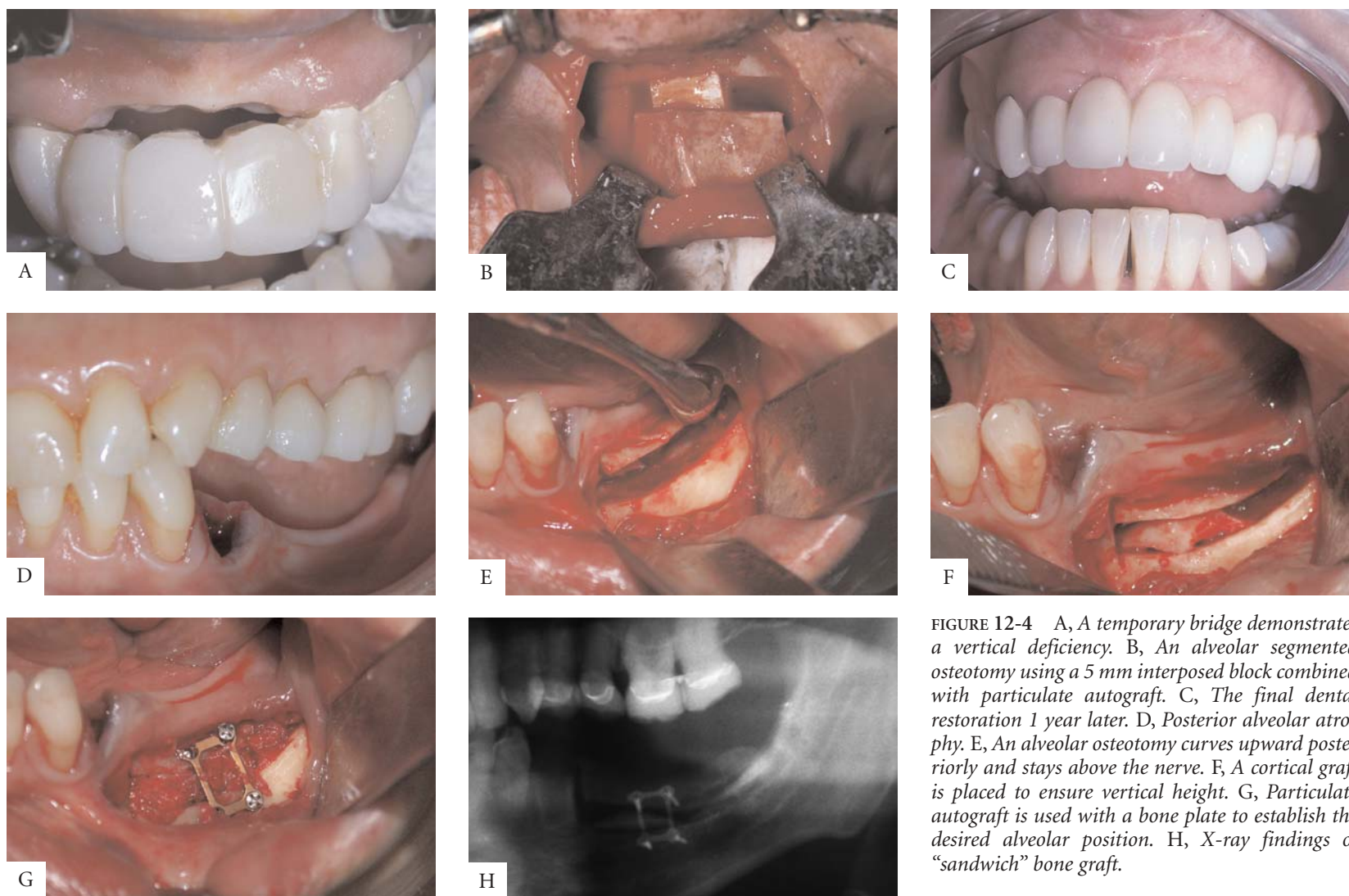


FIGURE 12-4 A, A temporary bridge demonstrates a vertical deficiency. B, An alveolar segmented osteotomy using a 5 mm interposed block combined with particulate autograft. C, The final dental restoration 1 year later. D, Posterior alveolar atrophy. E, An alveolar osteotomy curves upward posteriorly and stays above the nerve. F, A cortical graft is placed to ensure vertical height. G, Particulate autograft is used with a bone plate to establish the desired alveolar position. H, X-ray findings of “sandwich” bone graft.

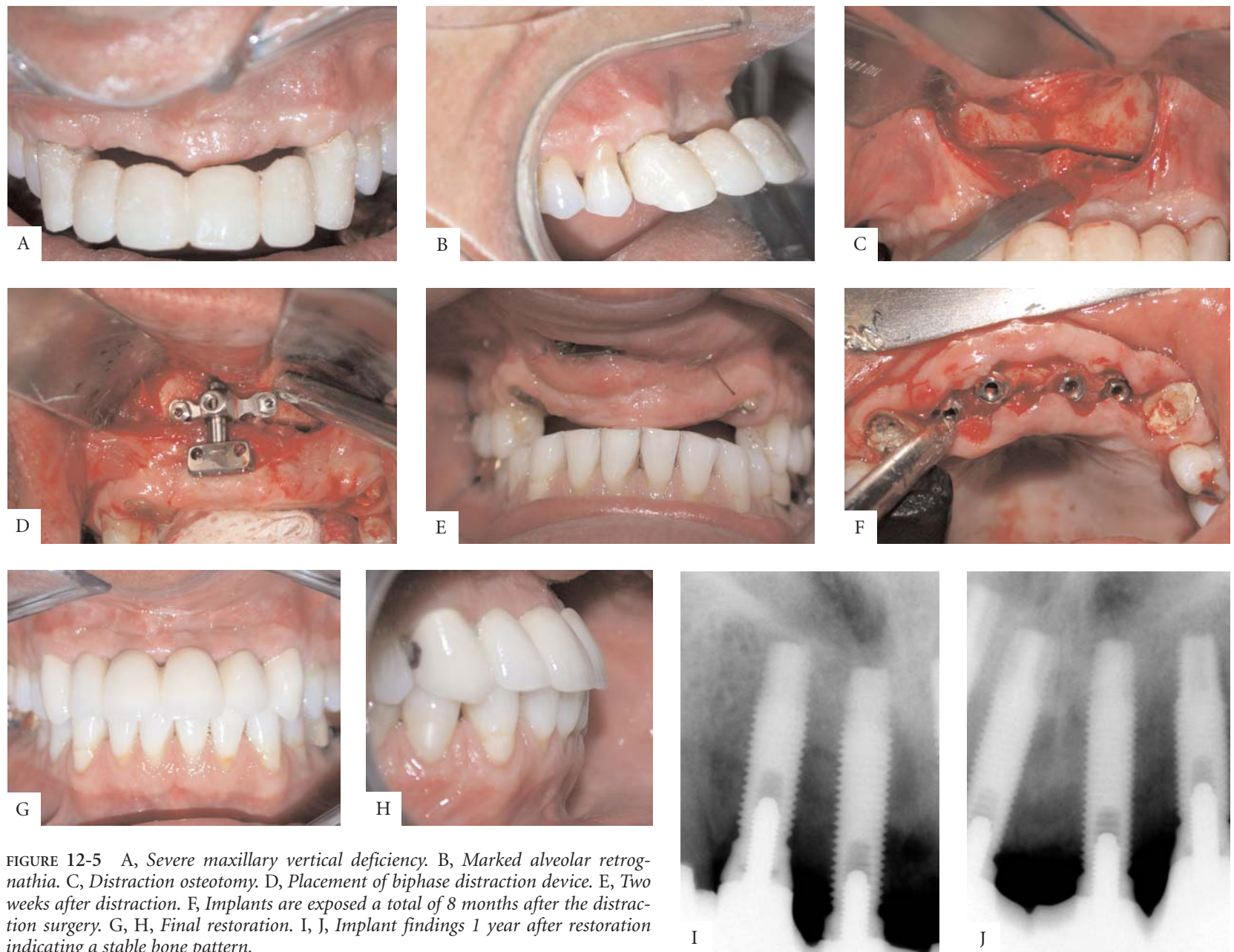


FIGURE 12-5 A, Severe maxillary vertical deficiency. B, Marked alveolar retrognathia. C, Distraction osteotomy. D, Placement of biphasic distraction device. E, Two weeks after distraction. F, Implants are exposed a total of 8 months after the distraction surgery. G, H, Final restoration. I, J, Implant findings 1 year after restoration indicating a stable bone pattern.

vestibular approach, a flared osteotomy was made (see Figure 12-5C). Then a biphasic distractor plate was placed in order to gain vertical and horizontal displacement (see Figure 12-5D). Following a vertical distraction of 12 mm (see Figure 12-5E), horizontal movement was achieved by tightening the nut on the horizontally placed screws for a 5 mm horizontal movement. Four months later, implants were placed (see Figure 12-5F). The final restoration was placed an additional 4 months later. A 1-year postrestorative finding is shown in

Figure 12-5G to J, indicating a stable bone pattern and reasonable esthetic restoration.

Iliac Corticocancellous Grafting

When the jaw is too deficient to do monocortical grafting or osteotomies, bone graft augmentation with iliac corticocancellous graft is needed. Major grafting is usually required when bone mass needs to be expanded in order to gain enough bone for osseointegration.

Figure 12-6A to G shows a patient who had severe maxillary atrophy in

which iliac bone graft was combined with sinus augmentation and Le Fort I advancement. Figure 12-6A shows the preoperative finding of severe bone loss including maxillary retrognathia. A 5 mm maxillary advancement with a Le Fort I osteotomy fixated with resorbable bone plates was done. The anterior reconstruction relied on onlay corticocancellous block graft supported by particulate marrow. Graft preservation strategies such as barrier membrane and titanium mesh may be helpful, but in this case a cortical

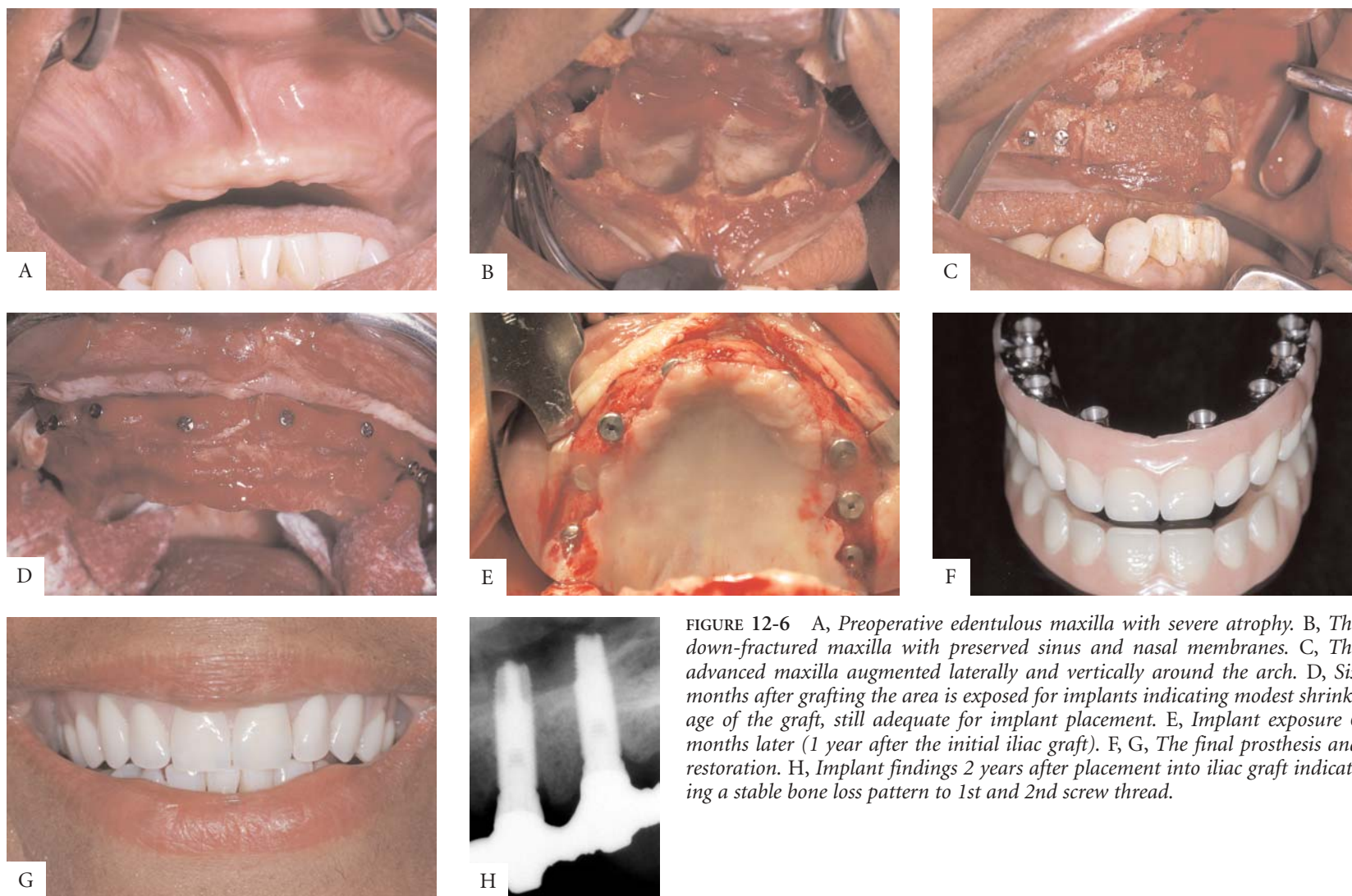


FIGURE 12-6 A, Preoperative edentulous maxilla with severe atrophy. B, The down-fractured maxilla with preserved sinus and nasal membranes. C, The advanced maxilla augmented laterally and vertically around the arch. D, Six months after grafting the area is exposed for implants indicating modest shrinkage of the graft, still adequate for implant placement. E, Implant exposure 6 months later (1 year after the initial iliac graft). F, G, The final prosthesis and restoration. H, Implant findings 2 years after placement into iliac graft indicating a stable bone loss pattern to 1st and 2nd screw thread.

graft was placed laterally, which minimizes the need for a barrier membrane. Figure 12-6B shows the down-fractured maxilla, where both sinus and nasal membranes are elevated and preserved. The advanced maxilla augmented laterally and vertically around the arch is shown in Figure 12-6C. Figure 12-6D shows the augmentation 6 months after grafting just prior to implant placement. Figure 12-6E shows exposure of the implants 6 months after that for a total of 1 year of bone graft consolidation. A final fixed-hybrid restoration is shown in Figure 12-6F and G. Two years after dental restoration bone levels remained stable, but there is some variation in graft consolidation and resorption within the graft (Figure 12-6H). Prosthet-

ic loading (temporary dentures) degraded the final vertical augmentation dimension, but not significantly. Typically, 6 to 8 mm of vertical gain is judged a success in the severely atrophic case.

Sinus Bone Graft

The sinus bone graft is well established as one of the most stable vertical augmentation procedures in the surgeon's armamentarium.

Three techniques are used, including:

1. Sinus intrusion osteotomy
2. Lateral approach sinus membrane elevation
3. Alveolar augmentation combined with sinus elevation (shown above)

The sinus intrusion osteotomy can be done on the day of extraction if the wound is clear of soft tissue and infection. In the case shown in Figure 12-7A, the intrusion was done with a bone graft and implant placement 6 weeks after the dental extraction. At this stage epithelial closure of the wound was present, and a residual infection had resolved. A bone graft was taken from the mandible and intruded into the sinus floor using an osteotome. Bone graft was also placed into defects within the extraction socket. Figure 12-7A to C show the sinus grafting and implant procedure. Figure 12-7D show the final bone graft consolidation 1 year after final restoration.

The lateral sinus graft is done through a Caldwell-Luc approach by elevating the

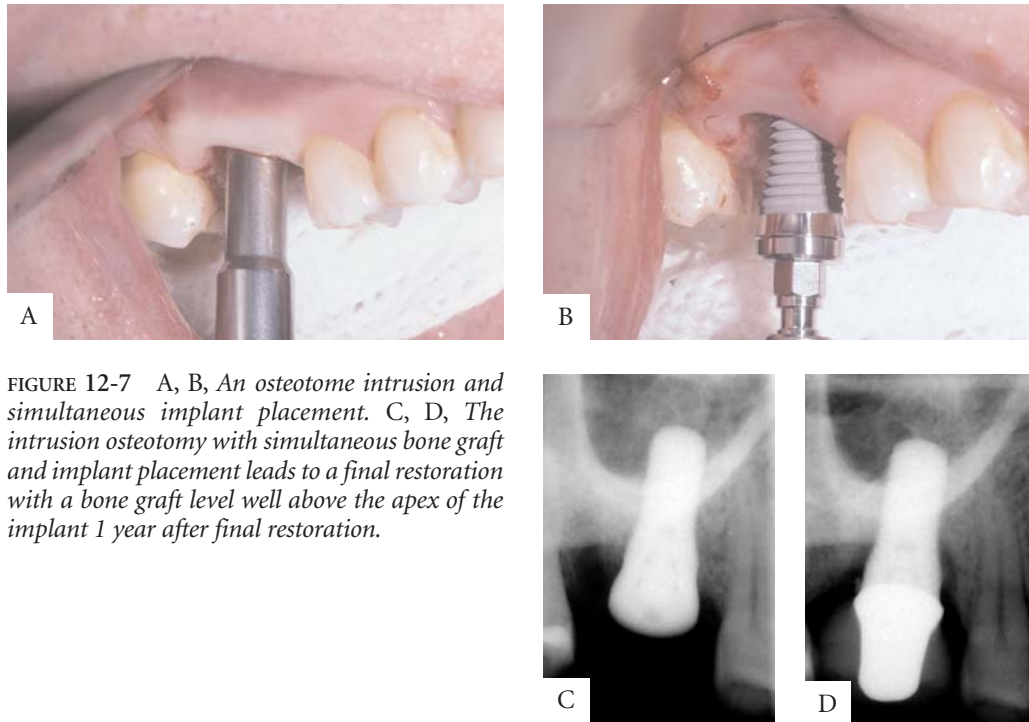


FIGURE 12-7 A, B, An osteotome intrusion and simultaneous implant placement. C, D, The intrusion osteotomy with simultaneous bone graft and implant placement leads to a final restoration with a bone graft level well above the apex of the implant 1 year after final restoration.

sinus membrane in order to preserve a “closed wound.” Bone graft material is packed against the sinus floor, taking care to remove all soft tissue that might be present there. This approach can be used for both simultaneous and delayed implant placement. Barrier membranes are usually not required but benefit over the grafted site if a large “window” is made. Small windows and the use of autogenous bone as graft material generally lead to primary osseous healing of the osteotomy site.

The use of piezoelectric surgery is helpful in avoiding perforation of the membrane. The technique is particularly helpful in areas where a robust thickness of bone is present or when the membrane is extremely thin. The advantage of using this technology is that piezoelectric surgery does not “cut” soft tissue, so sinus membrane perforation is much less likely to occur. Figure 12-8 demonstrates the piezoelectric procedure leading to elevation of the membrane without perforation.

After grafting, the period for consolidation of the bone graft varies with the grafting material used. Allogeneic bone actually slows down the consolidation

process. The use of combination grafts including bovine xenograft, algipore, or various other alloplasts all form bone adequate for osseointegration.¹⁸

Though bone quality varies considerably as shown by human trephine biopsy

results of the various grafting materials, the capabilities of the sinus graft to gain enough bone to form load-bearing osseointegration are remarkable. The 5-year failure rate of implants by almost any grafting technique is less than 20%.^{19,20}

Though grafting material must be osseoconductive, inductivity is not required in order for bone to form. The sinus floor grows bone with blood clot alone. Whatever the technique, bone migrates “endosteally” up the side of the implant. If only a few millimeters of migration occurs, in addition to the residual bone, there is often enough gain to form and maintain osseointegration. Therefore, the principal success of the sinus grafting is not one of implant macro- or microarchitecture or even the type of graft material, be it alloplast, allograft, or autograft, but the intrinsic bone-forming capacity of the sinus floor itself and to a lesser degree the investing sinus membrane.²¹

In cases of severe atrophy the surgeon must make every effort to use the best available technique and bone graft material

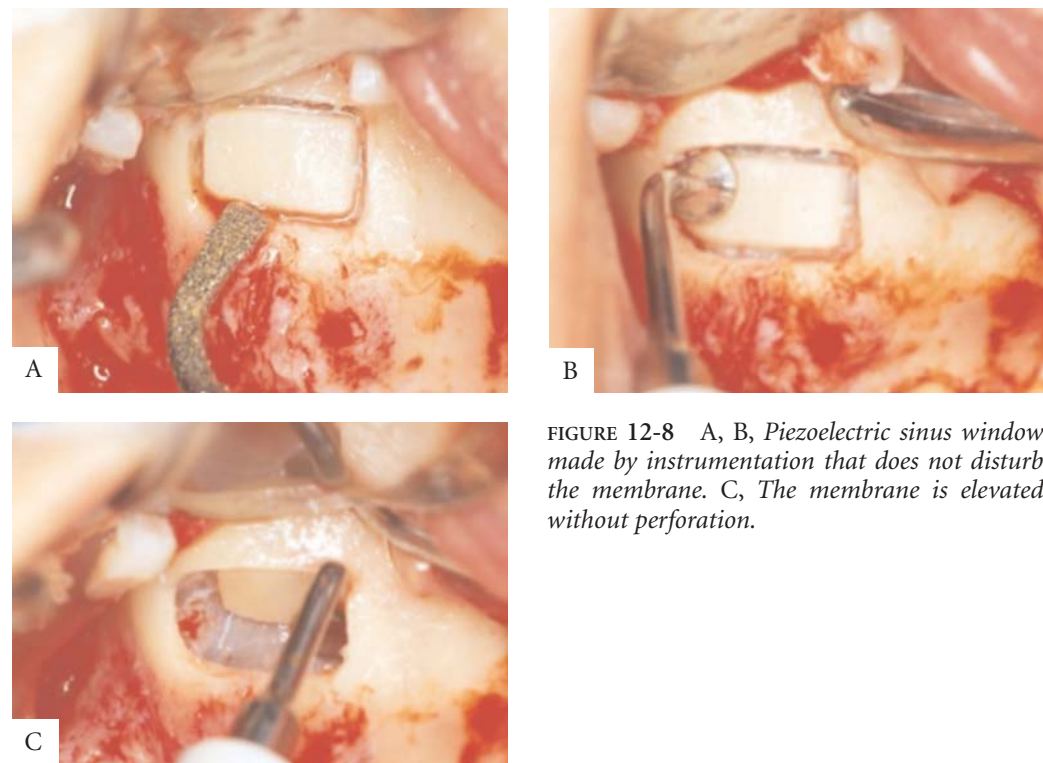


FIGURE 12-8 A, B, Piezoelectric sinus window made by instrumentation that does not disturb the membrane. C, The membrane is elevated without perforation.

possible in a highly compromised site. This setting argues for the use of particulate bone marrow harvested from the tibia or ilium and possibly adjuncts such as platelet-rich plasma.

Summary

The difficulty of treating alveolar vertical defects requires the surgeon to be skilled in all of the above modalities. In skilled hands, various approaches can be used in treating the same type of defect.

In most cases defect sites are not strictly vertically deficient. Skill in alveolar width augmentation, or combined treatment, is needed as well. With all of these measures, the ultimate restorative goal is to obtain orthoalveolar form, a concept that now encompasses a broad array of surgical innovation.

References

1. Davis WH, Delo RI, Ward B, et al. Long term ridge augmentation with rib graft. *J Maxillofac Surg* 1975;3:103–6.
2. Baker RD, Terry BC, Connole PW. Long term results of alveolar ridge augmentation. *J Oral Surg* 1979; 37:486–91.
3. Keller EE. The maxillary interpositional composite graft. In: Worthington P, Branemark P-I, editors. *Advanced osseointegration surgery: application in the maxillofacial region*. Chicago: Quintessence; 1992. p. 162–74.
4. Ayers R, Simska S, Nunes C, Wolford L. Long-term bone ingrowth and residual microhardness of porous block hydroxyapatite implants in humans. *J Oral Maxillofac Surg* 1998;56:1297–301.
5. Tinti C, Parma-Benefenati S. Vertical ridge augmentation: surgical protocol and retrospective evaluation of 48 consecutively inserted implants. *Int J Periodontics Restorative Dent* 1998;18:434–43.
6. Nystrom E, Kahnberg K-E, Gunne J. Bone grafts and Branemark implants in the treatment of the severely resorbed maxilla: a two year longitudinal study. *Int J Oral Maxillofac Implants* 1993;8:45–53.
7. Jensen OT, Shulman L, Block M, Iacono V. Report of the sinus consensus conference of 1996. *Int J Oral Maxillofac Implants* 1998;13 Suppl:11–45.
8. Misch CM, Misch CE, Resnik R, et al. Reconstruction of maxillary alveolar defects with mandibular symphysis grafts for dental implants: a preliminary procedural report. *Int J Oral Maxillofac Implants* 1992;7:360–6.
9. Misch CM. Comparison of intraoral donor sites for onlay grafting prior to implant placement. *Int J Oral Maxillofac Implants* 1997;12:767–76.
10. Sindet-Pedersen S, Enemark H. Reconstruction of alveolar clefts with mandibular or iliac crest bone grafts: a comparative study. *J Oral Maxillofac Surg* 1990;48:554–8.
11. Pikos MA. Buccolingual expansion of the maxillary ridge. *Dent Implantol Update* 1992; 3:85–7.
12. Pikos MA. Facilitating implant placement with chin grafts as donor sites for maxillary bone augmentation: part I. *Dent Implantol Update* 1995;6:89–92.
13. Pikos MA. Facilitating implant placement with chin grafts as donor sites for maxillary bone augmentation: part II. *Dent Implantol Update* 1996;7:1–4.
14. Pikos MA. Alveolar ridge augmentation with ramus buccal shelf autografts and impacted third molar removal. *Dent Implantol Update* 1999;4:27–31.
15. Pikos MA. Block autografts for localized ridge augmentation: part I. The posterior maxilla. *Implant Dent* 1999;8:279–84.
16. Pikos MA. Block autografts for localized ridge augmentation: part II. The posterior mandible. *Implant Dent* 2000;9:67–75.
17. Bidez MW, Misch CE. Force transfer in implant dentistry: basic concepts and principles. *Oral Implantol* 1992;18:264–74.
18. Kummer BKF. Biomechanics of bone: mechanical properties, functional structure, functional adaptation. In: Fung YC, Perrone H, Anliker M. *Biomechanics: foundations and objectives*. Englewood Cliffs (NJ): Prentice-Hall; 1972. p 273.
19. Jensen OT, Greer R. Immediate placement of osseointegrating implants into the maxillary sinus augmented with mineralized cancellous allograft and Gore-Tex: second-stage surgical and histological findings. In: Laney WR, Tolman DE, editors. *Tissue integration in oral, orthopedic, and maxillofacial reconstruction*. Chicago: Quintessence; 1992. p 321–33.
20. Jensen OT, Ueda M, Laster Z, et al. Alveolar distraction osteogenesis. *Select Readings Oral Maxillofac Surg* 2002;10:1–40.
21. Jensen OT, Sennerby L. Histologic analysis of clinically retrieved titanium microimplants placed in conjunction with maxillary sinus floor augmentation. *Int J Oral Maxillofac Implants* 1998;13:513–21.

The Zygoma Implant

Sterling R. Schow, DMD

Stephen M. Parel, DDS

Severely resorbed edentulous maxillae present very complex problems for the surgeon and restorative dentist.¹ Lack of internal osseous stimulation and nonphysiologic crestal bone loading results in continued resorption of an already atrophic edentulous maxilla. The end result is an inability to use a conventional full denture prosthesis.

In 1999 Dr. Per-Ingvar Brånemark and colleagues introduced the zygoma implant (P-I Brånemark, personal communication, 1999). In their initial study over a 10-year period, 110 implants were placed. Each patient had an additional two to four conventional implants placed in the anterior maxilla, which was restored with cross arch stabilization. Of the zygoma fixtures placed and restored in the initial study, only two were lost in the first year of occlusal loading, and three failed in the subsequent 8 years for a long-term success rate of > 95%.

The availability of the zygoma implant has provided a viable alternative for treatment of patients with extreme resorption of the edentulous maxilla or large pneumatized maxillary sinuses.^{1,2} Before the introduction of this fixture, implant-supported or -retained fixed or removable prostheses in the atrophic maxilla could only be considered after extensive ridge preparation. This preparation usually included major autologous bone grafting, prolonged treatment times, long-term

inability to wear any prosthesis, and a higher failure rate for conventional implants placed in large bone grafts.

Zygoma Implant

The zygoma implant is an extended-length (30–52.5 mm) machined titanium fixture that is placed through the crestal (slightly palatal) aspect of the resorbed posterior maxilla transantrally into the compact bone of the zygoma. In addition to two to four conventional fixtures in the anterior maxilla, initial stability of this elongated fixture is assured by its contact with four osseous cortices (Figure 13-1)^{3–5}:

1. At the ridge crest
2. The sinus floor
3. The roof of the maxillary sinus
4. The superior border of the zygoma

The zygoma implant provides posterior maxillary anchorage when the existing osseous structures do not allow standard implant placement. The alternative in this situation includes bone graft augmentation (sinus lifts and onlay grafts) with their attendant costs, discomfort, prolonged treatment times, and higher complication rates. The zygoma fixture is suggested in the following circumstances:

- When full maxillary edentulism is accompanied by advanced posterior resorption that would otherwise require grafting. At least two and

preferably four anterior standard implants are needed in combination with bilateral zygoma implants.

- In partial or incomplete maxillectomy patients when additional implants can be placed in other sites such as the

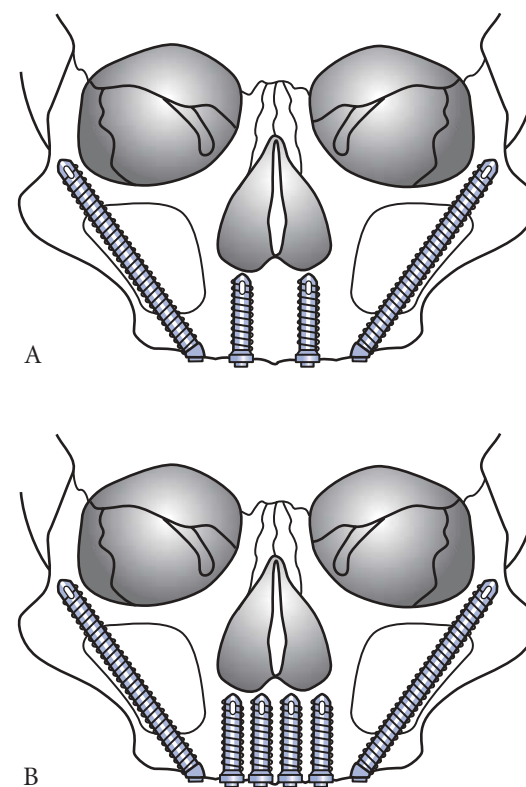


FIGURE 13-1 A, Schematic representation of minimal recommended zygoma and standard implant fixtures for restoration with cross-arch stabilization and fixed restoration. B, Schematic representation of ideal zygoma and standard implant fixtures for restoration with cross-arch stabilization and fixed restoration.

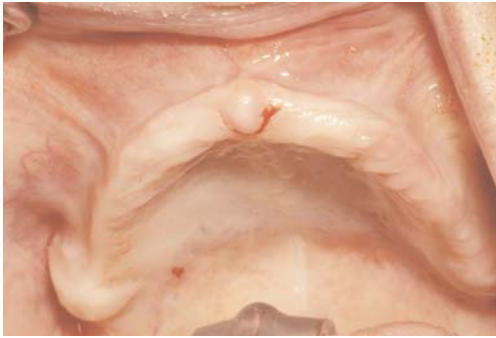


FIGURE 13-2 Most edentulous maxilla patients with a history of denture use will have some degree of moderate atrophy as depicted here. Grafting procedures for augmenting existing bone levels is a commonly recommended therapy for patients with this level of bone loss.

piriform sinus, orbital rims, palatal shelves, or pterygoid plates to support cross-arch stabilization.

Indications

While the zygoma implant is most often used in cases of moderate to severe atrophy, it can be considered a valuable procedure for any patient in need of posterior maxillary implant support with or without significant atrophy. The ability to avoid grafting in many patients, along with the continuous use of an interim maxillary prosthesis also makes the zygoma implant approach appealing as a treatment option.

Moderate Atrophy

The majority of patients who present with a medium- to long-term history of denture wear will have a moderate degree of atrophy (Figures 13-2 and 13-3). This category of denture experience constitutes the majority of patients who seek implant therapy to reverse the effects of continuing bone loss and prosthesis instability. Many will be candidates for grafting procedures, such as sinus augmentation or block onlay techniques, as a means of creating additional osseous structure to allow enough implant sites for predictable support. The ability to avoid such grafting is one of the principal benefits of considering the zygoma implant alternative (Figure 13-4).

Severe Atrophy

Although most of these patients will essentially be graft candidates, there are some who, because of history or physical circumstances, cannot or will not undergo these procedures. A history of consistent graft failure or a systemic compromise that contraindicates grafting are examples of mitigating factors that may require considering an alternative approach such as use of the zygoma implant (Figure 13-5A–D). Experience to date with these patients is not extensive, but early indications of implant survival are seen as encouraging, even with the most severely compromised maxillae (Figures 13-5E and 13-6).

Prosthesis design for the severely atrophic maxilla with implant support may be influenced by the relative size disparity between the two jaws. Most such atrophy results in an undersized maxilla relative to the corresponding mandible, even in cases where both arches are equally resorbed. Cantilever considerations and implant stress distribution may mandate the use of an overdenture prosthesis rather than a fixed restoration in order to manage occlusal alignment and lateral spacing (Figure 13-7).

Inadequate Posterior Support

Occasionally patients will present with adequate bone for anterior or premaxil-

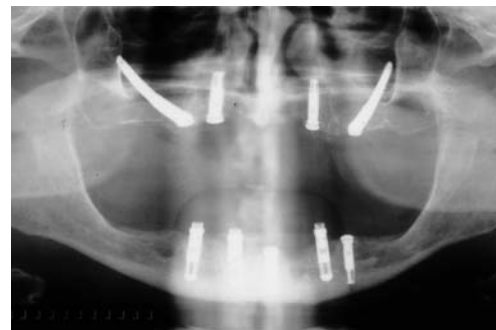

FIGURE 13-3 Posterior bone volumes are inadequate for conventional fixture placement, making this patient a candidate for grafting. This prospect was eliminated by the use of zygoma implants. Stable anterior implants are also required to complete the cross-arch effect.

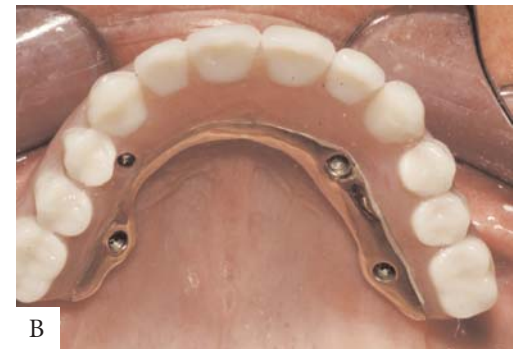
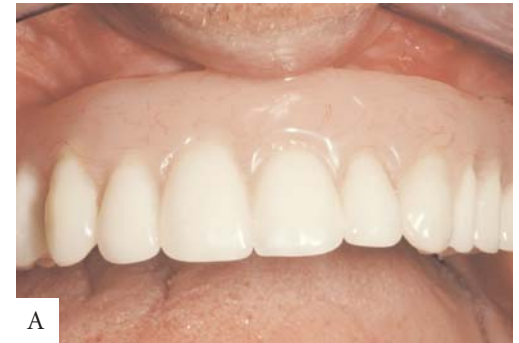
FIGURE 13-4 A, The completed fixed partial denture, facial view. B, Occlusal view illustrating the cantilever dimensions and screw retention sites.

lary implants but have sinus extensions that eliminate the potential for posterior implants without augmentation (Figure 13-8). If such grafting is indicated but countermanded by patient request or health considerations, the zygoma approach can be equally effective.

Syndrome Patients

Another less frequent indication for the zygoma approach can present in patients with various anodontias from syndromes such as cleidocranial dysostosis or ectodermal dysplasia. Radiographs may show either impacted and unerupted teeth or missing dentition, resulting in growth patterns of the maxilla that are disrupted and minimized (Figures 13-9 and 13-10). These individuals often present with insufficient bone for adequate numbers of implants and can be difficult to graft because of space or soft tissue limitations. Zygoma implants can be valuable in these instances when combined with conventional fixtures to provide the basis for

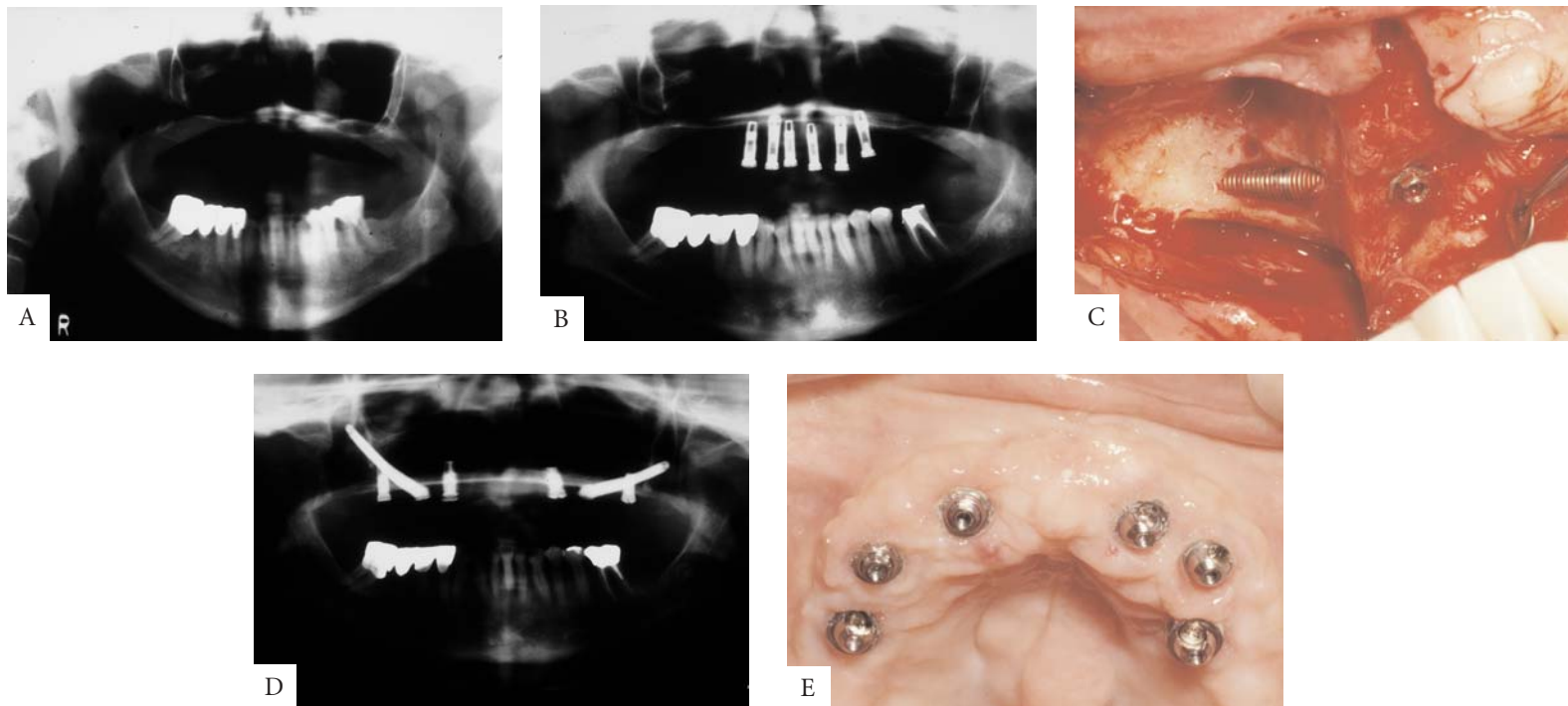


FIGURE 13-5 A, Severe maxillary atrophy is demonstrated on this survey film. The patient had a history of several failed onlay bone graft procedures. B, At one point, these implants were placed in graft and native bone. All failed, with a resultant destruction of functional support bone. C, Maxillary dimensions from continuous lateral atrophy resulted in a residual anatomy that did not require sinus invasion for implant placement. Even though this is unusual, it did not affect the structural integrity of the implants. D, Implants were placed on either side of the two zygoma fixtures for stability. E, All implants were successfully integrated and were positionally suitable for prosthesis construction.

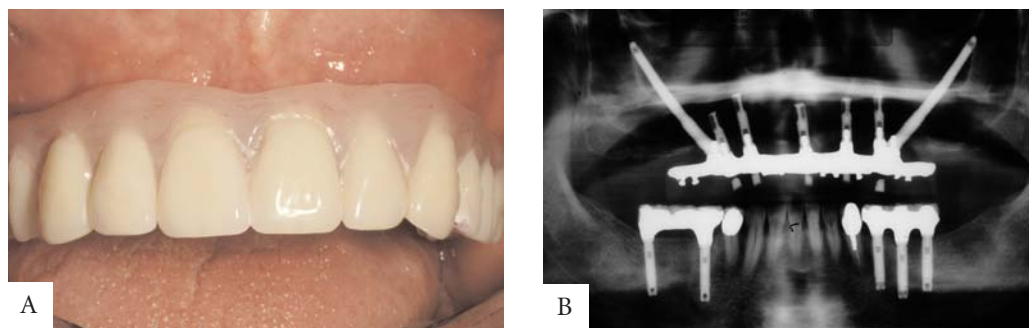


FIGURE 13-6 A, A definitive restoration has been functioning for over 5 years with no evidence of significant implant challenge. B, Radiographically, the 5-year follow-up shows normal bone response.

long-term prosthetic support at a relatively early age (Figures 13-11 and 13-12).

Acquired and Congenital Defects

Maxillary defects created by secondary intervention, such as tumor removal or by trauma, can often be treated with zygoma implant therapy to provide retention for an obturating prosthesis (Figures 13-13). Similarly, congenital defects such as an unrepaired adult cleft palate (which are

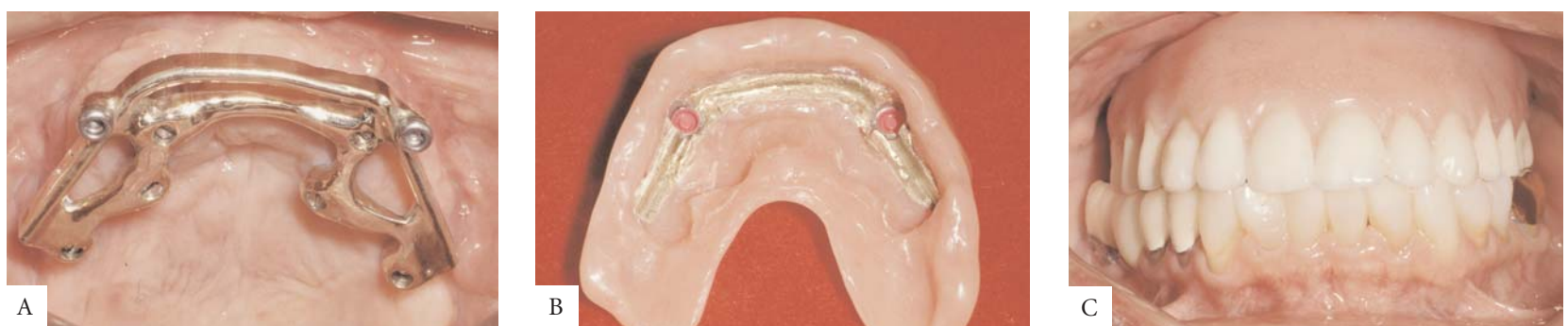

FIGURE 13-7 A, An overdenture bar splint was constructed with lateral extensions to keep the retentive elements aligned with the occluding surfaces. B, The undersurface of the overdenture illustrates the mechanical retention provided. C, Frontal view of the finished prosthesis.

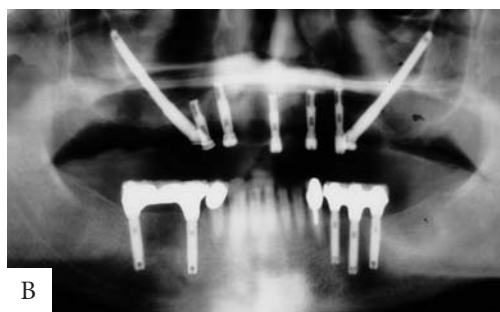
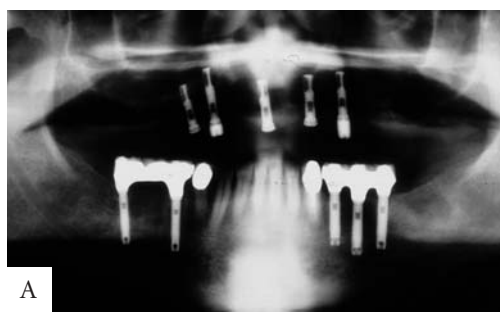


FIGURE 13-8 A, This patient initially presented with good bone and five anterior implants, which had not been loaded, opposing an intact restored lower dentition. His physical stature presented the possibility of heavy loading potential to the upper arch, and grafts were recommended posteriorly for additional implant placement. B, The patient refused grafting, so 52 mm zygoma implants were placed bilaterally to provide the necessary support posteriorly.

increasingly rare owing to early surgical closure) can often be treated with conventional implants in combination with zygoma fixtures to support a removable prosthetic appliance. Situations such as these are rarely the same because of the wide variations in residual soft tissue and bone anatomy, and each case will require careful individual planning to assess the potential

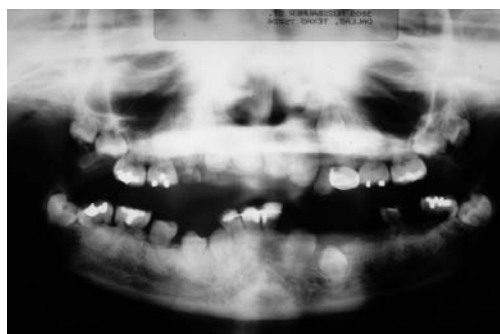

FIGURE 13-9 This ectodermal dysplasia patient presents with partial anodontia and associated findings typical of this syndrome.

for implant placement or zygoma use. For many, however, the ability to use remote bone anchorage with implants around the defect periphery can create excellent supplemental retentive possibilities for these often large and otherwise poorly supported prosthetic devices.

Immediate Loading

Literature citations supporting the possibility of immediate loading of maxillary implants increasingly support this concept.⁶⁻⁹ The criteria for attempting this approach are generally the same as for immediate loading anywhere in the oral cavity: adequate initial stability, good bone receptor sites, and initial cross-arch splinting with rigid materials (Figure 13-14A and B). In situations where these criteria can be met, the survival prospects for both conventional and zygoma fixtures appear to be equivalent to the rates attained with the delayed approach. The benefits in patient comfort, convenience, and enhanced function make this a desirable option in appropriately selected cases (Figure 13-14C-F).

Partial Edentulism

The original concept of the zygoma implant, used with anterior implants and cross-arch stabilization, would theoretically not have application for posterior maxillary partial edentulism (Figure 13-15A). In practice, however, there is potential for using the zygoma implant through the

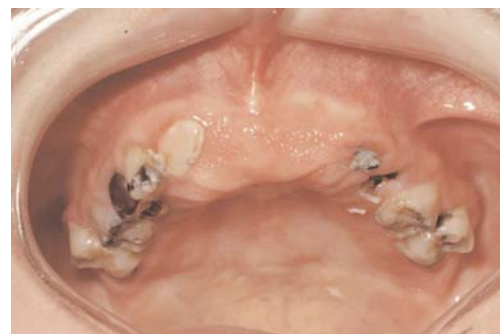

FIGURE 13-10 The effects of long-term overdenture use without adequate caries control are evident intraorally.

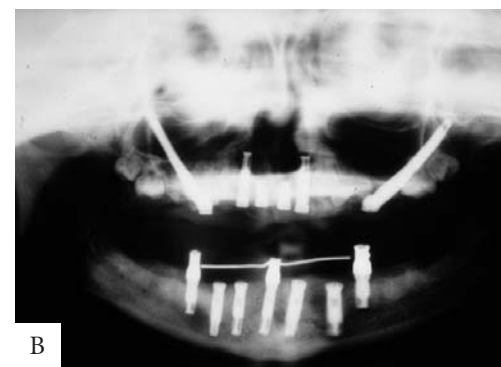
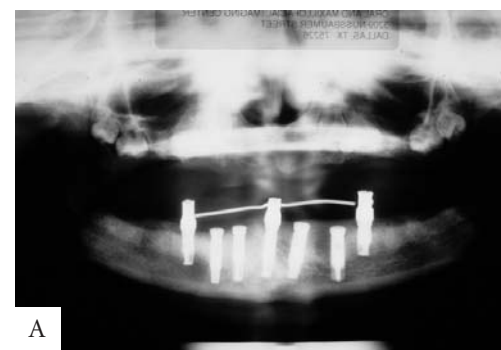

FIGURE 13-11 A, The arches were treated with a staged approach, which included mandibular extractions, implant placement, and immediate loading of several fixtures. The maxilla was debrided at the same time, with no implant placement. Tooth bud removal was incomplete. B, Eventual maxillary implant placement after healing included zygoma fixtures bilaterally in lieu of grafting procedures.

sinus, with additional fixtures on either side, to support a fixed partial denture (Figure 13-15B-E). This approach has not been thoroughly investigated, and clinical trials do not provide enough longevity to make a definitive statement regarding the efficacy of this technique. Being able to gain strong intermediate support through sinus areas that would otherwise have to be grafted does have enough merit, however, to warrant further investigation.

Contraindications

Other than the most obvious contraindications, such as systemic compromise or sinus disease, there are only two specific situations that would complicate the use of the zygoma implant or make it unnecessary. First, where adequate maxillary bone exists for implant placement in numbers

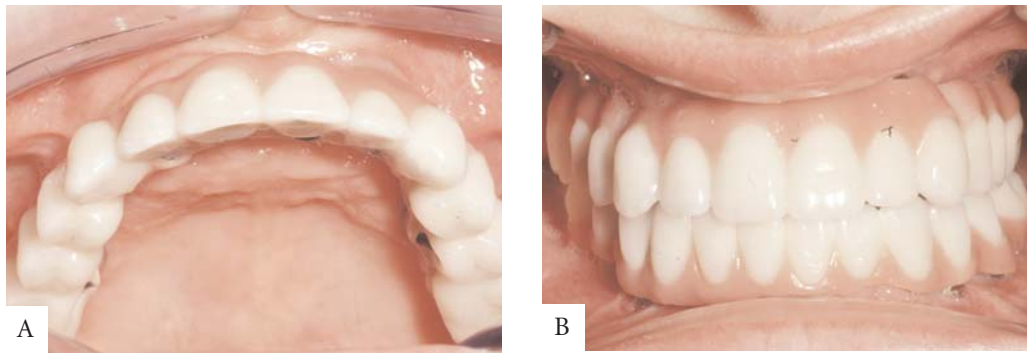


FIGURE 13-12 Both constructions used porcelain-fused-to-metal technology. A, The completed maxillary fixed partial denture. B, Frontal view of both restorations in occlusion.

and positions to support a prosthetic appliance, the zygoma implant is not needed. The second situation is where there is not enough premaxillary support for at least two stable implants with good potential longevity. Differential diagnosis, in

fact, often depends more on the volume and condition of anterior bone than existing posterior anatomy to determine whether some edentulous patients may be candidates for this procedure. In such instances, bone-grafting procedures should

be considered preprosthetically, to create an adequate osseous base for effective cross-arch stabilization.

Complications

The most significant complication to zygoma implant therapy is the loss of the implant (Figures 13-16A–C). Our experience to date indicates this is a relatively infrequent occurrence, but the impact on the original treatment plan is significant. Without this support element, posterior anchorage may be severely compromised and cantilever extensions to the first molar region may overstress the remaining components. Correcting the resultant imbalance using a zygoma approach will require a healing period for bone regeneration in the original site and eventual

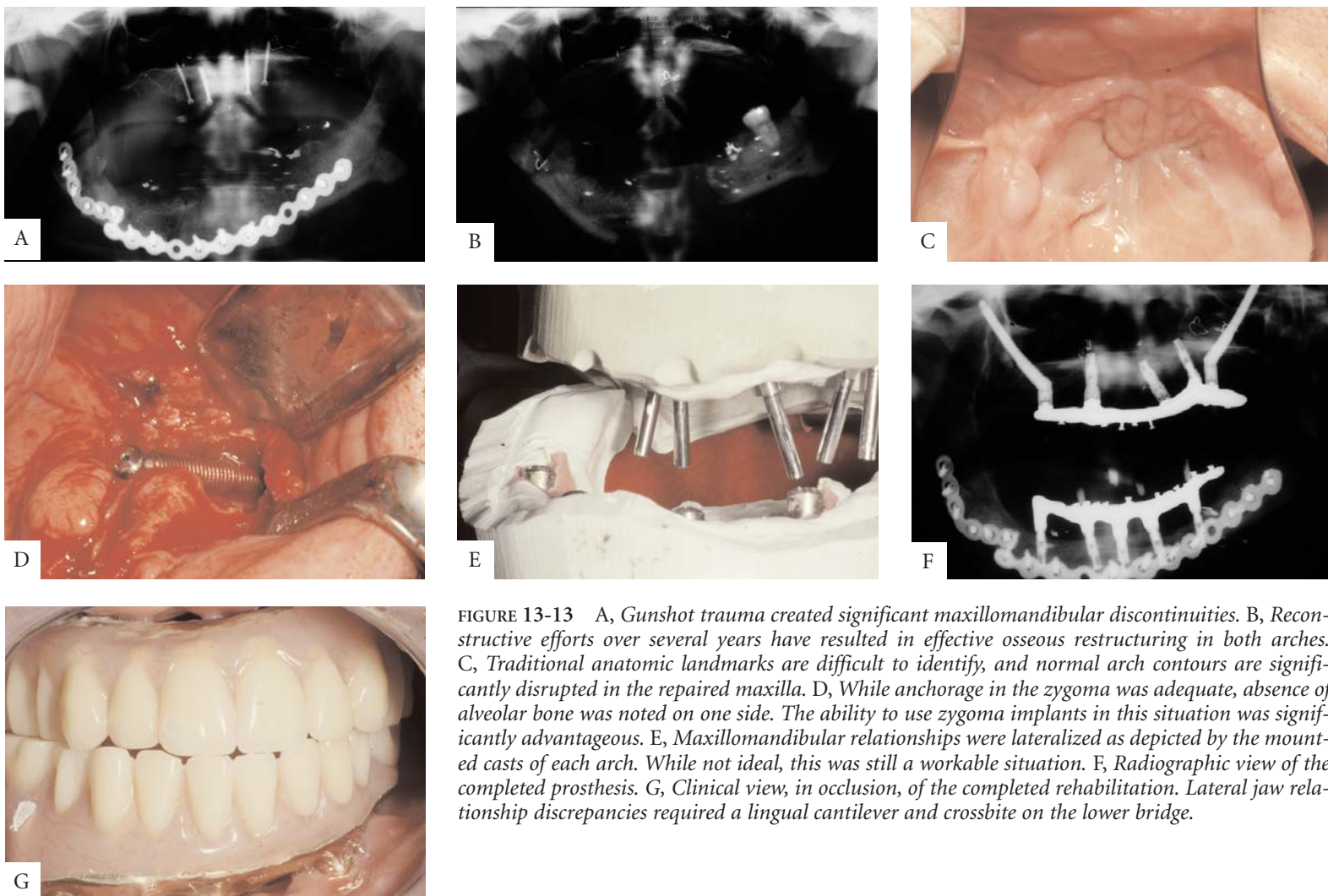


FIGURE 13-13 A, Gunshot trauma created significant maxillomandibular discontinuities. B, Reconstructive efforts over several years have resulted in effective osseous restructuring in both arches. C, Traditional anatomic landmarks are difficult to identify, and normal arch contours are significantly disrupted in the repaired maxilla. D, While anchorage in the zygoma was adequate, absence of alveolar bone was noted on one side. The ability to use zygoma implants in this situation was significantly advantageous. E, Maxillomandibular relationships were lateralized as depicted by the mounted casts of each arch. While not ideal, this was still a workable situation. F, Radiographic view of the completed prosthesis. G, Clinical view, in occlusion, of the completed rehabilitation. Lateral jaw relationship discrepancies required a lingual cantilever and crossbite on the lower bridge.

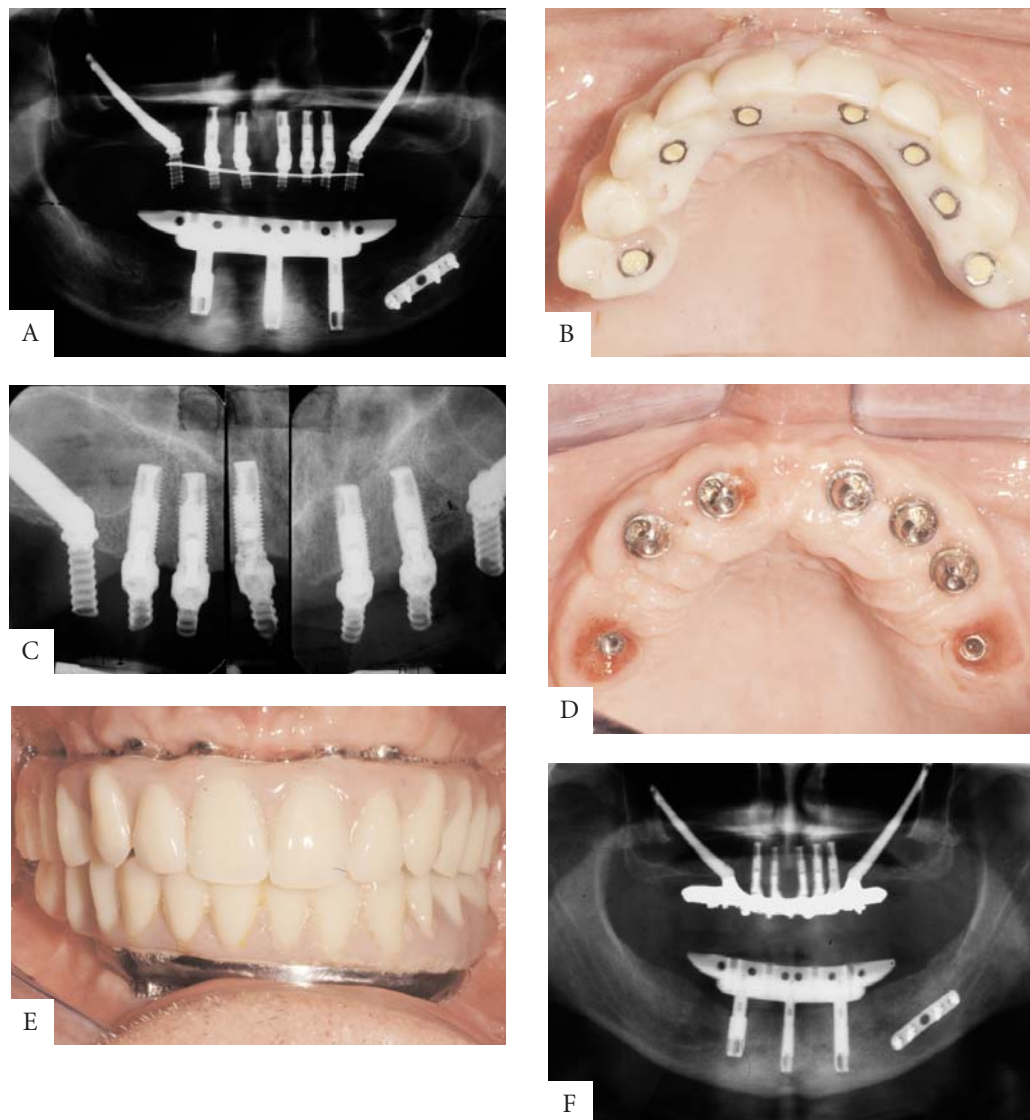


FIGURE 13-14 A, These five anterior and two zygoma implants were loaded immediately with a reinforced resin bridge converted from the original denture. B, The cantilever extensions are limited at the provisional stage, but the reinforced bridge provides a rigid cross-arch effect. This prosthesis was delivered immediately following surgery. C, Radiographically, all implants appear integrated at 5.5 months. The provisional fixed partial denture has not been removed during that time period. D, The soft tissue response viewed at removal of the provisional prosthesis shows relatively good epithelial recovery. The deep tissue response in the zygoma regions results from the long-term resin connection subgingivally. E, The definitive prosthesis was completed approximately 8 months after stage I surgery. F, Radiographically all implants appear well integrated and functioning normally.

replacement of a second implant. Interim therapy may include the use of a provisional restoration on the remaining integrated implants but should not include a cantilever extension on the affected side (Figure 13-16D). To date, this rescue approach has proven effective in the two instances that we have experienced in zygomatic implant failure. Both have ultimately been restored to com-

plete function using both the original and rescue zygoma fixtures for posterior support (Figure 13-16E–G).

Presurgical Assessment: Clinical

Current use of the zygoma implant dictates ultimate restoration with cross-arch stabilization of the fixtures with additional implants. Adequate bone must be available to place and retain at least two

but preferably four anterior maxillary conventional implant fixtures, which are joined to the zygoma fixtures with a cast base. The patient must have pathology-free maxillary sinuses and have acceptable soft tissues in the area in which the implants will be placed. The patient's treatment planning should be completed before insertion of the implants for both the maxillary and mandibular arches. Patients should be physically and medically stable enough to withstand a surgical procedure approximately 2 hours long and to tolerate a general anesthetic or deep intravenous sedation. The patient's mandibular range of motion must be adequate to provide access for placement of fixtures 30 to 52.5 mm long transpalatally in the area of the zygomatic buttress. The opposing mandibular teeth, if present, may limit access to the site of the zygoma fixture placement. If using deep sedation, local anesthesia in the mandibular arch, as well as in the surgical site itself, is advisable.

Presurgical Assessment: Radiographic

Adequate radiographic examination is needed prior to surgery to identify or rule out sinus or other pathology and to evaluate the osseous anatomy of both the zygoma and maxilla. The thickness of the remaining alveolar bone inferior to the sinus in the second premolar–first molar region should be sufficient to provide some support for the long implant near the abutment connection. The apex of the sinus just lateral to the orbital floor should be identified and the quality and quantity of the bone that will support the apical end of the zygoma implant evaluated. The anterior maxillary alveolus should also be evaluated to determine if enough residual bone is available to place two to four anterior implants. Panoramic, periapical, cephalometric, and plain tomography or computerized exposures are all helpful in this evaluation.

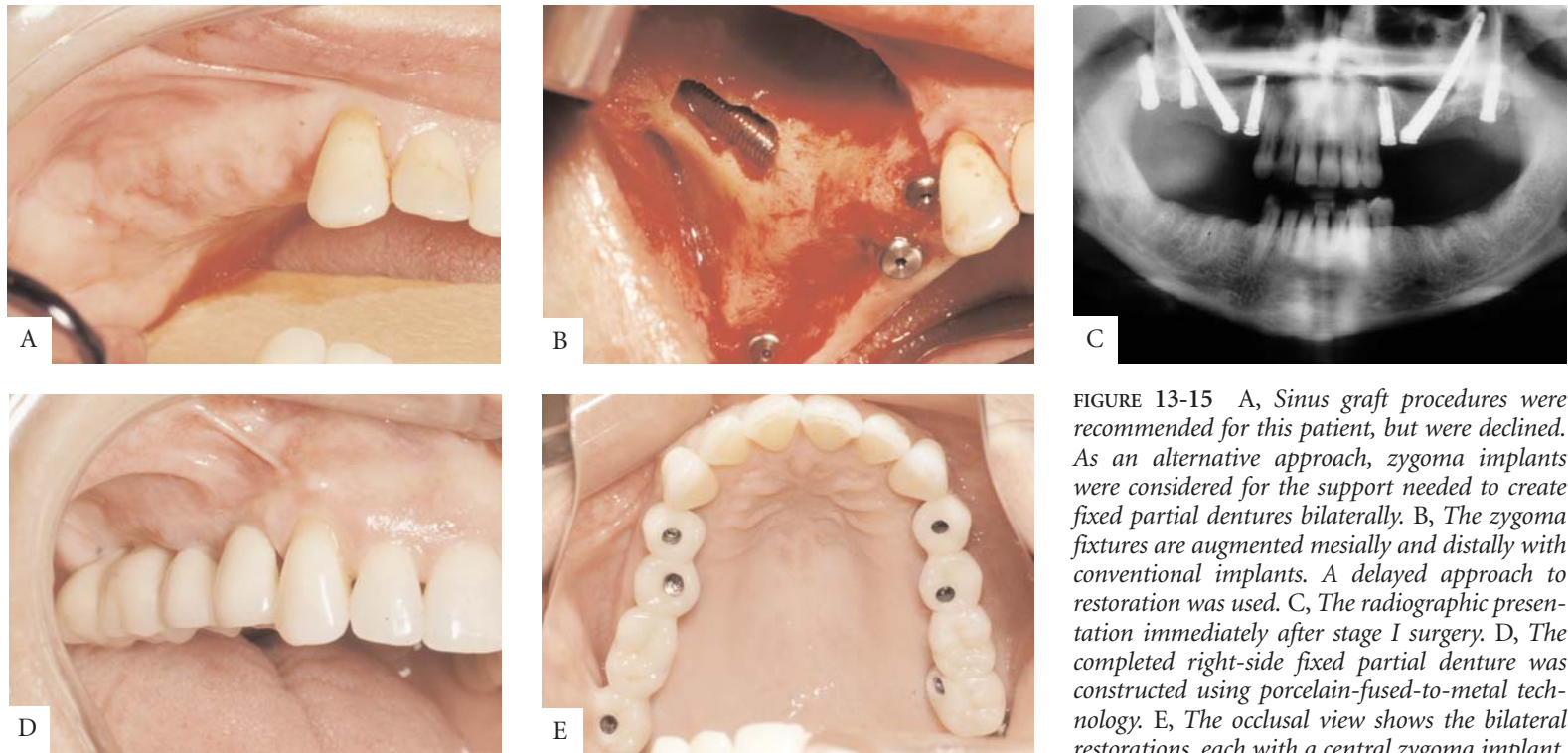


FIGURE 13-15 A, Sinus graft procedures were recommended for this patient, but were declined. As an alternative approach, zygoma implants were considered for the support needed to create fixed partial dentures bilaterally. B, The zygoma fixtures are augmented mesially and distally with conventional implants. A delayed approach to restoration was used. C, The radiographic presentation immediately after stage I surgery. D, The completed right-side fixed partial denture was constructed using porcelain-fused-to-metal technology. E, The occlusal view shows the bilateral restorations, each with a central zygoma implant.

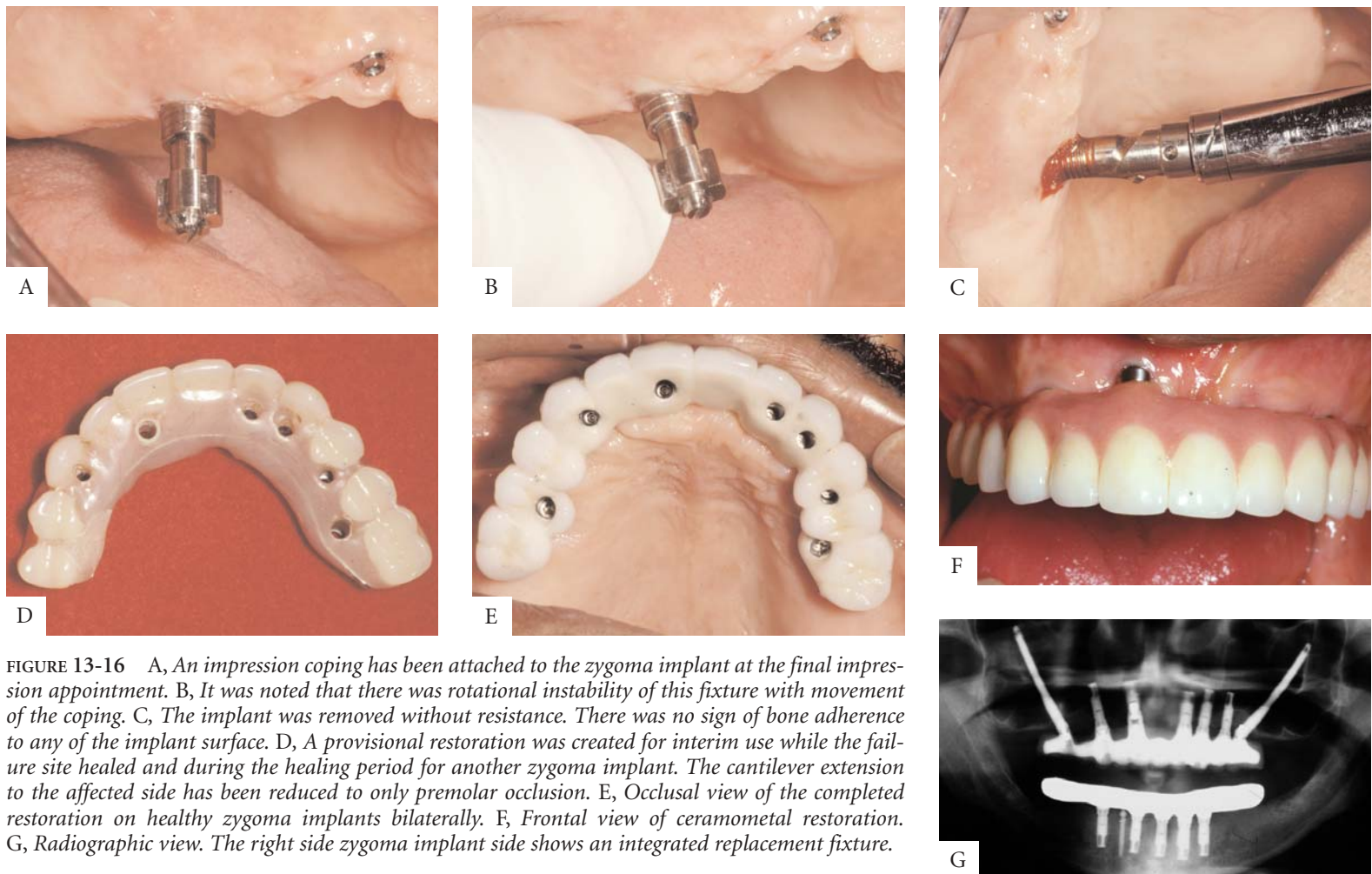


FIGURE 13-16 A, An impression coping has been attached to the zygoma implant at the final impression appointment. B, It was noted that there was rotational instability of this fixture with movement of the coping. C, The implant was removed without resistance. There was no sign of bone adherence to any of the implant surface. D, A provisional restoration was created for interim use while the failure site healed and during the healing period for another zygoma implant. The cantilever extension to the affected side has been reduced to only premolar occlusion. E, Occlusal view of the completed restoration on healthy zygoma implants bilaterally. F, Frontal view of ceramometal restoration. G, Radiographic view. The right side zygoma implant side shows an integrated replacement fixture.

Surgical Protocol

Surgery for zygoma implant placement is best performed using deep intravenous sedation or a general anesthetic. Local anesthesia with vestibular infiltration, second-division nerve blocks, and percutaneous blocks or infiltration lateral and superior to the zygomatic notch just lateral to the orbital rim should be administered. Bilateral inferior alveolar nerve blocks are also helpful if the procedure is performed with sedation because significant retraction of the tongue, lower lip, and mandible are needed to ensure adequate access for the procedure.

A crestal incision, placed slightly to the palatal aspect of the ridge in the first molar–second bicuspid region is made from the right- to left-tuberosity regions with bilateral releasing incisions at the incision ends. A releasing incision at the maxillary midline is also helpful for flap development and retraction. The lateral maxilla is exposed by elevating full-thickness mucoperiosteal flaps sufficient to visualize the zygomatic buttress from ridge crest to the superior surface of the zygoma at the zygomatic notch, just lateral to the orbit. The anterior maxilla is exposed to the piriform rims to avoid tearing the flap during retraction and to allow placement of conventional anterior maxillary implants. The entire lateral surface of the zygomatic buttress is exposed using a palpating finger extraorally at the zygomatic notch to ensure that the dissection is not directed into the orbital floor. During the dissection, the infraorbital nerve should be identified and protected.

A fissure bur, usually a 703 or 702, in a straight surgical handpiece is used to make a “slot” exposure vertically in the lateral wall of the sinus near the height of the zygomatic buttress.³ The slot should parallel the planned course of the zygoma implant just medial to the lateral sinus wall. The slot should extend from near the sinus floor at the planned site of implant placement superiorly to near the roof of

the sinus. Preparation of the slot in the sinus wall allows the surgeon to visualize directly the passage of all drill preparations and implant insertion through the lateral sinus. When preparing the slot, the schneiderian membrane in the sinus is removed to allow good visualization and to prevent its interference with site preparation and implant insertion. If portions of the membranes are “picked up” by the implant and carried into the implant preparation in the body of the zygoma, they could interfere with osseointegration.

A series of long drills are used for incremental preparation of the implant site. The zygoma implant varies in length from 30 to 52.5 mm (Figures 13-17 and 13-18). The apical two-thirds of the implant is 4 mm in diameter and the alveolar one-third is 5 mm in diameter. The initial drill is a round bur, which is used to start the implant preparation at the second bicuspid–first molar area as near the crest of the residual alveolar ridge as possible—usually slightly to the palatal aspect. The surgeon must preserve enough bone lateral to the site to fully surround the alveolar portion of the implant. The round bur is directed through the sinus floor and through the lateral sinus superiorly following the axis of the lateral wall slot preparation to the top of the sinus where it indents the site of the preparation in the zygoma body. The slot preparation allows direct visualization of the passage of the drill and the subsequent instrumentation and implant insertion (Figures 13-19–13-21). A custom-designed zygoma retractor with a toe-out tip is kept in position over the zygomatic notch throughout the site preparation to provide good visualization and protect the surrounding anatomy. The retractor also has a midline marker that parallels the site preparation and assists in orientation of the drills in the proper direction (see Figure 13-20). Subsequent drills to complete the preparation are, in sequence, long 2.9 mm diameter twist drills, a 2.9 mm to 3.5 mm pilot drill,

and a 3.5 mm twist drill. The preparation is carried through the body of the zygoma, through the cortical bone of the sinus roof, and through the cortex at the superior border of the zygoma body at the notch. The soft tissues at the superior portion of the preparation are protected by the zygoma retractor (Figure 13-22). Each fissure bur has incremental markings from 30 to 52.5 mm, which help the surgeon determine the needed implant length. When the

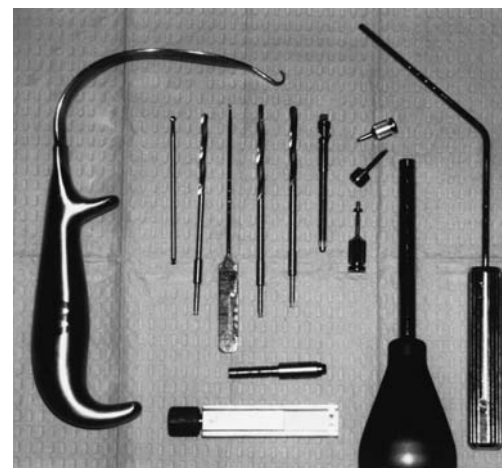


FIGURE 13-17 Zygoma implant armamentarium. From left to right: zygomatic retractor, round bur, 2.0 mm fissure bur, depth gauge, 3.5 mm pilot drill, 3.5 mm twist drill, 50 mm zygoma implant, mandrel and cover screw drivers, manual implant driver, final depth gauge chuck, chuck changer.




FIGURE 13-18 Zygoma implant. Apical two-thirds of implant is 4 mm in diameter. Alveolar one-third is 5 mm in diameter. Note 45°-angled abutment platform.

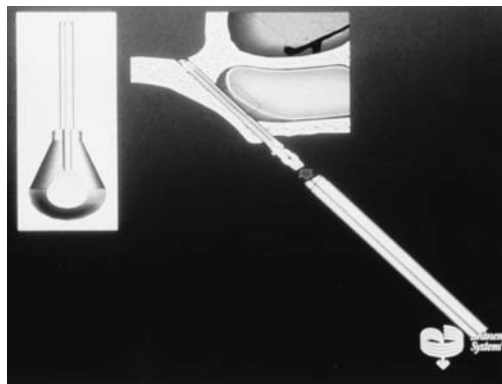


FIGURE 13-19 Diagrammatic representation of zygoma fixture placement from original protocol. Implant fixture platform is positioned palatal to alveolar crest. Fixture passes along lateral wall of maxillary sinus into the zygomatic body. Implant stabilization is supported by four cortical plates of bone and apically in the dense zygomatic body.

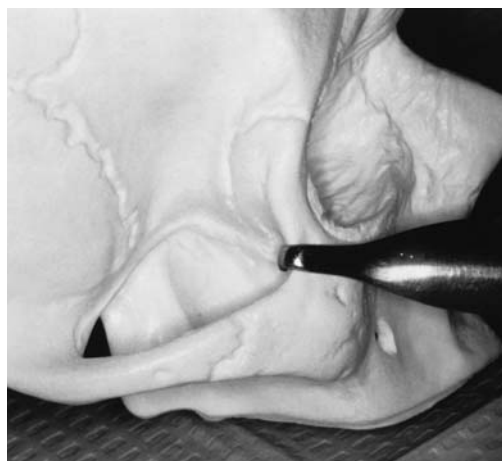

FIGURE 13-20 Zygoma retractor positioned on anatomic model. The ventral surface of the retractor is scored in the midline, vertically, to assist the surgeon in directing the drills and implant parallel to the retractor.

preparation is complete, final determination of implant length is made using the zygoma implant depth gauge. Lastly, if the residual alveolar bone is substantial, a 4 mm twist drill is used to complete the alveolar portion of the preparation. If the residual alveolar bone is spongy, this step is usually eliminated.

The zygoma implant has an angulated abutment platform. The 45° angulation allows the platform of the implant to emerge in the same plane as that of the conventional implants that will be placed

in the anterior maxilla. Premounted implant carriers are already attached to the zygoma implants for handling of the fixture with the handpiece. The implant is inserted with copious irrigation, directly visualizing its passage through the lateral sinus through the slot preparation (Figure 13-23). During insertion, the implant must stay in the same plane as the drills in the preparation site at the zygoma body. The slot preparation should be extended superiorly far enough to allow visualization of the preparation. When site preparation has been adequately performed, the handpiece will stall when the apical portion of the implant engages 2 to 3 mm of dense zygomatic bone. When this occurs, a manual driver is used to complete implant insertion. Proper angulation of the abutment platform is determined by placing a screwdriver in the implant carrier screw head and seating the implant until the screwdriver is perpendicular to the crest of the edentulous ridge. The implant carrier is removed and a cover screw is placed (Figure 13-24).

After placement of the zygoma implants, two to four regular platform Mark III or Mark IV Nobel Biocare implants are placed in the anterior maxilla (Figure 13-25). The flaps are repositioned and sutured. The maxillary denture is relieved, hollowed out at the implant emergence sites, and soft-lined with a tissue conditioner. Prior to closure, implant-level impressions are made. This allows for fabrication of a rigid bar to be placed at second-stage surgery about 6 months later.

The patient's denture prosthesis is relined as often as is necessary over the 6-month osseointegration period. At second-stage surgery, the cast rigid bar is attached to the implant fixtures, providing immediate cross-arch stabilization. The denture is further hollowed out and relined or a transitional fixed prosthesis is constructed and attached. Four to 6 weeks later, after the soft tissues are healed,

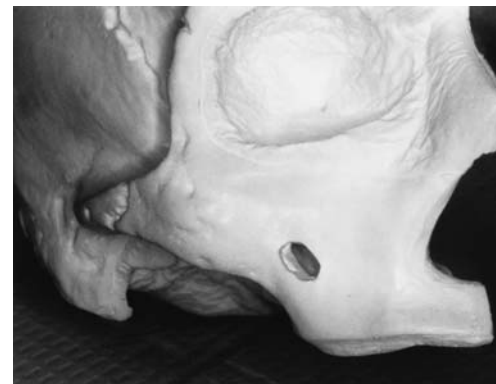

FIGURE 13-21 Laboratory model illustrating the "sinus window" in the zygomatic buttress. The window allows visualization of the drills and implant as they pass through the lateral portion of the maxillary sinus.

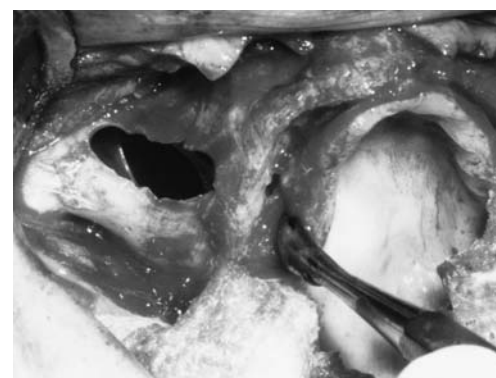


FIGURE 13-22 Surgical view of exposed implant site. The zygoma retractor is in position, the sinus slot is developed and the initial penetration of the round bur at the site of implant insertion has been completed.

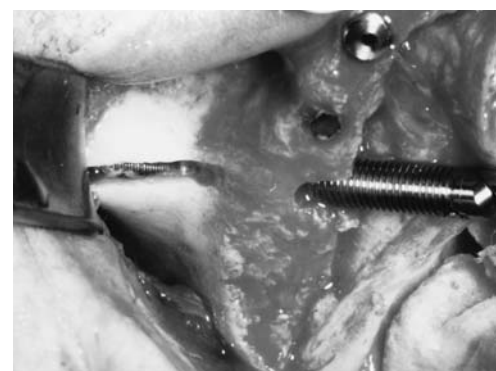

FIGURE 13-23 Surgical view of zygoma implant being inserted using a modified "sinus slot" technique. The sinus window is narrower and larger. Through the slot, the implant preparation can be visualized in the zygomatic body as the implant enters. The 45° abutment platform will be nearly centered on the alveolar crest—not to the palatal side.

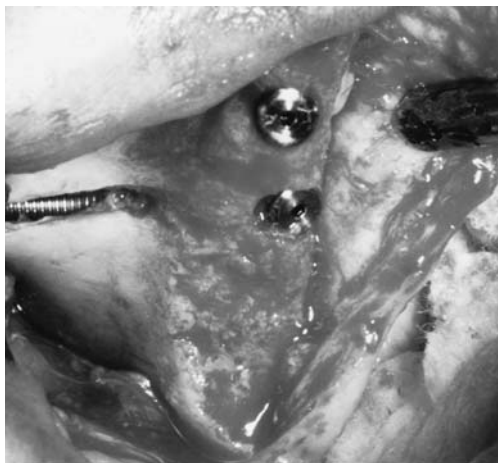


FIGURE 13-24 Zygoma implant fully inserted. Note the cover screw on the abutment platform positioned near the crest of the alveolar process. The implant “hugs” the lateral wall of the sinus.

impressions are made and the definitive prosthesis is constructed.

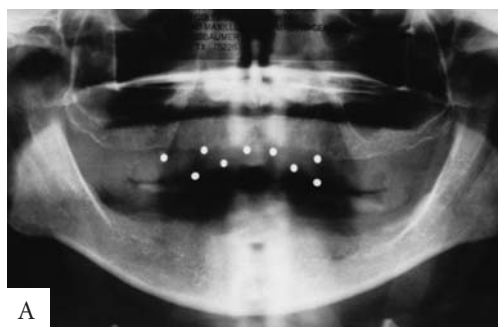
Prosthetic Procedure

Healing Phase

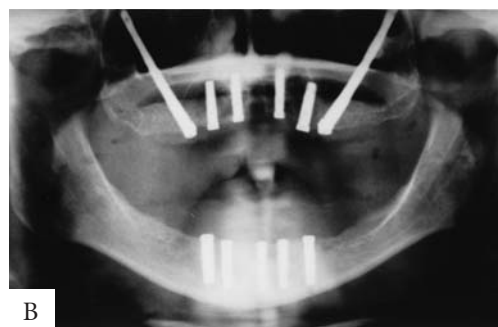
The maintenance of the zygoma implant patient is an ongoing process from the completion of stage I surgery through the entire healing phase (Figure 13-26). As noted earlier, the existing or provisional upper denture can be modified for immediate use (Figures 13-27–13-30), giving the patient a continuous esthetic presentation. There will be some significant limitations for functional use, such as changes in retention or chewing capability, but the option of having teeth throughout the entire process is usually far more appealing than the transitional periods of no prosthesis use that accompany many graft procedures.

Protective Splinting

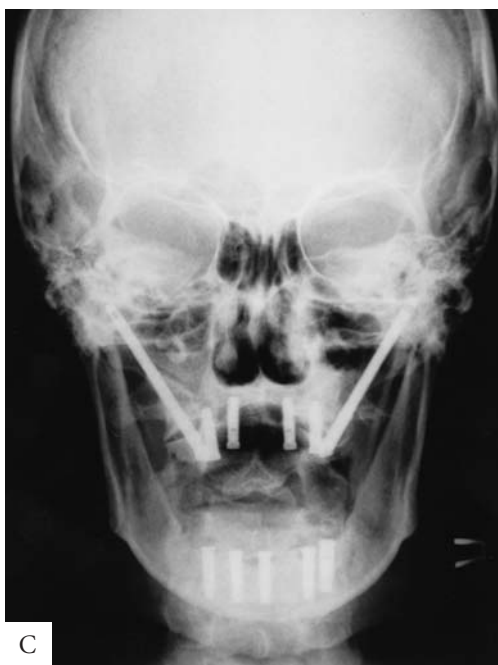
One of the unique features of these implants is the strength they provide when used with splinting and cross-arch stabilization. When used or loaded independently, however, it is felt that the off-axis load transfer can be detrimental and possibly counterproductive for maintenance of osseointegration.¹⁰ Immediately following stage II surgery, or exposure of all implants with abutment connections, it is recommended that some protective measures be used to prevent independent stress transfer from the denture base to the implants individually. To this end, the current protocol calls



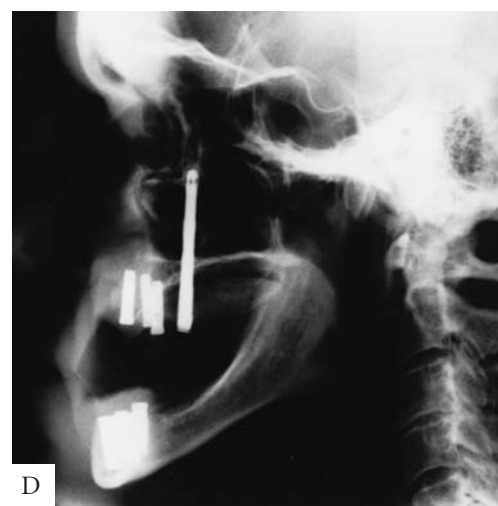
A



B



C



D

FIGURE 13-25 Near ideal positioning of the zygoma implants. A, Presurgical panoramic radiograph. B, Postsurgical panoramic radiograph. C, Posterior-anterior radiograph. D, Lateral head radiograph.

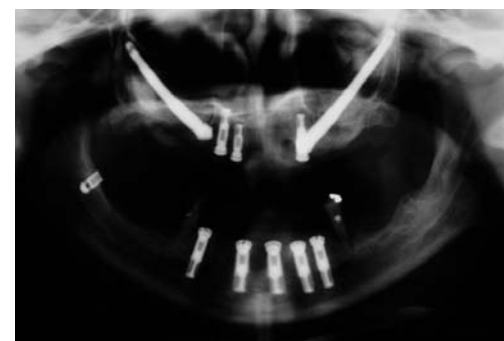

FIGURE 13-26 Immediately after implant placement cover screws are attached to all of the fixtures used in the maxillary arch, and the tissues are sutured to create a watertight primary closure. This radiograph shows the implant positions immediately after placement.

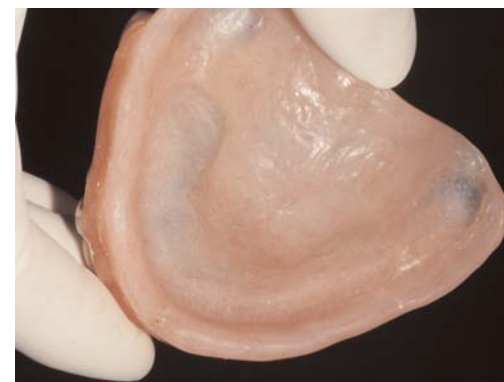


FIGURE 13-27 The patient's original denture is hollow ground in the area of the premaxillary ridge crest and distally onto the alveolar ridge and palatal mucosa areas where the two zygoma implants will eventually exit. It is also important to relieve the intaglio surface of the labial flange to prevent unnecessary apical pressure in the vestibular area.

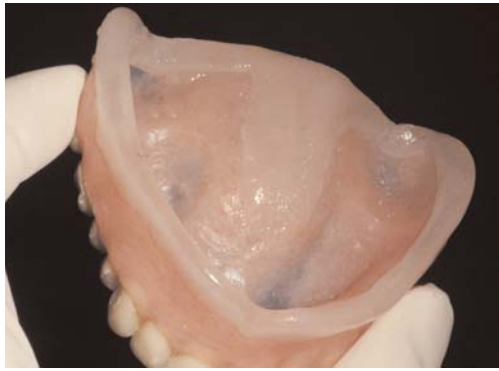


FIGURE 13-28 Denture conditioning material is mixed and allowed to set for approximately 8 to 10 minutes, at which time it will have a viscous consistency. The material is carefully applied to the borders of the modified denture and is then placed in the mouth and allowed to set while border molding.

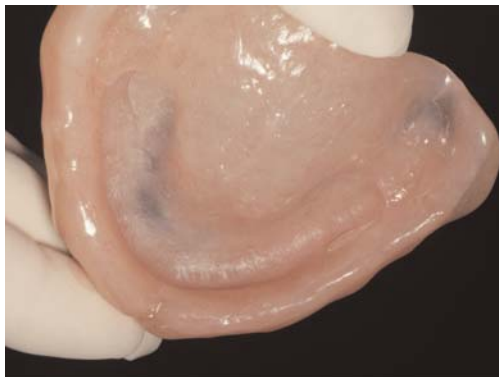


FIGURE 13-29 With border molding movements intraorally, the conditioning material is physiologically formed to create a peripheral seal. Any excess material is removed from the chamber so that no pressure is placed on the areas immediately over the implant sites.

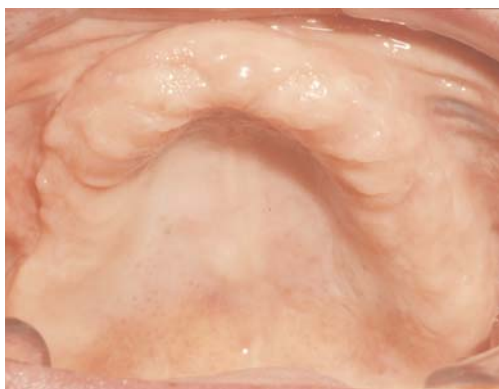


FIGURE 13-30 At the time of stage II surgery the patient should present with well-healed maxillary mucosal surfaces and may occasionally exhibit a proliferative reaction into the denture base chamber space as seen here. This excess tissue is not detrimental.

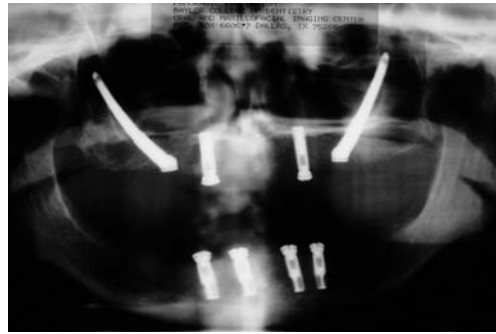


FIGURE 13-31 Radiographic analysis at approximately 5 months of healing shows the implants in both arches appear to be osseointegrated. Clinical validation of successful osseointegration is completed once the implants have been exposed and abutments have been connected.

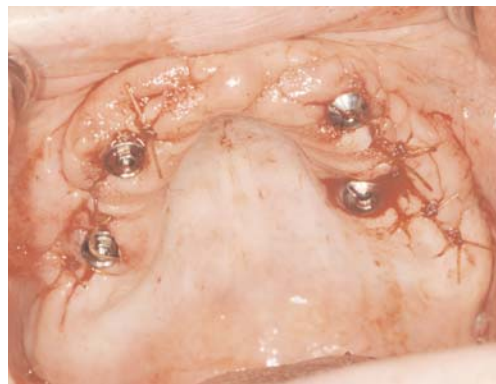

FIGURE 13-32 Abutments are selected at stage II surgery with as low a profile as possible in order to minimize extension of the provisional splint into the denture base area. In this case two 3 mm standard abutments have been selected for the right side, both of which terminate at the gingival tissue. The left side implants are covered with healing abutments since the tissue depth there is too shallow for 3 mm connections.

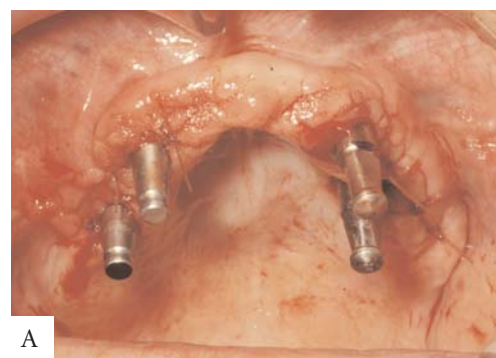
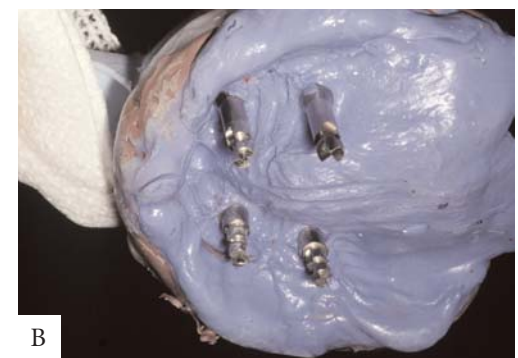

FIGURE 13-33 A, Tapered impression copings (right side) and fixture level impression copings (left side) are placed according to fixture and abutment locations at the time of stage II surgery. B, The tapered impression copings are transferred into the impression in their appropriate sites and the completed impression is sent to the laboratory.

for splinting all of the newly exposed implants with a soldered bar within 24 hours of abutment connection (Figures 13-31 and 13-32). This is accomplished by making an impression immediately after the abutments are delivered and sending it to the dental laboratory for rapid turnaround (Figure 13-33). A gold bar of approximately 2 mm in diameter is bent to contour so that it touches a set of gold cylinders attached to the abutment analogs on the cast (Figure 13-34). With a microwelding device the bar and cylinders can be soldered together and within a short time period a passive protective splint can be fabricated. The bar splint is delivered, usually the next day, and the denture is hollow ground to allow complete seating without bar interference (Figure 13-35). At this time, a complete soft liner can be applied to the upper prosthesis to enhance comfort and retention (Figures 13-36 and 13-37). The bar splint may not be necessary in situations where the patient is not wearing an upper prosthesis, but for all other cases where continuous denture wear is desirable, the bar splint protocol should be used.

Final Prosthesis Construction

Final impressions can be made following an adequate healing period, usually 3 to 4 weeks (Figures 13-38–13-40). The procedure for this and ensuing steps is the same as for all



fixed bridge construction on implants. Jaw relation records are obtained using implant-stabilized record bases and wax rims (Figure 13-41). The try-in with teeth follows the trial set-up done in the labora-

tory, and patient approval of the esthetic presentation is confirmed (Figures 13-42–13-44). Silicone putty indexes are made of the approved wax-up and are used to provide a matrix for creation of a metal bar

structure (Figures 13-45 and 13-46). Following a second try-in appointment for evaluation of passive fit and esthetics, the prosthesis is processed with heat polymerizing resin (Figure 13-47). Delivery is

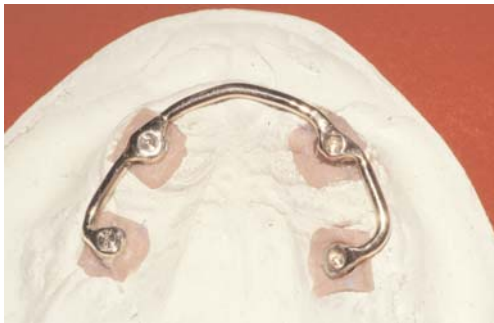

FIGURE 13-34 The surgical cast is poured in dental stone, and appropriate gold cylinders are attached to the abutment and fixture level replicas. The gold bar is bent to a shape that contacts each gold cylinder, and the connection is completed with a soldering procedure using a microwelding torch.

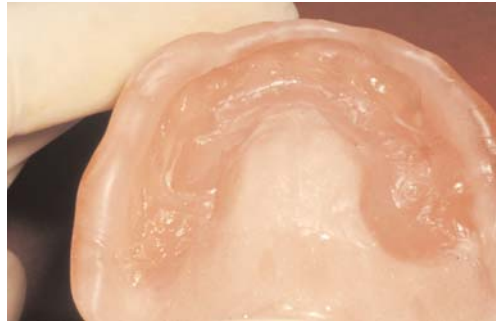


FIGURE 13-37 Soft tissue conditioning material can then be used over the entire denture base area to create tissue contact and a peripheral seal retention.

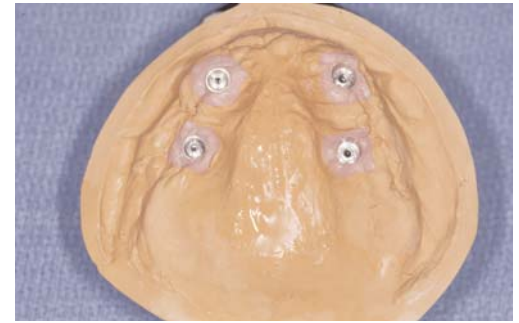

FIGURE 13-40 The master cast should be an absolute replica of the patient's presentation intraorally. It is usually necessary to use a verification jig to assure that the positions and orientation of the individual implant components are duplicated from the mouth.

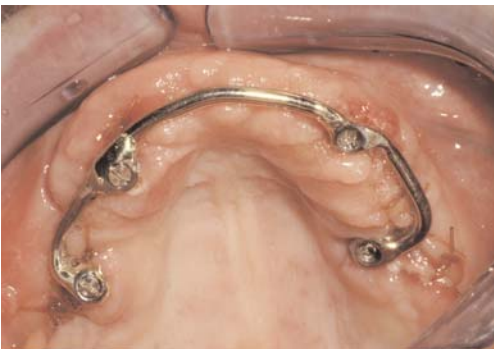

FIGURE 13-35 The protective splint is delivered within 24 to 48 hours of stage II surgery and serves to provide immediate protection and cross-arch stabilization of all of the implants during the final bridge construction.

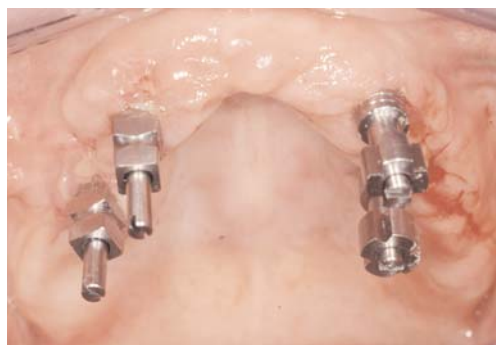

FIGURE 13-38 Following several weeks of healing, final impressions are made using square impression copings, which will eventually be joined together with a low distortion resin material prior to impressing.

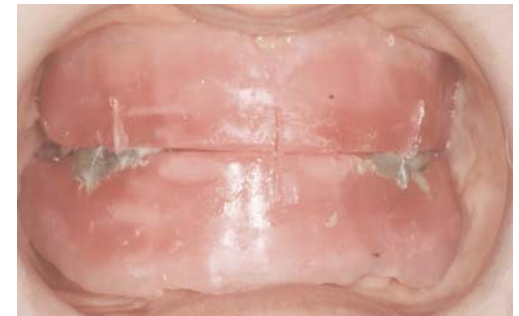

FIGURE 13-41 Stabilized record bases are used to record the centric jaw relation position at the patient's appropriate vertical dimension of occlusion.

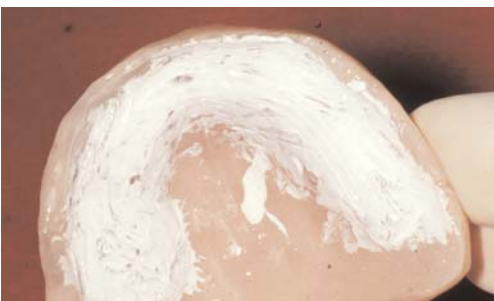

FIGURE 13-36 The previous denture conditioning material is removed from the patient's denture, and a disclosing material is used to identify any areas of excessive contact against the denture base.

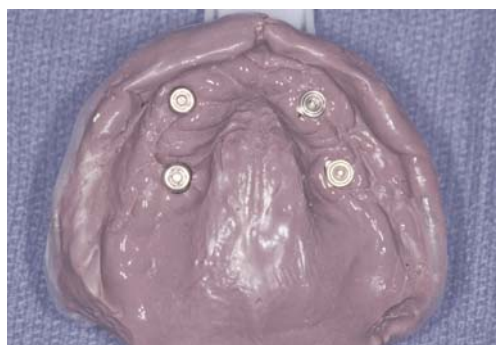


FIGURE 13-39 The final impression is made using a custom tray, to control material thickness, and an open top technique, which allows the individual copings to be picked up rather than transferred into the impression material.

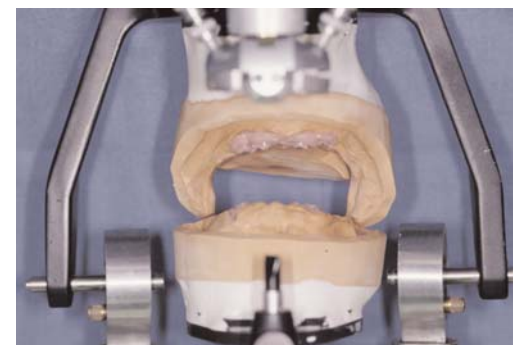

FIGURE 13-42 The mounted casts should be an articulated representation of the patient's jaw relationships.

accomplished using appropriate screws and screw torques to provide even and complete seating (Figures 13-48 and 13-49).

The bar structures are generally waxed and cast in precious metals but can also be

milled from solid blocks of titanium with excellent passive fit properties (Figures 13-50–13-54).¹¹ In select situations, such as minimal interocclusal distance or high load forces, it may be beneficial to use a

porcelain-fused-to-metal restoration. The procedure for constructing these prostheses is essentially the same up to the point of the patient-approved wax-up. The metal substructure will be designed to provide

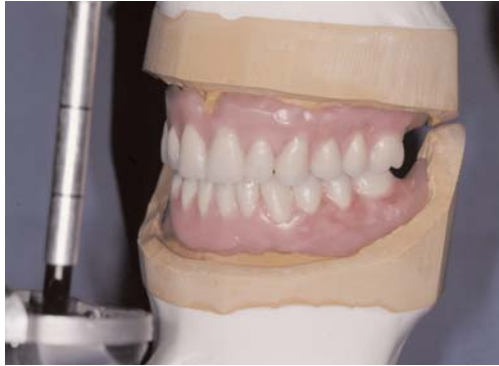

FIGURE 13-43 The teeth are waxed to contour in positions dictated by the record base procedure and are sent to the clinic for try-in and patient approval.

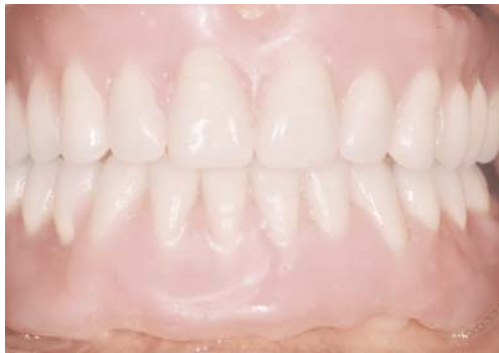

FIGURE 13-44 Final approval for esthetic display, occlusion, and vertical dimension are all obtained at this clinical visit.

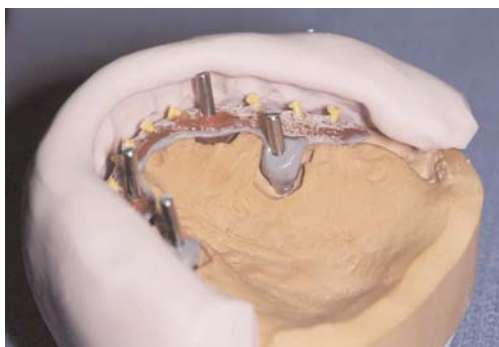


FIGURE 13-45 The cast framework design is based on available space and tooth position as dictated by the wax set-up from the trial denture base. These dimensions are captured using a buccal index that keys to the master cast.

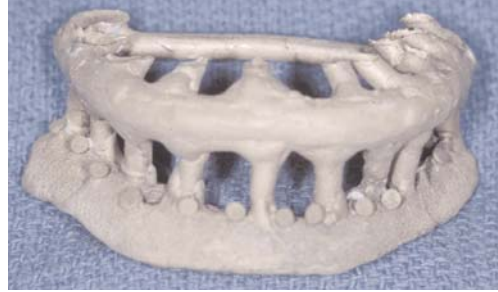

FIGURE 13-46 For greatest accuracy, the casting technique for these long-span restorations usually requires a runner bar and multiple sprue attachments to minimize distortion.

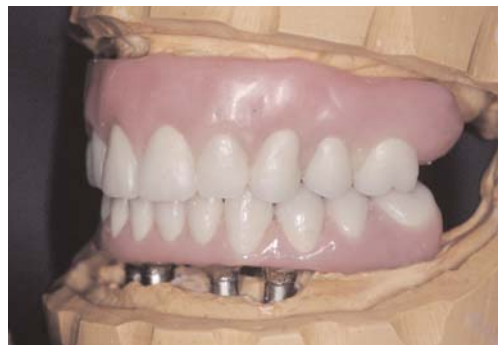

FIGURE 13-47 Using the buccal index, teeth are waxed to the gold casting for try-in. It is usually desirable to have a second try-in appointment to verify the casting accuracy intraorally and to obtain final approval for esthetics.

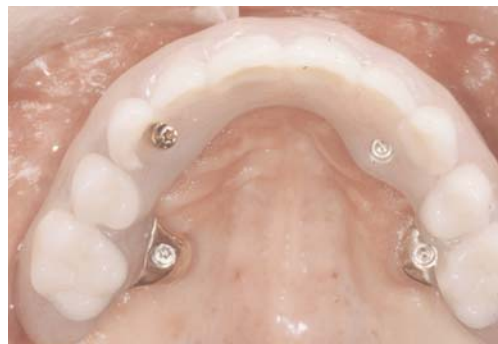

FIGURE 13-48 The completed restoration has been processed and is delivered using the manufacturer's recommended torque at each of the screw sites. The screw access holes can be covered with provisional materials for an interim period but will eventually be filled with cotton over the screws and a composite cover at the surface.

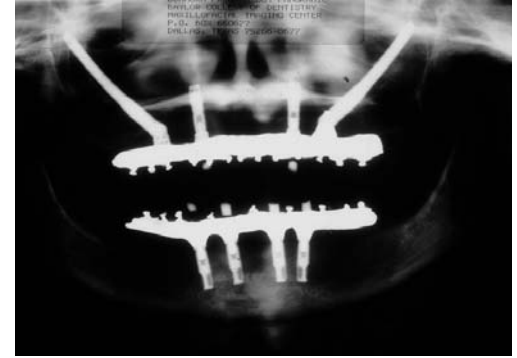

FIGURE 13-49 Radiographically, the definitive restoration appears to fit passively with all implants functioning successfully after 4 years.




FIGURE 13-50 An alternative to the gold-casting technique is available using Procera technology that allows the creation of a metal substructure out of a single piece of machined titanium.

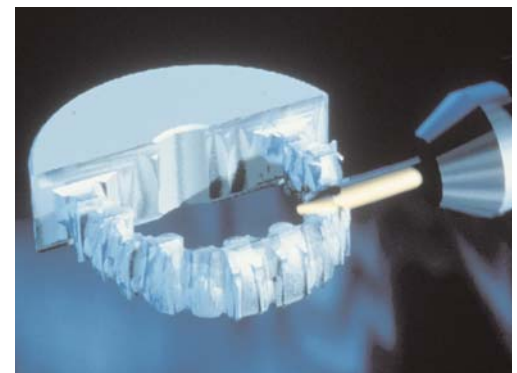

FIGURE 13-51 By entering scanning information into a computer bank, computerized lathes with precisely controlled cutting heads attack the titanium blank to create the milled bar structure.

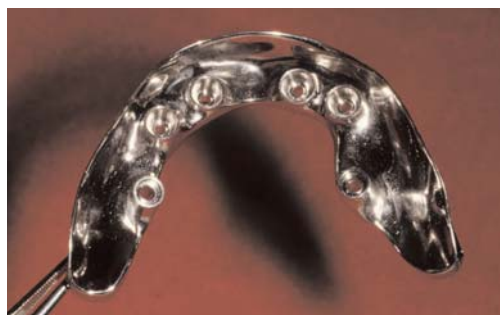

FIGURE 13-52 The milling process is completed at the fit surfaces with a very precise secondary cutting tool that creates fit tolerances in the range of single digit microns. These frameworks are very lightweight and fit with a degree of precision that is difficult to duplicate with conventional casting procedures.

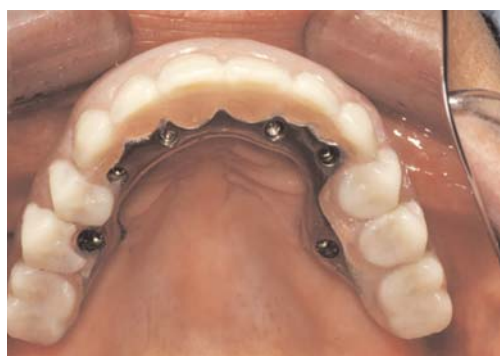

FIGURE 13-53 The completed restoration illustrated here uses the same hybrid denture tooth processing concept as previously illustrated, with the exception that the bar structure is now titanium rather than cast alloy.

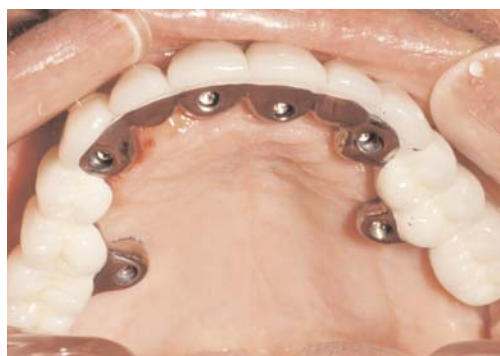

FIGURE 13-54 Procera technology can also be used to create porcelain-fused-to-metal restorations with a degree of passivity that is equivalent to that found with resin processing on cast substructures.

support for the veneering material and will therefore have a completely different archi-

tecture from the hybrid denture tooth design. It may be especially advantageous to use the milled titanium technology for these restorations, since they do not tend to distort through the thermocycling phases of veneering to the same degree as the precious metal alloy cast substructures (Figures 13-55 and 13-56).

Summary

The placement of implants and restoration of the extremely atrophic maxilla is a challenge to both the surgeon and prosthodontist. If conventional implants are to be used exclusively in this setting, extensive bone grafting is usually needed before implant insertion and usually includes sinus lifts and onlay grafts with large amounts of donor bone required. The inconvenience, prolonged treatment, costs, potential complications, lower implant success rates, and donor site morbidity are important considerations. This is further compounded by the patient's inability to wear a prosthesis for extended periods of time—a factor that keeps many patients from pursuing treatment. With the zygoma implant, bone grafts often may be avoided, treatment time is shortened, donor sites are unnecessary, and the patient may continue to wear a transitional prosthesis. This results in greater patient acceptance while providing the patient with a well-tolerated, stable, and esthetic fixed or removable prosthesis at completion of treatment.

The advantages of considering the zygoma implant include the following:

1. Donor site morbidity is reduced or eliminated entirely.
2. Treatment time is markedly reduced or eliminated entirely.
3. Bone graft survival and consolidation are not considerations.
4. The total number of implants to support a prosthesis is reduced.
5. The treatment is more affordable and less invasive than alternative treatments.

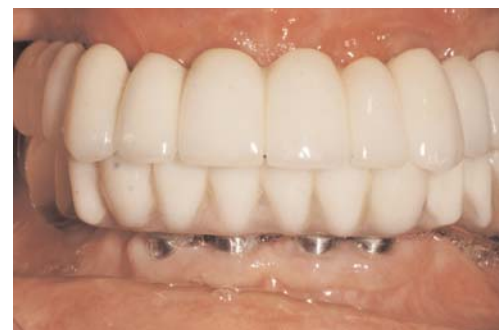

FIGURE 13-55 This porcelain-fused-to-metal fixed partial denture was indicated on the zygoma and standard implants because of the restricted vertical space available for bridge construction.

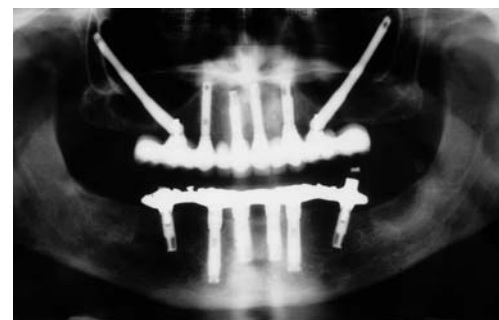

FIGURE 13-56 The principal advantage of the Procera titanium framework approach over conventional porcelain-fused-to-gold technology is the apparent absence of distortion as the porcelain is veneered through multiple firing cycles. The integrity of fit does not seem to be affected with these titanium restorations to the same degree as that found in comparable gold alloy ceramic restorations.

The disadvantages of the zygoma implant include the following:

1. Technically demanding surgery—should only be performed by well-trained surgeons capable of dealing with any surgical situation or complications that might arise
2. Risk of injury to adjacent structures—that is, orbit, orbital contents, facial nerve, lacrimal apparatus, infra-orbital nerve
3. Risk of postoperative sinusitis, although less than with sinus lift procedures
4. Fixture failure—although rare, more difficult to retreat

5. Surgical access difficult—deep sedation or general anesthetic required

As with all properly planned and executed implant prosthetic procedures, extensive coordination between the surgeon and the prosthodontist is necessary before initiating treatment. Ideally, the prosthodontist should be available at surgery. Similarly, the surgeon should become familiar with the prosthetic needs and techniques involved with fixture positioning and restoration. Finally, patient education, preparation, evaluation, and informed consent are major parts of the procedure and its ultimate success. Patient understanding, before treatment is initiated, should include the need for meticulous hygiene and maintenance.

The zygoma implant, when understood and appropriately used, provides a

treatment alternative for many patients with atrophic edentulous maxillae.

References

1. Bedrossian E, Stumpel L, Beckely M, Indersana T. The zygomatic implant: preliminary data on treatment of severely resorbed maxillae. A clinical report. *Int J Oral Maxillofac Implants* 2002;17:861–5.
2. Bedrossian E, Stumpel LJ. Immediate stabilization at stage II of zygomatic implants: rationale and technique. *J Prosthet Dent* 2001;86:10–4.
3. Stella JP, Warner MR. Sinus slot technique for simplification and improved orientation of zygomatic dental implants: a technical note. *Int J Oral Maxillofac Implants* 2000;15:889–93.
4. Parel SM, Brånemark PI, Ohnell LO, Svensson B. Remote implant anchorage for the rehabilitation of maxillary defects. *J Prosthet Dent* 2001;86:377–81.
5. Higuchi KW. The zygomatic fixture: an alternative approach for implant anchorage in the posterior maxilla. *Ann R Australas Coll Dent Surg* 2000;15:28–33.
6. Schnitman PA, Wohrle PS, Rubenstein JE, et al. Ten-year results for Brånemark implants immediately loaded with fixed prostheses at implant placement. *Int J Oral Maxillofac Implants* 1997;12:495–503.
7. Jaffin RA, Kumar A, Bermann CL. Immediate loading of implants in partially and fully edentulous jaws: a series of 27 case reports. *J Periodontol* 2000;71:833–5.
8. Salama H, Rose LF, Salama M, Betts NH. Immediate of bilaterally splinted titanium root-form implants in prosthodontics – a technique reexamined: two cases. *Int J Periodontol Rest Dent* 1995;15:344–60.
9. Tarnow DP, Emtiaz S, Classi A. Immediate loading of threaded implants at stage I surgery in edentulous arches: ten consecutive case reports with 1- to 5-year data. *Int J Oral Maxillofac Implants* 1997;12:319–24.
10. Zhao R, Skalak R, Brånemark PI. An analysis of a fixed prosthesis supported by the zygomatic fixture. (In press).
11. Parel SM. The single-piece milled titanium implant bridge. *Dent Today* 2003;21:106–8.

Implant Prosthodontics

Thomas J. Salinas, DDS

Biomechanical Considerations

Periimplant Biology

Considerations for tooth replacement with osseointegrated dental implants include the biologic principles of soft and hard tissues of adjacent teeth to the implant site. The placement of an implant between two periodontally healthy teeth is a unique situation whereby the bone and soft tissue is maintained in part by the teeth. Original studies by Waerhaug and Gargiulo and colleagues showed the width of the dentogingival complex surrounding natural teeth approaching 3 mm.^{1,2} Comparably, a similar study by Cochran and colleagues assimilated the periimplant tis-

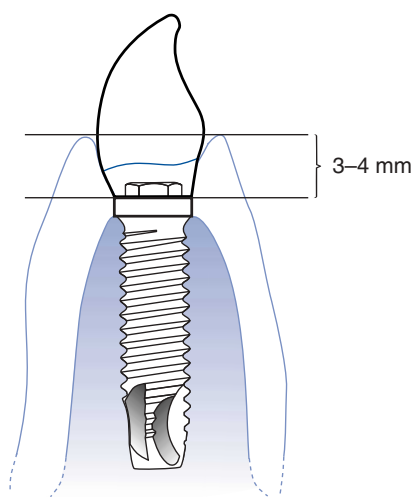


FIGURE 14-1 Osseointegrated implant placed at a depth of 3 to 4 mm for biologic width and emergence profile.

ues to a similar dimension. Based on these principles, the suggested depth of placement of an implant below the free margin of soft tissue is approximately 3 to 4 mm (Figure 14-1).³ This distance provides room for biologic width, proper emergence of restoration, and esthetics and also should allow for remodeling of the soft tissue and bone, which occurs between 6 months and 1 year.⁴ It has been postulated by some that the type of periodontium influences how extensive this remodeling process is. In other words, thin scalloped gingiva recedes more extensively than does thick nonscalloped gingiva.^{5, 6} Restorative interfaces with metal should be kept below the free margin of tissues in anticipation of this remodeling. Tarnow and colleagues have shown that there is a relationship of the underlying bone to soft tissue in the interdental spaces between natural teeth.⁷ Also a relationship from both implant to natural tooth and implant to implant as well has been demonstrated.⁸ Therefore, the distance suggested from the side of the implant to the adjacent tooth should be about 2 mm to avoid horizontal bone loss affecting the adjacent tooth. Similarly, Tarnow and colleagues showed the critical distance between implant surface and implant surface approached about 3 mm before the mutually destructive process of lateral bone resorption accelerated each other's processes (Figure 14-2). Typically, each implant loses peri-

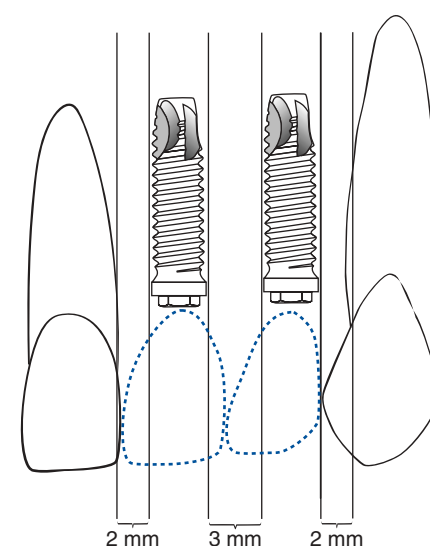


FIGURE 14-2 Suggested minimum distances of implant to natural tooth and implant to implant.

implant bone within the first year and then stabilizes—one criterion of success as outlined by Albrektsson and colleagues.⁹

Patient Factors

Soft tissue evaluation prior to implant placement is critical for long-term success and maintenance. A sufficient volume of keratinized and fixed tissue is needed to properly maintain hygiene around an implant, just as it is needed around a natural tooth. Occasionally it may be necessary to incorporate subepithelial connective tissue or full-thickness soft tissue grafts to prospective implant sites. When restoring single missing teeth, the interproximal bone between the remaining

teeth is a good prognostic indicator of the likelihood of creating and preserving interdental papilla. Generally, the distance from the residual alveolar bone to the contact area of the restoration can be assessed on a periapical film. The likelihood of having a papilla is depicted in Table 14-1.

Bone volume is best assessed by radiographic techniques, although a rudimentary estimate can be made clinically by palpation and inspection. Assessing a patient for mandibular implant reconstruction may include intraoral/extraoral palpation as well as panoramic, occlusal, and lateral cephalometric radiographs. Single-tooth replacement in the esthetic zone also can be assessed by comparison of the bony topography of the adjacent teeth as well as periapical/panoramic radiographs. Bone is a scaffold for soft tissue, and it is typical for bone loss to occur on a scale of 0.2 mm/yr after implant placement. Therefore, it is not unusual that soft tissue recession occurs in this period of time. This recession should be anticipated, especially when considering placing implants in the esthetic zone and elsewhere.

It is well documented that local and systemic factors such as cigarette smoking have a deleterious effect on the long-term success of dental implants.¹⁰⁻¹³ It is also well documented that smoking decreases bone density.¹⁴ In one study failure rates of implants placed in type 4 bone approached 35% in smokers; placement of implants into types 1, 2, and 3 bone of smokers resulted in a failure rate approaching 3%.¹⁵ Although osteoporosis can be a negating

factor to bone density, this disease seems to affect the hip and spine of those afflicted. No clear correlation can be demonstrated that osteoporosis is a contraindication to the placement of dental implants.¹⁶

Periodontal disease is a local factor that should be under control to avoid adverse effects of a unique population of microbiota affecting these diseased sites.¹⁷⁻¹⁹

Bruxism is another local factor that can compromise long-term success. Generally, bruxism promotes micromovement of the implant bone interface. In bone types 3 and 4, bruxism may have a more pronounced effect on the long-term osseointegration. Off-axis and lateral loading of dental implants by bruxism or other parafunctional forces can be deleterious in the long term with respect to accelerated bone loss and prosthetic failure. Self-awareness and occlusal splint therapy may provide appropriate protection. If these factors cannot be controlled preoperatively, alternative treatment should be considered.

Radiation to the head and neck in excess of 50 Gy is considered a contraindication to dental implant placement in most cases. There are instances in which the radiation has created a significant degree of xerostomia, which is incompatible with retaining natural teeth or stabilizing prostheses. Given the risks of osteoradionecrosis, hyperbaric oxygen should be considered if placement of implants would significantly improve the oral health and quality of life in these individuals.²⁰⁻²² However, there are several studies that refute the benefit of hyperbaric oxygen to the long-term survival of dental implants.^{23,24} Standard protocol suggested by Marx and Ames is 20 preoperative dives and 10 postoperative dives.²⁵

Systemic factors such as diabetes, connective tissue diseases, autoimmune diseases, and HIV are considered relative contraindications to treatment with osseointegrated implants.²⁶⁻³¹ If these dis-

ease processes are well controlled, it may be advisable to treat the patient to improve the overall quality of life. Chemotherapy given to patients during osseointegration has not been shown to be subtractive in success.³²⁻³⁴

Radiographic Evaluation

Periapical radiographs are an excellent way to evaluate single missing teeth since they depict a minimally magnified amount of bone and root topography. Adjacent root angulation, pulp chamber size, periodontal defects, interproximal bone, and residual pathology are some of the factors critical to the treatment planning of single-tooth implant restorations (Figure 14-3).

Occlusal radiographs for mandibular arch assessment also can give an appreciation of the size of the inner and outer cortices as well as the position of the mental foramina (Figure 14-4). It may be also feasible to incorporate a radiographic marker on the patient's denture to give a perspective of the relationship of the mental foramina to the overlying prosthesis. This can be done with either lead foil from a film packet taped to the underside of the patient's denture or a stainless steel wire attached with sticky

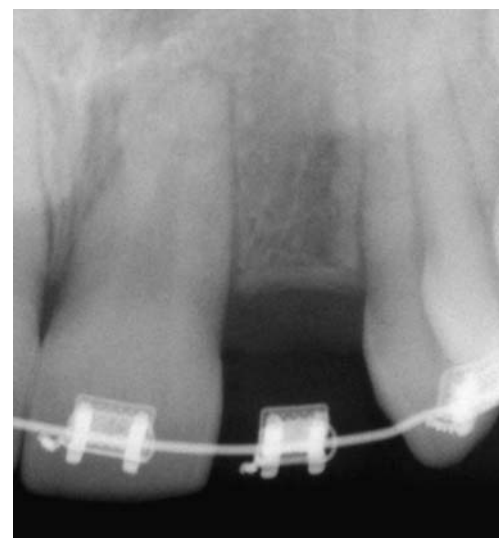


FIGURE 14-3 Presurgical planning for placement of an implant into site no. 10. Minimal magnification is noted from the periapical radiograph.

Table 14-1 Potential of Creating/Preserving Papilla

Distance from Bone to Contact Area (mm)	Chance of Creating Papilla (%)
4.0	100
5.0	100
6.0	56
7.0	27

Adapted from Tarnow DP et al.⁷

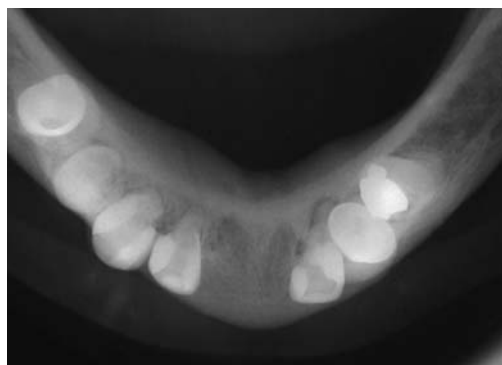


FIGURE 14-4 Occlusal radiograph gives the relative position of mental foramina and the taper of mandible.

wax to the buccal or occlusal portion of the mandibular denture.

Panoramic radiographs are excellent screening examinations that give a broad perspective on the inferior alveolar canal, maxillary sinus, mental foramina, and nasal floor; they are used for treatment planning of single and multiple missing teeth. The panoramic film generally has a magnification factor of about 25%, which should be anticipated on the work-up to gain a better appreciation of the actual position of vital structures and the size of implant to be selected. Methods of standardizing the magnification factor include the use of known-diameter stainless steel shots incorporated in a vacuum-formed stent worn at the time of radiography (Figure 14-5). This varies from patient to patient, by location, and also with the machine used. Panoramic radiographs are also useful for verifying complete seating of impression and restorative components. Use of this film over a standard periapical radiograph is preferable since the incident beam of the tube is more likely to be perpendicular to the long axis of the implant. Also, many edentulous patients have a shallow floor of mouth and flat palatal vault owing to resorption. It is far easier to obtain a perpendicular view of the implant platform in these circumstances, which is critical to the accurate performance in the treatment stages.

Lateral cephalograms assess the maxillo-mandibular relationship as well as that of the maxilla and mandible to the cranial base. A lateral cephalogram may give an appreciation of the concavity of the lingual surface of the anterior mandible vitally important to surgical consideration of implants in the anterior mandibular area. Development of anticipated implant occlusion is well assessed with lateral cephalography, which becomes especially useful when recreating anterior guidance and posterior occlusal schemes (Figure 14-6).

Linear tomography is a useful adjunct when considering a single-tooth implant or definitive positioning of the inferior alveolar canal, concavity of the nasal fossa, and the maxillary sinus. This feature is an extension of most modern panoramic radiographic units. It gives a three-dimensional perspective of the primary radiograph, which can help one anticipate grafting procedures or select an implant length and configuration (Figure 14-7).

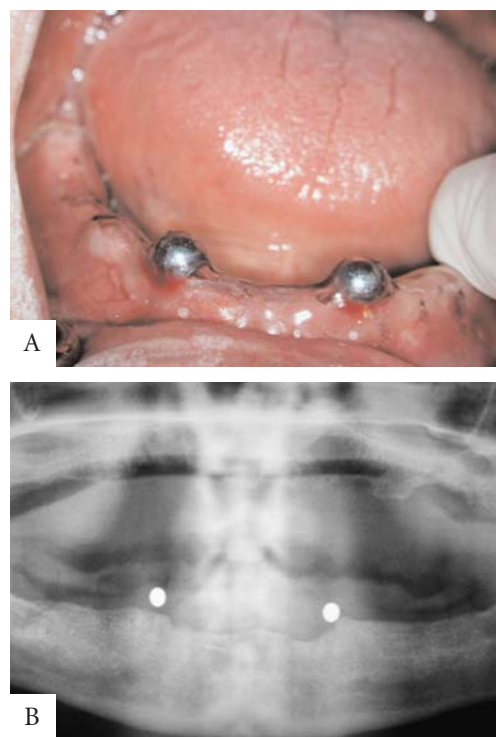


FIGURE 14-5 A and B, Five-millimeter stainless steel shots in vacuum-formed stent to calculate the magnification factor.

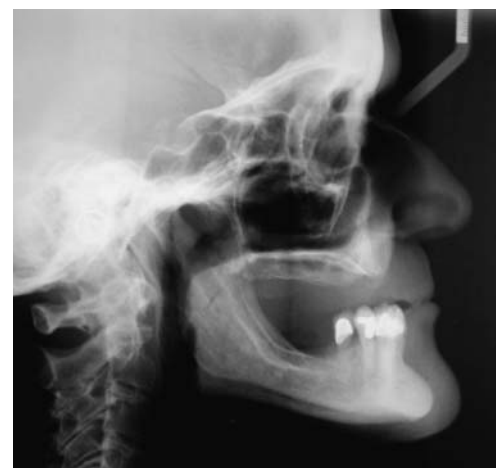

FIGURE 14-6 Lateral cephalograms may assist in the work-up for determining maxillo-mandibular relationships and occlusal schemes.

Computed tomography (CT) can be helpful when considering maxillary rehabilitation with a full complement of implants or when other craniofacial landmarks are planned for use. CT may be used in conjunction with computerized technology to aid implant placement. These images may be reformatted to construct a three-dimensional image of the selected part of the craniofacial skeleton. CT scans are useful in assessing the health of the maxillary sinus prior to augmentive procedures (Figure 14-8).

A radiographic or imaging stent can be used when there is a need to join the prosthetic information to the bony topographic information. In creating these stents, acrylic resin can be mixed with 30% or less barium sulfate as a radiographic marker to create the contour of the intended restoration. Some denture teeth are true to anatomic form and create a radiopaque appearance when included in the stent. As an alternative, access channels can be filled with gutta-percha as a radiographic marker. If verified radiographically, this imaging stent may double as a surgical stent.

Surgical Stents

Fabrication of surgical stents for implant placement should be part of every case since the placement is permanent and

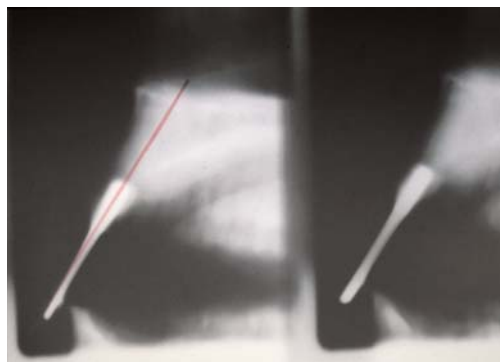


FIGURE 14-7 Linear tomograms give cross-sectional data when used with other films and radiographic stents.

irrevocable after integration. Planning of each case includes the collection of all diagnostic data as previously mentioned. Once this data has helped create a thorough treatment plan, fabrication of a surgical stent can begin from the diagnostic models and other information from the work-up.³⁵

Construction of prostheses begins with a confirmation of occlusal relationships and the need to direct occlusal forces over the long axes of the implants. This becomes exceptionally critical when a fixed restoration is to be used. On this basis, a site is selected and a stent made to guide the surgeon at placement (Figure 14-9). This information may also be translated from radiographic findings to a surgical stent in the position of the mental foramina (previously described). This information can be used to place implants far enough away from the foramina and each other to be mechanically advantageous. Again, parallelism is of paramount importance if a stud-retained overdenture is used. This stent can be as simple as a vacuum-adapted thermoplastic sheet over an edentulous cast or a clear processed duplicated denture.

Implant-supported overdenture construction may incorporate the use of the surgical stent to keep the implant fixtures away from the peripheral confines of the prosthesis. This may be beneficial to avoid encroaching on the peripheral seal in

either esthetic or functional areas. Also, occlusal forces may be better directed over the long axes of the implants. The stent can be either a duplicate of a diagnostic wax-up in clear resin or simply a duplicate of the patient's denture, if acceptable. A stent may be critical in this situation since it will be supported with a splinted structure in which cantilevering may be used.

Implant hybrid dentures mandate the use of a surgical stent since the occlusal access channels are desired to be through the posterior teeth and the lingual aspects of the anterior teeth. In these situations a slot can be created through these areas to provide the surgeon with latitude in site selection. A clear processed duplicate of the patient's denture may be the best technique in surgical stent design.

Surgical stent design for fixed prostheses is mandated in that selection of a specific prosthetic design may be entirely dependent on implant position and orientation. In the esthetic zone the cemented design may be the preferred method of prosthesis, and placement of an implant in an orientation just palatal through the incisal edge is optimal. Also, the implant platform should be approximately 3 to 4 mm below the free edge of the gingival margin. Two vital pieces of information contained on a surgical stent are the occlusal/incisal plane and gingival margin of the proposed restoration (Figure 14-10). To obtain this information a wax-up

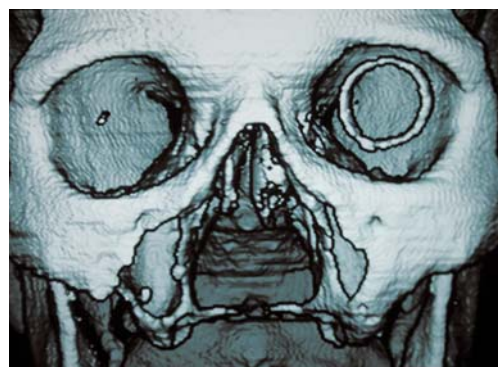


FIGURE 14-8 Three-dimensional reconstruction with computer software manipulation of computed tomographic data of a patient with a maxillectomy.

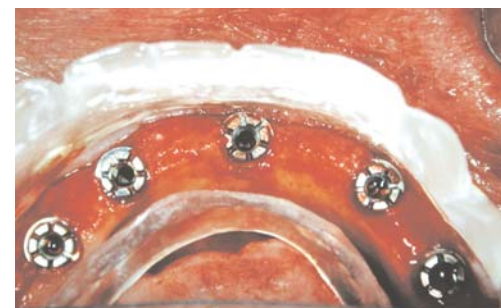

FIGURE 14-9 Stent used to place the implants within the confines of the denture base.

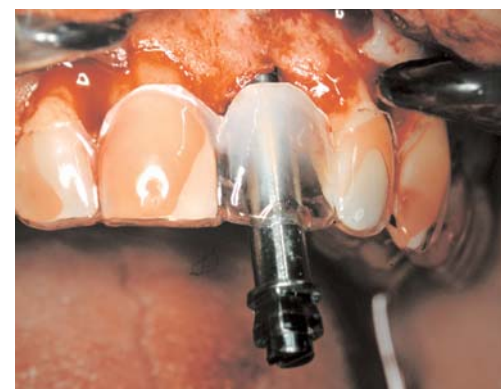

FIGURE 14-10 Surgical stent showing proposed gingival margin and incisal/occlusal plane. (Surgery performed by Michael S. Block, DMD)

is performed in the desired occlusal position. Once completed, this model should be duplicated into another cast. A vacuum-adapted stent can be made on this duplicate cast. The matrix can be trimmed with a hot knife and rotary instrument. Guide channels can be created with old surgical drills or laboratory burs. The constant access diameter of these stents is based on the concentric enlargement of each succeeding drill diameter. These stents are usually easily made, are cost effective, are self-retaining, and do not require prefitting. Since these stents fit well, it is only necessary to extend the stent two to three teeth on either side of the edentulous spaces for partially dentate cases.

Crown-to-Implant Ratio

Ideally, a crown-to-implant ratio of 1:1 or less is desired (Figure 14-11). For this reason, the minimum length needed approaches 10 to 12 mm since the clinical crown

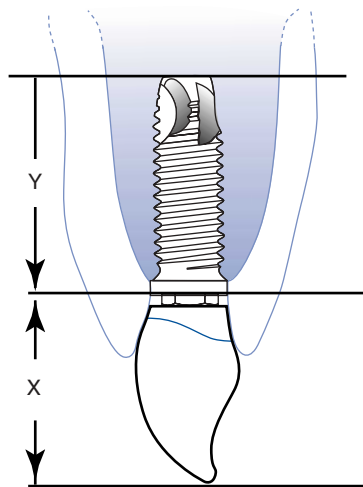


FIGURE 14-11 *Ideal crown-to-implant ratio occurs when $X \leq Y$.*

length frequently approaches this measurement. Standard implant diameters with shorter lengths have been shown to have a high failure rate.^{36,37} Often, replacement of teeth in a compromised site gives rise to single or multiunit restorations that have poor or unfavorable crown-to-implant ratios. If the restoration participates in anterior guidance, it should be splinted to other implants. If the restoration participates in posterior occlusion, it should be protected by natural canine teeth to limit lateral loads in excursions. If it is placed in conjunction with other implants in the posterior, it may be splinted for mutual support.

Occlusion

There are several axioms in implant dentistry relating to occlusion:

- Avoid lateral component forces whenever possible.³⁸
- Establish occlusal forces along the long axis of the implant.
- For added stability, splint implants when possible.
- When restoring occlusion of an entire arch, favor the weaker of the two arches. (In other words, an implant-borne restoration opposing a complete denture should be restored with bilateral balanced occlusion.)

One additional consideration is that, unlike natural teeth, implants have no proprioception. In fact, many patients restored with dental implants have a significantly increased bite force within the first year.^{39–41} In partially dentate cases, the implant restoration should have equal or slightly less occlusal loading than the natural tooth (Figure 14-12). Also, the occlusal contacts should preferably be placed over the platform of the implant to minimize the possibility of screw loosening. Although this often may not be possible, it should be striven for to minimize complications.

Full-Arch Restorations

Full-arch reconstructions of the maxilla should be based on placement of 8 to 10 implants splinted for cross-arch stability.^{42,43} Reasonable length implants (> 12 mm) should be considered especially in the posterior maxilla as shorter implants into this relatively soft bone have been shown to do poorly in the long term.⁴⁴ The maxillary sinuses may preclude placement of a full complement of implants, and sinus augmentation or perhaps the use of extended-length implants into the zygomatic bones bilaterally may allow an optimum force distribution for full-arch prostheses (Figure 14-13).

Full-arch reconstruction of the mandible can involve different considerations as the mandible is a dynamic bone

that flexes and rebounds as it opens and closes. Traditionally, mandibular full-arch reconstruction has involved placement of four to six implants between the mental foramina with a minimal cantilever to the posterior.⁴⁵ The greater the anterior posterior spread, the greater the amount of cantilever possible. On average, a 16 mm distal cantilever is permitted (Figure 14-14). To avoid using a cantilever, it may be necessary to place implants distal to the mental foramen. In such a case, division of the prosthesis into two components prevents unfavorable stress transfer. Another option is to use the distal fixtures for vertical support and not engage the abutment-implant junction with an abutment-coping screw.⁴⁶ This allows some flexure of the mandible without transferring stress to the prosthesis and/or implants. Prosthetic screw or implant failure may result if a solid prosthetic connection spans the splinted first molar regions.

Implant Selection

Historically, osseointegrated dental implants were introduced in their original configuration as a machined parallel walled screw. The implant possessed a platform with a 4.1 mm diameter, an external hex implant platform (originally used to drive the implant into position), and a 3.75 mm diameter body; this has been the most common implant type placed worldwide (Figure 14-15). The original applications were

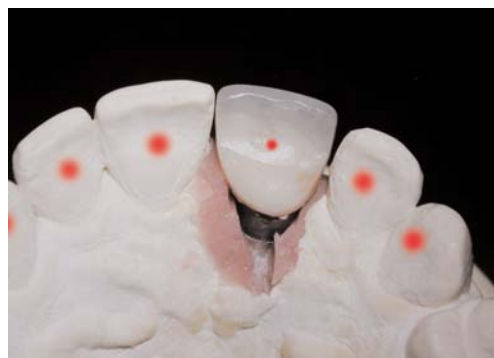

FIGURE 14-12 *Contact of the implant occlusion should be over the platform of the implant and slightly less intense than that of natural teeth.*

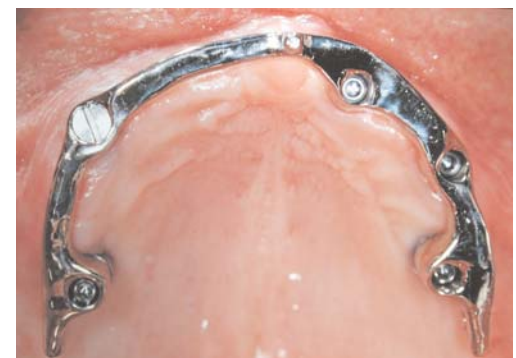

FIGURE 14-13 *Full-arch reconstruction using two zygomatic implants and three endosseous implants.*

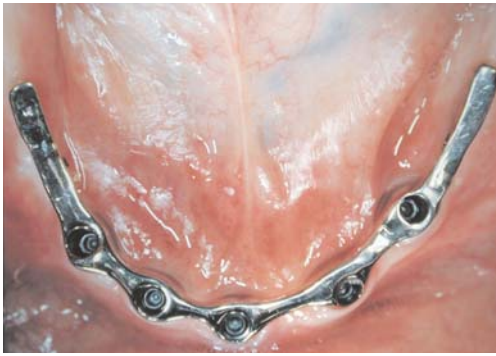


FIGURE 14-14 Cantilevering is about 16 mm.

piloted for the edentulous patient, and limited restorative options were available in the first years of its introduction. In later years the use of surface-textured press-fit type implants also became popular because their surgical installation was simplistic and achieved earlier integration into softer types of bone (Figure 14-16). At this time the connection of abutments or prostheses to the surface of the implant was characterized as a butt-joint connection. Abutment stability with single- and multiple-tooth replacement using standard externally hexed implants has a history of cyclic fatigue with abutment screw loosening.^{47,48} As extended applications developed for the use of replacements for single and multiple teeth and with immediate loading, an increased need for secure abutment connections, esthetic versatility, and improved

surgical stability in trabecular bone became more apparent. Significant mechanical improvement in abutment and screw-retained components occurred in the early 1990s and markedly decreased complications.⁴⁹ Current trends are toward the use of tapered macroretentive implant configurations, based on the fact that tapered screw-type implants have increased surgical stability in soft bone. An example of these types of implants is shown in Figure 14-17. With these trends it is apparent that internal connections are preferable for fixed tooth replacement since abutment screw loosening appears significantly less with internal connections than with butt-joint implants. The Morse taper, a cone within a cone attachment mechanism, is a feature of some implant systems that allow the abutment-prosthetic connection to facilitate installation and to maintain stability (Figure 14-18). This taper creates a seating effect of the connection to the internal aspects of the implant; therefore, fewer lateral stresses are transferred to the abutment screw, resulting in a less frequent incidence of screw loosening and fracture. Morse tapers are measured in percentage units that reflect the shaft length relative to the radius of the shaft. Thus, if for every centimeter of shaft the radius increases 0.01 cm, this would by definition be a 1% Morse taper. Most

Morse tapers are anywhere from 0 to 7%, and dentistry most commonly employs the 4 to 7% series. Use of specific implants resistant to the problems of abutment screw loosening and immediate stability is probably more critical in cases of single missing teeth or in which a cemented implant crown and bridge are planned. The traditional parallel walled screw continues to enjoy success in the general population of edentulous patients restored with implants^{50,51}; the vast majority of prospective and retrospective studies have concluded that this specific implant is highly successful for restorations in edentulous patients.⁵²⁻⁵⁴ Long-term development has resulted in an increased number of components for edentulous applications. The development of an extensive armamentarium of abutment connections and restorative components currently exists for restoration with esthetic fixed prostheses. Many well-known systems have this versatility available, which is especially important when considering implant restorations in the esthetic zone. It is advisable for the surgeon to become familiar with the restorative components available when treatment planning for implants cases. Consideration of the components makes it easier to select the appropriate system for both surgical installation and restoration.

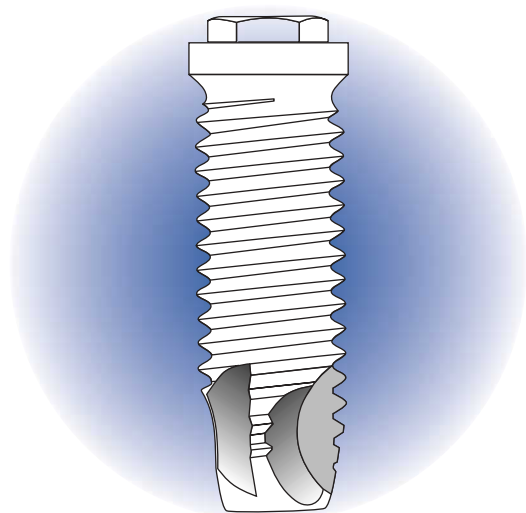


FIGURE 14-15 Standard externally hexed implant.

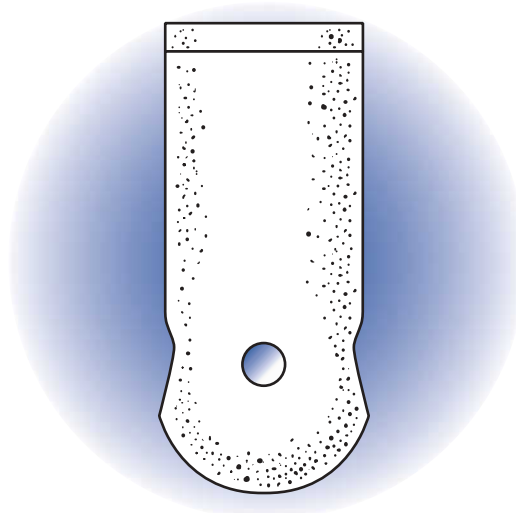


FIGURE 14-16 Press-fit cylinder-type implant.

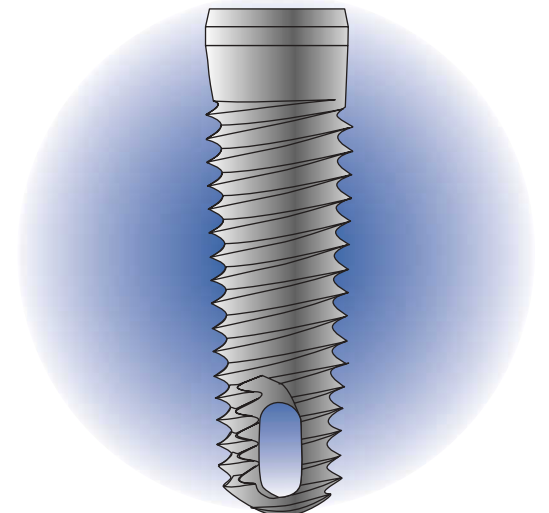


FIGURE 14-17 Tapered-wall screw implant.

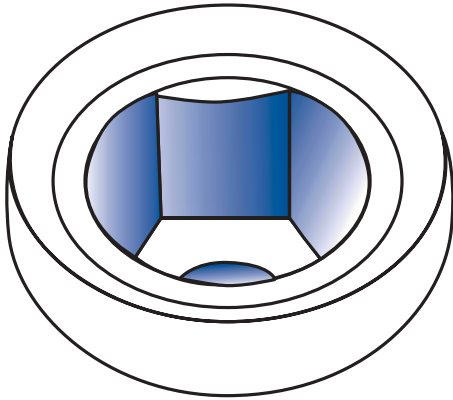


FIGURE 14-18 Morse taper internal connection.

Implant Components

There is a wide array of dental implant components for impression procedures, laboratory fabrication, and direct restorative dentistry. The various types of osseointegrated implants are discussed above.

Abutments are simply transmucosal extensions for the attachment of prostheses. Abutments can be used to provide a restorative connection above soft tissues and to provide for the biologic width. Abutments can be used for attachment of

screw-retained or cemented connections and can be made of metal or ceramic. The most commonly used abutment material is machined titanium, which has been shown to be strong and resistant to plaque retention, and to react favorably to soft tissues. Titanium abutments have been used historically for the attachment of screw-retained connections. Two of these types of abutments are shown in Figure 14-19. Titanium abutments are also used in many cases in which a cemented prosthetic connection is desired. With thin gingiva, the gray hue of these abutments can be problematic in esthetic areas. Cast yellow gold has been used for abutment connections owing to its blend with translucent gingival tissues. Although no hemidesmosomal attachment is found with cast alloys or dental porcelain,⁵⁵ yellow gold creates a warm appearance in esthetically critical areas. In esthetic areas ceramic abutments have also been used in cemented designs for single and multiple-unit crowns (Figure 14-20). Similar to titanium, these abutments manifest a biologic attachment. The material used in

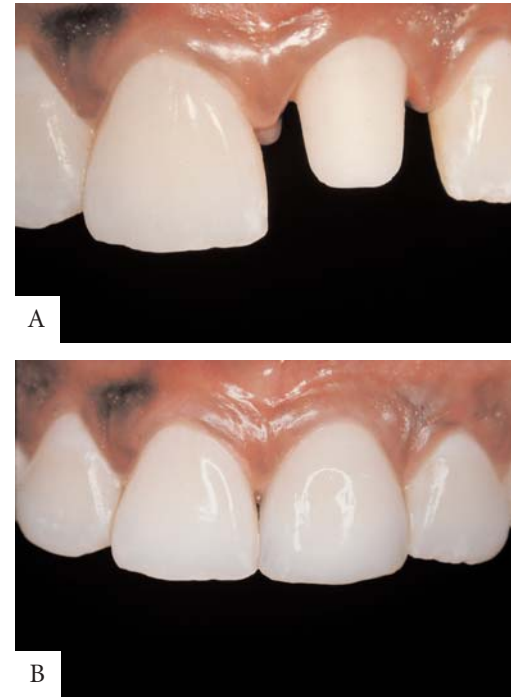


FIGURE 14-20 A and B, Aluminum oxide cemented abutment with an all-ceramic crown. (Prostheses prepared in collaboration with Avishai Sadan, DMD)

these products has been mainly aluminum oxide and zirconium.

The decision to use an abutment for screw-retained restorations can be made based on the depth of tissue. Generally 3 mm or more of tissue depth necessitates the use of an abutment. As with any restorative procedure, biologic width is the driving force between the alveolar bone and the prosthetic margin. If the tissue depth is < 3 mm, biologic width is probably created from a portion of the implant; therefore, the prosthesis may be connected directly to the implant, bypassing the need for an abutment. If the restorative dentist is unsure of which abutment to use, a fixture level impression can be recorded and the selection process completed in the laboratory.

Impression procedures used for dental implants are based on transferring either the abutment position or the implant position to the laboratory. If abutments are to be used for a screw-retained restoration, an impression

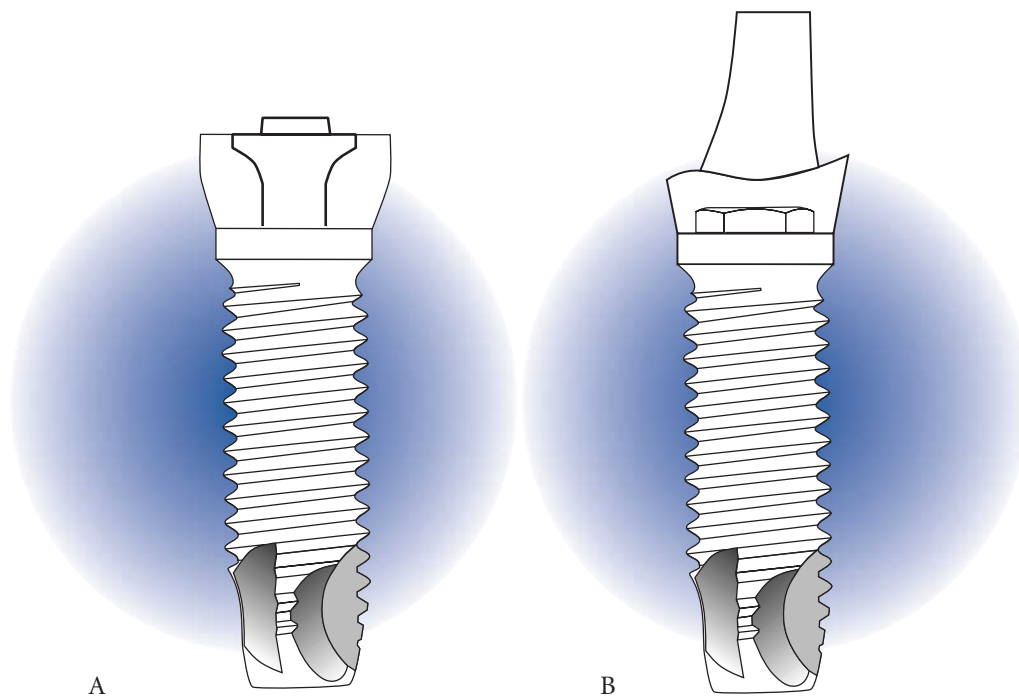


FIGURE 14-19 A, Premachined abutment for screw-retained restorations. B, Abutment for cement-retained restorations.

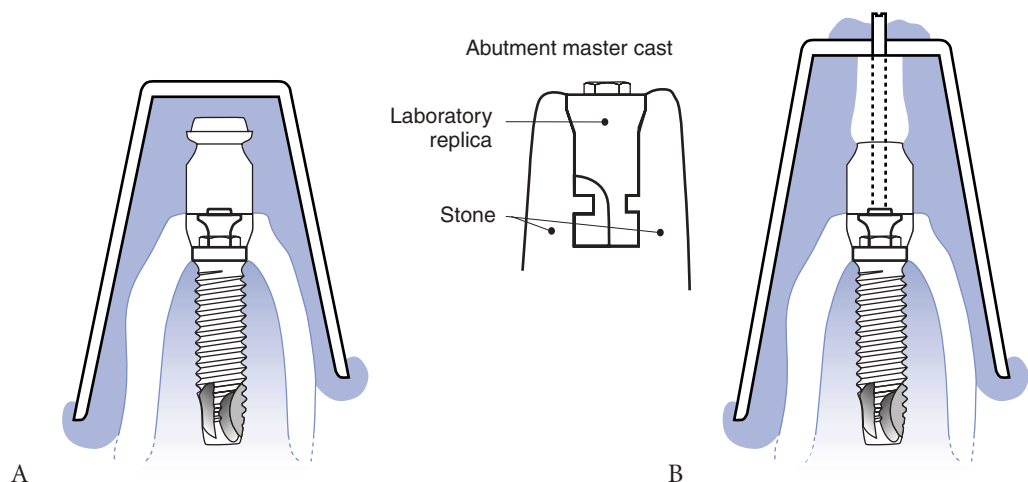


FIGURE 14-21 A, Abutment transfer impression using closed-tray technique. B, Abutment transfer impression using open-tray technique.

coping is placed on the abutment and either a closed- or an open-tray technique can be used (Figure 14-21). The open-tray technique is considerably more accurate and is indicated for multiple splinted units. At this point an abutment analog or replica is attached in the impression and a cast is poured in the laboratory to simulate the oral situation.

If no abutment is to be used or if a cemented design is to be employed, a fixture level impression with an impression post can be made in a similar open- or closed-tray technique. Subsequently an implant analog or replica is attached to the impression post in the impression and simulated gingival material is placed; then a cast is poured to create a soft tissue master model (Figure 14-22). The simulated gingival material allows the dentist or technician to select an appropriate abutment and/or design the prosthesis while preserving the actual position of the gingiva.

Single-Tooth Replacement

The Nonrestorable Tooth

Replacement of a single missing tooth should start with an evaluation of the periodontium and structural support. Periodontal defects, periapical pathology, bone loss, mobility, and pain are indica-

tions for periodontal/endodontic treatment or extraction. Other factors that require assessment prior to consideration for either restoration or extraction are the remaining coronal tooth structure, root fracture, and restorative space. The decimated tooth may have only one wall of the coronal structure missing. Horizontal deficits of this type can be restored by using intracoronal anchorage methods (ie, elective endodontics or post and core). However, vertical deficits that encroach upon the biologic width may necessitate crown elongation to provide enough tooth structure necessary for a ferrule or exter-

nal level, which provides encasement of remaining tooth structure. A 2 mm amount of coronal tooth structure has been shown to improve long-term structural resistance to failure⁵⁶⁻⁵⁸; in total, biologic width plus a 2 mm ferruled tooth structure necessitates about 4 to 5 mm of suprabony tooth structure. If this is not available, it may be created by either orthodontic extrusion or crown elongation, which may sometimes create unfavorable crown-to-root ratios or furcation exposure. In this scenario it may be prudent to consider extraction and either replacement with a fixed partial denture (FPD) or a single-tooth implant-supported restoration. The longevity of an FPD has been examined by a number of studies and is favorable over extended periods of time.⁵⁹⁻⁶¹ Much of the literature indicates standard FPD survival to be in the high eightieth percentile at 10 years and seventieth percentile at 15 years.^{62,63} However, typical complications occurring are related to endodontics, recurrent caries, periodontal factors, and failures in retention. Single-tooth implant studies reveal complications as well.⁶⁴⁻⁶⁷ The incidence of complications for single-tooth implant restorations appears to be significant in comparison with other types of implant prostheses⁶⁸; however, in comparison with

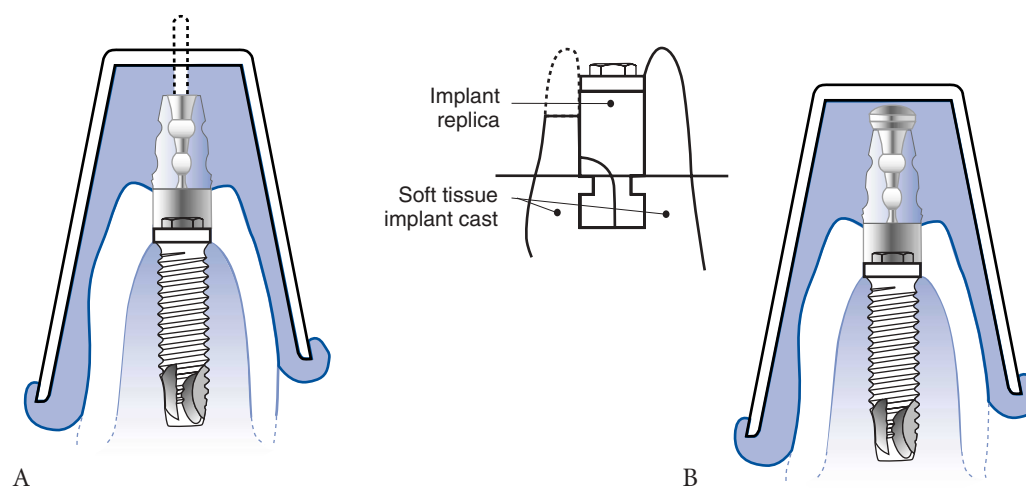


FIGURE 14-22 A, Implant level transfer impression using open-tray technique. B, Implant level transfer impression using closed-tray technique.

other implant restorations, the implant single crown is the most successful. If sufficient bone, soft tissue, and restorative dimension exist, replacement with an implant-supported single-tooth restoration is considered the standard of care and should be offered to the patient.^{69,70}

The success of removable prostheses relies on the combination of retention, support, and stability, which can be deficient. Implant dentistry today is rooted historically from treatment of mandibular edentulism,^{71,72} which is currently the most predictable form of dental implant therapy.⁷³⁻⁷⁶ This success is primarily owing to the high degree of success of osseointegration in the anterior mandible.⁵³ A conventional mandibular prosthesis should be evaluated for retention, support, and stability. Difficulty with speech, swallowing, and mastication should be considered when evaluating prostheses. Patient acceptance of conventional prostheses may be contingent on stability and comfort when masticating. A patient's chief complaint should be closely scrutinized and correlated with the clinical examination to help formulate the proper treatment; the complaint is the foundation for a wide array of considerations that determine avenues possible for a candidate considering treatment with osseointegrated implants. Many of these considerations help to determine which imaging studies, preparatory treatment, and number of ancillary procedures are needed; if the treatment goals are feasible; and what time and cost commitment is involved. Treatment should be targeted at specific goals to achieve a predictable outcome that addresses the patient's functional and/or esthetic problem. The treatment may encompass several different routes paying attention to time, cost, longevity, and levels of invasiveness.

The amount of keratinized/fixed tissue, vestibular depth, available bone, and opposing occlusion are all important factors to consider prior to implant treatment (ie, natural dentition, edentulous arch,

and implant-borne occlusion). It may be appropriate to recommend only an implant-retained overdenture for a favorable mandibular arch. However, mandibular arches with limited support, vestibular extension, and extensive bone resorption may require an implant-borne prosthesis.

The Esthetic Zone

Esthetic considerations encompass additional complex concerns such as gingival display, proportion of teeth in the esthetic zone, and bone density support. The esthetic zone is generally considered to be the maxillary anterior area. When considering replacement of a single tooth in the esthetic zone, the adjacent dentition should also be evaluated for proportionality and position. From a frontal plane the lateral incisor should be about two-thirds the width of the central incisor. Likewise, the width of the canine when viewed from the same vantage point should be about two-thirds the width of the lateral incisor, and so on. The width-to-length ratio of esthetically pleasing central incisors should be about 66 to 80%.⁷⁷ The axioms are ranges found in nature and are considered pleasing to the human eye. If these proportions are not present, they may be created by surgical periodontics, restorative dentistry, orthodontics, and, if appropriate, osseointegrated implants.

Occasionally, replacement of maxillary or mandibular canines may present a compromise in either occlusion or esthetics for the functional goal of eliminating lateral forces on the restoration/ implant. Esthetic and/or functional correction may dictate the need for pretreatment orthodontics, endodontics, periodontics, and concurrent restorative dentistry. A complete examination that includes diagnostic models, radiographs, and clinical photographs can be invaluable.

Esthetic considerations for removable prosthodontics may be a concern for lower edentulous arches when restoring the facial contours typically lost in

mandibular resorption. This is especially true when restoring the skeletal Class II patient. The use of a flange may be necessary to eliminate the labiomental fold usually apparent in these cases. Likewise the use of a flange in the edentulous maxillary arch may be beneficial to restore upper lip support as well as the esthetic integrity so critical to this area. A functional lingual maxillary alveolar seal is essential for correct labiodental consonant production; in cases of advanced resorption of the maxilla, an overdenture may be the appropriate treatment.

Cemented Single Units

Cemented prostheses may be preferable to screw-retained designs for single-unit crowns in the anterior areas. They tend to provide minimized bulk of the restoration. Overcontoured bulky restorations are not hygienic and are detrimental to the maintenance of periimplant tissues. The axis of implant placement should be aimed through the incisal edge for standard-diameter implants (Figure 14-23). This results in predictable esthetics and manageable soft tissues. If a comparably wider implant is placed (4.3, 5.0, or 6.0 mm) in an esthetic site, the long axis should traverse just palatal through the incisal edge. Errors in placement to the facial of the incisal edge produce not only difficulties with angulation correction, but also a soft

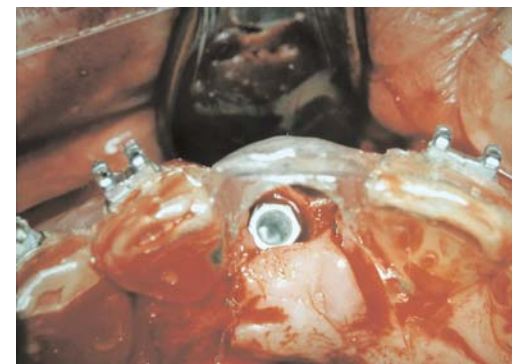


FIGURE 14-23 Long axis of implant placement through the incisal edge of the stent for cement-retained prostheses. (Surgery performed by Michael S. Block, DMD)

tissue problem because the bone support in this area is lost owing to the osteotomy (Figure 14-24). Errors in placement too far palatally create ridge-lapping and hygiene difficulties. The superior/inferior placement of the implant platform should be 3 to 4 mm below the anticipated free gingival margin. The use of a surgical stent in placement aids in creating an optimal site for implant restoration. The choice of cemented restorations for a posterior tooth is plausible and becomes especially useful when angulation in placement is less than ideal. However, the resistance and retention form of the abutment should be sufficient to resist dislodgment. The choice of specific abutments can be planned in advance if placement is based on an ideal scenario. Anatomy should not dictate placement of the implant position, but rather the placement should be based on restorative parameters. This information can be obtained by the use of surgical stents, which may provide critical information about where to develop the occlusion and where to recreate the emergent path as the restoration exits the gingival sulcus.

Screw-Retained Single Units

The treatment plan for replacement of a single tooth with screw retention is the professional preference of the restorative dentist. There are advantages and disadvantages to using this design for single and multiple missing teeth (Table 14-2). Screw-retained prostheses are simplistic

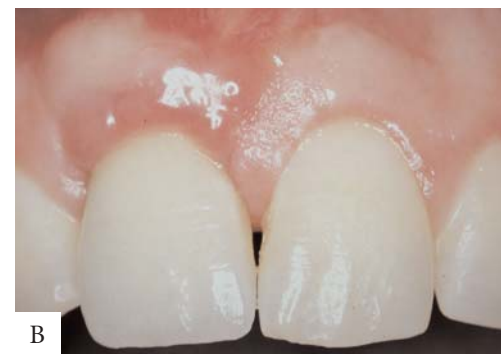
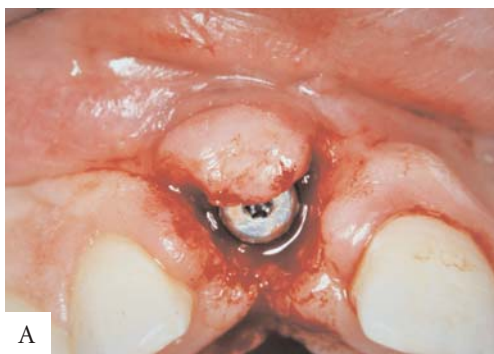
FIGURE 14-24 A and B, Implant placed too far facially resulting in compromised periimplant soft tissues.

to retrieve, easy to trial fit, and can be shaped to the desired emergence with either porcelain or metal. This design also eliminates the uncertainties of loosening and incomplete debris removal associated with cemented prostheses. However, using screw-retained prostheses requires strict attention to placement and confines the axis of the implant through the desired area of emergence within the restoration. Screw retention for single units in the esthetic area may be problematic with respect to hygiene as these sites frequently have a full complement of bone and soft tissue on adjacent teeth (Figure 14-25). This can create an almost unavoidable situation of ridge lapping to provide the palatal access channel needed. Screw-retained prostheses are especially useful in the posterior dentition as retrievability is much easier than with the cemented prosthetic design, and a controlled degree of retention is afforded as well.

Restorations for the Partially Edentulous Patient: FPDs

FPDs require the first assessment of site planning as with other types of restorations. It is of prime importance to understand that the implant bridge should be supported entirely by dental implants. Combining the support with natural teeth has been shown to involve prosthetic complications and intrusion of the abutment teeth for a number of reasons.^{78,79} Although these studies may use the specific scenario of a three-unit FPD supported by a natural tooth and implant, other studies have advocated strategic teeth in combination with implants for full-arch prostheses.^{80,81} It is prudent to keep the restoration supported entirely by dental implants to avoid problems concerning abutment fracture, screw loosening, tooth intrusion, malocclusion, and other complications.^{82,83} Designing the FPD to be screw retained as opposed to cement retained is largely based on personal

Table 14-2 Screw Retention versus Cement Retention

Advantages		Disadvantages	
Screw Retention	Cement Retention	Screw Retention	Cement Retention
Retrievability	Esthetic	Implant placement critical	Cement removal subgingivally
Porcelain emergence	Angle correction possible	Screw access channel visible	Abutment selection critical in anterior
Cost effective	Less bulk of restoration in anterior areas	Deep channels should be sealed	Provisional restoration needed in anterior
Elimination of cement retrieval	Built in load indicator by two interfaces		Cost factor with abutment/restoration
			Problematic retrievability

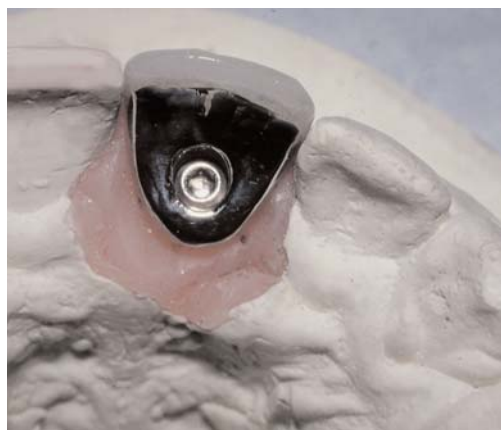

FIGURE 14-25 Screw-retained restorations in the esthetic area require more attention to placement orientation and hygiene.

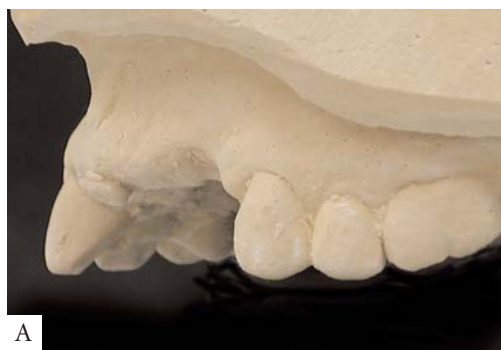preference but may be tailored to what can be serviced and maintained most easily.

FPDs in the Esthetic Zone

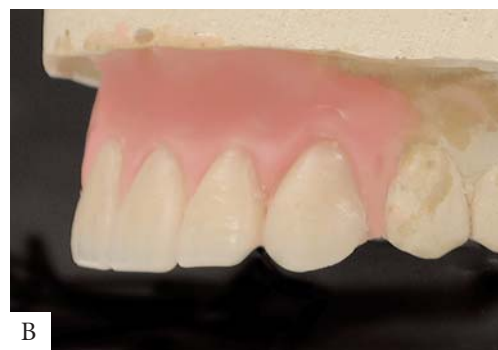Placement of multiunit restorations in the anterior maxilla should bring to mind several anatomic considerations for surgical planning:

- Length of the residual alveolar ridge to the nasal floor
- Buccolingual width of the bony ridge to provide for implant placement
- Available bone for angulation of implants to provide for either screw retention or cement retention
- Participation of the restoration in anterior guidance

Anterior FPDs or any restoration in the esthetic zone should first begin with a diagnostic wax-up or template (Figure 14-26).



A



B

FIGURE 14-26 A and B, Diagnostic cast and wax-up of missing maxillary anterior teeth.

This will give an idea as to the incisal edge position as well as the available restorative dimension, and should be verified in the patient's mouth to correspond with facial landmarks such as the center of the face and interpupillary line. Also, a proportional relationship should exist from the central incisor to the canine from an anterior perspective. This proportionality becomes critical in esthetically prominent areas. The wax-up may also indicate how much tissue has been lost as a result of the missing teeth, soft tissue, and associated alveolar process. In these cases it may be necessary to consider horizontal or vertical bone augmentative procedures as a first phase followed by placement of implants in a second phase. In some cases it may not be feasible to perform bone grafting owing to local or systemic factors. Making precision detachable bridgework that replaces teeth, soft tissues, and alveolar bone may be more predictable in these circumstances. If the surgical work-up determines implant placement will be done concomitantly with or without a bone graft, the diagnostic wax-up should be used to fabricate a surgical guide or stent for implant placement. If a bone graft is necessary, the surgical guide references the incisal edge and gingival aspect of the future restoration to aid in establishing the proper amount and positioning of the bone graft (Figure 14-27). Superior/inferior positioning of implants is virtually the same as for single units, described above. However, the mesiodistal assessment of restorative space should be done first to determine the

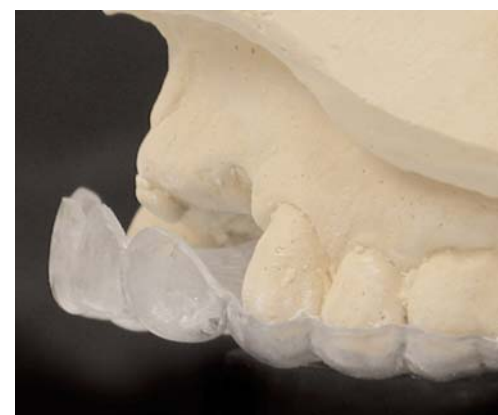

FIGURE 14-27 Surgical stent gives an indication of the location and amount of tissue loss.

appropriate implant number and dimension to be placed. Using a 2 mm rule from each adjacent tooth and a 3 mm rule from implant to implant, the appropriate implant number and dimension can be calculated (see Figure 14-2). If the available space does not allow an appropriate number of implants or encroachment upon the implant-implant proximity, either restorative dentistry and/or orthodontics may be indicated. Occasionally, use of a cantilevered bridge design can be advantageous where space constraints or insufficient bone prohibits placement. If it becomes necessary to cantilever the FPD either mesially or distally, a screw-retained design permits a framework that better withstands the cyclic loading of occlusion and subsequent problems with porcelain fracture or other material failure. Screw-retained prostheses require an entirely passive fit. It is considerably more difficult to create a passive-fitting screw-retained framework than a cemented framework that has intimate fit with the supporting abutments. Conversely, it becomes occasionally necessary to perform angle correction as there is frequent disparity between the long axes of tooth to the long axis of bone available in the anterior maxilla. An intimate fit of FPDs is far easier to achieve with a cemented prosthetic design than with a screw-retained restoration. The subtle inaccuracies of impression making, alloy casting, and

porcelain application make the simultaneous and coincident fit of screw-retained FPDs difficult; thus, a cemented prosthetic design is a more appropriate choice. With a cemented design, the creation of a surgical stent is critical for accurate placement and esthetic success of the implant restoration. After placement and uncovering of the implants, it is prudent to create provisional restorations to develop soft tissues.⁸⁴ Only in this way can an acceptable esthetic outcome become predictable in the esthetic zone.

FPDs in the Anterior Mandible

Placement of multiple-unit restorations in the anterior mandible requires similar forethought as with the anterior maxilla. Placement of multiple implants in the anterior mandibular area presents a unique challenge in that one-to-one replacement of teeth with implants can create proximity concerns (Figure 14-28). Tarnow and colleagues have outlined the pattern of bone loss to be about 3 mm from the edge of the implant to an adjacent implant.⁸ Therefore, placement of implants closer than 3 mm to each other creates accelerated bone loss patterns in these areas. This pattern seems to be somewhat less (about 2 mm) when the implant abuts a natural tooth. Since the anterior mandible is mostly composed of dense compact bone, an implant-to-tooth replacement ratio of 1:2 may be acceptable

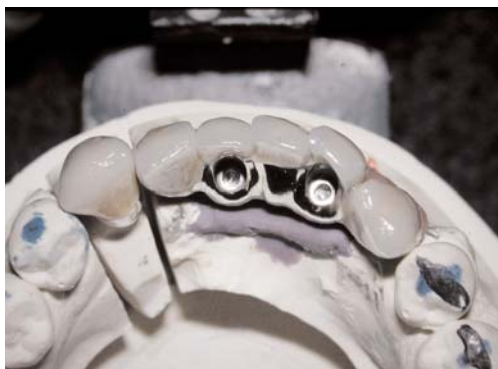

FIGURE 14-28 Placement of two implants in strategic locations to permit hygiene access and force distribution.

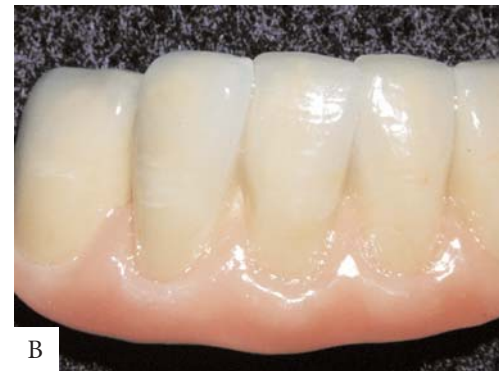
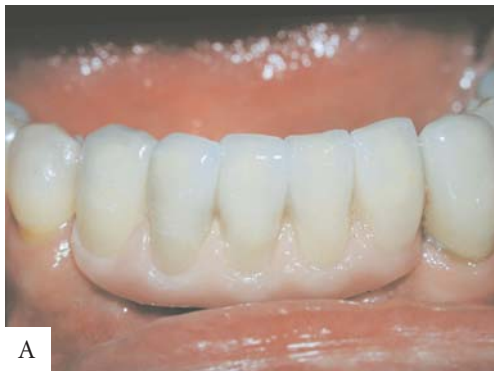
FIGURE 14-29 A and B, Screw-retained prosthesis permits hygiene access.

as long as the crown-to-implant length ratio is 1:1. Gingival adaptation in the anterior mandible is not as critical as it is in the anterior maxilla because phonetics are primarily made in relation to the maxilla. Screw-retained designs for FPDs in the anterior mandible seem to work well (Figure 14-29). Implant proximity should also be assessed prior to placement for hygiene procedures as the placement of even an appropriate number of small-diameter implants in this area can create hygiene difficulties.

FPDs in the Posterior Maxilla

Placement of implants in the posterior maxilla requires sufficient bone buccally and lingually as well as inferior to the maxillary sinus. In general, 12 mm of bone in actual height is the minimum required for a macroretentive screw-type implant to adequately support occlusal forces. After the loss of a tooth in the posterior maxilla, this required dimension might not be available (Figure 14-30). Progressive enlargement of the maxillary sinus is often seen after tooth loss as well as residual ridge resorption. Diagnosis of either of these problems helps one determine the appropriate treatment. If pneumatization has taken place, sinus augmentation procedures can be indicated either with concomitant or delayed implant placement. Residual ridge resorption or traumatic destruction of alveolar bone by trauma or periodontal disease may also have taken place. In these cases, onlay bone

grafting may be a more appropriate treatment (Figure 14-31). The decision to replace a posterior maxillary quadrant with individual crowns versus fewer splinted implants acting as an FPD may be related to the length of implant or the presence of natural canine teeth with cuspid-protected occlusion (Figure 14-32).⁸⁵ In general, horizontal forces acting on implants are considered destructive.^{86,87} It is desirable to use these implants as a vertical stop in the chewing cycle. If lateral components of the chewing cycle are unavoidably placed on the implant restorations, they should be splinted together. Other strategies place the implants in a slightly staggered configuration from buccal to lingual and then splint them together. Screw-retained designs seem to allow retrievability and offer advantages for modifying hygiene and performing reparative ceramometal procedures.

FPDs in the Posterior Mandible

As with the posterior maxilla, tooth loss for an extended time can result in residual ridge resorption. In such cases onlay bone grafting may provide an appropriate bone volume for implant installation. A limiting factor for implant placement in the posterior mandible is not only residual ridge resorption but also relative position of the inferior alveolar canal. Panoramic radiographs may give a full appreciation of the position of the inferior alveolar canal. In some patients this may assume a relatively high position making placement of

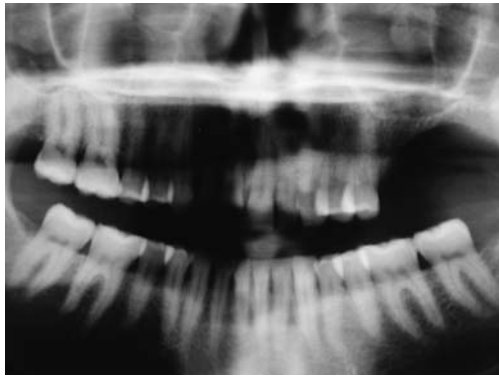


FIGURE 14-30 Alveolar bone loss resulting in the need for an onlay bone graft prior to implant placement.

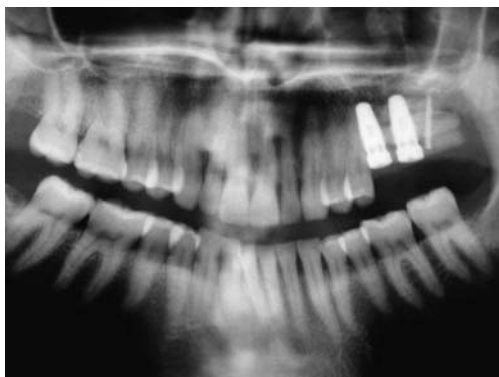

FIGURE 14-31 Cranial onlay bone graft in the posterior maxilla. (Image courtesy of Leon F. Davis, DMD, MD)

implants of reasonable length impossible. In these cases lateral positioning of the inferior alveolar nerve with implant placement may be the only option for treatment other than a removable partial denture. Nerve repositioning is an effective adjunct in implant placement, but the technique

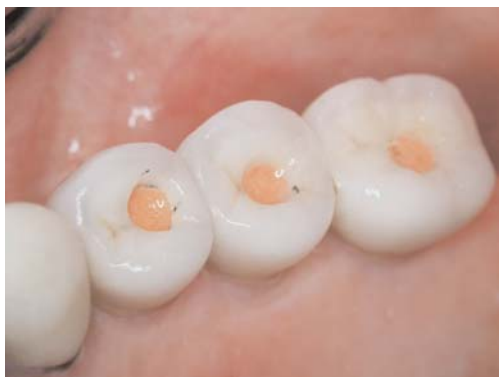

FIGURE 14-32 Individual fixed units protected from canine rise in lateral excursions.

can have significant adverse nerve injury (Figure 14-33).⁸⁸

Cantilevered FPDs

Cantilevered fixed prostheses may be used in implant dentistry provided there is adequate length to the supporting implants and limited distance to the cantilever. This may be especially useful when there is an insufficient amount of bone or when significant site morbidity may result. Posterior or cantilevering probably is a more common scenario, typically owing to a greater availability of bone in the anterior area of the jaws. Anterior cantilevering may be used in areas where posterior anchorage is superior to anterior anchorage (Figure 14-34). Cantilevering requires that a framework be connected at a maximum clamp force; such stability is best achieved with screw-retained frameworks. Occlusal contact created on the pontic should be very light to coincident.

Restorations for the Edentulous Patient

Implant-Retained Overdentures

Those over 65 years of age are said to represent a significant proportion of the US population, and the average life expectancy has risen by 30 years since 1900.⁸⁹ This is due mostly to the increase in medical advances and critical care. A sizable portion of this group is edentulous or partial-

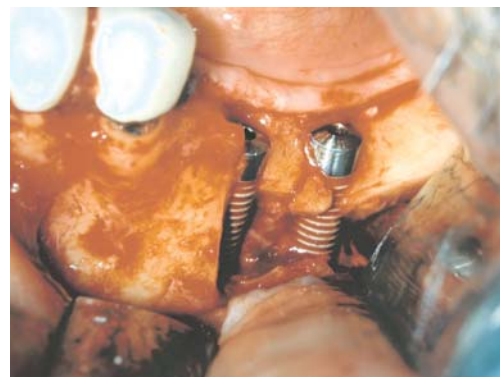

FIGURE 14-33 Placement of two implants in the posterior mandible after inferior alveolar nerve transpositioning.

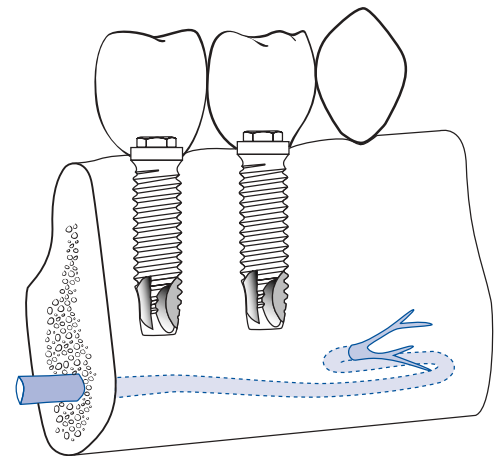


FIGURE 14-34 Anterior cantilever fixed partial denture.

ly dentate in at least one arch.⁹⁰ Many in this age group have difficulty wearing mandibular complete dentures owing to poor support and retention precipitated by advanced bone resorption, xerostomia, loss of attached keratinized tissue, and neuromuscular degeneration. The use of implants for these edentulous patients has been shown to actually preserve existing bone as opposed to results with conventional dentures.⁹¹ Increased support and anchorage can be improved with the use of at least two osseointegrated implants in the anterior mandible. The use of stud attachments connected to the implants can be a cost-effective measure to improve retention, stability, and support (Figure 14-35). If a stud-retained denture is planned, the implants should be as parallel

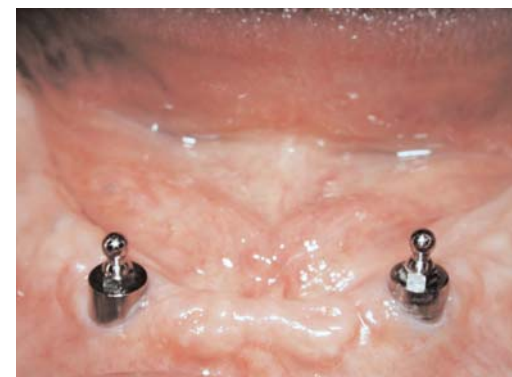

FIGURE 14-35 Stud-retained overdenture using O-ring attachments.

as possible to avoid premature wear of the attachment mechanism. The vertical height of the attachment should be considered as some edentulous mandibular arches do not provide > 4 mm of restorative dimension for the mandibular denture. Preoperative planning calls for the evaluation of the patient's present difficulty. Reasonable esthetics, occlusion, and extension should be evaluated first. If these factors seem to be appropriate, panoramic radiographs and possibly an occlusal radiograph are helpful in determining the position of the mental foramina. A prime objective is to place at least two implants as far apart as possible within this area. The anterior loop of the inferior alveolar nerve can extend as far forward as 7 mm prior to exiting the mental foramen; thus, consideration should be given to proper site selection.⁹² A radiographic marker such as a piece of foil taken from a film packet or a standardized stainless steel shot can be secured to the patient's denture and placed in the mouth prior to panoramic and/or occlusal radiography. This will give an indication of the correct site selection for implants in the anterior mandible. After the site has been selected, an open channel can be created in the stent to allow surgical latitude. Either duplication of the patient's denture or a wax trial tooth subsequently processed in clear acrylic resin can be helpful in determining the position. In general, tapered arch forms with extensive resorption may direct placement of implants in close proximity to each other. In other words, implants placed < 20 mm apart may not be mechanically advantageous for use independently as stud attachments. In these cases, it may be desirable to connect the implants with a bar attachment to create a wider base of anchorage (Figure 14-36). There are several reasons to plan the implant-retained denture for a bar attachment. First, short (10 mm or less) implants or implants placed in cancellous bone or types 3 and 4 bone, not typically

seen in the anterior mandibular area, may be better supported by the splinting effect of a bar attachment. Second, non-parallel implants create different paths of insertion, which subsequently serve to wear and disable the stud attachment prematurely. In these cases the bar attachment can correct this problem by providing a single path of insertion. Third, implants placed in close proximity to each other may provide better anchorage to the overdenture if a bar attachment is incorporated that places the attachment mechanism at a wider base than the interimplant distance.

There are some spatial considerations of using a bar attachment that should be evaluated prior to treatment planning. The vertical height needed for a bar attachment can approach 11 mm. This measurement is taken from the occlusal plane to the highest point of the alveolar process. This distance will provide for the height of the bar (2 to 4 mm), 2 mm under the bar for maintenance of hygiene, and at least 7 to 8 mm of restorative material in the overdenture (usually acrylic resin) (Figure 14-37).

Implant-retained overdentures for the maxilla should always incorporate the use of bar attachments. The literature cites poor long-term success for lone-standing implants supporting overdentures in the maxilla. A minimum of four implants in the anterior maxilla splinted with a bar seems to be appropriate treatment. When-

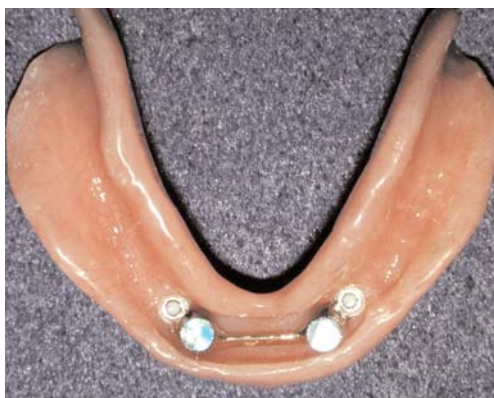

FIGURE 14-36 Bar-retained denture using distal attachments to widen the retentive base.

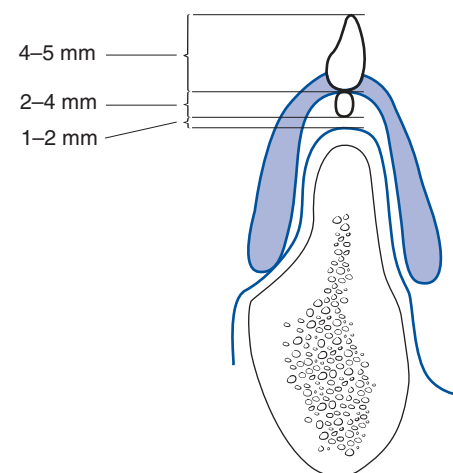


FIGURE 14-37 Minimum clearances needed for a bar-attached overdenture.

ever possible, cross-arch stabilization is preferred for maxillary implant-retained or supported overdentures. In these cases it may be prudent to also incorporate full palatal coverage to assist with some residual load transfer to the hard palate. The prosthetic treatment of these implant cases is assimilated to the Kennedy Class I partially edentulous arch in that stress-breaking attachments and stress distribution to the soft tissue support posteriorly are important considerations.

Implant-Supported Overdentures

Implant-supported overdentures may be indicated when a patient has significant difficulty in all factors of support, retention, and stability. Anatomically there may be cause to suspect that extensive resorption has taken place that has resulted in the loss of alveolar structure. Consequently, implant anchorage can be used to aid in the support and retention of overdenture prostheses.

Historically, most of the literature available on implant-supported restorations in the mandible has been planned for four to six implants intraforaminally.^{93,94} More contemporary literature suggests the use of four widely spaced implants in this region opposing an edentulous arch with equally successful rates.^{95,96} The strategy for using implants in the anterior mandibular

area allows segments to be cantilevered posteriorly in accordance with the antero-posterior spread of the implants.⁹⁷ On average, this equates to 10 to 20 mm or to the area of the lower first molar.^{98,99} The decision to extend the cantilever can be based on the arch form of the fixtures, fixture length, anterior cantilevering, natural maxillary dentition, and parafunctional habits.¹⁰⁰ Favorable factors for extension of the cantilever are a tapered arch with long fixtures, no anterior cantilevering, edentulous maxillary arch, and no parafunctional activity. The most posterior implant supports a load typically of compression in comparison to the anterior fixtures, which are placed under tension. Also, the mandible may be viewed as a dynamic bony structure undergoing flexure.¹⁰¹ This can approximate 2 mm at the mandibular angle upon maximum opening. For this reason, implants placed distal to the foramen should not be rigidly connected to the contralateral side.^{102,103} Implants planned for support of a prosthesis in the edentulous maxilla should involve at least eight fixtures. This may require the use of sinus augmentation or extended-length implants into the zygomatic process. The use of cantilever extensions in the maxilla should be limited to 10 mm.¹⁰⁴

Attachment mechanisms for implant-supported overdentures can range from the simple to the sophisticated. Bar-clip attachments are a cost-effective and predictable means of connecting implants. More sophisticated milled-bar and plunger attachments can be precision methods in telescopic placement of a removable prosthesis. The milled bar can be machined to a 2° taper, allowing a precise path of placement (Figure 14-38). The underside of this overdenture has a cast metallic housing that acts as a guide over the milled-bar attachment (Figure 14-39). Usually this restoration contains either plunger or swivel attachments that lock the overdenture as it comes to complete placement over the bar attachment. This



FIGURE 14-38 Bar attachment milled to a 2° taper for implant-supported overdenture.

technique is very effective but can allow a small degree of micromovement.

An additional method of electrical discharge machining, also known as spark erosion, can be used in these cases; it results in a precise fit between the superstructure and bar. This technology, which results in an essentially detachable fixed bridgework, may be prohibitive in costs. This three-level treatment in an edentulous patient has predictable results.

Fixed Detachable Prostheses

One alternative treatment method for an edentulous mandible is the use of a hybrid denture also known as a fixed removable restoration. This restoration contains a screw-retained metal framework with a veneer of acrylic resin and denture teeth, thus earning the term *hybrid*. Such restorations are fixed and are not removable by the patient; however, they do allow adequate room for oral hygiene procedures (Figure 14-40). As might be expected, no denture flange is present and a minimum vertical restorative space of 15 mm is necessary for structural integrity and hygiene access. Placement of implants for a hybrid denture must incorporate the use of a surgical stent as the exit sites for the access channels are critical. The surgeon may be cautioned against using a hybrid denture in those patients with a skeletal Class III or severe Class II relationship as revealed by cephalometric

radiography. Access to channel location and cantilevering and maintenance of hygiene would be the resultant problems if used in these patients. Recently, application of this immediate-load and immediate-restoration technique has become popular. Prefabricated versions of the technique have also enjoyed widespread success. Chapter 13, “The Zygoma Implant,” elaborates on this topic.

Of course, a full-arch ceramometal restoration could also be used in these circumstances in which a minimal restorative dimension exists. In this circumstance screw-retained prostheses would offer stable occlusal support while allowing some degree of posterior cantilevering.

Treating patients with an edentulous maxilla is dependent upon a number of factors. The primary determining factor is

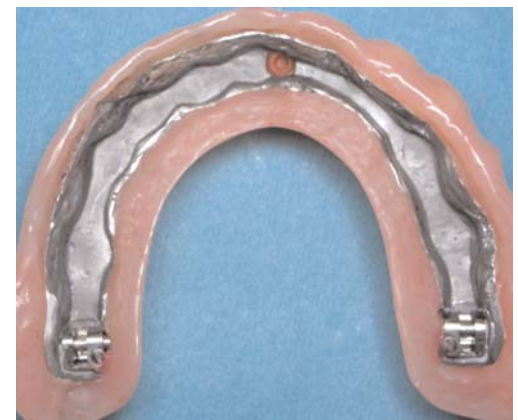

FIGURE 14-39 Precision detachable overdenture with attachments for engaging the bar. (Prostheses courtesy of Northshore Dental Laboratory, Lynn, MA)

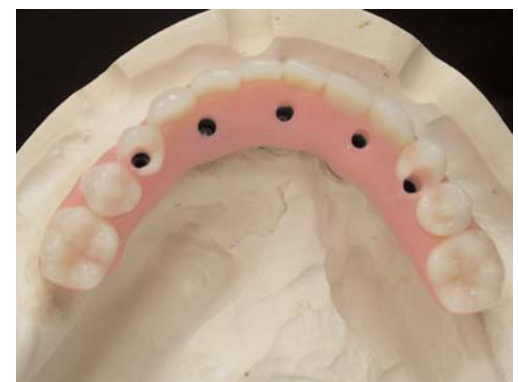

FIGURE 14-40 Mandibular hybrid denture.

one of available space. Generally, the more space available (13+ mm vertically), the more indication there is for an overdenture prosthesis. Incipient resorption or minimal space availability (9–12 mm vertically) may indicate the use of a ceramometal design (Figure 14-41). Implant-supported maxillary overdentures are frequently used in cases of moderate to severe resorption as they replace not only missing mastication and esthetics but also phonetic physiology as well. Speech production may rely heavily on adaptation of the prosthesis to the palatal gingiva. This is best accomplished with an overdenture prosthesis to seal this linguoalveolar area phonetically. Attachment mechanisms for the maxillary implant-supported overdenture are the same for the mandibular overdenture with the exception of plunger or locking attachments placed palatally (Figure 14-42).

Contemporary Techniques

Immediate Placement

Immediate placement of implants into extraction sockets has been considered for some time. Although it has been performed successfully, inflammation and infection should be eradicated for predictable osseointegration to occur. Considerations for using immediate placement capitalize on the osteogenic potential of a recent extraction site and the chance to

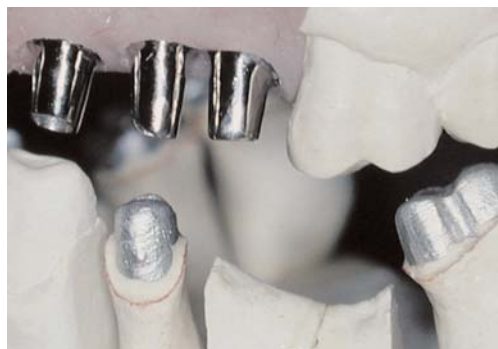

FIGURE 14-41 Full-arch ceramometal fixed prosthesis cemented on custom fixed abutments. (Prostheses courtesy Steven LoCascio, DDS)

preserve what bone remains.^{105,106} The use of tapered implants in these sites has become popular to obliterate the socket defect while being firmly anchored in the majority of the bony walls. A word of caution is advised for those teeth that have drifted or are not in an ideal location as tooth position influences implant position. Indications for placement into a recent extraction socket are freedom from infection and reasonable orientation of the existing tooth. Ways of facilitating this technique may incorporate orthodontic extrusion to create a smaller socket in the bone, facilitating extraction, and overcorrecting bone apposition to recreate missing architecture (Figure 14-43).¹⁰⁷ The extrusion should take place slowly, usually over 3 to 6 months.

Surgical Installation Stability

Installation of implants into bone usually is characterized by minimizing the inherent gap between the implant and bone surface. Although this can be accomplished with both screw-type and press-fit implants, parallel- and tapered-walled screws are uniquely suited to providing firm stability at surgical placement.^{108–110} This becomes an important consideration when achieving osseointegration under placement either in an extraction site, where a provisional restoration will also be inserted, or where other implants will be joined for an immediate-load prosthesis.

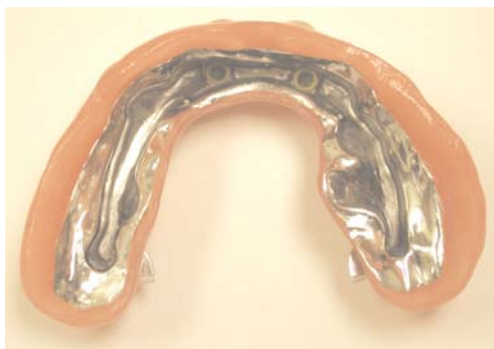

FIGURE 14-42 Swivel latches placed to the palatal aspect for a maxillary spark erosion overdenture prosthesis.

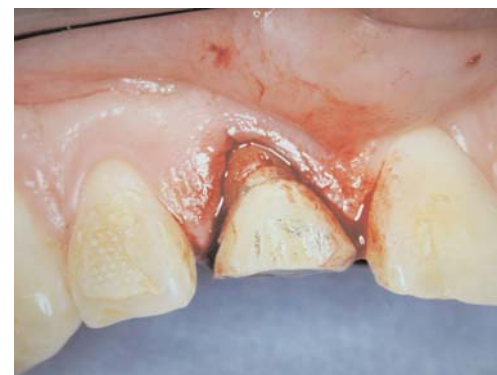

FIGURE 14-43 Orthodontic extrusion of a non-restorable tooth to aid with migration of the soft/hard tissue as well as atraumatic root removal.

For immediate placement after extraction, the socket should be obliterated by the implant and/or grafting materials. Micro-movement in excess of 50 to 75 μ m has been shown to inhibit osseointegration to a fibrous tissue deposition instead of bone apposition¹¹¹; therefore, occlusion placed on a provisional restoration during the critical period of osseointegration must be carefully controlled to eliminate this scenario. Interproximal contact with adjacent teeth should also be eliminated. If this modality is desired, a more controlled technique of protecting the occlusion with a centric relation splint orthotic may be appropriate. Immediate loading for single teeth mandates more data before it can be recommended for routine use. However, controlled immediate loading of multiple connected implants in the anterior mandible has been favorably surveyed and can be cautiously recommended as long as there are careful control of occlusion and passive splinting frameworks.¹¹²

Immediate Restoration

Immediate restoration of a single-tooth implant may be incorporated in the esthetic zone (Figure 14-44). The indications are freedom from occlusal overload and lateral forces. Sometimes, it is difficult to control occlusion, and the creation of an occlusal splint may be a prudent way to protect the implant while osseointegration

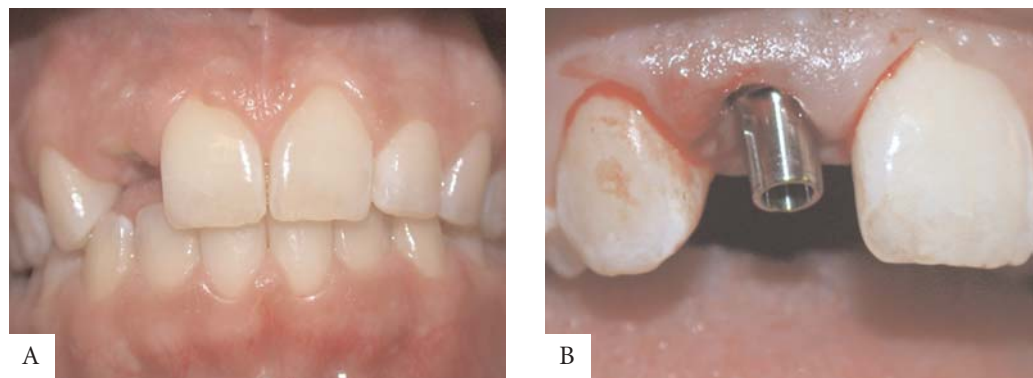

FIGURE 14-44 A and B, Nonrestorable fractured tooth replaced with an immediate implant.

takes place (Figure 14-45). The advantages of immediate restoration are the establishment and preservation of the periimplant tissues. It is easier to preserve this tissue than to recreate it by using a staged approach. Usually provisional restorations are placed upon single or multiple units during osseointegration.

Immediate Load

Single-Tooth Prostheses Studies of immediately loaded single-tooth implants are not widespread. However, data taken from a selected number of studies indicate an 85% success rate on single-tooth prostheses in the anterior maxilla and other areas.¹¹³⁻¹¹⁵ More data are needed before this can be recommended as a standard treatment. Protection of the implant from overloading is critical as osseointegration is interrupted at 50 to 150 μm of repeated movement.^{111,116} Therefore immediately loaded implants should be kept free from interproximal contacts as deflection mesiodistally can also promote micromovement.

Fixed or Overdenture Prostheses The use of splinted implants immediately loaded in the mandibular anterior region has been discussed by Schnitman and colleagues,¹¹⁷ Henry and Rosenberg,¹¹⁸ Randow and colleagues,¹¹⁹ and others.¹²⁰ Results indicate a favorable response. In fact, the Novum System (Nobel Biocare,

Yorba Linda, CA) is a prefabricated immediate-load fixed denture system that enjoys widespread success (Figure 14-46).¹²¹ The Novum System is discussed in Chapter 13, “The Zygoma Implant.” Controlled loading of splinted implants in the mandible using other techniques has produced favorable results, especially when the installation torque exceeds 45 Ncm. Passive retentive bar attachments are the requisite because loading is accomplished more effectively with mutual support of multiple implants.

Maxillofacial Prostheses

Patients treated for tumor ablative surgery of the oropharyngeal area may have a significant deficit of anatomic structures necessary for oral function. The incidence of oral cancer approaches about 5% of all new cancers diagnosed in the US general population.¹²² A significant number of

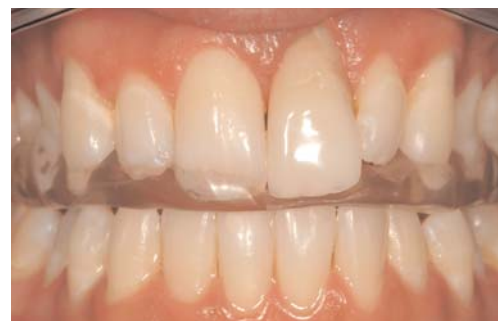

FIGURE 14-45 Use of occlusal splint to protect an immediately placed implant/restoration in site no. 9. Note that the splint is relieved from contacting tooth no. 9.

these patients are treated for malignant neoplasms of the lip, tongue, oropharynx, mandible, maxilla, soft palate, larynx, external ear, orbit, and external nose. To successfully eradicate disease, these tumors are treated with multimodal therapy of tumor ablative surgery, radiotherapy, and chemotherapy. The highest incidence of this disease afflicts those individuals with significant risk factors of excessive use of alcohol and tobacco, and other factors such as ultraviolet light exposure and infection with human papillomavirus. A common site of development of squamous cell carcinoma is seen in the lower lip and ventrolateral tongue. Occasionally, this disease expands by direct extension to involve structures of the mandible and maxilla.

Mandible Defects

Resection of a portion of the mandible may be necessary to control disease and may create a discontinuity defect. Since the mandible is so integral to oral physiology, it is desirable to preserve function as much as possible.

If a marginal mandibulectomy is performed, the remaining mandible may be reconstructed with osseointegrated dental implants. Preservation of the inferior alveolar nerve may preclude placement if there is minimal bone available above the canal position to stabilize implants (Figure 14-47). In these cases

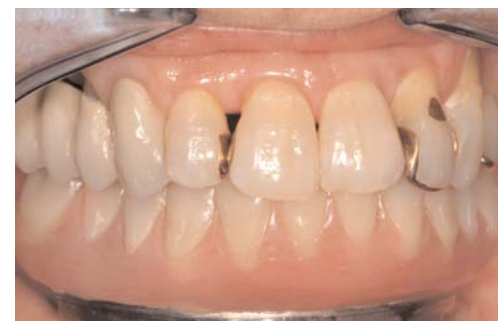

FIGURE 14-46 Novum restoration (Nobel Biocare, Yorba Linda, CA) installed into an edentulous mandible.

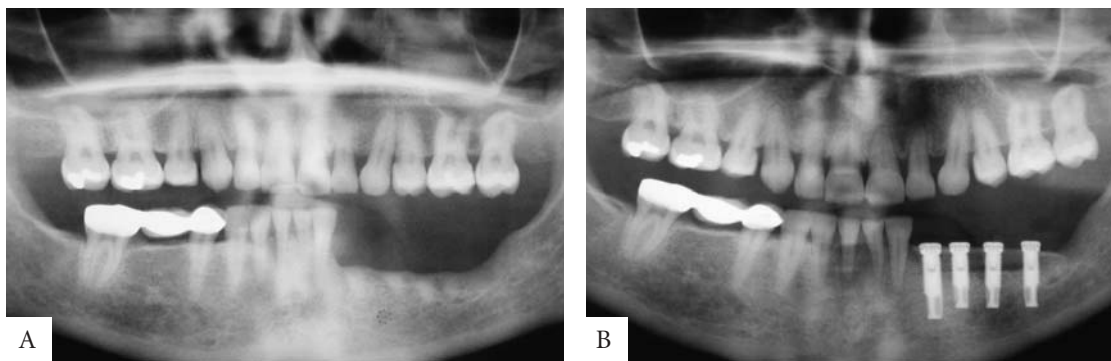


FIGURE 14-47 A, Mandible with insufficient supracanal height for implant installation. B, Iliac crest graft to mandible stabilized by placement of osseointegrated implants. (Surgery performed by Michael Miloro, DMD, MD)

either nerve transposition or onlay bone grafting may serve to provide osseointegrated rehabilitation. If mandibular continuity is not preserved with resection, it may be desirable to reconstruct the area with an autologous or alloplastic graft. Autologous grafts offer a greater volume of viable bone with progenitor cells capable of creating a more favorable environment for osseointegration. Nonvascularized or vascularized osteomyocutaneous flaps can be used for reconstruction. In previously operated fields it may be preferable to use a vascularized flap that may offer a secure opportunity for the graft to remain viable since the blood supply is preserved. The iliac crest has been used with some degree of success for mandibular defects and some maxillary defects as well. Introduced by Hidalgo, the use of fibular grafts has also shown a promising degree of success in reconstruction of these complex mandibular defects.^{123,124} Being a non-weight-bearing bone, the fibula is of reasonable dimension to functionally and cosmetically reconstruct the mandible. Bicortical stability for concomitant or delayed implant placement can be also well obtained at surgical installation, and long-term success has been observed (Figure 14-48).¹²⁵ The choice of whether to use either a sectional overdenture design or a screw-retained fixed prosthesis may be based on the amount of tissue missing, the function of

the tongue, peri-oral scarring, and adjacent/opposing occlusion. Frequently, the crown-to-implant ratio is seen to be > 1:1 (Figure 14-49). Passive splinting of these implants is crucial to their long-term success, and close attention must be paid to development of the occlusal scheme. Occasionally, it may be necessary to perform soft tissue revision procedures if the skin pedicle is thick or if a greater vestibular depth is needed. This ensures soft tissue health and visibility for hygiene procedures.

Maxillary Defects

The maxilla may require resection for tumor control, which creates a host of problems related to speech and esthetics. Traditional resection of the maxilla involves an infrastructure procedure, or may involve the medial portion or a total removal of the maxilla. Infrastructure maxillectomies are used to control incipient disease of the oral cavity and have been classified by Aramany based on frequency of occurrence.¹²⁶ Obviously, the more teeth, bone, and soft tissue available, the easier prosthetic rehabilitation can be employed. However, edentulous patients requiring this operation may have significant difficulty in obtaining stability with their prosthesis, and in these cases a consideration for the use of implants is warranted.

The use of sinus augmentation has been well documented and deemed to be success-

ful with the incorporated use of implants.^{127,128} This technique may be used on a nondefect side where a unilateral or posterolateral defect of the opposite side is present. Splinting of approximately four or five implants with a stress-breaking bar is generally suggested and provides the patient with a retentive stable prosthesis that may offer improved support as well (Figure 14-50). Recently the use of zygomatic implants has been suggested as an alternative to sinus lifting.^{129,130} The implant protocol for zygomatic implants mandates bilateral placement, and preservation of the defect side of the infraorbital rim may improve surgical stability.¹³¹ Both of the techniques require a screw-retained bar attachment to be made with the obturator (Figure 14-51).

Craniofacial Defects

Resection of portions of the craniofacial skeleton for disease control can result in

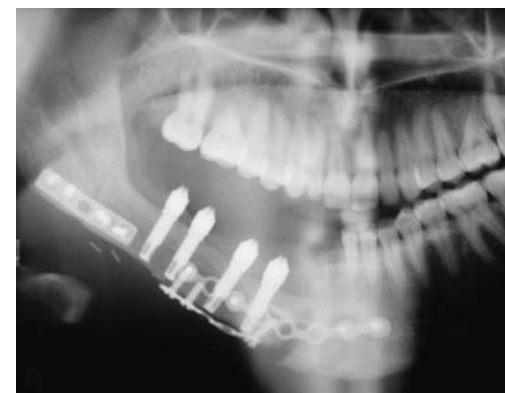

FIGURE 14-48 Implants placed into a vascularized fibula graft to the mandible. (Surgery performed by Perry Johnson, MD, and Michael Miloro, DMD, MD)

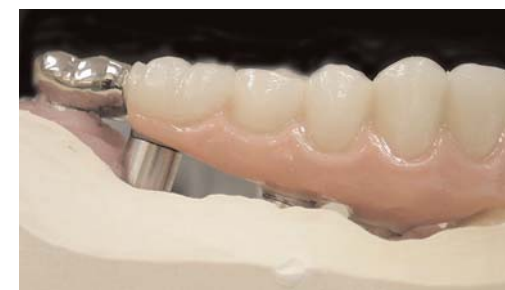

FIGURE 14-49 Mandibular fixed partial denture supported by a vascularized fibular graft in the patient viewed in Figure 14-48.

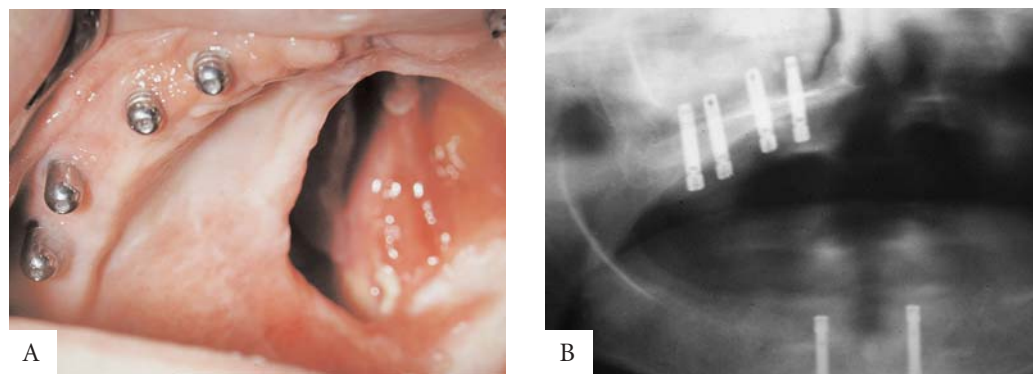


FIGURE 14-50 A and B, Implants placed in the nondefect side of a sinus-lifted maxilla. Reproduced with permission from Salinas TJ, Guerra LR, Rogers WA. Aesthetic considerations for maxillary obturators retained by implants. *Pract Proced Aesthet Dent* 1997;9:265–76.

both functional and esthetic defects. These defects may not be suited to plastic surgical reconstruction owing to local or regional factors. Traditional roles for prostheses are to replace architecture with alloplastic materials that mimic the color and textures of adjacent skin. A method of retaining these prostheses can be attachment by medical-grade adhesives, which may be unpredictable in holding and irritate underlying soft tissues. In such instances the use of osseointegrated technology can provide similar anchorage used intraorally. The rates of success in the craniofacial skeleton of implants are also well documented and should be planned out with specialized imaging.^{132–134} Three-dimensional reconstruction techniques may provide valuable information to maximize success of placement exclusively in the confines of intended site selection. The temporal bone is probably the best predictable site for the placement of implants in comparison to frontal nasal areas.¹³⁵ This is true even if radiation has been used to treat malignant tumors in this area. The choice of a minimum of two splinted implants in the temporal bone can serve well to provide a bar-retained prosthesis. Work-up should include computed tomographic images with 2 mm axial cuts while a radiographic stent is worn (Figure 14-52).¹³⁶ This should affirm site selection as well as placement into sound bone. Bone-anchored hearing aids (BAHAs) can be

used as well in treating patients with Treacher Collins syndrome or other forms of auditory agenesis.

Placement of implants into frontal nasal bone is possible with the use of specialized computer software to delineate the frontal sinus, anterior cranial fossa, orbit, and other vital structures adjacent to proposed site selection. Extraoral anchorage can in some cases assist with anchorage of an intraoral prosthesis as well (Figure 14-53).

Radiotherapy Concerns

Unlike elective implant placement, there are particular concerns when providing a patient with osseointegrated anchorage in cases in which optimal oral function is essential following tumor ablative surgery. Judicious use of interdisciplinary preoperative planning helps in deciding which

cases may be appropriate for osseointegrated implants. This becomes critical when consideration is given to the relative risks of complications after radiotherapy to the head and neck. As with any oncologic case, radiation therapy may be incorporated to improve long-term survival. Because of absorptive changes in the osseous tissues, osteoblast populations are typically affected by dosages exceeding 50 Gy. The possibility of creating osteoradionecrotic wounds increases with bone manipulation above this dosage. However, osseointegrated implants have been successfully employed in previously radiated fields without undue complications.¹³⁷ Hyperbaric oxygen therapy has been objectively shown to reduce the risk of osteoradionecrotic complications in both the craniofacial skeleton and intraoral regions.¹³⁸ As with any hypoxic wound, increasing oxygen tension above 40 PO_2 in comparison to a nonradiated control site increases the likelihood of healing. With this increase of O_2 concentration comes angiogenesis and the subsequent effect of pluripotential cell differentiation into osteoblasts.

Complications

Soft Tissue Complications

Soft tissue complications with dental implants can be seen in areas where the quantity of keratinized soft tissue is

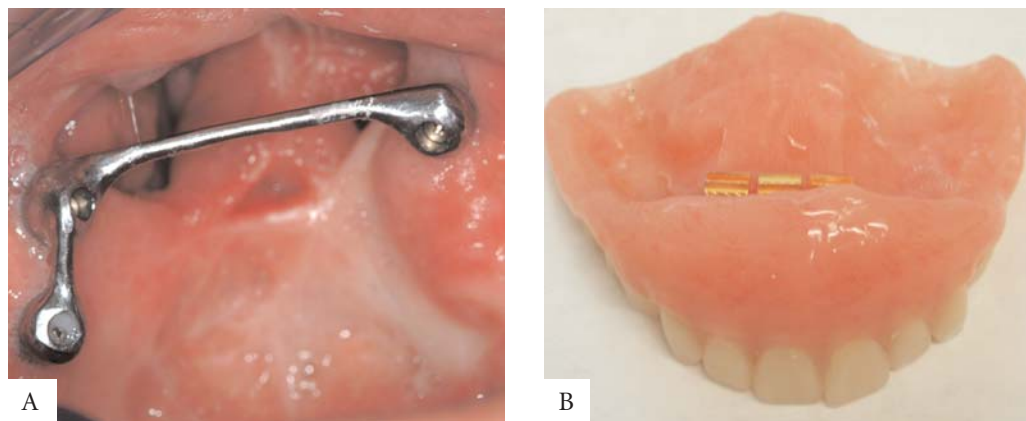


FIGURE 14-51 A and B, Implant-retained obturator using two zygomatic and one pterygoid implant.

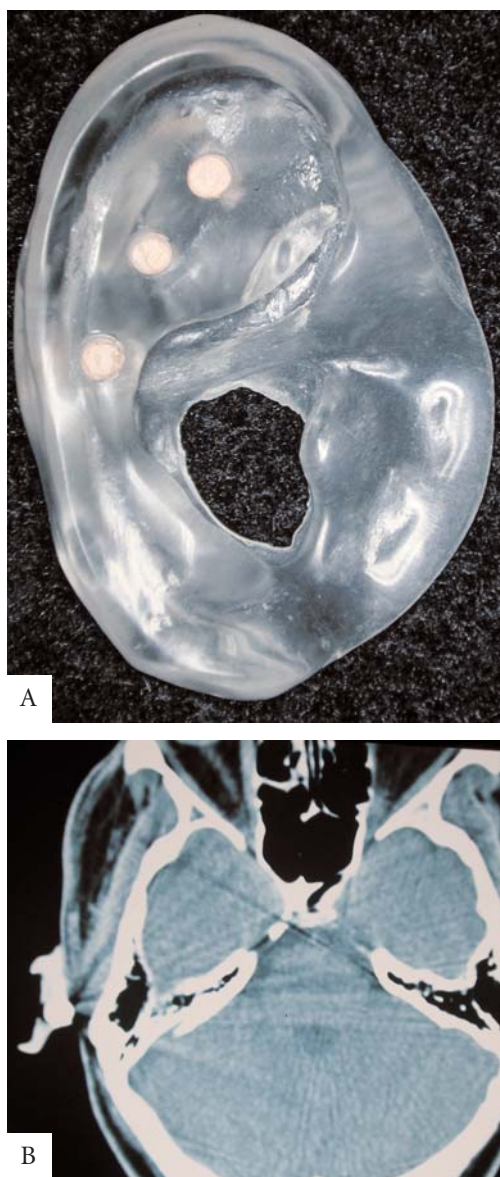


FIGURE 14-52 Stent (A) and computed tomography scan showing site selection (B) for implant placement into temporal bone.

minimal. As with natural teeth, implant restorations rely on attached and keratinized tissue for long-term maintenance. Soft tissues may also be compromised in sites where implant angulation is not ideal in an esthetic area. Finally, soft tissue depths surrounding implants exceeding 5 to 6 mm may present problems with long-term maintenance. This can be especially true for areas grafted with soft tissues or in osteomyocutaneous flaps where dermis is quite thick. In these cases it may be wise to reduce the soft tissue thickness

surgically prior to making a restoration or even placing the implants.

Radiographic Bone Loss

Bone loss is expected with the placement of any implant; however, this loss should not exceed 1.5 mm in the first 12 to 18 months. Bone loss in excess of this value exposes a significant portion of the implant surface, making hygiene procedures difficult. If the choice of implant is a machined titanium screw, this problem is less than with implants having a textured surface, but in either case it is desirable to see bone loss of no more than 0.2 mm/yr. Evaluation of implants in edentulous patients by panoramic radiography may be more formidable than when using periapical radiographs made with a silicone putty standardized bite block. In this way radiographs would be standardized at each exposure, allowing interpretation at a consistent incident beam angle.

Screw Loosening

Abutment and prosthetic screw loosening can be a recurrent problem seen often with single-tooth restorations. The incidence of screw loosening is sizable in cases restored with standard external hex platforms and gold screws. A method of reducing screw loosening is to use a new abutment or prosthetic screw, torque once to the recommended torque application, wait 5 minutes, and then torque again.¹³⁹ In these circumstances screw loosening is minimized. Repeated loosening of screws should bring to mind occlusal overload, heavy contact in lateral excursions, or implant mobility.

Abutment Fracture

Abutment fracture is a relatively uncommon occurrence but can be problematic, particularly for cemented restorations. Material choices for implants subjected to heavy occlusion or unavoidable lateral

loads should be carefully selected. Although strong, ceramic materials are used with caution in areas of high stress application. Pre-machined abutments used for screw-retained restorations can usually be replaced if they fracture.

Porcelain Fracture

Porcelain fracture is sometimes seen with implant prostheses owing to dynamic fatigue or contact overload.¹⁴⁰ Proprioceptive feedback is not present with implant restorations and impacts during the chewing cycle should be slightly less than those of natural teeth. This can be verified using 0.001-inch stainless steel shimstock.

Resin Base Fracture

Resin base fractures are fairly common occurrences because of unfavorable stress distribution, occlusal overload, and a lack of proprioception. The incidence can range from 1 to 16% over 5 years.¹⁴¹ Ways to combat this problem are to reinforce the base with a cast metallic housing.¹⁴¹

Maintenance

Patients restored with osseointegrated implants should receive regular and frequent follow-ups in the first year following implant placement. Factors to evaluate

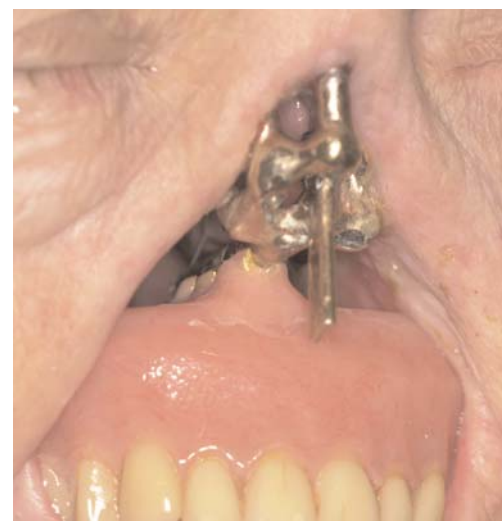

FIGURE 14-53 Facial and intraoral prosthesis anchored with two zygoma and three endosseous implants.

include bone loss, mobility, and pain. Clinical examination should include light percussion and gentle evaluation of soft tissue, which may include a standardized periimplant probing using nonmetallic standardized force probes. Radiographic evaluation includes both periapical and panoramic radiographs. If the restoration is screw retained, it can be removed every 2 years, cleaned, and resecured, or cleaned in position. Cleaning of implant and titanium abutment surfaces should be done with either gold or polyethylene (Teflon) instruments so as not to scratch these biologically critical surfaces and make them prone to plaque accumulation (Figure 14-54).¹⁴² Any scratches or crevices created by this or other processes impose a nidus for plaque and calculus accumulation. After cleaning, polishing with either toothpaste or a light prophylaxis paste is recommended. Since a perimucosal seal exists between the implant and abutment and tissue, it is not suggested that cemented restorations be removed routinely as this may jeopardize the integrity of the restoration and surrounding tissues. However, if the restoration is retrievable, the prosthesis and/or attachment should be removed every 18 to 24 months for débridement, inspection, and polishing.¹⁴³ If abutment or coping screws have been torqued previously, it is generally suggested that they be replaced to avoid future fatigue fracture.

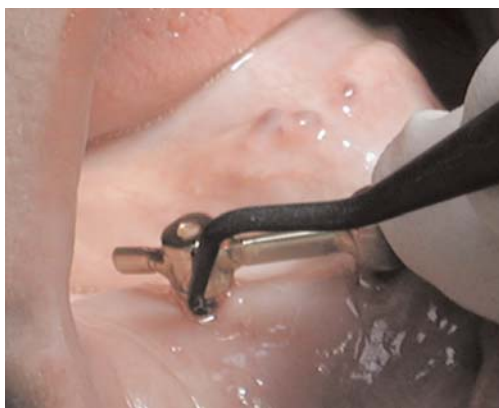

FIGURE 14-54 The use of polyethylene-tipped instruments facilitates plaque removal from titanium implant surfaces.

Success Criteria

Historically, the criteria of success have involved one of quantification of pain, mobility, and peri-implant radiolucency. These criteria were established by Albrektsson and colleagues and remain one of the standards in long-term evaluation of dental implants.¹⁴⁴ Recently additional criteria have been added for the assessment of hard and soft tissue responses. Marginal bone loss of < 4 mm or probing depth of < 4 mm and a crevicular fluid flow rate of < 2.5 mm are considered indicators of success.¹⁴¹ Mobility, if present, should be tested on an individual basis to best assess a true measure. Therefore, removing the prosthesis (especially if it is splinted with other implants) and gently percussing with either a blunt instrument or a standardized torque instrument will give an indication of mobility. Other methods involved the use of Periotest instruments or nanodevices that promote radiofrequency response from the osseointegrated implant to give an indication of mobility.

References

1. Waerhaug J. Anatomy, physiology and pathology of the gingival pocket. *Rev Belge Med Dent* 1966;21(1):9–15.
2. Gargiulo AW, Wentz FM, Orban B. Dimensions and relations of the dento-gingival junction in humans. *J Periodontol* 1961;32:261–7.
3. Cochran DL, Hermann JS, Schenk RK, et al. Biologic width around titanium implants. A histometric analysis of the implantogingival junction around unloaded and loaded nonsubmerged implants in the canine mandible. *J Periodontol* 1997;68:186–98.
4. Bengazi F, Wennstrom JL, Lekholm U. Recession of the soft tissue margin at oral implants. A 2 year longitudinal prospective study. *Clin Oral Implants Res* 1996;7:303–10.
5. Olsson M, Lindhe J. Periodontal characteristics in individuals with varying form of the upper central incisors. *J Clin Periodontol* 1991;18:78–82.
6. Sanavi F, Weisgold A, Rose LF. Biologic width and its relation to periodontal biotypes. *J Esthet Dent* 1998;10:157–63.
7. Tarnow DP, Magner AW, Fletcher P. The effect of the distance from the contact point to the crest of bone on the presence or absence of the interproximal dental papilla. *J Periodontol* 1992;63:995–6.
8. Tarnow DP, Cho SC, Wallace SS. The effect of inter-implant distance on the height of inter-implant bone crest. *J Periodontol* 2000;71:546–9.
9. Albrektsson T, Zarb GA, Worthington P, Ericsson RA. The long term efficacy of currently used dental implants: a review and proposed criteria of success. *Int J Oral Maxillofac Implants* 1986;1:11–25.
10. Bain CA, Moy PK. The association between the failure of dental implants and cigarette smoking. *Int J Oral Maxillofac Implants* 1993;8:609–15.
11. Kan JY, Rungcharassaeng K, Lozada JL, Goodacre CJ. Effects of smoking on implant success in grafted maxillary sinuses. *J Prosthet Dent* 1999;82:307–11.
12. De Bruyn H, Collaert B. The effect of smoking on early implant failure. *Clin Oral Implants Res* 1994;5:260–4.
13. Lindquist LW, Carlsson GE, Jemt T. Association between marginal bone loss around osseointegrated mandibular implants and smoking habits: a 10 year follow-up study. *J Dent Res* 1997;76:1667–74.
14. Kiel DP, Zhang Y, Hannan MT, et al. The effect of smoking at different life stages on bone mineral density in elderly men and women. *Osteoporos Int* 1996;6:240–8.
15. Jaffin RA, Berman CL. The excessive loss of Branemark fixtures in type IV bone: a 5 year analysis. *J Periodontol* 1991;62:2–4.
16. Zarb GA, Lekholm U, Albrektsson T, Tenenbaum H. Aging, osteoporosis, and dental implants. Chicago: Quintessence Publishing; 2002.
17. Mombelli A, van Oosten MAC, Schurch E, Lang NP. The microbiota associated with successful or failing osseointegrated titanium implants. *Oral Microbiol Immunol* 1987;2:145–51.
18. Quirynen M, Naert I, van Steenberghe D, et al. Periodontal aspects of osseointegrated fixtures supporting an overdenture. A 4-year retrospective study. *J Clin Periodontol* 1991;18:719–28.
19. Rutar A, Lang NP, Buser D, et al. Retrospective assessment of clinical and microbiological factors affecting periimplant tissue conditions. *Clin Oral Implants Res* 2001;12:189–95.
20. Esser E, Wagner W. Dental implants following radical oral cancer surgery and adjuvant radiotherapy. *Int J Oral Maxillofac Implants* 1997;12:552–7.
21. Jisander S, Grenthe B, Alberius P. Dental implant survival in the irradiated jaw: a

- preliminary report. *Int J Oral Maxillofac Implants* 1997;12:643–8.
22. Taylor TD, Worthington P. Osseointegrated implant rehabilitation of the previously irradiated mandible: results of a limited trial at 3 to 7 years. *J Prosthet Dent* 1993;69:60–9.
 23. Keller EE, Tolman DE, Zuck SL, Eckert SE. Mandibular endosseous implants and autogenous bone grafting in irradiated tissue: a 10-year retrospective study. *Int J Oral Maxillofac Implants* 1997;12:800–13.
 24. Keller EE. Placement of dental implants in the irradiated mandible: a protocol without adjunctive hyperbaric oxygen. *J Oral Maxillofac Surg* 1997;55:972–80.
 25. Marx RE, Ames J. The use of hyperbaric oxygen therapy in bony reconstruction of the irradiated and tissue deficient patient. *J Oral Maxillofac Surg* 1982;40:412–20.
 26. Olson JW, Shernoff AF, Tarlow JL, et al. Dental endosseous implant assessments in a type 2 diabetic population: a prospective study. *Int J Oral Maxillofac Implants* 2000;15:811–8.
 27. Balshi TJ, Wolfinger GJ. Dental implants in the diabetic patient: a retrospective study. *Implant Dent* 1999;8:355–9.
 28. Jensen J, Sindet-Pedersen S. Osseointegrated implants for prosthetic reconstruction in a patient with scleroderma: report of a case. *J Oral Maxillofac Surg* 1990;48:739–41.
 29. Isidor F, Brondum K, Hansen HJ, et al. Outcome of treatment with implant-retained dental prostheses in patients with Sjögren syndrome. *Int J Oral Maxillofac Implants* 1999;14:736–43.
 30. Rajnay ZW, Hochstetter RL. Immediate placement of an endosseous root-form implant in an HIV-positive patient: report of a case. *J Periodontol* 1998; 69:1167–71.
 31. Rocher P, Veron C, Vert M, et al. Risks and regulations related to materials used in implantology and maxillofacial surgery. *Rev Stomatol Chir Maxillofac* 1995;96:281–92.
 32. Kovacs AF. Influence of chemotherapy on endosteal implant survival and success in oral cancer patients. *Int J Oral Maxillofac Surg* 2001;30:144–7.
 33. Karr RA, Kramer DC, Toth BB. Dental implants and chemotherapy complications. *J Prosthet Dent* 1992;67:683–7.
 34. Steiner M, Windchay A, Gould AR, et al. Effects of chemotherapy in patients with dental implants. *J Oral Implantol* 1995;21:142–7.
 35. Sadan A, Raigrodski AJ, Salinas TJ. Prosthetic considerations in the fabrication of surgical stents for implant placement. *Pract Periodontics Aesthet Dent* 1997;9:1003–11.
 36. Chan MF, Narhi TO, de Baat C, Kalk W. Treatment of the atrophic edentulous maxilla with implant supported overdentures: a review of the literature. *Int J Prosthodont* 1998;11:7–15.
 37. Sennerby L, Roos J. Surgical determinants of clinical success of osseointegrated oral implants: a review of the literature. *Int J Prosthodont* 1998;11:408–20.
 38. Misch CE. *Contemporary implant dentistry*. 2nd ed. St. Louis: Mosby; 1999.
 39. Lindquist LW, Carlsson GE. Long term effects on chewing with mandibular fixed prostheses on osseointegrated implants. *Acta Odontol Scand* 1985;43(1):39–45.
 40. Haraldson T, Carlsson GE. Bite force and oral function in patients with osseointegrated oral implants. *Scand J Dent Res* 1977; 85:200–8.
 41. Jemt T, Carlsson GE. Aspects of mastication with bridges on osseointegrated implants. *Scand J Dent Res* 1986;94:66–71.
 42. Misch CE. Iliac crest grafts and endosteal implants to restore 35 severely resorbed total edentulous maxillae: a retrospective study. *Proceedings of the 2nd World Congress of Osseointegration*; 1996 Oct; Rome.
 43. Li KK, Stephens WL, Gliklich R. Reconstruction of the severely atrophic edentulous maxilla using the LeFort I osteotomy with simultaneous bone graft and implant placement. *J Oral Maxillofacial Surg* 1996;54:542–7.
 44. Jaffin RA, Berman CL. The excessive loss of Branemark fixtures in type IV bone: a 5-year analysis. *J Periodontol* 1991;62:2–4.
 45. Albrektsson T, Zarb GA, Brånemark PI. *Tissue-integrated prosthesis: osseointegration in clinical dentistry*. Chicago: Quintessence; 1983.
 46. McCartney JW. Cantilever rests: an alternative to the unsupported distal cantilever of osseointegrated implant supported prostheses for the edentulous mandible. *J Prosthet Dent* 1992;68:817–9.
 47. Jemt T, Linden B, Lekholm U. Failures and complications in 127 consecutively placed fixed partial prostheses supported by Brånemark implants from prosthetic treatment to first annual checkup. *Int J Oral Maxillofac Implant* 1992;7(1):40–4.
 48. Binon PP. Evaluation of machining accuracy and consistency of selected implants, standard abutments and laboratory analogs. *Int J Prosthodont* 1995;8:162–78.
 49. Eckert SE, Wollan PC. Retrospective review of 1170 endosseous implants placed in partially edentulous jaws. *J Prosthet Dent* 1998; 79:415–21.
 50. Naert I, De Clercq M, Theuniers G, Schepers F. Overdentures supported by osseointegrated fixtures for the edentulous mandible: a 2.5-year report. *Int J Oral Maxillofac Implants* 1988;3:191–6.
 51. Brånemark PI, Svensson B, van Steenberghe D. Ten-year survival rates of fixed prostheses on four or six implants ad modum Brånemark in full edentulism. *Clin Oral Implants Res* 1995;6:227–31.
 52. Adell R, Eriksson B, Lekholm U, et al. Long-term follow-up study of osseointegrated implants in the treatment of totally edentulous jaws. *Int J Oral Maxillofac Implants* 1990;5:347–59.
 53. Adell R, Lekholm U, Rockier B, Brånemark PI. A 15-year study of osseointegrated implants in the treatment of the edentulous jaw. *Int J Oral Surg* 1981;10:387–416.
 54. Thomason JM. The McGill consensus statement on overdentures. Mandibular 2-implant overdentures as first choice standard of care for edentulous patients. *Eur J Prosthodont Restor Dent* 2002;10:95–6.
 55. Abrahamsson I, Berglundh T, Glantz PO, Lindhe J. The mucosal attachment at different abutments. An experimental study in dogs. *J Clin Periodontol* 1998;25:721–7.
 56. Sorenson JA, Martinoff JT. Clinically significant factors in dowel designs. *J Prosthet Dent* 1984;52:28–35.
 57. Assif D, Oren E, Marshak BL, Aviv I. Photoelastic analysis of stress transfer by endodontically treated teeth to the supporting structure using different restorative techniques. *J Prosthet Dent* 1989;61:535–43.
 58. Milot P, Stein RS. Root fracture in endodontically treated teeth related to post selection and crown design. *J Prosthet Dent* 1992;68:428–35.
 59. Palmqvist S, Swartz B. Artificial crowns and fixed partial dentures 18 to 23 years after placement. *Int J Prosthodont* 1993;6:279–85.
 60. Walton JN, Gardner FM, Agar JR. A survey of crown and fixed partial denture failures: length of service and reasons for replacement. *J Prosthet Dent* 1986;56:416–21.
 61. Karlsson S. Failures and length of service in fixed prosthodontics after long-term function. *Swed Dent J* 1989;13:185–92.
 62. Scurria MS, Bader JD, Shugars DA. A meta analysis of fixed partial denture survival: prostheses and abutments. *J Prosthet Dent* 1998;79:459–64.
 63. Walton TR. An up to 15 year longitudinal study of 515 metal-ceramic FPD's. Part 1. Outcome. *Int J Prosthodont* 2002;15:439–45.
 64. Haas R, Mensdorff-Pouilly N, Mailath G, Watzek G. Brånemark single tooth implants: a preliminary report of 76 implants. *J Prosthet Dent* 1995;73:274–9.
 65. Schmitt A, Zarb GA. The longitudinal clinical

- effectiveness of osseointegrated dental implants for single-tooth replacement. *Int J Prosthodont* 1993;6:197–202.
66. Laney WR, Jemt T, Harris D, et al. Osseointegrated implants for single-tooth replacement: progress report from a multicenter prospective study after 3 years. *Int J Oral Maxillofac Implants* 1994;9:49–54.
 67. Andersson B, Odman P, Lindvall AM, Brånemark PI. Cemented single crowns on osseointegrated implants after 5 years: results from a prospective study on CeraOne. *Int J Prosthodont* 1998; 11:212–8.
 68. Goodacre CJ, Kan JY, Rungcharassaeng K, et al. Clinical complications of osseointegrated implants. *J Prosthet Dent* 1999;81:537–52.
 69. Bader HI. Treatment planning for implants versus root canal therapy: a contemporary dilemma. *Implant Dent* 2002;11:217–23.
 70. Curley AW. Dental implant jurisprudence: avoiding the legal failure. *J Calif Dent Assoc* 2001;29:847–53.
 71. Branemark PI, Adell R, Breine U, et al. Intraosseous anchorage of dental prostheses. I. Experimental studies. *Scand J Plast Reconstr Surg Hand Surg* 1969;3:81–100.
 72. Adell R, Hansson BO, Branemark PI, Breine U. Intraosseous anchorage of dental prostheses. II. Review of clinical approaches. *Scand J Plast Reconstr Surg Hand Surg* 1970;4:100–8.
 73. Lindquist LW, Carlsson GE, Jemt T. A prospective 15 year follow up study of mandibular fixed prostheses supported by osseointegrated implants. Clinical results and marginal bone loss. *Clin Oral Implants Res* 1996;7:329–36.
 74. Feine JS, Carlsson GE, Awad MA, et al. The McGill consensus statement on overdentures. Mandibular two-implant overdenture as first choice standard of care for edentulous patients. *Gerodontology* 2002; 19(1):3–4.
 75. Ferrigno N, Laureti M, Fanali S, Grippaudo G. A long term follow up study of non-submerged ITI implants in the treatment of totally edentulous jaws. Part I: ten-year life table analysis of a prospective multi-center study with 1286 implants. *Clin Oral Implants Res* 2002;13:260–73.
 76. Laney WR, Tolman DE, Keller EE, et al. Dental implants: tissue integrated prosthesis utilizing the osseointegration concept. *Mayo Clin Proc* 1986;61:91–7.
 77. Chiche G, Pinault A. Esthetics of anterior fixed prosthodontics. Chicago: Quintessence; 1990.
 78. Sheets CG, Earthman JC. Tooth intrusion in implant assisted prostheses. *J Prosthet Dent* 1997;77:39–45.
 79. Rangert B, Gunne J, Glantz P-O, Svensson A. Vertical load distribution on a three unit prosthesis supported by a natural tooth and a single tooth implant. An in vivo study. *Clin Oral Implants Res* 1995;6:40–6.
 80. Solnit GS, Schneider RL. An alternative to splinting multiple implants: use of the ITI system. *J Prosthodont* 1998;7:114–9.
 81. Ehrenkranz H, Langer B. The incorporation of teeth into the full arch implant reconstruction. *Quintessence Dent Technol Yearbook* 2002; 25:213–22.
 82. Lewis S. Treatment planning: teeth versus implants. *Int J Periodontics Restorative Dent* 1996;16:367–77.
 83. Block MS, Lirette D, Gardiner D, et al. Prospective evaluation of implants connected to teeth. *Int J Oral Maxillofac Implants* 2002;17:473–87.
 84. Zuhr O, Schenk G, Schoberer U, et al. Maintenance of the original emergence profile for natural esthetics with implant supported restorations. *Quintessence Dent Technol Yearbook* 2002;25:144–54.
 85. Rangert B, Sullivan RM, Jemt TM. Load factor control for implants in the partially edentulous segment. *Int J Oral Maxillofac Implants* 1997;12:360–70.
 86. Cliff SE, Fisher J, Watson CJ. Stress and strain distribution in the bone surrounding a new design of dental implant: a comparison with a threaded Branemark type implant. *Proc Inst Mech Eng [H]* 1993;207: 133–8.
 87. Piatelli A, Scarano A, Paolantonio M. Clinical and histologic features of a non-axial load on the osseointegration of a posterior mandibular implant: report of a case. *Int J Oral Maxillofac Implants* 1998;13:273–5.
 88. Kan JY, Lozada JL, Boyne PJ, et al. Mandibular fracture after endosseous implant placement in conjunction with inferior alveolar nerve transposition: a patient treatment report. *Int J Oral Maxillofac Implants* 1997;12:655–9.
 89. Cooper MR, Stewart DC, Kahl FR, et al. Medicine at the medical center then and now: one hundred years of progress. *South Med J* 2002;95:1113–21.
 90. Douglass CW, Shih A, Ostry L. Will there be a need for complete dentures in the United States in 2020? *J Prosthet Dent* 2002;87:5–8.
 91. Sennerby L, Carlsson GE, Bergman B, Warfvinge J. Mandibular bone resorption in patients treated with tissue integrated prostheses and in complete denture wearers. *Acta Odontol Scand* 1988;46:135–40.
 92. Arzouman MJ, Otis L, Kipnis V, Levine D. Observations of the anterior loop of the inferior alveolar canal. *Int J Oral Maxillofac Implants* 1993;8:295–300.
 93. Friberg B, Grondahl K, Lekholm U, Branemark PI. Long-term follow-up of severely atrophic edentulous mandibles reconstructed with short Brånemark implants. *Clin Implant Dent Relat Res* 2000;2:184–9.
 94. Triplett RG, Mason ME, Alfonso WF, McAnear JT. Endosseous cylinder implants in severely atrophic mandibles. *Int J Oral Maxillofac Implants* 1991; 6:264–9.
 95. Batenburg RH, Meijer HJ, Raghoebar GM, Vissink A. Treatment concept for mandibular overdentures supported by endosseous implants: a literature review. *Int J Oral Maxillofac Implants* 1998;13:539–45.
 96. Balshi TJ, Wolfinger GJ. Immediate loading of Branemark implants in edentulous mandibles: a preliminary report. *Implant Dent* 1997;6:83–8.
 97. Misch CE. Contemporary implant dentistry. 2nd ed. St. Louis: Mosby; 1999.
 98. Beumer J, Lewis SG. The Branemark Implant System, clinical and laboratory procedures. St. Louis: Ishiyaku EuroAmerica; 1989.
 99. Rubenstein JE. Implant rehabilitation of the mandible compromised by radiotherapy. In: Taylor TD, editor. Clinical maxillofacial prosthetics. Chicago: Quintessence; 2000. p. 189–203.
 100. Fredrickson EJ, Stevens PJ, Gress ML. Implant prosthodontics: clinical and laboratory procedures. St. Louis: Mosby; 1995.
 101. Goodkind RJ, Heringlake CB. Mandibular flexure in opening and closing movements. *J Prosthet Dent* 1973;30:134–8.
 102. Zarone F, Apicella A, Nicolais L, et al. Mandibular flexure and stress buildup in mandibular full-arch fixed prostheses supported by osseointegrated implants. *Clin Oral Implants Res* 2003;14:103–14.
 103. Jiménez-López V. Oral rehabilitation with implant-supported prostheses. Chicago: Quintessence; 1999.
 104. Taylor TD. Fixed implant rehabilitation for the edentulous maxilla. *Int J Oral Maxillofac Implants* 1991;6:329–37.
 105. Rosenquist B, Grenthe B. Immediate placement of implants into extraction sockets: implant survival. *Int J Oral Maxillofac Implants* 1996;11:205–9.
 106. Wilson TG Jr, Schenk R, Buser D, Cochran D. Implants placed in immediate extraction sites: a report of histologic and histometric analyses of human biopsies. *Int J Oral Maxillofac Implants* 1998;13:333–41.
 107. Salama H, Garber DA, Salama MA, et al. Fifty years of interdisciplinary site development: lessons and guidelines from periodontal prosthesis. *J Esthet Dent* 1998;10:149–56.
 108. Adriaenssens P, Hermans M. Immediate

- implant function in the anterior maxilla: a surgical technique to enhance primary stability for Brånemark Mk III and Mk IV implants. A randomized, prospective clinical study at the 1 year follow up. *Appl Osseointegration Res* 2001;2(1):17–21.
109. Glauser R, Portmann, Ruhstaller P, et al. Initial implant stability using different implant designs and surgical techniques. A comparative clinical study using insertion torque and resonance frequency analysis. *Appl Osseointegration Res* 2001;2(1):6–8.
 110. Rompen E, DaSilva D, Hockers T, et al. Influence of implant design on primary fit and stability. A RFA and histological comparison of MkIII and MkIV Brånemark implants in the dog mandible. *Appl Osseointegration Res* 2001;2(1):9–11.
 111. Pilliar RM, Deporter DA, Watson PA. Tissue-implant interface: micromovement effect. In: Vincenzini P, editor. *Materials in clinical applications. Proceeding of Topical Symposium VII on Materials in Clinical Applications of the 8th CIMTEC-World Ceramics Congress and Forum on New Materials; 1994 June 28–July 4; Florence, Italy. Faenza, Italy: Techna; 1995. p. 569–79.*
 112. Schnitman P, Whorle P, Rubenstein JE. Immediate fixed interim prostheses supported by 2 stage threaded implants; methodology and results. *J Oral Implants* 1990;16:96–105.
 113. Ericsson I, Nilson H, Nilner K. Immediate functional loading of Brånemark single tooth implants. A 5-year clinical follow-up study. *Appl Osseointegration Res* 2001;2:12–15.
 114. Buser D, Mericske-Stern R, Bernard JP, et al. Long-term evaluation of non-submerged ITI implants. Part I: 8-year life table analysis of a prospective multi-center study with 2359 implants. *Clin Oral Implants Res* 1997;8:161–72.
 115. Malo P, Rangert B, Dvårsäter L. Immediate function of Branemark implants in the esthetic zone. A retrospective clinical study with 6 months to 4 years of follow up. *Clin Implant Dent Relat Res* 2000;2:137–45.
 116. Brunski J. In vivo bone response to biomechanical loading at the bone/dental implant interface. *Adv Dent Res* 1999;13:99–119.
 117. Schnitman PA, Wöhrle PS, Rubenstein JE, et al. Ten year results for Branemark implants immediately loaded with fixed prostheses at implant placement. *Int J Oral Maxillofac Implants* 1997;12:495–503.
 118. Henry P, Rosenberg J. Single-stage surgery for rehabilitation of the edentulous mandible. Preliminary results. *Pract Periodontics Aesthet Dent* 1994;6:1–8.
 119. Randow K, Ericsson I, Nilner K, et al. Immediate functional loading of Brånemark dental implants. An 18 month clinical follow up study. *Clin Oral Implants Res* 1999;10:8–15.
 120. Ganeles J, Rosenberg MM, Holt RL, Reichman LH. Immediate loading of implants with fixed restorations in the completely edentulous mandible: report of 27 patients from a private practice. *Int J Oral Maxillofac Implants* 2001;16:418–26.
 121. Brånemark PI, Engstrand P, Ohrenell LO, et al. Branemark Novum: a new treatment concept for rehabilitation of the edentulous mandible. Preliminary results from a prospective clinical follow-up study. *Clin Implant Dent Relat Res* 1999;1:2–16.
 122. Canto MT, Devesa SS. Oral cavity and pharynx cancers incidence rates in the United States, 1975–1998. *Oral Oncol* 2002;38:610–7.
 123. Hidalgo DA. Fibula free flap: a new method of mandible reconstruction. *Plast Reconstr Surg Hand Surg* 1989;84(1):71–9.
 124. Zlotolow IM, Huryn JM, Piro JD, et al. Osseointegrated implants and functional prosthetic rehabilitation in microvascular fibula free flap reconstructed mandibles. *Am J Surg* 1992;164:677–81.
 125. Cordeiro PG, Disa JJ, Hidalgo DA, Hu QY. Reconstruction of the mandible with osseous free flaps: a 10-year experience with 150 consecutive patients. *Plast Reconstr Surg Hand Surg* 1999;104:1314–20.
 126. Aramany MA. Basic principles of obturator design for partially edentulous patients. Part I. Classification. *J Prosthet Dent* 1978;40:554–7.
 127. Boyne PJ. Analysis of performance of root-form endosseous implants placed in the maxillary sinus. *J Long Term Eff Med Implants* 1993;3:143–59.
 128. Olson JW, Dent CD, Morris HF, Ochi S. Long-term assessment (5 to 71 months) of endosseous dental implants placed in the augmented maxillary sinus. *Ann Periodontol* 2000;5(1):152–6.
 129. Boyes-Varley JG, Howes DG, Lownie JE. The zygomaticus implant protocol in the treatment of the severely resorbed maxilla. *SADJ* 2003;58:106–9, 113–4.
 130. Bedrossian E, Stumpel L III, Beckely ML, Indresano T. The zygomatic implant: preliminary data on treatment of severely resorbed maxillae. A clinical report. *Int J Oral Maxillofac Implants* 2002;17:861–5.
 131. Parel SM, Branemark PI, Ohrenell LO, Svensson B. Remote implant anchorage for the rehabilitation of maxillary defects. *J Prosthet Dent* 2001;86:377–81.
 132. Tjellstrom A, Lindstrom J, Hallen O, et al. Osseointegrated titanium implants in the temporal bone. A clinical study on bone anchored hearing aids. *Am J Otolaryngol* 1981;2:304–10.
 133. Parel SM, Tjellstrom A. The United States and Swedish experience with osseointegration and facial prostheses. *J Prosthet Dent* 1991;6:75–9.
 134. Wolfaardt JF, Wilkes GH, Parel SM, Tjellstrom A. Craniofacial osseointegration: the Canadian experience. *Int J Oral Maxillofac Implants* 1993;8:197–204.
 135. Nishimura RD, Roumanas E, Beumer J III, et al. Restoration of irradiated patients using osseointegrated implants: current perspectives. *J Prosthet Dent* 1998;79:641–7.
 136. Klein M, Menneking H, Neumann K, et al. Computed tomographic study of bone availability for facial prosthesis-bearing endosteal implants. *Int J Oral Maxillofac Surg* 1997;26:268–71.
 137. Visch LL, van Waas MA, Schmitz PI, Levendag PC. A clinical evaluation of implants in irradiated oral cancer patients. *J Dent Res* 2002;81:856–9.
 138. Granstrom G, Tjellstrom A, Brånemark PI. Osseointegrated implants in irradiated bone: a case controlled study using adjunctive hyperbaric oxygen therapy. *J Oral Maxillofac Surg* 1999;57:493–9.
 139. Binon PP, McHugh MJ. The effect of eliminating implant/abutment rotational misfit on screw joint stability. *Int J Prosthodont* 1996;9:511–9.
 140. Scholander S. A retrospective evaluation of 259 single-tooth replacements by the use of Branemark implants. *Int J Prosthodont* 1999;12:483–91.
 141. Behneke A, Behneke N, d’Hoedt B. A 5 year longitudinal study of the clinical effectiveness of ITI solid-screw implants in the treatment of mandibular edentulism. *Int J Oral Maxillofac Implants* 2002;17:799–810.
 142. Hallmon WW, Waldrop TC, Meffert RM, Wade BW. A comparative study of the effects of metallic, nonmetallic, and sonic instrumentation on titanium abutment surfaces. *Int J Oral Maxillofac Implants* 1996;11(1):96–100.
 143. Meffert RM. Follow up and maintenance. In: Babbush CA, editor. *Dental implants. The art and science.* Philadelphia: Saunders; 2001. p. 397–428.
 144. Albrektsson T, Zarb GA, Worthington P, Ericsson RA. The long term efficacy of currently used dental implants: a review and proposed criteria of success. *Int J Oral Maxillofac Implants* 1986;1:11–25.

Part 3

MAXILLOFACIAL INFECTIONS

Principles of Management of Odontogenic Infections

Thomas R. Flynn, DMD

The incidence, severity, morbidity, and mortality of odontogenic infections have declined dramatically over the past 60 years. In 1940 Ashbel Williams published a series of 31 cases of Ludwig's angina in which 54% of the subjects died.¹ Only 3 years later, he and Dr. Walter Guralnick published the first prospective case series in the field of head and neck infections, in which the mortality rate of Ludwig's angina was reduced to 10%.² This dramatic reduction in mortality from 54 to 10% was not due to the first use of penicillin in the treatment of these infections. Rather, Dr. Guralnick applied the principles of the initial establishment of airway security, followed by early and aggressive surgical drainage of all anatomic spaces affected by cellulitis or abscess. Since then, with the use of antibiotics and advanced medical supportive care, the mortality of Ludwig's angina has been further reduced to 4%.³

Dentistry has made great progress in the prevention and early intervention of odontogenic infections. Oral and maxillofacial surgeons, as noted above, have made great strides in managing and preventing mortality in severe odontogenic infections. These accomplishments, however, impose upon the oral and maxillofacial surgeon the obligation to remain intellectually prepared for the always unscheduled occurrence of severe odontogenic infections by keeping one's knowledge of the relevant anatomy and surgery fresh, and

by remaining abreast of current developments in the microbiology and antibiotic therapy of odontogenic infections.

The late Dr. Larry Peterson, who brought the first edition of this text to fruition, articulated the principles of management of odontogenic deep fascial space infections. These are eight sequential steps that, if followed with thoroughness and good judgment, will ensure a high level of care for these increasingly uncommon, yet occasionally life-threatening infections.

These principles outline the structure of this chapter. The eight steps in the management of odontogenic infections are as follows:

1. Determine the severity of infection.
2. Evaluate host defenses.
3. Decide on the setting of care.
4. Treat surgically.
5. Support medically.
6. Choose and prescribe antibiotic therapy.
7. Administer the antibiotic properly.
8. Evaluate the patient frequently.

This chapter will examine each of these principles in order and discuss and relate current knowledge to them.

Step 1: Determine the Severity of Infection

Within the first few minutes of the presentation of a patient with a significant odontogenic infection, the surgeon should have

accomplished the first three steps listed above. A careful history and a brief but thorough physical examination should allow the treating surgeon to determine the anatomic location, rate of progression, and the potential for airway compromise of a given infection. The host defenses, including immune system competence and the level of systemic reserves that can be called upon by the patient to maintain homeostasis, are largely determined by history. Given this initial database the surgeon must then decide upon the setting of care, which will have a great influence on the outcome.

The clinical presentation and relevant surgical anatomy of infections of the various deep fascial spaces of the head and neck have been well described in other texts.^{4,5} The borders, contents, and relations of the various anatomic deep spaces that are likely to be invaded by odontogenic infections are described in Tables 15-1 and 15-2.

Three major factors must be considered in determining the severity of an infection of the head and neck: anatomic location, rate of progression, and airway compromise.

Anatomic Location

The anatomic spaces of the head and neck can be graded in severity by the level to which they threaten the airway or vital structures, such as the heart and mediastinum or the cranial contents. The buccal, infraorbital vestibular, and subperiosteal

Table 15-1 Borders of the Deep Spaces of the Head and Neck

Space	Borders					
	Anterior	Posterior	Superior	Inferior	Superficial or Medial*	Deep or Lateral†
Buccal	Corner of mouth	Masseter m., pterygomandibular space	Maxilla, infraorbital space	Mandible tissue and skin	Subcutaneous	Buccinator m.
Infraorbital	Nasal cartilages	Buccal space	Quadratus labii superioris m.	Oral mucosa	Quadratus labii superioris m.	Levator anguli oris m., maxilla
Submandibular	Ant. belly digastric m.	Post. belly digastric, stylohyoid, stylopharyngeus mm.	Inf. and med. surfaces of mandible	Digastric tendon	Platysma m., investing fascia	Mylohyoid, hyoglossus sup. constrictor mm.
Submental	Inf. border of mandible	Hyoid bone	Mylohyoid m.	Investing fascia	Investing fascia	Ant. bellies digastric m.†
Sublingual	Lingual surface of mandible	Submandibular space	Oral mucosa	Mylohyoid m.	Muscles of tongue*	Lingual surface of mandible†
Pterygomandibular	Buccal space	Parotid gland	Lateral pterygoid m.	Inf. border of mandible	Med. pterygoid muscle*	Ascending ramus of mandible†
Submasseteric	Buccal space	Parotid gland	Zygomatic arch	Inf. border of mandible	Ascending ramus of mandible*	Masseter m.†
Lateral pharyngeal	Sup. and mid. pharyngeal constrictor mm.	Carotid sheath and scalene fascia	Skull base	Hyoid bone	Pharyngeal constrictors and retropharyngeal space*	Medial pterygoid m.†
Retropharyngeal	Sup. and mid. pharyngeal constrictor mm.	Alar fascia	Skull base	Fusion of alar and prevertebral fasciae at C6-T4	—	Carotid sheath and lateral pharyngeal space†
Pretracheal	Sternothyroid-thyrohyoid fascia	Retropharyngeal space	Thyroid cartilage	Superior mediastinum	Sternothyroid-thyrohyoid fascia	Visceral fascia over trachea and thyroid gland

Adapted from Flynn TR.⁵

ant. = anterior; inf. = inferior; lat. = lateral; m. = muscle; mm. = muscles; med. = medial; mid. = middle; post. = posterior; sup. = superior.

*Medial border; †lateral border.

spaces can be categorized as having low severity because infections in these spaces do not threaten the airway or vital structures. Infections of anatomic spaces that can hinder access to the airway due to swelling or trismus can be classified as having moderate severity. Such anatomic spaces include the masticatory space, whose components may be considered separately as the submasseteric, pterygomandibular, and superficial and deep temporal spaces, and the perimandibular spaces (submandibular, submental, and

sublingual). Infections that have high severity are those in which swelling can directly obstruct or deviate the airway or threaten vital structures. These anatomic spaces are the lateral pharyngeal and retropharyngeal, the danger space, and the mediastinum. Cavernous sinus thrombosis and other intracranial infection also have high severity. In 1999 Flynn and colleagues devised a severity score (SS) that assigned a numerical value of 1 to 4 for involvement of each of the low, moderate, severe, or extreme severity anatomic spaces, respec-

tively.⁶ Table 15-3 lists the severity score for each of the various deep fascial spaces. Thus, a patient with cellulitis or abscess of the right buccal (SS = 1), right pterygomandibular (SS = 2), and right lateral pharyngeal (SS = 3) spaces would have a total severity score of 6, which is the sum of the values assigned to each of the three anatomic spaces. Flynn and colleagues were able to explain by correlation analysis 66% of the length of hospital stay with a model that used the initial SS and the white blood cell count on admission.⁶

Table 15-2 Relations of Deep Spaces in Infections

Space	Likely Causes	Contents	Neighboring Spaces	Approach for Incision and Drainage
Buccal	Upper bicuspids Upper molars Lower bicuspids	Parotid duct Ant. facial a. and v. Transverse facial a. and v. Buccal fat pad	Infraorbital Pterygomandibular Infratemporal	Intraoral (small) Extraoral (large)
Infraorbital	Upper cuspid	Angular a. and v. Infraorbital n.	Buccal	Intraoral
Submandibular	Lower molars	Submandibular gland Facial a. and v. Lymph nodes	Sublingual Submental Lateral pharyngeal Buccal	Extraoral
Submental	Lower anteriors Fracture of symphysis	Ant. jugular v. Lymph nodes	Submandibular (on either side)	Extraoral
Sublingual	Lower bicuspids Lower molars Direct trauma	Sublingual glands Wharton's ducts Lingual n. Sublingual a. and v.	Submandibular Lateral pharyngeal Visceral (trachea and esophagus)	Intraoral Intraoral-extraoral
Pterygomandibular	Lower third molars Fracture of angle of mandible	Mandibular div. of trigeminal n. Inf. alveolar a. and v.	Buccal Lateral pharyngeal Submasseteric Deep temporal Parotid Peritonsillar	Intraoral Intraoral-extraoral
Submasseteric	Lower third molars Fracture of angle of mandible	Masseteric a. and v.	Buccal Pterygomandibular Superf. temporal Parotid	Intraoral Intraoral-extraoral
Infratemporal and deep temporal	Upper molars	Pterygoid plexus Internal maxillary a. and v. Mandibular div. of trigeminal n. Skull base foramina	Buccal Superf. temporal Inf. petrosal sinus	Intraoral Extraoral Intraoral-extraoral
Superficial temporal	Upper molars Lower molars	Temporal fat pad Temporal branch of facial n.	Buccal Deep temporal	Intraoral Extraoral Intraoral-extraoral
Lateral pharyngeal	Lower third molars Tonsillar infection in neighboring spaces	Carotid a. Internal jugular v. Vagus n. Cervical sympathetic chain	Pterygomandibular Submandibular Sublingual Peritonsillar Retropharyngeal	Intraoral Intraoral-extraoral

Adapted from Flynn TR.⁴

a = artery; div. = division; inf. = inferior; n = nerve; superf. = superficial; v = vein.

Table 15-3 Severity Scores of Fascial Space Infections

Severity Score	Anatomic Space
Severity score = 1 (low risk to airway or vital structures)	Vestibular Subperiosteal Space of the body of the mandible Infraorbital Buccal
Severity score = 2 (moderate risk to airway or vital structures)	Submandibular Submental Sublingual Pterygomandibular Submasseteric Superficial temporal Deep temporal (or infratemporal)
Severity score = 3 (high risk to airway or vital structures)	Lateral pharyngeal Retropharyngeal Pretracheal
Severity score = 4 (extreme risk to airway or vital structures)	Danger space (space 4) Mediastinum Intracranial infection

The severity score for a given patient is the sum of the severity scores for all of the spaces involved by cellulitis or abscess, based on clinical and radiographic examination.

Rate of Progression

Upon interviewing the patient with an infection, the surgeon can appraise the rate of progression by inquiring about the onset of swelling and pain and comparing those times to the current signs and symp-

toms of swelling, pain, trismus, and airway compromise. In their study of hospitalized odontogenic infections, Flynn and colleagues found that the number of days of swelling prior to admission correlated negatively with the initial severity score.⁶

This is probably because patients with more severe and rapidly progressive infections were frightened enough to seek hospital care early on.

Odontogenic infections generally pass through three stages before they resolve, the characteristics of which are listed in Table 15-4. During the first 1 to 3 days the swelling is soft, mildly tender, and doughy in consistency. Between days 2 and 5 the swelling becomes hard, red, and exquisitely tender. Its borders are diffuse and spreading. Between the fifth and seventh days the center of the cellulitis begins to soften and the underlying abscess undermines the skin or mucosa, making it compressible and shiny. The yellow color of the underlying pus may be seen through the thin epithelial layers. At this stage the term *fluctuance* is appropriately applied. Fluctuance implies the palpation of a fluid wave by one hand as the abscess is compressed by the other hand. The final stage of odontogenic infection is resolution, which generally occurs after spontaneous or surgical drainage of an abscess cavity. The swelling then begins to decrease in size, redness, and tenderness. The resolving swelling may stay firm for some time, however, as the inflammatory process is involved in removing necrotic tissue and bacterial debris.

Table 15-4 Stages of Infection

Characteristic	Inoculation	Cellulitis	Abscess
Duration	0–3 days	3–7 days	Over 5 days
Pain	Mild–moderate	Severe and generalized	Moderate–severe and localized
Size	Small	Large	Small
Localization	Diffuse	Diffuse	Circumscribed
Palpation	Soft, doughy, mildly tender	Hard, exquisitely tender	Fluctuant, tender
Appearance	Normal coloration	Reddened	Peripherally reddened
Skin quality	Normal	Thickened	Centrally undermined and shiny
Surface temperature	Slightly heated	Hot	Moderately heated
Loss of function	Minimal or none	Severe	Moderately severe
Tissue fluid	Edema	Serosanguineous, flecks of pus	Pus
Level of malaise	Mild	Severe	Moderate–severe
Degree of seriousness	Mild	Severe	Moderate–severe
Predominant bacteria	Aerobic	Mixed	Anaerobic

Adapted from Flynn TR.²⁹

A special note should be made of an especially rapidly progressive infection called necrotizing fasciitis. Occasionally found in the head and neck, frequently due to odontogenic sources, necrotizing fasciitis is a rapidly spreading infection that follows the platysma muscle down the neck and onto the anterior chest wall. Diabetes and alcoholism have been shown to be significant predisposing factors, whereas medical compromise, delay in surgery, and mediastinitis are associated with increased mortality.⁷ It can rapidly result in necrosis of large amounts of muscle, subcutaneous tissue, and skin, resulting in severe reconstructive defects (Figure 15-1). Similar processes may be involved in descending necrotizing infections of the neck, which frequently progress to the mediastinum. The earliest signs of necrotizing fasciitis are small vesicles and a dusky purple discoloration of the involved skin (Figure 15-2). Soon thereafter the skin may become anesthetic. Thereafter frank necrosis occurs.⁸

A suspicion of necrotizing fasciitis is a surgical emergency, requiring broad-spectrum antibiotics, repeated surgical drainage, antiseptic wound packing, and intensive medical supportive care, including fluids, calcium, and possibly blood transfusion.⁸ Repeated surgical débridement is the rule, not the exception. Hyperbaric oxygen therapy may also be of benefit.⁹

Airway Compromise

The most frequent cause of death in reported cases of odontogenic infection is airway obstruction. Therefore, the surgeon must assess current or impending airway obstruction within the first few moments of evaluating the patient with a head and neck infection.

Complete airway obstruction is, of course, a surgical emergency. In such cases insufficient or absent air movement in spite of inspiratory efforts will be apparent. In highly skilled hands one brief attempt at endotracheal intubation may be made, but

a direct surgical approach to the airway by cricothyroidotomy or tracheotomy is more predictably successful. In such extreme circumstances the presence of infection overlying the trachea is less important than the absence of ventilation. Therefore, infection in the region of surgical airway access is not a contraindication to an emergency cricothyroidotomy or tracheotomy.

In partial airway obstruction, abnormal breath sounds will be evident, consisting of stridor or coarse airway sounds suggestive of fluid in the upper airways. The patient may assume a special posture that straightens the airway, such as the “sniffing position,” in which the head is inclined forward and the chin is elevated, as if one were sniffing a rose. Other such postures include a sitting patient with the hands or elbows on the knees and the chest inclined forward with the head thrust anterior to the shoulders, which also straightens the airway and may allow secretions to drool outward onto the floor or into a pan. Occasionally a patient with a lateral pharyngeal space infection will incline the neck toward the opposite shoulder in order to position the upper airway over the laterally deviated trachea (Figure 15-3).

Trismus is an ominous sign in the patient suspected of odontogenic infection. A maximum interincisal opening that has decreased to 20 mm or less in a patient with acute pain should be considered an infection of the masticator space until proved otherwise. Infections of the pterygomandibular space are sometimes missed because trismus hinders the examiner’s view of the oropharynx. Therefore, it is important for the examiner to position the patient’s occlusal plane parallel to the plane of vision and to orient a light coaxial to that plane of view. Then the patient is asked to maximally open the mouth in spite of pain, and the tongue is depressed with a mirror or tongue blade. This should allow the examiner to get at least a glimpse of the position of the uvula and the condition of the anterior tonsillar pillars. The affected

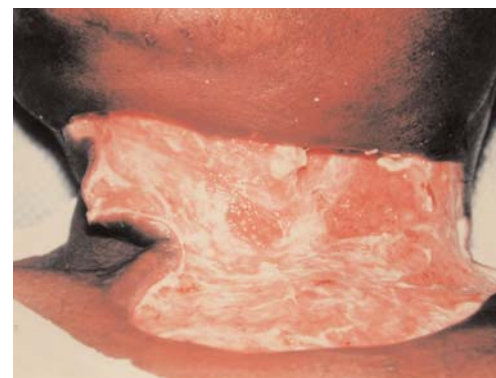


FIGURE 15-1 Necrotizing fasciitis. Large granulating skin defect extending from the inferior border of the mandible to the clavicle, 2 weeks after débridement. Reproduced with permission from Flynn TR.¹⁵

tonsillar pillar will usually be edematous and reddened, and it will displace the uvula to the opposite side (Figure 15-4). If the suspected site of infection is touched with the mirror or tongue blade, acute pain may be elicited, especially as compared to the opposite side. The patient’s report of pain should be distinguished from the gagging that is likely to occur.

Various clinical tests have been proposed with the aim of predicting difficult intubation. The Mallampati test has been correlated with difficult intubation by its

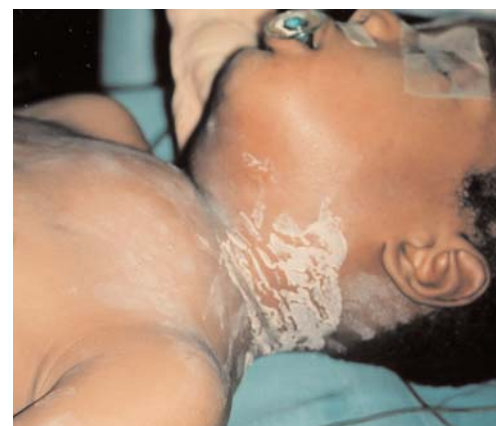

FIGURE 15-2 Necrotizing fasciitis. Early stage, with swelling extending from the inferior border of the mandible onto the anterior chest wall in a 7-year-old boy. The chalky material on the neck is calamine lotion that his mother used to treat the vesicles of presumed contact dermatitis due to poison ivy. Reproduced with permission from Flynn TR.¹⁵

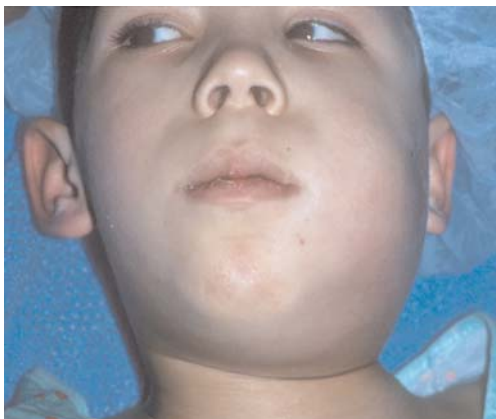

FIGURE 15-3 Left lateral pharyngeal space abscess. Note the swelling just anterior to the sternocleidomastoid muscle above the level of the hyoid bone and the deviation of the head toward the right shoulder, in an attempt to place the upper airway directly over the deviated trachea. Reproduced with permission from Flynn TR et al.²⁹

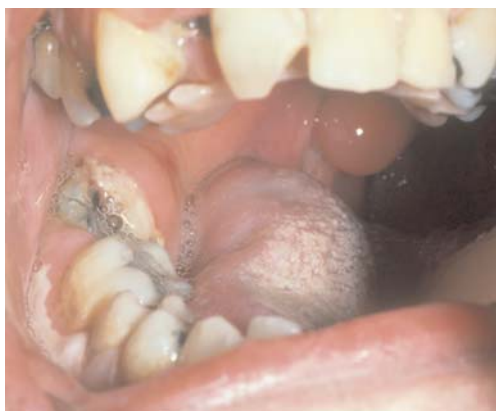

FIGURE 15-4 Right pterygomandibular space abscess. Note the swelling of the anterior tonsillar pillar and the deviation of the edematous uvula to the opposite side. Reproduced with permission from Flynn TR and Topazian RG.³⁰

initial proponent, as have trismus of less than 20 mm and decreased thyromental distance.^{10,11} These results, however, have not been confirmed by independent examiners, although the combination of an abnormal Mallampati test and a thyromental distance of less than 5 cm has been correlated with difficult intubation in one study.¹¹

In airway obstruction, the respiratory rate may be increased or decreased; yet one functional method of assessing the effectiveness of respiratory efforts readily avail-

able to the oral and maxillofacial surgeon is the pulse oximeter.¹²

An oxygen saturation of below 94% in an otherwise healthy patient is indeed an ominous sign because it indicates insufficient oxygenation of the tissues due to hypoperfusion or hypooxygenation. Given the patient with clinically apparent partial airway obstruction, an abnormally low oxygen saturation is an indication for immediate establishment of a secure airway.

Soft tissue radiographs of the cervical airway and chest can be quite valuable in identifying deviation of the airway laterally on a posteroanterior film or anterior displacement of the airway on a lateral view. These films can be taken fairly quickly, which can be an advantage for radiographic examination of the patient with a significant cervical swelling. During prolonged periods in the supine position, as required by the older generation of computed tomography (CT) scanners, an infected swelling may obstruct the airway. On the other hand, the newer high-speed CT scanners can obtain a computerized CT examination within seconds to minutes, which, if available, would make conventional soft tissue radiographs obsolete (Figure 15-5). In a prospective study Miller and colleagues found 89% accuracy, 95% sensitivity, and 80% specificity in identifying “drainable pus” by the combined use of contrast enhanced CT and clinical examination.¹³ By “drainable pus,” the authors meant a collection of 2 mL or more of pus. The high diagnostic yield therefore of contrast-enhanced CT and clinical examination makes this combination the method of choice for evaluation of potential airway obstruction, as well as characterizing the location and quality of infections in the head and neck.¹³

Step 2: Evaluate Host Defenses

Immune System Compromise

Table 15-5 lists the medical conditions that can interfere with proper function of the immune system, which is, of course,

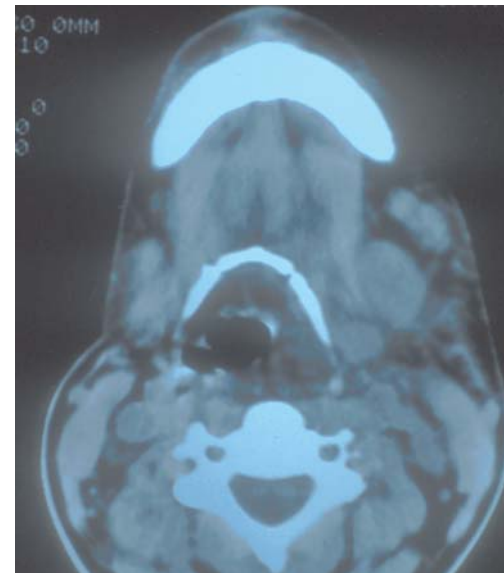


FIGURE 15-5 Axial computed tomography image at the level of the hyoid bone, demonstrating a cellulitis of the left lateral pharyngeal space that is deviating the airway to the opposite side and spreading into the retropharyngeal space. Reproduced with permission from Flynn TR.⁵

essential to the maintenance of host defense against infection. Diabetes is listed first because it is the most common immune-compromising disease. Diabetics have the combination of a white blood cell migration defect, which inhibits successful chemotaxis of white blood cells to the infected site from the blood stream, and a vascular defect that impairs blood flow to small vessel tissue beds, especially in end organs such as the foot. Orally, diabetics have an increased susceptibility to periodontal infections.

Table 15-5 Factors Associated with Immune System Compromise

Diabetes
Steroid therapy
Organ transplants
Malignancy
Chemotherapy
Chronic renal disease
Malnutrition
Alcoholism
End-stage AIDS

This disease also appears to decrease host resistance to more severe odontogenic infections such as necrotizing fasciitis and deep fascial space infections.

The iatrogenic use of steroids has increased over recent years with the use of these medications to treat asthma, skin conditions, autoimmune diseases, cancer, and other inflammatory conditions. Corticosteroids appear to stabilize the cell membranes of immunocompetent cells, thereby decreasing the immune response. Patients with organ transplants are often treated with corticosteroids, as well as other immunosuppressive medications such as cyclosporine and azathioprine, to suppress organ rejection reactions.

It has been postulated that every patient with malignant disease has some defect of the immune system. The mechanisms of immune compromise in malignancy are variable and not well identified, but the surgeon treating the patient with ongoing cancer should assume that there is some defect of the immune system. Cancer chemotherapy directly suppresses the immune system along with rapidly dividing cancer cells. Therefore, all patients who have received cancer chemotherapy within the past year should be considered immunocompromised.

Other conditions that impair immune function include malnutrition, alcoholism, and chronic renal disease. The role of human immunodeficiency virus (HIV) infection in diminishing host resistance to odontogenic infections is somewhat unclear and paradoxical. HIV infection first and primarily damages the T cell. On the other hand, most odontogenic infections are due to extracellular bacteria, which are attacked by B cells, the white blood cells that elaborate antibodies. Although HIV infection may damage B cells early in the course of the disease, its most devastating effects are seen on the T cells, which explains the increased rate of cancers and infections by intracellular pathogens in patients

with acquired immunodeficiency syndrome (AIDS) and pre-AIDS. Although patients with HIV seropositivity may suffer a more intense and/or prolonged hospital course than other patients, HIV seropositivity does not seem to increase the incidence of severe odontogenic infections.¹⁴

Systemic Reserve

The host response to severe infection can place a severe physiologic load on the body. Fever can increase sensible and insensible fluid losses and caloric requirements. A prolonged fever may cause dehydration, which can therefore decrease cardiovascular reserves and deplete glycogen stores, shifting the body metabolism to a catabolic state. The surgeon should also be aware that elderly individuals are not able to mount high fevers, as often seen in children. Therefore, an elevated temperature at an advanced age is not only a sign of a particularly severe infection, but also an omen of decreased cardiovascular and metabolic reserve, due to the demands placed on the elderly patient's physiology.¹⁵

In several studies, the white blood cell count at admission has been a significant predictor of the length of hospital stay.^{6,16} Therefore, evaluation of leukocytosis is important in determining the severity of infection as well as in estimating the length of hospital stay.

The physiologic stress of a serious infection can disrupt previously well-established control of systemic diseases such as diabetes, hypertension, and renal disease. The increased cardiac and respiratory demands of a severe infection may deplete scarce physiologic reserves in the patient with chronic obstructive pulmonary disease or atherosclerotic heart disease, for example. Thus, an otherwise mild or moderate infection may be a significant threat to the patient with systemic disease, and the surgeon should be careful to evaluate and manage concurrent sys-

temic diseases in conjunction with direct management of the infection.

Step 3: Decide on the Setting of Care

Table 15-6 lists the indications for hospital admission of the patient with a severe odontogenic infection. As previously stated, an elevated fever increases metabolic needs and fluid losses, which can lead to dehydration. In addition to the clinical signs of dry skin, chapped lips, loss of skin turgor, and dry mucous membranes, dehydration can be assessed in the presence of normal serum creatinine by an elevated urine specific gravity (over 1.030) or an elevated blood urea nitrogen (BUN), which indicates prerenal azotemia.

Infections in deep spaces that have a severity score of 2 or greater (see Table 15-3) can hinder access to the airway for intubation by causing trismus, directly compress the airway by swelling, or threaten vital structures directly. Thus, an odontogenic infection involving the masticator space, the perimandibular spaces, or deeper spaces indicates hospital admission.

Occasionally general anesthesia is required for patient management due to inability to achieve adequate local anesthesia, the need to secure the airway, or the inability of the patient to cooperate, as in a young child. Sometimes concurrent systemic disease indicates hospital admission and may even delay surgery, as in the need to reverse warfarin anticoagulation.

Table 15-6 Indications for Hospital Admission

Temperature > 101°F (38.3°C)
Dehydration
Threat to the airway or vital structures
Infection in moderate or high severity anatomic spaces
Need for general anesthesia
Need for inpatient control of systemic disease

In deciding whether to admit the patient with a serious odontogenic infection, it is generally safer to err on the side of hospital admission. The inpatient setting affords the patient with continual professional monitoring, supportive medical care, the availability of radiologic and medical consultative services, and, most importantly, a team that can rapidly secure the airway should it become compromised.

Step 4: Treat Surgically

Airway Security

The dramatic reduction in the mortality of Ludwig's angina from 54 to 10% in only 3 years, afforded by Williams and Guralnick, was made possible by their changed surgical policy of immediate establishment of airway security by early intubation or tracheotomy, followed by aggressive and early surgical intervention.² No antibiotics were used in their patients, except sulfa drugs in some cases. In the antibiotic era mortality has been further reduced to about 4%.³ It is therefore apparent that immediate establishment of airway security and early aggressive surgical therapy are the most important intervention steps in the management of severe odontogenic infections.

Table 15-7 lists the indications for an operating room procedure. The paramount indication is of course to establish airway security. The involvement of moderate or high severity anatomic spaces generally necessitates a more complicated airway management procedure, as well as surgical intervention in anatomic loca-

tions that are not amenable to profound local anesthesia. An infection that is rapidly progressing through the anatomic fascial planes, as in necrotizing fasciitis, indicates the prompt establishment of a secure airway, even if for anticipatory reasons, as well as the possible need to extend the anatomic dissection into regions that had not been contemplated preoperatively. Sometimes general anesthesia is required for patient management reasons alone, especially in the patient who is not able to cooperate, such as a young child or mentally handicapped individual.

Successful airway management in difficult situations requires a team approach. Preoperatively the surgeon should communicate with the anesthesiologist to establish the airway management plan. The anesthesiologist should be interested in understanding the anatomic location of the infection, as well as its implications for airway management. The anesthesiologist will value the opportunity to see any effacement, displacement, or deviation of the airway as demonstrated on clinical examination and CT. The airway management plan should include the projected initial management, as well as secondary procedures should the initial approach fail.

An infrequently used surgical technique that may aid in protecting the airway during intubation or tracheotomy is needle decompression. In this technique, under local anesthesia an abscess of the pterygomandibular, lateral pharyngeal, submandibular, or sublingual space is aspirated with a large-bore needle in order to decompress the surrounding tissues. This maneuver may decrease the risk of abscess rupture through taut, distended oropharyngeal tissues during instrumentation of the airway. Additional benefits of this procedure are the redirection of pus drainage into the oral cavity or onto the skin, where it can easily be removed, and obtaining an excellent specimen for culture and sensitivity testing.

Surgical Drainage

In general, surgery for management of severe odontogenic infections is not difficult. Given a thorough knowledge of the anatomy of the deep fascial spaces of the head and neck, the surgeon should be able, by using appropriate anatomic landmarks, to use small incisions and blunt dissection without direct exposure and visualization of the entire infected anatomic space. Figure 15-6 illustrates the appropriate locations for extraoral incision placement for drainage of the various anatomic deep spaces. In addition a vertical incision over the pterygomandibular raphe can be used to drain the pterygomandibular space as well as the anterior compartment of the lateral pharyngeal space, as illustrated in Figure 15-7. Lest the surgeon crush a vital structure within the beaks of a hemostat during blunt dissection, it is crucial to insert the instrument closed, then open it at the depth of penetration, and then withdraw the instrument in the open position. A hemostat should never be blindly closed while it is inside a surgical wound. Another important principle of surgical incision and drainage is the need to dissect a pathway for the drain that includes the locations where pus is most likely to be found. This can be guided by the preoperative CT examination and by knowledge of the pathways that odontogenic infection is most likely to take. For example, in drainage of the submandibular space, if incisions are placed over the anterior and posterior bellies of the digastric muscle at the submandibular, submental, and sublingual location and at the submandibular, sublingual location as shown in Figure 15-6, then the dissection must pass superiorly and medially until the medial (lingual) plate of the mandible is contacted. The most likely pathway for odontogenic infections to enter the submandibular space is through the thin lingual plate of the mandible, which also approximates the root apices of the lower molar teeth. By

Table 15-7 When to Go to the Operating Room

<ul style="list-style-type: none"> To establish airway security Moderate to high anatomic severity Multiple space involvement Rapidly progressing infection Need for general anesthesia
--

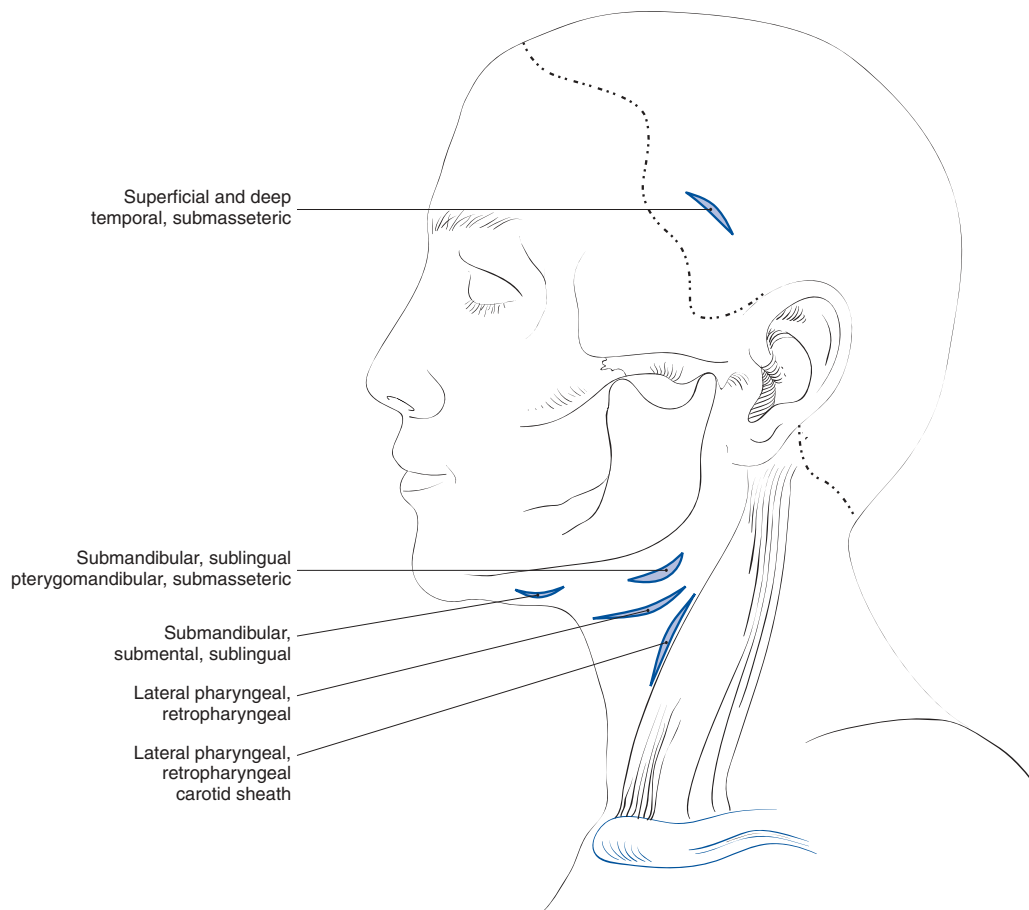


FIGURE 15-6 Incision placement for extraoral drainage of head and neck infections. Incisions at the following points may be used to drain infections in the indicated spaces: superficial and deep temporal, submasseteric; submandibular, submental, sublingual; submandibular, sublingual, pterygomandibular, submasseteric; lateral pharyngeal, retropharyngeal; lateral pharyngeal, retropharyngeal, carotid sheath. Adapted from Flynn TR.³¹

exploring this location, the surgeon may find a collection of pus that would otherwise have been missed. In order to pass a drain through the submandibular space effectively, the surgeon should therefore pass a large curved hemostat from one incision upward to the medial side of the mandible and then down to the other incision. A Penrose drain can then be grasped in the tip of the hemostat and pulled through the dissected pathway from one incision to the other, thus draining the entire submandibular space. The resulting pathway for a through-and-through drain in the submandibular space is illustrated in Figure 15-8.

The advantages of through-and-through drainage are the provision of two

pathways for the egression of pus, placement of the incisions in healthy tissue in cosmetically acceptable areas, and the ability to irrigate the infected wound with unidirectional flow from one incision to the other. Wound irrigation is facilitated especially by the use of a Jackson Pratt-type drain, which is noncollapsible and perforated. Such unidirectional superior-to-inferior drainage of the pterygomandibular space using intraoral and extraoral incisions and a Jackson Pratt drain is illustrated in Figure 15-9.

There is little evidence to indicate that frequent wound irrigation hastens the resolution of infection. However, it does make clinical sense to remove by irrigation bacteria, pus, clots, and necrotic tissue from

infected wounds as they accumulate. Similarly the use of bulky occlusive dressings has not been shown to substantially alter the outcome of cases of odontogenic infection. Nonetheless the use of such a dressing, as illustrated in Figure 15-10, may be more comfortable over the long run than a dressing that is taped to the skin, and it certainly helps to prevent the contamination of the hospital by pathogenic organisms. The need for this type of hygiene is bound to increase in coming years, as both antibiotic-resistant organisms and critically ill, sometimes immunocompromised patients increasingly inhabit hospitals.

Drains should be discontinued when the drainage ceases. They may be advanced gradually or removed all at once. There is no evidence in favor of either technique. Pus usually stops flowing from surgically drained abscesses in 24 to 72 hours, but this process may take somewhat longer when only cellulitis has been encountered. It should be kept in mind however that latex Penrose drains can be antigenic, and after several days they may cause exudation due to foreign body reaction alone.

Timing of Incision and Drainage

Much of the surgical literature on the management of deep fascial space infections of

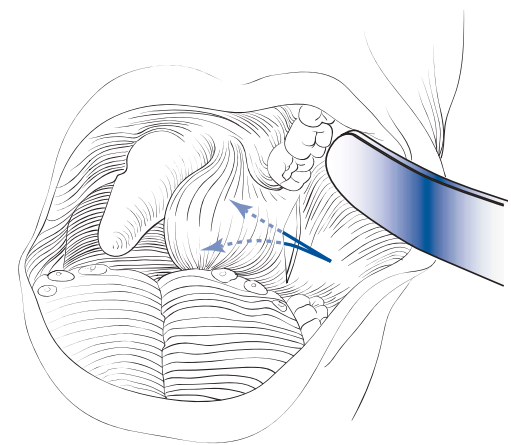


FIGURE 15-7 Intraoral incision placement for drainage of the anterior compartment of the lateral pharyngeal space (curved arrow) and the pterygomandibular space (straight arrow). Adapted from Flynn TR.³¹

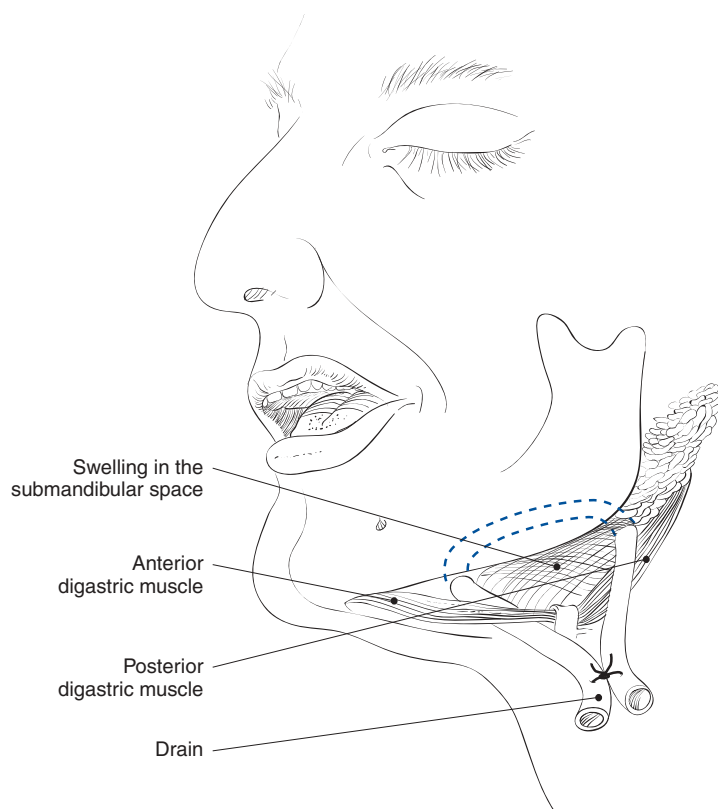


FIGURE 15-8 Pathway of a through-and-through drain of the submandibular space. Note that the drain passes deep to the medial surface of the mandible, below the attachment of the mylohyoid muscle. Adapted from Flynn TR.³¹

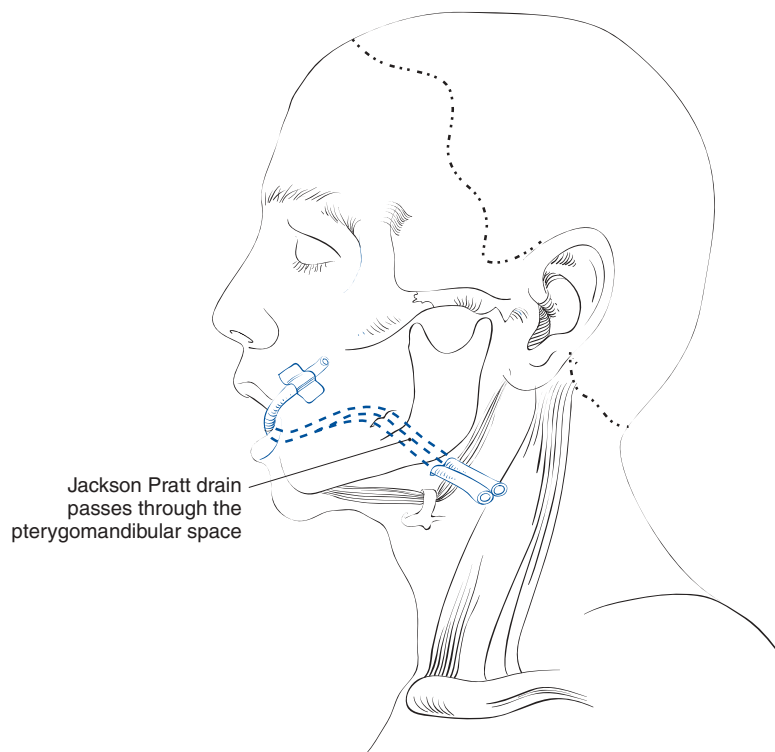


FIGURE 15-9 Jackson Pratt irrigating drain placed from an intraoral incision through the pterygomandibular space to an extraoral incision, allowing unidirectional irrigation and drainage. Adapted from Flynn TR.³¹

the head and neck advocates an expectant approach to surgical drainage of deep neck infections. The overall strategy of this approach is to use parenteral antibiotic therapy as a means of controlling, localizing, or even eradicating the soft tissue infection. Failure of the medical approach is determined by patient deterioration, impending airway compromise, and the identification of an abscess by CT or clinical examination or both. Only then is surgical drainage undertaken.¹⁷⁻¹⁹ The expectant approach to management of severe odontogenic infections has not been supported by empiric investigation.

The alternative strategy, successfully demonstrated by Williams and Guralnick, is the immediate establishment of airway security as necessary, and aggressive early surgical intervention.² Identification of an abscess is not required before surgical intervention. The approach by Williams and Guralnick is predicated on the concept that early incision and drainage aborts the spread of infection into deeper and more critical anatomic spaces, even when it is in the cellulitis stage. In a prospective case series of 34 patients hospitalized with severe odontogenic infections, Flynn and colleagues performed surgical drainage on all patients as soon as possible after admission.⁶ In none of their cases did incision and drainage seem to hasten the spread of infection. The need for reoperation was not significantly different between those patients in whom abscess and those in whom cellulitis was found.⁶

Culture and Sensitivity Testing

Infections that present in the low severity anatomic spaces (see Table 15-3) are not in an anatomic position that is likely to threaten the airway or vital structures. In the absence of immunologic or systemic compromise, such infections are very unlikely to become serious or life threatening. Straightforward treatments, such as removal of the involved teeth, intraoral

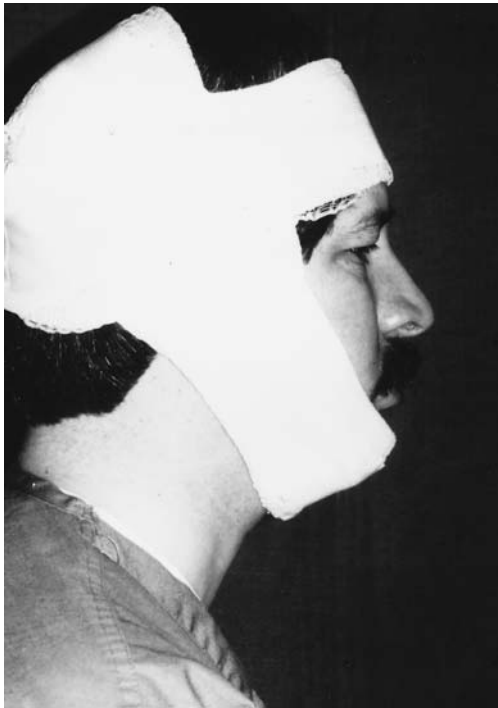

FIGURE 15-10 A properly placed Barton dressing, which avoids taping of the skin. It can occlude and absorb the drainage of a maxillofacial infection. Reproduced with permission from Flynn TR.¹⁵

incision and drainage, and empiric antibiotic therapy, are almost always successful. In this setting it can be hard to justify the increased cost of routine culture and antibiotic sensitivity testing. Furthermore, since most odontogenic pathogens are slow-growing species, identification can become an expensive and time-consuming task for the microbiology laboratory. This expense is hard to justify, given the fact that at least until recently, the oral flora is routinely sensitive to penicillin. Therefore, most microbiology laboratories, when given a specimen that grows out α -hemolytic streptococci mixed with short, anaerobic, weakly gram-negative rods, will report the growth of normal oral flora, thus avoiding the necessity for species identification and subsequent antibiotic sensitivity testing. For these reasons routine culture and sensitivity testing for minor oral infections does not appear to be justified.

When an infection involves anatomic spaces of moderate or greater severity, or when there is significant medical or immune system compromise, culture and sensitivity testing as early as possible in the course of infection is important because the final result of antibiotic sensitivity testing can be delayed for as much as 2 weeks when fastidious or antibiotic-resistant organisms are involved.

Culture and sensitivity testing is also justified when the surgeon is dealing with infections that have been subjected to multiple prior courses of antibiotic therapy or in chronic infections that are recalcitrant to therapy. Immunocompromised patients also tend to harbor unusual pathogens, such as *Klebsiella pneumoniae* in diabetes, methicillin-resistant *Staphylococcus aureus* in intravenous-drug abusers, and intracellular pathogens, such as mycobacteria in HIV/AIDS. In summary, culture and sensitivity testing should be performed in unusual infections, the medically and immune compromised, and certainly in all cases severe enough to require hospitalization.

Proper culture technique involves the harvesting of the specimen in a manner that minimizes contamination by normal oral or skin flora. Ideally the skin or mucosa should be prepared with antiseptic and isolated, and the culture should be obtained by aspiration from the point of maximum inflammation, where abscess is most likely to be found. If this is not possible, then at surgery a swab and culturette system can be used, although the surgeon must be careful to avoid contamination of the specimen by saliva or skin flora. Furthermore the culture transport system should be designed to maintain the viability of anaerobic organisms, which do not survive in commonly available aerobic culturette systems. Even though the surgeon may not encounter pus during aspiration attempts or surgical drainage, fluid aspirates and swab cultures of infected sites do yield valid cultures with readily

interpretable results. Therefore, specimens should be sent for culture and sensitivity testing even when pus is not obtained.

Step 5: Support Medically

Medical supportive care for the patient with a severe odontogenic infection is composed of hydration, nutrition, and control of fever in all patients. Maintenance or reestablishment of electrolyte balance and the control of systemic diseases may also be a crucial part of the necessary supportive medical care for some cases, and the reader is referred to appropriate texts for a more comprehensive discussion of these matters.

Initial temperature has been shown to be a significant predictor of the length of hospital stay with severe odontogenic infections.^{6,20} Fever below 103°F (39.4°C) is probably beneficial. Mild temperature elevations promote phagocytosis, increase blood flow to the affected area, raise the metabolic rate, and enhance antibody function. Above 103°F, however, fever can become destructive by increasing metabolic and cardiovascular demands beyond physiologic reserve capacity. Energy stores can be rapidly depleted and the loss of fluid is significantly increased.

Adequate hydration is perhaps the best method for controlling fever. Daily sensible fluid loss, consisting primarily of sweat, is increased by 250 mL per degree of fever. Insensible fluid loss, consisting mainly of evaporation from lungs and skin, is increased by 50 to 75 mL per degree of fever per day. Therefore, a 70 kg patient with a fever of 102.2°F would have a daily fluid requirement of about 3,100 mL. This would translate to a required intravenous infusion rate of approximately 130 mL per hour, assuming no oral intake and no other extraordinary fluid losses.²¹

The next approach to controlling fever is usually taken by the administration of acetaminophen or aspirin. Fevers are often exaggerated in children and decreased in

the elderly. Thus, an older patient with a relatively mild elevation of temperature may have a fairly significant infection. At the same time the surgeon may wish to control fever in the elderly at a lower temperature level than in the younger patient because of a fever's increased cardiovascular and metabolic demands.²¹ Fever can be controlled or reduced by a variety of other methods when necessary. These include cool water or alcohol sponge baths, chilled drinks when practical, or even an immersion bath using tepid water.

Fever also increases metabolic demand by 5 to 8% per degree of fever per day.²¹ Therefore, it may be necessary to supplement the infected patient's oral intake, which is likely to be significantly inhibited by the local effects of the infection and surgery, by using supplementary feedings or even enteral nutrition via a feeding tube.

Step 6: Choose and Prescribe Antibiotic Therapy

It is beyond the scope of this chapter to discuss the topic of antibiotic selection for head and neck infections comprehensively. This matter has been recently covered in detail elsewhere.²² The empiric antibiotics of choice for odontogenic infections are, however, listed in Table 15-8.

These antibiotic choices are separated by severity of infection. Mild or outpatient infections have been shown in a number of studies to respond well to the oral penicillins. There was no significant difference in pain or swelling at 7 days of therapy between penicillin and various other antibiotics, including clindamycin, amoxicillin, amoxicillin-clavulanate, and cephadrine, although these parameters improved more rapidly during the first 48 hours of therapy with the alternative antibiotics.²³⁻²⁵ In one pediatric study pain and swelling were significantly better at 7 days with amoxicillin.²⁶ In all of the above referenced studies the involved tooth or teeth were treated with extraction or root canal

Table 15-8 Empiric Antibiotics* of Choice for Odontogenic Infections	
Severity of Infection	Antibiotic of Choice
Outpatient	Penicillin Clindamycin Cephalexin (only if the penicillin allergy was not the anaphylactoid type; use caution) Penicillin allergy: Clindamycin Moxifloxacin Metronidazole alone
Inpatient	Clindamycin Ampicillin + metronidazole Ampicillin + sulbactam Penicillin allergy: Clindamycin Third-generation cephalosporin IV (only if the penicillin allergy was not the anaphylactoid type; use caution) Moxifloxacin (especially for <i>Eikenella corrodens</i>) Metronidazole alone (if neither clindamycin nor cephalosporins can be tolerated)

*Empiric antibiotic therapy is used before culture and sensitivity reports are available. Cultures should be taken in severe infections that threaten vital structures.
IV = intravenous.

therapy. Incision and drainage was performed as necessary. Therefore, penicillin continues to be a highly effective antibiotic for uncomplicated odontogenic infections, owing to its low cost and low incidence of unwanted side effects.

For severe infections warranting hospital admission the antibiotics of choice for odontogenic infections do not include penicillin. In 1999 Flynn and colleagues found a 26% failure rate of penicillin when used empirically in a series of 34 hospitalized cases of odontogenic infection.⁶ Of the 31 patients who were placed on penicillin (3 were allergic), 8 experienced clinical therapeutic failure of penicillin, which was determined by failure of improvement in swelling, temperature, and white blood cell count after adequate surgical drainage was verified by postoperative CT. This high clinical failure rate of penicillin in hospitalized odontogenic infections is clinically unacceptable because of the seriousness of these cases. Therefore, clindamycin has

become the empiric antibiotic of choice for odontogenic infections that are serious enough to warrant hospital admission.

Most resistance to penicillin that occurs among the oral pathogens is due to synthesis of β -lactamase. Approximately 25% of the strains of the *Prevotella* and *Porphyromonas* genera are able to synthesize this enzyme. β -Lactamase can also be found in some strains of *Fusobacterium* and *Streptococcus* species. Importantly, however, the oral strains of streptococci that synthesize β -lactamase are generally among the *S. mitis*, *S. sanguis*, and *S. salivarius* species. These species are members of the *Streptococcus viridans* group that are responsible for many cases of endocarditis. They are not frequently found in odontogenic abscesses. *Streptococcus anginosus*, *S. constellatus*, and *S. intermedius* are the viridans streptococci that comprise the *Streptococcus milleri* group. The *S. milleri* group is most commonly found in odontogenic abscesses, and fortunately it remains

sensitive to the natural and semisynthetic penicillins, such as penicillin V and amoxicillin. Therefore, it is reasonable to use penicillin plus a β -lactamase inhibitor such as ampicillin-sulbactam or a penicillin plus metronidazole as alternative antibiotics for serious odontogenic infections. The penicillins and metronidazole have the advantage of crossing the blood-brain barrier when the meninges are inflamed. Clindamycin, on the other hand, does not cross the blood-brain barrier. Therefore, it is appropriate to use penicillin plus metronidazole or ampicillin-sulbactam when there is a risk of an odontogenic infection entering the cranial cavity.²²

Few cephalosporins are able to cross the blood-brain barrier. Some third-generation cephalosporins, such as ceftazidime, can do so. In addition, ceftazidime is effective against the oral streptococci and most oral anaerobes. Among the cephalosporins, therefore, ceftazidime is the alternative antibiotic of choice.

A new fluoroquinolone antibiotic, moxifloxacin has great promise in the treatment of head and neck infections. Its spectrum against oral streptococci and anaerobes is excellent. Its absorption is virtually complete via either the oral or intravenous routes, and it penetrates bone readily. Therefore, this new antibiotic may become a significant addition to the oral and maxillofacial surgeon's armamentarium.

Even though metronidazole is active only against obligate anaerobic bacteria, its use alone in the treatment of odontogenic infections, when combined with appropriate surgical therapy, may be effective. In one study, ornidazole, a member of the nitroimidazole family, was effective when used alone in the management of odontogenic infections.²⁷ Thus, the use of metronidazole alone may be an appropriate stratagem when all of the other appropriate antibiotics are contraindicated. As with all antibiotics, the surgeon should be aware of the side effects and drug interactions of the anti-

otics he or she uses. Metronidazole has a disulfiram-like reaction with alcohol, and should be used with caution in pregnancy.

Step 7: Administer the Antibiotic Properly

The tissue level of antibiotics determines their effectiveness. Those tissue levels are of course dependent on the antibiotic's level in serum, through which the antibiotic must pass in order to achieve therapeutic levels in soft tissues, bone, brain, and abscess cavities. Administration of antibiotics by the oral route requires that the drug successfully navigate the vagaries of the highly acidic stomach, the chemical qualities of ingested foods, and the basic intestinal tract. Once an antibiotic is absorbed by the gastric or intestinal mucosa, it may then be subject to first-pass metabolism in the liver and subsequent excretion through the bile. Part of the excreted antibiotic may then be reabsorbed by the intestine, resulting in enterohepatic recirculation. For these reasons orally administered antibiotics achieve much lower serum levels at a slower rate than when they are injected directly into the vascular system intravenously.

Some antibiotics, however, are equally well absorbed intravenously and orally. The fluoroquinolones, such as ciprofloxacin and moxifloxacin, are the best examples of this. For this reason the fluoroquinolones are not given intravenously unless use of the oral route is contraindicated.

The minimum inhibitory concentration (MIC) is the concentration of an antibiotic that is required to kill a given percentage of the strains of a particular species, reported as 50% or 90% of strains (MIC₅₀ or MIC₉₀, respectively). The effectiveness of some antibiotics is determined by the ratio of the serum concentration of the antibiotic to the MIC required to kill a particular organism. For example, with the fluoroquinolones and the aminoglycosides, if the serum concentration achieved is three to four times the MIC for the

organisms involved, then maximum killing power will be achieved. These are examples of concentration-dependent antibiotics.²²

With time-dependent antibiotics, such as the β -lactams and vancomycin, antibiotic effectiveness is determined by the duration for which the serum concentration of the antibiotic remains above the MIC. With time-dependent antibiotics, it is necessary to know the serum elimination half-life ($t_{1/2}$) of the antibiotic in order to determine its proper dosage interval. The dosage interval can then be designed in order to maintain the serum concentration above the MIC for at least 40% of the dosage interval.²²

Fortunately, the mathematics involved in these calculations have already been determined by the drug manufacturer. Dosage intervals should not be changed from published guidelines by the surgeon. Nonetheless, the surgeon must be aware of the greater effectiveness of intravenous antibiotics over their oral counterparts. For example, when penicillin G is given every 4 hours intravenously, a peak serum blood level of 20 $\mu\text{g}/\text{mL}$ is achieved. Since the serum elimination half-life of penicillin G is 0.5 hours, after 3 hours (6 half-lives) the serum concentration will be approximately 0.3 $\mu\text{g}/\text{mL}$. Since the MIC₉₀ of *Streptococcus viridans* is 0.2 $\mu\text{g}/\text{mL}$, the serum concentration of penicillin G after an intravenous dose of 2 million units will remain above the MIC₉₀ for approximately 75% of the dosage interval. Therefore, penicillin G, 2 million units given intravenously every 4 hours, should be highly effective against the viridans group of streptococci, especially the abscess-forming *S. milleri* group.

By the same method the peak serum level that can be achieved with an oral dose of 500 mg of amoxicillin is 7.5 $\mu\text{g}/\text{mL}$, and its $t_{1/2}$ is only 1.2 hours. Since amoxicillin's MIC₉₀ for viridans streptococci is 2 $\mu\text{g}/\text{mL}$, the serum concentration of amoxicillin will fall below the MIC₉₀ at approximately 2 hours after

the peak serum level has been achieved, which is only 25% of the 8-hour dosage interval. Therefore, oral amoxicillin, even though it is considered by many to be a more effective antibiotic, is less likely to be effective against the viridans streptococci than intravenous penicillin G.

Another practical matter that must always be considered in administering antibiotics is their cost, especially their cost to the patient. When a patient does not have prescription drug insurance coverage, such as in the working poor and the elderly, the retail cost of the antibiotic can be a significant factor in whether the prescribed antibiotic is indeed followed. In 2003 the retail cost of 1 week's supply of penicillin V 500 mg taken 4 times per day was US\$12.09 at a large pharmacy chain in the northeastern United States. The retail cost of 1 week's supply of clindamycin 300 mg taken 4 times per day was US\$58.59. These prices reflect generic medications, not brand name antibiotics, which are significantly more expensive. Thus, an indigent patient may not be able to pay for a more expensive antibiotic, and therefore he or she may be forced to either take reduced amounts of the antibiotic, to extend the dosage interval, or to forgo taking the antibiotic entirely. Accordingly the astute clinician will take the cost factor into account. When appropriate, a frank discussion of the cost of the antibiotic as compared to the patient's means appears to be the best policy.

Step 8: Evaluate the Patient Frequently

In outpatient infections that have been treated by tooth extraction and intraoral incision and drainage, the most appropriate initial follow-up appointment is usually at 2 days postoperatively for the following reasons:

1. Usually the drainage has ceased and the drain can be discontinued at this time.
2. There is usually a discernible improvement or deterioration in signs and

symptoms allowing the next treatment decisions to be made.

For odontogenic deep fascial space infections that are serious enough for hospitalization, daily clinical evaluation and wound care are required. By 2 to 3 postoperative days the clinical signs of improvement should be apparent, such as decreasing swelling, defervescence, cessation of wound drainage, declining white blood cell count, decreased malaise, and a decrease in airway swelling such that extubation can be considered. Also at this time preliminary Gram's stains and/or culture reports should be available, which may provide some guidance as to the appropriateness of the empiric antibiotic therapy.

If the above signs of clinical improvement are not apparent, then it may be necessary to begin an investigation for possible treatment failure. The causes of treatment failure in odontogenic infections are listed in Table 15-9. One of the best methods of reevaluation is the postoperative CT. A postoperative CT can identify continued airway swelling that may preclude extubation, or further spread of the infection into previously undrained anatomic spaces, or it may confirm adequate surgical drainage of all the involved anatomic spaces by the visualization of radiopaque drains in all of the involved fascial spaces.

Sometimes it is difficult to determine whether the inability to extubate a patient is due to antibiotic resistance or inadequate surgical drainage. Figure 15-11 illustrates two such cases in which a postoperative CT was able to identify the most likely cause for the lack of clinical improvement. In Figure 15-11A, oropharyngeal swelling surrounds the endotracheal tube in spite of the presence of surgical drains in all of the infected spaces. This lack of improvement at 4 postoperative days was due to therapeutic failure of penicillin, which was treated by changing this patient's antibiotic to clindamycin. Subsequently the patient improved. In Figure

15-11B, there is continued oropharyngeal swelling surrounding the endotracheal tube at 5 postoperative days. On the other hand the infection has progressed from the successfully drained left pterygomandibular space to the left and right lateral pharyngeal spaces, as well as the retropharyngeal space. This patient was taken back to the operating room for repeated drainage of all of the infected spaces.

It should be noted, however, that in this author's experience the use of CT scanning to determine whether a patient can be extubated gives a late positive signal. The best available clinical test for the ability to extubate in the case of upper airway swelling is the air leak test (Figure 15-12). The air leak test is performed in the following manner in the spontaneously ventilating patient:

1. The endotracheal tube and trachea are suctioned.
2. The oxygen supply is reconnected and any coughing that was stimulated by the tracheal suctioning is allowed to subside.
3. The oropharynx and oral cavity are suctioned free of debris, hemorrhage, and secretions.
4. The cuff of the endotracheal tube is deflated while the oxygen supply is maintained.
5. After waiting for any coughing to subside, the oxygen supply is disconnected

Table 15-9 Causes of Treatment Failure

Inadequate surgery
Depressed host defenses
Foreign body
Antibiotic problems
Patient noncompliance
Drug not reaching site
Drug dosage too low
Wrong bacterial diagnosis
Wrong antibiotic

Adapted from Peterson LJ.³²

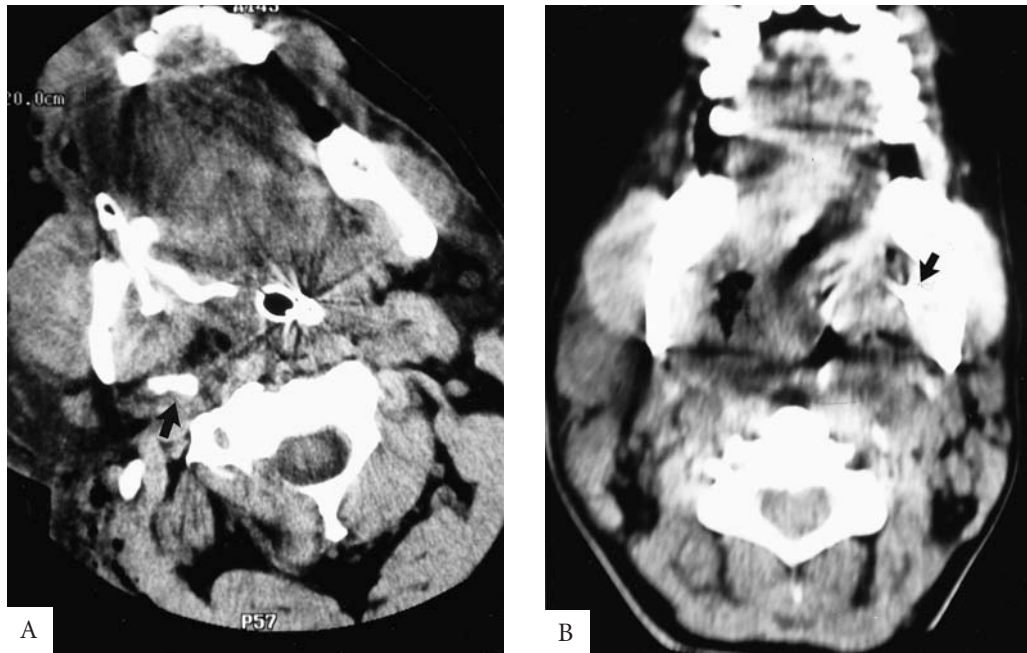


FIGURE 15-11 A, Four-days postoperative computed tomography (CT) image of a patient with a right pterygomandibular and lateral pharyngeal space abscess. Note the intraoral drains in the pterygomandibular and anterior compartments of the lateral pharyngeal space, and the extraoral drain in the posterior compartment of the lateral pharyngeal space (arrow). B, Five-days postoperative axial CT of a patient with a previously placed drain in the left pterygomandibular space (arrow). Note the extension of the infection into the right and left lateral pharyngeal spaces and the retropharyngeal space, with constriction and deviation of the airway. Reproduced with permission from Flynn TR.³¹

and the surgeon's thumb is placed to occlude the opening of the endotracheal tube.

6. The patient is then instructed to breathe spontaneously around the endotracheal tube, and if this can be done, a positive air leak test is obtained. If the patient cannot breathe around the occluded endotracheal tube, then a negative result is obtained, and extubation should be delayed.

Given a positive air leak test result, the best method for patient extubation involves extubation over a stylet or preferably an endotracheal tube changer. Consideration may be given to performing the extubation procedure in an operating room, where the best facilities for handling an airway emergency are available. One method for extubation over a tube changer is described as follows:

1. The patient is preoxygenated for 3 to 5 minutes.

2. The endotracheal tube and trachea are suctioned.
3. Five milliliters of 1% lidocaine without epinephrine is administered via the endotracheal tube, followed by oxygenation and then repeated tracheal suctioning.
4. The oral cavity and oropharynx are suctioned free of debris, hemorrhage, and secretions.
5. The oxygen supply is disconnected and a tube changer then is introduced into the trachea via the endotracheal tube.
6. The cuff of the endotracheal tube is deflated and the endotracheal tube is withdrawn over the tube changer until its tip is in the oropharynx.
7. If the patient is able to breathe around the tube changer as it remains in the trachea, then extubation can be completed.
8. If the patient is not able to breathe around the tube changer, then the

endotracheal tube is re-inserted over the tube changer into the trachea.

9. The endotracheal tube cuff is re-inflated, the tube changer is withdrawn, and oxygen is reconnected.

After extubation, the patient is closely monitored clinically and with pulse oximetry. Arterial blood gases may be drawn 1 hour after extubation in order to verify adequate oxygenation and ventilation.

Occasionally, the infecting flora, especially in a particularly severe infection with a prolonged course, will change during the course of treatment. This may be due to the selection pressure exerted by intensive antibiotic therapy, or it may be due to the subsequent introduction of hospital-acquired pathogens, resulting in a nosocomial infection. Therefore, in prolonged treatments and in especially severe cases it may be prudent to reculture infected sites, so that any new or previously undetected pathogens can be identified.

In cases where there is continued chronic drainage from an infected site, such as in diagnosed or suspected osteomyelitis, the surgeon's mnemonic for the causes of a fistula can be used. "FETID" stands for *foreign body, epithelium, tumor, infection, and distal obstruction*. In the maxillofacial region,

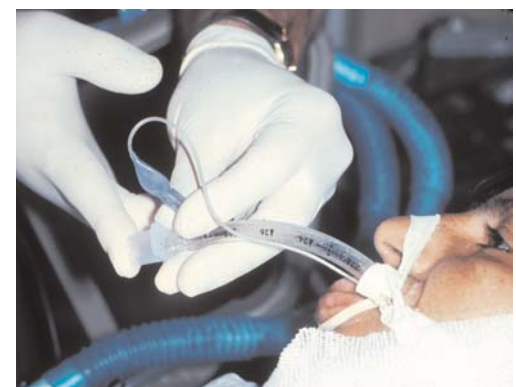

FIGURE 15-12 Air leak test, performed by occluding the endotracheal tube with a finger, to determine whether the patient can breathe around the outside of the endotracheal tube. Reproduced with permission from Bennett JD and Flynn TR.³³

this mnemonic can be used to provide a differential diagnosis for the chronic drainage of pus. Foreign bodies may be represented by bone plates and screws, or dental or cosmetic facial implants. Epithelium may cause chronic drainage simply because an epithelialized fistulous tract has not been completely excised or because an epithelium-lined cyst has drained externally. Tumors (especially malignant ones) that become infected do not heal, which may result in chronic drainage. Infection can of course drain chronically, which should alert the surgeon to suspect osteomyelitis or a chronic periapical abscess that is draining onto the skin, as in Figure 15-13. Distal obstruction classically refers to intestinal obstructions, but the concept can still be applied to the salivary ducts and to the natural sinus drainage pathways, such as the ostium of the maxillary sinus. When these openings for natural drainage of saliva or mucus become obstructed, then infection may result and drainage may

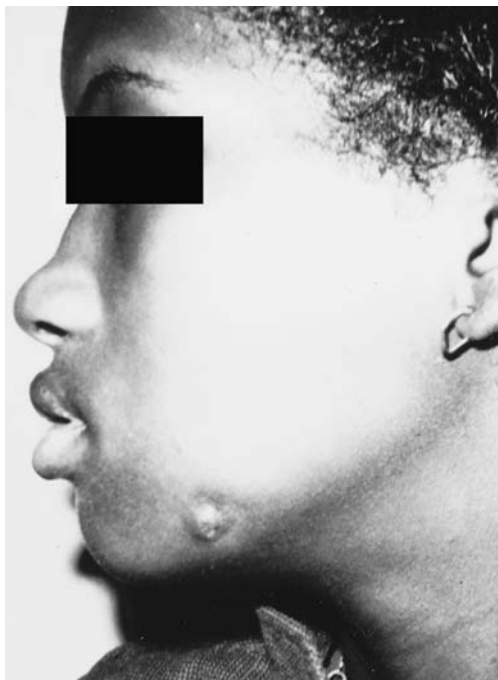

FIGURE 15-13 A draining sinus tract onto the face resulting from an untreated periapical abscess. Reproduced with permission from Flynn TR and Topazian RG.³⁰

occur by an alternate pathway, such as proximal fistulization of the submandibular salivary duct due to a salivary stone blocking the natural opening of Wharton's duct.

If a thorough search for previously undetected pathogens turns up negative or if another cause for treatment failure cannot be found, then the surgeon should consider the possibility of antibiotic failure, such as microbial resistance to empiric antibiotic therapy or the use of an incorrect dosage or route of administration for the antibiotic. The criteria for changing antibiotics are listed in Table 15-10. Because of the necessary time delay in obtaining culture and sensitivity reports, it is occasionally necessary to change from one empiric antibiotic to another. Ideally the surgeon should consider another of the empiric antibiotics of choice listed in Table 15-8. The input of an infectious disease consultant may also be valuable in this situation.

Summary

Severe odontogenic infections can be the most challenging cases that an oral and maxillofacial surgeon will be called on to treat. Often the patient with a severe odontogenic infection has significant systemic or immune compromise, and the constant threat of airway obstruction due to infections in the maxillofacial region raises the risk of such cases incalculably. Furthermore, the increasing rarity of these cases and the ever-changing worlds of microbiology and antibiotic therapy make staying abreast of this field difficult for the busy surgeon. Therefore, the eight steps in the treatment of severe odontogenic infections, first outlined by Dr. Larry Peterson, remain the fundamental guiding principles that oral and maxillofacial surgeons must use in successful management of these cases. The application of the eight steps must be thorough and the surgeon's mind must always remain open to the possibility of treatment failure, an error in initial diag-

Table 15-10 Criteria for Changing Antibiotics

Allergy, toxic reaction, or intolerance
Culture and/or sensitivity test indicating resistance
Failure of clinical improvement, given
Removal of odontogenic cause
Adequate surgical drainage (suggest postoperative imaging)
Other causes for treatment failure ruled out
48–72 h of the same antibiotic therapy

nosis, antibiotic resistance, and previously undiagnosed medically compromising conditions. Although adherence to these principles cannot always guarantee a successful result, it can assure the oral and maxillofacial surgeon that he or she is practicing at the highest standard of care.

Acknowledgment

The author wishes to thank Lisa Lavargna for her expert assistance in the preparation of this manuscript.

References

1. Williams AC. Ludwig's angina. *Surg Gynecol Obstet* 1940;70:140.
2. Williams AC, Guralnick WC. The diagnosis and treatment of Ludwig's angina: a report of twenty cases. *N Engl J Med* 1943; 228:443.
3. Hought RT, Fitzgerald BE, Latta JE, Zallen, RD. Ludwig's angina: report of two cases and review of the literature from 1945 to January 1979. *J Oral Surg* 1980;38:849–55.
4. Flynn TR. Anatomy and surgery of deep fascial space infections. In: Kelly JJ, editor. *Oral and maxillofacial surgery knowledge update 1994*. Rosemont (IL): American Association of Oral and Maxillofacial Surgeons; 1994. p. 79–107.
5. Flynn TR. Anatomy of oral and maxillofacial infections. In: Topazian RG, Goldberg MH, Hupp JR, editors. *Oral and maxillofacial infections*. 4th Ed. Philadelphia (PA): WB Saunders Company; 2002. p. 188–213.
6. Flynn TR, Wiltz M, Adamo AK, et al. Predicting length of hospital stay and penicillin failure in severe odontogenic infections. *Int J Oral Maxillofac Surg* 1999;28 Suppl 1:48.

7. Umeda M, Minamikawa T, Komatsubara H, et al. Necrotizing fasciitis caused by dental infection: a retrospective analysis of 9 cases and a review of the literature. *Oral Surg Oral Med Oral Pathol Oral Radiol Endod* 2003;95:283–90.
8. Balcerak RJ, Sisto JM, Bosack RC. Cervicofacial necrotizing fasciitis: report of three cases and literature review. *J Oral Maxillofac Surg* 1988;46:450–9.
9. Langford FPJ, Moon RE, Stolp BW, et al. Treatment of cervical necrotizing fasciitis with hyperbaric oxygen therapy. *Otolaryngol Head Neck Surg* 1995;112:274–8.
10. Mallampati SR, Gatt SP, Gugino SP, et al. A clinical sign to predict difficult tracheal intubation: a prospective study. *Can Anaesth Soc J* 1985;32:429–34.
11. Frerk CM. Predicting difficult intubation. *Anaesthesia* 1991;46:1005–8.
12. Flynn TR. Anesthetic and airway considerations in oral and maxillofacial infections. In: Topazian RG, Goldberg MH, editors. *Oral and maxillofacial infections*. 3rd Ed. Philadelphia (PA): WB Saunders Company; 1993. p. 496–517.
13. Miller WD, Furst IM, Sandor GKB, et al. A prospective blinded comparison of clinical examination and computed tomography in deep neck infections. *Laryngoscope* 1999; 109:1873–9.
14. Miller EJ Jr, Dodson TB. The risk of serious odontogenic infections in HIV-positive patients: a pilot study. *Oral Surg Oral Med Oral Pathol Oral Radiol Endod* 1998; 86:406–9.
15. Flynn TR. Odontogenic infections. *Oral Maxillofac Surg Clin North Am* 1991;3:311–29.
16. Dodson TB, Barton JA, Kaban LB. Predictors of outcome in children hospitalized with maxillofacial infections: a linear logistic model. *J Oral Maxillofac Surg* 1991;49:838–42.
17. Gidley PW, Ghorayeb BY, Stiernberg CM, et al. Contemporary management of deep neck space infections. *Otolaryngol Head Neck Surg* 1997;116:16–22.
18. Marra S, Hotaling AJ. Deep neck infections. *Am J Otol* 1996;17:287–98.
19. Shumrick KA. Deep neck infections. In: Paparella MM, editor. *Otolaryngology*. Vol 3. 3rd Ed. Philadelphia (PA): WB Saunders Company; 1991. p. 2556–63.
20. Biederman GR, Dodson TB. Epidemiologic review of facial infections in hospitalized pediatric patients. *J Oral Maxillofac Surg* 1994;52:1042–5.
21. Telford G. Postoperative fever. In: Condon RE, Nyhus LM, editors. *Manual of surgical therapeutics*. 6th Ed. Boston (MA): Little, Brown; 1985. p. 179.
22. Flynn TR, Halpern LR. Antibiotic selection in head and neck infections. *Oral Maxillofac Surg Clin North Am* 2003;15:17–38.
23. Fazakerley MW, McGowan P, Hardy P, et al. A comparative study of cephadrine, amoxicillin and phenoxymethylpenicillin in the treatment of acute dentoalveolar infection. *Br Dent J* 1993;174:359–63.
24. Gilmore WC, Jacobus NV, Gorbach SL, et al. A prospective double-blind evaluation of penicillin versus clindamycin in the treatment of odontogenic infections. *J Oral Maxillofac Surg* 1988;46:1065–70.
25. Lewis MA, Carmichael F, MacFarlane TW, et al. A randomised trial of co-amoxiclav (Augmentin) versus penicillin V in the treatment of acute dentoalveolar abscess. *Br Dent J* 1993;175:169–74.
26. Paterson SA, Curzon ME. The effect of amoxicillin versus penicillin V in the treatment of acutely abscessed primary teeth. *Br Dent J* 1993;174:443–9.
27. Von Konow L, Nord CE. Ornidazole compared to phenoxymethylpenicillin in the treatment of orofacial infections. *J Antimicrob Chemother* 1983;11:207–15.
28. Flynn TR. The timing of incision and drainage. In: Piecuch JF, editor. *Oral and maxillofacial surgery knowledge update 2001*. Rosemont (IL): American Association of Oral and Maxillofacial Surgeons; 2001. p. 75–84.
29. Flynn TR, Piecuch JF, Topazian RG. Infections of the oral cavity. In: Feigin RD, Cherry JD, editors. *Textbook of pediatric infectious diseases*. Vol 1. 4th Ed. Philadelphia (PA): WB Saunders Co.; 1998. p. 134–48.
30. Flynn TR, Topazian RG. Infections of the oral cavity. In: Waite D, editor. *Textbook of practical oral and maxillofacial surgery*. 3rd Ed. Philadelphia (PA): Lea & Febiger; 1987. p. 273–310.
31. Flynn TR. Surgical management of orofacial infections. *Atlas Oral Maxillofac Surg Clin North Am* 2000; 8:77–100.
32. Peterson LJ. Principles of management and prevention of odontogenic infections. In: Peterson LJ, Ellis E, Hupp JR, Tucker MR, editors. *Contemporary oral and maxillofacial surgery*. 4th Ed. St. Louis (MO): Mosby; 2003. p. 344–66.
33. Bennett JD, Flynn TR. Anesthetic considerations in orofacial infections. In: Topazian RG, Goldberg MH, Hupp JR, editors. *Oral and maxillofacial infections*. 4th Ed. Philadelphia (PA): WB Saunders Co.; 2002. p. 439–55.

Sinus Infections

Rakesh K. Chandra, MD

David W. Kennedy, MD

Chronic sinusitis is a disease with high prevalence in the American population, affecting up to 13.4% of the population and accounting for almost 2% of all ambulatory diagnoses rendered.¹ This condition is important not only because of its frequency but because complications of sinusitis may carry severe neurologic, ophthalmologic, and systemic consequences. Therefore it is incumbent on all practitioners, particularly those who manage structures of the maxillofacial complex, to be familiar with the features of sinonasal disease. Technologic advances in diagnostic imaging, endoscopy, and surgical instrumentation have revolutionized the diagnosis and treatment of sinusitis. Furthermore, both clinical experience and basic science knowledge have modified our perspective of sinusitis such that we now understand it as an inflammatory disorder, rather than a purely infectious process. This chapter attempts to synthesize a framework for understanding the etiology, clinical presentation, diagnosis, medical treatment, and surgery for sinonasal inflammatory disease. These elements are discussed in the context of our current knowledge base and the latest technologic innovations.

The diagnosis and management of sinusitis has traditionally been based on patient symptomatology and plain film imaging. The advent of sinonasal endoscopy and the wide availability of

computed tomography (CT) have enhanced diagnostic accuracy, treatment planning, and surgical capabilities. Prior to these developments, management primarily consisted of antibiotic therapy, with surgery (often performed via facial incisions) reserved for complications. Endoscopy and CT have permitted elective management of sinusitis for symptomatic improvement and the prevention of complications. Advances in our understanding of microbiology, allergy, and pharmacology have complemented these modalities.

The first fiber-optic nasal examination was performed by Hirshman using a modified cystoscope. Instrumentation was then refined after World War II, permitting the development of smaller scopes with improved illumination. Hopkins designed a series of rigid endoscopes in the early 1950s. They were relatively small in diameter and had wide field high-contrast optics and bright illumination. This technology was used by Professor W. Messerklinger of Graz, Austria, for systematic nasal airway evaluation. Importantly, Messerklinger observed that primary inflammatory processes of the lateral nasal wall, particularly the middle meatus, resulted in secondary disease of the maxillary and frontal sinuses.² This led to the definition of the osteomeatal complex (OMC; Figure 16-1) as the site of common drainage for the maxillary, frontal, and anterior ethmoid sinuses. Messerklinger

demonstrated that even small anatomic variations or inflammatory processes in this location may impair ventilation and drainage of the adjacent sinuses, with subsequent development of significant inflammatory disease in these regions. This observation led him to employ endoscopes for the surgical management of sinusitis such that disease processes affecting the natural sinus drainage pathways could be addressed. Particularly, he showed that even limited surgical procedures directed toward the OMC and anterior ethmoid sinuses can result in improvement of ventilation and drainage of the frontal and maxillary sinuses.

During the 1980s Stammberger, also of Graz, and Kennedy, in the United States, further refined and popularized these techniques.³ Since that time nasal endoscopy has been employed in the surgical management of sinonasal neoplasms as well as a multitude of both skull base and orbital pathologies. Although indications do exist for external approaches to the paranasal sinuses, endoscopic approaches are typically first line in the surgical management algorithm. Recent advances in surgical instrumentation have included the development of angled forceps, drills, and telescopes. Additionally, the availability of stereotactic navigational imaging has permitted more comprehensive surgery to be performed safely. The practices of optimal medical therapy,

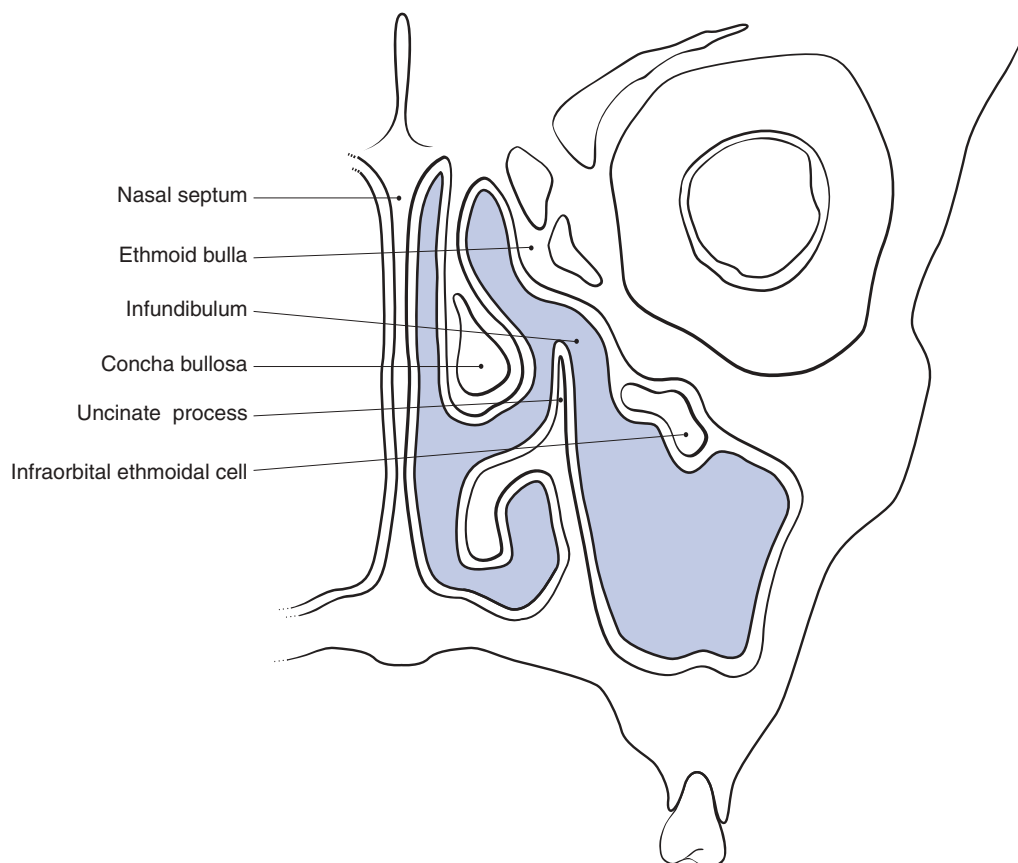


FIGURE 16-1 Diagram of coronal section through the region of the osteomeatal complex. Note the uncinat process, ethmoid bulla, infundibulum, nasal septum, infraorbital ethmoidal cell, and concha bullosa. (Courtesy of Tina Bales, MD, resident, Department of Otorhinolaryngology—Head and Neck Surgery, University of Pennsylvania [with adaptations])

both pre- and postoperatively, and meticulous postoperative care have further improved our treatment success. The remainder of this chapter highlights the state of the art in the diagnosis and management of sinusitis.

Clinical Presentation

Sinusitis is a clinical diagnosis that is confirmed by physical examination, including nasal endoscopy, and radiographic imaging. The Task Force on Rhinosinusitis sponsored by the American Academy of Otolaryngology—Head and Neck Surgery has established criteria to define a history consistent with sinusitis.³ These are based on patient signs and symptoms and are grouped into major and minor criteria, as outlined in Table 16-1. The presence of two or more major factors, or one major plus at least two minor factors, is consid-

ered a “strong history for sinusitis.” Of note, purulent nasal drainage alone is considered diagnostic for sinusitis. This finding is clearly visible on nasal endoscopy and may manifest as purulence in the middle meatus or within a sinus cavity

itself. This is described in greater detail below under “Diagnosis.” It also deserves clarification that fever is only considered a major factor in the setting of acute sinusitis but is otherwise a minor factor. Although the term *sinusitis* is commonly in use, the process may more accurately be described by the term *rhinosinusitis* because the nasal and sinus mucosal surfaces are contiguous and it would be impossible to have sinusitis without a coexisting rhinitis. The terms are used interchangeably in the present chapter.

Rhinosinusitis is classified as either acute, subacute, recurrent acute, or chronic. The distinctions are based solely upon the time course or temporal pattern in which the patient has symptoms. Patients may also have episodes of recurrent acute sinusitis superimposed on a baseline state of chronic sinusitis. A diagnosis of acute sinusitis requires that criteria satisfying a strong history for sinusitis are present for 1 to 4 weeks. Patients should exhibit signs and symptoms for at least 1 week before sinusitis is diagnosed because sinusitis typically involves a bacterial process, and the vast majority of patients with symptoms for < 1 week have simple viral upper respiratory infections. Strictly speaking, however, a viral upper respiratory infection is synonymous with an acute viral rhinosinusitis. Subacute sinusitis requires that these

Table 16-1 Factors Associated with a History of Rhinosinusitis*

Major Factors	Minor Factors
Facial pain/pressure	Headache
Facial congestion/fullness	Maxillary dental pain
Nasal drainage/discharge	Cough
Postnasal drip	Halitosis (bad breath)
Nasal obstruction/blockage	Fatigue
Hyposmia/anosmia (decreased or absent sense of smell)	Ear pain, pressure, or fullness
Fever (acute sinusitis only)	Fever
Purulence on nasal endoscopy (diagnostic by itself)	

*Either two major factors, or one major and two minor, are required for a diagnosis of rhinosinusitis. Purulence on nasal endoscopy is diagnostic. Fever is a major factor only in the acute stage.

criteria have existed for 4 to 12 weeks, and in chronic sinusitis the criteria are present for at least 12 weeks. In recurrent acute sinusitis, episodes last < 4 weeks, but the patient is asymptomatic between episodes. Rhinosinusitis may also have significant fungal components and may be influenced by environmental, general host, and local host factors (see below).

Etiology

Anatomy and Physiology of the Nose and Paranasal Sinuses

The pathophysiology of sinusitis must be understood in the context of the normal anatomy and physiology of the nose and paranasal sinuses. The paranasal sinuses are formed early in development as evaginations of respiratory mucosa from the nose into the facial bones. Cavity formation begins in utero, and pneumatization continues into early adolescent life. The ethmoid sinus develops into a bony labyrinth of 3 to 15 small air cells on each side. In contrast, the other sinus cavities develop as a single bony cavity on each side of the facial skeleton, although variations may exist. The ostium of each sinus represents the point at which out-pouching initiated.

The lateral nasal wall on each side is lined by three turbinate bones designated as inferior, middle, and superior (Figure 16-2). The space under each is known as either the inferior, middle, or superior meatus, respectively. The OMC is a space within the middle meatus into which the maxillary, anterior ethmoid, and frontal sinuses drain (see Figure 16-1). It is this region where pathology such as anatomic variation or inflammatory disease is most likely to impair sinus ventilation and drainage, resulting in the development of sinusitis. The posterior ethmoid sinuses drain into the superior meatus. The sphenoid sinus drains into an area known as the sphenothmoidal recess, which lies at the junction of the sphenoid and ethmoid

bones in the superior portion of the posterior nasal cavity (see Figure 16-2).

The remaining discussion details the anatomy of the middle meatus and the OMC, for this is the critical region in the development of sinusitis. These structures are mainly derived from the ethmoid bone, a T-shaped structure, of which the vertical part contributes to the nasal septum, middle (and superior) turbinate, ethmoid air cell system, and the lateral nasal wall (see Figure 16-1). The horizontal portion forms the cribriform plate of the skull base. The uncinata is a sickle-shaped process of ethmoid bone that lies along the lateral nasal wall. The cleft-like space lateral to this structure is known as the infundibulum, and this is the region into which the maxillary sinus drains. The medial opening of the infundibulum, where it opens into the middle meatus, is known as the hiatus semilunaris. The ethmoid bulla is a prominence of anterior ethmoid air cell(s) along the lateral nasal

wall that hangs just superior to the infundibulum. The drainage tract from the frontal sinus courses inferiorly from the sinus medial to the medial orbital wall, lateral to the middle turbinate, and anterior to the ethmoid bulla. This tract, known as the frontal recess, is highly variable and is often lined with variant anterior ethmoid air cells. It is apparent that even minimal inflammatory disease in the OMC can impair sinus ventilation and drainage of the adjacent ethmoid, maxillary, and frontal sinuses.

The paranasal sinuses and the majority of the nasal cavity itself are lined with pseudostratified columnar ciliated epithelium (respiratory type). The cilia suspend a mucous blanket, which is secreted by goblet cells in the mucous membrane (Figure 16-3). The cilia propel this blanket in a predetermined direction (Figure 16-4), in a manner similar to the “mucociliary escalator” of the tracheobronchial tree. This phenomenon is important because in the

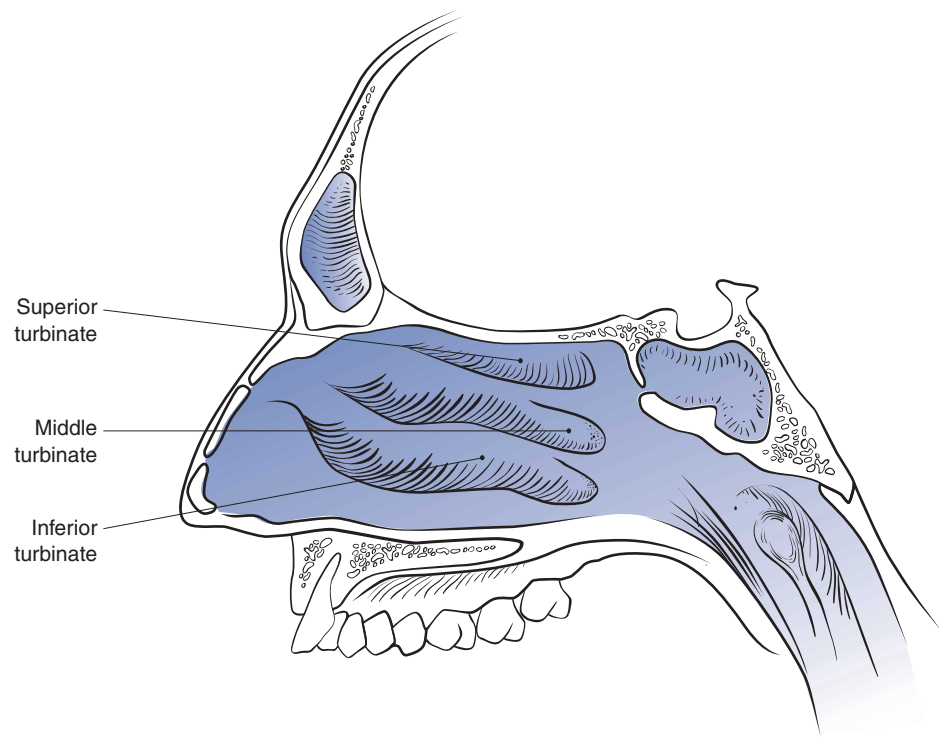


FIGURE 16-2 Structures of the lateral nasal wall. Note the position of the inferior, middle, and superior turbinates. (Courtesy of Tina Bales, MD, resident, Department of Otorhinolaryngology—Head and Neck Surgery, University of Pennsylvania [with adaptations])

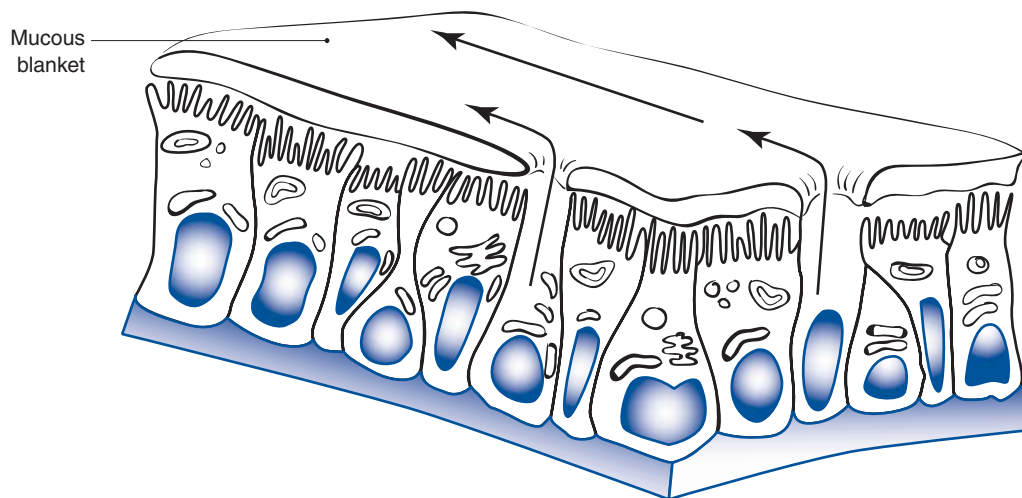


FIGURE 16-3 Histology of the sinonasal mucosa. Note the pseudostratified ciliated cells and the goblet cells. The cilia suspend and propel the mucous blanket. (Courtesy of Tina Bales, MD, resident, Department of Otorhinolaryngology—Head and Neck Surgery, University of Pennsylvania [with adaptations])

paranasal sinuses cilia propel mucus toward the natural ostium. This means that in the maxillary sinus cilia must propel mucus against gravitational forces. Any surgical procedures intended to promote sinus drainage must, however, be addressed to the natural ostium.

One or more of the following local factors may create a predisposition for sinusitis: (1) mechanical obstruction of mucociliary flow, particularly in the OMC region,

(2) defects in ciliary capability to propel the mucous blanket, and (3) abnormal quantity or quality of secretions. A combination of these factors results in the development of sinusitis by allowing stasis of secretions, resulting in bacterial colonization and infection with associated inflammation.⁴ In turn, this results in further ostial obstruction, stasis, and exacerbation of the inflammatory process. Furthermore, impairment of sinus ventilation creates acidic anaerobic conditions that cause ciliary damage and ineffective mucus clearance.⁵ A variety of local and systemic disease processes may promote sinusitis by influencing mucociliary clearance at the anatomic, histologic, immunologic, and biochemical levels (Figure 16-5).

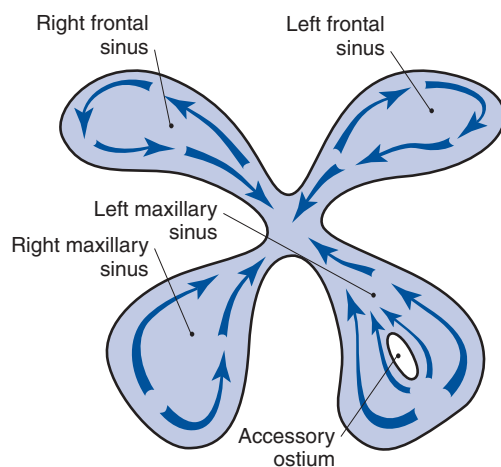


FIGURE 16-4 Cilia beat in a predetermined manner to direct mucus flow to the natural ostium and around accessory ostia. (Courtesy of Tina Bales, MD, resident, Department of Otorhinolaryngology—Head and Neck Surgery, University of Pennsylvania [with adaptations])

Anatomic Factors

Post-traumatic, congenital, or iatrogenic conditions involving the craniofacial skeleton may physically obstruct sinus ostia, contributing to the development of sinusitis. These may include abnormalities of the nasal septum, such as spurs and deviations, or variants of the middle turbinate including turbinate pneumatization (concha bullosa) or hypertrophy. These entities may narrow the middle meatal cleft, thus impairing mucus out-

flow with subsequent bacterial colonization and inflammation. Variations of the ethmoidal air system may also obstruct mucociliary outflow. Such examples include the infraorbital cell (Haller cell) and pneumatized middle turbinate (concha bullosa; see Figure 16-1).

Sinonasal tumors and polyps may also promote sinusitis by impairing the outflow of secretions. A discussion of sinonasal neoplasia is beyond the scope of this chapter. Nasal polyps by themselves are not a disease but a manifestation of advanced sinonasal inflammation. The origin of nasal polyps is therefore multifactorial and may include any combination of the infectious, allergic, immunologic, metabolic, and/or genetic conditions described below.

The presence of accessory ostia, either congenital or iatrogenic, may promote the development of chronic sinusitis by the mucus recirculation phenomenon. This is most apparent in the maxillary sinus. Mucus is physiologically propelled around accessory ostia and toward the natural ostium (see Figure 16-4). However, the presence of an accessory ostium allows mucus reentry into the sinus lumen. Earlier surgical techniques attempting to augment sinus ventilation and drainage included the creation of a “nasoantral window” in the inferior meatus, with the rationalization that this would permit drainage in a gravity-dependent manner. This approach, however, is suboptimal because cilia attempt to direct mucus around the iatrogenic ostium to the natural one.

In children adenoid hypertrophy is a frequent underlying cause of sinus infections. This impairs the outflow of secretions from the posterior nasal cavity into the nasopharynx. The diagnosis is suspected in children presenting with nasal obstruction, mouth breathing, and rhinorrhea. A nasal foreign body may also be observed in children with these findings and may either mimic or be the cause of rhinosinusitis. The

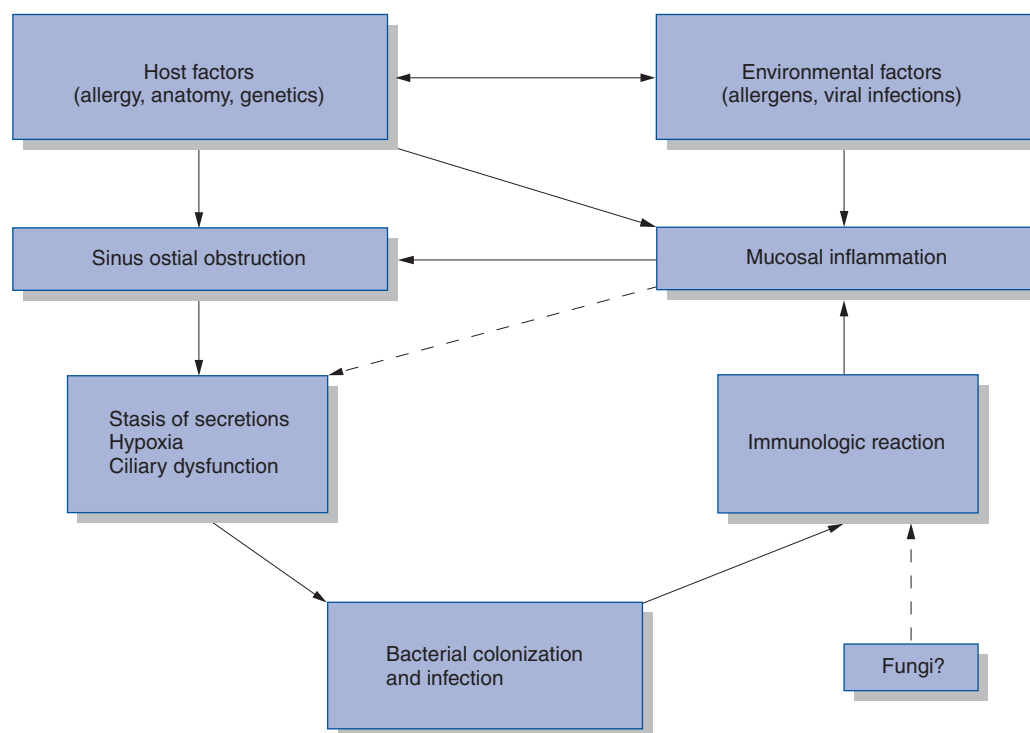


FIGURE 16-5 Sinusitis is a multifactorial process, of which bacterial infection is a component.

classic finding in these patients is unilateral foul-smelling rhinorrhea.

Miscellaneous anatomically related conditions that may increase the risk for developing sinusitis include the presence of nasotracheal or nasogastric tubes and barotrauma. Nasal intubation may impair sinonasal drainage, but other mechanisms may be involved as studies have observed sinusitis on the side opposite tube placement.⁶ Barosinusitis results from tissue edema induced by rapidly changing air pressures during diving, air travel, or hyperbaric oxygen therapy. Any preexisting anatomic narrowing of the OMC predisposes to barosinusitis as air pressure within the sinus cannot effectively equilibrate with the ambient pressure during ascent or descent.

Inflammatory Conditions

The most common inflammatory condition that predisposes to sinusitis is a viral upper respiratory infection, or the common cold, during which approximately 80% of patients have decreased patency of

the maxillary sinus ostium secondary to tissue edema.⁷ Mucociliary clearance is also impaired secondary to destruction and shedding of ciliated epithelial cells. Influenza virus appears to be the most destructive in this regard.⁸ Rhinovirus is the most common cause, with over 100 serotypes identified, and respiratory syncytial virus, parainfluenza virus, and coronavirus may also be implicated. Regardless of the offending virus, conditions of ostial obstruction and impaired mucociliary flow permit bacterial overgrowth.

Dental conditions may cause maxillary sinusitis secondary to direct extension of infectious or inflammatory processes through the apices of maxillary teeth into the sinus. Infection following a sinus lift procedure appears to be more likely when there is preexisting osteomeatal inflammation. Dental implant and root canal materials may also extrude into the sinus, initiating inflammation via a foreign body reaction or by acting as a nidus for bacterial colonization. Specifically, paraformaldehyde-containing pastes have been implicated.⁹

Chronic inflammatory disorders affecting the respiratory mucosa appear to correlate with sinusitis. Patients with allergic rhinitis frequently exhibit sinus mucosal disease, and, conversely, a large proportion of patients with chronic sinusitis have positive responses to allergy skin testing. This is thought to be an immunoglobulin E (IgE)-mediated (type I) immediate hypersensitivity, with cell-mediated late-phase responses. Our understanding of the mechanistic relationship between allergy and sinusitis is far from complete, however, and the exact concordance between the disorders is unknown.¹⁰ Nonetheless, it appears that atopic patients have an underlying predisposition for mucosal inflammation. Ostial obstruction and impaired mucociliary flow from allergen exposure may result in bacterial overgrowth and exacerbation of the inflammatory process. The effect of allergic disease persists even after surgical procedures that enlarge the natural sinus ostia. In fact, surgery may increase mucosal inflammation by enhancing allergen exposure to susceptible mucosa within the sinus, despite anatomic improvements in the drainage pathway.

Patients with asthma are also predisposed to sinusitis secondary to a generalized reactivity of the respiratory mucosa. Again, the exact relationship between these entities is unclear. However, there is evidence that asthma symptoms may even improve after surgical management of comorbid chronic sinusitis.^{11,12} One atopic syndrome that deserves discussion is the Aspirin-sensitivity triad (Samter's triad). These patients develop asthma in association with sinusitis and nasal polyposis, and Aspirin precipitates acute bronchospasm. Overall, it is estimated that up to 25% of patients with nasal polyposis develop bronchoconstriction in response to Aspirin administration.¹³ Aspirin-sensitivity triad is a defect of arachidonic acid metabolism and may have a genetic basis.¹⁴

Over 100 chemicals have been found to cause nasal irritation, many of which are found in cigarette smoke. Pollutants may contribute to sinusitis through several mechanisms. Deposition of irritant particles in the mucous blanket during respiration can increase the relative concentration to which the mucous membrane is exposed, resulting in direct chemical and physical irritation, which subsequently promotes the inflammatory process.¹⁵ The irritant effects of these chemicals may also induce neurogenic inflammation through vasodilation, tissue edema, and leukocyte influx. Specifically, neuropeptides such as substance P from unmyelinated sensory fibers have been implicated.¹⁶ Pollutants may also impair mucociliary clearance through alterations in mucus viscosity, inhibition of ciliary function, and increases in epithelial permeability. The typical chemical components of outdoor pollution have been shown to increase neutrophil counts in nasal lavage specimens.¹⁷ A study in Finland also correlated the increase in nasal polyposis and frontal sinusitis with air pollution. These studies provide circumstantial but objective evidence that pollutants play a significant role in the increasing prevalence of chronic sinusitis.¹⁸

Recently there has been investigation into a possible role for gastroesophageal reflux disease (GERD) in sinonasal inflammation, particularly in the pediatric population.^{19,20} In fact, GERD has been associated with a multitude of inflammatory processes of the upper aerodigestive tract including esophagitis, pharyngitis, and laryngitis. Evidence for its role in sinusitis, however, is circumstantial, and many feel that it is not a significant predisposing factor.²⁰ Nonetheless, GERD should be suspected in children whose inflammation appears refractory to medical and surgical management.

Bacteriology of Sinusitis

The type of bacteria involved in a sinus infection depends on multiple factors,

including the immune or metabolic status of the host, the duration of the disease process, whether the infection is community or hospital acquired, and antibiotic resistance patterns. In uncomplicated acute sinusitis, *Streptococcus pneumoniae* and *Haemophilus influenzae* are the most commonly isolated pathogens; *Moraxella catarrhalis* may also be a significant organism, particularly in the pediatric population. *Staphylococcus aureus*, *Streptococcus pyogenes*, coagulase-negative staphylococci, anaerobes, and gram-negative organisms are found in varying proportions. The pathogenic roles of staphylococcal species in acute sinusitis are unclear as these are found near the maxillary ostium in 60% of healthy asymptomatic adults.²¹ Anaerobes, when isolated, are typically a component of a mixed bacterial infection and may be the result of an extension of a dental abscess.²² It should also be noted that up to 50% of patients diagnosed clinically with acute sinusitis have sterile sinus aspirates. The reason for this is unclear, but it may reflect viral or allergic processes diagnosed as bacterial sinusitis. Nosocomial acute sinusitis may be caused by nasal intubation, nasal packing, patient immobility, chronic debilitation, and/or immunosuppression. The most common species isolated in these cases is *Pseudomonas*, although *S. aureus* is also frequently isolated, and the bacteriology may be unpredictable.

Patients with chronic sinusitis typically represent a population with several months to years of symptoms who have received multiple antibiotic courses. Thus the bacterial profile in these patients differs from that of acute sinusitis. Polymicrobial infections and antibiotic-resistant organisms are often found. In general, a higher proportion of *S. aureus*, coagulase-negative staphylococci, gram-negative bacilli, and streptococci are isolated in addition to the typical pathogens of acute sinusitis.^{23,24} The roles of *S. aureus* and coagulase-negative staphylococci are con-

troversial as these organisms are known to colonize the anterior nose and are less frequently isolated when the anterior nose is disinfected.²⁵ Most authors agree, however, that *S. aureus* is a significant pathogen and should be treated when identified.^{26,27} Gram-negative organisms that may be isolated include *Pseudomonas*, *Klebsiella*, and *Proteus*. Viridans streptococci, organisms commonly found among oral flora, are observed in up to one-third of cases.²⁴ Interestingly, one study identified anaerobes in 93% of specimens in children with chronic sinusitis.²⁸ However, because the upper aerodigestive tract is highly colonized with anaerobes,²⁹ their role in the infectious process is unclear. Postsurgically, the sinonasal mucosa is frequently colonized or infected with *Pseudomonas* and/or *S. aureus*, and patients may still be susceptible to acute exacerbations by the pathogens involved in acute sinusitis.

Role of Fungi

Much has evolved in our understanding of the role of fungi in sinusitis, and different patterns of fungal sinusitis exist. Fungal disease can be classified as noninvasive or invasive. Both fungal balls and allergic fungal sinusitis are part of the noninvasive group, although recently it has been suggested that fungus has a wider role as an active factor in the pathogenesis of eosinophilic chronic rhinosinusitis. Invasive fungal disease is typically a fulminant disease in immunocompromised individuals but can also occur occasionally as an indolent disease in patients who are immunocompetent. Fungal balls are typically seen in immunocompetent individuals with chronic (or recurrent acute) symptomatology that is often subtle and restricted to a single sinus. Patients may complain about the perception of a foul odor and occasionally report expelling fungal debris with nose blowing. Most commonly, a fungal ball consisting of *Aspergillus fumigatus* is found in the maxillary sinus with scant inflammatory cell

infiltration in the surrounding mucosa.³⁰ The condition is indolent, and cure is often achieved after surgical removal of the fungus ball and assurance of patency of the natural sinus ostium.

Allergic fungal sinusitis (AFS) is a form of noninvasive fungal sinusitis seen in immunocompetent patients, who exhibit a hypersensitivity reaction to fungal organisms in the nose and sinuses. The disease typically presents with unilateral nasal polyposis and thick tenacious secretions.³¹ The most commonly implicated fungi are those of the Dematiaceae family,³² but *Aspergillus* species are also seen. The exact pathophysiology is controversial but is thought to involve IgE-mediated (type I) responses. IgE-sensitized mast cells are activated by exposure to fungal antigens resulting in degranulation, influx of eosinophils, and exacerbation of inflammation via the release of major basic protein. Immune complex (type III) reactions involving IgG have also been identified. Patients have a severe inflammatory reaction with nasal polyposis and inspissated "allergic mucin" consisting of eosinophil breakdown products (Charcot-Leyden crystals) and fungal forms. AFS-like conditions have also been described in which mucin is observed, but fungal forms are not identified microscopically or by culture.³³ Recent studies by Ponikau and colleagues and Taylor and colleagues, however, revealed that fungi can be demonstrated with increased sensitivity using novel culture and staining techniques.^{34,35} In fact, this group showed that fungi are present in 93% of 101 patients with chronic sinusitis.³⁴ This has led to the hypothesis that the fungi, themselves, may induce an eosinophilic response, and that fungi may play a prominent role in chronic sinusitis, even in the absence of frank AFS. This area of research is progressing rapidly.

Patients with AFS may present with the typical signs and symptoms of chronic sinusitis. Underlying AFS must be suspected in a chronic sinusitis patient whose

course is unusually refractory to medical therapy. Additionally, advanced nasal polyposis with inspissated mucin and fungal debris may cause thinning of bone of the adjacent orbit and skull base. The goals for treatment of AFS are to eliminate the fungal antigenic load and to reestablish sinus ventilation, drainage, and mucociliary clearance. Surgery has a prominent role in these regards but must be complemented with medical therapies to both reduce inflammation and eliminate the fungal load.

Immunocompromised patients are at risk for developing fulminant invasive fungal sinusitis. This patient population is composed of diabetics, transplant patients, those receiving cancer chemotherapy, burn victims, the elderly, and patients with congenital or acquired immunodeficiency. In addition to the typical symptoms of sinusitis, patients with invasive fungal disease may present with severe pain, fever, proptosis, visual impairment, cranial neuropathy, other focal neurologic findings, seizures, and altered mental status. Invasive fungal sinusitis may begin as a noninvasive form with subsequent tissue invasion in a susceptible patient. *Aspergillus* and fungi of the Mucoraceae family are often implicated, with the latter being more common in diabetics. Black necrotic eschars of the nasal mucosa are noted during nasal endoscopy, with bone destruction on CT scans. Biopsy of the border of the eschar is essential to confirm the diagnosis. Biopsy is also necessary when pale insensate mucosa is discovered in a patient with a strong history and risk factors for invasive fungal sinusitis. Treatment requires aggressive surgical débridement of infected and devitalized tissues, topical and systemic antifungal medications, and management of predisposing conditions.

The chronic indolent form of invasive fungal sinusitis is more commonly observed in immunocompetent patients and is endemic in Sudan, but it has also been observed in type II diabetics.

Aspergillus flavus is the most common organism encountered. Symptoms of chronic sinusitis are initially present, but these progress to cause visual and neurologic signs. Nasal endoscopy may reveal granulomatous inflammation.³¹ Bone destruction ultimately occurs. Treatment includes surgical removal of fungal debris and affected tissues, as well as systemic and local antifungal therapy.

Genetic Disorders

Little is known regarding genetic influences on the risk of developing sinusitis, and the exact contribution of hereditary variables is difficult to quantify given the multifactorial nature of the disease. However, recently the *ADAM33* gene has been identified as being associated with the closely related disease asthma. Many of the predisposing inflammatory conditions discussed previously, particularly those involving an atopic response, also tend to cluster in families, suggesting a genetic component. Additionally, several defined congenital syndromes are associated with sinusitis. These include defects of metabolism, ciliary structure/function, and the immune system. Some of the more common pathologies with a primary genetic basis are outlined below.

Cystic fibrosis (CF) is an autosomal recessive disorder affecting epithelial transport of chloride and water via mutations in the *CFTR* gene. This results in abnormally viscous secretions, which become inspissated in the lung, pancreas, and sinonasal tract, ultimately leading to chronic inflammation and fibrosis. In the sinonasal tract, patients exhibit florid polyposis and colonization with *Pseudomonas*. A sweat test to detect elevated chloride levels is diagnostic and should be performed on any child presenting with nasal polyposis. Recent data also suggest that heterozygous carriers may be at increased risk for developing chronic sinusitis.³⁶ Aggressive medical management against *Pseudomonas* is necessary; treatment also includes surgery to remove

polyps and chronically infected tissue and to provide sinus ventilation. Pulmonary disease is typically the life-limiting manifestation of CF, but in the era of lung transplantation, patients may live well into the fourth or fifth decade.

Inherited disorders of ciliary structure or function also are associated with chronic sinus disease. Kartagener's triad is a syndrome involving sinusitis, bronchiectasis, and situs inversus.³⁷ Sinus, middle ear, and pulmonary diseases are observed in nearly all cases, and male patients are usually infertile secondary to sperm immobility. These manifestations are a consequence of structural defects in the dynein arms of cilia. Light microscopy reveals a reduction in ciliary beat frequency, and structural abnormalities can be observed under electron microscopy. Primary ciliary dyskinesia (or immotile cilia syndrome) is twice as common as Kartagener's syndrome and has similar sinopulmonary manifestations without situs inversus.³⁸ These patients often live a normal life span with timely management of sinopulmonary infections and prophylactic measures such as avoidance of environmental pollutants.

Young's syndrome is also associated with chronic sinusitis, lung disease, and male infertility.³⁹ The etiology of male infertility, however, is secondary to obstruction of the epididymis, and sperm motility is normal. There is no association with situs inversus. Sinus and lung disease usually do not progress beyond childhood, and few require sinus surgery.⁴⁰

Multiple inherited immunodeficiency disorders may be associated with sinusitis. These typically involve defects of antibody-mediated immunity, particularly IgG subclass deficiency, for which the inheritance pattern is unknown.⁴¹ Common variable immunodeficiency (dominant or recessive), IgA deficiency (dominant), X-linked agammaglobulinemia, and complement deficiencies are among the disorders iden-

tified.⁴²⁻⁴⁴ The particular type of immunodeficiency involved may dictate the nature of the superinfecting organism.⁴⁵ For example, complement defects are associated with gram-negative infections. Difficult-to-manage sinus disease should inspire an investigation into this area, including the quantitative measurement of immunoglobulins and possibly complement levels.

Diagnosis

Roles of Endoscopy and CT

Sinus infections are typically diagnosed based on clinical criteria described previously (see Table 16-1). Symptom severity and effect on quality of life can be scored on multiple different scales.^{46,47} Acute sinusitis is frequently diagnosed and managed by the primary care practitioner largely based on history, but recurrent acute sinusitis, chronic sinusitis, or that which has failed medical management requires endoscopic evaluation and radiographic imaging. This is important because over two-thirds of patients who meet the criteria for rhinosinusitis have negative results on endoscopy, and over 50% have negative results on CT scans.⁴⁶

Sinusitis can be diagnosed regardless of symptomatic criteria if pus is noted in the middle meatus during nasal endoscopy (Figure 16-6). In patients who have had surgical antrostomy, pus may be seen within the maxillary sinus. This can be cultured during the examination, with the results being useful in antibiotic selection. In addition to purulence, nasal endoscopy can detect mucosal inflammation, edema, polyposis (Figure 16-7), and anatomic variations such as a deviated septum. A recent study demonstrated that the findings of purulence, polyps, or mucosal edema correlate with sinusitis by CT, but anatomic variation was not a significant predictor. Also, negative endoscopy was a good predictor for CT scan results that were normal or indicated

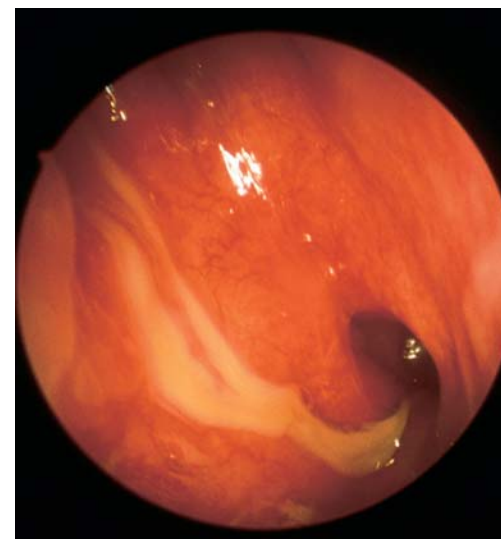

FIGURE 16-6 Purulent discharge from the middle meatus draining into the nasopharynx adjacent to the eustachian tube orifice. Reproduced with permission from Joe SA, Bolger WE, Kennedy DW. *Nasal endoscopy: diagnosis and staging of inflammatory sinus disease*. In: Kennedy DW, Bolger WE, Zinreich SJ, editors. *Diseases of the sinuses: diagnosis and management*. Hamilton: BC Decker Inc; 2001. p. 120.

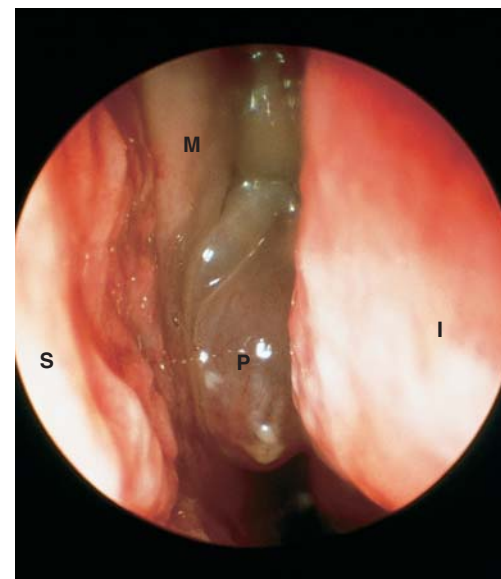


FIGURE 16-7 View into left nasal cavity demonstrates a polyp (P) extending from the middle meatus. S = septum; M = middle turbinate; I = inferior turbinate. Reproduced with permission from Joe SA, Bolger WE, Kennedy DW. *Nasal endoscopy: diagnosis and staging of inflammatory sinus disease*. In: Kennedy DW, Bolger WE, Zinreich SJ, editors. *Diseases of the sinuses: diagnosis and management*. Hamilton: BC Decker Inc; 2001. p. 123.

minimal disease.⁴⁶ Overall, these results underscore the need for endoscopy in the diagnostic evaluation of cases other than isolated episodes of uncomplicated acute sinusitis.

Approximately one-third of randomly selected asymptomatic people have some mucosal changes on CT scans, but patients with symptoms and some endoscopic findings do not necessarily have positive findings on CT scans.⁴⁸ Thus, although CT is a good predictor of moderate mucosal thickening, it probably should not be considered a gold standard for diagnosis. The decision to treat medically may be based rationally on endoscopic findings because such normal findings are associated with normal or near-normal CT results in over 75% of cases.⁴⁶ CT is necessary, however, when surgery is anticipated, complications are suspected, or when there is a significant discrepancy between history and endoscopic examination. In these situations CT not only helps to confirm the diagnosis but also aids in surgical planning. The coronal plane provides the best view of the OMC (Figure 16-8) and can be used to detect opacification, mucosal thickening, and neo-osteogenesis, all of which are indicative of chronic inflammation. Anatomic variations such as a concha

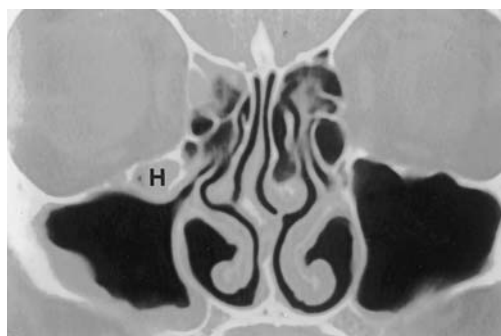

FIGURE 16-8 Coronal computed tomography scan of the sinus through the osteomeatal complex. An infraorbital ethmoid cell (Haller cell; H) is demonstrated. Also, see Figure 16-1. Reproduced with permission from Zinreich SJ, Gotwald T. *Radiographic anatomy of the sinuses*. In: Kennedy DW, Bolger WE, Zinreich SJ, editors. *Diseases of the sinuses: diagnosis and management*. Hamilton: BC Decker Inc.; 2001. p. 24.

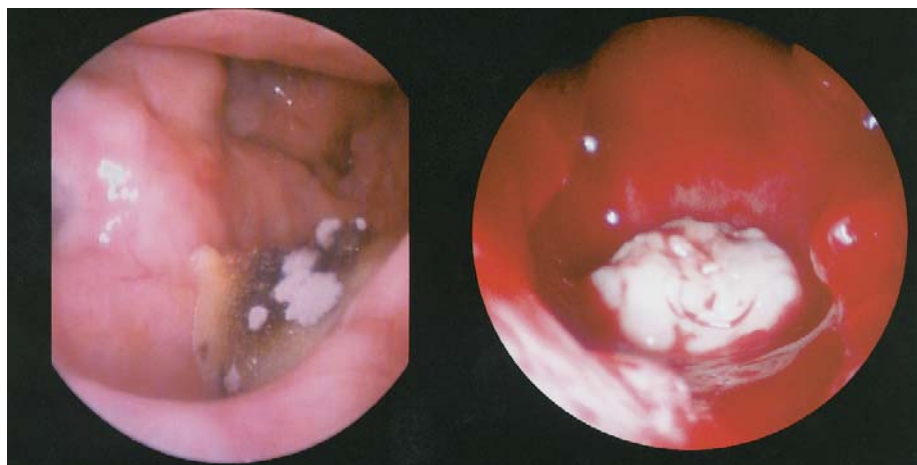


FIGURE 16-9 Examples of fungal balls of the maxillary sinus. Note the fungal debris and mucosal edema. Reproduced with permission from Dhong HJ, Lanza DC. *Fungal rhinosinusitis*. In: Kennedy DW, Bolger WE, Zinreich SJ, editors. *Diseases of the sinuses: diagnosis and management*. Hamilton: BC Decker Inc; 2001. p. 181.

bullosa (pneumatized middle turbinate) can be also detected. Scans can additionally be obtained in the axial plane, and images may be reconstructed in three planes: coronal, axial, and sagittal. This technology allows for precise anatomic localization of disease processes and intraoperative stereotactic navigational imaging (see “Surgery,” below). It should be noted that although plain films are widely available and inexpensive, much more precise data is obtained with a coronal CT, whose use has comparable costs and radiation exposure. Although plain films may detect complete sinus opacification or air-fluid levels, chronic inflammatory disease correlates with as little as 2 mm of mucosal thickening, which cannot be identified on plain films.⁴⁹

In an effort to reduce both costs and radiation exposure, protocols have been designed involving lowered radiation doses. These allow adequate bony detail and do not appear to cause diagnostic errors,⁵⁰ although soft tissue contrast is slightly reduced. For diagnostic purposes and for routine elective sinus surgery, images in the coronal plane alone are sufficient. These should be obtained at 3 mm cuts, although some centers attempt to further reduce costs by using thicker sections.⁵¹

Special Considerations

Fungal Sinusitis Fungal sinusitis, as outlined previously, may manifest in a spectrum of both invasive and noninvasive forms. Endoscopically, with noninvasive or chronically invasive disease, fungal forms may be evident (Figure 16-9), along with mucosal edema and/or polyposis. In allergic fungal sinusitis the allergic mucin that is inspissated among the nasal polyps and fungal debris has a peanut butter–like quality. Histologically this contains fungal forms, eosinophils, and Charcot-Leyden crystals (breakdown products of eosinophil granules; Figure 16-10). The mucous membranes of invasive fungal sinusitis typically contain black necrotic eschars but may be pale or gray in earlier phases. These findings are secondary to ischemic necrosis induced by fungal invasion of the mucosal vasculature and may extend to the gingivae and palate. Suspicion of invasive fungal sinusitis requires biopsy confirmation (Figure 16-11), followed by aggressive débridement of infected and devitalized tissues.

Typically, noninvasive fungal disease appears on CT scans as areas of increased density within the sinuses (Figure 16-12).

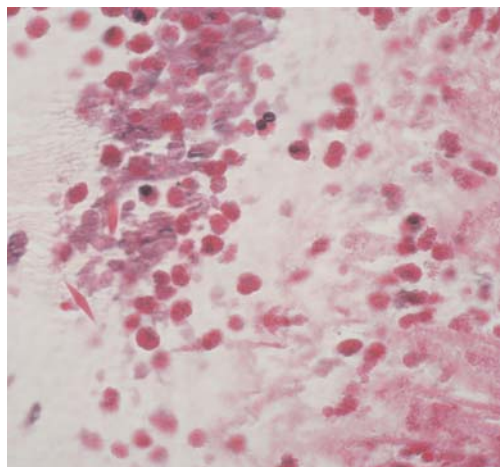


FIGURE 16-10 Allergic mucin of allergic fungal sinusitis. Microscopic evaluation reveals eosinophils and Charcot-Leyden crystals ($\times 400$ original magnification; stained with hematoxylin-eosin). Reproduced with permission from Dhong HJ, Lanza DC. Fungal rhinosinusitis. In: Kennedy DW, Bolger WE, Zinreich SJ, editors. *Diseases of the sinuses: diagnosis and management*. Hamilton: BC Decker Inc; 2001. p. 186.

This may be secondary to the affinity of fungi for magnesium, calcium, manganese, or ferromagnetic elements,⁵² although the exact mechanism for this finding is unclear. CT images may also reveal extensive soft tissue thickening or opacification secondary to polyposis or postobstructive

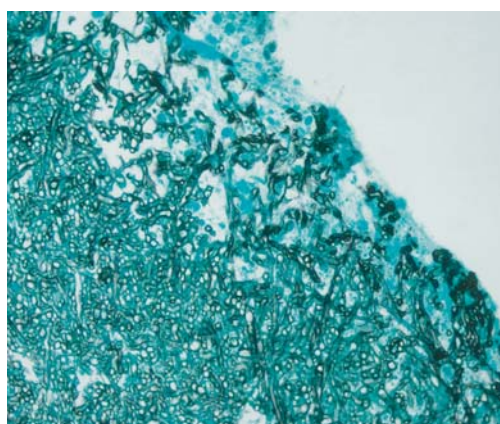


FIGURE 16-11 Silver-stained histopathologic section revealing tissue invasion in invasive fungal (*Aspergillus*) sinusitis ($\times 400$ original magnification). Reproduced with permission from Dhong HJ, Lanza DC. Fungal rhinosinusitis. In: Kennedy DW, Bolger WE, Zinreich SJ, editors. *Diseases of the sinuses: diagnosis and management*. Hamilton: BC Decker Inc; 2001. p. 182.

mucus retention. Bone thinning or destruction may be observed from the expansile nature of the inflammatory process or owing to tissue invasion.

Complications of Sinusitis Because of the proximity of the paranasal sinuses to the eyes and brain, complications of sinusitis are divided into two broad categories: orbital and intracranial. Infection extending into the orbit and associated soft tissues usually originates from the ethmoids and occurs through one of two mechanisms: (1) direct extension through the orbital wall or (2) retrograde spread through veins between the sinuses and the orbit. Lymphatic spread is not a significant factor because lymphatics are absent in the orbit. The spectrum of orbital complications of sinus infections has been classified in five categories (Figure 16-13).⁵³

Preseptal cellulitis, or periorbital cellulitis, is edema and inflammation of the skin and muscle anterior to the orbital septum secondary to impairment of venous drainage from these tissues.⁵⁴ There are no visual symptoms, restrictions of extraocular movement, or signs of chemosis as the infection has not invaded the intraconal soft tissues. In contrast, orbital cellulitis indicates edema and

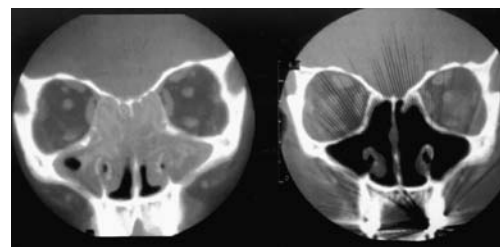


FIGURE 16-12 Pre- and postoperative computed tomography of the paranasal sinuses in this middle-aged woman with *Bipolaris specifera* allergic fungal rhinosinusitis. Note the hyperplastic mucosa with the hyperdensities seen on the bone windowing of the sinuses and the preoperative absence of turbinates. Reproduced with permission from Dhong H-J, Lanza DC. Fungal rhinosinusitis. In: Kennedy DW, Bolger WE, Zinreich SJ, editors. *Diseases of the sinuses: diagnosis and management*. Hamilton: BC Decker Inc; 2001. p. 185.

inflammation of the intraconal contents resulting in ophthalmoplegia, proptosis, and chemosis secondary to obstruction of venous outflow via the ophthalmic veins.

Subperiosteal abscess (Figure 16-14) is a collection of purulent material between the bony orbital wall and the orbital periosteum, usually from direct spread of acute infection in the ethmoid sinuses through the lamina papyracea. Depending on the size of the abscess and the associated mass effect, and the degree of inflammation, ocular muscles and visual acuity are variably affected. Progression of this subperiosteal process may subsequently result in an abscess of the orbital tissues. An orbital abscess may also occur with progression of orbital cellulitis. At this stage, restriction of extraocular mobility, proptosis, chemosis, and visual loss are often observed. When orbital cellulitis or subperiosteal or orbital abscesses are suspected, contrast-enhanced CT examination is necessary.⁵⁵

Cavernous sinus thrombosis is a grave complication that occurs from direct extension or retrograde thrombophlebitis (via the ophthalmic vein) of ethmoid or sphenoid infections.^{56,57} In addition to restriction of extraocular mobility, proptosis, chemosis, and visual loss, cranial neuropathies and signs of meningitis may be observed. Given the frequency of ocular findings, this entity is often categorized with the orbital complications of sinusitis, but if this or another intracranial complication is suspected, magnetic resonance imaging must be performed. Lumbar puncture may also be indicated.

Intracranial complications occur less frequently than do orbital complications and are most commonly related to the frontal or sphenoid sinuses (Figure 16-15).^{58,59} These complications may occur via either direct spread or retrograde thrombophlebitis. Pott's puffy tumor is a collection of pus under the forehead periosteum with inflammatory changes of the overlying skin and soft tissues.

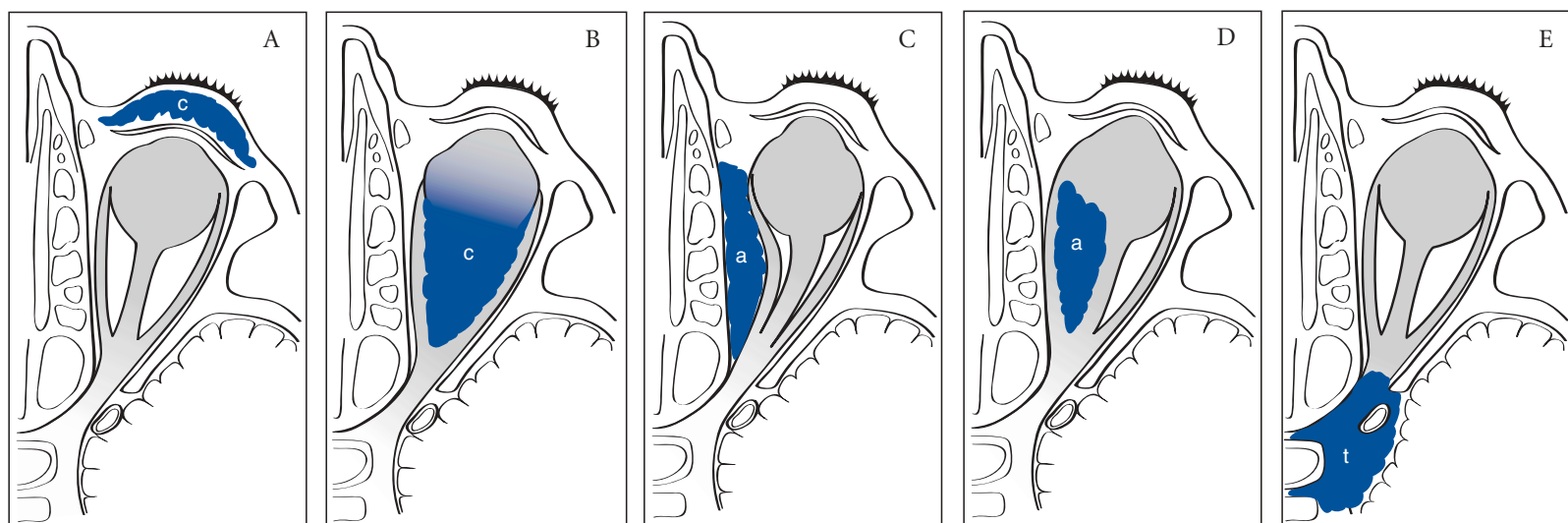


FIGURE 16-13 Orbital complications of sinusitis: A, preseptal cellulitis (c); B, orbital cellulitis (c); C, orbital subperiosteal abscess (a); D, orbital abscess (a); E, septic thrombosis of the cavernous sinus (t). Adapted from Lusk RP, Tychsens L, Park TS. *Complications of sinusitis*. In: Lusk RP, editor. *Pediatric sinusitis*. New York: Raven Press; 1992. p. 127–46.

This develops secondary to the spread of infection through emissary veins into the cranial bone marrow, and thus essentially represents osteomyelitis of the frontal bone.

An epidural abscess develops from osteitis of the posterior table of the frontal sinus extending into the space between the frontal bone and the dura. Patients present with low-grade fever and worsening headache from elevated intracranial pres-

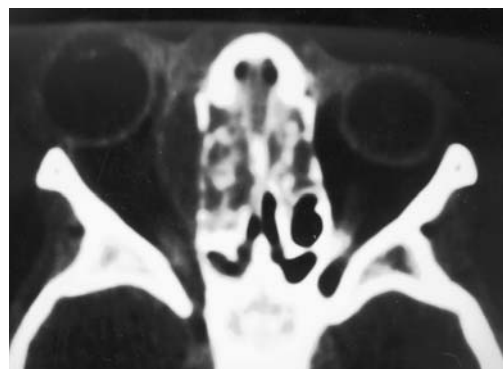


FIGURE 16-14 Axial computed tomography scan demonstrating a subperiosteal abscess adjacent to the right medial orbital wall secondary to acute infection in the ipsilateral ethmoid sinuses. Reproduced with permission from Choi SS, Grundfast KM. *Complications in sinus disease*. In: Kennedy DW, Bolger WE, ZinreichSJ, editors. *Diseases of the sinuses: diagnosis and management*. Hamilton: BC Decker Inc; 2001. p. 170.

sure. This complication may be surprisingly indolent because there are no focal neurologic signs and examination of the cerebrospinal fluid (CSF) is often normal.⁵⁹ In a manner analogous to the orbital abscess, subdural and brain abscesses can occur from the direct spread of an epidural abscess or from retrograde thrombophlebitis. Increased intracranial pressure is significant in these cases and may lead to herniation and death. Subdural abscess may cause septic venous thrombosis and venous infarction.⁶⁰ Brain abscess is associated with brain necrosis.

In contrast to the above intracranial conditions, which usually arise from the frontal sinus, meningitis typically arises from infection of the ethmoid or sphenoid sinus.⁶¹ The typical presenting symptoms and signs are high fever, headaches, seizures, and delirium. Lumbar puncture is necessary to establish the diagnosis and obtain culture results.

Treatment

Medical Management

The principle of therapy for sinusitis is to break the cycle of impaired mucociliary clearance, stasis, infection, and

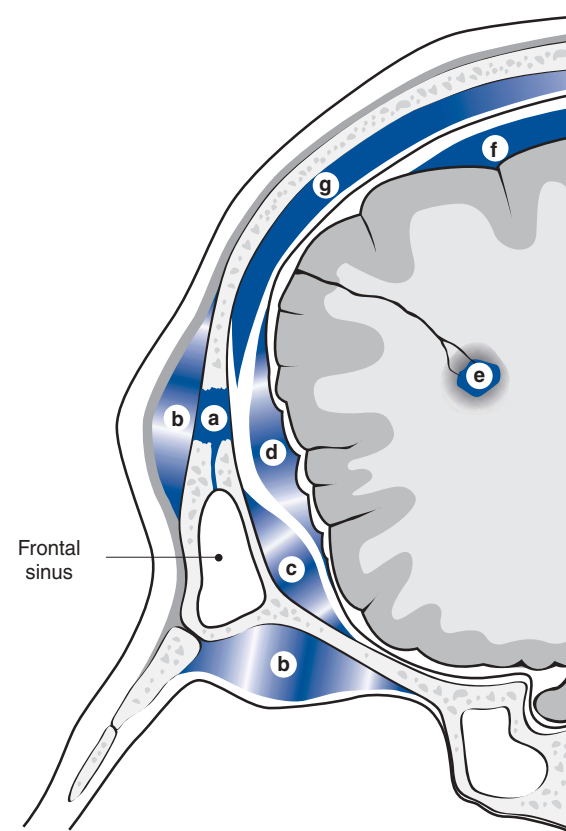


FIGURE 16-15 Intracranial complications of sinusitis. These include osteomyelitis (a), periorbital abscess (b), epidural abscess (c), subdural abscess (d), brain abscess (e), meningitis (f), and septic thrombosis of the superior sagittal sinus (g). Adapted from Choi SS, Grundfast KM. *Complications in sinus disease*. In: Kennedy DW, Bolger WE, ZinreichSJ, editors. *Diseases of the sinuses: diagnosis and management*. Hamilton: BC Decker Inc; 2001. p. 172.

inflammation. Treatment for uncomplicated acute sinusitis is primarily medical, with antibiotics representing the mainstay of therapy. In most primary care settings, it is acceptable to initiate antibiotic therapy when the criteria for acute sinusitis are met. First-line drugs for acute rhinosinusitis recommended by the Agency for Health Care Policy and Research Institute include amoxicillin (500 mg PO tid) and trimethoprim/sulfamethoxazole (double strength tablets, one PO bid). It has been further recommended that cephalosporins, macrolides, penicillinase-resistant penicillins, and fluoroquinolones should be reserved for failures of first-line therapy or for complications. However, some have questioned whether, given the high incidence of pneumococcal and *H. influenzae* resistance in many areas, this graduated antibiotic response is really appropriate. Treatment duration should be at least 10 to 14 days, and antibiotic doses must be adjusted for patient weight (in children) and for hepatorenal function, where appropriate. Recent trends have included the use of culture-directed therapy, which, at least theoretically, allows long-term cost effective management. This can be performed safely and accurately using a middle meatal swab under endoscopic guidance.⁶²

Oral decongestants such as pseudoephedrine and topical decongestants such as phenylephrine and oxymetazoline may be useful by decreasing tissue edema by α -adrenergic vasoconstriction. This allows sinus ventilation and symptomatic relief. Topical decongestants must be used judiciously, however, as continuance of these medications beyond 3 to 5 days is associated with reduced duration of action and rebound vasodilation, a condition known as *rhinitis medicamentosa*. The roles for antihistamines and topical nasal steroids in the management of acute infections are controversial. If allergy is thought to be a significant predisposing or coexist-

ing factor, antihistamines may be indicated. Topical steroids, although useful in chronic rhinosinusitis, have no proven efficacy in the treatment of acute sinusitis but may have a prophylactic effect in preventing recurrent acute episodes. Oral steroids (eg, prednisone or methylprednisolone) are not typically prescribed for acute sinusitis when a significant bacterial component is expected because the immunosuppressive effects may promote the development of complications. However, oral steroids are useful in the management of acute exacerbations of chronic sinusitis to control the baseline inflammatory tendencies of the sinonasal mucosa. Nasal saline irrigations and mucolytics (eg, guaifenesin 600 mg PO bid–qid) may have a role in the treatment of both acute and chronic sinusitis by assisting the mobilization of secretions.

Antibiotic therapy is also a major component in the treatment of chronic (and subacute) sinusitis. The principles of treatment, however, differ from those for acute sinusitis. First, the appropriate duration of therapy may be as long as 3 to 6 weeks.^{27,63} Additionally, empiric therapy requires regimens with coverage of *Staphylococcus* and anaerobes in addition to the common pathogens of acute sinusitis (*S. pneumoniae*, *H. influenzae*, and *M. catarrhalis*).²⁶ Culture-directed therapy is essential as antibiotic resistance is a significant problem in this patient population. Virtually all strains of *M. catarrhalis* and over 50% of those of *H. influenzae* are penicillin resistant.⁶⁴ Commonly employed regimens include clindamycin (150 mg PO qid) plus either trimethoprim/sulfamethoxazole or a fluoroquinolone. Amoxicillin-clavulanate and selected oral second- and third-generation cephalosporins may be useful as single-agent therapy. New-generation macrolides (clarithromycin, azithromycin) and other cephalosporins may be effective, depending on culture and sensitivity results.²⁶ Each antibiotic has a unique profile of toxicities and side effects that must

be considered. Recent trends have included the use of antibiotic-containing irrigations and nebulized aerosols, particularly in conjunction with endoscopic sinus surgery.⁶⁵

Steroids are also a mainstay in the treatment of chronic sinusitis. Steroids decrease inflammation nonspecifically via a variety of mechanisms. Primarily they inhibit cell-mediated immunity by blocking lymphocyte migration and proliferation.^{66,67} Eosinophil and basophil counts are reduced,⁶⁸ and the release of histamine and leukotriene from basophils is inhibited. Also, steroids decrease both vascular permeability and the secretory activity of submucosal glands.⁶⁹

Topical nasal steroids are effective in reducing mucosal inflammatory changes and are considered safe for long-term use.⁷⁰ With initiation of the medication, symptomatic improvement is not realized until > 1 week of use.⁷¹ Patients must be counseled in this regard because most patients expect the immediate relief provided by topical decongestants, which cannot be used long-term without rebound vasocongestion. Potential risks associated with nasal steroids include epistaxis and septal perforation. The complications of systemic steroid use, although possible, are rare with topical nasal steroids. Studies have demonstrated increased risk of acute open-angle glaucoma and ocular hypertension with inhaled but not intranasal steroid use.⁷² Suppression of the adrenocortical axis has been observed with higher-than-recommended dosages,⁷³ but other studies have shown that routine daily use is not associated with axis suppression.⁷⁴

Oral steroid therapy can be used intermittently in patients with chronic sinusitis to manage acute exacerbations. Several different steroid compounds are available, and each has its own relative potencies and side effects. Most often either prednisone or methylprednisolone is used. Doses usually begin at 30 mg daily (or equivalent) and are tapered over 2 to 3 weeks. Tapering doses are required after 5 to 7 days of ther-

apy secondary to suppression of the adrenocortical axis. Severe acute exacerbations may require higher dosages, and some patients with recalcitrant chronic rhinosinusitis may necessitate long-term steroid regimens. Often, protracted steroid courses are necessary for management of coexisting asthma in this patient population.¹² Systemic steroid therapy is potentially associated with serious side effects. Long-term use may result in osteopenia or osteoporosis, which may be reversible in early phases.⁷⁵ Patients on long-term oral steroids should therefore undergo bone-density studies regularly. Steroid use is also associated with cataracts, hyperglycemia, glaucoma, sodium retention, fat accumulation, and psychosocial changes.

Patients with chronic sinusitis with significant atopic components may be difficult to manage. The most important strategy in this population is avoidance. Antihistamine use should be limited to those with documented allergy by testing or clear allergic stigmata such as frequent sneezing or itchy watery eyes. Antihistamines may cause drying and thickening of nasal secretions resulting in impaired mucociliary flow; therefore, they must be used judiciously. A full discussion of allergy management is beyond the scope of this chapter, but it may include topical and oral steroids, antihistamines, and mast cell stabilizers. There is also mounting evidence supporting the use of immunotherapy, particularly in cases with an allergic fungal component.⁷⁶

Antifungal agents may also have a role in the treatment of sinusitis. Invasive forms often require intravenous therapy with amphotericin B. Use of this medication is limited by renal toxicity. Chronic sinusitis with an allergic fungal component may also be treated with antifungal agents including itraconazole (200 mg PO bid). Topical nasal irrigation with solutions containing amphotericin B or nystatin has also been employed in the treatment of fungal sinusitis. The efficacy of these treatments is an area of active research.

Surgery

Indications for surgery include (1) acute sinusitis with a pending or evolving complication, (2) chronic sinusitis that has failed maximum medical management including at least 3 weeks of broad-spectrum antibiotics, and (3) most forms of fungal sinusitis. In cases of complicated acute sinusitis and invasive fungal disease, surgery should be performed on an urgent or emergent basis.

In uncomplicated chronic sinusitis the goals of surgery are to eliminate mechanical obstruction of mucociliary flow, remove chronically inflamed mucosa and bone, manage/prevent complications, and rule out other disorders such as neoplasia. The determination that “maximal medical management” has failed must be individualized. It should be noted that the indications for surgery are more stringent in the pediatric population, for whom some advocate 3 weeks of intravenous antibiotic therapy prior to consideration of surgery.⁷⁷

Children with severe chronic sinusitis should first have thorough work-up and appropriate treatment for conditions such as allergy, GERD, CF, and immunodeficiency. Simple measures such as avoidance of pollutants (eg, secondhand cigarette smoke⁷⁸) and environmental allergens may avert the need for surgery. One study demonstrated allergies in 80% of children with sinusitis.⁷⁹ Children in day-care centers may be prone to upper respiratory infections and consequently chronic sinusitis.⁸⁰ Other series have shown that medical treatment of GERD may eliminate the need for sinus surgery in 90% of children otherwise considered surgical candidates.⁸¹

Prior to surgery it is important to evaluate the CT scan to assess the extent of inflammatory disease and the patient's anatomy. A mental checklist is developed to assess the depth of the ethmoid skull base and the position and integrity of the medial orbital walls. The presence of acces-

sory ethmoid air cells, such as the infraorbital cell or concha bullosa, and anatomic anomalies such as maxillary sinus hypoplasia are noted. Triplanar reconstructions of thinly cut CT scans are used as part of a stereotactic imaging protocol (Figure 16-16). This is useful to assess anatomy and pathology in the axial, coronal, and sagittal planes both preoperatively and intraoperatively, where the surgeon can correlate endoscopic and CT findings during dissection. Use of this technology is indicated when normal anatomic landmarks have been altered, as in patients who have had previous surgery and in cases of massive polyposis. Patients with advanced chronic inflammatory disease, particularly those with nasal polyposis, are treated with oral steroids for up to 2 weeks before surgery. Courses of oral and occasionally intravenous antibiotics are required in selected cases preoperatively.

Surgery is performed under the visualization of endoscopes (Figure 16-17), often with angled lenses, and with a variety of forceps and punches (Figure 16-18). Powered tissue shavers similar to those used in arthroscopic surgery are also used (Figure 16-19). The goals of surgery are to remove chronically inflamed tissue and to restore sinus ventilation, drainage, and mucociliary clearance. Evidence exists that in chronic sinusitis the inflammatory process involves the underlying bone.^{82,83} Thus, it is especially important to resect the bony ethmoid partitions underlying chronically inflamed mucosa. Diseased mucosa is resected, whereas normal mucosa is preserved. It is critical to avoid stripping of normal mucosa because denuded bone results in delayed healing,⁸⁴ and the regenerated mucosa does not regain normal ciliary density.

In performing maxillary antrostomy, the uncinat process is completely resected and the natural ostium (see Figure 16-19) is identified and subsequently enlarged. The opening must communicate with the natural ostium in a manner that permits

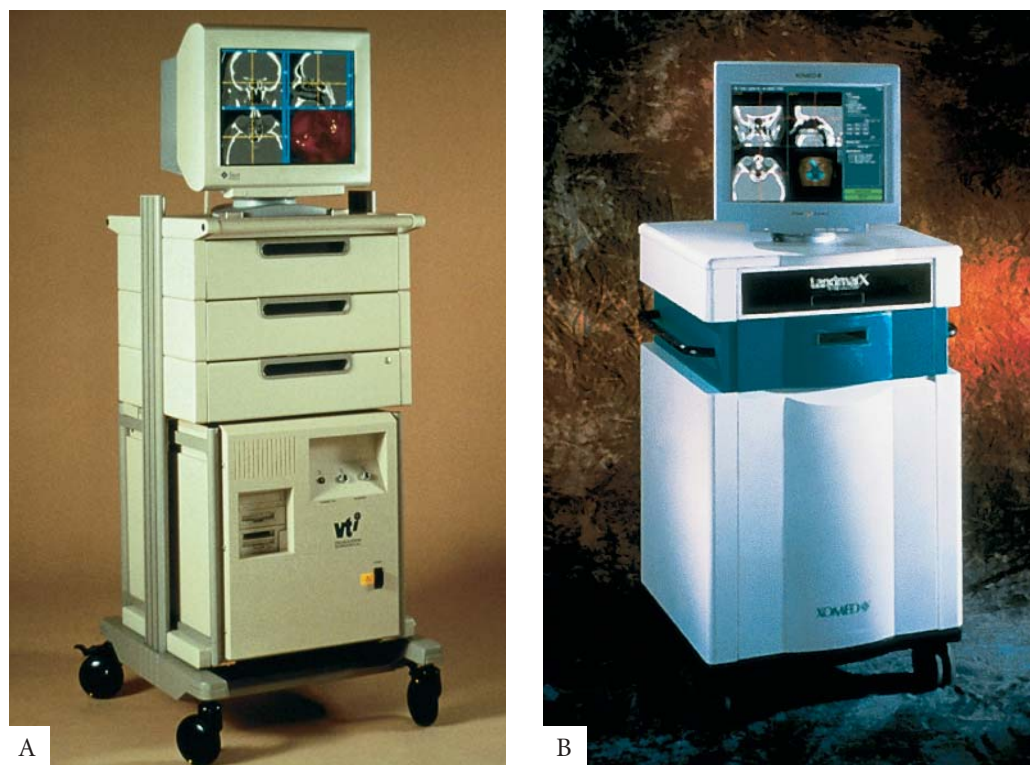

FIGURE 16-16 A and B, Devices for intraoperative stereotactic navigation. A selected point is identified in the coronal, sagittal, and axial planes using reconstructed computed tomographic data. Reproduced with permission from Kennedy DW. *Functional endoscopic sinus surgery: concepts, surgical indications, and instrumentation*. In: Kennedy DW, Bolger WE, Zinreich SJ, editors. *Diseases of the sinuses: diagnosis and management*. Hamilton: BC Decker Inc; 2001. p. 206.

physiologic mucociliary clearance patterns. The bone of this structure frequently exhibits osteitis. To avoid intracranial com-

plications, special care is necessary during the removal of diseased tissue along the skull base as well as during sphenoid and

frontal sinus surgery. Intraoperative stereotactic navigational imaging is useful in performing more comprehensive surgery in these regions (see Figure 16-16).

Prior to the widespread use of endoscopes, ethmoidectomy was performed with a headlight, surgical loupes, or a microscope. Endoscopic technology has greatly improved our ability to perform ethmoidectomy safely and comprehensively. In addition, external approaches including the Caldwell-Luc operation, external ethmoidectomy, and frontal sinus trephination were performed more commonly. The Caldwell-Luc operation, originally described in the late 1800s, is an approach to the maxillary sinus through the labiogingival sulcus and canine fossa (Figure 16-20). In the classically described operation to treat chronic maxillary sinusitis, mucosa of the maxillary sinus was curettaged, and an inferior meatal antrostomy was created. Our knowledge of the mucociliary clearance patterns and our ability to now address the natural ostium have made the classic Caldwell-Luc procedure obsolete in the primary surgical management of chronic maxillary sinusitis. Occasionally a sublabial approach is still required to the maxillary sinus in unusual circumstances; however, given our current understanding of the ability of the mucosa to respond to medical therapy and the long-term problems associated with mucosal stripping, only a very limited mucosal resection is performed when this is required. Overall, external approaches may have a limited role in the management of complicated sinusitis, but endoscopic surgery is preferred when technically possible to address the implicated pathology.

Major complications specific to sinus surgery occur in 0 to 5% and include bleeding, CSF leak and visual problems.⁸⁵ Intraoperative blood loss may range from 20 to 500 cc, depending on the extent of disease and surgery. Hemostasis is usually achieved in surgery with local vasoconstrictors

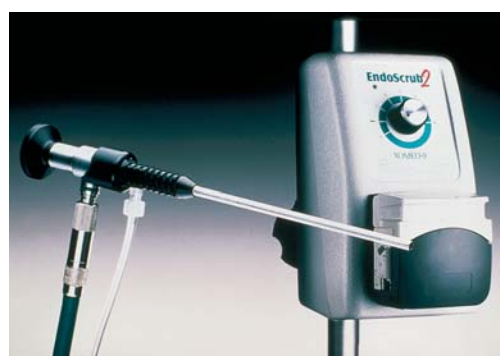

FIGURE 16-17 Nasal endoscope shown with its associated sheath used for irrigation. Reproduced with permission from Kennedy DW. *Functional endoscopic sinus surgery: concepts, surgical indications, and instrumentation*. In: Kennedy DW, Bolger WE, Zinreich SJ, editors. *Diseases of the sinuses: diagnosis and management*. Hamilton: BC Decker Inc; 2001. p. 203.

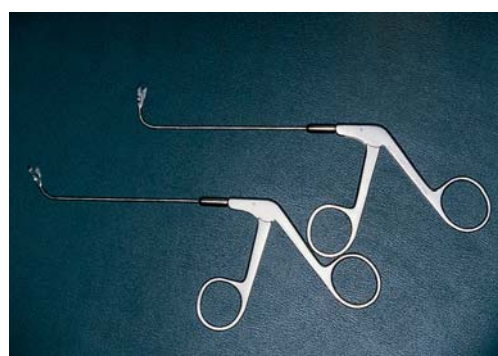

FIGURE 16-18 Surgical forceps of various sizes, angles, and cutting action are available for endoscopic surgery. Reproduced with permission from Kuhn FA. *Surgery of the frontal sinus*. In: Kennedy DW, Bolger WE, Zinreich SJ, editors. *Diseases of the sinuses: diagnosis and management*. Hamilton: BC Decker Inc; 2001. p. 294.

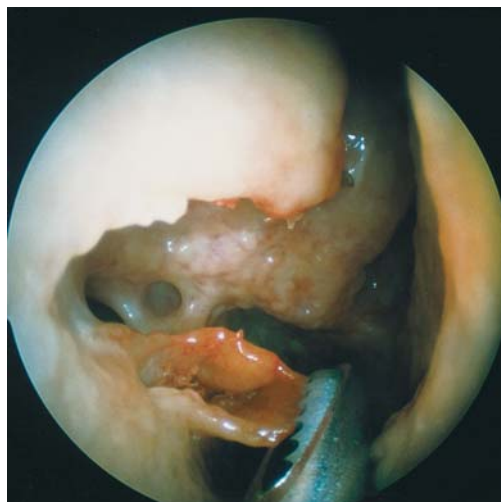

FIGURE 16-19 A powered tissue shaver is used to resect the inferior portion of the uncinus process, exposing the natural ostium of the maxillary sinus. Reproduced with permission from Parsons DS, Nishioka G. *Pediatric sinus surgery*. In: Kennedy DW, Bolger WE, Zinreich SJ, editors. *Diseases of the sinuses: diagnosis and management*. Hamilton: BC Decker Inc. 2001. p. 275.

and/or cautery. Although a small amount of bleeding is typical in the first few days following surgery, excess bleeding is rare and, if it does occur, seldom reaches transfusable quantities. The incidence and severity of postoperative hemorrhage may be increased in patients with acquired immunodeficiency syndrome, diffuse polyp disease, and revision cases.⁸⁶

CSF leak is a risk of surgery performed on the ethmoid bone. This occurs in 0.01 to 1.4% of cases.^{85,86} If recognized intraoperatively, a CSF leak should be repaired in the same operative setting. Patients diagnosed with an iatrogenic CSF leak postoperatively may present with meningitis, which requires medical treatment and surgical repair. The risk of orbital penetration during endoscopic sinus surgery is 2 to 4%, and in one-third of these cases, orbital emphysema is also observed. Fortunately the risk of blindness is low, approaching zero in several series.^{85,86} This devastating complication is usually secondary to an expanding intraorbital hematoma, although optic nerve injury is possible during surgery of the sphenoid and poste-

rior ethmoid. If blindness is encountered postoperatively, initial management is to remove any nasal packing and perform orbital massage to evacuate any bleeding. Emergent ophthalmologic consultation should be obtained, and lateral canthotomy or endoscopic orbital decompression may be required. Another complication of sinus surgery affecting the eye is nasolacrimal duct injury. Postoperatively, the patient presents with epiphora, or tearing. The nasolacrimal duct courses anterior to the natural ostium of the maxillary sinus and can be injured when the antrostomy is enlarged anteriorly.

The most common complication after endoscopic sinus surgery is the formation of synechiae, observed in approximately 8%.⁸⁶ Although these may be asympto-

matic, they may also contribute to ostial stenosis and obstruction and, ultimately, the need for revision surgery. Postoperatively, the surgically opened sinus cavities are débrided under endoscopic visualization in the office setting. Patients are asked to use nasal saline sprays and/or irrigations to reduce crusting and facilitate the débridement process. Recalcitrant cases may benefit from the addition of antibiotics to these irrigation solutions.⁸⁷

Postoperative medical management and long-term follow-up care is critically important. Patients are usually put on a course of oral antibiotics to prevent bacterial proliferation in the blood and mucus that may collect in the sinus cavities postoperatively. Antibiotic selection and the duration of treatment are individualized

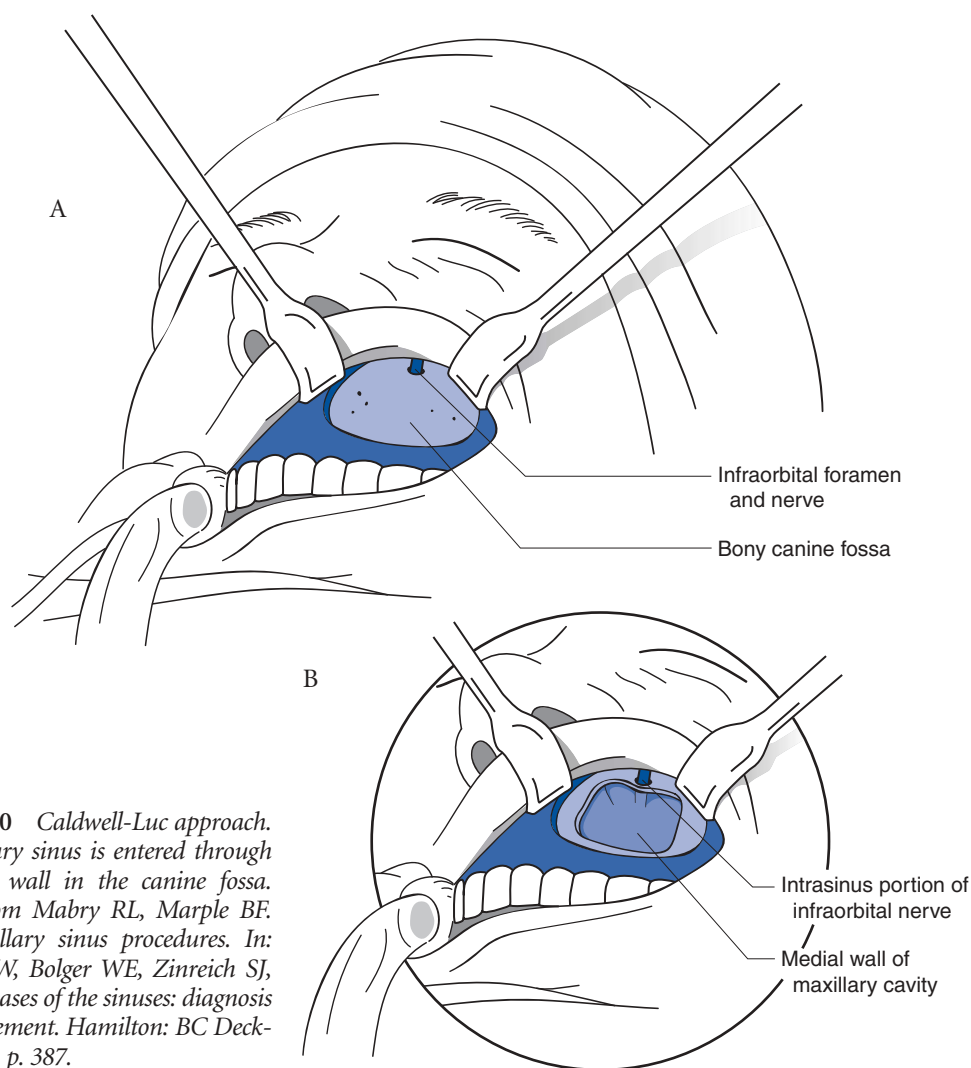


FIGURE 16-20 Caldwell-Luc approach. The maxillary sinus is entered through its anterior wall in the canine fossa. Adapted from Mabry RL, Marple BF. *Open maxillary sinus procedures*. In: Kennedy DW, Bolger WE, Zinreich SJ, editors. *Diseases of the sinuses: diagnosis and management*. Hamilton: BC Decker Inc. 2001. p. 387.

according to culture results and the degree of inflammation observed. Antibiotics can be discontinued once the mucosa has recovered and ciliary activity can offset the stagnation of secretions. Topical and oral steroids are often prescribed postoperatively to decrease inflammation and reduce scar formation during the healing process. Although some patients require long-term oral steroid therapy, it is preferably avoided, when possible, given the side effects. In contrast, patients almost universally require long-term treatment with topical nasal steroids. This is usually well tolerated and is considered safe.

Overall endoscopic sinus surgery is considered successful in 80 to 90% of patients after at least 2 years follow-up.^{86,88} The natural history for patients with nasal polyps undergoing surgery alone is recurrence since polyposis is multifactorial and is associated with a tendency toward mucosal inflammatory reactivity. One study demonstrated recurrent polyp disease in 55% of patients after a mean follow-up of 3 years and 5 months. Nonetheless, surgery has a clear role in these patients as is evidenced by the observation that over half were asymptomatic or significantly improved, and none were worse.⁸⁸ Diligent postoperative care including débridement, medical management, and possibly allergy therapy is essential to reduce or eliminate the tendency toward recurrence, and long-term endoscopic follow-up is required to evaluate for and treat even asymptomatic disease. Studies have also demonstrated that sinus surgery in patients with both asthma and nasal polyposis may decrease both pulmonary and nasal symptoms and reduce the dependency on oral steroids.

Conclusions

Ultimately, additional advancements in our management of sinus disease will require advancements in our understanding of the pathophysiology. At this time, a “common pathway,” through which patients with var-

ious risk factors develop sinusitis has not been defined. Sinusitis can be managed effectively, however, with medical therapy in most cases. There are clear roles for surgical intervention in acute sinusitis with complications (or pending complications), chronic sinusitis that has failed medical management, and the various forms of fungal disease. Combined with appropriate medical management, surgical outcomes can be maximized in these cases.

References

- Murphy MP, Fishman P, Short SO, et al. Health care utilization and cost among adults with chronic rhinosinusitis enrolled in a health maintenance organization. *Otolaryngol Head Neck Surg* 2002;127:367–76.
- Messerklinger W. Über die Drainage der menschlichen Nebenhöhlen unter normalen und pathologischen Bedingungen. 1. Mitteilung. *Monatsschr Ohrenheilkd Laryngol Rhinol* 1966;101:56–68.
- Lanza DC, Kennedy DW. Adult rhinosinusitis defined. *Otolaryngol Head Neck Surg* 1997;117:S1–7.
- Lanza DC, Kennedy DW. Nose and sinus mucosal inflammation. *Curr Opin Otolaryngol Head Neck Surg* 1994;2:27–32.
- Aust R, Drettner B. Oxygenation in the human maxillary sinus under normal and pathological conditions. *Acta Otolaryngol* 1973;78:264–9.
- Aust R, Drettner B. The patency of the maxillary sinus ostium in relation to body posture. *Acta Otolaryngol* 1975;80:443–6.
- Drettner B, Lindholm CE. The borderline between acute rhinitis and sinusitis. *Acta Otolaryngol* 1967;64:508–13.
- Turner BW, Cail WS, Hendley JO, et al. Physiologic abnormalities in the paranasal sinuses during experimental rhinovirus colds. *J Allergy Clin Immunol* 1992;90:474–8.
- Russel DI, Ryan WJ, Towers JF. Complications of automated root canal treatment. Apical perforation and overfilling. *Br Dent J* 1982;153:393–8.
- Furukawa CT. The role of allergy in sinusitis in children. *J Allergy Clin Immunol* 1992;90:515–7.
- Senior BA, Kennedy DW, Tanabodee J, et al. Long-term impact of functional endoscopic sinus surgery on asthma. *Otolaryngol Head Neck Surg* 1999;121:66–8.
- Palmer JN, Conley DB, Dong DG, et al. Efficacy of endoscopic sinus surgery in the management of patients with asthma and chronic sinusitis. *Am J Rhinol* 2001;15:49–53.
- Settipane GA. Epidemiology of nasal polyps. *Allergy Asthma Proc* 1996;17:231–6.
- Lockey RF, Rucknagel DL, Vanselow NA. Familial occurrence of asthma, nasal polyps, and aspirin intolerance. *Ann Intern Med* 1973;78:57–63.
- Trevino RJ. Air pollution and its effect on the upper respiratory tract and on allergic rhinosinusitis. *Otolaryngol Head Neck Surg* 1996;114:239–41.
- Nadel JA. Neutral endopeptidase modulates neurogenic inflammation. *Eur Respir J* 1991;4:745–54.
- Peden DB, Setzer RW, Devlin RB. Ozone exposure has both a priming effect on allergen-induced responses and an intrinsic inflammatory action in the nasal airways of perennially allergic asthmatics. *Am J Respir Crit Care Med* 1995;151:1336–45.
- Suonpaa J, Anttila J. Increase of acute frontal sinusitis in southwestern Finland. *Scand J Infect Dis* 1990;22:563–8.
- Barbero GJ. Gastroesophageal reflux and upper airway disease: a commentary. *Otolaryngol Clin North Am* 1996;29:27–38.
- Parsons DS. Chronic sinusitis: a medical or surgical disease? *Otolaryngol Clin North Am* 1996;29:1–9.
- Chow JM, Hartman J, Stankiewicz JA. Endoscopic directed cultures of the maxillary sinus ostium. *Oper Tech Otolaryngol Head Neck Surg* 1993;4:86–9.
- Williams BL, McCann GF, Schoenkecht FD. Bacteriology of dental abscesses of endodontic origin. *J Clin Microbiol* 1983;18:770–4.
- Doyle PW, Woodham JD. Evaluation of the microbiology of chronic ethmoid sinusitis. *J Clin Microbiol* 1992;29:2396–400.
- Orobello PW, Park RI, Belcher LJ, et al. Microbiology of chronic sinusitis in children. *Arch Otolaryngol Head Neck Surg* 1991;117:980–3.
- Jiang RS, Hsu CY, Leu JF. Bacteriology of ethmoid sinusitis in chronic sinusitis. *Am J Rhinol* 1997;11:133–7.
- Poole MD. Selecting an oral broad spectrum antibiotic. *Ear Nose Throat J* 1992;71:444–5.
- Benninger MS, Anon J, Mabry RL. The medical management of rhinosinusitis. *Otolaryngol Head Neck Surg* 1997;117:S41–9.
- Brook I. Microbiology and management of sinusitis. *J Otolaryngol* 1996;25:249–56.
- Busch DE. Anaerobes in infections of the head and neck and ear, nose, and throat. *Rev Infect Dis* 1984;Suppl 6:115–22.
- Ferreiro JA, Carlson BA, Cody T. Paranasal sinus fungal balls. *Head Neck* 1997;19:481–6.

31. deShazo RD, O'Brien M, Chapin K, et al. A new classification and diagnostic criteria for invasive fungal sinusitis. *Arch Otolaryngol Head Neck Surg* 1997;123:1181-8.
32. Manning SC, Holman M. Further evidence for allergic pathophysiology in allergic fungal sinusitis. *Laryngoscope* 1998;108:1485-96.
33. Cody DT, Neel HB, Ferrerio JA, Roberts GD. Allergic fungal sinusitis: the Mayo Clinic experience. *Laryngoscope* 1994;104:1074-9.
34. Ponikau JU, Sherris DA, Kern EB, et al. The diagnosis and incidence of allergic fungal sinusitis. *Mayo Clin Proc* 1999;74:877-84.
35. Taylor MJ, Ponikau JU, Sherris DA, et al. Detection of fungal organisms in eosinophilic mucin using a fluorescein-labeled chitin-specific binding protein. *Otolaryngol Head Neck Surg* 2002;127:377-83.
36. Wang XJ, Molan B, Leopold DA, et al. An increased frequency of CF mutations in patients with chronic sinusitis [abstract]. *Am J Hum Genet* 1998;63:55A.
37. Kartagener M. Zur oathogenese dur brochiektasien: brochiektasien bei situs viscerum inversus. *Beitr Klin Tuberk* 1933;83:498-501.
38. Cox DW, Talamo RC. Genetic aspects of pediatric lung disease. *Pediatr Clin North Am* 1979;26:467-80.
39. Young D. Surgical treatment of male infertility. *J Reprod Fertil* 1970;23:541-2.
40. Handelsman DJ, Conway AJ, Boylan LM, Turtle JR. Young's syndrome. Obstructive azoospermia and chronic sinopulmonary infections. *N Engl J Med* 1984;310:3-9.
41. Umetsu DT, Ambrosino DM, Quinti I, et al. Recurrent sinopulmonary infections and impaired antibody response to bacterial capsular polysaccharide antigens in children with selective IgG subclass deficiency. *N Engl J Med* 1985;313:1247-51.
42. Cunningham-Rundles C. Clinical and immunologic analyses of 103 patients with common variable immunodeficiency. *J Clin Immunol* 1989;9:33-5.
43. Plebani A, Ugazio AG, Monafo V, Burgio GR. Clinical heterogeneity and reversibility of selective immunoglobulin A deficiency in 80 children. *Lancet* 1986;1:829-31.
44. Lederman HM, Winkelstein JA. X-lined agammaglobulinemia: an analysis of 96 patients. *Medicine* 1985;64:145-56.
45. Ferguson BJ, Mabry RL. Laboratory diagnosis. *Otolaryngol Head Neck Surg* 1997;117:S12-26.
46. Stankiewicz JA, Chow JM. Nasal endoscopy and the definition and diagnosis of chronic rhinosinusitis. *Otolaryngol Head Neck Surg* 2002;126:623-7.
47. Piccirillo JF, Merritt MG Jr, Richards ML. Psychometric and clinimetric validity of the 20-item Sino-Nasal Outcome Test (SNOT-20). *Otolaryngol Head Neck Surg* 2002;126:41-7.
48. Havas TE, Motbey JA, Gullane PJ. Prevalence of incidental abnormalities on computerized tomographic scans of the paranasal sinuses. *Arch Otolaryngol Head Neck Surg* 1988;114:856-9.
49. Kuhn JP. Imaging of the paranasal sinuses: current status. *J Allergy Clin Immunol* 1986;77:6-9.
50. Melhelm ER, Oliverio PJ, Benson ML, et al. Optimal CT evaluation for functional endoscopic sinus surgery. *Am J Neuroradiol* 1991;12:849-54.
51. Zinreich SJ, Gottwald T. Radiographic anatomy of the sinuses. In: Kennedy DW, Bolger WE, Zinreich SJ, editors. *Diseases of the sinuses: diagnosis and management*. Hamilton: BC Decker Inc; 2001. p. 13-27.
52. Zinreich SJ, Kennedy DW, Malat J, et al. Fungal sinusitis: diagnosis with CT and MR imaging. *Radiology* 1988;169:439-44.
53. Chandler JR, Langenbrunner DJ, Stevens ER. The pathogenesis of orbital complications in acute sinusitis. *Laryngoscope* 1970;80:1414-28.
54. Gamble RC. Acute inflammation of the orbit in children. *Arch Ophthalmol* 1933;10:483-97.
55. Gutowski WM, Mulbury PE, Hengerer AL, et al. The role of CT scans in managing the orbital complications of ethmoiditis. *Int J Pediatr Otorhinolaryngol* 1988;15:117-28.
56. Southwick FS, Richardson EP, Schwartz MN. Septic thrombosis of the dural venous sinuses. *Medicine* 1986;158:82-106.
57. Sofferan RA. Cavernous sinus thrombophlebitis secondary to sphenoid sinusitis. *Ann Otol Rhinol Laryngol* 1964;73:210-7.
58. Clayman GL, Adams GL, Paugh DR, et al. Intracranial complications of paranasal sinusitis: a combined institutional review. *Laryngoscope* 1991;101:234-9.
59. Blitzer A, Carmel P. Intracranial complications of disease of the paranasal sinuses. In: Blitzer A, Lawson W, Friedman WH, editors. *Surgery of the paranasal sinuses*. Philadelphia: WB Saunders Co; 1985. p. 328-37.
60. Renaudin JW, Frazee J. Subdural empyema: importance of early diagnosis. *Neurosurgery* 1980;7:477-9.
61. Courville CB. Subdural empyema secondary to purulent frontal sinusitis. *Arch Otolaryngol* 1944;39:211-30.
62. Talbot GH, Kennedy DW, Scheld WM, Granito K. Rigid nasal endoscopy versus sinus puncture and aspiration for microbiologic documentation of acute bacterial maxillary sinusitis. *Clin Infect Dis* 2001;33:1668-75.
63. Druce HM. Diagnosis and management of recurrent and chronic sinusitis in adults. In: Gereshwin ME, Incaudo GA, editors. *Diseases of the sinuses*. Totowa (NJ): Humana Press; 1996. p. 215-33.
64. Kennedy DW, editor. *Sinus disease, guide to first line management*. Darien (CT): Health Communications; 1994.
65. Desrosiers MY, Salas-Prato M. Treatment of chronic rhinosinusitis refractory to other treatments with topical antibiotic therapy delivered by means of a large-particle nebulizer: results of a controlled trial. *Otolaryngol Head Neck Surg* 2001;125:265-9.
66. Rebuk JW, Mellinger RC. Interruption by topical cortisone of leukocytic cycles in acute inflammation in man. *Ann N Y Acad Sci* 1953;56:715-23.
67. Kelso A, Munck A. Glucocorticoid inhibition of lymphokine secretion by alloreactive T lymphocyte clones. *J Immunol* 1984;133:784-91.
68. Schleimer RP. Glucocorticoids: their mechanism of action and use in allergic diseases. In: Middleton E, Reed CE, Ellis EF, et al, editors. *Allergy: principles and practice*. 4th ed. St Louis: CV Mosby; 1993. p. 893-925.
69. Shimura S, Sasaki T, Ikeda K, et al. Direct inhibitory action of glucocorticoids on glycoconjugate secretion from airway submucosal glands. *Am Rev Respir Dis* 1990;141:1044-9.
70. Nuutinen J, Ruoppi P, Suonpaa J. One dose beclomethasone dipropionate aerosol in the treatment of seasonal allergic rhinitis. A preliminary report. *Rhinology* 1987;25:121-7.
71. Holmberg K, Juliusson S, Balder B, et al. Fluticasone propionate aqueous nasal spray in the treatment of nasal polyposis. *Ann Allergy Asthma Immunol* 1997;78:270-6.
72. Garbe E, Leloir J, Boivin JF, Suissa S. Inhaled and nasal glucocorticoids and the risks of ocular hypertension or open-angle glaucoma. *JAMA* 1997;277:722-7.
73. Knuttson U, Stierna P, Marcus C, et al. Effects of intranasal glucocorticoids on endogenous glucocorticoid peripheral and central function. *J Endocrinol* 1995;144:301-10.
74. Bryson HM, Faulds D. Intranasal fluticasone propionate: a review of its pharmacodynamic and pharmacokinetic properties and therapeutic potential in allergic rhinitis. *Drugs* 1992;43:760-75.
75. Laan RFJM, van Riel PLCM, van de Putte LBE, et al. Low dose prednisone induces rapid reversible axial bone loss in patients with rheumatoid arthritis. *Ann Intern Med* 1993;119:963-8.
76. Marple B, Newcomer M, Schwade N, Mabry R. Natural history of allergic fungal sinusitis: a 4 to 10-year follow-up. *Otolaryngol Head Neck Surg* 2002; 127:361-6.

77. Buchman CA, Yellon RF, Bluestone CD. Alternative to endoscopic sinus surgery in management of pediatric chronic rhinosinusitis refractory to oral antimicrobial therapy. *Otolaryngol Head Neck Surg* 1999;120:219–24.
78. Barr MB, Weiss ST, Segal MR, et al. The relationship of nasal diseases to lower respiratory tract symptoms and illness in a random sample of children. *Pediatr Pulmonol* 1992;14:91–4.
79. Parsons DS, Phillips SE. Functional endoscopic surgery in children: a retrospective analysis of results. *Laryngoscope* 1993;103:899–903.
80. Wald ER. Sinusitis in children. *Pediatr Infect Dis J* 1988;7:S150–8.
81. Bothwell M, Parsons DS, Talbot A, et al. Outcome of reflux therapy on pediatric chronic sinusitis. *Otolaryngol Head Neck Surg* 1999;121:255–62.
82. Kennedy DW, Senior BA, Gannon FH, et al. Histology and histomorphometry of ethmoid bone in chronic rhinosinusitis. *Laryngoscope* 1998;108:502–7.
83. Perloff J, Gannon FH, Bolger WE, et al. Bone involvement in chronic sinusitis: an apparent pathway for the spread of infection. *Laryngoscope* 2000;110:2095–9.
84. Moriyama H, Yanagi K, Otori N, et al. Healing process of sinus mucosa after endoscopic sinus surgery. *Am J Rhinol* 1996;10:61–6.
85. Ramadan HH, Allen GC. Complications of endoscopic sinus surgery in a residency training program. *Laryngoscope* 1995;105:376–9.
86. Stammberger H, Posawetz W. Functional endoscopic sinus surgery. Concept, indications, and results of the Messerklinger technique. *Eur Arch Otorhinolaryngol* 1990;247:63–76.
87. Leonard DW, Bolger WE. Topical antibiotic therapy for recalcitrant sinusitis. *Laryngoscope* 1999;109:668–70.
88. Danielsen A, Olofsson J. Endoscopic endonasal surgery—a long-term follow-up study. *Acta Otolaryngol* 1996;116:611–9.

Osteomyelitis and Osteoradionecrosis

George M. Kushner, DMD, MD

Brian Alpert, DDS

Osteomyelitis

Osteomyelitis is defined as an inflammation of the bone marrow *with a tendency to progression*. This is what differentiates it in the jaw from the ubiquitous dentoalveolar abscess, “dry socket” and “osteitis,” seen in infected fractures. It involves adjacent cortical plates and often periosteal tissues.

In the preantibiotics era, osteomyelitis of the mandible was not uncommon. With the advent of antibiotics, it became a rare disease. In recent years antimicrobials have become less effective and there has been a re-emergence of the disease, presenting major diagnostic and therapeutic challenges for practicing surgeons. Despite modern therapy it can still remain a major source of morbidity to the patient, requiring multiple surgeries and resulting in prolonged treatment with loss of teeth and/or jawbone.

The incidence of osteomyelitis is much higher in the mandible due to the dense poorly vascularized cortical plates and the blood supply primarily from the inferior alveolar neurovascular bundle. It is much less common in the maxilla due to the excellent blood supply from multiple nutrient feeder vessels. In addition the maxillary bone is much less dense than the mandible.

Diminished host defenses, both local and systemic, can contribute significantly to the emergence and clinical course of the disease. Osteomyelitis has been associated

with multiple systemic diseases including diabetes, autoimmune states, malignancies, malnutrition, and acquired immunodeficiency syndrome.¹ The medications linked to osteomyelitis are steroids, chemotherapeutic agents, and bisphosphonates.¹⁻³ Local conditions that adversely affect the blood supply can also predispose the host to a bony infection. Radiation therapy, osteopetrosis, and bone pathology can alter the blood supply to the area and provide a potential foothold for osteomyelitis to set in (Figure 17-1).

Pathogenesis

In the maxillofacial region, osteomyelitis primarily occurs as a result of contiguous spread of odontogenic infections or as a result of trauma. Primary hematogenous osteomyelitis is rare in the maxillofacial region, generally occurring in the very young. The adult process is initiated by an inoculation of bacteria into the jawbones. This can occur with the extraction of teeth, root canal therapy, or fractures of the maxilla or mandible. This initial insult results in a bacteria-induced inflammatory process

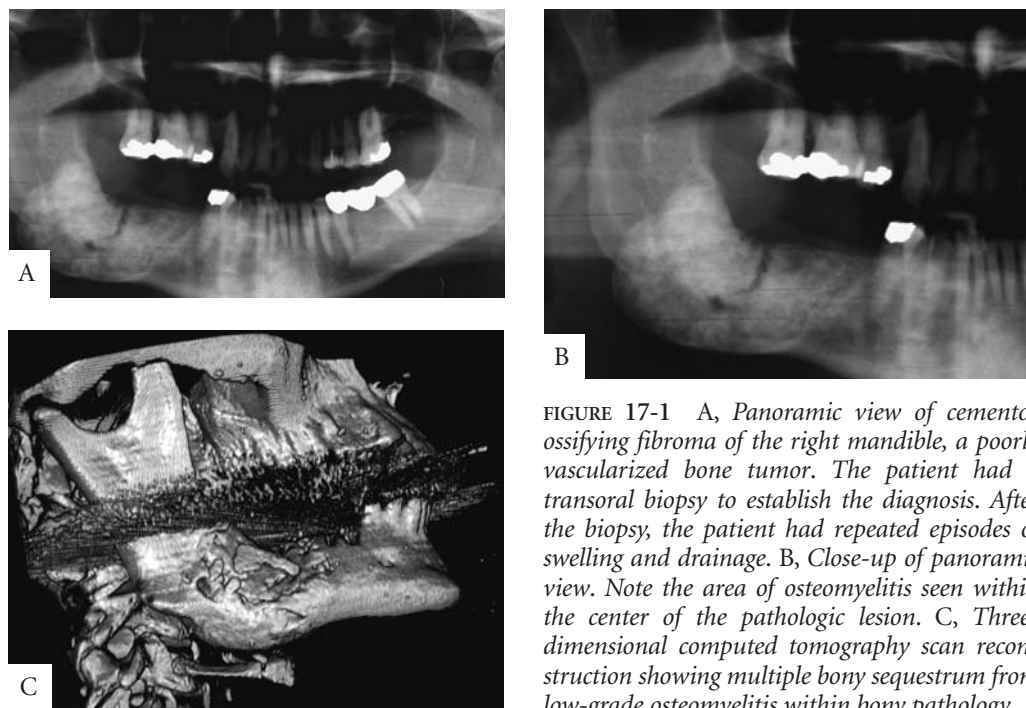


FIGURE 17-1 A, Panoramic view of cemento-ossifying fibroma of the right mandible, a poorly vascularized bone tumor. The patient had a transoral biopsy to establish the diagnosis. After the biopsy, the patient had repeated episodes of swelling and drainage. B, Close-up of panoramic view. Note the area of osteomyelitis seen within the center of the pathologic lesion. C, Three-dimensional computed tomography scan reconstruction showing multiple bony sequestrum from low-grade osteomyelitis within bony pathology.

or cascade. In the normal healthy host, this process is self-limiting and is a component of healing. Occasionally, however, in the normal host, and certainly in the compromised host, there is the potential for this process to progress to the point where it is considered pathologic. With inflammation there is hyperemia and increased blood flow to the affected area. Additional leukocytes are recruited to this area to fight off infection. Pus is formed when there is an overwhelming supply of bacteria and cellular debris that cannot be eliminated by the body's natural defense mechanisms. When the pus and subsequent inflammatory response occur in the bone marrow, an elevated intramedullary pressure is created which further decreases the blood supply to this region. The pus can travel via Haversian and Volkmann's canals to spread throughout the medullary and cortical bones. Once the pus has perforated the cortical bone and collects under the periosteum, the periosteal blood supply is compromised and this further aggravates the local condition. The end point occurs when the pus exits the soft tissues either by intraoral or extraoral fistulas.

Microbiology

More than 500 bacterial taxa have been identified in the mouth.⁴⁻⁶ The mouth and the anus are opposing ends of the same alimentary tube, and many clinicians consider them to be the most highly contaminated areas of the human body. In the past, staphylococcal species were considered the major pathogen in osteomyelitis of the jaws. However, with refinements in the collection and processing of microbiologic specimens, we are able to get a true picture of the disease-causing organisms. As with most oral infections the prime pathogenic species are streptococci and anaerobic bacteria. The anaerobes responsible are generally bacteroides or peptostreptococci species. Often, the infections are mixed, growing several pathogens on final cul-

ture. The clinician must begin empiric antibiotic treatment based on the most likely pathogens. This could include penicillin and metronidazole as dual-drug therapy or clindamycin as a single-drug treatment. Definitive antimicrobial therapy should be based on the final culture and sensitivities for optimal medical management results.

Classification

Over the years many ways of classifying osteomyelitis have been presented. A rather complex classification system was proposed by Cierny and colleagues.⁷ Osteomyelitis was classified as being either suppurative or nonsuppurative by Lew and Waldvogel.⁸ This classification was modified by Topazian.⁹ Additional authors classified osteomyelitis as being either hematogenous or secondary to a contiguous focus of infection.¹⁰ Another system proposed by Hudson essentially divided the presentation of osteomyelitis into acute and chronic forms.¹¹ With the multitude of classification systems, the controversy involved in adequately classifying osteomyelitis is clearly evident.

However, for simplicity's sake, the classification system offered by Hudson is the most advantageous to the clinician. Osteomyelitis is divided into acute or chronic forms based on the presence of the disease for a 1-month duration.¹¹

1. Acute osteomyelitis
 - a. Contiguous focus (Figure 17-2)
 - b. Progressive
 - c. Hematogenous
2. Chronic osteomyelitis
 - a. Recurrent multifocal (Figure 17-3)
 - b. Garré's (Figure 17-4)
 - c. Suppurative or nonsuppurative (Figure 17-5)
 - d. Sclerosing (Figure 17-6)

Clinical Presentation

Very often, as with any infection, the patient with osteomyelitis of the maxillo-

facial region will present with classic symptoms:

- Pain
- Swelling and erythema of overlying tissues
- Adenopathy
- Fever
- Paresthesia of the inferior alveolar nerve
- Trismus
- Malaise
- Fistulas

The pain in osteomyelitis is often described as a deep and boring pain, which is often out of proportion to the clinical picture. In acute osteomyelitis it is very common to see swelling and erythema of the overlying tissues, which are indicative of the cellulitic phase of the inflammatory process of the underlying bone. Fever often accompanies acute osteomyelitis, whereas it is relatively rare in chronic osteomyelitis. Paresthesia of the inferior alveolar nerve is a classic sign of a pressure on the inferior alveolar nerve from the inflammatory process within the medullary bone of the mandible. Trismus may be present if there is inflammatory response in the muscles of mastication of the maxillofacial region. The patient commonly has malaise or a feeling of overall illness and fatigue, which would accompany any systemic infection. Lastly both intraoral and extraoral fistulas are generally present with the chronic phase of osteomyelitis of the maxillofacial region.

Often these patients will have a laboratory work-up as part of their initial examination. In the acute phase of osteomyelitis it is common to see a leukocytosis with left shift, common in any acute infection. Leukocytosis is relatively uncommon in the chronic phases of osteomyelitis. The patient may also exhibit an elevated erythrocyte sedimentation rate (ESR) and C-reactive protein (CRP). Both the ESR and CRP are very sensitive

indicators of inflammation in the body and they are very nonspecific. Therefore, their main use is to follow the clinical progress of the osteomyelitis.

Nearly all patients will have some form of maxillofacial imaging. The orthopantomogram view is indispensable in the initial evaluation of osteomyelitis. This view is easily obtainable in most dental offices and can yield valuable information as to the radiographic changes with osteomyelitis, potential sources of the disease, and predisposing conditions such as fractures and underlying bone disease. One must bear in mind that radiographic images lag behind the clinical presentation since cortical involvement is required for any change to be evident. Therefore, it may take several weeks before the bony changes appear radiographically. Hence, it is possible to see a patient with acute osteomyelitis that has a normal-appearing orthopantomogram. However, one can often see the appearance of “moth-eaten” bone or sequestrum of bone, which is the classic appearance of osteomyelitis.

Computerized tomography (CT) scans have become the standard in evaluating maxillofacial pathology such as osteomyelitis. They provide three-dimensional imaging not available on an orthopantomogram view. The CT scan can give very detailed images as to early cortical erosion of bone in osteomyelitis. One can often see the extent of the lesion and bony sequestra along with pathologic fractures. CT scanning, like plain films, requires 30 to 50% demineralization of bone before changes can be seen, thus presenting an essential delay in diagnosis of osteomyelitis.¹²

Magnetic resonance imaging (MRI) is generally considered more valuable in the evaluation of soft tissue lesions of the maxillofacial region. However, MRI can assist in the early diagnosis of osteomyelitis by loss of the marrow signal before cortical erosion or sequestrum of

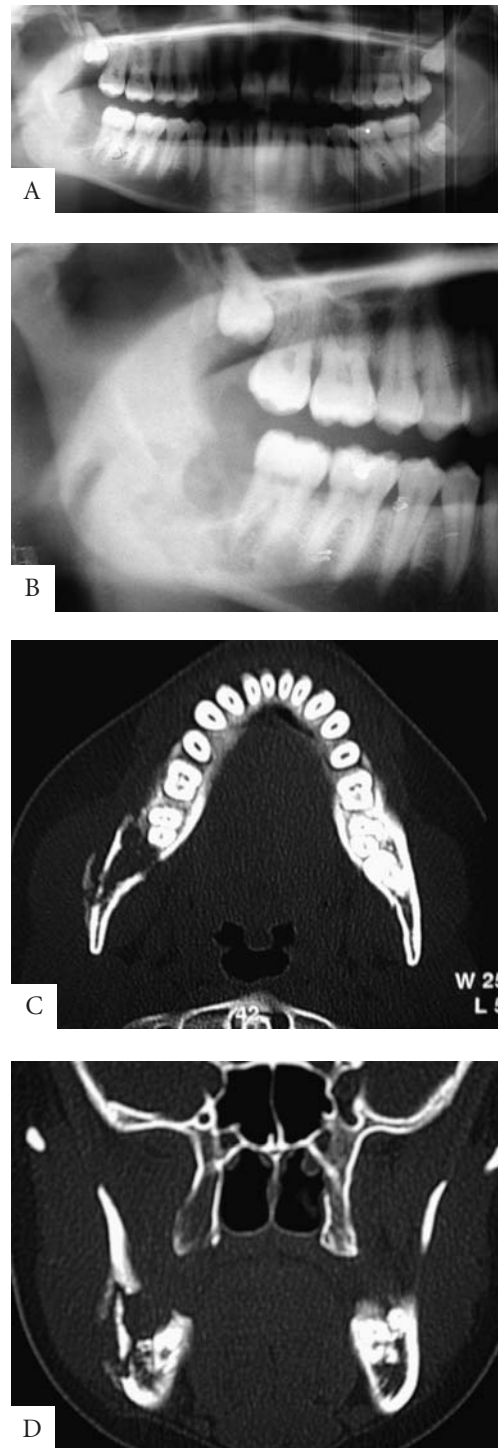
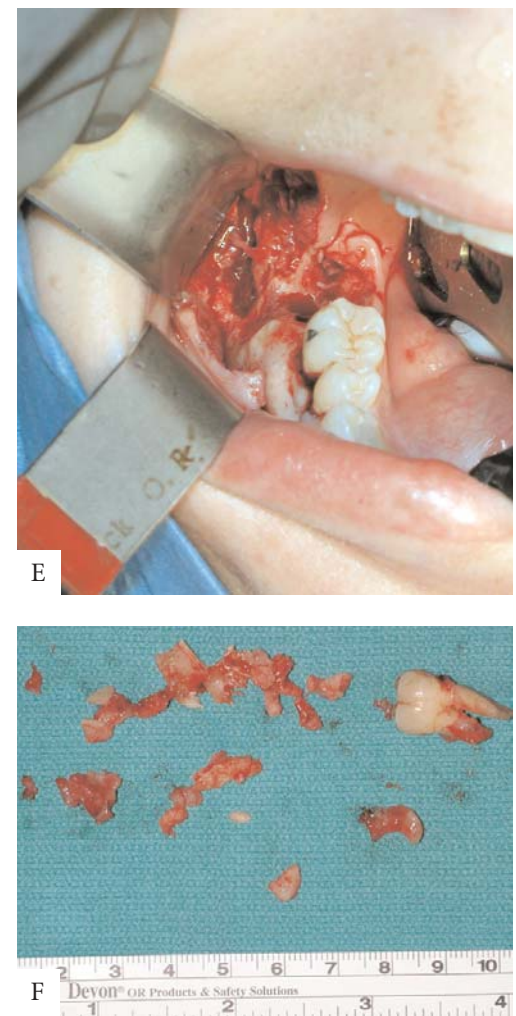


FIGURE 17-2 A, Panoramic view of extraction site of tooth no. 32 in an otherwise healthy 32-year-old patient. The patient experienced multiple episodes of pain and swelling in the right posterior mandible after tooth no. 32 was removed. B, Close-up of the panoramic view of the no. 32 site. C, Axial computed tomography scan of the no. 32 site. D, Coronal computed tomography scan of the no. 32 site. Note the moth-eaten bone and bone sequestrum. E, Transoral débridement of the right posterior mandible. F, Bone débrided and adjacent tooth no. 31 removed. Tissue was sent for culture and sensitivity and histopathology.



the bone appears. Thus, MRI may benefit in identifying the earlier stages of osteomyelitis.¹²

Nuclear medicine has evolved to aid in the diagnosis of osteomyelitis. Technetium 99 has been the workhorse of nuclear medicine imaging of the maxillofacial region. The technetium 99 bone scan is

very sensitive in highlighting areas of increased bone turnover; however, the scan is not very specific to areas of infection. With the addition of gallium 67 or indium 111 as contrast agents, one can differentiate areas of infection from trauma or postsurgical healing as these agents specifically bind to white blood cells.

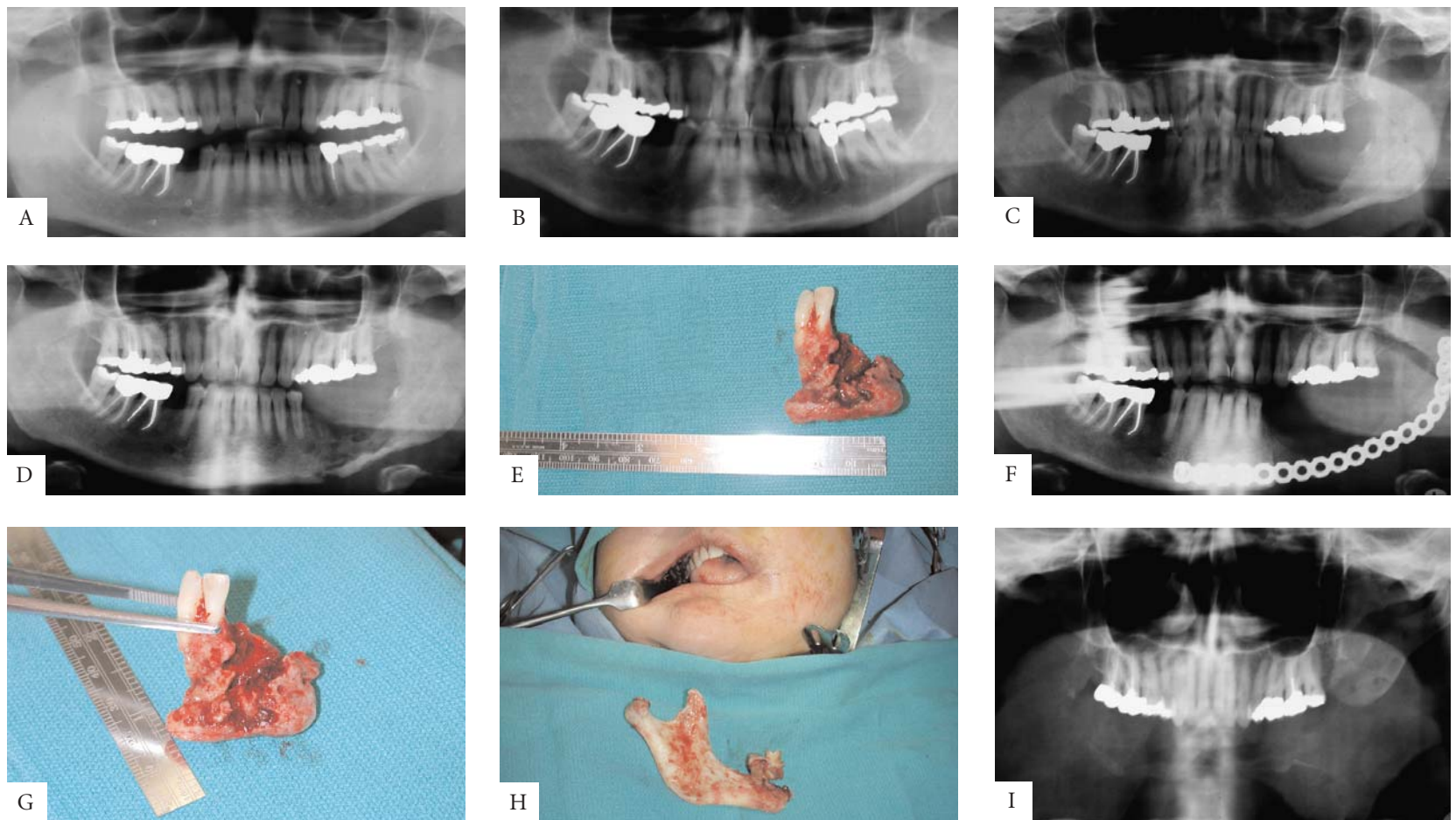


FIGURE 17-3 A, Panoramic view taken of a 55-year-old female before extraction of symptomatic tooth no. 17. The patient had a history of unusual infections and recurrent infections without a specific diagnosis. The patient began having pain and swelling in the left mandible after tooth no. 17 was extracted. B, Panoramic view of no. 17 site postoperatively. C, Panoramic view after intraoral débridements of the left mandible and extraction of teeth no. 18, 29, 20. Histopathology confirmed diagnosis of osteomyelitis. The patient was treated with antibiotics based on culture and sensitivity reports. D, Panoramic view shows radiographic worsening of disease. Note the classic appearance of moth-eaten bone and impending pathologic fracture of the left mandible. Medical work-up revealed hypogammaglobulinemia, a chronic immunocompromised state. E, Bone specimen showing osteomyelitis resected. F, Panoramic view after left mandible resection of osteomyelitis with pathologic fracture. Rigid internal fixation with a reconstruction plate allowed maintenance of space and facial form with continuous jaw function and mobility. G, The patient was asymptomatic for 2 years before having pain and swelling in the anterior mandible. Débridement revealed necrotic moth-eaten bone. H, The patient eventually required removal of the remainder of the right mandible due to uncontrollable osteomyelitis. The patient was hospitalized and received intravenous antibiotics based on multiple specific culture and sensitivity reports. She also received intravenous gamma globulin to correct hypogammaglobulinemia. Hyperbaric oxygen treatments were also used to treat refractory osteomyelitis. The patient had a prolonged in-patient hospital course with multiple surgeries. I, Panoramic view with subtotal mandibulectomy for osteomyelitis. Only the left ramus and condyle remain intact. The patient is currently on daily antibiotic immunosuppressive therapy for life, as well as monthly infusions of gamma globulin. Despite aggressive medical management by infectious disease experts, she still has bouts of recurrent pneumonia.

Treatment

The management of osteomyelitis of the maxillofacial region requires both medical and surgical interventions. In rare cases of infantile osteomyelitis, intravenous antibiotic therapy alone may eradicate the disease. Antibiotic therapy is rarely curative in later-onset cases, and the overwhelming majority of osteomyelitis cases require surgical intervention.

Clearly the first step in the treatment of osteomyelitis is diagnosing the condition correctly. The tentative diagnosis is made from clinical evaluation, radiographic evaluation, and tissue diagnosis. The clinician must be aware that malignancies can mimic the presentation of osteomyelitis and must be kept in the differential diagnosis until ruled out by tissue histopathology (Figure 17-7). Tissues from the affected site should

be sent for Gram stain, culture, sensitivity, and histopathologic evaluations. The clinical response to the treatment of any patient will be compromised unless altered host factors can be optimized. Medical evaluation and management in defining and treating any immunocompromised state is indicated and often helpful. For example, glucose control in a diabetic patient should be stabilized for best response to therapy.

Empiric antibiotic treatment should be started based on Gram stain results of the exudate or the suspected pathogens likely to be involved in the maxillofacial region. Definitive culture and sensitivity reports generally take several days or longer to be obtained but are valuable in guiding the surgeon to the best choice of antibiotics based on the patient's specific causative organisms.¹³ Infectious disease consultation may illustrate the most current antimicrobials and/or regimens.

Surgical Options

Classic treatment is sequestrectomy and saucerization. The aim is to débride the necrotic or poorly vascularized bony sequestra in the infected area and improve blood flow. Sequestrectomy involves removing infected and avascular pieces of bone—generally the cortical plates in the infected area. Saucerization involves the removal of the adjacent bony cortices and open packing to permit healing by secondary intention after the infected bone has been removed. Decortication involves removal of the dense, often chronically infected and poorly vascularized bony cortex and placement of the vascular periosteum adjacent to the medullary bone to allow increased blood flow and healing in the affected area. The key element in the above procedures is determined clinically by cutting back to good bleeding bone. Clinical judgment is crucial in these steps but can be aided by preoperative imaging that shows the bony extent of the pathology. It is often necessary to remove teeth adjacent to an area of osteomyelitis. In removing adjacent teeth and bone the clinician must be aware that these surgical procedures may weaken the jaw bone and make it susceptible to pathologic fracture (see Figure 17-6).

Supporting the weakened area with a fixation device (external fixator or reconstruction type plate) and/or placing the patient in maxillomandibular fixation is frequently used to prevent pathologic frac-

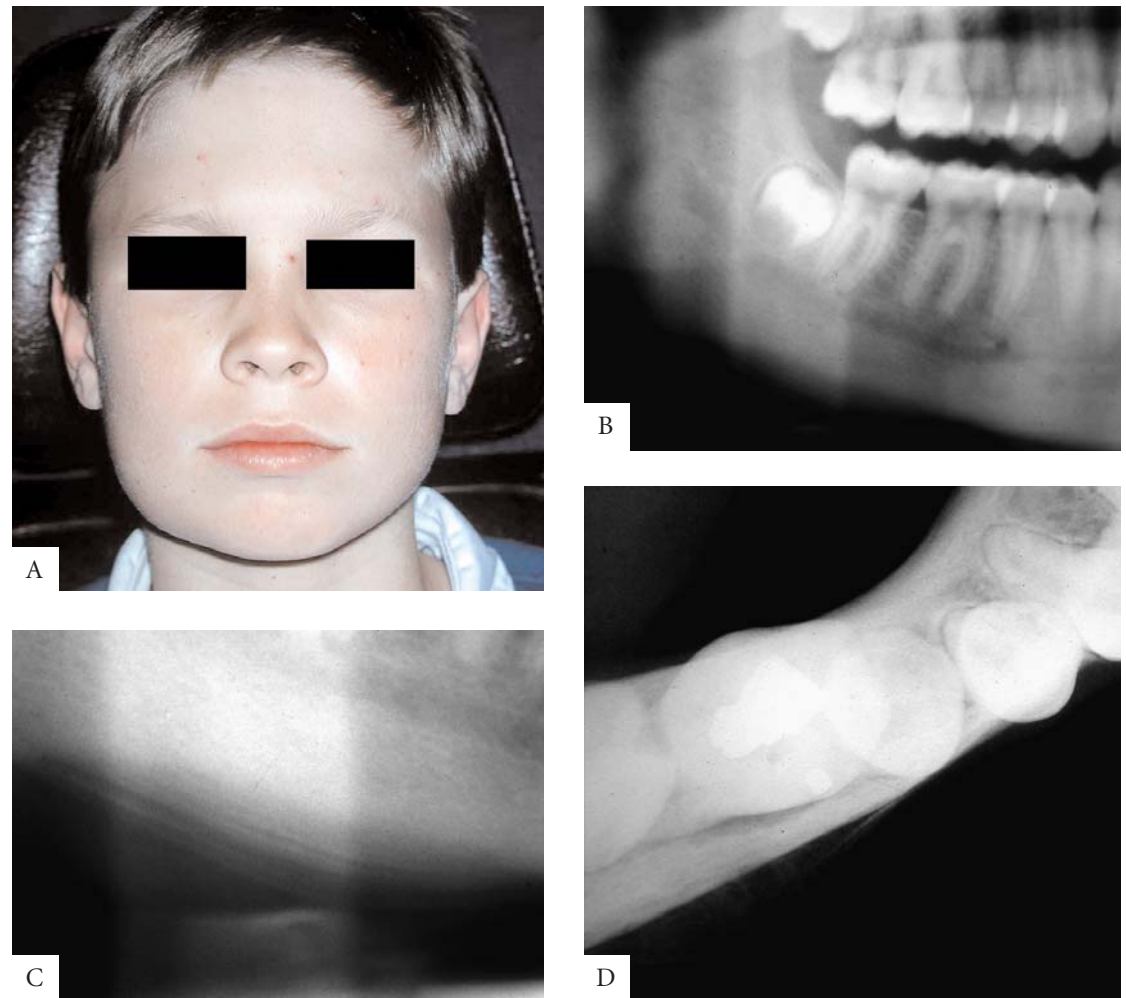


FIGURE 17-4 A, Facial view of a 13-year-old male, otherwise healthy. Note the swelling of the right mandible posterior body. B, Close-up of the panoramic view of the right mandible. Note the proliferative periostitis at the inferior border that is characteristic of Garré's osteomyelitis. C, Close-up of the right mandible inferior border with classic "onion skin" appearance. D, Occlusal view of the right mandible showing "onion skin" appearance. (Courtesy of Dr. Mark Bernstein)

ture. Indeed, we have primarily grafted such areas when the sequestrectomy and saucerization have been deemed adequate.

Some authors have proposed adjunctive treatment methods that deliver high doses of antibiotic to the area using antibiotic impregnated beads or wound irrigation systems.¹⁴⁻¹⁶ This therapy works on the premise that high local levels of antibiotics are made available and the overall systemic load is very low, thus reducing the possible side effect and complication rate.

Hyperbaric oxygen (HBO) treatment has also been advocated for the treatment of refractory osteomyelitis. This treat-

ment method works by increasing tissue oxygenation levels that would help fight off any anaerobic bacteria present in these wounds. The widespread use of HBO treatment of osteomyelitis still remains controversial.

Resection of the jaw bone has traditionally been reserved as a last-ditch effort, generally after smaller débridements have been performed or previous therapy has been unsuccessful or to remove areas involved with pathologic fracture. This resection is generally performed via an extraoral route, and reconstruction can be either immediate or delayed based on the surgeon's preference. Rigid internal fixation

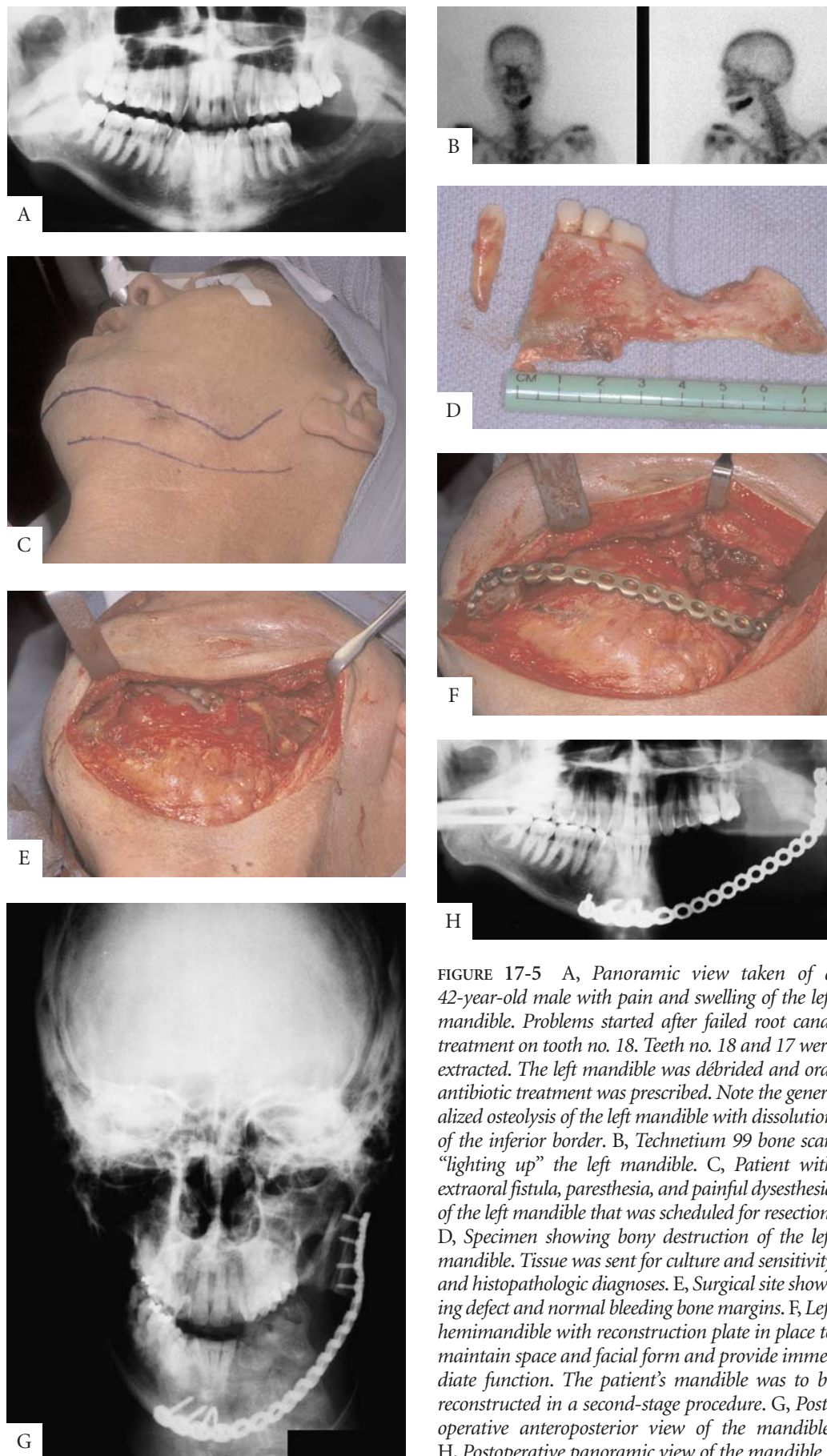


FIGURE 17-5 A, Panoramic view taken of a 42-year-old male with pain and swelling of the left mandible. Problems started after failed root canal treatment on tooth no. 18. Teeth no. 18 and 17 were extracted. The left mandible was débrided and oral antibiotic treatment was prescribed. Note the generalized osteolysis of the left mandible with dissolution of the inferior border. B, Technetium 99 bone scan “lighting up” the left mandible. C, Patient with extraoral fistula, paresthesia, and painful dysesthesia of the left mandible that was scheduled for resection. D, Specimen showing bony destruction of the left mandible. Tissue was sent for culture and sensitivity and histopathologic diagnoses. E, Surgical site showing defect and normal bleeding bone margins. F, Left hemimandible with reconstruction plate in place to maintain space and facial form and provide immediate function. The patient’s mandible was to be reconstructed in a second-stage procedure. G, Postoperative anteroposterior view of the mandible. H, Postoperative panoramic view of the mandible.

has simplified the postoperative course by providing a means for immediate function of the jaws.

We believe that early resection and reconstruction shorten the course of treatment. Once the patient develops paresthesia in mandibular osteomyelitis, resection and immediate reconstruction are indicated. At this point preservation of the mandible is highly unlikely and one should attempt to shorten the course of the disease and treatment (Figure 17-8).

Osteoradionecrosis

Radiation therapy is a valuable treatment modality in treating cancer of the maxillofacial region. Radiation therapy can be used alone or as adjunctive therapy in combination with surgery and chemotherapy. Radiation therapy like any treatment modality has deleterious side effects, including mucositis and xerostomia. One of the most dreaded side effects is osteoradionecrosis (ORN). Historically, ORN was felt to represent a radiation-induced osteomyelitis. However, Marx has shown that osteoradionecrosis represents a chronic nonhealing wound that is hypoxic, hypocellular, and hypovascular.¹⁷ In years past, the radiation therapist used orthovoltage therapy and there was a high incidence of ORN. However, the modern radiation therapists use megavoltage, which is felt to be kinder to the bone and soft tissues. In addition, collimation and shielding of tissues in conjunction with careful dental evaluation preoperatively have greatly decreased the incidence of ORN. The effects of radiation last a lifetime and do not decrease over time.

ORN is generally caused by trauma to the radiated area, usually by dental extraction, but it can also occur spontaneously. The clinical picture of ORN is most commonly seen with pain and exposed bone in the maxillofacial region (Figures 17-9 and 17-10). ORN is more common in the mandible than in the maxilla for reasons described earlier in this chapter. A dosage of

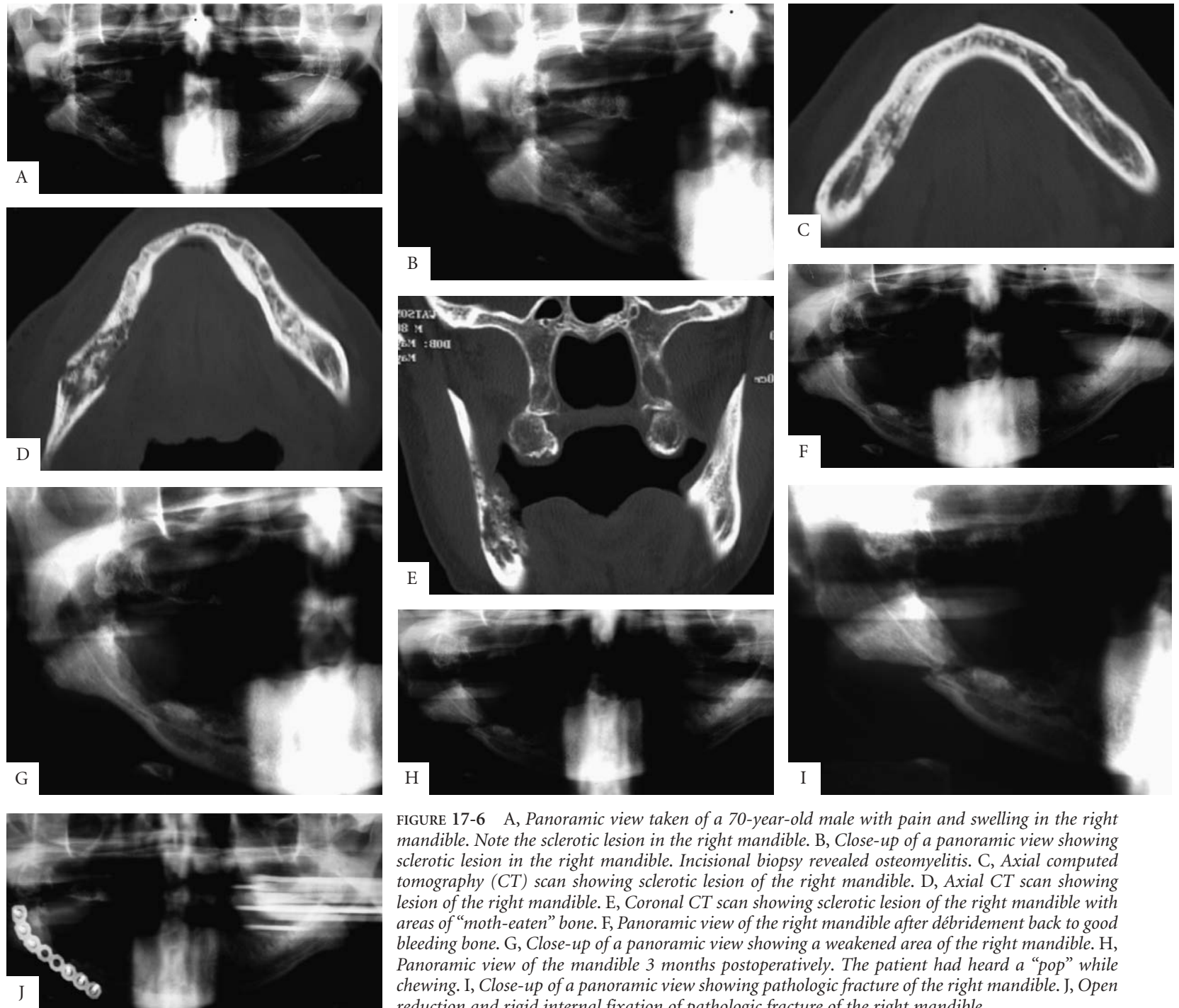


FIGURE 17-6 A, Panoramic view taken of a 70-year-old male with pain and swelling in the right mandible. Note the sclerotic lesion in the right mandible. B, Close-up of a panoramic view showing sclerotic lesion in the right mandible. Incisional biopsy revealed osteomyelitis. C, Axial computed tomography (CT) scan showing sclerotic lesion of the right mandible. D, Axial CT scan showing lesion of the right mandible. E, Coronal CT scan showing sclerotic lesion of the right mandible with areas of “moth-eaten” bone. F, Panoramic view of the right mandible after débridement back to good bleeding bone. G, Close-up of a panoramic view showing a weakened area of the right mandible. H, Panoramic view of the mandible 3 months postoperatively. The patient had heard a “pop” while chewing. I, Close-up of a panoramic view showing pathologic fracture of the right mandible. J, Open reduction and rigid internal fixation of pathologic fracture of the right mandible.

radiation above 5,000 to 6,000 rads is generally felt to make the mandible susceptible to ORN. Radiographically, the appearance on the orthopantomogram or CT scan resembles conventional osteomyelitis with areas of osteolysis and bony sequestrum. Often there is an appearance of moth-eaten bone present on these films.

The treatment of ORN is aimed at removing the nonviable (necrotic) tissue and allowing the body to heal itself. The clinician must always be aware that tissue removed in a prior cancer patient should be sent to pathology to rule out occult or recurrent malignant disease that is masquerading as a bony infection. Minor

débridements of exposed bone may work in the most minor cases of ORN. Current therapy calls for augmentation of tissue healing response by the use of HBO. HBO therapy consists of 100% oxygen delivered in a pressurized manner. Tissues treated with HBO have increased levels of oxygen, which has a negative effect on bacteria and

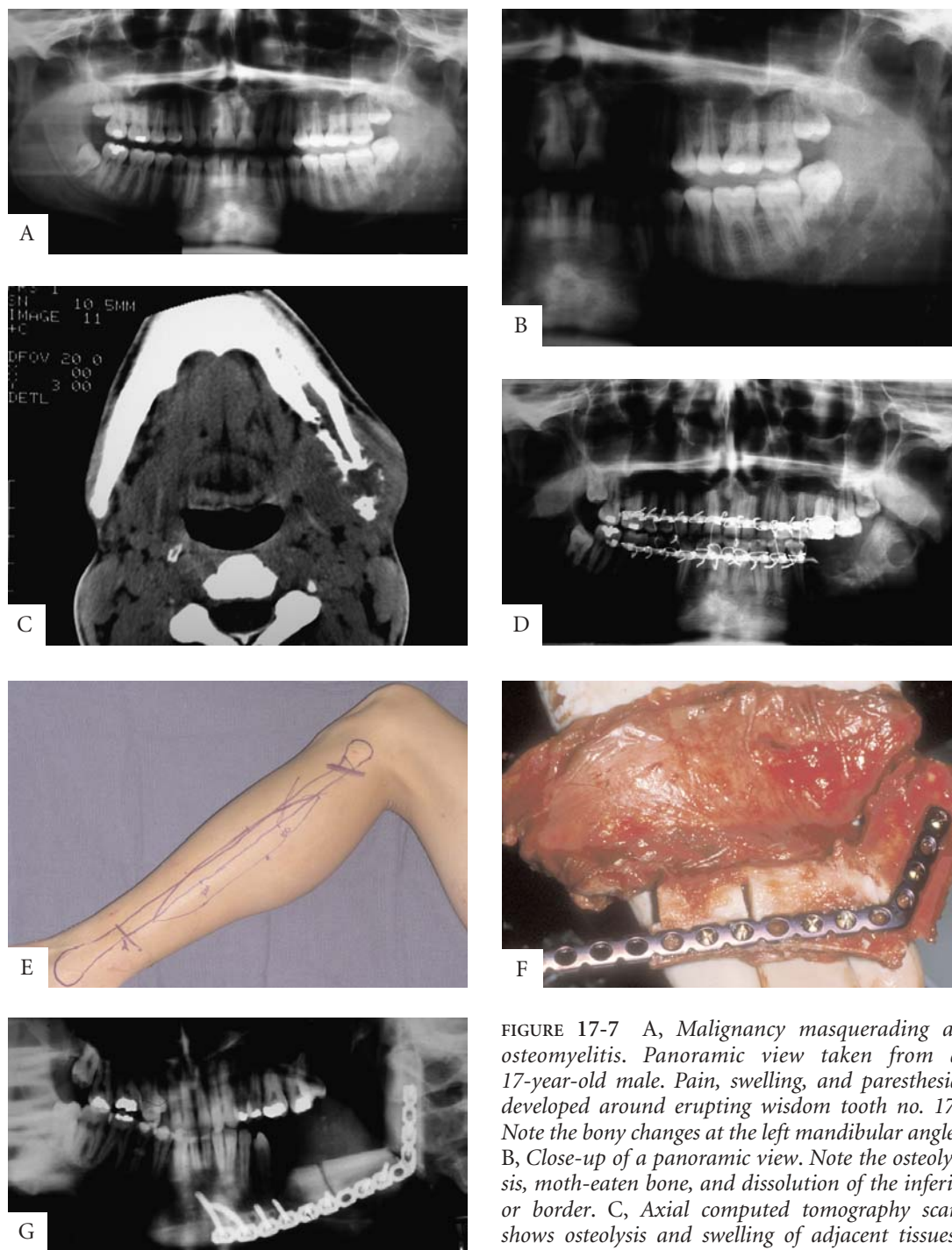


FIGURE 17-7 A, Malignancy masquerading as osteomyelitis. Panoramic view taken from a 17-year-old male. Pain, swelling, and paresthesia developed around erupting wisdom tooth no. 17. Note the bony changes at the left mandibular angle. B, Close-up of a panoramic view. Note the osteolysis, moth-eaten bone, and dissolution of the inferior border. C, Axial computed tomography scan shows osteolysis and swelling of adjacent tissues. Exploration and biopsy revealed Ewing's sarcoma. The patient underwent aggressive chemotherapy and radiation therapy. D, Panoramic view 2 years post-treatment. Pathologic fracture of the left mandibular angle with osteoradionecrosis. Biopsies revealed no recurrent malignancy. E, Fibula being prepared for free tissue transfer after resection of the left mandibular angle region. F, Fibula with osteotomies to create mandibular contour. Note the healthy soft tissue skin paddle attached. G, Panoramic view of the free fibula flap reconstruction of the left mandible.

a positive effect on angiogenesis and increased blood flow to the area. HBO has been used effectively to treat ORN and as an adjunctive treatment with maxillofacial reconstructive procedures such as dental extractions, dental implants, and jaw reconstruction in the radiated patient.

HBO treatment consists of dives or treatment sessions for 90 minutes based at 2.4 atm of pressure. Twenty to 30 dives are given preoperatively before any surgical intervention is performed. The area of ORN is then débrided and followed with 10 additional HBO treatments. Reconstruction of the maxillofacial region is based on the patient's response to the treatment protocol. HBO treatments are expensive and facilities are often scarce, available only in larger cities with medical centers or academic health science centers.

With the addition of microvascular surgery to the surgical armamentarium, there now exists an excellent surgical option in treatment of the patient with ORN. Microvascular surgery (free flaps) allows the surgeon to bring in hard and soft tissues that have their own independent blood supply. The fibula, iliac crest, scapula, and radius are all considered applicable donor sites.^{18,19} The fibula is very popular in maxillofacial reconstruction as the surgeon can bring an excellent length of bone which can be osteotomized and fabricated into a new mandible.^{20,21} There is an excellent skin paddle to provide soft tissue coverage (see Figure 17-7). The microvascular flap is plugged into the facial vessels or the carotid artery and jugular vein system for blood supply and drainage. The clinical advantage of microvascular surgery is that the surgeon does not have to rely on a compromised host bed from radiation therapy or a lack of soft tissue, which very often occur in ablative cancer surgery. In addition HBO treatments are not necessary with microvascular surgery. Lastly dental implant reconstruction has been used with free tissue transfer techniques and has

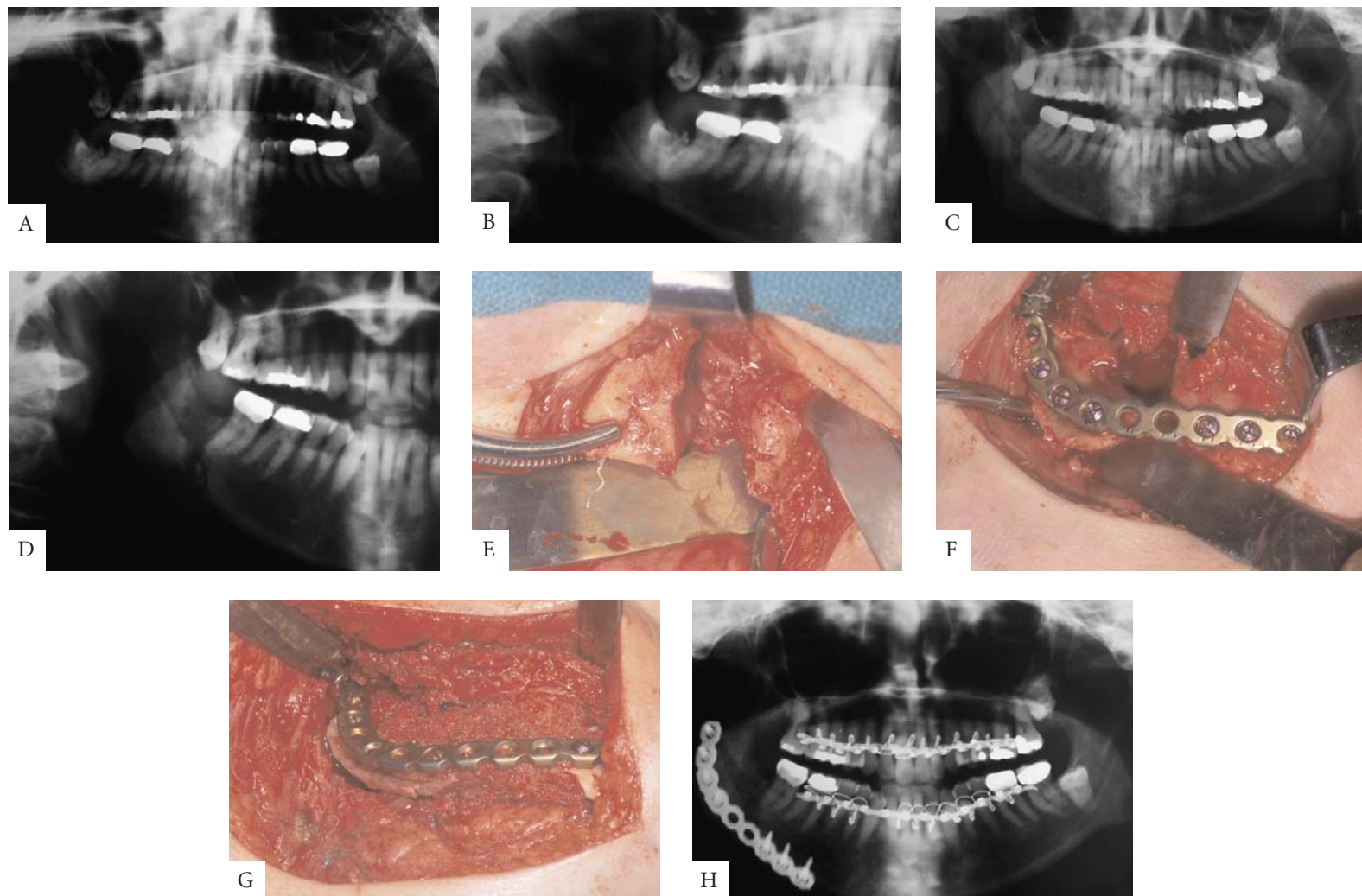


FIGURE 17-8 A, Panoramic view taken of a 64-year-old female with symptomatic tooth no. 32 scheduled for extraction. B, Close-up of a panoramic view showing decay in partially impacted tooth no. 32. C, Panoramic view of the mandible with pain, swelling, and paresthesia of the right mandible. D, Close-up of a panoramic view showing pathologic fracture with bone sequestrum at the right mandibular angle region. E, Right angle débrided via an extraoral approach. F, Rigid fixation applied to a “defect fracture.” No bony contact is present after osteomyelitis is débrided to normal bleeding time. G, The patient receives an autogenous bone graft as part of primary surgery. H, Panoramic view of débridements and reconstruction as a one-stage procedure.

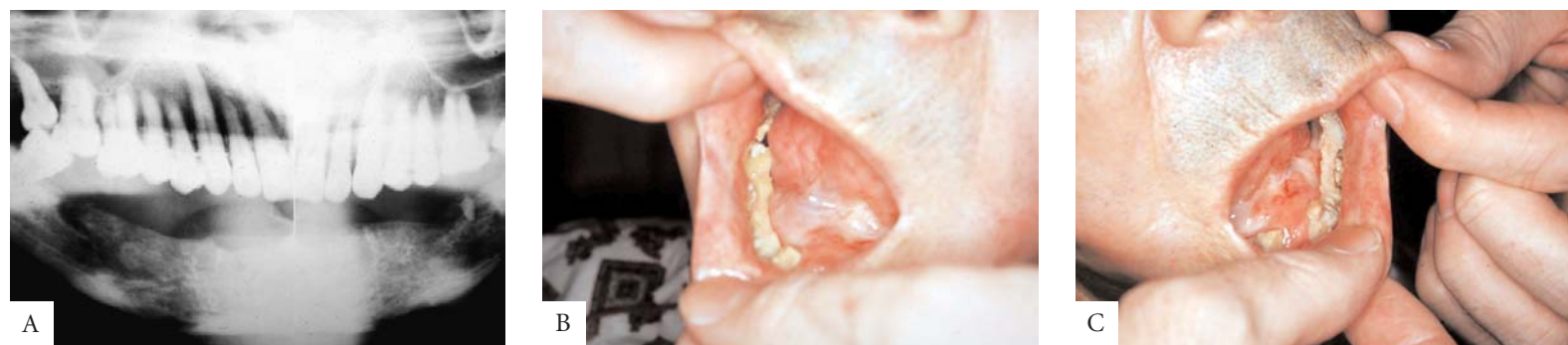

FIGURE 17-9 A, Panoramic view of the mandible post-radiation in a patient with oral squamous cell carcinoma. Note the large bony sequestrum. B and C, Intraoral views of the right and left mandible showing exposed bone. (CONTINUED ON NEXT PAGE)

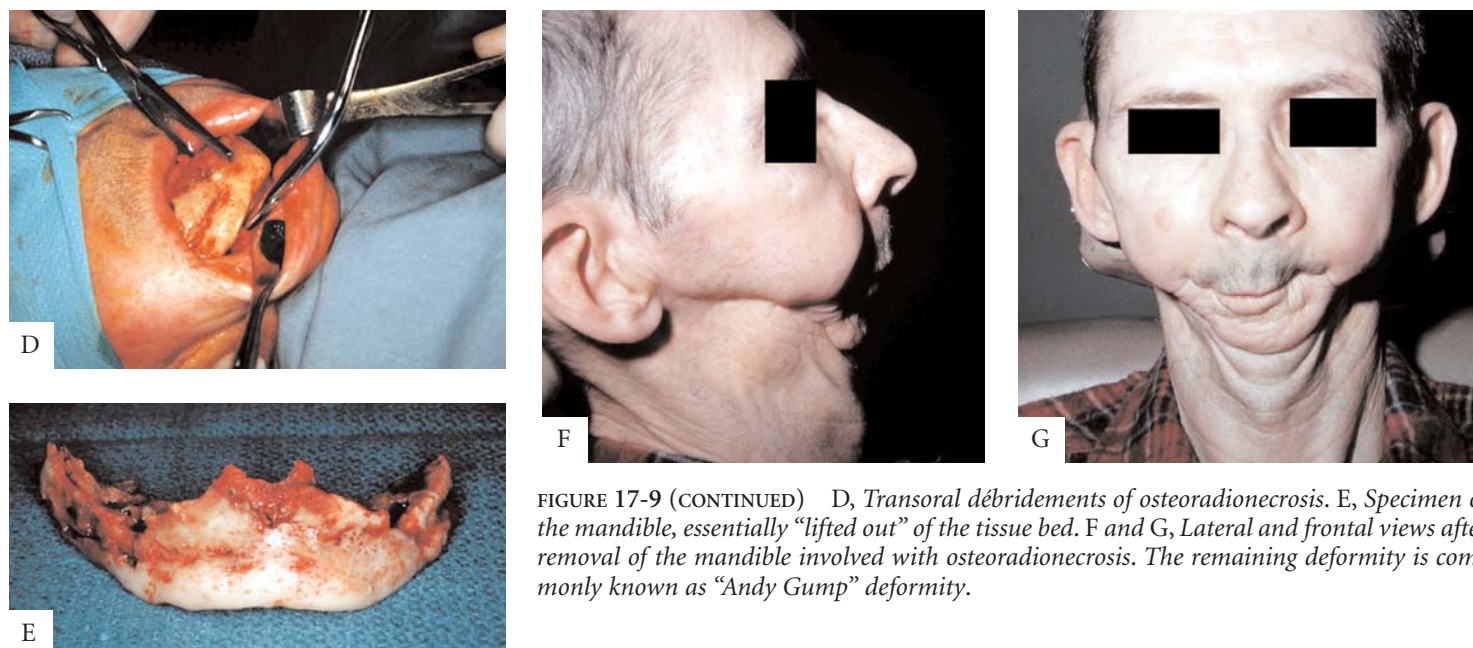


FIGURE 17-9 (CONTINUED) D, Transoral débridements of osteoradionecrosis. E, Specimen of the mandible, essentially “lifted out” of the tissue bed. F and G, Lateral and frontal views after removal of the mandible involved with osteoradionecrosis. The remaining deformity is commonly known as “Andy Gump” deformity.

proven successful in the dental reconstruction of these patients.²²

Conclusion

Osteomyelitis and osteoradionecrosis present an ongoing and potentially difficult clinical scenario to manage. Many patients will receive a combination of surgery and medical management to adequately heal from these diseases. Some patients will be required to undergo extensive and potentially disfiguring surgery to manage their disease. The medical management, including antibiotic therapy and HBO treatment, may be expensive, time consuming, and disruptive to the patient's life. Both of

these conditions can be started with something as innocuous and common as a *dental extraction*.

Clinicians must always be vigilant for post-treatment complications, including osteomyelitis and osteoradionecrosis. Despite advances in both medical management and surgical therapy, the absolute answer to the prevention and/or oral management of osteomyelitis and osteoradionecrosis has yet to be found.

References

1. Marx RE. Chronic osteomyelitis of the jaws. *Oral Maxillofac Surg Clin North Am* 1991;3:367–81.
2. Marx RE. Pamidronate and zoledronate induced avascular necrosis of the jaws. *J Oral Maxillofac Surg* 2003;61:1115–8.
3. Migliorati CA. Bisphosphonates and oral cavity avascular bone necrosis. *J Clin Oncol* 2003;21:4253–4.
4. Schuster GS. Microbiology of the orofacial region. In: Topazian G, Goldberg H, Hupp JR, editors. *Oral and maxillofacial infections*. 4th ed. Philadelphia (PA): W.B. Saunders; 2002.
5. Flynn TR. Anatomy and surgery of deep space infections of the head and neck – knowledge update. Rosemont (IL): American Association of Oral and Maxillofacial Surgeons; 1993. p. 30–42.
6. Peterson LJ. Microbiology of head and neck infections. *Oral Maxillofac Clin North Am* 1991;3:247–57.
7. Cierny G, Mader J, Pennick J. A clinical staging system for osteomyelitis. *Contemp Orthop* 1985;10:17.
8. Lew DP, Waldvogel FA. Osteomyelitis. *N Engl J Med* 1997;336:999–1007.
9. Topazian RG. Osteomyelitis of the jaws. In: Topazian G, Goldberg H, Hupp JR, editors. *Oral and maxillofacial infections*. 4th ed. Philadelphia (PA): W.B. Saunders; 2002.
10. Vighagool A, Calhoun J, Mader J, et al. Therapy of bone and joint infections. *Hosp Formul* 1993;28:66.
11. Hudson JW. Osteomyelitis and osteoradionecrosis. In: Fonseca RJ, editor. *Oral and maxillofacial surgery*. Vol 5. Philadelphia (PA): W.B. Saunders; 2000.
12. Schuknecht B, Carls F, Vulavanis, et al. Mandibular osteomyelitis: evaluation and staging in 18 patients using magnetic resonance imaging, computed tomography and conventional radiographs. *J Craniomaxillofac Surg* 1997;25:26.
13. Peterson L, Thomson R. Use of the clinical laboratory for the diagnosis and management of infectious diseases related to the oral cavity. *Infect Dis Clin North Am* 1999;13:775.
14. Alpert B, Colosi T, vonFraunhofer JA, et al. The in-vivo behavior of gentamicin PMMA beads in the maxillofacial region. *J Oral Maxillofac Surg* 1989; 47:46.
15. Chisholm B, Lew D, Sadasivan I. The use of tobramycin impregnated polymethylmethacrylate beads in the treatment of osteomyelitis of the mandible. *J Oral Maxillofac Surg* 1993;51:444.

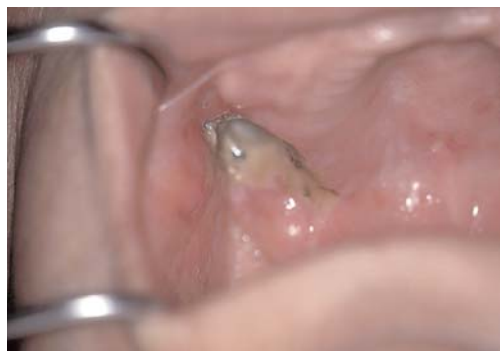

FIGURE 17-10 Rare case of maxillary osteoradionecrosis. Clinical presentation is one of exposed bone and pain.

16. Grime P, Bowerman J, Weller P. Gentamicin impregnated PMMA beds in the treatment of chronic osteomyelitis of the mandible. *Br J Oral Maxillofac Surg* 1990;28:367.
17. Marx RE. Osteoradionecrosis: a new concept of its pathophysiology. *J Oral Maxillofac Surg* 1983;41:283.
18. Disa JJ, Pusic AL, Hidalgo DA, et al. Simplifying microvascular head and neck reconstruction: a rational approach to donor site selection. *Ann Plast Surg* 2001;47:385–9.
19. Hidalgo DA, Disa JJ, Cordeiro PG, et al. A review of 716 consecutive free flaps for oncologic surgical defects: refinement in donor site selection and technique. *Plast Reconstr Surg* 1998;102:722–32.
20. Hidalgo DA, Pusic AL. Free flap mandibular reconstruction: a 10 year follow-up study. *Plast Reconstruct Surg* 2002;110: 438–9.
21. Cordeiro PG, Disa JJ, Hidalgo DA, et al. Reconstruction of the mandible with osseous free flaps: a 10 year experience with 150 consecutive patients. *Plast Reconstr Surg* 1999; 104:1314–20.
22. Disa JJ, Winters RM, Hidalgo DA. Long term evaluation of bone mass in free fibula flap mandibular reconstruction. *Am J Surg* 1997;174:503–6.

Part 4

MAXILLOFACIAL TRAUMA

Initial Management of the Trauma Patient

Michael P. Powers, DDS, MS

Michael S. Scherer, DDS, MD

The initial assessment and management of a patient's injuries must be completed in an accurate and systematic manner to quickly establish the extent of any injury to vital life-support systems. Nearly 25 to 33% of deaths caused by injury can be prevented when an organized and systematic approach is used.¹

Significant data exist to suggest that death from trauma has a trimodal distribution.² The first peak on a linear distribution of deaths is within seconds or minutes of the injury. Invariably these deaths are due to lacerations of the brain, brainstem, upper spinal cord, heart, aorta, or other large vessels. Few of these patients can be saved, although in areas with rapid transport, a few of these deaths have been avoided. The second death peak occurs within the first few hours after injury. The period following injury has been called the "golden hour" because these patients may be saved with rapid assessment and management of their injuries. Death is usually due to central nervous system (CNS) injury or hemorrhage. Recent analysis of trauma system efficacy suggests that trauma deaths could be reduced by at least 10% through organized trauma systems. These patients, whose numbers are significant, benefit most from regionalized trauma

care.³ The third death peak occurs days or weeks after the injury and is usually due to sepsis, multiple organ failure, or pulmonary embolism.⁴

Patients are assessed and treatment priorities are established based on patients' injuries and the stability of their vital signs. In any emergency involving a critical injury, logical and sequential treatment priorities must be established on the basis of overall patient assessment. Injuries can be divided into three general categories: severe, urgent, and nonurgent.² Severe injuries are immediately life threatening and interfere with vital physiologic functions; examples are compromised airway, inadequate breathing, hemorrhage, and circulatory system damage or shock. These injuries constitute approximately 5% of patient injuries but represent over 50% of injuries associated with all trauma deaths. Urgent injuries make up approximately 10 to 15% of all injuries and offer no immediate threat to life. These patients may have injuries to the abdomen, orofacial structures, chest, or extremities that require surgical intervention or repair, but their vital signs are stable. Nonurgent injuries account for approximately 80% of all injuries and are not immediately life

threatening. This group of patients eventually requires surgical or medical management, although the exact nature of the injury may not become apparent until after significant evaluation and observation. Laboratory studies, additional physical findings, radiographic examinations, and observations for several days or weeks may be required.⁵ The goal of initial emergency care is to recognize life-threatening injuries and to provide life-saving and support measures until definitive care can be initiated.

Assessment of the Severity of Injury

The primary goal of triage is to prioritize victims according to the severity and urgency of their injuries and the availability of the required care. With regional trauma centers in modern trauma systems, the goal of triage is to rapidly and accurately identify patients with life-threatening injuries and to treat those patients appropriately, while at the same time avoiding unnecessary transport of less severely injured patients (Figure 18-1).⁶⁻⁸ Over the past three decades many scales and scoring systems have been developed as tools to predict outcomes based on several criteria.

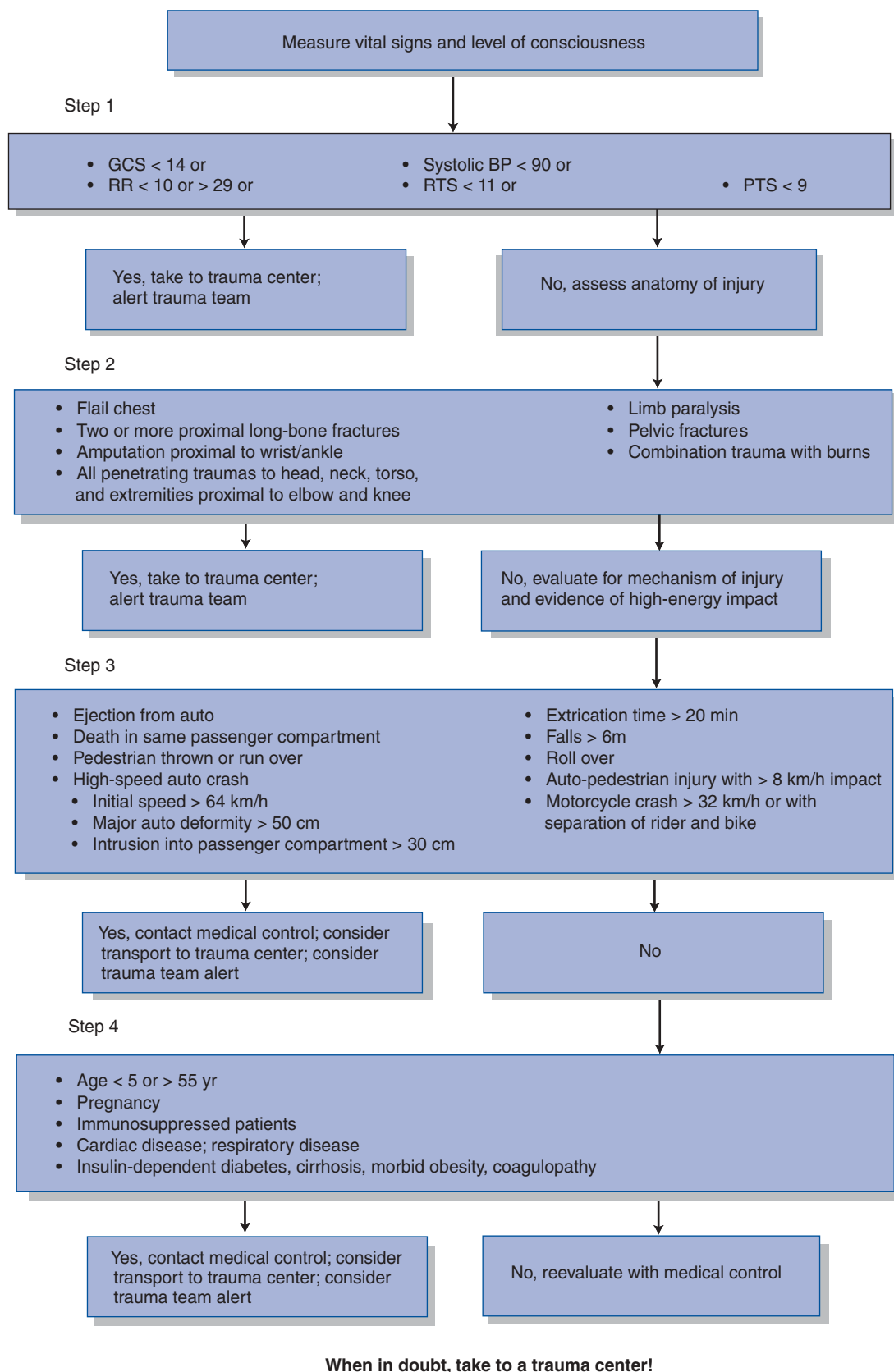


FIGURE 18-1 Triage decision scheme. BP = blood pressure; GCS = Glasgow Coma Scale; PTS = Pediatric Trauma Score; RR = respiratory rate; RTS = Revised Trauma Score. Adapted from American College of Surgeons Committee on Trauma. *Advanced trauma life support for doctors: student course manual*®. 6th ed. Chicago: American College of Surgeons; 1997.

Glasgow Coma Scale

The Glasgow Coma Scale (GCS) was developed in 1974 by Teasdale and Jennet.⁹ It was the first attempt to quantify the severity of head injury. The three variables included were best motor response, best verbal response, and eye opening (Table 18-1). Best motor response is a reflection of the level of CNS function, best verbal response shows the CNS's ability to integrate information, and eye opening is a function of brainstem activity. Scores range from 3 to 15, with a higher number representing an increased degree of consciousness. The use of the letter *T* designates that the patient was intubated at the time of the examination.

In a prospective multicenter study, patients with a head injury who had an admission GCS of 9 or less correlated with higher mortality rates, regardless of center volume, mechanism of injury, or treatment¹⁰; therefore, this system can be used to predict outcomes. The GCS has weaknesses in that it does not take into account focal or lateralizing signs, diffuse metabolic processes, or intoxication.

Trauma Score and Revised Trauma Score

The Trauma Score was developed by Champion and colleagues to quickly assess the extent of injury to vital systems and the severity of the injury to provide proper triage and treatment of the patient.¹¹ It was later modified by Champion and colleagues to become the Revised Trauma Score in 1989.¹²

The Trauma Score provided a means of characterizing the physiologic status of injured patients' cardiovascular, respiratory, and neurologic systems. The Trauma Score incorporated five variables: GCS, respiratory rate, respiratory expansion, systolic blood pressure, and capillary refill. The Revised Trauma Score omitted respiratory expansion and capillary refill owing to difficulty assessing these elements in the field and the wide margin for interpretation.

Table 18-1 Glasgow Coma Scale

Action	Score
Eye opening	
Spontaneously	4
To speech	3
To pain	2
None	1
Motor response	
Obeys	6
Localizes pain	5
Withdraws from pain	4
Flexion to pain	3
Extension to pain	2
None	1
Verbal response	
Oriented	5
Confused	4
Inappropriate	3
Incomprehensible	2
None	1

Adapted from Teasdale G and Jennett B.⁹
Patient's score determines category of neurologic impairment: 15 = normal; 13 or 14 = mild injury; 9–12 = moderate injury; 3–8 = severe injury.

With the original trauma score, the total points added to give a trauma score of 1 to 15, the higher the score, the better the prognosis. Thus, an injured patient who exhibits eye opening to painful stimulus (score 2), a verbal response that is incomprehensible (score 2) and withdrawal from a painful stimulus (score 4) would have a GCS of 8 points and would contribute 3 points to the trauma score.

The Revised Trauma Score has a coded value for each of three variables (Table 18-2). A value of 0 to 4 is assigned for each variable to give a total range of 0 to 12,

Table 18-2 Revised Trauma Score Variables

Glasgow Coma Scale	Systolic Blood Pressure (mm Hg)	Respiratory Rate	Coded Value
13–15	> 89	10–29	4
9–12	76–89	> 29	3
6–8	50–75	6–9	2
4 or 5	1–49	1–5	1
3	0	0	0

Adapted from Champion HR et al.¹²

with lower scores representing an increasing severity of injury. Trauma scores of around 8 indicate an approximate 33% probability for mortality (Table 18-3).^{13,14}

In 1989 Champion and colleagues performed the Major Trauma Outcome Study, consisting of an analysis of 33,308 trauma patients whose cases were submitted by 89 hospitals across the United States and Canada, with survival probabilities associated with admission trauma scores determined for 25,327 patients. They concluded that patients likely to benefit from prompt diagnosis and definitive care at level I trauma centers are those with an original trauma score of 12 or less.¹²

Injury Severity Score

The Injury Severity Score was developed to deal with multiple traumatic injuries. It compares death rates from blunt trauma using data that rate the severity of injury in each of the three most severely injured organ systems. Each injury is evaluated and categorized according to the injured organ system (respiratory, CNS, cardiovascular, abdominal, extremities, and skin) and graded according to the severity of the injury: 1 is minor; 2 moderate; 3 severe non-life threatening; 4 life threatening, survival probable; 5 survival not probable; 6 fatal cardiovascular, CNS, or burn injuries. The three highest scores for organ systems are then squared and added; the highest injury severity score possible is 108 ($6^2 + 6^2 + 6^2$). Mortality rates have been found to increase with greater severity of injury and age (Table 18-4).¹⁵

Table 18-3 Predicting Mortality Using the Revised Trauma Score

Trauma Score	Mortality Rate (%)
12	< 1
10	12
8	33
6	37
4	66
2	70
0	> 99

Adapted from Senkowski CK and McKenney MG.¹⁴

In addition to the field scales that measure abnormal physiologic signs for assessment of injury for triage decisions, mechanism-of-injury factors and anatomic factors are also important considerations. Mechanism-of-injury factors can provide insight to a possible significant injury that has not yet resulted in significant changes in vital signs. Those such factors that have a high correlation with life-threatening injuries include the following¹⁶:

- Evidence of a collision involving high-energy dissipation or rapid deceleration
- A fall of 6 m or more
- Evidence that the patient was in a dangerous environment when injured (eg, a burning building or icy water)
- An automobile accident in which it takes > 20 minutes to remove the patient, there is significant damage to the passenger compartment, rearward displacement of the front axle has occurred, the patient is ejected from the vehicle, a rollover occurs, or other passengers have died

Anatomic factors that correlate with mortality include penetrating trauma to the head, neck, torso, groin, or thigh; flail chest; major burns; amputations; two or more proximal long bone fractures; and paralysis. Concurrent disease or factors such as age of < 5 years or > 55 years and known cardiac or respiratory disease may sharply worsen a patient's prognosis, even in the presence of only a moderately severe injury.¹⁷

Table 18-4 Mortality Rates for Various Injury Severity Scores by Age Groups

Age (yr)	n	Mortality Rates for Scores (%)				
		15	25	35	45	55
0-49	1,540	3	8	32	61	89
50-69	316	5	21	56	68	100
70+	109	16	45	82	100	100

Adapted from Powers M.¹⁵

The American College of Surgeons Committee on Trauma Subcommittee on Advanced Trauma Life Support has developed a schematic orderly assessment of injured patients. The Advanced Trauma Life Support (ATLS) system consists of rapid primary evaluation, resuscitation of vital functions, a detailed secondary assessment, and, finally, the initiation of definitive care (see Figure 18-1).⁷

Other Scoring Systems

Many other scoring systems and tools have been created in attempts to accurately aid triage and to predict outcomes, including the Pediatric Trauma Score,¹⁸ the Trauma and Injury Severity Score,¹⁹ and A Severity Characteristic of Trauma score²⁰; recently scales using the ninth edition of International Classification of Diseases nomenclature have been implemented including an International Classification of Disease-Based Injury Severity Score.²¹

Primary Survey: ABCs

An algorithm for the initial systemic evaluation and stabilization of the multiply injured patient is presented in Figure 18-2. During the primary survey, life-threatening conditions are identified and reversed quickly. This period calls for quick and efficient evaluation of the patient's injuries and almost-simultaneous lifesaving intervention. The primary survey progresses in a logical manner based on the ABCs: *airway maintenance with cervical spine control, breathing and adequate ventilation, and circulation with control of hemorrhage.* Letters D and E have also been added: a brief

neurologic examination to establish degree of consciousness, and exposure of the patient via complete undressing to avoid injuries being missed because they are camouflaged by clothing.

Airway Maintenance with Cervical Spine Control

The highest priority in the initial assessment of the trauma patient is the establishment and maintenance of a patent airway. In the trauma patient, upper airway obstruction may be due to bleeding from oral or facial structures, aspiration of foreign materials, or regurgitation of stomach contents. Commonly, the upper airway is obstructed by the position of the tongue, especially in the unconscious patient (Figure 18-3). Initially a chin-lift or jaw-thrust procedure may position the tongue and open the airway. The chin-lift procedure is performed by placing the thumb over the incisal edges of the mandibular anterior teeth and wrapping the fingers tightly around the symphysis or the mandible. The chin is then lifted gently anteriorly and the mouth opened, if possible. This method should not hyperextend the neck.⁸ The other hand can be used to assist with access to the oral cavity, using the fingers in a sweeping motion to remove such things as debris, vomitus, blood, and dentures that may be responsible for the obstruction. A tonsillar suction tip is helpful to remove accumulations from the pharynx. Patients with facial injuries who may have basilar skull fractures or fractures of the cribriform plate may, with the routine use of a

soft suction catheter or nasogastric tube, be compromised as these tubes may inadvertently be passed into the contents of the cranial vault during attempts at a pharyngeal suction.

The jaw thrust procedure requires the placement of both hands along the ascending ramus of the mandible at the mandibular angle. The fingers are placed behind the inferior border of the angle, and the thumbs are placed over the teeth or chin. The mandible is then gently pulled forward with the fingers at the angle and rotated inferiorly with pressure from the thumbs. The elbows may be placed on the surface alongside the patient to assist with stability. The jaw-thrust procedure is the safest method of jaw manipulation in a patient with a suspected cervical injury. The jaw-thrust procedure does require two hands, and assistance must be available to clear the debris and other obstructions. After the jaw is opened, it may be possible to place a bite lock or large suction device to wedge the teeth open. An oral or nasal airway should be placed to elevate the base of the tongue and to maintain the patent airway.

With any patient sustaining injuries above the clavicle, one should assume there may be a cervical spine injury and avoid hyperextension or hyperflexion of the patient's neck during attempts to establish an airway. Excessive movement of the cervical spine can turn a fracture without neurologic damage into a fracture that causes paralysis. Maintenance of the cervical spine in the neutral position is best achieved with the use of a backboard, bindings, and purpose-built head immobilizers. The use of soft or semirigid collars allows, at best, only 50% stabilization of movement.²² Cervical spine injury should be assumed present and protected against until the patient can be stabilized and cervical injury can be ruled out during the secondary survey.

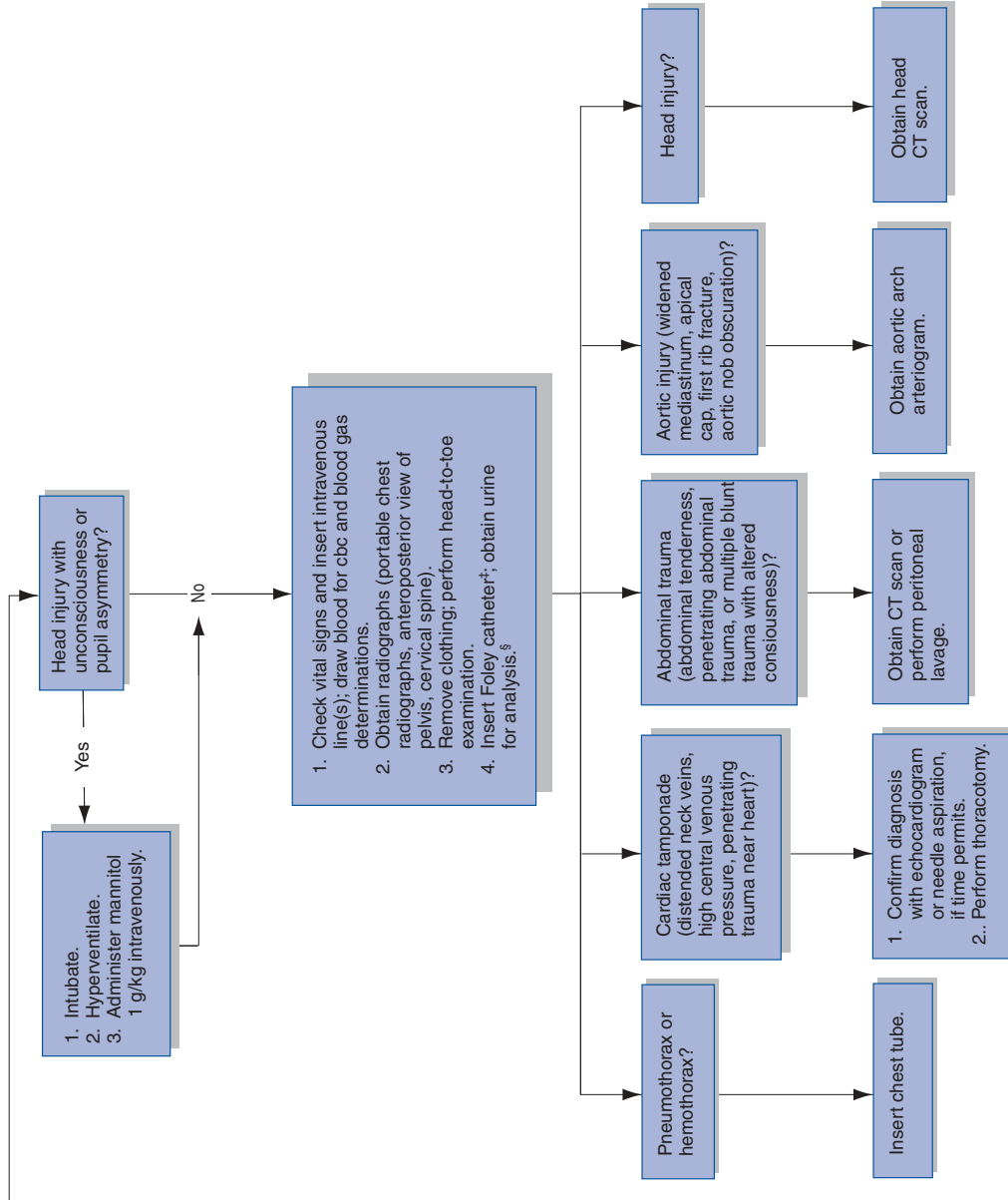
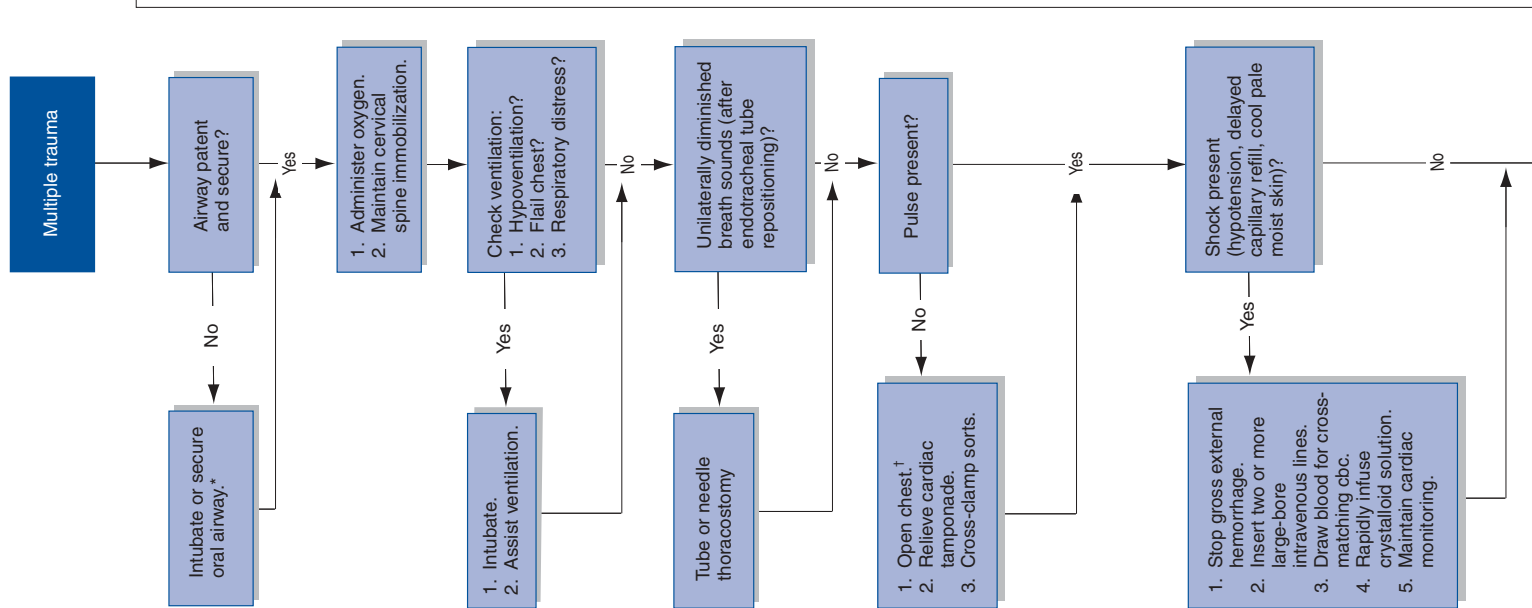


FIGURE 18-2 Multiple trauma algorithm. cbc = complete blood count; CT = computed tomography. *Maintain cervical spine precautions. Nasotracheal intubation (preferred) or orotracheal intubation with axial head traction. †Unlikely to be of benefit for blunt trauma with asystole. Perform only if experienced with the procedure and if there is adequate surgical support. ‡If not contraindicated (ie, high-riding prostate, meatal blood, scrotal hematoma). §If not contraindicated (ie, midface or cribriform plate fracture). Adapted from Trunkey DD In: Ho M, Saunders CE, editors. Current emergency diagnosis and treatment. 3rd ed. Norwalk (CT): Lange Publishing Co.; 1990.

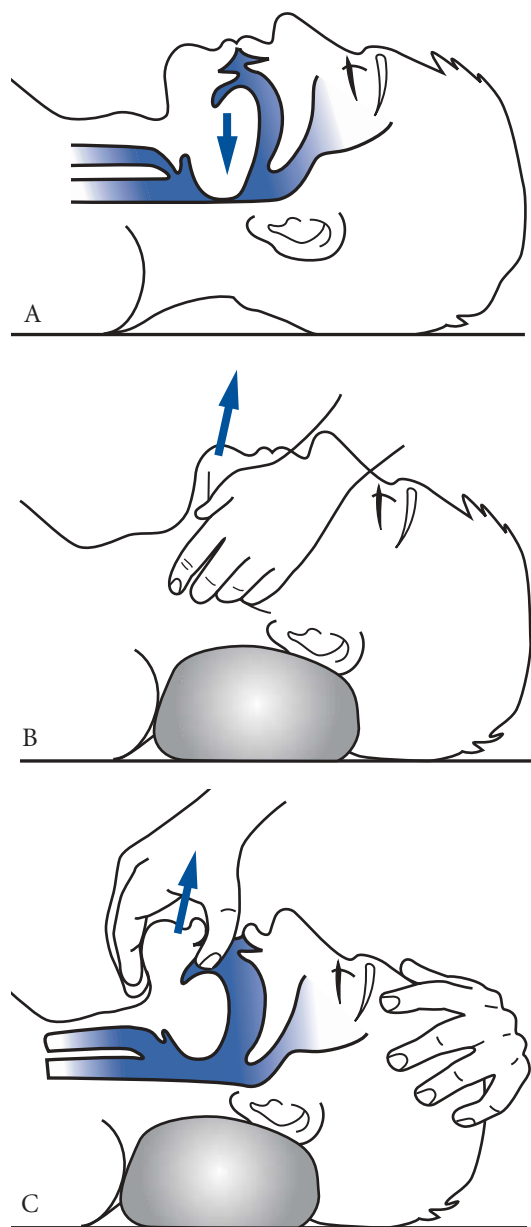


FIGURE 18-3 A, Commonly in the unconscious patient, the tongue drops posteriorly to occlude the airway. This may be especially true in the patient with mandibular fractures because the tongue loses support. A patient with a suspected maxillofacial or head trauma must have the head stabilized at all times to prevent hyperflexion of an injured cervical spine until the possibility of injury has been ruled out. B, With the cervical spine stabilized, a jaw-thrust may be used. C, A Chin-lift procedure also may be helpful to open the airway. Adapted from Powers M.¹⁵

Breathing

With establishment of an adequate airway, the pulmonary status must be evaluated. If the patient is breathing spontaneously—

confirmed by feeling and listening for air movement at the nostrils and mouth—supplemental oxygen may be delivered by face mask. The exchange of air does not guarantee adequate ventilation. The chest wall of a patient with a pneumothorax, flail chest, or hemothorax may move but not ventilate effectively. Also, shallow breaths with minimal tidal volumes do not ventilate the lungs effectively. Very slow or rapid rates of respiration usually suggest poor ventilation. The patient's status should be reevaluated constantly. If signs of adequate ventilation deteriorate, a secure airway should be placed (ideally an endotracheal tube) and assisted ventilation should be started. If the patient is not breathing after establishment of an airway, artificial ventilation should be provided with a bag-valve mask or a bag attached to an endotracheal tube. The patient who requires assisted positive pressure ventilation from an Ambu bag or ventilator must be carefully monitored if the chest status has not been completely evaluated. Changes in intrathoracic pressure may convert a simple pneumothorax into a tension pneumothorax. The chest should be exposed and inspected for obvious injuries and open wounds. There should be equal expansion of the chest wall without intercostal and supraclavicular muscle retractions during respiration. The rate of breathing should be evaluated for tachypnea or other abnormal breathing patterns. Signs of chest injury or impending hypoxia are frequently subtle and include an increased rate of breathing and a change in breathing pattern, frequently toward shallower respirations.⁷ The chest wall should also be inspected for bruising, flail chest, and bleeding, and the neck should be evaluated for evidence of tracheal deviation, subcutaneous emphysema, and distended jugular veins. The chest should be palpated for the presence of rib or sternal fractures, subcutaneous emphysema, and wounds. Auscultation of the chest may reveal a lack of breath sounds in an area,

suggestive of inadequate ventilation. Distant heart sounds and distended neck veins are suggestive of cardiac tamponade. Arterial oxygen tension (PaO_2) should be maintained between 70 and 100 mm Hg. Aside from airway obstruction, the causes of inadequate ventilation in the trauma victim result from altered chest wall mechanics. Open pneumothorax, flail chest, tension pneumothorax, and massive hemothorax are immediate life-threatening conditions and should be quickly identified and treated.

Open Pneumothorax An open pneumothorax is due to a defect in the chest wall, allowing the air to be moved in and out of the pleural cavity with each respiration (Figure 18-4). Because of the loss of chest wall integrity, equilibrium develops between intrathoracic pressure and atmospheric pressure. The involved lung collapses on inspiration and slightly expands on expiration, causing air to be sucked in and out of the wound; this is referred to as a sucking chest wound. If the opening in the chest wall is approximately two-thirds of the diameter of the trachea, air will pass through the path of least resistance—the chest wall defect. With the collapse of the involved lung and a loss of negative pleural pressure, the expired air from the normal lung passes to the involved lung instead of out of the trachea, and it returns to the normal lung on inspiration. This eventually results in a large functional dead space in the normal lung and, combined with loss of the involved lung, may develop into a severe ventilation-perfusion problem.

An open pneumothorax should be treated with coverage of the defect with a sterile occlusive dressing that is secured on three sides of the dressing to the chest. The unsecured side of the dressing acts as a one-way valve, allowing air to escape the pleural cavity on expiration. Secure taping of *all* edges of the dressing results in an accumulation of air within the thoracic

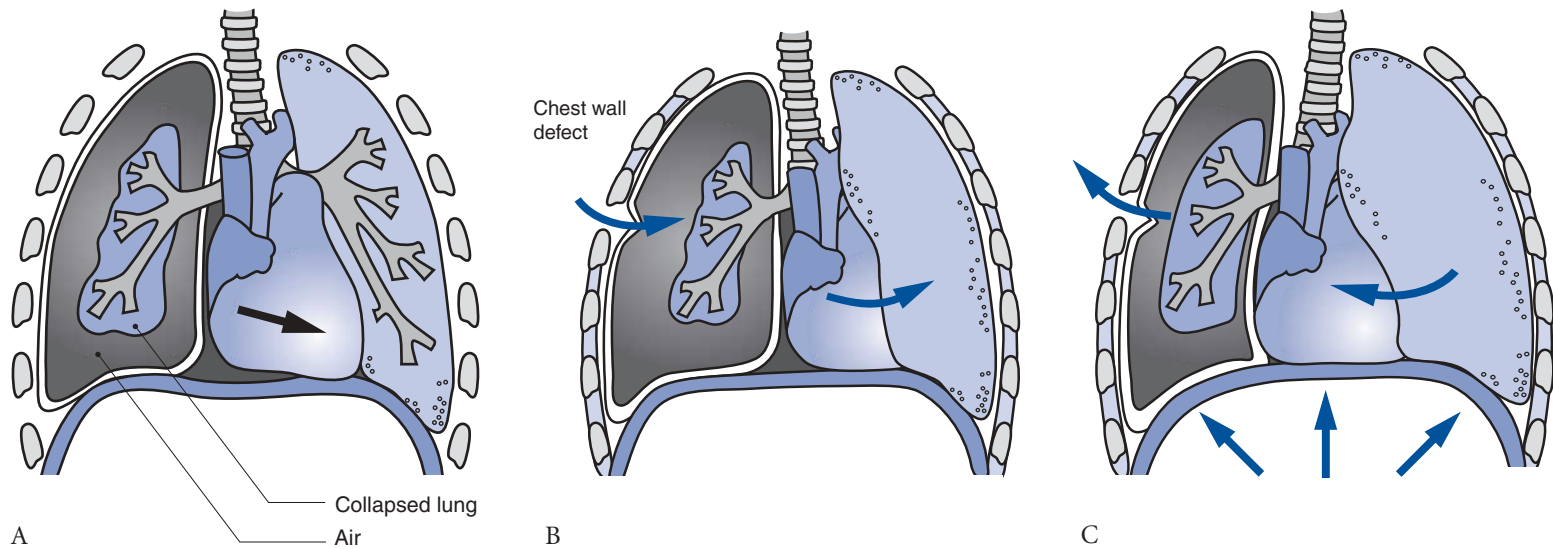


FIGURE 18-4 A, A pneumothorax develops from damage to the chest wall or laceration of the lung pleura, with a resulting loss of negative intrapleural pressure. A pneumothorax may be graded as small (15–60%) or large (> 60%). B and C, An open or communicating chest wound occurs when there is an open wound in the chest wall. Air can often be heard moving in and out of the wound during respirations; the condition may be referred to as a sucking chest wound. An open pneumothorax may be converted to a simple pneumothorax with the use of an occlusive dressing over the chest wall wound. Care must be taken not to create a trapdoor effect and cause a tension pneumothorax to develop. Adapted from Powers M.¹⁵

cavity and a subsequent tension pneumothorax. Occlusive dressings such as petrolatum gauze may be used as a temporary measure during initial examination or over large defects. A chest tube must be placed in a distant site on the affected chest wall to avoid development of a tension pneumothorax, and the wound must eventually be closed in the operating room. If the lung does not expand after closure of the defect or if signs of poor ventilation persist, the patient should be placed on a ventilator with positive end-expiratory pressure (PEEP) to expand the lung. The patient should be carefully monitored and have a chest tube in place to avoid the development of a tension pneumothorax caused by a tear in one of the bronchi or in the lung parenchyma. Signs of a tension pneumothorax in patients on ventilators include increased airway resistance and diminished tidal volume.

A closed pneumothorax may develop from blunt trauma to the chest or a lung laceration, possibly from a fractured rib. Air from the lung to the pleural space equalizes the pressures, and the lung collapses. A ventilation-perfusion deficit occurs because the blood circulated to the

affected lung is not oxygenated. With a pneumothorax, percussion of the chest shows hyperresonance. Breath sounds are usually distant or absent. Management of the pneumothorax is confirmed and evaluated with upright chest radiographs. An open pneumothorax that has a dressing placed over the chest wound becomes a closed pneumothorax.

Pneumothoraces that are traumatically induced are usually treated with a tube thoracostomy to correct any respiratory compromise. A small pneumothorax may be treated by hospitalization and careful observation if the patient is otherwise healthy, is symptom free, and does not need general anesthesia or positive pressure ventilation and if the size of the pneumothorax is not increasing as measured on serial 24-hour chest radiographs.^{23,24} This is rarely the case with the trauma victim, and a chest tube should be placed immediately in the multiply injured patient with a pneumothorax (Figure 18-5).

A moderate-sized chest tube (32–40F in adults or 26–30F in children) is generally placed either anteriorly in the second intercostal space midclavicular line or in the fourth or fifth intercostal space midax-

illary line. The midaxillary line is generally preferred for cosmetic reasons, and if the tube is positioned properly superiorly toward the apex of the lung, it can effectively remove both fluid and air.

A skin incision of approximately 3 cm in length is made one intercostal space below the intended placement of the tube. If the tube is to be placed through the fourth intercostal space, an incision is made through the skin along the fifth intercostal space. A gloved finger is used to tunnel transversely through the subcutaneous tissue to the inferior margin of the fourth rib. The intercostal muscles are separated with a large Kelly clamp, and the chest tube is inserted superiorly and posteriorly into the pleural cavity. The tube should be secured to the skin with sutures, and an occlusive dressing should be used to cover the defect around the tube. The tube is then connected to an underwater sealed drainage to remove the air or fluid. Upright posteroanterior and lateral chest radiographs should be taken to confirm the position of the chest tube, the position of the last drainage hole on the tube, and the position and amount of air or fluid remaining in the pleural cavity. Daily physical examination

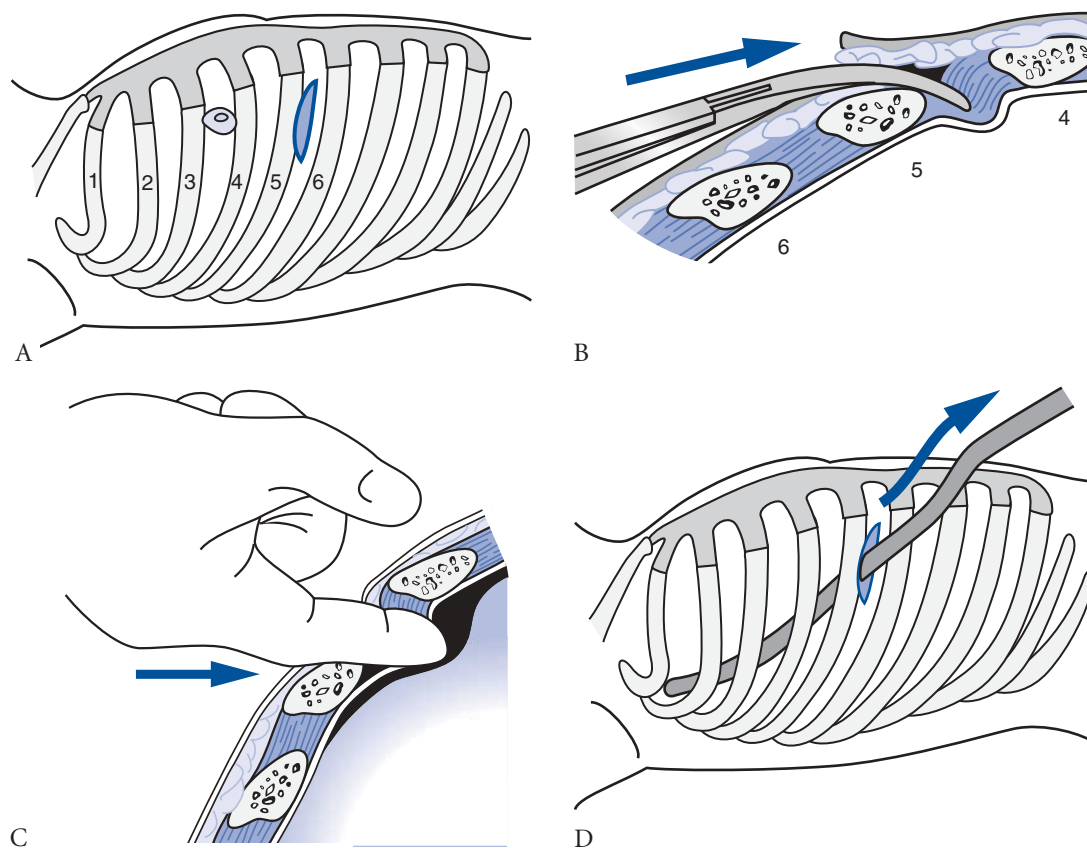


FIGURE 18-5 Chest tube placement. The patient should be supine with the arm positioned superiorly to assist with access to the midaxillary line. A, An incision is made through the skin and subcutaneous tissue along the inferior aspect of the fifth rib. B, A large Kelly clamp is used, with the tips placed inferiorly, to bluntly dissect over the fifth rib into the intercostal space between the fourth and fifth ribs. C, A gloved finger should be used to enter the pleural space to avoid possible laceration of structures, within the pleural space, such as the lung, or possible disruption of abdominal contents in case of a ruptured diaphragm. D, The chest tube is then passed along the finger, superiorly and posteriorly within the pleural cavity. The tube should be secured to the chest with sutures, covered with an occlusive dressing, and then connected to an underwater sealed drainage, which creates suction, following verification of tube position by chest radiographs. Adapted from Powers M.¹⁵

and radiographs should be performed to monitor progress of removal of air or fluid. If the tube becomes blocked and significant fluid or air remains, a new chest tube should be placed.

Tension Pneumothorax A tension pneumothorax develops when the injury acts as a one-way valve through the chest wall or from the lung into the pleural cavity without equilibration with the outside atmosphere (Figure 18-6). A dangerous progressive increase of intrapleural pressure develops as air enters the pleural cavity on inspiration but cannot escape on expiration, causing complete collapse of the

affected lung. As the pressure increases, the trachea and mediastinum are displaced to the opposite pleural cavity and impinge on the normal lung. The positive intrapleural pressure compresses the vena cava, leading to decreased cardiac output. The compression of the normal lung causes shunting of blood to nonventilated areas and severe ventilatory disturbances. These changes develop into a rapid onset of hypoxia, acidosis, and shock.²⁴

The most common causes of tension pneumothorax are mechanical ventilation with PEEP, spontaneous pneumothorax in which emphysematous bullae have failed to seal, and blunt chest trauma in

which the parenchymal lung injury has failed to seal. Occasionally, traumatic defects in the chest wall may lead to tension pneumothorax.⁷ The presence of a pneumothorax should be considered in patients who rapidly become acutely ill; develop severe respiratory distress; and exhibit decreased breath sounds, hyperresonance on one side of the chest, distended neck veins, and deviation of the trachea away from the involved side. If untreated, a tension pneumothorax results quickly in death. If a developing tension pneumothorax is suspected, the positive intrapleural pressure should be released as quickly as possible. The pressure can be released by inserting a large-bore needle (14–16 gauge) anteriorly into the affected hemithorax through the second or third intercostal space in the midclavicular line. This quickly converts the tension pneumothorax to a pneumothorax, which can be treated with placement of a chest tube (Figure 18-7).

Hemothorax Hemothorax is the collection of blood in the pleural cavity. It is commonly the result of penetrating injuries that disrupt the vasculature, but it can result from blunt trauma that tears the vasculature. The initial loss of blood collected in the pleural cavity may come from lung injuries, but because of low pulmonary arterial pressure, the blood loss is usually slowed. Massive hemothorax usually results from injuries to the aortic arch or pulmonary hilum; it may also result from injuries to the internal mammary arteries or intercostal arteries, which are branches of the aorta. A hemothorax may dangerously reduce the vital capacity of the lung and contribute to hypovolemic shock. A hemothorax is usually associated with a pneumothorax, and the subsequent blood loss causes hypotension, a decreased cardiac output, and metabolic acidosis, which, when combined with the ventilatory compromise, results in hypoxia and respiratory acidosis.

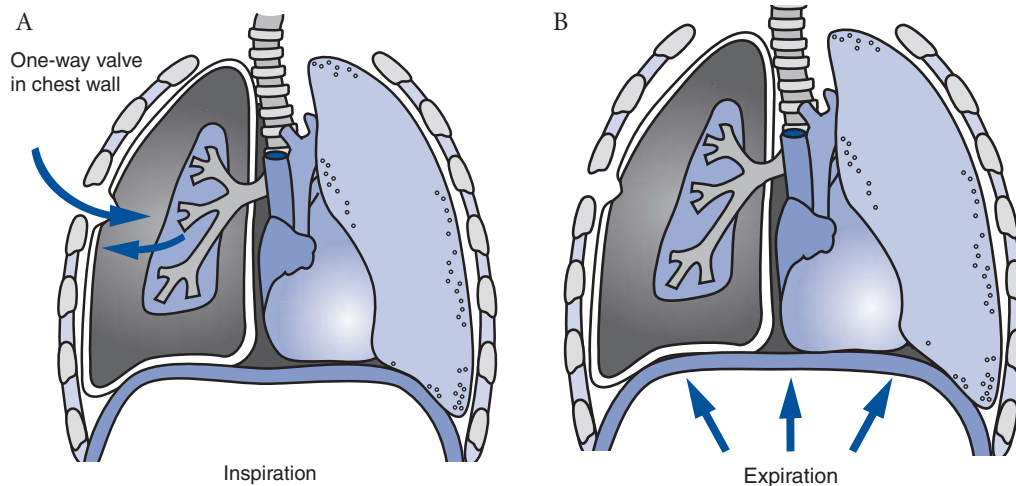


FIGURE 18-6 A tension pneumothorax develops as air enters the pleural cavity on inspiration but cannot leave during expiration (A), resulting in a progressive increase in intrapleural air pressure (B). The injury in the chest wall or trachea acts like a one-way valve, and the increasing intrapleural pressure results in a shift of the trachea and mediastinal structures away from the injury. The pressure on the vena cava does not allow for an adequate return of blood to the heart, and compression of the opposite lung (added to the injured lung) causes severe ventilatory disturbance. Adapted from Vukich DJ, Markovchick VJ. Pulmonary and chest wall injuries. In: Rosen R, editor. *Emergency medicine: concepts and clinical practice*. St. Louis: CV Mosby Co.; 1988.

A hemothorax should be suspected following penetrating or blunt chest trauma if the patient is in shock with reduced breath sounds and with a chest dull to percussion on one side. The neck veins may be flat because of severe hypovolemia or distended as a result of the mechanical effects of a chest full of blood.⁷ With the loss of a small amount of blood (< 400 mL), the diagnosis is difficult because there may be little or no change in the patient's appearance, vital signs, or physical findings. Fluid collections > 200 to 300 mL can usually be seen on a good upright chest radiograph with a blunting of the costophrenic angle. The supine radiograph is less accurate.²⁴

Treatment of a hemothorax consists of restoration of the circulating blood volume with transfusion of fluids, volume expanders, blood, or blood products through large-bore intravenous lines; control of the airway and support of the ventilation as required; and drainage of the accumulated blood from the pleural cavity. A large chest tube (36–40F) should be inserted in the fifth or sixth intercostal space in the midaxillary line and directed

posteriorly and superiorly to avoid damage to a possibly elevated diaphragm. The chest tube should be connected to an underwater seal and steady suction (20–30 cm of water). If the chest tube becomes clotted and fails to drain, another chest tube should be put in place rather than an attempt made to irrigate the first tube.

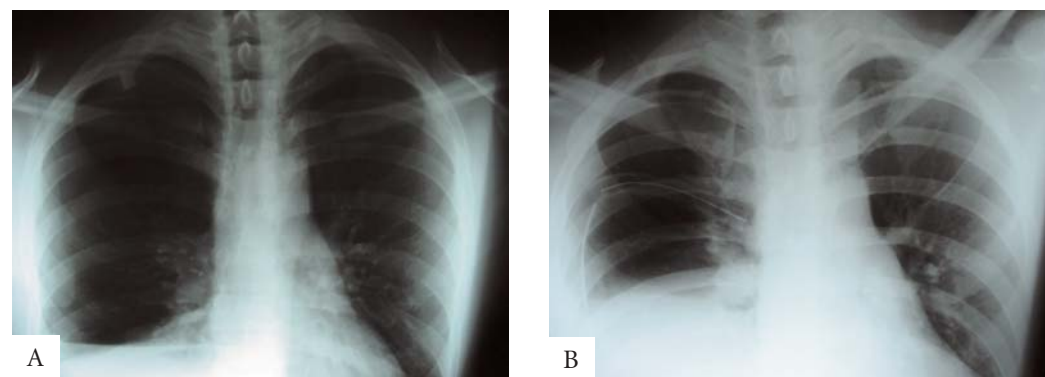


FIGURE 18-7 A, Right pneumothorax. A closed pneumothorax may develop from blunt trauma to the chest or a lung laceration, possibly from a fractured rib. Air from the lung to the pleural space equalizes the pressures, and the lung collapses. A ventilation-perfusion deficit occurs because the blood circulated to the affected lung is not oxygenated. With a pneumothorax, percussion of the chest shows hyperresonance. Breath sounds are usually distant or absent. Management of the pneumothorax is confirmed and evaluated with upright chest radiographs. B, Right pneumothorax following chest tube placement. A chest tube should be placed immediately in the multiply-injured patient with a pneumothorax. A moderate-sized chest tube (32–40° in adults or 26–30° in children) is generally placed either anteriorly in the second intercostal space midclavicular line or in the fourth or fifth intercostal space midaxillary line.

With massive bleeding, autotransfusion of the drained blood is possible until bank blood is available.²⁵

A persistent hemorrhage requires surgical exploration. Thoracotomy for intrathoracic bleeding is indicated for the following: initial thoracostomy tube drainage > 20 mL/kg of blood; persistent bleeding at a rate > 7 mL/kg/h; increasing hemothorax seen on chest radiographic studies; or the patient remaining hypotensive despite adequate blood replacement, and other sites of blood loss have been ruled out, or the patient decompensating after an initial response to resuscitation.²⁴ In a few instances, emergency thoracotomy in the emergency room may be necessary for control of blood loss. However, mortality from this procedure is very high.

Flail Chest A flail chest results when there are multiple rib fractures, usually at several sites along the rib (Figure 18-8). The resulting unstable segment of chest wall moves paradoxically during respirations—inward with inspiration and outward with expiration. A flail chest may affect respiratory ability to the point at which hypoxemia occurs. The pain associated with the

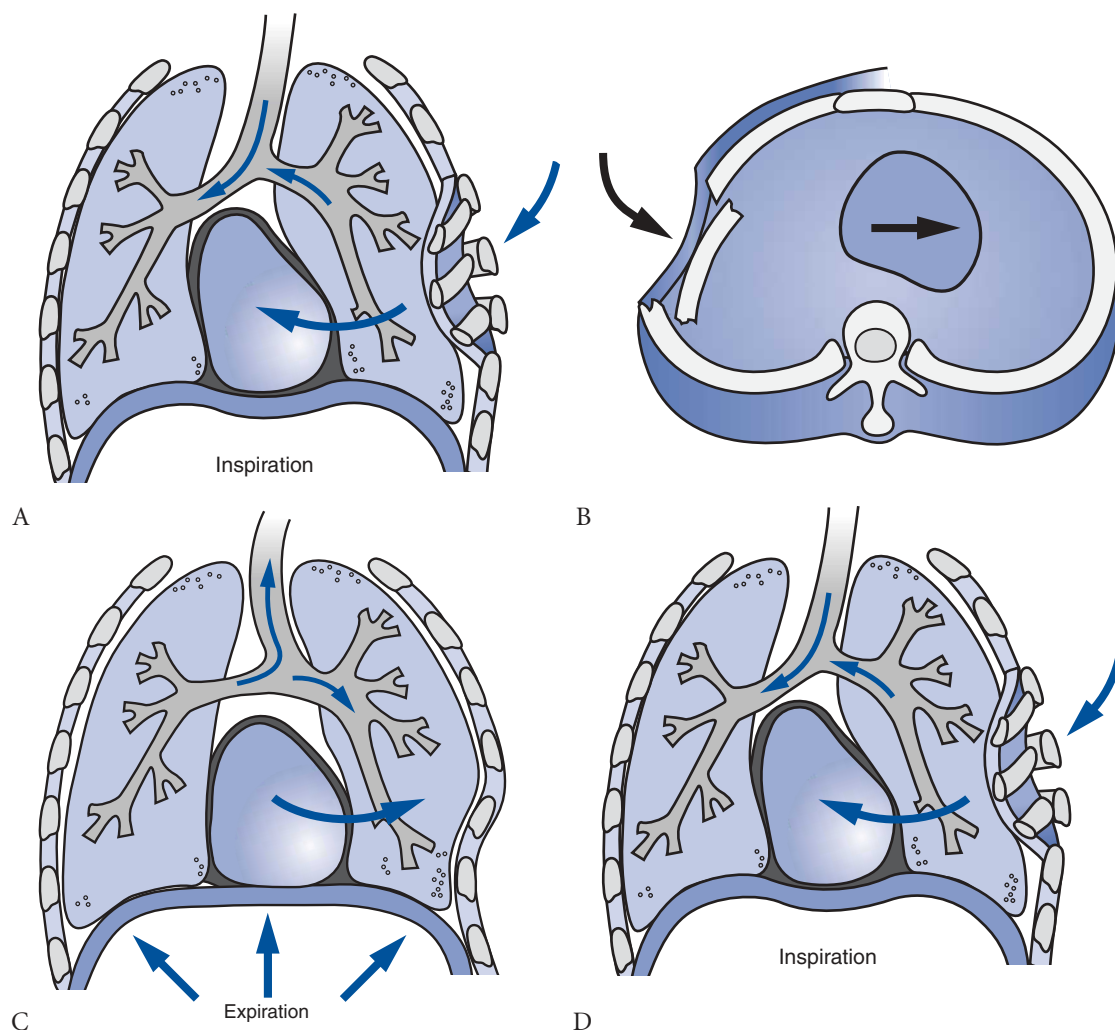


FIGURE 18-8 A flail chest occurs when three or more adjacent ribs are fractured in at least two locations, resulting in a freely moving segment of the chest wall during respirations. The chest wall moves paradoxically during inspiration and expiration owing to the flail segment. A, Upon inspiration the flail segment sinks inward as the chest wall expands, impairing the ability to produce negative intrapleural pressure. B, The heart and other contents of the mediastinum shift toward the noninjured side. C and D, During expiration the flail segment is pushed outward, and the chest wall cannot efficiently force air from the lungs. Air may shift uselessly from lung to lung. Adapted from Vukich DJ, Markovchick VJ. Pulmonary and chest wall injuries. In: Rosen P, editor. *Emergency medicine: concepts and clinical practice*. St. Louis: CV Mosby Co.; 1988. p. 477.

respiratory effort may also compromise the ventilatory compliance of the patient. The fractured ribs may have punctured the lung, causing a tension pneumothorax or hemothorax. A problem with flail chest and hypoxemia is the underlying pulmonary contusion from the injury. The contused lung may be asymptomatic in the initial presentation but develop complications later with gas exchange. Little abnormal breathing may be apparent immediately after the injury. Later, as fluid moves into the lung with the developing contusion,

lung compliance falls, and more pressure is needed to inflate the lungs. The pulmonary contusion underlying major chest wall injuries may be the primary cause of hypoxia and morbidity in patients with flail chest. Mortality in patients sustaining severe blunt chest trauma remains relatively high at 12 to 50%.²⁶

A flail chest is usually apparent on visual examination of the unconscious patient. It may not be initially apparent in the conscious patient because of splinting of the chest wall. The patient moves air

poorly as a result of paradoxical breathing, and movement of the thorax is asymmetric and uncoordinated. The region of the fractures may be tender to palpation.

Recommended management of flail chest involves three stages. The first stage is initial stabilization of the loose segment with an external splint, such as a sandbag, rolled sheet, or intravenous bag, taped over the location of the paradoxical movement to both stabilize that segment and to reduce the pain associated with its movement. Although this tends to reduce the vital capacity of the lung, it increases the efficiency of ventilation. This form of treatment can produce atelectasis if used for a prolonged period, but it is adequate for the first 30 minutes until more definitive treatment can be obtained. The next step for prolonged relief is intercostal nerve blocks to block the pain from the fractured ribs, thereby allowing the patient to breathe deeply and cough. The final step involves the use of a volume-cycled respirator with endotracheal intubation to provide PEEP and intermittent mandatory ventilation. This “internal splinting” with ventilatory support effectively manages the inadequate depth of ventilation, improves oxygen absorption in the segments of pulmonary contusion, and decreases atelectasis. If proper management with ventilatory assistance is initiated early, the respiratory support may be required for only 2 to 4 days. If management is delayed until the patient demonstrates respiratory difficulty, prolonged therapy for up to 14 days may be necessary.²⁶

Oxygenation After establishment of a patent airway and sustained breathing, the patient should be given supplemental oxygen to assist reversing of decreased tissue oxygenation during the immediate post-traumatic period. The patient will have diminished oxygen-carrying capacity as a result of injuries to the pulmonary or cardiovascular system: respiratory compromise

may be due to a head injury and disruption of cerebellar reflex systems, airway distress from maxillofacial or neck injuries, or pulmonary injuries such as pulmonary contusion, flail chest, and a tension or open pneumothorax that mechanically does not provide for proper delivery of oxygen to the cardiovascular system. Oxygen can be delivered through a nasal cannula, face mask, or endotracheal tube. A person breathing 100% oxygen can move five times more oxygen into the alveoli with each breath as when breathing normal air. Oxygen therapy can increase available oxygen by as much as 400% above normal.²⁷

Administered oxygen can increase the inspired oxygen to 8 L/min and can increase the fraction of inspired oxygen (FiO₂). A higher FiO₂ can be delivered by a Venturi mask, with the proper application of a bag and mask system. The greatest difficulty with this system is maintaining an adequate seal between the mask and face. The thumb and index finger are placed over the mask to hold the mask securely over the mouth and nose, and the other fingers are curled beneath the inferior border of the mandible. The FiO₂ can be increased in a bag and mask system with a rebreathing mask and an oxygen accumulator to deliver a high concentration of oxygen. Ventilation with the bag and mask system is difficult in patients with possible maxillofacial, cervical spine, or thoracic injuries, and the patient should be intubated if oxygen resuscitation is required.

Endotracheal intubation helps to protect the airway and facilitates adequate lung inflation with high FiO₂ in the injured patient. Oxygen administered through the endotracheal tube should increase the FiO₂ by 100% (especially if the patient is comatose) until arterial blood gas measurements confirm hemoglobin saturation (PaO₂ > 60–70 mm Hg), at which point FiO₂ can be lowered to between 40 and 60%.²⁸ Pulmonary oxygen toxicity may result if 100% oxygen is administered continuously for 24 hours;

therefore, 100% oxygen delivery is acceptable only until PaO₂ levels can be ascertained. Some concern exists about the suppression of the respiratory drive with oxygen therapy, but the hypoxic drive can be reestablished following stabilization of the injured patient.

The most important mechanism of delivery of oxygen to the tissues is the hemoglobin within the erythrocytes in the cardiovascular system. In a traumatized patient, hemorrhage may decrease the available hemoglobin to the point of hypooxygenation of vital organ tissues and cell death. A normal hemoglobin of 15 g/100 mL provides transport of 20% volume of oxygen, whereas a hemoglobin of 7 g/100 mL carries only a 10% volume of oxygen, which is the critical reserve level of oxygen consumption for most tissues, especially the myocardium and brain.²⁷ The treatment of shock in the patient with multisystem injuries is directed toward restoring cellular and organ perfusion with adequately oxygenated blood, rather than merely restoring the patient's blood pressure and pulse rate.⁸

Circulation

Following establishment of an adequate airway and breathing in the injured patient, the cardiovascular system of the patient must be assessed and control of baseline circulation to the tissues must be quickly restored. The most common cause of shock in the traumatized patient is hypovolemia caused by hemorrhage, either externally or internally into body cavities. Assessment of the degree of shock is important because inadequate tissue perfusion can cause irreversible damage to vital organs such as the brain or kidneys in a short time period. During the primary assessment a minimum of two large-bore (14–16 gauge) intravenous catheters should be placed peripherally if fluid resuscitation is required. At the time of placement of an intravenous catheter, blood should be drawn from the catheter

to allow for typing, cross-matching, and baseline hematologic and chemical studies. If there is any doubt of adequate ventilation, arterial blood should be obtained for blood gas analysis.

Tissue perfusion and oxygenation are dependent on cardiac output and are best initially evaluated by physical examination of skin perfusion, pulse rate, urinary output characteristics, and the mental status of the patient. Blood pressure levels are commonly used to measure cardiac output and to define hypovolemia, but in the emergency situation time does not permit blood pressure level measurement and the physical signs of hypovolemia are more sensitive to developing shock. The response of the blood pressure level to intravascular loss is nonlinear because compensatory mechanisms of increased cardiac rate and contractility, along with venous and arteriolar vasoconstriction, maintain the blood pressure in the young healthy adult during the first 15 to 20% of intravascular blood loss. After a blood loss of 20%, the blood pressure level may drop significantly. (In the elderly patient with less-efficient compensating mechanisms, the decline in blood pressure levels may begin to develop after a 10 to 15% blood loss.) The patient may arrest at an intravascular blood loss of 40%.²⁹

Blood pressure level may be insensitive to the early signs of shock, and a patient's blood pressure level may quickly drop following the initial assessment as the compensating mechanisms can no longer provide for the intravascular volume loss. Also, the usual baseline blood pressure level of the patient is often unknown. A patient who has a systolic pressure of 120 mm Hg but is normally hypertensive may have a significant loss, whereas a healthy young athlete may have a normal systolic pressure of 90 mm Hg and the blood loss might be assumed to be greater than it is.

Skin perfusion is the most reliable indicator of poor tissue perfusion during

the initial evaluation of the patient. The early physiologic compensation for volume loss is vasoconstriction of the vessels to the skin and muscles. The cutaneous capillary beds are one of the first areas to shut down in response to hypovolemia because of stimulus from the sympathetic nervous system and the adrenal gland through epinephrine and norepinephrine release. The release of the catecholamines causes sweating, and during palpation the skin may feel cool and damp. The lower extremities are usually first to be affected, and the first indication of intravascular loss may be paleness and coolness of the skin over the feet and kneecaps. A check of the capillary filling time by performing a blanch test gives an estimate of the amount of blood flowing to the capillary beds. In this test, pressure is placed on the fingernail, toenail, or hypothenar eminence of the hand (to evacuate blood from the capillary beds), followed by a quick release of the pressure. The time required for the blood to return to the capillary beds, represented by the restoration of normal tissue color, is usually < 2 seconds in the normovolemic patient. This indicates that the capillary beds are receiving adequate circulation.³⁰

The rate and character of the pulse is a good measure of the cardiac rate. The pulse rate is a more sensitive measure of hypovolemia than is the blood pressure, but it is affected by other factors commonly associated with the trauma situation, such as the patient's pain, excitement, and emotional response, resulting in tachycardia without underlying hypovolemia. However, in adults with tachycardia > 120 beats/min, hypovolemia should be expected and investigated further. Older patients generally are unable to exceed rates of 140 beats/min in a hypovolemic state, whereas younger patients may present rates of 160 to 180 beats/min with severe intravascular loss. In patients who have pacemakers, are taking heart-blocking medications such as propranolol or digoxin, or have conduction

abnormalities within the heart, hypovolemic status may not be represented by increased pulse rates.

The location of the pulse may give some indication of the cardiac output. Generally, if the radial pulse is palpable, the patient's systolic blood pressure is > 80 mm Hg; if the femoral pulse is palpable, the patient's systolic blood pressure is 70 mm Hg or higher; and if the carotid pulse is noted, the systolic blood pressure is > 60 mm Hg. Pulse rhythm and regularity may also provide clues to increasing hypovolemia and cardiac hypoxia. Cardiac dysrhythmias such as premature ventricular contractions or arterial fibrillations produce an irregular rate and rhythm, signaling the loss of compensating mechanisms maintaining myocardial oxygenation.

Decreased intravascular volume is immediately reflected in decreased urinary output because the compensatory mechanisms of the body decrease blood flow to the kidneys in favor of blood flow to the heart and brain. Any patient with significant trauma should always have an indwelling urinary catheter inserted to monitor urine volume every 15 minutes.²⁹ A minimally adequate urine output is 0.5 mL/kg/h, and fluid therapy should be initiated to maintain at least this level of urinary output. If the patient's injuries include pelvic fractures or blunt trauma to the groin, a urinary catheter should not be placed until a urethrogram can be evaluated for urethral injury. If urethral injury is unlikely, the urinary catheter may be placed with minimal concern. Classic signs of urethral injury include blood at the meatus, scrotal hematoma, or a high-riding boggy prostate on rectal examination.

Alterations in the mental status of the trauma patient caused solely by hypovolemia are uncommon, except in the most progressive preterminal stages of intravascular fluid loss. Compensatory mechanisms maintain blood flow to the brain, and hypoperfusion to the brain does not develop until the systolic blood

pressure falls below 60 mm Hg. The mental changes usually seen are agitation, confusion, uncooperativeness, anxiety, and irrationality. These alterations in mental status can also be seen in a patient with head trauma, spinal injury, drug or alcohol intoxication, hypoxia, or hypoglycemia. In the emergency situation these other causes of mental status changes should be investigated when hypovolemia is suspected in the agitated patient who has or possibly has suffered substantial blood loss.²⁹

Hypovolemia caused by hemorrhage may commonly cause flat neck veins. Distended neck veins, however, suggest either tension pneumothorax or cardiac dysfunction. As discussed earlier, with tension pneumothorax an examination of the chest may reveal absent breath sounds and a hyperresonant chest. Cardiac dysfunction results from cardiac tamponade, myocardial contusion or infarction, or an air embolus.

Cardiac tamponade presents a clinical picture that is similar to that of tension pneumothorax—distended neck veins, decreased cardiac output, and hypotension. Blunt or penetrating trauma may cause blood to accumulate in the pericardial sac. The blood in the pericardial sac results in inadequate cardiac filling during diastole, diminished cardiac output, and circulatory failure. Cardiac tamponade usually is associated with penetrating wounds to the chest that have injured the tissues of the heart. The classic Beck's triad of decreased systolic blood pressure levels, distended neck veins, and muffled heart sounds may be observed. The expected distended neck veins caused by increased central venous pressure may be absent because of hypovolemia. The neck veins, if distended, may become distended further during inspiration (Kussmaul's sign), and the pulsus paradoxus (lowering of the systolic pressure by > 10 mm Hg on normal inspiration) may be accentuated or absent. Tension pneumothorax may mimic cardiac tamponade or, because of the nature of the

penetrating injury, may develop at the same time as cardiac tamponade, thus presenting a confusing clinical presentation.

Cardiac tamponade is initially managed by prompt pericardial aspiration through the subxiphoid route (Figure 18-9). Because radiographs and physical examination are not helpful, a positive pericardial aspiration along with a history of chest trauma is frequently the only method of making a correct diagnosis. Because of the self-sealing qualities of the myocardium, aspiration of pericardial blood alone may temporarily relieve symptoms. All trauma patients with a positive pericardial aspiration require open thoracotomy and inspection of the heart. Pericardial aspiration may not be diagnostic or therapeutic if the blood in the pericardial sac has clotted, as occurs in 10% of patients with cardiac tamponade.²⁹ If aspiration does not lead to diagnosis or improvement of the patient's condition, only emergent thoracotomy can solve the problem.

Pericardial aspiration through the subxiphoid route involves the insertion of a needle, preferably covered by a plastic catheter (angiocatheter), at 90° slightly to the left of the xiphoid process. The needle is inserted until it clears the sternal border and is then directed at 45° toward the left scapula to directly enter the pericardium. Suction is placed on the needle hub to identify by blood return when the needle has entered the pericardial sac. If the needle is properly placed, as little as 50 cc of blood from the pericardial sac should result in a marked improvement in the patient's condition.

Control of Bleeding Hemorrhage is defined as an acute loss of circulating blood. Normally the blood volume is approximately 7% of the adult ideal body weight. A 70 kg male has approximately 5 L of circulating blood. The blood volume does not increase significantly in obese patients, and in children the blood volume is usually between 8 and 9% of body weight (80–90 mL/kg).⁷

Bleeding may be external or internal into body cavities. Most external hemorrhage can be controlled with direct pressure to the wound. If an extremity is involved, it should be elevated. Firm pressure should be continuous, and if the dressings become soaked they should not be removed but, rather, covered with additional dressings. Removal of a dressing may disrupt clot formation and promote further bleeding. Firm pressure on the major artery in the axilla, antecubital space, wrist, groin, popliteal space, or ankle may assist in control of hemorrhage distal to the site. Pressure points should only be used if direct wound pressure is not effective alone. Pressure bandages include the use of air-pillow splints and blood pressure cuffs. Pneumatic antishock garments (PASGs) and medical (military) antishock trousers (MASTs) previously used to increase blood pressure in cases of hypotension have been found to be detrimental in some situations such as instances of vascular injuries.³¹ The

PASG/MAST garments are still used by some to stabilize pelvic fractures. Scalp or skin wounds may best be managed with immediate closure with large monofilament sutures (without cosmetic closure considerations) and direct pressure until the hemorrhage is controlled.

Because of the rich blood supply to the face and neck, significant hemorrhage may be associated with large scalp wounds, nasal or midface fractures, and penetrating neck wounds. In a short period of time the scalp may lose a large amount of blood, which oozes from the galea and loose connective tissue layers. The wound can be approximated rapidly with 2-0 nonresorbable sutures without regard to cosmetic closure. Direct pressure should then be placed over the wound to control the hemorrhage and minimize hematoma formation. After the patient has been stabilized, the sutures may be removed and a more cosmetic approach

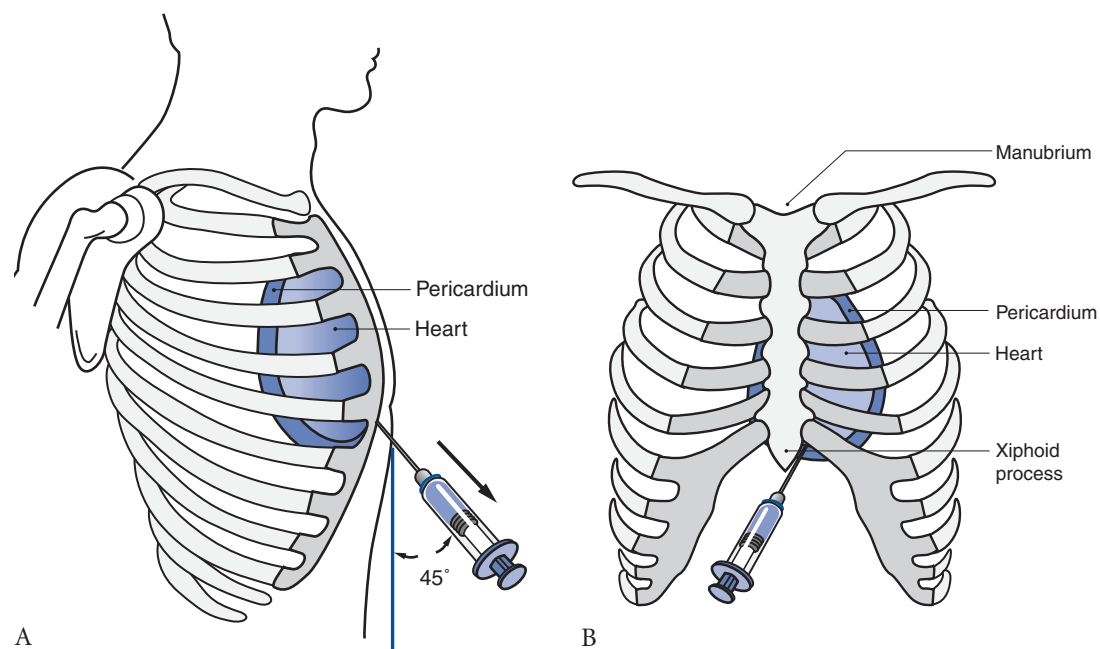


FIGURE 18-9 Pericardiocentesis can be transiently lifesaving when a significant cardiac tamponade develops. A and B, The patient is placed in a supine position, and a 16- or 18-gauge needle on a 60 cc syringe is introduced just to the left side of the xiphoid process. The needle should be introduced at a 45° angle to the chest wall, 45° off the midline and directed toward the posterior aspect of the left shoulder. A popping sensation may be felt as the pericardium is entered. If the blood within the pericardial sac is slightly clotted, it may interfere with the effectiveness of the procedure. Relief of a depressed systolic blood pressure level should be immediate, resulting from an increased stroke volume. The procedure may be required several times until definitive treatment can be initiated. Adapted from Powers M.¹⁵

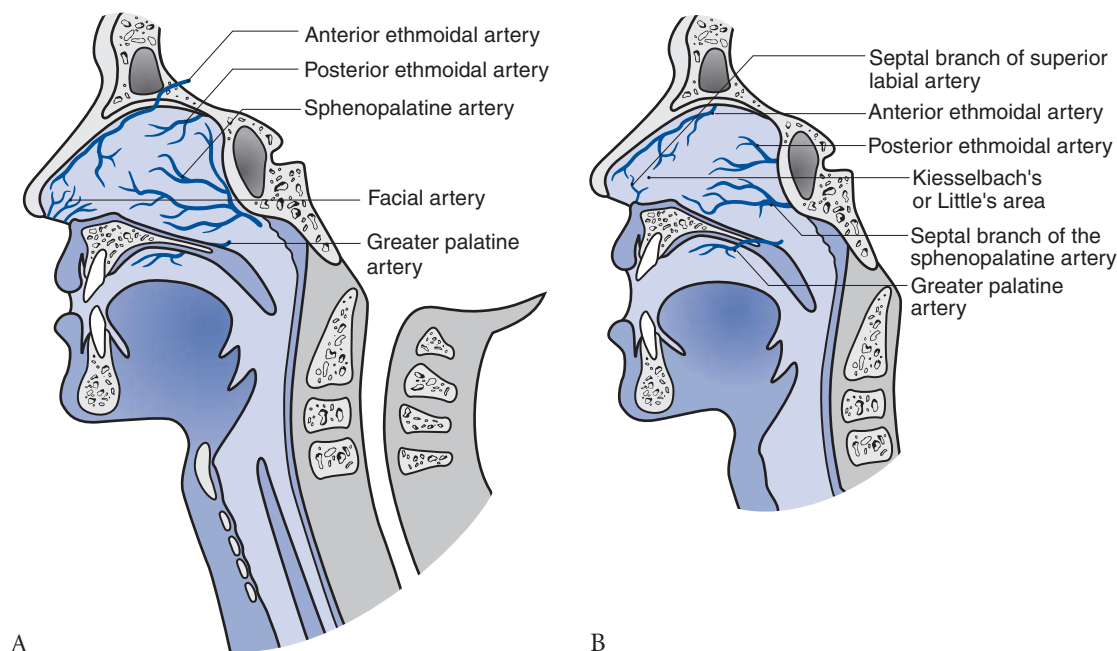


FIGURE 18-10 The lateral wall of the nasal cavity (A) and the nasal septum (B) receive a rich blood supply from both the internal and external carotid artery system. The superior aspect of these structures receives a blood supply through the internal carotid system from the anterior and posterior ethmoidal arteries. The middle and inferior aspects are supplied by vessels from the external carotid artery: the facial artery and the nasopalatine, greater palatine, and sphenopalatine arteries from the maxillary artery. The region commonly referred to as Kiesselbach's or Little's area, in the anterior inferior portion of the nasal septum, receives an abundant blood supply from all the vessels and is the region where most epistaxis originates. Adapted from Powers M.¹⁵

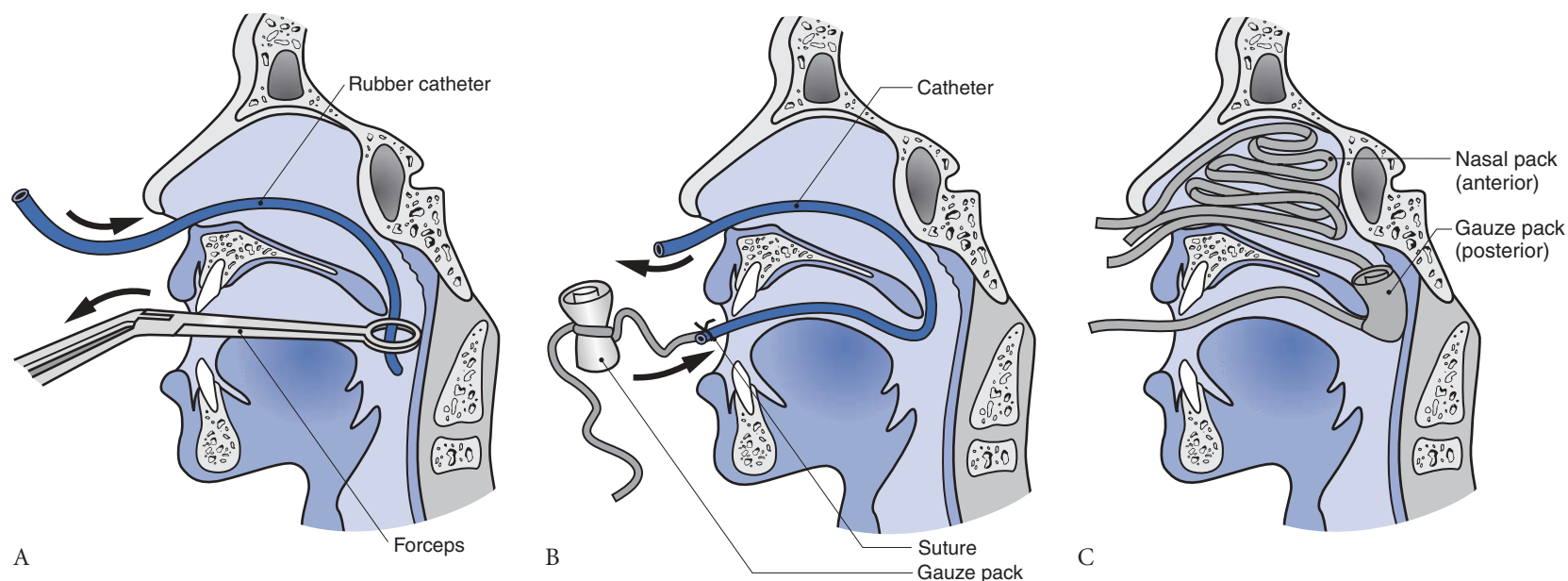


FIGURE 18-11 A combined technique used for anterior and posterior packing of the nasal cavity involves the following: A, A small red rubber catheter is introduced through the nostrils and carefully passed posteriorly along the floor of the nose until visualized in the oropharynx. Care must be taken with Le Fort II level, nasoethmoid, or other fractures involving the cribriform plate that the catheter does not pass through the fracture site into the cranial vault. Once the catheter is visualized, a forceps may be used to grasp the catheter and pull it into the oral cavity. B, The catheter is then sutured to a tape that is secured to a wad of gauze packing material. The catheter is drawn from the nasal cavity through the nostril, pulling the gauze pack into position in the nasopharynx against the posterior aspect of the nasal cavity. C, Once the posterior pack is in place, the anterior pack (consisting of 1 cm ribbon gauze) is packed in an orderly fashion along the nasal floor, building superiorly; this allows for easy removal and efficient packing of the nasal cavity. Adapted from Leigh JM. Primary care. In: Rowe NC, Williams JC, editors. Maxillofacial injuries. Edinburgh: Churchill-Livingston; 1985. p. 54–74.

with resorbable sutures may be used to close the galeal layer and to achieve good approximation and orientation of the hair-bearing dermal and skin layers.

Nasal or midface fractures may hemorrhage from tears of the ethmoidal arteries that arise from the internal carotid system or from branches of the maxillary artery system (Figure 18-10). Most hemorrhages from facial injuries can be controlled with direct pressure or packing (Figure 18-11). Internal maxillary artery bleeding from posterior maxillary wall fractures associated with Le Fort I or II level fractures usually can be controlled by pressure with gauze packing for extended periods. Liquid thrombin or epinephrine may be added to the gauze packing, and the patient's head may be elevated to assist with hemostasis. If direct control is necessary, good visualization of the damaged vessel is required. Blind clamping may cause further bleeding from vessels and soft tissues, as well as nerve damage.

Ligation of the external carotid artery may be required only in extreme cases; usually it is ineffective when used alone and without direct control of hemorrhage because of the collateral circulation of the face.

The potential internal sites of hemorrhage are the thoracic cavity, abdomen, retroperitoneum, and extremities. A complete physical examination with radiography and computed tomography (CT) is useful to identify hemorrhages into these areas (Figures 18-12 and 18-13). When there is no evidence of external or intrathoracic bleeding, continued severe hypovolemia is usually the result of bleeding into the abdomen or at fracture sites. Blood loss with fractures should be considered to be at least 1,000 to 2,000 mL for pelvic fractures, 500 to 1,000 mL for femur fractures, 250 to 500 mL for tibia or humerus fractures, and 125 to 250 mL for fractures of smaller bones. A hematoma the size of an apple usually contains at least 500 mL of blood. Control of hemorrhage into internal spaces is not done in the primary survey unless the hemorrhage may have damaging effects on the cardiovascular or pulmonary system. A slow internal hemorrhage may be controlled by secondary fixation of fractures; by the defense mechanisms of vascular

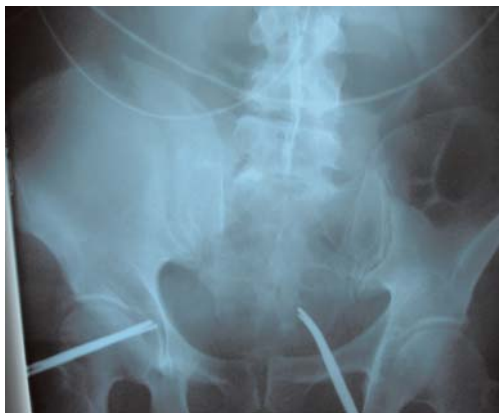

FIGURE 18-12 Pelvic fracture. Pelvic fractures, fractures of the femur, and multiple fractures of other long bones may cause hypovolemic shock and life-threatening blood loss, the primary site of which may be difficult to determine. Typical closed fractures of the pelvis may lose 1 to 5 L of blood, femur fractures 1 to 4 L, and arm fractures 0.5 to 1 L from the vasculature.

occlusion, refraction, and clot formation; or by open exploratory surgery.

Hypovolemic Shock in the Patient with Multisystem Injuries The most common cause of shock seen in the patient with multisystem injuries is hypovolemia caused by hemorrhage. Virtually all multisystemic injuries are accompanied by a degree of hypovolemic shock that presents as a graded physiologic response to hemorrhage. This response can be classified based on the percentage of acute blood loss (Table 18-5).

Class I Hemorrhage: Blood Loss of Up to 15% The clinical symptoms of blood loss of up to 750 mL in the 70 kg adult male are minimal. A mild tachycardia is noted, but the compensatory mechanisms of the body retain normal blood pressure levels, pulse pressure, respiratory rate, and tissue perfusion.

Class II Hemorrhage: Blood Loss of 15 to 30% Blood loss of 15 to 30% represents an 800 to 1,500 mL loss in the 70 kg adult male. Clinical symptoms commonly expected with this level of blood loss are tachycardia, tachypnea, and a decrease in the difference between systolic and diastolic blood pressure or pulse pressure. The decrease in pulse pressure level is due to the elevation of catecholamines and increased peripheral vascular resistance in response to the decreased intravascular components. The increase in diastolic pressure suggests hypovolemia because there is no noticeable increase in the systolic pressure in the early stages of blood loss. The peripheral vasoconstriction may show an elongated capillary refill time, and the skin may feel cold and moist.

Class III Hemorrhage: Blood Loss of 30 to 40% In the 70 kg adult male, a 30 to 40% blood volume loss represents a 1,500 to 2,000 mL loss, which is fairly detrimental to the survival of vital organ tissues. Patients present with the classic

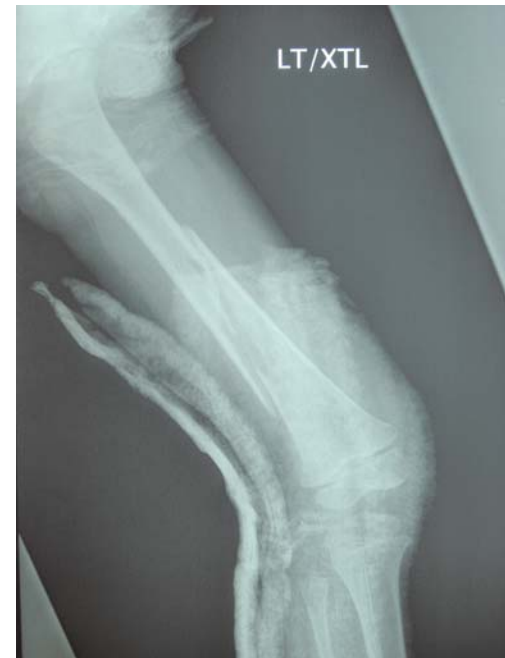

FIGURE 18-13 Femur fracture. Fat embolism syndrome is usually associated with major fractures of long bones, especially of the femur. The patient typically does well for 24 to 48 hours and then develops progressive respiratory and central nervous system deterioration. Concomitant laboratory value changes include hypoxemia, thrombocytopenia, fat in the urine, and a slight drop in hemoglobin. Fat enters the venous sinuoids at the fractured site and becomes lodged in the lung alveoli.

signs of inadequate tissue perfusion, including marked tachycardia (120 to 140 beats/min), tachypnea, marked vasoconstriction, a decreased systolic pressure level, diaphoresis, anxiety, restlessness, and decreased urinary output.

Class IV Hemorrhage: Blood Loss of > 40% Blood losses approaching half of the intravascular volume produce an immediately life-threatening situation. Symptoms include marked tachycardia, a significant decrease in the systolic blood pressure level to < 60 mm Hg, marked vasoconstriction with a very narrow pulse pressure, marked diaphoresis, obtunded mental state, and no urinary output.

Management In managing the trauma patient in shock, the speed with which resuscitation is initiated and the time

Table 18-5 Estimated Fluid and Blood Losses*

	<i>Class I</i>	<i>Class II</i>	<i>Class III</i>	<i>Class IV</i>
Blood loss (mL)	Up to 750	750–1,500	1,500–2,000	> 2,000
Blood loss (% vol)	Up to 15	15–30	30–40	> 40
Pulse rate	< 100	> 100	> 120	> 140
Blood pressure	Normal	Normal	Decreased	Decreased
Pulse pressure	Normal or increased	Decreased	Decreased	Decreased
Respiratory rate	14–20	20–30	30–40	> 35
Urine output (mL/h)	> 30	20–30	5–15	Negligible
Mental status	Slightly anxious	Mildly anxious	Anxious, confused	Confused, lethargic
Fluid replacement†	Crystalloid	Crystalloid and blood	Crystalloid and blood	Crystalloid

Adapted from American College of Surgeons Committee on Trauma. Advanced trauma life support for doctors: student course manual[®]. 6th ed. Chicago: American College of Surgeons; 1997. p. 98.

*Based on the initial presentation of a 70 kg man.

†The guidelines in the table are based on the “3-for-1” rule. This rule is derived from the empiric observation that most patients in hemorrhagic shock require as much as 300 mL of electrolyte solution for each 100 mL of blood loss. Applied blindly, these guidelines can result in excessive or inadequate fluid administration. For example, a patient with a crush injury to the extremity may have hypotension out of proportion with his or her blood loss and requires fluids in excess of the 3:1 guidelines. In contrast, a patient whose ongoing blood loss is being replaced by blood transfusion requires < 3:1. The use of bolus therapy with careful monitoring of the patient’s response can moderate these extremes.

required to reverse shock are the factors crucial to the patient’s outcome.³² The focus should again always be on controlling the hemorrhage, whether it be through basic measures such as pressure and elevation or through rapid imaging/surgical intervention. Two large-bore (16 gauge or larger) short angio-catheters are a minimum for beginning fluid therapy. Initial attempts should be made to place percutaneously the catheters in the basilic or cephalic veins in the antecubital fossa of both arms. Percutaneous placement of femoral, jugular, or subclavian vein catheters may also be used if there are no abdominal injuries or pelvic or femur fractures. When the patient is in an extreme hypovolemic state, placement of percutaneous catheters may be difficult; venous cut-down procedures to expose the saphenous vein provide venous access for fluid resuscitation. Flow is directly dependent on the catheter’s internal diameter and is inversely dependent on its length. Therefore, two

catheters of the same length and diameter, whether inserted peripherally or centrally, give the identical flow rate, but a longer central catheter delivers a lower possible maximum flow rate than does a shorter peripherally placed catheter. A central line through the subclavian or internal jugular vein routes usually takes longer to place than does a peripheral line and may require disruption of other resuscitation measures such as chest compressions during placement. Furthermore, a central line may complicate resuscitation of the trauma victim by causing or aggravating a developing pneumothorax or hemothorax or other potential complications associated with its placement. Therefore, peripheral intravenous lines are the access of choice in the primary management of the trauma patient.

Circulatory support and proper oxygenation of tissues require adequate systolic and diastolic blood pressure levels, pulse pressure levels, pulse rate characteristics, and capillary refill times. The clinical

observations of these parameters are difficult to quantitate, as is measuring improvement of stabilization of the circulatory system.

Adequate urine production is a predictable sign of renal function, except in cases in which urine production may be enhanced by the use of diuretics. For this reason, urinary output is a prime indication of resuscitation and patient response. A Foley catheter should be placed in the bladder as soon as possible to measure urinary flow. There are three contraindications for the insertion of a Foley catheter, and the catheter should not be placed until all have been ruled out. These contraindications in the traumatized patient are the presence of blood at the urethral meatus, of hemorrhage into the scrotum, and of a high-riding prostate (Figure 18-14A).^{33–35} Attempts to pass a catheter up an injured urethra can convert an incomplete laceration into a complete laceration and can introduce infection into the perineal and retropubic hematoma. A rectal examination should be performed in all trauma patients with suspected pelvic trauma before placement of a catheter. With posterior urethral disruption, the prostate may be forced superiorly by a hematoma; if the prostate cannot be palpated, a urethral injury should be suspected (Figure 18-14B).³⁶

The initial intravenous resuscitation fluid used in most hospitals is a balanced electrolyte solution such as lactated Ringer’s solution or 0.9% normal saline. During prolonged shock, isotonic fluid is lost from the intravascular and interstitial spaces to the extracellular space. Initially, the patient should be given 2 L of intravenous fluid (20 mL/kg for a pediatric patient) rapidly over 10 to 15 minutes and then observed. If this maneuver does not raise the systolic blood pressure to at least 80 to 100 mm Hg, the patient requires additional fluid, blood, and control of blood loss. There is still controversy about the use of colloids (albumin, plasma protein fractions) and artificial plasma

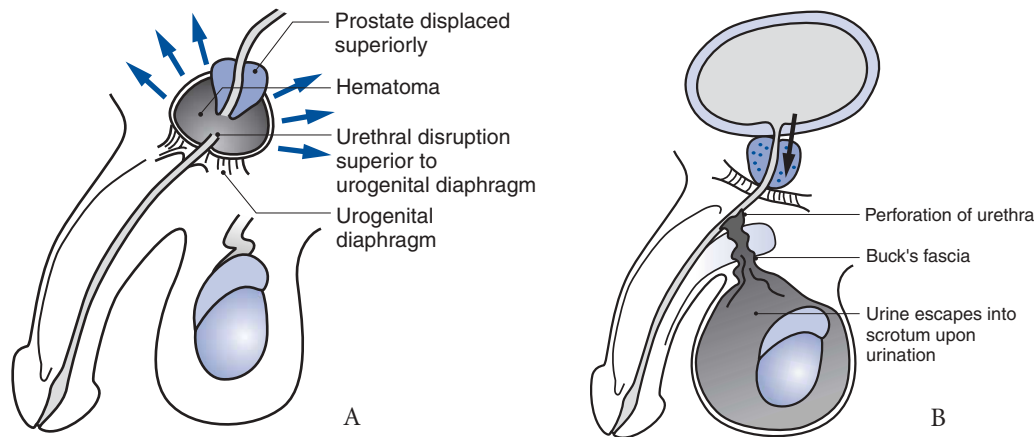


FIGURE 18-14 A, The contraindications for placement of a Foley catheter in the trauma patient are the presence of blood at the urethral meatus, hemorrhage into the scrotum, and a high-riding prostate. Blood at the urethral meatus may be a significant enough disruption of the urethra to prohibit passage of a catheter safely. B, The development of a hematoma or urine collection within the scrotum typically results from an anterior urethral disruption from perineal blunt trauma with a perforation of Buck's fascia. With a posterior urethral disruption, the prostate may be forced superiorly by the developing hematoma. Adapted from Powers M.¹⁵

expanders (dextran, hetastarch) to treat hypovolemia secondary to trauma. The cost of these materials does not appear to be justified by clinical data.^{37,38} Extensive meta-analysis shows a trend toward increased mortality with the use of colloids over crystalloids.³⁹ However, there is still support for their use, particularly if blood replacement is delayed or inadequate or in patients with severe head injuries that require fluid restriction therapy to control rising intracranial pressure (ICP) levels.

Most patients respond to initial fluid administration, but this improvement may be transient—especially in patients who have lost > 20% of their blood volume.⁷

With excess hemorrhage, red blood cells must be replaced in the intravascular circulation to maintain an optimum oxygen-carrying capacity. The safest type of blood to administer is blood that has been fully cross-matched. Obtaining fully cross-matched blood may require 30 minutes or more and is usually not possible immediately in the trauma situation. Type-specific blood is a safe alternative and can usually be ready within 5 to 15 minutes. With whole blood loss and requirements for early blood replacement, O-negative blood

may also be given in patients with excessive hemorrhage.⁵ The O blood group is the most common and contains no cellular antigens. Theoretically, O-negative blood can be given to persons regardless of the individual's blood group with minimal risk of antigen-antibody hemolytic reaction. However, no more than 4 U of O-negative blood should be given.⁴⁰

Fresh frozen plasma (FFP) is frequently used as a volume expander and provides all of the clotting factors except platelets. It also provides opsonins and some complement factors, which may be deficient in patients with severe trauma or shock. During massive transfusions, a unit of FFP is often given after every 5 U of blood, especially if packed red blood cells are administered in an attempt to prevent coagulation abnormalities. Additionally, platelet levels below $< 100,000/\text{mm}^3$ may be an indication for a platelet transfusion.⁴¹

The restoration and maintenance of body temperature is also important in the trauma patient. Appropriate body temperature increases the response to resuscitative measures and decreases the risk of worsening coagulopathy with massive transfusion. The use of body warmers and fluid warmers is strongly recommended.

If the patient initially responds to therapy, blood may not be required immediately, but the patient will require blood as hypovolemic shock continues to develop. A blood sample should be sent to the blood bank as soon as possible for full cross-matching. The patient who is resuscitated initially with O-negative unmatched blood or type-matched blood should be switched to fully cross-matched blood as soon as is reasonably possible to limit the risks of hemolytic reactions.⁴² Such blood is compatible within the AB-positive and Rh blood groups but may contain minor antigenic incompatibilities. Ideally, the amount of blood given should be equal to the amount lost by the patient, but this is difficult to assess in the trauma patient. In critically ill or injured patients, the ideal hemoglobin is 12.5 g/dL (hematocrit of 38% or higher). Although a hematocrit of 30 to 35% has been recommended in the past, higher levels improve the oxygen-carrying capacity, and the increased viscosity seems to cause relatively little reduction in cardiac output until the hematocrit exceeds 45 to 50%.

If the patient does not respond to initial fluid resuscitation and blood transfusions, either surgical intervention is required to control continued hemorrhage or the initial diagnosis of hypovolemia is incorrect. Measurement of the central venous pressure with a catheter or evaluation of the neck veins may assist with the assessment of hypovolemic shock. Those patients with exsanguinating hemorrhage should have a low central venous pressure, and those with other causes of shock should have a normal or elevated central venous pressure.⁷ The ultimate hemodynamic criterion in the treatment of hypovolemic shock is the patient's response. Adequate resuscitation is achieved when adequate circulation and urine output are restored.

A patient being treated for hypovolemic shock is usually placed in a head-down or Trendelenburg's position to empty the venous side of the peripheral

circulation back to the heart. Frequently, the patient with multisystem trauma has injuries to the abdomen or chest that may interfere with the respiratory capacity if the patient is in the Trendelenburg's position. Alternatively, both of the patient's legs can be elevated while the patient's trunk is maintained in a supine position.⁴³

Neurologic Examination

Upon completion of the assessment of the cardiovascular system and control of any external hemorrhage, a brief neurologic evaluation is performed to establish the patient's level of consciousness and pupillary size and reaction. This brief neurologic examination quickly identifies any severe CNS problems that require immediate intervention or additional diagnostic evaluation. A lack of consciousness with altered pupil reaction to light requires an immediate CT scan of the head and management with mannitol or fluid restrictions. Be aware of any medications that the patient may have received or drugs he or she may have taken that may affect the pupils.

The Committee on Trauma of the American College of Surgeons recommends the use of the mnemonic AVPU.^{7,8} In this system, each letter describes a level of consciousness in relation to the patient's response to external stimuli: *alert*, responds to *vocal* stimuli, responds to *painful* stimuli, and *unresponsive*.

A more detailed quantitative neurologic examination is part of the secondary survey of the trauma patient. The primary survey establishes a baseline; if the patient's neurologic condition varies from the primary to the secondary survey, a change in intracranial status may be present. A decrease in the level of consciousness may indicate decreased cerebral oxygenation or perfusion.

The reactivity of the pupils to light provides a quick assessment of cerebral function. The pupils should react equally. Changes represent cerebral or optic nerve

damage or changes in ICP. Further changes in pupil reactivity or levels of consciousness may be due to alterations in ventilation or oxygenation status. The most common causes of coma or depressed levels of consciousness are hypoxia, hypercarbia, and hypoperfusion of the brain.⁴² Depressed levels of consciousness and narrow pinpoint pupils may result after an opiate overdose. After an overdose with meperidine hydrochloride, the pupils may appear normal or dilated. In both cases, treatment requires the narcotic antagonist naloxone hydrochloride, 0.4 mg initially. Care should be taken to avoid a quick violent withdrawal phase in the opiate abuser; this is accompanied by profound distress, nausea, agitation, and muscle cramps.

Both hypoglycemia and hyperglycemia can cause depressed levels of consciousness. If a quick blood glucose level cannot be obtained (and depending on other injuries), the patient can be given an immediate bolus of 25 g of glucose to manage critical hypoglycemia. A benefit of the glucose load is the hyperosmolar status that may, for a short time, reduce cerebral edema.⁴⁴

Exposure of the Patient

The patient should be completely disrobed so that all of the body can be visualized, palpated, and examined for injuries or bleeding sites. The clothing must be completely removed, even if the patient is secured to a spinal backboard. The easiest method is to cut the clothing down the midline of the torso, arms, and legs to facilitate the examination and assessment. Frequent careful reevaluation of the injured patient's vital signs is important to monitor the patient's ability to maintain an adequate airway, breathing, and circulation (Figure 18-15).

Secondary Assessment

The secondary assessment does not begin until the primary assessment has been com-

pleted and management of life-threatening conditions has begun. During the secondary assessment the patient's vital signs and condition should be constantly monitored to evaluate the therapeutic interventions initiated during the primary assessment and to further assess the patient for any other life-threatening problems not evident during the primary survey. Changes in the patient's vital signs, respiratory and circulatory status, and neurologic func-

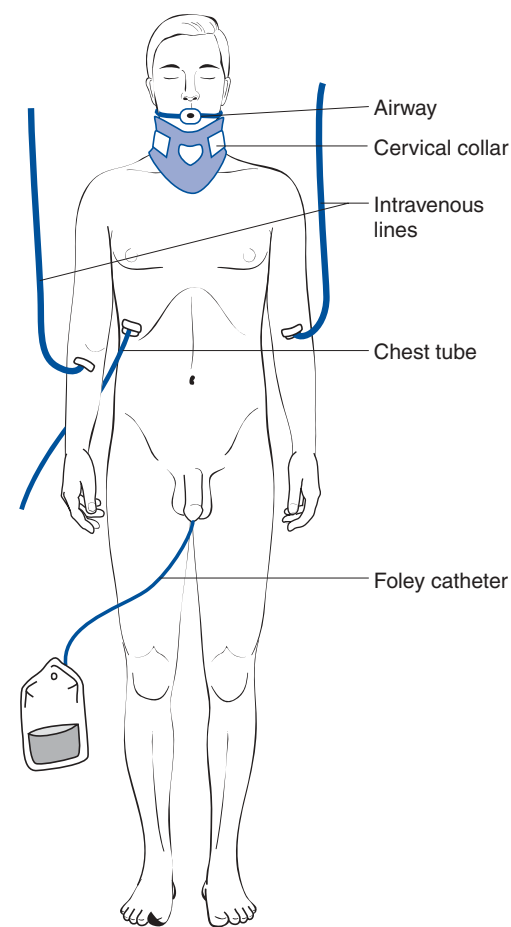


FIGURE 18-15 The primary assessment of the patient with multiple injuries requires evaluation and maintenance of an adequate airway with cervical protection, adequate breathing (including the placement of chest tubes to correct alterations in normal lung and chest wall physiologic conditions), and adequate circulation and hemodynamics, with the placement of two large-bore intravenous lines peripherally and the insertion of a Foley catheter after possible urethral damage is ruled out. The patient should be totally exposed so that the entire body can be examined for injuries. Adapted from Powers M.¹⁵

tions are expected in the first 12 hours.⁷ The secondary assessment includes a subjective and objective evaluation of the injured patient.

A subjective assessment should include a brief interview with the patient, if possible. A brief health history can be useful, including medications; allergies; previous surgery; a history of the injury; and the location, duration, time frame, and intensity of the chief complaint. Obviously, the comatose patient cannot provide useful subjective information, but family members, bystanders, or other victims may provide some details.

The objective assessment should involve inspection, palpation, percussion, and auscultation of the patient from head to toe. Each segment of the body (head and skull, chest, maxillofacial area and neck, spinal cord, abdomen, extremities, and neurologic condition) is evaluated to provide a baseline of the patient's present condition. Special procedures such as peritoneal lavage, radiographic studies, and further blood studies may be done at this time.

Head and Skull

Primary injuries to the head and skull may involve lacerations, abrasions, avulsions, and contusions of the scalp; fractures of the cranium and cerebral contusions; and intracranial bleeding to the brain from lacerations or shearing injuries. The brain may also suffer secondary insults from intracranial bleeding, hypoxia, and ischemia. Hypoxia is due to an impaired delivery of oxygen to the brain, whereas ischemia can result from arterial hypotension, elevated ICP, or pressure on intracranial vessels from expanding hematomas resulting in a herniation of the brain from the cranial vault (Figure 18-16). The secondary insults of hypoxia and various forms of ischemia are usually preventable. About one-half of patients with head injuries have some degree of reversible injury

caused by increased ICP that can be controlled with aggressive management. Failure to prevent increased ICP is the most frequent cause of death in hospitalized patients with a severe head injury. Hypertension with concomitant bradycardia may indicate increasing ICP (Cushing's phenomenon). Hypotension with tachycardia usually indicates blood loss. Shock is rarely associated with the primary neurologic injury, and systemic sources of blood loss should be investigated. The classic findings of Cushing's phenomenon are usually present < 25% of the time, even when the ICP is found to be > 30 mm Hg and a value > 15 mm Hg is considered abnormal.

Accurate continual neurologic assessment and examination for mass lesions with CT scans are rapid noninvasive techniques that are not life threatening for the patient with a head injury and that establish a baseline examination for future studies. When an intracranial injury is suspected, CT scans can quickly and easily be used to diagnose localized intracranial hemorrhage (Figure 18-17), contusion, foreign bodies, and skull fractures. In addition, secondary effects of trauma such as edema, ischemia, infarction, brain shift, and hydrocephalus can be seen on CT scans. In the acutely traumatized patient, CT scans can be used to diagnose intracerebral and extracerebral blood collections with nearly 100% accuracy. A significant mass lesion can cause cerebral ischemia by elevating ICP or by compressing vascular structures. A CT scan should be done immediately following stabilization of the injured patient, rather than waiting for signs of an expanding intracranial hematoma. Indications for a CT scan include seizure activity, unconsciousness lasting for more than a few minutes, abnormal mental status, abnormal neurologic evaluation, and evidence of a skull fracture found on physical examination. There is still controversy regarding when a head CT is appropriate. It has been sug-

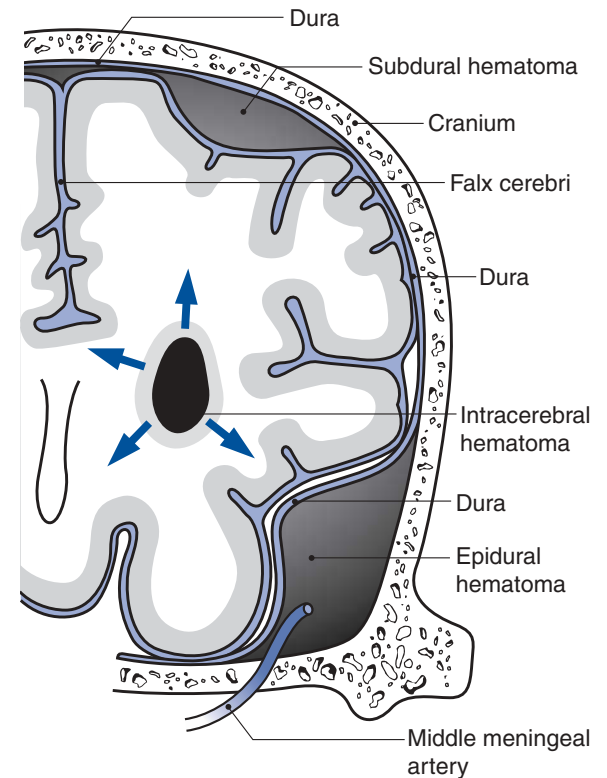


FIGURE 18-16 Mass lesions commonly associated with head trauma include epidural hemorrhage, subdural hemorrhage, and intracerebral hemorrhage. A subdural hematoma is usually caused by venous bleeding with progressive loss of neurologic function. The epidural hematoma is usually associated with skull fractures near the temporoparietal region, with tearing of the middle meningeal artery. Adapted from Powers M.¹⁵

gested that a CT of the head be obtained in all patients with blunt head trauma who have experienced a loss of consciousness or mild amnesia, even those with normal neurologic findings.⁴⁵

Extreme care should always be taken when moving a patient with a head trauma to the CT machine because of the high incidence of associated cervical spine fractures in patients with head and facial traumas.⁴⁶ If trauma to the spine is suspected, the cervical spine should be immobilized before the patient is moved and the CT examination should be extended to study the cervical spine as well. In addition, any suspected facial injuries should be examined by extending the CT examination inferiorly—as low as the inferior border of the mandible. Unfortunately, in many cases

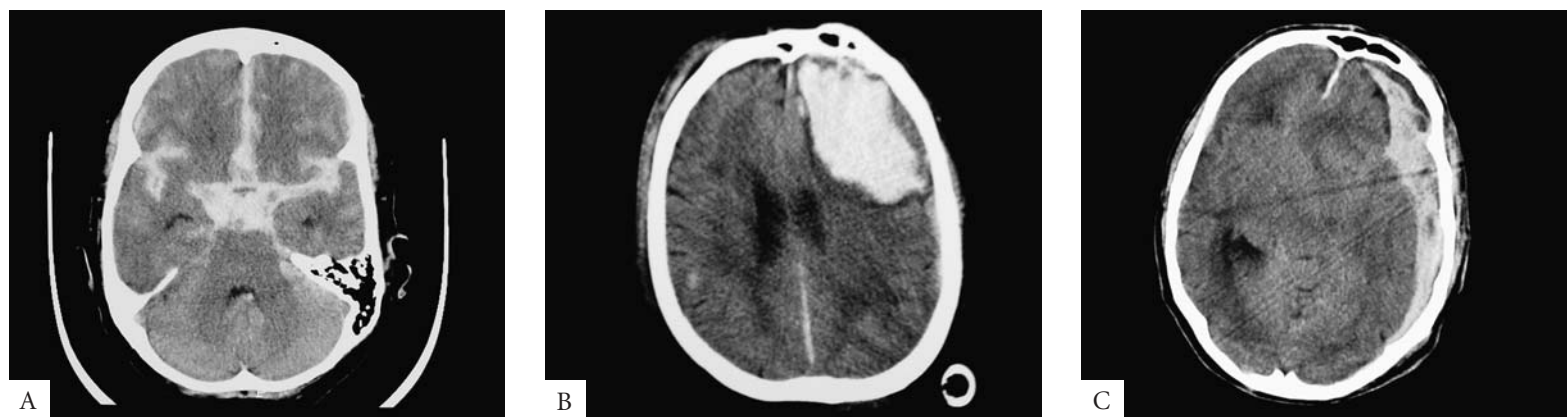

FIGURE 18-17 Computed tomography scans demonstrating anatomic variances associated with intracranial bleeding. A, Subarachnoid hemorrhage is defined as blood within the cerebral spinal fluid and meningeal intima and probably results from tears of small subarachnoid vessels. Blood is spread diffusely through the arachnoid matter and usually does not cause mass effect, but may predispose a patient to cerebral vasospasm. B, Intracerebral hemorrhage is formed deep within the brain tissue and is usually caused by shearing or tensile forces that mechanically stretch and tear deep small-caliber arterioles as the brain is propelled against irregular surfaces in the cranial vault. Note the surrounding edema and mass effect. C, Subdural hematomas are blood clots that form between the dura and the brain. They are usually caused by the movement of the brain relative to the skull, as is seen in acceleration-deceleration injuries. Note the considerable shift of midline to the right.

evaluation and treatment of facial injuries must be delayed for a significant time, which means that the patient is needlessly transported back to the radiology department for further studies because of failure to initially extend the CT examination.

As ICP increases above normal, a fairly standard progression of neurologic abnormalities ensues, involving sections of the brain sequentially: the cerebral cortex, producing an altered state of consciousness; the midbrain, producing dilation and then fixation of the pupils, initially on the side of the lesion, with varying degrees of bilateral hemiparesis; the pons, resulting in a loss of the corneal reflex and the occurrence of the doll's eye reflex (Figure 18-18); and the medulla, producing, in sequence, apnea, hypotension, and death.

The physical examination of the head should include an examination of the scalp for lacerations and foreign bodies. Because of the rich vascular supply of the scalp, especially in children, scalp injuries may result in significant blood loss. Lacerations may overlie an injury to the cranium, or intracranial hemorrhage may be present. An untreated scalp wound with a cranial injury may eventually act as a port for bacteria to enter the injured area, causing meningitis or a brain abscess.

The head should be examined for signs of a basilar skull fracture: hematoma over the mastoid process behind the ears (Battle's sign); hemotympanum; cerebrospinal fluid (CSF), rhinorrhea, or otorrhea; and subscleral hemorrhage. Whenever a basilar skull fracture is suspected, a nasogastric tube should not be used because the tube may inadvertently pass into the cranial vault.

The neurologic examination should be brief and should evaluate the level of consciousness, motor and cranial nerve function (suggestive of developing mass lesions), brainstem findings, and trends in the neurologic status. Alcohol and drug intoxication are frequently associated with injured patients in the trauma situation and may complicate the neurologic examination. A decreased level of consciousness should not be attributed to alcohol or other drugs until intracranial pathologic conditions have been ruled out.

The GCS (discussed above) provides a simple method of grading consciousness and functional capacity of the cerebral cortex (see Table 18-1). It can be used both in the field and as a reassessment tool to assess brain function, brain damage, and patient progress, based on the three behavioral responses: eye opening,

best verbal response, and best motor response. Two regions of the brain, if injured, can produce unconsciousness; the cerebral cortices bilaterally and the brainstem reticular activation system regardless of the cause of injury, can also depress the level of consciousness.⁷

Examination of the motor function is part of the GCS, which gives information about any asymmetry of function. The conscious patient should be asked to move the extremities in response to commands. An inability to do so may represent damage to the limb or spinal cord. In the unconscious patient, deep tendon reflex and plantar response testing can assess both sensory input and motor output. Of special concern is abnormal posturing and nonpurposeful movement to stimulus. Abnormal flexor activity (decorticate) involves flexion of the forearms on the chest with flexion of the wrists and fingers; in abnormal extensor posturing, the arms, hands, and fingers are extended with the hands abducted. In both cases the lower extremities are extended and no attempt is made to localize the point of stimulation. Although bilateral extensor plantar responses are nonspecific, a unilateral Babinski sign points to corticospinal tract damage.

Pupillary function, eye movements, and eye opening can provide information about the level of consciousness, as well as about brainstem function. The size, shape, and reactivity of the pupil to light provide information about second and third nerve function and midbrain activity. A sluggish reactive or a dilated nonreactive (blown) pupil on one side indicates compression of the third cranial nerve by brain herniation in the unconscious patient. The pupillary light reflex can be used to evaluate cranial nerve function and possible elevated ICP with brain herniation. In normal activity, when light is shone in one eye, both pupils constrict equally. The optic or second cranial nerve carries both visual and pupillary fibers. The optic nerves connect shortly after they leave the retina to form the optic chiasm. At the optic chiasm, the nasal fibers cross to join the temporal fibers from the other eye, and the visual fibers cross to the visual occipital cortex. The pupillary fibers are relayed bilaterally to the Edinger-Westphal nucleus of the oculomotor or third cranial nerve. The cranial nerve supplies the sphincter muscle of the iris, allowing it to contract. There is also

autonomic innervation of the eyes. The iris is supplied by both sympathetic and parasympathetic fibers. Stimulation of the sympathetic fibers causes the pupil to dilate and upper eyelid to elevate.

Thus, significant information about the trauma patient can be obtained by looking into the eyes. If a light is shone into the right eye and the left eye does not respond, there may be a disruption of the right optic or left oculomotor nerves. If the light is then shone into the left eye and it does not respond, a disruption of the third cranial nerve should be suspected. Pupillary dilatation of one eye may be due to a developing brain herniation on the ipsilateral side, with bilateral pupillary dilatation suggestive of significant midbrain injury or loss of parasympathetic function. Conversely, pinpoint pupils after head trauma may indicate drug overdose or loss of sympathetic tone as seen in Horner's syndrome.

The function of the brainstem may also be assessed with evaluation of the corneal reflex, which involves sensory input from the trigeminal (fifth) nerve. The oculocephalic maneuver, or test of the

doll's eye reflex, requires an intact vestibular or acoustic (seventh) nerve to permit head rotation to evaluate reflexive movement of the eyes (see Figure 18-18). Obviously this maneuver is not to be used with patients who have a suspected cervical spine injury. The oculo-vestibular response test evaluates the third, fourth, sixth, and eighth cranial nerves, as well as brainstem activity. In this test the external auditory canal is irrigated with cold water; there should be full eye movement toward the ear canal lavaged with cold water. If not, there may be a disruption along any of the neural tracts or of the tympanic membrane (see Figure 18-18).

A lumbar puncture should not be performed in patients with acute head injuries. The change in pressure associated with the removal of CSF from the lumbar region may precipitate cerebral herniation in the patient with an elevated ICP.

CSF emerging from the nose or ear is commonly associated with a basilar skull fracture. Clear or red-tinged fluid that drains from the nose or ear should be considered to be CSF. There is no reliable method available in the emergency

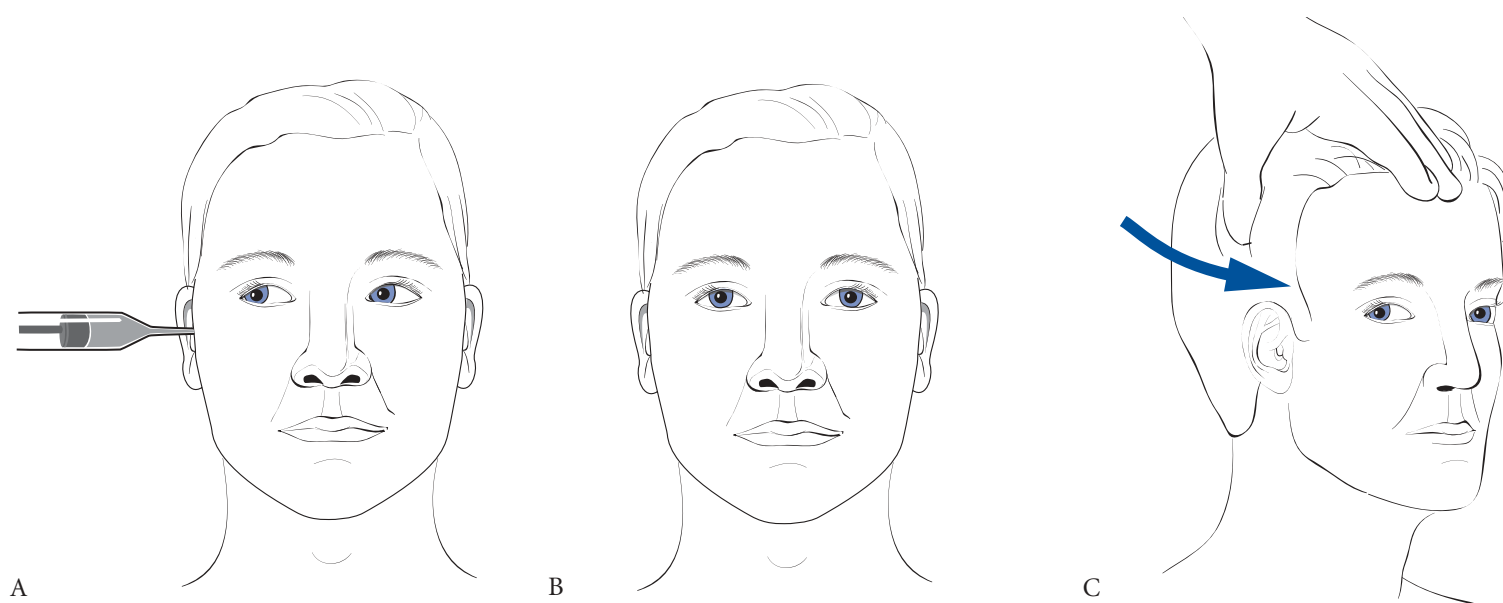


FIGURE 18-18 Responses that test the third, sixth, and eighth cranial nerves, as well as ascending brainstem pathways from the pontomedullary junction to the mesencephalon. A, The caloric response (oculovestibular maneuver) involves the placement of cold water into the ear. In a comatose patient, the eyes should tonically deviate toward the irrigated ear. B, Patient at rest. C, In the oculocephalic response (doll's eye reflex) in comatose patients, the head is turned from the midline and there is a reflex movement of the eyes in the opposite direction of head rotation. Adapted from Powers M.¹⁵

department for distinguishing CSF from nasal mucosa. The use of glucose indicator sticks is associated with a high incidence of false-positive results. A useful aid may be a “ring sign.” A drop of the fluid from the nose or ear is placed on a piece of filter paper. If the fluid is CSF, the blood components of the fluid remain in the center and rings of clear fluid form around them.⁷

A CT scan should be performed to determine whether there is a fracture site. The head of the bed should be elevated to 90°. If indicated, the fracture should be reduced. The leakage should cease after 7 days; if it does not, neurosurgical procedures may be indicated to repair the dural tear.

A rectal examination is an essential part of the examination of the patient with a head injury. Rectal sphincter tone is present if the injury is intracranial only; if there is no rectal tone, a coexisting spinal cord injury is present. Coexisting head and spine injuries should be suspected until proven otherwise.

A head injury is initially classified as mild (GCS 13–15), moderate (GCS 9–12), or severe (GCS \leq 8). Patients with head injuries who experience no loss of consciousness, no amnesia, no palpable fractures, and a GCS score of 15 can be discharged home to a reliable caretaker; brain imaging is unnecessary, although it is generally recommended that CT imaging be performed due to its low cost and its convenience. Patients who experience a loss of consciousness or amnesia, or have a GCS score of 13 or 14 must undergo an immediate head CT. If this noncontrast study finding is negative, the patient can be discharged to a reliable caretaker. If there is a focal neurologic finding on examination, a GCS score of $<$ 13, or an intracranial lesion seen on the head CT, the patient should be admitted to an intensive care unit or neurologic observation unit for continuing care. The administration of prophylactic phenytoin at a loading dose of 18 mg/kg IV is used by some for control

of possible seizure activity. Ongoing seizures may be controlled with a benzodiazepine. Neurosurgical consultation should be obtained early in the management of any obvious head trauma. Patients with severe head injuries (GCS $<$ 8) should undergo rapid sequence intubation technique for airway protection and better control of ICP. The patient’s ICP is controlled using various techniques, including reverse Trendelenburg position, osmotic diuresis (mannitol), hyperventilation of the intubated patient (although there is little or no documented benefit to this procedure), sedation, pharmacologic paralysis, and phenobarbital coma (last resort). Judicious use of resuscitative fluids and control of systemic hypertension also help to control ICP.

Chest

Throughout the secondary assessment of the multiply injured patient, the primary evaluation of airway, breathing, and circulation must be monitored for development of difficulties or overlooked problems. Pneumothorax, open pneumothorax, hemothorax, flail chest, and cardiac tamponade may develop after the primary assessment and must be treated accordingly. It is estimated that chest injuries are responsible for 20 to 25% of all trauma deaths per year in the United States.²⁶

The secondary assessment of chest trauma involves the evaluation of an upright chest radiograph for the presence of air in the mediastinum or under the diaphragm, widening of the mediastinum with a shift toward the midline, thoracic injuries and fractures that alter lung expansion, and the presence of fluid. Figure 18-19 shows a chest radiograph of a patient without chest trauma. In most instances the trauma patient needs to be immobilized on a backboard (Figure 18-20), and a supine film is substituted for an upright one. If a chest injury is suspected, a CT scan should also be obtained. An electrocardiogram, arterial blood gas analysis,

hematocrit, and urinalysis should be obtained. Six potentially lethal injuries to consider in the secondary assessment are pulmonary contusion, aortic disruption, tracheobronchial disruption, esophageal disruption, traumatic diaphragmatic hernia, and myocardial contusion.⁷

Pulmonary contusions are treated in the same manner regardless of whether there is an accompanying flail chest injury. Pulmonary contusions are common in blunt chest trauma because the capillary damage within the lungs results in interstitial and intra-alveolar edema and shunting. Pulmonary contusions and adult respiratory distress syndrome (ARDS) are the most common potentially lethal chest injuries seen in the United States because the resulting respiratory failure does not occur instantaneously but develops in 24 to 72 hours.²⁴ The patient may complain of pain and dyspnea, and blood gas levels tend to deteriorate progressively over the initial 48 to 72 hours as increasing edema develops in the alveoli. Chest radiographs reveal a developing opacification of the involved areas. Treatment involves adequate ventilation of the lungs, including chest physiotherapy, supplemental oxygen, coughing with deep breathing, and nasotracheal suction. If ventilatory assistance is required, spontaneous ventilation with intermediate mechanical ventilation

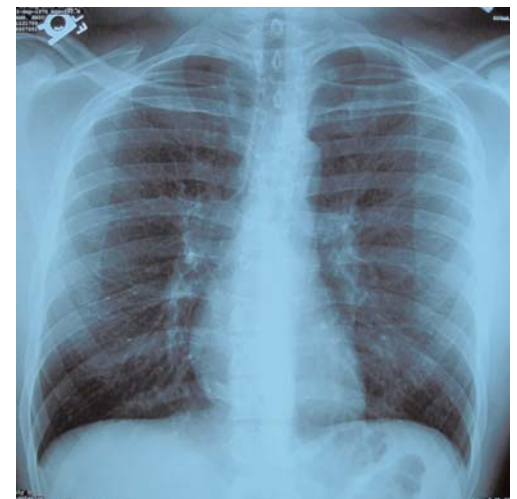


FIGURE 18-19 Normal upright chest radiograph.

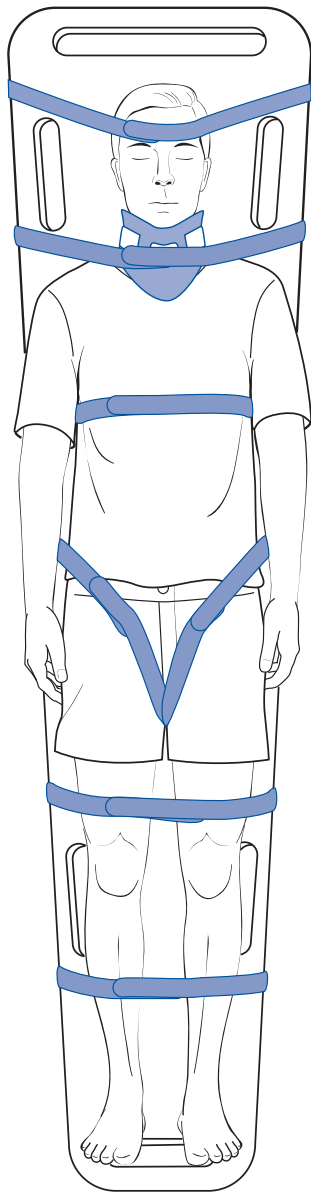


FIGURE 18-20 Stabilization of the trauma victim for transportation is best achieved with the use of a long backboard with bindings and sandbags to control the head in a neutral position. Adapted from Powers M.¹⁵

provides much better ventilation-perfusion matching, better hemodynamics, and quicker weaning than does assisted ventilation. The use of steroids is controversial.⁴⁷

Injury to intrathoracic large arteries or veins may develop with blunt or penetrating trauma; this is the most common cause of sudden death after an automobile accident or a fall from a great height.⁷ Common sites of injury are the aortic root

and the descending aorta at the origin of the ductus arteriosus and at the diaphragm. These injuries are fatal within a few minutes—only 15% of patients with thoracic aortic injuries are still alive on arrival at a hospital. It is not uncommon for the aorta intima and media to be fractured circumferentially, with only the adventitia and surrounding mediastinal tissues preventing fatal hemorrhage. The patient may appear clinically stable; yet, failure to recognize this vascular injury leads to eventual death. Adjunctive signs on chest radiographs that are suggestive of thoracic vascular injury include a widened mediastinum, fractures of the first and second ribs, obliteration of the aortic knob, deviation of the trachea to the right, the presence of a pleural cap, deviation of the esophagus to the left, and a downward displacement of the left mainstream bronchus.⁷ If an aortic rupture is suspected on clinical or radiographic examination, an aortography should be performed. While waiting for the aortogram, it is important not to let the patient become hypertensive or cough or gag excessively (eg, as may occur with the placement of a nasogastric tube).

Maxillofacial Area and Neck

Maxillofacial injuries may cause airway compromise from blood and secretions, from a mandibular fracture that allows the tongue to fall against the posterior wall of the pharynx, from a midface injury that causes the maxilla to fall down and back into the nasopharynx, and from foreign debris such as avulsed teeth or dentures. A large tonsillar suction tip should be used to clear the oral cavity and pharynx. An oral airway assists with tongue position; however, care must always be taken to avoid manipulation of the neck and to provide for access to the oral cavity and dentition for reduction and fixation of any fractures requiring some period of intermaxillary fixation. Neither midface fractures nor cerebrospinal rhinorrhea are

contraindications to nasal intubation. Care should be taken to pass the tube along the floor of the nose into the pharynx, and the tube should be visualized before intubation of the trachea.

The physical examination should begin with an evaluation for soft tissue injuries. Lacerations should be débrided and examined for disruption of vital structures such as the facial nerve or parotid duct. The eyelids should be elevated so that the eyes can be evaluated for neurologic and possible ocular damage. The face should be symmetric without discolorations or swelling suggestive of bony or soft tissue injury. The bony landmarks should be palpated, beginning with the supraorbital and lateral orbital rims, infraorbital rims, malar eminences, and zygomatic arches, and nasal bones should be palpated. Any steps or irregularities along the bony margin are suggestive of a fracture. Numbness over the area of distribution of the trigeminal nerve is usually noted with fractures of the facial skeleton.

The oral cavity should be inspected and evaluated for lost teeth, lacerations, and alterations in the occlusion. Any teeth lost at the time of injury must be accounted for because the tooth may have been aspirated or swallowed.

The neck should also be examined for injury. Subcutaneous air may be visualized if massive injury is present; if subtle, it may be detected only by palpation. The presence of air in the soft tissues may be the result of tracheal damage. Any externally expanding edema or hematoma of the neck must be observed closely for continued expansion and airway compromise. Carotid pulses should be assessed. Palpation for abnormalities in the contour of the thyroid cartilage and for the midline position of the trachea in the suprasternal notch should be performed.

Spinal Cord

There are > 10,000 spinal cord injuries per year in the United States, usually caused by

motor vehicle accidents. Multiple studies have reported a 10 to 20% association of cervical spine injuries with maxillofacial injuries in the multiply traumatized patient although recent data suggest no increase in cervical spine injury when facial trauma is present.^{48,49} Approximately 55% of spinal injuries occur in the cervical region, 15% in the thoracic region, 15% in the thoracolumbar junction, and 15% in the lumbosacral area.⁸ Identification of cervical spine injury is essential in the management of blunt trauma because a missed injury can result in catastrophic spinal cord damage. Tetraplegia as a result of cervical spine injury is not only a tragedy for the patient; it also represents a tremendous financial burden to society.⁵⁰ According to the National Spinal Cord Injury Center Databank, in July 1996, the average medical cost of the first year of a cord injury involving C1 through C4 was \$417,000 (US).⁵⁰ Patients can be expected to have medical costs of \$1,350,000 over the course of their lifetime as well as lost wages and productivity. Patients can then expect a greatly shortened life span, which varies according to the age of the patient at the time of injury.⁴⁸

A description of the mechanism of injury, especially high-velocity accident, may give clues to a possible injury of the spine such as a whiplash injury. The patient may experience little discomfort from major injury to the chest, abdomen, and extremities as a result of sensory loss from a spinal injury. Because of the loss of sympathetic tone with cervical injuries, the patient may present with a systolic blood pressure level of 70 to 80 mm Hg without the tachycardia, cool extremities, poor perfusion, and decreased urinary output noted in the patient with hypovolemic shock. The neurologic shock is due to dilatation of the arterial system, loss of muscle tone, and loss of reflexes. The absence of neurologic deficit does not exclude injury to the cervical spine. A complete series of cervical radiographs

should be obtained and read prior to the removal of stabilization. If a helmet is worn by the victim, the helmet should be secured to the long spine board with 8 cm cloth tape, and cervical spine radiographs should be taken and cleared for cervical spine injury before the attempted removal of the helmet.

Physical examination of the patient with a suspected spinal injury should be done carefully, with the patient in a neutral position and with minimal movement of the spine and head (see Figure 18-20). The presence of an unstable cervical spine injury must be considered in the evaluation and resuscitation of every patient with injuries associated with blunt trauma. The catastrophic physical consequences of irreversible quadriplegia, as well as the huge economic costs required to care for this lifelong disability, require that great care must be taken to rule out unstable cervical spine injury. The patient should be treated as if there has been an unstable injury to the nerves, bone, muscles, and other structures of the neck until there is positive clinical and radiographic evidence that there is no injury. The neck and spine should be carefully examined for deformity, edema, ecchymosis, muscle spasm, and tenderness while being carefully supported to avoid further damage associated with an unstable cervical neck injury.

The neurologic examination of the patient with a spinal injury is similar to that of the patient with closed head trauma. The mental status, motor function, sensation over dermatomes, brainstem reflex, and spinal reflexes should all be evaluated and charted. The patient should be carefully examined for rectal tone and bladder control as evidence of autonomic function. Hypoventilation caused by paralysis of the intercostal muscles results from injury to the lower cervical or upper thoracic spinal cord. If the upper or middle cervical spin is injured, the diaphragm will also be paralyzed as a result of involvement of the C3 through C5 spinal cord seg-

ments. Abdominal breathing and the use of the respiratory accessory muscles will be evident.⁷

Bachulis and colleagues evaluated 4,941 trauma victims between February 1981 and July 1985 and found that 1,923 (39%) had radiographs taken of their cervical spines.⁵¹ Injuries to the cervical spine were detected in 94 patients (5%). Ninety of these patients had cervical spine fractures; four had a disruption of the cervical longitudinal ligaments without bony injury and were quadriplegic. In the study the overall incidence of cervical spine injury in the trauma patient was 2%. Neurologic deficit did not develop in any patient with a neurologically intact spinal cord at the time of admission. The researchers found that, of the 94 patients, there were 65 alert patients with no neurologic deficits who had unstable cervical spine injuries. Without exception, these patients either complained of neck pain or of pain on palpation of the neck. Other studies have reported that no alert patient without neck pain was found to have any cervical injury.⁵¹ Fischer concluded that a screening radiographic examination of the cervical spine is not indicated in the alert, sober, and cooperative patient with no complaints of neck pain and no tenderness to palpation of the neck, even when significant injury is present; however, the author does recommend screening for all patients with decreased levels of consciousness and a history of an injury that could have conceivably injured the cervical spine, for all patients with neurologic deficits compatible with cervical origin, and for all patients with neck pain or tenderness.⁵¹ Cervical spine injuries may result from axial loading, flexion, extension, rotation, lateral bending, and distraction or combinations of these mechanisms of injury (Figure 18-21).

In the study by Bachulis and colleagues, lateral cross-table cervical spine radiographs were obtained in all injured patients and demonstrated cervical spine

injury in 70 patients but not in the other 24, for an unacceptable false-negative rate of 26%. The authors recommended that all patients at risk for cervical spine injury must have a complete initial radiographic examination, including lateral, anteroposterior, odontoid, and right and left oblique views of the cervical spine. CT scanning was found to be the most useful modality to confirm a cervical spine injury in those patients with a suspected injury to the cervical spine not confirmed on plain film radiographs. They recommend the use of CT scans of the neck for patients with a possible neck injury and associated head injury that requires a CT scan of the brain, for patients in whom radiographic visualization of C6 or C7 are difficult, and for patients with a suspected cervical injury that is not detected in screening radiographs.⁴⁶ A recent study by Griffen and colleagues concluded that CT scanning of the cervical spine should replace plain film studies in blunt trauma patients completely.⁵²

Visualization of all seven cervical vertebrae is important (see Figure 18-21). The shoulders must be distracted inferiorly by pulling down on the arms to provide a clear view of the spinal anatomy from C6 through T1. It is important that a clear view of the spine at the C6 and C7 level be obtained without obstruction by the shoulders to obtain a proper diagnostic study. If visualization of C6 and T1 cannot be obtained, the radiographic view may be improved by placing the arms in a “swimmer’s position,” with downward traction on one arm and upward traction on the other and the radiograph beam aimed through the axilla of the upward arm. Radiographs should be examined for fractures and fracture dislocations of the spine by evaluation the anteroposterior diameter of the spinal canal; the contour and alignment of the vertebral bodies; displacement of bony fractures of the laminae, pedicles, or neural fascicles; and soft tissue swelling.¹⁸ Three-way cervical views

(anteroposterior, oblique cervical, and lateral cervical) plus an open-mouth odontoid view or a CT scan of the neck coupled with adequate cervical spine immobilization during evaluation and resuscitation should allow the cervical spine to be viewed safely.

On a lateral cervical spine radiograph, the soft tissue thickness between the pharynx and osseous C3 should be < 5 mm. An increase in this area suggests a fracture. The distance may vary with inspiration or expiration.⁷ On the lateral view the features to be examined are the general contour of the spine, the vertical alignment of the anterior and posterior margins of the vertebral bodies, the midlaminar line, the width of the spinal column, and evidence of compression or fracture of individual vertebrae. On anteroposterior views the height and alignment of the spinous processes and the interspinous distances are examined. The discovery of any findings suggesting the presence of a cervical spinal injury mandates the use of protective measures. It has been demonstrated that a sta-

bilization device such a cervical collar allows significant movement of the cervical spine.⁵³ The recommended stabilization for patients with cervical fractures is a cervical collar in combination with a long spinal board. Appropriate head holders or sandbags should be used bilaterally to support the neck laterally, and the head should be secured with an 8 cm cloth tape across the forehead and around the board (see Figure 18-20). Obviously, maintaining a stable airway is critical in patients who have suffered significant head and neck trauma. Cervical neck protection as well as a nasal trumpet or similar airway protection device may be indicated to maintain a patent airway. If the airway becomes unstable, nasotracheal intubation or cricothyroidotomy should be performed, in that order, always ensuring that the cervical spine continues to be stabilized.

CT should be used for further evaluation of detected or suspected fractures, evaluation of questionable plain films, and to complete radiographic examination of areas not well visualized by plain films.

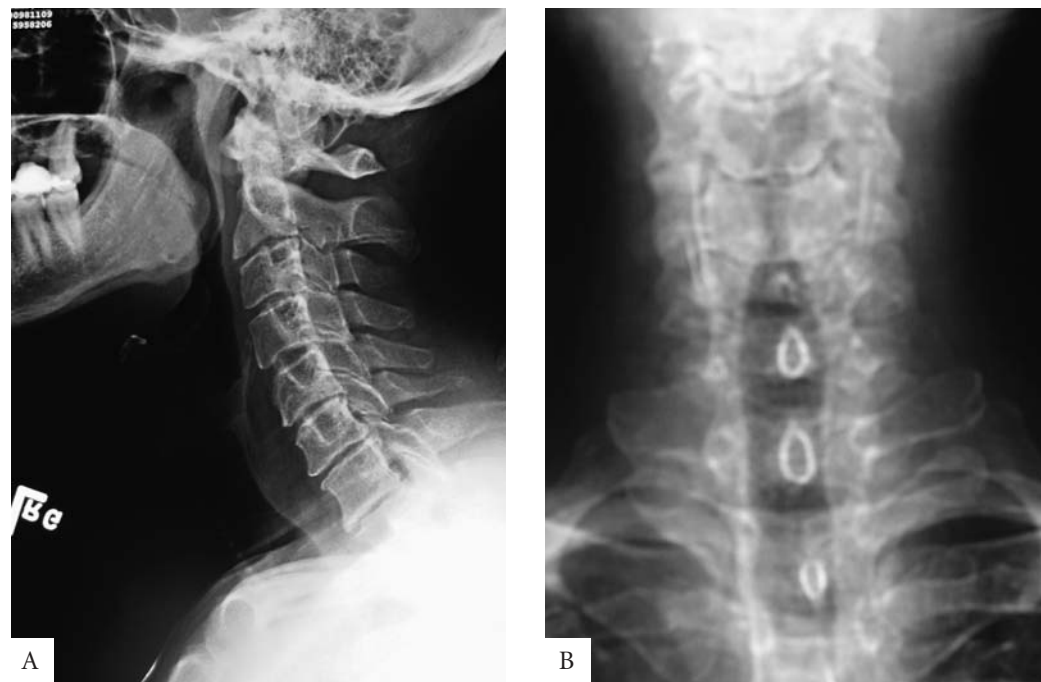

FIGURE 18-21 Normal cervical radiographs: A, lateral; B, anteroposterior. Radiographs should be examined for prevertebral edema, subluxation, widening of the interspinous distance, widening of the atlantodental interval, bony fractures, malalignment, or jumped facets.

The lower cervical spine often is not well visualized on radiographs, even with use of the swimmer's position, and a CT scan is frequently required.

Abdomen

With abdominal trauma, the physical examination is an informative portion of the diagnostic evaluation. Penetrating wounds must be identified, and many surgeons believe that the safest management of penetrating wounds is a laparotomy.⁷ The abdominal girth should be measured at the umbilicus soon after admission to establish a baseline against which to evaluate possible intra-abdominal bleeding. Abdominal rigidity and tenderness are important signs of peritoneal irritation by blood or internal contents, and they may be the main indications for a laparotomy of a patient injured by blunt trauma. Rectal and pelvic examinations are essential if there is a question of pelvic or perineal injury. A nasogastric tube should be passed, if possible, into the stomach to remove gastric contents.

Plain films have limited value in abdominal trauma. They can be useful in localizing foreign bodies, bony structures, and free air with the use of anteroposterior and cross-table views.

The use of diagnostic peritoneal lavage (DPL), once a standard diagnostic test used in blunt and occasionally penetrating abdominal traumas, has decreased significantly with the advancement in CT and ultrasonography. DPL is indicated in patients with a history of blunt abdominal trauma and increasing pain, patients with unexplained hypovolemia following multiple trauma, patients who are candidates for laparotomy but who have questionable findings, and patients who have experienced severe trauma and who may require an extended period under general anesthesia.⁷ Absolute contraindications to DPL are a history of multiple abdominal operations and obvious indications for an exploratory laparotomy—free air and penetrating trauma.

A DPL is usually performed with a sterile intravenous catheter inserted percutaneously through a small midline incision about 2.5 to 4 cm below the umbilicus. The catheter is advanced into the pelvis after the bladder has been emptied. If no blood, bile, or intestinal fluid is aspirated, the abdominal cavity is irrigated with 1 L of saline. The fluid is then drained from the abdomen through the intravenous tubing. It is generally felt that the presence of 100,000 red blood cells or 500 white blood cells per cubic millimeter after blunt trauma is sufficient to make a laparotomy mandatory (Table 18-6).

CT scanning of the abdomen is also acceptable if the patient is stable and emergent laparotomy is not indicated. The advantages to CT include that it is noninvasive; it is capable of discerning the presence, source, and approximate quantity of intraperitoneal hemorrhage; and it occasionally can demonstrate active bleeding. CT scanning coincidentally evaluates the retroperitoneum—an area not sampled by DPL—as well as the vertebral column and can be readily extended above or below the abdomen to visualize the thorax or pelvis. It is helpful in the evaluation of hematuria

and, if used early enough, in determining renal artery injury. Disadvantages include suboptimal sensitivity for injuries of the pancreas, diaphragm, small bowel, and mesentery. Injuries of the small bowel and mesentery can have profound morbidity and even mortality if not diagnosed early. In the absence of hepatic or splenic injuries, the presence of free fluid in the abdominal cavity suggests an injury to the gastrointestinal tract and/or its mesentery and mandates early surgical intervention. Complications also can result from intravenous contrast administration. The cost can also be significant, especially if established indications are not followed.

Ultrasonography or focused assessment with sonography for trauma is rapidly becoming an integral diagnostic component in trauma centers. Ultrasonography has undergone a large number of clinical evaluations in Europe, Asia, and the United States. Its primary role is detecting free intraperitoneal blood after blunt trauma. This is accomplished by a focused examination of specific anatomic areas where blood or fluid is most likely to accumulate. Ultrasonography can also evaluate the

Table 18-6 Parameters for Evaluation of Peritoneal Lavage Fluid

Positive	20 mL gross blood on free aspiration (10 mL in children) $\geq 100,000$ RBCs/mm ³ ≥ 500 WBCs/mm ³ (if obtained ≥ 1 h after the injury) ≥ 175 U amylase/100 mL Bacteria (determined with Gram's stain) Bile (by inspection of chemical determination of bilirubin content) Food particles (microscopic analysis of strained or spun specimen)
Intermediate	Pink fluid on free aspiration $50,000$ – $100,000$ RBCs/mm ³ 100 – 500 WBCs/mm ³ 75 – 175 U amylase/100 mL
Negative	Clear aspirate $\leq 50,000$ RBCs/mm ³ ≤ 100 WBCs/mm ³ < 75 U amylase/100 mL
Adapted from Powers M. ¹⁵ RBC = red blood cell; WBC = white blood cell.	

pericardial space and intraperitoneal spaces. Ultrasonography carries a host of advantages:

- It is a portable instrument that can be brought to the bedside in the trauma resuscitation area.
- Studies of the pericardial and intraperitoneal spaces can be accomplished in < 5 minutes.
- Sensitivity in detecting as little as 100 mL to, more typically, 500 mL of intraperitoneal fluid ranges from 60 to 95% in most recent studies, and specificity for hemoperitoneum is excellent.⁵⁴
- Unlike DPL, ultrasonography can rapidly gauge the mediastinum, is noninvasive, and can be performed serially and by multiple technicians.
- Unlike CT scanning, ultrasonography does not pose a potential radiation hazard and does not require administration of contrast agents.
- Performing focused ultrasonographic examinations with an abdominal trauma patient does not require the skill of a board-certified radiologist, which allows ultrasonography to be more readily accessible to injured patients. Accuracy correlates with length of training and experience, but expertise can be readily accomplished in emergency medicine and surgical training programs.⁵⁵
- Overall, ultrasonography can serve as an accurate and rapid test and is a less expensive diagnostic screening tool than are DPL and CT.

However, there are disadvantages to the use of ultrasonography, including the following:

- Indeterminate studies require follow-up.
- Ultrasonography is less sensitive and more operator dependent than is DPL in revealing hemoperitoneum and cannot distinguish blood from ascites.
- Ultrasonography (as well as DPL) does not detect the presence of solid parenchymal damage if free intraperitoneal blood is absent, as in subcapsular splenic injury.⁵⁶
- Finally, ultrasonography is poor for detecting a bowel injury in which hemorrhage tends to be inconsequential, and failure to diagnose hollow viscus perforation in a timely manner can have catastrophic results.

Table 18-7 presents indications, advantages, and disadvantages of ultrasonography, DPL, and CT in blunt abdominal trauma.

Genitourinary Tract

When an injury to the genitourinary tract is suspected, urologic consultation is required to further evaluate and diagnose the extent of injury. The major cause of urethral ruptures is blunt trauma. Over 95% of patients with a pelvic fracture have an associated posterior urethral rupture. The force of the injury causes a shearing effect between the urethra and the urogenital diaphragm.³⁴ Anterior urethral ruptures are also commonly associated with blunt trauma. Most of these injuries occur in men.⁵⁷

Blood at the urethral meatus is the single best indicator of urethral trauma.³⁵ The meatus must be carefully inspected for even the slightest amount of blood before inserting a urethral catheter. As is discussed above, attempts to introduce a Foley catheter up an injured urethra can convert an incomplete laceration into a complete laceration with a subsequent retropubic or perineal hematoma.³³ A rectal examination must be performed on all patients with a suspected pelvic injury. With posterior urethral disruption, the prostate may be

forced superiorly by a hematoma. If the prostate is not palpable, a genitourinary injury should be suspected.³³

Absence of blood at the meatus and palpability of the prostate on rectal examination are sufficient evidence to allow the passage of a urethral catheter. If resistance is noted, the catheter should be removed. Retrograde urethrography is the best method to establish continuity of or damage to the urethra.³³

Urine should be obtained and evaluated for the presence of blood. A urinalysis of 10 or more red blood cells on a high-power field is suggestive of a urinary system injury. Hematuria is the best indicator of renal injury, and the degree of hematuria may not correlate with the degree of injury. If the patient with a blunt injury is stable but has hematuria, a CT scan can be used to accurately visualize the genitourinary system and abdominal and retroperitoneal contents.

Extremities

Pelvic fractures, fractures of the femur, and multiple fractures of other long bones may cause hypovolemic shock and life-threatening blood loss, the primary site of which may be difficult to determine. Typical closed fractures of the pelvis may lose 1 to 5 L of blood, femur fractures 1 to 4 L, and arm fractures 0.5 to 1 L from the vasculature.⁵⁸ Certain extremity injuries are considered life threatening because of associated complications—massive open fractures with ragged dirty wounds; bilateral femoral shaft fractures (open or closed); vascular injuries, with or without fractures, proximal to the knee or elbow; crush injuries of the abdomen and pelvis; major pelvic fractures; and traumatic amputations of the arm or leg.⁷

Physical examinations should consist of inspection and palpation of the chest, abdomen, pelvis, and all four extremities. Areas of tenderness, discoloration, swelling, and deformity should be inspected, and proper radiographs should be

Table 18-7 Indications, Advantages, and Disadvantages of DPL, Ultrasonography, and CT in Blunt Abdominal Trauma

	DPL	Ultrasonography	CT
Indication	Document bleeding if ↓ BP	Document fluid if ↓ BP	Document organ injury if BP normal
Advantages	Early diagnosis and sensitive; 98% accurate	Early diagnosis; noninvasive and repeatable; 86–97% accurate	Most specific for injury; 92–98% accurate
Disadvantages	Invasive; misses injury to diaphragm or retroperitoneum	Operator dependent; bowel gas and subcutaneous air distortion; misses diaphragm, bowel, and some pancreatic injuries	Cost and time; misses diaphragm, bowel tract, and some pancreatic injuries

Adapted from American College of Surgeons Committee on Trauma. Advanced trauma life support for doctors: student course manual[®]. 6th ed. Chicago: American College of Surgeons; 1997. p. 166.
BP = blood pressure; CT = computed tomography; DPL = diagnostic peritoneal lavage.

obtained. All peripheral pulses should be examined for evidence of vascular injury. Pulse rates should be equal; any abnormality of distal pulse rates suggests a vascular injury and must be explained. Doppler examination of the extremity is useful, but angiography is the best test for definitively evaluating a suspected vascular injury when the diagnosis is in doubt.⁷

Direct pressure should be used to control hemorrhage, and fractures should be splinted as quickly as possible. Splints should generally include joints above and below the site of injury. Prompt orthopedic consultation should be obtained.

Fat embolism syndrome is usually associated with major fractures of long bones, especially of the femur. The patient typically does well for 24 to 48 hours and then develops progressive respiratory and CNS deterioration. Concomitant laboratory value changes include hypoxemia, thrombocytopenia, fat in the urine, and a slight drop in hemoglobin. Fat enters the venous sinusoids at the fractured site and becomes lodged in the lung alveoli. Fat embolism syndrome has been reported to occur with 30 to 50% of major long-bone and pelvis fractures.⁵⁹ However, with the current coordinated management of multiply injured patients, the incidence of both fat embolisms and ARDS is decreased by expeditious femoral shaft and pelvic

fracture treatment.⁵⁶ The primary treatment is ventilatory assistance. Therapy with steroids and acetylsalicylic acid has been shown to be helpful, possibly because of a reduction of platelet aggregation.

With a better understanding of fluid and electrolyte therapy, an early aggressive management of hemorrhagic shock and prompt surgical treatment are now possible. However, in the interest of acute resuscitation, orthopedic injuries are often overlooked initially and are treated at a later time. When these injuries involve the spine, pelvis, or femur, immobilization of the patient is necessary for the purpose of traction. In immobilized patients with unstable fractures, there is an increased morbidity caused by respiratory failure or sepsis with related multiple organ failure. The severely injured patient with orthopedic fractures who survives the acute phase of treatment generally undergoes a prolonged course in the intensive care unit. This leads to morbidity secondary to decreased musculoskeletal function (eg, muscle wasting, stiff joints, loss of limb length) caused by delays in fracture stabilization and subsequent patient mobilization.⁶⁰ Studies have shown that early fracture stabilization can significantly decrease mortality, musculoskeletal morbidity, and cardiopulmonary and metabolic consequences commonly associated with multiple trauma.⁵⁸

Long-bone fractures are a common cause of fat embolisms and ARDS. Operative fixation of long-bone fractures in patients with multiple injuries within the first few days of injury can minimize the development of fat embolisms.⁵⁶ Primary rigid fixation allows the patient to get out of bed and assume an upright position, thus improving pulmonary and musculoskeletal function. Early mobilization, along with the use of mechanical ventilation with PEEP, lowers the incidences of ARDS and remote organ failure.⁶⁰

References

1. Cales RH, Trunkey DD. Preventable trauma deaths: a review of trauma care systems development. *JAMA* 1985;254:1059–63.
2. Committee on Trauma of the American College of Surgeons. Hospital and prehospital resources for optimal care of the injured patient. *Bull Am Coll Surg* 1983;68:11.
3. Mann NC, Mullins RJ, MacKenzie EJ, et al. Systematic review of published evidence regarding trauma system effectiveness. *J Trauma*. 1999;47(3 Suppl):S25–33.
4. Acosta JA, Yang JC, Winchell RJ, et al. Lethal injuries and time to death in a level I trauma center. *J Am Coll Surg* 1998;186:528–33.
5. Shires GT. Principles of trauma care. 3rd ed. New York: McGraw-Hill; 1985.
6. Hoyt DB, Mikulaschek AW, Winchell RJ. Trauma triage and interhospital transfer. In: Mattox KL, Feliciano DV, Moore EE, editors. *Trauma*. 4th ed. New York: McGraw-Hill; 2000. p. 81–98.

7. Collicott PE. Advanced trauma life support course for physicians. Chicago (IL): American College of Surgeons Committee on Trauma, Subcommittee on Advanced Life Support; 1984.
8. American College of Surgeons Committee on Trauma. Advanced trauma life support for doctors: student course manual. Chicago (IL): American College of Surgeons; 1997.
9. Teasdale G, Jennett B. Assessment of coma and impaired consciousness: a practical scale. *Lancet* 1974;2:81–4.
10. Langfitt TW. Measuring the outcome from head injuries. *J Neurosurg* 1978;48:673–8.
11. Champion HR, Sacco WJ, Carnazzo AJ, et al. The trauma score. *Crit Care Med* 1981;9:672–6.
12. Champion HR, Sacco WJ, Copes WS, et al. A revision of the trauma score. *J Trauma* 1989;29:623–9.
13. Van Natta TL, Morris JA Jr. Injury scoring and trauma outcomes. In: Mattox KL, Feliciano DV, Moore EE, editors. *Trauma*. 4th ed. New York: McGraw-Hill; 2000. p. 69–80.
14. Senkowski CK, McKenney MG. Trauma scoring systems: a review. *J Am Coll Surg* 1999;189:491–503.
15. Powers M. Initial assessment and management of the trauma patient. In: Peterson LJ, Indresano AT, Marciani RD, Roser SM, editors. *Principles of oral and maxillofacial surgery*. Vol 1. Philadelphia (PA): JB Lippincott Company; 1992. p. 269–310.
16. Saletta JD, Geis WP. Initial assessment of trauma. In: Moylan JA, editor. *Trauma surgery*. Philadelphia: JB Lippincott Company; 1988:1–25.
17. American College of Surgeons Committee on Trauma. Field categorization of trauma patients. *Bull Am Coll Surg* 1986;71:10.
18. Tepas JJ, Mollitt DL, Talbert JL, Bryant M. The Pediatric Trauma Score as a predictor of injury severity in the injured child. *J Pediatr Surg* 1987;22:14–8.
19. Boyd CR, Tolson MA, Copes WS. Evaluating trauma care: the TRISS method. *J Trauma* 1987;27:370–8.
20. Champion HR, Copes WS, Sacco WJ, et al. A new characterization of injury severity. *J Trauma* 1990;30:539–45.
21. Osler T. ICISS: an International Classification of Disease-Based Injury Severity Score. *J Trauma* 1996; 41(3):380–6.
22. Cline JR, Scheidel E, Bigsby EF. A comparison of methods of cervical immobilization used in patient extraction and transport. *J Trauma* 1985;25:649–53.
23. Weissberg D, Refaely Y. Pneumothorax: experience with 1,199 patients. *Chest* 2000; 117(5):1279–85.
24. Eckstein M, Henderson S, Markouchick VJ. Thorax. In: Marx J, editor. *Rosen's emergency medicine: concepts and clinical practice*. 5th ed. St. Louis: Mosby Inc.; 2002. p. 387–8.
25. Symbas PN. Autotransfusion from hemothorax: experimental and clinical studies. *J Trauma* 1972;12:689–95.
26. Cogbill TH, Landercasper J. Injury to the chest wall. In: Mattox KL, Feliciano DV, Moore EE, editors. *Trauma*, 4th ed. New York: McGraw-Hill; 2000. p. 483–505.
27. Guyton AC. *Textbook of medical physiology*. 5th ed. Philadelphia: WB Saunders; 1976.
28. Pope PE, Hudson LD. Acute respiratory failure. In: Callaham ML, editor. *Current therapy in emergency medicine*. Toronto: BC Decker Inc; 1987.
29. Mullins RJ. Management of shock. In: Mattox KL, Feliciano DV, Moore EE, editors. *Trauma* 4th ed. New York: McGraw-Hill; 2000. p. 195–232.
30. Luce JM. Respiratory monitoring in critical care. In: Goldman L, Bennett JC, editors. *Cecil textbook of medicine*, 21st ed. New York: WB Saunders Co; 2000. p. 485–89.
31. Bikell WH, Pepe PE, Bailey ML, et al. Randomized trial of pneumatic antishock garments in the prehospital management of penetrating abdominal injuries. *Ann Emerg Med* 1987;16:653–8.
32. Sohmer PR, Dawson RB. Transfusion therapy in trauma: a review of the principles and techniques used in the MEIMSS program. *Am Surg* 1979;45:109–25.
33. McAninch JW. Traumatic injuries to the urethra. *J Trauma* 1981;21:291–7.
34. Pokorny M, Pontes JE, Pierce JM Jr. Urologic injuries associated with pelvic trauma. *J Urol* 1979;121:455–7.
35. McAninch JW. Assessment and diagnosis of urinary and genital injuries. In: McAninch JW, editor. *Trauma management; urogenital trauma*. New York: Theime Stratton; 1985. p. 285–301.
36. Devine PC, Devine CJ Jr. Posterior urethral injuries associated with pelvic fractures. *Urology* 1982;20:467–70.
37. Bell RM, Krantz BE. Initial assessment. In: Mattox KL, Feliciano DV, Moore EE, editors. *Trauma* 4th ed. New York: McGraw-Hill; 2000. p. 153–70.
38. Velanovich V. Crystalloid versus colloid fluid resuscitation: a meta-analysis of mortality. *Surgery* 1989;105:65–71.
39. Rizoli SB. Crystalloids and colloids in trauma resuscitation: a brief overview of the current debate. *J Trauma* 2003;54:S82–8.
40. Barnes A. Status of the use of universal donor blood transfusions. *Clin Lab Sci* 1973; 4:147–60.
41. Faringer PD, Mullins RJ, Johnson RL, Trunkey DD. Blood component supplementation during massive transfusion of AS-1 red cells in trauma patients. *J Trauma* 1993;34:481–7.
42. Garvin AS, Fisher RP. Resuscitation of trauma patients with typespecific uncross-matched blood. *J Trauma* 1984;24:327–31.
43. Guntheroth WG, Abel FL, Mullins GC. The effect of Trendelenburg's position on blood pressure and carotid flow. *Surg Gynecol Obstet* 1964;119:345–8.
44. McSwain NE, Kerstein MD, editors. *Evaluation and management of trauma*. Norwalk (CT): Appleton-Century-Crofts; 1987.
45. Nagy KK, Joseph KT, Krosner SM, et al. The utility of head computed tomography after minimal head injury. *J Trauma* 1999;46:268–70.
46. Bachulis BC, Long WB, Hynes GD, Johnson MC. Clinical indications for cervical spine radiographs in the traumatized patient. *Am J Surg* 1987;153:473–7.
47. Shuck JM, Snow NJ. Injury to the chest wall. In: Mattox KC, Moore EE, Feliciano DV, editors. *Trauma*. Norwalk (CT): Appleton & Lange; 1988. p. 115–23.
48. Ivy ME, Cohn SM. Addressing the myths of cervical spine injury management. *Am J Emerg Med* 1997;15:591–602.
49. Hills MW, Deane SA. Head injury and facial injury: is there an increased risk of cervical spine injury? *J Trauma* 1993;34:549–57.
50. National Spinal Cord Injury Statistical Center (NSCISC). *Spinal cord injury: facts and figures at a glance*. Birmingham (AL):NSCISC: July 1996.
51. Fischer RP. Cervical radiographic evaluation of alert patient following blunt trauma. *Ann Emerg Med* 1984;13:905–7.
52. Griffen MM, Frykberg ER, Kerwin AJ, et al. Radiographic clearance of blunt cervical spine injury: plain radiograph or computed tomography scan? *J Trauma* 2003;55:222–7.
53. Frame SB. Prehospital care. In: Mattox KL, Feliciano DV, Moore EE, editors. *Trauma*, 4th ed. New York: McGraw-Hill; 2000. p. 117.
54. Rozycki GS, Ballard RB, Feliciano DV, et al. Surgeon-performed ultrasound for the assessment of truncal injuries: lessons learned from 1540 patients. *Ann Surg* 1998;228:557–67.
55. Smith RS, Kern SJ, Fry WR, Helmer SD. Institutional learning curve of surgeon-

- performed trauma ultrasound. *Arch Surg* 1998; 133:530–5.
56. Shanmuganathan K, Mirvis SE, Sherbourne CD. Hemoperitoneum as the sole indicator of abdominal visceral injuries: a potential limitation of screening abdominal US for trauma. *Radiology* 1999; 212:423–30.
57. Condon RE, Nyhus CM, editors. *Manual of surgical therapeutics*. 5th ed. Boston: Little Brown and Co; 1981.
58. LaDuca JN, Bone LL, Seibel RW, Border JR. Primary open reduction and internal fixation of open fractures. *J Trauma* 1980; 20:580–6.
59. Riska EB, Von Bonsdorff H, Hakkinen S, et al. Prevention of fat embolism by early internal fixation of fractures in patients with multiple injuries. *Injury* 1976;8:110–5.
60. Johnson KD, Cadambi A, Seiber GB. Incidence of adult respiratory distress syndrome in patients with multiple musculoskeletal injuries: effect of early operative stabilization of fractures. *J Trauma* 1985;25:375–84.

Soft Tissue Injuries

Alan S. Herford, DDS, MD

G. E. Ghali, DDS, MD

In the United States over 11 million traumatic wounds are treated in emergency departments each year. Facial lacerations comprise approximately 50% of these wounds.¹ Facial injuries impact both function and esthetics. There is often a psychological aspect associated with the injury secondary to patient's concern regarding permanent scarring and subsequent facial disfigurement. According to a recent survey, cosmetic outcome is the single most important aspect of care to the patient.²

Principles of Management

The initial examination involves evaluating and stabilizing the trauma patient. Any life-threatening conditions should be identified and managed immediately. The conditions of the airway, breathing, and circulation are examined, followed by a general neurologic assessment with particular attention to cervical spine and cranial injuries.

It is important to achieve hemostasis when stabilizing and evaluating the patient who has sustained trauma. Most bleeding will respond to application of a pressure dressing. Occasionally surgical exploration and packing of the wound under general anesthesia may be indicated. In rare instances vessels in the neck may need to be ligated. Indiscriminate clamping inside the wound should be avoided because damage to important structures such as the facial nerve or

parotid duct may result. It is unusual for bleeding from soft tissue injuries to the face to result in a shock state. Lacerations involving the scalp can occasionally be difficult to control with pressure and may require clamping, ligation, or electrocautery.

In soft tissue injuries not involving the face the length of time from initial injury to treatment is important. Secondary risk of infection increases with the lapse of time.³ Because of the rich vascularity of the face there is no "golden period" for suture repair of facial wounds. In fact healing of facial wounds is unaffected by the interval between injury and repair.⁴

Patients who are immunized and have received a booster injection within the last 10 years do not require tetanus prophylaxis if the wound is not tetanus prone. Tetanus-prone wounds are those with heavy contamination from soil or manure, devitalized tissue, or deep puncture wounds. If the wound is tetanus prone and the patient has not received a booster injection within 5 years prior to the injury, a 0.5 mL tetanus toxoid boost injection should be given. If the patient has not received a booster within 10 years prior, they should receive a booster injection for any wound. Patients who are not immunized should receive both a booster injection and 250 units of tetanus immunoglobulin, followed by a full course of immunization.⁵

Treatment of soft tissue injuries involves early reconstructive procedures addressing both the soft tissue and the underlying bony injury in a minimum number of stages.^{6,7} Occasionally it is better to delay soft tissue repair until the facial fractures have been addressed. In patients with large avulsion of tissue, definitive early reconstruction of the tissue loss with regional or microvascular flaps may be required.^{8,9}

Anatomic Evaluation

Following the initial evaluation and resuscitation, injuries to the soft tissues should be evaluated during the secondary survey. Patients sustaining trauma often have associated soft tissue injuries. Facial injuries can be superficial but may extend to involve adjacent structures including bones, nerves, ducts, muscles, vessels, glands, and/or dentoalveolar structures. Associated injuries, including vascular injury, may develop acutely or days after the injury.^{10,11}

A thorough head and neck examination determines the extent of associated facial wounds. Peripheral cranial nerves are commonly involved with lacerations that involve the face. The facial nerve divides the parotid gland into deep and superficial portions (Figure 19-1). Any injury to the gland should raise suspicion for associated facial nerve injury.¹² The facial nerve exits the stylomastoid foramen and divides into

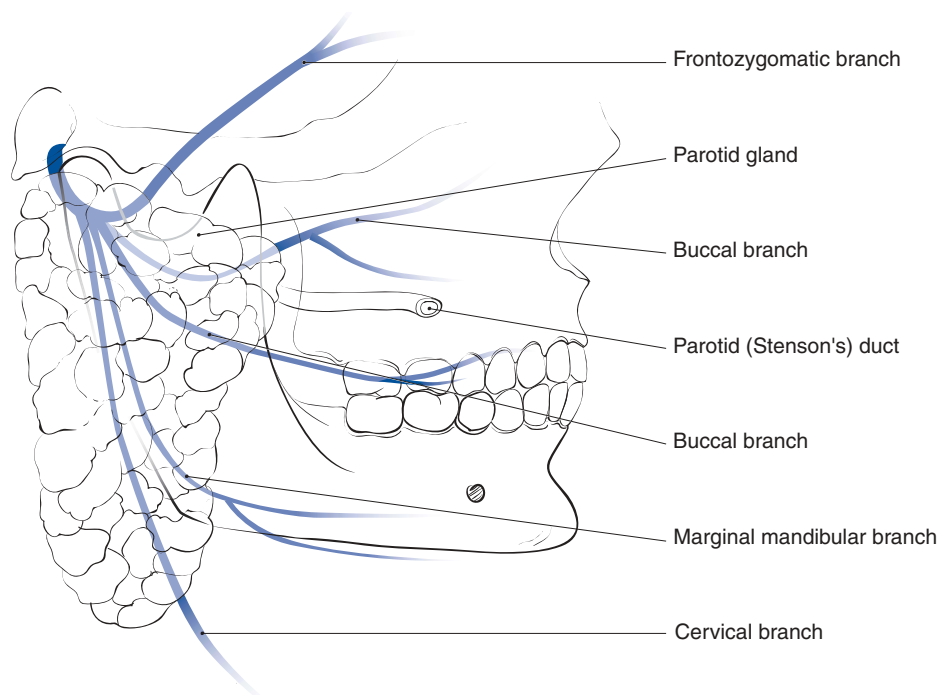


FIGURE 19-1 The facial nerve divides the parotid into a deep and superficial lobe.

five branches within the parotid gland (Figure 19-2). Proximal facial nerve injuries posterior to a vertical line drawn

from the lateral canthus should be repaired using microsurgical techniques. Because of the significant peripheral anastomoses,

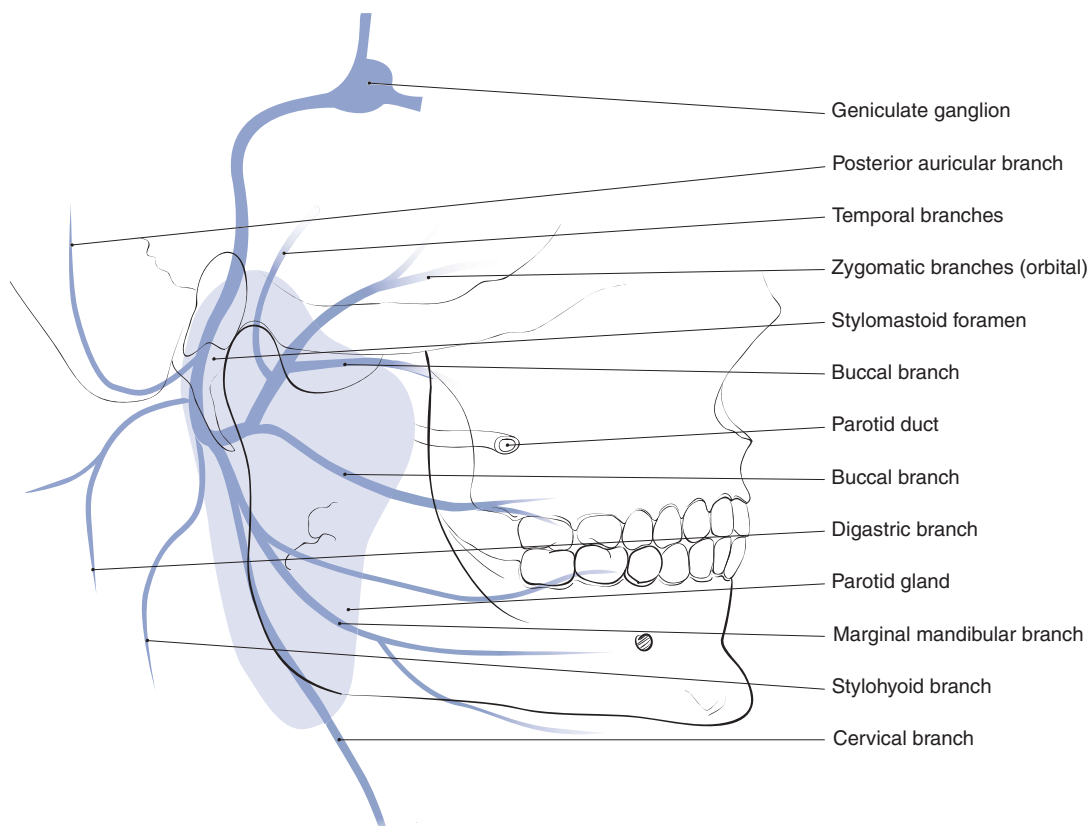


FIGURE 19-2 Anatomy of the facial nerve.

repair of facial nerve injuries involving distal branches anterior to the canthal plane is unnecessary (Figure 19-3).

Injury to the parotid gland can lead to leakage of saliva into the soft tissue. The parotid duct is approximately 5 cm in length and 5 mm in diameter. It exits the gland and runs along the superficial surface of the masseter muscle and then penetrates the buccinator muscle to enter the oral cavity opposite the upper second molar. Treatment of parotid duct injuries depends on the location of the injury. These injuries should be repaired in the operating room with the aid of magnification. If the injury involves the proximal duct while it is still in the gland, the parotid capsule should be closed and a pressure dressing placed. If the injury is located in the midregion of the duct, the duct should be repaired. Injuries involving the terminal portion of the duct should be drained directly into the mouth. Lacrimal probes are useful in cannulating the duct and identifying injuries.

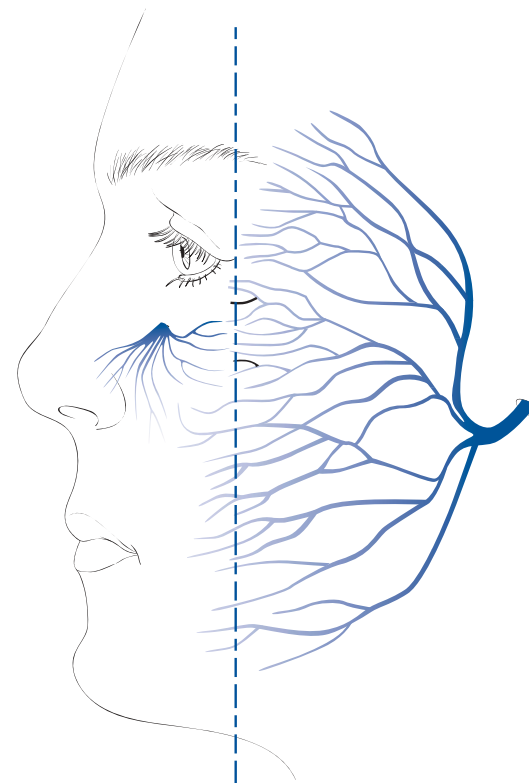


FIGURE 19-3 Zone of arborization of the facial nerve.

A polymeric silicone (Silastic) catheter is placed to bridge the defect. The severed ends are then sutured over the catheter, which is left in place for 10 to 14 days (Figure 19-4). The parotid capsule should be closed to prevent formation of a parotid duct fistula or sialocele. Lacerations are closed primarily and a pressure dressing is placed to prevent fluid accumulation.

There are several protocols for evaluation and treatment of penetrating injuries to the neck, face, and temporal bone. If there is suspicion that deep critical structures have been injured, the appropriate protocol should be followed.

Sequence of Repair and Basic Technique

A decision is made to repair the wound in the emergency department or to perform the repair in the operating room under a general anesthetic. Large complicated lacerations demand ideal lighting and patient cooperation. In injuries where there is a concern that deep structures have been damaged, a general anesthetic affords the best opportunity for exploration and repair. The patient may require repair of other traumatic injuries in the operating room, and on many occasions, definitive repair of associated facial soft tissue injuries can be performed at the same time.

Lidocaine is a popular local anesthetic and ranges in strength from 0.5 to 2%. It is usually administered with epinephrine 1:100,000. Lidocaine has a rapid onset of action, a wide margin of safety, and a low incidence of allergic sensitivity. A thorough evaluation of the seventh cranial nerve should be undertaken prior to injection of anesthetic or administration of a general anesthetic. Injecting local anesthetic prior to cleaning the wound will allow more effective preparation. Local anesthetics containing epinephrine have been used successfully in all areas of the face but may not be optimal in areas where tissue monitoring is critical or where extensive undermining of the soft tissue is necessary.¹³ One should avoid injecting directly into the wound when important landmarks could be distorted. Regional nerve blocks are beneficial in minimizing the amount of local anesthesia required and also prevent distortion of the tissues.¹⁴

After adequate anesthesia has been obtained, the wound is thoroughly débrided. Nonvital tissue is conservatively excised in an attempt to salvage most of the tissue. Devitalized tissue potentiates infection, which inhibits phagocytosis. Persistent infection at a wound site leads to the release of inflammatory cytokines from monocytes and macrophages, which delays wound healing. An anaerobic envi-

ronment results and limits leukocyte function.¹⁵ Soft tissue wounds are often contaminated with bacteria and foreign material. Treatment of these injuries involves copious irrigation and is aimed at minimizing the bacterial wound flora and removing any foreign bodies. With respect to infection rates, studies have shown no statistical difference in wounds irrigated with normal saline when compared to other solutions. Pulsatile-type irrigation devices may be helpful to remove debris, necrotic tissue, and loose material. Hydrogen peroxide impedes wound healing and has poor bactericidal activity. A good rule is to avoid irrigating the wound with any solution that would not be suitable for irrigating the eye. Careful and meticulous cleaning of the wounds primarily will avoid unfavorable results such as “tattooing,” infection, hypertrophic scarring, and granulomas. A scrub brush and detergent soap may be necessary to remove deeply imbedded foreign material. However, soaps may cause cellular damage and necrosis. A surgical blade may be helpful to scrape foreign material that is deeply embedded. Polymyxin B sulfate can be used to remove residual grease or tar in wounds.

Proper cleaning and good surgical technique are imperative in minimizing infection. Infections are rare when the

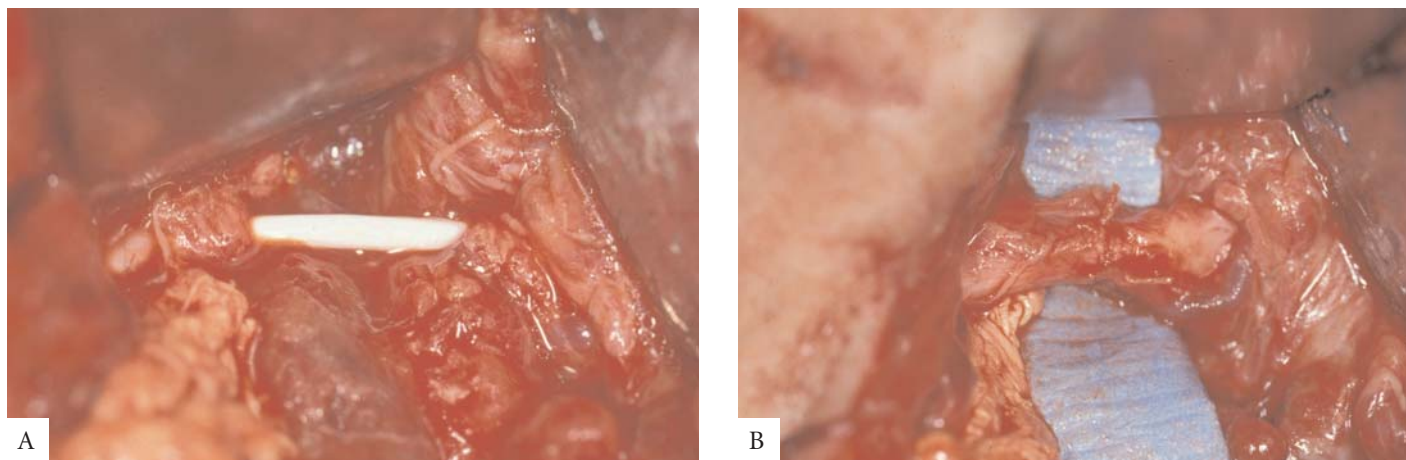


FIGURE 19-4 A, This laceration shows the parotid duct severed and cannulated with a polyethylene tube. B, The duct is sutured over the tubing.

wound is closed so that no dead space, devitalized tissue, or foreign bodies remain beneath the sutured skin. Hydrogen peroxide is minimally bactericidal and toxic to fibroblasts even when diluted to 1:100.¹⁶ Diluted hydrogen peroxide is useful in the postoperative period in cleaning crusts away from incision lines in order to minimize scarring.

Common methods for closing wounds include suturing, applying adhesives, and stapling. It is preferable to suture complex facial lacerations secondary to esthetic considerations. A layered closure is almost always necessary and eliminates dead space beneath the wound. If the dead space is not obliterated, accumulation of inflammatory exudates may occur. This leads to infection, which in turn may cause tension across the epidermis. Tension can cause necrosis of the skin edges due to impairment of the vascular supply and may cause an increase in scarring.¹⁷

Injuries involving anatomic borders such as the vermilion of the lip must be reapproximated precisely. Examples of these landmarks include eyebrows, lip margins, and eyelids. Lacerations should be closed by placing a suture in the center of the laceration to avoid creating excessive tissue on the end of the laceration (dog-ear). Deep layers should be reapproximated with 3-0 or 4-0 buried resorbable sutures. The superficial skin is closed with 5-0 or 6-0 suture. It is important to avoid causing puncture marks when grasping the wound edges. Margins should be undermined to allow slight eversion of the wound margin. Skin sutures should be removed 4 to 6 days after placement. By this time the wound has regained only 3 to 7% of its tensile strength and adhesive strips help support the wound margins.¹⁸

At 7 to 10 days following suture removal the collagen has begun to cross-link. The wound is now able to tolerate early controlled motion with little risk of disruption (Figure 19-5).¹⁹ As the wound

heals it will contract along its length and width and become inverted due to collagen and fibroblast maturation. Initial management is aimed at producing a slightly everted wound edge. The wound continues to remodel up to a year following injury but never regains greater than 80% of the strength of intact skin.

Tissue adhesives are gaining in popularity. Some studies have suggested similar cosmetic outcomes in wounds treated with octylcyanoacrylate when compared to standard wound closure techniques for non-crush-induced lacerations treated less than 6 hours after injury.²⁰⁻²² Closure of lacerations with octylcyanoacrylate is faster than standard wound closure methods. However, its use should be avoided in complex lacerations involving the face, where there are esthetic concerns.

Suture materials and different surgical techniques do not show substantial differences in relation to outcome. General characteristics of the patient (ie, sex and age) and of the wound (ie, length and site) seem to be important predictors of adverse tissue reaction.^{23,24} Suboptimal appearance is associated with wounds that are infected, wide, incompletely approximated, or have sustained a crush injury. The total number of bacteria is more important than the species of bacteria contaminating a wound. Greater than 10^5 aerobic organisms per gram of tissue are needed for contamination, and crush-type wounds are 100 times more susceptible to infection.²⁵

Delayed primary closure may be necessary in some instances. Patients who may benefit from a delayed procedure include those with extensive facial edema, a subcutaneous hematoma, or those with wounds that are severely contused and contain devitalized tissue. Secondary revision procedures are usually undertaken months later to allow for scar maturation.

Clinical examination and radiographs are used to diagnose fractures of the face. Facial fractures are ideally treated prior to

soft tissue repair. If repair of the facial bones is delayed, it is optimal to close the lacerations initially. The wounds can be reentered and revised if needed to access the fracture site.

Types of Injuries

Abrasions

Shear forces that remove a superficial layer of skin cause abrasions. The wound should be gently cleansed with a mild soap solution and irrigated with normal saline. These superficial injuries usually heal with local wound care. It is important to determine whether foreign bodies have been embedded in the wound. Failure to remove all foreign material can lead to permanent “tattooing” of the soft tissue. After the wound is cleansed the abrasion is covered with a thin layer of topical antibiotic ointment to minimize desiccation and secondary crusting of the wound.

Reepithelialization without significant scarring is complete in 7 to 10 days if the epidermal pegs have not been completely removed. If the laceration significantly extends into the reticular dermal layer, significant scarring is likely.

Contusions

Contusions are caused by blunt trauma that causes edema and hematoma formation in the subcutaneous tissues. The associated soft tissue swelling and ecchymosis can be extensive. Small hematomas usually resolve without treatment; hypopigmentation or hyperpigmentation of the involved tissue can occur, but is rarely permanent. Large hematomas should be drained to prevent permanent pigmentary changes and secondary subcutaneous atrophy.

Lacerations

Lacerations are caused by sharp injuries to the soft tissue (Figure 19-6). Lacerations can have sharp, contused, ragged, or stellate margins. The depth of penetration should be carefully explored in the acute

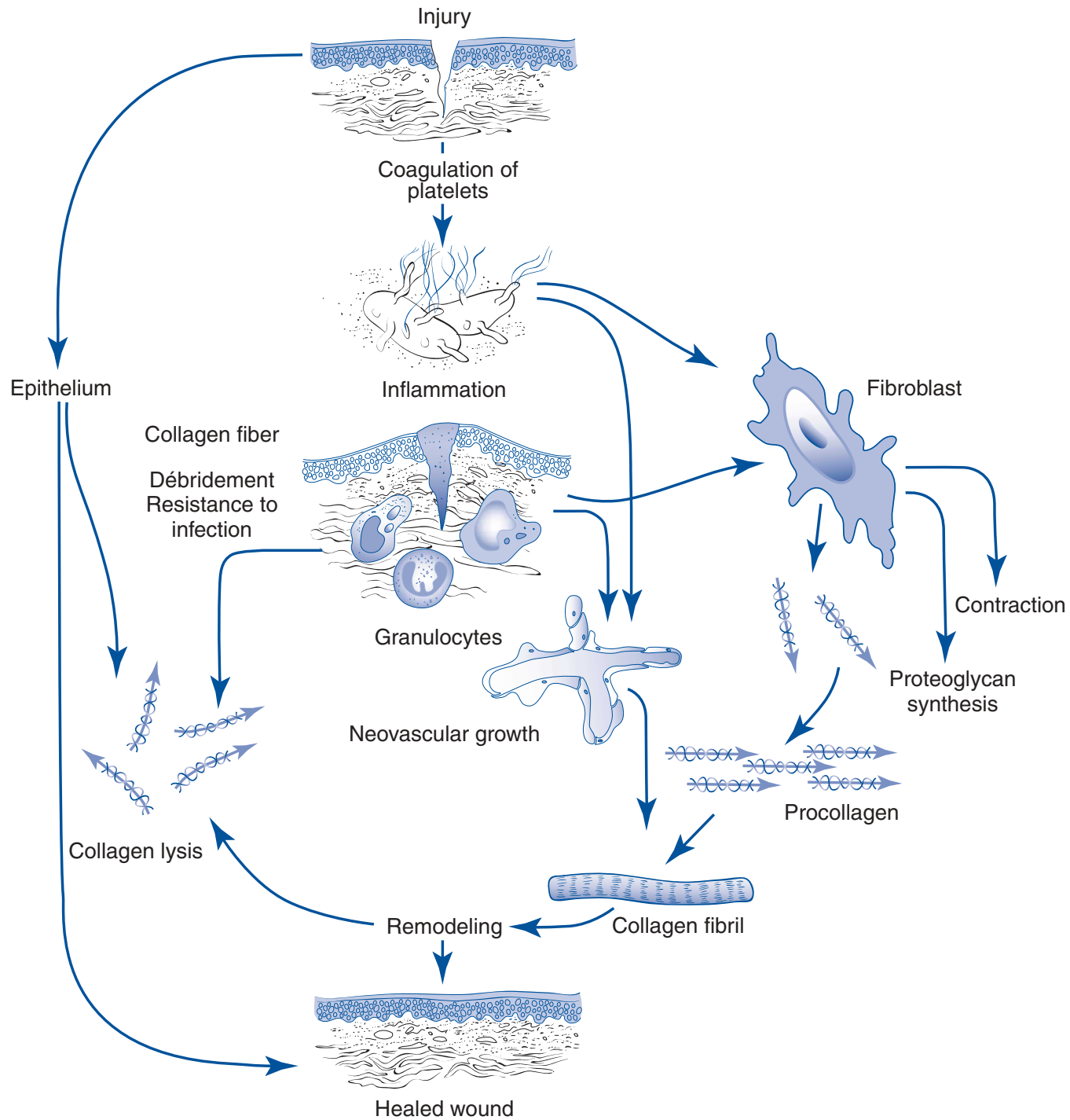


FIGURE 19-5 Stages of wound healing.

setting. Closure is performed using a layered technique. If the margins are beveled or ragged they should be conservatively excised to provide perpendicular skin edges to prevent excessive scar formation. Rarely is there an indication for changing the direction of the wound margins by Z-

plasty at the time of primary wound repair. Flap-like lacerations occur when a component of the soft tissue has been elevated secondary to trauma. Eliminating dead space by layered closure and pressure dressings is especially important in these “trapdoor” injuries.

Avulsive Injuries

Avulsive injuries are characterized by the loss of segments of soft tissue. Undermining the adjacent tissue, followed by primary closure, can close small areas. When primary closure is not possible, other options are considered. These include local flaps or

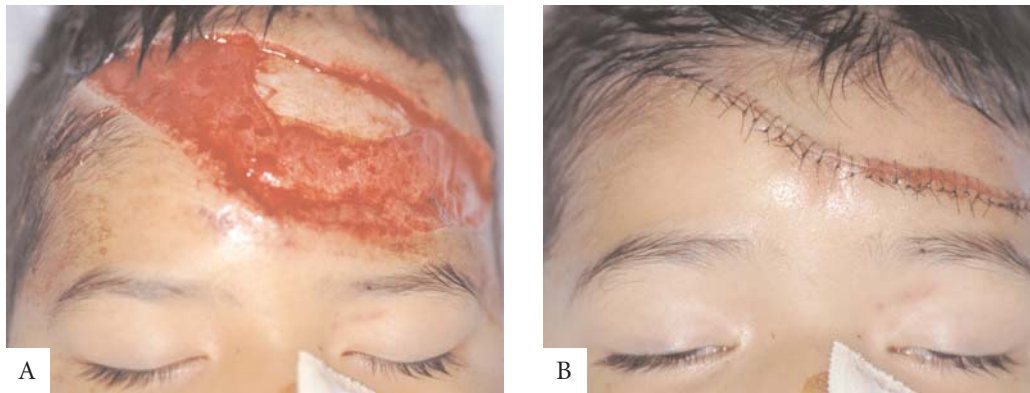


FIGURE 19-6 A, Patient with multiple lacerations. B, Closure of lacerations.

allowing the wound to heal by secondary intention followed by delayed soft tissue techniques. If a significant amount of soft tissue is missing, then a skin graft, local flaps, or free-tissue transfer may be necessary (Figure 19-7).

Animal and Human Bites

Dog bites are most common in children and the midface is frequently involved.^{26,27} Canines can generate 200 to 450 psi when biting, and examination for fractures should be performed.²⁸ Management of bite injuries involves liberal amounts of irrigation and meticulous primary closure.²⁹

Wound irrigation and débridement are important in reducing infection.

Animal and human bites are most often polymicrobial, containing aerobic and anaerobic organisms. Dog bites are often open and lend themselves to vigorous irrigation and débridement. Cats have a large quantity of bacteria in their mouth, with the most frequent and important pathogen being *Pasteurella multocida*.³⁰ Cat bites are associated with a twofold higher risk of infection than the more common dog bite wounds. Because their bites usually cause puncture wounds, they are difficult to clean. Hav-

ing the patient follow up 24 to 48 hours after the initiation of therapy allows the surgeon to monitor the wound for any signs of infection.

Antibiotic prophylaxis for animal bites continues to be debated with few good prospective studies available.^{26,31} Amoxicillin-clavulanate is the current drug of choice for bite wounds. Antibiotic prophylaxis should be directed at *Pasteurella multocida* for infections presenting within 24 hours of injury. For wounds that present after 24 hours of injury, *Streptococcus* and *Staphylococcus* species are more common, and antibiotic prophylaxis with a penicillinase-resistant antibiotic should be chosen.³²

Immediate closure of bite injuries is safe, even with old injuries.³³ There is approximately a 6% rate of infection when bite wounds are sutured primarily in lacerations where there are cosmetic concerns.³⁴ Extensive animal bite wounds involving the face should be treated according to the criteria of esthetic reconstructive surgery. Rabies prophylaxis should be given for bite wounds that occurred from an unprovoked domestic dog or cat that exhibits bizarre behavior or from an attack by a wild animal such as a raccoon, skunk, bat, fox, or coyote.³⁵

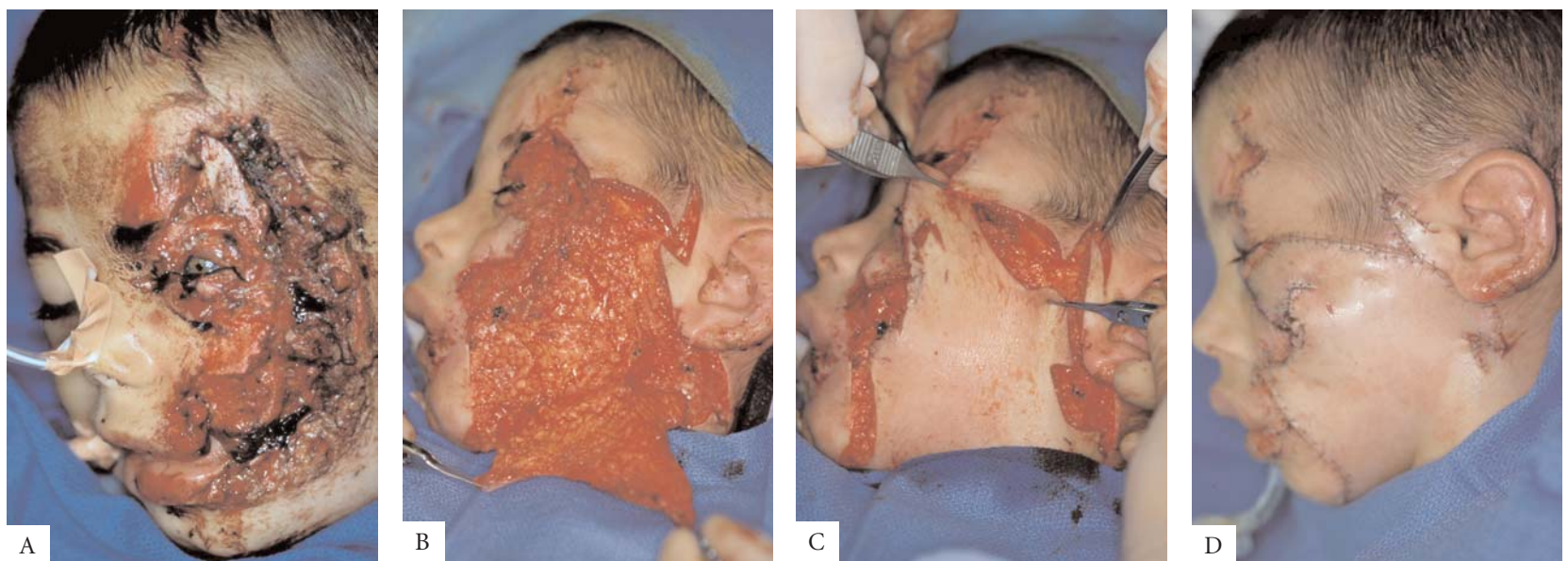


FIGURE 19-7 A, Patient with avulsive injuries including the upper and lower eyelids. B, Elevation of multiple advancement and rotation flaps to gain coverage. C, Securing the flaps into position. D, Closure of lacerations and flaps.

Gunshot Wounds to the Face

Gunshot wounds require careful attention and evaluation for associated facial fractures. Both entry and exit wounds should be evaluated. Exit wounds often produce marked tissue destruction and require acute débridement. Regional flaps can be useful in treating facial soft tissue defects caused by gunshot wounds (Figure 19-8).⁸

Ballistic facial injuries are grouped by etiology: gunshot, shotgun, and high-energy avulsive injuries.³⁶ Over the past 20 years advances in imaging and the intro-

duction of craniofacial approaches with rigid fixation have led to an evolution of treating facial injuries. The esthetic and functional results of facial injury are improved dramatically by the combination of a definitive open reduction of bone with early replacement of soft tissue into its primary position. Immediate definitive reconstructions with rigid fixation of the facial fractures and closure of the lacerations are recommended. Standard incisions often need to be modified because of the soft tissue wounds.

Regional Considerations

Certain anatomic areas deserve special consideration. Reestablishment of anatomic zones with proper orientation is critical in achieving optimal esthetic results.

Scalp and Forehead

Scalp wounds can occasionally cause a large amount of blood loss due to the rich vascular supply in this region and the inelasticity of the scalp preventing contraction and closure of the vessels. The layers of the scalp (SCALP) include the skin, subcutaneous tissue, aponeurosis layer, loose subepicranial space, and pericranial layer.

In patients sustaining scalp injuries it is important to evaluate for associated intracranial injuries. Careful inspection should be performed to look for evidence of skull fractures. Because the scalp has an excellent blood supply in the subcutaneous tissues as well as the pericranial layers, avulsed tissue, skin grafts, and various flaps have a high rate of survival. Hollander and colleagues found no significant difference in rate of infection in scalp lacerations that were irrigated compared to those that were not.³⁷

In avulsive defects in which the pericranium is intact and primary closure is not possible, a split-thickness skin graft can be used. A secondary reconstructive procedure involving various rotational and advancement flaps or tissue expansion can be undertaken after healing of the defect.³⁸ If the cranial bone is exposed with large avulsive defects, then various flap procedures are indicated primarily.

Reconstruction of the eyebrow is difficult secondarily, and efforts to repair lacerations primarily without distortion are important. Eyebrows should never be shaved, as regrowth of the hair is unpredictable. Closure of lacerations should attempt to salvage as much tissue as possible. Care should be taken to avoid damage to the remaining hair follicles. Scars can be removed 6 to 12 months later with

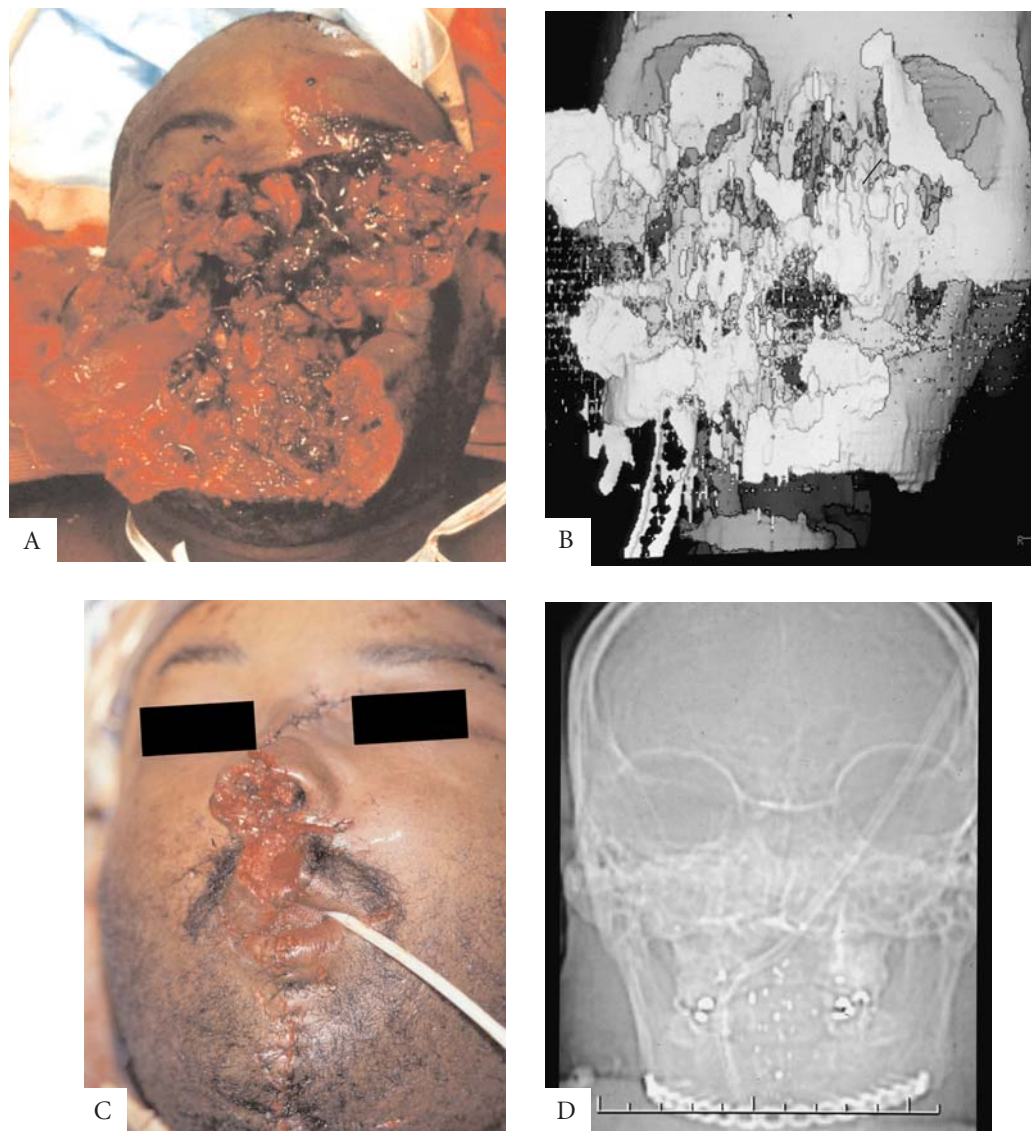


FIGURE 19-8 A, Patient who sustained a shotgun wound with avulsion of tissue. B, Preoperative radiograph showing associated comminuted facial fractures. C, Reapproximation of the bone and soft tissue. D, Postoperative radiograph showing the reduction of multiple facial fractures.

incisions made parallel to the hair follicles to avoid injury.

Eyelid and Nasolacrimal Apparatus

A thorough ophthalmologic examination is important to assess for injuries to the globe and to evaluate and document visual acuity. Closure of lacerations involving the eyelids is done in a layered fashion (Figure 19-9). Care should be taken to precisely reapproximate the eyelid margins and the tarsus (Figure 19-10). The conjunctiva and tarsus are closed with resorbable sutures with the knot buried to avoid irritating the cornea. The orbicular muscle is then closed followed by closure of the skin. Injuries involving the upper eyelid may include detachment of the levator aponeurosis and Müller's muscle from the tarsal plate. The muscles should be identified and reattached to the tarsal plate in order to prevent ptosis and restore levator function.

The lacrimal gland produces tears, which flow across the cornea and drain into canaliculi via the puncta of the upper and lower eyelid margins (Figure 19-11). From the canaliculi the tears enter the nasolacrimal duct and drain into the inferior meatus of the nose. Any lacerations that involve the medial third of the eyelid should be carefully inspected for damage to the canaliculus.³⁹ Repair is accomplished by introducing a lacrimal duct

probe into the puncta and into the wound (Figure 19-12). The ends of the lacerated duct are identified and approximated over a polymeric silicone tube (Crawford tube). The tube is left in place for 8 to 12 weeks. If only one canaliculus is intact and functioning, the patient most likely will have adequate drainage.⁴⁰ If the patient exhibits chronic epiphora postoperatively, then a dacryocystorhinostomy is indicated.

Avulsive injuries to the eyelids are treated with skin grafts and/or local flaps. Defects of up to 25% of the eyelid length can be closed primarily. Skin grafts harvested from the opposite eyelid provide excellent texture and color match.

Nose

The nose occupies a prominent position on the face and is often injured. Injuries of the internal nose should be evaluated using a nasal speculum. The septum should be evaluated for the presence of a hematoma, which appears as a bluish elevation of the mucosa. Hematomas involving the nasal septum should be evacuated with a small incision or needle aspiration. Nasal packing or polymeric silicone nasal splints can be placed to prevent recurrence of the hematomas and are removed in 7 to 10 days. A running 4-0 chromic gut mattress suture placed in and through the septum can prevent recurrence. Untreated hematomas can lead to infection and necrosis of the cartilage, which may cause

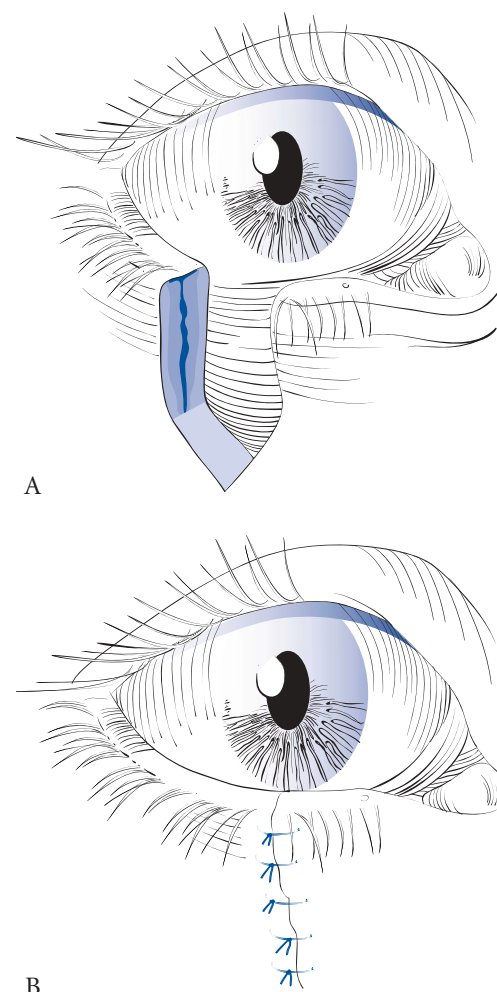


FIGURE 19-10 A, *Pentagonal resection of the lower lid allows straight closure of the tarsal plate.* B, *Closure is made with no suture material through the conjunctiva.*

collapse of the septum and a resultant “saddle nose.”

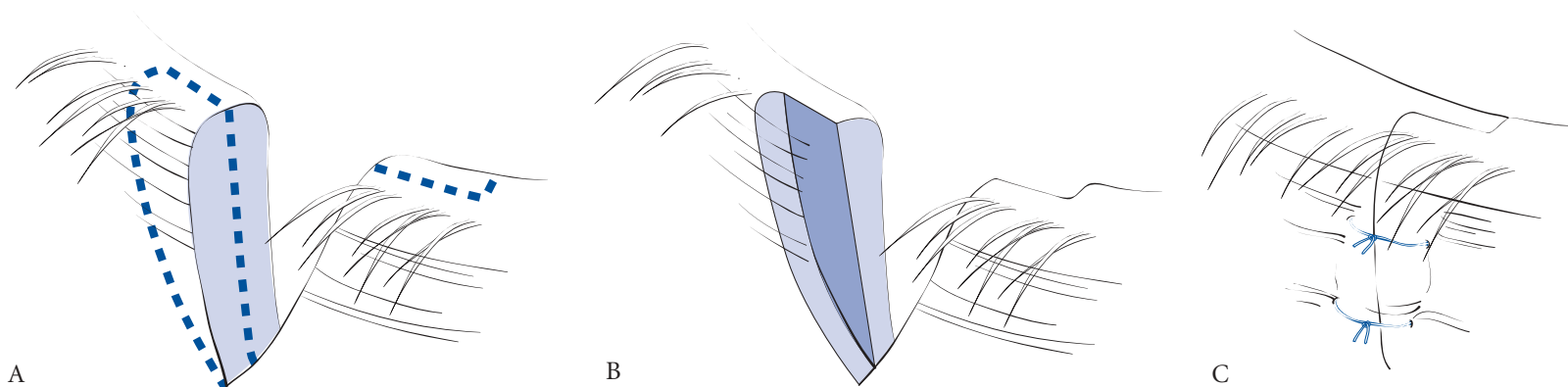


FIGURE 19-9 *Surgical repair of the eyelid. A, Excision of outer lamina on one side and inner lamina on the other. B, After excision. C, Closure. Inner sutures are buried to avoid suture material irritating the conjunctiva.*

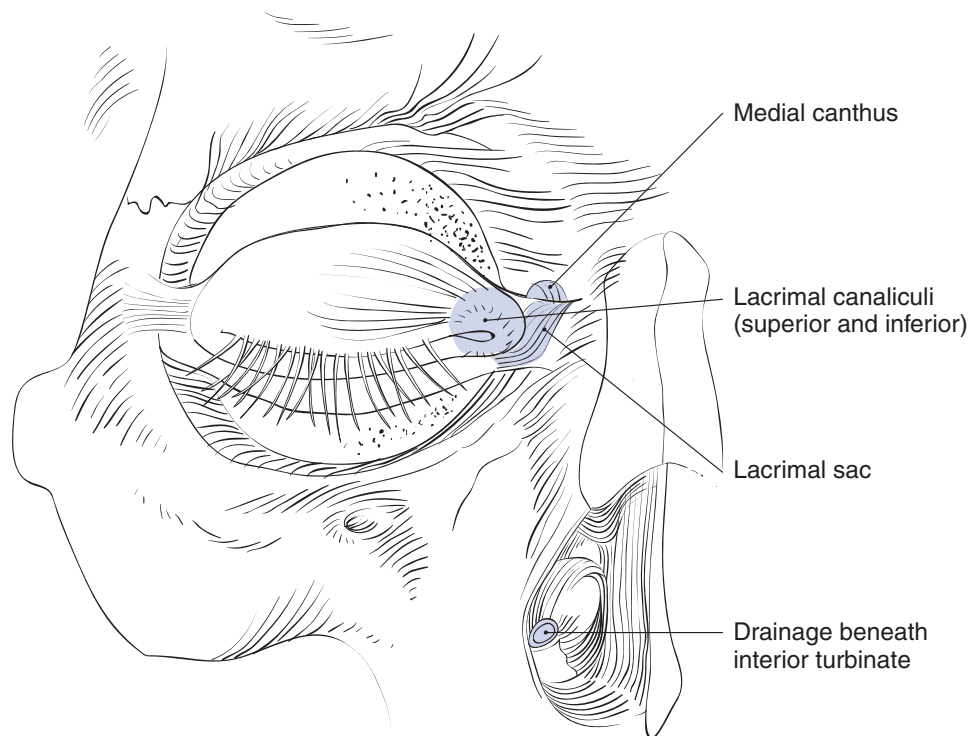


FIGURE 19-11 Nasolacrimal system anatomy.

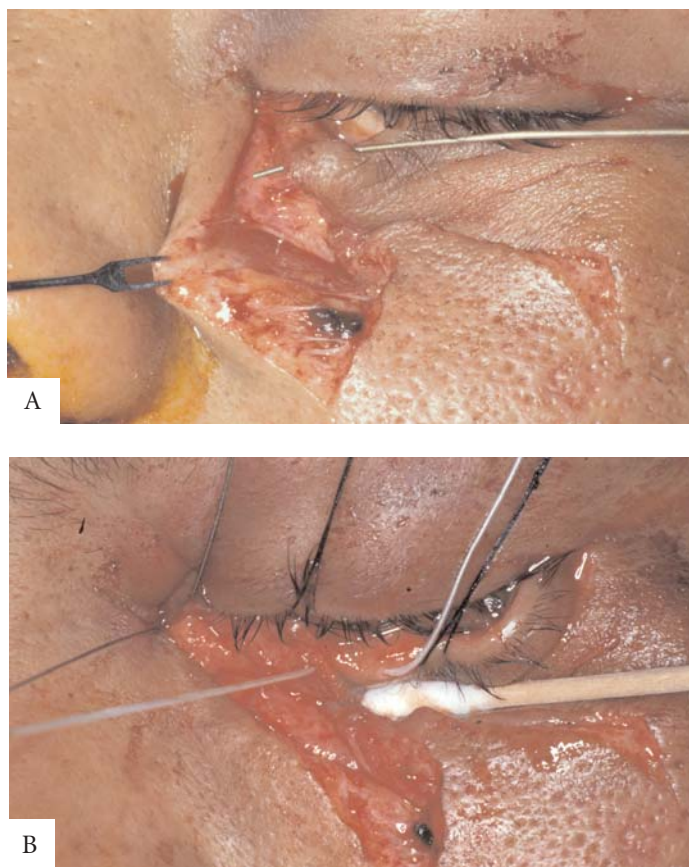


FIGURE 19-12 A, Lacrimal probe identifies the disrupted canalicular. B, A polymeric silicone tube is cannulated through the canalicular.

There is an excellent blood supply to the nose. Lacerations of the external nose should be closed with 6-0 nonabsorbable sutures. Key sutures should be placed to reapproximate anatomic landmarks to ensure proper orientation, especially around the nasal rim. Bone, cartilage, and/or skin grafts may be required to reconstruct avulsive defects of the nose. Skin grafts harvested from the periauricular regions provide excellent color and texture match.⁴¹ Local flaps may be required to restore missing tissue (Figure 19-13).

Ear

Injuries involving the external ear should alert one to the possibility of other injuries. An otoscopic examination of the external auditory canal and tympanic membrane combined with a hearing assessment should be performed prior to treatment. Injuries to the auricle include ecchymosis, abrasion, laceration, hematoma, and partial or total avulsion.

Hematomas involving the ear usually occur when the ear sustains a glancing blow. These should be drained with a needle or incision. An incision is often preferable to simple aspiration because there is less of a chance of reaccumulation of the hematoma.⁴² Evacuation of the hematoma prevents fibrosis and development of a “cauliflower ear” deformity. A bolster dressing should be placed to prevent recurrence of the hematoma. A stent can also be fabricated from polysiloxane impression material and kept in place for 7 days.⁴³

The ear has a very good vascular supply and can maintain tissue on a small pedicle. Injuries involving the cartilage often do not require sutures. If sutures are required a minimal amount are used to avoid devitalizing the region of cartilage (Figure 19-14). Avulsive injuries of the ear can involve a portion of the ear or the entire ear (Figure 19-15). If the avulsed segment is 1 cm or less, it can be reattached and allowed to revascularize.⁴⁴

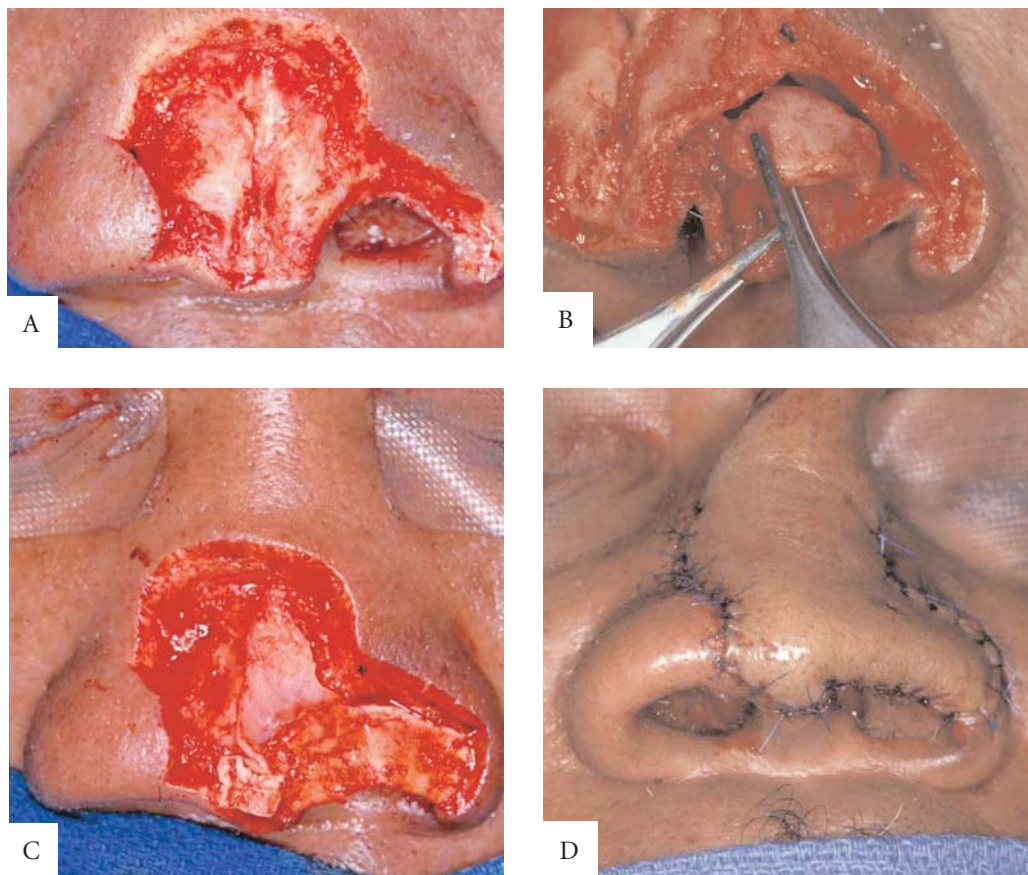


FIGURE 19-13 A, Nasal tip defect resulting from a bite. B, Elevation and advancement of local internal nasal flaps to provide mucosal coverage. C, Placement of cartilage and bone grafts to reconstruct the internal anatomy of the nose. D, The pedicled flap is sutured into place. The flap is divided 3 weeks later.

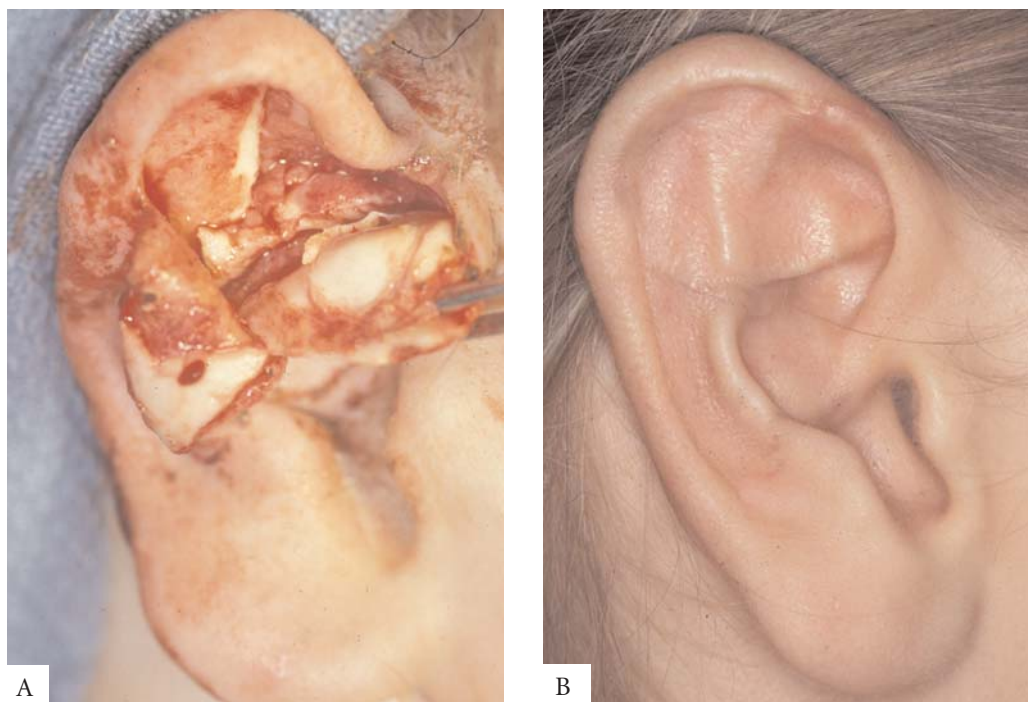


FIGURE 19-14 A, Auricle injury with lacerations involving the cartilage. B, Postoperative appearance.

For larger avulsive injuries the ear should be examined for vessels for the possibility of microvascular reattachment. A more predictable method is to use the “pocket principle” described by Mladick and colleagues (Figure 19-16).⁴⁵ The detached ear is dermabraded to remove the superficial dermis and reattached to the stump. It is then buried underneath a skin flap elevated in the posterior auricular region to provide vascular supply to the reattached ear. Approximately 2 to 3 weeks later the revascularized ear is uncovered and allowed to reepithelialize.

If salvage of the ear is not possible other alternatives include staged reconstruction with rib cartilage, skin flaps, or silicone implants. The introduction of osseointegrated implants has made prosthetic reconstruction an appealing treatment option (Figure 19-17).

Lip

The lip anatomy involves a transition of mucosal tissue to skin. Scars that affect the orbicularis oris may result in functional difficulties. Nerve blocks are helpful in wounds involving the lip to prevent distortion caused from injecting directly into the wound. A single suture should be placed initially to reapproximate the vermilion border exactly. Deep tissues are closed in layers, followed by closure of the mucosa with 4-0 chromic and skin closure with 6-0 nylon suture.

Avulsive defects of the lips require special attention. Up to one-fourth of the lip can be closed primarily with acceptable functional and esthetic results. Injuries that involve a greater amount of tissue loss can be reconstructed with a variety of flaps such as Abbe-Estlander or Karapandzic (Figure 19-18).

Neck

Successful management of penetrating injuries of the neck depends on a clear understanding of the anatomy of the region. Injuries can involve deep structures

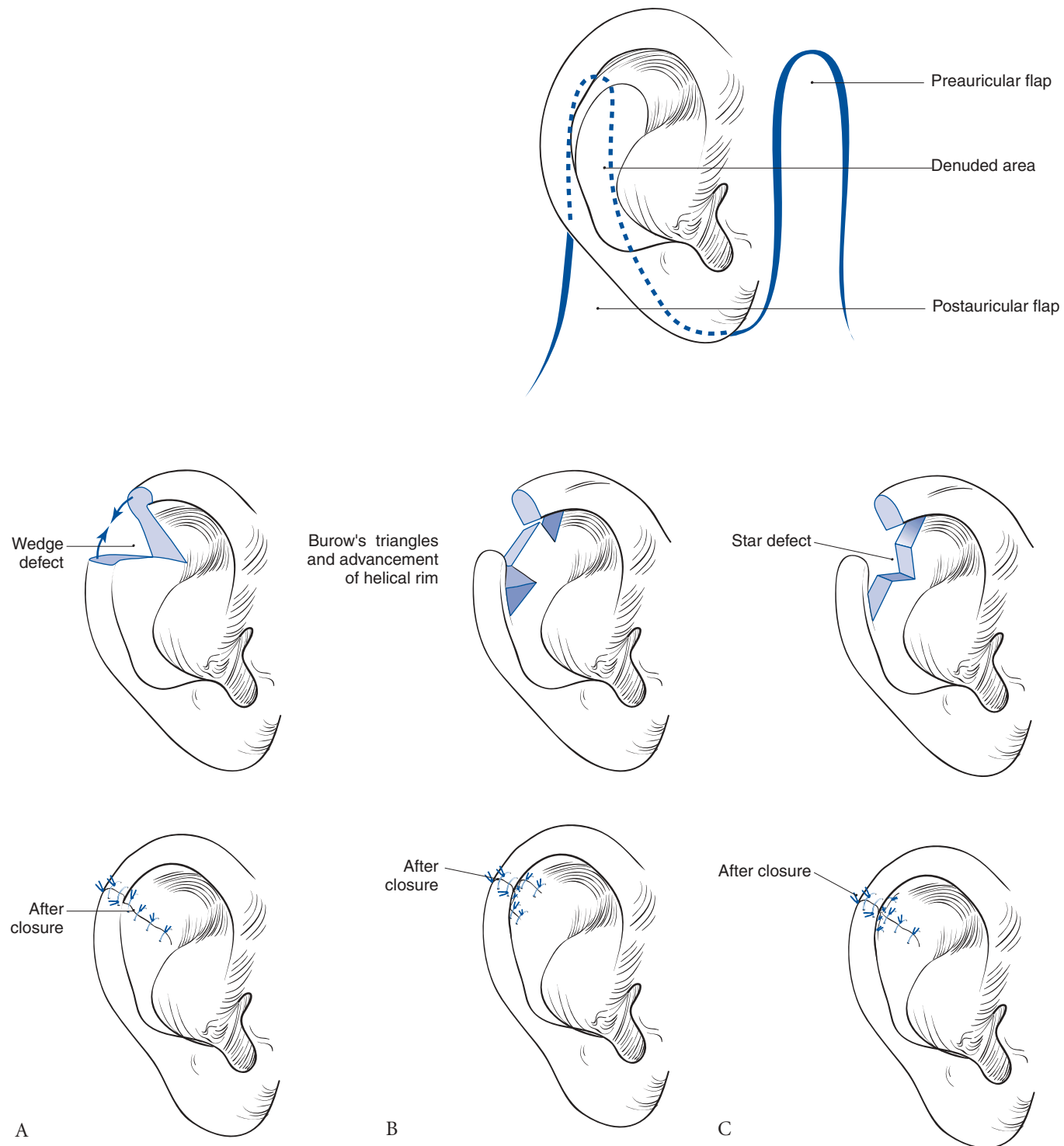


FIGURE 19-15 A, Conversion of a defect to a wedge. B, The use of Burow's triangles. C, Conversion of a defect to a star.

affecting the vascular, respiratory, digestive, neurologic, endocrine, and skeletal systems.⁴⁶ The neck is divided into three anatomic zones.⁴⁷ Zone I extends from the level of the clavicles and sternal notch to

the cricoid cartilage. Zone II is from the level of the cricoid cartilage to the angle of the mandible. It is the most surgically accessible and is the easiest to evaluate intraoperatively without the aid of preoper-

ative diagnostic testing. Zone III extends from the angle of the mandible to the base of the skull.

There is controversy regarding which penetrating neck wounds require exploration.⁴⁶⁻⁵⁰

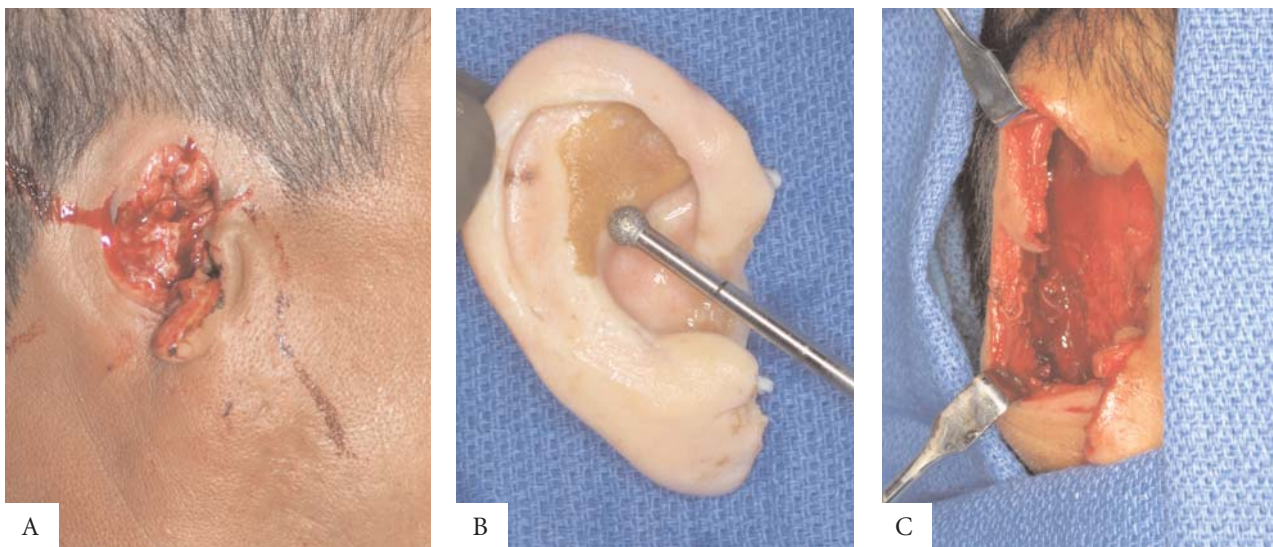


FIGURE 19-16 A, Avulsed ear. B, The ear is thoroughly dermabraded to remove the superficial layer of the dermis. C, Reimplantation of the ear. D, A posterior auricular “pocket” is created. E, The ear is buried beneath a skin flap and allowed to revascularize for 3 weeks prior to uncovering.

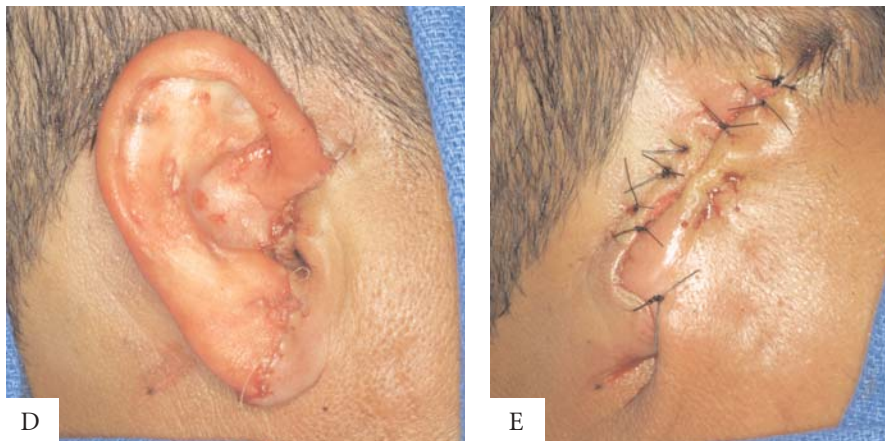


FIGURE 19-17 A, Osseointegrated implants are placed in the area of the defect. B, The prosthesis secured in place with magnets.

Serial physical examinations alone have been shown to be effective. In cases where serial physical examinations are not possible, mandatory exploration of neck wounds may be more beneficial. There should be a high index of suspicion for esophageal injuries because complications can be devastating if repair is delayed. Primary repair is most often indicated in tracheal and vascular injuries.

Postoperative Wound Care

Careful postoperative care and follow-up are important to optimize results. Wounds should be monitored closely to determine whether early intervention is indicated to minimize scar contracture or hypertrophic scarring. Local flaps and grafts may be indicated secondarily. Local injection of steroids provides an

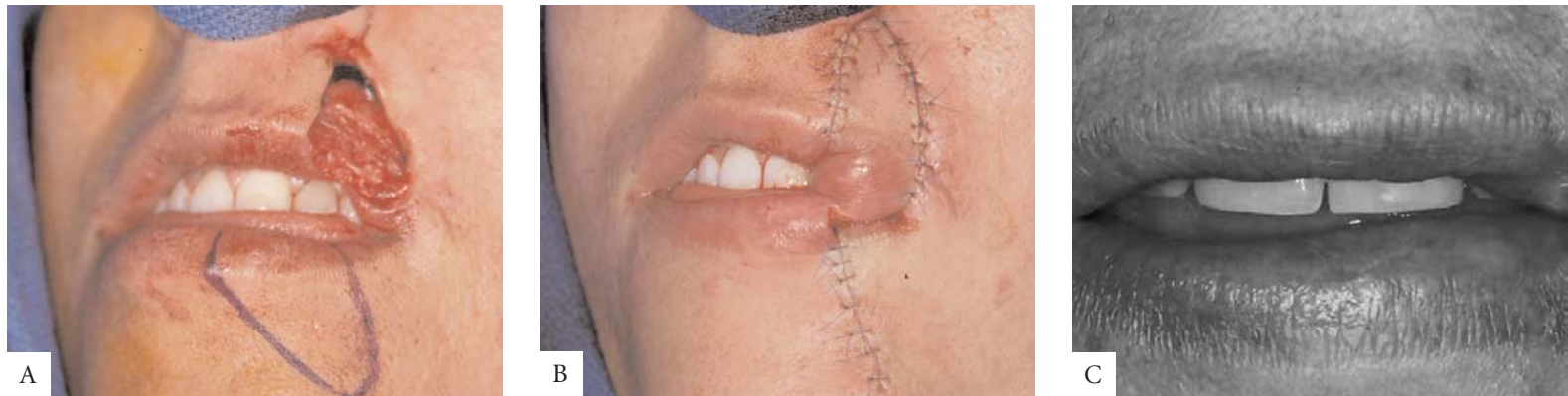

FIGURE 19-18 A, Avulsive lip resulting from a dog bite. The lower lip flap is outlined. B, The pedicled Abbe flap is sutured into place and divided 3 weeks later. C, After division of the flap.

adjunct in the management of specific types of injuries. Facial scars continue to mature over a period of 12 to 18 months. A recent study found no difference in outcome of surgical scars treated with pulsed carbon dioxide laser when compared with dermabrasion.⁵¹

Keeping a wound clean and scab free allows for more rapid reepithelialization.⁵² Epithelial cells survive and migrate better in a moist environment. Antibiotic ointment can enhance this migration. It is not epithelialization that provides strength to the wound but rather the collagen fibers supporting the surface. Rebuilding of fibers takes time, and suturing a wound splints the skin together until new connective tissue is built.

Cleaning daily with dilute hydrogen peroxide and dressing with antibiotic ointment is standard. Patients should avoid sun exposure for the first 6 months after the injury to prevent hyperpigmentation of the areas.

Summary

Soft tissue injuries involving the face can be devastating to the patient. Primary repair of these wounds is almost always advantageous over delayed secondary procedures. The primary goals of treatment are to restore patients to their preoperative state of function and to achieve an esthetic result.

References

- Hollander JE, Singer AJ, Valentine S, et al. Wound registry: development and validation. *Ann Emerg Med* 1995;25:675–85.
- Singer AJ, Mach C, Thode HC Jr, et al. Patient priorities with traumatic lacerations. *Am J Emerg Med* 2000;18:683–6.
- Pearson AS, Wolford RW. Management of skin trauma. *Prim Care* 2000;27:475–92.
- Berk WA, Osbourne DD, Taylor DD. Evaluation of the 'golden period' for wound repair: 204 cases from a Third World emergency department. *Ann Emerg Med* 1998;17:496–500.
- Hsu SS, Groleau G. Tetanus in the emergency department: a current review. *J Emerg Med* 2001;20:357–65.
- Moy LS. Management of acute wounds. *Dermatol Clin* 1993;11:759–66.
- Hollier L, Grantcharova EP, Kattash M. Facial gunshot wounds: a 4-year experience. *J Oral Maxillofac Surg* 2001;59:277–82.
- Motamedi MH, Behnia H. Experience with regional flaps in the comprehensive treatment of maxillofacial soft-tissue injuries in war victims. *J Craniomaxillofac Surg* 1999;27:256–65.
- Zide MF. Pexing and presuturing for closure of traumatic soft tissue injuries. *J Oral Maxillofac Surg* 1994;52:698–703.
- Punjabi AP, Plaisier BR, Haug RH, et al. Diagnosis and management of blunt carotid artery injury in oral and maxillofacial surgery. *J Oral Maxillofac Surg* 1997;55:1388–95.
- Morrisette MP, Chewing LC. Rapid airway compromise following traumatic laceration of the facial artery. *J Oral Maxillofac Surg* 1990;48:989–90.
- Lewkowicz AA, Hasson O, Nahlieli O. Traumatic injuries to the parotid gland and duct. *J Oral Maxillofac Surg* 2002;60:676–80.
- Leach J. Proper handling of soft tissue in the acute phase. *Facial Plast Surg* 2001;17:227–38.
- Zide BM, Swift R. How to block and tackle the face. *Plast Reconstr Surg* 1998;101:840–51.
- Hohn DC, MacKay RD, Halliday B, et al. Effect of oxygen tension on microbicidal function of leukocytes in wounds and in vitro. *Surg Forum* 1976;27:18–20.
- Lineweaver W, Howard R, Soucy D. Topical antimicrobial toxicity. *Arch Surg* 1985;120:267–70.
- Chantarasak ND, Milner H. A comparison of scar quality in wounds closed under tension with PGA (Dexon) and polydioxanone (PDS). *Br J Plast Surg* 1989;687–91.
- Thomas DW, O'Neill ID, Harding KG, et al. Cutaneous wound healing: a current perspective. *J Oral Maxillofac Surg* 1995;53:442–7.
- Key SJ, Thomas DW, Shepherd JP. The management of soft tissue facial wounds. *Br J Oral Maxillofac Surg* 1995;33(2):76–85.
- Singer AJ, Hollander JE, Valentine SM, et al. Prospective, randomized, controlled trial of tissue adhesive (2-octylcyanoacrylate) vs standard wound closure techniques for laceration repair. *Stony Brook Octylcyanoacrylate Study Group. Acad Emerg Med* 1998;5:94–9.
- Singer AJ, Quinn JV, Clark RE, et al. Closure of lacerations and incisions with octylcyanoacrylate: a multicenter randomized controlled trial. *Surgery* 2002;131:270–6.
- Singer AJ, Quinn JV, Thode HC Jr, et al. Determinants of poor outcome after laceration and surgical incision repair. *Plast Reconstr Surg* 2002;110:429–35.
- Gabrielli F, Potenza C, Puddu P, et al. Suture materials and other factors associated with tissue reactivity, infection, and wound dehiscence among plastic surgery outpatients. *Plast Reconstr Surg* 2001;107:38–45.

24. Hollander JE, Singer AJ, Valentine SM, et al. Risk factors for infection in patients with traumatic lacerations. *Acad Emerg Med* 2001;8:716–20.
25. Edlich RF, Rodeheaver GT, Morgan RF, et al. Principles of emergency wound management. *Ann Emerg Med* 1988;17:1284–302.
26. Wolff KD. Management of animal bite injuries of the face: experience with 94 patients. *J Oral Maxillofac Surg* 1998;56:838–43.
27. Kountakis SE, Chamblee SA, Maillard AA, et al. Animal bites to the head and neck. *Ear Nose Throat J* 1998;77:216–20.
28. Dire DJ. Emergency management of dog and cat bite wounds. *Emerg Med Clin North Am* 1992;10:719–36.
29. Morgan JP III, Haug RH, Murphy MT. Management of facial dog bite injuries. *J Oral Maxillofac Surg* 1995;53:435–41.
30. Garcia VF. Animal bites and *Pasturella* infections. *Pediatr Rev* 1997;18:127–30.
31. Gilbert DN, Moellering RC, Sande MA. The Sanford guide to antimicrobial therapy. Vol 32. Hyde Park (VT): Antimicrobial Therapy, Inc.; 2002. p. 36.
32. Callaham M. Prophylactic antibiotics in common dog bite wounds: a controlled study. *Ann Emerg Med* 1980;9:410–4.
33. Donkor P, Bankas DO. A study of primary closure of human bite injuries to the face. *J Oral Maxillofac Surg* 1997;55:479–81.
34. Chen E, Hornig S, Shepherd SM, et al. Primary closure of mammalian bites. *Acad Emerg Med* 2000;7:157–61.
35. Krebs JW, Strine TW, Childs JE. Rabies surveillance in the United States during 1992. *J Am Vet Med Assoc* 1993;203:1718–31.
36. Clark N, Birely B, Manson PN, et al. High-energy ballistic and avulsive facial injuries: classification, patterns, and an algorithm for primary reconstruction. *Plast Reconstr Surg* 1996;98(4):583–601.
37. Hollander JE, Richman PB, Werblud M, et al. Irrigation in facial and scalp lacerations: does it alter outcome? *Ann Emerg Med* 1998;31:73–7.
38. Welch TB, Boyne PJ. The management of traumatic scalp injuries: report of cases. *J Oral Maxillofac Surg* 1991;49:1007–14.
39. Beadles KA, Lessner AM. Management of traumatic eyelid lacerations. *Semin Ophthalmol* 1994;9:145–51.
40. Smit TJ, Mourits MP. Monocanalicular lesions: to reconstruct or not. *Ophthalmology* 1999; 106:1310–2.
41. Herford AS, Zide ME. Reconstruction of superficial skin cancer defects of the nose. *J Oral Maxillofac Surg* 2001;59:760–7.
42. Starck WJ, Kaltman SI. Current concepts in the surgical management of traumatic auricular hematoma. *J Oral Maxillofac Surg* 1992;50:800–2.
43. Starck WJ, McNeir DA. Semirigid stent for use after auricular cartilage graft harvest. *J Oral Maxillofac Surg* 1992;50:95–8.
44. Punjabi AP, Haug RH, Jordan RB. Management of injuries to the auricle. *J Oral Maxillofac Surg* 1997;55:732–9.
45. Mladick RA, Horton CE, Adamson JE, et al. The pocket principle: a new technique for the reattachment of a severed ear part. *Plast Reconstr Surg* 1971;48:219–23.
46. Thompson EC, Porter JM, Fernandez LG. Penetrating neck trauma: an overview of management. *J Oral Maxillofac Surg* 2002; 60:918–23.
47. Roon AJ, Christensen N. Evaluation and treatment of penetrating cervical injuries. *Trauma* 1979;19:391–7.
48. Sriussadaporn S, Pak-Art R, Tharavej C, et al. Selective management of penetrating neck injuries based on clinical presentations is safe and practical. *Int Surg* 2001;86:90–3.
49. Hersman G, Barker P, Bowley DM, et al. The management of penetrating neck injuries. *Int Surg* 2001; 86:82–9.
50. Mazolewski PJ, Curry JD, Browder T, et al. Computed tomographic scan can be used for surgical decision making in zone II penetrating neck injuries. *J Trauma* 2001;51:315–9.
51. Nehal KS, Levine VJ, Ross B, et al. Comparison of high-energy pulsed carbon dioxide laser resurfacing and dermabrasion in the revision of surgical scars. *Dermatol Surg* 1998;24:647–50.
52. Brown CD, Zitelli JA. Choice of wound dressings and ointments. *Otolaryngol Clin North Am* 1995;28:1081–91.

Rigid versus Nonrigid Fixation

Edward Ellis III, DDS, MS

Internal fixation simply implies the placement of wires, screws, plates, rods, pins, and other hardware *directly to the bones* to help stabilize a fracture. Internal fixation can be *rigid* or *nonrigid* depending on the nature of the fracture, and the type, strength, size, and location of the hardware placed. Since various degrees and many types of *nonrigid* fixation exist, it is useful to first define *rigid* internal fixation. By default any technique that does not satisfy this definition can then be considered nonrigid.

Rigid Internal Fixation

The term *rigid internal fixation* has many definitions. For instance, one definition is “any form of bone fixation in which otherwise deforming biomechanical forces are either countered or used to advantage to stabilize the fracture fragments and to permit loading of the bone so far as to permit active motion.”¹ This definition, although admittedly long and perhaps confusing, encompasses the essence of the technique as practiced today and includes clues to the methods of applying the appropriate hardware. A more basic definition which includes the same objectives is “any form of fixation applied directly to the bones which is strong enough to prevent interfragmentary motion across the fracture when actively using the skeletal structure.”² Most of the differences in technique are in the application of the fixation.

Inherent in these definitions is the prerequisite for surgical exposure to anatomically align the fragments (open reduction) and secure the fixation hardware. To rigidly stabilize fractures, an operative procedure is necessary.

Examples of rigid fixation in the mandible are the use of two lag screws or bone plates across a fracture, the use of a reconstruction bone plate with at least three screws on each side of the fracture, and the use of a large compression plate across a fracture (Figure 20-1). Properly applied, these fixation schemes are of sufficient rigidity to prevent interfragmentary mobility during the healing period.

An inseparable corollary to the prevention of interfragmentary mobility by rigid fixation is a peculiar type of bone healing where no callus forms. The bones instead go on to heal by a process of haversian remodeling. Histologically, osteoclasts cross the fracture gap and are followed by blood vessels and osteoblasts (Figure 20-2). New bone is laid down by the osteoblasts, forming osteons which cross the gap and impart microscopic points of bony union to the fracture.³ A remodeling phase then converts the entire area to morphologically normal bone. This type of bone healing is termed *primary* or *direct* bone union, and it requires absolute immobilization between the osseous fragments, that is, *rigid* fixation, and minimal distance (gap) between them.

Nonrigid Internal Fixation

Any form of bone fixation that is *not* strong (rigid) enough to prevent interfragmentary motion across the fracture when actively using the skeletal structure is considered *nonrigid*. The basic difference between rigid and nonrigid fixation centers on interfragmentary mobility. If there is mobility of the osseous fragments during active use of the skeletal structure following application of internal fixation devices, internal fixation is nonrigid. An example of nonrigid fixation is a transosseous wire placed across a mandibular fracture. The wire can only provide stability by virtue of its (limited) ability to prevent spreading of the gap, but by itself, the wire cannot neutralize torsion and/or shear forces. Additional fixation measures then become necessary, such as the use of maxillomandibular fixation (MMF) (Figure 20-3).

However, various forms of nonrigid fixation are recognized, and there is a continuum between rigid fixation and no fixation at all. There are some forms of nonrigid fixation that are strong enough to allow active use of the skeleton during the healing phase but not of sufficient strength to prevent interfragmentary mobility. These types of fixation have been called *functionally stable fixation*, indicating that there is adequate stability to allow function even though

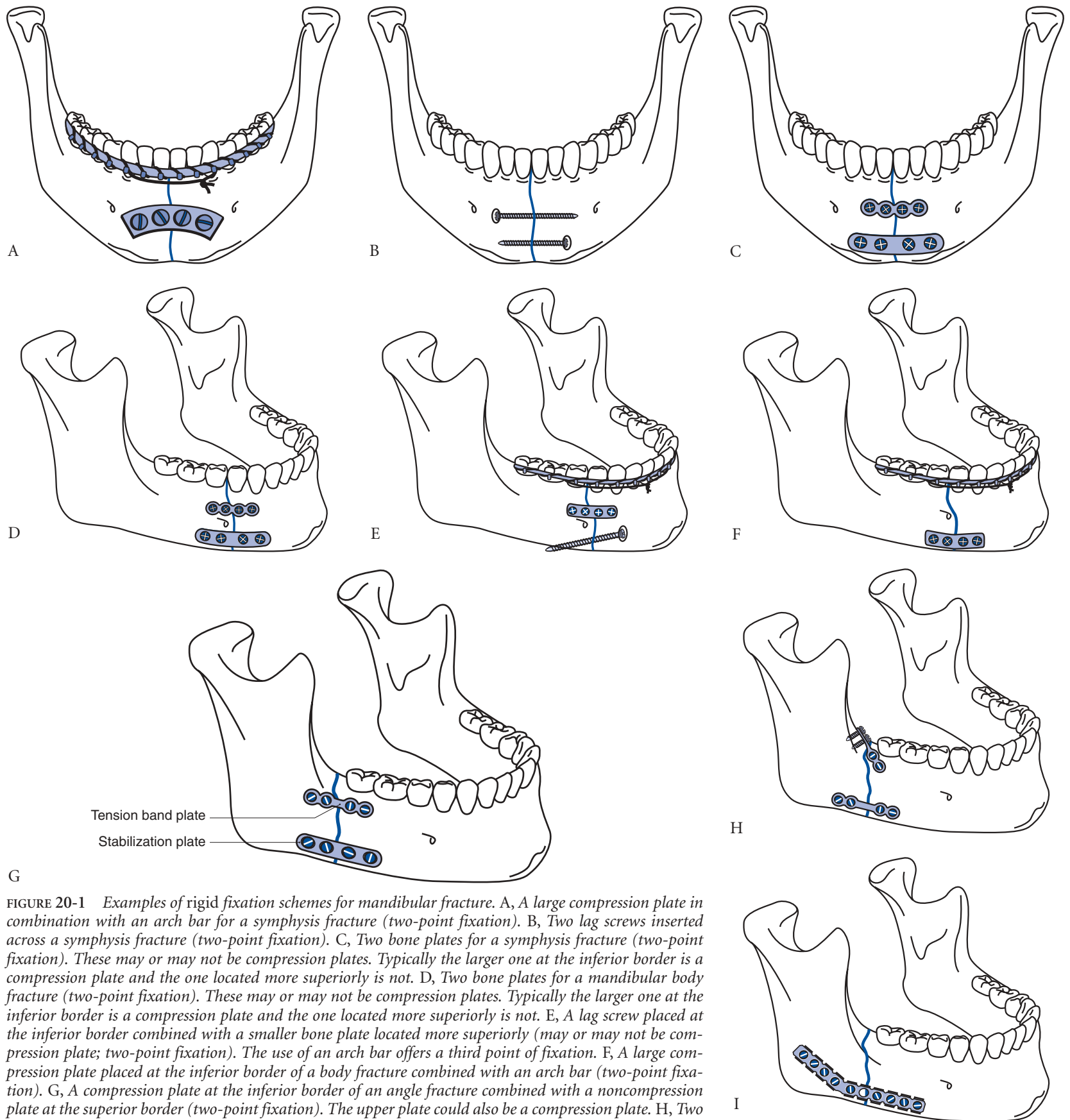


FIGURE 20-1 Examples of rigid fixation schemes for mandibular fracture. A, A large compression plate in combination with an arch bar for a symphysis fracture (two-point fixation). B, Two lag screws inserted across a symphysis fracture (two-point fixation). C, Two bone plates for a symphysis fracture (two-point fixation). These may or may not be compression plates. Typically the larger one at the inferior border is a compression plate and the one located more superiorly is not. D, Two bone plates for a mandibular body fracture (two-point fixation). These may or may not be compression plates. Typically the larger one at the inferior border is a compression plate and the one located more superiorly is not. E, A lag screw placed at the inferior border combined with a smaller bone plate located more superiorly (may or may not be compression plate; two-point fixation). The use of an arch bar offers a third point of fixation. F, A large compression plate placed at the inferior border of a body fracture combined with an arch bar (two-point fixation). G, A compression plate at the inferior border of an angle fracture combined with a noncompression plate at the superior border (two-point fixation). The upper plate could also be a compression plate. H, Two noncompression miniplates applied to an angle fracture (two-point fixation). I, Reconstruction bone plate applied to the inferior border of an angle fracture (one-point fixation). Rigidity is provided by virtue of the thickness (strength) of the plate and the use of at least three bone screws on each side of the fracture.

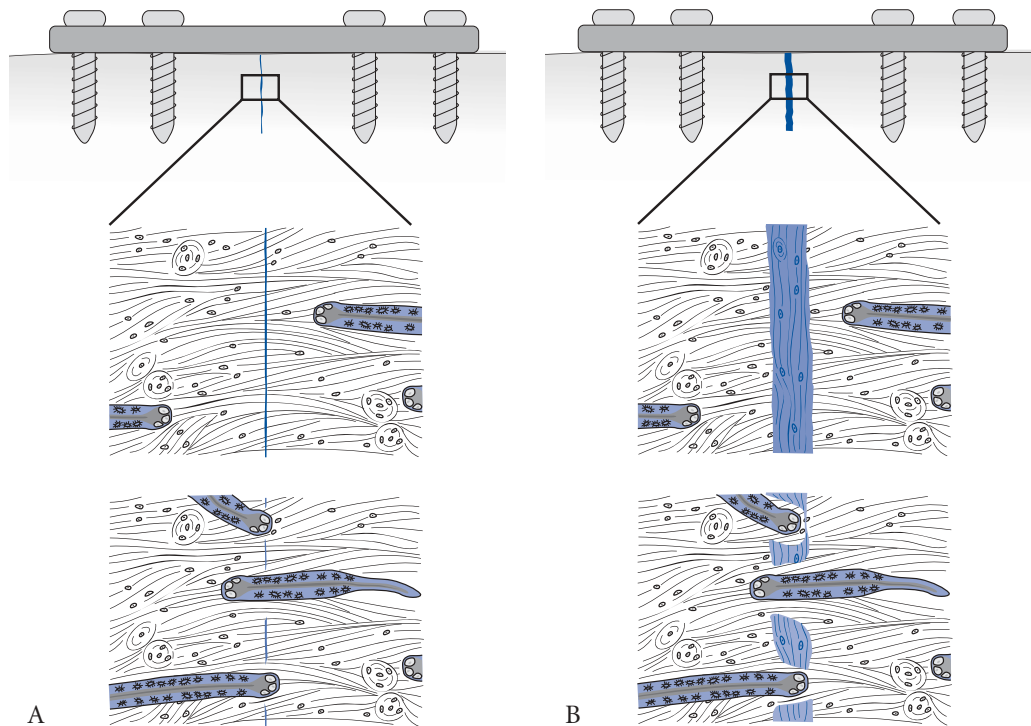


FIGURE 20-2 Types of primary bone healing. A, When there is minimal distance between the fragments, and the fragments are rigidly immobilized, osteoclasts from one fragment “drill” their way into the fracture gap and into the opposite fragment. Behind them come fibrovascular tissue and osteoblasts, which begin to lay down new bone. With maturation these become new haversian canals. This process is usually called contact healing. B, When a small gap exists between the rigidly immobilized fragments, lamellar bone is laid down within the fracture gap. Then the process described above (A) occurs, with new haversian canals crossing the gap. This process is sometimes called gap healing. With either of these types of primary bone healing, no external callus would be found along the outside of the fragments if they were rigidly immobilized. Adapted from Schenk R, Willenegger, H.³

there is not adequate stability to allow direct bone union. Many of the fixation schemes that are being used clinically in

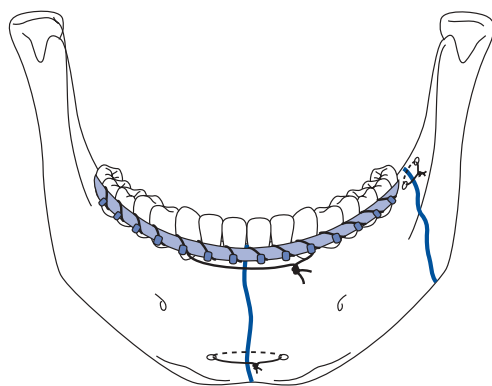


FIGURE 20-3 Internal wire fixation of symphysis and left angle fractures. Note that these wires are not sufficiently stable to allow use of the mandible during the healing process, so maxillo-mandibular fixation is applied for at least 5 weeks (in an adult) to maintain stability.

the maxillofacial area are not truly *rigid* fixation, but *functionally stable* fixation. Functionally stable fixation in maxillofacial surgery is a spectrum that varies from one region of the facial skeleton to another, from one fracture to the next, and from one patient to the next. Examples of functionally stable fixation include the single miniplate technique of treating mandibular angle or body fractures (Figure 20-4).⁴ In spite of the interfragmentary motion that these techniques may permit, the clinical outcomes are excellent, indicating that absolute immobility of the fragments is unnecessary for satisfactory recovery.

In the late 1950s the Swiss Association for the Study of Internal Fixation (AO/ASIF) promulgated four biomechanical principles in fracture management⁵:

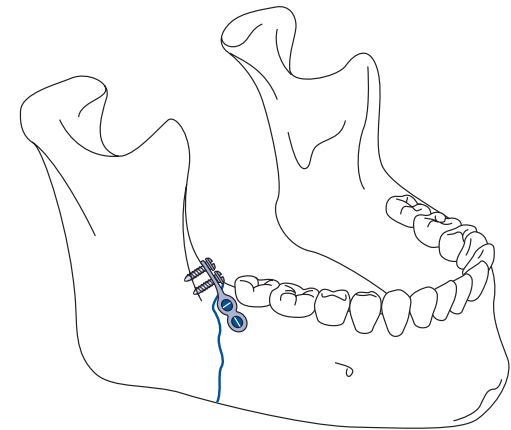


FIGURE 20-4 The Champy method of treating angle fractures using a single, noncompression miniplate attached with 2.0 mm monocortical screws. Because this plate is placed in the most biomechanically advantageous area for this region (superior border), a small plate can neutralize the functional forces and permit active use of the mandible during the healing process. However, although this technique is functionally stable, interfragmentary motion probably occurs to some extent during function. It is therefore not rigid fixation. Adapted from Champy M et al.⁴

1. Accurate anatomic reduction
2. Atraumatic operative technique preserving the vitality of bone and soft tissues
3. Rigid internal fixation that produces a mechanically stable skeletal unit
4. Avoidance of soft tissue damage and “fracture disease” by allowing early, active, pain-free mobilization of the skeletal unit

These principles had as their aim the rigid fixation of fractures. In recognition of the finding that functionally stable fixation is very effective clinically, in 1994, the AO/ASIF changed its third biomechanical principle from rigid internal fixation to functionally stable fixation.

Bone healing under the condition of mobility between the osseous fragments is termed *indirect* or *secondary* bone healing. In such circumstances there is deposition of periosteal callus, resorption of the fragment ends, and tissue differentiation through various stages from fibrous to osseous (Figure 20-5). Bone cannot

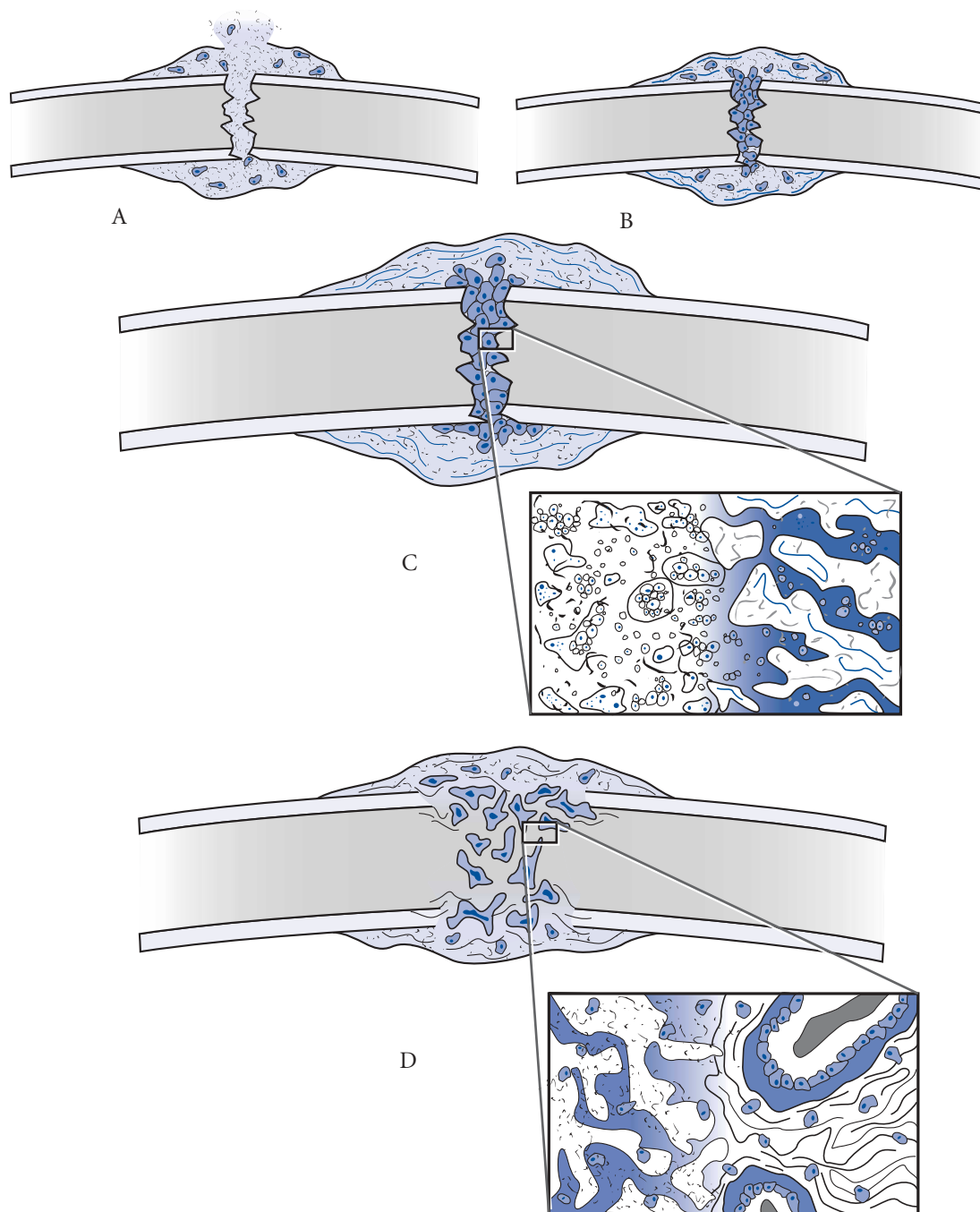


FIGURE 20-5 Secondary or indirect bone healing. A, After a fracture occurs, a subperiosteal hematoma is formed followed by initial invasion of granulation tissue. B, A thin rim of bone forms under the periosteum by membranous ossification. Hyaline cartilage is formed progressing toward and eventually penetrating the fracture gap. C, The cartilage cells form columns, increase in size, and narrow the intercellular matrix. Small fingerlike extensions of vessels penetrate these columns. The cartilage is replaced with woven bone. D, As the osseous matrix matures, remodeling and replacement of woven bone continues until a lamellar pattern is present. Adapted from Muller ME et al.⁵

form across a mobile gap. The formation of a callus can be thought of as nature's internal fixation, providing stability to the osseous fragments so that bone union can proceed. The appearance of a

callus on a radiograph indicates that there is mobility between the fragments, requiring the deposition of the callus to "immobilize" the fragments to allow ossification to proceed.

Selection of Fixation Schemes: How Much Fixation (Rigidity) is Enough?

With that prelude into definitions of fixation types, the remainder of this chapter will discuss some of the variables in the selection of fixation schemes for fractures of the mandible. Because the mandible is the only bone in the face that is mobile and subjected to deforming forces from powerful muscles, not much will be said about the midface. However, whether in trauma or orthognathic surgery, the type of fixation that is required in the midface is functionally stable "adaptation" osteosynthesis. The bones are simply placed into a certain position and the fixation devices are applied to maintain that position. One would therefore not use compression plates in the midface (with the possible exception of the frontozygomatic suture area) because of their ability to change the spatial relationship of the bones by applying an active force across the fracture or osteotomy. However, bone plates of sufficient strength must be applied across a fracture or osteotomy gaps to allow the transmission of functional forces across the gap without an alteration in the occlusion. The application of very thin bone plating systems seems to be able to provide such stability in most fractures or osteotomies when placed in multiple locations. For instance, at the Le Fort I level, four thin bone plates (1.3 or 1.5 mm systems) provide functionally stable fixation under most circumstances. However, when there has been a large movement of the maxilla such as in a maxillary advancement or inferior repositioning procedure, thicker and stronger bone plates would usually be required (Figure 20-6).

Biomechanic Studies versus Clinical Outcomes

When selecting a fixation scheme for a given fracture, one has to consider many things, such as the size and number of fix-

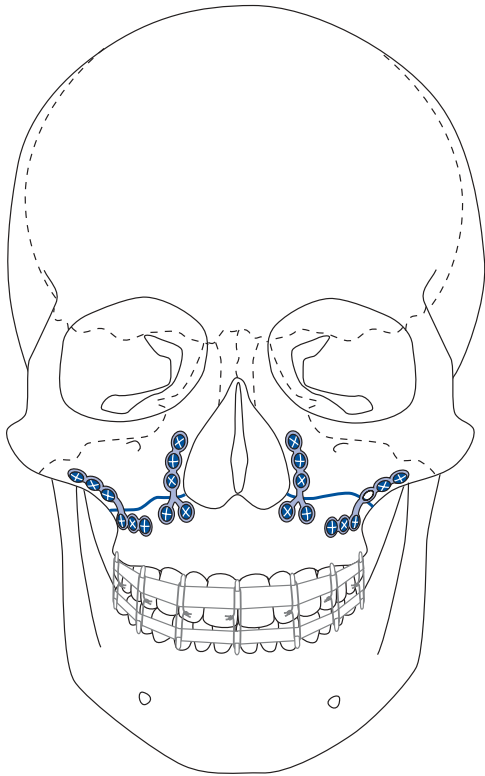


FIGURE 20-6 Use of four bone plates across the Le Fort I level of a fracture. These plates can be quite thin (ie, 1.3 or 1.5 mm) if four are used. However, stronger plates (ie, 2.0 mm) should be used where bone interfaces are less favorable, or when the maxilla is placed into a position that is resisted by soft tissue forces (ie, maxillary advancement or inferior repositioning).

ation devices, their location, the surgical approach, and the amount of soft tissue disruption necessary to expose the fracture and place the fixation devices. In choosing the fixation scheme for the fracture, one might intuitively feel that more rigid fixation is better than less rigid fixation. However, it is clear from the literature on outcomes of mandibular fractures that the stability of the fracture construct is only one variable in determining a successful outcome for the patient. The results from every study ever performed in the laboratory or in computer modeling have shown that two bone plates applied to a fracture are more stable than one.⁶⁻⁸ However, there has never been any statistically significant evidence from clinical studies that two plates perform better than one. In fact, the results of my own studies

for fractures of the angle of the mandible show that two plates perform much more poorly than does one plate in that location.⁹⁻¹³ One must therefore be very careful in applying treatment recommendations from laboratory studies to the patient. Fracture stability is only one factor in the treatment equation. There are many others, such as maintenance of blood supply, that must also be considered when determining treatment recommendations.

Load-Bearing versus Load-Sharing Fixation

The most simplistic way to discuss fixation schemes for fractures is to break them down into those fixation devices that are load-bearing and those that share the loads with the bone on each side of the fracture (load-sharing). Load-bearing fixation is a device that is of sufficient strength and rigidity that it can bear the entire load applied to the mandible during functional activities. Injuries that require load-bearing fixation are comminuted fractures of the mandible, those fractures where there is very little bony interface because of atrophy, or those injuries that have resulted in a loss of a portion of the mandible (defect fractures). In such cases the fixation device must bridge the area of comminution, minimal bone contact, or bone loss, and bear all of the forces transmitted across the injured area that are generated by the masticatory system. Load-bearing fixation is sometimes called bridging fixation because it bridges areas of comminution or bone loss. The most commonly used load-bearing device is a mandibular reconstruction bone plate (Figure 20-7). Such plates are relatively large, thick, and stiff. They use screws that are generally greater than 2.0 mm in diameter (most commonly 2.3 mm, 2.4 mm, or 2.7 mm). When secured to the fragments on each side of the injured area by a minimum of three bone screws, reconstruction bone plates can provide temporary stabili-

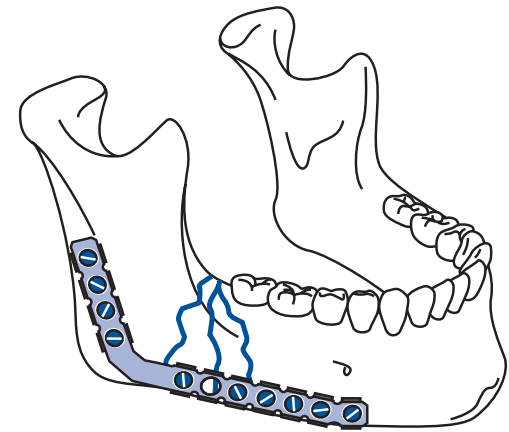


FIGURE 20-7 Example of load-bearing fixation. The application of a large reconstruction bone plate across an area of comminution or bone loss allows active use of the mandible. The plate bears all of the loads applied across the fracture. It therefore is unnecessary for the intervening bony fragments to share any of the load.

ty to the bone fragments. The bone plates are not prosthetic devices and will usually fail in time (several months to years later) by either loosening of the screws or fracture of the plate, but can provide stability until the comminuted fragments have consolidated and/or the missing bone has been replaced with grafts.

Load-sharing fixation is any form of internal fixation that is of insufficient stability to bear all of the functional loads applied across the fracture by the masticatory system. Such a fixation device(s) requires solid bony fragments on each side of the fracture that can bear some of the functional loads. Fractures that can be stabilized adequately with load-sharing fixation devices are simple linear fractures, and constitute the majority of mandibular fractures. Fixation devices that are considered load-sharing include the variety of 2.0 mm miniplating systems that are available from a number of manufacturers. Examples of load-sharing fixation for angle fractures are demonstrated in Figure 20-1A-H. Lag screw techniques are also load-sharing in that the bone that is compressed is sharing the functional loads with the screws. Simple linear fractures can also be treated by load-bearing fixa-

tion. Comminuted or defect fractures, or those where a minimum of bone contact is present, cannot be treated by load-sharing fixation because there is insufficient bone stock adjacent to the fracture to resist displacement by functional forces.

Regional Dynamic Forces

Different regions of the mandible undergo different magnitudes and direction of forces. In simplistic terms fractures of the angle under most functional situations tend to “open” at the superior border (Figure 20-8A and B). Therefore, the application of fixation devices at the

superior border is more effective in preventing this separation of fragments under function than applying them at the inferior border (Figure 20-8C and D). There is little tendency for isolated fractures of the angle to have medial or lateral displacement during function, so the fixation requirement is mainly to prevent separation of the superior border. Relatively small plates can therefore adequately control this fracture. The Champy miniplate technique functions extremely well for this fracture and consists of a 2.0 mm miniplate applied with monocortical screws along the superior

border (see Figure 20-4).⁴ Because metallic plates have high tensile strength, even thin plates work adequately at the angle to prevent the tendency for a gap to form at the superior border under function.¹³

Isolated fractures of the mandibular body behave similarly under function, with a tendency for a gap to form at the superior surface, but the more anterior the fracture, the more tendency for torquing of the fragments to occur, causing mediolateral misalignment of the inferior border. While the arch bar may provide sufficient resistance to the tendency for a gap to form between the teeth under function, a plate

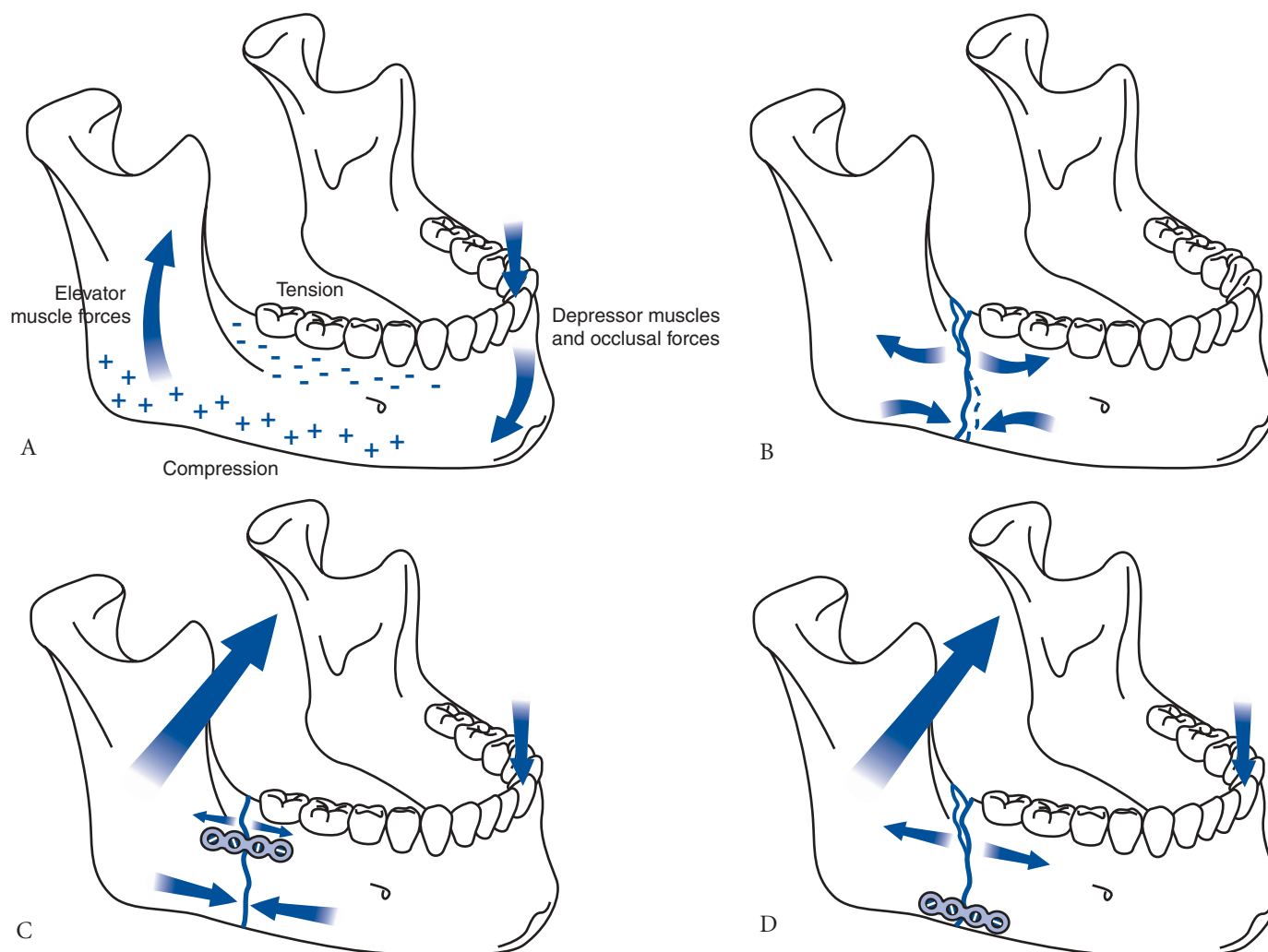


FIGURE 20-8 Functional forces acting across the intact mandibular angle or body region (A) and after a fracture (B). Note that a gap tends to form at the superior border of a fractured mandibular angle secondary to muscle and occlusal forces. The superior border is therefore called the zone of tension (separation), whereas the inferior border is under compressive force during function (compression zone). C, A small bone plate applied along the zone of tension (separation) is very effective in countering the forces of mastication, and effectively neutralizes the forces, maintaining closure of the fracture gap. D, A small plate applied in the zone of compression (inferior border) is very ineffective in neutralizing the muscle forces, and a gap will easily form superiorly in the zone of tension.

or lag screws somewhere else on the body of the mandible is necessary to prevent the mediolateral displacement that accompanies the torquing motion under function. For isolated body fractures, this can be a relatively small plate, such as a 2.0 mm miniplate or even a single lag screw combined with a solid arch bar (Figure 20-9).

The directions of forces that are distributed through the anterior mandible vary with the activity of the mandible. This means that the classical zones of tension on the superior and compression on the inferior surfaces of the mandible are not absolute.^{7,8} Instead, the anterior mandible undergoes shearing and torsional (twisting) forces during functional activities.^{4,14} Application of fixation devices must therefore take these factors into consideration. This is why most surgeons advocate two points of fixation in the symphysis: either two bone plates, two lag screws, or possibly one plate or lag screw combined with an arch bar (see Figure 20-1A-H).¹⁴

One-Point versus Two-Point Fixation

Mandibular fractures can be treated by the application of fixation devices at one place along the fracture or at more than one point, generally two. There is no doubt that the addition of a second point of fixation provides more stability to the fracture. However, to take mechanical advantage of more than one point of fixation, the fixation

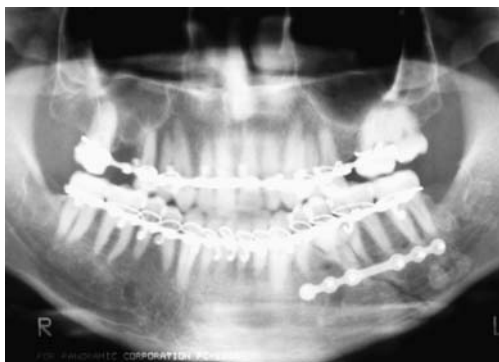

FIGURE 20-9 Example of a simple isolated mandibular body fracture treated by the application of arch bars and a single 2.0 miniplate.

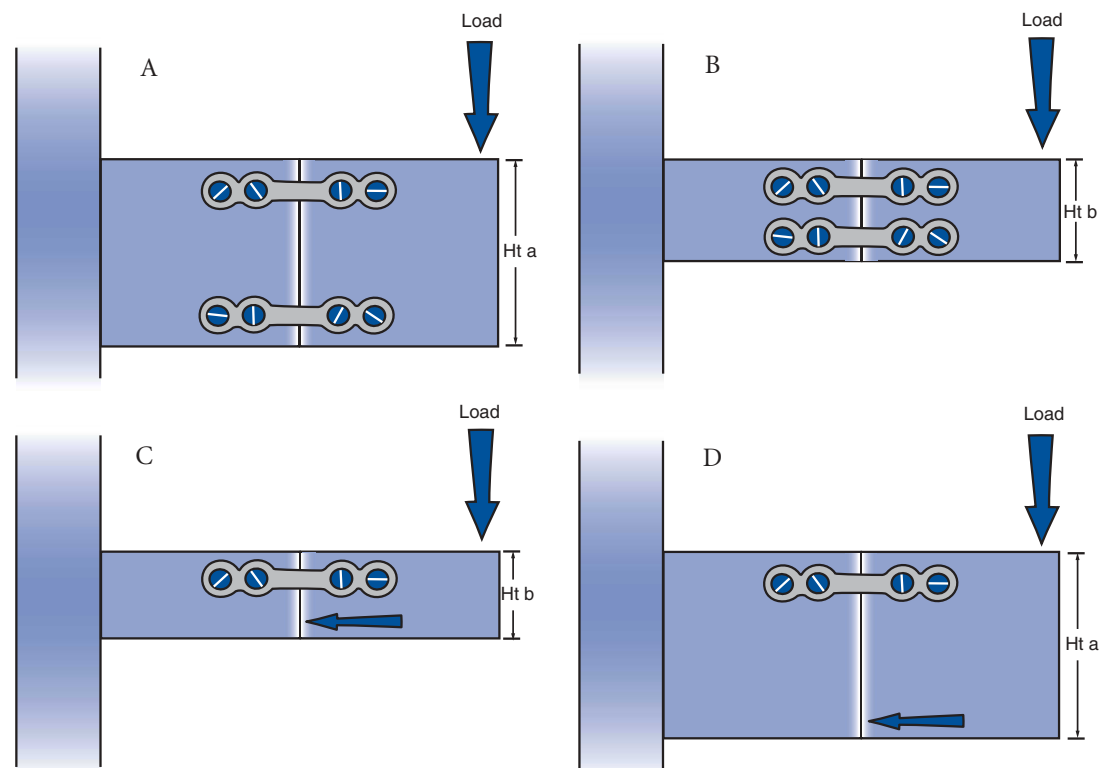


FIGURE 20-10 Biomechanical effectiveness of different constructs. A and B demonstrate biomechanical effectiveness of two plates when placed at different distances from one another. A, The load is applied to a fracture construct where there is a large fragment (Ht a) and a great separation between the two bone plates. This is a very stable construct. B, The load is applied to a fracture construct where the bone fragment is small (Ht b) and there is little distance between the two bone plates, in spite of the fact that the same two bone plates are applied. C and D demonstrate biomechanical effectiveness of two constructs when only one plate is applied. C, A single plate is applied to a construct with little vertical height (Ht b). D, A single plate is applied to a construct with a greater vertical height (Ht a). The construct with a greater vertical dimension (D) is much more stable because of the greater buttressing effect provided by the longer moment arm of the increased vertical dimension of bone.

devices should be placed as far apart from one another as possible. Because fixation devices are applied to the lateral surface of the mandible, the ability to use two-point fixation requires that there be sufficient height of bone so that the fixation devices can be placed far apart from one another. For instance, an atrophic mandibular fracture, where there is a vertical height of only 15 mm, would not gain much mechanical advantage from placing two bone plates on the lateral surface (Figure 20-10). In such instances a single stronger bone plate should be applied below the inferior alveolar canal (Figure 20-11). For the majority of fractures in the dentulous mandibular body and symphysis, there is sufficient height of bone to place one load-sharing plate along the infe-

rior and one along the superior aspect of the lateral cortex. However, the ability to do so will depend on the local anatomy. If one chooses to use two load-sharing bone plates to provide rigid fixation, one must be cognizant of the position of the tooth roots and the inferior alveolar/mental nerves. If there is insufficient room between the roots of the teeth and the inferior alveolar/mental nerves, one might choose to use a single bone plate along the inferior border rather than to risk injury to the tooth roots or inferior alveolar/mental nerves when placing the second bone plate (see Figure 20-1F). Depending on the size of the plate and whether or not an arch bar will also be used to provide another point of fixation, the fixation could be rigid or functionally stable.

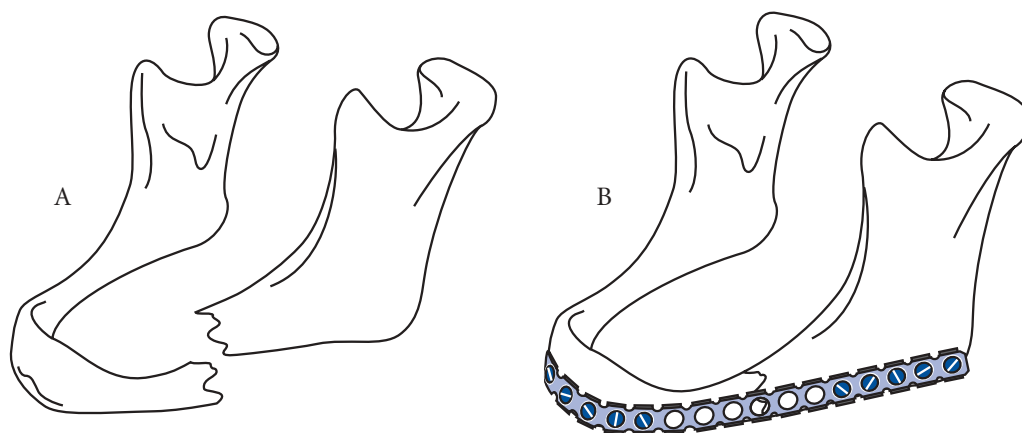


FIGURE 20-11 Use of a single strong bone plate (reconstruction plate) when the vertical height of the mandible is small. A, Atrophic mandible fractured through the body region. B, Reconstruction bone plate applied to the fracture to provide rigid fixation. Even if there were room to place two smaller bone plates on the lateral cortex, they would be so close to one another that their mechanical effectiveness would be minimal.

Compression versus Noncompression Plate Osteosynthesis

There are many types of bone plates that are available for clinical use. In their most simplistic forms plates are either compression plates or noncompression plates. Compression plates have the ability to compress the fractured bony margins, helping to bring them closer together, and imparting additional stability by increasing the frictional interlocking between them (Figure 20-12). While these properties might be advantageous, the application of compression by a plate creates a dynamic force that can work to one's disadvantage if the plate is not perfectly applied. Compression plates are safest to use in fractures where there is minimal obliquity, and where there are sound bony buttresses on each side of the fracture that can be compressed by the plate.

One should only use compression plates if one desires absolute rigidity across the fracture. If micromotion across the fracture occurs, compression plate osteosynthesis will often fail by becoming loose. Therefore, if compression plate osteosynthesis is desired, rigid fixation must also be desired. If this means that two plates are necessary to achieve absolute

rigidity, they should be used. If it means that a larger compression plate need be applied, then that should also be done.

Locking Plate–Screw Systems

Over the past 10 years, there has been an introduction of locking plate–screw systems into maxillofacial surgery. These

plates function as internal fixators, achieving stability by locking the screw to the plate. There are several potential advantages to such fixation devices. Conventional bone plate–screw systems require precise adaptation of the plate to the underlying bone. Without this intimate contact, tightening of the screws will draw the bone segments toward the plate, resulting in alterations in the position of the osseous segments and the occlusal relationship. Locking plate–screw systems offer certain advantages over other plates in this regard. The most significant advantage may be that it becomes unnecessary for the plate to intimately contact the underlying bone in all areas. As the screws are tightened they “lock” to the plate, thus stabilizing the segments without the need to compress the bone to the plate (Figure 20-13). This makes it impossible for the screw insertion to alter the reduction. This theoretical advantage is certainly more important when using large bone plates, such as reconstruction plates, which can

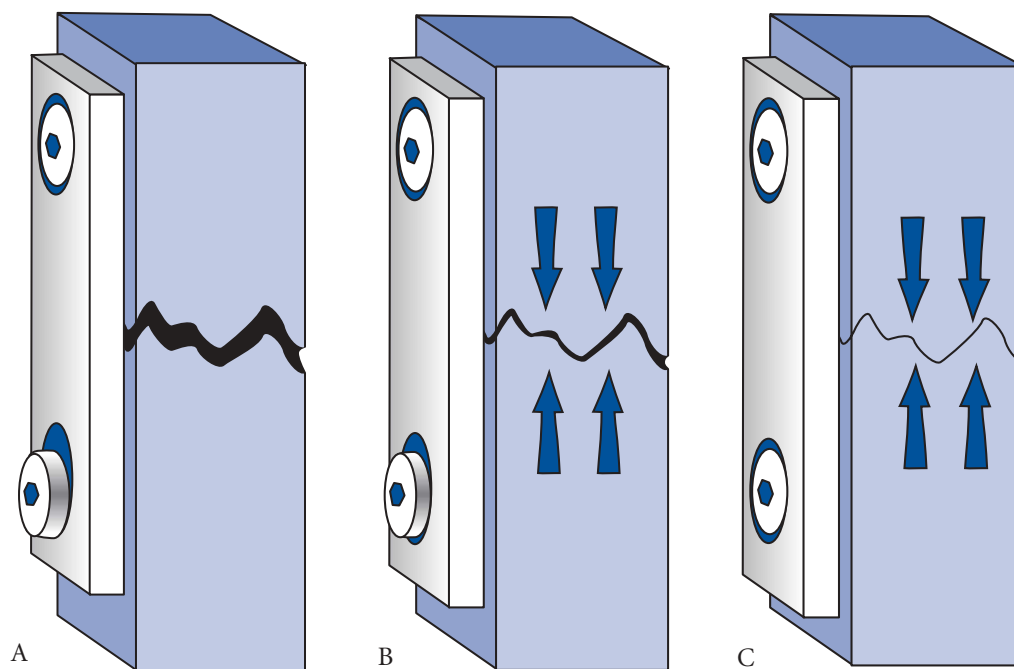


FIGURE 20-12 Compression plates help to minimize the fracture gap and to impart stability by the frictional interlock they induce. The screw holes in at least one of the oval bone plate holes is/are drilled eccentrically, that is, away from the fracture, so that as the screw(s) is/are tightened (A), the V-shaped undersurface of the screw head contacts the plate and forces the plate away from the fracture (B), imparting compression to the bone fragments and closing the gap (C).



FIGURE 20-13 A locking plate–screw system. Note the second set of threads just under the head of the screw that will lock into receptacle threads inside the hole of the bone plate.

be very difficult to perfectly adapt to the contours of the bone. Another theoretical advantage to the use of locking bone plate–screw systems is that the screws are unlikely to loosen from the bone. This means that even if a screw is inserted into a fracture gap, loosening of the screw will not occur. The possible advantage to this property of a locking plate–screw system is a decreased incidence of inflammatory complications from loosening of the hardware. It is known that loose hardware propagates an inflammatory response and promotes infection. For the hardware or a locking plate–screw system to loosen, loosening of a screw from the plate or loosening of all of the screws from their bony insertions would have to occur. Both of these are unlikely. A third advantage to a locking screw–plate system is that the amount of stability provided across the fracture gap is greater than when standard nonlocking screws are used.^{15,16}

While the possible advantages to a locking plate–screw fixation system are theoretical, whether clinical results can be improved is not clear from the literature. However, given the potential advantages that locking plate–screw systems provide, such systems should be considered whenever noncompression plates are chosen for a fracture.

Lag Screw Fixation

The lag screw fixation technique consists of using screws to compress fracture fragments without the use of bone plates. To apply the lag screw technique, two sound bony cortices are required because this technique shares the loads with the bone. The hole in the cortex under the head of the screw is called the gliding hole. It is the same diameter as the external diameter of the screw threads, so the threads will not engage this cortex. The screw threads on the terminal end of the screw engage the opposite cortex. By tightening the screw a tensile force is created within the screw that compresses the bony cortices together, tightly reducing the fracture (Figure 20-14).

As with using compression bone plates, lag screw fixation is a technique that should only be used to provide absolute rigid fixation. Micromotion across a fracture secured with lag screws will likely result in dissolution of the bone around the screws, with loss of stability. Therefore, lag screws should only be selected when there is sufficient bone available to place at least two screws into sound bone that can, in all likelihood, create rigidity across the fracture.

The use of lag screws has several advantages over the use of bone plates. It uses less hardware when compared to the use of plates thus making it more cost effective. When properly applied, lag screws are a very rigid method of internal fixation. Because there is no plate to be bent, the insertion of a lag screw is quicker and easier, and the reduction more accurate than when bone plates are used. One must understand completely that the lag screw technique of fixation is one that relies on compression of bone fragments. If the intervening bone is unstable due to comminution or is missing, compressing across this area will cause displacement of the bone fragments, overriding of segments, and/or shortening of the fracture gap, resulting in problems with the occlu-

sion. One should always place the lag screw in a direction that is perpendicular to the line of fracture to prevent overriding and displacement during tightening of the screws (Figure 20-15).

Plate Fatigue

Bone plates may break under function, resulting in possible loss of fixation, infection, nonunion and/or malunion. Plates break for a number of reasons, but most fracture in vivo because of fatigue. Plates used in maxillofacial surgery today are usually made of titanium. Titanium is a relatively biocompatible material and has material properties that are considered adequate for internal fixation when appropriate plates are selected. One of the undesirable properties of titanium is its brittleness (or lack of ductility) when compared to bone. One only has to bend a miniplate back and forth a couple of times to see how readily it will fracture. Placement of bone plates on areas of the mandible that are constantly and repeatedly deformed under function can result in fatigue fracture of the plates. Examples are 2.0 mm

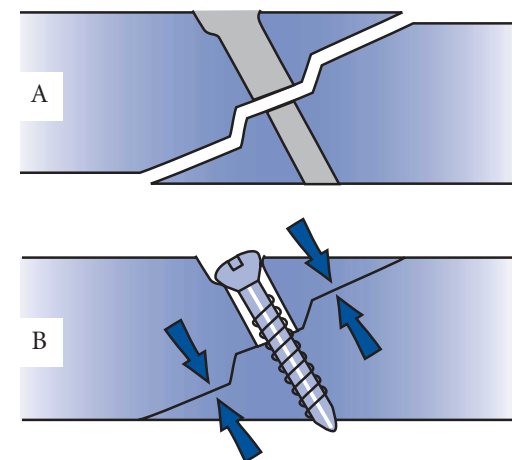


FIGURE 20-14 Technique of lag screw placement. A, The outer cortex is drilled to the external diameter of the screw threads, and is countersunk to receive the head of the screw. The inner cortex is drilled to the internal diameter of the screw. B, Screw tightening creates compression of the bony interfaces because the head of the screw compresses the outer cortex against the inner cortex that is engaged by the screw threads.

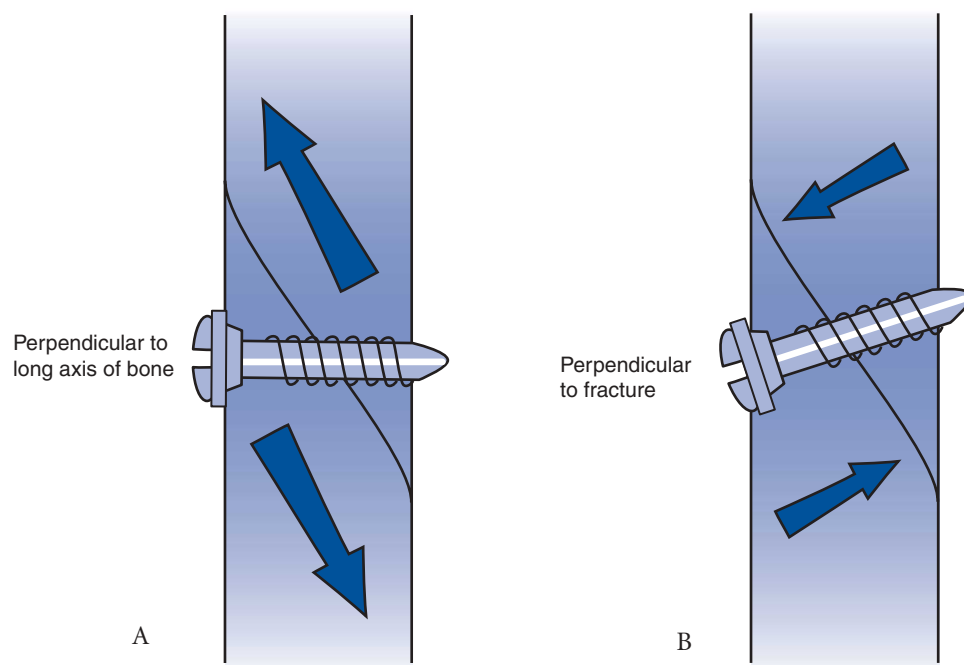


FIGURE 20-15 Improper (A) and proper (B) methods of placing lag screws. The screw should always be drilled perpendicular to the line of fracture to prevent sliding of the fragments during tightening of the screws.

miniplates or 2.0 mm adaptation plates applied to the condylar process, or similar plates applied to the atrophic mandible (Figure 20-16). The condylar process is constantly undergoing mediolateral tilting during opening and closing movements of

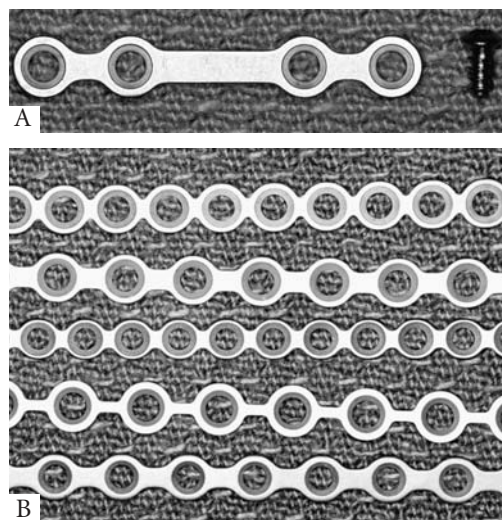


FIGURE 20-16 A standard 2.0 mm miniplate (A) and adaptation miniplates (B) (the 2.0 mm refers to the size of the screw that this plate accommodates, not the size of the plate). These plates have very good tensile strength, but readily fracture under cyclic loading because of their thin cross section.

the mandible. The atrophic mandible similarly undergoes “wishboning” during function (Figure 20-17).¹⁷ The less the amount of bone stock present, the higher the magnitude of these movements. Thus, atrophic mandibles undergo much more wishboning than do large dentulous mandibles. Because of the small cross-sectional area of the condylar process, this area of the mandible similarly flexes during function.

Bone plates applied to such areas of the fractured mandible have to be able to not only acutely withstand the deforming forces applied, but must also withstand the chronically applied cyclic loading until such time that the bone has healed. This is why several authors have recommended thicker, stronger 2.0 mm plates (mini-dynamic compression plates) (Figure 20-18) or two 2.0 mm miniplates for condylar process fractures, and reconstruction bone plates for atrophic mandibular fractures.^{18–21} This problem with the atrophic mandible is the reason the AO/ASIF has recommended, “The weaker the bone, the stronger the plate must be.”²¹

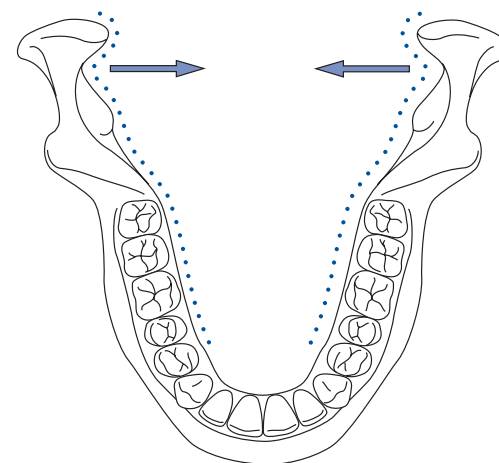


FIGURE 20-17 Under function, the mandible “wishbones” in and out.

Single versus Multiple Mandibular Fractures

Because of the shape of the mandible, fractures of the mandible are often multiple. Most surveys show that just under 50% are isolated, the same amount are doubly fractured, and a small percentage have more than two fractures. Fixation requirements for double (or multiple) fractures differ from isolated fractures. One can use less rigid forms of fixation on isolated fractures, because the forces generated during function are less complex than when a second or third fracture is present. For instance, there is minimal tendency for fractures of the symphysis, body, or angle to result in widening of the mandible unless fixation devices are incorrectly applied. The application of a single 2.0 mm miniplate along the lower



FIGURE 20-18 Example of a stronger 2.0 mm bone plate than the miniplate shown in Figure 20-16. The mini-dynamic compression plate shown in this photograph has a thicker cross-sectional area and a broader strap between the holes. This plate is useful for fractures of the mandibular condylar process and rarely fractures for that application.

border of the mandible combined with an arch bar is usually adequate fixation for isolated simple linear fractures of the symphysis and body regions (two-point fixation). If an arch bar is not used or the teeth are not sound, one should use either a stronger bone plate at the inferior border or add another 2.0 mm miniplate more superiorly along the lateral cortex. The application of a single 2.0 mm miniplate along the superior border is also adequate fixation for most isolated simple linear fractures of the angle region.⁴ Lag screws can also be used instead of or in addition to plates, where appropriate.

When two fractures are present there is a greater tendency for the segments to displace because of the bilateral loss of support that occurs. Widening of the mandible must be prevented by applying adequate internal fixation to resist that tendency. With bilateral simple linear fractures one should always consider using a more rigid form of fixation on at least one of the fractures. For instance, when an angle fracture is combined with a contralateral body or symphysis fracture, one should consider treating the body or symphysis fracture

with either two 2.0 mm miniplates, or a stronger bone plate at the inferior border, as well as using the arch bar as another point of fixation (Figure 20-19). The angle fracture can then be treated with a single superior border 2.0 mm miniplate. Similarly if an angle fracture is combined with a contralateral condylar process fracture, one should consider the application of more stable fixation at the angle if the condylar process is going to be treated closed using no MMF and functional therapy (Figure 20-20). In that case two 2.0 mm miniplates (or an alternative rigid treatment) should be considered. If the condylar process were going to undergo open reduction and internal fixation, or if several weeks of MMF were going to be used, then the angle fracture could be treated with a single superior border 2.0 mm miniplate (functionally stable but not rigid fixation).⁴

The fracture pattern that has the most tendency for widening is the midsymphysis fracture combined with condylar process fractures, especially when both condyles are fractured. In such cases the musculature attached to the lingual surface of the

mandible pulls the mandible posteriorly, and because there is no posterior support via the temporomandibular joints, the lateral mandibular fragments open like a book. Such fractures must be carefully managed to first restore the mandibular width and then to maintain it. A short thin bone plate, like a 2.0 mm miniplate, or even two 2.0 mm miniplates, may not offer sufficient resistance to the tendency to widen (Figure 20-21A). If one chooses to treat the condylar process fracture(s) closed, very stable fixation must be applied across the reduced mandibular symphysis to retain the normal width of the mandible. This can be achieved by several techniques, but the most stable is to either use a reconstruction plate applied across the symphysis (Figure 20-21B), or if the fracture is linear, two well-placed lag screws (see Figure 20-1B). The application of two thicker 2.0 mm bone plates (thicker than miniplates) would also suffice (see Figure 20-1C). If one chose to open the condylar process fractures, then the symphysis fracture can be treated as an isolated symphysis fracture, with whatever technique the surgeon usually chooses.

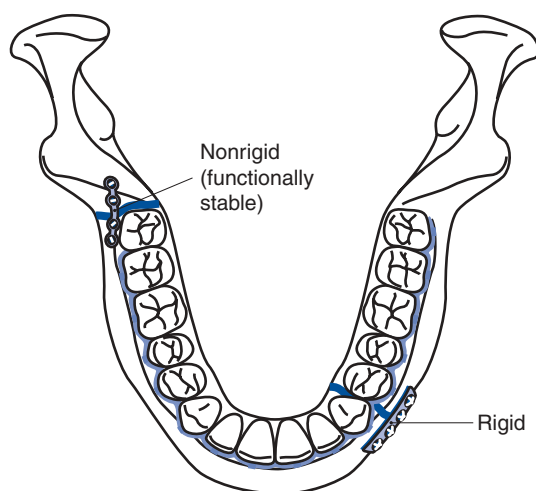


FIGURE 20-19 Possible fixation scheme for right angle and left body fractures of the mandible. The more accessible body fracture is treated with a more rigid form of fixation (eg, a thicker bone plate at the inferior border or two miniplates). The angle fracture can then be treated with a functionally stable form of fixation, which is easier to apply than would be a rigid technique at the angle. The angle fracture is thus treated as if it were an isolated fracture, with a single 4-hole 2.0 mm miniplate.

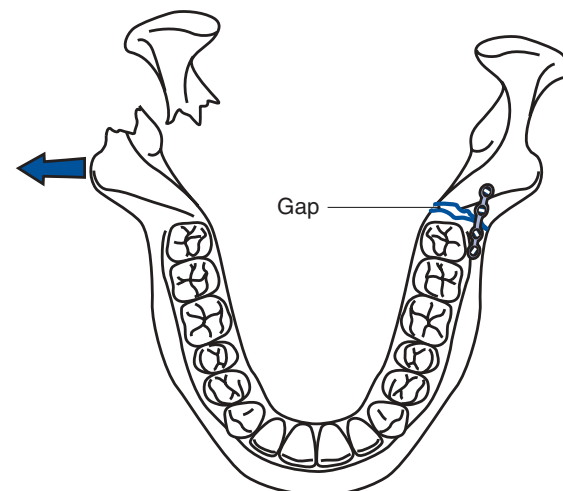


FIGURE 20-20 Demonstration of how widening of the mandible can occur after an angle fracture treated without rigid fixation is combined with closed treatment of a contralateral condylar process fracture. The single 4-hole 2.0 mm miniplate that works very well in this location for isolated fractures of the mandibular angle may not be able to prevent the tendency for widening. With the loss of the articulation at the temporomandibular joint on the right side, the entire right side of the mandible can also cause torquing at the left angle fracture under function, leading to displacement and malocclusion.

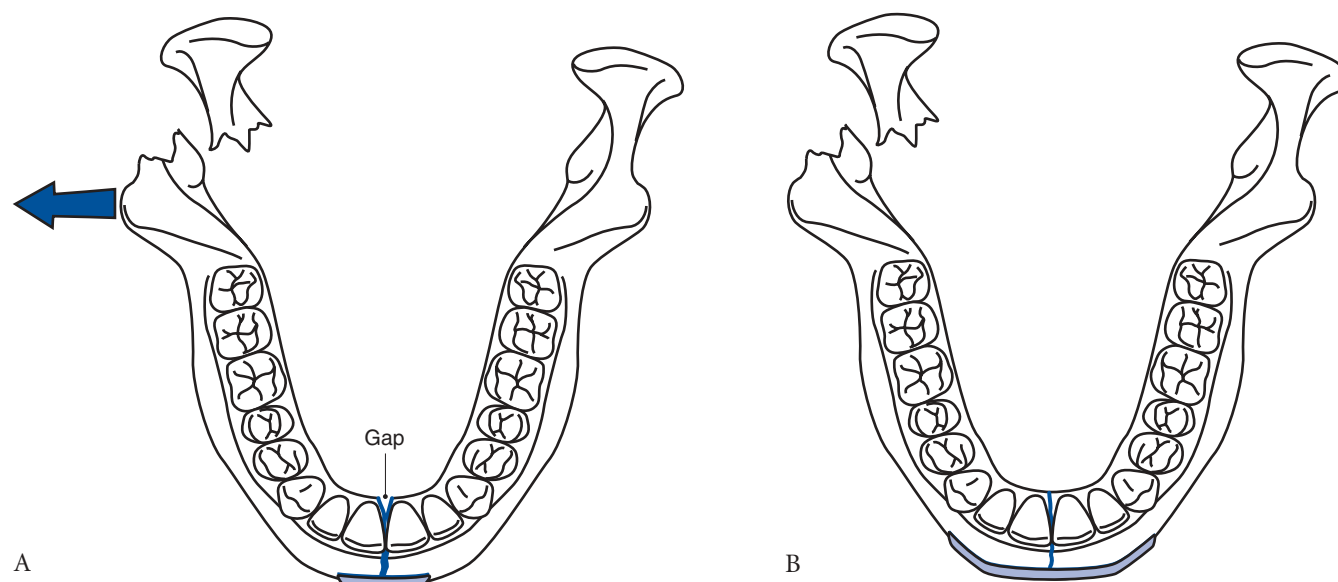


FIGURE 20-21 A, Combination of a symphysis fracture treated with a single short bone plate and concomitant closed treatment of a condylar process fracture can result in widening of the mandible. Because the bone plate is applied along the buccal cortex, it has a mechanical disadvantage in preventing widening of the mandible. To prevent this, a longer, thicker, stronger plate should be applied that “yolks” the mandible (B).

Summary

While the number of plating sets and fixation schemes are numerous, one can usually treat most fractures with very few instrument sets. It is possible to treat the majority of fractures of the mandible either with lag screws, 2.0 mm miniplates, or reconstruction bone plates. There are, however, fractures where one may wish to use 2.0 mm screws but thicker plates than miniplates, for instance, condylar process fractures or fractures of the atrophic mandible. In those cases one can use thicker and stronger bone plates that accommodate 2.0 mm screws. For these situations a locking 2.0 mm bone plating set that has plates of varying lengths and thicknesses allows one to choose the appropriate bone plate for almost any location.

References

- Allgöwer M, Spiegel PG. Internal fixation of fractures: evolution of concepts. *Clin Orthop* 1979;138:26–9.
- Ellis E. Rigid skeletal fixation of fractures. *J Oral Maxillofac Surg* 1993;51:163–73.
- Schenk R, Willenegger H. Morphological findings in primary fracture healing. *Symp Biol Hung* 1967;7:75.
- Champy M, Loddé JP, Schmitt R, et al. Mandibular osteosynthesis by miniature screwed plates via a buccal approach. *J Maxillofac Surg* 1978;6:14–9.
- Müller ME, Allgöwer M, Willenegger H. Manual of internal fixation. New York: Springer-Verlag; 1970.
- Choi BH, Kim KN, Kang HS. Clinical and in vitro evaluation of mandibular angle fracture fixation with two-miniplate system. *Oral Surg* 1995;79:692–5.
- Kroon FH, Mathisson M, Cordey JR, Rahn BA. The use of miniplates in mandibular fractures. An in vitro study. *J Craniomaxillofac Surg* 1991;19:199–204.
- Rudderman RH, Mullen RL. Biomechanics of the facial skeleton. *Clin Plast Surg* 1992;19:11–29.
- Ellis E, Karas N. Treatment of mandibular angle fractures using two mini-dynamic compression plates. *J Oral Maxillofac Surg* 1992;50:958–63.
- Ellis E, Sinn DP. Treatment of mandibular angle fractures using two 2.4 mm dynamic compression plates. *J Oral Maxillofac Surg* 1993;51:969–73.
- Ellis E, Walker L. Treatment of mandibular angle fractures using two noncompression miniplates. *J Oral Maxillofac Surg* 1994;52:1032–6.
- Ellis E, Walker LR. Treatment of mandibular angle fractures using one noncompression miniplate. *J Oral Maxillofac Surg* 1996;54:864–71.
- Potter J, Ellis E. Treatment of mandibular angle fractures with a malleable non-compression miniplate. *J Oral Maxillofac Surg* 1999;57:288–92.
- Niederdelmann H. Fundamentals of healing of fractures of the facial skull. 1. Biomechanics. In: Kruger E, Schilli W, editors. *Oral and maxillofacial traumatology*. Vol 1. Chicago (IL): Quintessence Publishing Co.; 1982. p. 125–8.
- Söderholm A-L, Lindqvist C, Skutnabb K, Rahn B. Bridging of mandibular defects with two different reconstruction systems: an experimental study. *J Oral Maxillofac Surg* 1991;49:1098–105.
- Gutwald R, Büscher P, Schramm A, et al. Biomechanical stability of an internal mini-fixation-system in maxillofacial osteosynthesis. *Med Biol Eng Comp* 1999;37 Suppl 2:280.
- Hylander WL, Johnson KR. Jaw muscle function and wishboning of the mandible during mastication in macaques and baboons. *Am J Phys Anthropol* 1994; 94:523–47.
- Ellis E, Dean J. Rigid fixation of mandibular condyle fractures. *Oral Surg* 1993;76:6–15.
- Hammer B, Schier P, Prein J. Osteosynthesis of condylar neck fractures: a review of 30 patients. *Br J Oral Maxillofac Surg* 1997;35:288–91.
- Choi B-H, Kim K-N, Kim H-J, Kim M-K. Evaluation of condylar neck fracture plating techniques. *J Craniomaxillofac Surg* 1999;27:109–12.
- Schilli W, Stoll P, Bähr W, Prein J. Mandibular fractures. In: Prein J, editor. *Manual of internal fixation in the cranio-facial skeleton*. Chapt. 3. Techniques recommended by the AO/ASIF Maxillofacial Group. Berlin: Springer-Verlag; 1998. p. 87.

Management of Alveolar and Dental Fractures

Richard D. Leathers, DDS

Reginald E. Gowans, DDS

History

Although there is speculation about whom the first dental surgeons were, dentoalveolar trauma has existed since humans began to walk the earth. Altercations with humans and animals, accidents, as well as dental treatment misadventures each have a part in the development of today's dentoalveolar treatment protocols.

Arguably, Hippocrates of Cos, who lived during the Greco-Roman period (350 BC–AD 750) was the first to document treatment regimens for dentoalveolar trauma in his writings. He discussed binding teeth together in mandible fractures. Gold wire or linen thread was used as “bridle wire.” He alluded to various splinting techniques that involved teeth that were distant to the fractured or subluxed area (Figure 21-1). In the same way, to expedite the healing process, he stressed recapturing proper occlusion, a concept that is still practiced today.

We could theoretically think of Hippocrates as one of the first investigators to see the value in “evidenced-based” treatment protocols; he is credited with separating the obscure religious beliefs from true medical observation.^{1,2}

Archigenes (~ 59 BC –AD 17), a Roman physician and dentist, believed that a bro-

ken tooth should initially be treated with a medieval endodontic procedure by intrapulpal cauterization with a hot iron instrument.³

Claudius Galen (~ AD 130–200), a Greek physician, also subscribed to the belief that reestablishing occlusion was essential in treating dentoalveolar fractures (see Figure 21-1).³

Etiology and Incidence

Dentoalveolar injuries commonly occur in the pediatric, teenage, and adult populations. Each group has specific etiologies that pertain to age, sex, and demographics.

In the pediatric group, the primary cause of these injuries is falls. Possibly during the first years of life, the early anatomical development and skeletal weight distri-

bution cause the poor coordination that leads to falls. In the larger surveys, the pediatric population accounts for 5% of all facial fractures.⁴ Andreasen reported a bimodal trend in the peak incidence of dentoalveolar trauma in children aged 2 to 4 years and 8 to 10 years. Likewise, there was an overall prevalence of 11 to 30% in the children with primary dentition. Those with permanent or mixed dentition ranged from 5 to 20%. The ratio of men to women was 2:1.⁵

Children and adolescents overlap with respect to the etiology of dentoalveolar injury. Contact sports and playground activities lead to most injuries. In fact, approximately one-third of all dental trauma is secondary to sporting accidents.⁶

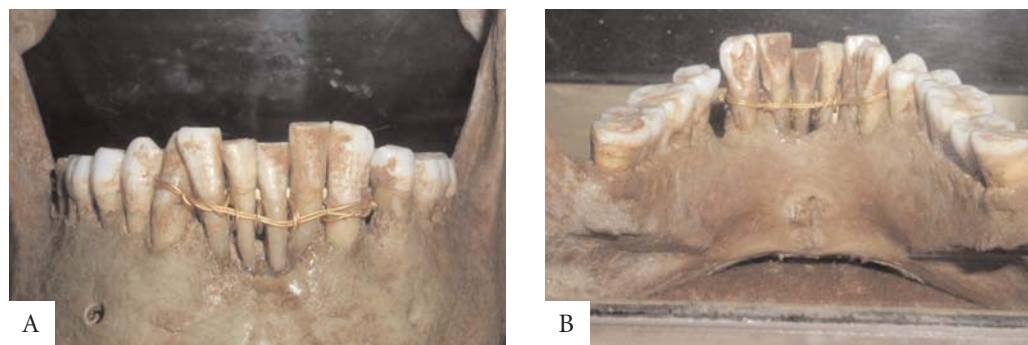


FIGURE 21-1 Mandible found at the ancient site of Sidon in Lebanon (dated 500 BC). Gold wire was used to splint periodontally involved anterior incisors. A, Frontal view. B, Lingual view. Reproduced with permission from *The Archaeological Museum, American University, Beirut, Lebanon*.

The use of mouthguards and appropriate head gear, however, has helped to decrease sport-related injuries.⁷

Child abuse appears to be another significant cause of dentoalveolar and facial injury. An alarming census of child abuse is documented in the literature. In the year 2000 an estimated 879,000 children were abused. Of these, 19.3% were physically abused.⁸ In the United States, over 50% of physical trauma in child abuse occurs in the head and neck region. Internationally, about 7% of all physical injuries involve the oral cavity, with 9% between ages 0 and 19 years.^{9,10}

Generally, adult injuries are caused by motor vehicle collisions, contact sports, altercations or assaults, industrial accidents, and iatrogenic medical or dental misadventures.

Demographic and behavioral research has increased the profession's understanding of psychosocial issues that relate to facial trauma.

Leathers and colleagues reported on orofacial injury profiles in an inner-city hospital. They found that most orofacial injuries resulted from intentional violence, and the victims were primarily socially and economically disadvantaged groups in the minority populations.^{11,12}

Black and colleagues related substance abuse—specifically alcohol and “street drugs”—with orofacial injuries. They found that a significantly greater proportion of patients who screened positive for drug and alcohol abuse at the time of injury had a previous history of head injury and/or orofacial injury. Further, we should consider the high rate of recidivism in this population as another behavioral factor.¹³

Other groups that are at increased risk of dentoalveolar trauma are those with seizure disorders, mental disorders, and congenital maxillofacial abnormalities.

Lockhart and colleagues reported findings, by the Risk Management Foundation, indicated that damage to the teeth was the most frequent anesthesia-related claim, often resulting in litigation.¹⁴ Poor laryn-

gосopy technique and the unmonitored biting force of the comatose patient also potentially caused dentoalveolar injury.^{15,16}

With direct trauma, maxillary incisors are the most frequently traumatized teeth, especially if they are associated with a Class II Division 1 malocclusion. Trauma to the primary dentition usually results in various luxations (~ 75%), whereas in permanent dentition, crown or crown-root fractures are the normal (39%).¹⁷ Indirect trauma to the dentition usually results from the forceful impact of the mandible with the maxilla, following a blow to the chin region. These traumas will often result in injury to the posterior teeth (Figure 21-2).⁵

History and Physical Examination

Obtain a thorough history of the patient and the traumatic incident. Preinjury data, such as biographic, demographic, past medical history, time of incident, occlusion, location of incident, loss of consciousness, and nature of the incident could potentially expedite the treatment process.^{18,19}

The potential for aspiration, airway compromise, and neurosensory deficit dictates that the clinician should thoroughly evaluate all dentoalveolar-injured patients prior to managing dental injuries. The initial examination should be systematic, methodic, and comprehensive (see Figure 21-2). Equally, an injury that could involve tooth or alveolar fracture may be substantial enough to cause a brief loss of consciousness. The clinical presentation of closed head injuries, such as basal skull fractures and epidural hematomas, may be occult. Hence, if these are not recognized early, they may have devastating consequences. Davidoff and colleagues reported that it was not uncommon for a closed head injury to result when a loss of consciousness of less than 1 hour occurred, along with facial trauma.²⁰ Signs of confusion followed by “lucid intervals” may require further radiographic and/or computed tomography (CT) scan studies.²¹

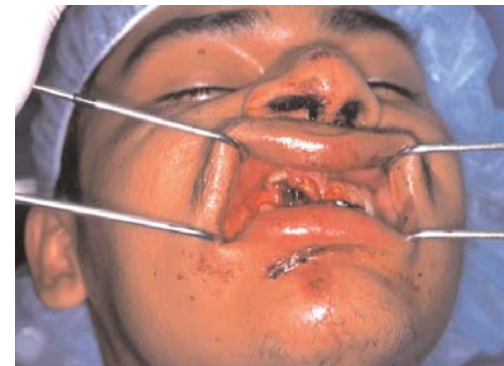

FIGURE 21-2 Blunt facial trauma resulting in soft tissue lacerations and dental and alveolar compromise.

Unaccounted for avulsed teeth, free tooth fragments, or dislodged restorations raise the suspicion of aspiration. For this reason, auscultation of the chest to rule out wheezing or labored breathing is essential. Owing to its anatomic position, the right mainstem bronchus is often the site of foreign body dislodgment. Support any positive finding with proper neck, chest, and abdominal radiographs.²² If foreign bodies exist in the abdomen, arrange follow-up for the patient with radiographs, and monitor for the risk of gastrointestinal (GI) obstruction until the foreign body is cleared.

Maxillofacial Examination

For medicolegal purposes, consider preoperative photographs prior to invasive treatment.

Include the following in the patient examination²³:

- Extraoral soft tissue
- Intraoral soft tissue
- Jaws and alveolar bone
- Teeth (displacement and mobility)
- Percussion and pulp testing

Ensure that the patient is cleaned extraorally with a mild antiseptic soap, while taking care not to further inoculate injury sites with debris or foreign bodies. Consider tetanus prophylaxis, depending on previous immunization compliance and wound presentation. (Table 21-1).²⁴

Table 21-1 Summary of Tetanus Prophylaxis

History of Adsorbed Tetanus	Nontetanus-Prone Wounds		Tetanus-Prone Wounds	
	Td*	TIG	Td*	TIG (250 U IM)
Unknown or ≤ 3 doses	Yes	No	Yes	Yes
≥ 3 doses†	No‡	No	No§	No

Td = tetanus and diphtheria toxoids adsorbed—for adult use; TIG = tetanus immune globulin—human.
 *For children < 7 yr old: DTP (DT, if pertussis vaccine is contraindicated) is preferred to tetanus toxoid alone. For persons ≥ 7 yr old, Td is preferred to tetanus toxoid alone.
 †If only three doses of fluid toxoid have been received, a fourth dose of toxoid, preferably an adsorbed toxoid, should be given.
 ‡Yes, if > 10 yr since last dose.
 §Yes, if > 5 yr since last dose. (More frequent boosters are not needed and can accentuate side effects.)
 Adapted from Alexander RH and Proctor HJ.²⁴

Thoroughly inspect superficial and deep lacerations, abrasions, or any soft tissue compromise. The mechanism of injury elicited in the history and the soft tissue defect alerts the surgeon to suspect underlying hard-tissue damage, such as to the maxilla, the mandible, the temporomandibular joint (TMJ), and alveolar fractures. Success rates are time-dependent with dentoalveolar trauma, and generally perioral soft tissue lacerations (lips) should be repaired after intraoral treatment, except in cases of poor hemorrhage control. In children, women, and the elderly, if the injury observed fails to correlate well with the history given, suspect and subsequently rule out abuse. Authorities, such as social services representatives, initiate proper legal protocols, if necessary.

Prior to any intraoral manipulations, obtain initial radiographic studies (eg, in the pediatric patient, knowledge of the errant deciduous tooth root to the permanent tooth bud position). The chance of further damage could be exponentially disastrous to both the future eruption and the morphology of the developing permanent tooth.^{25–27}

Approach intraoral soft tissue examination with caution. Carefully manipulate and handle traumatized tissues to avoid further compromise. Depending on the mechanism of injury, bone or tooth fragments may have penetrated these delicate areas. Closely inspect hematoma formation or ecchymotic areas. Buccal mucosal lacerations should raise the suspicion for

Stensen's duct or orifice injuries. The lips, the floor of the mouth, and the tongue regions are all areas at risk for penetrating or secondary injury and thus should be inspected accordingly. Account for all fractured or missing teeth and restorations or assume they were swallowed, aspirated, or lodged within adjacent structures. Similarly, arrange for radiographic evaluation of the maxillary and nasal sinuses prior to further treatment.^{28–30}

While examining for jaw and alveolar bone fractures, the presence of gross mobility or pericoronal bleeding of the involved teeth may be noted. Sublingual ecchymosis at the floor of the mouth is pathognomonic for an underlying mandible fracture. Step defects, crepitation, malocclusion, and gingival lacerations all raise suspicion of possible underlying bony defects.

Assess all fractured teeth for enamel, dentin, and pulpal involvement. Complete mobility of the crown may indicate crown-root fracture. Superficial crazing or infractions may be identified with a direct light source, transilluminating perpendicular to the long axis of the tooth from the incisal edge. Inspect and consider each tooth at risk, even at sites distal to the initial traumatic impact. Indirect trauma of the chin may cause posterior dentition defects, such as vertical or cusp fractures. Check occlusion and note any displacements, intrusions, or luxations. The direction of force is most commonly in a buccal-lingual direction.

Test percussion sensitivity and pulp vitality to rule out periodontal ligament injury or one of the many forms of fractures. Gentle tapping of the injured and noninjured control teeth is the technique of choice. Use the handle of a mouth mirror or a specially designed calibrated percussion instrument. Tactile, auditory, and visual senses are used. Dullness may alert the surgeon to the possibility of a luxation injury or alveolar fracture. The quality of this sound indicates that the teeth are not in optimal contact with the adjacent bony structure. If the enamel is fractured or infraction has occurred, the sound is reminiscent of a “cracked tea cup.”³¹ The typical sound of the uninjured tooth is that of solid metallic resonance. Percussion testing, in and of itself, can add insult to injury; thus, control and caution are warranted.

Evaluate tooth vitality via various pulp testing modalities. Mechanical, thermal, and electrical noxious stimuli are used. These tests use various stimuli to check for conduction disturbances at the sensory receptors of the pulp. The pulp comprises both nonmyelinated and myelinated nerve fibers, which regulate vascular changes and respond to pain stimuli, respectively. As the tooth develops, the pain fibers (ie, myelinated) increase, while simultaneously lowering the electrometric pulp stimulation.^{32,33} This concept sheds light on some of the treatment differences in open and closed apices of the permanent dentition.

Pulp testing in the acute phase of dentoalveolar fracture is controversial and heavily based on the cooperation and communication of the patient as well as the repair process of the injured pulp tissue. The fear of possibly experiencing increased pain during testing, especially in children, limits verbal objectivity and may render pulp testing too unreliable. Also, acutely injured teeth may revascularize in approximately 1 month, thus increasing the risk of false-negative results during pulp testing. The development stage of the involved

teeth also plays a significant role in the repair process. Incomplete apical development increases the chances of pulp repair and revascularization. As the tooth matures and apical width constriction starts, the chances of pulp repair decrease. Bacterial invasion in the pulp injury zone increases the risk of total pulp necrosis. Paradoxically, occasionally uninjured teeth may not respond as expected. Even with this controversy in mind, pulp testing continues. Some of the testing paraphernalia are listed as follows³⁴:

- Mechanical stimulation
 - Dental probe
 - Cavity prepping with drills
 - Saline-laden cotton pledget (fractured teeth)
- Thermal test
 - Heated gutta-percha
 - Ice
 - Ethyl chloride
- Carbon dioxide snow
 - Dichlorodifluoromethane
- Electrometric test
 - Electric pulp testers

Laser Doppler flowmetry (LDF), a relatively new pulp testing apparatus, has shown promise. A laser beam, which is directed at the coronal-labial aspect of the pulp, is scattered by pulp blood cells that in turn produce a Doppler frequency shift. The fraction of light scattered back is detected and processed to elicit a signal. The basic theory is that the pulp revascularization process can be monitored. Studies have shown that, in cases wherein electrometric tests were negative and LDF displayed vascular perfusion, the LDF accuracy of pulp vitality reached 100%. The drawbacks to this form of testing are poor light transmission when blood pigments from discolored teeth are encountered, complexity of equipment use, and poor price containment.^{35,36}

To ensure completeness, generate a standardized treatment record during the evaluation process, which systematically culminates in a diagnosis, treatment plan,

and prognosis. Figure 21-3 provides the dentoalveolar trauma record, which should include, but is not limited to, these entities.

Radiographic Examination

Radiographic examination is essential to determine whether any underlying structures are damaged and should include periapical, occlusal, and panoramic radi-

ographs. The periapical radiograph provides the most detailed information about root fractures and the dislocation of teeth. Following treatment, periapical films can confirm the proper positioning of an avulsed or luxated tooth into the alveolus.

Occlusal radiographs, however, provide a larger field of view, and the detail is almost as sharp as a periapical radiograph.

Dentoalveolar Trauma Record			
Name: _____	Date: _____		
Age: _____			
Sex: _____			
Incident:			
Cause			
Location			
Time			
Neurologic status:			
Locus of control			
Consciousness			
Headache			
Nausea, vomiting			
Extraoral findings:			
Intraoral findings:			
Radiographic findings:			
Posteroanterior			
Occlusal			
Panoramic			
Other			
Tooth vitality findings (pulp testing):			
Tooth mobility (+1, +2, +3):			
Ellis classification (I, II, III, IV):			
Luxation: Yes ___ No ___	Type _____		
Avulsion: Yes ___ No ___	Storage medium _____	Time _____	
Supporting structure trauma:			
Diagnosis:			
Treatment plan:			
Prognosis: Good ___	Fair ___	Guarded ___	
Examined by:			

FIGURE 21-3 Dentoalveolar trauma record.

When occlusal radiographs or periapical films are used to examine soft tissues for the presence of foreign bodies, reduce the radiographic exposure time.

The panoramic radiograph is a useful screening view and can demonstrate fractures of the mandible and maxilla as well as fractures of the alveolar ridges and teeth. In the hospital setting, dental radiographs may not be available. Although not ideal, plain films, such as the mandibular series and the Caldwell views, may reveal tooth and alveolar injuries.

In the trauma patient whose tooth has not been accounted for at the accident scene, arrange for chest films to rule out the possibility of aspiration. Abdominal radiographic films can determine whether displaced teeth or prosthetic appliances have been ingested.

Classification of Dentoalveolar Injuries

Once the diagnosis of dentoalveolar injury is made, the injury is classified for ease of communication and treatment planning. Many classification systems have been proposed over the years based on the anatomic site of injury, the cause, the treatment alternatives, or a combination of these. The two most common systems are those developed by Ellis and Davey (Figure 21-4) and Andreasen (Figures 21-5–21-7). The most commonly used simple and comprehensive classification of dentoalveolar injuries is one that was developed by Andreasen and originally adopted by the World Health Organization system for disease classification, using the International Classification of Diseases codes. The classification can be applied to both permanent and primary dentition. It includes descriptions of injuries to teeth, supporting structures, and gingival and oral mucosa. Injuries to the teeth and supporting structures are divided into dental tissues, pulp, periodontal tissues, and supporting bone as follows:

- Dental tissues and pulp
 - Crown infraction (ie, a craze line or crack in the tooth without loss of tooth substance)
 - Crown fracture that is confined to enamel, or enamel and dentin, with no root exposure (uncomplicated)
 - Crown fracture producing a pulp exposure (complicated)
 - Fracture involving the enamel, dentin, and cementum without pulp exposure (uncomplicated crown root fracture)
 - Fracture involving the enamel, dentin, and cementum with pulp exposure (complicated crown-root fracture)
 - Root fracture involving the dentin and cementum and producing a pulp exposure (root fracture)
- Injuries to periodontal tissues are divided into six categories and encompass what are commonly referred to as subluxations and avulsions.
 - Concussion: defined as an injury to the periodontium producing sensitivity to percussion without loosening or displacement of the tooth
 - Subluxation: the tooth is loosened but not displaced
 - Luxation (ie, lateral, intrusion, and extrusion) dislocation, or partial avulsion: the tooth is displaced without an accompanying comminution or fracture of the alveolar socket
- Injuries to the supporting bone
 - Comminution of the alveolar housing, often occurring with an intrusive or lateral luxation
 - Fracture of a single wall of an alveolus
 - Fracture of the alveolar process, en bloc, in a patient having teeth but without the fracture line necessarily extending through a tooth socket
 - Fracture involving the main body of the mandible or maxilla

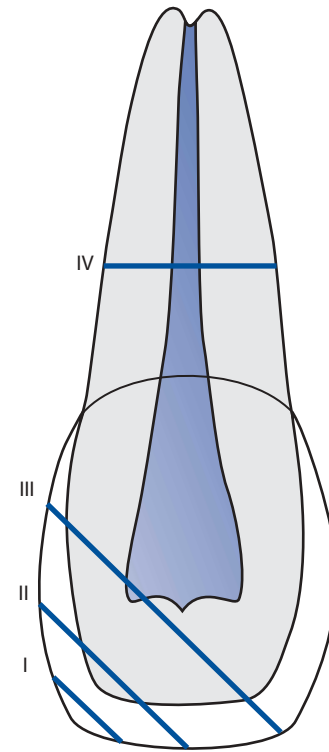


FIGURE 21-4 Ellis classification: I—fracture within enamel; II—fracture of enamel-dentin; III—fracture involving pulp; IV—fractures involving the roots.

Categories of injuries to the gingival or oral mucosa area include the following:

- Abrasion
- Contusion
- Laceration

Treatment of Injuries to the Hard Tissues and Pulp

Enamel Fractures (Crown Infraction)

These injuries include fractures, chips, and cracks that are confined to enamel, not crossing the enamel-dentin border but terminating at the border. The cracks or fractures can be seen by indirect light or transillumination.

Treatment involves smoothing the rough edges or repairing with composite resin. It is difficult to predict future pulpal vitality; for this reason, perform pulp testing immediately after the injury and again in 6 to 8 weeks.

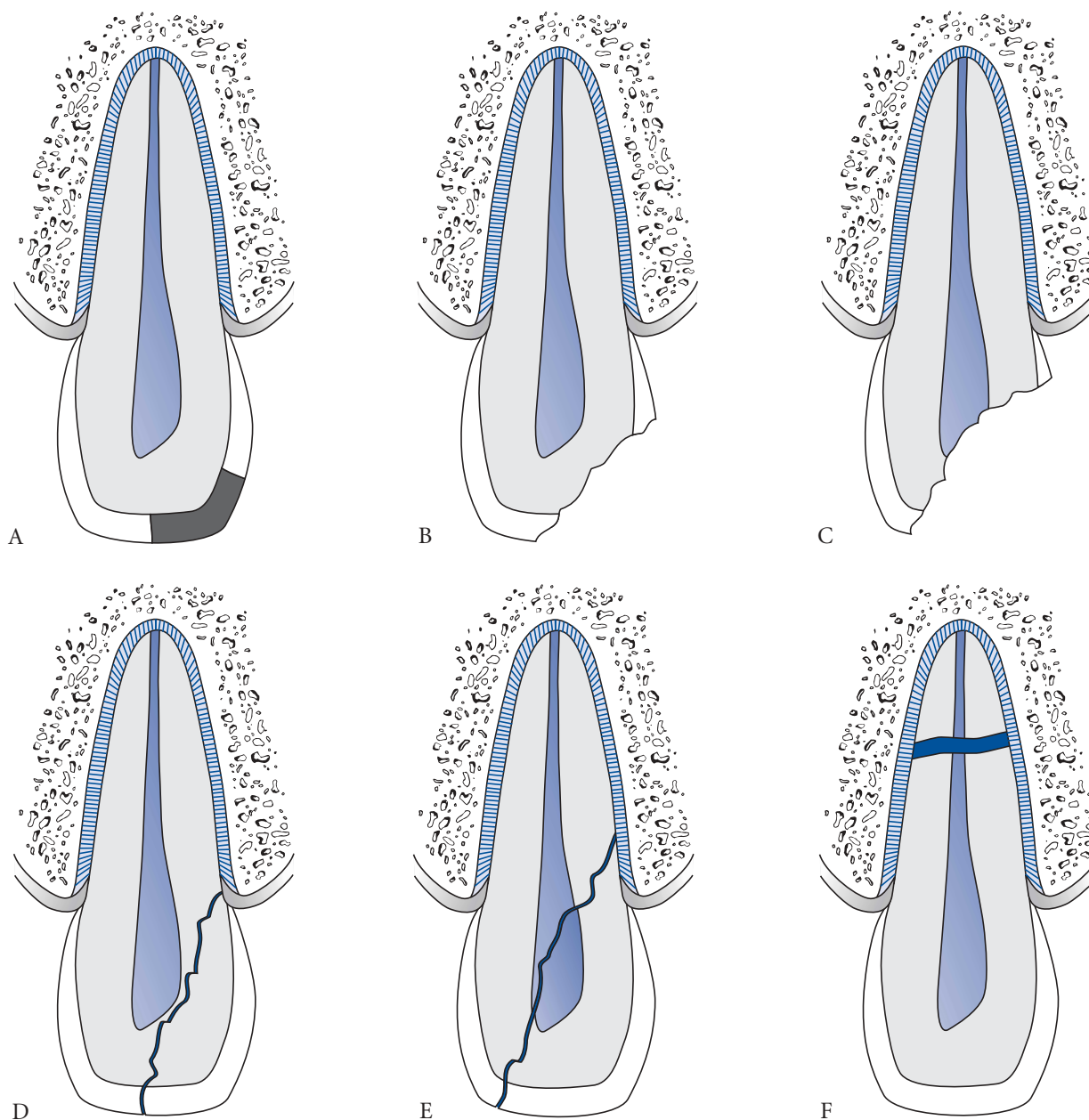


FIGURE 21-5 Diagram of injuries to dental tissue and pulp. A, Crown infraction. B, Crown fracture confined to enamel and dentin (uncomplicated crown fracture). C, Crown fracture directly involving pulp (complicated). D, Uncomplicated root fracture. E, Complicated crown-root fracture. F, Horizontal root fracture. Adapted from Andreasen JO, editor. *Traumatic injuries of the teeth*. 1st ed. Philadelphia (PA): W.B. Saunders; 1972.

Crown Fracture without Pulp Involvement

Crown fractures are the most frequent injuries in the permanent dentition. Crown fractures that expose dentinal tubules potentially may lead to contamination and inflammation of the pulp, eventually resulting in pulpal necrosis if untreated. Luxation injury concomitant to crown fractures, with or without pulp

exposure, is the primary source of pulpal complications following injury. Prognosis is better if the enamel-dentin fracture involves a tooth that has not been luxated because the blood supply to the pulp has not been disturbed, and the immunologic defense systems in the pulp will combat bacterial invasion (Figure 21-8).

Treatment is directed at protecting the pulp by sealing the dentinal tubules.

Although zinc oxide–eugenol cement has been one of the best agents for producing a hermetic antibacterial seal, it is generally not recommended at the site where a composite resin restoration is placed because the eugenol component may interfere with polymerization, at least with some composites. A similar effect has been seen with a hard-setting calcium hydroxide paste, resulting in bond strength reduction in

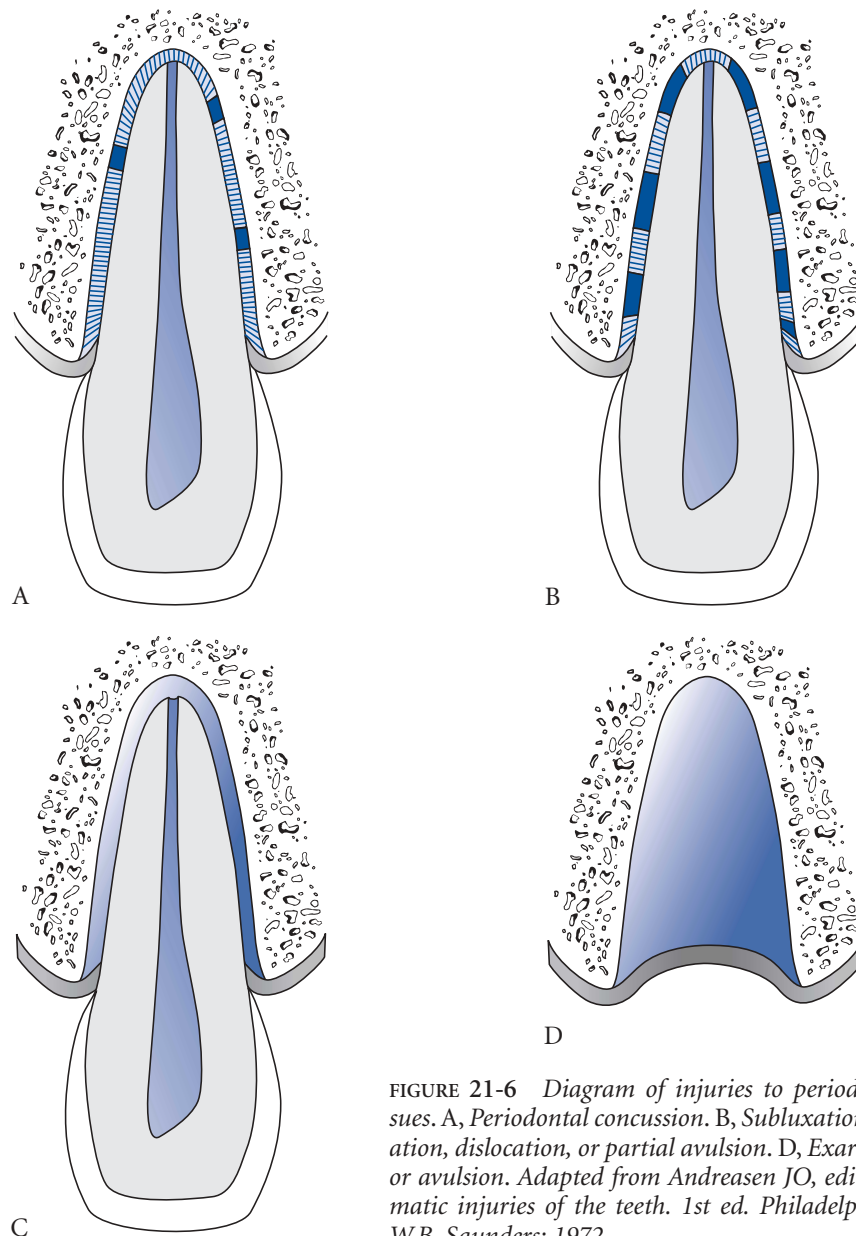


FIGURE 21-6 Diagram of injuries to periodontal tissues. A, Periodontal concussion. B, Subluxation. C, Luxation, dislocation, or partial avulsion. D, Exarticulation or avulsion. Adapted from Andreasen JO, editor. *Traumatic injuries of the teeth*. 1st ed. Philadelphia (PA): W.B. Saunders; 1972.

certain dental-bonding agents. In fractures with dentin exposure only, we recommend a dental bonding agent, followed by a composite restoration. With pulp exposure, the preferred treatment is calcium hydroxide placed directly over the exposure and sealed in place with a glass ionomer cement followed by a dentin bonding agent and composite.³⁷

Crown Fracture with Pulp Involvement

Crown fractures involving the enamel, dentin, and pulp are called complicated

crown fractures by Andreasen and Class III fractures by Ellis. Prognosis depends on the length of time that has elapsed since the injury occurred, the size of the pulp exposure, the condition of the pulp (vital or nonvital), and the stage of root development. Make every effort to preserve the pulp in immature teeth. Conversely, in mature teeth with extensive loss of tooth structure, pulp extirpation and root canal therapy are prudent before post, core and crown restoration. The prognosis is best for teeth with a vital pulp exposure if the fracture is treated within the first 2 hours.

Treatment requires direct pulp capping for small pinpoint exposures. If a patient's tooth has an open apex and a small pulp exposure is seen within 24 hours, it should be directly pulp-capped with calcium hydroxide. Perform calcium hydroxide pulpotomies for larger exposures and for small exposures in teeth with open apices over 24 hours old. The direct pulp cap of calcium hydroxide pulpotomy is designed to allow a tooth with an open apex to complete root development. Teeth that have calcium hydroxide pulpotomies usually require root canal therapy along with a post and core and ultimately coronal coverage.

In fractures with a vital pulp and a closed apex, perform a direct pulp cap if there is a small pulp exposure and if the patient is seen within 24 hours. If the pulp exposure is larger than 1.5 mm or if it has been present for over 24 hours, carry out root canal therapy.

Crown-Root Fracture

A fracture that is longitudinal and follows the long axis of the tooth or if the coronal fragment constitutes more than one-third of the clinical root, extraction is generally recommended. However, with a fracture line that is above or slightly below the cervical margin, appropriate forms of conservative therapy can usually be used to restore the tooth. Crown lengthening or orthodontic elevation of the involved tooth may be necessary.

Root Fracture

This type of fracture is limited to fractures involving the roots only (Ellis IV). Most root fractures occur in the apical and middle one-third and rarely in the cervical one-third. Root fractures are not always horizontal; in fact, they are often diagonal in angulation. Radiographs taken immediately after an injury may not show a horizontal or diagonal root fracture. After 1 or 2 weeks when inflammation, hemorrhage, and resorption have caused the fragments

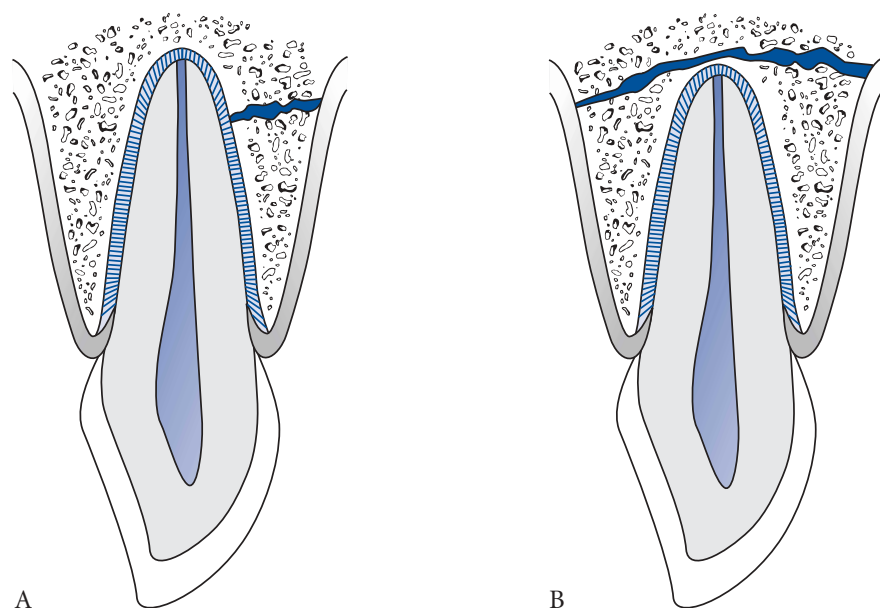


FIGURE 21-7 Diagram of injuries to supporting alveolar bone. A, Fracture of single wall of the alveolus. B, Fracture of the alveolar process. Adapted from Andreasen JO, editor. *Traumatic injuries of the teeth*. 1st ed. Philadelphia (PA): W.B. Saunders; 1972.

to separate, the radiograph will show the damage more conclusively.

Root fractures in the apical or middle one-third are usually not splinted unless there is excessive mobility (Figure 21-9). Treatment of mobile root fractures consists of apposition of the fractured segments with rigid splinting for 12 weeks.

Treatment for cervical one-third–root fractures usually involves extraction of the tooth or orthodontic extrusion of the root.

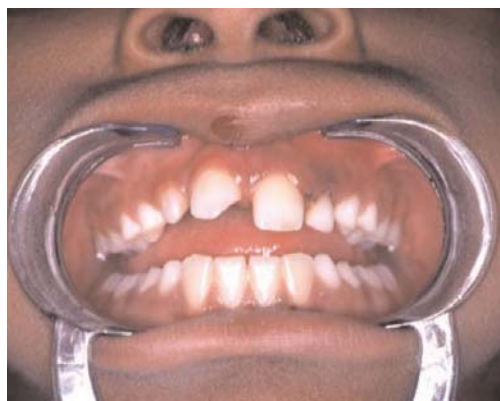

FIGURE 21-8 Crown fracture without pulp involvement. The fracture of the central incisor involved both enamel and dentin. Treatment involved sealing the dentinal tubules with a dentinal bonding agent followed by an esthetic composite restoration.

Periodontal Tissue Injury and Treatment

Injury to the periodontal tissue presents itself in many ways. Radiographically, this injury usually involves an evident dislocation or a movement of the tooth, and narrowing or loss of periodontal space may be seen. The fate of the tooth that has sustained a periodontal injury is twofold. Primarily, we see the injury from the localized impact and the late complication of the secondary resorptive process. The likely result of displacement injuries is the development of some type and degree of resorption. Thus, to better treat these types of injuries, it would behoove the surgeon to understand this process, both clinically and conceptually. This process affects both primary and permanent dentition. The etiology and pathogenesis is essentially identical to that seen in avulsion injuries, which we discuss later in this chapter in “Exarticulations (Avulsions).”

Classification of Root Resorption Root resorption is classified as either root surface resorption or root canal resorption. Root surface resorption, also known as

external root resorption, is most commonly seen after intrusive injuries and less in subluxation injuries. It is classified into three types: (1) surface resorption, (2) replacement resorption, and (3) inflammatory resorption.

Root Surface Resorption **SURFACE RESORPTION** Surface resorption indicates that the luxated or avulsed tooth root displays superficial resorption lacunae, which are repaired with newly formed cementum. Although not usually seen on radiographs, these may appear as vague excavations or cavities on the lateral root surface. A normal lamina dura is usually present. This development is a response to localized periodontal ligament and/or cementum injury. The process is less aggressive and self-limiting compared with the other resorption processes.

REPLACEMENT RESORPTION Replacement resorption also known as ankylosis, presents as an indistinguishable merging of bone and root substance. The root

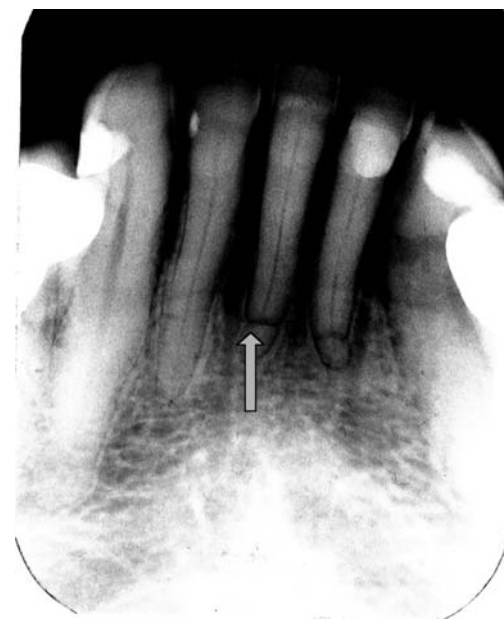

FIGURE 21-9 Mandibular central incisors with fractures of the apical one-third. No stabilization was used. Vital pulp testing was noted after 8 weeks. Note the interposition of connective tissue at the fracture site (arrow). (Courtesy of Dr. Thomas G. Dwyer and Dr. James R. Dow, Roseville, CA.)

substance is being ultimately replaced by bone, and radiographically a loss of the periodontal space and progressive root resorption is seen.

INFLAMMATORY RESORPTION Inflammatory resorption appears as well-circumscribed areas of cementum and dentin resorption. The localized adjacent periodontal tissue is markedly inflamed. The onset of inflammation is a result of the infected and necrotic pulp tissue within the root canal. The radiograph shows an appearance of root resorption with lines of adjacent bone radiolucency.

Root Canal Resorption Root canal resorption, also known as internal root resorption, presents less often than root surface resorption. Studies found that it appears in both permanent and primary teeth. Radiographic imaging may be equivocal; labial or lingual presentations of surface resorption may be erroneously superimposed over the root canal. To avoid a misdiagnosis supplemental radiographic views are warranted. Root canal resorption is classified as two types: (1) internal replacement resorption and (2) internal inflammatory resorption.

INTERNAL REPLACEMENT RESORPTION Internal replacement resorption shows metaplastic replacement of normal pulp tissue into cancellous bone, resulting in a widened pulp chamber. This is a characteristic process that is seen in root fractures and, to a lesser extent, in luxation injuries.

INTERNAL INFLAMMATORY RESORPTION Internal inflammatory resorption often located at the cervical region of the pulp, presents radiographically as an irregular or oval-shaped radiolucent enlargement within the pulp chamber. This condition relates to the ingress of bacteria via dentinal tubules within a necrotic pulp delineated as the necrotic pulp zone. Possibly, this zone is responsible for the progression of the process. Normal pulp tissue is altered and transformed into granulation tissue with giant cells that resorb the

dentinal walls of the root canal, giving the chamber an enlarged appearance. The cessation of this process will require root canal therapy (Figure 21-10).

The potential devastating effects of the resorptive process require immediate and proper treatment of periodontal injuries.

Classification of Periodontal Injuries Periodontal injuries are classified as concussions and displacements. Displacements include subluxations, intrusive luxations, extrusive luxations, and lateral luxations.

Concussion Often this injury is overlooked because no acute clinical or radiographic evidence of trauma is seen. No abnormal mobility, displacement, or bleeding is apparent; only minimal injury to the tissues was acquired. Frequently, the history of the insult guides the surgeon to the suspected tooth or teeth. The hallmark to diagnosis is a marked reaction to percussion in both the horizontal and vertical directions. The discomfort is similar to that of a “hot tooth,” hyperemic quality. Because a concussed tooth may take on a chronic course or exhibit progressive problematic sequelae, it warrants close monitoring.

Treatment includes taking the suspected tooth out of occlusion to avoid function. If at all plausible, consider occlusal adjustments on the opposing dentition, thereby limiting further trauma to the involved tooth.

Displacements Displacement injuries, or luxations, principally involve the primary and permanent maxillary central incisors. The mandibular teeth are less at risk, unless a Class III malocclusion exists. Generally, displacement injuries are more prevalent in primary dentition owing to the increased elasticity and resilience of the bony supporting structures. Conversely, permanent teeth will have an increased risk of tooth fracture.^{38,39} The specific luxation classification depends on the force

and direction of traumatic impact. Fifteen to 61% of luxation injuries occur in the permanent dentition and 62 to 73% in the primary dentition. Multiple teeth are usually involved in luxation injuries.⁴⁰

Subluxation Subluxation injuries occur when there is an injury to the tooth-supporting structures that causes abnormal loosening; however, there is no clinical or radiographic displacement of the involved tooth. The tooth is sensitive to percussion testing and occlusal forces. Rupture of the periodontal tissues is usually evident by bleeding at the gingival margin crevice (Figure 21-11).

Treatment is similar to that for concussion injuries with occlusal adjustments and vitality testing. Excessive mobility may necessitate nonrigid stabilization. Continue follow-up evaluation and vitality testing for 6 to 8 weeks.

Approximately 26% of injuries with this classification result in pulp necrosis, and endodontic treatment is indicated. Studies show that external resorption will

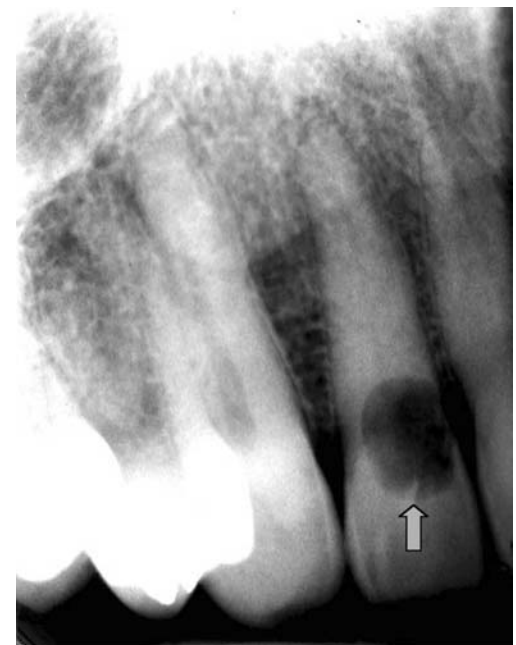

FIGURE 21-10 Maxillary lateral incisor with a history of periodontal injury (subluxation). Evidence of internal root resorption, specifically, internal inflammatory resorption (arrow), is seen.

occur in 4% of these injuries.⁴¹ Subluxation has the lowest frequency of periodontal tissue injury resorption.

Intrusive Luxation Intrusive luxations may cause marked displacement of the tooth into the alveolar bone, with possible comminution or fracture of the alveolar socket. Percussion sensitivity is limited, and decreased mobility is noted because the tooth is essentially locked in. A high-pitched metallic sound is elicited on percussion, reminiscent of an ankylized tooth. The intrusive injury is more commonly seen in the maxilla because of its less dense anatomy and irregular premaxillary configuration. The superiorly placed hollow cavities and thin floors of the nasal and maxillary sinuses create a formula for relative ease of dislodgement of teeth to these sites when intrusive forces are encountered. Intrusive injuries are the most severe of the luxation injuries that involve the pediatric patient. The intruded primary tooth may be impinging on the tooth bud of the permanent successors in a buccal-occlusal position.²⁶⁻²⁸ The incidence of pulp necrosis is relatively high (96%). Inflammatory resorption incidence may reach 52% as a result of the necrotic pulp (Figure 21-12).

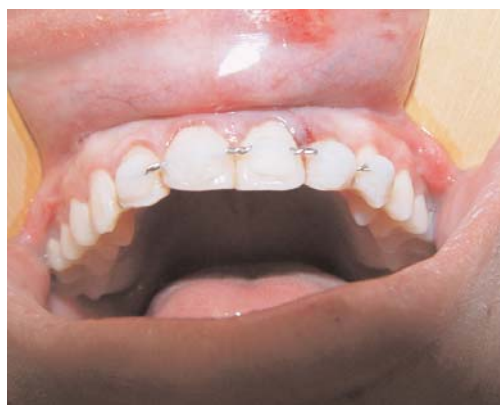

FIGURE 21-11 Patient with subluxed left maxillary central incisor. Bleeding and ecchymosis at the gingival margin crevice denotes rupture of the periodontal tissues. Treatment involved stabilization with a custom-fabricated nonrigid splint for 2 weeks.

Treating intrusive injuries depends on root development. If incomplete root development exists, allow the intruded tooth to re-erupt. Continue this process for approximately 3 months. If re-eruption does not occur, to facilitate this process, place an orthodontic extruding appliance. If pulp necrosis occurs, seek endodontic therapy. In cases of complete root development with closed apices, re-position the tooth atraumatically, and stabilize with a nonrigid splint. Then, initiate endodontic therapy in approximately 10 to 14 days after injury. Use CaOH as a canal filler in this therapy to retard or inhibit the inflammatory or replacement resorption process.⁴²⁻⁴⁴ In fact, use CaOH in any intrusive luxation injuries that result in the displacement of the tooth in excess of 3 to 5 mm, and initiate within 2 weeks. This, along with instrumentation of the canal, will eradicate the bacterial contamination and allow for the repair of the periodontal ligament.

Replace the CaOH filler if it resorbs during the healing process. Arrange for frequent radiographic follow-up at 3-month intervals, and continue for 6 to 12 months. Perform conventional root canal therapy with gutta-percha obturation when signs of resorption have ceased.

Extrusive Luxation Extrusive luxations are the partial displacement of the tooth out of the socket in a coronal or incisal direction with lingual deviation of the crown. This results in the rupture and severance of the neurovascular and periodontal ligament (PDL) tissues, respectively. There is gross mobility and bleeding at the gingival margin. Further, radiographically, the PDL space is widened. A dull sound is heard on percussion testing. Pulp necrosis occurs approximately 64% of the time, and a relatively low frequency of external resorption is seen at 7%.⁴¹

It is treated by delicately placing the extruded tooth back into the proper position in the socket. Check and re-check

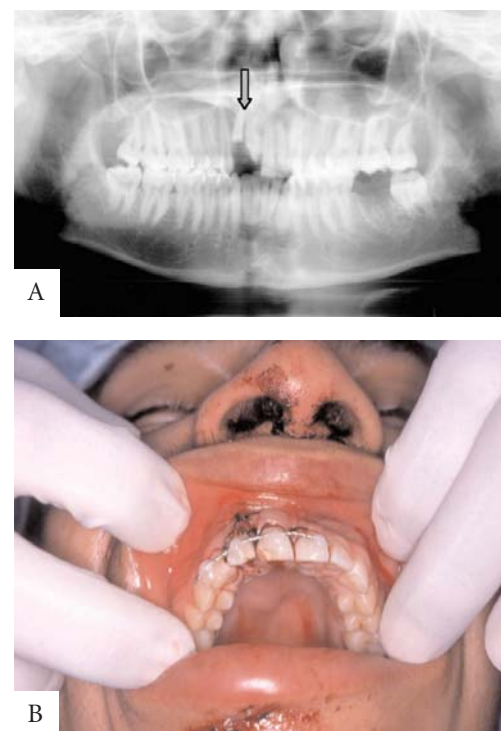


FIGURE 21-12 A, Panorex view depicting extent of intrusion. B, Teeth extruded, aligned, and stabilized with nonrigid splint. Soft tissue gingival wound repaired.

occlusion to ensure no rotation has occurred. Then, stabilize the tooth with a nonrigid splint for approximately 2 to 3 weeks. If signs of pulp necrosis occur, employ endodontic therapy.

Lateral Luxations Lateral luxations may result from traumatic forces that displace the tooth, or teeth, in many directions; however, the lingual direction appears to be the most prevalent. These luxations often involve the bony alveolar socket. The radiographic appearance is similar to the extruded tooth on occlusal views, with the PDL space widening in the apical direction. Linear or comminuted fractures are the norm. Lingual and buccal plate expansion may render the tooth mobile. Localized soft tissue compromise is often apparent. When bony defects exist beneath the gingiva, it is common to see complex lacerations and step defects. Because the tooth is often locked in an errant position, the percussion resonance and mobility resemble the intruded tooth.

The key to treatment is to reestablish preinjury occlusion. Delay soft tissue repair until this is completed. Manipulate the tooth or teeth back into the socket. If an alveolar segment is involved, reposition it. Digitally apply buccal and lingual pressure in cases of traumatic bony expansion to ensure early PDL repair. Apply a nonrigid splint that is extended to and is supported by the presumably uninjured adjacent teeth. Leave the splint in place for 2 to 8 weeks, depending on bony healing, which may require longer stabilization time. Avoid the use of disimpaction devices, such as forceps or hemostats, while attempting to reestablish proper alignment of teeth or segments. Excessive fulcruming forces may further compromise the tooth and/or supporting structure.

In persons who may have experienced delayed treatment in excess of 48 hours, reestablishing occlusion may be difficult and traumatic. Consider spontaneous or orthodontic realignment. Continue frequent radiographic follow-up and vitality testing for several months. Adjacent teeth that may have become devitalized warrant vitality testing. Any signs of pulp necrosis should be met with immediate endodontic therapy.

Another complication to consider is the loss of marginal bone support in both lateral and intrusive luxation injuries, which can occur as a temporary or permanent condition. It is seen clinically as an ingrowth of granulation tissue at the gingival crevice, resulting in a loss of attachment. This is the normal process of periodontium healing and takes up to 6 to 8 weeks. When this process occurs, continue maintenance of the splint and pay close attention to oral hygiene compliance to prevent further bone loss.

The frequency of this bony loss reaches 5% for lateral luxations and 31% in intruded luxations.⁴⁵

Exarticulations (Avulsions)

Seemingly, avulsion injuries are the worst of the dentoalveolar injuries. By defini-

tion, these injuries involve tooth, or teeth, that are completely dislodged from the socket for a period of time. Owing to the higher risk of aspiration, supporting structure damage, or actual physical loss of the tooth, these injuries require special attention. Old ideology and myths still plague the use of newer proven protocols.

Avulsion injuries occur from 0.5 to about 16% in the permanent dentition and occur less in the primary dentition (7 to 13%), with children ages 7 to 9 years being most associated with this injury. These injuries usually involve a single tooth, with the maxillary central incisor most often at risk, which is due to the relative instability of the periodontal ligament during the progressive eruption of these teeth.⁴⁶

The treatment of such injuries must be geared toward early reestablishment of periodontal ligament cellular physiology. The fate of the avulsed tooth depends on the cellular viability of the periodontal fibers that remain attached to the root surface prior to reimplantation. Although extraoral time is a factor, newer physiologically compatible solutions are available that can maintain and/or replenish periodontal ligament cell metabolites. Two such solutions are Hank's balanced salt solution and ViaSpan (Figures 21-13 and 21-14).⁴⁷⁻⁴⁹

Both Hank's solution and ViaSpan are physiologic with compatible pH and osmolality (Table 21-2). ViaSpan is the solution of choice for organ storage during transport for transplantation. The relative availability and cost effectiveness of Hank's solution makes it the medium of choice in storage of avulsed teeth. Commercially available by Phoenix Lazarus Inc., Save-A-Tooth, an emergency tooth preserving system that contains Hank's solution as its active ingredient, is a mainstay in many athletic first aid kits.

Other methods for temporarily storing an avulsed tooth are milk, saliva, and saline; however, their ability to replenish cellular metabolites has not been documented. Milk

is a readily available medium for the lay person, and, because time is of the essence, it is the medium of choice in the absence of Hank's solution or ViaSpan. Milk will only prevent further cellular demise; thus, it is used specifically when teeth have been extraoral for < 20 minutes. Any periodontal ligament extraoral exposure > 15 minutes will deplete most of the cell metabolites; for this reason, a longer period of extraoral time limits milk's effectiveness to maintain cellular viability. Unlike Hank's solution and ViaSpan, which can store avulsed teeth and replenish cellular metabolites for 24 hours and 1 week, respectively, milk as a storage medium becomes ineffective after approximately 6 hours.^{50,51}

Treatment Considering the root maturation, the extraoral time, and the general

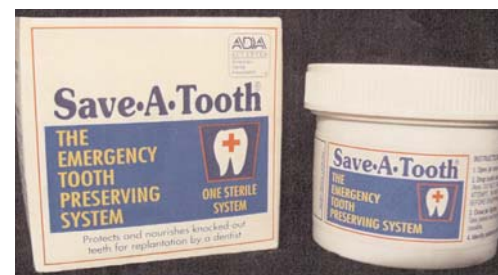

FIGURE 21-13 Hank's balanced salt solution, commercially available as Save-A-Tooth (Phoenix Lazarus, Inc.).

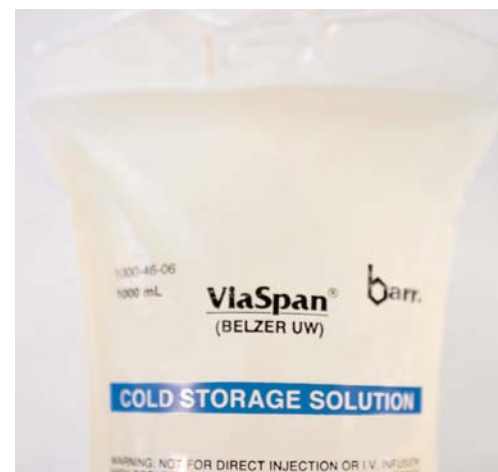

FIGURE 21-14 ViaSpan, cold storage solution currently available as an organ transport solution.

Table 21-2 Solutions to Replenish Periodontal Ligament Cell Metabolites

Solution	Characteristics
Hank's balanced salt solution	pH = 7.2 Osmolality = 320 mOsm
ViaSpan	pH = 7.4 Osmolality = 320 mOsm
Cow's milk	pH = 6.5–6.7 Osmolality = 225 mOsm

health of the tooth preinjury determines the route of treatment. The idea of early or immediate replantation should be adopted.

Teeth that are in poor condition from a hygiene standpoint are generally not replanted. Those that present with moderate to severe periodontal disease, gross caries involving the pulp, apical abscess formations, infection at the replanting site, and bony defects and/or alveolar injuries, in which supporting bone is lost are less likely to be considered for replantation.

To optimize success of treatment, replant and stabilize avulsed teeth within 2 hours (120 minutes); periodontal ligament cells become irreversibly necrotic after this time frame. Attempt to salvage avulsed teeth, even if the critical 2-hour period has passed, but the prognosis becomes progressively worse.

Teeth with open apices > 1 mm diameter have a prognosis that is much better than that of the more mature or closed-root apex. Treat the tooth with an open root within the 2-hour time frame by placing it in Hank's solution for about 30 minutes. Next, place the tooth in a 1 mg/20 mL doxycycline bath for 5 minutes, followed by immediate replantation and splint stabilization.^{47,52} If radiographic or clinical evidence of pathology is noted, perform an endodontic apexification procedure with a CaOH filling. The CaOH should be periodically replaced until the apex is closed, followed by conventional root canal therapy.

Newer materials for apexification procedures are on the market that decrease

the need for multiple CaOH replacements—one of which is ProRoot MTA (Mineral Trioxide Aggregate), marketed by Densply Tulsa Dental. Contrary to CaOH, MTA provides a hard-setting nonresorbable surface with cavity adaptation. It provides excellent tissue biocompatibility and allows for immediate apical seal.^{53,54}

The increased potential for reestablishment of pulpal circulation in teeth with open apices has been shown to improve prognosis of survival of the pulp and PDL in the avulsed tooth (Figures 21-15 and 21-16). This revascularization process is optimized by the topical application of doxycycline. Individuals who have avulsed teeth with mature or closed apices and who present within the 2-hour time frame are treated by placing the tooth in Hank's solution for about 30 minutes, followed by replantation and splinting for 7 to 10 days. Carry out endodontic cleansing and shaping of the canal, and place a CaOH filling just prior to splint removal. Final gutta-percha obturation is contingent on resolving canal and/or root pathology (6 to 12 months). Late failure of the replantation process is manifested as either inflammatory or replacement resorption

owing to a necrotic pulp or compromised PDL, respectively.

In individuals who experience an extraoral period that exceeds 2 hours, apical root morphology plays little role in the success rate. Eliminate the necrotic periodontal ligament strands manually or chemically in a sodium hypochlorite wash for approximately 30 minutes. Perform root canal therapy extraorally with conventional cleansing and shaping of the canal. Withhold final obturation until the canal, dentinal tubules, and root surface have been treated with various chemicals in a stepwise fashion. First, a citric acid bath for 3 minutes, followed by rinsing with 0.9% NaCl, will open and debride the dentinal tubules, thus allowing unimpeded ingrowth of connective tissue to the root surface. Second, the tooth should be moved to a 1% stannous fluoride solution for 5 minutes. This will decrease the risk of the resorption process.

Finally, set up a 5-minute bath of 1 mg/20 mL doxycycline, which will rid the root surface of residual bacterial remnants and facilitate pulpal revascularization. Complete the final obturation with gutta-percha. The tooth is then replanted into preinjury alignment and splinted for 7 to 10 days (Tables 21-3 and 21-4).^{50,52,55}

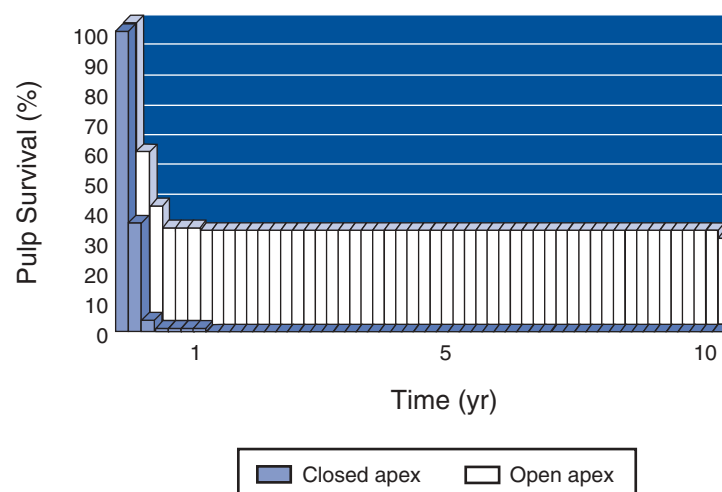


FIGURE 21-15 Studies by Andreasen and colleagues support the increased potential for pulpal healing after replantation related to stage of root development (closed vs open apex). Adapted from Andreasen JO and Andreasen FM.³⁴

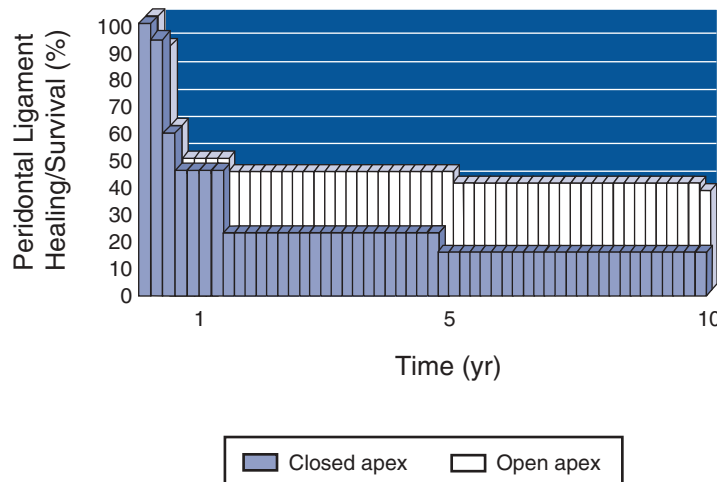


FIGURE 21-16 Periodontal healing/survival after replantation related to stage of root development (closed vs open). Adapted from Andreasen JO and Andreasen FM.³⁴

Splinting Protocol and Technique Splinting after avulsion and displacement injuries immobilizes the tooth or segment into proper preinjury alignment and allows for the initial pulpal revascularization and periodontal ligament healing course. Several techniques have been advocated in the past; however, the

acid-etch/resin splint (or variants of this technique) is the treatment of choice.^{56,57} This technique fulfills the requirements of acceptable splint utilization in a maxillofacial traumatic injury (Table 21-5).

The acid-etch technique is the only system that most closely adheres to these

recommendations (Figure 21-17). The arch bar, self-curing, Essig, intracoronal, and circumferential splints may rarely present with an indication but are not routinely recommended. Each has been demonstrated to violate one or many of the basic splint requirements. The arch bar, in particular, produces an eruptive or extrusive force because of the placement of the wire beneath the height of contour of the tooth. Also the rigid nature of these techniques will facilitate the external resorption process (Table 21-6).

Treatment of Fractures of the Alveolar Process

Owing to the exposed anatomy, alveolar fractures usually occur at the incisor and premolar regions. Treatment involves early reduction and stabilization of the involved segments. Depending on the fracture's

Table 21-3 Treatment Summary for Avulsed Teeth

< 2 h; open apex

1. Replant immediately if possible
2. Transport in Hank's solution or milk
3. Present to nearest qualified facility (decrease time call first)
4. Check ABCs; evaluate for associated injuries (history and physical examination)
5. Store in Hank's Solution for about 30 min
6. Transfer to a 1 mg/20 mL doxycycline bath for about 5 min
7. Perform radiography (posteroanterior, occlusal, panoramic, chest)
8. Initiate local anesthesia
9. Irrigate socket with saline solution
10. Perform tetanus prophylaxis as needed
11. Initiate antibiotic coverage
12. Replant tooth
13. Splint for 7–10 d
14. Perform apexification with CaOH in cases of pathosis

Closed apex

1. Store in Hank's solution for about 30 min
2. Replant
3. Splint for 7–10 d
4. Perform endodontic cleansing and shaping of canal at time of splint removal
5. Fill canal with CaOH (6–12 mo)
6. Perform final gutta-percha obturation (~6–12 mo)

ABC = airway, breathing, and circulation.

Table 21-4 Treatment Summary for Teeth Avulsed > 2 Hours*

1. Replant immediately, if possible
2. Transport in Hank's solution or milk
3. Present to nearest qualified facility (decrease time call first)
4. Check ABCs; evaluate for associated injuries (history and physical examination)
5. Bathe tooth in sodium hypochlorite for ~30 min vs manual débridement of the periodontal ligament
6. Perform extraoral RCT
7. Bathe tooth in citric acid (~3 min)
8. Bathe tooth in 1% stannous fluoride (~5 min)
9. Transfer to a 1 mg/20 mL doxycycline bath for ~5 min
10. Perform radiography (posteroanterior, occlusal, panoramic, chest)
11. Initiate local anesthesia
12. Perform tetanus prophylaxis as needed
13. Initiate antibiotic coverage
14. Replant tooth
15. Splint for 7–10 d

ABC = airway, breathing, circulation; RCT = root canal therapy

*Open or closed apex.

Table 21-5 Splint Requirements

The splint should

1. Be able to be applied directly in the mouth without delay owing to laboratory procedures
2. Stabilize the injured tooth in a normal position
3. Provide adequate fixation throughout the entire period of immobilization
4. Neither damage the gingiva nor predispose to caries and should allow for a basic oral hygiene regimen
5. Not interfere with occlusion or articulation
6. Not interfere with any required endodontic therapy
7. Preferably fulfill esthetic demands
8. Allow a certain mobility (nonrigid) to aid periodontal ligament healing in cases of fixation after luxation injuries and replacement of avulsed teeth; however, after root fracture, the splint should be rigid to permit optimal formation of a dentin callus to unite the root fragments
9. Be easily removed without re-injury to tooth

Adapted from Andreasen JO, Andreasen FM. Textbook and color atlas of traumatic injuries to the teeth. 3rd ed. Munksgaard; 1994. p. 347–8.

severity, use either an open or closed technique. Digital manipulation and pressure, along with rigid splint stabilization, will usually be sufficient in the closed technique. Leave the splint in place for approximately 4 weeks.

A gross displacement and/or impediment to reduction may necessitate the open technique. Inability to freely reduce fracture segments may be due to root or bony interferences or impaction (apical lock) (Figure 21-18). Access to the area involves an incision that provides adequate exposure and is located apical to the fracture lines. The segment is then disimpacted or freed up. Proper alignment and occlusion are then attained, and the segments are stabilized with suitable transosseous wire or a small (2.0 mm) monocortical plate. Ensure that the closure of the wound is meticulous to prevent exposure of bone and/or hardware to the ingress of bacteria.

Stabilize teeth that may be mobile in the fractured segment with an appropriate secondary splint after bony stabilization. Likewise, avoid removing teeth that are considered nonsalvageable and that are within the bony segment until the bony healing phase is completed (~ 4 weeks). Obvious infec-

tion and inadequate bony envelopment indicate early removal.

Successful treatment of alveolar fractures is associated with the pupal healing after the injury. When the fracture level is apical to the root tips, the vascular supply to the pulp is less at risk; however, if the line of the fracture and root apices are in contact, the teeth in the alveolar segment are at a higher risk for internal or external resorption.

In concomitant injuries, such as maxillary or mandibular fractures, early maxillomandibular fixation is accomplished with a technique that will allow

for dual treatment of the dental and/or alveolar injury and the jaw injury (eg, arch bars and maxillomandibular fixation). Perform the more invasive open reduction if indicated.

Avulsive injuries will often expose bone and jeopardize tooth support. Aim treatment at soft tissue coverage in the form of judicious mucosal advancement flaps. Consider early removal for teeth without bony support.

Treatment of Trauma to the Gingiva and Alveolar Mucosa

Traumatic injury to the oral soft tissue mainly consists of abrasion, contusion, and laceration. If these injuries are not addressed, they can place the underlying bony tissue at risk for devitalization. Frequently these injuries may alert the surgeon to underlying trauma. The ultimate goal of treatment is to reestablish vital soft tissue bony coverage.

Abrasion An abrasion is a superficial wound wherein the epithelial or gingival tissue is rubbed, worn, or scratched. Treatment consists of local cleansing with a mild disinfectant soap for the skin and saline rinsing and/or irrigation of the gingiva. Antibiotic coverage is seldom necessary. Inspect the wound for possible foreign body (asphalt) accumulation, which

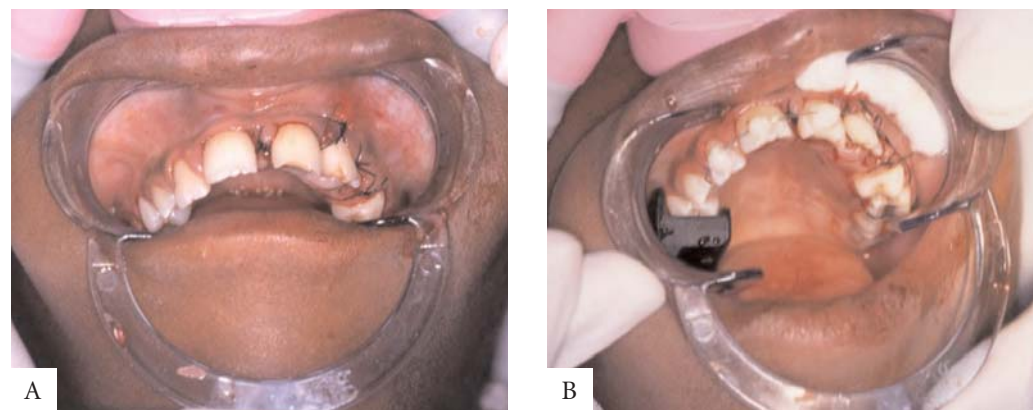


FIGURE 21-17 Acid-etch splinting technique. A, Subluxed tooth and alveolar fracture associated with maxillary left central incisors. B, Nonrigid passive placement of splint. Traumatized teeth are placed into preinjury alignment, acid-etched, and stabilized with composite resin. Splint is free of occlusion and soft tissue trauma.

Table 21-6 Sequence of Acid-Etch Splinting Technique*

1. Perform alveolar bony reduction and/or replantation
2. Perform localized cleansing and débridement
3. Isolate and dry area
4. Custom fabricate wire (~26 Ga), double-stranded monofilament nylon line, or paper clip
Extend wire to at least 1 or 2 teeth on either side of the involved tooth or teeth
5. Etch the incisal half of the labial surface of the involved and adjacent teeth with gelled phosphoric acid for 30–60 s
6. Remove etchant with water stream for ~20 s
7. Air dry etched surface; surface should appear chalky white
8. Passively place prefabricated wire to involved teeth
9. Stabilize splint with fast-setting autocure or light-cure composite resin
10. After resin is set, smooth rough edges with a fine acrylic or diamond finishing bur
(Check occlusion)
11. Perform soft tissue and gingival repair as needed
12. Remove splint in 7–10 d

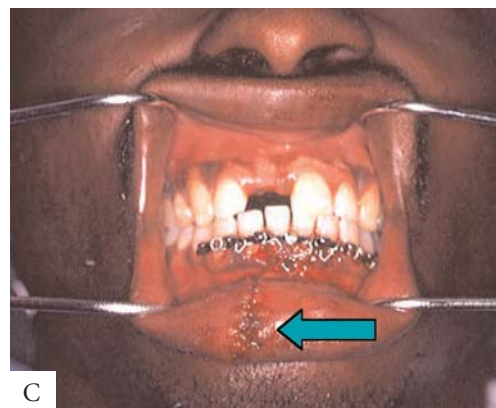
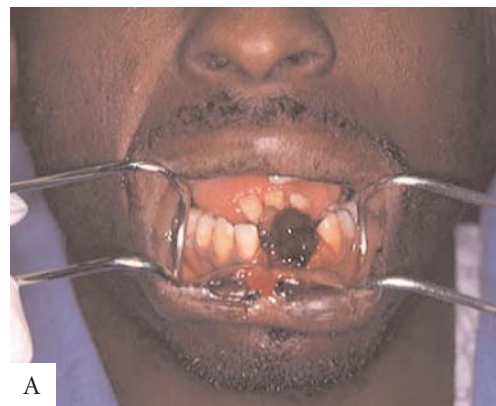
*It may be prudent to use a composite shade that differs from the natural color of the involved teeth as this will facilitate ease of removal and prevent trauma to enamel.

could lead to unsightly accidental tattooing. If present, carry out meticulous removal within 12 hours, with care not to further inoculate the patient.⁵⁸ The removal process includes a technique that aligns the surgical blade perpendicular to the direction of the abrasion.

Contusion A contusion, a hemorrhage of subcutaneous tissue without laceration or break of overlying soft tissue, is similar to a bruising injury caused by blunt trauma. Treating gingival contusion includes local cleansing and observation. This injury may be associated with an underlying hematoma or ecchymotic formation, which is generally self-limiting. Antibiotic coverage is usually unnecessary.

Laceration Lacerations are the most common form of facial injury. Gingival lacerations may involve an underlying bony defect. Treatment involves early cleansing and reapproximation. Remove devitalized tissue in a conservative manner, and suture in a manner that limits wound tension. Consider antibiotic and tetanus prophylaxis. More serious avulsive gingival wounds warrant close inspection of remaining tissue and underlying bony

integrity. Exposure of any underlying bony defect may indicate localized keratinized sliding or advancement flaps. If nonkeratinized tissue is used for coverage, future grafting may be indicated.



Pediatric Dentoalveolar Trauma Treatment

The poor coordination of pediatric patients who are learning to walk, as well as their relatively large pulp chamber-to-tooth ratio, accounts for most pediatric dentoalveolar injuries. Managing the patient may require sedation and restraint; thus, additional factors must be dealt with during the treatment regimen.

Displacement injuries are more prevalent than are tooth fractures in the primary dentition secondary to the relative resilience of the surrounding bone. Similarly, these injuries are more common in the pediatric dentition than in the permanent dentition.

Treating the primary dentition is dictated by the likelihood that the permanent tooth bud may be compromised, secondary to the buccal-occlusal position of the primary teeth to the permanent tooth bud (Figure 21-19). Transmission

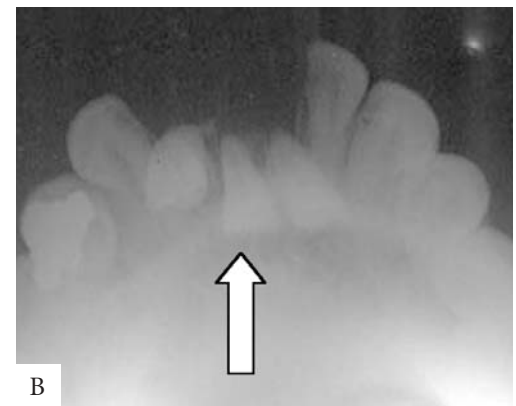


FIGURE 21-18 A, Blunt facial trauma resulting in alveolar fracture and perioral soft tissue lacerations. B, Occlusal radiograph confirming alveolar fracture with lingual displacement ("apical lock") of mandibular central incisors and left lateral incisors (arrow). C, Alveolar fracture disimpaction, reduction, and stabilization with arch wire. Débridement and repair of perioral soft tissues (arrow).

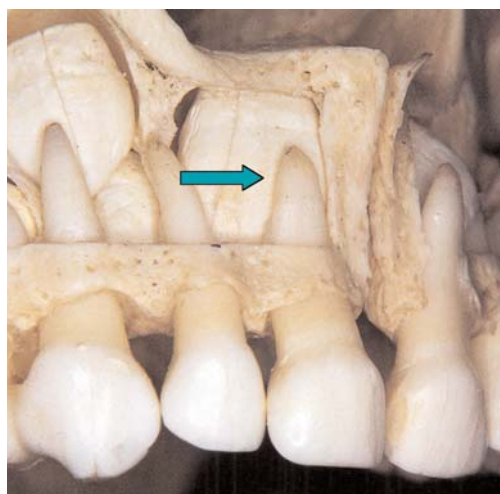


FIGURE 21-19 Anatomic position of the primary dentition to the developing permanent tooth bud. Note the “buccal-occlusal” and “buccal-incisal” position of the primary roots (arrow).

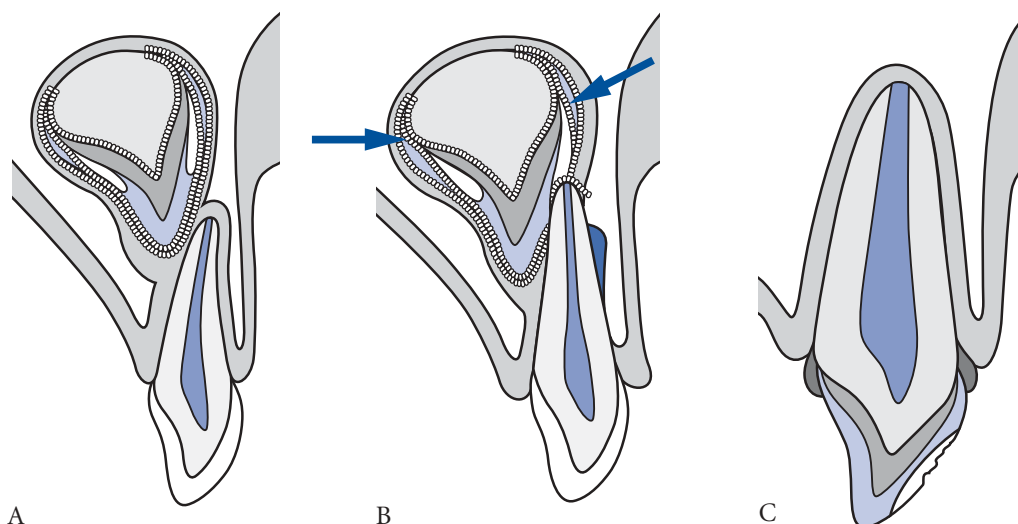


FIGURE 21-20 A, Normal position of primary tooth to permanent tooth bud. B, Apical intrusion of primary root impinging on permanent tooth bud. Blue arrows denote permanent tooth bud. C, Hypoplasia of permanent tooth secondary to apical intrusion.

of force to the developing tooth is possible in displacement injuries, which may cause interference with odontogenesis, ultimately resulting in enamel discoloration and/or hypoplasia (Figure 21-20).

Table 21-7 provides a summary of the treatment regimen.

Andreasen and Raven reported on the general prognosis of the traumatized permanent successors, secondary to forces

applied by the primary dentition. They found that the individual's age at the time of injury and the type of luxation play a major role in the errant development of the permanent dentition (Figure 21-21).^{21,22,59}

Table 21-7 Treatment of Pediatric Injuries

Type of Injury	Treatment
Crown fractures	
Class I (enamel only)	Smooth rough edges
Class II (enamel and dentin)	1. CaOH or glass ionomer liner over dentin 2. Composite resin restoration
Class III (pulpal involvement)	
Vital pulp	1. Formocresol pulpotomy 2. Coronal coverage
Nonvital pulp	1. ZnOH-eugenol pulpectomy 2. Coronal coverage
Class IV (root fracture)	
Apical third	No treatment; follow-up
Cervical third	1. Remove tooth fragments 2. Allow apical third to resorb if compromise to permanent tooth bud is expected
Luxations	
Subluxation	Monitor/follow-up
Lateral luxations	Realign/remove prn
Extrusion	Realign/remove prn
Intrusion	1. Allow to re-erupt 4–6 wk 2. Remove if in contact with permanent successor 3. Remove if infection presents

prn = as needed.

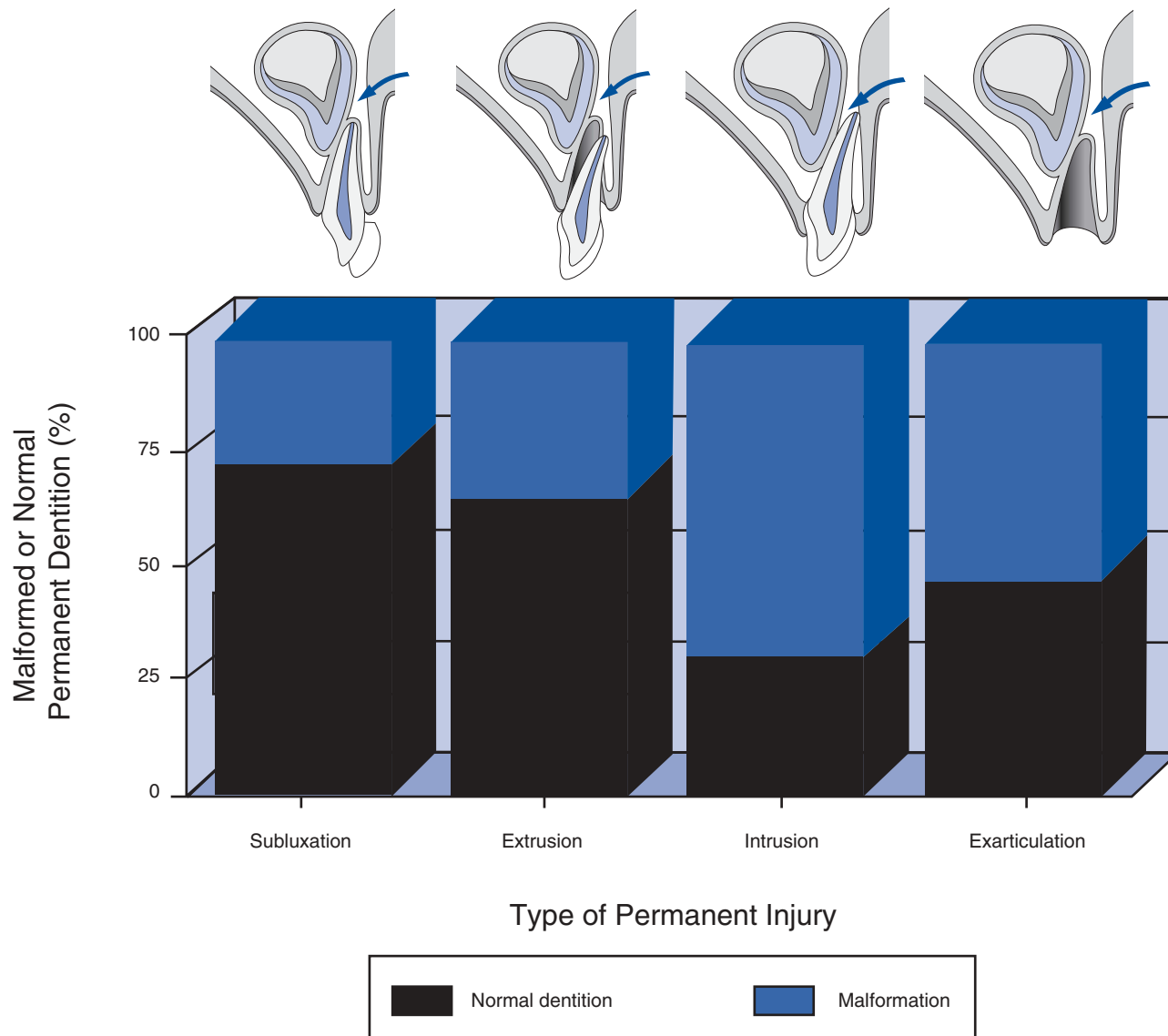


FIGURE 21-21 Association of the type of luxation injury with respect to the malformation of the permanent dentition. Adapted from Andreasen JO and Ravn JJ.⁵⁹

References

- Fonseca RJ, Walker RV, Betts NJ, Barber HD. Oral and maxillofacial trauma. 2nd ed. Vol 1. Philadelphia (PA):W.B. Saunders Co; 1997. p. 474.
- Shayne's Dental Site. History of dentistry, Greco-Roman dentistry (AD 350–750), Available at: <http://www.dental-site.itgo.com/grecoroman.htm> (accessed March 17, 2003).
- Shayne's Dental Site. History of dentistry, Islamic-Medieval Europe (AD 750–1200), Available at: <http://www.dental-site.itgo.com/Islamic.htm> (accessed March 17, 2003).
- James D. Maxillofacial injuries in children. In: Rowe NL, Williams JLL, editors. Maxillofacial injuries. 1st ed. Edinburg: Churchill Livingstone; 1985. p. 538.
- Andreasen JO. Classification, etiology and epidemiology. In: Andreasen JO, editor. Traumatic injuries of the teeth. 2nd ed. Copenhagen: Munksgaard; 1981. p.19.
- Lephart SM, Fu FH. Emergency treatment of athletic injuries. Dent Clin North Am 1991;35:707.
- Heintz WD. Mouth protection for athletics today. In: Godwin WD, Long BR, Cartwright CB, editors. The relationship of internal protection devices to athletic injuries and athletic performance. Ann Arbor (MI): University of Michigan; 1982.
- U.S. Department of Health and Human Services. Children's Bureau. National child abuse and neglect data system. Summary of key findings from calendar year 2000. April 2002. Available at: <http://www.acf.hhs.gov/news/press/2002/abuse.html> (accessed March 29, 2004).
- Peng L, Kazzi, AA. Dental, fractured tooth. eMedicine Journal 2001;2:6.
- Laskin DM. The recognition of child abuse. J Oral Surg 1978;36:349.
- Leathers RD, Shetty V, Black EE, Atchison K. Orofacial injury and patterns of care in an inner-city hospital. Int J Oral Biol 1998;23:53–8.
- Leathers RD, Le AD, Black EE, McQuirter JL. Orofacial injury in underserved minority populations. Dent Clin N Am 2003;47:127–39.
- Black EE, Atchison K, Shetty V, et al. The relationship of substance abuse to orofacial injuries in an inner-city population. Int J Oral Biol 1998;47:52.
- Lockhard PB, Feldbau EV, Gabel RA, et al. Dental complications during and after

- tracheal intubation. *J Am Dent Assoc* 1986; 112:480.
15. Piercell MP, White DE, Nelson R. Prevention of self-inflicted trauma in semicomatose patients. *J Oral Surg* 1974;32:903.
 16. Wright RB, Mansfield FF. Damage to teeth during the administration of general anesthesia. *Anesth Anal* 1974;53:405.
 17. Andreasen JO. Etiology and pathogenesis of traumatic dental injuries. *Scand J Dent Res* 1970;78:329.
 18. Fonseca RJ. Oral and maxillofacial surgery, trauma. Vol 3. Philadelphia (PA):W.B. Saunders Co; 2000. p. 46.
 19. Assael LA, Ellis EE. Soft tissue and dentoalveolar injuries. In: Peterson LJ, Ellis E, Hupp JR, Tucker MR, editors. *Contemporary oral and maxillofacial*. 2nd ed. St. Louis (MO): C.V. Mosby Co.; 1988. p. 230.
 20. Davidoff G, Jakubowski M, Thomas D, Alpert M. The spectrum of closed-head injury in facial trauma victims: incidence and impact. *Ann Emerg Med* 1988;17:27.
 21. Bucci MN, Phillips TJ, McGillicuddy JE. Delayed epidural hemorrhage in hypotensive multiple trauma patients. *Neurosurgery* 1986;19:65–8.
 22. Alexander RH, Proctor HJ. *Advance Trauma Life Support (ATLS) Course for Physicians*. 5th ed. Chicago (IL): American College of Surgeons; 1993. p. 21–37.
 23. Fonseca RJ, Marciani RD, Hendler BH. Oral and maxillofacial surgery, trauma. Vol 3. Diagnosis and management of dentoalveolar injuries. Philadelphia (PA):W.B. Saunders Co; 2000. p. 48–50.
 24. Alexander RH, Proctor HJ. *Advance Trauma Life Support (ATLS) Course for Physicians*. 5th ed. Chicago (IL): American College of Surgeons; 1993. p. 357.
 25. Tsukiboshi T. Treatment planning for traumatized teeth. Carol Stream (IL): Quintessence Publishing Co.; 2000. p.105–8.
 26. Andreasen JO, Sundstrom B, Ravn JJ. The effect of traumatic injuries to primary teeth on their permanent successors. I. A clinical, radiographic, microradiographic and electron-microscopic study of 117 injured permanent teeth. *Scand J Dent Res* 1970; 79:219–83.
 27. Andreasen JO, Ravn JJ. The effect of traumatic injuries to primary teeth on their permanent successors. II. A clinical and radiographic follow-up of 213 injured teeth. *Scand J Dent Res* 1970;79:284–94.
 28. Booth NA. Complications associated with treatment of traumatic injuries of the oral cavity-aspiration of teeth: report of a case. *J Oral Surg* 1953;11:242–342.
 29. Snawder KD, Bastawni AE, O'Toole TJ. Tooth fragments lodged in unexpected areas. *JAMA* 1976;233:1378–9.
 30. Gilliland RE, Taylor CG, Wade WM Jr. Inhalation of a tooth during maxillofacial injury: report of a case. *J Oral Surg* 1972;30:839–40.
 31. Rowe NL, Killey HC. The clinical examination of fractures of the middle third of the facial skeleton involving the dentoalveolar component. In: Rowe NL, Killey HC, editors. *Fractures of the facial skeleton*. 2nd ed. Baltimore (ML): Williams & Wilkins; 1970. p. 345.
 32. Fulling H-J, Andreasen JO. Influence of maturation status and tooth type of permanent teeth upon electrometric and thermal pulp testing. *Scand J Dent Res* 1976;84:286–90.
 33. Johnsen DJ. Innervation of teeth: qualitative, quantitative, and developmental assessment. *J Dent Res* 1985;64:555–63.
 34. Andreasen JO, Andreasen FM. Textbook and color atlas of traumatic injuries to the teeth. 3rd ed. Copenhagen: Munksgaard; 1994. p. 202–10.
 35. Wilder-Smith PEEB. A new method for the non-invasive measurement of pupal blood flow. *Int Endod J* 1988;21:307–12.
 36. Gazelius B, Olgart L, Edwall L. Non-invasive recordings of blood flow in human dental pulp. *Endod Dent Traumatol* 1986;2:219–21.
 37. Andreasen JO, Andreasen FM. *Essentials of traumatic injuries to the teeth*. 2nd ed. St. Louis (MO): C.V. Mosby Co.; 2000. p. 25.
 38. Andreasen JO, Ravn JJ. Epidemiology of traumatic dental injuries to primary and permanent teeth in a Danish population sample. *Int J Oral Surg* 1972;1:235–9.
 39. Schreiber CK. The effect of trauma on the anterior deciduous teeth. *Br Dent J* 1959; 106:340.
 40. Andreasen JO, Andreasen FM. Textbook and color atlas of traumatic injuries to the teeth. 3rd ed. Copenhagen: Munksgaard. 1994. p. 315–77.
 41. Andreasen JO. Luxation of permanent teeth due to trauma: a clinical and radiographic follow-up study of 189 injured teeth. *Scand J Dent Res* 1970;78:273.
 42. Cvek M. Treatment of non-vital permanent incisors with calcium hydroxide. II. Effect on external root resorption in luxated teeth compared with effect of root filling with gutta-percha: a follow-up. *Odontol Rev* 1973;24:343.
 43. Coccia CT. A clinical investigation of root resorption rates in replanted young permanent incisors: a five year study. *J Endod* 1980;6:413.
 44. Andreasen JO, Kristerson L. The effect of extra-alveolar root filling with calcium hydroxide on periodontal healing after replantation of permanent incisors in monkeys. *J Endod* 1981;7:349.
 45. Andreasen FM, Vestergaard Pedersen B. Prognosis of luxated permanent teeth – the development of pulp necrosis. *Endod Dent Traumatol* 1985;1:207–20.
 46. Andreasen JO, Andreasen FM. Textbook and color atlas of traumatic injuries to the teeth. 3rd ed. Copenhagen: Munksgaard; 1994. p. 383.
 47. Krasner P, Rankow HJ. New philosophy for the treatment of avulsed teeth. *Oral Surg Oral Med Oral Path Oral Radiol Endod* 1995;79:616.
 48. Krasner P, Persen P. Preserving avulsed teeth for replantation. *J Am Dent Assoc* 1992; 123:80.
 49. Thorp M, Friedman S. Periodontal healing of replanted teeth stored in Viaspan, milk, and Hank's balanced salt solution. *Endod Dent Traumatol* 1992;8:183.
 50. Fonseca RJ. Oral and maxillofacial surgery, trauma. Vol 3. Philadelphia (PA):W.B. Saunders Co.; 2000. p. 64–8.
 51. Hiltz J, Trope M. Vitality of human lip fibroblast in milk, Hank's balanced salt solution and Viaspan storage media. *Endod Dent Traumatol* 1991;7:69–72.
 52. Cvek M, Cleaton-Jones P, Austin J, et al. Effect of topical application of doxycycline on pulp revascularization and periodontal healing in reimplanted monkey incisors. *Endod Dent Traumatol* 1990;170.
 53. Cohen S, Burns RC. *Pathways of the pulp*. 8th ed. St. Louis (MO): C.V. Mosby Co.; 2002. p. 562–63.
 54. Lieblisch SE. Surgical aspects of apicoectomy with “hands on” demonstration of microapical preparation. *Surgical mini-lectures (M222)*. *J Oral Maxillofac Surg* 2003;100.
 55. Selvig KA, Bjorvatn K, Bogle GC, Wikesjo UME. Effect of stannous fluoride and tetracycline on periodontal repair after delayed tooth replantation in dogs. *Scand J Dent Res* 1992;100:200.
 56. Andreasen JO, Andreasen FM. Textbook and color atlas of traumatic injuries to the teeth. 3rd ed. Copenhagen: Munksgaard. 1994. p. 347–50.
 57. Kehoe JC. Splinting and replantation after traumatic avulsion. *J Am Dent Assoc* 1986; 112:224.
 58. Schultz RC. Facial injuries. 2nd ed. Year Book Medical Publishers Inc; 1977. p. 87–91.
 59. Andreasen JO, Ravn JJ. Enamel changes in permanent teeth after trauma to their primary predecessors. *Scand J Dent Res* 1973;81:203.

Principles of Management of Mandibular Fractures

Guillermo E. Chacon, DDS

Peter E. Larsen, DDS

Management of trauma has always been one of the surgical subsets in which oral and maxillofacial surgeons have excelled over the years. More particularly, our experience with dental anatomy, head and neck physiology, and occlusion provides us with unparalleled skills for the management of mandibular fractures.

The mandible is the second most commonly fractured part of the maxillofacial skeleton because of its position and prominence.^{1,2} The location and pattern of the fractures are determined by the mechanism of injury and the direction of the vector of the force. In addition to this, the patient's age, the presence of teeth, and the physical properties of the causing agent also have a direct effect on the characteristics of the resulting injury.³

Bony instability of the involved anatomic areas is usually easily recognized during clinical examination. Dental malocclusion, gingival lacerations, and hematoma formation are some of the most common clinical manifestations.

In the management of any bone fracture, the goals of treatment are to restore proper function by ensuring union of the fractured segments and reestablishing preinjury strength; to restore any contour defect that might arise as a result of the injury; and to prevent infection at the fracture site. Restoration of mandibular function, in particular, as part of the stomatognathic system must include the ability to

masticate properly, to speak normally, and to allow for articular movements as ample as before the trauma. In order to achieve these goals, restoration of the normal occlusion of the patient becomes paramount for the treating surgeon.

Basic principles of orthopedic surgery also apply to mandibular fractures including reduction, fixation, immobilization, and supportive therapies. It is well known that union of the fracture segments will only occur in the absence of excessive mobility. Stability of the fracture segments is key for proper hard and soft tissue healing in the injured area. Therefore, the fracture site must be stabilized by mechanical means in order to help guide the physiologic process toward normal bony healing.

Reduction of the fracture can be achieved either with an open or closed technique. In open reduction, as the name implies, the fracture site is exposed, allowing direct visualization and confirmation of the procedure. This is typically accompanied by the direct application of a fixation device at the fracture site (Figure 22-1). A closed reduction takes place when the fracture site is not surgically exposed but the reduction is deemed accurate by palpation of the bony fragments and by restoration of the functioning segments, for example, restoration of the dental occlusion by wiring the teeth together, using splints, or employing external pins (Figure 22-2).

Fixation must be able to resist the displacing forces acting on the mandible. It can take one of two forms: direct or indirect. When direct fixation is used, the fracture site is opened, visualized, and reduced; then stabilization is applied across the fracture site. The rigidity of direct fixation can range from a simple osteosynthesis wire across the fracture (ie, nonrigid fixation) to a miniplate at the area of fracture tension (ie, semirigid fixation) or a compression bone plate (ie, rigid fixation) to compression screws alone (lag screw technique). Indirect fixation is the stabilization of the proximal and distal fragments of the bone at a site distant from the fracture line. The

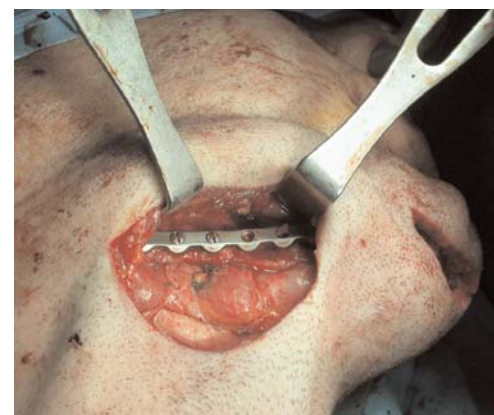


FIGURE 22-1 Open reduction with internal fixation implies surgical exposure, visualization, and manipulation with the placement of a stabilization device directly along the bone segments involved in the fracture. A locking reconstruction plate has been placed on this injury via a submandibular approach.

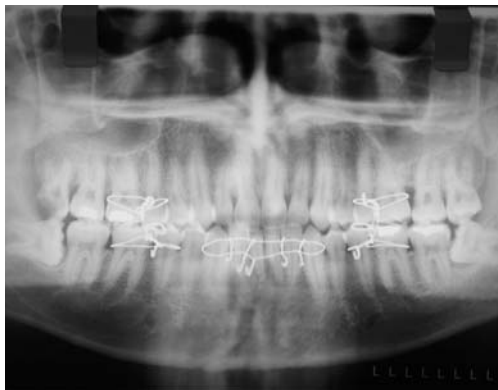

FIGURE 22-2 This panoramic radiograph demonstrates the use of wires to perform a closed reduction with intermaxillary fixation of a minimally displaced right parasymphysis fracture.

most commonly used method for mandibular fractures is the use of intermaxillary fixation (IMF). A further example of indirect fixation is the use of external biphasic pin fixation in combination with an external frame (Figure 22-3).

Over the past three decades many different techniques and approaches have been described in the literature to surgically correct facial fractures. More recently

the use of internal fixation utilizing plates has shown the highest success rates with the lowest incidence of nonunions and postoperative infections.⁴⁻⁶ The origin of plating as a treatment option for fractures can be traced to Dannis and colleagues, who reported the successful use of plates and screws for fracture repair in 1947.⁷ Later refinement of this technique is credited to Allgower and colleagues at the University of Basel, who successfully used the first compression plate for extremity fracture repair in 1969.⁸ However, it was not until 1973 that Michelet and colleagues reported on the use of this treatment modality for fractures of the facial skeleton.⁹ In 1976 following Michelet's success, a group of French surgeons headed by Champy developed the protocol that is now used for the modern treatment of mandibular fractures. But it was not until 1978 that these findings were published in the English literature.¹⁰

Basically, there are two categories of plating systems: rigid compression plates such as the AO/ASIF (Arbeits-gemein-

schaft für Osteosynthesefragen/Association for the Study of Internal Fixation) and the semirigid miniplates. The advantages and disadvantages of each system have been extensively discussed; however, the question remains: does compression of fractures really offer a clinically significant advantage in terms of better bone healing and fewer complications?

Proponents of the AO system state that primary or direct bone healing is the main advantage offered by this system. When a fracture is compressed, absolute interfracture immobilization is achieved with no resorption of the fragment ends, no callus formation, and intracortical remodeling across the fracture site whereby the fractured bone cortex is gradually replaced by new haversian systems.¹¹ However, in other studies it has been shown that absolute rigidity and intimate fracture interdigitation is far from mandatory for adequate bony healing. Compression is not necessary at the fracture site for healing, and it is questionable whether compression stimulates osteogenesis.^{12,13}

Biomechanical Considerations

Studies of the relationship between the nature, severity, and direction of traumatic force on the resultant mandibular injury were made by Huelke and colleagues.¹⁴⁻¹⁹ Before this, few experimental studies had been done with regard to the mechanism of mandibular fracture. Most literature regarding the mechanism of fracture was based on clinical impressions and opinions.

Early investigators showed that linear fractures in long bones were initiated by bone failure resulting from tensile strain rather than compressive strain.²⁰ Huelke and Harger applied forces of varying magnitudes and direction to dried mandibles and observed the resultant production of tension and compression.¹⁷ They found that > 75% of all experimentally produced fractures of the mandible were in primary areas of tensile strain, which supported a similar observation made earlier in long

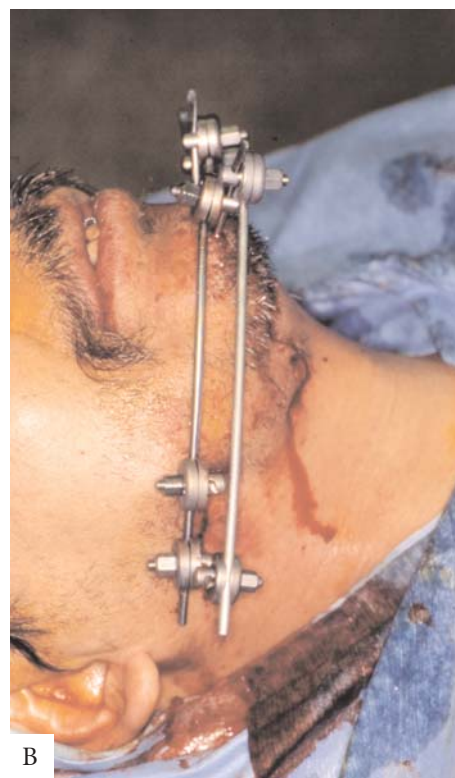
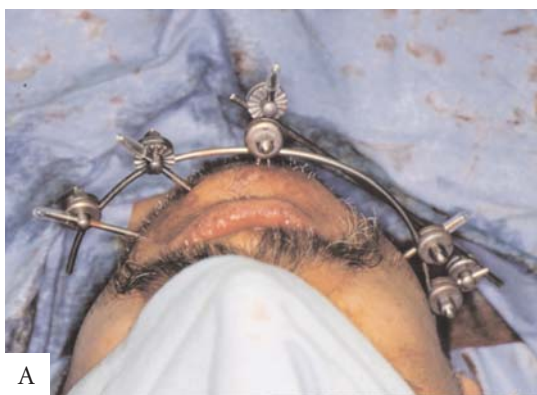
FIGURE 22-3 Superior (A) and lateral (B) views of a mandibular external fixator. In this particular system, biphasic pins are applied transcutaneously and are secured to one another using a universal joint system and rigid metal rods.

bones. A notable exception was that comminuted condylar head injury that was produced by a load parallel to the mandibular ramus was primarily the result of compressive force.

In response to loading, the mandible is similar to an arch because it distributes the force of impact throughout its length (Figure 22-4). However, unlike the arch, the mandible is not a smooth curve of uniform bone, but rather it has discontinuities such as foramina, sharp bends, ridges, and regions of reduced cross-sectional dimension like the subcondylar area. As a result, parts of the mandible develop greater force per unit area, and consequently, tensile strain is concentrated in these locations.

When a force is directed along the parasymphysis-body region of the mandible, compressive strain develops along the buccal aspect, whereas tensile strain develops along the lingual aspect.

This produces a fracture that begins in the lingual region and spreads toward the buccal aspect.¹⁷ The mobile contralateral condylar process moves in a direction away from the impact point until it is limited by the bony fossa and associated soft tissue. At this point, tension develops along the lateral aspect of the contralateral condylar neck, and a fracture occurs. If greater force is applied to the parasymphysis-body region, not only will tension develop along the contralateral condylar neck leading to fracture in this area, but continued medial movement of the smaller ipsilateral mandibular segment will lead to bending and tension forces along the lateral aspect and subsequent fracture of the condylar process on the ipsilateral side. Force applied directly in the symphysis region along an axial plane is distributed along the arch of the mandible. Because the condylar heads are free to rotate within the glenoid fossa to a certain degree,

tension develops along the lateral aspect of the condylar neck and mandibular body regions, as well as along the lingual aspect of the symphysis. This leads to bilateral condylar fractures and a symphysis fracture (Figure 22-5).

Variation from these standard fracture patterns occurs for two general reasons. First, there is a wide range in the possible magnitude and direction of the impact and in the shape of the object delivering the impact. Second, the condition of the dentition, position of the mandible, and influence of associated soft tissues could not be controlled in these studies.

Early observers felt that the presence of posterior dentition tended to reduce the incidence of condylar injury.²¹⁻²³ The implication was that, as the mandible was forced posteriorly and superiorly, the dentition would meet and absorb some of the force, thereby diminishing the force received at the condyle. This was supported

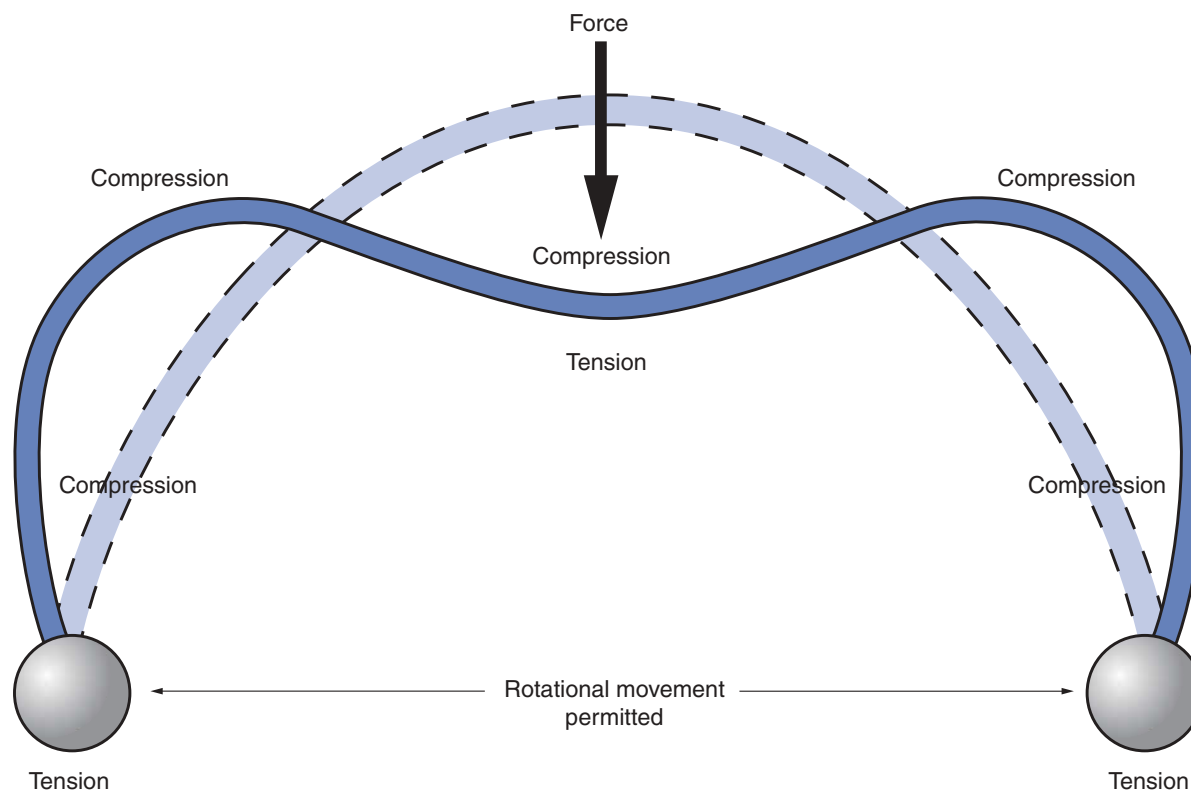


FIGURE 22-4 The effect of a load on an arch where ends are free to rotate. Adapted from Larsen PE. *Traumatic injuries of the condyle*. In: Peterson LJ, Indresano AT, Marciani RD, Roser SM, editors. *Principles of oral and maxillofacial surgery*. Vol 1. Philadelphia (PA): JB Lippincott Company; 1992. p. 444.

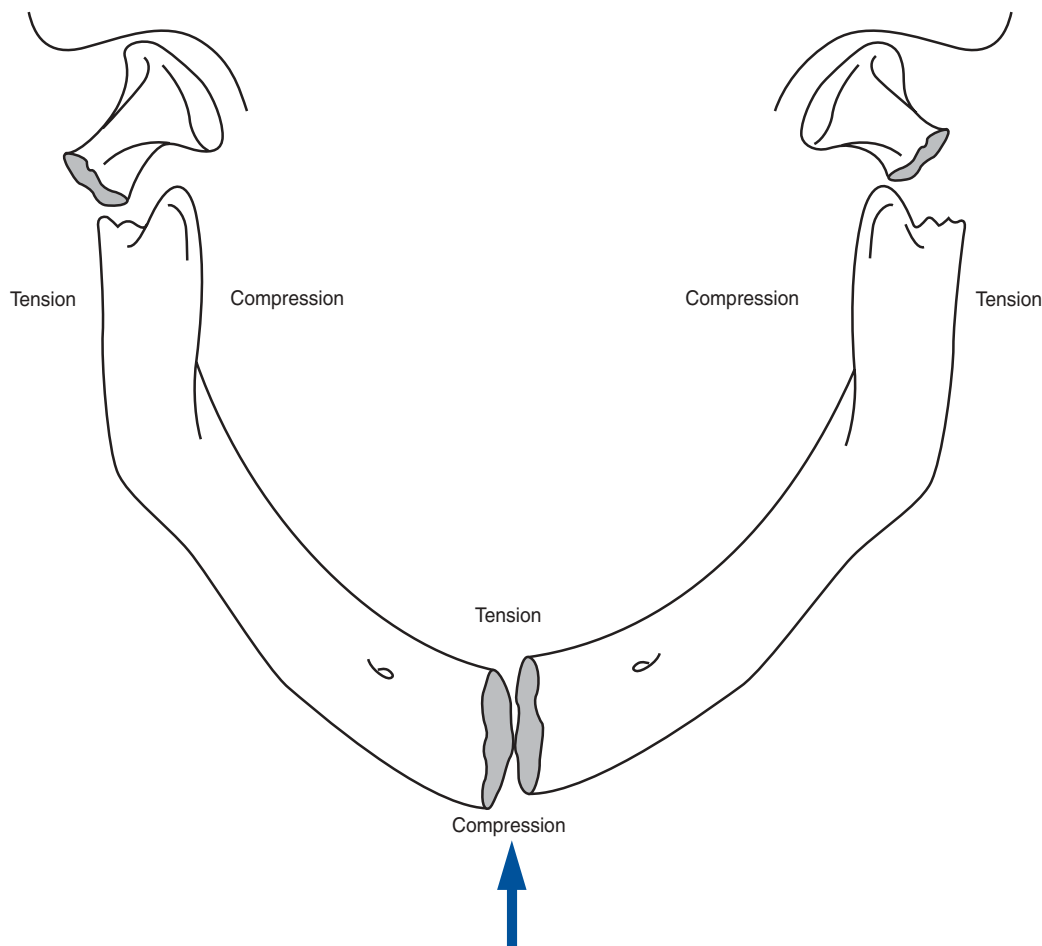


FIGURE 22-5 Force directed at the symphysis along an axial plane is distributed along the arch of the mandible. Tension is dissipated along the mandible, and the fracture occurs bilaterally in the area of least stability, the condylar neck. As in other fractures, a symphysis fracture may develop caused by tension from the blow. Adapted from Larsen PE. Traumatic injuries of the condyle. In: Peterson LJ, Indresano AT, Marciani RD, Roser SM, editors. *Principles of oral and maxillofacial surgery*. Vol 1. Philadelphia (PA): JB Lippincott Company; 1992. p. 445.

by the clinical observation that the posterior dentition was often fractured on the side of the condylar fracture. However, more recent findings do not support this theory and show that all types of fractures occur, irrespective of the occlusion, and that no correlation exists between the degree of dislocation, level of fracture, or type of fracture with the presence of a distal occlusion.²⁴ Although the presence or absence of a posterior dentition does not correlate with the incidence of fracture, the presence of specific teeth, particularly impacted third molars, has been shown to markedly affect the incidence of mandibular fractures. It was shown that, when impacted third

molars are present, this area represented a region of inherent weakness and the incidence of condylar fractures decreases, whereas the incidence of mandibular angle fractures increases.²⁵

Although unable to show that the occlusion played any role in the type of fracture produced, investigators have found that the relative degree of mandibular opening at the time of impact does play an important role in the type of fracture that occurs.^{23,26} More recent studies have shown that not only is the incidence of fracture higher when the mouth is open, but the level of fracture varies with degree of opening. When the mouth is opened,

the fractures tend to be located more in the condylar neck or condylar head region, whereas when it is closed, fractures are in the subcondylar area.²⁵

Evaluation of Mandibular Fractures

Traumatic craniofacial and skull base injuries require a multidisciplinary team approach. Trauma physicians must evaluate carefully, triage properly, and maintain a high index of suspicion to improve survival and enhance functional recovery. Frequently, craniofacial and skull base injuries are overlooked while treating more life-threatening injuries.²⁷ Unnoticed complex craniofacial and skull base fractures, cerebrospinal fluid fistulas, and cranial nerve injuries can result in blindness, diplopia, deafness, facial paralysis, or meningitis.

Following the principles of Advanced Trauma Life Support, during the initial assessment in the emergency department, the first and most critical obligation is to make sure that the airway is patent and free of potential obstruction. The tongue, which may have a tendency to fall back, must be controlled, and objects obstructing the airway must be removed. If an obstruction cannot be removed, a new airway must be established by endotracheal intubation (remembering possible cervical spine injuries) or cricothyrotomy. After the airway has been secured and respiration is occurring, vital signs must be assessed, including pulse rate and blood pressure. Any significant blood loss is likely to be coming from injuries apart from those of the face. Other critical injuries must be ruled out, including intracranial hemorrhages, cervical and other spinal injuries, chest injuries, abdominal trauma, and fractures of the long bones.

Local examination of the face and jaws should be conducted in a logical sequence. The first objective is to obtain an accurate history from the patient, or relative if the patient cannot cooperate. Pertinent to a

fractured mandible examination is notation of the size, number, and force of any blows to the face.

Patients often complain of the following:

- Pain or tenderness is often present at the site of impact with the possibility of a direct fracture, or at a distant site in the case of an indirect fracture.
- Difficulty chewing. Pain could be limiting mandibular function or there may be a malocclusion or mobility at the fracture site.
- Malocclusion. The patient may be able to tell the clinician of an alteration in the bite from normal; however, patients are not always reliable and may claim that the bite feels normal when it is not and vice versa.
- Numbness in the distribution of the inferior alveolar nerve. This usually indicates a displaced fracture in the region of the body or angle of the mandible on the affected side. A nondisplaced fracture often does not give rise to numbness in the distribution of the inferior alveolar nerve.

Clinical Examination

The clinical examination should consist of inspection and palpation. It is best to proceed in an orderly fashion and to perform this evaluation as a component part of the entire head and neck examination of the trauma patient. The skin of the face and, in particular, the area around the mandible should be inspected for swelling, hematomas, and lacerations. A common site for a laceration is under the chin, and this should alert the clinician to the possibility of an associated subcondylar or symphysis fracture. Typically, the patient who has suffered a fracture of the mandibular condyle will present with facial asymmetry (Figure 22-6). This is owing to the loss of the vertical height of the ramus on the side with the fracture, resulting in a shift of the mandible to the ipsilateral side.

The best routine to evaluate facial fractures is to start at the top and work down, assessing the stability of the anatomic structures in a mediolateral fashion. It is best to begin the examination from behind the seated or supine patient (Figure 22-7). The clinician should palpate the movement of the condyle both over the lateral aspect of the joint and through the external acoustic meatus and observe the movement of the mandible itself. If a unilateral condylar fracture is present, a subjective assessment can then be made between the palpable movement of one side compared with the other. Failure to detect the translation of the condyle, especially when associated with pain on palpation, is highly indicative of a fracture in this area. Palpation will frequently confirm tenderness over the lateral pole of the injured condyle with associated crepitation. However, in the case of fracture dislocations, the condyle may not be palpable.

Any significant deviation on opening may be indicative of subcondylar fracture on the side to which the mandible deviates. To better evaluate this area, the fifth finger is placed in each acoustic meatus and the patient is asked to open and close the mouth. On opening, the mandible frequently shifts even more toward the side of the fracture as a result of decreased translation of the condyle on the injured side. As mentioned before, in unilateral fractures, there is deviation of the occlusion toward the fractured side, with premature occlusal contact in the posterior region on that side. This results because the lateral pterygoid muscle on the fractured side pulls on the fractured segment and does not have any protruding influence on the mandible. The lateral pterygoid muscle on the contralateral side is unopposed and thus causes deviation to the fractured side. The midlines no longer coincide, and there is an open bite in the body region on the contralateral side. This is often accompanied by fracture of the posterior denti-

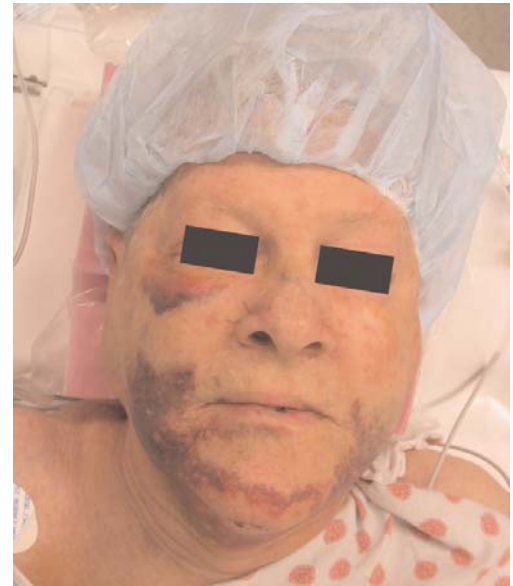

FIGURE 22-6 Patient with significant lower face ecchymosis and asymmetry as a result of a symphysis fracture, bilateral subcondylar fractures, and a Le Fort I fracture resulting from a direct impact to the chin during a fall.

tion on the same side as the condylar fracture (Figure 22-8).

If bilateral condylar fractures are present, the occlusion may not be deviated. The midlines are often coincident, and

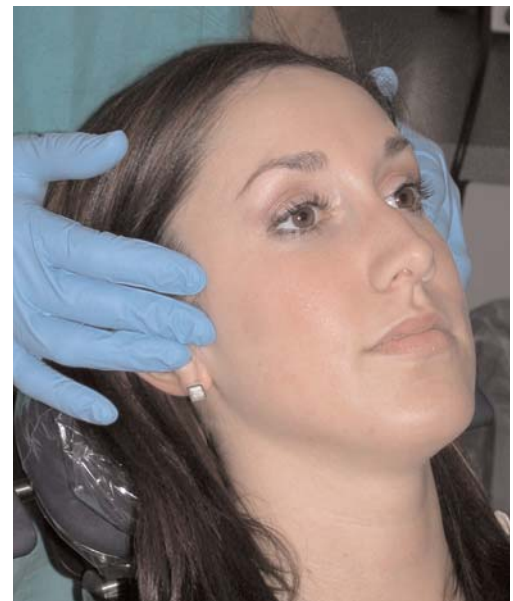


FIGURE 22-7 Bimanual palpation of the mandible by the surgeon in a cephalad position allows excellent evaluation and comparison of the anatomic structures.

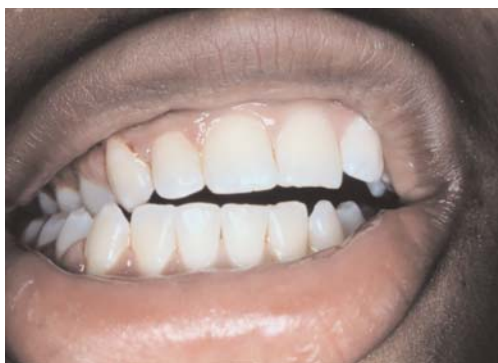

FIGURE 22-8 Significant midline deviation toward the fracture side along with buccal cusp tip fractures of both mandibular bicuspids and first molar.

premature contact is present bilaterally on the posterior dentition with an anterior open bite. The posterior dentition may be fractured on both sides in these situations.

Often the patient with a fracture of the condylar process also has a limited range of motion. This limitation, however, is primarily caused by voluntary restriction as a result of pain. One has to keep in mind that any limitation of mandibular movement may also be a result of reflex muscle spasm, temporomandibular effusion, or mechanical obstruction to the coronoid process resulting from depression of the zygomatic arch. Other less common findings include blood within the external auditory canal and, in the case of fracture dislocation, development of a prominent preauricular depression. Careful otoscopic evaluation of the external auditory canal is of particular importance in patients suspected to have suffered an injury at this level. Occasionally a fracture of the condylar process will produce a tear in the epithelial lining of the anterior wall of the canal, which produces bleeding from the acoustic meatus. It is important to determine that this bleeding is not coming from behind a ruptured tympanic membrane, which may signify a basilar skull fracture.

A detailed intraoral examination should be undertaken with good lighting and immediate availability of suction. The most common intraoral findings are mal-

occlusion, fracture of the dentition, and decreased interincisal opening.

Continuing with the systematic evaluation of the patient, it is suggested that examination of the soft tissues be undertaken next. The gingival tissue should be inspected for tears or lacerations. With the aid of a tongue blade, the floor of the mouth is examined; sublingual ecchymosis is almost pathognomonic of a fracture of the mandible. Next the dentition is examined for evidence of broken teeth and for steps or irregularities in the dental arch. The patient is asked to lightly bite the teeth together and to say whether the bite feels different from normal, following which the occlusion is inspected. Premature occlusal contacts are noted. The three causes of an altered occlusion in the trauma patient are a displaced fracture, a dental injury such as a displaced tooth, and a temporomandibular joint effusion or dislocation.

If the patient is edentulous and has intact dentures with him, these can be replaced in the mouth and the occlusion inspected (Figure 22-9). The mandible should then be grasped on each side of any suspected fracture and gently manipulated to assess mobility. If no fracture can be found but clinical suspicion remains high, the mandible may be compressed by applying pressure over both angles (Figure 22-10). This nearly always gives rise to

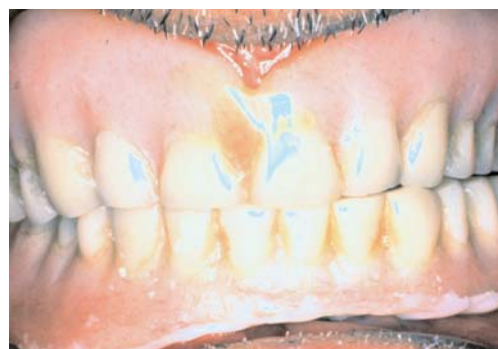

FIGURE 22-9 The patient's own dentures often become very useful instruments in the assessment and management of mandibular fractures in the edentulous patient, if they are intact or can be reasonably repaired.

pain at a fracture site. In the case of subcondylar fractures, firm posterior pressure on the chin will cause pain in the preauricular region.

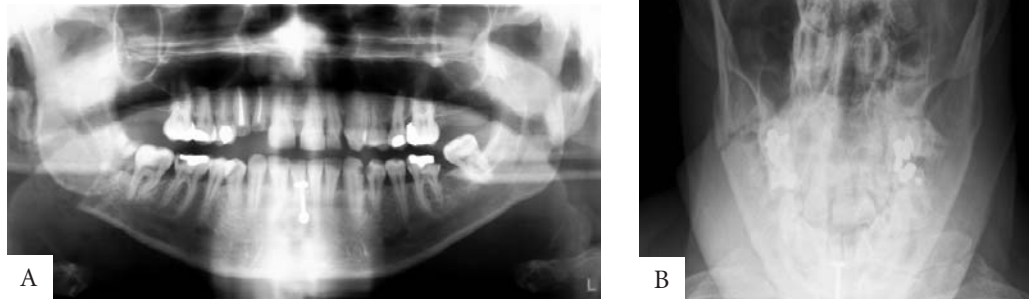
Radiographic Evaluation

To adequately screen for the presence of a mandibular fracture, at least two views at right angles to each other are necessary. A panoramic radiograph and a reverse Towne's view (Figure 22-11) are adequate screening studies for this purpose. If only one view is used, fractures can easily be missed.²⁸ In the multiple-trauma patient for whom panoramic radiographs are not possible, lateral oblique views may be substituted. Other radiographic views that may be useful depending on the circumstances are posteroanterior mandibular, mandibular occlusal, and periapical. Linear tomographies of the temporomandibular joints can also be useful in the evaluation of fractures at the level of the condylar process. However, intracapsular fractures

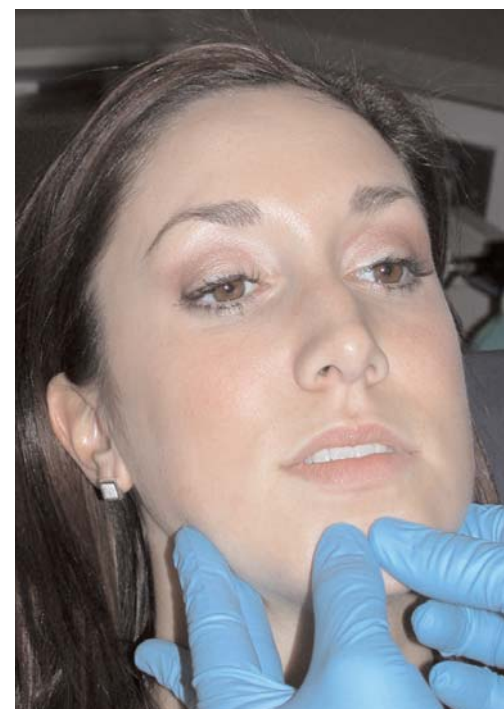

FIGURE 22-10 The application of gentle bimanual pressure over the angle regions can unmask a minimally displaced fracture in the anterior region of the mandible.

FIGURE 22-11 Obtaining at least two radiographic views of the mandible facilitates identification of discreet injuries and also allows for a better assessment of the degree of displacement of the fracture segments. A significantly rotated proximal segment of the right angle fracture is apparent in the panoramic radiograph (A), whereas the same fracture appears almost nondisplaced in the Towne's view (B).



of the condylar head are often difficult to visualize accurately on plain films.

The typical radiographic findings when a condylar fracture is present are the following: a shortened condylar-ramus length; the presence of a radiolucent fracture line or, in the case of overlapped segments, the presence of a radiopaque double density (Figure 22-12); and evidence of premature contact on the side of the fracture if the radiograph was taken with the patient in occlusion. If more accurate information of the involvement of the temporomandibular joint is required, axial and coronal computed tomography (CT) scans offer an excellent opportunity to study the fracture details.

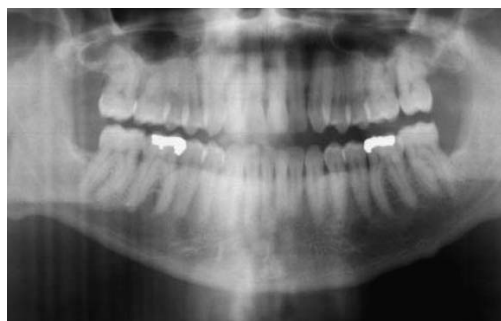

FIGURE 22-12 Panoramic radiograph showing clear findings of a right condylar neck fracture.

Indications for CT scans are the following:

1. Significant displacement or dislocation, particularly if open reduction is contemplated
2. Limited range of motion with a suspicion of mechanical obstruction caused by the position of the condylar segment
3. Alteration of the surrounding osseous anatomy by other processes, such as previous internal derangement or temporomandibular joint surgery, to the degree that a pretreatment baseline is necessary
4. Inability to position the multiple-trauma patient for conventional radiographs (CT scans may be the only useful radiograph that can be obtained)

Chayra and colleagues reviewed the need for a complete series of films.²⁹ They concluded that the initial screening of patients could be effectively undertaken with a panoramic radiograph alone. Ninety-two percent of fractures were seen on a panoramic radiograph alone, compared with only 66% on a routine radiographic series without a panoramic view. However, in order to accurately visualize displace-

ment it is recommended that the standard mandibular views consist of a panoramic radiograph, a posteroanterior mandibular view, and reverse Towne's view (Figure 22-13). The latter view allows for visualization of the degree of medial or lateral displacement of the fracture and unveils injuries in which only subtle deviation is present, such as is seen in greenstick fractures, which are not readily evident on panoramic view.

The panoramic radiograph usually requires the patient to be able to stand upright and also requires accurate patient positioning for good-quality films. In the severely traumatized patient, this may be difficult to achieve with some machines. Further, mesiolateral displacement in the ramus and body and anteroposterior displacement in the symphyseal regions may also be difficult to visualize. The traditional lateral oblique views of the mandible can be used when panoramic films are not possible. They require accurate positioning of the patient and film to obtain useful views, particularly in the condylar area. A transcranial temporomandibular view may be a good addition in these circumstances.

Accurate assessment of symphyseal fractures may be problematic with the standard views. A mandibular occlusal view is particularly useful in this scenario. It also aids in the assessment of the fracture of the lingual plate, particularly in very oblique fractures. Periapical views may also be necessary for evaluation of the teeth on either side of the fracture line to assess root fractures, periapical and periodontal pathology, and the relationship of the fracture line to the periodontal ligament of each tooth.

Classification

The first step in the development of an appropriate treatment plan is to establish a clear understanding of the type of injury the patient has suffered, in order to provide an adequate surgical solution. In the diagnostic work-up phase, the lack of standardized ways to assess and

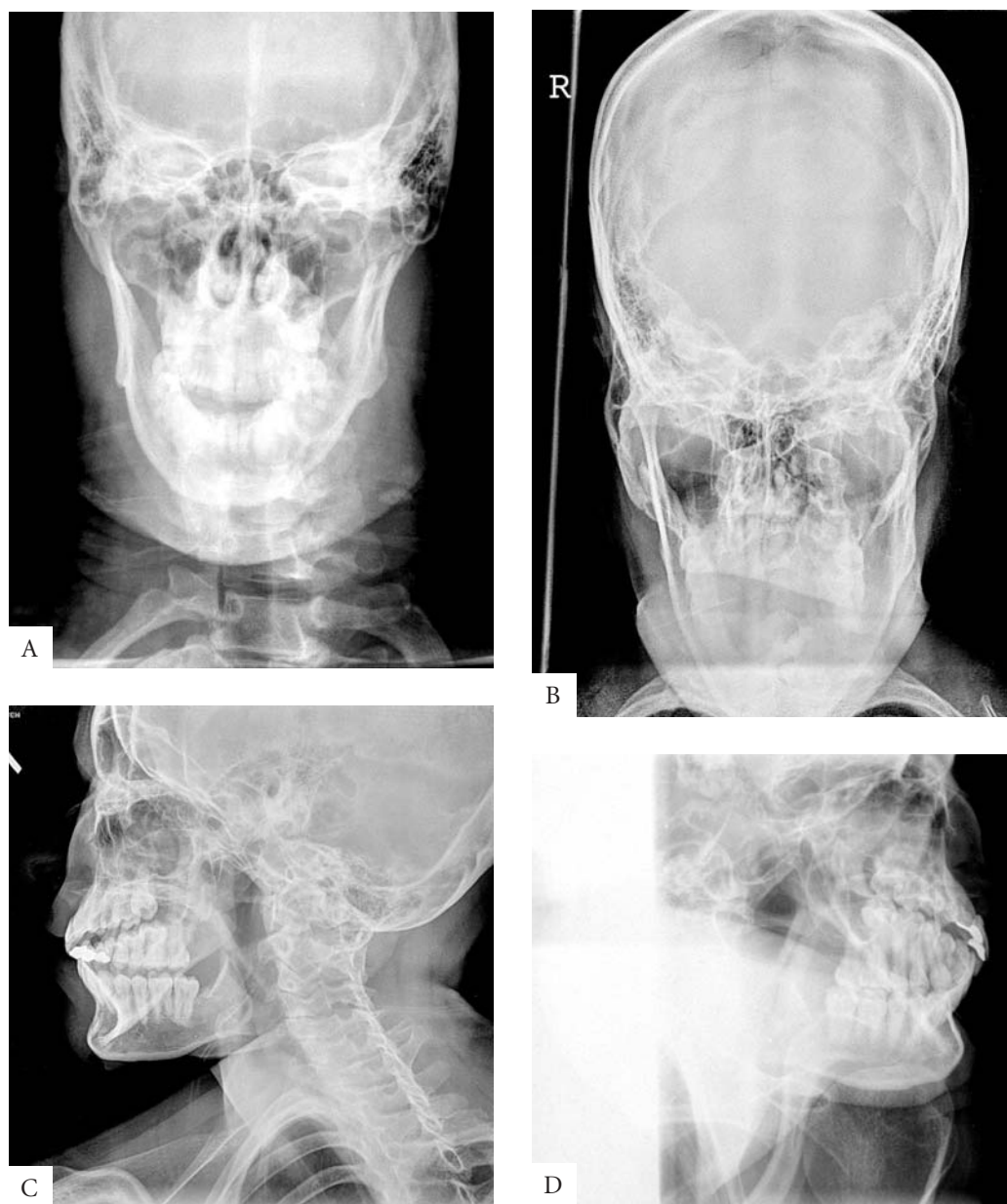


FIGURE 22-13 Mandible series of a patient with a left subcondylar fracture. The series consists of posteroanterior (A), Towne's (B), left lateral oblique, (C) and right lateral oblique (D) views. If a panoramic radiographic machine is readily available, the lateral oblique shots can be replaced by a panoramic view.

characterize the nature and severity of the orofacial injury engenders variation in practice patterns.³⁰ Probably the most basic question one should ask at the initial evaluation is whether the fractures are displaced or nondisplaced. Depending on the amount of energy transmitted to the facial skeleton and the vector in which such force is directed, there will be more or less disruption of the normal anatomic structures. Muscle attachment

and their counteracting forces also play a primary role in the pattern and direction of the fractures. It is the displacing forces of the muscles of mastication that influence favorableness (Figures 22-14 and 22-15). The principle of favorableness is based on the direction of a fracture line as viewed on radiographs in the horizontal or vertical plane. A horizontally favorable fracture line resists the upward displacing forces, such as the pull of the

masseter and temporalis muscles on the proximal fragment when viewed in the horizontal plane. A vertically favorable fracture line resists the medial pull of the medial pterygoid on the proximal fragment when viewed in the vertical plane. In the parasymphyseal region of the mandible, the combined action of the suprahyoid and digastric muscles on a bilateral fracture can pull on the distal fragment inferiorly in unfavorable fractures, putting the patient at risk for acute upper airway obstruction.

The first concern is whether there are indeed fractures present, and if there are, where they are located anatomically. Mandibular fractures may be further classified by the pattern of fracture (Figure 22-16) present and by anatomic location.

Many systems of classification have been applied to fractures involving the mandibular condyle.^{24,31-35} The recommended classification parallels the comprehensive classification set forth by Lindahl.²⁴ As mentioned before, it is imperative that radiographs be taken of the suspected injury in two planes at right angles to each other. The following major relations are noted: the level of the fracture; the relation of the condylar fragment to the mandible, termed the *degree of displacement*; and the relation of the condylar head to the fossa, or the *degree of dislocation*.

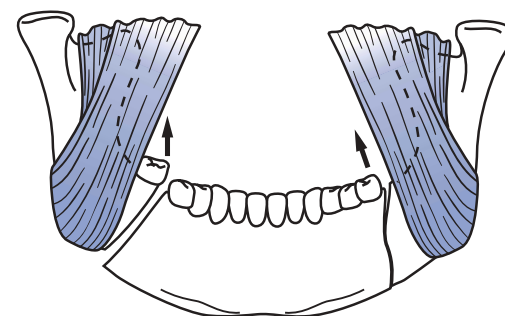


FIGURE 22-14 Diagram of horizontally unfavorable (left) and favorable (right) fracture lines. Arrows indicate displacing forces. Adapted from Luyk NH.⁸⁸ p. 410.

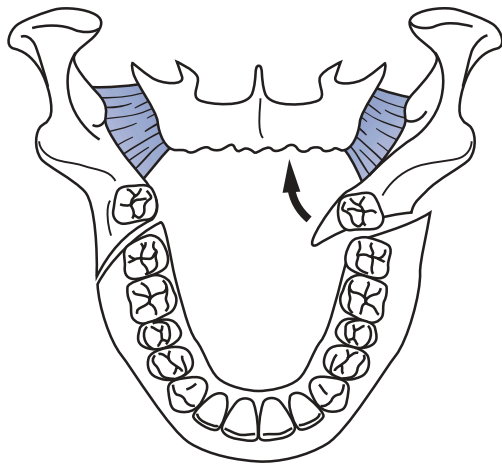


FIGURE 22-15 Diagram of vertically favorable (left) and unfavorable (right) fracture lines. Arrow indicates displacing force. Adapted from Luyk NH.⁸⁸ p. 410.

Anatomic Location

The following classification has been modified from Kelly and Harrigan's epidemiologic study in which they divided mandibular fractures based on their anatomic location³⁶:

- Dentoalveolar fracture: Any fracture that is limited to the tooth-bearing area of the mandible without disruption of continuity of the underlying osseous structure
- Symphysis fracture: Any fracture in the region of the incisors that runs from the alveolar process through the inferior border of the mandible in a vertical or almost vertical direction
- Parasymphysis fracture: A fracture that occurs between the mental foramen and the distal aspect of the lateral mandibular incisor extending from the alveolar process through the inferior border
- Body fracture: Any fracture that occurs in the region between the mental foramen and the distal portion of the second molar and extends from the alveolar process through the inferior border
- Angle fracture: Any fracture distal to the second molar, extending from any point on the curve formed by the junction of the body and ramus in the

retromolar area to any point on the curve formed by the inferior border of the body and posterior border of the ramus of the mandible

- Ascending ramus fracture: A fracture in which the fracture line extends horizontally through both the anterior and posterior borders of the ramus or that runs vertically from the sigmoid notch to the inferior border of the mandible
- Condylar process fracture: A fracture that runs from the sigmoid notch to the posterior border of the ramus of the mandible along the superior aspect of the ramus; fractures involving the condylar area can be classified as extracapsular or intracapsular, depending on the relation of the fracture to the capsular attachment

Pattern of Fracture

The following classification is based on pattern of fracture (see Figure 22-16):

- Simple fracture: A simple fracture consists of a single fracture line that does not communicate with the exterior. In mandibular fractures this implies a fracture of the ramus or condyle or a fracture in an edentulous portion with no tears in the periosteum.
- Compound fracture: These fractures have a communication with the external environment, usually by the periodontal ligament of a tooth, and involve all fractures of the tooth-bearing portions of the jaws. In addition, if there is a breach of the mucosa leading to an intraoral communication or a laceration of the

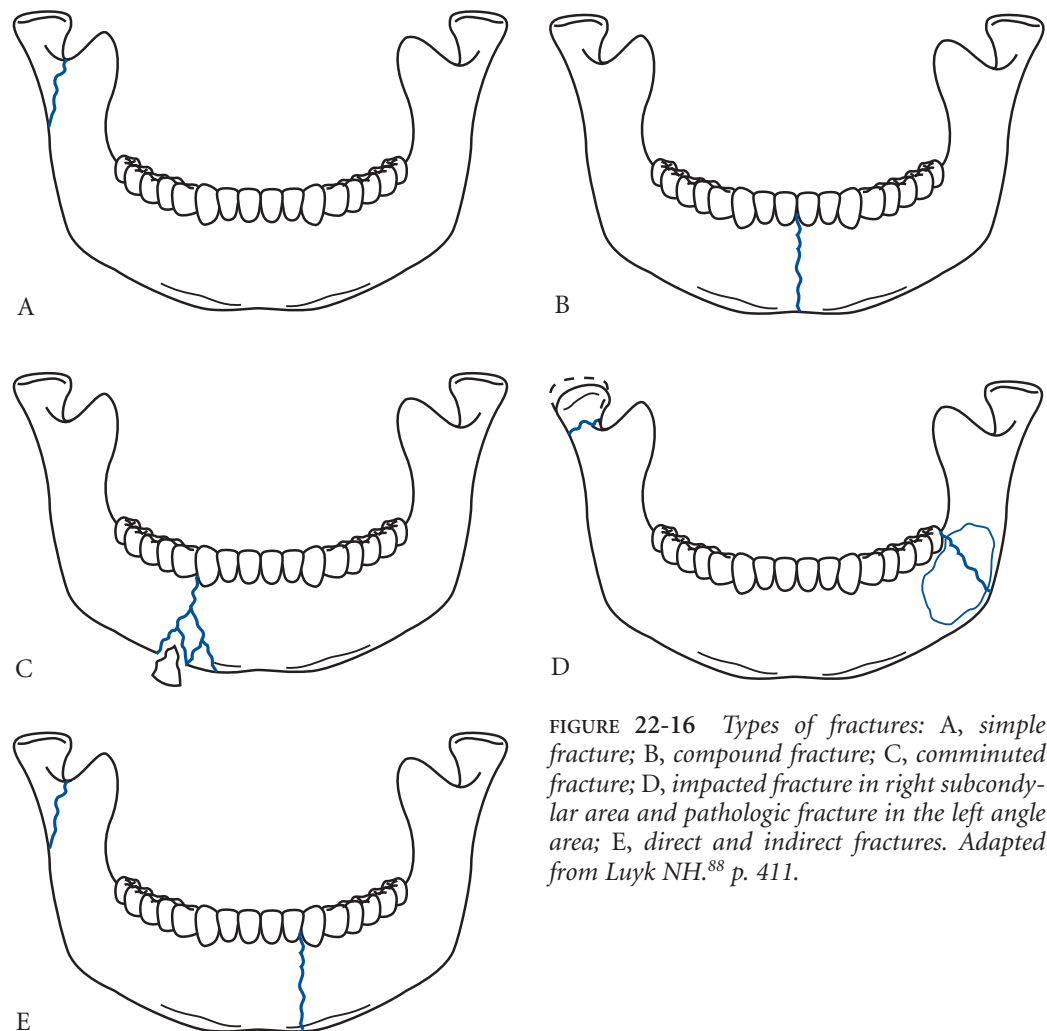


FIGURE 22-16 Types of fractures: A, simple fracture; B, compound fracture; C, comminuted fracture; D, impacted fracture in right subcondylar area and pathologic fracture in the left angle area; E, direct and indirect fractures. Adapted from Luyk NH.⁸⁸ p. 411.

skin communicating with the fracture site, edentulous portions of the mandible may be involved.

- Greenstick fracture: This type of fracture frequently occurs in children and involves incomplete loss of continuity of the bone. Usually one cortex is fractured and the other is bent, leading to distortion without complete section. There is no mobility between the proximal and distal fragments.
- Comminuted fractures: These are fractures that exhibit multiple fragmentation of the bone at one fracture site. These are usually the result of greater forces than would normally be encountered in simple fractures.
- Complex or complicated fracture: This type of injury implies damage to structures adjacent to the bone such as major vessels, nerves, or joint structures. This usually implies damage to the inferior alveolar artery, vein, and nerve in mandibular fractures proximal to the mental foramen and distal to the mandibular foramen. On rare occasions a peripheral branch of the facial nerve may be damaged or the inferior alveolar nerve injured in subcondylar fractures.
- Telescoped or impacted fracture: This type of injury is rarely seen in the mandible, but it implies that one bony fragment is forcibly driven into the other. This type of injury must be disimpacted before clinical movement between the fragments is detectable.
- Indirect fracture: Direct fractures arise immediately adjacent to the point of contact of the trauma, whereas indirect fractures arise at a point distant from the site of the fracturing force. An example of this is a subcondylar fracture occurring in combination with a symphysis fracture.
- Pathologic fracture: A pathologic fracture is said to occur when a fracture results from normal function or minimal trauma in a bone weakened by pathology. The pathology involved

may be localized to the fracture site, such as the result of a cyst or metastatic tumor, or as part of a generalized skeletal disorder, such as osteopetrosis.

- Displaced fracture: Fractures may be nondisplaced, deviated, or displaced. A nondisplaced fracture is a linear fracture with the proximal fragment retaining its usual anatomic relationship with the distal fragment. In a deviated fracture, a simple angulation of the condylar process exists in relation to the remaining mandibular fragment, without development of a gap or overlap between the two segments. *Displacement* is defined as movement of the condylar fragment in relation to the mandibular segment with movement at the fracture site. The fragment can be displaced in a lateral, medial, or anteroposterior direction. In displaced fractures the articular surface of the condyle remains within the glenoid fossa and does not herniate through the joint capsule.
- Dislocated fracture: A dislocation occurs when the head of the condyle moves in such a way that it no longer articulates with the glenoid fossa. When this is associated with a fracture of the condyle, it is termed a *fracture dislocation*. Fracture dislocations are discussed more completely later in this chapter. The mandibular condyle may also be dislocated as a result of trauma without an associated condylar fracture. Dislocations can occur anteriorly, posteriorly, laterally, and superiorly.
- Special situations: Other types of fractures that do not readily fit the above classification include grossly comminuted fractures or fractures involving adjacent bony structures, such as the glenoid fossa or tympanic plate; open or compound fractures; and fractures in which a combination of several different types of fractures exist. Open fractures of the condyle are usually caused by missiles such as bullets.

Nonfracture Injuries of the Articular Apparatus

The most commonly documented result of trauma to the articular apparatus and mandibular condyle is fracture. Other injuries occur as well and must be considered in the differential diagnosis (Table 22-1).

Anterior dislocation occurs when the condyle moves anterior to the articular eminence. This is by far the most common situation and represents a pathologic forward extension of the normal translational movement of the condylar head. Unlike subluxation, which is also a forward extension of the condyle, dislocation is not self-reducing. Dislocation may be caused by yawning, oral sex, phenothiazine use, and trauma. Traumatically induced anterior dislocation is most commonly bilateral, but it may occur unilaterally (particularly if associated with a concomitant fracture elsewhere in the mandible). The diagnosis of an anteriorly dislocated mandible is made by the following clinical features: an anterior open bite with the inability to close the mouth; severe pain in the region

Table 22-1 Injuries of the Articular Apparatus

Effusion
Hemorrhagic or serous
Soft tissue injury
Disk
Capsule
Ligaments
Dislocation of the condyle from the fossa
Without fracture
With fracture other than condyle
With associated condylar fracture
Fracture
Nondisplaced
Deviated
Displaced
Dislocated
Comminuted
Involving adjacent bony structures
Combinations of the above

anterior to the ear; absence of the condyle from the glenoid fossa with a visible and palpable preauricular depression; inability to move the mandible except to open the mouth slightly in a purely rotational manner; difficulty in speaking; and a prognathic lower jaw. Finally, if unilateral dislocation is present, the chin will be deviated to the opposite side (Figure 22-17). Patients with anterior dislocation of the mandibular condyles without other mandibular trauma should be approached using the following treatment protocol: 2 cc of local anesthetic solution should be deposited into the joint capsule followed by manual reduction. If this is unsuccessful or the patient is overly apprehensive, diazepam should be carefully titrated intravenously followed by further attempts at manual reduction. If these measures fail, then general anesthesia with the use of a muscle relaxant may be necessary.³⁷ It is usually possible to reduce an acute dislocation with

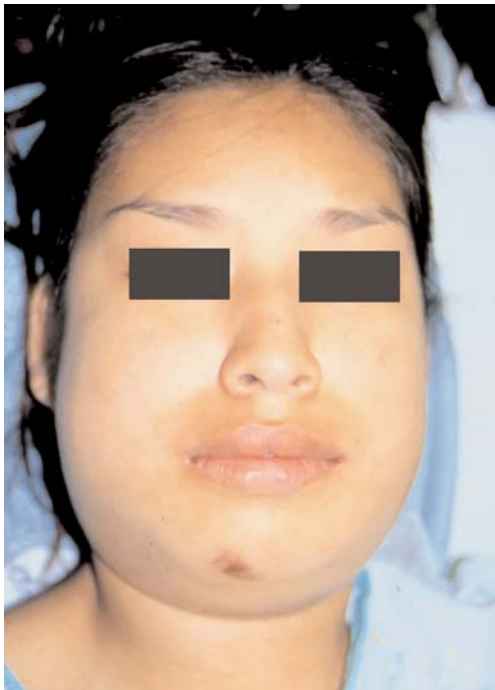

FIGURE 22-17 Prognathic appearance, chin deviation, and a large amount of swelling on the right side of the face as a result of a right unilateral condylar dislocation, which occurred as a result of a blow to the chin during a motor vehicle crash.

these maneuvers. In refractory cases or in cases associated with mandibular body and angle fractures in which the dislocated segment is difficult to control by manipulation, surgical intervention may be required. A percutaneous bone hook placed through the sigmoid notch or wires placed through the angle of the mandible allow for additional downward traction.^{38,39} Following successful reduction, the patient should be instructed to refrain from opening his or her mouth widely and to support the jaw with a hand under the chin when yawning for a period of 3 weeks to allow for healing of the injured soft tissue in and around the joint. IMF is not necessary for a first-time acute anterior dislocation of the jaw, unless it persistently dislocates after reduction. In persistent, recurrent dislocation, contributing factors, such as phenothiazine use, should be identified. A soft diet may also be recommended for several days along with a nonsteroidal anti-inflammatory analgesic.

When a blow to the mandible produces primarily a posterior vector of force and does not result in fracture of the condylar neck, the head of the condyle may be forced into a posterior dislocation. This injury is frequently associated with laceration and fracture of the external auditory canal leading to hemorrhage that is visible at the external acoustic meatus.²⁶ In most cases maintenance of the patient's occlusion and treatment of the associated ear injuries are the only management procedures necessary.

Lateral dislocation of the condylar head is always associated with a concomitant fracture either of the condyle or elsewhere within the mandible. The diagnosis of this condition is straightforward. The condylar head is palpable as a hard mass either in the preauricular region or in the lower part of the temporal space. This type of injury is associated with a marked crossbite, which is not attributable solely to the mandibular fracture but instead is secondary to the displaced condyle. Treatment requires reduc-

tion of the dislocation through manipulation of the dislocated segment by grasping it with a thumb on the dentition and with the fingers extraorally along the body of the mandible. If the proximal segment size is inadequate for this maneuver, a percutaneous towel clip through the angle or a small incision with placement of a wire through the angle (as described for anterior dislocation) may be necessary. After reduction of the dislocation, treatment of the associated fracture is accomplished, preferably with rigid internal fixation.

Superior dislocation into the middle cranial fossa without associated fracture of the mandibular condyle has been described. The patient is predisposed to this type of dislocation when the condylar head is small and rounded.⁴⁰ This injury is more common when the mouth is open at the moment of impact.⁴¹ This type of injury usually occurs with concomitant midface fractures that are telescoped, causing shortening of the vertical dimension of the face and allowing superior dislocation of the mandibular condyle. Superior dislocation of the mandibular condyle is associated with cerebral contusion and basilar skull fracture with facial nerve paralysis and deafness. These patients present with severe restriction of interincisal opening, pain in the area of the temporomandibular joint, bleeding from the external auditory canal or hemotympanum, and deviation of the jaw to the affected side. A variety of treatment modalities are recommended, including observation, condylectomy, elastic traction, condylectomy, and manual reduction.⁴² Neurosurgical consultation is required.

Effusion and hemarthrosis of the temporomandibular joint after trauma occur similarly as in other joints.²³ In most cases this leads to a distention of the joint capsule with varying amounts of discomfort. Frequently deviation of the mandible away from the affected side occurs as a result of downward pressure on the condyle from the production of

fluid within the joint. This produces facial asymmetry and malocclusion (Figure 22-18).

The treatment of traumatically induced effusions of the temporomandibular joint is aimed at the restoration of preinjury occlusion with return to function and relief of pain. If the patient presents with the subjective symptoms of a joint effusion but has a stable and reproducible occlusion, the condition may be managed with close daily observation, nonsteroidal anti-inflammatory medications, and a soft diet. Frequently the condition will resolve in a matter of days. If, however, the malocclusion is significant enough that the patient is unable to

achieve a stable occlusion without manipulation of the jaw, Ivy loop wiring or arch bars should be placed and guiding elastics used to produce a stable occlusion. Arthrocentesis, arthroscopy, or both are common therapies for hemarthrosis in other joints and may also be considered.⁴³ Regardless of the therapy chosen, care should be taken to avoid excessive IMF because this may result in a long-term limitation of function. It has been suggested that this limitation in function is a result of organization of the blood within the joint space with development of fibrosis and subsequent ankylosis. Many authors have emphasized the importance of this proposed mechanism in the development of ankylosis.^{44,45} Aspiration or arthroscopic lavage may alleviate this. It is possible, however, that the development of limited function and ankylosis is more dependent on the inability to maintain a full range of motion during the IMF period rather than on the hemarthrosis. This theory is supported by the failure of experimentally induced hemarthroses to produce ankylosis,⁴⁶ and by the absence of ankylosis and limited function after iatrogenically induced hemarthroses during joint injections or arthroscopy.⁴⁷ Most likely, decreased range of motion after joint effusion is the result of intra-articular fibrosis potentiated by prolonged IMF.

Treatment of Mandibular Fractures

Fractures of the mandible have been reported to comprise between 40 and 62% of all facial fractures,^{36,48,49} although these figures may not represent the true incidence because isolated nasal fractures are seldom included in such surveys. If these injuries are taken into account, the occurrence of mandibular fractures decreases to anywhere between 10 and 25% of all facial fractures depending on the mechanism of injury.⁵⁰ The literature is consistent on the fact that about one-half of all patients who suffer mandibular fractures are involved in a

motor vehicle accident.^{2,48,51-53} Males are overwhelmingly reported to be affected more frequently than females in a ratio ranging from 3:1 to 7:1 depending on the survey and especially the country involved.^{48,54,55} Predictably, such studies reveal the most susceptible age group for both sexes is between 21 and 30 years of age.^{54,56,57}

In most cases, mandibular fractures are encountered in isolation from any other facial fractures. But different studies have revealed that almost 20% of these patients have concomitant fractures in other anatomic structures of the facial skeleton,⁵⁸⁻⁶⁰ with the most common one being the zygomaticomaxillary complex.⁶¹ Further injury away from the facial region may also be present, including multiple-system trauma. In the study by Ellis and colleagues of 2,137 patients with mandibular fractures, 10.5% of subjects sustained other injuries outside the maxillofacial region.⁴⁸ Injury patterns are largely dependent on the mechanism of injury, with patients involved in motor vehicle accidents sustaining a great percentage of other injuries. The distribution of principal fracture sites has been reported as 33% involving the body, 29% in the condylar region, 23% the angle, and 8% in the symphysis region (Figure 22-19). It is not unusual to sustain more than one fracture site in the mandible. Mandibular fractures are multiple in more than 50% of the cases.^{48,62,63} The left side is more commonly involved, in particular the left angle, probably because most assailants are right-handed and the left side of the jaw would be the side most likely to be struck.⁵⁷ Falls show a greater proportion of subcondylar fractures, as high as 36.3% in one study.⁴⁹ When multiple fractures of the mandible are considered, the most common combinations are angle and opposite body, bilateral body, bilateral angle, and condyle and opposite body (Figure 22-20).³⁶

The site of fracture is also determined by the size, direction, and surface area of the impacting blow. An impact to the chin

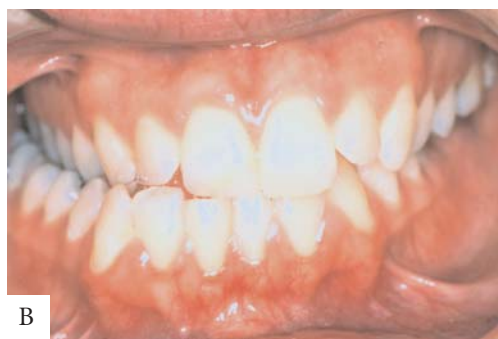
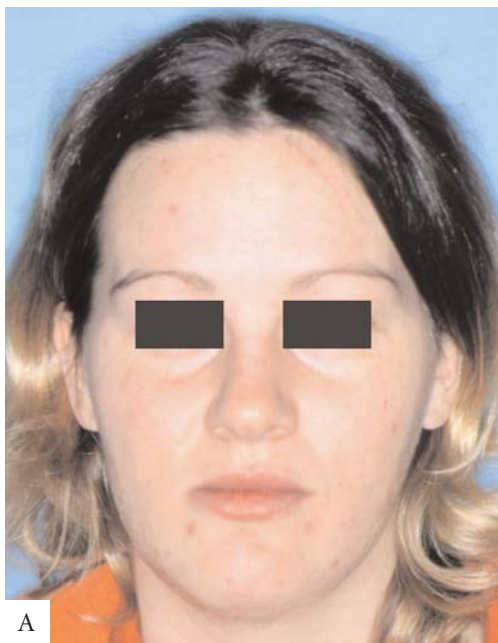
FIGURE 22-18 Significant facial asymmetry (A) and malocclusion (B) resulting from a large left temporomandibular joint hemarthrosis.

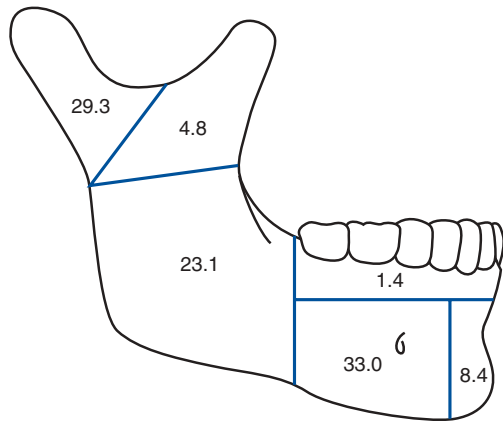


FIGURE 22-19 Percentage of mandibular fracture site distribution. Adapted from Luyk NH.⁸⁸ p. 411.

with a line of force through the symphysis and temporomandibular joints will produce a single subcondylar fracture at 193 kg (425 lb.) and a bilateral subcondylar fracture at about 250 kg (550 lb.), whereas symphyseal fractures require force between 250 and 408 kg (900 lb.).⁶⁴ An impact to the lateral aspect of the mandibular body using a 2.5×10 cm (1×4 in.) impact surface will produce a mandibular fracture at 136 to 317 kg (300–700 lb.). When an impact force is delivered to the mandible, the bone bends inward, producing compressive forces on the impacted (lateral) surface and tensile forces on the lingual (medial) surfaces of the bone opposite the impact site.¹⁸ Fracture results when the tensile strain overcomes the resistance of the bone, beginning on the medial side of the mandible and progressing through the bone toward the impact point.

Direct fracture may occur at the site of impact, but additional indirect fractures may result when higher forces are involved. An example would be a blow to the left angle, causing a direct fracture at the left-angle region and an indirect fracture in the right body. Occasionally, only indirect fracture results, usually in the subcondylar area as, for example, when a blow on the chin results in a fracture of either condylar neck. Indirect fractures demonstrate the opposite tensile strain patterns

and fracture outcomes from those of the direct fracture; that is, the tensile strain develops on the side opposite to the impact. In the case of greenstick fractures, the fracture occurs on the tension side and bending occurs on the compression side.

General Approach and Goals of Therapy

Deciding on the correct treatment is often more difficult than administering the treatment itself. The dilemma concerning the appropriate management of fractures of the mandibular condyle is most exemplary of this. Technically easy procedures such as closed reduction have experienced long-term successful results, whereas more complicated and technically demanding procedures of open reduction have continually and cyclically been employed in an attempt to improve on the results obtained with closed reduction. Although anatomic reduction with rigid internal stabilization of the fracture segments may be desirable, it is essential that the surgeon clearly define the goals of therapy and

choose the simplest and most effective surgical method available to reach them.

The goals to be achieved in treatment of fractures of the mandible are listed in Table 22-2. Maintenance of a stable occlusion is necessary for both functional and esthetic reasons. Complete range of motion also allows normal mastication and prevents the development of contralateral temporomandibular joint dysfunction. A normal range of motion is most dependent on postoperative retraining of the muscles and elimination of pain. Ideally, the disk-condylar relationship should remain intact without evidence of internal derangement. Some clinical signs of internal derangement such as joint noise can be tolerated if not associated with pain or decreased range of motion. Growth disturbance can result from ankylosis or from injury to the cartilaginous head of the condyle. A goal of treatment should include early mobilization to prevent ankylosis and close follow-up to identify growth changes early in their development. Attainment of an anatomic bony union is not a primary goal in treatment of

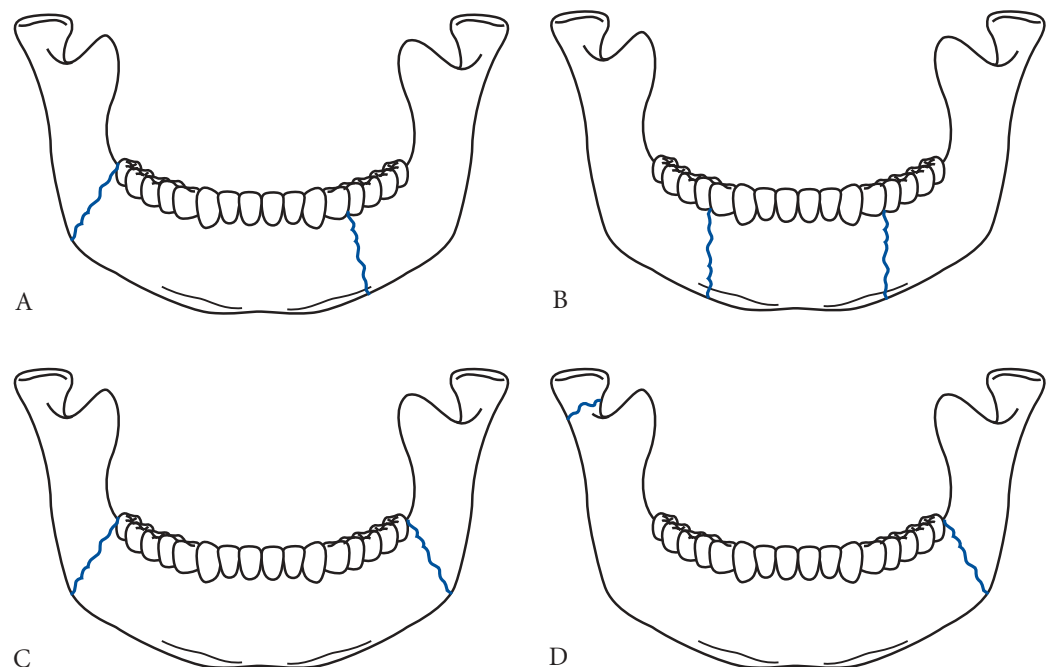


FIGURE 22-20 Most common multiple mandibular fracture sites: A, angle and opposite body; B, bilateral body; C, bilateral angle; and D, condyle and opposite angle. Adapted from Luyk NH.⁸⁸ p. 413.

Table 22-2 Goals of Therapy

1. Obtain stable occlusion.
2. Restore interincisal opening and mandibular excursive movements.
3. Establish a full range of mandibular excursive movements.
4. Minimize deviation of the mandible.
5. Produce a pain-free articular apparatus at rest and during function.
6. Avoid internal derangement of the temporomandibular joint on the injured or the contralateral side.
7. Avoid the long-term complication of growth disturbance.

condylar fractures, particularly if it must be done at the expense of other more important goals. A malunion or fibrous union that functions normally without pain is preferable to a radiographically excellent reduction that does not eliminate pain or limits motion.

Treatment Options

Closed Reduction If the principle of using the simplest method to achieve optimal results is to be followed, the use of closed reduction for mandibular fractures should be widely used. According to Bernstein, “It is safe to say that the vast majority of fractures of the mandible may be treated satisfactorily by the method of closed reduction.”⁶⁵ May and colleagues go further⁶⁶: “Many fractures are probably overtreated by open reduction. It is important to realize that the majority of fractures can be successfully managed by conservative means (closed reduction).” This concept becomes critical when one considers the economic significance of inflated hospital, operating room material, and personnel costs. Even more important, the need for general anesthesia is obviated. A patient with a mandibular fracture managed by closed technique can be successfully treated as an outpatient with either local anesthesia or conscious sedation.

Therefore, the indications for closed reduction may simply be stated as all cases in which an open reduction is either not indicated or is contraindicated. Several conditions deserve specific mention.

Grossly comminuted fractures are, as a general rule, best treated by closed reduction, because using open reduction techniques would jeopardize the blood supply to the small bone fragments and lead to an increased likelihood of infection. This category also includes gunshot wounds, which are particularly prone to infection.

Fractures in the severely atrophic edentulous mandible represent a difficult clinical situation. On the one hand, there is limited osteogenic potential; the majority of the blood supply comes from the periosteum, so an open reduction further disrupts the blood supply. On the other hand, a stable, nonmobile reduction and fixation of these fractures is difficult with closed reduction techniques. Open reduction with limited dissection of the soft tissue and rigid fixation may be the preferred technique. Later in this chapter we review in more detail the management of this group of patients.

In situations where there is a lack of soft tissue overlying the fracture site, soft tissue flaps have to be transposed to cover a fracture site (particularly if a through-and-through communication exists between the skin and oral cavity). The presence of bone plates, screws, and wires may increase the likelihood of infection under these circumstances.

Fractures in children involving the developing dentition are difficult to manage by open reduction because of the possibility of damage to the tooth buds or partially erupted teeth (Figure 22-21). Closed reduction of fractures of the mandible together with indirect fixation can be achieved by either the application of IMF or by applying a technique to the mandible only.

The overwhelming majority of published clinical series over the past 50 years

strongly promote closed reduction for the management of fractures of the mandibular condyle in both adults and children.^{21,22,33,34,67-70} These uniformly excellent results were obtained in all ages of patients treated.⁷¹ Conclusions drawn by various authors are the following: no correlation exists between the degree of radiographic displacement and the severity of clinical symptoms; no correlation exists between the radiographic alignment of the fracture segments and postoperative function; growth complications and ankylosis are exceedingly rare; open reduction with internal fixation is fraught with complications; and evidence supports the choice of closed reduction as the primary treatment modality for condylar fractures regardless of the degree of displacement.

Although the majority of the large studies reviewed patients in all age groups, some authors specifically studied children and their response to conservative management of condylar fractures.⁷²⁻⁷⁸ All obtained

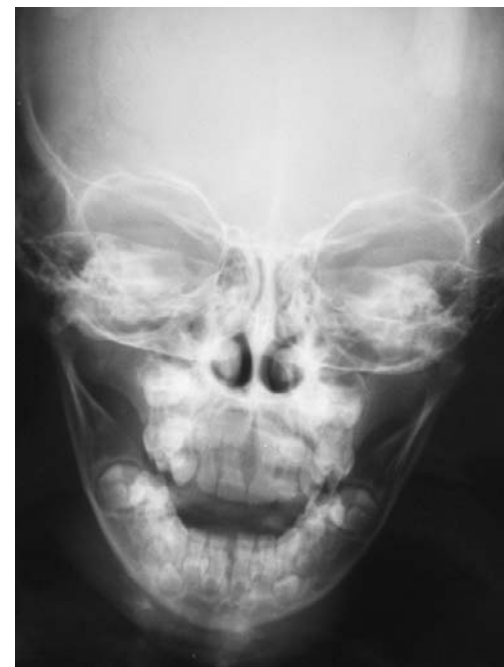

FIGURE 22-21 Posteroanterior mandibular view of a 4-year-old child with a symphysis fracture. Management of this injury through an open reduction with internal fixation poses a significant risk of damaging the developing permanent dentition.

excellent results with minimal complications when fractures of the condyle in children were treated with closed methods.

The superiority of closed reduction of condylar fractures is also supported by numerous animal studies. Experimentally induced fracture dislocation in rhesus monkeys has resulted in “a workable, usable mandibular articulation regardless of whether the condyle was left remaining at right angle to the ramus, pushed medially or anteriorly, or reduced and maintained via transosseous wire. There was little sacrifice of mandibular growth or symmetry.”⁷⁹ Further studies compared three methods of treatment for fracture dislocations in rhesus monkeys.^{80,81} No difference existed between those treated with internal fixation using wire ligature, those treated with maxillo-mandibular fixation, or those who received no treatment. No incidents of nonunion were reported with any closed technique.

Length of Fixation Traditionally the length of IMF used for adult mandibular fractures has been 6 to 8 weeks. However, this length of IMF is not without penalty. Often patients continue to lose weight during this period, they may not be able to return to work, and there is some evidence of histologic changes in the temporomandibular joint.^{82,83} Juniper and Awty were able to demonstrate that 80% of mandibular fractures treated by open or closed reduction and IMF were clinically united in 4 weeks.⁸⁴ They were also able to demonstrate a clear relationship between the age of the patient and the predictability of early fracture union. These results were confirmed by Amaratunga.⁸⁵ He found that 75% of mandibular fractures were clinically stable by 4 weeks, that almost all fractures in children healed in 2 weeks, and that a significant number of fractures in older patients took 8 weeks to heal. It appears that each individual case must be judged on its merits but that most uncomplicated fractures in children are united in 2 to 3 weeks, in adults 3 to

4 weeks, and in older patients in 6 to 8 weeks. Several other factors should be taken into account when deciding on the appropriate regime for a particular patient. The following situations generally require longer periods of IMF: comminuted fractures; fractures in alcoholics, particularly those with nutritional problems; fractures in patients with psychosocial handicaps; fractures treated late; and fractures with teeth removed in the line of the fracture.

Length of Fixation for Condylar Fractures

Ideally, the period of IMF should allow for reestablishment of the preinjury occlusion and should not be longer. Increased length of the time of fixation may result in limitation in function or ankylosis of the joint. In practice, a wide variety of opinions exists over the length of time that constitutes an adequate period of fixation. Differences depend on the age of the patient, the type of fracture, and the presence of other fractures. Most clinicians agree that a shorter period is needed in children, but they are no closer in agreement over what this time should be. Animal studies have shown excellent occlusion and postoperative function even in fracture dislocations when no IMF is used.⁷⁹⁻⁸¹ Some studies in humans also agree with this. However, the inability to occlude the teeth without pain is frequently present in patients with condylar fractures and does require some period of fixation. Attempts to predetermine which fractures will need longer IMF than others have been made.⁸⁵ The length of time has been based on the presence or absence of teeth, the type of fracture, and the age of the patient. However, Walker has suggested that a relatively short period of intermaxillary fixation is required for all patients regardless of age, occlusion, and type of fracture.^{86,87}

Intermaxillary Techniques DENTATE PATIENTS Intermaxillary techniques in dentate patients include application of arch bars (Figure 22-22), direct wiring, Ivy loop wiring (interdental eyelet wiring)

(Figure 22-23), continuous wire loop technique (Stout’s method, Obwegeser’s method), cast cap splints, and IMF screws (Figure 22-24).

Methods for dentate patients usually include 0.5 mm (25-gauge) soft stainless steel wires around the teeth. In general, the wires should be handled in a similar fashion for all methods, following certain principles:

1. Tighten the wires with a continuous tension.
2. Direct the force apically when tightening the wires.
3. Tighten all wires in a clockwise direction.
4. At the end of tightening, turn only half a turn at a time.
5. Turn the end of the wire into the interproximal embrasure.

These additional rules apply when arch bars are used:

1. Adapt the arch bar closely.
2. Use a cuspid wrap wire where indicated.
3. Avoid placing the wire across the intermaxillary stabilization lugs.
4. Use circumferential wires when single teeth stand alone, and intraosseous suspension or circum-mandibular wires in edentulous areas.
5. In the area of the fracture, reduction should be accomplished prior to stabilization of the arch bar on both sides of the fracture.

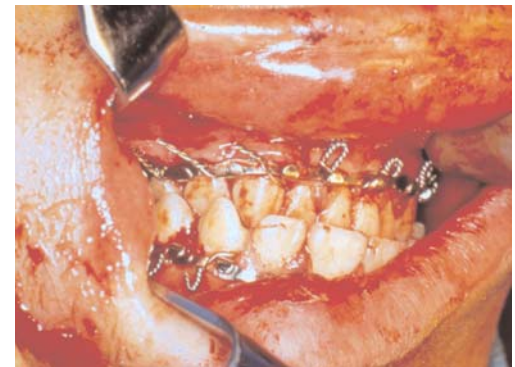
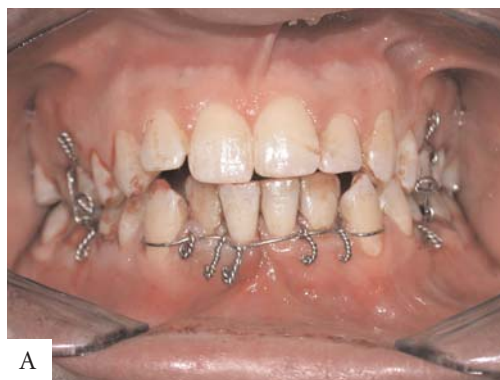
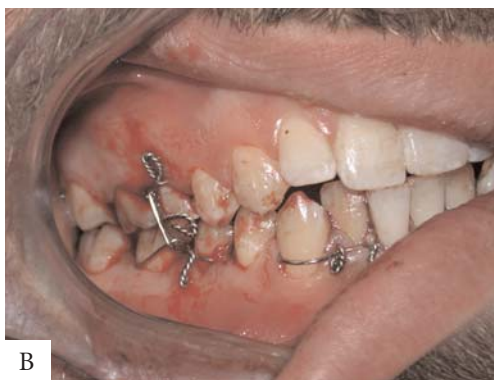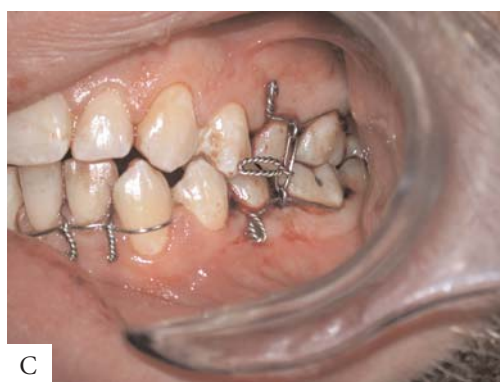FIGURE 22-22 Placement of Erich arch bars for noninvasive treatment of a mandibular fracture.



A



B



C

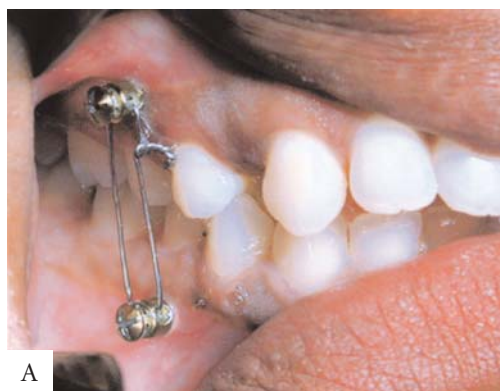
FIGURE 22-23 In patients with a full and stable occlusion, Ivy loops can be applied to achieve intermaxillary fixation after closed reduction. A, Frontal view. Note there is also an Essig wire in the anterior dentition to help maintain the reduction of the right parasymphysis fracture. B, Right buccal view. C, Left buccal view.

When IMF is used it may be applied with either elastics or wires. Elastics can be used for fracture reduction and for IMF; however, they apply a constant pressure, which can lead to muscle spasm and pain, particularly in the masseter muscle, and they are difficult to keep clean. Wires, on the other hand, are easier to keep clean and are passive. However, they do loosen over time and may need to be tightened or replaced over the period of fixation.

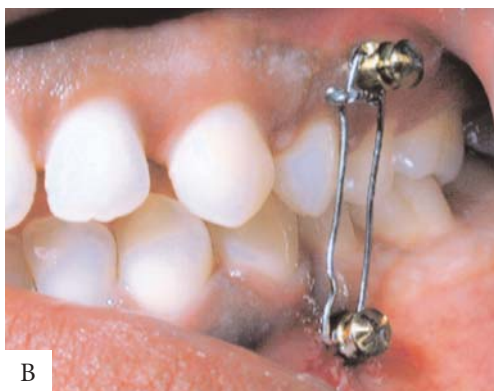LINGUAL OR LABIAL SPLINT To construct a lingual splint, an impression is taken of the lower arch and a stone model is poured (Figure 22-25). If there is displacement of the fracture site, an upper impression will also need to be taken. The lower stone model is then sectioned at the fracture site, and using the upper model as a guide (Figure 22-26), the correct occlusion is reconstructed. Then the sectioned model is waxed together in the correct

relationship, and the lingual surface is relieved with a 1 mm thickness of wax. A hard acrylic splint is then made and holes drilled so that it can be wired to the teeth (Figure 22-27). Just before placement a thin coating of soft liner is applied. The fracture is reduced, and the splint is wired into position.

EXTERNAL PIN FIXATION In external pin fixation usually two pins on both the proximal and distal fragments are placed, if possible. The biphasic extraoral technique uses a special transbuccal trocar set. This is used for each hole through individual skin incisions. A 2.2 mm twist drill is used to drill through both cortical plates at slow speed with constant irrigation. Specially designed self-tapping, coarse-threaded screws are then placed with a socket wrench. A series of locking plates and bars are secured to the four or more pins, and then a self-curing acrylic secondary splint is constructed (Figure 22-28). External pin fixation can be used in edentulous fracture sites in which there is bone loss secondary to gunshot injuries, pathologic fractures, or osteomyelitis, or in cases in which a bone-grafting procedure has been performed. It can also be used in fractures of the atrophic edentulous mandible or in mandibular fractures associated with midface fractures when a quick and simple method of fixation is required.



A



B

FIGURE 22-24 An option to obtain intermaxillary fixation in patients with a reliable occlusion is the use of intermaxillary fixation screws. In most cases two screws placed on each side is sufficient to maintain the reduction. A, Right buccal view. B, Left buccal view.



FIGURE 22-25 For the fabrication of a lingual splint, the cast must be carefully sectioned along the areas where the fractures are located.




FIGURE 22-26 Once the fracture segments have been manually realigned, the cast is waxed together and fast-setting stone is added to rebuild the base and allow for mounting and fabrication of the splint.

EDENTULOUS PATIENTS Closed reduction in edentulous patients is achieved with Gunning's splints or splints made from the patient's own dentures (Figure 22-29).

Open Reduction Open reduction of mandibular fractures has developed to become a more frequent treatment option for the management of these injuries over the last decade. With the development of improved fixation systems, which directly translates into reduced IMF times or no IMF at all, both surgeons and patients have become more comfortable with this treat-

ment option. Luyk stated that the significance of the rather large number of successfully managed patients using closed reduction was magnified when one considers that at the time there were no large studies on open reduction showing any improvement in the result or any decrease in the rate of complications.⁸⁸ Today, we know that this statement has to be dissected carefully and that depending on the time elapsed between the injury and treatment, and whether the patient is taking antibiotics, this will change the outcome tremendously. In contrast, those recommending open reduction of condylar fractures have failed to report complication rates for the proposed technique or, when cited, reported complication rates that are greater than those seen historically with closed reduction; they experienced complications that have not been seen with closed techniques; and they allowed inadequate follow-up before assessing the outcome.

The major indications for open reduction of a fractured mandible are summarized below.

Unfavorable or Unstable Fracture Unfavorable or unstable fractures arise in several circumstances. When an angle fracture is displaced at the time of injury and is horizontally or vertically unfavorable, it

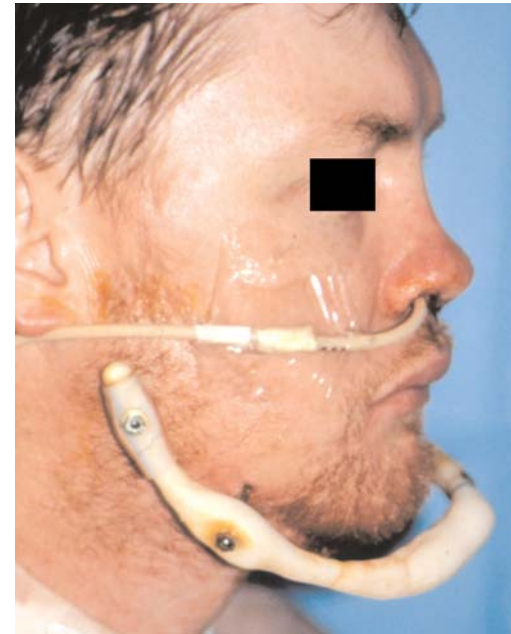

FIGURE 22-28 A Joe Hall Morris external fixator is used to manage a severe mandibular fracture resulting from a gunshot wound. This system consists of biphasic transcutaneous pins and an acrylic frame fabricated intraoperatively.

is unlikely that simple IMF will maintain the proximal segment in the correct position. Under the influence of the medial pterygoid or the powerful mandibular elevator muscles (temporalis and masseter), the proximal segment most likely will be displaced. This could lead to delayed healing and possibly permanent disruption of the inferior alveolar nerve. When the fracture is both horizontally and vertically unfavorable, an extraoral approach is recommended. Also, most fractures in the parasymphiseal region cannot be routinely treated satisfactorily by closed reduction because of the pull of the suprahyoid and digastric muscles. Fractures in this region tend to open at the inferior border and along the lingual surface with the superior aspects of the mandibular segments rotating medially at the point of fixation when closed reduction and IMF are used. With the medial rotation of the horizontal ramus the lingual cusps of all premolars and molars move out of occlusal contact. This results in masticatory inefficiency, and untoward periodontal changes will

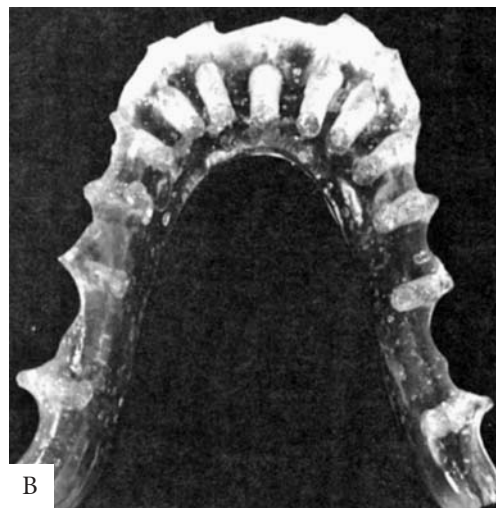
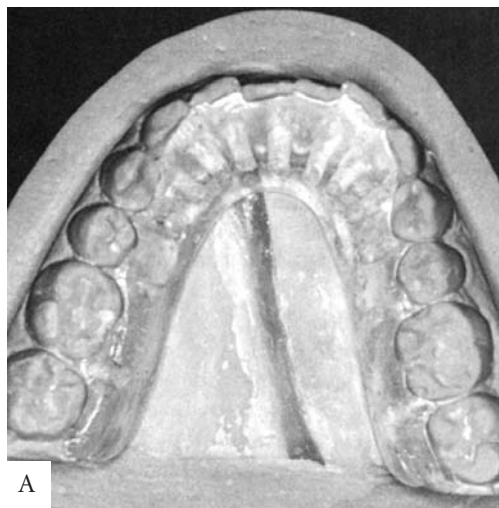


FIGURE 22-27 A, The splint is fabricated, trimmed, and polished to guarantee a passive fit in the modified cast. B, Drill holes are placed in the interdental areas to allow for wires to be passed and secured around the teeth.

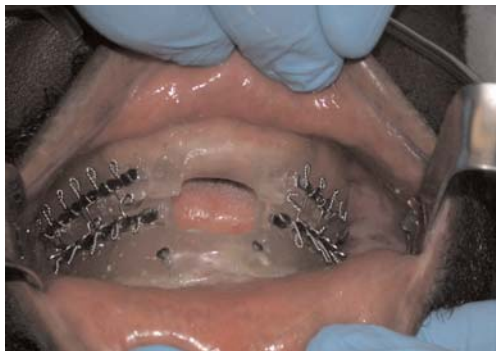

FIGURE 22-29 Intermaxillary fixation in an edentulous patient using Gunning's splints with arch bars imbedded into the acrylic.

follow.⁸⁹ If, in addition to a fracture in this area, the patient also has a concomitant angle or condylar fracture, the risk of lateral flaring of the mandibular angles is a very real possibility. This negative result can be much worse in cases in which bilateral condylar fractures are present and in patients with associated midfacial fractures, when the mandible is used as the base for the reconstruction.

Prolonged Delay in Treatment of the Fracture with Interpositional Soft Tissue

Occasionally when there has been an excessive delay in treating a fractured mandible, interpositional tissue between the two bone ends can prevent a satisfactory closed reduction. In this situation an open reduction is necessary to remove the soft tissue between the fragments.

Complex Facial Fractures The satisfactory reduction of complex facial fractures requires two stable reference points to which the maxillary complex can be reduced. These include a stable supraorbital bar of bone and also a stable mandible. This often necessitates open reduction and fixation of the mandibular fractures. Open reduction and fixation of a subcondylar fracture are indicated when there are bilateral subcondylar fractures in the presence of complex middle third fractures, so that a stable vertical platform is provided on which the face can be reconstructed.

Medically Compromised Patients Some patients with special medical conditions are best treated without IMF. They may be better treated with an open reduction. This group of patients includes those with decreased pulmonary function. Williams and Cawood have demonstrated significant decrease in pulmonary function associated with IMF.⁹⁰ Patients with gastrointestinal disorders who are on a liquid diet, particularly one based on milk products, may have difficulties. Those with severe seizure disorders in which airway difficulties may arise with IMF and patients with psychiatric or neurologic problems may be candidates for open reduction.

Concurrent Condylar Fracture Associated with Fractures Elsewhere in the Mandible

It is often advantageous to be able to mobilize condylar fractures early to prevent possible ankylosis. This is particularly true in cases of intracapsular fractures in which immobilization is more likely to lead to ankylosis. In this situation open reduction and fixation of angle, body, or symphyseal fractures will allow early mobilization of an associated condylar fracture.

There are certain contraindications to the use of open reduction of mandibular fractures. As a general principle, when a simpler means of treating a fracture can be used, it should be. This is often more cost-effective for the community at large and often results in fewer complications. However, each individual case must be judged on its merits.

The periosteal blood supply of multiple small fragments of bone can be jeopardized when an open reduction is attempted for comminuted fractures. This can lead to an increased likelihood of infection and delayed healing. Gunshot wounds are best managed by closed reduction whenever possible, because often the bone is comminuted and there is a greater risk of infection in these fractures. Atrophic edentulous mandibles must be treated with care. When an open reduction is nec-

essary, the maximal blood supply to the fracture site should be preserved.

If closed reduction is used for the treatment of a condylar process fracture, it is best that intermaxillary fixation be discontinued in all patients at approximately 10 to 14 days. If other mandibular fractures are associated with the fractured condyle, it is desirable to treat them with some form of additional stabilization, such as a lingual splint, external pins, or rigid internal fixation. This allows for the early release of IMF without compromising the healing of these other fractures.

Open Reduction of Condylar Fractures

A variety of useful techniques for open reduction have been described.^{73,91-94} The reason for employing open reduction in each case was to avoid the complications found in closed reduction. No data or follow-up of patients was presented to document this. Tanasen and Lamberg, Zide and Kent, and Raveh and colleagues followed patients with open reduction for up to 37 months.⁹⁵⁻⁹⁷ Complication rates of 85, 50, and 10% were seen, respectively, including facial nerve dysfunction and keloid formation. No comparison was made with patients treated with closed reduction during the same time period. Chuong and Piper attempted to compare closed reduction with open reduction, including concomitant disk repair in their study.⁹⁸ Eight of nine open reduction patients who were studied for an average of 11 months experienced complications (89%). Six of 12 patients receiving closed reduction were found to have malocclusion at the end of treatment (50%). It is possible that the high incidence of malocclusion in the closed reduction group might be a result of prolonged fixation, inadequate follow-up, and lack of supervised postoperative rehabilitation.⁸⁷

There is a lack of any controlled clinical data to indicate the superiority of open reduction techniques as a primary mode of management of condylar fractures in

children or adults. Although it is apparent that, in some situations, an unacceptable incidence of complications results when closed reduction is employed, it is inappropriate to assume that an open technique can avoid these complications until this is borne out in controlled clinical trials.

Despite the evidence in favor of closed reduction as the treatment of choice for the majority of fractured condyles in both children and adults, there are indications for the performance of open reduction (Table 22-3).

In the past the indication for open reduction of a condylar fracture was primarily a radiographic one. Essentially, it was thought that the condyle behaved like other areas of the mandible or other bones in the body and that it would respond better and heal with more satisfactory function if an ideal anatomic reduction were obtained.^{93,95,99,100} It has been shown that there is little if any correlation between the degree of displacement or dislocation of the fracture and the ability to obtain satisfactory function with a closed reduction. A more functional approach in assessing the need for open reduction was taken by Zide and Kent.^{96,101} According to these investigators, indications for open reduction of condylar fractures should rely on the identification of specific clinical entities that, when treated with closed reduction, would result in a high degree of failure. They also take into account an objective evaluation of function at the time of the planned reduction, the presence and condition of the patient's dentition, the likelihood of successfully performing a closed reduction, and the presence of other modifying factors such as the patient's medical condition or the existence of other facial fractures.

Absolute Indications Absolute indications for open reduction are present in those situations in which limitation in function is highly probable if a closed reduction is per-

formed or in those situations in which a closed reduction is not possible. Limitation of function may be caused by fracture with dislocation of the proximal segment into the middle cranial fossa, by invasion of the joint by a foreign body, by lateral extracapsular dislocation of the condylar head, or by the presence of any fracture dislocation that produces a mechanical stop, preventing mandibular movement. Inability to perform a closed reduction may result when the fracture is displaced so that it is impossible to manipulate the teeth into an appropriate occlusion.

Possible or Relative Indications Possible or relative indications for open reduction also exist and should be assessed on the basis of benefit as opposed to risk:

1. Bilateral condylar fractures with comminuted midfacial fractures. The ratio-

nale for open condylar reduction in these situations is that it allows for the establishment of a horizontal and vertical dimension of the midface when this cannot be achieved by other means. If rigid internal fixation of the midface is possible, then open reduction of the condyle may no longer be indicated.

2. Situations in which IMF is not feasible. Certain medical conditions, such as poorly controlled seizures, psychiatric disorders, or severe mental retardation, make maxillomandibular fixation difficult and possibly dangerous. Also, patients with multiple trauma, particularly head injury or chest injury, are at increased risk for complications if placed in maxillomandibular fixation unless tracheostomy is planned. In addition, maxillomandibular fixation is extremely difficult in those patients

Table 22-3 Indications for Open Reduction of Fractures of the Mandibular Condyle

<ol style="list-style-type: none"> 1. Absolute indications <ol style="list-style-type: none"> A. Limitation of function secondary to the following: <ol style="list-style-type: none"> 1. Fracture into middle cranial fossa 2. Foreign body within the joint capsule 3. Lateral extracapsular dislocation of condylar head 4. Other fracture dislocations in which a mechanical stop is present on opening, which is confirmed radiographically B. Inability to bring the teeth into occlusion for closed reduction 2. Relative indications <ol style="list-style-type: none"> A. Bilateral condylar fractures with comminuted midface fractures in which rigid internal fixation of the midface is not possible B. Situations when intermaxillary fixation is not feasible as a result of the following: <ol style="list-style-type: none"> 1. Medical restrictions <ol style="list-style-type: none"> a. Poorly controlled seizure disorder b. Psychiatric disorders c. Severe mental retardation d. Concomitant injuries such as head injury or chest injury (unless tracheostomy is planned) 2. Displaced fractures where dentures or splints are not feasible because of severe mandibular atrophy C. Bilateral fractures in which it is impossible to determine what the proper occlusion is as a result of loss of posterior teeth or the presence of a preinjury skeletal malocclusion D. In fracture dislocation in adults to restore the position and function of the meniscus (controversial)
--

with displaced condylar fractures in whom dentures are not present and splints are not feasible because of severe mandibular atrophy.

3. Bilateral fractures in which it is impossible to determine the proper occlusion. Occasionally, a patient with bilateral fractures will have such an ambiguous occlusion that, even with the use of study models and careful clinical examination, it is not possible to determine the appropriate maxillo-mandibular relation. This may lead to inappropriate placement of the mandible into malocclusion or to placement of a preexisting malocclusion into a normal relation, thereby predisposing the patient to nonunion or long-term functional disability.
4. Fracture dislocation in an adult patient to restore position and function of the disk. Previous emphasis on indications for open reduction have centered around the need for bony reduction and fixation without consideration of disk position. The unstated implication of most of the literature is that the position of the dislocated disk is not critical for optimal functional results after condyle fracture.⁹⁸ However, this is contradictory, given the present emphasis on the importance of correct condylar disk alignment for management of those patients with internal derangement of the temporomandibular joint. The disk is important in the prevention of post-traumatic ankylosis.⁴⁷ An interesting concept has been raised about the possible necessity for disk repositioning, especially in fracture dislocations, to allow for optimal temporomandibular joint function. Some clinicians have suggested that “open reduction and internal fixation of condylar fractures in conjunction with disk repair is a biologically sound approach....”⁹⁸ Based on their experience, it might be recommended

that, in fracture dislocations in which open reduction is indicated, an attempt should be made to reposition the disk at the time of the reduction. However, inadequate data exist to suggest that open reduction performed solely for the purpose of disk repositioning is valid.

Surgical Approach CONDYLAR FRACTURES

A variety of surgical approaches to the fractured condyle have been suggested, including intraoral, submandibular, retro-mandibular, preauricular, and, more recently, endoscopic. The most important factor in determining the approach used is the level at which the fracture has occurred. Modifying factors such as the degree of displacement or dislocation and the planned method of fixation may also have a bearing on the approach selected.

Traditionally fractures in the condylar neck and above were best approached through a preauricular or endaural incision.¹⁰¹ This approach also has the added advantage of allowing for surgical manipulation of the soft tissues within the joint, if desired. Subcondylar fractures and fractures extending into the upper ramus region are best approached using a retro-mandibular or Hinds approach.¹⁰² The incision begins approximately 1 cm below the lobe of the ear and 1 cm posterior to the ramus of the mandible. The dissection is carried down to the parotid gland, which is retracted anteriorly, providing access to the vertical fibers of the masseter muscle overlying the ramus. These fibers are not stripped but instead are separated bluntly along their vertical course, allowing access to the underlying ramus. Access can easily be gained to relatively high subcondylar fractures through this approach, and a variety of fixation techniques are possible without additional percutaneous puncture, as may be needed if a submandibular approach is used. Low subcondylar fractures, especially those without a significant degree of displacement,

may be easily approached from an intra-oral incision.¹⁰³ In severe anteromedial fracture dislocations in which the condylar head is not retrievable despite the choice of approach, a vertical ramus osteotomy, followed by removal of the osteotomized segment, has been recommended.^{104–106} This allows for access to the proximal condylar head, which is located medially and is also removed. Rigid fixation with plates or screws is carried out between the ramus segment and condylar head. The unit is returned as a free autogenous bone graft, and the osteotomy is plated. This technique is useful for high dislocated fractures and may be accomplished through a retromandibular approach.

OTHER MANDIBULAR FRACTURES

Open reduction of mandibular fractures prior to the advent of antibiotics was associated with a high incidence of infection. Following the introduction of antibiotics, most clinicians used the extraoral approach to the fracture site. This technique, however, is time-consuming, results in a visible surgical scar, and can damage adjacent structures, particularly the marginal mandibular branch of the facial nerve. Transoral open reduction has been advocated as an excellent alternative.^{107–110} The technique is claimed to be quicker to perform, results in no extraoral scar, and does not damage the facial nerve. Less postoperative wound care is required, and it is simple to perform the techniques under local anesthesia. Transoral open reduction of mandibular fractures is useful in tooth-bearing portions of the jaw (ie, in symphyseal, body, and angle fractures). Complications rates and infection rates appear to be similar between the two techniques when large numbers of cases are studied.^{111,112}

Occasionally, a combination of approaches is necessary, particularly in fracture dislocations in which a preauricular approach may be necessary to retrieve the proximal segment, while fixation is performed through another approach.¹¹³

Throughout the past decade, surgeons have become interested in the concept of minimally invasive surgical approaches to avoid potential patient morbidity from more traditional open surgical techniques. With the development of these techniques, management of these injuries via an endoscopic approach has gained great popularity among surgeons. In 1994 Ma and Fang were the first ones to describe the use of an endoscope to access the mandibular angle region.¹¹⁴ Later Jacobovicz and colleagues modified this technique for the management of condylar fractures.¹¹⁵ Recently, more authors have also described their experience with this approach.¹¹⁶⁻¹¹⁸

The surgical approach, as described by Miloro,¹¹⁸ requires a 15 to 20 mm modified Risdon incision to gain access to the lateral ramus. A subperiosteal dissection is then performed blindly to create an “optical cavity” on the lateral aspect of the ramus on the fracture side from the sigmoid notch to the inferior border and from the mandibular notch anteriorly to the posterior border of the ascending ramus posteriorly. A modified Storz retractor with a curved end is then placed through the incision and below the periosteum to engage the sigmoid notch. A 4 mm, 30° endoscope is used for retraction and visualization of the surgical site. Following irrigation and the use of a suction elevator, the sigmoid notch, inferior border, mandibular notch, posterior border, and the fracture site can be clearly identified endoscopically. The fractured segments are then repositioned and reduced. Inferior traction on the angle of the mandible, although limited by IMF, can be helpful in the mobilization of the segments. Fixation is achieved with a 2.0 mm titanium miniplate and screws through a preauricular stab incision and trocar (Figure 22-30). Following reduction and stabilization, the IMF is released for evaluation of the occlusion.

Methods of Fixation Once access to the fracture has been achieved, any number of

fixation devices may be employed (Figure 22-31). In a given situation, any one of these techniques may have certain advantages over the other. With the development of sophisticated rigid internal fixation systems and instrumentation for their placement, miniplate fixation of these fractures will be the technique most readily employed in most cases. Miniature bone plates can be applied using any of the previously discussed approaches. These plates have the advantage of being available in a wide variety of shapes and sizes; they are now readily available in most operating rooms; and they provide a more stable form of fixation than do wires or Kirschner wires. Theoretically, bone plates have another advantage—they can be placed on a relatively small proximal fragment first, allowing for the creation of a handle to more effectively manipulate the proximal segment into an appropriate reduction. Should the incision selected not allow for total access to the fracture, currently available bone-plating systems are equipped with instrumentation for percutaneous placement of screws.

WIRE Intraosseal wiring (wire osteosynthesis) can be placed either by an intra- or extraoral route using one of three basic techniques:

1. A simple straight wire across the fracture site (Figure 22-32A). This should be placed so that the direction of pull of the wire is perpendicular to the fracture site. This technique can be either through both the buccal and lingual cortical plate or it may be used on the buccal cortical plate only. This is useful in the angle region, where a third molar socket can be quickly and easily used for a simple straight buccal cortex wire.
2. Figure-of-eight wire (Figure 22-32B). This wiring technique has been shown to have increased strength compared with simple techniques at both the inferior and superior borders in angle fractures.¹¹⁹

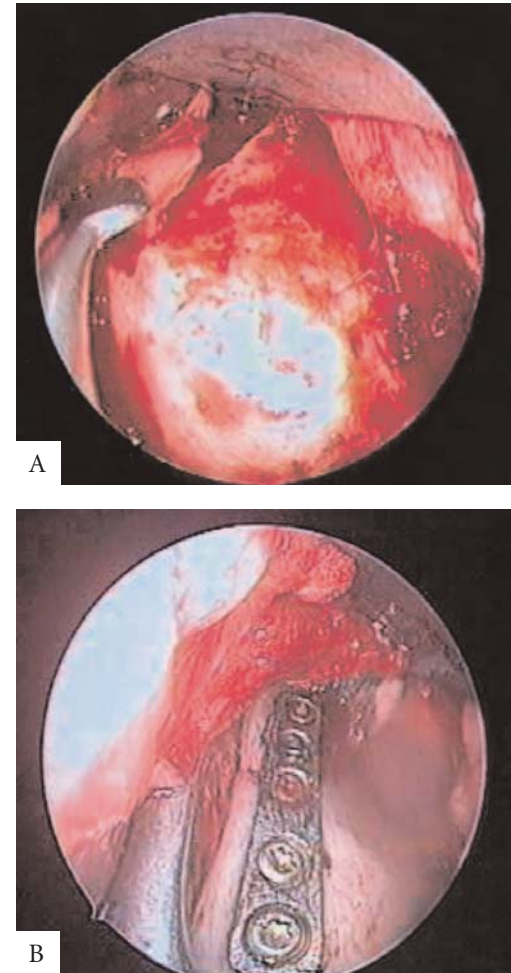


FIGURE 22-30 Endoscopic management of condylar fractures offers excellent reduction and fixation of the fracture segments, while reducing the morbidity of conventional open approaches to this site. A, Visualization of the condylar neck fracture. B, Titanium miniplate in place after reduction. (Photographs courtesy of Michael Miloro, DMD, MD)

3. Transosseous circum-mandibular wiring (Obwegeser's technique) (Figure 22-32C). This is a useful wiring technique when the fracture runs obliquely compared with the inferior border of the mandible. If the fracture line is too vertical the wire could become displaced into the fracture line.

The wire used should be a pre-stretched soft stainless steel, and the fracture should be held in a reduced position while the wire is being tightened so that the wire does not reduce the fracture and possibly lead to wire breakage.

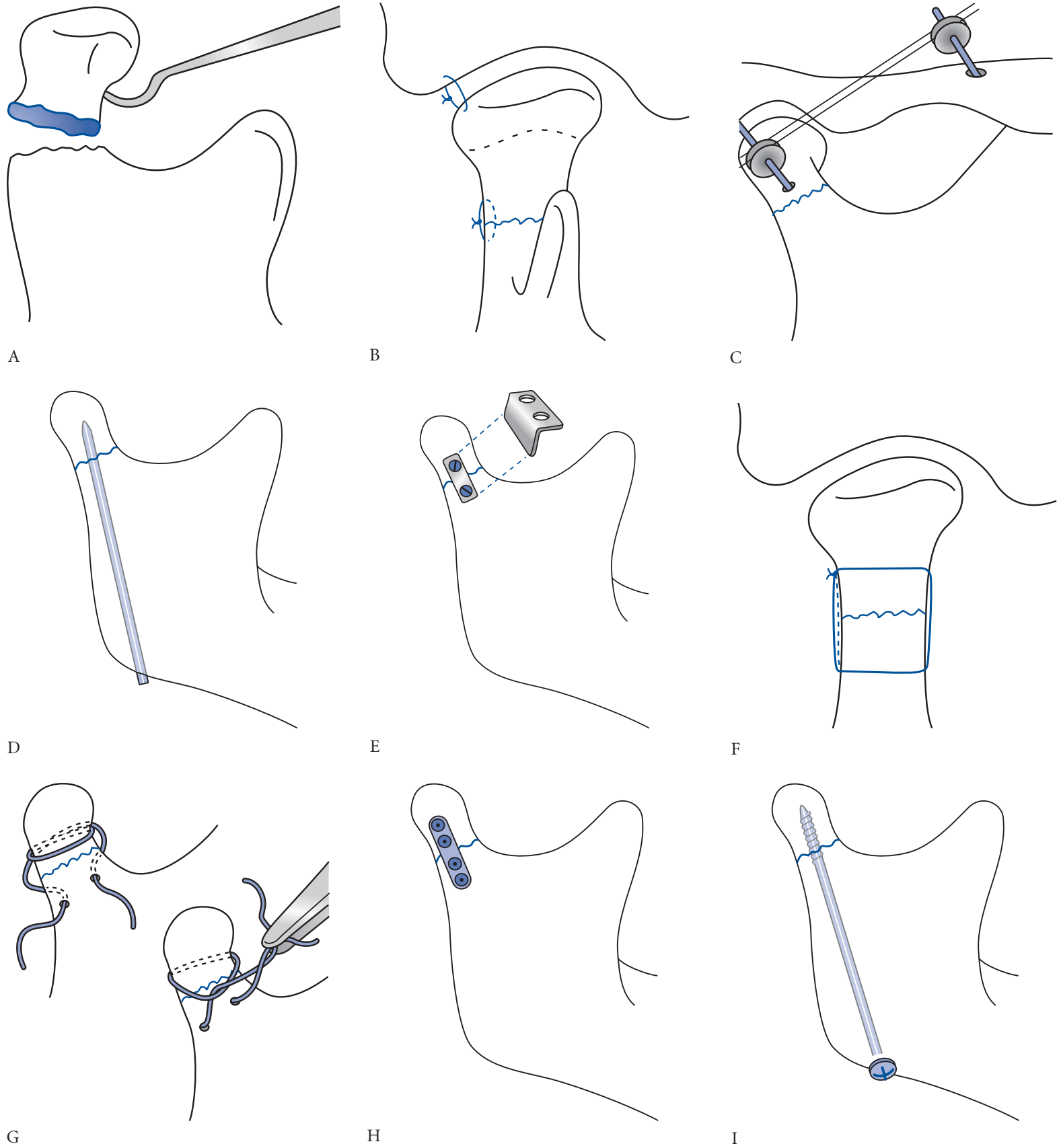


FIGURE 22-31 Previously reported techniques for direct stabilization of condyle fractures: A, Silverman (1925); B and C, Thoma (1945); D, Stephenson (1952); E, Robinson (1960); F, Robinson (1962); G, Messer (1972); H, Kobert (1978); I, Petzel (1982). (CONTINUED ON NEXT PAGE)

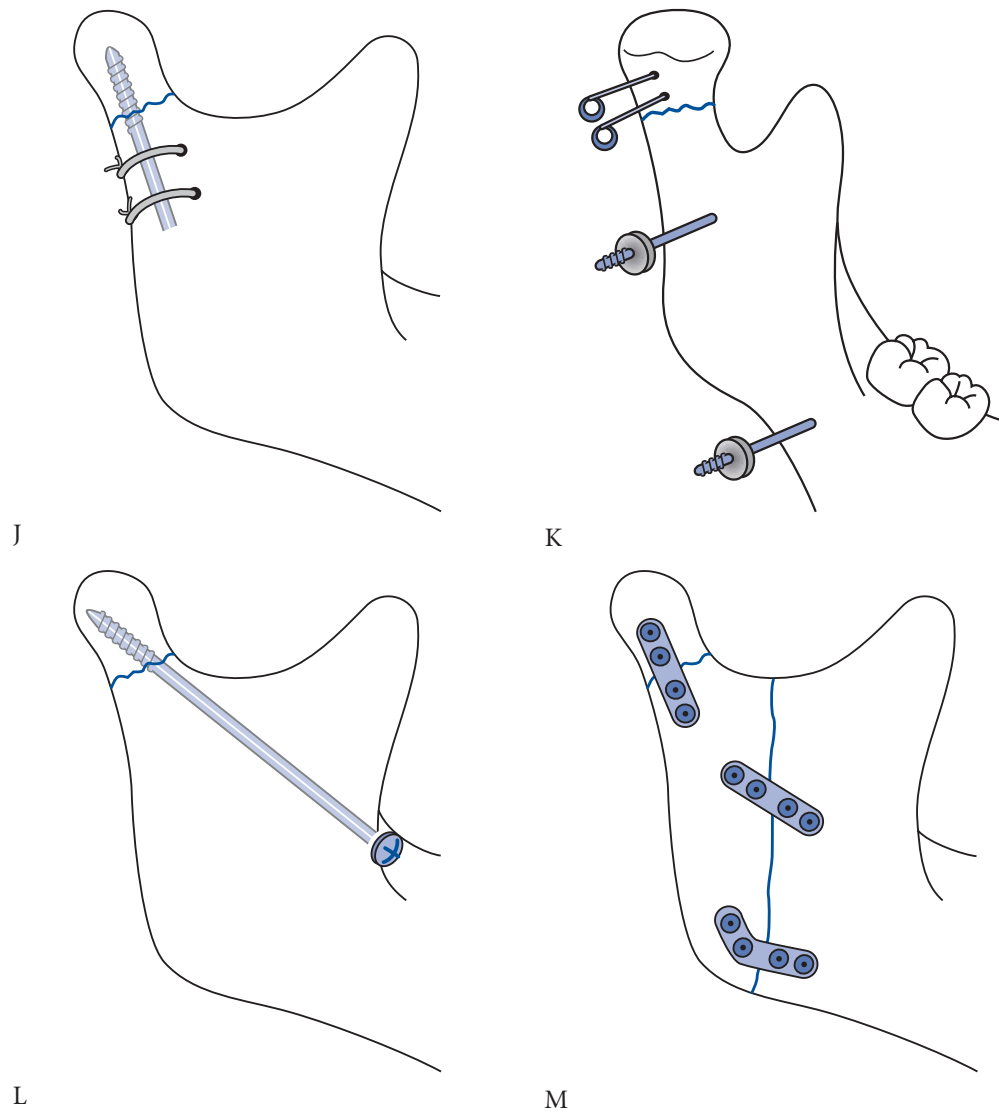


FIGURE 22-31 (CONTINUED) J, Brown (1984); K, Fernandez (1987); L, Kitayama (1989); M, Ellis (1989). Adapted from Larsen PE. Traumatic injuries of the condyle. In: Peterson LJ, Indresano AT, Marciani RD, Roser SM, editors. *Principles of oral and maxillofacial surgery*. Vol 1. Philadelphia (PA): JB Lippincott Company; 1992. p. 460.

RIGID FIXATION Dissatisfaction with the use of IMF as a means of treatment of mandibular fractures has resulted in the development of open reduction and fixation techniques that do not require the teeth to be wired together. Criticism of the disadvantages of prolonged immobilization of the jaws has included patient complaints of panic, insomnia, social inconvenience, phonetic disturbance, loss of effective work time, physical discomfort, weight loss, histologic changes in the condylar head, and difficulty recovering a normal range of jaw movement. This has led some clinicians to

seek alternative methods of treatment, including the use of rigid internal fixation.

The principal disadvantages of the compression plating systems for mandibular fractures are the use of an external approach, thus giving rise to facial scarring and the potential for damage to the mandibular branch of the facial nerve, and the use of very rigid plates, giving rise to “stress shielding,” although this has never been shown to be a problem in mandibular fractures. Also, the position of the teeth and inferior alveolar nerve and the use of bicortical screw fixation necessitate that the compression plates be

placed in areas of compression rather than tensile forces, and therefore, additional techniques are required to overcome the tension forces. Another disadvantage is that removal of the plates is advocated.

The second major group of plate fixation techniques is the monocortical miniplate osteosynthesis, which was first described by Michelet and colleagues and then modified and popularized by Champy and colleagues.^{9,10} The principal advantages of this technique over compression plating systems are the use of the intraoral approach and the positioning of the plates in the juxta-alveolar area where tensile strain occurs when the mandible is loaded. The healing that results from the use of this system in humans has not been demonstrated clearly. At least one group of authors claims that the system gives rise to rigid fixation and that it results in primary bone healing, although no evidence is provided to support this assertion.¹²⁰ In view of the small malleable nature of these plates and the fact that the system is monocortical, it would seem more likely that the technique is only semirigid and would result in callus formation and secondary bone repair. This is not to imply that it is an inferior technique, because callus formation generally gives rise to quicker and stronger early bone repair.¹²¹

Special Situations

Edentulous Fractures The edentulous mandible in the trauma patient has several factors modifying its behavior that the dentate mandible does not. The loss of the teeth results in resorption of the alveolar bone, which weakens the mandible. The loss of bone also means that there is less cross-sectional area of bone in contact in fracture patients and less periosteum and endosteum to supply the osteogenic cells for fracture healing. Because of the aging process the majority of the blood supply to the edentulous mandible is from the periosteum rather than the inferior alveolar

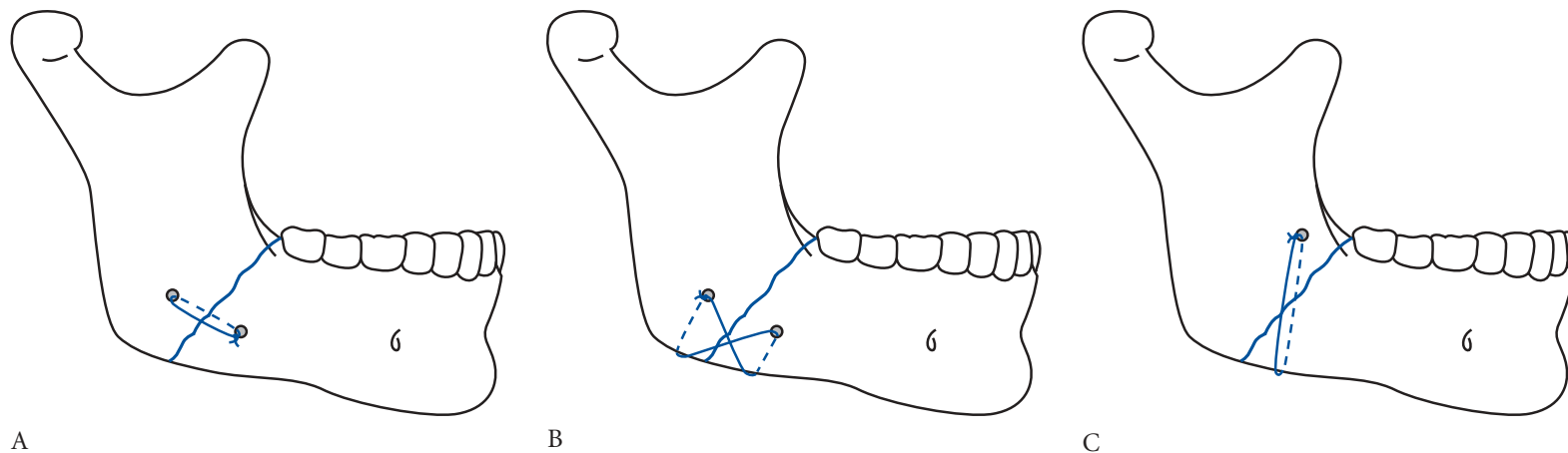


FIGURE 22-32 A, Simple wiring technique. B, Figure-of-eight wire. C, Transosseous circum-mandibular wire. Adapted from Luyk NH.⁸⁸ p. 427.

artery.¹²² A larger percentage of fractures in the edentulous patient are not compound because of the lack of teeth. Minor displacement of the bones can be easily accommodated in the construction of new dentures. The edentulous population also tends to have more health problems resulting from conditions such as osteoporosis, diabetes mellitus, and steroid therapy, which may directly affect bone healing. The site distribution of fractures tends to be different in the edentulous patient, with a higher percentage of body fractures (43.5%) and lower percentages of angle (15.2%) and symphyseal (4.3%) fractures (Figure 22-33).¹²³ A 20% incidence of nonunion has been reported in the treatment of edentulous fractures, particularly when nonrigid fixation was applied in open reduction cases.¹¹¹ Longer periods of immobilization have also been shown to be necessary to achieve satisfactory healing.^{124,125}

The anatomic site influences treatment. If the location of the fracture is posterior to the denture-bearing area, then either additional fixation (eg, external pin fixation) or open reduction and fixation may be necessary to control the proximal fragment. Muscle pull on the edentulous jaw is considerably weaker than in a dentate mandible and undisplaced fractures are often closed injuries. Therefore, if the fragments are undisplaced or minimally displaced and not mobile, conservative

therapy may be all that is necessary. More definitive treatment will be necessary if the fragments are displaced or excessively mobile. The bilateral body fracture deserves special mention because the pull of the suprahyoid muscles tends to displace this fracture inferiorly. These usually occur in the pencil-thin atrophic mandible. A variety of treatment modalities have been suggested to treat these difficult fractures including open reduction with rigid internal fixation, closed reduction with and without bone grafts, and external pin fixation. When the edentulous mandible is comminuted again because of the poor blood supply to the bone fragments, those fragments are best managed by closed reduction. The use of semirigid fixation systems without some form of IMF is not indicated in this patient subset.

External pin fixation by the biphasic technique is often used in edentulous fractures. It obviates the need for IMF, thus allowing early mobilization of the jaw and improving feeding in some patients. It can be used in comminuted fractures without jeopardizing blood supply to the fractures, and it can also bridge a bone loss gap before bone grafting.

Fractures in Children As previously mentioned, fractures in children are less common than in adults. Their management is complicated by the presence of deciduous teeth,

which may be mobile during the mixed dentition stage and whose shape has little in the way of undercut areas, which means that they do not retain wire as well as adult teeth. The presence of tooth buds reduces the area available for interosteal fixation, and there exists a greater potential for ankylosis and growth disturbances in the younger population. Also, children do not tend to tolerate IMF as well as adult patients. On the other hand, fractures tend to heal quicker in children and slight malocclusion problems can be compensated for by growth of the patient.

Children make up about 5% of all mandibular fractures. These fractures are rare in children under 5 years of age because of the greater elasticity of the bone and lighter weight of children, which lowers the

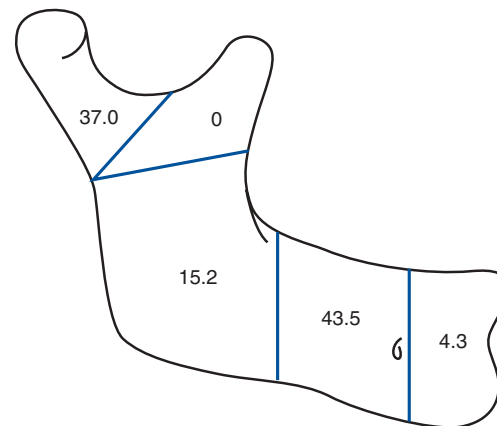


FIGURE 22-33 Percentage of fracture sites in edentulous patients. Adapted from Luyk NH.⁸⁸ p. 429.

forces of impact during falls. Condylar fractures appear to be common, affecting about 46% of patients either alone or in combination with other fractures.¹²⁶

Mandibular fractures in children can often be successfully managed by acrylic splint therapy of the mandible only or with eyelet wires and IMF.^{126,127} A shortened period of IMF, 2 to 3 weeks, is all that is required. When an open reduction is required, it has been successfully accomplished by the extraoral route using inferior border wiring in order to avoid the tooth buds.^{128,129}

If adequate bone height is available below the area where the tooth buds are located, the use of resorbable plates offers a great advantage to fixate these fractures (Figure 22-34).

Complications are rare in this group of patients. Malunion, nonunion, and infection tend to have a low incidence.⁶⁷ Two serious complications that can occur, however, are ankylosis and growth disturbances. Both of these tend to be more common with intracapsular condylar fractures and when the damage is of a crushing nature.¹³⁰ The incidence and severity of these complications can be reduced by shorter periods of IMF and close follow-up.

Management of Teeth in the Line of Fracture In the past, teeth in the line of the fracture were always removed.^{23,131,132} Their removal was advocated because fractures of the dentate portion of the jaws are compound via the periodontal ligament and it was believed that this communication fostered infection, osteomyelitis, and nonunion. However, Neal and colleagues, Kahnberg and Ridell, Schneider and Stern, and Amaratunga have all been able to show that the majority of teeth in the fracture line can be saved if appropriate antibiotic therapy and fixation techniques are used.¹³³⁻¹³⁶ The impacted mandibular third molar tooth deserves special mention. Most authors have advocated leaving the tooth in situ if the tooth is not in direct

communication with the mouth, no pericoronitis exists, and reduction of the fracture is achievable without removal. Shetty and Freymiller reviewed the indications for removal of teeth in the line of the fracture as follows¹³⁷:

1. Teeth grossly loosened, showing evidence of periapical pathology or significant periodontal disease
2. Partially erupted third molars with pericoronitis or associated cyst
3. Teeth that prevent reduction of fractures
4. Teeth with fractured roots
5. Teeth with exposed root apices or entire root surface from the apex to the gingival margin
6. An excessive delay from the time of fracture to definite treatment

Use of Antibiotics

Zallen and Curry demonstrated that with compound mandibular fractures, an infection rate of 50% can be expected in those patients who do not receive antibiotic therapy.¹³⁸ A prospective trial was undertaken in which only dentate compound mandibular fractures were evaluated. One-half of the patients in this study received “prophylactic antibiotics,” usually penicillin. It was not stated for how long the antibiotic therapy was continued or when it started in relation to the injury. One-half the patients who did not receive antibiotics had infections at the fracture site as opposed to only 6% of those who did receive antibiotics. It seemed to make little difference whether the fractures were treated by open or closed reduction. All fractures in this study were treated within 36 hours. Another study has confirmed these results in facial fractures and has suggested that short-term prophylaxis as is used in elective surgery may be as effective as the more usual 5-day course of antibiotics.¹³⁹ This group also found little difference in the incidence of infection whether there was a delay in treatment of mandibular fractures or not.

Penicillin should remain the antibiotic of choice for compound mandibular frac-

tures whether closed reduction or open reduction is contemplated. The antibiotic prophylaxis should begin preoperatively and be continued for not more than 24 hours postreduction.

Complications

Delayed Union and Nonunion

Nonunion is distinguished from delayed union by the potential of the bone to heal. Delayed union is a temporary condition in which adequate reduction and immobilization eventually produces bony union. On the other hand, nonunion may persist indefinitely without evidence of bone healing unless surgical treatment is undertaken to repair the fracture. Nonunion is generally characterized by pain and abnormal mobility following treatment. Malocclusion may be present in dentate cases and mobility exists across the fracture line. Radiographs demonstrate no evidence of healing and in later stages show rounding off of the bone ends. Delayed and nonunion occur in about 3% of fractures.¹⁴⁰

There are several causes and contributing factors. The most common reason is poor reduction and immobilization.¹⁴¹ This is more likely in edentulous fractures. Infection is often an underlying cause, and any tooth in the line of the fracture must be carefully assessed for root fracture and vitality. A decreased blood supply can lead to delays in healing. Excessive stripping of

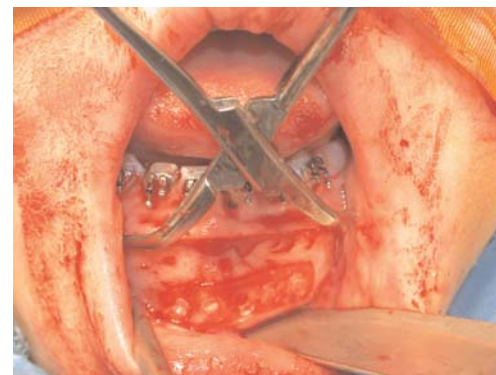


FIGURE 22-34 Use of a resorbable plate for fixation of a symphysis fracture in a 4-year-old child.

the periosteum, especially in comminuted and edentulous fractures, can lead to delayed healing. Metabolic deficiencies and alcoholism are also significant contributors to delayed healing. Cannell and Boyd showed a high incidence of delayed union and nonunion in a group of alcoholic patients.¹⁴² These patients were probably also at increased likelihood to sustain a mandibular fracture. Although the exact reasons for delayed healing in this group of patients is not known, they are known to have metabolic and vitamin deficiencies, poor compliance particularly with IMF, poor bony quality, and impaired local blood supply, all of which could be contributing factors. These patients should be treated whenever possible with closed reductions, because this treatment has a lower incidence of complications in this group of patients.¹⁴²

Treatment of delayed union and nonunion is aimed at eliminating the underlying cause of the problem. When infection is present it must be managed with débridement of sequestra, drainage, and antibiotic therapy. Loose fixation such as wires and plates must be removed, and adequate fixation with IMF, extraoral pin fixation, or even rigid plate fixation should be applied across the fracture site.¹⁴³ If there is a gap between the bone ends, a bone graft may be necessary.

Infection

Infection and osteomyelitis appear to be the most common complications (Figure 22-35). In some studies, particularly without antibiotics, it may occur in over 50% of cases.¹⁴⁴ Some of the underlying causes have already been discussed. These can be divided into systemic factors, such as alcoholism and no antibiotic coverage, and local factors, such as poor reduction and fixation, fractured teeth in the line of fracture, and comminuted fractures.

Most infections appear to be mixed in nature, with α -hemolytic *Streptococcus* and *Bacteroides* spp organisms found most

commonly.⁵⁸ Treatment has already been outlined as for delayed and nonunion of fractures.

Malunion

Malunions can be defined as a bone union of the fracture in which some displacement of the bones still exists. Not all malunions of fractured mandibles are clinically significant. Often malunions in edentulous patients or those involving the ramus and condylar area of the mandible result in no clinically detectable alteration in appearance or function. When, the dentate portion of the jaw is involved, however, a malocclusion can result. The rates of malocclusion in patients treated with IMF tend to be very low. In one prospective trial between rigid internal fixation and standard techniques the rate of malocclusion with the rigid fixation was three times higher. However, as the authors concede, they were initially inexperienced with the technique and others have reported a low incidence of maloc-

clusion.^{145,146} Malocclusion can be corrected by further or prolonged IMF in the early stages of healing, and selective tooth grinding, orthodontics, or osteotomies after complete bony union.

Malocclusion that does not result from growth alterations but from a malunion of the condyle fracture occurs infrequently if an adequate follow-up regimen is followed. If malocclusion does persist, its management is similar to the management of malocclusion from other causes. Judicious use of equilibration, orthodontics, and orthognathic surgery allows for restoration of a functional occlusion. Before reconstructing the occlusion to this new articulation, it is necessary to allow a period of 6 to 12 months for complete healing and for any remodeling of the articular apparatus to occur.

Nerve Injury

Traumatic injury to the inferior alveolar nerve is common in displaced fractures of the body and angle of the mandible. There

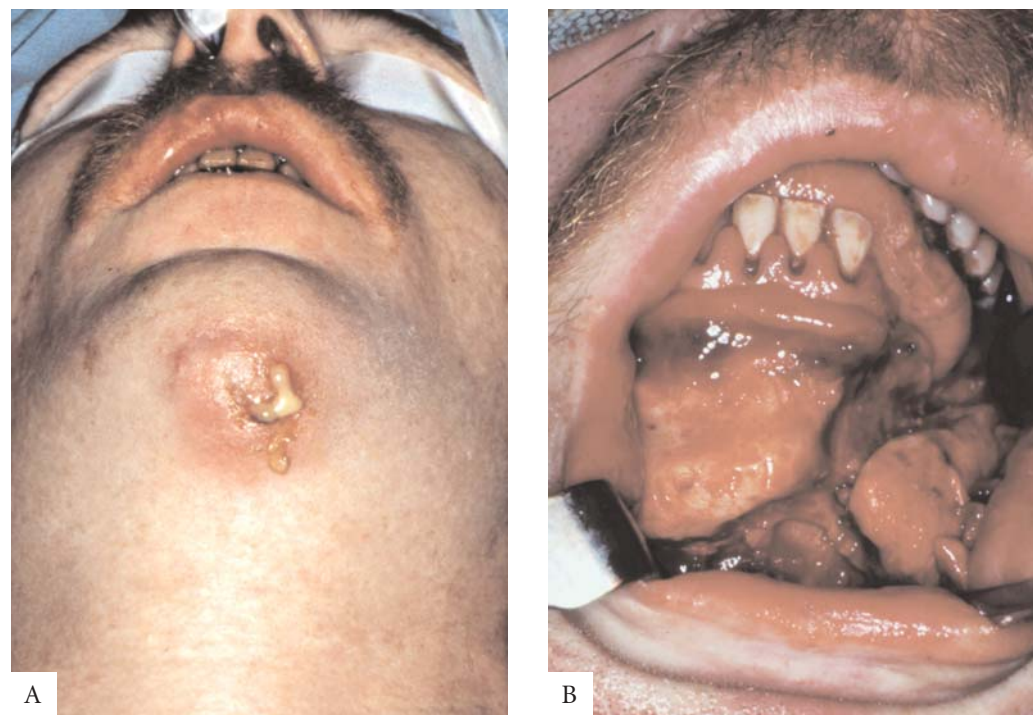

FIGURE 22-35 A, Sinus tract from an infected anterior mandibular fracture after open reduction with internal fixation. B, After hardware removal and bony débridement, a large defect can be observed in the left parasymphysis region.

are few studies documenting recovery of the nerve. Larsen and Nielsen reported a permanent disturbance in mental nerve function in 8% of 229 patients studied.¹⁴⁷ Return of nerve function depends on the degree of initial trauma to the nerve and an accurate reduction and adequate fixation of the mandibular fracture. Rarely other branches of the mandibular division of the trigeminal nerve can be affected. These include the masseteric nerve, auriculotemporal nerve (both with condylar fractures), and the buccal and lingual nerves associated with intraoral lacerations with body or angle fractures. Also rare is damage to the marginal mandibular branch of the facial nerve with fractures of the condyle, ramus, and angle of the mandible. It is more common to see this nerve damage caused by a laceration along its course.

Most fractures of the mandible heal with relatively simple management. All clinicians must be wary of overtreatment of simple cases that can lead to an increase in cost of treatment for both the patient and society and also an increase in complication rates.

Growth Alteration

Growth alterations as the result of condylar injury may occur as the result of two mechanisms. Over- or understimulation of normal growth may result from direct injury to the condyle, or a restriction of normal growth may occur secondary to fibrosis or scarring of the surrounding tissue.

It was once thought that fracture of the condyle produced a growth deficit in proportion to the age of the patient at the time of injury: the younger the child, the greater potential growth problem.¹²⁰ However, although it is true that children undergo several periods of rapid growth during their development and that an injury during one of these growth periods may be associated with a higher incidence of growth alteration,⁷⁸ other factors are involved that alter this simplistic

theory. Frequently, complete regeneration of the condyle occurs in young patients, with no residual deficit following fracture, and better regeneration occurs in actively growing patients, particularly those under the age of 12 years.^{148,149} This clinical observation is supported by experimental studies,¹⁰⁴ which found that, following surgically created fracture dislocations in young monkeys, excellent regeneration occurred with no growth disturbance in any of the animals. This ability for restitution of growth in children under the age of 12 years appears to account for the lack of direct correlation between the age of injury and the degree of growth disturbance—a correlation that would be expected if the sole determinant were the amount of growth left at the time of injury.

The concept that the condylar cartilage acts as a growth center has been replaced by the theory that the cartilage acts as a remodeling center.¹⁵⁰ The restitution of growth seen after condylar injury (which at times may actually lead to overgrowth of the affected condyle) is a direct result of this remodeling center within the condylar cartilage reacting to a traumatic episode. It is not unusual for a new condylar apparatus to develop, with resorption of the displaced or dislocated condylar head. This compensatory growth seems to depend on the potential space created by the displacement of the stump of the condylar process.¹⁵⁰ For this reason, it is important to maintain the mandible in its original occlusion, not only for a few weeks during healing, but also for the next several months while bony regeneration and compensatory growth occur. Even when occlusion is maintained and the patient is of the ideal age, 25% of subjects experience a growth disturbance.^{148,149,151} Because of this, adequate patient education and long-term follow-up for several years is necessary in children with fractures of the condyle (Figure 22-36).

Temporomandibular Joint Dysfunction

A wide range of temporomandibular joint problems may result from injuries to the condylar apparatus. Internal derangement and ankylosis are perhaps the two most common.

Internal Derangement A correlation exists between previous condylar fracture and the development of internal derangement of the temporomandibular joint. There is a greater incidence of temporomandibular joint pain, deviation on opening and joint noise in patients with previous condylar fractures.⁷¹ The resultant internal derangement primarily occurs in adults and is of two broad types. The first is internal derangement that occurs on the side of the fracture and results from soft tissue injury within the joint. Open reduction with direct repair of the injured soft

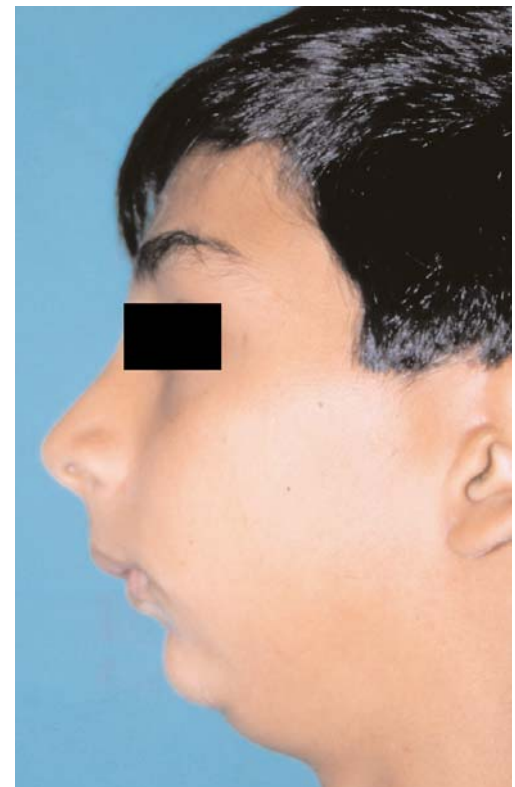


FIGURE 22-36 Significant mandibular hypoplasia in a 12-year-old boy, resulting from bilateral intracapsular condylar fractures suffered shortly after birth.

tissues has been advocated by some as a possible means of preventing this problem.^{98,99} No long-term data have established that this is effective. The other form of internal derangement occurs contralateral to the condylar injury. This derangement was described by Gerry as the “condylar postfracture syndrome.”³² Patients who develop a unilateral hinge type of joint after a fracture can rapidly develop overfunction of the contralateral joint with hypermobility and, ultimately, anterior dislocation of the disk.

Ankylosis Ankylosis is a rare complication of mandibular fractures. It is more likely to occur in children and is associated with intracapsular fractures and immobilization of the mandible. The most commonly accepted etiology is of intra-articular hemorrhage, leading to abnormal fibrosis and ultimately ankylosis.¹⁴¹ In children, if left untreated, it results in disturbed growth and underdevelopment of the affected side. Prevention is easier than cure, and the use of only short periods of IMF in children can help reduce the occurrence of this complication. Management once the condition is established is surgical with a temporomandibular joint arthroplasty, wide resection of the ankylotic portion of bone, coronoidectomy, and reconstruction with a costochondral rib graft, with active early and prolonged mobilization and exercises.¹⁵²

Although development of internal derangement seems to occur solely in adult patients, ankylosis is much more common in children (Figure 22-37).

Factors contributing to the development of ankylosis have been outlined.³⁵ They include the site and type of fracture, the age of the patient at the time of injury, the duration of IMF, and the extent of damage to the disk.

The site and type of fracture may play an important role in whether or not ankylosis occurs. It is widely accepted that intracapsular fractures are more likely to devel-

op ankylosis. The postinjury relation of the condylar stump with the glenoid fossa is also a factor. With fractures of the condylar head, a greater likelihood exists that there will be intimate contact between the proximal portion of the distal segment and the glenoid fossa, predisposing the patient to ankylosis.⁴⁸ Failure to produce ankylosis after experimentally induced condylar fractures,⁸¹ coupled with the clinical observation that the incidence of intracapsular fracture is much higher than that of ankylosis, leads one to believe that other factors besides the site of fracture must be operative in the production of ankylosis.

The condyle of a young child is more easily crushed than fractured,^{153,154} possibly because the cortical bone of the child is relatively thin and the condylar neck broad.¹⁵⁵ The immediate subarticular layer is also extensively vascularized. An impact leading to a crush injury is more common in a child because of these anatomic differences, and the resulting fragments of highly vascularized osteogenic material that are dispersed throughout the joint space may be the cause of ankylosis.¹⁵⁵ This theory helps to explain the clinical observation that there is a greater predisposition for post-traumatic ankylosis in patients sustaining such injuries before the age of 10 years.¹⁵⁶

It is widely accepted that the length of the maxillomandibular fixation may play a role in the development of ankylosis. Markey was unable to produce ankylosis after experimentally induced fracture with prolonged maxillomandibular fixation.¹⁵⁷ In studies performed by Beekler and Walker, ankylosis occurred with prolonged fixation, while no ankylosis could be created in a moving jaw.⁸¹ This confirms the observation that the duration of immobilization is contributory to the development of ankylosis, although it is not the primary determinant. The location and condition of the disk may be another determinant in the occurrence of temporomandibular joint ankylosis because one never finds the disk in the

area of temporomandibular joint ankylosis.⁴⁸ Experimentally, ankylosis has been created in a baboon by a combination of bilateral fractures of the condyloid process, diskectomy, and prolonged immobilization, while the same procedure without diskectomy did not produce ankylosis.⁴⁸ Thus far, this discussion has been limited to the development of true ankylosis with the formation of a bony or fibrous union within the joint itself. There is also the potential for the development of pseudo ankylosis if soft tissue trauma surrounding the joint leads to fibrosis and scarring or (in the case of zygomatic arch and coronoid fractures) a bony union develops between other fractured areas and not within the joint itself.

In summary, it is likely that the following groups of patients will be at high risk for development of ankylosis: patients under the age of 10 years at the time of injury; patients with intracapsular fractures and fracture dislocations with gross telescoping;

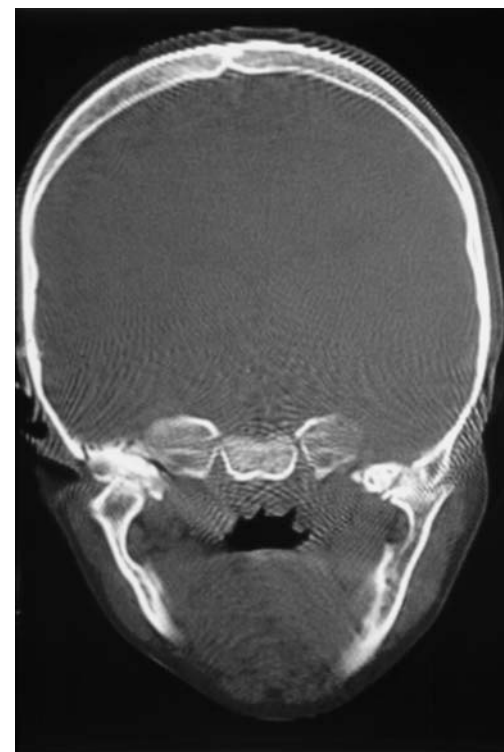

FIGURE 22-37 Coronal computed tomography scan of the patient in Figure 22-36 showing true bony ankylosis of both temporomandibular joints.

and patients with compound comminuted fractures, particularly if the coronoid process and zygoma are also involved.³⁵

Prevention of temporomandibular joint ankylosis is accomplished by recognition of those patients at risk, brief immobilization periods, and aggressive postoperative physiotherapy and long-term follow-up.

Other Complications Associated with Condylar Fractures

When the condylar head is forced posteriorly in the process of fracture, some force is directed against the posterior and superior walls of the glenoid fossa. Fracture of the tympanic plate may occur. In addition, partial obstruction of the external auditory canal may result, causing a conductive hearing loss because of the close proximity of the middle ear. Patients with a history of a condyle fracture should undergo a careful otoscopic examination to evaluate the condition of the anterior wall of the external auditory canal, as well as to observe for signs of potential middle ear injury. Appropriate consultation must be obtained if injuries of this nature are indicated by clinical examination or history. Basilar skull fracture along the floor of the middle cranial fossa may also occur from a similar mechanism, resulting in cerebral contusion. The fracture may also spread through the petrous portion of the temporal bone, resulting in injury of cranial nerves VII and VIII and a neurosensory hearing deficit (as opposed to a conduction deficit), facial nerve paralysis, and possibly Battle's sign.

If either of the fracture segments encroaches on the infratemporal fossa, trauma to the nerves or vessels in this area may occur. Damage of a large vessel can result in hematoma formation or development of a false aneurysm.¹⁵⁸ This expanding hematoma or false aneurysm may also cause injury to the seventh cranial nerve. The third division of the cranial nerve V may also be injured by the displaced

condylar segments.^{159,160} If aberrant reinnervation occurs from this injury, the late complication of auriculotemporal syndrome may result.^{160,161}

Postoperative Management

Regardless of the technique employed for treatment of the mandibular fractures, the postoperative management of the patient is critical for long-term successful rehabilitation and return to function.

In cases in which open reduction internal fixation is employed without the use of postoperative IMF, follow-up visits should be used as reinforcement sessions to remind the patient about proper diet and progressive increase in function. It has been our experience that in many respects this group of patients should be monitored more closely than those treated with IMF to prevent possible postoperative complications secondary to their injudicious or untimely return to normal diet and function.

The proper length of maxillo-mandibular fixation (if used), the duration and frequency of evaluation by the surgeon, the early detection of potential complications, the judicious use of physiotherapy, and proper patient education are all necessary. In most cases some form of IMF will have been employed. The length of the fixation period, as previously discussed, varies between 2 to 8 weeks depending on many factors. At the end of this period, a systematic approach for removal of the fixation is desirable. A follow-up regimen similar to that described by Walker must then be instituted.^{87,88} This allows for wound healing monitoring, oral hygiene reinforcement, and observation of adequate dietary intake. It also gives the clinician the opportunity to control the occlusion in those patients who need further stabilization, while encouraging early movement in those patients who have stable occlusions. It is impossible to predict on the basis of the type of fracture which patients will need continued aggressive elastic guidance to maintain their occlu-

sion. Children of less than 12 years of age rarely require more fixation, but patients over the age of 12 years show extreme variability, regardless of fracture type. If the occlusion is stable and reproducible at the time of IMF release, then jaw-opening exercises are begun. If aggressive physiotherapy is initiated after release of IMF for treatment of a condylar process fracture, the patient should be evaluated in 24 hours to confirm the presence of a stable occlusion. The arch bars are left in place and training elastics are used. The purpose of these elastics is to permit function, while maintaining the occlusion. An effective way to accomplish this is to gradually reduce the use of elastics over a period of time. Initially, elastics should be used 24 hours a day. They should be placed lightly during the daytime to assist in guiding the mandible into occlusion, particularly if significant deviation is present, and applied more tightly at night. After 1 week, it may be possible to completely abandon daytime elastic fixation and continue with relatively tight elastic fixation at night. After another 1 to 2 weeks of this therapy, assuming that continued maintenance of a normal occlusion is present, the patient should be allowed to function without any guiding elastic fixation for approximately 1 week. If, at that time, there continues to be a stable occlusion, further evaluation should continue for other problems, such as limited mouth opening or pain, and the arch bars may be removed. If, on the removal of the IMF or at any time during the training period, the occlusion becomes unstable and nonreproducible, an additional period of tight intermaxillary fixation with wires or elastics is indicated for 1 or 2 weeks. Clinical experience seems to indicate that a longer period of controlled elastic traction is often needed in adults with displaced or dislocated fractures, particularly if these are bilateral. Even with judicious use of guiding elastic fixation, patient education, and careful continued evaluation, malocclusion

persists in some patients. In these cases one must consider equilibration, orthodontics, osteotomies, or a combination of these to correct the malocclusion.

Throughout the post-IMF period, aggressive maintenance of range of motion is necessary. In some patients this may be as simple as instructing them to open their mouths as wide as possible in a symmetrical manner. Other patients may initially require daily evaluations and forced opening by the surgeon. Manually forcing the teeth apart, use of a ratchet, mouth props, progressive wedging of tongue blades between the teeth, or other more sophisticated physiotherapy devices are all effective means of regaining pre-injury interincisal opening.

The success or failure of any proposed treatment for the fractured mandible, whether by open or closed reduction, will necessarily hinge on the careful adherence to sound physiologic and surgical principles and to close post-operative follow-up.

References

- Ogundare BO, Bonnick A, Bayley N. Pattern of mandibular fractures in an urban major trauma center. *J Oral Maxillofac Surg* 2003; 61:713–8.
- Thaller SR. Management of mandibular fractures. *Arch Otolaryngol Head Neck Surg* 1994;120:44–7.
- Fasola AO, Obiechina AE, Arotiba JT. Incidence and pattern of maxillofacial fractures in the elderly. *Int J Oral Maxillofac Surg* 2003;32:206–8.
- Hoffman WY, Barton RM, Price M, Mathes SJ. Rigid internal fixation vs. traditional techniques for the treatment of mandible fractures; *J Trauma* 1990;30:1032–6.
- Kellman RM. Recent advances in facial plating techniques. *Facial Plast Surg Clin North Am* 1995;3:227–39.
- Dawson KH, Chigurupati R. Fixation of mandibular fractures: a tincture of science. *Ann R Australas Coll Dent Surg* 2002;16:118–22.
- Cawood JL. Small plate osteosynthesis of mandibular fractures. *Br J Oral Maxillofac Surg* 1985;77–91.
- Allgower M, Ehrsam R, Ganz R, Matter P, Perren SM. Clinical experience with a new compression plate (DCP). *Acta Orthop Scand* 1969;125:45–61.
- Michelet F, Deymes J, Dessus B. Osteosynthesis with miniaturized screwed plates in maxillofacial surgery. *J Maxillofac Surg* 1973; 1:79–84.
- Champy M, Lodde JP, Schmitt R, et al. Mandibular osteosynthesis by miniature screwed plates via a buccal approach. *J Maxillofac Surg* 1978;6:14–21.
- Rahn BA. Direct and indirect bone healing after operative fracture treatment. *Otolaryngol Clin North Am* 1987;20:425–40.
- Worthington P, Champy M. Monocortical miniplate osteosynthesis. *Otolaryngol Clin North Am* 1987;20:607–20.
- Davies BW, Cerdana JP, Guyuron B. Noncompression unicortical miniplate osteosynthesis of mandibular fractures. *Ann Plast Surg* 1992;28:414–9.
- Huelke DF. Mechanics in the production of mandibular fractures: a study with the “stresscoat” technique. I. Symphyseal impacts. *J Dent Res* 1964;43: 437–46.
- Huelke DF, Burdi AR, Eymen C. Mandibular fractures as related to site of trauma and state of dentition. *J Dent Res* 1961;40:1262–6.
- Huelke DF, Burdi AR, Eymen CE. Association between mandibular fractures and site of trauma, dentition and age. *J Oral Surg Anesth Hosp Dent* 1962;20:478–81.
- Huelke DF, Harger JH. Maxillofacial injuries: their nature and mechanisms of production. *J Oral Surg* 1969;27:451–60.
- Huelke DF, Harger JH. Mechanisms in the production of mandibular fractures: an experimental study. *J Oral Surg* 1968;26:86–9.
- Huelke DF, Patrick LM. Mechanics in the production of mandibular fractures: strain-gauge measurements of impacts to the chin. *J Dent Res* 1964;43:437–46.
- Evans FG, Pedersen HE, Lissner HR. The role of tensile stress in the mechanism of femoral fractures. *J Bone Joint Surg* 1951; 33:485–8.
- Kromer H. Closed and open reduction of condylar fractures. *Denl Rec* 1953;73:569–71.
- Chalmers J. Lyons Club. Fractures involving the mandibular condyle: a post-treatment survey of 120 cases. *J Oral Surg* 1974;9:233.
- Rowe NL, Killely HC. Fractures of the facial skeleton. 2nd ed. Edinburgh: Churchill-Livingstone; 1968.
- Lindahl L. Condylar fractures of the mandible. I. Classification and relation to age, occlusion and concomitant injuries of teeth and teeth supporting structures, and fractures of the mandibular body. *Int J Oral Surg* 1977;6:12–21.
- Petzel JR, Bulles G. Experimental studies of the fracture behaviour of the mandibular condylar process. *J Maxillofac Surg* 1981;9:211–5.
- Cope MR, Lawlor MG. An unusual mandibular dislocation. *Br J Oral Maxillofac Surg* 1985;23:112–7.
- Katzen JT, Jarrahy R, Eby JB, et al. Craniofacial and skull base trauma. *J Trauma* 2003; 54:1026–34.
- Chacon GE, Dawson KH, Myall RW, Beirne OR. A comparative study of 2 imaging techniques for the diagnosis of condylar fractures in children. *J Oral Maxillofac Surg* 2003;61:668–72.
- Chayra GA, Meador LR, Laskin DM. Comparison of panoramic and standard radiographs for the diagnosis of mandibular fractures. *J Oral Maxillofac Surg* 1986;44:677–9.
- Shetty V, Atchison K, Belin TR, et al. Clinician variability in characterizing mandible fractures. *J Oral Maxillofac Surg* 2001;59:254–61; discussion 261–2.
- Gilhuus-Moe O. Fracture of the mandibular condyle in the growth period. *Acta Odontol Scand* 1971;29:53–63.
- Gerry RG. Condylar fractures. *Br J Oral Surg* 1965;3:114–22.
- Blevins D, Gores RJ. Fractures of the mandibular condyloid process: results of conservative treatment in 140 patients. *J Oral Surg Anesth Hosp Dent* 1961;19:329–33.
- MacLennan WD. Consideration of 180 cases of typical fractures of the mandibular condylar process. *Br J Plast Surg* 1952;5:122–7.
- Bradley P. Injuries of the condylar and coronoid process. In: Rowe NL, Williams JL, editors. *Maxillofacial injuries*. Volume 1. Edinburgh: Churchill-Livingstone; 1985. p. 337–62.
- Kelly DE, Harrigan WF. A survey of facial fractures: Bellevue Hospital 1948–1974. *J Oral Surg* 1975;33:146–9.
- Luyk NH, Larsen PE. The diagnosis and treatment of the dislocated mandible. *Am J Emerg Med* 1989;7:329–35.
- Lello GE. Treatment of long standing mandibular dislocation of the mandible. *J Oral Maxillofac Surg* 1987;45:893–6.
- Hayward JR. Prolonged dislocation of the mandible. *J Oral Surg* 1965;23:585–94.
- da Fonseca GD. Experimental study on fractures of the mandibular condylar process (mandibular condylar process fractures). *Int J Oral Surg* 1974;3:89–101.
- Ihalainen U, Tasanen A. Central dislocation of the mandibular condyle into the middle cranial fossa: a case report and review of the literature. *Int J Oral Surg* 1983;12:39–45.
- Musgrove BT. Dislocation of the mandibular condyle into the middle cranial fossa. *Br J Oral Maxillofac Surg* 1986;24:22–7.

43. Harilainen A, Myllynen P, Anhla H, Seitsalo S. The significance of arthroscopy and examination under anesthesia in the diagnosis of fresh injury haemarthrosis of the knee joint. *Injury* 1988;19:21–4.
44. Fieldhouse J. Bilateral temporomandibular joint ankylosis with associated micrognathia: report of a case. *Br J Oral Surg* 1974;11:213–6.
45. Guralnick WC, Kaban LB. Surgical treatment of mandibular hypomobility. *J Oral Surg* 1976;34:343–8.
46. Hoaglund FT. Experimental hemarthrosis. *J Bone Joint Surg* 1967;49:285–98.
47. Laskin DM. Role of the meniscus in the etiology of posttraumatic temporomandibular joint ankylosis. *Int J Oral Surg* 1978;7:340–5.
48. Ellis E, Moos KF, El-Attar A. Ten years of mandibular fractures: An analysis of 2,137 cases. *Oral Surg* 1985;59:120–9.
49. Leathers R, Le AD, Black E, McQuirter JL. Orofacial injury in underserved minority populations. *Dent Clin North Am* 2003;47:127–39.
50. Calloway DM, Anton MA, Jacobs JS. Changing concepts and controversies in the management of mandibular fractures. *Clin Plast Surg* 1992;19:59–69.
51. Edwards TJ, David DJ, Simpson DA, Abott AA. Patterns of mandibular fractures in Adelaide, South Australia. *Aust N Z J Surg* 1994;64:307–11.
52. Fridrich KL, Pena-Velaso G, Olson AJ. Changing trends with mandibular fractures: A review of 1067 cases. *J Oral Maxillofac Surg* 1992;50:586–9.
53. Iizuka T, Lindqvist C. Rigid internal fixation of mandibular fractures: an analysis of 270 fractures using the AO/ASIF method. *Int J Oral Maxillofac Surg* 1992;21:65–9.
54. Hagan EH, Huelke DR. An analysis of 319 case reports of mandibular fractures. *J Oral Surg* 1961;19:93–104.
55. Van Hoof RF, Merckx CA, Stekenlenburg EC. The different pattern of fractures of the facial skeleton in four European countries. *Int J Oral Surg* 1977;6:3–11.
56. El-Degwi A, Mathog RH. Mandible fractures—medical and economic considerations. *Otolaryngol Head Neck Surg* 1993;108:213–9.
57. Olson RA, Fonseca RJ, Zeitler DL, Osborn DB. Fractures of the mandible: a review of 580 cases. *J Oral Surg* 1982;40:23–8.
58. Salem JE, Lilly G, Cutcher JL, Steiner M. Analysis of 523 mandibular fractures. *Oral Surg* 1968;26:390–5.
59. Haug RH, Prather J, Indresano AT. An epidemiologic survey of facial fractures and concomitant injuries. *J Oral Maxillofac Surg* 1990;48:926–32.
60. Luyk NH, Ferguson JW. The diagnosis and initial management of the fractured mandible. *Am J Emerg Med* 1991;9:352–9.
61. Motamedi MH. An assessment of maxillofacial fractures: a 5-year study of 237 patients. *J Oral Maxillofac Surg* 2003;61:61–4.
62. Kreutziger KL, Kreutziger KL. Comprehensive surgical management of mandibular fractures. *Southern Med J* 1992;85:506–18.
63. Walker RV, Bertz JE. Facial and extracranial head injuries. Care of the trauma patient. Shires GT, editor. New York: McGraw-Hill Book Co; 1966. p 478.
64. Huelke DF, Compton CP. Facial injuries in automobile crashes. *J Oral Maxillofac Surg* 1983;41:241–4.
65. Bernstein L. Practical points in the management of mandibular fractures. *Trans Am Acad Ophthalmol Otolaryngol* 1970;74:1068–73.
66. May M, Tucker HM, Ogura IH. Closed management of mandibular fractures. *Arch Otolaryngol* 1972;95:53–7.
67. Cook RM, MacFarlane WI. Subcondylar fracture of the mandible. *Oral Surg Oral Med Oral Pathol* 1969;27:297–304.
68. MacGregor AB, Fordyce GL. The treatment of fracture of the neck of the mandibular condyle. *Br Dent J* 1957;106:351.
69. Leake D, Doykos J, Habal M, et al. Long-term follow-up of fractures of the mandibular condyle in children. *Plast Reconstr Surg* 1971;47:127–31.
70. Lindahl L. Condylar fractures of the mandible. IV. Function of the masticatory system. *Int J Oral Surg* 1977;6:195–203.
71. De Riu G, Gamba U, Anghioni M, Sessena E. A comparison of open and closed treatment of condylar fractures: a change in philosophy. *Int J Oral Maxillofac Surg* 2001;30:384–9.
72. MacLennan WD, Simpson W. Treatment of the fractured mandibular condylar process in children. *Br J Plast Surg* 1965;18:423–7.
73. Thomson HG, Farmer AW, Lindsay WK. Condylar neck fractures of the mandible in children. *Plast Reconstr Surg* 1964;34:452–63.
74. Russell D, Nosti JC, Reavis C. Treatment of fractures of the mandibular condyle. *J Trauma* 1972;12:704–7.
75. Hotz RP. Functional jaw orthopedics in the treatment of condylar fractures. *Am J Orthod* 1978;73:365–77.
76. Rowe NL. Fractures of the jaws in children. *J Oral Surg* 1969;27:497–507.
77. Waite DE. Pediatric fractures of the jaw and facial bones. *Pediatrics* 1973;51:551–9.
78. Rakower W, Protzell A, Rosencrans M. Treatment of displaced condylar fractures in children. *J Oral Surg* 1961;19:517–21.
79. Walker RV. Traumatic mandibular condyle fracture dislocations. *Am J Surg* 1960;100:850–63.
80. Beekler DM, Walker RV. Condyle fractures. *J Oral Surg* 1969;27:563–4.
81. Boyne PJ. Osseous repair and mandibular growth after subcondylar fractures. *J Oral Surg* 1967;225:300–9.
82. Smets LM, Van Damme PA, Stoeltinga. Non-surgical treatment of condylar fractures in adults: a retrospective analysis. *J Craniomaxillofac Surg* 2003;31:162–7.
83. Glineburg RW, Laskin DM, Blankstein DL. The effect of immobilization on the primate temporomandibular joint: a histologic and histochemical study. *J Oral Maxillofac Surg* 1982;40:3–8.
84. Juniper RP, Awty MD. The immobilization period for fractures of the mandibular body. *J Oral Surg* 1973;36:157–63.
85. Amaratunga NA. The relation of age to the immobilization period required for healing of mandibular fractures. *J Oral Maxillofac Surg* 1987;45:111–3.
86. Walker RV. The consultant: condylar fractures. *J Oral Surg* 1966;24:367–9.
87. Walker RV. Open reduction of condylar fractures of the mandible in conjunction with repair of discal injury: discussion. *J Oral Maxillofac Surg* 1988;46:262–3.
88. Luyk NH. Principles of management of fractures of the mandible. In: Peterson LJ, Indresano AT, Marciani RD, Roser SM editors. Principles of oral and maxillofacial surgery. Philadelphia, PA: Lippincott-Raven; 1992. p. 381–434.
89. Messer EJ, Keller JJ. A rational approach to the mandibular parasymphseal fracture. *J Oral Surg* 1976;34:808–10.
90. Williams JG, Cawood JJ. Effect of intermaxillary fixation on pulmonary function. *Int J Oral Maxillofac Surg* 1990;19:76–8.
91. Wood GD. Assessment of function following fracture of the mandible. *Br Dent J* 1980;149:137–41.
92. Brown AE, Obeid G. A simplified method for the internal fixation of fractures of the mandibular condyle. *Br J Oral Maxillofac Surg* 1984;22:145–50.
93. Wennogle CF, Delo RI. A pin-in-groove technique for reduction of displaced subcondylar fractures of the mandible. *J Oral Maxillofac Surg* 1985;43:659–65.
94. Kitayama S. A new method of intraoral open reduction using a screw applied through the mandibular crest of condylar fractures. *J Craniomaxillofac Surg* 1989;17:16–23.
95. Tanasen A, Lamberg MA. Transosseous wiring in the treatment of condylar fractures of the mandible. *J Oral Maxillofac Surg* 1976;4:200–6.

96. Zide MF, Kent JN. Indications for open reduction of mandibular condyle fractures. *J Oral Maxillofac Surg* 1983;41:89-98.
97. Raveh J, Vuillemin T, Ladrach K. Open reduction of the dislocated fractured condylar process: indications and surgical procedures. *J Oral Maxillofac Surg* 1989;47:120-7.
98. Chuong R, Piper MA. Open reduction of condylar fractures of the mandible in conjunction with repair of discal injury: a preliminary report. *J Oral Maxillofac Surg* 1988;46:257-63.
99. Lund K. Unusual fracture dislocation of the mandibular condyle in a six year old girl. *Int J Oral Surg* 1972;1:53-60.
100. Henny FA. A technique for open reduction of fractures of the mandibular condyle. *J Oral Surg* 1951;9:233-5.
101. Zide MF. Open reduction of mandibular condyle fractures: indications and technique. *Clin Plast Surg* 1989;16:69-76.
102. Hinds EC, Girotti WJ. Vertical subcondylar osteotomy: a reappraisal. *J Oral Surg* 1967;24:164-70.
103. Jeter TS, Vansickels JE, Nishioka GJ. Intraoral open reduction with rigid internal fixation of mandibular subcondylar fractures. *J Oral Maxillofac Surg* 1988;11:13-6.
104. Ellis E, Reynolds ST, Park HS. A method to rigidly fix high condylar fractures. *Oral Surg Oral Med Oral Pathol* 1989;68:369-74.
105. Boyne PJ. Free grafting of traumatically displaced or resected mandibular condyles. *J Oral Maxillofac Surg* 1989;47:228-32.
106. Mikkonen P, Lindqvist C, Pihakari A, et al. Osteotomy-osteosynthesis in displaced condylar fractures. *Int J Oral Maxillofac Surg* 1989;18:267-70.
107. Hooley JR. Reduction of mandibular fractures by intraoral inferior border wiring. *J Oral Surg* 1969;27:87-91.
108. Paul JK. Intraoral open reduction. *J Oral Surg* 1968;26:516-22.
109. Rontal E, Meyerhoff W, Hohmann A. The transoral reduction of mandibular fractures. *Arch Otolaryngol* 1973;97:279-82.
110. Sazima HJ, Grafft ML, Fulcher CL. Transoral reduction of mandibular fractures. *J Oral Surg* 1971;29:247-54.
111. van Dijk L, Brons R, Bosker H. Treatment of mandibular fractures by means of stable internal wire fixation. *Int J Oral Surg* 1977;6:173-6.
112. Freilhofer HP Jr, Sailer HF. Experience with intraoral trans-osseous wiring mandibular fractures. *J Maxillofac Surg* 1973;1:248-52.
113. Takenoshita Y, Oka M, Tashiro H. Surgical treatment of fractures of the mandibular condylar neck. *J Craniomaxillofac Surg* 1989;17:119-24.
114. Ma S, Fang RH. Endoscopic mandibular angle surgery: a swine model. *Ann Plast Surg* 1994;33:473-5.
115. Jacobovitz J, Lee C, Trabulsky PP. Endoscopic repair of mandibular subcondylar fractures. *Plast Reconstr Surg* 1998;101:437-41.
116. Troulis MJ, Kaban LB. Endoscopic approach to the ramus/condyle unit: Clinical applications. *J Oral Maxillofac Surg* 2001;59:503-9.
117. Sandler NA. Endoscopic-assisted reduction and fixation of a mandibular subcondylar fracture: report of a case. *J Oral Maxillofac Surg* 2001;59:1479-82.
118. Miloro M. Endoscopic-assisted repair of subcondylar fractures. *Oral Surg Oral Med Oral Pathol Oral Radiol Endod* 2003;96:387-91.
119. Fisher IT, Cleaton-Jones PE, Lownie JF. Relative efficiencies of various wiring configurations commonly used in open reductions of fractures of the angle of the mandible. *Oral Surg Oral Med Oral Pathol* 1990;70:10-7.
120. Johansson B, Krekmanov L, Thomsson M. Miniplate osteosynthesis of infected mandibular fractures. *J Craniomaxillofac Surg* 1988;16:22-7.
121. Woo SL, Lothringer KS, Akeson WH, et al. Less rigid internal fixation plates: historical perspectives and new concepts. *J Orthop Res* 1984;1:431-49.
122. Bradley JC. Age changes in the vascular supply of the mandible. *Br Dent J* 1972;132:142-4.
123. Marciani RD. Invasive management of the fractured atrophic edentulous mandible. *J Oral Maxillofac Surg* 2001;59:792-5.
124. Amaratunga NA. A comparative study of the clinical aspects of edentulous and dentulous mandibular fractures. *J Oral Maxillofac Surg* 1988;46:3-5.
125. Bruce RA, Strachan DS. Fractures of the edentulous mandible: the Chalmers J. Lyons Academy study. *J Oral Surg* 1976;34:973-9.
126. Amaratunga NA. Mandibular fractures in children-A study of clinical aspects, treatment needs and complications. *J Oral Maxillofac Surg* 1988;46:637-40.
127. MacLennan WD, Simpson W. Treatment of fractured mandibular condylar processes in children. *Br J Plast Surg* 1965;18:423-7.
128. Krausen AS, Samuel M. Pediatric jaw fractures: indications for open reduction. *Otolaryngol Head Neck Surg* 1979;87:318-22.
129. Khosla M, Boren W. Mandibular fractures in children and their management. *J Oral Surg* 1971;24:116-21.
130. Walker DG. Facial development. *Ann R Coll Surg Engl*. 1957 Aug;21:90-118.
131. Kruger GO. *Textbook of oral surgery*. 3rd ed. St Louis (MO): C.V. Mosby; 1968.
132. Clark HB. *Practical oral surgery*. 2nd ed. Philadelphia (PA): Lea & Febiger; 1959.
133. Neal DC, Wagner W, Alpert B. Morbidity associated with teeth in the line of mandibular fractures. *J Oral Surg* 1978;36:859-62.
134. Kahnberg KE, Ridell A. Prognosis of teeth involved in the line of mandibular fractures. *Int J Oral Surg* 1979;8:163-72.
135. Schneider SS, Stern M. Teeth in the line of mandibular fractures. *J Oral Surg* 1971;29:107-9.
136. de Amaratunga NA. The effect of teeth in the line of mandibular fractures on healing. *J Oral Maxillofac Surg* 1987;45:312-4.
137. Shetty V, Freymiller E. Teeth in the line of fracture: a review. *J Oral Maxillofac Surg* 1989;47:1303-6.
138. Zallen RD, Curry IT. A study of antibiotic usage in compound mandibular fractures. *J Oral Surg* 1975;33:431-4.
139. Chole RA, Yee J. Antibiotic prophylaxis for facial fractures. *Arch Otolaryngol Head Neck Surg* 1987;113:1055-7.
140. Chuong R, Donoff RB, Guralnick WC. A retrospective analysis of 327 mandibular fractures. *J Oral Maxillofac Surg* 1983;41:305-9.
141. Mathog RH, Rosenberg Z. Complications in the treatment of facial fractures. *Otolaryngol Clin North Am* 1976;9:533-52.
142. Cannell H, Boyd R. The management of maxillofacial injuries in vagrant alcoholics. *J Maxillofac Surg* 1985;13:121-4.
143. Beckers HL. Treatment of initially infected mandibular fractures with bone plates. *J Oral Surg* 1979;37:310-3.
144. Abiose BO. Maxillofacial skeleton injuries in the western states of Nigeria. *Br J Oral Maxillofac Surg* 1986;24:31-9.
145. Dodson TB, Perrott DH, Kaban LB, Gordon NC. Fixation of mandibular fractures: a comparative analysis of rigid internal fixation and standard fixation technique. *J Oral Maxillofac Surg* 1990;48:362-6.
146. Tu HK, Tenhulzen D. Compression osteosynthesis of mandibular fractures: a retrospective study. *J Oral Maxillofac Surg* 1985;43:585-9.
147. Larsen OD, Nielsen A. Mandibular fractures. 1. An analysis of their etiology and location in 286 patients. *Scand J Plast Reconstr Surg* 1976;10:213-8.
148. Proffit WR, Vig KW, Turvey TA. Early fracture of the mandibular condyles: frequently an unsuspected cause of growth disturbances. *Am J Orthod* 1980;78:1-24.
149. Gilhuus-Moe O. Fractures of the mandibular condyle in the growth period. Histologic and autoradiographic observations in the contralateral, nontraumatized condyle. *Acta Odontol Scand* 1971;29:53-63.
150. Durkin JE, Heeley J, Irving JT. The cartilage of the mandibular condyle. *Oral Sci Rev* 1973;2:29-99.

151. Lund K. Mandibular growth and remodeling process after condylar fracture. A longitudinal roentgencephalometric study. *Acta Odontol Scand Suppl.* 1974;32:113–117.
152. Munro IR, Chen YR, Park BY. Simultaneous total correction of temporomandibular ankylosis and facial asymmetry. *Plast Reconstr Surg* 1986;77:517–29.
153. Dufuormental ML. Fractures of the mandible in the region of the joint. *Br Dent J* 1929;50:620–2.
154. Roushton MA. Growth of mandibular condyle in relation to some deformities. *Br Dent J* 1944;76:57–63.
155. Rowe NL. Ankylosis of the temporomandibular joint. *J R Col Surg Edinb* 1982;27:67–79.
156. Topazian RG. Etiology of ankylosis of the temporomandibular joint: analysis of 44 cases. *J Oral Surg* 1964;22:227–33.
157. Markey RG. Condylar trauma and facial asymmetry: an experimental study [thesis]. Seattle: University of Washington; 1974.
158. Kennedy JW, Kent JN. False aneurysm and partial facial paralysis secondary to mandibular fracture. *J Oral Surg* 1970;28:854–6.
159. Schmidseder R, Scheunemann H. Nerve injuries in fractures of the condylar neck. *J Maxillofac Surg* 1977;5:186–90.
160. Laws IM. Two unusual complications of fractured condyles. *Br J Oral Surg* 1967;5:51–9.
161. Martis C, Athanassiades S. Auriculotemporal syndrome (Freye's syndrome) secondary to fracture of the mandibular condyle. *Plast Reconstr Surg* 1969;44:603–4.

Management of Maxillary Fractures

Larry L. Cunningham Jr, DDS, MD

Richard H. Haug, DDS

The results of epidemiologic surveys on maxillary fractures differ with the politics and population density of the geographic region studied, the era in which the surveys were performed, the socioeconomic status of the population, and the institution whose experience was reviewed.¹⁻⁵ It is difficult to make generalized statements about the findings of these studies, but trends do exist, and these trends make it clear that maxillary fractures are more frequently associated with motor vehicle accidents and motorcycle accidents than with any other cause. Maxillary fractures most often occur in conjunction with other facial fractures and are most often associated with injuries such as lacerations, other facial fractures, orthopedic injury, and neurologic injury.^{1,2,5,6} Most maxillary fractures occur in young men aged 16 to 40 years; they are most common among patients between 21 and 25 years of age, and the risk of sustaining facial bone fractures increases as the age of the patient increases.⁶

History

Although maxillary fractures are commonly classified according to the Le Fort system, these fractures were described and treated thousands of years before René Le Fort was born. The first clinical examination of a maxillary fracture was recorded in 2500 BC in the Smith Papyrus.⁷ Many other early records

describe treatments for maxillary fractures or the iatrogenic fracture of the maxilla for therapeutic purposes. In 1822 Charles Fredrick William Reiche provided the first detailed treatise of maxillary fractures, entitled *De Maxillae Superioris Fractura*.⁷ In 1823 Carl Ferdinand van Graefe described the use of a head frame for treating a maxillary fracture.⁷ His device was as technically complex as those currently in use. In 1859 Bernhard R. K. Von Langenbeck described a technique for the osteoplastic resection of the maxilla.⁸ In 1867 David Cheever discussed complete mobilization of the maxilla with the use of chisels for the removal of a nasopharyngeal tumor.⁹ In 1893 Otto Lanz also described the creation of an iatrogenic maxillary fracture for access to a tumor.

It was not until 1901 that René Le Fort published his landmark works, a three-part experiment using 32 cadavers that were either intact or decapitated.¹⁰⁻¹² The heads of the cadavers were subjected to various types of trauma; the soft tissue was then removed and the bones were examined. Le Fort noted that, generally, if the face was fractured, the skull was not. He then stated that fractures occurred through three weak lines in the facial bony structure: those that protect the cranial cavity, those that circumscribe the midface, and those that cut across the face. From these three lines the Le Fort classification system was developed (Figure 23.1-1).

Le Fort Classification System

In his description of maxillary fractures Le Fort considered several factors: the vector

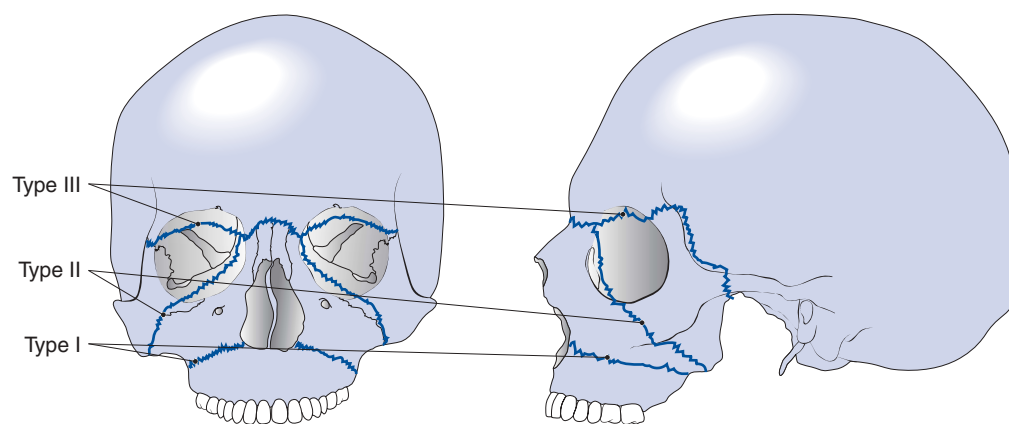


FIGURE 23.1-1 Anteroposterior and lateral views of the skull showing the Le Fort classification system of maxillary fractures.

of force overcoming the inertia of the face; the thickness of the bone and buttresses counteracting the mass, velocity, and point of application; and the maxilla, which he noticed was unaffected by muscle pull, unlike the long bones. These considerations resulted in a classification of three levels of fracture.

Le Fort I Level

Maxillary fractures at the Le Fort I level traverse the lateral antral wall, the lateral nasal wall, and the lower third of the septum, and they separate at the pterygoid plates. Thus, the entire mobilized segment consists of the maxillary alveolar bone, the palatine bone, the lower third of the nasal septum, and the lower third of the pterygoid plates. The superior two-thirds of these bones remain associated with the face.

Le Fort II Level

Maxillary fractures at the Le Fort II level involve most of the nasal bones, the maxillary bones, the palatine bones, the lower two-thirds of the nasal septum, the dentoalveolus, and the pterygoid plates. Unlike the horizontal separation noted in the Le Fort I fracture, the Le Fort II fracture is pyramidal in shape. The fracture extends from below the nasofrontal suture through the nasal bones along the maxilla to the zygomaticomaxillary suture and includes the medial inferior third of the orbit. The fracture then continues along the zygomaticomaxillary suture to and through the pterygoid plates. The septum is also separated superiorly. The segments may be intact below this line of fracture, but they are most often comminuted.

Le Fort III Level

Fractures at the Le Fort III level involve the nasal bones, the zygomas, the maxillae, the palatine bones, and the pterygoid plates. These fractures essentially separate the face along the base of the skull. The fracture line extends from the nasofrontal

suture along the medial wall of the orbit through the superior orbital fissure. It then extends along the inferior orbital fissure and the lateral orbital wall to the zygomaticofrontal suture. The zygomaticotemporal suture is also separated. The fracture then extends along the sphenoid bone, separating the pterygoid plates. The septum becomes separated at the cribriform plate of the ethmoid. Le Fort III fractures are most often comminuted. With highly comminuted fractures, patients may sustain fractures at more than one level. Virtually all combinations of Le Fort I, II, and III fractures are possible on either side of the face.

In Garretson's 1898 treatise the primary method of treating fractures of the maxillae was to construct a bandage or dressing that elevated the mandible into occlusion and secure it there.¹³ A number of materials were used to add stability to these bandages, including plaster of Paris, wood, gutta-percha, and vulcanized rubber. In addition to splinting the jaws Garretson advocated the use of interdental splints, stating "As a means of dressing in any complicated jaw fracture, the interdental splint is as invaluable and reliable as it is simple of construction and easy of application."¹³

Blair gave a very good description of the anatomy of maxillary fractures and of the examination for diagnosing such fractures.¹⁴ He noted that mandibular bandages were insufficient to stabilize maxillary fractures and advocated a maxillary splint, quoting an authority of the day, Dr. John L. Marshall:

Impressions of the upper and lower teeth were taken with the modeling compound by first molding it upon the upper teeth and while it was yet soft forcing the lower jaw upward until a correct occlusion of the teeth was obtained. This impression was trimmed to the desired shape; a

one-eighth-inch steel wire was imbedded in the sides on a line with the ends of the teeth, then bent backward upon itself opposite the cuspid teeth. . . . From this was constructed a hard-rubber splint, with the wires attached. . . . The splint is held in position by means of double elastic straps attached to the wire on each side and buckled to a close-fitting leather or net cap, which is reinforced with leather and laced firmly on the head. . . . The object of [the splint] was to furnish a sure guide to the normal position of the superior maxillae. Without this the correctness of the adjustment of the bones could not have been verified. Its importance therefore cannot be overestimated.¹⁴

Similar treatment modalities were presented by Brophy in 1918; he presented illustrations of the splints as well as preoperative and postoperative images of a patient.¹⁵

Anatomy

The two maxillae are paired structures connected by a midline suture; the bones together compose a five-sided pyramid. The anterior surface slopes downward from its superior contact with the frontal and nasal bones at an angle of approximately 15°. The most prominent point at the anterior surface is the anterior nasal spine. A number of protuberances exist on the maxilla, formed by the alveolar base and origins of the small facial muscles. The lateral surface of the maxillae forms the infratemporal fossae and buccal vestibule and attaches to the zygoma. Most of the superior surface forms the majority of the orbital floor.

The medial surface of each maxilla forms the midline suture and lateral nasal walls. This includes the nasal concha and

sinus ostia. The ostium of the nasolacrimal duct is beneath the inferior concha. The ostia of the maxillary sinus and middle ethmoids, as well as the opening of the nasofrontal duct, lie beneath the middle concha.

The inferior border composes the palatal vault and alveolus, which contain the teeth. The posterior border abuts the sphenoid bone and the pterygomaxillary suture.¹⁶ Within the maxilla is the maxillary sinus. This 34 × 33 × 25 mm air cavity is responsible for the weakness of the maxilla. The sinus is present at birth but does not pneumatize to its mature extent until the patient reaches 14 to 15 years of age. Minor changes in the sinus continue throughout life.¹⁷ The strong buttresses of the maxilla are the lateral piriform buttress, the zygomatic buttress, the greater palatine buttress, and the floor of the nose.

The palatine bone is L shaped and abuts the posterior maxilla as a paired structure. These bones assist the maxilla in forming the posterior sinus, the posterior lateral nasal wall, and the pterygomaxillary suture. When joined to the maxilla the four bones represent one unit (Figure 23.1-2).¹⁶

The nasal bones are paired structures that abut the frontal bone superiorly, the maxilla laterally, the septum posteriorly and medially, and each other anteriorly and medially. The bones are thicker superiorly;

therefore, fractures at the Le Fort II level may occur inferior to the nasofrontal suture. The nasal septum is a thin trapezoidal bone lying perpendicular to and joining the maxillae and palatine bones. The superior border is thick and articulates with the ethmoid bone.¹⁶

The ethmoid bone is cuboidal and extremely pneumatized; thus, it can be easily fractured and comminuted. The cribriform plate of the ethmoid composes the roof of the nasal cavity and communicates with the anterior cranial fossa through multiple foramina for the olfactory nerves. Lateral to the crista galli is a slit through which dura mater is exposed. Posterior and superior movements of the midface can easily comminute this bone, thus disrupting the dura mater and resulting in a cerebrospinal fluid leak.¹⁶

The zygoma abuts the frontal bone at the frontozygomatic suture and the temporal bone at the zygomaticotemporal suture. The maxilla and zygoma form two-thirds of the orbital rim and, along with the palatine bone, one-third of the walls and floor of the orbit.

The infraorbital nerve traverses the orbital floor and exits through the infraorbital foramen. The maxillary bone, along with the zygoma, forms the inferior orbital fissure. Through this fissure run the maxillary nerve, the infraorbital vessels, and

the ascending branches of the pterygopalatine ganglion. The frontal process of the maxilla contains the lacrimal apparatus, which is housed between the medial canthal ligaments.

The blood supply to the maxillae and palatine bones is through the periosteum, the incisive artery, and the greater and lesser palatine arteries. The internal maxillary artery, a source of potentially devastating hemorrhage, lies posterior to the maxillae and palatine bones and anterior to the pterygoid plates of the sphenoid.¹⁸ The blood supply to the nasal septum and the lateral nasal walls is provided by the anterior and posterior ethmoidal arteries, the sphenopalatine artery, and the greater palatine and superior labial arteries.¹⁶

Diagnosis

Clinical Examination

Advanced trauma life-support protocols should be followed for all patients who have suffered trauma. Detailed examination of maxillofacial fractures is completed in the secondary survey, after the primary survey and successful resuscitation have been completed. As has been done historically the clinical examination should begin with the initial observation of the patient, followed by palpation of the fractures.^{14,19} As was written by Blair in 1914, "...In all cases of injury of the face the dental arches and the palate should be inspected, and the facial bones outlined digitally."¹⁴ Lacerations, abrasions, and ecchymotic areas should be recorded. Periorbital ecchymosis and facial edema should be noted and are very typical of these fractures. Epistaxis with any evidence of cerebrospinal fluid leakage (clear fluid mixed with blood, "tram lines") should be identified. Asymmetry of the nose, traumatic telecanthus, a flat nasal bridge, and a dish-shaped face should all be noted. Intraorally the examiner may see fractured teeth, vestibular ecchymosis and edema, palatal ecchymosis, mucosal

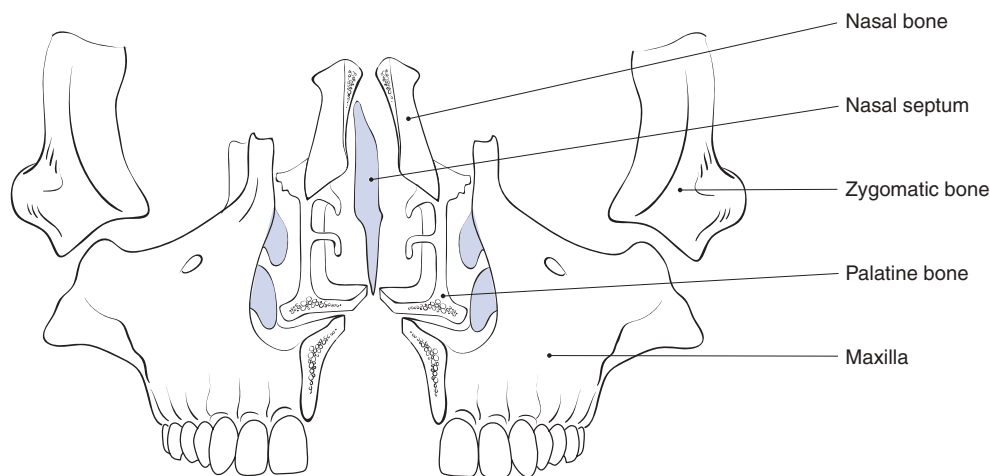


FIGURE 23.1-2 Disarticulated midfacial skeleton demonstrates the anatomy of the maxilla, the zygoma, the nasal bones, and the nasal septum.

lacerations and bleeding, steps or diastema in the maxillary teeth, and malocclusion.

The skeletal framework of the face should be carefully palpated. With respect to the maxilla, the alveolus should be palpated and any fractures or mobility noted. The examiner should also observe the maxilla for movement as a unit, while palpating the forehead, the nasal bridge, and the zygomaticofrontal sutures. The nose should be examined grossly for contour irregularity (Figure 23.1-3). A nasal speculum should be used to identify compound fractures of the septum or septal hematoma. Both hands should be used to palpate the orbital rims and in particular the zygomaticomaxillary suture. The intraoral examination should be complete, and the examiner should note accumulation of blood, debris, or avulsed teeth that could compromise the airway, as well as the presence of laceration, abrasion, or ecchymosis. Abnormal occlusion with an anterior open bite and posterior prematurities should be noted and correlated with

pretraumatic occlusion if possible (family members, photographs, dental records).

Imaging

Fractures are identified clinically and confirmed radiographically. In the past the Waters' view and lateral facial radiographs were used in identifying maxillary fractures and may still be used today in remote areas without access to a computed tomography (CT) scanner (Figure 23.1-4). Fine details of the fracture sites are difficult to visualize. Axial and coronal CT scans of the midface should be obtained if a scanner is available (Figure 23.1-5). If clinical evidence strongly indicates maxillary fracture (midface mobility and malocclusion with intact mandible), then CT imaging is a confirmatory test for maxillary fractures. Important indications for CT scanning are suspected orbital floor fractures (best diagnosed in the coronal view) and surgical planning. CT scans can also demonstrate the soft tissue differences of hematoma or edema of the subcutaneous tissue, muscle, and fat. For severe

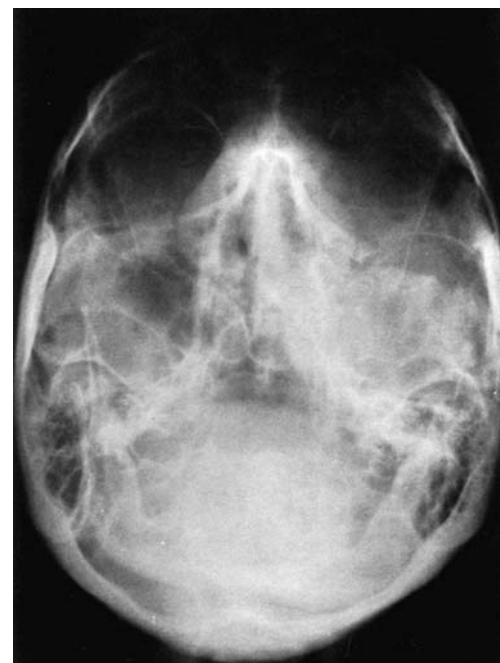

FIGURE 23.1-4 Waters' radiograph for evaluation of maxillary fractures.

midface trauma or maxillary displacement, the three-dimensional CT scan is a valuable tool (Figure 23.1-6).

Treatment

Patients do not die of maxillary fractures, but they may die of concomitant injury or failure to manage the sequelae of maxillary fractures. As is true for all injuries initial attention should be directed at establishing an airway and controlling hemorrhage. The most frequent cause of hemorrhage in Le Fort level fractures is a fractured septum. This bleeding may be addressed by placing nasal packs of one of a number of materials, including gauze packing, Mero-cel packing (Medtronic Xomed), Rhinorocket (Shippert Medical Technologies Corp.), and Epistat (Medtronic Xomed). Bleeding from sites of laceration or abrasion may be controlled by tamponade. Exsanguinating hemorrhage is rarely encountered with facial fractures; however, its occasional occurrence has long been noted: "Hemorrhage, which is not readily amenable to successful treatment, as in the case of rupture of the internal maxillary artery or its terminal branches, may be

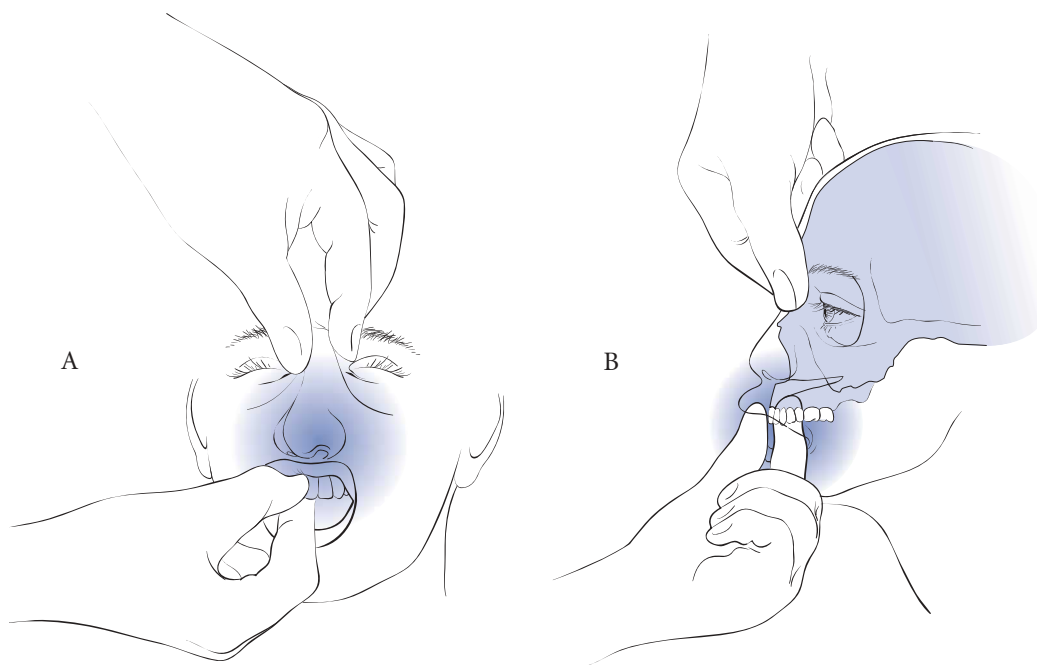


FIGURE 23.1-3 A, B, When the maxilla is examined for fracture the head is stabilized and the dentoalveolar process is manipulated so that gross movements of fractured segments can be detected. Checking for Le Fort II or III fractures requires that one hand holds the bridge of the nose while the other manipulates the maxilla. Movement at the nasofrontal suture suggests a Le Fort II or III fracture.

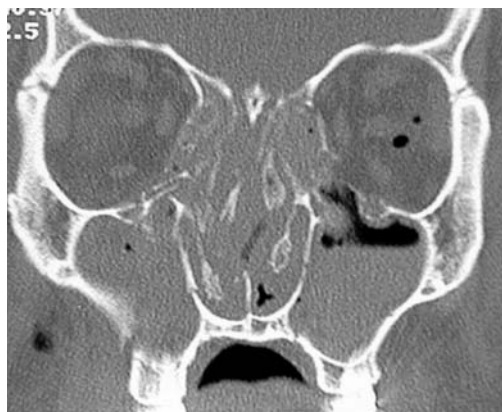

FIGURE 23.1-5 Computed tomography scan of midface trauma, including maxillary fracture.

followed by fatal results.¹⁵ Should uncontrollable bleeding be encountered, the patient should undergo angiographic evaluation with embolization of the injured artery if indicated.^{20–24} At least one group has suggested caution in the use of embolization because of the possible crossover of the embolic material between the external and internal carotid circulation.²⁵

Maxillary fractures isolated to the dentoalveolar process and involving bone should be manually reduced and rigidly fixated with arch bars and ligature wires. If the segment is too large to be stabilized with arch bars alone, acrylic can be added

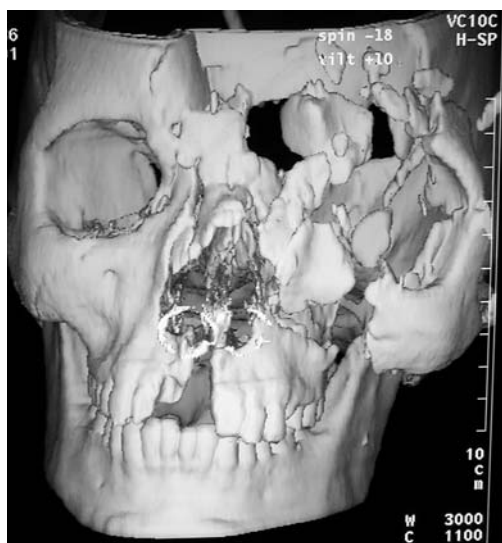

FIGURE 23.1-6 Three-dimensional computed tomography scans give an overall view of the injuries and offer valuable information.

to the facial surface of the arch bar, or an occlusal splint can be constructed and secured in place. Complications include bone resorption, ankylosis of teeth, external root resorption, and tooth loss.^{26,27}

In more extensive injuries the sequence of treatment of maxillary fractures depends largely on the associated injuries. Nasotracheal intubation is preferred when it is not contraindicated by the need for complicated repair of nasal and nasoethmoidal injuries. In such cases a submental intubation technique can be used^{28–32}; tracheotomy is a final option (Figure 23.1-7). After the airway has been secured and general anesthesia has been administered, arch bars should be placed, along with any required splints or stents. If teeth are deemed unsalvageable they should be removed at this time. The sequence of treatment depends on the surgeon's philosophy and the presence of other facial fractures. Whether the surgeon prefers to work from the "bottom up" or from the "outside in," anterior projection of the maxilla is most easily obtained when the mandible is intact. For this reason strong consideration should be given to the repair of any mandible fracture before the maxilla is stabilized. Intermaxillary fixation (to an intact mandible) is the most reliable technique for establishing anterior projection of the maxilla (Figure 23.1-8).

Although many wiring techniques have been described in the past, rigid internal fixation is the standard of care.^{19,33–36} The maxilla should be stabilized to the next highest stable facial structure, which varies with Le Fort fracture level. At the Le Fort I level, fixation is placed along the vertical buttresses of the maxilla at the piriform and zygomatic buttresses. At higher Le Fort levels it may be necessary to use fixation to the nasal bones, the orbital rims, or the zygomaticofrontal sutures. Although Le Fort levels are frequently referred to in discussions of patient treatment, high-quality CT scans and widespread use of rigid fixation have

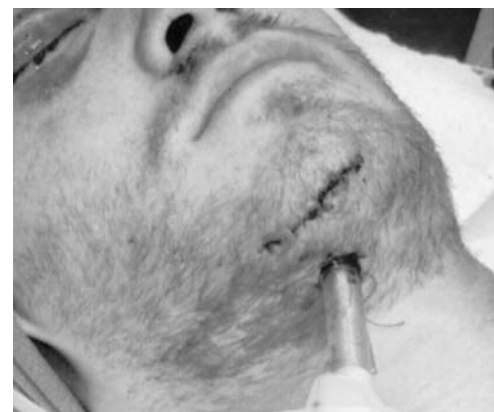

FIGURE 23.1-7 The patient's airway is protected by using a submental intubation technique.

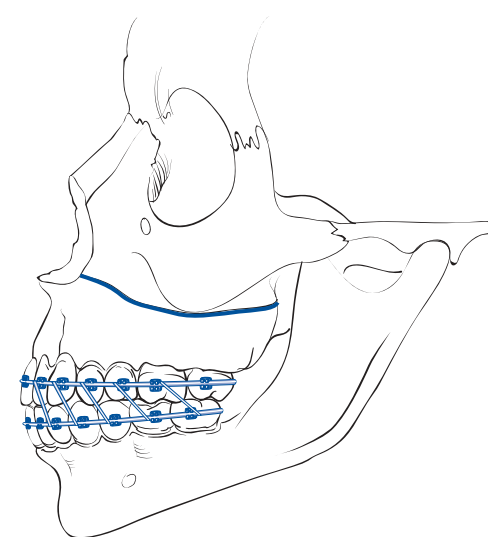


FIGURE 23.1-8 Arch bars and intermaxillary fixation are shown.

led to the treatment of multiple facial fractures as separate units. For example, a Le Fort I/II fracture would be treated as a Le Fort I fracture, a left orbital fracture, or a left zygomaticomaxillary complex fracture. In these cases it is advisable to restore midface projection with the repair of orbital or zygomatic fractures before fixation of the maxilla.

Contemporary bone plates and screws are made of titanium. For maxillary reconstruction these plates must be of sufficient rigidity to overcome the effects of gravity; the forces of mastication are resisted by bone contact. For this purpose screws with an outer diameter of 1.5 mm are adequate.

In areas such as the orbital rim or nasal bone, 1.3 mm or 1.0 mm systems may be used. In cases in which bone contact is decreased because of comminution, 1.7 mm or 2.0 mm systems may be used.

If resistance is encountered during mobilization of the maxilla, Rowe disimpaction forceps may be used to help reduce the fracture (Figure 23.1-9). The paired forceps are placed with the fat end in the nose and the bowed end on the palate. The surgeon stands over the patient's head and in an inferior-anterior movement disimpacts the maxilla. Further assistance may be provided with Hayton-Williams forceps used in conjunction with the Rowe disimpaction forceps.

If the maxillary fracture is incomplete (eg, greenstick fracture), the surgeon may have difficulty in mobilizing the maxilla. The fractured hemimaxilla may be impacted or telescoped, causing severe malocclusion with minimal mobility. In a

case such as this, severe difficulty with disimpaction of Le Fort level fractures can be easily overcome by completing the fracture with an osteotomy. This concept is not as novel as it might sound; in 1914, Blair wrote, "...if the impaction cannot be broken up... resort may be had to a small, sharp chisel."¹⁴ After down-fracture the maxilla can easily be moved into appropriate occlusion and stabilized without further difficulty (Figure 23.1-10).

Immediate bone grafting has been advocated for the severely comminuted maxillary antrum.³⁷ This treatment prevents prolapse of the facial soft tissue into the maxillary sinus and the facial deformation that results. Titanium mesh works well for this procedure; it is malleable, can be quickly fixated, resists pressure of the soft tissues of the face, becomes osseointegrated, and allows regrowth of the native tissue (ie, ciliated respiratory epithelium, goblet cells, squamous epithelium) (Figure 23.1-11).³⁸

Surgical Splints

In cases of gross comminution, periodontal disease, or inadequate partial dentition (less than three occluding teeth per sextant), occlusal wafers or palatal splints are useful. These splints are fabricated after impressions have been taken and model surgery has been completed. When an occlusal wafer is fabricated it should cover the occlusal surfaces and the heights of contour, but it should not encroach on the soft tissues. Holes should be placed between occlusal surfaces in the splint so that it may be ligated separately to the arch bar, as might be done with an orthognathic surgical splint.

The Gunning's splint has been used to establish intermaxillary fixation for edentulous patients; this splint is essentially a denture baseplate fabricated to the existing edentulous or partially edentulous ridge with arch bars or suspension brackets.³⁹ Dentures can also be secured to the jaws

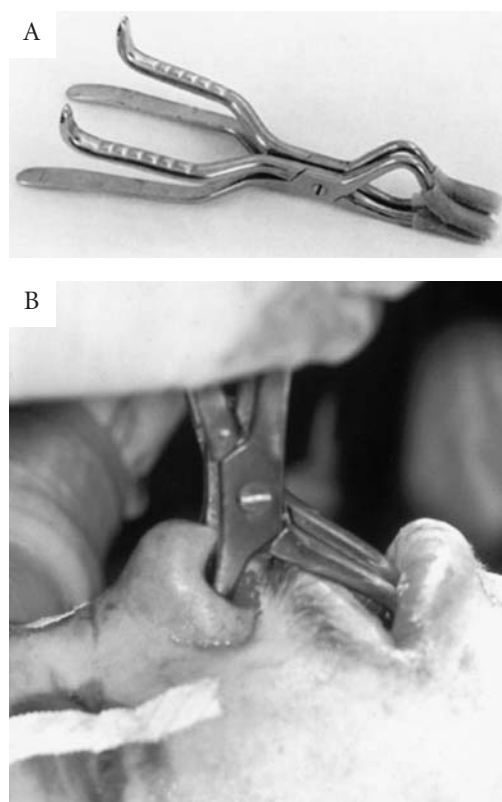


FIGURE 23.1-9 A, Rowe disimpaction forceps. B, Application of the forceps.

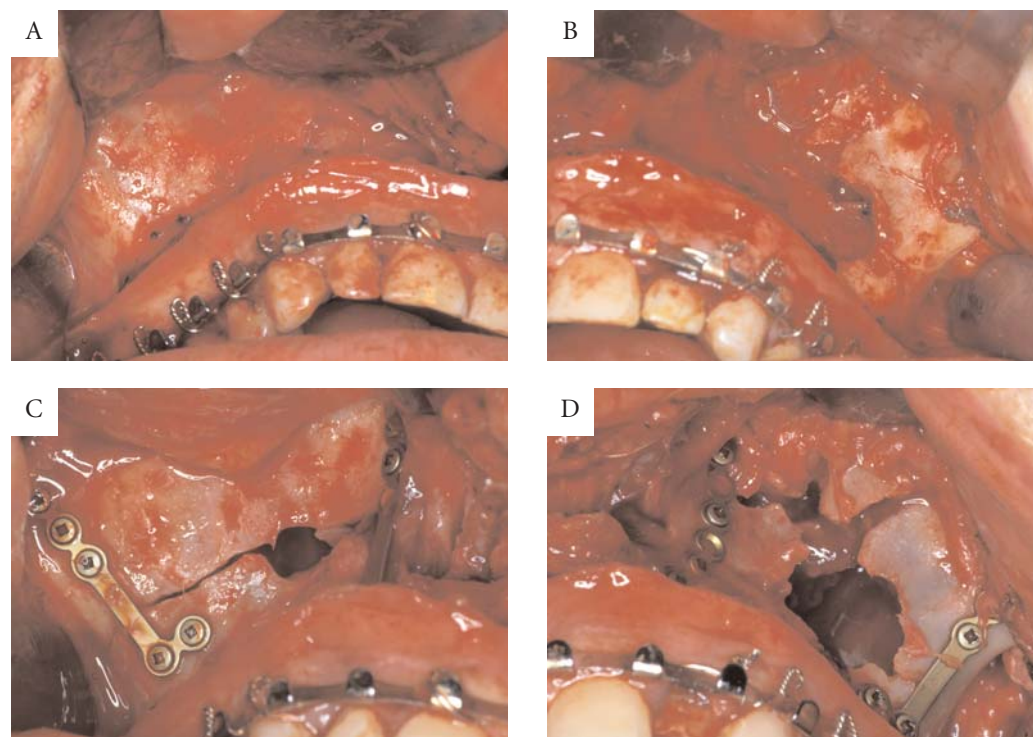


FIGURE 23.1-10 A, B, Clinical images showing an unfractured right maxillary antrum and a comminuted telescoped left maxillary fracture that was very difficult to reduce. C, D, After an osteotomy was performed at the Le Fort I level on the right side, the maxilla could be easily mobilized, and the fracture was reduced and fixated without further difficulty.

with bone screws before intermaxillary fixation is attempted.

Special Considerations

High-Force or Avulsive Injuries High-caliber high-velocity gunshot wounds, blast injuries, and high-speed motor vehicle accidents with unrestrained victims cause most avulsion injuries associated with maxillary fractures. The priority in treating these injuries is to preserve as much of the remaining tissue as possible. Consideration and administration of a narrow-spectrum antibiotic directed at oral and nasal contaminants, as well as tetanus prophylaxis, are a priority in these injuries. As is true for all injuries these wounds should be thoroughly evaluated for bleeding, foreign bodies, and extent of damage. Extensive irrigation with pulsed fluids should be used to remove debris.

Life-threatening hemorrhage should be addressed early for homeostasis and for airway management.⁴⁰ Hemorrhage that cannot be controlled by local measures such as packing (anterior and posterior) and electrocautery is an indication for angiography and embolization of the injured artery or arteries. Because of the collateral blood supply of the face, most tissues remain viable with only a small isthmus of blood supply. Fractures should be repaired with rigid fixation. Voids in bone should be addressed with a secondary reconstruction. Multiple lacerations with comminuted fractures will be associated with edema and substantial venous congestion. This tissue may provide satisfactory blood supply to existing segments but not to large bone grafts. Next the soft tissue lacerations should be addressed. Advancement flaps should be used only to cover exposed bone or to correct oronasal or oroantral fistulas. If too little soft tissue exists, flaps should not be advanced; such repairs should be addressed during a secondary reconstruction. Consideration should be given

to the use of vascularized free flaps in this situation.²⁰

For cases of avulsion, whether free flaps are used or not, implant reconstruction should be considered. Implants with obturators can be used, as is often seen in partial maxillectomy after tumor resection. Implant restorations can also be placed in bone from composite flap reconstructions.⁴¹

Injuries to Geriatric Patients Geriatric patients who suffer a Le Fort injury pose a special concern. Additional medical illnesses and disabilities may render general anesthesia quite risky for these patients. The surgeon should exercise judgment when morbid medical conditions coexist with minimally displaced fractures in edentulous patients. A new prosthesis may be more effective than reduction and fixation of the fracture.

The geriatric maxilla is less vascular and has more pneumatized antra, less alveolar bone, and less dense trabeculation. Should reduction and fixation be required, existing dentures may be modified by relining and affixing arch bars or intermaxillary fixation buttons. A Gunning's splint may also be fabricated. Such a splint may be fixed to the zygoma, the anterior nasal spine, the piriform rim, or the palate, either with wires or cortical bone screws.

Pediatric Maxillary Fractures Pediatric maxillary fractures occur infrequently. Because the pediatric sinuses are not highly pneumatized, these fractures tend to be less comminuted in children than in adults. No long-term studies have been undertaken with populations large enough to determine what alterations in maxillary growth will occur after pediatric maxillary fractures. When fixation is undertaken, consideration should be given to the contour and the root length of the primary dentition. The use of occlusal splints and skeletal fixation should be entertained.

Resorbable plating systems have been advocated for use in pediatric patients so

that potential complications of translocation, extrusion, and growth restriction can be avoided.^{42,43} Triana and Shockley reported the use of an L-lactic acid and glycolic acid resorbable plating system; advantages of the system include ease of contouring the plates, appropriate rigidity of the systems, resorption within 12 months, no increased risk of postoperative wound infection, and the apparent absence of growth restriction.⁴²

Complications

Complications associated with maxillary fractures and their repair are listed in Table 23.1-1. A number of these complications may not be readily apparent until weeks or months after injury, but the potential for their occurrence should be borne in mind during evaluation and treatment of the patient.

Perioperative and postoperative airway obstructions are unusual in cases of maxillary fracture alone. However, these conditions may occur in association with

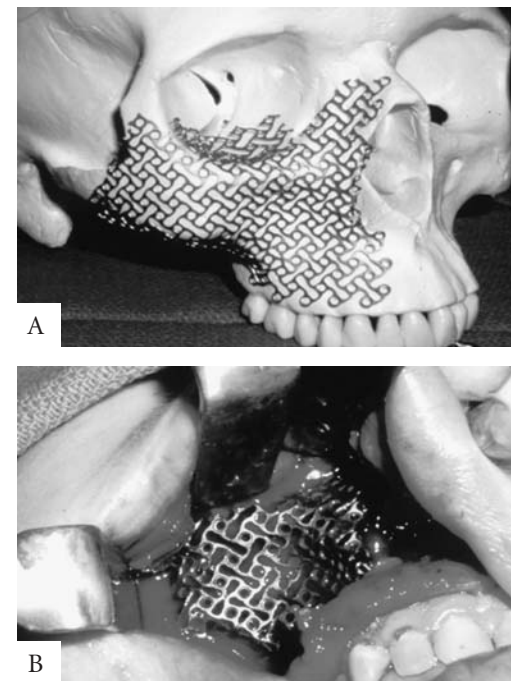


FIGURE 23.1-11 A, Titanium mesh is preformed before it is sterilized and used in maxillary reconstruction. Reproduced with permission from Haug RH et al.⁵¹ B, Intraoperative view of the use of titanium mesh.

Table 23.1-1 Complications Associated with Maxillary Fractures

Infraorbital nerve paresthesia
Enophthalmos
Infection
Exposed hardware
Deviated septum
Nasal obstruction
Altered vision
Nonunion
Malunion or malocclusion
Epiphora
Foreign body reactions
Scarring
Sinusitis

Adapted from Haug RH et al.⁵²

extubation while the patient is obtunded, with a septal hematoma or nasal packing, and with excessively edematous soft tissues that do not allow breathing through the nasal airways. Patients with intermaxillary fixation and complete dentition may have difficulty breathing during this time. Reintubation, opening nasopharyngeal airways, or merely removing the intermaxillary fixation may be effective. Uncorrected nasal septal fractures can lead to postoperative airway obstruction that remains after all soft tissue swelling has resolved. Acute sinusitis can result from prolonged nasotracheal intubation.⁴⁴ Acute or chronic sinusitis may also occur in the ethmoid, sphenoid, frontal, and maxillary sinuses because fractures may obliterate or obstruct the sinus ducts or ostia.

Postoperative hemorrhage occurs if arterioles and veins are not ligated when lacerations are repaired, if inadequate bone reduction allows continued oozing of blood, if an aneurysm is present, or if an artery is partially transected. Lacerations should be reexplored so that hemorrhage can be controlled. Hematomas should be drained. Oozing of blood from bone requires re-reduction or the use of bone wax. Hemorrhage from a major artery requires emergency tamponade; if the

source cannot be identified, then arteriography and embolization are indicated. Aneurysms and pseudoaneurysms are complications of maxillofacial trauma but rarely occur as the result of isolated maxillary fractures. They can also result in postoperative bleeding and are indications for angiography and embolization.⁴⁵

Because of the proximity of the maxilla to the orbits, complications associated with vision can occur. Blindness is rarely associated with midface fractures and is most often seen in fracture patterns involving the orbit, often with a more severe mechanism of injury.⁴⁶ Immediate postoperative blindness can be a complication of the reduction of high Le Fort fractures (Le Fort III or fractures involving the orbits) and occurs because of increased intraorbital hemorrhage or pressure, a retinal artery spasm, retrobulbar hemorrhage, or the impingement of bone fragments on the optic nerve.⁴⁷ An undiagnosed or inadequately treated orbital floor fracture (alone or in combination with a zygomatic component) can lead to enophthalmos and diplopia.

The most obvious postoperative complications are misplaced bone segments or fixation devices. These complications are readily identified by clinical examination (eg, malocclusion) or postoperative radiographic examinations. A second surgical procedure will correct such complications. Other complications related to rigid internal fixation include palpability, infection, extrusion or exposure, translocation, stress shielding, cortical osteopenia, and nonunion.^{48,49} Nonunion of the fractured segments can occur as the result of inadequate blood supply, inaccurate position, movement of segments, infection, or nutritional deficiencies.⁵⁰ Infections may be caused by contaminated soft tissue lacerations or foreign bodies, hematomas, or odontogenic infections from previously diseased or fractured teeth. Infection around bone plates and screws can occur years after their placement.

Malunion of maxillary fractures can obstruct the nasolacrimal ducts. This obstruction causes epiphora and may lead to episodes of dacryocystitis. Bone segments from fractured or improperly reduced maxillary fractures can also impinge on the infraorbital nerve, causing numbness of the distribution of the second division of the trigeminal nerve.

Although the reduction and fixation of maxillary fractures may at times seem straightforward, the proximity of complicated anatomic structures and the consequences of inaccurate repair make it incumbent on the surgeon to follow sound surgical principles in the management of these fractures.

Acknowledgments

The authors thank Flo Witte, MA, ELS, for her expert editorial assistance.

References

1. Haug RH, Prather J, Indresano AT. An epidemiologic survey of facial fractures and concomitant injuries. *J Oral Maxillofac Surg* 1990;48:926–32.
2. Turvey TA. Midfacial fractures: a retrospective analysis of 593 cases. *J Oral Surg* 1977; 35:887–91.
3. Kelly DE, Harrigan WF. A survey of facial fractures: Bellevue Hospital, 1948–1974. *J Oral Surg* 1975;33:146–9.
4. Adekeye EO. The pattern of fractures of the facial skeleton in Kaduna, Nigeria. A survey of 1,447 cases. *Oral Surg Oral Med Oral Pathol* 1980;49:491–5.
5. Iida S, Kogo M, Sugiura T, et al. Retrospective analysis of 1502 patients with facial fractures. *Int J Oral Maxillofac Surg* 2001;30:286–90.
6. Gassner R, Tuli T, Hachl O, et al. Cranio-maxillofacial trauma: a 10 year review of 9,543 cases with 21,067 injuries. *J Cranio-maxillofac Surg* 2003;31:51–61.
7. Dingman RO, Natvig P. The men of elder days. In: Dingman RO, Natvig P, editors. *Surgery of facial fractures*. Philadelphia (PA): W.B. Saunders; 1964. p. 29–35.
8. Drommer RB. The history of the “Le Fort I osteotomy.” *J Maxillofac Surg* 1986; 14:119–22.
9. Moloney F, Worthington P. The origin of the Le Fort I maxillary osteotomy: Cheever’s operation. *J Oral Surg* 1981;39:731–4.

10. Le Fort R. Etude experimentale sur les fractures de la machoire superieure. *Rev Chir* 1901; 23:208–27.
11. Le Fort R. Etude experimentale sur les fractures de la machoire superieure. *Rev Chir* 1901;23:360–79.
12. Le Fort R. Etude experimentale sur les fractures de la machoire superieure. *Rev Chir* 1901;23:479–507.
13. Garretson JE. A system of oral surgery and dentistry being a treatise on the diseases and surgery of the mouth, jaws, face, teeth and associate parts. London: J.B. Lippincott Co.; 1898. p. 1084.
14. Blair VP. Surgery and diseases of the mouth and jaws. St. Louis (MO): C.V. Mosby Co.; 1914. p. 603.
15. Brophy TW. Oral surgery: a treatise on the diseases, injuries and malformations of the mouth and associated parts. Philadelphia (PA): P. Blakiston's Son & Co.; 1918. p. 1090.
16. Williams PL, Bannister LH, Berry MM, et al. Gray's anatomy: the anatomical basis of medicine and surgery. New York (NY): Churchill Livingstone; 1995. p. 2092.
17. Salentijn L. Anatomy and embryology. In: Blitzed A, Lawson W, Freidman W, editors. Surgery of the paranasal sinuses. Vol 1. Philadelphia (PA): W.B. Saunders; 1985. p. 13–5.
18. Turvey TA, Fonseca RJ. The anatomy of the internal maxillary artery in the pterygopalatine fossa: its relationship to maxillary surgery. *J Oral Surg* 1980;38:92–5.
19. Rowe NL, Killey HC. Fractures of the facial skeleton. Edinburgh and London: E. & S. Livingstone Ltd.; 1955. p. 923.
20. Cunningham LL, Haug RH, Ford J. Firearm injuries to the maxillofacial region: an overview of current thoughts regarding demographics, pathophysiology, and management. *J Oral Maxillofac Surg* 2003; 61:932–42.
21. Hadfield PJ, Gane SB, Leighton SE. Epistaxis due to traumatic internal carotid artery aneurysm. *Int J Pediatr Otorhinolaryngol* 2002;66:193–6.
22. Kerwin AJ, Bynoe RP, Murray J, et al. Liberalized screening for blunt carotid and vertebral artery injuries is justified. *J Trauma* 2001;51:308–14.
23. Luo CB, Teng MM, Lirng JF, et al. Endovascular embolization of intractable epistaxis. *Zhonghua Yi Xue Za Zhi (Taipei)* 2000;63:205–12.
24. Borsa JJ, Fontaine AB, Eskridge JM, et al. Transcatheter arterial embolization for intractable epistaxis secondary to gunshot wounds. *J Vasc Interv Radiol* 1999;10:297–302.
25. Ardekian L, Samet N, Shoshani Y, Taicher S. Life-threatening bleeding following maxillofacial trauma. *J Craniomaxillofac Surg* 1993;21:336–8.
26. Dewhurst SN, Mason C, Roberts GJ. Emergency treatment of orodental injuries: a review. *Br J Oral Maxillofac Surg* 1998;36:165–75.
27. Dale RA. Dentoalveolar trauma. *Emerg Med Clin North Am* 2000;18:521–38.
28. Ball DR, Clark M, Jefferson P, Stewart T. Improved submental intubation. *Anaesthesia* 2003;58:189.
29. Johnson TR. Submental intubation versus tracheostomy. *Br J Anaesth* 2002;89:344–5.
30. Caron G, Paquin R, Lessard MR, et al. Submental endotracheal intubation: an alternative to tracheotomy in patients with midfacial and panfacial fractures. *J Trauma* 2000;48:235–40.
31. Nwoku AL, Al Balawi SA, Al Zahrani SA. A modified method of submental oroendotracheal intubation. *Saudi Med J* 2002;23:73–6.
32. Chandu A, Smith AC, Gebert R. Submental intubation: an alternative to short-term tracheostomy. *Anaesth Intensive Care* 2000;28:193–5.
33. Haug RH, Indresano AT. Management of maxillary fractures. In: Peterson LJ, editor. Principles of oral and maxillofacial surgery. Vol 1. Philadelphia (PA): J.B. Lippincott Co.; 1992. p. 469–88.
34. Sherman MJ. Intraoral reduction of maxillary fractures by malar suspension. *J Oral Surg* 1955;13:321.
35. Thoma K. Methods of fixation of the jaws and their indications. *Oral Surg* 1948;6:125–34.
36. Adams WM. Internal wiring fixation of facial fractures. *Surgery* 1942;12:523–40.
37. Gruss JS, Phillips JH. Complex facial trauma: the evolving role of rigid fixation and immediate bone graft reconstruction. *Clin Plast Surg* 1989;16:93–104.
38. Schubert W, Gear AJ, Lee C, et al. Incorporation of titanium mesh in orbital and midface reconstruction. *Plast Reconstr Surg* 2002;110:1022–32.
39. Chalian VA. Maxillofacial problems involving the use of splints and stents. In: Laney WR, editor. Maxillofacial prosthetics. Littleton (MA): PSG Publishing Co.; 1979. p. 216–9.
40. Ng M, Saadat D, Sinha UK. Managing the emergency airway in Le Fort fractures. *J Craniomaxillofac Trauma* 1998;4:38–43.
41. Hayter JP, Cawood JI. Oral rehabilitation with endosteal implants and free flaps. *Int J Oral Maxillofac Surg* 1996;25:3–12.
42. Triana RJ Jr, Shockley WW. Pediatric zygomatico-orbital complex fractures: the use of resorbable plating systems. A case report. *J Craniomaxillofac Trauma* 1998;4:32–6.
43. Haug RH, Cunningham LL, Brandt MT. Plates, screws and children: their relationships in craniomaxillofacial trauma. *J Long Term Eff Med Implants* 2003;13:271–87.
44. Bell RM, Page GV, Bynoe RP, et al. Post-traumatic sinusitis. *J Trauma* 1988;28:923–30.
45. Cunningham LL Jr, Van Sickels J, Brandt MT. Angiographic evaluation of the head and neck. *Atlas Oral Maxillofac Surg Clin North Am* 2003;11:73–86.
46. Ashar A, Kovacs A, Khan S, Hakim J. Blindness associated with midfacial fractures. *J Oral Maxillofac Surg* 1998;56:1146–51.
47. Giroto JA, Gamble WB, Robertson B, et al. Blindness after reduction of facial fractures. *Plast Reconstr Surg* 1998;102:1821–34.
48. Bhanot S, Alex JC, Lowlicht RA, et al. The efficacy of resorbable plates in head and neck reconstruction. *Laryngoscope* 2002;112:890–8.
49. Iizuka T, Lindqvist C. Rigid internal fixation of mandibular fractures. An analysis of 270 fractures treated using the AO/ASIF method. *Int J Oral Maxillofac Surg* 1992;21:65–9.
50. Rowe NL. Nonunion of the mandible and maxilla. *J Oral Surg* 1969;27:520–9.
51. Haug RH, Jenkins WS, Brandt MT. Advances in plate and screw technology: thought on design and clinical applications. *Semin Plast Surg* 2002;16:219–27.
52. Haug RH, Bradrick JP, Morgan JP. Complications in the treatment of midface fractures. In: Kaban LB, Pogrel MA, Perrott DH, editors. Complications in oral and maxillofacial surgery. Philadelphia (PA): W.B. Saunders; 1997. p. 153.

Management of Zygomatic Complex Fractures

Jonathan S. Bailey, DMD, MD

Michael S. Goldwasser, DDS, MD

The zygoma articulates with the frontal, sphenoid, temporal, and maxillary bones and contributes significantly to the strength and stability of the midface. The forward projection of the zygoma causes it to be injured frequently.¹ The zygoma may be separated from its four articulations. This is called a zygomatic complex fracture. The terms *trimalar* or *tripod fracture* are therefore inaccurate. These terms reflect an inability to easily identify the orbital (zygomaticosphenoid) portion of the injury before the advent of computed tomography (CT). The zygomatic arch may be fractured independently or as part of a zygomatic complex fracture.

The cause of zygomatic injuries varies with patient demographics and the location of the reporting institution. Matsunaga and Simpson at Los Angeles County/University of Southern California Medical Center found that a majority of the 1,200 zygomatic fractures studied were the result of motor vehicle accidents (MVAs).² In contrast, Ellis and colleagues found that 80% of zygomatic fractures in Glasgow, Scotland, resulted from assaults, falls, or sports injuries. Only approximately 13% of fractures in this series involved MVAs.³

In this chapter, the anatomic features, diagnosis, management, and com-

plications of zygomatic complex fractures are discussed.

Surgical Anatomy

The zygoma has four projections, which create a quadrangular shape: the frontal, temporal, maxillary, and the infraorbital rim. The zygoma articulates with four bones: the frontal, temporal, maxilla, and sphenoid. A zygomatic complex fracture includes disruption of the four articulating sutures: zygomaticofrontal, zygomaticotemporal, zygomaticomaxillary, and the zygomaticosphenoid sutures (Figure 23.2-1A and B).

All zygomatic complex fractures involve the orbital floor, and therefore an understanding of orbital anatomic features is essential for those treating these injuries. The orbit is a quadrilateral pyramid that is based anteriorly. The orbital floor slopes inferiorly and is the shortest of the orbital walls, averaging 47 mm.⁴ It is composed of the orbital plate of the maxilla, the orbital surface of the zygomatic bone, and the orbital process of the palatine bone.

The medial and lateral walls converge posteriorly at the orbital apex. The medial wall consists of the frontal process of the maxilla, the lacrimal bone, the orbital plate of the ethmoid, and a

small portion of the sphenoid body. The lateral orbital wall is the thickest and is formed by the zygoma and the greater wing of the sphenoid.

The orbital roof is composed of the frontal bone and lesser wing of the sphenoid (Figure 23.2-1C).

The zygomatic arch includes the temporal process of the zygoma and the zygomatic process of the temporal bone. The glenoid fossa and articular eminence are located at the posterior aspect of the zygomatic process of the temporal bone.

The sensory nerve associated with the zygoma is the second division of the trigeminal nerve. The zygomatic, facial, and temporal branches exit the foramina in the body of the zygoma and supply sensation to the cheek and anterior temporal region. The infraorbital nerve passes through the orbital floor and exits at the infraorbital foramen (see Figure 23.2-1C). It provides sensation to the anterior cheek, lateral nose, upper lip, and maxillary anterior teeth. Muscles of facial expression originating from the zygoma include the zygomaticus major and labii superioris. They are innervated by cranial nerve VII. The masseter muscle inserts along the temporal surface of the zygoma and arch and is innervated by

a branch of the mandibular nerve (see Figure 23.2-1A).

The temporalis fascia attaches to the frontal process of the zygoma and zygomatic arch (Figure 23.2-1D). The fascia produces resistance to inferior displacement of a fractured fragment by the downward pull of the masseter muscle.

The position of the globe in relation to the horizontal axis is maintained by Lockwood's suspensory ligament. This attaches medially to the posterior aspect of the lacrimal bone and laterally to the orbital (Whitnall's) tubercle (which is 1 cm below the zygomaticofrontal suture on the medial aspect of the frontal

process of the zygoma). The shape and location of the medial and lateral canthi of the eyelid are maintained by the canthal tendons. The lateral canthal tendon is attached to Whitnall's tubercle. The medial canthal tendon is attached to the anterior and posterior lacrimal crests. Zygomatic complex fractures are often

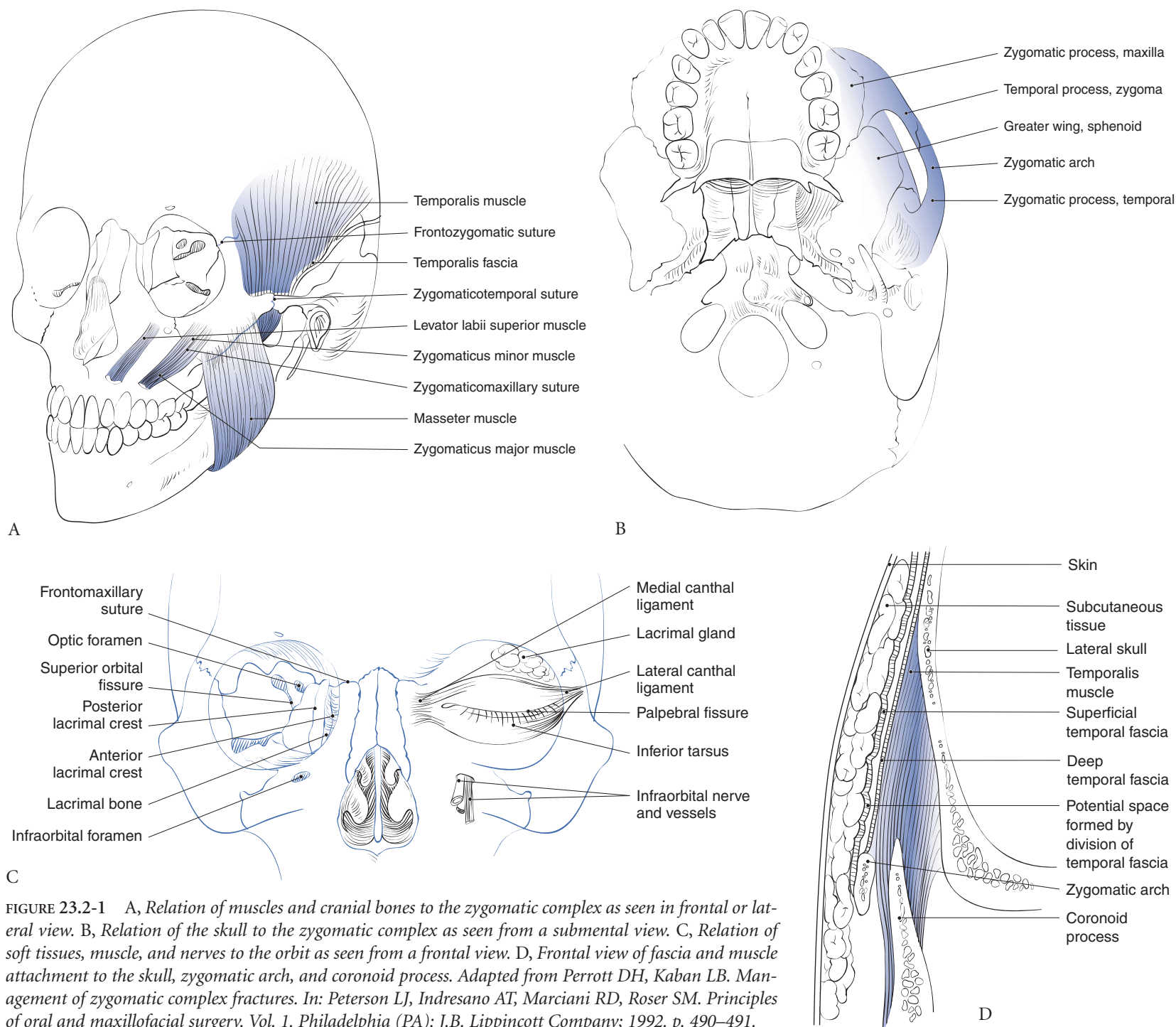


FIGURE 23.2-1 A, Relation of muscles and cranial bones to the zygomatic complex as seen in frontal or lateral view. B, Relation of the skull to the zygomatic complex as seen from a submental view. C, Relation of soft tissues, muscle, and nerves to the orbit as seen from a frontal view. D, Frontal view of fascia and muscle attachment to the skull, zygomatic arch, and coronoid process. Adapted from Perrott DH, Kaban LB. Management of zygomatic complex fractures. In: Peterson LJ, Indresano AT, Marciani RD, Roser SM. Principles of oral and maxillofacial surgery. Vol. 1. Philadelphia (PA): J.B. Lippincott Company; 1992. p. 490–491.

accompanied by an antimongoloid (downward) cant of the lateral canthal region caused by displacement of the zygoma (see Figure 23.2-1C).

Diagnosis

Zygomatic fractures are not life threatening and are usually treated after more serious injuries are stabilized and swelling has resolved 4 to 5 days after injuries.

Initial evaluation of the patient with a zygomatic fracture includes documentation of the bony injury and the status of surrounding soft tissue (eyelids, lacrimal apparatus, canthal tendons, and globe) and cranial nerves II to VI. Visual acuity and the status of the globe and retina should be established; an ophthalmologist should be consulted for suspected or questionable ophthalmic injury.

History

The nature, force, and direction of the injuring blow should be determined from the patient and any witnesses. A direct lateral blow, as in an assault, often results in an isolated zygomatic arch or an inferomedially displaced zygomatic complex fracture. A frontal blow usually produces a posteriorly and inferiorly displaced fracture.

The patient with a zygomatic complex fracture complains of pain, periorbital edema, and ecchymosis. There may be paresthesia or anesthesia over the cheek, lateral nose, upper lip, and maxillary anterior teeth resulting from injury to the zygomaticotemporal or infraorbital nerves. This occurs in 18 to 83% of all patients with zygomatic trauma.^{3,5-7} When the arch is medially displaced, the patient may complain of trismus. Epistaxis and diplopia may be present.³

Physical Examination

Ecchymosis and edema are the most common early clinical signs and are present in 61% of all zygomatic injuries.² Depression of the malar eminence and infraorbital rim produce flattening of the cheek. Sub-

conjunctival hemorrhage is often noted. Downward displacement of the zygoma produces an antimongoloid slant to the lateral canthus, enophthalmos, and accentuation of the supratarsal fold of the upper eyelid (Figure 23.2-2). Lacerations in the facial region should lead the surgeon to suspect underlying fracture.

Palpation of the zygomaticofrontal suture, the entire 360° of the orbital rim, and the zygomatic arch should be carried out in an orderly fashion. Tenderness, a step-off, or separation at the sutures are indicative of a fracture. Intraorally, disruption at the zygomaticomaxillary buttress area is palpable, and ecchymosis in the region of the canine fossa may be visible. The range of mandibular motion is evaluated to rule out impingement of the zygomatic arch on the coronoid process.

In isolated zygomatic arch fractures, a depression is observed and palpated anterior to the tragus (Figure 23.2-3). Pain and decreased mandibular motion are commonly present with these injuries, whereas orbital signs are usually absent.

Evaluation of the eye includes documentation of visual acuity, pupillary response to light, fundoscopic examination, ocular movement, and globe position. Limitation of motion of the extraocular muscles, diplopia, and enophthalmos may be noted if significant fractures of the orbital floor or medial or lateral walls are present. Lack of pupillary response and ptosis are present if cranial nerve III has been injured. Injuries to the optic nerve, hyphema, injury to the globe, retro-orbital hemorrhage, retinal detachment, and disruption of the lacrimal ducts may also be present.

Neurologic examination includes careful evaluation of all cranial nerves, with special attention directed toward cranial nerves II, III, IV, V, and VI.

Radiographic Evaluation

The diagnosis of zygomatic fractures is usually established by history and physical examination. CT scan of the facial bones, in axial and coronal planes, is standard for all patients with suspected zygomatic fractures.⁸⁻¹⁰ Radiographs are helpful for

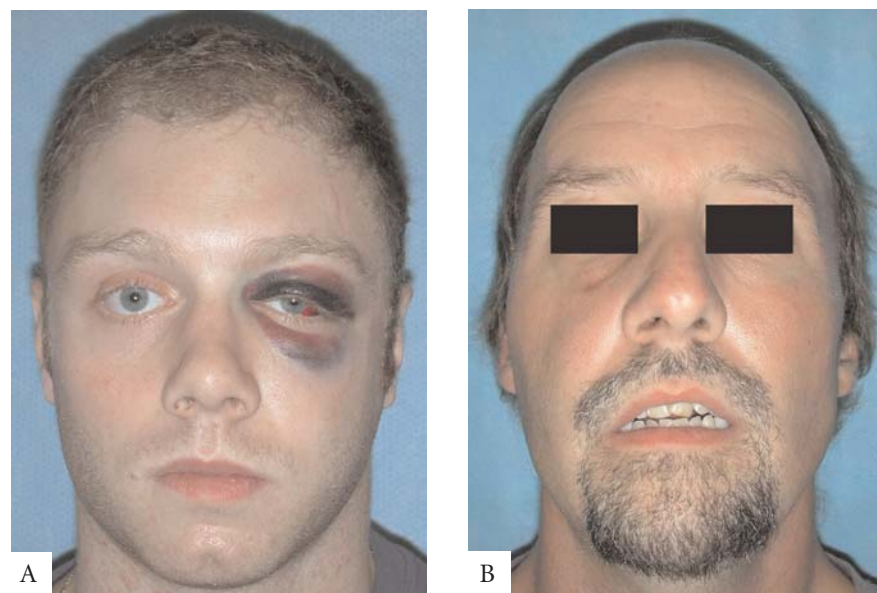

FIGURE 23.2-2 A, A 22-year-old male who sustained a blow to the right cheek. Frontal photograph illustrates the typical signs of zygomatic complex fracture: periorbital ecchymosis, edema, antimongoloid slant, and subconjunctival hemorrhage. B, A 38-year-old male who sustained a blow to the left cheek 2 weeks prior to presentation. Frontal photograph demonstrates resolving periorbital ecchymosis and malar depression.

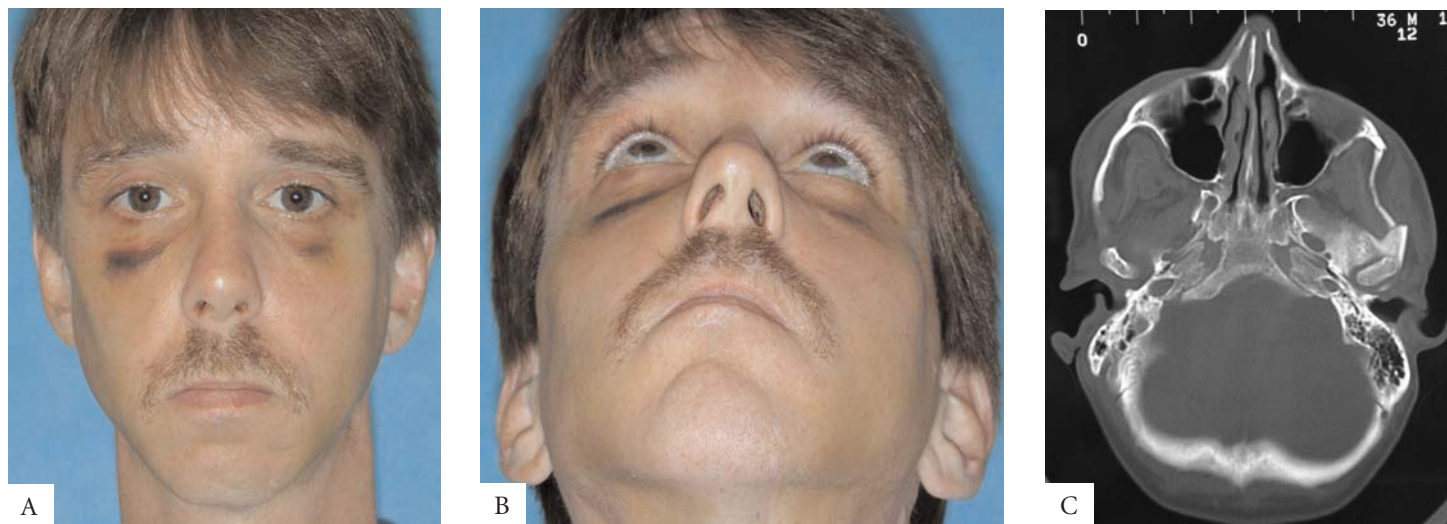


FIGURE 23.2-3 A 36-year-old male who sustained a blow to the left cheek. A, Frontal photograph illustrates the typical findings of a zygomatic arch fracture: preauricular depression. B, Worm's-eye view. C, Axial CT scan demonstrating isolated depressed left zygomatic arch fracture.

confirmation and for medicolegal documentation and to establish the extent of the bony injury.

Computed Tomography

CT is the gold standard for radiographic evaluation of zygomatic fractures. Axial and coronal images are obtained to define fracture patterns, degree of displacement, and comminution and to evaluate the orbital soft tissues. Specifically, CT scans allow for visualization of the buttresses of the midfacial skeleton: nasomaxillary, zygomaticomaxillary, infraorbital, zygomaticofrontal, zygomaticosphenoid, and zygomaticotemporal buttresses. Coronal views are particularly helpful in the evaluation of orbital floor fractures (Figure 23.2-4A).⁹ Soft tissue windows, in the coronal plane, are useful to evaluate the extraocular muscles and to evaluate for herniation of orbital tissues into the maxillary sinus.

Plain Radiographs

CT scans have replaced plain films for the diagnosis and management of zygomatic complex fractures. However, a fundamental working knowledge of this technique is required. In many emergency rooms and hospitals, trauma patients will still have plain film radiographic evaluation. The ability to

read and interpret these films to diagnose and treat these patients is mandatory.

Waters' View The single best radiograph for evaluation of zygomatic complex fractures is Waters' view. It is a posteroanterior projection with the head positioned at a 27° angle to the vertical and the chin resting on the cassette. This projects the petrous pyramids off the maxillary sinuses, permitting visualization of the sinuses, lateral orbits, and infraorbital rims (Figure 23.2-4B). When this is combined with an erect Waters' view, a stereographic view of the fracture can be obtained. In patients who are unable to assume a facedown position, a reverse Waters' projection provides similar information.

Caldwell's View Caldwell's view is a posteroanterior projection with the face at a 15° angle to the cassette. This study is helpful in the evaluation of rotation (around a horizontal axis).

Submentovertex View The submentovertex (jug-handle) view is directed from the submandibular region to the vertex of the skull. It is helpful in the evaluation of the zygomatic arch and malar projection (Figure 23.2-4C).

Classification of Fractures

Historically, the classification of zygomatic fractures was used to predict which fractures would remain stable after reduction. Clinically, this would allow the surgeon to identify those fractures that would require open reduction and some method of fixation.

In 1961 Knight and North classified zygomatic fractures by the direction of displacement on a Waters' view radiograph.¹¹

With the advent of CT scans and the increased use of rigid internal fixation, more modern classification schemes aim to identify those fractures that require aggressive surgical approaches.

In 1990, Manson and colleagues proposed a method of classification based on the pattern of segmentation and displacement.⁸ Fractures that demonstrated little or no displacement were classified as low-energy injuries. Incomplete fractures of one or more articulations may be present. Middle-energy fractures demonstrated complete fracture of all articulations with mild to moderate displacement. Comminution may be present (Figure 23.2-5). High-energy injuries were characterized by comminution in the lateral orbit and lateral displacement with segmentation of the zygomatic arch (Figure 23.2-6).

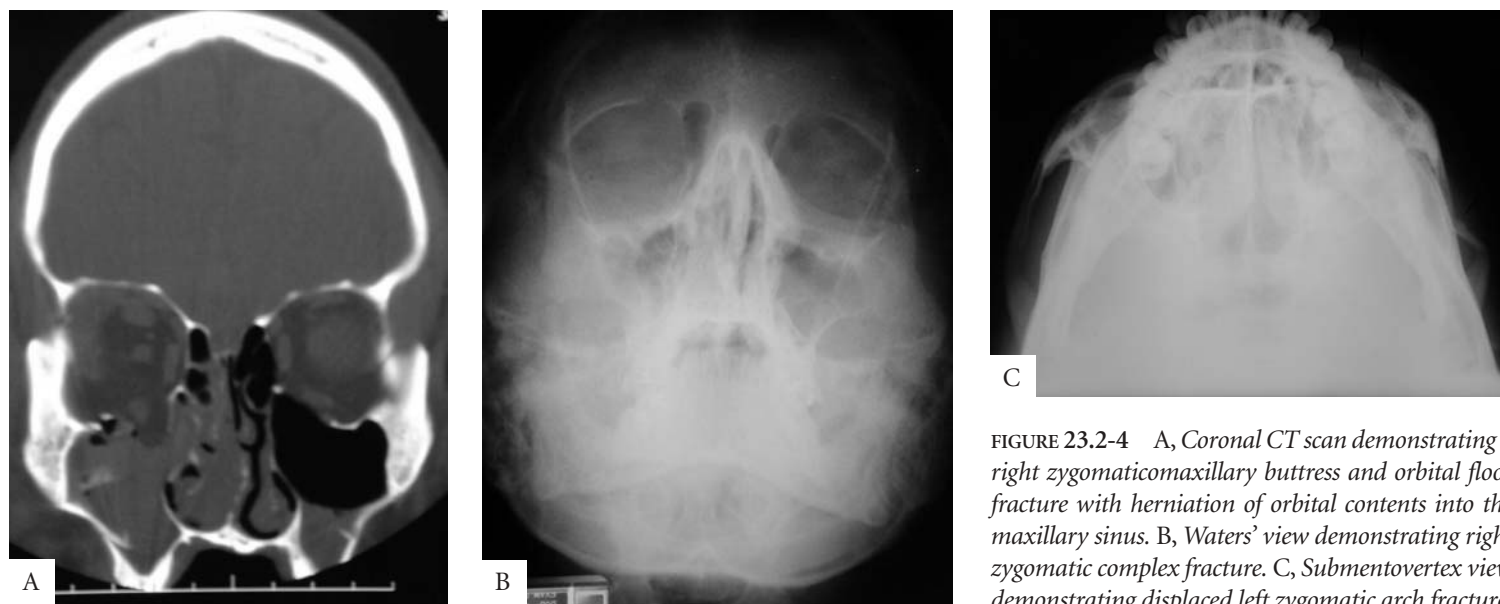


FIGURE 23.2-4 A, Coronal CT scan demonstrating a right zygomaticomaxillary buttress and orbital floor fracture with herniation of orbital contents into the maxillary sinus. B, Waters' view demonstrating right zygomatic complex fracture. C, Submentovertex view demonstrating displaced left zygomatic arch fracture.

Gruss and colleagues proposed a system that stressed the importance of recognizing and treating zygomatic arch fractures in association with the zygomatic body.¹² Like Manson and colleagues, Gruss stressed the importance of identifying and treating segmentation, comminution, and lateral bowing of the zygomatic arch.

Zingg and colleagues, in a review of 1,025 zygomatic fractures, classified these injuries into three categories.⁷ Type A frac-

tures were incomplete low-energy fractures with fracture of only one zygomatic pillar: the zygomatic arch, lateral orbital wall, or infraorbital rim. Type B fractures were designated complete “monofragment” fractures with fracture and displacement along all four articulations. Type C “multifragment” fractures included fragmentation of the zygomatic body.

Although all three classification schemes vary to some degree, each

method notes that as the amount of displacement and comminution increases, the role of open reduction and internal fixation increases.

Treatment

Treatment of zygomatic fractures must be based on a complete preoperative evaluation. This includes a CT scan with axial and coronal images to fully appreciate the nature of the injury. Classification techniques,

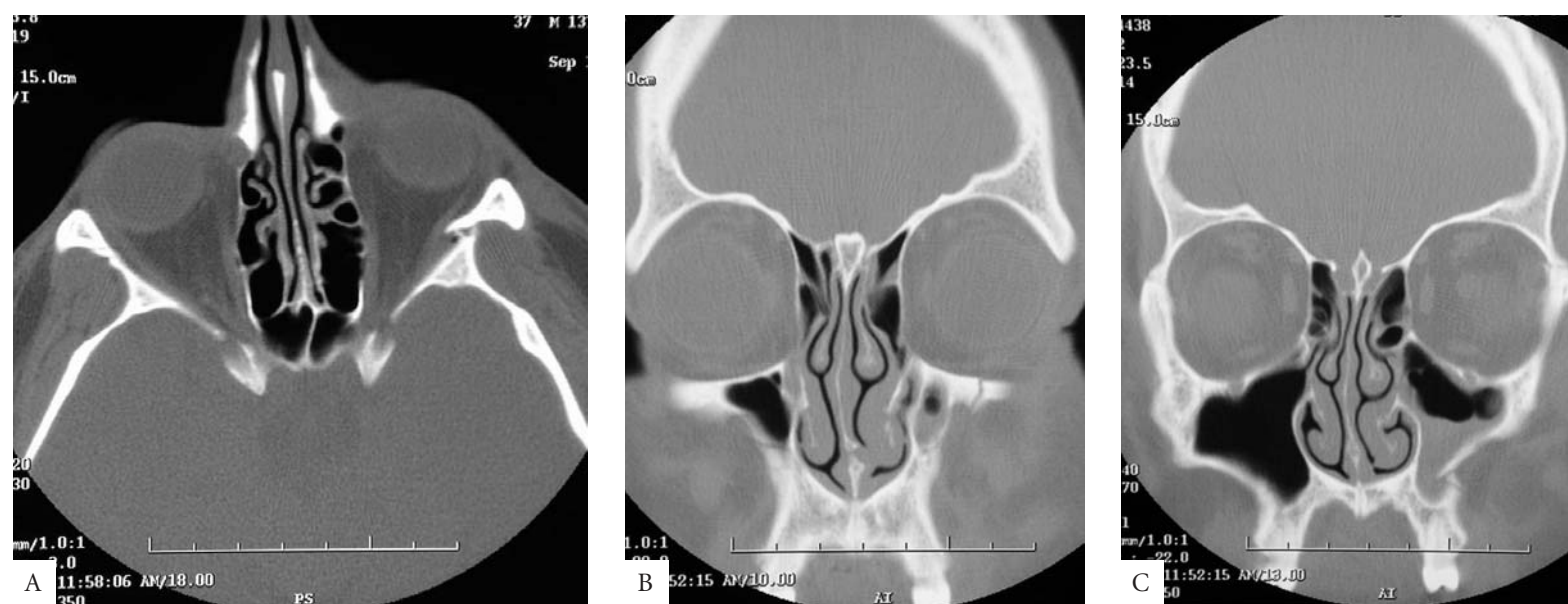


FIGURE 23.2-5 Middle-energy fracture. A, Axial CT scan demonstrating displacement of the lateral orbital wall. B, Coronal CT scan demonstrating fracture and minimal displacement of the infraorbital rim. C, Coronal CT scan demonstrating mild displacement of the zygomaticomaxillary buttress.

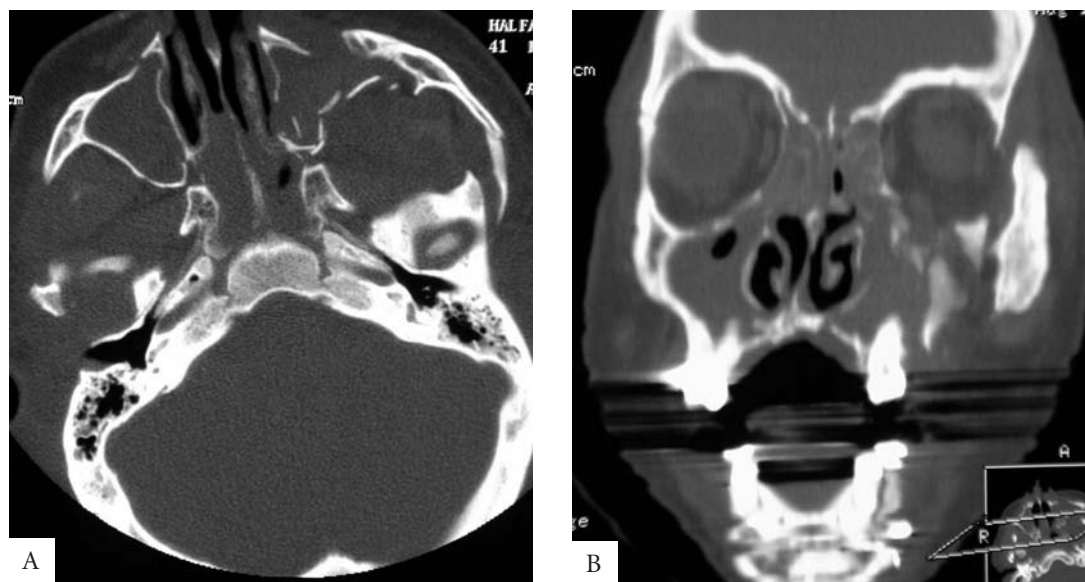


FIGURE 23.2-6 *High-energy fracture. A, Axial CT scan demonstrating lateral bowing and segmentation of the zygomatic arch. B, Coronal CT reconstructions demonstrate comminution of the zygomaticomaxillary buttress, infraorbital rim and orbital floor. This patient was unable to be positioned for true coronal scans because of a cervical spine injury. Note disruption of the right globe on coronal images resulting from orbital globe rupture.*

if they are accepted, are helpful to standardize terminology, to plan treatment, and to predict prognosis. However, the surgeon must individualize treatment based on a combination of history, physical examination, radiographic findings, and sound clinical judgment.

Management of zygomatic complex and zygomatic arch fractures depends on the degree of displacement and the resultant esthetic and functional deficits. Treatment may therefore range from simple observation of resolving swelling, extraocular muscle dysfunction, and paresthesia to open reduction and internal fixation of multiple fractures.

Zygomatic Arch Fractures

Nondisplaced and minimally displaced zygomatic arch fractures may require no surgical correction. Because these injuries usually do not result in significant functional deficits, it may be appropriate simply to observe the patient.

Duverney was the first surgeon to describe an operative technique for treatment of a fractured zygomatic arch.¹³ He used intraoral finger pressure to elevate

the depressed arch. Alternatively in this technique, the patient is instructed to bite on a block of wood, which results in temporalis muscle and tendon tension. This force, along with finger pressure in an outward direction, reduces the fracture.¹³

Goldthwaite in 1924 was the first to describe an intraoral approach to the zygomatic arch through a stab wound in the buccal sulcus.¹⁴ A sharp elevator is passed superiorly through the vestibule and behind the maxillary tuberosity, and forward pressure is applied to reduce the arch.

Quinn modified this technique by making an incision in the mucosa at the level of the maxillary alveolus and extending it inferiorly along the anterior border of the ramus. The dissection continues along the lateral aspect of the coronoid process, ending at the level of the maxillary alveolus and extending it inferiorly along the anterior border of the ramus. The dissection continues along the lateral aspect of the coronoid process, ending at the level of the zygomatic arch at the site of the fracture. An elevator is placed between the coronoid processes and zygomatic arch, and the fracture is reduced.¹⁵

The standard technique for treatment of zygomatic arch fractures, first described by Gillies, Kilner, and Stone in 1927, can also be used to reduce zygomatic complex fractures.¹⁶ A temporal incision (2 cm in length) is made behind the hairline. The dissection continues through the subcutaneous and superficial temporal fascia down to the glistening white deep temporal fascia (Figure 23.2-7A). The temporal fascia is incised horizontally to expose the temporalis muscle. A sturdy elevator, such as a urethral sound or Rowe zygomatic elevator, is inserted deep to the fascia, underneath the temporal surface of the zygoma. The elevator must pass between the deep temporal fascia and temporalis muscle or it will be lateral to the arch. The bone should be elevated in an outward and forward direction, with care taken not to put force on the temporal bone (Figure 23.2-7B). The arch should be palpated at all times as a guide to proper reduction. The wound is closed in layers.

An alternative technique uses a J-shaped curved hook elevator. This is inserted just below the zygomatic arch anterior to the articular eminence through a preauricular stab incision. The tip of the hook is directed under the displaced fragments, and reduction is achieved with controlled lateral traction.⁷

In a series of 2,067 zygomatic fractures, Ellis found 10 of 136 isolated zygomatic arch fractures required some form of fixation.³ Numerous methods of stabilization for zygomatic arch fractures have been proposed. These include temporarily packing the temporal fossa with ½-inch gauze, a nasogastric tube, or a urinary catheter.¹⁷⁻¹⁹ More conveniently, a transcutaneous circumzygomatic arch wire can be passed and tightened over a foam-backed aluminum eye shield to suspend the arch.

Although not a support technique, an aluminum foam-rubber-backed finger splint has been used to prevent the patient from placing undue force on the arch. The splint is formed into a U shape, taped to the face, and maintained for 3 to 5 days.²⁰

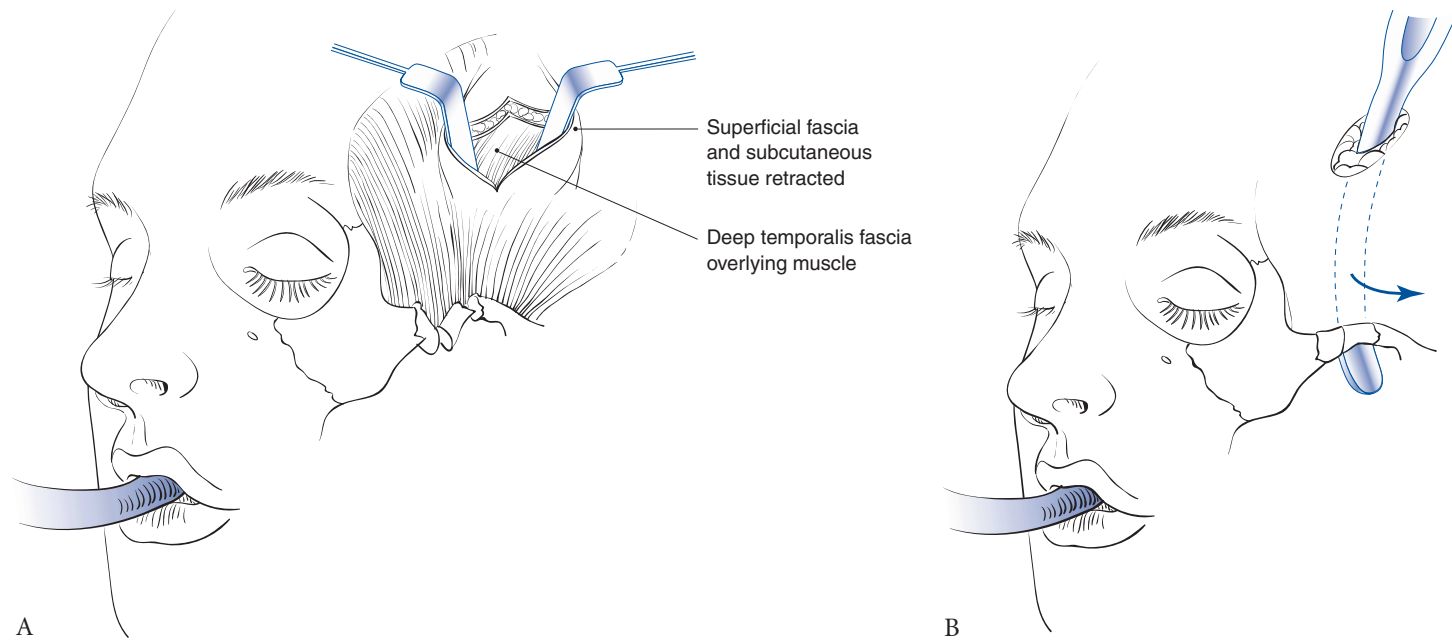


FIGURE 23.2-7 Gillies's approach to reduce zygomatic arch fracture. A, Temporal incision through subcutaneous and superficial fascia down to the deep temporal fascia. B, Reduction of fracture with elevator. Adapted from Perrott DH, Kaban LB. Management of zygomatic complex fractures. In: Peterson LJ, Indresano AT, Marciani RD, Roser SM. Principles of oral and maxillofacial surgery. Vol. 1. Philadelphia (PA): J.B. Lippincott Company; 1992. p. 498.

Open reduction with internal fixation is seldom necessary for treatment of isolated zygomatic arch fractures. Internal fixation with miniplates may be required as part of the management of high-energy comminuted zygomatic complex or panfacial fractures.

Zygomatic Complex Fractures

Low-Energy Zygomatic Complex Fractures Low-energy, nondisplaced or minimally displaced zygomatic complex fractures may require no operative correction. The patient should be observed longitudinally for signs of displacement, extraocular muscle dysfunction, and enophthalmos after swelling resolves. Stable, minimally displaced zygomatic complex fractures without significant clinical findings may require no treatment. The patient should be made to appreciate the risk of residual asymmetry of the cheek, orbit, and eyelid if the fracture is not reduced. Documentation, including photographs, is recommended.²¹

Middle-Energy Zygomatic Complex Fractures Middle-energy, displaced zygomatic complex fractures require reduction and internal fixation. Over the past 20 years there has been an increase in the use of open reduction and internal fixation. In 1984, Zachariadis and colleagues managed 45% of all zygoma fractures with the Gillies technique. At the same institution, in 1995, only 2.5% of these fractures were treated by this same method.²²

In 1996, Ellis and Kittidumkerng proposed an algorithm of treatment for isolated middle-energy zygomatic complex fractures that did not require orbital reconstruction (Figure 23.2-8).²³ The initial step in this algorithm is reduction of the fracture. Ellis and others recommend the use of a Carroll-Girard screw, which is inserted transcutaneously into the malar eminence (Figure 23.2-9). The Carroll-Girard screw provides excellent three-dimensional control to reduce the fracture.

If the reduction is unstable, or if there is question regarding the accuracy of the reduction, the author recommends pro-

ceeding to open reduction and internal fixation. The zygomaticomaxillary buttress is exposed first and stabilized with a plate if necessary.

The zygomaticofrontal buttress is exposed next and also stabilized with a plate if required. This method requires proper patient selection, experience, and meticulous technique to ensure accurate reduction and stabilization.

Other authors recommend routine exposure of two or more of the three anterior buttresses for middle-energy injuries: the zygomaticomaxillary buttress, zygomaticofrontal buttress, and the infraorbital rim (Figures 23.2-10–23.2-12). In this manner, multiple buttresses are visualized and the three-dimensional accuracy of the reduction can be confirmed.^{24–27}

High-Energy Zygomatic Complex Fractures A more aggressive surgical approach should be planned to treat high-energy fractures (Figure 23.2-13).^{12,23,24,28} There is often significant comminution of the anterior buttresses, making anatomic reduction

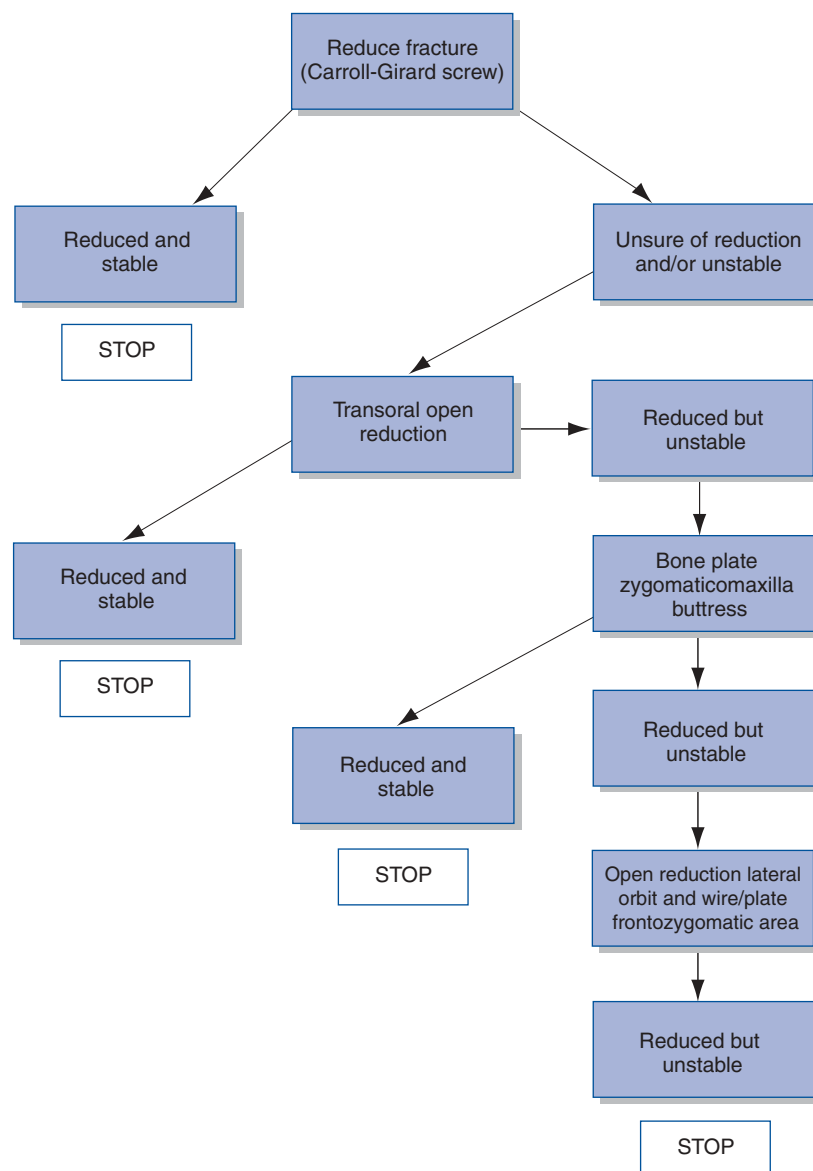


FIGURE 23.2-8 Zygomatic complex fracture without need for internal orbit reconstruction. Adapted from Ellis E and Kittidumkerng W.²³

difficult. With segmentation of the zygomatic arch, it is impossible to control this posterior buttress. Additionally, these fractures often require orbital reconstruction.

To restore proper projection, facial width, and orbital volume, exposure of the zygomatic arch and orbital floor is often required in addition to exposure of the anterior buttresses. A coronal flap is used to gain access to the zygomatic arch. A transcutaneous or transconjunctival incision is used to explore and reconstruct the internal orbit. With wide intraorbital exposure, the broad sphenozygomatic

suture may also be visualized to aid in anatomic reduction.^{12,23,24,28,29}

Surgical Approach to the Zygomaticomaxillary Buttress After a throat pack is placed and local anesthesia infiltrated, an incision is made in the maxillary vestibule 3 to 5 mm above the mucogingival junction. The incision extends from the canine area to the first or second molar region. The use of electrocautery may reduce bleeding. The periosteal incision is made, and a mucoperiosteal flap is elevated to expose the infraorbital nerve, piriform rim, and

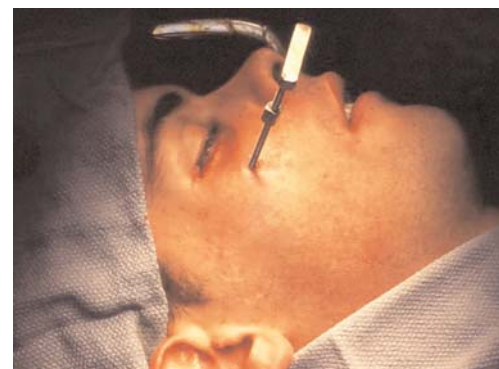

FIGURE 23.2-9 Carroll-Girard screw placed transcutaneously for reduction of a zygomatic complex fracture.

zygomaticomaxillary buttress (see Figure 23.2-10). Additional superior dissection is used to visualize the infraorbital rim.^{30,31}

Surgical Approach to the Zygomaticofrontal Buttress Access and exposure for open reduction of the zygomaticofrontal buttress can be achieved through a suprataral fold or lateral eyebrow incision (Figure 23.2-14A and B). If present, a preexisting laceration may be used for exposure of this region.

In 1996, Kung and Kaban described the use of a suprataral fold incision for approach to the lateral orbit (see Figures 23.2-11 and 23.2-14B).³² The incision is placed in a skinfold parallel to the superior palpebral sulcus above the tarsal plate. It is placed approximately 10 to 14 mm above the margin of the upper eyelid. A 2.0 cm incision is usually adequate but may be extended laterally into the crow's-foot for increased exposure. Blunt dissection parallel to the orbicularis oculi muscle fibers separates them and exposes the lateral orbital rim. The dissection is continued, superficial to the orbital septum and over the lateral orbital rim. A vertical periosteal incision is made, and subperiosteal dissection will expose the fracture. The incision provides access to the frontozygomatic suture and results in a less noticeable scar.

A lateral brow incision is performed by first palpating the frontozygomatic suture. A 2.0 cm incision is made within

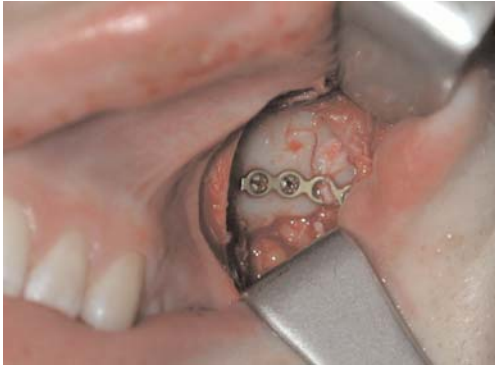


FIGURE 23.2-10 Intraoral exposure and fixation of zygomaticomaxillary buttress fracture.

the confines of the lateral eyebrow parallel to the superior lateral orbital rim (see Figure 23.2-14A). Dissection is continued through the orbicularis oris and the periosteum to the fracture site.

Surgical Approach to the Infraorbital Rim and Orbit Access and exposure for open reduction of the infraorbital rim and orbital floor can be achieved through a transcutaneous subciliary or transconjunctival incision. Protection of the globe with a scleral shield or tarsorrhaphy is recommended.

A subciliary incision is made 1 to 2 mm below and parallel to the lower eyelash

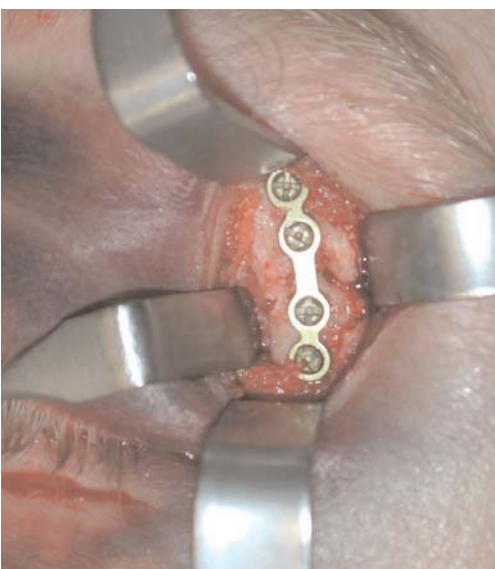

FIGURE 23.2-11 Exposure and fixation of zygomaticofrontal buttress fracture via a supratarsal fold incision.

margin (see Figures 23.2-13 and 23.2-14A). It should extend from lateral to the punctum in a natural skinfold. The fibers of the orbicularis muscle are separated horizontally at the same level as the skin incision, and a composite skin-muscle flap is elevated anterior to the orbital septum. A periosteal incision is made on the anterior surface of the infraorbital rim. Subperiosteal dissection is then completed to expose the orbital rim and floor.^{31,33} Multiple variations of this technique have been described including a skin-only flap, a stepped skin-muscle flap, and a subtarsal approach. These have been compared to each other and to the transconjunctival incision.³⁴⁻³⁶ Regardless of technique, transcutaneous approaches are associated with a higher incidence of ectropion, increased scleral show, and cutaneous scarring.³⁷⁻⁴⁰

To avoid the problems associated with cutaneous incisions, many authors recommend the transconjunctival approach.³⁷⁻⁴² Tessier described this approach in 1973 (Figures 23.2-14C and 23.2-15).⁴³ The lower lid is retracted, and an incision is made below the lower border of the tarsus. Dissection is extended inferiorly, and a preseptal dissection (superficial to the

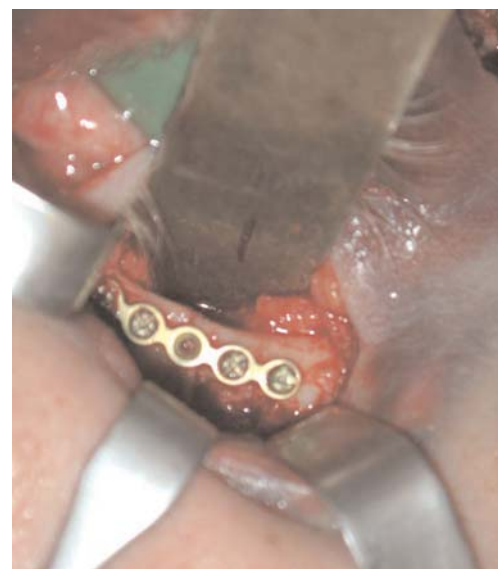

FIGURE 23.2-12 Exposure and fixation of infraorbital rim fracture via a subciliary incision.

orbital septum) is used to expose the infraorbital rim. Variations of this technique include a retroseptal dissection. This approach maintains the integrity of the lower lid but requires retraction of the orbital fat during fracture reduction and fixation (Figure 23.2-16).³¹

A lateral canthotomy can be used to increase exposure. Meticulous repair of the lateral canthotomy is required to prevent asymmetry.^{31,38,40,41}

Manson and colleagues described a method to expose the entire lateral orbit, infraorbital rim, and orbital floor through a single incision. This may be performed with a subciliary or transconjunctival approach and requires extended subperiosteal dissection with mobilization of the lateral canthal tendon.⁴⁴

Pitfalls in Surgical Approach to the Infraorbital Rim and Orbit All approaches to the infraorbital rim may result in complications. The subciliary and transconjunctival incisions may result in ectropion, entropion, and increased scleral show. Advocates of the transconjunctival approach cite increased rates of ectropion and scleral show with transcutaneous incisions (see Figure 23.2-13J).³⁷⁻⁴⁰ In 1993, Appling found a 12% rate of transient ectropion and 28% rate of permanent scleral show with a subciliary approach. In comparison, the transconjunctival approach had no transient ectropion and a 3% rate of permanent scleral show.³⁹

Multiple factors have been cited as the cause of increased scleral show and ectropion. During the dissection to the orbital rim, care should be taken to ensure that the placement of the periosteal incision is on the anterior surface of the maxilla. An incision placed on the superior rim or posterior to the orbital rim may violate the orbital septum. Subsequent scarring and contracture of the septum may result in increased scleral show or ectropion.⁴⁴

Improper wound closure may also contribute to lower lid complications.

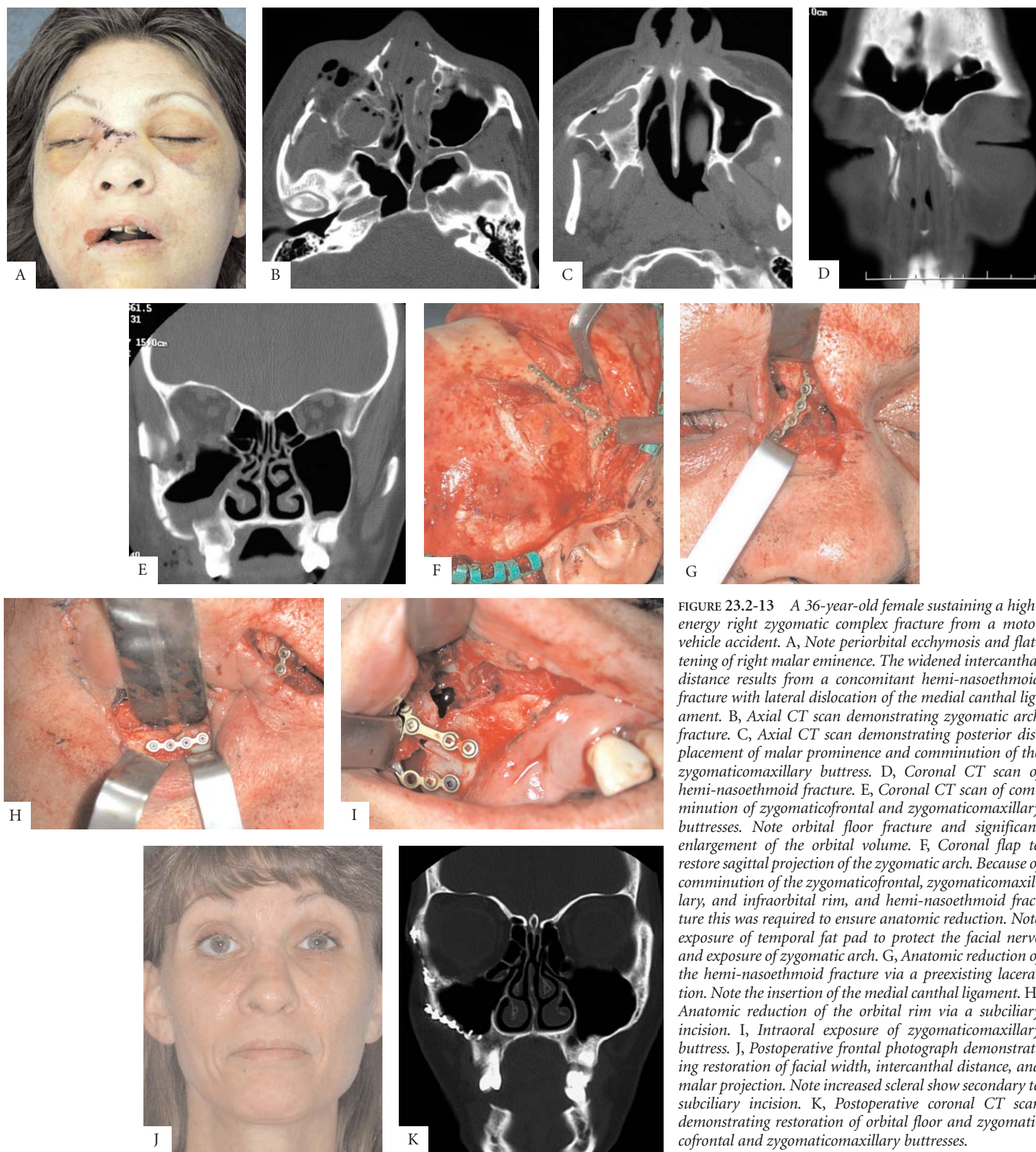


FIGURE 23.2-13 A 36-year-old female sustaining a high-energy right zygomatic complex fracture from a motor vehicle accident. A, Note periorbital ecchymosis and flattening of right malar eminence. The widened intercanthal distance results from a concomitant hemi-nasoethmoid fracture with lateral dislocation of the medial canthal ligament. B, Axial CT scan demonstrating zygomatic arch fracture. C, Axial CT scan demonstrating posterior displacement of malar prominence and comminution of the zygomaticomaxillary buttress. D, Coronal CT scan of hemi-nasoethmoid fracture. E, Coronal CT scan of comminution of zygomaticofrontal and zygomaticomaxillary buttresses. Note orbital floor fracture and significant enlargement of the orbital volume. F, Coronal flap to restore sagittal projection of the zygomatic arch. Because of comminution of the zygomaticofrontal, zygomaticomaxillary, and infraorbital rim, and hemi-nasoethmoid fracture this was required to ensure anatomic reduction. Note exposure of temporal fat pad to protect the facial nerve and exposure of zygomatic arch. G, Anatomic reduction of the hemi-nasoethmoid fracture via a preexisting laceration. Note the insertion of the medial canthal ligament. H, Anatomic reduction of the orbital rim via a subciliary incision. I, Intraoral exposure of zygomaticomaxillary buttress. J, Postoperative frontal photograph demonstrating restoration of facial width, intercanthal distance, and malar projection. Note increased scleral show secondary to subciliary incision. K, Postoperative coronal CT scan demonstrating restoration of orbital floor and zygomaticofrontal and zygomaticomaxillary buttresses.

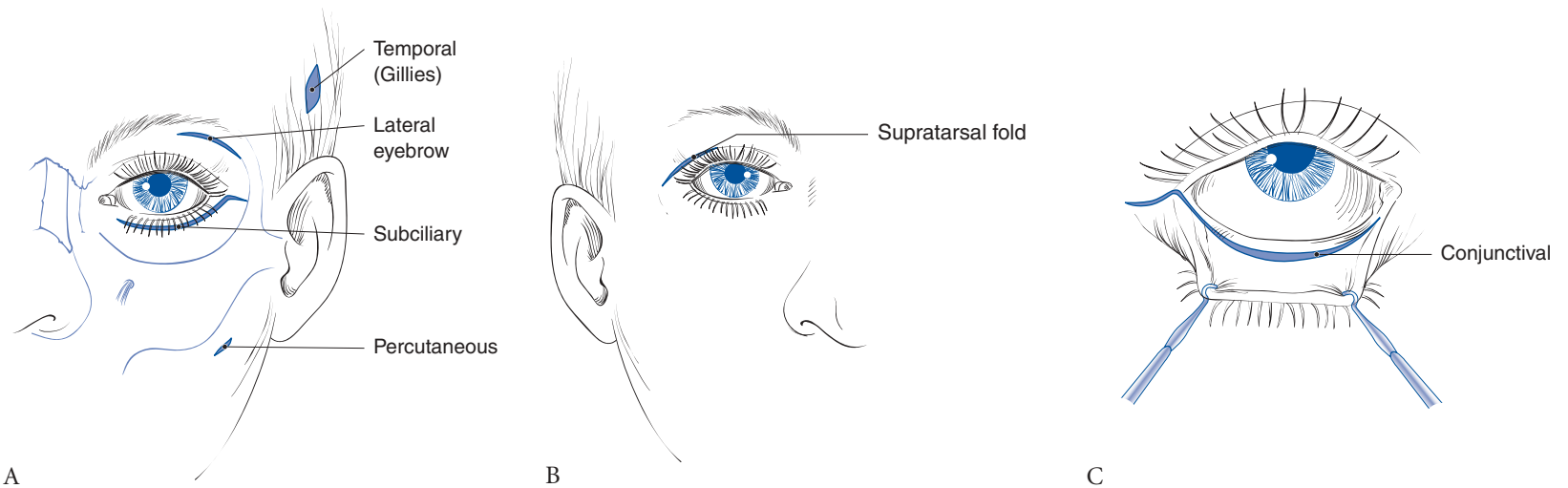


FIGURE 23.2-14 Frontal view illustrating periorbital incision sites. A, Four different incisions for repair of zygoma fractures. B, Upper eyelid incision within the lateral supratarsal fold. C, Transconjunctival incision below the lower border of the tarsus. Adapted from Perrott DH, Kaban LB. Management of zygomatic complex fractures. In: Peterson LJ, Indresano AT, Marciani RD, Roser SM. Principles of oral and maxillofacial surgery. Vol. 1. Philadelphia (PA): J.B. Lippincott Company; 1992. p. 500.

Following wide subperiosteal exposure, which is often required for complex fracture repair, the facial soft tissues may descend caudally, resulting in loss of anterior projection, accentuation of the nasolabial fold, increased scleral show, and ectropion. Phillips and colleagues recommend resuspension of the periosteum, muscle, and subcutaneous tissue. Multiple holes are drilled in the inferolateral orbital rim. The edge of the periosteum, muscle, and subcutaneous tissue is sutured to the orbital rim. This may minimize traction on the infraorbital tissue and subsequent ectropion or increased scleral show.³³

Lastly, postoperative support for the lower eyelid with a frost stitch has been

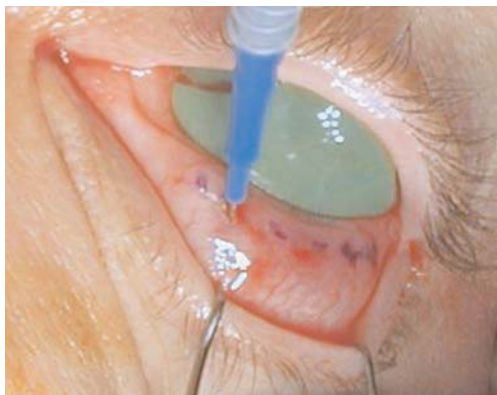

FIGURE 23.2-15 Transconjunctival incision for approach to the infraorbital rim.

proposed as a technique to prevent ectropion. This may encourage re-draping of the lower eyelid tissues.^{23,44}

Surgical Approach to the Zygomatic Arch

In high-energy zygomatic complex fractures or secondary correction of zygomatic deformities, access is limited with conventional incisions. To obtain adequate exposure, a coronal incision combined with a lower eyelid approach is recommended (see Figure 23.2-13F).

The initial incision is through the skin, subcutaneous tissue, and galea of the scalp. Elevation of the coronal flap proceeds in the subgaleal loose areolar connective tissue superficial to the pericranium. The temporal and preauricular plane of dissection is along the temporal fascia, which can be identified by its characteristic glistening white appearance. A horizontal periosteal incision is made 2 to 3 cm above the supraorbital rim, and a subperiosteal plane of dissection is developed to the superior and lateral orbit. An incision is made in the superficial layer of the temporal fascia from the posterior zygomatic arch to the previously exposed supraorbital region. The temporal fat pad should be identified (see Figure 23.2-13F). The dissection is extended inferiorly at this depth to the zygomatic arch

and anteriorly to the lateral orbital rim. The facial nerve is protected within the flap.^{12,31}

Internal Fixation Historically, many methods have been used for stabilization of zygomatic complex fractures. These have included antral packing, percutaneous wire fixation, and wire osteosynthesis. It is now accepted that miniplate or microplate fixation provides the best results and minimal complications.^{22,45-47}

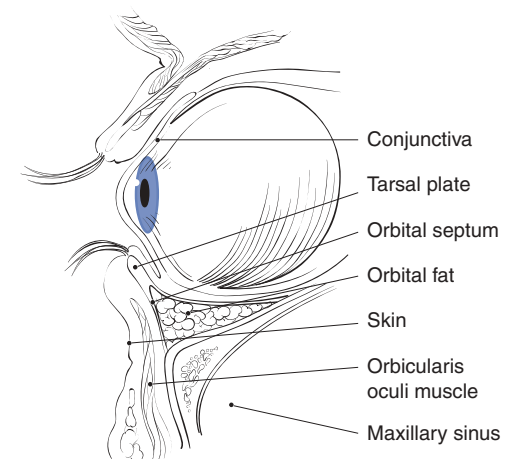


FIGURE 23.2-16 Sagittal view of eye illustrating relation of conjunctiva, orbital septum and fat, and orbicularis muscle to the eye and infraorbital rim. Adapted from Perrott DH, Kaban LB. Management of zygomatic complex fractures. In: Peterson LJ, Indresano AT, Marciani RD, Roser SM. Principles of oral and maxillofacial surgery. Vol. 1. Philadelphia (PA): J.B. Lippincott Company; 1992. p.501.

Controversy exists regarding the best location for internal fixation and the number and type of plates required. Multiple studies have tried to characterize the forces placed on the zygomatic complex and the amount of fixation required to achieve “stability.”^{23,24,29,48–54} These forces include the masseter and temporalis muscles and fascia and soft tissue contracture, which cause rotational movements in multiple axes around the zygomatic buttresses. Internal fixation must provide enough strength to resist these forces.

For low- and middle-energy fractures, stable fixation can be achieved at one or more of the anterior buttresses. The location of fixation and number of sites of fixation depends on the fracture pattern, location, vector of displacement, and degree of instability. Occasionally one-point fixation may be adequate.^{7,23,26,50,52} More commonly two- or three-point stabilization is required.^{7,23,24,26,27,45,50,55}

For high-energy injuries, a fourth point of fixation is required. The zygomatic arch is typically comminuted and laterally displaced. Open reduction and internal fixation is required to restore proper facial width and projection.^{7,12,23,24,45,55}

Internal Fixation of the Zygomaticomaxillary Buttress The zygomaticomaxillary buttress provides an ideal location for internal fixation for middle- and high-energy fractures.^{53,54} Anatomic reduction of this fracture assists in restoring malar projection, but is difficult if the buttress is comminuted. The overlying soft tissue is thick, and plate palpability is not a concern. Therefore, this fracture should be stabilized with 1.5 or 2.0 plates.^{23,26,55,56}

Internal Fixation of the Zygomaticofrontal Buttress The zygomaticofrontal buttress contains excellent bone for fixation and can accommodate a 2.0 plate.⁵⁵ The reduction and fixation of this fracture will reestablish the vertical height of the zygomatic complex. However, because of its narrow inter-

face, this buttress may not be as helpful in evaluating reduction of a rotated fracture.^{12,54} The thickness of the soft tissue overlying this region is variable. In some instances it may be quite thin and a large plate may be palpable. If stable fixation can be achieved at other sites, a smaller plate may be used.⁵⁵

Internal Fixation of the Infraorbital Rim Unlike the zygomaticofrontal buttress, the infraorbital rim has poor quality bone for internal fixation.⁵⁵ Additionally, the lower eyelid skin is quite thin, and large plates are easily palpable. Despite these concerns, fixation of this site is required to define the orbital volume and facial width.^{57–59} The infraorbital rim is typically displaced posteriorly and inferiorly.²⁸ The fracture should be mobilized anteriorly and superiorly and stabilized. Typically a 1.0 or 1.5 microplate is used to stabilize the infraorbital rim.^{26,27,30,55} A potential pitfall in reduction of this fracture is an unappreciated heminasoethmoid fracture (see Figure 23.2-13D). If the infraorbital rim is secured to this undiagnosed displaced segment, postoperative facial widening may occur.^{23,54,60}

Internal Fixation of the Zygomatic Arch Internal fixation of the zygomatic arch is required for high-energy fractures that demonstrate comminution and lateral displacement.^{12,23,24,28,55} Restoration of this sagittal buttress assists in restoring facial projection and facial width. When exposed, the zygomatic arch is often reduced and stabilized first in the sequence of repair of high-energy injuries. Caution must be used in restoring a “straight” arch and not a “curved” arch, which will decrease facial projection. This fracture typically requires a large plate to resist deformational forces.^{55,56}

Sequence of Internal Fixation As in the treatment of panfacial fractures, a systematic approach is helpful to ensure accurate restoration of facial height, width, and projection.^{28,53}

For middle-energy injuries with exposure of all three anterior buttresses, the zygomaticofrontal fracture may be stabilized temporarily with an interosseous wire.^{26,28} This is followed by fixation of the zygomaticomaxillary fracture and the infraorbital rim. The temporary wire at the zygomaticofrontal fracture is replaced with a plate. The orbital floor is reconstructed after the zygoma has been restored to its correct three-dimensional position.^{26,53}

In high-energy fractures, the zygomatic arch should be reconstructed first.^{12,24,28,45,53}

Management of the Orbital Floor

Patients with middle-energy zygomatic complex injuries and no clinical or radiographic evidence of orbital disruption do not require exploration.²³ Middle-energy injuries with displacement of the orbital rim or floor or herniation of soft tissue into the sinus should be explored (see Figure 23.2-4A). Clinical indications for orbital exploration include enophthalmos, limitation of extraocular muscle function with a positive forced duction test, and persistent diplopia. High-energy fractures require a more aggressive approach, and the orbital rim and floor should be explored and reconstructed.^{23,24,26,45,53,61}

Fujino and Makino classified orbital floor injuries as linear and pure blow-out fractures (Figure 23.2-17). A linear fracture occurs when the infraorbital rim is struck, displacing the orbital contents and floor posteriorly.⁶² The orbital septum is torn, herniating soft tissue into the maxillary sinus. When the force is removed, the orbital floor returns to its original position and the soft tissues are entrapped in the fracture site. Comminution of the orbital floor is produced by a force ten times greater than that required for a linear fracture. Fragments are forced inferiorly into the sinus, producing bony discontinuity.

Indications for exploration of isolated orbital floor fractures include CT scan evidence of a fracture and herniation of orbital tissue, enophthalmos, dystopia,

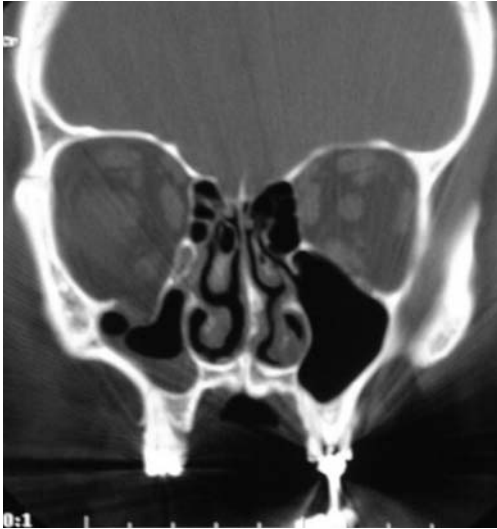

FIGURE 23.2-17 Isolated blow-out fracture with herniation of orbital contents into the maxillary sinus.

disabling diplopia that does not improve over 7 to 14 days, and a positive forced duction test.^{45,60,61,63–65}

Treatment Access to the floor is accomplished by a subciliary or transconjunctival incision. Simple linear fractures may require only removal of entrapped tissue. Larger defects require reduction of the soft tissue and bone fragments from the sinus and reconstruction of the floor with a bone graft or implant. Exploration of the orbital floor is completed prior to reduction of the fracture. Reconstruction of the floor is completed after reduction and stabilization of the orbital rim.^{26,55,61}

The orbital floor may be reconstructed with an autograft, an allograft, or a prosthetic implant. Autograft sources include calvaria, iliac crest, or nasal septal cartilage.^{66,67} Allograft sources include lyophilized dura and cartilage.⁶⁸ Alloplastic material such as titanium mesh^{27,66,69} offers a strong, malleable material that can accurately be adapted to span the orbital defect. Porous polyethylene implants and resorbable polydioxanone sheets have also been used for orbital reconstruction.^{45,70,71}

Regardless of the technique, anatomic restoration of the orbital volume is

required to prevent postoperative enophthalmos.^{57–59,66} In complex fractures, a significant portion of orbital floor may be comminuted or missing. The defect must be completely defined, and the graft or implant must be placed on an intact posterior “ledge,” which may be 35 to 38 mm posterior to the rim.^{72,73}

Forced duction tests should be performed before and after the orbital floor exploration, as well as after reconstruction.^{55,61}

Role of Bone Grafting Early bone grafting is indicated for severe injuries in which there is loss of bone or extensive comminution. Comminution of the orbital floor and zygomatic buttresses is common in high-energy injuries. These zygomatic complex fractures are often associated with other severe midface fractures that require treatment. Grafts may help to achieve anatomic reduction and stability, as well as to prevent soft tissue contraction.^{74,75}

Postoperative Care Zygomatic complex fractures violate the maxillary sinus. For this reason, antibiotics and decongestants are recommended. Ampicillin, amoxicillin, clindamycin, or cephalosporin may be used.⁶¹ A decongestant such as pseudoephedrine is also used to clear the airway.

Incisions are observed carefully for signs of infection, and the eye is examined to document visual acuity and to rule out complications such as corneal abrasion. Postoperative radiographs (Waters’ view and submentovertex view) are obtained to document reduction of the fracture. A CT scan may be obtained in comminuted fractures to evaluate the zygomatic complex reduction and orbital reconstruction.^{54,61}

Complications

Although complications of zygomatic complex and zygomatic arch fractures are uncommon, the surgeon must recognize their signs and symptoms to provide appropriate care. Complications may occur

in the early postoperative period or may only become manifest later in recovery.

Infraorbital Paresthesia

The incidence of sensory alterations of the infraorbital nerve following zygomatic trauma ranges from 18 to 83%.^{3,5–7} Studies by Vriens and colleagues and Taicher and colleagues have found improved recovery of infraorbital sensation following open reduction and internal fixation at the zygomaticofrontal suture compared with reduction without fixation.^{5,6} Presumably, anatomic reduction of the fracture may minimize compression of the nerve and allow for recovery. However, in Vriens’s study, the same degree of improvement was not seen in patients requiring orbital floor exploration and reconstruction.

Malunion and Asymmetry

Inadequate reduction or stabilization of zygomatic fractures may result in malunion or asymmetry.^{7,12,23,28} Poor malar projection is the result of uncorrected inferior and posterior rotation of the zygoma. Increased facial width, in addition to decreased malar projection, results from inadequate reduction of the zygomatic arch as part of a high-energy orbitozygomatic injury.²⁸

Malunion that is recognized up to 6 weeks after injury may be corrected using routine zygomatic reduction techniques. Correction of mild late deformities includes autogenous onlay grafts or placement of alloplastic implants such as porous polyethylene.²⁴ Severe late post-traumatic deformities may require zygomatic osteotomy and repositioning. Cranial bone grafting may also be required. Scarring and contraction of the periorbital soft tissue may also occur.⁷⁶ Lid retraction, entropion, ectropion, and canthal repositioning may need to be addressed in addition to osseous reconstruction.

Enophthalmos

Enophthalmos is one of the most troubling complications following orbitozygomatic

fractures. An increase in orbital volume is the most common etiology.⁵⁷⁻⁵⁹

Grant and colleagues described this clinical problem eloquently by comparing the shape of the orbit to that of a cone. The volume of a cone is $\frac{1}{3}(\pi r^2)h$. The orbital rim position determines the radius of the cone and the anteroposterior orbital length is the height of the cone. In this equation, the radius is squared and small increases in the radius result in dramatic increases in volume. Clinically, poor alignment of the orbital rim may significantly increase the orbital volume and result in enophthalmos.⁵⁸

Orbital floor blow-out fracture also may result in enophthalmos by increasing the orbital volume (Figure 23.2-18). With improved CT technology, calculation of orbital volume and its implication regarding orbital floor fractures is possible.^{73,77-80} Raskin and colleagues demonstrated that a 13% increase in orbital volume, at 4 weeks, results in significant enophthalmos (> 2 mm).⁷⁹ The critical size of the orbital defect and herniation of orbital tissues have also been studied. In 2002, Ploder and colleagues reported that a mean fracture area of 4.08 cm or a mean displaced tissue volume of 1.89 mL, was associated with greater than 2 mm of enophthalmos.⁸⁰ In general, approximately 1 cm³ of displaced tissue equals 1 mm of enophthalmos.⁸¹

Late repair of enophthalmos is technically challenging. Wide access with osteotomy of the zygoma, repositioning, and grafting is usually required. Re-draping of the periorbital soft tissue including a canthopexy may be required.⁵⁷⁻⁵⁹

Diplopia

Diplopia is a common sequela of midfacial fractures. The incidence varies between 17 and 83% and depends on the time of presentation following the injury and the pattern and severity of the injury.^{3,68,82-84} In a review of 2,067 zygomatic complex fractures, Ellis and colleagues noted a 5.4 to 74.5% incidence of diplopia.³ Nondisplaced

zygomatic complex fractures and isolated zygomatic arch fractures had the lowest incidence of diplopia, while pure blow-out fractures had the highest incidence.

The principal causes of diplopia include edema and hematoma, entrapment of the extraocular muscles and orbital tissue, and injury to cranial nerves III, IV, or VI. Histologic studies by Iliff and colleagues have shown post-traumatic fibrosis of the extraocular muscles in

response to injury. They hypothesize that this may impair contractility and decrease excursions of the muscles.^{45,82,85-87}

Axial and coronal CT scans and ophthalmologic consultation are recommended to assist in evaluation.^{45,82} Diplopia related to edema, hematoma, or neurogenic causes may resolve without intervention. Diplopia resulting from entrapment requires exploration and reduction of herniated orbital tissue (Figure 23.2-19).^{45,60,61,63-65,82}

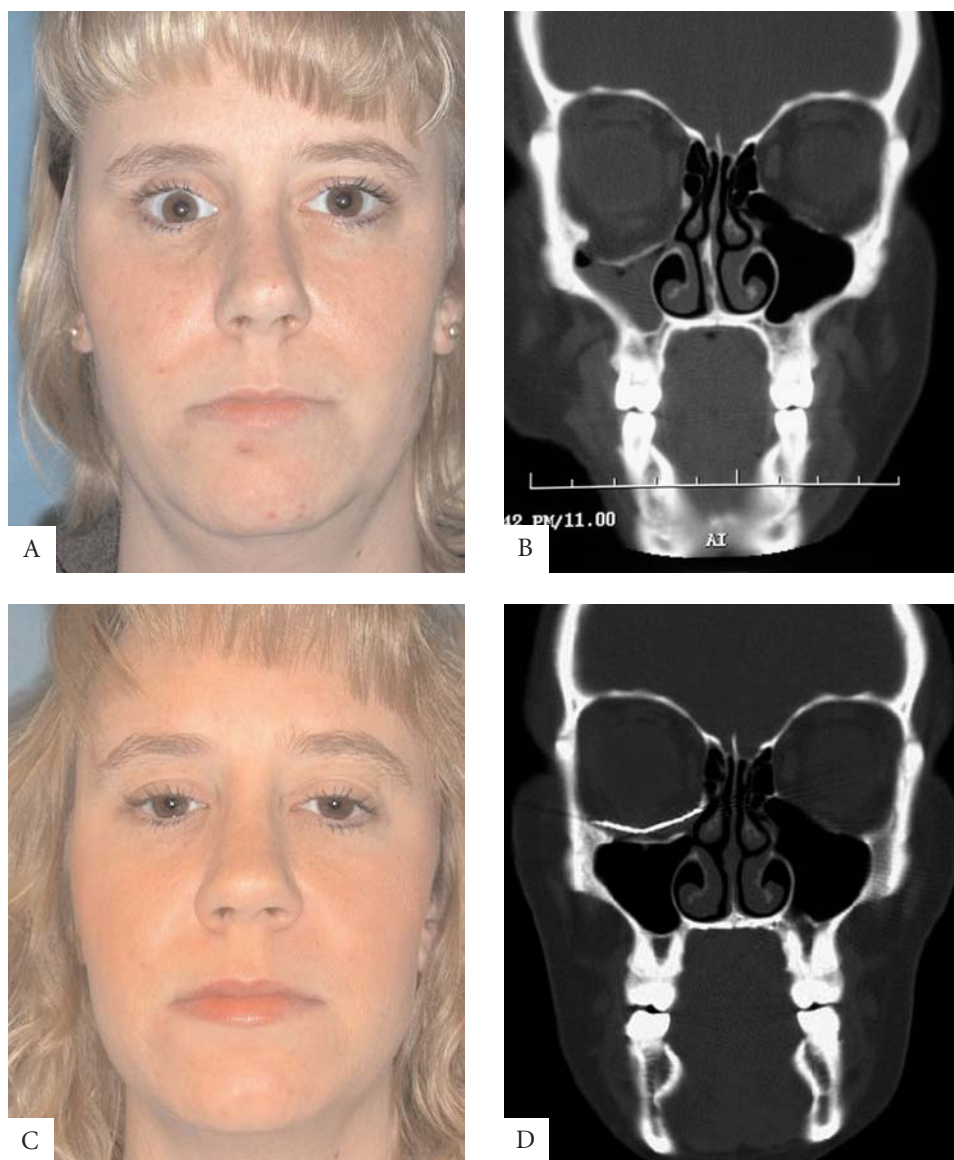


FIGURE 23.2-18 A, A 27-year-old female presented with late enophthalmos and diplopia after an undiagnosed orbital floor fracture. Note vertical dystopia and prominent supratarsal fold. B, Coronal CT scan demonstrating displacement of the orbital floor. C, One-year postoperative frontal photograph after transconjunctival reconstruction of the orbital floor with titanium mesh. Note the symmetry of the vertical globe position and the supratarsal fold. D, Post-operative coronal CT scan demonstrating titanium mesh reconstruction of the orbital floor.

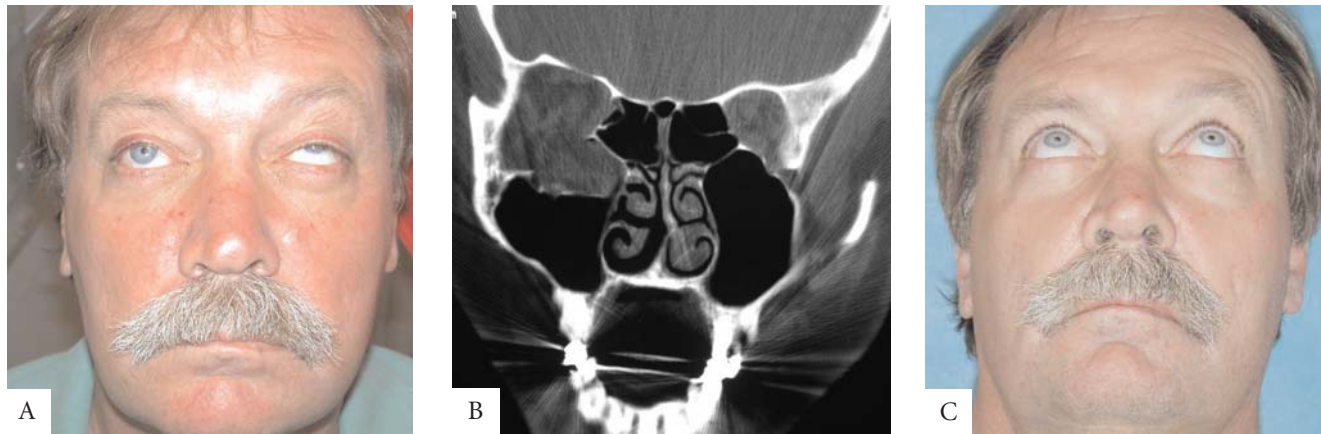


FIGURE 23.2-19 A, A 45-year-old male suffered a fall and presented with right orbital floor blow-out fracture and significant restriction of the inferior rectus and diplopia. B, Coronal CT scan demonstrating large orbital floor blow-out fracture with herniation of the orbital contents into the maxillary sinus. C, Postoperative view after transconjunctival reconstruction of the orbital floor with titanium mesh and return of normal extraocular muscle function. Note projection of the globes without evidence of enophthalmos.

Persistent bothersome diplopia that does not resolve may require treatment by an ophthalmologist. The condition may respond to exercise or surgery.^{45,61}

Traumatic Hyphema

Trauma to the eye may result in bleeding into the anterior chamber—the area between the clear cornea and the colored iris (Figure 23.2-20). Ophthalmology consultation is recommended. Goals of treatment include prevention of rebleeding, which may occur in 5 to 30% of patients, and maintenance of normal ocular tension.^{88,89}

Management of hyphema consists of supportive therapy including elevation of the head of bed and patching of the injured eye. Medical management includes topical cycloplegics, corticosteroids, and β -blockers. Systemic antifibrinolytics, carbonic anhydrase inhibitors, and osmotic agents may also be required. Rarely, surgical intervention by the ophthalmologist is required. Repair of fractures may be delayed.

Traumatic Optic Neuropathy

Traumatic optic neuropathy may manifest as conditions ranging from mild visual deficit to complete visual loss. An ophthalmologic consultation is mandatory. Treatment varies depending on the cause but

may include systemic steroids or surgery with orbital or optic nerve decompression. Treatment of facial fractures may be delayed.^{45,90}

Superior Orbital Fissure Syndrome

Superior orbital fissure syndrome is an uncommon complication following facial trauma. Presentation may include ptosis, ophthalmoplegia, forehead anesthesia, and a fixed dilated pupil. Proptosis may be present. Treatment may include reduction of fractures, steroids, orbital apex exploration, and aspiration of retrobulbar hematoma if present.⁹¹

Retrobulbar Hemorrhage

Retrobulbar hemorrhage is a rare but severe complication that may be the result of either the initial injury or the operative correction. Disruption of the retinal circulation may lead to irreversible ischemia and permanent blindness. In a review of 1,405 orbitozygomatic fractures, Ord reported a 0.03% incidence of postoperative retrobulbar hemorrhage with visual loss.⁹² An emergent ophthalmologic consultation is necessary; however, decompression with lateral canthotomy and cantholysis should not be delayed (see Figure 23.2-20).

Trismus

Patients with zygomatic fractures commonly present acutely with a complaint of trismus. However, there are few cases of

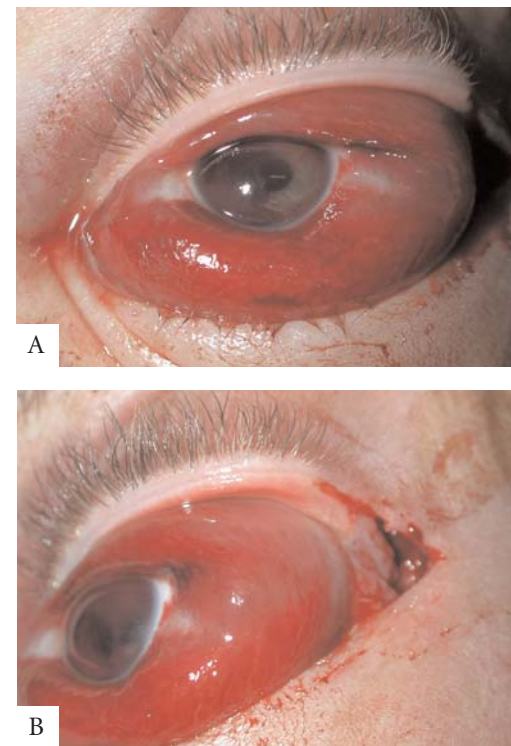


FIGURE 23.2-20 Retrobulbar hemorrhage. A, This patient presented with periorbital pain, fixed and dilated pupil, proptosis, and acute progressive loss of vision. Note hyphema. B, Immediate lateral canthotomy and cantholysis were performed.

long-term reduced mandibular range of motion following zygomatic complex fractures reported in the literature. The most likely cause is impingement of the zygomatic body on the coronoid process of the mandible. Trismus may also occur secondary to fibrous or fibro-osseous ankylosis of the coronoid to the zygomatic arch. A CT scan should be obtained to confirm the diagnosis. Coronoidectomy is the most common treatment. If the zygoma is improperly reduced, zygomatic osteotomy and repositioning may be necessary to restore unrestricted motion of the mandible.^{61,93}

Acknowledgment

The authors gratefully acknowledge Drs. Kaban and Perrott, the authors of the chapter on zygomatic complex fractures in the first edition of *Principles of Oral and Maxillofacial Surgery*, whose work served as the foundation of this chapter.

References

1. Leech TR, Martin BC, Trabue JC. An analysis of the etiology, treatment and complications of fractures of the malar compound and zygoma. *J Surg* 1956;92:920–4.
2. Matsunaga RS, Simpson W, Toffal PH. Simplified protocol for treatment of malar fractures. Based on a 1,220-case eight-year experience. *Arch Otolaryngol* 1977;103:535.
3. Ellis E, El-Attar A, Moos KE. An analysis of 2,067 cases of zygomatico-orbital fracture. *J Oral Maxillofac Surg* 1985;43:417.
4. Rontal E, Rontal M, Guilford FT. Surgical anatomy of the orbit. *Ann Otol Rhino Laryngol* 1979;88:382–6.
5. Vriens JP, van der Glas HW, Moos KE, Koole R. Infraorbital nerve function following treatment of orbitozygomatic complex fractures a multistep approach. *Int J Oral Maxillofac Surg* 1998;27:27.
6. Taicher S, Ardekian L, Samet N, et al. Recovery of infraorbital nerve after zygomatic complex fractures: a preliminary study of different treatment methods. *Int J Oral Maxillofac Surg* 1993;22:339.
7. Zingg M, Laedrach K, Chen J, et al. Classification and treatment of zygomatic fractures: a review of 1,025 cases. *J Oral Maxillofac Surg* 1992;50:778.
8. Manson PN, Markowitz B, Mirvis S, et al. Toward CT-based facial fracture management. *Plast Reconstr Surg* 1990;85:202.
9. Tanrikulu R, Erol B. Comparison of computed tomograph with conventional radiograph for midfacial fractures. *Dentomaxillofac Radiol* 2001;32:141.
10. Assael LA. Clinical aspects of imaging in maxillofacial trauma. *Radiol Clin North Am* 1993;31:209.
11. Knight JS, North JE. The classification of malar fractures: an analysis of displacement as a guide to treatment. *Br J Plast Surg* 1961;13:325.
12. Gruss JS, Van Wyck L, Phillips JH, Antonyshyn O. The importance of the zygomatic arch in complex midfacial fracture repair and correction of posttraumatic orbitozygomatic deformities. *Plast Reconstr Surg* 1990;85:878.
13. Smith HW, Yanagisawa E. Fracture-dislocations of zygoma and zygomatic arch. *Arch Otolaryngol* 1961;73:68.
14. Goldthwaite RH. Plastic repair of depressed fracture of the lower orbital rim. *J Am Med Assoc* 1924;82:628.
15. Quinn JH. Lateral coronoid approach for intra-oral reduction of fractures of the zygomatic arch. *J Oral Surg* 1977;35:321.
16. Gillies HD, Kilner TP, Stone D. Fractures of the malarzygomatic compound, with a description of a new x-ray position. *Br J Surg* 1927;14:651.
17. Dingman RO, Natvig P. *Surgery of facial fractures*. Philadelphia: W.B. Saunders; 1964. p. 226.
18. Mathog R. *Maxillofacial trauma*. Baltimore (MD): William & Wilkins; 1984. p. 3984.
19. Uglesic V, Virag M. A method of zygomatic arch stabilization. *Br J Oral Maxillofac Surg* 1994;32:396.
20. Thomson ERE. A simple zygomatic splint. *Br Dent J* 1983;155:257.
21. Feinstein FR, Krizek TJ. Fractures of the zygoma and zygomatic arch. In: Foster CA, Sherman JE, editors. *Surgery of facial bone fractures*. New York: Churchill Livingstone; 1987. p. 123.
22. Zachariades N, Mezitis M, Anagnostopoulos D. Changing trends in the treatment of zygomaticomaxillary complex fractures; a 12-year evaluation of methods used. *J Oral Maxillofac Surg* 1998;56(11):1152.
23. Ellis E, Kittidumkerng W. Analysis of treatment of isolated zygomaticomaxillary complex fractures. *J Oral Maxillofac Surg* 1996;54:386.
24. Yaremchuk MJ. Orbital deformity after craniofacial fracture repair: avoidance and treatment. *J Craniomaxillofac Trauma* 1999;5(2):7.
25. Makowski GJ, Van Sickels JE. Evaluation of results with three-point visualization of zygomaticomaxillary complex fractures. *Oral Surg Oral Med Oral Path* 1995;80:624.
26. Hollier LH, Thornton J, Pazmino P, Stal S. The management of orbitozygomatic fractures. *Plast Reconstr Surg* 2003;111:2386.
27. Adamo AK, Pollick SA, Lauer SA, Sterman HR. Zygomatico-orbital fractures: historical perspective and current surgical management. *J Craniomaxillofac Trauma* 1995;1(2):26.
28. Manson PN, Clark N, Robertson B, et al. Subunit principles in midface fractures: the importance of sagittal buttresses, soft-tissue reductions, and sequencing treatment of segmental fractures. *Plast Reconstr Surg* 1999;103:1287.
29. Rohner D, Tay A, Meng CS, et al. The sphenozygomatic suture as the key site for osteosynthesis of the orbitozygomatic complex in panfacial fractures: a biomechanical study in human cadavers based on clinical practice. *Plast Reconstr Surg* 2002;110:1463.
30. Swift JQ. Isolated zygoma fractures. *Atlas Oral Maxillofac Clin North Am* 1993;1:71–83.
31. Ellis E, Zide M. *Surgical approaches to the facial skeleton*. Baltimore (MD): William and Wilkins; 1995.
32. Kung DS, Kaban LB. Supratarsal fold incision for approach to the superior lateral orbit. *Oral Surg Oral Med Oral Path* 1996;81:522.
33. Phillips JH, Gruss JS, Wells MD, Chollett A. Periosteal suspension of the lower eyelid and cheek following subciliary exposure of facial fractures. *Plast Reconstr Surg* 1991;88:145.
34. Rohrich RJ, Janis JE, Adams WP. Subciliary versus subtarsal approaches to orbitozygomatic fractures. *Plast Reconstr Surg* 2003;111:1708.
35. Werther JR. Cutaneous approaches to the lower lid and orbit. *J Oral Maxillofac Surg* 1998;56:60.
36. Bahr W, Bagambisa FB, Schlegel G, Schilli W. Comparison of transcutaneous incisions for exposure of the infraorbital rim and orbital floor: a retrospective study. *Plast Reconstr Surg* 1992;90:585.
37. Wray RC, Holtmann B, Ribaud M, et al. A comparison of conjunctival and subciliary incisions for orbital fractures. *Br J Plast Surg* 1977;30:142.
38. Holtmann B, Wray RC, Little AG. A randomized comparison of four incisions for orbital fractures. *Plast Reconstr Surg* 1981;67:731.
39. Appling WD, Patrinely JR, Salzer TA. Transconjunctival approach vs. subciliary skin-muscle flap approach for orbital fracture repair. *Arch Otolaryngol Head Neck Surg* 1993;119:1000.

40. Patel PC, Sobota BT, Patel NM, et al. Comparison of transconjunctival versus subciliary approaches for orbital fractures: a review of 60 cases. *J Craniomaxillofac Trauma* 1998;4:17.
41. Waite PD, Carr DD. The transconjunctival approach for treating orbital trauma. *J Oral Maxillofac Surg* 1991;49:499.
42. Baumann A, Ewers R. Use of the preseptal transconjunctival approach in orbit reconstruction surgery. *J Oral Maxillofac Surg* 2001;59:287.
43. Tessier P. The conjunctival approach to the orbital floor and maxilla in congenital malformations and trauma. *J Maxillofac Surg* 1973;1:3.
44. Manson PN, Ruas E, Iliff N, Yaremchuk M. Single eyelid incision for exposure of the zygomatic bone and orbit reconstruction. *Plast Reconstr Surg* 1987;79:120.
45. Hammer B. *Orbital fractures diagnosis, operative treatment, secondary corrections*. Seattle (WA): Hogrefe and Huber; 2001.
46. Fonseca RJ. Discussion: changing trends in the treatment of zygomaticomaxillary complex fractures: a 12 year evaluation of methods used. *J Oral Maxillofac Surg* 1998;56:1156.
47. Shortinghuis J, Bos RR, Vissink A. Complications of internal fixation of maxillofacial fractures with microplates. *J Oral Maxillofac Surg* 1999;50:130.
48. Rudderman RH, Mullen RL. Biomechanics of the facial skeleton. *Clin Plast Surg* 1992; 19(2):11.
49. Dal Santo F, Ellis E, Throckmorton GS. The effects of zygomatic complex fracture on masseteric muscle force. *J Oral Maxillofac Surg* 1992;50:791.
50. Davidson J, Nickerson D, Nickerson B. Zygomatic fractures; comparison of methods of internal fixation. *Plast Reconstr Surg* 1990;86:25.
51. Kasrai L, Hearn T, Gur E, Forrest CR. A biomechanical analysis of the orbitozygomatic complex in human cadavers; examination of load sharing and failure patterns following fixation with titanium and bioresorbable plating systems. *J Craniofac Surg* 1999;10:237.
52. Fujioki M, Yamanoto T, Miyazalo O, Nishimura G. Stability of one-plate fixation for zygomatic bone fracture. *Plast Reconstr Surg* 2002;109:817.
53. Rohrich RJ, Hollier LH, Watumull D. Optimizing the management of orbitozygomatic fractures. *Clin Plast Surg* 1993;19:149.
54. Manson PN. Discussion: analysis of treatment for isolated zygomaticomaxillary complex fractures. *J Oral Maxillofac Surg* 1996; 54:400.
55. Prein J. *Manual of internal fixation in the cranio-facial skeleton*. New York: Springer-Verlag; 1998.
56. Manson PN. Discussion: the spenozygomatic suture as a key site for osteosynthesis of the orbitozygomatic complex in panfacial fractures; a biomechanical study in human cadavers based on clinical practice. *Plast Reconstr Surg* 2002;110:1472.
57. Longaker MT, Kawamoto HK. Enophthalmos revisited. *Clin Plast Surg* 1997;24:531.
58. Grant MP, Iliff NT, Manson PN. Strategies for the treatment of enophthalmos. *Clin Plast Surg* 1997;24:539.
59. Pearl RM. Enophthalmos correction: principles guiding proper treatment. *Op Tech Plast Reconstr Surg* 1998;5(4):352.
60. Smith ML, Williams JK, Gruss JS. Management of orbital fractures. *Op Tech Plast Reconstr Surg* 1998;5(4):312.
61. Fonseca RJ, Walker RV, Betts NJ, Barber HD. *Oral and maxillofacial trauma*. Philadelphia (PA): W.B. Saunders; 1997.
62. Fujino T, Makino K. Entrapment mechanism and ocular injury in orbital blow-out fracture. *Plast Reconstr Surg* 1980;65:571.
63. Catone GA, Morrissette MP, Carlson ER. A retrospective study of untreated orbital blow-out fractures. *J Oral Maxillofac Surg* 1988;46:1033.
64. Shumrick KA, Campbell AC. Management of the orbital rim and floor in zygoma and midface fractures: criteria for selective exploration. *Facial Plast Surg* 1998;14:77.
65. Hartstein ME, Roper-Hall G. Update on orbital floor fractures: indications and timing for repair. *Facial Plast Surg* 2000;16:95.
66. Ellis E, Tan Y. Assessment of internal orbital reconstructions for pure blow-out fractures: cranial bone grafts versus titanium mesh. *J Oral Maxillofac Surg* 2003;61:442.
67. Li KK. Repair of traumatic orbital wall defects with nasal septal cartilage: report of five cases. *J Oral Maxillofac Surg* 1997;55:1098.
68. Chen JM, Zingg M, Laedrach K, Raveh J. Early surgical intervention for orbital floor fractures; a clinical evaluation of lyophilized dura and cartilage reconstruction. *J Oral Maxillofac Surg* 1992;50:935.
69. Mackenzie DJ, Arora B, Hansen J. Orbital floor repair with titanium mesh screen. *J Craniomaxillofac Trauma* 1999;5(3):9.
70. Choi JC, Sims CD, Casanova R, et al. Porous polyethylene implant for orbital wall reconstruction. *J Craniomaxillofac Trauma* 1995;1(3):42.
71. Baumann A, Burggasser G, Gauss N, Ewers R. Orbital floor reconstruction with an alloplastic resorbable polydioxanone sheet. *Int J Oral Maxillofac Surg* 2002;31:367.
72. Manson PN, Clifford CN, Su CT, et al. Mechanisms of global support and post-traumatic enophthalmos I. The anatomy of the ligament sling and its relations to intermuscular cone orbital fat. *Plast Reconstr Surg* 1987;77:193.
73. Manson PN, Grivas A, Rosenbaum A, et al. Studies on enophthalmos II. The measurement of orbital injuries and their treatment by quantitative computed tomography. *Plast Reconstr Surg* 1986;77:203-14.
74. Gruss JS, Mackinnon SE, Kassel EE, Cooper PW. The role of primary bone grafting in complex craniomaxillofacial trauma. *Plast Reconstr Surg* 1985;75(1):17.
75. Manson PN, Crawley WA, Yaremchuk MJ, et al. Midface fractures: advantages of immediate extended open reduction and bone grafting. *Plast Reconstr Surg* 1985;76(1):1.
76. Spinelli HM, Forman DL. Current treatment of post-traumatic deformities. Residual orbital, adnexal, and soft-tissue abnormalities. *Clin Plast Surg* 1997;24:519.
77. Dolynchuk KN, Tadjalli HE, Manson PN. Orbital volumetric analysis: clinical applications in orbitozygomatic complex injuries. *J Craniomaxillofac Trauma* 1996;2:56.
78. Yab K, Tajima S, Ohba S. Displacement of eyeball in orbital blow-out fractures. *Plast Reconstr Surg* 1997;100:1409.
79. Raskin EM, Millman AL, Lubkin V, et al. Prediction of late enophthalmos by volumetric analysis of orbital fractures. *Ophthal Plast Reconstr Surg* 1998;14:19.
80. Ploder O, Klug C, Voracek M, et al. Evaluation of computer-based area and volume measurement from coronal computed tomography scans in isolated blow-out fractures of the orbital floor. *J Oral Maxillofac Surg* 2002;60:1267.
81. Manson PN, Iliff N, Robertson B. Discussion: evaluation of computer-based area and volume measurement from coronal computed tomography scans in isolated blow-out fractures of the orbital floor. *J Oral Maxillofac Surg* 2002;60:1273.
82. Al-Qurainy IA, Stassen LE, Dutton GN, et al. Diplopia following midfacial fractures. *Br J Oral Maxillofac Surg* 1991;29:302.
83. Carr RM, Mathog RH. Early and delayed repair of orbitozygomatic complex fractures. *J Oral Maxillofac Surg* 1997;55:253.
84. Hosal BM, Beatty RL. Diplopia and enophthalmos after surgical repair of blow-out fracture. *Orbit* 2002; 21(1):27.
85. Putterman AM, Stevens T, Urist MN. Nonsurgical management of blow-out fractures of the orbital floor. *Am J Ophthalmol* 1974;77:232.
86. Putterman AM. Late management of blow-out

- fractures of the orbital floor. In: Aston SJ, Hornblass A, Meltzer MA, Rees TD, editors. Third international symposium of plastic and reconstructive surgery of the eye adnexa. Baltimore (MD): Williams & Wilkins; 1982. p 86–95.
87. Iliff N, Manson PN, Katz J, et al. Mechanisms of extraocular muscle injury in orbital fractures. *Plast Reconstr Surg* 1999;103:787.
88. Gossman MD, Roberts DM, Barr CC. Ophthalmic aspects of orbital injury. *Clin Plast Surg* 1992;19(1):71.
89. Brandt MT, Haug RH. Traumatic hyphema: a comprehensive review. *J Oral Maxillofac Surg* 2001;59:1462.
90. Spoor TC, McHenry JG. Management of traumatic optic neuropathy. *J Craniomaxillofac Trauma* 1996;2(1):14.
91. Rohrick RJ, Hackney FL, Parikh RS. Superior orbital fissure syndrome: current management concepts. *J Craniomaxillofac Trauma* 1995;1(2):44.
92. Ord RA. Postoperative retrobulbar hemorrhage and blindness complicating trauma surgery. *Br J Oral Surg* 1981;19:202.
93. Ostrofsky MK, Lownie JF. Zygomatico-coronoid ankylosis. *J Oral Surg* 1977;35:752.

Orbital and Ocular Trauma

Mark W. Ochs, DMD, MD

Orbital Fractures

Anatomy

The orbit is the bony vault that houses the eyeball, or globe. It is a quadrangular-based pyramid that has its peak at the orbital apex. The average adult orbit has a volume of 30 cc; the globe averages 7 cc (Figure 24-1). Even a modest change in the position of one of the bony walls can have a significant impact on the orbital volume and, thus, globe position. The orbit serves to house and protect the globe. By age 5 years orbital growth is 85% complete, and it is finalized between 7 years of age and puberty.^{1,2}

The orbital rim is composed of dense cortical bone that generally protects the orbital contents and globe from direct blunt trauma. Seven bones form the orbit: maxillary, zygomatic, frontal, ethmoidal, lacrimal, palatine, and sphenoid. Besides forming a protective socket for the globe, these bones also provide origins for the extraocular muscles, and foramina and fissures for cranial nerves and blood vessels.³

The orbital walls vary considerably in their thickness. Whereas the superior lateral and inferior rims tend to be rather thick, the bones just posterior to these and the medial rim are usually fairly thin (< 1 mm). Fractures of the anterior and middle thirds of the bony orbit are fairly common. The orbital floor and medial wall are most frequently fractured owing to their thinness and lack of support. This is

fortunate since inward or medial displacement of midfacial or zygomatic bones can reduce the orbital volume and be accompanied by orbital hemorrhage. The subsequent increased intraorbital pressure is most often relieved by traumatic expansion of the walls with herniation of orbital

tissue into the maxillary sinus and/or ethmoid air cells adjacent to these walls. In essence, the paranasal sinuses and ethmoid air cells serve as air bags or shock absorbers to the globe and orbital contents. This protective mechanism explains why globe perforation is relatively uncommon following

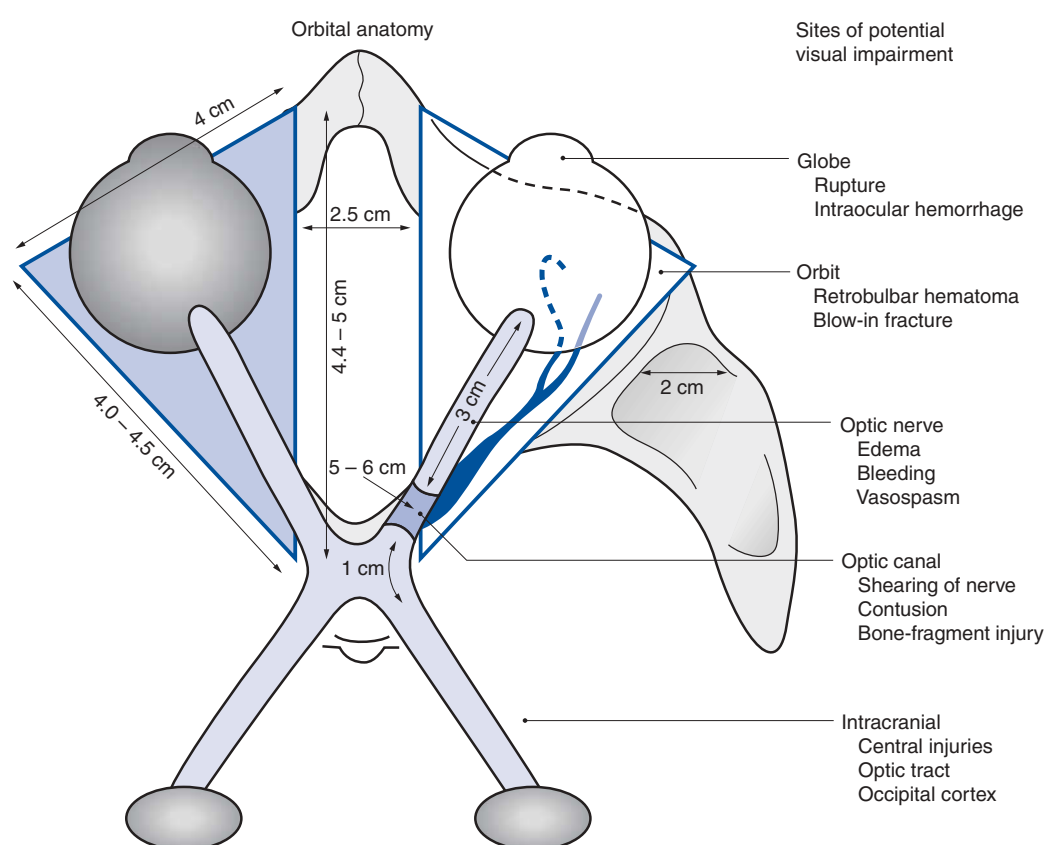


FIGURE 24-1 Orbital configuration with potential sites for traumatic injuries leading to visual impairment. Adapted from Ochs MW, Johns FR. Orbital trauma. In: Fonseca RJ, Marciani RD, Hendler BH, editors. *Oral and maxillofacial surgery: trauma*. Vol 3. Philadelphia (PA): W.B. Saunders; 2000. p. 207.

midfacial trauma. Orbital fractures that involve the frontal sinuses more commonly result in serious eye injuries.^{4,5} These fractures, following blunt trauma, and the associated blindness are probably not seen as often owing to the severity of forces and concomitant neurologic, cervical spine, and multisystem trauma. In short, they generally are not survivable events.

The orbital roof consists mainly of the frontal bone, with the anterior cranial fossa superior to it. The lesser wing of the sphenoid has a minor contribution posteriorly. The superior orbital rim is generally rather thick and then rapidly becomes quite thin (< 1 mm) posterior from the edge. In elderly patients the orbital roof may be resorbed in select areas, allowing the dura to become confluent with the periorbita. This should be kept in mind during orbital dissection and elevation in this region for both trauma and tumor work. Generally, the anterior portion of the orbital roof is occupied by the supraorbital extension of the frontal sinus. The frontal sinus begins to form around the age of 6 years and is unilateral in 5% of adults and lacking in another 5%. Anterolaterally there is a smooth broad fossa that houses the lacrimal gland. At the most medial extent is the trochlea, approximately 4 mm behind the rim. There the cartilaginous pulley has a dual insertion for the superior oblique muscle tendon. At the junction of the medial one-third and lateral two-thirds of the superior rim is the supraorbital notch. In one-fourth of adults, a supraorbital foramen is found, secondary to the ossification of the ligament crossing the inferior extent.⁶ When reflecting bicoronal flaps, a small triangular wedge osteotomy should be performed in these individuals to relieve the encased supraorbital nerve and vessels and to allow for a relaxed reflection of tissues at the rim.

The orbital floor is bordered laterally by the inferior orbital fissure. However, there is no distinct border medially (Figure 24-2).

The orbital floor is formed primarily by the orbital process of the maxilla—anterolaterally by a portion of the zygomatic bone, and posteriorly by a small portion of the palatine bone. The maxillary sinuses are present at birth and reach the orbital floor and infraorbital canal by age 2 years.⁷ The inferior orbital fissure gives rise to the infraorbital groove from its midportion, which is about 2.5 to 3 cm from the infraorbital rim. The infraorbital fissure converts to a canal halfway forward, carrying the infraorbital nerve and vessels and opening approximately 5 mm below the rim of the maxilla as the infraorbital foramen (Table 24-1).⁸ The infraorbital nerve provides sensory innervation to the upper lip, lateral nose, and anterior maxillary teeth and mucosa. The orbital floor can be as thin as 0.5 mm, with its weakest portion just medial to the infraorbital groove and canal. This explains the phenomenon that most blunt traumas resulting in orbital floor blow-outs are manifested primarily with injury and sagging of the medial orbital floor and orbital contents

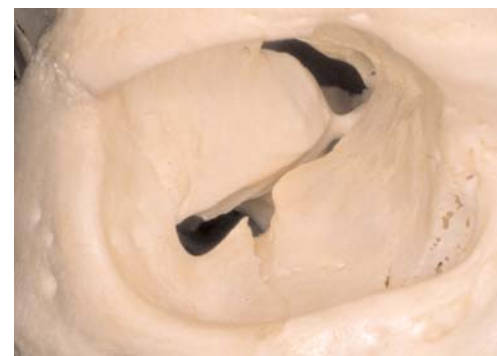

FIGURE 24-2 Right bony orbit. The inferior orbital fissure can be seen converting to a canal angling medially at the Y-shaped divide. The lacrimal fossa is characteristically thin. The lamina papyracea occupies the majority of the medial wall, with the frontoethmoidal suture at the superior extent.

into the underlying maxillary sinus with extension laterally to the infraorbital canal.

The lateral wall of the orbit is formed mainly by the greater wing of the sphenoid and portions of the zygoma. Although this tends to be the strongest wall, it is fairly commonly fractured along the frontozygomatic junction, extending slightly

Table 24-1 Orbital Fissures/Canals and Their Contents

Location	Contents
Superior orbital fissure—lesser and greater wings of sphenoid	Motor nerves: III (superior and inferior divisions), IV (trochlear), V (abducens) Sensory nerves: V ₁ (frontal, lacrimal, nasociliary), sympathetic fibers Vessels: superior ophthalmic vein, anastomosis of recurrent lacrimal and middle meningeal arteries
Inferior orbital fissure—greater wing of sphenoid; palatine, zygomatic, and maxillary bones	Sensory nerves: V ₂ (infraorbital and zygomatic), parasympathetic branches of pterygopalatine ganglion Vessel: inferior ophthalmic vein and branches to pterygoid plexus
Optic canal—lesser wing of sphenoid	Optic nerve, meninges, ophthalmic artery, sympathetic fibers
Anterior ethmoid canal—frontal and ethmoid bones	Nerve: anterior ethmoid becomes dorsal nasal Vessel: anterior ethmoid artery
Posterior ethmoid canal—frontal and ethmoid bones	Nerve: posterior ethmoid Vessel: posterior ethmoid artery
Nasolacrimal fossa—lacrimal and maxillary bones	Nasolacrimal sac and duct

posteriorly and then running vertically along the thinnest portion of the suture line, where the greater wing of the sphenoid and zygoma meet. This wall separates the orbit from the temporalis muscle. Owing to the heavy nature of this muscle and the direction of blunt forces, generally there is some mild degree of inward displacement. The lateral orbital walls, if they were to be extended posteriorly, would form a 90° angle to each other. Each lateral orbital wall forms a 45° angle at the orbital apex, with its medial wall counterpart. This is important to bear in mind when attempting to realign or reconstruct fractured walls. The superior orbital fissure separates the greater and lesser wings of the sphenoid and serves as the delineation between the orbital roof and lateral wall. At the orbital apex the lesser wing of the sphenoid forms the lateral portion of the ring of the optic canal. One centimeter below the frontozygomatic suture, and just internal (3–4 mm) to the lateral orbital rim, is Whitnall's tubercle (lateral orbital tubercle). This gentle outcropping of bone functions as the insertion point for the lateral retinacular structures. The lateral retinaculum is composed of the lateral horn of the levator aponeurosis; the lateral canthal tendon of the eyelids; and the inferior suspensory (Lockwood's) ligament and multiple fine check ligaments of the lateral rectus muscle. These soft tissue attachments are found anatomically in this order proceeding inferiorly and posteriorly from the rim. These multiple structures become confluent to form the common lateral retinaculum, which is the actual insertion to the tubercle.⁶ Clinically the point to remember is that reattachment of the lateral canthal tendon should be to the lateral orbital tubercle.

The medial wall of the orbit is by far the most complex and potentially problematic to manage in severe trauma. The medial orbital wall is composed anterior-to-posterior by a portion of the maxillary, lacrimal, ethmoid, and sphenoid bones.

The majority of the medial wall is formed by the extremely thin (0.2–0.4 mm) lamina papyracea of the ethmoid bone. Housed along the frontoethmoidal junction are the anterior and posterior ethmoidal foramina. The anterior ethmoidal foramen is 20 to 25 mm behind the medial orbital rim, and 12 mm beyond this is the posterior ethmoidal foramen. The foramina can be found approximately two-thirds of the way up the medial orbital wall, within the frontoethmoidal suture line, and serve as important surgical landmarks identifying the level of the corresponding cribriform plate. Orbital surgeons use these arteries as the landmarks for the superior extent of orbital wall decompression. The anterior ethmoidal foramen transmits the anterior ethmoidal artery and anterior ethmoidal branches from the nasociliary nerve from the orbit coursing into the nasal cavity. This is why otolaryngologists sometimes use a medio-orbital approach to ligate or cauterize the anterior ethmoidal artery to control recalcitrant nasal bleeding. Although the anterior ethmoidal vessel can be cauterized with few ill effects, the contents of the posterior ethmoidal foramen (posterior ethmoidal artery and, variably, a sphenothmoidal nerve from the nasociliary nerve) are generally allowed to remain intact since they serve as a useful delineation to the posterior extent of safe medial wall dissection.

Once beyond the orbital rims, subperiosteal dissection generally proceeds fairly easily, except for points of nerves or vessels perforating through foramina, orbital

fissures, or muscle origins such as that of the inferior oblique. When encountering resistance, surgeons should attempt to identify the exact anatomic reason for the resistance, such as structures that may need to be preserved or periorbital tissues that have become entrapped in fracture lines. Knowledge of the limits of safe subperiosteal dissection is mandatory. Also important is knowing the distance from the intact orbital rim, where vital structures can be identified. Generally, a subperiosteal dissection from the inferior lateral rims can be safely extended for 25 mm. An exploration distance of 30 mm from the superior orbital rim or anterior lacrimal crest (found on the frontal process of the maxilla) can be safe.⁵ A high medial wall dissection places the orbital apex and optic canal at risk. One caveat to these “safe surgical exploration distances” is that they are averages of known landmarks to intact adult orbital rims. When traumatic forces displace a portion of a rim, it is generally in a posterior or medial direction, which effectively reduces these distances. Knowledge of the bony orbital anatomy, with its foramina, fissures, and attachment areas, helps the surgeon to avoid injuries to vital structures contained within them.¹ Average distances for locating these critical structures as they relate to identifiable bony landmarks are contained in Table 24-2. Surgeons should avoid disrupting the medial canthal tendon, lacrimal apparatus, pulley of the superior oblique muscle, supraorbital nerves and vessel, attachments to Whitnall's tubercle, and the origin of the inferior oblique muscle.

Table 24-2 Distance of Vital Orbital Structures from Bony Landmarks

<i>Structure</i>	<i>Reference Landmark</i>	<i>Mean Distance (mm)</i>
Midpoint of inferior orbital fissure	Infraorbital foramen	24
Anterior ethmoidal foramen	Anterior lacrimal crest	24
Superior orbital fissure	Zygomaticofrontal suture	35
Superior orbital fissure	Supraorbital notch	40
Optic canal (medial aspect)	Anterior lacrimal crest	42
Optic canal (superior aspect)	Supraorbital notch	45

The anterior boundary of the orbit is defined by the orbital septum. The upper and lower eyelids are anatomically similar in their composition, with corresponding layers anteriorly to posteriorly. When one is looking downward, the lid retractors enable the lower eyelid to roll with the globe, thus avoiding a visual field cut. The lids have a very thin keratinized epithelium that is loosely attached to the underlying orbicularis oculi muscle (Table 24-3). The orbicularis oculi muscle is innervated by cranial nerve VII and acts as a sphincter and closing force for the eyelids. In the relaxed state the orbicularis oculi is opposed in the upper eyelid by the levator palpebrae superioris, which is innervated by cranial nerve III. The resting tone and level of the upper eyelid are partly determined by the amount of sympathetic input to Müller's muscle. The orbicularis oculi has two distinct layers: the outer superficial fibers (orbital portion) and the deeper fibers (palpebral portion). The palpebral section medially has intricate insertions and envelops the lacrimal sac by dividing into intertwined deep and superficial heads. The superficial portion inserts onto the anterior lacrimal crest. The inner deep head inserts into the fascia of the lacrimal sac and posterior lacrimal crest. The medial canthal tendon is formed by the condensation of the orbicularis muscle fibers. It is the superficial head of the canthal tendon that has a tenacious insertion into the anterior lacrimal crest. This is beneficial during orbital approaches since

the anterior insertion offers considerable resistance to dissection, which helps one avoid inadvertent injury to the lacrimal sac. At the lateral edge of the orbicularis oculi, the superficial fibers form an indistinct raphe, and it is the deeper fibers that comprise the lateral canthal tendon, inserting onto Whitnall's tubercle.⁹ The upper and lower lids should form a 30 to 40° angle at the lateral canthus, which is situated 1 cm below the frontozygomatic suture. Typically, the lateral canthus is situated 2 to 4 mm above the medial canthus.

Just posterior to the orbicularis oculi is the orbital septum. The orbital septum is continuous with the orbital periosteum and the periosteum of the facial bones overlying the rims. One to two millimeters below the inferior rim, where these layers converge on the facial aspect, is a periosteal thickening called the arcus marginalis.⁵ This is a useful landmark when performing an infraciliary or preseptal transconjunctival approach to the inferior rim. If one stays in front of the orbital septum and incises below the arcus marginalis, then orbital contents and fat do not herniate into the field. The distal edges of the orbital septum insert into the superior edge of the tarsal plates. The orbital septum and these insertions prevent the preaponeurotic orbital fat from herniating out into the eyelids. Superiorly there is a central and medial fat pad, and inferiorly there are three distinct fat pads (medial, central, and lateral). With aging, the orbital septum can become lax and, particularly in the lower lids, result in "baggy lids." Severe sagging of the lower lids is referred to as festooning.

The primary elevator of the upper eyelids is the levator palpebrae superioris muscle. Inferiorly it forms an aponeurosis below Whitnall's ligament that attaches broadly over the anterior tarsal plate. Approximately 15 to 20 mm above the tarsal plate, the aponeurosis consists of a thickened fascial band, which is termed Whitnall's ligament. This is a suspensory

ligament of the lid. Müller's muscle arises beneath the levator muscle and inserts into the superior border of the tarsal plate. Müller's is a smooth muscle that receives sympathetic input for its tone and helps regulate the resting position of the upper eyelids while the eyes are open. Increased stimulation or sympathetic input causes a "wide-eyed" look and a more alert appearance.¹⁰ The capsulopalpebral fascia and the inferior tarsal muscle in the lower eyelids are also termed the lower lid retractors. The lid retractors are formed from the fibrous attachments of the inferior rectus and inferior oblique muscles, and fuse with Lockwood's inferior suspensory ligament.

The tarsal plate is formed by dense fibrous connective tissue and is primarily responsible for the convex form of each of the lids. The tarsal border parallels the free margin of the eyelid. The horizontal length of each tarsus is approximately 30 mm. The height is greatest in the mid-portion of the lid. The height of the upper tarsus is 10 mm, whereas in the lower lid it is 4 mm. Embedded within the tarsal plates are a fine network of meibomian (sebaceous) glands. When obstructed and chronically inflamed, these glands can form a cyst-like mass called a chalazion.

The lacrimal system is responsible for the lubrication and wetting of the globe. Accessory lacrimal glands perform normal wetting of the eye, and the lacrimal gland produces reflex tearing. The lacrimal gland, which is situated in the anterior aspect of the superior lateral orbit, is divided into two lobes by the levator aponeurosis. The larger orbital lobe lies above the levator aponeurosis, and its tear ducts traverse the palpebral lobe, which has 6 to 12 tear ductules that empty into the superior lateral fornix. When drilling in this region, such as during a repair of a frontozygomatic fracture, one must take care not to injure the palpebral lobe or to inadvertently remove it, thinking that it is herniated fat; this error often results in a problematic dry eye. Lacrimal secretions,

Table 24-3 Eyelid Layers: Cutaneous (Anterior) to Conjunctival (Posterior)

Skin
Subcutaneous areolar tissue
Striated muscle (orbicularis oculi)
Submuscular areolar tissue (contains main sensory nerves to lids)
Fibrous layer with tarsal plates
Nonstriated smooth muscle
Mucous membrane or conjunctiva

or tears, traverse medially and inferiorly across the globe, wetting the cornea, and accumulate at the medial inferior aspect of the eye. The fluid is then either drawn or pumped into the lacrimal puncta of the upper and lower eyelids. These puncta are only 0.2 to 0.3 mm in diameter. The upper punctum is usually just slightly medial in relation to the lower punctum. When the lids close, the puncta come into contact. The upper and lower canaliculi travel within the lids, first vertically (2 mm), then horizontally for 8 to 10 mm, paralleling the lid margin. They join to form a common canaliculus just before entering the lateral aspect of the lacrimal sac, which is one-third of the way down from the upper portion of the sac. Typically, the lacrimal sac is 1 cm in length and 5 mm in diameter. The palpebral portion of the orbicularis oculi has dense intertwined insertions that envelope the lacrimal sac. Inferiorly, the sac drains into the nasolacrimal duct, which has a 12 mm intrabony canal coursing inferiorly and posteriorly that opens into the inferior meatus of the nasal cavity below the inferior concha. This opening is 30 to 35 mm from the edge of the external nares. Reflux of tears and nasal mucus back up into the nasolacrimal duct is prevented by a mucosal fold called Hasner's valve. With persistent epiphora following trauma or surgical intervention, it is important to establish the precise point of mechanical obstruction that exists within the lacrimal drainage system. Irrigation of the inferior canaliculus may relieve temporary obstruction owing to dry or thickened secretions. A dye disappearance test, Jones I or II, nasolacrimal irrigation, or dacryocystography can help one determine the precise point of obstruction and guide surgical planning. Following trauma or operative intervention, epiphora may be due to hypersecretion from a corneal abrasion, lash ptosis, foreign bodies, or entropion, all of which serve as persistent stimuli leading to reflex lacrimal gland secretion.

Fracture Configurations

Isolated orbital wall fractures account for 4 to 16% of all facial fractures. If fractures that extend outside the orbit are included, such as those of the zygomatic complex (ZMC) and naso-orbitoethmoid (NOE), then this accounts for 30 to 55% of all facial fractures.^{11,12}

ZMC fractures are the most commonly occurring facial fracture, second only to nasal fractures. By definition, ZMC fractures are the most common fracture with orbital involvement.¹³ The ZMC, or tripod, often hinges about the frontozygomatic suture with a medial, inferior, and posterior vector of rotational displacement. This is due to the direction and force of blunt trauma and the variable thicknesses of the components of the ZMC. The frontozygomatic area offers the thickest pillar. When fractured there is usually a slight vertical displacement with a reasonable anteroposterior alignment. The much thinner anterior maxillary and lateral orbital floor offers little resistance to fracture and displacement.

Fractures of the NOE are most often due to severe blunt midface trauma. These fractures create cosmetic deformities with a flattening of the nasal dorsum and a widening of the intercanthal distance; they can also be accompanied by a violation of the underlying dura with a cerebrospinal fluid (CSF) leak. Any persistent or copious clear nasal drainage should be tested to determine a β_2 -transferrin level to rule out a CSF leak. It is uncommon for the canthal tendons to become disinserted from the bones. This is particularly true of the lateral canthal tendon. Traumatic telecanthus with NOE fractures is a result of a flattening of the nasal bridge and a lateral splaying of the orbital rims and anterior lacrimal crest. Reduction and fixation of these bony segments and, less frequently, direct transnasal wiring are necessary for adequate restoration of medial intercanthal distance and alignment. In adult Caucasians this is typi-

cally 29 to 32 mm; it is slightly more in black and Asian individuals. Lacrimal drainage problems can also arise from severe NOE fractures owing to canalicular or lacrimal sac disruption or scarring.

Internal orbital fractures occur in numerous patterns. These fractures are typically described by their location and the size of the defect. Three basic patterns of internal orbital fractures have been described: linear, blow-out, and complex.¹⁴ Linear internal orbital fractures maintain periosteal attachments and typically do not result in a defect with orbital content herniation; however, they can result in a significant enlargement of the orbital volume with a resulting late enophthalmos. Blow-out fractures are the most common. By definition, these are limited to one wall and typically are 2 cm or less in diameter. The most commonly involved wall with a blow-out fracture is the anterior medial orbital floor, followed by the medial wall and, less frequently, the orbital roof, which can present as a *blow-in* fracture. Exploration, repair, or reconstruction of an orbital roof fracture may be indicated if a dural tear is suspected or to prevent a "pulsatile globe." This rhythmic inward and outward movement of the eye is due to the cerebrovascular pulsation and the influence of respiration on the overlying cerebral hemispheres. This phenomenon is typically not present acutely but occurs after resolution of edema, with the recovered patient complaining of persistent blurred or double vision. Complex internal orbital fractures consist of extensive fractures affecting two or more orbital walls; they often extend to the posterior orbit and may involve the optic canal. These complex fractures are usually associated with more severe trauma and surrounding fractures such as Le Fort II, Le Fort III, and frontal sinus fractures.

Clinical Examination

Even in the most severely injured patient, the mechanism of injury and surrounding

history should be ascertained before performing a clinical examination of the orbit and globe. A systematic approach assessing both the globes and orbits further defines functional and cosmetic defects. The initial ophthalmologic evaluation should include periorbital examination, visual acuity, ocular motility, pupillary responses, visual fields, and a fundoscopic examination.

Visual acuity should be independently tested on each eye using a Snellen chart at a standard 6 m (20 ft.) distance or with reading of standard-type print at 40 cm (16 in.). The patient should wear their corrective lenses during this examination. If over 40 years of age, the patient should be wearing his or her reading glasses. The eyelids and periorbital region should be inspected for edema, chemosis, ecchymosis, lacerations, ptosis, asymmetric lid drape, canalicular injury, and canthal tendon disruption. With significant acute periorbital ecchymosis, there should be an increased suspicion of a direct blunt globe injury or an internal orbital wall fracture. A lid retractor (Desmarres) is useful for separating swollen tight lids so that the globe and pupil can be adequately examined. Also, this retractor may serve to lift the edge of the lid to examine its inner aspect. With an upper eyelid laceration, any fat that is herniating below the level of the brow through the wound should cause concern that an underlying injury has occurred to the levator muscle. Likewise, if the palpebral conjunctiva has been violated, it is prudent to consult an ophthalmologist to rule out a globe perforation. With a medial vertical laceration of the lids, particularly the lower, gentle lateral retraction may reveal a cut canaliculus or medial canthal tendon disinsertion. Canalicular disruption warrants an urgent ophthalmology consult and usually requires surgical reanastomosis and silicone tube placement into the nasolacrimal system and surrounding supportive repair to prevent outflow obstruction and epiphora.

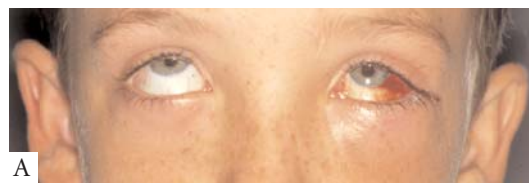Extraocular movements are evaluated to rule out mechanical entrapment or paresis. Diplopia, and the field of gaze in which it occurs, should be noted (Figure 24-3). Of greatest concern is diplopia in the primary (straight-ahead) and downward gazes. These are the two fields that are used most often. Mild or equivocal restriction ($< 5^\circ$) in extreme fields of gaze is common in the setting of severe orbital trauma with hemorrhage or edema. Computed tomography (CT) scan findings should be correlated with any clinically noted entrapment. If mechanical entrapment is suspected, then the eye should be topically anesthetized and a forced duction performed with a fine-toothed forceps. Typically, an Adson forceps is used at the inferior fornix with the beaks open, pressing inward against the depth of the fornix and toward the globe side, until the globe rolls downward slightly. The beaks are then pressed together, grasping the insertion of the inferior rectus. Upward, downward, and lateral motions can be evaluated. The point of doing a forced duction test is to determine whether the diplopia is due to a restriction of a muscle or paresis of a muscle.

Pupillary light reactivity, size, shape, and symmetry should all be assessed and noted. If unequal pupils (anisocoria) or an irregularly pointing pupil is found, then the patient should be queried regarding previous ocular trauma or eye surgery (cataracts). An irregular pupil often points toward the site of a globe penetration or injury. This is often teardrop shaped, with the narrow portion pointing toward the perforated side of the globe, which is usually concealed beneath the lid (Figure 24-4). An ophthalmologist should be consulted immediately and precautionary measures instituted, including protective Fox shield over the eye, head-of-bed elevation, bed rest, analgesics, and antiemetics to avoid sudden increases in intraocular pressure owing to Valsalva forces.

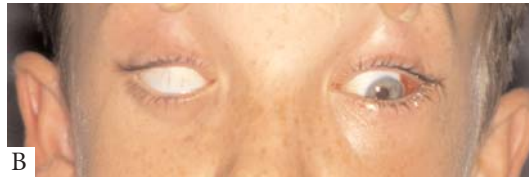Both globes should be evaluated for any acute enophthalmos, exophthalmos, or

vertical dystopia. This is often ascertained from above or by standing directly in front of the patient. Visual fields are tested for each eye, one at a time, by confrontation. The examiner and patient faces should be positioned directly toward each other, 0.6 m apart. The patient is asked to stare directly into the examiner's eyes, while the examiner's hand is held in their own extreme field of gaze, midway between the patient and the examiner. The patient is then asked to detect numbers of fingers showing, motion, or the digit displayed. In essence, the examiner's peripheral field of gaze is serving as a control for the patient.

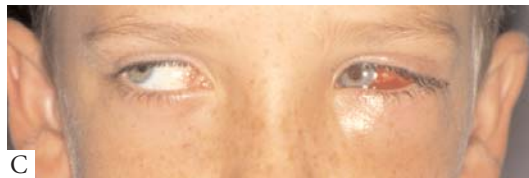Quadrant defects are indicative of post-chiasm injury. A fundoscopic examination should be performed in a dimly lit room to help maximize pupillary dilatation and ease of the examination. Lens dislocation, vitreous hemorrhage, retinal detachment, and foreign bodies may be noted or may be the cause for not being able to view the fundus. If history and initial clinical findings warrant a dilated fundoscopic examination, then neurologic status should be reevaluated and confirmed, and clearance from the primary treating physician or neurosurgeon first obtained. A dilated fundoscopic examination with indirect ophthalmoscopy is generally performed by an ophthalmologist to rule out more occult injuries or examine a greater portion of the globe toward the equator. The ophthalmologist may elect to perform tonometry or a slit-lamp examination. Tonometry indirectly measures intraocular pressure by placing the instrument on the surface of the eye. Normal (10–20 mm Hg) or symmetric bilateral readings are reassuring. However, this does not rule out a penetrating injury. With elevated pressures but an otherwise unremarkable examination, a history of glaucoma should be elicited. An acute abnormally high intraocular pressure with exophthalmos, limited globe movement, and resistance to retropulsion is indicative of a retrobulbar hematoma, which may



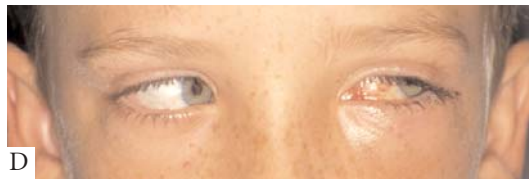A



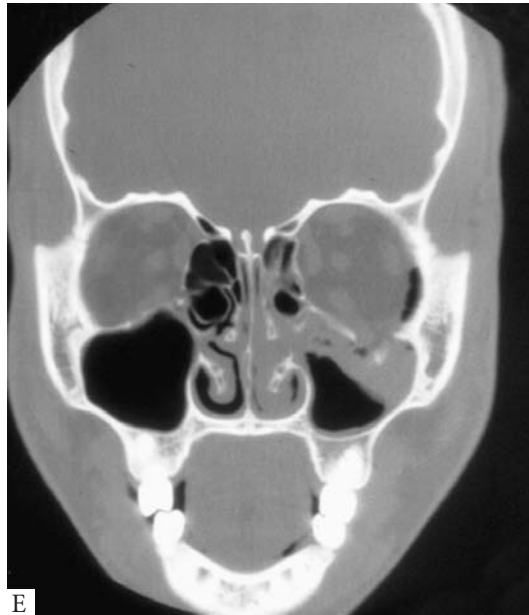
B



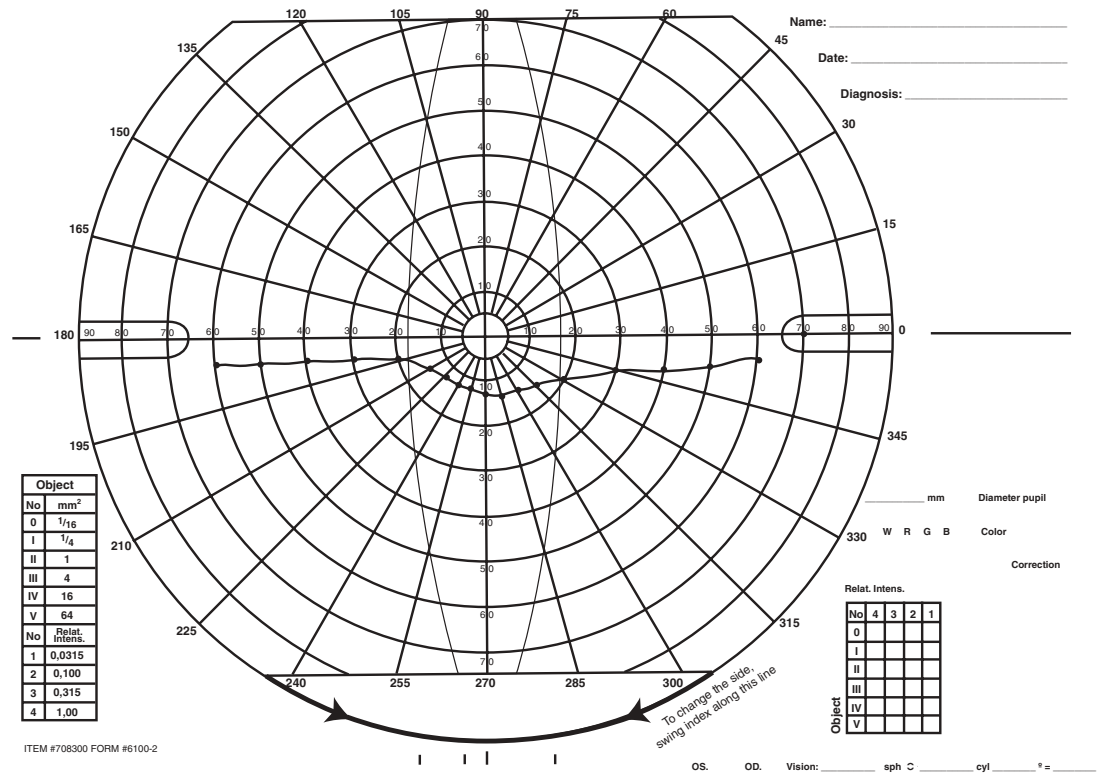
C



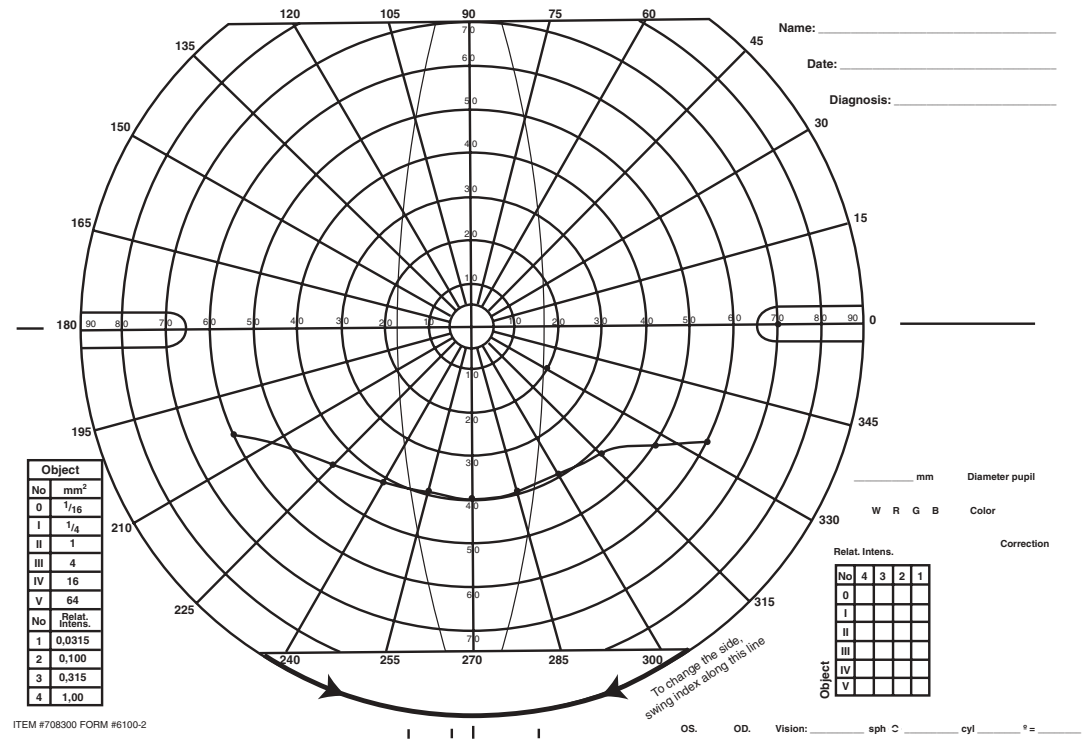
D



E



ITEM #708300 FORM #6100-2



ITEM #708300 FORM #6100-2

FIGURE 24-3 This 9-year-old child presented with complaint of “double vision and cheek numbness” after being struck in the left orbital region with a hardball. A, Note the lateral subconjunctival hemorrhage and that there was no difficulty in the upgaze. B, In downgaze he had severe firm fixed restriction of the left eye that was positive to a forced duction test. C, The right lateral gaze had trace restriction. D, The left lateral gaze was unremarkable. E, Direct coronal computed tomography (CT) scan of the bony window revealed a trapdoor fracture of the left orbital floor with herniation and a probable impingement of the inferior oblique muscle and fascial framework. F, Diplopic visual fields (Goldman visual field test). With binocular testing, patients are asked to look at the grid and track a pointed light that is shown from behind the chart. When patients experience double vision, they respond to the examiner who charts the abnormality. In this case, the upper grid was recorded at the initial presentation. Diplopia was experienced in all areas below the line (10–12°). This child’s severely limited downgaze, correlated with the CT findings, prompted surgical exploration and orbital floor repair within 12 hours. The lower grid was recorded at 10 days postoperatively and showed marked improvement in the downgaze, with diplopia occurring at 40° inferiorly.

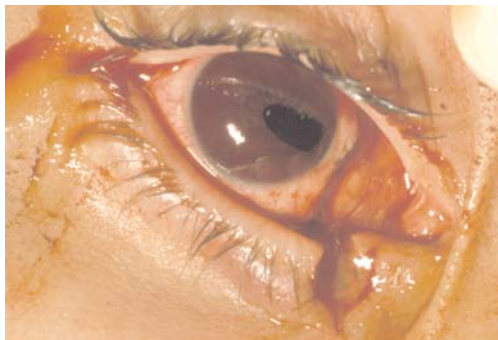


FIGURE 24-4 Laceration of the right lower medial eyelid that extends through the margin. At first the examiner thought there was simply a strand of clotted blood on the medial globe. Recognition of the irregular-pointing pupil led to the suspicion of a globe perforation, which was confirmed with a dilated ophthalmologic examination.

require acute evacuation via a lateral canthotomy. A “soft eye” with a relatively low pressure or deep anterior chamber is suggestive of a posterior scleral rupture.

A slit-lamp examination is generally performed with the patient in an upright position; if the patient is confined to a bed, a modified examination can be performed with a penlight. A handheld portable slit lamp can be used in the trauma setting. The purpose of this examination is to evaluate the surface contour of the globe and cornea to rule out conjunctival chemosis (swelling), hemorrhage, emphysema, and foreign bodies. The anterior chamber should be evaluated for depth, clarity, and hyphema (blood in the anterior chamber). Hyphema, if found, should be evaluated by an ophthalmologist so that surgical evacuation or medical management may be instituted in an effort to avoid occlusion of the trabecular meshwork, which may lead to glaucoma or a fixed iris. The iris’s shape and reactivity should also be noted. If a corneal abrasion or laceration is suspected, this may be more thoroughly evaluated with fluorescein dye and a Wood’s lamp (cobalt blue light). The fluorescein dye pools in the laceration or abrasion and fluoresces with a bright lime-green hue under the lamp-light (Figure 24-5).

Finally, the bony orbital rim should be palpated for steps, crepitus, and mobility. The patient should be queried about altered or lack of sensation, and neurosensory testing should be performed to evaluate the supraorbital, supratrochlear, and infraorbital nerves.

Imaging

Once a complete ophthalmologic and oral examination has been performed, selected studies such as CT or magnetic resonance imaging (MRI) can be ordered with defined parameters to provide meaningful results. Imaging is essential for proper diagnosis and treatment of orbital trauma. Noncontrasted CT is the primary imaging modality currently used for evaluating injuries from blunt or penetrating trauma, as well as for localizing most orbital foreign bodies.¹⁵ Other imaging modalities, such as plain radiography, reconstructed three-dimensional CT, MRI, ophthalmic ultrasonography, color Doppler imaging, and angiography, may provide necessary additional information in select instances. CT scans have become the standard of care in evaluating acute orbital injuries. Standard radiography is a readily available and inexpensive method for primary evaluations of orbital fractures. Plain radiography, however, is inadequate when used in evaluating internal orbital fractures, and it is difficult to localize foreign bodies with plain films

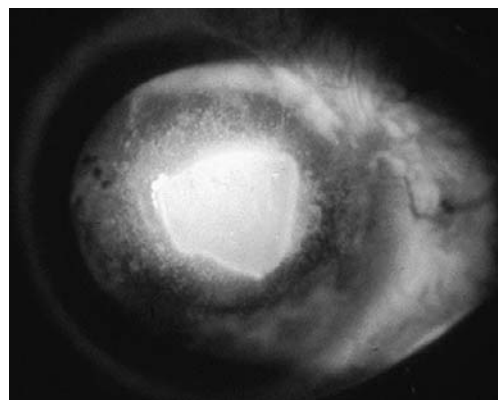


FIGURE 24-5 A broad corneal abrasion of the right eye illustrated with the pooled fluorescein dye under a cobalt blue (Wood’s) lamp.

alone. Waters’ projection allows visualization of the orbital roof and floor and is particularly useful for evaluating orbital floor blow-out fractures (Figure 24-6). With this 23° (preferably posteroanterior) view, the petrous portion of the temporal bones is projected below the maxillary sinuses and indirect signs of fracture can be noted, such as a teardrop formation or air-fluid levels. This is also an excellent view to assess a ZMC fracture.

If plain films reveal an internal orbital fracture that possibly warrants surgical intervention, then CT scans should be obtained. The fracture can then be fully evaluated for surgical treatment planning. CT allows excellent visualization of orbital soft tissues and permits one to simultaneously assess the cranial vault and brain during a “trauma scan.” A trauma CT scan series generally involves 10 mm axial cuts of the cranium and 5 mm cuts through the facial region. If finer detail or three-dimensional reconstructed images are desirable, then 1 mm fine cuts can be ordered. Internal orbital fractures are best evaluated when the imaging plane is perpendicular to the fracture line. Thus, images are usually obtained in

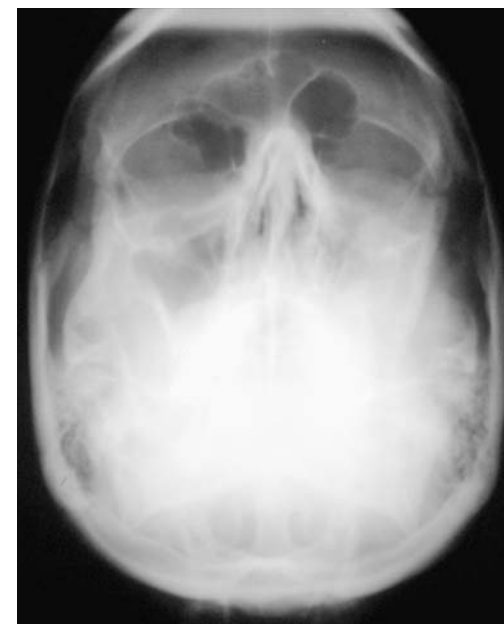

FIGURE 24-6 Waters’ view demonstrating opacification of the left maxillary sinus and a medially displaced left zygomatic buttress and arch.

both the axial and coronal planes to fully evaluate the fracture lines, patterns, and volume changes. This is particularly useful for comparison to the contralateral or uninjured side. The standard imaging approach for facial trauma is to obtain direct (non-reformatted) 3 to 5 mm sections in the axial and coronal planes. Intravenous contrast offers no advantages to the evaluation of acute bony facial injuries. Direct coronal views with 3 mm sections are preferred for evaluating orbital roof or floor fractures; however, they may be unobtainable owing to cervical spine precautions or the patient's inability to extend the neck and adequately position him- or herself for the coronal CT. In these patients, reformatted coronal images can be obtained based on the axial image data set. However, with this technique, there can be a loss of spatial resolution on the reformatted images. The axial images with fine detail (1 mm slices) must be obtained to allow for meaningful reformatted image quality. If an optic canal fracture is suspected, then 1 to 1.5 mm axial cuts should be obtained.^{16,17} This allows a better determination and correlation of any afferent visual defect owing to possible bony impingement.

Although MRI is generally accepted as a superior soft tissue imaging modality, CT scans adequately assess lens dislocation, vitreous hemorrhage, ruptured globe, retrobulbar hemorrhage, or avulsion of the optic nerve. CT is the imaging of choice in localizing metallic and most nonmetallic foreign bodies in relation to the globe, muscular cone (area inside the extraocular muscles), and the optic nerve.^{15,18} The location and extent of any subperiosteal hematoma formation, with possible mass effects, can also be adequately assessed with CT imaging. Computer-generated three-dimensional CT imaging can provide superior views and spatial orientation of fragments for complex orbital and facial fractures. In the majority of acute facial fractures, three-dimensional CT scanning is unnecessary. However, with complex facial trauma with

severe displacement, or for secondary reconstruction, three-dimensional CT scanning is invaluable for surgical treatment planning.¹⁹ Generally, 1 to 1.5 mm fine axial cuts are obtained; the patient must remain motionless for the entire scan, which may include more than 100 slices.

CT imaging has some drawbacks. As previously mentioned, patients may be unable to position themselves comfortably for direct coronal imaging. Sedation may be warranted in pediatric or uncooperative trauma patients. However, with facial bleeding, possible concomitant mandible fractures, or obtundation from alcohol or street-drug use, a secure airway must be maintained throughout the radiology procedure. This may require endotracheal intubation. CT scans may fail to reveal radiolucent foreign bodies such as wood or vegetative matter.²⁰ In these instances ultrasonography and MRI are most useful in detecting the radiolucent foreign body and localizing it. These studies should be obtained when the CT scans are equivocal or when physical examination suggests the presence of foreign bodies.

MRI can be useful in the setting of orbital trauma to assess soft tissue injury or entrapment of extraocular muscles in the area of the orbital suspensory framework. Standard radiographs or CT scans should be obtained before MRI is performed on patients with suspected intraocular or intraorbital ferromagnetic bodies because of the potential for displacement of the metallic fragments, resulting in further significant ocular or brain injury.^{21,22} With CT imaging, wood can appear isodense with fat or mimic intraorbital air. If the history or clinical examination indicates that fragments of wood may have penetrated the orbit or globe, then an MRI should be ordered. An MRI should also be performed when an apparent orbital emphysema (focal air collection) fails to resorb rapidly (within several days); this may suggest a space-occupying foreign body.²³

Ophthalmic ultrasonography is seldom used but is a readily available, safe, inexpensive, and noninvasive imaging modality.²⁴ Foreign bodies located in the orbit can be identified with ultrasonography but are much more difficult to detect when located in the orbital apex owing to signal reflection. Wood and other radiolucent materials can be detected with ultrasonography.²⁵ Color Doppler imaging is an ultrasound technique that provides simultaneous two-dimensional images and visualization of blood flow.²⁶ It can be useful in evaluating a post-traumatic high-flow carotid cavernous fistula. However, angiography remains the study of choice for definitively establishing this diagnosis.

Ocular Injuries and Disturbances

Patients who sustain midfacial trauma, particularly in motor vehicle accidents, often have concomitant neurologic and multisystem injuries. A neurologically impaired or uncooperative patient presents additional challenges in performing an adequate orbital and ophthalmologic examination. It is paramount that the primary tenets of advanced trauma life support be adhered to in securing the airway and protecting the cervical spine. When orbital fractures caused by severe blunt force trauma are detected, additional associated injuries should be sought, such as orbital canal or apex involvement, retrobulbar hematoma, or globe perforation. When there are multiple midface fractures, such as those of the ZMC, NOE, and frontal sinus, and Le Fort II or Le Fort III fractures, then more severe intraorbital injury, bleeding, and globe perforation are likely. Basilar skull fractures, as evidenced by clinical signs such as CSF otorrhea or rhinorrhea, Battle's sign, or CT evidence such as fracture lines or intracranial air, are generally caused by high-velocity impact and are often associated with severe neurologic injury.

Superior orbital fissure syndrome is characterized by impairment of cranial nerves III, IV, V, and VI secondary to compression by a fractured bony segment or hematoma formation in the region. Orbital apex syndrome has all the hallmarks of superior orbital fissure syndrome, with the addition of optic nerve (cranial nerve II) injury. Between 0.6 and 4% of patients suffering orbital fractures have a globe injury or optic nerve impairment, resulting in a significant or total loss of vision in one eye.^{27,28} This fact highlights the need for a thorough initial ophthalmologic and visual acuity assessment, with follow-up serial examinations as indicated.

Visual Impairment

Visual impairment or total vision loss can occur at various levels along the optic pathway. Direct injury or forces transmitted to the globe by displaced fracture segments can result in retrobulbar hematoma, globe rupture, hyphema, lens displacement, vitreous hemorrhage, retinal detachment, and optic nerve injury. Patients with orbital fractures and any degree of visual impairment who complain of severe ocular pain should be evaluated for retrobulbar hematoma. It is often the “less impressive” orbital fracture that leads to retrobulbar hematoma formation (Figure 24-7). This is due to bleeding within a relatively closed compartment

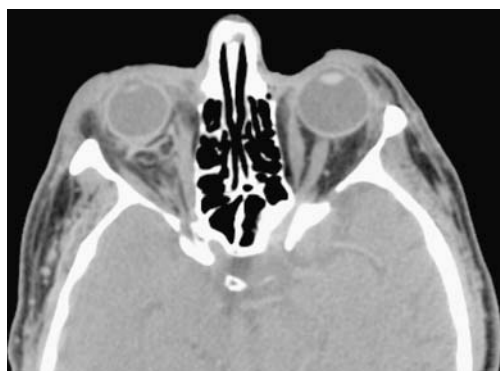

FIGURE 24-7 Axial computed tomography scan of a right retrobulbar hematoma. This diffuse infiltrative pattern is characteristic, whereas the discreet clot mass is less common.

and the lack of a potential drainage pathway through paranasal sinuses, such as the ethmoids or maxillary sinus. In essence, there is a compartment syndrome resulting from elevation of intraorbital pressure, which leads to central retinal artery compression, or ischemia of the optic nerve. The increased intraorbital pressures can secondarily raise the intraocular pressure, which, in turn, compromises the ocular blood supply.²⁹⁻³¹ In most instances requiring emergent treatment, there is a degree of exophthalmos and excessive tension of the lids. Although CT scanning to confirm the diagnosis is desirable, there should not be unnecessary delay in the surgical management. The immediate or urgent surgical management for retrobulbar hematoma evacuation consists of a lateral canthotomy, with or without inferior cantholysis, and disinsertion of the septum along the lower eyelid in a medial direction. A small Penrose drain is left in place for 24 to 48 hours to ensure adequate drainage and to prevent reaccumulation. Additional maneuvers to lower the intraocular pressure include administration of intravenous mannitol or acetazolamide or application of various glaucoma medications. Typically, blow-in fractures or inward rotation of the ZMC does not result in increased intraorbital or intraocular pressures with visual impairment. This is most likely due to pressure relief and volume expansion provided by additional orbital wall fractures such as the medial wall into the ethmoid or the floor sagging into the maxillary sinus.

A penetrating globe injury can result from what appears to be an innocuous small laceration or from horrific blunt-force trauma. When an eyelid laceration is accompanied by an asymmetric pupil, without a prior history of surgery, then a globe perforation likely exists (Figure 24-8). Blunt trauma can lead to globe perforation owing to a scleral rupture from the sudden instantaneous increased intraocular pressure. The most common site for

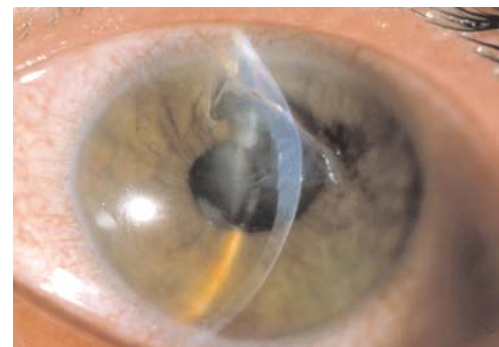


FIGURE 24-8 A full-thickness corneal laceration and an irregular pupil of the right eye is seen during a slit-lamp examination.

scleral rupture is at the site of previous cataract surgery, at the limbus, or just posterior to the insertion of the rectus muscles onto the globe, which is 5 to 7 mm from the edge of the limbus. The area under the muscle insertion is anatomically the weakest and thinnest portion of the sclera. With suspected globe perforation, pupillary dilatation and inspection by an ophthalmologist is mandatory. The inspection may be difficult—the injury may not be visible on fundoscopic examination since it is anterior to the equator of the globe and externally may be hidden underneath the rectus muscle insertion. Detection and surgical access for repair may require dissection of the bulbar conjunctiva with retraction of the extraocular muscles and external globe inspection. The penetrating injuries should be treated emergently, or within 12 hours, to decrease the risk of infection or ocular content herniation. The ultimate visual outcome directly correlates with the presenting visual acuity. Few eyes that cannot detect hand motions or have no light perception (NLP) regain useful vision. Globe injuries should be addressed before any facial lacerations are repaired. The exception is significant active blood loss from a severed vessel.

Hyphema is blood in the anterior chamber of the eye. It can be as severe as complete obliteration of the anterior chamber, termed “eight-ball hyphema,” or

more commonly a thin 1 to 2 mm layering at the inferior margin in the upright position (Figure 24-9). Some hyphemas are termed microhyphemas, with red blood cells floating in the anterior chamber and not layering out. The level and severity of the hyphema should be noted and recorded. The bleeding is from the rupture of an iris or ciliary body vessel and usually is the result of blunt trauma. Patients often complain of eye pain and, occasionally, visual loss if the amount of bleeding is severe. Medical management of hyphema is aimed at preventing rebleeding and venous congestion and promoting clearance of the existing blood. This may include hospitalization, bed rest, head-of-bed elevation, and longer-acting cycloplegics (topical agents such as scopolamine or atropine). Cycloplegics maintain a dilated pupil and thus immobilization of the iris, which discourages further rebleeding. Topical steroids may be administered to decrease further rebleeding and reduce intraocular inflammation. Oral aminocaproic acid is an antifibrinolytic recommended to reduce the incidence of rebleeding into the anterior chamber. In moderate to severe cases there should be daily monitoring of intraocular pressures and control of any high pressure increases with intravenous carbonic anhydrase inhibitors (acetazolamide, which

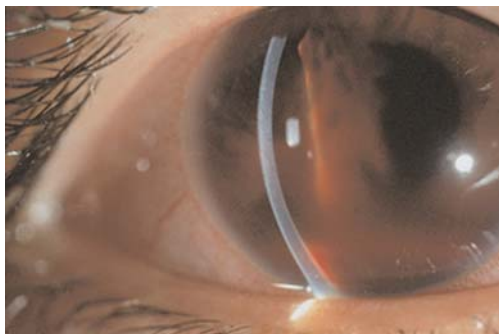

FIGURE 24-9 This partial hyphema of the right eye resulted from a punch to the face; a computed tomography scan showed a minimally displaced orbital floor fracture. The slit-lamp examination shows early layering. This patient received nonoperative management.

limits aqueous humor production) or hyperosmotics (mannitol). With severe hyphema, intraocular surgery to irrigate, aspirate, and evacuate the clot may be necessary to prevent optic atrophy owing to elevated pressures, or to avoid permanent corneal blood staining.³² The anterior chamber washout is the most commonly performed procedure for this purpose.

Vitreous hemorrhage can result from blunt trauma with the rupture of ciliary, retinal, or choroidal vessels. If, during fundoscopic examination, the retina cannot be visualized despite a normal-appearing anterior chamber and lens, vitreous hemorrhage is most likely present. As with hyphema, initial management typically involves hospitalization, bedrest with head-of-bed elevation, and serial clinical examinations. Vitreous hemorrhage is slow to resolve, and it may take months for this to clear, with symptomatic visual improvement.³³ A vitrectomy may be required after 6 months if satisfactory resorption has not occurred.

Lens dislocation may be detected by fundoscopic or slit-lamp examination. The lens, in its normal anatomic position, physically separates the anterior and posterior chambers, but it can be dislocated either partially or totally into either one. Symptoms include monocular diplopia and blurred vision; thus, it is important to check each eye's visual acuity independently. Posterior dislocation may be well tolerated; however, complete anterior dislocation can result in glaucoma and usually requires emergency extraction of the lens.

Rhegmatogenous retinal detachment and peripheral tears result from blunt force trauma. Characteristic symptoms include flashing lights and a field loss best described as a curtain or window shade coming over the eye. On fundoscopic examination, the retina may not be clearly visualized, or undulations may be present. Retinal detachments require surgery.³³ An emergency consultation with an ophthalmologist and initial maneuvers should be

instituted. Maneuvers involve bedrest in a head-up position and assurance that there is no Valsalva-type exertion; these prevent further extension of the detachment. Operative management may include any or all of the following: a scleral buckle, cryotherapy a vitrectomy, or endolaser. In-office pneumatic retinopexy works well with superior detachments: an inert expandable gas is injected into the vitreous and indirect laser treatment is applied.

Optic nerve injury or compromise can result from orbital fractures in the posterior region or optic canal. Optic nerve injury or vascular compromise is characterized by decreased visual acuity, diminished color vision, and a relative afferent pupillary defect. It is possible to retain very good vision and yet still have an optic nerve injury manifested by color deficits, afferent papillary defect, and visual field loss. Detection of early subtle changes require that a cooperative patient undergoes visual acuity testing, consisting of testing with a Snellen chart, finger counting, detection of motion, or light perception. Patients may present with NLP, which mandates an emergency consultation with an ophthalmologist and a fine axial CT imaging of the orbital apex. If NLP persists > 48 hours, then rarely does any meaningful vision return to the affected eye. Patients with NLP or severely decreased visual acuity may be suffering from traumatic optic neuropathy and should be given high-dose systemic methylprednisolone therapy for at least 48 to 72 hours (initial loading dose of 30 mg/kg IV methylprednisolone sodium succinate, followed by 15 mg/kg IV 2 h later and q6h thereafter).³⁴⁻³⁶ If the patient is uncooperative, heavily sedated, or unconscious, pupillary reaction can be monitored and followed as a sensitive test of optic nerve (cranial nerve II) function. This is best achieved in a dimly lit room; a penlight is moved alternating from one eye to the other every 2 to 3 seconds, and the pupillary response is observed. With

the light shining into the normal eye, both pupils should exhibit a brisk constriction. If the light is then directed from the uninjured to the injured eye the pupil on the injured eye will dilate. This is indicative of an optic nerve injury (relative afferent pupillary defect). A unilateral, fixed, dilated pupil is usually due to an efferent pathway injury (cranial nerve III), or some form of intracranial injury or bleed, which is usually accompanied by other neurologic lateralizing signs.

Diplopia

When a patient complains of seeing a double image of the same object, the examiner should first test each eye independently by covering the opposite eye to determine whether the diplopia is monocular or binocular. Monocular diplopia is usually due to lens dislocation or opacification, or another disturbance in the clear media along the visual axis. Acute binocular diplopia, secondary to trauma, derives from one of three basic mechanisms: edema or hematoma, restricted motility, or neurogenic injury. The most common cause of binocular diplopia following trauma is orbital edema and hematoma. This is usually found in peripheral fields of gaze, and, if other findings are absent, diplopia in the primary and downward gazes usually resolves along with the edema in 7 to 10 days. Slight diplopia in extreme peripheral fields of gaze may persist for months but is rarely problematic since individuals seldom require these extreme views for everyday function. Also the patient may complain that the phenomenon is transitory and that sudden looking “upward and outward” (superiorly and laterally, such as when looking in a rearview mirror) may cause instantaneous but brief diplopia. Binocular vision without diplopia is most important in the primary (straight-ahead) and downward fields of gaze. The majority of our daily activities, such as conversing, reading, and walking, use these visual fields. If diplopia

persists, an ophthalmologic consultation should be sought. Systemic corticosteroids hasten the resolution of orbital edema and the resulting diplopia, which is fairly common following blunt trauma to the orbit.

Persistent post-traumatic diplopia is best evaluated by an ophthalmologist. It is important to establish an accurate diagnosis and precise etiology. The basic evaluation should include assessing symmetry of the corneal light reflexes and testing of the ductions (following a finger in all eight fields of gaze) including a selective forced duction. The forced duction helps distinguish between restricted motion from entrapment, scarring, or fibrotic contractions versus a neurogenic motility disorder (cranial nerves III, IV, or VI). Ophthalmologists use diploic visual fields (see Figure 24-3F) to quantify and categorize the diplopia; serial examinations allow accurate tracking of spontaneous recovery or postsurgical progress. In the acute setting, restrictive disorders are managed with early bony orbital surgery and reconstruction, whereas neurogenic disorders are managed with the injection of botulinum toxin into select extraocular muscles whose forces are unopposed by the injured or restricted muscles. Following bony orbital reconstruction or selective botulinum toxin injections, there should be a 6- to 12-month waiting period for the diplopia to stabilize. Then, any residual and stable diplopia can be addressed with strabismus (extraocular muscle) surgery. Strabismus surgery has two basic maneuvers: a repositioning of muscle insertions onto the sclera or a weakening of the opposing muscles. After a period of healing, selective botulinum toxin injections or more minor revision strabismus surgery may be required to fine-tune the result. The important point to stress is that a healed abnormal bony wall position or orbital volume changes, resulting in enophthalmos or vertical dystopia, typically do not cause stable significant diplopia. In fact, vertical dystopia of up to

1 cm can be accommodated by the brain and should not result in diplopia in the primary fields of gaze. Therefore, any bony wall revision or reconstruction should be performed to correct a cosmetic or other functional defect without promise of correction or improvement in any coexisting diplopia. These reconstruction procedures should be performed and allowed to heal, and the diplopia allowed to stabilize for 6 months prior to the strabismus surgery, which would address the diplopia.

In the trauma setting, diplopia may be due to restricted ocular motility from a prolapse of the periorbital contents into the medially fractured ethmoid air cells or underlying maxillary sinus. Such diplopia may also be due to entrapment or direct impingement on the fine suspensory ligamentous system of the orbit or, less frequently, of the extraocular muscles. Restricted motility or entrapment is commonly found with orbital floor and medial wall fractures, less frequently with roof fractures, and rarely with lateral wall fractures. Significant medial wall fractures are manifested primarily by enophthalmos owing to volume expansion.

When testing range of motion, if there is repeatedly a firm fixed limited stop of unilateral eye motion, the eye should be anesthetized topically and a forced duction test performed. Occasionally the entrapment or incarceration of the supporting structures or muscles is mild, and during the forced duction, initial resistance may be encountered and then relieved. In such an instance, the positive forced duction test was both diagnostic and therapeutic. However, if the forced duction test is positive and mimics the voluntary active point of restricted motion, this should be correlated with CT scan findings (see Figure 24-3).³⁷ A repeatable fixed point of limitation is usually due to direct entrapment of the extraocular muscles or the capsulopalpebral fascia (fascia of Tenon). This is more common in linear floor fractures than in comminuted multiple wall fractures.

Patients with muscle or Tenon capsule incarceration confirmed by CT are candidates for urgent exploration and repair (within 12 h). Prolonged muscle entrapment with ischemia can lead to fibrosis (Volkmann's contracture) with permanent diplopia, despite surgical release of the entrapped tissues. When exploring these fractures, the entrapped fascia or muscle can be difficult to release. This classically occurs in the pediatric patient with an anteroposterior linear fracture of the orbital floor with no accompanying rim fracture. When an area of resistance is encountered initially and correlates to this same anatomic location on CT, then consideration should be given to inserting an instrument within the anterior fracture line and gently twisting or prying to open up the fracture, or taking a fine osteotome or instrument to fracture away a small adjacent strip of orbital floor so that a thin blunt malleable retractor on either side of the entrapped area can gently lift and reduce the entrapped soft tissues back into the orbit. Direct grasping of the tissues and tugging to reduce them back into the orbit may result in further contusion and injury.

Diplopia can be due to a central ophthalmoplegia owing to impairment of cranial nerves III, IV, or VI. The fourth nerve is the most commonly injured at the point where it passes over the petrous ridge of the temporal bone. This results in vertical diplopia and a compensatory head tilt to the opposite shoulder. These nerves have fairly long intracranial tracts and can be injured by direct skull fractures or be compressed by intracranial bleeds or diffuse cerebral edema after blunt head trauma. Cranial nerve palsies often spontaneously recover within 6 to 9 months. Recovery is quite variable and is dependent on severity and the type of injury.

Eyelid Lacerations

Eyelid lacerations, particularly those extending to the lid margin and gray line, should be thoroughly evaluated for

lacrimal drainage system injury, canthal tendon disruption, or injury to the tarsal plate and levator aponeurosis. After antibiotics and tetanus prophylaxis have been administered as necessary, the wound should be cleansed and débrided, taking care to protect the globe, possibly with a contact lens. The eyelid laceration should be repaired in a layered fashion, starting with the tarsal plate repair (with 6-0 polyglycolic acid), lid margin (two to three interrupted sutures with 6-0 silk, which is nonirritating to the cornea), orbicularis muscle re-apposition (multiple 6-0 plain gut sutures), and finally skin (with 6-0 nylon or 6-0 fast-absorbing gut). Topical ophthalmic ointment should be prescribed since these agents come in contact with the globe frequently, and sutures should be removed in 5 or 6 days. Patients should be followed up and monitored for potential complications such as scar contracture or lid notching. Several weeks post repair, if significant lid contracture or focal thickening is noted, then selective judicious steroid injections (triamcinolone acetonide, 40 mg/mL) can be administered with accompanying daily massage by the patient.

In my experience, avulsion or loss of eyelid soft tissue is rare. When this occurs, it is usually from an abrasive crushing macerated-type laceration sustained in such accidents as a rollover in an all-terrain vehicle or ejection from a motor vehicle. In evaluating these injuries, the examiner should moisten the rolled edges of the laceration and attempt to gently realign them. One should not abnormally align the tissues, borrowing them from the periphery and shortening them in the vertical dimension. This can result in lid retraction or lagophthalmos, with risks of corneal exposure and ulceration. It is best either to leave a small amount of denuded underlying tissues, which will reepithelialize secondarily, and possibly perform a temporary tarsorrhaphy, or, for larger defects, to harvest a thin

defatted skin graft for primary reconstruction (Figure 24-10).

Lacrimal Injuries

Injuries to the lacrimal drainage system most often result from direct eyelid lacerations at the medial edge of the lid, which traverse the lid margin and disrupt the inferior canaliculus. Canalicular lacerations also occur indirectly when strong forces are applied to the lateral aspect of the lids. This tension directed laterally causes the eyelid to split at the weakest point, which is just medial to the punctum (Figure 24-11). Damage to the lacrimal drainage system can also be seen with severe medial rim and orbital wall fractures. A disruption in the lacrimal system can be detected by passing a lacrimal probe through the punctum and visualizing the blunt-tipped probe within the laceration or wound. It is especially important to detect this with the inferior canaliculus since this system is dominant in the vast majority of patients.

Repair involves reanastomosis of the canaliculus and either mono- or bicanalicular intubation. With bicanalicular intubation, repair is performed by passing a silicone intubation tube through the puncta into the laceration and then locating the distal cut end of the drainage system for passing the tube into the nose, which is retrieved with a hook beneath the inferior turbinate. Typically both the superior and inferior canaliculi are intubated (usually one is uninjured); both silicone tubes are passed into the nose and are tied to each other. This allows for retention of the looped tube for 6 to 12 weeks. Intraoperatively, the silicone tubes are stretched toward the external nares, tied together, and typically oversewn or tied with a fine silk suture to allow for long-term retention. If no tension is applied to the cut ends of the silicone tubing while tying, then, postoperatively, the loop formed at the canaliculi puncta will migrate laterally toward the cornea, causing irritation or an annoying visual field disturbance.

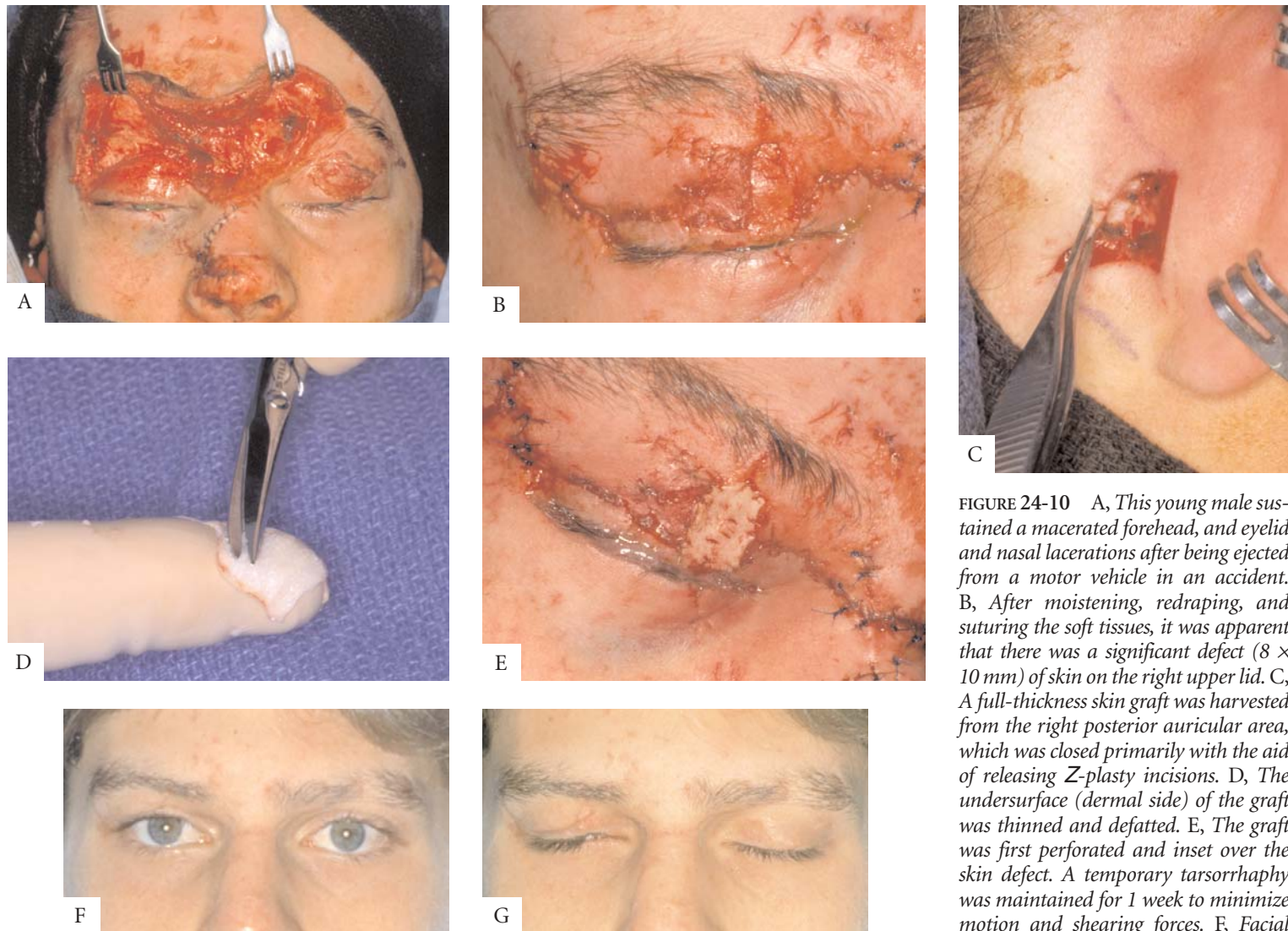


FIGURE 24-10 A, This young male sustained a macerated forehead, and eyelid and nasal lacerations after being ejected from a motor vehicle in an accident. B, After moistening, redraping, and suturing the soft tissues, it was apparent that there was a significant defect (8×10 mm) of skin on the right upper lid. C, A full-thickness skin graft was harvested from the right posterior auricular area, which was closed primarily with the aid of releasing Z-plasty incisions. D, The undersurface (dermal side) of the graft was thinned and defatted. E, The graft was first perforated and inset over the skin defect. A temporary tarsorrhaphy was maintained for 1 week to minimize motion and shearing forces. F, Facial appearance 3 months after repair. G, Passive lid patency was achieved. There was no further revision surgery.

Telecanthus

Traumatic telecanthus typically results from severe midfacial trauma (NOE) with displacement and splaying of the bones that serve as attachments for the medial canthal tendons. It is less frequently due to laceration and actual physical disruption and disinsertion of the canthal tendons from the underlying bone. Therefore, traumatic telecanthus from these injuries is best treated early (within 7–10 d) following injury to prevent scarring and secondary maladaptive changes that compromise the reestablish-

ment of the more normal narrow intercanthal distance. Preoperatively, one should determine whether the increased intercanthal distance is due to either a unilateral or a bilateral injury. Treatment typically includes an approach via a coronal incision, a Lynch (lateral nasal) approach, or a combination, with reduction and fixation of the displaced bones or direct transnasal wiring. External splinting rarely yields satisfactory results.

I have found that direct canthal tendon reattachment with transnasal wire fixation is best performed by passing a doubled-end loop of 30-gauge stainless steel wire

transnasally from the contralateral medial orbital wall and then suturing the medial canthus to the wire loop. The wire is then drawn to the opposite side by gradually twisting the two ends around a short section of titanium microplate situated in the opposite medial orbital wall (Figure 24-12).

Nonoperative Management of Orbital Fractures

Indications for nonoperative or, as it has previously been termed, *conservative* management of orbital fractures has been controversial for many years. Some historic

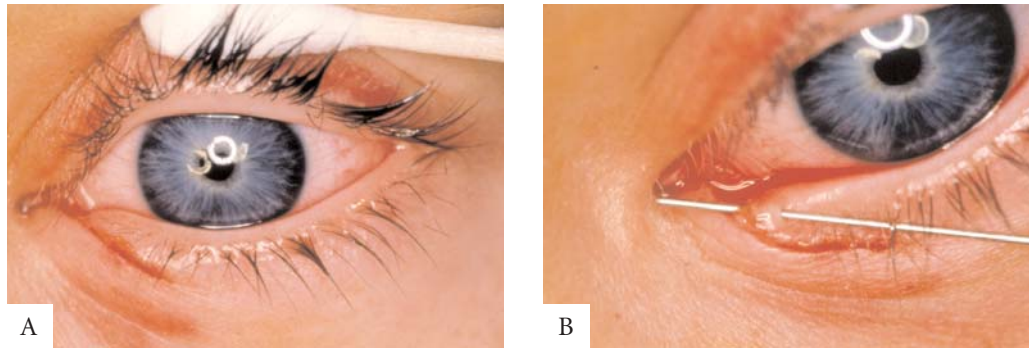


FIGURE 24-11 A, Innocuous-appearing small left lower medial lid laceration sustained from an incidental grab along the cheek during a touch football game. B, Slight lateral traction on the lower lid and probing of the inferior punctum revealed a full-thickness lid laceration medial to the punctum with severance of the inferior canaliculus. An oculoplastic surgeon repaired and managed this injury within 8 hours.

perspective and review is warranted since it provides insight into the evolution and current thinking regarding nonoperative orbital fracture treatment. In 1957 Smith and Regan coined the term *blow-out fracture* and advocated early surgical intervention for orbital floor fracture repair.³⁸ Following this, Converse and Smith endorsed surgical exploration and repair of all orbital fractures within the first 3 weeks of injury.³⁹ Even with surgical exploration and repair, they found that enophthalmos or functional difficulties would develop, and they attributed this to the blunt trauma forces and tissue damage rather than the surgical intervention. Crikelair and colleagues in 1972 promoted the concept that orbital floor fractures were overdiagnosed on plain films and, thus, were overoperated.⁴⁰ They introduced the concept of repairing only select orbital floor fractures, which were confirmed by tomography and only if diplopia or enophthalmos persisted after an observational period of 2 weeks. This marked an important change in thinking toward a more selective approach for surgical intervention of orbital floor fractures. This change was, in part, prompted by reports and articles documenting unacceptable complications such as a total loss of vision following surgical exploration of asymptomatic floor fractures.⁴¹ In 1974 Putterman and colleagues reported on a series of 57 patients

whom they had observed and on whom they had performed no surgical intervention whatsoever.⁴² Only a few of these individuals had any persistent diplopia, and there were no visual acuity disturbances 4 months following the trauma. This landmark article created a drastic shift in thinking—nonsurgical treatment of all orbital fractures was advocated. Putterman and colleagues proposed that patients with persistent diplopia should be managed by contralateral eye muscle surgery, or contralateral fat resection, to mask the enophthalmos or altered visual access of the injured side. Although this retrospective study and series of patients received much criticism from both the ophthalmology and facial trauma specialties, it did reveal that many orbital floor fractures healed uneventfully without surgical intervention and with the performance of eye-movement exercises.

Following Putterman and colleagues' report were a series of articles by various practitioners who attempted to refine and delineate the indications for surgical exploration and repair of orbital floor fractures. Dulley and Fells reported that only 50% of all patients with orbital floor fractures required surgical intervention.⁴³ All patients underwent a 2-week observational period; an individual would then undergo surgical intervention if one of the following criteria was present: enophthal-

mos > 3 mm, large herniation of tissue into the antrum, entrapment with limited upward gaze, or significant diplopia. Nevertheless, these criteria were somewhat subjective and were limited by the current imaging techniques. Crumley and colleagues used similar indications for surgery to those of the Putterman group, but based on these criteria, almost 90% of all their patients with orbital floor fractures underwent surgical repair.⁴⁴ Converse and Smith developed and further refined these same indications for orbital floor surgery and reinforced the need and importance of serial clinical examinations in patients who had shown no initial indications for surgery.⁴⁵ This group promoted the concept that serial examinations revealing the development of enophthalmos should be the criterion for surgical intervention and not simply that a large or comminuted floor fracture existed. They proposed that the development of significant postinjury enophthalmos is variable and could be due to either resolving hemorrhage and edema or orbital fat atrophy. In 1982 a survey by the American Society

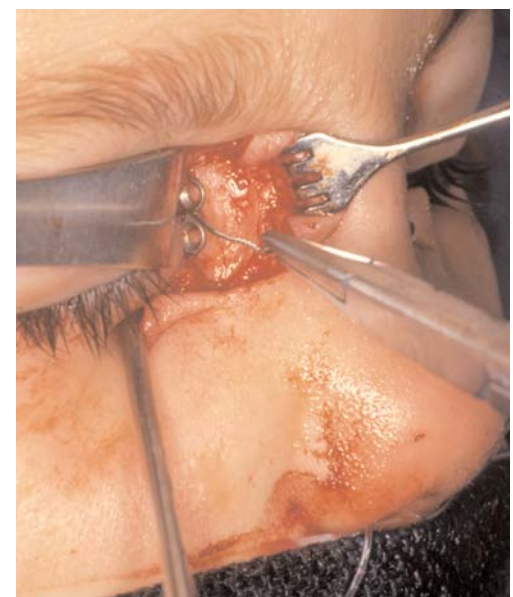

FIGURE 24-12 Reattachment and repositioning of the left medial canthus is fine-tuned by twisting a 30-gauge wire over a section of microplate situated along the right medial orbital wall just behind and above the posterior lacrimal crest.

of Ophthalmic, Plastic and Reconstructive Surgery revealed that two-thirds of oculo-plastic surgeons were operating within 2 weeks of injury with few serious complications or sequelae.⁴⁶ Although this was reassuring that current surgical approaches and techniques were safe, there was no inquiry into what the criteria or determinates were for undertaking surgical repair.

What was helpful was that several ensuing studies began to delineate which patients exhibiting functional deficits might benefit from surgical exploration as opposed to observation. Koorneef, in an anatomic study, showed that fine connective tissue septa surrounded the extraocular muscles.⁴⁷ He advocated eye movement exercises in patients with mild or moderate restrictive motility as long as there was demonstrated serial improvement in motility. He purported that edema, hemorrhage, and connective tissue entrapment were responsible for the majority of limited motility in patients with orbital floor injuries.

In 1984 Smith and colleagues introduced the concept that Volkmann's contracture might occur as a result of elevated intraorbital compartment pressures.⁴⁸ Although this phenomenon was well-known, documented, and proven in the orthopedic literature to occur with extremities, it was unproven to occur in the orbit. Volkmann's contracture is a paresis from muscle shortening and fibrosis that results in limited mobility. Applying this concept to the orbit, Smith and colleagues recommended surgical intervention in the elderly, in individuals who are hypotensive, and for small or linear orbital floor fractures with coexisting diplopia. They felt that these situations left patients at an increased risk for orbital compartment syndrome, thus developing permanent limited mobility owing to Volkmann-like contractures. Concurrent with these theories and recommendations was the report by Hawes and Dortzbach that emphasized the need for surgical repair within 2 weeks following injury in patients with persistent diplopia

within a 30° range of the primary visual (straight-ahead) gaze.⁴⁹ They based this on their findings that there were poor results when late repairs were performed in this patient group.

Clearly the advent and ready availability of CT for use in diagnosing "trapdoor" fractures with mechanical impingement of the orbital structures helped to refine diagnostic capabilities and to aid treatment planning. Several groups of authors emphasized the need for correlating a positive forced duction test with CT evidence of incarceration or impingement.^{50,51} Without specific evidence of a trapdoor phenomenon or direct impingement, orbital floor fractures with limited motility were observed for 2 weeks. Persistent symptoms or findings then prompted surgical intervention. Trapdoor fractures or fine linear breaks without rim fractures are much more common in pediatric patients. When severe limitation of movement is encountered (typically upward or downward gaze, or both) and is correlated with CT findings, this is a true emergency that should be treated surgically to relieve the entrapment as soon as possible.

Since his initial controversial 1974 article, Putterman has revised his indications for surgical intervention.⁵² Putterman and his colleagues' indications are now comparable to those of other surgeons. They advocate 7 days of systemic corticosteroids to speed the resolution of diplopia within the first 3 weeks. This may aid in resolving edema and helping determine who might benefit from surgery. Although persistent functional limitations are usually clear indications for surgery, controversy remains in treating those patients who demonstrate a steady but slow resolution of their diplopia that persists beyond 3 weeks.

When the surgeon is confronted with any orbital fracture, it is helpful to categorize the clinical deficits and goals of surgical treatment as being either functional or cosmetic. Simply operating on a radi-

ographic finding because it exists is not satisfactory. The surgeon, with the assistance of his ophthalmology colleagues, should determine what, if any, functional deficits and cosmetic deformities exist. A specific anatomic reason for these should be sought. Then, if the magnitude of the functional deficit or cosmetic deformity warrants surgery, the type of surgical approach, repair, and materials should specifically address the structural causes. In a patient with the clinical findings of only "soft" indications for surgery, a 2-week observational period seems prudent. Several studies have addressed cosmetic deformities as they relate to orbital floor fractures, offering indications for surgery versus observation. Hawes and Dortzbach used tomography and felt that orbital floor fractures involving > 50% of the surface area should be reconstructed within the first 2 weeks to avoid the predictable development of enophthalmos.⁴⁹ They also stated that patients with smaller orbital floor fractures but with > 2 mm of enophthalmos present at 2 weeks postinjury should undergo orbital floor reconstruction. This recommendation is based on the fact that later repair is technically more difficult with less optimal outcomes owing to scar contracture and muscle shortening. Parsons and Mathog were able to demonstrate, using a laboratory model, that orbital floor fracture and displacement of equal magnitude with the medial wall fracture and displacement had a much greater effect on globe position.⁵³ This study supports the practice of most surgeons, which is nonsurgical and observational management of isolated displaced medial wall fractures.

When orbital fractures are associated with other facial fractures such as Le Fort or ZMC fractures, several authors have advocated orbital floor exploration and repair with any evidence of prolapse of the orbital contents into the sinus.^{54,55} In 1991 Putterman and colleagues advocated following patients closely for the development of

enophthalmos, using objective measurement with a Hertel exophthalmometer, or serial measurements for vertical dystopia by aligning the top of a clear ruler to both undisturbed medial canthi and noting where the ruler bisects each eye.⁵² Despite numerous reports, clinical series, and author suggestions, controversy still remains regarding the management of those patients who develop only mild enophthalmos or hypo-ophthalmos (1–2 mm) without any functional deficits during the acute observational period.

Operative Management of Orbital Fractures

Indications

It is imperative that the surgeon has a complete understanding of the mechanism of injury and potential complications to make a full diagnosis and an appropriate treatment plan in each type of orbital fracture. Patients with a suspected or known orbital fracture should undergo thorough clinical examination, including fundoscopic examination; visual acuity; pupillary reactivity; detection of diplopia, extraocular movement with any limitations noted, enophthalmos, and vertical dystopia; forced duction testing; and recording of paresthesias. Radiographic studies should determine the full extent of the orbital fracture and any surrounding and associated facial fractures. CT scans, especially in the direct coronal plane, are the gold standard for use in orbital surgery treatment planning. Contraindications for surgery are hyphema, retinal tears, globe perforation, the patient sees only with the eye on the injured side, and life-threatening instability.

Indications for surgery can be divided into functional and cosmetic categories. A logical systematic approach is prudent in selecting patients who are suitable for acute or early surgical repair versus those who deserve an observational period with intervention when signs or symptoms warrant it (Figure 24-13). With regard to

function, diplopia and decreased visual acuity are the two main areas of concern. The majority of surgeons and articles in published literature support early surgical intervention in a patient with an orbital floor fracture that has mechanical restriction of gaze and a positive forced duction test with a CT scan that has a trapdoor appearance or suggestions of inferior rectus muscle incarceration.^{56,57} This phenomenon occurs more in children with linear fractures owing to the elasticity of their bones.⁵⁸ Pediatric or adult patients with these findings warrant early intervention to free up the tissues and hopefully prevent any permanent restriction owing to ischemic necrosis or scar contracture. In patients with less impressive restrictive motility (10–15°), a positive forced duction test, and no CT evidence of muscle entrapment, an observational period of several weeks is reasonable. These patients may only have entrapment of some of the fine connective tissue septa supporting the globe, and with routine daily function and/or eye exercises, this restriction typically steadily improves. Clinical follow-up with a series of examinations (two or three) within the first 14 days, steroid therapy, and eye movement exercises should optimize the outcome. In any patient with an orbital fracture that has persistent mechanical restriction or diplopia within 30° of their primary gaze, especially the downgaze (used during reading), surgical exploration is warranted. Prior to undertaking surgery, however, any neurogenic or central component should be ruled out. Although infrequently employed, electromyography can be used to distinguish neurogenic diplopia from mechanical restriction in problematic or brain-injured patients. Neurogenic or neuromuscular injuries are more suitably treated by strabismus surgery. With regard to decreased visual acuity, an ophthalmologist should assess the patient serially for resolution or improvement. In more severe cases—patients who can only see shadows or fig-

ures or who have NLP—the fine-cut axial CT scans of the orbital apex and canal should be reviewed with the radiologist to determine whether there is bony mechanical impingement, hematoma, and/or edema compressing the optic nerve or vascular supply. With the increasing popularity of endoscopic approaches to the cranial base (typically for tumor removal), most major medical centers have neurosurgeons and/or otolaryngology head and neck specialists that are competent in performing transnasal endoscopic optic canal decompression. If at all possible, this should be performed within 12 to 24 hours of the confirmed diagnosis of external optic nerve compression within the canal proper.

Cosmetic deformities such as enophthalmos or hypo-ophthalmos result from a bony orbital volume increase, extrusion of intraconal fat into extraconal spaces, or prolapse of orbital contents into the maxillary sinus or ethmoid air cells. Contrary to long-standing dogma, post-traumatic fat atrophy does not play a significant role in the development of these deformities.⁵⁹ Most surgeons currently undertake surgical intervention in orbital floor reconstruction if there is 2 to 3 mm or greater of enophthalmos or hypo-ophthalmos in the presence of orbital edema or hematoma. The rationale is that early repair offers the most favorable outcome and that the cosmetic deformity only worsens as the edema and hematoma resolve. Orbital floor defects of greater than half of the surface area with concomitant CT evidence of the disruption or prolapse into the underlining antrum generally should be repaired. Again, the rationale for this is that as the edema resolves, eventually there is some degree of enophthalmos or vertical dystopia that creates a cosmetically unacceptable or, less frequently, functional problem requiring surgery. With minimal floor disruption (< 50%) and no entrapment or significant herniation, observation for 2 weeks is prudent. If the patient develops any functional problems or enophthalmos

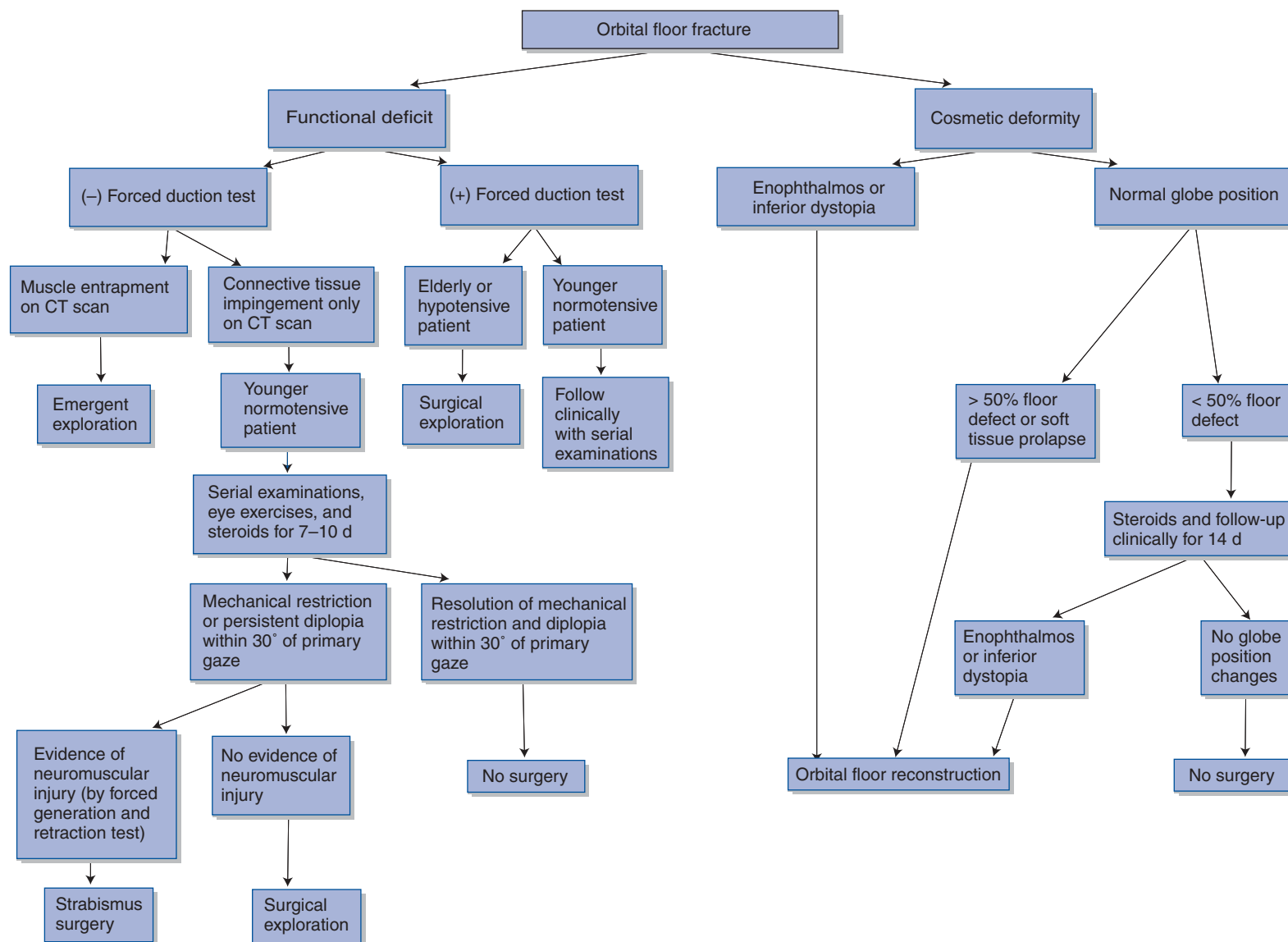


FIGURE 24-13 Orbital floor fracture evaluation and treatment decision diagram. CT = computed tomography; (-) = negative; (+) = positive.

> 2 mm, then surgery can be undertaken to treat the functional or cosmetic defect. Unnecessary delays approaching 6 weeks and beyond make the surgical repair more difficult and the ultimate outcome less desirable owing to scarring and muscle shortening.

Surgical Approaches

Once it has been determined a patient requires surgical intervention, a well-thought-out plan and sequential approach should be developed. Of paramount importance is the determination of which

of the anatomic areas need to be accessed with direct visualization and which intact bony edges or landmarks need to be found or fixated to accomplish the repair. This helps the surgeon determine which soft tissue incision should be employed. In general, most surgeons prefer to first grossly reduce and usually fixate all periorbital and facial fractures prior to accomplishing internal orbital repairs. The most commonly used surgical approaches and methods of reconstruction are presented here so that the surgeon can make an individualized and informed decision.

Inferior and Lateral Orbital Approaches

There are three basic incisions used for accessing the orbital floor: the infraorbital, subciliary, and transconjunctival (Figure 24-14). Although there are three basic approaches, there are numerous technical variations based on surgical training and individual preference. Clearly the subciliary and transconjunctival incisions are the most popular owing to their superior esthetics and generous access, and the fact that surgeons are familiar with their use. It is my opinion that the infraorbital or rim incision results in the worst esthetics and offers no

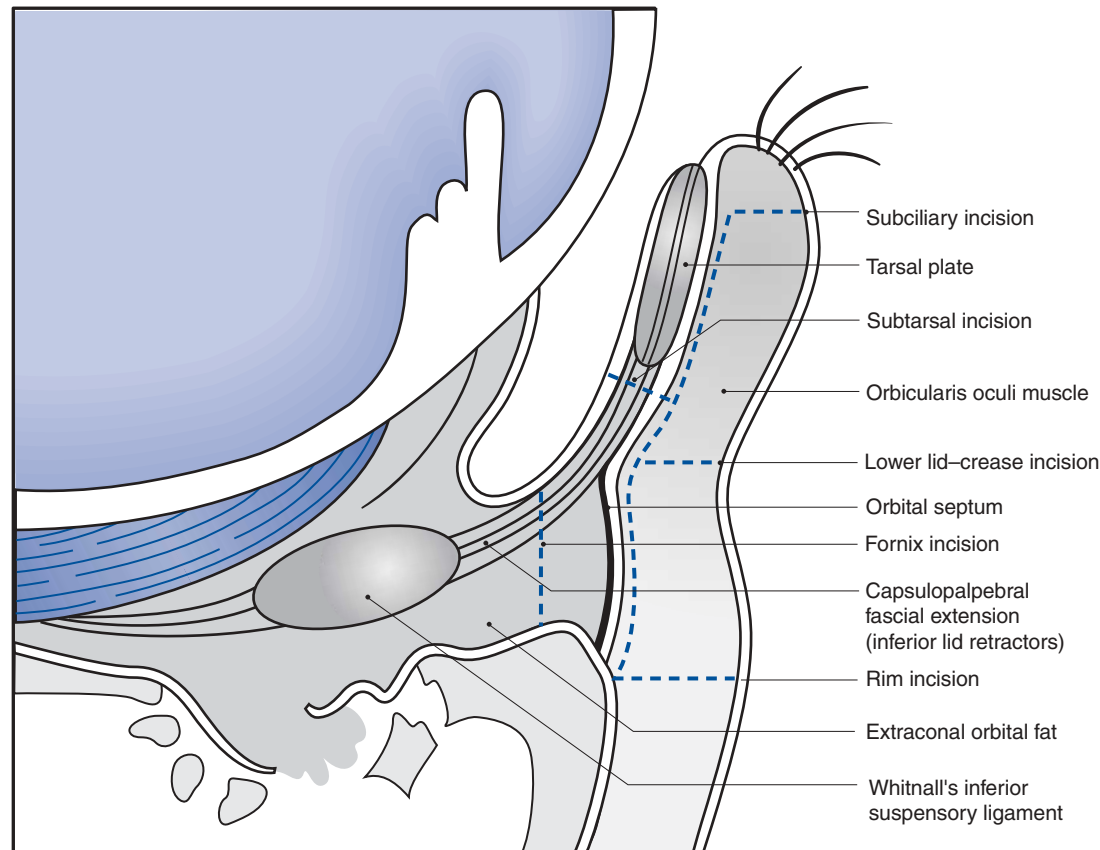


FIGURE 24-14 Cross-sectional view of the inferior lid and various floor approach incisions. Adapted from Ochs MW, Johns FR. *Orbital trauma*. In: Fonseca RJ, Marciani RD, Hendler BH, editors. *Oral and maxillofacial surgery: trauma*. Vol 3. Philadelphia (PA): W.B. Saunders; 2000. p. 208.

advantages over the two former approaches; therefore, it should not be employed.

The subciliary incision was popularized by Converse in 1944.⁶⁰ Typically a gently curved linear skin incision is made several millimeters below the lid edge or eyelash margin, preferably in a skin crease. The skin flap is then undermined in an inferior direction for several millimeters before traversing deeper inward directly through the orbicularis oculi muscle fibers and stopping when the orbital septum is encountered. The rationale for the division of the skin and muscle at different levels (stepping the incision lines) is that it helps to prevent direct or full-thickness scarring and tethering of the eyelid. Once the orbital septum has been encountered, the preseptal approach is then carried out inferiorly to the orbital rim, and the periosteum is incised just below the arcus

marginalis. The periosteum of the orbital rim is then reflected upward and inward, and dissection is carried out over the orbital rim. One must bear in mind that the orbital floor drops off several millimeters toward the inferior direction prior to heading straight posteriorly. The orbital floor dissection can then be extended posteriorly for a safe distance of 30 mm. With an intact adult rim, the optic canal is only 40 mm from the anterior lacrimal crest, and with any rim displacement inward, this margin of safety is further decreased. A modification of the subciliary approach is the “skin only” incision. This technique is comparable to the technique just described, except that after dividing the skin, the inferior dissection is carried out superficially to the orbicularis oculi muscle fibers until the inferior orbital rim is reached, and then the muscle is divided at

the same level as the periosteal incision. This approach is used less often owing to the amount of stretching on the unsupported large skin flap and the resultant high rate of ectropion (permanent in 8%) and potential skin necrosis, particularly in the elderly patient who has a history of heavy smoking.⁶¹ These complications prompted the development of an alternative technique called the “skin-muscle flap.” With this procedure a similar incision is accomplished 1 to 2 mm below the lid margin but is carried through both the skin and muscle at the same level down to the tarsal plate. Again, the plane of dissection is carried out anterior or superficial to the orbital septum (preseptal) until the orbital rim is encountered. This approach results in excellent esthetics, a simplified dissection, and a decreased incidence of hematoma formation or skin necrosis.

This skin-muscle flap still carries a 6% rate of early ectropion⁶²; however, it is generally temporary and resolves within several weeks with gentle massage. This was confirmed by several investigators who correlated preoperative periorbital edema and increased age positively with the development of this temporary ectropion with the subciliary approach.⁶³ A revision of this approach or technique is to use a relaxed skin tension line incision.

The transconjunctival approach for orbital floor fractures was first popularized by Tessier and Converse and colleagues in 1973 for orbital floor fractures.^{64,65} The two basic variations of this approach to the orbital rim are retroseptal or preseptal approaches. Although the retroseptal approach is a more direct approach to the rim, it exposes the orbital fat, which herniates into the surgical field and may interfere with the surgery and result in more fat atrophy, especially with cautery, and hence enophthalmos. For this reason, the preseptal approach is generally favored.⁶⁶ The preseptal approach (see Figure 24-14) as described by Tessier involves an incision through the palpebral conjunctiva just 2 to 3 mm below the inferior edge of the tarsus that is extended through the inferior lid retractors and orbital septum.⁶⁴ Next, a preseptal vertical dissection is carried out down several millimeters below the orbital rim, and the periosteum is incised. The dissection of the facial aspect of the rim and the floor is then carried out. This obviates orbital fat herniation in a fairly bloodless field. The necessity for a periosteal closure is controversial owing to the possibility of entropion or ectropion with inadvertent suturing of the periosteum to the orbital septum or other layers.^{64,67} Some surgeons advocate a Frost suture for a period of 24 to 48 hours to allow for proper lower lid redraping during early healing. Most surgeons find this unnecessary. If there is any difficulty in identifying opposing edges of the cut periosteum, then no suturing should be

performed rather than an inappropriate tethering of more superficial or superior eyelid layers and structures to the underlying rim. Many instances of “early ectropion” or a “shortened lid” are the result of improper suturing. The transconjunctival preseptal approach enjoys a low incidence of unfavorable scarring with ectropion or entropion (1.2%).⁵⁵ However, one drawback to this approach remains a somewhat-limited view during the preseptal dissection and limited exposure once the orbital floor has been accessed. For this reason, the lateral canthotomy and complete severance of the lower limb of the lateral canthal tendon (inferior cantholysis) was introduced by McCord and Moses in 1979.⁶⁸ This procedure allows for a generous tension-free exposure to the orbital floor, lateral orbital wall, and medial area. The surgical exposure obtained with the transconjunctival approach with the inferior cantholysis is superior to that of a subciliary incision. Also, the much smaller cutaneous incision is placed in a more favorable area of the crow’s-feet.

The majority of surgeons currently use the transconjunctival incision with or without canthotomy or the subciliary incision (preseptal approach) for orbital rim and floor access.⁶⁹ Both of these basic incisions provide good exposure with excellent esthetics and an extremely low rate of complications. Each surgeon’s own training, familiarity, and personal preference should guide which rim approach is used.

Superior and Medial Orbital Approaches

Access to the superior orbital rim and zygomaticofrontal (ZF) suture can be accomplished via a lateral eyebrow incision, upper blepharoplasty incision, coronal incision, or lateral canthotomy incision that is an extension of a subciliary or transconjunctival incision with a superior cantholysis. The eyebrow incision, if performed properly, results in excellent esthetics and is quickly and easily performed; therefore, it is one of the more

common approaches used for the lateral orbital rim or ZF suture area. The other incisions described are used more often when extensive facial fractures are present that require extensive skeletal exposure of the superior rim, cranial vault, or zygomatic arch.

The lateral brow incision is placed on the extreme outer aspect of the eyebrow, usually just superior to the ZF suture. The ZF suture line is usually approximately 1 cm above the lateral canthus. Generally, the skin of the lateral brow is tented over the superior lateral orbital rim, and a 1.5 cm curvilinear incision is made in a beveled fashion paralleling the hair follicles. Double-pronged skin hooks are then placed on the skin margins, and traction is maintained with digital palpation of the internal edge of the orbital rim. The skin incision opening is then gently retracted inferolaterally more directly over the ZF suture, and a needle-tipped Bovie cautery is used to divide the orbicularis oculi muscle fibers overlying the rim and ZF suture. Additional undermining and dissection is carried out in an inferolateral direction to provide full and adequate access to the fracture and enough adjacent bone to allow for rigid fixation. The advantages of not extending the skin incision beyond the brow obviously involve esthetics (placing it in the well-camouflaged and hidden area of the hair follicles) but also include that the skin is stepped and muscle incisions are made in distinct layers, which provide for more favorable healing. This incision also allows access for placing a blunt curved instrument deep to the zygomatic arch for the reduction of the ZMC or arch fractures. Closure should be accomplished in three distinct layers of periosteum, subcutaneous tissue, and skin. The periosteal, muscle, and deep subcutaneous closures are particularly important in that they provide the bulk of soft tissue over any plates and screws in the region.

The upper blepharoplasty incision can also be used for access to the ZF suture.

The incision is placed in one of the upper eyelid skin creases, preferably the deepest crease (which can be marked preoperatively, with the patient awake). The skin incision is then carried down through subcutaneous tissue, retracted somewhat laterally, and extended through the orbicularis oculi and periosteum by sharp dissection. Generally a 1 cm length of the lateral blepharoplasty incision is all that is required for complete access to the lateral orbital rim. This is due to the suppleness and mobility of the thin eyelid skin. Care should be taken to not over-retract the tissue, and the skin incision should be extended slightly laterally if excessive retraction forces are apparent. Separate suturing of the periosteum and skin are all that is required.

The coronal incision allows for excellent access to the entire supraorbital rim, roof, frontal sinus, superior aspects of the nasal bone, lateral orbital rim and wall, medial orbital rim and wall, and zygomatic arch.⁷⁰ This approach is generally necessary for extensive facial fractures involving the zygoma, frontal sinus, and NOE complex and for Le Fort III fractures. Numerous variations of the incision design exist, but generally a curvilinear incision is placed at least 2 cm posterior to the hairline (in the midline) and then extended posteriorly, paralleling the hairline, and finally inferiorly into the preauricular region. It is generally helpful to carry the vertical component of the coronal incision overlying the temporalis muscle just posterior to the junction of the superior helix and the scalp. It is then sharply angled forward, hugging the anterior helix and preauricular skin crease down to the pretragal area. By doing so, the superficial temporal vessels are generally not encountered or violated and retracted forward with the flap, allowing for a much drier field. It is not necessary to shave the scalp, but a 1 cm area of hair can be trimmed at the incision to allow for ease of closure, postoperative hygiene, and suture

removal. Local anesthesia with vasoconstrictors is helpful for hemostasis and often obviates the need for compression (Raney) clips. The incision is carried out through the skin, subcutaneous connective tissue, and galea aponeurotica into the loose areolar tissue in the midline. The subgaleal plane of dissection is contiguous with a plane deep to the parietotemporal fascia in the area of the temporalis muscle. The incision is then extended laterally in the supraperiosteal plane; it is helpful to insert a Metzenbaum or curved Mayo scissors in this plane prior to extending the incision laterally. This prevents inadvertent incising or nicking of the temporalis in an otherwise dry field. The dissection is carried out laterally to the superior temporal line bilaterally. Dissection is then carried anteriorly to the frontal bone, and a horizontal incision is made through the periosteum approximately 2 cm above the superior orbital rim. The incision is carried laterally to the superior temporal line and joined with the preauricular area inferiorly through the superficial layer of the deep temporal fascia to protect the temporal and frontal branches of the facial nerve.⁷¹ The facial nerve courses in a plane superficial to the deep temporal fascia approximately 1 to 3 cm from the tragus along the zygomatic arch.⁷² This approach provides complete access to the medial, lateral, and superior orbital rims. When a more extensive view of the medial orbital wall is required, subperiosteal dissection and release of the superior trochlea can be performed—the flap is retracted more inferiorly over the nasal dorsum, with a direct view of the medial wall. No attempts should be made to re-attach the trochlea since, when the soft tissues are re-draped, the trochlea re-adheres on its own. Sutureing may actually pierce or violate the trochlear tendon and result in ocular motility disturbances. Closure of the coronal flap should include suspending the deep temporal fascia over the temporalis muscle, deep closure of the galea aponeu-

rotica, subcutaneous buried suturing, and closure of the skin. It is important to remember that when a hemicoronal incision is employed, the medial extent of the incision should be carried beyond the midsagittal plane and extended completely to the hairline. This allows for adequate reflection and retraction over the entire zygoma and orbital rim structures.

When a transconjunctival incision is used with a lateral canthotomy, an extension of the dissection superiorly can be used for access to the ZF suture by severing the superior limb of the canthal tendon.⁶⁷ This approach provides good access to the lateral and infraorbital skeleton; however, it is less frequently used because it requires a more complex closure and re-anchoring of the lateral canthal tendon complex. Any misalignment results in canthal dystopia, usually in an inferior direction, and a rounded-out “almond-shaped” eye appearance. If the superior canthal tendon and its origin to the internal rim are allowed to remain intact, it provides a highly reliable landmark to which the inferior canthal limb can be sewn, resulting in excellent sharp-angled (30–40°) esthetics.

The entire lateral wall and rim is easily accessed through a standard blepharoplasty incision that extends only to the lateral orbital rim. This approach is commonly used for lateral orbital decompressions in cases of severe thyroid orbitopathy and it affords excellent exposure also to portions of the orbital roof and to the apex of the orbit laterally.

Medial Orbital Approaches Access to the medial orbital rim and superior aspect of the medial orbital wall can be accomplished through a coronal incision, as previously described. However, a separate lateral nasal incision can be used for isolated medial wall exploration or to access the inferior aspect of the medial orbital floor. This can be a transconjunctival or subciliary approach to the inferior rim and floor. The entire medial wall can be visualized by

extending the transconjunctival incision through the caruncle. The medial orbital wall and rim, by definition, are involved in fractures of the NOE complex, Le Fort II and III fractures, extensive frontal sinus fractures, and, occasionally, large blow-out fractures. The lateral nasal incision is most often used for access to the medial orbital rim to reconstruct a detached medial canthal tendon with direct transnasal wiring. This type of injury often occurs with NOE fractures and Le Fort III fractures. As stated earlier, medial orbital wall fractures generally do not result in any entrapment or ocular mobility problems. Generally the upper one-third of the medial orbital wall is uninvolved or nondisplaced, simply because it is the very thick extension of the cranial base. The lower two-thirds of the medial orbital wall overlies the ethmoid air cells and can be displaced inward, resulting in volume expansion. Unless there is extensive involvement, generally the resulting increase in orbital volume does not result in the development of enophthalmos. If the inferior two-thirds of the medial wall or orbital floor are involved and require surgical repair, then the previously described approaches to the orbital floor should suffice. However, fractures that extend farther superiorly (above the frontoethmoidal suture/anterior ethmoidal foramen) may require a lateral nasal approach or coronal incision. The lateral nasal approach involves a vertical gentle curvilinear 1 cm incision approximately 5 to 10 mm medial to the insertion of the medial canthus. Care should be taken not to place this incision too close to the medial canthus as this can result in a scar contracture with “webbing” and an abnormal epicanthal fold postoperatively. The incision should be placed over the lateral nasal structures properly, and after the skin incision is made, the dissection should be carried straight medially through skin, subcutaneous tissue, and a rudimentary portion of the orbicularis oculi muscle and periosteum. There is no

need to step these layers. The periosteum can then be reflected posteriorly and superiorly to the medial orbital rim and wall. The medial canthal tendon and lacrimal sac lie posterior and just inferior to the incision. The anterior ethmoidal vessels lie posteriorly and superiorly approximately 24 mm from the anterior lacrimal crest. These vessels can be gently divided with bipolar cautery, providing excellent hemostasis and improved access for identifying an intact bony ledge. However, one should bear in mind that any bony violation or entry superior to this line carries the potential risk for entry into the anterior cranial fossa. When an orbital implant is required along the medial wall, anterior fixation of the implant is recommended.

Acute Repair

Internal orbital fractures have varied patterns and degrees of severity. It is helpful to attempt to classify them either as linear, blow-out, or complex fractures. Linear fractures are those in which the bone fragments and walls remain intact. However, owing to angulation or overlap, they may result in either a bony orbital volume increase or decrease. Overlap fractures generally result in a bony defect of one orbital wall (typically the medial orbital floor) and are the most common orbital fracture. Blow-in fractures can occur in any orbital wall but most commonly occur in the roof and are associated with frontal sinus fractures. Blow-in and blow-out fractures of the orbital roof occur with equal frequency. Complex fractures are those that involve two or more walls, are > 2 cm in diameter, or are comminuted with displaced and unretrievable segments. Often these complex fractures are associated with fractures that extend beyond the orbital frame such as Le Fort II or III and frontal sinus fractures. These are termed combined fractures. The goals of acute or primary reconstruction of primary orbital fractures are to alleviate any functional deficit and to restore the facial esthetics.

Linear fractures are generally caused by blunt forces directly to the globe or partially to the rim and most often result in an esthetic deformity such as enophthalmos or hypo-ophthalmos. Functional deformities with entrapment are less common with linear orbital fractures. However, isolated linear fractures can have an instantaneous trapdoor effect owing to momentary expansion and entrap the edge of soft tissues including the inferior rectus. Once tightly pinched between these bony segments, this manifests itself as severe ocular motility restriction that is reproducible on serial examinations at the same point of limitation. There is also a positive result to the forced duction test. This type of fracture necessitates immediate surgical intervention to prevent the ischemic necrosis of the extraocular muscles. The majority of linear fractures in the orbit do not result in esthetic deformities such as enophthalmos or hypo-ophthalmos unless there is an associated facial fracture such as a fractured ZMC with a medial and downward rotation. It is the volume changes that account for the abnormal globe position. The goal of reconstruction is to restore the anatomic position of the bony rim and associated facial bones and to reapproximate, to the best of one's ability, the normal bony orbital volume with a reconstructive material. Numerous materials have been described in the literature for these purposes, such as porous polyethylene, bioresorbable polydioxanone, nylon, gelatin film, titanium mesh, and autogenous bone grafts (split-thickness calvarium and, less frequently, iliac crest).⁷³⁻⁷⁹ Each material has advantages and disadvantages related to the strength, application, reactivity, infection rate, biointegration, and complication rate associated with its use.

For linear and blow-out fractures, I prefer to use thin (0.85 mm) porous polyethylene sheeting. This alloplastic material is extremely biocompatible and nonresorptive. It has more than adequate tensile strength and does not cause any capsule

formation such as that seen with polymeric silicone sheeting. It has considerable flexibility (which can be improved with placement in an autoclaved saline) and little memory properties. The pore size allows tissue ingrowth, which reduces the risk of migration.⁸⁰ However, I still recommend anchoring the porous polyethylene sheeting to the anterior lateral orbital floor with a single titanium screw (Figure 24-15). The greatest advantages of this material are its ease of contouring, in situ carving, burring, and that it can be layered posteriorly behind the orbital equator to achieve proper orbital volume and contour.⁵²

Titanium mesh, with fixation to surrounding intact orbital rims, is quite useful when there are severe or comminuted injuries and a cantilevering is required

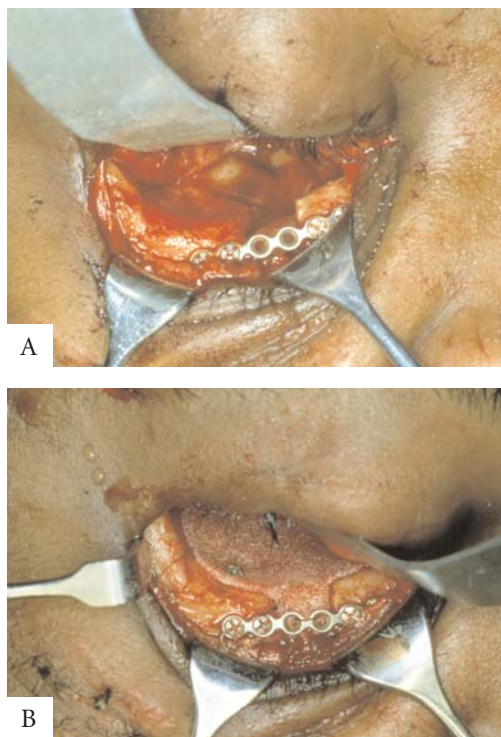


FIGURE 24-15 A, Right inferior orbital rim and floor fracture reduced and fixated with a 1.7 mm microplate. A portion of the mid-rim was suctioned away from the antrum and was missing. B, The floor defect was reconstructed with 0.85 mm thick porous polyethylene sheeting secured with a single 4 mm long 1.7 mm screw at the anterior lateral intact floor. A tab extension of the sheeting was fashioned at the rim defect, curved, and secured with a 5-0 nylon mattress suture.

because intact internal medial or posterior bony margins have not been identified or accessed. However, the possibility of unacceptable postoperative scarring to the mesh may occur, resulting in limited ocular motility. Therefore, when titanium mesh is employed, I still prefer to overlay it with either a split-thickness calvarial graft or a sheet of porous polyethylene sheeting. These materials are secured to the underlying mesh with either 30-gauge stainless steel wire or suturing.

Blow-out fractures typically involve one orbital wall (usually the anterior or medial portion of the orbital floor) and are < 2 cm in diameter. Enophthalmos associated with orbital blow-out fractures is due to an enlargement of the orbital bony volume that allows the orbital fat to be distributed within a larger compartment.³⁹ Fat atrophy contributes little, if anything, to the development of early or late enophthalmos.⁸¹ The reverse mechanism, often referred to as blow-in fracture, may result in a decreased orbital volume. Exophthalmos and ocular motility disturbances are uncommon unless there are surrounding severe associated fractures such as ZMC or frontal sinus fractures.

In 1960 Converse and Smith introduced the concept of “pure” (isolated floor) and “impure” (floor and rim) blow-out fractures.³⁹ Pure fractures are thought to be caused by a sudden instantaneous increase in intraorbital pressures from direct blunt-force trauma to the globe itself. Impure fractures are purported to be caused by direct trauma and compression of the bony rim and collapse of the surrounding facial bones, and result in the disruption of the internal orbital walls. What is most disconcerting is the finding of associated globe trauma such as hyphema, iridoplegia (ciliary body paralysis), and retinal hemorrhage in 90% of patients with pure blow-out fractures. This supports the notion that pure blow-out fractures are created by substantial instantaneous direct globe trauma. This fact should heighten

one’s awareness of the potential for serious globe injury when dealing with isolated or pure blow-out fractures.

The goal of primary reconstruction of blow-out fractures is to restore the configuration of the orbital walls, return prolapsed orbital contents to the orbit proper, and eliminate any impingement or entrapment of orbital soft tissues. In contrast to the orbital floor blow-out fractures, isolated blow-out fractures to the roof or medial walls usually do not contribute significantly to the development of cosmetic deformities or result in entrapment or limited ocular motility. As a result, medial and roof defects are managed by observation, serial examinations, and intervention when symptoms warrant. The most difficult area of the orbital floor blow-out fracture to repair is the posterior medial extent, which is beyond the globe axis. Often, an intact bony ledge cannot be identified or the graft material is not extended posteriorly enough to support the orbital contents in this region. This area is often responsible for a failed enophthalmos repair in orbital blow-out fractures. It is the reconstruction of this posterior medial floor to its normal contour that is the key to restoring normal globe position both anteroposteriorly and vertically. It is this scenario that is problematic in delayed reconstructions since attempts to create a normal anteroposterior position of the globe may result in inappropriate overpositioning of the globe in a superior direction. I prefer to use gelatin film as a temporary barrier for small or linear defects, simply to prevent entrapment during normal active ocular motion. This film is resorbed rather rapidly and does not provide much structural support; therefore, it is not used for larger defects in which herniation of contents into the underlying sinus is a possibility. Generally, the orbital blow-out fracture is explored in all of the intact bony walls identified. Once the malleable ribbon or globe retractors have supported the globe and orbital

contents superiorly, then the reconstructive material can be slid underneath them and overlap the intact bony margins slightly at the majority of areas to provide adequate support. I prefer to use porous polyethylene for moderate to large blow-out fractures. The porous polyethylene sheeting can be secured with a single positional screw (usually 1.7 mm external thread diameter) or an extended tab of this material can be sutured to the orbital rim orbital plate (see Figure 24-15). Care should be taken to not extend the grafts up to the orbital rim or over the edge since these will be palpable and would improperly reconstruct the normal anatomic contour to the floor, which should dip down behind the rim for several millimeters before proceeding posteriorly. Also, the extension of semirigid grafts onto the orbital rim has an undesirable ramping effect, which tends to position the globe in an abnormal posterior direction, resulting in enophthalmos. After the floor graft is placed and secured, trimming or smoothing should be accomplished and a forced duction test performed prior to any wound closure to ensure that no impingement of the soft tissues has occurred.

Complex orbital fractures are generally associated with additional surrounding midfacial and frontal sinus fractures. Primary reconstruction of these defects is challenging owing to the extent of these injuries, the lack of any normal identifiable anatomy, and poor surrounding bony support for rigid fixation and anchoring of reconstructive materials. However, it is in this group of individuals that primary repair with normal anatomic realignment is critical for acceptable esthetic and functional outcomes. Delaying the primary repair beyond 7 to 10 days usually results in some secondary soft tissue changes, the inability to completely retrieve small bony segments, and a less-than-desirable outcome. The initial step in the reconstruction of complex facial fractures is adequate exposure of all midfacial structures with adequate alignment and reduction prior to rigid fixation of any components with plates and screws (Figure 24-16). This helps one avoid misalignment, over-reduction, or improper angulation of these segments. Achieving adequate exposure requires more extensive subperiosteal dissection than is done for most other orbital fractures. It may be desirable to

also completely dissect and expose all internal orbital fractures prior to fixation of the surrounding periorbital or midfacial fractures. Generally the orbital rim is plated with 1.7 mm or finer plating systems. Care should be taken at the inferior orbital rim and especially the lateral orbital rim to keep the plates several millimeters from the edge of the rim; otherwise, they will be annoyingly palpable once the soft tissue edema has subsided. Once the orbital rims and midfacial bones have been fixated, the moderate to large orbital floor defects are generally repaired with porous polyethylene and anchored to the anterior inferior floor with a single screw. Sometimes layering of this material with an additional sheet posteriorly is required to achieve correct anteroposterior globe positioning. More extensive defects may require titanium mesh or orbital floor plates with screw fixation to the rims and autogenous bone grafts. Several bone grafts can be secured to the metallic mesh framework to independently reconstruct the floor, medial wall, and, less frequently, the lateral orbital walls. The advantage of having bone overlie the metallic mesh is that remodeling can

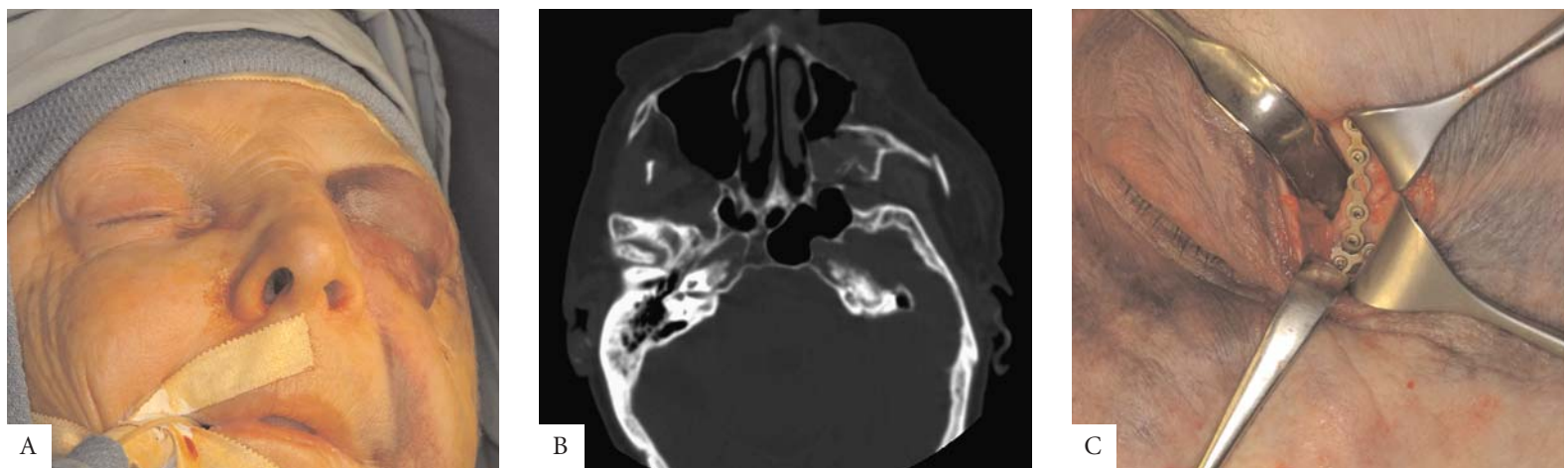


FIGURE 24-16 A, An elderly female sustained a severely displaced left zygomatic complex (ZMC) fracture with > 75% orbital floor disruption. She was on warfarin sodium and had moderately decreased left visual acuity with increased ocular pressures. B, Axial CT scan revealed a ZMC fracture with a severe posterior, medial, and moderate inferior displacement. C, The patient was taken urgently (within 12 h) for surgical treatment to reduce the fracture and re-expand the orbital volume. Serial examination and ocular pressure checks were performed every 2 hours pre- and postoperatively. Owing to cardiac risk factors, the anticoagulation was not reversed, nor was the patient treated with fresh frozen plasma. The zygomaticofrontal (ZF) suture area was first approached through a lateral brow incision. After the intraoral vestibular and then transconjunctival approaches were accomplished, the ZF fracture was plated. (CONTINUED)

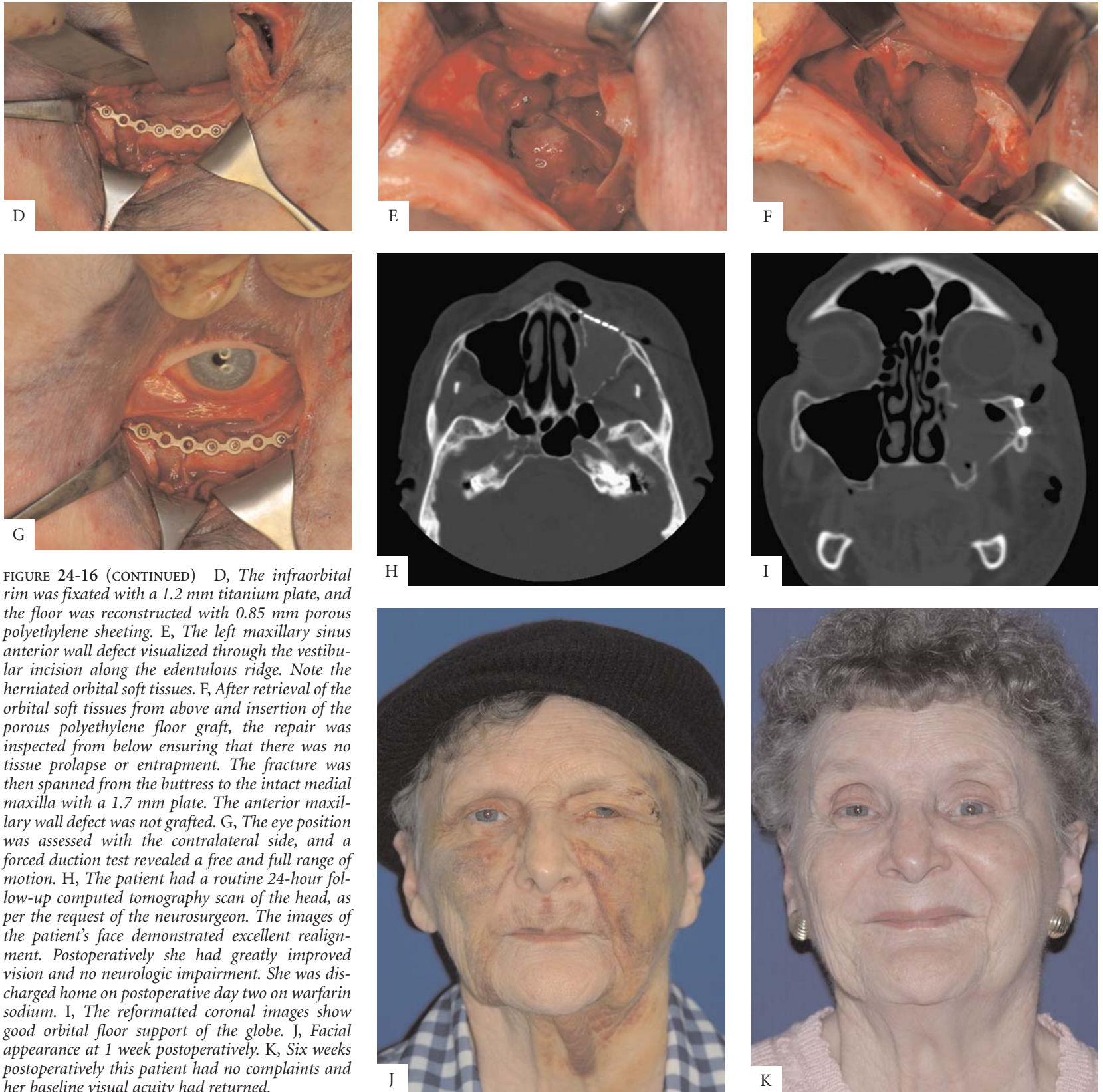


FIGURE 24-16 (CONTINUED) D, The infraorbital rim was fixated with a 1.2 mm titanium plate, and the floor was reconstructed with 0.85 mm porous polyethylene sheeting. E, The left maxillary sinus anterior wall defect visualized through the vestibular incision along the edentulous ridge. Note the herniated orbital soft tissues. F, After retrieval of the orbital soft tissues from above and insertion of the porous polyethylene floor graft, the repair was inspected from below ensuring that there was no tissue prolapse or entrapment. The fracture was then spanned from the buttress to the intact medial maxilla with a 1.7 mm plate. The anterior maxillary wall defect was not grafted. G, The eye position was assessed with the contralateral side, and a forced duction test revealed a free and full range of motion. H, The patient had a routine 24-hour follow-up computed tomography scan of the head, as per the request of the neurosurgeon. The images of the patient's face demonstrated excellent realignment. Postoperatively she had greatly improved vision and no neurologic impairment. She was discharged home on postoperative day two on warfarin sodium. I, The reformatted coronal images show good orbital floor support of the globe. J, Facial appearance at 1 week postoperatively. K, Six weeks postoperatively this patient had no complaints and her baseline visual acuity had returned.

occur—secondary revision surgery is enhanced when dissecting along a healed bony surface versus bare mesh. In severe or

large defects with comminution, overcorrection of the enophthalmos component (but not a hyper-ophthalmic deformity)

by several millimeters is often necessary to take into account the orbital edema that exists. In addition, with bone grafts, some

mild resorption can take place with subtle settling. However, it is the resolution of the edema that accounts for the majority of postoperative globe position changes.

ZMC fractures are second only to nasal fractures in incidence. These fractures are described in greater detail in Chapter 23.2, “Management of Zygomatic Complex Fractures” and Chapter 25, Management of Frontal Sinus and Naso-orbitoethmoid Complex Fractures.” Some discussion is warranted here, as ZMC fractures relate to orbital involvement and appropriate intraoperative sequencing. Nonfragmented or single-piece ZMC fractures are generally displaced in an inferior, medial, and posterior direction, with a pivot-point rotation about the ZF suture. As a result, the orbital floor suffers the most disruption. On initial inspection, the coronal CT scans may not reveal the degree of orbital floor disruption, but if one envisions the outward reduction of the zygomatic buttress and the resulting medial floor void, the magnitude of the injury can be appreciated. Only after reduction and stabilization of the entire external orbital framework and surrounding facial bones should the internal orbital defects be repaired (see Figure 24-16C–G). The internal orbital injuries associated with fragmented ZMC fractures usually involve multiple orbital walls and larger defects. Therefore, more extensive exposure is generally necessary and more rigid materials are usually required for reconstruction.

NOE injuries result mainly from extreme blunt force trauma and have a high degree of associated intracranial and neurologic injuries. Additionally, injuries to the nasal airway and lacrimal system can occur.⁸² Injuries to the lacrimal system can be managed by the placement of small silicone tubes. Even though canalicular disruption is more common with laceration-type injuries, these tubes can still be inserted with blunt trauma when a fair amount of edema is present and the sur-

rounding anatomy is obscured. This prophylactic intubation of the superior and inferior canaliculi and the lacrimal system helps to avoid iatrogenic injury during the extensive dissection required to treat this type of injury. The tubes can be allowed to remain in place several weeks postoperatively during the resolution of edema. Repair of NOE injuries is recommended within the first 7 to 10 days after injury, before the soft tissues have had the chance to re-adapt with significant scarring contracture and generally a flattened and splayed appearance to the orbits and mid-face. NOE injuries generally do not cause entrapment simply because of the orbital walls involved and the degree of comminution. However, entrapment of the medial rectus can occur during reconstruction, fixation, and suturing; therefore, a forced duction test should be performed at the completion of these phases. The primary defects associated with NOE injuries are medial canthal disruption with telecanthus and increased bony volume resulting in enophthalmos. If there are no other indications for coronal dissection, such as frontal bone or zygomatic arch fractures, then the medial orbital component of the NOE fracture is best approached directly through a lateral nasal (Lynch) incision. Often accessing the inferior medial wall or positioning the inferior edge of the medial wall graft requires an additional inferior rim and orbital floor approach, such as the subciliary or transconjunctival approach. Traumatic telecanthus should be treated by direct fixation techniques, using 1.0 to 1.7 mm plating systems. External splinting may provide some reasonable nasal bone molding, but it generally does little to improve traumatic telecanthus. Generally, the medial canthal ligament heals in a position that is too superficial and inferior. Postoperatively the entire area fills with dense scar tissue, and it is difficult to secondarily dissect and reposition the canthus in its normal position. With NOE fractures the medial canthal tendons usually maintain their attachment to

the bony segments. Therefore, proper reduction and fixation of the bony skeleton to the surrounding stable bone (maxilla, orbital, and frontal) often corrects the telecanthus deformity. This should be accomplished and the medial canthal position reassessed. If the canthal position is still unacceptable, then a fine stainless steel wire (30-gauge) can be secured directly to the canthal tendon or preferably, sutured to the wire that has been passed transnasally.

The double-armed wire is inserted from the contralateral orbit to the side that will be anchored, with the entry point on the medial wall being just posterior and superior to lacrimal fossa. This can be accomplished by prethreading the double-armed wire into a gently curved 16-gauge needle, passing it transnasally through small burr holes, retrieving the double-armed wire on the side to be fixated, and withdrawing the needle canula. The canthus is then sutured to the wire loop with a half-round needle (4.0 Mersilene S-2 needle), and the wire is drawn to the contralateral side and the limbs twisted gradually around a short section of plate to fine-tune the canthal position (see Figure 24-12). This is a much easier way to accomplish precise canthal positioning than are direct suturing techniques.

Summary

Orbital fractures are often associated with ocular injuries and midfacial fractures. A thorough ophthalmologic evaluation is mandatory to detect ocular injuries and to preserve vision. Surgical intervention should be based on either a functional deficit or a cosmetic deformity. The surgical sequencing and timing of the repair should be well thought out. When visual compromise exists, an ophthalmologist should be involved in the treatment planning.

References

1. Rontal E, Rontal M, Guilford FT. Surgical anatomy of the orbit. *Ann Otol Rhinol Laryngol* 1979;88(3 Pt 1):382–6.

2. Waitzman AA, Posnick JC, Armstrong DC, Pron GE. Craniofacial skeletal measurements based on computed tomography. Part II. Normal values and growth trends. *Cleft Palate Craniofac J* 1992;2:118–28.
3. Ochs MW, Buckley MJ. Anatomy of the orbit. *Oral Maxillofac Surg Clin North Am* 1993;5:419–29.
4. Frenkel REP, Spoor TC. Neuro-ophthalmologic manifestations in trauma. In: Spoor TC, Nesi FA, editors. *Management of ocular, orbital, and adnexal trauma*. New York: Raven Press; 1988. p. 195–245.
5. Rootman J. Basic anatomic considerations. In: Rootman J, editor. *Diseases of the orbit*. Philadelphia: JB Lippincott; 1988. p. 3–18.
6. Hollinshead WH. *The head and neck*. 3rd ed. Philadelphia: Harper and Rowe; 1982. p. 93–155.
7. Som PM, Shugar JM, Brandwein MS. Anatomy and physiology of the sinonasal cavities. In: Som PM, Curtin HD, editors. *Head and neck imaging*. St. Louis: Mosby; 2003. p. 87–147.
8. Zide BM, Jelks GW. *Surgical anatomy of the orbit*. New York: Raven Press; 1985.
9. Bergin DJ. Anatomy of the eyelids, lacrimal system, and orbit. In: McCord CD Jr, Tanenbaum M, editors. *Oculoplastic surgery*. 2nd ed. New York: Raven Press; 1987. p. 41–71.
10. Hart WM Jr. The eyelids. In: Hart WM Jr, editor. *Adler's physiology of the eye*. 9th ed. St. Louis: Mosby; 1992. p. 1–16.
11. Nakamura T, Gross C. Facial fractures: analysis of five years of experience. *Arch Otolaryngol* 1973;97:288–90.
12. Gwyn PP, Carraway JH, Horton CE, et al. Facial fractures—associated injuries and complications. *Plast Reconstr Surg* 1971;47:225–30.
13. Ellis E III. Fractures of the zygomatic complex and arch. In: Fonseca RJ, Walker RF, editors. *Oral and maxillofacial trauma*. Vol 1. Philadelphia: WB Saunders; 1991. p. 435–514.
14. Hammer B. Orbital fractures, diagnosis, operative treatment and secondary corrections. *Gottingen (Germany): Hogrefe and Huber*; 1995. p. 10–11.
15. Kelly JK, Lazo A, Metes JJ. Radiology of orbital trauma. In: Spoor TC, Nesi FA, editors. *Management of ocular, orbital and adnexal trauma*. New York: Raven Press; 1988. p. 247–68.
16. Unger JM. Orbital apex fractures: the contribution of computed tomography. *Radiology* 1984;150:713–7.
17. Guyon JJ, Brant-Zawadzki M, Seiff SR. CT demonstration of optic canal fractures. *AJR Am J Roentgenol* 1984;143:1031–4.
18. Lindahl S. Computed tomography of intra-orbital foreign bodies. *Acta Radiol* 1987;28:235–40.
19. Gillespie JE, Isherwood L, Barker GR. Three dimensional reformations of computed tomography in the assessment of facial trauma. *Clin Radiol* 1987;38:523–6.
20. Roberts CF, Leehey PJ III. Intra-orbital wood foreign bodies mimicking air at CT. *Radiology* 1992;185:507–8.
21. Kelly WM, Paglen PG, Pearson JA, et al. Ferromagnetism of intraocular foreign body causes unilateral blindness after MR study. *AJNR Am J Neuroradiol* 1986;7:243–5.
22. Otto PM, Otto RA, Virapongse C, et al. Screening test for detection of metallic foreign objects in the orbit before magnetic resonance imaging. *Invest Radiol* 1992;27:308–11.
23. Sprecht CS, Varga JH, Jalai MM, Edelstein JP. Orbitocranial wooden foreign body diagnosed by magnetic resonance imaging: dry wood can be isodense with air and orbital fat by computed tomography. *Surv Ophthalmol* 1992;36:341–4.
24. Byrne SF, Green RL. Trauma and periodontal disease. In: Byrne SF, Green RL, editors. *Ultrasound of the eye and orbit*. St. Louis: Mosby Year Book; 1992. p. 431–61.
25. Reshef DS, Osoinig KC, Nerad JA. Diagnosis and intraoperative localization of a deep orbital organic foreign body. *Orbit* 1987;6:3–15.
26. Berges O. Color Doppler flow imaging of the orbital veins. *Acta Ophthalmol* 1992;204:55–8.
27. McCoy FJ. Applications to new advances to treatment of facial trauma. *Ann Plast Surg* 1986;17:354–5.
28. Tschanz A, Hammer B, Prein J. *Visusverlust bei Verletzungen der Orbita* [unpublished medical thesis]. University Hospital, Basel (Switzerland); 1994.
29. Katz B, Herschler J, Brich DC. Orbital hemorrhage and prolonged blindness: a treatable posterior optic neuropathy. *Br J Ophthalmol* 1983;67:549–53.
30. Kersten RC, Rice CD. Subperiosteal orbital hematoma: visual recovery following delayed drainage. *Ophthalmic Surg* 1987;18:423–7.
31. Ord RA, El Attar H. Acute retrobulbar hemorrhage complicating a malar fracture. *J Oral Maxillofac Surg* 1982;40:234–6.
32. Ahn BH, Baek NH, Shin DH. Management of traumatic hyphema. In: Spoor TC, Nesi FA, editors. *Management of ocular, orbital, and adnexal trauma*. New York: Raven Press; 1988. p. 69–80.
33. Hammer ME, Grizzard WS. Management of retinal and vitreous injuries. In: Spoor TC, Nesi FA, editors. *Management of ocular, orbital, and adnexal trauma*. New York: Raven Press; 1988. p. 81–128.
34. Seiff SR. High-dose corticosteroids for treatment of vision loss due to indirect injury to the optic nerve. *Ophthalmic Surg* 1990;21:389–95.
35. Spoor TC, Hartel WC, Lensink DB, Wilkinson MJ. Treatment of traumatic optic neuropathy with corticosteroids. *Am J Ophthalmol* 1990;110:665–9.
36. Mauriello JA, DeLuca J, Krieger A, et al. Management of traumatic optic neuropathy—a study of 23 patients. *Br J Ophthalmol* 1992;76:349–52.
37. Fujino T, Makino K. Entrapment mechanisms and ocular injury in orbital blow-out fractures. *Plast Reconstr Surg* 1980;65:571–6.
38. Smith B, Regan W. Blowout fractures of the orbit. *Am J Ophthalmol* 1957;44:733–9.
39. Converse JM, Smith B. Blowout fractures of the orbit. *Trans Am Acad Ophthalmol Otolaryngol* 1960;64:676–88.
40. Crikelair G, Rein J, Potter G. A critical look at the blowout fracture. *Plast Reconstr Surg* 1972;49:374–9.
41. Nicholason D, Guzak S. Visual loss complicating repair of orbital floor fractures. *Arch Ophthalmol* 1971;86:369–76.
42. Putterman AM, Stevens T, Urist MJ. Nonsurgical management of blowout fractures of the orbital floor. *Am J Ophthalmol* 1974;77:232–8.
43. Dullely B, Fells P. Orbital blowout fractures. *Br Orthoped J* 1974;31:47–54.
44. Crumley R, Leibsahn J, Krause C, Burton T. Fractures of the orbital floor. *Laryngoscope* 1976;87:934–47.
45. Converse JM, Smith B. Editorial on the treatment of blowout fractures of the orbit. *Plast Reconstr Surg* 1978;62:100–4.
46. Wilkins RB, Havins WE. Current treatment of blowout fractures. *Ophthalmology* 1982;89:464–6.
47. Koorneef L. Current concepts on the management of orbital blowout fractures. *Ann Plast Surg* 1982;9:185–200.
48. Smith B, Lisman RD, Simonton J, DellaRocca R. Volkmann's contracture of the extraocular muscles following blowout fractures. *Plast Reconstr Surg* 1984;74:200–16.
49. Hawes M, Dortzbach RL. Surgery on orbital floor fractures: influence of time on repair and fracture size. *Ophthalmology* 1983;90:1066–70.
50. deMann K. Fractures of the orbital floor: indications for exploration and for the use of a floor implant. *J Oral Maxillofac Surg* 1984;12:73–7.

51. Dortzbach R, Elnor V. Which orbital floor blowout fractures need surgery [editorial]? *Adv Ophthalmic Plast Reconstr Surg* 1987;6:287-9.
52. Dutton JJ, Manson P, Putterman A. Management of blowout fractures of the orbital floor [editorial]. *Surv Ophthalmol* 1991;35:279-80.
53. Parsons GS, Mathog RH. Orbital wall and volume relationships. *Arch Otolaryngol Head Neck Surg* 1988;114:743-7.
54. Roncevic R, Malinger B. Experience with various procedures in the treatment of orbital floor fractures. *J Oral Maxillofac Surg* 1981;9:81-4.
55. Zingg M, Chowdhury K, Ladrach K. Treatment of 813 zygoma-lateral orbital complex fractures. *Arch Otolaryngol Head Neck Surgery* 1991;11:611-20.
56. Thaller S, Yvorchuk W. Exploration of the orbital floor: an indicated procedure? *J Craniomaxillofac Surg* 1990;1:187-90.
57. Sacks A, Friedland J. Orbital floor fractures: should they be explored early? *Plast Reconstr Surg* 1979;64:190-3.
58. deMann K, Hes WJ, deJong PT, Wijngaarde R. Influence of age on the management of blowout fractures of the orbital floor. *Int J Oral Maxillofac Surg* 1991;20:330-6.
59. Manson PN, Clifford CM, Su CT, Iliff NT. Mechanisms of global support and post-traumatic enophthalmos. I. The anatomy of the ligament sling and its relation to intramuscular cone orbital fat. *Plast Reconstr Surg* 1986;77:193-202.
60. Converse JM. Two plastic operations for repair of the orbit following severe trauma and extensive comminuted fracture. *Arch Ophthalmol* 1944;31:323-5.
61. Wray RC, Holtman BN, Rebaudo JM, et al. A comparison of conjunctival and subciliary incisions for orbital fractures. *Br J Plast Surg* 1983;10:309-13.
62. Heckler F, Songcharoen S. Subciliary incision and skin-muscle eyelid flap for orbital fractures. *Ann Plast Surg* 1983;10:309-13.
63. Pospisil OA, Fernando TD. Review of the blepharoplasty incisions as a surgical approach to zygomatic orbital fractures. *Br J Oral Maxillofac Surg* 1984;22:261-8.
64. Tessier P. The conjunctival approach to the orbital floor and maxilla in congenital malformation and trauma. *J Oral Maxillofac Surg* 1973;1:3-8.
65. Converse JM, Firmin F, Wood-Smith D, Friedland J. The conjunctival approach in orbital floor fractures. *Plast Reconstr Surg* 1973;52:656-7.
66. Ochs MW. Use of preseptal transconjunctival approach in orbital reconstruction surgery [discussion]. *J Oral Maxillofac Surg* 2001;59:291-2.
67. Manson PN, Ruas E. Single eyelid incision for exposure of the zygomatic bone and orbital reconstruction. *Plast Reconstr Surg* 1987;79:120-6.
68. McCord C, Moses J. Exposure of the inferior orbit with fornix incision and lateral canthotomy. *Ophthalmic Surg* 1979;10:53-63.
69. Baumann A, Ewers R. Use of preseptal transconjunctival approach in orbital reconstruction surgery. *J Oral Maxillofac Surg* 2001;59:287-91.
70. Ellis E III, Zide MF, editors. Coronal approach. In: *Surgical approaches to the facial skeleton*. Philadelphia: Williams and Wilkins; 1995. p. 63-94.
71. Stuzin JM, Wagstron L, Kawamoto H, et al. Anatomy of the frontal branch of the facial nerve: the significance of the temporal fat pad. *Plast Reconstr Surg* 1989;83:265-71.
72. Al-Kayat A, Bramley P. A modified preauricular approach to the temporomandibular joint and malar arch. *Br J Oral Surg* 1979;17:91-103.
73. Rubin L. *Biomaterials in reconstructive surgery*. St. Louis: CV Mosby; 1983.
74. Berghaus A. Porous polyethylene in reconstructive head and neck surgery. *Arch Otolaryngol Head Neck Surg* 1985;111:154-60.
75. Ilizuka T, Mikkonen P, Paukku P, Lindqvist C. Reconstruction of orbital floor with polydioxanone plate. *Int J Oral Maxillofac Surg* 1991;20:83-7.
76. Loftfield K, Jordan DR, Fowler J, Anderson RL. Orbital cyst formation associated with Gelfilm use. *Ophthal Plast Reconstr Surg* 1987;3:187-91.
77. Rubin PA, Shore JW, Yaremchuk MJ. Complex orbital fracture repair using rigid fixation of the internal orbital skeleton. *Ophthalmology* 1999;99:553-9.
78. Ilankovan V, Jackson T. Experience in the use of calvarial bone grafts in orbital reconstruction. *Br J Oral Maxillofac Surg* 1992;30:92-6.
79. Gruss JS, MacKinnon SE. The role of primary bone grafting in complex craniomaxillofacial trauma. *Plast Reconstr Surg* 1985;75:17-24.
80. Cestero HJ, Salyes KE, Toranto IR. Bone growth into porous carbon, polyethylene, and polypropylene prostheses. *J Biomed Mater Res* 1975;9:1-7.
81. Whitehouse RW, Batterbury M, Jackson A, Noble JL. Prediction of enophthalmos by computed tomography after "blowout" orbital fracture. *Br J Ophthalmol* 1994;78:618-20.
82. Gruss JS, Hurwitz JJ, Nik NA, Kassel EE. The pattern and incidence of nasolacrimal injury in naso-orbital-ethmoid fracture: the role of delayed assessment and dacryocystorhinostomy. *Br J Plast Surg* 1985;38:116-21.

Management of Frontal Sinus and Naso-orbitoethmoid Complex Fractures

Larry L. Cunningham Jr, DDS, MD

Richard H. Haug, DDS

Fractures of the frontal bone and the naso-orbitoethmoid (NOE) complex are infrequent, occurring among 2 to 15% of patients with facial fractures.¹⁻⁴ When these fractures occur, they can cause devastating complications because of their proximity to the brain, eyes, and nose. Complications include blindness or other forms of visual disturbance, orbital cellulitis or abscess, meningitis, brain abscess, and facial deformation. Although reports of the surgical management of the diseased frontal sinus have existed for > 100 years,⁵ no consensus has yet been reached on ideal care after traumatic injury.⁵⁻⁷

Most victims are male (66–91%) and young (usually 20–30 yr of age, range 6–72 yr),^{1,7-20} and most frontal sinus and NOE injuries are sustained in motor vehicle or motorcycle collisions (44–85%).^{1,3,7,8,10,11,14-24} NOE fractures can occur in isolation, but they most often occur in association with other midface fractures.^{23,25} As many as 60% of patients with NOE fractures have associated nonfacial injuries.²⁴

The distribution between fractures of the supraorbital rim and fractures of the frontal sinus is almost equal. The pub-

lished frequency of fractures of the anterior wall, the posterior wall, and the floor of the frontal sinus varies rather widely: 43 to 61% of reported patients had anterior table fractures only, 19 to 51% had anterior and posterior table fractures, 2.5 to 25% had injuries to the nasofrontal duct, and 0.6 to 6% had posterior fractures only.^{2,3,8}

Anatomy and Physiology

Embryology of the Sinus

The frontal bone is an intramembranous bone that develops from two paired structures that begin to ossify at the eighth or ninth week in utero.^{10,26} The ossification begins in the frontal processes of the squamous regions, progresses to the orbital and squamous regions, and reaches the frontal and temporal regions by the twelfth week. The metopic suture in the midline closes during the second year of life.²⁷ The forehead is displaced anteriorly by sutural growth, inner table resorption, and outer table deposition.²⁸

The frontal sinus is a small outpouching at birth and undergoes almost all of its development thereafter. The sinus may

develop from one or several different sites: as a rudiment of the ethmoid air cells, as a mucosal pocket in or near the frontal recess, as an evagination of the frontal recess, or from the superior middle meatus.²⁰ Initial pneumatization begins during the fourth month in utero. Secondary pneumatization begins at the age of 6 months to 2 years and develops laterally and vertically. The sinus is radiographically identifiable by the time the child reaches the age of 6 years.²⁹ Most pneumatization is completed by the time the child is 12 to 16 years old, but it continues until the age of 40 is reached.^{5,20,26,30} The configuration of the sinus and the position of the septa are extremely variable.

Physiology of the Sinus

The entire surface area of the frontal sinus is covered with respiratory epithelium ranging in thickness from 0.07 to 2.0 mm.³¹ The mucosa consists of pseudostratified ciliated epithelium, mucus-producing goblet cells, a thin basement membrane, and a thin lamina propria that contains seromucous glands.³¹ When the mucosa is healthy, a blanket of mucin

overlies the epithelium. The cilia flow at 250 cycles/min. The mucin blanket flows in a spiral fashion in a medial-to-lateral direction; the flow is slowest at the roof and fastest at the nasofrontal duct.³² The mucin empties at the nasofrontal duct at a rate of 5.0 g/cm². The physiologic characteristics of the sinus and the status of the nasofrontal duct dictate the treatment of the frontal sinus in trauma.³³

Osteology

The frontal bone is shaped as a concave disk with a horizontal table forming the orbital rim. From the nasion the bone extends approximately 12.5 cm superiorly,

8.0 cm laterally, and 5.5 cm posteriorly. Two frontal tuberosities are noted lateral to the midline and superior to the supraorbital run. The thickest area of the bone is the supraorbital rim from the frontozygomatic process to the nasal bones. The ethmoid plate is bound on three surfaces along the floor of the frontal bone in the midline. As the floor of the frontal bone extends laterally, it becomes concave and forms the orbital roof. The supraorbital and frontal foramen are located at the most superior portion of the orbital rim. The supratrochlear foramen is located medial to the supraorbital foramen or notch and lateral to the nasal bones. A spine or con-

cavity exists on the frontal bone along the medial anterior orbital roof; the trochlea of the superior oblique muscle is attached to this spine (Figure 25-1).^{34,35}

Paired triangular sinuses are found within the frontal bone. These sinuses are asymmetric and are separated by a frontal septum. The average height of the sinuses is 32 mm, and their average width is 26 mm.^{29,35} The surface area is approximately 720 mm².³² The frontal bone is thinnest in the region of the glabella at the anterior wall and floor of the sinus. The duct of the frontal sinus empties into the ethmoid air cells of the middle meatus of the nose.

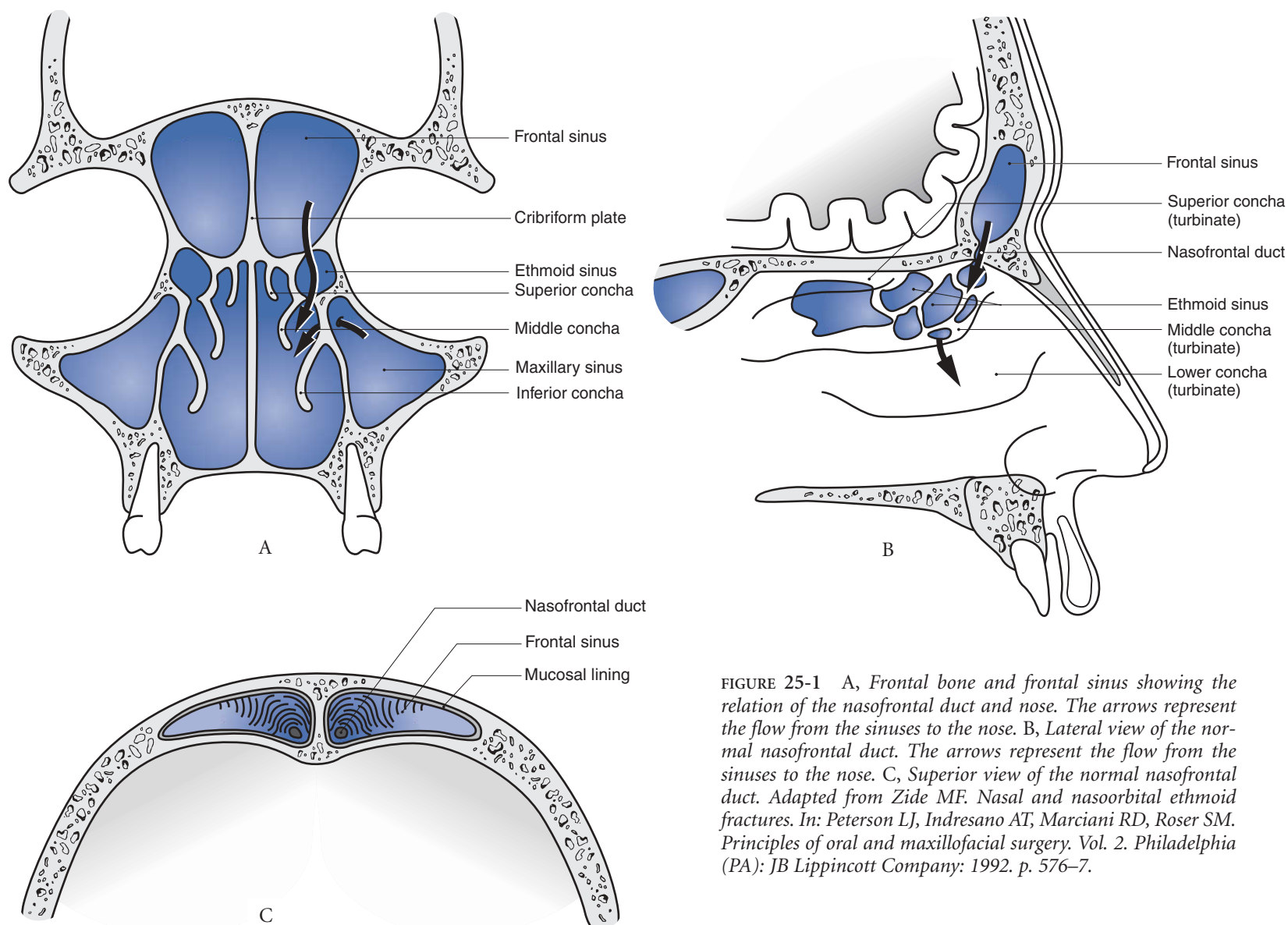


FIGURE 25-1 A, Frontal bone and frontal sinus showing the relation of the nasofrontal duct and nose. The arrows represent the flow from the sinuses to the nose. B, Lateral view of the normal nasofrontal duct. The arrows represent the flow from the sinuses to the nose. C, Superior view of the normal nasofrontal duct. Adapted from Zide MF. Nasal and nasoorbital ethmoid fractures. In: Peterson LJ, Indresano AT, Marciani RD, Roser SM. Principles of oral and maxillofacial surgery. Vol. 2. Philadelphia (PA): JB Lippincott Company; 1992. p. 576–7.

The internal concave surface of the frontal bone forms the anterior cranial fossa that houses the brain. The floor of the frontal bone outlines the roof of the orbit. The convex outer table is bounded by the scalp and the frontalis, orbicularis, and procerus muscles. The osseous structures that abut the frontal bone are the lacrimal and ethmoid bones inferiorly, the sphenoid inferiorly and posteriorly, the parietal posteriorly and superiorly, the zygoma laterally, the nasal bones anteriorly, and the maxilla anteriorly and inferiorly. The ethmoid air cells and nasal apparatus are situated inferiorly.

The nasal part of the frontal bone extends inferiorly deep to the nasal bones and the frontal process of the maxilla, adding support to the NOE complex. The nasal bones and the maxilla make up the piriform rim. The articulation of the nasal bones forms a crest posteriorly and inferiorly; this crest articulates with the frontal bone, the perpendicular plate of the ethmoid (forming the upper third of the nasal septum), and the septal cartilage. The NOE region is supported structurally by a vertical buttress—the frontal process of the maxilla—and two horizontal buttresses: the supraorbital and infraorbital rims.³⁶

The medial walls of the orbit begin behind the frontal process of the maxilla. The thin lacrimal bone and a frail lamina papyracea in the anterior are weak and susceptible to fracture. Higher up, the frontoethmoid suture delineates the level of the cribriform plate and crista galli.

Neurovascular Structures

The arterial blood supply to the frontal sinus is from the supraorbital and anterior ethmoid arteries. Two foramina are present along the suture line: the anterior ethmoid foramen, through which course the nasociliary nerve and the anterior ethmoidal artery; and the posterior ethmoidal foramen, through which pass the vessel and nerve of the same name.

Further posterior along the medial orbital wall, the optic nerve exits through the body of the sphenoid bone, 3.5 to 5 mm behind the posterior ethmoidal foramen in a line parallel to the two foramina. The frontal bone is supplied by the supraorbital, anterior superficial temporal, anterior cerebral, and middle meningeal arteries.^{27,34,35} Venous drainage is transosseous through the anastomosis of vessels of the subcutaneous, orbital, and intracranial structures. The primary venous drainage is through the supratrochlear, supraorbital, superficial temporal, frontal diploic (veins of Breschet), superior ophthalmic, and superior sagittal sinuses.^{27,34} The relationship of the diploë to the anterior cranial fossae is important to understand because these structures can become a conduit for the spread of infection.

Interorbital Space

The nasofrontal suture is the continuation of the frontoethmoid suture and corresponds to the plane of the base of the skull or frontal sinus. The interorbital space is bounded laterally by the medial wall of the orbits. In the middle is the perpendicular plate of the ethmoid and nasal septum. The anterior wall is composed of the paired nasal bones, the frontal processes of the maxilla, and the nasal processes of the frontal bone.

The ethmoid air cells within the interorbital space occupy the upper half of the wall lateral to the nasal fossa. The dimensions of the anterior end of the ethmoid labyrinth are approximately 2.5 cm vertically and 1 cm transversely. The pyramid-shaped sinus measures 3.5 to 5 cm from front to back.

The ethmoid air cells drain into the middle meatus, as does the nasofrontal duct. The nasofrontal duct is located in the posterior medial floor of the frontal sinus at the junction of the ethmoid and nasal portions of the floor, and it courses through the anterior ethmoid in the middle meatus or just anterior to the middle

turbinate. The length of the duct may vary from a few millimeters to a centimeter or more (Figure 25-2).

Medial Canthal Tendon

The orbicularis oculi muscle has three portions: the orbital, the preseptal, and the pretarsal. The pretarsal portions of the upper and lower lids unite at the canthus to form the medial canthal tendon (MCT).

The MCT may be subdivided into a superficial portion and a deeper portion with the lacrimal sac between them. The superficial portion has two “legs” and inserts into the frontal process of the maxilla, providing support to the eyelids and maintaining the integrity of the palpebral fissure.^{36,37} The anterior leg attaches to the posterolateral surface of the nasal bones, and the superior leg inserts at the junction of the frontal process of the maxilla and the angular process of the frontal bone. The deeper portion (also known as Horner’s muscle or the pars lacrimalis) attaches to the posterior lacrimal crest.

NOE injuries may cause avulsion of the tendons from the bone or, more commonly, fractures of the bone that contains the attachment of tendons. This portion of the orbital rim is an important anatomic region with regard to reconstruction of NOE fractures.³⁶

Lacrimal Apparatus

The lacrimal drainage system is intimately related to the NOE region and can be damaged during trauma to or reconstruction of this area. The system removes any excess tears that accumulate after lubrication of the surface of the globe. The superior and inferior lacrimal canaliculi drain the lacrimal lake. The puncta of the canaliculi open just lateral to the lacrimal lake and are surrounded by Horner’s muscle. The orifice of the upper punctum faces downward and backward, and the orifice of the lower punctum faces upward and backward. The superior punctum is approximately 3 mm medial to the inferior

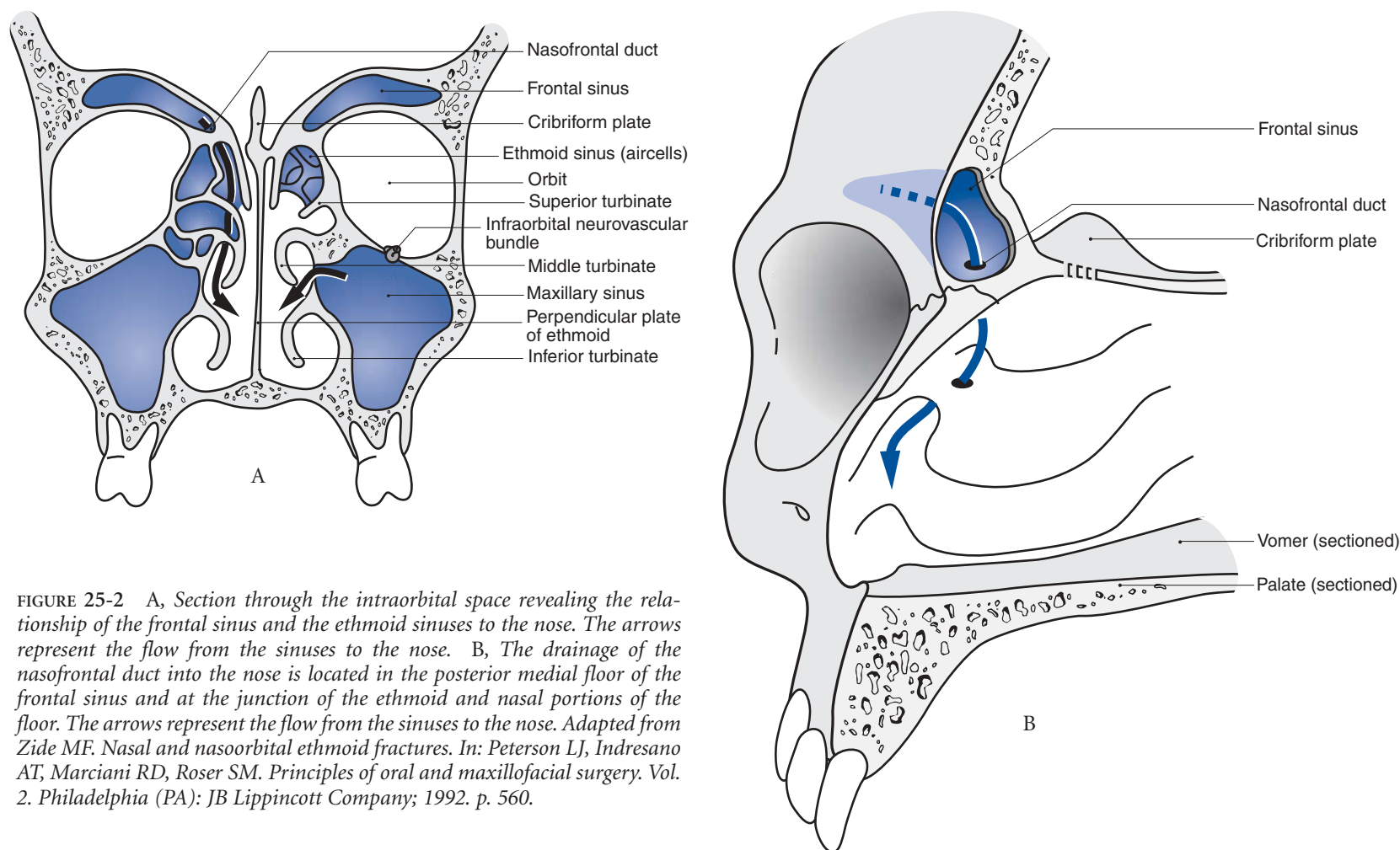


FIGURE 25-2 A, Section through the intraorbital space revealing the relationship of the frontal sinus and the ethmoid sinuses to the nose. The arrows represent the flow from the sinuses to the nose. B, The drainage of the nasofrontal duct into the nose is located in the posterior medial floor of the frontal sinus and at the junction of the ethmoid and nasal portions of the floor. The arrows represent the flow from the sinuses to the nose. Adapted from Zide MF. Nasal and nasoorbital ethmoid fractures. In: Peterson LJ, Indresano AT, Marciani RD, Roser SM. *Principles of oral and maxillofacial surgery*. Vol. 2. Philadelphia (PA): JB Lippincott Company; 1992. p. 560.

punctum. The two canaliculi pierce the lacrimal fascia and enter the lacrimal sac at or very near a common point. The canaliculi lie mostly behind the medial palpebral ligament and are surrounded by the pars lacrimalis.^{38,39} The lacrimal canaliculi are lined with nonkeratinized and non-mucin-producing stratified squamous epithelium. The epithelium is 75 to 150 μ thick and consists of a few layers of squamous cells, polyhedral cells, and a basal cell layer.³⁹

The lacrimal sac lies in a fossa on the anteromedial wall of the bony orbit. It is lined with pseudostratified columnar epithelium and is approximately 12 mm long.³⁹ The apex of the sac ends blindly in a superior fundus, and the sac continues inferiorly into the nasolacrimal duct,

which is housed in a bony canal. The duct empties into the inferior meatus in the nasal cavity.³⁸

Patient Evaluation

Clinical Findings

Periorbital ecchymosis and pain are the most common signs and symptoms associated with fractures of the frontal bone.^{5,40-44} When the bone bleeds and the periosteum is interrupted, leakage of blood into the adjacent facial planes results in periorbital ecchymosis. Through this same mechanism, subconjunctival hemorrhage may occur. If the nose and zygomas are unaffected, a finding of subconjunctival hemorrhage is sufficient for the diagnosis of frontal bone fracture.

Fractures of the NOE complex can produce the following signs: nasal deformity, edema and ecchymosis of the eyelids, subconjunctival hemorrhage, cerebrospinal fluid (CSF) leakage, hyposmia, traumatic telecanthus, increased canthal angles, and blindness (Figure 25-3).^{23,45}

Soft tissue lacerations in the region of the glabella and the supraorbital rims are also commonly found in association with frontal bone fractures and may be associated with anesthesia or paresthesia of the distribution of the supraorbital and supra-trochlear nerves.^{5,40-44} Depression of the bone with flatness and cosmetic deformity is noted if the patient is examined soon after injury. Examination of a patient with NOE fractures detects mobility of the nasal bones, traumatic telecanthus,

depression of the radix, a wide and flattened nasal dorsum, and an upturned nasal tip (Figure 25-4). From 1 hour to 5 days after injury, there may be enough edema to hide the contour depression. Palpation may reveal crepitation and tenderness over the fracture site.^{40–44}

Fractures involving the posterior table of the frontal sinus or the cribriform plate may cause CSF leakage.^{40–43,46} Confirmation of the presence of CSF can be made by collecting this fluid and comparing its concentrations of glucose and chloride with the patient's serum concentrations. Concentrations of chloride and glucose can be determined in as little as 0.1 mL of fluid. Chloride concentrations in the collected fluid that are greater than concentrations in serum and glucose concentrations less than those in serum indicate the presence of CSF. Collected fluid can also be tested for the presence of β_2 -transferrin; a positive result confirms the presence of CSF (Table 25-1).⁴⁷

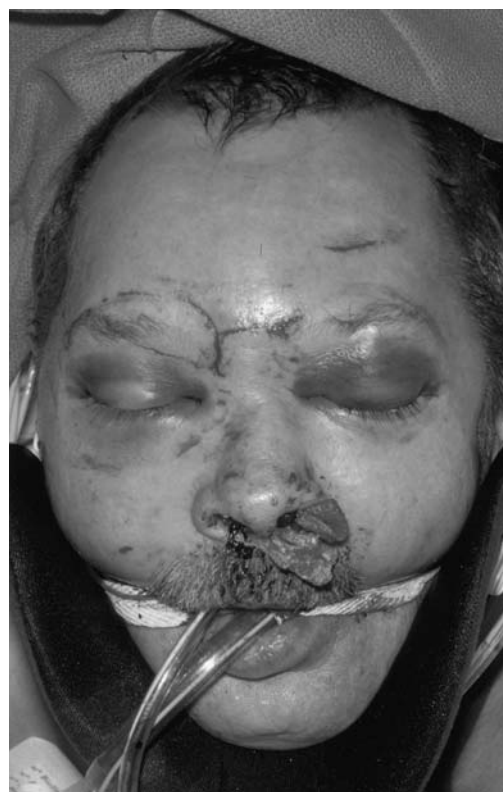

FIGURE 25-3 Initial appearance of a patient with a frontal sinus fracture. Note the bilateral periorbital ecchymosis and forehead laceration.

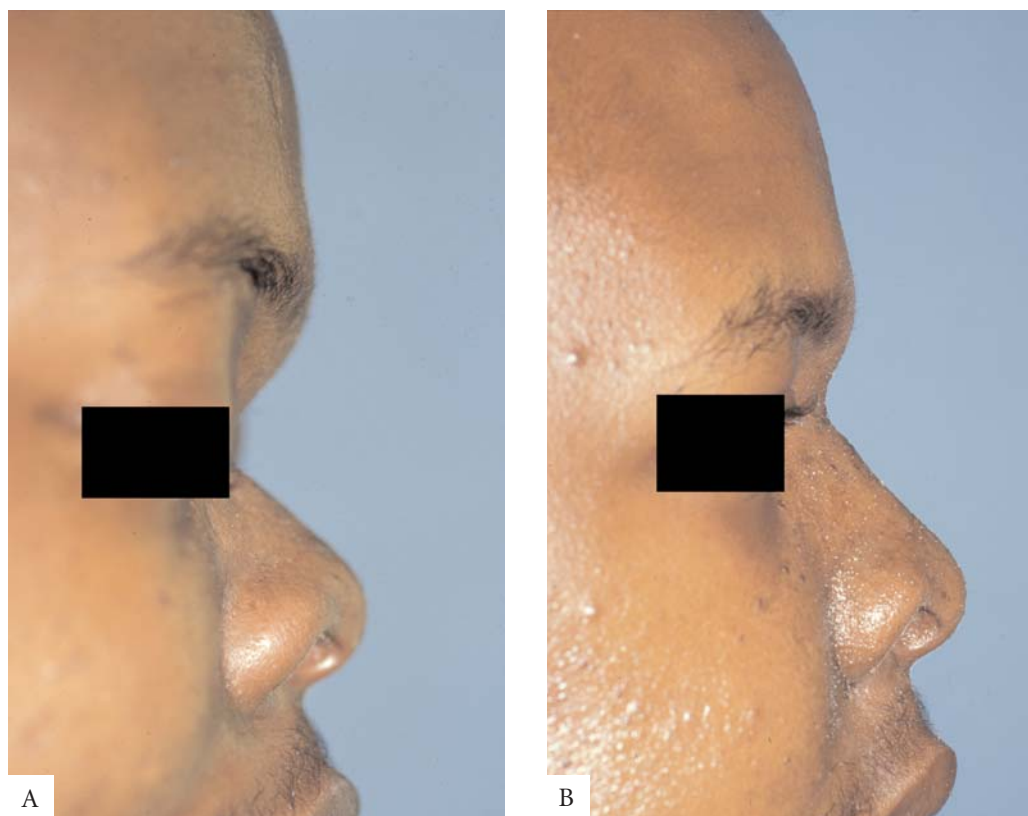


FIGURE 25-4 Pre- (A) and postoperative (B) images of a patient with an NOE fracture showing a severely depressed radix.

The depression of bone fragments into the orbit may cause exophthalmos, proptosis, or ptosis. A depressed injury also causes restricted ocular movement if the superior rectus muscle, the superior oblique muscle, or the trochlea is damaged.^{43,44} Medial orbital wall fractures

associated with NOE fractures can also cause enophthalmos.

A thorough examination is important to distinguish between a nasal fracture and an unstable NOE fracture. The examiner should place the thumb and index finger over the medial canthus bilaterally. Mobility

Table 25-1 Normal Values of Constituents of CSF, Serum, and Nasal Secretions

Constituent	CSF	Serum	Nasal Secretions
Osmolarity	295 mOsm/L	295 mOsm/L	277 mOsm/L
Sodium	140 mEq/L	140 mEq/L	150 mEq/L
Potassium	2.5–3.5 mEq/L	3.3–4.8 mEq/L	12–41 mEq/L
Chloride	120–130 mEq/L	100–106 mEq/L	119–125 mEq/L
Glucose	58–90 mg/100 mL	80–120 mg/100 mL	14–32 mg/100 mL
Albumin	50–75%	55%	57%
Total protein	5–45 mg/dL	6.0–8.4 mg/dL	335–636 mg/dL
(% of total protein)			
Immunoglobulin G	3.5 mg/100 mL	1,140 mg/100 mL	51 mg/100 mL
β_2 -Transferrin (% of total transferrin)	15%	0%	0%

Adapted from Brandt MT et al.⁴⁷
CSF = cerebrospinal fluid.

of these fragments may vary, but any movement implies instability and requires open reduction and stabilization.³⁶ A ruler or caliper should be used to measure the intercanthal distance. The normal distance is 28.6 mm to 33.0 mm for adult women; it is 28.9 mm to 34.5 mm for adult men. Increased widths suggest an NOE fracture. Two tests that can aid in the diagnosis of instability of the medial canthus are the “bowstring” test and the bimanual examination. The bowstring test involves pulling the lid laterally while palpating the tendon area to detect movement of fracture segments.^{48,49} The Furness test may also be performed by grasping the skin overlying the medial canthus with a small-tissue forceps (Figure 25-5). A lack of creasing or resistance by the underlying bone is indicative of an underlying fracture.⁵⁰ The bimanual examination requires placing an instrument (eg, a Kelly clamp) high into the nose, with its tip directly beneath the MCT. Gentle lifting with the contralateral finger palpates the canthal tendons and

allows an assessment of the instability of the tendon attachment and the necessity for open reduction.⁵¹

Imaging

Poor outcomes after the treatment of NOE fractures and frontal sinus fractures typically result from misdiagnosis, inadequate planning, lack of exposure, inadequate reduction or fixation of soft tissue or bone, stripping of the medial canthi, or loss of nasal contour with insufficient primary grafting.^{36,52} In the past, Waters’ projections, reverse Towne’s projections, lateral skull films, and laminar tomograms were used to visualize midface and upper-face fractures. It is clear that appropriate preoperative imaging can help to prevent misdiagnosis and can aid in proper treatment planning. Today computed tomography (CT) scans are the gold standard for imaging these fractures (Figure 25-6).^{5,10,36,52–56}

The plane of choice for frontal sinus imaging is the axial view, preferably with slice thicknesses of 1.0 or 1.5 mm.^{22,26,30} The

high degree of detail required for imaging NOE fractures necessitates axial and coronal views with slice thicknesses of 1.0 or 1.5 mm.^{25,36} Indeed, it has been shown that for severe fractures of the NOE region, two- and three-dimensional CT scans provide the most information about the medial orbital wall, the medial maxillary buttress, and the piriform aperture.^{36,57}

Patency of the Nasofrontal Duct

Although the newest CT scanners provide exceptional views and can often provide slices through the nasofrontal duct, evidence of their reliability in detecting obstruction of the ducts is scant.^{54,55} Duct obstruction should be suspected with fractures involving the medial supraorbital rim or the frontal bone with nasal ethmoidal component fractures, and it should always be considered when a CSF leak is present.¹² In these situations an open or intraoperative evaluation of patency is indicated. This evaluation is important because the condition of the nasofrontal duct has the most influence on the health of the frontal sinus (Figure 25-7).^{12,20,22,33,54,58–62}

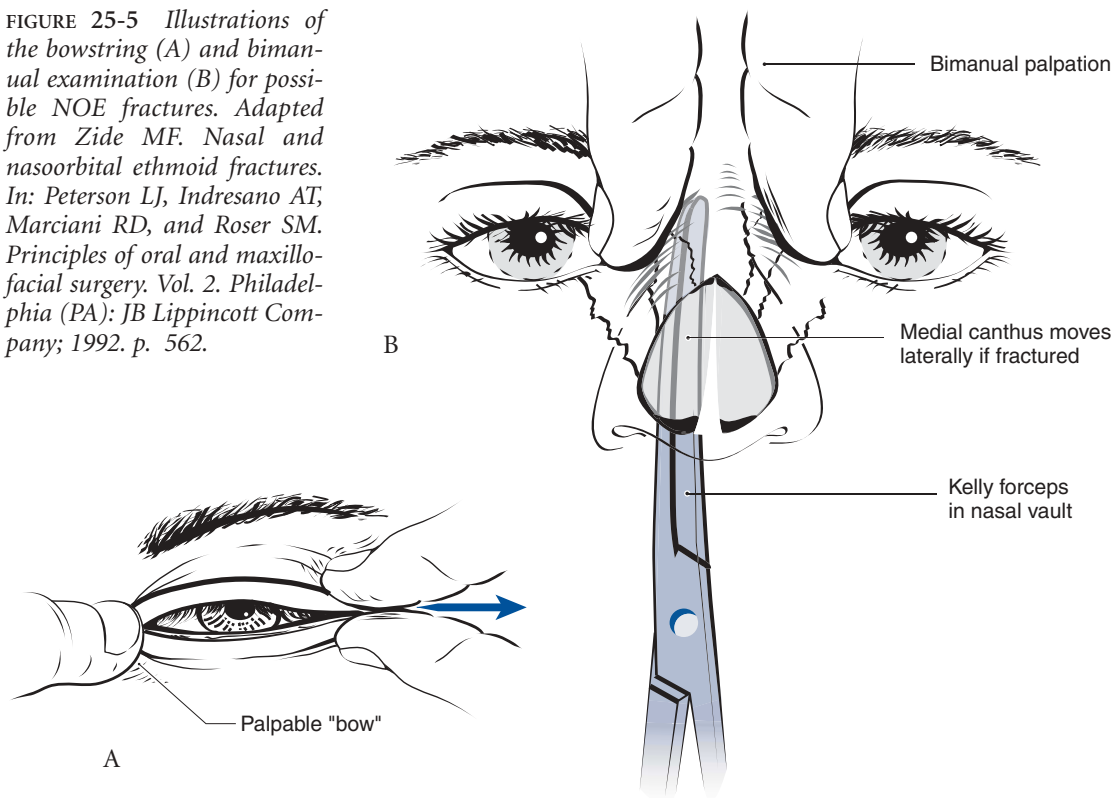
Classification of NOE Fractures

As with all fractures, NOE fractures are classified as unilateral or bilateral, open or closed, and simple or comminuted. Three types of NOE fractures have been well described.^{25,36,38,63} A type I fracture maintains the attachment of the MCT to a large single nasoethmoidal fracture segment; repairing this type of fracture is straightforward. A type II fracture shows more comminution yet maintains the attachment of the medial canthus to a sizable bony segment. Type III fractures display severe comminution with possible avulsion of the MCT from its bony attachment (Figure 25-8).

Classification of Frontal Sinus Fractures

Traditional fracture classifications can be used with reference to frontal bone fractures

FIGURE 25-5 Illustrations of the bowstring (A) and bimanual examination (B) for possible NOE fractures. Adapted from Zide MF. Nasal and nasoorbital ethmoid fractures. In: Peterson LJ, Indresano AT, Marciani RD, and Roser SM. Principles of oral and maxillofacial surgery. Vol. 2. Philadelphia (PA): JB Lippincott Company; 1992. p. 562.



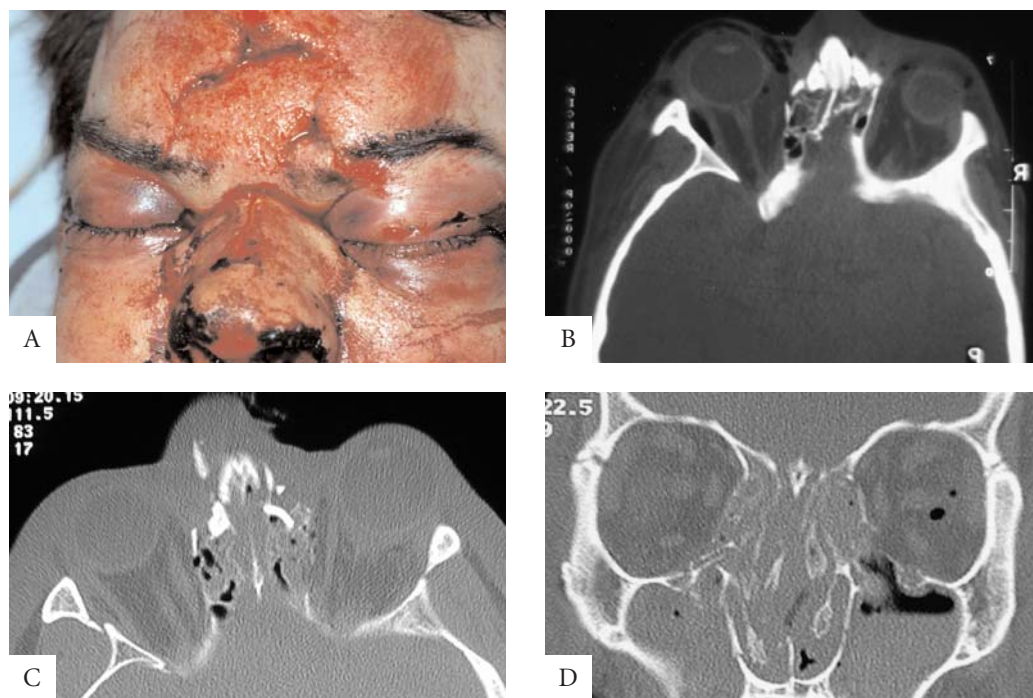


FIGURE 25-6 The detail of fracture anatomy is clearly superior in computed tomographic (CT) scans when compared with traditional radiography. A, Initial appearance of a patient with an NOE fracture. B, Axial CT scan showing the fracture. C and D, Axial and coronal CT scans of another patient illustrating detailed fracture anatomy.

(eg, open or closed). Numerous other classification schemes have been proposed in the surgical literature in an attempt to simplify surgical decision making. Although these schemes are well intended, some are so complex that they actually complicate decision making and are of no value. Consideration must always be given to the condition of the anterior table, the posterior table, and the nasofrontal ducts and to the presence of comorbid intracranial injury and concomitant craniomaxillofacial injuries.^{5,8,14,20,64} The simplest and most helpful classification schemes distinguish possible complications and treatments on the basis of types of fractures.

Isolated anterior table fractures should be treated so that cosmetic deformities can be prevented. Posterior table fractures, alone or in combination with anterior table fractures, should be treated so that neurologic sequelae, including meningitis and brain abscess, can be avoided. Combinations of fractures that compromise the nasofrontal duct should

be treated so that the development of mucocoeles and pyocoeles can be prevented. These fracture combinations include fractures of the anterior table and the posterior table, fractures of the anterior table and the NOE, and fractures of the anterior table and the medial superior orbital rim.

Treatment

Surgical Access

The coronal approach to surgery provides the greatest access to the frontal bone and sinus and produces the most desirable cosmetic results.^{5,10,22,61} Although lacerations may be considered as an approach to the fracture, their size and shape rarely provide enough access without undue and unsightly extension. Gullwing or spectacle incisions result in unattractive scars that are highly visible because of their prominence on the brow and the resulting reflection of light. These scars can be camouflaged only with wide-rimmed glasses. The “open sky” approach is equally deforming,

leaving an H-shaped scar over the brows and nasion.

Although the coronal approach has been well described,⁶⁵ the preparation required for a coronal incision varies. If a neurosurgical procedure is anticipated, the hair may be shaved and the skin degreased with alcohol and then prepared with an antimicrobial skin preparation agent, preferably povidone-iodine solution. If a neurosurgical procedure is not anticipated, the hair should be parted coronally from preauricular region to preauricular region. Water soluble lubricant is helpful in maintaining the part. The hair may then be braided in multiple pigtails and gathered anteriorly and posteriorly on either side of the part. Local anesthetic with a vasoconstrictor is used to aid in hemostasis. Electrocautery should not be used for the initial incision because it may damage hair follicles. The incision is made to the depth of the loose aponeurotic layer. The flap is undermined along this plane and above the periosteum in an anterior direction. Raney clips are helpful in achieving hemostasis; however, hemorrhage may recur when they are removed, and electrocautery may need to be used carefully at the end of the procedure as the individual clips are removed. Again, care must be taken to avoid hair follicles to preserve scar camouflage.

The flap is elevated to within 2.0 cm of the fracture or within 3.0 cm of the supra-orbital rims. The pericranium is then

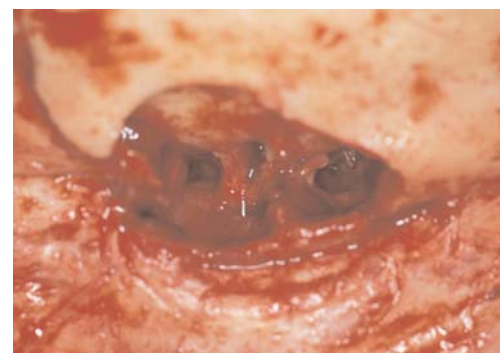

FIGURE 25-7 Intraoperative view of the floor of the frontal sinus with nasofrontal ducts.

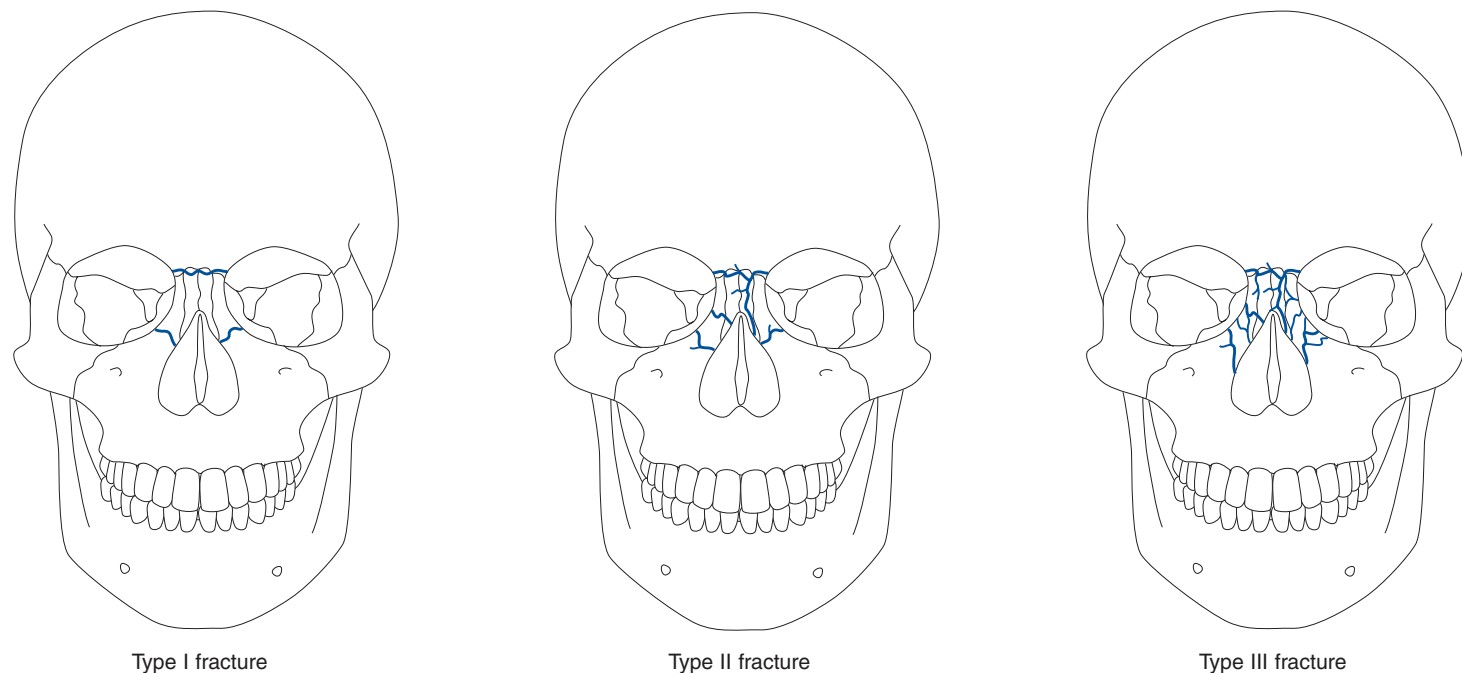


FIGURE 25-8 Naso-orbitoethmoid fracture classification.

incised, and the reflection of the flap continues deep to the pericranium so that the branches of the facial nerve can be protected. Further reflection can be obtained with greater exposure by extension of the preauricular incision, galeal splitting (if a vascularized galeal flap is not anticipated), or release of the supraorbital nerve from its foramen or notch.

Osseous Recovery and Access

Recovery of bony fragments in comminuted fractures is best undertaken during the reflection of the coronal flap. Fragments of the anterior table should be released from the periosteum and removed one at a time. Some method of organizing the fragments should be used. For example, the fragments could be numbered and their positions recorded on a map. They should be arranged in the same order on a back table (Figure 25-9). If contaminated, segments of bone may be cleansed with copious irrigation, scrubbing, and even povidone-iodine solution, and then used for reconstruction as free grafts.⁶⁶ Once the anterior table has been removed, access should be adequate for sinus exploration, posterior

table inspection, and sinus floor (nasofrontal duct) evaluation.

If a more extensive neurosurgical procedure is anticipated, osseous recovery may be performed in concert with a craniotomy bone flap. Before small fragments are recovered, the osseous flap design should be mapped out on the frontal bone (with care taken to avoid the sagittal sinus). Bur holes are created at three or four corners of the frontal bone. The tenuous and adherent dura is released through the bur holes, and a craniotome is used to connect the bur holes. The dura is carefully reflected as the bone flap is removed. Recovery of the rest of the osseous fragments can then be completed.

A perimeter-marking technique can be used for removal of the anterior table that is unfractured.⁶⁷ The removal of the entire anterior table is important when obliteration of the sinus is anticipated because this procedure requires thorough removal of sinus mucosa. One side of a hemostat or pick-up instrument can be inserted into the sinus, and a small bur hole can be made at the tip of the superficial arm of the instrument. Fixation plates

can be adapted before the removal of the remaining anterior table segment.

Intraoperative Evaluation of the Nasofrontal Duct

After access has been obtained and osseous exploration and recovery have been performed, the condition of the frontal sinus floor and the nasofrontal ducts can be assessed by direct visualization (see Figure 25-7). The relative patency of the duct can then be evaluated by placing an

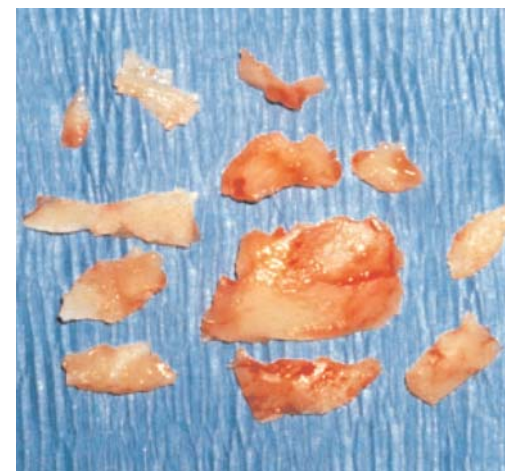


FIGURE 25-9 Comminuted frontal sinus segments arranged prior to reconstruction.

angiocatheter into the nasofrontal duct and introducing an appropriate fluid medium so that flow can be assessed. A 3.8 cm (1.5 inch) 18-gauge angiocatheter is the best instrument for this purpose. Patency of the nasofrontal duct can be confirmed by introducing normal saline and observing its emergence from beneath the medial turbinate or its collection in the posterior pharynx (Figure 25-10). Because of its dramatic hue, methylene blue dye has been offered as an appropriate fluid for evaluating patency. However, this blue dye can disrupt visualization of the surgical field because completely removing the dye is difficult during a surgical procedure (Figure 25-11). Fluorescein is an excellent alternative because it is clear, colorless, water soluble, and radiolucent.⁶⁸ However, its visualization sometimes requires using an ultraviolet light source and then dimming the operating room lights. Radiopaque dye has been suggested for use as a diagnostic

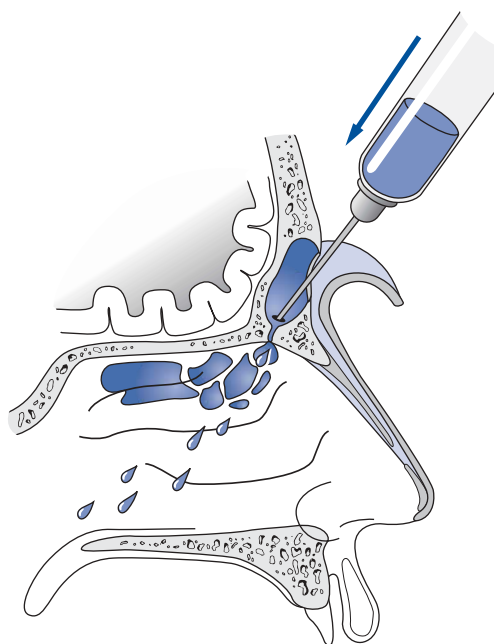
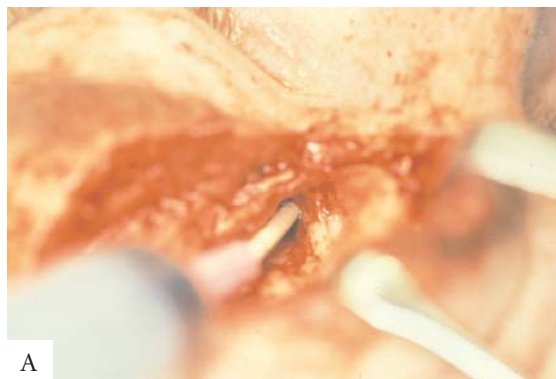

FIGURE 25-10 Technique of identifying a patent nasofrontal duct. Adapted from Zide MF. Nasal and naso-orbital ethmoid fractures. In: Peterson LJ, Indresano AT, Marciani RD, Roser SM. Principles of oral and maxillofacial surgery. Vol. 2. Philadelphia (PA): JB Lippincott Company; 1992. p. 582.

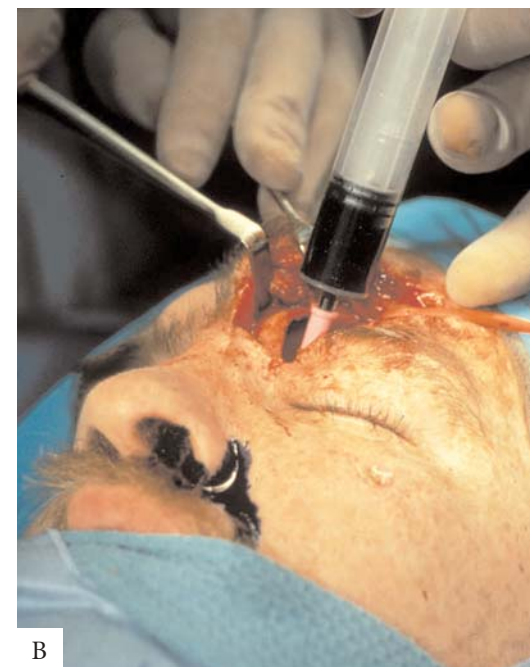FIGURE 25-11 A and B, Intraoperative evaluation of nasofrontal duct patency by injection of methylene blue. In B, note the methylene blue coming from the patient's nostril. Reproduced with permission from Haug RH and Cunningham LL.⁶⁴



medium for nasofrontal duct fractures, but its visualization requires a C-arm fluoroscopy unit.⁶⁰ Moreover, any spilled radiopaque dye must be completely cleared before additional radiographs or computed tomographic images are obtained. Indigo carmine is another acceptable dye, but Congo red is neurotoxic.

Anterior Table Fractures

The thinnest area of the frontal bone is the region of the glabella, the anterior wall of the frontal sinus, and this region is highly susceptible to fracture. These fractures may seem straightforward but still deserve careful attention. Simple greenstick or nondisplaced anterior wall fractures do not require operative treatment.⁶⁹ Displaced anterior table fractures require open reduction. The surgeon should closely inspect the sinus floor, the posterior wall, and the patency of the nasofrontal duct. If the posterior wall and the floor are free of injury, the pieces of the anterior wall may be fixated with low-profile bone plates.^{64,66,70,71} Any void remaining in the anterior wall after reconstruction can be closed by placing titanium mesh, methylmethacrylate, or other



bone substitutes. The soft tissue injuries may then be repaired.

Posterior Table Fractures

Fractures to the posterior table of the frontal sinus are more concerning because of the proximity to the anterior cranial fossae (Figure 25-12). Posterior table fractures can be subclassified into three categories: nondisplaced, displaced, and displaced with gross neurologic injury. Each of the subclassifications is invariably associated with anterior wall penetration. Each is treated differently, and each requires neurosurgical consultation or joint management with a neurosurgeon. Antibiotic coverage is particularly important in preventing infection.¹⁶

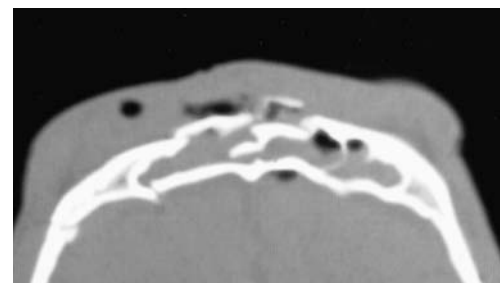


FIGURE 25-12 CT scan demonstrating anterior and posterior table fractures of the frontal sinus.

The surgeon should check carefully for displacement of the fracture, CSF leak, entrapment of sinus membranes, and dural tears. If the injury is not substantial and the nasofrontal duct is patent, the anterior table is replaced and fixed and the soft tissue injuries are repaired. Continuation of the posterior table, penetrating injury, CSF leak with extensive dural damage, or frontal lobe damage requires frontal sinus cranialization: complete removal of the posterior table, thereby effectively increasing the size of the anterior cranial fossa.^{5,20,58,59,62,64} In one review of cases, as many as 16% of patients undergoing frontal sinus surgery required a cranialization procedure.⁵ In such a case the posterior table would be gently removed, either with a diamond bur or with rongeurs. Care should be taken in the area of the sagittal sinus to avoid severe bleeding. All irregularities of the sinus are smoothed with a bur. After bone removal the dura should be repaired with primary closure, a fascia or synthetic patch, or a galeal or pericranial flap.^{5,64}

The wound is closed in layers. Strict attention must be given to meticulous removal of all of the mucosal elements from the walls, cul-de-sacs, and septa of the sinus and from all bone fragments.⁷²⁻⁷⁴ Failure to remove such elements may result in a mucocele or pyocele. The mucosa is then reflected down into the nasofrontal duct, and the orifice is obstructed by local bone or muscle. The harvested fat is placed into the sinus and packed until the sinus is full. Finally, the outer table is reassembled and restored as would be done for a simple anterior wall fracture.

Orbital Roof and Supraorbital Bar Reconstruction

Once the posterior wall and the sinus floor have been explored, inspected, and evaluated for damage, the orbital roof and supraorbital bar may be reconstructed. After these procedures have been complet-

ed, a galeal flap should be reflected, the sinus obliterated, and the nasofrontal duct obstructed. The free osseous fragments that have been recovered, mapped, and arranged on a back table should be rigorously curetted for removal of any respiratory epithelium that could become entrapped between them during reconstruction. Every remnant of respiratory epithelium should be removed from every crevice and cul-de-sac so that the possibility of future mucocele formation is minimized. This procedure is followed with local osteotomy with a no. 8 round diamond bur and copious amounts of saline. The arranged bone fragments should be consolidated with titanium microscrews (1.0–1.3 mm) and with appropriate plates, mesh, or both.^{75,76} Mesh has an advantage in that it provides support and consolidation of the segments in three planes of space (Figure 25-13).^{75,76} Titanium mesh has been shown to be compatible with soft tissue, undergoing incorporation with indigenous cells.⁷⁷ Resorbable technology continues to show promise, even for frontal bone injury⁷⁸; however, the resorbable systems currently available are not as versatile as titanium mesh in their ability to be contoured or to stabilize small bone fragments. Before final placement of the consolidated titanium and bone segments, the sinus should be copiously irrigated and hemostasis achieved. Once this phase of the procedure has been completed, the nasofrontal ducts may be obstructed (if indicated), the sinus obliterated, the brain isolated with a galeal flap (if indicated), and, finally, the anterior table replaced.

Nasofrontal Duct Obstruction

Nasofrontal duct obstruction should not be confused with sinus obliteration. Sinus obliteration is the elimination of dead space by the introduction of another material. Duct obstruction is one of the methods of isolating the sinus (or brain) from nasal contamination, basically by plugging it with another material.

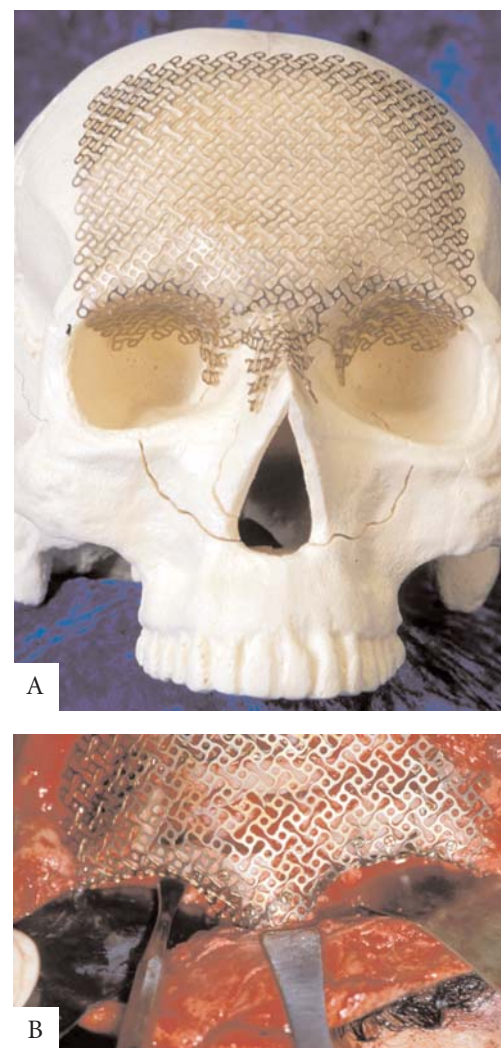


FIGURE 25-13 Reconstruction of the frontal bar and frontal sinus with titanium mesh. A, The mesh is adapted to a dried skull and then sterilized prior to surgery. B, Intraoperative view of reconstruction of the frontal bar and nasal dorsum with mesh.

As stated above, the condition of the nasofrontal duct is the most important factor in maintaining the health of the frontal sinus.^{12,20, 22,33,54,58-62} This duct permits the exit of mucin, seroma, or hematoma after injury. If the duct is injured and obstructed, sinusitis, meningitis, or osteomyelitis may develop. The condition of the duct should be considered in the evaluation of fractures of the NOE complex, the supraorbital rim, or the sinus floor. If the duct is not patent, thorough removal of every possible remnant of sinus mucosa is performed by curettage.^{20,58,68,73,74} This procedure is

followed by removal of additional mucosa from every cul-de-sac and crevice with a small (no. 8 or larger) diamond bur under copious amounts of irrigation and with the aid of magnification. Any remaining remnants of the nasofrontal duct mucosa are then inverted into the nose.

A number of materials can be used to obstruct the nasofrontal duct. Temporal fascia, temporal muscle, or both can be harvested from the adjacent temporal region through a bitemporal flap. Tensor fascia lata is another alternative, but it may produce morbidity at the second surgical site. Estimating the surface area to be covered is an important technical point. A suture package is a good template for measurement and recording. Because fascia shrinks, it is important to harvest approximately 20% more graft material than is indicated by the template. Bone graft material can be harvested from the sinus septum, the inner table, or elsewhere on the cranium.⁷⁹ Commercial tissue sealants prepared from human plasma and containing bovine-derived aprotinin are available. These sealants have been shown to be effective tissue adhesives and hemostatic agents.^{80–82} Autologous platelet gel and autologous fibrin glue have also been used for similar indications.^{83,84} In addition, a new fibrin sealant from the American Red Cross has been reported to show promise as a hemostatic agent without the addition of bovine aprotinin.⁸⁵

Whatever products are chosen, the organization and arrangement of the obstructive media are important. For example, a tissue sealant may be placed after inversion of the sinus mucosa. Fascia or muscle may then be introduced into the remnants of the duct to block passage of nasal contaminants, followed by inner-table cranium or remnants of septal bone from the sinus, followed by another layer of tissue sealant. Tissue sealants can be used effectively to seal off the sinus from the nasal cavity when they are applied layer by layer as described above.

Sinus Obliteration

Nasofrontal duct obstruction is necessary to seal off the frontal sinus from nasal contaminants. Sinus obliteration adds one more layer to the seal but also eliminates the “dead space” or air within the sinus that may permit fluids to accumulate, thus causing a seroma or a hematoma. Furthermore, after cranialization, sinus obliteration cushions and protects the brain. Historically, sinus obliteration has been accomplished in a number of ways, including inserting no substance or object (theoretically permitting bone fill after curettage) or hydroxylapatite, glass wool, bone, cartilage, muscle, absorbable gelatin sponge, absorbable knitted fabric, acrylic, or fat.^{16,73,74,86–92} The use of fat has been reported most frequently, and this method historically has provided the most desirable results.

Harvesting fat is simple and may be performed by liposuction or an open approach.⁸⁹ With the open approach the skin is first cleansed with an antimicrobial agent from below the umbilicus to above the escutcheon of the genitalia. A transverse semilunar incision is made within the “bikini” line, 5.0 cm superior to the symphysis pubis (Pfannenstiel’s incision); an incision 5.0 to 8.0 cm long is adequate. An alternative to this approach is a vertical incision from below the umbilicus to above the symphysis pubis. The incision is carried through skin and subcuticular tissue to the fat. The fat is grasped with an Allis clamp and retracted. Scissors are used to dissect the fat subcutaneously, moving laterally, inferiorly, superiorly, and caudally to the fascia overlying the abdominis rectus muscles, which are then connected, releasing the fat. Irrigation and meticulous attention to hemostasis are important before closure of the incision to avoid hematoma and infection (Figures 25-14 and 25-15).

NOE Reconstruction

Early surgical management is important in the reduction of NOE fractures.^{25,38,45} The

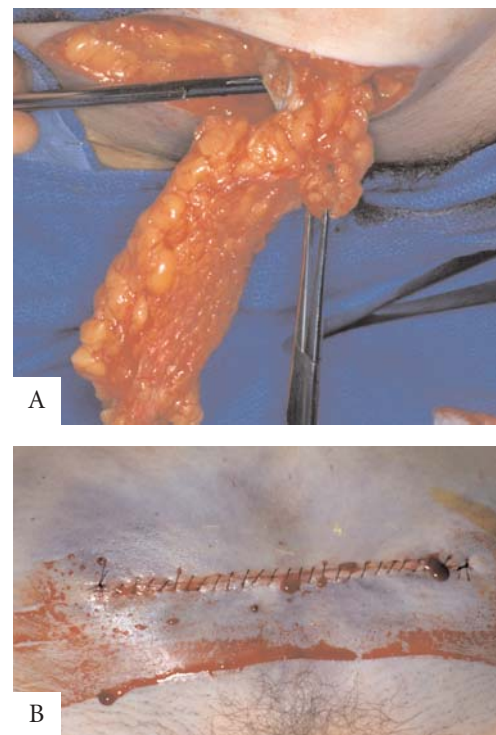


FIGURE 25-14 A, Abdominal fat graft harvest showing the amount of fat obtainable. B, Subsequent hematoma formation, which necessitated a return to the operating room for evacuation.

deformities that result from unrepaired NOE fractures are severe and difficult to correct, requiring NOE osteotomies and grafting, and satisfactory results are rarely achieved.

In addition to the coronal approach, complete exposure of the NOE area often necessitates lower eyelid incisions (transconjunctival or subciliary) and a maxillary vestibular incision.³⁶ These approaches aid in the treatment of displaced infraorbital rims and maxillary antrum or piriform rims.

Type I fractures are less difficult to treat and can at times be reduced transnasally and treated without fixation. More often, single-segment NOE fractures are reduced through a coronal incision and secured at the nasofrontal junction, the maxillary buttress, and the infraorbital rims.^{36,38}

Transnasal wiring is recommended for fractures graded as Markowitz type II or higher.²² Although we are truly in an era of rigid fixation (bone plates and screws),

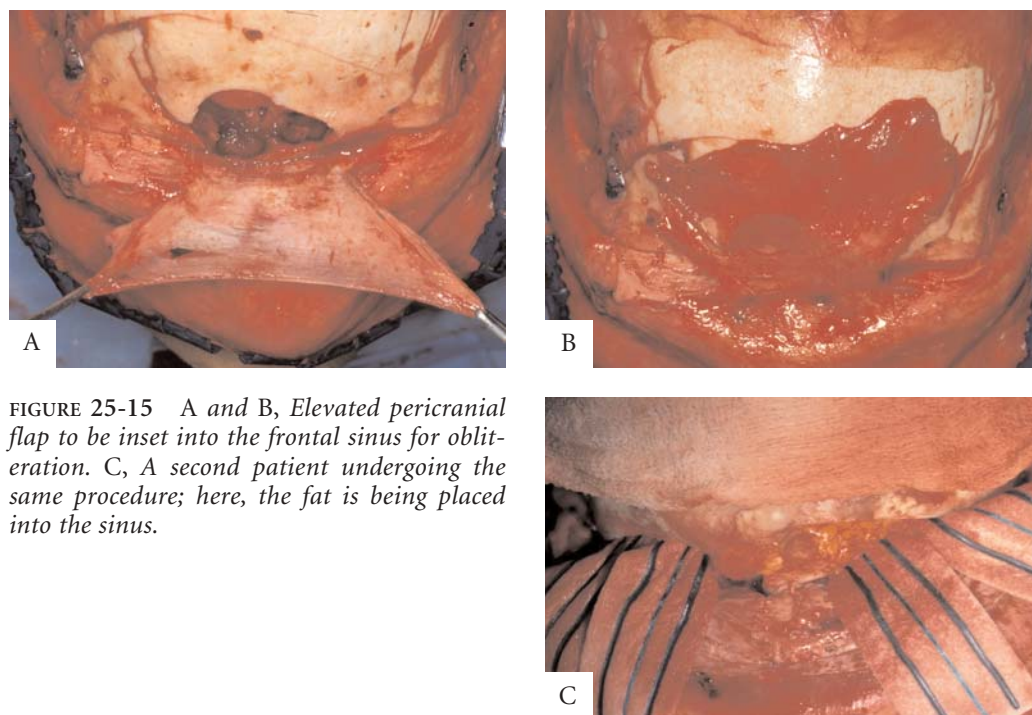


FIGURE 25-15 A and B, Elevated pericranial flap to be inset into the frontal sinus for obliteration. C, A second patient undergoing the same procedure; here, the fat is being placed into the sinus.

complete reduction of the NOE area and reattachment of the MCT, or replacement of a small bone segment, seem never to be adequate with microplates alone. For NOE fractures including avulsion of the MCT or in which the MCT is attached to a small bone segment, transnasal wiring should be considered. The point of fixation of the wires should be directed posterior and superior to the lacrimal fossa so that the medial canthal distance is decreased and widening of the nasal bones and blunting of the medial canthal area can be avoided.²² Wires must be passed through the medial orbital bone and the superior nasal septum or the perpendicular plate of the ethmoid. Their passage can be facilitated with the use of a spinal needle or a wire-passing awl. Drill holes can also be used to aid in wire passing. Some clinicians have advocated temporary removal of the nasal bone for identification of the “canthal bearing bone” and for facilitation of the passage of transnasal wires.^{22,36} The MCT and its bony segment can be incorporated into the transnasal wire fixation, or an avulsed MCT can be attached to the transnasal wire with sutures. Slight overcorrection of

the medial canthal distance is desired. In cases in which fracture comminution prevents adequate fixation of the MCT to a bone segment, stabilization with fixation to a calvarial bone graft has been advocated.³⁶ In cases in which sufficient medial orbital wall remains, placing a microplate and screw for attaching the MCT behind the lacrimal crest has been suggested.³⁸

Bone grafting may often be necessary in cases of severe comminution of the nasal bones or the medial orbital walls. Onlay of cranial bone grafts to maintain dorsal height and nasal tip projection can be performed through a coronal incision, and these grafts can be fixated rigidly or with wire.

Medical Therapy of the Sinus Postoperatively

Saline solution nasal spray can reduce symptoms of rhinosinusitis.⁹³ This therapy can prevent crusting of the nasolacrimal duct as well as the frontonasal duct and the ostia of the maxillary sinus. Because this treatment is inexpensive and involves little or no risk, it can be made a part of reasonable postoperative care regimens.

There have been no clinical trials related to post-traumatic medical treatment of the sinus. However, for patients in whom the frontal sinus has been left intact, there may be at least a temporary decrease in function of the mucociliary apparatus.^{94–96} In addition, the trauma of surgery causes edema in the sinus tissues. Mucolytics have been advocated for use in patients with rhinosinusitis to thin the mucus secretions and to improve clearance.⁹³ During the post-traumatic or postoperative period, the use of mucolytics such as guaifenesin may be beneficial.

Decongestants may also be considered in the immediate postoperative period. Decongestant medications (eg, pseudoephedrine or oxymetazoline hydrochloride) act by stimulating α -adrenergic receptors in the mucosa of the upper respiratory tract. This action causes vasoconstriction in the respiratory mucosa, thereby shrinking the mucosa and increasing the size of the airways or ducts.^{93,97,98} Topical agents have fewer systemic side effects but are known to have a rebound potential and should be used for no more than 3 days.

Because there is no consensus regarding the use of postoperative antibiotics, their use should be based on the individual patient and type of injury. The extent of soft tissue injury, presence of wound contamination, a concomitant CSF leak, and other associated injuries should all be considered. Current recommendations regarding the use of prophylactic antibiotics for head and neck injuries include a duration of therapy of no more than 24 hours.^{99,100} In cases of contamination by a foreign body, this treatment may be continued for 10 days. In the absence of gross contamination of the wound, a limited number of postoperative doses can be considered, or none at all. Antibiotics used to treat acute rhinosinusitis include amoxicillin, amoxicillin-clavulanate, azithromycin, cefpodoxime proxetil, cefprozil, cefuroxime axetil, clarithromycin, levofloxacin, loracarbef, and trimethoprim-sulfamethoxazole.⁹³ Penicillin is still the drug of choice for treating facial fractures.¹⁰¹

Complications

Complications of frontal bone injury vary in severity and may occur many years after the injury. The principal types of complications are those that occur directly at the time of injury, those of an infectious nature, and those that are chronic problems.

The most devastating complications are neurologic problems resulting from displacement or penetration of the frontal bones into the brain. These injuries can result in concussion, severe brain injury, or death. Displacement of the floor of the frontal bone can cause orbital damage. The most frequent ocular complication is diplopia. Damage to the superior oblique muscles or trochlea may result in limited range of motion of the globe. Severing of the supraorbital nerve by the injury or during reflection of the osteoplastic flap leaves a permanent anesthesia of the distribution of the forehead.¹⁰² Trauma to the floor of the frontal sinus or displacement of the medial supraorbital rim may cause a CSF leak. Generally, reduction of the fractures corrects this problem. If it is persistent, however, neurosurgical repair is indicated.

Infectious complications most frequently arise from occlusion of the nasofrontal duct or contamination of the sinus by penetrating foreign bodies. The most frequently encountered infection is meningitis.⁸⁸ If the nasofrontal duct is occluded, blood may accumulate in the sinus, creating an environment that is conducive to the growth of anaerobic bacteria.^{13,103} Frontal sinus abscess is spread by direct extension through small fractures of the frontal bone or through transosseous anastomotic vessels.⁵⁹ The result is brain abscess, meningitis, cavernous sinus thrombosis, or (if the abscess is long term) osteomyelitis.

Mucoceleles are the most common chronic problems.¹⁰⁴⁻¹⁰⁶ Respiratory mucosa trapped between fracture segments or left behind during obliteration procedures may continue to grow. This continued growth

may lead to the formation of mucoceleles or pyoceleles. The size of the growth determines how much damage occurs to adjacent bone and neurologic tissue. Frontal sinus imaging (CT or magnetic resonance imaging) should be ordered to detect a postoperative mucocele or pyocele. Imaging studies should be performed at 1, 2, and 5 years after surgery or whenever symptoms appear.¹⁰⁷ Complications can occur as late as up to 20 years postoperatively, and patients should be encouraged to have routine yearly follow-ups.⁵⁹

Pain and headache may be chronic and may persist without an identifiable cause.¹³ Cosmetic deformities such as contour deficits and irregularities stem from several causes. Bone loss at the time of injury may not be noticed for months. Osteomyelitis with subsequent débridement leaves voids in bone. Even if the fractures are properly treated at the time of injury, remodeling may leave irregularities.

Anosmia—the loss of the sense of smell—and hyposmia are known complications of NOE fractures and can occur in as many as 38% of patients with high central midface fractures.¹⁰⁸ In addition, 23% of patients with high midface fractures report a decreased sense of taste (hypogeusia).¹⁰⁸

Dacryocystorhinostomy

Dacryocystorhinostomy (DCR) is the repair of the lacrimal drainage system through the creation of a new “ostomy” or track from the lacrimal canaliculi to the nasal cavity. Techniques that have been described include open (external), endonasal, and soft tissue conjunctivorhinostomy.¹⁰⁹⁻¹¹¹

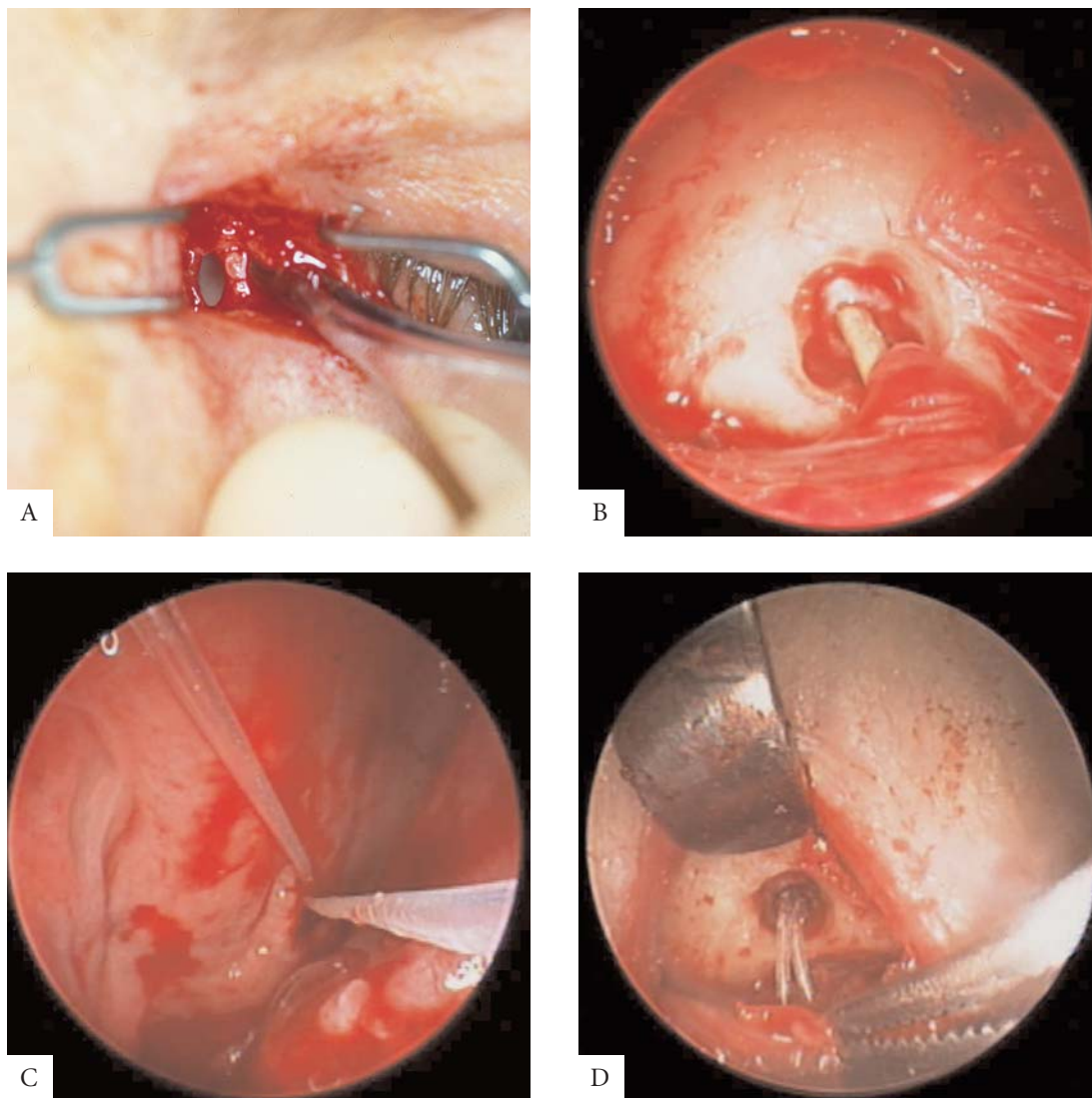
Perhaps the best-described technique is the open DCR. This procedure is performed through a 10 mm vertical incision placed 10 to 12 mm medial to the medial canthus of the affected eye. Blunt dissection is then used to approach the lacrimal crest. A periosteal incision is followed by careful dissection of the lacrimal sac away from the bony fossa, and an osteotomy is

placed posterior to the lacrimal crest. The deep surface of the bone in this region is lined with nasal mucosa, which should remain intact during the osteotomy. Placement of a lacrimal probe can facilitate visualization of the lacrimal sac. After the sac has been freed, it is incised on its medial surface, and superior and inferior releasing incisions are made on the superficial side of the sac (posterior flap). This procedure is followed by a vertical incision of the nasal mucosa and anterior releasing incisions (anterior flap). At this point Crawford tubes are used to intubate both the superior and the inferior canaliculi. When intubation is complete, the ends of the Crawford tubes are visible in the lacrimal sac and can be inserted through the lacrimal osteotomy and retrieved intranasally inferior to the middle turbinate. These ends are then cut to extend to the nasal vestibule and are sutured in place to the lateral nasal wall (Figure 25-16).^{39,110}

Closure is then begun with anastomosis of the lacrimal sac and the nasal mucosa. The anterior flap of the nasal mucosa is closed to the posterior flap of the lacrimal sac. Often this is technically challenging, and an alternative is to suture the anterior lacrimal sac flap to periosteum to maintain the opening between the lacrimal sac and the nasal mucosa. Care should be taken to avoid suturing the retained polymeric silicone tubing during flap closure. The remainder of the incision is closed in two layers. The tubing is left in place for 4 to 6 months, and patients should use saline nasal sprays to prevent crusting of the tubes (Figure 25-17).

The endonasal approach is conceptually the same procedure, except that the dissection is performed from inside of the nose with the aid of endoscopic instruments and a fiber-optic light, which are introduced into the sac through the canaliculi. The nasal mucosa is incised and reflected over an area transilluminated from above. The illuminated area is

FIGURE 25-16 A, Incision of lacrimal sac. B, Osteotomy, made with a round bur, through which the polymeric silicone tubes are placed. C, View of the polymeric silicone tubes exiting through the nasal mucosa into the nose. D, The lacrimal sac flap is shown being held in the forceps over the polymeric silicone tubing that exits into the nasal cavity.



most commonly seen beneath the middle turbinate, which may need to be displaced medially so that appropriate exposure can be obtained. The transilluminating light can be seen most readily through the lacrimal bone posterior to the frontal process of the maxilla. The frontal process can be removed with a Freer elevator or with a 2 mm Kerrison rongeur. The lacrimal sac is then gently lifted free from the lacrimal bone with a Freer elevator. The thin lacrimal bone overlying the sac is then removed. An opening is then made into the lacrimal sac, and the Crawford tubing is inserted as before. Polymeric silicone tubes are left in place for 1 month, and saline spray and lacrimal irrigation are recommended.¹¹¹

Correction of Post-traumatic Deformity

Six months to 1 year after the initial surgical correction, secondary deformities of the frontal bone may be addressed. Contour defects result from failure to fully elevate depressed fractures, from voids in bone lost at the time of the trauma, and from infection. A multiplicity of materials has been used to correct contour defects, including bone from the adjacent calvaria, ileum, or rib; cartilage; titanium or stainless steel; polymeric silicone, methylmethacrylate, hydroxylapatite granules, silver, a cobalt-chromium alloy, polytef, polyethylene terephthalate fiber, nylon, polyethylene, and aluminum.^{112,113} The

procedures for correcting such defects involve one-stage indirect prosthetic techniques, two-stage techniques, single-stage direct techniques, or computer-generated single-stage techniques.¹¹⁴⁻¹¹⁶ The one-stage indirect technique requires that an impression be taken of the defect through the skin. The impression negative is then filled with plaster to form a positive image on which an onlay prosthesis may be fabricated. Acrylic, polyethylene, tantalum, titanium, and cobalt-chromium prostheses may be fabricated with this technique. A full-thickness flap is then reflected, and the prosthesis is secured.

The single-stage direct technique requires that a full-thickness flap be reflected beyond the margins of the defect.

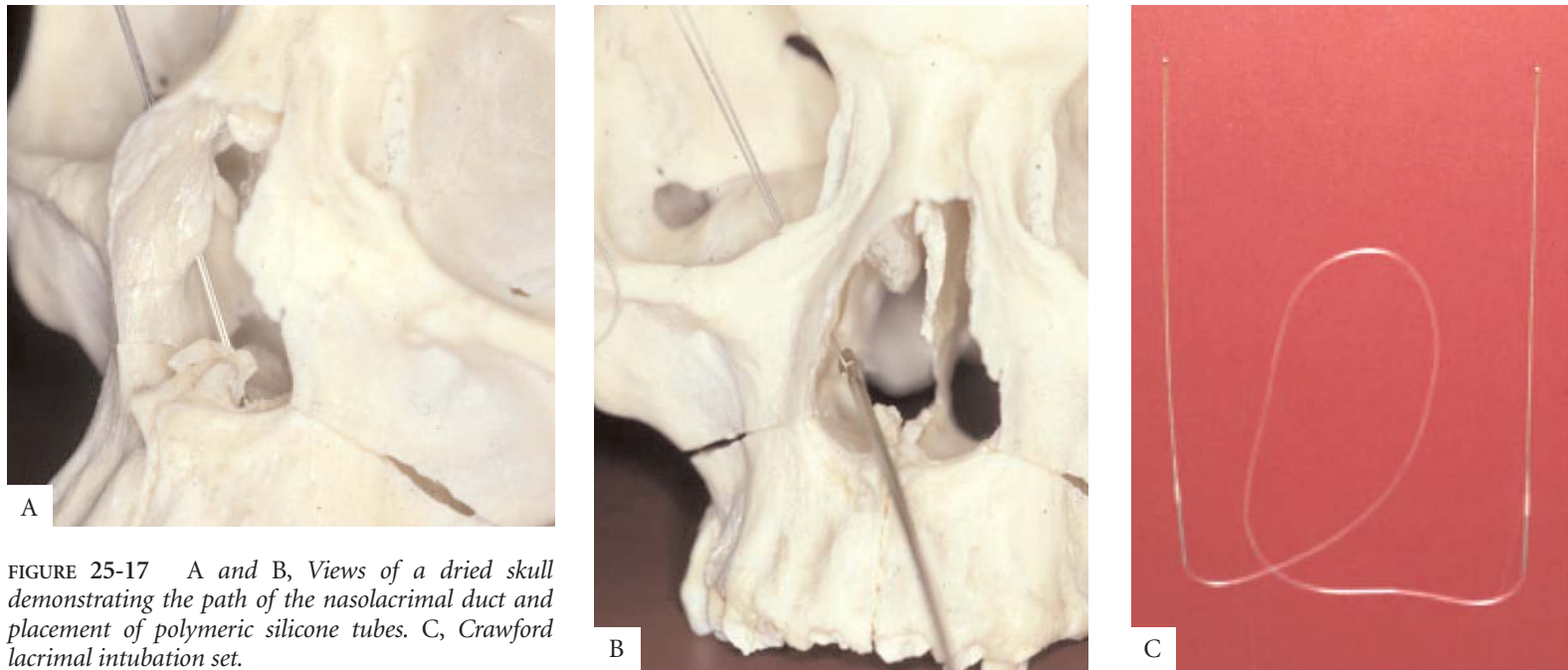


FIGURE 25-17 A and B, Views of a dried skull demonstrating the path of the nasolacrimal duct and placement of polymeric silicone tubes. C, Crawford lacrimal intubation set.

Onlay cartilage or bone grafts then may be secured if an autograft is desired. Otherwise, an acrylic resin may be used. The bone is moistened, and acrylic is mixed and placed on a glass or polytef slab and rolled to a uniform thickness. The acrylic is placed directly over the bone and covered with a sheet of separating foil. The full-thickness flap is replaced to ensure proper contour and then is again reflected. A copious amount of saline is used to irrigate the area so that the material does not cause thermal damage to the skull. The flap is then replaced and sutured.

Improvements in computer design and technology now enable the fabrication of prostheses for one-stage reconstructions. The patient undergoes a three-dimensional CT before the operative procedure is performed.¹¹⁴ A computer-assisted diagnosis/computer-assisted manufacturing (CAD/CAM) protocol is then used to create a model of the frontal bone and defect. A prosthesis may be created from polymeric silicone, acrylic, a cobalt-chromium alloy, or hydroxylapatite-coated metals. During the operative procedure, the prosthesis is inserted as described above.

Acknowledgment

The authors thank Flo Witte, MA, ELS, for her expert editorial assistance.

References

- Schultz RC. Supraorbital and glabellar fractures. *Plast Reconstr Surg* 1970;45:227–33.
- Onishi K, Nakajima T, Yoshimura Y. Treatment and therapeutic devices in the management of frontal sinus fractures. Our experience with 42 cases. *J Craniomaxillofac Surg* 1989;17:58–63.
- Xie C, Mehendale N, Barrett D, et al. 30-year retrospective review of frontal sinus fractures: the Charity Hospital experience. *J Craniomaxillofac Trauma* 2000;6:7–15.
- May M, Ogura JH, Schramm V. Nasofrontal duct in frontal sinus fractures. *Arch Otolaryngol* 1970;92:534–8.
- Manolides S. Management of frontal sinus trauma. *Semin Plast Surg* 2002;16:261–71.
- Coleman CC. Fracture of the skull involving the paranasal sinuses and mastoids. *JAMA* 1937;109:1613–6.
- Gonty AA, Marciani RD, Adornato DC. Management of frontal sinus fractures: a review of 33 cases. *J Oral Maxillofac Surg* 1999; 57:372–81.
- Gerbino G, Rocca F, Benech A, Caldarelli C. Analysis of 158 frontal sinus fractures: current surgical management and complications. *J Craniomaxillofac Surg* 2000; 28:133–9.
- Wilson BC, Davidson B, Corey JP, Haydon RC. III. Comparison of complications following frontal sinus fractures managed with exploration with or without obliteration over 10 years. *Laryngoscope* 1988;98:516–20.
- Helmy ES, Koh ML, Bays RA. Management of frontal sinus fractures. Review of the literature and clinical update. *Oral Surg Oral Med Oral Pathol* 1990; 69:137–48.
- Donald PJ. Frontal sinus ablation by cranialization. Report of 21 cases. *Arch Otolaryngol* 1982;108:142–6.
- Stanley RB Jr, Becker TS. Injuries of the nasofrontal orifices in frontal sinus fractures. *Laryngoscope* 1987;97:728–31.
- Duvall AJ III, Porto DP, Lyons D, Boies LR Jr. Frontal sinus fractures. Analysis of treatment results. *Arch Otolaryngol Head Neck Surg* 1987;113:933–5.
- Wallis A, Donald PJ. Frontal sinus fractures: a review of 72 cases. *Laryngoscope* 1988; 98:593–8.
- Ioannides C, Freihofer HP, Bruaset I. Trauma of the upper third of the face. Management and follow-up. *J Maxillofac Surg* 1984;12:255–61.
- Larrabee WF Jr, Travis LW, Tabb HG. Frontal sinus fractures—their suppurative complications and surgical management. *Laryngoscope* 1980;90:1810–3.
- Peri G, Chabannes J, Menes R, et al. Fractures of the frontal sinus. *J Maxillofac Surg* 1981;9:73–80.
- Lee TT, Ratzker PA, Galarza M, Villanueva PA. Early combined management of frontal sinus and orbital and facial fractures. *J Trauma* 1998;44:665–9.

19. Wright DL, Hoffman HT, Hoyt DB. Frontal sinus fractures in the pediatric population. *Laryngoscope* 1992;102:1215-9.
20. Rohrich RJ, Hollier LH. Management of frontal sinus fractures. Changing concepts. *Clin Plast Surg* 1992;19:219-32.
21. Whited RE. Anterior table frontal sinus fractures. *Laryngoscope* 1979;89:1951-5.
22. Fedok FG. Comprehensive management of nasoethmoid-orbital injuries. *J Craniomaxillofac Trauma* 1995;1:36-48.
23. Ashar A, Kovacs A, Khan S, Hakim J. Blindness associated with midfacial fractures. *J Oral Maxillofac Surg* 1998;56:1146-50.
24. Cruse CW, Blevins PK, Luce EA. Naso-ethmoid-orbital fractures. *J Trauma* 1980;20:551-6.
25. Leipziger LS, Manson PN. Nasoethmoid orbital fractures. Current concepts and management principles. *Clin Plast Surg* 1992;19:167-93.
26. Stevens M, Kline SN. Management of frontal sinus fractures. *J Craniomaxillofac Trauma* 1995;1:29-37.
27. Salentijn L. Anatomy and embryology. In: Friedman W, editor. *Surgery of the paranasal sinuses*. Vol 1. Philadelphia: W. B. Saunders; 1985. p. 15-9.
28. Enlow D. The facial growth process. In: Enlow D, editor. *Handbook of facial growth*. Philadelphia: WB Saunders; 1982. p. 66-186.
29. Brown WA, Molleson TI, Chinn S. Enlargement of the frontal sinus. *Ann Hum Biol* 1984;11:221-6.
30. Godin DA, Miller RH. Frontal sinus fractures. *J La State Med Soc* 1998;150:50-5.
31. Tos M, Mogensen C, Novotny Z. Quantitative histologic features of the normal frontal sinus. *Arch Otolaryngol* 1980;106:143-8.
32. Urken ML, Som PM, Lawson W, et al. The abnormally large frontal sinus. I. A practical method for its determination based upon an analysis of 100 normal patients. *Laryngoscope* 1987;97:602-5.
33. Rohrich RJ, Hollier L. The role of the nasofrontal duct in frontal sinus fracture management. *J Craniomaxillofac Trauma* 1996;2:31-40.
34. Williams PL, Bannister LH, Berry MM, et al. *Gray's anatomy: the anatomical basis of medicine and surgery*. New York: Churchill Livingstone; 1995.
35. Williams P, Warwick R. The paranasal sinuses. In: Warwick R, editor. *Gray's anatomy*. Philadelphia: WB Saunders; 1980. p. 332-4, 1148-9.
36. Sargent LA, Rogers GF. Nasoethmoid orbital fractures: diagnosis and management. *J Craniomaxillofac Trauma* 1999;5:19-27.
37. Zide BM, McCarthy JG. The medial canthus revisited—an anatomical basis for canthopexy. *Ann Plast Surg* 1983;11:1-9.
38. Lew D, Sinn DP. Diagnosis and treatment of midface fractures. In: Walker RV, editor. *Oral and maxillofacial trauma*. Vol 2. Philadelphia: W. B. Saunders Co.; 1997. p. 653-713.
39. Kominami R, Yasutaka S, Taniguchi Y, Shinohara H. Anatomy and histology of the lacrimal fluid drainage system. *Okajimas Folia Anat Jpn* 2000;77:155-60.
40. Holt GR. Ethmoid and frontal sinus fractures. *Ear Nose Throat J* 1983;62:357-64.
41. Sataloff RT, Sariago J, Myers DL, Richter HJ. Surgical management of the frontal sinus. *Neurosurgery* 1984;15:593-6.
42. Lanigan DT, Stoelinga PJ. Fractures of the supra-orbital rim. *J Oral Surg* 1980;38:764-70.
43. Miller SH, Lung RJ, Davis TS, et al. Management of fractures of the supraorbital rim. *J Trauma* 1978; 18:507-12.
44. Rowe N, Kiley H. The surgical anatomy, diagnosis, and treatment of fractures of the nasal region, frontal sinus and paranasal air sinus. In: Kiley H, editor. *Fractures of the facial skeleton*. Baltimore: Williams & Wilkins Co.; 1970. p. 251-75.
45. Zide MF. Nasal and naso-orbital ethmoid fractures. In: Peterson LJ, editor. *Principles of oral and maxillofacial surgery*. Vol 1. Philadelphia: J. B. Lippincott Co.; 1992. p. 547-74.
46. Ginsburg CM. Frontal sinus fractures. *Pediatr Rev* 1997;18:120-1.
47. Brandt MT, Jenkins WS, Fattahi TT, Haug RH. Cerebrospinal fluid: implications in oral and maxillofacial surgery. *J Oral Maxillofac Surg* 2002;60:1049-56.
48. Furnas DW, Bircoll MJ. Eyelash traction test to determine if the medial canthal ligament is detached. *Plast Reconstr Surg* 1973;52:315-7.
49. Achauer BM, Allyn PA, Furnas DW, Bartlett RH. Pulmonary complications of burns: the major threat to the burn patient. *Ann Surg* 1973;177:311-9.
50. Haug RH, Indresano AT. Management of maxillary fractures. In: Peterson LJ, editor. *Principles of oral and maxillofacial surgery*. Vol 1. Philadelphia: J. B. Lippincott Co.; 1992. p. 469-88.
51. Paskert JP, Manson PN. The bimanual examination for assessing instability in naso-orbitoethmoidal injuries. *Plast Reconstr Surg* 1989;83:165-7.
52. Manson PN, Clark N, Robertson B, et al. Subunit principles in midface fractures: the importance of sagittal buttresses, soft-tissue reductions, and sequencing treatment of segmental fractures. *Plast Reconstr Surg* 1999;103:1287-306.
53. Olson EM, Wright DL, Hoffman HT, et al. Frontal sinus fractures: evaluation of CT scans in 132 patients. *AJNR Am J Neuroradiol* 1992;13:897-902.
54. Heller EM, Jacobs JB, Holliday RA. Evaluation of the frontonasal duct in frontal sinus fractures. *Head Neck* 1989;11:46-50.
55. Harris L, Marano GD, McCorkle D. Nasofrontal duct: CT in frontal sinus trauma. *Radiology* 1987;165:195-8.
56. Manson PN, Markowitz B, Mirvis S, et al. Toward CT-based facial fracture treatment. *Plast Reconstr Surg* 1990;85:202-12.
57. Remmler D, Denny A, Gosain A, Subichin S. Role of three-dimensional computed tomography in the assessment of naso-orbitoethmoidal fractures. *Ann Plast Surg* 2000;44:553-63.
58. Stanley RB Jr. Management of severe fronto-basilar skull fractures. *Otolaryngol Clin North Am* 1991;24: 139-50.
59. Ioannides C, Freihofer HP. Fractures of the frontal sinus: classification and its implications for surgical treatment. *Am J Otolaryngol* 1999;20:273-80.
60. Pollak K, Payne EE. Fractures of the frontal sinus. *Otolaryngol Clin North Am* 1976;9:517-22.
61. Haug RH, Likavec MJ. Frontal sinus reconstruction. *Atlas Oral Maxillofac Surg Clin North Am* 1994; 2:65-83.
62. McGraw-Wall B. Frontal sinus fractures. *Facial Plast Surg Clin North Am* 1998;14:59-66.
63. Markowitz BL, Manson PN, Sargent L, et al. Management of the medial canthal tendon in nasoethmoid orbital fractures: the importance of the central fragment in classification and treatment. *Plast Reconstr Surg* 1991;87:843-53.
64. Haug RH, Cunningham LL. Management of fractures of the frontal bone and frontal sinus. *Selected Readings Oral Maxillofac Surg* 2002;10:1-32.
65. Ellis E, Zide MF. *Surgical approaches to the facial skeleton*. Baltimore: Williams & Wilkins; 1995. p. 63-5.
66. Nadell J, Kline DG. Primary reconstruction of depressed frontal skull fractures including those involving the sinus, orbit, and cribriform plate. *J Neurosurg* 1974;41:200-7.
67. Schmitz JP, Lemke RR, Smith BR. The perimeter marking technique for rigid fixation of frontal sinus fractures: procedure and report of cases. *J Oral Maxillofac Surg* 1994;52:1120-5.
68. Hybels RL. Posterior table fractures of the frontal sinus: II. Clinical aspects. *Laryngoscope* 1977;87:1740-5.
69. Levine SB, Rowe LD, Keane WM, Atkins JP Jr. Evaluation and treatment of frontal sinus fractures. *Otolaryngol Head Neck Surg* 1986;95:19-22.

70. McGrath MH, Smith CJ. A simple method to maintain reduction of unstable fractures of the frontal sinus. *Plast Reconstr Surg* 1981;68:948–9.
71. Nichols RD. Treatment of frontal sinus fractures. In: Mathog RH, editor. *Maxillofacial trauma*. Baltimore: Williams & Wilkins; 1984. p. 288–96.
72. Hybels RL, Newman MH. Posterior table fractures of the frontal sinus: I. An experimental study. *Laryngoscope* 1977;87:171–9.
73. Dickinson JT, Cipicic JA, Kamerer DB. Principles of frontal reconstruction. *Laryngoscope* 1969;79: 1019–74.
74. Valenzela C. Treatment of traumatic disease of the frontal sinus by adipose implant obliteration. *Laryngoscope* 1967;77:1695–705.
75. Lazaridis N, Makos C, Iordanidis S, Zouloumis L. The use of titanium mesh sheet in the fronto-zygomatico-orbital region. *Case reports. Aust Dent J* 1998;43:223–8.
76. Lakhani RS, Shibuya TY, Mathog RH, et al. Titanium mesh repair of the severely comminuted frontal sinus fracture. *Arch Otolaryngol Head Neck Surg* 2001;127:665–9.
77. Schubert W, Gear AJL, Lee C, et al. Incorporation of titanium mesh in orbital and midface reconstruction. *Plast Reconstr Surg* 2002;110:1022–30.
78. Wiltfang J, Merten HA, Schultze Mosgau S, et al. Biodegradable miniplates (LactoSorb): long-term results in infant minipigs and clinical results. *J Craniomaxillofac Surg* 2000;11:239–43.
79. Stanley RB Jr, Schwartz MS. Immediate reconstruction of contaminated central craniofacial injuries with free autogenous grafts. *Laryngoscope* 1989;99:1011–5.
80. Davis BR, Sandor GK. Use of fibrin glue in maxillofacial surgery. *J Otolaryngol* 1998; 27:107–12.
81. Siedentop KH, Park JJ, Shah AN, et al. Safety and efficacy of currently available fibrin tissue adhesives. *Am J Otolaryngol* 2001;22:230–5.
82. Al-Yamany M, Del Maestro RF. Prevention of subdural fluid collections following transcortical intraventricular and/or paraventricular procedures by using fibrin adhesive. *J Neurosurg* 2000;92:406–12.
83. Man D, Plosker H, Winland-Brown JE. The use of autologous platelet-rich plasma (platelet gel) and autologous platelet-poor plasma (fibrin glue) in cosmetic surgery. *Plast Reconstr Surg* 2001;107:229–39.
84. Stover EP, Siegel LC, Hood PA, et al. Platelet-rich plasma sequestration, with therapeutic platelet yields, reduces allogeneic transfusion in complex cardiac surgery. *Anesth Analg* 2000;90:509–16.
85. Kheirabadi BS, Pearson R, Tuthill D, et al. Comparative study of the hemostatic efficacy of a new human fibrin sealant: is an antifibrinolytic agent necessary? *J Trauma* 2002;52:1107–15.
86. Rosen G, Nachtigal D. The use of hydroxyapatite for obliteration of the human frontal sinus. *Laryngoscope* 1995;105:553–5.
87. Failla A. Operative management of injuries involving the frontal sinuses. A study of eighteen operated cases. *Laryngoscope* 1968;78:1833–52.
88. Sessions RB, Alford BR, Stratton C, et al. Current concepts of frontal sinus surgery: an appraisal of the osteoplastic flap–fat obliteration operation. *Laryngoscope* 1972; 82:918–30.
89. Denny JC III. Frontal sinus obliteration using liposuction. *Otolaryngol Head Neck Surg* 1986;95:15–9.
90. Petruzzelli GJ, Stankiewicz JA. Frontal sinus obliteration with hydroxyapatite cement. *Laryngoscope* 2002; 112:32–6.
91. Sailer HF, Gratz KW, Kalavrezos ND. Frontal sinus fractures: principles of treatment and long-term results after sinus obliteration with the use of lyophilized cartilage. *J Craniomaxillofac Surg* 1998;26:235–42.
92. Wolfe SA, Johnson P. Frontal sinus injuries: primary care and management of late complications. *Plast Reconstr Surg* 1988; 82:781–91.
93. Benninger MS, Anon J, Mabry RL. The medical management of rhinosinusitis. *Otolaryngol Head Neck Surg* 1997;117:541–9.
94. Rivero DH, Lorenzi Filho G, Pazetti R, et al. Effects of bronchial transection and reanastomosis on mucociliary system. *Chest* 2001;119:1510–5.
95. Ochi K, Sugiura N, Komatsuzaki Y, et al. Patency of inferior meatal antrostomy. *Auris Nasus Larynx* 2003;30 Suppl:S57–S60.
96. Sapci T, Sahin B, Karavus A, Akbulut UG. Comparison of the effects of radiofrequency tissue ablation, CO₂ laser ablation, and partial turbinectomy applications on nasal mucociliary functions. *Laryngoscope* 2003;113:514–9.
97. Hoffman BB. Catecholamines, sympathomimetic drugs, and adrenergic receptor antagonists. In: Limbird LE, editor. *The pharmacological basis of therapeutics*. New York: McGraw-Hill; 2001. p. 215–65.
98. Delafuente JC, Davis TA, Davis JA. Pharmacotherapy of allergic rhinitis. *Clin Pharm* 1989;8:474–85.
99. Namias N, Harvill S, Ball S, et al. Cost and morbidity associated with antibiotic prophylaxis in the ICU. *J Am Coll Surg* 1999;188:225–30.
100. American Society of Health System Pharmacists. ASHP therapeutic guidelines on antimicrobial prophylaxis in surgery. *Am J Health Syst Pharm* 1999;56:1839–88.
101. Peterson LJ. Principles of surgical and antimicrobial infection management. In: Hupp JR, editor. *Oral and maxillofacial infections*. Philadelphia: W. B. Saunders Co.; 2002. p. 99–111.
102. Lindorf HH. A contribution on revisional and drainage of the frontal sinus by osteoplastic operation. *J Maxillofac Surg* 1986;14:34–9.
103. Schenck NL, Tomlinson MJ. Frontal sinus trauma: experimental reconstruction with Proplast. *Laryngoscope* 1977;87:398–407.
104. Schenck NL, Rauchbach E, Ogura JH. Frontal sinus disease. II. Development of the frontal sinus model: occlusion of the nasofrontal duct. *Laryngoscope* 1974;84:1233–47.
105. Abramson AL, Eason RL. Experimental frontal sinus obliteration: long-term results following removal of the mucous membrane lining. *Laryngoscope* 1977; 87:1066–73.
106. Larson CH, Adkins WY, Osguthorpe JD. Post-traumatic frontal and frontoethmoid mucoceles causing reversible visual loss. *Otolaryngol Head Neck Surg* 1983;91:691–4.
107. Constantinidis J, Steinhart H, Schwerdtfeger K, et al. Therapy of invasive mucoceles of the frontal sinus. *Rhinology* 2001;39:33–8.
108. van Damme PA, Freihofer HP. Disturbances of smell and taste after high central midface fractures. *J Craniomaxillofac Surg* 1992; 20:248–50.
109. Murube J, Rojo P, Chenzhuo L. Soft tissue conjunctivo-rhinostomy. *Eur J Ophthalmol* 2001;11:323–7.
110. Barna NJ, Piacentini MA, Della Rocca RC. External dacryocystorhinostomy. In: Arthurs BP, editor. *Ophthalmic plastic surgery: decision making and techniques*. New York: McGraw-Hill; 2002. p. 189–98.
111. Codere F, Arthurs BP. Endonasal dacryocystorhinostomy. In: Arthurs BP, editor. *Ophthalmic plastic surgery: decision making and techniques*. New York: McGraw-Hill; 2002. p. 199–204.
112. McNulty JS. Frontal sinus reconstruction with bone or cartilage grafts. *Ear Nose Throat J* 1986;65:512–6.
113. Zide MF, Kent JN, Machado L. Hydroxylapatite cranioplasty directly over dura. *J Oral Maxillofac Surg* 1987;45:481–6.
114. Kaplan EN. 3-D CT images for facial implant design and manufacture. *Clin Plast Surg* 1987;14:663–76.
115. Remsen K, Lawson W, Biller HF. Acrylic frontal cranioplasty. *Head Neck Surg* 1986;9:32–41.
116. Conroy B. Maxillofacial prosthetics and technology. In: Williams JL, editor. *Maxillofacial injuries*. New York: Churchill Livingstone; 1985. p. 32–41.

Gunshot Injuries

Jon D. Holmes, DMD, MD

The greater the ignorance,
the greater the dogmatism.

—William Osler

Management of gunshot injuries to the face led in many ways to the development of modern maxillofacial surgery, and it remains a cornerstone of the specialty of oral and maxillofacial surgery. There is an aura that surrounds the management of these complex wounds that affects residents as well as experienced clinicians. The mystique that developed in the earliest accounts of management of gunshot wounds (GSWs) persists with the passing along of myths and dogma to subsequent generations of residents. Readers are encouraged to use the information in this chapter as a guide, to combine it with their own experience, and hopefully to continue the evolution in treatment of these unique wounds.

History

The introduction of Chinese gunpowder to Europe around the thirteenth century was quickly followed by the development of projectile weapons based on its explosive properties. The first recorded use of a cannon was by Edward III against the Scots in 1327, and small arms carried by one or two soldiers began appearing in the fourteenth century.¹ Early weapons that used modified arrows were replaced with more efficient stone and, ultimately, metallic projectiles. Improvements in pro-

jectiles and firearms led to increasing numbers of more devastating wounds. Surgeons accustomed to dealing with a variety of wounds from blunt, bladed, and pointed weapons were faced with blast and projectile injuries of a completely different nature. Contamination and devitalized tissues led to increasing numbers of infections, which surgeons of the day incorrectly attributed to the gunpowder itself, and to the anticipation of “laudable pus.” Subsequent advances in surgical knowledge went on to closely parallel the evolution of firearms. Knowledge gained on the battlefield by famed military surgeons such as Ambroise Paré (1510–1590) elevated the art of surgery to a learned profession.¹ Unfortunately, the battlefield has moved to the urban areas with increasing numbers of civilian gunshot injuries.

Demographics

GSWs are second only to motor vehicle accidents as a source of injury and death, and rank as the eighth leading cause of death in the United States.² Recently the number of firearm-related deaths and injuries in children and adolescents has declined.³ According to the National Center for Injury Prevention and Control, firearm-related deaths have shown a continual decline from approximately 15 per 100,000 in 1993 to approximately 11 per 100,000 in 1998.⁴ Because of past difficulties with surveillance, however, most

reports likely underestimate unintentional firearm-related deaths and injuries overall.^{5,6} Interestingly, Patton and Woodward reported that although GSW admissions decreased at the Henry Ford Hospital in Detroit by 45%, the number of patients who required operations actually increased by 17%. The number of gunshot victims dead on arrival remained steady. A possible explanation is that an increased number of patients are discharged from the emergency department after significant injury requiring admission has been ruled out; these patients are therefore not counted as admissions.⁷

The demographics of gunshot injuries are telling. Most victims are young males (< 38 yr). Suicides and assaults far outnumber unintentional and accidental shootings. Firearms are implicated in 58% of male suicides and 37% of female suicides. Importantly, the number of patients surviving and requiring treatment of gunshot injuries outnumber firearm fatalities by approximately 5:1.^{8,9}

Currently there are an estimated 135,000 GSWs treated annually in the United States. The incidence of firearm-related injury and death in the United States exceeds that of other developed countries.¹⁰ Although there appears to be a relationship between the rate of household firearm ownership and the homicide rate, most agree that other social factors are required to explain the number of firearm injuries in

the United States in comparison with other developed countries.⁹ Indeed, in countries in which firearm ownership is required for militia duty, firearm injuries are lower on a per-capita basis than in the United States. The majority of civilian firearm injuries are sustained from handguns (86%), followed by shotguns (8%) and rifles (5%). Approximately 12 to 14% of unintentional and assault gunshot injuries involve the head and neck, whereas 51% of self-inflicted gunshot injuries involve the head and neck.⁴ Clark and colleagues reported on their experience at the Maryland Shock Trauma Center and found that of 178 GSWs to the face, 40% involved the frontal bone and cranium, 9% involved the orbits, 14% involved the lower midface (maxilla), 13% involved the mandible, and 24% involved multiple sites. Shotgun injuries more commonly involved the mandible and midface.¹¹ Demetriades and colleagues reported on the extensive experience of the University of California at Los Angeles. Of 4,139 patients admitted with gunshot injuries over a 4-year period, 6% (247) had GSWs to the face. Thirty-eight percent of these had isolated wounds to the face, whereas the remaining 62% had associated injuries to other body areas. They reported that the mandible was the most commonly involved facial bone (54 cases), followed by the maxilla and zygoma (21 cases each). The orbits and nasal bones were involved in 18 and 15 cases, respectively. Thirty-six patients died following admission. All of the deaths were secondary to injuries to the chest, abdomen, or brain. There were no deaths associated with isolated facial injuries.¹²

Aside from the tragedy of firearm-related injuries and the emotional toll such injuries take on victims, their families, and communities, the financial burden to society of firearm-related injuries is significant. This is especially true with regard to the long-term rehabilitation and multiple reconstructive surgeries that many victims of facial GSWs require. Cook and colleagues reported approximately 115,000

firearm-related injuries in the United States yearly, with an annual cost of treating firearm injuries of approximately \$2.3 billion; of this, taxpayers pay \$1.1 billion. Although this cost represents only one-quarter of 1% of the US health care budget of \$950 billion, it is significant considering that the group most affected typically involves younger healthier patients that usually require very little medical care.¹³

Ballistics

Ballistics is the science of projectile motion. A prerequisite to understanding the injuries caused by various firearms is knowledge of the language of ballistics. The potential problems of a wound caused by a projectile can be better anticipated if one has some knowledge of the weapon and projectile type that caused the wound. For example, if the surgeon is aware that a patient suffered a high-energy wound caused by a high-power, high-velocity cartridge, he can better appreciate the potential for extensive areas of devitalized tissue that may declare later. In addition, an understanding of firearm nomenclature allows the surgeon some ability to predict the types of weapons that are commonly involved in various types of civilian gunshot injuries. For this reason, the clinician dealing with gunshot injuries should be conversant in the rudiments of ballistics, types of firearms, and projectiles.

Ballistic science seeks to explain the behavior of the projectile and is typically divided into three stages:

1. *Internal (or interior) ballistics* describes the forces that apply to a projectile from the time the propellant is ignited to the time the projectile leaves the barrel. An important consideration is barrel length. In general, longer barrels (rifles) allow the force of the propellant to act on the projectile longer and generate higher velocities than do shorter-barreled weapons. In addition, a longer barrel serves to stabilize the bullet over longer distances.
2. *External ballistics* refers to forces that act on the bullet in flight. The primary factors that govern external ballistics are the weight and shape of the bullet.
3. *Terminal ballistics* is the study of bullet behavior once it impacts the target and is primarily concerned with how much energy is transferred to the target material and the resultant damage. The science of terminal ballistics is most important to the surgeon and is the most common source of controversy when discussing ballistic wounding. Attempts to reproduce the interaction of bullets with living tissue by using various target media such as ballistic gel have led to many myths surrounding wounding and the “stopping power” of various bullets and weapons. Similarly, surgeons have passed on many myths of their own regarding GSWs and the firearms that cause them.

Energy and Wounding Power

Traditionally, kinetic energy has been used as the basis to explain wounds caused by a gunshot. Simple physics can be applied to the projectile using the following formula:

$$KE = mv^2$$

where *KE* is kinetic energy, *m* is the mass of the projectile, and *v* is the velocity of the projectile.

Wounding power is typically related to the amount of kinetic energy transferred to the target:

$$P = m(V_{\text{impact}} - V_{\text{exit}})^2$$

where *P* is power, *m* is mass of the projectile, and *V* is velocity.

Based on these formulas, the velocity of a projectile has traditionally been considered far more important than its mass in wounding power. Indeed, often guns are classified as low velocity (< 350 m/s), medium velocity (350–600 m/s), and high velocity (> 600 m/s). Considering a typically sized projectile, a velocity of approxi-

mately 50 m/s is required to penetrate the skin, and a velocity of around 65 m/s will fracture bone.¹⁴ See Table 26-1 for a comparison of commonly encountered pistol and rifle cartridges.

In general, there is an inverse relationship between a bullet's diameter (caliber) and velocity. Unfortunately, the realities of wounding are not as clear cut, and the emphasis on velocity and kinetic energy of the weapon as it relates to treatment strategies is excessive.¹⁵ In an excellent review, Fackler debunks many of the commonly held beliefs of ballistic injury, including the idolatry of velocity, the exaggeration of the effects of temporary cavitation and pressure, bullet tumbling, the exaggerated role of kinetic energy transfer, and, most importantly, the emphasis on extensive wound débridement.¹⁶ The heterogeneity of the human body, which is composed of tissues of varying densities and elasticities, does not allow formulas to explain all of the nuances of wounding caused by projectiles of different velocities, sizes, and weights. Practically, there is a balance between velocity, projectile mass, and projectile size that governs the

amount of energy transferred to the target and resultant tissue wounding. These factors govern the four components of projectile wounding: penetration, permanent cavity formation, temporary cavity formation, and fragmentation.

Penetration allows the projectile to transmit kinetic energy and destroy tissue. A bullet must penetrate to a sufficient depth to cause damage. Likewise, a projectile that over-penetrates or passes completely through nonvital tissue may result in little damage.

The permanent cavity describes the space that results from direct tissue disruption and destruction. It is a function of the penetration and size of the projectile. It is generally considered to be the most important factor in the wounding and stopping power of a particular cartridge and bullet.

The temporary cavity is produced as the projectile travels through the target tissue. Transfer of kinetic energy results in a stretching of elastic tissues. Although they may remain intact, some of these tissues may be irrecoverably damaged. Arteries may suffer pseudoaneurysm for-

mation and rupture, and nerves may fail to recover function.

Fragmentation, which may not be present in a GSW, refers to the projectile (certain projectiles are designed to fragment; see below) or secondary fragments such as clothing or bone that develop from being struck by the projectile.

Despite claims by many bullet manufacturers, fragmentation of the projectile does not reliably occur in most handgun wounds. Bullets specifically designed as fragmentation rounds typically suffer from low-penetration ability. High-velocity rifle rounds are known, however, for their devastating fragmentation.

The effects of the temporary cavity on wounding are often exaggerated in ballistic literature. Because most tissue has an elastic nature and ability to recover from stretching (certain tissues such as brain are exceptions), damage from temporary cavitation is not as important as many expound. The massive zones of necrotic tissue that were felt to develop from temporary cavitation do not exist in reality. The most important factors in projectile wounding remain penetration and the size of the permanent cavity. A very small projectile traveling at high velocity striking an area of low density (eg, fat) may impart far less damage than a larger projectile traveling at a lower velocity and striking an area of high density (eg, bone). The realities of stopping power further call into question many of the claims promulgated through ballistic literature as well as surgical practices. In reality, the power transferred to the victim is the same as what the recoil imparts on the shooter. Again, simple physics explains that the impact of a 9 mm pistol round (see below) is the same as that created by a 0.45 kg weight dropped from a height of 1.82 m or of a 4.53 kg weight dropped from a height of 1.82 cm. In more practical terms, the amount of energy delivered to a body by a bullet is approximately equivalent to that transmitted when one is hit with a baseball.¹⁷

Table 26-1 Comparison of Approximate Cartridge Velocities and Muzzle Energy*

Cartridge	Bullet Weight (grains) [†]	Velocity (ft./s)	Muzzle Energy (ft./lb.)
.22 LR	29	1,225	140
.32 auto	71	900	129
.380 auto (9 mm short)	95	955	190
.38 special	145	680	170
.357 magnum	110	1,565	535
9 mm	124	1,100	345
.45 auto	230	790	370
.44 magnum	240	1,420	741
.223 (NATO 5.56 × 45)	55	3,100	1,280
.308 (NATO 7.62 × 51)	110	3,000	2,650
.300 magnum	180	2,900	3,500
20-gauge shotgun	547	1,185	1,400
12-gauge shotgun	820	1,250	2,600

Adapted from Federal Ammunition Company high power ammunition handbook. Minneapolis; 1983.

*Velocities and muzzle energy can vary within different cartridges depending on the weight of bullet, powder type, and other variables such as barrel length.

[†]1 oz. = 437.5 grains.

It is important to understand that the science of wounding power is more than simple physics; it is a complex interplay of projectile and target tissue characteristics that makes each wound unique. For this reason, categorization of wounds based on projectile characteristics such as velocity, although useful, should not promote dogmatic management schemes but instead should serve as guides. Surgeons should be wary of strict categorization schemes and treatment algorithms based only on velocity or another bullet characteristic and should bear in mind Lindsey's statement, "I will keep treating the wound, not the weapon."¹⁵

Firearm Terminology

As with ballistics, some knowledge of firearms is necessary for surgeons managing GSWs. It is a prerequisite for communicating with law enforcement officers and other clinicians.

Firearms are generally classified as handguns, rifles, and shotguns. Handguns are also referred to as pistols and revolvers, depending on their mechanical actions. With few exceptions, most are low or medium velocity, typically < 600 m/s, and usually cause tissue damage along the bullet tract only. Rifles range from low to high velocities. Shotguns typically are smooth-bore weapons that fire shells filled with lead shot of various sizes. Some shotguns may be modified with rifled barrels to fire shells containing a solid lead projectile referred to as a *slug*. Although they are of low velocity, close-range shotgun injuries are devastating, especially with larger lead shot such as buckshot (see below).

Rifles and handguns are classified by caliber. The caliber of a weapon is the diameter of the muzzle bore, which is the same as the diameter of the projectile (bullet). *Cartridge* or *round* refers to the case containing the ignition system (primer), the propellant, and the projectile (bullet). Measurements for American firearms are typically in inches. For example, the .45 caliber pistol bullet is 0.45 in. (1.14 cm) in

diameter. Firearms of European origin, such as the 9 mm, have classically used the metric system. The American military round for the M-16 (military version of the AR-15) is usually the 223, which is 0.223 in. (0.57 cm) in diameter, whereas the Soviet AK-47 fires a 30-caliber projectile, or 7.62×39 (39 refers to the length of the case containing the propellant in millimeters; Figure 26-1).

Shotguns were originally designed to be used on small fast-moving game and typically fired small pellets that dispersed in flight to form a pattern. Typical muzzle velocities range from 335 to 427 m/s. They

are usually referred to by *gauge*, which is an English measurement that describes how many lead balls equaling 1 lb. (0.45 kg) would fit into a particular diameter of the barrel. For example, it would take 12 lead balls equal in diameter to the internal diameter of a 12-gauge shotgun barrel to make 1 lb. A 12-gauge shotgun has an internal barrel diameter of 1.85 cm, whereas a 28-gauge shotgun has an internal barrel diameter of 1.41 cm. It is clear that the higher the gauge, the smaller the diameter of the barrel (Figure 26-2A). There are some exceptions to this classification scheme. For example, a 410 shotgun has a



FIGURE 26-1 A, Representative rifle cartridges. From left to right: .300 Winchester magnum, 30-06, .308 (7.62 × 51 NATO), .223 (5.56 × 45 NATO), 7.39 (AK-47 round), and .17 rimfire. B, Representative pistol cartridges. From left to right: .44 magnum, .357 magnum, .38 special, .45 auto, .40 auto, 9 mm auto, .380 auto (9 mm short), .22 rimfire.

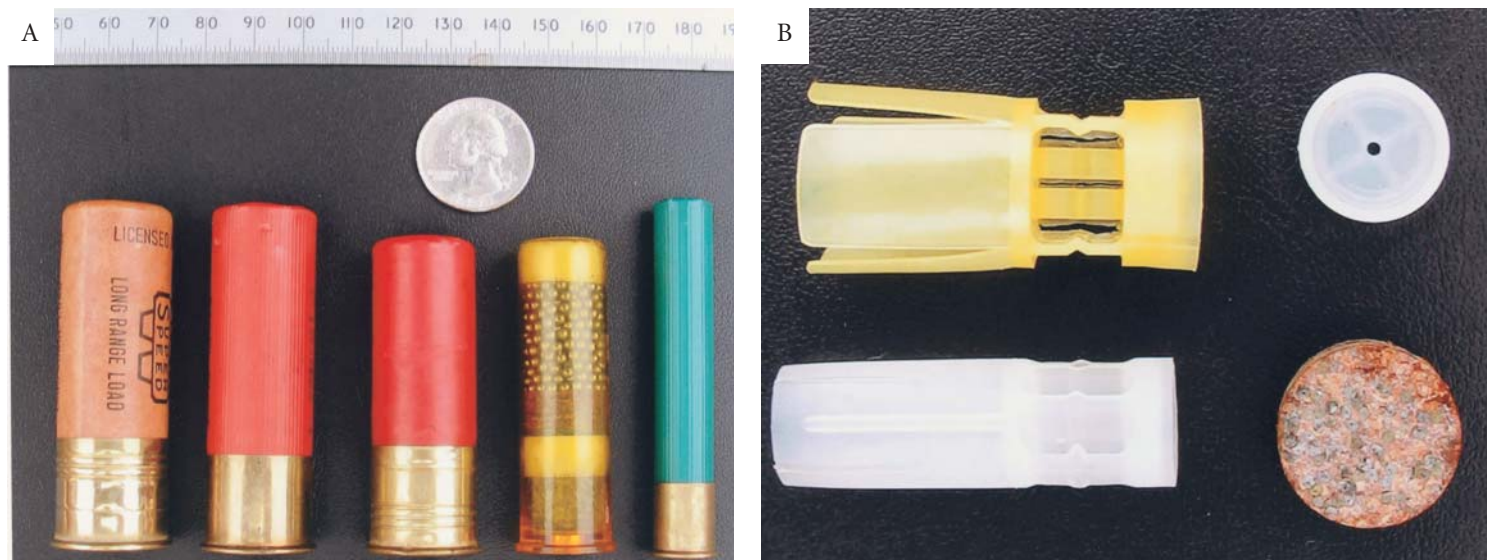


FIGURE 26-2 A, Representative shotgun shells. From left to right: 10 gauge; 3 in. 12 gauge; 2¼ in. 12 gauge; 20 gauge “Demonstrator” shell with shot, wadding, and powder visible; .410 gauge. B, Plastic and felt shotgun wadding.

barrel whose internal diameter is 0.410 in. (1.04 cm). In general, the lower the gauge, the more powder and shot the shell can contain.

Shot is also classified by size. Commonly encountered shot sizes range from 8 shot (0.23 cm), with approximately 500 pellets in a 12-gauge shell, to number 00 buckshot (0.83 cm), with 9 to 15 pellets in a 12-gauge shell. Shells come in different lengths within the same gauge as well. For example, a 12-gauge shell may be a 2¼ in. (6.99 cm) or 3 in. (7.62 cm) shell. Longer shells hold a larger charge of powder and shot, which can be used for larger game or game at further distances. As a general rule, longer-barreled shotguns and those with a full choke (a constriction of the end of the barrel) keep the pellets in a tighter pattern over longer distances. Finally, some shotguns may be modified with rifled barrels to fire shells containing a solid lead projectile referred to as a slug. Shot is usually selected based on the size of game. *Buckshot* refers to larger pellets meant for large game or human targets; it is particularly devastating because its impact is similar to multiple low- to medium-velocity handgun wounds, depending on the range.¹⁸ It is also important to note the

different makeup of a shotgun shell (see Figure 26-2A). The pellets are typically separated from the propellant by wadding that helps to contain and transfer the power of the charge to the pellets. This partition can be made of felt or plastic and may be found embedded in close-range wounds (Figure 26-2B).

Most handguns and rifles have barrels with internal grooves referred to as *rifling* that impart a spin to the bullet. This keeps the projectile stable in flight over longer distances. In early firearms that were loaded from the muzzle (muzzleloaders), the tight fit between the bullet and the barrel that resulted from rifling significantly slowed loading. For this reason, most early military weapons were smoothbore. Sacri-

fices in long-range accuracy were a trade-off for rapid rates of fire. This obstacle was overcome in 1847 by Captain Minié, who developed a projectile with a hollow conical base that loaded easily but expanded for a tight fit when the propellant enlarged behind it (Figure 26-3). Ultimately, breech-loading weapons, in which a self-contained round enclosing the ignition system (primer), propellant, and projectile was loaded from the beginning of the barrel instead of the end, overcame these difficulties. The development of rifling, however, allowed high-velocity projectiles that would remain stable in flight over long distances. Eventually, all projectiles become unstable in flight because the center of gravity lies well behind the center of



FIGURE 26-3 Left, Early round projectile and Minié ball with expanding base. Right, Modern full-jacketed and soft point rounds with “boat tail” to improve flight characteristics.

resistance (the bullet tip) causing them to take on various motions during flight.

Oscillation around the long axis of the bullet is referred to as *yaw*. Rifling seeks to stabilize yaw but imparts its own motion, referred to as *precession* (circular yawing), around the center of gravity, creating a decreasing spiral and nutation, which is a rotational movement in small circles.¹⁹ These motions occur during flight through air. Bullets may be modified in an attempt to decrease these motions in flight; an example is a “boat tail” bullet, intended to be stable over longer distances. Upon encountering a denser substance such as tissue, the projectile immediately starts tumbling. Increased tumbling causes more tissue wounding because it presents a larger surface area. Bullets have undergone a variety of modifications in an attempt to control these motions and increase wounding and stopping power.

The simplest and earliest projectile was a stone or lead ball (see Figure 26-3). Over time the projectile evolved to the conical-shaped Minié ball. The lead conical bullet remains in use. Modifications are made based on intended use. In general, military rounds are restricted by the Hague convention (1899) to the full-metal jacket. Fragmentation rounds have been outlawed, although some countries continue to use flechette rounds (designed to fire small metal spikes or fragments). Simple lead bullets referred to as *wadcutter*s are inexpensive and often used as target rounds. Jacketed bullets with exposed lead tips (soft points) are designed to expand on impact for maximum tissue destruction (maximum permanent cavity) and are typically designed for hunting. A variety of modifications have been made to handgun bullets in an attempt to make up for their lack of velocity and to increase wounding (Figure 26-4). Because of their low velocity, handgun bullets have difficulty expanding reliably in tissue. Attempts to overcome this have centered on the creation of bullets with various



FIGURE 26-4 Full-jacketed bullet compared with various hollow-point rounds designed to aid the expansion of lower-velocity bullets.

open ends, so-called hollow points (see Figure 26-4). Some of these are partially covered with a metal jacket in attempt to control expansion. As noted earlier, despite manufacturers’ claims to the contrary, reliable expansion is difficult to obtain in low-velocity rounds. Some manufacturers have created +P ammunition, which contains different gunpowder to obtain a higher velocity. Also, some bullets are designed to explode on impact by incorporating an explosive into a hollow cavity in the bullet (devastator rounds).

The ignition of most cartridges is accomplished by a firing pin striking a primer. Some cartridges use a primer built into the case and are referred to as *rimfire* because the firing pin strikes the edge of the cartridge rim to discharge the propellant.

Mention should be made of other projectiles that have been associated with injury. Modern airguns can achieve velocities sufficient to cause tissue damage. The proliferation of paint-ball guns has led to an increase in the number of ophthalmologic injuries.²⁰ Finally, unorthodox bullets such as wooden, rubber, and “bean bag” projectiles are being used increasingly in crowd-control situations. Although meant to be nonlethal methods of deterrence, these rounds can cause significant tissue damage and even death. They are frequently associated with facial fractures.²¹

Classification Schemes

Classification of traumatic injuries is helpful in guiding treatment and, more importantly, tracking outcomes for various treatment modalities. A number of trauma scoring systems and classifications for various injuries have been developed and validated. Similarly, attempts have been made to classify GSWs to assist the surgeon in selecting appropriate management strategies. Many of these classification schemes were developed on the battlefield. Dissimilarities between civilian and military gunshot injuries, such as ammunition, wounding potential of military weapons, and treatment objectives, make these classification schemes of little use in the urban trauma center, which most commonly deals with low- to medium-velocity handgun injuries.^{22,23}

Trauma systems have attempted to incorporate gunshot injuries into existing classification and trauma scoring systems. Unfortunately, current schemes have not proven beneficial in guiding treatment and judging outcomes to develop ideal approaches. Attempts to distinguish GSWs as low or high velocity have suffered from the shortcomings noted above. In addition, velocity is less critical than bullet type, mass, distance to target, and specific vital organs involved because most civilian

injuries are caused by low- or medium-velocity weapons.

One of the earliest and simplest classification schemes classifies GSWs as non-penetrating (grazing or blast wound), penetrating (bullet does not exit), perforating (in and out), and avulsive. The International Committee of the Red Cross introduced the armed conflict classification system to improve information gathering and communication regarding war wounds. Because of the diversity of battlefield weaponry, by necessity the system ignores weapon type and instead concentrates on wound severity in terms of tissue damage and anatomic structures involved.^{22,23} Gugala and Lindsey suggested a civilian gunshot injury classification scheme. It takes into account energy (high or low), involvement of vital structures (neural and vascular), wound type (non-penetrating, penetrating, perforating), fracture (intra-articular and extra-articular), and contamination. Primarily used in orthopedics, its usefulness in gunshot injuries to the head and neck is limited.²³

Shotgun Wounds

Because of their unique ballistic profile, shotgun injuries are often classified based on the distance to the target. Shotgun pellets have significant aerodynamic resistance and give up substantial amounts of kinetic energy during flight. In type I shotgun injuries (< 5 m), the pellets strike the target as a single mass, resulting in massive kinetic energy transfer, tissue avulsion, and a high mortality rate (85–90%). Patients that survive suicide attempts with shotguns typically survive because, in an attempt to reach the trigger with the muzzle under the chin or in the mouth, the head is hyperextended, which causes the pellets to create devastating injuries to the face but avoid the cranium. Fragments of paper or plastic wadding may be found in the wound. Type II injuries (5–12 m) usually result in much less tissue destruction. At these distances there is significant dispersal of the pellets

and loss of energy. Penetration may occur through deep fascia, but fractures are rare. Ocular injuries can occur as well as embolization of lead pellets, but mortality is less (15–20%). At distances > 12 m (type III), usually only the skin is penetrated and mortality is rare (0–5%).^{24,25} Because specific information on shooting distances is not often available to the clinician, a system was suggested that evaluated the maximum distance of pellet scatter. Type I injuries had > 25 cm of pellet scatter. Type II injuries had 10 to 25 cm of scatter. Type III injuries had < 10 cm of scatter and would roughly correspond to a type I injury in the classification of Sherman and Parrish.²⁴ This classification scheme was developed and applied to abdominal shotgun wounds in an attempt to guide therapy.²⁶ Again, the difficulty lies in applying this scheme, or any scheme, universally to GSWs involving different anatomic sites and weapon types.

It should be noted that rifle and shotgun injuries, although rare in assaults, are frequently encountered in attempted suicide patients. A characteristic wound profile is seen because of the head position assumed when the patient places the barrel of the weapon in the mouth or under the chin and subsequently hyperextends to reach the trigger. Characteristic powder burns are seen at the entrance wound (Figure 26-5). The face frequently takes the full effect of the blast, whereas lethal intracranial involvement is avoided.²⁷ If a high-energy weapon such as a shotgun or rifle is used, the injury can be devastating with significant tissue loss.

Although classification schemes can serve useful purposes in research as well as clinical practice, strict adherence to treatment algorithms based on wound classification can lead to mismanagement. Importantly, information regarding types of firearm and other details of the shooting are frequently not available, and clinical assessment of the wound remains the most reliable method for determining treatment approaches.

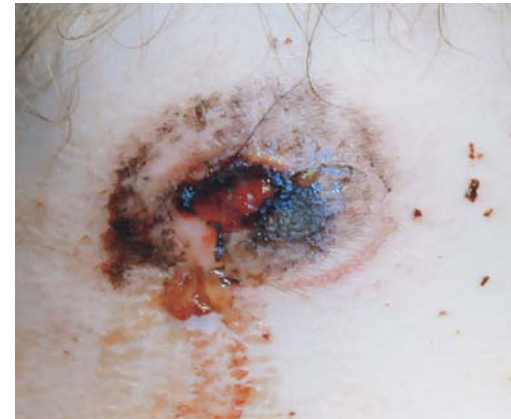

FIGURE 26-5 Submental entrance wound with powder burns characteristic of a suicide attempt by placing a gun under the chin.

Management

General Principles

On admission victims of gunshot injuries are best managed by standard advanced trauma life support (ATLS) protocols. Even seemingly innocuous wounds deserve attention, given the erratic nature of the wounds. Specific attention must be given to the possibility of multiple injuries; it is imperative to thoroughly inspect the patient for multiple entrance and exit wounds. Visually disturbing but nonlife-threatening facial gunshot injuries can distract medical personnel from other more subtle lethal injuries such as a penetrating thoracic wound that entered through the back. Ophthalmologic and neurosurgical consultations are obtained when indicated. Approximately 17% of patients with a GSW to the face have associated brain injuries, and 8% have associated C-spine injuries.^{12,28} Eye injuries are present in approximately 13% (Figure 26-6).²⁸ Certain considerations for gunshot injuries should be emphasized.

Airway

Loss of the airway is the single most likely cause of death in an isolated GSW to the face. When confronted with a patient with a facial GSW, surgeons should have a low

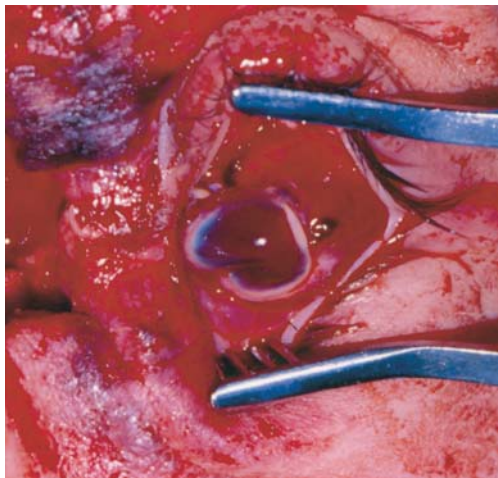


FIGURE 26-6 *Perforated globe with shotgun pellet.*

threshold for establishing a definitive airway through intubation or a surgical airway if intubation is not possible. Intubation either in the field or the emergency department is required in 25 to 36% of patients. Wounds involving the mandible have the highest rate of intubation (37–53%), followed by those of the mid-face (18–36%).^{28–31} Excluding patients that require airway control for associated brain injuries, Demetriades and colleagues found that 17.4% of patients required urgent airway control for facial injuries.¹² Gunshot injuries to the neck may result in tracheal damage and require an emergent

surgical airway (cricothyroidotomy). Intubation with fiber-optic assistance is possible, but paralytics should be avoided owing to the risk of expanding hematomas or massive edema. Cricothyroidotomy or an awake tracheostomy is more appropriate in this setting. The need to convert an intubated airway to a tracheostomy depends on several factors. Tracheostomy can make repair of injuries involving the mandible and midface easier. Patients who will require multiple return trips to the operating room for wound débridements and “second looks” will benefit from the decreased risk of multiple intubations. Delayed swelling can be anticipated with trauma to the upper aerodigestive tract including the tongue (Figure 26-7A); this may influence the decision to proceed with tracheostomy. Associated tracheal injuries are another indication for tracheostomy (Figure 26-7B). Lastly, multiple system injuries with anticipated long-term ventilation is an indication for early tracheostomy. Most experienced surgeons would agree that it is rare to regret having performed a tracheostomy, but tragic to regret not performing one.

Hemorrhage Control

Life-threatening hemorrhage is unusual in civilian gunshot injuries. Low-velocity

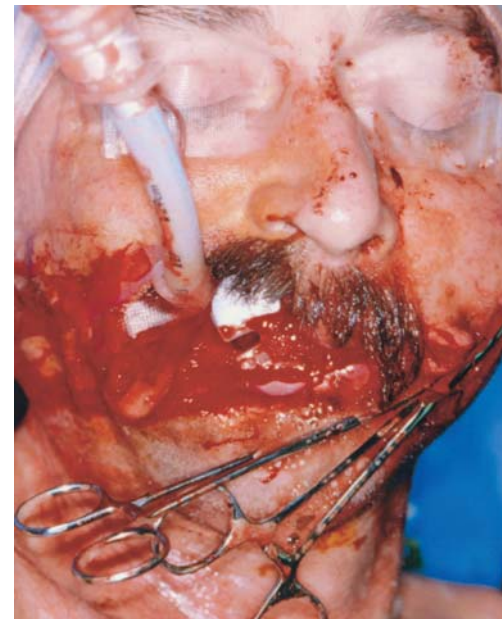
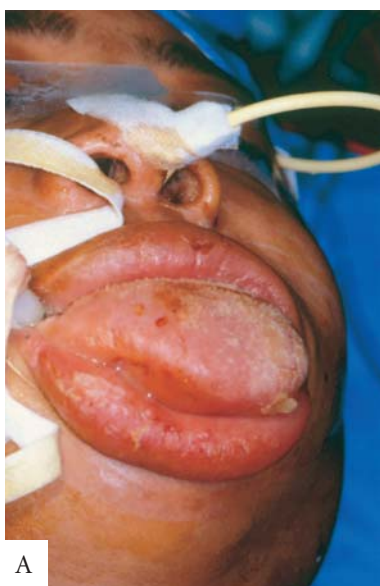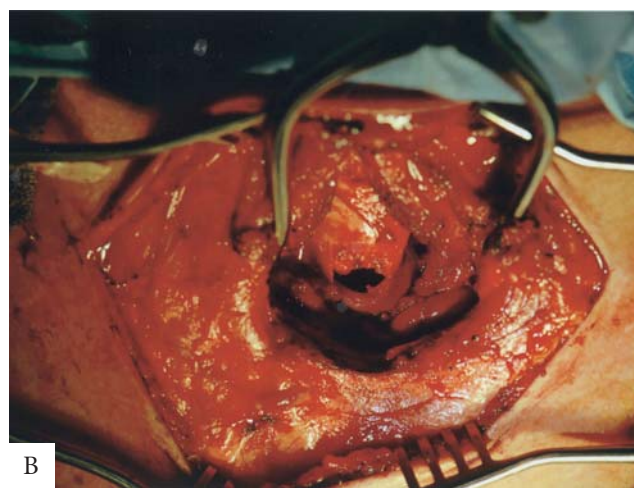


FIGURE 26-8 *Blind clamping in the emergency department management of a facial gunshot wound.*

handgun injuries typically do not involve the great vessels. Demetriades and colleagues in Los Angeles reported only 7.5% of patients with isolated gunshot wounds to the face to be in shock upon admission (systolic blood pressure < 90 mm Hg). In their report 70 patients (28.3% of the total) required angiography, and 10 of these required embolization.¹² Overall the literature reports angiography in 17 to 63% of patients with a GSW to the face, with positive findings in 15 to 51%. Indications for angiography include expanding hematoma and bleeding that persists despite local measures.^{29,32,33} The most commonly involved vessels in these cases were the maxillary and facial arteries. Gunshot injuries associated with high-velocity weapons or fractures, however, can result in significant blood loss. Initial attempts to control hemorrhage in the emergency department center on direct pressure and packing. Blind clamping should be avoided because of the attendant risk of damage to other structures (Figure 26-8). Standard methods for epistaxis control such as Foley catheters or specially designed balloon catheters will control most midface bleed-



A



B

FIGURE 26-7 *A, Massive late tongue edema. B, Tracheal injury from a gunshot wound. (Courtesy of Eric J. Dierks, MD, Portland, OR)*

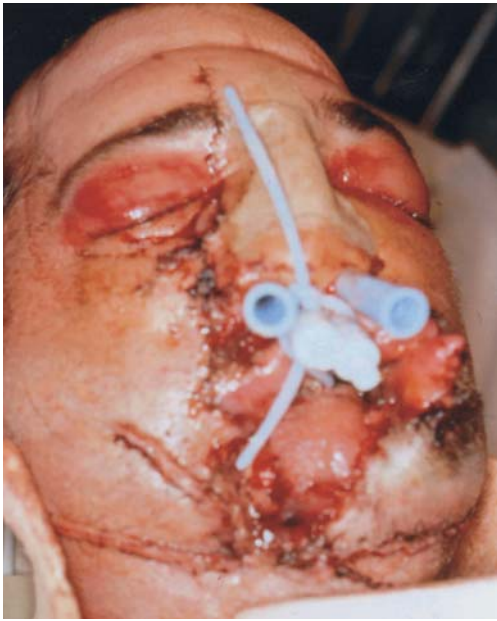

FIGURE 26-9 Nasal packing with anterior and posterior balloon catheters.

ing (Figure 26-9). In cases of mandible fractures, temporary reduction of the fracture may be required. Penetrating injuries can require that the surgeon make difficult choices. Injuries at the skull base may benefit from angiography and embolization (see “Penetrating Neck Injuries,” below). Unfortunately, the time necessary to mobilize the angiography suite often makes this an impossible choice for the unstable trauma patient in the middle of the night. For this reason, control of life-threatening hemorrhage is typically best performed in the operating room. Ligation of multiple vessels is required. “Tying off” the carotid is usually ineffectual and dangerous; an attempt should be made to control specific vessels. Lacerations of the internal jugular artery are best controlled with ligation or repair (Figure 26-10). Packing and reduction of fractures should be performed to control bleeding from the midface if possible. There is possibility of late pseudoaneurysm formation and delayed hemorrhage, and selective angiography should be performed as indicated. Additionally, the possibility of bullet or fragment embolization should be considered.

Penetrating Neck Injuries

Gunshot wounds involving the face may be associated with an entrance or exit wound in the neck, which is divided into three zones originally described by Monson and colleagues from Cook County Hospital³⁴:

- Zone I is most commonly defined as the area from the clavicles to the cricoid cartilage. It contains the inferior aspect of the trachea and esophagus along with the major vessels of the thoracic inlet: the common carotid arteries, thyrocervical trunk, internal jugular veins, brachiocephalic trunk,
- Zone II represents the area from the cricoid cartilage to the angle of the mandible. It contains the common carotid arteries, internal and external carotid arteries, internal jugular veins, larynx, hypopharynx, and cra-

subclavian arteries and veins, thoracic duct, thyroid gland, and spinal cord. Risk of injury to the great vessels is common in this area, and, consequently, injuries to zone I carry a high mortality rate (approximately 12%). Some authors place the junction of zones I and II at the cricoid cartilage, whereas others define it as being at the top of the clavicles.

- Zone II represents the area from the cricoid cartilage to the angle of the mandible. It contains the common carotid arteries, internal and external carotid arteries, internal jugular veins, larynx, hypopharynx, and cra-

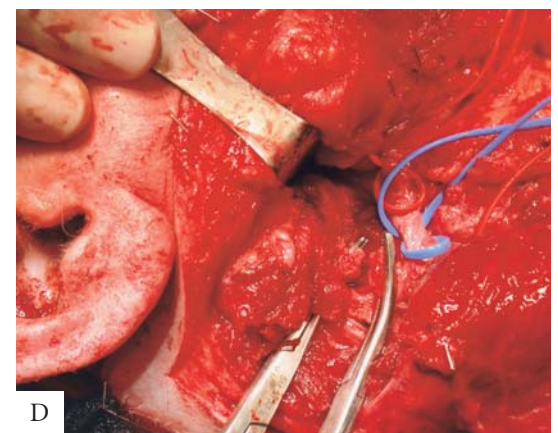
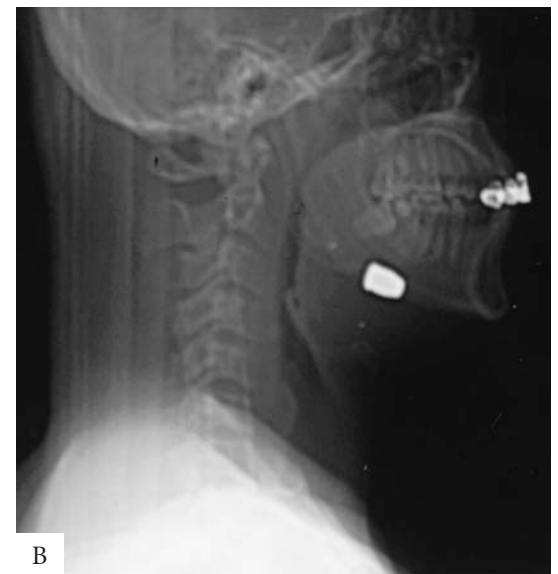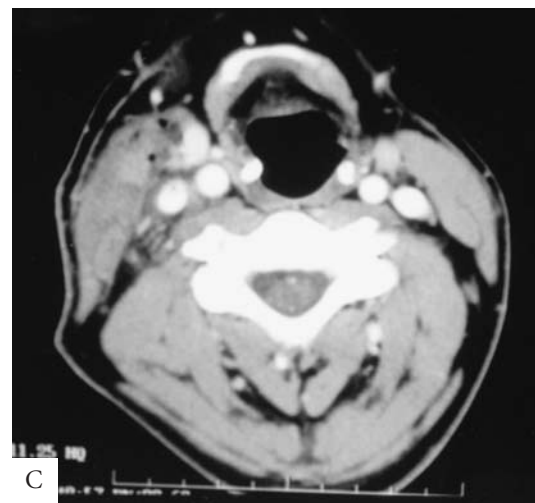

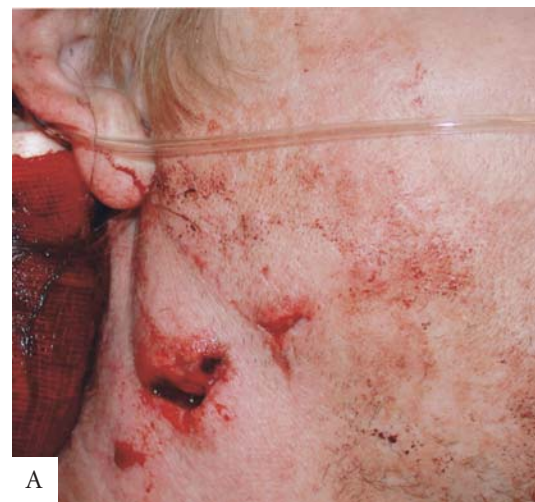
FIGURE 26-10 A, Gunshot wound to zone II associated with a mandible fracture. B, Plain film demonstrating the bullet in zone II. C, Computed tomographic angiography failing to demonstrate tamponaded laceration in internal jugular vein but showing subcutaneous air and edema of neck injury. D, Lacerated internal jugular vein (clamped) found on neck exploration.

nial nerves X, XI, and XII. It is the largest area and therefore the most commonly involved zone in penetrating neck trauma.

- Zone III spans the region from the skull base to the angle of the mandible. It contains the carotid arteries, the internal jugular veins, and the pharynx along with multiple cranial nerves exiting the skull base. It should be appreciated that gunshot wounds that involve mandibular fractures are accompanied by injuries to zone III.

Van As and colleagues reported on 116 patients shot in the neck in South Africa. Of these, 70 suffered a direct hit to the neck; in 46 patients the bullet traversed the face or chest first. Of the 116 patients 85 suffered some vascular injury, although most were minor branches, 61 had some injury to the airway, and 32 had an injury to the pharynx or esophagus.³⁵ Many patients had more than one injury. Management strategies for penetrating neck injuries are typically based on the zone(s) involved.^{36,37} Gunshot wounds to the head and neck frequently involve projectiles that traverse or involve more than one zone. For this reason, surgeons may have to modify management plans based on the situation at hand. Although a complete discussion of penetrating neck trauma is beyond the scope of this chapter, general principles should be understood by surgeons managing facial gunshot injuries.

Initially the patient's stability from an airway and hemodynamic status guides the decision-making for penetrating neck injuries (Figure 26-11). In the stable patient, a complete examination is part of the secondary survey of ATLS. Signs of tracheal injury, such as subcutaneous emphysema, stridor, hoarseness, dysphonia, or hemoptysis require urgent intervention. Hard signs of vascular injury, such as expanding hematoma, and pulse or neurologic deficit, also signal the need for urgent

management. In the absence of urgent management needs, the surgeon must rule out occult injuries based on the zones involved.

Injuries to zone I can be associated with significant bleeding because of the large vessels in this area. This is especially true with regard to injuries caused by high-energy weapons. Although serving to protect the vessels, the clavicles are a hindrance to the application of direct pressure to the area and to rapid surgical exposure. In the stable patient most surgeons advocate routine angiography and an evaluation of the esophagus via rigid esophagoscopy or a barium swallow. The choice between barium swallow and esophagoscopy varies according to the surgeon's preference as both are reasonably accurate at diagnosing injury (90% and 86%, respectively). In addition, there is some controversy regarding the appropriate contrast media. Although meglumine diatrizoate causes less inflammatory response than does barium when it extravasates into tissues owing to an esophageal perforation, it results in a severe chemical pneumonitis if aspirated. For this reason, barium should be used if there is any impairment to the gag and cough reflexes; if there is a leak, early operative intervention allows it to be washed out during surgery. Penetrating injuries to the left neck, and rarely to the right, can result in a chyle leak (Figure 26-12). The surgeon should take care to exclude this at the initial exploration, if possible, and to repair it by oversewing the duct with local tissues. It is useful to have the anesthesiologist apply positive pressure and to place the patient in Trendelenburg's position. Delayed management is much more difficult after the tissues have been exposed to chyle. Conservative management with a diet of medium-chain triglycerides, which are not carried by the gut lymphatics, and drainage should be attempted initially if the leak presents in the postoperative setting. Exploration is indicated for leaks of > 400 to 500 cc/d for a week.

Penetrating injuries to zone II are the most common and are most amenable to surgical exploration, if warranted. For asymptomatic patients, computed tomographic angiography is becoming an important tool for screening and can assist in determining whether operative exploration is warranted. Patients can undergo serial examinations over 24 hours if the angiography results are negative. Computed tomographic angiography is faster and less invasive than angiography but is of lower specificity. It should also be noted that injuries that have "tamponaded" themselves can be missed on either (see Figure 26-10C). Some surgeons recommend the use of a barium swallow or rigid esophagoscopy, whereas others recommend observation only if the index of suspicion for injury is low, as with wounds from low-energy guns. If patients have associated mandible fractures, the neck can be explored while the mandible fractures are exposed for fixation.

Imaging is required in zone III injuries if the patient is stable. Diagnosis of vascular injuries at the skull base typically requires angiography, which can also allow intervention if indicated. Injuries to zone III are rarely amenable to surgical intervention.

Overall, angiography remains the gold standard for exploration of vascular injuries of the neck. In Van As and colleagues' report, 89 patients underwent angiography for GSWs to the neck; results were positive in 12 patients, with most lesions occurring in the common carotid followed by the internal and external carotids (3 cases each), the vertebral artery (2 cases), and the subclavian artery (1 case).³⁵ Currently ultrasonography is gaining popularity as a rapid noninvasive technique for the evaluation of a variety of traumatic injuries in the emergency department. Ginzburg and colleagues evaluated the usefulness of duplex ultrasonography to evaluate vascular injuries in a double-blind study using angiography as a control. They reported a 100% true-negative rate, 100% sensitivity, and

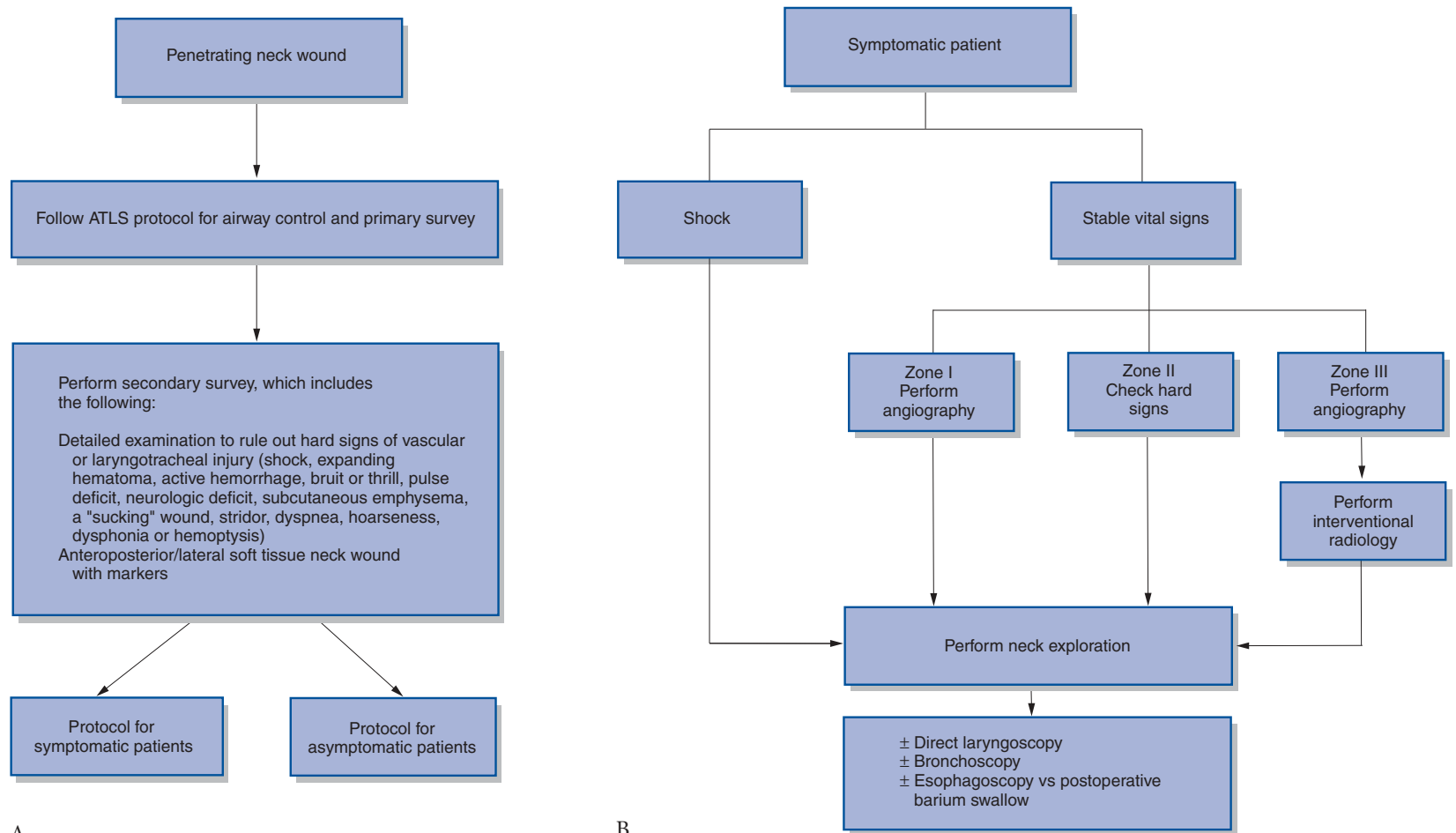


FIGURE 26-11 A, Initial decision tree for penetrating neck trauma. B, Management of the symptomatic patient with a penetrating neck wound. ATLS = advanced trauma life support.

85% specificity in detection of arterial injury. Ultrasonography will most likely continue to grow in popularity as a screening tool because of its cost and the speed at which it can be performed.³⁸ Further improvements in noninvasive vascular evaluation techniques, such as helical computed tomographic angiography and ultrasonography, will reduce the number of patients undergoing traditional angiography and improve patient selection for nonoperative management.

Nutrition

The majority of civilian gunshot wounds affect young healthy males. Nutritional status becomes an issue only in patients whose injuries preclude oral alimentation for an extended period (> 4 or 5 d). Feeding via nasogastric intubation allows

bypass of the oral cavity and improved hygiene in the early days following injury. Consideration should be given to percutaneous endoscopic gastrostomy if long-term bypass of the oral cavity is necessary, the patient will be unable to eat, or the patient has a preexisting nutritional deficit.

Imaging

Following the ATLS protocol, standard C-spine and chest radiographs should be obtained. These can be valuable for visualizing the bullet fragments and in gaining some insight into the path of the bullet (see Figure 26-10B). It is important to recall, however, that projectiles rarely follow a straight path once they enter tissue.

The ability to obtain accurate three-dimensional images in a rapid fashion has been one of the most important advances

in dealing with gunshot injuries to the face. Spiral computed tomography combined with three-dimensional reconstructions allows the surgeon an unparalleled view of

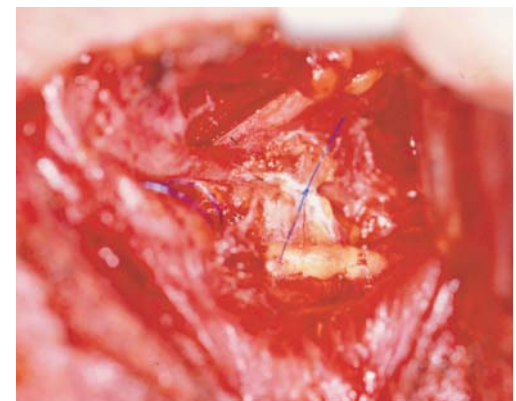


FIGURE 26-12 Chyle leak following penetrating injury to zone I of neck oversewn with nonabsorbable suture and covered with a flap from the sternocleidomastoid muscle.

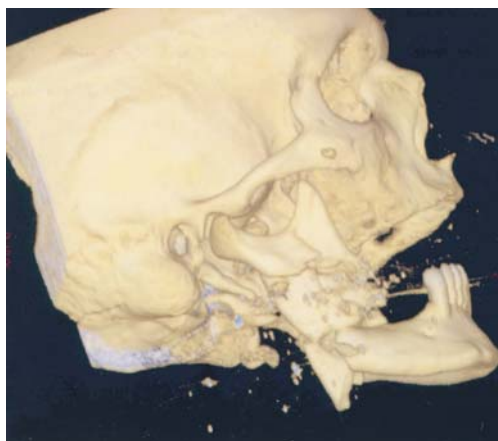

FIGURE 26-13 Three-dimensional computed tomography scan demonstrating fragmentation of the mandible resulting from a gunshot wound. (Courtesy of James R. Koehler, MD, Birmingham, AL)

the extent of damage to the maxillofacial skeleton, which lies beneath the skin (Figures 26-13 and 26-14). Although it does not accurately demonstrate the amount of soft tissue damage, clinical inspection combined with three-dimensional imaging allows an accurate assessment. As discussed

previously, the importance of temporary cavitation and emphasis on the amount of devitalized tissue distant from the primary wound has probably been overstated in the past. Computed tomographic angiography can also be useful in certain situations for evaluating vascular damage, especially in cases of penetrating neck injuries. It should be remembered, however, that angiography remains the gold standard to evaluate the vasculature. Also, angiography allows the ability to intervene with embolization of active bleeding vessels that are difficult to approach surgically (see “Penetrating Neck Injuries” above). Patients who are not sufficiently stable for imaging should be stabilized in the operating room, and definitive repair should be deferred until appropriate imaging can be obtained.

Operative Procedure

Paralleling the evolution of firearms has been development in the management of gunshot injuries to the head and neck. The earliest surgeons dealing with gunshot

injuries blamed complications on gunpowder that would later be ascribed to contamination and infections. The mystique that surrounded gunshot injuries persists in some ways to modern times in surgical dogma that is passed down. During World War I, high-energy close-range gunshot and shrapnel wounds to the face necessitated the development of maxillofacial surgery. Kazanjian and Converse described their approach to gunshot wounds as three phases consisting of initial débridement and suturing, immobilization of bony fragments with splints and ligatures, and, finally, reconstruction following healing of the soft tissue.³⁹ Many of the principles developed at that time persist today, with surgeons advocating a phased approach with delayed closure of wounds, débridement of tissue, and secondary reconstruction.⁴⁰ Many surgeons still advocate closed reduction and division of care into early (first 10 d), intermediate (10–60 d), and late (> 60 d) phases.²⁸ The different nature of civilian gunshot wounds and improved management techniques have led to a reappraisal of staged approaches, and current management principles should more properly be considered a continuum that is based on the wound and patient profile.^{11,41,42} The successful application of rigid fixation principles to blunt traumatic injuries resulted in incorporation of these techniques to gunshot injuries. Early surgeons understood the importance of immobilization on the healing of GSWs but lacked the ability to truly immobilize bony structures of the face. The development of rigid fixation techniques and their application to GSWs was an important advance. Early concerns regarding placement of hardware into contaminated sites proved unfounded. By allowing the early stabilization of bone segments, percolation of contaminated oral fluids was prevented, primary bone healing was made possible, and the effects of scar contracture were minimized. This has led most surgeons to advocate early definitive repair of the majority of civilian gunshot

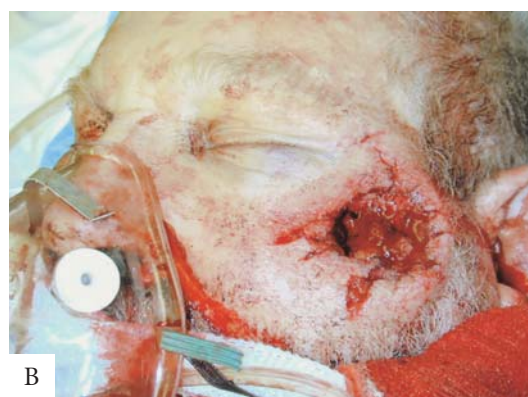
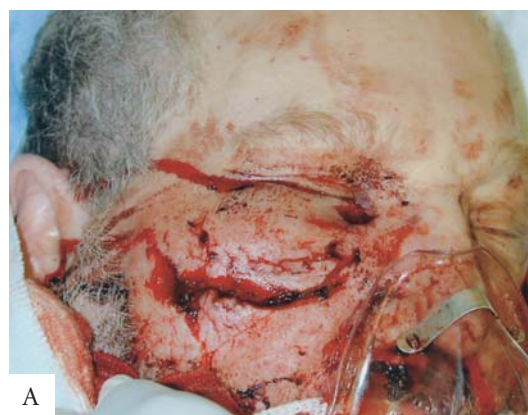
FIGURE 26-14 A, High-velocity entrance wound of the right cheek. B, High-velocity exit wound of left cheek. C, Three-dimensional computed tomography scan demonstrating extensive bony comminution associated with a high-velocity gunshot wound. (Courtesy of James R. Koehler, MD, Birmingham, AL)

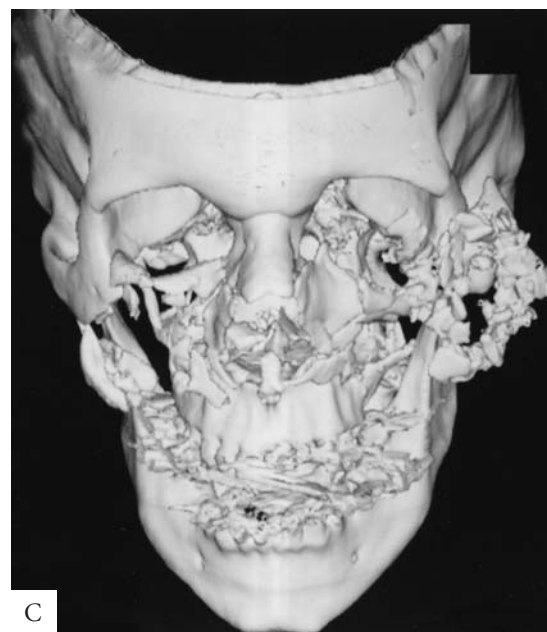

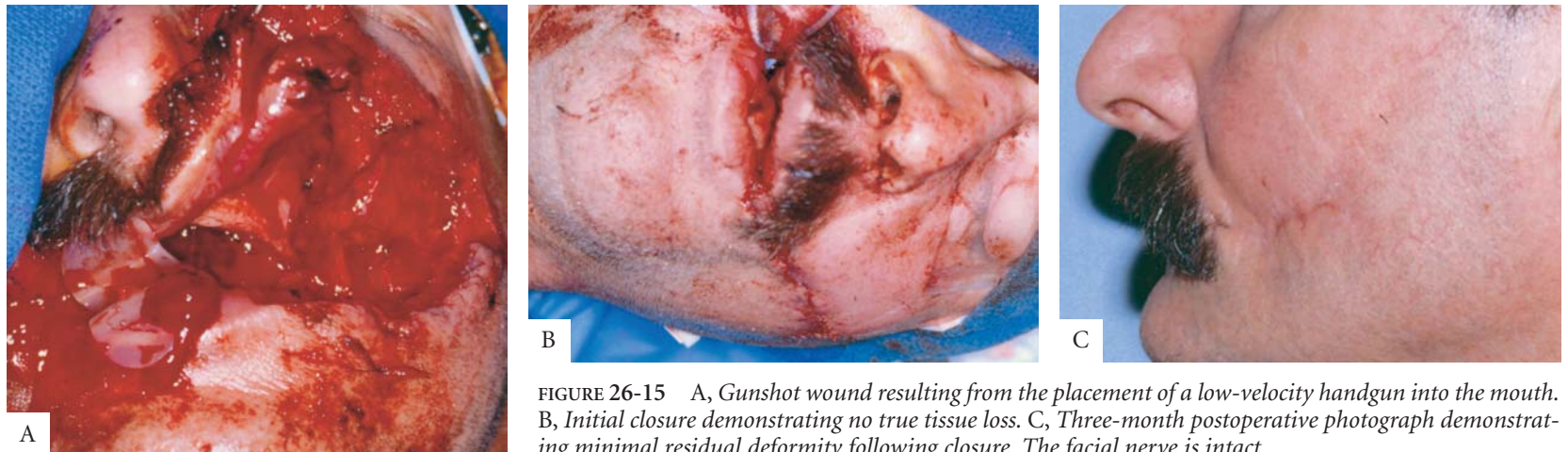


FIGURE 26-15 A, Gunshot wound resulting from the placement of a low-velocity handgun into the mouth. B, Initial closure demonstrating no true tissue loss. C, Three-month postoperative photograph demonstrating minimal residual deformity following closure. The facial nerve is intact.

wounds, which generally are inflicted with low-velocity weapons.

An operative plan for a gunshot injury to the face is best formulated after characterization of the wound as low or high energy (Figures 26-15 and 26-16). The surgeon facing a gunshot injury should consider the concept introduced by Manson for evaluation of four components: soft tissue injury, bone injury, soft tissues loss (true avulsion), and bone loss.⁴³ After evaluation of the wound, a decision is made regarding early definitive repair versus the need for delayed repair. The majority of civilian gunshot wounds resulting from assaults can be managed with early definitive repair because these injuries usually result in injury to the soft tissue and bone but rarely loss of these tissues. Impressive soft tissue injuries are usually not avulsive, and most can be closed primarily (see Figure 26-15). Extensive débridement of soft tissue is not indicated. Wound debris should be removed, and wounds should be lavaged with normal saline. Antibiotic solutions such as saline and bacitracin (50,000 U/L) have not been shown to be more effective than normal saline but are still popular. A pulsating irrigator is useful to mechanically agitate debris from the tissue. Obvious devitalized and loose teeth should be removed. Fractures are reduced and fixed rigidly. Otherwise, teeth should be maintained if possi-

ble to aid in restoration of occlusion and proper jaw relations. Drains are often indicated; whether closed suction or Penrose is used depends on the wound. Pressure dressings can also be used to minimize dead space. In cases of true soft tissue avulsion, a decision must be made regarding whether primary flaps or grafting is indicated. In wounds that are relatively clean, local flaps and skin grafts may be appropriate. In grossly contaminated wounds, delayed closure or grafting may be necessary. Closing mucosa to skin can be a useful technique, but many cases can be managed with dressing changes and incorporation of an early flap procedure. Free tissue transfer, although useful, should be delayed until the initial phase of wound healing, when its accompanying vascular spasm and attendant hypercoagulable state has decreased.

In wounds with extensive soft and hard tissue damage and true loss of soft and hard tissue, an approach using early stabilization of bone fragments with maxillomandibular fixation, external fixation, or internal fixation with reconstruction plates combined with conservative management of soft tissue is indicated. In this era of rigid internal fixation, the utility of maxillomandibular fixation should not be overlooked.^{12,28} In addition, external fixation devices are still useful in select cases. Second-look operations with conservative

wound washouts and débridement of only obviously dead tissue, which have gained popularity in orthopedics, have great utility in injuries to the maxillofacial skeleton. Second débridements should be performed 24 to 48 hours after the initial surgery. This allows for the maintenance of tissue considered “borderline,” which can be excised if it truly becomes devitalized. Skin grafts can be used as permanent or temporary replacement for missing tissue to reduce deformity from scar contrac-

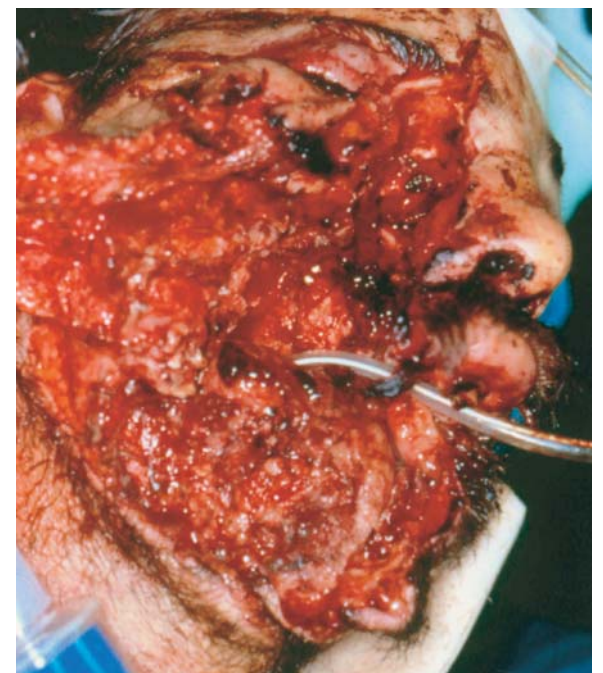


FIGURE 26-16 Extensive wound resulting from a high-velocity weapon.

ture. Once the soft tissues have stabilized, a decision can be made regarding early replacement of lost tissues with free tissue transfer or delayed reconstruction. In general, earlier repair leads to improved outcomes with less scar contracture and resultant deformity. Bone grafts at the time of initial surgery may be indicated in the midface (see below). Again, management strategies should be considered a continuum that is modified as necessary rather than strict distinct stages.

Contamination

It should be remembered that projectiles from firearms are not sterile. This fact is well known to those who have dipped their bullets in feces prior to assassination attempts but lost on clinicians who have taught that gunshot wounds are indeed sterile. The heat generated by the discharge of the propellant as well as the friction between the bullet and barrel is not sufficient to sterilize the bullet.^{44,45} Contamination can occur from the bullet and also from skin flora and foreign bodies (clothing) carried into the wound. Historically, streptococcal bacteremia was the most important cause of death on the battlefield in the preantibiotic era.⁴⁶ Wounds in which the bullet traverses the aerodigestive tract or paranasal sinuses are at particular risk. Devitalized tissue and vascular congestion leads to an ideal environment for bacterial growth. Prophylactic coverage with broad-spectrum antibiotics, typically a second-generation cephalosporin, and tetanus prophylaxis, when indicated, should be initiated in all gunshot wounds. Extensive surgical débridement is rarely indicated in wounds consistent with low-velocity projectiles to prevent infection.

Removal of projectiles, a well-worn tradition in Hollywood, is less commonly indicated in reality. The need for the removal of bullets must be balanced against the real risk of increasing damage. Lead toxicity is a rare complication that does not typically justify the routine

removal of bullet fragments.⁴⁷ Removal of intra-articular bullet fragments should be considered when the increased risk of lead toxicity is associated with fragments within joint spaces and the potential for long-term deterioration of the joint.⁴⁸ Finally, consideration may be given to the removal of brass- or copper-jacketed bullets that are in close proximity to central or major peripheral nerves because of potential neurotoxicity.^{49,50}

It is important to remember that bullet fragments are potential evidence and an appropriate chain of custody is required. Most hospitals have a protocol in place to ensure that this chain is unbroken from the time they are retrieved to when they are logged in as evidence. This usually involves a police officer or other designee taking direct possession of the bullet or fragments in the operating room or nearby. Documentation of injuries with photographs can aid in reconstructing the events leading to the injury and recording where fragments were retrieved. Since some assaults have injury patterns similar to suicides, it is important to consider this chain of custody because subsequent investigations may reveal that an apparent suicide was actually an assault.⁵¹

Specialized Structures

Facial Nerve

Damage to the facial nerve is present in only 3 to 6% of civilian GSWs to the face.^{12,28} This is most likely because low-energy weapons are involved in most of these cases. However, such damage is not uncommon in injuries inflicted by higher-velocity firearms. Careful documentation at the earliest possible opportunity is important. If a functioning nerve becomes nonfunctional secondary to swelling, the surgeon can be reasonably confident that function will return. Obvious transection of the nerve requires repair. In heavily contaminated wounds, repair should be delayed for 48 to 72 hours, given the pos-

sibility that grafts will be required to span damaged segments. Beyond 72 hours distal branches of the facial nerve will not respond to a nerve stimulator, making their identification difficult. If possible, tagging the branches with suture at the initial surgery is invaluable. Extensive damage to the proximal nerve may require a temporal bone dissection to identify a viable proximal nerve for grafting. Injuries distal to a line dropped vertically from the lateral canthus (zone of arborization) do not typically require repair because of the multiple interconnections distal to this line and the reasonable expectation of return of function, even if the nerve is temporarily nonfunctioning (see Figure 26-15).

Salivary Ducts

Transected salivary ducts may be repaired or ligated depending on the amount of damage. The parotid duct can be repaired over an intravenous catheter or polymeric silicone tubing, which is then sutured to the buccal mucosa. It is best to avoid bringing the tubing out of the mouth because of the tendency for it to be dislodged. In injuries that penetrate the parotid-masseteric fascia, there is a potential for development of a sialocele or fistula. These typically resolve with drainage and pressure dressings. Aspiration may be required multiple times, and, rarely, anti-sialagogues may be indicated. In addition, removal of any associated foreign bodies may be necessary to resolve the fistula and hasten healing. Dermal grafts can be used at the time of repair (Figure 26-17).

Controversies: Delayed versus Early Management and Closed versus Open Fracture Management

Proponents exist both for closed management of fractures with delayed reconstruction as well as aggressive early management with open reduction of fractures and replacement of missing tissue as soon as

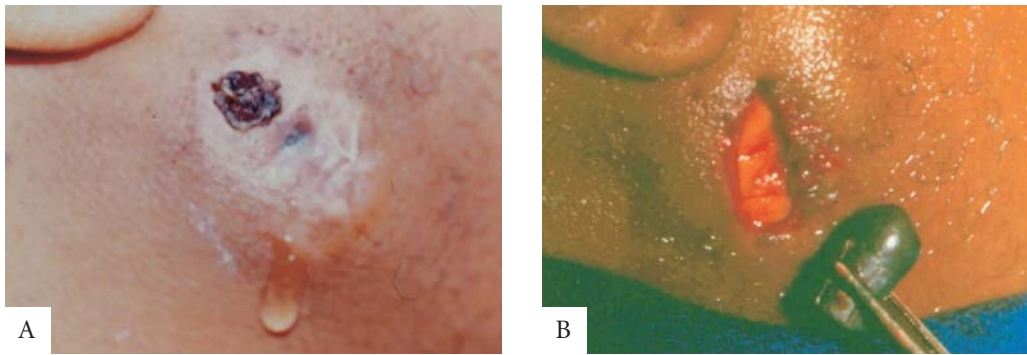
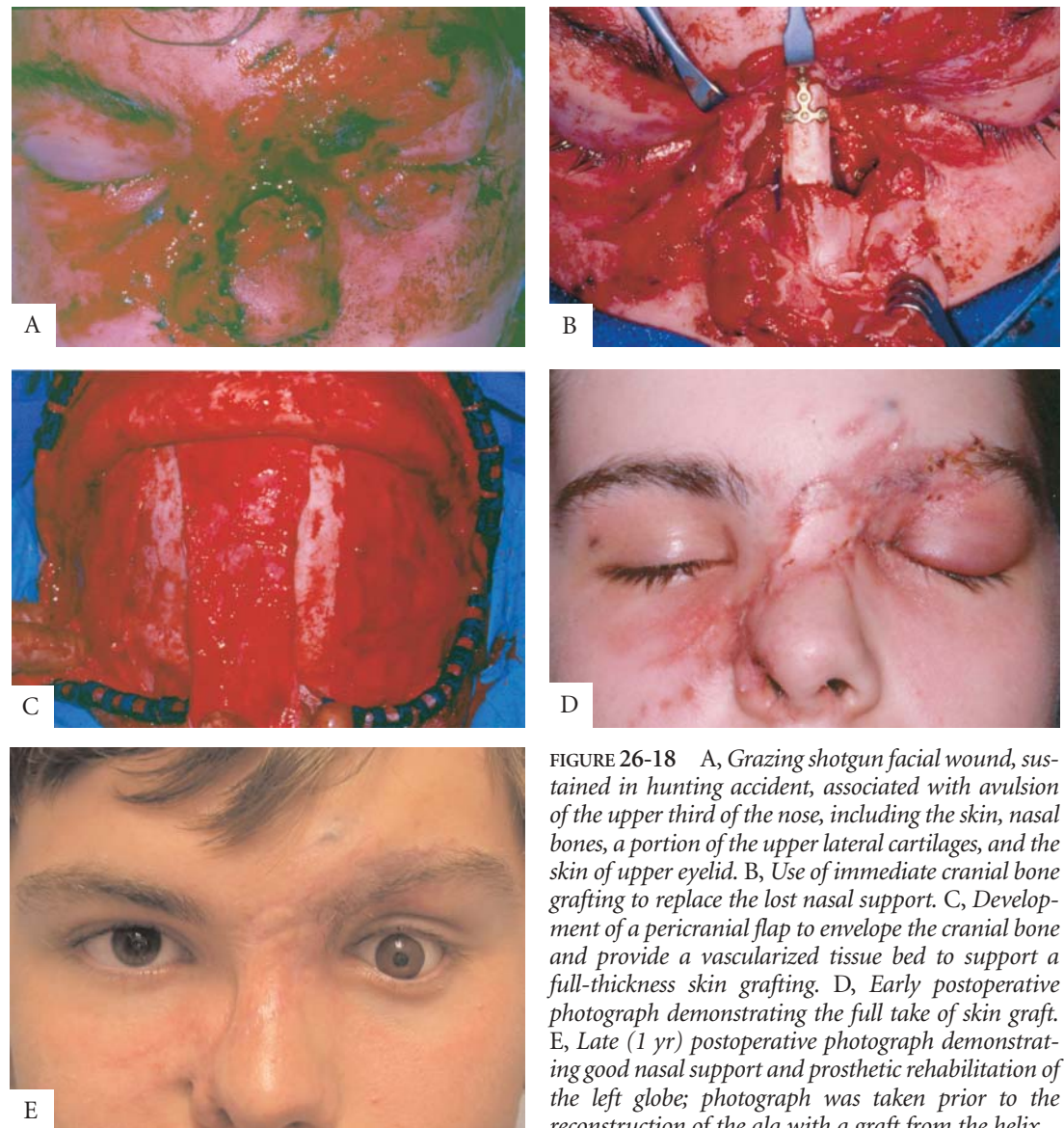


FIGURE 26-17 A, Salivary-cutaneous fistula associated with a retained bullet fragment. B, The bullet was removed and a dermal graft was placed.

possible. Both groups point to failures and shortcomings of the other to justify their approach. Advocates of delayed repair point to a higher incidence of infection and to benefits of closed treatment, whereas those advocating more aggressive management report improved functional and esthetic outcomes.^{52,53} Since neither approach is likely to ever be subjected to a randomized trial measuring outcomes, surgeons must base their treatment decisions on a critical review of the literature and their own experience. As with most arguments in surgical science, the truth most likely lies somewhere in the middle. Certainly the advantages of aggressive early management are appealing (Figure 26-18). Early return to function and decreased numbers of revision surgeries are laudable goals. Currently techniques involving open reduction and fixation of fractures resulting from GSWs seem to be gaining in popularity, and patients are less likely to be treated with closed reduction. Given that most of these injuries are low energy, this is acceptable. The main disadvantage of open reduction is infection, which primarily affects the mandible. The reported rate of infection with open reduction and fixation of mandible fractures resulting from a gunshot is around 16 to 17%.⁵⁴ However, rigid fixation can frequently be maintained in the event of wound problems and still serves to stabilize mandibular segments. Surgeons should avoid the application of a set protocol to every GSW situation and

should instead rely on a careful appraisal of the wound and decide on the amount of early repair that is indicated.



Bone Grafting

Bone grafts are frequently required in the management of GSWs to the face, whether for replacement of true loss of bone (avulsive injuries) or in cases in which comminuted and misplaced fragments need to be replaced or reinforced. Reconstruction with bone grafts gained popularity in World War I, and much of what we know about the healing of free bone grafts was learned following their introduction for late reconstruction of gunshot injuries in wartime. Iliac bone grafts were popular for late reconstruction. Surgical dogma was against early or

FIGURE 26-18 A, Grazing shotgun facial wound, sustained in hunting accident, associated with avulsion of the upper third of the nose, including the skin, nasal bones, a portion of the upper lateral cartilages, and the skin of upper eyelid. B, Use of immediate cranial bone grafting to replace the lost nasal support. C, Development of a pericranial flap to envelope the cranial bone and provide a vascularized tissue bed to support a full-thickness skin grafting. D, Early postoperative photograph demonstrating the full take of skin graft. E, Late (1 yr) postoperative photograph demonstrating good nasal support and prosthetic rehabilitation of the left globe; photograph was taken prior to the reconstruction of the ala with a graft from the helix.

primary bone grafting and stipulated waiting until soft tissue healing had occurred. More recently the use of bone grafts in the early setting has gained popularity. Gruss and colleagues have published extensively on their success with early bone grafting to stabilize and support soft tissues, and to decrease scar contracture and distortion.⁵⁵ The use of cranial bone in blunt injuries was extended to include GSWs with some success. Currently many surgeons advocate the use of primary bone grafting in the midface. Some surgeons also advocate immediate bone grafting of mandible defects.⁵⁶ Most agree, however, that delayed grafting of discontinuity defects of the mandible is still indicated because of the high risk of exposure and loss of bone grafts in this site, and that immediate grafting in the mandible should be avoided.^{11,52} Clark and colleagues reported a 35% incidence of wound complications in patients undergoing immediate reconstruction of significantly comminuted mandible fractures resulting from GSWs. Conversely, primary bone grafting was uniformly successful in the cranium and midface.¹¹ Rigid fixation maintains the mandibular segments. Even if the titanium plate becomes exposed, wound care will allow it to be maintained until definitive reconstruction.^{43,55} In summary, primary bone grafting in the early phase of gunshot wound management can be useful, but it should be limited to the upper and midface. Maintenance of mandibular segments with rigid reconstruction plates combined with delayed grafting or free flap reconstruction offers a predictable result, and in most cases primary grafting of the mandible is not indicated.

Late Reconstruction

Delayed bone reconstructions frequently suffer from a scarred hypovascular environment that does not support the graft. In addition, there is typically a deficiency in soft tissue that becomes more pro-

nounced when wounds are opened. In these cases vascularized tissue transfer offers the ability to import soft tissue and/or bone into the site. As noted previously, free tissue transfer is usually delayed until after the acute setting to decrease the incidence of flap loss secondary to clotting of the vascular pedicle. Preoperative angiography often is beneficial to identify appropriate vessels in the neck. Vascularized bone grafts can support osseointegrated implants to complete the reconstruction. Anthony and colleagues reported on the use of the fibula in patients in whom previous reconstructive attempts for gunshot injuries had failed.⁵⁷ Both cases involved secondary reconstructions. Some surgeons have advocated delayed reconstruction in gunshot wounds that resulted from suicide attempts because of the potential for repeat suicide attempts, arguing that there is a high rate of recidivism and that patients should be stabilized psychologically for some period of time prior to undertaking an extensive (and expensive) reconstructive effort. However, Cusick and colleagues found an incidence of only 8% confirmed mortality in the follow-up of 91 patients who had attempted suicide.⁵⁸ All were patients who had long-standing chronic mental illness. De Leo and colleagues found a higher rate in an elderly European population. In a 1-year follow-up, they found 24% had attempted suicide again, with approximately half being successful in their second attempt.⁵⁹ With modern techniques, however, primary reconstruction has become more attractive in most patients who have self-inflicted gunshot wounds.^{1,60} It should be noted, however, that some authors still recommend delayed reconstructive efforts. Siberchicot and colleagues reviewed 165 patients with self-inflicted gunshot injuries between 1982 and 1996 and suggested that delayed definitive reconstruction was more likely to achieve satisfactory results in appearance and function.⁵³

Conclusions

The development of firearms heralded a new era in surgery as well as warfare. Evolution of more efficient weapons continues to force surgeons to improve techniques. Similarly, improvement in the management of GSWs to the face has paralleled the advancement of oral and maxillofacial surgery. Advances by Varaztad Kazanjian, the “miracle man of the Western front” during World War I, continued through the wars of the twentieth century. Improvements in casualty management and triage in the Korean and Vietnam conflicts led to increased survival of those with devastating facial injuries. Techniques and skills developed by oral and maxillofacial surgeons in the management of these injuries translated directly to other areas such as bone grafting, and promoted the growth and expanding scope of the specialty. These efforts are continued today in urban trauma centers dealing with gunshot injuries to the face. Improvements in imaging and fixation techniques have resulted in an evolution in management, with an emphasis on earlier repair and a focus on improvement in quality of life.

Acknowledgment

Special thanks to David H. Holmes, DDS, for his assistance and guidance with the section on ballistic science.

References

1. Ellis H. The surgery of warfare. In: A history of surgery. London: Greenwich Medical Media Limited; 2001. p. 125–50.
2. Burney RE, Maio RF, Maynard F, Karunas R. Incidence, characteristics, and outcome of spinal cord injury at trauma centers in North America. *Arch Surg* 1993;128:596–9.
3. Fingerhut LA, Christoffel KK. Firearm related death and injury among children and adolescents. *Future Child* 2002;12:24–37.
4. Goetsch KE, Annest JJ, Mercy JA, et al. Surveillance for fatal and nonfatal firearm related injuries: United States, 1993–1998. *MMWR Morb Mortal Wkly Rep* 2001;50:1–34.
5. Barber C, Hemenway D, Hochstadt J, Azrael D.

- Underestimates of unintentional firearm fatalities: comparing supplementary homicide report data with the National Vital Statistics System. *Inj Prev* 2002; 8:252–6.
6. Mercy JA, Ikeda R, Powell KE. Firearm related injury surveillance. An overview of progress and the challenges ahead. *Am J Prev Med* 1998;15:6–16.
 7. Patton JH, Woodward AM. Urban trauma centers: not quite dead yet. *Am Surg* 2002; 68:319–22.
 8. Wintemute GJ. Firearms as a cause of death in the United States, 1970–1982. *J Trauma* 1987;27:532–6.
 9. Miller M, Azrael D, Hemenway D. Rates of household firearm ownership and homicide rates across US regions and states, 1988–1997. *Am J Public Health* 2002;92:1988–93.
 10. Bostman O, Marttinen E, Makitie I, Tikka S. Firearm injuries in Finland 1985–1989. *Ann Chir Gynaecol Suppl* 1993;82:47–9.
 11. Clark N, Birely B, Manson PN, Slezak S. High-energy ballistic and avulsive facial injuries: classification, patterns and an algorithm for primary reconstruction. *Plast Reconstr Surg* 1996;98:583–601.
 12. Demetriades D, Chahwan S, Gomez H, et al. Initial evaluation and management of gunshot wounds to the face. *J Trauma* 1998;45:39–41.
 13. Cook PJ, Lawrence BA, Ludwig J, Miller TR. The medical costs of gunshot wounds injuries in the United States. *JAMA* 1999;282:447–54.
 14. Belkin M. Wound ballistics. *Prog Surg* 1978; 16:7–24.
 15. Lindsey D. The idolatry of velocity, or lies, damn lies, and ballistics. *J Trauma* 1980; 20:1068–9.
 16. Fackler ML. What's wrong with wound ballistic literature and why. Letterman Army Institute of Research Report; 1987. Report No.: 239. *J Internl Wound Ballistics Assoc* 2001;5(1):37–42.
 17. Goddard S. Some issues for consideration in choosing between 9 mm and .45 ACP handguns. Presented to the FBI Academy, Columbus (OH): Battelle Labs, Ballistic Sciences, Ordnance Systems and Technology Section; 1988. <http://www.firearms-tactical.com/hwfe.htm> (accessed Oct 25, 2003).
 18. Demuth WE, Nicholas GG, Munger BL. Buckshot wounds. *J Trauma* 1976;18:53–7.
 19. Osborne TE, Bays RA. Pathophysiology and management of gunshot wounds to the face. In: Fonseca RJ, Walker RV, editors. *Oral and maxillofacial trauma*. Vol 2. Philadelphia: WB Saunders; 1991. p. 672–701.
 20. Farr AK, Fekrat S. Eye injuries associated with paintball guns. *Int Ophthalmol* 1998–1999; 22:169–73.
 21. Mahajna A, Aboud N, Harbaji I, et al. Blunt and penetrating injuries caused by rubber bullets during the Israeli-Arab conflict in October, 2000: a retrospective study. *Lancet* 2002;359:1795–800.
 22. Rowley DI. The management of war wounds involving bone. *J Bone Joint Surg* 1996; 78B:706–9.
 23. Gugala Z, Lindsey R. Classification of gunshot injuries in civilians. *Clin Orthop* 2003; 408:65–81.
 24. Sherman RT, Parrish RA. Management of shotgun injuries: a review of 152 cases. *J Trauma* 1963;3:76–85.
 25. Ordog GJ, Wasserberg J, Balasubramanian S. Shotgun wound ballistics. *J Trauma* 1988; 28:624–31.
 26. Glezer JA, Minard G, Croce MA, et al. Shotgun wounds to the abdomen. *Am J Surg* 1993; 59:129–32.
 27. Henriksson TG. Close range blasts toward the maxillofacial region in attempted suicide. *Scand J Plast Reconstr Surg Hand Surg* 1990;24:81–6.
 28. Kihitir T, Ivatury RR, Simon RJ, et al. Early management of civilian gunshot wounds to the face. *J Trauma* 1993;35:569–77.
 29. Dolin J, Scalea T, Mannor L, et al. The management of gunshot wounds to the face. *J Trauma* 1992;33:508–14.
 30. Cole RD, Browne JD, Phipps CD. Gunshot wounds to the mandible and midface: evaluation, treatment, and avoidance of complications. *Otolaryngol Head Neck Surg* 1994;111:739–45.
 31. Chen AY, Stewart MG, Raup G. Penetrating injuries to the face. *Otolaryngol Head Neck Surg* 1996;115:464–70.
 32. Yao ST, Vanecko RM, Corley RD, et al. Gunshot wounds of the face. *J Trauma* 1972;12:523–8.
 33. May M, Cutchavaree A, Chadaratana P. Mandibular fractures from gunshot wounds: a study of 20 cases. *Laryngoscope* 1973;83:369–73.
 34. Monson DO, Saletta JD, Freeark RJ. Carotid vertebral trauma. *J Trauma* 1969;9:987–99.
 35. Van As AB, van Deurzen DF, Verleisdonk EJ. Gunshots to the neck: selective angiography as part of conservative management. *Injury* 2002;33:453–6.
 36. Holmes JD, Koehler JR. Management of penetrating neck trauma: current practices and report of a case. *J Oral Maxillofac Surg* 2003. [Submitted]
 37. Biff WL, Moore EE, Rehse DH, et al. Selective management of penetrating neck trauma based on cervical level of injury. *Am J Surg* 1997;174:678–82.
 38. Ginzburg E, Montalvo B, LeBlang S, et al. The use of duplex ultrasonography in penetrating neck trauma. *Arch Surg* 1996;131:691–3.
 39. Kazanjian VH, Converse JM. Gunshot wounds. In: *The surgical treatment of facial injuries*. Baltimore: Williams and Wilkins; 1949. p. 78.
 40. Broadbent TR, Wolf RM. Gunshot wounds of the face: initial care. *J Trauma* 1972; 12:229–33.
 41. Hallock GG. Self-inflicted gunshot wounds of the lower half of the face; the evolution toward early reconstruction. *J Craniomaxillofac Trauma* 1995;1:50–5.
 42. Haug RH. Gunshot wounds to the head and neck. In: Kelly JP, Piecuch JF, Assael LA, editors. *Oral and maxillofacial surgery knowledge update*. Vol 1, Pt II. Chicago: American Association of Oral and Maxillofacial Surgeons; 1995. p. 65–82.
 43. Thorne CH. Gunshot wounds to the face: current concepts. *Advances in craniomaxillofacial fracture management*. *Clin Plast Surg* 1992;19:233–44.
 44. Thoresby FP, Darlow HM. The mechanisms of primary infection of bullet wounds. *Br J Surg* 1967;54:359–61.
 45. Wolf AW, Benson DR, Shoji H, et al. Autosterilization in low-velocity bullets. *J Trauma* 1978;18:63–7.
 46. Ireland MW, Callender GR, Coupal JF. *The Medical Department of the US Army in World War I*. Washington: US Government Printing Office; 1929.
 47. Selbst SM, Henritig F, Fee MA, et al. Lead poisoning in a child with a gunshot wound. *Pediatrics* 1986;3:413–6.
 48. Kent JN, Neary JP, Silvia C, Zide MF. Open reduction of fractured mandibular condyles. *Oral Maxillofac Surg Clin North Am* 1990;2:69–102.
 49. Messer HD, Cerza PF. Copper jacketed bullets in the central nervous system. *Neuroradiology* 1976;12:121–9.
 50. Sherman IJ. Brass foreign body in the brain system. *J Neurosurg* 1960;17:483–5.
 51. Azmak D, Altun G, Koc S, et al. Intra- and perioral shooting fatalities. *Forensic Sci Int* 1999;101:217–27.
 52. Deveci M, Sengenzler M, Selmanpakoglu M. Reconstruction of gunshot wounds of the face. *Gazi Med J* 1998;9:47–56.
 53. Siberchicot F, Pinsolle J, Majoufre C, et al. Gunshot injuries of the face. Analysis of 165 cases and reevaluation of the primary treatment. *Ann Chir Plast Esthet* 1998;43:132–40.
 54. Neupert EA, Boyd SB. Retrospective analysis of

- low-velocity gunshot wounds of the mandible. *Oral Surg Oral Med Oral Pathol* 1991;72:383–97.
55. Gruss JS, Mackinnon SE, Kassell EE, Copper PW. The role of primary bone grafting in complex craniomaxillofacial trauma. *Plast Reconstr Surg* 1985;15:17–24.
56. Dufresne CR. The use of immediate grafting in facial fracture management: indications and clinical considerations. *Clin Plast Surg* 1992;19:207–17.
57. Anthony JP, Foster RD, Pogrel MA. The free fibula bone graft for salvaging failed mandibular reconstructions. *J Oral Maxillofac Surg* 1997;55:1417–21.
58. Cusick TE, Chang FC, Woodson TL, Helmer SD. Is resuscitation after traumatic suicide attempt a futile effort? A five year review at a level I trauma center. *Am J Surg* 1999; 65:643–6.
59. De Leo D, Padoani W, Lonnqvist K, et al. Repetition of suicidal behaviour in elderly Europeans: a prospective longitudinal study. *J Affect Disord* 2002;72:291–5.
60. Suominen E, Tukianen E. Close range shotgun and rifle injuries to the face. Head and neck reconstruction. *Clin Plast Surg* 2001;28:323–37.

Pediatric Craniomaxillofacial Fracture Management

Jeffrey C. Posnick, DMD, MD

Bernard J. Costello, DMD, MD

Paul S. Tiwana, DDS, MD, MS

Historic Perspectives

The management of craniomaxillofacial trauma, and the treatment of facial fractures in children in particular, has evolved gradually. A review of the historic landmarks in its treatment is important for understanding what has yet to be accomplished.

At the turn of the century Rene Le Fort was the first to document a tendency for the occurrence of specific patterns of midface fractures after direct facial trauma.¹ Within a few years thousands of combined soft and hard tissue facial injuries resulted from the trench warfare of World War I and required urgent treatment and secondary reconstruction. Two physicians in particular, V.H. Kazanjian and H. Gillies, stand out for their work during this period.^{2,3} During and after World War I and again during World War II, these men laid the foundation for what we now know as craniomaxillofacial surgery. Rowe and Killey, Dingman and Natvig, and others refined the basic principles laid down by their mentors, set out to educate their peers, and brought these treatment principles to the civilian population after the two world wars.^{4,5} At the same time, the use of antibiotics and improved airway and metabolic management of the trauma patient increased survival rates.⁶

The extensive surgical procedures that were often required to improve the quality of life of the multiply traumatized patient also became a reality.

Knowledge of the successful repair of traumatic facial injuries brought hope to people with congenital facial deformities. Gillies and Harrison pioneered the elective (extracranial) total midface advancement (Le Fort III osteotomy) for Crouzon syndrome.³ In 1967 Tessier described a cranial base approach to the management of skeletal deformities associated with Crouzon syndrome and Apert syndrome. His landmark presentation and publications were the beginning of modern craniofacial surgery. In 1968, Hans Luhr, a young maxillofacial surgeon, proposed that miniature (metal) bone plates and screws could be constructed and used effectively to fixate a mandibular fracture together for improved healing.⁷ Despite his enthusiasm these concepts of internal fixation for the craniomaxillofacial skeleton were not put into wide practice until the mid-1980s.

The concept of a hospital-based civilian trauma service that functioned 24 hours a day, 7 days a week, coupled with immediate “in-the-field” emergency recon-

struction of the trauma patient followed by rapid transport to the trauma center, was pioneered by R.A. Cowley with the development of the University of Maryland’s shock trauma center.⁸ This concept of accurate and rapid verification of injuries by the trauma surgeon, combined with well-trained and immediately available surgical subspecialists, hospital support staff, and technology, led to remarkable patient recoveries in otherwise hopeless situations.

The importance of managing the facial injuries of the multiple-trauma patient became evident early in the trauma center’s experience. Following the basic philosophy of total patient rehabilitation, Gruss and colleagues in Canada and Manson and colleagues in the United States developed new concepts for the management of craniomaxillofacial trauma.^{9–13} Their basic approach incorporated the early accurate preoperative diagnosis of all skeletal injuries by clinical examination with verification using computed tomography (CT) scanning techniques, wide (direct) surgical exposure of all fractures for open reduction of displaced and mobile segments, use of stable internal fixation techniques (plates and screws), and primary autogenous bone

grafting to replace missing or irreversibly damaged skeletal units. The rapid dissemination of their concepts and basic clinical approach to everyday surgical practice around the world is a tribute to Gruss and Manson, who remain dedicated to the highest standards of clinical care, research, and education.

Children with facial injuries have not benefited equally from this rapid refinement in the management of facial trauma in adults. In 1943 Waldron and colleagues were the first to bring to the maxillofacial surgeon's attention the often unique facial injuries in the traumatized child.¹⁴ MacLennan, and then Rowe, wrote about the rarity of facial fractures in children and suggested a basic approach with a philosophy toward conservatism.^{15,16} Other published articles have also tended toward conservatism, with only limited incorporation of the principles described earlier by Gruss and Manson.¹⁷⁻³⁹ Only recently have the distinct advantages of accurate primary repair and the stable fixation of facial fractures been applied to the rehabilitation of injuries in children.⁴⁰⁻⁴⁷ Also, resorbable materials have been made available as a fixation option for pediatric craniomaxillofacial fracture management.

Special Considerations in Children

The general principles for resuscitating multiply injured patients follow the advanced trauma life-support principles created by the American College of Surgeons.⁴⁸ This systematic approach to trauma in adult patients has been modified for the management of trauma in the child, taking into account several critical differences:

- Children frequently swallow air when they are injured or frightened, resulting in gastric dilatation. This may be a source of confusion when evaluating the patient to rule out an acute abdomen.
- Abdominal girth and the volume of the peritoneal cavity in infants and young children are relatively small. Significant intra-abdominal bleeding results in a rapid change in girth.
- Children may maintain a normal or borderline blood pressure level despite significant fluid loss and then decompensate rapidly.
- Children have a larger body surface area-to-overall mass ratio than adults and are therefore more prone to hypothermia.

Children are generally injured in low-velocity accidents secondary to falls from low heights, playground equipment, or riding toys. Most commonly they arrive at the emergency room in a state of hemodynamic stability. With regard to the frequency of organs injured, the kidney is the solid organ that is the most frequently injured, followed by the spleen, liver, and pancreas. Hollow viscus perforations are much less common compared with adult injury patterns. In contrast nonaccidental trauma is more insidious and devastating. The pattern of organs injured, especially in the toddler, is the reverse of that seen in accidental trauma. With child abuse the history is often vague and inconsistent.^{49,50} A history of prior injuries and hollow viscus perforation is common.

Airway management in children with facial trauma has undergone significant change. With the widespread use of soft endotracheal tubes in the 1960s, the number of tracheostomies carried out for perioperative airway management decreased.^{51,52} Use of fiberoptic laryngoscopy has further decreased the incidence of tracheostomy for acute airway management in the pediatric trauma patient. Kaban and Posnick and colleagues reported no tracheostomies for airway management in their series con-

sisting of 262 and 137 pediatric facial trauma patients, respectively.^{30,53} Also cervical spine injuries are exceedingly rare.^{30,53,54}

Anatomic Considerations

Maxillofacial injuries are much less common in younger children than in adolescents and adults. This lower incidence of facial trauma in infants and young children is a result of socioenvironmental, general physical, and craniomaxillofacial anatomic factors.^{55,56}

Before the age of 5 years most children live a relatively protected existence, with close adult supervision, strict limitations on their physical environment, and constant safeguards to limit injury. Although falls from limited heights are frequent the momentum gained by the child's small body is of a low velocity. These low-impact forces can usually be absorbed by their well-padded skin, elastic skeleton, and cartilaginous growth centers.

After the age of 5 to 7 years, rapid progression of neuromotor development results in a general desire for independent activity, more frequent social interactions with other children, and a wider range of activities outside of the house, with less stringent parental and adult supervision. These factors result in increased opportunity for direct facial trauma. Additionally, increasing numbers of automobiles on the road and participation in pedestrian activities in public areas result in competition for space with motorized vehicles.

Ongoing craniomaxillofacial growth results in a changing anatomy (Figure 27-1).⁵⁷ For the first several years of life the cranium follows the rapid pace of brain growth and results in a relatively large and prominent forehead. The ocular globes and orbits also develop rapidly early in life and join the forehead in their relative prominence early in life. This early period of life is marked by a lack of paranasal sinus and dental development, resulting in limited vertical height, horizontal projection, and transverse width of

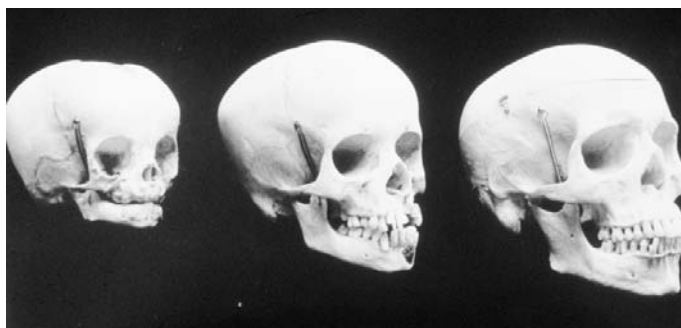

FIGURE 27-1 Oblique view of dry skulls of various ages. Ages of skulls (left to right) are approximately 6 months, 11 years, and 20 years. Reproduced with permission from Posnick JC.¹³²

the maxillomandibular regions early in childhood. These factors result in a high skull-to-face ratio, leaving the frontal and upper orbital regions more exposed to trauma while the lower face remains relatively protected.

The mandible defines the lower border of the facial skeleton. Its evolving anatomy throughout growth and development significantly affects the pattern of injuries that occur in the lower face throughout childhood. During infancy and early childhood, the condylar process of the mandible has a well-vascularized marrow space with a thick and short neck. The condylar injuries seen involve compression, whereas neck fractures are more rare. This is in contrast with the condylar process's tall and cortical characteristics later in childhood and adolescence, which leave it vulnerable to neck fractures. The mandible and maxilla continue to grow throughout childhood, maintaining a high cancellous-to-cortical-bone ratio and resulting in greater elasticity of the jaws, with more greenstick and nondisplaced fractures than are seen in adulthood. During the first few years of life the developing permanent tooth buds are small, and the tooth-to-bone ratio of the jaws is relatively low. In the mixed dentition phase (6 to 12 years) a higher tooth-to-bone ratio weakens the mandible in specific locations and encourages fracture through the developing tooth crypts when trauma occurs. After 5 years of age the paranasal

sinuses develop gradually, resulting in areas of skeletal weakness, which results in ease of separation of the midface from the base of the skull when facial trauma occurs. Another factor in children is the highly osteogenic periosteum, which results in early healing of a fracture with more extensive remodeling after bone union has occurred.

Prevention

The increased use of age- and weight-specific protective restraints, lower speed limits, more strict alcohol abuse laws, and use of air bags have greatly diminished the incidence of motor vehicle-related trauma.^{58,59} For the infant and young child (less than 100 lb) release of the automobile's air bag may in itself cause trauma and even death (suffocation). The recognition that conventional lap belts do not properly restrain or protect infants and young children is a relatively recent finding. Special harness restraints, marketed since 1967, are required for children weighing less than 44 lb to prevent forward movement, to support the head, and to distribute the force of injury over a larger surface area. Current recommendations state that children weighing less than 100 lb or younger than 12 years should not be placed in an air bag-equipped seat. Infants should face the rear of the vehicle until they are at least 1 year of age. Vehicle safety belts are not to be used until the shoulder belt can be positioned across the chest

with the lap belt low and snug across the thighs. Larger children may use booster seats, which have been shown to be protective in many motor vehicle crashes.⁵⁸ A booster seat is used until the standard shoulder and lap belts fit appropriately. Public acceptance, with mandatory laws, has progressively increased their use. Adults have a particular obligation to ensure that children riding in their automobiles are properly restrained in devices that are appropriate for their size and age.

Popular multispeed bicycles, dirt bikes, and off-road vehicles placed in the hands of untrained or unprotected children and adolescents have contributed to an increasing number of maxillofacial injuries in these users. Demas and Braun reviewed the injuries of all-terrain vehicle accident victims at a major pediatric trauma center and found that 37% of these patients sustained facial injuries.⁶⁰ Participation in everyday sport activities is another source of pediatric facial fractures. Proper helmets, mouth protectors, and face guards are not always mandatory equipment, even in many organized contact sport leagues.

The awareness and recognition of child abuse and parental and family violence as a cause of facial trauma is another consideration that must not be overlooked by the pediatric or general dentist, pediatrician, and emergency room or trauma physician.⁶¹

Diagnostic Studies

When facial trauma is suspected in the child, either by history or physical examination, radiographic documentation is mandatory. For the isolated mandible fracture the panoramic tomogram provides an excellent image of the entire mandible. However, for many patients with significant mechanisms of trauma, unclear history, or other factors, CT scanning provides the necessary information to make a complete diagnosis of any facial fractures. CT scanning has for the most

part supplanted standard radiography as the preferred method of imaging pediatric facial trauma.^{62,63} Multiple CT scan planar views (coronal, axial, sagittal) performed with spiral scanning through all of the facial structures of interest, with three-dimensional reformation of the CT scan data, confirm the location and extent of skeletal, soft tissue, and visceral injuries (ie, brain or eye trauma). The patient is placed in the CT gantry and when necessary given sedation or, occasionally, general anesthesia. The radiation doses required for imaging are generally much lower than that for standard tomograms and have more limited scatter. Spiral and multislice techniques have reduced the dose of radiation significantly when compared with older CT methods.⁶⁴ These techniques also allow for reformatted images in other planes (eg, coronal views) that are of excellent quality. This is helpful in patients who have been immobilized in a cervical collar. For isolated mandibular injury the panoramic tomogram still gives the best overall perspective of dentoalveolar and condylar head (of the mandible) anatomy and injuries and can be taken with a cervical collar in place.

Epidemiology and General Treatment Concepts

The patterns of facial injury in the pediatric population are considerably different than those for adults. Understanding these differences in injury presentation helps the surgeon during the evaluation and treatment phases. The objectives of the study previously published by Posnick and colleagues were to record the pattern of facial injuries treated over a 4-year period at a pediatric tertiary trauma unit and to document the treatment provided and any complications that occurred (Tables 27-1–27-4).⁵³ The information gained from this study remains pertinent because it illustrates the common injury patterns seen in pediatric facial trauma at a major referral center for acute treatment.

All patients with acute facial fractures evaluated at a single tertiary care pediatric hospital over a 4-year period and treated by the author (J.C.P.) were enrolled in the study.⁵³ The mechanism of injury, location and pattern of facial fractures, and extent of associated soft tissue injuries were evaluated. For each fracture the method of reduction, the type of fixation, and the need for primary bone grafts were recorded. Patients were placed into two groups: (1) those requiring acute care who received their primary treatment and evaluation at a single hospital, by Posnick; and (2) those treated for secondary (or residual) deformity, who were referred to Posnick for management at varying times after their injuries. All perioperative complications were catalogued. Follow-up of the patient group ranged from 1 to 5.5 years at the close of the study.

Fracture patterns were classified according to their complexity. Group 1 included all isolated fractures limited to one bone, group 2 included all multiple fractures occurring in a single bone, and

group 3 included multiple fractures occurring in multiple anatomic regions within the facial skeleton. Because of the hospital's entrance restrictions the oldest child in this population was 18 years.

The facial trauma population consisted of 137 patients (318 fractures) seen over a 4-year period.⁵³ Most of the patients (42%) were between 6 and 12 years of age, and the total population averaged 10.2 years of age. Boys (63%) outnumbered girls (37%) in the study (see Table 27-2). Of the 137 patients, 81 were treated for acute fractures (171 fractures) and 56 were evaluated for reconstruction of secondary deformities resulting from the initial fractures (147 fractures). Of the 171 acute fractures, 121 were treated surgically.

Fifty percent of the patients were injured in traffic accidents, followed in frequency by falls and injuries related to sports and altercations (see Table 27-1). Causal mechanisms appeared to be distributed similarly between sexes, except for a slightly higher number of males with fractures attributable to an altercation or

Table 27-1 Mechanism of Pediatric Facial Fracture by Age Category

Age Group (year)	Traffic Accident	Falls	Sports-Related and Altercations	Other
< 3	1	9	0	2
3 to 5	12	8	4	1
6 to 12	32	12	9	4
13+	23	3	15	2
Total	68	32	28	9

Adapted from Posnick JC et al.⁵³

Table 27-2 Patient Age and Occurrence of Pediatric Fractures by Region

Age Group (year)	Cranium	Orbit	Zygoma	Midface	Mandible
< 1	0	1	0	0	3
1 to 2	2	2	1	0	4
3 to 5	2	5	2	3	19
6 to 12	8	16	9	8	27
13+	4	17	9	12	22
Total	16	41	21	23	75

Adapted from Posnick JC et al.⁵³

to recreational vehicle accidents. The likelihood of high-velocity injuries increased with age (10% in the 1- to 2-year age group, increasing to 55% in the 6- to 12-year age group). Falls as a cause declined with age (55% in the 1- to 2-year age group, dropping to 8% in the 13+ year age group). The number of facial fractures tended to increase in the summer months; 45% of all fractures occurred between the months of May and August.

Of the 137 children with facial fractures, 66 (48%) sustained isolated fractures (group 1), 27 (20%) had multiple fractures in a single bone (group 2), and 44 (32%) had multiple fractures in multiple sites within the craniofacial skeleton (group 3). Children younger than 3 years were more likely to sustain only single fractures (see Tables 27-2 and 27-3). The children experienced one or more fractures in the following craniofacial regions: mandibular (55%), orbital (30%), dentoalveolar (23%), midface (17%), nasal (15%), zygoma (14%), and cranium (12%). Fracture pattern profiles were similar in both the acute care and secondary treatment groups. Midface (20 of 23) and zygoma (18 of 21) fractures were more likely to occur in children older than 6 years of age (see Table 27-2).

The distribution of fractures by anatomic region and degree of complexity is presented in Table 27-3. Similar anatomic patterns were seen in both the acute and secondary cases. Most of the fractures occurred as part of a complex injury pattern, with the exception of mandibular fractures, which occurred as isolated fractures with nearly equal frequency.

Eighty-one patients with acute injuries were seen for evaluation during the period of the study. These patients sustained 175 fractures, requiring 121 operative interventions. Injuries occurring at high velocity, such as traffic-related events (74%), more frequently required interventions than those occurring at low velocity, such as falls (51%). Boys did not require

Table 27-3 Pediatric Fracture Pattern by Anatomic Region and Complexity

Anatomic Region	No. of Subjects	No. of Fractures	Fracture Complexity*		
			Group 1	Group 2	Group 3
Cranium	25	27	9	1	15
Orbit	41	73	7	5	29
Zygoma	21	22	4	0	17
Midface	23	31	2	0	21
Nose	17	23	6	4	7
Mandible	75	107	38	17	20
Dentoalveolar	32	44	8	11	13

Adapted from Posnick JC et al.⁵³
 *Fracture complexity resulting from trauma was represented by three groups: group 1, trauma involving a single fracture in a single anatomic region; group 2, trauma involving multiple fractures in a single anatomic region; and group 3, trauma involving multiple fractures in multiple anatomic regions.

significantly more operations than girls. Necessity for operative intervention increased significantly with the increasing complexity of facial fractures (group 1 to group 3) but not with age.

Open or closed reduction techniques were used with approximately the same frequency. When closed reduction was used, most patients (93%) underwent reduction and stabilization of the fracture with maxillomandibular fixation (eg, Erich arch bars, skeletal suspension wires, Stout wires). An external fixation device was used for only one patient. Only four fractures were reduced and not stabilized. Thirteen fractures (20%) were opened and explored without any form of fixation. Most of these were orbital floor fractures with associated bone-grafting procedures. Of the fractures treated by open reduction, 35 (55%) were managed with only one form of fixation to stabilize the reduction and 14 (21%) with multiple forms. Use of plates (miniplates or

microplates) and screws accounted for 82% (40 of 49) of the internal fixation methods used. Although age was not a factor in the choice of plate-and-screw fixation, review of the data indicated that this method was not used on any patient younger than 3 years (only three of the children in our population were younger than 3 years). Plates and screws were used most often in the mandible (40%) and orbits (26%). Bone grafts (21) were used for fractures of the orbit (16), cranial vault (2), mandible (2), and nose (1). The preferred donor sites included cranium (10), anterior maxillary wall (4), and hip (2).

Complications in treating pediatric facial trauma are rare if good principles are adhered to and precise surgical execution is achieved. This is due, at least in part, to the excellent healing capabilities of most children. Nonunion is very rare due to the excellent healing potential of pediatric bone. Malunion may occur but is

Table 27-4 Management of Acute Pediatric Fractures*

No Surgical Treatment	Closed Reduction (No. of Fractures)	Open Reduction (No. of Fractures)
50	Reduction only (4) Maxillomandibular fixation External fixation	Exploration only (13) Single fixation method (35) More than 1 fixation method (14)

*N = 171.
 Adapted from Posnick JC et al.⁵³

usually due to inadequate reduction. In Posnick and colleagues study no deaths, tooth loss, or injuries to the eye or brain were directly attributable to any operative procedure. Two patients developed soft tissue infections that responded to treatment by incision, drainage, and administration of antibiotics. Another developed a small area of alopecia after a coronal flap procedure. One patient, in whom a fracture extended through a tooth root, developed a periapical tooth abscess. This condition was treated with extraction and systemic antibiotic therapy. One miniplate was removed 1 year later because it was palpable and visible below thin forehead skin.

Of the 137 patients in this series, 77 (56%) had associated soft tissue injuries. These included lacerations to the scalp (31%), and injuries to the ear (20%), chin (13%), tongue (8%), forehead (6%), and eyelid (6%). Thirty-three percent in the facial fracture group had injuries to other organ systems. Associated head injuries accounted for 42% of this group, followed by damage to the extremities (24%), eyes (22%), thorax (10%), and abdomen (2%). None of our patients sustained injuries to the cervical spine. As expected, the more complex the facial injury, the greater the likelihood of associated injury ($p = .03$); 19% of group 1, 26% of group 2, and 36% of group 3 patients had an associated injury. Six percent required emergency endotracheal intubation when first evaluated; no emergency tracheostomies were required.

Patterns of Pediatric Facial Fracture Injury and Methods of Management

Anterior Cranial Vault and Supraorbital Ridge Fractures

Fractures of the forehead and upper orbital regions, combined with brain injury and dural tears with cerebrospinal fluid (CSF) leakage, constitute a frequent pattern of injury in infants and in children younger than 5 years when major anterior craniofa-

cial trauma occurs (Figure 27-2).⁵³ Isolated cranial vault fractures (18 of 318 fractures, 6%) occurred infrequently in this series. When they did occur, the anterior cranial vault was the most common location (13), followed by the posterior vault (4) and frontal sinus (1). Complete evaluation using CT scanning of the brain, eyes, and craniofacial skeleton, combined with neurosurgical, ophthalmologic, and craniofacial assessment, should be performed to evaluate the injuries completely. A combined neurosurgical and craniofacial reconstructive procedure is necessary for repair of the injured brain, dura, and skeleton. A coronal (skin) incision provides the best exposure of the fractured regions and surrounding normal structures. Once the brain and dural injuries have been managed by the neurosurgeon, reduction and stable fixation (microplates and screws) of all fractures are completed by the craniofacial surgeon. When massive comminution exists, bony defects are present, or complete orbital roof reconstruction is required, then autogenous cranial bone is harvested and used. In a normally developing child the skull will mature into three clinically reliable layers (outer table, medullary cavity, inner table) between the ages of 2 and 5 years. In these instances the bone of the cranial vault is suitable for splitting, yielding bone for grafting. These techniques and a team approach to the early diagnosis and management of combined injuries are cost effective and result in a rapid facial rehabilitation for the injured child.

Naso-orbitoethmoid and Frontal Sinus Fractures

The prevalence of naso-orbitoethmoid fractures closely follows the development of the paranasal sinuses. They are rarely seen in children younger than 5 years, but they become progressively more common in adolescents and adults (Figure 27-3). Rowe reviewed his series of pediatric fractures and found that injuries to the middle

third of the face made up only 0.5% of all pediatric fractures.¹⁶ Kaban and colleagues reported no midface fractures in 109 pediatric facial fracture patients from 1965 to 1975.³¹ During the next 10 years, with another 184 fractures, they reported only 5 midface fractures, all Le Fort III level injuries. Posnick and colleagues reported that midface injuries seen at a major pediatric trauma center during a 4-year period made up 17% of a series of 318 fractures in 137 patients.⁵³ Kaban associated this increased prevalence of midface injuries with the increase in survival of persons involved in serious motor vehicle accidents, which may result in more extensive facial injuries in the survivors.⁶⁵ When displaced naso-orbitoethmoid fractures do occur in children, we have adopted the same open reduction and internal fixation (ORIF) techniques generally accepted for adult-type injuries. Stable internal fixation techniques (micro- and miniplates and screws) and primary autogenous cranial bone grafts when indicated, result in the anatomic healing required to achieve satisfactory rehabilitation of the child with facial injury.^{28,33,66-74}

As in the adult, when the medial canthal ligament is displaced, it usually remains attached to a bone fragment. The medial canthal ligament and bone fragment are repositioned and fixed without the need for a direct medial canthopexy. Formal medial canthopexies often contribute to an unnatural appearance and should be avoided if possible. Often the bony fragment(s) can be repositioned with the aid of microplates and screws with or without the use of a transnasal wire.

Frontal sinus injuries in children are approached in a similar way to those in their adult counterparts.^{75,76} Anterior frontal sinus wall fractures are anatomically reconstructed and stabilized to prevent contour deformity. When the fracture components are severely comminuted, autogenous cranial bone grafts can be used to replace the entire unit. Depending on the

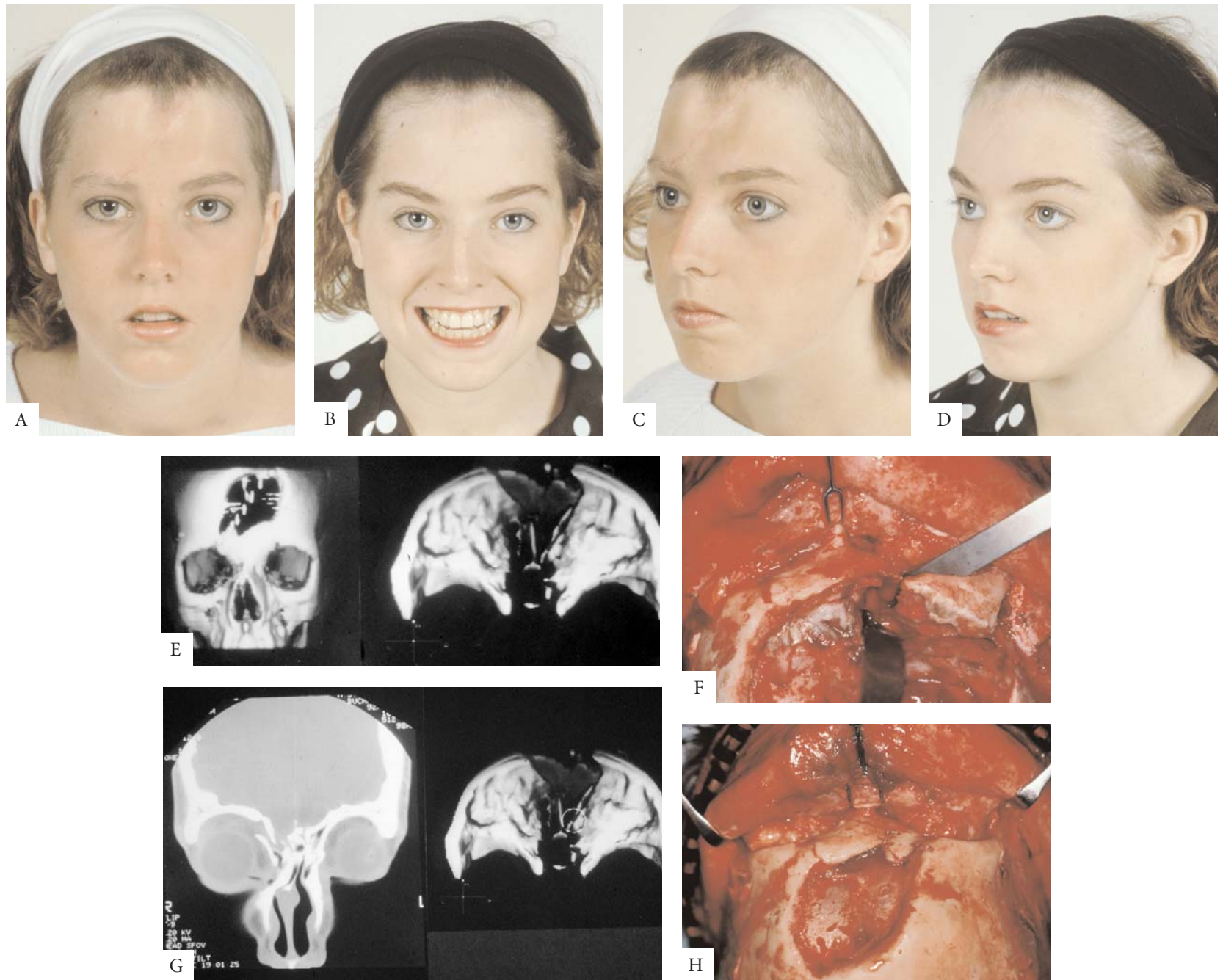

FIGURE 27-2 A 16-year-old girl sustained frontal and upper orbital trauma when she hit her forehead on the dashboard in a motor vehicle accident. Initially the cerebrospinal fluid (CSF) leak was repaired through a local scalp laceration; minimal attention was given to her frontal and orbital fractures. Ongoing CSF leak with meningitis and loss of the frontal bone flap occurred, after which she was referred to Posnick and colleagues, and a delayed combined neurosurgical/craniofacial approach was carried out. A, Frontal view before the delayed surgery. B, Frontal view 1 year after reconstruction. C, Oblique view before the delayed surgery. D, Oblique view 1 year after reconstruction. E, Three-dimensional computed tomography (CT) scan of frontal bone defect. F, Intraoperative view of dural tear resulting in traumatic encephalocele. Access craniotomy/osteotomies allow exposure for reconstruction of orbital roof/medio-orbital wall defects. G, CT scan of the anterior cranial base and orbital roof/medio-orbital wall defects. H, Intraoperative view of frontal bone defect and displaced orbital rim fractures. (CONTINUED ON NEXT PAGE)

extent of frontal sinus development and injury, the mucous membranes may require débridement with maintenance of a patent frontonasal duct or, in cases of fractures of the ducts, sinus obliteration with sealing of

the duct. If the posterior frontal sinus wall is injured, neurosurgical consultation helps determine whether cranialization of the sinus through an intracranial approach is required.⁷⁷ Since CSF leaks are common

with dural tears in these injuries, it is often helpful to place bone, fibrin glue, and a pericranial flap in the defect to prevent CSF leaking. A double-ring sign is seen on filter paper when CSF is present within nasal

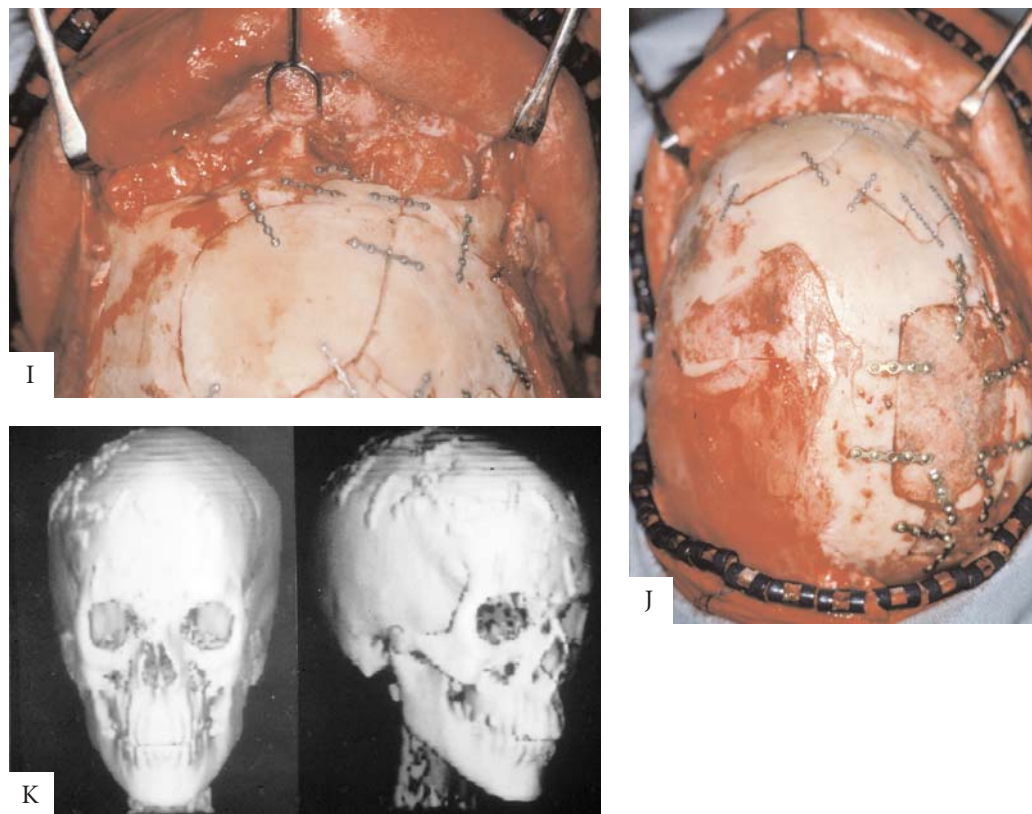


FIGURE 27-2 (CONTINUED) I, Intraoperative view of fronto-orbital reconstruction with split cranial grafts and plate/screw fixation. Note the right parietal donor site with split cranial reconstruction. J, Intraoperative view of cranial vault after reconstruction. K, Three-dimensional CT scan views of reconstructed cranial vault and orbits. Reproduced with permission from Posnick JC et al.¹³³

fluid. Alternatively, β_2 -transferrin can be measured within the nasal fluid to determine if nasal leaking is indeed CSF. Endoscopic techniques with imaging guidance can be used to effectively repair persistent leaking that may occur postoperatively.

Le Fort (Midface) Fractures

The prevalence of Le Fort midface fractures increases rapidly once aeration of the maxillary and ethmoid sinus cells has occurred. The rapid development of the sinuses takes place between 6 and 12 years of age. Consequently maxillary fractures in children do not follow the patterns seen in adults. Displaced midface fractures should be treated with ORIF techniques similar to those used in adults.^{13,78} This is necessary to achieve and maintain anatomic restoration. Closed reduction techniques may be preferred in specific clinical situations to avoid injury to the

unerupted permanent dentition, but the dental injuries are generally the result of the trauma event rather than of reduction and fixation techniques that have been carried out by an experienced surgeon familiar with the dentition.

In Posnick and colleagues study 23 patients sustained 31 fractures in the midfacial region. These included nasofrontoethmoid fractures (13 of 31, 42%), Le Fort I (8 of 31, 26%), Le Fort II (5 of 31, 16%), and Le Fort III (5 of 31, 16%). Midfacial fractures generally occurred as part of a complex facial fracture pattern; only 2 of 31 (6%) occurred in isolation. Although few acute midfacial fractures occurred, the majority (9 of 12) required surgery (Figure 27-4). Unstable or displaced fractures were treated with open reduction and internal fixation. The surgical goals in such cases are to restore midface projection, facial width, and orbital volume, and to normalize occlusal

relationships. Seven of nine midfacial fractures were stabilized with plates and screws.

A circumvestibular intraoral mucosal incision provides ideal exposure of maxillary fractures through the zygomatic buttress, anterior maxillary wall, and piriform nasal aperture regions. When additional access to the zygomatic arch, frontozygomatic suture, supraorbital ridge, and frontonasal junction is required, a coronal (skin) incision is also used. If specific exploration of the infraorbital rims, orbital floors, and lower aspects of the medial orbital walls is required, a subciliary, lower lid, or transconjunctival incision is added. Palatal incisions are to be avoided, and preservation of the gingiva is important to the child's periodontal health. As in the case of adults the restoration of normal anatomic position of the midfacial skeleton generally requires open reduction, stable fixation (miniplates and microplates and screws) and may rarely require autogenous cranial bone grafts or the placement of alloplastic materials.

Zygomatic Complex Fractures

A zygomatic complex fracture describes a fracture through the frontozygomatic suture, zygomatic arch, infraorbital rim, and zygomatic buttress. Fracture through the orbital floor and lateral orbital wall completes the quadripod injury. The extent of displacement of the zygomatic complex fracture is best clarified through CT scanning in the axial and coronal planes and defines the extent of surgery necessary to restore and maintain preinjury anatomy. The child's presenting physical findings are similar to those seen in the adult. They generally include periorbital ecchymosis; paresthesia over the zygomatic arch, lateral nose, cheek, upper lip, and anterior maxillary teeth; and subconjunctival hemorrhage.⁷⁹ Ophthalmologic consultation is essential to determine baseline ocular globe and extraocular muscle injury and dysfunction. Since the base of the lateral orbit is made up of the zygomatic bone,

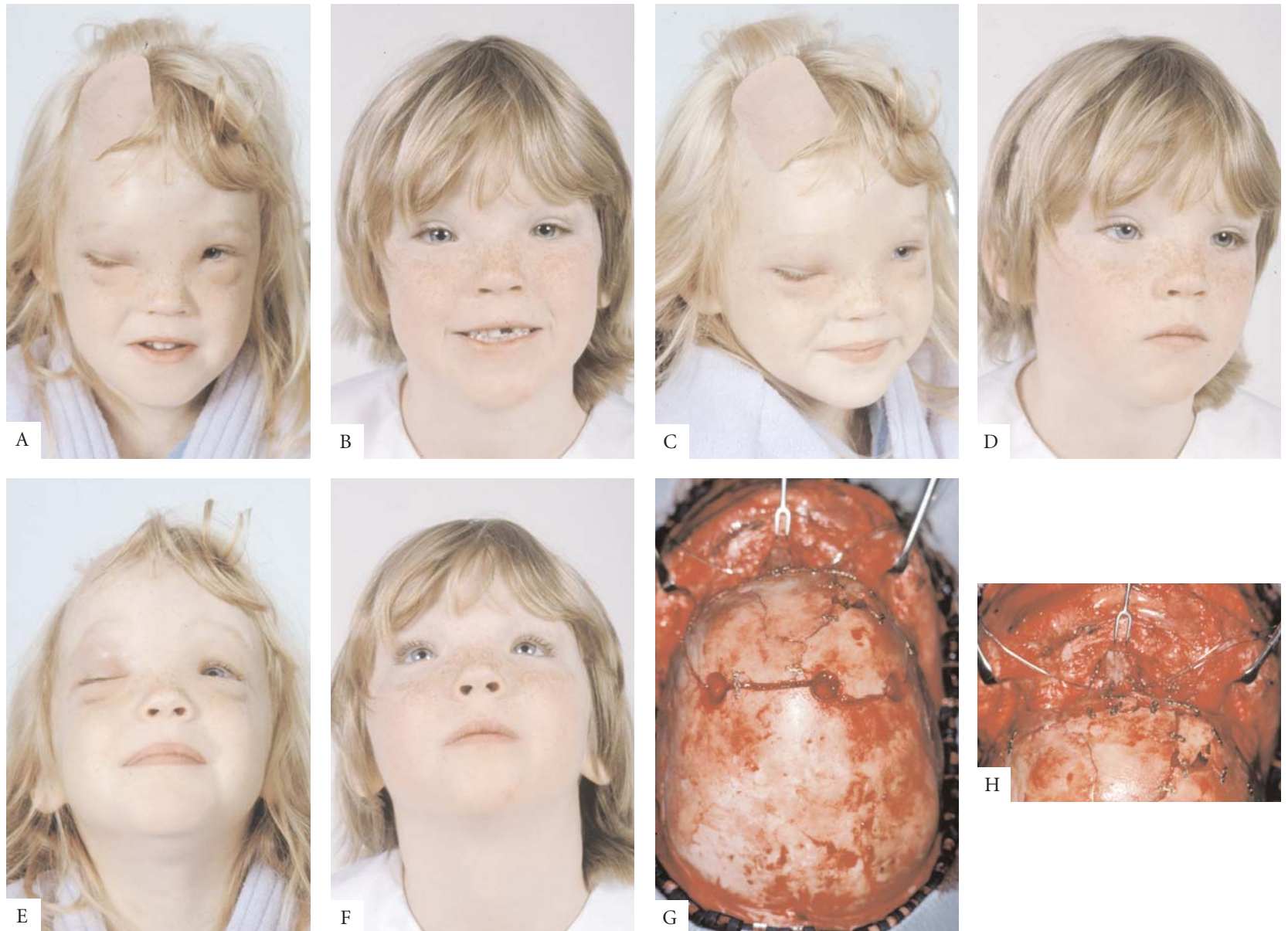

FIGURE 27-3 A 5-year-old girl who was in a motor vehicle accident sustained orbitonasal, ethmoid, and frontal bone fractures with associated brain and dural injury with cerebrospinal fluid leak. She required a combined neurosurgical/craniofacial procedure. A, Frontal view 6 days after surgery. B, Frontal view 2 years after (single-stage) reconstruction. C, Oblique view 6 days after surgery. D, Oblique view 2 years after reconstruction. E, Worm's-eye view 6 days after surgery. F, Worm's-eye view 2 years later. G, Intraoperative view of reconstructed orbitonasal and frontal fractures. Stabilization is with titanium plates and screws. H, Intraoperative close-up view of reduced orbitonasal and frontal fractures stabilized with titanium plates and screw fixation. Medial canthopexies were also carried out (note location of wires). Reproduced with permission from Posnick JC.¹³⁴

fractures within the orbital floor frequently require management in conjunction with repositioning of the zygoma. Some injuries require reconstruction of the orbital floor with autogenous bone or synthetic materials. Of the eight acute zygoma fractures observed in Posnick and colleagues' study, three were minimally displaced and managed without surgery. The five displaced

fractures were comminuted injuries that were treated with open reduction and internal fixation. Three of these fractures were stabilized with plates and screws.

Most zygomatic complex fractures can be approached and reduced using multiple approaches such as maxillary vestibular, lower eyelid, and brow incisions. If a badly comminuted zygomatic arch is associated

with a displaced zygomatic complex fracture, a coronal (scalp) incision may be used with intraoral and subciliary (or lower lid or transconjunctival) incisions to expose, explore, reduce, graft, and internally fix all fractured regions.⁷⁸ With a minimally displaced or incomplete fractured zygoma, more limited treatment is used to achieve adequate fracture reduction. This can be

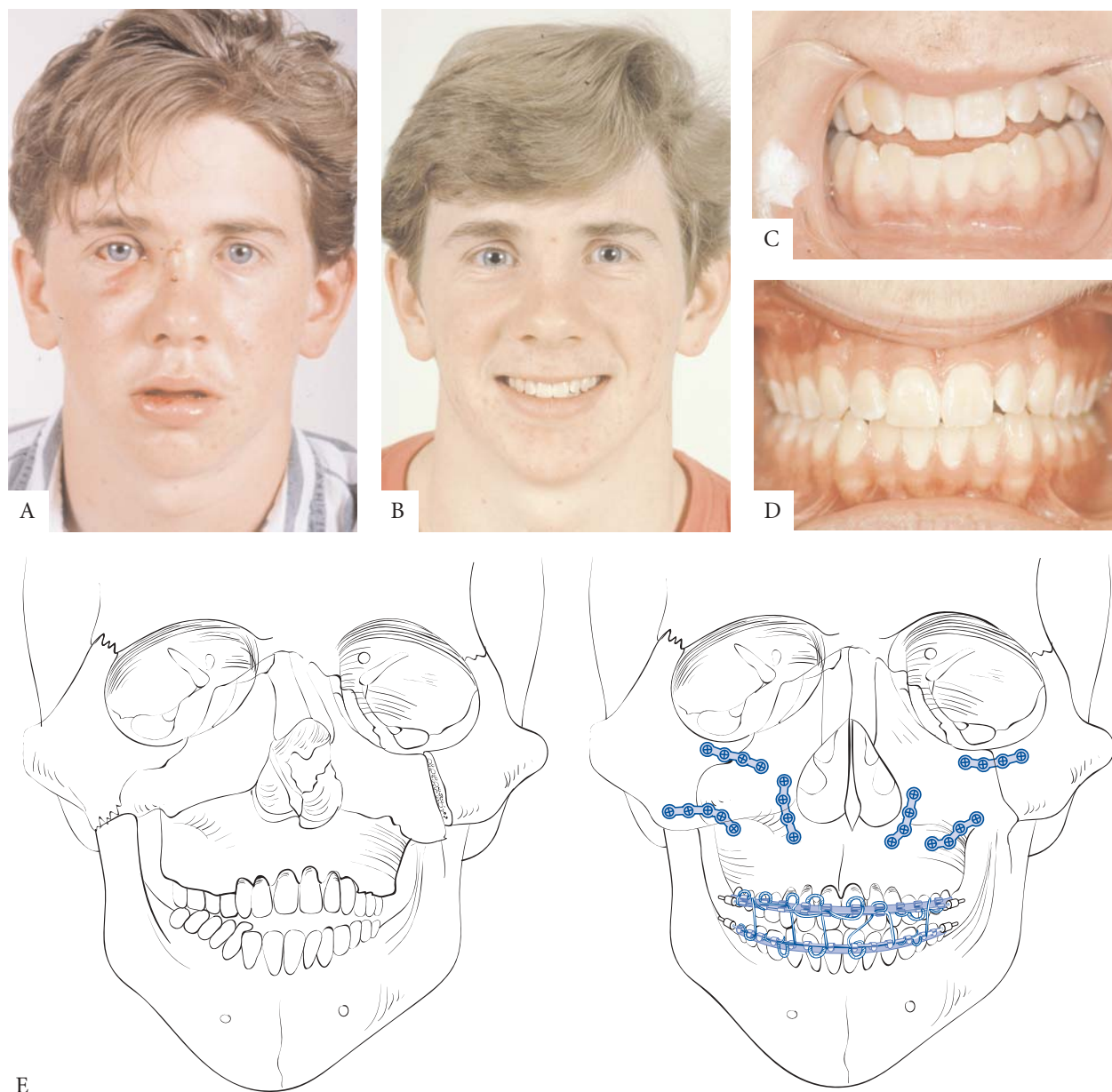


FIGURE 27-4 A 14-year-old boy sustained combined Le Fort I and II fractures with bilateral orbital blow-out fractures when he was accidentally kicked in the face while playing competitive soccer. A, Frontal view before repair. B, Frontal view 1 year after (single-stage) reconstruction. C, Occlusal view before repair. D, Occlusal view 1 year after reconstruction. E, Illustration before and after reduction and fixation. (CONTINUED ON NEXT PAGE)

done through a Gillies' approach within the temporal scalp, an eyebrow incision, or a Keene approach from an intraoral vestibular incision.

Blow-Out and Blow-In Fractures of the Orbit

Blow-in and blow-out fractures of one or more orbital walls and/or floor may be associated with more complex fractures

(eg, anterior cranial vault/upper orbital, naso-orbitoethmoid, Le Fort midface, or zygomatic complex fractures) or may occur as isolated injuries.⁸⁰⁻⁸³ The key to thorough evaluation is complete clinical, ophthalmologic, and CT scan assessments.⁸⁴ A thin-sliced axial and coronal CT scan is completed to visualize all four orbital walls and/or floors to ensure that the presence and extent of all blow-in or

blow-out fractures are recognized. The ophthalmologic assessment may require pupillary dilatation and slit-lamp evaluation in the ophthalmologic suite.

Orbital fractures are common in children and were frequent in Posnick and colleagues' study; 41 patients sustained 73 separate fractures of the orbit. The distribution of fractures within the orbit included the floor (23 of 73, 32%), medial wall

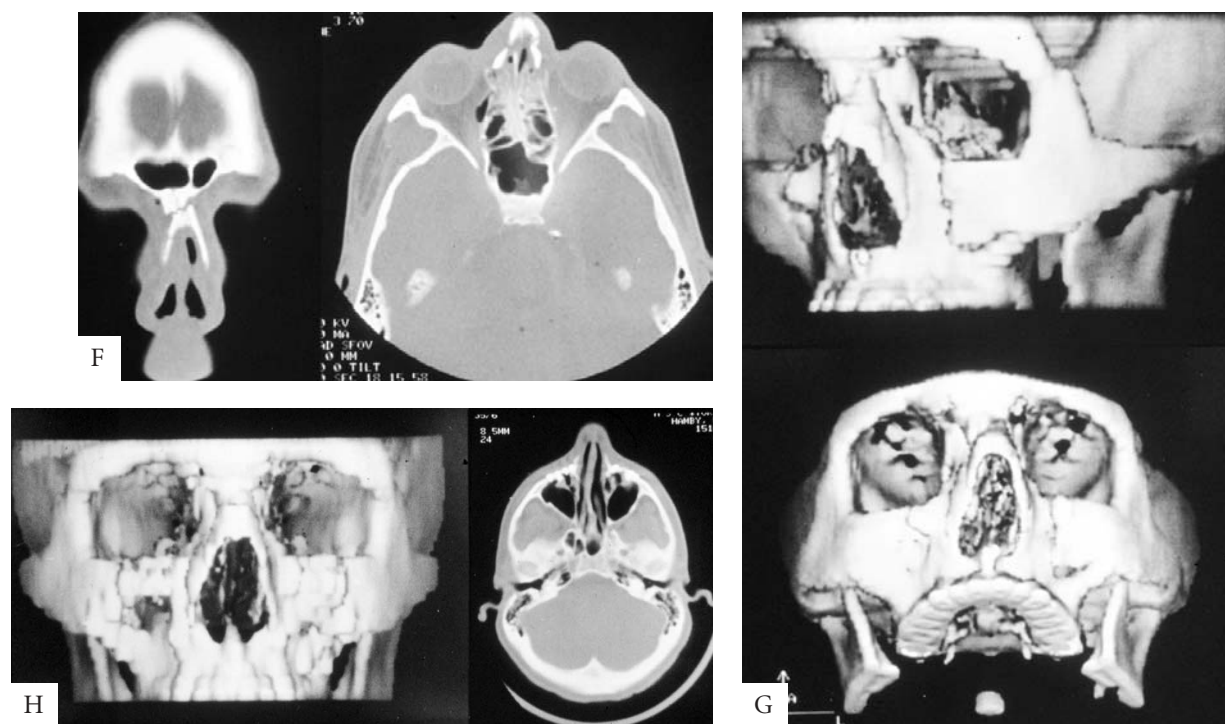


FIGURE 27-4 (CONTINUED) F, Computed tomography (CT) scan demonstrating nasofrontal bone separation and comminuted medial orbital walls. G, Three-dimensional CT views demonstrate Le Fort II fracture with nasofrontal separation and location of the infraorbital rim and maxillary fractures. H, CT scans demonstrating the morphology of the midface after reconstruction. A–D, F–H reproduced with permission, E adapted from Posnick JC.¹³²

(14 of 73, 19%), and orbital roof (13 of 73, 18%). Only 7 of these orbital fractures were sustained as isolated injuries. Of the acute fracture group, 21% of the fractures were orbital fractures. These were treated both surgically (59%) and nonsurgically (41%) (see Table 27-4). Most of the orbital injuries that were managed operatively were minimally displaced floor fractures. Thirty-two percent of orbital fractures were managed by exploration, reduction, and grafting with autogenous material but without graft fixation (Figure 27-5). Plate-and-screw fixation was used in six orbital rim fractures and three roof fractures. With the collaboration of a neurosurgeon, displaced roof fractures (blow-in fractures) were routinely treated with open reduction via an intracranial approach. The roof was reconstructed with contoured calvarial bone grafts fixed with plates and screws.

Once a clinically and radiographically significant orbital wall and/or floor injury is

recognized, early exploration and repositioning of the soft tissues back into the orbit with simultaneous reconstruction of injured orbital walls and/or floor to appropriate dimensions and overall intraorbital volume is carried out.^{80,85} Because the complications of extraocular muscle entrapment, diplopia, and enophthalmos are difficult to treat later, early evaluation of patients at high risk, followed by prompt surgical intervention, is encouraged. Orbital wall and/or floor fractures heal rapidly in children and result in a higher incidence of scar cicatrization of the herniated orbital soft tissues than in adults.

Nasal Fractures

Nasal fractures are also common in the pediatric population. Of the few acute nasal fractures that occurred in the author's series (12 of 171, 7%), 58% were minimally displaced and did not require surgery, and 33% were treated by closed means. Only one fracture required open reduction. Many isolated nasal fractures were treated

on an outpatient basis. The nasal fractures seen by Posnick and colleagues in this study were generally associated with other facial fractures and were therefore not representative of nasal fractures seen in general at the hospital (emergency department).

Development of the nasal septum is thought to be a major factor in midface growth. In theory, trauma to the nasal region early in childhood will negatively impact on midface growth.⁸⁶ Although the nose is the most frequently fractured part of the face in a child, extensive midface growth retardation after trauma has only rarely been documented.⁸⁶

Nasal injuries are often recognized but then ignored as unimportant. Two serious pitfalls in treating nasal fractures in children are (1) failure to recognize adjacent bony injuries extending outside the nose and (2) septal hematoma after nasal trauma (which may in theory result in septal necrosis and perforation). Diagnosis of nasal and septal fractures is usually based

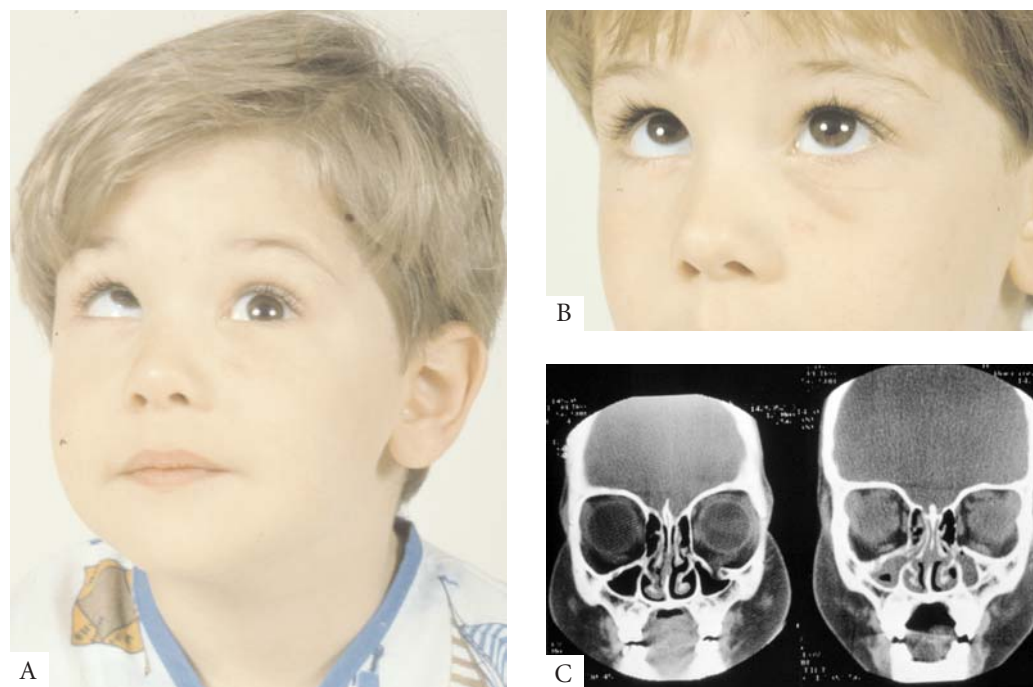


FIGURE 27-5 A 4-year-old boy sustained an isolated blow-out fracture of the left orbital floor with entrapment of the inferior rectus muscle through the floor defect. He underwent explorative surgery with repositioning of the orbital contents back into the orbit. Reconstruction of the orbital floor defect was with a split cranial graft taken from the temporoparietal region. A, Frontal view with eyes in upward gaze demonstrating left inferior rectus entrapment. B, Close-up view early after reconstruction demonstrating improved upward gaze ability. C, Comparison of two-dimensional coronal sliced computed tomography scans through the midorbits before (left) and after (right) reconstruction. Reproduced with permission from Posnick JC.¹³²

on clinical examination. Radiographic confirmation can be made with CT scans or plain films of the nose, but these are usually not necessary for clinically apparent and isolated nasal septal fractures. Displaced nasal bone and nasal septal fractures should be reduced and stabilized with splints in a similar manner as is done in adults. This should be completed within several days of the injury, as children heal more quickly than adults, making repositioning of the small nasal bone fragments more difficult with time.

Mandibular Fractures

The lower jaw of a child represents an evolving anatomy that affects the pattern of fractures seen at varied ages (Figures 27-6 and 27-7). Mandibular fracture patterns are affected by the fact that the child's jaws are filled with teeth at various stages of development at different

ages.^{15,18,40-46,64,87-91} Injury to the developing bone and tooth buds may result from the trauma of the fracture, the surgical technique, or complications of treatment (eg, nonunion, malunion, infection).⁴⁷

In Posnick and colleagues' study mandibular fracture sites included the condyle (59 of 107, 55%), parasymphysis (29 of 107, 27%), body (10 of 107, 9%), and angle (9 of 107, 8%). Thirty-nine percent of all fractures in the study were of the mandible. Of those treated, 18 of 28 (64%) were treated with closed reduction, most of which were condylar process fractures with an element of malocclusion. Only two condylar process fractures were opened. Both were low subcondylar mandibular neck fractures associated with other injuries in the mandible. Minimally displaced body and angle fractures with a satisfactory occlusal relationship were frequently treated with maxillomandibular fixation. Displaced or comminuted fractures

were treated with open reduction and internal fixation, and this treatment was used most frequently for parasymphyseal injuries (53%) and angle fractures (24%) (see Table 27-4).

A surgeon familiar with the evolving dentition is able to apply arch stabilization and maxillomandibular fixation, when indicated, in dentulous children of all ages. Obstacles to the usual application of surgical arch bars are overcome with the use of skeletal fixation: circum-mandibular, circumzygomatic, infraorbital, anterior nasal spine, and piriform aperture wires are used for additional support. When internal fixation techniques are required, careful application of microplate or miniplate and screw fixation, generally with unicortical screws strategically placed along the thick cortical inferior border combined with arch bar stabilization, is often the least traumatic and most stable option. Knowledge of the location of developing teeth allows the surgeon to place internal fixation as needed, with minimal trauma.

The general principles of treating mandibular fractures are the same in children and adults: anatomic reduction is combined with stabilization adequate to maintain it until bone union has occurred. With the exception of mandibular condyle fractures, we frequently find that the judicious use of ORIF is preferable to the closed reduction and immobilization techniques with splints when treating fractures in the deciduous and mixed dentition. Some surgeons believe that minor degrees of malunion may be self-correcting in children or at least amenable to orthodontic alignment. This margin of safety should not be used as an excuse for inadequate treatment.

Mandibular Condyle and Subcondyle Fractures Injury to the mandibular condylar process may affect jaw growth and temporomandibular joint (TMJ) function.^{18,31,33,92-109} The mandible is the final facial bone to complete normal growth, and injury to the condylar growth center before skeletal maturity may lead to growth retardation on the

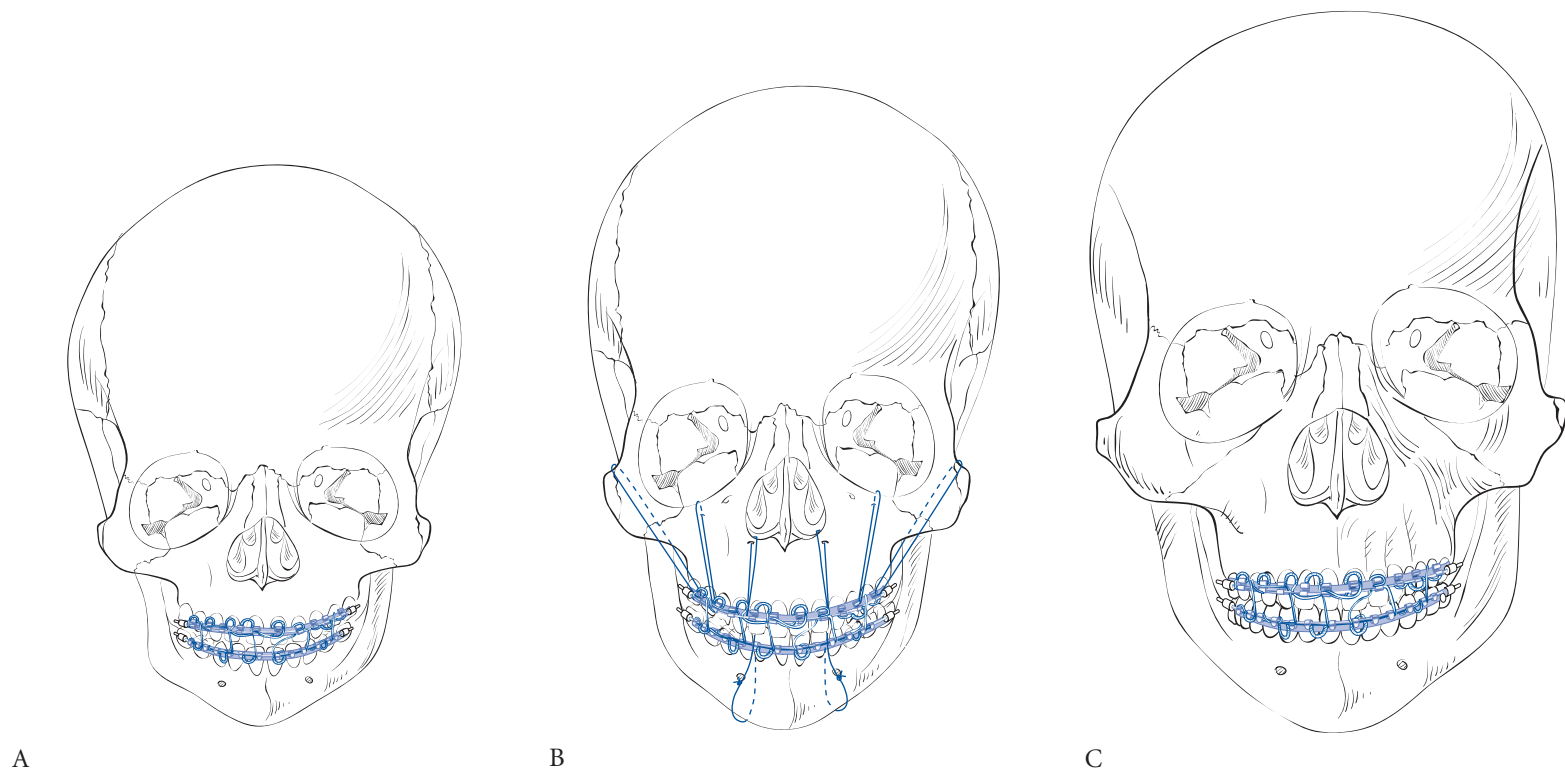


FIGURE 27-6 Illustration of three skulls of various ages (A, 2 years; B, 6 years; C, 12 years). Different methods of achieving arch bar stabilization at different ages including circum-mandibular, circumzygomatic, infraorbital, and piriform aperture wires. Adapted from Posnick JC.¹³⁵

ipsilateral side, resulting in facial asymmetry and malocclusion.

Once a mandibular condylar fracture occurs, a degree of TMJ degenerative changes or growth restriction is a likely scenario despite the treatment option selected. Condylar injuries represent a wide spectrum of fractures, dislocations, and compression injuries. They may be intracapsular or extracapsular, displaced or nondisplaced, comminuted or noncomminuted, open or closed, located low or high in the condylar neck, medial or lateral pole fractures, and isolated injuries or associated with more complex facial fractures.

The treatment of a fracture of the mandibular condyle remains controversial.^{110–124} Most authors and clinicians continue to advocate a nonoperative approach, whereas a few prefer the use of open reduction techniques. The frequency of less than ideal results seen with varied treatments given for similar injuries is a reflection of the irreversible injury that may occur to

the highly differentiated and specialized TMJ structure. Despite a great deal of surgeon interest and experience over the years with open reduction techniques, its proponents have not been able to convincingly demonstrate a lower incidence of growth disturbance, TMJ ankylosis, internal derangement of the TMJ, loss of posterior facial height, or malocclusion in their patients. Although endoscopic techniques have been reported, a detailed analysis of outcomes is lacking and the benefits remain to be seen.¹²⁵

Open reduction of a condyle fracture may be warranted in a child in some instances.^{122–124} Indications may include the following:

- Displacement into the middle cranial fossa
- Unacceptable occlusion after a closed technique trial has failed
- Avulsion of the condyle from the capsule

- Bilateral fractures of the condyles with comminuted midface fractures

We continue to advocate a nonoperative approach for most condylar and subcondylar fractures in young children. A short period of partial immobilization with elastics is generally useful for patient comfort, to encourage soft tissue healing, and to limit the conversion of a greenstick or minimally displaced fracture into a complete or fully displaced one. Ten to 14 days of use of firm elastics is generally enough to accomplish these goals and still allow early increased range of motion to limit the likelihood of the development of TMJ fibrosis or ankylosis. Instituting a regimen of physical therapy for several months is important to avoid TMJ fibrosis or ankylosis.

When a condyle fracture occurs and the use of firm elastics needs to be limited to reduce the incidence of TMJ sequelae, the fixation technique selected for additional simultaneous maxillary and mandibular

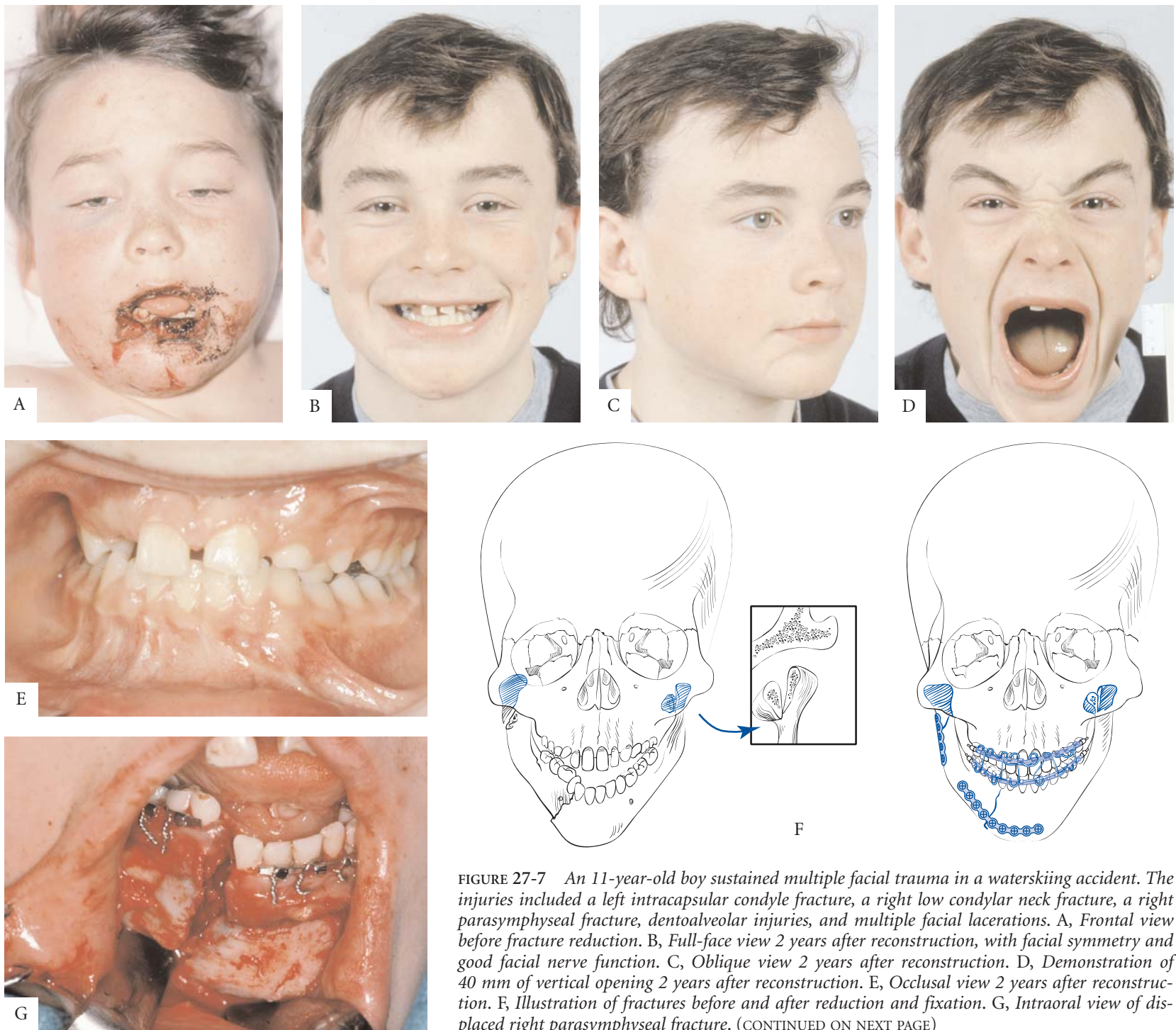


FIGURE 27-7 An 11-year-old boy sustained multiple facial trauma in a waterskiing accident. The injuries included a left intracapsular condyle fracture, a right low condylar neck fracture, a right parasymphiseal fracture, dentoalveolar injuries, and multiple facial lacerations. A, Frontal view before fracture reduction. B, Full-face view 2 years after reconstruction, with facial symmetry and good facial nerve function. C, Oblique view 2 years after reconstruction. D, Demonstration of 40 mm of vertical opening 2 years after reconstruction. E, Occlusal view 2 years after reconstruction. F, Illustration of fractures before and after reduction and fixation. G, Intraoral view of displaced right parasymphiseal fracture. (CONTINUED ON NEXT PAGE)

fractures should be carefully considered. The common occurrence of a combined parasymphiseal and condylar fracture will warrant a more stable form of parasymphiseal fracture fixation (miniplates and screws) so that early active mandibular range of motion with TMJ function can occur. Instituting a liquid diet for a limited

time period even after firm elastic use may be helpful in preventing displacement of parasymphysis or body fractures. When a mandibular angle fracture occurs in the presence of a condyle fracture, the combined forces may be significant enough to cause displacement unless ORIF at the angle fracture is carried out.

The advantages of continuous passive motion (CPM) for the healing of injured joint surfaces have been well documented in experimental animals.¹²⁶⁻¹²⁸ Salter and colleagues concluded that chondrogenesis in the healing of full-thickness defects in the rabbit femur occurs through differentiation of the pluripotential cells of the subchondral

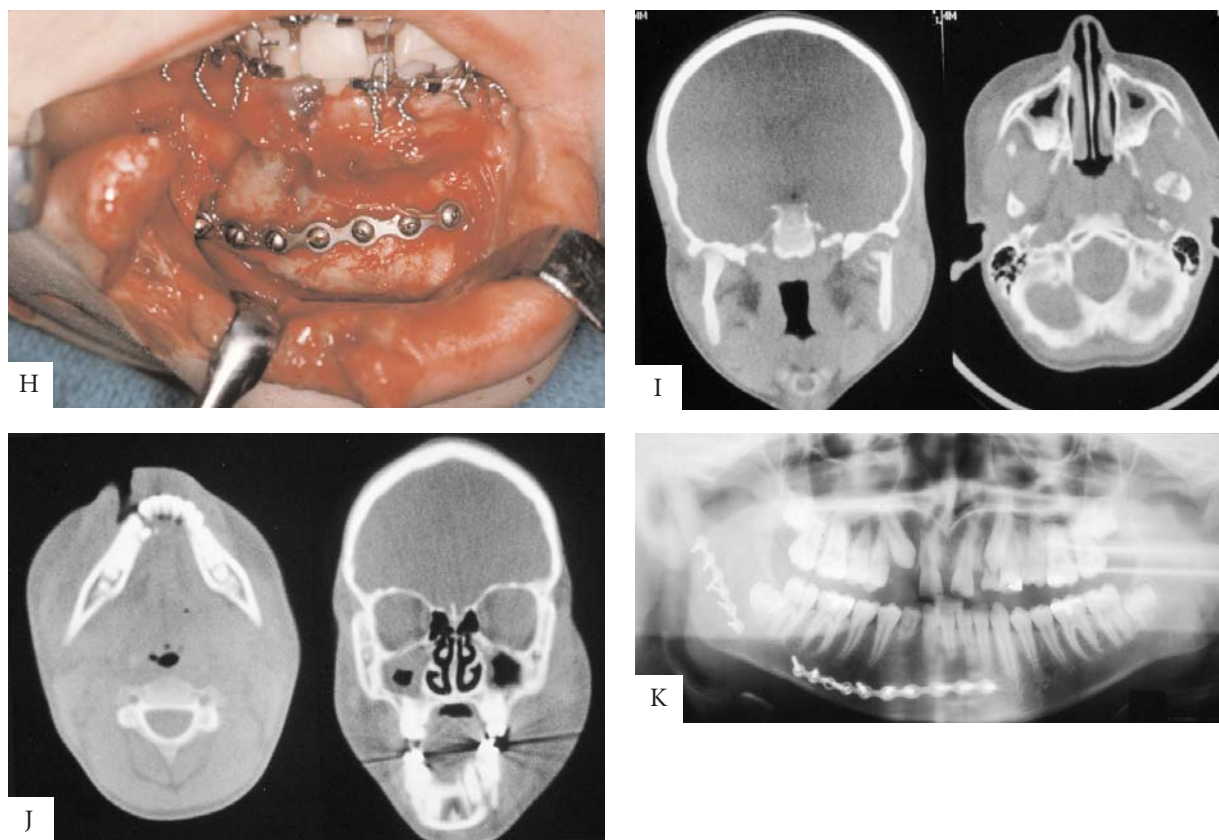


FIGURE 27-7 (CONTINUED) H, Intraoral view of reduced and plate/screw stabilized right parasymphyseal fracture. I, Computed tomography (CT) scans demonstrating left intracapsular condyle fracture and right condylar neck fracture. J, CT scans demonstrating right parasymphyseal fracture. K, Postoperative Panorex radiograph demonstrating reduction and fixation of fractures. A–E, G–K reproduced with permission, F adapted from Posnick JC.¹³⁵

bone to chondrocytes as a result of the stimulation provided by CPM of the joint.^{126,127} They documented improved healing of intra-articular fractures with the use of CPM compared with immobilization.¹²⁸ The use of CPM in the treatment of TMJ disorders and for the early management of acute TMJ injuries seems to have promise but has not been used often. Conversely the use of extended periods of immobilization of the acutely injured TMJ appears to be counterproductive. A regimen of physical therapy for the TMJ after an initial phase of immobilization is recommended for optimal rehabilitation. Also, functional appliances have been used in an attempt to reestablish vertical height to foreshortened fracture sites in the early injury phase. Although case series have shown good results, no outcome data are available that show a clear advantage to using this technique.¹⁰⁴ Since growth distur-

bance is a concern with these injuries, long-term follow-up is necessary to evaluate the possible development of asymmetry.

Parasymphyseal Fractures When marginal reduction and fixation techniques are used for parasymphyseal or symphyseal fractures, a small dentoalveolar gap often occurs between the two teeth adjacent to the fracture site. Using open reduction techniques with stable (miniplate and screw) fixation at the inferior border, combined with reduction and stabilization at the dentition with an arch bar, gives a more reliable bony union of the injury without displacement. Plating at the tension-band zone is not recommended in the mixed dentition.

Body Fractures Body fractures of the mandible usually have favorable “muscle

pull” vectors on the segments, which encourage reduction rather than displacement. In these situations closed reduction techniques with maxillomandibular fixation generally suffice. Alternatively the skilled surgeon can place inferior border plates and screws with the aid of a transcutaneous trocar and intraoral incision. When extended maxillomandibular fixation must be avoided (eg, associated condyle fracture or severe trauma), more stable forms of internal fixation (plates and screws) are indicated.

Dentoalveolar Injuries Anterior maxillary and mandibular teeth and their supporting alveolar structures often bear the brunt of lower face injuries, and as a result dentoalveolar injuries are very common in the pediatric population.^{43,111,129–131} The teeth may be concussed, subluxed,

partially or totally avulsed, or intruded. In Posnick and colleagues' study dentoalveolar fractures were evenly distributed between the mandible and the maxilla. Thirty-two children sustained 44 fractures, 8 of which were isolated. Teeth that are loosened should be returned to their normal position in the tooth socket and alveolar segments reduced to their preinjury position. The reduced teeth and alveolar segments should be immobilized until healing occurs. Isolated dentoalveolar injuries may be adequately reduced under local anesthesia and then stabilized with the application of acid-etch bonding techniques and a braided wire. Arch bars can be helpful in select cases but often will extrude the teeth. The selected splinting techniques must meet certain criteria, including easy fabrication, maintenance of only passive forces on the teeth, lack of irritation to the soft tissues, maintenance of normal occlusion, allowance of good oral hygiene, access for subsequent endodontic treatment, and easy removal. Longitudinal reassessment with a pediatric or general dentist is important because ankylosis of primary teeth may prevent the normal eruption of permanent teeth.

Resorbable Fixation Materials

Titanium alloy plates and screws are the standard for craniomaxillofacial fixation. The use of plate and screw titanium fixation in the craniomaxillofacial skeleton has consistently resulted in low complication rates and excellent biocompatibility. However, controversy associated with their use in growing bones has led to the development of resorbable fixation materials. Issues of biocompatibility, strength, bulk, inflammatory response, and predictable resorption rates continue to be discussed. Most resorbable plate and screw fixations use isomer configurations of alpha-hydroxy polylactic and polyglycolic acids.

Possible advantages of resorbable fixation include the following:

- Degradation of the material by the citric acid cycle into CO₂ and H₂O
- No interference with imaging (CT, magnetic resonance imaging, standard radiographs)
- No effect on postoperative radiation treatment
- The possibility of integrating substances such as antibiotics within the fixation material

Possible disadvantages of resorbable fixation include the following:

- Less mechanical strength when compared with titanium alloys of similar sizes
- "Memory" of the material, which may distort reduction of fracture
- Increased reactivity during the degradation phase
- Increased operative working time

Summary

The pattern of craniomaxillofacial fractures seen in children and adolescents varies with evolving skeletal anatomy and socioenvironmental factors. Facial fractures in children may go unrecognized as a result of limited communication, incomplete radiographic examination, or the late presentation of the patient by the family. Recognition of the differences between children and their adult counterparts is important in facial rehabilitation. Consideration should be given to open reduction of the fractures, primary autogenous cranial bone grafting, and the use of stable forms of fracture fixation (miniplates and microplates and screws). Late sequelae of pediatric fractures occur even when appropriate and prompt treatment is instituted. The effects of the trauma event as well as the surgical intervention or lack of treatment on growth and development may be contributing factors. Long-term follow-up by appropriate practitioners is mandatory to monitor these events.

References

1. Le Fort R. Experimental study of fractures of the upper jaw: parts I and II. *Rev Chir Paris* 1901;23:208–27, 360–79.
2. Converse JM, Kazanjian VH. *Surgical treatment of facial injuries*. 2nd ed. Baltimore (MD): Williams & Wilkins; 1949. p. 1–574.
3. Gillies H, Millard DR Jr. *The principles and art of plastic surgery*. Boston (MA): Little, Brown; 1957. p. 1–652.
4. Rowe NL, Killey HC. *Fractures of the facial skeleton*. 2nd ed. Baltimore (MD): Williams & Wilkins; 1968. p. 1–894.
5. Dingman RE, Natvig P. *Surgery of facial fractures*. Philadelphia (PA): W.B. Saunders; 1964. p. 1–380.
6. Wainwright M. *Miracle cure: the story of penicillin and the golden age of antibiotics*. Cambridge (MA): Basil Blackwell; 1990. p. 13–4.
7. Luhr HG. Zur stabilen osteosynthese bei unterkieferfrakturen. *Dtsch Zahnarztl Z* 1968;23:754.
8. Cowley RA, Dunham CM. *Shock trauma: critical care manual*. Baltimore (MD): Maryland University Press; 1982.
9. Gruss JS, MacKinnon SE, Kassel EE, et al. The role of primary bone grafting in complex craniomaxillofacial trauma. *Plast Reconstr Surg* 1985;75:17–24.
10. Gruss JS, MacKinnon SE. Complex maxillary fractures: the role of buttress reconstruction and immediate bone grafts. *Plast Reconstr Surg* 1986;78:9–22.
11. Manson PN, Crawley WA, Yaremchuk MJ, et al. Midface fractures: advantages of immediate extended open reduction and bone grafting. *Plast Reconstr Surg* 1985;76:1–12.
12. Manson PN. Skull and midface injuries. In: Mustarde JC, Jackson IT, editors. *Plastic surgery in infancy and childhood*. 3rd ed. New York (NY): Churchill Livingstone; 1988. p. 317–45.
13. Manson PN. Facial injuries. In: McCarthy JG, editor. *Plastic surgery*. Vol 2: the face. Philadelphia (PA): W.B. Saunders; 1990. p. 1108.
14. Waldron CW, Balkan SG, Peterson RG. Fractures of the facial bones in children. *J Oral Surg* 1943;1:215.
15. MacLennan WD. Fractures of the mandible in children under the age of 6 years. *Br J Plast Surg* 1956;9:125.
16. Rowe NL. Fractures of the facial skeleton in children. *J Oral Surg* 1968;26: 497–507.
17. Adekey EO. Pediatric fractures of the facial skeleton: a survey of 85 cases from Kaduna, Nigeria. *J Oral Surg* 1975;38:355–8.
18. Anderson PJ. Fractures of the facial skeleton in children. *Injury* 1995;26:47–50.

19. Bales CR, Randall P, Lehr HB. Fractures of the facial bones in children. *J Trauma* 1972;12:56–66.
20. Bernstein L. Maxillofacial injuries in children. *Otolaryngol Clin North Am* 1969;2:397.
21. Carroll MJ, Hill CM, Mason DA. Facial fractures in children. *Br Dent J* 1987;163:289.
22. Fortunato MA, Fielding AF, Guernsey LH. Facial bone fractures in children. *Oral Surg* 1982;53:225–30.
23. Freid MG, Baden E. Management of fractures in children. *J Oral Surg* 1954;12:129.
24. Gwyn PP, Carraway JH, Horton CE, et al. Facial fractures: associated injuries and complications. *Plast Reconstr Surg* 1971;47:225–30.
25. Hall RK. Injuries of the face and jaws in children. *Int J Oral Surg* 1972;1:65–72.
26. Hall RK. Facial trauma in children. *Aust Dent J* 1974;19:336–45.
27. Haug RH, Foss J. Maxillofacial injuries in the pediatric patient. *Oral Surg Oral Med Oral Pathol Oral Radiol Endosc* 2000;90:126–34.
28. Iizuka T, Thoren H, Anaino DJ, et al. Midfacial fractures in pediatric patients. *Arch Otol Head Neck Surg* 1995;121:1366–71.
29. James D. Maxillofacial injuries in children. In: Rowe NL, Williams JL, editors. *Maxillofacial injuries*. London (UK): Churchill Livingstone; 1985. p. 538–58.
30. Kaban LB. Diagnosis and treatment of fractures of the facial bones in children. *J Oral Maxillofac Surg* 1993;51:722–9.
31. Kaban LB, Mulliken JB, Murray JE. Facial fractures in children: an analysis of 122 fractures in 109 patients. *Plast Reconstr Surg* 1977;59:15–20.
32. Kim DB, Sacapano M, Hardesty RA. Facial fractures in children. *West J Med* 1997;167:100.
33. Koltai PJ, Rabkin D. Management of facial trauma in children. *Pediatr Clin North Am* 1996;43:1253–75.
34. Koumakis SE, Raife J, Ghorayeb B, Stiernberg CM. Pediatric gunshot wounds to the head and neck. *Otolaryngol Head Neck Surg* 1996;114:756–60.
35. Maniglia AJ, Kline SN. Maxillofacial trauma in the pediatric age group. *Otolaryngol Clin North Am* 1983;16:717–30.
36. McCoy FJ, Chandler RA, Crow ML. Facial fractures in children. *Plast Reconstr Surg* 1966;37:209–15.
37. Ramba J. Fractures of the facial bones in children. *Int J Oral Surg* 1985;14:472–8.
38. Schultz RC. Facial trauma in children. In: Marshall DK, editor. *Facial injuries*. 3rd ed. Chicago (IL): New York Medical Publishers; 1988, p. 1–682.
39. Thoren H, Iizuka T, Hallikainen D, et al. An epidemiological study of patterns of condylar fractures in children. *Br J Oral Maxillofac Surg* 1997;35:306–11.
40. Khosla VM, Boren W. Mandibular fractures in children and their management. *J Oral Surg* 1971;29:116–21.
41. Lehman JA Jr, Saddawi ND. Fractures of the mandible in children. *J Trauma* 1976;16:773–7.
42. Lustmann J, Milhem I. Mandibular fractures in infants: review of the literature and report of seven cases. *J Oral Maxillofac Surg* 1994;52:240–6.
43. Moos K, El-Attar A. Mandible and dental injuries. In: Mustarde JC, Jackson IT, editors. *Plastic surgery in infancy and childhood*. 3rd ed. New York (NY): Churchill Livingstone; 1988. p. 345–64.
44. Posnick JC. Pediatric cranial base surgery. In: Janecka IP, editor. *Problems in plastic and reconstructive surgery*. Philadelphia (PA): J.B. Lippincott; 1993. p. 107–29.
45. Morgan WC. Pediatric mandibular fractures. *Oral Surg* 1975;40:320–6.
46. Panagopoulos AP. Management of fractures of the jaws in children. *J Int Coll Surg* 1957;8:806.
47. McGowan DA. Neurosensory disturbances of the trigeminal nerve: a long-term follow-up of traumatic injuries [discussion]. *J Oral Maxillofac Surg* 1995;53:505.
48. American College of Surgeons. *Advanced trauma life support courses*. Chicago (IL): American College of Surgeons; 1989.
49. Needleman HL. Orofacial trauma in child abuse: types, prevalence, management, and the dental professional involvement. *Pediatr Dent* 1986;8:71–80.
50. Warlock P, Stower M, Barbor P. Patterns of fractures in accidental and non-accidental dental injury in children: a comparative study. *Br Med J* 1986;293:100–2.
51. Bridges CP, Ryan RF, Longnecker CG, et al. Tracheostomy on children: a 20 year study at Charity Hospital in New Orleans. *Plast Reconstr Surg* 1966;37:117–20.
52. Line WAS, Hawkins DB, Kahistrom EJ, et al. Tracheostomy in infants and young children: the changing perspective, 1970–1985. *Laryngoscope* 1986;96:510–5.
53. Posnick JC, Wells M, Pron G. Pediatric facial fractures: evolving patterns of treatment. *J Oral Maxillofac Surg* 1993;51:836–44.
54. Lewis VL Jr, Manson PN, Morgan RF, et al. Facial injuries associated with cervical fractures: recognition, patterns and management. *J Trauma* 1985;25:90–3.
55. McGraw BL, Cole RR. Pediatric maxillofacial trauma: age-related variations in injury. *Arch Otolaryngol Head Neck Surg* 1990;116:41–5.
56. Pasternack JS, Veenema KR, Callahan CM. Baseball injuries: a little league survey. *Pediatrics* 1996;98:445–8.
57. Maisel H. Postnatal growth and anatomy of the face. In: Mathog RH, editor. *Maxillofacial trauma*. Baltimore (MD): Williams & Wilkins; 1984, p. 1–415.
58. Bull MJ, Sheese J. Update for the pediatrician on child passenger safety: five principles for safer travel. *Pediatrics* 2000;106:1113–6.
59. Dodson TH, Kaban LB. California mandatory seat belt laws: the impact on maxillofacial injuries. *J Oral Maxillofac Surg* 1988;46:875–80.
60. Demas PN, Braun TW. Pediatric facial injuries associated with all-terrain vehicles. *J Oral Maxillofac Surg* 1992;50:1280–3.
61. Ledbetter DJ, Tapper D. Injuries caused by child abuse. *Compr Ther* 1989;15:9–13.
62. Fiala TGS, Novelline RA, Yaremchuk MJ. Comparison of CT imaging artifacts from craniomaxillofacial internal fixation devices. *Plast Reconstr Surg* 1993;92:1227–32.
63. Kassel EE, Noyek AM, Cooper PW. CT in facial trauma. *J Otolaryngol* 1983;12:2–15.
64. Hirabayashi A, Unamoto N, Tachi M, et al. Optimized 3-D CT scan protocol for longitudinal morphological estimation in craniofacial surgery. *J Craniofac Surg* 2001;12:126–40.
65. Kaban LB. Facial trauma: I. Midface fractures. In: Kaban LB, editor. *Pediatric oral and maxillofacial surgery*. Philadelphia (PA): W.B. Saunders; 1990. p. 209–32.
66. Alpert B, Seligson D. Clinical controversies in oral and maxillofacial surgery: II. Removal of asymptomatic bone plates used for orthognathic surgery and facial fractures. *J Oral Maxillofac Surg* 1996;54:618–21.
67. Beiser IH, Kanat IO. Biodegradable internal fixation: a literature review. *J Am Podiatr Med Assoc* 1990;80:72–5.
68. Borah GL, Ashmead D. The fate of teeth transfixed by osteosynthesis screws. *Plast Reconstr Surg* 1996;97:726–9.
69. Ellis E III. Rigid skeletal fixation of fractures. *J Oral Maxillofac Surg* 1993;51:163–73.
70. Haug RH. Clinical controversies in oral and maxillofacial surgery: I. Retention of asymptomatic bone plates used for orthognathic surgery and facial fractures. *J Oral Maxillofac Surg* 1996;54:611–7.
71. Manson P. The long-term effects of rigid fixation on the growing craniomaxillofacial skeleton [commentary]. *J Craniofac Surg* 1991;2:69.
72. Posnick JC. The effects of rigid fixation on the craniofacial growth in rhesus monkeys [discussion]. *Plast Reconstr Surg* 1994;93:11.
73. Resnick JI, Kinney BM, Kawamoto HK, et al.

- The effect of rigid internal fixation on cranial growth. *Ann Plast Surg* 1990;25:372–4.
74. Sarnet BG. Differential craniofacial skeletal changes after postnatal experimental surgery in young and adult animals. *Ann Plast Surg* 1978;1:131–45.
 75. Burstein F, Cohen S, Hudgins R, et al. Frontal basilar trauma: classification and treatment. *Plast Reconstr Surg* 1997;99:1314–21.
 76. Markowitz BL, Manson PN. Frontal basilar trauma: classification and treatment [discussion]. *Plast Reconstr Surg* 1997;99:1322.
 77. Wolfe SA, Johnson P. Frontal sinus injuries: primary care and management of late complications. *Plast Reconstr Surg* 1988;82:781–91.
 78. Posnick JC. Craniomaxillofacial fractures in children. *Oral Maxillofac Clin North Am* 1994;1:169–85.
 79. Sandstedt P, Sorensen S. Neurosensory disturbances of the trigeminal nerve: a long-term follow-up of traumatic injuries. *J Oral Maxillofac Surg* 1995;53:498–505.
 80. Posnick JC. Pediatric orbital fractures. *Oral Maxillofac Clin North Am* 1993;5:495–506.
 81. Messinger A, Radkowski MA, Greenwald MA, et al. Orbital roof fractures in the pediatric population. *Plast Reconstr Surg* 1989;84:213–6.
 82. Nahum AM. The biomechanics of maxillofacial trauma. *Clin Plast Surg* 1975;2:59–64.
 83. Raflo GT. Blow-in and blow-out fractures of the orbit: clinical correlations and proposed mechanisms. *Ophthalmic Surg* 1984;15:114–9.
 84. Manson PN, Clifford CM, Su CT, et al. Mechanisms of global support and posttraumatic enophthalmos: I. The anatomy of the ligament and its relation to intramuscular cone orbital fat. *Plast Reconstr Surg* 1986;77:193–202.
 85. Wolfe SA. Application of craniofacial surgical principles in orbital reconstruction following trauma and tumor removal. *J Maxillofac Surg* 1982;10:212–23.
 86. Moss ML, Bromberg BE, Song IC, et al. The passive role of nasal septal cartilage in midfacial growth. *Plast Reconstr Surg* 1968;41:536–42.
 87. Graham GG, Peltier R. The management of mandibular fractures in children. *J Oral Surg* 1960;18:416.
 88. Keniry AJ. A survey of jaw fractures of children. *Br J Oral Surg* 1971;8:231–6.
 89. Posnick JC. Mandibular fractures in infants: review of the literature and report of seven cases [discussion]. *J Oral Maxillofac Surg* 1994;52:245.
 90. Rowe NL. Fractures of the jaws in children. *J Oral Surg* 1969;27:497–507.
 91. Thoren H, Iizuka T, Hallikainen D, et al. Different patterns of mandibular fractures in children: an analysis of 220 fractures in 157 patients. *J Craniomaxillofac Surg* 1992;20:292–6.
 92. Anderson MF, Alling CC. Subcondylar fracture in young dogs. *Oral Surg* 1965;19:263.
 93. Boyne PJ. Osseous repair and mandibular growth after subcondylar fractures. *J Oral Surg* 1967;25:300–9.
 94. Chalmers J, Lyons C. Fractures involving the mandibular condyle: a post-treatment survey of 120 cases. *J Oral Surg* 1947;5:45.
 95. Coccaro PJ. Restitution of mandibular form after condylar injury in infancy (a 7-year-study of a child). *Am J Orthod Dentofac Orthop* 1969;55:32–49.
 96. Dahlstrom L, Kahnberg KE, Lindahl L. Fifteen years' follow-up on condyle fractures. *Int J Oral Maxillofac Surg* 1989;18:18–23.
 97. Gilhaus-Moe O. Fractures of the mandibular condyle in the growth period. Stockholm: Scandinavian University Books; 1969.
 98. Jeter TS. Analysis of possible factors leading to problems after nonsurgical treatment of condylar fractures [discussion]. *J Oral Maxillofac Surg* 1994;52:793–9.
 99. Leake D, Doykos J III, Habal MB, et al. Long-term follow-up of fractures of the mandibular condyle in children. *Plast Reconstr Surg* 1971;47:127–31.
 100. Miller RI, McDonald DK. Remodelling of bilateral condylar fractures in a child. *J Oral Maxillofac Surg* 1986;44:1008–10.
 101. Nørholt SE, Krishnan V, Sindet-Pedersen S, et al. Pediatric condylar fractures: a long-term follow-up study of 55 patients. *J Oral Maxillofac Surg* 1993;51:1302–10.
 102. Nowak AJ, Casamassimo PS. Oral opening and other selected facial dimensions of children 6 weeks to 36 months of age. *J Oral Maxillofac Surg* 1994;52:845–7.
 103. Posnick JC, Goldstein JA. Surgical management of temporomandibular joint ankylosis in the pediatric population. *Plast Reconstr Surg* 1993;91:791–8.
 104. Proffitt WR, Vig KW, Turvey TA. Early fractures of the mandibular condyles: frequently an unsuspected cause of growth disturbances. *Am J Orthod Dentofac Orthop* 1980;78:1–24.
 105. Rubenstein LK. Oral opening and other selected facial dimensions of children 6 weeks to 36 months of age [discussion]. *J Oral Maxillofac Surg* 1994;52:848.
 106. Silvennoinen U, Iizuka T, Oikarinen K, et al. Analysis of possible factors leading to problems after nonsurgical treatment of condylar fractures. *J Oral Maxillofac Surg* 1994;52:793–9.
 107. Walker DG. Mandibular condyle: fifty cases demonstrating arrest in development. *Dent Pract* 1957;7:160.
 108. Walker RV. Traumatic mandibular condylar fracture dislocations: effect of growth in the *Macaca rhesus* monkey. *Am J Surg* 1960;100:850.
 109. Winstanley RP. Collapse of the condylar head of the mandible in children and subsequent ankylosis. *Br J Oral Surg* 1978;16:3–11.
 110. Alexander R, Stark MM. An accurate method for open reduction and internal fixation of high and low condylar process fractures. *J Oral Maxillofac Surg* 1994;52:808–12.
 111. Andreasen JO, Ravn JJ. The effect of traumatic injuries to primary teeth on their permanent successors: II. A clinical and radiographic follow-up study of 213 teeth. *Scand J Dent Res* 1971;79:284–94.
 112. Chen CT, Lai JP, Chen YR. Costochondral graft in acute mandibular condylar fracture. *Plast Reconstr Surg* 1997;100:1234–9.
 113. Hall MB. Condylar fractures: surgical management. *J Oral Maxillofac Surg* 1994; 52:1189–92.
 114. Kaplan SL, Mark HI. Bilateral fractures of the mandibular condyles and fracture of the symphysis menti in an 18-month-old child: two year preliminary report with a plea for conservative treatment. *Oral Surg* 1962;15:136.
 115. MacLennan WD, Simpson W. Treatment of fractured mandibular condylar processes in children. *Br J Plast Surg* 1965;18:423–7.
 116. MacLennan WD. Consideration of 180 cases of typical fractures of the mandibular condylar process. *Br J Plast Surg* 1952;5:122.
 117. McGrath CJR, Egbert MA, Tong DC, et al. Unusual presentations of injuries associated with the mandibular condyle in children. *Br J Oral Maxillofac Surg* 1996;34:311–4.
 118. Rakower W, Protzell A, Rosencrans M. Treatment of displaced condylar fractures in children: report of cases. *J Oral Surg* 1961;19:517.
 119. Rowe NL. Mandibular joint lesions in infants and adults. *Int Dent J* 1960;10:484.
 120. Schettler D, Rehrmann A. Long-term results of functional treatment of condylar fractures with the long bridle according to A. Rehrmann. *J Maxillofac Surg* 1975;3:14–22.
 121. Walker RV. Condylar fractures: nonsurgical management. *J Oral Maxillofac Surg* 1994;52:1185–8.
 122. Zide MF, Kent JN. Indications for open reduction of mandibular condyle fractures. *J Oral Maxillofac Surg* 1983;41:89–98.
 123. Zide MF. Open reduction of the mandibular condyle fractures: indications and techniques. *Clin Plast Surg* 1989;16:69–76.
 124. Zide MF. An accurate method for open reduction and internal fixation of high and low condylar process fractures [discussion]. *J Oral Maxillofac Surg* 1994;52:812.

125. Troulis M, Kaban LB. Endoscopic approach to the ramus/condyle unit: clinical applications. *J Oral Maxillofac Surg* 2001;59:503–9.
126. Salter RB, Ogilvie-Harris DJ. The healing of intra-articular fractures with continuous passive motion. In: Cooper R, editor. *AAOS Instructional Course Lectures*. St Louis (MO): C.V. Mosby; 1979. p. 102.
127. Salter RB, Simmonds DF, Malcolm BW, et al. The biological effect of continuous passive motion on the healing of full-thickness defects in articular cartilage. *J Bone Joint Surg Am* 1980;62:1232–51.
128. Schenck RR. Dynamic traction and early passive movement for fractures of the proximal interphalangeal joint. *J Hand Surg Am* 1986;1:850–8.
129. Gelbier S. Injured anterior teeth in children: a preliminary discussion. *Br Dent J* 1967; 123:331–5.
130. Lu M. Reimplantation of an avulsed anterior teeth in patients with jaw fractures. *Plast Reconstr Surg* 1973;51:377–83.
131. MacLennan WD. Injuries involving the teeth and jaws in young children. *Arch Dis Child* 1957;37:492.
132. Posnick JC. The role of plate and screw fixation in the treatment of pediatric facial fractures. In: Yaremchuk MJ, Gruss JS, Manson PN, editors. *Rigid fixation of the craniomaxillofacial skeleton*. Stoneham (MA): Butterworth-Heinemann; 1992. p. 396–419.
133. Posnick JC, Goldstein JA, Armstrong D. Reconstruction of skull defects in children and adolescents by the use of fixed cranial bone grafts: long-term results. *Neurosurgery* 1993;32:785–91.
134. Posnick JC. Management of facial fractures in children and adolescents. *Ann Plast Surg* 1994;33:442–57.
135. Posnick JC. Diagnosis and management of pediatric craniomaxillofacial fractures. In: Peterson LJ, Indressano AT, editors. *Principles of oral and maxillofacial surgery*. Vol I. Part V. Philadelphia (PA): J.B. Lippincott; 1992. p. 623–40.

Management of Panfacial Fractures

Patrick J. Louis, DDS, MD

Management of patients with multiple displaced and comminuted fractures can be extremely challenging not only for those who are inexperienced but also for experienced surgeons. Improper diagnosis, treatment planning, and sequencing produce inadequate results and can lengthen procedure time. However, with the availability of detailed imaging,¹⁻³ rigid fixation,⁴⁻⁶ bone grafting techniques,⁷⁻⁹ and proper sequencing,^{4,10,11} outcomes can be optimized.

All facets of facial form and function are important, and one should strive to preserve them. The importance of proper occlusion cannot be underestimated since acute changes in the way teeth come together can be readily detected by the individual.¹² Such alterations can result in myofascial or temporomandibular joint pain.¹³ Reestablishing the patency of the nasal cavity is important in the prevention of nasal obstruction and potential problems such as sinusitis and obstructive sleep apnea.^{14,15} It is also required to establish the proper quality of speech.¹⁶ Small changes in orbital volume can result in enophthalmos and/or diplopia.^{17,18} The reestablishment of facial height, width, and projection is important for the prevention of facial deformities and for the psychological and social well-being of the individual.¹⁹⁻²¹ No one of these factors can be considered more important than the other; together they constitute the face and its associated functions.

In this chapter, discussion is presented on some of the historic perspectives, etiology, anatomic considerations, imaging, bone grafting, soft tissue resuspension, sequencing of treatment, and complications as they relate to the management of panfacial fractures.

Historic Perspective

Panfacial fractures are defined as those involving the upper, middle, and lower thirds of the face.⁴ These complex injuries are fractures that involve the frontal bones, zygomaticomaxillary complex, nasoorbitoethmoid region, maxilla, and mandible. Complex facial injuries such as these are generally the result of high-velocity trauma.²² Prior to the advent of rigid fixation techniques,²³⁻²⁵ these fractures were treated with wire fixation and head frames.²⁶⁻²⁸ With these techniques it was difficult to establish and maintain the three-dimensional stability of the facial skeleton.

There have been several important advances in the management of maxillofacial trauma that have resulted in improved outcomes. These include the development of high-resolution computed tomography, rigid fixation techniques, soft tissue resuspension, and primary bone grafting. All of these have made a significant impact on the diagnosis and treatment of panfacial injuries; each is discussed later in this chapter.

Etiology

Panfacial fractures result from motor vehicle collisions, assault, sports-related accidents, industrial accidents, and gunshot wounds.^{22,29-32} Since gunshot wounds are addressed in Chapter 26, and because there is usually associated soft tissue damage causing them to generally require different principles of management, they are not discussed in this chapter.

Anatomic Considerations

Facial Buttresses

Many authors have described the buttresses of the face both in vertical and horizontal planes.^{10,32-34} The vertical buttresses include the nasomaxillary, zygomaticomaxillary, and pterygomaxillary buttresses (Figure 28-1). The nasomaxillary buttress includes the maxillary process of the frontal bone and the frontal process of the maxilla, extending lateral to the piriform rim. The zygomaticomaxillary buttress is composed of the zygomatic process of the frontal bone, lateral orbital rim, lateral zygomatic body, and zygomatic process of the maxilla. The pterygomaxillary buttress includes the pterygoid plates of the sphenoid and maxillary tuberosities. Usually the nasomaxillary and zygomaticomaxillary buttresses are reconstructed, but the pterygomaxillary buttress is not because of inaccessibility. The condyle and posterior mandibular

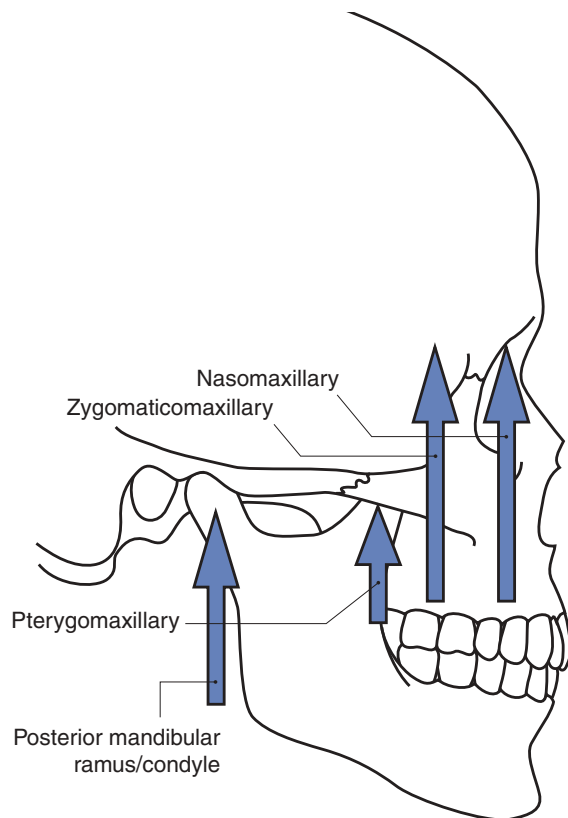


FIGURE 28-1 Vertical buttresses of the face.

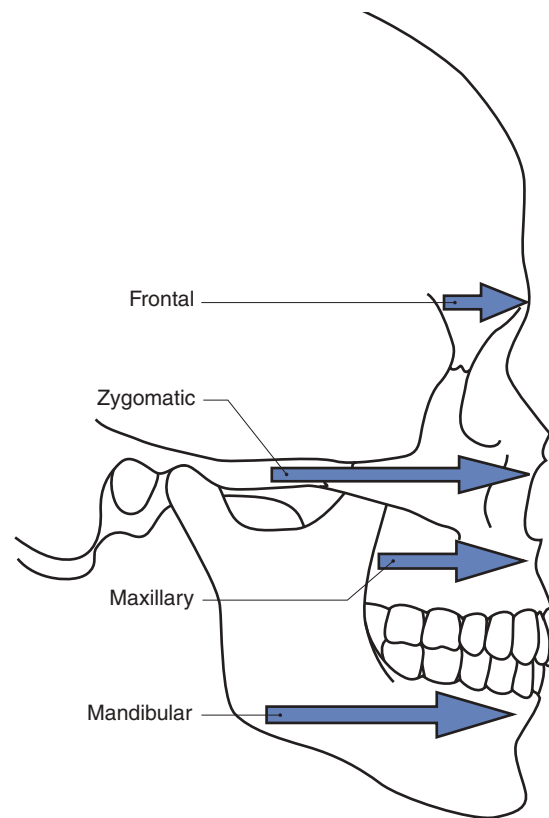


FIGURE 28-2 The horizontal buttresses of the face.

ramus make up yet another buttress establishing posterior facial height.

The horizontal buttresses are also described as *anterior posterior buttresses*.¹⁰ These include the frontal, zygomatic, maxillary, and mandibular buttresses (Figure 28-2). The frontal buttress is composed of the supraorbital rims and the glabellar region. The zygomatic buttress consists of the zygomatic arch, zygomatic body, and infraorbital rim. The maxillary and mandibular buttresses are composed of the basal bone of the maxilla and mandible arches.

None of these buttresses exists in a vacuum. Together they give the facial skeleton its structural integrity. The bone is generally thicker over these described areas to neutralize the forces of mastication or impact. With the proper reduction of these buttresses, we are able to reconstruct the height, width, and projection of the face.

Key Landmarks

When there are multiple facial fractures involving the upper, middle, and lower face, reconstruction should be approached as a puzzle. Known landmarks and anatomy can be used to reconstruct more precisely those areas that have been damaged. Some key landmarks that may help in establishing the proper positioning of the facial skeleton include the dental arches, mandible, sphenozygomatic suture, maxillary buttress, and intercanthal region.

Dental Arches

When one or both of the dental arches are intact, they can be used as guides. For example, if the patient has suffered a Le Fort fracture but no midpalatal split, the maxilla, as an intact arch, can be used to set the mandibular arch and establish proper width. Particularly problematic is the situation in which there is a mid-

palatal split and the mandible is also fractured along the tooth-bearing region, with associated condyle fractures. This can easily lead to widening of the entire facial complex if these segments are not properly reduced. One approach to this problem is to reestablish the maxillary width by exposing the palatal fracture, then reducing and fixating the region (Figure 28-3).³⁴⁻³⁷ This approach works well if there is a solitary midpalatal fracture without comminution or avulsion. A second approach is to obtain impressions for fabrication of dental models. Simulated surgery can then be performed on the upper and lower casts and a surgical splint fabricated (Figure 28-4).^{38,39} This is by no means a foolproof method when both the upper and lower arches are fractured. The more severe the injury (ie, multiple segments), the more difficult it is to establish a preinjury occlusion. If the patient has dental models of his preinjury occlusion

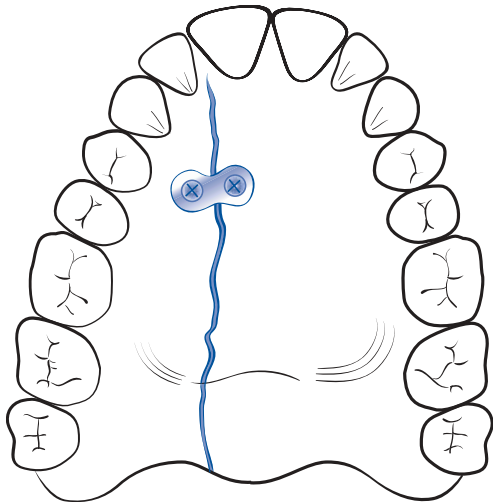


FIGURE 28-3 Reduction and fixation of a palatal fracture using a miniplate.

from previous orthodontic or prosthetic rehabilitation, these can provide invaluable clues to establishing the proper arch form. A third option is to reconstruct the mandible since this is generally a robust bone that can undergo anatomic reduction if attention is paid to detail.

The Mandible

Anatomic reduction at the symphysis and/or body can be achieved with an extraoral exposure of the fracture. Such exposure allows for direct visualization

of the inferior border and, to a lesser degree, the lingual cortex. The reduction of both the buccal and lingual cortical surfaces prior to fixation yields better results (Figure 28-5).^{40,41} When bilateral subcondylar fractures are present, they must be treated to establish the posterior facial height and facial width. When bilateral subcondylar fractures are present and there is an associated fracture along the symphysis and/or body region, the mandible may undergo splaying, with a resultant increase in facial width. The lateral pterygoid muscle attachment at the pterygoid fovea, as well as the lateral capsular ligament of the temporomandibular joint, acts to prevent extremes of movement laterally. The mandibular condyle can be reconstituted to the mandibular ramus to help establish facial height and width.

Sphenozygomatic Suture

The sphenozygomatic suture, along the internal surface of the lateral orbital wall, has been shown in cadaver studies to be a key landmark for both the reduction and fixation of the zygomaticomaxillary complex.⁴²⁻⁴⁴ If other aspects of the facial skeleton are ignored, use of this suture alone can result in errors; however, if the

orbital roof and superior lateral orbit are intact, this suture can be an important landmark for the proper positioning of the zygoma and zygomatic arch. The sphenozygomatic suture is usually exposed along the internal surface of the lateral orbital wall (Figure 28-6).

Once reduced, a small plate is placed across this fracture for fixation. Since the

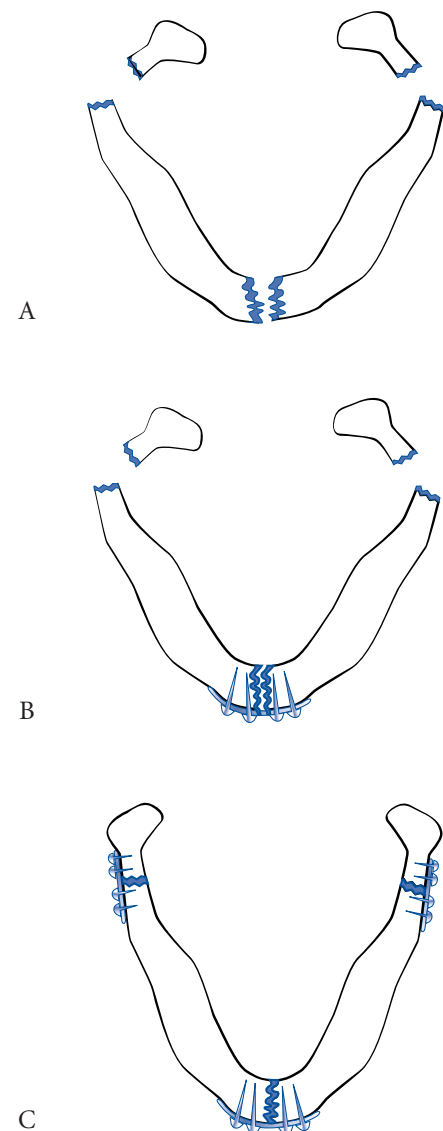


FIGURE 28-5 Nonreduced mandibular fracture involving the symphysis and condylar process (A). Poorly reduced mandibular symphysis fracture with nonreduced lingual cortex and lateral displacement of the mandibular angles (B). Well-reduced mandibular symphysis and condylar process fractures (C). Note the approximation of the lingual cortex in the symphysis region.

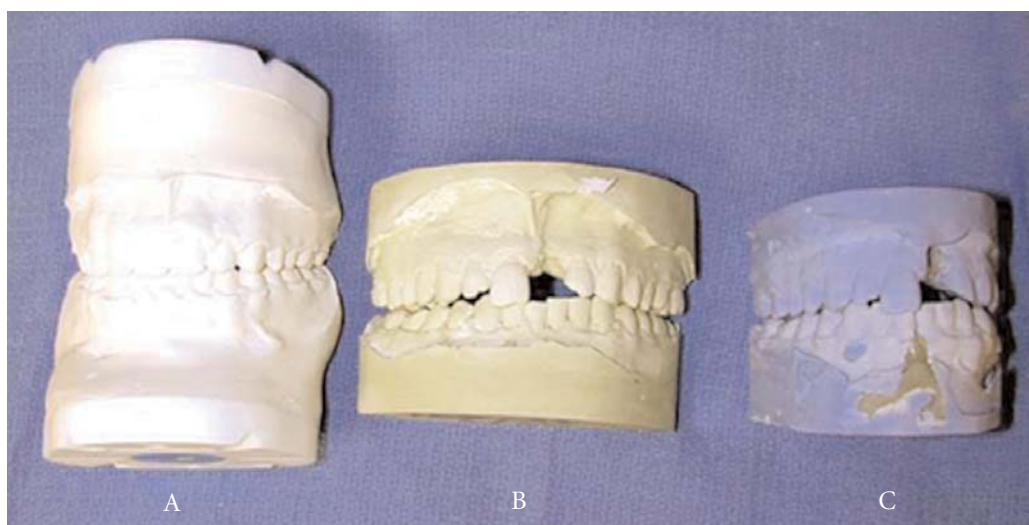


FIGURE 28-4 Dental models from one patient: postorthodontic models (A), post-trauma models (B). Model surgery has been performed on these casts using the postorthodontic models as a guide (C).

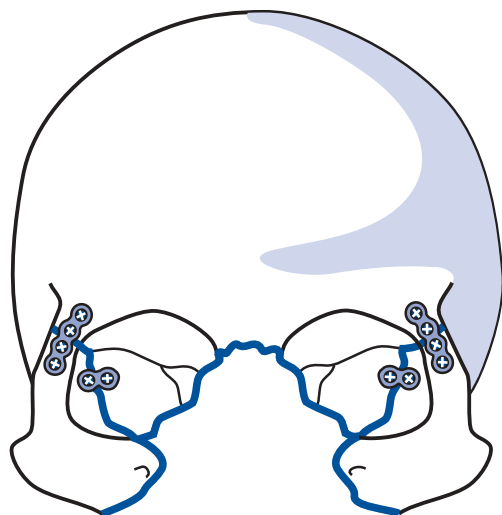


FIGURE 28-6 Reduction and fixation of the sphenozygomatic suture.

orbital roof and superior lateral orbit are rarely fractured, they are usually accurate landmarks. Likewise, the zygomatic buttress is important in establishing the proper position of the zygoma and/or maxilla. Once the zygoma is in the proper place, the location of the maxilla can be verified. This broad area of surface contact aids in the reduction and fixation process. If there is significant bone loss in this region, consideration should be given to primary grafting to reestablish this buttress.

Intercanthal Region

The intercanthal region may also be used to reestablish midfacial width since the intercanthal distance is fairly constant in the adult facial skeleton.⁴⁵ Restoration of the proper intercanthal distance via reduction of the naso-orbitoethmoid complex can help to determine facial width (Figure 28-7).¹⁰ This depends mainly on the fracture type. If there is minimal or no comminution in the region, proper reduction can aid in reestablishment of facial form. Unfortunately, many times this area is severely comminuted and is of little help. Establishing the proper intercanthal distance through measurement is usually performed in cases with severe comminution.

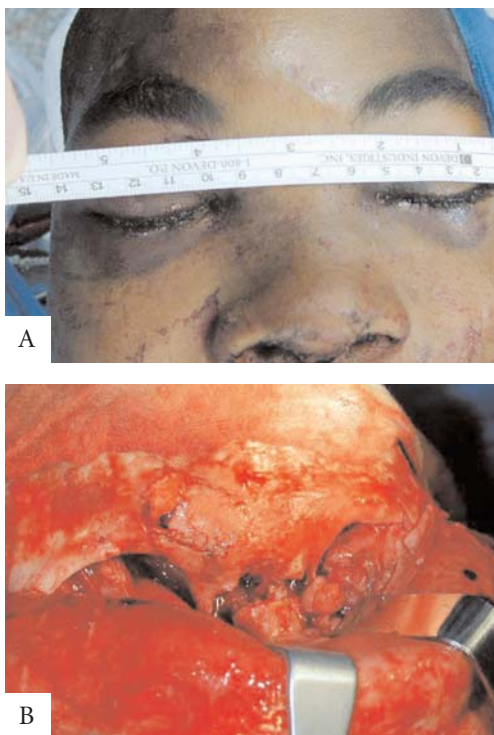

FIGURE 28-7 A, Clinical photograph of patient who has a naso-orbitoethmoid fracture with an intercanthal distance of 43 mm. B, Intraoperative photograph showing exposure of the naso-orbitoethmoid fracture.

Imaging

Imaging of the facial skeleton has gone through a gradual evolution in the area of facial trauma. Plain film radiography and

linear tomography were the gold standard until the advent of computed tomography (CT).⁴⁶⁻⁴⁹ CT has improved our ability to image the facial skeleton and obtain details not possible with plain films (Figure 28-8).¹ It allows the clinicians to determine not only the location of fractures but also the degree and direction of displaced segments.^{2,3} Since the introduction of CT, it has undergone an evolution both in the quality of the images and its application. In a previous article authors reported on “sophisticated CT,” in which 5 mm cuts through the facial skeleton were presented.² It is now a routine practice at the University of Alabama at Birmingham to obtain 0.75 mm axial cuts with coronal reconstructions. This allows for three-dimensional reconstruction (Figure 28-9), if needed, and decreases the number of repeat scans.^{50,51} The scans are loaded onto the hospital information system and can be viewed on computers throughout the medical center and at remote locations. This decreases costs by avoiding the production of multiple hard copies, and it improves efficiency.

With current CT technology, the maxillofacial trauma surgeon can evaluate the fracture pattern by viewing individual cuts or the three-dimensional reconstructions.³ This allows the surgeon to view necessary

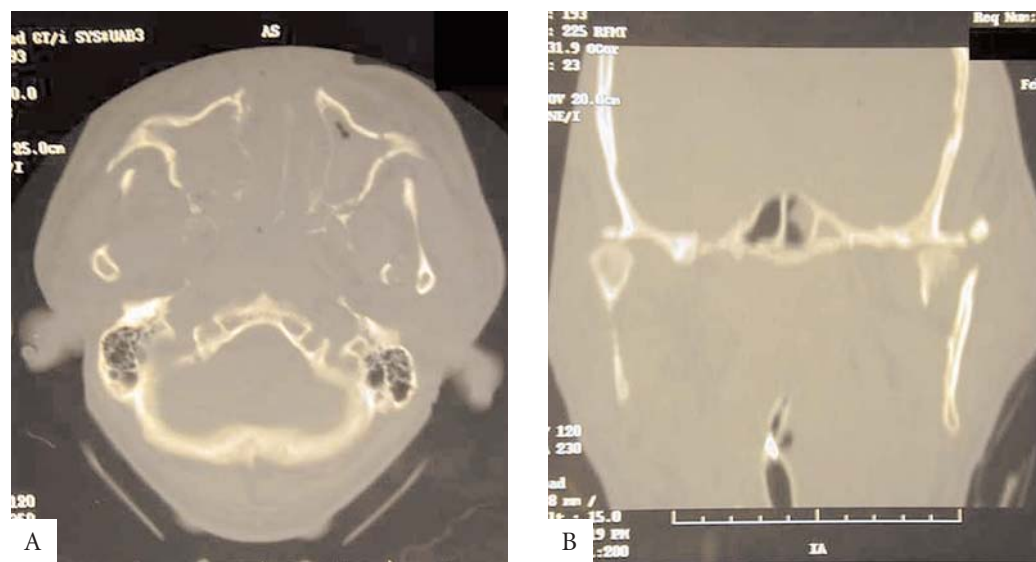


FIGURE 28-8 Computed tomography showing midfacial fractures and a left condylar head fracture on the axial view (A), and a left condylar head fracture on the coronal view (B).

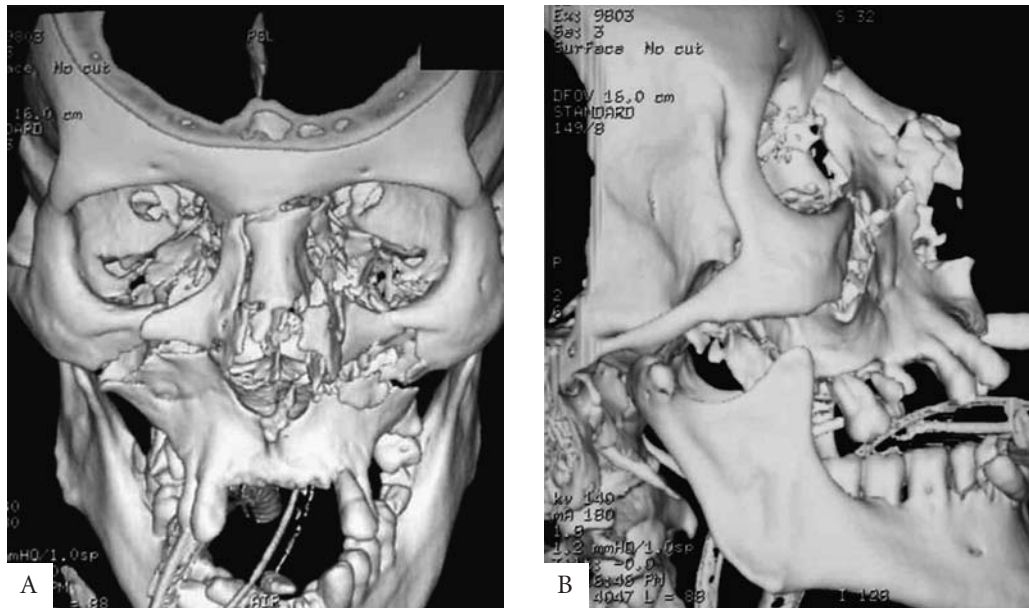


FIGURE 28-9 A and B, Three-dimensional computed tomography images of patient with extensive midface injuries. Note the detail and quality of the images.

details or the overall injury pattern. By manipulating the image windows on a monitor, the surgeon can view hard and soft tissue details. Soft tissue details that can be viewed on CT are not readily apparent on plain films. These include intracranial injuries, injuries to the globe, presence and location of foreign bodies, extraocular muscle entrapment, soft tissue avulsion, displaced teeth, and the airway. If a cervical spine injury is suspected, it may be imaged at the time of cranial and maxillofacial imaging.

The combination of physical examination and current CT imaging allows a clear treatment plan to be generated. This helps greatly with sequencing at the time of surgery.

Surgical Approaches

Approaches to the facial skeleton in panfacial trauma should permit wide exposure of the fracture to allow for anatomic reduction. The location and extent of exposure are dependent on fracture severity and combination. The following describes which fractures can be accessed through the various surgical approaches (Figure 28-10):

- Bicoronal flap procedure: frontal sinus, naso-orbitoethmoid (superior aspect), medial canthal tendon, supra-orbital rim, orbital roof, superior aspect of the medial and lateral orbital wall, zygomatic arch, and mandibular condyle (with preauricular extension)
- Subciliary and transconjunctival incision with lateral canthotomy: infra-orbital rim, medial and lateral orbital wall, and orbital floor. The transconjunctival incision with lateral canthotomy does allow access to the frontozygomatic suture. This requires detachment of the lateral canthal tendon and incision through the orbicularis oculi muscle and periosteum deep to the lateral periorbital skin. The subciliary approach may allow better access to the lateral nasal region
- Upper eyelid crease incision: superior and lateral regions of the orbit. It is generally used to expose the frontozygomatic suture. This incision is not needed when the bicoronal incision is used
- Perinasal incisions: naso-orbitoethmoid region, medial canthal tendon, and nasolacrimal sac. These incisions are generally avoided because of the

potential for significant scarring. This incision is not needed when the bicoronal incision is used

- Maxillary vestibular incision: maxilla and zygomaticomaxillary buttress
- Mandibular vestibular incision: mandible from the ramus to the symphysis. This approach is not usually recommended for comminuted fractures
- Cervical incisions: mandible, except for when there is a high condylar neck fracture. The approach is generally indicated when anatomic reduction is crucial. It allows the surgeon to visualize the reduction of the lingual cortex. It is also indicated for comminuted and complicated fractures such as a fracture of the atrophic edentulous mandible

Bone Grafting and Soft Tissue Resuspension

Two procedures have improved outcomes in the management of panfacial trauma:

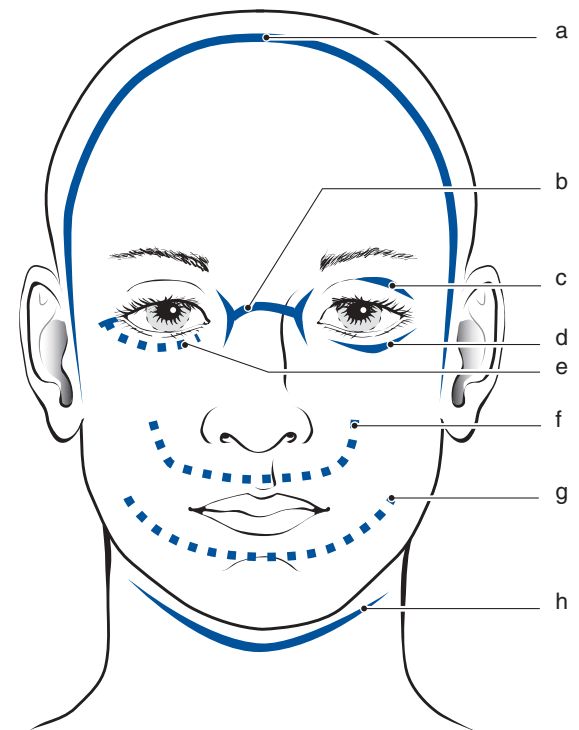


FIGURE 28-10 Surgical approaches to the facial skeleton: bicoronal with preauricular extension (a), paranasal (b), superior tarsal crease (c), subciliary (d), transconjunctival with lateral canthotomy (e), maxillary vestibule (f), mandibular vestibule (g), cervical crease (h).

primary bone grafting and resuspension of the soft tissue after extensive exposure of the facial skeleton.⁷⁻⁹ As previously discussed, the facial buttresses are areas that can serve as guides in the reduction of the facial skeleton and provide stabilization of fractures. With high-velocity trauma, comminution and loss of bony segments can occur in the buttress and “nonbuttress” areas of the face. When these defects are significant, the surgeon may consider the use of bone grafting to prevent soft tissue collapse and to allow for structural support of the facial skeleton. Previous articles have reported on primary bone grafting with few complications.⁷⁻⁹ Even when the bone graft becomes exposed, secondary wound healing generally occurs. Common areas that may require primary bone grafting include the frontal bone, nasal dorsum, orbital floor, medial orbital wall, and zygomaticomaxillary buttress.

There are many potential sources of bone for a graft, but calvarial bone may be the best. Access is often achieved through a bicoronal flap that has already been created during the management of the fractures. These grafts have been shown to resist resorption better than endochondral bone.⁸ Rigid fixation of these grafts has been shown to decrease resorption (Figure 28-11).⁸

Soft tissue resuspension after surgical access to facial fractures is important for

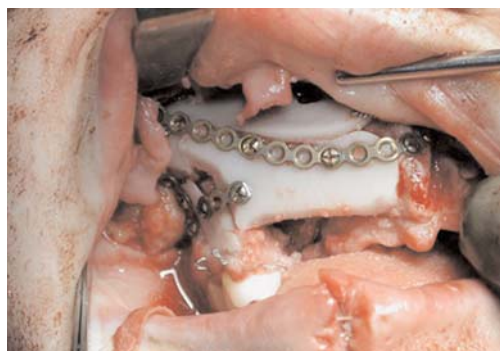


FIGURE 28-11 Primary bone graft rigidly fixed into position to reconstruct the anterior maxillary sinus wall including the nasomaxillary and zygomaticomaxillary buttress. (Courtesy of James Koehler, DDS, MD.)

long-term facial esthetics.^{42,52,53} Resuspension may be especially beneficial in the midface region. For repair of midface fractures, the region is usually exposed transorally and from a periorbital approach.⁵² The soft tissue attachment over the midface is customarily completely stripped. This frequently results in sagging of the soft tissue, with reattachment at a more inferior position. Manson and colleagues stated that there are two steps to placing the soft tissue back into proper position after exposure of the facial skeleton: reattachment of the periosteum or fascia to the skeleton, and closure of the periosteum, muscle fascia, and skin where incisions have been made.⁴² The periosteum is inflexible and limits soft tissue lengthening and migration. Its reattachment is usually accomplished by drilling holes in key locations to fix the periosteum to the bone. Areas where periosteal closure should be obtained include the frontozygomatic suture, infraorbital rim, deep temporal fascia, and muscular layers of maxillary and mandibular incisions.^{32,42,52,54} Areas where periosteal reattachment should be obtained include the malar eminence and infraorbital rim, temporal fascia over the zygomatic arch, medial and lateral canthi, and mentalis muscle.⁴²

Sequence of Treatment

Airway Management

How to maintain the airway is a crucial decision in the management of panfacial fractures. There are several options that are dictated by the fracture pattern and extent of other injuries. When there are extensive head injuries and prolonged intubation is anticipated, tracheostomy should be considered.⁵⁵⁻⁵⁷ Likewise, tracheostomy is an appropriate option to facilitate the management of multiple facial fractures.^{10,56,57} In many cases there are extensive injuries to the naso-orbitoethmoid region, making nasal intubation difficult and hazardous.^{58,59} With nasal intubation, access to

the frontal sinus and naso-orbitoethmoid region is hindered.

Oral intubation may be an option when maxillomandibular fixation is either not possible or not indicated. When prolonged intubation is not anticipated, options include submental intubation^{60,61} or passing the tube behind the dentition, if space permits. If an extraoral approach is indicated to manage a mandibular body/angle fracture or a symphysis fracture, submental intubation may hinder access.

Fracture Management

Much has been written about the proper sequencing of treatment for panfacial fractures.^{10,28,42,52,62} Sequences such as “bottom up and inside out” or “top down and outside in” have been used to describe two of the classic approaches for the management of panfacial fractures. To my knowledge there have been no randomized studies to ascertain whether one approach is superior to the other. The bottom up and inside out approach predates the use of rigid fixation but it is still a valid approach. It establishes the mandible as a foundation for setting the rest of the face and includes open reduction and internal fixation of subcondylar fractures, as well as the remainder of the mandible. The occlusion is set by placing the patient in maxillomandibular fixation; then, the maxilla should be in the proper position. Realignment of the zygomatic buttresses follows in this sequence; however, fixation at this point may lead to inaccuracies in upper midface position. Instead, a break in the sequence is usually preferred here. The zygomaticomaxillary complex is reduced and fixated first. This allows for a more accurate repositioning of the upper midface before fixation at the zygomatic buttress. The maxilla is now fixated along the zygomaticomaxillary buttress. Last, the naso-orbitoethmoid fracture is reduced and stabilized (Figure 28-12).⁶²

The opposite approach, top down and outside in, starts at the zygomatic region. The sphenozygomatic suture is reduced

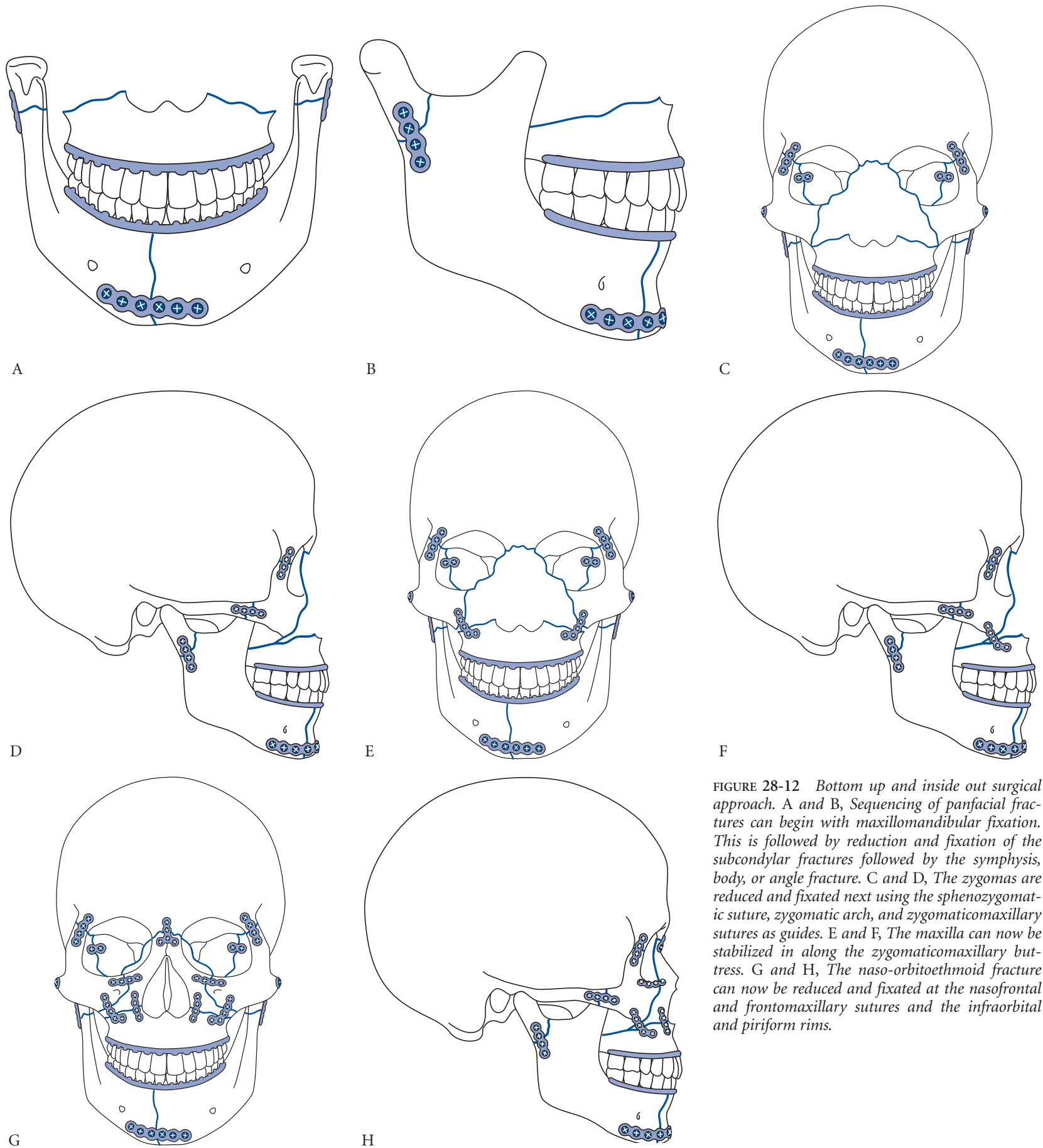


FIGURE 28-12 Bottom up and inside out surgical approach. A and B, Sequencing of panfacial fractures can begin with maxillomandibular fixation. This is followed by reduction and fixation of the subcondylar fractures followed by the symphysis, body, or angle fracture. C and D, The zygomas are reduced and fixated next using the sphenozygomatic suture, zygomatic arch, and zygomaticomaxillary sutures as guides. E and F, The maxilla can now be stabilized in along the zygomaticomaxillary buttress. G and H, The naso-orbitoethmoid fracture can now be reduced and fixated at the nasofrontal and frontomaxillary sutures and the infraorbital and piriform rims.

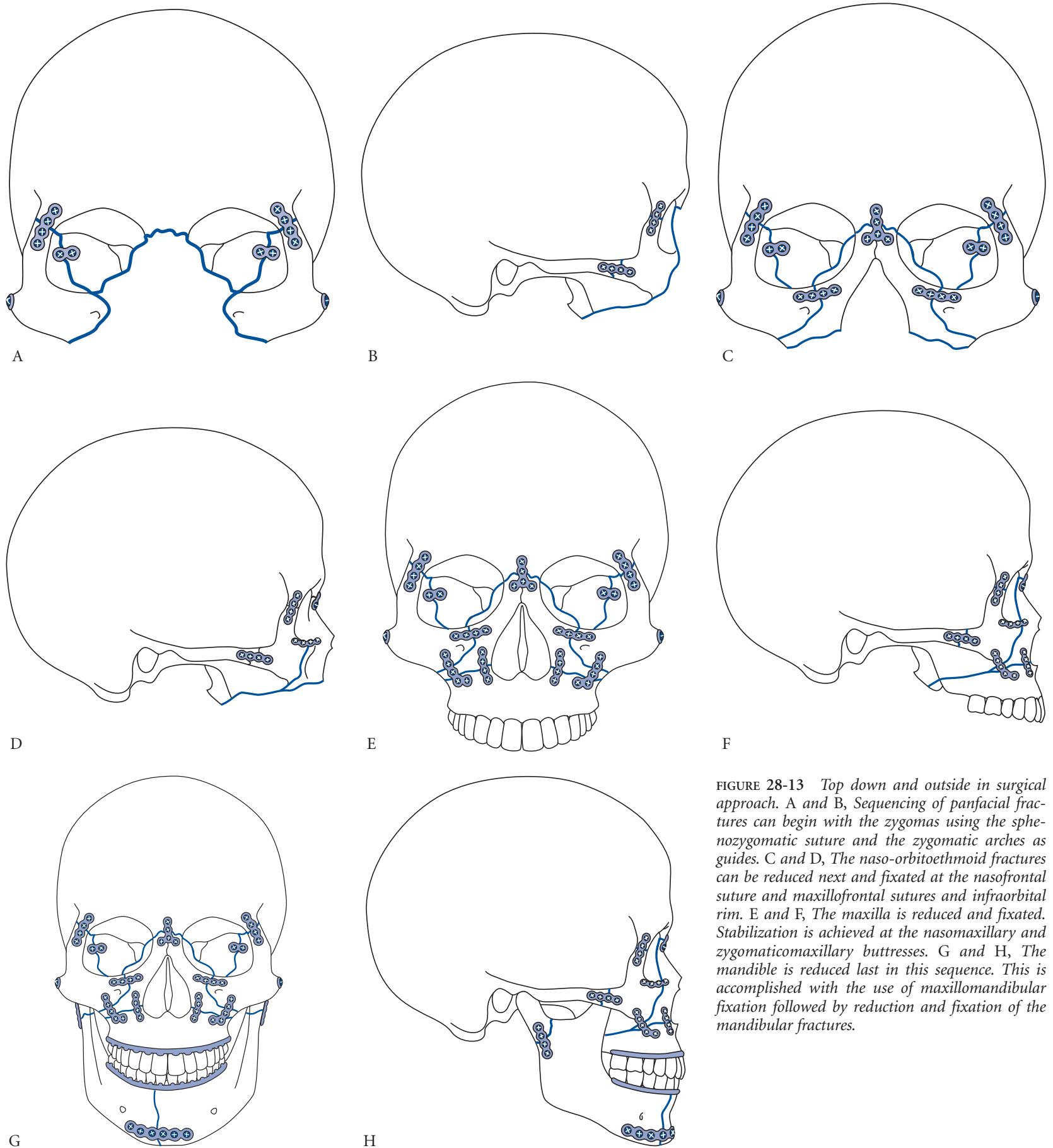


FIGURE 28-13 Top down and outside in surgical approach. A and B, Sequencing of panfacial fractures can begin with the zygomas using the sphenozygomatic suture and the zygomatic arches as guides. C and D, The naso-orbitoethmoid fractures can be reduced next and fixated at the nasofrontal suture and maxillofrontal sutures and infraorbital rim. E and F, The maxilla is reduced and fixated. Stabilization is achieved at the nasomaxillary and zygomaticomaxillary buttresses. G and H, The mandible is reduced last in this sequence. This is accomplished with the use of maxillomandibular fixation followed by reduction and fixation of the mandibular fractures.

and fixated inside the orbit. The zygomatic arch is reduced and plated. If the arches are not properly reduced, underprojection of the midface can result. The alignment of the arch can be verified by the proper position of the sphenozygomatic suture. From this point the zygomas can be further positioned and fixated at the frontozygomatic suture. The naso-orbitoethmoid complex is then positioned to the supraorbital rims, infraorbital rims, and maxillary process of the frontal bones. The maxilla is addressed next using the position of the zygomaticomaxillary buttress and piriform rim as a guide. Maxillomandibular fixation can then be established (Figure 28-13).⁵² Reduction and fixation of the mandibular condyle and the symphysis/body/angle fractures are then performed.

Some surgeons feel that there is a significant advantage to the top down and outside in approach because open treatment of the condyles may not be necessary. The patient is treated with varying periods of maxillomandibular fixation, which may be a valid approach in the case of comminuted intracapsular fractures. Although this is a viable option in some cases, there are two potential complications. One is an unrecognized rotation of the body or ramus of the mandible, resulting in widening. A second complication is temporomandibular joint ankylosis caused by the inability to begin early physical therapy. One author reviewed closed treatment of mandibular condyle fractures and showed compromised results.⁶³ Early function of patients with condylar head fractures is usually indicated, along with guiding elastics to maintain the range of motion of the temporomandibular joint.

Neither one of these techniques will achieve optimal results in every situation. Instead, an approach that goes from known to unknown is certainly more accurate. For example, if there is a significant calvarial injury, it may be difficult to start from the cranium and proceed caudally. In this case, a sequence that starts

caudally and proceeds cranially may achieve more optimal results, allowing the surgeon to reconstruct the damaged cranial portion last. On the other hand, if there is significant comminution of the mandible or if key segments are missing, it may be more appropriate to start cranially and proceed caudally. Thus, the maxillofacial trauma surgeon must be comfortable with both approaches and use known landmarks to achieve optimal results.

In Tables 28-1 and 28-2, two common sequences of management of facial fractures are illustrated. Other sequences exist, but they are variations of these two major approaches.

Complications

There are many complications that are associated with various fractures; these are discussed elsewhere in the text, with reference to the specific fracture type. However, a significant complication associated with panfacial fractures that I will discuss here is widening of the facial complex. This occurs when the surgeon fails to properly reduce key areas that guide in establishing facial width.⁴² If the first area approached is fixated in an improper location, subsequent fragments will be reduced and fixed in an improper spatial arrangement, resulting in a series of errors and, usually, a widened facial complex. To prevent this, the surgeon must use stable segments, known landmarks, and anatomic reduction in the management of panfacial fractures.

If the complication does occur, the surgeon must assess the patient and determine the severity and location of the problem. This is done through physical examination and CT imaging (Figure 28-14). In severe cases three-dimensional computed tomographic reconstruction of the entire facial skeleton can be obtained and, if indicated, a three-dimensional stereolithographic model can be made.^{64,65} The model allows the surgeon to identify and recreate the fractures during model surgery. The fracture may be reduced anatomically and

stabilized with plates, which can then be sterilized and used at the time of surgery. This technique and the use of proper landmarks can aid in the proper reduction and fixation of the fractures.

Conclusions

The management of panfacial fractures is extremely complex. There are, however, many technologic advances that can aid the surgeon in the proper management of these fractures. The most important of these advancements is imaging. With the advent of high-resolution scanners, the surgeon has a more accurate picture of the fracture

Table 28-1 Sequence A: Bottom Up and Inside Out*

1. Tracheostomy
2. Repair of palatal fracture
3. Maxillomandibular fixation
4. Repair of condyle fracture
5. Repair of mandibular fractures (body/symphysis/ramus)
6. Repair of zygomaticomaxillary complex fracture (including arches)
7. Repair of frontal sinus fracture
8. Repair of naso-orbitoethmoid complex fracture
9. Repair of maxilla

*See Figure 28-12.

Table 28-2 Sequence B: Top Down and Outside In*

1. Tracheostomy
2. Repair of frontal sinus fracture
3. Repair of bilateral zygomaticomaxillary complex (including arch) fracture
4. Repair of naso-orbitoethmoid fracture
5. Repair of Le Fort fracture (including midpalatal split)
6. Maxillomandibular fixation
7. Repair of bilateral subcondylar fractures
8. Repair of mandibular fracture (symphysis/body/ramus)

*See Figure 28-13.

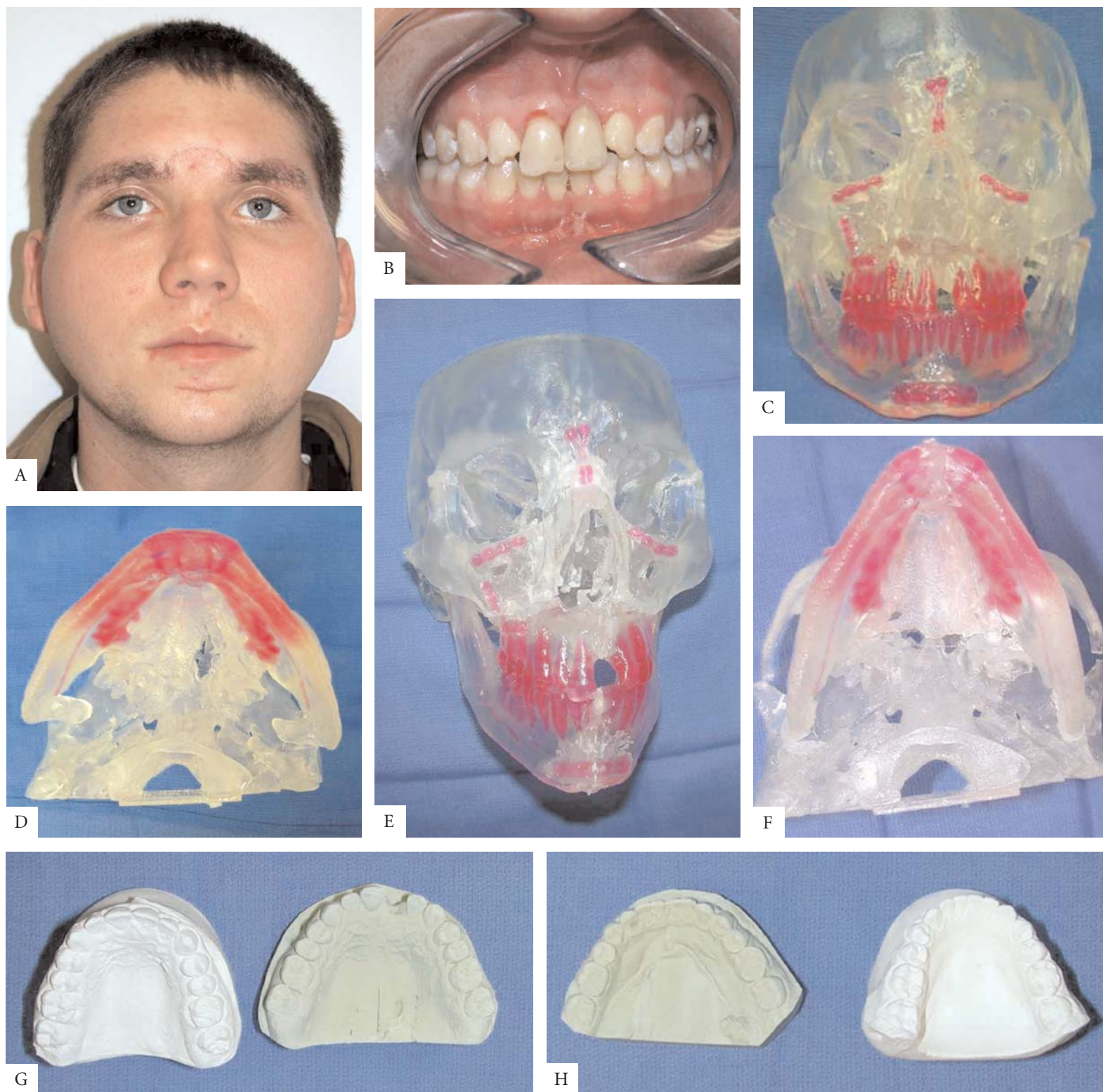


FIGURE 28-14 A and B, Twenty-one-year-old male who fell from a height of two stories. Facial fractures included the frontal sinus, naso-orbitoethmoid, bilateral zygomaticomaxillary complex, Le Fort I with midpalatal split and avulsion of tooth no. 9, mandibular symphysis, and bilateral intracapsular condyle fractures. In this photograph it is evident that the patient has significant facial widening owing to a failure to establish proper facial width. He also has bilateral bony ankylosis of the condyles secondary to a closed reduction of the condyle fractures. C and D, Three-dimensional stereolithographic models generated from CT imaging. Note the significant widening of the mandible and midface. E and F, Simulated surgery was performed on this model and mandibular plates were prebent. Note the significant narrowing of the model. Mandibular condyles are now positioned in the fossae. G and H, Model surgery was performed on the dental cast, based on the preorthodontic models that were brought in by the family. A surgical splint was fabricated. (CONTINUED ON NEXT PAGE)

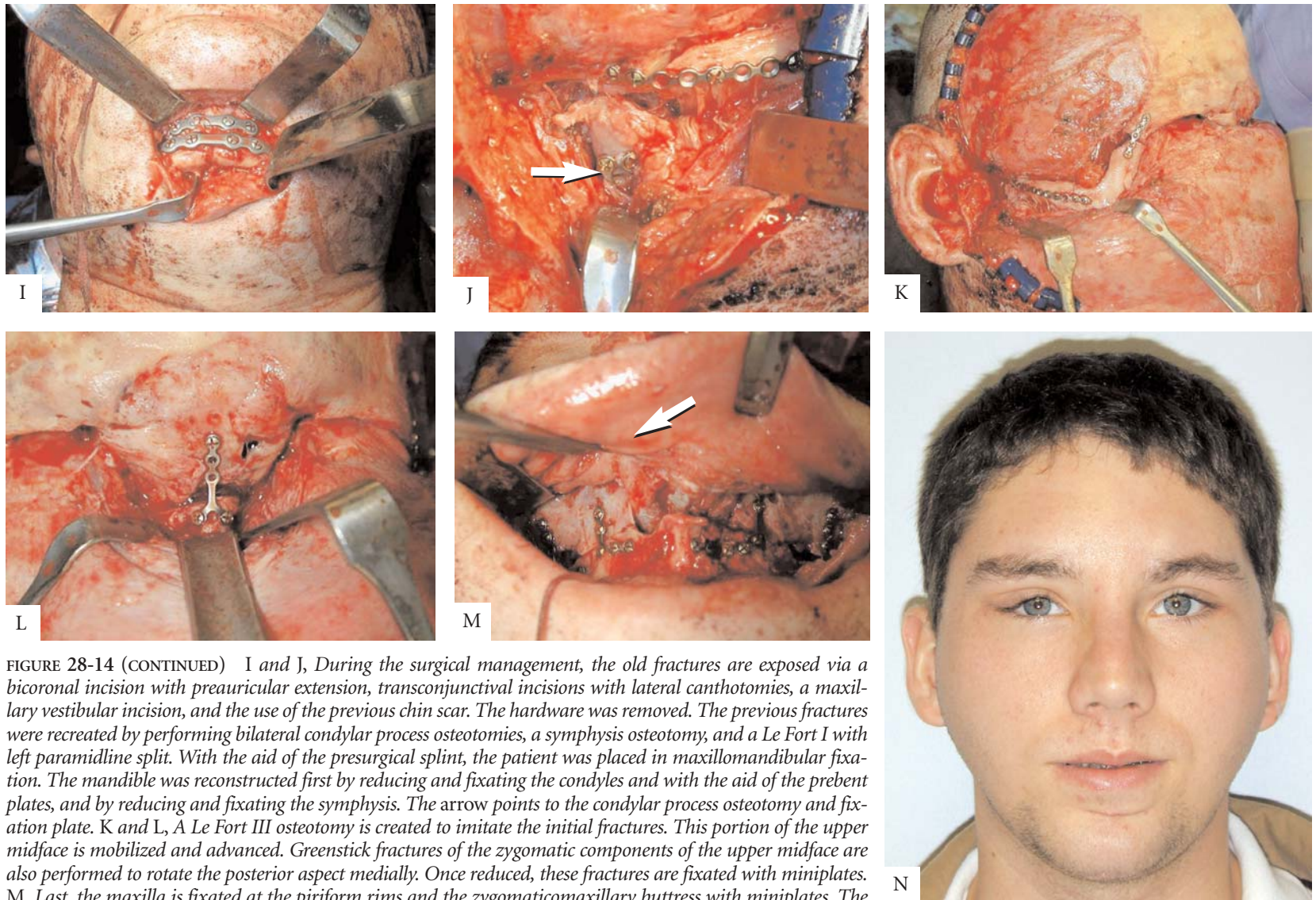


FIGURE 28-14 (CONTINUED) I and J, During the surgical management, the old fractures are exposed via a bicoronal incision with preauricular extension, transconjunctival incisions with lateral canthotomies, a maxillary vestibular incision, and the use of the previous chin scar. The hardware was removed. The previous fractures were recreated by performing bilateral condylar process osteotomies, a symphysis osteotomy, and a Le Fort I with left paramidline split. With the aid of the presurgical splint, the patient was placed in maxillomandibular fixation. The mandible was reconstructed first by reducing and fixating the condyles and with the aid of the prebent plates, and by reducing and fixating the symphysis. The arrow points to the condylar process osteotomy and fixation plate. K and L, A Le Fort III osteotomy is created to imitate the initial fractures. This portion of the upper midface is mobilized and advanced. Greenstick fractures of the zygomatic components of the upper midface are also performed to rotate the posterior aspect medially. Once reduced, these fractures are fixated with miniplates. M, Last, the maxilla is fixated at the piriform rims and the zygomaticomaxillary buttress with miniplates. The patient is taken out of fixation to verify the occlusion and begin early function. N, Early postoperative result. Note the decrease in facial width and increase in facial height. Patient also had zygomatic and recontouring nasal augmentation, bone grafting to the orbits, lateral canthopexy, midface resuspension, and genioplasty. (Courtesy of Dr. Patrick Louis and Dr. John Grant.)

pattern. Once the proper diagnosis is established, the surgeon should be able to institute an appropriate sequence of treatment.

References

1. Noyek AM, Kassel EE, Wortzman G, et al. Sophisticated CT in complex maxillofacial trauma. *Plast Reconstr Surg* 1980;66:1-17.
2. Rowe LD, Miller E, Brandt-Zawadzki M. Computed tomography in maxillofacial trauma. *Laryngoscope* 1981;91:745-57.
3. Tessier P, Hemmy D. Three dimensional imaging in medicine. A critique by surgeons. *Scand J Plast Reconstr Surg* 1986;20:3-11.
4. Wenig BL. Management of panfacial fractures. *Otolaryngol Clin North Am* 1991;24:93-101.
5. Gruss JS, Phillips JH. Complex facial trauma: the evolving role of rigid fixation and immediate bone graft reconstruction. *Clin Plast Surg* 1989;16:93-104.
6. Schilli W, Weers R, Niederdellmann H. Bone fixation with screws and plates in the maxillofacial region. *Int J Oral Surg* 1981;10 Supp 1: 329-32.
7. Gruss JS, Mackinnon SE, Kassel EE, et al. The role of primary bone grafting in complex craniomaxillofacial trauma. *Plast Reconstr Surg* 1985;75:17-24.
8. Phillips JH, Forrest CR, Gruss JS. Current concepts in the use of bone grafts in facial fractures. Basic science considerations. *Clin Plast Surg* 1992;19:41-58.
9. Manson PN, Crawley WA, Yaremchuk M, et al. Midface fractures: advantages of immediate extended open reduction and bone grafting. *Plast Reconstr Surg* 1985;76:1-12.
10. Markowitz BL, Manson PN. Panfacial fractures: organization of treatment. *Clin Plast Surg* 1989;16:105-14.
11. Tullio A, Sesenna E. Role of surgical reduction of condylar fractures in the management of panfacial fractures. *Br J Oral Maxillofac Surg* 2002;36:472-6.
12. Okeson JP. Management of temporomandibular disorders and occlusion. 3rd ed. St. Louis: Mosby Year Book; 1993. p. 510.
13. Jacobs R, Schotte A, van Steenberghe D. Influence of temperature and foil hardness on interocclusal tactile threshold. *J Periodont Res* 1992;27:581-7.

14. Gnoy AR, Gannon PJ, Ganjian E, et al. A potential role for nasal obstruction in development of acute sinusitis: an infection study in rabbits. *Am J Rhinol* 1998;12:399–404.
15. Alwani A, Rubinstein I. The nose and obstructive sleep apnea. *Curr Opin Pulm Med* 1998;4:361–2.
16. Dalton RM, Warren DW, Dalston ET. A preliminary investigation concerning the use of nasometry in identifying patients with hyponasality and/or nasal airway impairment. *J Speech Lang Hear Res* 1991;34:11–8.
17. Converse JM, Smith B. Enophthalmos and diplopia in fractures of the orbital floor. *Br J Plast Surg* 1957;9:265–74.
18. Grant MP, Iliff NT, Manson PN. Strategies for the treatment of enophthalmos. *Clin Plast Surg* 1997;24: 539–50.
19. Kleck RE, Rubenstein C. Physical attractiveness, perceived attitude, similarity, and interpersonal attraction in opposite-sex encounter. *J Pers Soc Psychol* 1975;31:107–14.
20. Kleck RE. Emotional arousal in interactions with stigmatized persons. *Psychol Rep* 1996;19:1226.
21. Kleck RE. Physical stigmata and task oriented interactions. *Hum Rel* 1969;22:53–60.
22. Sawhney CP, Ahuja RB. Faciomaxillary fractures in North India: a statistical analysis and review of management. *Br J Oral Maxillofac Surg* 1998;26:430–4.
23. Hansmann M. Eine neue Methode der Fixierung der Fragmente bei komplizierten Frakturen. *Verh Dtsch Ges Chir* 1836;15:134.
24. Michelet FX, Daymes J, Dessus B. Osteosynthesis with miniaturized screw plates in maxillofacial surgery. *J Maxillofac Surg* 1973;1:79–84.
25. Horster W. Experience with functionally stable plate osteosynthesis. *J Maxillofac Surg* 1980;8:176–81.
26. Chopart F, Desault PJ. *Traite des maladies chirurgicales et des operations qui leur conviennent*. Paris: Villier, IV; 1795. p. 392.
27. Von Graefe CF. *J Chir Augenheilk* 1823;IV:592–3.
28. Wolfe SA, Baker S. History of facial fracture treatment. In: Goin JM, editor. *Facial fractures*. New York: Thieme Medical Publishers Inc; 1993. p. 1–5.
29. Khan AA. A retrospective study of injuries to the maxillofacial skeleton in Harare, Zimbabwe. *Br J Oral Maxillofac Surg* 1988;26:435–9.
30. Cohen MA, Shakenovskiy BN, Smith I. Low velocity handgun injuries of the maxillofacial region. *J Maxillofac Surg* 1986;14:26–33.
31. Zaytoun GM, Shikhan AH, Salman SD. Head and neck war injuries: 10-year experience at the American University of Beirut Medical Center. *Laryngoscope* 1986;96:899–903.
32. Manson PN, Hoopes JE, Su CT. Structural pillars of the facial skeleton: an approach to the management of Le Fort fractures. *Plast Reconstr Surg* 1980;66:54–62.
33. Gruss JS, Mackinnon SE. Complex maxillary fractures: role of buttress reconstruction and immediate bone grafts. *Plast Reconstr Surg* 1986;78:9–22.
34. Manson PN, Glassman D, Vander Kolk C, et al. Rigid stabilization of sagittal fractures of the maxilla and palate. *Plast Reconstr Surg* 1990;85:711–17.
35. Mosby EL, Markle TL, Zulian MA, Hiatt WR. Technique for rigid fixation of Le Fort and palatal fractures. *J Oral Maxillofac Surg* 1986;44:921–2.
36. Hendrickson M, Clark N, Manson PN, et al. Palatal fractures: classification patterns and treatment with internal rigid fixation. *Plast Reconstr Surg* 1998;101:319–32.
37. Denny AD, Celik N. A management strategy for palatal fractures: a 12-year review. *J Craniomaxillofac Surg* 1999;10:49–57.
38. Gunning TB. Treatment of fractures of the lower jaw by interdental splints. *Br J Dent Sci* 1866;9:481–9, 529–49.
39. Cohen SR, Leonard DK, Markowitz BL, Manson PN. Acrylic splints for dental alignment in complex facial injuries. *Ann Plast Surg* 1993;31:406–12.
40. Vogel R. *Interfragmentare druckwerte bei der anwendung verschiedener dynamischer kompressionsplatten. Eine experimentelle Studie am unterkiefer [dissertation]*. Basel: Universitat Basel; 1984.
41. Spiessl B. *Internal fixation of the mandible. A manual of AO/ASIF principles*. Berlin: Springer-Verlag; 1989.
42. Manson PN, Clark N, Robertson B, et al. Subunit principles in midface fractures: the importance of sagittal buttresses, soft tissue reductions and sequencing treatment of segmental fractures. *Plast Reconstr Surg* 1999;103:1287–1306.
43. Stanley RB Jr. The zygomatic arch as a guide to reconstruction of comminuted malar fractures. *Arch Otolaryngol Head Neck Surg* 1989;1150:1459–62.
44. Rohner D, Tay A, Meny CS, et al. The sphenozygomatic suture as a key site for osteosynthesis of the orbitozygomatic complex in panfacial fractures: a biomechanical study in human cadavers based on clinical practice. *Plast Reconstr Surg* 2002;110:14630–71.
45. Freihofer HPM. Inner intercanthal and interorbital distances. *J Maxillofac Surg* 1980;8:324.
46. Ingram FL. *Radiology of the teeth and jaws*. 2nd ed. London: Edward Arnold; 1965.
47. Massiot J. *History of tomography medicine*. Mundi 1974;19:106–15.
48. Oldendorf WH. The quest for an image of brain: a brief historical and technical review of brain imaging techniques. *Neurology* 1978;28:517–33.
49. Houndfield GN. Computerized transverse axial scanning (tomography): part I. Description of system. *Br J Radiol* 1973;46:1016–22.
50. Hoeffner EG, Quint DJ, Peterson B, et al. Development of a protocol for coronal reconstruction of the maxillofacial region from axial helical CT data. *Br J Radiol* 2001;74:323–7.
51. Rosenthal E, Quint DJ, Johns M, et al. Diagnostic maxillofacial coronal images reformatted from helically acquired thin-section axial CT data. *AJR Am J Roentgenol* 2000;175:1177–81.
52. Phillips JH, Gruss JS, Chir B, et al. Periosteal suspension of the lower eyelid and cheek following subciliary exposure of facial fractures. *Plast Reconstr Surg* 1991;88:145–8.
53. Manson PN. Facial fractures. *Perspect Plast Surg* 1998;2:1–36.
54. Kelly KJ, Manson PN, Van der Kolk C, et al. Sequencing Le Fort fracture treatment. *J Craniomaxillofac Surg* 1990;1:168–78.
55. Stone DJ, Bogdonoff DL. Airway considerations in the management of patients requiring long-term endotracheal intubation. *Anesth Analg* 1992;74:276–87.
56. Haug RH, Indresano AT. Management of maxillary fractures. In: Peterson LJ, editor. *Principles of oral and maxillofacial surgery*. Philadelphia: JB Lippincott; 1992. p. 469–88.
57. Demas PN, Sotereanos GC. The use of tracheostomy in oral and maxillofacial surgery. *J Oral Maxillofac Surg* 1988;46:483–6.
58. Seebacher J, Nozik D, Mathieu A. Inadvertent intracranial introduction of a nasogastric tube, a complication of severe maxillofacial trauma. *Anesthesiology* 1975;42:100–2.
59. Muzzi DA, Losasso TJ, Cucchiara RF. Complication from a nasopharyngeal airway in a patient with a basilar skull fracture. *Anesthesiology* 1991;74:366–8.
60. Gordon NC, Tolstunov L. Submental approach to oroendotracheal intubation in patients with midfacial fractures. *Oral Surg Oral Med Oral Pathol Oral Radiol Endod* 1995;79:269–72.

61. Caron G, Paquin R, Lessard MR, et al. Submental endotracheal intubation: an alternative to tracheotomy in patients with midfacial and panfacial fractures. *J Trauma* 2000;48:235–40.
62. Mercuri LG, Steinberg MJ. Sequencing of care for multiple maxillofacial injuries. In: Peterson LJ, editor. *Principles of oral and maxillofacial surgery*. Philadelphia: JB Lippincott Co; 1992. p. 615–22.
63. Hlawitschka M, Eckelt U. Assessment of patients treated for intracapsular fractures of the mandibular condyle by closed techniques. *J Oral Maxillofac Surg* 2002;60:784–91.
64. Powers DB, Edgin WA, Tabatchnick L. Stereolithography: a historical review and indications for use in the management of trauma. *J Craniomaxillofac Trauma* 1998;4:16–23.
65. Kermer C, Linder A, Friede I, et al. Preoperative stereolithographic model planning for primary reconstruction in craniomaxillofacial trauma surgery. *J Craniomaxillofac Surg* 1998;26:136–9.

Part 5

MAXILLOFACIAL PATHOLOGY

Differential Diagnosis of Oral Disease

John R. Kalmar, DMD, PhD

Carl M. Allen, DDS, MSD

One of the major roles of the oral and maxillofacial surgeon is that of diagnostician. From private practices in small communities to large tertiary care medical centers, these specialists are called upon to evaluate and diagnose a wide variety of conditions affecting the face, jaws, head, and neck as well as the tissues of the oral cavity. The term *diagnose* comes from the Greek words *dia* (“through,” “apart”) and *gnosis* (“knowledge”), meaning literally to know apart or to distinguish. Indeed, although the ability to correctly diagnose is important to virtually all professions, it is perhaps most strongly linked to the clinical practice of medicine and dentistry. For health care practitioners, a *diagnosis* is defined as the determination of the nature of a disease or pathologic condition. An accurate diagnosis is obviously important and occasionally critical to the patient so that the most appropriate treatment can be initiated as soon as possible. Early determination of the true diagnosis can further benefit the patient by avoiding the need for expensive unnecessary laboratory studies, the use of ineffective or improper medications, and the inconvenience of additional costly consultation(s).

A variety of terms related to the diagnostic process may be used during the

evaluation of the patient. Occasionally the diagnosis is relatively straightforward. Usually, however, a variety of conditions with similar clinical features need to be considered, and a *differential diagnosis* is prepared. The differential diagnosis represents a listing of the more likely diagnostic considerations for a particular pathologic finding or condition, ranked in descending order of probability. Therefore, the number one consideration from the initial differential diagnosis should represent the culmination of the clinician’s evaluation and is termed the *clinical diagnosis* (ie, *working* or *tentative diagnosis*, *clinical impression*). Although construction of the differential is initially based upon clinical signs, symptoms, and history, this list of diagnoses is subject to modification or refinement following additional studies such as radiographic imaging and hematologic or serum analysis (Figure 29-1).^{1,2} As is discussed below, the differential listing may vary widely depending upon the experience and knowledge base of the treating clinician. The designation of *final diagnosis* is used when the clinician believes that the nature of the disease has been identified to a reasonable degree of certainty. This progression from information to possible diagnoses to final diagnosis

is known as the *diagnostic process* or *method*. A case example is provided below. Although the determination of a final diagnosis often represents the end of the diagnostic phase of patient care, it is worth remembering that the “final” diagnosis is not always correct. As is stressed below, observation of the patient’s response to therapy and careful monitoring of the subsequent disease course are essential aspects of comprehensive patient management. Should a lesion or condition not behave in the expected manner, reevaluation and revision of the final diagnosis may ultimately be required.

The Diagnostic Process

The clinician begins the diagnostic process by gathering or accumulating information. In some instances this information includes a significant historic component, whereas in other cases (eg, asymptomatic lesions discovered upon routine examination) the data may be limited strictly to the findings of the physical examination, together with any necessary diagnostic studies or tests. Depending upon the experience and expertise of the practitioner, a confident final diagnosis may require nothing more than clinical inspection. In many cases, however, even the most

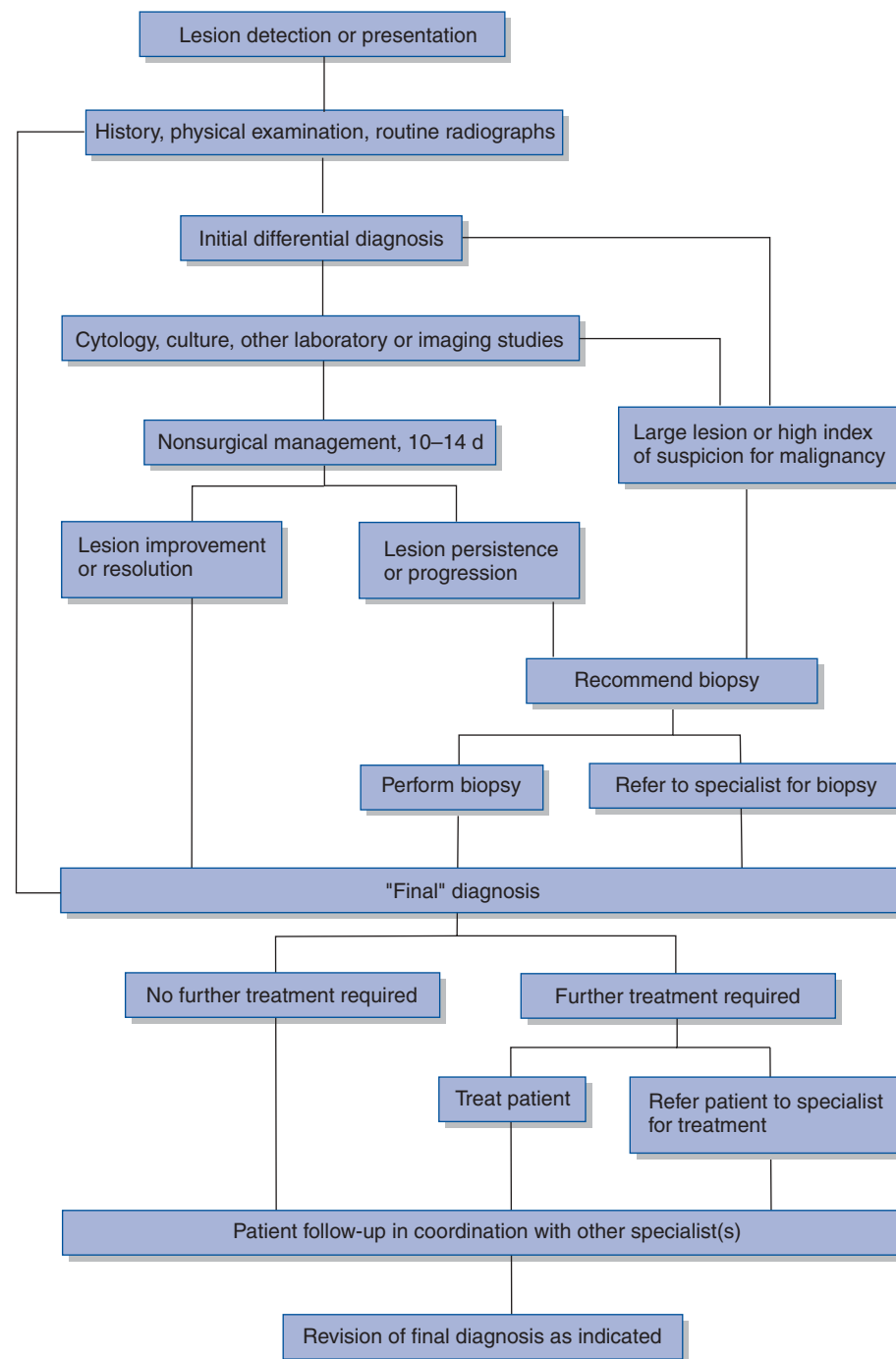


FIGURE 29-1 The diagnostic process. Adapted from Ellis E III.¹

experienced diagnostician requires additional information from appropriate imaging or laboratory studies.

Case Study: From Differential Diagnosis to Final Diagnosis

A 25-year-old male presents with a 3-month history of gradual painless enlargement of the right anterior lower

jaw. His medical history is unremarkable, and he denies recent trauma to the area. Clinical examination reveals a 1.5 cm bony firm swelling of the right mandibular alveolus in the area of teeth no. 26 and 27 causing primarily buccal expansion with an unremarkable overlying mucosa. The area is nontender to palpation, and the adjacent teeth are vital.

Initially, the clinical differential diagnosis focuses on the most common conditions that could present in a fashion similar to the lesion in this patient. Likely considerations include central giant cell granuloma, central ossifying fibroma, ameloblastoma, and odontogenic keratocyst.

Important additional information is easily obtained in this case with routine dental radiography. A panoramic film reveals a 2 cm unilocular radiolucent lesion of the right mandible with a well-defined sclerotic border that contains scattered small particles of radiodense material. With this additional information, the differential diagnosis is revised to exclude conditions not usually associated with calcification and possibly to include other less common conditions that have a radiopaque component: central ossifying fibroma, desmoplastic ameloblastoma, and calcifying epithelial odontogenic tumor.

A biopsy of the lesional tissue reveals a well-circumscribed cellular proliferation of benign spindle cells containing scattered trabeculae of osteoid and bone. The final diagnosis is central ossifying fibroma.

History

Most attempts at formulating a differential diagnosis begin with data gathering that includes the history of the specific problem being investigated as well as the patient's medical and social history. The patient's perception of the duration of the lesion can be important as long-standing lesions may suggest a developmental or benign process, whereas rapidly evolving problems often represent reactive, infectious, or malignant disease. Exceptions to these generalizations are numerous, however, since mycobacterial infections may develop slowly, as do some neoplasms that are considered malignant (eg, basal cell carcinoma). Furthermore, the reliability of the patient to provide an accurate history is occasionally compromised owing to the patient's inattention, limited mental capacity, or denial of disease.

Symptoms, particularly related to pain or tenderness, are important in developing a differential diagnosis. Pain and tenderness (pain on palpation) are often signs of an inflammatory or infectious process, although malignancies can also produce such symptoms, particularly late in their course. A notable exception to this is adenoid cystic carcinoma, which is infamous for the early onset of low-grade intractable pain. Other symptoms such as paresthesia or numbness can also be significant and may be related to pressure on nerves caused by a cystic lesion or tumor mass.

Reported changes in the lesion may also provide important insights. If a mass gradually enlarges, the possibility of neoplasia has to be entertained, whereas a mass that fluctuates in size is more suggestive of a reactive process. In addition, changes in symptoms may be significant. Decreasing pain or tenderness likely represents a resolving inflammatory or infectious process, whereas pain that develops in a long-standing previously asymptomatic mass may be an indication of malignant transformation (eg, carcinoma arising in pleomorphic adenoma).

Clinical Examination

Following a review of the patient's medical history and history of the present lesion or condition, the clinician typically proceeds with gathering objective data through careful clinical examination. A variety of lesional parameters should be evaluated and recorded, including (1) site, (2) size, (3) character (eg, macule, ulcer, mass), (4) color, including an assessment of its homogeneity, (5) surface morphology (eg, smooth, pebbly, granular, verrucous), (6) the border (eg, smooth, irregular, indistinct, sharply defined), (7) consistency on palpation, (8) local symptoms, and (9) the distribution if multiple or confluent lesions are observed.

The precise anatomic site or location of a lesion can provide essential diagnostic information and is discussed later in greater detail.

Lesion size can have diagnostic implications, particularly when combined with an estimate of lesion duration to give an approximate rate of growth or enlargement. The finding of a large lesion may indicate a locally aggressive or malignant neoplasm if the history suggests a relatively recent onset. Yet, even when abnormal tissue has been noted for several months or years, a history of progressive increase in the size of the affected area should be viewed suspiciously (Figure 29-2). As mentioned above, relying on the accuracy (or veracity) of the patient history can be problematic and should be weighted accordingly in the differential diagnosis. Confirmation of the clinical history through other health care practitioners can be helpful in this regard.

Establishing the character of the lesion is an essential aspect of the clinical evaluation. Ulcers can be seen with traumatic, infectious, or neoplastic conditions, whereas masses or swellings more commonly indicate neoplasms, reactive proliferations, cysts, or enlarged lymph nodes. A history or evidence of vesicle or bulla formation might be suggestive of a viral condition, an immunobullous disorder, or possibly an inherited mucocutaneous disease.

Macular lesions, which are completely flat by definition, usually represent an area

of color change. A brown or black macule is often the result of melanin pigment; a red or purple macule usually represents hemoglobin in either its oxygenated or reduced form, respectively. A dull flat white implies keratin production, an area of translucent whitish change may mean increased epithelial edema, and a shiny creamy yellow-white appearance is usually a sign of an ulcer's fibrinous pseudomembrane. A blue or grayish macule is frequently associated with exogenous (amalgam, foreign body) or endogenous (melanin) pigmented material that is deposited within the connective tissue below the level of the epithelium. Although additional information regarding the margin or border of a lesion is provided below, it should be mentioned that most pigmented lesions in the oral cavity are relatively homogeneous in color and have a smooth well-defined margin. By contrast, a pigmented lesion that exhibits significant border irregularity and color variegation should be considered as suspicious for melanoma (Figure 29-3).

The surface morphology of a lesion can be virtually diagnostic for certain conditions. Examples include the "tapioca pudding" appearance of the surface of a lymphangioma or the papillary epithelial fronds of squamous papilloma. Similarly,

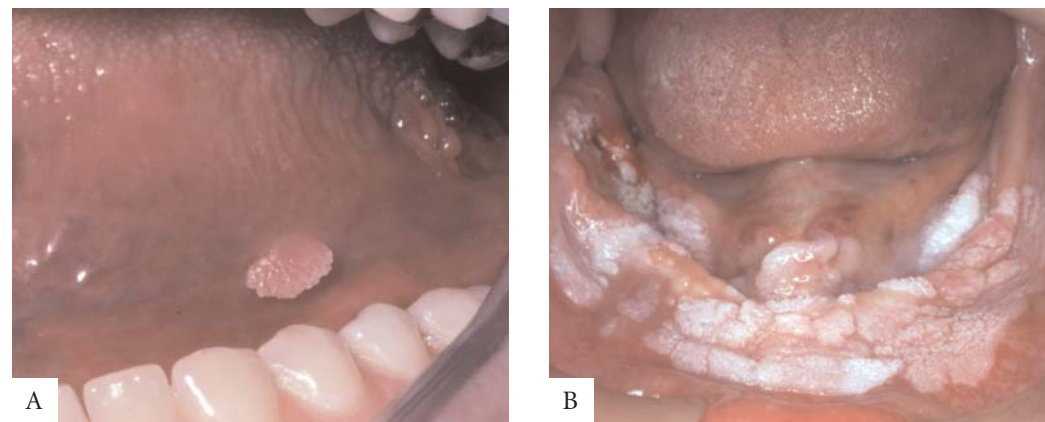


FIGURE 29-2 A, Asymptomatic papillary epithelial lesion in a 50-year-old male that has been present for approximately 2 years without apparent increase in size. Clinical diagnosis: squamous papilloma. B, Asymptomatic epithelial lesion in a 65-year-old male with a papillary or granular surface that has been present for approximately 2 years with slow progressive enlargement. Clinical diagnosis: verrucous carcinoma.

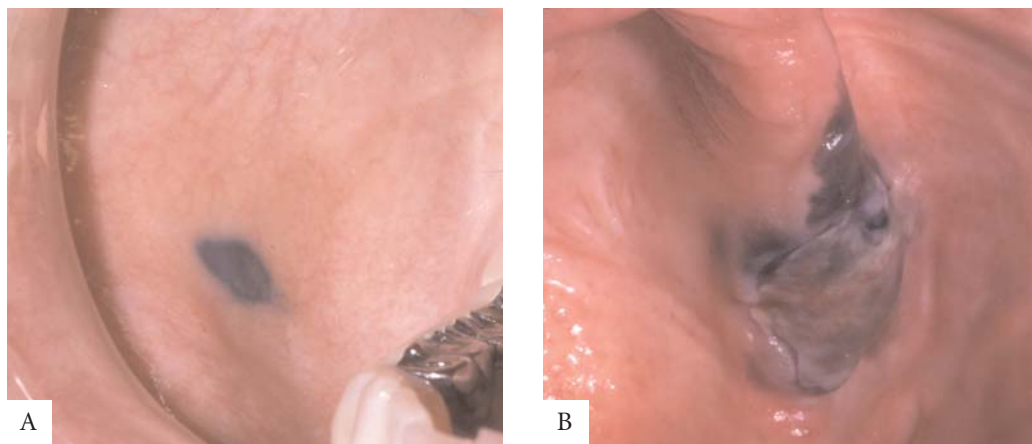


FIGURE 29-3 A, Macular grayish 0.8 cm pigmentation with well-defined borders of right posterior buccal mucosa in a 52-year-old female. The patient reported that it had been present for years. Clinical diagnosis: amalgam tattoo. B, Ulcerated area of macular pigmentation affecting posterior maxillary left alveolar mucosa in a 65-year-old male. Note the border irregularity and color variegation. Clinical diagnosis: melanoma.

an irregularly papular or granular surface architecture can be seen with malignant tumors as well as granulomatous processes that can range from deep fungal or mycobacterial infections to foreign-body reactions to immune-mediated conditions such as Crohn's disease or sarcoidosis.

Palpation of the lesion is necessary to assess its consistency, the lateral or deep margins, and the presence or absence of tenderness. When assessing consistency, detection of a doughy soft mass suggests a cystic lesion or a benign fatty tumor. A rubbery-firm character may be detected with a variety of benign or neoplastic disorders, whereas an even firmer consistency can reflect metastatic disease within a lymph node. A hard or bony consistency naturally indicates a mineralized or calcified component to the lesion.

The border or margin of a primarily submucosal or subcutaneous lesion is usually described as encapsulated, well-demarcated, or infiltrative. An encapsulated process is often freely movable within the deep soft tissues, a finding common to a variety of benign neoplasms and cysts. The margins of some benign lesions (eg, neurofibroma) and some low-grade malignancies (eg, acinic cell carcinoma) may be well-demarcated, but they are gen-

erally less mobile compared with encapsulated lesions. The margins of many malignancies are indistinct, as the tumor invades and blends with the surrounding host tissues.

As noted earlier, the finding of a local symptom such as tenderness is usually associated with an inflammatory process, especially acute inflammation. Although malignant neoplasms may also present with tenderness or dysesthesia (eg, adenoid cystic carcinoma), this feature is usually a later-stage development secondary to tumor invasion of local nerves or surface ulceration. Tenderness may also be a prominent clinical feature of certain benign tumors such as traumatic neuroma.

Finally, the presence of multiple identical or similar lesions can suggest a number of conditions, depending upon their particular character (eg, ulcerations, papules, vesicles) and distribution. Multiple small painful recurrent ulcerations bilaterally on the ventrolateral surface of the tongue in a young adult female patient are most suggestive of the herpetiform variant of recurrent aphthous stomatitis. On the other hand, the finding of a focus of several small relatively painless ulcerations in a unilateral distribution on the left hard palate would be more consistent with

a recurrent intraoral herpes infection. Similarly, multiple purplish plaques involving the oral mucosa and skin of a 35-year-old male who is positive for the human immunodeficiency virus would be strongly suggestive of Kaposi's sarcoma.

Developing the Differential Diagnosis

After collecting the historic and clinical information, the final diagnosis may be obvious; however, in many instances the diagnosis is not readily apparent and the formulation of a differential diagnosis is appropriate. Several approaches have evolved over the centuries of medical practice to assist in the categorization or grouping of diseases. These grouping techniques permit the large number of possible diagnostic considerations for a given lesion to be reduced to the more probable conditions. The resultant narrowing of the differential diagnosis, in turn, aids in the selection of additional diagnostic tests that are most useful in securing a final diagnosis. The major diagnostic strategies or approaches that have been used to group or organize the differential are based on (1) the history and clinical presentation, (2) the potential disease histogenesis, and (3) the disease location (more specifically, the frequency of a given condition in a particular location). In actual practice, more experienced clinicians typically employ all of the categories simultaneously. As a consequence, the specialist is able to rapidly produce a much narrower and usually more precise list of initial diagnostic considerations (see the case study below).

Evaluation of the physical characteristics of a given lesion in the context of the history and clinical setting often permits the clinician to arrive at a reasonable list of diagnostic possibilities. For example, a firm fixed painless 2 cm nodule of uncertain duration in the anterior cervical area of the neck is suspicious for possible metastatic disease or lymphoma. By contrast, if the nodule were soft, mobile, and

tender to palpation, an inflammatory process would be more likely.

Another useful approach to developing a differential diagnosis is to consider whether the clinical and historic aspects of the lesion can be explained by any, some, or all of the broad categories of disease histogenesis. These categories include developmental, inflammatory/immune-mediated, infectious, neoplastic, and metabolic conditions. This is a time-honored systematic method of diagnosis, and many clinicians find it useful to critically consider diagnostic possibilities from each category. For example, an asymptomatic lesion that has been present for several years and feels encapsulated upon clinical palpation would be most consistent with a developmental or benign neoplastic process. Although inflammatory conditions, malignant neoplasms, and metabolic conditions might not be excluded completely, they would not receive primary consideration in the initial differential. Similarly, if the lesion presented as a chronic ulceration of the lateral tongue in an adult patient, disorders from the neoplastic (especially malignancies), infectious (eg, mycobacterial or deep fungal infections), and immune-mediated (eg, Wegener's granulomatosis or regional enteritis) categories would have to be considered.

The third diagnostic grouping strategy relies on the identification of lesions that most commonly present in a particular anatomic location. The tendency for certain conditions to occur with increased frequency at certain sites is well recognized. For example, a nontender bluish fluctuant mass of recent onset involving the lower labial mucosa very likely represents a mucocele. By contrast, mucocele would not be included in the differential diagnosis of a painless persistent bluish mass of the attached gingiva as salivary gland tissue is not normally present at that site. This latter clinical finding would, however, be completely

consistent with a gingival cyst of the adult. A nonhealing relatively insensitive ulceration of the lateral tongue in an adult patient that has no identifiable source of irritation or trauma would be highly suspicious for squamous cell carcinoma. Salivary gland neoplasia would be a strong consideration for a rubbery firm mass of the posterior hard palate.

Case Study: Neophyte versus Expert Clinician

An otherwise healthy 72-year-old woman complains of sores in her mouth for the past year. Her medical history is unremarkable and she is not taking any medications. She has not been aware of any blisters, and she feels the problem is getting worse. The lesions tend to wax and wane in severity and have affected several areas of the mouth, including the hard and soft palates, the labial mucosa, and the ventral tongue.

Examination shows several shallow erosions and ulcerations with ragged margins. The lesions range from 0.5 to 1.0 cm in diameter and involve the lower labial mucosa, the ventral tongue bilaterally, and the anterior soft palate. No vesicles or bullae are seen, and no white striae are evident.

The inexperienced diagnostician who is not very familiar with oral lesions might provide a differential diagnosis based on conditions that are primarily ulcerative: herpesvirus infection, aphthous ulcers, erosive lichen planus, squamous cell carcinoma, and candidiasis. On the basis of this list, the patient would likely be placed on one or possibly more courses of antiviral medication. The patient's condition would not improve, and she might then be switched to antifungal medication(s). After that approach has failed to resolve the problem, topical corticosteroids might be prescribed. Following several weeks of topical corticosteroid use with little or no impact on the patient's oral sores, the diagnostician may recommend that a

biopsy be performed. In this situation, the patient has invested several months' time and spent hundreds of dollars on inappropriate or ineffective medications—all in the absence of a clear diagnosis.

For the experienced diagnostician who is more familiar with oral conditions, the differential would be much smaller: cicatricial pemphigoid or pemphigus vulgaris. With a greater understanding of oral disease, the specialist should be able to eliminate many of the considerations that the first clinician entertained. For example, recurrent herpesvirus infection does not typically affect nonkeratinized mucosa in an immunocompetent patient and would not wax and wane in severity. Although aphthous ulcers often exhibit a waxing-and-waning course, the lesional margins are usually smooth, not ragged. Erosive lichen planus would be considered unlikely owing to the lack of radiating white striae at the periphery of the oral lesions, as well as the lack of buccal mucosa involvement. Squamous cell carcinoma would not be reasonable because of the multifocal presentation and the history of waxing and waning. Finally, although candidiasis is occasionally associated with tenderness or irritation of the oral mucosa, it does not induce true ulceration and would therefore have a low probability of representing the actual diagnosis.

Based on the patient's age, the distribution of the lesions, the history of the process, and the clinical appearance of the lesions, a differential diagnosis that centers on immune-mediated disease would be most appropriate. In this situation biopsies for examination with both light microscopy and direct immunofluorescence (DIF) would be requested or performed after the initial consultation. Histopathologic evidence of acantholysis and DIF findings of interepithelial deposits of immunoglobulin G (IgG) and complement component 3 (C3) would establish the final diagnosis of pemphigus vulgaris in a relatively rapid and

cost-effective manner. Besides the monetary savings, a more timely and correct diagnosis often saves the patient from unnecessary suffering and mental anguish, both by initiating effective treatment earlier and by relieving the anxiety that many patients experience when they do not know the nature of their disease. Early diagnosis and treatment of conditions such as pemphigus vulgaris may also reduce disease progression or the need for more aggressive therapy.

Determining the Final Diagnosis: Additional Diagnostic Methods

If the final diagnosis cannot be determined based on historic findings and physical examination alone, a variety of procedures and tests can be used to assist in the diagnostic process. Generally, diagnostic tests should be ordered so that the most likely diagnosis can be either confirmed or eliminated. The methodic application of this process together with a proper rationale for selecting each test typically leads to the correct diagnosis in the most rapid cost-effective manner. Tests that do not address the most likely diagnostic possibilities should be delayed as the probability that they will provide useful information is small, yet they can dramatically increase costs to the patient. An exception to this statement would be a situation in which a particular test is performed to rule out a rare or unusual condition of serious clinical significance. Finally, diagnostic tests should be interpreted by individuals with specialty training in that area whenever possible to ensure the most timely and accurate result or final diagnosis.

Diagnostic studies are not necessarily complex or expensive. For example, a putative vascular lesion can be evaluated easily by pressing it with a glass slide to test for possible blanching (diascopy). The bruit of a vascular malformation may be heard upon auscultation using a stethoscope. Operative findings at the time of

surgery occasionally provide important diagnostic clues, such as the presence of cheesy keratotic debris within a cystic lesion associated with an impacted tooth, suggestive of an odontogenic keratocyst, or the empty bone cavity seen with traumatic bone cyst. Finally, follow-up evaluation of a lesion is a straightforward procedure that can provide important diagnostic insight with respect to biologic behavior. Those conditions that persist or progress 2 weeks after initial inspection often require additional tests to establish the diagnosis.

Diagnostic Imaging

Depending on the clinical setting, imaging studies may be both appropriate and necessary to the work-up of an oral lesion. Additional information on this topic is available in an excellent radiology text edited by White and Pharoah.³ Briefly, imaging studies can include plain radiographic films, sialography, ultrasonography, computed tomography (CT), magnetic resonance imaging (MRI), radionuclide imaging, and positron emission tomography (PET).

Plain Films For evaluation of bone lesions, plain films are the most commonly employed imaging modality and, together with CT, are often the most useful. With the increased use of panoramic radiographs as a screening study in many current dental practices, it is not unusual for these films to detect a previously unidentified skeletal abnormality. Evaluation of such a lesion includes an assessment of features such as localization (single, multifocal, generalized), margins (well defined, poorly defined), internal structure (radiolucent, radiopaque, mixed), effects on surrounding structures (teeth, inferior alveolar canal, cortical bone), and whether there have been any associated symptoms. For example, a single radiolucent lesion at the apex of a nonvital tooth most likely represents a periapical cyst or granuloma.

A similar-appearing radiolucency below the level of the inferior alveolar canal in the posterior mandible more likely represents a Stafne defect. Sharply defined margins indicate a benign process in most instances, whereas poorly defined margins can sometimes signify malignancy. Notable exceptions to this rule include osteomyelitis and fibrous dysplasia, both of which typically have borders that blend with the surrounding bone. Radiolucent lesions are produced by conditions that do not generate a calcified product. Radiopaque and mixed lesions represent conditions that can produce a mineralized product, such as bone, cementum, dentin, or enamel. It is generally safe to assume that the vast majority of lesions associated with the crown of an impacted tooth are odontogenic in origin. If the teeth are erupted, however, determining whether a lesion is of odontogenic origin can be problematic since there are few areas in the jaws in which a 2 cm lesion does not appear to be tooth-related. Symptoms such as pain or paresthesia may suggest infection or malignancy, but benign conditions can occasionally present in this fashion.

Sialography Sialography has almost become a lost art. This technique relies on retrograde injection of a radiopaque fluid, also known as contrast medium, into the duct system of either the parotid or submandibular salivary gland. A plain radiograph is made, and the pattern of distribution of the contrast medium is assessed. Many of the previous indications for sialography such as evaluation of salivary gland neoplasia have been supplanted by newer imaging modalities such as MRI. Nonetheless, sialography can be useful in assessing chronic obstructive salivary gland disease and gland function. The characteristic sialographic finding of punctate sialectasis (“blossoms on a branchless tree” pattern) seen in patients affected by Sjögren’s syndrome is helpful in supporting that diagnosis.

Ultrasonography Ultrasonography is most useful in the evaluation of deeply seated masses and is often helpful in distinguishing a solid mass from one that is cystic. This technique relies on the fact that different tissue densities result in different degrees of reflection or echo production of a beam of high-frequency sound waves. Although ultrasonography does not expose the patient to ionizing radiation, the tissue resolution is typically less than that achieved with either CT or MRI technology.

CT CT is a cross-sectional radiologic imaging technique that is particularly useful in the evaluation of bone lesions. Not only can the density and margins of the lesion in question be evaluated with this technique but cortical expansion and fine internal details can often be more readily appreciated compared with plain film images. Use of contrast media has extended the utility of this technique in areas of soft tissue pathology. Furthermore, more recent designs such as spiral CT scanners have made data acquisition much more rapid and have reduced radiation dose to the patient while maintaining or improving resolution.

MRI MRI is a newer form of cross-sectional imaging that does not expose patients to ionizing radiation. Although primarily used in the evaluation of soft tissue lesions, it is also capable of providing diagnostic information regarding bony lesions. Two distinct views are typically generated: T1 and T2. Adipose tissue has the highest signal in the T1-weighted image, and this view is often used for identifying anatomic structures. By comparison, the T2 image highlights tissues with high water content and is especially useful in depicting inflammatory processes and neoplasms.

Radionuclide Imaging Radionuclide imaging relies on the specific uptake of any one of several isotopes by various

types of tissues or cells. Localization of the isotope is determined by examining the patient with a gamma scintillation camera. The most commonly used isotope, technetium 99m pertechnetate, can demonstrate areas of high metabolic activity. It is useful in identifying inflammatory conditions such as osteomyelitis, areas of active skeletal lesions of fibrous dysplasia or osteitis deformans, and metastatic disease.

PET Scan PET scan is the most recently developed cross-sectional imaging technology. This technique relies on the identification of metabolically active cells, such as metastatic deposits of squamous cell carcinoma, that exhibit preferential uptake of radionuclide-labeled glucose. In conjunction with CT/MRI, preoperative PET imaging of patients with head and neck cancer has led to increased sensitivity and specificity for detection of oral cavity carcinoma, esophageal carcinoma, and clinically occult metastatic disease in the neck.⁴⁻⁸ PET scans have proved particularly useful in the post-treatment follow-up by helping to distinguish altered anatomic landmarks or areas of fibrosis from recurrent tumor as well as the detection of distant metastases from head and neck primaries.⁶⁻⁸ The technique is not recommended for neoplasms that are relatively inactive metabolically (eg, low-grade mucoepidermoid carcinoma). In addition, the lower limit of tumor mass detection by current technology is no better than that of CT/MRI, and false-positives owing to inflammatory changes are reported.

Analysis of Lesional Tissue: Histopathologic, Immunopathologic, and Molecular Evaluation

In a large number of cases, the final diagnosis depends on the results of histopathologic examination of lesional tissue. In some situations the diagnosis is straightforward, whereas in others a definitive diagnosis cannot be made until sophisticated immunohistochemical or

complementary DNA studies are performed. As with imaging, a variety of techniques are available to the pathologist, and their selection varies on a case-by-case basis, depending on the diagnostic challenges posed by the individual patient specimen.

Exfoliative Cytology Exfoliative cytology is a relatively inexpensive noninvasive technique that may be used to provide additional information related to lesions of surface origin. The utility of this technique in the diagnosis of conditions such as candidiasis, herpesvirus (herpes simplex virus, human herpesviruses 1 and 2) infections, and pemphigus vulgaris is well documented.

More recently a modified form of cytologic sampling that employs an oral brush instrument to collect epithelial cells followed by automated histopathologic evaluation has been introduced to dentistry. Suggested advantages include improved sampling of all epithelial layers and increased sensitivity and specificity in the detection of precancerous and cancerous lesions versus results with routine exfoliative cytology. This new technique does not provide a definitive diagnosis, however, and cannot be used as a substitute for scalpel biopsy and routine histopathologic examination (see below). Therefore, in a clinical setting where the index of suspicion for possible precancerous or cancerous change is high, such as the high-risk areas for oral cancer (ie, ventrolateral tongue, floor of mouth, tonsillar pillars, soft palate), or in a patient with significant risk factors (ie, heavy smoking, heavy alcohol use, or both), use of brush cytology would not be recommended due to the inherent delay in definitive diagnosis of the lesional tissue and any subsequent treatment. In cases in which a persistent mucosal lesion is identified but the index of suspicion is low, the brush cytology technique may be useful in excluding the presence of precancerous or malignant

epithelial changes. For such innocuous lesions, a finding of abnormal cells could trigger scalpel biopsy (and definitive diagnosis) before the surgical procedure might otherwise have been deemed necessary.

Fine-Needle Aspiration Fine-needle aspiration (FNA) is a useful method for evaluating subcutaneous or more deeply situated mass lesions, although obtaining a diagnostic sample and interpreting the results accurately requires specialized training. This type of procedure is most widely used in determining the nature of salivary gland or neck masses. Currently FNA is available in most large urban areas throughout the United States, usually in conjunction with tertiary care medical centers.

Incisional Biopsy Incisional biopsy is generally indicated for large lesions (> 2 cm) and those that could represent unencapsulated or potentially malignant neoplasms. By definition an incisional biopsy is a diagnostic surgical procedure in which a sample or portion of a lesion is removed for histopathologic review, leaving the remainder of the lesion at the biopsy site. In cases of suspected malignancy, an incisional biopsy is usually the procedure of choice unless the clinician performing the biopsy will also be involved in definitive treatment of the cancer (see below).

Excisional Biopsy Excisional biopsy is typically used to manage clinically benign lesions that are < 2 cm in diameter. An excisional biopsy is defined as a diagnostic surgical procedure in which all clinically abnormal tissue is removed for microscopic analysis. Excision of a small but potentially malignant lesion (eg, squamous cell carcinoma with a primary tumor [T], regional nodes [N], and metastasis [M] staging of T1N0M0) may be appropriate in settings in which the surgeon performing the biopsy is also responsible for final treatment. With rare exceptions, an excisional biopsy should not be performed on a sus-

pected malignant lesion unless the performing clinician is involved in definitive treatment. Otherwise, the surface mucosa may be completely healed by the time the patient is referred to the oncologist, obscuring the extent of the original lesion and unnecessarily hindering definitive treatment planning.

Specimen orientation is recommended whenever a clinician suspects that a neoplastic process may have recurrent or malignant potential, including conditions such as epithelial dysplasia or pleomorphic adenoma. This can be accomplished by careful identification of the anatomic margins of the biopsy specimen with suture(s), an accompanying sketch of the specimen, and its orientation to the surrounding tissues or both. Such anatomic orientation of the tissue sample allows the pathologist to properly subdivide and process the specimen so that the adequacy of excision can be assessed at all surgical margins. The terms *negative* or *clear margins* are used when the surgical margins appear free from tumor involvement. When tumor is transected or lies immediately adjacent to the surgical margin without evidence of a capsule, proper specimen orientation permits the location of the *positive margin(s)* to be determined as precisely as possible. With this information the surgeon can then plan the most conservative surgical approach that will also accomplish the primary goal of therapy: complete removal of residual neoplastic tissue.

Specimen Information Although obtaining an adequate biopsy specimen is an important result of proper surgical technique, proper diagnostic technique requires that the surgeon also transmit adequate clinical information to the pathologist through use of the specimen or biopsy data sheet. Inflammatory, reactive, and even neoplastic conditions can have overlapping histopathologic features that are difficult (if not impossible) to distinguish without an adequate description of

the clinical setting. Lacking this information, the pathologist may not be able to provide a completely accurate or specific diagnosis. Pertinent details from the medical or dental history, the history of the lesion, the location and physical characteristics of the lesional tissue, and, when applicable, the radiographic features can assist with the histopathologic analysis. Clinical findings at the time of biopsy can also provide essential information. A good example is the discovery of an empty cavity during the exploration of a radiolucent lesion of bone. This situation often means that only minimal tissue can be submitted for review; however, the operative finding is virtually pathognomonic for traumatic bone cyst. Quality close-up clinical photographs including digital images can be helpful, particularly for specialists who have dental training such as oral and maxillofacial pathologists. Biopsies of bony pathology should be accompanied by radiographs (originals or copies), whenever possible, as correlation may be needed to help distinguish conditions such as fibrous dysplasia, ossifying fibroma, and focal cemento-osseous dysplasia.

A final piece of information that should always be submitted together with the biopsy specimen is the clinical diagnosis. The clinical diagnosis is important at two levels. First, it helps the pathologist by providing an educated “best guess” as to what the lesional tissue was thought to most likely represent by the clinician. Should the initial histopathology of the submitted specimen appear substantially different from the clinical diagnosis, the pathologist may request deeper sections, rotation of the specimen, or special studies to ensure that all aspects of the biopsy material have been thoroughly examined. Second, in cases where the final histopathologic diagnosis varies significantly from the working diagnosis, it is the clinician who should proceed cautiously. After discussing the case directly with the sign-out pathologist, the surgeon may be

satisfied with the unexpected diagnosis and plan accordingly. If not, the clinician may request a second opinion on the original biopsy material or choose to perform a second biopsy procedure. In essence, the clinical diagnosis serves as a “litmus test” for both the pathologist and surgeon, an important function that ultimately benefits the patient.

For the oral and maxillofacial surgeon, this type of discordance may be minimized if the tissue specimen is initially reviewed by an oral and maxillofacial pathologist. The oral and maxillofacial pathologist receives highly specialized training in the pathology of the head and neck, including odontogenic cysts and tumors and salivary gland diseases. The typical general surgical pathologist, by comparison, has a modest degree of experience with respect to oral conditions and may be unfamiliar with the unique microscopic features of lesions from this area. To give some perspective, individuals trained in oral and maxillofacial pathology programs review tens of thousands of oral biopsy specimens prior to graduation. By contrast, it is unusual for general surgical (anatomic) pathology residents to examine more than a few hundred specimens from the orofacial region during their training. Furthermore, the oral and maxillofacial pathologist has a command of the terminology used by the dental profession to describe oral disease and can more readily correlate the clinical and radiographic features with the microscopic findings. Just as a general surgeon may be able to remove a set of impacted third molars, the general pathologist may be able to provide an adequate diagnosis for an oral biopsy. In most situations, however, the professionals who are trained specifically to manage problems related to the oral and maxillofacial region are able to accomplish their respective tasks more efficiently and accurately.

The Microscopic Differential Diagnosis

On occasion a final diagnosis cannot be made after examining routine hematoxylin and eosin–stained sections of a lesion. In such a situation, the pathologist is faced with a *microscopic* or *histopathologic differential diagnosis*. For some cases, special chemical stains may be useful in the detection of suspected microorganisms or the identification of tissue products such as mucin or amyloid. In other cases, particularly spindle-cell malignancies and a group of undifferentiated neoplasms termed small blue-cell tumors, the final diagnosis can be even more challenging. Thankfully, even though these tumors may appear undifferentiated at the light microscopic level, they often continue to produce molecules that relate either to their cellular origin or to their newly acquired form of differentiation. To more accurately classify such tumors, these molecular products of origin or differentiation are routinely assessed in the lesional cells through the use of *immunohistochemical* (IHC) studies. These techniques employ a wide variety of monoclonal and polyclonal antibodies that are directed against specific cellular or integrated viral antigens (eg, those produced by the Epstein-Barr virus) that are usually expressed even in otherwise “undifferentiated” neoplasms. The antibodies are linked to an enzyme that is capable of cleaving a selected chemical substrate. This activity produces a pigmented product (often brown; hence the term “brown stains”) that is deposited in the tissues wherever the target antigens are expressed. The diagnosis of a particular tumor often requires the analysis of a number of antigens to fully explore the histopathologic differential. In cases of malignant lymphoma, for example, it is not uncommon for a panel of 10 or more “probes” to be used to characterize the neoplastic process and permit a therapy that is optimized for that particular tumor.

Although routine formalin-fixed paraffin-embedded tissue sections can

generally be used to perform most IHC studies, an important exception involves tumors that require analysis by *flow cytometry*. Typically used to permit rapid and highly specific subclassification of lymphomas and leukemias, flow cytometry employs IHC probes, but the tissue samples must not be fixed and should be analyzed immediately following collection. Another exception to this rule concerns the definitive diagnosis of immunobullous disorders such as cicatricial pemphigoid. When such conditions are considered within the differential, perilesional tissue should be obtained and submitted in a special holding medium known as Michel’s solution (Michel’s Media). A holding medium is necessary because the molecular structure of the diagnostic antigens in these conditions (eg, immunoglobulins, complement, and fibrinogen) is usually destroyed by formalin fixation. These specimens are processed as frozen sections and are evaluated by DIF, a special form of IHC that employs antibodies tagged with fluorescent markers. When a special ultraviolet-capable microscope is used, these markers reveal the presence and pattern of immunoreactants necessary to confirm or refute a potential autoimmune disease process. *Indirect immunofluorescence* (IIF) is used for conditions such as pemphigus vulgaris, in which elevated levels of circulating autoantibody are often seen. For indirect immunofluorescent studies, patient serum is incubated with a segment of control substrate (typically monkey esophagus). The serum is removed and the substrate is then incubated with antibody probes similar to those used in DIF studies. As with DIF, ultraviolet microscopy is used to examine the substrate for evidence of serum-derived antibody binding to epithelial or basement membrane components.

In a few instances even the more sophisticated immunohistochemical techniques cannot provide a definitive diagnosis. In those situations newly developed *molecular techniques* are being used with

greater frequency. These techniques include sophisticated cytogenetic studies such as *fluorescence in situ hybridization* (FISH) as well as molecular probes that use complementary deoxyribonucleic acid (cDNA) to identify disease-specific DNA sequences in human tissue samples. Examples include restriction fragment length polymorphism analysis with Southern blot or antigen receptor gene rearrangement analysis by polymerase chain reaction for the determination of clonality in B- or T-cell proliferations.

Patient Follow-Up

One of the most important aspects in the diagnosis and management of a given oral lesion or condition is the follow-up evaluation. This appointment permits the clinician to assess the abnormality for physical or symptomatic changes, gain insight into the kinetics of growth or rate of resolution, and assess the impact of initial conservative treatment measures or recommendations to the patient. These additional pieces of information may support the working diagnosis, and no further work-up may be required (see Figure 29-1). Alternatively, the follow-up findings may indicate that further investigation of

the differential considerations is warranted such as biopsy and histopathologic review. Finally, careful follow-up should be considered mandatory for patients who have been previously diagnosed with or treated for oral dysplasia or carcinoma.

Although an important part of the practice of dentistry and medicine, formal guidelines for the management of oral lesions that are not clearly premalignant or cancerous have only recently been suggested.⁹ Such guidelines are helpful to clinicians as they provide systematic protocols for the management of oral pathologic conditions and serve to reduce the medicolegal risk associated with this important aspect of patient care (Table 29-1).

After the initial evaluation and careful documentation of an oral lesion, a follow-up examination should be scheduled for 7 to 14 days later, with or without any treatment. If there is evidence of lesion enlargement or other physical or symptomatic changes that do not suggest normal healing or resolution, then biopsy is indicated. If the lesion remains relatively unchanged and the index of suspicion for malignancy is low, the clinician should help the patient decide the next course of action based upon experience, advanced training, or

both. Whenever available, referral to an oral and maxillofacial pathologist may be helpful in this regard. If the patient and clinician decide to defer biopsy, this decision should be documented and re-evaluation of the area should be scheduled at 1, 3, 6, and 12 months following the initial examination. During the follow-up period, diagnostic options include the brush cytology technique (to identify evidence of atypical epithelial cells in surface lesions) or incisional biopsy (to establish a firm diagnosis). The need for these options varies depending on the concerns of the patient or the experience and expertise of the clinician. At any time point, however, evidence of significant lesional change should immediately trigger a recommendation of biopsy. After a year most unchanged lesions can be monitored at routine semiannual or annual dental visits.

Finally, it should be recognized that these recommendations, although sound, do not represent rigid guidelines or medicolegal standards of care that cover every clinical scenario. Each patient and abnormality deserves individual attention and management that may vary from the protocol above, based upon training, experience, and the clinical judgement of the practitioner.

Table 29-1 Follow-Up Protocol for Oral Pathology

1. Initial re-evaluation: 7–14 d following lesion detection/examination
2. If no evidence of lesional progression or suspicious clinical alterations, reevaluate at 1, 3, 6, and 12 mo intervals; thereafter, re-examine in conjunction with normal recall visits (every 6–12 mo)
3. If lesional progression or suspicious clinical changes noted, incisional or excisional biopsy should be performed as soon as possible, and specimen should be reviewed by oral and maxillofacial pathologist
4. If no evidence of preneoplastic change (dysplasia) or malignancy (carcinoma or sarcoma) reported, schedule follow-up as in step 2 and document subsequent findings in patient record
5. When diagnosis of dysplasia (pre malignancy) or malignancy is reported, refer or schedule immediately for appropriate work-up and therapy; following definitive treatment, begin follow-up evaluations as in step 2 or similar protocol

Adapted from Alexander RE et al.⁹

References

1. Ellis E III. Principles of differential diagnosis and biopsy. In: Peterson LJ, Ellis E, Hupp JR, Tucker MR, editors. *Contemporary oral and maxillofacial surgery*. 4th ed. St. Louis: Mosby, Inc.; 2003. p. 458–78.
2. Halstead CL, Blozis GG, Drinnan AJ, Gier RE, editors. Diagnostic process. In: *Physical evaluation of the dental patient*. St. Louis: The C.V. Mosby Company; 1982. p. 8–12.
3. Frederiksen NL. Specialized radiographic techniques. In: White SC, Pharoah MJ, editors. *Oral radiology: principles and interpretation*. 4th ed. St. Louis: Mosby, Inc.; 2000. p. 217–41.
4. Hlawitschka M, Neise E, Bredow J, et al. FDG-PET in the pretherapeutic evaluation of primary squamous cell carcinoma of the oral cavity and the involvement of cervical lymph nodes. *Mol Imag Biol* 2002;4:91–8.

5. Kato H, Kuwano H, Nakajima M, et al. Comparison between positron emission tomography and computed tomography in the use of the assessment of esophageal carcinoma. *Cancer* 2002;94:921–8.
6. Hubner KF, Thie JA, Smith GT, et al. Clinical utility of FDG-PET in detecting head and tumors: a comparison of diagnostic methods and modalities. *Clin Positron Imaging* 2000;3:7–16.
7. McGuirt WF, Greven K, Williams D III, et al. PET scanning in head and neck oncology: a review. *Head Neck* 1998;20:208–15.
8. Schmid DT, Stoeckli SJ, Bandhauer F, et al. Impact of positron emission tomography on the initial staging and therapy in locoregional advanced squamous cell carcinoma of the head and neck. *Laryngoscope* 2003;113:889–91.
9. Alexander RE, Wright JM, Thiebaud S. Evaluating, documenting and following up oral pathological conditions: a suggested protocol. *J Am Dent Assoc* 2001;132:329–35.

Odontogenic Cysts and Tumors

Eric R. Carlson, DMD, MD

Odontogenic cysts and tumors are relatively uncommon lesions of the oral and maxillofacial region that must be considered whenever examining and formulating a differential diagnosis of an expansile process of the jaws. The clinical presentation, radiographic appearance, and natural history of these lesions varies considerably, such that odontogenic cysts and tumors represent a diverse group of lesions of the jaws and overlying soft tissues. Collectively speaking, their occurrence is frequent enough to warrant a thorough discussion. As a whole, these pathologic entities have been studied and reported on extensively.

Purely defined, *odontogenic* refers to derivation from a tooth-related apparatus. Tooth formation is a complex process that involves both connective tissues and epithelium. Three major tissues are involved in odontogenesis including the enamel organ, the dental follicle, and the dental papilla. The enamel organ is an epithelial structure that is derived from oral ectoderm. The dental follicle and dental papilla are considered ectomesenchymal in nature because they are in part derived from neural crest cells.

For each tooth, odontogenesis begins with the apical proliferation from the oral mucosa of epithelium known as the dental lamina (Figure 30-1). The dental lamina, in turn, gives rise to the enamel organ, a cap-shaped structure that subsequently

evolves into a bell shape. After forming the enamel organ, the cord of dental lamina normally fragments and degenerates; however, small islands of the dental lamina may remain after tooth formation and are believed to be responsible for the development of several of the odontogenic cysts and tumors.

The enamel organ has four types of epithelium. The innermost lining is referred to as the inner enamel epithelium and becomes the ameloblastic layer that forms tooth enamel. The second layer of cells adjacent to the inner enamel epithelium is the stratum intermedium. Adjacent to this layer is the stellate reticulum, followed by the outer enamel epithelium. Surrounding the enamel organ is loose connective tissue known as the dental papilla. Contact with the enamel organ epithelium induces the dental papilla to make odontoblasts that form dentin. As the odontoblasts deposit dentin, they induce the ameloblasts to begin forming enamel.

Following the initial formation of the crown, a thin layer of the enamel organ epithelium known as Hertwig's root sheath proliferates apically to provide the stimulus for odontoblastic differentiation in the root portion of the developing tooth. This epithelial extension later becomes fragmented but leaves behind small nests of epithelial cells known as rests of Malassez in the periodontal ligament space. The rests of Malassez are

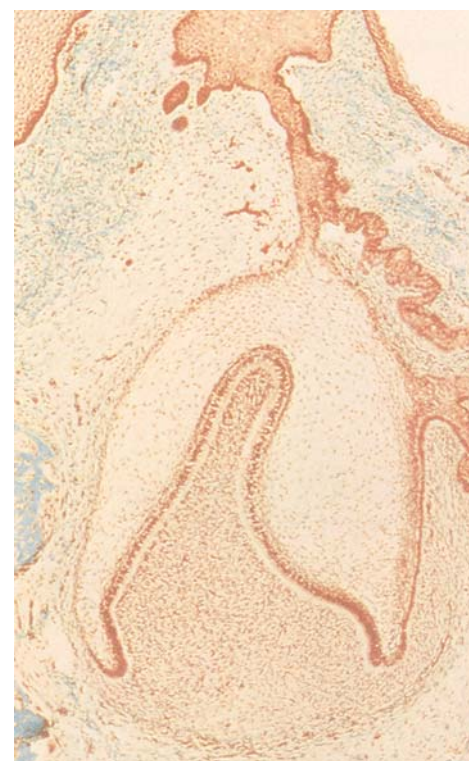


FIGURE 30-1 The enamel organ is seen emanating from the dental lamina (hematoxylin and eosin; original magnification $\times 20$) Reproduced with permission from Cawson RA, Eveson JW, editors. *Oral pathology and diagnosis. Color atlas with integrated text.* Philadelphia (PA): W.B. Saunders; 1987.

believed to be the source of epithelium for most periapical cysts but generally are not believed to give rise to any of the odontogenic neoplasms, with the possible exception of the squamous odontogenic tumor.

In the development of a tooth, following completion of enamel formation, the

enamel organ epithelium atrophies to form a thin flattened layer of cells that covers the enamel of the unerupted tooth. This layer of epithelium is known as the reduced enamel epithelium. In the normal sequence of events, this reduced enamel epithelium later merges with the surface epithelium and forms the initial gingival crevicular epithelium of the newly erupted tooth. However, if fluid accumulates between the reduced enamel epithelium and the crown of the tooth before tooth eruption, a cyst is formed that is known as a dentigerous or follicular cyst.

An understanding of the progression of odontogenic cysts and tumors within the oral and maxillofacial region requires a thorough knowledge of the cell cycle of these lesions and an appreciation of the concept of proliferation versus apoptosis (programmed cell death). Most of the pathogenetic mechanisms of odontogenic cysts and tumors can be explained via the cell cycle (Figure 30-2). Normally cell division is divided into four phases: G₁ (gap 1), S (deoxyribonucleic acid synthesis), G₂ (gap 2), and M (mitosis). A key event is the progression from G₁ to the S phase. Genetic alterations, if unrepaired in the G₁

phase, may be carried into the S phase and perpetuated in subsequent cell divisions. The G₁-S checkpoint is normally regulated by a well-coordinated and complex system of protein interactions whose balance and function are critical to normal cell division.¹ As can be seen in Figure 30-2, once genetic change occurs that encourages the development of an odontogenic cyst or tumor, a series of events mediated by the odontogenic lesion occur that may promote proliferation. Such events support the pathogenetic mechanism involved in the progression of the cyst or tumor.

It is the purpose of this chapter to review the clinically significant and more commonly encountered odontogenic cysts and tumors. In so doing, salient clinical and radiographic features are discussed, as are the pathogenetic mechanisms supporting proliferation of some of the more aggressive odontogenic cysts and tumors. Recommendations for treatment and prognostic information are also offered.

Odontogenic Cysts

With rare exceptions, epithelium-lined cysts in bone are seen only in the jaws.² Other than a few cysts that may result

from the inclusion of epithelium along embryonic lines of fusion, most jaw cysts are lined by epithelium that is derived from odontogenic epithelium, hence the term *odontogenic cysts*. These cysts are subclassified as developmental or inflammatory in nature. Although the cell type is often known, developmental cysts are of unknown origin; however, they do not seem to be the result of an inflammatory reaction. Inflammatory cysts, on the other hand, are the result of inflammation (Table 30-1).

Dentigerous Cyst

By definition, a dentigerous cyst occurs in association with an unerupted tooth, most commonly mandibular third molars. Other common associations are with maxillary third molars, maxillary canines, and mandibular second premolars.² They may also occur around supernumerary teeth and in association with odontomas; however, they are only rarely associated with primary teeth.^{2,3} Although dentigerous cysts occur over a wide age range, they are most commonly seen in 10- to 30-year-olds. There is a slight male predilection, and their prevalence appears to be higher in Whites than in Blacks. Many dentigerous cysts are small asymptomatic lesions that are discovered serendipitously on routine radiographs, although some may grow to considerable size causing bony expansion that is usually painless until secondary infection occurs.

Radiographically, the dentigerous cyst presents as a well-defined unilocular radiolucency, often with a sclerotic border (Figure 30-3). Since the epithelial lining is derived from the reduced enamel epithelium, this radiolucency typically and preferentially surrounds the crown of the tooth. A large dentigerous cyst may give the impression of a multilocular process because of the persistence of bone trabeculae within the radiolucency. However, dentigerous cysts are grossly and histopathologically unilocular processes

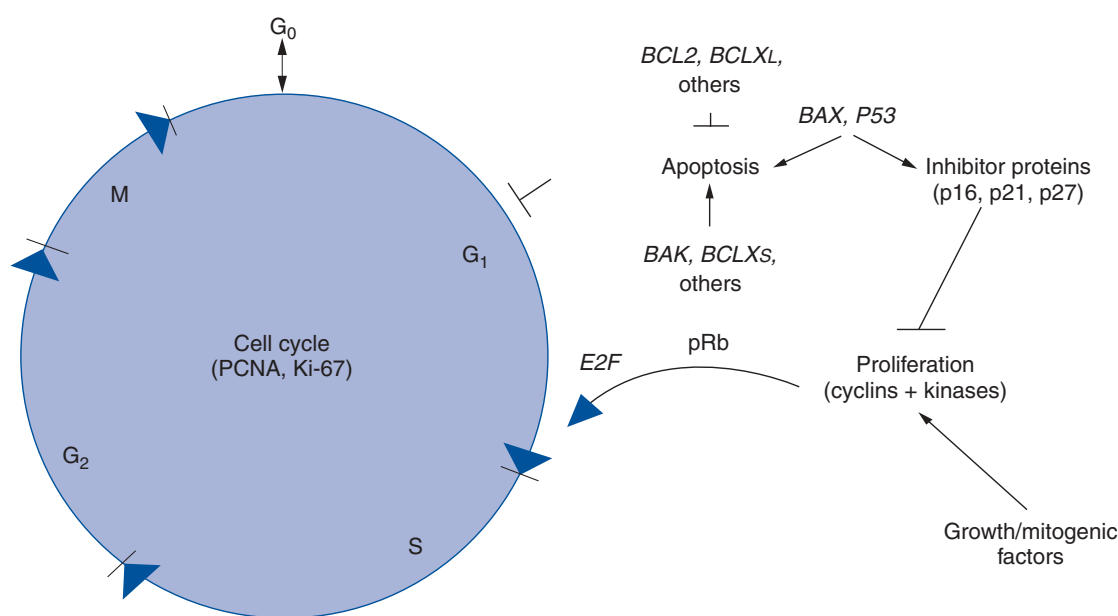


FIGURE 30-2 The cell cycle—a concept of proliferation versus apoptosis. PCNA = proliferating cell nuclear antigen.

Table 30-1 Classification of Odontogenic Cysts

Developmental	
Dentigerous cyst	
Eruption cyst	
Odontogenic keratocyst	
Orthokeratinized odontogenic cyst	
Gingival (alveolar cyst of the newborn)	
Gingival cyst of the adult	
Lateral periodontal cyst	
Calcifying odontogenic cyst	
Glandular odontogenic cyst	
Inflammatory	
Periapical (radicular cyst)	
Residual periapical (radicular cyst)	
Buccal bifurcation cyst	

and probably are never truly multilocular lesions.² Three types of dentigerous cyst have been described radiographically, including the *central* variety, in which the radiolucency surrounds just the crown of the tooth, with the crown projecting into the cyst lumen. In the *lateral* variety, the cyst develops laterally along the tooth root and partially surrounds the crown. The *circumferential* variant of the dentigerous cyst exists when the cyst surrounds the crown but also extends down along the root surface, as if the entire tooth were located within the cyst.

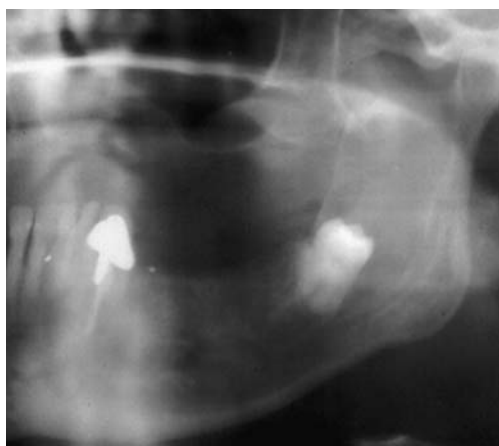


FIGURE 30-3 This unilocular radiolucency of the left mandibular ramus associated with impacted tooth no. 17 was discovered serendipitously when the patient was evaluated for routine dental work.

One diagnostic dilemma for oral and maxillofacial surgeons is distinguishing between a dentigerous cyst and an enlarged dental follicle. This distinction becomes clinically significant when the surgeon considers whether to submit tissue removed with an impacted third molar for histopathologic examination as opposed to clinical designation as a follicle, with simple disposal of the tissue. The radiographic distinction becomes somewhat arbitrary; however, any pericoronal radiolucency that is > 4 or 5 mm is considered suggestive of cyst formation and should be submitted for microscopic examination. It is noteworthy that pathologists also struggle with the distinction between dental follicles associated with developing teeth and odontogenic lesions.^{4,5} It seems that odontogenic cysts, odontogenic fibroma, and odontogenic myxoma are the lesions most often inappropriately diagnosed by surgical pathologists owing to a general unfamiliarity with the normal process of odontogenesis.⁴

Of perhaps even greater concern is the large unilocular radiolucency. Although most commonly classified radiographically as dentigerous cysts, it is incumbent upon the surgeon to section these excised specimens in the operating room and to consider frozen-section analysis. In fact, some specimens may contain a focus of unicystic ameloblastoma and therefore require consideration of more extensive treatment.

The histologic features of dentigerous cysts may vary greatly depending mainly on whether or not the cyst is inflamed. In the noninflamed dentigerous cyst, a thin epithelial lining may be present with the fibrous connective tissue wall loosely arranged (Figure 30-4). In the inflamed dentigerous cyst, the epithelium commonly demonstrates hyperplastic rete ridges, and the fibrous cyst wall shows an inflammatory infiltrate.

Treatment and Prognosis Most dentigerous cysts are treated with enucleation of the cyst and removal of the associated

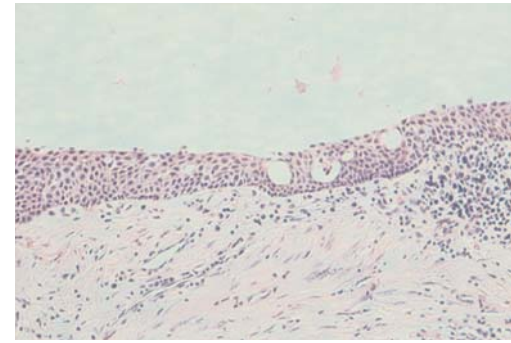

FIGURE 30-4 The biopsy of the radiolucency in Figure 30-3 shows an atrophic stratified squamous epithelium without significant associated inflammation. The diagnosis is dentigerous cyst (hematoxylin and eosin; original magnification $\times 40$).

tooth, often without a preceding incisional biopsy (Figure 30-5). Larger cysts that are treated in the operating room should probably undergo frozen-section diagnosis and appropriate treatment that might be dictated by other diagnoses. Curettage of the cyst cavity is usually advisable at the time of removal of the cyst in the event that a more aggressive cyst is diagnosed histopathologically following removal in an office setting. Such diagnoses would include odontogenic keratocyst and unicystic ameloblastoma.

Large dentigerous cysts may be treated with marsupialization (Figure 30-6) when enucleation and curettage might otherwise result in neurosensory dysfunction or predispose the patient to an increased chance of pathologic fracture. Some patients who are not candidates for general anesthesia may also be treated with a marsupialization procedure in an office setting under local anesthesia. This permits decompression of the large dentigerous cyst with a resultant reduction in the size of the cyst and bony defect. At a later date the reduced cyst can be removed in a smaller-scale surgery.

I emphasize the need for histopathologic examination of all radiolucencies that are empirically diagnosed as dentigerous cysts. This includes those that are enucleated as well as those that undergo marsupialization, during which it is important to inspect the cyst lumen and submit a

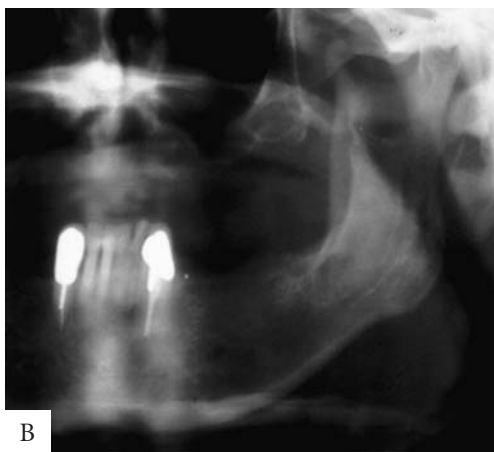
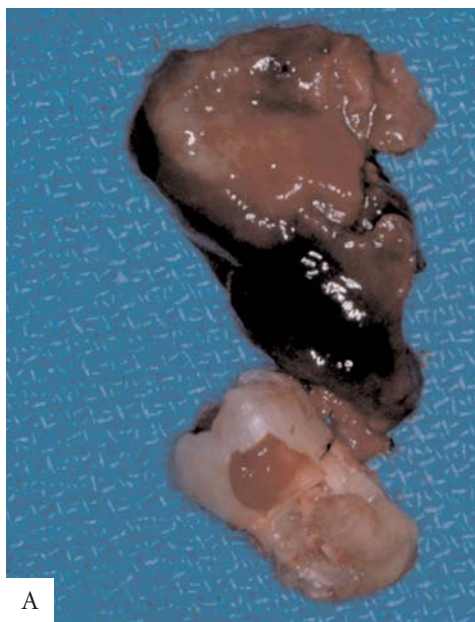

FIGURE 30-5 A, The dentigerous cyst in Figure 30-3 is treated with enucleation and curettage of the cyst and removal of the etiologic tooth. B, The 5-year postoperative radiograph shows an acceptable bony fill.

representative piece for histopathologic examination. Support of this statement stems from the occasional formation of a squamous cell carcinoma, mucoepidermoid carcinoma, or ameloblastoma from or in association with a dentigerous cyst.⁶⁻⁸ The prognosis for most histopathologically diagnosed dentigerous cysts is excellent, with recurrence being a rare finding.

Odontogenic Keratocyst

The odontogenic keratocyst is a distinctive form of developmental odontogenic cyst that deserves special consideration because of its specific histopathologic features and aggressive clinical behavior. Two variants of

this cyst are well known; the sporadic cyst and the cyst associated with the nevoid basal cell carcinoma syndrome. Both variants of the odontogenic keratocyst are believed to be derived from remnants of the dental lamina. This cyst shows a different growth mechanism and biologic behavior from the previously described dentigerous cyst. Most authors believe that dentigerous cysts continue to enlarge as a result of increased osmotic pressure within the lumen of the cyst. This mechanism does not appear to hold true for odontogenic keratocysts, and their growth may be related to unknown factors inherent in the epithelium itself or enzymatic activity in the fibrous wall.⁹

Adequate diagnosis and treatment of the odontogenic keratocyst is important for three reasons: (1) this cyst is recognized as being more aggressive than other odontogenic cysts,¹⁰ (2) the odontogenic keratocyst has a higher rate of recurrence than other odontogenic cysts,¹¹ and (3) the association with nevoid basal cell carcinoma syndrome requires that the clinician examine a patient with multiple cysts of the jaws for physical findings that might diagnose this syndrome.¹²⁻¹⁴

Odontogenic keratocysts may be found in patients ranging in age from infancy to old age; however, 60% of cases are seen in people between 10 and 40 years old.¹⁵ In his series of 312 cases, Brannon found a mean age of nearly 38 years.¹⁶ The peak prevalence was in the second and third decades of life, with only 15% occurring past the age of 60 years. Woolgar and colleagues reviewed 682 odontogenic keratocysts from 522 patients and found a mean age of 40 years for patients with single nonrecurrent cysts and 26.2 years for patients with multiple cysts of the nevoid basal cell carcinoma syndrome.¹⁷ A slight male predilection is usually seen, and 60 to 80% of cases involve the mandible, particularly in the posterior body and ascending ramus.² Although it is rare for a dentigerous cyst to appear multilocular on radiographs, it is most common for odontogenic keratocysts to appear multilocular (Figure 30-7). Many

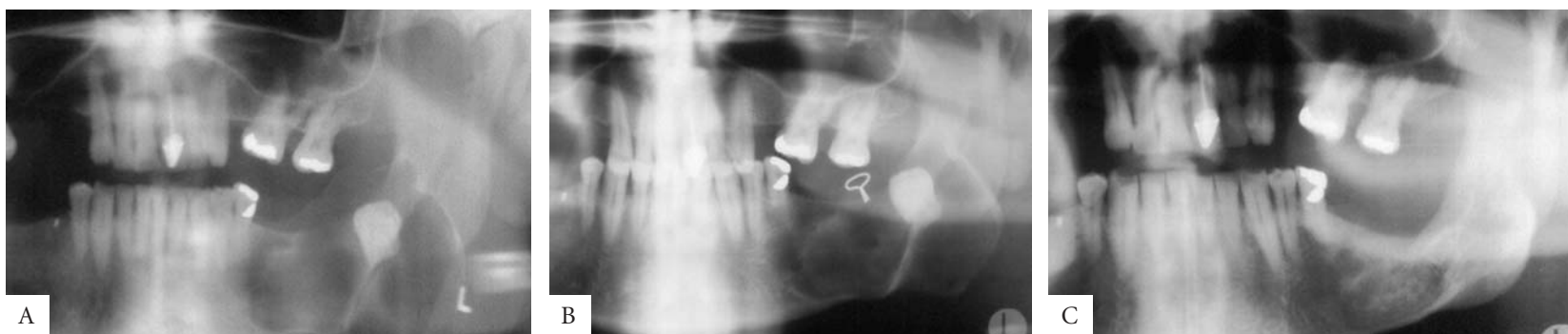


FIGURE 30-6 A, This large biopsy-proven dentigerous cyst occurred in an elderly patient who had coronary artery disease. Owing to the size of the cyst and the compromised cardiac status of the patient, a relatively noninvasive marsupialization was performed. B, An acrylic plug with a wire handle was placed in a small surgical entrance into the cyst cavity. The cyst shrunk considerably, after which time the etiologic impacted tooth was removed with a small remnant of dentigerous cyst. C, The 5-year postmarsupialization radiograph shows an excellent fill of bone.

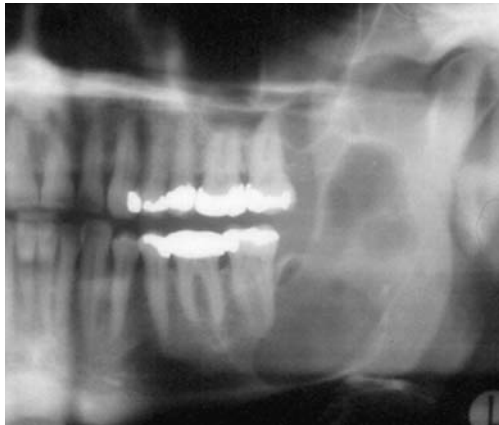

FIGURE 30-7 This multilocular radiolucency, present in a 54-year-old man, should suggest an odontogenic keratocyst when formulating a differential diagnosis.

appear unilocular and can therefore be confused with dentigerous cysts. It is clear, therefore, that the differential diagnosis of a unilocular radiolucency must include both entities and that treatment should include curettage in the event that the diagnosis is odontogenic keratocyst. When multiple multilocular radiolucencies are noted on a panoramic radiograph, the clinician must perform an incisional biopsy and investigate the possibility of nevoid basal cell carcinoma syndrome (Table 30-2).

Histologically, the odontogenic keratocyst is readily recognized. A uniform layer of stratified squamous epithelium, usually six to eight cells in thickness, is present (Figure 30-8). The parakeratotic surface is characteristically corrugated. The wall is usually thin and friable, which can pose problems for removal in one piece intraoperatively. Epithelial budding and the presence of daughter cysts may be noted in the connective tissue wall. It is generally advisable to ask the pathologist to examine the sections carefully for these two features as they generally impart a more aggressive character to the cyst.

Treatment and Prognosis Like the treatment of most odontogenic cysts, the odontogenic keratocyst may be treated with enucleation and curettage and must

be removed in one piece, which requires acceptable access and lighting (Figure 30-9). As such, many patients are suitably treated in an operating room setting under general anesthesia. This is particularly helpful when removing large cysts. It is my experience and that of others that a large majority of sporadic odontogenic keratocysts may be effectively managed with a thorough enucleation and curettage surgery.^{18,19} MacIntosh has advocated the resection of odontogenic keratocysts with 5 mm linear margins as the preferred primary method of treatment, and has reported on 37 patients with 43 lesions emphasizing the efficacy and superior

results of resection over all other therapeutic undertakings.²⁰

The reported frequency of recurrence of the odontogenic keratocyst ranges from 2.5% to 62.5% in various studies.¹¹ This wide variation may be related to the total number of cases studied, the length of follow-up periods, and the inclusion or exclusion of orthokeratinized cysts in the study group. Several reports that include large numbers of cases indicate a recurrence rate of approximately 30%.² Regezi and colleagues point out that the recurrence rate for solitary odontogenic keratocysts is 10 to 30%.²¹ They indicate that approximately 5% of patients with odontogenic keratocysts have multiple sporadic jaw cysts (nonsyndromic) and that their recurrence rate is greater than that for solitary lesions.²¹ Brannon has suggested three mechanisms responsible for recurrence: (1) remnants of dental lamina within the jaws not associated with the original odontogenic keratocyst being responsible for de novo cyst formation; (2) incomplete removal (persistence) of the original cyst secondary to a thin friable lining and cortical perforation with adherence to adjacent soft tissue; and (3) remaining rests of dental lamina and satellite cysts following enucleation.²² Vedtofte and Praetorius reviewed 72 patients with 75 odontogenic keratocysts and observed remnants of dental lamina between the cyst membrane

Table 30-2 Clinical Features of the Basal Cell Nevus Syndrome

≥ 50% frequency
Multiple basal cell carcinomas
Odontogenic keratocysts
Epidermal cysts of the skin
Palmar/plantar pits
Calcified falx cerebri
Enlarged head circumference
Rib anomalies (splayed, fused, partially missing, bifid)
Mild ocular hypertelorism
Spina bifida occulta of cervical or thoracic vertebrae
15–49% frequency
Calcified ovarian fibromas
Short fourth metacarpals
Kyphoscoliosis or other vertebral anomalies
Pectus excavatum or carinatum
Strabismus (exotropia)
< 15% frequency (but not random)
Medulloblastoma
Meningioma
Lymphomesenteric cysts
Cardiac fibroma
Fetal rhabdomyoma
Marfanoid build
Cleft lip and/or palate
Hypogonadism in males
Mental retardation

Adapted from Gorlin FJ.¹⁴

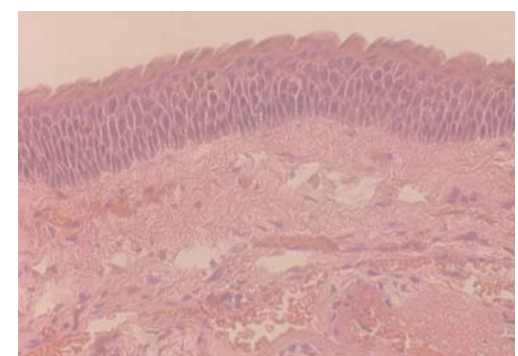


FIGURE 30-8 The classic histologic appearance of an odontogenic keratocyst from the incisional biopsy of the lesion in Figure 30-7 (hematoxylin and eosin; original magnification $\times 40$).

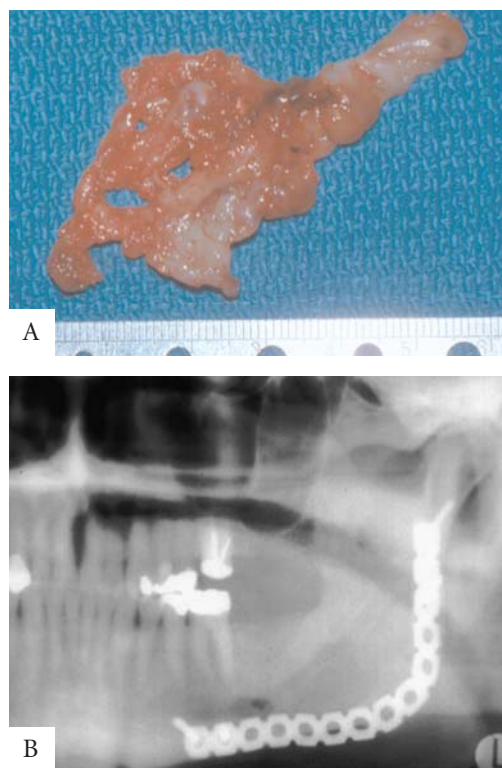


FIGURE 30-9 A, A very thin cyst lining was encountered when performing the enucleation and curettage of the odontogenic keratocyst in Figure 30-7. B, The 7-year postoperative radiograph shows an excellent fill of bone. A reconstruction bone plate was placed at the time of the enucleation and curettage to prevent a pathologic fracture of the mandible.

and overlying mucosa.²³ As such, they advocated the excision of overlying mucosa in conjunction with removal of the cyst. Williams and Connor recommended a primary enucleation and curettage surgery for odontogenic keratocysts, including the use of methylene blue as a marking agent, followed by a 3-minute application of Carnoy's solution.¹¹ They indicated that resection should be considered for the treatment of a recurrent odontogenic keratocyst, with inclusion of appropriate bone and soft tissue margins.

Pathogenetically, the odontogenic keratocyst expresses cell cycle phenomena that support its proliferation.²¹ These include the release of the cytokines interleukin 1a (IL-1a) and IL-6 as well as parathyroid hormone-related protein that encourage resorption of bone.^{21,24} Moreover, the

expression of proliferating cell nuclear antigen (PCNA) in odontogenic cysts has been assessed. It is hypothesized that the identification of the proliferative activity in odontogenic cysts and tumors may be useful to predict their biologic behavior. The same may be true of the Ki-67 antigen. In fact, two studies have been performed that have quantified these parameters.^{25,26} The conclusion of both studies is that an increased proliferative activity for the odontogenic keratocyst in comparison with the dentigerous cyst is noted consistently. These results are in agreement with the more aggressive behavior seen with the odontogenic keratocyst.

The orthokeratinized odontogenic cyst, once thought to be a variant of the odontogenic keratocyst, is now generally well accepted as being a different clinicopathologic entity from the more common parakeratinized odontogenic keratocyst; it should therefore be placed in a different category. These cysts usually appear as unilocular radiolucencies, but occasional examples have been multilocular. A majority of these cysts are encountered in a lesion that appears clinically and radiographically to represent a dentigerous cyst, most often involving an unerupted mandibular third molar tooth. Histologically, the epithelium is thin and orthokeratinized, and a prominent palisaded basal layer, characteristic of the odontogenic keratocyst, is not present. Enucleation and curettage of the orthokeratinized cyst is curative in most cases. The reported rate of recurrence of 2% is far lower than the previously quoted statistics for recurrence of the odontogenic keratocyst.²

Nevoid Basal Cell Carcinoma Syndrome

The nevoid basal cell carcinoma syndrome (basal cell nevus syndrome, Gorlin's syndrome) is an autosomal-dominant inherited condition that exhibits high penetrance and variable expressivity. It is caused by mutations in the *PTCH* tumor suppressor gene, mapped to chromosome

9q22.3-q31. Affected patients (Figure 30-10A) may demonstrate frontal and temporoparietal bossing, hypertelorism, and mandibular prognathism (see Table 30-2).¹⁴ Other frequent skeletal anomalies include bifid ribs and lamellar calcification of the falx cerebri (Figure 30-10B).¹⁴ The

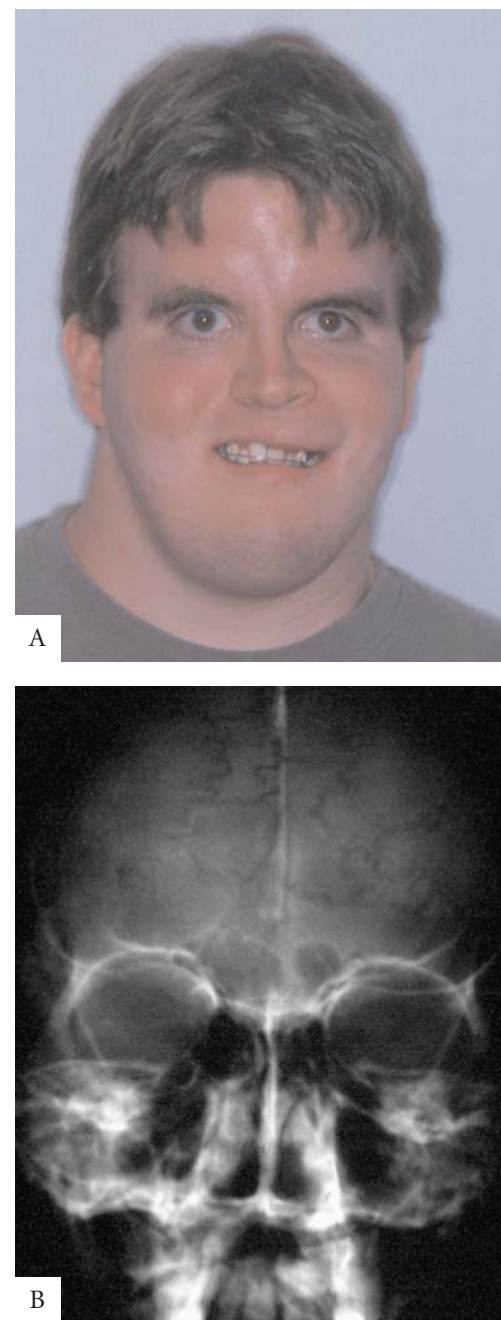


FIGURE 30-10 A, This 18-year-old shows some of the clinical features of the nevoid basal cell carcinoma syndrome including frontal bossing and mandibular prognathism. B, The radiograph from another patient shows a calcified falx cerebri.

most significant clinical feature is the tendency to develop multiple basal cell carcinomas that may affect both exposed and non-sun-exposed areas of the skin. Pitting defects on the palms and soles can be found in nearly two-thirds of affected patients (Figure 30-11). The discovery of multiple odontogenic keratocysts is usually the first manifestation of the syndrome that leads to the diagnosis. For this reason, any patient with an odontogenic keratocyst should be evaluated for this condition. Although the cysts in patients with nevoid basal cell carcinoma syndrome cannot definitely be distinguished microscopically from those not associated with the syndrome, they often demonstrate more epithelial proliferation and daughter cyst formation in the cyst wall.

The treatment of the odontogenic keratocyst in patients with nevoid basal

cell carcinoma syndrome can be difficult owing to the large number of “recurrences” in these patients. As a matter of point, I choose to refer to these as new primary cysts owing to the autosomal-dominant penetrance of the syndrome and cyst development. It is certainly possible that many of these cysts are persistent, particularly when considering how common it can be to retain rests of the dental lamina when enucleating an odontogenic keratocyst. Whatever the mechanism, a resection hardly seems to be warranted. Marsupialization is a more desirable procedure (Figure 30-12) and has been shown to result in complete resolution of the sporadic cyst, with no histologic signs of cystic remnants, daughter cysts, or budding of the basal layer of the epithelium.²⁷ Although all of the eight cases in the series by Pogrel and Jordan were sporadic cysts,²⁷ a similar approach to syndrome patients with odontogenic keratocysts that had been operated on multiple times has been performed with success in a small sample size.¹⁸

Glandular Odontogenic Cyst

The glandular odontogenic cyst (sialodontogenic cyst) is a rare and recently described cyst of the jaws that is capable

of aggressive behavior and recurrence. Although it is generally accepted as being of odontogenic origin, it shows glandular or salivary features that seem to point to the pluripotentiality of odontogenic epithelium as cuboidal/columnar cells, mucin production, and cilia are noted in these cysts. Glandular odontogenic cysts occur most commonly in middle-aged adults, with a mean age of 49 years at the time of diagnosis.² Eighty percent of cases occur in the mandible,²¹ and a strong predilection for the anterior region of the jaws has been reported, with many mandibular lesions crossing the midline (Figure 30-13). These cysts may appear either unilocular or multilocular radiographically.

There is a histologic similarity between the glandular odontogenic cyst and the predominantly cystic intraosseous mucoepidermoid carcinoma. However, the epithelial lining of the glandular odontogenic cyst is typically thinner and does not show evidence of the more solid or microcystic epithelial proliferations seen in mucoepidermoid carcinoma (Figure 30-14). Waldron and Koh reviewed the similarities between the two lesions and concluded that it is entirely possible that some cases previously diagnosed as central mucoepidermoid

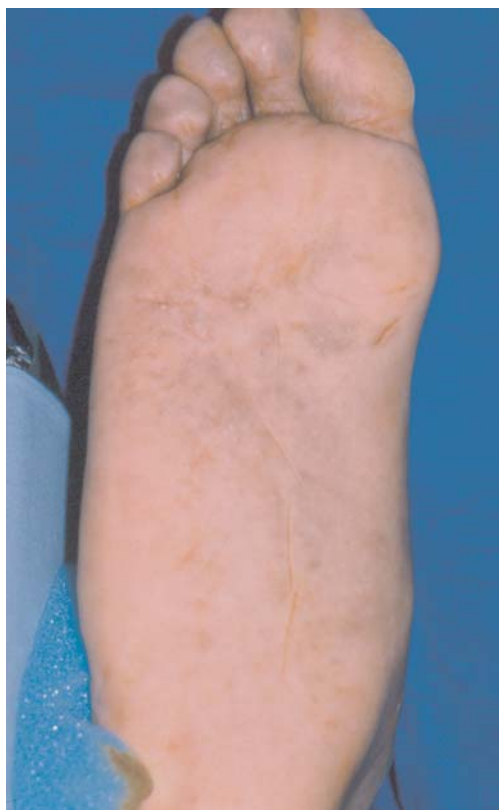

FIGURE 30-11 Plantar pitting can be observed by immersing the foot in povidone-iodine solution followed by a conservative wash of the foot with saline. The solution is taken up in the pits present in the plantar surface of the foot.

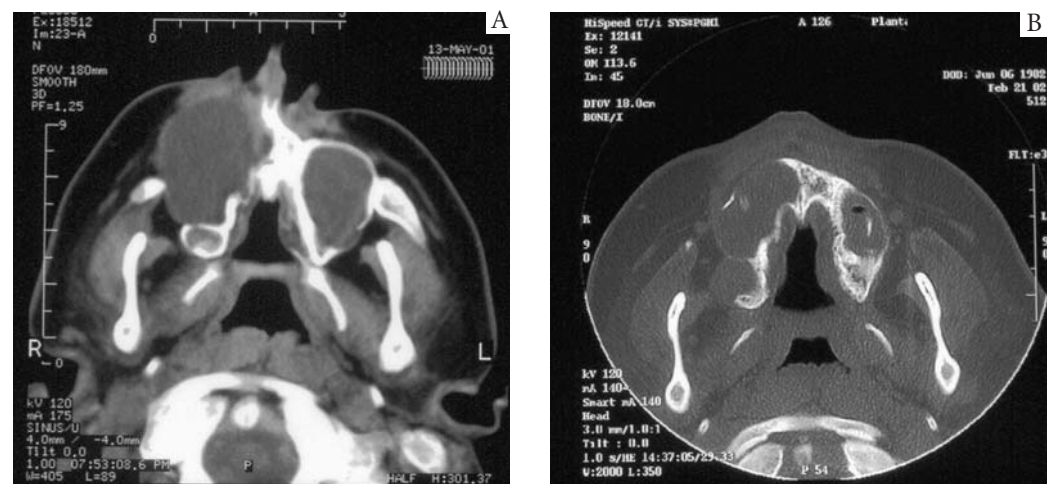


FIGURE 30-12 The patient in Figure 30-10A had previously undergone three enucleation and curettage surgeries for bilateral maxillary odontogenic keratocysts. A, Development of new large cysts in this area led to additional treatment with marsupialization. B, Six months later the axial computed tomography shows regression of the cysts.

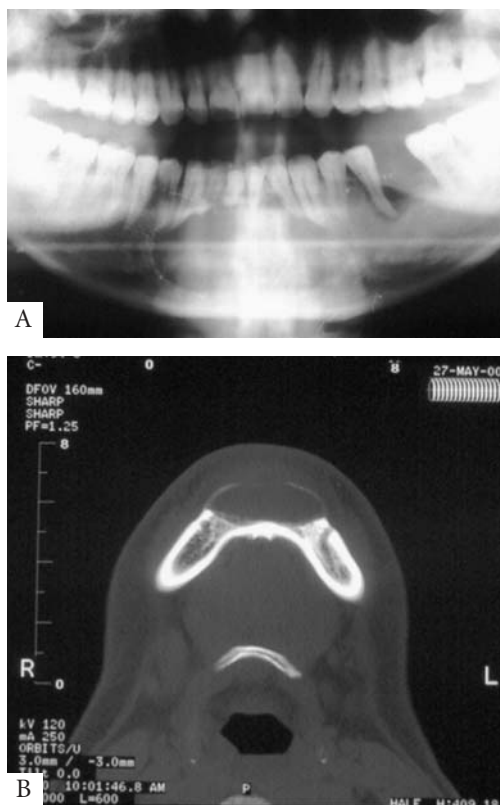


FIGURE 30-13 A and B, This glandular odontogenic cyst presented with a unilocular radiolucency of the anterior mandible crossing the midline.

tumors may be reclassified as examples of glandular odontogenic cysts.²⁸

Treatment and Prognosis Most glandular odontogenic cysts are treated with enucleation and curettage (Figure 30-15). Some authors, however, point to a recur-

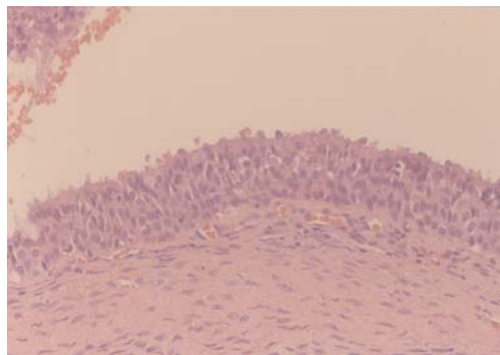


FIGURE 30-14 Histopathology of the lesion in Figure 30-13 shows a nonkeratinized stratified squamous epithelium with intraepithelial mucous cells and cilia (hematoxylin and eosin; original magnification $\times 40$).

rence rate of approximately 30% and therefore recommend resection.²⁹

Calcifying Odontogenic Cyst

The calcifying odontogenic cyst (COC), or Gorlin's cyst, is an uncommon lesion that demonstrates considerable histopathologic diversity and variable clinical behavior. Although designated as a cyst, some investigators provide evidence for subclassification as a neoplasm as well.^{30,31} In addition, the COC may be associated with other recognized odontogenic tumors, most commonly the odontoma. Adenomatoid odontogenic tumors and ameloblastomas have also been associated with the COC. Ghost cell keratinization, the characteristic microscopic feature of this cyst, is also a defining feature of the cutaneous lesion known as the calcifying epithelioma of Malherbe or pilomatixoma. The World Health Organization's classification of odontogenic tumors groups the COC with all its variants as an odontogenic tumor rather than an odontogenic cyst. The commentary on the second edition by Kramer, Pindborg, and Shear points out that some COCs appear to be non-neoplastic, but others show an infiltrative pattern of growth.³² They further indicate that more experience with the COC may provide reliable criteria for their reclassification. The review by Hong and colleagues designated 79 of 92 cases of COC as cysts with the remaining 13 cases being neoplastic in nature.³⁰

The COC is predominantly an intraosseous lesion, although 13 to 30% of reported cases occur as peripheral lesions.² Both the peripheral and central lesions occur with about equal frequency in the maxilla and mandible. There appears to be a predilection for the incisor and canine areas. Patients range in age from infant to elderly, with a mean age of occurrence of about 30 years. COCs that are associated with odontomas tend to occur in younger patients, with a mean age of 17 years.² The more rare neoplastic variant of the COC appears to occur in elderly patients. Most

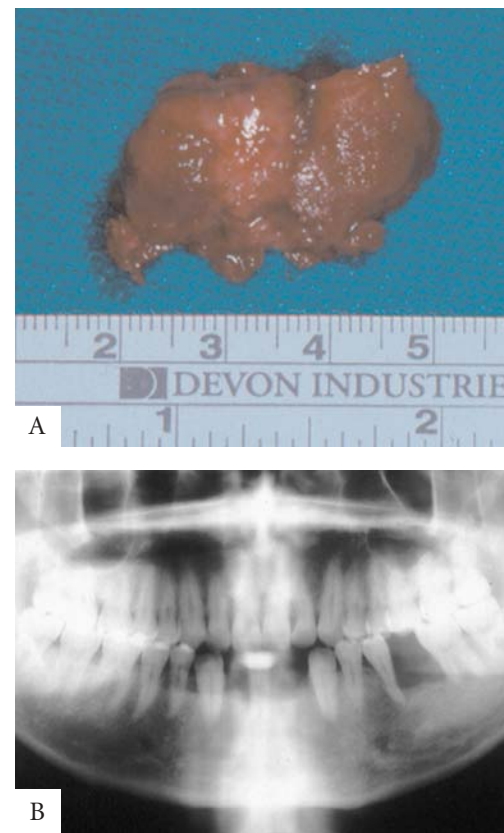


FIGURE 30-15 A, The patient whose radiograph appears in Figure 30-13 underwent an enucleation and curettage of the cyst as well as removal of the anterior mandibular teeth. B, The 3-year postoperative radiograph shows acceptable bony fill.

COCs appear radiographically as unilocular well-defined lesions. The radiopaque structures within the lesions have been described as either irregular calcifications or toothlike densities.

Treatment and Prognosis The standard treatment for the COC is enucleation and curettage (Figure 30-16). A limited number of recurrences have been reported after such treatment. When a COC is associated with another recognized odontogenic tumor such as an ameloblastoma, the treatment and prognosis are likely to be the same as for the associated tumor. Although only a few cases have been reported,³¹ a carcinoma arising in a COC may occur. One such reported case resulted in multiple pulmonary metastases and was referred to as an odontogenic ghost

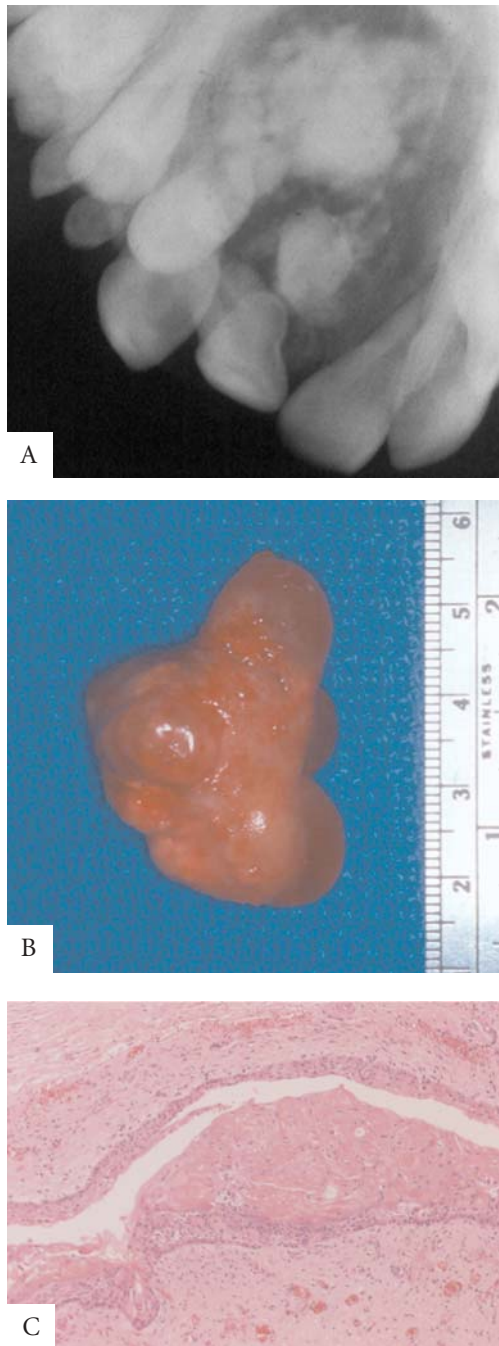


FIGURE 30-16 A, This calcifying odontogenic cyst appears as a mixed radiolucent/radiopaque lesion on the occlusal radiograph. B, This patient underwent enucleation and curettage of the lesion. C, The histopathology shows characteristic ghost cells (hematoxylin and eosin; original magnification $\times 40$).

cell carcinoma by the authors.³³ It has not been demonstrated whether the malignant COC arose from previously benign lesions and, if so, whether that precursor was the cystic or neoplastic type.

Odontogenic Tumors

Odontogenic tumors comprise a complex group of lesions of great importance to oral and maxillofacial surgeons. Many of these lesions are true tumors, whereas some are hamartomas. Like normal odontogenesis, odontogenic tumors demonstrate varying inductive interactions between odontogenic epithelium and odontogenic ectomesenchyme. This ectomesenchyme was formerly referred to as *mesenchyme* because it was thought to be derived from the mesodermal layer of the embryo. It is now accepted that this tissue differentiates from the ectodermal layer in the cephalic portion of the embryo; hence, the designation *ectomesenchyme*. Odontogenic tumors are typically subclassified by their tissues of origin (Table 30-3). Tumors of odontogenic epithelium are composed only of odontogenic epithelium without any participation of the odontogenic ectomesenchyme. Other odontogenic neoplasms, referred to as mixed odontogenic tumors, are composed of odontogenic epithelium and ectomesenchymal elements. A third group, tumors of odontogenic ectomesenchyme, includes those tumors composed principally of ectomesenchymal elements. Although some odontogenic epithelium may be included within these lesions, it does not appear to play an essential role in their pathogenesis.

The frequency of odontogenic tumors seems to be geographically determined (Table 30-4). Studies from North America seem to indicate that odontogenic tumors represent approximately 1% of all accessions in oral pathology laboratories,^{34,35} whereas African studies have a much higher incidence of odontogenic tumors.³⁶⁻⁴¹ Moreover, the ameloblastoma is more commonly encountered in African and other underdeveloped countries than in North America.

Ameloblastoma

The ameloblastoma is the most common clinically significant and potentially lethal

Table 30-3 Classification of Odontogenic Tumors

Tumors of odontogenic epithelium
Ameloblastoma
• Malignant ameloblastoma
• Ameloblastic carcinoma
Calcifying epithelial odontogenic tumor
Squamous odontogenic tumor
Clear cell odontogenic carcinoma
Primary intraosseous carcinoma
Tumors of odontogenic epithelium with odontogenic ectomesenchyme \pm dental hard tissue formation
Ameloblastic fibroma
Ameloblastic fibro-odontoma
Ameloblastic fibrosarcoma
Odontoameloblastoma
Odontoma
• Compound composite
• Complex composite
Adenomatoid odontogenic tumor
Tumors of odontogenic ectomesenchyme \pm included odontogenic epithelium
Odontogenic fibroma
Granular cell odontogenic tumor
Odontogenic myxoma
Cementoblastoma

odontogenic tumor. Excluding odontomas, its incidence equals or exceeds the combined total of all other odontogenic tumors. These tumors may arise from rests of the dental lamina, a developing enamel organ, the epithelial lining of an odontogenic cyst, or the basal cells of the oral mucosa.² The ameloblastoma occurs in three different variants, each with specific implications for treatment and a unique prognosis: solid or multicystic, unicystic, and peripheral. In an analysis of the international literature, 3,677 cases of ameloblastoma were reviewed, of which 92% were solid or multicystic, 6% were unicystic, and 2% were peripheral.⁴²

Solid or Multicystic Ameloblastoma
This variant of the ameloblastoma is

Table 30-4 Incidence of Odontogenic Tumors

Specimens	Study (yr)		
	Regezi JA et al. ³⁴ (1978)	Odukoya O ³⁶ (1995)	Daley TD et al. ³⁵ (1994)
Total	54,534	1,511	40,000
Total odontogenic tumors	706 (1.3%)*	289 (19.1%)*	445 (1.1%)*
Ameloblastoma	78 (11.0%)†	169 (58.5%)†	79 (17.8%)†
Adenomatoid odontogenic tumor	22 (3.1%)†	18 (6.2%)†	14 (3.1%)†
Odontoma	473 (67.0%)†	12 (4.2%)†	204 (45.8%)†
Myxoma	20 (2.8%)†	34 (11.8%)†	24 (5.4%)†

*Percentage of total specimens in respective study.
†Percentage of total odontogenic tumors in respective study specimens.

encountered in patients over a wide age range.⁴³ It is rare in children in their first decade of life and relatively uncommon in the second decade.⁴⁴ The tumor shows a relatively equal rate of occurrence in the third through seventh decades. There is no gender predilection, and racial predilection is most controversial. About 85% of this variant of the ameloblastoma occur in the mandible, most commonly in the molar/ramus region.⁴⁵ About 15% of multicystic ameloblastomas occur in the maxilla, usually in the posterior regions.⁴⁶⁻⁴⁹ A painless expansion of the jaws is the most common clinical presentation; neurosensory changes are uncommon, even with large tumors (Figure 30-17). Slow growth is the rule, with untreated tumors leading to tremendous facial disfigurement (Figure 30-18).⁵⁰

The most common radiographic feature is that of a multilocular radiolucency. Buccal and lingual cortical expansion is common, frequently to the point of perforation. Resorption of adjacent tooth roots is common. Histologic patterns include *follicular*, in which the stellate reticulum is located within the center of the odontogenic island (Figure 30-19); *plexiform*, in which the stellate reticulum is located outside of the odontogenic rest; *acanthomatous*, in which squamous differentiation of the odontogenic epithelium is present; *granular cell*, in which the tumor islands exhibit cells that demonstrate abundant

granular eosinophilic cytoplasm; *desmoplastic* owing to extremely dense collagenized stroma that supports the tumor; and the least common *basal cell* variant, in which nests of uniform basaloid cells are present, with a strong resemblance to basal cell carcinoma. In this latter tumor stellate reticulum is not present in the central portions of the nests. One additional exception surrounds the desmoplastic variant, which is generally not a radiolucent tumor radiographically owing to its high content of collagenized stroma.

Pathogenetically, the proliferative capacity of ameloblastomas has been studied. As might be conjectured, the recurrent ameloblastoma is associated with the highest number of PCNA-positive cells, followed by the previously unoperated ameloblastomas.²⁶ The nuclear PCNA positivity of the unicystic ameloblastoma was notably lower than the positivity of the solid multicystic ameloblastoma.²⁶ Other cell cycle features supporting the aggressive behavior of the ameloblastoma include the overexpression of *BCL2* and *BCLX*, as well as the expression of IL-1 and IL-6.⁵¹

Treatment and Prognosis The ameloblastoma continues to be a subject of fascination in the international literature. Unfortunately, although most agree that aggressive treatment is essential for cure of this tumor, the fact remains that a consensus has not been reached on the biologic behavior of

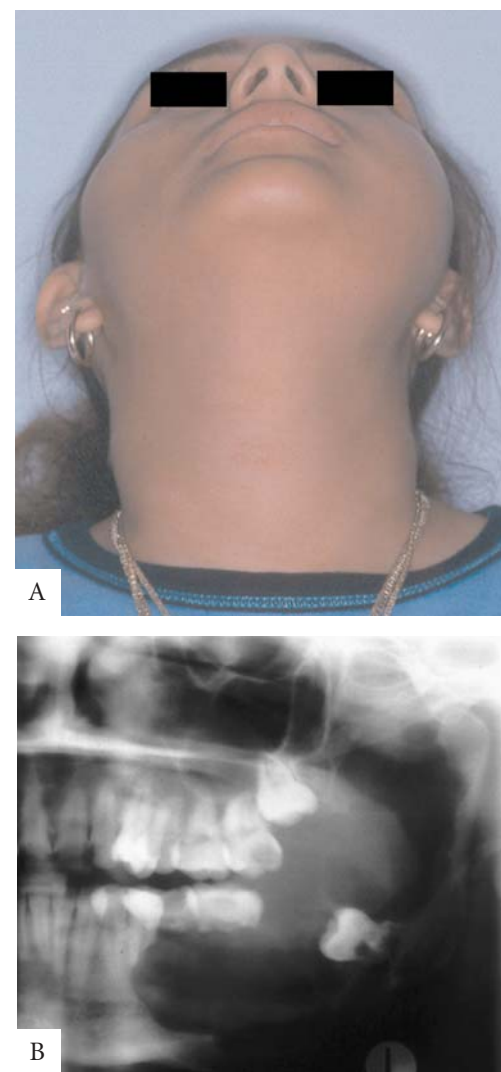


FIGURE 30-17 A 17-year-old girl with obvious facial expansion (A) related to a multilocular radiolucency of the left mandible associated with impacted tooth no. 17 (B). Note the advanced root resorption on teeth no. 18 and 19, indicative of the aggressive nature of this tumor. The incisional biopsy showed solid/multicystic ameloblastoma.

this neoplasm and how best to treat it.⁵² The literature is therefore paradoxically a source of both information and misinformation. Conflicting opinion, extending backward in time, has served both to educate and to confuse, and it has been left to generations of surgeons to sift and interpret what they consider to be clinically valid. It is my strong opinion that this neoplasm is both highly aggressive and curable. This notwithstanding, numerous methods of treatment have

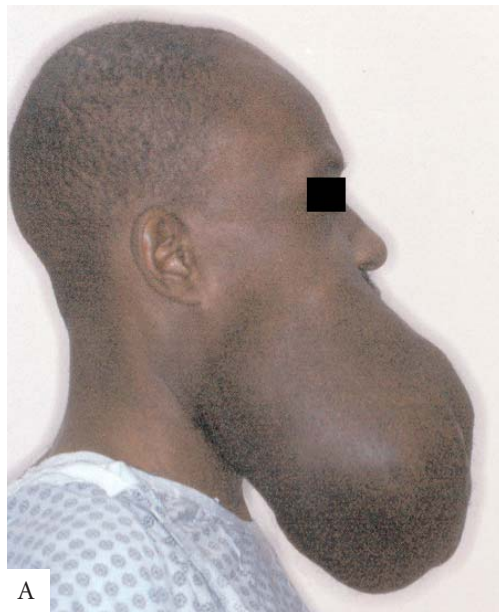
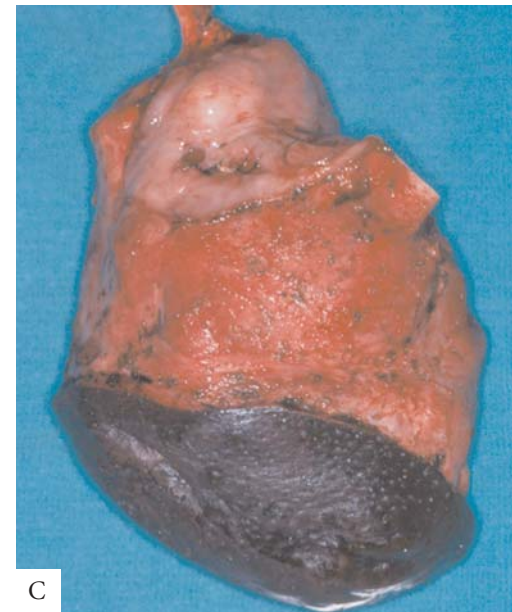
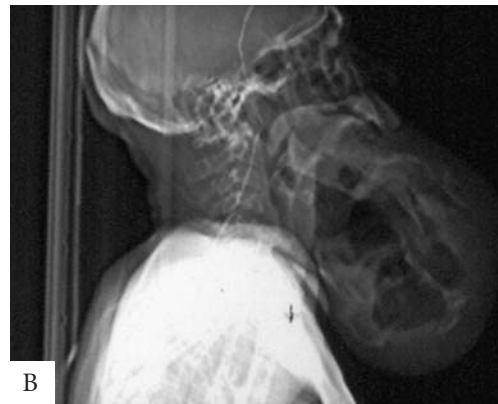
FIGURE 30-18 Twenty years of undisturbed growth of a solid/multicystic ameloblastoma led to significant facial disfigurement (A), with an impressive radiographic appearance (B). A segmental resection of the right mandible was performed (C).



been recommended, ranging from simple enucleation and curettage to resection.^{53–59} The solid or multicystic ameloblastoma tends to infiltrate between intact cancellous bone trabeculae at the periphery of the tumor before bone resorption becomes radiographically evident. Therefore, the actual margin of the tumor often extends beyond its apparent radiographic or clinical margin.⁶⁰ Attempts to remove the tumor by curettage, therefore, predictably leave behind small islands of tumor within the bone, which are later determined to be recurrent disease. These must be realized as *persistent disease* as the tumor was never controlled from the outset. When a small burden of tumor is left behind, it may be

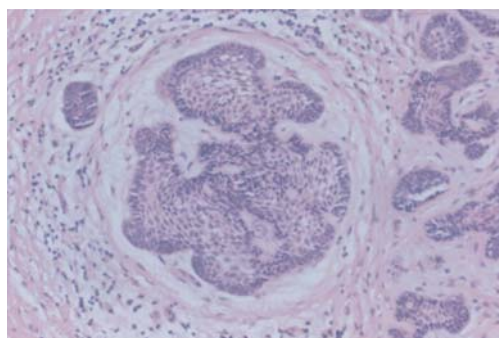


FIGURE 30-19 The incisional biopsy of the patient in Figure 30-17 shows follicular variant of the solid/multicystic ameloblastoma (hematoxylin and eosin; original magnification $\times 60$).

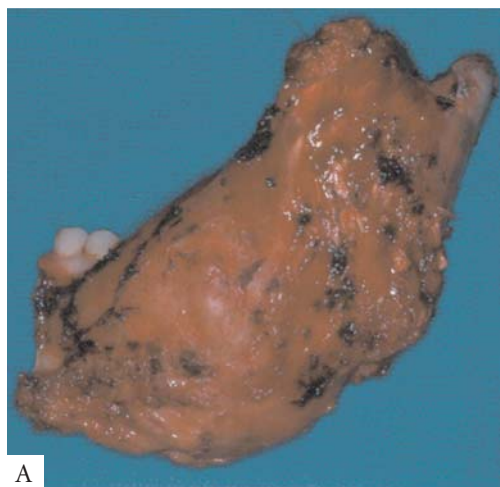decades before this persistent disease becomes clinically and radiographically evident, and long after a surgeon falsely proclaimed the patient to be cured.

Owing to the highly infiltrative and aggressive nature of the solid or multicystic ameloblastoma, I recommend resection of the tumor with 1.0 cm linear bony margins (Figure 30-20). This linear bony margin should be confirmed by intraoperative specimen radiographs. Soft tissue margins are best managed according to the anatomic barrier margin principles whereby one uninvolved surrounding anatomic barrier is sacrificed on the periphery of the specimen.⁶¹ When all soft and hard tissue margins are histologically negative, the patient is likely to be cured of this neoplasm. Unfortunately, any less aggressive treatment modality may be fraught with inevitable persistence discovered at variable times postoperatively.⁶² Moreover, although the persistent and occasionally nonresectable ameloblastoma is radiosensitive, once this otherwise benign tumor defies curative surgical therapy, radiation is of questionable use in salvaging these patients.^{63,64}

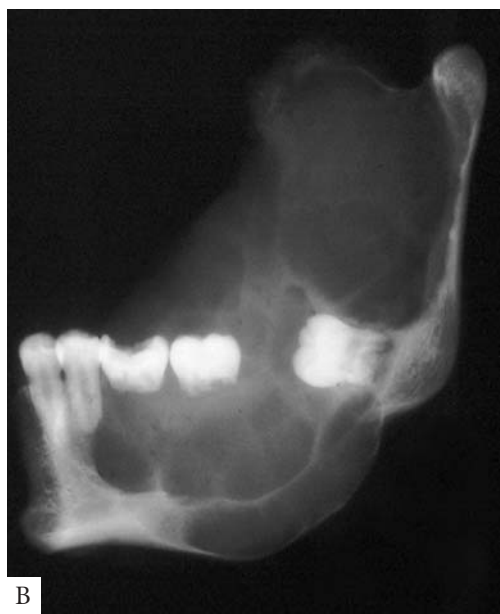Unicystic Ameloblastoma In 1970 Vickers and Gorlin published their findings regarding the histologic alterations associ-

ated with neoplastic transformation of ameloblastomatous epithelium.⁶⁵ These histologic changes were (1) hyperchromatism of basal cell nuclei of the epithelium lining the cystic cavities, (2) palisading and polarization of basal cell nuclei of the epithelium lining the cystic cavities, and (3) cytoplasmic vacuolization, particularly of basal cells of cystic linings. They referred to these changes as early histopathologic features of neoplasia. *Unicystic ameloblastoma* refers to a pattern of epithelial proliferation that has been described in dentigerous cysts of the jaws that does not exhibit the histologic criteria for ameloblastoma published by Vickers and Gorlin.^{66–69} This entity deserves separate consideration based on its clinical, radiographic, and pathologic features. Moreover, in many cases it may be treated more conservatively than the solid or multicystic ameloblastoma with the same degree of cure.⁷⁰

Unicystic ameloblastomas are most commonly seen in young patients, with about 50% of these tumors being diagnosed during the second decade of life. The average age of patients with unicystic ameloblastomas has been reported as 22.1 years, compared with 40.2 years for the solid or multicystic variant.⁴² More than 90% of these tumors are found in the



A



B

FIGURE 30-20 A, Treatment of the ameloblastoma of the patient in Figure 30-17 required a disarticulation resection of the left mandible. B, The effectiveness of the bony linear margin should always be evaluated by intraoperative specimen radiographs.

mandible, usually in the molar/ramus region.⁷¹ A unilocular radiolucency, mimicking a dentigerous cyst, is the most common radiographic presentation for the unicystic ameloblastoma (Figure 30-21). Most, if not all, unicystic ameloblastomas are unilocular radiolucencies.² Three histopathologic variants of unicystic ameloblastoma have been described that impact treatment and prognosis. In the *luminal unicystic ameloblastoma*, the tumor is confined to the luminal surface of the cyst (Figure 30-22). The lesion con-

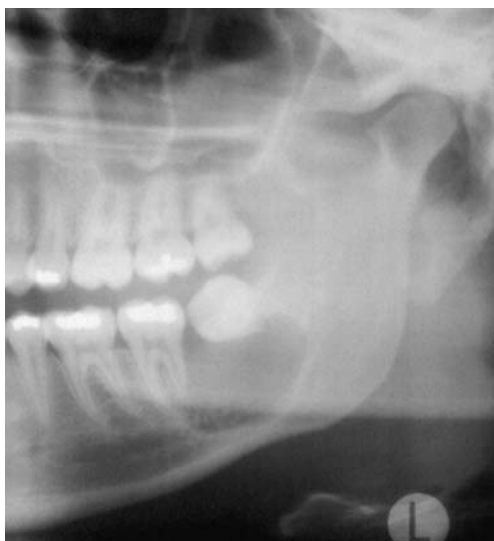

FIGURE 30-21 This unilocular radiolucency associated with tooth no. 17 should generate a differential diagnosis of dentigerous and other odontogenic cysts.

sists of a fibrous cyst wall with a lining that consists totally or partially of ameloblastic epithelium. The *intraluminal unicystic ameloblastoma* contains one or more nodules of ameloblastoma projecting from the cystic lining into the lumen of the cyst. These nodules may be relatively small or largely fill the cystic lumen, and are noted to show a plexiform pattern that resembles the plexiform pattern seen in conventional ameloblastomas. As such, these tumors are referred to as plexiform unicystic ameloblastomas. In the third variant, known as *mural unicystic ameloblastoma*, the fibrous wall of the cyst is infiltrated by typical follicular or plexiform ameloblastoma. The extent and depth of the ameloblastic infiltration may vary considerably.

Pathogenetically, the unicystic ameloblastoma seems to have a proliferative capacity between that of the odontogenic keratocyst and the solid or multicystic ameloblastoma.²⁶

Treatment and Prognosis The clinical and radiographic findings in most cases of unicystic ameloblastoma suggest that the lesion is an odontogenic cyst, most commonly a dentigerous cyst. Under the circumstances

the surgeon should routinely open a “cystic” lesion and look for luminal proliferation of tumor. When able, histopathologic examination of such a process should occur with frozen sections. This is particularly important when dealing with large cysts. With a histologic diagnosis of unicystic ameloblastoma, the surgeon should request the pathologist to obtain multiple sections through many levels of the specimen to properly subclassify the variant of unicystic ameloblastoma. When the ameloblastic elements are confined to the lumen of the cyst with or without intraluminal tumor extension, the enucleation has probably been curative treatment. When the cyst wall has been violated by the tumor as in a mural variant of unicystic ameloblastoma, the most appropriate surgical management is quite controversial. If this diagnosis is made postoperatively, the surgeon may wish to adopt close indefinite follow-up examinations of the patient. If a preoperative incisional biopsy provides a diagnosis of mural unicystic ameloblastoma, the surgeon might recommend a resection of the tumor owing to the fact that this variant of the unicystic ameloblastoma has a higher rate of persistence than do the luminal or intraluminal unicystic ameloblastomas.

The treatment of a luminal or intraluminal variant of the unicystic ameloblastoma is enucleation and curettage (Figure 30-23). In a collective sense, the “recurrence” rate of all unicystic ameloblastomas

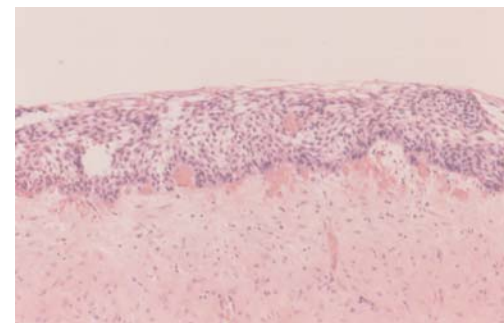


FIGURE 30-22 The histopathology of the lesion in Figure 30-21 shows luminal unicystic ameloblastoma (hematoxylin and eosin; original magnification $\times 40$).

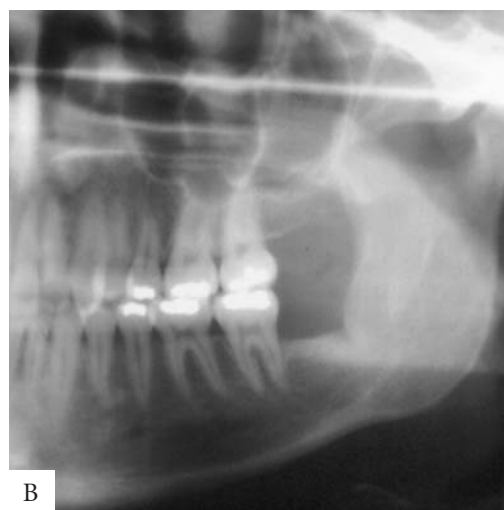
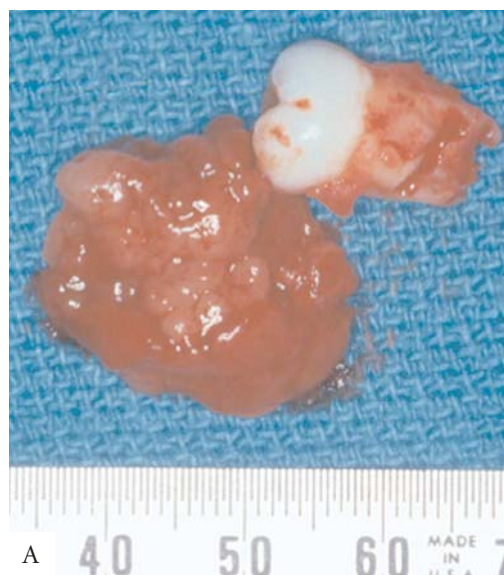

FIGURE 30-23 A, The luminal unicystic ameloblastoma in Figure 30-21 is treated with an enucleation and curettage surgery. B, The 5-year postoperative radiograph shows an acceptable bony fill.

has been reported as 10 to 20% following enucleation and curettage.⁷⁰ This is significantly lower than that of enucleation and curettage of the solid or multicystic ameloblastoma. The question then arises as to when to resect a unicystic ameloblastoma. Three instances are likely to require such treatment. The first is the recurrent unicystic ameloblastoma. A tumor that recurs following a well-performed enucleation and curettage should probably be approached with the more aggressive resection. Second is the mural ameloblastoma. This variant of the unicystic

ameloblastoma is probably more aggressive than the luminal and intraluminal variants of the unicystic ameloblastoma owing to the presence of tumor in the cyst wall and therefore closer to the surrounding bone. It seems logical to approach these tumors with a surgery similar to that for the solid or multicystic ameloblastoma (Figure 30-24). The final indication for resection of a unicystic ameloblastoma is in the management of very large tumors

(see Figure 30-24) with significant expansion such that an enucleation and curettage surgery would effectively result in a resection of the involved jaw.

Peripheral Ameloblastoma The peripheral or extraosseous ameloblastoma is the most rare variant of the ameloblastoma. This tumor probably arises from rests of dental lamina or the basal epithelial cells of the surface epithelium and shows the

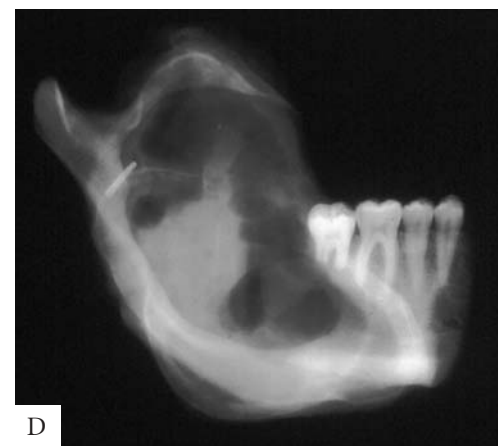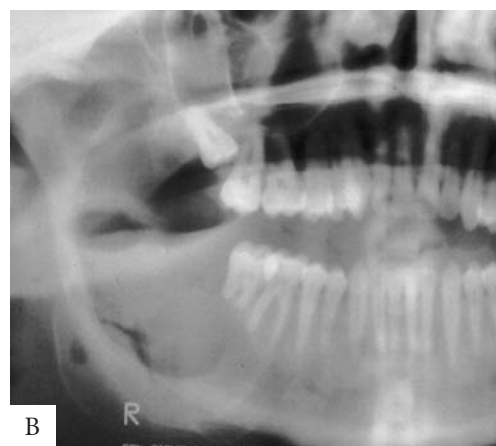
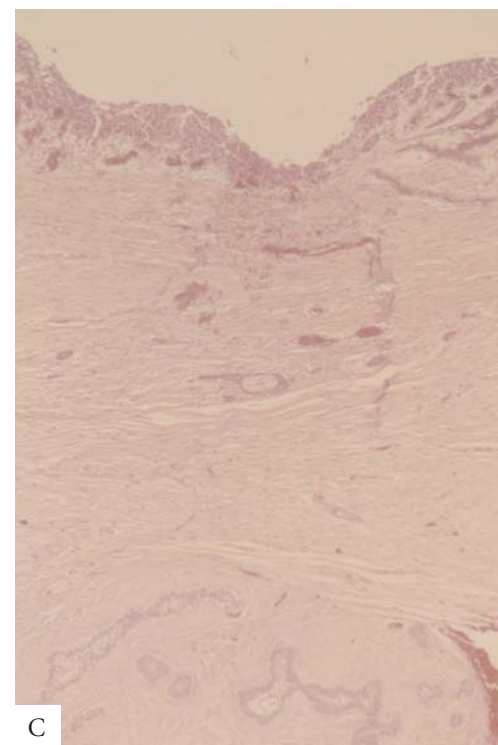

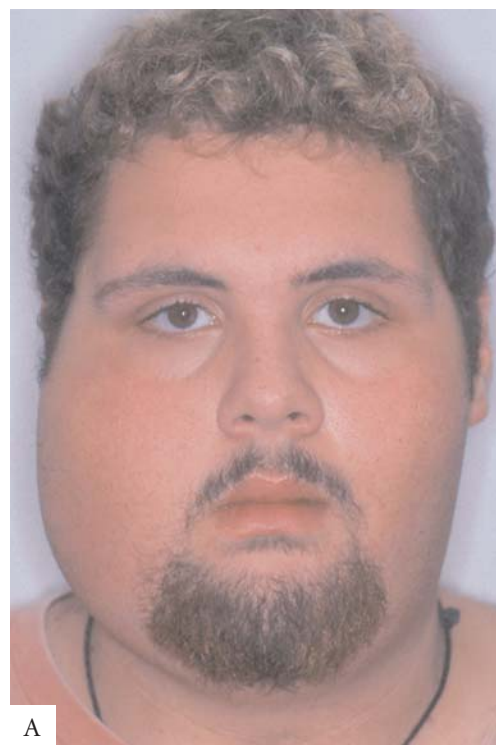
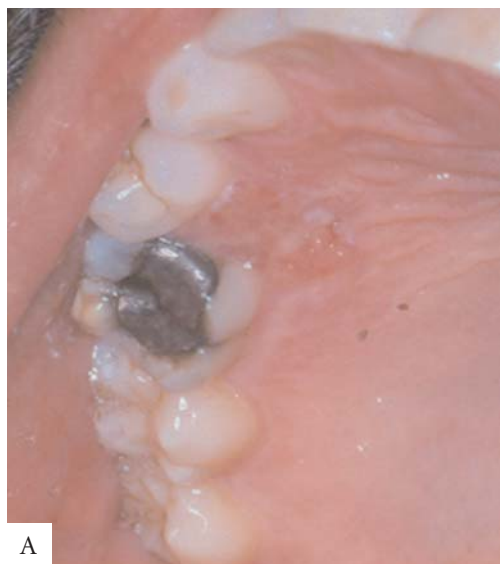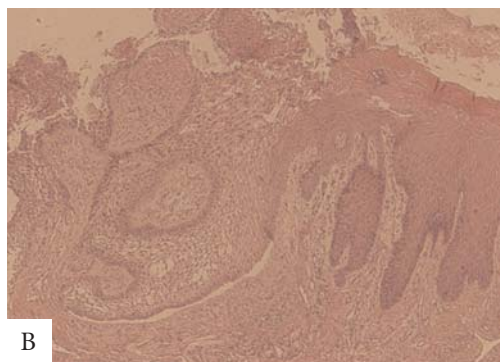
FIGURE 30-24 This 18-year-old presented with significant right facial expansion (A) associated with the destructive radiolucency of the right mandible noted on the panoramic radiograph (B). The incisional biopsy documented the mural variant of unicystic ameloblastoma (hematoxylin and eosin; original magnification $\times 20$) (C). A disarticulation resection was performed (D).

same features of the intraosseous form of the tumor.⁷² Clinically, these tumors present as nonulcerated sessile or pedunculated gingival lesions (Figure 30-25). Most examples are < 1.5 cm and usually occur over a wide age range, with an average reported age of 52 years. Although these tumors do not infiltrate bone, they may be seen to “cup out” bone in the jaws (Figure 30-26).

Treatment and Prognosis The peripheral ameloblastoma is most appropriately treated with a wide local excision. When surgical margins are negative for tumor, cure is the likely consequence. Malignant transformation of a peripheral ameloblastoma is very rare.⁷³



A



B

FIGURE 30-25 This lesion of the right palatal mucosa (A) showed peripheral ameloblastoma on incisional biopsy (hematoxylin and eosin; original magnification $\times 40$)(B).

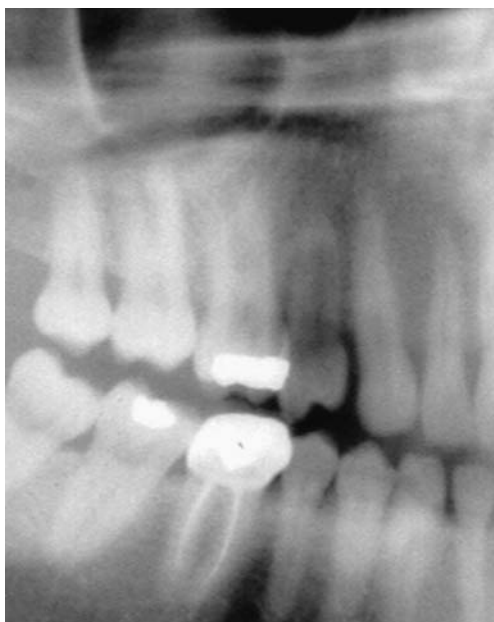

FIGURE 30-26 A “cupped out” lesion in bone at tooth no. 4 is noted in the patient in Figure 30-25.

Malignant Odontogenic Tumors

Malignant odontogenic tumors are very rare. They may arise from the epithelial components of the odontogenic apparatus. The rests of Malassez, the reduced enamel epithelium surrounding the crown of an impacted tooth, the rests of Serres in the gingiva, and the linings of odontogenic cysts represent the precursor cells for malignant transformation. Odontogenic carcinomas are classified in Table 30-5.⁷⁴ In general, all of these tumors exhibit typical microscopic features of malignancy, with the exception of the malignant (metastasizing) ameloblastoma and the clear cell odontogenic carcinoma. Behaviorally, all of these tumors have the potential for either regional nodal or distant metastases.

Malignant (Metastasizing) Ameloblastoma Malignant ameloblastomas are best described as neoplasms that have the histologic features of benign ameloblastoma as shown by the primary growth in the jaws and by any metastatic growth.⁷⁵

The most common sites of metastatic disease are the lungs (Figure 30-27), followed by the cervical lymph nodes and visceral

Table 30-5 Classification of Odontogenic Carcinomas

Malignant (metastasizing) ameloblastoma
Ameloblastic carcinoma
Primary
Dedifferentiated
Peripheral
Primary intraosseous squamous cell carcinoma
Solid
Cystogenic
• Nonkeratinizing cyst
• Odontogenic keratocyst
Clear cell odontogenic carcinoma
Malignant epithelial odontogenic ghost cell tumor

Adapted from Eversole LR.⁷⁴

organs.^{76–78} Lung metastases have sometimes been regarded as aspiration phenomena, yet the peripheral location of many of these deposits supports hematogenous spread. Eversole points out that instances of metastasis have arisen from solid or multicystic ameloblastomas rather than unicystic tumors.⁷⁴

Ameloblastic Carcinoma Ameloblastic carcinomas are malignant epithelial odontogenic tumors that exist in the background of benign ameloblastomas. This designation is reserved for an

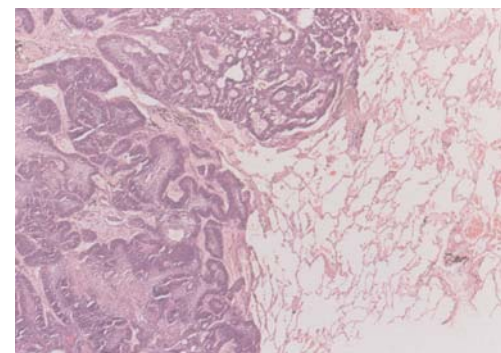


FIGURE 30-27 Histologically benign ameloblastoma is noted in the lung. This finding satisfies the definition of malignant ameloblastoma (hematoxylin and eosin; original magnification $\times 20$).

ameloblastoma that has cytologic features of malignancy in the primary tumor (Figure 30-28), in a recurrence, or in any metastatic deposit. Although ameloblastic carcinomas have been reported to metastasize to the lungs and distant organs,^{79,80} many cases do not metastasize. In Corio and colleagues' series of eight cases of ameloblastic carcinoma, rapid growth and pain were common symptoms.⁸¹ These symptoms are recognized as being uncommon in patients with benign ameloblastomas.

Primary Intraosseous Squamous Cell Carcinoma Squamous cell carcinomas that are encountered in the jaws, lack any continuity with the oral or antral mucosa, and occur in the absence of a primary carcinoma located elsewhere are termed primary intraosseous squamous cell carcinomas. These cases are assumed to arise from odontogenic epithelium. They typically occur in elderly patients and tend to occur in the mandibular

body region. The 5-year survival rate is 30 to 40%.⁷⁴ Squamous cell carcinomas may also arise from the linings of odontogenic cysts. Cystogenic carcinomas are seen in patients > 50 years of age and typically occur in the mandible. Finally, dentigerous cysts can undergo glandular metaplasia, and there are rare instances of central mucoepidermoid carcinomas reported to arise from odontogenic cyst lining.

Clear Cell Odontogenic Carcinoma Although the clear cell odontogenic carcinoma is of putative odontogenic origin, histologic similarities to the developing tooth germ are lacking in many instances.⁷⁴ The differential diagnosis includes metastasis from a distant site, especially the kidney. The clear cell variant of renal cell carcinoma is the chief entity to consider. The clear cell odontogenic carcinoma is generally seen in elderly women, with the maxilla and mandible being affected equally.

Malignant Epithelial Odontogenic Ghost Cell Tumor The epithelial odontogenic ghost cell tumor, also known as dentinogenic ghost cell tumor, is the solid variant of the calcifying odontogenic cyst. Both epithelial and ectomesenchymal odontogenic elements are present; however, only the epithelial component shows cytologic features of malignancy.

Ameloblastic Fibroma

The ameloblastic fibroma is considered to be a true tumor in which the epithelial and mesenchymal tissues are both neoplastic. This is in distinction to the ameloblastic fibro-odontoma and odontoma that represent developmental stages of the same hamartomatous lesion.^{82,83} The ameloblastic fibroma tends to occur in young patients in the first two decades of life. The posterior mandible is affected in 70% of cases (Figure 30-29). Radiographically, either a unilocular or multilocular lesion is observed.

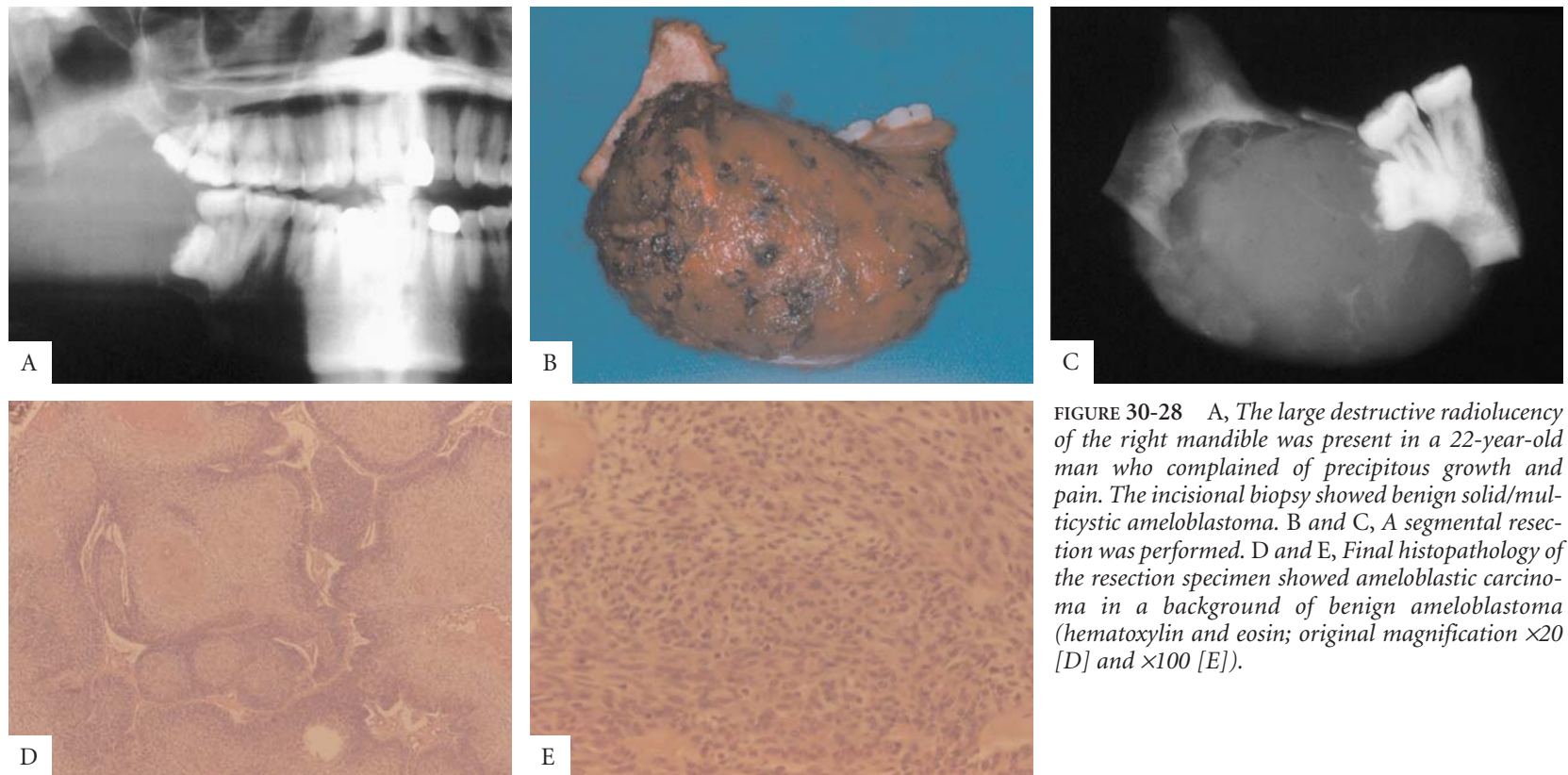


FIGURE 30-28 A, The large destructive radiolucency of the right mandible was present in a 22-year-old man who complained of precipitous growth and pain. The incisional biopsy showed benign solid/multicystic ameloblastoma. B and C, A segmental resection was performed. D and E, Final histopathology of the resection specimen showed ameloblastic carcinoma in a background of benign ameloblastoma (hematoxylin and eosin; original magnification $\times 20$ [D] and $\times 100$ [E]).

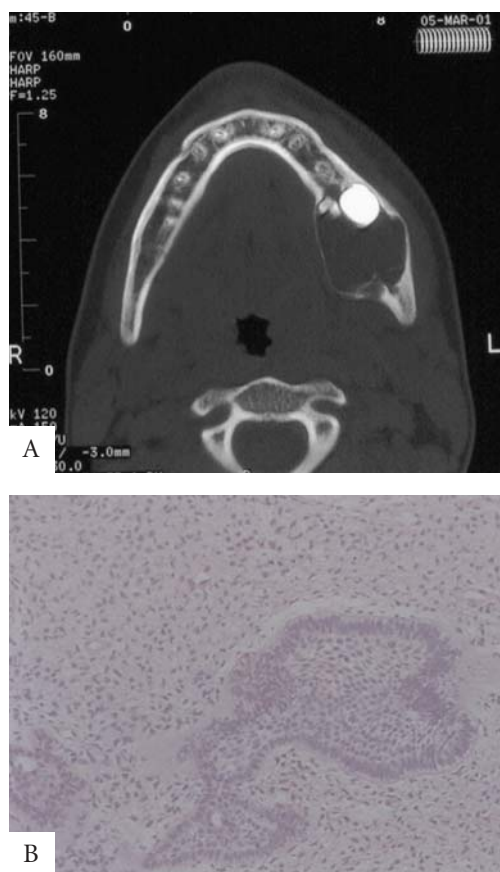

FIGURE 30-29 A, A destructive unilocular radiolucency is present in a 15-year-old boy. B, Incisional biopsy confirmed ameloblastic fibroma (hematoxylin and eosin; original magnification $\times 40$).

Treatment and Prognosis The ameloblastic fibroma is recognized as an indolent tumor that is effectively treated by an enucleation and curettage surgery (Figure

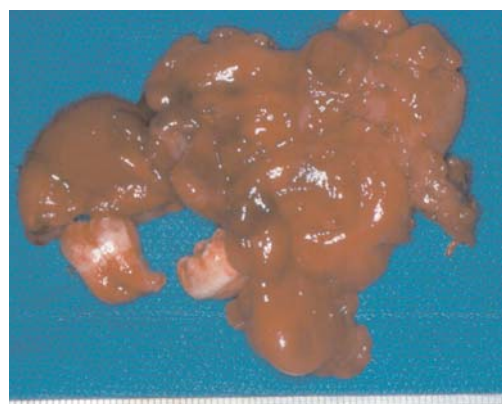

FIGURE 30-30 An enucleation and curettage surgery is performed in the patient in Figure 30-29. The associated permanent teeth are removed with the tumor.

30-30). Although recurrence is rare under the circumstances, resection should be reserved for recurrent lesions. Approximately 45% of ameloblastic fibrosarcomas develop in the setting of a recurrent ameloblastic fibroma.²

Ameloblastic Fibro-odontoma

The ameloblastic fibro-odontoma, as previously discussed, probably represents a hamartoma. Moreover, some investigators believe that this lesion is only a stage in the development of an odontoma and does not represent a separate entity. Slootweg points out that when one considers the data on age, site, and sex, it seems that the ameloblastic fibro-odontoma is an immature complex odontoma.⁸² As with ameloblastic fibromas, the ameloblastic fibro-odontoma occurs more frequently in the posterior regions of the jaws. This lesion is commonly asymptomatic and is discovered serendipitously or when radiographs are exposed to provide a diagnosis for asymmetric eruption of the dentition in children (Figure 30-31). These lesions are distinctly well circumscribed and appear as mixed radiopaque/radiolucent masses.

Treatment and Prognosis The ameloblastic fibro-odontoma is treated effectively

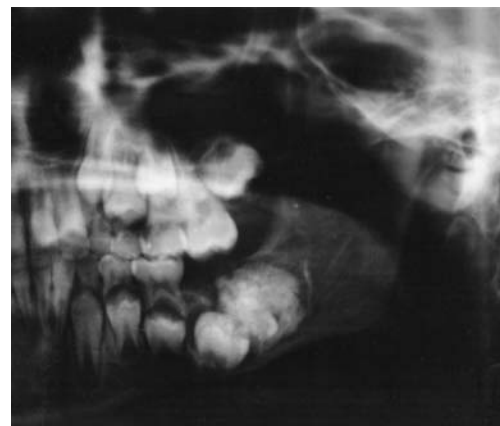

FIGURE 30-31 A panoramic radiograph of a 9-year-old boy shows a mixed radiolucent/radiopaque lesion of the left posterior mandible. Ameloblastic fibro-odontoma is a likely diagnosis owing to the patient's age as well as the radiographic character of the lesion.

with an enucleation and curettage surgery (Figure 30-32). Recurrence after this approach is very rare. Malignant transformation of ameloblastic fibro-odontoma has been reported but is exceedingly rare.⁸⁴

Odontoma

Odontomas are the most frequently occurring odontogenic tumors, with prevalence exceeding that of all other odontogenic tumors combined. As stated

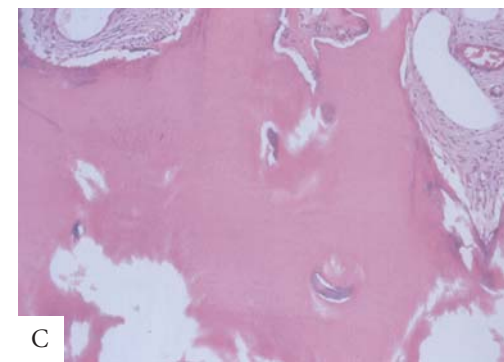
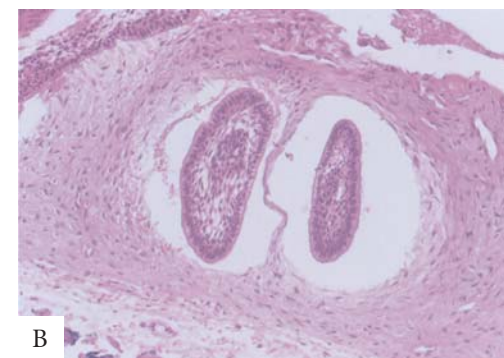
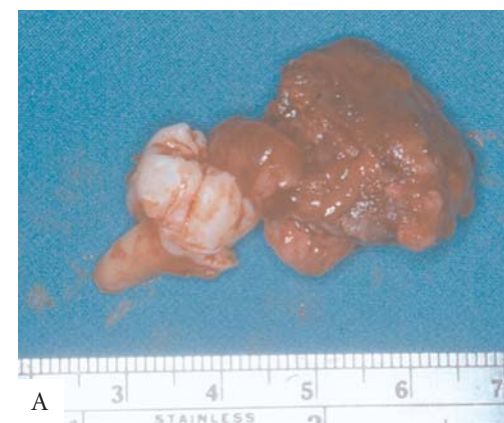

FIGURE 30-32 A, Enucleation and curettage is performed of the lesion in Figure 30-31. The permanent tooth is removed with the lesion. B and C, The histopathology shows ameloblastic fibro-odontoma (hematoxylin and eosin; original magnification $\times 20$).

previously, these lesions are generally well accepted as representing hamartomas. Odontomas present centrally within the jaws in one of two forms: compound, in which multiple small toothlike structures exist; and complex, in which irregular masses of dentin and enamel are present with no anatomic resemblance to a tooth. Compound odontomas are predominantly seen in the anterior maxilla (Figure 30-33), whereas complex odontomas are typically seen in the posterior maxilla or mandible (Figure 30-34).

Treatment and Prognosis Odontomas are treated with simple enucleation and curettage and are not known to recur.

Odontogenic Myxoma

The odontogenic myxoma is an uncommon benign neoplasm of the jaws that is thought to be derived from ectomes-

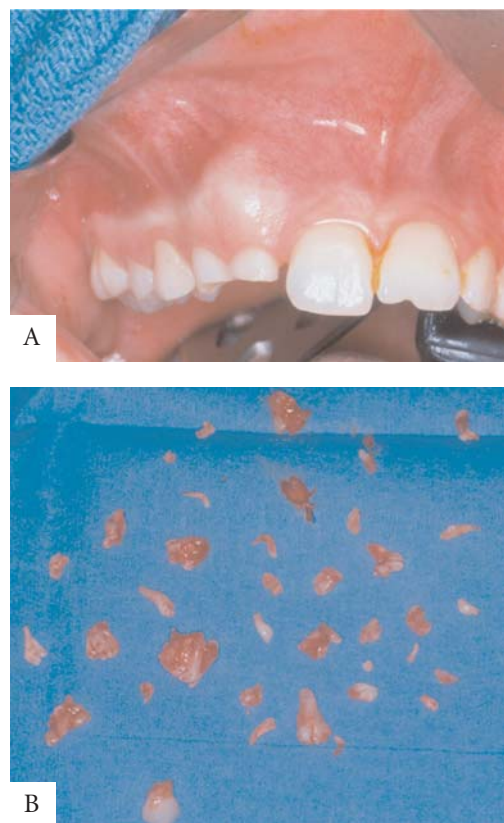


FIGURE 30-33 A, An expansile lesion of the right maxilla. B, Multiple small toothlike calcified structures are removed that represent compound odontoma.

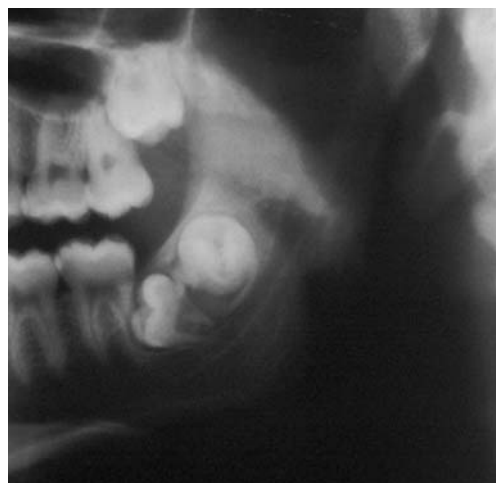

FIGURE 30-34 A complex odontoma of the left posterior mandible.

enchyme and histologically resembles the dental papilla of the developing tooth. These tumors are slow growing with a potential for aggressive behavior and a high recurrence rate after subtherapeutic removal.⁸⁵ They occur over a wide age range but seem to occur most commonly in the third decade of life. Although the tumor can occur anywhere in the jaws, the posterior mandible is most common location (Figure 30-35). Histologically, the tumor is composed of haphazardly arranged stellate, spindle-shaped, and round cells in an abundant loose myxoid stroma that contains only a few collagen fibrils (Figure 30-36). Radiographically, the odontogenic myxoma appears as a unilocular or multilocular radiolucency that may displace or cause root resorption of teeth in the area of the tumor. Although not pathognomonic of the odontogenic myxoma, the radiolucent defect may contain thin wispy trabeculae of residual bone, which are often arranged at right angles to one another in a “stepladder” pattern (see Figures 30-35B and 30-37). In some patients the tumor may have a greater tendency to form collagen fibers; such lesions are designated fibromyxomas.

Pathogenetically, the proliferation and aggressive behavior of the odontogenic myxoma may be related to overex-

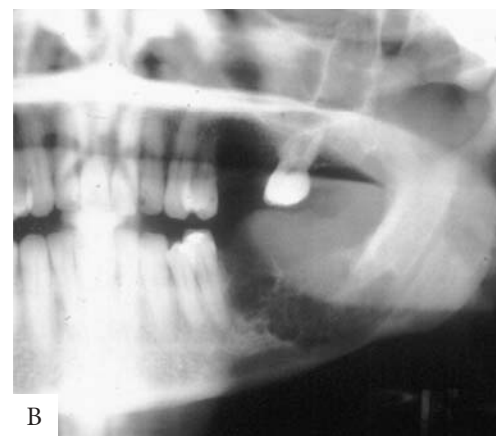
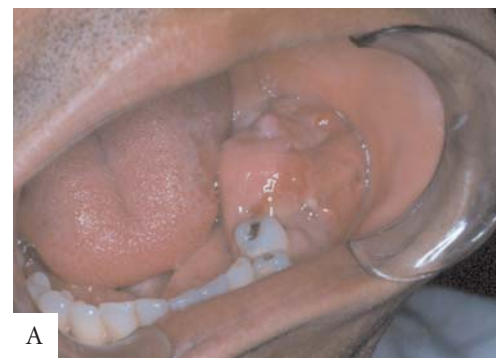

FIGURE 30-35 A large soft tissue mass of the left posterior mandibular gingiva (A) associated with an underlying radiolucent lesion of the mandible (B).

pression of antiapoptotic cytokines *BCL2* and *BCLX*.⁵¹

Treatment and Prognosis Odontogenic myxomas should be treated with resection with 1.0 cm bony linear margins as confirmed with a specimen radiograph (Figure

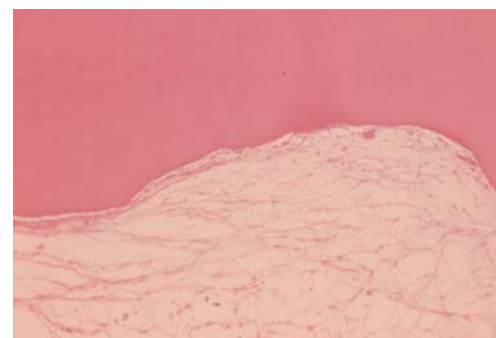


FIGURE 30-36 The odontogenic myxoma shows a loose myxoid stroma, in this case, eroding into the cementum of a tooth root (hematoxylin and eosin; original magnification $\times 40$).

30-37). These tumors are not encapsulated and tend to infiltrate the surrounding bone such that complete removal by curettage is nearly impossible. Resection of the tumor with a normal surrounding margin of bone and soft tissue that shows negative margins should be curative.

Calcifying Epithelial Odontogenic Tumor

The calcifying epithelial odontogenic tumor, also known as the Pindborg tumor, is an uncommon lesion that accounts for < 1% of all odontogenic tumors. It is particularly noteworthy that the three studies depicted in Table 30-4 reported only 15 cases of this odonto-

genic tumor among a collective series of 1,440 odontogenic tumors. Fewer than 200 cases have been reported in the international literature. Although this tumor has been reported over a wide age range, it is most often encountered in patients between 30 and 50 years of age.⁸⁶ Approximately two-thirds of these neoplasms occur in the mandible.⁸⁷ A painless slow-growing mass is the most common presenting sign. Radiographically, the most common presentation is a mixed radiopaque/radiolucent lesion, frequently associated with an impacted tooth (Figure 30-38).

Histologically, the Pindborg tumor is quite unique. Discrete islands, strands, or sheets of polyhedral epithelial cells in a fibrous stroma are noted. Large areas of amorphous eosinophilic hyalinized (amyloid-like) material are also present. Calcifications, which are a distinctive feature of the tumor, develop within the amyloid-like material and form concentric rings, known as Liesegang rings (Figure 30-39). The precise nature of the amyloid-like material is unknown. The material does stain as amyloid when stained with Congo red or thioflavine T. After Congo red staining, the amyloid exhibits apple-green birefringence when viewed with polarized light. It has been illustrated that the amyloid-like material may actually represent amelogenins or other enamel proteins secreted by the tumor cells.⁸⁸

Treatment and Prognosis Although slow growing, the Pindborg tumor is highly infiltrative and destructive and is capable of aggressive behavior.^{88,89} Owing to the small number of reported cases and lack of consistent follow-up, evidence-based recommendations for treatment are not available. Nonetheless, the tumor is generally recommended to be treated identically to the ameloblastoma and odontogenic myxoma, with 1.0 cm bony linear margins and the appropriate attention to soft tissue anatomic barriers (Fig-

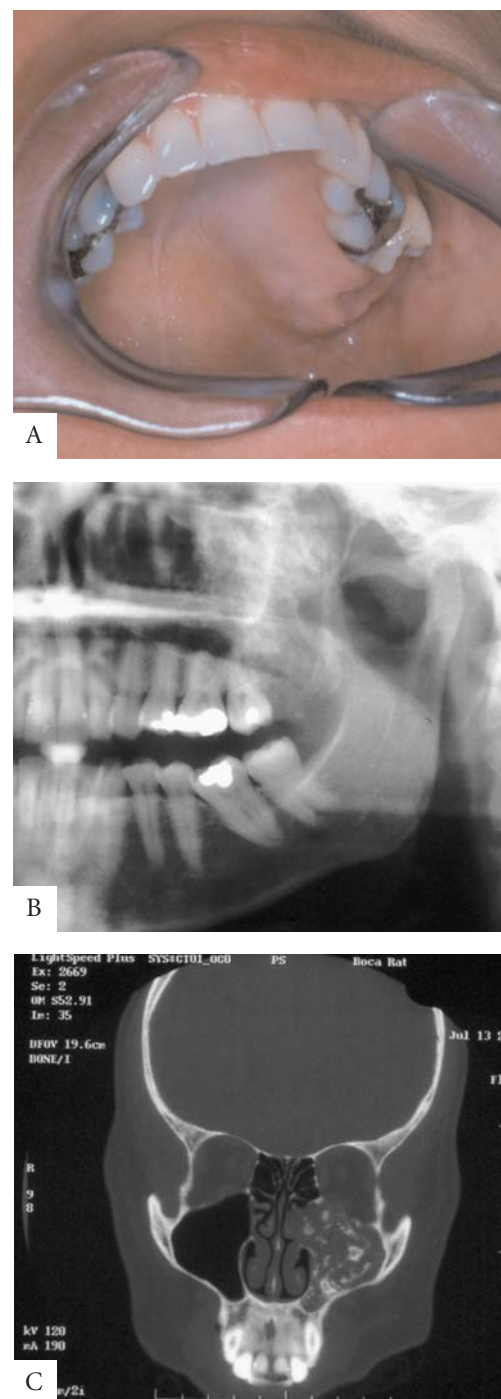


FIGURE 30-38 A 40-year-old woman with a 5-year history of an expansile mass of the left maxilla (A). The panoramic radiograph (B) and the coronal computed tomography scan (C) show a mixed radiolucent/radiopaque lesion of the left posterior maxilla.

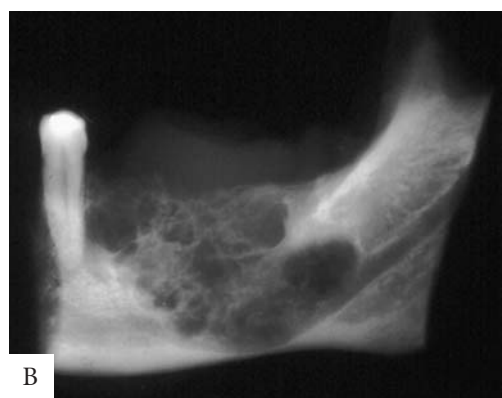
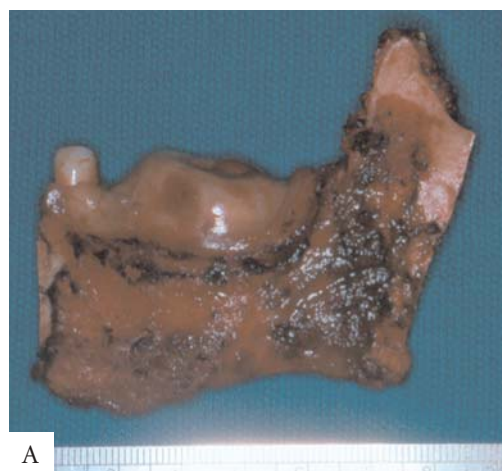
FIGURE 30-37 A, The patient in Figure 30-35 underwent a segmental resection of his odontogenic myxoma. B, As with the ameloblastoma, specimen radiographs should be obtained when resecting an odontogenic myxoma to verify the bony linear margin. A better depiction of the "stepladder" pattern of the odontogenic myxoma is noted on this specimen radiograph.

ure 30-40). When this treatment was undertaken for Franklin and Pindborg's series of tumors, only one patient undergoing resection experienced recurrence.⁸⁷

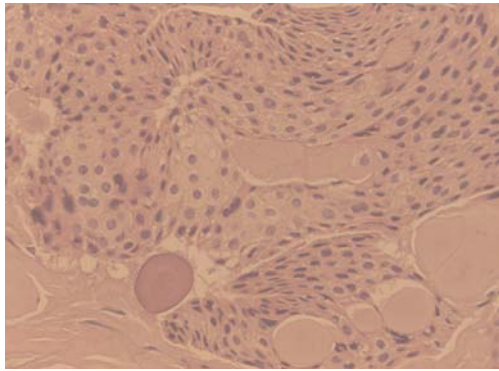


FIGURE 30-39 Incisional biopsy of the patient in Figure 30-38 shows signs indicative of the Pindborg tumor including discrete islands of odontogenic epithelium, calcification (Liesegang rings), and hyalinized material suggestive of amyloid (hematoxylin and eosin; original magnification $\times 40$).

Adenomatoid Odontogenic Tumor

The adenomatoid odontogenic tumor, regarded by many as a hamartoma, is an uncommon odontogenic lesion, accounting for 3 to 7% of all odontogenic tumors. This lesion was once believed to be a variant of ameloblastoma and was previously designated *adenoameloblastoma*.^{90,91} Its clinical features and biologic behavior permit distinction from the ameloblastoma (Figure 30-41). These lesions are limited to young

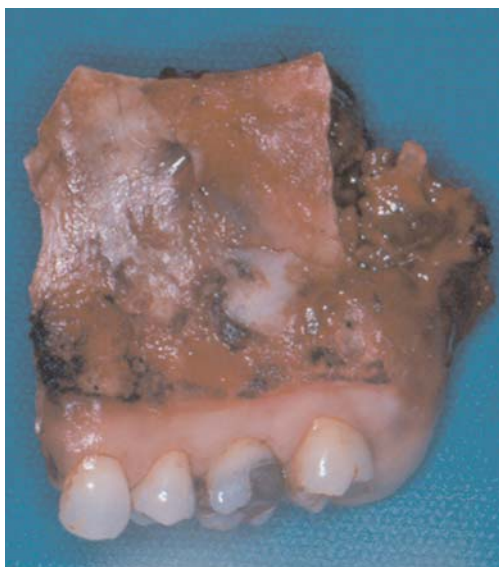

FIGURE 30-40 The patient with the Pindborg tumor in Figure 30-38 is treated with hemimaxillectomy.

patients, and two-thirds of all cases are diagnosed in the second decade.^{92–95} The tumor is extremely uncommon in patients > 30 years. It has a predilection for the anterior region of the jaws and is found twice as often in the maxilla than in the mandible. Females are affected about twice as often as males. Most adenomatoid odontogenic tumors are small, rarely exceeding 3 cm in diameter. In about 75% of cases, the lesion appears as a well-circumscribed unilocular radiolucency that involves the crown of an erupted tooth, frequently a canine.

Histologically, the adenomatoid odontogenic tumor is a well-defined lesion that is usually surrounded by a thick fibrous capsule (Figure 30-42). When the lesion is bisected, the central portion of the tumor may be essentially solid or may show varying degrees of cystic change with intraluminal proliferation of tissue. The lesion is composed of

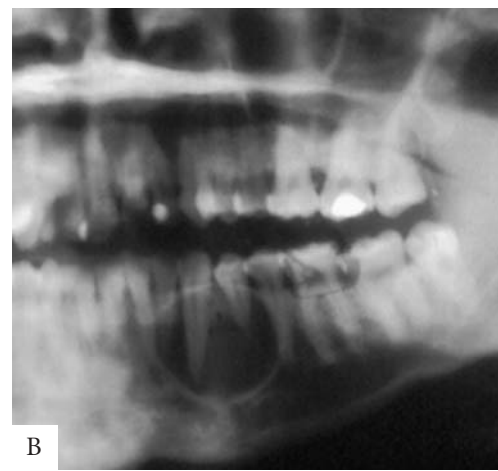
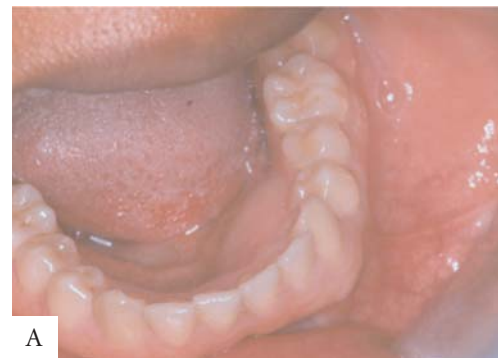

FIGURE 30-41 An expansile lesion of the lingual aspect of the left mandible (A) associated with a unilocular radiolucency of the left mandible (B).

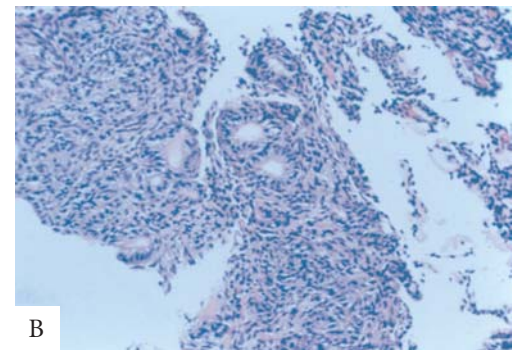
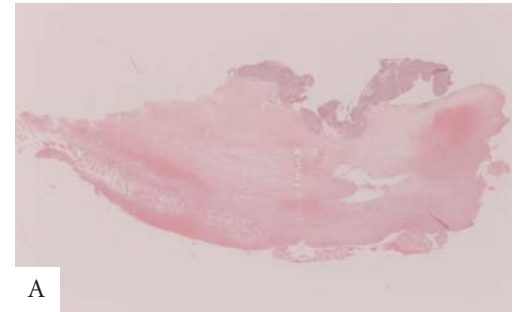

FIGURE 30-42 Incisional biopsy of the lesion in Figure 30-41 shows a well-encapsulated lesion (hematoxylin and eosin; original magnification $\times 10$) (A) with duct-like structures and rosettes (hematoxylin and eosin; original magnification $\times 40$) (B). These findings are indicative of the adenomatoid odontogenic tumor

spindle-shaped epithelial cells that form sheets, strands, or whorled masses of cells in a scant fibrous stroma. The epithelial cells may form rosette-like structures about a central space that may be empty or contain small amounts of eosinophilic material that may stain for amyloid.^{96–98} Tubular or duct-like structures are characteristic for the adenomatoid odontogenic tumor (see Figure 30-42). These consist of a central space surrounded by a layer of columnar or cuboidal epithelial cells whose nuclei exhibit reverse polarization.

Treatment and Prognosis Owing to this lesion being encapsulated, it separates easily from the surrounding bone. As such, an enucleation and curettage surgery is curative (Figure 30-43). Of the 499 cases of adenomatoid odontogenic tumor reported in the literature, only 1 acceptable case of recurrence has been documented.⁹⁹

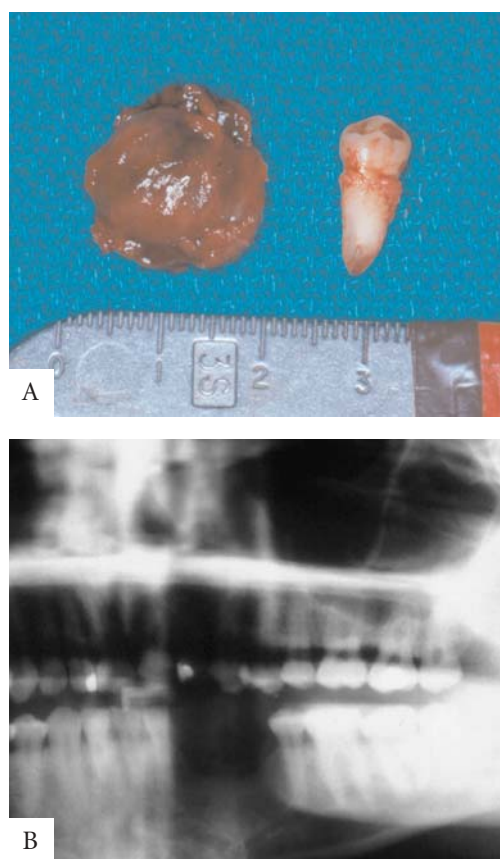


FIGURE 30-43 A, An enucleation and curettage surgery is performed for the patient in Figure 30-41, along with removal of the involved teeth. Erosion of the cementum of the premolar tooth is noted. B, The 5-year postoperative radiograph shows acceptable bony healing.

References

1. Regezi JA, Sciubba JJ, Jordan RCK. Ulcerative conditions. In: Regezi JA, Sciubba JJ, Jordan RCK, editors. Oral pathology. Clinical pathologic correlations. St. Louis: WB Saunders; 2003. p. 23–74.
2. Neville BW, Damm DD, Allen CM, Bouquot JE. Odontogenic cysts and tumors. In: Neville BW, Damm DD, Allen CM, Bouquot JE, editors. Oral and maxillofacial pathology. Philadelphia: WB Saunders; 2002. p. 589–642.
3. Kusakawa J, Irie K, Morimatsu M, et al. Dentigerous cyst associated with a deciduous tooth. A case report. Oral Surg Oral Med Oral Pathol 1992;73:415–8.
4. Suarez PA, Batsakis JG, El-Naggar AK. Don't confuse dental soft tissues with odontogenic tumors. Ann Otol Rhinol Laryngol 1996;105:490–4.
5. Kim J, Ellis GL. Dental follicular tissue: misinterpretation as odontogenic tumors. J Oral Maxillofac Surg 1993;51:762–7.
6. Johnson LM, Sapp JP, McIntire DN. Squamous cell carcinoma arising in a dentigerous cyst. J Oral Maxillofac Surg 1994;52:987–90.
7. Eversole LR, Sabes WR, Rovin S. Aggressive growth and neoplastic potential of odontogenic cysts. With special reference to central epidermoid and mucoepidermoid carcinomas. Cancer 1975; 35:270–82.
8. Leider AS, Eversole LR, Barkin ME. Cystic ameloblastoma. Oral Surg Oral Med Oral Pathol 1985; 60:624–30.
9. Donoff RB, Harper E, Guralnick WC. Collagenolytic activity in keratocysts. J Oral Surg 1972;30:879–84.
10. Ahlfors E, Larsson A, Sjogren S. The odontogenic keratocyst: a benign cystic tumor? J Oral Maxillofac Surg 1984;42:10–9.
11. Williams TP, Connor FA. Surgical management of the odontogenic keratocyst. Aggressive approach. J Oral Maxillofac Surg 1994; 52:964–6.
12. Mustaciuolo VW, Brahney CP, Aria AA. Recurrent keratocysts in basal cell nevus syndrome: review of the literature and report of a case. J Oral Maxillofac Surg 1989;47:870–3.
13. Pritchard LJ, Delfino JJ, Ivey DM, et al. Variable expressivity of the multiple nevoid basal cell carcinoma syndrome. J Oral Maxillofac Surg 1982;40:261–9.
14. Gorlin FJ. Nevoid basal cell carcinoma syndrome. Medicine 1987;66:98–113.
15. Meara JG, Li KK, Shah SS, Cunningham MJ. Odontogenic keratocysts in the pediatric population. Arch Otolaryngol Head Neck Surg 1996;122:725–8.
16. Brannon RB. The odontogenic keratocyst: a clinicopathologic study of 312 cases. Part I: clinical features. Oral Surg Oral Med Oral Pathol 1976 ;42:54–72.
17. Woolgar JA, Rippin JW, Browne RM. The odontogenic keratocyst and its occurrence in the nevoid basal cell carcinoma syndrome. Oral Surg Oral Med Oral Pathol 1987;64:727–30.
18. Eyre J, Zakrzewska JM. The conservative management of large odontogenic keratocysts. Br J Oral Maxillofac Surg 1985;23:195–203.
19. Meiselman F. Surgical management of the odontogenic keratocyst: conservative approach. J Oral Maxillofac Surg 1994;52:960–3.
20. MacIntosh RB. The role of osseous resection in the management of odontogenic keratocysts. American Association of Oral and Maxillofacial Surgeons Scientific Sessions; 2002 Oct 5; Chicago: American Association of Oral and Maxillofacial Surgeons; 2002.
21. Regezi JA, Sciubba JJ, Jordan RCK. Cysts of the jaws and neck. In: Regezi JA, Sciubba JJ, Jordan RCK, editors. Oral pathology. Clinical pathologic correlations. St. Louis: WB Saunders; 2003. p. 241–65.
22. Brannon RB. The odontogenic keratocyst: a clinicopathologic study of 312 cases. Part II: histologic features. Oral Surg Oral Med Oral Pathol 1977;43: 233–55.
23. Vedtofte P, Praetorius F. Recurrence of the odontogenic keratocyst in relation to clinical and histologic features. A 20 year follow-up study of 72 patients. Int J Oral Surg 1979;8:412–20.
24. Li TJ, Browne RM, Matthews JB. Immunocytochemical expression of parathyroid hormone related protein (PTHrP) in odontogenic jaw cysts. Br J Oral Maxillofac Surg 1997;35:275–9.
25. Sloodweg PJ. p53 protein and Ki-67 reactivity in epithelial odontogenic lesions. An immunohistochemical study. J Oral Pathol Med 1995;24:393–7.
26. Piattelli A, Fioroni M, Santinelli A, Rubini C. Expression of proliferating cell nuclear antigen in ameloblastomas and odontogenic cysts. Oral Oncol 1998; 34:408–12.
27. Pogrel MA, Jordan RCK. Marsupialization as a definitive treatment for odontogenic keratocysts. American Association of Oral and Maxillofacial Surgeons Scientific Sessions; 2002 Oct 4; Chicago: American Association of Oral and Maxillofacial Surgeons; 2002.
28. Waldron CA, Koh ML. Central mucoepidermoid carcinoma of the jaws: report of four cases with analysis of the literature and discussion of the relationship to mucoepidermoid, sialodontogenic and glandular odontogenic cysts. J Oral Maxillofac Surg 1990;48:871–7.
29. Hussain K, Edmondson HB, Browne RM. Glandular odontogenic cysts. Diagnosis and treatment. Oral Surg Oral Med Oral Pathol 1995;79:593–602.
30. Hong SP, Ellis GL, Hartman KS. Calcifying odontogenic cyst. A review of ninety-two cases with reevaluation of their nature as cysts or neoplasms, the nature of ghost cells, and subclassification. Oral Surg Oral Med Oral Pathol 1991;72:56–64.
31. Buchner A. The central (intraosseous) calcifying odontogenic cyst: an analysis of 215 cases. J Oral Maxillofac Surg 1991;49:330–9.
32. Kramer IRH, Pindborg JJ, Shear M. The WHO histological typing of odontogenic tumours. A commentary on the second edition. Cancer 1992;70:2988–94.
33. Grodjesk JE, Dolinsky HB, Schneider LC, et al. Odontogenic ghost cell carcinoma. Oral Surg Oral Med Oral Pathol 1987;63:576–81.
34. Regezi JA, Kerr DA, Courtney RM. Odontogenic tumors: analysis of 706 cases. J Oral Surg 1978;36:771–8.

35. Daley TD, Wysocki GP, Pringle GA. Relative incidence of odontogenic tumors and oral and jaw cysts in a Canadian population. *Oral Surg Oral Med Oral Pathol* 1994; 77:276–80.
36. Odukoya O. Odontogenic tumors: analysis of 289 Nigerian cases. *J Oral Pathol Med* 1995;24:454–7.
37. Daramola JO, Ajagbe HA, Oluwasanmi JO. Recurrent ameloblastoma of the jaws—a review of 22 cases. *Plast Reconstr Surg* 1980;65:577–9.
38. Adekeye EO, Lavery KM. Recurrent ameloblastoma of the maxillofacial region. Clinical features and treatment. *J Maxillofac Surg* 1986;14:153–7.
39. Raubenheimer EJ, Heerden WFP, Noffke CEE. Infrequent clinicopathological findings in 108 ameloblastomas. *J Oral Pathol Med* 1995; 24:227–32.
40. Adekeye EO. Ameloblastoma of the jaws: a survey of 109 Nigerian patients. *J Oral Surg* 1980;38:36–41.
41. Olaitan AA, Adeola DS, Adekeye EO. Ameloblastoma: clinical features and management of 315 cases from Kaduna, Nigeria. *J Craniomaxillofac Surg* 1993;21: 351–5.
42. Reichart PA, Philipsen HP, Sonner S. Ameloblastoma: biological profile of 3677 cases. *Eur J Cancer Oral Oncol* 1995; 31B:86–99.
43. Ueno S, Nakamura S, Mushimoto K, Shirasu R. A clinicopathologic study of ameloblastoma. *J Oral Maxillofac Surg* 1986; 44:361–5.
44. Takahashi K, Miyauchi K, Sato K. Treatment of ameloblastoma in children. *Br J Oral Maxillofac Surg* 1998;36:453–6.
45. Williams T. The ameloblastoma: a review of the literature. Selected readings in oral and maxillofacial surgery. Vol 2. San Francisco: The Guild for Scientific Advancement in Oral and Maxillofacial Surgery; 1991. p. 1–17.
46. Nastri AL, Wiesenfeld D, Radden BG, et al. Maxillary ameloblastoma: a retrospective study of 13 cases. *Br J Oral Maxillofac Surg* 1995;33:28–32.
47. Jackson IT, Callan PP, Forte RA. An anatomical classification of maxillary ameloblastoma as an aid to surgical treatment. *J Craniomaxillofac Surg* 1996; 24:230–6.
48. Sehdev MK, Huvos AG, Strong EW, et al. Ameloblastoma of maxilla and mandible. *Cancer* 1974;33:324–33.
49. Komisar A. Plexiform ameloblastoma of the maxilla with extension to the skull base. *Head Neck Surg* 1984;7:172–5.
50. Petriella VM, Rogow PN, Baden E, Williams AC. Gigantic ameloblastoma of the mandible: report of case. *J Oral Surg* 1974;32:44–9.
51. Regezi JA, Sciubba JJ, Jordan RCK. Odontogenic tumors. In: Regezi JA, Sciubba JJ, Jordan RCK, editors. *Oral pathology. Clinical pathologic correlations*. St. Louis: WB Saunders; 2003. p. 267–88.
52. Gold L. Biologic behavior of ameloblastoma. *Oral Maxillofac Surg Clin North Am* 1991;3:21–71.
53. Feinberg SE, Steinberg B. Surgical management of ameloblastoma. Current status of the literature. *Oral Surg Oral Med Oral Pathol* 1996;81:383–8.
54. Huffman GG, Thatcher JW. Ameloblastoma—the conservative surgical approach to treatment: report of four cases. *J Oral Surg* 1974;32:850–4.
55. Vedtofte P, Hjorting-Hansen E, Jensen BN, Roed-Petersen B. Conservative surgical treatment of mandibular ameloblastomas. *Int J Oral Surg* 1978;7:156–61.
56. Gardner DG, Pecak AMJ. The treatment of ameloblastoma based on pathologic and anatomic principles. *Cancer* 1980;46:2514–9.
57. Muller H, Slootweg PJ. The ameloblastoma, the controversial approach to therapy. *J Maxillofac Surg* 1985;13:79–84.
58. Sampson DE, Pogrel MA. Management of mandibular ameloblastoma: the clinical basis for a treatment algorithm. *J Oral Maxillofac Surg* 1999;57:1074–7.
59. Gardner DG. A pathologist's approach to the treatment of ameloblastoma. *J Oral Maxillofac Surg* 1984; 42:161–6.
60. Kramer IRH. Ameloblastoma: a clinicopathological appraisal. *Br J Oral Surg* 1963; 1:13–28.
61. Carlson ER. Pathologic facial asymmetries. *Atlas Oral Maxillofac Surg Clin North Am* 1996;4:19–35.
62. Oka K, Fukui M, Yamashita M, et al. Mandibular ameloblastoma with intracranial extension and distant metastasis. *Clin Neurol Neurosurg* 1986;88:303–9.
63. Atkinson CH, Harwood AR, Cummings BJ. Ameloblastoma of the jaw. A reappraisal of the role of megavoltage irradiation. *Cancer* 1984;53:869–73.
64. Gardner DG. Radiotherapy in the treatment of ameloblastoma. *Int J Oral Maxillofac Surg* 1988; 17:201–5.
65. Vickers RA, Gorlin RJ. Ameloblastoma: delineation of early histopathologic features of neoplasia. *Cancer* 1970;26:699–710.
66. Robinson L, Martinez MG. Unicystic ameloblastoma. A prognostically distinct entity. *Cancer* 1977;40: 2278–85.
67. Gardner DG. Plexiform unicystic ameloblastoma; a diagnostic problem in dentigerous cysts. *Cancer* 1981;47:1358–63.
68. Haug RH, Hauer CA, Smith B, Indresano AT. Reviewing the unicystic ameloblastoma: report of two cases. *J Am Dent Assoc* 1990;121:703–5.
69. Gardner DG, Corio RL. The relationship of plexiform unicystic ameloblastoma to conventional ameloblastoma. *Oral Surg Oral Med Oral Pathol* 1983;56:54–60.
70. Gardner DG, Corio RL. Plexiform unicystic ameloblastoma. A variant of ameloblastoma with a low recurrence rate after enucleation. *Cancer* 1984;53:1730–5.
71. Gardner DG, Morton TH, Worsham JC. Plexiform unicystic ameloblastoma of the maxilla. *Oral Surg Oral Med Oral Pathol* 1987;63:221–3.
72. Woo SB, Smith-Williams JE, Sciubba JJ, Lipper S. Peripheral ameloblastoma of the buccal mucosa: case report and review of the English literature. *Oral Surg Oral Med Oral Pathol* 1987;63:78–84.
73. Tajima Y, Kuroda-Kawasaki M, Ohno J, et al. Peripheral ameloblastoma with potentially malignant features: report of a case with special regard to its keratin profile. *J Oral Pathol Med* 2001;30:494–8.
74. Eversole LR. Malignant epithelial odontogenic tumors. *Semin Diagn Pathol* 1999;16:317–24.
75. Slootweg PJ, Muller H. Malignant ameloblastoma or ameloblastic carcinoma. *Oral Surg Oral Med Oral Pathol* 1984;57:168–76.
76. Byrne MP, Kosmala RL, Cunningham MP. Ameloblastoma with regional and distant metastases. *Am J Surg* 1974;128:91–4.
77. Newman L, Howells GL, Coghlan KM, et al. Malignant ameloblastoma revisited. *Br J Oral Maxillofac Surg* 1995;33:47–50.
78. Laughlin EH. Metastasizing ameloblastoma. *Cancer* 1989;64:776–80.
79. Dorner L, Sear AJ, Smith GT. A case of ameloblastic carcinoma with pulmonary metastases. *Br J Oral and Maxillofac Surg* 1988;26:503–10.
80. Simko EJ, Brannon RB, Eibling DE. Ameloblastic carcinoma of the mandible. *Head Neck* 1998;20:654–9.
81. Corio RL, Goldblatt LI, Edwards PA, Hartman KS. Ameloblastic carcinoma: a clinicopathologic study and assessment of eight cases. *Oral Surg Oral Med Oral Pathol* 1987;64:570–6.
82. Slootweg PJ. An analysis of the interrelationship of the mixed odontogenic tumors—ameloblastic fibroma, ameloblastic fibro-odontoma, and the odontomas. *Oral Surg Oral Med Oral Pathol* 1981;51:266–76.

83. Gardner DG. The mixed odontogenic tumors. *Oral Surg Oral Med Oral Pathol* 1984; 57:395–7.
84. Howell RM, Burkes J. Malignant transformation of ameloblastic fibro-odontoma to ameloblastic fibrosarcoma. *Oral Surg Oral Med Oral Pathol* 1977; 43:391–401.
85. Barker BF. Odontogenic myxoma. *Semin Diagn Pathol* 1999;4:297–301.
86. Regezi JA. Odontogenic cysts, odontogenic tumors, fibrousseous, and giant cell lesions of the jaws. *Mod Pathol* 2002; 15:331–41.
87. Franklin CD, Pindborg JJ. The calcifying epithelial odontogenic tumor. A review and analysis of 113 cases. *Oral Surg Oral Med Oral Pathol* 1976; 42:753–65.
88. Veness MJ, Morgan G, Collins AP, Walker DM. Calcifying epithelial odontogenic (Pindborg) tumor with malignant transformation and metastatic spread. *Head Neck* 2001;23:692–6.
89. Baunsgaard P, Lontoft E, Sorensen M. Calcifying epithelial odontogenic tumor (Pindborg tumor): an unusual case. *Laryngoscope* 1983;93:635–8.
90. Berk RS, Baden E, Ladov M, Williams AC. Adenoameloblastoma (odontogenic adenomatoid tumor): report of case. *J Oral Surg* 1972;30:201–8.
91. Halperin V, Carr RF, Peltier JR. Follow-up of adenoameloblastomas. Review of thirty-five cases from the literature and report of two additional cases. *Oral Surg Oral Med Oral Pathol* 1967;24:642–7.
92. Poulson RC, Greer RO. Adenomatoid odontogenic tumor: clinicopathologic and ultrastructural concepts. *J Oral Maxillofac Surg* 1983;41:818–24.
93. Toida M, Hyodo I, Okuda T, Tatematsu N. Adenomatoid odontogenic tumor: report of two cases and survey of 126 cases in Japan. *J Oral Maxillofac Surg* 1990; 48:404–8.
94. Courtney RM, Kerr DA. The odontogenic adenomatoid tumor. A comprehensive study of twenty new cases. *Oral Surg Oral Med Oral Pathol* 1975;39:424–35.
95. Mendis BRRN, MacDonald DG. Adenomatoid odontogenic tumour. A survey of 21 cases from Sri Lanka. *Int J Oral Maxillofac Surg* 1990;19:141–3.
96. Lee KW. A light and electron microscopic study of the adenomatoid odontogenic tumor. *Int J Oral Surg* 1974;3:183–93.
97. Smith RRL, Olson JL, Hutchins GM, et al. Adenomatoid odontogenic tumor. Ultrastructural demonstration of two cell types and amyloid. *Cancer* 1979; 43:505–11.
98. Yamamoto H, Kozawa Y, Hirai G, et al. Adenomatoid odontogenic tumor: light and electron microscopic study. *Int J Oral Surg* 1981;10:272–8.
99. Philipsen JP, Reichart PA, Zhang KH, et al. Adenomatoid odontogenic tumor: biologic profile based on 499 cases. *J Oral Pathol Med* 1991;20:149–58.

Benign Nonodontogenic Lesions of the Jaws

M. Anthony Pogrel, DDS, MD

Benign nonodontogenic lesions of the jaws represent a mixed group of tumors, which in many cases are difficult to classify. Additionally, there are some lesions within this group that actually only seem to occur in the jaws, and, therefore, although they do not contain any histologic or immunohistochemical evidence of odontogenic structures, the mere fact that they only occur in the jaws may mean that they are in fact odontogenic.

The subjects discussed in this chapter are fibro-osseous disease, osteoblastoma and osteoid osteoma, aggressive mesenchymal tumors of childhood, benign tumors of bone-forming cells, synovial chondromatosis and osteochondroma, lesions containing giant cells, vascular malformations, Langerhans cell histiocytosis, nonodontogenic cysts of the jaws, neurogenic tumors, Paget's disease, massive osteolysis (Gorham's disease), and tori.

Benign Fibro-osseous Disease

Differences remain in the classification and diagnosis of fibro-osseous disease.¹ There is a general consensus that the common entity for all of the lesions is the replacement of normal bone with a tissue composed of collagen fibers and fibroblasts that contain varying amounts of mineralized substance, which can be either bone or cementum-like material. It is difficult to differentiate con-

clusively between bone and cementum with light microscopy.

For the purposes of this chapter, the term *fibro-osseous disease* is taken to include the following groups of lesions: fibrous dysplasia, cemento-osseous dysplasia, and fibro-osseous neoplasms.

Fibrous Dysplasia

Fibrous dysplasia is considered to be a developmental hamartomatous fibro-osseous disease of unknown etiology. It may represent developmental arrest in a benign fibro-osseous proliferation that lacks the ability to fully differentiate.² Somatic mutations in the GS α -gene have been proposed to cause monostotic and polyostotic conditions and Albright's syndrome.^{3,4}

Fibrous dysplasia is normally subdivided into four different forms:

1. Monostotic fibrous dysplasia affecting only one bone
2. Polyostotic fibrous dysplasia affecting multiple bones
3. Albright's syndrome in which multiple lesions are associated with hyperpigmentation and endocrine disturbances, predominantly precocious puberty and/or hyperthyroidism⁵
4. Craniofacial fibrous dysplasia confined to bones of the craniofacial complex

The jaws are commonly associated with all forms of fibrous dysplasia. In the jaws the onset is usually during the first and second decades, and it produces painless swelling of the involved bones (Figure 31-1). Classically, the radiographic appearance shows a ground-glass opacity without clearly defined borders (Figure 31-2). In its craniofacial form the maxilla, zygoma, sphenoid, frontal bones, nasal bones, and base of the skull can be involved. Expansion can cause compression of nerves and blood vessels. The optic canal can be narrowed by fibrous dysplasia, although it seems unlikely that

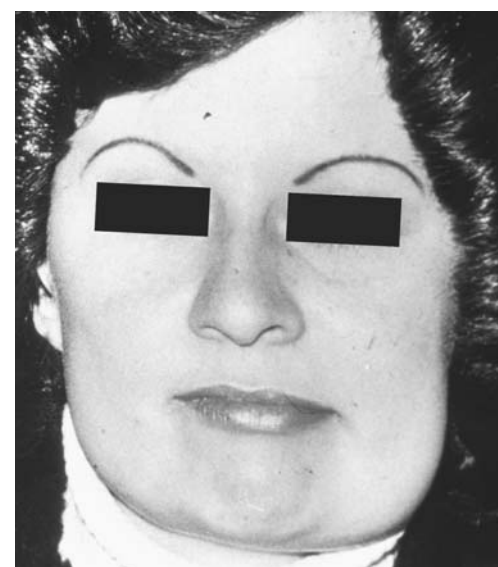


FIGURE 31-1 Swelling of the left mandible and maxilla owing to fibrous dysplasia.

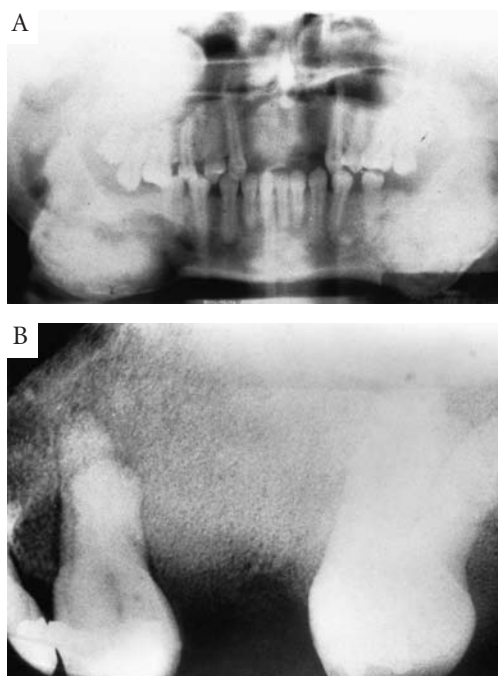


FIGURE 31-2 A, Radiographic appearance of patient in Figure 31-1 showing ground-glass appearance of lesions. B, Periapical view of typical ground-glass appearance of fibrous dysplasia.

any associated vision loss can be relieved by orbital decompression.⁶ The maxilla appears to be affected more often than the mandible, and females are affected more commonly than males. Typically lesions undergo periods of activity and periods of quiescence. When they are active, they are often symptomatic in that the patient may perceive a throbbing or discomfort, the

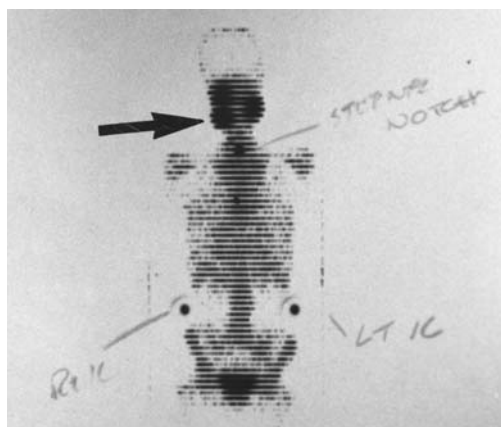


FIGURE 31-3 Bone scan of patient in Figures 31-1 and 31-2 showing area of increased uptake of isotope in both sides of the mandible and the left maxilla (arrow). The isotope used was Tc 99m diphosphonate.

swelling increases, and the lesions appear hot on a bone scan (Figure 31-3) and can, in fact, mimic osteomyelitis.⁷⁻¹¹ In a quiescent phase they may be totally asymptomatic. Teeth can be displaced by the lesion (Figure 31-4). Familial cases of fibrous dysplasia have been noted.¹²

The lesions of fibrous dysplasia may be under hormonal control, particularly in Albright's syndrome, and cases of increased activity and reactivation during pregnancy have been noted.^{13,14} Although not normally recognized as a premalignant lesion, sarcomatous change has been noted in fibrous dysplasia.^{15,16} Early cases appear to have been associated with the use of radiation therapy for treatment,^{17,18} but cases of spontaneous sarcomatous degeneration have been noted.¹⁹ Additionally, some cases have been difficult to diagnose and may have represented a low-grade osteosarcoma from the outset.²⁰

Classically, fibrous dysplasia appears to be a lesion that "burns itself out" when the patient is in the late teens or early twenties, although cases of active fibrous dysplasia have been noted much later than this.

Treatment is generally symptomatic; if the lesions are asymptomatic, a biopsy diagnosis alone may be adequate without carrying out any definitive treatment. Surgical treatment should be limited during an active phase because the lesions are vascular and can bleed quite profusely. Treatment is best reserved for quiescent periods, at which time cosmetic recontouring is the normal treatment of choice. Regrowth, however, can be expected following this treatment in 25 to 50% of cases, particularly if undertaken at a young age. Some investigators have suggested more aggressive surgical procedures including mandibular and maxillary resections.²¹

Cemento-osseous Dysplasia

The cemento-osseous dysplasias represent a pathologic process of the tooth-bearing areas and probably represent the commonest manifestation of fibro-osseous disease;

however, since they are frequently asymptomatic and require no treatment, they are less of a diagnostic and clinical dilemma than are the other forms of fibro-osseous disease. In this condition there is a disordered production of bone and cementum-like tissue in the jaws. The three forms include periapical, focal, florid osseous dysplasias, and familial gigantiform cementoma, which are probably variants of the same pathologic process but which can be differentiated by clinical and radiographic features. The etiology of these lesions remains in doubt, but local trauma may play some part, even such benign trauma as abnormal occlusal forces. There is a predominance of cases occurring in females and also in African Americans.²² It is suspected that the periodontal ligament may be the origin of the fibrous tissue found in the cemento-osseous dysplasias. Histologically the three types of cemento-osseous dysplasia are indistinguishable, showing new woven bone trabeculae and/or spherules of cementum-like material, which often blend into the cortical bone. A fibrous tissue stroma is present. There is very little inflammatory component. Traumatic bone cysts have been reported in conjunction with this lesion.²³

Periapical Cemento-osseous Dysplasia

Periapical cemento-osseous dysplasia presents as circumscribed lesions in periapical areas associated with vital teeth, with the anterior mandible being most usually

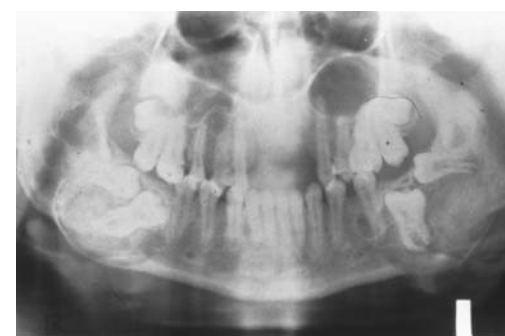

FIGURE 31-4 Teeth displaced by lesions of fibrous dysplasia.

involved. African American females are predominantly affected. Radiographically the lesions can be radiolucent, of mixed density, or radiopaque, depending on their stage of development (Figure 31-5). Studies indicate that they may occur in around 6% of African American females.²⁴

Focal Cemento-osseous Dysplasia Lesions of focal cemento-osseous dysplasia have a predilection for middle-aged African American females and present as nonexpansile radiolucencies with associated opacities, often in edentulous areas of the mandible. They frequently occur in sites of previous dental extractions and may represent some type of abnormal healing following dental extraction. Since they are usually asymptomatic, cases are often noted on routine panoramic radiographs. They are normally well circumscribed and rarely exceed 2 cm. Differentiation from ossifying fibroma may be difficult.²⁵

Florid Cemento-osseous Dysplasia Florid cemento-osseous dysplasia has a predilection for middle-aged African American females and presents as a painless nonexpansile lesion often involving two or more jaw quadrants. Radiographically it appears as multiple confluent lobular radiopaque masses in tooth-bearing areas (Figure 31-6). Lesions may be associated with superimposed infection and osteomyelitis, and have also been associated with idiopathic bone cysts.²⁶ Histologically they have an unencapsulated proliferation of cellular fibrous tissue with trabeculae or woven bone and calcification. More mature lesions may become acellular and avascular with coalescent sclerotic bone masses. Although common in African Americans, florid cemento-osseous dysplasia has been noted in all racial groups. Many patients are partially or totally edentulous when the condition is first discovered. Cortical expansion is usually absent or of limited degree. It has been suggested that chronic diffuse sclerosing osteomyelitis may represent a variant of

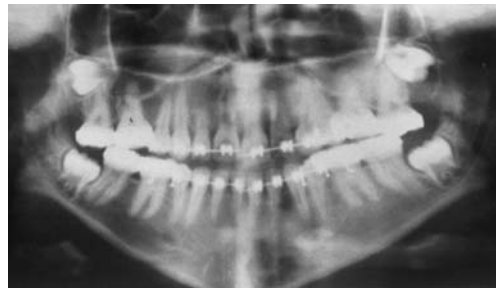

FIGURE 31-5 *Periapical cemento-osseous dysplasia of the left maxilla (an atypical site). All associated teeth are vital. The patient is a 48-year-old African American female.*

this condition, but it probably represents a different condition, inflammatory in nature. The differences between the two conditions have been noted and described.^{8,27,28} However, the role of bacteria in chronic diffuse sclerosing osteomyelitis has proven elusive, and, in general, even authorities who strongly support an infectious origin have had difficulty isolating organisms.^{29,30}

Familial Gigantiform Cementoma Familial gigantiform cementoma represents an autosomal dominant variant of osseous dysplasia usually involving multiple quadrants with variably expansile lesions, often in the anterior mandible.³¹ This particular form of osseous dysplasia has no racial predilection. The lesions often evolve during childhood and can grow rapidly. Treatment is usually surgical and symptomatic and is limited to cosmetic recontouring.

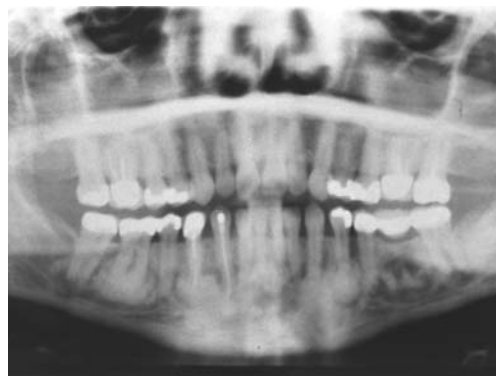

FIGURE 31-6 *Florid cemento-osseous dysplasia of the mandible in a 49-year-old African American female. All associated teeth are vital.*

Fibro-osseous Neoplasms

Ossifying Fibroma Ossifying fibroma (cemento-ossifying fibroma) usually presents as a well-demarcated mixed radiolucency/radiopacity with smooth and often sclerotic borders (Figure 31-7). The lesions are usually solitary and most commonly occur in the mandible. Histologically they contain a relatively avascular cellular fibrous stroma with reticular bone trabeculae and cementum-like spherules. Most authorities now feel comfortable clearly differentiating this lesion from fibrous dysplasia. Chromosomal abnormalities have been identified in an ossifying fibroma and a cementifying fibroma.^{32,33} The ossifying fibroma is felt to be a true neoplasm and occurs at a later age than does fibrous dysplasia, being most common later in the third and early in the fourth decades. Ossifying fibroma appears to be confined to the jaws and craniofacial complex, although similar lesions have been reported in the long bones.³⁴⁻³⁶ There is, again, a female predominance but no racial predominance, and growth rates are variable. Since it is felt to be a neoplasm, the treatment is surgical; in fact, the lesions often shell out easily at surgery, although there is recurrence, the rate of which has variously been reported from 1 to 63%.³⁷⁻³⁹ For these reasons, some authorities recommend aggressive treatment for more aggressive lesions, including aggressive curettage,

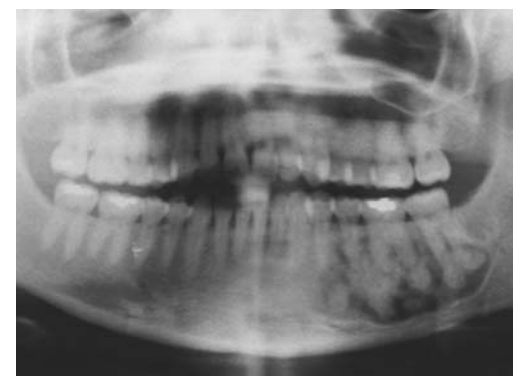


FIGURE 31-7 *Ossifying fibroma of the left mandible. It appears as a well-defined mixed radiolucency/ radiopacity.*

localized surgical resection, and segmental mandibular resection.^{40,41} When present in the craniofacial complex, treatment may have to be more aggressive to protect the vital structures.⁴²

Juvenile Aggressive Ossifying Fibroma

Juvenile aggressive ossifying fibroma was first described in 1952 as a variant of ossifying fibroma.⁴³ The lesions classically occur in younger children and adolescents and present with an aggressive behavior, but they have been noted in older patients and are not always particularly aggressive. The World Health Organization defines juvenile aggressive ossifying fibroma as “an actively growing lesion mainly affecting individuals below the age of 15 years, which is composed of a cell-rich fibrous tissue containing bands of cellular osteoid without osteoblastic rimming together with trabeculae of more typical woven bone. Small foci of giant cells may be present, and in some parts there may be abundant osteoclasts related to the woven bone. Usually no fibrous capsule can be demonstrated, but the lesion is well demarcated from the surrounding bone.”⁴⁴ Two variants have been described: trabecular and psammomatous. The trabecular variant usually occurs in childhood, with a slight maxillary predominance, and may contain clustered multinuclear giant cells. The psammomatous variant can occur in adults as well as adolescents and often affects the orbit and paranasal tissues; frequently it contains a whorled pattern of closely packed spheric ossicles and a myxoid component with aneurysmal bone cyst–like areas.

Although felt to be more aggressive than the commoner ossifying fibroma that is found at a later age, this condition is not considered to necessitate truly aggressive surgery; conservative excision is still the recommended treatment, although lesions involving the craniofacial structures may require more extensive surgery. Recurrence rates of between 20 and 50% have

been reported, and recurrences may be commoner in younger patients.¹

Osteoblastoma and Osteoid Osteoma

Osteoblastoma and osteoid osteoma are generally felt to be variants of the same lesion and are related to fibro-osseous disease. Cementoblastoma and gigantiform cementoma are the equivalent cemental lesions and are associated with teeth. The alternative name for the osteoblastoma is giant osteoid osteoma, and it is generally felt to represent a larger version of the osteoid osteoma. Both are benign processes and are felt to represent true neoplasms. The osteoblastoma occurs primarily in the vertebrae and long bones, but it has been described in the jaws.^{45–47} Clinically it often grows rapidly and the predominant clinical feature is pain, which is generally localized to the lesion itself. Although felt to be a true neoplasm, there have been reports of regression after biopsy or incomplete removal, which could point to it being a reactive process of some kind.⁴⁸ Most cases of osteoblastoma occur in the second decade of life; they rarely occur after age 30 years. Males appear to be affected more commonly than females. In the head and neck, the mandible is the most common site.

Radiographic features are variable, usually consisting of a combination of radiolucency and radiopacity (Figure 31-8). The designation *osteoblastoma* is normally reserved for lesions > 2 cm in diameter. They are well circumscribed radiographically with a thin radiolucency surrounding the variably calcified contents. A sunray pattern of new bone formation similar to that described in malignant bone tumors may be evident.

The histologic appearance shows irregular trabeculae of osteoid and immature bone within a predominantly vascular stromal network. There are various degrees of calcification present. Stromal cells are generally small and slender. Differentiation

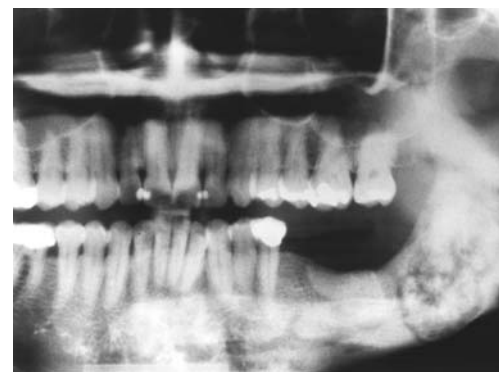

FIGURE 31-8 *Osteoblastoma of the left mandible in 24-year-old female. Note mixed radiolucency/radiopacity with a radiolucent rim.*

must be made from the ossifying fibroma, fibrous dysplasia, and osteosarcoma.

Treatment of the osteoblastoma is generally confined to conservative surgical excision either with curettage or local excision. Recurrences are rare but have been reported and may necessitate more aggressive treatment such as en bloc resection.⁴⁹ Rare examples of malignant transformation have been reported,^{50,51} but some of these may be related to an incorrect initial diagnosis.⁴⁵

The osteoid osteoma represents a smaller version of the osteoblastoma and is felt to be a true neoplasm. It is normally < 2 cm in diameter clinically and radiographically. It again occurs in the second and third decades of life with a male predominance. Pain is again the major clinical feature. Classically, the pain is worse at night and is relieved by acetylsalicylic acid. If the lesion is located near the cortex, it may produce a localized tender swelling. Radiographically the lesion again shows a well-defined mixed radiolucency/radiopacity with a small radiolucent rim around the lesion, which is walled by sclerotic bone. Histologically it resembles the osteoblastoma with a rich vascular stroma with trabeculae of osteoid and immature bone. The bone is rimmed by layers of active osteoblasts. Histologically it is impossible to differentiate it from the osteoblastoma. Treatment is again conservative surgical excision. Spontaneous regression has also been reported clinically.

Chondroma

A chondroma is a benign tumor of mature cartilage. The occurrence of these lesions in the jaws is extremely rare⁵²; in fact, whether they ever occur in the jaws or whether they are usually described as chondromyxomas or chondromyxoid fibromas has been questioned.^{53–57} In many cases the true diagnosis in those reported cases is actually low-grade chondrosarcoma.⁵⁸ Most reports concern the mandibular condyle, suggesting that these lesions may arise from cartilaginous remnants.^{59,60} The chondroma presents as a painless slowly progressive swelling, which may result in mucosal ulceration. The gender distribution is equal, and most tumors occur under the age of 50 years. Radiographically they present as irregular radiolucent lesions, although foci of calcification may occasionally be present. Resorption of tooth roots has been reported. Histologically the lesions contain well-defined lobules of mature hyaline cartilage. Treatment is localized, and conservative surgical excision is normally recommended. Because of the doubtful nature of these lesions and the always-present possibility of a lesion representing a low-grade chondrosarcoma, some authorities have suggested wide excision for all of these lesions as a kind of insurance policy.⁵⁸

Osteoma

Osteomas are benign tumors consisting of mature compact or cancellous bone. They may arise on the surface of bone (periosteal osteomas) or centrally within the bone (endosteal osteomas).⁶¹ They are often discovered as asymptomatic radiopacities.

Osteomas are most commonly discovered during the second and fifth decades of life, although they have been noted in all age groups. Males appear to be affected more frequently than females.

Gardner's syndrome is an autosomal dominant condition in which patients have intestinal polyposis, multiple osteomas (usually endosteal) of the jaws, fibro-

mas of the skin, epidermal cysts, impacted teeth, and odontomas.^{62–65} The specific gene associated with the condition has now been identified on the long arm of chromosome 5.^{66–68} Many cases of incomplete manifestation of the syndrome have been reported. The clinical significance of this syndrome is that the intestinal polyps, which frequently occur in the colon and rectum, are premalignant and have a very high rate of malignant transformation. The associated osteomas are often found in the jaws, particularly in the angle region of the mandible, as well as the facial bones and long bones. It has been suggested that any patient with multiple mandibular osteomas should be investigated for the possibility of Gardner's syndrome. Investigation should include a detailed history of gastrointestinal disturbance and, if positive, follow-up with colonoscopy; if the diagnosis is confirmed, a prophylactic colectomy should be performed.

Periosteal osteomas usually present as asymptomatic slow-growing bony masses. Endosteal osteomas are usually asymptomatic and are noted on routine radiographs. Radiographically they appear as well-circumscribed sclerotic radiopaque masses (Figure 31-9). Histologically they consist of either dense compact bone with sparse marrow spaces or lamellar trabeculae of cancellous bone with fibrofatty marrow spaces. Osteoblastic activity is often predominant.

Treatment of osteomas is surgical excision (Figure 31-10). This is often necessary

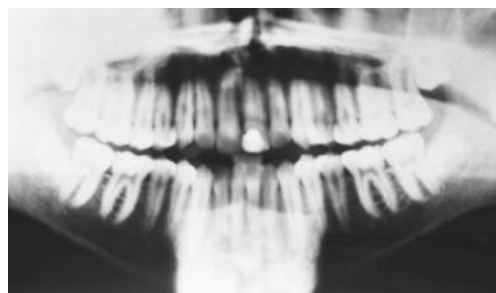

FIGURE 31-9 Radiograph of an endosteal osteoma in the ascending ramus of the left mandible.

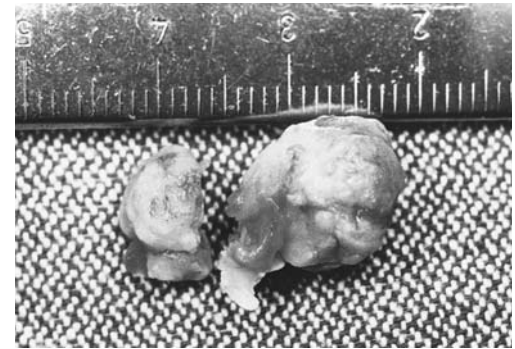

FIGURE 31-10 Surgical specimen from the osteoma shown radiographically in Figure 31-9.

to establish the diagnosis. Asymptomatic cases may be followed up clinically and radiographically without treatment. Following excision, recurrences are very rare.

Synovial Chondromatosis and Osteochondroma

Both synovial chondromatosis and osteochondroma are conditions that occur in the temporomandibular joints and may be considered variants of the chondroma and osteoma. In synovial chondromatosis there is a proliferation of small particulate, generally unattached chondromas within the confines of the joint capsule. Although most frequently found in the knee, they have been reported in most joints. Well-recognized cases have occurred in the temporomandibular joints with symptoms normally consisting of pain and swelling but most often with deviation of the mandible toward the unaffected side (Figure 31-11).^{69,70} The etiology is unknown, but trauma has been suggested.⁷¹ When

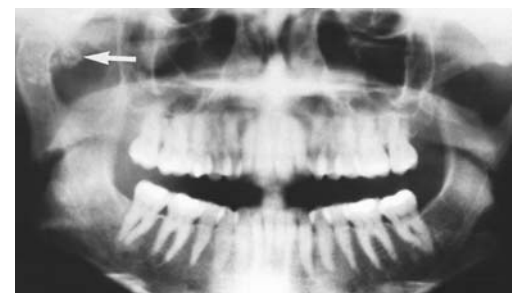


FIGURE 31-11 Panoramic radiograph showing a number of radiopaque foreign bodies in the right temporomandibular joint (arrow).

these lesions become symptomatic, they should be removed via a standard preauricular approach. Since it is felt that they arise from metaplasia within the synovial lining cells of the joint, it is often advocated that the lining be removed at the same time.⁷² Cases have been reported in which up to 200 of these bodies were present within the temporomandibular joint (Figure 31-12).¹² Following removal, recurrence has not been reported.

The osteochondroma is felt to be a benign lesion that arises predominantly in long bones from a herniation of cartilage through the epiphyseal plate. It tends to present with a predominantly osseous core with a cartilaginous cap. The lesion becomes symptomatic when function is affected, for example, a malocclusion or mandibular asymmetry develops (Figure 31-13). Cases have been reported in the mandibular condyle.⁷³ Cases in the temporomandibular joints appear identical in all respects to lesions in other bones of the body. However, the association with the epiphyseal plate that occurs in the long bones is not present in the temporomandibular joint. On magnetic resonance imaging it appears as an extraneous appendage to the temporomandibular joint and is usually more radiopaque than the surrounding mandible (Figure 31-14). Treatment is symptomatic; when symptoms occur, localized excision is recommended via the nor-

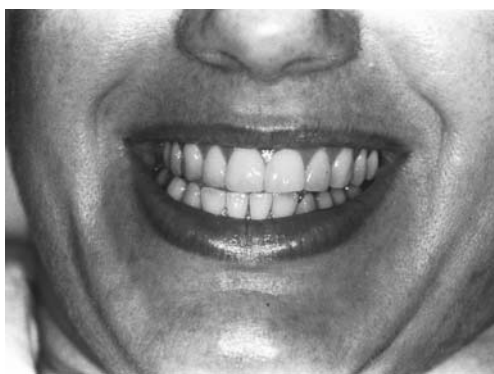

FIGURE 31-13 A malocclusion caused by an osteochondroma of the left temporomandibular joint.

mal temporomandibular approach. Recurrence has been reported but is unusual.⁷⁴⁻⁷⁷

Aggressive Mesenchymal Tumors of Childhood

It is recognized that children and young adults can develop an aggressive and rapidly growing tumor of bone, which, although often having a benign mesenchymal appearance, nevertheless behaves very aggressively. The exact nature of these lesions remains unknown, but many have been classified as desmoplastic fibromas, which is the hard tissue equivalent of fibromatosis in the soft tissues. Any bone can be affected including the jaws.

The etiology and pathogenesis are in doubt since their aggressive behavior suggests a neoplastic process, but genetic, endocrine, and traumatic factors have also been suggested. Most occur in persons under the age of 20 years, and there is no gender predilection. The mandible is affected more frequently than the maxilla.⁷⁸ Radiographically a unilocular or multilocular radiolucency is noted with poorly defined margins, cortical perforation, and root resorption often being present (Figures 31-15 and 31-16). Histologically the lesion consists of interlacing bundles in a whirled aggregate of collagenous tissue with elongated and spindle fibroblasts. Hypocellularity is often present. However, atypia and mitotic features are not found. Osteoid material is not produced by this lesion.

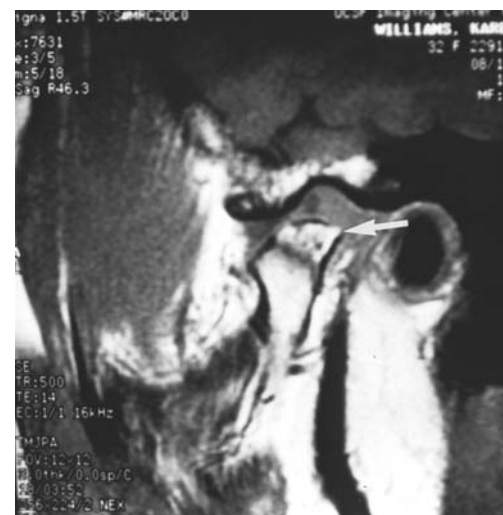

FIGURE 31-14 Magnetic resonance image of an osteochondroma of the left temporomandibular joint (arrow) in the patient shown in Figure 31-13.

In treating this lesion, the adage “treat the biology, not the histology” is of paramount importance. Although the lesion looks benign histologically, it often behaves aggressively,⁷⁹ and the appropriate treatment is aggressive surgery, which often involves mandibular or maxillary resection (Figure 31-17). This is psychologically difficult for the surgeon to perform in a young child without a histologic diagnosis of malignancy, but the recurrence rate is very high following more conservative procedures. For lesions in inaccessible areas such as the base of the skull, radiation therapy and/or chemotherapy has been attempted with variable degrees of success.^{80,81}

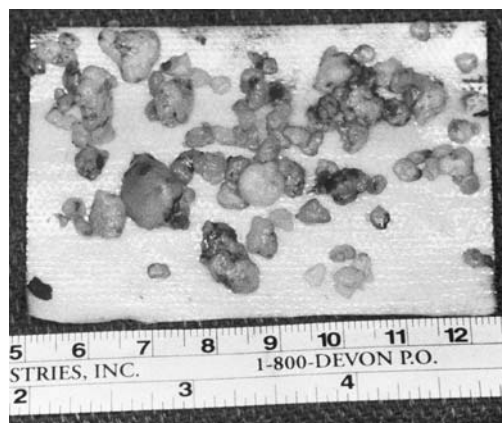


FIGURE 31-12 The synovial chondromas removed from the jaw of the patient in Figure 31-11.

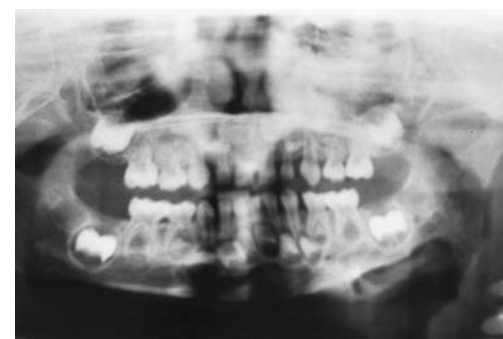

FIGURE 31-15 A desmoplastic fibroma presenting as a well-defined radiolucency at the lower border of the body of the left mandible in a 3-year-old patient.

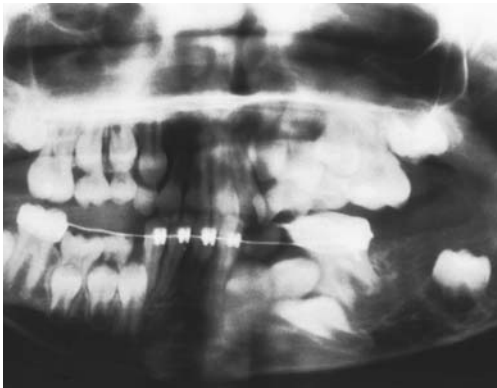


FIGURE 31-16 A desmoplastic fibroma presenting as an ill-defined radiolucency of the left mandible causing displacement of teeth in a patient aged 8 years.

Lesions Containing Giant Cells

There are a number of lesions that occur in the jaws that contain giant cells within them. Their relationship to each other, however, is ill defined. Histologically all of the giant cell lesions appear similar, if not identical, and they usually cannot be distinguished on light microscopy alone. The clinical history, immunohistochemistry, or genetic markers have to be used to differentiate the lesions.

Central Giant Cell Granuloma

Central giant cell granuloma is a lesion occurring almost exclusively in the jaws. (A similar lesion has been described in the small bones of the fingers and toes, but its relationship to the central giant cell granuloma is unknown.⁸²) Although not normally considered an odontogenic lesion,

the fact that it only occurs in the jawbones probably indicates some relationship to the teeth or tooth-bearing structures. It occurs primarily in the anterior parts of the jaws in people in the second and third decades of life, but it has been recorded in all sites at all ages. Its histogenesis remains speculative. When first described it was called a reparative giant cell granuloma,⁸³⁻⁸⁵ and it was considered a reparative lesion that was essentially self-healing. There was little evidence of this, however, and only oblique references to its self-healing properties can be found. Worth showed in a study of a number of non-treated lesions that resolution often did occur as seen radiographically; even when the lesions did not resolve completely radiographically, only a fibrous scar was noted on surgical exploration.⁸⁶ The current consensus, however, is that these are not reparative lesions and that if they are not treated, they are progressive. Most appear to follow a fairly benign course, but more aggressive lesions have been noted.⁸⁷⁻⁸⁹ The true nature of the central giant cell granuloma remains speculative. It has been suggested that it may be an inflammatory lesion, a reactive lesion, a true tumor, or an endocrine lesion. It may behave most like a reactive lesion.

Older theories about the origin of these lesions suggested that they may be derived from the odontoclasts that were responsible for resorption of the deciduous teeth; this was said to explain why they

are normally found in areas where deciduous teeth were present and are found after the deciduous teeth have resorbed.

Radiographically the central giant cell granuloma can take a number of forms from a well-defined radiolucency, a more ill-defined radiolucency or a multilocular radiolucency. Teeth can be displaced by the lesion, although resorption of teeth is uncommon (Figures 31-18 and 31-19).

Histologically these granulomas contain focal arrangements of giant cells within a vascular stroma with thin-walled capillaries adjacent to the giant cells. There is a spindle cell stroma. Immunohistochemistry has shown that the giant cells are in fact osteoclasts,⁹⁰ and the spindle cells are probably the cells of origin of this lesion.⁹¹

Treatment is usually surgical and consists of local curettage, which is usually curative.⁹² However, there is a 15 to 20% recurrence rate, and if the lesions are large, even conservative curettage may involve the loss of many teeth and possibly the inferior alveolar nerve in the mandible, and it may have sinus and nasal implications in the maxilla. With the aggressive variants, more aggressive surgery has been suggested including mandibular resection and appropriate reconstruction.⁹³

Since the central giant cell granuloma and the brown tumor of hyperparathyroidism cannot be separated histologically, it is advocated that hyperparathyroidism be excluded from the diagnosis by serum calcium, phosphate, and parathormone

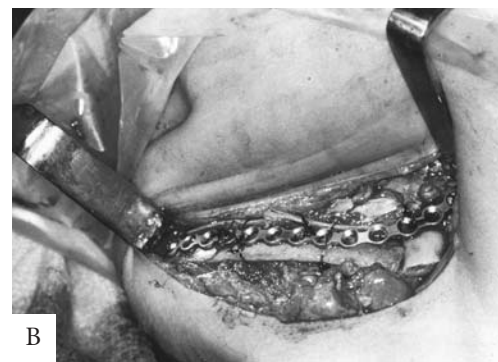
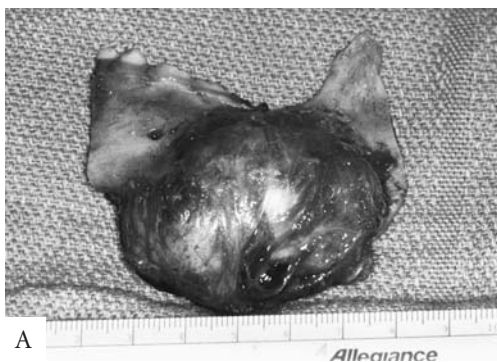
FIGURE 31-17 A, Resected specimen from the patient in Figure 31-15. B, Immediate reconstruction with ribs can often be performed in young children. Reconstruction plate and rib grafts in place.

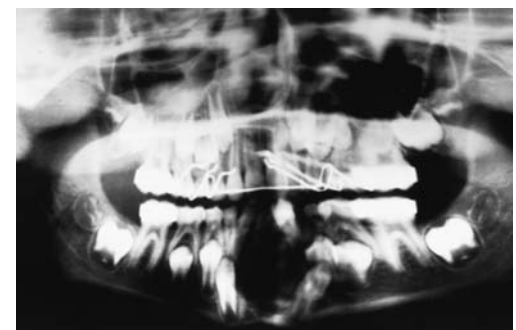

FIGURE 31-18 A central giant cell granuloma of the anterior mandible causing the displacement of teeth.

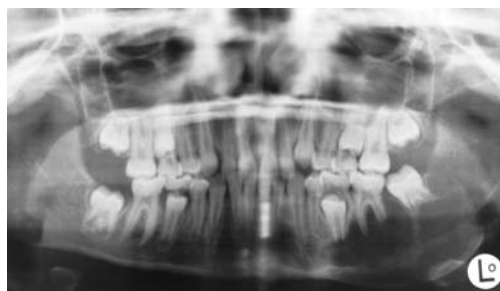

FIGURE 31-19 A central giant cell granuloma of the left angle region of the mandible, appearing as an ill-defined multilocular radiolucency, causing resorption of the distal root of the first molar (unusual).

and parathormone-related protein assays in all but the single small and more benign lesions.⁹⁴

A number of nonsurgical treatments have been suggested, all of which have their advocates. Intralesional steroids (usually triamcinolone injected into the lesion once per week for 6 wk) have been advocated and have shown some success.⁹⁵⁻⁹⁸ Their mode of action is unknown, but they may work by suppressing the inflammatory component of the lesion. They are probably best reserved for smaller lesions that can be more easily treated by intralesional injections (Figure 31-20).

Calcitonin given by subcutaneous injection has also been advocated and has met with some success (Figure 31-21).⁹⁹⁻¹⁰⁶ The theory behind this treatment is that the lesion may be caused by an as-yet undiscovered parathormone-like hormone, and that the use of calcitonin antagonizes its action and allows the lesion to heal. Since some of the giant cells have been shown to have calcitonin receptors on them, this may explain calcitonin's effectiveness.⁹⁴

α -Interferon given by subcutaneous injection has also been advocated in the treatment of the central giant cell granuloma and has again met with some success.^{106,107} The rationale for this therapy is that the antiangiogenic action of the α -interferon suppresses the angiogenic component of this lesion, causing healing to occur. In most cases surgery is still

required after the α -interferon treatment, but it may be less radical surgery and there may be a smaller chance of recurrence.

It has again been suggested that the central giant cell granuloma may, in fact, be a self healing lesion, with the natural healing process stimulated by the nonsurgical therapy employed.¹⁰⁵

Giant Cell Tumor

The giant cell tumor is normally found in the long bones and its presence in the jaws is not universally accepted; if it does occur, it is extremely rare. This lesion is an aggressive one and is felt by some to be a variant of a low-grade osteosarcoma. The recurrence rate after local curettage is high, and the appropriate treatment is in doubt. Some authorities advocate local curettage, whereas some have advocated resection. Histologically it is very similar to the central giant cell granuloma, except that the giant cells are larger with more nuclei, and they are more evenly spread throughout the lesion and not as focally placed as in the central giant cell granuloma. However, in any particular case it may be extremely difficult to make this distinction.⁴⁵

Hyperparathyroidism

In hyperparathyroidism (primary, secondary, or tertiary), calcium is mobilized from the bones into the blood stream to maintain homeostasis in the face of increased renal excretion. Mobilization from bone takes place focally and produces lesions in the bones (including the jaws) that are known as brown tumors because of their fairly distinctive coloration on surgical exploration.¹⁰⁸ Clinically and histologically they are identical to the central giant cell granuloma and cannot be distinguished on either clinical or histologic grounds (Figure 31-22). Therefore, whenever a lesion such as this is recurrent, aggressive, or multiple, hyperparathyroidism must be excluded by means of serum calcium, phosphate, and parathormone and parathormone-related protein assays. If these confirm a diagnosis

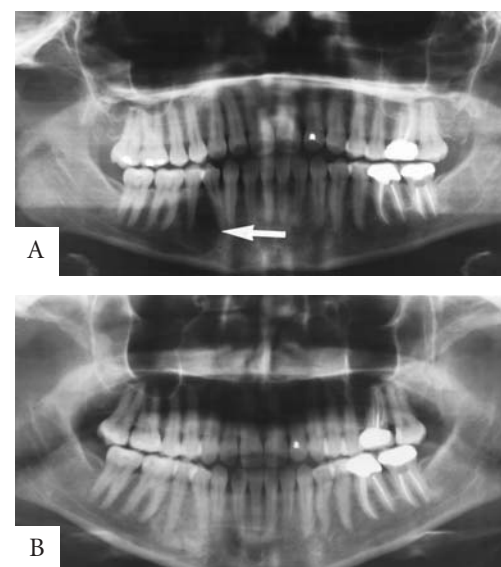


FIGURE 31-20 A, A central giant cell granuloma of the right mandibular bicuspid region causing displacement of the root of the first bicuspid (arrow). B, One year after a course of six intralesional injections of triamcinolone (10 mg/cc). Note that the area is now radiopaque.

of hyperparathyroidism, it should be treated appropriately. The lesions normally resolve without any further treatment being required.

Cherubism

Cherubism is a familial genetically dominant condition first described by Jones in a family in 1933.¹⁰⁹ Affected family members have multiple lesions mainly affecting the facial bones. Because of the involvement of the maxilla and orbital floor, the face has a rounded appearance and the eyes tend to look upward, giving the patient a cherubic appearance (Figure 31-23). The genetic defect in this condition has been identified on chromosome 4p16.3.^{110,111}

Expression is variable, with some patients having subclinical lesions discovered only on radiographs and some having extensive and clinically obvious lesions. Spontaneous mutations also occur. Radiographically the lesions appear honeycombed and can be very extensive. Teeth are often displaced, and in active periods the lesions are extremely vascular (Figures 31-24 and 31-25).

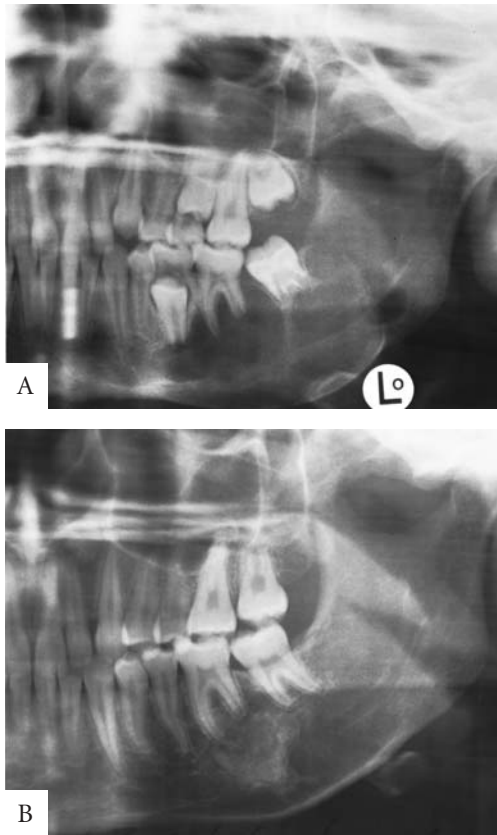


FIGURE 31-21 A, A central giant cell granuloma of the left posterior mandible (same case as Figure 31-19). B, Same case 2 years after an 18-month course of subcutaneous calcitonin injections. Note the continued development of the roots of the second molar, the cessation of resorption of the distal root of the first molar, and the radiopacity replacing radiolucency.

Histologically the lesions are very similar to central giant cell granuloma, with focal accumulations of giant cells in a spindle cell matrix. Perivascular cuffing is often present, and in some cases can be used to differentiate the two lesions.

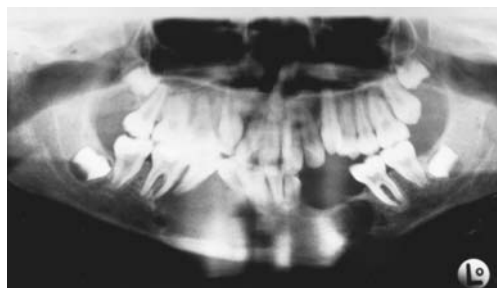

FIGURE 31-22 Hyperparathyroidism showing a recurrent lesion of the left mandible with a pathological fracture and a lesion of the right mandible.

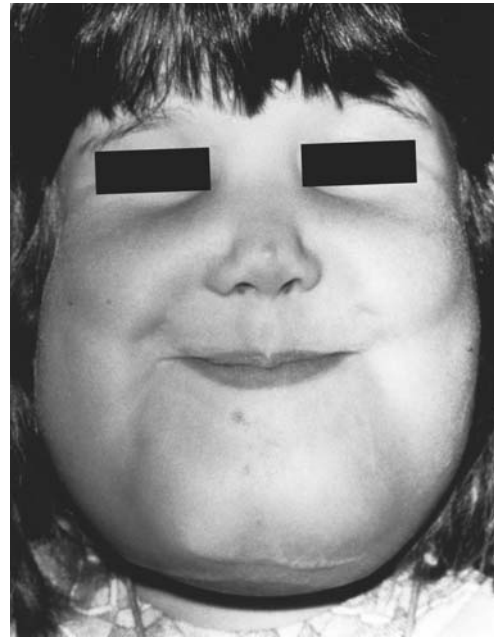

FIGURE 31-23 A 7-year-old female with cherubism affecting the maxillofacial region.

Because of its histologic similarity to central giant cell granuloma, calcitonin has been used in an attempt to cause resolution, but it has not met with success, suggesting that they are, in fact, different lesions.¹¹²

Treatment of cherubism is usually conservative and expectant and into the teenage years is devoted to trying to aid eruption of the teeth, which is often abnormal. Later it is directed toward cosmetic recontouring of the affected bones. The lesions normally become less active and less vascular toward the end of the second decade and into the third decade, and it is at this time that most cosmetic remodeling is carried out.

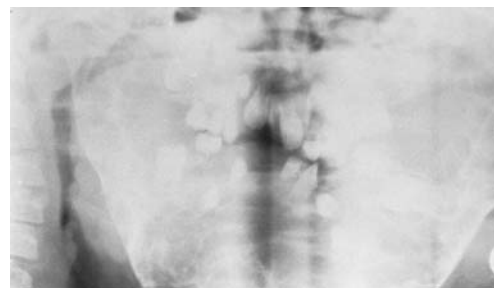

FIGURE 31-24 A panoramic radiograph of the patient shown in Figure 31-23. Note the extensive multilocular radiolucencies.

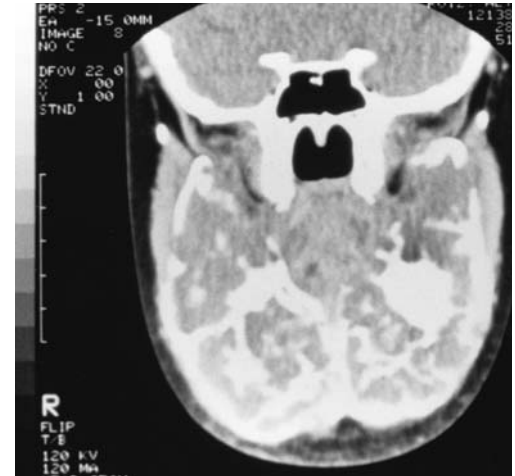


FIGURE 31-25 A coronal computed tomographic scan of the patient in Figure 31-23, showing extensive involvement of the mandible and maxilla by cherubism.

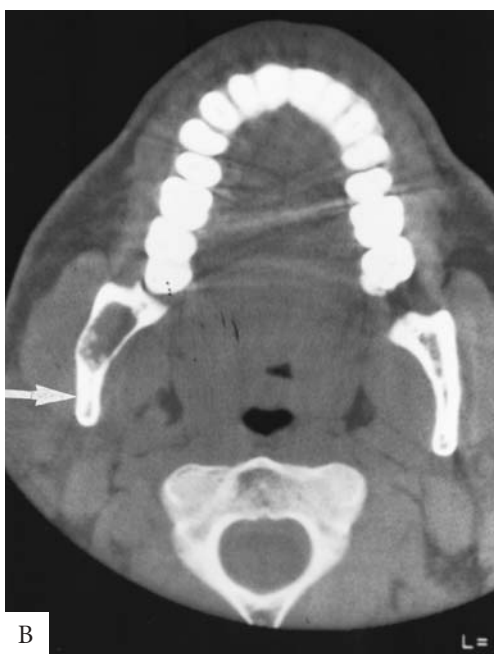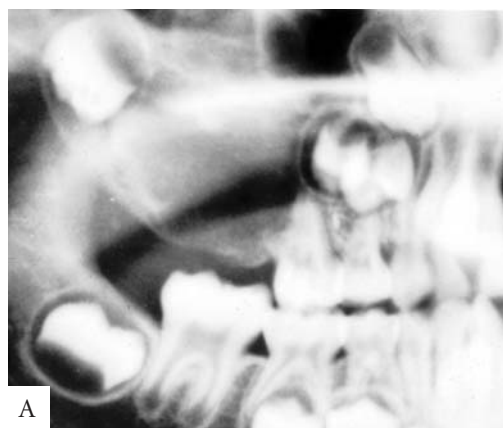Aneurysmal Bone Cyst

Aneurysmal bone cyst is most commonly found in the jawbones and appears to be a combination of a sinusoidal vascular lesion with a giant cell component. Radiographically the lesion appears as a well-circumscribed soap bubble-type lesion (Figure 31-26). Histologically the giant cell component resembles the central giant cell granuloma, whereas the vascular component is thin-walled sinusoids. Some authorities consider this to be a vascular variant of a central giant cell granuloma; others consider it a separate lesion. It responds well to moderately aggressive curettage, although hemorrhage can be a problem. Recurrences are rare.

Vascular Malformations

Vascular malformations can occur anywhere in the body and are felt to be developmental lesions, which can occur in soft tissue or bone. Central vascular malformations of the jaws are a rare but well-documented entity. They are in contrast to the true hemangioma, which is a neoplasm of vascular endothelium and is normally present at birth, often enlarges, and then frequently involutes.¹¹³ The vascular malformation generally is not present at

FIGURE 31-26 A, The “soap bubble” appearance of an aneurysmal bone cyst of the right maxilla. B, An axial computed tomographic scan of an aneurysmal bone cyst of the angle of the right mandible (arrow).



birth, appears later, and does not involute. Vascular malformations can take a number of forms. The most practical classification is to divide them into high-flow and low-flow vascular malformations. The high-flow vascular malformations are either arterial lesions or arteriovenous fistulas. The low-flow malformations are mainly venous in nature. The clinical significance of a vascular malformation is that a central high-flow vascular malformation can cause torrential hemorrhage when surgical intervention ensues. This has been fatal on occasion.¹¹⁴ Many of these lesions are asymptomatic and may even be difficult to detect preoperatively

on radiographs. If there is a clinical presentation, it is often a slow-growing asymmetric expansile lesion of the jaw, and if it is high flow, it may be associated with a bruit. Radiographically a high-flow malformation may appear as an irregular poorly defined soap bubble-type lesion, which may cause resorption of the roots of teeth and does not normally cause nerve involvement (Figure 31-27). Low-flow malformations are similar but are often somewhat better defined and may contain calcifications or phleboliths within them. The presence of phleboliths is

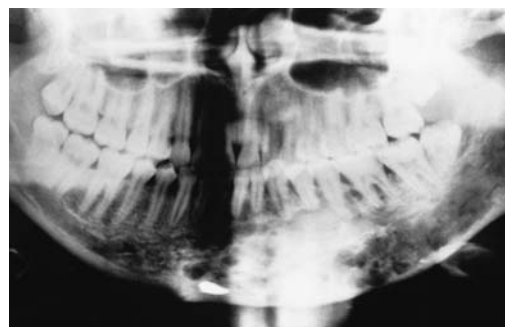


FIGURE 31-27 Radiograph of a high-flow vascular malformation of the left mandible crossing the midline. It appears as an ill-defined “soap bubble” radiolucency causing some root resorption.

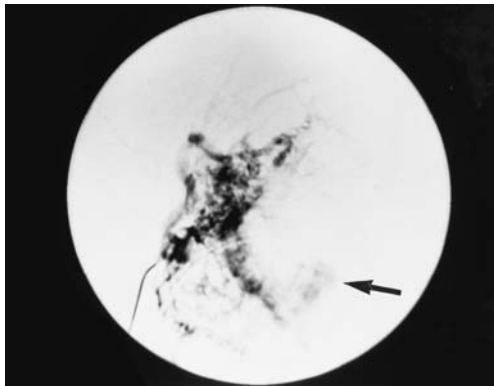


FIGURE 31-28 Subtraction angiogram of a high-flow vascular malformation of the mandible. Oblique lateral view with lower incisors (arrow).

diagnostic of a low-flow malformation. Diagnosis is usually confirmed by computed tomography.

To avoid the possibility of inadvertently carrying out a tooth removal or a biopsy in the presence of a high-flow malformation, a diagnostic needle aspiration should be carried out preoperatively. If bright red blood under pressure is encountered, surgery should be abandoned. Since the radiographic and clinical appearances of a vascular malformation are not diagnostic, the differential diagnosis normally includes a number of odontogenic and nonodontogenic lesions, including the central giant cell granuloma, the aneurysmal bone cyst, ameloblastoma, odontogenic keratocyst, and odontogenic myxoma. All of these lesions should undergo needle aspiration prior to biopsy or surgical treatment to rule out a high-flow vascular malformation. When a vascular malformation is suspected or diagnosed, selective angiography is normally performed via a femoral approach (Figure 31-28). If a high-flow vascular malformation is diagnosed, treatment is normally preoperative embolization followed by wide resective surgery. The embolization can involve a number of materials, including muscle, polyvinyl, pellets, and platinum coils, which are inserted via the angiography catheter or on direct puncture. On entering the lesion they unwind and expand (Figure 31-29).^{115,116} Postembolization angiography carried out immediately after the embolization normally shows a diminution in blood flow to the lesion. However, because of the powerful angiogenic effect of these lesions (probably by production of angiogenesis growth factor), reestablishment of smaller collateral vessels usually occurs within a few days, and it is often impossible to reembo- lize these smaller collateral vessels. Therefore, definitive surgery should be carried out within a small number of days of embolization. Definitive surgery normally takes the form of resection under

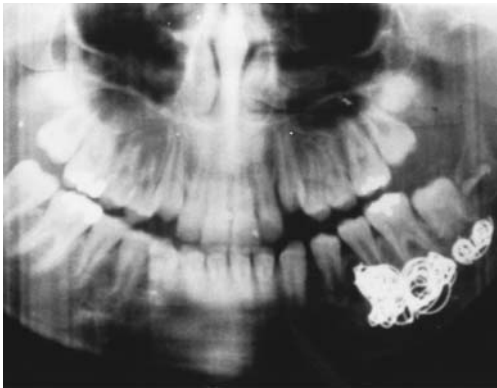


FIGURE 31-29 A high-flow vascular malformation embolized with a platinum coil.

hypotensive anesthesia with adequate resuscitative measures available.¹¹⁷⁻¹¹⁹ Following resection appropriate reconstruction can be performed. This can include the re-insertion of the resected portion of bone after curettage, thinning, perforation, and simultaneous bone grafting (Figure 31-30). Other approaches such as injection of a variety of substances into the lesion including glue, fibrin gel, and platinum coils,¹¹⁵ for example, have been attempted; also, case reports exist of lesions being treated by means of local curettage following embolization, but this is not normally recommended.

Low-flow or venous malformations are not as life-threatening and are normally treated with direct puncture and an attempt to thrombose the lesion by

intralesional injection of a variety of agents, including sclerosing agents, an absorbable gelatin sponge, and platinum coils. This may bring about thrombosis, allowing the necessary dental or surgical treatment to be carried out. Often mandibular resection is not necessary but, rather, a local surgical procedure.

Langerhans Cell Histiocytosis

Langerhans cell histiocytosis is the term currently employed for what was previously known as histiocytosis X, and before that the three separate conditions Letterer-Siwe disease, Hand-Schüller-Christian disease, and eosinophilic granuloma. Lichtenstein first suggested that the three diseases were related and that the common factor was the presence of histiocytes.¹²⁰ The cells of origin of this disease have now been identified as the Langerhans cells, which are dendritic cells in the skin and mucosa that have a macrophage-like function. At the present time what causes these cells to proliferate in a clonal fashion with phenotypic evidence of activation and give rise to Langerhans cell disease is unknown.¹²¹ The nature of this disease also eludes us. Some recent studies have suggested that it may have some of the properties of a tumor or have a viral etiology.^{122,123} Other studies propose that it may be a response to an overwhelming allergenic challenge, and they report cases of

eosinophilic granuloma that have resolved spontaneously, further adding to the puzzle.^{121,124} The Histiocyte Society has attempted to define all of the histiocytic diseases in a logical manner,¹²⁵ and Letterer-Siwe disease is now felt to represent the acute disseminated form of Langerhans cell histiocytosis, whereas Hand-Schüller-Christian disease represents the chronic disseminated form, and eosinophilic granuloma represents the chronic localized form.

The acute disseminated form usually affects young children. It is multisystem in nature, affecting the skin, bones, and internal organs (especially lungs and liver), and is frequently fatal. Treatment is chemotherapy.

The chronic disseminated form of the disease is classically associated with a triad of punched-out bone lesions (often affecting the skull and jaws), diabetes insipidus (owing to posterior pituitary involvement), and exophthalmos (owing to deposits in the posterior orbit). This normally affects an older age group, often in the second and third decades but sometimes much older. The bone lesions often affect the jaws. Although they usually appear as fairly well-defined punched-out radiolucencies (Figure 31-31), they can also be less well defined and can affect the apices of the teeth only and lead to a possible differential diagnosis of periapical infection. A frequent aspect of presentation is loose teeth; radiographically they often appear as “floating teeth” (Figure 31-32). The treatment of the chronic disseminated form of the disease is variable, and for well-circumscribed lesions can consist of local curettage. However, for more aggressive forms, chemotherapy is frequently employed as well. Low-dose radiation therapy has also been used on isolated lesions, and it does remain one of the very few indications for low-dose radiation therapy, often in the region of a few hundred centigray.

The chronic localized form of the disease is commonly found in the jaws and usually shows as a well-defined radiolu-

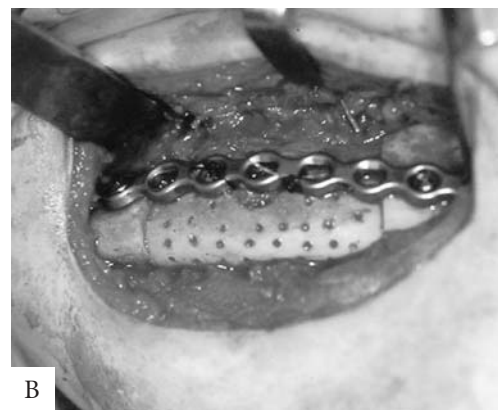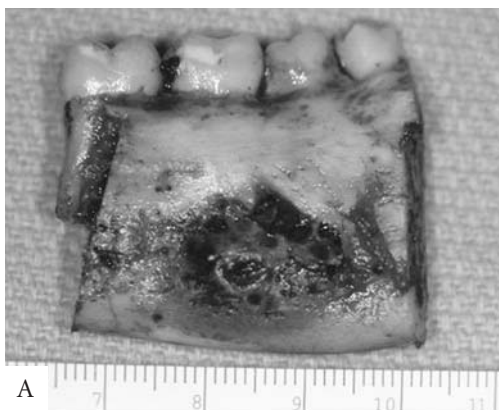


FIGURE 31-30 A, Resected mandible containing a high-flow vascular malformation that had been embolized previously. B, The same resected specimen reduced to a hollow perforated tray, filled with autogenous iliac crest cancellous bone, and replaced for an immediate reconstruction. (Photographs courtesy of J.S. Lee, DDS, MD.)

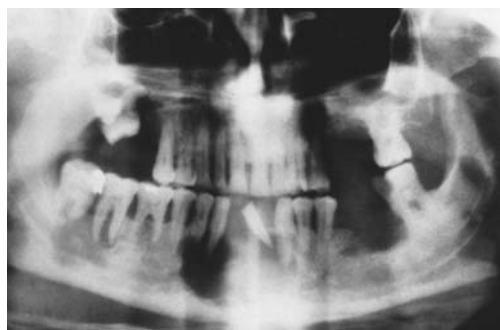


FIGURE 31-31 The multiple irregular radiolucent lesions of chronic disseminated Langerhans cell histiocytosis in a 53-year-old male whose son died of the acute form of the disease at age 11 years.

ency, often in the bicuspid region and more frequently in the mandible. Differential diagnosis in this case includes any fairly well-defined radiolucency. Treatment usually consists of aggressive local curettage, and the recurrence rate is low. Teeth are sacrificed as necessary. Intralesional steroids have also been employed with some success, and cases of spontaneous regression have been reported.^{124,126}

It is generally felt that the occurrence of Langerhans cell histiocytosis is sporadic, but clusters have been noted and there are a number of reports of a familial incidence.¹²¹ I have seen the disease in a father and son. The father was diagnosed with the chronic disseminated form of the disease at age 53 years (see Figure 31-31), whereas his son died from the acute disseminated form of the disease at age 11 years.

Nonodontogenic Cysts of the Jaws

In this section the following are discussed: globulomaxillary lesion, nasolabial lesion, median mandibular cyst, nasopalatine duct cyst, all of which are also known as fissural cysts, traumatic bone cyst, and Stafne's bone cyst. Aneurysmal bone cyst has been discussed under "Lesions Containing Giant Cells," above.

Globulomaxillary Lesion

Globulomaxillary lesion was initially defined as a globulomaxillary cyst and was felt to be

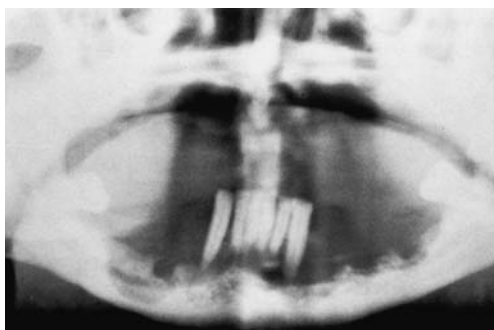


FIGURE 31-32 The "floating teeth" of Langerhans cell histiocytosis.

a fissural cyst caused by retained epithelial remnants at the fusion of the maxillary process with the globular process. It is normally found in the second or third decade. In the classic description, the lesion presents as a pear-shaped well-defined radiolucency in the maxilla between the lateral incisor and canine. Associated teeth are classically vital, and the lesion is lined by cystic epithelium with occasional globular or ciliated epithelia.

Current thinking is that although this lesion does exist as a radiographic and clinical entity (Figure 31-33), it is not, in fact, a fissural cyst since the proposed embryonic derivation is now known to be flawed and the supposed fusion line does not exist. It is felt that most lesions previously diagnosed as globulomaxillary cysts can now be reclassified as odontogenic keratocysts, radicular cysts, periapical granulomas, lateral periodontal cysts, central giant cell granulomas, calcifying odontogenic cysts, and odontogenic myxomas.⁴⁵

Tooth roots may be diverged by the lesion, and biopsy is usually necessary to confirm the diagnosis and enable appropriate surgical treatment to be carried out. Treatment normally consists of enucleation and curettage.

Nasolabial Cysts

The nasolabial cyst was felt to be the soft tissue counterpart of the globulomaxillary cyst. Again, it was felt to be formed at the lines of fusion of the globulomaxillary processes. Similarly, this lesion does exist,

but its true origin remains in doubt. It could be derived from remnants that form the nasolacrimal duct. This cyst manifests itself as a soft tissue swelling in the lateral aspect of the upper lip, fairly high in the sulcus (Figure 31-34). The cyst lining is typically a pseudostratified columnar type with numerous goblet cells. Treatment is local excision.

Median Mandibular Cyst

Median mandibular cyst is a rare cyst found in the midline of the mandible. It was originally felt to form at the line of fusion of each half of the mandibular arch. Again, the embryologic theory behind this lesion is no longer felt to be applicable, and it is believed that those lesions found in the anterior mandible represent some other type of odontogenic cyst or tumor.

Nasopalatine Duct Cyst

Nasopalatine duct cyst is also known as incisive canal cyst and is generally located on the palatal end of the nasopalatine duct. It frequently presents as a soft swelling behind the upper anterior teeth. It is felt to be derived from the epithelial remnants of the paired embryonic nasopalatine ducts within the incisive canal, and that either infection or trauma may be the stimulus for the cells to proliferate and form a cyst. These cysts appear to occur more frequently in males than in females and are commonest in the fourth to sixth decades of life. Most cases are asymptomatic and are either found by chance on radiograph or present as a soft tissue swelling in the palate. Radiographically this cyst appears as a well-defined radiolucency found in the midline of the anterior palate (Figure 31-35). In many patients the nasopalatine duct can be identified on an occlusal radiograph; the question then arises as to when the diagnosis of nasopalatine duct cyst should be entertained. A fairly arbitrary cutoff point of 7 mm has been suggested—if the nasopalatine duct appears to be > 7 mm in diameter, the presence of a cyst should be suspected.¹²⁷

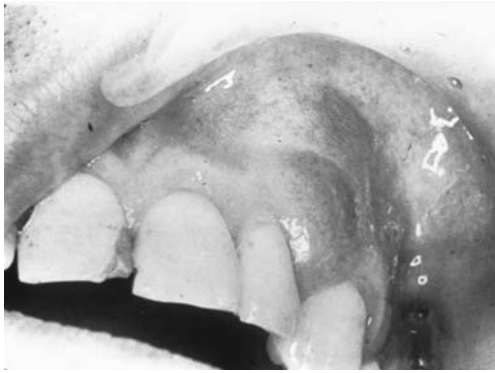

FIGURE 31-33 A globulomaxillary cyst appearing as a pear-shaped swelling between the lateral incisor and canine tooth.

Diagnosis is by biopsy, which normally shows a pseudostratified columnar epithelium lining. Treatment, if required, is surgical and consists of local curettage. This almost inevitably requires the sacrifice of the nasopalatine vessels and nerves, which results in a small area of anesthesia over the anterior palate behind the upper incisor teeth. Some patients (particularly more elderly patients) find this particularly troublesome in the articulation of some words. Recurrence rate is very low following treatment.

Traumatic Bone Cyst

Traumatic bone cyst has been called a number of names, including idiopathic bone cyst, simple bone cyst, and latent bone cyst. It is almost always asymptomatic and a chance finding on radi-

ographs. It occurs most commonly in the mandible, particularly in the posterior mandible. It classically appears on a radiograph as a fairly well-defined radiolucency, which usually has a scalloped margin beneath the tooth roots (Figure 31-36). It is not quite as well defined as an odontogenic cyst, and the description made by Howe was that it appears as a “pencil sketch for a final pen and ink drawing.”¹²⁸

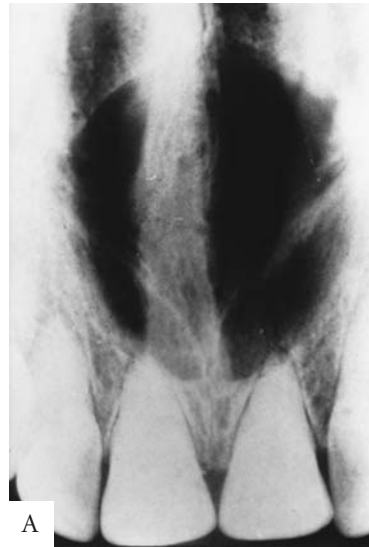
The etiology of this lesion is in doubt, and suggestions have included that it may result from intramedullary hemorrhage from trauma, which can be quite mild. Instead of organization and new bone formation occurring, for some reason the

blood clot liquefies and is then resorbed, leaving an empty space. On surgical exploration these lesions are normally found to have either no lining whatsoever or just a very thin filmy lining. They are normally empty except, possibly, for a little straw-colored fluid in the base of the lesion, which could represent the last remnants of an absorbing blood clot. Studies have shown that the gaseous contents of the lesion are mainly nitrogen, and this is presumably because they contain air and the oxygen is absorbed preferentially into the blood stream.¹²⁹

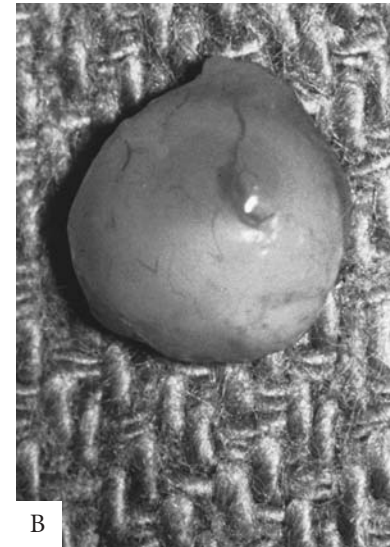
Although these lesions have been shown to regress spontaneously, a biopsy is almost always performed to determine a diagnosis. The biopsy is normally curative since anything that causes bleeding into the lesion causes resolution. Suggested treatments have included everything from no treatment whatsoever to curettage or injection of autologous blood or packing with an absorbable gelatin sponge.¹³⁰ Recurrences are extremely rare but have been reported, as have bilateral cases.¹³⁰

Stafne’s Bone Defect

Stafne’s bone defect is also known as static bone cyst; it is always asymptomatic and found by chance on a radiograph. It

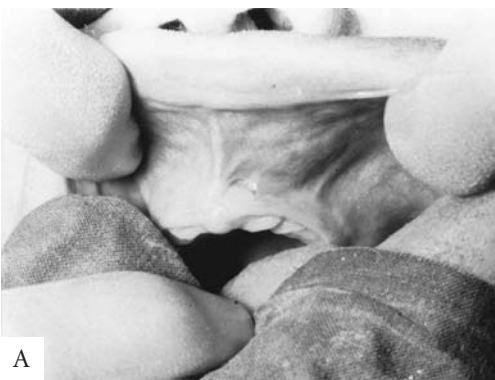

A

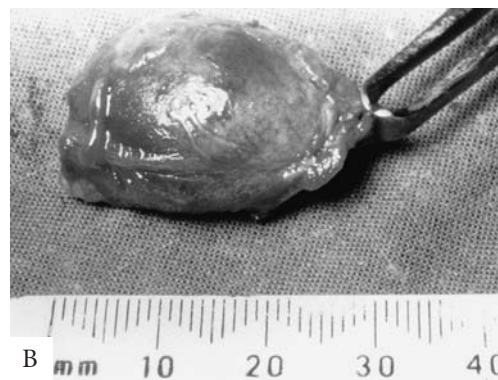

B

FIGURE 31-35 A, Palatine duct cyst appearing as a well-defined midline radiolucency. B, The same cyst enucleated.



A



B

FIGURE 31-34 A, A nasolabial cyst causing a swelling in the buccal sulcus in the lateral incisor area. B, The enucleated cyst, which was confined to the soft tissues with no bony extension. Histology showed squamous epithelium with goblet cells.

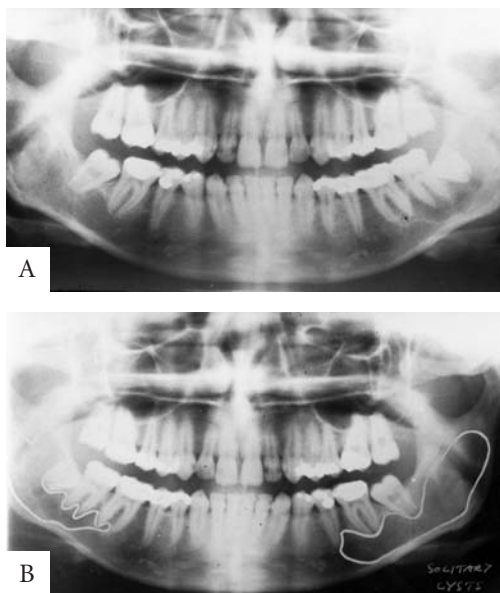


FIGURE 31-36 A, Bilateral poorly defined traumatic bone cysts. (Bilateral cysts are unusual.) B, Same radiograph shown in Figure A with cysts outlined, showing the size and scalloped margins around teeth.

presents as a well-defined radiolucency on the lower border of the mandible, below the inferior alveolar nerve (Figure 31-37). The appearance is so diagnostic that biopsy is often not required. When this defect is explored surgically, one normally finds that it is not a totally intrabony lesion but, in fact, an indentation of the mandible on the lingual side (Figure 31-38). The indentation is normally filled with an offshoot of the submandibular salivary gland. This can be confirmed by sialography, which

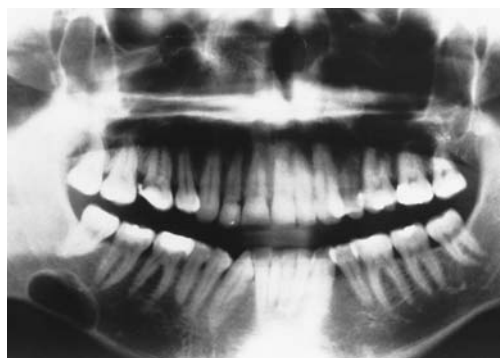

FIGURE 31-37 Appearance of a Stafne's bone defect on panoramic radiograph below the inferior alveolar nerve on the right body of the mandible.

shows filling of the defects with the radiopaque media. Cases have also been seen that include lymphoid tissue in the cavity. It is felt that these may represent developmental lesions, although they may not present until adult life. Such lesions may represent the entrapment of the salivary gland or lymphoid tissue during development of the mandible or the subsequent erosion of the lingual plate of the mandible by the tissue. Treatment is unnecessary, but enucleation is often performed as a process of diagnosis.¹³¹

Neurogenic Tumors

Schwannoma

The schwannoma is a benign tumor of the neurilemma or nerve sheath. Although usually found in the soft tissues, it can occur in bone, where it usually exists as a well-defined radiolucency. Following biopsy to confirm the diagnosis, treatment usually consists of surgical excision. Recurrences are rare. Histologically lesions are well encapsulated and predominantly of spindle cells showing either an Antoni A (spindle cells arranged in palisaded whorls and waves) or Antoni B (spindle cells with a more haphazard appearance).

Neurofibroma

Neurofibromas are felt to be derived from the fibrous elements of the neural sheath and may exist as solitary lesions or as part of generalized neurofibromatosis or von Recklinghausen's disease. This latter condition is autosomal dominant, and two distinct subsets have been defined associated with the *NF1* and *NF2* genes.

Although most commonly reported in soft tissues, neurofibromas do occur in bone and have been reported on the inferior alveolar nerve, where they appear as a fusiform swelling in continuity with the inferior alveolar canal (Figure 31-39). Other bone changes associated with neurofibromatosis can include cortical erosion from adjacent soft tissue lesions or medullary resorption

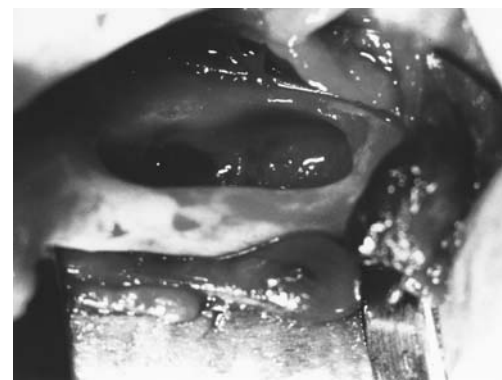


FIGURE 31-38 Clinical photograph of a Stafne's bone defect on the lingual side of the mandible. This defect contained lymphoid tissue.

from interosseous lesions. In cases associated with the inferior alveolar nerve, pain or paresthesia can result.

The normally recommended treatment following biopsy is localized excision. The lesions are often vascular, and extensive blood loss has been reported from surgical management of mandibular lesions. Mandibular resection has been advocated by some authorities. The malignant transformation rate to neurogenic sarcoma of

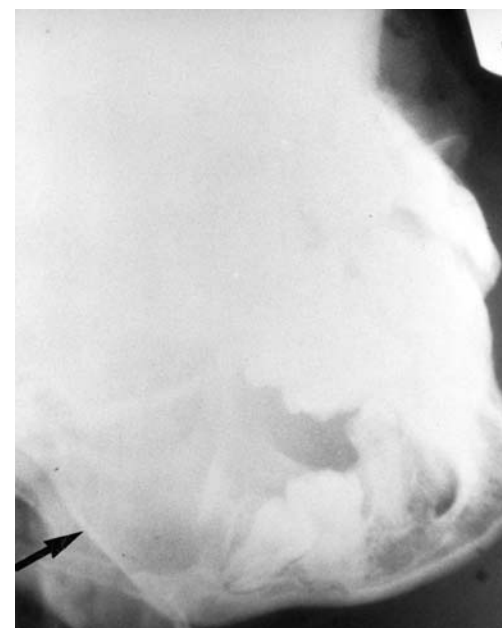

FIGURE 31-39 A neurofibroma on the left inferior alveolar nerve presenting as a large fairly well-defined radiolucency in the mandibular ramus (arrow). The patient also had café-au-lait spots.

5 to 15% in the generalized form of the disease could be a further indication for surgical removal of these lesions.

Traumatic Neuroma

Traumatic neuroma represents a misguided attempt at nerve regeneration whereby following an injury to a nerve, neurons sprout from the site of injury but for anatomic or physiologic reasons cannot result in a functional nerve repair. If a nerve is sectioned, an amputation neuroma can develop on the stump; if a nerve is injured along its length, either an discontinuity or lateral neuroma can result (Figure 31-40). In the oral cavity these latter neuromas are most often noted on the lingual and inferior alveolar nerves. On the inferior alveolar nerve they can occur as a fusiform enlargement of the inferior alveolar canal and result most commonly following mandibular trauma, resection of pathologic lesions, and nerve involvement following dentoalveolar surgery (Figure 31-41).

If the symptoms are severe, appropriate treatment is resection of the neuroma and appropriate nerve reconstruction. Since the inferior alveolar nerve cannot be stretched significantly in the canal, repair normally involves a graft of some kind. Nerve grafts from the sural nerve or great auricular nerve have been reported, as have vein

grafts, with some success.¹³² The approach can be either intraoral or extraoral, but the extraoral approach generally gives better access and clinical results. However, it does have a higher morbidity, with possible risks of scarring and of damage to the mandibular branch of the facial nerve.

Paget's Disease

First described by Sir James Paget in 1876,¹³³ this entity still carries his name. Its alternative name is osteitis deformans. It is a slowly progressive bone condition of unknown etiology, predominantly affecting males over the age of 50 years. One unproven theory is that Paget's disease may be a delayed or slow reaction to a myxovirus stimulus.

Clinically there is hyperactive bone turnover with alternate resorption of bone, a vascular phase, and finally a sclerosing phase. Most bones of the body are involved, and the disease can result in considerable deformity. In the facial region the maxilla is affected more often than the mandible. Family histories have been obtained in this disease, and the genetic basis of the condition is being defined.

The classic presentation used to be a patient whose hat or gloves no longer fitted correctly, or in whom false teeth, particularly the maxillary denture, did not fit owing to bone swelling. Today these presentations are much fewer since well-fitting hats, gloves, and dentures are less commonly encountered. Initial presentation is usually related to bone deformity or pain. In the head and neck, headaches and symptoms owing to vascular and nerve compression have been noted.

The classic radiographic appearance is of a "cotton-wool" appearance in the skull and maxilla of affected patients (Figure 31-42), with hypercementosis around the roots of teeth, and loss of lamina dura and obliteration of the periodontal ligament space. This does make tooth extraction extremely difficult in these patients. Root resorption has also been noted.

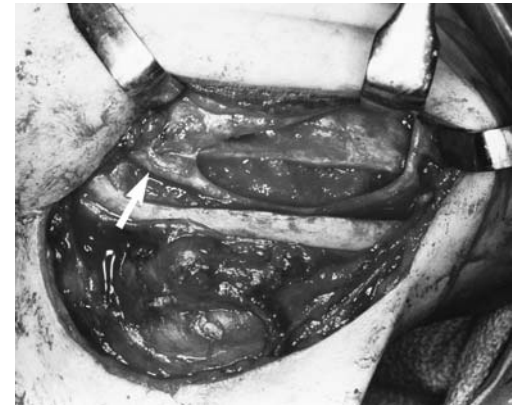


FIGURE 31-41 An discontinuity neuroma on the inferior alveolar nerve (arrow) as a result of the removal of a third molar. The nerve is exposed via an extraoral approach and lateral corticotomy.

The histopathology shows the typical reversal lines of alternate resorption and bone deposition (Figure 31-43). Classically, patients have markedly elevated serum alkaline phosphatase levels.

Treatment is both systemic and local. Systemic treatment currently consists of




FIGURE 31-40 An excised lateral neuroma that was on the lingual nerve.

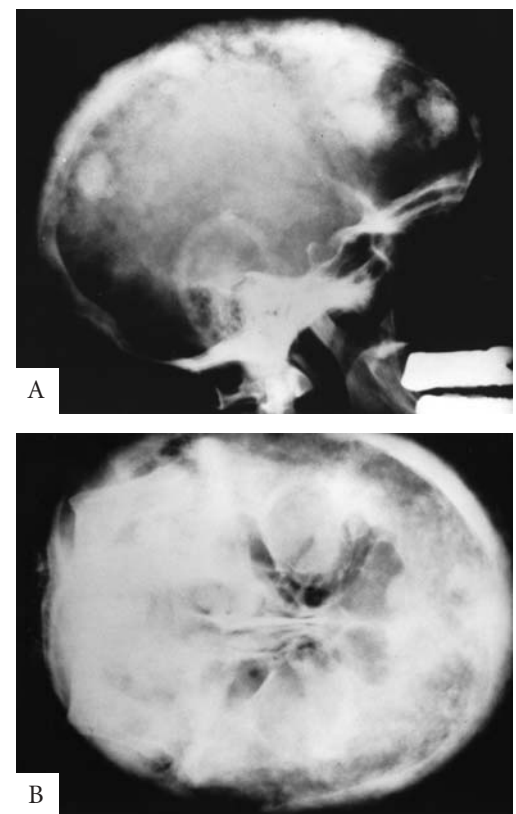


FIGURE 31-42 A, Lateral and B, frontal radiographs of a patient with Paget's disease showing typical "cotton wool" appearance.

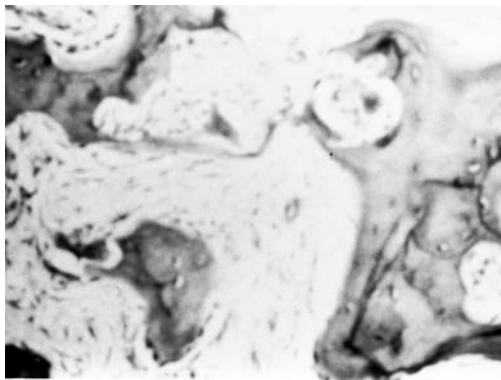


FIGURE 31-43 Histology of Paget's disease showing reversal lines of new bone deposition and resorption ($\times 40$ original magnification; stained with hematoxylin and eosin).

the use of salmon calcitonin or diphosphonates to inhibit bone resorption. Calcitonin can be taken either subcutaneously or by nasal spray, and diphosphonates are taken orally or by injection. Treatment causes stabilization of the bone and a lowering of the raised alkaline phosphatase levels. Localized treatment is directed to cosmetic and/or functional recontouring of bone. It should be noted that the bone of Paget's disease is often vascular, and bleeding during recontouring can be extensive. Somewhat paradoxically, however, healing is often delayed owing to the intervening sclerotic areas of bone.

The classic causes of death in patients with Paget's disease are heart failure and osteosarcoma. Heart failure caused by the excessive blood supply to the remodeling bone can cause high output or left heart failure in elderly persons. Sarcomatous change has been reported in 5 to 15% of patients with Paget's disease, which should be considered a premalignant condition.¹³⁴

Gorham's Disease

Although first described in 1838,¹³⁵ this disease was named after Gorham, who reviewed the literature and added three new cases in 1954.¹³⁶ Its alternative name is massive osteolysis. Gorham's disease is a rare disease of unknown etiology, usually occurring in the second to third decades of life, although it has been reported in all age

groups. There is no sex or racial predilection, although an autosomal dominant inheritance pattern has been suggested. The diagnosis is usually one of exclusion. Any bone can be affected, and there is usually massive osteolysis, which is generally asymptomatic until a pathologic fracture occurs (Figures 31-44 and 31-45). The bone is usually replaced with fibrous tissue. The majority of cases are monostotic, but polyostotic cases have been reported.¹³⁵ There is no specific treatment for this disease; however, radiation therapy and surgical resection have been beneficial in selected cases. Serum biochemistry is usually normal, and isotope bone scans do not show excessive activity. Osteoclasts are not a prominent feature of the condition. The long-term prognosis is uncertain, but some long-term remissions have been reported.¹³⁵

Tori

Torus Palatinus

The palatine torus appears as a bony hard swelling along the midline of the palate. It can be discrete or may be large and lobular (Figure 31-46). It usually occurs in the second or third decade of life, and has a tendency to grow throughout life. It is tempting to feel that these lesions may be embryologic in their development and form at the line of fusion of the two palatal plates, but this is probably incorrect and the true nature of these lesions remains unknown. Larger versions may require surgical removal because of their interference either with speech or feeding or with prosthodontic reconstruction. The common surgical approach is via a double Y-shaped incision (Figure 31-47) and subsequent bone removal. The bone is virtually always solid cortical bone and is actually fairly difficult to remove. The recommended technique is to make a number of vertical cuts in the bone with a fissure bur (Figure 31-48). Then the intervening ridges of bone can be snapped off and a final smoothing of the residual bone car-

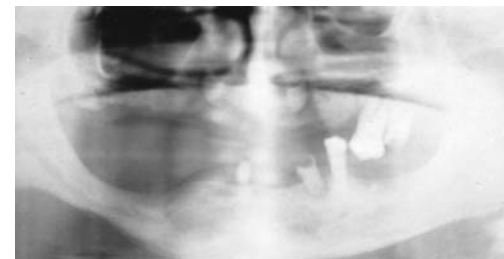


FIGURE 31-44 Early case of Gorham's syndrome with a partial loss of the right body of the mandible.

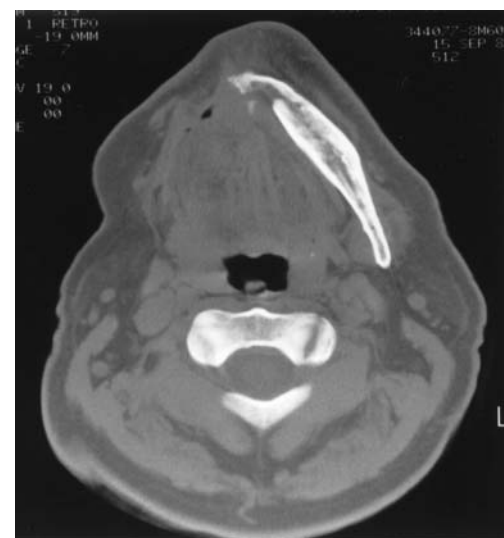

FIGURE 31-45 Axial computed tomographic scan of patient in Figure 31-44 2 years later; note the complete loss of the right mandible.

ried out, taking care not to perforate through into the nasal cavity (Figure 31-49). It may be advisable to insert a dressing plate after the procedure to prevent excessive hematoma formation and possible recurrence of the torus (Figure 31-50).

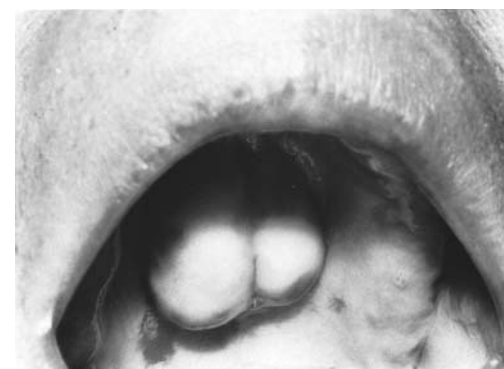

FIGURE 31-46 Large bilateral torus palatinus.

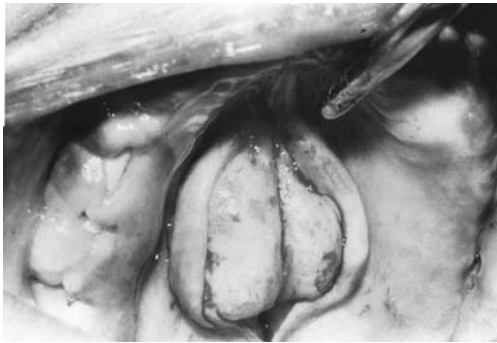

FIGURE 31-47 *Torus palatinus in Figure 31-46 exposed via a double Y-shaped incision.*

Torus Mandibularis

Mandibular tori are bony exophytic growths that present on the lingual aspect of the mandible opposite the bicuspids (Figure 31-51). They are virtually always

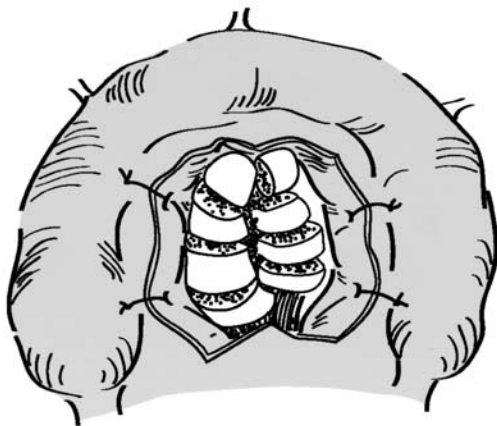


FIGURE 31-48 *Diagram of the method of reducing a large torus palatinus with a number of parallel grooves.*

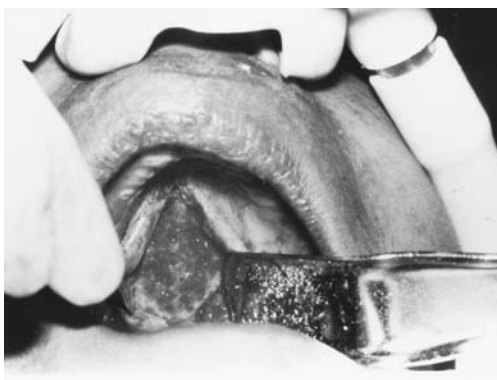


FIGURE 31-49 *Torus palatinus in Figures 31-46 and 31-48 removed with the technique described in the text.*

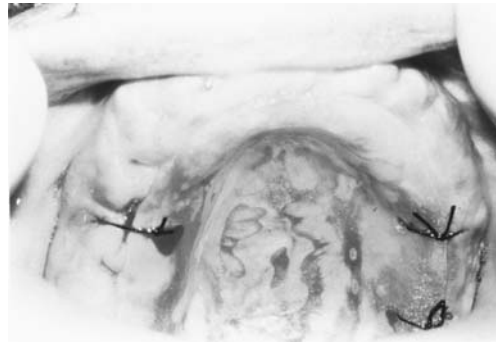


FIGURE 31-50 *Dressing plate sutured in place over the wound.*

bilateral. Again, they present in early midlife and tend to grow with age. Larger versions may require removal because they interfere with tongue positioning, speech, and prosthodontic reconstruction, as well as with oral hygiene around the lower posterior teeth. The etiology of these lesions is in doubt; again, it is tempting to think of them as being embryologic lesions formed at the junction of the original Meckel's cartilage and the neomandible, but this is almost certainly not correct.

If surgical removal is required, it is carried out via an extensive gingival margin incision with a possible lingual-releasing incision, followed by removal of the bone. This is carried out by making a number of vertical cuts with a fissure bur, as with the maxillary torus, and then snapping off the intervening ridges of bone with a periosteal elevator. The residual irregularities are then smoothed with a larger bur. Occasionally mandibular tori

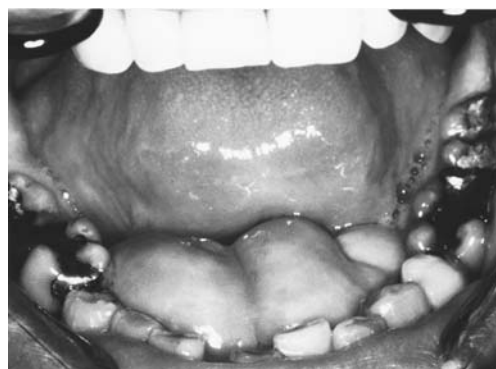

FIGURE 31-51 *Large bilateral torus mandibularis.*

are on a fairly narrow neck and can be removed in toto with a well-directioned blow from a mallet and chisel.

Recurrence of tori is rare, and it has often been noted that palatal and mandibular tori rarely occur in the same patients.

References

1. Brannon RB, Fowler CB. Benign fibro-osseous lesions: a review of current concepts. *Adv Anat Pathol* 2001;8:126–43.
2. Eversole LR. Craniofacial fibrous dysplasia and ossifying fibrous. *Oral Maxillofac Surg Clin North Am* 1997;9:625–42.
3. Song HD, Chen FL, Shi WJ, et al. A novel, complex heterozygous mutation within Gsalpha gene in patient with McCune-Albright syndrome. *Endocrine* 2002;18:121–8.
4. Pollandt K, Engels C, Kaiser E, et al. Gsalpha gene mutations in monostotic fibrous dysplasia of bone and fibrous dysplasia-like low-grade central osteosarcoma. *Virchows Arch* 2001;439:170–5.
5. Bolger WE, Ross AT. McCune-Albright syndrome: a case report and review of the literature. *Int J Pediatr Otorhinolaryngol* 2002;65:69–74.
6. Lee JS, FitzGibbon E, Butman JA, et al. Normal vision despite narrowing of the optic canal in fibrous dysplasia. *N Engl J Med* 2002;347:1670–6.
7. Sueti Y, Tanimoto K. Diffuse sclerosing osteomyelitis and florid osseous dysplasia. *Oral Surg Oral Med Oral Pathol Oral Radiol Endod* 1996;82:360–1.
8. Groot RH, van Merkesteyn JP, Bras J. Diffuse sclerosing osteomyelitis and florid osseous dysplasia. *Oral Surg Oral Med Oral Pathol Oral Radiol Endod* 1996;81:333–42.
9. Kozlowski K, Barrett I. Polyostotic fibrous dysplasia and chronic osteomyelitis in a 12-year-old boy. Diagnostic difficulties in double bone pathology. *Radiol Med (Torino)* 1987;73:151–3.
10. von Wowern N, Hjørtting-Hansen E, Edeling CJ. Bone scintigraphy of benign jaw lesions. *Int J Oral Surg* 1978;7:528–33.
11. Johannsen A. Chronic sclerosing osteomyelitis of the mandible. Radiographic differential diagnosis from fibrous dysplasia. *Acta Radiol Diagn (Stockh)* 1977;18:360–8.
12. Hunter AG, Jarvis J. Osteofibrous dysplasia: two affected male sibs and an unrelated girl with bilateral involvement. *Am J Med Genet* 2002;112:79–85.
13. Obuobie K, Mullik V, Jones C, et al. McCune-

- Albright syndrome: growth hormone dynamics in pregnancy. *J Clin Endocrinol Metab* 2001;86:2456–8.
14. Daly BD, Chow CC, Cockram CS. Unusual manifestations of craniofacial fibrous dysplasia: clinical, endocrinological and computed tomographic features. *Postgrad Med J* 1994;70:10–6.
 15. Gross CW, Montgomery WW. Fibrous dysplasia and malignant degeneration. *Arch Otolaryngol* 1967;85:653–7.
 16. Chetty R, Kalan MR, Kranold DH. Malignant transformation in fibrous dysplasia. A report of 3 cases. *S Afr J Surg* 1990;28:80–2.
 17. Tanner H, Dahlin, DC, Childs, DS. Sarcoma complicating fibrous dysplasia. Probable role of radiation therapy. *Oral Surg Oral Med Oral Pathol* 1961;14:837–46.
 18. Mock D, Rosen IB. Osteosarcoma in irradiated fibrous dysplasia. *J Oral Pathol* 1986;15:1–4.
 19. Slow IN, Friedman EW. Osteogenic sarcoma arising in a preexisting fibrous dysplasia: report of case. *J Oral Surg* 1971;29:126–9.
 20. Koury ME, Regezi JA, Perrott DH, Kaban LB. “Atypical” fibro-osseous lesions: diagnostic challenges and treatment concepts. *Int J Oral Maxillofac Surg* 1995;24:162–9.
 21. Chen YR, Noordhoff MS. Treatment of craniofacial fibrous dysplasia: how early and how extensive? *Plast Reconstr Surg* 1990;86:835–44.
 22. Waldron CA. Fibro-osseous lesions of the jaws. *J Oral Maxillofac Surg* 1993;51:828–35.
 23. Melrose RJ, Abrams AM, Mills BG. Florid osseous dysplasia. A clinical-pathologic study of thirty-four cases. *Oral Surg Oral Med Oral Pathol* 1976; 41:62–82.
 24. Neville BW, Albenesius RJ. The prevalence of benign fibro-osseous lesions of periodontal ligament origin in black women: a radiographic survey. *Oral Surg Oral Med Oral Pathol* 1986;62:340–4.
 25. Summerlin DJ, Tomich CE. Focal cemento-osseous dysplasia: a clinicopathologic study of 221 cases. *Oral Surg Oral Med Oral Pathol* 1994;78:611–20.
 26. Ariji Y, Ariji E, Higuchi Y, et al. Florid cemento-osseous dysplasia. Radiographic study with special emphasis on computed tomography. *Oral Surg Oral Med Oral Pathol* 1994;78:391–6.
 27. Slater L. Fibro-osseous lesions. *Oral Maxillofac Knowledge Update* 1995;1:33–47.
 28. Schneider LC, Mesa ML. Differences between florid osseous dysplasia and chronic diffuse sclerosing osteomyelitis. *Oral Surg Oral Med Oral Pathol* 1990;70:308–12.
 29. Marx RE, Carlson ER, Smith BR, Toraya N. Isolation of *Actinomyces* species and *Eikenella corrodens* from patients with chronic diffuse sclerosing osteomyelitis. *J Oral Maxillofac Surg* 1994;52:26–34.
 30. Jacobsson S, Dahlen G, Moller AJ. Bacteriologic and serologic investigation in diffuse sclerosing osteomyelitis (DSO) of the mandible. *Oral Surg Oral Med Oral Pathol* 1982;54:506–12.
 31. Young SK, Markowitz NR, Sullivan S, et al. Familial gigantiform cementoma: classification and presentation of a large pedigree. *Oral Surg Oral Med Oral Pathol* 1989;68:740–7.
 32. Gollin SM, Storto PD, Malone PS, et al. Cytogenetic abnormalities in an ossifying fibroma from a patient with bilateral retinoblastoma. *Genes Chromosomes Cancer* 1992;4:146–52.
 33. Dal Cin P, Sciort R, Fossion E, et al. Chromosome abnormalities in cementifying fibroma. *Cancer Genet Cytogenet* 1993;71:170–2.
 34. Sissons HA, Steiner GC, Dorfman HD. Calcified spherules in fibro-osseous lesions of bone. *Arch Pathol Lab Med* 1993;117:284–90.
 35. Sissons HA, Kancherla PL, Lehman WB. Ossifying fibroma of bone. Report of two cases. *Bull Hosp Jt Dis* 1983;43:1–14.
 36. Povysil C, Matejovsky Z. Fibro-osseous lesion with calcified spherules (cementifying fibromalike lesion) of the tibia. *Ultrastruct Pathol* 1993;17:25–34.
 37. Hamner JE III, Scofield HH, Cornyn J. Benign fibro-osseous jaw lesions of periodontal membrane origin. An analysis of 249 cases. *Cancer* 1968;22:861–78.
 38. Waldron CA, Giansanti JS. Benign fibro-osseous lesions of the jaws: a clinical-radiologic-histologic review of sixty-five cases. II. Benign fibro-osseous lesions of periodontal ligament origin. *Oral Surg Oral Med Oral Pathol* 1973;35:340–50.
 39. Dehner LP. Tumors of the mandible and maxilla in children. I. Clinicopathologic study of 46 histologically benign lesions. *Cancer* 1973;31:364–84.
 40. Eversole LR, Leider AS, Nelson K. Ossifying fibroma: a clinicopathologic study of sixty-four cases. *Oral Surg Oral Med Oral Pathol* 1985;60:505–11.
 41. Said-al-Naief NA, Surwillo E. Florid osseous dysplasia of the mandible: report of a case. *Compend Contin Educ Dent* 1999;20: 1017–9, 1022–32.
 42. Commins DJ, Tolley NS, Milford CA. Fibrous dysplasia and ossifying fibroma of the paranasal sinuses. *J Laryngol Otol* 1998; 112:964–8.
 43. Johnson L. Proceedings of the Seminar of the Southwestern and South-Central Regions, College of American Pathologists; 1952.
 44. Kramer IR. The World Health Organization: histological typing of odontogenic tumours: an introduction to the second edition. *J Dent Assoc S Afr* 1992;47:208–10.
 45. Stewart J. Clinical pathologic correlations. In: Regezi JA, Sciubla JJ, Jordan RCK, editors. *Oral pathology*. 4th ed. Philadelphia: Saunders; 2003. p. 295–6.
 46. Gordon SC, MacIntosh RB, Wesley RK. A review of osteoblastoma and case report of metachronous osteoblastoma and unicystic ameloblastoma. *Oral Surg Oral Med Oral Pathol Oral Radiol Endod* 2001;91:570–5.
 47. Miller AS, Rambo HM, Bowser MW, Gross M. Benign osteoblastoma of the jaws: report of three cases. *J Oral Surg* 1980;38:694–7.
 48. Eisenbud L, Kahn LB, Friedman E. Benign osteoblastoma of the mandible: fifteen year follow-up showing spontaneous regression after biopsy. *J Oral Maxillofac Surg* 1987;45:53–7.
 49. Colm SJ, Abrams MB, Waldron CA. Recurrent osteoblastoma of the mandible: report of a case. *J Oral Maxillofac Surg* 1988;46:881–5.
 50. Ohkubo T, Hernandez JC, Ooya K, Krutchkoff DJ. “Aggressive” osteoblastoma of the maxilla. *Oral Surg Oral Med Oral Pathol* 1989;68:69–73.
 51. Benoist M. Experience with 220 cases of mandibular reconstruction. *J Maxillofac Surg* 1978;6:40–9.
 52. Webber PA, Hussain SS, Radcliffe GJ. Cartilaginous neoplasms of the head and neck (a report on four cases). *J Laryngol Otol* 1986;100:615–9.
 53. Lingen MW, Solt DB, Polverini PJ. Unusual presentation of a chondromyxoid fibroma of the mandible. Report of a case and review of the literature. *Oral Surg Oral Med Oral Pathol* 1993;75:615–21.
 54. Batsakis JG, Raymond AK. Chondromyxoid fibroma. *Ann Otol Rhinol Laryngol* 1989;98:571–2.
 55. Fujii N, Eliseo ML. Chondromyxoid fibroma of the maxilla. *J Oral Maxillofac Surg* 1988;46:235–8.
 56. Lustmann J, Gazit D, Ulmansky M, Lewin-Epstein J. Chondromyxoid fibroma of the jaws: a clinicopathological study. *J Oral Pathol* 1986;15:343–6.
 57. Browne RM, Rivas PH. Chondromyxoid fibroma of the mandible: a case report. *Br J Oral Surg* 1977;15:19–25.
 58. Gallia L, Tideman H, Bronkhorst F. Chondrosarcoma of mandible misdiagnosed as chondromyxoid fibroma. *Int J Oral Surg* 1980;9:221–4.
 59. Chandu A, Spencer JA, Dyson DP. Chondroma of the mandibular condyle: an example of a

- rare tumour. *Dentomaxillofac Radiol* 1977;26:242–5.
60. Lurie R. Solitary enchondroma of the mandibular condyle: a review and case report. *J Dent Assoc S Afr* 1975;30:589–93.
 61. Schneider LC, Dolinsky HB, Grodjesk JE. Solitary peripheral osteoma of the jaws: report of case and review of literature. *J Oral Surg* 1980;38:452–5.
 62. Gardner E, Stevens F. Cancer of the lower digestive tract in one family group. *Am J Hum Genet* 1955;2:41–8.
 63. Payne M, Anderson J, Cook J. Gardner's syndrome—a case report. *Br Dent J* 2002; 193:383–4.
 64. Takeuchi T, Takenoshita Y, Kubo K, Iida M. Natural course of jaw lesions in patients with familial adenomatosis coli (Gardner's syndrome). *Int J Oral Maxillofac Surg* 1993;22:226–30.
 65. Halling F, Merten HA, Lepsien G, Honig JF. Clinical and radiological findings in Gardner's syndrome: a case report and follow-up study. *Dentomaxillofac Radiol* 1992; 21:93–8.
 66. Yuwono M, Rossi TM, Fisher JE, Tjota A. Oncogene expression in patients with familial polyposis coli/Gardner's syndrome. *Int Arch Allergy Immunol* 1996;111:89–95.
 67. Davies DR, Armstrong JG, Thakker N, et al. Severe Gardner syndrome in families with mutations restricted to a specific region of the APC gene. *Am J Hum Genet* 1995;57:1151–8.
 68. Dangel A, Meloni AM, Lynch HT, Sandberg AA. Deletion (5q) in a desmoid tumor of a patient with Gardner's syndrome. *Cancer Genet Cytogenet* 1994;78:94–8.
 69. Miyamoto H, Sakashita H, Wilson DF, Goss AN. Synovial chondromatosis of the temporomandibular joint. *Br J Oral Maxillofac Surg* 2000;38:205–8.
 70. Tominaga K, Fujiki T, Mizuno A, et al. Synovial chondromatosis of the temporomandibular joint. *Dentomaxillofac Radiol* 1995;24:59–62.
 71. Reinisch EI, Feinberg SE, Devaney K. Primary synovial chondromatosis of the temporomandibular joint with suspected traumatic etiology. Report of a case. *Int J Oral Maxillofac Surg* 1997;26:419–22.
 72. Avdin M, Kurtay A, Celebioglu S. A case of synovial chondromatosis of the TMJ: treatment based on stage of the disease. *J Craniomaxillofac Surg* 2002;13:670–5.
 73. Saito T, Utsunomiya T, Furutani M, Yamamoto H. Osteochondroma of the mandibular condyle: a case report and review of the literature. *J Oral Sci* 2001;43:293–7.
 74. Vezeau PJ, Fridrich KL, Vincent SD. Osteochondroma of the mandibular condyle: literature review and report of two atypical cases. *J Oral Maxillofac Surg* 1995;53:954–63.
 75. Wang-Norderud R, Ragab RR. Osteochondrocartilaginous exostosis of the mandibular condyle. Case report. *Scand J Plast Reconstr Surg* 1975;9:165–9.
 76. Peroz I, Scholman HJ, Hell B. Osteochondroma of the mandibular condyle: a case report. *Int J Oral Maxillofac Surg* 2002;31:455–6.
 77. Wolford L, Mehra P, Franco P. Use of conservative condylectomy for treatment of osteochondroma of the mandibular condyle. *J Oral Maxillofac Surg* 2002;60:262–8.
 78. Hopkins KM, Huttula CS, Kahn MA, Albright JE. Desmoplastic fibroma of the mandible: review and report of two cases. *J Oral Maxillofac Surg* 1996;54:1249–54.
 79. Iwai S, Matsumoto K, Sakuda M. Desmoplastic fibroma of the mandible mimicking osteogenic sarcoma: report of a case. *J Oral Maxillofac Surg* 1996;54:1370–3.
 80. Sanfilippo NJ, Wang GJ, Larner JM. Desmoplastic fibroma: a role for radiotherapy? *South Med J* 1995;88:1267–9.
 81. Kwon PH, Horswell BB, Gatto DJ. Desmoplastic fibroma of the jaws: surgical management and review of the literature. *Head Neck* 1989;11:67–75.
 82. Yamaguchi T, Dorfman HD. Giant cell reparative granuloma: a comparative clinicopathologic study of lesions in gnathic and extragnathic sites. *Int J Surg Pathol* 2001;9:189–200.
 83. Jaffe H. Giant cell reparative granuloma, traumatic bone cysts and fibrous (fibroosseous) dysplasia of jaw bones. *J Oral Surg* 1953;6:159–75.
 84. Bernier J, Cahn LR. The peripheral giant cell reparative granuloma. *J Am Dent Assoc* 1954;49:141–8.
 85. Bernier J. The management of oral diseases. St. Louis: Mosby; 1955.
 86. Worth H. Principles and practice of oral radiology interpretation. Chicago: Chicago Year Book Medical Publishers; 1963.
 87. Chuong R, Kaban LB, Kozakewich H, Perez-Atayde A. Central giant cell lesions of the jaws: a clinicopathologic study. *J Oral Maxillofac Surg* 1986;44:708–13.
 88. Eckardt A, Pogrel MA, Kaban LB, et al. Central giant cell granulomas of the jaws. Nuclear DNA analysis using image cytometry. *Int J Oral Maxillofac Surg* 1989;18:3–6.
 89. Ficarra G, Kaban LB, Hansen LS. Central giant cell lesions of the mandible and maxilla: a clinicopathologic and cytometric study. *Oral Surg Oral Med Oral Pathol* 1987;64:44–9.
 90. Flanagan AM, Nul B, Tinkler SM, et al. The multinucleate cells in giant cell granulomas of the jaw are osteoclasts. *Cancer* 1988;62:1139–45.
 91. O'Malley MP, Pogrel MA, Stewart JC, Silva RG, Regezi JA. Central giant cell granulomas of the jaws; phenotype and proliferation-associated markers. *J Oral Pathol Med* 1997;26:159–63.
 92. Stern ME, Eisenbud L. Management of giant cell lesions of the jaws. *Oral Maxillofac Surg Clin North Am* 1991;3:165–71.
 93. Whitaker S. Giant cell lesions of the jaws. *Oral Surg Oral Med Oral Pathol* 1993; 75:199–208.
 94. Pogrel MA, Regezi JA, Harris ST, Goldring SR. Calcitonin treatment for central giant cell granulomas of the mandible: report of two cases. *J Oral Maxillofac Surg* 1999;57:848–53.
 95. Jacoway J, Howell FV, Terry BC. Central giant cell granuloma: an alternative to surgical therapy. *Oral Surg Oral Med Oral Pathol* 1988;66:572.
 96. Terry BJJ. Management of central giant cell lesions: an alternative to surgical therapy. *Oral Maxillofac Surg Clin North Am* 1994;6:579–600.
 97. Kermer C, Millesi W, Watzke IM. Local injection of corticosteroids for central giant cell granuloma. A case report. *Int J Oral Maxillofac Surg* 1994;23:366–8.
 98. Carlos R, Sedano HO. Intralesional corticosteroids as an alternative treatment for central giant cell granuloma. *Oral Surg Oral Med Oral Pathol Oral Radiol Endod* 2002;93:161–6.
 99. Harris M. Central giant cell granulomas of the jaws regress with calcitonin therapy. *Br J Oral Maxillofac Surg* 1993;31:89–94.
 100. O'Regan EM, Gibb DH, Odell EW. Rapid growth of giant cell granuloma in pregnancy treated with calcitonin. *Oral Surg Oral Med Oral Pathol Oral Radiol Endod* 2001;92:532–8.
 101. Lannon DA, Earley MJ. Cherubism and its charlatans. *Br J Plast Surg* 2001;54:708–11.
 102. de Lange J, Rosenberg AJ, van den Akker HP, et al. Treatment of central giant cell granuloma of the jaw with calcitonin. *Int J Oral Maxillofac Surg* 1999;28:372–6.
 103. Rosenberg AJ, Bosschaart AN, Jacobs JW, et al. [Calcitonin therapy in large or recurrent central giant cell granulomas of the lower jaw]. *Ned Tijdschr Geneesk* 1997;141:335–9.
 104. Penfold CN, Evans BT. Giant cell lesions complicating Paget's disease of bone and their response to calcitonin therapy. *Br J Oral Maxillofac Surg* 1993;31:267.
 105. Pogrel MA. Alternative therapies for the central

- giant cell granuloma. *J Oral Maxillofac Surg* 2003;61:649–53.
106. Kaban LB, Mulliken JB, Ezekowitz RA, et al. Antiangiogenic therapy of a recurrent giant cell tumor of the mandible with interferon alfa-2a. *Pediatrics* 1999;103:1145–9.
107. Kaban LB, Troulis MJ, Ebb D, et al. Antiangiogenic therapy with interferon alpha for giant cell lesions of the jaws. *J Oral Maxillofac Surg* 2002;60:1103–13.
108. Hunter D. Hyperparathyroidism: generalised osteitis fibrosa. *Br J Surg* 1931;19:203–84.
109. Jones WA. Familial multi-ocular cystic disease of the jaws. *Am J Cancer* 1933;17:946–50.
110. Tiziani V, Reichenberger E, Buzzo CL, et al. The gene for cherubism maps to chromosome 4p16. *Am J Hum Genet* 1999;65:158–66.
111. Mangion J, Rahman N, Edkins S, et al. The gene for cherubism maps to chromosome 4p16.3. *Am J Hum Genet* 1999;65:151–7.
112. Southgate J, Sarma U, Townend JV, et al. Study of the cell biology and biochemistry of cherubism. *J Clin Pathol* 1998;51:831–7.
113. Kaban LB, Mulliken JB. Vascular anomalies of the maxillofacial region. *J Oral Maxillofac Surg* 1986;44:203–13.
114. Lamberg MA, Tasanen A, Jaaskelainen J. Fatality from central hemangioma of the mandible. *J Oral Surg* 1979;37:578–84.
115. Perrott D, Schmidt B, Dowd C, Kaban L. Treatment of a high-flow arteriovenous malformation by direct puncture and coil embolization. *J Oral Maxillofac Surg* 1994;52:1083–6.
116. Kaneko R, Tohnai I, Ueda M, et al. Curative treatment of central hemangioma in the mandible by direct puncture and embolisation with *N*-butyl-cyanoacrylate (NBCA). *Oral Oncol* 2001;37:605–8.
117. Bunel K, Sindet-Pedersen S. Central hemangioma of the mandible. *Oral Surg Oral Med Oral Pathol* 1993;75:565–70.
118. Ozdemir R, Alagoz S, Uysal AC, et al. Intraosseous hemangioma of the mandible: a case report and review of the literature. *J Craniomaxillofac Surg* 2002;13:38–43.
119. Beziat J, Marcelino J, Bascoulergue Y, Vitrey D. Central vascular malformation of the mandible: a case report. *J Oral Maxillofac Surg* 1997;55:415–9.
120. Lichtenstein L. Histiocytosis X. Integration of eosinophilic granuloma of bone, “Letterer-Siwe disease” and “Schuller-Christian disease” as related manifestations of a single nosologic. *AMA Arch Pathol* 1953;56:84–102.
121. Arico M, Danesino C. Langerhans’ cell histiocytosis—is there a role for genetics? *Haematologica* 2001;86:1009–14.
122. Willman C, Busque L, Griffith B, et al. Langerhans’ cell histiocytosis (histiocytosis X)—a clonal proliferative disease. *N Engl J Med* 1994;331:154–6.
123. Kawakubo Y, Kishimoto H, Sato Y, et al. Human cytomegalovirus infection in foci of Langerhans cell histiocytosis. *Virchows Arch* 1999;434:109–15.
124. Boutsen Y, Esselinckx W, Delos M, Nisolle JF. Adult onset of multifocal eosinophilic granuloma of bone: a long-term follow-up with evaluation of various treatment options and spontaneous healing. *Clin Rheumatol* 1999;18:69–73.
125. Jaffe R. The histiocytoses. *Clin Lab Med* 1999; 19:135–55.
126. Watzke IM, Millesi W, Kermer C, Gisslinger H. Multifocal eosinophilic granuloma of the jaw: long-term follow-up of a novel intraosseous corticoid treatment for recalcitrant lesions. *Oral Surg Oral Med Oral Pathol Oral Radiol Endod* 2000; 90:317–22.
127. Roper-Hall HT. Cysts of developmental origin in the premaxillary region, with special reference to their diagnosis. *Br Dent J* 1938;65:405–34.
128. Howe GL. Hemorrhagic cysts of the mandible. *Br J Oral Surg* 1965;3:55–76.
129. Toller P. Radioactive isotope and other investigations in case of hemorrhagic cyst of the mandible. *Br J Oral Surg* 1964;2:86–93.
130. Pogrel M. Bilateral solitary bone cysts: report of case. *J Oral Surg* 1978;36:55–8.
131. Stafne EC. Bone cavities situated near the angle of the mandible. *J Am Dent Assoc* 1942;29:1969–72.
132. Pogrel MA. The results of microneurosurgery of the inferior alveolar and lingual nerve. *J Oral Maxillofac Surg* 2002;60:485–9.
133. Paget J. On a form of chronic inflammation of bone (osteitis deformans). *Trans R Medico Chirurg Soc* 1876;60:37–63.
134. Schneider D, Hofmann M, Peterson J. Diagnosis and treatment of Paget’s disease of bone. *Am Fam Physician* 2002;65:2069–72.
135. Fisher K, Pogrel MA. Gorham’s syndrome (massive osteolysis): a case report. *J Oral Maxillofac Surg* 1990;48:1222–5.
136. Gorham LW, Wright AW, Schultz HH, et al. Disappearing bones: a rare form of massive osteolysis. *Am J Med* 1954;17:674–82.

Oral Cancer: Classification, Staging, and Diagnosis

G. E. Ghali, DDS, MD

M. Scott Connor, DDS, MD

Estimates indicate that more than 1.3 million new cancers will be diagnosed in the United States this year, and 27,700 will be located in the mouth and oropharynx.¹ This number represents approximately 3% of all cancers and is the eighth most common cancer affecting males in the United States. Globally, more than 360,000 new cases of oral cancer will be diagnosed this year.² Mortality rates remain high despite some advances in locoregional control. There will be approximately 200,000 deaths worldwide, of which 7,200 will occur in the United States. Most patients will present for diagnosis with either regional or distant disease. Data have shown a trend for African Americans to have more advanced disease compared with white Americans (68% vs 52%) at the time of diagnosis. Even more alarming is the fact that, when compared with equal stages at the time of diagnosis, African Americans have a poorer 5-year relative survival rate compared with other races. A review of trends in 5-year relative survival rates over the past three decades has shown a statistical difference between the time periods of 1974 to 1976 and 1992 to 1996 (54% vs 59%); the improvement in sur-

vival again fails to hold true for the African American population.¹

Approximately 85 to 95% of all oral cancer is squamous cell carcinoma (SCC).^{3,4} However, multiple other malignant lesions can be found in the oral cavity such as sarcoma, minor salivary gland tumors, mucosal melanoma, lymphoma, or metastatic disease from nearly any site in the body.

Risk Factors for SCC of the Oral Cavity

The etiology of SCC of the oral cavity has been studied extensively. Numerous risk factors have been suggested as etiologic agents for the development of these malignancies. While no single causative agent can be attributed to the development of all oral cancers, several carcinogens have been identified, and of those tobacco and alcohol appear to have the greatest impact on malignancy development. Both extrinsic and intrinsic factors likely play a role in the development of SCC of the oral cavity.

The risk of oral cancer associated with tobacco use is noted to be 2 to 12 times higher than in the nonsmoking population, and 90% of individuals with oral cancer will have a smoking history.⁵⁻⁹ The

combination of various carcinogens within tobacco, combined with the heat, may lead to a variable number of genetic mutations in the epithelium of the upper aerodigestive tract. At some point these continued mutations, coupled with the patients' own inherent genetic susceptibility, expressed in the hetero- or homogeneity of certain tumor suppressor genes or oncogenes (*TP53*, *c-myc*), may lead to the development of a cell line capable of unregulated growth.

Alcohol in itself is not a recognized initiator in the development of oral SCC. However, the role of alcohol as a promoter in the development of oral cancer when coupled with the use of smoking tobacco has been shown.¹⁰ This may be related to the effects of contaminants in alcohol and its ability to solubilize carcinogens and enhance their penetration into oral mucosa.^{5,11}

A possible viral etiology has been demonstrated in oral cancers, especially by the human papilloma virus (HPV). The HPV subtypes 16 and 18, similar to those causing cervical cancer, have been implicated. Smith and colleagues showed that when individuals in his study had other risk factors adjusted, such as smoking, alcohol, and

age, the presence of HPV in the oral cavity was associated with a 3.7 times greater chance of cancer development than in the noninfected individual.¹² Other authors have noted a unique subset of characteristics in individuals that may develop SCC as a result of HPV infection, showing less association with tobacco or alcohol abuse, frequently involving the tonsils, and having an improved prognosis.¹³

The study of the tumor biology of SCC has exploded in the past decade. The accepted molecular theory concerning genetic alterations of SCC is that of a “multihit” tumorigenesis ultimately leading to unregulated cell growth and function.^{14,15} It is thought that multiple exogenous insults (tobacco, alcohol, viral) can lead to activation of oncogenes or inactivation of tumor suppressor genes. Oncogene dysregulation leads to a gain of function alteration, and transforming growth factor alpha (TGF- α) and eukaryotic initiation factor 4E (eIF4E) are two examples of well-studied genes that have proven up-regulation in SCC.¹⁶ Loss of tumor suppressor gene function requires loss of both normal alleles, which leads to the inactivation of the critical function of that gene. The most studied of the tumor suppressor genes are *TP53* and *P16*.^{15,17-19} No single gene alteration is responsible for carcinogenesis, but rather a host of altered genes contribute. Attempts have been made to use genes and their products to identify oncologically safe margins operatively with minimal success.²⁰ Gene therapy trials that target these specific genes hold better promise.

Premalignant Disease

Premalignant disease can be divided into that occurring as an isolated lesion or that associated with a condition. A precancerous lesion is defined as morphologically altered tissue in which the development of malignancy is more likely than with normal mucosa. A precancerous condition is a condition or generalized disease that does

not necessarily alter the appearance of the mucosa but may be associated with a greater risk for the development of cancer.²¹ Precancerous lesions are broadly classified as leukoplakia and erythroplakia.

Leukoplakia is defined as a white patch or plaque that cannot be characterized clinically or ascribed to any other pathologic disease.²² Leukoplakia cannot be scraped or rubbed off and is therefore primarily a diagnosis of exclusion. Lesions caused by lichen planus, white sponge nevus, nicotine stomatitis, or other plaque-causing diseases do not qualify as leukoplakia. Leukoplakia is strictly a clinical diagnosis and does not imply any specific histologic diagnosis. Leukoplakia is generally asymptomatic and clinically appears as a white or off-white lesion that may be flat, slightly elevated, rugated, or smooth (Figure 32-1). It may be found as isolated or multifocal lesions and may change in morphology over time. More than 70% of the time leukoplakia occurs on two or more surfaces and has a strong male predilection.^{23,24} A more aggressive variant exists and is referred to as proliferative verrucous leukoplakia (Figure 32-2). The lower lip vermilion, buccal mucosa, and gingiva account for most oral cavity leukoplakia; however, lesions found on the tongue and floor of the mouth account for most lesions exhibiting dysplasia or carcinoma.²³⁻²⁶ These relative frequencies change with different geographic locations and are based on local habits.

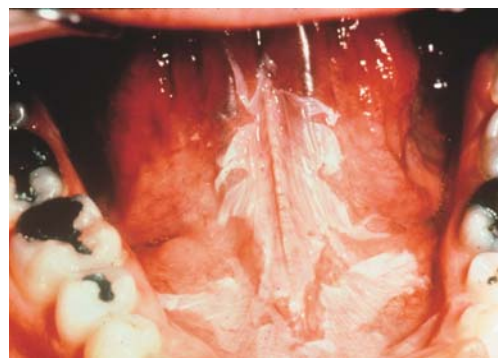


FIGURE 32-1 Typical appearance of floor-of-mouth leukoplakia.

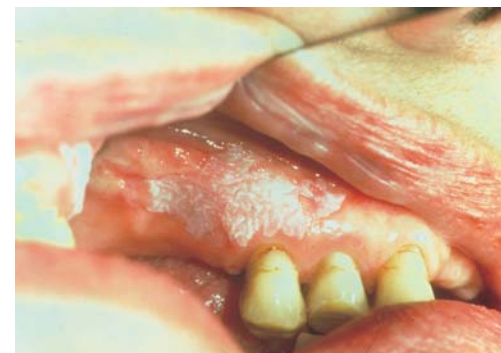

FIGURE 32-2 Common presentation of proliferative verrucous variant of leukoplakia on gingiva.

The only consistent histology found in all leukoplakia is the presence of hyperkeratosis. The underlying epithelium may range from normal to invasive carcinoma. The true etiology for the development of leukoplakia is unknown; however, several causative factors have been proposed. Tobacco use, whether smoked or smokeless, is most closely associated with the development of leukoplakia, and more than 70% of patients with leukoplakia are smokers.²³ While several studies have shown elimination of tobacco use to be associated with resolution or decrease in the size of the lesion, others have shown poor improvement with its cessation.

Ultraviolet radiation to the lower lip is frequently observed in the development of lower lip vermilion leukoplakia. Individuals with chronic unprotected exposure to sunlight are at highest risk for development. These leukoplakia lesions are frequently associated with actinic cheilitis (Figure 32-3).²⁷

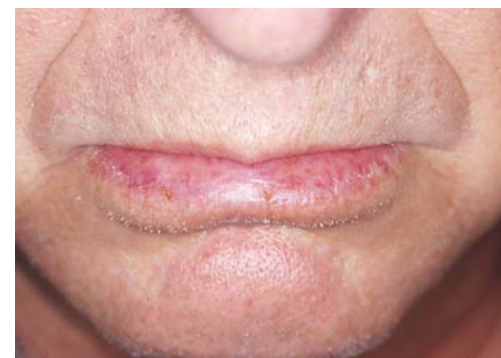

FIGURE 32-3 Actinic cheilitis of the lower lip secondary to chronic unprotected sun exposure.

Trauma is also associated with the development of leukoplakic lesions. Ill-fitting dentures, sharp edges on oral prostheses or teeth, or parafunctional oral habits with objects such as toothpicks can be associated with leukoplakia. Obvious traumatic lesions to the buccal mucosa such as the development of a linea alba are not considered leukoplakia.

The frequency of dysplasia and carcinoma within leukoplakia is most closely associated with the lesion's location and patient's habits. Waldron and Shafer in their study of 3,256 lesions submitted to their respective oral pathology departments as "leukoplakia" found that 43% of floor-of-mouth lesions and 24% of both tongue and lip lesions contained some degree of dysplasia or carcinoma.²⁵ Several studies have also looked at malignant transformation over time and found it to vary from 0.13 to 17.5%.^{23-26,28} The results of these studies vary according to suspected causes of the leukoplakia (geographic habits) and the length of follow-up or time to biopsy of the lesion. The malignant transformation of these lesions has been studied extensively by Silverman and colleagues.²³ They note that, while a definite rate of transformation cannot be stated, their 257 patients had a 17.5% transformation rate with an average follow-up time of 7.1 years. The second year of follow-up in their series exhibited the greatest rate of malignant transformation at 5%. If those lesions initially noted to be dysplastic on biopsy were followed, they had an even higher rate of malignant transformation, at 36.4%. Earlier studies by Silverman and colleagues found malignant transformation rates of 0.13% and 6%.^{26,28} The variability in transformation rates of most studies is attributed to differences in ethnicity, drinking alcohol and tobacco usage, location of the lesions, and duration of follow-up.

Erythroplakia is a red patch that cannot be scraped off or characterized clinically or ascribed to any other pathologic

disease (Figure 32-4). Almost all true erythroplakia demonstrates dysplasia, carcinoma in situ, or invasive carcinoma. Shafer and Waldron's review of biopsies submitted under this clinical diagnosis revealed that 51% were invasive SCC, 40% were carcinoma in situ or severe dysplasia, and 9% were mild to moderate dysplasia.²⁹ The most common sites of occurrence are the floor of the mouth and retromolar trigone. Lesions appear as bright red, are frequently "velvety" in appearance, and have a sharply demarcated border. The etiology of these lesions is unknown but thought to be the same as that for leukoplakia. Frequently these lesions are noted to be nonhomogeneous in appearance with adjacent or intralesional leukoplakia. When observed with this morphology, they are referred to as erythroleukoplakia or "speckled erythroplakia" (Figure 32-5). These lesions also harbor an ominous potential as rates of malignant transformation have been noted of up to 23%.²³

Oral submucous fibrosis (OSF) is a precancerous condition seen predominantly in India and Southeast Asia. It is a chronic, progressive mucosal disorder most frequently associated with the habit of chewing betel quids; however, there is evidence that this lesion is multifactorial in nature with genetic, immunologic, nutritional, and autoimmune factors possibly involved.^{30,31} The condition is characterized by a mucosal rigidity that leads to trismus, odynophagia with spicy foods,

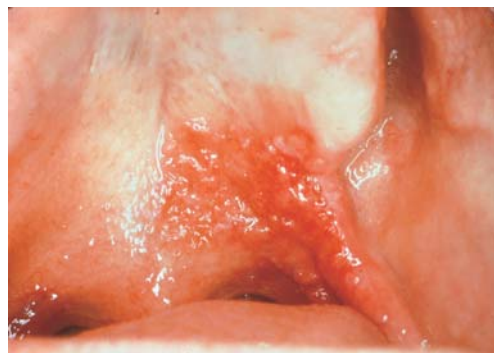

FIGURE 32-4 Typical appearance of erythroplakia located on left posterior soft palate.

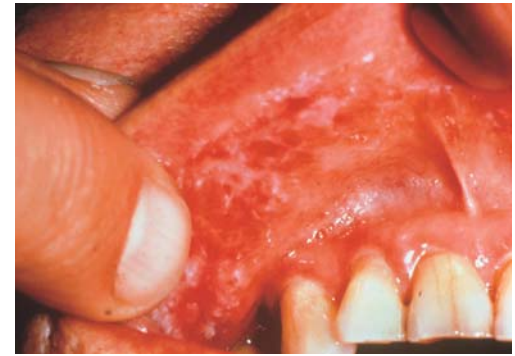

FIGURE 32-5 Typical appearance of erythroleukoplakia on labial and buccal mucosa.

and difficulty with speech and swallowing. Unlike tobacco pouch keratosis, OSF does not regress with the cessation of betel quid use. Longitudinal studies have shown a malignant transformation rate of 7.6% over a 17-year period.³²

Cervical Lymph Node Levels

The neck is divided into six "surgical levels" based on anatomic structures (Figure 32-6). Each anatomic area of the oral cavity has a predictable lymphatic drainage pattern to the over 300 lymph nodes in the

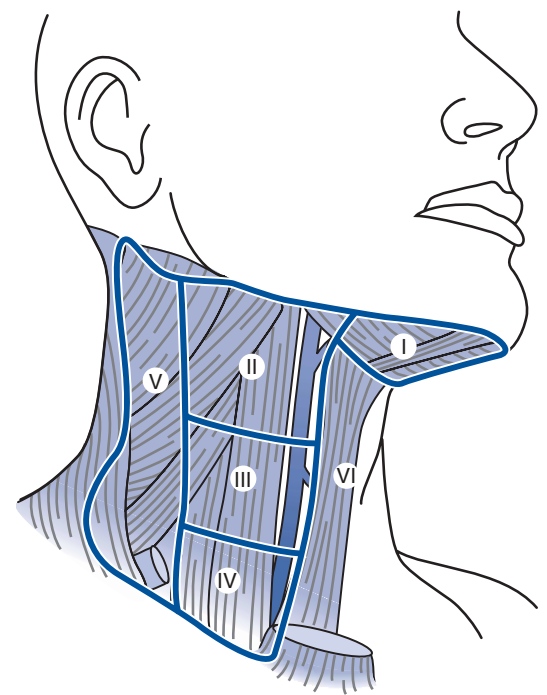


FIGURE 32-6 Lymph node levels of the neck. Levels I to VI are subdivided and described in text.

neck.³³ By grouping defined nodal groups into surgical levels, clinicians are afforded the ability to communicate with each other. It also allows clinicians to tailor their surgical management of the neck based on these known drainage patterns.

Level I includes the submental and submandibular nodal groups.

Level IA, the submental group, is bounded by the hyoid bone inferiorly, the mandibular symphysis superiorly, and the anterior bellies of the digastric muscles laterally.

Level IB, the submandibular group, is bounded by the posterior belly of the digastric inferiorly, the mandibular body superiorly, the anterior belly of the digastric muscle anteriorly, and the stylohyoid muscle posteriorly.^{34,35}

Level II includes upper jugular lymph nodes surrounding the internal jugular vein and adjacent spinal accessory nerve.

Level IIA is bounded inferiorly by a horizontal plane made by the inferior body of the hyoid bone, superiorly by the skull base, anteriorly by the stylohyoid muscle, and posteriorly by a vertical plane defined by the spinal accessory nerve.

Level IIB is bounded inferiorly by a horizontal plane made by the inferior body of the hyoid bone, superiorly by the skull base, anteriorly by a vertical plane defined by the spinal accessory nerve, and posteriorly by the lateral border of the sternocleidomastoid muscle (SCM).^{34,35}

Level III includes middle jugular lymph nodes surrounding the internal jugular vein. It is bounded inferiorly by a horizontal plane defined by the inferior border of the cricoid cartilage, superiorly by the horizontal plane defined by the inferior body of the hyoid bone, anteriorly by the lateral border of the sternohyoid musculature, and posteriorly by the lateral border of the SCM or sensory branches of the cervical plexus.^{34,35}

Level IV includes the lower jugular lymph nodes surrounding the internal jugular vein. It is bounded inferiorly by the

clavicle, superiorly by the horizontal plane created by the inferior border of the cricoid cartilage, anteriorly by the lateral border of the sternohyoid musculature, and posteriorly by the lateral border of the SCM or sensory branches of the cervical plexus.^{34,35}

Level V includes all the nodes in the posterior triangle, the spinal accessory and transverse cervical nodes, and all of the upper, middle, and lower jugular lymph nodes on the posterior aspect of the SCM.

Level VA is bounded inferiorly by the horizontal plane created by the inferior border of the cricoid cartilage, superiorly at the apex found at the convergence of the SCM and trapezius muscles, anteriorly by the posterior belly of the SCM or sensory branches of the cervical plexus, and posteriorly by the anterior belly of the trapezius muscle.

Level VB is bounded inferiorly by the clavicles, superiorly by the horizontal plane created by the lower border of the hyoid bone, anteriorly by the posterior belly of the SCM or sensory branches of the cervical plexus, and posteriorly by the anterior border of the trapezius muscle.^{34,35}

Level VI includes the pretracheal, paratracheal, and prelaryngeal or so-called Delphian lymph nodes. It is bounded inferiorly by the suprasternal notch, superiorly by the hyoid bone, and laterally by the common carotid arteries. This level is also known as the anterior compartment.^{34,35}

Clinical Correlation Based on Site

The boundaries of the oral cavity extend from the vermilioncutaneous junction of the lips to the junction of the hard and soft palate posterior-superiorly and to the line created by the circumvallate papilla posterior-inferiorly. Posterior-laterally the boundaries are represented by the anterior faucial pillars. The American Joint Committee on Cancer (AJCC) has divided the oral cavity into seven distinct anatomic locations from which primary lesions may develop.³⁶ The sites have defined bound-

aries, and in developing these sites the AJCC has attempted to produce a means of better studying and treating oral cancer.

Mucosal Lip

The lip begins at the junction of the vermilion border with the skin and includes only the vermilion surface or that portion of the lip that comes into contact with the opposing lip. It is well defined into an upper and lower lip joined at the commissures of the mouth.²⁶ It is supported by the orbicularis oris muscle and receives its blood supply from branches of the facial artery. Sensory innervation is provided by the mental nerve and motor function via branches of the facial nerve.

Mucosal lip cancers represent approximately 2 to 42% of oral cavity cancers.^{4,37-41} Mucosal lip cancer is seen almost exclusively in older white men as a result of chronic sun exposure (Figure 32-7). Its infrequent occurrence in dark-skinned races is further evidence of its etiology. Nodal metastasis in lip cancer is infrequent, 10% of lower lip cancers and 20% of cancers in the upper lip and commissure are found to metastasize to the nodes.⁴² Metastasis from the lower lip is to the submental, submandibular, and perifacial nodes (level I more commonly than level II). Preauricular, periparotid, and submandibular nodes drain cancers of the upper lip and commissure (level II more commonly than level I). Bilateral

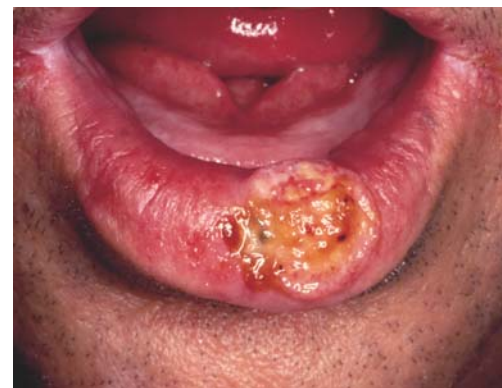

FIGURE 32-7 Neglected carcinoma of the lower lip.

neck metastasis may develop if the lower lip lesion is near or has crossed the midline; however, the upper lip rarely exhibits crossover between right- and left-side lymphatics.⁴³

Buccal Mucosa

Buccal mucosa includes all the lining of the inner surface of the cheeks and lips from the line of contact of the opposing lips (mucovermilion junction) to the line of attachment of mucosa to the alveolar ridge (upper and lower) and pterygomandibular raphe.³⁶ The buccal mucosa is supported by the buccinator muscle posteriorly and the obicularis oris anteriorly. The vascular supply to the posterior aspect is derived from the buccal artery, a branch of the internal maxillary artery; innervation is from the buccal branches of the facial nerve along with the long buccal branch of the third division of the trigeminal nerve.

Carcinoma of the buccal mucosa represents 2 to 10% of all SCC of the oral cavity (Figure 32-8).^{4,37,38,44} In Central and Southeast Asia the use of “pan” (a combination of tobacco, betel nut, and lime) has been linked to buccal mucosa carcinoma and represents more than 40% of all oral cavity SCC.⁴⁵ First-echelon lymphatic drainage from the buccal mucosa is level I followed by level II.⁴⁶ Cervical metastases are observed in 10 to 27% of presenting patients.^{44,47,48}

Alveolar Ridge

The alveolar ridge mucosa may be divided into lower (mandibular) and upper (maxillary) components. The mucosa overlying the alveolar process of the mandible extends from the line of attachment of mucosa in the buccal gutter to the line of free mucosa of the floor of the mouth. Posteriorly it extends to the ascending ramus of the mandible.³⁶ The mucosa overlying the alveolar process of the maxilla extends from the line of attachment of mucosa in the upper gingival buccal gutter to the junction of the hard palate. Its pos-

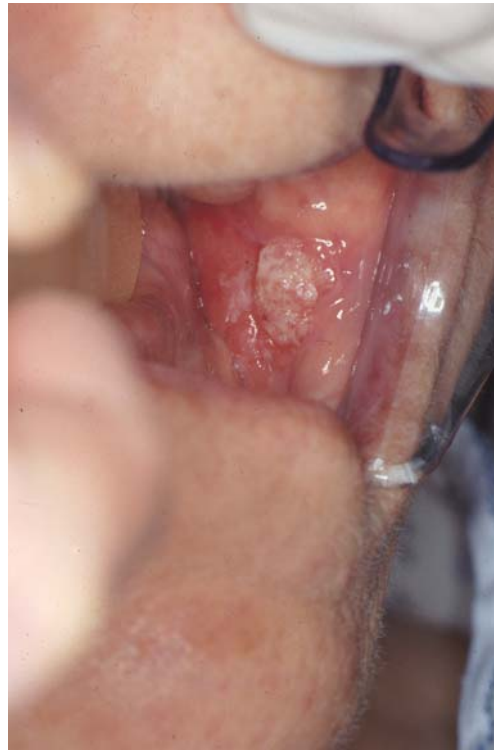

FIGURE 32-8 Squamous cell carcinoma of the left buccal mucosa.

terior margin is the upper end of the pterygopalatine arch.³⁶

Alveolar ridge or gingival carcinoma represents 2 to 18% of oral cancers and occurs predominantly on the mandibular alveolus (64 to 76%).^{4,37-41,49,50} At diagnosis, approximately one-third of these tumors exhibit some bony involvement.^{50,51} Lymph node metastasis tends to occur more frequently in mandibular ridge tumors than in maxillary tumors. Nodal drainage is principally to levels I and II for both the maxillary and mandibular lesions and is found in 24 to 28% of patients at diagnosis.^{46,49-51} Alveolar ridge carcinomas are frequently insidious tumors masquerading as inflammatory lesions, periodontitis or gingivitis, tooth abscesses, or denture sores (Figure 32-9).

Retromolar Gingiva (Retromolar Trigone)

The retromolar gingiva is a triangular region of attached mucosa overlying the ascending ramus of the mandible from the

level of the posterior surface of the last molar tooth superiorly to the tuberosity of the maxilla. Laterally this area merges with buccal mucosa and medially is in continuity with the soft palate, anterior tonsillar pillar, and floor of the mouth.³⁶

Tumors of the retromolar trigone frequently involve adjacent anatomic sites at the time of diagnosis (Figure 32-10). Primary symptomatic complaints with these tumors are sore throat, otalgia, and trismus. Tumors of the retromolar trigone represent 2 to 6% of all oral cavity carcinomas.^{4,38,39} Lymphatic drainage from this area is predominantly to the submandibular nodes (level IB) and the upper jugulodigastric nodes (level II).^{46,52} Lesions of this region tend to be more aggressive in nature with regard to developing cervical metastasis, because 27 to 56% of individuals present with metastatic disease.⁵³⁻⁵⁵

Floor of the Mouth

The floor of the mouth is a semilunar space over the mylohyoid and hyoglossus muscles, extending from the inner surface of the lower alveolar ridge to the undersurface of the tongue. Its posterior boundary is the base of the anterior faucial pillar of the tonsil. It is divided by the frenulum of the tongue and contains the ostia of the submandibular and sublingual salivary glands.³⁶ Anatomically it consists of the

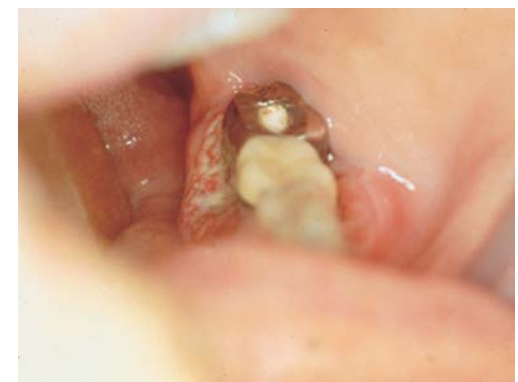

FIGURE 32-9 Biopsy-proven squamous cell carcinoma of the mandibular alveolar ridge resulting in erosion of underlying bone and loosening of dentition.

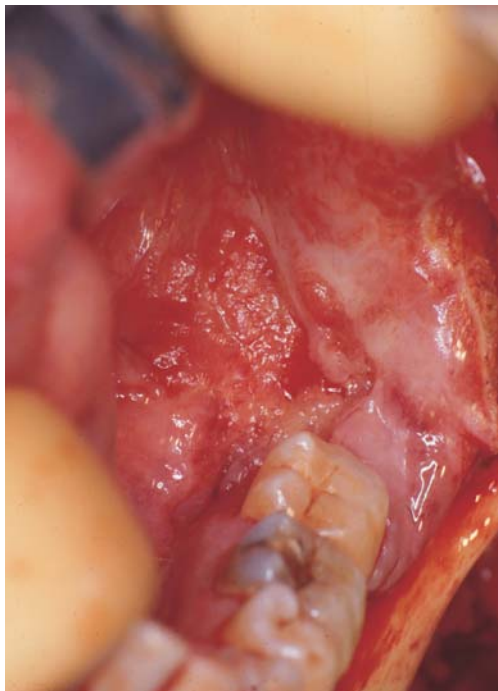

FIGURE 32-10 Ulcerative carcinoma of left retromolar trigone with extension towards the anterior tonsillar pillar.

unattached mucosa overlying the mylohyoid and hyoglossus muscles.

Carcinoma of the floor of the mouth represents 8 to 25% of oral cavity SCC, and several studies have shown a fairly dramatic increase in incidence (Figure 32-11).^{4,38-41} Two distinct lymphatic drainage systems have been identified in the floor of the mouth.⁵⁶ The superficial system drains bilaterally into the submandibular nodes (level I), while the deep system drains into the ipsilateral submandibular, upper and

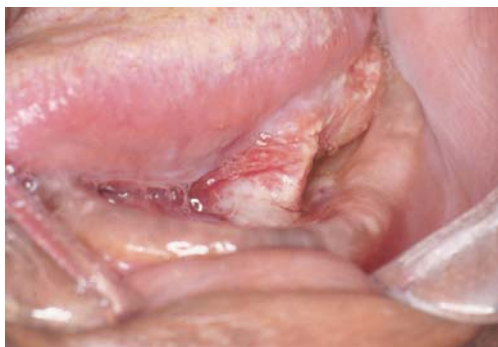

FIGURE 32-11 Carcinoma of anterior floor of the mouth presents with induration, ulceration, and mild tongue fixation.

middle jugulodigastric nodes (levels I, II, and III). Studies have shown that nearly one-half of all patients presenting with a floor-of-mouth carcinoma will have metastatic disease at presentation.⁵⁷⁻⁵⁹ Shaha and colleagues demonstrated that 60% of individuals with metastatic disease will have multiple levels involved.⁵⁷

Hard Palate

The hard palate is between the upper alveolar ridge and the mucous membrane covering the palatine process of the maxillary bones. It extends from the inner surface of the posterior edge of the palatine bone and can be divided into a hard and soft component.³⁶ In the United States, only 25% of palatal SCC occurs in the hard palate with 75% occurring in the soft palate (anatomically a part of the oropharynx).⁶⁰⁻⁶² In India and Southeast Asia, where reverse smoking is popular, the proportion of hard palate lesions is greater.

The hard palate represents 3 to 6% of all oral cavity SCC (Figure 32-12).^{4,37-39} There is a paucity of lymphatics to the hard palate. Approximately 10 to 25% of individuals present with evidence of metastasis, generally to levels I and II.^{61,63} Hard palate lesions may also metastasize to retropharyngeal nodes or nodes that are not palpable on a clinical examination or readily removable with a traditional neck dissection. Nonhealing ulcers and poor-fitting dentures are common complaints

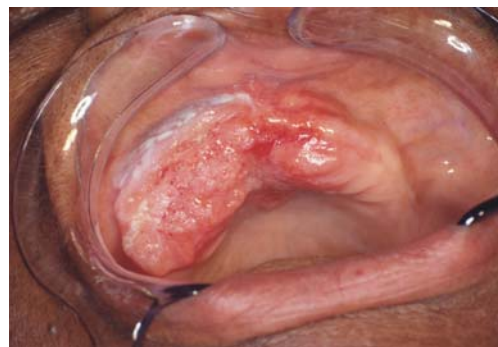

FIGURE 32-12 Carcinoma of the hard palate with extension to alveolar mucosa.

among individuals who develop disease at this site.

Anterior Two-Thirds of the Tongue (Oral Tongue)

The anterior two-thirds of the tongue is the freely mobile portion that extends anteriorly from the line of circumvallate papillae to the undersurface of the tongue at the junction of the floor of the mouth. It has four areas: the tip, the lateral borders, the dorsum, and the undersurface (nonvillous ventral surface of the tongue). The undersurface of the tongue is considered a separate category by the World Health Organization.³⁶ The tongue is entirely a muscular structure composed of the extrinsic muscles, the genioglossus, hyoglossus, styloglossus, and palatoglossus, as well as the intrinsic muscles of the tongue. Blood supply to the tongue is from the paired lingual, sublingual, and deep lingual arteries. The tongue receives motor innervation via the hypoglossal nerve and taste and sensation from lingual branches of the trigeminal nerve.

In the United States, SCC of the tongue is found mainly on the anterior two-thirds (75%), versus the posterior one-third (25%).⁶⁴ Tongue carcinoma represents 22 to 49% of all oral cancer diagnosed (Figure 32-13).^{4,37-41} Several epidemiologic reviews have shown the unfortunate trend of an increase in tongue cancer and an alarming increase in the

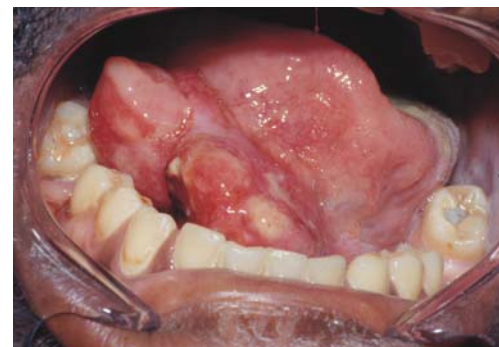


FIGURE 32-13 Carcinoma proliferating from ventral tongue to encompass full thickness of the tongue.

incidence of those diagnosed before 45 years of age.^{40,41,65-67} Lymphatic drainage of the oral tongue is principally to level II, followed by levels III and I.^{46,52} Carcinoma of the lateral border generally metastasizes ipsilaterally, but SCC of the tip or body of the tongue may exhibit bilateral metastases. Approximately 40% of patients have evidence of clinical node metastasis at the time of diagnosis.⁶⁸

Staging

The TNM system devised by the AJCC is designed to stratify cancer patients into different stages based on the characteristics of the primary tumor (T), regional lymph node metastasis (N), and distant metastasis (M). It is an attempt to help guide treatment and estimate patients' 5-year survivability. *T* refers to the primary lesion and is graded on greatest dimension and presence of adjacent tissue infiltration (Table 32-1). *N* refers to regional lymph node involvement and is graded on the presence of nodes, greatest dimension, and side of involvement in relation to the primary tumor (Table 32-2). *M* grades distant metastasis and is based simply on its presence (M1) or absence (M0). The AJCC staging system (Table 32-3) is designed for clinical use; however, the patient may be restaged based on final pathology after

<i>Node</i>	<i>Description</i>
NX	Regional lymph nodes cannot be assessed
N0	No regional lymph node metastasis
N1	Metastasis in a single ipsilateral lymph node, 3 cm or less in greatest dimension
N2	Metastasis in a single ipsilateral lymph node, more than 3 cm but not more than 6 cm in greatest dimension; or in multiple ipsilateral lymph nodes, none more than 6 cm in greatest dimension; or in bilateral or contralateral lymph nodes, none more than 6 cm in greatest dimension
N2a	Metastasis in a single ipsilateral lymph node more than 3 cm but not more than 6 cm in greatest dimension
N2b	Metastasis in multiple ipsilateral lymph nodes, none more than 6 cm in greatest dimension
N2c	Metastasis in bilateral or contralateral lymph nodes, none more than 6 cm in greatest dimension
N3	Metastasis in a lymph node more than 6 cm in greatest dimension

Adapted from Greene FL et al.^{35,36}

resection and designated with a *p* prefix (pTNM) or at autopsy with an *a* (aTNM). If synchronous tumors are found at presentation, the higher stage tumor should be used for stage designation, and an *m* suffix may be used to denote the multiple primary tumors (TmNM).^{36,69}

Assessment of Primary Lesion

Proper lesional assessment is based on a thorough clinical evaluation. Accurate

measurement of the primary lesion before biopsy is essential. Often, biopsied SCCs are referred without accurate measurements, leaving the treating surgeon in a difficult situation relative to properly assigning a T group. Additionally, postbiopsy inflammation could lead to over- or underestimates of the lesion's true dimensions.

A complete evaluation of all anatomic locations within the oral cavity must be performed by visual examination and palpation to detect any mucosal abnormality. The goal in evaluating the patient is to detect any abnormal tissue and assess the extent of disease. Patients may present with myriad complaints such as a nonhealing sore in the mouth, loosening of teeth, ill-fitting dental prosthesis, trismus, otalgia, or weight loss. Examination of the oral cavity should include removal of all dental appliances and use of a dental mirror for indirect evaluation of the nasopharynx and hypopharynx. Bimanual palpation is critical to assess any involvement of structures such as the deep musculature of the tongue, floor of the mouth, buccal mucosa, salivary structures, or bony mandibular

<i>Tumor</i>	<i>Description</i>
TX	Primary tumor cannot be assessed
T0	No evidence of primary tumor
Tis	Carcinoma in situ
T1	Tumor 2 cm or less in greatest dimension
T2	Tumor more than 2 cm but not more than 4 cm in greatest dimension
T3	Tumor more than 4 cm in greatest dimension
T4a*	Tumor invades adjacent structures (eg, through cortical bone, into deep [extrinsic] muscle of the tongue, maxillary sinus, skin of face) (resectable)
T4b	Tumor invades masticator space, pterygoid plates, or skull base or encases internal carotid artery (unresectable)

*Superficial erosion alone of bone or tooth socket by an alveolar primary is not sufficient to classify a tumor as T4.
Adapted from Greene FL et al.^{35,36}

Stage	Characteristics		
Stage 0	Tis	N0	M0
Stage I	T1	N0	M0
Stage II	T2	N0	M0
Stage III	T3	N0	M0
	T1	N1	M0
	T2	N1	M0
	T3	N1	M0
Stage IVA	T4a	N0	M0
	T4a	N1	M0
	T1	N2	M0
	T2	N2	M0
	T3	N2	M0
	T4a	N2	M0
Stage IVB	Any T	N3	M0
	T4b	Any N	M0
Stage IVC	Any T	Any N	M1

Adapted from Greene FL et al.^{35,36}

structures. Assessment of the lateral tongue and posterior pharynx is assisted by anterior and lateral traction on the tongue with cotton gauze (Figure 32-14).

The AJCC describes the possible growth patterns of a tumor as endophytic, exophytic, or ulcerated.³⁶ These characteristics play no part in staging the primary tumor. While depth of invasion is not used to clinically stage the patient, several studies have shown that depth of invasion does play a prognostic role in the development of regional metastasis, especially in tongue and floor-of-mouth cancers.⁷⁰⁻⁷² The study performed by Spiro and coworkers at Memorial Sloan-Kettering Cancer Center looked at primary tumor thickness in relation to risk of cervical node metastasis in SCC of the tongue and floor of the mouth.⁷⁰ They found that patients with thin (< 2 mm) cancer of these respective areas had a failure rate of 1.9% and lymph node metastasis present in 7.5% of

patients versus patients whose primary tumor was thick (> 2 mm), who had a 45.6% failure rate and metastatic node disease was present in 38%. Rarely, primary tumors may be located in areas that are difficult to assess or may be painful to assess, requiring an evaluation under anesthesia along with panendoscopy.

Panendoscopy, or “triple endoscopy,” involves the use of a rigid bronchoscope, esophagoscope, and laryngoscope to sequentially examine and take biopsies, if required, from the aerodigestive tract. Warren and Gates first described the notion of synchronous and metachronous tumors in 1932.⁷³ A synchronous tumor is described as a second histologically confirmed malignancy. This malignancy must be distinct and geographically separated by normal non-neoplastic mucosa and not of metastatic origin from the index lesion. It must also be discovered at the time of initial tumor evaluation. If the second primary tumor is discovered at a later time it is considered a metachronous tumor.

Slaughter and colleagues described the concept of “field cancerization” secondary to the panmucosal effects of smoked tobacco irritants and alcohol.⁷⁴ This theory explains the relatively high prevalence of second primary malignancies in the upper aerodigestive tract and has been described on a molecular level.⁷⁵ Panendoscopy became the gold standard for discovering

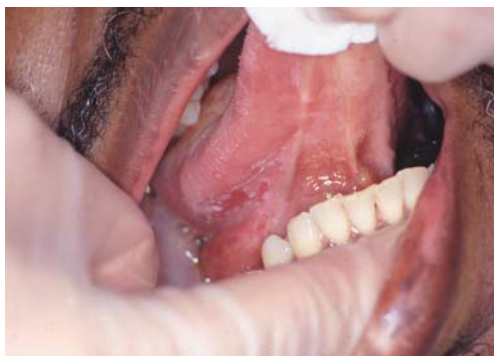

FIGURE 32-14 Anterior manual traction of the tongue with the aid of a cotton gauze improves visualization of this lateral and ventral tongue mass.

an often asymptomatic synchronous lesion. McGuirt reported a synchronous primary lesion rate of 16% in his prospective study of 100 head and neck cancer patients.⁷⁶ The discovery of the synchronous lesions frequently led to an alteration in the treatment plan of the index lesion. Other reported incidences of synchronous primary tumors range from 2 to 9%.⁷⁷⁻⁸¹ Panendoscopy can be performed quickly and at a minimal price for the patient in terms of cost and added morbidity.

The availability of flexible endoscopes, especially nasopharyngoscopes, has led to their use in many institutions, along with the conversion to flexible bronchoscopes and esophagoscopes. Additionally with the advent of tomographic imaging, routine preoperative panendoscopy is currently undergoing reevaluation in many institutions. Many authors believe that the low yield of bronchoscopy compared with chest imaging should preclude its use, while others have called for selective endoscopy to investigate only symptom-driven complaints.⁸¹⁻⁸⁴ Should multiple primary tumors be discovered during patient evaluation, each lesion should be staged separately.

Assessment of Regional Metastasis

Evaluation of the neck is perhaps the most critical and difficult aspect of staging oral or any head and neck cancer. The presence of a single lymph node with metastatic disease reduces the patient's 5-year survival by 50%. In turn, the presence of extracapsular spread decreases this survival by another 50%.⁸⁵ A retrospective study by Snow and colleagues showed a surprisingly high rate of extracapsular tumor spread in even small lymph nodes. His analysis showed that lymph nodes greater than 3 cm had a 73.7% chance of extracapsular spread, 2 to 3 cm a 53.3% chance, 1 to 2 cm a 44.3%, and less than 1 cm a 28.8% chance.⁸⁶ Other studies have concurred with this high rate of extracapsular spread.^{87,88} These drastic

reductions in long-term survival underscore the importance of preoperative staging for an appropriate prognosis and treatment plan. It should be noted that staging depends not on specific lymph node level involvement, but rather on presence of nodes, size, number, and whether they are ipsilateral, contralateral, or bilateral in relation to the lesion.

Traditionally, the gold standard in staging the neck has been through digital palpation of all levels of the neck bilaterally. The neck has a large number of palpable structures and a large area to be surveyed for the presence of lymph nodes. While there is no correct order in which to evaluate the neck, each clinician should develop a sequence to use consistently to avoid missing any part of the examination. Observation of the neck is important to note any asymmetries or skin changes. Most clinicians prefer to palpate the neck standing behind the patient, simultaneously palpating each aspect of the neck. We find it helpful to break the neck down into muscular triangles and examine them sequentially from the submandibular triangle to the posterior triangle. Lymph node chains should be evaluated for the presence of palpable masses, noting their size, surgical neck level, and whether the mass is fixed or moveable. Bending the patient's head forward or slightly to the side will ease taut tissues of the neck allowing for better palpation. Other important palpable structures of the neck to be evaluated in the examination include the parotid gland, the thyroid gland, and the postauricular, occipital, and supraclavicular lymph node chains. The parotid gland should be evaluated for the presence of any palpable disease or masses and the thyroid gland for any nodule, masses, or thyromegaly. The trachea should be inspected for any deviation or fixation.

The past decade has seen a relatively high incidence of observer error.^{89,90} Deficiencies have been observed in both the ability to recognize the presence of a

clinically palpable node and also in the ability to assess its size. A study by Alderson and colleagues showed that both residents and staff involved in the treatment of head and neck malignancies consistently underestimated the size of smaller nodes, and accuracy of assessment was independent of experience.⁹⁰

With the advent of advanced imaging, both computed tomography (CT) and magnetic resonance imaging (MRI) have been used as adjuncts to the physical examination for both evaluating nodal disease and helping to delineate the nodes in relation to vital structures such as the carotid artery. Studies have shown that clinically negative tumor-positive nodes may be detected on CT or MRI in 7.5 to 19% of cases.⁹¹⁻⁹⁶

Computed Tomography

CT is generally performed preoperatively with intravenous contrast to help delineate vascular from lymph structures. The scan generally involves 3- to 5-mm slices from the skull base to the clavicles. Important radiographic markers for the presence of suspicious adenopathy include lymph node size, shape, and central necrosis. A lymph node is considered abnormal when it is greater than 1.5 cm in the jugulodigastric region or greater than 1 cm in other regions of the neck.^{92,96} Shape has been suggested as a criterion to help distinguish pathologic nodes. The shape of a normal or hyperplastic lymph node resembles a bean, as opposed to round or sphere-like metastatic nodes frequently present. Next to size, the most specific indicator of metastatic nodal disease on tomographic imaging is the presence of intranodal necrosis, independent of size and shape (Figure 32-15). Only an intranodal abscess or fatty hilar metaplasia can simulate central tumor necrosis.

Magnetic Resonance Imaging

MRI is another method of neck imaging that has gained popularity in the past decade. With superior soft tissue detail, one would expect better delineation of

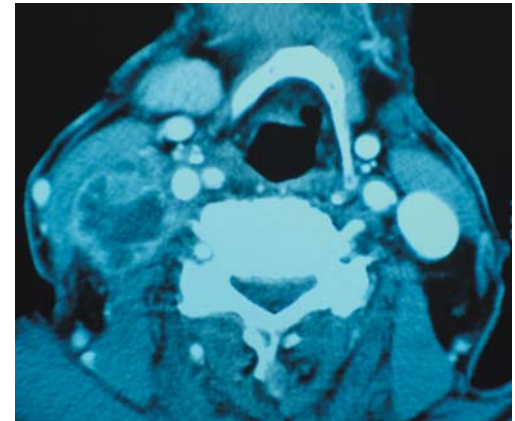


FIGURE 32-15 Axial computed tomography scan with contrast demonstrates large right cervical node with criteria for regional metastasis.

lymph node pathology; however, the fat that surrounds the cervical lymph nodes can interfere with imaging detection. The T1-weighted, fat-suppressed contrast-enhanced image is perhaps the optimal sequence to evaluate cervical metastatic disease.^{92,97} MRI provides the distinct advantage of viewing the neck and primary tumor in planes not available by CT. Difficulty with the use of MRI concerns both the time and motionlessness required for an acceptable study to be performed. Individuals with oral cancer frequently have large lesions that may compromise the airway while supine for extended periods of time. When using MRI for evaluating the neck the same criteria concerning nodal size, shape, and central necrosis should be applied as when evaluating with CT.

Ultrasound

Ultrasound (US) evaluation of the neck has become increasingly popular in European countries. Sonography is relatively inexpensive and is tolerated well. It may be used as an initial study to help guide the clinician in deciding whether further imaging studies of the neck may be required. This is especially true in the clinically N0 neck. Sensitivity of sonography in the detection of cervical lymph node metastasis is 89 to 95%, and specificity is 80 to

95%.^{98–100} This specificity can be increased with the use of US-guided fine-needle aspiration.¹⁰¹ Criteria for the evaluation of potentially malignant cervical nodes with sonography also involve the assessment of nodal size, shape, and presence of central necrosis. Metastatic nodes are characteristically round to spherical in shape and are frequently hypoechoic. In the presence of extracapsular spread, loss of border definition is observed. Normal lymph nodes are frequently difficult to detect because of their high echogenicity mimicking that of the surrounding fatty tissue.

Positron Emission Tomography

The use of 2-¹⁸F-fluoro-2-deoxy-D-glucose (FDG) positron emission tomography (PET) relies on the enhanced metabolic activity of tumoral tissue in the body, of which increased glycolysis is usually the biochemical hallmark. FDG, a radiolabeled glucose analog, is preferentially taken up within tumor cells that exhibit increased glycolysis; they can be detected from the increased signaling in that tissue (Figure 32-16). This study is

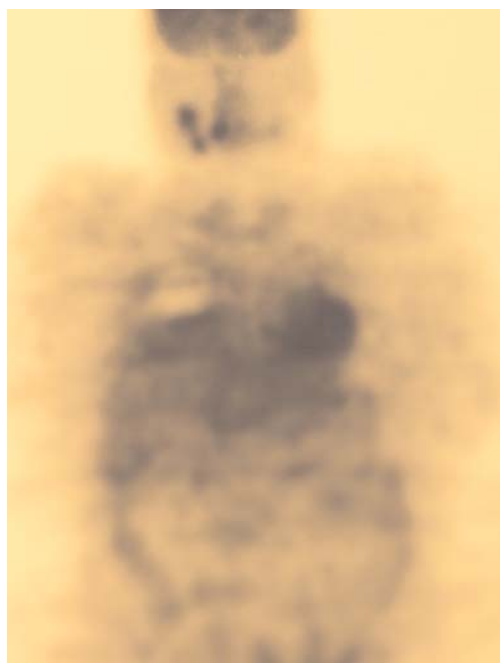

FIGURE 32-16 Preoperative positron emission tomography scan demonstrates increased activity in right tongue and right neck at levels II and III.

unique in that it represents a functional imaging scan as opposed to a morphologic imaging scan. A prospective study by Adams and colleagues showed a higher sensitivity and specificity for FDG-PET (90%, 94%) compared with CT (82%, 85%) and MRI (80%, 79%).¹⁰² Several other studies have produced similar results.^{103–105} As with ultrasound, FDG-PET may have a unique role in the evaluation of the clinically N0 neck.¹⁰⁶ FDG-PET has found a place in the evaluation of an unknown primary with success rates reported from 10 to 60% in the identification of the index lesion.^{107–109}

Drawbacks to the use of FDG-PET for evaluation of the neck include the inability to differentiate between cancerous and reactive inflammatory lymph nodes and the poor anatomic delineation of the primary tumor and neck nodes in relation to surrounding structures, particularly those of a vascular nature.

Assessment of Distant Metastasis

Final evaluation of the oral cancer patient involves a work-up for possible distant metastasis. Although the percentage of individuals who present with an untreated primary tumor who already have distant metastasis is low, it is prudent to have thoroughly staged the individual for optimal treatment planning. Distant metastasis from the oral cavity most frequently involves the lung, followed by liver and bone. Therefore, routine posterior-anterior and lateral chest radiographs and the evaluation of liver function tests (LFTs) are considered the minimum metastatic work-up for head and neck cancer patients. Depending on abnormalities found in the chest radiograph or LFTs, locoregional extent of the disease, and degree of clinical suspicion, the surgeon may also choose to obtain a CT of the chest or abdomen and pelvis. Obtaining other studies such as bone scans should be symptom-driven. An added advantage of an FDG-PET study in the evaluation of

distant metastatic oral cancer is its whole body imaging of possible tumor spread.

The infrequency of distant metastasis was recognized early by Crile.¹¹⁰ Studies produced from the patient database at Memorial Sloan-Kettering Cancer Center have also shown relatively low rates in the eventual development of distant metastasis, ranging from 13% in individuals with floor-of-mouth cancer to 15% in patients with carcinoma of the tongue.^{57,111} As new therapies lead to better locoregional control of disease, we can expect to see a greater incidence of distant metastasis in long-term follow-up.

Diagnosis

A thorough clinical examination is the first line of defense in the detection of oral cancer. Prognosis is directly dependent on the tumor stage at diagnosis. Nearly one-half of all oral cancers are not detected until they are in advanced stages. This delay may be because symptoms may not develop until later in the disease process or the socioeconomic group most likely to develop oral cancer is unable to seek treatment until it has reached an advanced stage. Studies have shown that only 14% of adults in the United States have ever had an oral cancer examination.¹¹² A study by Holmes and colleagues showed that detection of oral and oropharyngeal SCC during non-symptom-driven examinations was associated with a lower stage at diagnosis.¹¹³ These detections occurred in the dental office, whether by a dentist, dental hygienist, or oral and maxillofacial surgeon.

Toluidine Blue

Oral cancer can have various clinical appearances, ranging from subtle mucosal color or texture changes to gross ulceration or a fungating lesion. These mucosal alterations are particularly difficult to assess in early cancers and dysplasia. It was recognized in the 1960s that toluidine blue stained malignant cells in vivo. Tolu-

idine blue is a metachromic dye that has been used as a nuclear stain. The dye uptake has been shown to aid in the early recognition and diagnosis of oral SCC.¹¹⁴ While the dye's exact mechanism of action is unknown, theories have been proposed that the dye selectively stains cells with increased deoxyribonucleic acid synthesis or quantitatively more nucleic acids than other cells.¹¹⁵ It has also been suggested that the dye binds to sulfated mucopolysaccharides, found in higher quantities in actively growing cells. Several studies have borne out toluidine blue's sensitivity (89 to 100%) and specificity (62 to 90%) for oral SCC.¹¹⁵⁻¹¹⁷ This specificity increases when a protocol is followed involving a second rinse 14 days after the initial application to allow for resolution of any inflammatory lesions that may be present. The sensitivity of toluidine blue in detecting dysplastic lesions is not as high as that for SCC. Sensitivity rates have been recorded ranging from 74 to 84.6%.^{115,117} These dysplastic lesions stain inconsistently, and toluidine blue cannot be used as reliably.

Toluidine blue is currently marketed as a commercially available kit. Our opinion is that its use should be limited to the screening of high-risk individuals, and assisting in directing biopsies from a large area of abnormal-appearing tissue. In the end, toluidine blue cannot be substituted for a thorough oral examination and biopsies when clinical suspicion is high.

Biopsy

Once a clinically suspicious lesion is identified in the oral cavity, tissue diagnosis must be obtained prior to rendering any treatment. This biopsy can usually be done in an office setting or rarely under general anesthesia with panendoscopy if the lesion is difficult to access and patient tolerance is low. The traditional biopsy, whether incisional or excisional (for small lesions), is the gold standard. It should be emphasized that an accurate dimension of the

lesion should be acquired prior to biopsy in order to properly stage the lesion. When faced with a large lesion, it is best to take several biopsies from different sites in an attempt to decrease any sampling error that might be read as dysplasia, necrosis, or inflammation.

Brush cytology has gained acceptance in the dental community as a safe, minimally invasive technique for use in the screening of clinically suspicious lesions.¹¹⁸ Brush cytology differs from exfoliate cytology in that it removes an entire transepithelial layer for cytologic evaluation as opposed to the sloughing surface layer of the mucosa. Commercially available kits exist that include a brush biopsy instrument, glass slide, and fixative. The suspicious lesion is sampled by rubbing or rotating the sampling brush against its surface until pinpoint bleeding at the biopsy site is obtained, indicating sampling to the basement membrane and an adequate specimen. This specimen is then transferred to the slide, fixed in the office, and sent to the corporation for evaluation by both a computer and oral cytopathologist. Brush biopsy results are classified as "negative" when no epithelial abnormality is noted, "positive" when definite cellular evidence of dysplasia or carcinoma is found, "atypical" when abnormal epithelial changes of uncertain diagnostic significance are observed, and "inadequate" when an incomplete transepithelial specimen was submitted. The largest study of brush cytology by Scubba and colleagues found a sensitivity and specificity of 100%.¹¹⁹ However, as some authors have pointed out, a lack of investigation with scalpel biopsy of atypical results in "innocuous-appearing" lesions has resulted in a possible specificity exaggeration of this technique; other studies have borne this result out with reported sensitivities of approximately 90% but a specificity of only 3%.¹²⁰

Brush biopsies' best value may lie in the general dentist's hand where he or

she may encounter epithelial abnormalities on a daily basis and is reluctant to refer the patient for biopsy. It is our opinion that brush cytology is only a screening tool, and any atypical or positive results must be confirmed by an incisional biopsy. The same should be said about highly suspicious lesions read as "negative." If clinical suspicion remains high despite a negative cytology result, a biopsy should be obtained.

Conclusions

SCC of the oral cavity continues to be a common disease worldwide including in the United States. Despite research and advances in surgical and adjuvant therapy, long-term survival remains poor. It is a disease all clinicians will be faced with, and early recognition and diagnosis of premalignant and malignant disease is directly related to outcome. Proper staging of the primary lesion and neck with a thorough clinical examination and imaging is paramount to designing a successful treatment plan.

References

1. Jemal A, Murray T, Samuels A, et al. Cancer statistics, 2003. *CA Cancer J Clin* 2003;53:5-26.
2. Parkin DM, Pisani P, Ferlay J. Global cancer statistics. *CA Cancer J Clin* 1999;49:33-64.
3. Funk GF, Karnell LH, Robinson RA, et al. Presentation, treatment, and outcome of oral cavity cancer: a national cancer data base report. *Head Neck* 2002;24:165-80.
4. Strong EW, Spiro RH. Cancer of the oral cavity. In: Myers EN, Suen JY, editors. *Cancer of the head and neck*. 2nd ed. New York: Churchill Livingstone; 1987. p. 417-64.
5. Blot WJ, McLaughlin JK, Winn DM, et al. Smoking and drinking in relation to oral and pharyngeal cancer. *Cancer Res* 1988;48:3282-7.
6. Jovanovic A, Schulten EA, Kostense PJ, et al. Tobacco and alcohol related to the anatomical site of oral squamous cell carcinoma. *J Oral Pathol Med* 1993;22:459-62.
7. Mashberg A, Boffetta P, Winkelmann R, et al. Tobacco smoking, alcohol drinking, and cancer of the oral cavity and oropharynx among U.S. veterans. *Cancer* 1993;72:1369-75.
8. Neville B, Day TA. Oral Cancer and precancerous lesion. *CA Cancer J Clin* 2002;52:195-215.
9. Klotch DW, Muro-Cacho C, Gal TJ. Factors

- affecting survival for floor of mouth carcinoma. *Otolaryngol Head Neck Surg* 2000;122:495–8.
10. Rothman K, Keller A. The effect of joint exposure to alcohol and tobacco on risk of cancer of the mouth and pharynx. *J Chronic Dis* 1972;25:711–6.
 11. Kato I, Nomura A. Alcohol in the etiology of upper aero-digestive tract cancer. *Eur J Cancer B Oral Oncol* 1994;30:75–81.
 12. Smith EM, Hoffman HT, Summersgill KS, et al. Human papillomavirus and risk of oral cancer. *Laryngoscope* 1998;108:1098–103.
 13. Gillison ML, Koch WM, Capone RB, et al. Evidence for a causal association between human papillomavirus and a subset of head and neck cancers. *J Natl Cancer Inst* 2000;92:709–20.
 14. Vogelstein B, Kinzler KW. The multistep nature of cancer. *Trends Genet* 1993;9:138–41.
 15. Jeffries S, Foulkes WD. Genetic mechanisms in squamous cell carcinoma of the head and neck. *Oral Oncol* 2001;37:115–26.
 16. Wong DTW. TGF- α and oral carcinogenesis. *Eur J Cancer* 1993;29(B):3–7.
 17. Weinberg RA. Tumor suppressor genes. *Science* 1991;254:1138–46.
 18. Shin DM, Kim J, Ro JY, et al. Activation of p53 gene expression in premalignant lesions during head and neck tumorigenesis. *Cancer Res* 1994;54:321–6.
 19. Pfeifer GP, Denissenko MF, Olivier M, et al. Tobacco smoke carcinogenesis, DNA damage and p53 mutations in smoking associated cancers. *Oncogene* 2002;21:7435–51.
 20. Tabor MP, Brakenhoff RH, van Houten VMM, et al. Persistence of genetically altered fields in head and neck cancer patients: biological and clinical implications. *Clin Cancer Res* 2001;7:1523–32.
 21. Pindborg JJ. *Oral cancer and precancer*. Bristol: John Wright and Sons Ltd.; 1980.
 22. WHO Collaborating Centre for Oral Precancerous Lesions. Definition of leukoplakia and related lesions: an aid to studies on oral precancer. *Oral Surg Oral Med Oral Pathol* 1978;46:518–39.
 23. Silverman S, Gorsky M, Lozada F. Oral leukoplakia and malignant transformation: A follow up study of 257 patients. *Cancer* 1984;53:563–8.
 24. Banoczy J. Follow-up studies in oral leukoplakia. *J Maxillofac Surg* 1977;5:69–75.
 25. Waldron CA, Shafer WG. Leukoplakia revisited. *Cancer* 1975;36:1386–92.
 26. Silverman S, Bhargava K, Mani J, et al. Malignant transformation and natural history of oral leukoplakia in 57,518 industrial workers of Gujarat, India. *Cancer* 1976;38:1790–5.
 27. Neville BW, Damm DD, Allen CM, Bouquot JE, editors. *Epithelial pathology*. In: *Oral and maxillofacial pathology*. Philadelphia: WB Saunders; 1995. p. 315–87.
 28. Silverman S, Rosen RD. Observations on the clinical characteristics and natural history of leukoplakia. *J Am Dent Assoc* 1968;76:772–6.
 29. Shafer WG, Waldron CA. Erythroplakia of the oral cavity. *Cancer* 1975;36:1021–8.
 30. Pillai R, Balaram P, Reddiar KS. Pathogenesis of oral submucosal fibrosis. Relationship to risk factors associated with oral cancer. *Cancer* 1992;69:2011–20.
 31. Canniff JP, Harvey W, Harris M. Oral submucous fibrosis: its pathogenesis and management. *Br Dent J* 1986;160:429–34.
 32. Murti PR, Bhonsle RB, Pinborg JJ, et al. Malignant transformation rate in oral submucosal fibrosis over a 17-year period. *Community Dent Oral Epidemiol* 1985;13:340–1.
 33. Rouviere H. *Anatomy of the human lymphatic system*. Tobies MJ, translator. Ann Arbor (MI): Edwards Brother; 1938.
 34. Robbins KT, Clayman G, Levine PA, et al. Neck dissection classification update: Revisions proposed by the American Head and Neck Society and the American Academy of Otolaryngology-Head and Neck Surgery. *Arch Otolaryngol Head Neck Surg* 2002;128:751–8.
 35. Greene FL, Page DL, Fleming ID, et al, editors. *Head and neck sites*. In: *AJCC cancer staging manual*. 6th ed. New York: Springer-Verlag; 2002. p. 17–22.
 36. Greene FL, Page DL, Fleming ID, et al, editors. *Lip and oral cavity*. In: *AJCC cancer staging manual*. 6th ed. New York: Springer-Verlag; 2002. p. 23–32.
 37. Kralls SO, Hoffman S. Squamous cell carcinoma of the oral soft tissues: a statistical analysis of 14,253 cases by age, sex and race of patients. *J Am Dent Assoc* 1976;92:571–4.
 38. Chen J, Eisenberg E, Krutchkoff DJ, et al. Changing trends in oral cancer in the United States, 1935 to 1985: a Connecticut Study. *J Oral Maxillofac Surg* 1991;49:1152–8.
 39. Antunes JLF, Biazevic MGH, de Araujo ME, et al. Trends and spatial distribution of oral cancer mortality in Sao Paulo, Brazil, 1980–1998. *Oral Oncol* 2001;37:345–50.
 40. Worrall SF. Oral cancer incidence between 1971 and 1989. *Br J Oral Maxillofac Surg* 1995;33:195–6.
 41. Crosher R, Mitchell R. Incidence of oral cancer in Scotland 1971–1989. *Br J Oral Maxillofac Surg* 1995;33:333–4.
 42. Jorgensen K, Elbroud O, Anderson AP. Carcinoma of the lip: a series of 869 cases. *Acta Radiol Ther Phys Biol* 1973;12:177–90.
 43. Zitsch RP. Carcinoma of the lip. *Otolaryngol Clin North Am* 1993;26:265–77.
 44. Diaz EM, Holsinger PC, Zuniga ER, et al. Squamous cell carcinoma of the buccal mucosa: one institution's experience with 119 previously untreated patients. *Head Neck* 2003;25:267–73.
 45. Rao DN, Ganish B, Rao RS, et al. Risk assessment of tobacco, alcohol and diet in oral cancer- a case-control study. *Int J Cancer* 1994;58:469–73.
 46. Shah JP, Candela FC, Poddar AK. The patterns of cervical lymph node metastases from squamous carcinoma of the oral cavity. *Cancer* 1990;66:109–13.
 47. Urist MM, O'Brien CJ, Soong SJ, et al. Squamous cell carcinoma of the buccal mucosa: analysis of prognostic factors. *Am J Surg* 1987;154:411–4.
 48. Chhetri DK, Rawnsley JD, Calcaterra TC. Carcinoma of the buccal mucosa. *Otolaryngol Head Neck Surg* 2000;123:566–71.
 49. Gomez D, Faucher A, Picot V, et al. Outcome of squamous cell carcinoma of the gingiva: a follow-up study of 83 cases. *J Craniomaxillofac Surg* 2000;28:331–5.
 50. Soo KC, Spiro RH, King W, et al. Squamous carcinoma of the gums. *Am J Surg* 1988;156:105–9.
 51. Overholt SM, Eicher SA, Wolf P, et al. Prognostic factors affecting outcome in lower gingival carcinoma. *Laryngoscope* 1996;106:1335–9.
 52. Lindberg, R. Distribution of cervical lymph node metastases from squamous cell carcinoma of the upper respiratory and digestive tracts. *Cancer* 1972;29:1446–9.
 53. Lo K, Fletcher GH, Byers RM, et al. Results of irradiation in the squamous cell carcinomas of the anterior faucial pillar-retromolar trigone. *Int J Radiat Oncol Biol Phys* 1987;13:969–74.
 54. Byers RM, Anderson B, Schwartz EA. Treatment of squamous carcinoma of the retromolar trigone. *Am J Clin Oncol* 1984;7:647–52.
 55. Kowalski LP, Hashimoto I, Magrin J. End results of 114 extended “commando” operations for retromolar trigone carcinoma. *Am J Surg* 1993;166:374–9.
 56. Ossoff RH, Bytell DE, Hast MH, et al. Lymphatics of the floor of mouth and perioral: anatomic studies with possible clinical correlations. *Otolaryngol Head Neck Surg* 1980;88:652–7.
 57. Shaha AR, Spiro RH, Shah JP, et al. Squamous carcinoma of the floor of the mouth. *Am J Surg* 1984;148:100–4.
 58. Nason RW, Sako K, Beecroft WA, et al. Surgical management of squamous cell carcinoma

- of the floor of the mouth. *Am J Surg* 1989;158:292–6.
59. Tomich CE. Squamous-cell carcinoma of the floor of the mouth. *Oral Surg Oral Med Oral Pathol* 1978;45:568–79.
 60. Martin H. Tumors of the palate (benign and malignant). *Arch Surg* 1942;44:599–635.
 61. Ratzner ER, Schweitzer RJ, Frazell EL. Epidermoid carcinoma of the palate. *Am J Surg* 1970;119:294–7.
 62. Evans JF, Shah JP. Epidermoid carcinoma of the palate. *Am Surg* 1981;142:451–5.
 63. Chung CK, Johns ME, Cantrell RW, et al. Radiotherapy in the management of primary of the hard palate. *Laryngoscope* 1980;90:576–84.
 64. Frazell EL, Lucas JC Jr. Cancer of the tongue. Report of the management of 1,554 patients. *Cancer* 1962;15:1085–99.
 65. Atula S, Grenman R, Laippala P, et al. Cancer of the tongue in patients younger than 40 years. A distinct entity? *Arch Otolaryngol Head Neck Surg* 1996;122:1313–9.
 66. Martin-Granizo R, Rodriguez-Campo F, Naval L, et al. Squamous carcinoma of the oral cavity in patients younger than 40 years. *Otolaryngol Head Neck Surg* 1997;117:275.
 67. Myers JN, Elkins T, Roberts D et al. Squamous cell carcinoma of the tongue in young adults: increasing incidence and factors that predict treatment outcomes. *Otolaryngol Head Neck Surg* 2000;122:44–51.
 68. Spiro RH. Squamous cancer of the tongue. *CA Cancer J Clin* 1985;35:252–6.
 69. Greene FL, Page DL, Fleming ID, et al, editors. Purposes and principles of staging. In: *AJCC cancer staging manual*. 6th ed. New York: Springer-Verlag; 2002. p. 3–8.
 70. Spiro RH, Huvos AG, Wong GY, et al. Predictive value of tumor thickness in squamous cell carcinoma confined to the tongue and the floor of the mouth. *Am J Surg* 1986;152:345–50.
 71. Mohit-Tabataba M, Sobel HJ, Rush BF, et al. Relation of thickness of floor of mouth stage I and II cancers to regional metastasis. *Am J Surg* 1986;152:351–3.
 72. Brown B, Barnes L, Mazariegos J, et al. Prognostic factors in mobile tongue and floor of mouth carcinoma. *Cancer* 1989;64:1195–202.
 73. Warren S, Gates O. Multiple primary malignant tumors. A survey of the literature and a statistical study. *Am J Cancer* 1932;16:1358–414.
 74. Slaughter DP, Southwick HW, Smejkal W. “Field cancerization” in oral stratified squamous epithelium. *Cancer* 1953;6:963–8.
 75. Braakhuis BJM, Tabor MP, Leemans R, et al. Secondary primary tumors and field cancerization in oral and oropharyngeal cancer: Molecular techniques provide new insights and definitions. *Head Neck* 2002;24:198–206.
 76. McQuirt WF. Panendoscopy as a screening examination for simultaneous primary tumors in head and neck cancer: a prospective sequential study and review of the literature. *Laryngoscope* 1982;92:569–76.
 77. Vrabec DP. Multiple primary malignancies of the upper aerodigestive system. *Ann Otol Rhinol Laryngol* 1979;88:846–54.
 78. Vaamonde P, Martin C, Rio MD, et al. Second primary malignancies in patients with cancer of the head and neck. *Otolaryngol Head Neck Surg* 2003;129:65–70.
 79. Shikhani AH, Matanoski GM, Jones MM, et al. Multiple primary malignancies in head and neck cancer. *Arch Otolaryngol Head Neck Surg* 1986;112:1172–9.
 80. Leipzig B, Zellmer JE, Klug D, et al. The role of endoscopy in evaluating patients with head and neck cancer. *Arch Otolaryngol* 1985;11:589–94.
 81. Maisel RH, Vermeersch H. Panendoscopy for second primaries in head and neck cancers. *Ann Otol Rhinol Laryngol* 1981;90:460–4.
 82. Benninger MS, Enrigue RR, Nichols RD. Symptom-directed selective endoscopy and cost containment for evaluation of head and neck cancer. *Head Neck* 1993;15:532–6.
 83. Shaha A, Hoover E, Marti J, et al. Is routine triple endoscopy cost effective in head and neck cancer? *Am J Surg* 1988;155:750–3.
 84. Davidson J, Gilbert R, Irish J, et al. The role of panendoscopy in the management of mucosal head and neck malignancy- a prospective evaluation. *Head Neck* 2000;22:449–54.
 85. Som PM. Lymph nodes. In: Som PM, Cutin HD, editors. *Head and neck imaging*. 3rd ed. St. Louis (MO): Mosby-Year Book; 1996. p. 772–93.
 86. Snow GB, Annyas AA, Van Slooten A, et al. Prognostic factors of neck node metastasis. *Clin Otolaryngol* 1982;7:185–92.
 87. Coatesworth AP, MacLennan K. Squamous cell carcinoma of the upper aerodigestive tract: the prevalence of microscopic extracapsular spread and soft tissue deposits in the clinically N0 neck. *Head Neck* 2002;24:258–61.
 88. Grandi C, Alloisio M, Moglia D, et al. Prognostic significance of lymphatic spread in head and neck carcinomas: therapeutic implications. *Head Neck Surg* 1985;8:67–73.
 89. Merritt RM, Williams MF, James TH, et al. Detection of cervical metastasis: a meta-analysis comparing computed tomography with physical examination. *Arch Otolaryngol Head Neck Surg* 1997;123:149–52.
 90. Alderson DJ, Jones TM, White SJ, et al. Observer error in the assessment of nodal disease in head and neck cancer. *Head Neck* 2001;23:739–43.
 91. Mancuso AA, Harnsberger HR, Muraki AS, et al. Computed tomography of cervical and retropharyngeal lymph nodes: normal anatomy, variants of normal, and applications in staging head and neck cancer. *Radiology* 1983;148:715–23.
 92. Som P. Detection of metastasis in cervical lymph nodes: CT and MR criteria and differential diagnosis. *AJR Am J Roentgenol* 1992;158:961–9.
 93. van den Brekel MWM, Stel HV, Castelijns JA, et al. Cervical lymph node metastasis: assessment of radiologic criteria. *Radiology* 1990;177:379–84.
 94. Feinmesser R, Freeman JL, Nojek AM, et al. Metastatic neck disease: a clinical/radiographic/pathologic correlative study. *Arch Otolaryngol Head Neck Surg* 1987;113:1307–10.
 95. Mancuso AA, Maceri D, Rice D et al. CT of cervical lymph node cancer. *AJR Am J Roentgenol* 1981;136:381–5.
 96. Sakai O, Curtin HD, Romo IV, et al. Lymph node pathology: benign proliferative, lymphoma, and metastatic disease. In: Weber AL, editor. *The radiology clinics of North America. Radiologic evaluation of the neck*. Philadelphia: WB Saunders Company; 2000. p. 971–98.
 97. van den Brekel MWM, Castelijns JA, Stel HV, et al. Detection and characterization of metastatic cervical adenopathy by MR imaging: comparison of different MR techniques. *J Comput Assist Tomogr* 1990;14:581–9.
 98. Delorme S. Sonography of enlarged cervical lymph nodes. *Imaging* 1993;60:267–72.
 99. Eichhorn T, Schroder HG. Ultrasound in metastatic neck disease. *ORL J Otorhinolaryngol Relat Spec* 1992;55:258–62.
 100. Vassallo P, Wernecke K, Roos N, et al. Differentiation of benign from malignant superficial lymphadenopathy: the role of high resolution US. *Radiology* 1992;183:215–20.
 101. Koischwitz D, Gritzmann N. Ultrasound of the neck. In: Weber AL, editor. *The Radiology Clinics of North America. Radiologic evaluation of the neck*. Philadelphia: WB Saunders Company; 2000. p. 1029–45.
 102. Adams S, Baum RP, Stuckensen T, et al. Prospective comparison of ¹⁸F-FDG PET with conventional imaging modalities (CT, MRI, US) in lymph node staging of

- head and neck cancer. *Eur J Nucl Med* 1998;25:1255–60.
103. Stuckensen T, Kovacs AF, Adams S, et al. Staging of the neck in patients with oral cavity squamous cell carcinomas: a prospective comparison of PET, ultrasound, CT, and MRI. *J Craniomaxillofac Surg* 2000;28:319–24.
104. Sigg MB, Steinert H, Gratz K, et al. Staging of head and neck tumors: (¹⁸F) Fluorodeoxyglucose positron emission tomography compared with physical examination and conventional imaging modalities. *J Oral Maxillofac Surg* 2003;61:1022–9.
105. Laubenbacher C, Saumweber D, Wagner-Manslau C, et al. Comparison of fluorine-18-fluorodeoxyglucose PET, MRI, and endoscopy for staging head and neck squamous-cell carcinomas. *J Nucl Med* 1995;36:1747–57.
106. Myers LL, Wax MK, Nabi H, et al. Positron emission tomography in the evaluation of the N0 neck. *Laryngoscope* 1998;108:232–6.
107. Braams JW, Pruijm J, Kole AC, et al. Detection of unknown primary head and neck tumors by positron emission tomography. *Int J Oral Maxillofac Surg* 1997;26:112–5.
108. Davis JP, Maisey NM, Chevreton EB. Positron emission tomography, a useful imaging technique for otolaryngology, head and neck surgery? *J Laryngol Otol* 1998;112:125–7.
109. Keyes JW, Watson NE, Williams DW, et al. FDG PET in head and neck cancer. *AJR Am J Roentgenol* 1997;169:1663–9.
110. Crile G. Excision of cancer of the head and neck with special reference to the plan of dissection based on one hundred and thirty-two operations. *JAMA* 1906;47:1780–8.
111. Callery CO, Spiro RH, Strong EW. Changing trends in the management of squamous carcinoma of the tongue. *Am J Surg* 1984;148:449–54.
112. Horowitz AM, Nourjah PA. Factors associated with having oral cancer examinations among US adults 40 years of age or older. *J Public Health Dent* 1996;56:331–5.
113. Holmes JD, Dierks EJ, Homer LD, et al. Is detection of oral and oropharyngeal squamous cancer by a dental health care provider associated with a lower stage at diagnosis? *J Oral Maxillofac Surg* 2003;61:285–91.
114. Mashberg A, Samit A. Early diagnosis of asymptomatic oral and oropharyngeal squamous cancers. *CA Cancer J Clin* 1995;45:328–51.
115. Silverman S Jr, Dillon WP, Fischbein NJ. Diagnosis. In: Silverman S Jr, editor. *Oral cancer*. 4th ed. Lewiston: BC Decker, 1998. p. 41–66.
116. Mashberg A. Final evaluation of telenium chloride rinse for screening of high-risk patients with asymptomatic squamous carcinoma. *J Am Dent Assoc* 1983;106:319–23.
117. Warnakulasuriya KAAS, Johnson NW. Sensitivity and specificity of Orascan® toluidine blue mouth rinse in the detection of oral cancer and precancer. *J Oral Pathol Med* 1996;25:97–103.
118. Christian DC. Computer-assisted analysis of oral brush biopsies at an oral cancer screening program. *J Am Dent Assoc* 2002;133:357–62.
119. Sciubba JJ, US Collaborative Oral CDX Study Group. Improving detection of precancerous and cancerous oral lesions. *J Am Dent Assoc* 1999;130:1445–57.
120. Rick GM, Slater L. Oral brush biopsy: the problem of false positives. *Oral Surg Oral Med Oral Pathol Oral Radiol Endod* 2003;96:252.

Oral Cancer Treatment

Jon D. Holmes, DMD, MD

Eric J. Dierks, DMD, MD

Oral cavity cancers account for 30% of head and neck cancers and represent a significant challenge to clinicians. Treatment requires multidisciplinary expertise and is complicated by the complex role that the oral cavity plays in speech, mastication, and swallowing. Oral squamous carcinomas account for 90% of malignancies affecting the oral cavity, and will be the focus of this chapter. Although discussion will be limited to the treatment of squamous cell cancers, oncologic principles outlined in this chapter can be applied to other malignancies affecting the oral cavity.¹⁻³

Regardless of advances in diagnosis and treatment, mortality from oral cancer has not changed significantly in the past 50 years. Approximately 50% of patients diagnosed with oral cancer will ultimately die of their disease.^{4,5} Early detection and appropriate treatment of cancers remain the most effective weapons against cancers of the oral cavity. Unfortunately public and professional awareness and knowledge of oral cancer is low. A recent editorial referred to oral cancer as “The Forgotten Disease.”⁶ Incidence and mortality for oral cancer is nearly double that of cancer of the cervix (30,300 vs 13,500 and 8,000 vs 4,400, respectively); yet few adults can remember their last oral cancer examination, whereas most women are aware of their last gynecologic examination and Pap smear.⁷ Patient knowledge of other cancers, such as skin, breast, and prostate, has

increased in recent years because of public awareness campaigns. Only recently, however, has oral cancer begun to receive some of the same attention. The American Cancer Society recommends a cancer-related check-up, including examination for cancers of the oral cavity, every 3 years for asymptomatic men and women aged 20 to 39 years and yearly for men and women aged 40 years and older.⁸ Although the oral cavity is readily accessible for examination, results of a study by Holmes and colleagues questioned whether health care professionals were screening for asymptomatic cancers.⁹ Additionally, smaller symptomatic cancers often went undetected in their study and were ultimately detected at a later stage. Interestingly all asymptomatic cancers were referred from dental practices, and the average clinical and pathologic stage of cancers referred from physician offices were statistically higher.⁹ This is unfortunate since the population at highest risk for development of an oral cancer is four to six times more likely to seek care from a physician than a dentist.^{10,11} Clearly there is a need for increasing the public’s awareness of oral cancer and improving screening for early oral cancers in order to improve outcomes regardless of treatment modality employed.

Histology

Just as the molecular events leading to the development of squamous cell carcinoma

are a multistep process, the histologic progression of benign mucosa to invasive cancer typically follows an orderly progression. Although squamous cell carcinoma is the most common, other variations require alterations in treatment.

Verrucous carcinoma is generally considered an uncommon variant of squamous cell carcinoma, representing only 5% of oral cancers.¹² It has a predilection for the buccal mucosa, and typically appears as a thick white cauliflower-like growth (Figure 33-1). The basement membrane is typically intact and the cells are very well differentiated. It is not uncommon to find focal areas of invasive squamous cell carcinoma within the excised specimen, and patients should be prepared for this eventuality. The prognosis is excellent following adequate excision.

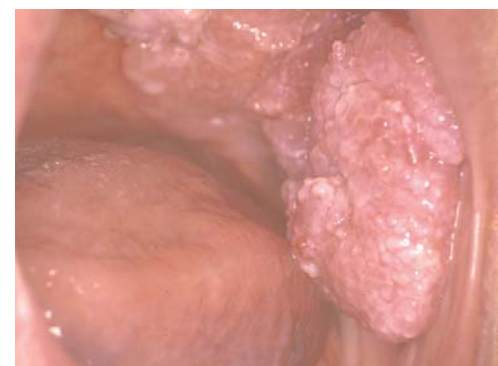

FIGURE 33-1 Verrucous carcinoma of buccal mucosa with extension onto the adjacent maxillary alveolus.

Basaloid squamous cell carcinoma represents a rare aggressive form of squamous carcinoma. It affects males predominately, and is associated with a high rate of cervical and distant metastases.¹³ Histologically basaloid cells are arranged in nests or cords. Perineural invasion and a high mitotic index are common and coincide with its tendency to recurrence and worse prognosis, with a 38% mortality at 17-month follow-up.¹⁴ Given the aggressive nature of basaloid squamous cell carcinoma, elective treatment of the neck and postoperative radiotherapy with or without adjunct chemotherapy are probably indicated.

It is helpful to request from the pathologist a depth-of-invasion measurement on more superficial lesions, given its predictive value in regard to occult metastases, and determining the need for elective neck dissection (see discussion on elective neck dissection in this chapter). Depth of invasion will not influence treatment of deep indurated or fixed lesions. Slowly resorbing sutures, which will serve as a marker if an excisional biopsy is performed, is best if closure is required.

Management of Premalignant Lesions

Leukoplakia is defined as a predominately white lesion of the oral mucosa that cannot be characterized as any other definable lesion (Figure 33-2).¹⁵ Worldwide estimates of its prevalence range from 1.5 to

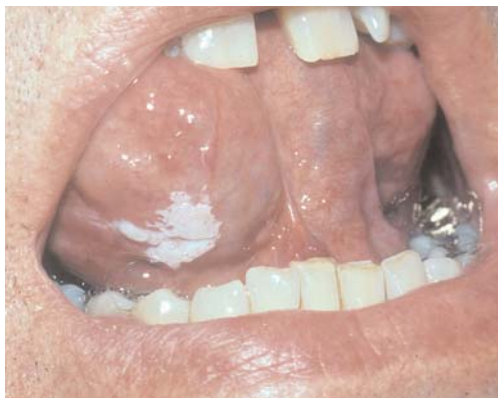

FIGURE 33-2 *Leukoplakia of the ventral tongue.*

2.6%.¹⁶ Lower socioeconomic status seems to be associated with higher prevalence.¹⁷ The potential for malignant transformation of oral leukoplakia to invasive squamous cell carcinoma is well recognized, and leukoplakia can be considered a precancerous lesion (ie, “a morphologically altered tissue in which cancer is more likely to occur than in its apparent normal counterpart”).¹⁵ Estimated rates of transformation, however, vary widely. This most likely relates to the heterogeneity of the lesions included in most studies. While homogeneous white leukoplakia has a relatively low risk, erythroleukoplakia has a high incidence of associated dysplasia, carcinoma in situ, and frank carcinoma. In their oft-quoted study of 257 patients followed for a mean of 8 years, Silverman and colleagues found transformation rates for leukoplakia to range from 6.5% for homogeneous lesions to 23.4% in erythroplasia.¹⁸ Lesions containing dysplasia had a transformation rate of 36.4%.¹⁸ The annual transformation rate in one population was less than 1%, which still demonstrated a 36-fold risk increase for squamous cell carcinoma in patients with oral leukoplakia over the population in general.¹⁹

Predicting which lesions will ultimately transform is currently not possible. Given its asymptomatic nature, the sole indication for treatment of leukoplakia is an attempt to prevent subsequent malignant transformation. Treatment modalities include excision, ablation, and chemoprevention. Unfortunately no treatment modality has been shown to prevent subsequent development of squamous cell carcinoma.

The first Cochrane review on therapy for leukoplakia did not find any reliable therapy to prevent the transformation of leukoplakia to oral squamous cell carcinoma.²⁰ Also, there were no effective preventive measures to halt the development of oral leukoplakia. No surgical procedures were included in this review because of the lack of randomized clinical trials evaluat-

ing surgical excision. Chemopreventive agents including retinoids, beta carotene, green tea, and bleomycin were evaluated. Retinoids held the most promise and were associated with resolution of lesions. The ultimate goal remains prevention of subsequent malignant transformation, and unfortunately none of the agents demonstrated this reliably. In addition associated side effects were problematic (see section “Chemoprevention” in this chapter).^{20,21}

Surgical excision remains an alternative for dealing with worrisome lesions. CO₂ laser excision has been used to treat widespread superficial lesions in an attempt to limit scarring and morbidity associated with large excisions. Laser ablation allows the destruction of large superficial lesions. It does not provide a histologic specimen, however, and biopsies from any areas of ulceration or erythroplasia are probably indicated prior to ablation. Unfortunately recurrence following laser excision or ablation is not uncommon, and it does not necessarily prevent malignant transformation.²²

Given the high rates of multiple lesions and their propensity to recur, photodynamic therapy (PDT) is gaining popularity as a potential method for dealing with multiple diffuse lesions. PDT relies on a complex interaction of a photosensitizing agent, which is preferentially concentrated in abnormal tissue, with light of various wavelengths, depending on the photosensitizer, to create necrosis through a nonthermal reaction. Tissue necrosis is mediated through the creation of singlet oxygen, a highly reactive species that induces cellular damage through several mechanisms. Advantages of PDT include minimal damage to surrounding tissues and no cumulative damage, which theoretically allows unlimited treatments. Given the propensity for these patients to develop multiple lesions, this is an important advantage over excision or ablation using traditional methods. Disadvantages include marked photosensitivity, especially

with regard to sun exposure, for variable lengths of time after the administration of the agent. Areas treated undergo healing through mucosalization with minimal or no scarring. Although a complete review of PDT is beyond the scope of this chapter, excellent reviews are available.^{23–25}

PDT has been used with some success in the endoscopic treatment of dysplastic Barrett's esophagitis to prevent its transformation to adenocarcinoma.²⁶ Similarly attempts have been made to treat diffuse oral leukoplakia with PDT with some success.²⁷ In addition to its role in the management of leukoplakia, initial trials of PDT applied to invasive squamous cell carcinoma of selected sites in the head and neck are being reported. Copper and colleagues reported on 25 patients with T1 and T2 lesions of the oral cavity and oropharynx treated with PDT. Complete remission was noted in 86% of lesions. Recurrences were salvaged with conventional therapy.²⁸ In addition to its application to mucosal lesions, interstitial delivery of light may allow treatment of more deeply situated tumors. Although results are promising, PDT for leukoplakia and oral cavity cancers remains investigational, and its role in the management of leukoplakia and squamous cell cancers of the head and neck awaits clarification.

Role of Panendoscopy in Treatment Planning

Once a histologic diagnosis of oral cancer has been made, a patient evaluation is initiated in an attempt to define the extent of the locoregional disease, as well as the existence of distant metastases. The discussion that was started with the patient when the biopsy was performed is now continued with the knowledge that a malignancy is present, but that continued work-up is necessary to define the extent of disease. Patients frequently feel a sense of urgency once a diagnosis of cancer is rendered. They want treatment initiated quickly. It is important to convey that cancer is not a

surgical emergency and that the growth rate of epithelial malignancies allows for an appropriate evaluation that must be completed prior to making treatment recommendations. It should also be remembered that there is a high incidence of depression in the head and neck cancer patient population. The level of family and community support should be gauged, and appropriate referrals should be made if deemed necessary. The patient's overall medical condition should also be assessed in preparation for any planned treatment. Aside from the standard history and physical examination, including head and neck examination, nasopharyngoscopy or indirect laryngoscopy in the office should be considered. This evaluation may be forgone if panendoscopy or "triple endoscopy" is planned to search for synchronous primary cancers.

Following McGuirt's 1982 study of panendoscopy, examination of the esophagus, larynx, and bronchus was considered mandatory in the work-up of the patient with cancer of the head and neck.²⁹ A mirror examination of the nasopharynx was also frequently included. McGuirt's finding of synchronous tumors in 16% of patients led most clinicians to include panendoscopy in their evaluation.²⁹ Recently its routine use has been called into question for a variety of reasons, including cost containment, improved imaging modalities, and lower rates of synchronous primary tumors of the head and neck than previously expected. Some clinicians still feel there is a role for an examination of the primary cancer under general anesthesia, along with panendoscopy. They argue that the ability to examine some larger primary cancers is compromised in the clinical setting because of patient discomfort, and that the panendoscopy affords the clinician an invaluable opportunity to examine the primary cancers without this constraint. Others argue that the low yield of bronchoscopy over chest radiographs and computed tomography (CT) scans and the

ability to perform an examination of the larynx with flexible nasopharyngoscopy mitigate against the usefulness of rigid laryngoscopy and bronchoscopy. Also, the majority of patients with cancer of the head and neck receive a flexible esophagoscopy along with placement of a percutaneous endoscopic gastrostomy tube. For these reasons panendoscopy should probably be symptom driven.³⁰

Choosing a Treatment

Once the initial evaluation, data collection, and staging are complete, a discussion regarding treatment is undertaken. The clinician and the patient are faced with deciding which treatment modality or combination offers not only the best chance for cure, but also quality of life. Quality-of-life issues are becoming increasingly important in treatment planning. Despite media hyperbole on cancer treatment "breakthroughs," cancer treatment still falls into three basic categories: surgery, radiation, or chemotherapy, or some combination thereof. Choosing the appropriate treatment relies on many factors, including the patient's medical condition as well as the modalities available to the clinician. Certain therapeutic modalities, such as neutron beam radiotherapy, may hold promise for certain tumors, but are limited in their availability. Although each will be discussed separately in the upcoming sections, most patients will ultimately receive more than one form of treatment.

Surgery

Surgery remains the cornerstone of most treatment regimens for oral cavity cancer. Surgery offers several advantages, including the harvest of a specimen for histopathologic analysis and the possibility of removing the cancer with one treatment modality at one session. For most stage I and stage II cancers of the oral cavity, surgical resection with frozen section analysis of the margins is advocated by most clinicians. Although primary radiation to

T1 and T2 lesions may offer similar disease control, the side effects of radiation to the oral cavity outweigh those of surgery in most situations. In addition, given the rate of second primary cancers in the head and neck cancer patient population, it is often better to hold radiation if possible in case it is needed in the future. The oral cancer patient population is prone to the development of second primary cancers and some would argue that radiation for borderline indications might be withheld for future use should the need arise. Reirradiation, although possible in some circumstances, is associated with a high degree of morbidity.

The importance of obtaining clear histologic margins has been a foundation for surgical treatment of oral cavity cancer and has been supported by several studies that have demonstrated decreased survival associated with positive margins, even if follow-up radiation is given. Unfortunately clear pathologic margins are not always an assurance of a good outcome. Field cancerization is a concept that was proposed by Slaughter and colleagues in 1953, after they reviewed resection specimens from the oral cavity and oropharynx. They found multiple foci of cancer in 11% of specimens. Areas of dysplasia also existed distant from the primary site.³¹ Additional studies have shown that margins that are clear histologically may still have cells at the margin that demonstrate premalignant changes, and this can be associated with recurrence. A recent study demonstrated that an altered *P53* gene existed in 52% of reviewed patients and that recurrence occurred in almost half of these patients.³² Other markers have been shown through molecular analysis to exist at margins that are clear histologically; specifically the proto-oncogene *eIF4E* has been shown to be associated with a decreased disease-free interval when present at the resection margin.³² In an interesting study Thomson performed biopsies in patients with unilateral squamous cell

carcinomas or premalignant lesions.³³ These biopsies were taken on the opposite side of the mouth in the same area as the contralateral cancer or premalignant lesion. These so-called “mirror image” biopsies revealed frank dysplasia or carcinoma in situ in 30% of patients.³³ This concept of “condemned mucosa” has caused clinicians to question the ability of surgeons to obtain clear margins in some cancers. Studies have clearly shown, however, a decreased local control and survival in patients with positive margins.

Jacobs and colleagues analyzed patients who had received postoperative radiation; patients with satisfactory margins suffered an 11% relapse rate, whereas patients with unsatisfactory margins relapsed 26% of the time.³⁴ This is most likely due to the inability of radiation therapy to deal with the increased tumor cell burden in some cases of final positive margins.³⁴ These studies have led some to investigate addition of brachytherapy to external beam postoperative radiation to patients with unsatisfactory margins, and to subsequently demonstrate improved survival in patients with positive margins who received this intensive radiation.³⁵ It is agreed by most that surgeons should strive for clear margins, given this impact of positive margins on survival. Excision with 1 to 1.5 cm of normal tissue beyond the obvious tumor edge is generally sufficient. Margins should then be harvested from either the specimen or the wound resection periphery depending on the surgeon's preference. These thin strips are oriented for the pathologist using a specimen map (Figure 33-3). Mucosal margins as well as deep margin specimens are submitted; however, frozen-section analysis is accurate but not infallible. Indeed the role of frozen analysis of margins in oral cavity cancer has been heavily debated and its cost effectiveness called into question, leading some surgeons to abandon the practice. Although frozen-section analysis is highly accurate and has a high correla-

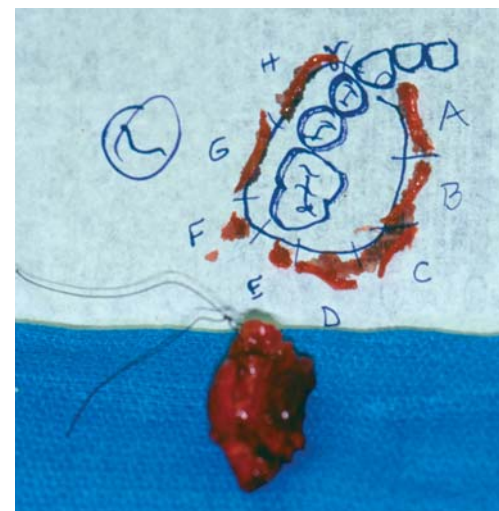


FIGURE 33-3 Specimen map for demonstration of the orientation of frozen section specimens to the pathologist.

tion with final histologic analysis of the submitted tissue samples, its ability to predict whether the entire tumor surface of the final specimen will be clear of close or involved margins is not as reliable. For this reason frozen sections appear to be more beneficial in smaller localized tumors.^{36–38}

On occasion a surgeon will be faced with a situation where the frozen margins were negative but the final processed specimen shows involvement of one or more margins. This phenomenon can have several explanations. First, sampling error can occur. Secondly, if the margins analyzed by frozen technique were taken from the tumor resection bed, then it might lie just beyond the cancerous margin. Also, tumor shrinkage of approximately 25 to 30% occurs when the tumor is removed from the body. Faced with this dilemma the surgeon has several options. Re-excision of a positive soft tissue margin is difficult and rarely productive. Wound closure or reconstruction of the defect distorts tissue, and it is frequently impossible to determine exactly where the positive margin was. For this reason a final positive margin may represent an indication for postoperative radiation therapy (see section “Radiation” below). Conversely clearance of cancer within bone with radiation is difficult

and recurrence rates are high, suggesting that patients with positive bone margins should be strongly considered for re-excision. Recent reports illustrate that pathologic margins that are positive on final analysis are more likely a reflection of the aggressiveness of the particular cancer than a reflection on the surgical procedure. Sutton and colleagues found that final positive margins had a high correlation with aggressive histologic parameters such as perineural and lymphovascular invasion.³⁹ Thus, the biologic aggressiveness suggested by positive margins may in itself account for the poorer outcome of patients with positive surgical margins, and be an indication for multimodality therapy instead of attempts at re-excision.

Surgery in patients with head and neck squamous cancer presents unique challenges that surgeons should be prepared to face. The following discussion offers an overview of some of the perioperative issues facing patients and surgeons. Subsequent sections will review surgical points pertinent to specific sites within the oral cavity.

Perioperative Issues in Oral Cavity Cancer Treatment

The decision to operate on a patient with head and neck cancer must involve consideration of potential complications. Studies have demonstrated that age itself is not associated with increased complications, but comorbidities are associated with increased complications and lengthy hospital stays. This is especially true regarding complex reconstructive efforts, such as vascularized tissue transfer.⁴⁰ Several factors deserve special attention in the patient undergoing surgery for a malignancy of the upper aerodigestive tract.

Airway If there is any doubt concerning the ability of a patient to maintain an airway in the perioperative period, a tracheotomy is advisable. A tracheotomy tube does not prevent aspiration, and paradoxi-

cally may actually increase its likelihood because of tethering of the trachea and impaired glottic closure. Tracheotomy is not without its own risks, and the nursing staff performing tracheotomy care must be well versed in suctioning and maintenance. Decanulation can generally be performed soon after edema has decreased.

Perioperative Antibiotics Operations on the oral cavity are considered “clean-contaminated,” and therefore, perioperative antibiotics are indicated. Several well-controlled studies have demonstrated that antibiotics started prior to the incision and continued for no more than 24 hours serve to minimize perioperative infections and emergence of resistant strains. First-generation cephalosporins and clindamycin represent the most commonly used prophylactic antibiotics in oral cancer surgery. Topical antimicrobials such as chlorhexidine and clindamycin rinses have also been shown to successfully reduce the incidence of infections.^{41,42}

Alcohol Withdrawal Many patients with oral cavity cancer will be dependent on alcohol. Alcohol withdrawal is common if precautions are not taken and can culminate in delirium tremens leading to cardiovascular collapse and death. Appropriate prophylaxis with benzodiazepines is recommended if the patient drinks daily. Lorazepam is commonly used because of its predictable onset and lack of active metabolites. Intravenous alcohol (5 to 10% alcohol with 5% dextrose in water) can be used in the postoperative period and slowly tapered as the patient recovers from surgery.

Deep Venous Thrombosis Patients who will be immobilized for a significant time during surgery or following surgery should receive prophylaxis for deep venous thrombosis. This prophylaxis most commonly takes the form of mechanical compression devices that cause endothelial cells to

release antithrombogenic factors and prevent stasis. It is important that these be placed and activated before surgery. Pharmacologic agents are generally reserved for known cases of thrombosis because of their propensity to cause bleeding in the postoperative setting. Low-molecular-weight heparin may be an option in this setting. If the patient has undergone microvascular reconstruction, aspirin or low-molecular-weight dextran may be indicated.

Fluid Management Most patients undergoing surgery for oral cavity cancers can be managed without invasive monitoring of fluid status. Colloids may be needed to prevent undue amounts of crystalloid leading to a significant increase in edema. Preoperative and daily weights can be used to track fluid status. In patients with compromised cardiovascular reserve or in those undergoing large resections and free-flap reconstruction, invasive monitoring with central venous monitoring or via a Swan-Ganz catheter may be necessary. Although uncommonly performed, patients requiring bilateral resection of the internal jugular veins will need fluid restriction.

Transfusion Opinions regarding the need for transfusion vary. In general a hematocrit less than 25 requires transfusion, and those between 25 and 30 may need transfusion based on clinical parameters.

Nutrition Many patients with head and neck cancer will present with decreased nutrition reserves. Even patients without weight loss are often faced with therapies that will leave them unable to maintain their nutrition. The ability to bypass the upper digestive tract during intense multimodality therapy by the endoscopic placement of a gastric feeding tube (percutaneous endoscopic gastrostomy or PEG tube) is invaluable. This procedure offers a minimally invasive “lifeline” for patients undergoing intensive therapy to the head

and neck. Placement of a PEG tube has become commonplace in head and neck cancer patients. Although rare there have been anecdotal reports of seeding squamous cell carcinoma to the abdominal wall if the PEG is placed prior to resection.⁴³ This complication, although rare, has led some surgeons to recommend placement in the postoperative period. Even if a PEG is placed, the patient should be encouraged to continue some oral intake, as the risk of esophageal stenosis increases if the patient completely stops oral alimentation during radiation treatment. This is especially true during combined chemoradiation protocols.

Complications of Surgery

Complications of surgical resection are many and vary directly with the patient's comorbidities, such as ischemic cardiac disease, chronic pulmonary disease, and alcoholism. Medical manifestations of preexisting chronic disease states, such as myocardial infarction, stroke, and pneumonia, can be precipitated by major surgery, a long general anesthetic, and a prolonged intensive care unit stay. Significant morbidity or death can be the result. Technical surgical complications, such as failure of reconstructive flaps, development of fistulas, and the other myriad problems that may require return to surgery for management, pale in significance to the greatest complication—locoregional recurrence of the cancer.

Radiation

A complete review of radiation physics and medicine is beyond the scope of this chapter, and excellent reviews on the topic are available.⁴⁴ Surgeons dealing with oral cancer should have an understanding of radiation therapy and its advantages and disadvantages. This entails a familiarity with radiation biology and the interaction of radiation with living tissue, as well as the biology of cell death. Cell death can be divided into two types: reproductive cell death, which results from damage to cel-

lular genetic material, or apoptosis, which is programmed cell death. Reproductive cell death can occur as a result of single DNA strand breaks, which are common and easier for the cell to repair, or double-strand breaks, which are more difficult for the cell to recover. Apoptosis occurs when a cell enters a programmed cell death mode as a result of damage. Radiation can cause either type of cell death and also slows cellular division. Classically radiation is discussed in terms of the four R's: repair, reoxygenation, redistribution, and regeneration.

Radiotherapy is primarily given by external beam using electromagnetic radiation or particulate components. X-rays and gamma rays represent photons. X-rays are produced by a man-made source and gamma rays are produced by radioactive decay, most commonly of cobalt 60. Particulate radiation using electrons plays an important role in head and neck cancer. Another form of particulate radiation is neutron radiotherapy, which may have a specific role in salivary gland malignancy.⁴⁵ Regardless of the source, radiation interacts with tissue to produce several types of damage to cells. The radiation particle-cell interaction may be either direct, or more commonly impact with H₂O molecules to create secondary particles that interact with cellular DNA. Absorbed dose is reported as a gray (Gy), which is one joule of absorbed dose per kilogram. Previously dose was reported as a rad, which was defined as 100 ergs absorbed per gram. One gray is equal to 100 rad and one centigray (cGy) equals one rad (1 cGy = 1 rad).

In the early to mid-twentieth century, radiation was given as orthovoltage (125 to 500 KeV). Currently radiation is delivered as megavoltage (> 1 MeV). Megavoltage results in more radiation delivered to deeper tissues with less superficial (skin) damage. In comparison a superficial radiograph unit (x-ray machine) delivers 30 to 125 KeV. Radiation therapy is typically

given in daily doses of 200 cGy, except in altered fractionation schedules.

Fractionation refers to the schedule on which the radiation dose is administered. Standard radiotherapy is administered daily, 5 days a week, with weekends off. In an effort to maximize damage to the more rapidly dividing tumor cells while sparing normal tissues as much as possible, fractionation schedules have been altered. Although used primarily in clinical trials, clinicians should be familiar with the advantages and disadvantages of other fractionation schedules because it is likely that their use will become more widespread. *Accelerated fractionation* refers to an overall reduction in treatment time accomplished by giving two or more daily-dose fractions of close to conventional size. *Hyperfractionation* implies that the overall treatment time is conventional or slightly reduced, but an increase in total dose is achieved by giving two or more small-dose fractions on each treatment day. Each of these regimens is associated with varying degrees of early and late toxicities. For example, some clinicians feel that long-term effects such as osteoradionecrosis are increased with hyperfractionated schedules, especially when combined with concomitant chemotherapy. This view is not universal, however, and as more experience is gained, questions regarding toxicity will be answered.^{46,47}

Aside from changes in radiation schedules, other facets of radiation delivery technique have undergone recent changes. Radiation is delivered to a specific target area that is limited by shielding (defined as radiation portals or "ports") that is placed to protect areas that are not suspected of harboring tumor or that are less tolerant of radiation (ie, the spinal cord). The radiation treatment plan is typically standardized for each subsite in the oral cavity. *Conformal radiation treatment* refers to more localized delivery of radiation to the suspect site. By linking CT images with the ability to manipulate the

radiation beams, radiation therapists are able to more accurately focus the radiation dose on the tumor bed and avoid adjacent uninvolved areas that may be more susceptible to radiation damage (Figure 33-4). There is still concern that highly conformal treatment plans may result in increased recurrence rates because of the more limited field of radiation. Intensity modulated radiotherapy is an example of a conformal treatment plan combined with varying radiation doses to limit the collateral damage to surrounding areas.^{48,49}

Brachytherapy or interstitial radiotherapy is administered by placing a radioactive source, typically radium (²²⁶Ra) or iridium (¹⁹²Ir), directly in the tumor mass using needles or loop catheters. In this manner radiation is delivered continuously. This does not allow the tumor cells to “repopulate” between fractions as in external beam therapy. Unfortunately cells native to the area cannot recover either, resulting in extensive radiation-induced fibrosis and osteoradionecrosis. This technique allows a higher total dose of radiation to be given to a primary site than does external beam because the radiation is placed directly in the tumor mass. Brachytherapy has devel-

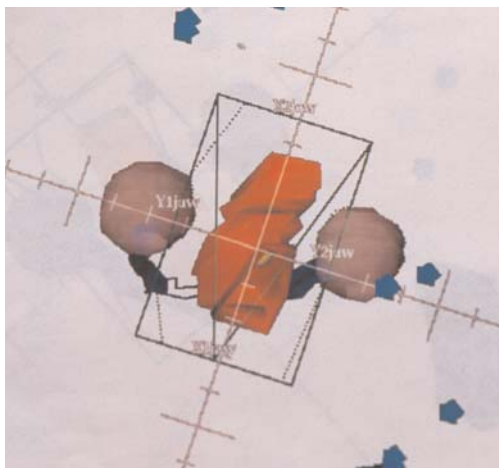


FIGURE 33-4 Three-dimensional conformal mapping of postoperative radiotherapy for esthesioneuroblastoma of the olfactory bulb. Globes and optic nerves are depicted to ensure minimal radiation damage to these structures.

oped a reputation for creating chronic wounds and may lead to osteoradionecrosis when used adjacent to the mandible. Its current use is generally limited to treatment of tongue or tongue base primaries, and is usually combined with external beam radiation. Brachytherapy has also been advocated for treatment of close or positive margins following surgical excision.³⁵ Brachytherapy patients may require a tracheotomy for airway control because of airway compromise from edema. Wound healing is also severely compromised. Some clinicians have recommended only limited biopsies in the treated area if recurrence is suspected because chronic nonhealing wounds can develop.^{50,51}

Radiation can be administered with curative intent in the preoperative setting or as an attempt to shrink a tumor presurgically (neoadjuvant). When the primary tumor is to be treated with radiation, the clinician must also consider elective radiation of the neck for control of occult metastases. Because of its dependence on oxygen for effectiveness, bulky neck disease with its attendant hypoxic core should probably be treated with neck dissection, either before radiation or as a planned procedure within 4 weeks of completion of radiation. Early-stage oral cavity cancer (T1 or T2) responds equally well to radiation or surgery. The morbidity of radiation and the inability to use it again in the case of a second primary cancer or recurrent disease makes surgery a more attractive modality in most situations. Larger tumors (T3 and T4) generally respond poorly to radiation alone. Preoperative radiation given in an attempt to shrink larger tumors is hampered by the fact that tumors do not shrink concentrically. Viable islands of tumor cells can be left beyond the new clinically evident margins. In theory surgeons are committed to excising to the original margins, something that seldom happens in clinical practice.

The primary role for radiation in oral cavity cancer is in the postoperative setting

when there is potential for persistent disease. Clinical protocols vary among institutions, but there are accepted indications for postoperative radiation therapy:

- Two or more lymph nodes containing metastatic disease in a neck dissection (many clinicians contend that one positive node is an indication)
- Extracapsular extension (ECS) of cancer beyond the confines of a node
- Poor histologic factors: extensive perineural or perivascular invasion, positive (close) soft tissue margins
- Large (T3 or T4) primary cancers

Reports have found ECS to be associated with decreased survival: disease limited to the node was associated with a 70% survival, whereas ECS was associated with a 27% survival at 5 years.⁵² Million and colleagues found that 35% of patients with clinically negative necks converted to positive if the primary cancer was treated with surgery alone.⁵³ This dropped to 5% if radiation therapy was added. Even microscopic evidence of extracapsular extension is associated with a higher rate of recurrence and death.⁵⁴ The decision to add radiation treatment must be made with a clear understanding of the morbidity of its use.

In advanced disease, clinicians are faced with a choice of preoperative or postoperative radiation treatment. Planned preoperative radiation treatment is rarely used but may lower the probability of positive margins and may allow smaller surgery (controversial). Lower doses of radiation are required because of the improved oxygenation in areas not disturbed by surgery. Postoperative radiation treatment allows easier surgery and better healing in tissues not disturbed by radiation-induced fibrosis. Frozen-section analysis of margins is easier in this setting, and surgery allows improved treatment planning based on final pathology. Postoperative radiation therapy remains the mainstay in most cases of resectable cancers of the oral cavity. A study by the Radiation Therapy Oncology Group,

RTOG 73-03, compared 50 Gy preoperative radiotherapy to 60 Gy postoperative radiotherapy. The 10-year follow-up demonstrated no survival advantage to either regimen, but postoperative radiation treatment demonstrated superior locoregional control.⁵⁵ How much is enough? Results from an MD Anderson Cancer Center (University of Texas, USA) study showed that 54 Gy was needed in the postoperative setting, and 57.6 Gy was needed if extracapsular extension was present.⁵⁶

Timing of initiation of radiation therapy following surgery is controversial. Vikram demonstrated a clear survival advantage in patients whose radiation therapy was started within 6 weeks of surgery.⁵⁷ For this reason reconstructive options that led to reliable healing in this amount of time were advocated.⁵⁷ A more recent study failed to replicate Vikram's earlier findings, leading some to challenge the supposed impact of timing on ultimate outcome. Other studies have reported improved outcomes when postoperative radiation begins within 6 weeks and ends within 100 days of surgery for oral cavity squamous cancers.^{58,59}

The future direction for radiation treatment may include the development of effective radioprotectants and radiosensitizers. Radioprotectants, such as amifostine, are given in an attempt to protect normal tissues. Amifostine was developed by the military as a possible protection from nuclear attack and has recently been applied to head and neck cancer patients to protect salivary gland function during radiation therapy.⁶⁰ Xerostomia is a long-term problem that has a significant effect on patients treated with radiation therapy to the head and neck, with 64% of patients reporting moderate to severe permanent xerostomia.⁶¹ Decreased incidence of candidiasis, a frequent side effect observed in patients with radiation-induced xerostomia, has been used as an end point in amifostine therapy used for its protective effect on salivary gland function.⁶² Its use is asso-

ciated with side effects, such as hypotension, and some patients do not tolerate it. It is costly and there remains some fear that its radioprotective effects might extend to the cancer cells as well, resulting in higher recurrence rates. Radiosensitizers are chemotherapeutic agents that enhance that effectiveness of radiation (see section "Chemotherapy" below).

Chemotherapy

Until 1991 the role of chemotherapy in head and neck cancer was limited to its use in the management of recurrent and/or metastatic disease. A landmark study that changed our view of chemotherapy was reported by the Cooperative Studies Program of the Department of Veterans Affairs Laryngeal Cancer Study Group who reported a multi-institutional trial on patients with advanced laryngeal cancer.⁶³ Their study demonstrated larynx preservation and equivalent survival among patients who received induction chemotherapy followed by radiation, as opposed to traditional laryngectomy and postoperative radiation.⁶³ Although criticized by some for its lack of a radiation-only control group, the results fostered a renewed interest in use of chemotherapy in the management of advanced head and neck malignancy, including squamous cell carcinoma of the oral cavity. Several reviews are available on the evolving role of chemotherapy in head and neck cancer. The following summarizes the basics of chemotherapy in oral cavity cancer and discusses several potential future applications.

Prior to analyzing the results of chemotherapy in oral cavity cancer, an understanding of the basic biology of chemotherapy and the associated terminology is necessary. In many ways chemotherapy for cancer is conceptually similar to chemotherapy for infections; however, the immune system in general is not inherently competent to destroy the cancer. Chemotherapeutic agents kill a constant fraction of cancer cells leaving

behind a certain amount of resistant cells. These resistant cells subsequently divide and the tumor mass once again increases. In infectious diseases the body's immune system aids in the destruction of the decreased burden of cells, whereas in cancer the patient usually does not have an immune system that can deal with the rogue cell line. Similar to infections with resistant strains, multidrug protocols have been developed to counter the development of resistant cell lines in cancer. Principles of chemotherapy have been developed to overcome the development of resistant cell lines such as the use of multiple agents that have demonstrated independent activity against the cancer type, the combination of drugs with differing toxicities to allow maximum dosing of each agent, and the maintenance of short intervals between dosing agents while allowing adequate recovery of normal tissues. Solid tumor growth is governed by Gompertzian kinetics, which means that growth slows as tumor bulk increases. Since chemotherapeutic agents are most effective against cells undergoing replication, smaller and faster growing tumors are more susceptible.⁶⁴

Assessment of the literature regarding chemotherapy is complicated if one does not understand the definitions of complete response, partial response, stable disease, and progression. Each of these is determined by the sum of the product of the perpendicular diameters of all measurable tumors. Measurements are obtained at the beginning of treatment and at completion.

- Complete response: Defined as the disappearance of all evidence of disease
- Partial response: At least a 50% reduction in size as defined by the formula above
- Stable disease: Less than a 50% reduction in tumor size
- Progression: An increase of 25% or appearance of new lesions

An important point to remember is that tumor regression must only last for 4 weeks. It is understandable, therefore, that reports of a complete response often have little impact on improved survival. The response rate represents the total percent of patients achieving complete and partial responses. An additional problem with chemotherapy trials is patient selection bias. Increasingly the role of comorbidities in ultimate outcome and the impact of performance status on survival are being recognized as important contributors to survival in head and neck cancer (see discussion below). Performance status is typically reported using the Karnofsky performance status (PS), which rates patients on a scale of 0 (death) to 100 (normal, no evidence of disease) or the Eastern Cooperative Oncology Group scale, which rates patients on a scale of PS 0 (fully active) to PS 5 (death).^{65,66} Most clinical trials require a certain PS to qualify, leading to enrollment of healthier patients and improved outcomes.

Timing of chemotherapy has been the subject of much investigation. Again, definitions are the key to understanding and interpretation of results of clinical trials. *Palliative chemotherapy* is given to patients with incurable disease to temporarily reduce tumor volume in the hope of improving quality of life and lengthening survival. This is typically the arena that serves as a testing ground for new therapeutic agents. *Adjuvant chemotherapy* is given to patients who have undergone treatment of their primary cancer site with surgery and/or radiation. Goals of treatment include elimination of occult disease, especially distant metastases. As the patient no longer has visible or palpable tumor with which to gauge response, agents must be selected that have proven activity against the cancer type. *Neoadjuvant chemotherapy* (also known as *induction chemotherapy*) is given to patients prior to definitive treatment of the primary cancer site.⁶⁴ This tactic is generally

chosen in an attempt to decrease the size of the primary cancer to make definitive treatment possible. For example, a tumor deemed unresectable may be “downstaged” by neoadjuvant chemotherapy to a resectable tumor. As stated earlier tumors do not shrink concentrically and islands of tumor may remain beyond the visible margin. An additional advantage to neoadjuvant therapy is the ability to evaluate response. Squamous cell carcinomas represent a heterozygous population even within the same tumor. Some will be exquisitely responsive to a particular regimen, whereas others will not. Medical oncologists can tailor their treatment more accurately if visible or palpable tumor is available to evaluate response. The biggest criticism of neoadjuvant therapy is that it delays the definitive treatment of the primary cancer. Local failure is still the biggest cause of death in oral cavity cancer, and delaying treatment of the primary site increases the difficulty of obtaining control of the primary cancer. In addition initial chemotherapy can theoretically select more hardy cell lines that are resistant to all therapy. Indeed critics of the Department of Veterans Affairs Laryngeal Cancer Study Group larynx trial contend that neoadjuvant chemotherapy simply selected out less aggressive cancers that would respond to radiation treatment. Currently the role of chemotherapy that has generated the most interest is combination with radiation treatment for an “organ sparing” approach. Chemotherapy in combination with radiation treatment can be given in a sequential or a concurrent strategy. Concurrent therapy takes advantage of the radiosensitization of certain drugs and avoids delay in treating the primary cancer site. The downside is a marked increase in side effects and toxicity that can lead to breaks in radiation treatment, which have been shown to be associated with a decrease in local control. In an attempt to control some of these toxicities, chemotherapy is usually given at

the beginning of radiation treatment and frequently at the completion of radiation. Sometimes radiation therapy is interrupted (split-course radiation) on purpose, and chemotherapy is given. Again, radiation breaks are considered to be associated with decreased control and are therefore not recommended.

Chemotherapeutic agents are under constant development and a complete discussion of available agents is beyond the scope of this chapter. Several principles deserve mention. In general drugs can be divided into cell cycle-specific and noncell cycle-specific agents, depending on whether the particular agent requires that the target cell be in a certain phase (G_0 , S, G_1 , or mitosis) to be effective. Agents can also be categorized based on their principle mode of action. Antimetabolites, such as methotrexate and 5-fluorouracil, block development of certain metabolites critical for cell metabolism. 5-Fluorouracil is a fluoridated pyrimidine analog that inhibits thymidylate synthetase, blocking the generation of thymidine, which is necessary for DNA synthesis. It is frequently used in the treatment of head and neck squamous cell carcinoma. Typically it is combined with other agents, and it is a radiosensitizer. Methotrexate, an analog of folic acid, blocks conversion of dihydrofolate to tetrahydrofolic acid, which is a precursor of thymidylic acid and purine. This results in an interruption of DNA, RNA, and protein synthesis. Once a standard for head and neck squamous cell carcinoma, methotrexate is now typically only used for palliation. Its side effect profile and ability to be administered intramuscularly on an outpatient basis make it a good option for this purpose. Cisplatin and carboplatin are alkylating agents that form cross-links in DNA and arrest cell division. Cisplatin is more effective in squamous cell cancer but is associated with more renal and neurologic side effects than carboplatin. Other agents used less frequently in head and neck squamous cell cancer

include paclitaxel, which stabilizes microtubular formation and arrests cells in G₂, and bleomycin, which creates DNA breaks. Agents under development include flavopiridol, a cyclin-dependent kinase inhibitor that has been shown to induce apoptosis (programmed cell death) in squamous cell cancer lines in vitro, and for which a phase 1 trial is underway.^{67,68}

Standard therapy for resectable disease remains surgery followed by radiotherapy, if indicated. To date, induction chemotherapy followed by surgery has not shown a survival benefit in oral cavity cancer. The question of adding chemotherapy in the postoperative setting remains unanswered. Currently no study has shown definitive improvement. Cooper and colleagues reported on the results of the RTOG 95-01/Intergroup phase 3 trial that evaluated concurrent chemoradiotherapy in postoperative treatment of high-risk squamous cell carcinoma of the head and neck, defined as multiple lymph nodes involved, extracapsular disease, and positive margins. The locoregional control and overall 2-year survival were not improved significantly, and the small improvement in disease-free survival was at the expense of a significant increase in toxicity.⁶⁹ Adding chemotherapy following surgery and radiation has been shown to decrease the incidence of distant metastases, but this has not been associated with improved survival. At this point chemotherapy in the postoperative setting is not indicated except in cases of known metastatic disease, and its use outside of clinical trials should probably be discouraged.⁷⁰⁻⁷²

Currently the role for chemotherapy in oral cavity cancer is limited to use in unresectable disease in which it is combined with radiation treatment, metastatic disease, or recurrence. Organ preservation (not to be confused with organ function) through the use of concurrent chemoradiation protocols has received much attention. Meta-analyses by El-Sayed and Nelson, and Munro have demonstrated that

concurrent treatment is better than neoadjuvant therapy. Locoregional control and survival were improved in advanced head and neck cancers.^{73,74}

In an attempt to avoid the systemic effects of chemotherapy, investigators have attempted to deliver agents topically, as well as intratumorally with both intra-arterial injections and intratumoral depot forms via polymers and gels (see section in this chapter on recurrent tumors). A novel form of concurrent chemoradiation is the intra-arterial cisplatin and radiotherapy (RAD-PLAT) protocol popularized by researchers at the University of California, San Diego, and University of Tennessee at Memphis, which has shown promise for advanced cancers with bulky primary cancers and nodal disease.⁷⁵ Treatment involves supradose cisplatin delivered directly into feeder vessels of the tumor bed by microarterial catheters placed under angiography. Sodium thiosulfate, which is a neutralizing agent for cisplatin, is administered systemically, allowing doses five times larger than standard protocols. Results of patients with T4 N2-3 disease treated with the protocol revealed 4-year local control of 84%, disease-specific survival of 46%, and overall survival of 29%.⁷⁵ Unfortunately, the protocol is associated with significant toxicity, including death. Use of the RADPLAT protocol is currently limited to centers that have gained familiarity with the technique and management of the toxicities associated with it. Most of these concurrent chemoradiation protocols involved oropharyngeal and hypopharyngeal cancers, and are plagued by noncompliance because of toxicity and side effects. Mucositis is intense and placement of a PEG tube is usually mandatory.⁷⁵

Other novel techniques for minimizing the systemic side effects of chemotherapeutic regimens are under development, including the PDT discussed above under the management of leukoplakia.

Trials of chemotherapy limited to the oral cavity are few. At this time the clearest

indication for chemotherapy in oral cancer is in metastatic and recurrent disease. The most commonly used chemotherapeutic regimen for metastatic or recurrent oral cavity squamous cell carcinoma involves combinations of cisplatin or carboplatin and 5-fluorouracil. Median survival rates of 5 to 7 months and 1-year survival of 20% demonstrate the need for improved regimens. Investigations continue to define a role for chemotherapy in advanced squamous cell carcinomas of the oral cavity. Unfortunately early responses to chemotherapy have not demonstrated improvement in overall survival and only modest gains in median survival time.⁷⁶

Current research in chemotherapeutic agents focuses on agents that bind to specific receptors in an attempt to limit effects to target cells. Similar to the hormonal therapy used in breast and prostate cancers, investigators are experimenting with agents such as epidermal growth factor inhibitors.⁷⁷ Gene therapy that targets known alterations in head and neck squamous cell cancer lines, such as *TP53*, is also an area of growing research.⁷⁸ Restoration of these altered genes, possibly through viral vectors, holds promise in certain populations.⁷⁹ A recent review by Milas and colleagues at the MD Anderson Cancer Center offers insight into the current state of chemotherapy in head and neck cancer, as well as newer chemotherapeutic agents on the horizon.⁸⁰

Chemoprevention

An additional area of intensive research is development of chemoprevention agents, which are defined as agents that reverse or suppress premalignant carcinogenic progression to invasive malignancy (see section "Management of Premalignant Lesions," above). The role of such agents would be twofold: (1) to treat premalignant lesions to prevent their evolution to invasive carcinoma, and (2) to prevent development of second primary squamous cell cancers in patients who have

already undergone treatment of cancer. Given its accessibility to clinical observation, leukoplakia has been used to monitor responsiveness to certain chemoprevention agents in clinical trials. Of the agents evaluated, including retinoids, beta carotene, and vitamin E derivatives, retinoids have demonstrated the most efficacy in eliminating leukoplakia. It is important to note, however, that reversal of these lesions has not been demonstrated to reduce the risk of developing cancer, and the lesions soon return after cessation of treatment. 13-*Cis*-retinoic acid, which is more commonly used to treat acne, has been studied extensively in both the treatment of premalignant lesions and in the prevention of second primary cancers. It may act through the up-regulation of a distinct retinoic acid receptor, RAR- β , whose down-regulation is associated with development of head and neck cancer. Results of trials to date have been mixed. Although effective in eliminating leukoplakia, side effects limit its use, and lesions return after discontinuing the drug. Secondary primary tumors occur in 4 to 7% of patients treated for head and neck squamous cancer and are the major concern-related cause of death in early-stage cancer. The prevention of these tumors is therefore important. Studies of 13-*cis*-retinoic acid have shown decreased incidence of second primary cancer but no effect on primary disease recurrence. This suggests that retinoids may prevent cancerous development in damaged cells but will not treat fully transformed cancer cells. Also, overall survival was not affected. Required doses of retinoids have side effects, including mucocutaneous toxicity (peeling and cheilitis) and elevation of liver function tests. Development of second-generation retinoids may attenuate some of these side effects. One study demonstrated a worrisome increased incidence of primary lung cancer in patients treated with beta carotene.^{81,82} In addition, Wang and colleagues recently reported on

a novel tretinoin biofilm that allows sustained topical delivery to the oral cavity.⁸³

Investigators continue to search for chemotherapeutic agents with more acceptable side effect profiles. One of these agents is the Bowman-Birk inhibitor, a protein derived from soybeans that has shown clinical activity against leukoplakia without the attendant side effects of retinoids.⁸⁴ Nonsteroidal anti-inflammatory drugs have also been investigated since chemoprevention activity was found in some cyclooxygenase-2 (COX-2) inhibitors. COX-2 influences several steps in the development of malignancies, such as apoptosis, angiogenesis, invasiveness, and immune surveillance.^{85,86} COX-2 expression has been noted in high-risk premalignant lesions.⁸⁷ In addition to their potential role in chemoprevention, COX-2 inhibitors hold promise in the treatment of invasive squamous cell carcinomas.⁸⁸ Although chemoprevention offers hope for patients at high risk for development of second primary cancers and treatment of patients with high-risk lesions (see discussion on premalignant lesions above), its use is currently restricted to clinical trials and off-label use. Further work is needed to establish a safe and effective chemopreventive regimen.

Special Treatment Considerations by Site

The Lip

Although classified as an oral cancer, squamous cell carcinomas of the lip typically follow a different clinical course than those of oral mucosal cancers. The primary etiologic agent, sun exposure, is different from oral cancers, and the location of lip cancers usually leads to earlier discovery. The behavior of squamous cell cancers of the vermilion border is usually intermediate between squamous cell carcinoma of the skin and that of the mucosa. The vast majority arise on the lower lip where sun exposure is

greatest. Most lip cancers are treated by surgical resection using 0.5 to 1.0 cm margins and frozen-section control. Although often referred to as a “wedge” resection, the actual specimen more closely resembles a shield with parallel sides and a tapering base. “Wedge” excisions may be combined with a vermilionectomy or “lip shave” procedure, removing vermilion that has suffered extensive actinic damage or contains carcinoma in situ (Figure 33-5). CO₂ laser ablation of the surface of the lip is also useful as an alternative to vermilionectomy for diffuse actinic changes. Squamous cell carcinoma of the lip shares with squamous cell carcinoma of other cutaneous sites a potential for perineural invasion. A large perineural tumor deposition along the inferior alveolar nerve, several years after a lip cancer, can be mistaken for primary intraosseous carcinoma (Figure 33-6).

Neck dissection is usually not indicated for lip cancer unless there is clinical evidence of lymph node involvement by examination or imaging. Cancers of the upper lip and commissure can metastasize to the parotid lymph nodes, and superficial parotidectomy may be required if there are clinically enlarged nodes. Some larger lesions can be treated with radiation alone if surgical resection will result in unacceptable compromise in appearance and function.

Five-year survival for lip cancer is good for early-stage disease (90% for stages I and II).^{89,90}

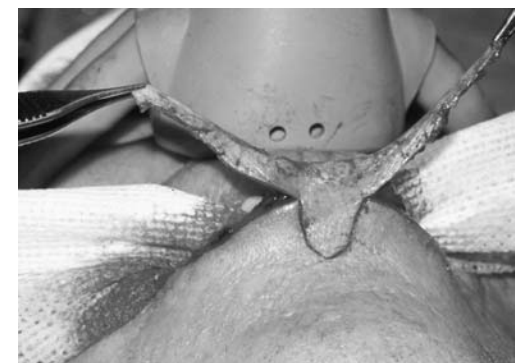

FIGURE 33-5 Vermilionectomy combined with wedge resection of lip cancer associated with diffuse actinic changes across the remainder of the lip.

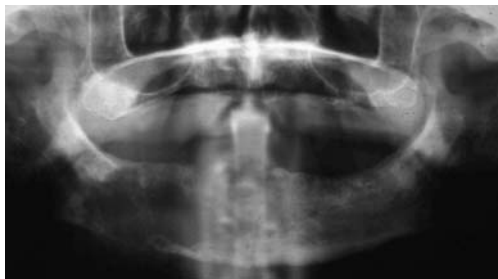


FIGURE 33-6 Apparent intraosseous squamous cell carcinoma arising from perineural spread of a previous lip carcinoma. Review of the original lip resection specimen demonstrated perineural invasion.

Buccal Mucosa

Buccal squamous cell carcinomas represent approximately 10% of oral cavity cancers in the United States compared to 41% in India. Squamous cell carcinomas of the buccal mucosa can be deceptive in their clinical course. Because of the intimacy to the buccal space and deeper structures, cancers that penetrate the buccinator muscle can be difficult to eradicate (Figure 33-7). Patients may present with involvement of the pterygoid space posteriorly or the parotid gland laterally. Extension either superiorly or inferiorly can lead to invasion of the maxillary alveolus or mandibular alveolus respectively. These cancers often arise in wide areas of damaged mucosa, and adequate excision of these lesions often results in complex defects of the cheek that can be difficult to reconstruct. Primary radiation may be an option for smaller lesions. Although up to 50% of patients with buccal squamous cell carcinoma can present with neck metastases, the rate of occult disease in the neck is around 10%.⁹¹ As with other oral cancer sites elective treatment of the neck with radiation or surgery is indicated in T3 or T4 lesions. Consideration should also be given to elective treatment of the neck in deep T1 (> 4 mm) and larger T2 lesions. Vikram and Farr concluded that combined therapy for large lesions with surgery and radiation offered the best chance for cure.⁹²

Two-year overall survival rates for early-stage disease treated with a variety of treatment modalities range from 83 to 100%. Stage III survival rate is 41% and stage IV is 15%. Available survival statistics, however, are often not accurate because of the inclusion of verrucous carcinoma in some of the published reports.

Diaz and colleagues at the MD Anderson Cancer Center reported on 119 consecutive patients with buccal squamous cell carcinomas, the majority of which were treated with surgery followed by radiation if indicated (positive margins, nodal involvement).⁹³ Five-year survival rates for patients with stages I, II, III, and IV disease were 78%, 66%, 62%, and 50% respectively. The significant impact of nodal involvement was noted. Diaz and colleagues found 5-year survival rates of 69% with nodal involvement, which decreased to 24% in cases with extracapsular extension.⁹³

Retromolar Trigone

Given their proximity to the pterygomandibular space, tonsillar pillars, mandible, and tongue base, squamous cell carcinomas of the retromolar trigone (RMT) can behave in a more aggressive fashion, like an oropharyngeal primary cancer (Figure 33-8). Smaller lesions are amenable to wide local excision with or without a marginal mandibulectomy depending on the proximity to the bone (see discussion below). Larger lesions may invade the pterygomandibular space and extend cephalad towards the skull base. Such tumors require segmental composite resections with neck dissection. Significant trismus can be an indication of pterygoid involvement and may make radiation treatment with or without concomitant chemotherapy a better option than surgery. Elective neck radiotherapy or elective neck dissection with a selective neck dissection should be considered in T2 or greater lesions. As with other sites a depth of invasion greater than 4 mm in T1

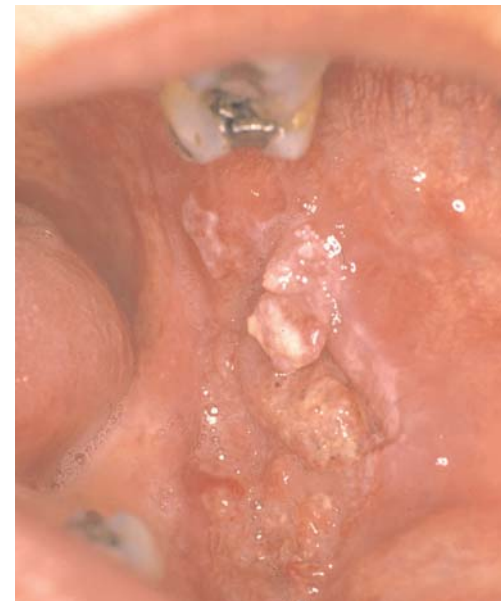

FIGURE 33-7 Squamous cell carcinoma of the buccal mucosa, deeply invading through the buccinator muscle.

lesions may be an indication for elective treatment of the neck.

Kowalski and colleagues reported on 114 RMT cases treated with surgery with or without radiation and found 5-year survivals of 80% (T1), 57.8% (T2), 46.5% (T3), and 65.3% (T4).⁹⁴ Overall 5-year survival was 55.3%. They recommended adjunctive radiation in stages III and IV.⁹⁴ In an excellent review of the management of RMT cancers, Genden and colleagues also suggested that the addition of preoperative or postoperative radiation confers a survival advantage.⁹⁵

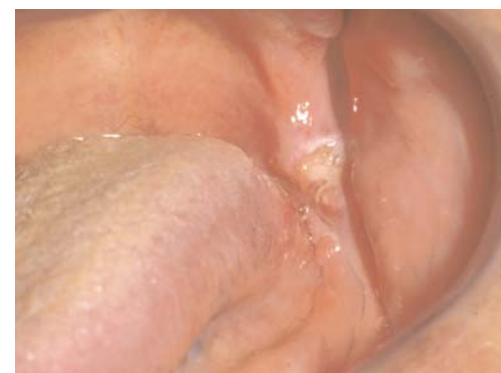

FIGURE 33-8 Squamous cell carcinoma of the retromolar trigone.

The Tongue

The oral tongue, that portion anterior to the circumvallate papillae, is the most common location for intraoral squamous cell carcinomas. They typically present as painless indurated ulcerations. If pain is present it is usually due to secondary infection. The behavior and treatment of oral tongue cancers is sufficiently different than that of posterior tongue lesions (oropharyngeal tongue or tongue base) to allow clinicians to determine the epicenter of the tumor and classify it correctly. This may be challenging in the case of larger cancers. The oral tongue poses significant challenges to clinicians. Seemingly small lesions can metastasize early and recur after treatment. Control rates for small lesions of the tongue (60 to 80%) are poorer than those of similar size in other oral cavity subsites. There are minimal barriers in the tongue to tumor invasion, and there is frequent invasion into adjacent or deeper structures at presentation. Although more commonly associated with oropharyngeal primary cancers, referred otalgia is not uncommon for cancers of the oral tongue, and limitation of tongue mobility with resultant dysarthria is associated with invasion of the deeper musculature. Magnetic resonance imaging (MRI) can be useful in evaluating the depth of invasion (Figure 33-9). Treatment of tongue lesions should be aggressive, and strong consideration for elective treatment of the neck should be given in all cases except for the most superficial lesions (< 2 mm). Although Fakih and colleagues were not able to demonstrate a survival advantage in patients who underwent an elective neck dissection versus a watch-and-wait policy, they did demonstrate that deeper lesions were associated with a significant rate of cervical metastases.⁹⁶ Up to 10 to 12% of tongue cancers with metastases to the neck can demonstrate “skip” metastases to level IV. Consideration should be given to extending the neck dis-

section to include level IV.⁹⁷ Postoperative radiation should be considered in situations where multiple frozen-section specimens were sent before obtaining clear margins, perineural invasion, microvascular or microlymphatic invasion, or other worrisome findings that are present.

Smaller superficial tumors are amenable to wide local excision and reconstruction via primary closure, split-thickness skin grafting, or healing by secondary intention. Larger tumors are reconstructed with vascularized tissue transfer, and mandibulotomy may be needed for adequate access to large or posterior lesions. Radial forearm or lateral arm microvascular free flaps allow excellent mobility and little bulk (Figure 33-10). Unilateral or bilateral pedicled nasolabial flaps can occasionally be used for anterior tongue lesions. Large oral tongue cancers that cross the midline present the surgeon with a difficult choice. If resection is chosen it is often better to tailor the radial forearm flap smaller than the resected area to allow the remaining tongue musculature less bulk to move during excursions (Figure 33-11). Near total glossectomy (resection of the oral tongue with only tongue base remaining) almost always results in high morbidity and is associated with a high incidence of aspiration that may ultimately require laryngectomy for aspiration control. Treatment with external beam radiation alone is associated with unacceptable failure rates. In this setting consideration should be given to organ-sparing protocols with concomitant chemoradiation therapy if surgery will be associated with unacceptable morbidity. Brachytherapy combined with external beam radiation is the treatment of choice at some centers. Technical expertise is required, and most patients require tracheotomy for airway control.

Tongue base tumors, although actually an oropharyngeal subsite and not considered an oral subsite, are discussed here for completeness. The tongue base allows tumors to grow silently, and diagnosis at an

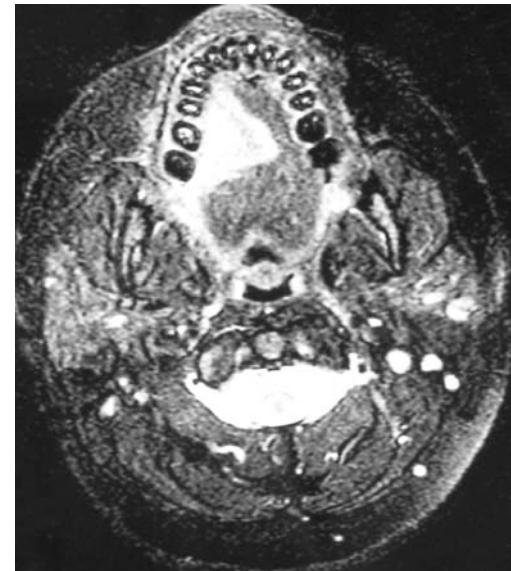

FIGURE 33-9 Enhanced, T2-weighted magnetic resonance imaging of a tongue showing right tongue tumor deeply invading tongue musculature.

early stage is the exception rather than the rule. Most small (T1 and some T2) lesions should be treated with combined therapy, typically surgery plus radiation treatment. Larger tumors are typically treated with an organ-sparing approach using chemoradiation therapy or external beam therapy, sometimes combined with brachytherapy. Results with external beam alone have been disappointing. Reconstruction of smaller posterior tongue defects is best accomplished by radial forearm or lateral arm flaps, if primary closure or healing by secondary intention is inappropriate. Larger

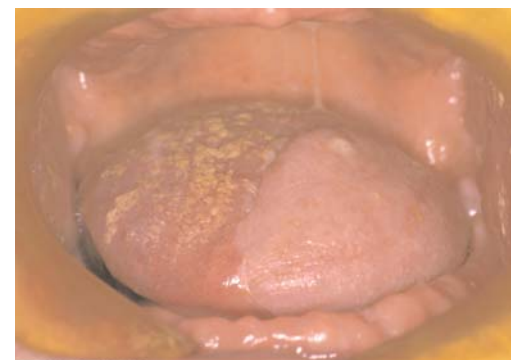


FIGURE 33-10 Radial forearm flap used to reconstruct large tongue defect with nearly normal speech and swallowing.

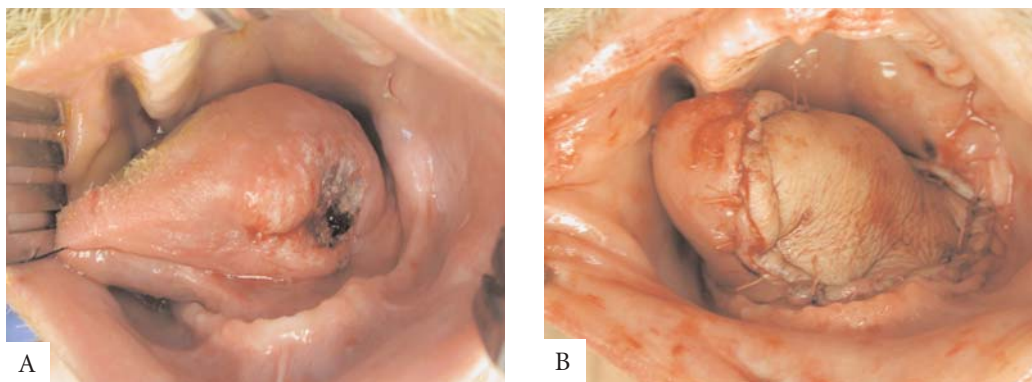


FIGURE 33-11 A, Large deeply infiltrative squamous cell carcinoma of the lateral tongue. B, Radial forearm flap tailored to the size of the resection, not the apparent size of the defect.

excisions (75% to total) typically are reconstructed with a free rectus flap.⁹⁸

Most treatment failures of the oral tongue involve locoregional recurrence. Second primary cancer rates are high (30%) and this also contributes to treatment failure and death. Three-year survival for T1 and T2 lesions is 70 to 80%, but this decreases to 15 to 30% in patients with lymph node metastases.^{99,100} Some clinicians have reported that tongue squamous cell carcinoma arising in young patients may represent a more aggressive subset and warrant more aggressive therapy. Overall survival for younger patients is actually similar to those of older patients with the same stage because of their lack of intercurrent illnesses. It was found, however, that oral tongue cancers in younger women did behave more aggressively and were associated with higher recurrence rates. This subset may warrant more aggressive initial therapy.^{101,102}

Floor of Mouth

The floor of mouth (FOM) is the second most common location for oral cavity squamous cell cancers (Figure 33-12). FOM cancers can extend along the ventral tongue and cause fixation. In addition FOM tumors can become fixed to the mandible or extend into level I of the neck. McGuirt and colleagues have demonstrated improved outcome with elective treatment of the neck, and elective treatment of

the neck should be considered in all but the smallest thin lesions (< 3 mm).¹⁰³ Sagittal mandibulectomy may be considered in tumors that abut the mandible without evidence of invasion (see discussion below). Small primary cancers can be equally treated with surgery or radiation, although surgery is the choice of most clinicians. Anterior lesions may require sialodochoplasty to reroute the submandibular ducts if the submandibular gland is not removed by ipsilateral neck dissection.

Smaller FOM defects can be closed primarily or left to heal by secondary intention. A partial closure of the defect will often suffice. Larger FOM defects, particularly those that include mylohyoid resection, benefit from a bulkier reconstruction, such as a vascularized radial forearm flap or bilateral nasolabial flaps placed in a one- or two-stage operation.

Local recurrence remains a problem with FOM squamous cancers, and results in high rates of locoregional failure. Five-year survival rates are 64 to 80% (stage I), 61 to 84% (stage II), 28 to 68% (stage III), and 6 to 36% (stage IV).¹⁰⁴

Alveolus and Gingiva

Gingival squamous cell cancers represent a unique subset in oral cavity cancers that arise on the attached gingiva and that should be differentiated from those that arise on the unattached mucosa of the

alveolus. Occult neck metastasis is rare, and elective treatment of the neck is not necessary in smaller lesions. Larger lesions may require partial maxillectomy, or marginal or segmental mandibulectomy, if bone invasion is suspected. Indications and variations on mandibulectomy are discussed below. In general control rates are excellent for gingival primary cancers if treated with adequate margins.

Alveolar cancer arises from the unattached mucosa of the alveolar ridge and has a different clinical behavior than gingival carcinomas. It requires more aggressive therapy and more extensive resection of bone.

Most anterior and some posterior maxillectomies for alveolar and gingival squamous cells can be accomplished via a transoral approach using techniques of orthognathic surgery (Figure 33-13).¹⁰⁵ The pterygoid plates require removal only if there is evidence of invasion through the posterior maxilla. Posterior extension may indicate the need for a transfacial (Weber-Fergusson) approach for adequate exposure. Reconstruction of maxillary defects can be accomplished with local flaps, such as the temporoparietal fascial or temporalis muscle flap, or free-flap reconstruction. The complex nature of maxillary defects and the bulk of some of the flaps, however, often leave a less-than-satisfactory result. Prosthetic obturation of the defect

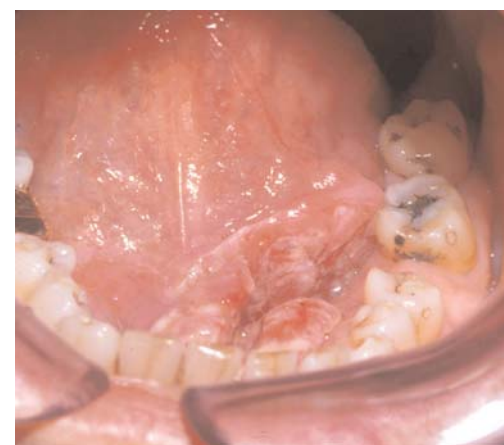


FIGURE 33-12 Advanced squamous cell carcinoma of the anterior floor of the mouth.

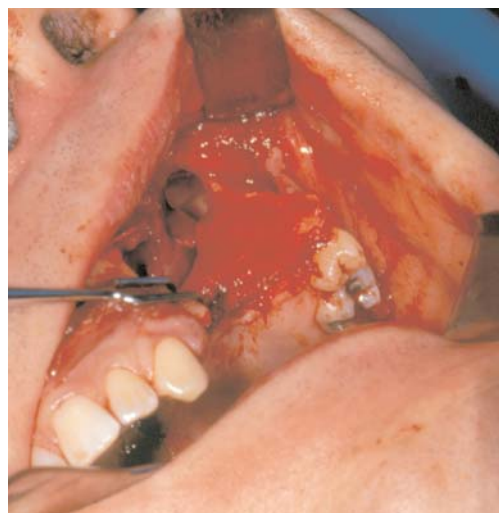


FIGURE 33-13 *Le Fort I island approach to a posterior maxillary tumor, without Weber-Fergusson incision.*

offers several advantages, including a simpler operation, easier early detection of recurrence, and replacement of teeth.

Most maxillary alveolus and gingival squamous cells that invade the sinus involve the infrastructure lying below Ohngren's line, an artificial line that runs from the medial canthus to the angle of the mandible and separates the maxillary sinus into an infra- and supra-structure. Defects arising from cancers resected below this line are easily reconstructed with obturators. Cancers that require true total maxillectomy (resection of one of the paired maxillas, including the orbital floor) tend to require flap reconstruction. If dura mater is exposed as part of a skull base resection, flap coverage is advisable.

Overall 5-year survival for alveolar ridge carcinoma is 50 to 65% for both the upper and lower alveolar ridge. Poor outcome is associated with advanced stage, perineural spread, and positive margins. Adjunctive radiation is recommended if nodal metastases, perineural spread, or positive margins are present.¹⁰⁶

The Palate

Squamous cell cancers of the palate, hard and soft, are rare. The soft palate is considered an oropharyngeal subsite (Figure

33-14). Cancers arising from the hard palate may extend onto the soft palate and vice versa. The periosteum of the palate acts as a significant barrier, and smaller lesions can be treated with wide local excision. Healing by secondary intention under a protective stent secured to the palate is a viable reconstructive option if the palatal bony structure is not removed. Oral-nasal communications in the hard palate can be treated with an obturator or a local flap, such as an anteriorly based midline tongue flap. Oral-nasal fistulas in the soft palate are best treated with temporary obturation, as the majority will close spontaneously. Occult cervical metastases are rare among hard palate cancers (10 to 25%), and elective treatment of the neck is generally not indicated except in T3 or T4 lesions.^{107,108} Also, metastases may occur to the retropharyngeal nodes, and consideration should be given to irradiation of the neck to include this area if suspected.

Management of the Mandible in Oral Cavity Cancer

Management of the mandible in oral cavity cancer has been the subject of much controversy. In the past the mandible was routinely sacrificed in the treatment of FOM and tongue cancers, as it was felt that the regional lymphatics coursed through the mandibular periosteum, necessitating an in-continuity resection of the tongue, FOM, mandible, and neck dissection (Commando's operation). The morbidity of this approach was felt necessary to eradicate in-transit metastases, a belief that was likely based on mistranslation by McGregor of an article published by Polya and von Navratil in 1902, in which they actually recommended removal of the periosteum or rim of mandible and not a segment.¹⁰⁹

Marchetta and colleagues subsequently demonstrated that lymphatics did not flow through the mandible, and that the periosteum of the mandible actually served as a barrier to invasion.¹¹⁰ It was found that squamous cell carcinoma inva-

sion occurs most commonly through the periodontal ligament in the dentate mandible and through the porous occlusal surface of the edentulous mandible.¹¹⁰ O'Brien and colleagues also demonstrated that an inflammatory front preceded cancer that stimulated subperiosteal resorption and the creation of bony clefts that allowed cancer to invade the cortex.¹¹¹ Once the cortex was invaded, the inferior alveolar canal was usually involved, especially in edentulous mandibles.^{111,112} This finding has led to surgeons advocating preservation of mandibular continuity through the use of a marginal mandibulectomy, in cases without obvious bony involvement. These principles apply only to the nonirradiated mandible. Cancer invasion of a previously irradiated mandible occurs through multiple sites. The clinical and radiographic evaluations of mandibular involvement, however, are frequently inaccurate. Clinical findings such as impairment of inferior alveolar nerve function or fixation of the tumor to the mandible raise the index of suspicion. The history of an extraction of a tooth in an area of a cancer may suggest local mandibular invasion. Although used by some, bone scans are cumbersome to obtain and interpret accurately. A high-quality panoramic radiograph is probably the most commonly used tool to decide on mandibular resection versus segmental resection. CT scanning using DentaScan

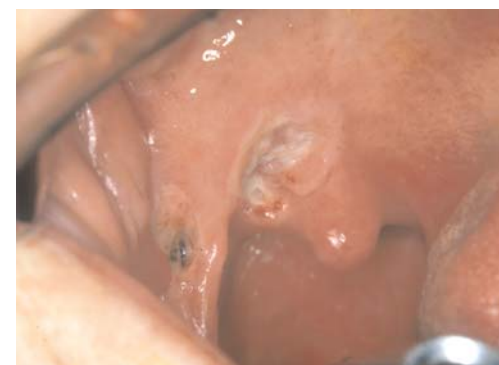

FIGURE 33-14 *Squamous cell carcinoma of the right soft palate invading posteriorly to involve the anterior pole of the tonsil.*

software has also been used, although recent studies have shown that an MRI demonstrating enhancement of the marrow signal was a better predictor of mandibular involvement. Also, newer techniques that modulate the magnetic field in an attempt to examine changes in the bone marrow hold promise for evaluating mandibular involvement. Tumor invasion into the marrow space is accompanied by a lower intermediate signal. A strong bright marrow signal associated with normal marrow fat underlying the dark cortex typically excludes mandibular involvement.³⁸

At this time the most accurate assessment of mandibular involvement occurs at the time of surgery when the surgeon can inspect the bone. In addition, some surgeons send periosteum for frozen-section analysis, whereas others submit cancellous scrapings for frozen analysis.¹¹³ Once a decision has been made to perform a marginal mandibulectomy, the surgeon has several choices for osteotomy design. Some surgeons advocate rim mandibulectomy, preserving at least a 1 cm inferior border, whereas others advocate a sagittal marginal mandibulectomy or a variation thereof.¹¹⁴ An important point is the avoidance of right angles in the osteotomy design that serve as stress risers and may lead to fracture. We prefer an osteotomy that begins in the sigmoid notch and sweeps inferiorly and anteriorly for lesions located in the posterior mandible (Figure 33-15). It is important to note that the thick cortical bone along the posterior ramus is rarely involved, even when the mandible is invaded, and it can usually be preserved and serves as an area for plating. Edentulous mandibles are generally not candidates for marginal resection although this is not an absolute rule. Wax and colleagues, and Shah have published excellent reviews of the topic of segmental and marginal resection, and the reader is directed to their reviews for a more in-depth discussion.^{115,116} If the surgeon is

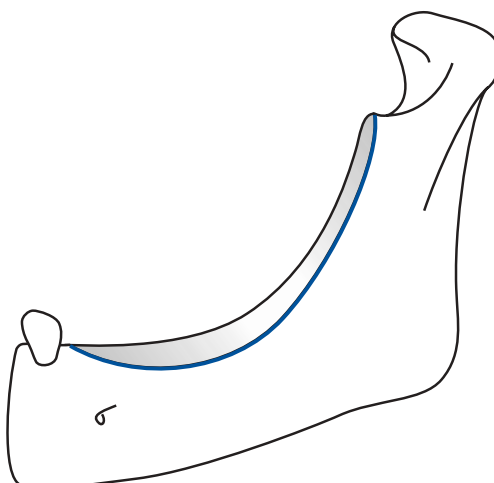


FIGURE 33-15 Outline of marginal mandibulectomy suitable for resection of tumors of the retromolar trigone and posterior maxillary alveolus.

anticipating a marginal resection, and a segmental resection becomes indicated based on operative findings, he or she is faced with a surgery for which both surgeon and patient might not be prepared. Frank discussions before surgery help prepare the patient and their family for this eventuality. Mention should be made of the possible return to the operating room if final pathologic analysis reveals an unexpected amount of bone involvement

necessitating a segmental resection and more elaborate reconstruction.

Splitting the mandible, or mandibulotomy, is often necessary for access to large cancers, especially of the posterior tongue (Figure 33-16). Technical refinement of mandibulotomy helps avoid complications. Mucosal incisions should not be placed directly overlying the proposed osteotomy site. Division of the mandible at the parasymphysis or symphysis is preferred over an osteotomy in the body region. If the mandibular osteotomy is being performed for access to the tongue, the cut should be made anterior to the mental nerve to preserve it. Preadaptation of plates will allow reestablishment of the preoperative occlusion and contour.

Management of the Cervical Lymph Nodes in Oral Cavity Squamous Cancer

Management of the regional lymphatics is a consideration in any cancer. The ability of a cancer to metastasize most commonly manifests itself by growth of cancer in lymph nodes. Surgical treatment of the neck is justified for two reasons: the removal of gross disease in patients with

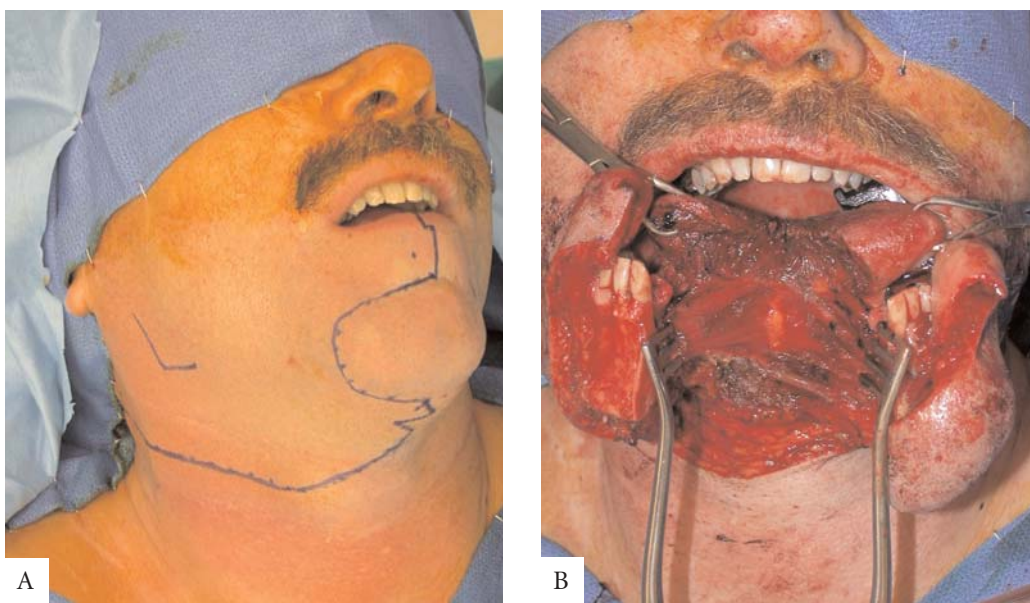


FIGURE 33-16 A, Outline of incision for lip-splitting approach to the posterior oral cavity and oropharynx. B, Midline division of the tongue following midline mandibulotomy.

clinical evidence of nodal involvement (therapeutic neck dissection) or a high enough index of suspicion of occult cervical metastases to justify an elective neck dissection (END). Some surgeons would also suggest that unreliable patients should undergo END as follow-up may be irregular. Excluding the hard palate and lip, approximately 30% of patients with oral cavity cancer will present with cervical metastases.¹¹⁷ The decision to treat the N0 neck is based on the probability of nodal involvement. Evaluation of the neck for cervical metastases remains a critical component of the evaluation of the patient with oral cavity cancer. Manual palpation is regarded as the first step in this process and is usually accomplished before biopsy to avoid postbiopsy inflammatory nodal enlargement. In most necks a lymph node must be at least 1 cm in diameter to be palpable. The accuracy and reliability of palpation is low, with an overall error of approximately 30% in several studies.¹¹⁸ Imaging modalities including CT, MRI, ultrasonography, and positron emission tomography (PET) have become increasingly important in the evaluation for cervical metastases and in guiding therapy.

A CT scan with contrast from the skull base to clavicles has become the most common imaging modality used for detection of cervical metastases (Figure 33-17). Specific criteria for nodal metastases, including node size greater than 1 cm (except the jugulodigastric node, which must be greater than 1.5 cm), central necrosis, and morphology (round instead of oval) have increased sensitivity to over 90%.¹¹⁹ MRI neck evaluation has gained popularity in recent years, and is typically used if the primary site is being imaged with MRI, such as for a tongue cancer. CT and MRI, in that order, are the most widely used imaging modalities for detection of occult metastases in the United States.

The characteristics of the primary tumor may also predict metastases. Spiro and colleagues demonstrated that depth of

invasion in tongue cancer was a reliable predictor of lymph node metastases in cancer of the oral tongue.¹²⁰ They found that cancers with 2 to 8 mm depth of invasion had a significantly higher rate of lymph node metastases than those with invasion of less than 2 mm (25.7% vs 7.5%). Depth of invasion greater than 8 mm was associated with a 41% rate of occult metastasis. Tumor thickness less than 2 mm has been associated with a 13% incidence of lymph node metastases and 3% would ultimately succumb to their disease, whereas greater than 9 mm of invasion was associated with a 65% incidence of lymph node metastases and 35% would die of their disease.^{120,121} O-charoenrat and colleagues also demonstrated an increased risk of cervical metastasis in tongue cancers with a depth of invasion greater than 5 mm, and correlated this with poor outcome even in early stage (I and II) tongue cancers.¹²² Similar results were reported by Kurokawa and colleagues, who found that depth greater than 4 mm was associated with an increased risk for development of late cervical metastases in patients with moderately differentiated squamous cell cancers of the tongue, and diminished overall survival.¹²³ This has led to recommendations that even in the absence of evidence of lymph node metastases, the neck should receive elective treatment (either elective neck dissection or irradiation) for thicker primary tumors. Other investigators have suggested that depth of invasion be added to the staging of oral squamous cell carcinomas. Aside from depth, clinicians have looked at other characteristics such as DNA aneuploidy and histologic grade. At this time applications of this technology have not been adopted in the routine clinical setting.

Two additional imaging modalities used for evaluating nodal metastases deserve mention. Ultrasonography and PET with fluorodeoxyglucose are gaining in popularity for initial staging and follow-up staging of patients with head and neck can-

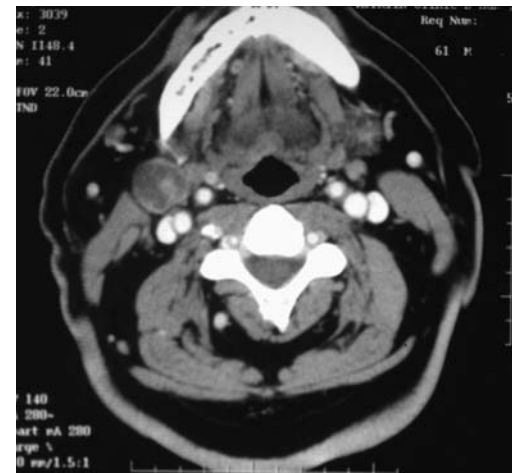


FIGURE 33-17 Computed tomography scan with contrast showing peripheral rim enhancement and central lucency of lymph node harboring metastatic squamous cell carcinoma.

cer. Although not commonly used in the United States, ultrasonography has been used in outpatient clinics for evaluation of oral cancer patients in Europe for some time. Ultrasonography criteria for malignant changes include nodal size and changes in echogenicity, central necrosis that will lead to an echogenic hilum, and a hypoechoic periphery. Its ability to improve on manual palpation of cervical lymphadenopathy has led to its increased use in the United States. It can also help to evaluate carotid or jugular invasion. When performed by an experienced clinician and combined with aspiration cytology, ultrasonography is very accurate.¹²⁴ Knappe and colleagues reported a sensitivity of 89.2% and a specificity of 98.1% in 56 patients who underwent preoperative ultrasound-guided fine-needle aspiration followed by elective or therapeutic neck dissections.¹²⁵

Recently PET has become increasingly popular in the staging and follow-up of patients with head and neck squamous cell carcinoma. By identifying areas of high glucose uptake, PET scans allow clinicians to identify potential metastases in the preoperative work-up (Figure 33-18). Presence of distant metastases may influence the choice of initial treatment. The role of PET scans in the evaluation of occult cervical metastases

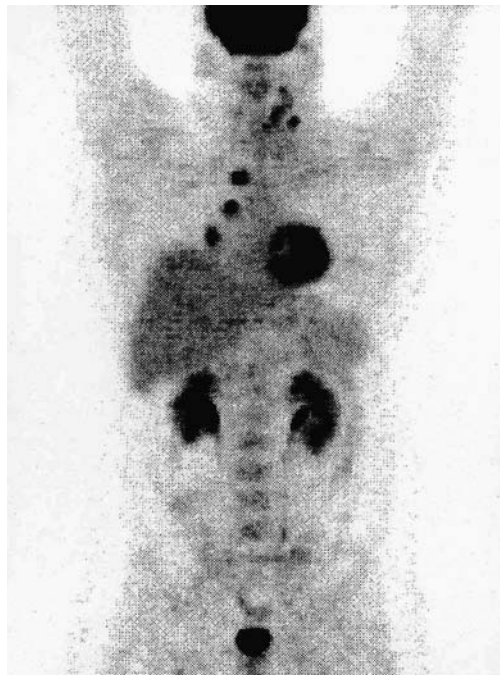


FIGURE 33-18 Positron emission tomography scan showing recurrent cancer in the left neck with three mediastinal metastases. Note the heavy physiologic uptake in the brain, heart, kidneys, and bladder.

is limited by the need for at least 5 to 10 mm³ of tumor for detection. Their role in the work-up of patients with cervical metastases and unknown primaries continues to be explored.¹²⁶ PET is also used to examine patients who have undergone chemoradiotherapy for recurrent disease.¹²⁷ These patients are notorious for their difficulty in examination secondary to extensive changes in the soft tissue. It is recommended that at least 3 months pass prior to obtaining a PET scan because of the persistent inflammation associated with radiation and the tumoricidal effects that persist after radiation is completed. It should also be remembered that current technology requires that a focus of squamous cell carcinoma be several millimeters to be detected.¹²⁸ In the past it was stated that distant metastases were a late finding in head and neck cancer patients and most patients succumbed to locoregional disease. It was felt that less than 1% of head and neck cancer patients had distant disease at presentation. As the use of PET scanning in the initial evaluation of patients

with oral cavity cancers becomes more widespread, detection of distant metastases at the initial evaluation may become more common. One result of these improvements in detection of distant disease is *stage migration*. In other words, as our ability to detect distant disease improves, more patients are staged higher. This does not mean that patients are being diagnosed later in the course of their disease than in the past but simply that our diagnostic abilities have improved.

Neck Dissection in Oral Cavity Squamous Cell Cancer

The goals of neck dissection are to remove gross disease in patients with clinical evidence of nodal involvement (therapeutic neck dissection) or to remove occult metastases in patients whose tumor characteristics make one suspicious of occult cervical metastases (elective neck dissection or END). The importance of treating the cervical lymph nodes was stressed by Crile in his landmark 1906 paper, and was later popularized by Martin and colleagues.^{129,130} Generations of surgeons were trained in the classic radical neck dissection (Figure 33-19). Improved understanding of the regional lymphatic flow and nodal basins at risk for metastases from different primary locations has led to an increasing number of modifications of the standard radical neck dissection. The resultant, often misused, terminology of neck dissection was standardized by the American Academy of Otolaryngology's Committee for Head and Neck Surgery and Oncology in 1991.¹³¹ Revisions were proposed in 2002 to improve communication among clinicians.¹³² These proposed changes were primarily in regard to the selective neck dissections, and specific names such as supraomohyoid neck dissection were eliminated in favor of the phrase "selective neck dissection" followed in parentheses by the levels removed. The definitions pertinent to oral cavity cancer are listed below:

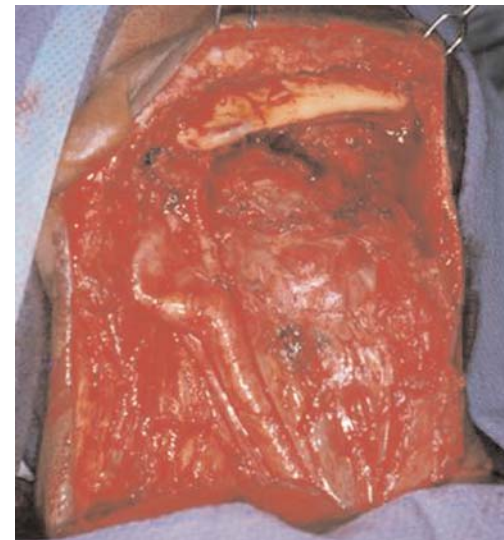


FIGURE 33-19 Standard radical neck dissection of the right neck. Note the communication with the oral cavity where an oral cancer has also been resected.

- Radical neck dissection: Refers to the removal of all ipsilateral cervical lymph node groups extending from the inferior border of the mandible to the clavicle, from the lateral border of the sternohyoid muscle, hyoid bone, and contralateral anterior belly of the digastric muscle medially, to the anterior border of the trapezius. Included are levels I through V. This entails the removal of three important nonlymphatic structures—the internal jugular vein, the sternocleidomastoid muscle, and the spinal accessory nerve.
- Modified radical neck dissection: Refers to removal of the same lymph node levels (I through V) as the radical neck dissection, but with preservation of the spinal accessory nerve, the internal jugular vein, or the sternocleidomastoid muscle. The structures preserved should be named. Some authors propose subdividing the modified neck dissection into 3 types:

Type I preserves the spinal accessory nerve.

Type II preserves the spinal accessory nerve and the sternocleidomastoid muscle.

Type III preserves the spinal accessory nerve, the sternocleidomastoid muscle, and the internal jugular vein.

- Selective neck dissection: Refers to the preservation of one or more lymph node groups normally removed in a radical neck dissection. In the 1991 classification scheme there were several “named” selective neck dissections. For example, the supraomohyoid neck dissection removed the lymph nodes from levels I to III (Figure 33-20). The subsequent proposed modification in 2001 sought to eliminate these “named” dissections. The committee proposed that selective neck dissections be named for the cancer that the surgeon was treating and to name the node groups removed. For example, a selective neck dissection for oral cavity cancer would encompass those node groups most at risk (levels I to III) and be referred to as a selective neck dissection (levels I to III).
- Extended neck dissection: Refers to the removal of one or more additional lymph node groups, nonlymphatic structures, or both, not encompassed

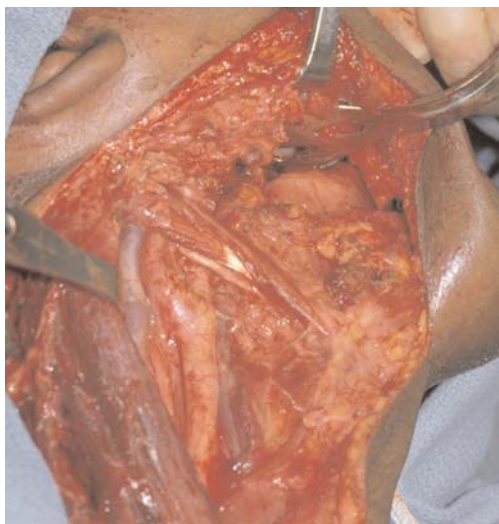

FIGURE 33-20 Supraomohyoid neck dissection, or selective neck dissection, levels I to III. The sternocleidomastoid muscle, nerve XI, and internal jugular vein are preserved.

by a radical neck dissection. For example, mediastinal nodes or nonlymphatic structures such as the carotid artery or hypoglossal nerve.

It is important to remember that classification schemes are continually changing, and as science evolves the indications for different dissections will certainly change. For an oral cavity primary without evidence of lymph node metastases, a selective neck dissection removing lymph nodes from levels I to III is the generally accepted procedure. Shah and colleagues demonstrated supraomohyoid neck dissection to eradicate occult metastatic disease in 95% of patients.¹³³ Some surgeons, however, advocate including level IV (extended supraomohyoid neck dissection) to decrease the risk, however small, of missed occult metastases. Extension on the left side does entail an increased risk to the thoracic duct and attendant chyle leak.⁹⁸ Modifications of neck dissections have been made in an attempt to prevent the morbidity of radical neck dissection (Figure 33-21). Preservation of the spinal accessory nerve decreases the incidence of painful shoulder syndrome. Extensive skeletonization of the nerve, however, can result in significant dysfunction even if the nerve is preserved (Figure 33-22). Several studies have suggested that dissection of level IIb (above the nerve) is unnecessary in the clinically negative neck because of the low incidence of metastases in this area (1.6%), and is recommended only if bulky disease is present in level IIa.¹³⁴

If there is clinical evidence of lymph node metastases, controversy exists over the proper type of neck dissection (see section “Therapeutic Neck Dissection,” below). The application of supraomohyoid neck dissection to the N positive neck (therapeutic neck dissection) has yielded mixed results.¹³⁵ Previous studies have demonstrated that patients undergoing selective neck dissections for N0 necks have a higher rate of recurrence in the

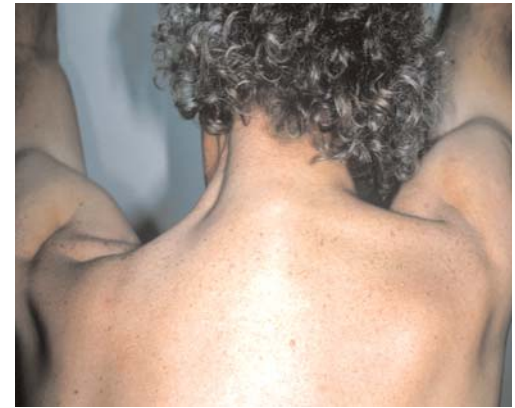

FIGURE 33-21 Denervation of a patient's left trapezius following sacrifice of spinal accessory nerve during radical neck dissection.

neck if positive nodes are ultimately found in the pathologic specimen. This can be improved by the addition of postoperative radiation treatment.¹³⁶ The question remains as to whether this is due to the type of neck dissection or simply the biology of the tumor.^{137,138} Most surgeons advocate some form of neck dissection if there is demonstrable evidence of metastatic disease in the neck, and a diminishing number of surgeons maintain that the evidence of lymph node metastases is justification for nothing less than a standard radical neck dissection.

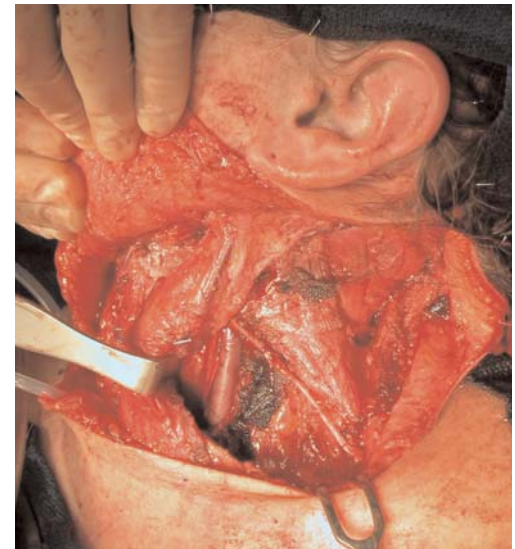


FIGURE 33-22 Dissection and skeletonization of spinal accessory nerve can produce shoulder dysfunction even if nerve is preserved.

Another controversy regarding the evolution of neck dissection concerns the concept of in-continuity versus discontinuous neck dissections. In the past it was considered mandatory to remove the primary tumor in direct continuity with the neck dissection, in one specimen. Work by Spiro and Strong found no adverse impact on survival when neck dissection was performed in a discontinuous manner. Bias might have occurred, however, as smaller lesions were in the discontinuity group.¹³⁹ A study by Leemans and colleagues found worse outcomes in stage II cancer of the tongue with discontinuous neck dissection, with local recurrence rates of 19.1% versus 5.3% and a 5-year survival of 63% versus 80%.¹⁴⁰ Most surgeons prefer an in-continuity approach if technically feasible, without the resection of obviously uninvolved structures such as the mandible.

The controversy surrounding elective neck dissection versus elective neck irradiation (without neck dissection) continues. Advantages of surgery include the production of a surgical specimen that guides the need for further treatment. If no lymph nodes are identified, radiation can be held. The possibility of future second, third, or even fourth primary cancer arising in this at-risk population makes reserving radiation attractive. A comprehensive discussion of the management of cervical lymph nodes in head and neck cancer is beyond the scope of this chapter. Three excellent reviews are available and recommended.^{117,141,142} Although several studies have failed to demonstrate a survival advantage in patients who undergo elective neck dissection versus careful follow-up and therapeutic neck dissection if a metastasis develops, most surgeons would agree that the morbidity associated with a selective neck dissection is minimal and would have a low threshold for performing it.

Sentinel Node Biopsy

As the evolution toward less invasive surgical modalities proceeds, dissection of the

N0 neck (staging neck dissection or elective neck dissection) is becoming increasingly limited. The sentinel node technique, first popularized for melanoma, has been investigated for use in head and neck cancer.^{143,144} Theoretically it allows the identification and removal of the first-echelon lymph node (“sentinel node”) that would first receive metastases from a given site. The technique involves injecting the area surrounding the primary site with a radioactive-labeled material, ^{99m}Tc-sulfur colloid. Various molecular weights can be chosen depending on the transit time desired. A radiograph is then taken to identify and locate the sentinel node. The patient is then taken to the operating room where the surgeon may inject isosulfan blue dye around the primary tumor site. The dye will also drain to the sentinel node and stain it blue, assisting the surgeon in identification during surgery (Figure 33-23). The surgeon will also use a gamma detection probe counterprobe to identify the node with the highest concentration of radioactive colloid. The node is then removed, and if it is histologically positive, further treatment such as radiation may be indicated. In melanoma, sentinel node biopsy has a reported sensitivity of 82 to 100%, and very few false-negatives.^{145,146}

The technique has been investigated in the head and neck with varying results. Problems with the application of the sentinel node technique to squamous cell cancer of the oral cavity relate to the rich lymphatic drainage with possible bilateral drainage as well as the complex anatomy in the neck, leading to difficulty in dissecting out a single node. In addition close proximity of the sentinel node to the primary cancer, for example, an FOM primary cancer and submental node, can lead to the accumulation of colloid around the primary cancer, which obscures the sentinel node. The rich lymphovascular network can also lead to drainage to several nodes. Cevantos and colleagues used the sentinel node technique in 18 oral cavity cancers

with N0 necks.¹⁴⁷ They compared sentinel node biopsy to CT images and PET images by obtaining a CT and PET followed by sentinel node biopsy and neck dissection. They found 10 true-positives, 6 positive nodes identified on frozen section, 2 positive nodes on evaluation of permanent pathologic specimens, and 2 on immunoperoxidase staining for cytokeratin. In 6 specimens, the sentinel node was the only positive node. They also found 7 true-negatives and 1 false-negative. In 1 case the sentinel node identified by the radioactive colloid did not contain cancer, but another cervical node did. They also found that tumor in the node can lead to obstruction and redirection of lymphatic flow.¹⁴⁷ Pitman and colleagues further demonstrated the use of the sentinel node biopsy technique for the N0 neck.¹⁴⁸ Hyde and colleagues reported on 19 patients whose radiographic and clinical test results on their necks were negative and who underwent sentinel lymph node biopsy and PET scanning followed by conventional neck dissection.¹⁴⁹ In 15 of the 19 patients the sentinel node as well as the remaining nodes were negative. In 3 of the 19 patients the sentinel node was positive along with other nodes. In 1 patient the sentinel node was negative, but another node removed in the neck dissection was positive. The node was located close to the primary cancer, which often leads to difficulty discriminating activity due to the tumor and that of adjacent nodes. Interestingly PET failed to

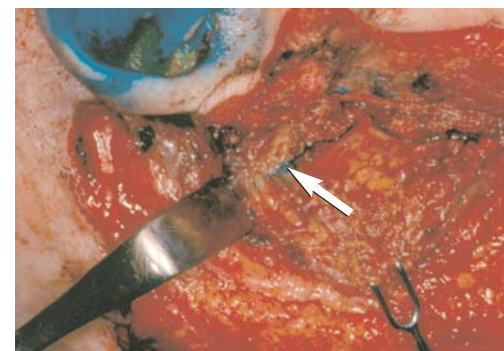


FIGURE 33-23 Sentinel node biopsy. Note the dark staining of the sentinel node.

reveal cancer in the 4 patients with subsequently identified cervical metastasis (see discussion on PET scanning, above).¹⁴⁹ In the future the sentinel node biopsy may become the operative procedure of choice for dealing with the N0 neck. In an excellent review Pitman and colleagues concluded that sentinel lymph node biopsy remains an experimental technique in head and neck cancers and has not become a standard of care.¹⁵⁰

Therapeutic Neck Dissection

Patients presenting with nodal disease will usually undergo some type of therapeutic neck dissection, the nature of which varies with surgeon's preference. Some surgeons will treat all patients with suspected cervical metastases with a radical neck dissection. Most consider a modified radical neck dissection adequate, removing the internal jugular vein or sternocleidomastoid muscle if indicated. There is some evidence that selective neck dissection may be adequate for the N positive neck in certain carefully selected patient populations (see discussion of selective neck dissections, above). Anderson and colleagues reported the results of three academic centers in which patients with previously untreated clinically and pathologically N positive necks underwent neck dissection.¹⁵¹ They reported a regional control rate of 94.3%. Their results were comparable to patients undergoing more extensive neck dissections.¹⁵¹ Patients presenting with massive nodal disease who are going to be treated with chemoradiation therapy or combination of brachytherapy and external beam therapy can present a challenge to surgeons who are faced with the option of surgery before or following radiation. Not infrequently surgeons are faced with complete clinical resolution of disease and the prospects of a neck dissection in a heavily irradiated field. There is some variation in approaches to this dilemma. Some surgeons recommend pretreatment neck dissection to remove bulky disease, whereas

others plan a neck dissection 4 to 6 weeks after treatment regardless of response. Still others recommend a CT scan at 4 weeks and CT-guided biopsy of any suspicious nodes. This is followed by neck dissection if the node biopsy is positive for cancer. McHam and colleagues found that clinical factors did not predict patients with residual disease following chemoradiation therapy and recommended neck dissection in all patients initially seen with N2 to N3 disease.¹⁵² This recommendation was made in light of a 26 to 35% complication rate in patients undergoing neck dissections following chemoradiation therapy.¹⁵² The role of PET scanning in this situation is unclear, but patients with recurrent cancer following multimodality therapy typically have a poor outcome, making salvage surgery an unattractive alternative.

Surgical management of cervical lymph node metastasis, both occult and evident, continues to evolve. It is clear that metastases are an indication of aggressiveness and portend a poorer prognosis. Once the cancer has developed the necessary genetic mutations to break free and colonize independent of the primary tumor, the chance of cure with single modality therapy diminishes. In his presidential address to the New England Surgical Society, Blake Cady referred to "... lymph node metastases as the speedometers of the oncologic vehicle, not the engine. Indicators, not governors of survival."¹⁵³ Clearly the role for the radical neck dissection has diminished greatly over the past few decades, as less invasive surgical techniques for dealing with the cervical lymphatics have gained popularity. This trend will likely continue, as the role of surgery in the control of metastatic disease is better defined.¹⁵⁴⁻¹⁵⁶

Recurrence and Follow-Up Surveillance

In 1984 Vikram and colleagues published a series of reports that discussed patterns of failure in patients treated with multi-

modality therapy for head and neck cancer.¹⁵⁷⁻¹⁵⁹ This classic series of articles outlined failure characteristics at the local site, neck, distant sites, as well as development of second malignant neoplasms in patients treated at Memorial Sloan-Kettering Cancer Center, NY, USA.^{136,157-159} Ninety percent of patients who will suffer a recurrence of oral cavity cancer will do so in the first 2 years. For this reason patients are placed in a structured follow-up. Stage at recurrence is the most important predictor of survival, with stage I at recurrence associated with a median survival of 24.3 months and a disease-free survival at 2 years of 73%, whereas stage IV recurrence was associated with a median survival of 9.3 months and a 2-year disease-free survival of 22%.¹⁶⁰ Follow-up protocols vary widely and are intended to detect recurrences early. De Visscher and Manni suggested the following¹⁶¹:

1. Every 2 months for 1 year
2. Every 3 months for year 2
3. Every 4 months for year 3
4. Every 6 months for years 4 and 5
5. Then yearly

Despite this and other suggested follow-up protocols, the follow-up schedule must be tailored to the individual patient and must take into account the patient's likelihood of having a recurrence, possible continuation of smoking or other habits, ability to travel and keep appointments, and the potential availability of local medical or dental care that might assist in follow-up surveillance. Follow-up appointments include an update of patient history and review of systems as well as clinical examination for recurrence or detection of new primaries. Questions raised by physical examination should prompt an appropriate imaging study, rebiopsy, or examination under anesthesia. Caution should be used, however, in performing biopsies in patients who have received intensive multimodality therapy, such as RADPLAT, brachytherapy, or hyperfractionated radiation schedules

combined with chemotherapy. Extensive biopsy wounds are notorious for slow healing and can lead to chronic wounds.

Appropriate imaging, including a baseline CT or MRI at the completion of multimodality therapy, is invaluable. The role of PET scanning in follow-up continues to evolve.

Failure at the primary cancer site will ultimately occur in approximately 20% of patients, and regional recurrence in the neck will occur in 10%. Death from distant metastases is rare, occurring in only about 1 to 4% of cases in which locoregional control is maintained. An unfortunate consequence of improved control at the primary cancer site with multimodality therapy is an increasing incidence of distant metastases. In addition to recurrences, prospective studies have demonstrated that second primary cancers develop at a rate of 4 to 7% annually in patients who have had a head and neck squamous cancer. Second primary cancers are the leading cause of death among patients who have undergone treatment for early-stage oral cancers.^{136,157-159}

The ability of a cancer to metastasize depends on the development of a series of genetic mutations, allowing for cells to disseminate from the primary tumor, arrest in the microcirculation, extravagate, infiltrate into stroma, and survive and proliferate as a new colony. Surveillance for distant metastases therefore becomes an important component of the follow-up evaluation. The lungs are the most common site for distant metastases, followed by the liver and bone. Yearly or biannual chest radiographs allow for detection of lung metastases, the most common distant site metastasized for oral cavity cancer, and primary lung cancers, which are not uncommon in the population at risk for oral cancer.¹⁶² Given the current unavailability of an effective treatment regimen, however, some authors have questioned the use of annual or semiannual chest radiographs.¹⁶³ PET scanning may prove

to be a more valuable alternative for detection of distant disease. Yearly lab work to include liver function studies is also recommended. In patients who have received radiation as part of their treatment, periodic thyroid function tests are helpful, as many will ultimately become hypothyroid with attendant fatigue and decreased wound healing ability.

Collins stated that patients with head and neck cancer are probably never cured, and that it is better to consider that the host-tumor relationship has been durably altered in favor of the host.¹⁶⁴ It is important to realize that approximately one-third of patients with presumed localized disease will relapse and die of cancer. In advanced head and neck squamous cell carcinoma 20 to 30% will survive, 40 to 60% of patients will suffer locoregional recurrence, and 20 to 30% will succumb to distant metastases. Hence the majority of treatment failures remain recurrence of locoregional disease.¹⁶⁴ Patients with recurrent disease are restaged, which requires a similar evaluation as the original. Panendoscopy and examination under anesthesia take on greater importance when a clinician is faced with examination of tissue scarred and distorted by previous surgery and radiation. Distant metastases should be ruled out to the extent possible prior to deciding on aggressive re-treatment. If the patient does have recurrence that is confined to the locoregional area, treatment decisions are limited by previous therapy. Reirradiation protocols exist but are accompanied by significant morbidity.¹⁶⁵ Intensive reirradiation and chemotherapy protocols are being investigated and show some promise.¹⁶⁶ The morbidity of such treatments is significant, and their use should be restricted to clinical trials at this time. Surgical salvage remains the primary option, but the extent of salvage surgery must be considerably broader than might initially be considered. Goodwin reported on the outcome of salvage surgery for recurrent head and neck

cancers, and found benefit in stages I and II.¹⁶⁰ Success was limited in more advanced disease.¹⁶⁰ Clearly defined goals should be established between surgeon and patient for salvage surgery. Is the operation for cure or palliation? Palliative surgery should be undertaken very cautiously as surgical complications may greatly overshadow the palliative goals. Patients and their families must have realistic expectations as well as understand that there is no benefit from repeated surgical intervention for recalcitrant cancer.

Patients with inoperable cancer pose a unique challenge to the clinician. As cure is no longer a realistic option, treatment modalities to prolong life and improve quality of life assume a higher priority. Pain control becomes a significant issue in patients with recurrent head and neck cancer. Long-acting sustained release formulations such as transdermal narcotic patches combined with short-acting narcotics for breakthrough pain are typically required. Rhizotomy is an option for intractable pain. Pain control can be a goal of palliative chemotherapy or radiotherapy. Novel methods for the targeted delivery of chemotherapeutic agents into the tumor are under development. A combination of cisplatin and epinephrine gel injected into recurrent tumors demonstrated significant palliation without significant side effects in most.¹⁶⁷ Wound management becomes an important issue, and dealing with large malodorous wounds can be taxing on patients and families. Patients presenting with advanced head and neck cancer will typically survive 6 to 12 months without treatment, and patients with end-stage head and neck cancer will have a median survival of 101 days.¹⁶⁴

There is a natural tendency for clinicians to avoid the dying patient. There is a reluctance to face a disease whose biology has resisted their best efforts and whose treatment has left patients debilitated and frequently deformed. While

family members and clinicians are discussing further treatment options, patients are frequently simply concerned with pain control and the effects of massive doses of narcotics on bowel function. Frank, thoughtful discussions must be held with the patients and their families regarding end-of-life issues and will help surgeons deal with these very real concerns. Hospice provides an excellent resource, and once enrolled most families are appreciative of the support offered by these professionals in end-of-life care.

In this era of improved treatment modalities for local and regional disease, clinicians are finding that factors unrelated to the primary cancer and beyond their control are influencing survival. It is becoming increasingly evident that factors affecting outcome in oral cancer patients are multiple and may relate more to patient characteristics than the cancer itself or the treatment they receive. Researchers are finding that genetic factors of the primary cancer have an impact on the response of the particular tumor to any treatment.¹⁶⁸ High expression of epidermal growth factor receptors is associated with poor outcome, and may indicate the need for more intensive multimodality therapy. Alterations in *TP53* have been associated with recurrence in squamous cell cancer of the head and neck that was refractory to radiation treatment. Future treatments may include restoration of *TP53* function.¹⁶⁹

Importantly studies are also demonstrating that comorbidities and performance status predict survival independent of stage at diagnosis. Performance status has been shown to be a predictor of survival independent of tumor, regional nodes, and metastasis (TNM) stage. Many head and neck cancer patients suffer other medical problems related to tobacco and alcohol use, and these can result in decreased overall survival despite cancer-specific survival. Ribeiro and colleagues found that daily alcohol consumption,

smoking, poor body mass index, and other comorbidities had an independent impact on prognosis.¹⁷⁰ As discussed earlier there may indeed be a more aggressive form of squamous cell carcinoma that affects younger patients, but data from the National Cancer Data Base indicate that younger patients have a survival advantage that is most likely related to their lack of comorbidities.¹⁷¹ Frequently 5- and 10-year survival curves are impacted more by these comorbidities than the tumor characteristics recorded in the TNM system (see discussion below).¹⁷² The TNM staging system will continue to undergo revisions to enhance its use.

Future Treatments

In the future, biologic markers hold out promise as the key to treatment of head and neck squamous cancers. Serving as potential targets for gene therapy, biologic markers may also determine appropriate treatment strategies and may select which patients should be treated with surgery, radiation treatment, chemotherapy, or combination treatment. Certain subpopulations of squamous cancers, those with high levels of *TP53* expression and low levels of the marker Ki-67 for example, have higher relapse rates following initial therapy. These patients may benefit from more aggressive combination treatments.^{168,169}

Every few years a new cancer therapy is heralded as the end of cancer surgery. For the present, surgery will continue to play the key role in management of oral cavity cancers, and surgeons must be knowledgeable in all diagnostic and treatment modalities as they continue their captainship of the oral cancer team. The surgeons treating oral cancer, regardless of their discipline, must learn from the contributions and mistakes of their forebears and add the benefit of their own training and experience. They must then use their knowledge base and the input of other treating colleagues to synthesize a plan of treatment tailored to the patient who sits

before them. They must interact effectively with colleagues of other disciplines with the patient's benefit their foremost concern. They must execute the surgical components of the treatment plan with accuracy and skill. They must be supportive to their patients and their patients' families at a time of great stress in their lives and must not turn away from adversity or complication. They must accept the fact that not all patients can be cured. They should derive inspiration from those who survive and satisfaction from those who might succumb in a way made more favorable by the surgeon's input.

References

1. Parkin DM, Pisani P, Farley J. Global cancer statistics. *CA Cancer J Clin* 1999;49:33-64.
2. Jemal A, Murray T, Samuels A, et al. Cancer statistics, 2003. *CA Cancer J Clin* 2003; 53:23-47.
3. Canto MT, Devesa SS. Oral cavity and pharynx cancer incidence rates in the United States, 1975-1998. *Oral Oncol* 2002;38:610-7.
4. Greenlee RT, Murray T, Bolden S, et al. Cancer statistics, 2000. *CA Cancer J Clin* 2000; 50:7-33.
5. Swango PA. Cancers of the oral cavity and pharynx in the United States: an epidemiologic overview. *J Public Health Dent* 1996;56:309-18.
6. Meskin LH. Oral cancer: the forgotten disease [editorial]. *J Am Dent Assoc* 1994;125: 1042-5.
7. Smart CR. Screening for cancer of the aerodigestive tract. *Cancer* 1993;72 Suppl:1061-5.
8. Smith RA, Cokkinides V, Eyre HJ. American Cancer Society guidelines for the early detection of cancer, 2003. *CA Cancer J Clin* 2002;53:27-43.
9. Holmes J, Dierks E, Homer L, Potter B. Is detection of oral and oropharyngeal squamous cancer by a health care provider associated with a lower stage at diagnosis? *J Oral Maxillofac Surg* 2003;61:285-91.
10. Guggenheimer J, Weissfield JL, Kroboth FJ. Who has the opportunity to screen for oral cancer? *Cancer Causes Control* 1993;4:63-6.
11. Choido GT, Eigner T, Rosenstein DI. Oral cancer detection: the importance of routine screening for prolongation of survival. *Postgrad Med* 1986;80:231-6.
12. Elliott GV, MacDougal JA, Elliott JD. Problems of verrucous squamous carcinoma. *Ann Surg* 1973; 177:21-9.

13. Coppola D, Catalano E, Tang C, et al. Basaloid squamous cell carcinoma of floor of mouth. *Cancer* 1993;72:2299–305.
14. Raslan WF, Barnes L, Krause JR, et al. Basaloid squamous cell carcinoma of the head and neck: a clinicopathologic and flow cytometric study of 10 new cases with review of the English literature. *Am J Otolaryngol* 1994;15:204–8.
15. Axell T, Pindborg JJ, Smith CJ, Van der Waal I. Oral white lesions with special reference to precancerous and tobacco related lesions: conclusions of an international symposium held in Uppsala, Sweden, May 18–21, 1994. International Collaborative Group on oral white lesions. *J Oral Pathol Med* 1996;25:49–54.
16. Petti S. Pooled estimates of world leukoplakia prevalence: a systemic review. *Oral Oncol* 2003;39:770–80.
17. Hashibe M, Jacob BJ, Thomas G, et al. Socioeconomic status, lifestyle factors and oral premalignant lesions. *Oral Oncol* 2003;39:664–71.
18. Silverman S, Gorsky M, Lozada F. Oral leukoplakia and malignant transformation: a follow-up study of 257 patients. *Cancer* 1984;53:563–8.
19. Scheifele C, Reichart PA. Is there a natural limit of the transformation rate of oral leukoplakia? *Oral Oncol* 2003;39:470–5.
20. Lodi G, Sardella A, Bez C, et al. Interventions for treating oral leukoplakia (Cochrane review). In: *The Cochrane Library*. Issue 4. Oxford: Update Software; 2002.
21. Lodi G, Sardella A, Bex C, et al. Systematic review of randomized trials for the treatment of oral leukoplakia. *J Dent Educ* 2002;66:896–902.
22. Ishii J, Fujita K, Komori T. Laser surgery as a treatment for oral leukoplakia. *Oral Oncol* 2003;39:759–69.
23. Hopper C. Photodynamic therapy: a clinical reality in the treatment of cancer. *Lancet Oncol* 2000;1:212–9.
24. Grant WE, Speight PM, Hopper C, Brown SG. Photodynamic therapy: an effective but non-selective treatment for superficial cancers of the oral cavity. *Int J Cancer* 1997;71:937–42.
25. Zhao FY, Zhang KH, Jiang F, Wu MJ. Photodynamic therapy for treatment of cancers of the oral and maxillofacial regions: a long term follow up study in 72 complete remission cases. *Lasers Med Sci* 1991;6:201–4.
26. Ackroyd R, Kelty CJ, Brown NJ, et al. Eradication of dysplastic Barrett's oesophagus using photodynamic therapy: long-term follow-up. *Endoscopy* 2003; 35:496–501.
27. Sieron A, Adamek M, Kawczyk-Krupka A, et al. Photodynamic therapy (PDT) using topically applied delta-aminolevulinic acid (ALA) for the treatment of oral leukoplakia. *J Oral Pathol Med* 2003;32:330–6.
28. Copper MP, Tan IB, Oppelaar H, et al. Metatetra(hydroxyphenyl)chlorine photodynamic therapy in early stage squamous cell carcinoma of the head and neck. *Arch Otolaryngol Head Neck Surg* 2003;129:709–11.
29. McGuirt WF. Panendoscopy as a screening examination for simultaneous primary tumors in head and neck cancer: a prospective, sequential study and review of the literature. *Laryngoscope* 1982;92:569–76.
30. Benninger MS, Enrique RR, Nichols RD. Symptom-driven selective endoscopy and cost-containment for evaluation of head and neck cancer. *Head Neck* 1993;15:532–6.
31. Slaughter DP, Southwick HW, Smejkal W. Field cancerization in oral stratified squamous epithelium: clinical implications of multicentric origin. *Cancer* 1953;6: 963–8.
32. Nathan CA, Amirghahri N, Rice C, et al. Molecular analysis of surgical margins in head and neck squamous cell carcinoma patients. *Laryngoscope* 2002;112:2129–40.
33. Thomson PJ. Field change and oral cancer: new evidence for widespread carcinogenesis? *Int J Oral Maxillofac Surg* 2002; 31:262–6.
34. Jacobs JR, Ahmad K, Casiano R, et al. Implications of positive surgical margins. *Laryngoscope* 1993;103:64–8.
35. Beitler JJ, Smith RV, Silver CE, et al. Close or positive margins after surgical resection for the head and neck cancer patient: the addition of brachytherapy improves local control. *Int J Radiat Oncol Biol Phys* 1998;40:313–7.
36. Ord RA, Aisner S. Accuracy of frozen sections in assessing margins in oral cancer resection. *J Oral Maxillofac Surg* 1997;55:663–9; discussion 669–71.
37. Dinardo LJ, Lin J, Karageorge LS, Powers CN. Accuracy, utility and cost of frozen section margins in head and neck cancer surgery. *Laryngoscope* 2000; 110:1773–6.
38. Ribeiro NF, Godden DR, Wilson GE, Butterworth RT. Do frozen sections help achieve adequate surgical margins in the resection of oral carcinoma? *Int J Oral Maxillofac Surg* 2003;32:152–8.
39. Sutton DN, Brown JS, Rogers SN, et al. The prognostic implications of the surgical margin in oral squamous cell carcinoma. *Int J Oral Maxillofac Surg* 2003;32:30–4.
40. Borggreven PA, Kuik DJ, Quak JJ, et al. Comorbid condition as a prognostic factor for complications in major surgery of the oral cavity and oropharynx with microvascular soft tissue reconstruction. *Head Neck* 2003;25:808–15.
41. Becker GD, Parell GJ. Cefazolin prophylaxis in head and neck cancer surgery. *Ann Otol* 1979;88:183–6.
42. Mombelli G, Coppens L, Dor P, Klustersky J. Antibiotic prophylaxis in surgery for head and neck cancer: comparative study of short and prolonged administration of carbicillin. *J Antimicrob Chemother* 1981; 7:665–71.
43. Ananth S, Amin M. Implantation of oral squamous cell carcinoma at the site of a percutaneous endoscopic gastrostomy: a case report. *Br J Oral Maxillofac Surg* 2002;40:125–30.
44. Janjan N, Miller M, Schusterman MA. Therapeutic principles and options in radiation oncology. *Plast Reconstr Surg* 1995; 96:1463–73.
45. Buchholz TA, Laramore GE, Griffin BR, et al. The role of fast neutron radiation therapy in the management of advanced salivary gland malignant neoplasms. *Cancer* 1992;69:2779–88.
46. Vikram B. Does hyperfractionation reduce late complications in head and neck cancer [letter]? *Int J Radiat Oncol Biol Phys* 1992;23:1097–8.
47. Taylor JM, Mendenhall WM, Lavey RS. Dose, time and fraction size for late effects in head and neck cancers. *Int J Radiat Oncol Biol Phys* 1992;22:3–11.
48. Eisbruch A, Marsh LH, Martel MK, et al. Comprehensive irradiation of head and neck cancer using conformal multisegmental fields: assessment of target coverage and noninvolved tissue sparing. *Int J Radiat Oncol Biol Phys* 1998;41:559–68.
49. Eisbruch A, Foote RL, O'Sullivan B, et al. Intensity-modulated radiation therapy for head and neck cancer: emphasis on the selection and delineation of the targets. *Semin Radiat Oncol* 2002;12:238–49.
50. Langlois D, Hoffstetter S, Malissard L, et al. Salvage irradiation of oropharynx and mobile tongue with 192-Iridium brachytherapy in Centre Alexis Vautrin. *Int J Radiat Oncol Biol Phys* 1988;14:849–53.
51. Matsumoto S, Takeda M, Shibuya H, Suzuki S. T1 and T2 squamous cell carcinomas of the floor of mouth: results of brachytherapy mainly using 98 Au grains. *Int J Radiat Oncol Biol Phys* 1996;34:833–41.
52. Noone RB, Bonner H, Raymond S, et al. Lymph node metastases in oral carcinoma. A correlation of histopathology with survival. *Plast Reconstr Surg* 1974;53:158–66.

53. Mendenhall WM, Million RR, Cassisi NJ. Elective neck irradiation in squamous cell carcinoma of the head and neck. *Head Neck* 1980; 3:15–20.
54. Woolger JA, Rogers SN, Lowe D, et al. Cervical lymph node metastasis in oral cancer: the importance of even microscopic extracapsular spread. *Oral Oncol* 2003;39:130–7.
55. Tupchong L, Scott CB, Blitzer PH, et al. Randomized study of preoperative versus postoperative radiation therapy in advanced head and neck carcinoma: long-term follow-up of RTOG 73-03. *Int J Radiat Oncol Biol Phys* 1991;20:21–8.
56. Peters LJ, Goepfert H, Ang KK, et al. Evaluation of the dose for post-operative radiation therapy of head and neck cancer: first report of a randomized trial. *Int J Radiat Oncol Biol Phys* 1993;26:3–11.
57. Vikram B. Importance of time interval between surgery and postoperative radiation therapy in the combined management of head and neck cancer. *Int J Radiat Oncol Biol Phys* 1979;5:1837–40.
58. Schiff PB, Harrison LB, Strong EW, et al. Impact of the time interval between surgery and postoperative radiation therapy on locoregional control in advanced head and neck cancer. *J Surg Oncol* 1990;43:203–8.
59. Parsons JT, Mendenhall WM, Stringer SP, et al. An analysis of factors influencing the outcome of postoperative irradiation for squamous cell carcinoma of the oral cavity. *Int J Radiat Oncol Biol Phys* 1997;39:137–48.
60. Brizel DM, Wasserman TH, Henke M, et al. Phase III randomized trial of amifostine as a radioprotector in head and neck cancer. *J Clin Oncol* 2000; 18:3339–45.
61. Wijers OB, Levendag PC, Braaksmma MM, et al. Patients with head and neck cancer cured by radiation therapy: a survey of the dry mouth syndrome in long-term survivors. *Head Neck* 2002;24:737–47.
62. Nicolatou-Galitis, O, Sotiropoulou-Lontou A, Velegaki A, et al. Oral candidiasis in head and neck cancer patients receiving radiotherapy with amifostine cytoprotection. *Oral Oncol* 2003;39:397–401.
63. Wolf GT, Hong KT, Fisher SG, et al. Induction chemotherapy plus radiation compared with surgery plus radiation in patients with advanced laryngeal cancer. *N Engl J Med* 1991;324:1685–90.
64. Karnofsky DA, Burchenal JH. The clinical evaluation of chemotherapeutics in cancer. In: Macleod CM, editor. *Evaluation of chemotherapeutic agents*. New York: Columbia Press; 1949. p. 191–205.
65. Miller AB, Hoogstraten B, Staquet M, Winkler A. Reporting results of cancer treatment. *Cancer* 1981;47:207–10.
66. DeVita VT Jr. Principles of chemotherapy. In: DeVita VT Jr, Hellman S, Rosenberg SA, editors. *Cancer: principles and practices of oncology*. Philadelphia (PA): JB Lippincott Co.; 1993. p. 276–92.
67. Mihara M, Shintani S, Nakashiro K, Hamakawa H. Flavopiridol, a cyclin dependent kinase (CDK) inhibitor, induces apoptosis by regulating Bcl-x in oral cancer cells. *Oral Oncol* 2003;39:49–55.
68. Patel V, Senderowicz AM, Pinto D, et al. Flavopiridol, a novel cyclin-dependent kinase inhibitor, suppresses the growth of head and neck squamous cell carcinomas by inducing apoptosis. *J Clin Invest* 1998; 102:1674–81.
69. Cooper JS, Pajak TF, Forastiere AA, et al. 2002 abstract ASCO online. Available at: <http://www.asco.org> (accessed November 21, 2003).
70. Cmelak AJ, Murphy BA, Day T. Combined modality therapy for locoregionally advanced head and neck cancer. *Oncology* 1999;13:83–91.
71. Robbins KT. The evolving role of combined modality therapy in head and neck cancer. *Arch Otolaryngol Head Neck Surg* 2000;126:265–9.
72. Dimery IW, Hong WK. Overview of combined modality therapies for head and neck cancer. 1993;85:95–111.
73. El-Sayed S, Nelson N. Adjuvant and adjunctive chemotherapy in the management of squamous cell carcinoma of the head and neck region: a meta analysis of prospective and randomized trials. *Clin Oncol* 1996;14:838–47.
74. Munro AJ. An overview of randomized controlled trials of adjuvant chemotherapy in head and neck cancer. *Br J Cancer* 1995;71:83–91.
75. Robbins KT, Kumar P, Regine WF, et al. Efficacy of supradose intra-arterial targeted (SIT) cisplatin (P) and concurrent radiation treatment (RT) in the treatment of unresectable stage III-IV head and neck carcinoma: the Memphis experience. *Int J Radiat Oncol Biol Phys* 1997;38:263–71.
76. Andreadis C, Vahtsevanos K, Sideras T, et al. 5-Fluorouracil and cisplatin in the treatment of advanced head and neck cancer. *Oral Oncol* 2003;39:380–5.
77. Myers JN, Holsinger C, Bekele N et al. Targeted molecular therapy for oral cancer with epidermal growth factor receptor blockade: a preliminary report. *Arch Otolaryngol Head Neck Surg* 2002;128:875–9.
78. Ganly I, Soutar DS, Kaye SB. Current role of gene therapy in head and neck cancer. *Eur J Surg Oncol* 2000;26:338–43.
79. Yarbrough WG. The ARF-p16 gene locus in carcinogenesis and therapy of head and neck squamous cell carcinoma. *Laryngoscope* 2002;112:2114–28.
80. Milas L, Mason KA, Zhongxing L, Ang KK. Chemoradiotherapy: emerging treatment improvement strategies. *Head Neck* 2003;25:152–67.
81. Hong WK, Lippman SM, Wolf GT. Recent advances in head and neck cancer —larynx preservation and cancer chemoprevention: the Seventh annual Richard and Hinda Rosenthal Foundation award lecture. *Cancer Res* 1993;53:5113–20.
82. Garewal HS, Katz RV, Meyskens F, et al. Beta-carotene produces sustained remissions in patients with oral leukoplakia. *Arch Otolaryngol Head Neck Surg* 1999;125:1305–10.
83. Wang Z, Polavaram R, Fuentes CF, et al. Topical chemoprevention of oral cancer with tretinoin biofilm. *Arch Otolaryngol Head Neck Surg* 2003;129:869–73.
84. Armstrong WB, Wan XS, Kennedy AR, et al. Candidate's thesis: development of the Bowman-Birk inhibitor for oral chemoprevention and analysis of Neu immunohistochemical staining intensity with Bowman-Birk inhibitor concentrate treatment. *Laryngoscope* 2003;113:1687–702.
85. Mohan S, Epstein JB. Carcinogenesis and cyclooxygenase: the potential role of COX-2 inhibition in upper aerodigestive tract cancer. *Oral Oncol* 2003;39:537–46.
86. Dempke W, Rie C, Grothey A, et al. Cyclooxygenase-2: a novel target for cancer chemotherapy? *Am J Pathol* 2002;160:389–401.
87. Sudbo J, Ristimaki A, Sondresen JE, et al. Cyclooxygenase-2 (COX-2) expression in high-risk premalignant oral lesions. *Oral Oncol* 2003;39:497–505.
88. Lin DT, Subbaramaiah K, Shah JP, et al. Cyclooxygenase-2: a novel molecular target for the prevention and treatment of head and neck cancer. *Head Neck* 2002;24:792–99.
89. Baker SR, Krause CJ. Carcinoma of the lip. *Laryngoscope* 1980;90:19–25.
90. Duplechain G, Amedee RG. Carcinoma of the lip. *J La State Med Soc* 1992;144:441–2.
91. Bloom ND, Spiro RH. Carcinoma of the cheek mucosa: a retrospective analysis. *Am J Surg* 1980;140:556–60.
92. Vikram B, Farr HW. Adjuvant radiation therapy in locally advanced head and neck cancer. *CA Cancer J Clin* 1983;33:134–8.
93. Diaz EM, Holsinger FC, Zuniga ER, et al. Squamous cell carcinoma of the buccal mucosa: one institution's experience with

- 119 previously untreated patients. *Head Neck* 2003;25:267–73.
94. Kowalski LP, Hasimoto I, Magrin J. End results of 114 extended “commando” operations. *Am J Surg* 1993;166:374–9.
 95. Genden EM, Ferlito A, Shaha A, Rinaldo A. Management of cancer of the retromolar trigone. *Oral Oncol* 2003;39:633–7.
 96. Fakhri AR, Rao RS, Borges AM, Patel AR. Elective versus therapeutic neck dissection in early carcinoma of the oral tongue. *Am J Surg* 1989;158:309–13.
 97. Crean S, Hoffman A, Potts J, et al. Reduction of occult metastatic disease by extension of the supraomohyoid neck dissection to include level IV. *Head Neck* 2003;25:758–62.
 98. Harrison LB, Ferlito A, Shaha AR, et al. Current philosophy on the management of cancer of the base of the tongue. *Oral Oncol* 2003;39:101–5.
 99. Lydiatt DD, Robbins KT, Byers RM, Wolfe PF. Treatment of Stage I and II oral tongue cancer. *Head Neck* 1993;15:308–12.
 100. Krupala JL, Gianoli R. Carcinoma of the oral tongue. *J La State Med Soc* 1993;145:421–6.
 101. Vargas H, Pitman KT, Johnson JT, Galati LT. More aggressive behavior of squamous cell carcinoma of the anterior tongue in young women. *Laryngoscope* 2000;110:1623–6.
 102. Pitman KT, Johnson JT, Wagner RL, Myers EN. Cancer of the tongue in patients less than forty. *Head Neck* 2000;22:297–302.
 103. McGuirt WF, Johnson JT, Myers EN, et al. Floor of mouth carcinoma — the management of the clinically negative neck. *Arch Otolaryngol Head Neck Surg* 1995;121:278–82.
 104. Rodgers LW, Stringer SP, Mendenhall WM, et al. Management of squamous cell carcinoma of the floor of mouth. *Head Neck* 1993;15:16–9.
 105. Dierks EJ, Holmes JD. The LeFort island approach: an alternative access for partial maxillectomy. *J Oral Maxillofac Surg* 2002;60:1377–9.
 106. Byers RM, Newman R, Russell N, et al. Results of treatment of squamous cell carcinoma of the lower gum. *Cancer* 1981;47:2236–8.
 107. Patzer ER, Schweitzer RJ, Frazell EL. Epidermoid carcinoma of the palate. *Am J Surg* 1970;119:294–8.
 108. Chung CK, Johns ME, Cantrell RW, et al. Radiotherapy in the management of primary malignancies of the hard palate. *Laryngoscope* 1980;90:576–84.
 109. McGregor ED. A classic paper revisited: Polya and Von Navratil (1902). *Head Neck Surg* 1987;9:325–8.
 110. Marchetta FA, Kumao S, Murphy BJ. The periosteum of the mandible and intraoral carcinoma. *Am J Surg* 1971;122:711–3.
 111. O’Brien CJ, Carter RL, Soo RC, et al. Invasion of the mandible by squamous carcinomas of the oral cavity and oropharynx. *Head Neck* 1986;8:247–56.
 112. Barttelbort SW, Aryan S. Mandible preservation with oral cavity carcinoma: rim mandibulectomy versus sagittal mandibulectomy. *Am J Surg* 1993;166:411–5.
 113. Forrest LA, Schuller DE, Lucas JG, Sullivan MJ. Rapid analysis of mandibular margins. *Laryngoscope* 1995;105:475–7.
 114. White RD. Modified sagittal osteotomy of the mandible for marginal oncologic resection. *J Oral Maxillofac Surg* 2003;61:272–4.
 115. Wax MK, Bascom DA, Myers LL. Marginal mandibulectomy versus segmental mandibulectomy: indications and controversies. *Arch Otolaryngol Head Neck Surg* 2002;128:600–3.
 116. Shah JP. The role of marginal mandibulectomy in the surgical management of oral cancer. *Arch Otolaryngol Head Neck Surg* 2002;128:604–5.
 117. Collins SL. Controversies in management of cancer of the neck. In: Thawley SE, Panje WP, Batsakis JG, Lindberg RD, editors. *Comprehensive management of head and neck tumors*, Philadelphia (PA): W.B. Saunders; 1999. p. 1479–563.
 118. Van den Brekel MW. Computed tomography, magnetic resonance, ultrasound guided aspiration cytology for the assessment of the neck. In: Van den Brekel MV, doctoral thesis. The Netherlands, Amsterdam: Free University; 1992.
 119. Close LG, Merkle M, Vultch MF, et al. Computed tomographic evaluation of regional lymph node involvement in cancer of the oral cavity and oropharynx. *Head Neck* 1989;11:309–14.
 120. Spiro RH, Huvos AG, Wong GY, et al. Predictive value of tumor thickness in squamous cell carcinoma confined to the tongue and floor of the mouth. *Am J Surg* 1986;152:345–50.
 121. Snow GB, Annyas AA, vanSloote EA, et al. Prognostic factors of neck node metastasis. *Clin Otolaryngol* 1982;7:185–92.
 122. O-charoenrat P, Pillai G, Patel S, et al. Tumor thickness predicts cervical nodal metastases and survival in early tongue cancer. *Oral Oncol* 2003;39: 386–90.
 123. Kurokawa H, Yamashita Y, Takeda S, et al. Risk factors for late cervical lymph node metastases in patients with stage I or II carcinoma of the tongue. *Head Neck* 2002;24:731–6.
 124. Schwartz R, Chan NH, MacFarlane JK. Fine needle aspiration cytology in the evaluation of head and neck masses. *Am J Surg* 1990;159:482–9.
 125. Knappe M, Louw M, Gregor RT. Ultrasonography-guided fine needle aspiration for the assessment of cervical metastases. *Arch Otolaryngol Head Neck Surg* 2000;126:1091–6.
 126. Jungehulsing M, Scheidhauer K, Damm M, et al. $^{2}[18F]$ -fluoro-2-deoxy-D-glucose positron emission tomography is a sensitive tool for the detection of occult primary cancer (carcinoma of unknown primary syndrome) with head and neck lymph node manifestation. *Otolaryngol Head Neck Surg* 2000;126:1457–61.
 127. Lonneux M, Lawson G, Ide C, et al. Positron emission tomography with fluorodeoxyglucose for suspected head and neck tumor recurrence in the symptomatic patient. *Laryngoscope* 2000;110:1493–7.
 128. Fischbein N, Anzai Y, Mukherji SK. Application of new imaging techniques for the evaluation of squamous cell carcinoma of the head and neck. *Semin Ultrasound CT MR* 1999;20:187–212.
 129. Martin H, Delvalle B, Ehrlich H, et al. Neck dissection. *Cancer* 1951; 4:441–99.
 130. Crile G. Excision of cancer of the head and neck with special reference to the plan of dissection based upon one-hundred thirty-two operations. *JAMA* 1906;47:1780–6.
 131. Robbins KT, Medina JE, Wolfe GT, et al. Standardizing neck dissection terminology official report of the Academy’s Committee for Head and Neck Surgery and Oncology. *Arch Otolaryngol Head Neck Surg* 1991;117:601–5.
 132. Robbins KT, Clayman G, Levine PA, et al. Neck dissection classification update: revisions proposed by the American Head and Neck Society and the American Academy of Otolaryngology Head and Neck Surgery. *Arch Otolaryngol Head Neck Surg* 2002;128:751–8.
 133. Shah JP, Candela FC, Poddar AK. The patterns of cervical lymph node metastases from squamous cell carcinoma of the oral cavity. *Cancer* 1990;66:109–13.
 134. Silverman DA, El-Hajj M, Strome S, Esclamado RM. Prevalence of nodal metastases in the submuscular recess (level IIb) during selective neck dissection. *Arch Otolaryngol Head Neck Surg* 2003;129:724–8.
 135. Kowalski LP, Carvalho AL. Feasibility of supraomohyoid neck dissection in N1 and N2a oral cancer patients. *Head Neck* 2002;24:921–4.
 136. Vikram B, Strong EW, Shah JP, Spiro R. Failure

- in the neck following multimodality treatment for advanced head and neck cancer. *Head Neck Surg* 1984;6:724–9.
137. Spiro JD, Spiro RH, Shah JP, et al. Critical assessment of supraomohyoid neck dissection. *Am J Surg* 1988;156:286–9.
138. Kerrebijin JDE, Freeman JL, Irish JC, et al. Supraomohyoid neck dissection. Is it diagnostic or therapeutic? *Head Neck* 1999;21:39–42.
139. Spiro RH, Strong EW. Discontinuous partial glossectomy and radical neck dissection in selected patients with epidermoid carcinoma of the mobile tongue. *Am J Surg* 1973;126:544–6.
140. Leemans CR, Tiwari R, Nauta JJ, et al. Discontinuous vs in-continuity neck dissection in carcinoma of the oral cavity. *Arch Otolaryngol Head Neck Surg* 1991;117:1003–6.
141. Ghali GE, Li BD, Minnard EA. Management of the neck relative to oral malignancy. *Selected Readings Oral Maxillofac Surg* 1998; 6(2):1–36.
142. Pillsbury HC, Clark M. A rationale for therapy of the N 0 neck: Joseph H. Ogura Lecture. *Laryngoscope* 1997;107:1294–315.
143. Morton DL, Wen DR, Wong JH, et al. Technical details of intraoperative lymphatic mapping for early stage melanoma. *Arch Surg* 1992;127:392–99.
144. Morton DL, Wen DR, Foshag LJ, et al. Intraoperative lymphatic mapping and selective cervical lymphadenectomy for early stage melanomas of the head and neck. *J Clin Oncol* 1993;11:1751–6.
145. Krag DN, Meijer SJ, Weaver DL, et al. Minimal access surgery for staging of malignant melanoma. *Arch Surg* 1995;130:654–8.
146. Glass LF, Messina JL, Cruse W, et al. The use of intraoperative radiolymphoscintigraphy for sentinel node biopsy in patients with malignant melanoma. *Dermatol Surg* 1996;22:715–20.
147. Cevantos FJ, Gomez C, Duque C, et al. Sentinel node biopsy in oral cavity cancer: correlation with PET scan and immunohistochemistry. *Head Neck* 2003;25:1–9.
148. Pitman KT, Johnson JT, Brown ML, et al. Sentinel lymph node biopsy in head and neck squamous cell carcinoma. *Laryngoscope* 2002;112:2101–13.
149. Hyde NC, Prvulovich E, Newman L, et al. A new approach to pre-treatment assessment of the N0 neck in oral squamous cell carcinoma: the role of sentinel node biopsy and positron emission tomography. *Oral Oncol* 2003;39:350–60.
150. Pitman KT, Ferlito A, Devaney KO, et al. Sentinel lymph node biopsy in head and neck cancer. *Oral Oncol* 2003;39:343–9.
151. Anderson PE, Warren F, Spiro J, et al. Results of selective neck dissection in management of the node positive neck. *Arch Otolaryngol Head Neck Surg* 2002;128:1180–4.
152. McHam SA, Adelstein DJ, Rybicki LA, et al. Who merits a neck dissection after definitive chemoradiotherapy for N2-N3 squamous cell head and neck cancer? *Head Neck* 2003;25:791–7.
153. Cady B. Lymph node metastases: indicators but not governors of survival. *Arch Surg* 1984;119:1067–72.
154. Robbins KT, Atkinson JL, Byers RM, et al. The use and misuse of neck dissection for head and neck cancer. *J Am Coll Surg* 2001; 193:91–102.
155. Ferlito A, Rinaldo A, Robbins KT, et al. Changing concepts in the surgical management of cervical node metastasis. *Oral Oncol* 2003;39:429–35.
156. Kowalski LP, Magrin J, Waksman F, et al. Supraomohyoid neck dissection in the treatment of head and neck tumors: survival results in 212 cases. *Arch Otolaryngol Head Neck Surg* 1993;119:958–63.
157. Vikram B, Strong EW, Shah JP, Spiro R. Failure at the primary site following multi-modality treatment in advanced head and neck cancer. *Head Neck Surg* 1984;6:720–3.
158. Vikram B, Strong EW, Shah JP, Spiro R. Failure at distant sites following multi-modality treatment in advanced head and neck cancer. *Head Neck Surg* 1984;6:730–3.
159. Vikram B, Strong EW, Shah JP, Spiro R. Second primary neoplasms in patients successfully treated with multimodality treatment for advanced head and neck cancer. *Head Neck Surg* 1984;6:734–7.
160. Goodwin WJ. Salvage surgery for patients with recurrent squamous cell carcinoma of the aerodigestive tract: when do the ends justify the means? *Laryngoscope* 2000;110:1–18.
161. De Visscher AV, Manni JJ. Routine long-term follow-up in patients treated with curative intent for squamous cell carcinoma of the larynx, pharynx and oral cavity. Does it make sense? *Arch Otolaryngol Head Neck Surg* 1994;120:934–9.
162. Stalpers LJ, Vierzen PB, Brouns JJ, et al. The role of yearly chest radiography in the early detection of lung cancer following oral cancer. *Int J Oral Maxillofac Surg* 1989;18:99–103.
163. Merckx MA, Boustahji JH, Kaanders AM, et al. A half-yearly chest radiograph for early detection of lung cancer following oral cancer. *Int J Oral Maxillofac Surg* 2002;31:378–82.
164. Collins SL. Controversies in multi-modality therapy for head and neck cancer: clinical and biologic perspectives. In: Thawley SE, Panje WP, Batsakis JG, Lindberg RD, editors. *Comprehensive management of head and neck tumors*. Philadelphia (PA): W.B. Saunders; 1999. p. 157–281.
165. Crevoisier DR, Bourhis J, Dometge P, et al. Full-dose reirradiation for unresectable head and neck carcinoma: experience at the Gustave-Roussy Institute in a series of 169 patients. *J Clin Oncol* 1998;16:3556–62.
166. Spencer S, Wheeler R, Peters G, et al. Phase I trial of combined chemotherapy and reirradiation for recurrent unresectable head and neck cancer. 2003;25:118–22.
167. Castro DJ, Sridhar KS, Garewal HS, et al. Intratumoral cisplatin/epinephrine gel in advanced head and neck cancer: a multicenter, randomized, double-blind, phase III study in North America. *Head Neck* 2003;25:717–31.
168. Ganly I, Soutar DS, Brown R, Kaye SB. p53 alterations in recurrent squamous cell cancer of the head and neck refractory to radiotherapy. *Br J Cancer* 2000; 82:392–8.
169. Raybaud-Diogene H, Fortin A, Morency R, et al. Markers of radioresistance in squamous cell carcinomas of the head and neck: a clinicopathologic and immunohistochemical study. *J Clin Oncol* 1997;15:1030–8.
170. Ribeiro KC, Kowalski LP, Latorre MR. Perioperative complications, comorbidities, and survival in oral and oropharyngeal cancer. *Arch Otolaryngol Head Neck Surg* 2003; 129:219–28.
171. Funk GF, Karnell LH, Robinson RA. Presentation, treatment and outcome of oral cavity cancer: a national cancer data base report. *Head Neck* 2002;24:165–80.
172. Piccirillo JF. Inclusion of comorbidity in a staging system for head and neck cancer. *Oncology* 1995;9:831–6.

Lip Cancer

James W. Sikes Jr, DMD, MD

G. E. Ghali, DDS, MD

Lip cancer, one of the most common cancers of the head and neck region, is one of the most easily diagnosed, with generally a good prognosis. In some individuals, lip cancer may behave aggressively, manifested by recurrence or mortality in up to 15% of patients.¹⁻⁴ The most common malignancy of the lip is squamous cell carcinoma, whereas basal cell carcinoma accounts for only 1% of all lip carcinomas.⁴⁻⁶ Other malignancies of the lip have been reported but are less common.^{7,8}

Epidemiology and Etiology

The incidence of lip cancer varies throughout the world, resulting in 30% of all malignant tumors of the oral cavity in certain regions. In the sunbelt region of the United States, lip cancer is the most common cancer of the oral cavity, and its incidence is second only to skin malignancy of the head and neck. Australia, northern Spain, and Newfoundland have a reported annual incidence ranging from 11 to 50 cases per 100,000 population.⁹

In the United States, the incidence of lip cancer is 1.8 per 100,000 population, with the state of Utah having the highest regional rate of almost 12 cases per 100,000.¹⁰ Generally, the behavior of lip cancer resembles skin cancer more than carcinoma of mucosal origin in the oral cavity proper. The lower lip is the most common site for lip cancer (88 to 98%), with only 2 to 7% arising from the upper

lip and 4% at the oral commissures.^{1,4-6,11-13} The most common age at diagnosis is 54 to 65 years.⁴ Although a condition seen in middle age, lip cancer occasionally occurs in patients under age 30 years.¹⁴ Lip cancer has a predilection for men, with men to women ratios ranging from 35:1 to 6:1, depending on the location of the lesion.⁴

The etiology of lip cancer is incompletely understood at present. Several factors have been associated with lip cancer development, but direct cause and effect has not been proven. Approximately one-third of patients with lip cancer have outdoor occupations, suggesting that sun exposure may be an etiologic factor. Because of its prominence, the lower lip is at a higher risk for exposure to the sun, compared with the upper lip. Hence, this results in the discrepancy in the distribution between upper and lower lip cancers.^{15,16} Carcinoma of the lip principally affects those individuals with fair skin complexions. The prevalence of lip cancer is at least 10 times higher in whites than in those with darker skin and is extremely rare among Blacks.^{11,17} Although it has never been proven, darker-skinned individuals are believed to have a protective pigment in the vermilion of the lips that provides protection from solar injury.¹⁰

Multiple factors have been linked to lip cancer, including tobacco use, pipe smoking, thermal injury, lip trauma, poor oral

hygiene, exposure to chemicals, mechanical irritants, immunosuppression, and chronic infections.^{11-13,16,18-23} Several case series have reported that a large proportion of lip cancer patients regularly use tobacco, indicating that tobacco use is etiologically associated with lip cancer development.^{5,11,15,19,24-28} In 1984, Douglass and Gammon reassessed the epidemiology of oral cancer and declared that there was insufficient proof for declaring tobacco as an etiologic factor in the development of lip cancer.¹⁰ Additional case-controlled studies concluded that no statistically significant relation exists between tobacco exposure and lip carcinoma.^{29,30} The smoking of cigars and pipes is often considered an important etiologic factor; however, no convincing evidence exists that supports a causal relationship between tobacco use and developing lip carcinoma. Cigar and pipe smoking today, at best, are likely responsible for only a small fraction of lip cancers. Because alcohol and tobacco exposure—the two factors most strongly associated with developing oral carcinoma—seem to have limited influence on the developing lip carcinoma, the most consistently associated factor with lip cancer appears to be prolonged and cumulative exposure to ultraviolet radiation from sunlight.^{4,18-20, 24, 29, 31}

Anatomic Considerations

Embryologically, the upper lip forms by fusing the two maxillary processes with a

central median nasal process (Figure 34-1). As a result, a central midline mass with two larger lateral segments is formed. The separation of the lateral segments by this central midline mass makes metastasis from upper lip cancers to the contralateral neck exceedingly rare. Conversely, the lower lip, formed by fusion in the midline of two mandibular processes, is at an increased risk for contralateral neck metastasis, particularly with lesions near the midline. The lateral and superior borders of the upper lip are well defined at the nasolabial creases bilaterally and at the nasal base superiorly. The inferior border of the lower lip is defined along the transversely oriented labiomental crease.

The formal definition of lip cancer, established by the American Joint Committee on Cancer for the purpose of staging lip cancer, describes the lip as “beginning at the junction of the vermilion border with the skin and including only the vermilion surface or that portion of the lip that comes into contact with the opposing lip. It is well

defined into an upper and lower lip joined at the commissures of the mouth.”³² This definition focuses on the unique epithelial surface of the lip vermilion and excludes cancers that arise from the adjacent skin or labial mucosa. In statistical reporting, cancers of the lip are commonly grouped with those of the oral cavity, because the lip is defined as part of the oral cavity by the American Joint Committee on Cancer.^{9,32}

Lymphatic drainage of the lower lip originates as an interconnecting network of lymph vessels beneath the submucosa of the vermilion.³³ It subsequently gives rise to five or six lymphatic collecting trunks that eventually terminate into regional lymph nodes. The lymphatic trunks of the central one-third of the lower lip typically drain into the submental lymph nodes. The trunks that arise from each lateral one-third of the lower lip typically drain into the ipsilateral submandibular lymph nodes. In certain individuals, the lymphatic trunks from the central one-third of the lip may drain to the submandibular lymph nodes on either side.

Cervical metastasis from lip cancer occurs in fewer than 10% of patients with cancer of the lower lip and in up to 20% in cancer of the upper lip and commissure.⁵ In the upper lip, crossover of lymphatic drainage between the right and left halves typically does not occur.³³ The upper lip also possesses five or six collecting trunks on each side of the midline that originate as delicate lymphatic vessels in the submucosa of the vermilion. The trunks ultimately terminate in the submandibular lymph nodes but occasionally also drain to the ipsilateral preauricular or infraauricular parotid lymph nodes. Metastasis that results from cancer of the lip most commonly involves the submandibular and submental lymph nodes (level 1).^{34–36} Metastasis to level II of the jugular chain rarely occurs. Cancer involving the upper lip may occasionally metastasize to the parotid lymph nodes, but contralateral metastasis is unusual for cancers of the

upper lip that do not cross the midline and for lower lip cancers that do not involve the central one-third of the lower lip.

Metastasis from the lower lip is primarily to the submental, submandibular, and perifacial nodes. Metastasis is found in the submandibular lymph nodes in about 80 to 90% of patients with metastasis from cancer of the lower lip.^{5,37} Although the upper lip is responsible for fewer than 10% of lip cancer cases, its pattern of metastasis is fairly predictable, with the submandibular and parotid lymph node groups being most commonly involved.³⁸ Carcinoma of the commissure and upper lip spreads to the preauricular, periparotid, and submandibular nodes. Bilateral metastasis may develop if the lesion is near or has crossed the midline of the lip. Crossover between the lymphatics of the right and left sides of the upper lip rarely occurs.⁴

Cervical metastasis occurs late in the course of lip cancer in fewer than 10% of patients with cancer of the lower lip and up to 20% in cancer of the upper lip and commissure.⁵ Lymph node metastasis to the upper jugular digastric chain is seen in only about 15% of all patients who have lymph node metastasis and is almost always seen in conjunction with ipsilateral submandibular metastasis.^{5,37}

Management

Evaluation

Because carcinomas of the lip occur on a highly visible and constantly exposed region of the body, a relatively early diagnosis is often feasible. The clinical presentation of lip carcinomas is quite characteristic, generally presenting as an exophytic or ulcerated lesion on the vermilion border, along with variable degrees of infiltration of the underlying musculature or invasion of the overlying skin or labial mucosa (Figure 34-2). Well-differentiated squamous cell carcinomas are often associated with hyperkeratosis and leukoplakia of the vermilion border of the lip. Any lip lesion that

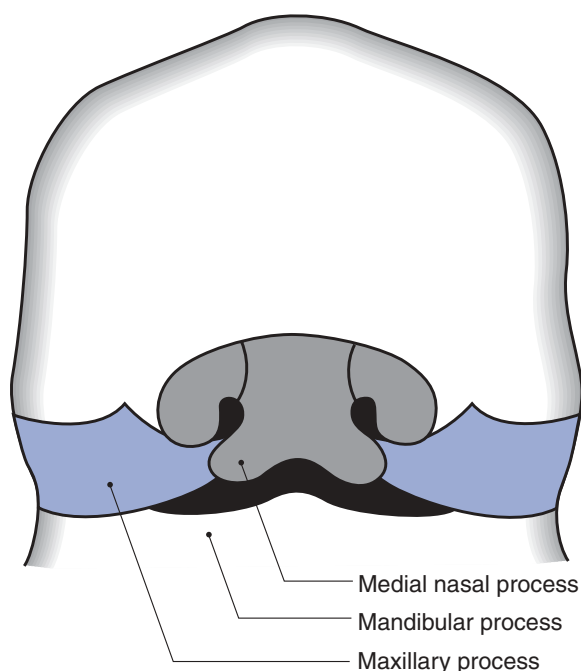


FIGURE 34-1 Developing upper lip, receiving contributions from a central medial nasal process and bilateral maxillary processes. Developing lower lip receiving contributions solely from bilateral mandibular processes.

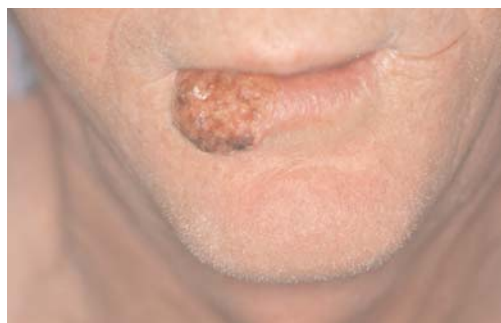

FIGURE 34-2 Typical presentation of a large exophytic squamous cell carcinoma of the lower lip.

the clinician views as a possible malignancy should undergo an incisional biopsy that includes both a portion of the lip lesion and a small portion of normal appearing tissue at the margin. The factors that should be considered in planning surgical resection and reconstruction of the lips include the tumor stage, lip subsite of origin, patient preference, and the histopathologic type and grade of the tumor.

Staging of lip cancers is similar to that employed for tumors of the oral cavity (Table 34-1).³² Tumors less than 2 cm in greatest dimension are staged as T1, whereas massive tumors with invasion of deep soft tissues, adjacent bone, or overlying skin are staged as T4 (Table 34-2).

Table 34-1 Tumor Stage Grouping			
Stage 0	Tis	N0	M0
Stage I	T1	N0	M0
Stage II	T2	N0	M0
Stage III	T3	N0	M0
	T1	N1	M0
	T2	N1	M0
Stage IV	T3	N1	M0
	T4a	N0	M0
	T4a	N1	M0
	T1	N2	M0
Stage IVB	T2	N2	M0
	T3	N2	M0
	T4a	N2	M0
Stage IVB	Any T	N3	M0
	T4b	Any N	M0
Stage IVC	Any T	Any N	M1

Radiographic evaluation of tumors detected at an early stage that involve the lip is generally unnecessary. On the other hand, advanced tumors that adhere to or invade the adjacent mandible require further radiologic evaluation. Detailed studies of the mandible, including panoramic radiographs and computed tomography scans, may be necessary to delineate the extent of the bony invasion, as well as any involvement of the inferior alveolar canal. Melanomas and squamous cell carcinomas are known to be neurotropic and may spread along the inferior alveolar nerve via the mental foramen.³⁹⁻⁴¹ Patients who complain of numbness or paresthesia warrant further radiologic evaluation.

Surgical Treatment

The ultimate goal of lip cancer management is long-term control of the carcinoma

with preservation of the competency and esthetics of the perioral region. Although external beam irradiation or surgical excision can control small primary tumors of the lip equally well, surgery is quicker and leaves little esthetic or functional impairment. Larger lip cancers require planned surgical resection, with reconstruction in most cases. In the past 100 years, clinicians have employed many methods to manage lip cancer. Some of the less effective methods have included direct applications of caustic agents, such as hydrochloric acid, arsenic paste, or nitric acid. In addition, laser surgery, electrocoagulation, and cryotherapy have been advocated by some. However, the two modalities that have been the most thoroughly evaluated and that have undergone the test of time are surgery and radiation therapy. These two techniques yield excellent results for very early

Table 34-2 Tumor Node Metastasis System for Lip Cancer

T = Tumor Size	
TX	Primary tumor cannot be assessed
T0	No evidence of primary tumor
Tis	Carcinoma in situ
T1	< 2 cm
T2	> 2 cm and ≤ 4 cm
T3	> 4 cm
T4	Tumor invades through cortical bone inferior alveolar nerve, floor of mouth, or skin of face (ie, chin or nose)
N = Nodal Metastasis (regional)	
NX	Regional lymph nodes cannot be assessed
N0	No regional nodes palpable
N1	Single ipsilateral node < 3 cm
N2	Metastasis in a single ipsilateral lymph node, > 3 cm but ≤ 6 cm; or in multiple ipsilateral lymph nodes, none > 6 cm; or in bilateral or contralateral lymph nodes, none > 6 cm
N2a	Single ipsilateral node > 3 cm but ≤ 6 cm
N2b	Multiple ipsilateral nodes ≤ 6 cm
N2c	Bilateral or contralateral nodes ≤ 6 cm
N3	Node > 6 cm
M = Distant Metastasis	
MX	Distant metastasis cannot be assessed
M0	No distant metastasis
M1	Distant metastasis

lip cancers, and surgery is the most common treatment selected for managing lip carcinoma of any size, particularly the larger T3 and T4 tumors.

The determination of an adequate surgical margin around a lip cancer is somewhat nebulous, and few objective data have been gathered to substantiate any recommendations for adequate excision margins. The size of the primary lesion is the most common factor that we use to determine the extent of the marginal excision. Larger cancers have typically mandated wider margins than have smaller cancers. Based on these general guidelines, a minimum of 8 to 10 mm of normal tissue around a lip cancer is recommended to facilitate its complete removal.^{2,11,25,42-44} Smaller lip cancers, less than 1 cm in greatest dimension, can often be managed with slightly smaller margins of 5 mm.⁴⁴ In our experience, the locally advanced T4 squamous cell carcinomas of the lip are optimally treated with a slightly larger margin of approximately 15 to 20 mm.

The lip shave, or vermillionectomy procedure, is ideal for those situations wherein areas of leukoplakia, actinic cheilitis, or carcinoma in situ involve the vermillion of the lips (Figure 34-3).⁴⁵⁻⁵⁴ These premalignant conditions require treatment but not complete full-thickness excision of the lip. This operation involves partial or entire excision of the lip vermillion. The vermillionectomy may also be used, in conjunction with a full-

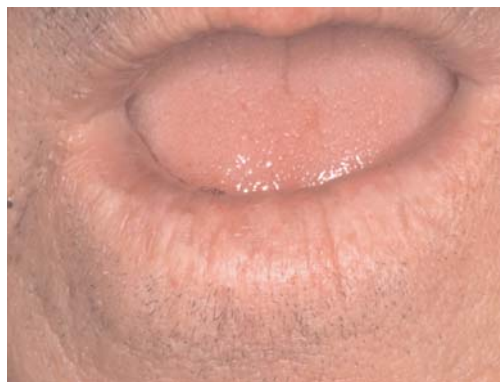

FIGURE 34-3 Actinic cheilitis involving the vermillion of the lower lip.

thickness lip excision, in individuals possessing invasive lip carcinoma and premalignant vermillion changes. Following the vermillionectomy, the residual defect is primarily closed with labial mucosal advancement flaps.

In situations with invasive lesions, the lip shave procedure is contraindicated, and full-thickness excision of the involved portion of the lip is the traditional procedure for management. The most commonly selected configuration of lip excision is a V, W, or a shield (Figure 34-4). The defects resulting from the V and W excisions can easily be closed primarily with no additional mobilization of adjacent tissues (Figure 34-5). The rectangular form of excision, however, requires advancement of laterally based lip flaps to achieve a satisfactory closure. These forms of excision are selected purely on the basis of cosmetic and functional considerations for all T1 and most T2 lip carcinomas.

Invasion of the mandible, involvement of the mental or inferior alveolar nerve, tumor sizes of T3 or greater, or associated regional lymph node metastasis generally necessitate a more aggressive resection. Aggressive treatment requires an excision and reconstruction that is more complex than the standard full-thickness V or W excision, and will be discussed in detail in the following section on lip reconstruction. Include a marginal mandibulectomy with the resection of lip cancers that approximate the alveolar ridge or outer labial cortex of the mandible. Likewise, for rare lesions that actually demonstrate radiographic invasion of the mandible, include a segmental mandibulectomy in the treatment plan.

Lip Reconstruction

Lip reconstruction following surgical excision of cancer should reestablish the function and appearance of the lip. The key to functional restoration is the reconstitution of the orbicularis oris muscle. Primary surgical restoration of the orbicularis

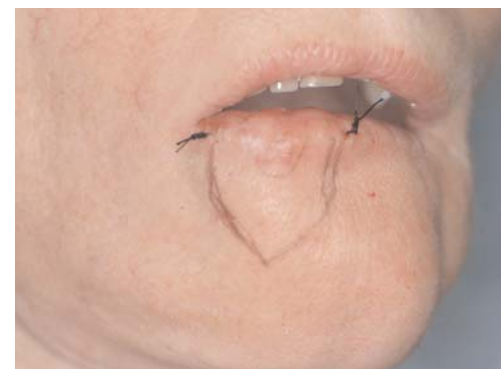

FIGURE 34-4 The proposed incisions for a shield excision of lower lip are delineated.

muscle following resections that exceed two-thirds to three-quarters of the lip length will create microstomia.

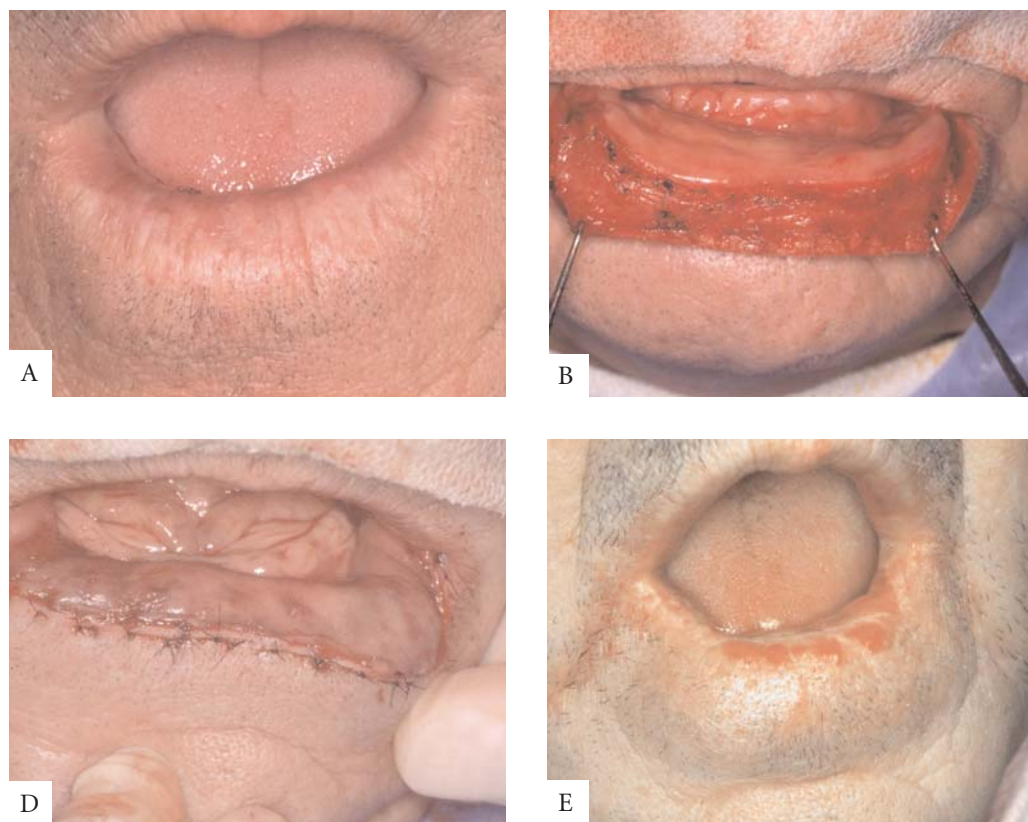
Defects of the vermillion resulting from a lip shave procedure are generally restored with labial mucosal advancement flaps.⁵⁵⁻⁵⁷ The labial mucosal flap develops by creating a plane between the minor salivary glands and the inner surface of the orbicularis oris muscle. This flap may be mobilized into the buccal vestibule if necessary. The flap is secured to the anterior cutaneous margin of the excision to create a new vermillion cutaneous border (Figure 34-6). Other less commonly used flaps for vermillion reconstruction after a lip shave include cross-lip buccal mucosa flaps and tongue flaps.⁵⁷⁻⁵⁹

Closure may be achieved primarily when a full-thickness excision of the upper or lower lip results in a defect of up to one-third of the lip length (Figure 34-7). The

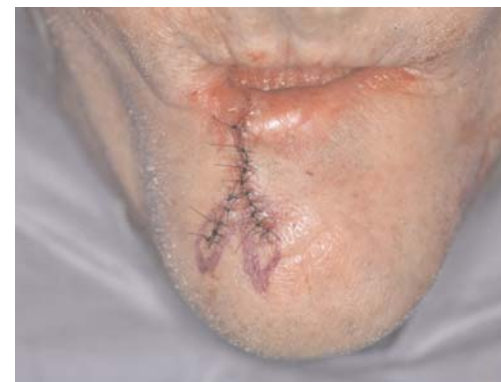
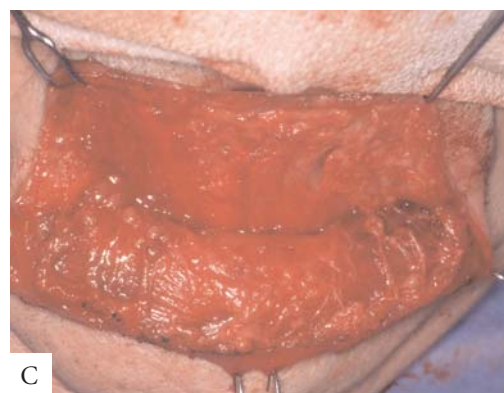
FIGURE 34-5 Primary closure of a W excision of the lower lip.

FIGURE 34-6 A, Actinic cheilitis of the lower lip with atypia noted on biopsy. B, Completed excision of the lower lip vermilion. C, Complete undermining of the mucosa and removal of adjacent minor salivary glands help prevent rolling of the lower lip and mucocele formation, respectively. D, Mucosal advancement and primary closure of the surgical defect has been completed. E, Early postoperative results following the lip shave procedure.



V-shaped excision design is most commonly used when a primary closure is anticipated. Typically, the apex of the V is placed at or slightly above the nasolabial fold or labiomental crease.^{55-58,60-62} A minimum of a three-layered closure comprising mucosa, muscle, and skin is necessary to avoid unesthetic notching of the lip as the scar matures.

Lip cancers that extend more deeply into the lip substructure but still involve a superficial length of vermilion that would otherwise produce a defect may be closed primarily via the W-shaped modification of the V configuration (Figure 34-8). This excision uses an M-plasty in place of the single apex of the V. A three-layered closure of the defect, with careful attention to detail in the reconstruction of the orbicularis oris muscle layer is achieved (see Figure 34-5).

The need to reconstruct lip defects greater than one-third of the lip length led

to the development of various circumoral flap advancement techniques.^{56-58,60,62-64} The most popular of these techniques includes the Karapandzic reconstruction flap (Figure 34-9). This flap consists of a transfer of the remaining lip tissue to reconstitute the lips and mouth opening. The Karapandzic flap uses release incisions within the labiomental crease, extending around the region of the oral commissures and continuing superiorly within the nasolabial creases bilaterally. Combining sharp and blunt dissection

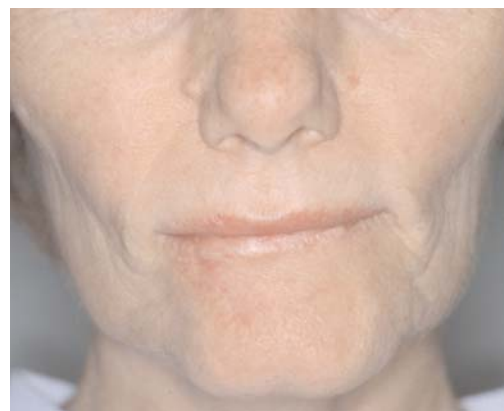

FIGURE 34-7 Good esthetic results following shield excision and primary closure of a right lower lip defect involving one-third the total length of the lower lip.

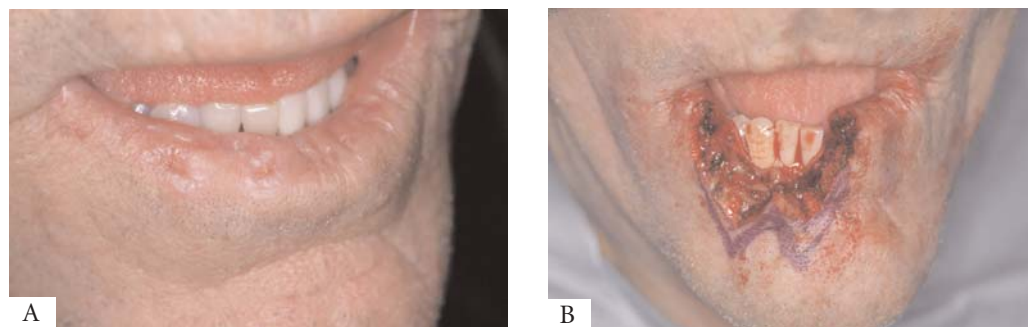


FIGURE 34-8 A, Typical presentation of squamous cell carcinoma of the right lower lip. B, W excision of the lesion sparing the right commissure.

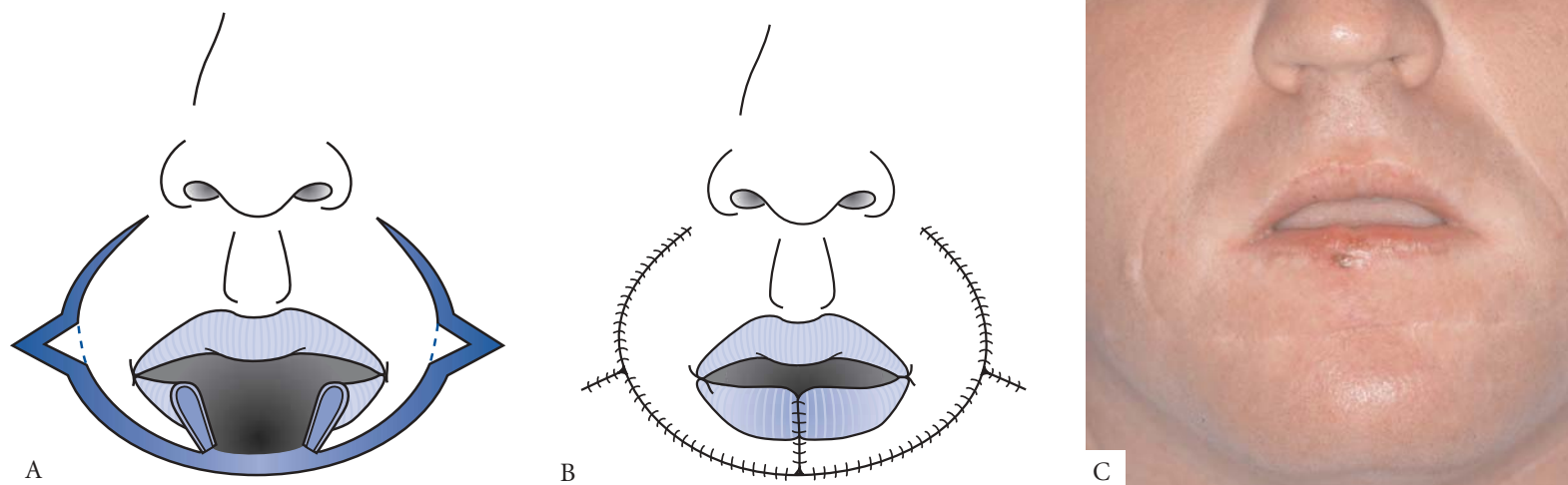


FIGURE 34-9 A, Defects greater than one-third of the lip may require circumoral flaps, such as the Karapandzic flap depicted by this schematic. B, Schematic depicting the closure of the Karapandzic flap. C, Esthetic postoperative results of a Karapandzic flap can be achieved. Note the recurrence of the lesion in the midline.

separates the orbicularis muscles from the surrounding facial expression muscles. Neurovascular structures are preserved and transposed medially, along with the flap, and intraoral buccal mucosal release incisions are often necessary.

For this reason, the Karapandzic flap is ideally suited in situations where two-thirds to three-quarters, or more, of the lower lip is resected, particularly when the resection is centrally located and leaves the lateral ends near the commissures intact. The incisions for elevation of the Karapandzic flap require mobilization of the skin and subcutaneous tissues that are superficial to the orbicularis oris muscle and mucosa and deep to the orbicularis oris muscle. At the same time, the muscle itself must be kept intact, with its nerve and blood supply preserved as tissues are rotated and sutured medially.

Among other reconstructive options for the lip, the cross-lip flaps are particularly useful in repairing moderate lip defects of one-third the length of one lip.^{60,65-67} These techniques transfer a full-thickness segment of lip tissue into a defect on the opposite lip. Estlander and Abbe developed the most commonly used cross-lip flap repair techniques.^{66,67} The Abbe flap, as originally described, transfers

tissue from the lower lip to a defect in the central component of the upper lip. It is, however, most often used to reconstruct lower lip defects by transferring tissue from the upper lip (Figure 34-10). The Estlander flap was used to reconstruct defects of the upper or lower lip in a single stage by transferring lip tissue around the

oral commissure (Figure 34-11). All cross-lip flaps are generally referred to as Abbe-Estlander type flaps.

The principle of the Abbe-Estlander flap repair is that the width of the base of the triangular flap is one-half that of the width of the base of the triangular surgical defect. The vertical length of the flap

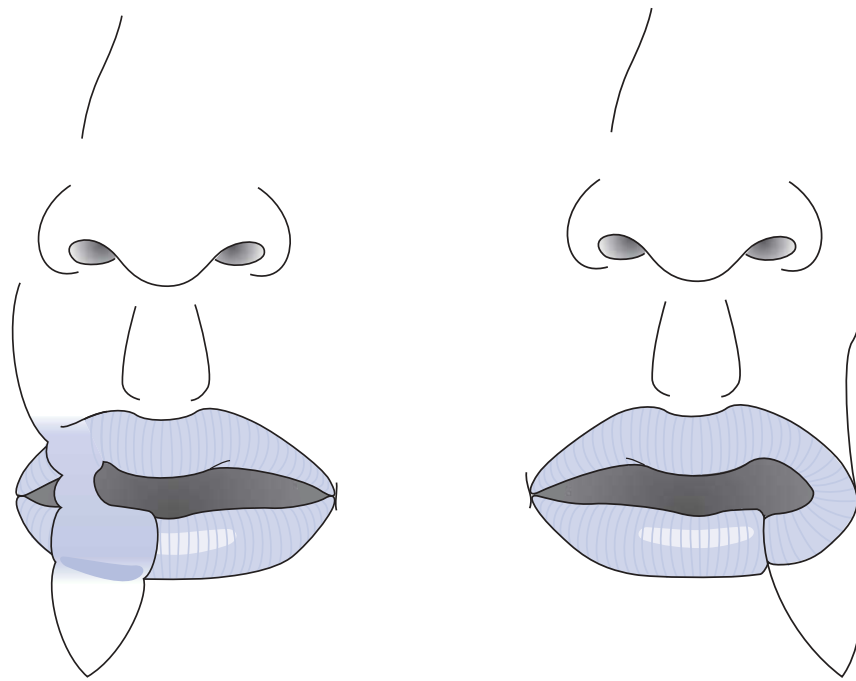


FIGURE 34-10 A drawing of the two-stage Abbe flap, demonstrating the cross-lip transfer that is divided at approximately 3 weeks postoperatively.

FIGURE 34-11 A schematic drawing of the one-stage Estlander flap with the classic rounding of the commissure region.

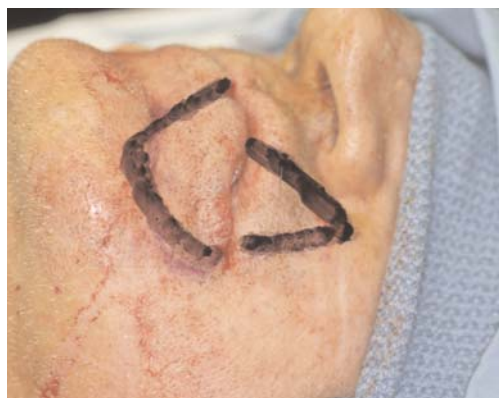

FIGURE 34-12 In the cross-lip flap, the transfer portion in most cases need only be 50% as large as the defect. Care should be taken to prevent injury to the superior labial artery.

should match that of the defect. The cross-lip flap includes and depends on a small pedicle that carries the labial artery from the donor lip.

Generally, mark out the flap on the upper lip on the same side as the planned excision (Figure 34-12). Make a skin incision at the previously marked outline of the Abbe-Estlander flap on the lateral aspect of the upper lip. The lateral incision is deepened through both the musculature and the mucosa, extending from the vermilion border up to the apex of the flap. With extreme caution, perform an incision along the medial margin of the flap, beginning at the apex of the flap and working toward the vermilion border to avoid injury to the labial artery. As mobilization of the flap toward the vermilion border proceeds, separate the musculature of the upper lip bluntly with a hemostat, and divide a little at a time small segments of the muscle fibers with scissors. Once the labial artery is identified, under direct vision, divide the other attachments of the musculature of the upper lip around the labial artery, while keeping the mucosa of the vermilion border intact. In addition, to allow flap rotation, divide the intraoral labial mucosa on the medial aspect of the flap, from the apex of the flap toward the lip. Rotate the flap 180° to fill the surgical defect in the lower lip.

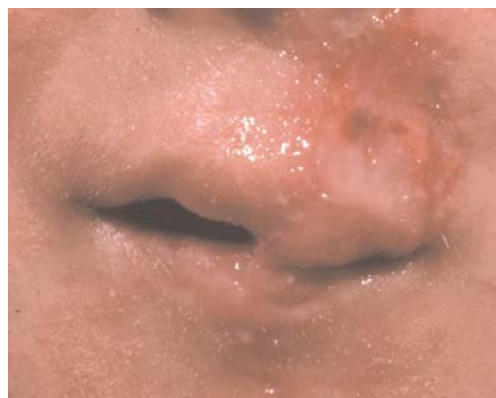

FIGURE 34-13 Typical appearance of the cross-lip transfer flap at the time of suture removal, demonstrated in this lower to upper lip transfer.

Inset of the flap begins by accurate approximation of the vermilion edges of the flap and the lower lip, followed by careful multilayered closure. Bring the vascular pedicle across the open mouth, and perform the second-stage release 3 weeks later (Figure 34-13). Preoperatively, instruct the patient to avoid trauma to this intervening pedicle during the immediate postoperative period.

When one commissure of the lip must be sacrificed along with the excision of the lip cancer, then employ a nonbridged Estlander flap (Figure 34-14). This flap is cre-

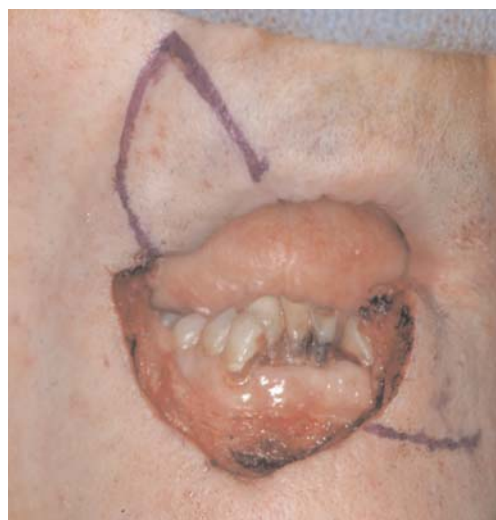

FIGURE 34-14 At times an extension into the labiomental crease may aid in closure of the defect, as seen marked during this cross-lip transfer flap.

ated as a single-stage procedure without the need for secondary pedicle division. The downside of this type of flap is the development of a somewhat unnatural, rounded commissure. The Abbe-Estlander flap can be used in reverse when a lesion of the upper lip is excised by elevating the flap from the lower lip. Alternatively, a cheek advancement flap with Burow's triangle is often useful for repairing lateral defects of the upper lip (Figure 34-15).

Several techniques designed for lip defects are too extensive for reconstruction using the Karapandzic or Abbe-Estlander techniques.⁶⁸⁻⁷⁰ These techniques use adjacent cheek tissue in the form of laterally based advancement flaps. In the Bernard flap, the lower lip may be excised in its entirety, along with soft tissues of the mental region, and the resulting defect is closed by lateral cheek flaps to form a new lower lip (Figure 34-16). To set back the commissure and to reduce the incidence of a "fish-mouth" deformity, excise triangles of the skin from both sides of the upper lip. Preserve the mucous membrane to help form a new vermilion border. Excise the triangular wedges of skin from the nasolabial crease on both sides, subsequent to excision of the primary tumor. The base of this triangular excision extends from the commissure of the

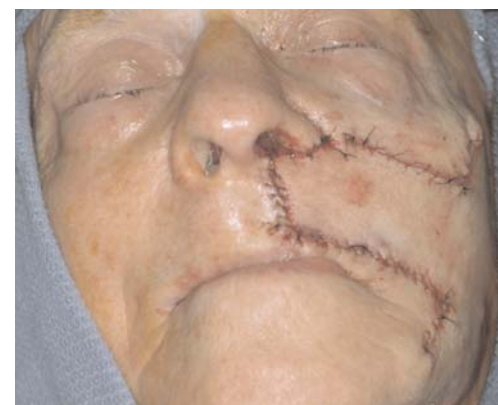

FIGURE 34-15 In situations that do not require reconstruction of the vermilion surface of the lip, a cutaneous advancement flap may be appropriate, as in this case with Burow's triangles to aid in advancement.

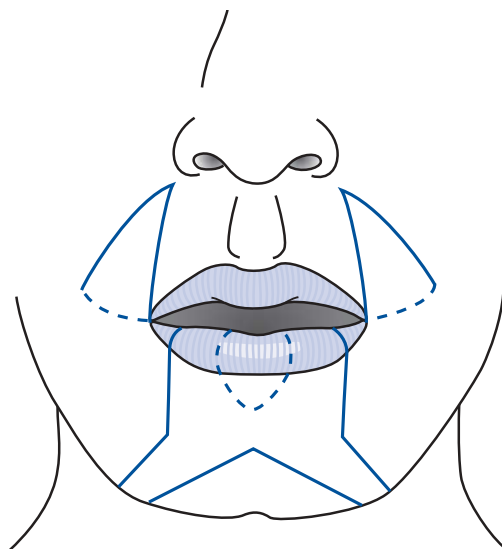


FIGURE 34-16 In situations requiring complete excision of the lower lip, the Bernard flap may provide a means for reconstruction with circumoral tissues, depicted in this schematic drawing.

mouth, up to the nasolabial crease, depending on the width of the cheek flap to be mobilized (Figure 34-17A). After excising the triangular wedges, incise the mucosae from their inner aspect, except for the base, and shift the triangular flaps of the upper lip mucosa medially, along with the flaps (Figure 34-17B). Make a counter incision in the lower mucogingival sulcus bilaterally, and mobilize both cheek flaps medially. Perform a closure of the lip musculature on both sides with interrupted sutures. The triangular wedges of the mucosa from the upper lip are everted and rolled inferiorly to provide a new vermilion surface. Mucosal closure is completed inferiorly in the mucogingival sulcus (Figure 34-17C and D).

The main advantage of the Bernard flap is its ability to reconstruct almost the whole lower lip in a single-stage procedure. The main disadvantage is reducing the size of the orifice and creating a so-called permanent smile deformity of the lips, most often produced in edentulous individuals.

The reconstruction of more massive defects that include total lip excision, as well as excising the adjacent floor of the mouth, skin, or mandible, requires the use

of distant flaps, such as the deltopectoral or pectoralis major myocutaneous flap. Alternatively, use free vascularized composite flaps to reconstruct these large defects. A free flap that has recently shown to be particularly useful is the composite radial forearm-palmaris longus free flap.^{71,72}

Cervical Lymphadenectomy

Patients with early cancer of the lip (stages I and II) do not generally need elective treatment of the cervical lymph nodes, because the rate of occult metastasis is low. The risk for cervical metastasis increases with poorly differentiated cancer, recurrent cancer, or with cancer that extends into the labial mucosa or that invades the mandible. Given the infrequency with which stage I and stage II lip cancers spread to regional lymph nodes, elective treatment of the neck is not always required. One report indicated that there was delayed cervical metastasis between 35 and 40% from lip cancer tumors 2 to 4 cm

in size.⁴ This report confirms a much larger rate of metastasis than that usually seen in clinical practice.

With advanced disease (stages III and IV), elective neck dissection of levels I through III is recommended (Figure 34-18). Thus, even if the patient has no palpable adenopathy (N0 neck), the clinician should still use elective radiation therapy or elective neck node dissection in managing patients, owing to the high rate of microscopic lymph node metastasis in these patients. In patients with lesions of the upper lip, commissure, or both, include a superficial parotidectomy. Clinically apparent lymph nodes require either radiation therapy or neck dissection for N1 nodes and combined therapy (neck dissection and radiation) for N2 and N3 nodes.⁷³

Treatment Results

The cure rate for T1 and T2 lip cancers without regional metastasis is greater than 90% with surgery or radiation.^{4,48} The

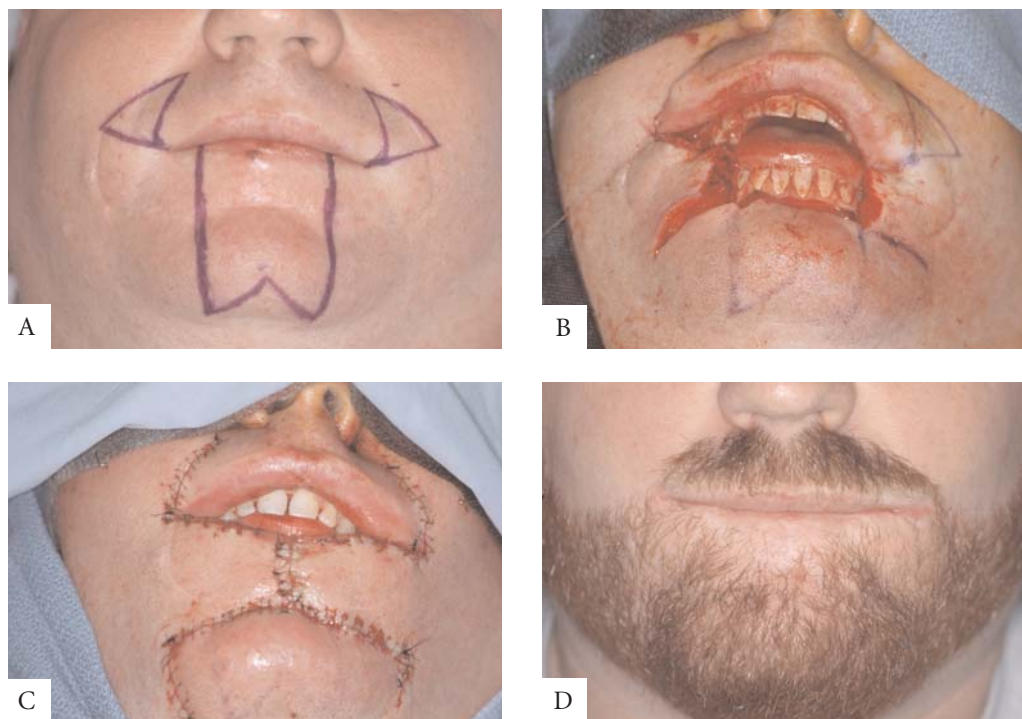


FIGURE 34-17 A, Proposed incisions for a classic Bernard flap reconstruction of the lower lip. B, The development of the Bernard flap after resection of the lower lip. C, Closure of the wound includes the mucosal layer, orbicularis oris layer, dermal layer, and the skin closure. D, Postoperative follow-up at 1 year demonstrates no recurrence and good esthetic results.

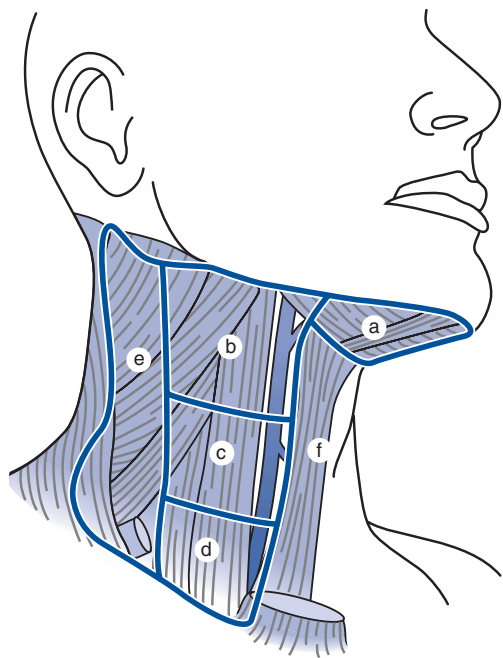


FIGURE 34-18 Diagram depicting the levels of the neck. a = level one; b = level two; c = level three; d = level four; e = level five; f = level six.

5-year determinate survival is approximately 80%.¹ The cure rates for cancer of the lips suggest a better prognosis than for other cancers of the oral cavity. Cancer involving the oral commissure is more aggressive, with a 5-year cure rate ranging between 34 and 50%. Cancers that include areas larger than 2 cm have cure rates of < 80%, and those that invade deep enough to involve the mandible have a cure rate of < 50%.^{4,74} The primary cause of failure is local recurrence, rather than regional node metastasis. Other adverse prognostic factors include poor histologic grade, tumor thickness > 6 mm, desmoplasia, stromal sclerosis, muscular invasion, and perineural invasion.⁷⁵⁻⁷⁷ Angiogenesis has not been shown to have prognostic significance.⁷⁸ While *TP53* mutations are seen in 50% of lip cancers, the clinical significance of this observation is unknown.⁷⁹

Generally, elective lymph node dissection in the N0 neck is reserved for advanced stage disease (stage III and stage IV).^{74,80} About 5 to 10% of patients with lip cancer will develop evidence of

nodal involvement.^{1,81,82} Without question, the presence of cervical lymph node metastasis affects survival. The average 5-year survival for patients with cervical metastasis of lip carcinoma is approximately 50%, with a range of 29 to 68%. Recurrence rates in the neck after treatment of regional metastasis are 40% for N1 disease and up to 100% for N3 disease.¹ The risk of developing a metachronous lip cancer is estimated at about 20% by 10 years follow-up.⁸³

Conclusions

Lip cancer accounts for a significant percentage of all head and neck malignancies in the United States. Lip cancer arises from the lower lip in nearly 90% of cases. Etiologic factors associated with lip cancer include sun exposure, alcohol, and tobacco abuse. Commissure involvement is an adverse prognostic factor. Regional cervical lymph node metastasis is directly related to a poor prognosis. With overall cure rates of 80 to 90%, lip cancers have a more favorable prognosis than most other head and neck cancers.

References

- Baker SR, Krause CG. Carcinoma of lip. *Laryngoscope* 1980;90:19-27.
- Cruse CW, Radocha RF. Squamous cell carcinoma of the lip. *Plast Reconstr Surg* 1987;80:787-91.
- Heller KS, Shah JP. Carcinoma of the lip. *Am J Surg* 1979;138:600-3.
- Zitsch RP, Park CW, Renner GJ, et al. Outcome analysis for lip carcinoma. *Otolaryngol Head Neck Surg* 1995;113:589-96.
- Jorgensen K, Elbron O, Andersen AP. Carcinoma of the lip: a series of 869 cases. *Acta Radio* 1973;12:177-90.
- MacKay EN, Sellers AH. A statistical review of carcinoma of the lip. *Can Med Assoc J* 1964;90:670-2.
- Bailey BM. A rare malignant connective tumor arising in the upper lip. *Br J Oral Surg* 1983;21:129-35.
- Miller RL. Non-Hodgkin's lymphoma of the lip: a case report. *J Oral Maxillofac Surg* 1993;51:420-2.
- Blot WF, Devesa SS, McLaughlin JK, et al. Oral and pharyngeal cancers. In: Doll R, Fraumeni JF Jr, Muir CS, editors. *Trends in cancer incidence and mortality*. Plainview (NY): Cold Spring Harbor Laboratory Press; 1994. p. 23-42.
- Douglass CW, Gammon MD. Reassessing the epidemiology of lip cancer. *Oral Surg* 1984;57:631-42.
- Martin H, MacComb WS, Blady JV. Cancer of the lip. Part I. *Ann Surg* 1941;114:226.
- Linqvist C, Teppo L. Is upper lip cancer "true" lip cancer? *J Cancer Res Clin Oncol* 1980;97:187-91.
- Broders AC. Squamous-cell epithelioma of the lip: a study of five hundred and thirty-seven cases. *JAMA* 1920;74:656-64.
- Teichgraeber JF, Larson DL. Some oncologic considerations in the treatment of lip cancer. *Otolaryngol Head Neck Surg* 1988;98:589-92.
- Lee ES, Wilson JSP. Cancer of the lip. *Proc R Soc Med* 1970;63:685-90.
- Ju DM. On the etiology of cancer of the lower lip. *Plast Reconstr Surg* 1973;52:151-4.
- Keller AZ. Cellular types, survival, race, nativity, occupations, habits and associated diseases in the pathogenesis of lip cancer. *Am J Epidemiol* 1969;91:486-99.
- Penn I. Cancer in the immunosuppressed organ recipient. *Transplant Proc* 1991;23:1771-2.
- Molnar L, Ronay P, Tapolesany I. Carcinoma of the lip. *Oncology* 1974;29:101-21.
- Ward GE, Hendrick JW. Results of treatment of carcinoma of the lip. *Surgery* 1950;27:321-42.
- Figi FA. Epithelioma of the lower lip. *Surg Gynecol Obstet* 1934;59:810-819.
- Bradford CR, Hoffman HT, Worf GT, et al. Squamous carcinoma of the head and neck in organ transplant recipients: possible role of oncogenic viruses. *Laryngoscope* 1990;100:190-4.
- Brewer GE. Carcinoma of the lip and cheek. *Surg Gynecol Obstet* 1923;36:169-184.
- Creely JJ, Peterson HD. Carcinoma of the lip. *South Med J* 1974;67:779-84.
- Wurman LH, Adams GL, Meyerhoff WL. Carcinoma of the lip. *Am J Surg* 1975;130:470-4.
- Ashley FL, McConnell DV, Machida R, et al. Carcinoma of the lip: a comparison of five year results after radiation and surgical therapy. *Am J Surg* 1965;110:549-51.
- Marshall KA, Edgerton MT. Indications for neck dissection in carcinoma of the lip. *Am J Surg* 1976;133:216-7.
- Cross JE, Guralnick E, Daland EM. Carcinoma of the lip; a review of 563 case records of carcinoma of the lip at the Pondville Hospital. *Surg Gynecol Obstet* 1948;87:153.
- Dardanoni L, Lorenzo G, Rosario P, et al. A

- case-control study on lip cancer risk factors in Ragusa (Sicily). *Int J Cancer* 1984;34:355-7.
30. Blomqvist G, Hirsch JM, Alberius P. Association between development of lower lip cancer and tobacco habits. *J Oral Maxillofac Surg* 1991;49:1044-7.
 31. Baker SR. Risk factors in multiple carcinomas of the lip. *Otolaryngol Head Neck Surg* 1980;88:248-51.
 32. American Joint Committee on Cancer. Manual for staging of cancer. 6th ed. New York (NY): Springer-Verlag; 2002. p. 23-32.
 33. Feind CR. The head and neck. In: Haagensen CD, Feind CR, Herter FP, et al, editors. *The lymphatics in cancer*. Philadelphia (PA): WB Saunders; 1972. p. 59-230.
 34. Shah JP, Candela FC, Poddar AK. The patterns of cervical lymph node metastasis from squamous carcinoma of the oral cavity. *Cancer* 1990;66:109-13.
 35. Spiro RH. The management of neck nodes in head and neck cancer: a surgeon's view. *Bull NY Acad Med* 1985;61:629-37.
 36. Lindberg R. Distribution of cervical lymph node metastasis from squamous cell carcinoma of the upper respiratory and digestive tracts. *Cancer* 1972; 29:1446-9.
 37. Sack JG, Ford CN. Metastatic squamous cell carcinoma of the lip. *Arch Otolaryngol* 1978;104:282-5.
 38. Brown RG, Poole MD, Calamel PM, et al. Advanced and recurrent squamous carcinoma of the lower lip. *Am J Surg* 1976; 132:492-7.
 39. Byers RM, O'Brien J, Waxler J. The therapeutic and prognostic implications of nerve invasion in cancer of the lower lip. *Int J Radiat Oncol Biol Phys* 1978;4:215-7.
 40. Anderson C, Krutchkoff D, Ludwig M. Carcinoma of the lower lip with perineural extension to the middle cranial fossa. *Oral Surg Oral Med Oral Pathol* 1991;69:614-8.
 41. Kolin ES, Castro D, Jabour BA, et al. Perineural extension of squamous cell carcinoma. *Ann Otol Rhinol Laryngol* 1991; 100:1032-4.
 42. Lore JM, Kaufman S, Grabau JC, et al. Surgical management and epidemiology of lip cancer. *Otolaryngol Clin North Am* 1979; 12:81-95.
 43. Luce EA. Carcinoma of the lower lip. *Surg Clin North Am* 1986;66:3-11.
 44. Brodland DG, Zitelli JA. Surgical margins for excision of primary cutaneous squamous cell carcinoma. *J Am Acad Dermatol* 1992;27:241-8.
 45. van Zile WN. Early carcinoma of the lip: diagnosis and treatment. *J Oral Surg* 1965; 23:50-9.
 46. Birt BD. The "lip shave" operation for premalignant conditions and micro-invasive carcinoma of the lower lip. *J Otolaryngol* 1977;6:407-11.
 47. Brufeuau C, Canteras M, Armijo M. Our experience in the surgical treatment of cancer and precancerous lesions of the lower lip. *J Dermatol Surg Oncol* 1985;11:908-12.
 48. Frierson HF, Cooper PH. Prognostic factors in squamous cell carcinoma of the lower lip. *Hum Pathol* 1986;17:346-54.
 49. Hjortdal O, Naess A, Berner A. Squamous cell carcinomas of the lower lip. *J Craniomaxillofac Surg* 1995;23:34-7.
 50. Mehregan DA, Roenignk RK. Management of superficial squamous cell carcinoma of the lip with Mohr micrographic surgery. *Cancer* 1990;66:463-8.
 51. Picascia DD, Robinson JK. Actinic cheilitis: a review of the etiology, differential diagnosis, and treatment. *J Am Acad Dermatol* 1987;17:255-64.
 52. van der Wal JE, de Visscher JGA, Baart JA, et al. Oncologic aspects of vermilionectomy in microinvasive squamous cell carcinoma of the lower lip. *Int J Oral Maxillofac Surg* 1996;25:446-8.
 53. Robinson JK. Actinic cheilitis. A prospective study comparing four treatment methods. *Arch Otolaryngol Head Neck Surg* 1989;115:848-52.
 54. Sanchez-Conejo-Mir J, Perez-Barnal AM, Moreno-Gimenez JC, et al. Follow-up of vermilionectomies: evaluation of the technique. *J Dermatol Surg Oncol* 1986; 12:180-4.
 55. Renner GJ. Cancer of the lip. In: Gates G, editor. *Current therapy in otolaryngology-head and neck surgery*. Vol 4. Philadelphia (PA): BC Decker; 1989. p. 188.
 56. Renner G, Zitsch RP. Reconstruction of the lip. *Otolaryngol Clin* 1990;23:975-90.
 57. Zide BM. Deformities of the lips and cheeks. In: McCathy JG, editor. *Plastic surgery. The face*. Vol 3. Philadelphia (PA): WB Saunders; 1990. p. 2009.
 58. Mazzola RF, Lupo G. Evolving concepts in lip reconstruction. *Clin Plast Surg* 1984; 11:583-617.
 59. McGregor IA. The tongue flap in lip surgery. *Br J Plast Surg* 1966;19:253-63.
 60. Calhoun KH, Stiernberg CM. *Surgery of the lip*. New York (NY): Thieme Medical Publishers; 1992.
 61. Panje WR. Lip reconstruction. *Otolaryngol Clin North Am* 1982;15:169-78.
 62. Smith PG, Muntz HR, Thawley SE. Local myocutaneous advancement flaps. *Arch Otolaryngol* 1982;108:714-8.
 63. Clairemont AA. Versatile Karapandzic lip reconstruction. *Arch Otolaryngol* 1977; 103:631-3.
 64. Karapandzic M. Reconstruction of lip defects by local arterial flaps. *Br J Plast Surg* 1974; 27:93-7.
 65. Abbe RA. A new plastic operation for the relief of deformity due to double harelip. *Plast Reconstr Surg* 1968;42:481-3
 66. Estlander JA. Eine methode aus der linen lippe substanzuerluste der anderen zu ersetzen. *Arch Klin Chirurg* 1872;14:622. Reprinted with English translation. *Plast Reconstr Surg* 1968;442:361.
 67. Templer J, Renner G, Davis WE, et al. A modification of the Abbe-Estlander flap for defects on the lower lip. *Laryngoscope* 1981;91:153-6.
 68. Webster RE, Coffey RJ, Kellcher RE. Total and partial reconstruction of the lower lip with innervated muscle-bearing flaps. *Plast Reconstr Surg* 1960;25:360-7.
 69. von Burow CA. Beschreibung einer neuen Transplantations-Methode (Meth ode der seitlichen dreiecke) zum weiderersatz verlorengegangener Teile des Gesichts. Berlin: Nauck; 1855.
 70. Bernard C. Cancer de la leure inferieure opere par un procede nouveau. *Bull Mem Soc Chir Paris* 1853;3:357.
 71. Sadove RC, Luce EA, McGrath PC. Reconstruction of the lower lip and chin with the composite radial forearm-palmaris longus free flap. *Plast Reconstr Surg* 1991;88:209-14.
 72. Furuta S, Sukaguchi Y, Imasarva M, et al. Reconstruction of the lips, oral commissure, and full-thickness cheek with a composite radial forearm-palmaris longus free flap. *Ann Plast Surg* 1994;33:544-7.
 73. Duplechain G, Amedee RG. Carcinoma of the lip. *J La State Med Soc* 1992;144:441-2.
 74. Zitsch RP. Carcinoma of the lip. *Otolaryngol Clin North Am* 1993;26:265-77.
 75. Saywell MS, Weedon D. Histological correlates of metastasis in primary invasive squamous cell carcinoma of the lip. *Australas J Pathol* 1996;36:193-5.
 76. Breuninger H, Schaumburg-Lever G, Holzschuh J. Desmoplastic squamous cell carcinoma of skin and vermilion surface: a highly malignant subtype of skin cancer. *Cancer* 1997;79:915-9.
 77. Dos Santos LR, Cernea CR, Kowalski LP. Squamous cell carcinoma of the lower lip: a retrospective study of 58 patients. *Rev Paulista Med* 1996;114:1117-26.
 78. Tahan SR, Stein AL. Angiogenesis in invasive squamous cell carcinoma of the lip: tumor

- vascularity is not an indicator of metastatic risk. *J Cutan Pathol* 1995;22:236–40.
79. Ostwald C, Gogacz P, Hillmann T, et al. p 53 Mutational spectra are different between squamous-cell carcinoma of the lip and the oral cavity. *Int J Cancer* 2000;88:82–6.
80. Krabel MR, Koranda FC, Panje WR. Squamous cell carcinoma of the upper lip. *J Dermatol Surg Oncol* 1982;8:487–91.
81. Sack JG, Ford CN. Metastatic squamous cell carcinoma of the lip. *Arch Otolaryngol* 1978;104:282–5.
82. Nuutinen J, Karja J. Local and distant metastasis in patients with surgically treated squamous cell carcinoma of the lip. *Clin Otolaryngol* 1981;6:415–9.
83. McCombe D, MacGill K, Ainslie J, Beresford J, Matthews J. Squamous cell carcinoma of the lip: a retrospective review of the Peter MacCallum Cancer Institute experience. *ANZ J Surg* 2000;70:358–61.

Salivary Gland Disease and Tumors

Robert A. Ord, MD, DDS, MS

Alex E. Pazoki, MD, DDS

The salivary glands consist of three major paired glands (the parotid, submandibular, and sublingual) as well as numerous minor salivary glands, situated mostly in the oral cavity but also found in the pharynx, larynx, trachea, and sinuses. In the oral cavity 700 to 900 minor salivary glands are found, the majority of which are located at the junction of the hard and soft palates. These glands produce saliva, which functions as a lubricant for speech and swallowing, assists taste, has antibacterial and immunologic properties, and contains digestive enzymes. The salivary glands are affected by many different disease processes, some of which are surgical in nature while others have a medical basis. Surgical diseases include tumors, stones, and cysts, whereas medical diseases include viral infections, autoimmune diseases, and sarcoidosis. This chapter will concentrate on the salivary gland diseases that are of most interest to the surgeon.

Tumors

Tumors of the salivary glands show a wide variety of pathologic types varying from benign to highly malignant. Salivary cancers are comparatively rare and comprise 3% of head and neck cancers, which in turn account for 3% of all malignancies.

These neoplasms will be discussed according to their histopathologic diagno-

sis and the surgical principles dictated by the site of the tumor.

Histopathology

The large variety of tumors that occur in the salivary glands make an exhaustive list of all types impossible in a chapter of this length. The most common epithelial salivary gland tumors will be reviewed in order to illustrate the fundamentals of management of salivary neoplasia.

Benign Tumors *Pleomorphic Adenoma*

The pleomorphic adenoma is the most common benign salivary tumor at all sites. Approximately 80% of all pleomorphic adenomas (PSAs) occur in the parotid, and despite their slow growth they can become extremely large if neglected. This tumor is thought to arise from both salivary ducts and myoepithelial cells and is a true “mixed tumor.” Because of its derivation, histologically, many different patterns can occur, from cellular, glandular, and myxoid types to cartilagenous and even ossified forms. These features can be seen in different areas of the same tumor, accounting for its name, *pleomorphic* (Greek for *many forms*). The important feature from a surgical standpoint is the presence of a “pseudo capsule,” which contains outgrowths or pseudopodia of the

tumor. Attempts at “enucleation” of the tumor from within its “capsule” will inevitably leave viable tumor cell nests and predispose the patient to multifocal recurrence. Some authorities believe that younger patients with pleomorphic adenomas have a higher chance of tumor recurrence and increased growth during pregnancy. Malignant change is rare and usually takes place in long-standing tumors, the most common type being carcinoma ex pleomorphic adenoma. Prognosis will depend on the type of malignancy and involvement of the capsule. Rarely, malignant change in both elements of the pleomorphic adenoma (ductal and myoepithelial) will occur giving rise to the carcinosarcoma or true mixed malignant (biphasic) pleomorphic adenoma. On rare occasions, an apparently histologically benign tumor will metastasize into the so-called benign metastasizing pleomorphic adenoma.

Warthin’s Tumors This benign tumor is almost exclusively found in the parotid. It occurs mostly in men and is more common in smokers. It is thought to derive from salivary duct cells that are entrapped in lymph nodes during embryonic development. The tumor consists of large cystic spaces with a surrounding columnar epithelium and a

stroma of lymphocytes. Surgically these tumors may be multiple in one parotid gland or bilateral, or involve lymph nodes adjacent to the parotid gland.^{1,2}

Hemangi endothelioma In children the most common cause of parotid mass is a hemangioma or hemangi endothelioma.³ These are benign tumors that may appear soon after birth and grow rapidly. Usually, conservative treatment while waiting for involution is recommended.

Malignant Tumors Mucoepidermoid Carcinoma Mucoepidermoid carcinoma (MEC) is the most common malignant salivary gland neoplasm in both adults and children, and the most common salivary gland cancer of the parotid and minor salivary glands. This tumor can be of low grade or high grade depending on its histology. Low-grade MECs have multiple macrocysts and abundant mucus-producing cells. High-grade varieties have multiple squamous cells and very few mucus-producing cells or cysts, and mucicarmine or periodic acid–Schiff stains may be needed to identify intracellular mucus to characterize this tumor. There are three cell types of MEC: mucus producing, intermediate, and squamous. The respective ratio of mucus-producing cells to squamous cells will determine the clinical aggressiveness of the tumor (see above). Low-grade MECs can be very slow growing and nonmetastasizing, and can generally behave like a benign tumor. High-grade MECs can exhibit aggressive growth and invasion resulting in widespread metastasis and death. High-grade tumors usually show increased pleomorphism and meiotic figures. High-grade lesions may metastasize to cervical lymph nodes or spread hematogenously to the lung, liver, and bone.

Adenoid Cystic Carcinoma Although this tumor is very slow growing, its relentless course, with repeated recurrence and metastasis via the blood stream, gives low 20-year

survival rates.⁴ Adenoid cystic carcinoma is the most common malignancy of the submandibular gland and is the second most common salivary gland cancer overall. Three histologic types are seen: tubular, cribriform (the classic “Swiss cheese” pattern), and solid. The solid type has the worst prognosis, especially when areas of necrosis are present. The infiltrative nature of this lesion and the frequency of perineural involvement with spread along the nerve mandate wide resection margins. Perineural spread is a bad prognostic sign for both local recurrence and distant metastasis. Clinical and radiologic examination of this tumor frequently underestimate its true extent, and follow-up of 15 to 20 years is required as late recurrences occur.

Low-Grade Polymorphous Adenocarcinoma Low-grade polymorphous adenocarcinoma occurs almost exclusively in the minor salivary glands and is second only to mucoepidermoid carcinoma at these sites. It arises from terminal duct cells and is characterized by cytologically bland monotonous cells that can assume many different patterns (glandular, cribriform, and lobular) within the same tumor. Characteristically “Indian file” cells and perineural involvement are seen. Although this tumor behaves in a very low-grade manner, local recurrence will occur with inadequate excision.⁵ The important pathologic features seen from the surgeon’s viewpoint are frequent misdiagnosed on initial biopsy, due to the different patterns that may be sampled. Common misdiagnoses are adenoid cystic carcinoma, pleomorphic adenoma, and malignant pleomorphic adenoma. It is also important to be aware that the frequent presence of perineural involvement does not lead to a worse prognosis, as is the case for adenoid cystic carcinoma.

Site of Tumor

Parotid Gland The surgical principles of treating parotid tumors are dictated by the histopathology of the tumor and the

need to preserve the facial nerve. Diagnostic imaging with computed tomography (CT) or magnetic resonance (MR) is desirable for superficial lobe tumors but is essential for suspected deep-lobe neoplasms, especially those with a parapharyngeal component. Since 80% of parotid tumors are benign and 80% of these are pleomorphic adenomas, a solitary mass in the parotid with no features of malignancy is most likely a PSA. Open biopsy of such a mass is therefore contraindicated as this will rupture the “capsule” and “seed” the PSA, increasing the complexity of subsequent surgery and chances of recurrence. Fine-needle aspiration biopsy (FNAB) for cytology is the preferred method of diagnosis.⁶ Clinically only one-third of malignant tumors will have symptoms or signs of malignancy, such as pain, ulceration of skin, facial nerve palsy, or metastatic cervical nodes.⁷ Thus virtually all parotid tumors will initially be treated as benign unless FNAB shows definite malignancy or there is clinical evidence of malignancy (Figure 35-1). The majority of tumors occur in the superficial lobe, and superficial lobectomy with preservation of the facial nerve has been the standard operation for many years. Recent minor modifications have included the use of a face-lift incision, the use of the superficial musculoaponeurotic system to prevent Frey’s syndrome, the use of flaps or alloplasts to augment defects, and the suggestion that “capsular dissection” without the need to remove the entire superficial parotid may be sufficient.^{8–10} Superficial lobectomy is suitable for benign and low-grade malignant tumors, and even in high-grade malignancies only branches of the nerve that are actually infiltrated will be sacrificed. If the nerve or portions of it have to be resected, immediate grafting is recommended. In deep-lobe tumors a total parotidectomy is performed, with the superficial lobe being dissected first to expose the nerve. Good margins with

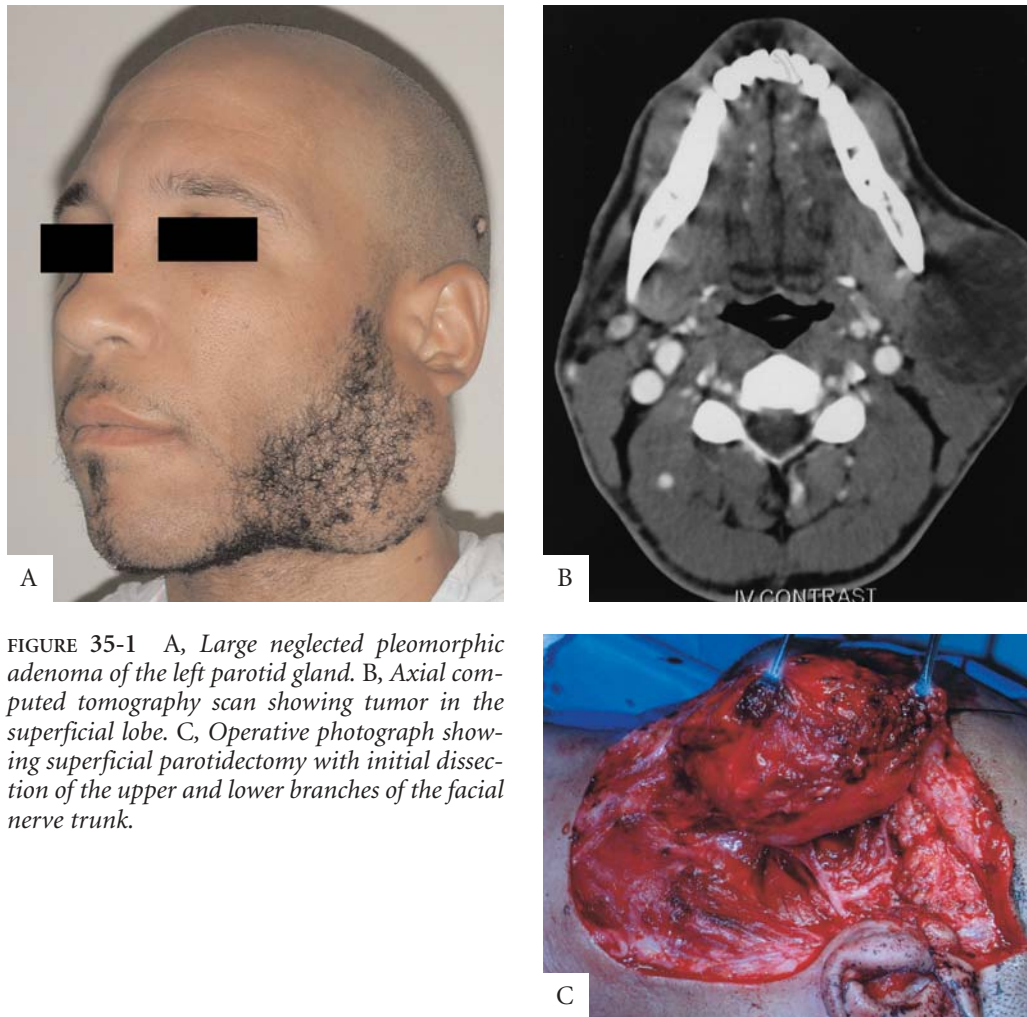


FIGURE 35-1 A, Large neglected pleomorphic adenoma of the left parotid gland. B, Axial computed tomography scan showing tumor in the superficial lobe. C, Operative photograph showing superficial parotidectomy with initial dissection of the upper and lower branches of the facial nerve trunk.

surrounding normal salivary gland tissue are more difficult to obtain on deep-lobe tumors, which tend to be large as they are often detected late. In high-grade tumors, surrounding tissues such as skin, masseter, and mandible may require sacrifice, as dictated by the need to obtain clear margins. In these instances consideration should be given to neck dissection. Where clinically positive nodes are present, a modified radical neck dissection is usually the operation of choice.¹¹ Where the patient is N0 clinically, but at high risk for occult nodal disease, a selective neck dissection of levels I to IV or levels II to IV is indicated. In high-grade tumors postoperative radiation therapy is usually indicated. Chemotherapy has not been shown to convey a survival benefit for these lesions.

Submandibular Gland In suspected submandibular neoplasms, CT imaging, MR imaging, and FNAB are all useful in the diagnostic work-up. Fifty percent of tumors will be malignant, adenoid cystic carcinoma being the most common. In benign neoplasms (PSAs) removal of the submandibular gland with an extracapsular dissection of the tumor and 2 to 3 mm of surrounding soft tissue is sufficient. For malignant tumors the minimum resection will be an en bloc removal of level I. If indicated the overlying platysma superficially and the mylohyoid muscle deeply will be excised. In most malignant tumors with N0 necks, the cervical incision necessary for removal of level I will dictate extending this to a supraomohyoid neck removing levels I to III. The adenoid cystic carcinoma does not usually metastasize via the lym-

phatics; instead it spreads hematogenously and neck dissection may not be indicated. The mandibular branches of the facial, lingual, and hypoglossal nerves are all in close relation to the submandibular gland. If these nerves appear to be involved by cancer, they should be traced until the nerve appears normal. After resection, frozen sections should be sent from the cut nerve trunk to confirm clearance, although “skip” lesions do occur. Radiation may be useful postoperatively.

Minor Salivary Glands *The Palate* The majority of minor salivary gland tumors occur at the junction of the hard and soft palates. In this location 50% are malignant, the most common being low-grade mucoepidermoid carcinoma followed by low-grade polymorphous adenocarcinoma. Coronal and axial CT scans with bony windows are helpful to demonstrate bone destruction and involvement of the sinuses or nasal cavity. Biopsy through the middle of the lesion is indicated as the overlying mucosa will be excised.¹² In PSA, excision with a 5 mm margin is adequate. The periosteum is a good deep margin if the bone is uninvolved, as is usually the case with PSA (Figure 35-2). In low-grade lesions a 1 cm margin and similar approach

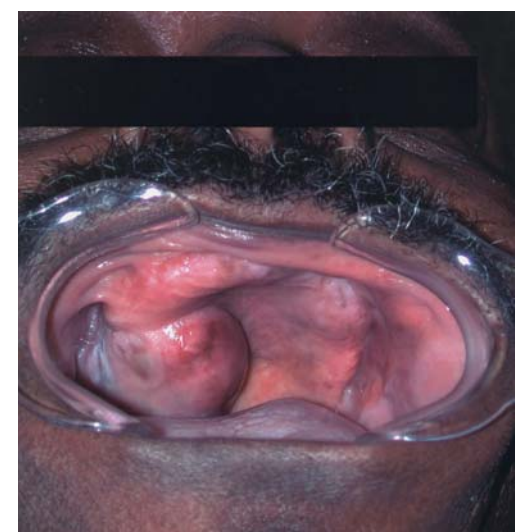


FIGURE 35-2 Large pleomorphic adenoma of the right palate.

are used. Local flap reconstruction or the use of a palatal plate with subsequent secondary healing by granulation is used for reconstruction. Where bone invasion has occurred, as in adenoid cystic carcinoma or high-grade tumors, a partial maxillectomy will be required. In the case of adenoid cystic carcinoma, attention must be given to the greater palatine nerve, with frozen section clearance obtained. Cranial extension, orbital involvement, and infiltration posteriorly into the pterygoids will increase the extent of surgery and its morbidity, with a decrease in survival (Figure 35-3). Reconstruction is usually with an obturator, although primary maxillary reconstruction has been revisited with the development of interosseous implants and composite microvascular free flaps.

The Retromolar Fossa Although this is a relatively unusual site for minor salivary gland tumors, virtually 100% are malignant and are low-grade mucoepidermoid carcinomas. The surgeon should be aware that a cystic soft tissue mass distal to the third molar, with or without radiographic mandibular involvement, is unlikely to be a mucocele, and incisional biopsy should be undertaken to confirm the diagnosis.

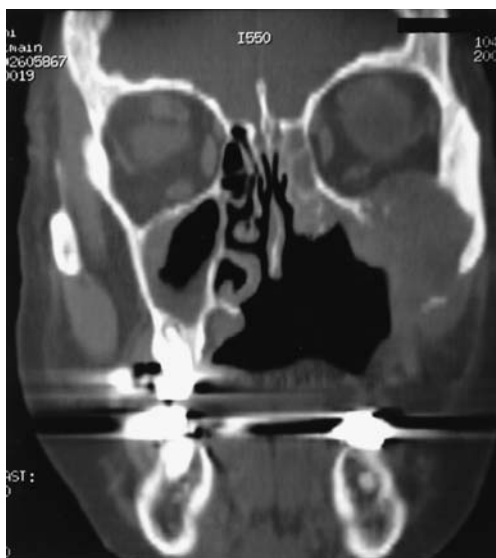


FIGURE 35-3 Recurrent low-grade polymorphous adenocarcinoma of the palate postmaxillectomy with invasion of the orbital floor and orbital fat.

Intrabony Tumors Although intrabony (central) salivary gland tumors are rare, the vast majority are malignant low-grade mucoepidermoid carcinomas.¹³ These are mostly seen in the third molar region of the mandible and are frequently multilocular. The tumors are often diagnosed radiologically as ameloblastomas, or odontogenic keratocysts. Resection with a 1 cm margin and sacrifice of the inferior alveolar nerve and overlying soft tissue in areas of perforation are required. Neck dissection is usually not necessary, but if the neck has been opened widely for mandibular resection a supraomohyoid neck dissection can be undertaken. A reconstruction plate is placed and either primary reconstruction with a fibular or deep circumflex iliac artery microvascular flap or secondary posterior iliac crest corticocancellous reconstruction may be used.

Other Intraoral Sites Interestingly, the proportion of benign to malignant tumors varies according to site, with virtually all upper lip tumors being benign and a higher proportion of lower lip tumors being malignant. Salivary gland neoplasms of the tongue and buccal mucosa tend to be malignant and require wide soft tissue dissection to obtain margins.

The Sublingual Gland Less than 1% of all salivary gland tumors occur in the sublingual gland but almost 100% are malignant. Surgical approach will be dictated by the histology and required access for margins. In most cases we have preferred a lip split and mandibulectomy to allow good visualization of the tumor, direct examination of the mandibular lingual cortical plate, and the ability to trace back the lingual nerve when necessary.

Obstructive Disease

Obstruction to the salivary glands is usually seen in the submandibular and parotid glands. It may be due to calcified stones

(most common in the submandibular gland) or mucous plugs (most common in the parotid) or strictures of the duct. Stone formation is classically due to stasis of flow, infection, and alteration of the duct contents. Calcified stones are formed by the precipitation of calcium salts around a nidus of mucous plugs, epithelial cells, or microorganisms. Approximately 80% of sialoliths occur in the submandibular gland.¹⁴ Microliths in the minor salivary glands have been described.

As calcified sialoliths increase in size they may give rise to symptoms, especially when they are present in the duct. Classically the patient reports pain and swelling when eating or drinking or sometimes even from the smell of food (Figure 35-4). Examination of the gland may show a tender swelling with inability to milk saliva from the duct orifice.

Plain radiography is used to demonstrate calcified stones, the lower occlusal film for the submandibular gland, and an occlusal or periapical dental film held in the cheek for the parotid. Lateral oblique mandibular films or panoramic radiographs will show parotid duct stones and calcified stones in the hilum or glandular substance of the submandibular gland. CT

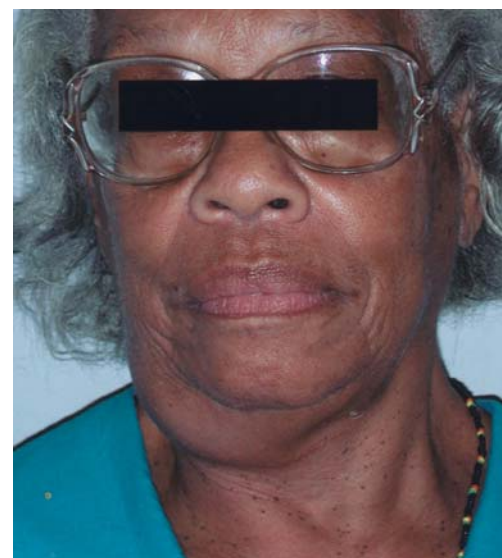

FIGURE 35-4 Right submandibular gland swelling and sialadenitis secondary to an obstructing sialolith.

scans and ultrasonography have also been used. When a noncalcified (mucous plug) obstruction is suspected, sialography may demonstrate a filling defect (Figure 35-5). Acute infection should be managed with antibiotics prior to sialography. Treatment of the stone will depend on its location.

Submandibular Gland

Anterior Duct If the stone is palpable in the anterior floor of the mouth close to the orifice of Wharton's duct, an intraoral approach may be used. Although the anterior duct is traditionally regarded as a line between the first molars, the floor of the mouth slopes downward following the mylohyoid muscle as the premolars are reached, and technical difficulty is increased as the stone is more distal (Figure 35-6). Initially a suture is passed

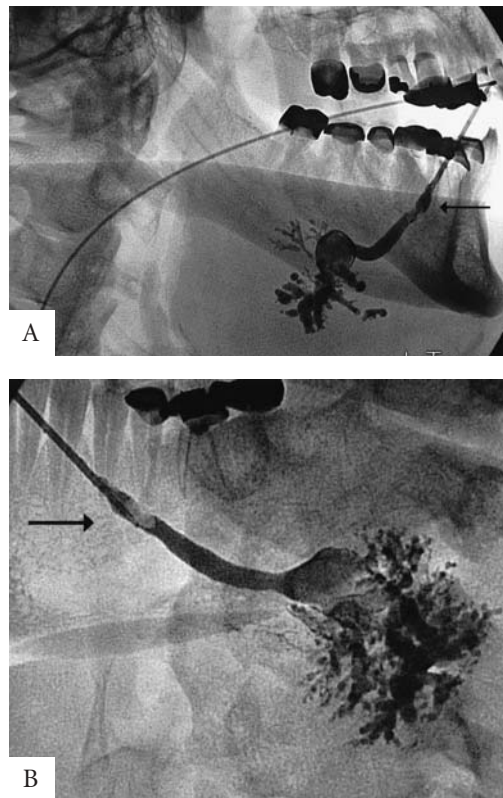


FIGURE 35-5 A, Sialogram showing a large calcified stone in the hilum, with dilated intraglandular ducts. Note the filling defect at the proximal duct from the mucous plug (arrow). B, The filling defect is confirmed by this sialogram to be at the terminal duct (arrow).

behind the sialolith around Wharton's duct to use as a traction suture, tenting the duct upward and preventing posterior displacement of the stone during surgical manipulation. An incision in line with the duct is made through the mucosa and dissection carried down to the duct. This is opened in its long axis allowing removal of the stone. The posterior suture is removed and the gland is milked or explored with a lacrimal probe to find other stones. The duct is sutured open to the edges of the mucosa (fish tailed) to prevent stricture.

Posterior Duct Stones in the posterior submandibular duct are much more technically difficult to remove intraorally, requiring general anesthesia, excellent light, and retraction, as well as the help of an assistant to push the gland upward into the mouth from extraorally. Even so, irritating bleeding can occur and the lingual nerve must be visualized and protected (see Figure 35-6).

Stones in the Hilum or Gland

When the stone is below the posterior edge of the mylohyoid muscle, removal of the gland is necessary. Although intraoral submandibular gland excision has been described, the potential for bleeding from branches of the facial vein and artery and possible scarring of the anterior pole of the gland to the mylohyoid muscle can make this a technically challenging and hazardous procedure.¹⁵ We believe that the conventional cervical approach gives the best access and is the safest procedure.

Under general anesthesia an approximately 5 cm incision is made over the submandibular gland at 1½- to 2-finger breadths below the mandible. This incision should be parallel to the neck skin creases, not to the lower border of the mandible (Figure 35-7). The platysma is sectioned and the inferior pole of the submandibular gland visualized. The gland is exposed by subcapsular dissection at the inferior posterior pole. Blunt finger dissection will release

the deep surface of the gland. The authors do not routinely tie the facial artery and vein at this stage as these can usually be dissected off the gland, although clipping

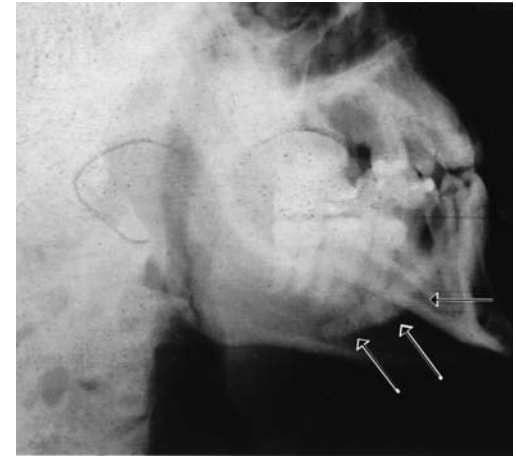


FIGURE 35-6 Lateral oblique radiograph of the mandible showing the entire Wharton's duct occupied by calcified sialolith. Note how the stone passes inferiorly and deeply, the farther posteriorly it is placed (arrows).

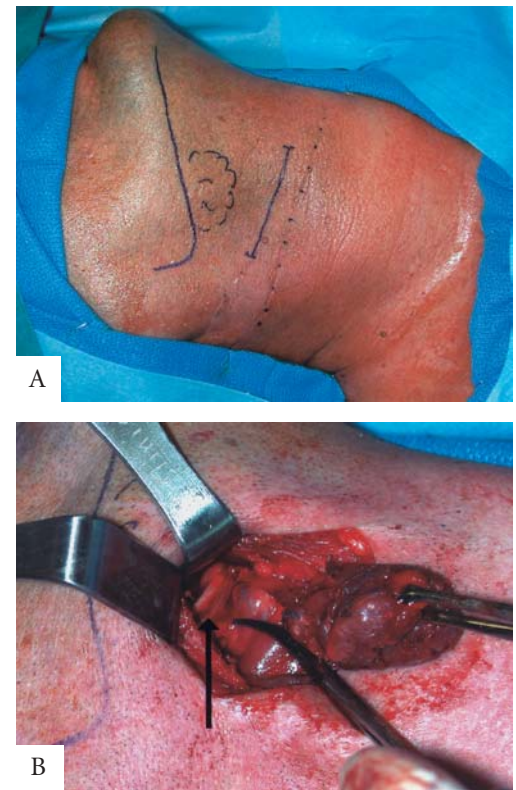


FIGURE 35-7 A, Incision for submandibular gland excision parallel to the neck crease. B, Submandibular gland mobilized and retracted through the wound. The arrow points to the lingual nerve in the superior part of the wound.

multiple arterial branches to the gland can be tedious. The anterior pole of the submandibular gland is mobilized off the mylohyoid muscle, and in cases of chronic sialadenitis, sharp dissection may be necessary due to dense fibrosis. The superior pole of the gland is dissected in a subcapsular plane and the gland mobilized posteriorly. The posterior edge of the mylohyoid muscle is retracted to expose the lingual nerve and the branch to the gland is tied and sectioned (see Figure 35-7B). The submandibular duct is dissected superiorly into the floor of the mouth as far as possible, tied, sectioned, and the gland removed.

Parotid Gland

Most obstructive symptoms in the parotid gland are associated with noncalcified stones or mucous plugs. Although these can sometimes be removed with tweezers following duct dilatation or “milked” from the duct, they often cause repeated bouts of pain and swelling. Sialography is helpful in evaluating the extent of damage to the ductal architecture. Sialograms may show changes varying from mild sialectasis to gross dilatation of Stensen’s duct with loss of secondary and tertiary ducts (Figure 35-8). Sialograms are frequently helpful symptomatically, with cure or

improvement in many patients. In advanced cases with no improvement, parotidectomy may be required.

Stones in the Terminal Duct Radiographically opaque stones at Stensen’s papilla can be managed intraorally in a similar manner to those of the anterior portion of Wharton’s duct. Following placement of a posterior traction suture, the duct is opened with an incision running in the long axis of the duct.

Stones in the Posterior Duct When the stone involves the extraglandular portion of the duct lateral to the buccinator muscle, both intraoral and extraoral approaches are described.^{16,17} The intraoral approach involves a Y-shaped mucosal incision, dissection through the buccinator muscle, and the use of a traction suture to pull the duct into the mouth. The extraoral approach requires the duct to be displaced laterally with a finger placed in the mouth, with blunt dissection down to the stone, avoiding the facial nerve.

Parotid Gland Stones Stones at the hilum of the gland or intraglandular stones usually require a parotidectomy if they are symptomatic. The facial nerve

dissection may be challenging due to extensive fibrosis (Figure 35-9).

Nonsurgical Approaches

Miniature endoscopes have been used to visualize sialoliths and remove them with baskets.¹⁸ Lithotripsy has also been attempted either via endoscopes (intracorporeal) or extracorporeally. Intracorporeal lithotripsy uses shock waves produced by lasers, electrohydraulic sources, or a pneumballistic source. In a review of 6 series of extracorporeal lithotripsy ranging from 33 to 104 stones, Escudier reported a stone-free range of 18.2 to 52.9% with residual fragments occurring in 47.1 to 81.8% of cases.¹⁹

Mucocele and Ranulas

Mucocele are mostly due to extravasation of mucus from a salivary gland, although a few are true retention phenomena. The most common site is the lower lip, due to trauma (usually following an accidental bite in a child). Mucoceles are simple to treat and they should not recur if the underlying damaged minor salivary gland has been removed. Following a vertical incision through the mucosa over the mucocele, a number of minor salivary glands are usually identified. As it may be impossible

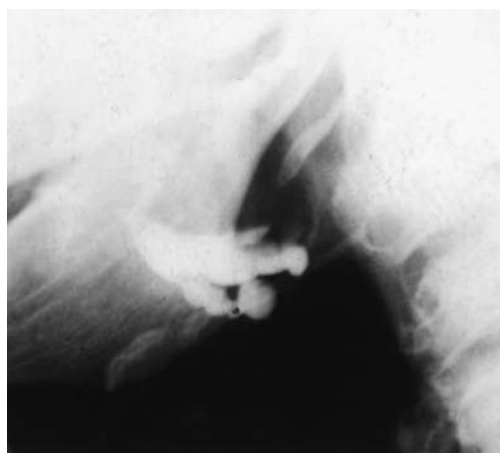

FIGURE 35-8 Sialogram showing gross destruction of the parotid ductal architecture with dilatation of the glandular ducts into large mucus-filled sacs.

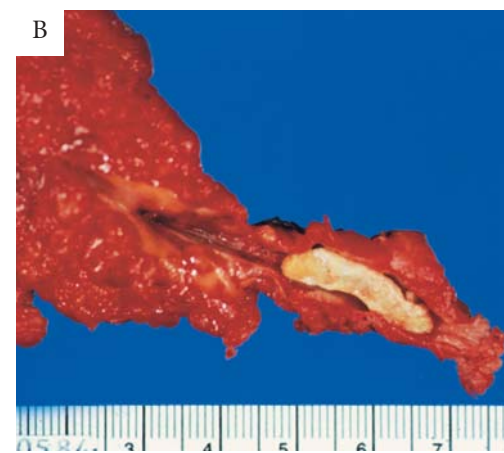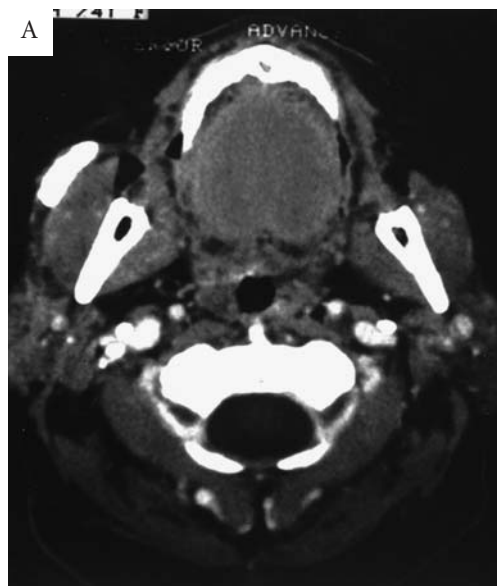


FIGURE 35-9 A, Computed tomography scan showing a large parotid stone at the hilum of the gland. B, Parotid duct opened to show the sialolith in situ, following parotidectomy.

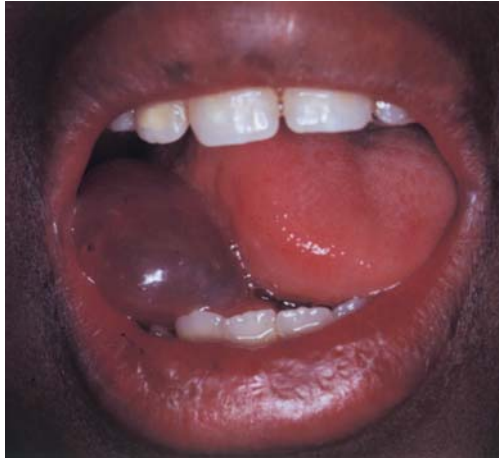

FIGURE 35-10 Large ranula overlapping the occlusal plane in a 10-year-old boy.

to identify the damaged gland, all these minor glands should be removed before carefully suturing the mucosal incision.

Ranulas are large retention phenomena that occur in the floor of the mouth in relation to the sublingual gland. They may be large enough to elevate the tongue and interfere with speech and swallowing (Figure 35-10). Where dehiscence in the mylohyoid muscle occurs, the mucus can drain into the submandibular space as a “plunging ranula.” The treatment of ranulas has been reviewed at length in a classic paper by Catone.²⁰ He concluded that definitive therapy was removal of the sublingual gland. Several large series have been reported comparing sublingual gland excision with so-called marsupialization, demonstrating 100% cure for gland excision and 43 to 63% cure for marsupialization.^{21,22}

Despite this evidence some authorities still plead the case for marsupialization or “marsupialization with packing,” which they claim has a lower recurrence rate of 10 to 12%.²³ We subscribe to the view that

ranulas should be treated by sublingual gland excision.

An intraoral approach is made with an incision along the axis of the gland lateral to the ductal orifices. The submandibular duct is identified, either by dissection or following cannulation with a lacrimal probe. The gland is dissected in a subcapsular plane with meticulous hemostasis. At its posterior pole the lingual nerve is identified as it crosses the duct and is preserved. The sublingual gland is dissected from anteriorly, and the final excision is the posterior pole after visualizing the lingual nerve.

References

- Lamelas J, Terry JH, Alfonso JE. Warthins tumor; multicentricity and increasing incidence in women. *Am J Surg* 1987;154:347–51.
- Snyderman C, Johnson JT, Barnes EL. Extraparotid Warthin's tumor. *Otolaryngol Head Neck Surg* 1986;94:169–75.
- Lack EE, Upton MP. Histopathologic review of salivary gland tumors in childhood. *Arch Otolaryngol Head Neck Surg* 1988; 114:898–906.
- Ampil FL, Misra PP. Factors influencing survival of patients with adenoid cystic carcinoma of salivary glands. *J Oral Maxillofac Surg* 1987;45:1100–10.
- Castle JT, Thompson LD, Frommelt RA, et al. Polymorphous low grade adenocarcinoma: a clinicopathologic study of 164 cases. *Cancer* 1999;86:207–19.
- Lindberg LG, Ackerman M. Aspiration cytology of salivary gland tumors — diagnostic experience for 6 years of laboratory work. *Laryngoscope* 1976;86: 584–94.
- Ord RA. Surgical management of parotid tumors. *Atlas Oral Maxillofac Surg Clin N Am* 1995;7:529–64.
- Witt RL. The significance of the margin in parotid surgery for pleomorphic adenoma. *Laryngoscope* 2002;112:2141–54.
- To EW, Pang PC, Chiu GM. The use of modified rhytidectomy for parotidectomy [letter]. *Br J Plast Surg* 2000;53:1:80.
- Gooden EA, Gullane PJ, Irish J, et al. Role of the sternocleidomastoid muscle flap preventing Frey's syndrome and maintaining facial contour following superficial parotidectomy. *J Otolaryngol* 2001;30:98–101.
- Kaplan MJ, Johns ME. Salivary gland cancer. *Clin Oncol* 1986;5:525–47.
- Pogrel MA. The diagnosis and management of salivary gland tumors. *Atlas Oral Maxillofac Surg Clin N Am* 1993;5:319–30.
- Brookstone MS, Huvos AG. Central salivary gland tumors of the mandible and maxilla: a clinicopathologic study of 11 cases with review of the literature. *J Oral Maxillofac Surg* 1992;50:229–36.
- Berry RL. Sialadenitis and sialolithiasis: diagnosis and management. *Atlas Oral Maxillofac Surg Clin N Am* 1995;7:479–504.
- Miloro M. The surgical management of submandibular gland disease. *Atlas Oral Maxillofac Surg Clin N Am* 1998;6:29–50.
- Baily BJ, editor. Anatomy and physiology of the salivary glands. In: *Head and neck surgery — otolaryngology*. Vol 1. Philadelphia (PA): JB Lippincott; 1993. p. 453.
- Ord RA. Salivary gland disease. In: Fonseca RJ, editor. *Oral and maxillofacial surgery*. Vol 5. Philadelphia (PA): WB Saunders; 2000. p. 279–80.
- Nahlieli O, Baruchin AM. Sialoendoscopy: three years experience as a diagnostic and treatment modality. *J Oral Maxillofac Surg* 1997;55:912–8.
- Escudier MP. The current status and possible future for lithotripsy of salivary calculi. *Atlas Oral Maxillofac Surg Clin N Am* 1998;6:117–31.
- Catone GA. Sublingual gland mucous escape. Pseudocysts of the oro-cervical region. *Atlas Oral Maxillofac Surg Clin N Am* 1995;7:431–77.
- Yoshimura Y, Obara S, Kondoh T, Naitoh ST. A comparison of three methods used for the treatment of ranula. *J Oral Maxillofac Surg* 1995;53:280–2.
- Crysdale WS, Mandelsohn JD, Conley S. Ranulas-mucocoeles of the oral cavity experience in 26 children. *Laryngoscope* 1988;98:296–8.
- Baurmash HD. Mucocoeles and ranulas. *J Oral Maxillofac Surg* 2003;61:369–78.

Management of Mucosal and Related Dermatologic Disorders

Michael W. Finkelstein, DDS, MS

Steven D. Vincent, DDS, MS

Fungal Disease of the Oral Cavity

Fungal diseases of the oral cavity can be classified as superficial or deep in relation to the primary tissue(s) involved in the infection. Most oral fungal infections are opportunistic in nature. Persons living in geographic areas endemic to one or more of these fungi may show immunologic reactivity to the surface antigens without having historic features of active disease. The deep fungi usually infect the lungs before dissemination to other organ systems, including the oral cavity. Deep fungal diseases, including histoplasmosis, coccidioidomycosis, blastomycosis, and cryptococcosis, present clinically as chronic proliferative ulcerated granulomatous tissue lesions that may be single or multiple and painful or asymptomatic. They may simulate clinical features of a malignant neoplasm.

Candidosis

Although numerous deep and superficial fungal diseases can involve the oral cavity, candidosis is by far the most common. The term *candidosis* is the correct nomenclature describing an infection with one of several species of *Candida* organisms. However, many publications use the term

candidiasis to describe the same disease, even though the suffix “-iasis” is characteristically used to describe parasitic infections such as schistosomiasis or amebiasis.

One or more species of *Candida* can be found as a component of the normal oral flora in about 60% of healthy adults. The organism can exist in one of three states: the yeast form consisting of blastospores measuring 1.5 μm to 5 μm in diameter, elongated pseudohyphae, and chlamydozoospores measuring 7 μm to 17 μm in diameter. In its commensal state, the organism usually exists only as spores or pseudohyphae.

Candidosis is usually an opportunistic infection caused by a localized or systemic suppression of the immune system. Commonly recognized causes of candidosis include the use of broad-spectrum antibiotics, xerostomia, chronic diseases of the immune system, and therapy for malignant disease including chemotherapy or radiation.

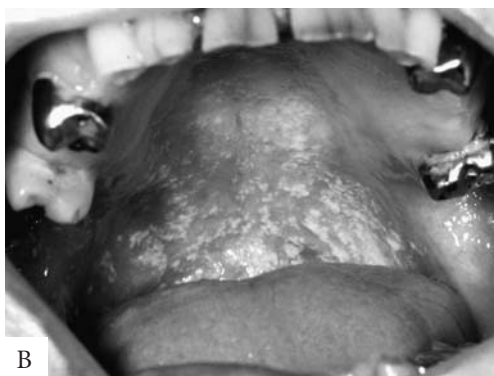
Oral infections involving *Candida* species may appear as one of three clinical forms: acute, chronic, and mucocutaneous. Candidosis characteristically shows erythematous mucosa with or without overlying white plaques, which may be rubbed away with light abrasive pressure (Figure 36-1). The dorsum of the tongue

usually shows diffuse patches of papillary atrophy (Figure 36-2). Occasional small or confluent ulcerations may be noted. Angular cheilitis is a prominent clinical feature of oral candidosis. Patients characteristically complain of an oral “burning” sensation. *Denture-sore mouth* (denture stomatitis) is a clinical term used to describe patients with mucosal erythema or inflammatory papillary hyperplasia, usually related to a localized candidosis under a removable prosthodontic appliance.

Clinical features of oral candidosis usually include foci of mucosal erythema, which is the result of inflammation and mucosal atrophy, areas of ulceration, and sometimes white pseudomembranous plaques, which are seen to consist of candidal pseudohyphae and spores if examined microscopically (Figure 36-3). These pseudomembranous plaques, although usually present in acute-onset cases of candidosis, are frequently absent in cases of chronic candidosis such as those related to prosthetic appliances. The lack of white pseudomembranes should not therefore preclude consideration of candidosis in cases of chronic mucositis. Candidosis has also been noted in lesions characterized by focal increases in keratinization such as lichen planus, focal keratosis with or

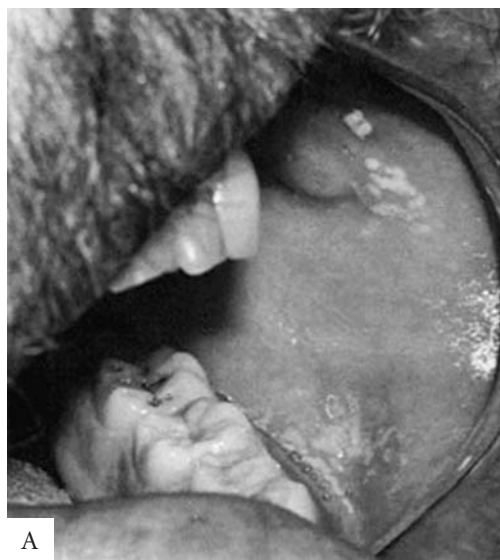
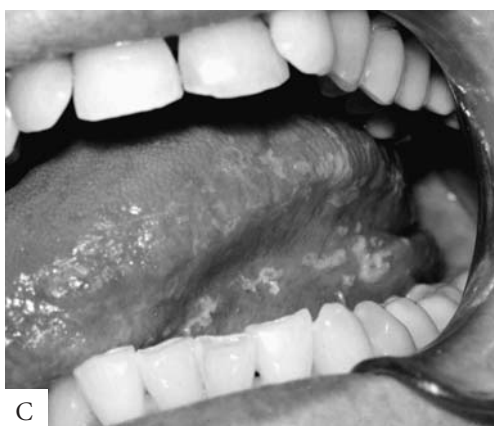
FIGURE 36-1 A to C, Oral candidosis. White pseudomembranous plaques that can be removed with light abrasion involving buccal, lateral-glossal, and soft palatal mucosa.



without dysplasia (leukoplakia), hairy tongue, hairy leukoplakia, and even squamous cell carcinoma. A recent study showed the presence of candidal hyphae and spores in 31% of biopsy specimens showing oral lichen planus. However, a possible cause-and-effect relationship between candidosis and increased keratinization of the epithelium is difficult to show.

Cytologic Preparations Clinical diagnoses of oral candidosis are easily and quickly confirmed using exfoliative cytology studies. Cytologic specimens are prepared using a wooden tongue blade to scrape the oral mucosa of the involved areas; the exfoliated material is smeared onto a glass slide. The slide is air dried for 5 minutes and then fixed in ethanol (hair sprays with a high alcohol content can be used as fixatives in a clinical setting). The slides are stained with potassium hydroxide, periodic acid–Schiff modified for fungi, or any one of several other stains that delineate the fungal hyphae and

spores. The infection can be further delineated as a species using cultures on Sabouraud dextrose or blood agar.

Oral candidosis is the most common diagnosis made in patients whose chief complaint involves a chronic nonspecific mucositis or burning sensation. Other diseases included in the clinical differential diagnosis include lichen planus, pemphigus, pemphigoid, and medication-related toxic mucositis. As stated above, candidosis may be a secondary component of other chronic oral diseases or localized epithelial thickening lesions.

Management The initial management of oral candidosis following confirmation of the clinical impression with exfoliative cytology studies is the use of one or more antimycotic agents. Of greatest therapeutic value in most patients is ketoconazole, administered in one 200 mg tablet daily for 10 to 14 days. If systemic factors contraindicate the use of ketoconazole, clotrimazole troches, administered in one 10 mg

tablet dissolved in the oral cavity up to five times daily, or chlorhexidine in a 0.12% mouthrinse in a 5 to 10 mL dose twice daily NPO for 1 hour, are usually effective. Nystatin powder or cream may be used to line dentures in patients with denture sore mouth. Of vital importance is a review of the patient's past medical history and current medical status in an attempt to identify the causative factors for this opportunistic infection. In patients who have no identifiable predisposing factors or if the predisposing factors are not correctable, multiple recurrences may be anticipated.

Median Rhomboid Glossitis

Although the early reports of median rhomboid glossitis suggested an origin from the tuberculum impar, many investigators now favor classification of this lesion as a localized candidosis (Figure 36-4).¹ Although the exact cause-and-effect relationship is unclear, *Candida* spp are found in association with many of these lesions, and recent studies have shown the prevalence of median rhomboid glossitis to be higher in adults than in children, a finding contrary to the developmental theory of origin. The lesion appears clinically as an

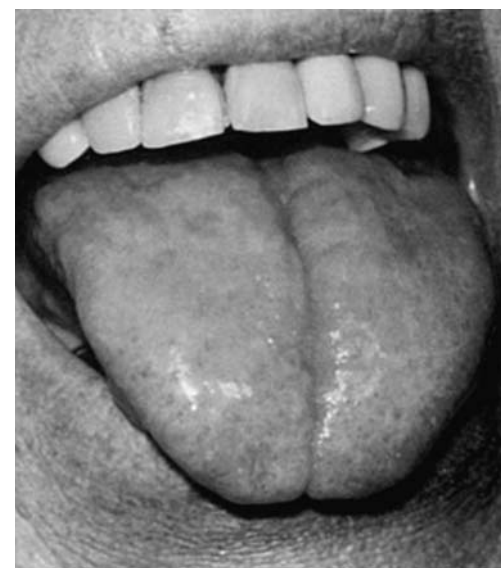


FIGURE 36-2 Oral candidosis. Atrophy of the filiform papillae on the dorsal tongue.

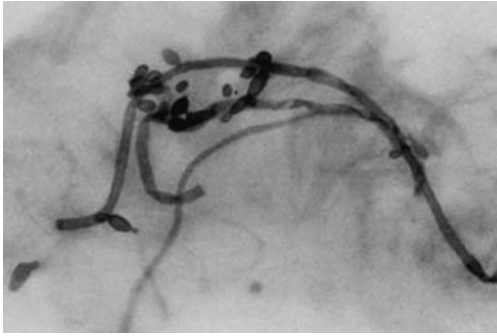


FIGURE 36-3 Oral candidosis. Cytologic preparation showing hyphae and spore form characteristic of *Candida sp* ($\times 160$ original magnification; stained with periodic acid-Schiff stain modified for fungal organisms).

erythematous patch, which may be roughly ovoid or rhomboid in shape, is asymptomatic, and is located on the dorsal midline of the tongue just anterior to the circumvallate papillae. The area is usually smooth and devoid of filiform papillae.

Unless the lesion is symptomatic, no treatment is indicated. For symptomatic cases, management with antifungal regimens is usually beneficial. The lesions are generally regarded as having no malignant potential.

Bacterial Infections of Oral Mucosa

Acute Necrotizing Ulcerative Gingivitis

Acute necrotizing ulcerative gingivitis is a rare and clinically painful ulcerative disease that presents with progressive necrosis of the interdental papillae, usually beginning in the mandibular incisor region. The interdental papillae necrosis may spread or remain localized. The necrotic papillae are usually covered with a pseudomembrane of necrotic epithelial cells, plaque, and microbial organisms. The patient may have systemic signs and symptoms including fever and regional lymphadenopathy. Patients have a characteristic rancid halitosis caused in part by the presence of necrotic material in the oral cavity.^{2,3}

The probable cause of this disease involves a symbiotic infection by two bacteria, a fusiform bacillus and a spirochete. However, inoculation of these bacteria into healthy tissues does not produce disease, and because moderate numbers of these organisms can be found in otherwise clinically healthy mouths, other factors such as stress and smoking, both of which can affect the host's immune system, have been implicated as causative factors.

Local débridement by scaling and curettage, sometimes under local anesthesia, usually brings about a marked relief of symptoms. A therapeutic dose of an antibiotic such as tetracycline may be indicated for patients with extensive disease or evidence of regional lymph node enlargement. The use of topical antiseptics such as chlorhexidine or diluted hydrogen peroxide is of value for initial management of the lesions. The lesions usually heal within 2 to 3 weeks, and the interdental papillae often regenerate, seldom requiring gingival surgery. Improved oral hygiene through use of a soft-bristled toothbrush and floss is the best long-term therapy and is aimed at recurrence prevention.

Syphilis

Syphilis is a venereal infection that has been documented extensively, beginning in about the fourteenth or fifteenth century. Before the introduction of penicillin in the early 1940s, over 500,000 new cases were documented in the United States each year. The Centers for Disease Control and Prevention reported 6,657 cases of primary and secondary syphilis in the United States in 1999.⁴

The disease is caused by the spirochete *Treponema pallidum* and is acquired by contact with an active lesion. The spirochete can also be transmitted by transfused blood, and it crosses the placental barrier from maternal to fetal circulation.

In cases involving transmission from an active lesion, the site of infection forms

a chancre or ulceration, which is usually accompanied by regional lymphadenopathy. The ulcer and lymphadenopathy usually persist for 3 to 10 weeks and then resolve spontaneously. This initial disease manifestation constitutes primary syphilis. Assuming no treatment is rendered, secondary syphilis develops following a latency period of several weeks. In this stage the now widely disseminated disease causes fever, malaise, a maculopapular rash, and multiple ulcerations or mucous patches on mucosal surfaces. Broad-based, proliferative slightly raised ulcerations known as condyloma latum may occur during secondary syphilis. These lesions also persist for 5 to 10 weeks and then resolve without treatment. If the patient is still untreated, several recurrences of the manifestations of secondary syphilis may occur or the disease may enter a prolonged latency period lasting months or years.⁵⁻⁷

Fortunately tertiary syphilis develops in only a few patients. There are many manifestations of tertiary syphilis, owing to the extensive involvement of organ systems. Central nervous system involvement can present as a generalized paralysis or tabes dorsalis. Inflammation of the circulatory system can result in aneurysms, especially in the aorta. Intraoral manifestations include granulomatous proliferations known as gummas, as well as a poorly understood generalized glossitis.

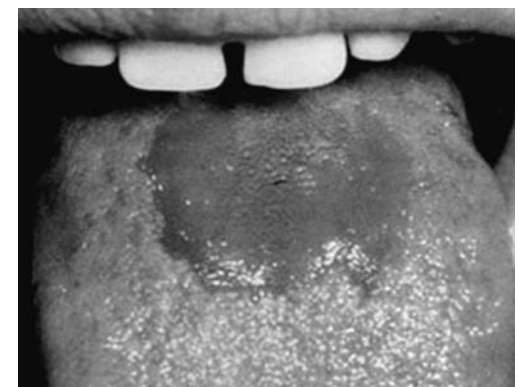

FIGURE 36-4 Median rhomboid glossitis. A localized form of atrophic candidosis.

The diagnosis of syphilis is usually made following serologic studies, including Venereal Disease Research Laboratory and fluorescent treponemal antibody absorption tests. The treatment of choice for syphilis remains 2.4 million U of benzathine penicillin. For patients allergic to penicillin, erythromycin or tetracycline may be substituted.

Gonorrhoea

Gonorrhoea is currently the most widespread human bacterial infection in the world and is caused by *Neisseria gonorrhoeae*, a gram-negative diplococcus.

Transmission is usually venereal, involving genital, oral, or pharyngeal mucosa. The incubation period is about 1 week with the initial features ranging from no evidence of disease to mucosal ulcers and regional lymphadenopathy. These features, although reported in the oral cavity, are rare compared with the much more common pharyngeal infection. Therefore, in patients who present with chronic aphthous-like ulcerations and erythema predominantly involving the pharyngeal mucosa rather than the oral mucosa, a gonorrhoeal infection should be part of the clinical differential diagnosis. The microscopic features are nonspecific, and the clinical features of the disease seldom indicate a biopsy. The diagnosis is based on demonstration of the organism in culture media or through the use of immunofluorescent antibody techniques.^{8,9}

The treatment of choice for gonorrhoea continues to be penicillin. Occasional penicillin-resistant strains are noted during sensitivity cultures and require management with alternative antibiotics.

Pigmented Lesions of Oral Mucosa and Skin

Pigmented lesions of oral mucosa and skin can be divided into generalized lesions, which are diffuse and multifocal, and localized lesions involving one or several locations.

Generalized Pigmentations

Some of the common causes of generalized pigmentations are listed in Table 36-1.

The most common type of generalized pigmentation is hereditary or racial. The pigmentation is diffuse, symmetric, and most commonly located on the gingiva and labial mucosa. Pregnancy and ingestion of oral contraceptives may produce melanin pigmentation called chloasma or melasma. Pigmented macules occur on the labial mucosa, forehead, malar prominences, and around the eyes and lips.¹⁰⁻¹³

Smokers sometimes have melanin pigmentation of the attached gingiva. Numerous medications may cause pigmentation of skin and/or oral mucosa. Antimalarials such as quinine, chloroquine, and amodiaquine may cause pigmentation in approximately 25% of patients taking them for > 3 to 4 months. Cancer chemotherapeutic drugs such as busulfan, cyclophosphamide, and bleomycin have been reported to cause pigmentation, primarily of skin. Hydantoin may produce facial pigmentation resembling chloasma. Minocycline may cause pigmentation of skin, bones, teeth, oral mucosa, and the thyroid. Pigmentation secondary to heavy metals is due to deposition of metals in the skin and oral mucosa. This type of pigmentation is not commonly seen today because of their decreased value as therapeutic agents.

Peutz-Jeghers syndrome is characterized by multiple pigmented macules of the hands and feet; areas surrounding the mouth, eyes, and nose; and intraorally on the buccal mucosa, labial mucosa, gingiva, and palate. Multiple hamartomatous polyps are present in the gastrointestinal tract. Patients with this syndrome have an increased incidence of cancer both within and outside the gastrointestinal tract.

Patients with Addison's disease have increased pigmentation of the skin, lips, gingiva, buccal mucosa, and tongue. Systemic manifestations are prominent and include malaise, weakness, nausea, vomiting, diarrhea, weight loss, and hypotension.

Table 36-1 Generalized Pigmentations of Skin and Oral Mucosa

Hereditary (racial)
Pregnancy (chloasma, melasma)
Smoking (smoker's melanosis)
Medications
Antimalarials
Oral contraceptives
Busulfan
Cyclophosphamide
Bleomycin
Phenytoin
Phenothiazines
Minocycline
Heavy metals
Bismuth
Lead
Silver
Gold
Arsenic
Mercury
Syndromes and systemic diseases
Peutz-Jeghers syndrome
Addison's disease
Neurofibromatosis
Albright's syndrome

Neurofibromatosis is a relatively common autosomal dominant inherited syndrome. Virtually all patients have six or more brown cutaneous macules > 1.5 cm in diameter known as café au lait spots. Numerous freckles 2 or 3 mm in diameter are often present in the axilla and other intertriginous regions. Other features of neurofibromatosis include multiple neurofibromas, central nervous system tumors, seizures, intellectual handicap, and speech impediments.

Albright's syndrome consists of polyostotic fibrous dysplasia plus multiple café au lait spots. Endocrine abnormalities, most commonly precocious puberty in young females, are also present.

Localized Pigmented Lesions

Localized pigmented lesions can be divided into four classes based on their cause and clinical features: (1) melanocytic,

(2) vascular, (3) extravasated blood, and (4) tattoos.

Melanocytic Lesions Melanocytic lesions are due to increased amounts of melanin pigment in the tissue and/or a proliferation of melanocytes or nevus cells. Melanocytic lesions are gray, brown, black, or blue and do not blanch on pressure.

Ephelides The ephelis or freckle is a small circumscribed brown or black macule that occurs on sun-exposed areas of skin. It appears in childhood and darkens in the summer and fades during the winter. Microscopically, the ephelis shows increased melanin in the basal cell layer of the epidermis but no increase in the number of melanocytes. Ephelides are not premalignant and require no treatment once the diagnosis is established.

Oral Melanotic Macules The oral melanotic macule is an oral mucosal pigmentation with similar microscopic features to ephelis. The lesions are well-circumscribed flat macules that are gray, brown, blue, or black. Most are 1 to 3 mm in diameter. The most common locations are the vermilion border of the lip, gingiva, and buccal mucosa. They are often confused clinically with tattoos and nevi.^{14,15}

Microscopically, oral melanotic macules show increased melanin in the basal cell layer, lamina propria, or both. The cause of oral melanotic macules is unknown, although they may be an atypical manifestation of physiologic pigmentation because the microscopic appearance is identical to racial pigmentation. These macules do not recur or undergo transformation into melanoma, but they may be difficult to distinguish it from nevi or melanoma in situ. They should be excised for microscopic diagnosis or checked frequently.

Lentigo Simplex Lentigo simplex is a macular brown-to-black lesion that is not associated with sun exposure and may occur on

any skin surface. It is not premalignant and requires excision only for microscopic diagnosis. Microscopically, lentigo simplex demonstrates an increased number of melanocytes in the basal cell layer, an increased amount of melanin in the melanocytes and the basal keratinocytes, and elongation of the rete ridges. Macrophages containing melanin (melanophages) are present in the upper dermis.¹⁶

Nevi A nevus is a proliferation of nevus cells or melanocytes. Nevi are extremely common lesions on skin but are relatively uncommon on oral mucosa. Most nevi of skin are absent at birth and appear in childhood. They progress through a series of stages, and then decline in number with increasing age. Nevi begin as junctional nevi, with nests of nevus cells at the dermal-epidermal junction. Compound nevi demonstrate nevus cell nests in the epidermis and upper dermis. Intradermal nevi have nevus cell nests only in the dermis.

Clinically, junctional nevi are flat pigmented macules. The compound nevus is slightly elevated and sometimes has a papillomatous surface. Intradermal nevi are dome shaped and pedunculated. Compound and intradermal nevi may not be pigmented. Normal nevi are round to oval, have a smooth border, and are sharply demarcated from the surrounding skin. They are most commonly found on sun-exposed skin above the waist.^{17,18}

Dysplastic nevi are precursors to melanoma. They may occur sporadically or in an autosomal dominant inherited syndrome in which they are quite numerous. Dysplastic nevi have irregular borders that are indistinct and fade into the surrounding skin. They may demonstrate a mixture of colors, including tan, dark brown, and pink. Dysplastic nevi are typically larger than normal nevi.

It is not necessary to remove normal cutaneous nevi unless they are irritated by clothing. Since dysplastic nevi have an increased potential for developing into

melanoma, they should be removed. In patients with numerous dysplastic nevi, the lesions should be closely monitored and excised if they change.

Nevi of the oral mucosa are usually between 1 and 6 mm in diameter and are most commonly located on the hard palate and buccal mucosa. They are occasionally nonpigmented. The majority of oral nevi are raised and thickened, but a significant number may be flat.

Microscopically, the majority of oral nevi have been reported as intramucosal, but blue, compound, and junctional nevi also occur.¹⁷

Because of the small number of reported cases of oral nevi, their potential for evolving into melanoma is not known. Because of this, lesions in which nevus is part of the clinical differential diagnosis should be completely excised.

Melanomas Melanoma is a malignant neoplasm of nevus cells or melanocytes. Microscopically, melanomas begin at the dermal-epidermal junction and then may demonstrate two different patterns of growth. In radial growth, or melanoma in situ, melanoma cells grow laterally along the dermal-epidermal junction but do not invade the underlying dermis. A melanoma may remain in the radial growth phase for years, and during this time it does not metastasize. During vertical growth the melanoma cells grow into the dermis and are capable of invading vascular channels and nerves and metastasizing.¹⁹⁻²²

Microscopically, melanoma cells are described as epithelioid or spindle shaped. Epithelioid cells are round to cuboidal and form nests. The spindle cells are elongated and do not form nests. The tumor cells demonstrate nuclear pleomorphism, anaplasia, and mitotic figures. The amount of melanin within tumor cells is variable. The Fontana-Masson stain demonstrates melanin in some of the amelanotic-appearing tumor cells. The dopa reaction is more reliable for

demonstrating melanin, but it requires fresh tissue.

There are four types of cutaneous melanoma: lentigo maligna melanoma, superficial spreading melanoma, acral-lentiginous melanoma, and nodular melanoma.

Lentigo maligna (melanotic freckle of Hutchinson) represents lentigo maligna melanoma in situ. It presents as a brown macule with black flecks and irregular margins located on sun-exposed surfaces of elderly persons. It may remain in the radial growth phase for 10 to 15 years before progressing to invasive lentigo maligna melanoma, indicated by the development of nodularity.

Superficial spreading melanoma constitutes about 70% of cutaneous melanomas. It occurs on both exposed and unexposed surfaces, most commonly on the upper back in men and lower legs in women. This melanoma has irregular borders and great variation in color within one lesion, including tan, brown, black, pink, blue, and white areas (Figure 36-5). It often demonstrates nodularity and ulceration. Superficial spreading melanoma remains in the radial growth phase for a shorter time than does lentigo maligna melanoma and thus has a poorer prognosis.

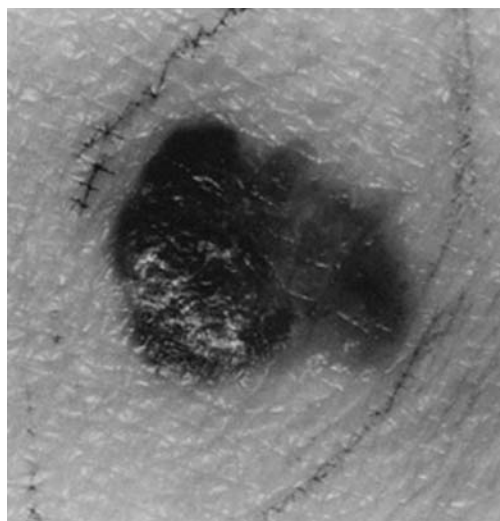


FIGURE 36-5 Melanoma. Alteration in color of a nevocellular nevus with apparent expansion into the surrounding normal skin.

Acral-lentiginous melanoma is the most common melanoma in black persons. It occurs primarily on the palms, soles, and in association with nails. It can metastasize early.

Nodular melanoma presents as a rapidly growing darkly pigmented nodule that is often ulcerated. It is not associated with sun exposure. Since it grows vertically from the beginning, it is often deeply invasive by the time it is diagnosed.

Treatment of cutaneous melanoma usually consists of wide surgical excision. Chemotherapy is sometimes used, but radiation therapy has not proven effective. Incisional biopsy is not thought to cause metastasis of melanomas.

The most important prognostic factor for cutaneous melanoma is the thickness of the lesion. One study reported a 10-year survival rate of 99.5% for patients with melanomas < 0.76 mm thick, as opposed to 48% survival for those with melanomas 3 mm and greater in thickness.²³

Melanoma of oral mucosa is a rare neoplasm most commonly located on the hard palate and maxillary gingiva of patients > 50 years of age. About one-third of patients have preexisting melanosis, or macular hyperpigmentation, which probably represents radial growth of the lesion. This may be present for years before vertical growth occurs. At the time of diagnosis, many oral melanomas are large, ulcerated, and have caused bony erosion. A significant number of tumors are amelanotic.

Treatment of oral melanoma is wide local excision with or without lymph node dissection. The prognosis is quite poor. The 5-year survival in one series was only 13%.²³ This may be due to the advanced stage of oral melanomas at the time of diagnosis.

Vascular Lesions Vascular lesions are due to increased numbers of blood vessels, or blood vessels of increased diameter. These lesions are compressible, blanch on pressure, and are red, blue, or purple.

Hemangioma Hemangioma is a proliferation of blood vessels that is usually congenital and may regress spontaneously. It is commonly found on the skin and in the oral cavity.

Hemangioma of skin may present as a soft tissue enlargement or a flat surface lesion. Nevus flammeus, or port-wine stain, is a red-to-blue macule present at birth. Sturge-Weber syndrome (encephalotrigeminal angiomas) includes congenital port-wine stain in the distribution of the trigeminal nerve, hemangiomas of the leptomeninges, and ipsilateral hemangiomas of the face, skull, jaws, and oral cavity. The hemangiomas often contain calcifications and may result in seizure disorders and other neurologic problems.

Hemangiomas of the oral cavity are compressible red or blue soft tissue enlargements that blanch on pressure. They present most commonly in the lips, tongue, and buccal mucosa.

Microscopically, hemangiomas are classified as cavernous or capillary. Cavernous hemangiomas consist of large vessels lined with a single layer of endothelial cells, whereas capillary hemangiomas contain numerous smaller vessels. During their period of growth, capillary hemangiomas demonstrate marked endothelial proliferation and only a few capillary lumina.

Hemangiomas are unencapsulated lesions and can be difficult to remove surgically. Other treatment modalities include sclerosing agents, cryotherapy, and laser surgery. Treatment is not recommended unless lesions are a functional or cosmetic problem.

Varix A varix is a dilated vein. It occurs most commonly on the lip, buccal mucosa, and ventral surface of the tongue. It increases in frequency with increasing age.

The typical varix is blue, compressible, and blanches on pressure. A thrombosed varix is firm to palpation, does not blanch, and resembles a nevus.

No treatment is necessary for a varix unless nevus or melanoma is included in the clinical differential diagnosis.

Kaposi's Sarcoma Kaposi's sarcoma is a malignancy of endothelial cell origin that occurs in three settings. It was first described as a disease involving the skin of the distal portion of the lower extremities in elderly males of Mediterranean or Jewish origin. It is also endemic in black African children and adults. The African form involves viscera and lymph nodes as well as skin. Recently it has become a common lesion in patients with immunosuppression secondary to organ transplantation or human immunodeficiency virus (HIV) infection.

Kaposi's sarcoma frequently involves the oral cavity, especially in patients with HIV infection. Oral lesions are most common on the hard palate and gingiva. The lesions may be single or multiple, flat or exophytic, and red, blue, or brown. The exophytic lesions blanch on pressure.

The microscopic appearance of early lesions of Kaposi's sarcoma resembles granulation tissue. Increased numbers of dilated capillaries and a chronic inflammatory infiltrate are present. Advanced lesions have vascular and spindle cell components. The vascular channels are lined with prominent endothelial cells. Strands of pleomorphic spindle cells line narrow slits containing erythrocytes. Extravasated erythrocytes and hemosiderin in the stroma help distinguish Kaposi's sarcoma from fibrosarcoma.

Treatment of Kaposi's sarcoma includes radiation therapy, surgery, and/or chemotherapy. African patients and patients with Kaposi's sarcoma secondary to immunosuppression have a poor prognosis. The disease causes death in 10 to 20% of elderly males with the disease.

Lesions Owing to Extravasated Blood Because these lesions are due to the presence of blood outside of blood vessels, they do not blanch on pressure.

Hematoma A hematoma is a blood blister or a circumscribed pool of blood outside of a vessel. It is typically caused by trauma and is most commonly found on the buccal mucosa along the occlusal plane. It appears blue to purple and is compressible to palpation. A hematoma requires no treatment and resolves spontaneously in several weeks.

Ecchymosis and Petechiae An ecchymosis, or bruise, is caused by diffuse bleeding into the tissue secondary to trauma. It is not palpable. It is initially blue but evolves through many color changes before resolving.

Petechiae are multiple discrete round hemorrhagic spots < 2 mm in diameter. They are more reddish than are ecchymoses or hematomas. Petechiae are a result of capillary bleeding. They may be associated with a viral disease or a blood dyscrasia.

Tattoos Tattoos are the most common oral pigmentation. They are the result of intentional or accidental implantation of foreign material, such as amalgam, graphite, ink, or metal, into the skin or oral mucosa. A tattoo on the hard palate is often a result of a child falling on a pencil held in his or her mouth and pushing graphite into the tissue. Amalgam tattoo is usually seen on the gingiva, alveolar mucosa, buccal mucosa, and floor of the mouth.

The most common presentation of a tattoo is an asymptomatic flat nonthickened blue-to-black pigmentation. Occasionally, however, a tattoo may be thickened owing to fibrosis or may enlarge because of phagocytosis of the foreign material by macrophages or incorporation of the material into collagen fibers. Rarely, the foreign material may incite a foreign body granuloma with multinucleated giant cells and macrophages. Radiographs may be helpful in detecting foreign material in the tissue, but not all foreign material can be visualized radiographically.

Excision of a tattoo is necessary only when a nevus or melanoma is included in the clinical diagnosis.

Vesicular, Ulcerated, and Erythematous Lesions

Numerous diseases cause vesicles and/or ulcers of the oral cavity. Some diseases such as herpes simplex and aphthous ulcers are important because they are frequently encountered in practice. Other diseases such as epidermolysis bullosa and pemphigus are serious life-threatening diseases.

Because vesicles are so transient in the oral cavity, it is usually impossible to determine if an ulcer was preceded by a vesicle. If a vesicle was present, then aphthous ulcers, ulcers of infectious mononucleosis, traumatic ulcers, and ulcers owing to bacteria can be excluded from the clinical diagnosis.

A thorough history should be obtained from patients with vesicular/ulcerative diseases and should include the following questions:

1. How long have the lesions been present?
2. Are the lesions recurrent?
3. If yes, how often do they recur?
4. Do they recur in the same locations?
5. Have you noticed vesicles?
6. Have you noticed lesions on the skin, eyes, or genitals?
7. Have you been aware of fever, malaise, and lymphadenopathy in association with the lesions?
8. What medications do you take?

Since there are a large number of diseases that can cause vesicles or ulcers, one of the convenient ways to classify the diseases is by their cause. The discussion of vesicular, ulcerated, and erythematous lesions below is arranged by the cause of lesions, for example, hereditary, viral, or autoimmune.

Hereditary Diseases

Epidermolysis Bullosa The most important hereditary vesicular/ulcerative disease

is epidermolysis bullosa (EB). There are at least 18 types of EB including some that are not inherited.

The current classification of EB is based on where the split that forms the blisters occurs, inheritance, and clinical findings. Intraepidermal forms are non-scarring and have autosomal dominant or X-linked inheritance. The split occurs within the epithelium and is associated with defective tonofilaments of the basal squamous epithelial cells. Junctional forms of EB have autosomal recessive inheritance and demonstrate skin atrophy. The split occurs within the basement membrane and is due to decreased numbers of hemidesmosomes and tonofilaments. Dermal forms have autosomal dominant or recessive inheritance with atrophy and scarring of skin and mucosa. The split occurs in the upper dermis or lamina propria owing to defects in anchoring fibrils associated with the basal lamina. Typing of patients requires the use of electron microscopy, immunofluorescence, and immunohistochemistry.²⁴⁻²⁶

EB simplex Koebner type is an intraepidermal form. Blisters mainly involve the feet, hands, and neck. They begin in infants and are exacerbated by heat. Abnormal nails are sometimes present. Oral blisters are occasionally seen, but the teeth are normal. The disease improves at puberty and is compatible with a normal life span.

EB atrophicans generalisata gravis Herlitz type is a junctional form with autosomal recessive inheritance. Blisters begin within a few days after birth and involve the hands and feet, followed by the trunk, face, and scalp. The nails are lost or dystrophic. Death within the first few months of life is common. Oral blisters and ulcers are found in almost all patients. Enamel is hypoplastic, pitted, and extensively involved with caries.

EB dystrophica Cockayne-Touraine type is a dermal form with autosomal dominant inheritance characterized by

blisters of the ankles, knees, hands, elbows, and feet that produce scars. Milia (epidermal cysts) are common. Nails are thick and dystrophic. Onset is birth to 5 years of age, and the condition improves with age. Some patients have oral bullae.

Another dermal type is EB dystrophica Hallopeau-Siemens. It has autosomal recessive inheritance. Blisters are present shortly after birth and may involve any skin surface. Scars form and cause contraction. Formation of a clawhand and/or mitten-like hand are common. Nails are dystrophic or absent. The larynx, pharynx, and esophagus may be involved. Oral bullae and scarring may result in diminished oral opening, ankyloglossia, tongue atrophy, loss of buccal and vestibular sulci, and perioral stricture. Teeth have hypoplastic enamel, delayed eruption, and retention.

EB bullosa acquisita is a noninherited type that begins in adulthood. Blisters form in areas of trauma. Oral lesions have been reported but are rare.²⁷

EB is a disease that cannot be cured. The treatment is supportive and symptomatic and includes corticosteroids and antibiotics to fight secondary infections.⁵

Viral Infections

The majority of viral infections are subclinical and asymptomatic. We know of their existence because of the development of antibodies in the patients. Symptomatic viral vesicular and ulcerative diseases often have systemic manifestations of malaise, fever, tender lymphadenopathy, and lymphocytosis. They generally have an acute onset and a vesicular stage, with the exception of infectious mononucleosis. Multiple lesions are present.

The herpesvirus family consists of herpes simplex virus (HSV) types 1 and 2, varicella-zoster virus, Epstein-Barr virus (EBV), and cytomegalovirus. Herpesviruses can assume a latent state in the patient. Cytomegalovirus is important in neonates and immunocompromised patients; it is not discussed further in this chapter.

HSV The primary infection with HSV may occur in seronegative patients of any age and results in acute herpetic gingivostomatitis. The patient experiences the abrupt onset of malaise, fever, and tender cervical lymphadenopathy. Multiple vesicles and ulcers can involve any oral mucosal surface and are accompanied by gingival swelling and erythema. The fluid-filled vesicles contain numerous virions and are infectious. The mouth can become extremely painful, resulting in difficulty eating and drinking (Figure 36-6).

After primary infection of the oral mucosa, HSVs travel centripetally along peripheral nerves to nerve cell bodies of the trigeminal ganglion. The viruses remain latent in the ganglion. Reactivation of the latent virus causes transport of viral

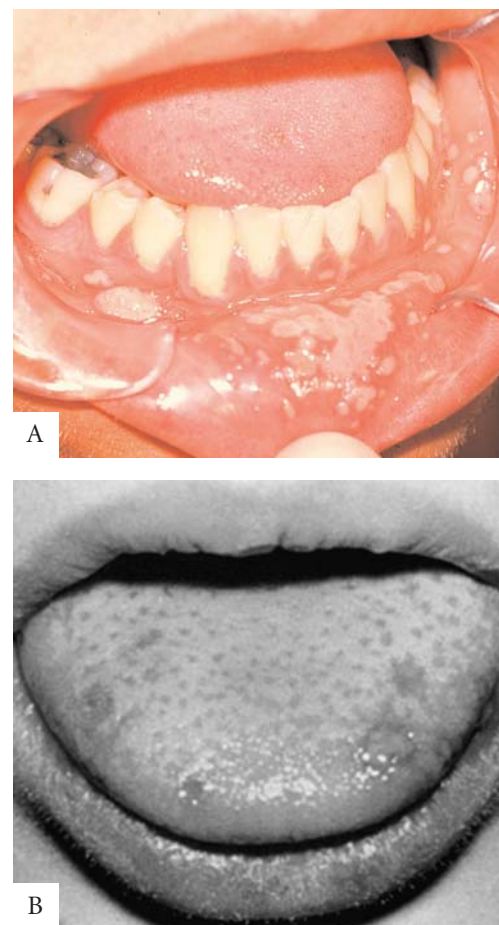


FIGURE 36-6 A and B, Primary herpetic gingivostomatitis. Acute-onset vesicles rupture almost immediately leaving 1 to 2 mm ulcers of keratinized and nonkeratinized oral mucosa.

genomes to the epithelial surface, where replication occurs. Recurrent lesions may result. The most important factors associated with recurrent lesions are ultraviolet radiation, immunosuppression, and local trauma. With regard to immunosuppression, patients with defects in cell-mediated immunity have herpes infections that are more frequent and severe.²⁸⁻³¹

The vesicles and ulcers of recurrent (secondary) herpes occur in small clusters on the lip, gingiva, and hard palate, and they tend to recur in the same location. The lesions are often preceded by a prodrome of tingling, pain, or numbness in the area. Systemic manifestations are not present.

Recurrent herpetic lesions are often confused with aphthous ulcers. They occur on the lip and keratinized oral mucosa, whereas aphthae occur on nonkeratinized mucosa. Recurrent herpetic lesions consist of multiple small ulcers in a group; aphthae consist of one to several larger widely distributed ulcers.

Herpes simplex infection of the finger is called herpetic whitlow (Figure 36-7). The primary infection presents abruptly with edema, erythema, vesicles, and pain in the infected finger, often accompanied by fever and axillary and epitrochlear lymphadenopathy. The lesions may recur.

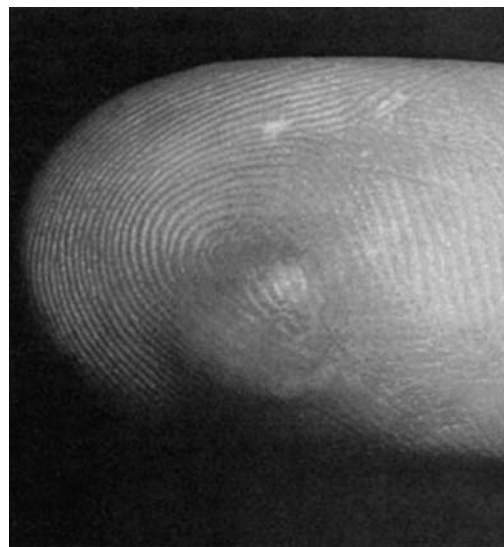

FIGURE 36-7 Herpetic whitlow. Epidermal vesicles of the index finger.

Either HSV-1 or -2 can infect the oral mucosa and skin. HSV-1 has a predilection for oral mucosa and skin outside of the genital area, whereas HSV-2 prefers the genital region. Genital HSV-1 infections and oral HSV-2 infections have a greatly decreased incidence of recurrence.

The diagnosis of mucocutaneous herpes is usually apparent on the basis of clinical features, so biopsy is rarely done. Microscopic examination of a fluid-filled herpetic lesion demonstrates an intraepithelial vesicle with marked acantholysis. The epithelial cells have swollen homogeneous eosinophilic cytoplasm, known as ballooning degeneration, and one or multiple nuclei. Inclusion bodies may be seen in the nuclei of balloon cells as eosinophilic structures surrounded by a clear halo. Cytologic preparation of a fluid-filled vesicle can also demonstrate multinucleated epithelial cells, and the diagnosis can be augmented by using immunoperoxidase techniques to show antibodies to HSV (Figure 36-8). The diagnosis can also be confirmed by isolating the virus in tissue culture.

Lesions of primary and recurrent herpes resolve spontaneously in 10 to 14 days, and treatment is often unnecessary. When treatment is required, acyclovir is the current drug of choice. Acyclovir inhibits viral replication but has no effect on normal host cell function. However, it does not prevent or eliminate the latent viral state.

Acyclovir is very useful in the treatment of herpes simplex infections in immunocompromised patients. It has been reported to decrease the duration of viral shedding from lesions, the duration of pain, the time to scabbing, and the time to healing of lesions. It can reduce the number of recurrences, but infection can recur after the medication is discontinued.

Acyclovir can decrease viral shedding, time to healing, new lesion formation, and duration of symptoms in primary genital HSV infections. Primary oral herpes would be expected to respond in a similar

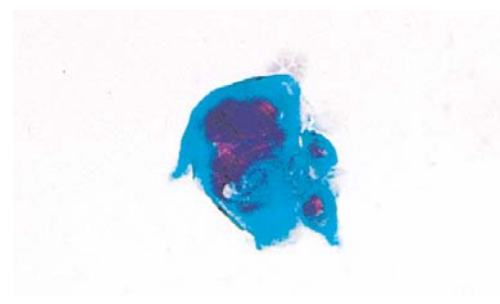


FIGURE 36-8 Herpes cytology. Cytologic preparation showing epithelial cells with enlarged nuclei resulting from viral replication ($\times 160$ original magnification; stained with Papanicolaou's stain).

manner, but the medication must be administered during the first 3 days.

The use of topical acyclovir in healthy patients with recurrent herpes labialis has given conflicting results. To have any effect, the medication must be used during the prodrome, or within the first few hours after onset of lesions. Topical sun-blocking agents are useful in reducing the frequency of recurrences of herpes labialis.

In summary, acyclovir is most helpful in the treatment of herpes simplex infections in immunocompromised patients and in patients with frequent or severe recurrences. It appears to have little value in healthy patients with infrequent minor recurrences of herpes labialis.

Varicella-Zoster Virus The primary infection with varicella-zoster virus causes varicella, or chickenpox. Varicella typically has mild systemic manifestations accompanied by papules, vesicles, and ulcers on the skin and mucosa. Successive crops of lesions begin on the trunk and move to the face and extremities. Lesions in various stages are present at the same time and are quite pruritic. Vesicles and ulcers resembling primary herpes sometimes occur on oral mucosa.

Therapeutic management for varicella is symptomatic and is aimed at reducing the pruritus. Antihistamines and topical lotions are helpful in this respect. Varicella typically has a mild clinical course, and complications are rare, except in neonates,

the elderly, and immunocompromised patients. Complications include bacterial infections of skin, encephalitis, Reye's syndrome, and pneumonia.

Infection with the varicella-zoster virus results in a latent state, as in herpes simplex. The recurrent disease is called herpes zoster, or shingles. Reactivation of varicella-zoster virus is not as common as with HSV, except in elderly or immunocompromised patients.

Zoster has a prodrome of pain, burning, or paresthesia, followed by grouped vesicles on an erythematous base. The lesions are unilateral and follow the distribution of a peripheral sensory nerve. They are most common on the trunk and in the distribution of the trigeminal nerve (Figure 36-9). Oral lesions can have a painful prodrome that mimics a toothache in some cases. The lesions in zoster resolve in several weeks, but severe pain in the nerve distribution (postherpetic neuralgia) can persist for weeks to months after the lesions have resolved. The prevalence and duration of pain increases with age. Involvement of the facial nerve can cause Bell's palsy.

The microscopic features of tissues infected with varicella-zoster are identical to those infected with herpes simplex.

Valacyclovir has been shown to be of some value in the treatment of zoster when the drug is started within the first few days of onset of infection.

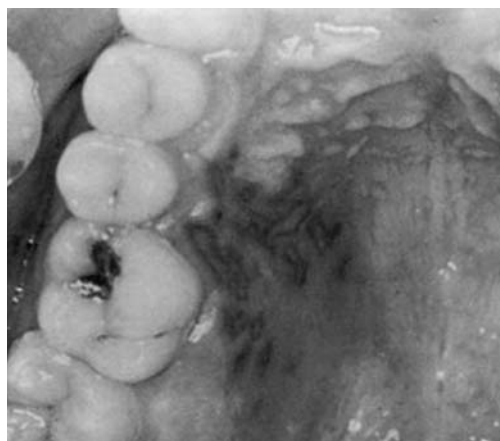

FIGURE 36-9 *Herpes zoster. Acute-onset ulceration localized to left maxillary soft tissues.*

EBV The EBV causes infectious mononucleosis and is also associated with hairy leukoplakia, Burkitt's lymphoma, nasopharyngeal carcinoma, and lymphoblastic leukemia. EBV infects B lymphocytes and salivary glands and persists within these tissues for the lifetime of the host. The ability of EBV to reactivate depends on the competency of the cellular immune system.

Infants and children infected with EBV usually have an asymptomatic course, but about one-half of infected adolescents and adults develop acute infectious mononucleosis. The clinical features include malaise, fever, pharyngitis, and lymphadenopathy of cervical, axillary, and inguinal chains. Splenomegaly, hepatomegaly, and hepatitis with abnormal liver function tests may be present. Occasionally an erythematous skin rash is seen.

Ulcers may involve the oral mucosa, but a vesicular stage does not occur. The ulcers are secondary to decreased host resistance and appear after the systemic manifestations. Petechiae occur on the palate in about one-third of patients. The oropharynx is inflamed and may be ulcerated.

Laboratory features of acute infection include an increase in relative and absolute numbers of lymphocytes and monocytes exceeding 50%, with > 10% atypical lymphocytes in the peripheral blood. The atypical lymphocytes are called Downey cells, and they have indented or horseshoe-shaped nuclei and abundant basophilic foamy cytoplasm. The total leukocyte count is between 10,000 and 20,000 by the second or third week of the illness. Serologic findings include high titers of heterophil antibodies, which clump red blood cells of sheep. The antibodies may not appear until several weeks after the onset of signs and symptoms, and they decline during the ensuing 3 to 6 months.

Involved lymph nodes microscopically show reactive lymphadenitis. Lymphoid nodules in the inner cortex are hyperplastic. The germinal centers are markedly enlarged and contain macrophages with

nuclear debris and numerous mitoses. Sometimes very large cells with multilobed nuclei and prominent nucleoli resemble Reed-Sternberg cells of Hodgkin's disease.³²

There have been reports of a chronic fatigue syndrome associated with EBV. Patients describe this as a flulike illness with muscle aches, pharyngitis, tender lymphadenopathy, low-grade fever, and persistent severe fatigue. Elevated titers of immunoglobulin G (IgG) antibodies to viral capsid or early antigens of EBV are present.

Treatment of infectious mononucleosis is supportive. The acute disease usually resolves within 2 to 4 weeks. Splenic rupture is one of the few fatal complications of the disease, but it is extremely rare.

Group A Coxsackievirus The two most important group A coxsackievirus infections involving the oral cavity are herpangina and hand, foot, and mouth disease. Herpangina begins with fever, pharyngitis, and anorexia. Vesicles and ulcers occur primarily on the soft palate, uvula, and anterior tonsillar pillar. The disease resolves in several days and requires only symptomatic treatment.

Hand, foot, and mouth disease has a prodrome of fever, malaise, and headache, followed by macules and vesicles on the palms and soles. Vesicles and ulcers can be located anywhere in the oral cavity. Treatment is symptomatic, and the disease resolves within several weeks.

Measles Although a vaccine for measles exists, outbreaks of the disease still occur, primarily on college campuses. Measles begins with high fever, conjunctivitis, photophobia, cough, and nasal discharge. Leukopenia is common during this prodromal phase. Red vesicles with white centers (Koplik's spots) appear on the buccal mucosa, followed in several days by an erythematous maculopapular skin rash. The rash first appears on the face and then spreads to the trunk and extremities.³¹

Microscopic examination of the oral mucosal vesicles reveals epithelial necrosis, intercellular edema, cytoplasmic and nuclear inclusions, and multinucleated epithelial giant cells. Lymph nodes and tonsils show lymphoid hyperplasia and giant cells (Warthin-Finkeldey cells).

Therapeutic management for measles is symptomatic. It is usually a self-limited disease but may have a number of serious complications, including croup, bacterial pneumonia, otitis media, and encephalitis.

Rubella Rubella (German measles) is a mild infectious disease, but it can cause serious fetal malformations when it occurs in pregnant women. The prodrome consists of malaise, fever, mild conjunctivitis, and lymphadenopathy. Oral vesicles and ulcers may be present, but they are not distinctive. A maculopapular skin rash begins on the face and spreads downward to the trunk and extremities. It usually lasts for about 3 days. Arthralgia may involve wrists, fingers, and knees. Rubella may be completely asymptomatic or consist of lymphadenopathy without the rash.^{33,34}

Congenital rubella syndrome usually results from maternal infection during the first trimester of pregnancy. The classic parts of the syndrome include cardiac malformations of patent ductus arteriosus, interventricular septal defect, or pulmonary stenosis; eye lesions of cataracts, chorioretinitis, and microphthalmia; mental retardation; and deafness.

Rubella is usually a benign disease requiring only symptomatic treatment. A live attenuated vaccine is effective, but it should not be given to pregnant women or to those who may become pregnant within 2 months of vaccination.

HIV HIV infects and destroys helper T lymphocytes, resulting in profound immunosuppression that predisposes to opportunistic infections and malignant tumors.

HIV is transmitted by sexual intercourse, through contact with blood or blood products, and perinatally. It is found in saliva, but transmission by saliva is unlikely.

The clinical spectrum of HIV infection includes an acute viral syndrome with malaise, fever, and lymphadenopathy; an asymptomatic carrier state in which there are circulating antibodies to HIV, and a wasting syndrome. Neurologic disorders are common and range from subtle memory loss to dementia. Numerous opportunistic infections, both fatal and nonfatal, and malignant neoplasms are a characteristic part of acquired immunodeficiency syndrome (AIDS). Many of these can be present in the oral cavity.³⁵

Oral Manifestations OPPORTUNISTIC INFECTIONS A common oral disease in HIV-infected patients is candidosis. Four clinical types of candidosis can be present in HIV patients. Pseudomembranous candidosis appears as white plaques that rub off, leaving an erythematous and/or bleeding base. Hyperplastic candidosis presents as white rough plaques that do not rub off. Erythematous candidosis is characterized by diffuse or localized patches of red mucosa. Angular cheilitis presents as cracks or fissures of the commissures, sometimes associated with white plaques. Candidosis in HIV infection responds to antimycotic medications, but it is chronic and recurrent.³⁶

Hairy leukoplakia consists of unilateral or bilateral white rough plaques that do not rub off, most commonly found on the lateral surface of the tongue. It is seen mainly in homosexual males but is also found in other HIV-risk groups. Deoxyribonucleic acid (DNA) hybridization demonstrates EBV in epithelial cells of the lesion. Hairy leukoplakia is pathognomonic of HIV infection and is highly predictive that the patient will develop AIDS.^{36, 37}

Microscopically, hairy leukoplakia is a lesion of squamous epithelium demon-

strating hyper-keratosis, acanthosis, and swollen ballooning epithelial cells.

Hairy leukoplakia is usually an asymptomatic infection requiring no treatment. For those patients requiring treatment, acyclovir 200 mg tablets 12 times per day for 3 weeks has been used with some temporary success. In addition, cytology smears for candidosis should be performed and antifungal medication prescribed for patients with candidal organisms.

Herpes simplex and herpes zoster are more frequent and severe in HIV patients as are nonspecific aphthous-like ulcers. Prolonged postzoster neuralgia can be extremely painful. High-dose acyclovir can be useful in the treatment of either disease.^{38, 39}

PERIODONTAL DISEASE A unique form of periodontal disease is present in many HIV patients. Clinical features include chronic gingival erythema, severe pain, soft tissue necrosis, and rapid destruction of alveolar bone and the periodontal attachment. Pocket formation is minimal or absent. The cause of HIV periodontitis may be an overgrowth of virulent organisms possessing tissue-damaging capabilities. This is probably a result of compromised immunity owing to HIV infection.

HIV periodontitis does not respond to conventional therapy alone. However, it does reportedly respond to twice-daily rinsing with chlorhexidine combined with conventional methods.⁴⁰

MALIGNANT NEOPLASMS The most common malignant neoplasms involving the oral cavity in HIV patients are Kaposi's sarcoma, non-Hodgkin's lymphoma, and squamous cell carcinoma. Most HIV patients with Kaposi's sarcoma have oral lesions, and these may be the first sign of the disease. The lesions are red, blue, or purple and may be flat or elevated. They are most common on the hard palate and gingiva. Treatment includes radiation therapy, laser surgery, and/or chemotherapy.⁴¹⁻⁴³

Non-Hodgkin's lymphoma of the oral cavity in HIV patients is characterized by

rapid growth, tendency to occur on the palate or alveolar ridge, and poor prognosis. Most of these lymphomas are of B-cell origin, and in situ hybridization techniques often reveal Epstein-Barr virus DNA in the tumor cells.

Other oral manifestations of HIV infection include salivary gland enlargement, xerostomia, and ulcerations similar to aphthous ulcers.³⁶

Autoimmune Diseases

Autoimmune diseases typically have a gradual onset and a chronic progressive course with exacerbations and remissions. Lymphadenopathy is rare.

It is important to perform an incisional biopsy to establish a definitive diagnosis. A gingival biopsy should be avoided, if possible, because nonspecific gingival inflammation makes microscopic diagnosis difficult. Topical or systemic corticosteroids usually control but do not cure autoimmune diseases.

Pemphigus Two types of pemphigus, vulgaris and vegetans, have oral manifestations. Pemphigus vulgaris is the most common and is characterized by flaccid bullae that quickly rupture forming painful ulcers. Large areas of skin and mucosa can be involved, causing serious problems with infection.

Oral mucosal lesions are almost always present, and they are the initial lesions in the majority of cases. Extensive areas of mucosa may be involved, making eating extremely painful and difficult. Rubbing or blowing air on clinically uninvolved mucosa creates a blister, a phenomenon called Nikolsky's sign. A Nikolsky's sign is most commonly associated with pemphigus vulgaris and benign mucous membrane pemphigoid, but it may also be present in bullous pemphigoid and lichen planus. In pemphigus vegetans the blisters have a rough warty surface.^{44, 45}

Pemphigus is caused by circulating autoantibodies directed against desmo-

somes of squamous epithelium. This results in loss of epithelial cell cohesion and formation of an intraepithelial blister in the lower spinous cell layer. The basal epithelial cells remain attached to the underlying connective tissue. Acantholytic epithelial cells floating in the vesicle are termed Tzanck cells. They have rounded cytoplasm and large hyperchromatic nuclei. Cytologic preparation made from an early blister and stained with Papanicolaou's stain can demonstrate Tzanck cells. A cytologic smear gives only a preliminary diagnosis and does not replace a biopsy.

Direct immunofluorescent studies, using the patient's own skin or mucosa, reveal in vivo bound IgG antibody in the intercellular spaces of the epithelium in almost all cases (Figure 36-10). IgA, IgM, and C3 are present less often. Indirect immunofluorescence tests for autoantibodies in the patient's serum. In pemphigus, circulating IgG antibodies can be demonstrated in the serum in most patients at some time during the course of the disease. Indirect immunofluorescence is not as sensitive as the direct technique. However, the titer of antibodies in the serum is often proportional to the severity of the disease.

Early diagnosis of pemphigus is important because it is a serious disease requiring aggressive treatment with corticosteroids. It is often fatal if not treated. Even with treatment, 10 to 15% of patients die owing to the effects of corticosteroids.

Cicatricial Pemphigoid In cicatricial pemphigoid (benign mucous membrane pemphigoid [BMMP]), autoantibodies are formed against components in the epithelial basement membrane. This results in painful vesicles and ulcers that may heal with scarring. BMMP has a marked predilection for females and adults past middle age.⁴⁶

BMMP initially involves oral mucosa in almost all cases. The lesions consist of erythema, vesicles, and ulcers, most commonly involving the gingiva. Because the

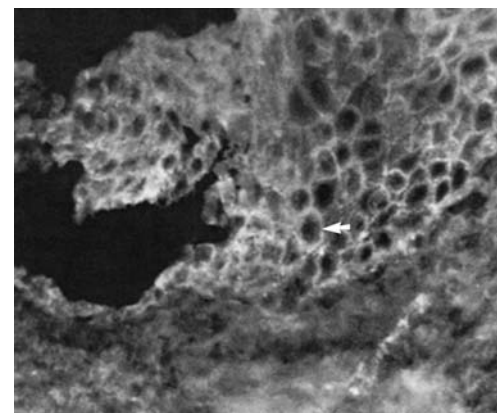


FIGURE 36-10 Pemphigus antibodies. Immunoglobulin G antibodies revealed via immunofluorescence in stratum spinosum ($\times 160$ original magnification).

epithelium becomes detached from the connective tissue, BMMP is sometimes called chronic desquamative gingivitis, a nonspecific clinical description that can be applied, less commonly, to pemphigus and lichen planus (Figure 36-11). BMMP can also involve conjunctiva; nasal, pharyngeal, esophageal, and vaginal mucosa; and skin. Scarring and adhesion between the bulbar and palpebral conjunctivae (symblepharon) causes visual impairment.

The microscopic features of BMMP include subepithelial vesicle formation and nonspecific inflammatory infiltrate in the connective tissue (Figure 36-12). Direct immunofluorescence reveals linear

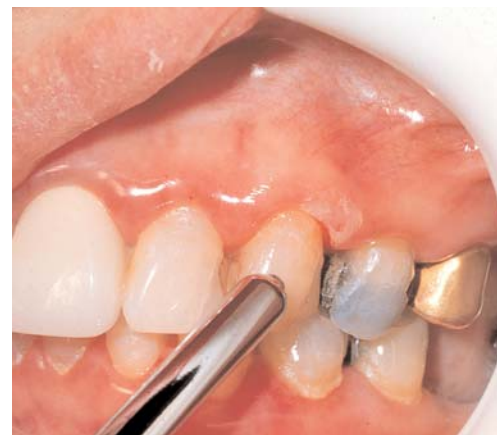

FIGURE 36-11 Cicatricial pemphigoid. A Nikolsky's sign caused by an air syringe directed at marginal gingiva.

continuous deposits of IgG and C3 along the basement membrane zone. Circulating IgG antibodies against the basement membrane zone are present in low titer and in only a minority of cases.

Topical and/or systemic corticosteroids usually control the disease. The most serious aspect of BMMP is conjunctival scarring, which can lead to blindness.⁴⁷⁻⁵²

Bullous Pemphigoid Bullous pemphigoid (BP) and BMMP have similar causes and microscopic features but a different distribution of lesions. The skin in all patients with BP demonstrates large thick-walled bullae, but oral mucosal lesions are less common.

Direct immunofluorescent findings are identical in BMMP and BP. Indirect immunofluorescence reveals circulating IgG antibodies against the basement membrane in the vast majority of BP patients but only rarely in patients with BMMP. There appears to be no correlation between antibody titer and disease severity in BP.^{47,52}

Lupus Erythematosus Lupus erythematosus is an autoimmune disease in which autoantibodies form to a wide variety of tissues including skin and oral mucosa. The autoantibodies can be directed against the cell's nuclear material (antinuclear antibodies [ANA]) or cytoplasmic antigens.^{53,54}

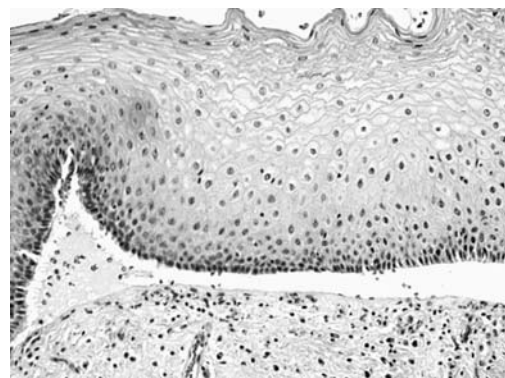


FIGURE 36-12 *Cicatricial pemphigoid. Uniform separation of epithelium from underlying connective tissue at the level of the basement membrane (×60 original magnification; stained with hematoxylin and eosin).*

Discoid lupus erythematosus (DLE) is a skin disease that most commonly involves the face, scalp, and ears. The skin lesions appear as erythematous patches, often scaly and hyperpigmented. Older lesions may have atrophic scarring centrally and hyperkeratosis at the periphery.

Oral lesions of DLE are uncommon in the absence of skin lesions. They characteristically show central erythema with white spots and a border zone of white striae surrounded by telangiectases. Less typical oral lesions can resemble lichen planus or hyperkeratosis.

Systemic lupus erythematosus (SLE) is a chronic multisystem disease most common in young women between the ages of 15 and 40 years. Arthritis is typically present, often at the onset. Central nervous system manifestations include seizures and psychoses. The leading cause of death is renal disease, leading to destruction of glomeruli and hypertension. Other manifestations include vasculitis, Raynaud's phenomenon, pleurisy, and pericarditis.

Numerous laboratory abnormalities may be present in SLE. The most important include elevated titers of antibody to native DNA, positive LE cell preparation, persistent false-positive serologic test for syphilis, anemia, leukopenia, thrombocytopenia, proteinuria > 0.5 g/d, and cellular casts in the urine.

The classic skin lesion of SLE is an erythematous rash located on sun-exposed surfaces such as the malar eminences. The oral lesions are similar to those of DLE. Oral ulceration is a well-known manifestation of SLE. Oral candidiasis secondary to corticosteroid therapy is common in SLE.

Certain medications have been reported to cause lupus-like reactions. The most common of these include procainamide, hydralazine, phenytoin, penicillamine, methyl dopa, trimethadione, primidone, thiouracil, and carbamazepine. Systemic involvement is less common with the drug-induced syndrome, and the signs

and symptoms usually resolve when the drug is withdrawn.

The microscopic appearance of lupus is variable. The epithelium is hyperkeratotic and shows alternating areas of atrophy and hyperplasia. The lamina propria is edematous and has dense perivascular and deep inflammatory infiltrates. Periodic acid-Schiff stain demonstrates deposits subjacent to the epithelium and thickening of blood vessel walls.

Direct immunofluorescence on oral lesions reveals deposits of Ig and C3 in the basement membrane zone of the epithelium in the majority of cases of DLE and SLE.

Therapeutic management of oral lesions of lupus includes topical and/or systemic corticosteroids and antimycotic medications as necessary for candidiasis. DLE has a good prognosis. The prognosis for SLE depends upon the extent of systemic involvement of the disease.

Idiopathic Vesiculoulcerative Diseases

Idiopathic diseases have causes that are unknown or poorly understood. They do not have clinical characteristics common to the entire class, and they must be considered individually when formulating a clinical differential diagnosis.

Aphthous Ulcers Aphthous ulcers are common painful lesions that have periodic recurrences. Most patients have only a single ulcer during a given episode, although occasionally two or three ulcers may be present (Figure 36-13). Vesicles do not occur. Unlike recurrent herpes, aphthous ulcers are found on nonkeratinized oral mucosal surfaces. They have an acute onset, and each ulcer heals spontaneously without scarring in 10 to 14 days. There are no systemic manifestations and usually no lymphadenopathy.⁵⁵⁻⁶¹

Major aphthae, also known as peradenitis mucosa necrotica recurrens, or Sutton's disease, is characterized by multiple large mucosal ulcers. A patient has at

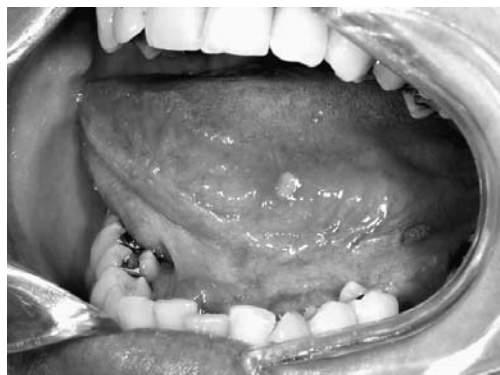

FIGURE 36-13 *Aphthous stomatitis*. Well-circumscribed nonindurated ulcer of the ventral glossal mucosa.

least one ulcer present all the time. The ulcers may take up to 6 weeks to heal, and healing is accompanied by scarring.

Behçet's syndrome is a systemic disease that can affect most organ systems. The most common lesions are recurrent oral aphthous ulcers, genital ulcers, skin lesions, and eye lesions. The skin lesions consist of erythema nodosum-like eruptions and thrombophlebitis. The eye may be affected by recurrent iritis, uveitis, and retinitis, which can lead to blindness. Other less common problems include arthritis, ileal and colonic ulcers, aneurysms, arterial and venous occlusion, and a variety of central nervous system diseases.

Aphthous ulcers have been associated with a number of factors, but the cause is unclear. Aphthae do not appear to be caused by deficiencies in serum vitamin B₁₂, red blood cell folate, iron, or total iron-binding capacity, or malabsorption enteropathies. An allergic response to certain foods such as walnuts, strawberries, and tomatoes does not appear to be important.

Genetic factors are significant as the frequency of human leukocyte DR7 antigen is significantly increased in aphthae patients, and aphthae are more common in related persons. Women commonly state that the ulcers appear with the onset of menstruation, supporting the role of endocrine factors.

The microscopic features of aphthous ulcers are those of any nonspecific ulcer

and are not diagnostic. The history and clinical findings determine the diagnosis.

The goal of therapeutic management is to decrease the inflammatory response; topical corticosteroids accomplish this for most patients. Patients with major aphthae usually require systemic corticosteroids.

Lichen Planus Lichen planus is a chronic disease of skin and mucosa. Skin lesions are often extremely pruritic and appear as violet-colored flat-topped papules and plaques with a shiny surface. The lesions are most commonly located on the volar surface of the wrists, anterior surface of the legs, and penis.

Oral lesions of lichen planus are most common in adults > 40 years. The lesions have several forms. The reticular form presents as a network of lacy white lines called Wickham's striae (Figure 36-14). The plaque form appears as white homogenous plaques. The white lesions in both forms are nonpainful, rough to palpation, and do not rub off. The atrophic form consists of erythematous mucosa plus a reticular keratotic pattern along the periphery. The erosive form combines ulcerations with atrophic features (Figures 36-15 and 36-16). The atrophic and erosive forms are typically symptomatic. Occasionally, vesicles are seen, which quickly rupture to form painful ulcers. Ulcers and erosions can involve the attached gingiva producing a

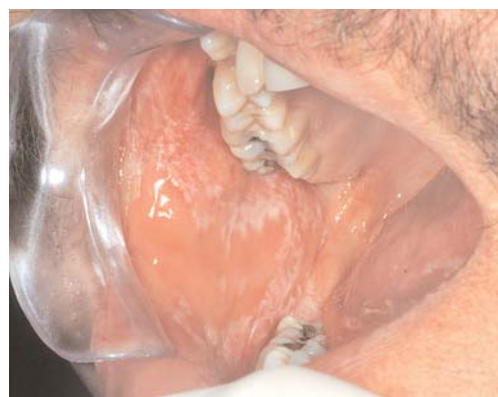

FIGURE 36-14 *Lichen planus*. Hyperkeratotic striations of the buccal mucosa.

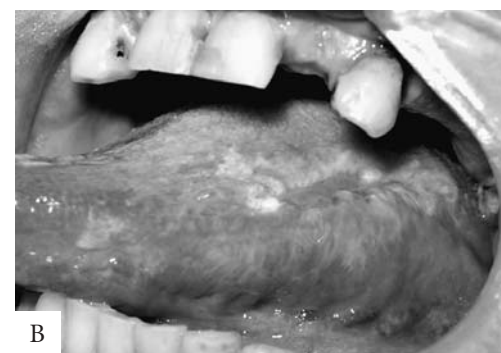
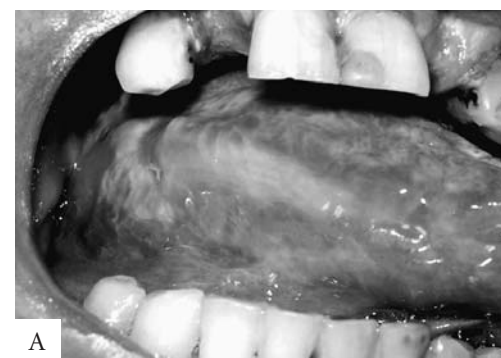
FIGURE 36-15 A and B, *Lichen planus*. Hyperkeratotic striations, erythema, and ulceration of lateroventral glossal mucosa.

desquamative gingivitis pattern in 25% of patients. Candidosis is another common finding in patients with lichen planus. Oral lesions of lichen planus are multifocal and can involve any mucosal surface. The most common locations are the buccal mucosa, followed by gingiva and the tongue. One-fifth of patients with oral lesions have skin lesions.⁶²⁻⁶⁸

Drugs can cause lichenoid reactions of skin and mucosa that are clinically similar

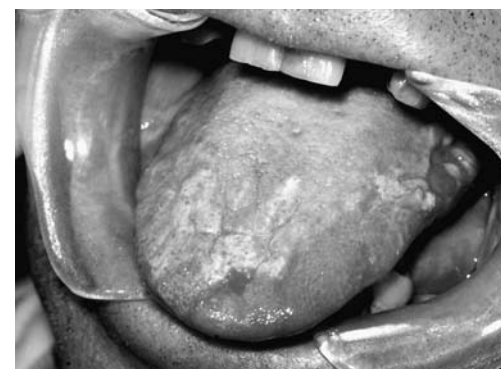

FIGURE 36-16 *Lichen planus*. Dorsal tongue lichen planus often characterized by hyperkeratotic plaques rather than striations.

to lichen planus. The reactions resolve when the drug is discontinued. The most commonly implicated drugs include methyl dopa, amiphenazole, chloroquine, hydroxychloroquine, quinacrine, chlorpropamide, tolbutamide, tetracycline, chlorothiazide, practolol, dapsone, furosemide, phenothiazines, quinidine, triprolidine, para-aminosalicylic acid, arsenicals, bismuth, gold salts, and mercury. Lichenoid reactions also occur during the chronic phase of graft-versus-host disease following bone marrow transplantations.

Lichen planus is considered a disease of the cellular immune system involving T lymphocytes, Langerhans' cells, and macrophages. The Langerhans' cells and macrophages process antigens and present the antigenic material to T lymphocytes. The lymphocytes proliferate and become cytotoxic for basal cells of the squamous epithelium. A similar immune mechanism has been reported in graft-versus-host disease and erythema multiforme.

The microscopic features of lichen planus are variable, and clinical features are important in establishing the diagnosis. The primary microscopic features include hyperkeratosis and a band-like inflammatory infiltrate, consisting primarily of lymphocytes, subjacent to the epithelium (Figure 36-17). The epithelium-connective tissue interface is obscured owing to liquefaction degeneration of the epithelial basal cell layer and/or infiltration with lymphocytes. An eosinophilic band may be seen between the inflammatory infiltrate and the epithelium. The spinous cell layer is often hyperplastic. Colloid or Civatte bodies, representing necrotic epithelial cells, are occasionally seen as eosinophilic bodies in the lower layers of the epithelium.

Direct immunofluorescence reveals fibrinogen deposition in the basement membrane zone in almost all cases, and less commonly in colloid bodies and walls of blood vessels.

Lichen planus is a chronic or recurrent disease that only rarely undergoes spontaneous remission. The goal of treatment is control of symptoms. Asymptomatic lesions require no treatment, whereas symptomatic cases are usually controlled with topical and/or systemic corticosteroids. In one study of 570 patients with oral lichen planus, 63% experienced improvement and 29% experienced complete remission while maintained on corticosteroids.⁶⁹ Antifungal medication is necessary if candidosis is present.

It appears that oral carcinoma occurs in lichen planus patients at a slightly higher rate than in the general population. However, the frequency of malignant transformation is unknown, and the classification of lichen planus as a premalignant lesion does not appear justified. Periodic recall examinations are necessary.

Erythema Multiforme Erythema multiforme (EM) can involve skin and oral mucosa independently or simultaneously. It has traditionally been described as acute and self-limited, requiring an average of 3 weeks for resolution. Some patients have a variable pattern of recurrence. In other patients EM has a chronic course.

The cause of EM is unknown, although it appears to be some type of immune dysfunction. It may be related to immune complexes deposited in walls of blood vessels in the dermis or submucosa. In about half the cases EM appears to be triggered by infections or drugs. The most common infections reported include herpes simplex viruses, tuberculosis, and histoplasmosis. The most frequently implicated drugs are sulfonamides, barbiturates, phenylbutazone, oxy-phenbutazone, phenazone, penicillins, chlorpropamide, phenytoin, and carbamazepine.

The skin lesions of EM include macules, papules, vesicles, and bullae. The most characteristic lesion, known as the iris or target lesion, appears as a central vesicle surrounded by erythematous and

skin-colored rings. The lesions are symmetrically distributed, most commonly on the extremities and face.

One-fourth to one-half of patients with skin lesions have oral lesions (Figure 36-18). Ulcers are present, most commonly on the lips, buccal mucosa, and tongue, as well as erythematous mucosa. The oral lesions vary from mild to so severe that patients cannot speak or eat. The lesions may be accompanied by headache, fever, and malaise.^{70,71}

Stevens-Johnson syndrome is a severe form of EM with more serious systemic manifestations. Extensive skin lesions, conjunctivitis, and oral and genital mucosal lesions are present. The oral lesions often begin as vesicles, which rupture forming painful ulcers. Lesions on the labial mucosa may have a bloody crust.

Toxic epidermal necrolysis is an even more serious form of EM characterized by large flaccid bullae and sloughing of the epidermis in large sheets. Oral lesions may be prominent, especially on the buccal

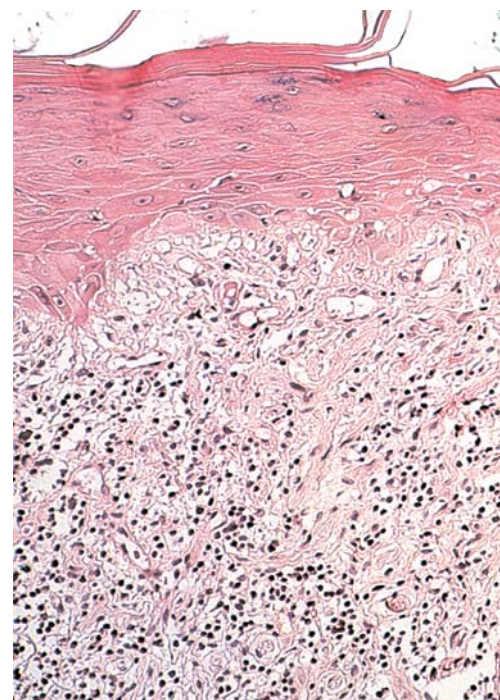


FIGURE 36-17 Lichen planus. Focal hyperkeratosis, basal cell liquefaction degeneration, and a superficial infiltration of lymphocytes ($\times 60$ original magnification; stained with hematoxylin and eosin).

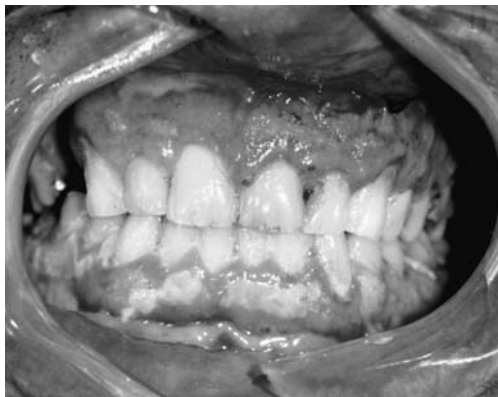

FIGURE 36-18 *Erythema multiforme*. Acute-onset ulcerative mucositis involving palatal, buccal, gingival, and labial mucosa.

mucosa. Toxic epidermal necrolysis is usually caused by drugs. The patient is acutely ill, and the disease is often fatal.

The microscopic features of EM are not diagnostic. The epithelium demonstrates edema and necrosis of keratinocytes. The connective tissue contains perivascular infiltrates of lymphocytes, plasma cells, and macrophages. Immunofluorescence reveals deposits of IgM and C3 in the vascular walls, suggesting immune complex deposition is important in the pathogenesis.

Treatment may not be necessary for mild forms of EM, which have a good prognosis, although they may be recurrent. More serious types respond well to corticosteroids; however, Stevens-Johnson syndrome is occasionally fatal.

References

1. Van der Wall I, Beemster G, van der Kwast W. Median rhomboid glossitis caused by *Candida*? Oral Surg Oral Med Oral Pathol 1979;47:31–5.
2. Horning GM, Cohen ME. Necrotizing ulcerative gingivitis, periodontitis and stomatitis: clinical staging and predisposing factors. J Periodontol 1995;66:990–8.
3. Rowland RW. Necrotizing ulcerative gingivitis. Am Periodontol 1999;4:65–73.
4. The Centers for Disease Control. Primary and secondary syphilis in the United States, 1999. MMWR Morb Mortal Wkly Rep 2001;50:113–7.
5. Centers for Disease Control. Morbidity and mortality report: congenital syphilis. New York City 1986–1988. Arch Dermatol 1990;126:288–9.
6. Ficarra G, Zaragoza AM, Stendardi L, et al. Early oral presentation of lues maligna in a patient with HIV infection: a case report. Oral Surg Oral Med Oral Pathol 1993;75:728–32.
7. Laskaris G. Oral manifestations of infectious diseases. Dent Clin North Am 1996;49:395–423.
8. Darville T. Gonorrhoea. Pediatr Rev 1999;20:125–8.
9. Fox KK, Whittington WL, Levine WC, et al. Gonorrhoea in the United States 1981–1996. Demographic and geographic trends. Sex Transm Dis 1998;25:386–93.
10. Levantine A, Almeydn J. Drug induced changes in pigmentation. Br J Dermatol 1973;89:105–12.
11. Argenyi ZB, Finelli L, Bergfeld WP, et al. Minocycline-related cutaneous hyperpigmentation as demonstrated by light microscopy, electron microscopy and x-ray energy spectroscopy. J Cutan Pathol 1987;14:176–80.
12. Odell EW, Hodgson RP, Haskell R. Oral presentation of minocycline-induced black bone disease. Oral Surg Oral Med Oral Pathol Oral Radiol Endod 1995;79:459–61.
13. Giardiello FM, Welsh SI III, Hamilton SR, et al. Increased risk of cancer in the Peutz-Jeghers syndrome. N Engl J Med 1987;316:1511–4.
14. Buchner A, Hanson LS. Melanotic macule of the oral mucosa: a clinicopathologic study of 105 cases. Oral Surg 1979;48:244–9.
15. Kargers GE, Heise AP, Riley WT, et al. Oral melanotic macules: a review of 353 cases. Oral Surg Oral Med Oral Pathol 1993;76:59–61.
16. Buchner A, Merrell PW, Hansen LS, et al. Melanocytic hyperplasia of the oral mucosa. Oral Surg Oral Med Oral Pathol 1991;71:58–62.
17. Buchner A, Hansen LS. Pigmented nevi of the oral mucosa: a clinicopathologic study of 36 new cases and a review of 155 cases from the literature. Part I: a clinicopathologic study of 36 new cases. Oral Surg Oral Med Oral Pathol 1987;63:566–72.
18. Buchner A, Hansen LS. Pigmented nevi of the oral mucosa: a clinicopathologic study of 36 new cases and a review of 155 cases from the literature. Part II: analysis of 191 cases. Oral Surg Oral Med Oral Pathol 1987;63:676–82.
19. Greenspan MIL, Clark WH, Tucker MA, et al. Acquired precursors of cutaneous malignant melanoma: the familial dysplastic nevus syndrome. N Engl J Med 1985;312:91–7.
20. Barker B, Carpenter WM, Daniels TE, et al. Oral mucosal melanomas: the WESTOP Banff workshop proceedings. Oral Surg Oral Med Oral Pathol Oral Radiol Endod 1997;83:672–9.
21. Batsakia JG, Suarez P, El-Naggar A. Mucosal melanomas of the head and neck. Ann Otol Rhinol Laryngol 1998;107:626–9.
22. Weyers W, Euler M, Diaz-Cascajo C, et al. Classification of cutaneous malignant melanoma. Cancer 1999;86: 288–99.
23. Freidman RJ, Rigel DS, Kopf AW. Early detection of malignant melanoma: The role of physician examination and self-examination of the skin. CA: Cancer J Clinicians 1985;35:130–51.
24. Fine JD, Bauer EA, Briggaman RA, et al. Revised clinical and laboratory criteria for subtypes of inherited epidermolysis bullosa. J Am Acad Dermatol 1991;24:119–35.
25. Woodley D. Clearing of epidermolysis bullosa acquisita with cyclosporin. J Am Acad Dermatol 1990;22:535–6.
26. Wright J, Fine J, Johnson L. Oral soft tissues in hereditary epidermolysis bullosa. Oral Surg Oral Med Oral Pathol 1991;71:440–6.
27. Sedano HO, Gorlin RJ. Epidermolysis bullosa. Oral Surg 1989;67:555–63.
28. Eversol R. Viral infections of the head and neck among HIV-seropositive patients. Oral Surg Oral Med Oral Pathol 1992;73:155–63.
29. Fiddian A, Ivanyi L. Topical acyclovir in the management of recurrent herpes labialis. Br J Dermatol 1983;109:321–6.
30. Spruance S, Stewart J, Rowe N, et al. Treatment of recurrent herpes simplex labialis with oral acyclovir. J Infect Dis 1990;161:185–90.
31. Kaplan LJ, Daum RS, Smaron M, et al. Severe measles in immunocompromised patients. J Am Med Assoc 1992;276:1237–41.
32. Grogan TM. Hodgkin's disease. In: Jaffe ES, editor. Surgical pathology of the lymph nodes and related organs. Philadelphia: W.B. Saunders; 1985. p. 97–8.
33. Rosa C. Rubella and rubeola. Semin Perinatol 1998; 22:318–22.
34. Watson JC, Hadler SC, Dykewicz CA, et al. Measles, mumps, and rubella—vaccine use and strategies for elimination of measles, rubella and congenital rubella syndrome and control of mumps: recommendations of the Advisory Committee on Immunization Practices. MMWR Morb Mortal Wkly Rep 1998;47(RR-8):1–57.
35. MacPhail L, Greenspan D, Feigal D, et al. Recurrent aphthous ulcers in association with HIV infection. Oral Surg Oral Med Oral Pathol 1991;71:678–83.
36. Greenspan D, Greenspan JS. Oral manifestations

- of human immunodeficiency virus infection. *Dent Clin North Am* 1993;37:21–32.
37. Lozada-Nur F, Robinson J, Regezi JA. Oral hairy leukoplakia in immunosuppressed patients. *Oral Surg Oral Med Oral Pathol* 1994;78:599–602.
38. Phelan J, Eisig S, Freedman P, et al. Major aphthous-like ulcers in patients with AIDS. *Oral Surg Oral Med Oral Pathol* 1991;71:68–72.
39. Flaitz CM, Nichols CM, Hicks MJ. Herpesviridae-associated persistent mucocutaneous ulcers in acquired immunodeficiency syndrome. *Oral Surg Oral Med Oral Pathol Oral Radiol Endod* 1996;81:433–41.
40. Holmstrup P, Westergaard J. HIV infection and periodontal diseases. *Periodontol* 2000 1998;18:37–46.
41. Epstein J, Scully C. HIV infection: clinical features and treatment of thirty-three homosexual men with Kaposi's sarcoma. *Oral Surg Oral Med Oral Pathol* 1991;71:38–41.
42. Miles SA. Pathogenesis of AIDS-related Kaposi's sarcoma: evidence of viral etiology. *Hematol Oncol Clin North Am* 1996;10:1011–21.
43. Epstein JB. Management of oral Kaposi's sarcoma and a proposal for clinical staging. *Oral Dis* 1997;3(Suppl 1):124–8.
44. Dabelsteen E. Molecular biological aspects of acquired bullous diseases. *Crit Rev Oral Biol Med* 1998;9:162–78.
45. Nousari HC, Anhalt GJ. Pemphigus and bullous pemphigoid. *Lancet* 1999;354:667–72.
46. Silverman S, Gorsky M, Lozada-Nur F, Liu A. Oral mucous membrane pemphigoid. A study of 65 patients. *Oral Surg* 1986;61:233–7.
47. Anhalt G. Pemphigoid: bullous and cicatricial. *Dermatol Clin* 1990;8:701–16.
48. Dayan S, Simmons RK, Ahmed AR. Contemporary issues in the diagnosis of oral pemphigoid. *Oral Surg Oral Med Oral Pathol Oral Radiol Endod* 1999;88:424–30.
49. Jonsson R, Mountz J, Koopman W. Elucidating the pathogenesis of autoimmune disease: recent advances at the molecular level and relevance to oral mucosal disease. *J Oral Pathol Med* 1990;19:341–50.
50. Scully C, Carrozzo M, Gandolfo E, et al. Update on mucous membrane pemphigoid. *Oral Surg Oral Med Oral Pathol Oral Radiol Endod* 1999;88:56–68.
51. Vincent SD, Lilly GE, Baker KA. Clinical, historic and therapeutic features of cicatricial pemphigoid. *Oral Surg Oral Med Oral Pathol* 1993;76:453–9.
52. Scully C, Porter SR. The clinical spectrum of desquamative gingivitis. *Semin Cutan Med Surg* 1997;16:308–13.
53. De Rossi SS, Glick M. Lupus erythematosus: clinical considerations for dentistry. *J Am Dent Assoc* 1998;129:330–9.
54. Lahita RG. Overview of lupus erythematosus. *Clin Dermatol* 1993;10:389–92.
55. Lo Muzio L, della Valle A, Mignogna MD, et al. The treatment of oral aphthous ulceration or erosive lichen planus with topical clobetasol propionate in three preparations: a clinical and pilot study on 54 patients. *J Oral Pathol Med* 2001;30:611–7.
56. Lozada-Nur F, Miranda C, Maliksi R. Double-blind clinical trial of 0.05% clobetasol propionate in orabase and 0.05% fluocinonide ointment in the treatment of patients with oral vesiculoerosive diseases. *Oral Surg Oral Med Oral Pathol* 1994;77:598–604.
57. O'Duffy J. Behçet's syndrome. *N Engl J Med* 1990;323:326–7.
58. Pedersen A. Recurrent aphthous ulceration: virologic and immunologic aspects. *APMIS* 1993;Suppl 37:1–37.
59. Ship JA. Recurrent aphthous stomatitis: an update. *Oral Surg Oral Med Oral Pathol Oral Radiol Endod* 1996;81:141–7.
60. Porter SR, Scully C, Pedersen A. Recurrent aphthous stomatitis. *Crit Rev Oral Bio Med* 1998;9:306–21.
61. Vincent SD, Lilly GE. Clinical, histories, and therapeutic features of aphthous stomatitis. Literature review and open clinical trial employing steroids. *Oral Surg Oral Med Oral Pathol* 1992;74:79–86.
62. Vincent SD, Fetus PG, Baker KA, Williams TP. Oral lichen planus: the clinical, historical and therapeutic features of 100 cases. *Oral Surg Oral Med Oral Pathol* 1991;70:165–71.
63. Van der Meij EH, Schepman KP, Smeele LE, et al. A review of the recent literature regarding the malignant transformation of oral lichen planus. *Oral Surg Oral Med Oral Pathol Oral Radiol Endod* 1999;88:307–10.
64. Boisnic S, Francis C, Branchet MC, et al. Immunohistochemical study of oral lesions of lichen planus: diagnostic and pathophysiologic aspects. *Oral Surg Oral Med Oral Pathol* 1990;70:462–5.
65. Holmstrup P, Scholtz AW, Westergaard J. Effect of dental plaque control on gingival lichen planus. *Oral Surg Oral Med Oral Pathol* 1990;69:585–90.
66. Kaliakatsou F, Hodgson TA, Lewsey JD, et al. Management of recalcitrant ulcerative oral lichen planus with topical tacrolimus. *J Am Acad Dermatol* 2002;46:35–41.
67. Porter SR, Kirby A, Olsen I, et al. Immunologic aspects of dermal and oral lichen planus. *Oral Surg Oral Med Oral Pathol Oral Radiol Endod* 1997;83:358–66.
68. Regezi JA, Dekker NP, MacPhail LA, et al. Vascular adhesion molecules in oral lichen planus. *Oral Surg Oral Med Oral Pathol Oral Radiol Endod* 1996;81:682–90.
69. Silverman S, Gorsky M, Lozada-Nur F. A prospective follow-up study of 570 patients with oral lichen planus—persistence, remission, and malignant potential. *Oral Surg Oral Med Oral Pathol* 1985;60:30–4.
70. Paquet R, Pierard GE. Erythema multiforme and toxic epidermal necrolysis: a comparative study. *Am J Dermatopathol* 1997;19:127–32.
71. Singla R, Brodell RT. Erythema multiforme due to herpes simplex virus. Recurring target lesions are the clue to diagnosis. *Postgrad Med* 1999;106:151–4.

Head and Neck Skin Cancer

Michael F. Zide, DMD

Yan Trokel, MD, DDS

Skin cancer is the most common cancer afflicting mankind. In the United States alone, an estimated 1 million new lesions are diagnosed each year.¹ Skin cancer may be grouped into two subsets: nonmelanoma skin cancer (NMSC) and melanoma. NMSC comprises 95% of all skin cancers. Melanoma, of which 1 to 8% occurs in the head and neck, fills the remaining 5%.²⁻⁴

Even with this low incidence, melanoma is responsible for about 75% of skin cancer-related deaths. The overall mortality for NMSC is relatively low, with an estimated 5-year survival rate of 95%.^{5,6} Regardless, NMSC may be locally aggressive, leading to significant morbidity, disfigurement, loss of function, and high health care costs.⁷ This chapter focuses on the epidemiology, etiology, clinical characteristics, and management (medical and surgical) of these cutaneous malignancies.

Nonmelanoma Skin Cancer

Epidemiology

The NMSCs include basal cell carcinoma (BCC; 75% of NMSCs), squamous cell carcinoma (SCC; 20% of NMSCs), and a few rarer malignancies, such as Merkel cell tumor, dermatofibrosarcoma protuberans, and adnexal tumors.⁵ Incidence data for the United States should be interpreted skeptically as most NMSCs are treated in outpatient clinics or private offices and are not routinely reported to cancer reg-

istries.³ Reported yearly skin cancer rates are approximately 2 in 1,000 in the continental United States, 1 in 100 on the island of Kauai, and > 2 in 100 in Australia.⁸

Epidemiologic studies demonstrate a positive correlation between ultraviolet (UV) radiation exposure and the incidence of NMSC. NMSC is predominantly a Caucasian disease ($\geq 98\%$) but does occur in Blacks and Hispanics.³ The risk of developing NMSC increases the closer one lives to the equator, and the more one's outdoor activities increase the concentration of sun exposure through reflection.^{8,9} Examples of the latter include work around snow, water, cement, and roofing.

For all races 75% of NMSCs appear on body areas most chronically exposed to sunlight, such as the head, face, neck, and dorsum of the hands.⁵ The incidence of BCC and SCC at early ages is comparable for men and women, but men > 45 years have a three times greater incidence of NMSC, specifically SCC.^{10,11} In men common sites are the ears and nose, whereas in women the nose and lower extremities are most common.

The incidence of NMSC had been increasing for decades. The mortality rate, however, has recently leveled off and is now beginning to decrease, perhaps owing to public information programs.¹² Overall, NMSC has an excellent prognosis, but approximately 2,000 deaths occur annually, three-fourths of which are from metastatic SCC.^{13,14}

Etiology

The etiology of NMSC is multifactorial but can be broadly categorized into host-related and environmental causes. Host factors include an individual's phenotype, genetic syndromes, precursor lesions, and immunologic issues. Environmental variables include exposure to UV radiation, ionizing radiation, and chemicals.²

Host Factors Tanning is the body's defense mechanism against NMSC. One's ability to tan is directly related to the amount of melanin in the skin, which is genetically determined and cannot be influenced. Skin melanin determines a person's photosensitivity. The more melanin an individual has, the less damage UV radiation inflicts. Deleterious effects of UV radiation are attenuated by the stratum corneum via refraction, reflection, and direct absorption by melanin.

Fitzpatrick classified skin into six different groupings or types (Table 37-1).¹⁵ Each group was categorized based on the results of 30 minutes of direct sunlight to the skin in the northern hemisphere. The groups are based on the amount of melanin an individual possesses, inherent pigmentation, and sensitivity to UV light. For example, a person in type 1 is the classic freckle-faced light-eyed redhead who burns and never tans, a Celtic type. People in type 1 are highly susceptible to skin cancer but remarkably also heal from

Table 37-1 Fitzpatrick Skin Types*

Type	Characterization
1	Always burns easily, shows no immediate pigment darkening, and never tans
2	Always burns easily, shows trace immediate pigment darkening, tans minimally and with difficulty
3	Burns minimally, + immediate pigment darkening, tans gradually and uniformly (light brown)
4	Burns minimally, ++ immediate pigment darkening, tans well (moderate brown)
5	Rarely burns, +++ immediate pigment darkening, tans very well (dark brown)
6	Rarely burns, +++ immediate pigment darkening, tans profusely (black)

*Fitzpatrick skin phenotypes portray the outcomes of 30 min of sun exposure at midday in the northern hemisphere. + indicates a relative level of pigment darkening, with +++ being the highest. From Fitzpatrick TB.¹⁵

reconstruction wounds with the least perceptible scar. Type 2 is typified by the blond-haired blue-eyed person, a Scandinavian type. A type 3 person has olive skin and often dark eyes and occasionally burns but tans readily, a Mediterranean type. The descent of people in type 4 is Hispanic, type 5 is Arabic/Indian, and type 6 is African. Remarkably, as resistance to skin cancer increases, scarification becomes more obvious, often pigmentation or forming keloids.

Host factors contribute to a patient's ongoing risk of developing new cancers. A patient with a prior history of NMSC has a 36 to 52% 5-year risk of another cancer arising.^{16,17}

Syndromes Genetics plays a starring role in determining who gets skin cancer. Newer drugs to treat skin cancers, for example, 5% imiquimod cream applied topically three times per week, show great promise in treating skin cancers through inherent immune responses.¹⁸ There are several syndromes that predispose a person to skin cancer:

- Basal cell nevus syndrome (Gorlin's syndrome) is an autosomal dominant disorder characterized by multiple BCCs, odontogenic keratocysts, bifid ribs, scoliosis, brachymetacarpalism, palmar and plantar pits, calcification

of the falx cerebri, prominent supra-orbital ridges, and hypertelorism. The BCCs that are produced look like small nevi (Figure 37-1) but act just like common nodular BCC. Control with a CO₂ laser or curettage and electrodesiccation (C and E) is critical before enlargement destroys anatomic structures.^{19–21}

- Xeroderma pigmentosa is an autosomal recessive disorder resulting in defects in repair of deoxyribonucleic acid (DNA). UV radiation results in skin DNA damage; therefore, xeroderma pigmentosa is characterized by hypersensitivity to sun exposure and the development of multiple skin cancers. Children with this disorder must modify their lifestyles to function as night people. There are summer camps for them, at which activities begin at their wake-up time—sundown
- Albinism is an autosomal recessive disorder resulting in the absence of melanin with a subsequent increase in development of skin cancer, especially SCC
- Epidermodysplasia verruciformis is an autosomal recessive disorder. It results in the development of BCC from flat warts in sun-exposed areas in homozygous individuals infected with human papillomavirus type 3 or 5

Predisposing Lesions Several congenital and acquired lesions predispose to skin cancer:

- Nevus sebaceus of Jadassohn is a well-circumscribed slightly raised hairless lesion on the scalp or face present at birth that becomes verrucous and nodular during puberty. Approximately 10% of such lesions undergo malignant transformation to BCC (Figure 37-2)
- Actinic keratosis (AK), also known as solar or senile keratosis, is the most common precancerous lesion of the epidermis. AK is characterized by red, yellow, brown, or colorless macules or papules with scaly irregular surfaces, ranging in size from a few millimeters to several centimeters. Left untreated, there is a 10 to 13% risk of malignant transformation of AK to SCC (Figure 37-3); therefore, the American Academy of Dermatology recommends treatment.^{22–25} All suspicious lesions should undergo biopsy. Treatment options include chemical peel, laser, cryotherapy, C and E, tangential excision, or 5-fluorouracil (5-FU)
- Cutaneous horns are hard keratotic growths that protrude from the skin. Histologically they are advanced AK. Approximately 10% of these lesions have an underlying SCC²⁶

Immunologic Factors Immunosuppression predisposes a person to several types of cancers including skin cancer. Immunosuppression alters the immune surveillance mechanism that typically destroys potentially malignant cells.³ Human immunodeficiency virus infection, lymphoproliferative disease, occult malignancy, organ transplantation, and a variety of other medical conditions result in immunosuppression. Renal transplantation patients on long-term immunosuppressive therapy not only have a higher incidence of SCC and metastasis, their

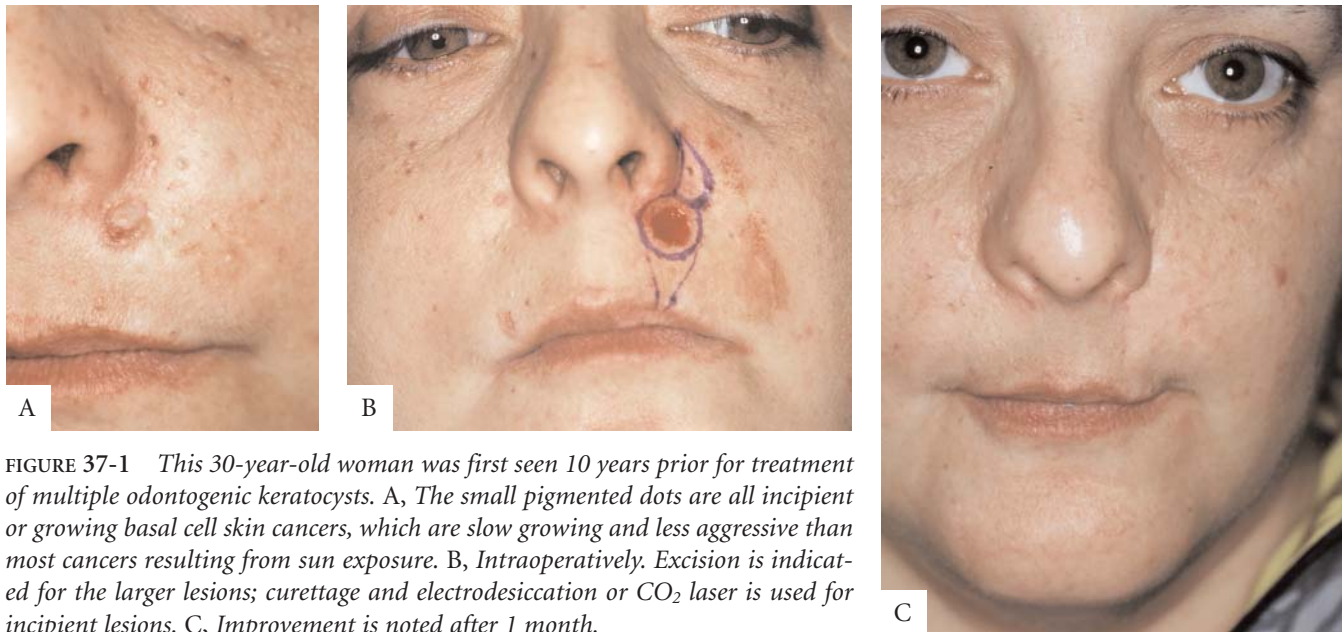


FIGURE 37-1 This 30-year-old woman was first seen 10 years prior for treatment of multiple odontogenic keratocysts. A, The small pigmented dots are all incipient or growing basal cell skin cancers, which are slow growing and less aggressive than most cancers resulting from sun exposure. B, Intraoperatively. Excision is indicated for the larger lesions; curettage and electrodesiccation or CO₂ laser is used for incipient lesions. C, Improvement is noted after 1 month.

tumors appear years earlier than in any control population.^{27–30} However, most studies suggest that some other risk factor such as ionizing radiation or viral infection, along with a decreased immune system, is necessary for the development of these tumors in this subset of patients.^{3,31}

Environmental Factors Ionizing radiation, certain chemicals, and skin damage from the environment can also cause skin

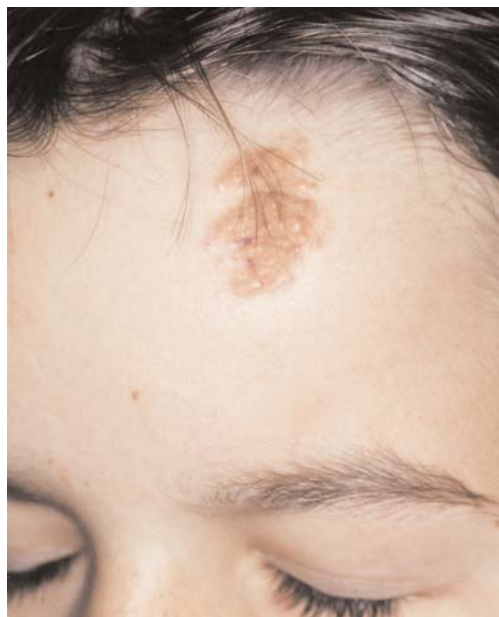

FIGURE 37-2 Nevus sebaceus.

cancer. UV radiation has been fingered as the primary environmental culprit. There are three types of UV radiation: UVA (320–400 nm), UVB (290–320 nm), and UVC (200–280nm). UVB rays are the most carcinogenic, triggering skin cancer via photochemical damage to DNA, injury to DNA repair mechanisms, and partial suppression of cell-mediated immunity.^{5,32} UVA, originally thought to be harmless, is now known to enhance the effects of UVB as a cocarcinogen.³ Most UVC is filtered out by the ozone layer. As the ozone layer thins, as it has over Antarctica and parts of Australia, UVC enhances the development of skin cancer. The most common historic reports for NMSC as well as melanoma are two to three childhood blistering sunburns or ≥ 3 years of intense sun exposure.

A comment must be made about the two methods of tanning used in tanning parlors. The method using UVA light, in our estimation, enhances new skin cancers.³² We have seen skin cancers even in teenagers who have used tanning parlors. The “California” spray tan, a skin dye that lasts for 3 to 5 weeks, is harmless.

Chemicals such as arsenic, polycyclic aromatic hydrocarbons, and psoralens used in combination with UVA (a treat-

ment for psoriasis) have all been implicated as originators for NMSC.³³ Patients suffering from chronic inflammatory skin conditions, such as chronic radiation keratosis, burn scars, and ulcers, have an increased risk of developing skin cancers.

Prevention

Although a doctor may be capable of treating skin cancer effectively, the informed patient is the greatest resource against the development of new cancers. Preventive measures can be classified into three types: sunscreens, clothing, and education. Sun protection is rated by sun protection factor

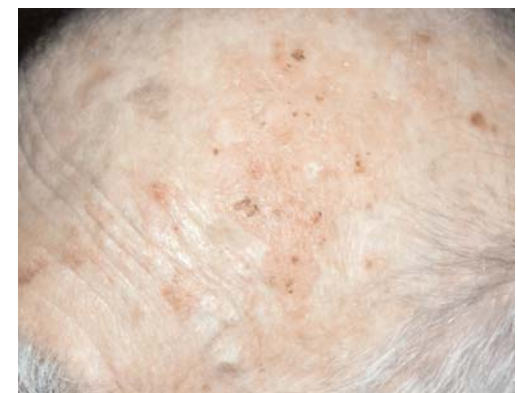

FIGURE 37-3 Scaly actinic keratoses on the scalp, some of which have progressed to squamous cell carcinoma (*in situ*).

(SPF). The SPF is a ratio of the smallest amount of radiation needed to produce erythema on protected skin compared with the same degree of redness produced on unprotected skin. Sunscreens function either chemically or physically. Chemical sunscreens, such as para-aminobenzoic acid, benzophenones, and cinnamates, reduce UV skin penetration by absorbing solar rays. Physical sunscreens including titanium dioxide, zinc oxide, and kaolin, act as physical barriers.

It is now known that regular application of SPF 30 sunblock may reduce the evolution of new actinic keratoses by 50% after 3 years. Additionally, patients should be told that the application of SPF 30 does not abrogate the need for behavioral modification. For example, a farmer who applies SPF 30 at the start of the day will have the protection wear off shortly after a few hours of sweating.

Clothing may provide some protection, but a wet T-shirt has an SPF of 0 to 1.³³ High SPF clothing is available, but it is expensive and not very comfortable.

Basal Cell Carcinoma

Basal cell tumors originate from pluripotential cells in the epidermis and hair follicles. They are often slow growing and may take years to enlarge significantly.³³

Typically, patients with BCC are categorized as Fitzpatrick types 1 to 3 with a history of sun exposure. Eighty to 93% of the cancers occur on sun-exposed areas of the head and neck, and 26 to 30% occur on the nose.³⁴ BCCs can be divided into several subtypes: superficial, nodulo-ulcerative (or nodular), pigmented, infiltrative, micronodular, morphea-like, and basosquamous.

Superficial BCC represents approximately 10% of all BCCs (Figure 37-4).³⁵ They present as slightly elevated plaques or discrete macules that may be scaly. They can resemble eczema or fungal infections.

Nodulo-ulcerative BCC is the most common type, accounting for approxi-

mately 75% of all BCCs (see Figure 37-4).³⁵ Clinically, they present as well-defined translucent pearly nodules that are either round or oval with rolled borders and occasional ulcerations. Telangiectasias are commonly seen coursing through the lesion.

Pigmented BCCs range from brown to blue-black and can be mistaken for melanoma. Morphea-like BCCs present as firm plaques that are yellow or white with an ill-defined border. They can be quite large and do not show more than 1 to 2 mm elevation. This tumor is likely to have positive margins after excision.

Basosquamous carcinomas have both basal and squamous cell differentiations. They have a higher growth rate as well as a higher metastatic potential than do other BCCs.

Micronodular, infiltrative, and morphea-like BCCs are the more aggressive variants of BCC and together account for 10% of BCCs.⁷

Death from BCC is rare, with a rate of metastasis of 0.0028 to 0.1%.³⁶ Size, depth of invasion, and histologic type are important predictors for metastasis.¹⁰ Favored sites of metastasis include regional lymph nodes, liver, lung, bone, and skin. This rare metastasis is twice as common in males as in females.³⁶

Squamous Cell Carcinoma

SCC is the second most common skin cancer and accounts for 20% of all NMSC cases. SCC is a malignant proliferation of epidermal keratinocytes. Histologically SCC is composed of nests and cords of atypical squamous cells from the epidermis infiltrating into the dermis; it often contains keratin pearls. The lifetime risk of developing SCC is 4 to 14%, and the incidence has increased by 20% in the past decade alone.^{11,37,38}

Men with a fair complexion who are > 50 years and have had heavy sun exposure in the past several years typically get multiple actinic keratoses and SCC. SCC presents as a painless poorly defined ery-

thematous nodule with raised borders (Figure 37-5). Cutaneous horns or a hyperkeratotic crust with ulcerations may be present. The surrounding skin may reveal signs of chronic sun damage.

Unlike BCC, SCC may grow rapidly and metastasize. Metastasis is most common in lesions > 4 mm deep. The cumulative rate of metastasis is between 2 and 6%, and the 5-year survival rate for metastatic SCC is only 34%.^{11,38} Metastasis can occur either through the lymphatics or by hematogenous spread, with common sites being the regional lymph nodes, the lungs, and the liver. The location of the primary lesion influences the rate of recurrence and metastasis. SCCs occurring on the lip, ear, melolabial crease, and periorbital and preauricular areas have higher rates of recurrence and metastasis (10–14%).^{38,39}

The most common precursor for SCC is AK. The rate of transformation of AK to SCC is 1 in 1,000 per year.³⁹ Approximately 40% of people > 40 years have had at least one AK. Keratoacanthoma is a commonly confused with SCC, both clinically and histologically. Keratoacanthoma is a self-healing raised growth lesion with a central keratin-filled plug. It grows quickly but often spontaneously involutes after 2 to 6 months, leaving only a depressed white scar.

Bowen's disease is an in situ SCC presenting as a slow-growing erythematous scaling plaque with an irregular but sharp outline. These lesions rarely transform into invasive SCC.

SCC may evolve from chronically unhealed or unstable wounds, burn scars, or ulcers. These lesions, sometimes called Marjolin's ulcers, have a 20% higher rate of lymph node metastasis than does UV-induced SCC.^{40,41}

Histologic features, such as the degree of differentiation, depth of invasion, and perineural involvement, as well as tumor size are prognostic indicators that may dictate selection of width of the excisional margin. More differentiated lesions have a lower invasive tendency and, hence,

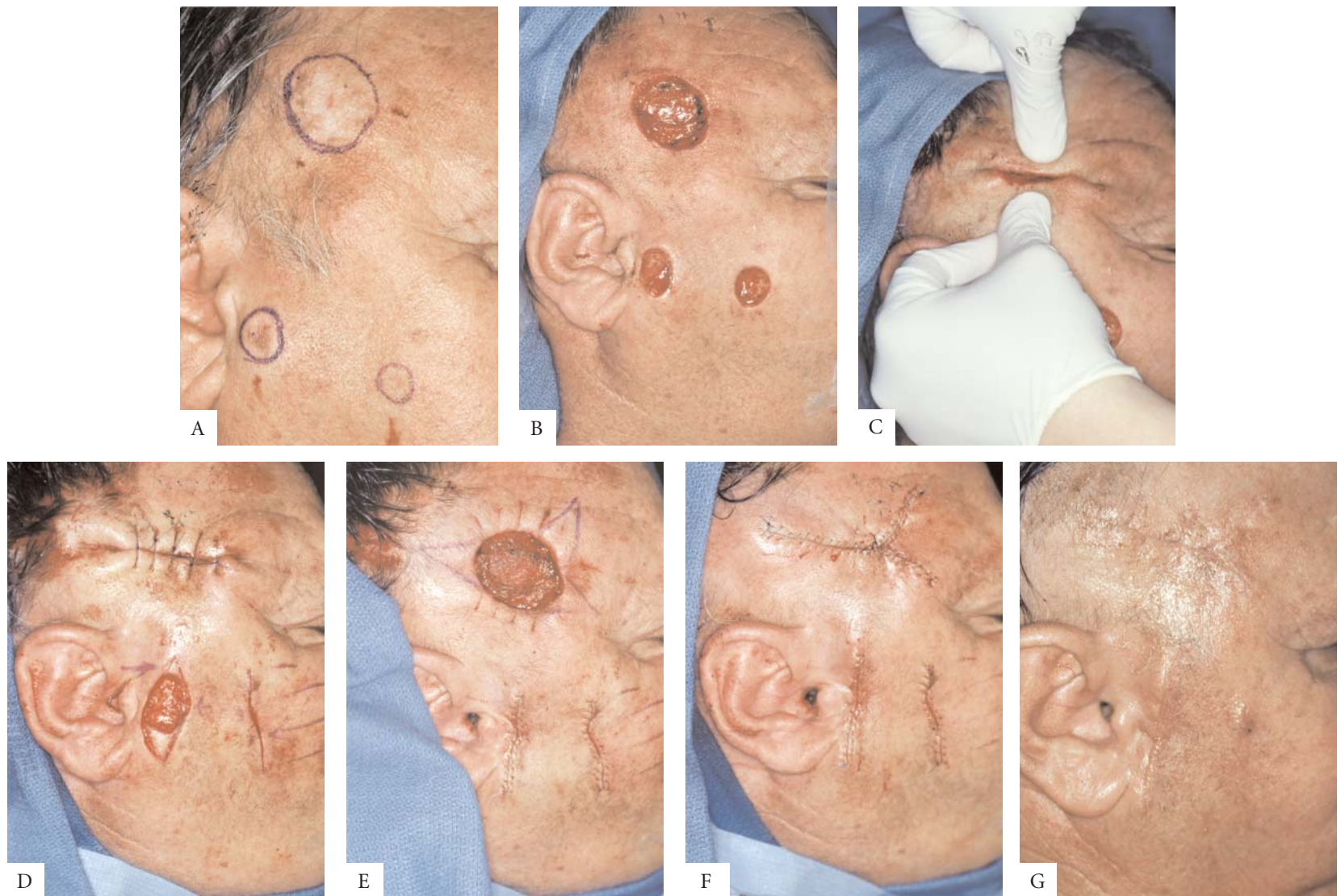


FIGURE 37-4 A, Superficial and nodulo-ulcerative basal cell carcinomas (confirmed with biopsy) are excised under local anesthesia in the office. The specimens are sent for permanent histopathology. B, Five days later, in the operating room, the defects are ready for reconstructive closure. C, Finger pressure (inherent elasticity) reveals that the largest defect is tight but amenable to advancement flap closure. D, The upper defect is presutured with 3-0 nylon (mechanical creep). E, Margins are excised (0.5–1 mm sharp squaring of the rounded edges with scraping of debris) and complex closures of the lower defects are accomplished. F, The nylon sutures are released and the tension-free upper defect is repaired with an advancement flap and M-plasty. G, Results at suture removal 1 week later.

a better prognosis. Larger tumors and those that invade deeply along tissue planes have a greater risk of recurrence and metastasis. Tumors > 2 cm have a twofold increase in recurrence rate and are three times more likely to metastasize. Tumors arising in scars or wounds are usually more aggressive and have a metastasis rate between 18 and 38%.⁷ With SCC the first shot at cure is crucial as recurrent SCCs have a metastatic rate of 24 to 45%; if they metastasize the 5-year survival rate is around 50%.⁷

Melanoma

Melanoma is a potentially deadly and aggressive neoplasm resulting from the malignant transformation of melanocytes. The incidence of melanoma is increasing faster than any other cancer. It is estimated that the frequency of melanoma will double every 10 to 15 years, and that > 40,000 new cases of melanoma will be diagnosed this year in the United States alone.^{7,41,42} Melanoma occurrence increases the closer one's residence is to the equator, with resi-

dents of Queensland, Australia, having the highest rate of melanoma, approaching 1 in 14.⁴³ An estimated 1 in 75 people develop melanoma in their lifetime, up from 1 in 150 persons in 1985.⁴⁴ Melanoma accounts for over three times more deaths than the combined fatalities from all other skin malignancies.⁴⁵

Risk Factors

People in Fitzpatrick groups 1 and 2 are the most susceptible to melanoma. The role of UV is not precisely known for

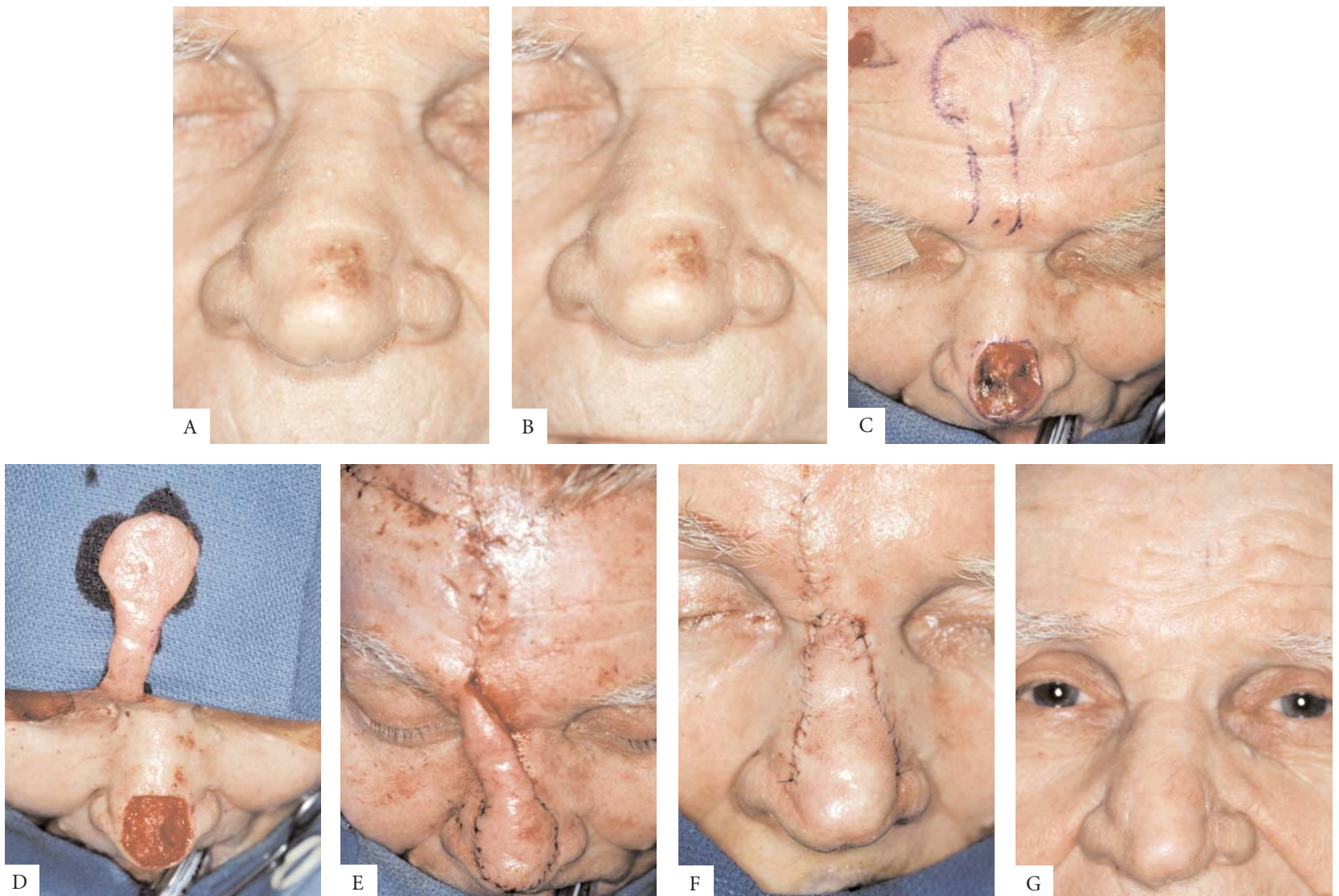


FIGURE 37-5 A, This 60-year-old has confirmed squamous cell cancer on his nasal tip (and basal cell cancers elsewhere). B, Five days after excision of the cancers, with permanent histology assuring margin clearance, the patient undergoes Doppler ultrasonography in preparation to identify the location of the axial vessel for a paramedian forehead flap. C, The flap is designed on the right supratrochlear vessels. D, The lower recipient site has been trimmed sharply, and the pink vascular flap is ready for inset. E, The flap in place. F, The sutured flap revascularizes for 3 weeks. At this time, it may be thinned again or divided and inset according to topographic principles. G, Two months postoperatively, the results of surgery are inconspicuous.

melanoma, but lots of freckles and a history of three or more blistering sunburns, the use of a tanning bed, and having undergone psoralen plus UVA therapy have been implicated.^{43,46}

Several additional risk factors for melanoma have been identified. About 10% of patients with melanoma have a first-degree relative with the disease.⁴⁷ “Common moles,” also known as acquired melanocytic nevi, can be a risk factor. Individuals with > 100 of these moles

have a tenfold risk of developing melanoma.^{4,48} When combined with a family history of melanoma, dysplastic nevi (atypical moles), which are present in approximately 10% of the population, represent a significantly increased risk of developing melanoma. Congenital (black hairy) nevi have a 4% lifetime risk of developing into melanomas.⁴³ Lentigo maligna, or melanotic freckle of Hutchinson, is a precursor in situ lesion that becomes malignant in approximately 5%

of cases (Figure 37-6). Thirty percent of melanomas arise from preexisting lesions, whereas 70% arise de novo.

Clinical and Histologic Description

The mnemonic *ABCD* is useful in categorizing the characteristics of melanomas: *asymmetry*, *border irregularity*, *color changes or variation*, *diameter of lesion* (< or > 6 mm). The practitioner should not place the patient under

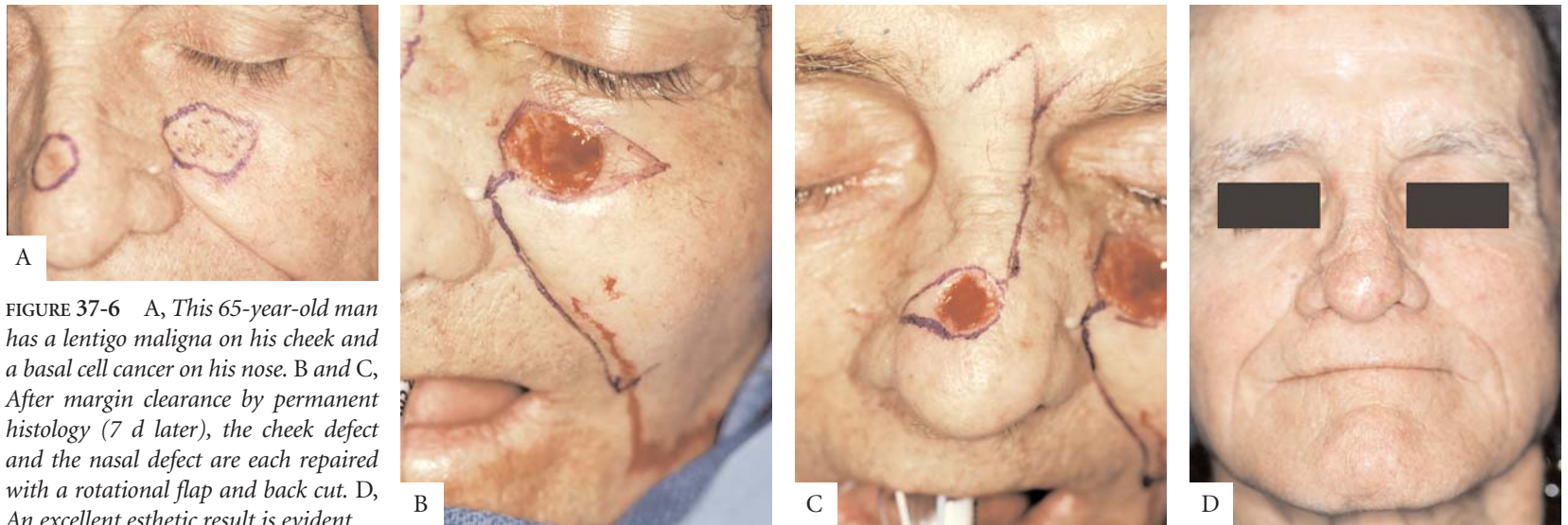

FIGURE 37-6 A, This 65-year-old man has a lentigo maligna on his cheek and a basal cell cancer on his nose. B and C, After margin clearance by permanent histology (7 d later), the cheek defect and the nasal defect are each repaired with a rotational flap and back cut. D, An excellent esthetic result is evident.

casual observation (ie, not perform a biopsy) just because these common indicators might be absent. Approximately 40% of board-certified dermatologists and 50%+ of other clinicians do not identify melanoma correctly by clinical intuition alone. Other suspicious factors include the color pink in a dark lesion and persistent itching.

Melanoma in situ is an intraepithelial lesion that can progress to an invasive lesion. When it is still in the epithelium, it is described as being in a horizontal growth phase, but when it invades dermis and approximates blood vessels, it is in a vertical growth phase and thickens. Hence, deeper melanomas are more deadly. Histopathologically, malignant melanoma presents as a proliferation of atypical melanocytes. The tumor originates at the epidermal-dermal junction. The cells then invade upward into the epidermis or extend downward into the dermis.

Melanomas are categorized into four main clinical and histologic subtypes: superficial spreading melanoma, nodular melanoma, lentigo maligna melanoma, and acral-lentiginous melanoma. Superficial spreading melanoma accounts for 70% of all melanomas. Clinically superficial spreading melanoma is a flat or slightly elevated dark lesion with asymmetric

borders; it can be present for up to 5 years prior to invasion of the dermis.

Nodular melanoma is the second most common variant, accounting for 15 to 30% of melanomas. It appears as a raised black, brown, blue, or red nodule, perhaps with ulcerations, bleeding, or crusting. It may look just like a BCC, but contrary to BCC, the lesion grows rapidly over a few months. Around 5% of nodular melanomas lack pigmentation and are pinkish “amelanotic” melanomas. Nodular melanomas are thicker and metastasize rapidly.

Lentigo maligna melanoma comprises 4 to 10% of melanomas. It arises in sun-exposed areas and occurs in the elderly.

Acral-lentiginous melanoma accounts for 2 to 8% of all melanomas in Caucasians but is the most common type in African Americans, Asians, and Hispanics. Clinically, they present as pigmented lesions with irregular borders. Papules and nodules are frequently seen within the lesion.

Biopsy is the only fail-safe method to prove or disprove melanoma. If melanoma is suspected, incisional and excisional biopsies are much more diagnostic and prognostic than is a shave biopsy. Regardless, if a shave biopsy is performed and melanoma returns as the diagnosis, the

next step is to obtain a full-thickness specimen (via punch or incisional biopsy) to ascertain the diagnosis and confirm true depth. Neither incisional nor excisional biopsy disseminates tumor.

Incisional biopsy should be reserved for lesions > 2 cm or those located at anatomically restricted areas (eg, eyelids, ears). The biopsy should be at the most raised site or the darkest area of the lesion (Figure 37-7). Full-thickness excisional biopsy with a 2 mm margin is the preferred method for lesions < 2 cm.

Once the diagnosis has been established, melanoma is staged either by measuring the tumor depth from the granular cell layer of the epidermis to the farthest depth of tumor invasion (Breslow classification) or by determining the anatomic level of invasion (Clark classification). Melanomas measuring < 0.76 mm have a 5-year survival rate of > 93%, whereas lesions > 4 mm thick have a 5-year survival rate of < 50%.^{49,50} Melanomas with ulceration or histologically high mitosis rates predictably worsen prognoses. Discovery of locoregional or distant metastasis lowers 5-year survival to 40% or 5%, respectively.⁵¹ The most frequent sites of melanoma metastasis include the skin, lymph nodes, lung, liver, brain, bone, and gastrointestinal tract. On the other hand, the presence of a

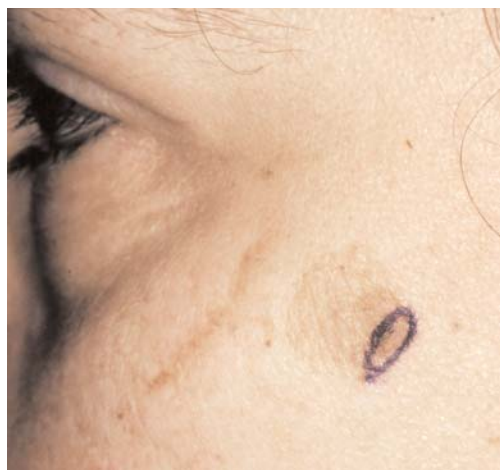

FIGURE 37-7 Large multicolored pigmented lesions should undergo biopsy with a full-thickness incision at the darkest area.

great number of tumor-infiltrating lymphocytes and a lack of vascular invasion improve survival prognosis.⁷

Controversy exists regarding the value of elective lymph node dissection (ELND), although it is well accepted that there is no benefit to ELND performed concurrently with primary tumor resection. Our current management protocol is not to suggest ELND or sentinel node biopsy for lesions measuring < 1 mm or > 4 mm. Intermediate depth tumors (1–4 mm) are referred for sentinel node biopsy based on studies suggesting that it increases the 5-year survival rate by 10% (ie, from 35 to 45%) (Tables 37-2 and 37-3).⁵²

Management of NMSC Lesions

Regardless of the obvious appearance of some cancers, a biopsy should be performed for histologic confirmation and

Table 37-3 Melanoma: Biopsy Strategies		
Tumor Thickness	Margin Excision	Lymph Node Dissection?
Lentigo maligna, in situ	5 mm–1.0 cm	No
Melanoma < 1.00 mm	1 cm	No
Melanoma 1.01–4.00 mm	2 cm	Possible sentinel lymph node dissection 1.0–4.0 mm
Melanoma > 4.01 mm	2–3 cm	For diagnostic purposes

typing. The histologic characteristics influence clinical behavior, recurrence, and metastatic potential. Determination of margin size for tumor clearance should be based on a compilation of all available information.

Biopsy techniques are personal. Any technique that delivers adequate histologic material for diagnosis is acceptable. Shave biopsy with a scalpel or curved razor blade is simple. Shave biopsy leaves a 5 to 6 mm saucer-shaped defect, removing epidermis and some dermis. The only drawback to shave biopsy is that histologic and prognostic features may be deeper than the shave. Thus, a shave biopsy might potentially be so superficial as to limit pathologic differentiation between an in situ versus an invasive lesion. Shave biopsy is contraindicated in potential melanomas. A “pseudoshave” biopsy might be performed with a curetted specimen prior to electrodesiccation.

Punch biopsy garners a full-thickness specimen. The punch has a circular cutting edge, which is pushed and turned into a suspicious lesion just like a hole saw. The punched out defect may be sutured or may heal secondarily. Punch biopsies, although

worthwhile for melanoma in which depth discernment is critical, may be too aggressive for a superficial lesion as the punch may force the tumor deeper into tissue.

Incisional and excisional biopsies are well known to surgeons. Deciding whether to use one revolves around whether the diagnosis is obvious (eg, a dysplastic nevus in a patient with a history of them), the tumor size, and whether a small biopsy will influence the excision clearance margin. When indicated, excisional biopsies should be oriented with sutures or dye for tumor margin clearance.

Fine-needle aspiration (FNA) may also be used to obtain specimens for histologic examination of deep material. FNA is worthwhile to differentiate a dermal cyst from a parotid tumor in the periauricular region. With FNA the pathologist aspirates tissue with a 23- or 25-gauge needle and stains and fixes the material on a glass slide.

Once the pathologic diagnosis of skin cancer is confirmed, the surgeon plans for tumor destruction by correlating tumor characteristics with patient’s age, skin history, medical history, social history, and cosmetic expectations. Treatment options

Table 37-2 Melanoma: Survival Rates			
Breslow Classification	Clark Classification	Tumor Thickness (mm)	5-Year Survival (%)
No evidence of primary tumor	I. Tumor in epidermis (noninvasive)	< 0.76	99
Thickness > 0.76 mm	II. Melanoma cells in papillary dermis	0.76–1.5	94
Thickness 0.76–1.5 mm	III. Melanoma cells fill papillary dermis	1.51–2.25	83
Thickness 1.51–3.0 mm	IV. Melanoma cells in reticular dermis	2.26–3.0	72
Thickness > 3.0 mm	V. Melanoma cells in subcutaneous fat	> 3.0	< 50

might include liquid nitrogen cryotherapy, standard excision, Mohs' micrographic surgery (MMS), radiation, C and E, topical chemotherapy, laser ablation, photodynamic therapy, interferon, and retinoids. We review most of these options below.

Standard Excision

Commonly, skin cancers are excised and assessed for margin clearance. Exceptions include some AKs and some superficial SCCs or BCCs, which may be treated by other modalities.⁵² Excision may be done under local anesthesia or in the outpatient surgery setting. Tables 37-4 and 37-5 outline acceptable margins for clearing most lesions.

The lesion and indicated margin for clearance is outlined with a marking pen. Local anesthesia with epinephrine does not affect pathologic margin assessment but may reduce the surgeon's ability to monitor vascularity to an adjacent random flap. Clearer delineation of tumor margins may be enhanced with adjunctive procedures for melanoma, BCC, and AK. In the case of melanoma, subcutaneous extension should be viewed with a Wood's light. In the cases of BCC and AK, pre-excision curettage delineates tumor margins more accurately. Some BCCs, morphea-like and infiltrative, may not be as curetable as soft tumors, but the BCCs that are curetable have a 25% higher chance of being cleared with the first excision than if excised without curettage (Figure 37-8).⁵²

Ideally, specimens should be examined histologically on the entire lateral and deep margin. Circumstances may reduce the likelihood of this beneficial extensive eval-

Table 37-5 Margin Control for Basal Cell Cancers

<i>Tumor Description</i>	<i>Margin Control</i>
5 mm or less	2 mm
5 mm–1 cm	3–4 mm
1–2 cm	5–7 mm
> 2 cm, morphea-like, or unusual pathologic behavior	7–10 mm margin or Mohs' micrographic surgery or delayed reconstruction following permanent histology
Unusual pathologic behavior, recurrent tumors, tumors on lips, ear, nose, medial canthus, eyelids	Mohs' micrographic surgery or delayed reconstruction following permanent histology

uation. For example, frozen histologic evaluations (while the patient is anesthetized in the operating room) are often three to four representative "loaf-of-bread" slices. You can imagine how much time would be consumed should the pathologist section and examine a large tumor in toto.² To abrogate the inherent limitations of frozen sections, many surgeons routinely delay reconstruction until after all margins are cleared by permanent histology, or send the patient to a specialist in MMS.

Permanent histology after office excision and subsequent delayed reconstruction provides benefits to surgeon and patient alike. Office excision allows the patient to visualize the extent of the defect and to add input into personal reconstructive desires and expectations. The surgeon has the option to research effective methods of reconstruction away from the operating room and to subsequently go to the operating room with a plan; the patient will know prior to the surgery exactly where the scars will be located. Delayed reconstruction has been proven beneficial for patients receiving skin grafts as the

delay eliminates the potential for hematoma and may allow buildup of a higher granulation base.

MMS offers the same "delayed" opportunity. The patient's entire tumor is resected prior to reconstruction, which may be performed on an elective basis often up to a week later. The only surgical difference between immediate (within 24 h) and delayed reconstruction (≥ 48 h) is that defects reconstructed later are circumferentially excised for 0.5 to 1 mm to expose a new distinct margin. Debris may also need to be curetted from the base. Regardless, this step-by-step delayed technique is almost painless and does not foster infection (Figure 37-9).^{51,53} Antibiotics are not necessary.

Mohs' Micrographic Surgery

MMS is based on two principles: (1) most tumors spread by contiguous growth and (2) all tumor cells must be excised for cure. Dermatologist Frederic E. Mohs, MD, originated his method in the 1930s and published results in 1941. Mohs' technique evaluates the entire circumference and deep margins after frozen sections. Unlike the representative breadloaf method, in which the pathologist might suggest further removal of an entire positive superior margin of the tumor, Mohs' technique pinpoints the actual location of tumor extension. Identified tumor extensions are re-excised

Table 37-4 Margin Control for Squamous Cell Cancers

<i>Tumor Description</i>	<i>Margin Control</i>
Small, well differentiated	5 mm with orientation
> 1 cm	Increase margin size
Lesion on upper lips, eyelids, nose, ears, etc.	Consider Mohs' micrographic surgery

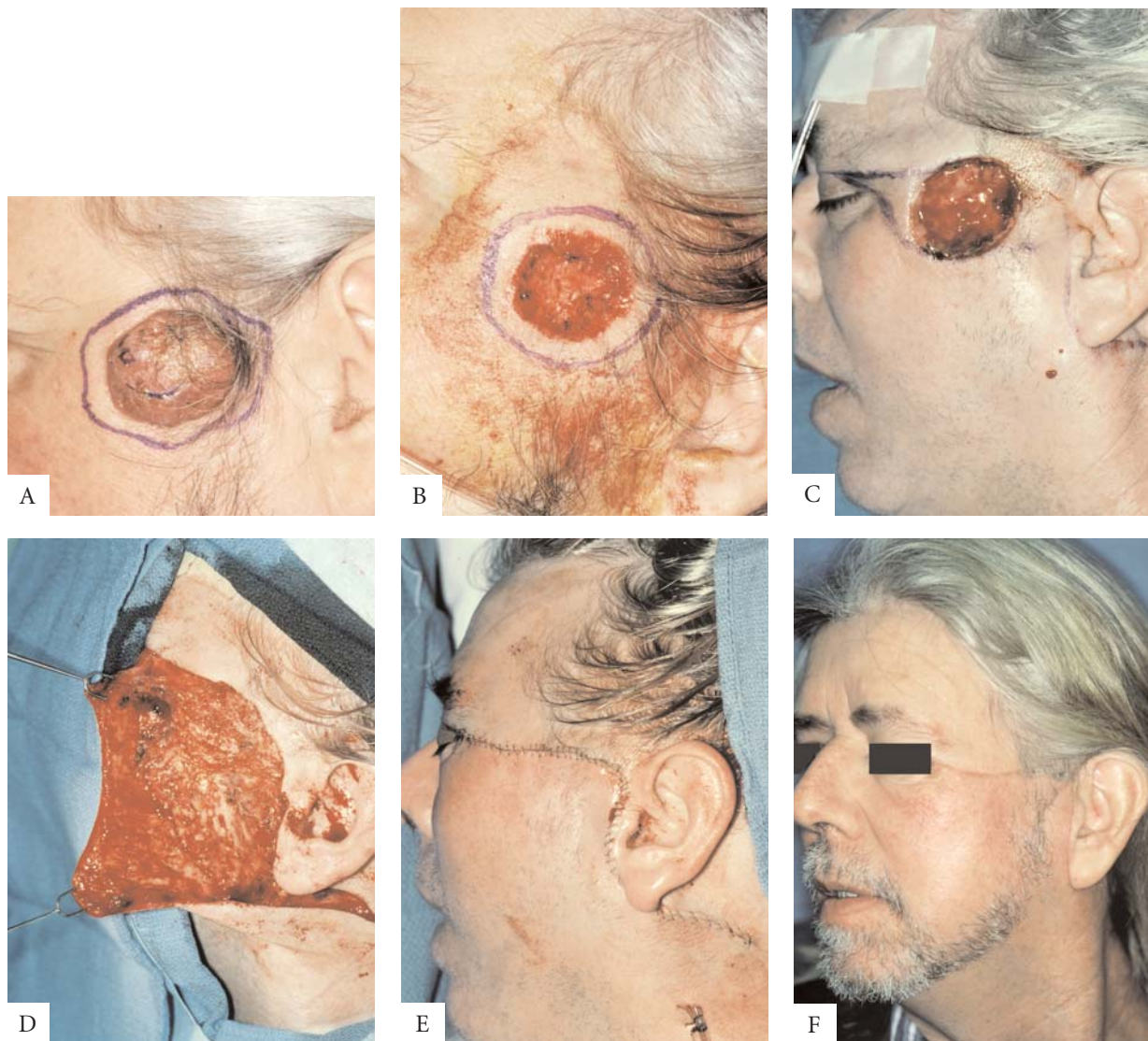

FIGURE 37-8 A, This 50-year-old man has what appears to be an imposing basal cell cancer. B, Curettage of the soft tumor allows easy visualization and control of peripheral and deep margins. C, Seven days after resection and margin clearance by permanent histology, a cervicofacial-type flap above the superficial musculoaponeurotic system is planned. D, The flap is advanced superiorly. E, Hairlines and sideburns are realigned. F, At 2 weeks the results are very esthetic.

and rescrutinized until the tumor is totally removed. Hence, MMS is more predictable for total cure and tissue sparing as well.^{54–56}

Over the years we have noted certain limitations to Mohs' technique, such as overconservative treatment for some aggressive tumors. This deficiency, not inherent in the Mohs' technique, is proved by the fact that not all microscopic extensions are visible to the human eye; therefore, even tumors excised with Mohs' techniques may recur. As a result, we believe

that a large SCC of the scalp is better served with an aggressive non-Mohs' excision. Controversy exists as to whether Mohs' technique is justified for melanoma and dermatofibrosarcoma protuberans, for example.

For a 1 cm nodulo-ulcerative BCC, Mohs' technique proceeds as follows: the lesion is debulked with a curette and then excised with a 2 to 3 mm margin angled at 45° toward the center of the tumor. The specimen is anatomically oriented, subdivided into numbered color-coded sec-

tions, and mapped. Mapped segments are pressed flat on their freshly cut border, frozen, and sectioned so that the entire fresh border is visualized.

The cure rates for primary BCCs < 2 cm treated with MMS approach 99% (vs 90–95% by routine pathologic examination).^{56,57} Standard vertical breadloaf sections evaluate < 1% of the surgical margins. Recurrent BCC cure rates range from 94 to 96% with MMS versus 85% with other modalities.^{56,57} For primary SCC, MMS boasts a cure

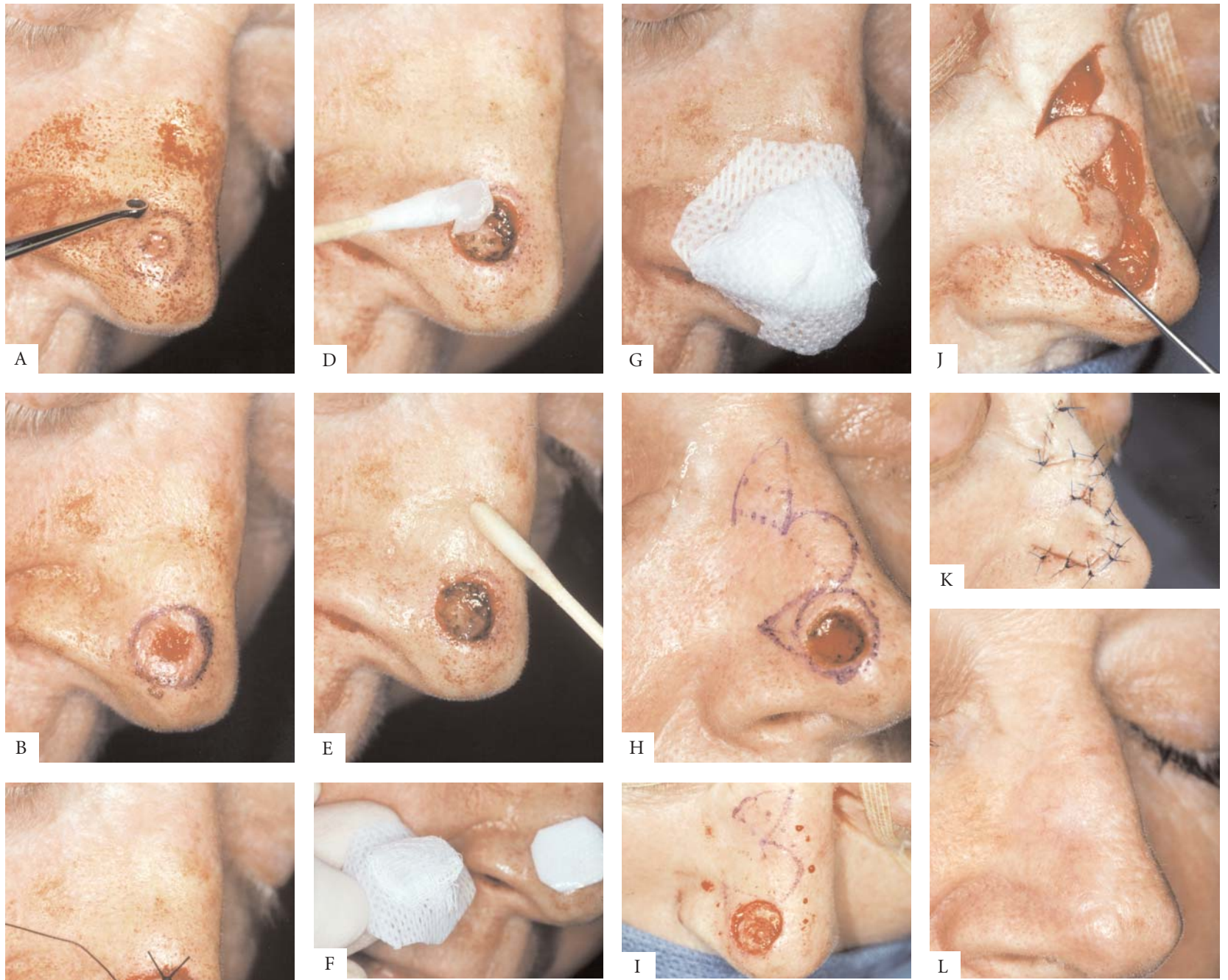


FIGURE 37-9 A, In the office the surgeon, donning nonsterile gloves, curettes (with a dermatologic curette, pictured) this biopsy-proven nasal basal cell cancer. The patient is under local anesthesia. B, Curettage reveals that the tumor is small and superficial. C, After tagging the tumor for margin identification (always short 12:00 superior and long left or lateral), the wound is dressed very specifically. (If there is any potential bleeding, a piece of surgicel may be placed at the base). D, Bacitracin is swabbed only within the defect. E, Mastisol or tincture of benzoin is wiped peripherally. F, A nonadherent dressing covers the wound base; the overdressing has an absorbent piece of gauze within a conforming mesh bandage, which is placed over the wound. One or 2 days later, in the office the surgeon, donning nonsterile gloves, removes the dressing. This procedure is performed without the use of anesthesia. The area is cleaned with 50:50 peroxide and water, and the patient is instructed how to redress the wound daily after a shower (which includes washing out the defect with mild soap and water). G, The patient dresses the wound with bacitracin, a nonadhesive dressing, and tape only. No scabs should form. In this case the histology analysis returned declaring that the superior tumor margin was within one high-power field. H, On the day of surgery, a small amount of tissue is planned for excision superiorly (and peripherally to square the margins), and a bilobed flap is planned as the defect is < 1.5 cm in diameter. I, The excisions have been made. J, During the closure the entire nasal dorsum is undermined submuscularly and supraperichondrally. K, The second lobe of the flap is oriented perpendicular to the alar rim to avoid lifting the rim. L, After 2 months the result is excellent.

rate from 94 to 99% as opposed to 90% for non-Mohs' techniques.^{39,54,58} Recurrent SCC cure rates with MMS approach 90% as opposed to 76% for other treatment modalities.⁵⁴

Under these circumstances MMS is indicated for the treatment of recurrent BCC, histologically difficult BCC (ie, micronodular, infiltrative, and morphealike), and BCCs in which conservation of tissue is critical (eg, on the nose, lip, ear). For SCC, MMS might be indicated for lower lip cancer, some poorly differentiated SCCs, and areas where maximum tissue preservation is essential.⁷

Radiation Therapy

Radiation therapy (RT) has been mentioned for treatment of skin malignancies for almost a century, but currently it plays a role as an adjunctive or salvage measure, rarely a curative role. The curative advantage of radiation is preservation of normal tissue next to the irradiation site. RT might therefore be considered for the eyelid, lip, nose, and ear. Unfortunately, RT conveys some unwanted potential side effects: cutaneous erythema, necrosis, hypopigmentation, telangiectasia, atrophy, fibrosis, hair loss, delayed healing, and risk of the development of future NMSCs when administered to younger patients.⁵⁹

RT of tumors < 2 mm has a cure rate of 90% and 85 to 95% for BCC and SCC, respectively.^{60,61} However, larger lesions have a much lower success rate. For melanoma, local recurrence rates of up to 50% have been reported.⁶² Thus, RT for melanoma is only a viable option for medically compromised patients who cannot withstand surgery or for patients who refuse surgery.

Cryosurgery

Cryosurgery destroys skin cancers and some adjacent tissue by freezing. Cryosurgery cure rates for AK, BCC, SCC, and lentigo maligna range from 94 to

99%.^{63,64} Liquid nitrogen may be sprayed on the lesion directly or through a cryoprobe. Rapid freezing of the treated skin occurs as heat is transferred from the skin to the probe. Intracellular ice crystals form, and cell membranes disrupt as the temperature is lowered to -50°C to -60°C . When thawing occurs electrolytes recrystallize, resulting in vascular stasis and local alterations in the microcirculation, thus producing further tissue damage.^{2,65}

Most doctors freeze lesions plus a 4 to 6 mm margin to account for tumor extension. Freeze-thaw cycles may be repeated for maximal effect. Healing occurs by secondary intention, with a flat hypopigmented scar.

The side effects of cryosurgery include pain, erythema, edema, blistering, exudation, and scarring. This technique is inexpensive, and there are no costs for pathology. Hence, a lesion chosen for cryotherapy should be relatively small and well demarcated.

Curettage and Electrodesiccation

C and E is a cost-effective but technique-dependent therapy of NMSC. The lesion area is cleaned with alcohol, outlined with a provisional margin by a skin marker, and anesthetized. The lesion is curetted aggressively with the skin tensed, after which electrodesiccation (hyfrecation) for hemostasis and adjacent tissue kill occurs. This cycle may be repeated three to five times.

The major advantage to C and E is expedience, fostering treatment of multiple lesions within a single visit. Disadvantages include prolonged healing, often weeks depending on size and care, hypopigmentation, and possibly hypertrophic scar. Material from curettage may be sent for initial pathology, but margin control after C and E is not possible (unless curettage is used as a precursor to excisional pathology).

The clinician's experience and the tumor's anatomic site and size are prognostic factors limiting success following

C and E. BCCs < 5 mm have an 8.5% recurrence rate after C and E by an experienced clinician.⁶⁶ Lesions of the nose, ear, and perioral and periocular areas may recur at a rate of 16%.⁶⁶ This rate soars to 26% for lesions > 20 mm.⁶⁶ Therapeutic C and E is therefore contraindicated for larger lesions, poorly differentiated SCC, or melanoma.

Topical Chemotherapy

Topical 5-FU or 5% imiquimod medically eliminates surface lesions. Retinoids are occasionally used concurrently. 5-FU is a thymine analog that interferes with DNA synthesis causing cell death by acting as an inhibitor of thymidylate synthase. Imiquimod induces production of interferon- α and messenger ribonucleic acid cytokines. Application of 5-FU is recommended twice daily for 2 to 3 weeks for superficial AK and for 3 to 6 weeks for more diffuse worrisome lesions. Imiquimod is applied only three times per week but currently is much more expensive than 5-FU. Cure rates with 5-FU and imiquimod range from 92% for SCC in situ to 95% for superficial BCC and AK.^{2,67}

Patients need to be warned that there is an ugly inflammatory scabby reaction during topical therapy, but the cosmetic outcome is usually very good as long as compliance is nurtured.

Lasers

The CO₂ laser focuses a beam of light with a wavelength of 10,600 nm. Laser light is absorbed by water and nonselectively vaporizes the skin. The CO₂ laser can be used as a cutting instrument (in the focused mode) to excise or ablate lesions (in a defocused mode) such as multiple AKs, superficial BCC, and SCC. We have found its greatest benefit in ablation of superficial AK and superficial SCC, both on the skin and lower lips. Presurgical skin preparation with retinoids may foster more rapid healing. We have not prescribed preoperative antibiotics or antivirals for small

localized areas but continue to do so when large areas of the face are treated.

Photodynamic Therapy

Photodynamic therapy is not widely accepted for skin cancer therapy but has been applied to lung, breast, colon, and bladder cancers. Aminolevulinic acid is wiped on a lesion; it is metabolized in cancer cells to produce porphyrins, which act as photosensitizers. Four to 6 hours later, the area is irradiated with visible light from a laser or noncoherent light source. Reactive O₂ species are generated within the cells producing cell death.⁶⁸

Cure rates for photodynamic therapy for AKs, superficial SCC, and BCC are reported to be > 90% in some studies, but tumors thicker than 2 mm are photoresistant.⁶⁹

Interferons

Interferons are cytokines that may effect cell growth and differentiation and accent immune responses and antiviral activity. Intralesional injection of interferon- α can attain cure rates of > 80% for superficial and nodulo-ulcerative BCC.^{70,71}

Retinoids

Retinoids are vitamin A derivatives that are crucial for control of cell growth, differentiation, and apoptosis. Topical retinoids are somewhat effective against AKs but much less so against even superficial BCCs and SCCs. Application of retinoids as a skin cancer preventative is a long-term proposition as the effects of the drug plateau at around 6 months and reverse shortly after discontinuation.

Retinoids do appear to act synergistically with 5-FU and may be applied in an exfoliation regimen. Noted complaints include dryness and flaking, minor side effects compared with the clinical effects of 5-FU.

Applied Skin Anatomy

The skin is composed of two layers: the superficial epidermis and, beneath it, the

dermis. The epidermis is composed of four distinct layers. From deep to superficial, they are as follows: basal cell (stratum basale), prickle cell (stratum spinosum), granular cell (stratum granulosum), and keratin (stratum corneum). Cells from the stratum basale divide and migrate upward toward the stratum corneum. The dynamic epidermis turns over and exfoliates every 30 days. This is why buried epithelium from a cyst might continue to produce sebaceous keratin.

The epidermis contains four cell types: keratinocytes, Langerhans' cells, melanocytes, and Merkel cells. Keratinocytes constitute 80% of the epidermal cell makeup.

Langerhans' cells are antigen-presenting cells, which capture and process antigens and present them to skin-specific lymphocytes. Aging and significant sun exposure both lessen the total number of Langerhans' cells. This is one partial explanation for the increase of skin neoplasms in the elderly.⁷²

Melanocytes are of neural crest origin and are found in the basal layer. Melanocytes produce melanin, which, in turn, protects the nucleus of the keratinocyte from UV radiation. Although numbers of melanocytes are constant for all individuals, the activity of the melanocytes differs from one race to the next. For example, melanocyte activity in darkly pigmented skin is higher than in light-colored skin. As with Langerhans' cells, numbers of melanocytes decrease with age, another explanation for more skin cancers developing as we get older.^{73,74} Merkel cells, found in the epidermis and dermis, have an unclear function.

The dermis, situated between the epidermis and subcutaneous fat, adheres to the epidermis at the basement membrane. The basement membrane mechanically supports the epidermis and acts as a mechanical barrier. The two dermal layers are the superficial papillary dermis and a deeper thicker reticular layer. The dermis is com-

posed of collagen, elastic tissue, and ground substance. Collagen decreases by 1% a year throughout adulthood.⁷⁵ Topical tretinoin inhibits dermal collagenase, thus slowing the degradation rate of collagen.^{76,77}

Elastic fibers in the dermis provide skin with recoil. With aging, elastic fibers decrease causing skin laxity, bags, and jowls. Chronic sun exposure thickens elastic fibers, and clumps form in the papillary layer. Chemical peels, dermabrasion, and laser resurfacing can remove some of these clumps.⁷⁸

The dermal ground substance is made up of glycosaminoglycans, hyaluronic acid, chondroitin 4-sulfate, fibronectin, and dermatan sulfate. These constituents hydrate the skin and maintain tensile elasticity.⁷⁸ The principle cell of the dermis is the fibroblast, whose functions include production of collagen, elastin, and ground substance. Fibroblasts enhance wound healing through contraction and production of scar.

Aging affects skin quality. Fine wrinkling, dermal atrophy, and a decrease in subdermal adipose tissue are aging phenomena. Epidermal regeneration may slow down by up to 50%, retarding secondary wound healing.⁷⁹ (Note: Isotretinoin retards epithelial regeneration chemically; hence, elective surgery should be limited on patients having used isotretinoin until the medication has been discontinued for 6–8 mo.) Natural collagen decreases in quality and quantity. Skin becomes more compact as the collagen rearranges itself into thick coarse bundles or loosely woven straight fibers. The dermal blood vessels may be collapsed, disorganized, or absent in the elderly, potentiating a greater risk for flap necrosis.^{21,80}

Skin has a rich nerve supply. In the epidermis the Merkel cell may provide touch perception. Meissner's corpuscles, located in the papillary dermis, provide fine touch sensation. Pacinian corpuscles, located in the deeper subcutaneous tissue, mediate deep pressure and vibratory

sensation. Autonomic efferent nerves innervate blood vessels and appendageal structures. Hair-bearing skin is commonly referred to as nonglabrous and smooth non-hair-bearing skin as glabrous. Skin conditions vary between individuals and from region to region with respect to mobility, color, scars, Fitzpatrick type, texture, thickness, and adnexal structures.⁸¹

The blood supply to the skin serves two functions: nutrition and thermal regulation. Two major routes of blood supply exist—musculocutaneous and septocutaneous arteries.⁸² The musculocutaneous system traverses the muscle and enters the subcutaneous tissue in a random pattern (the basis for random skin flaps). Random-pattern blood flow to the tip of the flap is via the interconnecting subdermal plexus. The superficial vascular plexus located in the reticular dermis provides the capillary loops in the dermal papillae. The deeper vascular plexus, or subdermal plexus, lies between the dermis and subcutaneous fat. A septocutaneous vessel travels through the septal fascia and courses parallel to the skin surface with an accompanying vein. Named septocutaneous vessels (eg, supratrochlear) provide an axially based flap with a rich blood supply. A large interconnecting vascular arcade exists between the systems.⁸³ Understanding the facial vascular network is crucial to creating flaps that survive.

Flaps and Grafts and Secondary Intention Healing

Definitions and Concepts The removal of any tumor leaves a defect. The hole created after tumor excision may be called the primary defect. The secondary defect is the wound created after tissue is transposed to close the primary defect. Every flap creates a potential secondary defect. Ideally, secondary defects should be easy to close, within relaxed skin tension lines (RSTLs), in areas of loose adjacent tissue, and within anatomic boundaries.⁸⁴

Options for defect repair include (1) primary closure, (2) local or distant flap, (3) graft, and (4) healing by secondary intention. Elasticity and movability are two inherent skin characteristics that enable relocation and, perhaps, primary closure. Elasticity is the ability of the skin to stretch. Skin in the cheek and neck is very elastic. Movability is not related to elasticity. Temple skin is less movable than cheek skin, and the scalp is relatively immobile.

Flaps move tissue, skin and subcutaneous from one area to another with an accompanying vascular supply. Flaps are cosmetic, use well-matched skin, and functionally protect underlying structures such as bone or cartilage, which may not have adequate blood supply to support a graft. Three types of “impure” flap movements are classically defined—advancement, rotation, and transposition—although some suggest there are only two types of movement—sliding and lifting.^{84–86} *Sliding* refers to stretching or mobilizing tissue from one site to another (advancement and rotation). *Lifting* tissue across a bridge of normal tissue to close a defect is similar to transposition.⁸⁴ All flaps (except free flaps) have some pivotal restraint, whether it be adjacent skin, subcutaneous tissue, or blood vessels.

Delay increases viability to a flap by enlarging and realigning the subdermal vasculature plexus. It is now known that skin flap reliability is based on “angiosome” units; therefore, wide and thin random flaps run out of blood supply in roughly the same location. Delay may augment survivability. Methods include raising and suturing tissue without disturbing the pedicle, and tissue expansion. Subsequently (9–12 d later), the flap is mobilized.^{84,87} The mechanisms that increase the blood flow with delay include the depletion of vasoconstricting substances, formation of vascular collaterals and reorientation of vascular channels, stimu-

lation of an inflammatory response, and release of vasodilating substances.

Esthetic flaps are not mere hole fillers. They are designed to complement natural esthetic units and facial borders. Defects that trespass multiple esthetic units are designed to reproduce these independent units. For example, a cheek tumor defect that encroaches on the nose might be reconstructed with different flaps and/or grafts for the cheek and nose.

Grafts are easy to position into recipient defects and are ideal for monitoring tumors. Grafts must be placed on a well-vascularized bed. Sometimes exposed bone should be allowed to build a granulation base before grafting. Grafts may be of full thickness or split thickness. Harvesting methods include punching, shaving with a dermatome, and excision. Graft donor sites are selected based on esthetic and tumor considerations. Ideally, grafts to the nose are well matched with preauricular skin, but any supraclavicular facial graft (from the blush area) matches the facial color better than does any torso or thigh graft.

Healing by secondary intention is a painless but time-consuming process. It is indicated for patients who do not want more surgery, who can accept or obtain the daily care, and who can accept a scarred result. Secondary healing can be used for small defects (< 1 cm) or for larger defects in areas where the resulting scar would be inconspicuous or tumor observation is critical.

Healing by secondary intention is similar to open-wound therapy. Following tumor excision and hemostasis, the wound is dressed with antibiotic ointment (eg, bacitracin and/or polymyxin B sulfate). The outer edges of the wound are coated with an adhesive (eg, adhesive bandage or tincture of benzoin). A nonadherent dressing is applied over the wound and a small rim of peripheral tissue. This is topped with a dry piece of gauze to absorb any blood, which is then covered with a

contour mesh tape. When the defect is atop bone, the raw bone may be covered with two layers of moisture-retaining wet gauze, but any method that abrogates desiccation is acceptable (Figure 37-10).

Three days later the dressing is removed and the wound inspected. Any oozing and crusting should be removed with a 50:50 peroxide and water solution. The wound is redressed in three layers—antibiotic ointment within the wound followed by a nonadherent dressing, which is then covered with mesh tape. The patient redresses the wound in this fashion on a daily basis to keep the area moist and free

of scabs. Areas amenable to secondary epithelialization include the scalp, the retroauricular area, and some concavities away from mobile apertures. Secondary epithelialization would be a poor choice around the mouth, for example, where retraction might distort the lips.

Three caveats regarding secondary healing are useful to keep in mind. First, scabs should not form. Scabs hinder epithelialization and harbor bacteria. Second, continuous application of antibiotic ointment can lead to allergic reactions and yeast infections. This is more common with ointments that contain neomycin

sulfate than with bacitracin. Alternatively, petrolatum can be substituted for the antibiotic ointment. Finally, some patients can be so incapacitated by their medical illnesses that they cannot dress their wounds. Home health care nursing can be enlisted to aid in their daily wound care.

Skin Biomechanics Skin is a heterogeneous material with unique mechanical properties. As skin is stretched, the randomly oriented collagen and elastic fibers are stretched in the direction of the applied force. This continues until all of the available collagen and elastic fibers are

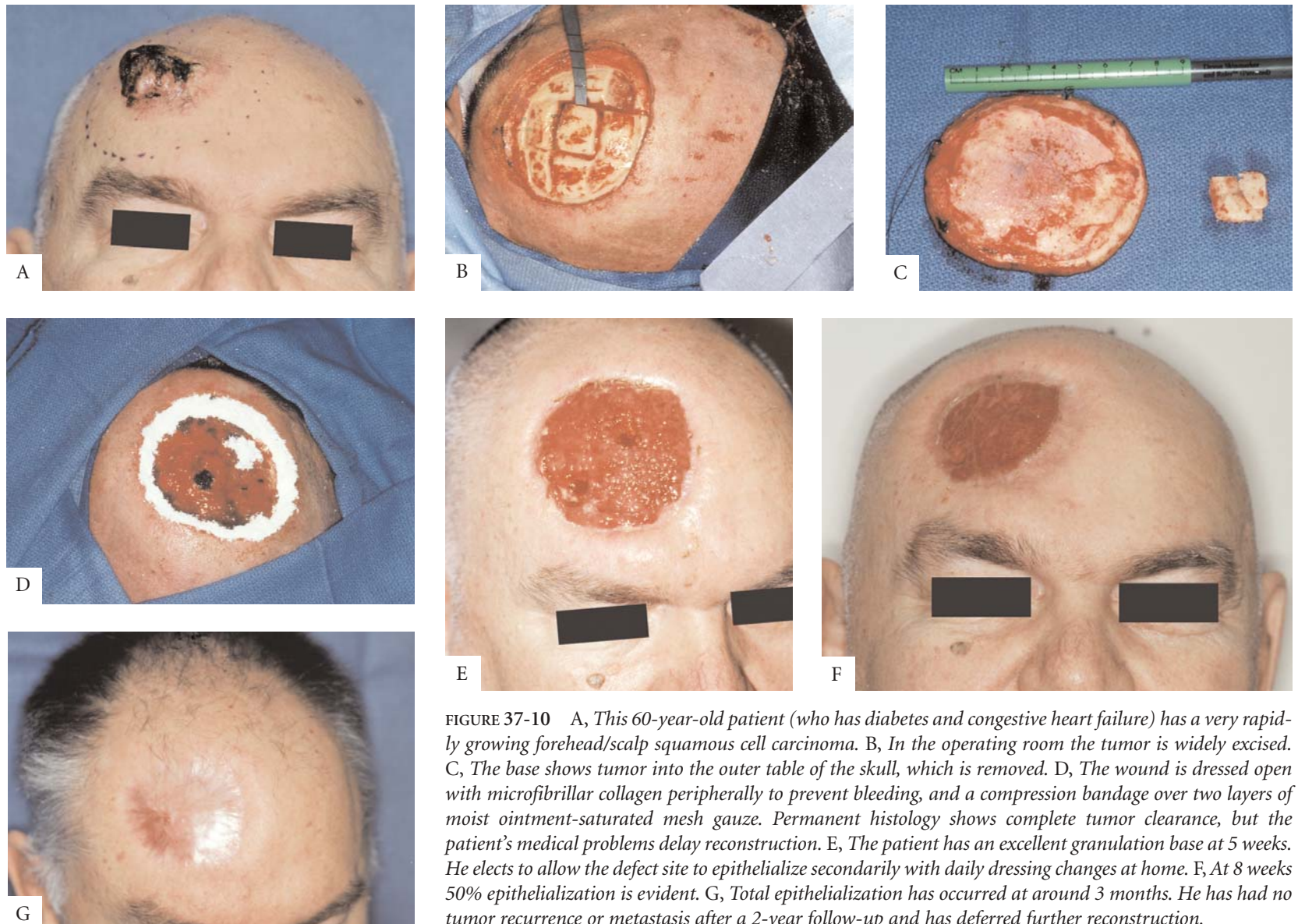


FIGURE 37-10 A, This 60-year-old patient (who has diabetes and congestive heart failure) has a very rapidly growing forehead/scalp squamous cell carcinoma. B, In the operating room the tumor is widely excised. C, The base shows tumor into the outer table of the skull, which is removed. D, The wound is dressed open with microfibrillar collagen peripherally to prevent bleeding, and a compression bandage over two layers of moist ointment-saturated mesh gauze. Permanent histology shows complete tumor clearance, but the patient's medical problems delay reconstruction. E, The patient has an excellent granulation base at 5 weeks. He elects to allow the defect site to epithelialize secondarily with daily dressing changes at home. F, At 8 weeks 50% epithelialization is evident. G, Total epithelialization has occurred at around 3 months. He has had no tumor recurrence or metastasis after a 2-year follow-up and has deferred further reconstruction.

recruited and no further lengthening occurs. After the maximum amount of stretch is reached, the skin may rupture. Permanent striae may scar the skin surface, as is often noted in pregnancy. Overstretching the skin collagen effaces the blood vessels under tension; thus, necrosis secondary to decreased perfusion to a distal flap may occur (Figure 37-11).⁸⁸

Skin tension exists in all directions on the face but is greatest along the RSTLs. Ideally, elective incisions should be placed parallel to the RSTLs. Incisions made perpendicular to RSTLs (or in the lines of maximum extensibility [LME]) gape and heal with more obtrusive scars.⁸⁹ The rhombic flap, once considered by many as the “workhorse” facial flap, has been used less over time because some of the final legs lie within the LME. Today flaps are more commonly designed with topographic units and RSTLs as primary considerations, rather than just to fill a hole.

Skin is elastic and stretches easily at low stress levels. This is related to the inherent extensibility of the skin. At higher forces skin may become viscoelastic,

that is, it can extend out a little more in spite of its thick state. This phenomenon is explicable through the two time-dependent characteristics: creep and stress relaxation.⁸⁸

Mechanical creep refers to the change in length that is seen when skin is held under a constant stress or force. The force that is exerted to stretch skin decreases with time.⁸⁸ The surgeon routinely notes this mechanism at work after he *tightly* sutures an avulsive forehead wound. Two days later the forehead is relaxed again. High stress loads therefore produce a degree of creep. The skin may not be totally relaxed for several months. Serial excision is a technique that harnesses the relaxation of skin over time. Wide defects may be closed sequentially over time.

Stress relaxation is the decrease in stress that occurs over time when skin is held under tension at a constant strain or is cyclically loaded.⁸⁸ It may be effected intraoperatively with the placement of a balloon under the skin or by scoring the scalp galea and pulling the skin. Additionally, there are skin stretchers that are made for this purpose (Figure 37-12).

Finally, *biologic creep* is a slow methodic stretching of skin, yielding brand new skin.⁸⁸ Skin expanders do just that (Figure 37-13).

Flap Undermining Safe flap closure of a defect is dependent on harnessing the inbred stretchable bendable nature of skin without exceeding the limits of stretch or blood supply. Some tissues can be stretched for centimeters without undermining occurring, whereas others must be separated from tethering subcutaneous tissues. On the other hand, a subcutaneous island flap, totally separated from the tether of skin, depends on the mobile vascular subcutaneous pedicle.

Undermining releases the vertical attachments between the dermis and subcutaneous planes, thereby reducing shearing forces and allowing the skin to slide and redrape in another position.⁷⁸ The mobilization benefits from undermining facial skin usually occur within the first 2 cm. Animal studies reveal that undermining beyond 4 cm produces little skin edge advance and possibly a more difficult stretch of tissue.^{90,91}

A correct undermining level provides the critical balance between mobility and blood supply. For example, simple random flaps, undermined in the superficial fat, are easy to raise on the cheek. Submuscular flaps maintain a robust blood supply to small relatively immobile nasal flaps.

Flap Designs *Advancement Flaps* An advancement flap is advanced linearly over a defect. It consists of a classic elliptic closure with adjacent undermining; there are no rotational or pivotal movements. Tissue elasticity provides adequate horizontal motion with a flat closure effected as Burow's triangles are removed from the ends. The length of the ellipse is three to four times the width of the defect.

Advancement flaps can be constructed with multiple modifications: simple,

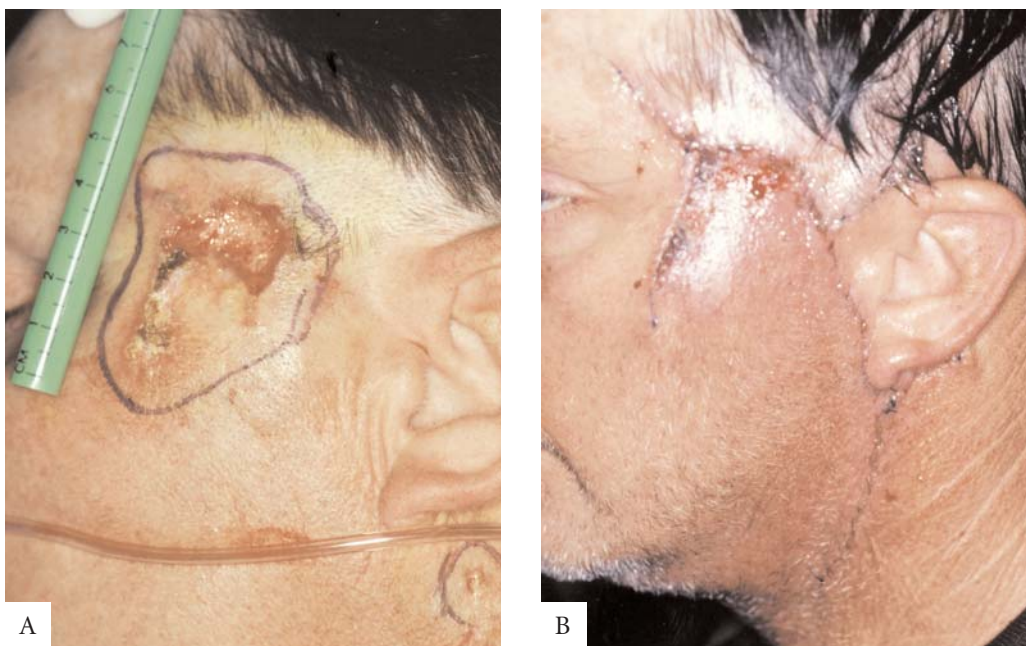

FIGURE 37-11 This large basal cell cancer was excised (A) and closed with two flaps (B). The patient, a smoker, had excess tension placed on the lower flap, leading ultimately to almost 1 cm of tip necrosis.

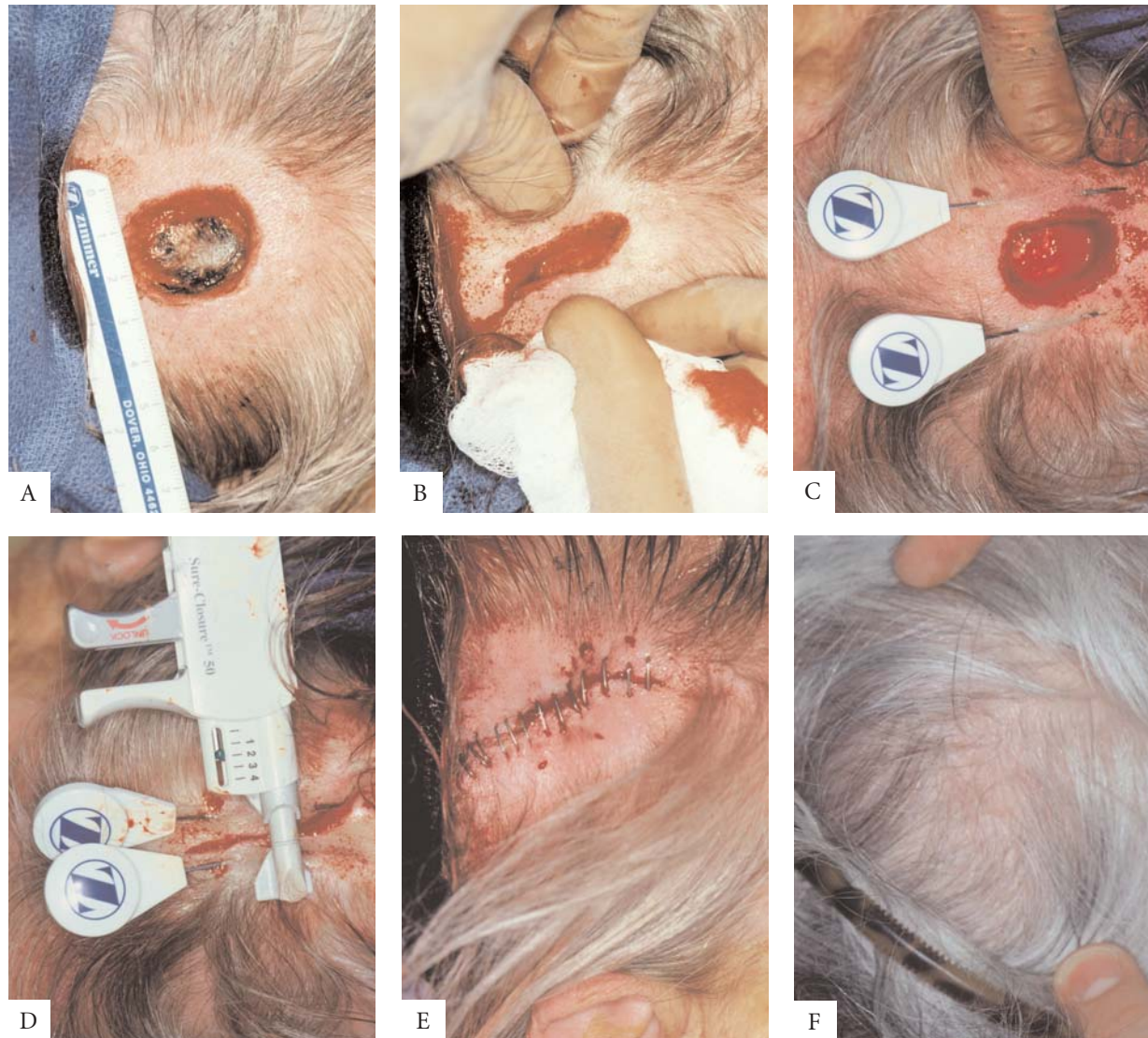


FIGURE 37-12 A, This 95-year-old woman has a relatively small scalp defect. B, Finger pressure shows that significant tension is necessary to close it elliptically. C, After limited subgaleal undermining, two pins are placed subcutaneously. D, A skin stretcher (courtesy of Life Sciences Medical) is hooked onto the pins. Slow loading is applied for 30 minutes. E, After the end triangles are excised, the wound is stapled closed. F, The site after 2 months.

square, bilateral, Burow's triangle repositioning, and A- or O- to T-shaped designs.⁹² The experienced surgeon realizes that the tethering forces of advancing skin also constrict the size of the leading edge. Modifications are useful in specific instances. All flaps, including simple advancement flaps, presuppose that the surgeon can disguise, adjust, transpose, or eliminate “dog-ears” or excess tissue that gathers as tissue is transposed.

There are seven ways to deal with dog-ears^{93–96}:

1. Do nothing; this approach works well on the scalp as bunched up tissue lies down with time
2. Close opposite lines of uneven lengths by spreading out the problem—halving (Figure 37-14A)
3. Remove the excess to a hidden area—an end or middle triangle (Figure 37-14B)
4. Lengthen the incision. This eliminates bunching (Figure 37-14C)
5. Perform an M-plasty (sometimes called a T-plasty), which shortens the problem (Figure 37-14D)
6. Reverse the S loop and hide the excess elsewhere (Figure 37-14E)
7. Advance the dog-ear as a flap (subcutaneous “island”) or use it as a free graft (Figure 37-14 F; also see Figure 37-6)

Rotational Flaps Curvilinear rotation flaps rotate from a tethered pivot point. These flaps fill triangular defects. The length of the arc is dependent on many variables, such as existing laxity, the size of the defect, the location, and blood supply to the flap.^{85,97–101} Rotation flaps rarely fit

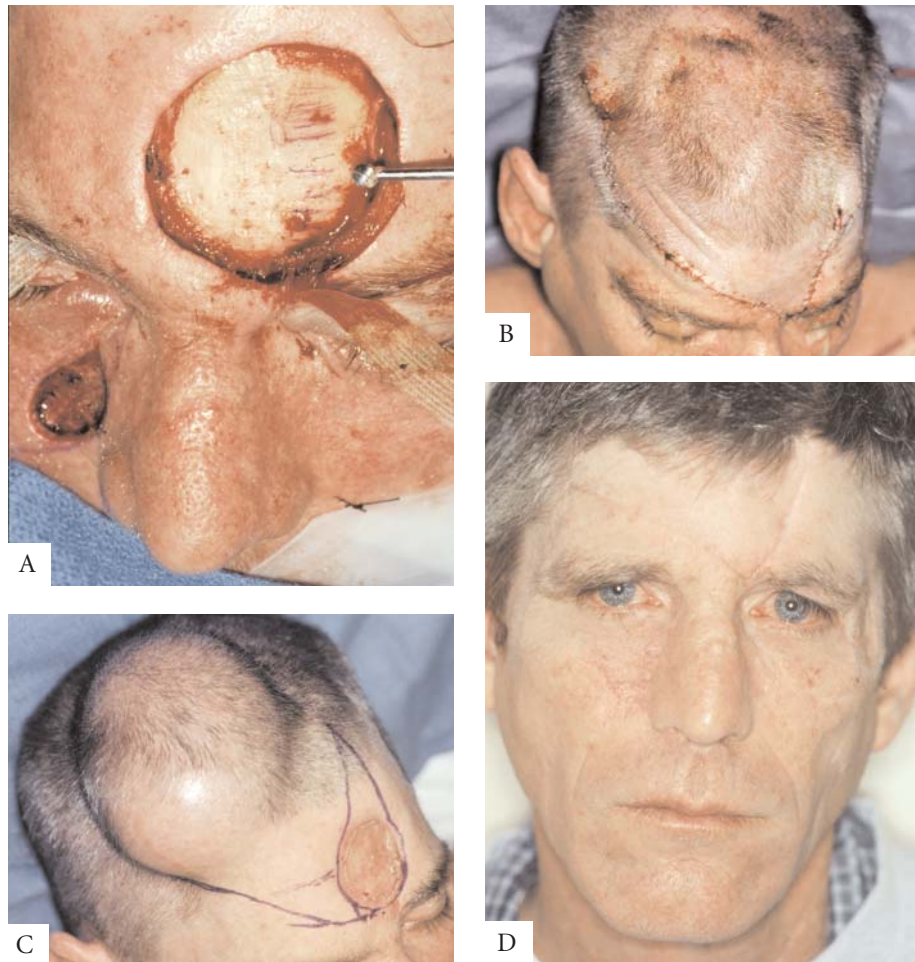

FIGURE 37-13 A, This 45-year-old heavy smoker had a squamous cell cancer removed from his midforehead and a basal cell cancer from the left temple. Direct advancement closure was impossible. B, After allowing some granulation tissue to form at the base, a split graft was placed on the midforehead. An 8×6 cm skin expander was placed laterally and expanded twice weekly for just over 2 months. C, The expanded rotation flap was mobilized to cover the midforehead defect. D, The result 1 month after closure. Note the well-healed direct closure of the right cheek defect and the depression of the left temple full-thickness skin graft.

perfected geometric schemes of success. Rather, the surgeon often finds himself adjusting to the specific variables of a given situation (Figure 37-15). There are two exceptions to this complexity that have been worked out fairly precisely:

1. The nasal bilobed flap of Zitelli has excellent results when applied toward lower or middle nasal defects of 1.5 cm or less.¹⁰² This occurs as long as the second lobe of the flap is perpendicular to the alar rim and the first lobe does not cross deep concavities such as the alar groove

2. The scalp rotation method of Ahuja fills defects of up to 3 cm with minimal adjustments¹⁰³

Advantages to rotational flaps include broad-based reliable vascularity, flexibility in design, and easy placement of scars into esthetic/cosmetic zones or RSTLs. A major advantage is that the flap can be rotated again should additional tissue need to be removed secondary to tumor concerns or should laxity be lacking.^{98,104}

Disadvantages to rotational flaps include the problems associated with any pivotal flap such as standing cutaneous

deformities and the need for larger flaps. Regardless, rotational flaps may be ideally designed to reconstruct medium to large defects of the cheek, neck, scalp, and forehead.

Transposition Flaps Transposition flaps transfer defined tissue along an arc of rotation, often over normal tissue, to repair a primary defect. Actual tissue movement may be rotational, linear, or both (Figure 37-16). Transposition flaps tend to be more confined than are rotation flaps, and design is critical for success. The design/location of the pivot point is the most important factor. After tissue is transposed, flap tensions should be diffused to prevent strangulation of tissue and distortion of adjacent structures. The regional differences in tissue mobility impact the geometry of the flap design, with the classic transposition being a rhombus.

The rhombic flap is an equilateral parallelogram with oblique angles. The (Limberg) rhombic flap, first described in 1963, was an equilateral rhombus with 60° and 120° internal angles.¹⁰⁵

According to the classic (Borges) design, eight potential rhombic flaps may close a defect. These flaps are constructed as umbrellas, drawn off the obtuse side of two potential parallelograms. These parallelograms each have two sides parallel to the LME. These LME are always perpendicular to RSTLs and run in the direction that tissue stretches most efficaciously.

The rhombic flap, whose short diagonal line parallels the LME and whose mobilization does not interfere with adjacent structures, is usually chosen for the rhombic transposition. The resulting tension vector in rhombic flaps lies 20° from the short diagonal in a loose tissue plane.

Dufourtmental, Webster, and others modified the classic rhombic design.¹⁰⁶ The Dufourtmental flap was designed to close rhombic defects with acute angles approximating 90° or a square defect. As

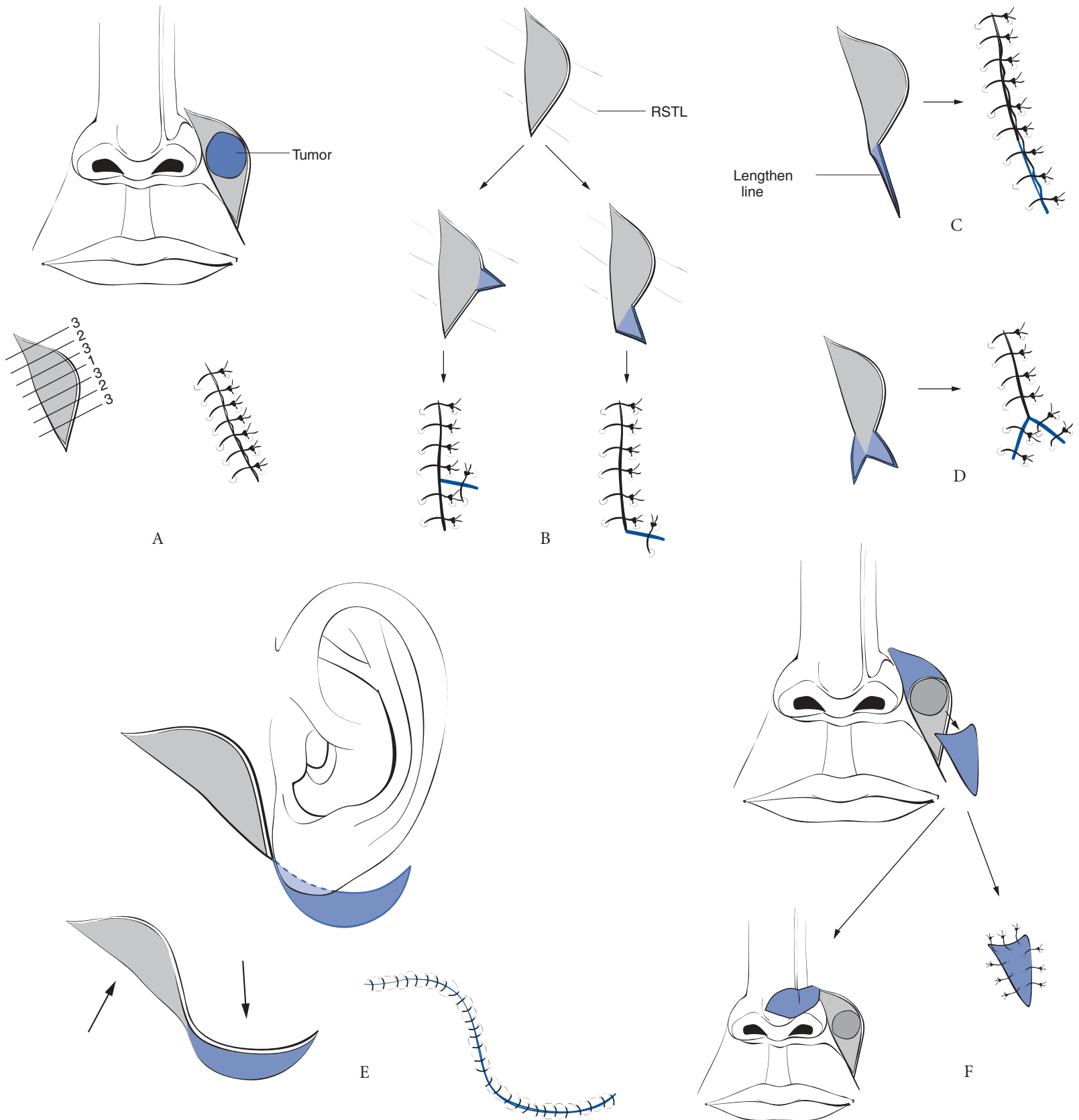


FIGURE 37-14 Six of the seven ways to deal with dog-ears (the seventh being to do nothing). A, Halving. Close opposite lines of uneven lengths by spreading out the problem. B, End or middle triangle. Remove the excess in a hidden area. C, Lengthen the incision. This eliminates bunching. D, M-plasty (sometimes called a T-plasty). This procedure shortens the problem. E, Reverse the S. Hide the excess elsewhere. F, Advance the dog-ear as a flap (subcutaneous island) or use it as a free graft (see also Figure 37-6). RSTL = relaxed skin tension lines.

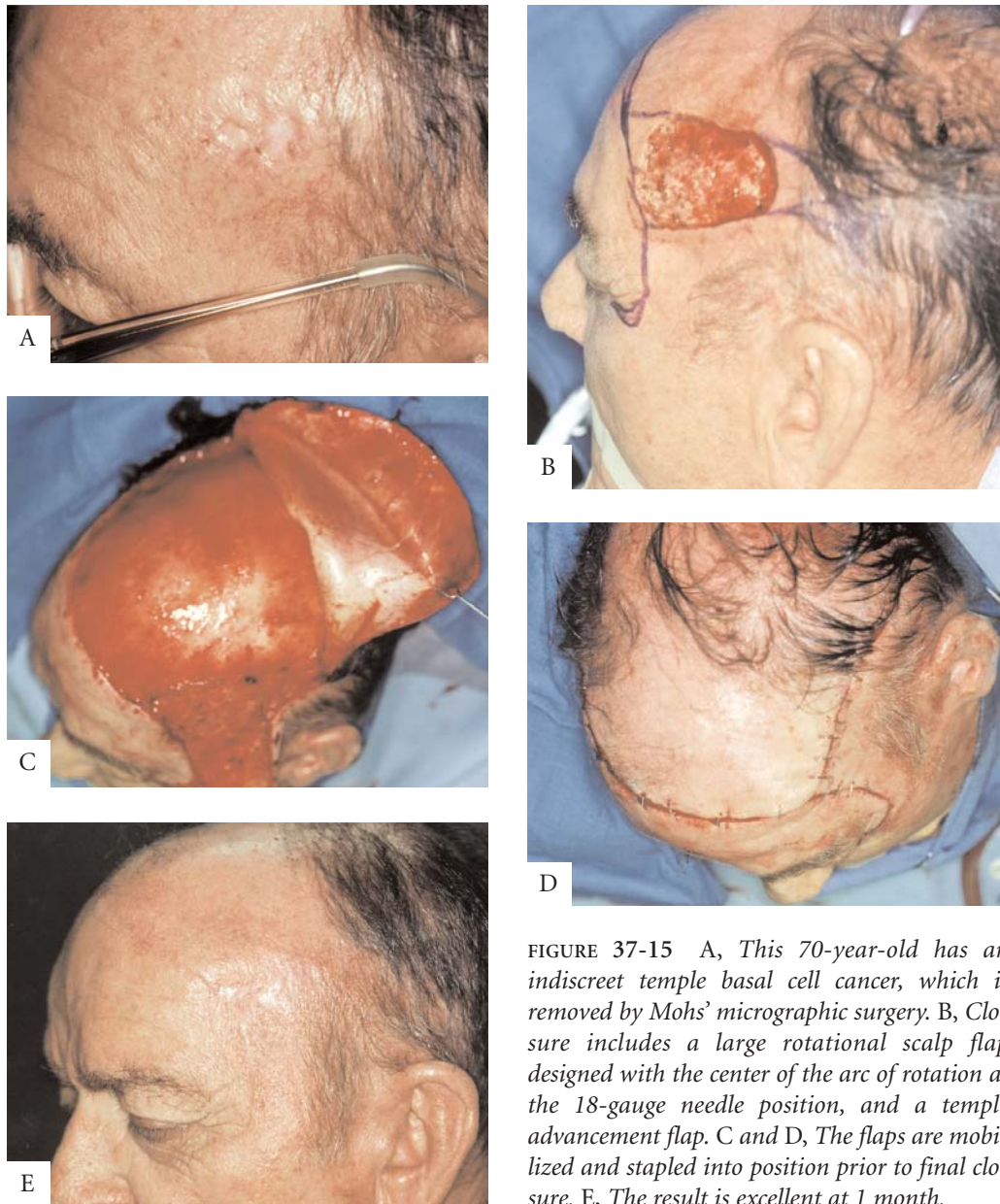

FIGURE 37-15 A, This 70-year-old has an indiscreet temple basal cell cancer, which is removed by Mohs' micrographic surgery. B, Closure includes a large rotational scalp flap designed with the center of the arc of rotation at the 18-gauge needle position, and a temple advancement flap. C and D, The flaps are mobilized and stapled into position prior to final closure. E, The result is excellent at 1 month.

with the Limberg design, the peripheral lines were equal in length, but unlike the rhombic flap, the short diagonal differed in angle size. Dufourtmental designed two isosceles triangles situated base to base. Once the sides of the triangles were drawn, the short diagonal was extended, as was one of the adjacent sides. A third line bisecting these two lines creates the first flap. The cutback line was drawn paralleling the long diagonal completing the second flap. The Webster 30° flap allowed for easier closure by bisecting the 60° angle into two 30° angles via an M-plasty.

Here, the short diagonal had to be at least 110° to prevent puckering and to maintain flap viability.

Rhombic, banner, note flaps, and others have been modified to close circular defects over all areas of the face.

Axial Pattern Flaps Axial pattern flaps are based on named vessels in the head and neck. Classic designs include the Abbe (Figure 37-17) and Estlander flaps and the paramedian forehead flap.⁹⁷ A full description of these flaps is discussed in Chapter 38, "Local and Regional Flaps."

Skin Grafts Skin grafting involves the removal of donor skin (epidermis and varying levels of dermis, fat, or muscle) from one area to revascularize at another. The success of skin grafts is based on factors that affect angiogenesis and capillary ingrowth into the graft.

Recipient bed vascularity and intimate graft-host contact as well as overall host health or condition affect graft success. Wounds with a poor vascular supply may not support a graft or may need to be prepared before grafting. Cartilage base; irradiated tissue; fibrosis; and foreign, crushed, or nonviable tissue can compromise success. Additional procedures, such as bringing in vascular tissue from elsewhere, may be required to optimize the recipient bed prior to skin grafting.⁹⁸

Bed vascularity may be compromised by bleeding or cautery to arrest bleeding. Thus, there is an inherent benefit to delaying grafting or placing a pressure bolster bandage on top of the graft to prevent bleeding. We do not touch full-thickness graft bolsters for 6 or 7 days.

Mechanical shear forces may disrupt contact between the graft and recipient bed, promoting graft failure. Although this may be minimized with appropriate suturing techniques as well as the placement of dressings, the force of a hard shower can dislodge a graft and should be avoided.

Wound infections rarely jeopardize skin grafts in the head and neck. It is common for surgeons to confuse the dark eschar of a failing graft in a smoker with infection. Regardless, some local measures that decrease wound bacteria include saline dressings, sulfadiazine silver, mafenide acetate cream, acetic acid solutions, sodium hypochlorite solutions, and vinegar and water.

A patient's overall medical health can influence the success of skin grafting. Autoimmune diseases such as rheumatoid arthritis, systemic lupus erythematosus, hematologic disorders, diabetes mellitus,

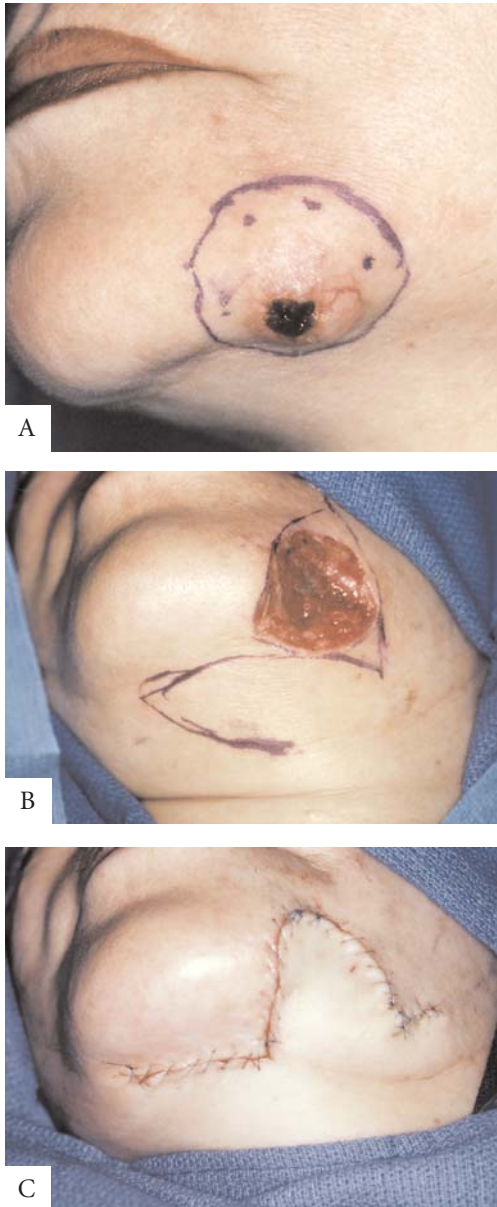


FIGURE 37-16 A, This 45-year-old woman has had a basal cell carcinoma for the past 3 years. B, It is repaired with a simple submental transposition flap. C, Perhaps the lateral submandibular bulkiness will need to be removed in the future, but the submental fat removal was highly esthetic.

poor nutrition, and smoking as well as medications such as corticosteroids and chemotherapeutic agents may compromise graft success.^{99–101}

Full-Thickness Skin Grafts Full-thickness skin grafts (FTSGs) are chosen when local or distant flaps are not feasible or when the FTSG would offer acceptable cosmesis

and function. Examples include the multi-operated face, upper nasal surface defects, nasal lining tissue, and medial canthal area. FTSGs resist contraction and may possess the texture and color of normal skin. In children FTSGs have the potential to grow.⁹⁸

The FTSG is preferred over the split-thickness skin graft (STSG) in areas where a wound contracture may lead to a functional deformity. An example is the lower eyelid, where wound contracture would result in ectropion. An excellent FTSG for this example would include upper eyelid skin and orbicularis oculi muscle, which has been shown to predictably revascularize.

Selection criteria for a head and neck FTSG directs the surgeon to carefully consider particulars of a variety of sites—the upper eyelid, post- or preauricular skin, and the lateral neck or supraclavicular region. For example, postauricular skin is photoprotected and has few adnexal structures, which may not be suitable for nasal defects. Preauricular skin grafts in males can lead to sideburn asymmetry. Supraclavicular and neck skin is thin and may be more photodamaged than the face. In addition, a supraclavicular scar may be a nuisance for women who wear clothing with low necklines.

The harvesting of most FTSGs involves cutting out a simple template of the defect (eg, from suture packaging) (Figure 37-18). Since an FTSG contracts by 10 to 15% after harvest, the donor graft pattern must be enlarged by around 20%.¹⁰² This contracture issue is critical in areas of mobility such as in the lower eyelid. Here, grafts should be enlarged by 150 to 200% vertically to avoid ectropion/contraction occurring.^{98,101}

The FTSG may be defatted with serrated scissors or by scraping with a blade. Defatting is complete when the shiny dermis is homogeneously exposed. FTSG should fit into a wound bed with maximum surface contact without any tenting.

Basting sutures may be used to affix the graft to the underlying bed to squeeze out dead space prior to peripheral suturing.^{98,103} Peripheral sutures are easier to insert when passed from the graft through the host skin with a tapered needle.

Any nonadherent (to the graft) bolster of cotton, gauze petrolatum dressing, or plastic, for example, secured a few millimeters outside the grafted tissue is acceptable. Some surgeons prefer to remove the bolster after 48 hours to inspect the surgical site

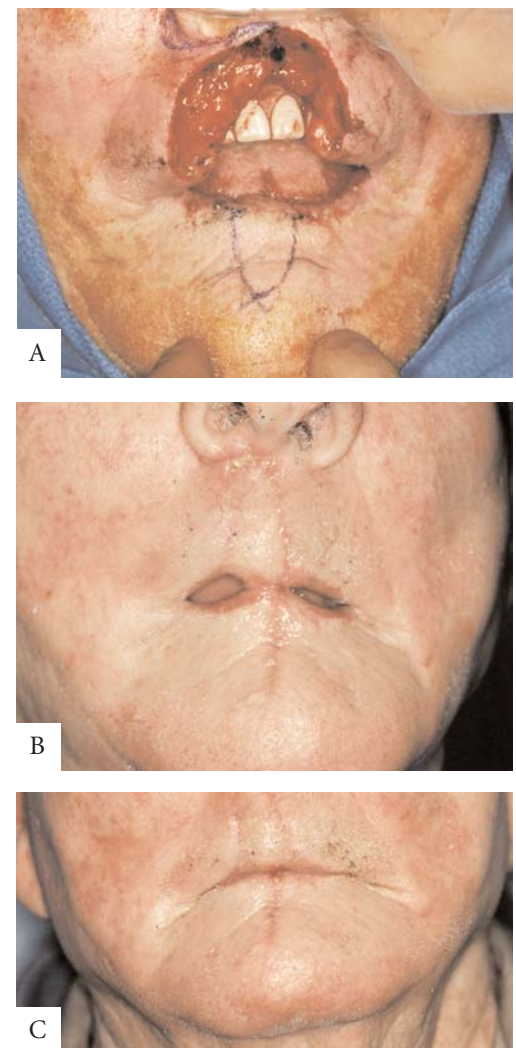


FIGURE 37-17 A, This 70-year-old man has a large basal cell cancer removed by Mohs' micrographic surgery. B, Subsequently a midline axially based Abbe flap is inserted. C, Three weeks later, the Abbe flap is divided and inset as an in-office procedure. The esthetic result 2 weeks later shows the flap is not exactly in the midline but simulates the philtral area effectively.

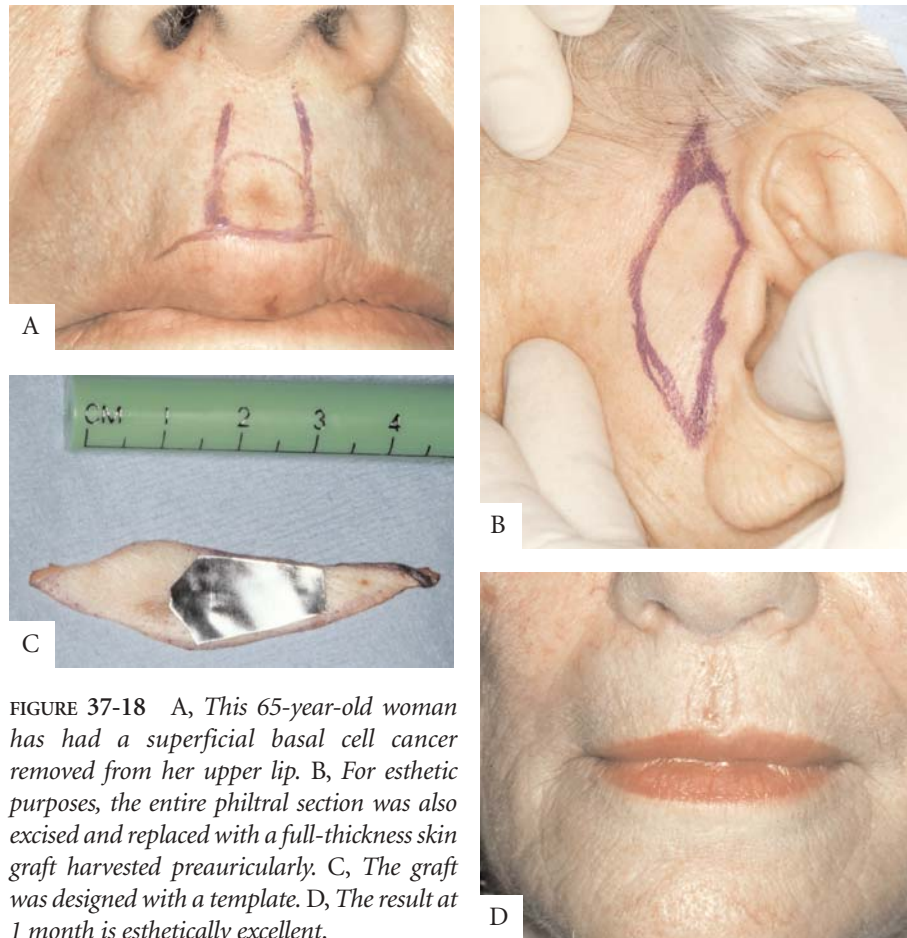


FIGURE 37-18 A, This 65-year-old woman has had a superficial basal cell cancer removed from her upper lip. B, For esthetic purposes, the entire philtral section was also excised and replaced with a full-thickness skin graft harvested preauricularly. C, The graft was designed with a template. D, The result at 1 month is esthetically excellent.

and then replace the bolster with a more conventional dressing.

FTSGs undergo an evolutionary sequence. Initially, a graft is white followed by a period of cyanosis or a bluish/violaceous hue. Subsequently there is a period of hyperemia or a red state, which fades over time until the graft assumes its normal color. If the graft fails, the entire epidermis turns black and sloughs off, followed by reepithelialization.⁹⁸ The necrotic graft acts as a biologic dressing, allowing healing to occur by secondary intention from the wound edges as well as from adnexal structures.

Split-Thickness Skin Grafts An STSG is defined as thin if its thickness measures 0.02 to 0.03 cm, medium from 0.03 to 0.046 cm, and thick from 0.046 to 0.076 cm. Thinner STSGs have improved survival rates compared with thicker ones because there is

greater exposure of the graft to the underlying vasculature, and less tissue is needed for revascularization. STSGs have a higher degree of contraction than do FTSGs and do not grow in children. Thin grafts afford less protection to the underlying tissues and do not withstand repeated trauma well. For example, an STSG may be chosen to cover a bare pericranium/skull after removal of a scalp tumor; subsequently, the patient may report breakdown sites or scabs from sleeping on the grafted sites.

STSGs are generally less pleasing cosmetically than are FTSGs and are employed for functional reconstruction (Figure 37-19).

STSGs are worthwhile for (1) wounds too large to repair with a local flap or an FTSG, (2) wounds requiring monitoring for tumor recurrence, or (3) temporary coverage of a wound prior to definitive

reconstruction. Contraindications include areas that might compromise functional or esthetic expectations.

STSG donor sites for facial reconstructions include the “blush zone” of the lateral neck and supraclavicular area and the scalp, owing to their similarity in color and texture. The hip, thigh, buttock, abdomen, torso, and inner aspect of the arm are also applicable at times.^{98,100,104}

There are varying types of dermatomes ranging from machine to manual. The Brown dermatome allows for precise modification of graft thickness. The graft dimensions should be at least 25% larger than the wound defect.⁹⁸ Other dermatomes include the Padgett, Davol-Simon, Castroviejo, Reese, and Padgett-Hood dermatomes and the Weck knife.

The sterile donor site is lubricated with mineral oil. Traction and countertraction are applied, and the dermatome is engaged and advanced with a slight downward and forward pressure. The donor site bleeds if it is cut in the correct plane. After pressure or thrombin control, a semipermeable occlusive dressing covers the donor site and is left in place for 1 week to 10 days. Semipermeable membrane dressings decrease the pain of the donor site and enhance wound healing by maintaining a moist environment.⁹⁷

Other dressing materials include Allevyn and Nobecutane spray. Allevyn is a hydrophilic polyurethane material that is highly absorbable and nonadherent. Its outer layer is waterproof and bacteria proof. The dressing is soft, absorbent, and comfortable for the patient. Nobecutane spray when applied on the wound forms a transparent plastic film. Nobecutane contains a modified acrylic resin in an organic solvent along with the bactericidal-fungicidal agent tetramethylthiuram disulfide. Brodovsky and colleagues showed that this spray is an effective temporary dressing that promotes rapid painless healing. The film is shed spontaneously with epidermal regeneration.¹⁰⁷

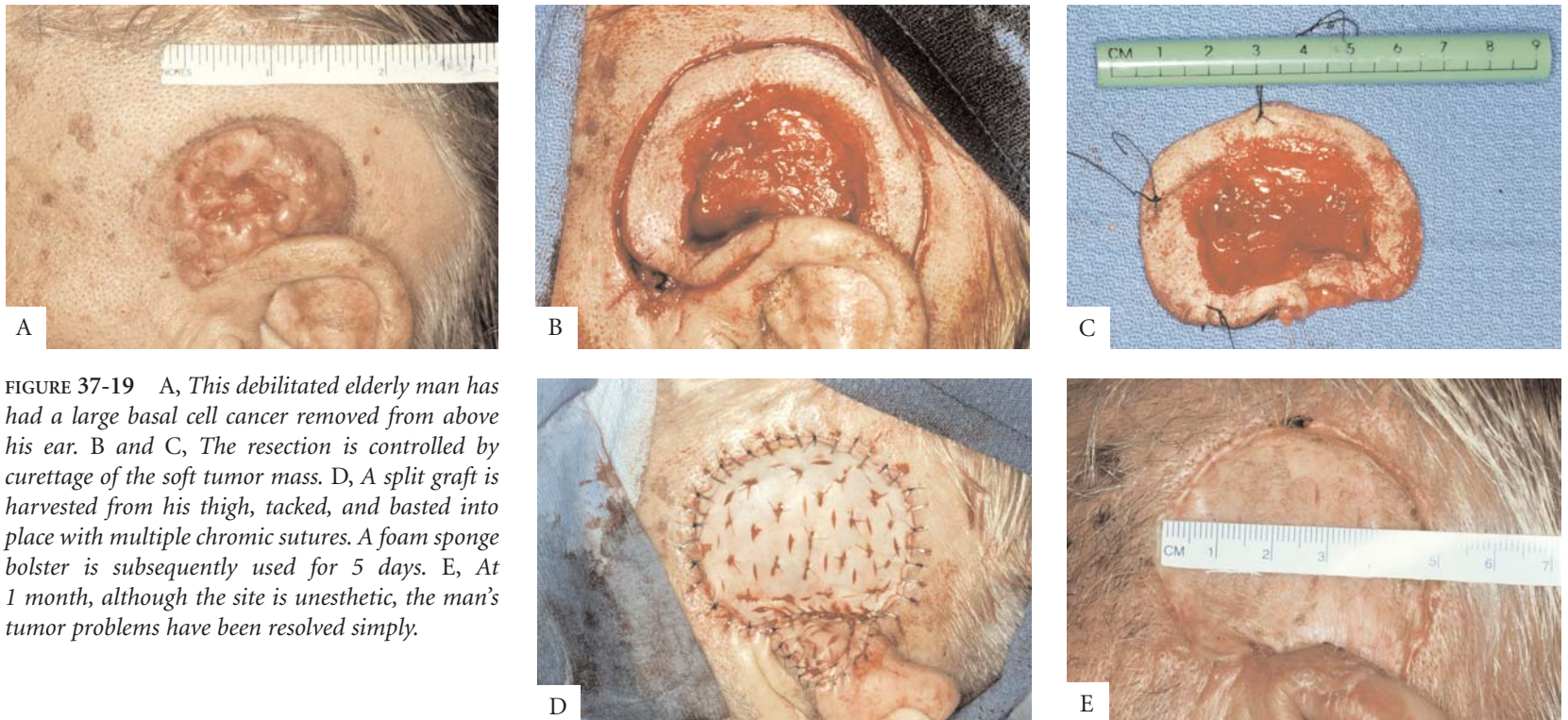


FIGURE 37-19 A, This debilitated elderly man has had a large basal cell cancer removed from above his ear. B and C, The resection is controlled by curettage of the soft tumor mass. D, A split graft is harvested from his thigh, tacked, and basted into place with multiple chromic sutures. A foam sponge bolster is subsequently used for 5 days. E, At 1 month, although the site is unesthetic, the man's tumor problems have been resolved simply.

Unlike for an FTSG, a tie-over dressing may not be necessary for STSG. A good compression dressing and/or basting stitches may suffice to promote adherence between the graft and underlying tissue and to prevent fluid accumulation. A variation to placing interrupted basting sutures is the spiral basting stitch. The suture is started at the edge of the graft with the “tail” left long.¹⁰⁸ The suture is then run along the periphery of the graft, spiraling toward the center, and then tied to the tail. The graft can then be dressed in a similar fashion to that for an FTSG.

Composite Grafts Composite grafts contain two or more tissue layers. Composite grafts are ideal for reconstructing the nasal ala rim, auricular defects, and eyebrows. Composite grafts are able to maintain the thinness and contour of the structure with minimal contracture. The most common donor site for composite grafts is the ear, including the crus of helix, rim, antihelix, tragus, and earlobe.

A major disadvantage to composite grafts is the risk of graft failure, which is higher than for FTSG and STSG and is attributed to the high metabolic demands of the grafts. Harvesting (donor) adjacent dermis attached to the composite graft and inserting the de-epithelialized dermis into adjacent subcutaneous tunnels (recipient) may improve vascularity substantially.¹⁰⁹ Cooling the composite graft with ice for 24 hours also helps.

Regardless, composite grafts are technique sensitive. Generally, composite grafts should be no larger than 1.5 to 2.0 cm. Avelar and colleagues have shown composite grafts greater than 2.0 cm grafted successfully to nasal and auricular defects.¹¹⁰ Similarly, Skouge has effectively grafted larger defects using a “tongue and groove” technique and turndown hinged flaps.¹⁰⁴ The postoperative appearance of composite grafts is distinctive. At placement, the graft is white or blanched. Within 6 hours it becomes pink, and by 24 hours it is cyanotic. By postoperative day 3, it resumes its pink

color. Grafts that fail develop an eschar with subsequent necrosis and sloughing.

Complications There are risks to all procedures. Patients who receive skin cancer procedures should be warned of the potential for recurrence of the tumor as well as revision of any reconstructive procedure. Flap problems include necrosis, infection, hematoma, wound dehiscence, and scarring.

Smoking greatly increases the risk of necrosis. Patients who smoke one pack per day triple the risk of flap or graft necrosis compared with nonsmokers. Smoking affects the blood supply via two mechanisms. First, nicotine is a potent vasoconstrictor that may lower tissue oxygenation by > 50%. Nicotine effects are visible within 10 minutes and can last up to 50 minutes. Second, carbon monoxide is a competitor with oxygen for hemoglobin. It has a higher affinity for hemoglobin than does oxygen, resulting in high levels of carboxyhemoglobin. This leads to tissue hypoxia.

Infection Infections are rare in vascularized head and neck tissues, and necrosis may be mistaken for infection. More common causes of redness include stitch abscesses, which are foreign body reactions, and allergies to antibiotic ointment. Infections, handled by drainage (when indicated), irrigation, and antibiotics, usually resolve readily.

Bleeding Bleeding may be caused by patient factors or surgical issues. Patient factors include medical conditions such as renal failure, liver failure, collagen vascular disease, various cancers (hematopoietic malignancies), and medications. Medications that can cause bleeding include warfarin, heparin, antithrombotics, nonsteroidal anti-inflammatory drugs, acetylsalicylic acid, and cold remedies. Furthermore, commonly used herbal medications such as garlic, feverfew, and vitamin E can inhibit thrombocyte function.

The surgeon must weigh the benefits of discontinuing anticoagulants against the risks of surgery since there have been several documented cases of stroke when anticoagulants were stopped prior to dermatologic surgery. Consultation and coordination with the patient's internist and appropriate preoperative laboratory data are helpful. There is no need to discontinue any anticoagulant prior to performing a biopsy.

Surgical issues may arise intraoperatively or during the postoperative period. Decisions must be made concerning judicious cautery, the use of drains, the effect of vasoconstrictors, and postoperative pressure. Seepage may occur from any facial flap, but hematoma may necrose the flap. A hematoma, in the space created between the flap and underlying tissue is detrimental to flap circulation because it creates tension, and it acts as a physical barrier preventing cohesion to the underlying tissue base. Additionally, stagnating blood may promote wound infection.

An early hematoma may often be pushed out and washed away, but a

reforming hematoma must be explored. Likewise, late collections of jellied blood should be manually extruded.

Poor Cosmetic Results Facial flaps should restore anatomic continuity, maintain functional integrity, and provide an esthetically pleasing result. In spite of well-executed surgical techniques, less than optimal results may occur because of unpredictable scarring and trapdoor deformity.

References

- Housman TS, Williford PM, Feldman SR. Non-melanoma skin cancer: an episode of care management approach. *Dermatol Surg* 2003;29:700–11.
- Hochman M, Lang P. Skin cancer of the head and neck. *Med Clin North Am* 1999;83:261–82.
- Strom SS, Yamamura Y. Epidemiology of non-melanoma skin cancer. *Clin Plast Surg* 1997;24:627–36.
- Swetter SM. Malignant melanoma from the dermatologic perspective. *Surg Clin North Am* 1996;76:1287–98.
- Gloster HM, Brodland DG. The epidemiology of skin cancer. *Dermatol Surg* 1996;22:217–26.
- Liu T, Soong S. Epidemiology of malignant melanoma. *Surg Clin North Am* 1965;76:1205–22.
- Padgett J, Hendrix J. Cutaneous malignancies and their management. *Otolaryngol Clin North Am* 2001;34:523–50.
- Green A, Battistutta D. Incidence and determinants of skin cancer in a high risk Australian population. *Int J Cancer* 1990;46:356–61.
- Green A, Beardmore G, Hart V, et al. Skin cancer in Queensland population. *J Am Acad Dermatol* 1988;19:1045–52.
- Randle HW. Basal cell carcinoma: identification and treatment of the high risk patient. *Dermatol Surg* 1996;22:255–61.
- Skidmore RE, Flowers FP. Nonmelanoma skin cancer. *Med Clin North Am* 1998;82:1309–23.
- Marks R. The epidemiology of non-melanoma skin cancer: who, why and what can we do about it. *J Dermatol* 1995;22:853–7.
- Friedman RJ, Rigel DS, Kopf AW, et al, editors. *Cancer of the skin*. Philadelphia: WB Saunders; 1991.
- Preston DS, Stern RS. Nonmelanoma cancers of the skin. *N Engl J Med* 1992;327:1649–62.
- Fitzpatrick TB. The validity and practicality of sun reactive skin types I through VI. *Arch Dermatol* 1988;124:869–71.
- Karagas MR, Stukel TA, Greenberg, EK, et al. Risk of subsequent basal cell carcinoma and squamous cell carcinoma of the skin among patients with prior skin cancer. *JAMA* 1992;267:3305–10.
- Robinson JK. Risk of developing another basal cell carcinoma. *Cancer* 1987;60:118–20.
- Miller RI, Gerster JE, Owens ML, et al. Imiquimod applied topically: a novel immune response modifier and a new class of drug. *Int J Immunopharmacol* 1999;21:1–14.
- Gorlin RJ, Goltz RW. Multiple nevoid basal cell epithelioma, jaw cysts and bifid ribs: a syndrome. *N Engl J Med* 1960;262:908–12.
- Rayner CRW, Towers JF, Wilson JSP. What is Gorlin's syndrome? The diagnosis and management of the basal cell naevus syndrome based on a study of thirty-seven patients. *Br J Plast Surg* 1976;30:62–7.
- Shumrick KA, Coldiron B. Genetic syndromes associated with skin cancer. *Otolaryngol Clin North Am* 1993;26:117–37.
- Marks R, Foley P, Goodman G, et al. Spontaneous remission of solar keratoses: the case for conservative management. *Br J Dermatol* 1986;115:649–55.
- Marks R, Rennie G, Selwood TS. Malignant transformation of solar keratoses to squamous cell carcinoma. *Lancet* 1998;1:795–7.
- Graham JH. Selected precancerous skin and mucocutaneous lesions. In: *Neoplasms of skin and malignant melanoma*. Chicago: Year Book; 1976. p. 69–121.
- Schwartz RA. The actinic keratosis: a perspective and update. *Dermatol Surg* 1997;23:1009–19.
- Swandbank M. Basal cell carcinoma at the base of cutaneous horn (cornu cutaneum). *Arch Dermatol* 1971;104:97–98.
- Boyle J, Briggs JD, Mackie RM, Junor BJR. Cancer: wart, and sunshine in renal transplant patients: a case control study. *Lancet* 1984;1:702–5.
- Purdie KJ, Sexton CJ, Proby CM, et al. Malignant transformation of cutaneous lesions in renal allograft patients. *Cancer Res* 1993;53:5328–33.
- Johnson TM, Rowe DE, Nelson BR, Swanson NA. Squamous cell carcinoma of the skin (excluding lip and oral mucosa). *J Am Acad Dermatol* 1992;26:467–84.
- Pecquex JC, Swartz A, Dieckmann KP, Offermann G. Cancer incidence in patients on chronic dialysis and in renal transplantation recipients. *Urol Int* 1990;45:290–2.
- Gafa L, Filippazo MG, Tumino R, et al. Risk factors of nonmelanoma skin cancer in Ragusa, Sicily: a case control study. *Cancer Causes Control* 1991;2:395–9.

32. Diffey BL. Analysis of the risk of skin cancer from sunlight and solarium in subjects living in northern Europe. *Photodermatol* 1987; 4:118–26.
33. Zbar RI, Cottle WI. Skin tumors I: non-melanoma skin tumors. *Selected Readings Plast Surg* 2000;9:5.
34. Shanoff LB, Spira M, Hardy SB. Basal cell carcinoma: a statistical approach to rational management. *Plast Reconstr Surg* 1967;39:617–24.
35. Wade TR, Ackerman AB. The many faces of basal-cell carcinoma. *J Dermatol Surg Oncol* 1978;4:23–8.
36. Goldberg DP. Assessment and surgical treatment of basal cell skin cancer. *Clin Plast Surg* 1997;24:673–86.
37. Bernstein SC, Lim KK, Brodland DG, et al. The many faces of squamous cell carcinoma. *Dermatol Surg* 1996;22:243–54.
38. Roth JJ, Granick MS. Squamous cell and adnexal carcinomas of the skin. *Clin Plast Surg* 1997;4:687–703.
39. Goldman GD. Squamous cell cancer: a practical approach. *Semin Cutan Med Surg* 1998;17:80–95.
40. Novick M, Gard OA, Hardy SB, et al. Burn scar carcinoma: a review and analysis of 46 cases. *J Trauma* 1977;17:809–17.
41. Akoz T, Erdogan B, Gorgu M, Aslan G. The necessity for aggressive treatment with Marjolin's ulcers of the scalp. *Plast Reconstr Surg* 1997;100:805–6.
42. Katsambas A, Nicolaidou E. Cutaneous malignant melanoma and sun exposure. *Arch Dermatol* 1996;132:444–50.
43. Lang PG Jr. Malignant melanoma. *Med Clin North Am* 1998;82:1325–58.
44. Rigel DS, Friedman RJ, Kopf AW. The incidence of malignant melanoma in the United States: issues as we approach the 21st century. *J Am Acad Dermatol* 1996;34:839–47.
45. Weinstock MA. Issues in the epidemiology of melanoma. *Hematol Oncol Clin North Am* 1998;12:681–99.
46. Mackie RM. Incidence, risk factors and prevention of melanoma. *Eur J Cancer* 1998;34:S3–6.
47. Langley RG, Barnhill RL, Mihm MC, et al. Neoplasms: cutaneous melanoma. In: Freedberg IM, Eisen AZ, Wolff K, et al, editors. *Dermatology in general medicine*. 5th ed. New York: McGraw Hill; 1999. p. 1080–117.
48. Holly EA, Kelly JW, Shpall SN, et al. Number of melanocytic nevi as a major risk factor for malignant melanoma. *J Am Acad Dermatol* 1987;17:459–68.
49. Breslow A. Thickness, cross-sectional areas and depth of invasion in the prognosis of cutaneous melanoma. *Ann Surg* 1970;172:902–8.
50. Clark WHJ. A classification of malignant melanoma in man correlated with histogenesis and biologic behavior. In: Montagna W, Hu F, editors. *Advances in biology of the skin*. Elmsford (NY): Pergamon Press; 1967. p. 621–47.
51. Zide MF. Treatment decisions for skin cancer of the head and neck. *Selected Readings Oral Maxillofac Surg* 2000;8(5):1–47.
52. Werlinger KD, Upton G, Moore AY. Recurrence rate of primary nonmelanoma skin cancers treated by surgical excision compared to electrodesiccation—curettage in a private dermatological practice. *Dermatol Surg* 2002;28:1138–42.
53. Escobar V, Zide MF. Delayed repair of skin cancer defects. *J Oral Maxillofac Surg* 1999;57:271–9.
54. Nelson BR, Railan D, Cohen S. Mohs' micrographic surgery for nonmelanoma skin carcinomas. *Clin Plast Surg* 1997;24:705–18.
55. Robinson JK. Mohs' micrographic surgery. *Clin Plast Surg* 1993;20:149–56.
56. Shriner DL, McCoy DK, Goldberg DJ, et al. Mohs' micrographic surgery. *J Am Acad Dermatol* 1998; 39:79–97.
57. Lawrence CM. Mohs' micrographic surgery for basal cell carcinoma. *Clin Exp Dermatol* 1999;24:130–3.
58. Holmkvist KA, Roenigk RK. Squamous cell carcinoma of the lip treated with Mohs' micrographic surgery: outcome at 5 years. *J Am Acad Dermatol* 1998; 38:960–6.
59. Halpern JN. Radiation therapy in cancer: a historical perspective and current applications. *Dermatol Surg* 1997;23:1089–93.
60. Anscher M, Montano G. Radiotherapy. *Surv Ophthalmol* 1993;38:203–12.
61. Morrison WH, Garden AS, And KK. Radiation therapy for nonmelanoma skin carcinomas. *Clin Plast Surg* 1997;24:719–28.
62. Geara FB, Ang KK. Radiation therapy for malignant melanoma. *Surg Clin North Am* 1996;76:1383–98.
63. Kuflik EG. Cryosurgery updated. *J Am Acad Dermatol* 1994;31:925–44.
64. Lindgren G, Larko O. Long term follow up of cryosurgery of basal cell carcinoma of the eyelid. *J Am Acad Dermatol* 1997;36:742–6.
65. Mallon E, Dawber R. Cryosurgery in the treatment of basal cell carcinoma. *Dermatol Surg* 1996;22:854–8.
66. Spencer JM, Tannenbaum A, Sloan L, et al. Does inflammation contribute to the eradication of basal cell carcinoma following curettage and electrodesiccation? *Dermatol Surg* 1997;23:625–31.
67. Goette DK. Topical chemotherapy with 5-fluorouracil. *J Am Acad Dermatol* 1981; 4:633–45.
68. Allison RR, Mang TS, Wilson BD. Photodynamic therapy for the treatment of non-melanomatous cutaneous malignancies. *Semin Cutan Med Surg* 1998; 17:153–63.
69. Morton CA, Mackie RM, Whitehurst C, et al. Photodynamic therapy for basal cell carcinomas: effect of tumor thickness and duration of photosensitizer application on response. *Arch Dermatol* 1998;134:248–9.
70. Cornell RC, Greenway HT, Tucker SB, et al. Intralesional interferon for basal cell carcinoma. *J Am Acad Dermatol* 1990;23:694–700.
71. Edwards L, Tucker SB, Perendia D, et al. The effect of an intralesional sustained-release formulation of interferon alfa-2b on basal cell carcinoma. *Arch Dermatol* 1990;126:1029–32.
72. Thiers BH, Maize JC, Spicer SS, et al. The effect of aging and chronic skin exposure on human Langerhans' cell populations. *J Invest Dermatol* 1984;82:223–6.
73. Gilchrist BA, Blog FB, Szabo G. Effects of aging and chronic sun exposure on melanocytes in human skin. *J Invest Dermatol* 1979;73:141–3.
74. Hu F. Aging of melanocytes. *J Invest Dermatol* 1979;73:70–9.
75. Shuster S, Black MM, McVitie E. The influence of sex and age on skin thickness, skin collagen and density. *Br J Dermatol* 1975; 93:639–43.
76. Woodley DT, Zelickson AS, Briggaman RA, et al. Treatment of photoaged skin with topical tretinoin increases epidermal-dermal anchoring fibrils. *JAMA* 1990;263:3057–9.
77. Zelickson AS, Mottaz JH, Weiss JS, et al. Topical tretinoin in photoaging: an ultrastructural study. *J Cutan Aging Cosmet Dermatol* 1988;1:41–7.
78. Johnson TM, Nelson BR. Anatomy of the skin. In: Baker SR, editor. *Local flaps in facial reconstruction*. St. Louis: Mosby; 1995. p. 3–14.
79. Grove GL. Age related differences in healing of superficial skin wounds in humans. *Arch Dermatol* 1982;272:381–5.
80. Montagna W, Carlisle K. Structural changes in aging human skin. *J Invest Dermatol* 1979;73:47–53.
81. Bennet RG. Anatomy and physiology of the skin. In: Papel ID, Nachlas NE, editors. *Facial plastic and reconstructive surgery*. St. Louis: Mosby; 1992. p. 3–13.
82. Whetzel TP, Mathes SJ. Arterial anatomy of the face: an analysis of vascular territories and perforating cutaneous vessels. *Plast Reconstr Surg* 1992;89:591–603.
83. Gaboriau HP, Murakami CS. Skin anatomy and flap physiology. *Otolaryngol Clin North Am* 2001;34:555–69.
84. Swanson NA. Classifications, definitions, and

- concepts in flap surgery. In: Baker SR, editor. Local flaps in facial reconstruction. St. Louis: Mosby; 1995. p. 63–74.
85. Jackson IT. Local flaps in head and neck reconstruction. St. Louis (MO): CV Mosby Co; 1985.
86. Grabb WC, Meyers MB, editors. Skin flaps. Boston: Little Brown; 1975.
87. Goding GS, Hom DB. Skin flap and physiology. In: Baker SR, editor. Local flaps in facial reconstruction. St. Louis: Mosby; 1995. p. 15–30.
88. Ridenour BD, Larabee WF. Biomechanics of skin flaps. In: Baker SR, editor. Local flaps in facial reconstruction. St. Louis: Mosby; 1995. p. 31–8.
89. Borges AF. Relaxed skin tension lines. *Dermatol Clin* 1989;7:169–77.
90. Larabee WF. Immediate repair of facial defects. *Dermatol Clin* 1989;7:661–76.
91. Larabee WF, Holloway GA, Sutton D. Variation of skin stress-strain curves with undermining. *Surg Forum* 1981;32:553–5.
92. Brown MD. Advancement flaps. In: Baker SR, editor. Local flaps in facial reconstruction. St. Louis: Mosby; 1995. p. 91–107.
93. Borges AF. Dog ear repair. *Plast Reconstr Surg* 1982;69:707–13.
94. Dzubow LM. The dynamics of dog-ear formation and correction. *J Dermatol Surg Oncol* 1985;11:722–8.
95. Salasche SJ, Roberts LC. Dog-ear correction by M-plasty. *J Dermatol Surg Oncol* 1984;10:478–82.
96. Cox KW, Larabee WF. A study of skin flap advancement as a function of undermining. *Arch Otolaryngol* 1982;108:151–5.
97. Zide MF, Fuselier C. The partial-thickness cross-lip flap for correction of postoncologic surgical defects. *J Oral Maxillofac Surg* 2001;59:1147–53.
98. Glogau RG, Haas AF. Skin grafts. In: Baker SR, editor. Local flaps in facial reconstruction. St. Louis: Mosby; 1995. p. 247–71.
99. Rudolph R, Ballantyne DL. Skin grafts. In: McCarthy JG, editor. Plastic surgery, Vol 1. General principles. Philadelphia: WB Saunders; 1990. p. 221–74.
100. Skouge JW. Skin grafting. New York: Churchill Livingstone; 1991.
101. Salasche SJ, Feldman BD. Skin grafting: perioperative technique and management. *J Dermatol Surg Oncol* 1987;13:863–69.
102. Hill TJ. Reconstruction of nasal defects using full thickness grafts: a personal reappraisal. *J Dermatol Surg Oncol* 1983;12:995–1001.
103. Adnot J, Salasche SJ. Visualized basting sutures in the application of full thickness skin grafts. *J Dermatol Surg Oncol* 1987;13:1236–9.
104. Skouge JW. Techniques for split-thickness skin grafting. *J Dermatol Surg Oncol* 1987;13:841–9.
105. Bray DA. Clinical applications of the rhomboid flap. *Arch Otolaryngol* 1983;109:37–42.
106. Bray DA. Rhombic flaps. In: Baker SR, editor. Local flaps in facial reconstruction. St. Louis: Mosby; 1995. p. 151–64.
107. Brodovsky S, Dagan R, Ben-Bassatt M. Nobecutane spray as temporary dressing of skin graft donor sites. *J Dermatol Surg Oncol* 1986;12:386–8.
108. Glogau RG, Stegman SJ, Tromovich TA. Refinements in split thickness skin grafting technique. *J Dermatol Surg Oncol* 1987;13:853–8.
109. Chandawarkar RY, Cervino AL, Wells MD. Reconstruction of nasal defects using modified composite grafts. *Br J Plast Surg* 2003;56:26–32.
110. Avelar JM, Psillakis JM, Viterbo F. Use of large composite grafts in the reconstruction of deformities of the nose and ear. *Br J Plast Surg* 1984;37:55–60.

Part 6

MAXILLOFACIAL RECONSTRUCTION

Local and Regional Flaps

Alan S. Herford, DDS, MD

G. E. Ghali, DDS, MD

Flap Principles

Over the past 50 years the development and application of several different flaps has led to reliable reconstruction of facial defects. Most defects can be reconstructed immediately, leading to better restoration of form and function with early rehabilitation.¹ Reconstructing facial defects can be both challenging and rewarding. Missing tissue most often results from either trauma or oncologic surgery. Commonly there is a wide range of options for repairing a given defect, including healing by secondary intention, primary closure, placement of a skin graft, or mobilization of local or regional tissue. Compared to skin grafts, local flaps often produce superior functional and esthetic results.²⁻⁶ A great advantage of local tissue transfer is that the tissue closely resembles the missing skin in color and texture. These flaps can be rotated, advanced, or transposed into a tissue defect. Regional tissue can also be recruited to repair facial defects.

When deciding which option to use, there should be a progression from simple to complex treatments. Consideration should be given to primary closure or the use of skin grafts first, followed by local, then regional, and finally distant pedicled or microsurgical free tissue transfer. Flaps require additional incisions and tissue movement, which increase the risks of postoperative bleeding, hematoma, pain,

and infection. Confirmation of tumor-free margins should be done prior to flap reconstruction if a malignant lesion has been excised.⁷

Some defects are amenable to closure with a single flap, but others require a combination of flaps for optimal results.⁸ An advantage of using multiple flaps is that they can be harvested from separate esthetic units. This decreases the size of the secondary defect and may allow placement of scars between esthetic units, thus improving scar camouflage leading to better cosmesis. Often, separated repair of individual facial subunits with separate flaps provides a better cosmetic result than if a single flap is used to reconstruct the entire defect.

Flaps differ from grafts in that they maintain their blood supply as they are moved. Abundant dermal and subdermal plexus allow for predictable elevation of random cutaneous flaps. A cutaneous flap may also have its arterial supply based on a dominant artery in the subcutaneous layer. Muscular perforating arteries are important contributors to the cutaneous vascular bed. The most important variable for flap viability is not the length-to-width ratio but, rather, the perfusion pressure and vascularity at the pedicle base.⁹ Because local flaps provide their own blood supply, they are particularly useful in patients with compromised recipient sites such as those that have been irradiated.

As local flaps heal, regaining of blood flow and cutaneous sensibility increases. The rate of blood flow and two-point discrimination on the surface of local flaps is statistically no different when compared with the corresponding area of the unoperated side.¹⁰ The recovery of sensory nerve function in facial flaps is dependent on the intimacy of contact between the flap and the recipient bed and on the viability of the type of restoration.

Relaxed skin tension lines (RSTLs) result from vectors within the skin that reflect the intrinsic tension of the skin at rest. They are due to the microarchitecture of the skin and represent the directional pull on wounds. The RSTLs are generally parallel to the facial rhytids. Lines of minimal tension (rhytids) result from repeated bending of the skin from muscular contraction. A permanent crease results from the adhesions between the dermis and deeper tissues. These natural skin creases run perpendicular to the direction of muscle pull and can guide incision orientation for optimal scar camouflage and cosmesis.

The face is composed of esthetic subunits.^{11,12} The areas where these subunits meet are referred to as anatomic borders. The esthetic subunit principle is based on the fact that our eyes see objects as a series of block images that are spatially organized. Scars that are located at the junction of two adjacent anatomic subunits are

inconspicuous because one expects to see a delineation between these areas.

Flap Nomenclature

There are many methods described for classifying cutaneous flaps: by the arrangement of their blood supply, their configuration, location, tissue content, and method of transferring the flap.

Blood Supply

Cutaneous flaps consist of skin and subcutaneous tissue and can be characterized by their predominant arterial supply. These include random pattern, axial pattern, and pedicle flaps (Figure 38-1). Random flaps are supplied by the dermal and subdermal plexus alone and are the most common type of flap used for reconstructing facial defects. Axial pattern flaps are supplied by more dominant superficial vessels that are oriented longitudinally along the flap axis. Pedicle flaps are supplied by large named arteries that supply the skin paddle through muscular perforating vessels. Free tissue transfer refers to flaps that are harvested from a

remote region and have the vascular connection reestablished at the recipient site.

Location

Another means of classification is by the region from which the tissue is mobilized. This includes local, regional, and distant flaps. Local flaps imply use of tissue adjacent to the defect, whereas regional flaps refer to those flaps recruited from different areas of the same part of the body. Distant flaps are harvested from different parts of the body.

Configuration

Flaps are often referred to by their geometric configuration. Examples of these flaps include bilobed, rhombic, and Z-plasty.

Tissue Content

The layers of tissue contained within the flap can also be used to classify a flap. *Cutaneous flap* refers to those flaps that contain the skin only. When other layers are incorporated into the flap they are classified accordingly. Examples include myocutaneous and fasciocutaneous flaps.

Method of Transfer

The most common method of classifying flaps is based on the method of transfer. Advancement flaps are mobilized along a linear axis toward the defect (Figure 38-2). Rotation flaps pivot around a point at the base of the flap (Figure 38-3). Although most flaps are moved by a combination of rotation and advancement into the defect, the major mechanism of tissue transfer is used to classify a given flap. *Transposition flap* refers to one that is mobilized toward an adjacent defect over an incomplete bridge of skin. Examples of transposition flaps include rhombic flaps and bilobed flaps (Figure 38-4). Interposition flaps differ from transposition flaps in that the incomplete bridge of adjacent skin is also elevated and mobilized. An example of an interposition flap is a Z-plasty. Interpolated flaps are those flaps that are mobilized either over or beneath a complete bridge of intact skin via a pedicle. These flaps often require a secondary surgery for pedicle division. Microvascular free tissue transfer

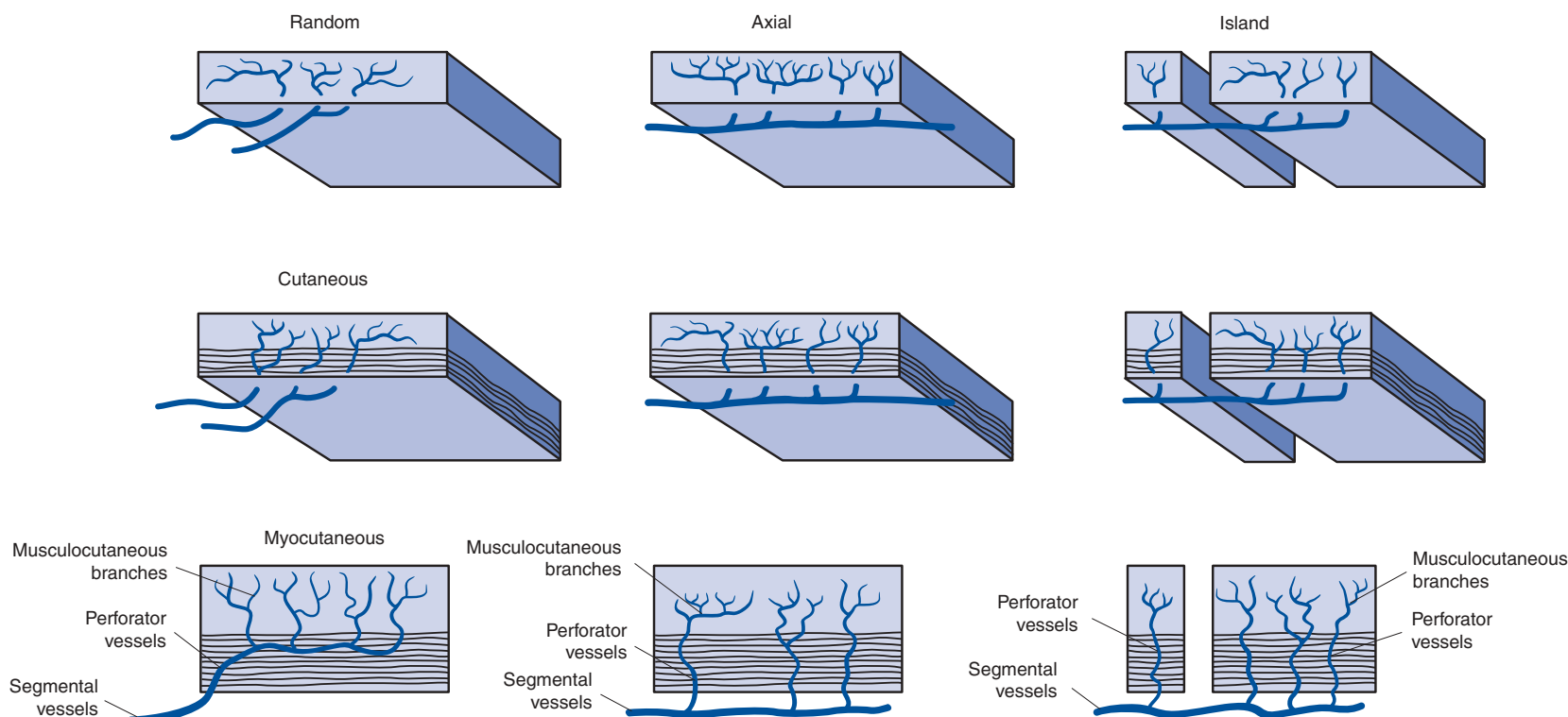


FIGURE 38-1 Diagrammatic representation of cutaneous blood supply in skin and myocutaneous flaps. Adapted from Ariyan S.⁴¹

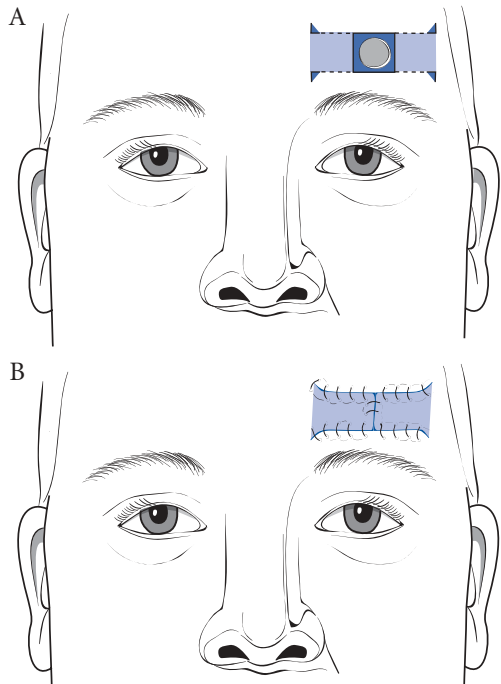


FIGURE 38-2 A, Double advancement flaps with Burow's triangles. B, Closure of the defect.

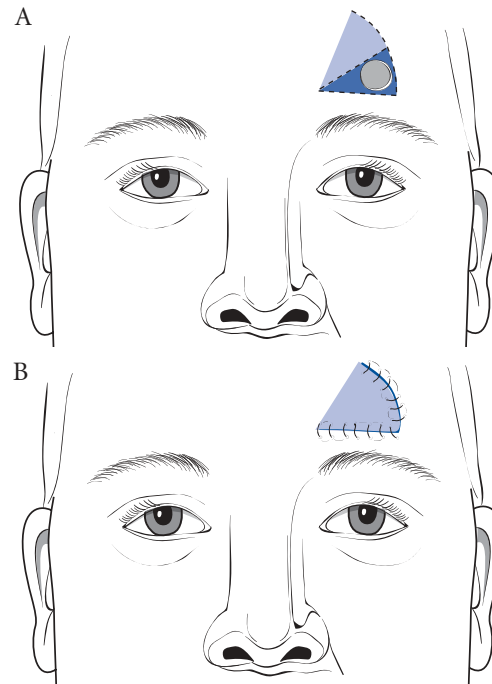


FIGURE 38-3 A, Rotation flap for closure of a forehead defect. B, Closure of the defect.

from a different part of the body relies on reanastomosis of the vascular pedicle.

Designing the Flap

There are many options for reconstructing facial defects. Often the optimal method is not readily apparent. A stepwise approach can be helpful in selecting and designing a flap. The characteristics of the defect and adjacent tissue must be analyzed. These include color, elasticity, and texture of the missing tissue. The defect size, depth, and location are evaluated as well as the availability and characteristics of adjacent or regional tissue. It is important to determine the mobility of adjacent structures and to identify those anatomic landmarks that must not be distorted. The orientation of the RSTLs and esthetic units should be analyzed closely.

Potential flap designs should be drawn on the skin surface being careful to avoid those designs that obliterate or distort anatomic landmarks. The final location of the resultant scar should be anticipated by previsualizing suture lines and choosing flaps that place the lines in normal creases.

The secondary defect that is created as the tissue is transferred into the primary defect must be able to be closed easily. When designing a flap, it is important to avoid secondary deformities that distort important facial landmarks or affect function. Avoid obliterating critical anatomic lines that are essential for normal function and appearance.

Proper surgical technique involves gentle handling of the tissue by grasping the skin margins with skin hooks or fine-toothed tissue forceps. Avoid traumatizing the vascular supply by twisting or kinking the base of the flap. Deep pexing sutures minimize tension on the flap and eliminate dead space. Excessive tension on the flap may decrease blood flow and cause flap necrosis. Meticulous hemostasis should be achieved prior to final suturing so that a hematoma does not develop beneath the flap. It is important to

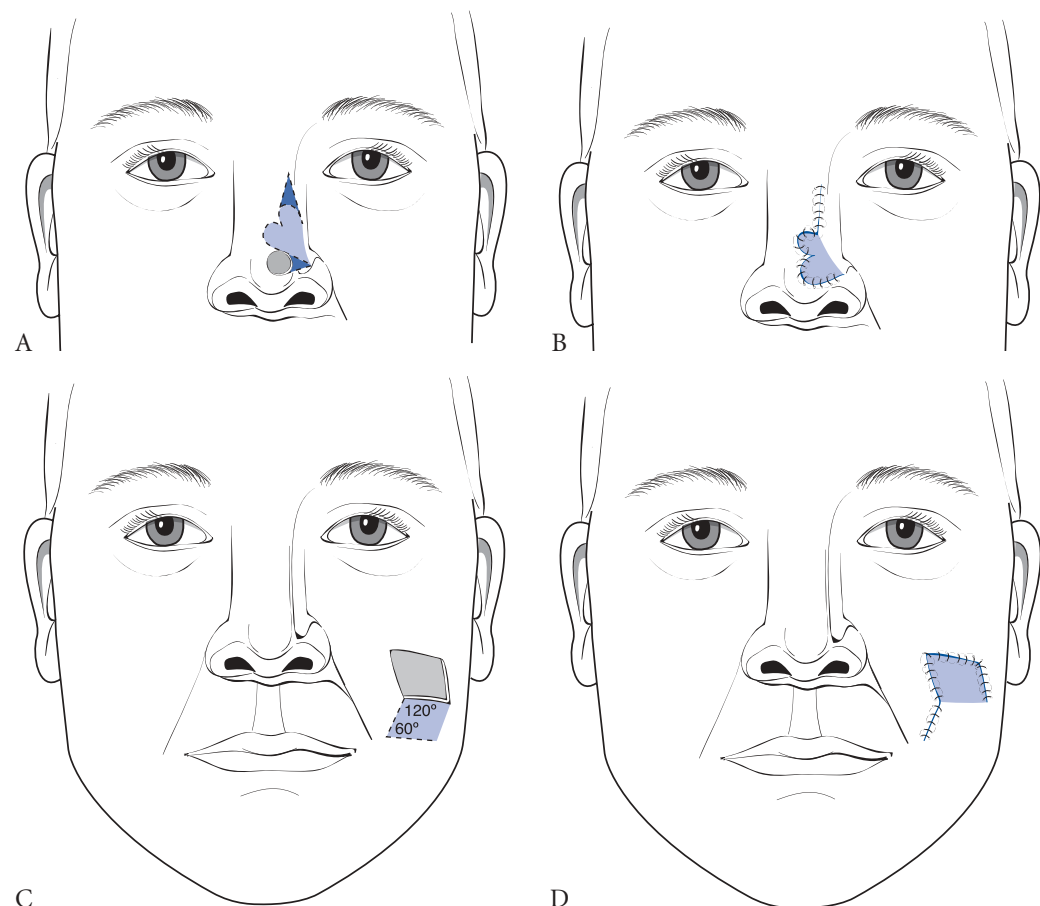


FIGURE 38-4 A, Bilobed flap for closure of a nasal tip defect. B, Closure of the defect. C, Rhombic flap for closure of a cheek defect. Note the 120 and 60° angles. D, Closure of the defect.

adequately mobilize and extend the flap, which should be of adequate size to remain in place without tension to minimize the chance of dehiscence, scarring, or ectropion.

Types of Flaps

Local Flaps

Advancement Flaps Advancement flaps have a linear configuration and are advanced into the defect along a single vector. These flaps can be single or double. Advancement flaps are often chosen when the surrounding skin exhibits good tissue laxity and the resulting incision lines can be hidden in natural creases. Advancement flaps limit wound tension to a single vector with minimal perpendicular tension. They are often helpful in reconstructing defects involving the forehead, helical rim, lips, and cheek. In these areas advancement flaps capitalize on the natural forehead furrows without causing vertical distortion of the hairline superiorly or the eyebrow inferiorly (Figure 38-5).

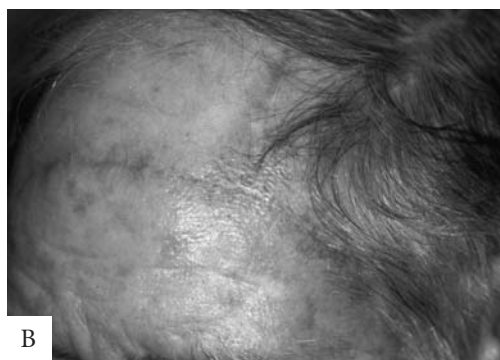
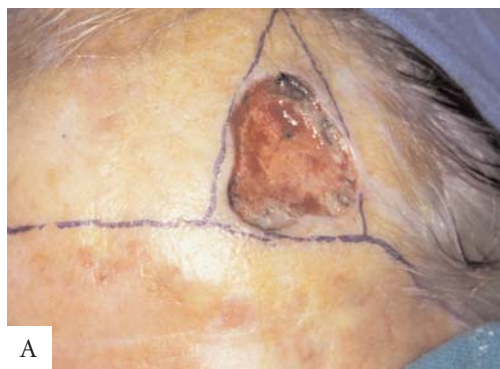

FIGURE 38-5 A, Advancement flap for closure of forehead defect. B, Closure of defect with incision lines placed in natural forehead crease.

Advancement flaps are created by parallel incisions approximately the width of the defect. Standing cutaneous deformities (“dog ears”) are usually created and are managed with excision. A Z-plasty incision or Burow’s triangle may be performed at the base of the flap, reducing the standing cutaneous deformities.

A variation of the advancement flap is the V-Y flap. A triangular island of tissue adjacent to the defect is isolated and attached only to the subcutaneous tissue. It relies on a subcutaneous pedicle for blood supply. As it is advanced into the defect, the secondary defect is closed primarily in a simple V-Y manner. These flaps are especially amenable for cheek defects along the alar facial groove and are generally avoided where there are superficial nerves because of the depth of the incisions.

Intraoral uses of advancement flaps include covering oroantral fistulas and alveolar clefts. A disadvantage of buccal advancement flaps is the decrease in vestibular sulcus depth (Figure 38-6).

Rotation Flaps Rotation flaps have a curvilinear configuration. Defects reconstructed with rotation flaps should be somewhat triangular or modified by removing normal tissue to create a triangular defect. These flaps have a large base and are usually random in their vascularity but may be axial. One or more rotation flaps are often used to reconstruct scalp defects. Because of the relative inelasticity of the scalp tissue, these flaps must be large relative to the size of the defect. Scoring of the galea is helpful in gaining additional rotation and advancement (Figure 38-7).

The axial frontonasal flap is a modified simple rotation flap with a back cut.¹³⁻¹⁶ It is useful for closing nasal defects (Figure 38-8). The flap is based on a vascular pedicle at the level of the medial canthus. This pedicle consists of a branch of the angular artery and the supraorbital artery.

Rotated palatal flaps are helpful for closing large oroantral fistulas.^{8,17} Fistulas < 5 mm in diameter usually close

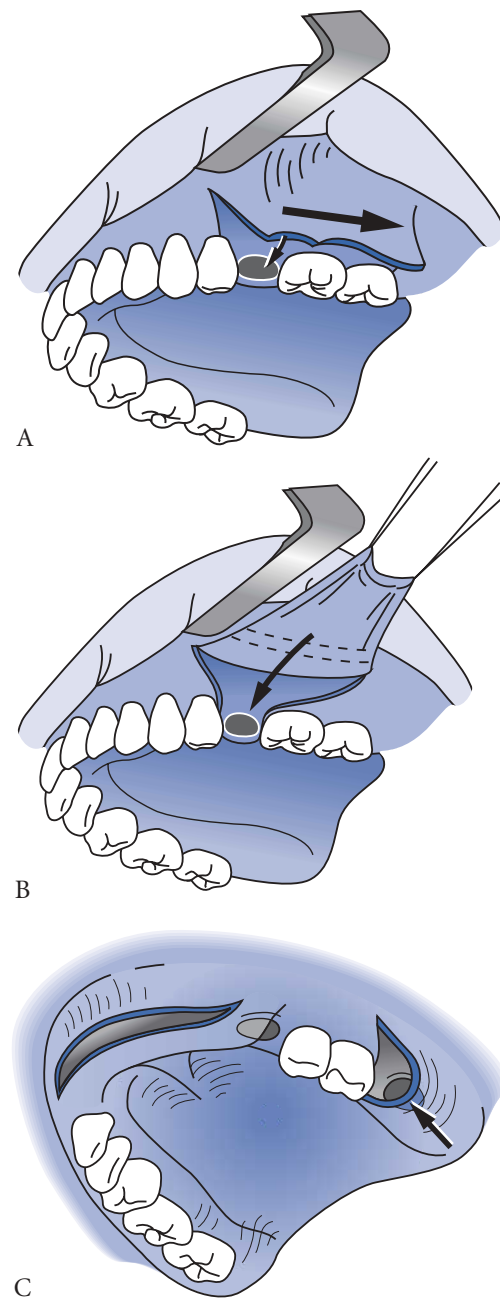


FIGURE 38-6 Buccal advancement flaps can be used to cover an oroantral fistula. A, A Moczaik buccal sliding trapezoidal flap is slid (arrow) to use the papilla of the adjacent tooth to rotate into the defect. B, Rehrman's buccal advancement flap uses a flap that has vertical extensions. To adequately mobilize this flap to cover the defect without tension, the periosteum must be incised (broken line) along its base and the flap advanced (arrow) over the defect. C, If the fistula is present along an edentulous region, a transverse flap or bipedicle flap can be used.

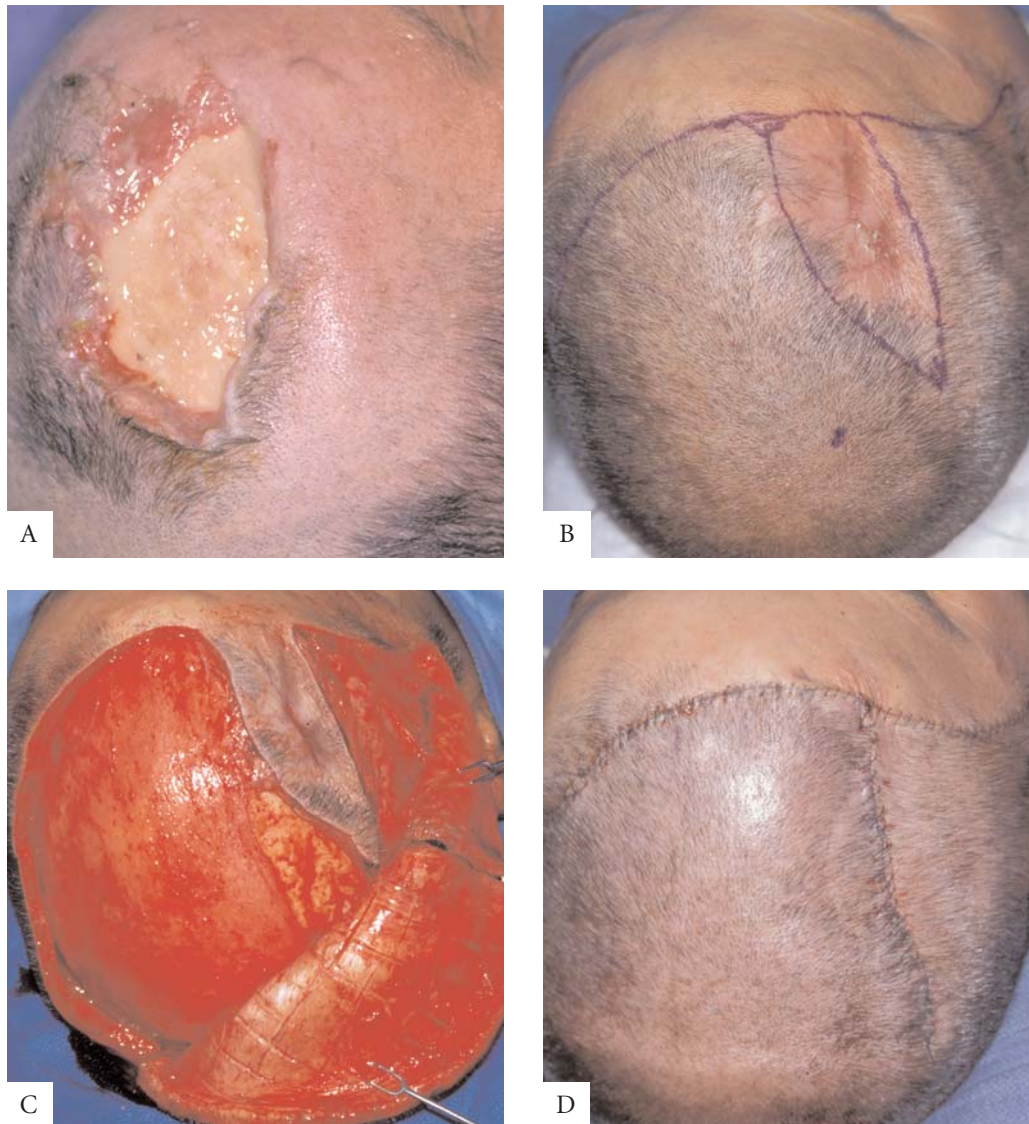


FIGURE 38-7 A, A large scalp defect secondary to trauma. B, Outline of scalp flaps. C, Elevation of flaps with scoring of the galea. D, Closure of the defect.

spontaneously.^{18,19} Local flaps or grafts can be used to close larger fistulas. Two-layer closures are less prone to developing

recurrence of oroantral fistulas. Approximately 75% of the palatal soft tissue can be rotated to cover adjacent defects.

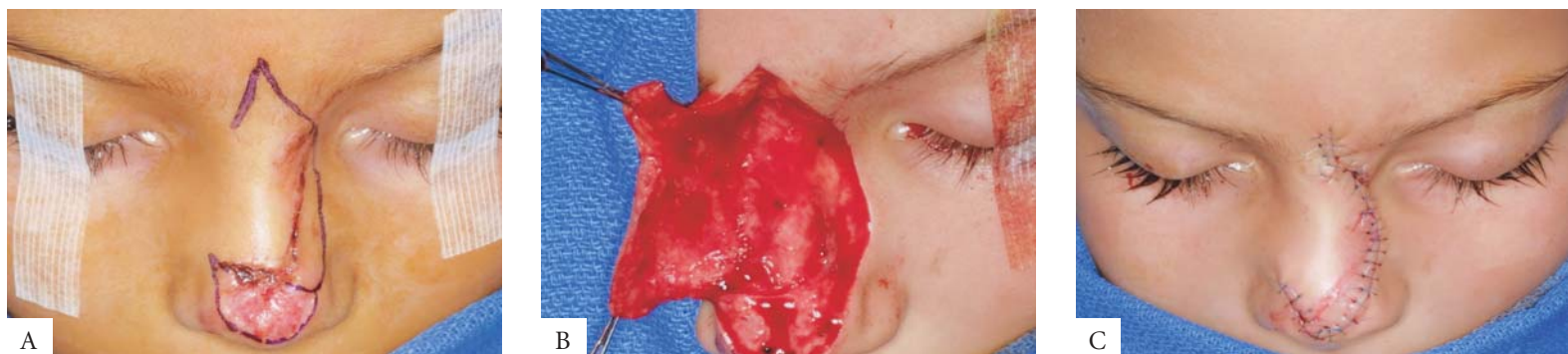

FIGURE 38-8 A, Axial frontonasal flap for repair of a nasal defect. B, Elevation of the flap with thorough undermining. C, Closure of the defect

Transposition Flaps These flaps are rotated and advanced over adjacent skin to close a defect. Examples of transposition flaps include rhombic flaps and bilobed flaps. These flaps are advantageous in areas where it is desired to transfer the tension away from closure of the primary defect and into the repair of the secondary defect. Transposition flaps have a straight linear axis and are usually designed so that one border of the flap is also a border of the defect. An advantage of this type of flap is that it can be developed at variable distances. Areas where these flaps are often used include the nasal tip and ala, the inferior eyelid, and the lips.

The rhombic flap is a precise geometric flap that is useful for many defects of the face.^{20,21} The traditional rhombic (“Limberg”) flap is designed with 60 and 120° angles and equal-length sides. The angle of the leading edge of the rhombic flap is approximately 120° but may vary. The flap is begun by extending an incision along the short axis of the defect that is equal to the length of one side of the rhombic defect. Another incision is then made at 60° to the first and of equal length (Figure 38-9). Disadvantages of the rhombic flap are the significant tension at the closure point as well as the amount of discarded tissue to transform a circular defect into a rhombus.

The bilobed flap is a transposition flap with two circular skin paddles (see Figure 38-4).^{22,23} Esser is credited with the design of the bilobed flap in 1918. It

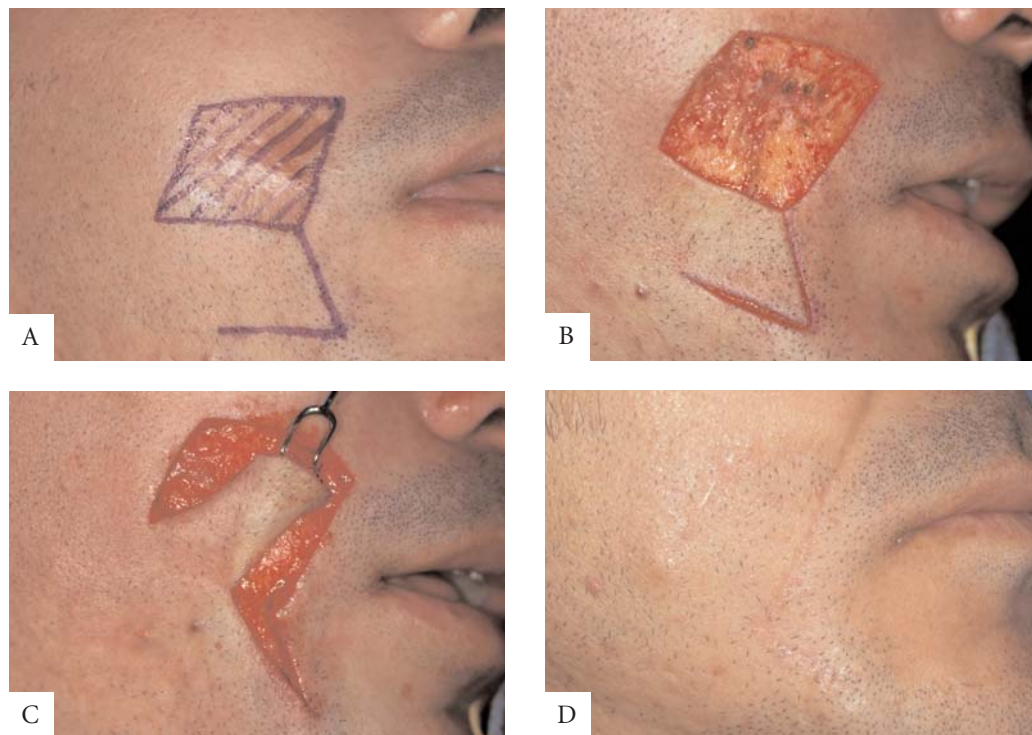


FIGURE 38-9 A, Outline for a rhombic flap. B, Resection of the lesion. C, The flap is transposed into the defect. D, Postoperative result with the incisions placed in the relaxed skin tension lines.

is useful for skin repairing of lateral nose and nasal tip defects up to 1.5 cm. The bilobed flap has a random pattern blood supply. The flap is primarily rotated around a pivot point and the paddles are transposed over an incomplete bridge of skin. The second lobe allows the transfer of tension further from the primary defect closure. The bilobed design rotates around an arc that is usually 90 to 100°. In the bilobed flap the first lobe closes the defect and the second closes the first lobe defect. The flap is designed with a pivot point approximately a radius of the defect away from the wound margin. The first lobe is usually the same size as the defect, and the second lobe is slightly smaller with a triangular apex to allow for primary closure. The axis of the second flap is roughly 90 to 100° from the primary defect and undermined widely to distribute the tension.

An advantage of the bilobed flap is that one can construct a flap at some distance from the defect with an axis that is independent of the linear axis of the

defect. A disadvantage of this flap is that it leaves a circular scar that does not blend with the existing skin creases. During healing the flap may become elevated (“pin cushioning”) because of the narrow pedicle that is prone to congestion, scar tissue that impedes lymphatic drainage, and curvilinear scars that tend to bunch the flap up as they shorten.

Interpolation Flaps Interpolation flaps contain a pedicle that must pass over or under intact intervening tissue. A disadvantage of these types of flaps is that for those passing over bridging skin, the pedicle must be detached during a second surgical procedure. Occasionally it is possible to perform a single-stage procedure by de-epithelializing the pedicle and passing it under the intervening skin. Advantages of interpolation flaps include their excellent vascularity, and also their skin color and texture match.

The forehead flap (median and paramedian) is a commonly used interpolation flap and remains the workhorse flap for

large nasal defects.²⁴⁻²⁷ It is a robust and dependable flap. The forehead flap is primarily based on the supratrochlear vessel, is relatively narrow, and uses a skin paddle from the forehead region. The flap is supplied by a rich anastomosis between the supratrochlear and angular arteries. Because of the marked vascularity, it is possible to incorporate cartilage or tissue grafts for nasal reconstruction. The forehead flap has abundant tissue available, allowing resurfacing of the entire nasal unit with a single flap and provides a good texture and color match to the native nose.

The technique for elevating the forehead flap is straightforward. The flap can be designed directly in the midline or in a paramidline location. A template of the defect is used to outline the flap. Elevation of the flap proceeds in either a subgaleal or subcutaneous plane. The pedicle is always elevated in such a way as to incorporate the frontalis muscle. The width of the pedicle is usually 1.0 to 1.5 cm, which allows for easy rotation of the pedicle. Prior to inset the skin paddle is selectively thinned to match the native skin thickness. The pedicle is divided approximately 3 weeks later, with the base of the pedicle inset into the glabellar area to reestablish brow symmetry. The incision, and resulting scar, is perpendicular to the RSTLs but tends to heal well (Figure 38-10).

The nasolabial flap (melolabial) is useful for reconstructing defects involving the oral cavity and those involving the lower third of the nose (Figure 38-11).²⁸⁻³¹ It can be used as an interpolation flap with either a single or staged technique. The flap is supplied by the angular artery, intraorbital artery, and infratrochlear artery and can be based either superiorly or inferiorly. The area of recruitment for nasal reconstruction is in closer proximity to the primary defect than is the forehead flap. A disadvantage of the nasolabial flap is that there is a limited amount of tissue available, and asymmetry can occur along the

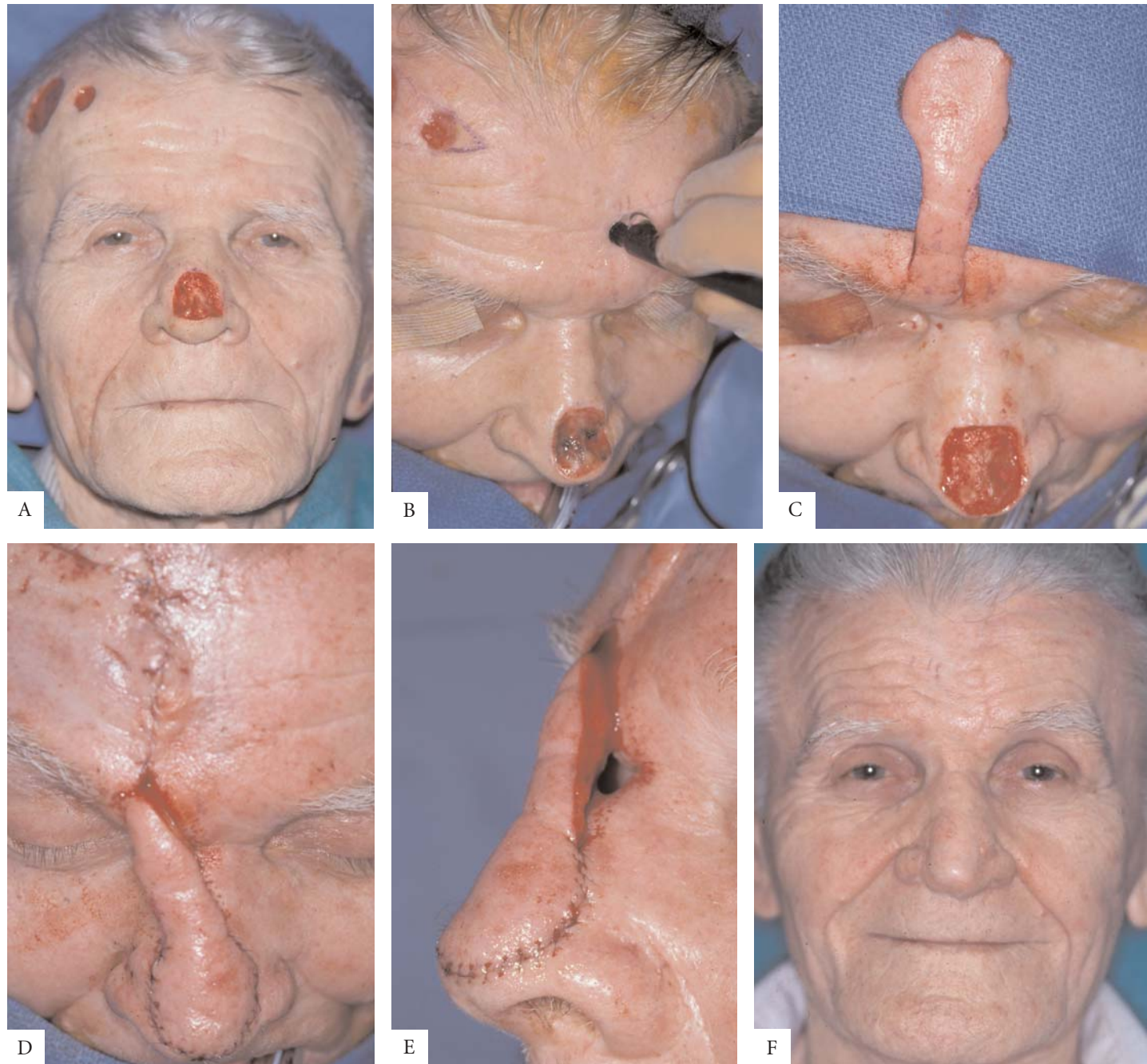


FIGURE 38-10 A, Nasal defect after excision of squamous cell carcinoma lesion. B, Use of Doppler ultrasonography to locate the supra-trochlear artery. C, The forehead flap has been elevated. D, The flap is turned 180° and sutured into place. E, The pedicle is divided 2 to 3 weeks later. F, Postoperative result

nasolabial flap folds. When the pedicle is divided, the defect can be closed primarily by placing the scar in the nasal facial junction and the nasolabial flap fold.

The lip-switch flap (Abbe) can be taken from either lip, but it is most commonly switched from the lower to the upper lip.³²⁻³⁴ This flap can be used to reconstruct as much as one-third of the

upper lip. The lower lip can supply a flap of one-quarter of its length, and the Abbe flap offers immediate replacement of total lip anatomy (Figure 38-12). The labial artery supplies the flap and should be maintained with a small cuff of subcutaneous tissue and muscle surrounding the vascular pedicle. The pedicle is divided after approximately 2 to 3 weeks.

Tongue flaps are excellent flaps for intraoral reconstruction. They use adjacent tissue, have an excellent blood supply, and are associated with minimal morbidity. The tongue has excellent axial and collateral circulation, with the lingual artery providing the main blood supply. Up to one-half of the tongue can be rotated for tissue coverage without compromising speech,

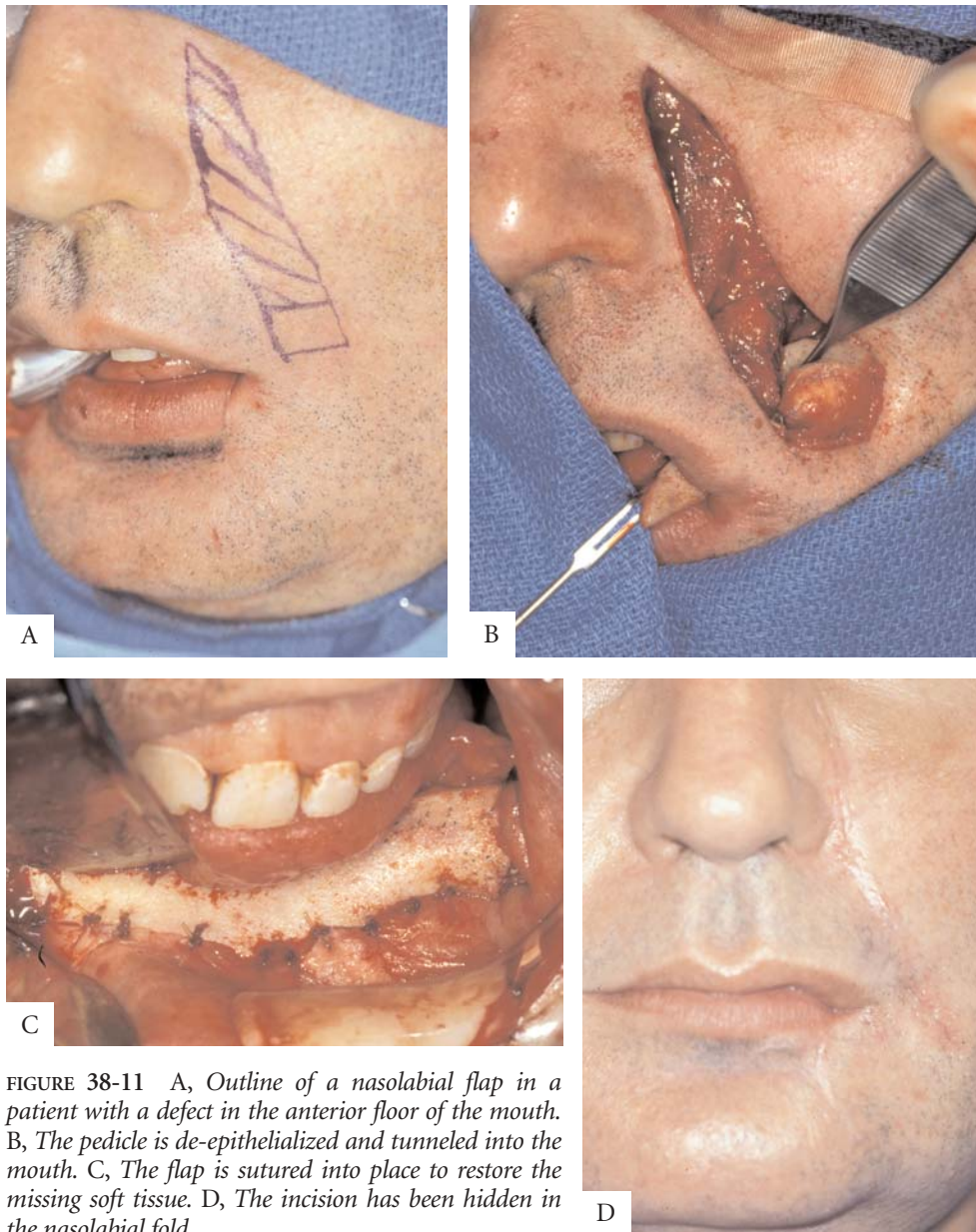


FIGURE 38-11 A, Outline of a nasolabial flap in a patient with a defect in the anterior floor of the mouth. B, The pedicle is de-epithelialized and tunneled into the mouth. C, The flap is sutured into place to restore the missing soft tissue. D, The incision has been hidden in the nasolabial fold.

mastication, or deglutition.³⁵ A variety of flap designs have been described including anterior- and posterior-based tongue flaps (Figure 38-13). Some indications include repair of oral defects and fistula closure. These flaps are helpful for providing closure of large oroantral fistulas.

Regional Flaps

For large facial defects, local flaps may not provide sufficient tissue to adequately restore the missing tissue. In these cases consideration should be given to using a regional flap.^{36,37} Regional flaps are

defined as those that are located near a defect but are not in the immediate proximity. They are frequently harvested from the neck, chest, or axilla and can provide coverage of large surface areas on the face. Selection of a specific regional flap depends on the size and location of the defect and also on the intrinsic properties of the flap. Advantages of regional flaps include the large amount of soft tissue and skin available. Disadvantages of these types of flaps include poor color and texture match, excessive bulkiness of the flap, and donor site morbidity.

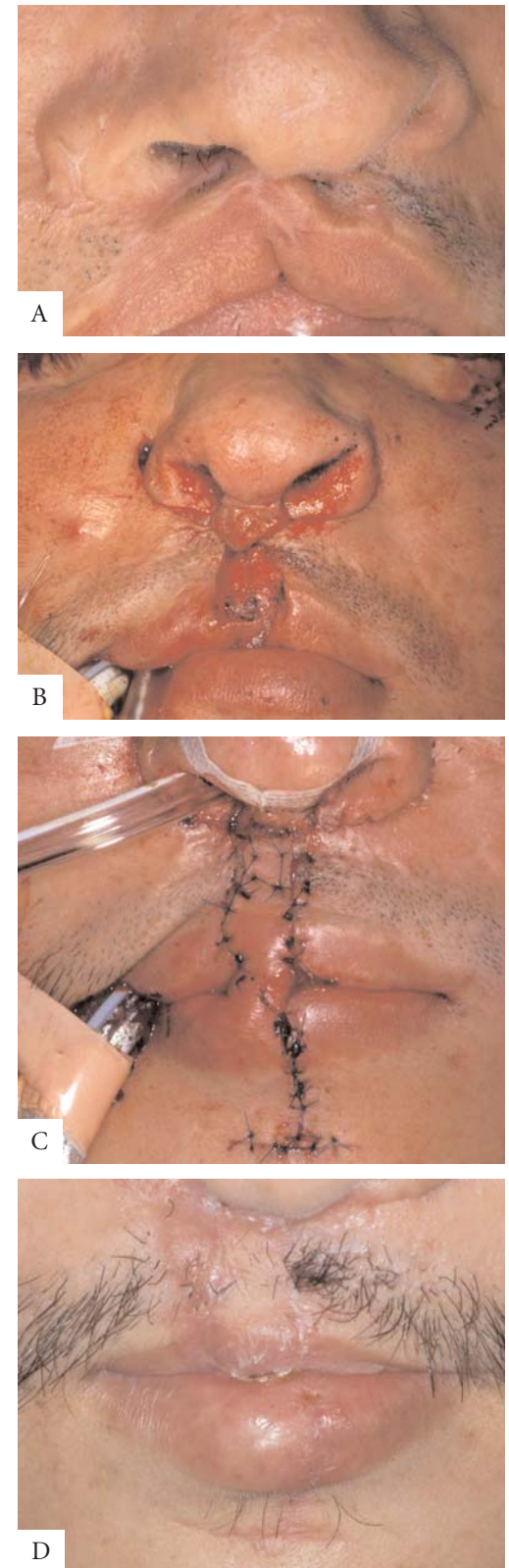


FIGURE 38-12 A, Patient with a traumatic lip deformity with avulsion of a portion of his upper lip. B, Reapproximation of the orbicularis oris muscles and perialar advancement flaps to reestablish upper lip length. C, An Abbe flap is used to restore the missing philtrum. D, Postoperative result.

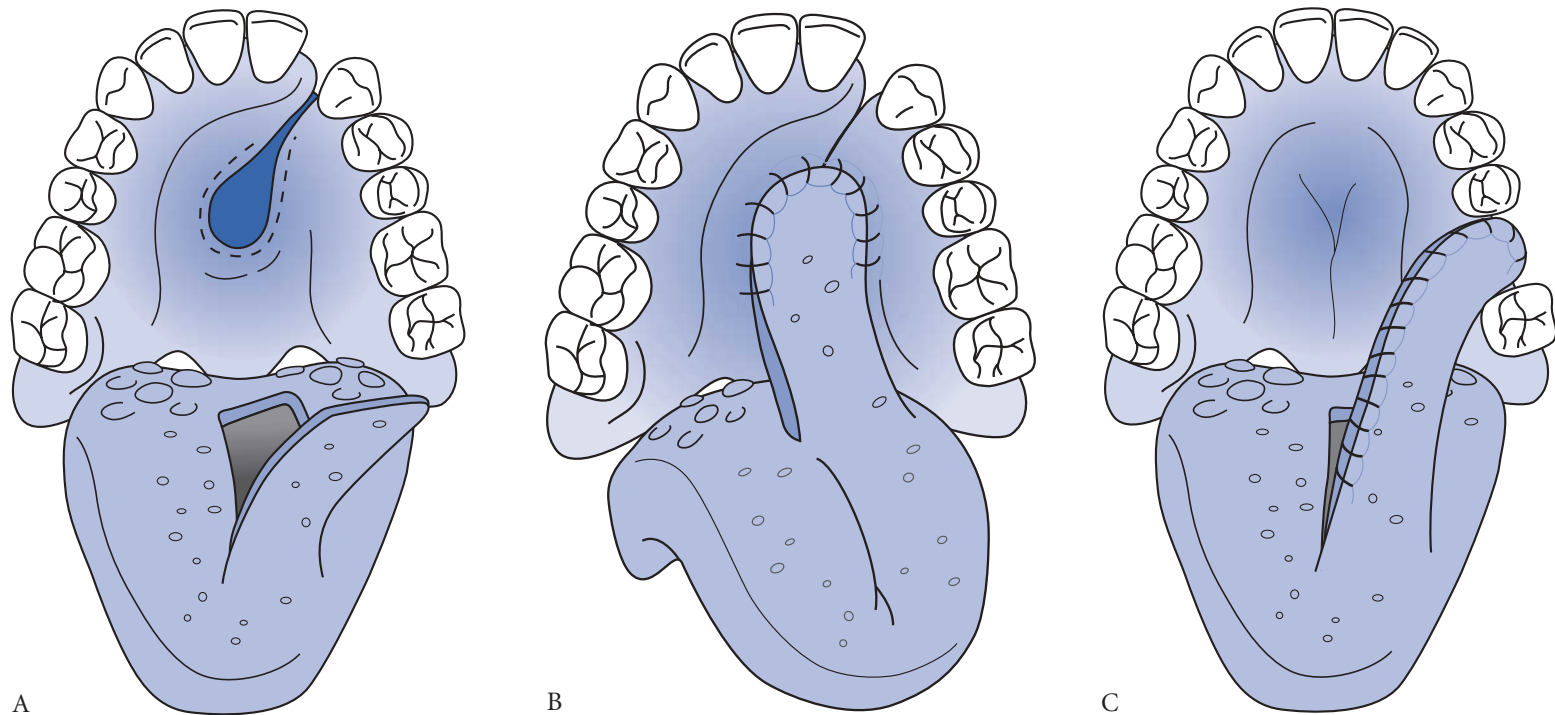


FIGURE 38-13 A and B, Use of an anteriorly based tongue flap to cover the soft tissue deficit resulting from an alveolar cleft. C, This type of flap is also useful for closing large oroantral fistulas..

Pectoralis Major Myocutaneous Flap

The pectoralis major myocutaneous flap remains a workhorse of reconstructive surgery.³⁸⁻⁴⁰ The flap was introduced by Ariyan⁴¹ and has provided a reliable method of soft tissue reconstruction of bone and soft tissue defects of the mandible and maxilla. The pectoralis major myocutaneous flap can be rotated around a pivot point 180° and is supplied by two separate blood supplies (Figure 38-14). The thoracoacromial artery arises from the second portion of the axillary artery and forms four branches as it penetrates the fascia. The pectoral branch is the major artery that supplies the pectoralis major myocutaneous flap. The position of the vascular pedicle can be approximated by drawing a line from the shoulder point to the xiphoid. The pectoral branch descends at a right angle from the middle of the clavicle until it meets this line. Branches of the internal mammary artery supply the medial portion of the muscle and skin over the sternum. The flap provides good coverage

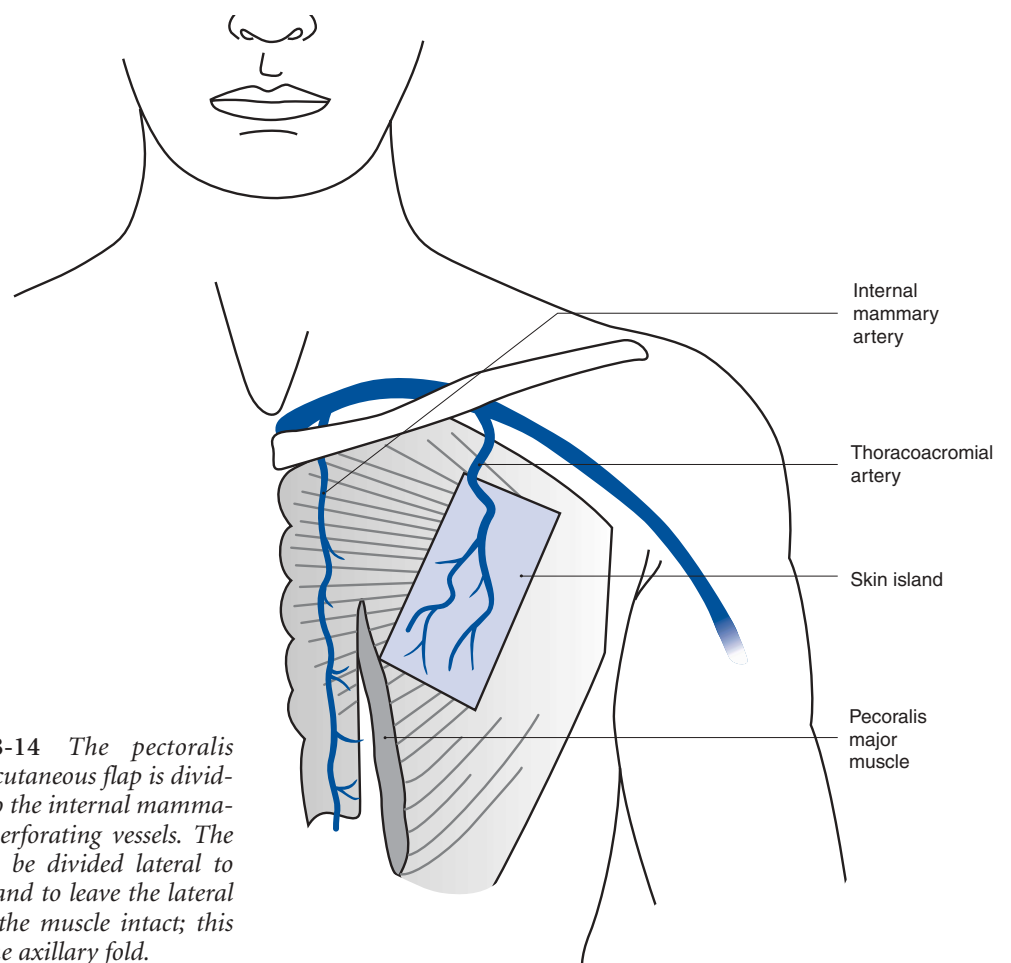


FIGURE 38-14 The pectoralis major myocutaneous flap is divided lateral to the internal mammary artery perforating vessels. The muscle can be divided lateral to the skin island to leave the lateral portion of the muscle intact; this preserves the axillary fold.

for the carotid artery when combined with a neck dissection.

Deltopectoral Flap The introduction of the deltopectoral flap by Bakamjian and colleagues represented a significant improvement for reconstructing large ablative resections for head and neck cancer.⁴²⁻⁴⁴ Currently it is used as an alternative to the pectoralis major myocutaneous flap for soft tissue reconstruction of the mandible and maxilla. This flap is composed of fascia, subcutaneous tissue, and skin but does not contain muscle (Figure 38-15). Perforators from the internal mammary artery provide vascular supply to the flap. The secondary defect is covered with a skin graft.

Temporalis Flap The temporalis flap was introduced by Golovine in 1898 and remains useful for covering intraoral defects (Figure 38-16).⁴⁵⁻⁴⁸ The outer portion of the muscle is invested by the deep temporal fascia. This fascia is supplied by the middle temporal vessel, which originates just below the zygomatic arch. The temporalis muscle is supplied by both the anterior and posterior deep temporal arteries, which arise from the second portion of

the internal maxillary artery. This dual blood supply allows for splitting of the muscle into anterior and posterior flaps.

When elevating the muscle, it is important to remain on the deep temporal fascia beneath the superficial temporal fascia to avoid damage to the frontal branch of the facial nerve. Elevation of

the inferior portion of the flap is performed in a subperiosteal plane to avoid damage to the deep temporal arteries, which lie on the undersurface of the muscle. An osteotomy of the zygomatic arch is often helpful to facilitate placement of the muscle into the mouth. The arch can be put back into place and secured with

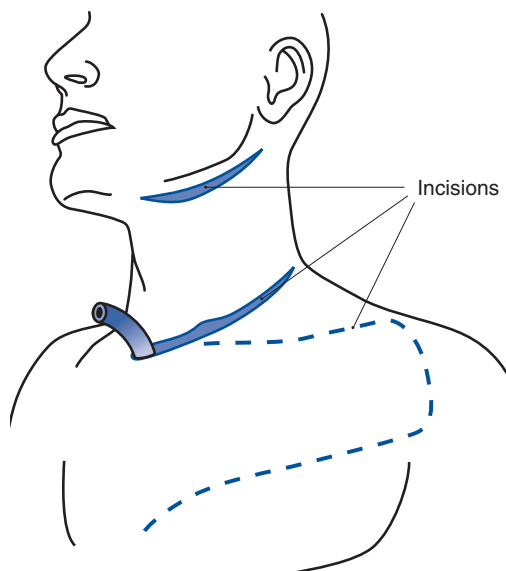


FIGURE 38-15 Incisions for a deltopectoral flap.

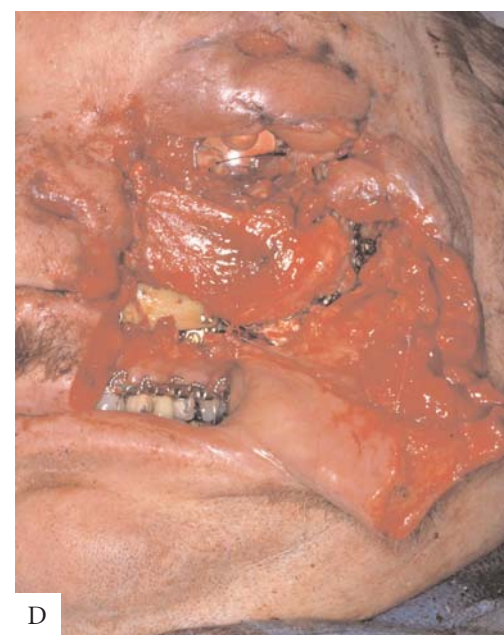
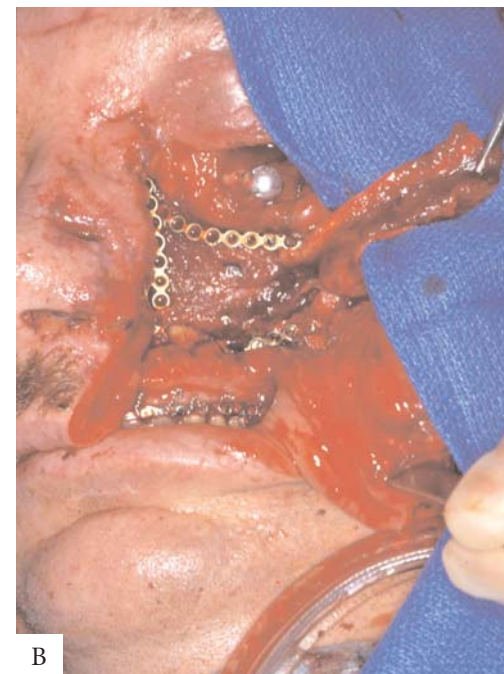
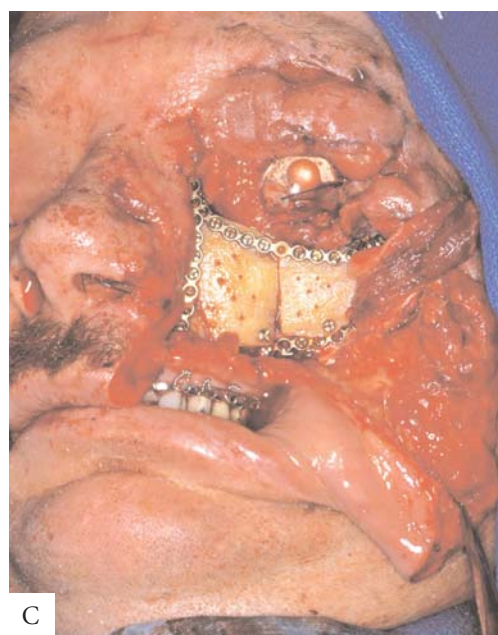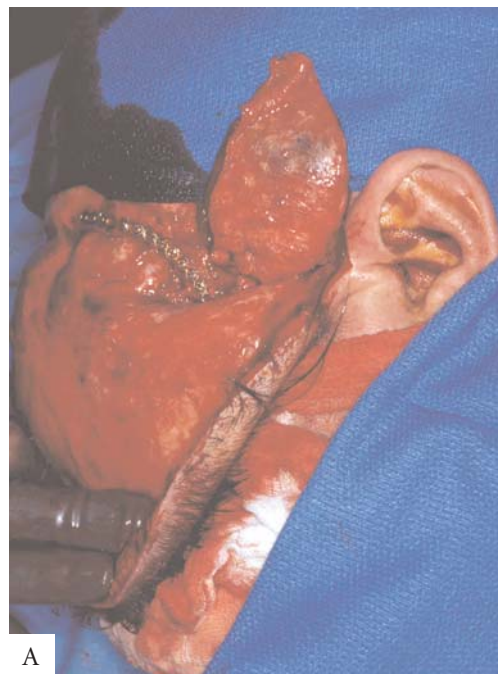FIGURE 38-16 A, Temporalis muscle flap for repair of a midface defect caused from a shotgun wound. B, The temporalis muscle is divided, and the posterior portion is sutured into place. C, Cranial bone is used to restore the missing tissue. D, The anterior portion of the temporalis flap is sutured into place to “sandwich” the bone grafts.

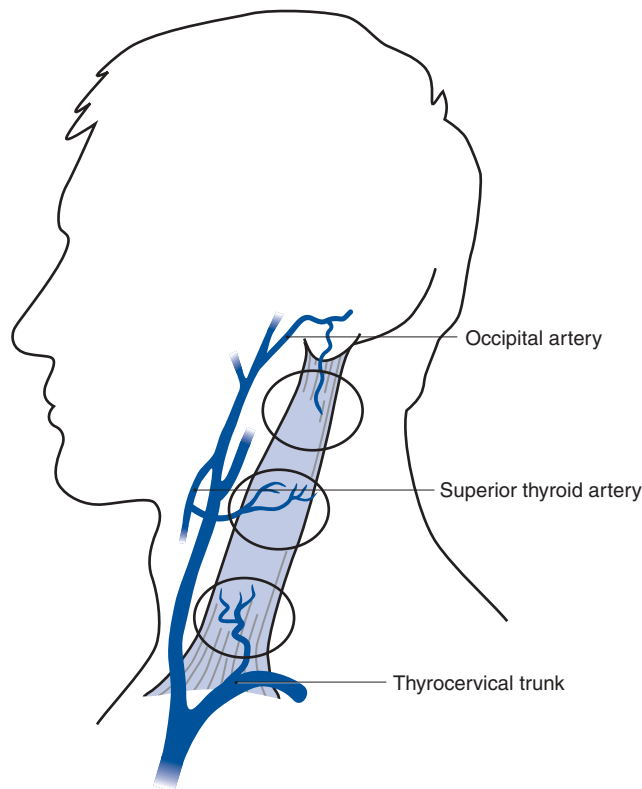


FIGURE 38-17 Blood to the sternocleidomastoid muscle is supplied through three arteries.

plates and screws. A disadvantage of the temporalis flap is the minimal cosmetic deformity of hollowing in the temporal region; this can be corrected with autogenous or alloplastic materials and can be minimized by using either an anterior or a posterior flap.

Sternocleidomastoid Flap First described by Jinau in 1909 for facial reanimation, the sternocleidomastoid flap was repopularized by Owens.^{49–55} The muscle is invested by the deep cervical fascia and is supplied by three arteries. The dominant vessel is the occipital artery, which

enters the muscle below the mastoid tip and supplies the superior portion of the muscle. The superior thyroid artery supplies the middle portion, and the thyrocervical trunk supplies the inferior third of the muscle.

The muscle is elevated over the deep cervical fascia superior to the carotid sheath. It is recommended to maintain two of the three vessels when elevating the flap to enhance the viability of the flap. The spinal accessory nerve enters the deep portion of the muscle approximately at the carotid bifurcation and should be preserved to prevent denervation atrophy of the muscle (Figure 38-17). Advantages of the sternocleidomastoid flap include its close proximity to the defect and minimal donor site defect (Figures 38-18 and 38-19).

Trapezius Myocutaneous Flap The trapezius myocutaneous flap is supplied by three arteries, allowing several flaps to be used. The main vessel supplying the trapezius muscle is the transverse cervical artery, which is a branch of the thyrocervical trunk. The upper portion of the muscle is supplied by the occipital artery. The trapezius myocutaneous flap is a ready source of skin of uniform thickness without excessive

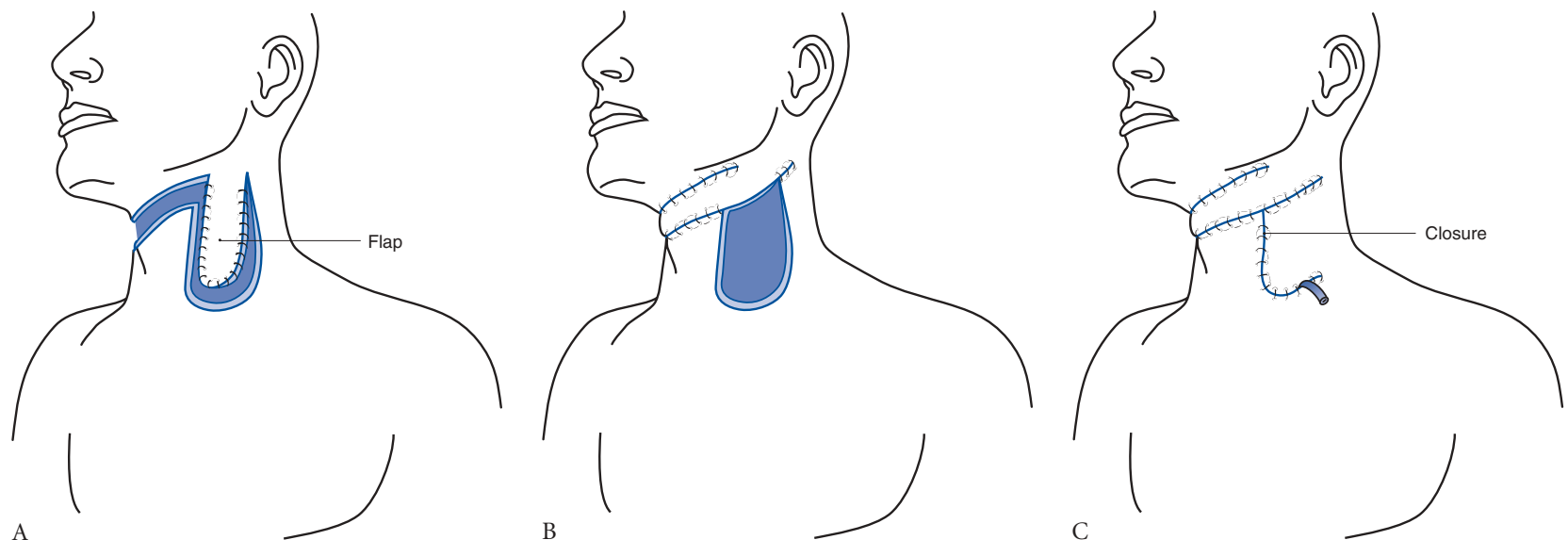


FIGURE 38-18 A, Superiorly based flap with skin pedicle. B, Transposition of the flap. C, Closure of the donor defect.

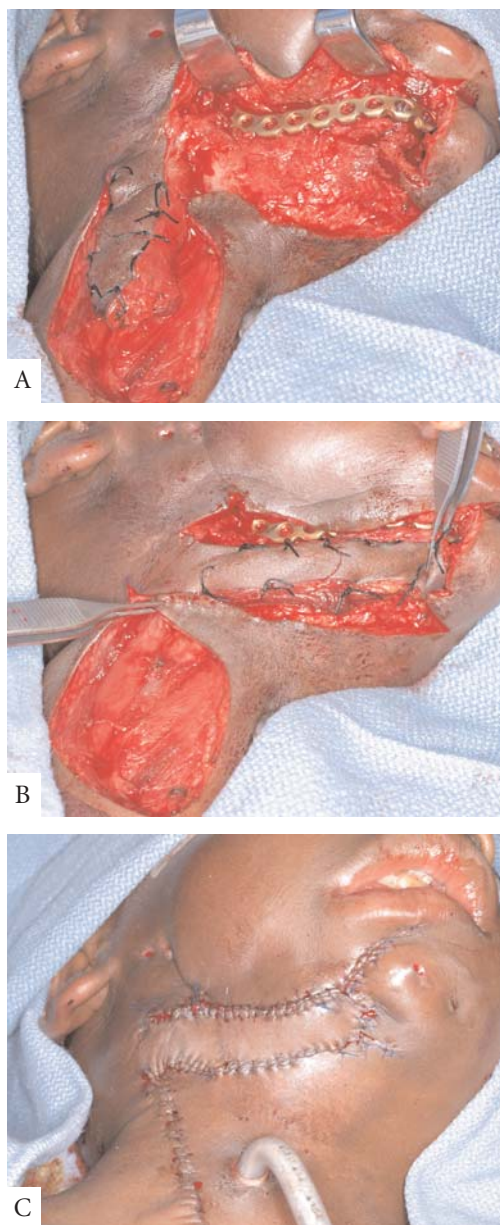


FIGURE 38-19 A, The sternocleidomastoid flap is elevated with a superior base. B, The flap is rotated in place to provide soft-tissue coverage over the reconstruction plate. C, The flap is sutured into place and the donor site closed primarily.

muscle bulk.⁵⁶ The main disadvantage is the limited rotation and the short pedicle.

Latissimus Dorsi Myocutaneous Flap
Quillen and colleagues first described the use of the latissimus dorsi myocutaneous flap for head and neck reconstruction in 1978.^{57,58} The flap is not commonly used for head and neck reconstruction unless other flaps are unavailable or there are

very large defects requiring coverage. The muscle is supplied by the thoracodorsal artery, which is the dominant vessel, and also by four to six perforators from the posterior intercostals and lumbar vessels. The main advantage of the latissimus dorsi flap is the large amount of skin provided. The main disadvantages are the need to reposition the patient during the operation and morbidity from the donor site.

Complications

Postoperative complications can be minimized with careful preoperative planning of flap design and by early recognition of problems.⁵⁹ A medical history can be used to identify patients with risk factors involving small vessels. These risk factors include smoking, diabetes, hypertension, previous radiation, and preexisting scars.^{60,61} Complications may be reversible or irreversible. Early recognition and treatment can minimize complications and prevent them from becoming irreversible. Two main unwanted outcomes are flap failure and unacceptable cosmetic results.

Flap survival depends on early recognition of flap compromise. Ischemia is defined as an inadequacy of perfusion in providing tissue needs. Signs of arterial ischemia include a pale and cool flap that does not blanch with pressure and typically does not bleed with a pinprick. Flaps are somewhat ischemic initially because the original tissue perfusion has been compromised by flap elevation. Most tissue can survive on 10% of its average blood flow.⁵⁹ Whether the flap will undergo necrosis depends on patient-related and surgery-related factors that influence the risk of necrosis in facial flaps. Smoking is associated with an increased risk of flap failure. The deleterious effects of smoking on flap survival include hypoxemia and vasoconstriction. Patients should be advised to quit smoking during the perioperative period.

Common causes of bleeding in facial reconstruction with local flaps include

inadequate hemostasis and drug-induced coagulopathy. Hematoma formation should be identified and decompressed within 24 hours.⁶² Decompression can be accomplished with aspiration using a 22-gauge needle or by taking out one or two sutures and applying gentle compression on the flap. Hematoma formation may diminish tissue perfusion and can lead to ischemia or necrosis by inducing vasospasm, stretching the subdermal plexus, or separating the flap from its recipient bed. Patients should be questioned carefully about the use of medications that affect coagulation such as acetylsalicylic acid, nonsteroidal anti-inflammatory drugs, and vitamin E. If possible, these medications should be avoided for 2 weeks prior to and 1 week after surgery.

Congestion is the most common vascular problem associated with facial flaps. Signs of a congested flap include warmth, edema, and a purple color that blanches with pressure then immediately refills. A pinprick will cause release of dark venous blood. Venous congestion can lead to arterial compromise and flap necrosis. Management of congested flaps may include temporarily releasing sutures to allow decompression at the flap edges or possible impingement involving the flap pedicle. Tight bandages around the flap pedicle should be removed. Medicinal leeches (*Hirudo medicinalis*) may be useful in decompressing congested flaps.^{63,64} Saliva from the leech contains an anticoagulant and a vasodilator that facilitate continued oozing from the site even up to 6 hours after they detach.

Hyperbaric oxygen (HBO) has been shown to be beneficial in improving the vascularity of marginal tissues.⁶⁵ Prophylactic HBO therapy in cutaneous flap surgery in the irradiated tissue bed may be particularly helpful to combat the hypoxia and hypocellularity. HBO is beneficial in treating both venous congestion and arterial ischemia by creating a local

arterial vasoconstriction through the rise in arterial oxygen content, which reduces the amount of inflow. The tissue oxygen levels continue to rise owing to the improved diffusion even though there is vasoconstriction and a reduction in vascular perfusion. The flap can maintain viability while continued neovascularization occurs. Other options include the use of heparin and dipyridamole to help increase the survival of an ischemic flap.⁶⁶

Infection can complicate flap healing.⁶⁷ The postoperative infection rate for clean wounds in facial surgery is as low as 2.8%, with higher rates in facial reconstruction with local flaps.⁶⁸ Tissue oxygenation is an important factor in prevention of wound infection and is closely related to blood supply. Infections involving local flaps may result in flap failure or poor cosmetic outcome secondary to wound dehiscence and scarring.

Conclusion

A variety of facial flaps are available to the reconstructive surgeon for repairing facial defects. The goal of flap surgery is to restore form, function, and esthetics. There are many advantages to using local and regional flaps, which can lead to optimal esthetic results.

References

- Schliephake H, Furrert K, Schneller T. Prospective study of the quality of life of cancer patients after intraoral tumor surgery. *J Oral Maxillofac Surg* 1996;54:664-9.
- Kruger E. Reconstruction of bone and soft tissue in extensive facial defects. *J Oral Maxillofac Surg* 1982;40:714-20.
- Summers BK, Siegle RJ. Facial cutaneous reconstructive surgery: general aesthetic principles. *J Am Acad Dermatol* 1993;29:669-81.
- Baker SR. Resurfacing flaps in reconstructive rhinoplasty. *Aesthetic Plast Surg* 2002;26:17-23.
- Baker SR. Local cutaneous flaps. *Otolaryngol Clin North Am* 1994;27:139-59.
- Baker SR. Regional flaps in facial reconstruction. *Otolaryngol Clin North Am* 1990;23:925-46.
- Escobar V, Zide MF. Delayed repair of skin cancer defects. *J Oral Maxillofac Surg* 1999;57:271-9.
- Ducic Y, Herford AS. The use of palatal island flaps as an adjunct to microvascular free tissue transfer for reconstruction of complex oromandibular defects. *Laryngoscope* 2001;111:1666-9.
- Milton S. Pedicled skin-flaps: the fallacy of the length:width ratio. *Br J Surg* 1970;57:502-8.
- Schliephake H, Schmelzeisen R, Neukam FW. Long-term results of blood flow and cutaneous sensibility of flaps used for the reconstruction of facial soft tissues. *J Oral Maxillofac Surg* 1994;52:1247-52.
- Gonzalez-Ulloa M. Restoration of the face covering by means of selected skin in regional aesthetic units. *Br J Plast Surg* 1956;9:212-21.
- Burget GC, Menick FJ. The subunit principle in nasal reconstruction. *Plast Reconstr Surg* 1985;76:239-47.
- Rieger RA. A local flap for repair of the nasal tip. *Plast Reconstr Surg* 1967;40:147-9.
- Marchac D, Toth B. The axial frontonasal flap revisited. *Plast Reconstr Surg* 1985;76:686-94.
- Haneke E. Surgical treatment of defects on the tip of the nose. *Dermatol Surg* 1998;24:711-7.
- Herford AS, Zide MF. Reconstruction of superficial skin cancer defects of the nose. *J Oral Maxillofac Surg* 2001;59:760-7.
- Millard DR. The island flap in cleft palate surgery. *Surg Gynecol Obstet* 1963;116:197-8.
- Liposky RB. Immediate repair of the oroantral communication: a preventative dental procedure. *J Am Dent Assoc* 1981;103:727-9.
- Yih WY, Merrill RG, Howerton DW. Secondary closure of oroantral and oronasal fistulas: a modification of existing techniques. *J Oral Maxillofac Surg* 1988;46:357-64.
- Limberg AA. *Planimetrie und Stereometrie der Hautplastik*. Jena, Germany: Fischer Verlag; 1967.
- Borges AF. Choosing the correct Limberg flap. *Plast Reconstr Surg* 1978;62:542-5.
- Zitelli JA. The bilobed flap for nasal reconstruction. *Arch Dermatol* 1989;125:957-9.
- Iida N, Ohsumi N, Tonegawa M, et al. Simple method of designing a bilobed flap. *Plast Reconstr Surg* 1999;104:495-9.
- Shumrick KA, Smith TL. The anatomic basis for the design of forehead flaps in nasal reconstruction. *Arch Otolaryngol Head Neck Surg* 1992;118:373-9.
- Burget GC, Medick FJ, editors. The paramedian forehead flap. In: *Aesthetic reconstruction of the nose*. St. Louis: Mosby; 1994. p. 57-92.
- Burget GC. Aesthetic restoration of the nose. *Clin Plast Surg* 1985;12:463-80.
- McCarthy JG, Lorenc ZP, Cutting C, et al. The median forehead flap revisited: the blood supply. *Plast Reconstr Surg* 1985;76:866-9.
- Ducic Y, Burye M. Nasolabial flap reconstruction of oral cavity defects: a report of 18 cases. *J Oral Maxillofac Surg* 2000;59:1104-8.
- Kakinuma H, Iwasawa U, Honjoh M, Koura T. A composite nasolabial flap for an entire ala reconstruction. *Dermatol Surg* 2002;28:237-40.
- Maurer P, Eckert AW, Schubert J. Functional rehabilitation following resection of the floor of the mouth: the nasolabial flap revisited. *J Craniomaxillofac Surg* 2002;30:369-72.
- Lazaridis N, Zouloumis L, Venetis G, et al. The inferiorly and superiorly based nasolabial flap for reconstruction of moderate-sized oronasal defects. *J Oral Maxillofac Surg* 1998;56:1255-9.
- Zide MF, Fuselier C. The partial-thickness cross-lip flap for correction of postoncologic surgical defects. *J Oral Maxillofac Surg* 2001;59:760-7.
- Yih WY, Howerton DW. A regional approach to reconstruction of the upper lip. *J Oral Maxillofac Surg* 1997;55:383-9.
- Schulte DL, Sherris DA, Kasperbauer JL. The anatomical basis of the Abbe flap. *Laryngoscope* 2001;111:382-6.
- Massengill R, Pickrell K, Mladick R. Lingual flaps: effect on speech articulation and physiology. *Ann Otol Rhinol Laryngol* 1970;79:853-7.
- Motamedi MH, Behnia H. Experience with regional flaps in the comprehensive treatment of maxillofacial soft-tissue injuries in war victims. *J Craniomaxillofac Surg* 1999;27:256-65.
- Blackwell KE, Buchbinder D, Biller HF, Urken ML. Reconstruction of massive defects in the head and neck: the role of simultaneous distant and regional flaps. *Head Neck* 1997;19:620-8.
- Ariyan S. The pectoralis major myocutaneous flap. A versatile flap for reconstruction in the head and neck. *Plast Reconstr Surg* 1979;63:73-81.
- Ariyan S. Further experiences with the pectoralis major myocutaneous flap for the immediate repair of defects from excisions of head and neck cancers. *Plast Reconstr Surg* 1979;65:605-12.
- Marx RE, Smith BR. An improved technique for development of the pectoralis major myocutaneous flap. *J Oral Maxillofac Surg* 1990;48:1168-80.
- Ariyan S. Pectoralis major, sternomastoid, and other musculocutaneous flaps for head and neck reconstruction. *Clin Plast Surg* 1980;7(1):89-109.

42. Bakamjian VY. Total reconstruction of pharynx with medially based deltopectoral skin flap. *NY State J Med* 1968;68:2771–8.
43. Sasaki K, Nozaki M, Honda T, et al. Deltopectoral skin flap as a free skin flap revisited: further refinement in flap design, fabrication and clinical usage. *Plast Reconstr Surg* 2001;107:1134–41.
44. Lazaridis N, Tilaverdis I, Dalambiras S, et al. The fasciocutaneous cervicopectoral rotation flap for lower cheek reconstruction: report of three cases. *J Oral Maxillofac Surg* 1997;55:1166–71.
45. Golovine SS. Procède de cloture plastique de l'orbite après l'exenteration. *Arch Ophthalmol* 1898;18:679.
46. Alonso del Hoyo J, Fernandez Sanroman J, Gildiez JL, et al. The temporalis muscle flap: an evaluation and review of 38 cases. *J Oral Maxillofac Surg* 1994;52:143–7.
47. Burggasser G, Happak W, Gruber H, Freilinger G. The temporalis: blood supply and innervation. *Plast Reconstr Surg* 2002;109:1862–9.
48. Abubaker AO, Abouzia MB. The temporalis muscle flap in reconstruction of intraoral defects: an appraisal of the technique. *Oral Surg Oral Med Oral Pathol Oral Radiol Endod* 2002;94:24–30.
49. Jinau A. Die Chirurgische Behandlung der facialen Lachmung. *Dtsch ZF Chin* 1909;102:377–81.
50. Owens NA. A compound neck pedicle designed for the repair of massive facial defects. *Plast Reconstr Surg* 1955;15:369–89.
51. Zhao YF, Zhang WF, Ahao JH. Reconstruction of intraoral defects after cancer surgery using cervical pedicle flaps. *J Oral Maxillofac Surg* 2001;59:1142–6.
52. Ariyan S. Further experience with the sternocleidomastoid myocutaneous flap. *Plast Reconstr Surg* 2003;111:381–2.
53. Kerawala CJ, McAloney N, Stassen LF. Prospective randomized trial of the benefits of a sternocleidomastoid flap after superficial parotidectomy. *Br J Oral Maxillofac Surg* 2002;40:468–72.
54. Kierner AC, Zelenka I, Gstoettner W. The sternocleidomastoid flap—its indications and limitations. *Laryngoscope* 2001;111:2201–4.
55. Marx RE, McDonald DK. The sternocleidomastoid muscle as a muscular or myocutaneous flap for oral and facial reconstruction. *J Oral Maxillofac Surg* 1985;43:155–62.
56. Papadopoulos O, Tsakoniatis N, Georgiou P, Christopoulos A. Head and neck soft-tissue reconstruction using the vertical trapezius musculocutaneous flap. *Ann Plast Surg* 1999;42:457–8.
57. Quillen CG, Shearing JG, Georgiade NG. Use of the latissimus dorsi myocutaneous island flap for reconstruction in the head and neck area. *Plast Reconstr Surg* 1978;62:113–7.
58. Posnick JC, McCraw JB, Magee W Jr. Use of a latissimus dorsi myocutaneous flap for closure of an orocutaneous fistula of the cheek. *J Oral Maxillofac Surg* 1988;46:224–8.
59. Vural E, Key JM. Complications, salvage, and enhancement of local flaps in facial reconstruction. *Otolaryngol Clin North Am* 2001;34:39–51.
60. Goldminz D, Bennett RG. Cigarette smoking and flap and full-thickness graft necrosis. *Arch Dermatol* 1991;127:1012–5.
61. Kinsella JB, Rassekh CH, Wassmuth ZD, et al. Smoking increases facial skin flap complications. *Ann Otol Rhinol Laryngol* 1999;108:139–42.
62. Mulliken JB, Healey NA. Pathogenesis of skin flap necrosis from an underlying hematoma. *Plast Reconstr Surg* 1979;63:540–5.
63. Utley DS, Koch RJ, Goode RL. The failing flap in facial plastic and reconstructive surgery: role of the medicinal leech. *Laryngoscope* 1998;108:1129–35.
64. Dabb RW, Malone JM, Leverett LC. The use of medicinal leeches in the salvage of flaps with venous congestion. *Ann Plast Surg* 1992;29:250–6.
65. Zamboni WA, Roth AC, Russell RC, et al. The effect of hyperbaric oxygen on reperfusion of ischemic axial skin flaps: a laser Doppler analysis. *Ann Plast Surg* 1992;28:339–41.
66. Kerrigan CL, Daniel RK. Pharmacologic treatment of the failing skin. *Plast Reconstr Surg* 1982;70:541–8.
67. Bumpous JM, Johnson JT. The infected wound and its management. *Otolaryngol Clin North Am* 1995;28:987–1001.
68. Sylaidis P, Wood S, Murray DS. Postoperative infection following clean facial surgery. *Ann Plast Surg* 1997;39:342–6.

Bony Reconstruction of the Jaws

Randall M. Wilk, DDS, PhD, MD

Overview and Goals

Bony reconstruction of the jaws represents one of the most daunting tasks presenting to the oral and maxillofacial surgeon. The demands of reconstruction of the mandible and maxilla represent challenges for the following reasons. The requirements for success follow a strict criterion for occlusion of the dentition and oral rehabilitation. Minor malpositionings result in occlusal problems that are both perceptible to the patient and provide a formidable task to the restorative dentist. Major malpositions may make oral rehabilitation near impossible. The functional loads to be carried on the bone can challenge both hardware and the reconstituted mandible and maxilla. The environment of the oral cavity can be hostile for adequate healing and regeneration. Indigenous flora of the oral cavity is one of the most diverse in the human body, and the bacterial load can be considerable. When pathogenic flora is present, as is not uncommon in the compromised host, healing can be further challenging. The bones themselves represent complex morphologies, curved shapes, and complex relationships with adjacent structures. Reproducing these parameters adds to the complexity of the task. The jaws by virtue of their prominent placement on the exposed face impart considerable esthetic requirements. Unlike other parts of the body, which are hidden by clothing, the face is rarely concealed.

The goals of reconstruction under the aforementioned conditions are to provide morphology and position of the bone in relation to its opposing jaw, provide adequate height and width of bone, restore continuity of the mandible and maxilla, and provide facial contour and support for soft tissue structures. While these concepts may seem straightforward, surgeons have struggled for centuries to achieve them and success is often elusive. Various success rates have been described for bony reconstruction of the jaws, but criteria have usually been incomplete and rates uninspiring.

The factors leading to the lack of adequate bone development or loss of bone in the first place have a role in the types and methods used to begin a reconstruction. Ablative loss of both bone and associated soft tissue from treatment of neoplastic or other pathologic processes represent a far different task from loss of bone from trauma or infection. Other modulating factors include the presence of systemic diseases, exposure to therapeutic doses of ionizing radiation, or failure of development of normal bony structures. Success rates in irradiated jaws are typically lower by significant amounts, and rates of complications have been reported as high as 81.3%.¹ Complete graft loss in 30% of irradiated patients undergoing bone grafting to the jaws and an additional 50% of patients experiencing partial graft loss after reconstructive procedures have been

reported.² Use of hyperbaric oxygen therapy and microvascular reconstruction has improved these rates.^{3,4}

Bony reconstruction begins with assessing the bone to be reconstructed. The location, size, and relationship to the other structures are the prime factors in planning a reconstruction. A large defect of the angle region is managed differently than a small defect in the same region. A defect in the alveolus of the maxilla is managed differently than a similar-size defect in the hard palate. Defects in areas that are opposed by natural dentition are managed differently than those that are in areas that have little functional consequence.

Anatomic Considerations in Reconstruction of the Jaws

Anatomically the mandible can be divided into four broad regions (Figure 39-1) with somewhat indistinct boundaries: condylar portion, ramus, body, and alveolus. Several subsets or overlapping areas have been described. The coronoid region can be considered as part of the ramus, the angle region encompasses both part of the ramus and body, and the symphysis is the anterior part of the body. Each of the areas presents unique characteristics, and the decision to reconstruct or repair certain areas is dependent on the goals to be achieved.

The condylar region is critical to the masticatory functions of the jaws and overall movements of the mandible. In the

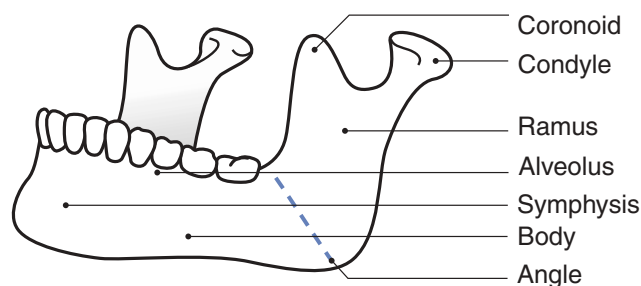


FIGURE 39-1 Mandibular regions.

young and growing patient there are implications for growth of the jaw. The relationship of this area with the temporal bone and the interarticular disk is beyond the scope of this chapter. Anatomic features of the condylar region are the muscular attachments and morphologic support of facial height. The lateral pterygoid muscle attaches to the condylar region and provides for translatory movement of the mandible and its excursive movements. When reconstructing large or entire portions of the condyle with grafts, failure of reattachment of the lateral pterygoid muscles will result in impairment or loss of these functions. The condylar region contributes to the posterior vertical height of the mandible. Loss of the condylar region or insufficient reconstruction results in reduced height with resulting malocclusion and esthetic contour deficiencies. Not only does the reconstructed condyle need to have adequate bulk and form, but it also needs to be placed in appropriate relationship to the temporomandibular joint fossa.

The ramus area participates in masticatory function as the site of attachment of the major muscles of mastication. The masseter, medial pterygoid, and temporalis muscles all attach here and provide the major input for developing bite force. These muscles also serve as a potent blood supply for the reconstructed bone and serve as an excellent recipient bed. The ramus region provides bulk, facial contour, and continuity between major segments of the mandible. Damage or loss of bone structure in this area can lead to

decreased posterior mandibular height with resulting malocclusion, facial contour defects, and decreased masticatory function. The major sensory nerve of the mandible enters this area and is prone to injury during reconstructive efforts. The coronoid process is considered part of the ramus, and its loss can be considered to be trivial. There are no good reasons to reconstruct a coronoid process. As in other parts of the mandible, the relationship of the coronoid process to the surrounding bones is critical. Malpositioning of the coronoid process can impede opening of the jaw owing to interferences with the zygoma and zygomatic arch.

The body of the mandible is probably the most complex area of the mandible to reconstruct for several reasons. It has a complex curved shape that makes reconstruction difficult, it is along the lever of the mandible and has the highest loads placed on it, it contains a sensory nerve that is prone to injury, and it is the site of attachment of a complex array of muscles. The mylohyoid, geniohyoid, digastric, mentalis, buccinator, and tongue musculature all have attachment to this part of the bone. Their presence helps to serve as an excellent recipient bed, but the forces they exert on the bone present problems in reconstruction and maintaining the contour of the bone. In the anterior region the muscle attachments serve a vital function in maintaining airway patency through attachment of the tongue musculature and support of the hyoid complex. The body of the mandible supports the alveolus and tooth-

bearing structures, and it has a critical relationship to the opposing jaw.

The alveolus of the mandible is the site of the functional component of the mandible, the dental occlusion. This portion of the mandible is dependent on the position of the mandibular body for its relationship to the maxillary arch. The alveoli need proper height and width to subservise the functions of the dentition. In the maxilla the alveolus is in relationship to the maxillary sinus and nasal cavity, and this relationship alters reconstructive efforts. In the anterior portion of the jaws this alveolar component is essential to maintaining position of the overlying soft tissue, especially the lips. Loss in this area or inadequate reconstruction can lead to both functional and esthetic deficiencies.

The maxilla, or upper jaw (Figure 39-2), is a complex bone comprising the bulk of the midface. It has relationships with the opposing mandible, the orbital complex, paranasal sinuses, zygoma, and nasal cavity. The palate forms the roof of the mouth and serves to partition the oral and nasal cavities. Incomplete reconstruction of the palate leads to hypernasal speech and regurgitation of the oral cavity contents, unless obturated. The paucity and quality of soft tissue surrounding this region makes bony reconstruction especially difficult. At the posterior aspect of the maxilla, a complex array of muscles attaches and subserves the functions of the

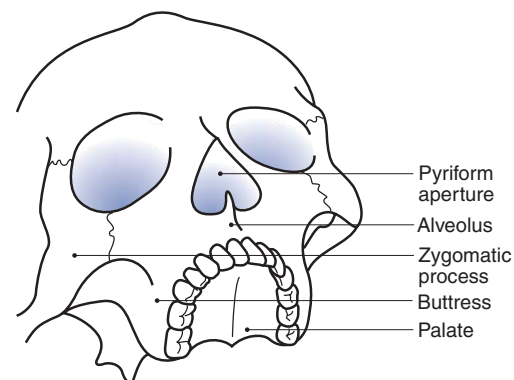


FIGURE 39-2 Maxillary regions.

soft palate. These attachments are involved not only in speech and swallowing but also in eustachian tube function. In the alveolar portion of the maxilla, the relationship to the maxillary sinus is an often-confounding factor in reconstruction. Highly pneumatized sinuses provide little support for grafting procedures. In the anterior region of the maxilla, support for nasal and orbital structures is required for maintaining nasal airway support and facial contour and esthetics for the nose.

Defects of the Mandible

Defects of the mandible can involve single subsets of the mandible, several segments, or the entire mandible. Marginal defects involve loss of the mandibular bone with the inferior and posterior portions left intact. In marginal defects the continuity of the mandible is intact, and reconstructive efforts are focused on maintaining bulk and contour. Segmental defects involve loss of mandibular bone and either the posterior or inferior border and confer a continuity defect of the mandible. Descriptions of the size of the defect are usually expressed in centimeters, measured at the inferior border. This measurement will serve as a guide in estimating the amount of bone necessary to reconstruct the defect. Segmental defects can cause a wide variety of reconstructive challenges, depending on their anatomic location. Small lateral continuity defects are surprisingly well tolerated, and following ablative procedures, it was not unusual to defer or omit reconstructive techniques. Segmental defects of the anterior mandible, however, are not well tolerated because of unfavorable anatomic and biomechanical features. Maintenance of tongue position and interramal width are severely compromised with large anterior segmental defects. The defects need to be interpreted not only in terms of their relationship to the rest of the mandible but also in relation to the opposing maxillary structures, both dental and nondental.

Identifying and categorizing defects of the mandible in terms of both size and extent represent the first step in bony reconstruction of the lower jaw.

Defects of the Maxilla

Defects of the maxilla can be divided into those that disrupt partitioning of cavities and those that represent inadequate bulk or position of bone in one of the subsets. Partitioning disruptions need to be evaluated in terms of both size and location. Small defects in the bone interfering with partitioning can be managed by soft tissue procedures only and may not necessarily need to undergo bony reconstruction. Larger defects in bone interfering with partitioning can be successfully obturated by maxillofacial prostheses and, similarly, may not need bony reconstruction. Many reconstructive options exist for these types of defects. The demands of occlusal restoration or stability of the upper jaw represent the majority of needs for bony reconstruction. Positioning of the upper jaw segments can be managed through orthognathic surgery, which is not the focus of this chapter. With defects in the alveolar portion of the jaws, evaluation of adequate bone in terms of height, width, and relationship to bone in the opposing mandible is the critical first step in reconstruction of the upper jaw.

Limitation of Bony Reconstruction

Bony reconstruction of the jaws depends largely on the amount of soft tissue available. Soft tissue coverage and recipient bed nourishment need to be addressed prior to any bony reconstruction. The soft tissue evaluation and management should precede any efforts at bony reconstruction. The limitations of bony reconstruction lie largely in the imagination and skills of the practitioner. Host limitations relate to the existing soft tissue envelope in terms of both bulk and blood supply and systemic factors in the patient. Identification of all

factors influencing outcome will be a critical step in determining choice of best methods for bony reconstruction.

Bone Biology

The hallmark of reconstruction of the jaws is the grafting of bone into sites of loss or need. Bone, unlike most other tissues of the body, heals not by formation of scar tissue but by regeneration of bone. Advances in the understanding of bone physiology, immunologic concepts, and technology have made successful reconstruction of the jaws possible and somewhat predictable. The success of jaw reconstruction today is several times what it was only three decades ago. Bone reconstruction on a physiologic level is accomplished by combinations of three processes: osteogenesis, osteoconduction, and osteoinduction. Osteogenesis is the formation of new bone from osteocompetent cells. Osteoconduction is the formation of new bone along a scaffold from the host's osteocompetent cells. Osteoinduction is the formation of new bone from the differentiation and stimulation of mesenchymal cells by the bone-inductive proteins.

The understanding of the basic biologic processes in bone has blossomed over the past thirty years. Key discoveries in the bioactive molecules began with the findings of Urist and Strates relating to the bone morphogenetic proteins (BMPs).^{5,6} BMP is not a single protein but a family of proteins belonging to the transforming growth factor- β superfamily (TGF- β). At least 13 BMPs have been identified (BMP-1 does not belong to the TGF- β superfamily). The ones that are of clinical interest and are involved in human bone metabolism are BMP-2, BMP-4, and BMP-7 (also called osteogenic protein 1 [OP-1]).⁷ As with most biologic systems, antagonists to these molecules exist for biologic regulation.⁷⁻¹⁴ These antagonists called noggin, chordin, gremlin, dan, and cerberus are proteins that bind to BMPs and thus govern cartilage and skeletal morphogenesis.¹⁵

BMPs 2, 4, and 7 have effects on stem cells and osteoblast precursor cells to convert them to mineralizing osteoblasts. BMPs bind and initiate a cell signal through a transmembrane receptor complex and generate an intracellular response involving Smad proteins that promotes osteoblast differentiation. The Smad proteins function as inducible transcriptional activators associated with a component that binds deoxyribonucleic acid (DNA) when they enter the osteoblast nucleus. Research into the specific genes activated is an active area of work and definitive elucidation of the mechanisms is ongoing.

Bone Grafting Biology

Axhausen initially described the repair of bone and divided it into two phases.¹⁶ The first phase consists of cellular proliferation and production of osteoid in a disorganized fashion. The second phase is characterized by resorption of the osteoid and replacement by more organized lamellar bone. During the first phase of bone regeneration the transplanted cells within the graft proliferate and form new osteoid over the course of a few weeks. The amount of bone regeneration is dependent on the amount of bone cells that survive the transplantation procedure. These cells' survival is integrally related to the nourishment from the recipient bed. For the first 3 to 5 days diffusion by plasmatic circulation is the source of nutrients; by day 5, capillary ingrowth from the surrounding soft tissue and bone edges penetrate the graft.¹⁷

Free grafts of bone can be either cancellous, cortical, or corticocancellous blocks (Table 39-1). Within a graft, cancellous bone revascularizes sooner than cor-

ticocancellous or cortical block grafts. Endosteal osteoblasts proliferate and form osteoid on the surface of cancellous bone trabeculae.¹⁸ Those cells within the trabeculae may die as a result of their encasement in mineralized matrix and impaired diffusion through it. Osteocytes within their lacunae appear to survive if they are less than 0.3 mm from the surface.¹⁹ In cortical grafts, revascularization is much slower because the process follows preexisting haversian systems from the periphery into the interior.²⁰ A histologic difference in cortical grafts is the initiation of osteoclastic rather than osteoblastic activity. The osteoclasts will enlarge the haversian systems peripherally, then centrally. The haversian systems of a cortical graft will undergo significant resorption before osteoblastic activity will fill in the resorbed areas. The process of osteoclastic resorption followed by osteoblastic deposition is termed "creeping substitution." New bone may be deposited throughout the graft, leaving areas of necrotic bone covered by viable bone. The necrotic bone areas may persist indefinitely.²⁰ The osteoid from the transplanted cells and from the endosteum fuse in a process called consolidation.

A second phase of bone growth follows the initial consolidation and begins at about 2 weeks. Fibroblasts and other mesenchymal cells differentiate into osteoclasts and begin a resorption of the osteoid. This differentiation of cells is accomplished by BMPs found in the transplanted bone. New bone is laid down in a more orderly fashion. The two-phase theory of bone healing applies to all types of autogenous grafts. In summary: (1) cancellous grafts are revascularized more rapidly than cortical grafts, (2) cancellous bone incorporates by an appositional phase followed by a resorptive phase but cortical grafts incorporate by a resorptive phase followed by an appositional phase, and (3) cancellous grafts tend to repair completely whereas cortical grafts remain a mixture of necrotic and viable bone.

Table 39-2 Bone Grafts

Autogenous grafts: free grafts, composite grafts
Homologous grafts (allografts)
Heterogeneous grafts (xenografts)

Bone grafts improve in their mechanical properties over time. Cancellous bone grafts tend to be strengthened over time with the addition of new bone. As the necrotic cores are replaced, the strength of the bone returns to normal. Cortical grafts have a different time course and actually undergo a weakening of the bone during the osteoclastic phase. Cortical grafts have been shown to be 40 to 50% weaker than normal bone from 6 weeks to 6 months following transplantation, a period in which the porosity of the graft increases approximately 15%.²¹ After 1 to 2 years the mechanical strength becomes equal to normal bone.

Other sources of bone are available for grafting, but none has surpassed autogenous grafts (Table 39-2). Grafts can be either homologous grafts (Table 39-3) (allografts) or heterografts (xenografts). The ability to obtain grafted bone without donor site morbidity to the patient has been a longtime goal of reconstructive surgeons. Autogenous bone grafts have been shown to be superior to allogeneic bone, xenogeneic bone, bone substitutes, and alloplasts in terms of the function, form, and adaptability.²² The superiority is due to the transfer of a greater number and density of osteocompetent cells.²³ Homologous grafts, also known as allografts or allogeneic grafts come from another person. Allogeneic grafts are genetically dissimilar and to avoid tissue rejection

Table 39-1 Free Autogenous Grafts

Cancellous
Cortical
Corticocancellous

Table 39-3 Allografts

Undemineralized
Partially demineralized
Totally demineralized

phenomena must be rendered nonantigenic. These grafts serve a purpose merely as a scaffold for reconstruction and do not transfer osteocompetent cells. Grafts of the mandible can be used in conjunction with an autogenous cancellous graft with the allogeneic bone used as a scaffolding with desired contour, size, and shape.²⁴ There are many methods for rendering an allograft less antigenic including boiling, deproteinizing, merthiolating, freezing, freeze-drying, irradiating, and dry heating. The most common method used is freeze-drying (lyophilization). The major source of antigenicity in allografts is the cellular elements of bone. Boiling, drying, or chemically treating the bone will kill the cells but has a deleterious effect on coagulation of organic elements, reducing or eliminating their inductive effects and making their removal by host cellular processes difficult.²⁵ Heat in excess of 80°C destroys the biologic properties of the bone matrix.²⁶

Allograft materials have been used in several jaw reconstructive procedures, but their volume and lack of osteocompetent cells make their use limited.²⁷⁻³⁰

Alloplastic graft materials include hydroxylapatite crystals, bioactive glasses, calcium sulfate, beta tricalcium phosphate, and biphasic calcium phosphate.³¹⁻³³ Hydroxylapatites are the most commonly used alloplasts. Porous nonresorbable hydroxylapatite found in coral has been used but with only limited success. New bone can grow into the pores, but the nonresorbable coral matrix shields the new bone from stress and prevents it from maturing as well as might be desired.

Bone Morphogenetic Proteins

BMPs are an attractive restorative material. Although technically a graft, this material derives its ultimate effect by bone formation in the host. The role of BMPs in reconstruction of the jaws, indications for and limitations of their use, and the ideal carrier to deliver the material have yet to be

defined.³⁴⁻³⁷ The safety of BMPs has been studied extensively in orthopedic applications, with most of the studies having been conducted with grafting to the spine and reported in the orthopedic literature.³⁸⁻⁴⁰ With a goal to increase the available bone for placement of endosseous implants in the maxilla, BMPs have been placed into the maxillary sinus with collagen sponges as a carrier to induce new bone formation.^{41,42} With a similar goal in mind BMP-7 has been placed in fresh extraction sites prior to the placement of dental implants in dogs showing greater amount, density, and degree of remodeling of bone.⁴³ They have been placed in alveolar ridges with a resorbable collagen sponge as a carrier; however, safety and feasibility was assessed in only one study.^{44,45} They have also been placed with a poly(α -hydroxy acid) carrier into alveolar cleft defects in dogs with equivocal results.⁴⁶ Large mandibular defects (3 cm segmental) in animal studies have been reconstituted with BMPs.⁴⁷⁻⁴⁹ Only two human BMP studies have been published.^{42,50}

Autogenous Bone Grafting Sites

Intraoral Bone Grafts

Grafts that can be obtained from a local or regional site are attractive in that they are easily obtained, often in the same surgical field (Figure 39-3). They are, however, usually limited in size, quality, or cancellous bone content. Intraoral donor sites include the symphysis (chin), ramus, mandibular inferior border, mandibular body, coronoid process, and zygoma.⁵¹⁻⁶⁴ Limited amount of bone is available from these sites, and the amount of cancellous bone is sparse.

For harvesting of grafts from the chin either an intrasulcular or vestibular incision can be made. The periosteum and mentalis muscle are stripped from the chin region, and osteotomies are performed on the buccal surface beginning below the apices of the teeth. Alternatively a trephine can be used to obtain the graft. The mid-

line is usually left intact, and grafts can be harvested from the right and left sides simultaneously if necessary; graft volumes of 1 to 3 cc have been reported.³ A mild pressure dressing is applied to the chin region for 5 days. Temporary paresthesia of the chin has been reported in at least 43% of cases.⁶⁵

For harvesting of ramal grafts, several incisions can be used. In the edentulous patient a crestal incision is used extending posteriorly to the ascending ramus at the level of the occlusal plane. With healthy natural teeth, an intrasulcular incision is used, extending it posteriorly to the ascending ramus. When prosthetic crowns are present, consideration should be given to a submarginal incision along the mucogingival line, again extending to the ascending ramus. Following any of these incisions, a full thickness mucoperiosteal flap is developed along the lateral aspect of the mandible, exposing the lateral ramus of the mandible. A rectangular block of cortical bone up to 4 mm in thickness, up to 3.5 cm in anteroposterior dimension, and up to 1 cm superoinferiorly can be harvested. The medialmost osteotomy cut is lateral to the teeth and 4 to 6 mm medial to the external oblique line. The osteotomies can be cut with burs, saws, or a small diamond wheel (especially useful for the inferiormost cut). Using osteotomes and chisels the block can be

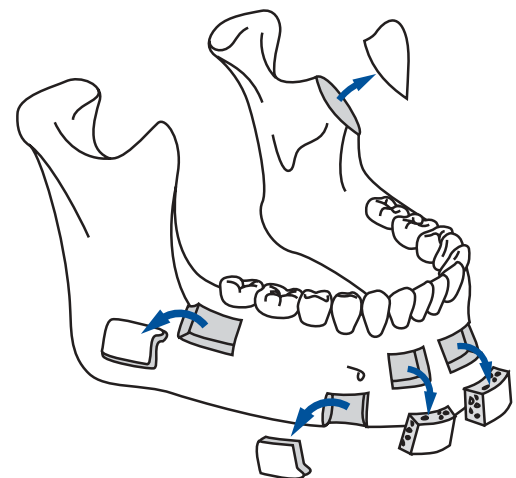


FIGURE 39-3 Intraoral bone graft donor sites.

removed. Alternatively, trephines can be used to obtain bone. Morbidity from this procedure includes fracture of the mandible, lingual or inferior nerve neurosensory disturbance, bleeding, and incision dehiscence, although these events are considered rare.⁶⁶

Cranial Bone Grafts

Cranial bone is a time-honored site for obtaining bone for grafting. Initially described for use in facial reconstruction by Tessier and refined by Jackson and colleagues, the technique can yield considerable amounts of cortical bone but limited amounts of cancellous bone.^{67,68} There is an age-dependent relationship of the development of diploic space in the calvarial bones: 80% of children have a diploic space by the age of 3 years, and when present it is less than 50% of its adult thickness.⁶⁹ The grafts can be harvested from either the inner or outer cortical tables and the procedure is well tolerated by patients. Fearon looked at postharvest magnetic resonance imaging (MRI) of the brain in 20 patients and did not detect any abnormalities, even though 3 of the patients had a full thickness breach.⁷⁰ The thickness of the bone should be at least 6.0 mm to consider in situ harvesting. Koenig and colleagues recommend not performing in situ bone graft harvesting from this site prior to 9 years of age.⁶⁹ Selection of the side of the head to use should be in the nondominant hemisphere. Grafts from the areas of the parietal bone are the most useful; although harvest from the frontal or occipital regions has been described, the temporal region should be avoided. The incision through the scalp for obtaining the graft can be either coronal (full or partial) or sagittal (Figure 39-4). The dissection of the scalp flap should proceed in the subgaleal plane, and then the pericranium of the calvaria should be incised sharply. The area of the graft is marked out with a bur staying at least 2 cm from the sagittal suture to avoid overlying the sagittal sinus

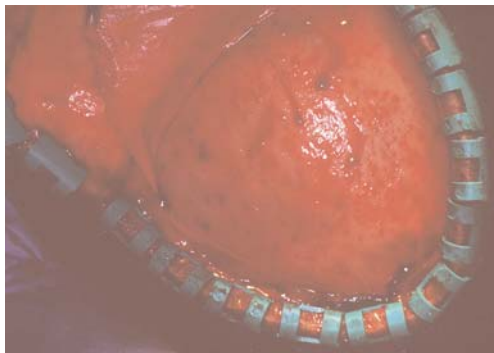
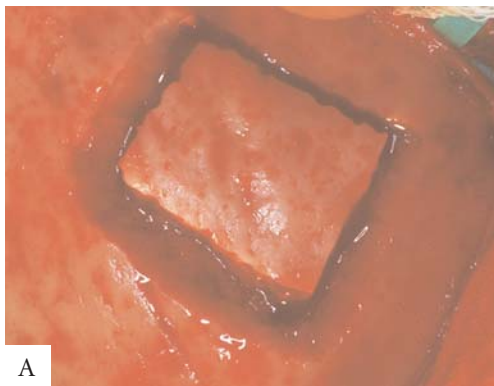


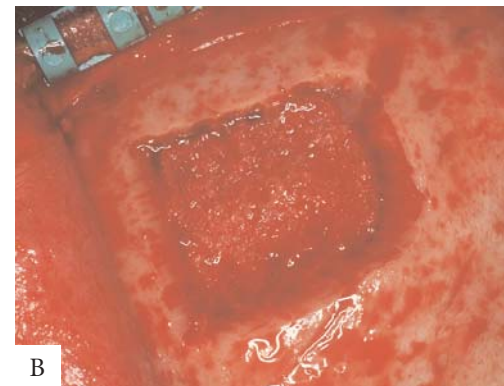
FIGURE 39-4 Exposure for cranial bone graft harvest.

or arachnoid granulations. The graft donor site should also be chosen to avoid other sutures.

For harvest of small areas of bone, a single block can be obtained (Figure 39-5). A bur is used to make initial cuts through the outer cortex of the calvaria. One side is beveled to allow insertion of a curved osteotome in a plane parallel to the outer surface and at the diploic level. For larger block grafts (Figure 39-6) it is advisable to bevel two or more sides to avoid inadvertent perforation of the inner cortex. When larger amounts of graft are needed it may be safer to harvest the bone as several strips, rather than a single block (Figure 39-7). Once the graft has been harvested the donor bed is checked to assure integrity of the inner cortex, and a piece of gelatin foam is placed over the site. The periosteum is reapproximated and the scalp closed in layers, with the galea being



A



B

FIGURE 39-5 A and B, Harvest of small cranial bone graft.

reapproximated. The skin can be closed with either staples or sutures.

For grafts from the inner table of the skull (internal table of calvaria), a formal craniotomy is performed and the bone flap is handled *ex vivo* (Figure 39-8). The graft is obtained from the inner cortex, and the flap is replaced after resuspending the dura then fixated.

In a series of 212 in situ cranial bone graft harvests, Zins and colleagues noted a 0.5% incidence of dural tear and a 2.4% incidence of dural exposure without tear.⁷¹ No infections, seromas, or bleeding were encountered in his series. In a large series of 12,672 cranial bone graft harvests, the total complications comprised only 0.18%.⁷² Inadvertent exposure of the dura (not reported as a complication) occurred in 11%.

Costochondral Grafts

Grafts from the rib are useful in that they contain both bony and cartilaginous tissues. The cartilaginous component is useful for providing an articular surface for the temporomandibular joint and for providing a growth center in growing patients. This source of bone, however, is limited by the size, curvature, and strength of the rib. For reconstructing the temporomandibular joint the contralateral rib usually has the more favorable contours. Ribs from either side can be harvested, but most surgeons prefer to use the right side over the left side

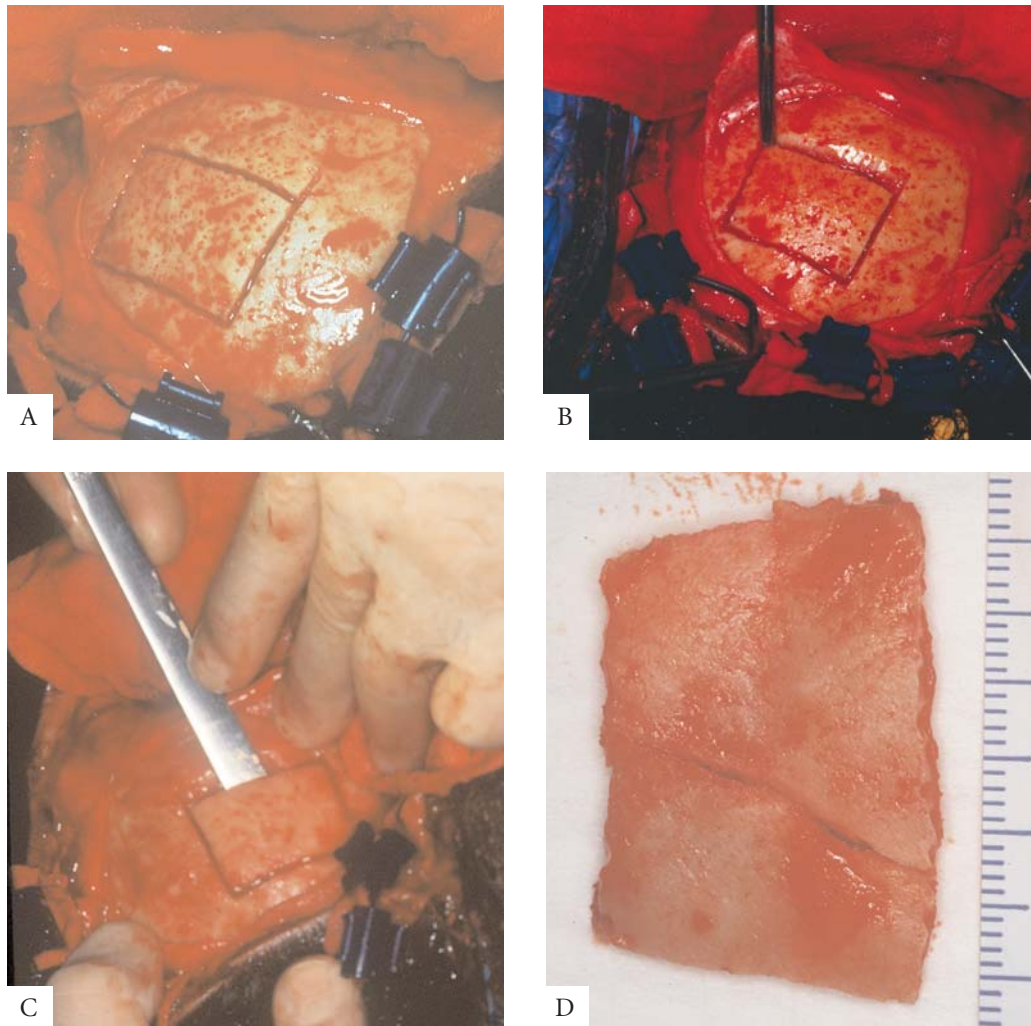


FIGURE 39-6 A to D, Harvest of a larger cranial bone block graft.

because of the position of the heart. An incision is used that corresponds to the submammary crease (Figure 39-9). This incision is well hidden in women and is a minor concern in men. The incision will

usually overlie the sixth rib. A curvilinear incision is used and the skin is incised sharply; sharp dissection is used to enter the plane overlying the ribs from the costochondral junction to the midaxillary line.

Either the fifth or sixth rib can be harvested. The sixth rib is usually the inferiormost origin of the pectoralis major muscle, and its use will entail the least amount of stripping of the muscle. A longitudinal incision is made over the bony portion of the rib, and a careful subperiosteal dissection is performed circumferentially around the rib. Care is to be used at the inferior and deep aspect of the rib to avoid the neurovascular bundle. Either saws or rib cutters can be used to divide the rib. The rib can be harvested with a variable amount of cartilage attached to the end. Once the rib is harvested the cut edge of the residual rib remaining in the patient is rounded to avoid sharp edges. Sterile saline is placed in the donor site, and the patient's lungs are inflated to assess for pneumothorax. The wound is closed in layers and a long-acting local anesthetic is administered to the harvest site.

Iliac Crest Bone Grafts

The ilium is the most preferred donor site for bone grafting. Grafts may be obtained from either the anterior or posterior portions of the bone. It contains the greatest absolute cancellous bone volume and has the highest cancellous-to-cortical bone ratio. Greater amounts of bone can be obtained from the posterior ilium. From a single side, the maximum amount of obtainable bone approaches 50 cc. From the posterior ilium, the maximum obtainable bone approaches 90 cc. Documented

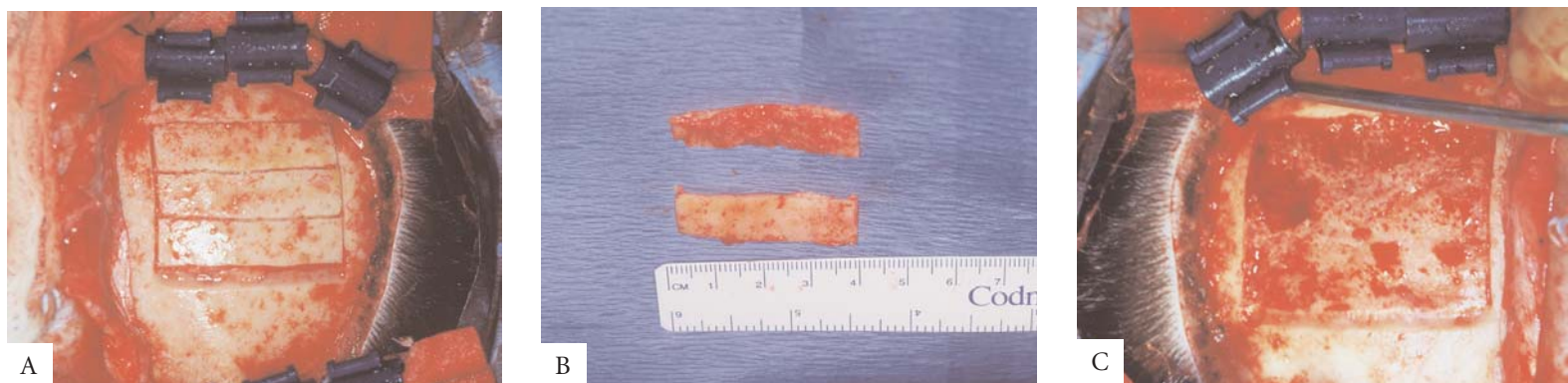

FIGURE 39-7 A to C, Harvest of several cranial strip grafts.

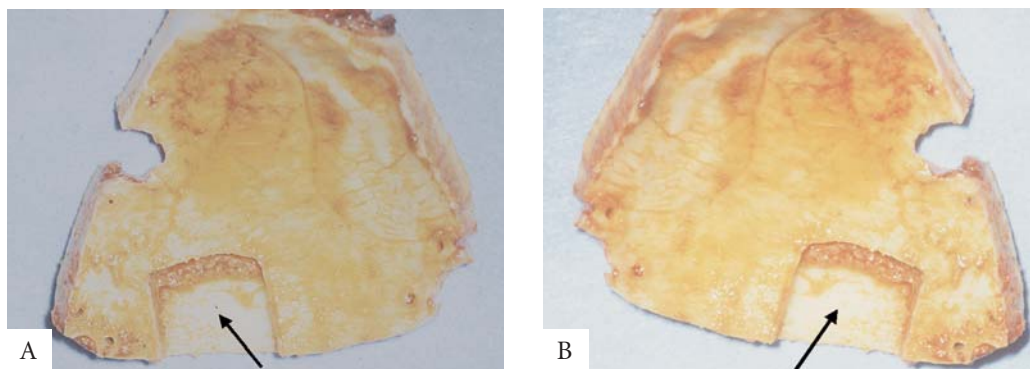


FIGURE 39-8 A and B, Inner table cranial bone graft (arrow).

donor site complications include hematoma, seroma, nerve and arterial injuries, gait disturbances, fractures of the iliac wing, peritoneal perforation, infection, sacroiliac instability, and pain. Major complications have been reported to be less common (0.7–25%) than minor ones (1.8–15.4%). The reported prevalence of complications following anterior or posterior iliac crest bone grafting has varied.⁷³

Harvest of the anterior iliac crest bone graft begins with site selection. Harvesting of the graft from the ipsilateral or con-

tralateral side from the recipient site is largely determined by positioning of the patient relative to the rest of the operating room team. A separate field is used to avoid contamination of donor and recipient sites, and the contralateral side is usually preferred. The anatomic landmarks of the anterior superior iliac crest and relative position of nerve structures are marked (Figure 39-10). The nerve branches that are most at risk are the lateral cutaneous branch of the subcostal nerve (T12) and the lateral cutaneous branch of the iliohy-

pogastric nerve (L1). The lateral femoral cutaneous nerve is located anterior and medial to the anterosuperior iliac tubercle; careful delineation of landmarks will avoid damage to this nerve. Anesthesia or paresthesia of the skin following harvesting of iliac crest bone grafts has ranged from 8 to 38% of patients.^{73–78} The skin overlying the iliac crest is gently pulled superiorly and medially to allow the incision to rest in a position inferior and lateral to the prominence of the bone. The resultant scar should be in a position where it is not rubbed or chafed afterward by a belt or clothing (Figure 39-11A). The incision is made parallel to the crest of the iliac bone and approximately 2 cm posterior to the anterosuperior iliac tubercle. A 3 cm incision is usually adequate to gain access to the iliac bone. The skin is incised sharply down to the subcutaneous fat. Using electrocautery, the subcutaneous tissue is incised down to the fascia overlying the fascia lata and external oblique muscles. An incision is made along the crest of the bone down to and through the periosteum. This incision can usually be made with minimal cutting into the muscle fibers. Once the incision is made through the periosteum, the subperiosteal dissection can proceed onto the medial or lateral surfaces of the ilium, depending on the approach used and the need for a multilaminar graft. In the anteromedial approach the subperiosteal dissection continues onto the medial side of the bone (Figure 39-11B). Care is taken not to strip muscle from the lateral surface of the ilium. Keeping the tendons of the tensor fascia lata attached to the ilium minimizes gait disturbances and pain. Acute ambulation difficulty has been reported in as many as 50% of patients immediately following iliac crest bone harvest, with long-term ambulation difficulty ranging from 3 to 12.7%.^{75,78,79} A Bennett retractor is helpful to protect the iliacus muscle and peritoneal contents.

In the anterolateral approach, the periosteum is stripped from the lateral

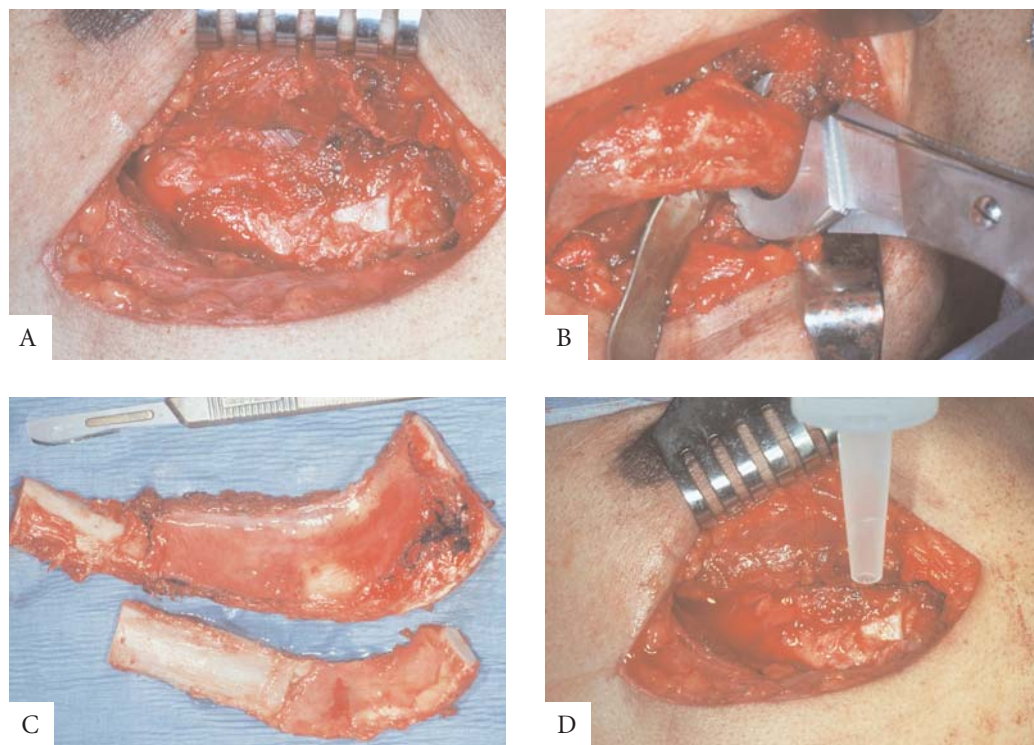


FIGURE 39-9 A, Incisions for access. B, Dividing the rib. C, Harvested ribs. D, Assessing for entry into the pleural space.

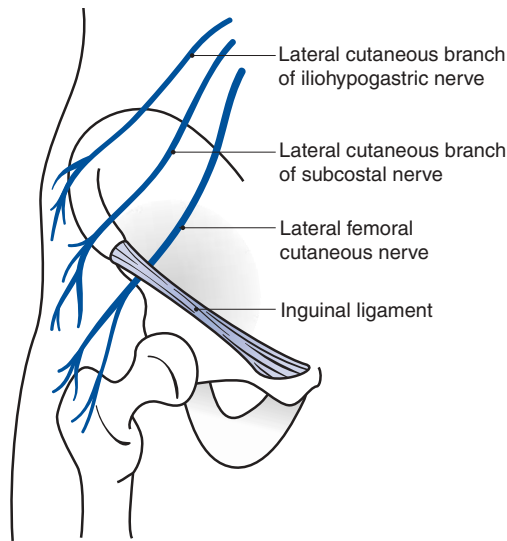


FIGURE 39-10 *Diagram of nerves. Adapted from Lew D, Hinkle RM. Bony reconstruction of the jaws. In: Peterson LJ, Indresano AT, Marciano RD, Roser SM. Principles of oral and maxillofacial surgery. Vol. 2. Philadelphia: J.B. Lippincott Company; 1992. p. 923.*

surface of the ilium for easier access but at a cost of increased incidence of gait disturbance. Once the ilium is exposed by any approach, the bone can be harvested as a corticocancellous block graft, a cortical graft,

or a cancellous graft (Figure 39-11C–F). The size of the graft is outlined, and using saws, osteotomes, or a bur, osteotomies are performed. The cancellous graft can be harvested with curettes, gouges, or trephines.^{74,79–82} Hemostasis is obtained with the use of gelatin foam or other hemostatic agents if necessary. Use of drains at the donor sites of either posterior or anterior approaches is not indicated; and no difference has been shown in wound healing.⁸³ Injection of a long-acting local anesthetic agent into the overlying soft tissue provides some comfort in the immediate postoperative period.⁸⁴

Harvest of the posterior iliac crest is another well-documented source for bone.^{85–88} Patient positioning in the supine position for most maxillofacial procedures involves a patient repositioning when posterior iliac crest bone is harvested. Larger amounts of bone available from this approach may make it worthwhile to consider this option. The patient is positioned in the prone position with a small amount of flexion and placement of a hip roll. The

landmarks identified are the spinous processes of the vertebra and the posterosuperior iliac crest and spine. A 5 cm curvilinear incision is made through the skin overlying the iliac crest. Nerves at risk are the superior and middle cluneal nerves (L1 to S3). Using sharp and blunt dissection through the subcutaneous tissues, the posterosuperior crest is identified and the fascia divided between the abdominal and gluteal muscles. A subperiosteal dissection proceeds, and the tissue is reflected laterally. Care is used to avoid the sacroiliac ligaments. Bone can be harvested as a corticocancellous block graft, a cortical graft, or a cancellous graft similar to the approach to the iliac crest. Complication rates for posterior iliac crest bone harvest are, in general, lower than those for anterior harvest.^{73–77,79}

Tibial Bone Graft

The tibial metaphysis is another important source of autogenous bone. O'Keefe and colleagues reported the first large series (230 cases) using the tibia as a donor site.⁸⁹ They found adequate bone for grafting

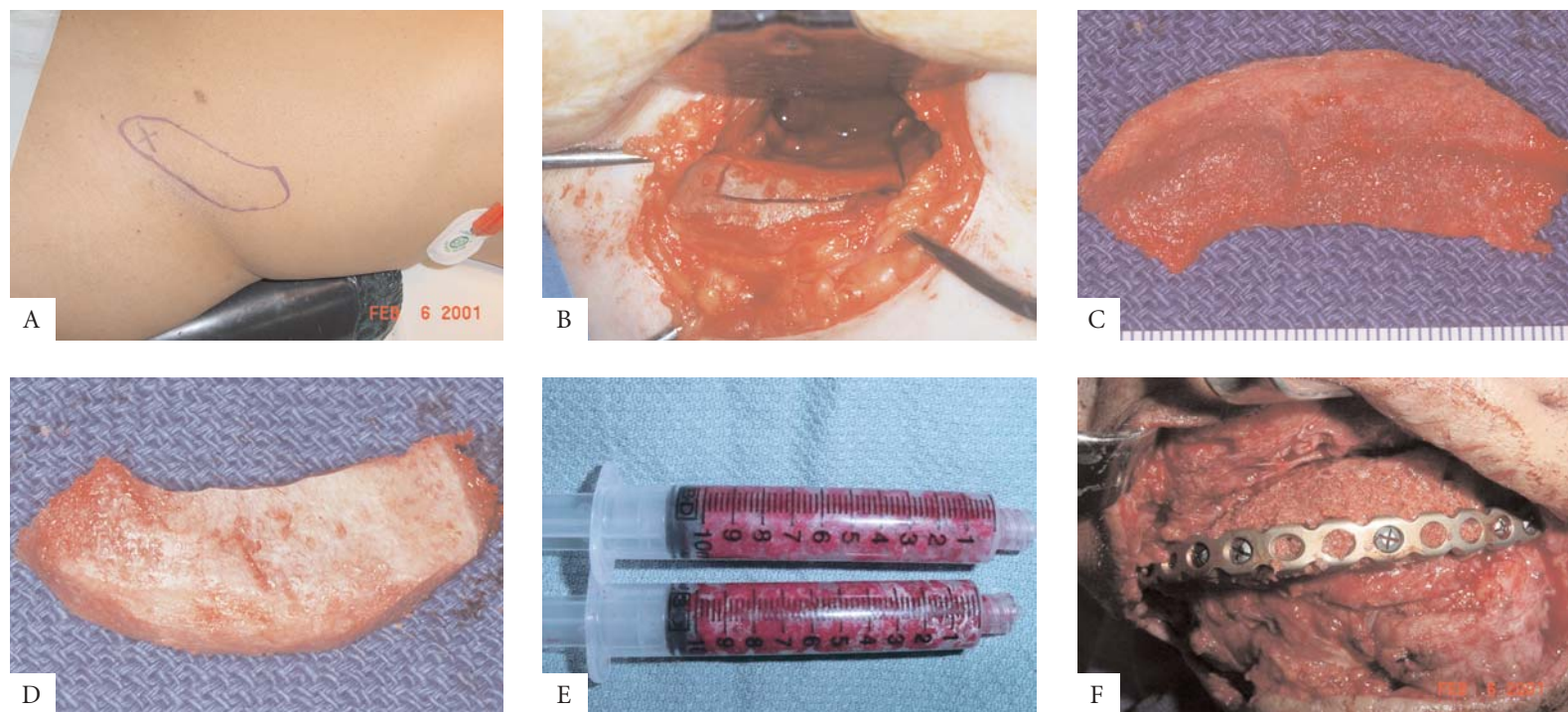


FIGURE 39-11 A, Landmarks for obtaining graft. B, Osteotomies for harvest. C, Corticocancellous grafts. D, Cortical surface of graft. E, Cancellous graft. F, Cancellous graft applied.

and a low incidence (1.3%) of complications, none of which were long-term. The tibial region heals exceptionally well, but radiographic findings in the donor site may persist indefinitely.⁹⁰ The use of this site is relatively contraindicated in growing patients because of the risk of disturbance to a growth center site, although its use has been reported in the repair of alveolar clefts.⁹¹ Catone and colleagues described the use of tibial bone in maxillofacial surgery and was able to obtain up to 42 mL of uncompressed cancellous bone per site.⁹² Bone from the tibial site was successfully used to graft mandibular nonunions, in orthognathic surgery, as a sinus augmentation, and in mandibular reconstruction. Comparison of tibial grafts against iliac crest grafts in secondary alveolar clefts shows similar bone densities at 6 months.⁹¹

The graft is usually harvested with the patient in the supine position, although the graft can be harvested with the patient in the prone position.⁸⁹ A 3 cm longitudinal and slightly angled incision (Figure 39-12) is made through the skin overlying Gerdy's tubercle. Gerdy's tubercle is a prominence of bone on the anterior surface of the proximal end of the tibia located lateral to the tibial tuberosity. It is the distalmost insertion of the iliotibial tract. Sharp dissection is used to obtain a suprapariosteal dissec-

tion overlying and inferior to Gerdy's tubercle. The dissection should be medial to the tibialis anterior muscle and lateral to the patellar ligament. If a cortical graft is desired, the dissection can proceed in a subperiosteal plane, exposing Gerdy's tubercle.⁸⁹ If no cortical bone is required, an osteoperiosteal flap can be created by incising through the periosteum in a "U" shape, leaving periosteum attached to the cortex.⁹² A cortical window is made with burs, saws, or osteotomes measuring 1 cm by 1 cm. The window should incorporate the crest of the tubercle at the superior portion of the window. The crest represents a simple and reliable landmark to avoid the articular surface of the tibia and the joint space. It is recommended to keep at least a 2 cm distance from the articular surface of the tibia to avoid damage.⁹³ A medial approach to the tibia has also been advocated that avoids the insertion of the iliotibial tract and several other anatomic landmarks.^{94,95} In the medial approach, the landmarks are two lines: one vertical line drawn through the patella and tibial tuberosity and the other perpendicular to the first, through the tibial tuberosity. It is recommended that an oblique skin incision be made centered over a point 15 mm superior to the horizontal line and 15 mm medial to the vertical line.⁹⁵ Dissection continues through the periosteum overlying the bone underneath the incision. A bone window is made to provide access to the cancellous bone. Regardless of the approach (medial vs lateral) used, once the window has been removed or elevated, the cancellous bone can be harvested with curettes. Equal amounts of bone are available from either lateral or medial approaches.⁹⁵ For larger volumes of grafts, bilateral grafting can be done, with some possible impairment to early ambulation. No attempt is made to fill the metaphyseal dead space, and no drains are used. The wound is closed in layers. If smaller amounts of bone are needed (< 15 cc), the procedure can continue through a small stab incision and with use

of a trephine or curettes.^{92,96} van Damme reported up to 40 cc of cancellous bone obtained through this method.⁹⁶

Microvascular Free Flaps

Many microvascular free flaps have been described for reconstruction of the mandible and maxilla, including the fibula, iliac crest, and scapula. Free microvascular flaps have the advantage of having their own blood supply independent of the local tissue bed, and they behave as a microvascular transfer of tissue, except where they interface with the existing recipient bone. In areas of poor vascular supply they have superiority over other bone grafts. Additionally they may be transferred as composite grafts including soft tissue components. A detailed discussion of microvascular free flap reconstruction is presented in Chapter 40, "Microvascular Free Tissue Transfer."

Platelet-Rich Plasma

With the advent of blood factor fractionation in hematology and the search for hemostatic agents, interest has increased in platelet-rich plasma (PRP) fractions. PRP is a volume of autologous plasma that has a platelet concentration higher than normal. In general, PRP contains $> 1 \times 10^6$ platelets/ μL . In clinical practice, PRP is applied to the site of a bone graft to deliver a high concentration of growth factors from platelets.⁹⁷ Once the PRP-containing high concentrations of fibrinogen and platelets are mixed with thrombin and calcium, a gel is formed resulting in the release of growth factors from the platelet (α) granules. Within 10 minutes the platelets secrete 70% of their stored growth factors and close to 100% within the first hour.⁹⁸ The platelets then synthesize additional amounts of growth factors for about 8 days until they are depleted and die. The precise content and concentration of growth factor has yet to be fully elucidated. The α -granules of platelets release at least seven growth factors, including platelet-derived growth factor, TGF- β , platelet-

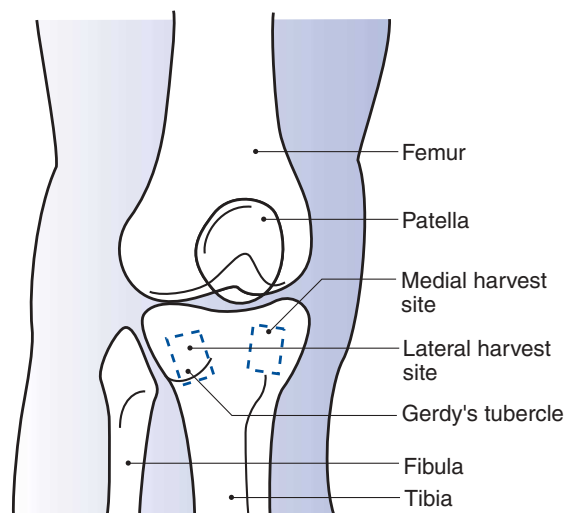


FIGURE 39-12 Incision for tibial bone graft.

derived epidermal growth factor, platelet-derived angiogenesis factor, insulin-like growth factor-1, and platelet factor-4.⁹⁹ There is a complex interplay between the growth factors that depends on their concentration, local microenvironment, and interactions with other molecules. Many of these growth factors can have effects that are in opposite directions depending on the context of expression.¹⁰⁰ The PRP constellation of growth factors allows the complex interplay of these agents to be exploited to better advantage than relying on a single growth factor agent.

PRP is an autologous preparation; therefore, the risk of disease transmission from its use should theoretically be nil. There has been some concern about the antigenicity of the bovine thrombin used, although this has not been a problem in maxillofacial applications.¹⁰¹ It is believed that some of the antigenicity attributed to thrombin results from contamination from bovine factor V in the thrombin preparation. Another gelling agent, ITA, has been used in place of bovine thrombin but its constituents are proprietary and unknown.¹⁰²

There are several systems for preparing PRP (Figure 39-13) ranging from the simple to the complex, from those that require whole units of blood to those that require only 50 mL. The most complex are the general-purpose cell separators that are widely used by blood banks and hospitals. Using a plasmapheresis technique, 450 mL of whole blood is drawn off into a collection bag containing an anticoagulant, usually citrate phosphate dextrose. Other anticoagulants are available; anticoagulant citrate dextrose-A is also used and may be preferred.⁹⁸ Edetic acid is avoided since it fragments the platelets.¹⁰² The preparation is then centrifuged first at high speed to separate the plasma from the red cells and the buffy coat. The centrifuge is then slowed down and run for a period of time to further separate the PRP and the platelet-poor plasma (PPP). Approxi-

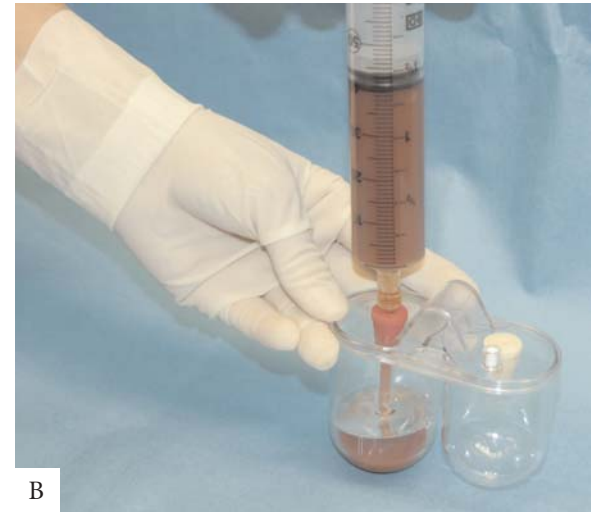

FIGURE 39-13 A, Machine for harvest of platelet-rich plasma. B, Fractionated sample containing platelet-rich plasma.

mately 30 cc of PRP can be obtained from the sample in about 30 minutes. Platelet counts of 0.5 to $1.0 \times 10^6/\mu\text{L}$ can usually be attained with this method. It is recommended that the PRP be used within 6 hours of being procured. Once developed, PRP is stable and remains sterile in the anticoagulated state for 8 hours.⁹⁸

In a quest to achieve a concentrated delivery of platelets at a reasonable cost, several systems were developed that use smaller procurements of whole blood, are faster, produce more concentrated product, and are less expensive.^{97,102,103} Two of the units that are currently approved by the US Food and Drug Administration are the Harvest SmartPrep Platelet Concentrate System and the 3i Platelet Concentrate Collection System. These systems both use tailored centrifuge containers to manipulate the blood cells to achieve the separation and sequestration of platelets. They both have long and short spin cycles. Average platelet counts of 1.4 to $1.8 \times 10^6/\mu\text{L}$ are obtained in a 5 mL sample.⁹⁹ Run times for the preparation are usually 15 to 20 minutes.

Once the PRP has been prepared, the coagulation process is initiated using a mixture of 100 US units of topical bovine

thrombin (TBT) powder suspended in 10 mL sterile saline and 10% calcium chloride. In a 10 cc syringe, 6 mL of PRP is mixed with 1 mL of 10% CaCl_2 , 1 mL TBT, and 1 mL air for mixing. The mixture is applied to the bone grafts in a layered fashion. Some of the newer systems have special syringe tips that combine the constituents from several syringes simultaneously. Once applied, the mixture sets in a matter of minutes.

There is a paucity of strong clinical data to support many of the claims being made for PRP in the jaws; only one prospective trial is published.¹⁰⁴ The majority of the publications are case series or case reports. Marx and coworkers evaluated the effect of PRP on bone graft reconstructions of mandibular continuity defects 5 cm or greater, showing a maturity index of about twice actual maturity at 2 and 4 months.⁹⁷ In a case series of 15 patients, PRP has been added to freeze-dried demineralized bone to augment the maxillary sinus and alveolar ridge.¹⁰⁵ The authors posit that use of PRP may allow for earlier implant placement and loading, but this conclusion will require further study to be supported. In another cases, 24 maxillary sinuses were

augmented with a combination of PRP and deproteinized bovine bone along with simultaneous insertion of endosseous implants.¹⁰⁴ In three of these cases bone density measurements made at 4 months showed increased density compared with the surrounding native bone. Only preliminary data are available to date on the histologic evaluation of the PRP-augmented sinuses.^{106,107} A case report of use of PRP with autogenous bone and a titanium mesh for a large anterior maxillary defect has also been described.¹⁰⁸ Fourier and fractal analysis of radiographs of maxillary alveolar ridge repair using PRP and inorganic bovine bone showed trabecular patterns of the regenerated bone similar to but lower in complexity than the native bone, which the authors attributed to the PRP.¹⁰⁹

Hyperbaric Oxygen Therapy

After success with treating osteoradionecrosis of the mandible with hyperbaric oxygen therapy, the modality was applied to patients undergoing mandibular reconstruction.¹¹⁰ Applying fairly stringent success criteria, a rate of 94% was reported. Hyperbaric oxygen therapy consists of breathing 100% O₂ at 2.4 atm for 90 minutes, commonly referred to as a dive. Protocols for reconstructive procedures differ from those used to treat osteoradionecrosis and consist of 20 dives preoperatively and 10 dives postoperatively.

The mechanisms by which hyperbaric oxygen therapy exerts its effects are biochemical, cellular, and physiologic.¹¹¹ During a dive, arterial oxygen tensions in excess of 2,000 mm Hg, and tissue oxygen tensions of almost 400 mm Hg have been attained. Physiologically at 2.4 atm, oxygen not only saturates the available hemoglobin but dissolves in the plasma to more than 10 times the amount at sea level (0.3 mL/dL). Tissue irradiated beyond 5,000 cGy exhibits hypoxia, hypovascularity, and hypocellularity. This predisposes the tissue to infection and poor wound healing in addition to making it a poor donor bed for a bone

graft. Hypoxia inhibits and decreases the neutrophil-mediated killing of bacteria by free radicals. Tissue PO₂ levels in irradiated patients have been documented as low as 5 mm Hg and often range between 5 and 15 mm Hg. During hyperbaric oxygen therapy the tissue PO₂ rises to between 100 and 250 mm Hg but falls to baseline within 10 minutes following a dive in the initial period of therapy. Improved collagen formation and fibroblast proliferation occur when the tissue oxygen tension is raised over 20 to 30 mm Hg.¹¹² Capillary proliferation occurs along collagen laid down following hyperbaric oxygen exposure. As this neovascularization spreads, tissue oxygenation improves between 20 and 35 mm Hg in the hours after treatment. The improvement plateaus after 10 to 20 dives; dives beyond this time do not marginally improve the host bed.

Complications of hyperbaric oxygen therapy include reversible myopia; barotrauma to the middle ear, lungs, teeth, and sinuses from rapid pressure changes; seizures (self-limited and causing no permanent damage); claustrophobia; reversible tracheobronchial symptoms (chest tightness, substernal burning sensation, and cough). No evidence of a tumorigenic effect of hyperbaric oxygen has been found to date.¹¹³

Reconstruction of the Mandible

Reconstruction of the mandible can occur immediately at the conclusion of an ablative procedure of the jaw (primary reconstruction); delayed (secondary), after an appropriate time of primary soft tissue healing; or, in the case of developmental or gradually acquired defects, at the time of recognition of the need for reconstruction. The first step in reconstruction is to classify the defect determined by its size, location, and functional or cosmetic impairment. The size of the defect in three dimensions will define the magnitude of the reconstruction. Small defects of the alveolus may require limited bone grafting, while larger defects may require more extensive or

staged procedures. Some defects may not necessarily be restored to the original size and bulk of the missing part. Loss of a significant portion of a ramus may be adequately managed by providing continuity from the condyle to the body of the mandible without restoring a coronoid process or several centimeters of anteroposterior width. The bulk of the bone need only be enough to provide for adequate strength to manage the functional loads. Location is important as some defects may not need to be restored, such as the very posterior of the body of the mandible (distal to the first or second molar) where no plan is made for restoration of the dental occlusion of the mandible or opposing dental arch. The functional deficits that exist and those that are to be addressed play a role in the choice of reconstruction.

Once the area of bony defect has been defined and the assessment of how much bone to reconstruct has been determined, attention should be directed to how to best achieve these goals. The available soft tissue in terms of quantity and quality is paramount in choosing a reconstructive method. Indeed the soft tissue will determine to a large extent the available options. If the soft tissue is adequate in both of these parameters, the options will be many. If, however, the soft tissue is inadequate in size or bulk, efforts will need to be made to provide adequate soft tissue before undergoing bony reconstruction. This can be accomplished by introducing more soft tissue through local flaps, pedicled flaps, or microvascular free flaps. Composite flaps are an option for simultaneous hard and soft tissue reconstruction. Techniques such as distraction osteogenesis can provide increased bone and soft tissue simultaneously like the composite grafts. If the quantity of soft tissue is adequate but the quality of the soft tissue is poor, the reconstruction will be compromised or the options limited. Tissue that has been irradiated or has extensive scarring will provide a poor host bed for any

grafting procedures. Adjunctive procedures such as hyperbaric oxygen therapy or soft tissue flaps may be necessary to provide an adequate donor bed.

The functional and esthetic requirements will dictate the goal to be accomplished; multiple-stage procedures are the norm rather than the exception.

Reconstruction of the Maxilla

The same general parameters in approaching the mandibular reconstruction are operative in the maxilla. Identification of the goals of reconstruction will dictate the course of reconstruction to take. Once the goal has been delineated, attention is first given to the soft tissue envelope to support bony reconstruction of the maxilla. Appropriate grafting procedures are undertaken, and provision is made for interim prosthetics. The following cases illustrate specific points of consideration in reconstruction of the areas of the jaws.

Case Example 1: Reconstruction of Large Traumatic Mandibular Defect

The patient is a 17-year-old man who suffered a gunshot wound to the anterior mandible with loss of both hard and soft tissue (Figure 39-14). The maxilla was unaffected. The first step in this case is to define the defect in terms of both hard and soft tissue and decide on a strategy for reconstruction. As this is a contaminated

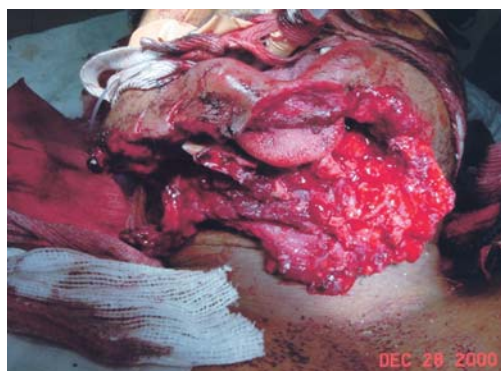

FIGURE 39-14 Gunshot wound to mandible.

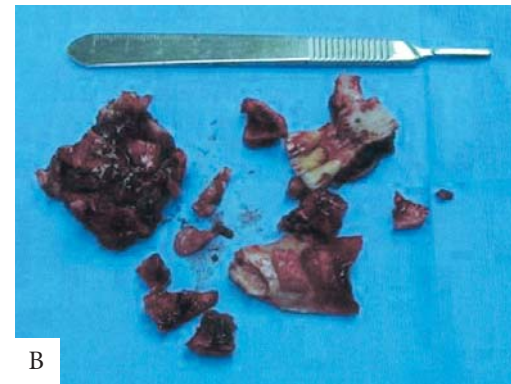
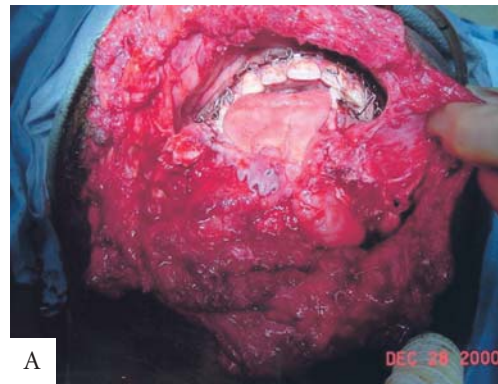


FIGURE 39-15 A and B, Débridement of nonviable hard and soft tissues.

wound with ill-defined areas of vital hard and soft tissue, delayed reconstruction is the preferred option. Débridement of free bone fragments and grossly nonperfused soft tissue will enhance the rapidity of primary healing (Figure 39-15). Once the débridement is complete, the bone components are aligned using available dental landmarks (Figure 39-16) and soft tissue components are reapproximated (Figure 39-17). To aid the ease of reconstruction, anatomic relations are maintained and stabilized with fixation devices (Figure 39-18) to preserve interramal width. At this time a more accurate assessment of soft tissue and bone deficits can be appreciated in three dimensions. There is a segmental mandibular defect with inadequate soft tissues and an opposing dental arch. The functional requirements for reconstruction include (1) restoration of continuity of the mandible, (2) adequate bone height and width to allow restoration of the occlusion, and (3) restoration of mandibular morphology for esthetic and functional requirements. Because of the avulsive nature of the defect, the soft tissue is inadequate in terms of quality and quantity. A period of weeks to months may be required for the soft tissues to mature and heal. Before bony reconstruction can begin, soft tissue must be brought in to provide for an adequate recipient bed for grafting and restoration of contours. In this otherwise healthy individual, autogenous grafting will most effectively supply the adequate bulk and form nec-

essary to achieve the goals. A pedicled myocutaneous graft (pectoralis major) with a skin paddle will provide the blood supply to nourish the graft and to provide adequate bulk of skin in the chin region. The residual bilateral condyle-ramal complexes will be stabilized with a titanium reconstruction plate (Figure 39-19). An appropriately sized skin paddle will restore

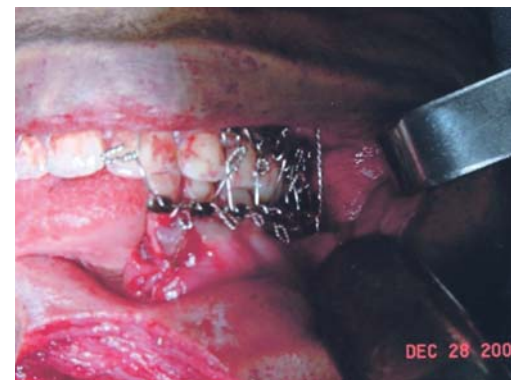

FIGURE 39-16 Alignment using dental landmarks.

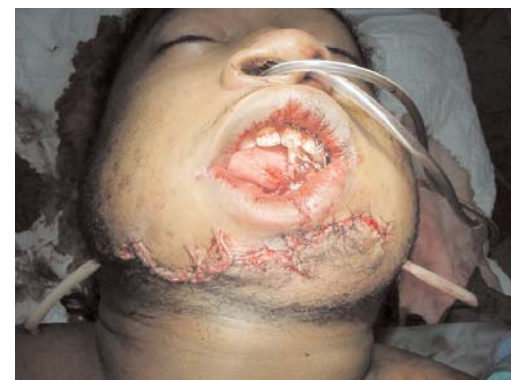

FIGURE 39-17 Reapproximation of skin and mucosa.

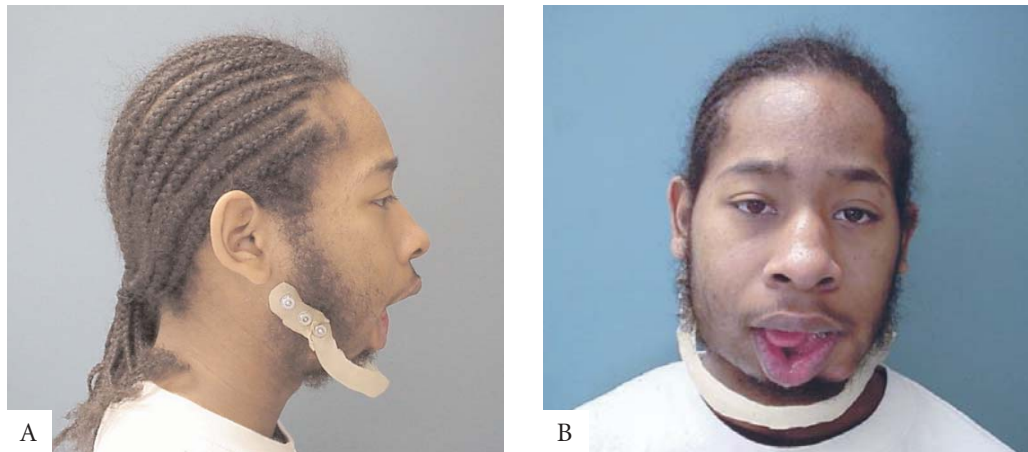

FIGURE 39-18 A and B, Stabilization with external fixator.

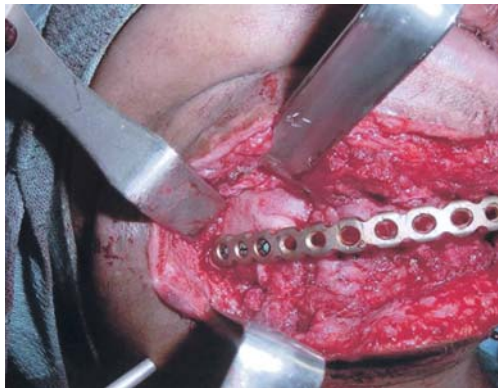


FIGURE 39-19 Stabilization of mandible with titanium reconstruction plate.

the missing skin over the chin (Figure 39-20). The muscle is positioned to restore bulk to the region and to approximate the area of the future bone graft. The soft tis-

sues are then allowed to heal over several weeks prior to definitive bone grafting (see Figure 39-20D). Both allografts and autografts will be used, with a cadaveric mandibular crib (Figure 39-21) secured to the reconstruction plate used to maintain the proper morphology of the mandible. A cancellous marrow graft is obtained to provide adequate bulk (Figure 39-22). Restoration of the contours and functionality of the mandible results at the completion of the reconstruction (Figure 39-23).

Case Example 2: Delayed Reconstruction of an Ablative Defect of the Mandible

A swelling with associated radiolucency of the mandible is noted (Figure 39-24). Both

the medial and lateral cortices have been destroyed in the area of the lesion. Because of the location and size of the defect, reconstruction of the defect is indicated to restore bulk and strength of the residual mandible following treatment. After adequate soft tissue healing, an anterior iliac crest cancellous bone graft is obtained and placed in the defect (see Figure 39-24B). One year following reconstruction, the bone graft has matured with a normal trabecular pattern. The graft is maintained and the bone is adequate for oral rehabilitation 2 years after grafting (see Figure 39-24E).

Case Example 3: Reconstruction of the Anterior Maxilla

A 37-year-old man had undergone avulsive trauma to the anterior maxilla during a motor vehicle accident. The residual defect was from the loss of anterior maxillary teeth and a large portion of the alveolus (Figure 39-25A). Dental models were obtained, and a diagnostic wax-up was prepared to assess the ideal position of the restored teeth. The bony reconstructive effort is therefore guided by the prosthetic plan so that adequate bulk and position of the grafted bone can be assured. The defect in the upper jaw consisted of inadequate bone in terms of height and width and inadequate soft tissues. No oral–nasal cavity partitioning defect existed. A wide pedicled flap is raised

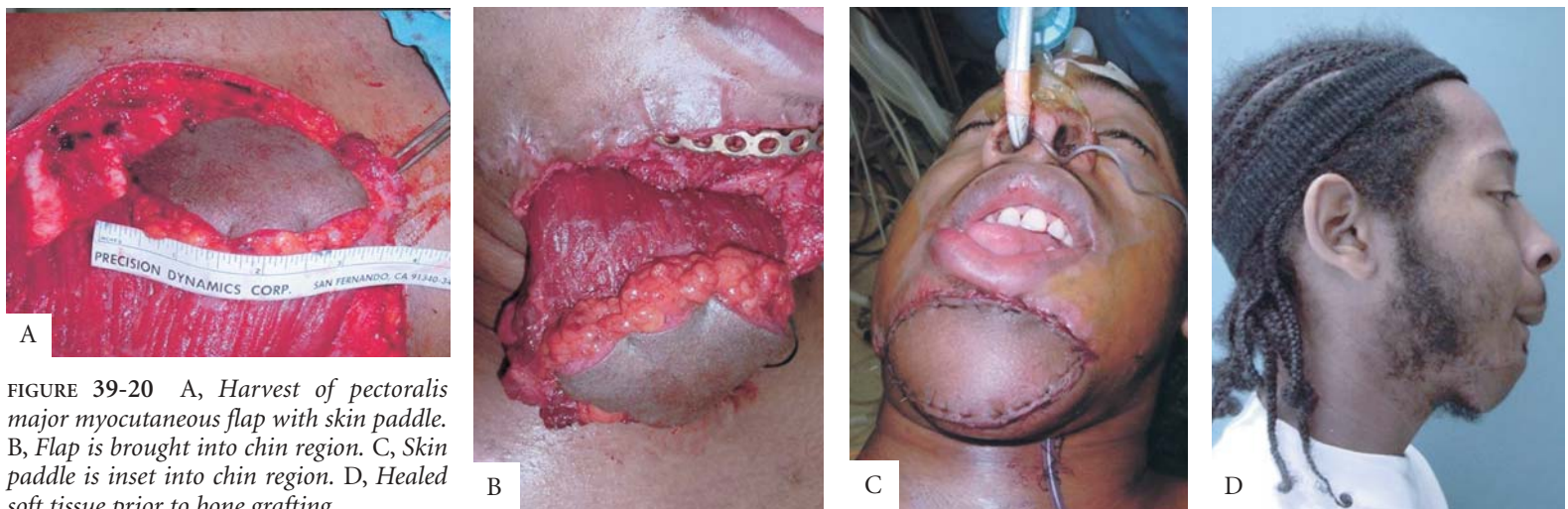


FIGURE 39-20 A, Harvest of pectoralis major myocutaneous flap with skin paddle. B, Flap is brought into chin region. C, Skin paddle is inset into chin region. D, Healed soft tissue prior to bone grafting.

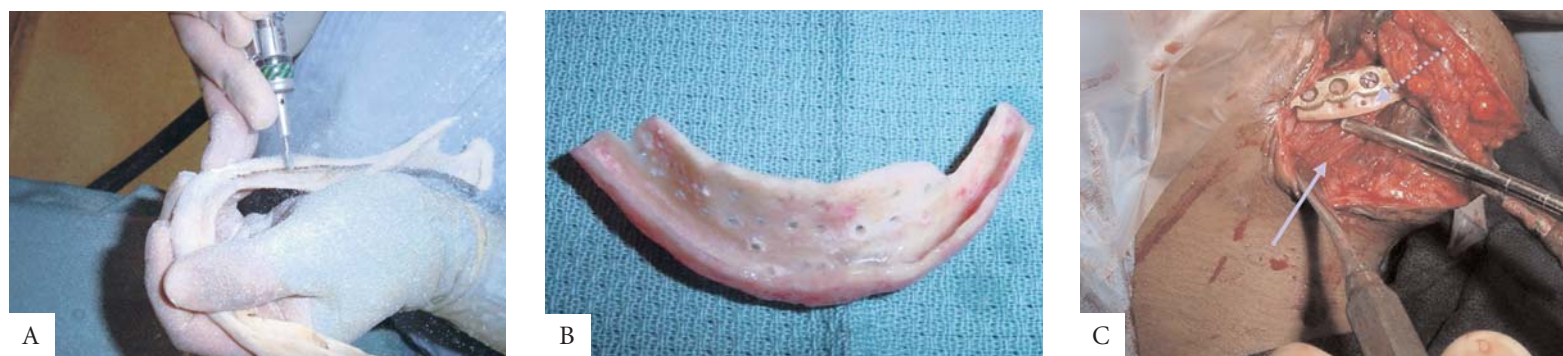

FIGURE 39-21 A, A freeze-dried allogeneic cadaver mandible is obtained and hollowed out. B, Useful section of the crib is perforated. C, The crib is secured to the plate (arrow) with the pectoralis major muscle (arrow) nourishing the bone graft.

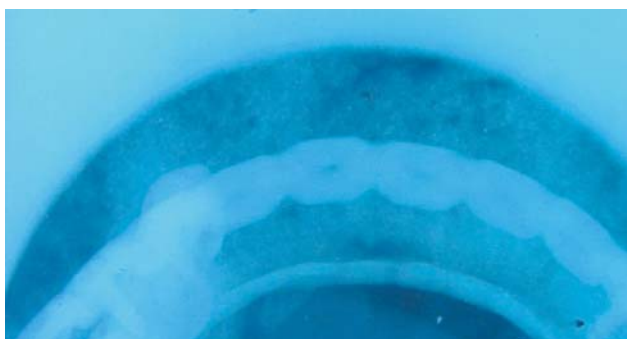

FIGURE 39-22 Occlusal radiograph in the area of the graft.

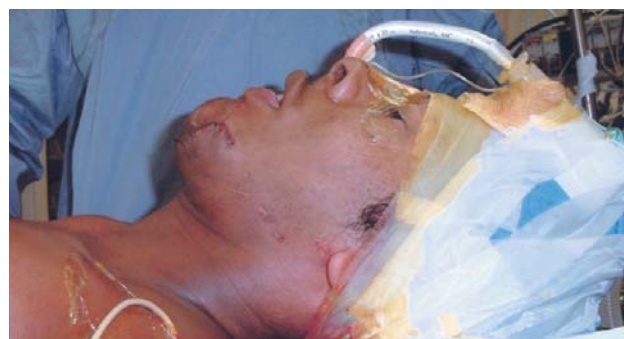

FIGURE 39-23 Restoration of contour of chin.

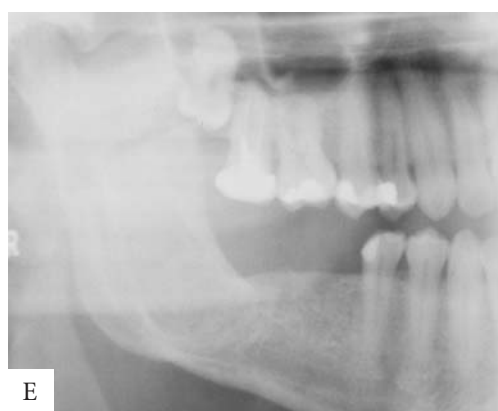
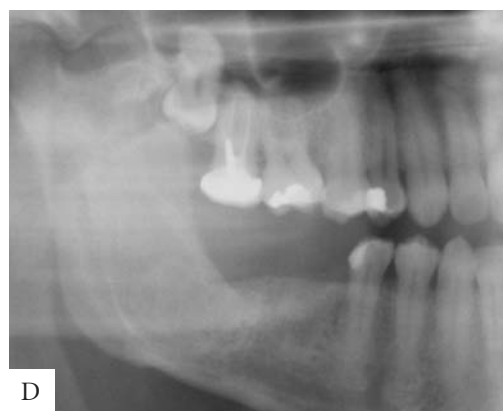
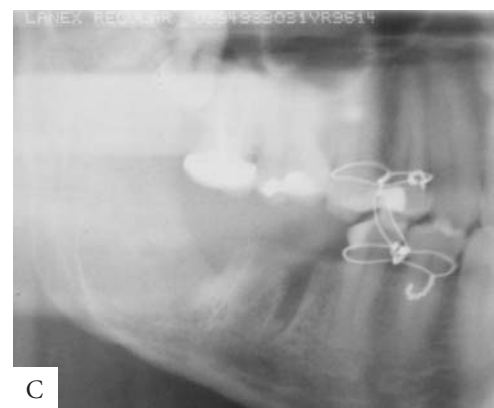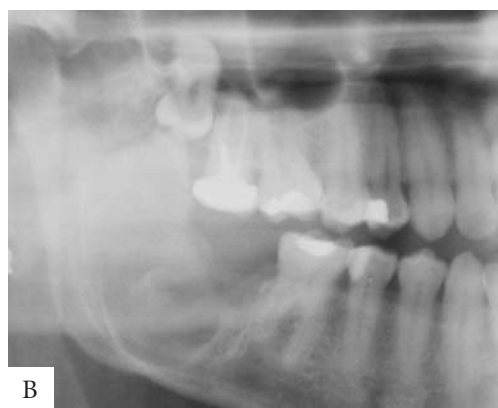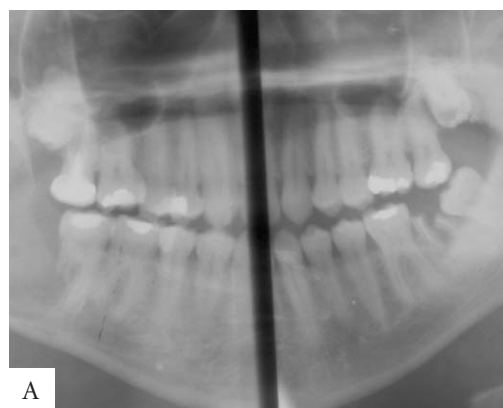FIGURE 39-24 Radiographs illustrating delayed reconstruction of an ablative defect of the mandible: A, prebiopsy; B, immediately post-graft; C, 2 weeks post-graft; D, 1 year post-graft; E, 2 years post-graft.

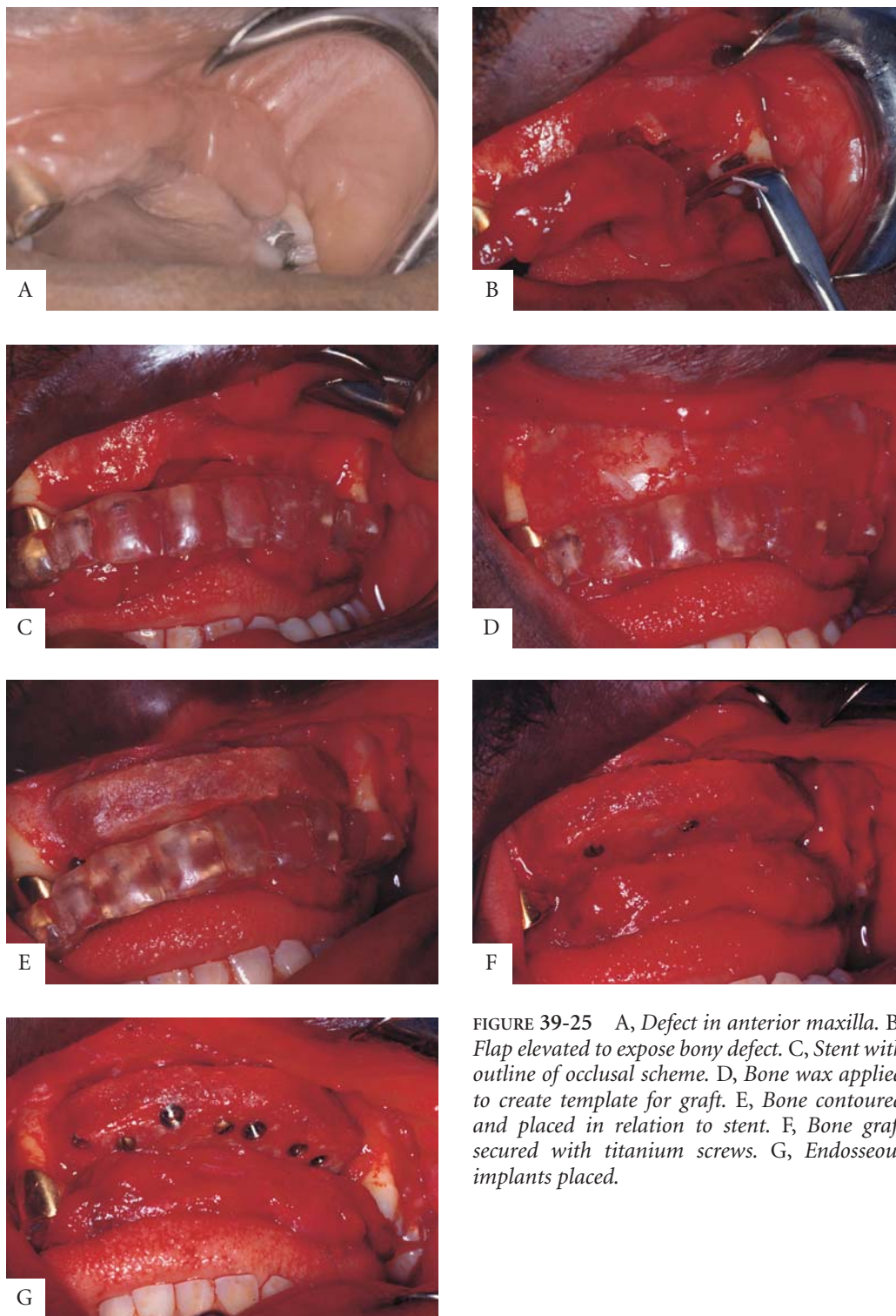


FIGURE 39-25 A, Defect in anterior maxilla. B, Flap elevated to expose bony defect. C, Stent with outline of occlusal scheme. D, Bone wax applied to create template for graft. E, Bone contoured and placed in relation to stent. F, Bone graft secured with titanium screws. G, Endosseous implants placed.

(Figure 39-25B) to expose the bony defect, and a stent prepared from the diagnostic wax-up is used to assess the bony defect more accurately (Figure 39-25C). Sterile bone wax is used to prepare a template for the graft dimensions (Figure 39-25D). A

corticocancellous graft is obtained from the anterior iliac crest, contoured from the template and secured with titanium screws (Figure 39-25E and F). Using the stent as a guide, endosseous root-form implants are placed in the graft (Figure 39-25G).

References

1. Adamo AK, Szal RL. Timing, results, and complications of mandibular reconstructive surgery: report of 32 cases. *J Oral Surg* 1979;37:755–60.
2. Obwegesser HL, Sailer HF. Experience with intraoral resection and immediate reconstruction in cases of radio-osteomyelitis of the mandible. *J Maxillofac Surg* 1978; 6:257–66.
3. Marx RE, Ames JR. The use of hyperbaric oxygen therapy in bony reconstruction of the irradiated and tissue deficient patient. *J Oral Maxillofac Surg* 1982;40:412–20.
4. Hidalgo DA. Fibula free flap: a new method of mandibular reconstruction. *Plast Reconstr Surg* 1989;84:71–9.
5. Urist MR. Bone: formation by autoinduction. *Science* 1965;150:893–9.
6. Urist MR, Strates BS. Bone morphogenetic protein. *J Dent Res* 1971;50:1392–406.
7. Schmitt JM, Hwang K, Winn SR, Hollinger JO. Bone morphogenetic proteins: an update on basic biology and clinical relevance. *J Orthopedic Res* 1999;17:269–78.
8. Wozney JM. Overview of bone morphogenetic proteins. *Spine* 2002;27:52–8.
9. Wozney JM, Rosen V. Bone morphogenetic protein and bone morphogenetic protein gene family in bone formation and repair. *Clin Orthop Rel Res* 1998;346:26–37.
10. Ebara S, Nakayama K. Mechanism for the action of bone morphogenetic protein and regulation of their activity. *Spine* 2002; 27:S10–5.
11. Lieberman JR, Daluiski A, Einhorn TA. The role of growth factors in the repair of bone. *J Bone Joint Surg* 2002;84A:1032–44.
12. Reddi AH. Bone morphogenetic proteins: from basic science to clinical application. *J Bone Joint Surg* 2001;83:S1–5.
13. Sakou T. Bone morphogenetic proteins: from basic science to clinical approaches. *Bone* 1998;22:591–603.
14. Ten Dijke P, Fu J, Schaap P, Roelen AJ. Signal transduction of bone morphogenetic proteins in osteoblast differentiation. *J Bone Joint Surg* 2003;85A:34–8.
15. Brunet LJ, McMahon JA, McMahon AP, Harland RM. Noggin, cartilage morphogenesis and joint formation in the mammalian skeleton. *Science* 1998;280:1455–7.
16. Axhausen W. The osteogenic phases of regeneration of bone, a historical and experimental study. *J Bone Joint Surg* 1956;38:593–601.
17. Gray JC, Elves MW. Early osteogenesis in compact bone isografts: a quantitative study of the different graft cells. *Calcif Tissue Int* 1979;29:225–37.

18. Bassett, CAL, Creighton DK, Stinchfield FE. Contributions of endostium, cortex, and soft tissue to osteogenesis. *Surg Gynecol Obstet* 1961;112:145–52.
19. Heslop BK, Zeiss IM, Nisbet NW. Studies on transference of bone. A comparison of autologous and homologous transplants with reference to osteocyte survival, osteogenesis, and host reaction. *Br J Exp Pathol* 1960;41:269–72.
20. Enneking WF, Burchardt H, Puhl JJ, et al. Physical and biological aspects of repair in dog cortical-bone transplants. *J Bone Joint Surg* 1975;57:237–52.
21. Enneking WF, Eady JL, Burchard H. Autogenous cortical bone grafts in the construction of segmental skeletal defects. *J Bone Joint Surg* 1980;62:1039–58.
22. Habal MB, Reddi AR. Bone grafts and bone induction substitutes. *Clin Plast Surg* 1994;21:525–42.
23. Friedenstein AJ, Piatetzky-Shapiro II, Petrakova KV. Osteogenesis in transplants of bone marrow cells. *J Embr Exp Morph* 1966;16:381–90.
24. Marx RE, Kline SN, Johnson RP, et al. The use of freeze-dried allogeneic bone in oral and maxillofacial surgery. *J Oral Surg* 1981;39:264–74.
25. Williams G. Experiences with boiled cadaveric cancellous bone from fractures of long bones. *J Bone Joint Surg* 1964;46:398–403.
26. Dubuc FL, Urist MR. The accessibility of the bone induction principle in surface decalcified bone implants. *Clin Orthop* 1967;55:217–23.
27. Callan DP, Salkeld SL, Scarborough N. Histologic analysis of implant sites after grafting with demineralized bone matrix putty and sheets. *Implant Dent* 2000;9:36–44.
28. Feuille F, Knapp CI, Brunsvold MA, Mellonig JT. Clinical and histologic evaluation of bone-replacement grafts in the treatment of localized alveolar ridge defects. Part 1: mineralized freeze dried bone allograft. *Int J Periodontics Restorative Dent* 2003;23:29–35.
29. Merckx MAW, Maltha JC, Stoeltinga PJW. Assessment of the value of anorganic bone additives in sinus floor augmentation: a review of clinical reports. *Int J Oral Maxillofac Surg* 2003;32:1–6.
30. Artzi Z, Dayan D, Alpern Y, Nemcovsky CE. Vertical ridge augmentation using xenogenic material supported by a configured titanium mesh: clinicopathologic and histochemical study. *Int J Oral Maxillofac Implants* 2003;18:440–6.
31. Schepers E, Declercq M, Ducheyne P, Kempeners R. Bioactive glass particulate material as a filler for bone lesions. *J Oral Rehab* 1991;18:439–52.
32. Knapp CI, Feuille F, Cochran DL, Mellonig JT. Clinical and histologic evaluation of bone-replacement grafts in the treatment of localized alveolar ridge defects. Part 2: bioactive glass particulate. *Int J Periodontics Restorative Dent* 2003;23:129–37.
33. Wiltfang J, Schlegel KA, Schultze-Mosgau S, et al. Sinus floor augmentation with β -tricalciumphosphate (β -TCP): does platelet-rich plasma promote its osseous integration and degradation? *Clin Oral Impl Res* 2003;14:213–8.
34. Boyne PJ. Animal studies of the application of rhBMP-2 in maxillofacial reconstruction. *Bone* 1996;19:S83–92.
35. Einhorn TA. Clinical applications of recombinant human BMPs: early experience and future development. *J Bone Joint Surg* 2003;85A:82–8.
36. Boyne PJ, Shabahang S. An evaluation of bone induction delivery materials in conjunction with root form implant placement. *Int J Periodontics Restorative Dent* 2001;21:333–43.
37. Seeherman H, Wozney J, Li R. Bone morphogenetic protein delivery systems. *Spine* 2002;27:S16–23.
38. Poynton AR, Lane JM. Safety profile for the clinical use of bone morphogenetic proteins in the spine. *Spine* 2002;27:S40–8.
39. Valentin-Opran A, Wozney J, Csimma C, et al. Clinical evaluation of recombinant human bone morphogenetic protein-2. *Clin Orthop and Rel Res* 2002;395:110–20.
40. Sandhu HS, Khan SN. Recombinant human bone morphogenetic protein-2: use in spinal fusion applications. *J Bone Joint Surg* 2003;85A:89–95.
41. Nevins M, Kirker-Head C, Nevins M, et al. Bone formation in the goat maxillary sinus induced by absorbable collagen sponge implants impregnated with recombinant human bone morphogenetic protein-2. *Int J Periodont Res Dent* 1996;16:9–19.
42. Boyne PJ, Marx RE, Nevins M, et al. A feasibility study evaluating rhBMP-2/absorbable collagen sponge for maxillary sinus augmentation. *Int J Periodont Restor Dent* 1997;17:11–25.
43. Cook SD, Salkeld SL, Rueger DC. Evaluation of recombinant human osteogenic protein (rhOP-1) placed with dental implants in fresh extraction sites. *J Oral Implantol* 1995;21:281–9.
44. Howell TH, Fiorellini J, Jones A, et al. A feasibility study evaluating rhBMP-2/absorbable collagen sponge device for local alveolar ridge augmentation. *Int J Periodontics Restorative Dent* 1997;17:124–39.
45. Wikesjo UME, Sorensen RG, Kinoshita A, Wozney JM. RhBMP-2/ α BSM induces significant vertical alveolar ridge augmentation and dental implant osseointegration. *Clin Impl Dent Rel Res* 2002;4:174–82.
46. Mayer M, Hollinger J, Ron E, Wozney J. Maxillary alveolar cleft repair in dogs using recombinant human bone morphogenetic protein-2 and a polymer carrier. *Plast Reconstr Surg* 1996;98:247–59.
47. Toriumi DM, Kotler HS, Luxenberg DP, et al. Mandibular reconstruction with a recombinant bone-inducing factor: functional, histologic and biomechanical evaluation. *Arch Otolaryngol Head Neck Surg* 1991;117:1101–12.
48. Yudell RM, Block MS. Bone gap healing in the dog using rhBMP-2. *J Oral Maxillofac Surg* 2000;58:761–6.
49. Terheyden H, Knak C, Jepsen, et al. Mandibular reconstruction with a prefabricated vascularized bone graft using recombinant human osteogenic protein-1: an experimental study in miniature pigs. *Int J Oral Maxillofac Surg* 2001;30:373–9.
50. Philippart P, Brasseur M, Houxiaux D, Pochet R. Human recombinant tissue factor, platelet-rich plasma, and tetracycline induce a high-quality human bone graft: a 5-year study. *Int J Oral Maxillofac Implants* 2003;18:411–6.
51. Zeiter DJ, Ries WL, Sanders JJ. The use of a bone block graft from the chin for alveolar ridge augmentation. *Int J Periodontics Restorative Dent* 2000;20:619–27.
52. Cranin AN, Katzap M, Demirdjan E, Ley J. Autogenous bone ridge augmentation using the mandibular symphysis as a donor. *J Oral Implantol* 2001;27:43–7.
53. Balaji SM. Management of deficient anterior maxillary alveolus with mandibular parasymphyseal bone graft for implants. *Implant Dent* 2002;11:363–9.
54. Matsumoto MA, Filho HN, Francischone CE, Consolaro A. Microscopic analysis of reconstructed maxillary alveolar ridges using autogenous bone grafts from the chin and iliac crest. *Int J Oral Maxillofac Implants* 2002;17:507–16.
55. Kaufman E, Wang PD. Localized vertical maxillary ridge augmentation using symphyseal bone cores: a technique and case report. *Int J Oral Maxillofac Implants* 2003;18:293–8.
56. Misch CM. Comparison of intraoral donor sites for onlay grafting prior to implant placement. *Int J Oral Maxillofac Implants* 1997;12:767–76.
57. Pikos MA. Block autografts for localized ridge augmentation: part II the posterior mandible. *Implant Dent* 2000;9:67–74.
58. Misch CM. Use of the mandibular ramus as a

- donor site for onlay bone grafting. *2000;26:42-9.*
59. Sethi A, Kraus T. Ridge augmentation using mandibular block bone grafts: preliminary results of an ongoing prospective study. *Int J Oral Maxillofac Implants* 2001;16:378-88.
 60. Proussaefs P, Lozada J, Kleinman A, Rohrer MD. The use of ramus autogenous block grafts for vertical alveolar ridge augmentation and implant placement: a pilot study. *Int J Oral Maxillofac Implants* 2002;17:238-48.
 61. Capelli M. Autogenous bone graft from the mandibular ramus: a technique for bone augmentation. *Int J Periodontics Restorative Dent* 2003;23:277-85.
 62. Cotter CJ, Maher A, Gallagher C, Sleeman D. Mandibular lower border: donor site of choice for alveolar grafting. *Br J Oral Maxillofac Surg* 2002;40:429-32.
 63. Li KK, Schwartz HC. Mandibular body bone in facial plastic and reconstructive surgery. *Laryngoscope* 1996;106:504-6.
 64. Kainulainen VT, Sandor GKB, Oikarinen KS, Clokie CM. Zygomatic bone: an additional donor site for alveolar bone reconstruction. Technical note. *Int J Oral Maxillofac Implants* 2002;17:723-8.
 65. Ragheobar GM, Louwerse C, Kalk WWI, Vissink A. Morbidity of chin bone harvesting. *Clin Oral Impl Res* 2001;12:503-7.
 66. Nkenke E, Radespiel-Troger M, Wiltfang J, et al. Morbidity of harvesting of retromolar bone grafts: a prospective study. *Clin Oral Impl Res* 2002;13:514-21.
 67. Tessier P. Autogenous bone grafts taken from the calvarium for facial and cranial applications. *Clin Plast Surg* 1982;9:531-9.
 68. Jackson IT, Pellet C, Smith JM. The skull as a bone graft donor site. *Ann Plast Surg* 1983;11:527-34.
 69. Koenig WJ, Donovan JM, Pensler JM. Cranial bone grafting in children. *Plast Reconstr Surg* 1995;95:1-4.
 70. Fearon JA. A magnetic resonance imaging investigation of potential subclinical complications after in situ cranial bone graft harvest. *Plast Reconstr Surg* 2000;105:1935-9.
 71. Zins JE, Weinzeig N, Hahn J. A simple fail-safe method for the harvesting of cranial bone. *Plast Reconstr Surg* 1995;96:1444-7.
 72. Klein RM, Wolfe SA. Complications associated with the harvesting of cranial bone grafts. *Plast Reconstr Surg* 1995;95:5-13.
 73. Ahlmann E, Patzakis M, Roidis N, et al. Comparison of anterior and posterior iliac crest bone harvest in terms of harvest site morbidity and functional outcomes. *J Bone Joint Surg* 2002;84:716-20.
 74. Marx RE, Morales MJ. Morbidity from bone harvest in major jaw reconstruction: a randomized trial comparing the lateral anterior and posterior approaches to the ilium. *J Oral Maxillofac Surg* 1988;48:196-203.
 75. Kurz LT, Garfin SR, Booth RE. Harvesting autogenous iliac crest bone grafts: a review of complications. *Spine* 1989;14:1324-31.
 76. Banwart JC, Asher MA, Hassanein RS. Iliac crest bone graft donor site morbidity: a statistical evaluation. *Spine* 1995;20:1055-60.
 77. Arrington ED, Smith WJ, Chambers HG, et al. Complications of iliac crest bone graft harvesting. *Clin Orthop* 1996;329:300-9.
 78. Silber JS, Anderson DG, Daffner SD, et al. Donor site morbidity after anterior iliac crest bone harvest for single level anterior cervical discectomy and fusion. *Spine* 2003;28:134-9.
 79. Burstein FD, Simms C, Cohen SR, et al. Iliac crest bone graft harvesting techniques: a comparison. *Plast Reconstr Surg* 2000;105:34-9.
 80. Sandor GKB, Rittenberg BN, Clokie CML, Caminiti MK. Clinical success in harvesting autogenous bone using a minimally invasive trephine. *J Oral Maxillofac Surg* 2003;61:164-8.
 81. Westrich GH, Geller DS, O'Malley MJ, et al. Anterior iliac crest harvesting using the corticocancellous reamer system. *J Orthop Trauma* 2001;15:500-6.
 82. Caminiti MF, Sandor GK, Carmichael RP. Quantification of bone harvested from the iliac crest using a power-driven trephine. *J Oral Maxillofac Surg* 1999;57:801-5.
 83. Sasso RC, Williams JI, Dimasi N, Meyer PR. Postoperative drains at the donor sites of iliac crest bone grafts. A prospective randomized study of the morbidity at the donor site in patients who have had a traumatic injury to the spine. *J Bone Joint Surg* 1998;80:631-5.
 84. Puri R, Moskovich R, Gusmorino P, Shott S. Bupivacaine for postoperative pain relief at the iliac crest bone graft harvest site. *Am J Orthop* 2000;29:443-6.
 85. Albee FH. Evolution of bone graft surgery. *Am J Surg* 1944;63:421-36.
 86. Dick IL. Iliac bone transplantation. *J Bone Joint Surg* 1946;18:1-14.
 87. Bloomquist DS, Feldman GR. The posterior ilium as a donor site for maxillofacial bone grafting. *J Maxillofac Surg* 1980;8:60-4.
 88. Robertson PA, Wray AC. Natural history of posterior iliac crest bone graft donation for spinal surgery. *Spine* 2001;26:1473-6.
 89. O'Keefe RM, Reimer BL, Butterfield SL. Harvesting of autogenous cancellous bone grafts from the proximal tibial metaphysis. *J Orthop Trauma* 1991;5:469-74.
 90. Daffner RH. Case report 592. *Skeletal Radiol* 1990;19:73-5.
 91. Sivarajasingam V, Fell G, Morse M, Shepherd JP. Secondary bone grafting of alveolar clefts: a densitometric comparison of iliac crest and tibial bone grafts. *Cleft Palate Craniofac J* 2001;38:11-4.
 92. Catone GA, Reimer BL, McNeir D, Ray R. Tibial autogenous cancellous bone as an alternative donor site in maxillofacial surgery: a preliminary report. *J Oral Maxillofac Surg* 1992;50:1258-63.
 93. Meeder PJ, Eggers C. Techniques for obtaining autogenous bone graft. *Injury* 1994;25:A5-16.
 94. Jakse N, Seibert FJ, Lorenzoni M, et al. A modified technique of harvesting tibial cancellous bone and its use for sinus grafting. *Clin Oral Implants Res* 2001;12:488-94.
 95. Herford AS, King BJ, Audia F, Bector J. Medial approach for tibial bone graft: anatomic study and clinical technique. *J Oral Maxillofac Surg* 2003;61:358-63.
 96. van Damme PA, Merckx MA. A modification of the tibial bone graft harvesting technique. *Int J Oral Maxillofac Surg* 1996;25:346-8.
 97. Marx RE, Carlson ER, Eichstaedt SR, et al. Platelet-rich plasma: growth factor enhancement for bone grafts. *Oral Surg Oral Med Oral Path Oral Radiol Endol* 1998;85:638-46.
 98. Marx RE. Platelet-rich plasma (PRP): what is PRP and what is not PRP. *Implant Dent* 2001;10:225-8.
 99. Sanchez AR, Sheridan PJ, Kupp LI. Is platelet rich plasma the perfect enhancement factor? A current review. *Int J Oral Maxillofac Implants* 2003;18:93-103.
 100. Schmitz JP, Hollinger JO. The biology of platelet rich plasma. *J Oral Maxillofac Surg* 2001;29:1119-20.
 101. Marx RE, Morales MJ. Morbidity from bone harvest in major jaw reconstruction: a randomized trial comparing the lateral anterior and posterior approaches to the ilium. *J Oral Maxillofac Surg* 1988;48:196-203.
 102. Landesberg R, Roy M, Glickman RS. Quantification of growth factor levels using a simplified method of platelet-rich plasma gel preparation. *J Oral Maxillofac Surg* 2000;58:297-300.
 103. Sonleitner D, Huemer P, Sullivan DY. A simplified technique for producing platelet-rich plasma and platelet concentrate for intraoral bone grafting techniques: a technical note. *Int J Oral Maxillofac Implants* 2000;15:879-82.

104. Rodriguez A, Anastassov GE, Lee H, et al. Maxillary sinus augmentation with deproteinated bovine bone and platelet rich plasma with simultaneous insertion of endosseous implants. *J Oral Maxillofac Surg* 2003;61:157–63.
105. Kassolis JD, Rosen PS, Reynolds MA. Alveolar ridge and sinus augmentation utilizing platelet-rich plasma in combination with freeze-dried bone allograft: case series. *J Periodontol* 2000;71:1654–61.
106. Danesh-Meyer MJ, Filstein MR, Shanaman R. Histological evaluation of sinus augmentation using platelet rich plasma (PRP) a: a case series. *J Int Acad Periodontol* 2001;3:48–56.
107. Lozada JL, Caplanis N, Proussaefs P, et al. Platelet-rich plasma application in sinus graft surgery: part 1—background and processing techniques. *J Oral Implant* 2001;27:38–42.
108. Thor A. Reconstruction of the anterior maxilla with platelet gel, autogenous bone, and titanium mesh: a case report. *Clin Implant Dent Rel Res* 2002;4:150–5.
109. Wojtowicz A, Chaberek S, Kryst L, et al. Fourier and fractal analysis of maxillary alveolar ridge repair using platelet rich plasma (PRP) and inorganic bovine bone. *Int J Oral Maxillofac Surg* 2003;32:84–6.
110. Marx RE, Ames JR. The use of hyperbaric oxygen therapy in bony reconstruction of the irradiated and tissue-deficient patient. *J Oral Maxillofac Surg* 1982;40:412–20.
111. Tibbles PM, Edelsberg JS. Hyperbaric oxygen therapy. *N Engl J Med* 1996;334:1642–8.
112. Hunt TK, Pai MP. The effects of varying ambient oxygen tensions on wound metabolism and collagen synthesis. *Surg Gynecol Obstet* 1972;135:561–7.
113. Kindwall EP. Hyperbaric oxygen's effect on radiation necrosis. *Clin Plast Surg* 1993;20:473–83.

Microvascular Free Tissue Transfer

Joseph I. Helman, DMD

Remy H. Blanchaert Jr, MD, DDS

Reconstruction of the maxillofacial region has been a challenge due to the significant complexity of function and esthetics. The introduction of free tissue transfer to the armamentarium of available techniques has facilitated this task, and therefore allowed for a better quality of life for our patients. Following the description of the history of free flaps in this chapter, the surgical techniques are reviewed and discussed along with the most common specific donor sites: the radial forearm flap, the free fibula flap, and the iliac crest with the deep circumflex iliac vessels.

History of the Surgical Microscope

The development of microsurgical free tissue transfer resulted in a dramatic evolution in head and neck reconstruction, allowing for a significant increase in the available choices of anatomic and functional rehabilitation. There is no doubt that the availabilities of surgical loupes and intraoperative microscopes have been the facilitating factors to performing microvascular and microneurosurgical anastomoses.

In 1590 Dutch opticians Zacharias and Hans Janssen aligned two lenses within a sliding tube, thereby inventing the microscope. Galileo Galilei independently developed the same device a decade later by inverting his “tubum opticum” or telescope.

From the sixteenth to the nineteenth centuries many technical advances were

made, including the mathematical formulas of Ernst Abbe who predicted and standardized optical qualities, allowing Zeiss to mass produce high-quality microscopes. Operating spectacles were introduced in the 1860s and surgical loupes were used for the first time in surgery by the German physician Saemisch in 1876. The first surgical microscope was built by Dr. Carl Nylén, a Swedish otolaryngologist who used it for the first time in the operating theater in 1921.¹

History of Free Tissue Transfer for Head and Neck Reconstruction

Early attempts to achieve free tissue transfer resulted in few successes. Carrel first reported free vascularized transfer of intestine into the cervical region of experimental animals in 1907.² In the late 1950s and early 1960s Jacobson and Suarez performed successful anastomosis of carotid arteries in dogs and rabbits with a 100% patency rate.³ When Jacobson presented the outcome of his research at a national meeting, a leading surgeon at a prestigious institution stated in front of the audience, “This is very nice work, but it is simply ridiculous to bring a microscope into the operating room.”¹ During the 1960s the art of microsurgery was promoted by neurosurgeons and plastic surgeons with encouraging results.

New flaps were designed for reconstruction of the head and neck based on the ability to transfer distant tissues and provide immediate viability through a vascular anastomosis.

In 1975 Taylor and colleagues described the free fibula flap, while Hidalgo applied the technique for mandibular reconstruction in 1989.^{4,5} In 1981 Yang developed the radial forearm flap, while Soutar and colleagues popularized the technique for intraoral reconstruction with and without the addition of a portion of the radius in the mid-1980s.^{6–8} In 1978 Taylor described the transfer of the iliac crest as an osteomyocutaneous flap based on the blood supply from the circumflex artery and vein.^{9,10}

Free flaps became popular in the head and neck region due to the ability to transfer vascularized bone and soft tissue in one stage at the time of the resection, with predictable high success rates. It is also obvious that they increased the choices of tissue availability, as well as pliability, texture, color, etc, in the quest to achieve an ideal reconstruction and a functional rehabilitation of the patient.

Principles of Microvascular Anastomosis

Instrumentation

The microsurgery instruments require the following specifications:

1. Their weight must not exceed 15 to 20 g. Titanium instruments usually have less weight.
2. They must be at least 10 cm long so that they lie loosely in the hand.
3. The closing pressure of some instruments such as forceps or scissors should lie between 50 and 60 g. Tremor increases with higher closing pressure.
4. The vascular clamps must exert an evenly distributed pressure over the whole length of the jaw of the clamp. The jaws must lie parallel with each other.
5. Microscissors should have an opening of less than 4 mm. They can be either straight or curved, but it is imperative that they cut tissue in a clean fashion in order to reduce the risk of a thrombosis in a vascular anastomosis or the formation of a neuroma in a crushed nerve.
6. Watchmaker forceps are extremely useful, either straight or angled. They can be used as needle holders as long as there is no need to exert a significant force on the needle, in which case a microneedle holder would be the instrument of choice.
7. Microsurgical bipolar coagulation allows for concentrated coagulation between the two ends of the forceps, avoiding unnecessary devitalization of tissues.
8. Microscope and/or loupes. Surgical microscopes were developed by Zeiss in the early days and presently there are several similar microscopes manufactured by other companies. A magnification of 10× is usually enough for anastomosis. The zoom allows for regulation from a magnification of 10× while performing the anastomosis, to a lower magnification (4× to 6×) while the suture is being knotted.¹¹

Anastomosis Technique

The suture (usually 9-0) is passed at a distance from the margin of the vessel similar to that of the thickness of the wall. It is rec-

ommended to apply a counterforce while passing the needle through the vessel by holding the forceps open inside the lumen (Figures 40-1A and B) instead of grasping the vessel wall which may damage the edge of the vascular structure (Figure 40-1C). After the suture has passed through both ends of the vessel, a small “tail” of 2 to 3 mm is left in order that the knot can be performed while seeing the suture end within the field of the surgical microscope (Figures 40-1D and E).

After the first suture is placed the second suture is usually placed 180° from the first. The third suture is placed in between the first and the second, and two more interrupted sutures are placed on the same side. After finishing one side the vascular clamps are turned to expose the other side of the anastomosis. The sutures should always be at the same distance as the edges of the vessel as well as the same distance between each one of the sutures (Figure 40-2).

When the vascular anastomosis cannot be performed “end-to-end” due to very significant differences in the diameter of

the lumen, an “end-to-side” anastomosis is a viable alternative (Figure 40-3). An oval excision of the wall of the large-diameter artery is performed, and the sutures are executed in a similar fashion as explained in the end-to-end anastomosis.

Radial Forearm Free Flap

Many types of free flaps have been used in head and neck reconstruction. The radial forearm flap is perhaps the most commonly used soft tissue microvascular flap for intraoral and oropharyngeal defects. It has gained wide acceptance because of its reliability, adaptability, ease of harvest, and the thin pliable nature of the flap. The flap allows restoration of the complex three-dimensional anatomy inherent in oral and oropharyngeal defects. This is demonstrated by the commonplace reconstruction of combined tongue and floor-of-mouth defects. Folding the flap on itself to simultaneously reconstruct the tongue and floor of mouth creates redundancy and allows the residual tongue to retain outstanding mobility (Figure 40-4).

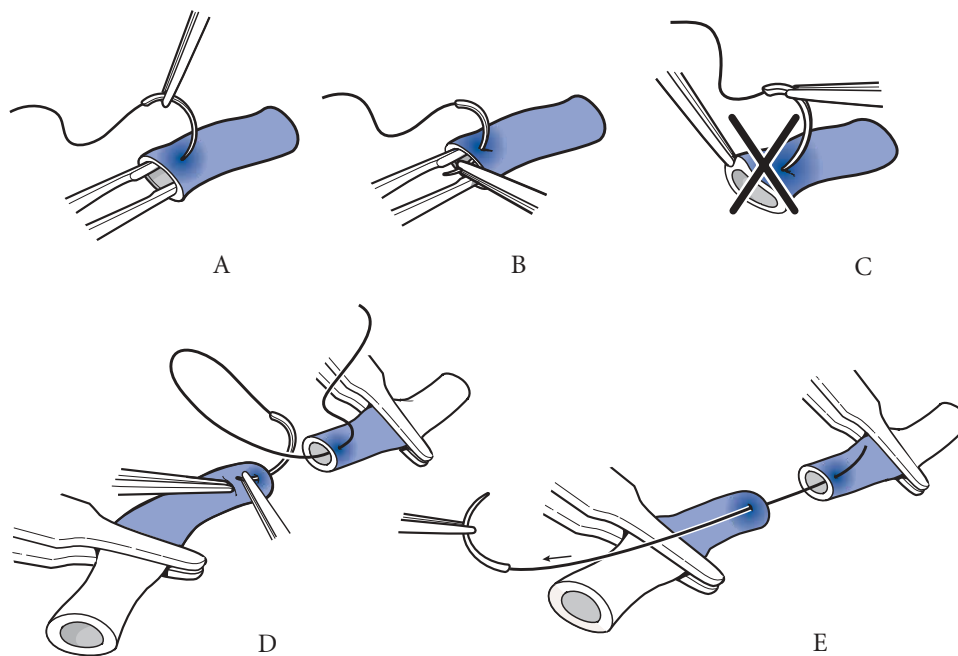


FIGURE 40-1 A and B, It is recommended to apply counterforce while suturing by holding the forceps open inside the lumen. C, Grasping the vessel with the forceps may damage the edge of the vessel. While passing the needle the motion should be circular, following the needle shape in order to avoid a tear of the vascular structure. D and E, A small “tail” of 2 to 3 mm should be left at the end of the suture to perform the knot within the microscope surgical field. Adapted from Medhorn HM and Muller GH.¹¹

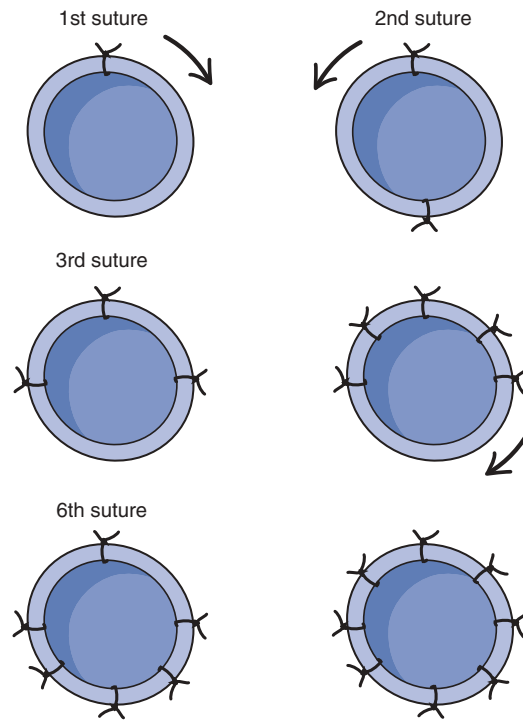


FIGURE 40-2 The first and second sutures are performed 180° from each other. The third suture is placed between the first two while holding the vessel on both sides with the tails of the first and second sutures. After interrupted sutures are placed on one side of the vessel, the microvascular clamps are turned to expose the other side of the anastomosis and proceed in a similar fashion as on the first side. Adapted from Medhorn HM and Muller GH.¹¹

Clinically the skin paddle of the radial forearm flap often takes on an appearance similar to that of oral mucosa following its transfer to the oral cavity. This change in appearance has been shown to be reactive in nature and does not represent true metaplasia.¹²

Development

The history of the spread of understanding of the flap is interesting. Soutar and colleagues reported and referenced the introduction of the flap to German surgeons visiting China in 1980.⁷ Subsequently these surgeons published in the German language literature on the use of the radial forearm as a donor site for the creation of neurofasciocutaneous and osteocutaneous flaps in neck and in hand reconstructions.

Soutar and colleagues reported the use of the radial forearm flap in primary mandibular reconstruction in 1983.⁷ Corrigan and O'Neill published a report of the cases outlining the technique of osteocutaneous flap harvest and transfer, and included a description of complications encountered.¹³ The most devastating of these complications is distal radius frac-

ture, which results in significant deformity. Vaughan documented extensive experience with 120 radial forearm flaps, praising the adaptability and applicability of the flap in head and neck reconstruction.^{14,15} Published reports have demonstrated it to be possible to perform defini-

tive mandibular reconstruction using the osteocutaneous radial forearm flap and dental implants.¹⁶ The volume and height of the bone compare poorly to those of other flaps. The fibula and deep circumflex iliac artery flap appear to have the most suitable bone stock to facilitate dental implant-based mandibular rehabilitation and are therefore more popular when bone is necessary.¹⁷

Refinement and adaptation of the radial forearm flap continued throughout the early 1990s. Urken and colleagues reported on the use of the neurofasciocutaneous radial forearm flap in head and neck reconstruction.¹⁸ This report included a means of monitoring buried or poorly accessible flaps that could be facilitated by the inclusion of a skin paddle on the proximal fascial/subcutaneous element of the flap. Protection of the flap vessels and augmentation of the contour deformity created by neck dissection are additional advantages of this modification.^{19,20} The literature abounds with descriptions of suitable adaptations of the radial forearm flap to specific sites within the head and neck. Urken and Biller published a

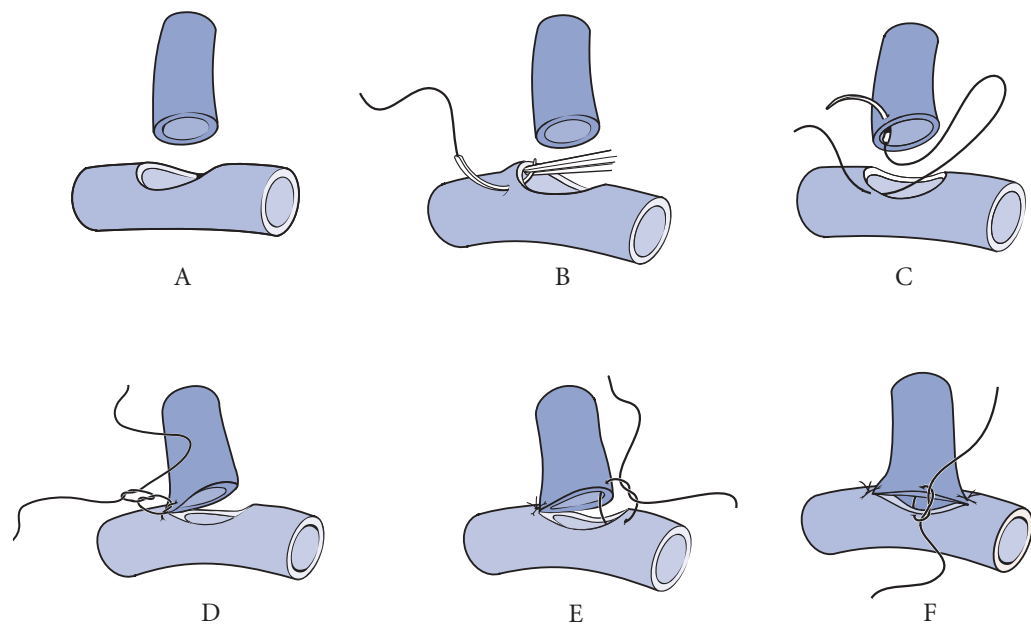


FIGURE 40-3 A–F, The end-to-side anastomosis is performed after excision of an oval segment of the “side” donor vessel. The sequence of suturing is similar to the technique described in Figure 40-2. Adapted from Medhorn HM and Muller GH.¹¹

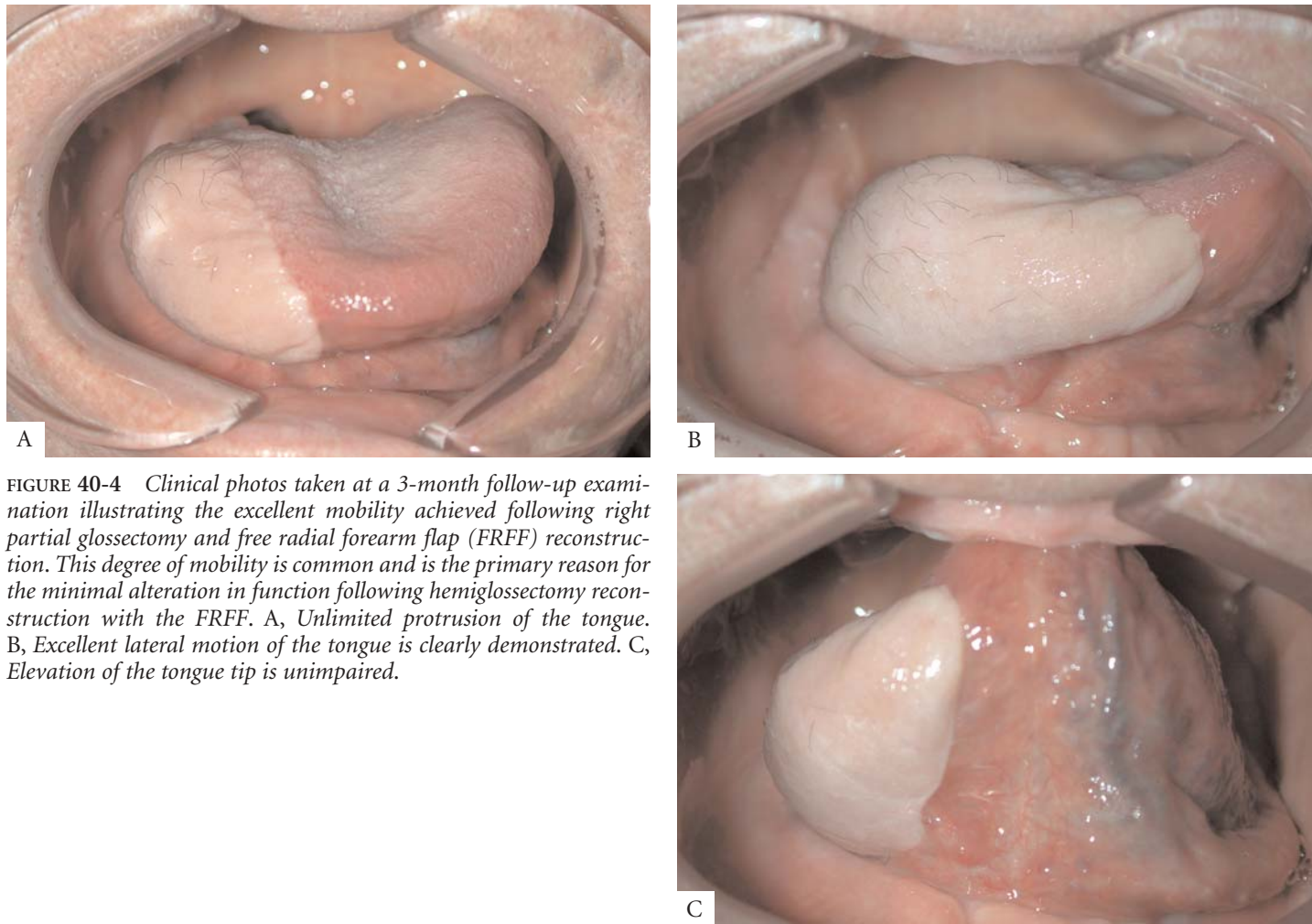


FIGURE 40-4 Clinical photos taken at a 3-month follow-up examination illustrating the excellent mobility achieved following right partial glossectomy and free radial forearm flap (FRFF) reconstruction. This degree of mobility is common and is the primary reason for the minimal alteration in function following hemiglossectomy reconstruction with the FRFF. A, Unlimited protrusion of the tongue. B, Excellent lateral motion of the tongue is clearly demonstrated. C, Elevation of the tongue tip is unimpaired.

description of a bilobed neurofasciocutaneous flap for hemiglossectomy defects that allows preservation of residual tongue function.²¹ Oromandibular reconstruction has been reported using the free radial forearm flap alone or in combination with a fibula free flap.^{7,13,22,23} Lower lip reconstruction has been described wherein the palmaris longus tendon provides support and suspension to the flap.^{24,25} Simultaneous lip and cheek, full-thickness cheek, and soft palate reconstruction have also been described.²⁴⁻²⁸ Oral cavity and pharyngoesophageal reconstruction with the radial forearm flap has advantages over other reconstructive modalities, demonstrating good functional outcomes.^{29,30} Reconstruction of facial defects (forehead, nasal) has also been described as an appropriate use of the radial forearm flap.^{31,32}

Extreme uses of the flap include reports of the creation of hybrid flaps, wherein the cephalic vein remains pedicled for use in cases with inadequate venous outflow and the simultaneous use of bilateral flaps.^{33,34}

Throughout the development of the free radial forearm flap, reinnervation of the flap has received considerable attention. Many authors have discussed the role of sensory reinnervation in functional outcomes in oral cavity and oropharynx reconstruction.^{17,18,21,35,36} Recall that some of the earliest descriptions of the use of the flap were neurofasciocutaneous flaps.⁷ The neurofasciocutaneous radial forearm flap is typically designed to include only the median antebrachial cutaneous nerve (see Figure 40-6). Sensory nerve mapping accomplished by cadaveric microdissection and selective nerve block technique

in 8 forearms of 4 human subjects has revealed that much of the skin territory harvested with the flap is supplied by either the lateral antebrachial cutaneous nerve or the superficial radial sensory nerve.³⁷ This brings into question the means by which the radial forearm flap achieves reinnervation. Many authors have postulated that reinnervation occurs by ingrowth of nerve fibers from the recipient bed and peripheral or adjacent tissues.^{27,36,38-41} Close and colleagues compared spontaneous sensory recovery in myocutaneous pectoralis major flaps and radial forearm fasciocutaneous flaps and found the forearm flaps to exhibit significantly better sensation.³⁵ This supports the idea that the characteristics of both the flap and the recipient bed influence the sensory recovery within non-reinnervated

soft tissue flaps. Netscher and colleagues studied 12 patients who underwent free radial forearm flap reconstruction of the tongue and floor of mouth.³⁹ Seven patients received reinnervated flaps and 5 received flaps without intentional neural anastomosis. Improved sensory recovery in the patients who received reinnervated flaps was documented, but no statistically significant difference in function could be found.

Santamaria and colleagues reported objectively evaluated sensory recovery in reinnervated flaps to be near normal when neural anastomosis was accomplished to the lingual or inferior alveolar nerve.³⁶ Sensation was found to be poor if the anastomosis was carried out to other recipient nerves (posterior auricular nerve, cervical plexus, hypoglossal nerve). The study also found the recovery of sensation to be significantly diminished in patients who received postoperative radiotherapy. In summary the decision to perform the radial forearm flap as a neurofasciocutaneous flap must be made on a case-by-case basis dependant on the defect characteristics and location, recipient bed, and the ability to accomplish anastomosis to the lingual or inferior alveolar nerve.

Anatomic Considerations

Blood Supply The arterial blood supply of the radial forearm fasciocutaneous flap is based on perforators of the radial artery. The fascial plexus supplied by these perforators supplies the skin of nearly the entire forearm. There are discrete groups of these perforators. The most clinically relevant is the small number of perforators at the site where the flexor carpi radialis and brachioradialis muscles overlap. One particularly relevant implication of this is the ability to develop multiple skin flap elements based on a single vascular pedicle without the requirement of preservation of the entire fascial element.^{42,43} The bone element of the flap is supplied by branches of the radi-

al artery within the lateral intramuscular septum. Branches that form a longitudinal plexus within the periosteum pass through the insertion of this fascia.⁴⁴

The venous drainage of the radial forearm flap occurs through the interconnecting superficial (cephalic vein) and deep (venae comitantes) systems. Thoma and colleagues published an excellent description of the variation on the pattern of venous drainage identified in 40 clinical cases.²² Five distinct patterns were described. The type I pattern, found 20% of the time, exhibits wide communication of an anastomosing vein of the venae comitantes and the cephalic vein, which split to separate cephalic median and basilic median veins. The type II pattern existed 43% of the time and was similar to type I, with the exception that no division of the fusion of vessels occurred. The type III pattern, seen 18% of the time, displayed an anastomosis of the paired venae comitantes that remained separate from the cephalic vein. The type IV pattern occurred 5% of the time and exhibited no fusion of the venae comitantes of near equal size. Although pattern V, seen 15% of the time, also exhibited no fusion of the two systems, there was clearly a dominant venae comitantes.⁴⁵ Thoma and colleagues made a strong recommendation for completing multiple venous anastomoses. Their view appears to be common in early free flap and replant experiences. However, a single venous anastomosis has been shown to be adequate in the more recent literature. Futran and Stack compared outcomes and operating time in 43 consecutive radial forearm flaps.⁴⁶ Two anastomoses were performed in 16 patients and one anastomosis was performed in 23 patients. They reported no difference in flap survival and no flaps were re-explored for venous complications. Twenty-one to 36 minutes less surgical time was documented in cases in which a single venous anastomosis was completed. Surgeon preference and individual patient and flap

characteristics determine the most appropriate vein for anastomosis. Clearly in cases with a superficial venous system compromised by trauma or extensive venipuncture, the deep system (venae comitantes) must be used. The reliability of the deep system has been well documented.⁴⁷ Netscher and colleagues used dye injection to study the venous drainage system.⁴⁸ They found that careful mapping of the cephalic vein was necessary to ensure its capture within the flap, occasionally necessitating localization of the flap skin paddle over a portion of the dorsum of the forearm. Venae comitantes vessel diameters were found to be less than 2 mm in several specimens. The study also concluded that selection of the site for venous anastomosis significantly alters the vessel diameter. In order to obtain the greatest diameter, the confluence of the venae comitantes must be identified. This may result in venous pedicle redundancy and kinking. The superficial venous drainage system exhibits a larger diameter throughout its entire length and is significantly easier to elevate, and its separation from the arterial pedicle increases options for recipient vein selection with acceptable vessel geometry.

Vascular Abnormalities Preoperative evaluation of the arterial supply to the hand is required prior to harvest of the free radial forearm flap. This is traditionally accomplished by an Allen's test. Accurate performance of the test involves exsanguination of the hand by clenching and releasing the fist multiple times while both the radial and ulnar arteries are compressed. Return of color to the blanched thenar eminence and thumb following release of the ulnar artery confirms adequate communication between the superficial (ulnar) and deep (radial) palmar arches. Thus harvest of the flap would not compromise the blood supply to the hand. A single published report of acute ischemia to the hand following radial forearm flap

harvest despite a “normal” Allen’s test initiated further investigation into forearm vascular anatomy.⁴⁹ The subjective nature of the Allen’s test has led to the use of adjunctive clinical aids such as Doppler and pulse oximetry to ensure adequate perfusion of the thumb with radial artery occlusion. In their description of a method for preoperative vascular assessment, Nukols and colleagues reported the use of an “objective Allen’s test” in a clinical series of 65 patients.⁵⁰ Twenty-five patients were thought to have inadequate flow by subjective testing, 18 of whom were found to have acceptable flow by objective testing. The authors concluded that objective testing was more reliable in identifying potential problem donor sites. Color flow duplex assessment of 18 patients revealed 5 with unilateral or bilateral arteriopathy. This finding impacted the site selection of the radial forearm harvest or resulted in the use of alternate reconstructive modalities in those 5 cases.⁵¹ Interestingly, color flow duplex quantifications of the flow rates in the upper extremities of 11 patients preoperatively and 4 to 5 months postoperatively revealed overall increased flow rates (mean 162 mL/min to 215 mL/min). The increased flow resulted from dramatic increases in blood flow through the anterior and posterior interosseous arteries. In fact the anterior interosseous artery was found to take on a flow rate (33% of the total) that was nearly equal to that of the radial artery before flap harvest (39%).^{51,52}

Many authors have published case reports of vascular abnormalities of the radial artery.^{39,53–57} Funk and colleagues published a review of the literature on forearm vascular anomalies that included clinical correlation based on 52 patients.⁵⁸ The paper described six types of anomalies, the most common of these being a high origin (proximal to the antecubital fossa) of the radial artery occurring in approximately 15% of all upper extremities. The majority of radial arteries in these patients originate from the brachial artery,

but 10 to 25% were reported to arise directly from the axillary artery. This anomaly poses no problem for safe radial forearm flap harvest. The second most common anomaly reported was a superficial ulnar artery. The superficial location of the ulnar artery places the vessel at risk in flaps involving the entire volar surface of the forearm. Surgeons are strongly encouraged to palpate the entire antecubital fossa and volar forearm in order to rule out this anomaly. The abnormal vessel course is typically best palpated overlying the flexor carpi muscle. The superficial ulnar artery anomaly reported in 2.5% of upper extremities should prompt the surgeon to preferentially use other sites for flap harvest because of the risk incurred in selection of such a donor site. The flap can be done safely with this anomaly if the flap is positioned more to the radial side of the ventral forearm. Distal takeoff of the radial artery has been reported once. No risk of vascular insufficiency is incurred with this anomaly, and there is no reason to believe it could be identified prior to flap elevation. The other anomalies reported result in significant risk of vascular insufficiency to the hand in the case of radial artery flap harvest and should be easily identified on the basis of abnormal Allen’s tests (Figure 40-5).

Complications In general, patients with head and neck defects tend to be less than ideal surgical candidates because of medical comorbidities. Comorbidities are common and are related to advanced age, alcohol abuse, and tobacco abuse. Complications can occur at the operative sites directly or they may be medically related. Singh and colleagues analyzed a cohort of 200 consecutive patients with head and neck defects who had undergone free tissue transfer, to determine factors that influence both surgical site and medical complication rates.⁵⁹ Successful free tissue transfer was accomplished in 98% of cases. Complications occurred in 56 cases (28%) with 21 (10.5%)

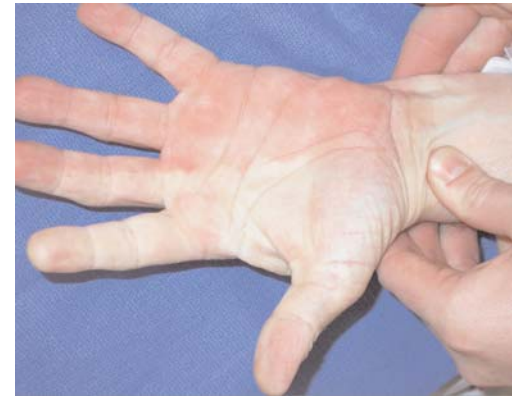

FIGURE 40-5 An abnormal Allen’s test. Note the clearly delineated vascular territory of the ulnar artery.

patients developing multiple complications. Using univariate analysis, statistically significant factors that increased the risk of complication included prior radiation therapy, anesthesia time >10 hours, and advanced Charlson comorbidity grade. However, after multivariate analysis only advanced Charlson grade proved significant. Prior radiation therapy appeared to have no significant effect on flap survival, as reported in other studies, although significant alteration in technique including vein grafting may be required.^{60,61} Surgical time has also been shown to correlate significantly with increased rates of surgical site infection, which is the most common factor in late vascular compromise of free tissue transfers through direct effect on the vascular pedicle.^{62,63}

The free radial forearm flap is a very reliable reconstruction. The international microvascular research group published a multi-institutional prospective study of 493 free flaps.⁶⁴ In a subgroup of the report, 84 free radial forearm flaps exhibited a thrombosis rate of 8.3% and a flap failure rate of 3.6%, indicating a significant role for flap monitoring and flap salvage surgery in head and neck reconstruction.

Monitoring of the radial forearm flap is required in order to identify early compromise of the flap vasculature. Conventional techniques of monitoring have been shown to be adequate for this purpose. These

techniques include visual inspection for color, capillary refill assessment, Doppler probe assessment, and needlestick test. Flap design for deep or buried flaps in which direct observation is not possible should include either a monitor skin paddle that can be directly evaluated or an implantable Doppler probe.^{20,65} An extensive review of 750 consecutive microvascular flaps demonstrated a re-exploration rate of 8.5% and a flap loss rate of 2.3%.⁶⁵ The majority of those flaps salvaged were re-explored at < 48 hours due to observed changes in the parameters monitored. Late re-exploration at > 72 hours was most commonly the result of wound infection causing compromise of the vascular pedicle by pressure or thrombosis. Late re-exploration is associated with high rates of flap loss.

Several assessments of donor site morbidity of the radial forearm flap harvest have been carried out.⁶⁶⁻⁷⁰ Complete or partial failure of split thickness skin graft at the donor site is the most common complication encountered. This can lead to flexor tendon exposure and prolonged healing. Many methods have been devised to decrease the incidence of this complication including coverage of the defect with rotation/advancement flaps, preoperative tissue expansion and primary closure, full-thickness grafting, suprafascial dissection, and the use of vacuum-assisted wound care.⁷¹⁻⁷⁹

A devastating complication of osteocutaneous radial forearm flap harvest is postoperative radius fracture. Prophylactic plating is strongly recommended when bone is included in the flap.^{80,81} Selection of an alternative donor site seems a more prudent alternative provided that one is available. Overall, with the exception of cases in which a radius fracture occurs, donor site function, though objectively altered, is subjectively insignificant.^{62,66,68}

Flap Technique

Simultaneous clinical evaluation of the tumor defect site by both the ablative and

reconstructive surgeons is particularly useful in design of the radial forearm flap and allows planning for the most appropriate vessel geometry. Careful examination of the proposed donor site is required to verify the patency of the superficial venous system and to document the arterial anatomy of the hand. An Allen's test is mandatory and should be supplemented with Doppler or pulse oximetry whenever the examination is inconclusive. Palpation of the entire forearm to determine the vascular anatomy should be done without a tourniquet (arterial assessment) and with the use of a venipuncture tourniquet and dependant positioning of the upper extremity (venous anatomy).

Preliminary planning is supplemented by the intraoperative examination of both the resection specimen and the defect site. Occasionally modifications are required due to extension of the planned resection to achieve tumor margins or due to vascular insufficiency identified in access flaps following a lip split-mandibulotomy procedure. Accurate determinations of the pedicle length required allow further tailoring of the flap harvest to the specifics of the defect site. This facilitates flap harvest because the surgeon need not dissect the entire available vascular pedicle length. This also facilitates the anastomosis procedure because the surgeon can skeletonize the region of the pedicle at which the anastomosis will be completed during a non-ischemic period.

The donor site is prepared for surgery by removing hair in the surgical field with clippers. The radial artery is outlined along its length with a surgical marker. A venipuncture tourniquet is applied to distend the veins and the superficial venous system is outlined with a surgical marker. A preliminary outline of the flap is then marked on the wrist that will be refined following the completion of the resection and identification of the most appropriate recipient vessels. For most cases a fascio-subcutaneous segment of the flap proxi-

mal to the skin paddle can be included to optimize the blood supply, resist vessel kinking, and protect the vascular pedicle. The surgical site is prepared with a chlorhexidine surgical scrub and isolated using extremity drapes. A standard arm-board is sufficient for support of the extremity throughout surgery. Care is taken to ensure absolute isolation of the arm from the head and neck field. Cross-contamination has been implicated in causing suppurative tenosynovitis resulting in a frozen hand.⁸²

Upon completion of the resection or refining of the defect site, the neck is carefully explored to identify likely recipient vessels. The selected vessels should be checked for patency, presence of atherosclerosis, and intimal injury. Loupe magnification facilitates this process. Although any suitable vessel can be used as a recipient vessel, the facial artery and common facial vein are most commonly selected as recipient vessels in intraoral reconstruction. Because these vessels lie central in the lateral neck, less alteration of the flap vessel geometry occurs on extreme head movement when these vessels are used. The reader is reminded of the transverse cervical artery (a branch of the thyrocervical trunk) because of its similar diameter to the radial artery. Because of the position of the transverse cervical artery low in the neck, it is commonly available and in good condition following prior selective neck dissection or radiotherapy. Although the available pedicle length allows for use of neck vessels, when performing an upper facial reconstruction the superficial temporal artery and vein or the facial artery and vein are often used.

Daily aspirin therapy to decrease platelet aggregation is initiated on the evening of surgery and continued for 6 weeks. Flap harvest is accomplished following exsanguination of the upper extremity and inflation of a tourniquet to 250 mm Hg. Tourniquet control facilitates the flap harvest by maximizing visualization. This

creates an excellent environment for teaching the microvascular flap harvest technique. Enough cannot be said about the crucial role that gentle tissue/vessel handling plays in the ultimate viability of the microvascular transfer. The distal flap is elevated first, requiring ligation of the distal radial artery and cephalic vein. A subfascial plane of dissection allows capture of all available communications between the elements of the vascular supply of the flap without significantly increased morbidity (Figure 40-6).

The superficial radial nerve is resected to avoid violation of the fascial compartment. This can be used as a free nerve graft of 4 to 6 cm length if needed. The sensory defect is limited to the dorsal portion of the thumb and index finger. We have found that skin graft placement over a preserved dorsal radial nerve provides insufficient protection. Severe pain can result from stimulation of the nerve by a sleeve or wristwatch.

Continued dissection around the circumference of the designed flap is accomplished deep to fascia laterally and deep to the dermis proximally. Skin flaps are then elevated proximally coincident with the

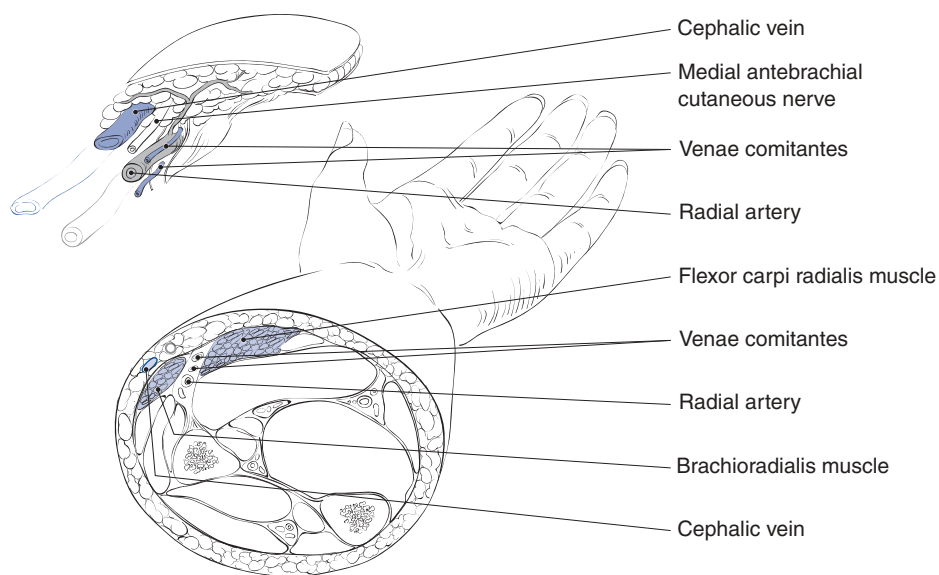


FIGURE 40-6 Cross-sectional anatomy of the radial forearm free flap donor site. The harvested flap demonstrates subfascial dissection of the flexor compartment. Adapted from Urken ML.⁹⁹

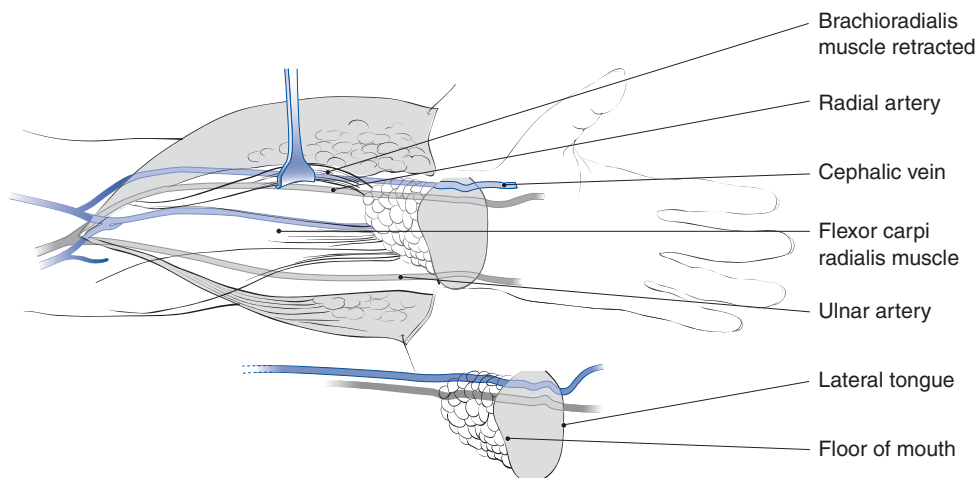


FIGURE 40-7 The harvest of the flap. Note the retraction of the brachioradialis muscle required to dissect the radial artery.

volume of the planned fasciosubcutaneous element of the flap. Proximal to this the cephalic vein and antebrachial cutaneous nerve are isolated. Proximal dissection of the arterial vascular pedicle requires the separation of the fascia joining the flexor carpi radialis and brachioradialis muscles and the lateral retraction of these muscles (Figure 40-7).

The venae comitantes are dissected from the radial artery for a few centimeters either side of the planned arterial

anastomosis and are preserved. Where one of the venae comitantes is clearly dominant, only this vessel is preserved. Numerous interconnections exist between these two vessels and careful dissection is required to achieve their separation. With the vascularity assured the flap is then elevated distal to proximal. This requires identification and ligation of deep branches of the radial artery. We prefer to use titanium vessel clips to accomplish this. These facilitate rapid flap harvest and are excellent markers of the pedicle position in the event that the neck must be explored at a later date. After completion of the flap harvest, the tourniquet is released. Careful examination of the flap during this reperfusion interval should be accomplished to ensure absolute hemostasis because access following inset and reanastomosis will be limited. The surgeon should examine the hand for adequate perfusion. Tourniquet time less than 45 minutes is the norm following familiarity with the flap harvest. This can be significantly less with increased surgical experience.

The vascular pedicle is then transected following a suitable period of reperfusion (30 minutes on average). The flap vessels should be occluded with appropriately sized microvascular clamps during completion of the inset. The flap is then transferred

to the defect site. Care must be taken to avoid rotation or kinking of the flap vessels, particularly when the flap must be passed through a tunnel to the defect site. Insetting should be accomplished completely prior to microvascular anastomosis to allow accurate determination of the vascular pedicle geometry. Meticulous closure with gentle eversion to achieve a watertight seal is necessary because of the deleterious effects of saliva on the flap vessels. Care is taken to achieve a flap vessel–recipient vessel geometry that contains only slight curves to prevent vessel kinking. We prefer end-to-end interrupted sutured anastomoses with the vessels secured in Acland frame clamps. The artery is approximated first because the recipient artery is generally deeper than the venous structures. Heparinized saline (500 U/100 cc NS) is used to irrigate during the anastomosis. Papavarine is occasionally used if arterial spasm is noted. It should be recognized that gentle handling is the best defense against spasm. Following the release of the approximator clamps, the flap should be carefully evaluated. Evaluation of color and capillary refill is generally adequate for flap monitoring. In situations wherein this is difficult or the status of the flap is unclear, pricking the flap with a 25-gauge needle confirms flap perfusion. Color and character of the bleeding are important. A venous-compromised flap will bleed dark blood that does not clot as well as serous fluid.

Closed-suction drains are used in the neck with care taken to prevent them being displaced onto the vascular pedicle. The proximal skin flaps at the donor site are approximated over a closed-suction drain. The distal skin elements are sutured to the muscle to fixate them. A split-thickness skin graft is placed over the donor site defect and secured. A compressive dressing and volar splint or vacuum-assisted closure dressing are applied. These remain in place for 5 days. Active and passive range-of-motion exercises are initiated at 2 weeks post flap harvest.

The free radial forearm fasciocutaneous flap is extremely useful in head and neck reconstruction. The flap's reliability, adaptability, ease of harvest, and the similar character of the thin pliable skin to the lining tissues of the oral cavity make its use commonplace in modern maxillofacial reconstruction.

Free Fibula Flap

Anatomic Considerations

The fibula is ideal for large bony defects since it offers up to 25 cm of vascularized cortical bone. If we view the fibula in a cross section, we can identify a triangular shape established by three borders. The anterior border is the area of attachment of the anterior intermuscular septum, and the interosseous or medial border is the point of attachment of the interosseous membrane that binds the fibula to the tibia. The posterior intermuscular septum attaches to the posterior border (Figure 40-8).

In the proximal aspect the fibula articulates with the tibia and the knee joint, whereas in the distal aspect it articulates with the tibia and the talus.

Above the knee the popliteal artery divides into the anterior and posterior tibial arteries. Distal to the knee the posterior

tibial artery has a collateral branch, the peroneal artery. The blood supply to the fibula is delivered through perforators originating in the peroneal artery which is usually between 2 and 4 mm in diameter. The venae comitantes provide the venous drainage; these are paired vessels that run along the artery (Figure 40-9).

A significant limitation of the free fibula flap is the common presence of peripheral vascular disease in the lower extremities. In population-based studies that evaluated the incidence of arterial disease in the lower extremity in patients older than 55 years, the parameter was an ankle-brachial index lower than 0.9.⁸³ The value was obtained by dividing the systolic blood pressure measured at the ankle by that obtained at the brachial artery. A Danish study that included 700 individuals aged 60 years showed a prevalence of lower extremity arterial disease of 16% in men and 13% in women.⁸⁴ A similar study from Edinburgh showed an overall incidence of 17%.⁸³

Unfortunately the same risk factors (age and tobacco) are a common denominator for head and neck cancer patients as well as patients with peripheral vascular disease; therefore, it is indicated to perform either a conventional angiography or

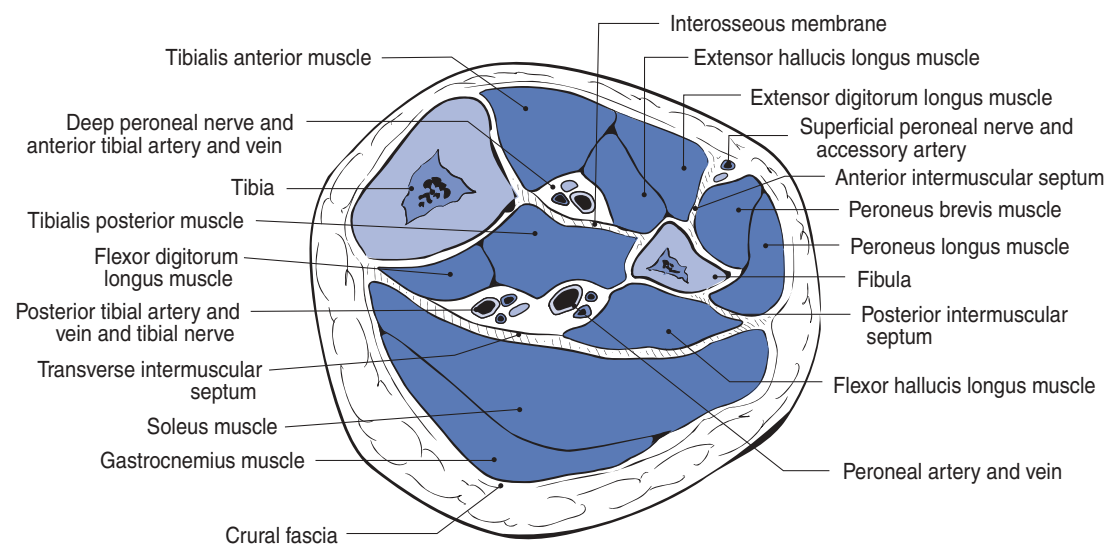


FIGURE 40-8 Cross-sectional view of the tibia and fibula with the surrounding anatomic structures. Adapted from Serafin D.⁹³

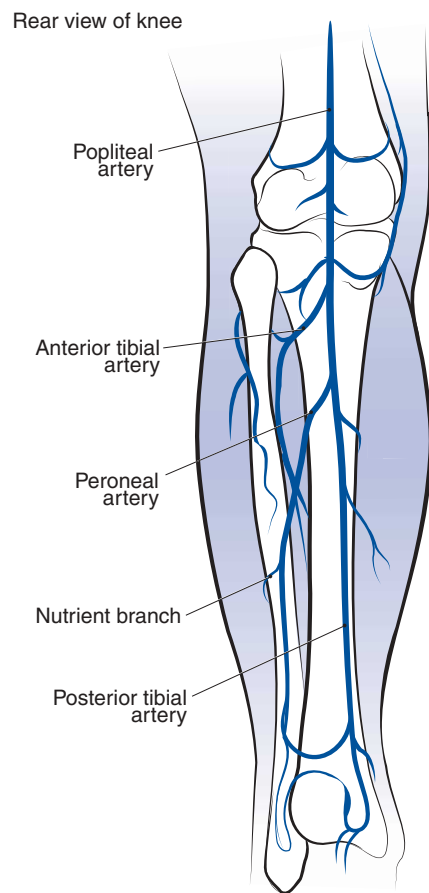


FIGURE 40-9 Vascular anatomy of the fibula, view from a posterior view of the leg. Adapted from O'Leary MJ et al.⁸⁸

a magnetic resonance angiography to establish the safety of harvesting the flap.

In a recent retrospective study Smith and colleagues reviewed 17 potential free fibula flap candidates (34 legs) evaluated by both a color flow Doppler (CDF) and angiography. Sixteen legs were normal by both studies, 18 legs showed abnormal CFD study results, and the angiogram revealed anatomy that was considered to represent a high risk for fibula flap harvest in 16 legs and considered safe in the other 2 legs.⁸⁵

The free fibula flap can be raised with or without a skin paddle. The skin paddle had a poor prognosis, based on the original series by Hidalgo who harvested the attached skin based on septocutaneous perforators.⁵ Schusterman and colleagues later performed an anatomic study that showed more soleus musculocutaneous

perforators than septal perforators.⁸⁶ Furthermore the clinical success of the skin paddle is above 90% when the musculocutaneous perforators are incorporated in the flap, whereas the viability of the skin is only 33% when the flap is based on septal branches.

Neurosensory potential to the skin paddle was described by Hayden and colleagues by incorporating the lateral cutaneous nerve of the calf (LCNC) and/or the sural communicating nerve (SCN) in order to restore intraoral sensation by anastomosis of the lingual nerve to the LCNC and/or the inferior alveolar nerve to the SCN.^{87,88}

Flap Technique

The patient is placed in the supine position, the hip and the knee are slightly flexed, and a pneumatic tourniquet is placed in the proximal aspect of the leg. A line is drawn from the lateral malleolus to the fibular head. If a skin paddle is included, it should be centered more posteriorly than the axis of the fibula in order to include both the septocutaneous and the musculocutaneous perforators.

The dissection is carried down to the crural fascia that is incised. The dissection continues through the anterior border of the peroneal muscles while maintaining a cuff of 2 to 3 mm of muscle surrounding the bone. The extensor digitorum longus and the extensor hallucis longus are elevated anteriorly, exposing the interosseous septum that connects between the fibula and the tibia. The peroneal vessels and the anterior tibial vessels are located posterior to the interosseous septum; therefore, careful dissection with fine dissecting scissors should be performed in order to avoid damage to the vascular structures or to the deep peroneal nerve. At this stage, two horizontal incisions are performed in the proximal and distal aspects of the fibula where the osteotomy is being planned. The bony cuts are performed with a Gigli, a reciprocating, or an oscillating saw while the medial aspect is protected with a malleable

retractor. The peroneal vessels are ligated in their distal aspect and the vascular pedicle is carefully dissected superiorly until the branching of the peroneal artery from the posterior tibial is identified. The flexor hallucis longus muscle and part of the soleus muscle are included in the flap, especially if a skin paddle is planned (Figure 40-10).

It is recommended to perform the osteotomies to shape the fibula while pedicled to the proximal vessels in order to minimize the ischemia time as well as preparation of the vessels in the recipient site before ligation of the proximal aspect of the peroneal artery.

The skin defect in the leg can be closed primarily or through the addition of a split-thickness skin graft.

An example of the application of this technique is as follows:

A patient presented with a large mass in the anterior aspect of the mandible with an obvious clinical deformity due to significant buccal expansion of the buccal cortical bone, with a progressive growth during the 3 years previous to his clinical evaluation (Figure 40-11). Panoramic radiography showed a multilocular lesion extending from tooth no. 21 to tooth no. 31 (Figure 40-12).

A histopathologic diagnosis of ameloblastoma was obtained through an incisional biopsy of the lesion. A magnetic resonance angiogram was obtained which showed a normal vascular pattern in both lower extremities. A segmental resection of the lesion was performed along with the mental and inferior alveolar nerves (Figure 40-13).

The defect was immediately reconstructed with a free fibula flap without the need for a skin paddle since residual mucosa was available for primary closure. Two osteotomies were performed in the fibula to allow for appropriate contour, resulting in three bony segments that were fixated to the recipient mandible by means of a reconstruction plate (Figure 40-14). A postoperative panoramic radiograph was obtained

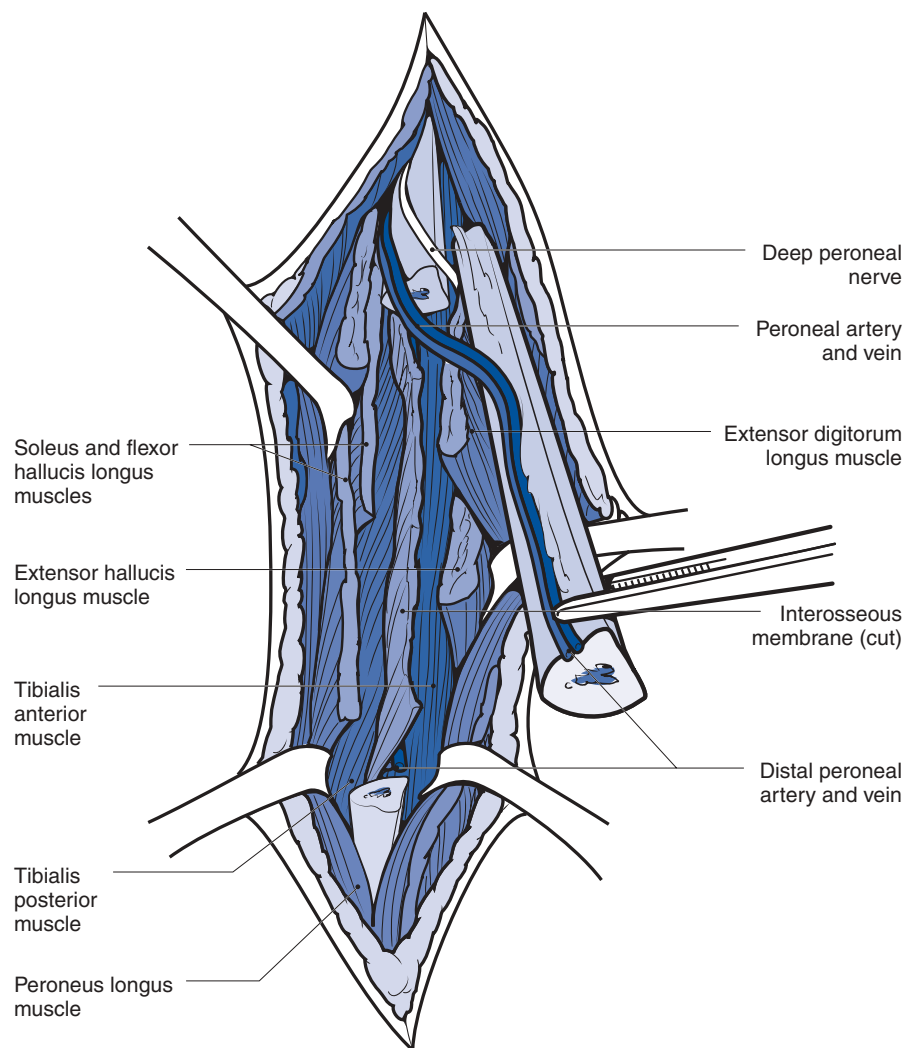


FIGURE 40-10 Elevation of the free fibula flap after the osteotomy of the distal and proximal attachments. The ligation of the feeding vessels is obvious in the distal aspect of the flap, while the proximal blood supply is maintained until the osteotomies are performed. Adapted from Serafin D.⁹³

which showed good continuity of the bony segments (Figure 40-15). In a previous retrospective study it was reported that radiographic bony healing was achieved in 93% of osteotomy sites of free fibula flaps.⁸⁹

The amount of bone available in free flaps in order to place osseointegrated implants has been investigated in an anatomic study in 28 cadavers evaluating the most commonly employed donor sites.⁹⁰ Implantability was established based on measurements of height, width, and cross-sectional area. The results showed that the iliac crest was the most implantable donor site (83%), followed by the scapula (78%), the fibula (67%), and the radius (21%).⁹⁰

A retrospective analysis of patients treated with a free fibular flap for mandibular reconstruction was performed by Disa and colleagues evaluating the long-term bone mass of the fibula.⁸⁹ Only patients with at least 24 months of follow-up were included in the study. The comparative measurements of fibular height revealed that central segments underwent a mean decrease in height by 4%, body segments decreased by 7%, and ramus segments decreased by 5%. The findings were not affected by the site of reconstruction, patient age, length of follow-up, adjuvant radiation therapy, or placement of osseointegrated implants.

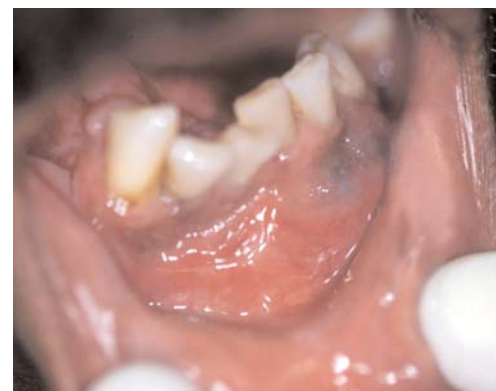

FIGURE 40-11 Clinical aspect of a patient with buccal expansion of the mandible due to a large ameloblastoma.

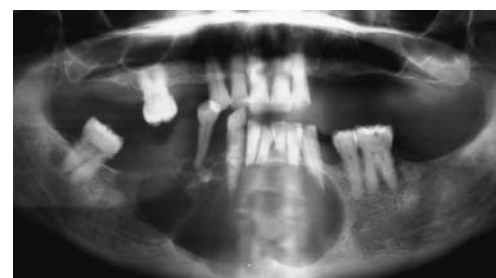


FIGURE 40-12 Radiographic view of the patient in Figure 40-11 with a large ameloblastoma of the mandible.

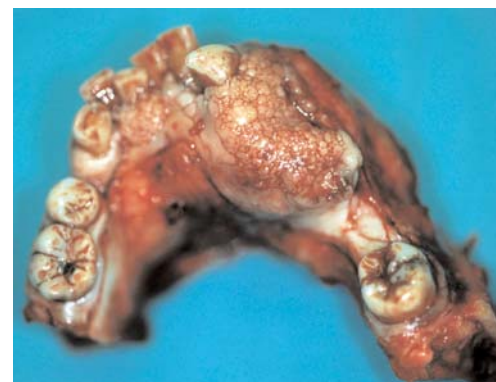

FIGURE 40-13 Mandibular specimen after surgical resection of the ameloblastoma.

Morbidity following Free Fibula Flaps

A retrospective analysis of donor site morbidity was performed by Shindo and colleagues on 53 consecutive patients who underwent fibula osteocutaneous free tissue transfer.⁹¹ Donor site wound complications occurred in 15 patients, 4 of whom (8%) had extensive wound breakdown,

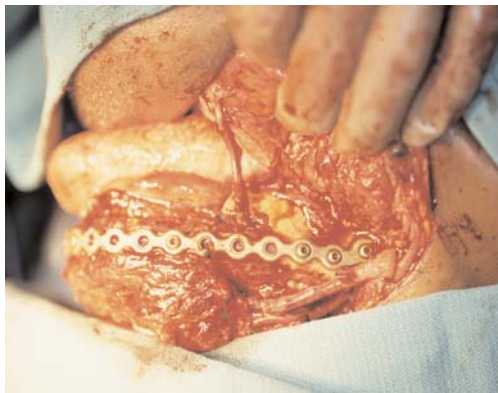


FIGURE 40-14 Reconstruction of the surgical defect with a free fibula flap. The structures located superior to the reconstruction plate are the spared inferior alveolar and mental nerves. The vascular structures below the screws and the reconstruction plate at the level of the angle of the mandible are the peroneal vessels after microanastomosis to the facial vessels.

muscle necrosis, and/or exposure of tendon and/or bone, whereas the other 11 patients (21%) had only minor wound complications limited to superficial skin slough.

Shindo and colleagues recommended avoiding skin closure under tension since the group with the higher complication rate had primary closure of the donor site.⁹¹ Other reported complications have included weakness of great toe dorsiflexion, reduced spring action of the donor leg, ankle stiffness, and in a few cases, ankle instability. Despite the mentioned deficits, all patients were able to resume daily and recreational activities.⁹²

Iliac Crest Osteomyocutaneous Free Flap

Anatomic Considerations

The blood supply to the osteomyocutaneous iliac crest flap is based on the deep circumflex iliac artery (DCIA) and vein. The DCIA takes origin from the external iliac artery or femoral artery in the region of the inguinal canal (42% below the inguinal ligament from the femoral artery, 41% behind the inguinal ligament from the external iliac artery, and 17% above the inguinal ligament from the external iliac artery).⁹³

The artery courses a distance of about 5 to 7 cm between its origin and the anterior superior iliac spine, following thereon the inner aspect of the iliac crest. The DCIA provides an ascending branch that perforates through the transversus abdominis muscle giving blood supply to the transversus as well as the internal and external oblique muscles (Figure 40-16).

Through its pathway the artery provides multiple perforators to the bone, muscle, and overlying skin. The deep circumflex iliac vein follows the arterial course.

The lateral femoral cutaneous nerve crosses the DCIA near the anterior superior iliac spine. The nerve should be dissected, retracted, and protected during the harvesting of the vascular pedicle and the flap.

Flap Technique

The skin paddle is designed by drawing a line from the femoral artery to the inferior angle of the scapula. The skin paddle is then designed with an axis on the above-mentioned line and centered on the iliac crest, including the myocutaneous perforators which enter the skin along the inner aspect of the crest.

The external oblique muscle (with the attached overlying skin) is incised, leaving a cuff of about 3 cm of muscle attached to the inner aspect of the iliac crest. If a significant portion of the internal oblique muscle has to be harvested in order to cover soft tissue defects in the oropharyngeal region, then the muscle is divided in a horizontal fashion

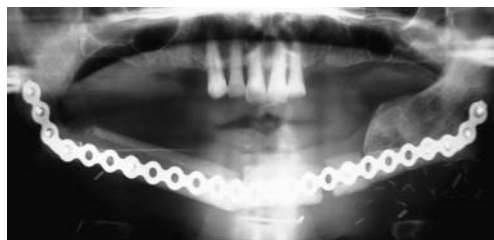

FIGURE 40-15 Radiographic view of the reconstructed mandible with a free fibula flap.

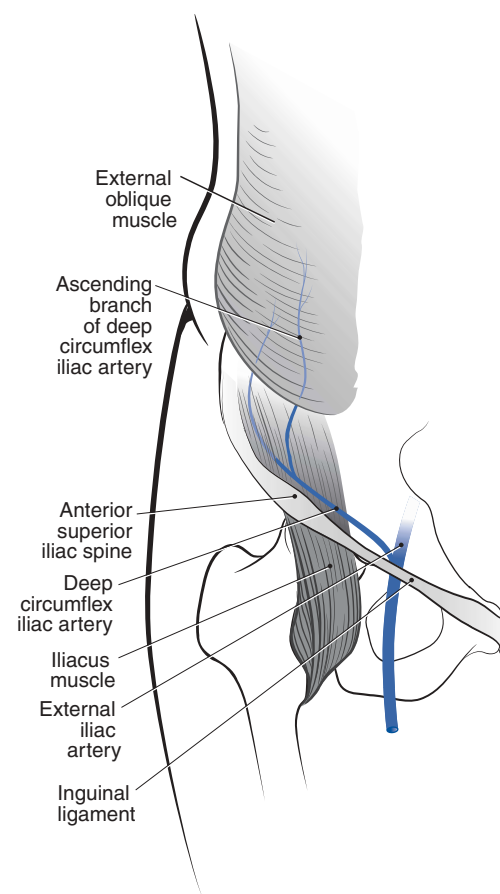


FIGURE 40-16 Anatomy of the deep circumflex iliac artery (DCIA). Adapted from Strauch B, Yu HL, editors. *Atlas of microvascular surgery*. New York: Thieme Medical Publisher Inc.; 1993. p. 142–58.

below the costal margin, and the dissection is initiated in the superior, medial, and lateral aspects while incorporating the ascending branch of the DCIA. After identifying the ascending branch of the DCIA in the inner aspect of the internal oblique muscle, the deep circumflex iliac vessels are dissected proximally. The transversus abdominis muscle is incised parallel to the crest, leaving a cuff of about 3 cm attached to the inner aspect of the crest.

The peritoneum is then retracted medially and the iliacus muscle is identified. The transversalis fascia fuses with the iliacus fascia, and the deep circumflex vessels consistently travel lateral to this fascial fusion. A 1 to 2 cm incision is performed medial to the insertion of the iliacus fascia down to the periosteum.

The lateral or lower aspect of the skin paddle is incised, proceeding through the deep fascia of the thigh and the gluteus muscle, detaching them from the periosteum of the lateral aspect of the iliac crest until achieving the desired bone depth (Figure 40-17).

When both the medial and lateral cortices are exposed, the osteotomy is performed.

If additional osteotomies are necessary in order to contour the bone, it is recommended to proceed while the tissue is still pedicled to the feeding deep circumflex vessels.

After the flap is harvested the muscles are approximated in layers to prevent the potential complication of herniation of the abdominal contents. The transversalis fascia and transverse abdominis muscle are sutured to the iliacus fascia and the iliacus muscle. The fascia lata and the gluteus are sutured to the external oblique muscle. The inguinal ligament should be reattached if it had been divided.

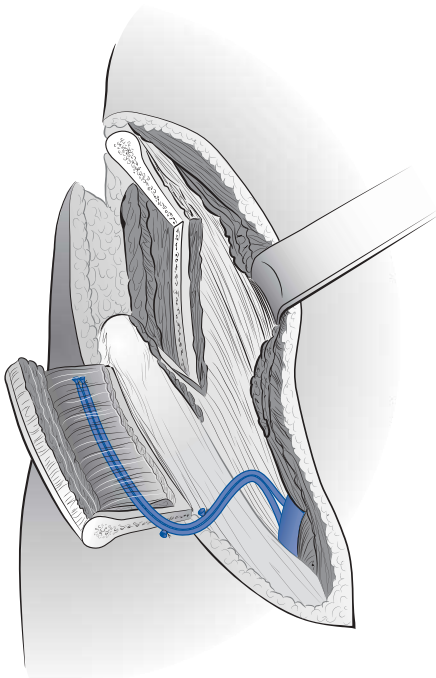


FIGURE 40-17 Harvesting of a full-thickness iliac crest bone flap. Adapted from Strauch B, Yu HL, editors. *Atlas of microvascular surgery*. New York: Thieme Medical Publisher Inc.; 1993. p. 142–58.

In most cases the inner aspect of the iliac crest is sufficient to reconstruct a mandibular defect, having the advantages of a less deforming defect and avoiding the lateral dissection of the gluteus medius muscles (Figure 40-18).

Morbidity following Iliac Crest Free Flaps

Rogers and colleagues analyzed the associated morbidity and the quality of life of patients who had undergone harvesting of either a deep circumflex iliac or a fibula free flap.⁹⁴ They used the University of Washington Quality of Life questionnaire, which showed no statistical differences between the patients in their activity, anxiety, mood, pain, recreation, or shoulder function. Rogers reported that the patients reconstructed with free fibula flaps had lower scores for swallowing and taste. On the other hand, for maxillectomy defects, they preferred the deep circumflex iliac flap over the fibula free flap, the latter being almost exclusively used for mandibular continuity defects. The known incidence of inguinal hernia was about 10% for patients who underwent free iliac flap harvesting.

Overall the conclusion is that both flaps are viable options for complex reconstructive needs in the head and neck regions requiring bone and soft tissue coverage. Donor site morbidity should be presented to the patient with emphasis on the potential impact on their quality of life.

Discussion

The iliac crest provides a significant segment of bone that may reach 4 cm in height and 11 cm in length. The dimensions of the flap may allow for a reconstruction of a hemimandibulectomy or anterior mandibular defect.

There are two significant advantages to the iliac crest/internal oblique free flap: (1) the amount of bone available for potential reconstruction with osseointegrated implants; and (2) the availability of

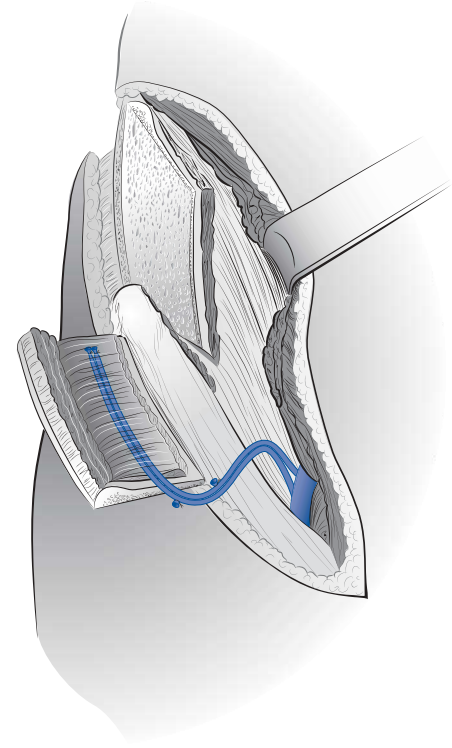


FIGURE 40-18 Harvesting of a split-thickness iliac crest bone flap. Adapted from Strauch B, Yu HL, editors. *Atlas of microvascular surgery*. New York: Thieme Medical Publisher Inc.; 1993. p. 142–58.

a thin and broad muscle that can be left to heal by secondary epithelization intraorally. Brown and colleagues developed the concept of reconstruction of the maxillary alveolus with the iliac crest while the palate was reconstructed with the muscle.^{95,96}

The disadvantage of the flap is the relatively short vascular pedicle and the potential for herniation of the abdominal contents.

Versatility of Free Tissue Transfer

The flaps described in the current chapter are the most commonly used in head and neck reconstruction. The ability to transfer vascularized tissues allows for a significant variety of options.

The rectus abdominis free flap has been used mostly for base of skull reconstruction and tongue reconstruction. It is based on two vascular pedicles: the deep superior epigastric vessels, which are a continuation of the mammary vessels; and

the deep inferior epigastric vessels, which are branches of the external iliac artery. The deep inferior epigastric vessels have a larger diameter and a longer vascular pedicle which makes them the preferred choice for anastomosis to the recipient vessels with very high reliability and success.⁹⁷

The free scapular flap has been used for mandibular and maxillary reconstructions. The flap can be elevated together with the latissimus dorsi muscle, adding a large amount of soft tissue to large and complex defects of the maxillofacial region. The vascular supply to the scapular bone is provided by the scapular vessels, whereas the blood supply to the latissimus dorsi muscle is provided by the thoracodorsal vessels.

Urken and colleagues have described this combination of flaps as the subscapular system and specified some of its unique features⁹⁸:

- Long length and large caliber of the vascular pedicle
- Abundant surface area of thin skin that can be transferred
- Separation between the soft tissue and bony flaps which provides freedom for three-dimensional inseting
- The potential to combine the latissimus dorsi and the serratus anterior muscles with overlying skin and adjacent segments of rib

Other flaps have been used for oropharyngeal reconstruction, including free omentum for oral lining, gracilis muscle free flaps with the anterior obturator nerve for facial reanimation, and lateral thigh or lateral arm free flaps for pharyngeal reconstruction. Even free temporoparietal fascial flaps have been used based on the superficial temporal vessels for intraoral lining or combined with the overlying skin or underlying bone.

When the reconstructive options are maximized, the selection of the donor site may resemble most accurately the functional needs of the recipient site.

References

1. Kriss TC, Kriss VM. History of the operating microscope: from magnifying glass to microneurosurgery. *Neurosurgery* 1998; 42:899–907.
2. Carrel A. The surgery of blood vessels. *Johns Hopkins Hosp Bull* 1907;19:18–28.
3. Jacobson JH, Suarez EL. Microsurgery in anastomosis of small vessels. *Surg Forum* 1960;11:243–5.
4. Taylor GI, Miller GDH, Ham FJ. The free vascularized bone graft: a free vascularized bone graft. *Plast Reconstr Surg* 1975; 55:533–44.
5. Hidalgo DA. Free fibula flap: a new method of mandibular reconstruction. *Plast Reconstr Surg* 1989;84:71–9.
6. Yang G, Chen B, Gao Y, et al. Forearm free skin graft transplantation. *Nat Med J China* 1981;61:139.
7. Soutar DS, Schecker LR, Tanner NSB, McGregor IA. The radial forearm flap: a versatile method for intraoral reconstruction. *Br J Plast Surg* 1983;36:1–8.
8. Soutar DS, McGregor IA. The radial forearm flap in intraoral reconstruction: the experience of 60 consecutive cases. *Plast Reconstr Surg* 1986;78:1–8.
9. Taylor GI, Watson N. One-stage repair of compound leg defects with free, revascularized flaps of groin skin and iliac bone. *Plast Reconstr Surg* 1978;61:494–506.
10. Taylor GI. Reconstruction of the mandible with free composite iliac bone grafts. *Ann Plast Surg* 1982;9:361–76.
11. Mehdorn HM, Muller GH. *Microsurgical exercises*. New York: Thieme Medical Publishers Inc.; 1989. p. 1–16.
12. Badran D, Soutar DS, Robertson AG, et al. Behavior of radial forearm skin flaps transplanted into the oral cavity. *Clin Anat* 1998;11:379–89.
13. Corrigan AM, O'Neill TJ. The use of the compound radial forearm flap in oro-mandibular reconstruction. *Br J Oral Maxillofac Surg* 1986;24:86–95.
14. Vaughan ED. The radial forearm free flap in orofacial reconstruction. A personal experience in 120 consecutive cases. *J Craniomaxillofac Surg* 1990;18:2–7.
15. Vaughan ED. The radial forearm flap in orofacial reconstruction. *Int J Oral Maxillofac Surg* 1994;23:194–204.
16. Martin IC, Cawood JL, Vaughan ED, Barnard N. Endosseous implants in the irradiated composite radial forearm free flap. *Int J Oral Maxillofac Surg* 1992;21:266–70.
17. Frodel JL, Funk GF, Capper DT, et al. Osseointegrated implants: a comparative study of bone thickness in four vascularized bone flaps. *Plast Reconstr Surg* 1993;92:449–55.
18. Urken ML, Weinberg H, Vickery C, Biller HF. The neurofasciocutaneous radial forearm flap in head and neck reconstruction: a preliminary report. *Laryngoscope* 1990; 100:161–73.
19. Moscoso JF, Urken ML. Radial forearm flaps. *Otolaryngol Clin North Am* 1994; 27:1119–40.
20. Urken ML, Futran N, Moscoso JF, Biller HF. A modified design of the buried radial forearm flap in oral cavity and pharyngeal reconstruction. *Arch Otolaryngol Head Neck Surg* 1994;120:1233–9.
21. Urken ML, Biller HF. A new bilobed design for the sensate radial forearm flap to preserve tongue mobility following significant glossectomy. *Arch Otolaryngol Head Neck Surg* 1994;120:26–31.
22. Thoma A, Khadaroo R, Grigenas O, et al. Oro-mandibular reconstruction with the radial-forearm osteocutaneous flap: experience with 60 consecutive cases. *Plast Reconstr Surg* 1999;104:368–78.
23. Serletti JM, Coniglio JU, Tavin E, Bakamjian VY. Simultaneous transfer of free fibula and radial forearm flaps for complex oro-mandibular reconstruction. *J Reconstr Microsurg* 1998;14:297–303.
24. Sadove RC, Luce EA, McGrath PC. Reconstruction of the lower lip and chin with the composite radial forearm-palmaris longus free flap. *Plast Reconstr Surg* 1991;88:209–14.
25. Serletti JM, Tavin E, Moran SL, Coniglio JU. Total lower lip reconstruction with a sensate composite radial forearm-palmaris longus free flap and a tongue flap. *Plast Reconstr Surg* 1997;99:559–61.
26. Furuta S, Sakaguchi Y, Iwasawa M, et al. Reconstruction of the lips, oral commissure, and full-thickness cheek with a composite radial forearm palmaris longus free flap. *Ann Plast Surg* 1994;33:544–7.
27. Savant DN, Patel SG, Deshmukh SP, et al. Folded free radial forearm flap for reconstruction of full-thickness defects of the cheek. *Head Neck* 1995;17:293–6.
28. Brown JS, Zuydam AC, Jones DC, et al. Functional outcome in soft palate reconstruction using a radial forearm free flap in conjunction with a superiorly based pharyngeal flap. *Head Neck* 1997;19: 524–34.
29. Anthony JP, Singer MI, Mathes SJ. Pharyngoesophageal reconstruction using the tubed free radial forearm flap. *Clin Plast Surg* 1994;21:137–47.
30. Jacobson MC, Franssen E, Fliess DM, et al. Free

- forearm flap in oral reconstruction. Functional outcome. *Arch Otolaryngol Head Neck Surg* 1995;121:959–64.
31. Baird W, Wornom I, Culbertson J. Forehead reconstruction with a modified radial forearm flap: a case report. *J Reconstr Microsurg* 1988;4:363–7.
 32. Santamaria E, Grandos M, Barrera-Franco JL. Radial forearm free tissue transfer for head and neck reconstruction: versatility and reliability of a single donor site. *Microsurgery* 2000;20:195–201.
 33. To EW, Wang JC. Radial forearm free flap: hybrid version. *Plast Reconstr Surg* 1999;104:1066–9.
 34. Kirn DS, Finical SJ, Kenady DE. Bilateral radial forearm free flaps for oral cavity reconstruction. *J Reconstr Microsurg* 1998;14:551–3.
 35. Close L, Truelson J, Milledge R, Schweitzer C. Sensory recovery in noninnervated flaps used for oral cavity and oropharyngeal reconstruction. *Arch Otolaryngol Head Neck Surg* 1995;121:967–72.
 36. Santamaria E, Wei F, Chen I, Chuang D. Sensation recovery on innervated radial forearm flap for hemiglossectomy reconstruction by using different recipient nerves. *Plast Reconstr Surg* 1999;103:450–7.
 37. Boutros S, Yuksel E, Weinfield AB, et al. Neural anatomy of the radial forearm flap. *Ann Plast Surg* 2000;44:375–80.
 38. Lvoff G, O'Brien CJ, Cope C, Lee KK. Sensory recovery in noninnervated radial forearm free flaps in oral and oropharyngeal reconstruction. *Arch Otolaryngol Head Neck Surg* 1998;124:1206–8.
 39. Netscher D, Armenta AH, Meade RA, Alford EL. Sensory recovery of innervated and non-innervated radial forearm free flaps: functional implications. *J Reconstr Microsurg* 2000;16:179–85.
 40. Shindo ML, Sinha UK, Rice DH. Sensory recovery in noninnervated free flaps for head and neck reconstruction. *Laryngoscope* 1995;105:1290–3.
 41. Vriens JP, Acosta R, Soutar DS, Webster MH. Recovery of sensation in the radial forearm free flap in oral reconstruction. *Plast Reconstr Surg* 1996;98:649–56.
 42. Timmons MJ. The vascular basis of the radial forearm flap. *Plast Reconstr Surg* 1986;77:80–92.
 43. Yousif NJ, Ye Z, Grunert BK, et al. Analysis of the distribution of cutaneous perforators in cutaneous flaps. *Plast Reconstr Surg* 1998;101:72–84.
 44. Cormack G, Duncan MJ, Lamberty B. The blood supply of the bone component of the compound osteocutaneous radial artery forearm flap – an anatomical study. *Br J Plast Surg* 1986;39:173–5.
 45. Thoma A, Archibald S, Jackson S, Young JEM. Surgical patterns of venous drainage of the free forearm flap in head and neck reconstruction. *Plast Reconstr Surg* 1994;93:54–9.
 46. Futran ND, Stack BC. Single versus dual venous drainage of the radial forearm flap. *Am J Otolaryngol* 1996;17:112–7.
 47. Demirkan F, Wei FC, Lutz BS, et al. Reliability of the venae comitantes in venous drainage of the free radial forearm flaps. *Plast Reconstr Surg* 1998;102:1544–52.
 48. Netscher DT, Sharma S, Alford EL, et al. Superficial versus deep: options in venous drainage of the radial forearm free flap. *Ann Plast Surg* 1999;36:536–41.
 49. Jones BM, O'Brien CJ. Acute ischemia of the hand resulting from elevation of a radial forearm flap. *Br J Plast Surg* 1985;38:396–7.
 50. Nukols DA, Tsu TT, Toby EB, Girod DA. Preoperative evaluation of the radial forearm free flap with the objective Allen's test. *Otolaryngol Head Neck Surg* 2000;123:553–7.
 51. Ciria-Llorens G, Gomez-Cia T, Talegon-Melendez A. Analysis of flow changes in forearm arteries after raising the radial forearm flap: a prospective study using colour duplex imaging. *Br J Plast Surg* 1999;52:440–4.
 52. Talegon-Melendez A, Ciria-Llorens G, Gomez-Cia T, Mayo-Iscar A. Flow changes in forearm arteries after elevating the radial forearm flap: prospective study using color duplex imaging. *J Ultrasound Med* 1999;18:553–8.
 53. Fatah MF, Nancarrow JD, Murray DS. Raising the radial artery forearm flap: the superficial ulnar artery "trap." *Br J Plast Surg* 1985;38:394–5.
 54. Madares A, McGibbon IC. Anatomic variation in the blood supply of the radial forearm flap. *J Reconstr Microsurg* 1993;9:277–9.
 55. Mordick TG. Vascular variation of the radial forearm flap: a case report. *J Reconstr Microsurg* 1995;11:345–6.
 56. Porter CJ, Mellow CG. Anatomically aberrant forearm arteries: an absent radial artery with co-dominant median and ulnar arteries. *Br J Plast Surg* 2001;54:727–8.
 57. Saski K, Nozaki M, Aiba H, Isono N. A rare variant of the radial artery: clinical considerations in raising a radial forearm flap. *Br J Plast Surg* 2000;53:445–7.
 58. Funk GF, Valentino J, McCulloch TM, et al. Anomalies of forearm vascular anatomy encountered during elevation of the radial forearm flap. *Head Neck* 1995;17:284–92.
 59. Singh B, Cordiero PG, Santamaria E, et al. Factors associated with complications in microvascular reconstruction of head and neck defects. *Plast Reconstr Surg* 1999;103:403–11.
 60. Kiener JL, Hoffman WY, Mathes SJ. Influence of radiotherapy on microvascular reconstruction in the head and neck region. *Am J Surg* 1991;162:404–7.
 61. Mulholland S, Boyd JB, McCabe S, et al. Recipient vessels in head and neck microsurgery: radiation effect and vessel access. *Plast Reconstr Surg* 1993;92:628–32.
 62. Blanchaert RH. Identification, management, and prevention of infections after head and neck surgery. In: Topazian RG, Goldberg MH, Hupp JR, editors. *Oral and maxillofacial infections*. 4th ed. Philadelphia: W.B. Saunders; 2002. p. 399–409.
 63. Cole RR, Robbins KT, Cohen JL, Wolf PF. A predictive model for wound sepsis in oncologic surgery of the head and neck. *Otolaryngol Head Neck Surg* 1987;96:165–71.
 64. Khouri PK, Cooley BC, Kunselman AR, et al. A prospective study of microvascular free-flap surgery and outcome. *Plast Reconstr Surg* 1998;102:711–21.
 65. Disa JJ, Cordiero PG, Hidalgo DA. Efficacy of conventional monitoring techniques in free tissue transfer: an 11 year experience in 750 consecutive cases. *Plast Reconstr Surg* 1999;104:97–101.
 66. Brown MT, Cheney ML, Gliklich RL, et al. Assessment of functional morbidity in the radial forearm free flap donor site. *Arch Otolaryngol Head Neck Surg* 1996;122:991–4.
 67. Brown MT, Couch ME, Huchton DM. Assessment of donor-site functional morbidity from radial forearm fasciocutaneous free flap harvest. *Arch Otolaryngol Head Neck Surg* 1999;125:1371–4.
 68. Richardson D, Fisher SE, Vaughan ED, Brown JS. Radial forearm flap donor-site morbidity: a prospective study. *Plast Reconstr Surg* 1997;99:109–15.
 69. Timmons MJ, Missotten FE, Poole MD, Davies DM. Complications of radial forearm flap donor sites. *Br J Plast Surg* 1986;39:176–8.
 70. Toschka H, Feifel H, Erli HJ, et al. Aesthetic and functional results of harvesting radial forearm flap, especially with regard to hand function. *Int J Oral Maxillofac Surg* 201;30:42–8.
 71. Akyurek M, Safak T. Direct closure of radial forearm free-flap donor sites by double opposing rhomboid transposition flaps: case report. *J Reconstr Microsurg* 2002;18:33–6.

72. Avery CM, Pereira J, Brown AE. Suprafascial dissection of the radial forearm flap and donor site morbidity. *Int J Oral Maxillofac Surg* 2001;30:37–41.
73. Bardsley AF, Soutar DS, Elliot D, Batchelor AG. Reducing morbidity in the radial forearm flap donor site. *Plast Reconstr Surg* 1990;86:287–92.
74. Berge SJ, Wiese KG, von Lenden JJ, et al. Tissue expansion using osmotically active hydrogel systems for direct closure of the donor defect of the radial forearm flap. *Plast Reconstr Surg* 2001;108:1–5.
75. Chang SC, Miller G, Halbert CF, et al. Limiting donor site morbidity by suprafascial dissection of the radial forearm flap. *Microsurgery* 1996;17:136–40.
76. Fenton OM, Roberts JO. Improving the donor site of the radial forearm flap. *Br J Plast Surg* 1985;38:504–5.
77. McGregor AD. The free radial forearm flap – the management of the secondary defect. *Br J Plast Surg* 1987;40:83–5.
78. Samis AJ, Davidson JS. Skin-stretching device for intraoperative primary closure of radial forearm donor site. *Plast Reconstr Surg* 2000;105:698–702.
79. Sleeman D, Carton AT, Stassen LF. Closure of radial forearm free flap defect using full-thickness skin from the anterior abdominal wall. *Br J Oral Maxillofac Surg* 1994;32:54–5.
80. Nunez VA, Pike J, Avery C, et al. Prophylactic plating of the donor site of osteocutaneous radial forearm flaps. *Br J Oral Maxillofac Surg* 1999;37:210–2.
81. Werle AH, Tsue TT, Toby EB, Girod DA. Osteocutaneous radial forearm free flap: its use without significant donor site morbidity. *Otolaryngol Head Neck Surg* 2000;123:711–7.
82. Hallock GG. Complications of free-flap donor site from a community hospital perspective. *J Reconstr Microsurg* 1991;7:331–4.
83. Fowkes FGR, Housley E, Cawood EM, et al. Edinburgh Artery Study: prevalence of asymptomatic and symptomatic peripheral arterial disease in the general population. *Int J Epidemiol* 1991;20:384–92.
84. Reunanen A, Takkunen H, Aromaa A. Prevalence of intermittent claudication and its effect on mortality. *Acta Med Scand* 1982;211:249–56.
85. Smith RB, Thomas RD, Funk GF. Fibula free flaps: the role of angiography in patients with abnormal results on preoperative color flow Doppler studies. *Arch Otolaryngol Head Neck Surg* 2003;129:712–5.
86. Schusterman MA, Reece GP, Miller MJ, et al. The osteocutaneous free fibula flap: is the skin flap reliable? *Plast Reconstr Surg* 1992;90:787–93.
87. Hayden RE. The neurocutaneous free fibula flap [abstract]. Third International Conference on Head and Neck Cancer, San Francisco, 1992 Jul 27. American Head and Neck Society.
88. O’Leary MJ, Martin PJ, Hayden RE. The neurocutaneous free fibula flap in mandibular reconstruction. *Otolaryngol Clin North Am* 1994;27:1081–96.
89. Disa JJ, Winters RM, Hidalgo DA. Long term evaluation of bone mass in free fibula flap mandible reconstruction. *Am J Surg* 1997;174:503–6.
90. Moscoso JF, Keller J, Gender E, et al. Vascularized bone flaps in oromandibular reconstruction. A comparative study of bone stock from various donor sites to assess suitability for endosseous dental implants. *Arch Otolaryngol Head Neck Surg* 1994;120:36–43.
91. Shindo M, Fong B, Fung G, et al. The fibula osteocutaneous flap in head and neck reconstruction: a critical evaluation of donor site morbidity. *Arch Otolaryngol Head Neck Surg* 2000;126:1467–72.
92. Anthony JP, Rawsley JD, Benhaim P, et al. Donor leg morbidity and function after fibula free flap mandible reconstruction. *Plast Reconstr Surg* 1995;20:146–52.
93. Serafin D. Atlas of microsurgical composite tissue transplantation. Philadelphia: W.B. Saunders Co.; 1996. p. 525–35.
94. Rogers SN, Lakshmiah SR, Narayan B, et al. A comparison of the long term morbidity following deep circumflex iliac and fibula free flaps for reconstruction following head and neck cancer. *Plast Reconstr Surg* 2003;112:1517–25.
95. Brown JS, Jones DC, Summerwill A, et al. Vascularized iliac crest with internal oblique muscle for immediate reconstruction after maxillectomy. *Br J Oral Maxillofac Surg* 2002;40:183–90.
96. Brown JS. Deep circumflex iliac artery free flap with internal oblique muscle as a new method of immediate reconstruction of maxillectomy defect. *Head Neck* 1996;18(5):412–21.
97. Urken ML, Turk J, Weinberg H, et al. The rectus abdominis free flap in head and neck reconstruction. *Arch Otolaryngol Head Neck Surg* 1991;117:857–66.
98. Urken ML, Cheney ML, Sullivan MJ, Biller HF. Subscapular system. In: Urken ML, Cheney ML, Sullivan MJ, Biller HF, editors. Atlas of regional and free flaps for head and neck reconstruction. New York (NY): Raven Press; 1995. p. 213–6.
99. Urken ML. Radial forearm. In: Urken ML, Cheney ML, Sullivan MJ, Biller HF, editors. Atlas of regional and free flaps for head and neck reconstruction. New York (NY): Raven Press; 1995. p. 152.

Microneurosurgery

Michael Miloro, DMD, MD

Injuries to the terminal branches of the trigeminal nerve may occur commonly following a variety of routine oral and maxillofacial surgical procedures, and the overwhelming majority of these injuries undergo spontaneous recovery without treatment. Third molar surgery is responsible for most of the injuries to both the inferior alveolar and lingual nerves. The reported incidence of nerve injury varies in the literature, but generally both temporary and permanent paresthesia must be considered. Nerve injury may occur following mandibular and maxillary orthognathic surgery, maxillofacial trauma, dental implant placement, endodontic therapy, facial fractures, and treatment of pathology. The anatomy of the trigeminal nerve system is unique since it carries, in some branches, both general sensory information and special (eg, taste) sensation. Injury to a nerve may result in neuroma formation, which can manifest in a variety of clinical signs and symptoms. Nerve injuries are classified by two popular classification schemes, which are based on the likelihood of an injured nerve recovering spontaneously. A basic understanding of nerve terminology (Appendix) and normal neural wound healing is essential to most appropriately manage clinical situations.

The initial evaluation of patients with nerve injuries must proceed in an orderly fashion, with several levels of testing to

determine most accurately the degree of individual nerve injury. A standardized clinical neurosensory test (CNT) may be employed for most patients; however, some advanced testing is available for special circumstances. A variety of nonsurgical and pharmacologic treatments are available for the patient with nerve injury. For most patients with dysesthesia, pharmacologic therapy is the mainstay of treatment.

Once the decision is made to proceed with microneurosurgery, a sequence of surgical steps must be followed meticulously. Specific surgical techniques depend on which specific nerve is involved, as well as the extent of the injury. In general, microneurosurgical repair of a trigeminal nerve injury involves neurolysis and preparation of the nerve stumps to perform neuroorrhaphy. The deleterious effects of tension on a nerve repair site have been well documented, so the inability to perform a primary tension-free repair warrants consideration for an autogenous nerve graft or another option for nerve gap management such as conduit repair. Following microneurosurgery, postoperative sensory re-education may play a role in the regenerative process. The overall success rates of microneurosurgical repair of the trigeminal nerve vary considerably; however, an important factor in determining success is the length of time from injury to repair since this impacts on the degree of ganglion cell death, wallerian degeneration, and cor-

tical somatosensory reorganization. The American Association of Oral and Maxillofacial Surgeons Clinical Interest Group on Maxillofacial Neurologic Disorders has promulgated certain treatment time recommendations for the patient who sustains a trigeminal nerve injury.¹

The field of microneurosurgery is in its infancy. As more surgeons become familiar with the diagnosis and management of patients with trigeminal nerve injuries, more laboratory, radiologic, and clinical information will become available to guide therapy. Also, residency programs will become more capable of training residents in the principles and practice of microneurosurgery and will thus foster access to this aspect of specialty care throughout the country and abroad.

Demographics

Trigeminal nerve injuries result from a variety of routine oral and maxillofacial surgical procedures, such as third molar odontectomy, management of facial trauma, orthognathic surgery, endosseous dental implant placement, salivary duct and gland surgery, treatment of benign and malignant lesions of the head and neck, preprosthetic surgery, and endodontic and periradicular surgery. Complications of third molar removal are responsible for the majority of nerve injuries.² These can occur during any phase of third molar surgery, including local anesthetic injection, incision

and flap design, the use of a high-speed drill for bone removal or tooth sectioning, elevation of the tooth with trauma to the lingual soft tissues, socket curettage with exposed neurovascular tissue, removal of remnants of an assumed “dental follicle” that may contain neural or vascular tissue, the use of medicaments in the extraction site to aid healing or prevent alveolar osteitis (eg, tetracycline-containing compounds^{3,4}), and the placement of sutures. The efficacy of lingual nerve retraction during lower third molar surgery has shown that although the incidence of temporary lingual nerve paresthesia is increased owing to a slight stretching or manipulation (6.4% with retraction vs 0.6% without retraction), the difference in long-term dysfunction is not significant (0.6% with retraction vs 0.2% without retraction).⁵ Other studies have indicated a temporary paresthesia rate of approximately 10 to 15% with lingual nerve retraction and protection, with a permanent rate of < 1%.

The incidence of trigeminal nerve injury may be estimated based on a review of the available literature. Overall the incidence of inferior alveolar nerve (IAN) injury from third molar surgery is 0.41 to 7.5% and from sagittal split osteotomy is 0.025 to 84.6%, whereas the lingual nerve is affected 0.06 to 11.5% of the time following third molar removal. However, the more important clinical distinction is to differentiate temporary from permanent paresthesia rates. For sagittal split osteotomies, temporary inferior alveolar paresthesia may be as high as 80 to 100%, but permanent rates are < 1 to 5%. For third molar surgery, both inferior alveolar and lingual nerve temporary paresthesias range from 2 to 6% each, whereas permanent rates are approximately 25% of the temporary rates, or 0.5 to 2% overall. Many risk factors for nerve injury during third molar surgery have been reported and include advanced patient age, female sex (recent animal studies indicate that

gender may play a role in spontaneous neurosensory recovery following injury), depth of impaction, mesiodistal angulation of the tooth (distoangular), lingual angulation of the tooth, integrity of the lingual cortex, the need for tooth sectioning, removal of bone distal to the third molar, and surgeon experience. Certainly the risk of an IAN injury may be influenced by so-called Rood radiographic predictors of potential tooth proximity to the inferior alveolar canal.⁶ These seven radiographic predictors on panoramic radiograph may indicate the potential for increased risk of injury to the IAN, and they are listed in Table 41-1. In cases with a high index of suspicion of nerve injury (eg, deep impaction, advanced age), intentional coronectomy with close observation should be considered.⁷ As opposed to the relatively consistent course of the IAN, the lingual nerve position is variable; and it is injured less often than the IAN following third molar surgery.⁸⁻¹² The position of the lingual nerve has been documented clinically,¹³ in cadaveric dissections,^{14,15} and radiologically.¹⁶ On average, in the third molar region, the lingual nerve lies 2.5 mm medial to the lingual plate of the mandible and 2.5 mm inferior to the lingual crest. The lingual nerve may be in direct contact with the lingual plate in 25% of cases (Kisselbach and Chamberlain reported 62%¹³) and may lie above the lingual crest in 10 to 15% of cases (Kisselbach and Chamberlain reported 17.6%¹³) based on an undisturbed radiographic assessment of the nerve.

Mandibular blocks may result in inferior alveolar and lingual nerve injuries; however, the incidence is unknown owing to unreported cases. An estimated 1 in 100,000 to 1 in 500,000 blocks result in paresthesia. Perhaps the largest study of its kind, Harn and Durham’s study of 9,587 mandibular blocks showed a 3.62% incidence of temporary paresthesia and a 1.8% incidence of long-term paresthesia lasting > 1 year.¹⁷ Several theories have

been proposed to explain the mechanism of injury. Direct neural trauma is unlikely owing to abundant interfascicular neural components resulting in separation of the fascicles by a needle or suture without direct neural disruption.¹⁸ The resultant edema may be responsible for the transient paresthesia that resolves spontaneously. Local anesthetic toxicity may be responsible for prolonged paresthesia following a mandibular block, especially if the solution is deposited within the confines of the epineurium. Recent reports indicate that prilocaine and articaine may be associated with an increased risk of long-term paresthesia compared with other local anesthetic solutions, but further investigation is warranted.¹⁹⁻²¹ The third potential mechanism of injury involves the formation of an epineurial hematoma. The epineurium and perineurium contain a vast plexus of vessels that nurture the neural elements, and a needle may cause disruption of one or more vessels. The localized bleeding most certainly tamponades itself owing to the surrounding epineurium, and the pressure may impinge on select groups of fascicles contained within the nerve. The resultant clinical signs and symptoms of localized paresthesia, not involving the entire distribution of the inferior alveolar/mental nerve, nicely match the expected histologic situation, making this theory plausible. Also, lymphatic drainage of the localized hematoma over the few days to weeks

Table 41-1 Rood’s Radiographic Predictors of Potential Tooth Proximity to the Inferior Alveolar Canal

1. Darkening of the root
2. Deflection of the root
3. Narrowing of the root
4. Dark and bifid root apex
5. Interruption of the white line of the canal
6. Diversion of the canal
7. Narrowing of the canal

Adapted from Rood JP and Shehab AAN.⁶

following surgery coincides with the clinical resolution of symptoms in most cases. The final theory is that of the needle-barb mechanism of injury.²² During a mandibular block injection, the needle may be advanced to the medial ramus where a small barb may form at the needle tip. On withdrawal, if the needle has passed through or in the vicinity of the lingual nerve or IAN, fascicular disruption may occur with potentially long-standing clinical consequences. Recent trends in our clinical understanding of injection-related nerve injuries are the following:

- These injuries are difficult to predict and prevent
- The classic electric-shock sensation is reported uncommonly by patients who sustain these injuries
- Injection injuries are more likely to result in dysesthesia than are other causes of nerve injuries
- There may be a nonanatomic distribution of nerve involvement (including the second and third divisions of the trigeminal nerve)
- Injection injuries occur more commonly in females
- The lingual nerve, which is stretched more upon mouth opening than is the IAN, is more commonly affected
- The majority of cases resolve within 8 weeks, and if paresthesia persists for > 8 weeks, then only one-third of those injuries resolve spontaneously

Microneurosurgery is a poor option for patients with injection-related nerve injuries because surgical access is difficult; therefore, most cases are managed with pharmacologic therapy. One of the difficulties for microneurosurgeons is differentiating a mandibular block injury from a third molar injury to the IAN. On rare occasions the third molar site of the IAN has been explored and found to be normal, with the assumption that the injury occurred as a result of injection rather than extraction.²³

It is well known that orthognathic surgery may result in nerve injury. The IAN is affected more often than is the lingual nerve, and rarely the facial nerve may be affected (0.67% with sagittal split osteotomy in one study²⁴). Certainly much is known about the risks of IAN injury associated with sagittal split osteotomy, as well as screw overpenetration injury to the lingual nerve.^{25,26} Unfortunately, the reported incidence of immediate and long-term neurosensory deficit varies considerably (from < 5% to > 90%) owing to poorly controlled factors inherent in the study designs, such as individual operator variability and surgeon experience, lack of standardization of neurosensory testing, lack of control sites for normal cutaneous facial sensibility, and variation in the periods of neurosensory testing. Several studies have examined the specific parameters of neurosensory recovery after bilateral sagittal split osteotomy by using objective and subjective assessment.²⁷ One study found a 39% incidence of neurosensory dysfunction following sagittal ramus surgery,²⁸ and others have shown < 15% dysfunction at 6 months.²⁹ Although the incidence of nerve dysfunction varies, there are well-known risk factors for nerve injury, including the following³⁰: patient age³¹; increased length of the surgical procedure; proximal or distal segment fracture (“bad splits”); concomitant third molar removal; concomitant genioplasty procedures; compression during fixation; inadvertent use of chisels; nerve entrapment in the proximal segment; nerve manipulation in the area of the osteotomy and, perhaps more significantly, in the lingual region during medial dissection (based on intraoperative recordings of IAN somatosensory evoked potentials)³²; the location of the inferior alveolar canal close to the inferior border; low corpus height and retrognathism (IAN closer to buccal cortex)³³; and frank nerve transection during surgery. Unfortunately, long-term neurosensory dysfunction following

orthognathic surgery is not generally amenable to surgical correction. However, most patients tolerate the paresthesia well following correction of a significant dentofacial deformity. Two caveats are that patients tolerate mild paresthesia following major surgery well (with informed consent) and that the magnitude of neurosensory dysfunction decreases as the time from injury increases. This certainly applies to orthognathic nerve injuries.

Maxillofacial trauma may result in injury to any of the terminal branches of the trigeminal nerve. Mandible fractures that violate the IAN canal result in temporary or permanent paresthesia. Treatment of mandible fractures with inadvertent placement of screws may cause iatrogenic nerve injury. In general, reduction of the fracture aids in realigning the natural conduit (ie, the IAN canal) that will help to guide spontaneous neurosensory recovery even with a transection injury.

Also, the presence and/or treatment of oral pathologic lesions may result in nerve injury. The use of Carnoy’s solution (ferric chloride 0.1 g/mL, absolute alcohol 6 mL, chloroform 3 mL, glacial acetic acid 1 mL) following treatment of pathology has been shown to have a critical exposure time in an animal model of 5 minutes, after which time there may be long-term irreversible neural injury.^{34,35} Following a resection procedure, consideration should be given to immediate or delayed neural reconstruction using autogenous nerve grafts.

Although preprosthetic surgery is performed less frequently today than in the past, procedures such as torus mandibularis reduction and vestibuloplasty place the terminal branches of the mental nerve and infraorbital nerve at risk of injury. Surgical repair of small terminal nerve fibers is difficult and often results in scarring and a poor chance of neurosensory recovery. The maxilla and mandible are excellent sources of autogenous bone grafts; however, they are not without potential morbidity. The majority of patients who undergo genial

bone graft harvest complain of desensitization of the mandibular anterior teeth. Depending on the specific technique employed for posterior mandibular ramus grafting, the IAN may be at risk of iatrogenic injury. Mandibular endodontic therapy and periapical surgery may result in an injury to the IAN, depending on the proximity of the root apex to the canal. Some endodontic filling materials may be neurotoxic, and to prevent irreversible paresthesia that in many cases results in dysesthesia, consideration should be given to prompt exploration and débridement of medications that have permeated through the root apex and are in direct contact with the nerve. Distraction osteogenesis of the mandible has been shown to induce transient changes in neuronal conduction without significant long-term nerve dysfunction.^{36,37} On a clinical level, a younger patient would certainly tolerate a “stretch-type” of injury to the nerve well. Recent data indicate that with a corticotomy and distraction rates of 1 mm/d neural changes are unlikely but that rates greater than this may be deleterious to nerve function; however, more studies are necessary.³⁸

Finally, implant-related injuries to the IAN are common (30–40%) and problematic to manage appropriately. Unfortunately there is a lack of data regarding appropriate patient assessment and management, with a lack of consensus on treatment protocols. In the posterior mandible the likely cause of nerve damage is that the initial pilot (depth) drill penetrates the superior cortex of the canal and violates the IAN vein (or artery, which is less likely). This results in some bleeding that, on placement of the implant, tamponades itself. The resultant increased pressure in the closed environment creates a compartment syndrome, with harmful effects on neurosensory function. This type of injury commonly results in long-term unpleasant altered sensation (dysesthesia) rather than simple decreased sensation (hypoesthesia). The recognition

postoperatively that the patient has paresthesia and that the implant is within the confines of the canal warrant the clinician to consider removal of the implant, with or without immediate replacement with a shorter implant. If, however, the injury was due to a compartment syndrome effect, then implant removal without replacement may be prudent. For patients with persistent paresthesia, referral to a microneurosurgeon may be warranted. The procedure of IAN repositioning (lateralization and transpositioning) is an option that theoretically would induce a “controlled” injury to the nerve and protect it during implant preparation. With lateral decortication of the mandible and nerve exposure, a compartment syndrome is not possible. Despite the potential advantages of nerve repositioning, there is a high incidence of long-term paresthesia ranging from 0 to 77%, with a mean of approximately 30 to 40%.³⁹ With appropriate surgeon experience, proper patient selection, and informed consent, this procedure remains a viable option in posterior mandibular reconstruction.

Trigeminal Nerve Anatomy and Physiology

A brief review of the trigeminal nerve is necessary to understand clinical diagnosis and management. The trigeminal nerve (Figure 41-1) is composed of a mesoneurium that suspends the nerve within the surrounding tissues and is continuous with the outer epineurium that defines and surrounds the nerve trunk. The epineurium contains a vast plexus of vessels called the vasa nervorum, as well as lymphatic channels. The epineurium is divided into outer and inner epineuriums, and the inner layer is composed of a loose connective tissue sheath with longitudinal collagen bundles that protect against compressive and stretching forces imposed on the nerve. Individual fascicles are defined by the perineurium, which is a continuation of the pia-arachnoid layer of the cen-

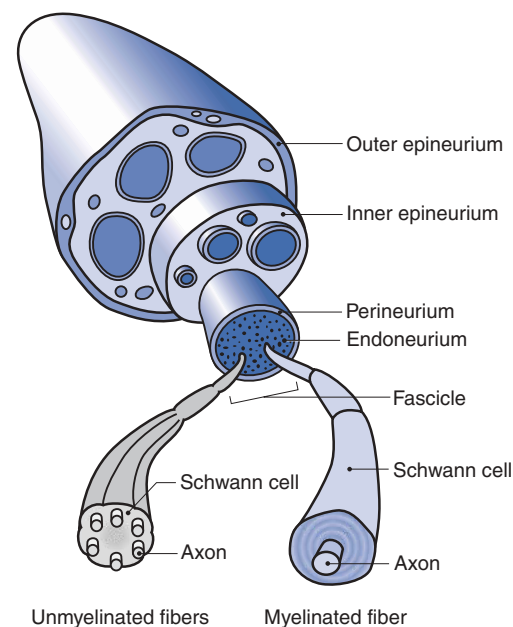


FIGURE 41-1 Trigeminal nerve anatomy.

tral nervous system. It functions to provide structural support and act as a diffusion barrier, similar to the blood-brain barrier that prevents the transport of certain molecules. The individual nerve fibers and Schwann cells are surrounded by the endoneurium, which is composed of collagen, fibroblasts, and capillaries. There are three types of neural fascicular patterns: monofascicular (one large fascicle), oligofascicular (2–10 fascicles), and polyfascicular (> 10 fascicles) (Figure 41-2). The inferior alveolar and lingual nerves are polyfascicular in nature. Polyfascicular nerves have abundant interfascicular connective tissue—the importance of which is that needle penetrations rarely cause direct neural trauma and that nerve repair with realignment of the fascicles is challenging. The nerve is composed of a functional unit with differing fiber types that transmit a variety of information (Table 41-2). The A alpha fibers are the largest myelinated fibers with the fastest conduction velocity; they mediate position and fine touch through muscle spindle afferents and skeletal muscle efferents. The A beta fibers mediate proprioception. The smallest myelinated fibers are the A delta

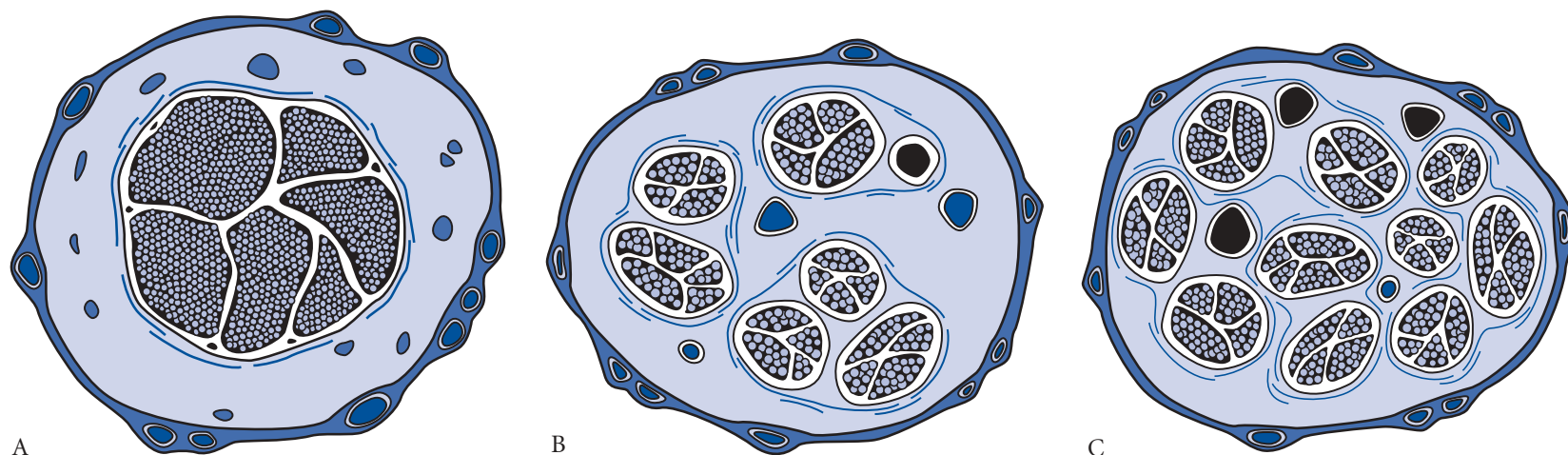


FIGURE 41-2 Three types of neural fascicular patterns: A, monofascicular; B, oligofascicular; C, polyfascicular. Adapted from Lundborg G. *The nerve trunk*. In: Lundborg G, editor. *Nerve injury and repair*. New York: Churchill Livingstone; 1998. p. 198.

fibers that carry pain (“first” or “fast” pain) and temperature information. The smaller-diameter and slower-conducting unmyelinated C fibers mediate “second” or “slow” pain and temperature sensations. The Schwann cells surround both myelinated (one Schwann cell per nerve fiber) and unmyelinated (one Schwann cell per several nerve fibers) nerves, and they play a major role in nerve survival and regeneration following injury. Although the myelin sheath may not survive a nerve injury, the Schwann cells do, and they provide a supportive role in the production of neurotrophic and neurotropic factors (such as nerve growth factor) that enhance neural recovery. The nodes of Ranvier are the 0.3 to 2.0 μm unmyelinated segments between the myelin sheaths that are responsible for the diffusion of certain ions that cause nerve depolarization and repolarization

and the saltatory conduction of a nerve impulse along the nerve.

Following nerve injury many changes occur, but the basic process of nerve healing involves both degeneration and regeneration (Figure 41-3).^{40,41} The nerve cell body responds with an increased metabolic phase with a heightened production of ribonucleic acid and breakdown of Nissl’s substance for export from the cell body. At the site of injury, there is edema and particulate cellular debris. In addition, there is a proliferation of phagocytes, and macrophages begin to clean the area. Within days there are axonal sprouts that extend from the proximal nerve stump. Each axon may have as many as 50 collateral sprouts. There is proliferation and a high level of activity of Schwann cells as well. These begin to lay down new myelin for the arrival of the new axons. Addition-

ally, nerve growth factors are produced that influence the direction of sprouting and guide the new axons into the newly

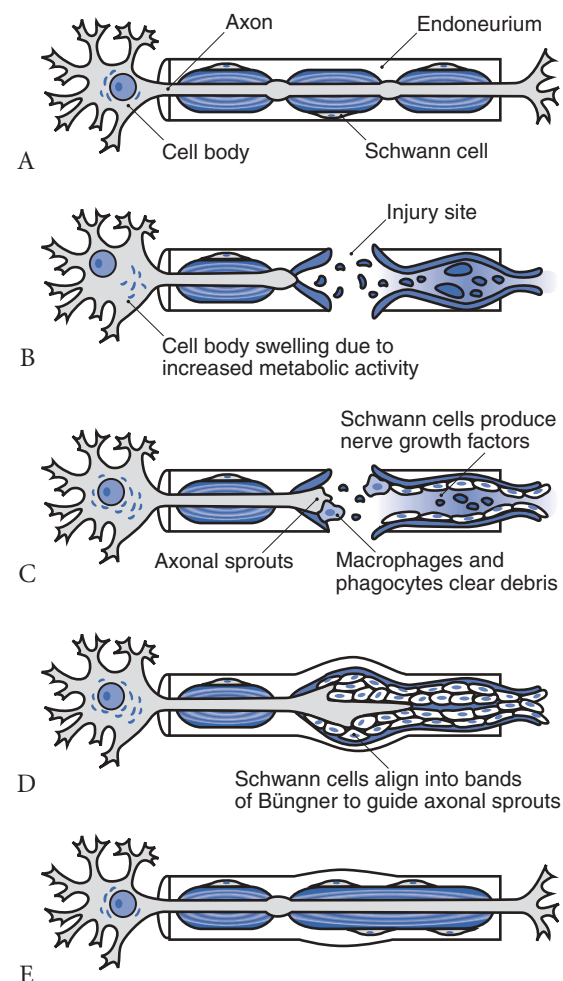


FIGURE 41-3 A to E, Neural wound-healing mechanisms.

Table 41-2 Trigeminal Nerve Fibers

Fiber	Size (μ)	Conduction Velocity (m/s)	Function
A alpha (myelin)	12–20	70–120	Position, fine touch
A beta (myelin)	6.0–12	35–170	Proprioception
A delta (thin myelin)	1.0–6.0	2.5–3.5	Superficial (first) pain, temperature
C (unmyelinated)	0.5–1.0	0.7–1.5	Deep (second) pain, temperature

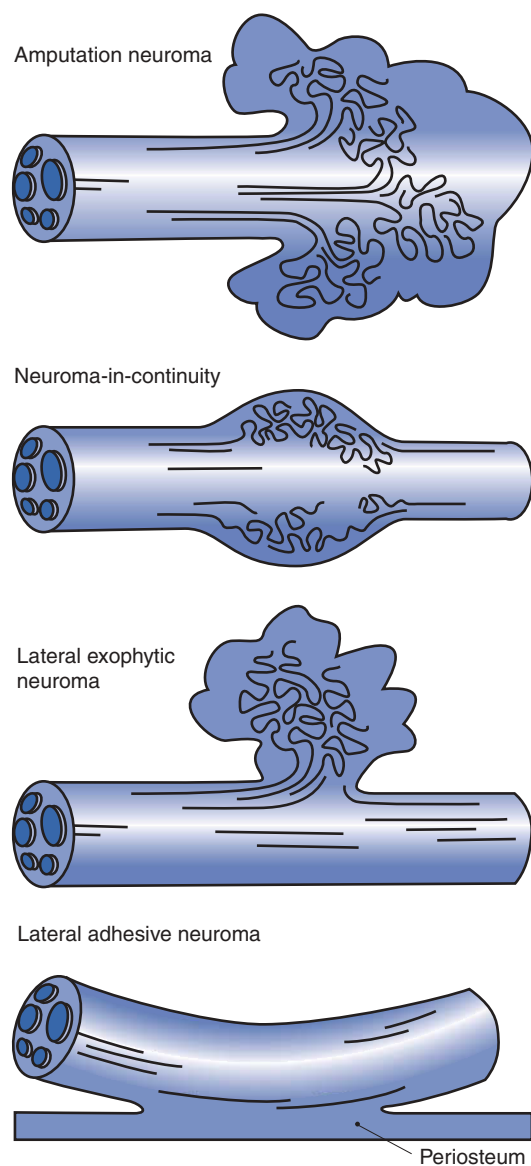


FIGURE 41-4 Neuroma types: amputation neuroma, neuroma-in-continuity, lateral exophytic neuroma, lateral adhesive neuroma.

formed myelin sheaths, known as the bands of Büngner. In the event that all of these interrelated processes occur appropriately, then spontaneous neural regeneration occurs. In the event that one or more of the reparative processes fail, there may be neuroma formation. A neuroma is simply a disorganized mass of collagen fibers and randomly oriented small nerve fascicles (sprouts). Neuromas are classified by gross morphology into the following types (Figure 41-4): amputation (stump) neuroma, neuroma-in-continuity (central or

fusiform neuroma), and lateral neuromas that are either lateral exophytic neuromas or lateral adhesive neuromas.

Nerve Injury Classification

There are two acceptable classification schemes used to describe the histologic changes that occur following nerve injury. Seddon described a three-stage classification system in 1943,⁴² and Sunderland revised and further subclassified nerve injuries into five grades in 1951 (Figure 41-5 and Table 41-3).⁴³ A neurapraxia (Seddon) or first-degree (Sunderland) injury is characterized as a conduction block from transient anoxia owing to acute epineurial/endoneurial vascular interruption resulting from mild nerve

manipulation (traction or compression), with rapid and complete recovery of sensation and no axonal degeneration. Damage is confined to within the endoneurium. Sunderland further subdivides first-degree injuries into types I, II, and III. Type I results from mild nerve manipulation with rapid (hours) return of sensation when neural blood flow is restored. Type II is due to moderate traction or compression with the formation of transudate or exudate fluid and intrafascicular edema, with return of sensation following edema resolution (days). Type III injuries result from more severe nerve manipulation that may result in segmental demyelination, with recovery within days to weeks. An axonotmesis (Seddon) corre-

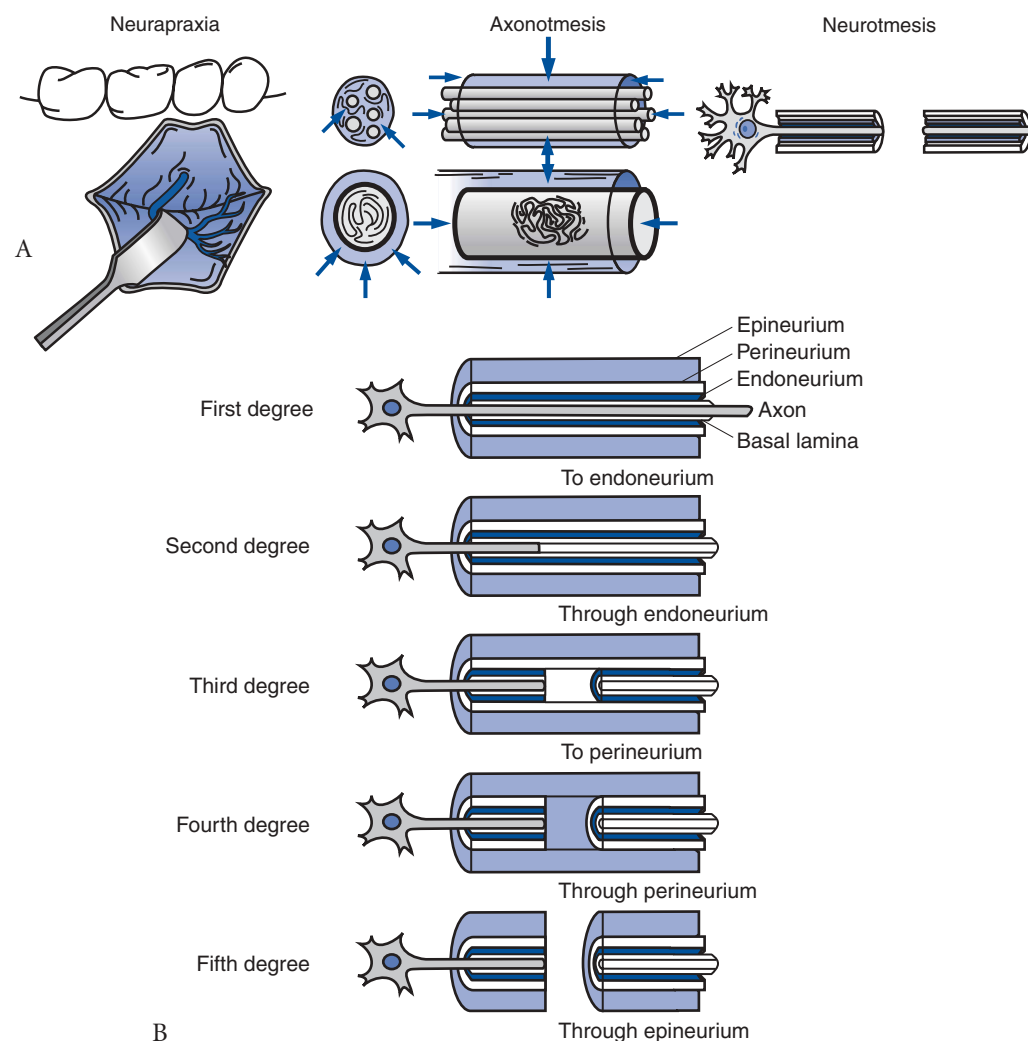


FIGURE 41-5 Nerve injury classifications: A, Seddon classification; B, Sunderland classification.

Table 41-3 Nerve Injury Classifications: Seddon versus Sunderland

<i>Seddon</i>	<i>Sunderland</i>	<i>Histology</i>	<i>Outcomes</i>
Neurapraxia	First degree	No axonal damage, no demyelination, no neuroma	Loss of sensation, rapid recovery (days to weeks), no microneurosurgery
Axonotmesis	Second, third, and fourth degrees	More axonal damage, demyelination, possible neuroma	Loss of sensation, slow incomplete recovery (weeks to months), possible microneurosurgery
Neurotmesis	Fifth degree	Severe axonal damage, epineurial discontinuity, neuroma formation	Loss of sensation, spontaneous recovery unlikely, microneurosurgery

sponds to second-, third-, and fourth-degree (Sunderland) injuries, with the difference being the degree of axonal damage. Second-degree injuries are due again to traction or compression that results in ischemia, intrafascicular edema, or demyelination. This damage extends through and includes the endoneurium with no significant axonal disorganization. Recovery is slow and may take weeks to months, and it may not be complete. Third-degree injuries continue the spectrum of more advanced injury owing to more significant neural trauma with variable degrees of intrafascicular architectural disruption and damage extending to the perineurium. Recovery is variable; it may take months and be incomplete. Fourth-degree injuries result in damage to the entire fascicle that extends through the perineurium to the epineurium, but the epineurium remains intact. There is axonal, endoneurial, and perineurial damage with disorganization of the fascicles. Spontaneous recovery is unlikely, but minimal improvement may occur in 6 to 12 months. Finally, neurotmesis (Seddon) and fifth-degree (Sunderland) injuries result from complete or near complete transection of the nerve with epineurial discontinuity and likely neuroma formation. Spontaneous neurosensory recovery is unlikely. For completeness, in 1988 Dellon and Mackinnon described a sixth-degree injury, which recognizes that many nerve injuries exhibit features of different degrees of injury according to Sunderland (Table 40-4).⁴⁴ The Seddon and Sunder-

land classification schemes attempt to correlate histologic changes with clinical outcome (see Table 41-3).

Clinical Neurosensory Testing

The patient who sustains an injury to the trigeminal nerve may present with a variety of signs and symptoms. These may be divided into nonpainful anesthesia, hypoesthesia, hyperesthesia, or painful anesthesia (anesthesia dolorosa), hypoesthesia, or hyperesthesia (allodynia—pain from a nonpainful stimulus—or hyperpathia—increased pain owing to a painful or nonpainful stimulus). The history usually indicates the etiologic event, and the chief complaint may include the following descriptive terms: numbness, itchy, crawling, stretched, drooling, painful, tingling, tickling, pulling, burning, stinging, pins and needles, hot sensation, cold sensation, inability to feel food on lip, inability to taste, inability to shave, inability to smile, and loss of consortium. The history of present illness should be explored in depth

with a description of the onset and progression of symptoms, change in symptoms, treatment received and response, aggravating and alleviating factors, and present symptoms.

The McGill Pain Questionnaire (MPQ) may be used to assess pain and altered sensation, and it is a useful tool for monitoring progression of neurosensory recovery. The MPQ uses three classes of descriptive words to assess the level of dysfunction and interference with activity: sensory class (temporal, spatial, thermal, punctate, incisive, constrictive, traction pressure), affective class (tension, fear, autonomic properties, punishment), and evaluative class (patient perception). Perhaps the simplest and most reliable measure of subjective patient assessment is the use of a visual analog scale. Generally, this is a 10 cm five-degree scale, with a degree marked every 2.5 cm (Figure 41-6). This is a useful tool for monitoring subjective improvement. It must be remembered that subjective and objective nerve testings are

Table 41-4 Sunderland Grade and Recovery Patterns

<i>Degree of Injury</i>	<i>Recovery Pattern</i>	<i>Rate of Recovery</i>	<i>Treatment</i>
First degree	Complete	Fast (days to weeks)	None
Second degree	Complete	Slow (weeks)	None
Third degree	Variable	Slow (weeks to months)	Possible nerve exploration
Fourth degree	None	Unlikely recovery	Microneurosurgery
Fifth degree	None	No recovery	Microneurosurgery
Sixth degree*	Varies [†]	Varies [†]	Varies [†]

*Sixth-degree injury data from Dellon AL and Mackinnon SE⁴⁴
[†]Depending on specific injury pattern.

Please indicate with an "X" on each of the two lines your perception of your current level of sensation.

Right	1 Complete absence of sensation	2 Almost no sensation	3 Reduced sensation	4 Almost normal sensation	5 Fully normal sensation
Left	1 Complete absence of sensation	2 Almost no sensation	3 Reduced sensation	4 Almost normal sensation	5 Fully normal sensation

FIGURE 41-6 Visual analog scale.

rarely at the same level. For example, in one study of nerve testing following sagittal split osteotomy, the subjective neurosensory deficit was 26.0%, whereas the objective tests revealed an 89.5% deficit.⁴⁵ Treatment planning decisions must be based on an assessment of both the subjective and objective testing results. Also, a radiographic assessment may reveal prior radiographic predictors of root proximity to the canal, retained root fragments, distal bone removal, or the presence of foreign bodies in extraction sites.

Clinical examination begins with inspection of the oral cavity, which may show signs of self-induced trauma, a lingually placed third molar incision scar, or atrophic changes of the tongue fungiform papillae.⁴⁶ Palpation may induce a Tinel's sign, which is a provocative test of regenerating nerve sprouts that it is performed by light palpation over the area of suspected injury. This maneuver elicits a distal referred "tingling" sensation at the target site. This sign is thought to indicate small-diameter fiber recovery; however, it is poorly correlated with functional recovery and is often confused with neuroma formation. To perform the CNT appropriately, the patient should be seated comfortably in a quiet room, and the specific testing procedures should be explained clearly to the patient, with confirmation that there is an understanding of what the patient is being asked to do and what possible responses are acceptable. The specific tests are performed

with the patient's eyes closed, and the contralateral uninjured side serves as the control, when appropriate.

The CNT is performed at three levels: A, B, and C (Table 41-5).⁴⁷ The CNT involves a dropout algorithm that attempts to correlate the results of the test with the level of nerve injury (Figure 41-7). If the results of level A testing are normal, then the CNT is terminated and the patient is considered normal; this would correspond to a Sunderland first-degree injury. An abnormal result at level A indicates the need to proceed to level B testing. If the results of level B testing are normal, then the patient is considered mildly impaired (Sunderland second-degree injury). If level B results are abnormal, then level C testing is performed. If level C results are normal, then the patient is moderately impaired (Sunderland third-degree injury). If level C results are abnormal, then the patient is considered severely impaired (Sunderland fourth-degree injury). If the patient's test results are abnormal at levels A, B, and C and there is no response to any noxious stimulus, the patient is considered completely impaired (Sunderland fifth-degree injury). Level A testing includes brush-stroke directional and static two-point discriminations. These tests assess function of the larger myelinated A alpha and beta fibers. These fibers are the most sensitive to compression and traction injuries; therefore, the CNT is terminated if level A is normal. Brush-stroke directional discrimination is performed with a fine sable or

camel hair brush. The brush is stroked gently across the area of involvement at a constant rate, and the patient is asked to indicate the direction of movement (ie, to the left or right) and the correct number of patient statements out of 10 is recorded. Two-point discrimination is performed in a static fashion (vs a moving two-point discrimination) and with blunt tips to avoid A delta and C fiber stimulation. This test can be performed with any device that is capable of allowing the distance between two points to be measured consistently (eg, a Boley gauge). The closest distance (in millimeters) at which the patient can consistently discern the two points is recorded. At level B testing, contact detection is performed with Semmes-Weinstein monofilaments or von Frey hairs, which, again, assess the A beta fiber integrity and function. These devices are acrylic resin or plastic transparent/translucent rods with nylon filaments of varying diameters. The stiffness of each filament determines the force necessary to deflect or bend the filament. The narrowest diameter filament that requires the least amount of force to deflect that is detected consistently is recorded. At level C testing, pinprick nociception and thermal discrimination assess the smaller A delta and C fibers, which are most resistant to injury. Pinprick nociception may be performed simply with a 30-gauge needle; however, a pressure sensitive device is more appropriate. Thermal discrimination may be performed with suprathreshold methods using ice or ethyl chloride or hot water on a cotton swab, but other options are

Table 41-5 Clinical Neurosensory Testing

Subjective assessment: visual analog scale
Objective assessment
Level A: static two-point discrimination, brush-stroke directional discrimination
Level B: contact detection
Level C: pinprick nociception, thermal discrimination

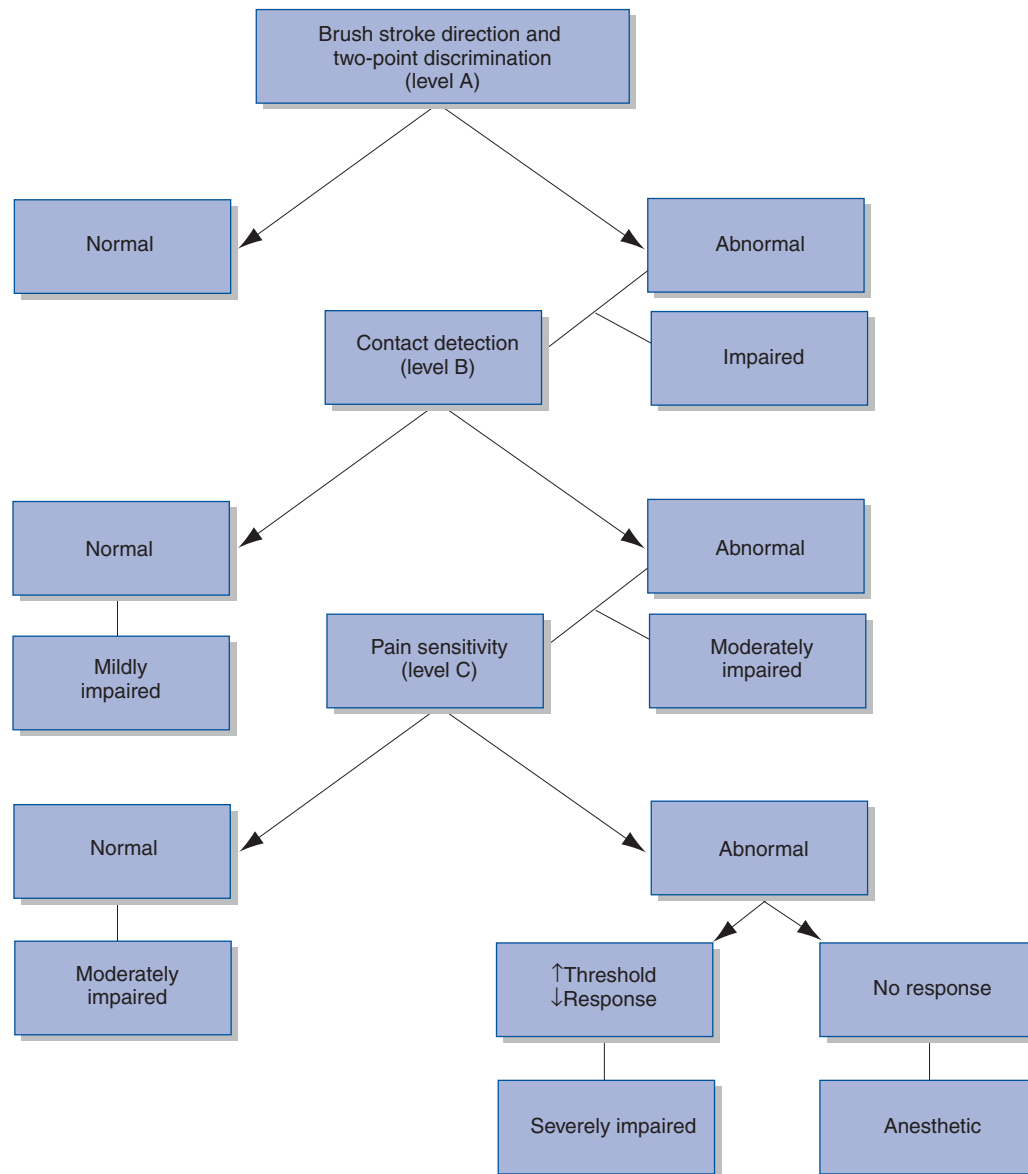


FIGURE 41-7 Algorithm for objective clinical neurosensory test.

available. Minnesota thermal disks made of copper, stainless steel, glass, and polyvinyl chloride can be used.

Although the tests employed in the CNT are considered objective tests, they are, in reality, subjective since they require a patient response. There are few purely objective tests of nerve function available, and these include trigeminal somatosensory evoked potentials and magnetic source imaging.⁴⁸ Unfortunately, these tests are not readily available and are not considered a part of the routine assessment of a nerve-injured patient. Also, there is little data on the trigeminal nerve

and the patterns of responses based on specific injuries.

Finally, taste can be assessed by a variety of means, but generally it is performed as either whole-mouth or localized testing. Solutions such as 1 M sodium chloride (salt), 1 M sucrose (sweet), 0.4 M acetic acid (sour), and 0.1 M quinine (bitter) may be used. There are many difficulties with taste assessment in the patient with a lingual nerve injury. The perception of taste alteration is extremely variable and has little correlation with the degree of lingual nerve injury. For example, a patient with a fourth- or fifth-degree lingual nerve

injury may not report any taste alteration subjectively but may test abnormally with different solutions. The complex sense of taste is mediated not only by the chorda tympani branch of the facial nerve but also through feedback mechanisms in the nasopharynx, oropharynx, and hypopharynx, as well as the nucleus tractus solitarius in the brainstem.⁴⁹ Regarding lingual nerve repair, objective and subjective neurosensory recovery also is inconsistent.⁵⁰

Diagnostic nerve blocks can be a useful component of the patient evaluation when dysesthesia or unpleasant sensations predominate the clinical scenario. The primary purpose of the diagnostic block is to localize the source of pain and determine the prognosis for recovery following either pharmacologic or surgical therapy. The preferred local anesthetic solution is of a low concentration (eg, 0.25% lidocaine) to selectively block the smaller A delta and C fibers while not affecting the larger myelinated fibers. If the low concentration fails to relieve the pain, a higher concentration is used in the same location. Diagnostic blocks begin peripherally and proceed centrally with constant reassessment of the area of involvement both objectively and subjectively. If patients present with symptoms consistent with sympathetically mediated pain or causalgia, a stellate ganglion block may be performed. These symptoms indicate a problem not amenable to peripheral microneurosurgery. Other pain syndromes that generally are not relieved with diagnostic nerve blocks include anesthesia dolorosa and deafferentation pain; these also are not managed surgically but, rather, pharmacologically.

Nonsurgical Treatment

Pharmacologic management of peripheral nerve injuries is reserved for patients who present with unpleasant abnormal sensations or dysesthesia. In the majority of cases, pharmacologic treatment should be managed with a consultation from an experienced individual such as a neurologist or

Table 41-6 Systemic Pharmacologic Agents

Local anesthetics
Corticosteroids
Nonsteroidal anti-inflammatory agents
Antidepressants
Narcotic analgesics
Anticonvulsants
Muscle relaxants
Benzodiazepines
Antisymphathetic agents

facial pain specialist. Many systemic (Table 41-6) and topical (Table 41-7) medications are available.⁵¹ Whereas the systemic drugs may have significant side effects, topical agents offer the advantages of little systemic absorption, possibly only minor irritation (which can be relieved with a period of abstinence), and over-the-counter availability in many cases. There are also many combinations of topical agents that can be used, such as a eutectic mixture of local anesthetics (EMLA) that contains 2.5% lidocaine and 2.5% prilocaine. Many of the topical agents are prepared in a pleuronic lecithin organogel base. For most oral surgeons long-term pharmacologic management is not part of their routine practice, so the prompt referral to a microneurosurgeon or neurologist may offer the best chance for long-term success. Consideration may be given to a trial of a topical

agent such as capsaicin cream 0.025% tid and/or a systemic medication with few side effects, such as baclofen 10 mg tid or gabapentin 100 mg tid.

Some oral surgeons manage perioperative paresthesia following third molar removal or implant placement with a short course of corticosteroid therapy in an attempt to decrease perineural edema. Although there is little evidence to suggest that systemic steroids actually provide any effect, the use of steroids when a nerve injury occurs, indicates that the surgeon has recognized a problem and has taken an action to improve outcome, which is advantageous when considering medico-legal involvement issues.

Perhaps the most important consideration should be prompt referral, when indicated, to a specialist for pharmacologic or surgical management of the patient with a nerve injury. The indications for referral include but are not limited to those listed in Table 41-8.

In the past, prior to consideration of surgical management, a variety of neuroablative techniques have been used to manage painful neuropathies. Some of these include radiofrequency thermal neurolysis, cryoneurolysis, and alcohol and glycerol injections at the site of injury as well as at the gasserian ganglion. Based on the complications and recurrence rates of dysesthesia, caution should be employed when

Table 41-8 Microneurosurgeon Referral Indications

Observed nerve transection
Complete postoperative anesthesia
Persistent paresthesia (lack of improvement in symptoms) at 4 wk
Presence or development of dysesthesia

considering these options.^{52,53} The use of a low-level laser (gallium-aluminum-arsenide, wavelength 820 nm) has promise in the area of neural healing. Several studies have shown improvement in objective and subjective neurosensory recoveries with the use of laser therapy in some of the more difficult cases, such as long-standing injuries, orthognathic IAN paresthesia, and prolonged dysesthesia unresponsive to pharmacologic or surgical therapy.⁵⁴⁻⁵⁶ However, the current limited availability of the low-level laser and the lack of approval by the US Food and Drug Administration preclude its routine use for patients with nerve injuries.

Treatment Algorithms

The decision to proceed with microneurosurgery must be made following a careful patient assessment over a defined period of time. The dilemma is that sufficient time must be given to allow for spontaneous neurosensory recovery but that prompt surgical intervention may afford the best chance for recovery. Time is a critical issue for three main reasons. First, at the site of injury, distal nerve degeneration (wallerian degeneration—named for Augustus Waller in 1892) occurs owing to the interruption of axonal transport. This progressive loss of neural tissue may compromise future repair attempts. Second, at the nerve cell bodies there is ganglion cell death that occurs early following injury.⁵⁷ Third, as the time from nerve injury increases, there is a higher likelihood that central cortical changes may occur, and these would make peripheral repair ineffective.⁵⁸ As a result, if 30 to 50% of gan-

Table 41-7 Topical Medications

Category	Example
Topical anesthetics	5% viscous lidocaine gel; 20% benzocaine gel; 2.5% lidocaine with 2.5% prilocaine
Neuropeptides	Capsaicin cream (0.025% or 0.075%)
Nonsteroidal anti-inflammatory drugs	Ketoprofen 10–20% PLO base; diclofenac 10–20% PLO base
Sympathomimetics	Clonidine 0.01% PLO base or patch
N-methyl-D-aspartate blocking agents	Ketamine 0.5% PLO base
Anticonvulsants	Carbamazepine 2% PLO base
Tricyclic antidepressants	Amitriptyline 2% PLO base
Antispasmodics	Baclofen 2% PLO base

PLO = pleuronic lecithin organogel.

glion cells have undergone necrosis, the best possible success rate from surgical repair may also be 30 to 50%.

Microneurosurgery is indicated for persistent paresthesia that fails to improve over successive examinations. This includes both subjective and objective assessments. Surgery is not indicated if

there is continued improvement at each subsequent assessment. The current recommendations are to consider surgery for the lingual nerve within 1 to 3 months following the injury, and for the IAN within 3 to 6 months following the injury (Figure 41-8). The rationale for the difference in time is that the IAN lies within a bony

canal that can guide spontaneous regeneration, so more time is allotted for that process, whereas a lingual nerve injured within soft tissue does not have a “physiologic conduit” to guide regeneration. In general, the oral surgeon should have follow-up examinations with the patient over a period of approximately 4 weeks. If there is persistent paresthesia or a worsening of symptoms, referral should be made to a microneurosurgical specialist.

For an unobserved nerve injury, the plan should be to continue neurosensory testing for 1 month and then to refer for surgery in the 1- to 3-month (lingual nerve) or 3- to 6-month (IAN) time periods. For an observed nerve injury, treatment should focus on the specific etiology. For a suspected traction injury (Sunderland first-, second-, and third-degree injuries), the patient should be tested for 1 month for signs of expected spontaneous recovery. In the case of nerve compression, immediate decompression should be considered. This includes removal of a root displaced into the IAN canal, removal or replacement when there is evidence of implant impingement within the confines

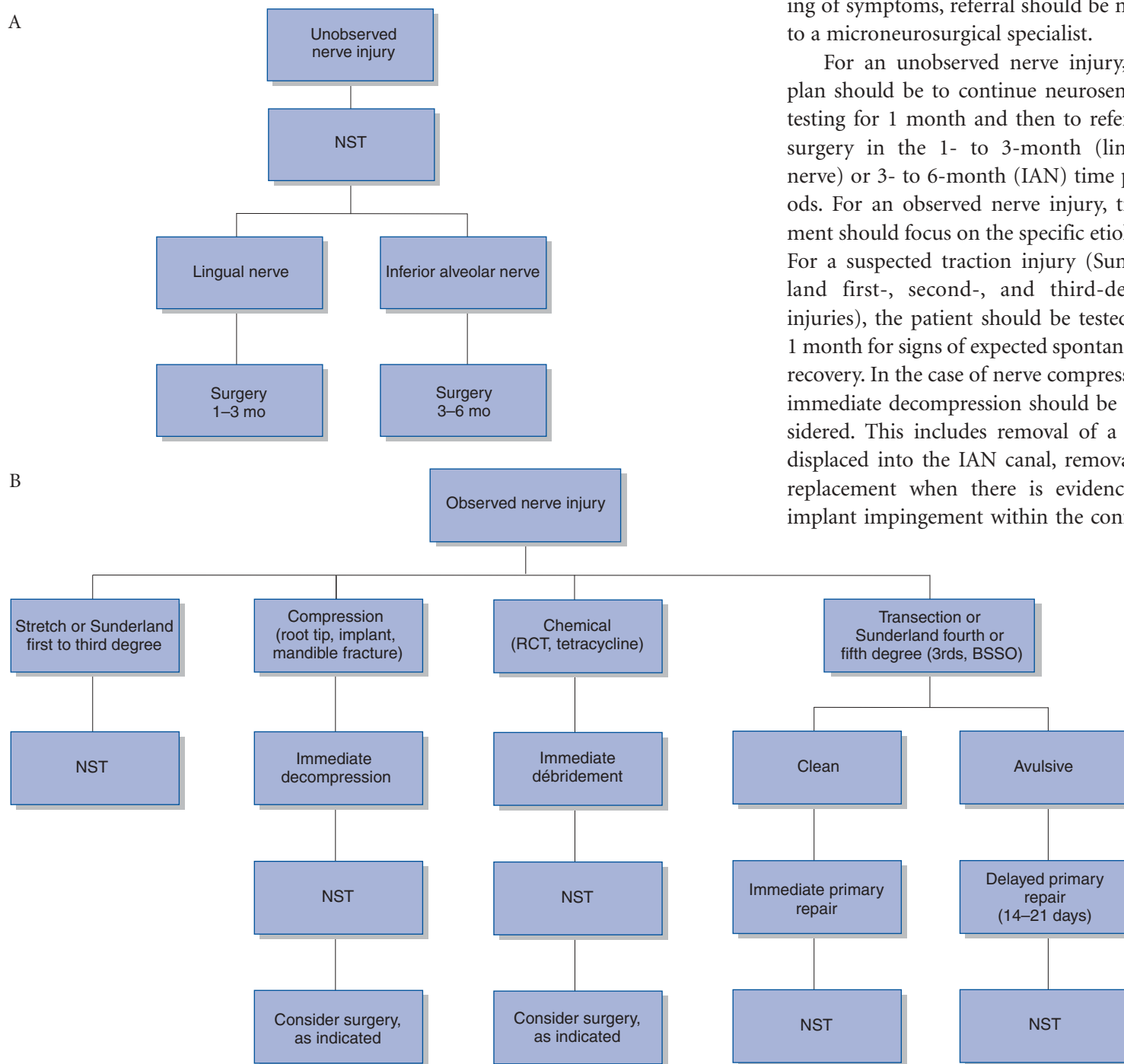


FIGURE 41-8 Nerve treatment algorithms: A, unobserved nerve injury; B, observed nerve injury. BSSO = bilateral sagittal split osteotomy; NST = neurosensory testing; RCT = root canal therapy.

of the IAN canal, or reduction and alignment of a displaced posterior mandible fracture including the IAN canal. Neurosensory testing should be performed following decompression, and microneurosurgery should be considered as indicated. Chemical injuries should be débrided promptly. For observed transection injuries (Sunderland fourth- or fifth-degree injuries), an immediate primary repair may be performed for a clean transection injury (eg, scalpel transection). For an avulsive injury (eg, lingual nerve entangled in a bur), consideration is given to a delayed primary repair performed at 3 weeks following the injury. This allows time for the proximal and distal nerve stumps to define the degree of injury, and to determine whether the surrounding environment is conducive to nerve surgery, when there are high levels of neurotropic and neurotrophic factors. After surgery, patients should be followed up with repeat neurosensory testing.

The success rates of microneurosurgical reconstruction following nerve injury are variable in the literature. This is due to many factors including the lack of standardization with the following⁵⁹: age, the etiology of injury, the time of delay from injury to repair, specific surgical techniques used, the length of the nerve gap, the method of neurosensory examination, the use of normative values for control sites, follow-up period variability, and criteria to define success (Table 41-9). A global review of the literature might indicate a success rate of 30 to 50% following microneurosurgery, including direct and gap repairs. In general, direct repair is preferred over gap repair (eg, using an autogenous nerve graft) and has higher reported success rates.⁶⁰ Perhaps the largest study to date indicates an overall “success” rate of 76.2% in 521 patients.⁶¹ The success criteria were defined as light touch detected > 80% of the time and a 30% decrease in postoperative pain level. The study results suggested some important trends in outcome.

Hypoesthetic injuries improved better following microneurosurgery than did hyperesthetic injuries, the lingual nerve recovered better than did the IAN overall, and there was a decrease in success associated with a delay of > 6 months. A recent report of 51 microneurosurgical reconstructions (direct and gap repairs) found that 10 patients subjectively reported good improvement, 18 patients some improvement, 22 patients no improvement, and 1 patient reported feeling worse following surgery.⁶² This indicates that 55% of patients showed some improvement. In another study of 53 surgical patients, with a mean follow-up of 13 months, light touch improved from 0 to 51% and pinprick nociception improved from 34 to 77%. Patients also experienced improved taste and an increased number of fungiform papillae, and there was a decrease in incidence of accidental tongue biting. Interestingly, there was no correlation of success with delay from time of injury to repair. No patient became completely normal, and there was no reduction in dysesthesia; however, most patients considered the surgery worthwhile. There is certainly a need for standardization in all aspects of evaluation and management of microneurosurgical patients.

Surgical Treatment

Microneurosurgical reconstruction involves a sequence of surgical procedures including exposure, dissection, assessment, manipulation, and repair. Many of the techniques of trigeminal nerve repair follow those of hand surgery and use similar instruments. In general, surgical loupe magnification ($\times 3.5$ magnification) is adequate. An operating microscope ($\times 12$ magnification) is cumbersome and difficult to use with a transoral exposure, although it may be more useful with a transfacial approach.

Exposure

Surgical access to the lingual or IAN may be accomplished transfacially or transoral-

ly. The transfacial approach affords wide exposure and access; however, it necessitates a facial incision with subsequent scar formation. The intraoral approach provides a more difficult surgical access and requires more diligence in microsurgery in the posterior regions of the oral cavity, but it avoids a facial incision. The decision regarding surgical access depends on an individual patient's anatomy, the site of nerve injury, planned surgical procedures, patient preference, and surgeon's skill and experience.

External Neurolysis

Microdissection of the nerve once exposed involves liberation of the nerve from the surrounding tissues to facilitate inspection. For the lingual nerve this procedure may involve the release of the nerve from a lateral adhesive neuroma in the area of the lingual plate in the third molar region, whereas for the IAN a corticotomy is generally required for external neurolysis. Sev-

Table 41-9 Classification of Sensory Recovery

Grade (Stage)	Recovery of Sensibility
S0	No recovery
S1	Recovery of deep cutaneous pain
S1+	Recovery of some superficial pain
S2	Return of some superficial pain and tactile sensation
S2+	S2 with over-response
S3*	Return of some superficial pain and tactile sensation without over-response; two-point discrimination > 15 mm
S3+	S3 with good stimulus localization; two-point discrimination = 7–15 mm
S4	Complete recovery, S3+; two-point discrimination = 2–6 mm

*S3 score indicates significant clinical recovery (Wyrick JD, Stern PJ. Secondary nerve reconstruction. *Hand Clin* 1992;8:587).

Adapted from Mackinnon SE. Surgical management of the peripheral nerve gap. *Clin Plast Surg* 1989;16:587.

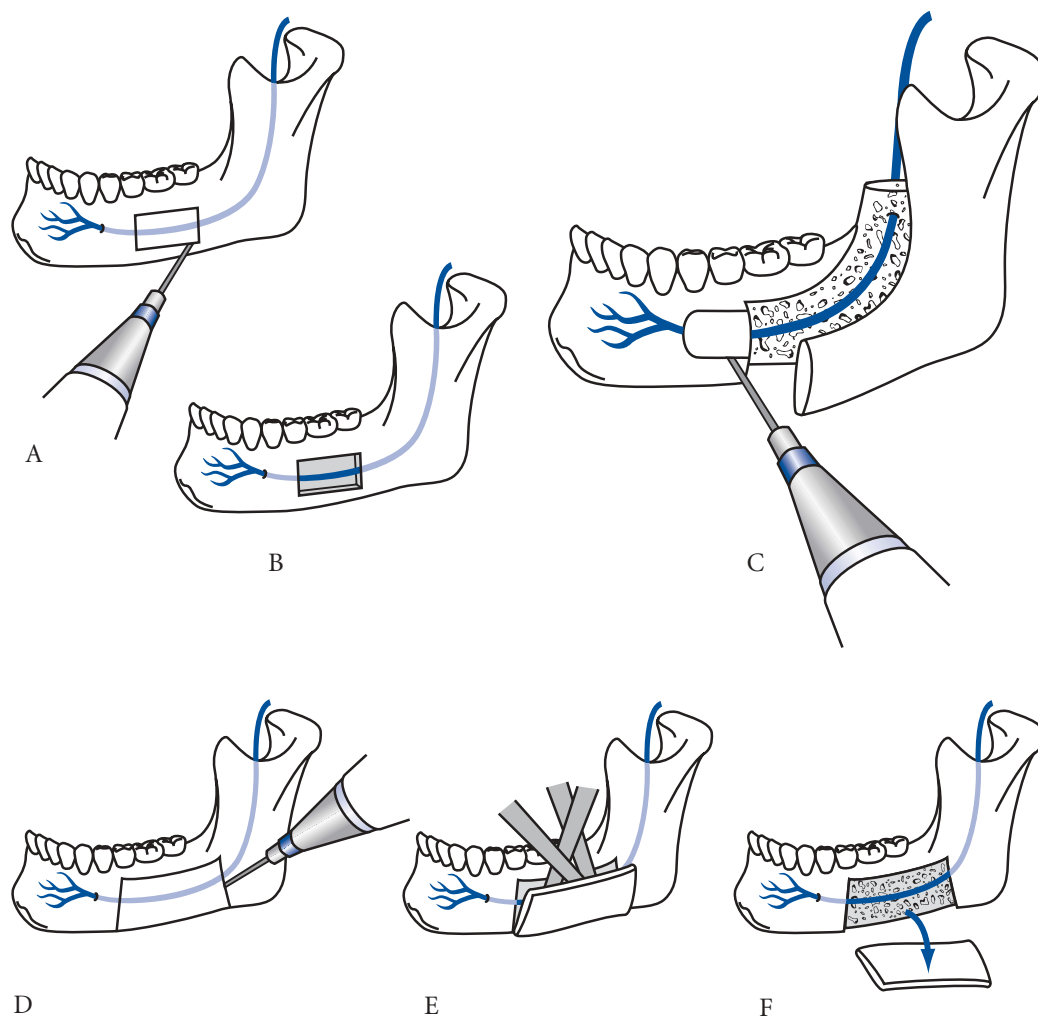


FIGURE 41-9 Exposure techniques for the IAN: A, Lateral decortication of the mandible; B, with exposure of the inferior alveolar neurovascular bundle. C, Sagittal ramus osteotomy with anterior extension via lateral decortication to the mental foramen. D, Lateral mandibular decortication. E, Bone removal with chisels. F, Wide exposure of the neurovascular bundle.

eral techniques have been described for lateral decortication in the area of the third molar for IAN exposure, and these range from a simple nerve transpositioning to a modified buccal corticotomy or a unilateral sagittal split ramus osteotomy (Figure 41-9).⁶³ The location of the injury and the surgeon's preference frequently dictate the specific approach used. The lingual nerve is usually exposed via a modified incision used for third molar surgery with a sulcular lingual extension (Figure 41-10). For the infraorbital nerve, external neurolysis may be performed secondary to reduction and fixation of a displaced zygomaticomaxillary complex fracture impinging on the neurovascular bundle at the infraorbital foramen. It has been suggested that external neurolysis may provide definitive treatment for a nerve injury if the nerve compression is < 25% of the normal diameter, if the paresthesia is of short duration (< 6 mo), and if there is no evidence of neuroma formation.⁶⁴

Internal Neurolysis

The term *internal neurolysis* refers to surgical manipulations within the epineurium to prepare the nerve for repair. Sophisticated maneuvers may compromise repair by unnecessary removal of tissue and

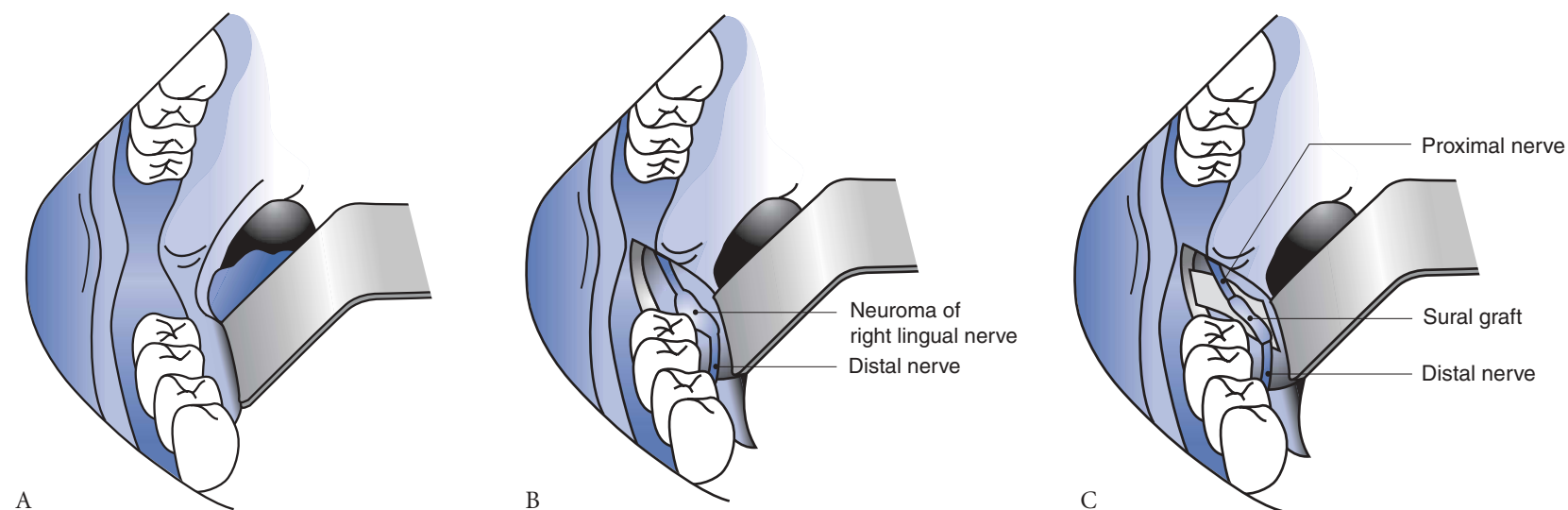


FIGURE 41-10 Lingual nerve exposure. A, Incision design via a distobuccal extension and lingual gingival sulcus approach. B, Right lingual nerve exposure with neuroma. C, Right lingual nerve repair with an interpositional nerve graft.

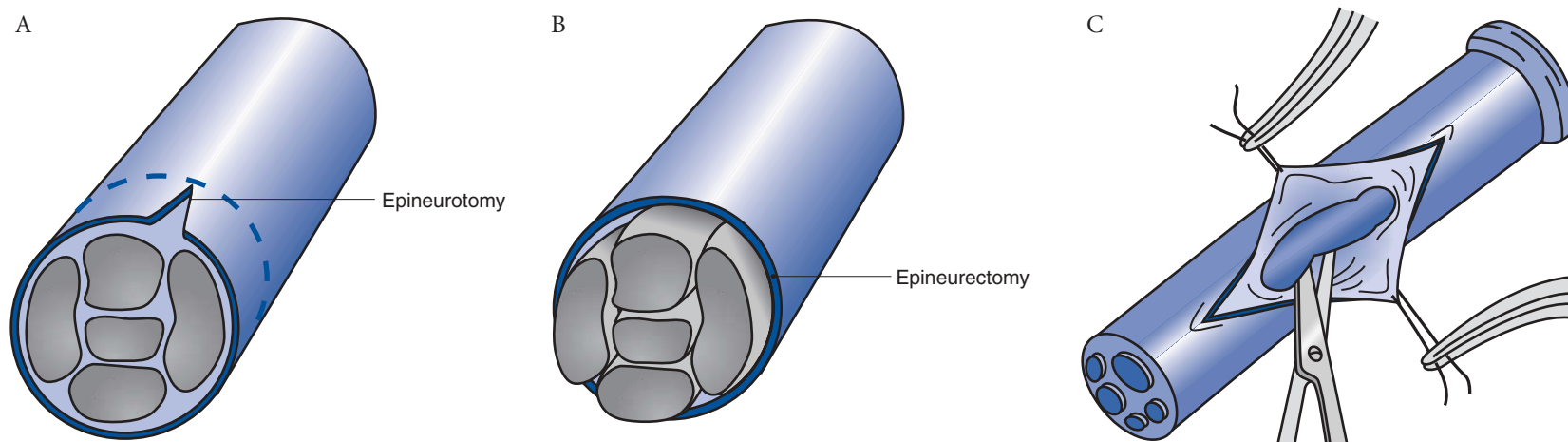


FIGURE 41-11 Internal neurolysis: A, epifascicular epineurotomy; B, epifascicular epineurectomy; C, interfascicular epineurectomy. A and B adapted from LaBanc JP. *Reconstructive microneurosurgery of the trigeminal nerve*. In: Peterson LJ, Indresano AT, Marciani RD, Roser SM. *Principles of oral and maxillofacial surgery*. Vol 2. Philadelphia: J.B. Lippincott Company; 1992. p. 1067.

induction of cicatrix formation owing to excessive manipulation. Several types of internal neurolysis have been described, including epifascicular epineurotomy, epifascicular epineurectomy, and interfascicular epineurectomy (Figure 41-11). The first two prepare the epineurium for repair; any interfascicular surgery may cause further fascicular disruption and scarring. Extensive internal neurolysis procedures should be used with caution.

Nerve Stump Preparation

Perhaps the most critical portion of the surgical procedure involves the inspection of the proximal and distal nerve stumps via magnification. The preparation of the nerve stumps follows exposure; there may already be an existing discontinuity from a transection injury. When a neuroma is present, meticulous excision is required (Figure 41-12). It must be recognized that with any neuroma, the clinical appearance of neuronal edema or atrophy is less than the internal fascicular changes (see Figure 41-12A). Failure to resect enough nerve tissue to reach normal fascicles results in a failure of neurosensory recovery. Once the nerve is divided, if necessary, into proximal and distal stumps, care must be taken to resect small (1 mm) portions of the nerve trunk in both directions (see Figure

41-12B) until healthy glistening white mushrooming fascicles are seen to herniate through the edges of the epineurium (see Figure 41-12C).

Approximation

The trigeminal nerve is similar to other peripheral nerves in that it does not tolerate tension well; therefore, tension-free closure is mandatory.⁶⁵ The deleterious effects of tension result from vascular compromise and subsequent fibrosis at the nerve repair site. Approximation is the act of

bringing the nerve stumps into contact and assessing the degree of tension that is present. At the time of approximation a decision must be made regarding whether to use an interpositional graft. In general, mobilization with primary epineurial repair is possible for lingual nerve gaps < 10 mm and for IAN gaps < 5 mm.

Coaptation

Coaptation is the process of aligning the proximal and distal nerve stumps into the premorbid cross-sectional fascicular ori-

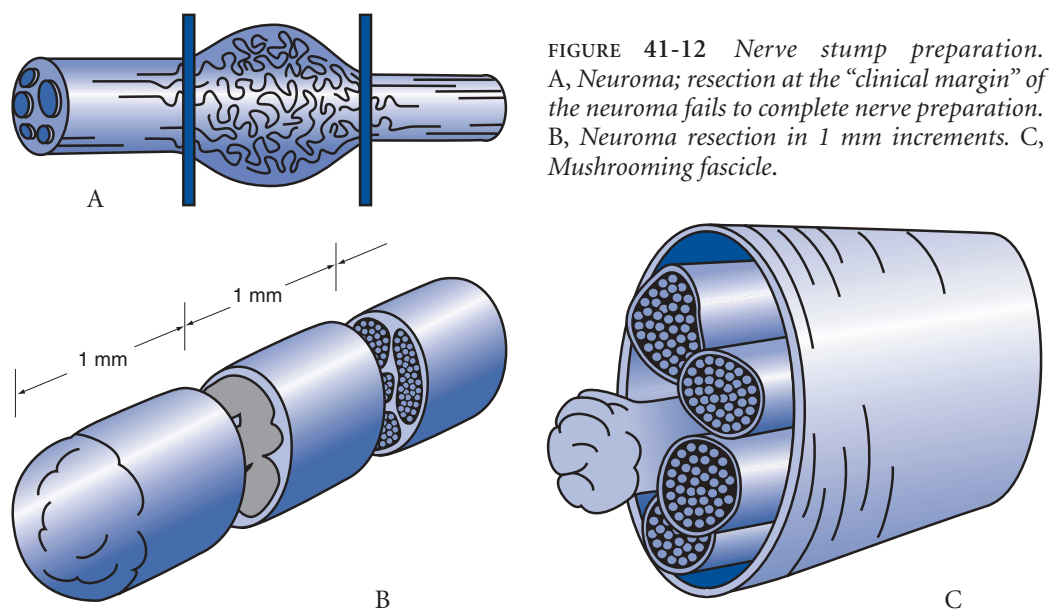


FIGURE 41-12 Nerve stump preparation. A, Neuroma; resection at the “clinical margin” of the neuroma fails to complete nerve preparation. B, Neuroma resection in 1 mm increments. C, Mushrooming fascicle.

entation. This is a difficult maneuver with a polyfascicular nerve that has undergone any degree of distal nerve changes in diameter or fascicular pattern. This step is usually not performed painstakingly in trigeminal nerve repair because of the complex polyfascicular pattern.

Neurorrhaphy

Neurorrhaphy is the act of nerve suturing for both direct and gap repairs. The trigeminal nerve is repaired using epineurial sutures, not perineurial sutures (Figure 41-13). Generally, an 8-0 monofilament nonresorbable nylon suture is chosen since a resorbable material would invoke inflammation and disturb the area of anticipated neural healing. At least two sutures are used per anastomosis site to prevent rotation, but not more than three or four sutures should be used per anastomosis. The first suture is placed on the medial side of the anastomosis since it is more difficult to access. The epineurium is pierced with the needle 0.5 to 1.0 mm from the edge of the nerve. The second suture is placed 180° from the first suture, and then an assessment is made regarding the need for more sutures.

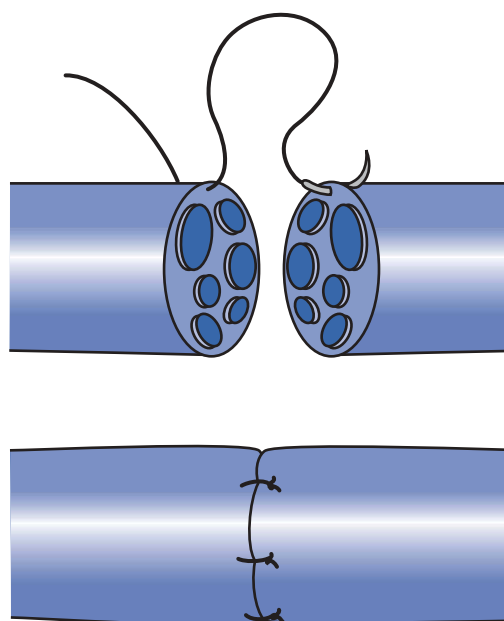


FIGURE 41-13 Direct epineurial neurorrhaphy.

Table 41-10 Size of Donor Nerve Grafts Relative to Injured Nerve

Injured Nerve	Donor Nerve		
	Sural (2.1 mm)	Greater Auricular (1.5 mm)	Greater Auricular Cable (3.0 mm)
Inferior alveolar (2.4 mm)	88%	63%	125%
Lingual (3.2 mm)	66%	47%	94%

Adapted from Brammer JP and Epker BN.⁶⁸

Nerve Grafts

When neurorrhaphy is not possible without tension and a nerve gap exists, an interpositional graft must be considered for indirect neurorrhaphy.⁶⁶ The options for autogenous nerve grafting include but are not limited to the sural nerve, the greater auricular nerve, and possibly the medial antebrachial cutaneous nerve.⁶⁷ The sural nerve is the preferred nerve for grafting since it most appropriately matches the nerve diameter and the fascicular number and pattern of the trigeminal nerve (Table 41-10).⁶⁸ The area of the nerve superior to the lateral malleolus exhibits less branching than at or below the lateral malleolus. The sural nerve, or medial sural cutaneous nerve, is a branch of the sacral plexus (S1, S2) and supplies sensory information to the posterior lower extremity and the dorsolateral foot. Sural grafts up to 20 cm in length are possible, and patients tolerate the donor site deficit well.⁶⁹ The greater auricular nerve is a poor choice for trigeminal repair. As a branch of the cervical plexus (C1, C2), the greater auricular nerve supplies sensation to the pre- and postauricular regions, the lower third of the ear, and the skin overlying the posteroinferior border at the angle of the mandible. Patients are generally not amenable to sacrificing one facial region for another. Additionally, the small diameter of the nerve makes it useful only when used as a cable graft (Figure 41-14). The sole advantage of a greater auricular graft over a sural graft is in situations when it can be harvested via the same incision for another procedure, such as the repair of an

extraoral mandibular fracture or management of pathology. The basic premise with graft repair is that the graft supplies the Schwann cells and growth factors necessary to support and encourage axonal sprouting through the graft toward the target site.

Entubulation Techniques

In an attempt to avoid donor site morbidity, a variety of entubulation techniques have been proposed to create conduits during nerve regeneration (Figure 41-15). These conduits involve both autogenous and alloplastic materials (Table 41-11). The autogenous options include vein,⁷⁰⁻⁷² collagen,^{73,74} and muscle grafts.⁷⁵ Alloplastic

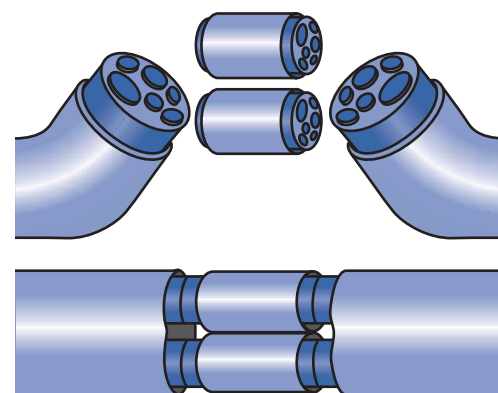


FIGURE 41-14 Greater auricular nerve cable graft.

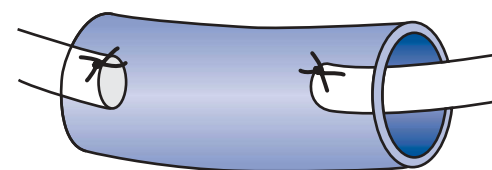


FIGURE 41-15 Entubulation (conduit) nerve repair.

Table 41-11 Materials for Entubulation (Conduit) Repair

Autogenous materials
Collagen
Muscle
Fascia
Vein
Alloplastic materials
Polyglycolic acid
Polyester
Polytetrafluoroethylene (PTFE)
Expanded PTFE
Silicone, polymeric silicone

materials include polyglycolic acid,⁷⁶ polymeric silicone,⁷⁷ and expanded polytetrafluoroethylene.⁷⁸⁻⁸¹ It appears that the use of these alloplastic materials has a high success in the animal model but poor clinical outcomes. Further investigation is warranted as new materials are developed.

Postsurgical Management

In the majority of cases, patients experience a variable period of complete anesthesia following nerve repair. In general, nerve regeneration progresses at approximately 1 mm/d (about 3 cm/mo) from the cell body to the target site. For example, with a direct IAN repair, the approximate distance from the trigeminal ganglion to the lower lip and chin is 10 cm; therefore, complete nerve regeneration takes about 100 days or 12 weeks following repair. With graft repair the time frame is lengthened owing to slowed regeneration through the graft site, but recovery is variable. A poor outcome following microneurosurgery may preclude future surgical options; therefore, the best chance for microneurosurgical success is at the first (and most likely, the last) surgical intervention.

Medicolegal Issues

Oral and maxillofacial surgeons currently practice during a time of “malpractice crisis,” and nerve injuries secondary to third molar removal account for a large propor-

tion of the complaints.⁸² Based on the information contained in this chapter and recent trends in malpractice, all oral and maxillofacial surgeons should have a minimum of understanding of the diagnosis and management of nerve injuries according to the so-called legal parameters of care.⁸³ These are summarized as follows:

- Spontaneous sensory recovery occurs in most but not all patients. It is difficult to predict early, it may not be “complete,” and it may not be to the patient’s satisfaction. Nerves in soft tissue (lingual nerve) have a lower rate of spontaneous regeneration than do those in bony canals (IAN)
- All nerve injuries should be documented and evaluated with a history, examination, and neurosensory testing (objective and subjective). The injury should be classified (Seddon or Sunderland). In cases of observed or known nerve injury, prompt referral for microsurgery provides the best opportunity for sensory recovery
- Repeat examinations at frequent intervals may be necessary. Patients should be followed up for at least 1 month. Complete recovery in 1 month indicates neurapraxia, and no further treatment is indicated. Neurosensory dysfunction that lasts > 1 month indicates a higher-grade injury with uncertain spontaneous neurosensory recovery. Microneurosurgical consultation should be considered
- Nerve injuries that show improvement (objective and/or subjective) may be followed up expectantly. Once improvement stops for a period of time, it usually does not begin again
- Most nerve injuries resolve within 3 to 9 months, but *only* if improvement begins prior to 3 months. Patients who are anesthetic at 3 months usually do not achieve significant neurosensory recovery. Prompt microsurgery is usually indicated
- Patients with partial sensory loss and/or painful sensations *that they find unacceptable* should be considered for microsurgery if objective and subjective findings have not improved or returned to normal by 4 months. Microsurgical delay decreases the chance of success because progressive distal nerve degeneration and/or the development of a central pain syndrome occur
- Some painful neuropathies may be managed nonsurgically under the supervision of a microneurosurgeon or other experienced individual (eg, neurologist)
- Angry uninformed patients with nerve injuries are less likely to improve with any treatment, surgical or nonsurgical. A discussion regarding options and the risk of nerve injury should be provided so that the patient can give informed consent. Local anesthetic injections carry a risk of nerve injury
- Early surgical intervention (ie, at 3–4 mo) is *more likely* to produce neurosensory improvement than is late intervention. Surgery delayed beyond 12 months is seriously compromised by distal nerve degeneration and the development of chronic pain syndromes
- Surgery is *more likely* to improve responses to objective sensory testing and/or to reduce functional impairment than it is to reduce pain or subjective feelings of numbness

References

1. American Association of Oral and Maxillofacial Surgeons. Parameters and pathways: clinical practice guidelines for oral and maxillofacial surgery (AAOMS ParPath 01), Version 3.0. J Oral Maxillofac Surg 2001;59 Suppl.
2. Pogrel MA, Thamby S. The etiology of altered sensation in the inferior alveolar, lingual, and mental nerve as a result of dental treatment. J Calif Dent J 1999;27:531, 534–8.
3. Zuniga JR, Leist JC. Topical tetracycline-induced neuritis: a case report. J Oral Maxillofac Surg 1995;53:196.
4. Leist JC, Zuniga JR. Experimental topical

- tetracycline-induced neuritis in the rat. *J Oral Maxillofac Surg* 1995;53:427.
5. Pichler JW, Beirne OR. Lingual flap retraction and prevention of lingual nerve damage associated with third molar surgery: a systematic review of the literature. *Oral Surg Oral Med Oral Pathol Oral Radiol Endod* 2001;91:395.
 6. Rood JP, Shehab AAN. The radiological prediction of inferior alveolar nerve injury during third molar surgery. *Br J Oral Maxillofac Surg* 1990;28:20.
 7. Pogrel MA, Lee JS, Muff DF. Coronectomy in lower third molar removal. *J Oral Maxillofac Surg* 2003;61 Suppl 1:25.
 8. Alling CC. Dysesthesia of the lingual and inferior alveolar nerves following third molar surgery. *J Oral Maxillofac Surg* 1986;44:454.
 9. Gulicher D, Gerlach KL. Sensory impairment of the lingual and inferior alveolar nerves following removal of impacted third molars. *Int J Oral Maxillofac Surg* 2001; 30:306.
 10. Carmichael FA, McGowan DA. Incidence of nerve damage following third molar removal: a West Scotland Oral Surgery Research Group study. *Br J Oral Maxillofac Surg* 1992;30:78.
 11. Valmaseda-Castellon E, Berini-Aytes L, Gay-Escoda C. Lingual nerve damage after third lower molar surgical extraction. *Oral Surg Oral Med Oral Pathol Oral Radiol Endod* 2000;90:567.
 12. Valmaseda-Castellon E, Berini-Aytes L, Gay-Escoda C. Inferior alveolar nerve damage after lower third molar surgical extraction: a prospective study of 1117 surgical extractions. *Oral Surg Oral Med Oral Pathol Oral Radiol Endod* 2001;92:377.
 13. Kisselbach JE, Chamberlain JG. Clinical and anatomic observations on the relationship of the lingual nerve to the mandibular third molar region. *J Oral Maxillofac Surg* 1984; 42:565.
 14. Pogrel MA, Renaut A, Schmidt B, Ammar A. The relationship of the lingual nerve to the mandibular third molar region: an anatomic study. *J Oral Maxillofac Surg* 1995; 53:1178.
 15. Holzle FW, Wolff KD. Anatomic position of the lingual nerve in the mandibular third molar region with special consideration of an atrophied mandibular crest: an anatomical study. *Int J Oral Maxillofac Surg* 2001; 30:333.
 16. Miloro M, Halkias LE, Slone HW, Chakeres DW. Assessment of the lingual nerve in the third molar region using magnetic resonance imaging. *J Oral Maxillofac Surg* 1997;55:134.
 17. Harn SD, Durham TM. Incidence of lingual nerve trauma and postinjection complications in conventional mandibular block anesthesia. *J Am Dent Assoc* 1990;121:519.
 18. Pogrel MA, Bryan J, Regezi J. Nerve damage associated with inferior alveolar nerve blocks. *J Am Dent Assoc* 1995;126:1150.
 19. Pogrel MA, Thamby S. Permanent nerve involvement resulting from inferior alveolar nerve blocks. *J Am Dent Assoc* 2000; 131:901.
 20. Pogrel MA, Schmidt BL, Sambajon V, et al. Lingual nerve damage due to inferior alveolar nerve blocks: a possible explanation. *J Am Dent Assoc* 2003;134:195.
 21. Van Eeden SP, Patel MF. Letter: prolonged paraesthesia following inferior alveolar nerve block using articaine. *Br J Oral Maxillofac Surg* 2002;40:519.
 22. Stacy GC, Hajjar G. Barbed needle and inexplicable paresthesias and trismus after dental regional anesthesia. *Oral Surg Oral Med Oral Pathol* 1994;77:585.
 23. Pogrel MA, Schmidt BL. Trigeminal nerve chemical neurotrauma from injectable materials. *Oral Maxillofac Surg Clin North Am* 2001;13:247.
 24. Behrman S. Complications of sagittal osteotomy of the mandibular ramus. *J Oral Surg* 1972;35:554.
 25. Hegdvedt AK, Zuniga JR. Lingual nerve injury as a complication of sagittal ramus osteotomy. *J Oral Maxillofac Surg* 1990;48:647.
 26. Schow SR, Triplett RG, Solomon JM. Lingual nerve injury associated with overpenetration of bicortical screws used for rigid fixation of a bilateral sagittal split osteotomy. *J Oral Maxillofac Surg* 1996;54:1451.
 27. August M, Marchena J, Donady J, Kaban L. Neurosensory deficit and functional impairment after sagittal ramus osteotomy: a long-term follow-up study. *J Oral Maxillofac Surg* 1998;56:1231.
 28. Westermarck A, Bystedt H, von Konow L. Inferior alveolar nerve function after mandibular osteotomies. *Br J Oral Maxillofac Surg* 1998;36:425.
 29. Karas ND, Boyd SB, Sinn DP. Recovery of neurosensory function following orthognathic surgery. *J Oral Maxillofac Surg* 1990;48:124.
 30. Teerijoki-Oksa T, Jaaskelainen SK, Forssell K, et al. Risk factors of nerve injury during mandibular sagittal split osteotomy. *Int J Oral Maxillofac Surg* 2001;31:33.
 31. Nishioka GJ, Zysset MK, van Sickels JE. Neurosensory disturbance with rigid fixation of the bilateral sagittal split osteotomy. *J Oral Maxillofac Surg* 1987;45:20.
 32. Jones DL, Wolford LM. Intraoperative recording of trigeminal evoked potentials during orthognathic surgery. *Int J Adult Orthodon Orthognath Surg* 1990;5:167.
 33. Hallikainen D, Iizuka T, Lindqvist C. Cross-sectional tomography in evaluation of patients undergoing sagittal split osteotomy. *J Oral Maxillofac Surg* 1992;50:1269.
 34. Frerich B, Cornelius C-P, Wietholter H. Critical time of exposure of the rabbit inferior alveolar nerve to Carnoy's solution. *J Oral Maxillofac Surg* 1994;52:599.
 35. Loescher AR, Robinson PP. The effect of surgical medicaments on peripheral nerve function. *Br J Oral Maxillofac Surg* 1998;36:327.
 36. Block MS, Daire J, Stover J, Matthews M. Changes in the inferior alveolar nerve following mandibular lengthening in the dog using distraction osteogenesis. *J Oral Maxillofac Surg* 1993;51:652.
 37. Hu J, Zou S, Tang Z, et al. Response of Schwann cells in the inferior alveolar nerve to distraction osteogenesis: an ultrastructural and immunohistochemical study. *Int J Oral Maxillofac Surg* 2003;32:318.
 38. Hu J, Tang Z, Wang D, Buckley MJ. Changes in the inferior alveolar nerve after mandibular lengthening with different rates of distraction. *J Oral Maxillofac Surg* 2001;59:1041.
 39. Louis P. Inferior alveolar nerve transposition for endosseous implant placement: a preliminary report. *Oral Maxillofac Surg Clin North Am* 2001;13:265.
 40. Zuniga JR. Normal response to nerve injury: histology and psychophysics of degeneration and regeneration. *Oral Maxillofac Surg Clin North Am* 1992;4:323.
 41. Muller HW, Stoll G. Nerve injury and regeneration: basic insights and therapeutic interventions. *Curr Opin Neurol* 1998;11:557.
 42. Seddon JJ. Three types of nerve injury. *Brain* 1943; 66:237.
 43. Sunderland S. A classification of peripheral nerve injuries produced by loss of function. *Brain* 1951;74:491.
 44. Dellon AL, Mackinnon SE. Basic scientific and clinical applications of peripheral nerve regeneration. *Surg Annu* 1988;20:59.
 45. Coglán KM, Irvine GH. Neurological damage after sagittal split osteotomy. *Int J Oral Maxillofac Surg* 1986;15:369.
 46. Zuniga JR, Cheng N, Miller I, Phillips C. Regeneration of taste receptors and recovery of taste after lingual nerve repair. *J Oral Maxillofac Surg* 1994;52 Suppl 2:128.
 47. Zuniga JR, Meyer RA, Gregg JM, et al. The accuracy of clinical neurosensory testing for nerve injury diagnosis. *J Oral Maxillofac Surg* 1998;56:2.
 48. McDonald AR, Roberts TPL, Rowley HA,

- Pogrel MA. Noninvasive somatosensory monitoring of the injured inferior alveolar nerve using magnetic source imaging. *J Oral Maxillofac Surg* 1996;54:1968.
49. Scrivani SJ, Moses M, Donoff RB, Kaban LB. Taste perception after lingual nerve repair. *J Oral Maxillofac Surg* 2000;58:3.
 50. Hillerup S, Hjorting-Hansen E, Reumert T. Repair of the lingual nerve after iatrogenic injury: a follow-up study of return of sensation and taste. *J Oral Maxillofac Surg* 1994;52:1028.
 51. Padilla M, Clark GT, Merrill RL. Topical medications for orofacial neuropathic pain: a review. *J Am Dent Assoc* 2000;131:184.
 52. Gregg JM, Small EW. Surgical management of trigeminal pain with radiofrequency lesions of peripheral nerves. *J Oral Maxillofac Surg* 1986;44:122.
 53. Fardy MJ, Patton DW. Complications associated with peripheral alcohol injections in the management of trigeminal neuralgia. *Br J Oral Maxillofac Surg* 1994;32:387.
 54. Khullar S, Emami B, Westermark A, Haanes H. Effect of low-level laser treatment on neurosensory deficits subsequent to sagittal ramus osteotomy. *Oral Surg Oral Med Oral Pathol Oral Radiol Endod* 1996;82:132.
 55. Khullar S, Brodin E, Barkvoll B, Haanes H. Preliminary study of low-level laser treatment of long-standing sensory aberrations of the inferior alveolar nerve. *J Oral Maxillofac Surg* 1996;54:2.
 56. Miloro M, Repasky M. Low-level laser effect on neurosensory recovery after sagittal ramus osteotomy. *Oral Surg Oral Med Oral Pathol Oral Radiol Endod* 2000;89:12.
 57. Zuniga JR. Trigeminal ganglion cell response to mental nerve section and repair in the rat. *J Oral Maxillofac Surg* 1999;57:427.
 58. Pons TP. Massive cortical reorganization after sensory deafferentation in adult macaques. *Science* 1991; 252:1159.
 59. Dodson TB, Kaban LB. Recommendations for management of trigeminal nerve defects based on a critical appraisal of the literature. *J Oral Maxillofac Surg* 1997;55:1380.
 60. Smith KG, Roninson PP. An experimental study of three methods of lingual nerve defect repair. *J Oral Maxillofac Surg* 1995; 53:1052.
 61. LaBanc JP, Gregg JM. Trigeminal nerve injuries: basic problems, historical perspectives, early successes, and remaining challenges. *Oral Maxillofac Surg Clin North Am* 1992;4:277.
 62. Pogrel MA. The results of microneurosurgery of the inferior alveolar and lingual nerve. *J Oral Maxillofac Surg* 2002;60:485.
 63. Miloro M. Surgical access for inferior alveolar nerve repair. *J Oral Maxillofac Surg* 1995;53:1224.
 64. Joshi A, Rood JP. External neurolysis of the lingual nerve. *Int J Oral Maxillofac Surg* 2002; 31:40.
 65. Millesi H, Terzis JK. Nomenclature in peripheral nerve surgery. *Clin Plast Surg* 1984;11:3.
 66. Eppley BL, Snyders RV. Microanatomic analysis of the trigeminal nerve and potential nerve graft donor sites. *J Oral Maxillofac Surg* 1991;49:612.
 67. McCormick SU, Buchbinder D. Microanatomic analysis of the medial antebrachial cutaneous nerve as a potential donor nerve in maxillofacial grafting. *J Oral Maxillofac Surg* 1994;52:1022.
 68. Brammar JP, Epker BN. Anatomic-histologic survey of the sural nerve: implications for inferior alveolar nerve grafting. *J Oral Maxillofac Surg* 1988;46:111.
 69. Miloro M. Subjective outcomes following sural nerve harvest. *J Oral Maxillofac Surg* 2002;60 Suppl 1:75.
 70. Miloro M. Inferior alveolar nerve regeneration through an autogenous vein graft. *J Oral Maxillofac Surg* 1996;54:65.
 71. Pogrel MA, Maghen A. The use of autogenous vein grafts for inferior alveolar and lingual nerve reconstruction. *J Oral Maxillofac Surg* 2001;59:985.
 72. Miloro M. Discussion: the use of autogenous vein grafts for inferior alveolar and lingual nerve reconstruction. *J Oral Maxillofac Surg* 2001;59:988.
 73. Kitahara AK, Suzuki Y, Qi P. Facial nerve repair using a collagen conduit in cats. *Scand J Plast Reconstr Surg Hand Surg* 1999; 33:187.
 74. Eppley BL, Delfino JJ. Collagen tube repair of the mandibular nerve: a preliminary investigation in the rat. *J Oral Maxillofac Surg* 1996;46:41.
 75. DeFranzo AJ, Morykwas MJ, LaRosse JR. Autologous denatured muscle as a nerve graft. *J Reconstr Microsurg* 1994;10:145.
 76. Mackinnon SE, Dellon AL. Clinical nerve reconstruction with a bioabsorbable polyglycolic acid tube. *Plast Reconstr Surg* 1990;85:419.
 77. Eppley BL, Snyders RV, Winkelmann T. Efficacy of nerve growth factor in regeneration of the mandibular nerve: a preliminary report. *J Oral Maxillofac Surg* 1991;49:61.
 78. Miloro M, Macy J. Expanded polytetrafluoroethylene entubulation of the rabbit inferior alveolar nerve. *Oral Surg Oral Med Oral Pathol* 2000;89:292-8.
 79. Miloro M, Halkias L, Mallery S, et al. Low level laser effect on neural regeneration in Gore-Tex tubes. *Oral Surg Oral Med Oral Pathol Oral Radiol Endod* 2002;93:27-34.
 80. Pitta MC, Wolford LM, Mehra P, Hopkin J. Use of Gore-Tex tubing as a conduit for inferior alveolar and lingual nerve repair: experience with 6 cases. *J Oral Maxillofac Surg* 2001;59:493.
 81. Pogrel MA, McDonald AR, Kaban LB. Gore-tex tubing as a conduit for repair of lingual and inferior alveolar nerve continuity defects: a preliminary report. *J Oral Maxillofac Surg* 1998;56:319.
 82. Lydiatt DD. Litigation and the lingual nerve. *J Oral Maxillofac Surg* 2003;61:197.
 83. Deegan AE. The numbing truth. *Monitor* 1998;9:1.

APPENDIX Nerve Terminology Review*

allodynia: Pain due to a stimulus that does not normally provoke pain.

analgesia: Absence of pain in the presence of stimulation that would normally be painful.

anesthesia: Absence of any sensation in the presence of stimulation that would normally be painful or nonpainful.

anesthesia dolorosa: Pain in an area or region that is anesthetic.

atypical neuralgia: A pain syndrome that is not typical of classic nontraumatic trigeminal neuralgia.

axonotmesis (Seddon) or second- through fourth-degree injuries (Sunderland): Nerve injury characterized by axonal injury with subsequent degeneration and regeneration.

causalgia: Burning pain, allodynia, and hyperpathia after a partial injury of a nerve.

central pain: Pain associated with a primary central nervous system lesion (spinal cord or brain trauma, vascular lesions, tumors).

chemoreceptor: A peripheral nerve receptor that is responsive to chemicals, including catecholamines.

deafferentation pain: Pain occurring in a region of partial or complete traumatic nerve injury in which there is interruption of afferent impulses by destruction of the afferent pathway or other mechanism.

dysesthesia: An abnormal sensation, either spontaneous or evoked, that is unpleasant. All dysesthesias are a type of paresthesia but not all paresthesias are dysesthesias.

endoneurium: A connective tissue sheath surrounding individual nerve fibers and their Schwann cells.

epineurium: A loose connective tissue sheath that encases the entire nerve trunk.

fascicle: A bundle of nerve fibers encased by the perineurium.

hyperalgesia: An increased response to a stimulus that is normally painful.

hyperesthesia: An increased sensitivity to stimulation, excluding the special senses (ie, seeing, hearing, taste, and smell).

hyperpathia: A painful syndrome characterized by increased reaction to a stimulus, especially a repetitive stimulus. The threshold is increased as well.

hypoalgesia: Diminished pain in response to a normally painful stimulus.

hypoesthesia: Decreased sensitivity to stimulation, excluding the special senses (ie, seeing, hearing, taste, and smell).

mechanoreceptor: A peripheral nerve receptor preferentially activated by physical deformation from pressure and associated with large sensory axons.

mesoneurium: A connective tissue sheath, analogous to the mesentery of the intestine, that suspends the nerve trunk within soft tissue.

monofascicular pattern: Characteristic cross-section of a nerve containing one large fascicle.

neuralgia: Pain in the distribution of a nerve or nerves.

neurapraxia (Seddon) or first-degree injury (Sunderland): Nerve injury characterized by a conduction block, with rapid and virtually complete return of sensation or function and no axonal degeneration.

neuritis: A special case of neuropathy now reserved for inflammatory processes affecting nerves.

neurolysis: The surgical separation of adhesions from an injured peripheral nerve.

neuroma: An anatomically disorganized mass of collagen and nerve fascicles, and a functionally abnormal region of a peripheral nerve resulting from a failed regeneration following injury.

neuropathy: A disturbance of function or a pathologic change in a nerve.

neurotization: Axonal invasion of the distal nerve trunk.

neurotmesis (Seddon) or fifth-degree injury (Sunderland): Nerve injury characterized by severe disruption of the connective tissue components of the nerve trunk, with compromised sensory and functional recovery. Third-degree injury: Characterized by axonal damage and a breach of the endoneurial sheath, resulting in intrafascicular disorganization. The perineurium and epineurium remain intact. The mechanism is typically traction or compression.

Fourth-degree injury: Characterized by disruption of the axon, endoneurium, and perineurium, resulting in severe fascicular disorganization. The epineurium remains intact. Possible mechanisms include traction, compression, injection injury, and chemical injury. Fifth-degree injury: Characterized by

complete disruption of the nerve trunk with considerable tissue loss. Possible mechanisms include laceration, avulsion, and chemical injury.

nociceptor: A receptor preferentially sensitive to a noxious stimulus or to a stimulus that would become noxious if prolonged.

oligofascicular pattern: Characteristic cross-section of a nerve containing 2 to 10 rather large fascicles.

paresthesia: An abnormal sensation, either spontaneous or evoked, that is not unpleasant. A global term used to encompass all types of nerve injuries.

perineurium: A thick connective tissue sheath surrounding fascicles.

polyfascicular pattern: Characteristic cross-section of a nerve containing > 10 fascicles of different sizes, with a prevalence of small fascicles.

protopathia: The inability to distinguish between two different modes of sensation, such as a painful and nonpainful pinprick.

sympathetically mediated pain: A general term that refers to a family of related disorders including causalgia, reflex sympathetic dystrophy, minor causalgia, Sudeck's atrophy, and postherpetic neuralgia, which may be sympathetically maintained.

synesthesia: A sensation felt in one part of the body when another part is stimulated.

wallerian degeneration: The distal degeneration of the axon and its myelin sheath following injury.

*Adapted from LaBanc JP, Gregg JM. Glossary. Trigeminal nerve injury: diagnosis and management. *Oral Maxillofac Surg Clin North Am* 1992;4:563.

Cleft Lip and Palate: Comprehensive Treatment Planning and Primary Repair

Bernard J. Costello, DMD, MD

Ramon L. Ruiz, DMD, MD

The comprehensive treatment of cleft lip and palate deformities requires thoughtful consideration of the anatomic complexities of the deformity and the delicate balance between intervention and growth. Comprehensive and coordinated care from infancy through adolescence is essential in order to achieve an ideal outcome, and surgeons with formal training and experience in all of the phases of care must be actively involved in the planning and treatment.¹⁻³ Specific goals of surgical care for children born with cleft lip and palate include the following:

- Normalized esthetic appearance of the lip and nose
- Intact primary and secondary palate
- Normal speech, language, and hearing
- Nasal airway patency
- Class I occlusion with normal masticatory function
- Good dental and periodontal health
- Normal psychosocial development

Successful management of the child born with a cleft lip and palate requires coordinated care provided by a number of different specialties including oral/maxillofacial surgery, otolaryngology, genetics/dys-

morphology, speech/language pathology, orthodontics, prosthodontics, and others.⁴ In most cases care of patients with congenital clefts has become a subspecialty area of clinical practice within these different professions. In addition to surgery for cleft repair, treatment plans routinely involve multiple treatment interventions to achieve the above-stated goals. Because care is provided over the entire course of the child's development, long-term follow-up is critical under the care of these different health care providers. The formation of interdisciplinary cleft palate teams has served two key objectives of successful cleft care: (1) coordinated care provided by all of the necessary disciplines, and (2) continuity of care with close interval follow-up of the patient throughout periods of active growth and ongoing stages of reconstruction. The best outcomes are achieved when the team's care is centered on the patient, family, and community rather than a particular surgeon, specialty, or hospital. The idea of having an objective team that does not revolve around the desires of one particular individual or discipline is sometimes impeded by competitive interactions between surgical special-

ties. Historic battles over surgical domains between surgical specialties and economic factors contribute to these conflicts and negatively affect the work of the team. Healthy team dynamic and optimal patient care are achieved when all members are active participants, when team protocols and referral patterns are equitable and based on the surgeons' formal training and experience instead of specialty identity, and when the needs of the child are placed above the needs of the team.

This chapter presents an overview of the concepts for reconstruction of the cleft lip and palate deformity. The surgical reconstruction of clefts requires that the surgeon undertaking this important work maintain a cognitive understanding of the complex malformation itself, the varied operative techniques employed, facial growth considerations, and the psychosocial health of the patient and family. The objectives of this chapter will be to present the overall staged reconstructive approach for repair of cleft lip and palate from infancy through the time of skeletal maturity, as well as a focused discussion of the specific surgical procedures involved in primary cleft lip and palate repair. Secondary revision procedures, bone

graft reconstruction of the cleft maxilla, and orthognathic surgery for cleft-related dysmorphology are discussed in Chapter 43, “Reconstruction of the Alveolar Cleft,” Chapter 44, “Reconstruction of Cleft Lip and Palate: Secondary Procedures,” and Chapter 61, “Orthognathic Surgery in the Patient with Cleft Palate.”

History of Cleft Lip and Palate Repair

The history of cleft lip and palate care has always been closely linked to dentistry and oral and maxillofacial surgery. The birth and roots of what is now the American Cleft Palate-Craniofacial Association are strongly rooted in dentistry.

The first documented cleft lip repair was performed in AD 390 on a patient who later became the Governor General of several regions in China, although nothing is known about the actual surgeon.^{5,6} Jehan Yperman is believed to have been the first to describe unilateral and bilateral cleft lip repair.^{6,7} The first diagrammatic representation of cleft lip repair and cleft palate obturator use is credited to Ambrose Pare in the fourteenth century.^{6,8} Much later the first documented successful cleft palate repair was performed by a dentist, Le Monnier, in 1766 in Paris.^{6,9} The concepts of cleft lip and palate repair have evolved from straight line repairs to a variety of techniques using various cutbacks, triangles, and Z-plasties.⁶⁻¹⁴ During the 1950s, Asensio, an oral and maxillofacial surgeon from Guatemala, developed a novel technique for cleft lip repair, which involved the rotation of the philtral segment inferiorly and advancement of the lateral segment medially using a quadrangular flap. Although he used this approach in Guatemala throughout the 1950s, he did not report it until much later.^{15,16} Ralph Millard of Miami described his classic rotational-advancement technique in the mid-1950s, and his concepts changed cleft repair forever.^{17,18} Millard is credited with perhaps the most important technical development related to cleft lip

repair, and today the majority of surgeons use his original technique or some close modification of it.

In the mid-nineteenth century, Hüllihen, recognized as the father of American oral and maxillofacial surgery, published a treatise on comprehensive care of cleft lip and palate deformities.¹⁹ Another pioneer, Truman Brophy, was the professor of oral surgery and dean of the Chicago College of Dentistry and contributed greatly to the care of many patients with clefts. Brophy published a text detailing his experiences with the management of various malformations of the mouth and their surgical repairs including the details of cleft repair.²⁰ One of his pupils was Chalmers Lyons who started a residency program in oral surgery at the University of Michigan in 1917.²⁰ Lyons developed the largest cleft practice in America and contributed extensively to the literature.²⁰

Many of the concepts related to interdisciplinary care with a cleft palate team care were introduced by Robert Ivy, an oral and maxillofacial surgeon who later became dually qualified in plastic surgery.²⁰ Robert Ivy trained both in dentistry and medicine at the University of Pennsylvania. After his training in dentistry, Ivy further developed his interests in maxillofacial surgery as an assistant to his uncle, Matthew Cryer, who was a professor in oral surgery at the University of Pennsylvania. Robert Ivy became interested in clefts during his training as the first dental intern at Philadelphia General Hospital at the University of Pennsylvania. His interests in maxillofacial injury led him to serve in France in World War I as an assistant to Vilray Blair. After the war Ivy and Blair's collaboration resulted in two landmark publications by Ivy, *Essentials of Oral Surgery* and *Fractures of the Jaws*. Through work with his state representatives in Harrisburg, Pennsylvania, he was able to start the very first cleft palate clinics in Lancaster, Pittsburgh, Philadelphia, Erie, and Scranton that provided interdisciplinary

care to children for cleft lip and palate deformities. When Reed Dingman put forth a resolution of the American Society of Maxillofacial Surgeons condemning oral and maxillofacial surgeons practicing in the hospital setting, Ivy resigned his membership and sent a letter of protest to the organization that he helped build in support of his dental colleagues.²⁰

In the 1950s the concept of primary or early bone grafting of the cleft maxillary defect was introduced by Schmid.²¹ Although the concept was initially met with enthusiasm from a number of surgeons, primary bone grafting was eventually abandoned due to unfavorable outcomes. During the decades that followed, the negative skeletal, dental, and growth-related consequences of primary bone grafting became better understood.^{22,23} During the early 1970s oral and maxillofacial surgeons Boyne and Sands were the first to publish their favorable outcomes using autogenous particulate bone grafts for reconstruction of the cleft maxilla/alveolus later in childhood during the mixed dentition rather than earlier in life.²⁴ Although their work and results represented a landmark discovery in the field of cleft reconstruction, cleft palate teams were slow to integrate his approach into their treatment protocols because of the negative associations that lingered following the days of primary bone grafting. Today their principles of secondary bone grafting represent the standard approach for almost all of the world's cleft centers.^{24,25}

Orthognathic reconstruction of the patient with cleft deformities has been discussed by many authors.²⁶⁻³⁶ Early techniques limited some surgeons' options to procedures centered on mandibular setback.³⁷ During the 1970s the use of total maxillary osteotomy was pioneered by Bell.³⁸ His novel ideas provided oral and maxillofacial surgeons with an understanding of the biologic basis for maxillary osteotomy, described the vascular supply that allowed the procedures to be performed safely, and as a result incorporated

the Le Fort I osteotomy into modern-day practice.³⁸ Since that time a number of technical refinements have been described for use of the Le Fort I osteotomy specifically in the cleft patient. Much of this work has been done by two of Bell's former pupils, Fonseca and Turvey, who went on to make substantial contributions to the skeletal reconstruction of patients with clefts.³⁹ Another dual qualified oral and maxillofacial surgeon, Posnick, has published the most complete descriptions of surgical technique modifications for patients undergoing midfacial advancement in the absence of prior bone graft reconstruction and his extensive experiences with the long-term stability of midfacial advancement after correction of various types of cleft deformities with orthognathic techniques.²⁶⁻³⁰ Distraction osteogenesis has gained recent popularity for correction of midfacial hypoplasia but has yet to show significant advantages over traditional techniques for the majority of patients.^{32,33,40-42}

Comprehensive and coordinated care has become more prevalent across the world, involving many different types of specialty care for children with clefts. Posnick has provided the most comprehensive, succinct, and evidenced-based discussions on the topic of cleft lip and palate reconstruction from infancy through adolescence.²⁶ These efforts as well as craniofacial training programs associated with oral and maxillofacial surgery have helped to solidify the role of oral and maxillofacial surgery in the comprehensive care of patients with clefts.

Embryology

To understand the goals of lip and palate repair from an anatomic standpoint the cleft surgeon must have an appreciation for the failure of embryogenesis that results in clefting. There are critical points in the development of the fetus when the fusion of various prominences creates continuity and form to the lip, nose, and palate. Anomalies occur when the normal developmental

process is disturbed between these components. Each of these prominences is made up of ectomesenchyme derived from neural crest tissue of the mesencephalon and rhombencephalon. Mesoderm is also present within these prominences as mesenchymal tissue. The prescribed destiny of each of these cells and tissues is controlled by various genes to alter the migration, development, and apoptosis and form the normal facial tissues of the fetus. At the molecular level there are many interdependent factors such as signal transduction, mechanical stress, and growth factor production that affect the development of these tissues. Currently only portions of this complex interplay of growth, development, and apoptosis are clear.

At approximately 6 weeks of human embryologic development the median nasal prominence fuses with the lateral nasal prominences and maxillary prominences to form the base of the nose, nostrils, and upper lip. The confluence of these anterior components becomes the primary palate. When this mechanism fails, clefts of the lips and/or maxilla occur. At approximately 8 weeks the palatal shelves elevate and fuse with the septum to form the intact secondary palate. When one palatal shelf fails to fuse with the other components, then a unilateral cleft of the secondary palate occurs. If both of the palatal shelves fail to fuse with each other and the midline septum, then a bilateral cleft of the palate occurs.

Fusion occurs when programmed cell death (apoptosis) occurs at the edges of the palatal shelves. The ectodermal component disintegrates and the mesenchyme fuses to form the intact palate. Soon after this the anterior primary palate fuses with the secondary palate and ossification occurs. At any point, if failure of fusion occurs with any of the above components, a cleft will occur of the primary and/or secondary palates. Clefts may be complete or incomplete based on the degree of this failure of fusion.

Genetics and Etiology

Clefts of the upper lip and palate are the most common major congenital craniofacial abnormality and are present in approximately 1 in 700 live births.⁴³ Although inheritance may play a role, cleft lip and palate is not considered a single-gene disease. Instead clefts are thought to be of a multifactorial etiology with a number of potential contributing factors. These factors may include chemical exposures, radiation, maternal hypoxia, teratogenic drugs, nutritional deficiencies, physical obstruction, or genetic influences. One prevailing theory relates the process of clefting as a threshold in which multiple factors come together to raise the individual above a threshold at which time the mechanism of fusion fails.^{44,45} Recently multiple genes have been implicated in the etiology of clefting.⁴⁶⁻⁴⁸ Some of these genes include the *MSX*, *LHX*, *gooseoid*, and *DLX* genes. Additional disturbances in growth factors or their receptors that may be involved in the failure of fusion include fibroblast growth factor, transforming growth factor- β , platelet-derived growth factor, and epidermal growth factor.

Clefts of the lip occur more commonly in males than in females.⁴⁹ In addition left-sided cleft lips are more common than right-sided cleft lips, and unilateral cleft lips are more common than the bilateral cleft of the lip.⁵⁰ Bilateral clefts of the lip are most often associated with clefting of both the primary and secondary palates. Cleft palate alone is seen in approximately 1 in 2,000 live births and this incidence is similar in all racial groups.⁵¹ Significant differences in the prevalence of clefts exist when specific ethnic/racial populations are examined. For example, African Americans have a birth prevalence that is less common than the total population, but Asians tend to have a higher prevalence.

In the majority of cases unilateral cleft lip and palate is an isolated nonsyndromic

birth defect that is not associated with any other major anomalies.^{43,52,53} By comparison a much greater proportion of patients with an isolated cleft palate will have an associated syndrome or sequence.^{43,53} Some of the more common syndromes seen in this group include Stickler's, Van der Woude's, or DiGeorge syndromes. It is important to identify the diagnosis early, as functional issues may arise early in life and go unnoticed. For example, patients with an isolated cleft palate should be evaluated early by an experienced pediatric ophthalmologist to evaluate the possibility of Stickler's syndrome. Patients with Stickler's syndrome may have ocular abnormalities that lead to retinal detachment. In an otherwise healthy-appearing child these findings may be difficult to diagnose and so early visual loss may go unnoticed. In many cases long-term genetics follow-up is necessary to make a definitive diagnosis and to provide genetic counseling.

The chances of a recurrence of clefting within a family are dependent on many factors, including family history, severity, gender, degree of relationship to

the affected individual, and the expression of a syndrome. Predicting the inheritance patterns of families who have a history of cleft lip and/or palate can be complicated. A skilled geneticist/dysmorphologist is best equipped to make these determinations based on pedigree analysis and genetic testing. Since most clefts are sporadic the chances of a family having another child with a cleft after having a child with a unilateral cleft lip and palate in which there was no family history of clefting is approximately 2 to 4%. The chances are higher if additional family history is present or if the cleft is bilateral.^{54,55} The nature of any genetic influence will have an effect on the presence of a cleft. Such is the case in patients with autosomal dominant syndromes such as Stickler syndrome where 50% of the children may express the syndrome if one of the parents carries the altered gene.

Classification

The typical classification system used clinically to describe standard clefts of the lip and palate is based on careful anatomic description. Clefts can be unilateral or

bilateral; microform, incomplete, or complete; and may involve the lip, nose, primary palate, and/or secondary palates (Figure 42-1). The presentation of clefts is extremely variable, and the individual repairs are custom-tailored to achieve the best symmetry and balance. More severe facial clefting is most commonly described using Tessier's orbitocentric system of numbering (Figure 42-2).⁵⁶ Other systems exist that are based on embryologic fusion planes, but these are cumbersome to use in routine clinical practice.⁵⁷

Prenatal Counseling

Recent advances in ultrasound imaging have revolutionized prenatal care and maternal-fetal medicine. Currently ultrasound images of clefts of the lip can be visualized as early as 16 weeks.⁵⁸⁻⁶⁰ Diagnostic images of the palate are more difficult to acquire, making the correct prenatal diagnosis of a cleft palate less predictable. Palatal structures may be visualized using sagittal and coronal views, but this currently requires the very latest technology and a skilled ultrasonographer with experience performing this type of study.

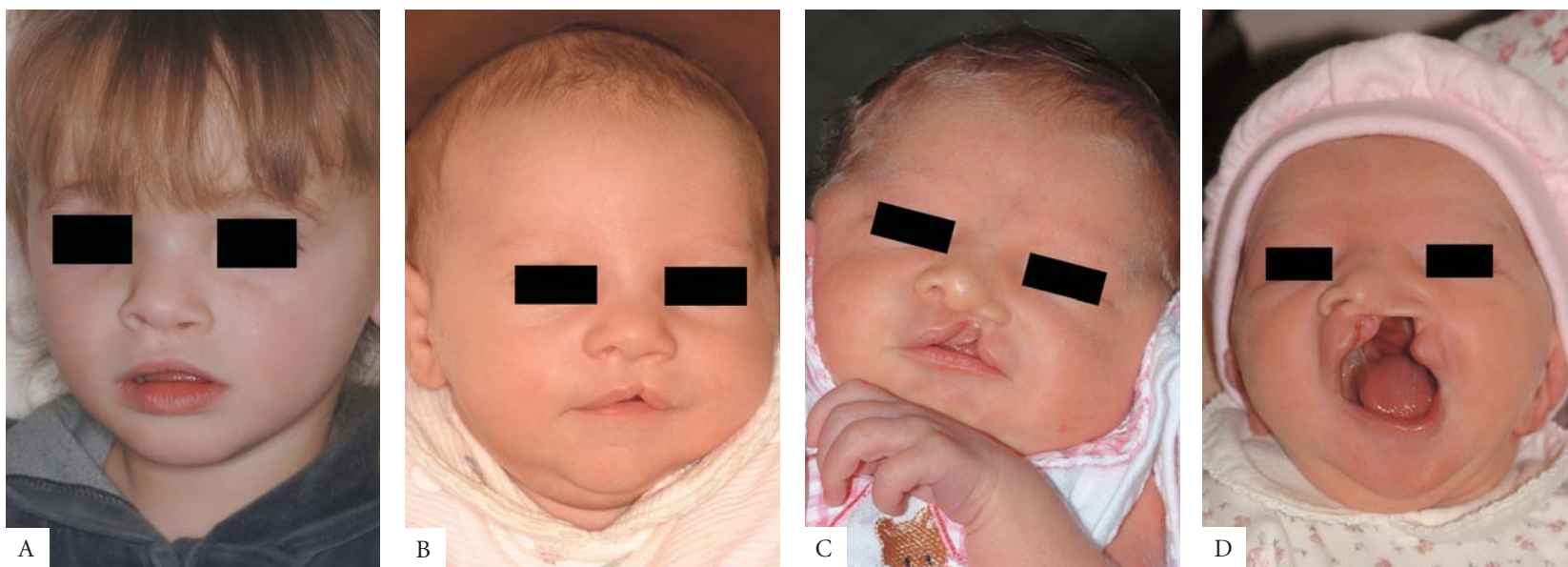

FIGURE 42-1 Cleft lips come in a variety of configurations, such that each repair must be customized to establish the most normal morphology. A, Microform left unilateral cleft lip only, not requiring primary repair. B, Minor left incomplete unilateral cleft lip only. C, Left incomplete unilateral cleft lip and palate with a Simonart's band. D, Wide left complete unilateral cleft lip and palate.

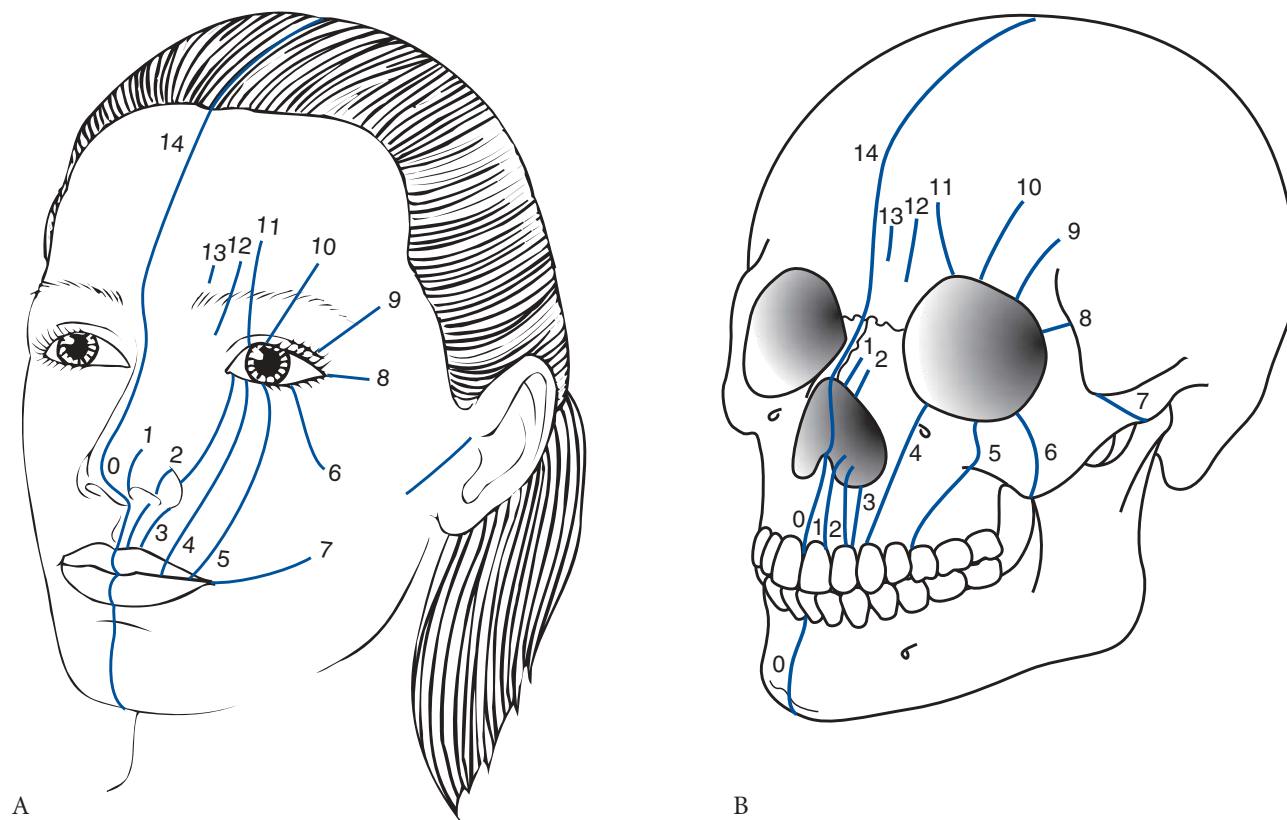


FIGURE 42-2 A and B, Complex facial clefts can be classified based on Tessier's original orbitocentric system of numbering. Clefts may involve all tissue planes including skin, mucosa, bone, teeth, muscle, brain, peripheral nerve, and other specialized tissues.

When the diagnosis of cleft lip is made during pregnancy the family can then be referred to an experienced surgeon for a prenatal discussion. A prenatal consultation provides an excellent opportunity to explain the diagnosis, review the different stages of cleft lip and palate reconstruction that may be necessary, and prepare the parents for practical considerations such as feeding of a child with a cleft palate. This gives the family the opportunity to ask questions, calm fears, and learn about feeding techniques that will be important during the first week of life for their baby. Parents are empowered with this new knowledge, and the preparations made during a prenatal consultation allow them to anticipate the delivery of their baby with a greater comfort level regarding the necessary care of the child during the early postnatal period. The family is then referred to a cleft and craniofacial team in order to undergo a more thorough interdisciplinary approach.

Critical to this process is consultation with a geneticist/dysmorphologist to further discuss the issues associated with the birth and the possibility of other associated deformities. Additional testing may be warranted to evaluate the possibility of associated deformities, syndromes, or sequences that could affect the birthing process. Exceptionally skilled ultrasonographers can visualize airway development and other abnormalities that may require early intervention with fetal surgery, exit procedures, extracorporeal membrane oxygenation, or surgical airway management (tracheotomy) at the time of delivery.

In some medical centers fetal diagnosis and treatment teams are in place to deal with issues associated with various deformities diagnosed in the prenatal period. These teams foster a cohesive environment where information is exchanged through consultation. Much like in the environment of a cleft and craniofacial team, fam-

ilies can get the best information available to consider their child's treatment decisions using an interdisciplinary care model that is patient (mother and fetus), family, and community oriented.

Feeding Concerns

Children born with isolated cleft lip can feed quite well and even have the opportunity to breastfeed in most instances. However, infants with cleft palate can have difficulty feeding due to the inability to form an adequate seal between the tongue and palate for creation of sufficient negative pressure to suck fluid from a bottle. Nasal regurgitation and inefficient handling of secretions and foodstuffs may also be observed during early development. Specialized nipples and bottles are necessary to improve feeding immediately after birth. The most useful devices combine oversized nipples with reservoir spaces and large openings, a squeezable bottle to push fluid

into the nipple assembly, and a one-way valve that allows the bolus of fluid to pass from the bottle to the nipple only in order to minimize the amount of work the child must perform to feed. These include a variety of nipples with reservoirs that collect a variable volume of liquid that can be expressed more easily when sucking is inefficient or not possible. Bottles that can be squeezed to allow for manual flow of liquid to the infant are helpful for improving feeding. No single bottle and nipple combination tends to work better than another, but trials with a variety of types using different techniques are helpful in optimizing feeding early in life. Close attention to weight gain is necessary for these children. Generally, in 24 hours each infant should have approximately 2 to 3 ounces of milk for each pound of weight. Feeding sessions should last no longer than 35 minutes as longer sessions are fatiguing and burn more calories than the baby can consume. Infants should be weighed at least weekly using the same scale, preferably at their pediatrician's office.

The subject of breast-feeding an infant with a cleft palate is controversial, with some practitioners encouraging the practice and others strongly opposed to it. There are clear advantages to breast-feeding a newborn, including passive immunologic contribution of the mother to the child in the form of secretory immunoglobulin A and an experience that enhances bonding between the mother and child during such a critical period.^{61,62} At the same time the infant's inability to create negative oral pressure will often make successful nursing difficult, if not impossible. It is relatively common to encounter an exclusively breast-fed infant with severe dehydration and failure to thrive secondary to these difficulties. This is especially a concern in infants that have a wide cleft of the secondary palate, where breast-feeding may not be possible. The authors' approach with regard to breast-feeding in the presence of a cleft palate is

to use a combined protocol that includes intermittent feeding with the use of a specialized bottle (as described above) and attempts at nursing. Breast milk may be pumped for use with the specialized nipple and bottle that will provide the nutritional and immunologic benefits desired. This also allows the parents to keep a more quantitative record of how many ounces have been ingested over the course of the day since this is normally difficult with breast-feeding alone. At the same time the mother and baby are not deprived of an opportunity to incorporate breast-feeding into the daily regimen. This approach obviously requires rigorous documentation of the child's weight, consultation with a lactation consultant and infant feeding specialist, and frequent follow-up evaluations through the surgeon and/or pediatrician.

Treatment Planning and Timing: Overview

The timing of cleft lip and palate repair is controversial. Despite a number of meaningful advancements in the care of patients with cleft lip and palate, a lack of consensus exists regarding the timing and specific techniques used during each stage of cleft reconstruction. Surgeons must continue to carefully balance the functional needs, esthetic concerns, and the issue of ongoing growth when deciding how and when to intervene. In no other type of surgical problem is the issue of early surgery's effect on growth more apparent than in the treatment of cleft lip and palate deformities. The decision to surgically manipulate the tissues of the growing child should not be made lightly and should take into account the possible growth restriction that can occur with early surgery. Nevertheless many patients with congenital deformities will benefit from surgical intervention based on functional or psychosocial reasons. Understanding the growth and development of the craniofacial skeleton is critical to the treatment

planning process.³³ In many cases waiting for a greater degree of growth to occur is advantageous unless compelling functional or esthetic issues are present that can not or should not wait.

Due to many different treatment philosophies the timing of treatment interventions is considerably variable amongst cleft centers. Therefore, it is difficult to produce a timing regimen that everyone agrees on. Each stage of surgical reconstruction and the suggested timing based on the patient's age are presented in Table 42-1. Special considerations may alter the sequencing or timing of the various procedures based on individual functional or esthetic needs.

Cleft lip repair is generally undertaken at some point after 10 weeks of age. One advantage of waiting until the child is 10 to 12 weeks of age is that it allows a complete medical evaluation of the patient so that any associated congenital defects affecting other organ systems (eg, cardiac or renal anomalies) may be uncovered. The surgical procedure itself may be easier when the child is slightly larger and the anatomic landmarks more prominent and well defined. Historically the anesthetic risk-related data suggested that the safest time period for surgery in this population of infants could be outlined simply by using the "rule of 10's." This referred to the idea of delaying lip repair until the child was at least 10 weeks old, 10 pounds in weight, and with a minimum hemoglobin value of 10 dL/mg.^{63,64} Today more sophisticated pediatric techniques, advances in intraoperative monitoring, and improved anesthetic agents have all resulted in the ability to provide safe general anesthesia much earlier in life.⁶⁵ Despite the ability to provide safe anesthesia earlier in life, there is no measurable benefit to performing lip repair prior to 3 months of age.^{64,66,67} Some surgeons have advocated that lip repair be carried out in the first days of infancy based on the idea of capitalizing on early "fetal-like" healing. Unfortunately these hoped-for benefits have not been

Table 42-1 Staged Reconstruction of Cleft Lip and Palate Deformities

Procedure	Timing
Cleft lip repair	After 10 weeks
Cleft palate repair	9–18 months
Pharyngeal flap or pharyngoplasty	3–5 years or later based on speech development
Maxillary/alveolar reconstruction with bone grafting	6–9 years based on dental development
Cleft orthognathic surgery	14–16 years in girls, 16–18 years in boys
Cleft rhinoplasty	After age 5 years but preferably at skeletal maturity; after orthognathic surgery when possible
Cleft lip revision	Anytime once initial remodeling and scar maturation is complete but best performed after age 5 years

observed, and problems with excessive scarring and less favorable outcomes have been encountered instead.^{68–70} Children may have more scarring at this early age, and their tissues are smaller and more difficult to manipulate. Consequently the esthetic outcomes may be worse if surgery is performed at an earlier age, and since there are no clear benefits to earlier repair the recommendations for repair stand at approximately 3 months of age.

Cleft palate repair is usually performed at approximately 9 to 18 months of age. In deciding the timing of repair the surgeon must consider the delicate balance between facial growth restriction after early surgery and speech development that requires an intact palate. Most children will require an intact palate to produce certain speech sounds by 18 months of age. If developmental delay is present and speech will not likely develop until later, then the repair can be delayed further. There is little evidence to suggest any benefit to palate repair prior to 9 months of age.^{71–73} Repairs prior to this time are associated with a much higher incidence of maxillary hypoplasia later in life and show no improvements in speech. For these reasons most surgeons will perform primary palate repair at approximately 9 to 12 months of age.

As the child continues to develop, approximately 20% of children will have inadequate closure of the velopharyngeal

mechanism (velopharyngeal insufficiency or VPI), and this may produce hypernasal speech.⁷⁴ These children are usually diagnosed at 3 to 5 years of age when a detailed speech examination can be obtained by a skilled speech pathologist familiar with clefts. When VPI is shown to be consistent and due to a definable anatomic defect, surgery is often helpful in correcting this problem. A pharyngeal flap or sphincter pharyngoplasty may be used to treat VPI, with the goal of improving closure between the oral and nasal cavities and reducing nasal air escape during the production of certain sounds. The details of assessment, diagnosis, and treatment of VPI associated with cleft palate are discussed in Chapter 44, “Reconstruction of Cleft Lip and Palate: Secondary Procedures.” Approximately 75% of patients with any type of cleft will present with clefting of the maxilla and alveolus.^{24–26} Bone graft reconstruction of this site is performed during the mixed dentition prior to the eruption of the permanent canine and/or the permanent lateral incisor. The timing of this procedure is based on dental development and not chronologic age. Based on work by Boyne and Sands, most surgeons reconstruct this area during the mixed dentition prior to eruption of the permanent canine. Earlier reconstruction of this area has been associated with a high degree of maxillary

growth restriction requiring orthognathic correction later in life in a much higher percentage of patients.^{22,24} The gold standard for reconstruction in this area is autogenous bone from the anterior iliac crest. Cranial bone, rib, tibia, symphysis of the mandible, zygoma, and allogeneic bone have all been studied, but none have been shown to be appreciably better than the iliac crest.^{26,75,76}

Orthognathic reconstruction of maxillary and mandibular discrepancies is performed at 14 to 18 years of age based on individual growth characteristics.^{26–36,38} This is done in conjunction with orthodontics prior to and after surgery. However, in some cases of severe maxillary hypoplasia, early Le Fort I osteotomy may be performed to optimize facial esthetics and occlusion with the supposition that revision osteotomies will likely be necessary. These early osteotomies may complicate later treatment. Early orthognathic correction is reserved for the most severe dysmorphology, and in most cases the authors prefer standard orthognathic techniques.^{31–33} Attempts at using distraction osteogenesis have been associated with a higher complication rate than with standard orthognathic techniques.^{32,42,77} Orthognathic correction of the deformities associated with cleft lip and palate defects is discussed in Chapter 61, “Orthognathic Surgery in the Patient with Cleft Palate.”

As with the timing of other interventions, lip and nasal revision is best reserved until after the majority of growth is complete. Most of the lip and nasal growth is complete after age 5 years. Lip revision can be considered prior to school age at about 5 years of age. However, this may be performed earlier if the deformity is severe. Nasal revision is performed after age 5 years as most of the nasal growth is also complete by this time. If orthognathic reconstruction is likely, then rhinoplasty is usually best performed after orthognathic surgery as maxillary advancement improves many characteristics of nasal

support. However, when nasal deformity is particularly severe, rhinoplasty can be considered earlier even if orthognathic surgery is expected. Multiple early revisions of the lip or nose should be avoided so that excess scarring does not potentially impair ongoing growth. Secondary revisions of cleft lip and palate deformities are discussed in Chapter 44, “Reconstruction of Cleft Lip and Palate: Secondary Procedures.”

Cleft Lip and Palate Repair

Presurgical Taping and Presurgical Orthopedics

Facial taping with elastic devices is used for application of selective external pressure and may allow for improvement of lip and nasal position prior to the lip repair procedure. In the authors’ opinions these techniques often have greater impact in cases of wide bilateral cleft lip and palate where manipulation of the premaxillary segment may make primary repair technically easier. Although one of the basic surgical tenets of wound repair is to close wounds under minimal tension, attempts at improving the arrangement of the segments using taping methods have not shown a measurable improvement.^{78–80}

Some surgeons prefer presurgical orthopedic (PSO) appliances rather than lip taping to achieve the same goals.^{81,82} PSO appliances are composed of a custom-made acrylic base plate that provides improved anchorage in the molding of lip, nasal, and alveolar structures during the presurgical phase of treatment (Figure 42-3). Although the use of appliances probably makes for an easier surgical repair, there has been a lack of clinical evidence to demonstrate that there is any measurable improvement in esthetics of the nose or lip, dental arch relationship, tooth survival, or occlusion. Studies have looked at the dental arch relationship outcomes in patients who have infant presurgical orthopedic devices, and no improvement in dental arch relationship was seen.^{83,84} Addition-

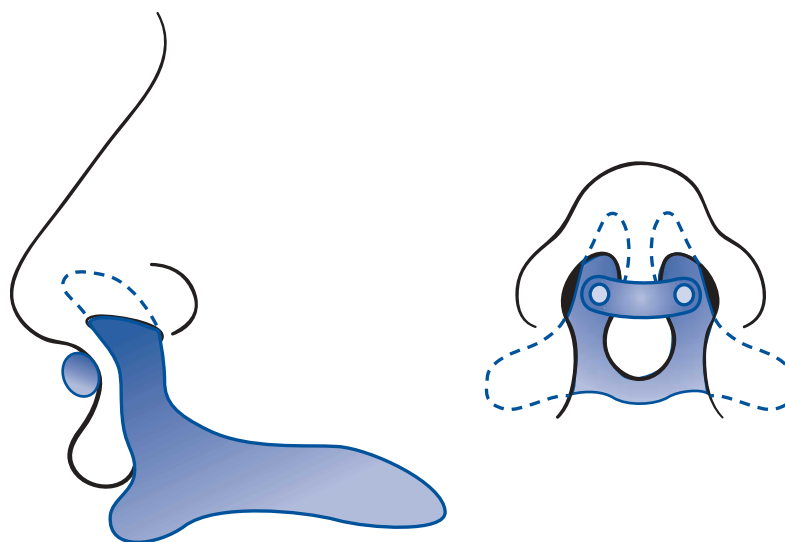


FIGURE 42-3 Frontal and lateral views of the Grayson nasoalveolar molding appliance showing the nasal projections that help to theoretically mold the nasal cartilages and maxillary segments into a more appropriate configuration prior to repair.

ally no long-term improvement in speech outcome has been demonstrated in patients who had PSOs.⁸⁵ Furthermore concerns regarding potential negative consequences with these types of appliances have been raised.⁸⁶ PSOs also add significant cost and time to treatment early in the child’s life. Many appliances require a general anesthetic for the initial impression used to fabricate the device. Frequent appointments are necessary for monitoring of the anatomic changes and periodic appliance adjustment.

The Latham appliance was popular for expanding and aligning the maxillary segments of the patient with a cleft palate.⁸⁷ It is a pin-retained device that is inserted into the palate with acrylic extensions onto the alveolar ridges. A screw mechanism is then used to manipulate the segments as desired. The Latham appliance has been shown to be associated with significant growth restriction of the midface when used in infancy to approximate the segments prior to definitive repair.⁸⁶ Children who have had Latham appliances have been shown to have significant midfacial growth restriction in adolescence 100% of the time whereas children who have not had the

Latham appliance have midface hypoplasia 25 to 35% of the time.^{42,80,86}

The nasoalveolar molding appliance has become popular with some surgeons in attempts to manipulate the segments without pin retention prior to lip and nose repair (see Figure 42-3). The appliance popularized by Grayson is adjustable by removing or adding acrylic and manipulating protrusive elements that attempt to mold the nasal cartilages. This device attempts to align the alveolar segments, lip structures, and nasal cartilages to optimize repair. Unfortunately the hoped-for advantages of this appliance have not been realized. Additionally no long-term data are available regarding growth in the craniofacial skeleton after using this protocol. The limited short-term data that are available cannot be extrapolated to determine the ultimate outcome on growth, function, or esthetics. Some surgeons use gingivoperiosteoplasty in conjunction with the PSO, using limited flaps to close the alveolus cleft during the primary repair of the lip or palate. Many surgeons who use this appliance in conjunction with their primary lip repairs will perform a gingivoperiosteoplasty in attempts to have bone form at the

alveolus. This is more easily performed with the segments aligned in close proximity as the flaps are small.⁸² Experiences with similar techniques in the 1960s involving primary bone grafting were poor with respect to growth.^{22,23} Additionally there has been no convincing long-term objective data showing improvement in either lip or nose esthetics.

In their current state of technical refinement there is no evidence that any of the PSOs offer an improved outcome with respect to esthetics, function, or growth in patients with cleft lip and palate. Coupled with the fact that appliances are time-consuming and have a high cost of fabrication and utilization, it is difficult to advocate their uniform use. As with other interventions considered for patients with clefts, costly and unproven interventions should be avoided, although they may prove to be helpful in some select cases.⁸⁸ Hopefully, long-term data will be forthcoming and positive to help determine which patients may benefit from PSO appliance treatment.

Lip Adhesion

Some surgeons attempt to surgically approximate the segments of the cleft lip prior to definitive lip repair in an attempt to achieve a better relationship of both the lip structures and the dental arches.⁸⁹⁻⁹¹ This is achieved by advancing small flaps of tissue across the cleft site. While some surgeons advocate the use of this technique in wide bilateral clefts, it is rarely performed in unilateral cases. When used, the lip adhesion is usually completed at 3 months of age. In most cases this will convert a wide complete cleft into a wide incomplete cleft as the scar will eventually be excised from the cleft site recreating a similar wide deformity. The definitive lip repair is then completed 3 to 9 months later by excising the scar and reapproximating the remaining lip structures. Furthermore at the second procedure there is usually less supple tissue to work with

when performing the definitive repair due to scarring. As with most endeavors in cleft surgery, repeated early interventions tend to complicate later refinements due to excessive scarring. In general adequate mobilization of the flaps in one stage will make tension-free skin closure possible in almost every case without the need for taping, presurgical orthopedic appliances, and/or lip adhesion.

Unilateral Cleft Lip Repair

Clefts of the lip and nose that are unilateral present with a high degree of variability, and thus each repair design is unique (see Figure 42-1).^{26,92} The repair technique preferred by the authors for cleft lip and nasal deformities is shown in Figures 42-4 and 42-5 and is usually performed after 10 weeks of age.^{17,18,26,63} The basic premise of the repair is to create a three-layered closure of skin, muscle, and mucosa that approximates normal tissue and excises hypoplastic tissue at the cleft margins. Critical in the process is the reconstruction of the orbicularis oris musculature into a continuous sphincter. The Millard rotation-advancement technique has the advantage of allowing for each of the incision lines to fall within the natural contours of the lip and nose. This is an advantage because it is difficult to achieve “mirror image” symmetry in the unilateral cleft lip and nose with the normal side immediately adjacent to the surgical site. A Z-plasty technique such as the Randall-Tennison repair may not achieve this level of symmetry because the Z-shaped scar is directly adjacent to the linear nonclefted philtrum (Figure 42-6). Achieving symmetry is more difficult when the rotation portion of the cleft is short in comparison to the advancement segment.

Primary nasal reconstruction may be considered at the time of lip repair to reposition the displaced lower lateral cartilages and alar tissues. Several techniques are advocated, and considerable variation exists with respect to the exact nasal reconstruc-

tion performed by each surgeon.^{93,94} The primary nasal repair may be achieved by releasing the alar base, augmenting the area with allogeneic subdermal grafts, or even a formal open rhinoplasty. Since lip repair is done at such an early point in growth and development, the authors prefer minimal surgical dissection due to the effects of scarring on the subsequent growth of these tissues. McComb described a technique that has become popular, consisting of dissecting the lower lateral cartilages free from the alar base and the surrounding attachments through an alar crease incision.^{93,95-97} This allows the nose to be bolstered and/or stented from within the nostril to improve symmetry.

Bilateral Lip Repair

Bilateral cleft lip repair can be one of the most challenging technical procedures performed in children with clefts. The lack of quality tissue present and the widely displaced segments are major challenges to achieving exceptional results, but superior technique and adequate mobilization of the tissue flaps usually yields excellent esthetic results (Figures 42-7–42-10). Additionally the columella may be quite short in length, and the premaxillary segment may be significantly rotated. Adequate mobilization of the segments and attention to the details of only using appropriately developed tissue will yield excellent results even in the face of significant asymmetry.

Some surgeons have used aggressive techniques to surgically lengthen the columella and preserve hypoplastic tissue using banked fork flaps.^{98,99} Early and aggressive tissue flaps in the nostril and columella areas do not look natural after significant growth has occurred and result in abnormal tissue contours. While surgical attempts at lengthening the columella may look good initially, they frequently look abnormally long and excessively angular later in life (Figure 42-11). Revision of these iatrogenic deformities is difficult

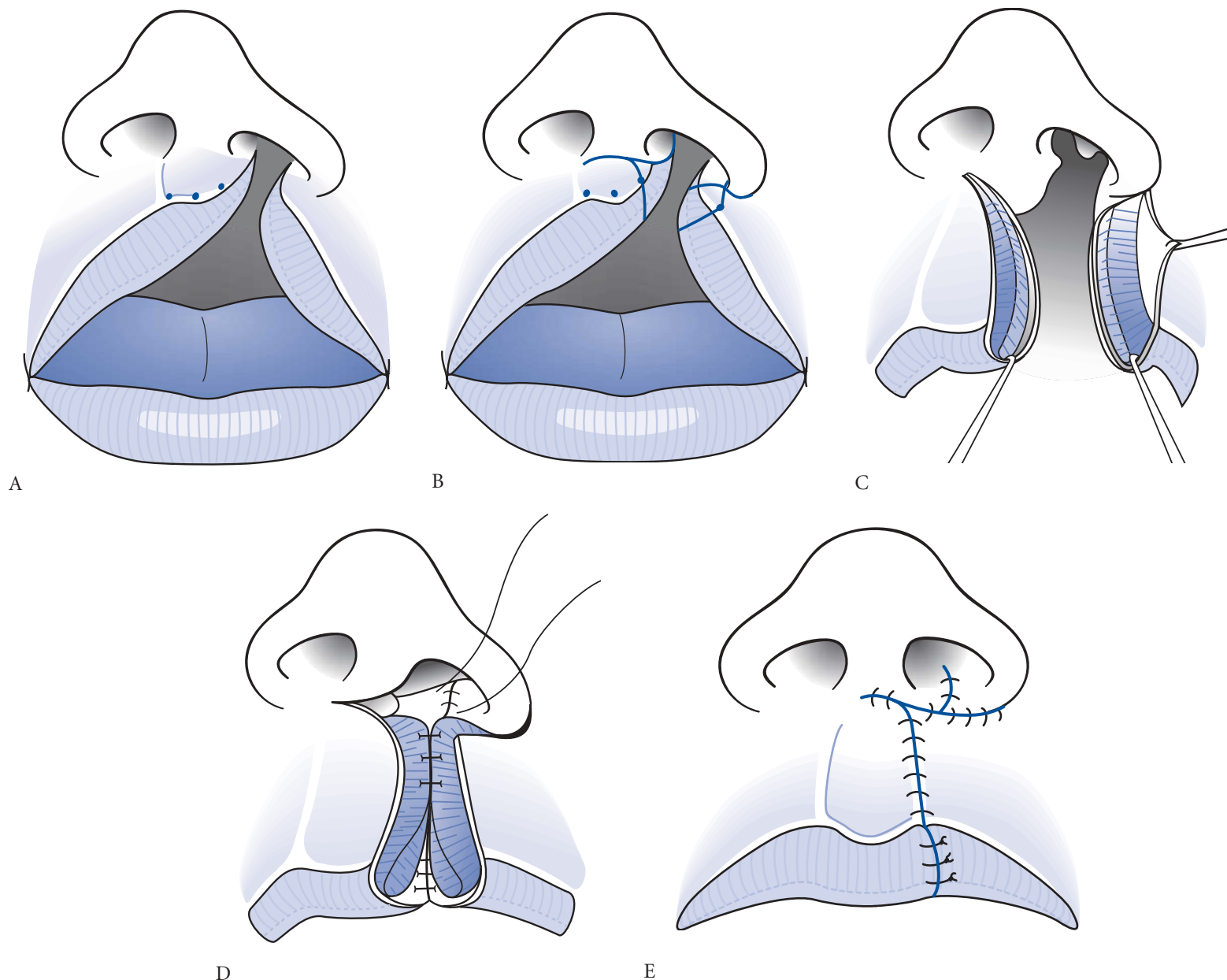


FIGURE 42-4 A, A complete unilateral cleft of the lip is shown highlighting the hypoplastic tissue in the cleft site that is not used in the reconstruction. Note the nasal deformities that are typical in the unilateral cleft, including displaced lower lateral nasal cartilages, deviated anterior septum, and nasal floor clefting. B, The typical markings for the authors' preferred repair are shown highlighting the need to excise the hypoplastic tissue and approximate good vermilion and white roll tissue for the repair. C, Once the hypoplastic tissue has been excised, the three layers of tissue are dissected (skin, muscle, and mucosa). It is important to completely free the orbicularis oris from its abnormal insertions on the anterior nasal spine area and lateral alar base. Nasal flaps are also incorporated into the dissection to repair the nasal floor (not shown). D, The orbicularis oris muscle is approximated with multiple interrupted sutures, and the vermilion border/white roll complex is reconstructed. The nasal floor and mucosal flaps are approximated. E, The lateral flap is advanced and the medial segment is rotated downward to create a healing scarline that will resemble the natural philtral column on the opposite side. The incision lines are hidden in natural contours and folds of the nose and lip.

and some of the contour irregularities will not be able to be revised adequately. Usually if the hypoplastic tissue is excised and incisions within the medial nasal base and columella are avoided, the long-term esthetic results are excellent.

The authors prefer a primary nasal reconstruction that can be performed in a similar fashion to the unilateral technique described by McComb.¹⁰⁰ This allows for release and repositioning of the lower lateral cartilages and alar base on both sides

without aggressive degloving of the entire nasal complex. Other open rhinoplasty techniques have been suggested using either direct incision on the nasal tip or through prolabial unwinding techniques.¹⁰⁰⁻¹⁰³ As with most early maneuvers

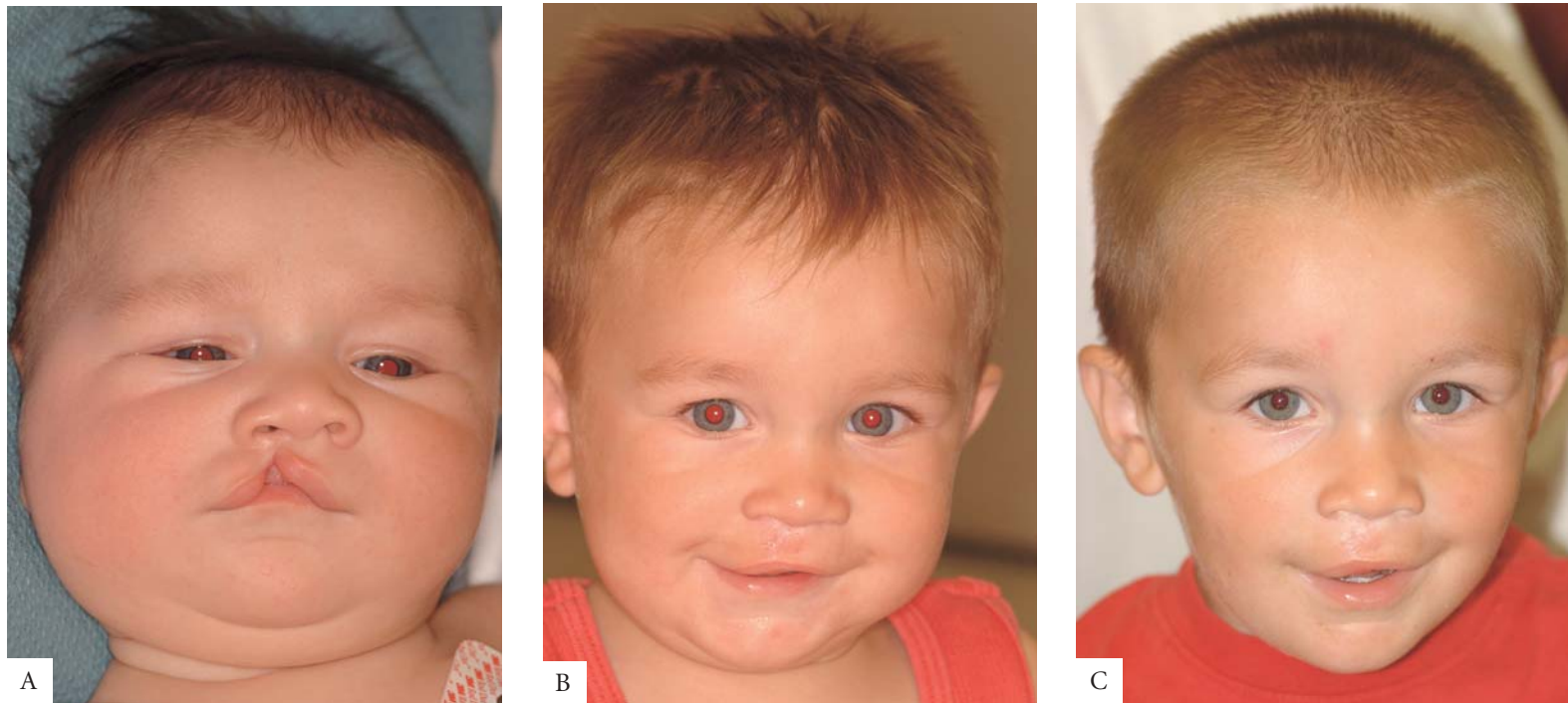


FIGURE 42-5 A, Three-month-old child with a right-sided incomplete unilateral cleft lip. Note the short philtrum near the midline that must be rotated downward to avoid notching and to improve symmetry. B, Nine-month-old boy after the rotation-advancement repair of his cleft lip and nasal deformities. C, The same child in B 2½ years after his cleft lip and nasal repairs.

aggressive rhinoplasty at this time may incur early scarring that affects the growth potential of the surrounding tissues, making revision more difficult and long-term esthetics less than ideal.

Cleft Palate Repair

The term *primary palate* is used to describe the anatomic structures anterior to the incisive foramen (eg, the alveolar ridge, maxilla, piriform rim). The term *secondary palate* refers to those structures posterior to the incisive foramen. Therefore, when surgeons refer to the initial or “primary” cleft palate repair, they are actually describing the closure of the secondary palate structures that include the hard palate, soft palate, and uvula. The structures of the embryologic primary palate are reconstructed later in childhood during the cleft maxillary/alveolar bone graft procedure.

There are two main goals of cleft palate repair during infancy: (1) the water-tight closure of the entire oronasal communication involving the hard and soft palate; and

(2) the anatomic repair of the musculature within the soft palate that is critical for normal creation of speech. The soft palate, or velum, is part of the complex coupling and decoupling of the oral and nasal cavities involved in the production of speech. When a cleft of the soft palate is present there are abnormal muscle insertions located at the posterior edge of the hard palate. Surgery must not simply be aimed at closing the palatal defect but rather at the release of abnormal muscle insertions. Muscle continuity with correct orientation should be established so that the velum may serve as a dynamic structure.

The exact timing of repair of a palate cleft is controversial. Generally the velum must be closed prior to the development of speech sounds that require an intact palate. On average this level of speech production is observed by about 18 months of age in the normally developing child. If the repair is completed after this time, compensatory speech articulations may result. Repair completed prior to this time allows

for the intact velum to close effectively, appropriately separating the nasopharynx from the oropharynx during certain speech sounds.^{104–107}

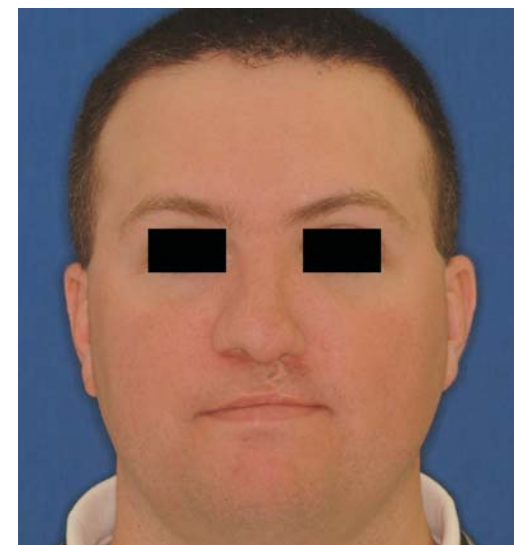

FIGURE 42-6 A typical scar that may result from a Z-type lengthening repair. Although the length and symmetry of the lip is good, an unnatural contour can occur due to the Z shape of the closure.

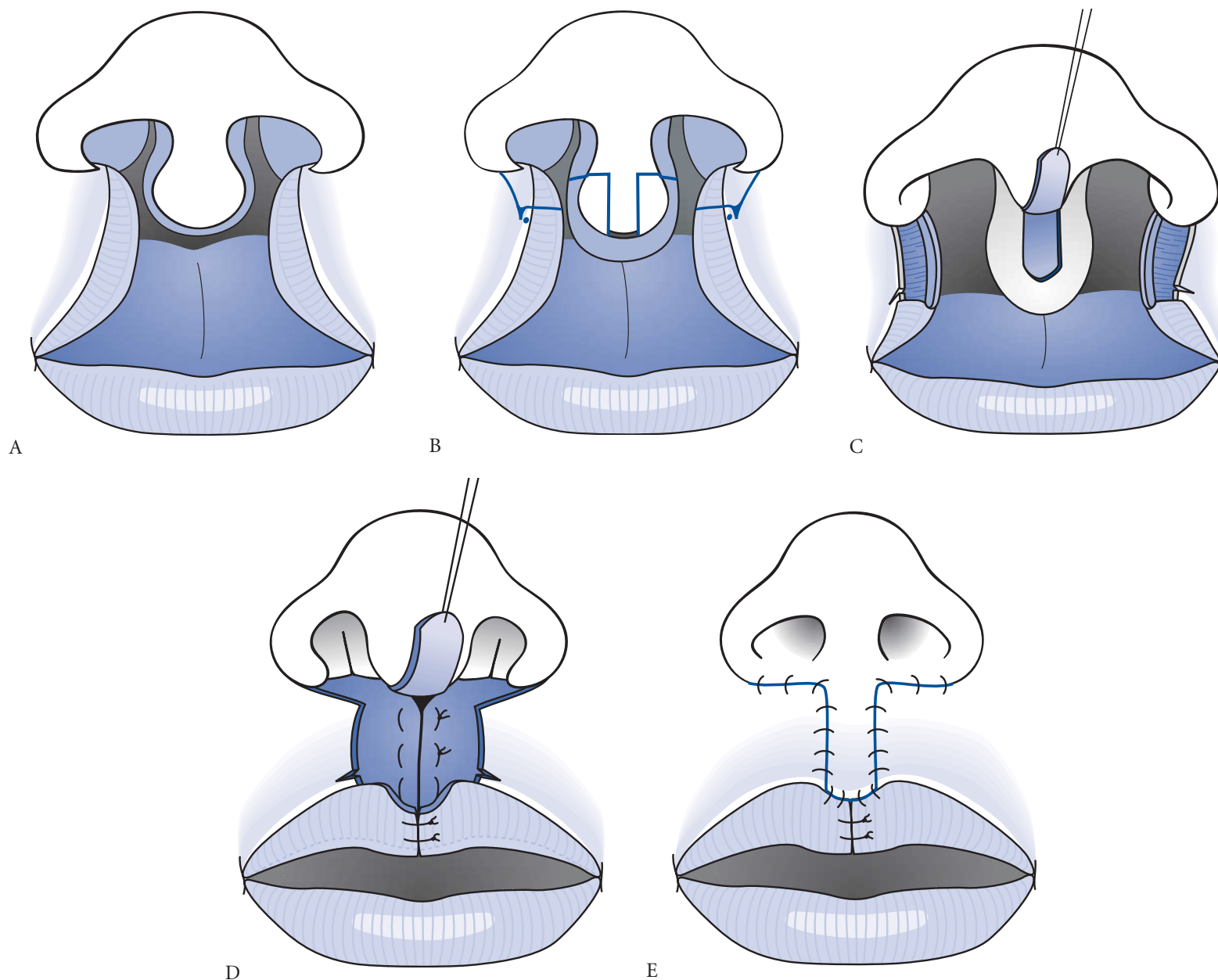


FIGURE 42-7 A, The bilateral cleft of the lip and maxilla shown here is complete and highlights the hypoplastic tissue along the cleft edges. The importance of the nasal deformity is evident in the shorter columella and disrupted nasal complexes. B, Markings of the authors' preferred repair are shown with an emphasis on excision of hypoplastic tissue and approximating more normal tissue with the advancement flaps. C, A new philtrum is created by excising the lateral hypoplastic tissue and elevating the philtrum superiorly. Additionally the lateral advancement flaps are dissected into three distinct layers (skin, muscle, and mucosa). Nasal floor reconstruction is also performed. D, The orbicularis oris musculature is approximated in the midline with multiple interrupted and/or mattress sutures. This is a critical step in the total reconstruction of the functional lip. There is no musculature present in the pre-maxillary segment, and this must be brought to the midline from each lateral advancement flap. The nasal floor flaps are sutured at this time as well. The new vermillion border is reconstructed in the midline with good white-roll tissue advanced from the lateral flaps. E, The final approximation of the skin and mucosal tissues is performed leaving the healing incision lines in natural contours of the lip and nose.

In patients with cleft palate, concerns for normal speech development are frequently balanced with the known biologic consequences of surgery during infancy; namely, the problem of surgery during the growth

phase resulting in maxillary growth restriction.^{33,72,73,108} When repair of the palate is performed between 9 and 18 months of age, the incidence of associated growth restriction affecting the maxillary development is

approximately 25%.^{31,33,109-111} If repair is carried out earlier than 9 months of age, then severe growth restriction requiring future orthognathic surgery is seen with greater frequency.^{22,26,31,33,109,112-114} At the

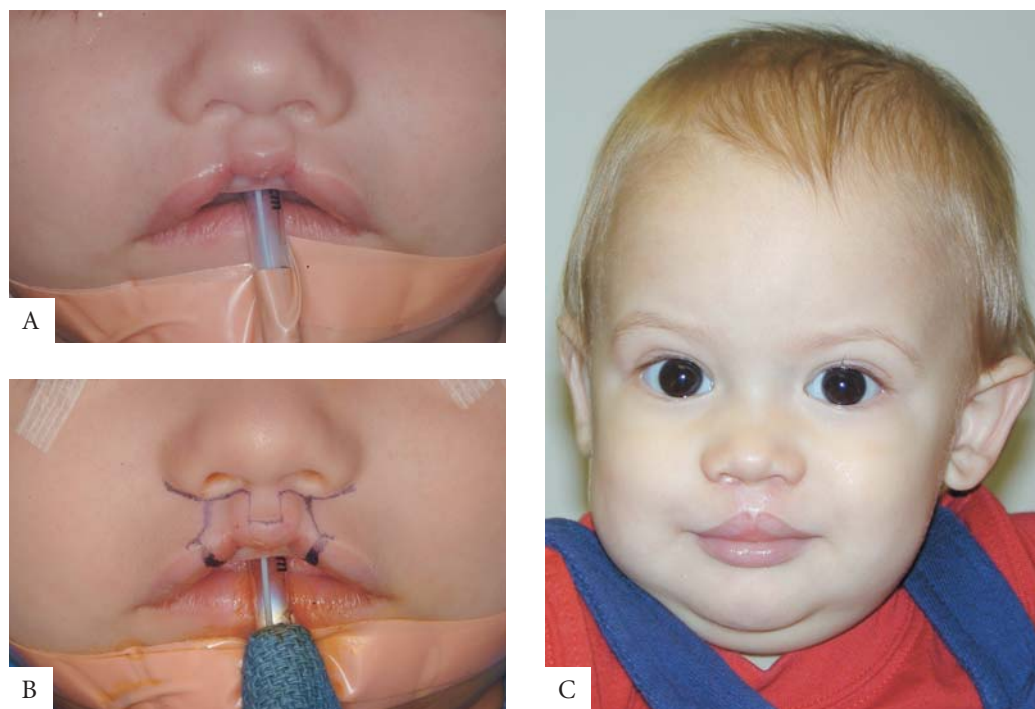


FIGURE 42-8 A, Presurgical appearance of the incomplete bilateral cleft lip of a 3-month-old boy. B, Surgical markings for excision of the hypoplastic tissue and the planned creation of a new philtrum. Advancement flaps from the lateral lip segments bring good white-roll to the midline via small cut-backs. C, The same child at 1 year of age after the repair of his bilateral cleft lip.

same time proceeding with palatoplasty prior to 9 months of age is not associated with any increased benefit in terms of speech development so the result is an increase in growth-related problems with an absence of any functional benefit.^{115,116} Using only the chronologic age it seems that carrying out the operation during the 9 to 18 months timeline best balances the need to address functional concerns such as speech development with the potential negative impact on growth. To date no case-controlled rigorous clinical trial has examined what is likely the most critical factor in dictating the exact timing of cleft repair—the individual child's true language age. In cases where significant developmental delay is present surgery should be delayed since speech formation is not yet an issue and there is a likely benefit in terms of growth of the maxilla. Delaying palatal closure is relevant in situations where the cleft palate is associated with other complex medical conditions, neurodevelopmental delay, complex craniofacial anomalies, and/or the presence of a tracheotomy.

Another approach used to balance speech issues with growth-related concerns is to stage the closure of the secondary palate with two operations. Generally this involves the repair of the soft palate early in life as an initial step, fol-

lowed by closure of the hard palate later in infancy. The idea is that timely repair of the soft palate, which is critical for speech, is accomplished while hard palate repair with mucoperiosteal stripping is delayed until growth is further along.^{117,118} Although this technique is not advocated by the majority of surgeons, some surgeons may feel that repairing the hard palate portion later may offer the advantages of less growth restriction, easier repair of larger clefts, and less chance for fistula formation. No convincing data exist to favor this approach over a single-stage repair, but the practice is continued by some centers where anecdotal evidence suggests that there may be some benefit. In contrast most North American speech and language pathologists prefer closure of the palate as a single operation.¹¹⁷

Cleft palate reconstruction requires the mobilization of multilayered flaps to reconstruct the defect due to the failure of fusion of the palatal shelves. Generally when the initial palate closure is performed, this refers to closure of the tissues posterior to the incisive foramen. This is done in a layered fashion by first closing the nasal mucosa and then the oral mucosa. Since the main function of the palate is to close the

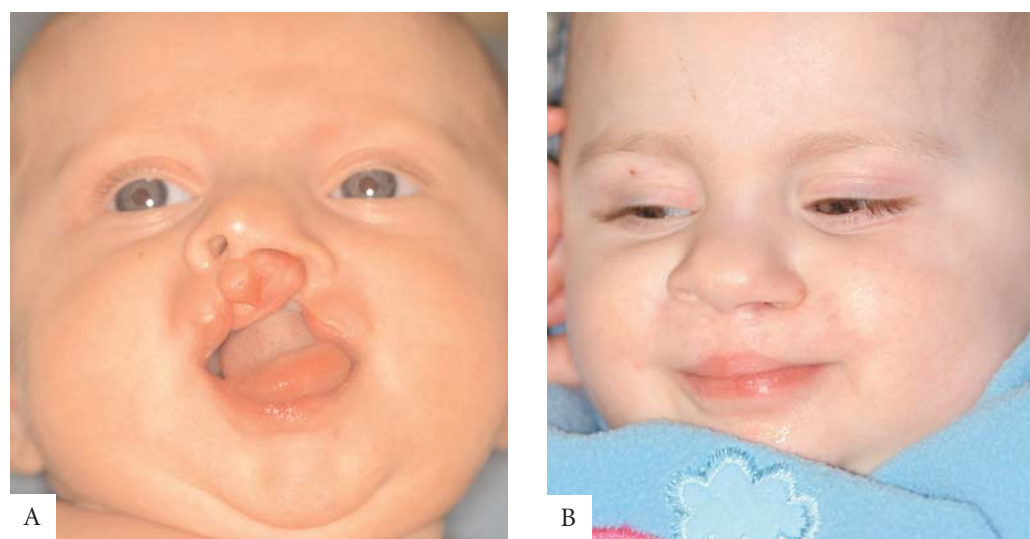


FIGURE 42-9 A, Presurgical appearance of a bilateral cleft lip and palate with impressive asymmetry and rotation of the premaxillary segment. Note the significant nasal asymmetry and bunching of the orbicularis oris laterally. B, The same child at 14 months of age.

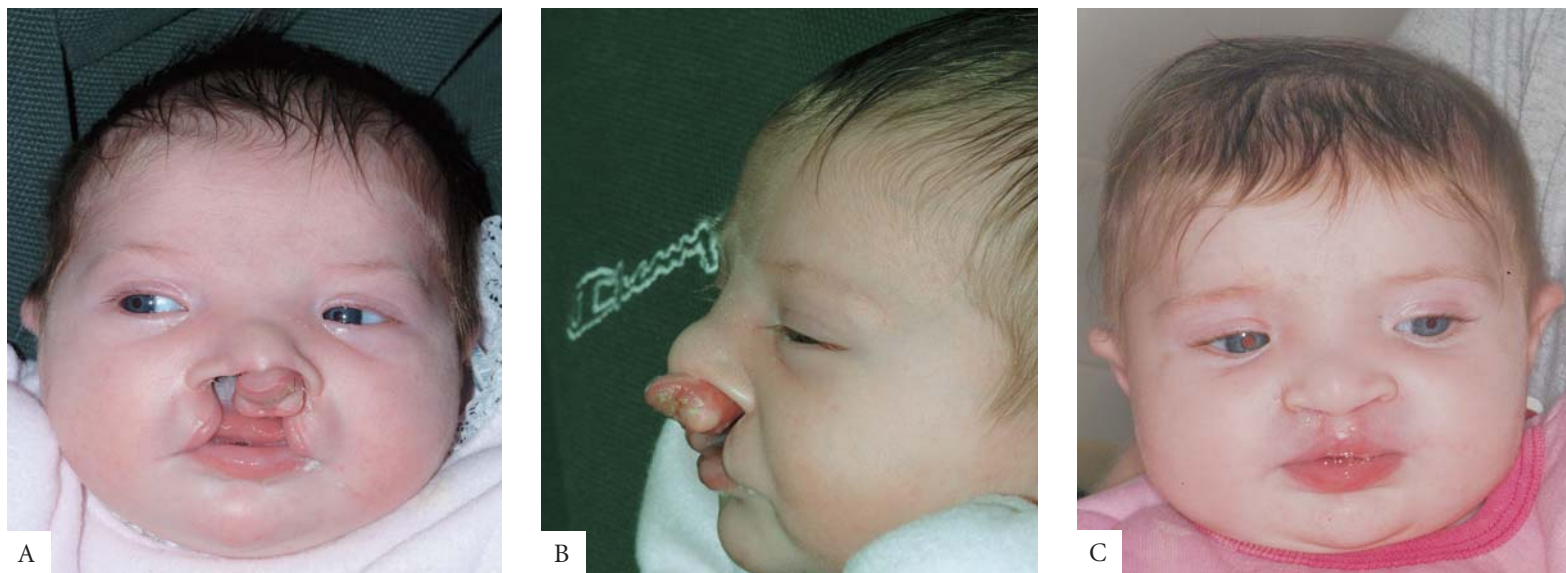


FIGURE 42-10 A, Presurgical frontal view of a wide bilateral cleft lip and palate with significant asymmetry and lack of columella length. B, Presurgical left lateral view of a wide bilateral cleft lip and palate with a protrusive premaxillary segment. Note the short columella length. C, The same child at 10 months of age after repair of her bilateral cleft lip and palate. No presurgical taping or orthopedic appliances were used.

space between the nasopharynx and oropharynx during certain speech sounds, the surgeon must also reconstruct the musculature of the velopharyngeal mechanism. The musculature of the levator palatini is abnormally inserted on the posterior aspect of the hard palate and therefore must be disinserted and reconstructed in the midline.^{26,119} Therefore, the soft palate is closed

in three layers by approximating the nasal mucosa, levator musculature, and the oral mucosa. The hard palate portion is closed in two layers using nasal mucosa flaps and then oral mucosa flaps. Both the hard and soft palate repairs must be done in a tension-free manner to avoid wound breakdown and fistula formation. Adequate mobilization of the flaps during the dissec-

tion is essential to achieve tension-free closure. At times some surgeons may elect to incorporate vomer flaps into the repair if there is difficulty in mobilizing the lateral flaps to the midline.

Many techniques have been described for repair of the palate.¹²⁰⁻¹²⁷ The Bardach two-flap palatoplasty uses two large full-thickness flaps that are mobilized with

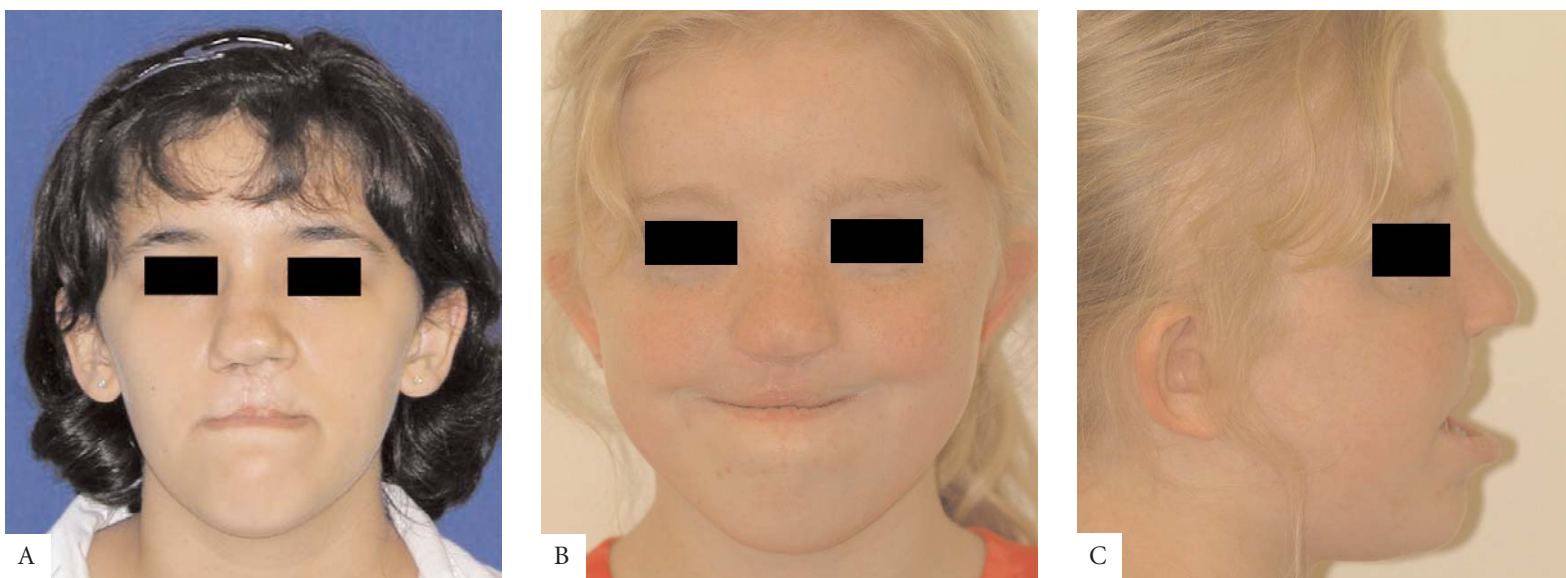


FIGURE 42-11 A, Frontal view of a teenage girl who had undergone columella lengthening and banked fork flaps during her initial repair and multiple attempts at secondary rhinoplasty by another surgeon prior to orthognathic surgery. B, Frontal view of a patient who underwent columella lengthening and banked fork flaps during her initial repair. C, Lateral view of the patient from B with a columella that is curved upwards and abnormally angular.

layered dissection and brought to the midline for closure (Figure 42-12).^{26,120} This technique preserves the palatal neurovascular bundle as well as a lateral pedicle for adequate blood supply. The von Langenbeck technique is similar to the Bardach palatoplasty but preserves an anterior pedicle for increased blood supply to the flaps.^{26,121} This technique is also successful in achieving a layered closure but may be more diffi-

cult when suturing the nasal mucosa near the anteriorly based pedicle attachments. The authors do not favor push-back techniques as they may incur more palatal scarring, restrict growth, and do not show a measurable benefit in speech.

Another common technique is the Furlow double-opposing Z-plasty, which attempts to lengthen the palate by taking advantage of a Z-plasty technique on both

the nasal mucosa and the oral mucosa (Figure 42-13).^{26,124-127} This technique can be effective at closing the palate but has been reported by some to have a higher rate of fistula formation at the junction of the soft and hard palates where theoretical lengthening of the soft palate may compromise the closure.^{26,128-133} No benefit has been convincingly demonstrated with any particular repair technique when one looks at dental arch form, speech outcome, feeding, or any other functional variable. At this point in our understanding surgeons often consider their own experiences and training when repairing clefts, since definitive data suggesting that one repair is preferable over another are lacking.

In very wide clefts some surgeons will advocate the consideration of a pharyngeal flap at the primary palatoplasty procedure to assist in closure since revision palatoplasty is sometimes unsuccessful in eradicating fistulas. Those who use this technique usually perform it in extremely wide clefts and do so very selectively. This allows the central portion of the closure to be filled with posterior pharyngeal wall tissue making the closure of the nasal and palatal mucosa easier. Patients with Pierre Robin syndrome or Treacher Collins syndrome may have exceptionally wide clefts that are difficult to close with no tension, and this technique may be considered. The drawbacks of using a pharyngeal flap during the repair of the palate include a significantly increased risk for complications such as bleeding, snoring, obstructive sleep apnea, or hyponasality. The details of pharyngeal flap surgery and revision palatoplasty techniques are discussed in Chapter 44, "Reconstruction of Cleft Lip and Palate: Secondary Procedures."

Complex Facial Clefting

Clefting of the facial structures other than the typical nasolabial region is rare and often presents difficult challenges to the reconstructive cleft surgeon. Therefore it is important to consider referring patients

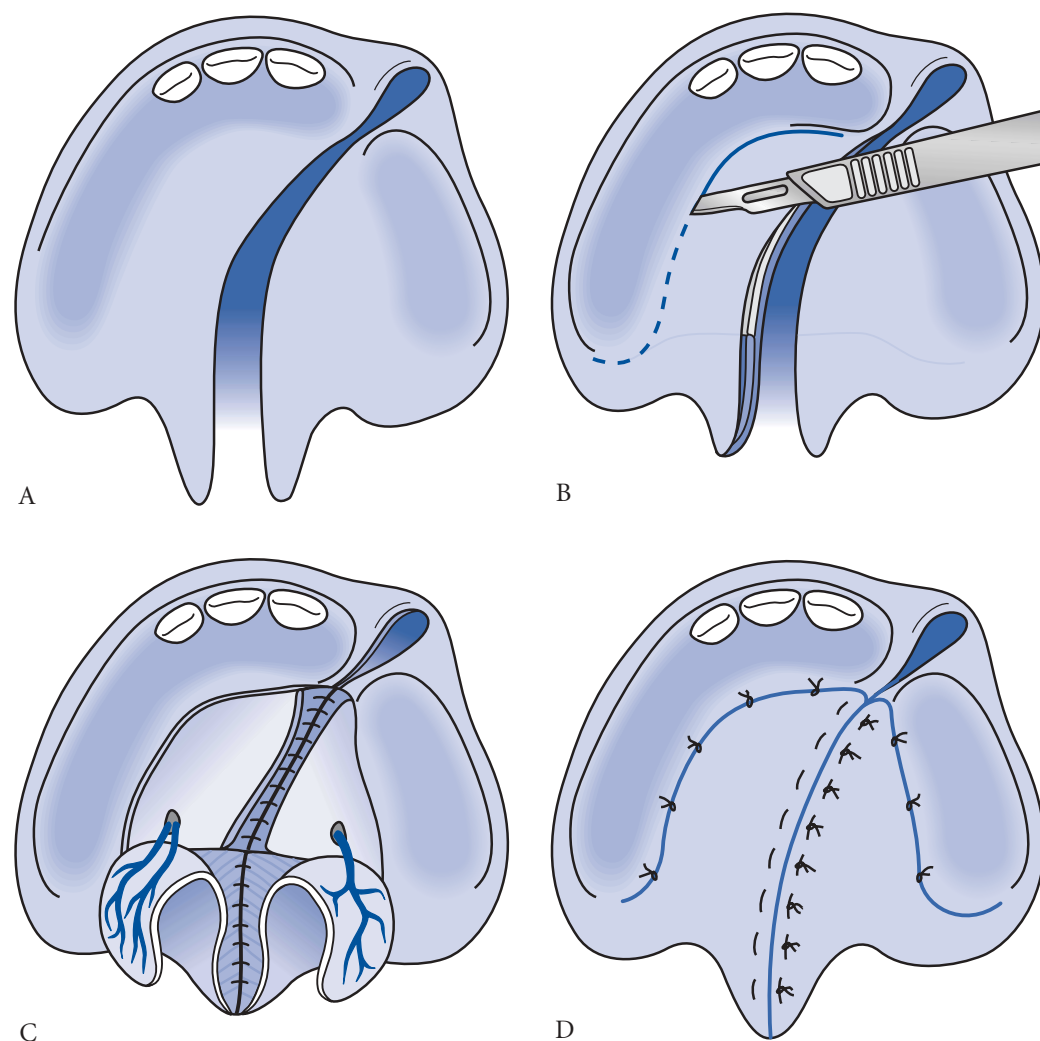


FIGURE 42-12 A, A unilateral cleft of the primary and secondary palates is shown with the typical involvement from the anterior vestibule to the uvula. B, The Bardach palatoplasty technique requires two large full-thickness mucoperiosteal flaps to be elevated from each palate shelf. The anterior portion (anterior to the incisive foramen) of the cleft is not reconstructed until the mixed dentition stage. C, A layered closure is performed in the Bardach palatoplasty by reapproximating the nasal mucosa. The muscle bellies of the levator palatini are elevated off of their abnormal insertions on the posterior palate. They are then reapproximated in the midline to create a dynamic functional sling for speech purposes. D, Once the nasal mucosa and musculature of the soft palate are approximated, the oral mucosa is closed in the midline. The lateral releasing incisions are quite easily closed primarily due to the length gained from the depth of the palate. In rare cases, in very wide clefts a portion of the lateral incisions may remain open and granulate by secondary intention.

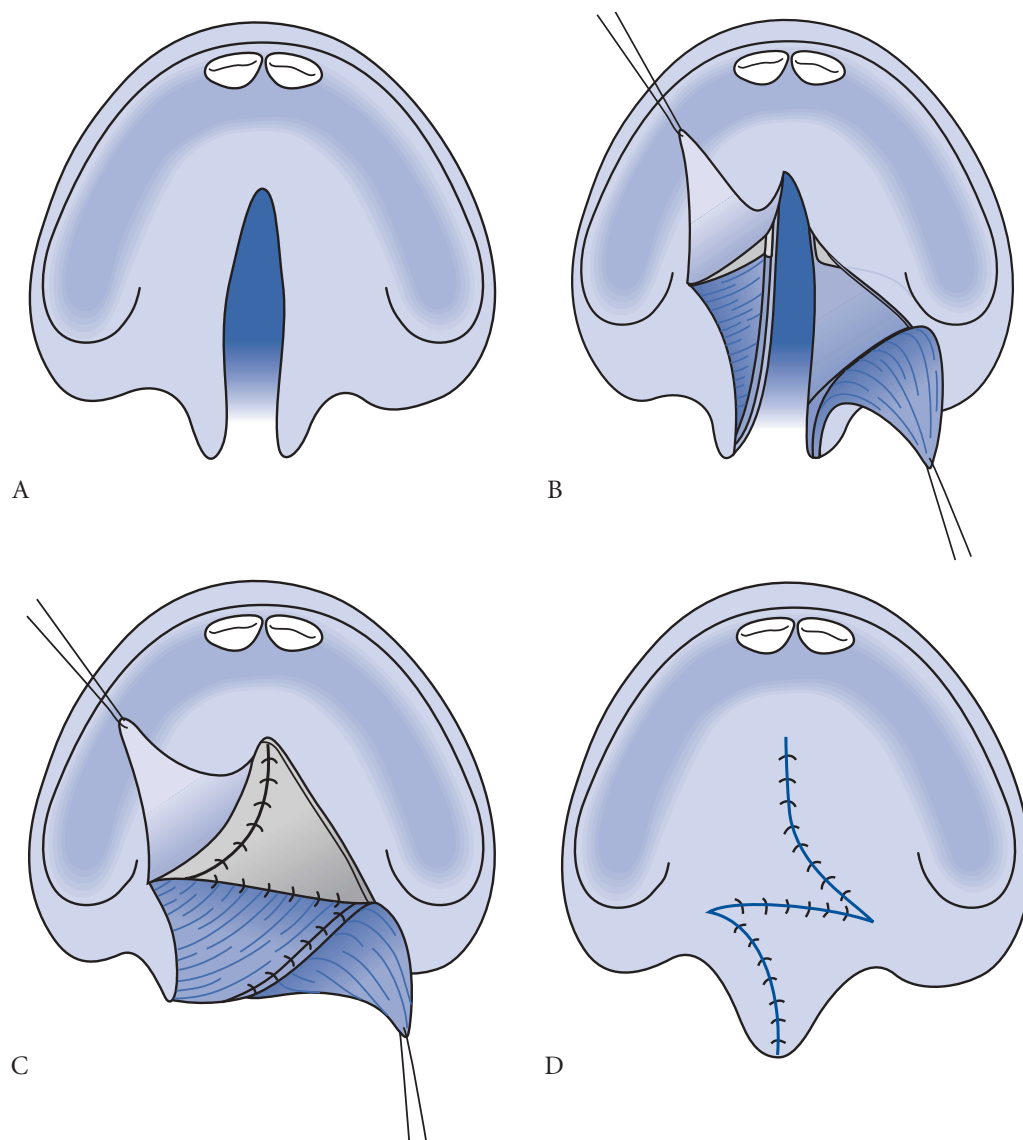


FIGURE 42-13 A, A complete cleft of the secondary palate (both hard and soft) is shown from the incisive foramen to the uvula. B, The Furlow double-opposing Z-plasty technique requires that separate Z-plasty flaps be developed on the oral and then nasal side. Note the cutbacks creating the nasal side flaps highlighted in blue. C, The flaps are then transposed to theoretically lengthen the soft palate. A nasal side closure is completed in the standard fashion anterior to the junction of the hard and soft palate. Generally this junction is the highest area of tension and can be difficult to close. This contributes to the higher fistula rate in this type of repair. D, The oral side flaps are then transposed and closed in a similar fashion completing the palate closure.

with complex facial clefting to surgeons with experience in this particular area. Comprehensive interdisciplinary care is mandatory to achieve the best results including involvement of neurosurgery, ophthalmology, orthodontics, speech pathology, and other members of the craniofacial team. Some interventions such as eye lubrication may be necessary within hours after birth, and accurate pre-

natal diagnosis of severe facial clefting is helpful in planning for early care.

The etiology of the various facial clefts may be related to failure of embryologic fusion, physical obstruction in fetal life, association with an encephalocele or tumor, amniotic bands, or other anatomic disruptions during fetal life.⁵⁵ The vast majority of complex facial clefts are sporadic events and not related to a single

gene disease. Many complex facial clefts involve the orbit, and the classification system most often used is orbitocentric in design (see Figure 42-2). Paul Tessier described a numbering system for facial clefting phenomena to make description and surgical planning more easily discussed.⁵⁶ Other systems exist but have a more cumbersome nomenclature.⁵⁷

Primary repair of severe facial clefts is often more difficult than even the most difficult standard bilateral clefts.¹³⁴⁻¹³⁶ While mobilization of the lip and nose structures is rather straightforward, the closure of clefts in the orbital region can be challenging due to the lack of eyelid and adjacent tissue for advancement and/or rotation. Revision surgery is the norm in this group and should include a skilled ophthalmologic surgeon early in the process for the best results.

The staged reconstruction of these types of severe facial clefts is similar to the more common cleft lip and palate protocols. However, several functional issues are present in patients with complex facial clefting that require more immediate attention. For example, patients with large Tessier no. 7 clefts may have problems with retaining foodstuffs in their oral cavities due to the discontinuity of the orbicularis oris (Figure 42-14). This may prompt early repair and reestablishment of the orbicularis oris musculature for functional concerns.

For those patients with orbital clefts a skilled pediatric ophthalmologist should evaluate the child early to avoid severe corneal abrasion and desiccation. Immediate lubrication of the globes is necessary to prevent severe irreversible corneal damage until eyelid structures can be mobilized to cover the globe adequately. Early after birth tarsorrhaphy stitches can be used to gain adequate closure of the lids for corneal protection. Ignoring the need for eye protection may result in severe corneal scarring that may cause blindness and prompt consideration for corneal transplantation. Corneal transplants in infants

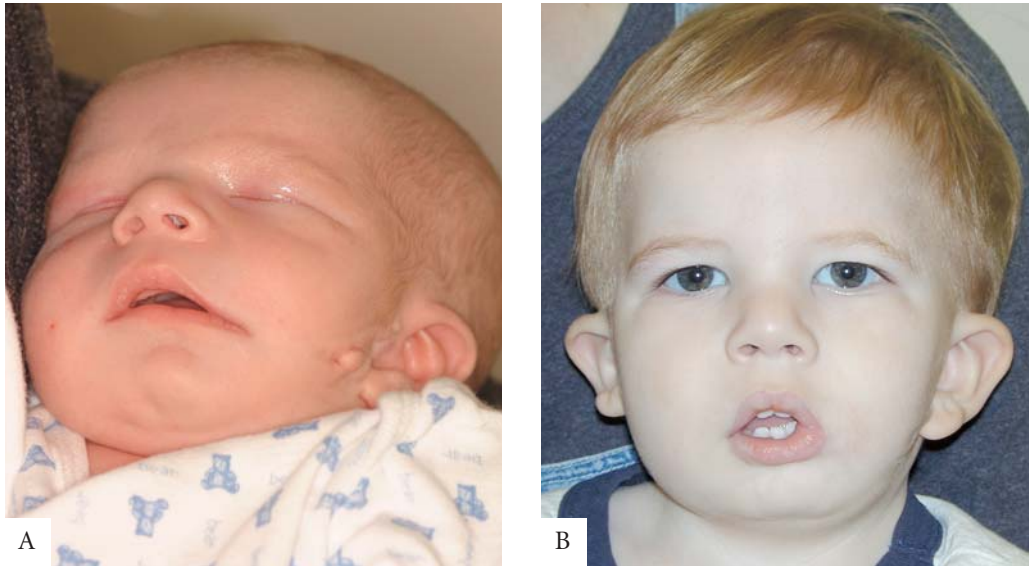

FIGURE 42-14 A, A 2-month-old boy with a Tessier no. 7 left facial cleft associated with craniofacial microsomia (Kaban type IIb), congenital ear anomalies, a lateral tongue cleft, and a left-sided epibulbar dermoid. B, The same child at 8 months after the primary repair.

are often not successful but are possible in patients with severe orbitofacial clefts. Another concern is the support of the globes at the orbit floor that may be involved in some facial clefts. The timing of orbital reconstruction is dependent on the functional needs of the cleft area in each patient. These are just some of the concerns present in complex facial clefting, and a customized treatment plan must be formulated for each patient.

Outcome Assessment

Decision-making in cleft care should be based on evidenced-based research and a critical look at outcomes. Unfortunately there is little evidenced-based research available to guide clinicians through the many treatment protocols for cleft care.¹¹³ Although the clinical experience of the surgeon certainly has value, this must be integrated with a constant review of evidence-based research. Typically enthusiasm by a surgeon or a particular group of surgeons regarding a specific intervention because of personal experiences may help popularize that intervention but with little outcome data to support its use. Too frequently the long-term results are not forthcoming, and

the treatment regimen may still persist. Unfortunately some of the treatment regimens used today are based on the poor outcomes and mishaps of previous surgeons rather than regimens chosen as a consequence of published evidence of the actual success of a particular treatment.

Additionally the pressures of a costly health care system have made treatment decision questions even harder to investigate.⁸⁸ A need to understand the outcome differences between treatment philosophies will be critical to help determine which protocols will be most beneficial to the patient without extending valuable health care resources on unproven or ineffective methods. For this reason among many others, the need to discard unproven and unnecessary interventions has never been greater. Outcomes studies based on functional results such as appearance, facial growth, occlusion, patient satisfaction, and psychosocial development are all critical in this process. Surgeons involved in the care of patients with clefts must critically review the literature on a regular basis and not be tempted by poorly evaluated techniques popularized by clinical reports.

Conclusions

The comprehensive care of patients with clefts requires an interdisciplinary approach that demands precise surgical execution of the various procedures necessary to correct cleft deformities, as well as frequent long-term follow-up. Clinicians experienced in the comprehensive interdisciplinary care of patients with clefts are best equipped to deal with these concerns. The treatment of patients with cleft and craniofacial deformities should be free of bias and should demand team care that is patient, family, and community oriented. Only in this fashion can the overall treatment be optimally successful. This type of care maximizes the patient's ability to grow into adulthood and succeed in life without focusing on their deformity.

References

1. Adams GR. The effects of physical attractiveness on the socialization process. In: Lucker GW, Ribbens KA, McNamara JA, editors. Psychological aspects of facial form. Craniofacial growth series monograph no. 11. Ann Arbor: University of Michigan Press; 1981. p. 25–47.
2. Kapp K. Self concept of the cleft lip and palate child. *Cleft Palate J* 1979;16:171.
3. Kapp-Simon KA. Psychological interventions for the adolescent with cleft lip and palate. *Cleft Palate Craniofac J* 1995;32:104–8.
4. American Cleft Palate-Craniofacial Association. Parameters for the evaluation and treatment of patients with cleft lip/palate or other craniofacial anomalies. *Cleft Palate Craniofac J* 1993;30 Suppl 1:4.
5. Boo-Chai K. An ancient Chinese text on a cleft lip. *Plast Reconstr Surg* 1966;38:89.
6. Rogers BO. Harelip repair in colonial America: a review of 18th century and earlier surgical techniques. *Plast Reconstr Surg* 1964;34:142.
7. Bushe G. An essay on the operation for cleft palate. New York (NY): William Jackson; 1835.
8. Pare A. *Dix Livres de la Chirurgie*. Paris: Jean le Royer; 1564. p. 211.
9. LeMesurier AB. Method of cutting and suturing lip in complete unilateral cleft lip. *Plast Reconstr Surg* 1949;4:1.
10. Veau V. Operative treatment of complete double harelip. *Ann Surg (Paris)* 1922;76:143.
11. Tennison CW. The repair of unilateral cleft lip

- by the stencil method. *Plast Reconstr Surg* 1952;9:115.
12. Skoog T. A design for the repair of unilateral cleft lip. *Am J Surg* 1958;95:223.
 13. Brauer RO. Repair of unilateral cleft lip. Triangular flap repairs. *Clin Plast Surg* 1985;12:595.
 14. Randall P. Long-term results with the triangular flap technique for unilateral cleft lip repair. In: Bardach J, Morris H, editors. *Multidisciplinary management of cleft lip and palate*. Philadelphia (PA): W.B. Saunders; 1990. p. 173.
 15. Asensio OE. Labioleporino y paladar heindido. *Acta Odontol Venez* 1971;3:229–42.
 16. Asensio OE. A variation of the rotation-advancement operation for repair of wide unilateral cleft lips. *Plast Reconstr Surg* 1974;53:167–73.
 17. Millard DR. *Cleft craft*. Vol 1. Boston (MA): Little Brown; 1976. p. 165–73.
 18. Millard DR. A primary camouflage of the unilateral harelip. In: *Transactions of the international congress of plastic surgeons*. Baltimore (MD): Williams & Wilkins; 1957. p. 160–6.
 19. Hullihen SP. A treatise on hare-lip and its treatment. Baltimore (MD): Woods and Crane; 1844.
 20. The building of a specialty: oral and maxillofacial surgery in the United States 1918–1998. *J Oral Maxillofac Surg*. 1998;7 Suppl 56.
 21. Schmid E. Die Annäherung der Kieferstumpfe bei Lippen-Kiefer-Gaumenspalten: Ihre schadlichen Folgen und Vermeidung. *Fortschr Kiefer Gesichtschir* 1955;1:37.
 22. Pruzansky S. Presurgical orthopaedics and bone grafting for infants with cleft lip and palate: a dissent. *Cleft Palate J* 1964;1:164.
 23. Robertson NR, Jolleys A. Effects of early bone grafting in complete clefts of the lip and palate. *Plast Reconstr Surg* 1968;42:414–21.
 24. Boyne PJ, Sands NR. Secondary bone grafting of residual alveolar and palatal clefts. *J Oral Surg* 1972;30:87–92.
 25. Millard DR. *Cleft craft: the evolution of its surgery*. Alveolar and palatal deformities. Vol 3. Boston (MA): Little Brown; 1980.
 26. Posnick JC. The staging of cleft lip and palate reconstruction: infancy through adolescence. In: Posnick JC, editor. *Craniofacial and maxillofacial surgery in children and young adults*. Philadelphia (PA): W.B. Saunders; 2000. p. 785–826.
 27. Posnick JC, Tompson B. Cleft-orthognathic surgery. Complications and long-term results. *Plast Reconstr Surg* 1995;96:255.
 28. Posnick JC. Cleft-orthognathic surgery: the unilateral cleft lip and palate deformity. In: Posnick JC, editor. *Craniofacial and maxillofacial surgery in children and young adults*. Philadelphia (PA): W.B. Saunders; 2000. p. 860–907.
 29. Posnick JC. Cleft-orthognathic surgery: the bilateral cleft lip and palate deformity. In: Posnick JC, editor. *Craniofacial and maxillofacial surgery in children and young adults*. Philadelphia (PA): W.B. Saunders; 2000. p. 908–50.
 30. Posnick JC. Cleft-orthognathic surgery: the isolated palate deformity. In: Posnick JC, editor. *Craniofacial and maxillofacial surgery in children and young adults*. Philadelphia (PA): W.B. Saunders; 2000. p. 951–78.
 31. Ruiz RL, Costello BJ, Turvey T. Orthognathic surgery in the cleft patient. In: Ogle O, editor. *Oral and maxillofacial surgery clinics of North America: secondary cleft surgery*. Philadelphia (PA): W.B. Saunders; 2002. p. 491–507.
 32. Costello BJ, Ruiz RL. The role of distraction osteogenesis in orthognathic surgery of the cleft patient. *Selected Readings Oral Maxillofac Surg* 2002;10(3):1–27.
 33. Costello BJ, Shand J, Ruiz RL. Craniofacial and orthognathic surgery in the growing patient. *Selected Readings Oral Maxillofacial Surg* 2003;11(5):1–20.
 34. Braun TW, Sotereanos GC. Orthognathic and secondary cleft reconstruction of adolescent patients with cleft palate. *J Oral Surg* 1980;38:425–34.
 35. Kiehn CL, DesPrez JD, Brown F. Maxillary osteotomy for late correction of occlusion and appearance in cleft lip and palate patients. *Plast Reconstr Surg* 1968;42:203–7.
 36. Westbrook MT, West RA, McNeill RW. Simultaneous maxillary advancement and closure of bilateral alveolar clefts and oronasal fistulas. *J Oral Maxillofac Surg* 1983;41:257–60.
 37. Georgiade NG. Mandibular osteotomy for the correction of facial disproportion in the cleft lip and palate patient. *Symposium on management of cleft lip and palate and associated deformities*. *Am Plast Reconstr Surg* 1974;8:238.
 38. Bell WH. Le Fort I osteotomy for correction of maxillary deformities. *J Oral Surg* 1975;33:412–26.
 39. Fonseca RJ, Turvey TA, Wolford LM. Orthognathic surgery in the cleft patient. In: Fonseca RJ, Baker SJ, Wolford LM, editors. *Oral and maxillofacial surgery*. Philadelphia (PA): W.B. Saunders; 2000. p. 87–146.
 40. Polley JW, Figueroa AA, Charbel FT, et al. Monoblock craniomaxillofacial distraction osteogenesis in a newborn with severe craniofacial synostosis: a preliminary report. *J Craniofac Surg* 1995;6:421–3.
 41. Polley JW, Figueroa AA. Rigid external distraction: its application in cleft maxillary deformities. *Plast Reconstr Surg* 1998;102:1360–72.
 42. Posnick JC, Ruiz RL. Management of secondary orofacial cleft deformities [discussion]. In: Goldwyn RM, Cohen MN, editors. *The unfavorable result in plastic surgery: avoidance and treatment*. 3rd ed. Philadelphia (PA): Lippincott Williams & Wilkins; 2000.
 43. Tolarova MM, Cervenka J. Classification and birth prevalence of orofacial clefts. *Am J Med Genet* 1998;75: 126–37.
 44. Tolarova M. Etiology of clefts of lip and/or palate: 23 years of genetic follow-up in 3660 individual cases. In: Pfeifer G, editor. *Craniofacial abnormalities and clefts of the lip, alveolus, and palate*. Stuttgart: Thieme; 1991.
 45. Gundlach KKH, Abou Tara N, von Kreybig T. Tierexperimentelle Ergebnisse zur Entstehung und Prävention von Gesichtsspalten und anderen kraniofazialen Anomalien. *Fortschr Kieferorthop* 1986;47:356–61.
 46. Prescott NJ, Lees MM, Winter RM, Malcolm S. Identification of susceptibility loci for non-syndromic cleft lip with or without cleft palate in a two stage genome scan of affected sib pairs. *Hum Genet* 2000;106:345–50.
 47. Suzuki K, Hu D, Bustos T, et al. Mutations of PVRL1 encoding a cell-cell adhesion molecule/herpesvirus receptor, in cleft lip/palate-ectodermal dysplasia. *Nat Genet* 2000;25:427–30.
 48. Van den Boogaard MJ, Dorland M, Beemer FA, van Amstel HKP. MSX1 mutation is associated with orofacial clefting and tooth agenesis in humans. *Nat Genet* 2000;24:342–3.
 49. Oliver-Padilla G, Martinez-Gonzales V. Cleft lip and palate in Puerto Rico: a 33 year study. *Cleft Palate J* 1986;23:48–57.
 50. Lettieri J. Human malformations and related anomalies. In: Stevenson RE, Hall JG, Goodman RM, editors. *New York (NY): Oxford University Press*; 1993. p. 367–81.
 51. Wyszynski DE, Beaty TH, Maestri NE. Genetics of non-syndromic and syndromic oral clefts revisited. *Cleft Palate Craniofac J* 1996;33:16406–17.
 52. Saal HM. Syndromes and malformations associated with cleft lip with or without cleft palate. *Am J Hum Genet* 1998;64:A118.
 53. Jones MC. Etiology of facial clefts: prospective evaluation of 428 patients. *Cleft Palate J* 1988;25:16–20.
 54. Gorlin R, Cohen MJ, Levin L. *Syndromes of the head and neck*. 4th ed. New York (NY): Oxford University Press; 2003.
 55. Cohen MM. Etiology and pathogenesis of

- orofacial clefting. Cleft lip and palate: a physiological approach, *Oral Maxillofac Clin North Am* 2000;12:379–97.
56. Tessier P. Anatomical classification of facial, cranio-facial, and latero-facial clefts. *J Maxillofac Surg* 1976;4:69–92.
 57. Van der Meulen J, Mazzola B, Vermey-Keers, et al. A morphogenetic classification of craniofacial malformations. *Plast Reconstr Surg* 1983;71:560.
 58. Pretorius DH, House M, Nelson TR, Hollenbach KA. Evaluation of normal and abnormal lips in fetuses: comparison between three- and two-dimensional sonography. *Am J Roentgenol* 1995;165:1233–7.
 59. Pretorius DH, Nelson TR. Fetal face visualization using three-dimensional ultrasonography. *J Ultrasound Med* 1995;14:349–56.
 60. Shaikh D, Mercer NS, Sohan K, et al. Prenatal diagnosis of cleft lip and palate. *Br J Plast Surg* 2001;54:288–9.
 61. Lawrence RA. Breastfeeding: benefits, risks, and alternatives. *Curr Opin Obstet Gynecol* 2000;12:519–24.
 62. Hamosh M, Peterson JA, Henderson TR, et al. Protective function of human milk: the milk fat globule. *Semin Perinatol* 1999;23:242–9.
 63. Thompson JE. An artistic and mathematically accurate method of repairing the defect in cases of harelip. *Surg Gynecol Obstet* 1912;14:498.
 64. Marsh JL. Craniofacial surgery: the experiment on the experiment of nature. *Cleft Palate Craniofac J* 1996;33:1.
 65. Van Boven MJ, Pendeveille PE, Veyckemans F, et al. Neonatal cleft lip repair: the anesthesiologist's point of view. *Cleft Palate Craniofac J* 1993;30:574–7.
 66. Eaton AC, Marsh JL, Pigram TK. Does reduced hospital stay affect morbidity and mortality rates following cleft lip and palate repair in infancy? *Plast Reconstr Surg* 1994;94:916–18.
 67. Field TM, Vega-Lahr N. Early interactions between infants with craniofacial anomalies and their mothers. *Infant Behav Dev* 1984;7:527.
 68. Estes JM, Whitby DJ, Lorenz HP, et al. Endoscopic creation and repair of fetal cleft lip. *Plast Reconstr Surg* 1992;90:743–6.
 69. Hallock GG. Endoscopic creation and repair of fetal cleft lip [discussion]. *Plast Reconstr Surg* 1992;90:747.
 70. Hedrick MH, Rice HE, Vander Wall KJ, et al. Delayed in utero repair of surgically created fetal cleft lip and palate. *Plast Reconstr Surg* 1996;97:906–7.
 71. Dorf DS, Curtin JW. Early cleft palate repair and speech outcome. *Plast Reconstr Surg* 1982;70:74–81.
 72. Dorf DS, Curtin JW. Early cleft palate repair and speech outcome: a ten year experience. In: Bardach J, Morris HL. *Multidisciplinary management of cleft lip and palate*. Philadelphia (PA): W.B. Saunders; 1990. p. 341–8.
 73. Copeland M. The effect of very early palatal repair on speech. *Br J Plast Surg* 1990;43:676.
 74. Costello BJ, Ruiz RL, Turvey T. Surgical management of velopharyngeal insufficiency in the cleft patient. In: *Oral and maxillofacial surgery clinics of North America: secondary cleft surgery*. Philadelphia (PA): W.B. Saunders; 2002. p. 539–51.
 75. Sadove AM, Nelson CL, Eppley BL, et al. An evaluation of calvarial and iliac donor sites in alveolar cleft grafting. *Cleft Palate J* 1990;27:225–8.
 76. Sindet-Pedersen S, Enemark H. Reconstruction of alveolar clefts with mandibular or iliac crest bone graft: a comparative study. *J Oral Maxillofac Surg* 1990;48:554–8.
 77. Lo LJ, Hung KF, Chen YR. Blindness as a complication of LeFort I osteotomy for maxillary disimpaction. *Plast Reconstr Surg* 2002;109:688–98.
 78. Poole R, Farnworth TK. Preoperative lip taping in the cleft lip. *Ann Plast Surg* 1994;32:243–9.
 79. Shaw WC, Semb G. Current approaches to the orthodontic management of cleft lip and palate. *J R Soc Med* 1990;83:30–3.
 80. Ross RB, MacNamera MC. Effect of presurgical infant orthopedics on facial esthetics in complete bilateral cleft lip and palate. *Cleft Palate Craniofac J* 1994;31: 68–73.
 81. Grayson BH, Cutting CB, Wood R. Preoperative columella lengthening in bilateral cleft lip and palate. *Plast Reconstr Surg* 1993;92:1422–3.
 82. Grayson BH, Santiago PE, Brecht LE, et al. Presurgical nasoalveolar molding in infants with cleft lip and palate. *Cleft Palate Craniofac J* 1999;36:486–98.
 83. Prael C, Kuijpers-Jagman AM, Van'tHof MA, et al. A randomized prospective clinical trial of the effect of infant orthopedics in unilateral cleft lip and palate: prevention of collapse of the alveolar segments (Dutchcleft). *Cleft Palate Craniofac J* 2003;40:337–42.
 84. Chan KT, Hayes C, Shusterman S, et al. The effects of active infant orthopedics on occlusal relationships in unilateral complete cleft lip and palate. *Cleft Palate Craniofac J* 2003;40:511–7.
 85. Konst EM, Rietveld T, Peters HFM, et al. Language skills of young children with unilateral cleft lip and palate following infant orthopedics: a randomized clinical trial. *Cleft Palate Craniofac J* 2003;40:356–62.
 86. Berkowitz S. The comparison of treatment results in complete cleft lip/palate using conservative approach vs. Millard-Latham PSOT procedure. *Semin Orthod* 1996;2:169.
 87. Georgiade NG, Latham RA. Maxillary arch alignment in the bilateral cleft lip and palate infant, using the pinned coaxial screw appliance. *Plast Reconstr Surg* 1975;56:52–60.
 88. Strauss RP. Health policy and craniofacial care: issues in resource allocation. *Cleft Palate Craniofac J* 1994;31:78–80.
 89. Randall P, Graham WP. Lip adhesion in the repair of bilateral cleft lip. In: Grabb WC, Rosenstein SW, Bzoch KR, editors. *Cleft lip and palate*. Boston (MA): Little Brown; 1971.
 90. Millard DR. A preliminary adhesion. In: *Cleft craft, Vol 1: the unilateral deformity*. Boston (MA): Little Brown; 1976.
 91. Vander Woude DL, Mulliken JB. Effect of lip adhesion on labial height in two-stage repair of unilateral complete cleft lip. *Plast Reconstr Surg* 1997;100:567–72.
 92. Mulliken JB, Pensler JM, Kozakewich HPW. The anatomy of cupid's bow in normal and cleft lip. *Plast Reconstr Surg* 1993;92:395–403.
 93. McComb H. Primary correction of unilateral cleft lip nasal deformity: a 10 year review. *Plast Reconstr Surg* 1985;75:791–9.
 94. Horswell BB, Pospisil OA. Nasal symmetry after primary cleft lip repair: comparison between Delaire cheilorhinoplasty and modified rotation-advancement. *J Oral Maxillofac Surg* 1995;53:1025–30.
 95. Schendel SA. Nasal symmetry after primary cleft lip repair: comparison between Delaire cheilorhinoplasty and modified rotation-advancement [discussion]. *J Oral Maxillofac Surg* 1995;53:1031.
 96. Trier WC. Bilateral complete cleft lip and nasal deformity: an anthropometric analysis of staged to synchronous repair [discussion]. *Plast Reconstr Surg* 1995;96:24.
 97. Takato T, Yonehara Y, Mori Y, et al. Early correction of the nose in unilateral cleft lip patients using an open method: a 10-year review. *J Oral Maxillofac Surg* 1995;53:28–33.
 98. Millard DR. Columella lengthening by a forked flap. *Plast Reconstr Surg* 1958;22:454.
 99. Cronin TD. Lengthening the columella by use of skin from nasal floor and alae. *Plast Reconstr Surg* 1958;21:417.
 100. McComb H. Primary repair of the bilateral cleft lip nose: a 15-year review and a new treatment plan. *Plast Reconstr Surg* 1990;86:882–9.
 101. Mulliken JB. Bilateral complete cleft lip and

- nasal deformity: an anthropometric analysis of staged to synchronous repair. *Plast Reconstr Surg* 1995;96:9–23.
102. Trott JA, Mohan NA. A preliminary report on one-stage open tip rhinoplasty at the time of lip repair in bilateral cleft lip and palate. The Alo Setar experience. *Br J Plast Surg* 1993;46:215–22.
 103. Cutting C, Grayson B. The prolabial unwinding flap method for one-stage repair of bilateral cleft lip, nose and alveolus. *Plast Reconstr Surg* 1993;91:37–47.
 104. Maher W. Distribution of palatal and other arteries in cleft and non-cleft human palates. *Cleft Palate J* 1977;14:1–12.
 105. Ross RB, Johnston MC. *Cleft lip and palate*. Baltimore (MD). William & Wilkins; 1972.
 106. Broomhead I. The nerve supply of the soft palate. *Br J Plast Surg* 1957;10:81.
 107. Riski JE, DeLong E. Articulation development in children with cleft lip/palate. *Cleft Palate J* 1984;21:57–64.
 108. Devlin HB. Audit and the quality of clinical care. *Ann R Coll Surg Engl* 1990;72 Suppl 1:3–14.
 109. Trotman CA, Ross RB. Craniofacial growth in bilateral cleft lip and palate: ages six years to adulthood. *Cleft Palate Craniofac J* 1993;30:261–73.
 110. Bishara SE. Cephalometric evaluation of facial growth in operated and unoperated individuals with isolated clefts of the palate. *Cleft Palate J* 1973;10:239–46.
 111. Bardach J, Kelly KM, Salyer KE. Relationship between the sequence of lip and palate repair and maxillary growth. An experimental study in beagles. *Plast Reconstr Surg* 1994;93:269–78.
 112. Semb G. A study of facial growth in patients with bilateral cleft lip and palate treated by the Oslo CLP team. *Cleft Palate Craniofac J* 1991;28:22–48.
 113. Shaw WC, Asher-McDade C, Brattstrom V, et al. A six-center international study of treatment outcome in patients with clefts of the lip and palate. Part 5. General discussion and conclusions. *Cleft Palate Craniofac J* 1992;29:413–8.
 114. Canaday JW, Thompson SA, Colburn A. Craniofacial growth after iatrogenic cleft palate repair in a fetal ovine model. *Cleft Palate Craniofac J* 1997;34:69–72.
 115. Peterson-Falzone SJ. Speech outcomes in adolescents with cleft lip and palate. *Cleft Palate Craniofac J* 1995;32:125–8.
 116. Dalston RM. Timing of cleft palate repair: a speech pathologist's viewpoint. In: Lehman JA, editor. *Problems of plastic surgery in cleft palate surgery*. Philadelphia (PA): J.B. Lippincott; 1992. p. 30–8.
 117. Witzel MA, Salyer KE, Ross RB. Delayed hard palate closure: the philosophy revisited. *Cleft Palate J* 1984;21:263–9.
 118. Schweckendiek W. Primary veloplasty: long-term results without maxillary deformity. A twenty-five year report. *Cleft Palate J* 1991;15:268–74.
 119. Kriens O. Fundamental anatomic findings for an intravelar veloplasty. *Cleft Palate Journal* 1970;7:27–36.
 120. Bardach J, Nosal P: Geometry of the two-flap palatoplasty. In: Bardach J, Salyer K, editors. *Surgical techniques in cleft lip and palate*. 2nd ed. St. Louis (MO): Mosby-Year Book; 1991.
 121. Von Langenbeck B. Operation der angeborenen totalen spaltung des harten gaumens nach einer neuen methode. *Dtsch Klin* 1861;8:231.
 122. Wardill WFM. Cleft palate: results of operation for cleft palate. *Br J Plast Surg* 1928;16:127.
 123. Wardill WFM. The technique of operation for cleft palate. *Br J Surg* 1937;25:117.
 124. Furlow LT. Cleft palate repair by double opposing Z-plasty. *Plast Reconstr Surg* 1986;78:724–38.
 125. Furlow LT. Bilateral buccal flaps with double opposing Z-plasty for wider palatal clefts [discussion]. *Plast Reconstr Surg* 1997;100:1144–5.
 126. Randall P, LaRossa D, Solomon M, Cohen M. Experience with the Furlow double-reversing Z-plasty for cleft palate repair. *Plast Reconstr Surg* 1986;77:569–76.
 127. Horswell BB, Castiglione CL, Poole AE, et al. The double-reversing z-plasty in primary palatoplasty: operative experience and early results. *J Oral Maxillofac Surg* 1993; 51:145–9.
 128. Reid DA. Fistulae in the hard palate following cleft palate surgery. *Br J Plast Surg* 1986; 77:569.
 129. Abyholm FE. Palatal fistulae following cleft palate surgery. *Scand J Plast Reconstr Surg* 1979;13:295–300.
 130. Cohen SR, Kalinowski J, La Rossa D, et al. Cleft palate fistulas: a multivariate statistical analysis of prevalence, etiology, and surgical management. *Plast Reconstr Surg* 1991; 87:1041–7.
 131. Emory RE, Clay RP, Bite U, et al. Fistula formation and repair after palatal closure: an institutional perspective. *Plast Reconstr Surg* 1997;99:1535–8.
 132. Rintala AE. Surgical closure of palatal fistulae: follow-up of 84 personally treated cases. *Scand J Plast Reconstr Surg Hand Surg* 1980;14:235–8.
 133. Schultz RC. Management and timing of cleft palate fistula repair. *Plast Reconstr Surg* 1986;78:739–47.
 134. Tessier P. Colobomas: vertical and oblique complete facial clefts. *Panminerva Med* 1969;11:95–101.
 135. Kawamoto HK. The kaleidoscopic world of rare craniofacial clefts: order out of chaos (Tessier Classification). *Clin Plast Surg* 1976;3:529–72.
 136. Posnick JC. Rare craniofacial clefts: evaluation and treatment In: Posnick JC, editor. *Craniofacial and maxillofacial surgery in children and young adults*. Philadelphia (PA): W.B. Saunders; 2000. p. 487–502.

Reconstruction of the Alveolar Cleft

Peter E. Larsen, DDS

In the management of patients with cleft lip and cleft palate, the decision regarding alveolar cleft grafting is one of the most controversial. Is grafting of the residual alveolar defect indicated? If so, at what age is it most appropriate, what material is most ideal, and should adjunctive procedures such as orthodontic expansion be used before or after grafting? Lastly, what are appropriate measures of success? This chapter reviews what is known, discusses these controversies, and provides a rationale for the approach to the residual alveolar cleft defect.

Rationale for Grafting

Although some authors have advocated nongrafting techniques¹ or prosthodontic approaches, the general consensus is that achieving continuity between the cleft alveolar segments has significant advantages, regardless of how and when this is accomplished. Potential advantages include the following²:

1. Grafting achieves stability of the arch and prevents collapse of the alveolar segments. This provides improved orthodontic stability
2. Grafting preserves the health of the dentition. Grafting provides room for the canine and lateral incisors to erupt into the arch into stable alveolar bone and maintains bony support of teeth adjacent to the cleft^{3,4}
3. Grafting restores continuity not only of the alveolus, but also of the maxilla at the piriform rim. This supports the ala and provides improved stability and support for the nose. This may have a direct esthetic benefit and may also prove to be of long-term benefit when formal rhinoplasty procedures are performed³
4. Palatal and nasolabial fistulas are often present even following palatoplasty. Grafting of the alveolar defect provides an opportunity for the surgeon to address the residual oronasal fistula. This may have potential benefit for both hygiene and speech. Many cleft patients present with chronic upper respiratory and sinus disease, which may be related to reflux into the nasal cavity and sinus. There is some evidence that the residual fistula, whether labial or palatal can have an effect on speech articulation and nasality. There is evidence that closure of the fistula and grafting the cleft defect can improve nasal emission and nasality⁵

Measuring Outcomes

Prior to discussing the controversies associated with reconstruction of the residual alveolar cleft, it is important to accept some consistent measure of successful outcome. Most reports rely on descriptive data. This makes comparison

of different approaches difficult. To evaluate bone graft success, Bergland and colleagues described a semiquantitative approach that divided grafts into four types based on alveolar crest height.⁶ While this is effective, it has been suggested that occlusal alveolar bone height does not adequately measure success.⁷ Support of the ala and opportunity for successful tooth movement into the site or placement of an endosseous implant also requires apical bone formation. A modification of the Bergland scale that measures both occlusal and basal bone height may be a better tool for evaluating graft success. Although the Bergland scale and modifications of it rely on a two-dimensional radiograph to evaluate bone fill within a three-dimensional cleft, studies show good correlation between bone volume as predicted by these two-dimensional radiographs and that shown on three-dimensional computed tomography scans.⁸

Timing of the Graft

Perhaps the most controversial topic in managing the alveolar cleft is when grafting should be performed. In the traditional literature, terminology is not consistent. Outcome measures for various approaches are also defined inconsistently, which makes comparison difficult. Here, alveolar grafting will be grouped according to timing as defined below (Table 43-1).

Table 43-1 Timing of Alveolar Bone Grafting

<i>< 2 Years of Age: Primary Grafting</i>	
After lip repair	
Before palate repair	
<i>≥ 2 Years of Age: Secondary Grafting</i>	
Age in years	
2–5: Early secondary	
6–12: Mixed dentition secondary (after central incisor eruption and before the canine erupts)	
6–8: Early mixed dentition	
9–12: Late mixed dentition	
> 12: Late secondary grafting	

Primary Grafting

Some define primary alveolar bone grafting as that which is performed simultaneously with lip repair.⁹ Others have stated that any grafting that is performed at less than 2 years of age is considered primary grafting. Still others have defined primary grafting as grafting that is performed before the palate is repaired.^{10,11}

Primary grafting performed at the time of lip repair has failed to result in acceptable outcome. Long-term studies show abnormal maxillary development with maxillary retrognathia, concave profile, and increased frequency of crossbite compared with patients without grafts.^{12,13}

Primary grafting performed after the closure of the lip and before the closure of the palate has proven successful in a limited number of centers when a very specific protocol is followed.^{10,11} A prosthesis is placed before the lip is closed to mold the alveolar segments into close proximity. The lip is then closed, and this further aids in molding the segments. The segments must be in close proximity with good arch form before an onlay rib graft is placed across the labial surface of the cleft in a subperiosteal tunnel that is developed by limited dissection.

Advocates of this approach have not experienced problems with altered facial growth and malocclusion, most likely the

result of the limited dissection used in these cases. They have reported improved occlusion and graft success in these patients, compared with patients grafted at other ages.¹⁴ It is still difficult to wholeheartedly endorse this approach. Several additional anesthetics and surgeries are needed at a young age. This technique may not be possible in all patients, such as those with isolated alveolar clefts without palatal clefting or those patients in whom segments cannot be orthopedically aligned. In one center, because of these limitations, nearly one-half of patients could not be treated with primary grafting.¹⁰ Outcomes may also not be as good as with other approaches. In one study,¹⁵ there was an increased incidence of malformation of permanent lateral incisors in the primary graft group and decreased success of the graft, with only 41% of primary grafts (54% if pregrafting orthopedics was included) resulting in adequate bone height when measured with a Bergland scale. This was compared with 73% success of those sites grafted in the mixed dentition stage (after eruption of the permanent central incisors and before eruption of the maxillary canine).

Early Secondary Grafting

Grafting after the child reaches 2 years of age and before 6 years is considered early secondary grafting. The literature does not support early secondary grafting.

Secondary Grafting During the Mixed Dentition (after Eruption of the Maxillary Central Incisors and before Eruption of the Canine)

Alveolar reconstruction with grafting during the eruption of the permanent dentition may be best for various reasons. Rationale for grafting and for timing of grafting during this time period include the following:

1. There is minimal maxillary growth after age 6 to 7 years, and the effect of

grafting at this time will result in minimal to no alteration of facial growth^{16,17}

2. Cooperation with orthodontic and perioperative care is predictable. General anesthesia is not required for routine orthodontic procedures such as expansion
3. The donor site for graft harvest is of acceptable volume for predictable grafting with autogenous bone
4. Bone volume may be improved by eruption of the tooth into the newly grafted bone¹⁸
5. Grafting during this phase allows placement of the graft before eruption of permanent teeth into the cleft site, which achieves one of the primary goals of grafting — to enhance the health of teeth in and adjacent to the alveolar cleft

The landmark papers by Boyne and Sands established that grafting in the mixed dentition achieves many of the goals of reconstruction of the cleft alveolus.^{19,20} The ideal patient is between the ages of 8 and 12 years with a maxillary canine root that is one-half to two-thirds developed. This timing is supported by several well-documented studies.^{6,21–25} However, some authors have suggested that earlier grafting should be considered as a means of preserving the lateral incisor as well.^{12,26,27} These authors have suggested that grafting be considered as early as 6 years of age. There is some evidence that grafting between the ages of 6 and 8 years, in addition to achieving the expected goal of preserving the canine, can preserve the lateral incisor as well, but this remains controversial. Despite clear indications that grafting in the mixed dentition is preferable to either primary, early secondary, or late secondary grafting, it is not entirely clear whether this grafting should be performed early (age 6–8 years) or late (age 8–12 years). Various individual factors should be evaluated when determining the ideal time for grafting during the mixed dentition (Table 43-2).

Table 43-2 Factors Contributing to Timing of Grafting During the Mixed Dentition

Dental age vs chronologic age
Presence of the lateral incisor
Position of the lateral incisor
Degree of rotation/angulation of the central incisor
Trauma/mobility of premaxillary segment (bilateral clefts)
Social issues
Size of the patient and of the cleft
Occlusion
Need for adjunctive procedures
Dynamic of the team

Dental Versus Chronologic Age Many outcomes of grafting are related to preserving health of the dentition adjacent to and erupting into the cleft site. It makes sense that the timing of the graft be determined on the basis of dental rather than chronologic age. When the maxillary central incisors begin to erupt, regardless of chronologic age, the patient should be evaluated for grafting, taking into consideration the other factors discussed below. In some patients this may be much earlier than the traditionally recommended age for evaluation.

Presence of the Lateral Incisor Many proponents of earlier mixed dentition grafting advocate this timing because of the opportunity to salvage the lateral incisor.^{12,24,26} During the evaluation, attention should be directed to the presence of the lateral incisor and to whether this tooth appears to be normally formed. The incidence of congenitally missing permanent lateral incisors within the alveolar cleft is between 35 and 60%.^{15,28} If a lateral incisor is present and appears to be well formed, earlier grafting may be beneficial. Even if the tooth is not perfectly formed, it may still be beneficial to attempt to preserve it. The grafted alveolus will often thin to the point that alveolar width is not adequate for definitive reconstruction

with an endosseous implant without additional grafting.²⁹ Retaining the lateral incisor will maintain bone width and perhaps eliminate the need for yet another graft at the time of implant placement.

Position of the Lateral Incisor If the lateral incisor is mesial to the cleft it often has adequate space for eruption. However, if the lateral incisor is located in the posterior segment, earlier grafting may be necessary to preserve the lateral incisor.⁹ In one review, 36% of patients with cleft lip and alveolus had missing lateral incisors. Of the 64% who had lateral incisors, 90% of the lateral incisors were located distal to the cleft. In the same series of patients, 57% of those with cleft lip and palate had missing lateral incisors, and of the remaining 43%, 86% of the lateral incisors were located distal to the cleft.²⁸ Therefore, a significant number of patients may benefit from earlier grafting to preserve the lateral incisor (Figure 43-1).

Rotation of the Central Incisor The maxillary permanent central incisor will often erupt in a rotated and angled position (Figure 43-2). This reflects the morphology of the underlying bone. In extreme cases, the crowding of the two incisors can preclude normal oral hygiene methods, and this can lead to decay of the central incisor. The patient or parent may also be concerned with the position of the incisors for social reasons. If a decision is made to rotate these teeth into alignment, it may be necessary to graft the alveolar defect prior to this orthodontic tooth movement.³⁰ Failure to consider the morphology of the bone on the distal surface of the erupted central incisor can result in bone loss and periodontal defects as a result of orthodontic tooth movement. Since the incisor teeth erupt around age 6 years, the surgeon may choose to graft at an earlier age so that orthodontic movement of the incisors can be accomplished.

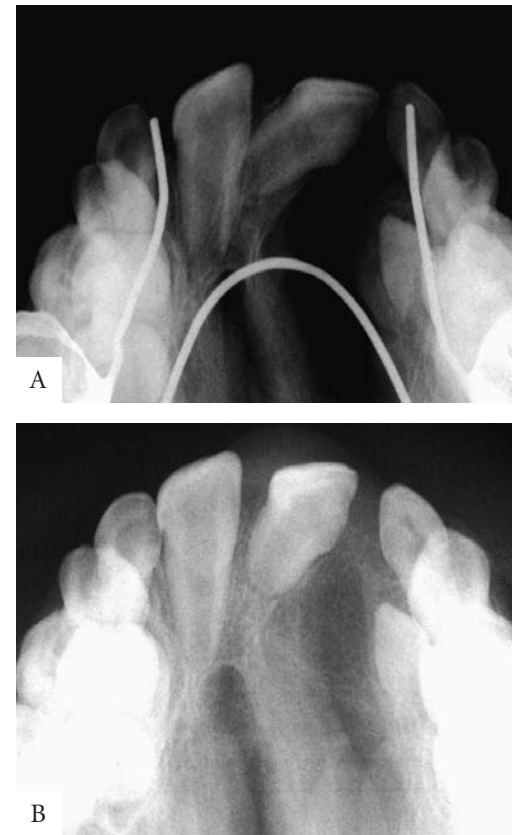


FIGURE 43-1 A, Occlusal radiograph shows lateral incisor distal to the cleft. B, Grafting which was done at age 7 years to facilitate eruption of the lateral incisor.

Social Issues The window for mixed dentition grafting is large (age 6–12 years). This is also during a period of tremendous social development for the patient. If a graft is necessary, the timing of surgery should respect the social and educational development of the child. Slightly earlier grafting, when it may cause less interference with education or other important opportunities for social development, may be preferable to grafting at an exact stage of dental development.

Size of the Patient and of the Cleft Petite patients with large cleft defects are challenging. Adequate closure of the defect may be difficult, and harvesting an adequate amount of graft material may be challenging as well. This is particularly true for large bilateral cleft defects. In these patients, the lateral incisor is often absent, the oronasal communication is often quite

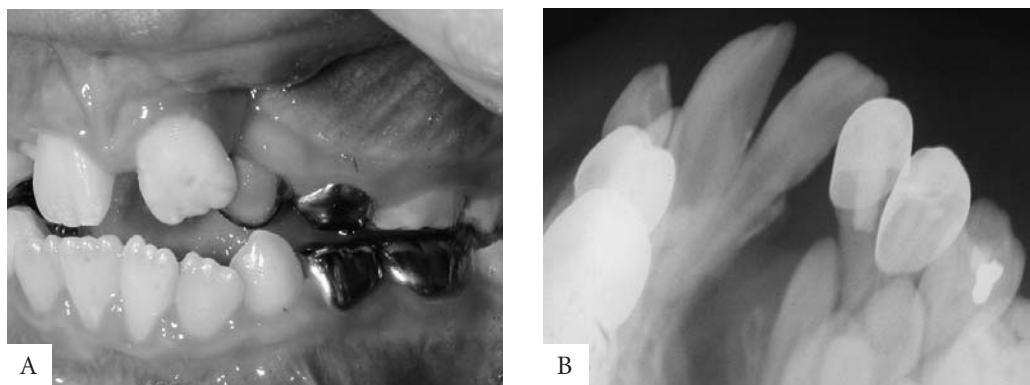


FIGURE 43-2 A, Photograph of a typical unilateral cleft. There is rotation of the central incisor and angulation of the crown toward the cleft. This maintains bone support for the root of the tooth. B, Occlusal radiograph shows that the cleft defect is larger than it appears clinically and support for the incisor root is provided by only a thin margin of bone.

large, and the premaxilla is frequently in less than ideal position. In these large defects, later grafting is often better, to wait for growth of the patient and orthodontic alignment of the cleft segments.

Need for Other Procedures Patients are often evaluated for velopharyngeal incompetence, minor esthetic revision of the nose or the lip, and pressure-equalizing tubes for otitis media. It is reasonable to coordinate the timing of surgery for the alveolar cleft with other procedures that may be necessary. If velopharyngeal flap surgery is planned during the mixed dentition phase, it should take precedence over the alveolar graft. Improved speech is more important to the child's development than achieving continuity of the alveolus. Alveolar grafting would be compromised if performed simultaneously with velopharyngeal flap surgery, and in these patients, it is appropriate to delay the graft until the velopharyngeal flap surgery is accomplished and speech therapy re-instituted. Minor soft tissue, nasal, and lip revision are often desired by the patient and parents. These can be accomplished with alveolar grafting. The grafting process can distort the nose and soft tissue; these soft tissue procedures should be performed first with alveolar grafting undertaken in the same setting and with care not to disrupt the esthetic procedures already done.

Dynamic of the Team Cleft management should always involve a multidisciplinary team, with the wide expertise to develop a proper treatment plan. Difficulties may arise when the priorities of one specialty compete with those of another. If the surgical team is faced with an orthodontic provider who feels strongly that it is appropriate to align the maxillary central incisors as soon as they erupt, it will be necessary for the alveolar defect to be grafted earlier to prevent compromise of osseous support for the central incisors. Some orthodontists and surgeons believe that palatal expansion is necessary prior to grafting. These teams may find that it is more appropriate to graft patients at a later age, as it may take months to achieve the desired expansion prior to the graft.

Secondary Grafting after Eruption of the Permanent Canine (Late Secondary Grafting)

Late secondary grafting has received some support; however, data show that when all the goals of alveolar reconstruction are considered it has a less than acceptable outcome. Patients older than 12 years of age who undergo grafting have been reported to have decreased success when evaluated using the Bergland scale,^{6,15,25,27,31,32} loss of osseous support of teeth adjacent to the cleft,¹⁸ and increased morbidity.²⁷ There is less

opportunity to salvage the lateral incisor, and there is a delay in correction of the orthodontic condition. This delayed grafting does allow for increased options with regard to donor site for graft material, as harvest of the mandibular symphysis becomes possible. Such grafts are difficult in the mixed dentition stage, where it is difficult to obtain adequate bone without damaging unerupted teeth.

Source of Bone Graft

The selection of the ideal grafting material is somewhat dependent on the timing of the graft. In primary bone grafting, the rib is the only site for adequate quantity of bone with acceptable morbidity. In the mixed dentition stage, the rib is not as appropriate as other sites such as the calvaria or iliac crest. These options would also be possible sources for bone for late secondary grafting, as well as grafts from the mandibular symphysis and possibly the tibia.

As the data suggest that grafting during the mixed dentition is ideal, discussion will focus on comparing various sources of graft material for this group of patients. The advantages and disadvantages of various potential sources of bone are outlined in Table 43-3.

Iliac Crest

Potential advantages of the iliac crest bone graft include low morbidity and high volume of viable osteoblastic cells (cancellous bone); two teams may work simultaneously, and this procedure is well accepted by the patient.

Bone can be harvested from the iliac crest through various approaches. Some have suggested that a lateral approach is appropriate in the growing patient.³³ This procedure disrupts the iliotibial tract and has a higher incidence of gait disturbance and postoperative pain.³⁴ In theory it may be appropriate to avoid the anterior crest, which does not complete its growth until after age 20 years.³⁴ However, the carti-

Table 43-3 Comparison of Graft Sources

Site	Advantage	Disadvantage	Considerations
Ilium	Large quantity cancellous bone, two teams	Mild transient gait disturbance	All clefts, particularly large and bilateral clefts
Calvaria	Minimal postoperative discomfort, incision hidden, low morbidity	Limited cancellous/diploic bone, increased operative time	Unilateral clefts, lower success
Mandibular symphysis	Same operative field, rapid procurement, minimal pain	Limited bone	Older children with small defects
Rib	Two teams	Poor source cancellous bone, postoperative pain, visible scar, risk of pneumothorax	Not recommend except for primary grafting
Proximal tibia	Abundant cancellous bone, easy procedure, mild postoperative pain, two teams	—	Not recommend in patients that have not completed growth

Adapted from Ochs MW.⁴⁹

lignous cap overlying the crest is reduced in thickness to about 1cm by age 9 years. Damage to the crest at this time could lead to disturbance in growth and cosmetic deformity of the crest; however, splitting the crest longitudinally, which allows access to the underlying cancellous marrow, has been used for harvest of bone in this age-group with no reported growth alteration and less postoperative gait disturbance than with the lateral subcrestal approach.^{35,36}

Calvarial Bone

Calvarial bone has been recommended by some as an alternative to iliac crest grafting.^{37,38} Some authors have concerns about the potential for success when calvaria is used as a graft source.^{39,40} This may be related to the technique of harvest. Bone grafts consisting of diploic bone have been shown to be more successful than those grafts harvested using a high-speed rotary device to shave off primarily cortical bone from the surface of the calvaria.⁴⁰ However, even when harvesting calvarial bone in such a way as to maximize diploic bone, results may not be as good as with iliac crest bone. In one study where primarily diploic bone was carefully harvested from the calvaria, the results were still less successful (80% graft success) than with tra-

ditional iliac crest bone (93% graft success).⁴¹ It is likely that either source is effective as long as primarily diploic bone is used. This limitation may render calvaria as a less useful source for large clefts and bilateral clefts.

Calvarial grafts may have decreased morbidity compared with iliac crest harvest. There is less postoperative pain and no gait disturbance. Other potential advantages include decreased surgery time. Cranial bone grafts can be harvested more quickly than iliac crest grafts. If a single team is performing surgery, this may be significant. However, it is not possible to harvest the cranial graft simultaneously with the alveolar cleft repair; grafting from the iliac crest if two teams are used can decrease overall operating time compared with calvarial grafting. Lastly, the incision for graft harvest is hidden in the hairline, which may have a cosmetic advantage.

Grafting from the calvaria has potential disadvantages. There is a perceived increased risk by patients and their families, although several studies show that the morbidity of bone harvest from the calvaria is minimal.³⁴ As mentioned previously, the volume of diploic bone is limited, making this less predictable for large or bilateral clefts.

Allogeneic Bone and Bone Substitutes

In an effort to eliminate the morbidity and time necessary to harvest bone from any autogenous site, some authors have evaluated allogeneic bone as a potential source of graft material. Studies have shown that allogeneic bone can be used successfully to graft secondary alveolar cleft defects and that results can be compared favorably with those achieved with autogenous bone.⁴² However, the demands of bone healing in the alveolar defect where there is potential communication between the graft and the nasal and oral cavity may make this less predictable in large cleft defects or bilateral clefts. In general, bone healing with autogenous bone is biologically different than with allogeneic bone. Autogenous bone grafts initiate an angioblastic response early in the healing process, and some of the transplanted cells remain viable, resulting in a more rapid formation of new bone. In contrast, allogeneic bone grafts demonstrate slower revascularization, as there are no viable cells transferred with the graft.^{42,43} There is also a theoretical risk of disease transmission from allogeneic sources of bone. Mathematically the risk is quite small but may be of concern to patients and families.

Preliminary work suggests that bone morphogenic proteins and other tissue-derived growth factors could be useful in eliminating the need for autogenous bone harvest in this patient population; however, there are insufficient outcome data and availability of these products commercially to make them the material of choice.

In summary, autogenous bone harvested from either the iliac crest or calvaria remains the most predictable technique for cleft reconstruction. The iliac crest has some potential advantage over the calvarial graft; however, this certainly depends on technique and surgeon preference.

Pre- versus Postsurgical Orthodontics

Controversy exists regarding the use of orthopedic expansion of the cleft segments and the relationship between expansion and grafting. This issue has not been entirely settled. Most authors prefer presurgical expansion, citing easier expansion because of less resistance, improved access to the cleft for closure of the nasal floor, better postoperative hygiene, and less chance of reopening the oronasal fistula.^{23,24} Presurgical expansion may also allow orthopedic movement of the premaxillary segment in the bilateral cleft patient, which can eliminate traumatic occlusion that can negatively impact graft success. Proponents of

expansion following grafting cite advantages of improved bone consolidation when the graft is placed under a dynamic load during healing, a smaller soft tissue defect to close, less difficulty procuring an adequate volume of bone, and a narrower defect, which will regenerate bone more quickly.²⁶ Both approaches have been used in conjunction with autogenous grafting in the mixed dentition stage with success.⁹

In practice, both approaches are valid, and the decision should be based on individual clinical presentation.³¹ Small unilateral clefts with collapse of the arch may be easier to graft with some presurgical expansion. In these cases, such expansion may not increase the size of the defect appreciably, and better alignment of the segments can improve hygiene of the teeth adjacent to the cleft and improve access (Figure 43-3). In these cases, the end point of presurgical expansion is improved arch form, not necessarily resolution of crossbite. Bilateral clefts with collapse of the lateral segments may also benefit from presurgical expansion. Expanding the lateral segments may allow the premaxilla, which is often anteriorly positioned, to be brought back into better relation with the arch, improving arch form, and, in some cases, eliminating traumatic occlusion (Figure 43-4). If this is not done prior to grafting, it may be difficult to

obtain ideal arch continuity, and positioning of the segments after grafting may be difficult. In patients with reasonable arch form, good alignment of the segments, and dental development corresponding to ideal timing for grafting, it makes little sense to delay grafting in order to expand preoperatively, even in the presence of a buccal crossbite. These crossbites may be related only to the anterior-posterior discrepancy, and even if they are truly representative of transverse deficiency, they can be treated easily with expansion following the graft. These clefts can be expanded without opening the oronasal fistula or having a negative effect on the graft.

Not only is there controversy regarding pre- versus postsurgical expansion, there are also two schools of thought regarding orthodontic movement of the erupted teeth adjacent to the cleft. Some authors suggest that aligning the teeth adjacent to the cleft produces better hygiene and an improved result.²³ However, orthodontic movement of teeth adjacent to the cleft is not typically desired.⁴⁴ Orthodontic movement of teeth adjacent to the cleft prior to grafting increases the risk of moving these teeth into the cleft site, compromising osseous support. Studies have directly correlated the success of grafting with the presence of adequate bone on the distal surface of the central incisor preoperatively.⁴⁵ These defects cannot subsequently be

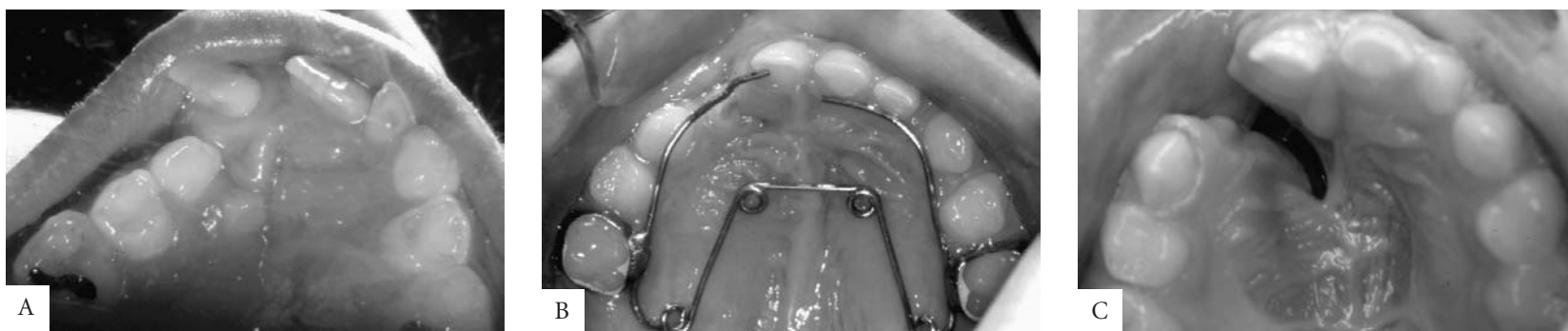

FIGURE 43-3 A, Occlusal photograph of a typical unilateral cleft. There is rotation of the central incisors and collapse of the lesser segment. Expansion of the lesser segment will bring the arch into better form and facilitate grafting without widening the cleft. B, Similar cleft that has been expanded. C, This cleft is already wide without any expansion. It would not be appropriate to expand this cleft before grafting even if a crossbite is present.

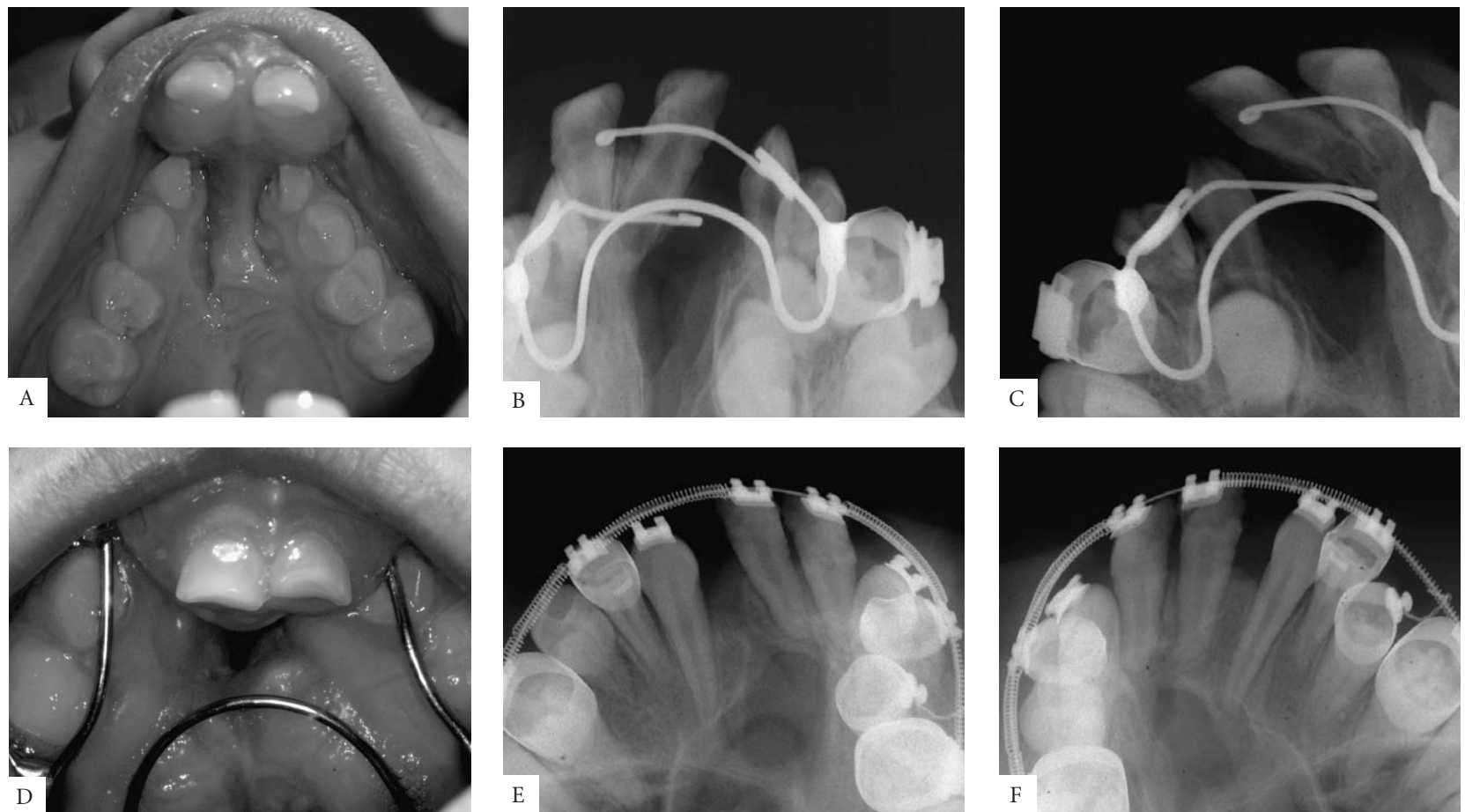


FIGURE 43-4 A, Occlusal photograph of bilateral cleft with collapse of the lateral segments and protrusion of the premaxilla. B and C, Right and left oblique occlusal radiographs show the cleft defect. D, Expansion of the bilateral cleft allows the premaxilla to move posteriorly and improves arch form and alignment of the segments. E and F, Occlusal radiographs of the same patient following grafting with eruption of the canine.

grafted as the bone graft will not adhere to the tooth surface. The central incisor adjacent to the cleft site is usually rotated and angled with the crown tipped toward the cleft. This rotation and angulation decreases the mesial-distal dimension of the tooth and allows for the best bony support of the tooth (see Figure 43-2). Orthodontic forces of rotation and tipping will have the undesirable effect of increasing the mesial-distal dimension, encroaching on the bony support at the cemento-enamel junction of the tooth. Orthodontic root torque to correct the angulation of the tooth will have the undesired effect of pushing the apical portion of the root toward the cleft site. The underlying osseous cleft is frequently much larger than the overlying soft tissue defect may indicate, giving a false sense of securi-

ty to the orthodontist who may want to move these teeth in the absence of a graft (Figure 43-5).

Surgical Technique for Grafting the Cleft Alveolus

The ideal technique will meet the following criteria:

1. Predictable closure of the nasal floor produces a watertight barrier between the graft and the nasal cavity
2. There is access to closure of residual palatal and labial fistula
3. Keratinized attached tissue is maintained around the teeth adjacent to the cleft and in the site where the yet unerupted lateral incisor and canine will erupt

4. Mobilization of tissue is adequate to close large defects without tension, when such defects are present

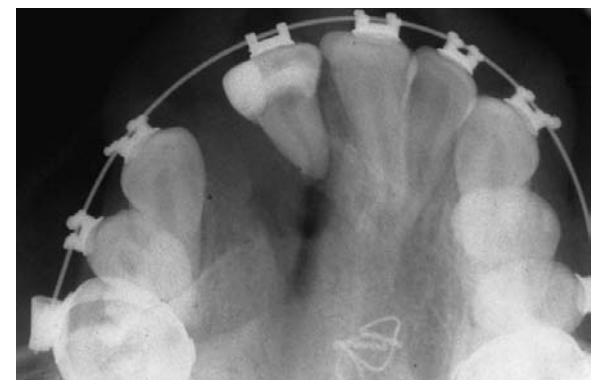

FIGURE 43-5 Occlusal radiograph of a patient that had orthodontic rotation of the maxillary central incisor adjacent to the cleft prior to grafting the defect. There is loss of bone on the distal surface of the root to the apex. The tooth required removal.

5. The vestibule is not shortened, and scarring is not excessive

Given these requirements, the technique most often used employs advancing buccal gingival and palatal flaps. This approach has some disadvantages, including the following:

1. Difficulty obtaining closure in large bilateral clefts, which heal by secondary intention of full-thickness wounds created by the advancement
2. A four-corner suture line that approximates the flaps directly overlying the graft, which may lead to dehiscence
3. The possibility that elevating large full thickness mucoperiosteal flaps leads to growth alteration in young patients. However, when compared with finger flaps and trapezoidal flaps, which can shorten the vestibule and place nonkeratinized tissue around the dentition, this approach remains the best

The procedure can be broken down as follows. The first step requires development

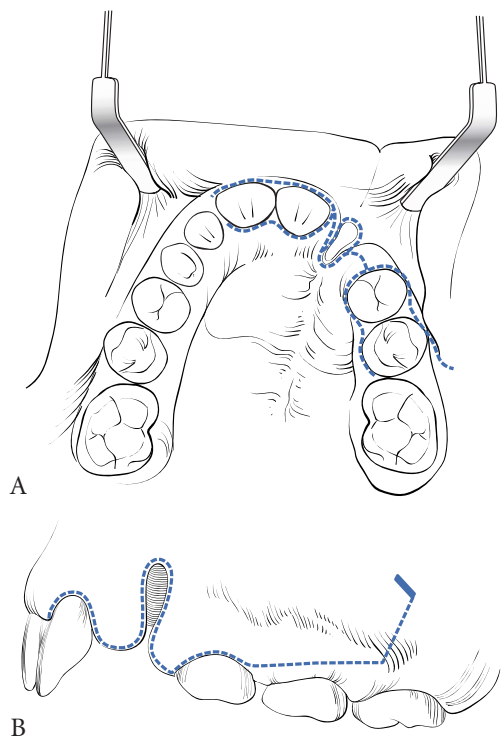


FIGURE 43-6 A and B, Sulcular incision used to develop sliding flaps for closure over the graft. Adapted from Hall HD and Posnick JC.²³

of full-thickness mucoperiosteal buccal flaps (Figure 43-6). Some authors may recommend papilla preservation. When grafting is done in the mixed dentition, especially if early, this is not necessary as the papilla will regenerate. Palatal flaps are then developed, incorporating whatever residual palatal defect may be present to allow for closure of the residual palatal fistula. Some diagrams show this incision being made from a palatal approach. This may be possible in wide clefts but in practice is more easily accomplished by starting reflection of the palatal flaps from a sulcular incision that is placed on the palatal side of the dentition followed by reflection of full-thickness palatal flaps toward the palatal defect. The palatal flaps can then be separated from the nasal tissue along the cleft margin by sharp dissection with scissors from the anterior extending posteriorly as the flaps are elevated (Figure 43-7A). In this manner, the maximum palatal soft tissue is preserved for closure, while assuring adequate nasal mucosa to obtain a watertight nasal closure. Once the buccal and palatal flaps have been developed, access is readily obtained to the nasal mucosa, which is then reflected and sutured, burying the knots to obtain a watertight nasal closure (Figure 43-7B and C). Most schematic diagrams of cleft closure show this portion of the procedure being performed from the palatal aspect. However, it is generally most readily accomplished in narrow clefts from the anterior through the cleft defect. Once the nasal mucosa is closed, the palatal defect is closed by first closing the palatal flaps, converting the cleft palate into a single flap (Figure 43-7D). The graft material is then placed into the cleft from the anterior, making certain to fill all voids completely to the piriform rim. Graft material can be condensed using an orthodontic band pusher or periosteal elevator (Figure 43-7E). It is helpful to place a malleable retractor to protect the nasal floor as the bone is packed into place. Finally, the labial flaps can be advanced, and they are sutured to each other and then to the palatal flap producing the

classic four-corner closure over the crest of the ridge (Figure 43-7F and G). In most cases, the sliding flaps will be advanced one papilla on either side of the cleft, or, in some cases, only a single papilla advancement from the posterior segment is necessary. It may be necessary to perform a small back cut or to release or score the periosteum to obtain a tension-free closure. It is best to use a resorbable monofilament suture.

A palatal stent can be used to stabilize the cleft and protect the soft tissue closure. This may compromise hygiene and blood supply to the palatal flaps and, in most cases, is not required for success. In the bilateral cleft, if there is a traumatic occlusion to the anterior maxillary dentition, a mandibular bite plane is helpful to open the bite and prevent mobility of the premaxilla.

It is appropriate to use intraoperative antibiotics. Previous studies show that graft success and incidence of infection are not improved by the use of postoperative antibiotics.⁴⁶ Some surgeons feel more comfortable with a 1-week course of antibiotics, particularly when the soft tissue closure is questionable.

The postoperative diet should be limited to full liquids for approximately 5 days. This can be advanced to a soft mechanical diet. However, it is critical that the patient refrain from incising food with the anterior dentition; rather the patient should cut food into small pieces and masticate primarily on the posterior teeth. In bilateral cases, this is particularly important as any trauma to the premaxilla will cause mobility of the segment leading to graft failure. Radiographic evidence of graft consolidation should be visible within 8 weeks. The surgeon should confirm successful consolidation of the graft prior to any orthodontic manipulation of the teeth adjacent to the cleft.

Overview

This chapter has outlined historic benefits of grafting, discussed many of the controversies, and provided data on the benefits and disadvantages of several approaches.

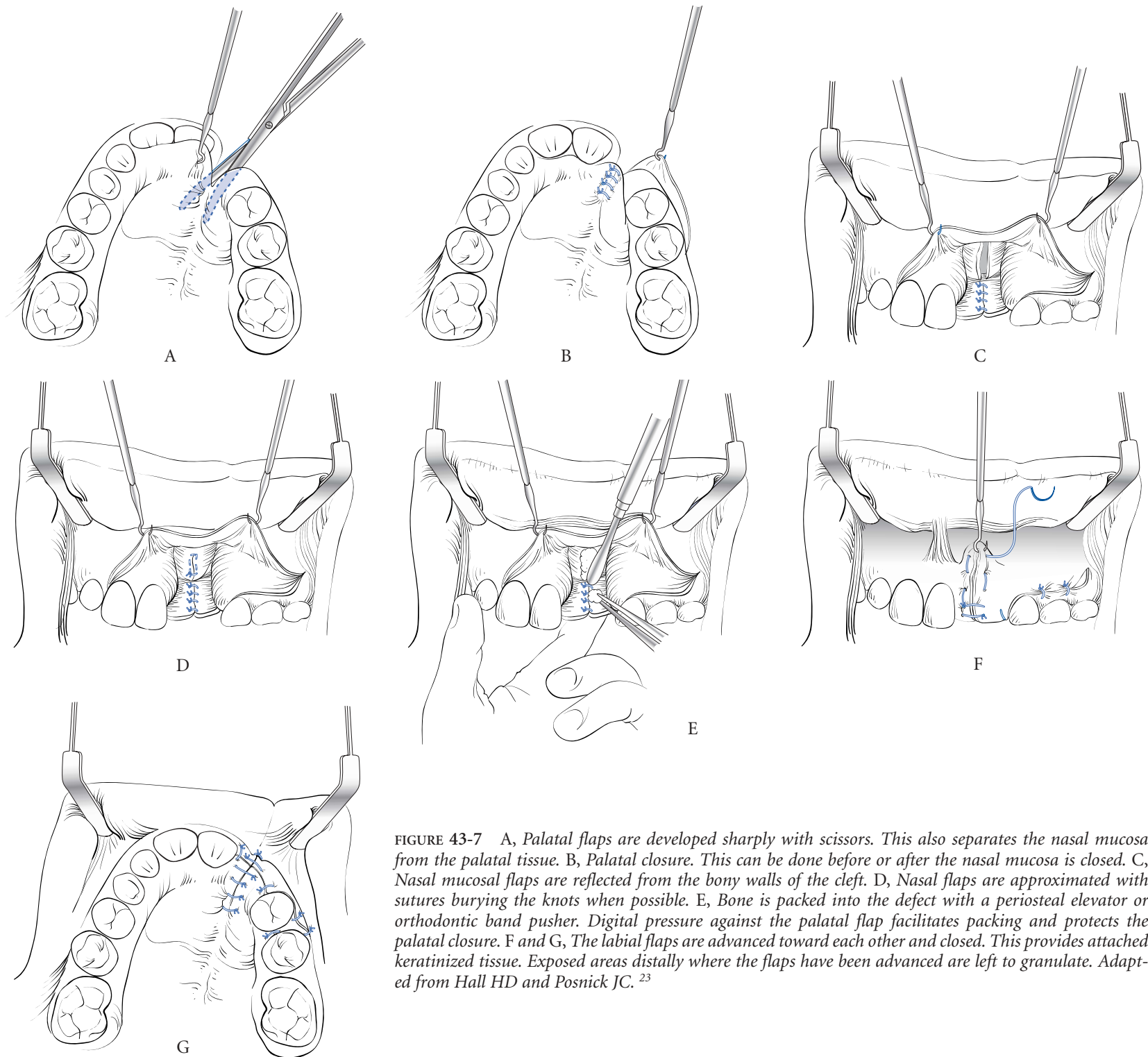


FIGURE 43-7 A, Palatal flaps are developed sharply with scissors. This also separates the nasal mucosa from the palatal tissue. B, Palatal closure. This can be done before or after the nasal mucosa is closed. C, Nasal mucosal flaps are reflected from the bony walls of the cleft. D, Nasal flaps are approximated with sutures burying the knots when possible. E, Bone is packed into the defect with a periosteal elevator or orthodontic band pusher. Digital pressure against the palatal flap facilitates packing and protects the palatal closure. F and G, The labial flaps are advanced toward each other and closed. This provides attached keratinized tissue. Exposed areas distally where the flaps have been advanced are left to granulate. Adapted from Hall HD and Posnick JC.²³

The following is a stepwise approach to managing the alveolar cleft from one perspective.

1. At age 5 to 6 years an orthodontic evaluation is performed. The ability of the patient to cooperate with ortho-

odontic treatment is assessed, the arch is evaluated for collapse, and erupted supernumerary teeth in the area of the cleft are identified. Radiographic examination should include a panoramic film as well as an intraoral view that allows detailed evaluation of

the cleft site. Periapical films can be used for this, but a lateral oblique occlusal film is best. An occlusal film is placed in the standard position while directing the beam obliquely to the midline along the long axis of the cleft (Figure 43-8)

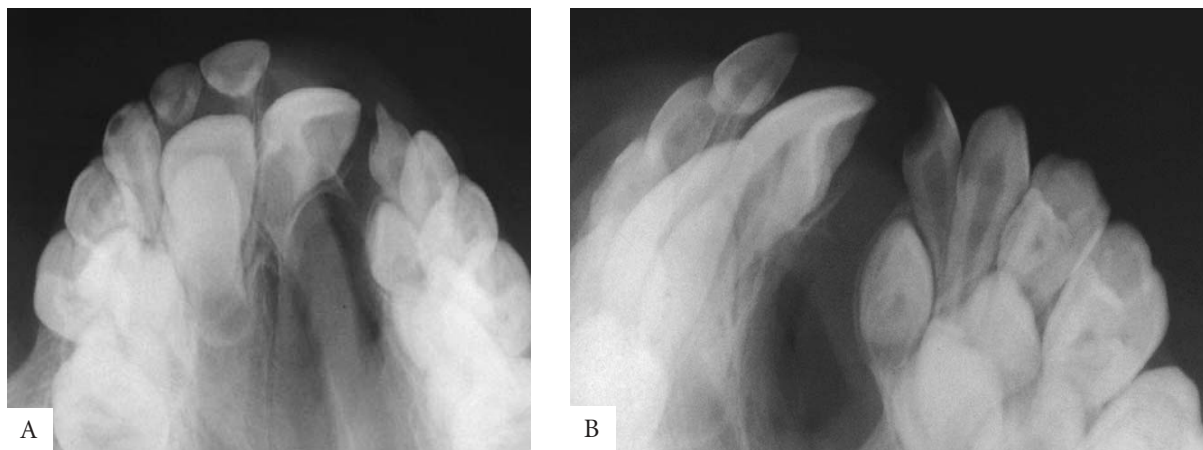


FIGURE 43-8 A, Traditional maxillary occlusal radiograph. The cleft is identifiable, but overlap of the bone makes it difficult to determine the size of the defect and relationship of the teeth to the defect. B, Oblique occlusal radiograph is exposed by directing the beam obliquely to the midline, along the long axis of the cleft. Note that the morphology of the cleft is better identified, as is the relationship of unerupted teeth to the defect.

2. If erupted supernumerary teeth are identified in the area of the cleft, these are extracted now or, at a minimum, 8 weeks before the graft (Figure 43-9A)
3. Orthodontic expansion is performed if there are specific goals that can be met prior to grafting. These would include decreasing traumatic occlusion to the premaxillary segment in bilateral cleft patients and correcting arch collapse that will compromise grafting. No attempt is made to correct the crossbite at this stage, and there is no attempt to orthodontically correct rotation of the permanent central incisor (see Figure 43-9A)
4. The alveolar cleft is grafted when the patient is between 6 and 8 years of age. Two teams perform the surgery with graft harvest from the iliac crest simultaneous with the cleft closure
5. The graft is evaluated with a lateral oblique occlusal radiograph 3 months following surgery (Figure 43-9B)
6. Final orthodontic expansion is performed if indicated, and permanent incisor teeth are then rotated into proper alignment
7. Conventional orthodontic treatment is performed at a more traditional age, following eruption of the remaining permanent dentition. Patients are periodically monitored for eruption of the canine in the cleft. Some authors have indicated that in 30 to 73% of patients, eruption of the canine into the alveolar graft requires surgical uncovering of the tooth or uncovering and orthodontic assistance.^{12,47,48} Others have reported that nearly all of these teeth can be expected to erupt without surgical intervention²⁴ (Figure 43-9C).

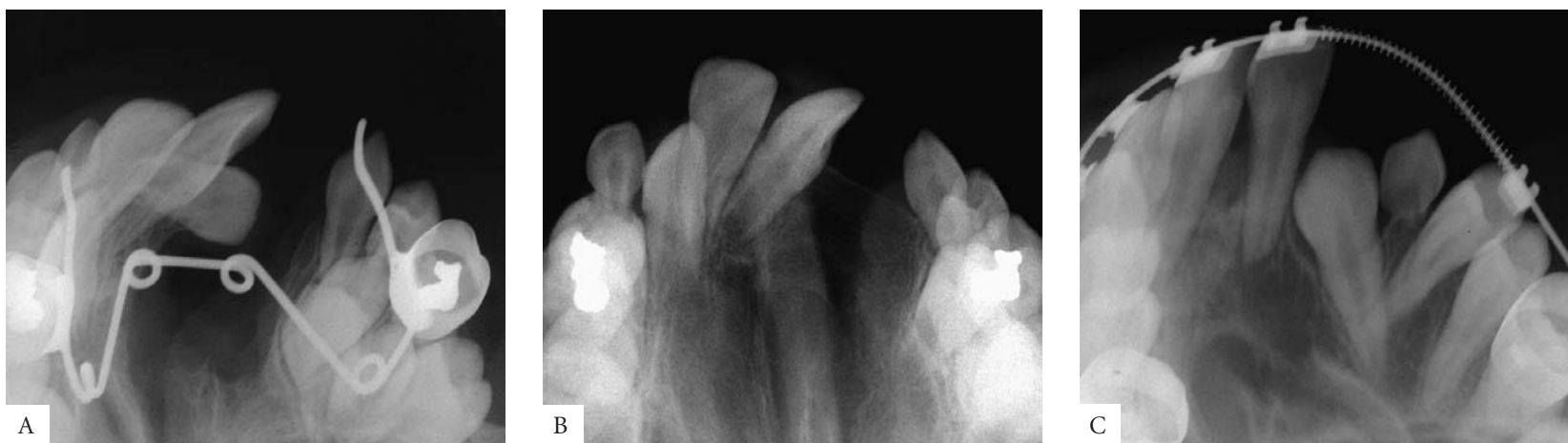

FIGURE 43-9 A, The cleft has been expanded. The canine is in position to begin eruption. There is a supernumerary/malformed lateral incisor erupting horizontally into the cleft. B, The supernumerary tooth has been removed. The defect was grafted 2 months following extraction and the film shows good bone consolidation. C, The maxillary canine can be seen erupting into the graft.

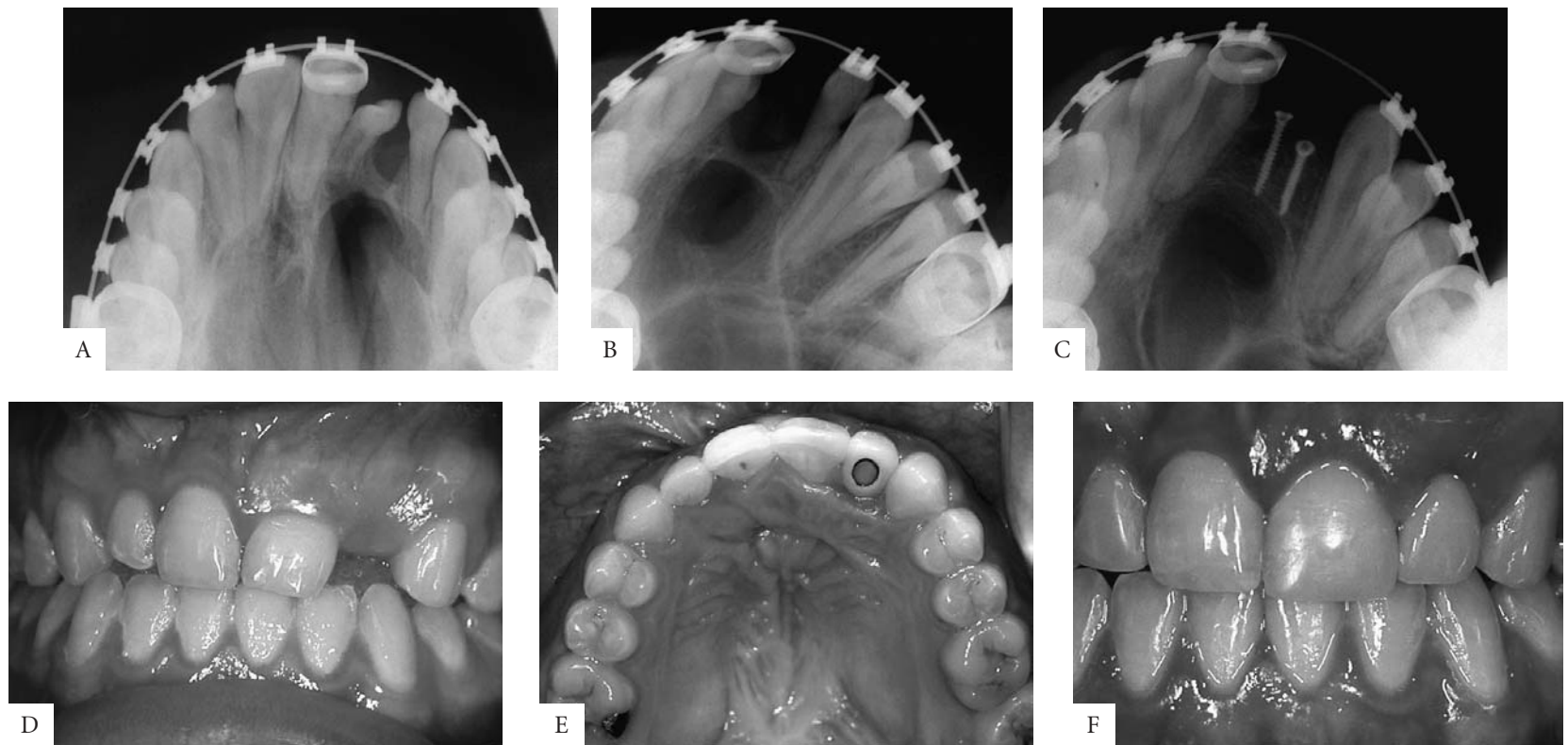


FIGURE 43-10 A, Occlusal radiograph shows thin bridge of bone with inadequate height. A malformed lateral incisor was maintained to preserve as much width as possible. B, The tooth was removed. C, After 2 months of healing, an onlay bone graft was placed. D, Clinical view after grafting. E and F, View following placement of the implant and reconstruction.

If uncovering is necessary, techniques to preserve attached tissue are used as would be appropriate for impacted canines in noncleft patients

8. Missing lateral incisors are managed with space development and implant placement, as opposed to canine substitution. This is accomplished following definitive orthodontic treatment and orthognathic surgery if indicated, after maxillary growth is complete. Even when bone height is adequate and teeth adjacent to the graft have good support, the graft undergoes resorption resulting in a narrow ridge. This is not unlike the bone resorption found with congenitally absent lateral incisors in noncleft patients. Successful implant restoration is possible, but further grafting is likely needed before adequate labial-palatal width is available for implant placement³⁰ (Figure 43-10). Attention to soft and hard tis-

sue is critical in these patients to achieve esthetic results

Conclusion

Restoration of the cleft alveolus and maxilla by grafting is a critical part of the overall management of the patient with cleft palate. A systematic approach can improve predictability. This is best accomplished during the mixed dentition stage. Adjunctive expansion may be accomplished before or after grafting, depending on the needs of the patient.

References

1. Santiago PE, Grayson BH, Cutting CB, et al. Reduced need for alveolar bone grafting by pre-surgical orthopedics and primary gingivoperiosteoplasty. *Cleft Palate Craniofac J* 1998;35:77-80.
2. Horswell BB, Henderson JM. Secondary osteoplasty of the alveolar cleft defect. *J Oral Maxillofac Surg* 2003;61:1082-90.
3. Kalaaji A, Lilja J, Friede H. Bone grafting at the stage of mixed and permanent dentition in patients with clefts of the lip and primary palate. *Plast Reconstr Surg* 1994;93:690-6.
4. Teja A, Persson R, Omnell ML. Periodontal status of teeth adjacent to nongrafted unilateral alveolar clefts. *Cleft Palate Craniofac J* 1992;29:357-62.
5. Bureau S, Penko M, McFadden L. Speech outcome after closure of oronasal fistulas with bone grafts. *J Oral Maxillofac Surg* 2001; 59:1408-13.
6. Bergland O, Semb G, Abyholm RD. Elimination of the residual alveolar cleft by secondary bone grafting and subsequent orthodontic treatment. *Cleft Palate J* 1986;23:175-205.
7. Hynes PJ, Earley MJ. Assessment of secondary alveolar bone grafting using a modification of the Bergland grading system. *Br J Plast Surg* 2003;56:630-6.
8. Dado DV, Rosenstein SW, Adler ME, Kernahan DA. Long term assessment of early alveolar bone grafts using three-dimensional computer assisted tomography: a pilot study. *Plast Reconstr Surg* 1997; 99:1840-5.
9. Vig KWL, Turvey TA, Fonseca RJ. Orthodontic and surgical considerations in bone grafting in the cleft maxilla and palate. In: Turvey TA, Vig KWL, Fonseca RJ, editors. *Facial*

- clefts and craniostyosis: principles of management. Philadelphia: WB Saunders; 1996. p. 396.
10. Eppley B. Alveolar cleft bone grafting (part 1): Primary bone grafting. *J Oral Maxillofac Surg* 1996;54:74–82.
 11. Rosenstein SW. Early bone grafting of alveolar cleft deformities. *J Oral Maxillofac Surg* 2003;61:1078–81.
 12. Kwon JK, Waite DE, Stickel FR, Chisholm T. The management of alveolar cleft defects. *J Am Dent Assoc* 1981;102:848–53.
 13. Robertson NRE, Jolleys A. An 11 year follow up of the effects of early bone grafting in infants born with complete clefts of the lip and palate. *Br J Plast Surg* 1983;36:438–43.
 14. Helms JA, Speidel M, Denis KL. Effect of timing on long-term clinical success of alveolar cleft bone grafts. *Am J Orthod Dentofacial Orthop* 1987; 92:232–40.
 15. Brattstrom V, McWilliam J. The influence of bone grafting age on dental abnormalities and alveolar bone height in patients with unilateral cleft lip and palate. *Eur J Orthod* 1989;11:351–8.
 16. Daskalogiannakis J, Ross RB. Effect of alveolar bone grafting in the mixed dentition on maxillary growth in complete unilateral cleft lip and palate patients. *Cleft Palate Craniofacial J* 1997;34:455–8.
 17. Witsenburg B. The reconstruction of anterior residual bone defects in patients with cleft lip, alveolus and palate: a review. *J Maxillofac Surg* 1985;13:197–208.
 18. Dempf R, Teltzrow T, Kramer FJ, Hausamen JE. Alveolar bone grafting in patients with complete clefts: a comparative study between secondary and tertiary bone grafting. *Cleft Palate Craniofac J* 2002; 39:18–25.
 19. Boyne PJ, Sands NR. Combined orthodontic-surgical management of residual palato-alveolar cleft defects. *Am J Orthod* 1976; 70:20–37.
 20. Boyne PJ, Sands NR. Secondary bone grafting of residual alveolar and palatal clefts. *J Oral Surg* 1972;30:87–92.
 21. Abyholm RE, Bergland E, Semb G. Secondary bone grafting of alveolar clefts. *Scand J Plast Reconstr Surg* 1981;15:127–40.
 22. Broude D, Waite DE. Secondary closure of alveolar defects. *Oral Surg* 1974;37:829.
 23. Hall HD, Posnick JC. Early results of secondary bone grafts in 106 alveolar clefts. *J Oral Maxillofac Surg* 1983;41:289–94.
 24. Turvey TA, Vig K, Moriarty J. Delayed bone grafting in the cleft maxilla and palate: a multidisciplinary analysis. *Am J Orthod* 1984;86:244–56.
 25. Yi-Lin J, James DR, Mars M. Bilateral alveolar bone grafting: a report of 55 consecutively treated patients. *Eur J Orthod* 1998; 20:299–307.
 26. Boyne PJ. Bone grafting in the osseous reconstruction of alveolar and palatal clefts. *Oral Maxillofac Clin North Am* 1991;3:589–97.
 27. Hall HD, Werther JR. Conventional alveolar cleft bone grafting. *Oral Maxillofac Clin North Am* 1991; 3:609–16.
 28. Suzuki A, Watanabe M, Nakano M, Takahama Y. Maxillary lateral incisors of subjects with cleft lip and or palate: part 2. *Cleft Palate Craniofac J* 1992; 29:380–4.
 29. Kearns G, Perrott DH, Sharma A, et al. Placement of endosseous implants in grafted alveolar clefts. *Cleft Palate Craniofac J* 1997;34:520–5.
 30. Vig KWL. Alveolar bone grafts: the surgical/orthodontic management of the cleft maxilla. *Ann Acad Med Singapore* 1999;28:721–7.
 31. Enemark H, Sindet-Pedersen S, Bundgaard M. Long-term results after secondary bone grafting of alveolar clefts. *J Oral Maxillofac Surg* 1987;45:913–8.
 32. Paulin G, Astrand P, Rosenquist JB, Bartholdson L. Intermediate bone grafting of alveolar clefts. *J Craniomaxillofac Surg* 1988; 16:2–7.
 33. Crockford DA, Converse JM. The ilium as a source of bone grafts in children. *Plast Reconstr Surg* 1972;50:270–4.
 34. Larsen PE. Sources of autogenous bone grafts in pediatric patients. *Oral Maxillofac Clin North Am* 1994;6:137–52.
 35. Rudman RA. Prospective evaluation of morbidity associated with iliac crest harvest for alveolar cleft grafting. *J Oral Maxillofac Surg* 1997;55:219–23.
 36. Wolfe SA, Kawamoto HK. Taking the iliac bone graft. *J Bone Joint Surg* 1978;60:411.
 37. Harsha BC, Turvey TA, Powers SK. Use of autogenous cranial bone grafts in maxillofacial surgery. *J Oral Maxillofac Surg* 1986; 44:11–5.
 38. Turvey TA. Donor site for alveolar cleft bone grafts (letter). *J Oral Maxillofac Surg* 1997; 45:834.
 39. Jackson IT, Helden G, Marx R. Skull bone grafts in maxillofacial and craniofacial surgery. *J Oral Maxillofac Surg* 1986; 44:949–56.
 40. Kortebein MJ, Nelson CL, Sadove MA. Retrospective analysis of 135 secondary alveolar cleft grafts using iliac or calvarial bone. *J Oral Maxillofac Surg* 1991;49:493–8.
 41. Sadove MA, Nelson CL, Epply BL, Nguyen B. An evaluation of calvarial and iliac donor sites in alveolar cleft grafting. *Cleft Palate Craniofac J* 1990;27:225–9.
 42. Maxson BB, Baxter SD, Vig KWL, Fonseca RJ. Allogeneic bone for secondary alveolar cleft osteoplasty. *J Oral Maxillofac Surg* 1990; 48:933–41.
 43. Marx RE, Miller RI, Ehler WJ, et al. A comparison of particulate allogeneic and particulate autogenous bone grafts into maxillary alveolar clefts in dogs. *J Oral Maxillofac Surg* 1984;42:3–9.
 44. Vig KWL, D'orth RCS, Turvey TA. Orthodontic-surgical interaction in the management of cleft lip and palate. *Clin Plast Surg* 1985;12:735–48.
 45. Aurouze C, Moller KT, Bevis RR, et al. The presurgical status of the alveolar cleft and success of secondary bone grafting. *Cleft Palate Craniofac J* 2000;37:179–84.
 46. Larsen PE, Myers G, Beck MF. Morbidity of alveolar cleft grafting in the early mixed dentition (<8years). *J Oral Maxillofac Surg* 1997; 55(Suppl 3):127.
 47. Eldeeb M, Messer LB, Lehnert MW, et al. Canine eruption into grafted bone in maxillary alveolar cleft defects. *Cleft Palate J* 1988;19:9–16.
 48. Enemark H, Sindet-Pedersen S, Bundgaard M, Simonsen EK. Combined orthodontic-surgical treatment of alveolar clefts. *Ann Plast Surg* 1988;21:127–33.
 49. Ochs MW. Alveolar cleft bone grafting (part 2): secondary bone grafting. *J Oral Maxillofac Surg* 1996; 54:83–8.

Reconstruction of Cleft Lip and Palate: Secondary Procedures

Ramon L. Ruiz, DMD, MD

Bernard J. Costello, DMD, MD

A congenital cleft of the lip and palate represents a complex malformation involving the hard and soft tissues of the face. Children born with cleft lip and palate face several unique functional and esthetic challenges requiring a combined (interdisciplinary) treatment approach in order to obtain an ideal outcome relative to speech, occlusion, facial appearance, and individual self-esteem. This successful reconstruction routinely requires multiple phases of surgical intervention. Because treatment is carried out during periods of growth, the benefit-risk ratio of any planned surgical procedure must be carefully considered in order to provide the maximum benefit to the patient.^{1,2} Surgeons caring for these children must maintain a firm cognitive understanding of the three-dimensional

anatomy of the cleft lip and palate malformation and the complex interplay that exists between the surgical procedures and ongoing facial growth.

The various surgical procedures involved in staged reconstruction of cleft lip and palate have been described extensively in the literature and are presented in Chapters 42, “Cleft Lip and Palate: Comprehensive Treatment Planning and Primary Repair,” Chapter 43, “Reconstruction of the Alveolar Cleft,” and Chapter 61, “Orthognathic Surgery in the Patient with Cleft Palate.”³⁻⁶ In addition, the American Cleft Palate–Craniofacial Association (ACPCA) has developed parameters of care in order to facilitate the coordinated interdisciplinary treatment of individuals affected with cleft lip and palate deformities.⁷ The ACPCA document summarizes a

management protocol that is centered around thoughtful timing of specific interventions based on the patient’s dental, skeletal, speech, and psychological development. The general staged approach to cleft lip and palate reconstruction from infancy through adolescence is presented in Table 44-1. Contemporary management protocols involve several phases of surgery during infancy (cleft lip repair and palate closure) and early childhood (bone graft reconstruction of the cleft maxilla and alveolus) that are considered required operations in all cases of complete unilateral or bilateral cleft lip and palate. In addition to those primary stages of repair, several children will go on to require additional procedures for correction of secondary problems. Secondary reconstruction of cleft lip and palate may involve

Table 44-1 Stages of Cleft Lip and Palate Reconstruction: Infancy through Adolescence

<i>Surgical Treatment</i>	<i>Age</i>	<i>Timing Considerations</i>
Cleft lip repair*	10 to 12 weeks	
Cleft palate repair*	9 to 18 months	Exact timing of repair is based on child’s speech/language age
Secondary palate surgery for VPI	3 to 5 years	
Bone graft reconstruction of cleft maxilla/alveolus*	6 to 9 years	Based on dental development
Orthognathic surgery	14 to 16 years for females, 16 to 18 years for males	
Dental implant placement	16 to 18 years	
Lip/nasal revision	After age 5 years	Varies widely depending on clinical findings and psychosocial concerns. Definitive nasal surgery usually delayed until adolescence.

*Reconstruction stage is required for all patients with complete cleft lip and palate. VPI = velopharyngeal insufficiency.

surgery for treatment of velopharyngeal dysfunction, bone graft reconstruction of bony clefts of the maxilla, correction of residual skeletal disproportion with malocclusion, closure of palatal fistulas, normalization of lip and nasal form, and prosthetic rehabilitation of the cleft dental gap. Although the indications for each of the primary and secondary surgical undertakings are different and the decision-making processes may vary, one cannot view each of these procedures as isolated events. This chapter reviews the different phases of secondary cleft lip and palate reconstruction that may be required after primary cleft lip and palate repair with the purpose of providing an organized description of the contemporary philosophy and rationale for surgical interventions and specific timing.

Fistula Closure

Background

When a child is born with a cleft palate, there is an abnormal communication between the oral and nasal cavities. One of the principles essential to successful surgical repair involves the separation of oral and nasal side soft tissues from each other and then reconstruction of those distinct tissue layers to establish separate nasal floor and oral mucosal linings. The result is closure of the hard palate in two layers (nasal mucosa and oral mucosa) and closure of the soft palate in three layers (nasal side, levator musculature, and oral side mucosa).

Residual abnormal oronasal communications, or “fistulas,” following the initial repair are relatively frequent problems that require subsequent surgical procedures in patients with cleft palate. Before addressing the specific management approach to residual fistulas, one must define the clinical situation based on the patient’s age, previous surgical history, and the exact location of the fistula. Another important consideration is the extent to which the cleft defect involves the primary and secondary palates. The primary palate comprises the anatom-

ic structures anterior to the incisive foramen (alveolus, maxilla, piriform, lip). The secondary palate comprises the anatomic structures between the incisive foramen and the uvula. Using this terminology, a complete cleft of the primary and secondary palates would involve the maxilla, alveolus, hard palate, and soft palate. An isolated cleft palate involving the hard and soft palate (without affecting the alveolar ridge) would be described as a complete cleft of the secondary palate while a cleft involving only the soft palate (and not the hard palate or alveolus) is described as an incomplete cleft of the secondary palate.

Even when a child is born with a complete cleft palate (ie, affecting the primary and secondary palate), the primary repair involves closure of the secondary palate only—those structures from the incisive foramen to the uvula. The goals of cleft palate repair during infancy are twofold: first, to establish complete watertight closure of the secondary palate for separation of the oral and nasal cavities and, second, to repair the levator musculature in order to allow for normal speech formation. Repair of the skeletal maxillary/alveolar cleft defect and its associated oronasal communication are not generally undertaken at this stage. Many surgeons consider this alveolar defect part of the original cleft deformity that has been purposely left unrepaired instead of a true “fistula.” Definitive repair of the anterior alveolar or nasolabial fistula is instead incorporated into the bone graft reconstruction performed during midchildhood based on the child’s dental development.^{5,6,8,9} Bone graft reconstruction of the cleft defect is presented in greater detail in Chapter 43, “Reconstruction of the Alveolar Cleft.”

Ideally, a child with a complete cleft palate will undergo palate repair during infancy with successful closure of the hard and soft (or secondary) palates and then bone graft reconstruction of the maxilla/alveolus (or primary palate) with closure of any residual nasolabial fistula

during childhood. Unfortunately, residual palatal fistulas are frequently encountered after the initial palate repair. The risk of fistula formation seems to be closely associated with the size of the original cleft defect.^{10,11} The type of repair used by the surgeon may also affect the fistula rate. Recent reports indicate that a two-flap palatoplasty technique is associated with the lowest rate (3.4%) of palatal fistula formation.¹² Another frequently employed technique, the Furlow double opposing Z-plasty, is associated with a higher incidence of oronasal fistula.⁵ This difference in the rate of fistula occurrence is probably more noticeable when the cleft defect being repaired is very wide. The most common location for development of a residual palatal fistula following cleft palate repair is the junction of the hard and soft palates followed by the anterior hard palate and incisive foramen region.^{5,6,11,13} The incidence of palatal fistula following single-stage palatoplasty varies greatly, with the reported rates as high as 50%.¹¹

Indications for Fistula Repair and Timing of Surgery

Most fistulas are noted early on in the post-surgical period following palate repair and are the direct result of local wound breakdown owing to tension or vascular compromise. Another time period when a palatal fistula may be encountered is during Phase I (pre-bone graft) orthodontic treatment, especially if maxillary expansion has been undertaken. There is disagreement about the causal relationship of orthodontic expansion and development of a palatal fistula. However, most experienced cleft surgeons believe that fistula defects discovered during maxillary expansion are preexisting oronasal communications and are not actually caused by the orthodontic treatment. Small fistulas present since infancy can be hidden within a narrow palate by collapsed maxillary segments and then uncovered as the maxillary arch form is expanded by orthodontic or orthopedic means.

The recommended timing of fistula closure may vary significantly and remains a controversial topic. Some surgeons and cleft teams may advocate relatively aggressive management with early closure of any fistula present after the initial palate repair. We prefer to take a more long-range view of these problems and delay surgery for several years whenever possible.

In infants, the closure of a small (1 to 4 mm), nonfunctional fistula can generally be deferred until later in childhood. In such cases, fistula repair may be incorporated into any future necessary procedures such as pharyngeal surgery for velopharyngeal insufficiency or bone graft reconstruction of the cleft maxilla and alveolus as long as there are no functional speech or feeding-related concerns. When a larger (> 5 mm) fistula is present, there is a greater likelihood that functional concerns will be encountered, such as nasal air escape which impacts speech, nasal reflux of food and liquids, and hygiene-related difficulties. In clinical situations where significant functional problems exist, earlier closure of the persistent fistula is indicated. As part of the decision-making process, surgeons must weigh the benefits of fistula repair against the negative effects of a second palatal surgery involving stripping of mucoperiosteum on subsequent maxillary growth. Another consideration in planning the exact timing of fistula closure is the type of repair technique being used for the repair. Attempts to close a fistula with local flaps or repeat palatoplasty may be undertaken during infancy and early childhood. On the other hand, in cases in which the use of a regional (eg, tongue) flap is required, the child must be old enough to cooperate with the perioperative regimen.

Operative Techniques for Closure of Palatal Fistulas

The repair of residual palatal fistulas following cleft palate repair has been described using several different techniques.^{5,10,14-16} Current operations used

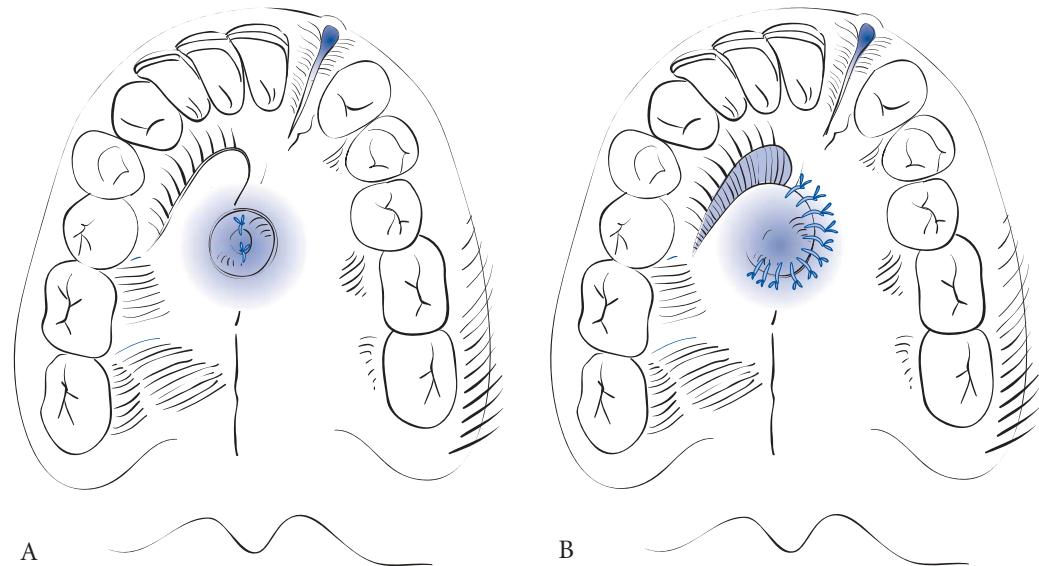


FIGURE 44-1 The use of a small, rotational flap for closure of a residual palatal fistula. This type of repair has a high failure rate. A, Turnover flaps are used to establish a nasal side closure and a palatal mucosal flap is outlined. B, Random pattern, full-thickness mucoperiosteal flap is elevated and mobilized for coverage of defect.

for fistula repair include local palatal flaps, modifications of the von Langenbeck and two-flap palatoplasty techniques, palatoplasty with incorporation of a pharyngeal flap, and the use of a tongue flap. Other regional flaps, including the tongue, buccal mucosa, buccinator myomucosal, temporalis muscle, and vascularized tissue transfer are less frequently used but have been described.^{14,17-21}

One of the most frequently described procedures for closure of residual fistulas is the use of local soft tissue flaps created within the palatal mucosa and rotated over the defect for closure (Figure 44-1). The components of this approach are the creation of turnover flaps around the defect for nasal side closure, elevation of a palatal finger flap, and rotation of the flap for coverage of the defect. A significant area of exposed bone is left at the donor site, and this is allowed to heal by secondary intention. Unfortunately, this type of repair is useful only for very small palatal defects and is associated with a relatively high failure rate.¹⁴ Small rotational flaps within palatal tissues that contain extensive scarring from prior surgical procedures are difficult to

mobilize without residual tension and may have diminished blood supply resulting in a less-than-ideal healing capacity and a greater chance of wound breakdown.

Our preferred approach to residual palatal fistulas involves the modification of one of the primary palate repair techniques, namely the Bardach or von Langenbeck procedures.^{5,22} These approaches allow adequate coverage of even large defects with the use of bulky soft tissue flaps, a layered repair of the nasal and oral sides, and a tension-free line of closure (Figures 44-2 and 44-3). In addition, the amount of bone that is left exposed after the repair is minimal to none. This is because the vertical depth of the palatal vault translates into soft tissue extension medially, and so the result is palatal soft tissue flaps that adequately cover the underlying bone with a layer of dead space between the palatal shelves and the oral mucosa lining. The Bardach (two-flap) palatoplasty is our preferred operation in cases where the fistula defect is 5 mm or larger. The primary advantage of this approach is the ability to raise large soft tissue flaps, which can be mobilized easily and allow for easy visualization and closure of

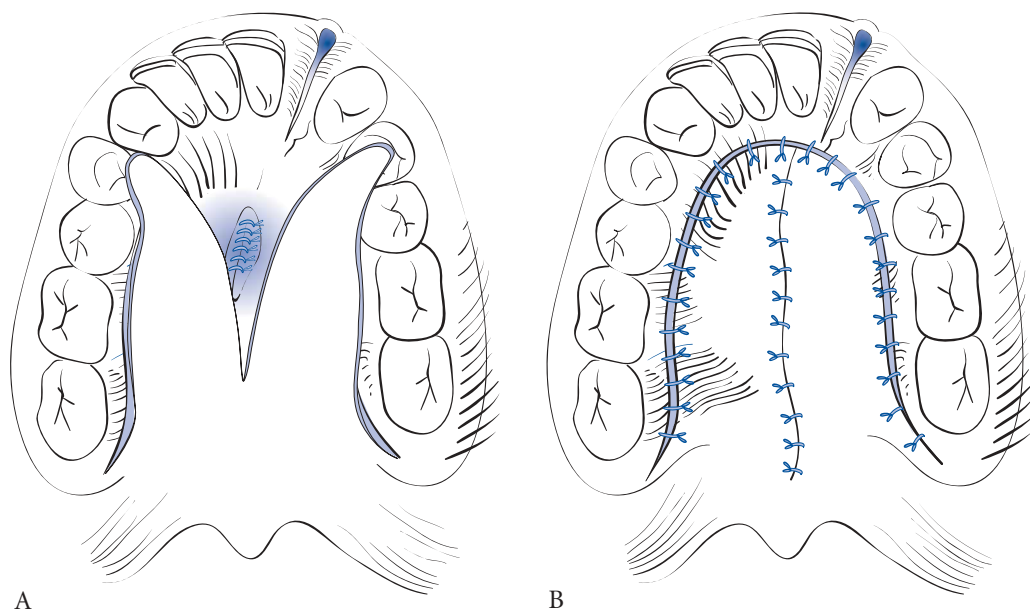


FIGURE 44-2 Modification of the two-flap palatoplasty technique for closure of a residual palatal fistula. A, Two large mucoperiosteal flaps are developed with dissection extended to a point posterior of the fistula defect. The nasal mucosa is repaired as a separate layer. B, Closure of the oral side. The midline is closed first using multiple interrupted sutures, and then the lateral incisions are reapproximated.

the nasal mucosa. By comparison, one of the theoretical advantages of the von Langenbeck procedure is the creation of bipediced flaps that maintain anterior and posterior blood supplies. While the anterior pedicles do provide additional perfusion, they also result in less freely movable flaps with limited access and visualization of the nasal side tissues. For this reason, we use the von Langenbeck technique only for relatively small defects within the hard palate.

In situations where there is a much larger (> 1.5 cm) defect, successful closure may dictate that the surgeon recruit additional soft tissue using a regional flap. Fistula defects within the posterior hard palate or soft palate may be addressed with the use of a modified palatoplasty procedure as described above in combination with a superiorly based pharyngeal flap. After the palatal flaps are developed and the nasal side dissection is complete, a pharyngeal flap is harvested. The pharyngeal flap soft tissue is then incorporated into the nasal side closure of the area where the fistula was present. Using this technique, a substantial amount of addi-

tional soft tissue can be recruited for tension-free repair of a large palatal defect. When the fistula is located within the anterior two-thirds of the hard palate, the

procedure of choice for recruitment of additional soft tissue is the anteriorly based dorsal tongue flap (Figure 44-4). First, nasal side closure of the palatal defect is performed using turnover flaps with multiple interrupted sutures. Next, this technique calls for development of an anteriorly based tongue flap that is approximately 5 cm in length by one- to two-thirds the width of the tongue. The tongue flap is elevated along the underlying musculature and then inset using multiple mattress sutures for closure of the oral side. The recipient bed within the tongue is closed primarily. After the initial surgery, the tongue flap is allowed to heal for approximately 2 weeks. At that time, the patient is returned to the operating room. Nasal fiber-optic intubation is indicated for the second procedure since the tongue is still sutured to the palate, restricting normal visualization of the airway. The flap is sectioned and the stump at the donor site is freshened and inset into the tongue. The use of laterally and posteriorly based tongue flaps has also been

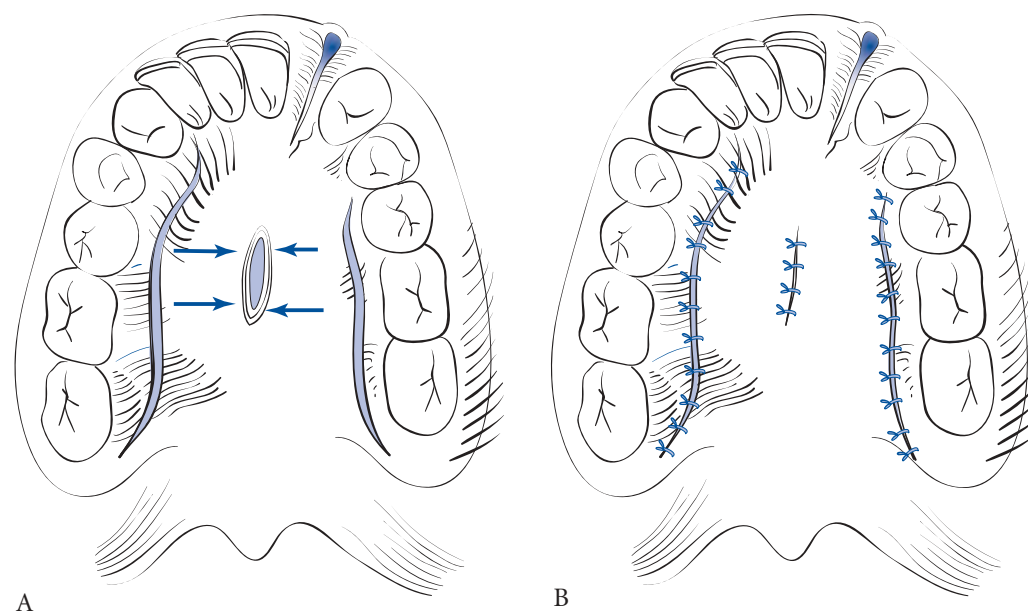


FIGURE 44-3 Modification of the von Langenbeck technique for closure of a residual palatal fistula. A, Incisions are created at the fistula defect along the junction of oral and nasal mucosa, and laterally in order to develop palatal flaps. Care is taken to maintain anterior soft tissue attachment for improved blood supply. This may make flap mobilization and visualization of the defect difficult. B, The nasal side is closed first, and then oral side closure is accomplished with interrupted sutures.

presented in the cleft literature.^{23,24} In our opinion, however, an anteriorly based flap is better tolerated by most patients and allows for the greatest degree of tongue mobility with less risk of tearing the flap from its palatal insertion.

Secondary Cleft Palate Surgery for Management of Velopharyngeal Dysfunction

Background

The secondary palate is composed of a hard (bony) palate anteriorly and a soft palate or “velum” posteriorly. Within the soft palate, the levator veli palatini muscle forms a dynamic sling that elevates the velum toward the posterior pharyngeal wall during the production of certain sounds. Other muscle groups within the velum, the tonsillar pillar region,¹ and pharyngeal walls also impact resonance quality during speech formation (Table 44-2). The combination of the soft palate and pharyngeal wall musculature jointly form what is described as the velopharyngeal (VP) mechanism (Figure 44-5A). The VP mechanism functions as a sphincter valve in order to regulate airflow between the oral and nasal cavities and create a combination of orally based and nasally based sounds.

Children born with a cleft palate have, by definition, a malformation that dramatically impacts the anatomic components of the VP mechanism. Specifically, clefting of the secondary palate causes division of the musculature of the velum into separate muscle bellies with abnormal insertions along the posterior edge of the hard palate (Figure 44-5B). The initial palatoplasty is not carried out simply for closure of the palatal defect (oronasal communication) itself, but is aimed also at addressing these underlying anatomic discrepancies involving the musculature. During surgery for palatal closure, care must be taken to sharply separate the muscles off of the palatal shelves, realign them, and establish continuity in order to create

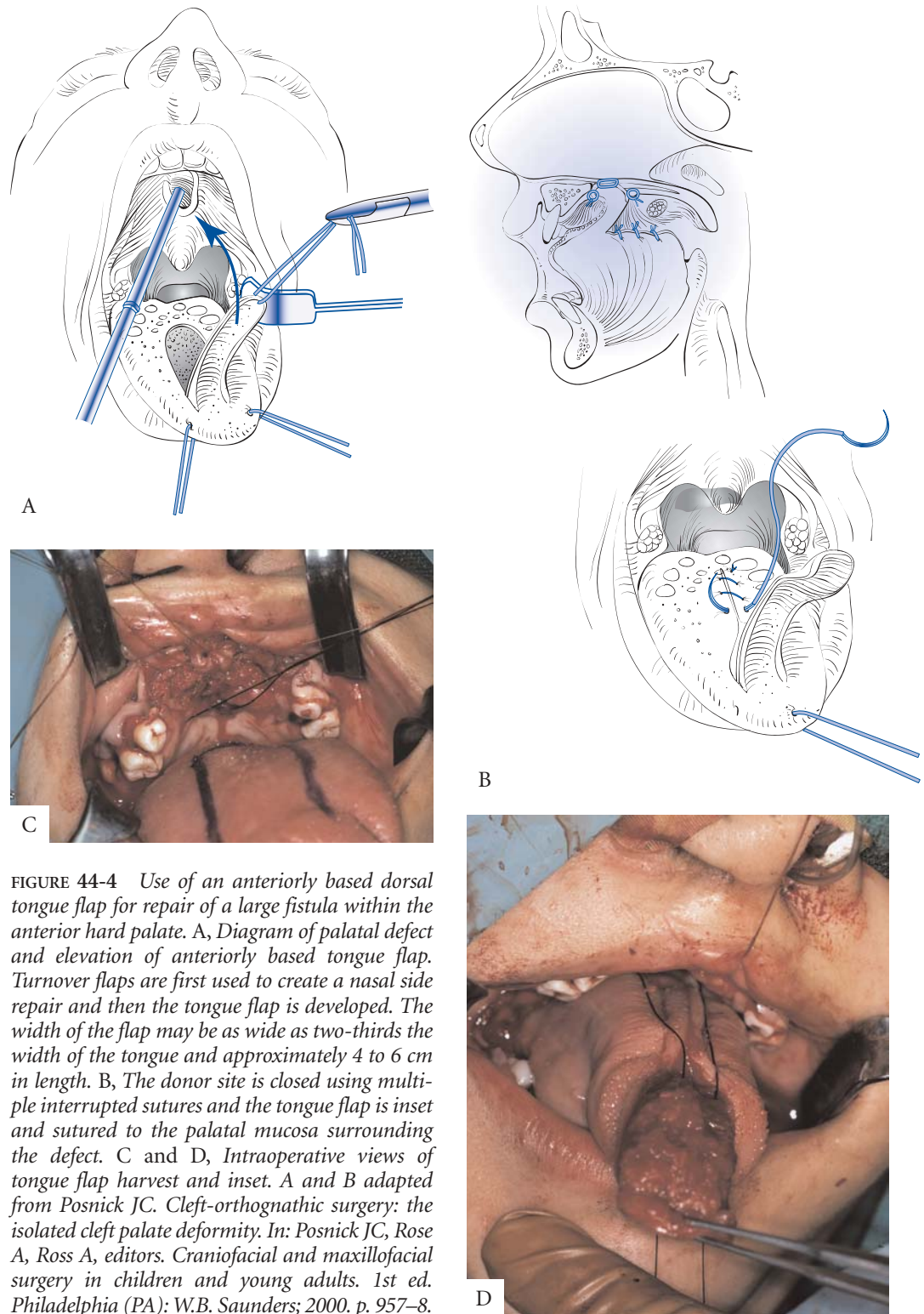


FIGURE 44-4 Use of an anteriorly based dorsal tongue flap for repair of a large fistula within the anterior hard palate. A, Diagram of palatal defect and elevation of anteriorly based tongue flap. Turnover flaps are first used to create a nasal side repair and then the tongue flap is developed. The width of the flap may be as wide as two-thirds the width of the tongue and approximately 4 to 6 cm in length. B, The donor site is closed using multiple interrupted sutures and the tongue flap is inset and sutured to the palatal mucosa surrounding the defect. C and D, Intraoperative views of tongue flap harvest and inset. A and B adapted from Posnick JC. Cleft-orthognathic surgery: the isolated cleft palate deformity. In: Posnick JC, Rose A, Ross A, editors. *Craniofacial and maxillofacial surgery in children and young adults*. 1st ed. Philadelphia (PA): W.B. Saunders; 2000. p. 957–8.

a functional palatal-levator muscle sling. Some describe this primary repair of the palatal musculature as “intravelar veloplasty,” a component of the cleft palate closure. Although this description helps to

articulate the importance of addressing the levator muscle, it may confuse some clinicians by suggesting that muscle repair or intravelar veloplasty is a separate procedure. Irrespective of the type of cleft palate

Table 44-2 Muscle Groups Contributing to the Velopharyngeal Mechanism

Muscle	Insertion	Origin	Function
Uvulus muscle	Mucous membrane of soft palate	Palatal aponeurosis	Velar extension
Tensor veli palatini	Soft and hard palates	Medial pterygoid plate	Opens auditory tube
Salpingopharyngeous	Palatopharyngeal aponeurosis	Torus tubarius	Motion of the lateral walls
Superior constrictor	Medial pharyngeal raphe	Velum; medial pterygoid plate	Posterior and lateral wall sphinctering
Levator veli palatini	Soft palate	Temporal bone	Elevation of the velum
Palatopharyngeous	Soft palate aponeurosis	Pharyngeal wall	Adduction of posterior pillars; sphinctering of velum
Palatoglossus	Tongue	Soft palate	Retracts tongue; antagonistic to the levator during speech

repair technique employed (von Langenbeck, Bardach, Furlow, etc), meticulous release of abnormal muscle insertions and velar muscle reconstruction must be incorporated as a critical element of the surgical procedure.

Most children who undergo successful cleft palate repair during infancy (9 to 18 months) will go on to develop speech that is normal or to demonstrate minor speech abnormalities that are amenable to treatment with speech therapy. In a smaller segment of this patient population, however, the velopharyngeal mechanism

will not demonstrate normal function despite surgical closure of the palate.²⁵ “Velopharyngeal insufficiency” (VPI) is defined as inadequate closure of the nasopharyngeal airway port during speech production. The exact etiology of VPI following successful cleft palate repair is a complex problem that remains difficult to completely define. Inadequate surgical repair of the musculature is one cause of VPI, but even muscles that have been appropriately realigned and reconstituted may fail to heal normally or function properly because of congenital defects with

their innervation. The role of postsurgical scarring and its impact on muscle function and palatal motion is poorly understood. When using a Furlow double opposing Z-plasty procedure for the initial palate repair, the theoretical advantages include better realignment of the palatal muscles and lengthening of the soft palate, but these benefits may be negatively balanced by a velum that demonstrates less motion or elevation owing to the additional scarring associated with two separate sets of Z-plasty incisions. In addition, it must be considered that the repaired cleft palate is

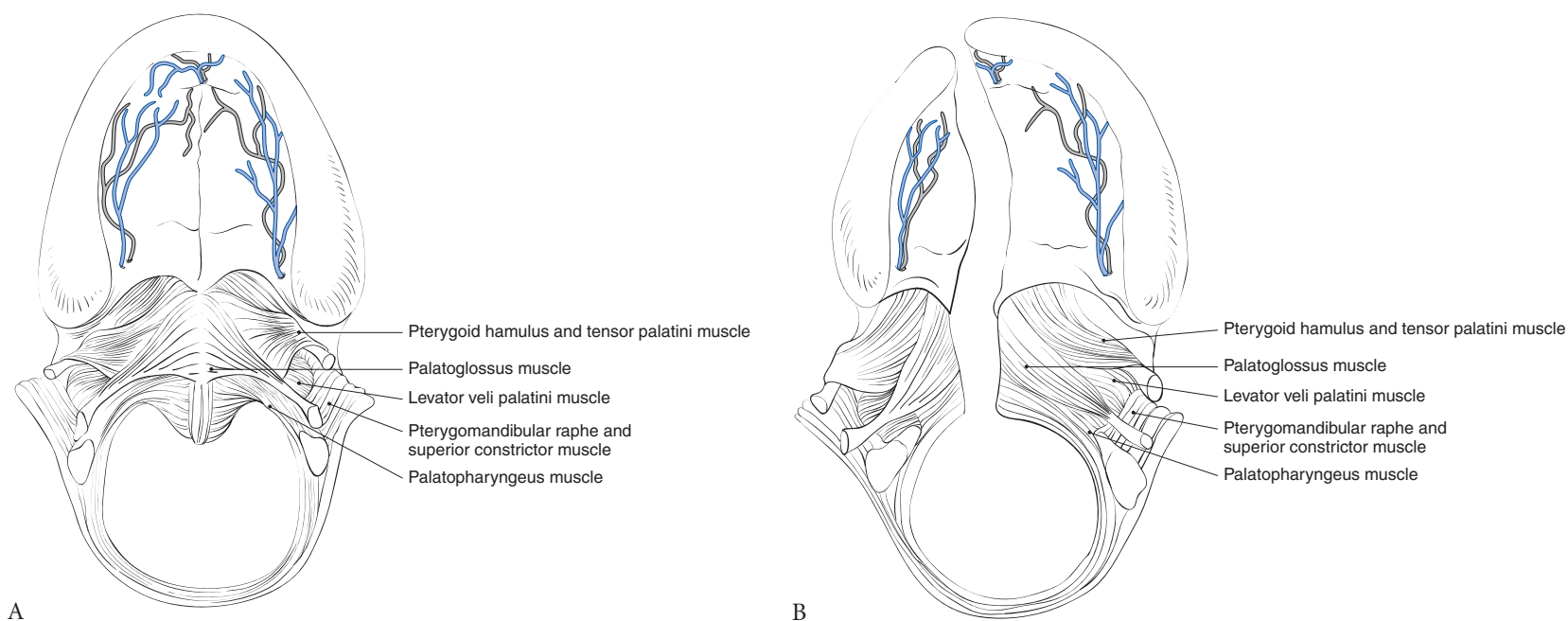


FIGURE 44-5 Anatomy of the velopharyngeal mechanism. A, Normal anatomy. B, Anatomic distortions associated with complete cleft of the primary and secondary palate. Note abnormal insertions of levator veli palatini muscle along the posterior edge of the hard palate.

only one factor contributing to VP function, and other abnormalities related to oropharyngeal morphology, lateral and posterior pharyngeal wall motion, and nasal airway dynamics may all contribute to VP dysfunction. Certainly, these other structures may also play a role in compensating for the palatal deformity. For example, a short, scarred soft palate that does not elevate very well may be compensated for by the recruitment and hypertrophy of muscular tissue within the posterior pharyngeal wall (“activation of Passavant’s ridge”).^{26–28}

The audible nasal air escape with resultant hypernasal speech that is associated with VPI is perhaps the most debilitating consequence of the cleft palate malformation. Approximately 20% of children with VPI following palatoplasty will go on to require management involving additional palatal surgery.²⁵ Left untreated, nasal air escape-related resonance problems will lead to other speech abnormalities, namely, abnormal compensatory articulations. Warren’s elegant aerodynamic demands theory provides the best explanation of what occurs with severe VPI.²⁹ His theory states that nasal air escape owing to inadequate VP closure will cause the patient to articulate pressure consonants at the level of the larynx or pharynx instead of within the oral cavity. These abnormal, compensatory, misarticulations further complicate problems with speech formation and decrease speech intelligibility in patients with cleft palate–related VPI.

Indications for Surgery and Timing

Following the initial cleft palate repair, periodic evaluations are critical in order to assess the speech and language development of each child. Typically, this involves a standardized screening examination performed by a speech and language pathologist as part of an annual visit to the cleft palate team. In patients with speech problems such as VPI, more detailed studies including the use of

videofluoroscopy and nasopharyngoscopy may be indicated. Videofluoroscopy studies are used to radiographically examine the upper airway with the aid of an oral contrast material. These techniques allow dynamic testing of the VP mechanism with views of the musculature in action. In addition, details of the upper airway anatomy including residual palatal fistulas can be visualized and their contribution to speech dysfunction evaluated during the study. For a videofluoroscopy study to be of diagnostic value, it must include multiple views of the VP mechanism and a speech pathologist must be present in order to administer verbal testing in the radiology suite. Nasopharyngoscopy using a small, flexible, fiber-optic endoscope is routinely used for the evaluation of patients with VPI. Nasopharyngoscopy allows for direct visualization of the upper airway and specifically the VP mechanism from the nasopharynx. This technique avoids the radiation exposure associated with videofluoroscopy but requires preparation of the nose with a topical anesthetic, skillful maneuvering of the scope, and a compliant patient. Once the endoscope is inserted, observations of palatal function, airway morphology, and pharyngeal wall motion are made while the patient is verbally tested by the speech pathologist.⁵ The opportunity for direct visualization of the VP mechanism in action during speech formation provides information that is critical to clinical decision-making related to secondary palatal surgery in cases of confirmed or suspected VPI.

Secondary palatal surgery in young children is indicated when VPI causes hypernasal speech on a consistent basis and is related to the anatomical problem.^{30–32} The exact timing of surgery for VPI remains controversial, however, with recommendations ranging from 2.5 to 5 years of age. In children 2.5 to 4 years of age, obtaining enough diagnostic information to make a definitive decision regarding treatment is often difficult. In such a young age group, variables such as the

child’s language and articulation development and a lack of compliance during the speech evaluation compromise the diagnostic accuracy of preoperative assessments.^{33–35} By the time a child reaches 5 years of age, compliance with nasopharyngoscopy is better, and there is enough language development to allow for a more thorough perceptual speech evaluation. These factors allow for more definitive conclusions regarding the status of VP function or dysfunction in the child with a repaired cleft palate. One final salient point is that decisions regarding the advisability of surgery for VPI must be made only through close collaboration with an experienced speech and language pathologist. The decision to go forward with additional surgery for VPI simply is not an isolated surgical judgment.

The problem of VPI with hypernasal speech may also be encountered later in life in patients that require orthognathic surgery for correction of cleft-related maxillary deficiency. As discussed in Chapter 61, “Orthognathic Surgery in the Patient with Cleft Palate,” approximately 25% of patients who have undergone cleft palate repair during infancy will require additional surgery for correction of midfacial deficiency during adolescence when they are nearing skeletal maturity.³⁶ This usually involves midfacial advancement at the Le Fort I level with or without mandibular surgery in order to normalize skeletal position, correct malocclusion, and improve facial form. Large advancements of the maxilla in patients with a repaired cleft palate may worsen preexisting VPI or may be the cause of new-onset VPI.^{37–39} A minority of patients with borderline VP closure preoperatively will develop hypernasal speech even after relatively small degrees of maxillary forward displacement. Since predicting exactly how each patient will respond to maxillary advancement is difficult, formal speech assessment and detailed counseling of the patient and family regarding the possibility of developing postoperative VPI is recommended prior to

undertaking any cleft orthognathic surgery involving maxillary advancement. Fortunately, most patients who develop VPI following maxillary advancement will recover adequate VP closure without the need for additional palatal surgery. In a study by Turvey and Frost, pressure-flow studies were used to examine VP function after maxillary advancement in patients with repaired cleft palate.⁴⁰ In their study group of patients with adequate VP closure before surgery, the VP apparatus demonstrated three different responses following midfacial advancement: (1) adequate VP closure after surgery, (2) deterioration with inadequate VP function after surgery followed by a gradual improvement and recovery of normal closure over a 6-month period, and (3) inadequate VP closure after surgery without improvement necessitating pharyngeal flap surgery. When maxillary advancement does result in clinically significant VPI, additional corrective surgery should be delayed at least 6 months. In most cases, postoperative neuromuscular adaptation allows the VP mechanism to recover, and the patient returns to a baseline level of function with resolution of hypernasal speech without the need for additional operative intervention.

Operative Techniques

Contemporary surgical management of VPI generally involves the use of either of two types of procedures: (1) the superiorly based pharyngeal flap, and (2) the sphincter pharyngoplasty. The use of autogenous and alloplastic implants for augmentation of the posterior pharyngeal wall has been described, but is not a commonly used procedure. More recently, some surgeons have advocated the use of a second palatoplasty operation as an attempt at palatal lengthening in the patient with VPI; however, limited data exist to support this as a preferred technique.

The superiorly based pharyngeal flap remains the standard approach for surgical management of VPI after palate repair.

The procedure was initially described by Schoenborn in 1876.⁴¹⁻⁴³ Surgical maneuvers are directed at recruiting tissue by developing a superiorly based soft tissue flap from the posterior pharyngeal wall (Figure 44-6). The soft palate is then divided along midsagittal plane from the junction of the hard and soft palate to the uvula and the flap from the posterior pharyngeal wall is inset within the nasal layer of the soft palate. As a result, a large nasopharyngeal opening which cannot be completely closed by the patient's VP mechanism is converted into two (right and left) lateral pharyngeal ports. Closure of these ports is easier for the patient to accomplish as long as adequate lateral pharyngeal wall motion is present. When randomly applied to patients with VPI, the superiorly based pharyngeal flap procedure is effective 80% of the time.⁴⁴ When the flap is applied using careful preoperative objective evaluations, success rates as high as 95 to 97% have been reported.^{45,46} Shprintzen and colleagues have advocated custom tailoring of the pharyngeal flap width and position based on the particular characteristics of each patient as seen on nasopharyngoscopy.^{44,47} The high overall success rate and the flexibility to design the dimensions and position of the flap itself are advantages of the superiorly based pharyngeal flap procedure. The disadvantages of the pharyngeal flap procedure are primarily related to the possibility of severe nasal obstruction resulting in mucous trapping and postoperative obstructive sleep apnea.

Inferiorly based pharyngeal flaps for management of VPI are rarely used. Previous reports have documented increased morbidity without better speech outcomes associated with inferiorly based flaps.⁴⁸ In addition, inferiorly based flaps tend to cause downward pull on the soft palate following healing and contracture of the flap. The result may be a tethered palate with decreased ability to elevate during the formation of speech sounds.

The dynamic sphincter pharyngoplasty is another option for the surgical management of VPI. This procedure was described by Hynes in 1951 and modified by several other authors.⁴⁹⁻⁵⁴ The operative procedure involves the creation of two superiorly based myomucosal flaps created within each posterior tonsillar pillar (Figure 44-7). Each flap is elevated with care taken to include as much of the palatopharyngeal muscle as possible. The flaps are then attached and inset within a horizontal incision made high on the posterior pharyngeal wall. The goal of this procedure is the creation of a single nasopharyngeal port (instead of the two ports of the superiorly based pharyngeal flap) that has a contractile ridge posteriorly to improve VP valve function. The main advantage of the sphincter pharyngoplasty over the superiorly based flap is a lower rate of complications related to nasal airway obstruction as described above.⁵⁵⁻⁵⁷ Despite this advantage, there is no evidence that pharyngoplasty procedures achieve superior outcomes in the resolution of VPI. Also, the use of a sphincter pharyngoplasty technique may be associated with increased scarring along the tonsillar pillar region.

In the past, augmentation of the posterior pharyngeal wall has been attempted in order to facilitate closure of the nasal airway. Various autogenous and alloplastic materials have been used including local tissue, rib cartilage, injections of Teflon, silicon, Silastic, Proplast, and collagen.^{58,59} Improvement in speech after augmentation of the posterior pharyngeal wall is unpredictable. Problems with migration or extrusion of the implanted material and an increased rate of infection added to the problems with these techniques. For these reasons, pharyngeal wall implants are rarely used.

Some surgeons advocate the use of a revisional palatoplasty instead of a pharyngeal flap or pharyngoplasty procedure in the management of patients with VPI after

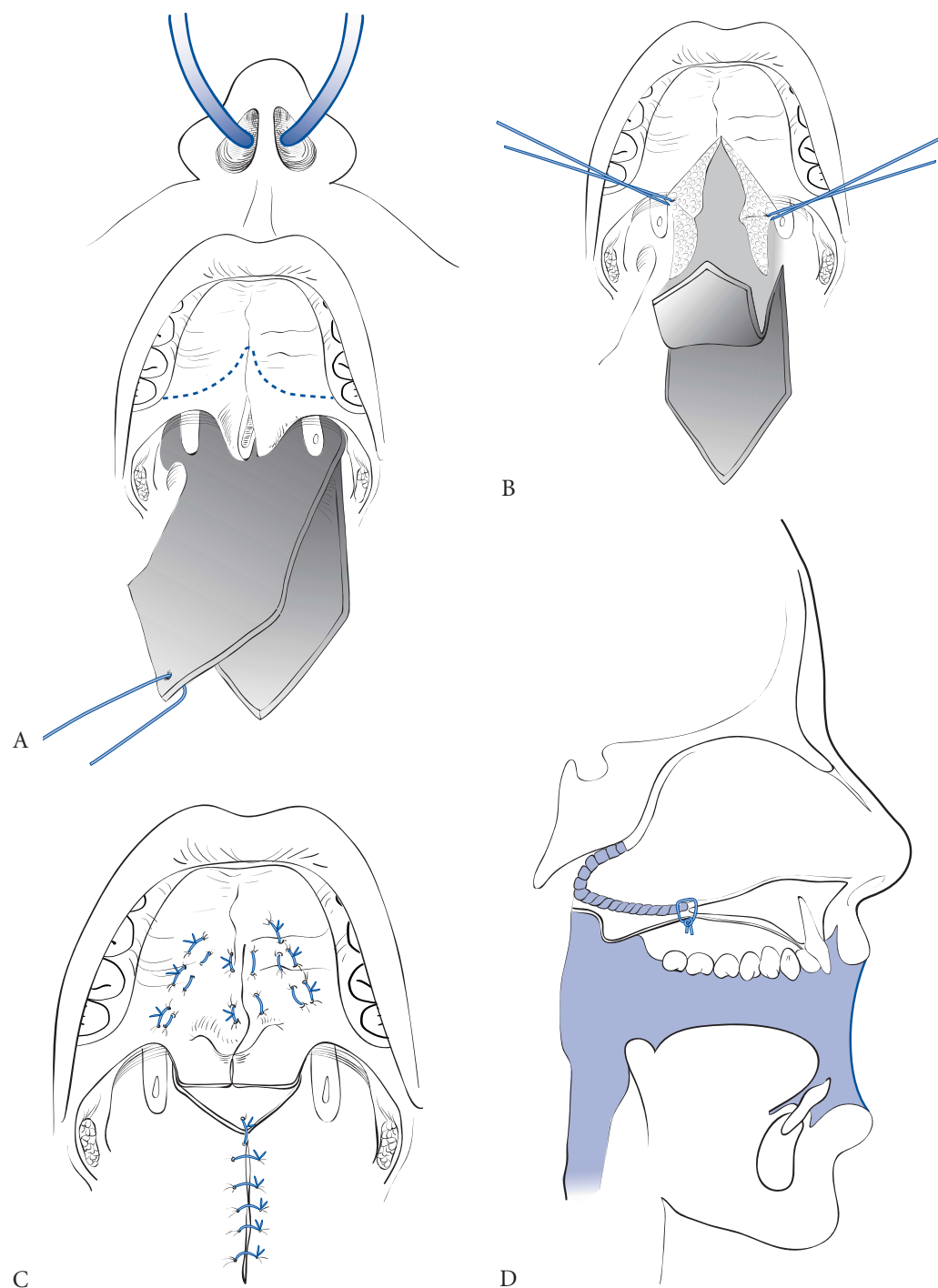


FIGURE 44-6 Illustration of superiorly based pharyngeal flap operative procedure. A, Creation of superiorly based flap of posterior pharyngeal wall soft tissues. The pharyngeal flap is developed and elevated off of the prevertebral fascia. Soft palate is divided with a midline incision from the uvula to the junction of the hard and soft palates. B, Soft palate oral, nasal, and muscle layer dissection in preparation for flap inset. Nasopharyngeal airways are placed in order to help size each lateral pharyngeal port. C, The flap is sutured into the nasal side of the soft palate before the nasal side is repaired and the oral mucosa and underlying musculature are repaired. D, Sagittal view demonstrating appropriate vertical level of flap inset.

cleft palate repair in infancy.⁶⁰ Specifically, a Furlow double opposing Z-plasty palatoplasty is carried out in order to lengthen

the soft palate and facilitate VP closure. Unfortunately, the anticipated benefits of these second palatoplasties have never been

established. The clinician also must consider the disadvantages of this type of surgical procedure and weigh them against potential benefits. The double opposing Z-plasty procedure requires a more aggressive dismantling of the palate than what is required during a conventional pharyngeal flap procedure. The result may be a slightly longer palate, but one with more extensive scarring and less physiologic movement. Another consideration is the significantly higher rate of fistula formation associated with this type of repair.

Complications Related to Surgical Procedures for VPI

Surgery involving airway structures is always associated with the potential for complications related to postoperative hemorrhage and edema. As a result, patients who undergo attachment of a pharyngeal flap require admission to the surgical intensive care unit with continuous airway monitoring during the first 24 hours following surgery. This type of setting permits the rapid recognition and prompt management of complications that may result in airway compromise. Of all the procedures related to cleft care, the pharyngeal flap and sphincteroplasty operations carry the greatest risk for early airway compromise. Airway loss and compromise are not common but require immediate management when they are encountered in order to avoid life-threatening consequences.

Long-term postoperative complications related to the superiorly based pharyngeal flap are frequently associated with problems related to increased airway resistance. Insertion of a pharyngeal flap will decrease the size of the nasopharyngeal airway, facilitate VP closure, decrease nasal air escape, and make speech more intelligible. At the same time, however, the procedure may create a pathologic level of upper airway obstruction that leads to new problems. In several cases, patients who have undergone pharyngeal flap surgery

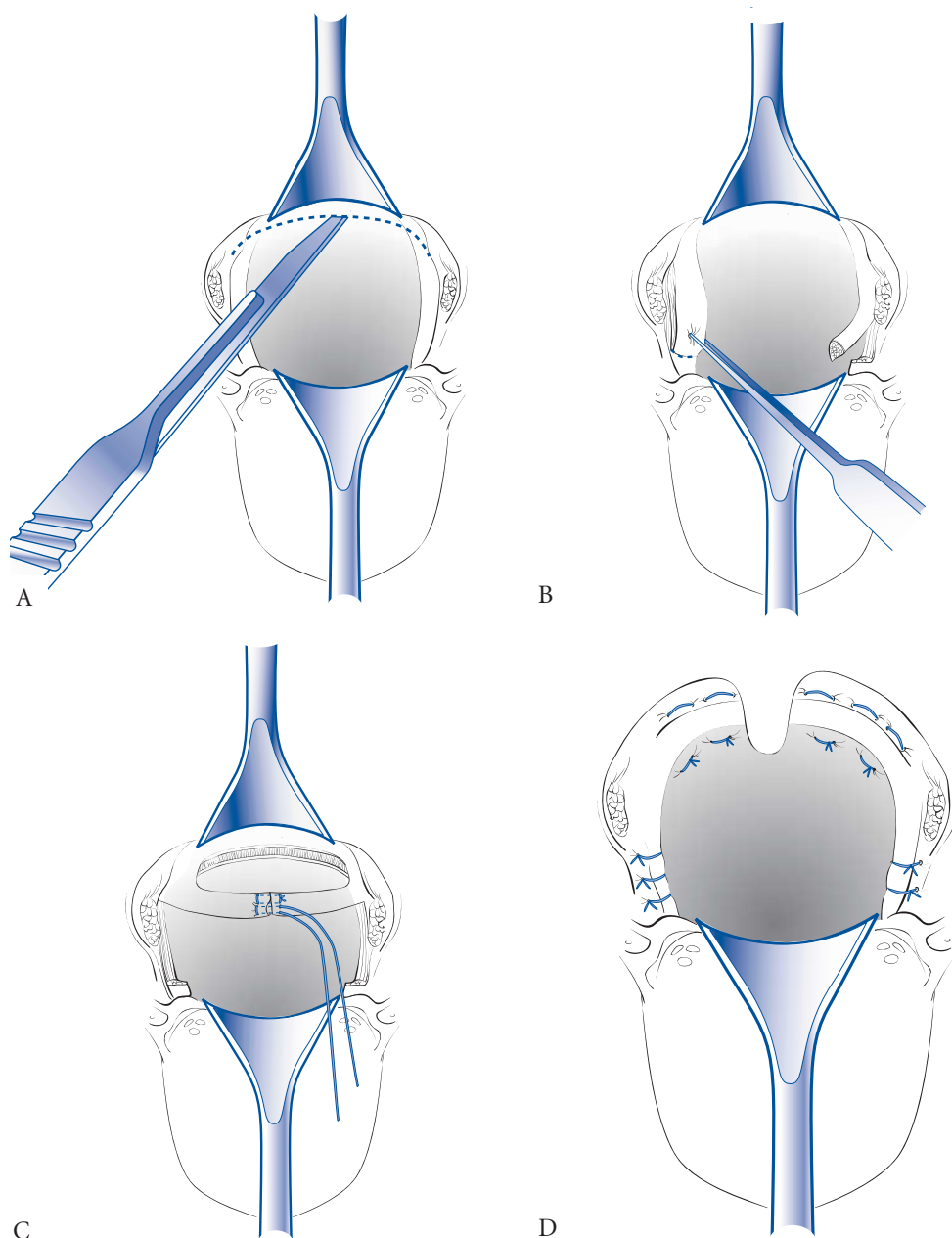


FIGURE 44-7 Sphincteroplasty procedure. A, Incision of the posterior pharyngeal wall and the posterior tonsillar pillars. B, Elevation of bilateral myomucosal flaps within the tonsillar pillars. Care is taken to include palatopharyngeous muscle. C, The mobilized flaps are then sutured to each other at the midline. D, Closure is then achieved by inseting the joined flaps within the posterior pharyngeal wall incision. The donor site of each flap is also closed with interrupted sutures.

start snoring. Snoring itself does not represent any significant pathophysiology but may concern parents or significant others who observe the patient during sleep. When the degree of upper airway resistance is more severe, the result may be postoperative obstructive sleep apnea (OSA). OSA is a cessation of breathing during sleep secondary to upper airway

obstruction that disrupts the sleep cycle, compromises effective oxygenation, and may cause behavioral changes and daytime somnolence in affected individuals. Left untreated, OSA is associated with severe cardiac and pulmonary consequences. When OSA is suspected in a child who has previously undergone a pharyngeal flap procedure, a formal work-up

including nasopharyngoscopy and sleep study (polysomnography) is indicated. Care should be taken to evaluate the entire airway in order to determine the level of the obstruction. Surgeons may initially assume that the airway obstruction is related to the flap only to discover that a more severe problem exists somewhere else in the upper airway tract. Often, a thorough clinical evaluation yields abnormal findings that contribute to the problem of OSA at multiple levels of the upper airway. Because of the complexity of these clinical problems, the decision to modify or take down a pharyngeal flap in a child with OSA must be made only after discussions between the surgeon, airway expert (eg, pediatric otolaryngologist or pediatric pulmonologist), and speech and language pathologist. Interestingly, many patients who have had pharyngeal flap placement during their childhood will tolerate surgical division of the flap without a recurrence of severe VPI or hypernasal speech. On the rare occasion when VPI does recur following flap take-down, interval treatment with a prosthetic device such as a palatal lift appliance for at least 6 months should be considered prior to embarking on any further airway surgery.

Management of the Submucous Cleft Palate

A submucous cleft palate is another form of the congenital cleft palate malformation in which the overlying mucosal layer is intact, but the underlying soft palate musculature is divided. As described by Calnan, the classic clinical findings with a submucous cleft palate are a triad of bifid uvula, hard palate bony notch, and separation along the median raphe of the soft palate especially during elevation of the velum.⁶¹

When a submucous cleft palate is present, the levator muscle is clefted and abnormally inserts into the posterior edge of the hard palate. The primary functional concern related to submucous cleft palate is

the possibility that the patient will develop VPI and resultant hypernasal speech as encountered in other cleft palate patients. Despite this concern, the majority of patients with a submucous cleft palate will not require surgical intervention. In fact, 44% of patients will actually remain completely asymptomatic until childhood.⁶²

As described above, the bifid uvula is often the most easily detected feature of the submucous cleft palate triad of clinical findings. However, a bifid uvula may also be observed in the absence of any other features of submucous clefting (eg, notched hard palate, velar separation, hypernasality). In fact, the incidence of bifid uvula is approximately 1:80 while the incidence of submucous cleft palate is 1:280.⁶³ Previous investigation has suggested a connection between the isolated finding of a bifid uvula and VP dysfunction when otherwise asymptomatic patients were evaluated using a nasopharyngoscopic protocol.⁶⁴ As a result, the clinical finding of an isolated bifid uvula may be considered an indicator of increased risk for VPI in a patient who is to undergo adenoidectomy. This underscores the value of a thorough clinical examination before any of these surgical procedures are undertaken and the importance of presurgical speech evaluation and family counseling regarding the potential risks of postsurgical VPI.

A certain proportion of children will present with an occult submucous cleft palate. The occult submucous cleft palate does not have any of the classic triad of physical findings. In most cases, the reason for consultation is VPI-related speech difficulties that have been noted during childhood speech development or that have arisen following a surgical intervention (eg, adenoidectomy). In our experience, the proportion of children with occult submucous cleft palate approaches 10% and preoperative diagnosis is often difficult. Prior reports have attempted to describe characteristic facial features, cephalometric findings, and voice studies

that can assist in the presumptive diagnosis of submucous cleft palate.⁶⁵

The vast majority of patients with a submucous cleft palate will require either no treatment or speech therapy only. Surgical intervention is not undertaken simply because the diagnosis of submucous cleft palate has been made. The speech of these individuals is closely monitored during childhood with interval speech evaluations, and surgery is reserved for only those cases where VPI is diagnosed and not amenable to speech therapy. The type of specific surgical procedure used to manage submucous cleft-related VPI varies depending on the preference of the surgeon and speech pathologist. Several early procedures emphasized exploration of the soft palate through a limited midline incision with repair of the levator muscle. Contemporary methods primarily involve the use of a standard palatoplasty (two-flap, push-back, or Furlow) and repair of the velar musculature, with or without a simultaneous pharyngeal flap procedure.

Bone Graft Reconstruction of the Cleft Maxilla and Palate

Approximately 75% of all orofacial clefts will involve the maxilla.⁵ Despite successful lip repair and closure of the hard and soft palate during infancy, a residual nasolabial fistula and bony cleft defect that involves the alveolar ridge, maxilla, and piriform rim will remain. These residual deformities are addressed by secondary bone grafting performed during middle childhood (6 to 9 years of age). The objectives of bone graft reconstruction of the cleft maxilla are to establish adequate bony matrix for eruption of the permanent cuspid tooth, close any residual alveolar fistula communication, establish bony continuity of the maxillary ridge, and improve the underlying bony support of the nasal base. In the case of bilateral cleft lip and palate, an added benefit of bone graft reconstruction is the stabilization of the previously mobile premaxilla segment.

The details of bone graft reconstruction of the cleft maxilla are discussed in greater detail in Chapter 43, "Reconstruction of the Alveolar Cleft."

Orthognathic Surgery for Correction of Midfacial Deficiency

Patients who have undergone cleft palate repair during infancy will often exhibit some degree of maxillary growth restriction. This disproportionate jaw growth is the biological consequence of prior surgical intervention and is not related to the congenital cleft deformity. Previous authors have reported a 25% incidence of maxillary hypoplasia that is severe enough to produce a clinically significant dentofacial deformity with negative effects on speech and occlusion.^{5,6,17,36} The successful correction of these secondary skeletal deformities frequently requires treatment protocols that include orthognathic surgery in conjunction with the final phase of orthodontic treatment. Simultaneous bone grafting is used for contouring the dysmorphic skeletal structures. The use of orthognathic techniques to correct residual skeletal problems in the patient with cleft lip and palate is discussed in greater detail in Chapter 61, "Orthognathic Surgery in the Patient with Cleft Palate."

Revisional Surgery for Cleft Lip and Nasal Deformities

Reconstruction of the Cleft Nasal Deformity

Congenital clefts that involve the lip, nose, and underlying skeletal structure will cause a complex three-dimensional deformity of the nasal complex that affects both form and function.^{66,67} In the case of a complete unilateral cleft, the typical nasal deformity is characterized by splaying of the alar base, inferior displacement of the alar rim, deviation of the nasal tip, and irregularity of the caudal nasal septum. Abnormal fibrous insertions exist between the lateral crus of the lower lateral cartilage and the lateral

piriform rim on the cleft side. At the time of the initial lip repair procedure, maneuvers for primary nasal reconstruction include dissection along the lower lateral cartilage in order to separate the overlying skin from the cartilage and sharp release of the fibrous insertions along the piriform rim so that the nostril can be repositioned appropriately. Despite effective primary cleft lip and nasal repair during infancy, most patients will demonstrate enough residual nasal dysmorphism that secondary nasal surgery for correction of the cleft-associated malformation or improvement in nasal airflow will be required later in life.

The timing of cleft nasal revisional surgery also remains controversial. Some surgeons take a more aggressive approach and undertake extensive nasal reconstruction during early childhood. Our philosophy is to delay the definitive cleft rhinoplasty until the nasal complex is close to mature size. If the patient's reconstructive treatment plan also requires maxillary advancement, then nasal surgery should be delayed until approximately 6 months following the orthognathic procedure. This allows for a more predictable outcome and long-lasting improvement in nasal function and facial esthetics. Early surgery is reserved for individuals with severe airway or nasal airflow problems or children that have the potential to experience psychosocial consequences such as teasing at school. When possible, early nasal surgery should be timed after the bone graft reconstruction of the maxilla so that a stable bony foundation along the piriform rim and nasal base exists first.

Secondary cleft-nasal reconstruction will often require dorsal reduction, lower lateral cartilage sculpting, cartilage grafting, and nasal osteotomies. Cartilage grafting is a critical component of the final nasal reconstruction and is used for augmentation of the dysmorphic lower lateral cartilage and improvement of nasal tip projection^{5,68,69} (T.J. Tejera, DMD, MD,

personal communication, November 2003). Several different donor sites may be used including auricular cartilage, nasal septum, and rib cartilage. Ear cartilage is most useful in situations where augmentation of hypoplastic cleft-side lower lateral cartilage is required. Septal cartilage is most easily accessible and provides an excellent scaffold for repositioning of the lower lateral cartilages and improvement of nasal tip symmetry and projection. Unfortunately, patients may present for definitive nasal reconstruction having undergone previous septal cartilage harvest and not have sufficient quantity for a second septal cartilage graft. In these cases, the use of costochondral cartilage is another excellent option. Rib cartilage provides adequate amounts of graft material, but requires a distant donor surgical site. We have found this type of cartilage graft to provide excellent strength for straightening the nasal tip and alar complex. These techniques are best carried out through an open rhinoplasty approach.⁵ A transcolumellar splitting incision is combined with marginal incisions in order to provide wide access and direct visualization of the nasal dorsum, upper and lower lateral cartilages, and nasal septum.

A similar rationale is applied when considering the timing of secondary nasal reconstruction in the bilateral cleft lip patient, but the specific dysmorphism addressed is somewhat different. Generally, nasal asymmetry is less problematic, and the dysmorphism is characterized by deficient columellar length. Previous literature has focused on the secondary lengthening of the columella through the use of banked forked flaps or columellar lengthening using soft tissue flaps from the floor of the nose and alar flaps.^{70,71} Unfortunately, these types of surgical procedures often result in a distorted columellar-labial angle, excessive "railroad" scars that extend onto the nasal tip, and additional distortion of the broad nasal tip. We find that the approach described by Posnick

using septal cartilage strut grafts attached to the caudal nasal septum and lower lateral cartilages yields the most natural-looking results.^{5,6} The objective is correction of the underlying cartilaginous anatomy with stretching of the overlying soft tissue envelope, instead of direct surgical manipulation of the columellar skin.

Secondary Surgery for Cleft Lip Scar Revision

Even when the initial cleft lip repair procedure is considered to be successful, the vast majority of children will go on to require an additional operation for lip revision at some point in their lifetime.^{4,72} Although revisional procedures are often viewed as optional phases of cleft lip reconstruction, surgeons must advise families of this likelihood.

As a child grows, the hard and soft tissues of the maxillofacial complex grow and change, and the repaired lip is affected. Ongoing growth often makes it difficult to predict which children will need additional lip surgery. A child's lip may initially look satisfactory and over time demonstrate unfavorable changes necessitating revision. On the other hand, favorable changes may occur during the healing process that actually improve the appearance of the repaired cleft lip. At approximately 8 to 10 weeks following surgery, significant lip contracture may be seen during the fibroblastic phase of healing. The result is vertical shortening of the repaired cleft side that will seemingly require further surgery. If the same child is reevaluated 6 months later, after additional wound maturation, they may demonstrate perfectly acceptable lip esthetics and not be considered a candidate for revision.

Ideally, only one lip scar revision is undertaken, when the child is between the ages of 5 and 15 years. The procedure is staged for as late in childhood as possible. When a severe deformity persists or psychosocial concerns exist, lip revision may be carried out earlier in life before the child becomes school aged.

The surgical objectives of cleft lip revision include excision of residual scar, reapproximation of key anatomic landmarks such as the vermilion-cutaneous junction and vermilion-mucosal junction, and leveling of vertical lip lengths (philtral columns). Critical to an acceptable outcome is the meticulous repair of the orbicularis oris muscle as a distinct layer. The cleft surgeon must dissect and repair all layers (skin or vermilion, muscle, oral mucosa) in order to establish improved lip form and normalize lip function and animation (Figure 44-8). Often this requires complete take-down of the lip and recreation of a full-thickness defect.

Comprehensive Dental and Prosthetic Rehabilitation

In patients with a cleft of the primary palate (maxilla and alveolus), three possibilities exist with regard to the status of the permanent lateral incisor: (1) the lateral is present and erupts normally, (2) the lateral is congenitally missing, or (3) the lateral is present, but is dysmorphic and not a restorable tooth. When the lateral incisor is this dysmorphic, extraction is usually

required prior to or at the time of bone graft reconstruction.

In those cases where a lateral incisor is not present, management of the residual dental gap will eventually be required. Treatment options include the placement of a three-unit fixed prosthesis, replacement of the missing tooth with an endosseous dental implant, or orthodontic substitution of the ipsilateral cuspid tooth for the lateral incisor.

In contemporary practice, the use of a three-unit bridge for replacement of a congenitally missing incisor is generally avoided, especially in young patients. This prosthetic option has several disadvantages: it usually requires preparation of two otherwise perfectly healthy teeth (central and cuspid), hygiene is more difficult around the pontic, and even in the best of circumstances the prosthetic restoration will require replacement several times during the patient's lifetime.

Over the course of the past two decades, the use of titanium dental implants has revolutionized the prosthetic rehabilitation of patients with missing teeth. This technology has also been

applied to patients born with cleft lip and palate (Figure 44-9).⁷³⁻⁷⁵ The use of an implant-supported crown provides a natural-looking restoration with excellent long-term viability and obviates the need for instrumentation of the surrounding teeth. When a dental implant is being considered, pertinent treatment-planning concerns include the maintenance of adequate space for the implant and restoration and the quantity of alveolar bone available for placement of the titanium fixture. Our preferred approach involves the preservation of approximately 7 mm of interdental space in order to allow for placement of a 3.5 mm dental implant. In most patients who have undergone previous successful bone grafting, the vertical dimension of the alveolar ridge seems to be well maintained until the time of implant placement. Facial-palatal width of the ridge, however, may be more problematic, and a significant number of cleft patients may require some additional minor bone grafting approximately 3 to 4 months prior to implant surgery. In most cases, the width of the alveolus can be nicely augmented with bone harvested from the mandibular symphysis or ramus region. Implant placement requires that the patient be at or near skeletal maturity.

Another option for management of the cleft dental gap when the lateral incisor is not present is the use of orthodontic therapy in order to substitute the missing lateral incisor with the ipsilateral cuspid tooth. Interestingly, this maneuver frequently results in very acceptable dental esthetics even if prosthetic modification of the cuspid is not undertaken. Like the use of a dental implant, this treatment option also obviates the need for preparation of the adjacent healthy tooth structure. In most cases, the substitution option also eliminates the need for any prosthetic component at all. Another advantage of this treatment option is that it may be undertaken at a younger age than the other prosthetic options. Limiting factors

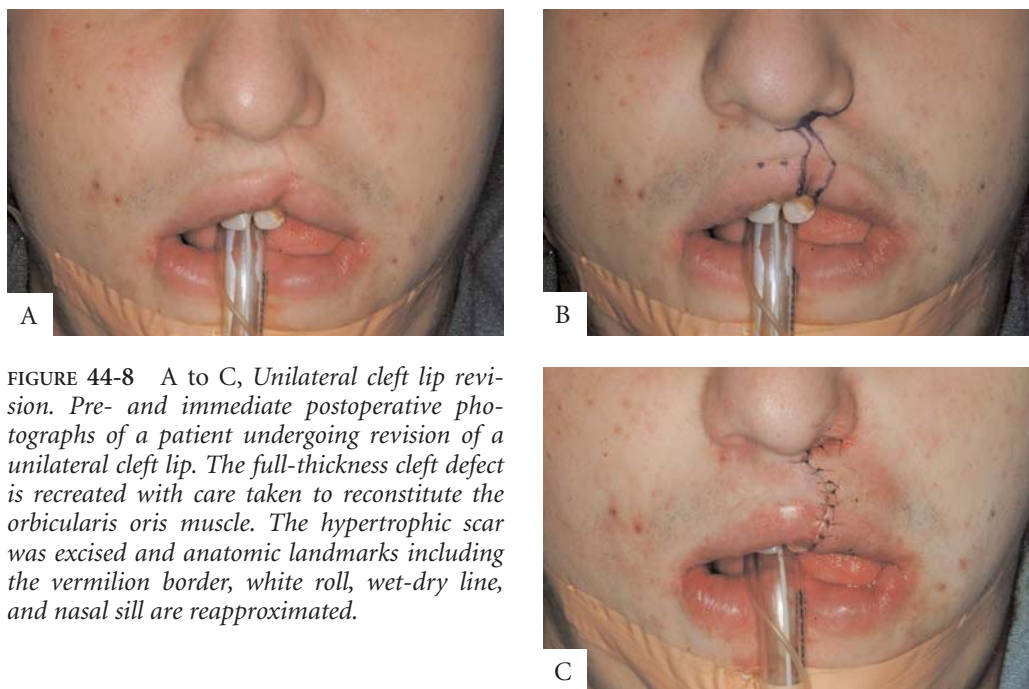


FIGURE 44-8 A to C, Unilateral cleft lip revision. Pre- and immediate postoperative photographs of a patient undergoing revision of a unilateral cleft lip. The full-thickness cleft defect is recreated with care taken to reconstitute the orbicularis oris muscle. The hypertrophic scar was excised and anatomic landmarks including the vermilion border, white roll, wet-dry line, and nasal sill are reapproximated.

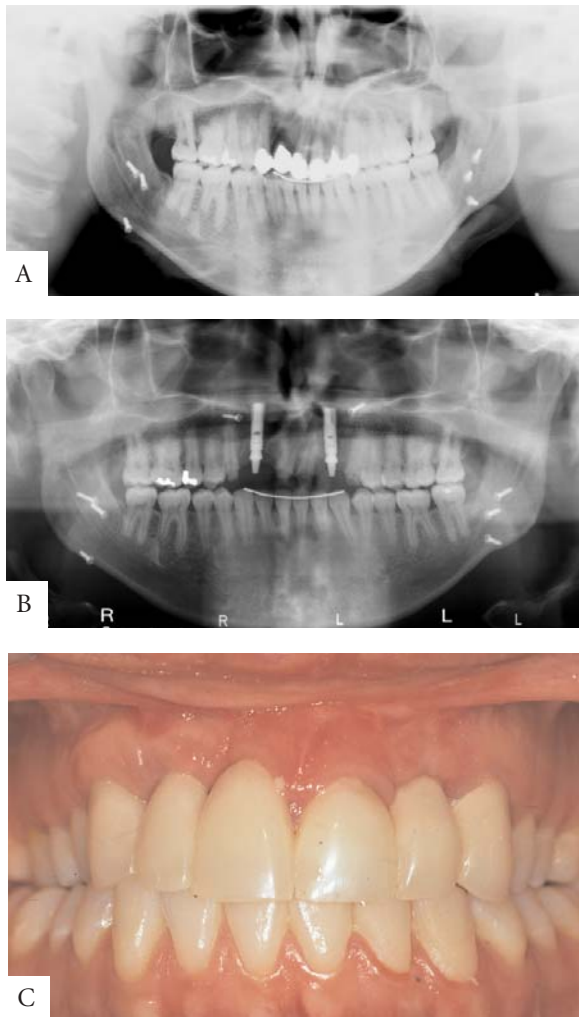


FIGURE 44-9 Prosthetic rehabilitation of a 27-year-old patient with previously unrepaired bilateral maxillary alveolar clefts. She had undergone primary lip and palate repair during infancy but never underwent bone graft reconstruction. Treatment consisted of bone graft reconstruction of the bony clefts using autogenous corticocancellous bone graft obtained from the anterior iliac crest followed by dental implant placement 6 months later. A, Preoperative panoramic radiograph reveals large bilateral bony cleft defects. B, Panoramic radiograph following bone graft reconstruction and implant placement. C, Temporary prosthetic restoration. Implant placement was performed as a single-stage procedure with construction of temporary bilateral three-unit bridges.

related to this option are primarily related to issues of orthodontic anchorage.

Summary

Orofacial clefts are complex malformations that affect the three-dimensional anatomy of the maxillofacial hard and soft tissues and have profound functional and

esthetic consequences. Successful reconstruction of these defects involves multiple stages of surgical intervention. Primary surgery is centered on initial closure of the lip and palatal defects. Secondary surgical procedures are then carried out in order to close residual oronasal communication, address VPI, reconstruct the bony maxillary cleft, normalize maxillary skeletal position and occlusion, improve lip and nasal esthetics and function, and facilitate the dental prosthetic rehabilitation of the patient. Because multiple, separate surgical interventions are carried out during active growth, thoughtful timing of each stage of reconstruction is critical in order to maximize the benefit for the patient and mitigate the potentially negative biologic consequences related to growth. Surgeons must maintain a thorough understanding of the anatomy, the intricacies of the cleft malformation, and the underlying patterns of growth and development of the craniomaxillofacial region.

References

- Leonard BJ, Brust JD, Abrahams G, et al. Self concept of children and adolescents with cleft lip and/or palate. *Cleft Palate Craniofac J* 1991;28:347.
- Strauss RP. Health policy and craniofacial care: issues in resource allocation. *Cleft Palate Craniofac J* 1994;31:78.
- Bergstrom LV. Congenital and acquired deafness in clefting and craniofacial syndromes. *Cleft Palate J* 1978;15:254.
- Cohen SR, Corrigan M, Wilmot J, et al. Cumulative operative procedures in patients aged 14 years and older with unilateral or bilateral cleft lip and palate. *Plast Reconstr Surg* 1995;96:267.
- Posnick JC. The staging of cleft lip and palate reconstruction: infancy through adolescence. In: Posnick JC. *Craniofacial and maxillofacial surgery in children and young adults*. Philadelphia (PA): W.B. Saunders; 2000.
- Posnick JC, Ruiz RL. Stages of cleft lip and palate reconstruction: infancy through adolescence. In: Wyszynski DF, editor. *Cleft lip and palate: from origin to treatment*. New York; Oxford University Press; 2002.
- American Cleft Palate–Craniofacial Association. Parameters for the evaluation and treatment of patients with cleft lip/palate or other craniofacial anomalies. *Cleft Palate Craniofac J* 1993;30(Suppl 1):4.
- Abyholm FE, Bergland O, Semb G. Secondary bone grafting of alveolar clefts. *Scand J Reconstr Surg* 1981;15:127.
- Turvey TA, Vig K, Moriarty J, et al. Delayed bone grafting in the cleft maxilla and palate: a retrospective multidisciplinary analysis. *Am J Orthod* 1984;86:244.
- Cohen SR, Kalinowski J, LaRossa D, Randall P. Cleft palate fistulas: a multivariate statistical analysis of prevalence, etiology, and surgical management. *Plast Reconstr Surg* 1991;87:1041.
- Ogle OE. The management of oronasal fistulas in the cleft palate patient. *Oral Maxillofacial Surg Clin North Am* 2002;14:553–62.
- Wilhelmi BJ, Appelt EA, Hill L, Blackwell SJ. Palatal fistulas: rare with the two-flap palatoplasty repair. *Plast Reconstr Surg* 2001;107:315–8.
- Stal S, Spira M. Secondary reconstructive procedures for patients with clefts. In: Serafin D, Georgiade NG, editors. *Pediatric plastic surgery*. St Louis (MO): C.V. Mosby; 1984.
- Lehman JA. Closure of palatal fistulas. *Op Tech Plast Surg* 1995;2:255–62.
- Schendel SA. Secondary cleft surgery. *Select Read Oral Maxillofac Surg* 1992;3(6): 1–27.
- Posnick JC. Cleft orthognathic surgery: the isolated cleft palate deformity. In: Posnick JC. *Craniofacial and maxillofacial surgery in children and young adults*. Philadelphia (PA): W.B. Saunders; 2000.
- Turvey TA, Vig KWL, Fonseca RJ. Maxillary advancement and contouring in the presence of cleft lip and palate. In: Turvey TA, Vig KWL, Fonseca RA, editors. *Facial clefts and craniosynostosis: principles and management*. Philadelphia (PA): W.B. Saunders; 1996.
- Posnick JC, Ruiz RL. Invited discussion. Repair of large anterior palatal fistulas using thin tongue flaps: long-term follow-up of 10 patients. *Ann Plast Surg* 2000;45:115–7.
- Bozola AR, Ribeiro-Garcia ERB. Partial buccinator myomucosal flap, posteriorly based. *Op Tech Plast Surg* 1995;2:263–9.
- Ninkovic M, Hubli EH, Schwabegger A, Anderl H. Free flap closure of recurrent palatal fistula in the cleft lip and palate patient. *J Craniofac Surg* 1997;8:491–5.
- Posnick JC. The treatment of secondary and residual dentofacial deformities in the cleft patient. Surgical and orthodontic treatment. *Clin Plast Surg* 1997;24:583–97.
- Bardach J. Two-flap palatoplasty: Bardach's technique. *Op Tech Plast Surg* 1995; 2:211–4.

23. Johnson PA, Banks P, Brown AE. Use of the posteriorly-based lateral tongue flap in the repair of palatal fistula. *Int J Oral Maxillofac Surg* 1992;23:6–9.
24. Kinnebrew MC, Malloy RB. Posteriorly based, lateral lingual flaps for alveolar cleft bone graft coverage. *J Oral Maxillofac Surg* 1983;41:555–61.
25. Costello BJ, Ruiz RL, Turvey TA. Velopharyngeal insufficiency in patients with cleft palate. *Oral Maxillofac Surg Clin* 2002;14:539–51.
26. Glaser ER, Skolnick ML, McWilliams BJ, Shprintzen RJ. The dynamics of Passavant's ridge in subjects with and without velopharyngeal insufficiency. A multiview videofluoroscopic study. *Cleft Palate Journal* 1979;16:24–33.
27. Passavant G. On the closure of the pharynx in speech. *Archiv Heilk* 1863;3:305.
28. Passavant G. On the closure of pharynx in speech. *Virchows Arch* 1869;46:1.
29. Warren DW. Compensatory speech behaviors in cleft palate: a regulation/control phenomenon. *Cleft Palate J* 1986;23:251–60.
30. Henningsson G, Isberg A. Velopharyngeal movements in patients alternating between oral and glottal articulation: a clinical and cineradiographical study. *Cleft Palate J* 1986;23:1.
31. Isberg A, Henningsson G. Influence of palatal fistula on velopharyngeal movements: a cineradiographic study. *Plast Reconstr Surg* 1987;79:525.
32. Lohmander-Agerskov A, Dotevall H, Lith A, et al. Speech and velopharyngeal function in children with an open residual cleft in the hard palate, and the influence of temporary covering. *Cleft Palate Craniofac J* 1996;33:324.
33. Shprintzen RJ, Bardach J. The use of information obtained from speech and instrumental evaluations in treatment planning for velopharyngeal insufficiency. In: *Cleft palate speech management: a multidisciplinary approach*. St Louis (MO): Mosby Year Book; 1995. p. 257.
34. Golding-Kushner KJ, Argamaso RV, Cotton RT, et al. Standardization for the reporting of nasopharyngoscopy and multi-view videofluoroscopy: a report from an international working group. *Cleft Palate J* 1990;27:337.
35. Warren DW, Dalston RM, Mayo R. Hypernasality and velopharyngeal impairment. *Cleft Palate Craniofac J* 1994;31:257.
36. Turvey TA, Ruiz RL, Costello BJ. Surgical correction of midface deficiency in the cleft lip and palate malformation. *Oral Maxillofac Surg Clin* 2002;14:491–507.
37. Fonseca RJ, Turvey TA, Wolford LM. Orthognathic surgery in the cleft patient. In: Fonseca RJ, Baker SJ, Wolford LM, editors. *Oral and maxillofacial surgery*. Philadelphia (PA): W.B. Saunders Co; 2000. p 87–146.
38. Posnick JC, Tompson B. Cleft-orthognathic surgery: complications and long-term results. *Plast Reconstr Surg* 1995;96:255–66.
39. Posnick JC, Ruiz RL. Discussion of management of secondary orofacial cleft deformities. In: Goldwyn RM, Cohen MM, editors. *The unfavorable result in plastic surgery: avoidance and treatment*. 3rd ed. Philadelphia (PA): Lippincott, Williams and Wilkins; 2000.
40. Turvey TA, Frost D. Maxillary advancement and velopharyngeal function in the presence of cleft palate. Abstract of presentations at the 38th annual meeting of the American Cleft Palate Association, Lancaster, Pennsylvania, May 1980.
41. Bernstein L. Treatment of velopharyngeal incompetence. *Arch Otolaryngol* 1967;85:67–74.
42. Rosseli S. Divisione palatine 3 sua aura chirurgico. *Alu Congr Internaz Stomatal* 1935-36;391–92.
43. Schoenborn D. Uber eine neue Methode der Staphylorrhaphies. *Arch Klin Chirurgie* 1876;19:528.
44. Shprintzen RJ. The use of multiview videofluoroscopy and flexible fiberoptic nasopharyngoscopy as a predictor of success with pharyngeal flap surgery. In: Ellis F, Flack E, editors. *Diagnosis and treatment of palatoglossal malfunction*. London: College of Speech Therapists; 1979. p 6–14.
45. Argamaso RV, Levandowski G, Golding-Kushner KJ, et al. Treatment of asymmetric velopharyngeal insufficiency with skewed pharyngeal flap. *Cleft Palate Craniofac J* 1994;31:287.
46. Shprintzen RJ, Lewin ML, Croft CB, et al. A comprehensive study of pharyngeal flap surgery: tailor-made flaps. *Cleft Palate J* 1979;16:46.
47. Shprintzen RJ, McCall GN, Skolnick ML, Lencione RM. Selective movement of the lateral aspects of the pharyngeal walls during velopharyngeal closure for speech, blowing, and whistling in normals. *Cleft Palate J* 1975;12:51–8.
48. Randall P, Whitaker LA, Noone RB, Jones WD. The case for the inferiorly based pharyngeal flap. *Cleft Palate Craniofac J* 1978;15:262–5.
49. Hynes W. Pharyngoplasty by muscle transplantation. *Br J Plast Surg* 1951;3:128.
50. Hynes W. The results of pharyngoplasty by muscle transplantation in "failed cleft palate" cases, with special reference to the influence of the pharynx on voice production. *Ann R Coll Surg Engl* 1953;13:17.
51. Orticochea M. Physiopathology of the dynamic muscular sphincter of the pharynx. *Plast Reconstr Surg* 1997;100:1918–23.
52. Orticochea M. Constriction of a dynamic muscle sphincter in cleft palates. *Plast Reconstr Surg* 1968;41:323–7.
53. Jackson I, Silverton JS. The sphincter pharyngoplasty as a secondary procedure in cleft palates. *Plast Reconstr Surg* 1983;71:180.
54. Jackson IT. Sphincter pharyngoplasty. *Clin Plast Surg* 1985;12:711–7.
55. Guilleminault C, Stoohs R. Chronic snoring and obstructive sleep apnea syndrome in children. *Lung* 1990;168:912.
56. Sirois M, Caouette-Laberge L, Spier S, et al. Sleep apnea following a pharyngeal flap: a feared complication. *Plast Reconstr Surg* 1994;93:943.
57. Ysunza A, Garcia-Velasco M, Garcia-Garcia M, et al. Obstructive sleep apnea secondary to surgery for velopharyngeal insufficiency. *Cleft Palate Craniofac J* 1993;30:387.
58. Bluestone CD, Musgrave RH, McWilliams BJ. Teflon injection pharyngoplasty—status 1968. *Laryngoscope* 1968;78:558–64.
59. Smith JK, McCabe DF. Teflon injection in the nasopharynx to improve velopharyngeal closure. *Ann Otol Rhinol Laryngol* 1977;86:559–86.
60. Chen PK, Wu JT, Chen YR, Noordhoff MS. Correction of secondary velopharyngeal insufficiency in cleft palate patients with the Furlow palatoplasty. *Plast Reconstr Surg* 1994;94:933.
61. Calnan J. Submucous cleft palate. *Br J Plast Surg* 1954;6:264–82.
62. McWilliams BJ. Submucous clefts of the palate: how likely are they to be symptomatic? *Cleft Palate J* 1991;28:247–8.
63. Paradise JL. Tonsillectomy and adenoidectomy. In: Bluestone CD, Stool SE, Alper CU, et al, editors. *Pediatric otolaryngology*. Philadelphia (PA): W.B. Saunders Co.; 2003. p. 1218.
64. Shprintzen RJ, Schwartz RH, Daniller A, Hoch L. Morphologic significance of bifid uvula. *Pediatrics* 1985;75:553–61.
65. Kaplan EN. The occult submucous cleft palate. *Cleft Palate J* 1975;12:356–68.
66. McComb H. The nasal deformity in clefts. In: Kernahan DA, Rosenstein SW, editors. *Cleft lip and palate: a system of management*. Baltimore (MD): Williams and Wilkins; 1990. p. 68–73.
67. Horswell BB, Pospisil OA. Nasal symmetry after primary cleft lip repair: comparison between Delaire cheilorhinoplasty and modified rotation-advancement. *J Oral Maxillofac Surg* 1995;53:1025.

68. Gubiscla W. How to obtain symmetries in a unilaterally cleft nose. *Eur J Plast Surg* 1990;13:241.
69. Takato T, Yonehara Y, Mori Y, et al. Correction of the nose in unilateral cleft lip patients using an open method: a 10-year review. *J Oral Maxillofac Surg* 1995;53:28.
70. Millard DR. Bilateral cleft lip and a primary forked flap: a preliminary report. *Plast Reconstr Surg* 1967;30:50.
71. Cronin TD. Lengthening columella by use of skin from nasal floor and alae. *Plast Reconstr Surg* 1958;21:417.
72. Harper DC. Children's attitudes to physical differences among youth from Western and non-Western cultures. *Cleft Palate Craniofac J* 1995;32:114.
73. Laine J, Vahatalo K, Peltola J, et al. Rehabilitation of patients with congenital unrepaired cleft palate defects using free iliac crest bone grafts and dental implants. *Int J Oral Maxillofac Implants* 2002;17:573–80.
74. Fukuda M, Takahashi T, Yamaguchi T, et al. Dental rehabilitation using endosseous implants and orthognathic surgery in patients with cleft lip and palate: report of two cases. *J Oral Rehabil* 2000;27:546–51.
75. Jensen J, Sindet-Pedersen S, Enemark H. Reconstruction of residual alveolar cleft defects with one-stage mandibular bone grafts and osseointegrated implants. *J Oral Maxillofac Surg* 1998;56:460–6.

Nonsyndromic Craniosynostosis

G. E. Ghali, DDS, MD

Douglas P. Sinn, DDS

In its basic form craniosynostosis represents premature suture fusion. It occurs in approximately 1 per 1,000 live births in the United States. Craniosynostosis may be classified as nonsyndromic or syndromic. Most forms of craniosynostosis are isolated and not associated with any other conditions and are therefore nonsyndromic. Syndromic craniosynostosis will be covered in another chapter. The pathogenesis of craniosynostosis is complex and probably multifactorial. Moss theorized that craniosynostosis such as seen in Apert and Crouzon syndromes results from abnormal tensile forces transmitted to the dura from an anomalous cranial base through key ligamentous attachments.¹ This hypothesis fails to explain craniosynostosis in patients with a normal cranial base configuration. The cause of craniosynostosis may be postulated to be the result of either primary suture abnormalities, sufficient extremes of forces that overcome the underlying expansive forces of the brain, inadequate intrinsic growth forces of the brain, or various genetic and environmental factors.² Cranial vault growth achieves approximately 80% of the adult size at birth and definitive size by 2.5 to 3 years of age.³ The existence of the six major sutural regions allows for head expansion as well as transvaginal head deformation.⁴ Recall that posterior fontanelle closure (3–6 mo) generally precedes anterior fontanelle closure (9–12 mo).

Functional Considerations

The major functional problems associated with craniosynostosis are intracranial hypertension, visual impairment, limitation of brain growth, and neuropsychiatric disorders.⁵ In general the functional problems increase as the number of sutures involved increases.⁵ These functional abnormalities are gradual in their development, difficult to detect, and often irreversible in nature.

Intracranial Hypertension

Intracranial hypertension is defined as a pressure of greater than 15 mm Hg. Studies by Marchac and Renier have demonstrated a 13% incidence of intracranial hypertension with single suture stenosis and up to a 42% incidence in multisuture-stenosed children.⁶ The clinical symptoms of intracranial hypertension include headaches, irritability, and difficulty sleeping. The radiographic signs may include cortical thinning or a lückenschädel (hammered metal) appearance of the inner table of the skull; these clinical and radiographic signs are relatively late developments. If intracranial hypertension goes untreated, it affects brain function; if persistent this may necessitate early operative intervention during the first few months of life. Intracranial hypertension most likely affects those with the greatest disparity between brain growth and intracra-

nial capacity and may occur in as many as 42% of untreated children with more than one suture affected. Currently intracranial volume is measured using computed tomography (CT) scans, a noninvasive method appropriate for use in children with craniosynostosis. It might be possible to identify individuals who are at a greater risk for developing intracranial hypertension and would benefit the most from early surgery.

Visual Impairment

Intracranial hypertension, if left untreated, may lead to papilledema, typically acute. After chronic intracranial hypertension, eventually optic atrophy develops, which results in complete or partial blindness. Some forms of craniosynostosis may involve orbital hypertelorism and may lead to compromised visual acuity and restricted binocular vision.

Limitation of Brain Growth

Brain volume in the normal child almost triples during the first year of life. By 2 years of age the cranial capacity is four times that at birth. If brain growth is to proceed unhindered, open sutures at the level of the cranial vault and base must spread during phases of rapid growth for marginal ossification.

In craniosynostosis, premature suture fusion is combined with continuing brain growth. Depending on the number and

location of prematurely fused sutures and the timing of closure, the growth potential of the brain may be limited. Surgical intervention can provide suture release and reshaping to restore a more normal intracranial volume. In general this does not completely reverse craniosynostosis, and diminished volume is often the end result.

Neuropsychiatric Disorders

Neuropsychiatric disorders are believed to be secondary to cerebral compression. Disorders range from mild behavioral disturbances to overt mental retardation. Several studies have shown that children with craniosynostosis and associated neuropsychiatric disorders often improve after cranial vault reconstruction.

Diagnosis

One should suspect craniosynostosis in any infant with an abnormal head shape. Definitive diagnosis is based on clinical and radiographic evaluations. The clinical evaluation involves the palpation of the skull for any movement, ridging, and presence of the anterior and posterior fontanelles. Quantitative measurements of the superior orbital rims, relative to the most anterior aspect of the cornea, also may help in planning treatment for superior orbital rim advancements.

The radiographic evaluation of craniosynostosis is used to define quantitatively aberrant anatomy, plan surgical procedures, and, most importantly, provide a means to demonstrate to the parents the difference between stenosed and nonstenosed sutures. Conventional skull radiographs, such as plain skull films and lateral cephalograms, are inexpensive and widely available. The preoperative assessment of patients with suspected or known craniosynostosis is based on these conventional radiographs. Most cases of synostosis can be demonstrated on plain skull films. Normal or patent cranial sutures manifest as a line. The absence of a radiolucent line in the normal anatomic position of a suture may suggest craniosynostosis.

Currently, CT scans provide improved hard tissue imaging. The definition of these elements of the bony facial structures on high-resolution CT images with or without three-dimensional reconstruction is unmatched by other imaging techniques (Figure 45-1). The development of CT scanning, particularly three-dimensional reformatting, and the maturation of readily available means of craniofacial surgery have led to a close dependence on CT scanning for preoperative surgical planning. CT scanning also has been used to document surgical changes in vivo and to follow developments longitudinally.⁷⁻¹⁸

Classification

The classification of craniosynostosis is based on the shape of the skull, which usually reflects the underlying prematurely fused suture or sutures.^{19,20} The major cranial vault sutures that may be involved include the left and right coronal, metopic, sagittal, and lambdoid sutures.

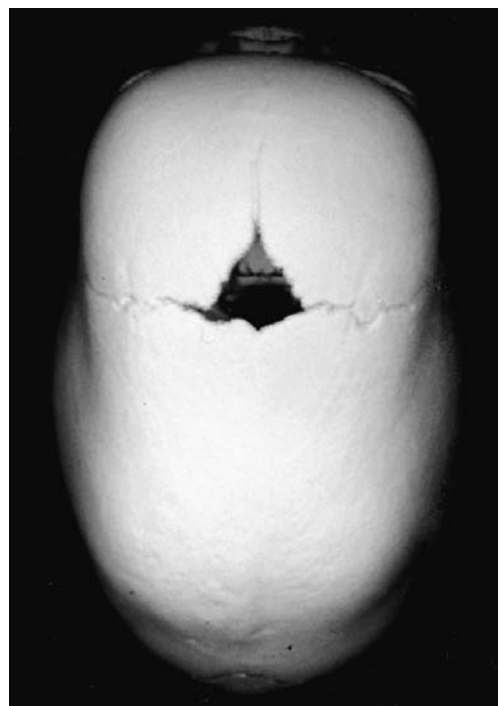


FIGURE 45-1 Computed tomography scan with three-dimensional reconstruction. Patency of metopic and coronal sutures as well as anterior fontanelle; premature fusion of sagittal suture. Reproduced with permission from Ghali GE et al.⁴⁶ p. 3.

Unilateral Coronal Synostosis

Unilateral coronal synostosis results in flatness on the ipsilateral side of the forehead and supraorbital ridge region. The head is inherently asymmetric in shape with a flattened or repositioned forehead on the ipsilateral side, especially when viewed from the top (Figure 45-2). The term for this deformity is “anterior plagiocephaly.” One should rule out infant molding or positional plagiocephaly and congenital torticollis as other possible diagnoses. Premature fusion of the unilateral

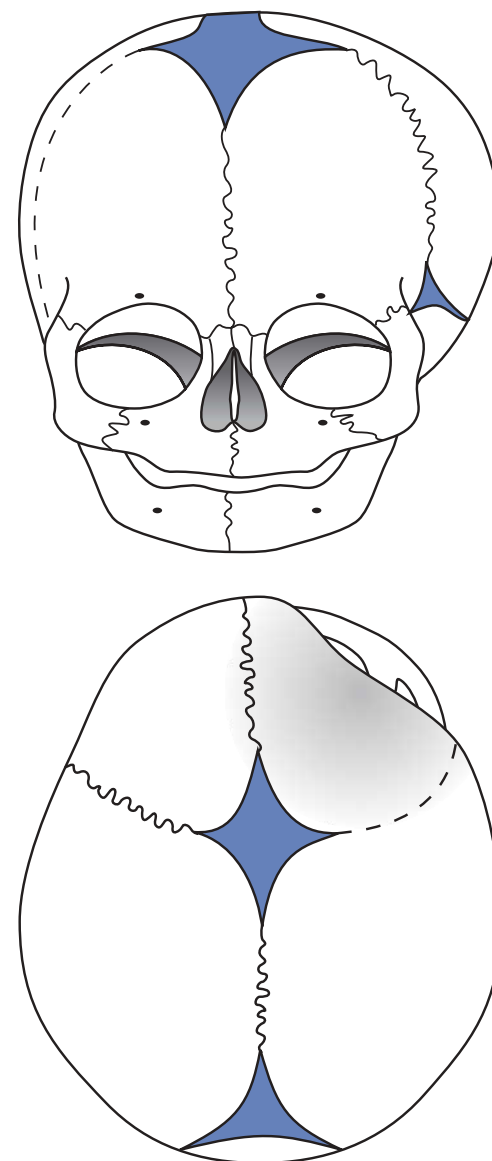


FIGURE 45-2 Frontal and superior views. Characteristic right anterior plagiocephaly. Adapted from Ghali GE et al.⁴⁶ p. 4.

coronal suture represents 20% of the isolated or nonsyndromic cases of synostosis in the United States. Characteristic morphologic features occur on the ipsilateral side. The frontal bone is flat, and the supraorbital ridge and lateral orbital rim are recessed (Figure 45-3). The orbit is shallow, and the anterior cranial base is short in the anteroposterior dimension. The root of the nose may be constricted and deviated to the affected side (Figure 45-4). The ipsilateral zygoma and infraorbital rim also may be flat and recessed.



FIGURE 45-3 Superior view. Recessed frontal bone, supraorbital ridge, and lateral orbital rim on patient's right side. Reproduced with permission from Ghali GE et al.⁴⁶ p. 5.

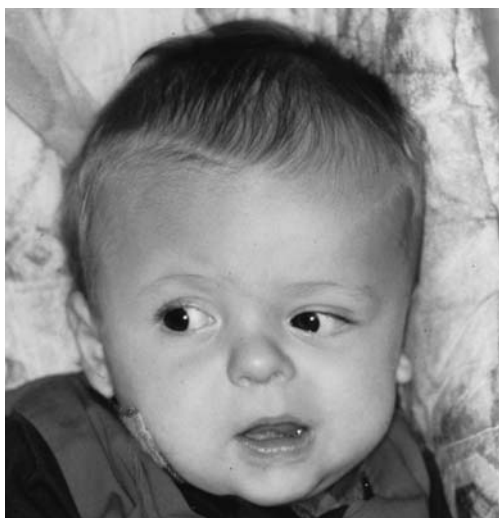

FIGURE 45-4 Frontal view. Nasal bridge and root deviation to the affected (right) side characteristic in plagiocephaly. Reproduced with permission from Ghali GE et al.⁴⁶ p. 5.

Bilateral Coronal Synostosis

Bilateral coronal synostosis is the most common cranial vault suture synostosis pattern associated with Apert and Crouzon syndromes. Bilateral coronal synostosis results in recession of the supraorbital ridges, which causes the overlying eyebrows to sit posterior to the corneas. In addition to the recessed supraorbital bone, the forehead appears to be lower and there is sagittal shortening of the skull (Figure 45-5). The term for this cranial vault deformity is "brachycephaly." The anterior cranial base is short in the anteroposterior dimension and wide transversely. The

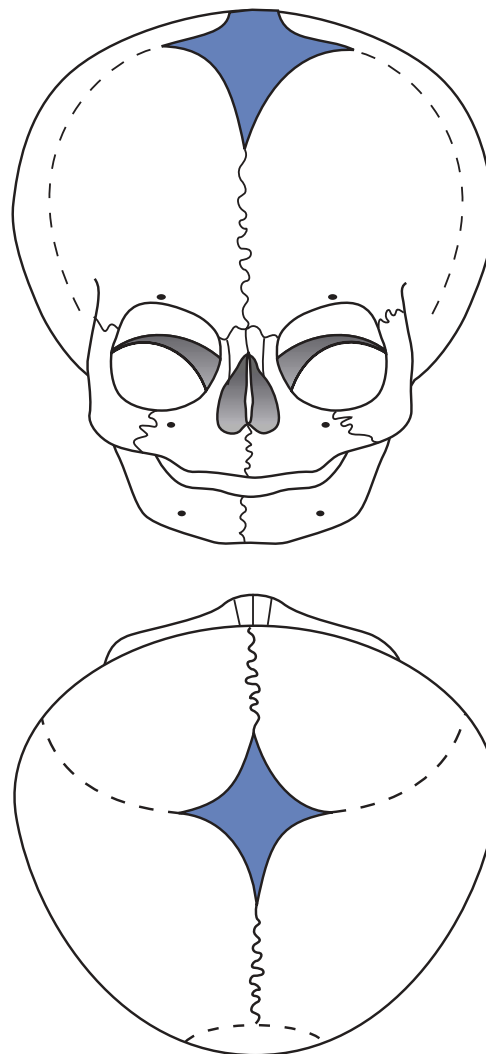


FIGURE 45-5 Frontal and superior views. Characteristic brachycephaly. Adapted from Ghali GE et al.⁴⁶ p. 4.

overlying cranial vault is high in the superior-inferior dimension, with anterior bulging of the upper forehead that results from compensatory growth of the patent metopic suture (Figure 45-6). The orbits are also shallow (exorbitism), with the eyes bulging (exophthalmus) and abnormally separated (orbital hypertelorism). Brachycephaly represents 20% of the isolated craniosynostosis cases in the United States and is the most common syndrome-associated synostosis.

Metopic Synostosis

Metopic synostosis usually occurs in isolation and results in a triangular shape to the skull (Figure 45-7). The term for this cranial vault deformity is "trigonocephaly." The associated cranial vault deformity consists of relative hypotelorism, an elevated supraorbital ridge medially, and posterior-inferior recession of the lateral orbital rims and lateral aspect of the supraorbital ridges. Palpation often reveals a prominent midline keel in the region of the metopic suture. (Figure 45-8). The bitemporal width is decreased, which results in an

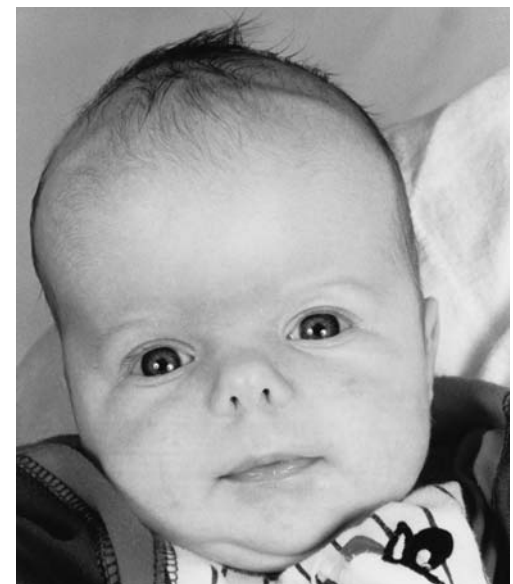


FIGURE 45-6 Frontal view. High cranial vault and transverse widening characteristic of brachycephaly. Note visible ridging in the bicoronal suture region. Reproduced with permission from Ghali GE et al.⁴⁶ p. 7.

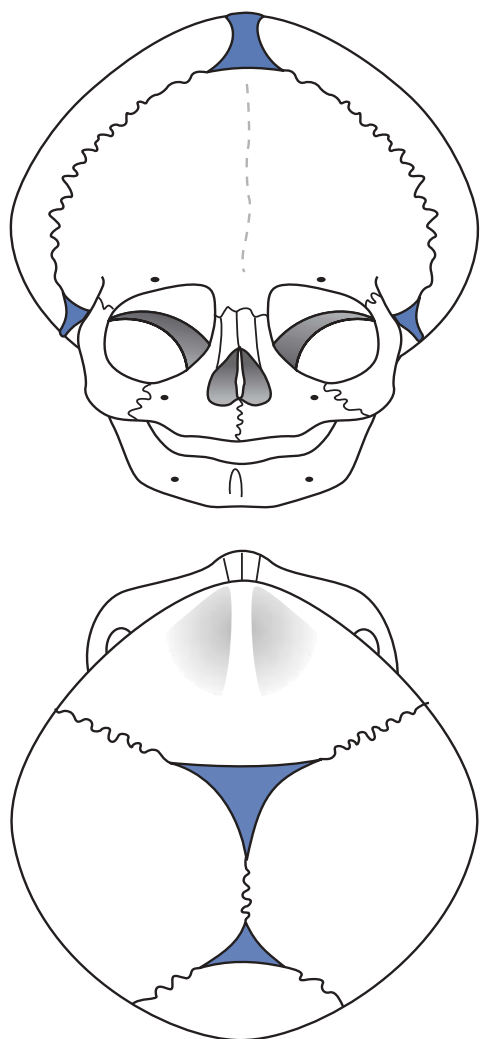


FIGURE 45-7 Frontal and superior views. Characteristic trigonocephaly. Adapted from Ghali GE et al.⁴⁶ p. 8.

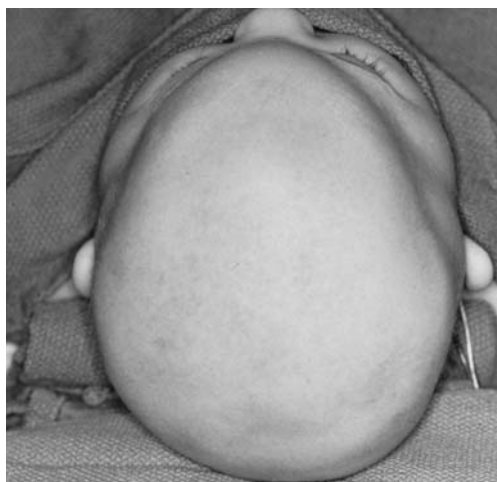

FIGURE 45-8 Intraoperative view following shaving of the head demonstrates prominent midline ridging. Reproduced with permission from Ghali GE et al.⁴⁶ p. 9.

abnormal anterior cranial vault shape and decreased anterior cranial vault volume. The overlying forehead is sloped posteriorly to approximately the level of the coronal sutures. Trigonocephaly represents 10% of the nonsyndromic craniosynostosis cases in the United States.

Sagittal Synostosis

Sagittal synostosis, the most common form, is rarely associated with increased intracranial pressure. The skull typically has anteroposterior elongation with a compensatory transverse narrowing (Figure 45-9). The term for this cranial vault deformity is “scaphocephaly.” The deformity consists of an elongated anteroposterior dimension and a narrow transverse dimension to the cranial vault (Figure 45-10). Usually, the midface and anterior cranial vault sutures are not affected. Scaphocephaly represents 50% of all single-suture craniosynostosis cases in the United States.

Unilateral Lambdoid Synostosis

Unilateral lambdoid synostosis results in flatness of the affected ipsilateral parieto-occipital region. The location of the ear canal and external ear are more posterior and inferior on the ipsilateral side compared with the contralateral side. This configuration is more noticeable when the patient is examined from the superior view and is relatively inconspicuous from the frontal or profile views. The term for this cranial vault deformity is “posterior plagiocephaly.” One should rule out infant molding and congenital torticollis (Figure 45-11). With positional (or deformational) plagiocephaly, the ipsilateral ear and forehead are positioned anteriorly, and the ear is not inferiorly displaced as it is with true unilateral lambdoid fusion. The use of head-molding helmet therapy has received renewed interest in the past decade as the preferred treatment of children with positional head shape abnormalities.²¹ The overall incidence of true unilateral lambdoid synostosis is less than 3% of all isolated synostosis cases in the United States.

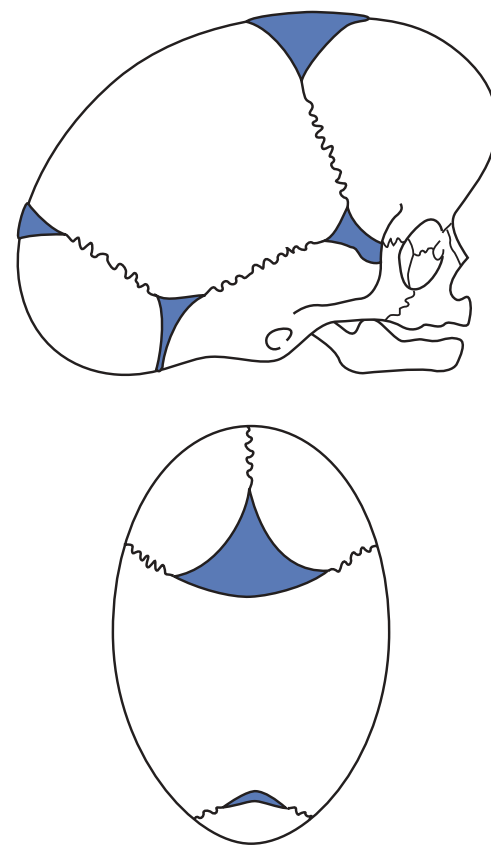


FIGURE 45-9 Lateral and superior views. Characteristic scaphocephaly. Adapted from Ghali GE et al.⁴⁶ p. 10.

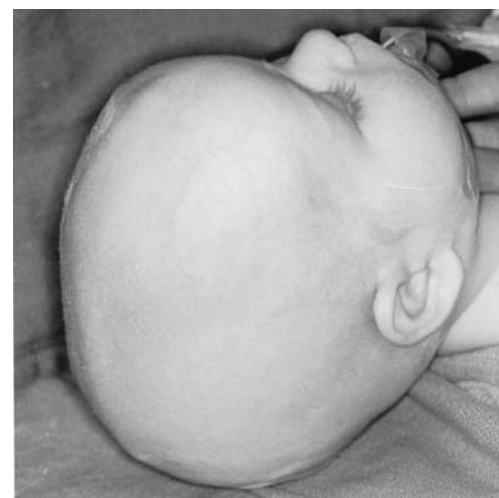

FIGURE 45-10 Intraoperative view following shaving of the head demonstrates prominent sagittal suture ridging associated with scaphocephaly. Reproduced with permission from Ghali GE et al.⁴⁶ p. 11.

Principles of Management

Multidisciplinary Team Approach

The multidisciplinary team approach was developed in response to the failures that commonly occurred when various aspects of care were not coordinated and when the relationships among coexisting problems were not known.^{3,22} The objectives of this approach are diagnosis, formulation, and execution of treatment plans and longitudinal follow-up for patients with craniofacial deformities; the team should meet at least monthly for regular outpatient evaluations. Transcripts of these evaluations are forwarded with recommendations to primary care providers and appropriate agencies. Children under the age of 5 years are usually evaluated annually, whereas children over 5 years of age are seen every other year. The frequency of evaluation varies with the stability of the deformity and its consequences.

The craniofacial team should consist of a pediatric anesthesiologist, a pediatric ophthalmologist, a surgeon, an audiologist, a maxillofacial prosthodontist, an orthodontist, a psychologist, a geneticist, an otolaryngologist, a pediatrician, social workers, a speech pathologist, and a nurse.^{23–27} All these team members have integral roles at various times in the child's development.^{28,29}

Current Surgical Approach

The goals of craniosynostosis suture release are twofold. The first goal is to allow the brain to grow and expand without restriction. The second goal is to establish a more normal contour to the forehead, supraorbital ridges, and skull.^{30–32} In most cases, an intracranial approach is used for cranial vault and orbital osteotomies, with reshaping and advancement of bony segments for ideal age-appropriate bony morphology. When planning the time and type of surgical

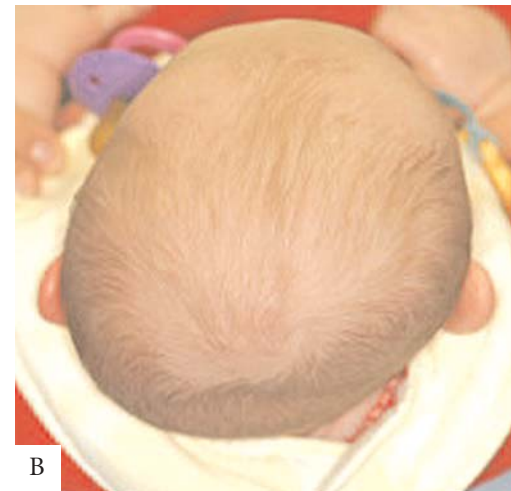


FIGURE 45-11 Frontal (A) and superior (B) views of a child with positional plagiocephaly. Radiographic and clinical examination demonstrated no evidence of craniosynostosis; note asymmetry of external ear position.

intervention, one must consider the functions, future growth, and the development of the craniofacial skeleton and the maintenance of normal body image. Simple craniosynostosis can be managed successfully with frontocranial remodeling.

Although the timing of craniosynostosis repair remains controversial and individualized, we prefer early surgical repair between the ages of 4 and 8 months.^{33–35} Early surgical repair allows for rapid frontal lobe growth, which supports the forehead and supraorbital ridge advancement. At this age, the cranium is highly malleable and therefore easier to contour; a positive effect on facial growth may be achieved and future deformities may be lessened. Also during this period of rapid growth, residual bony defects heal more rapidly. In severe forms of craniosynostosis, additional revision of the cranial vault and orbit is necessary during infancy or early childhood to increase intracranial volume further, which allows for continued brain growth and avoids or reduces the likelihood of intracranial hypertension.

A craniotomy is performed by a pediatric neurosurgeon to remove the deformed section of cranium and provide

access for osteotomies to be performed in the cranial base. The skeletal segments are reshaped and replaced into a new position. Although many of the following examples of surgical repair depict transosseous wiring and titanium plating, the current trend includes the use of resorbable plates and screws. These plates, which are composed of polylactic and polyglycolic acid, are completely resorbed by hydrolysis within 9 to 14 months while maintaining tensile strength for initial stabilization.^{36–38} As a result, growth restrictions are minimized, as is the potential for transcranial migration.

Surgical Considerations

Unilateral Coronal Synostosis

Multiple surgical approaches for the correction of unilateral coronal synostosis (Figures 45-12 and 45-13) have been described.^{39–41} Good long-term results are obtained when treatment of coronal synostosis includes suture release along with cranial vault and orbital osteotomies for reshaping and advancement in infancy. At the Louisiana State University Health Sciences Center in Shreveport, unilateral orbital rim advancement and

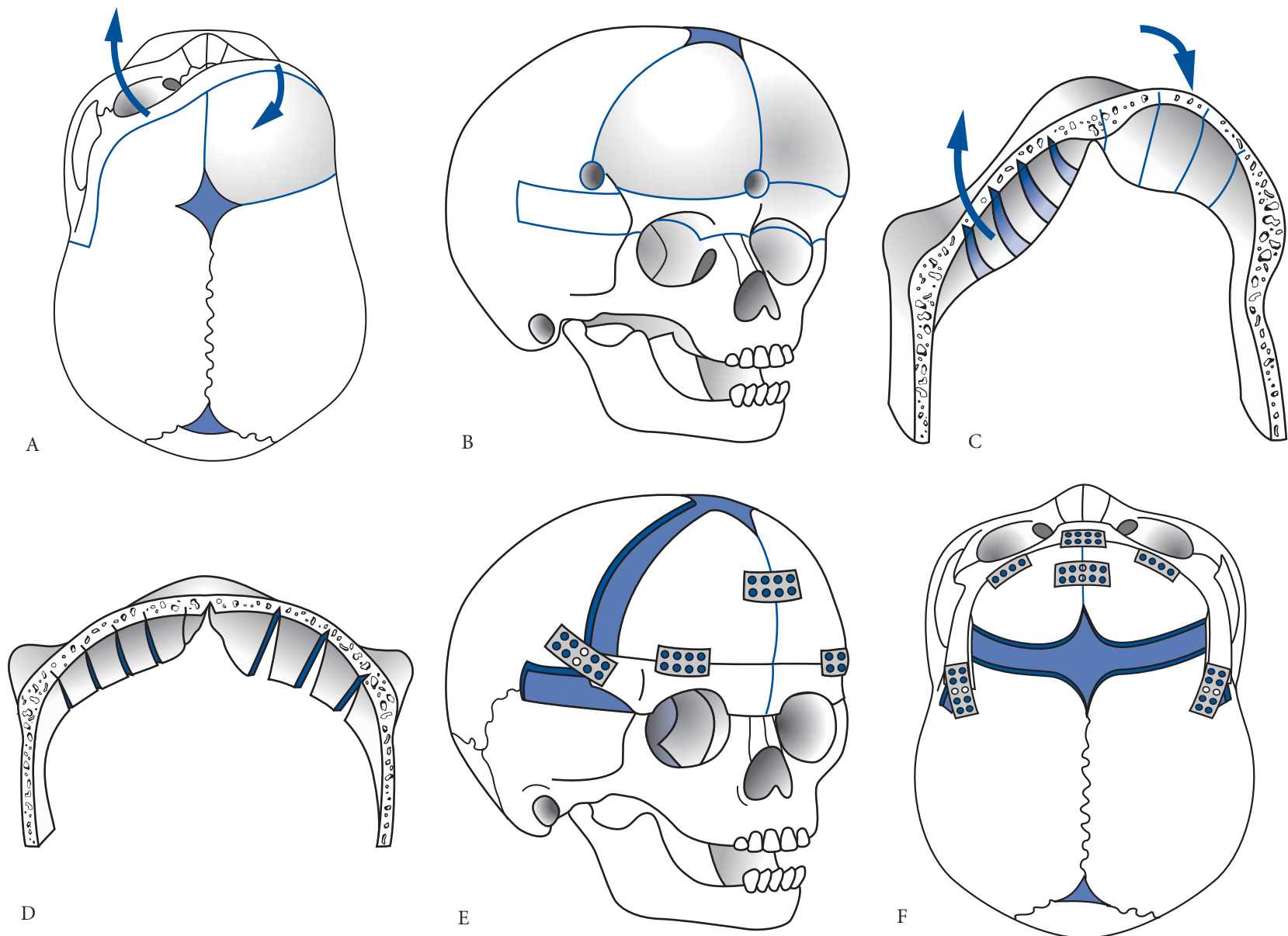


FIGURE 45-12 A child with unilateral coronal synostosis resulting in left-sided anterior plagiocephaly. A, Asymmetric forehead and orbit viewed from above. Note marked left supraorbital retrusion and right forehead and cranial vault bulging. B, Bur holes prepared for bifrontal craniotomy at the level of the supraorbital region, allowing a 1 cm fronto-orbital unit (bandeau), which extends into the temporal fossa via tongue-in-groove (tenon) extensions. Note that the degree of extension into the lateral and inferior orbital rims is variable based on esthetics. C, The removed bandeau is contoured bilaterally via removal of wedges from the left orbital roof and scoring the right orbital roof. D, The bandeau is reshaped to achieve symmetry by bending the left side and straightening the right side. E and F, Stabilization of forehead and bandeau achieved via resorbable plates and screws. Adapted from Ghali GE et al.⁴⁶ p. 14–15.

frontal bone reshaping are ideally performed at 6 to 8 months of age. Other centers have reported good results when treatment is provided between the ages of 2.5 and 3 years. To achieve optimal symmetry, we prefer to use a bilateral surgical approach. Symmetry of the cranial vault and orbit must be achieved during surgery, because results generally do not improve over time. Stabilization is

achieved by using direct intraosseous wires or resorbable plates and screws.

Bilateral Coronal Synostosis

The treatment of bilateral coronal synostosis (Figures 45-14 and 45-15) requires suture release and simultaneous bilateral orbital rim and frontal bone advancements.^{42,43} Surgery is performed when the patient is between 6 and 8 months of age.

Other centers have reported good results with children treated between the ages of 2.5 and 3 years of age. The osteotomies for the bilateral orbital rim advancement are made superior to the nasofrontal and frontozygomatic sutures and extend to the squamous portion of the temporal bone. Stabilization is achieved with direct transosseous wires or resorbable plates and screws. The more normalized shape provides the needed increase

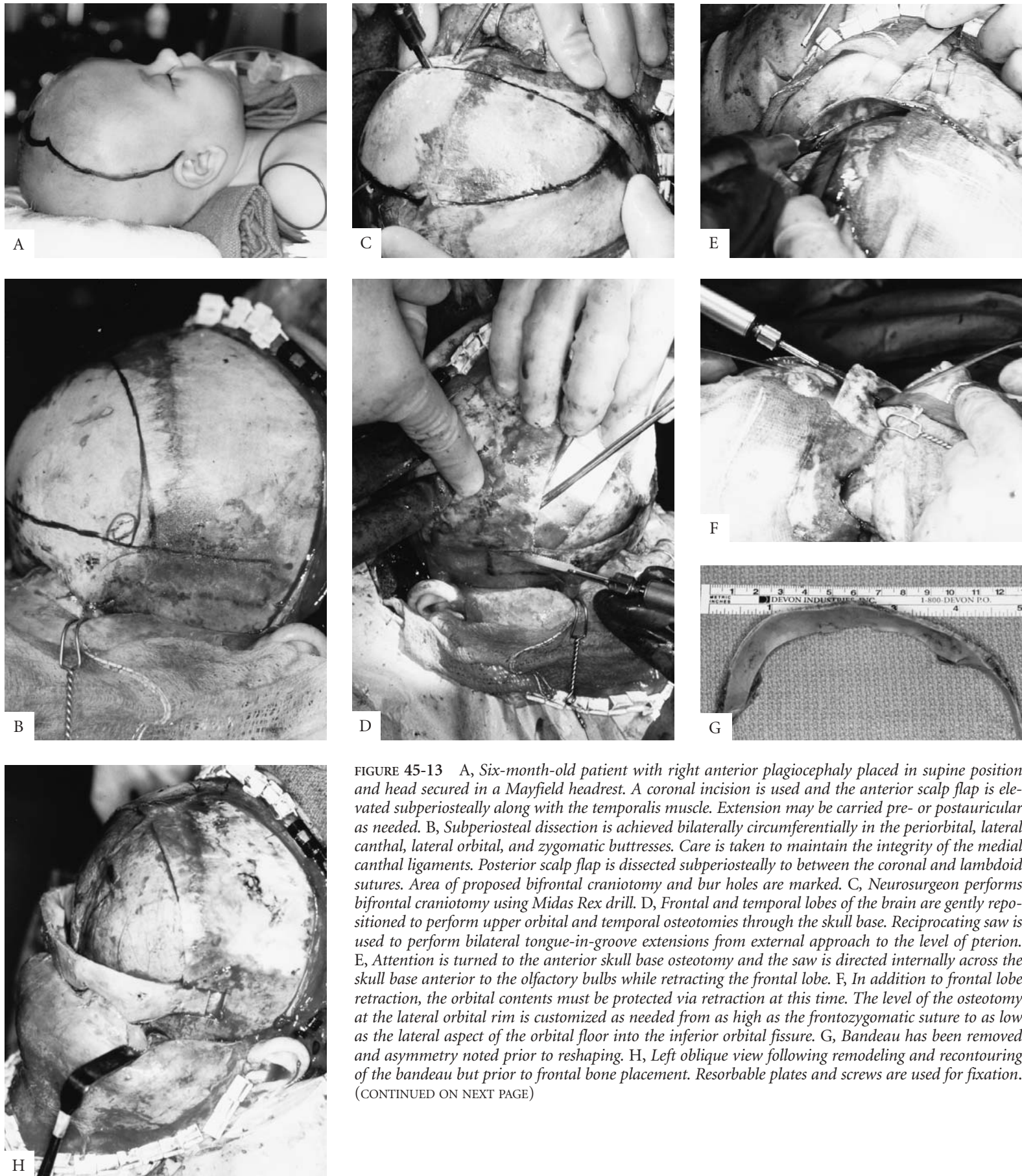


FIGURE 45-13 A, Six-month-old patient with right anterior plagiocephaly placed in supine position and head secured in a Mayfield headrest. A coronal incision is used and the anterior scalp flap is elevated subperiosteally along with the temporalis muscle. Extension may be carried pre- or postauricular as needed. B, Subperiosteal dissection is achieved bilaterally circumferentially in the periorbital, lateral canthal, lateral orbital, and zygomatic buttresses. Care is taken to maintain the integrity of the medial canthal ligaments. Posterior scalp flap is dissected subperiosteally to between the coronal and lambdoid sutures. Area of proposed bifrontal craniotomy and bur holes are marked. C, Neurosurgeon performs bifrontal craniotomy using Midas Rex drill. D, Frontal and temporal lobes of the brain are gently repositioned to perform upper orbital and temporal osteotomies through the skull base. Reciprocating saw is used to perform bilateral tongue-in-groove extensions from external approach to the level of pterion. E, Attention is turned to the anterior skull base osteotomy and the saw is directed internally across the skull base anterior to the olfactory bulbs while retracting the frontal lobe. F, In addition to frontal lobe retraction, the orbital contents must be protected via retraction at this time. The level of the osteotomy at the lateral orbital rim is customized as needed from as high as the frontozygomatic suture to as low as the lateral aspect of the orbital floor into the inferior orbital fissure. G, Bandeau has been removed and asymmetry noted prior to reshaping. H, Left oblique view following remodeling and recontouring of the bandeau but prior to frontal bone placement. Resorbable plates and screws are used for fixation. (CONTINUED ON NEXT PAGE)

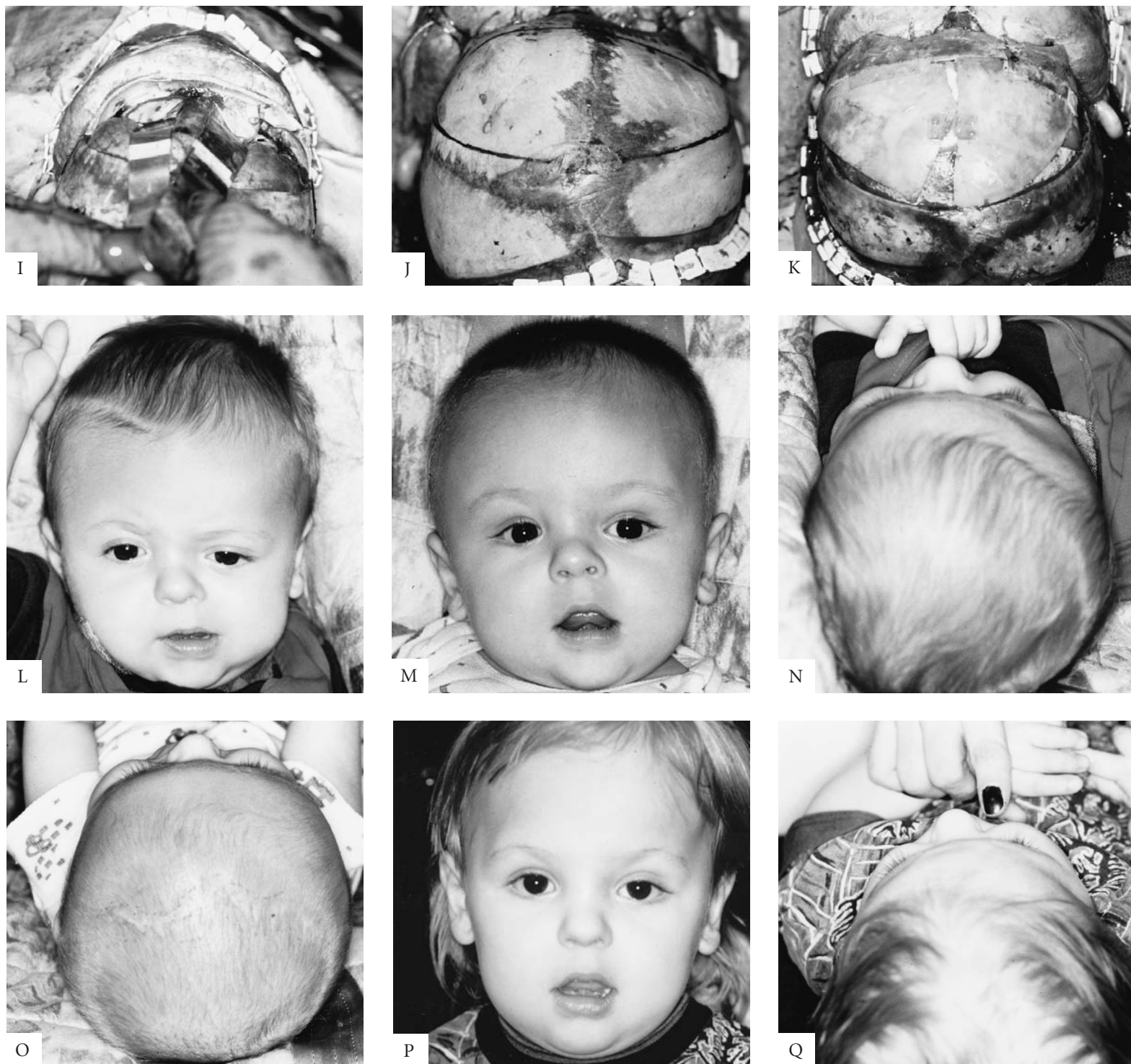


FIGURE 45-13 (CONTINUED) I, Retraction of bifrontal lobes demonstrates differential degree of advancement on the right side at anterior skull base. J, Superior view of anterior cranial vault prior to reshaping. K, Superior view of anterior cranial vault after osteotomies, reshaping, and resorbable plate and screw fixation of the bone segments. Barrel-staving cuts may be made in the temporal and parietal bones as needed for reshaping purposes. L, A 6-month-old boy with right unilateral plagiocephaly. He underwent anterior cranial vault and bilateral superior orbital rim osteotomies with reshaping and advancement by the procedure described. Preoperative frontal view is shown. M, Frontal view 6 weeks after reconstruction. N, Preoperative superior view. O, Superior view 6 weeks after reconstruction. P, Frontal view 2 years after reconstruction. Q, Superior view 2 years after reconstruction. Reproduced with permission from Ghali GE et al.⁴⁶ p. 16–24.

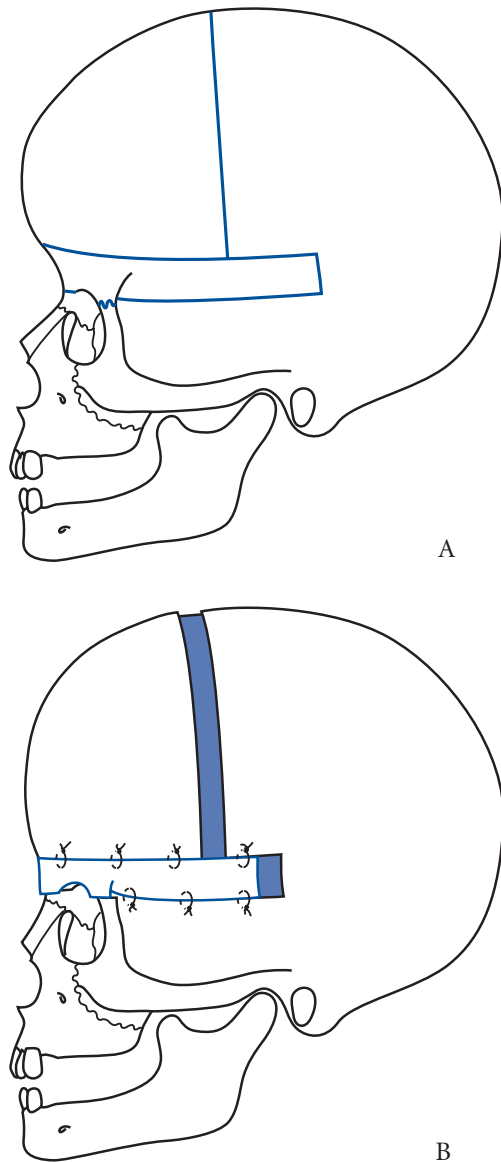


FIGURE 45-14 Brachycephaly before and after anterior cranial vault and bilateral superior orbital rim osteotomies, reshaping, and advancements. A, Site of osteotomies as indicated. Dissection and osteotomies are similar to that previously described for plagiocephaly repair. B, After osteotomies, reshaping, and fixation of bandeau and frontal plates. Adapted from Ghali GE et al.⁴⁶ p. 25.

in intracranial volume within the anterior cranial vault.

Metopic Synostosis

Surgical treatment of metopic synostosis (Figures 45-16 and 45-17) involves metopic suture release, simultaneous bilateral orbital rim advancements, and lateral widening via frontal bone

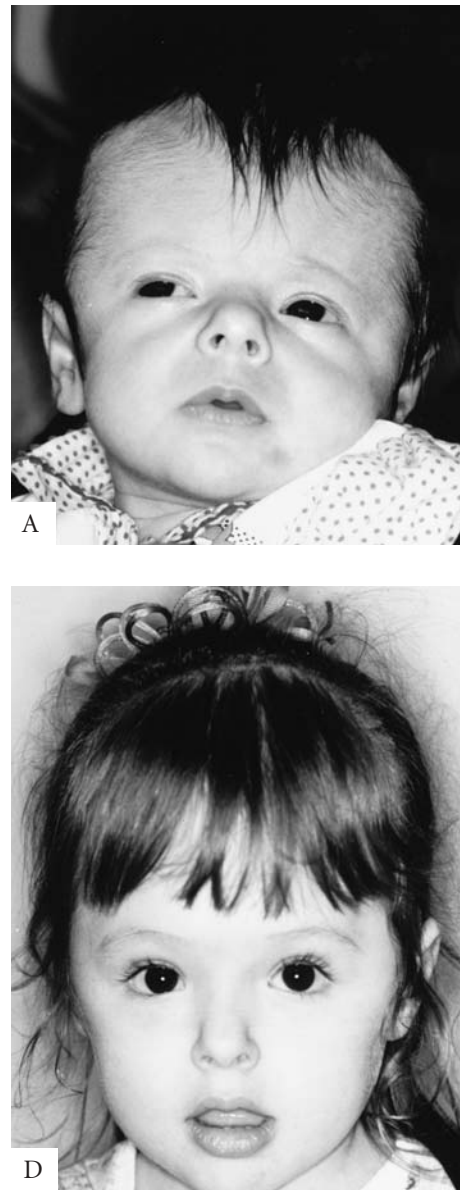


FIGURE 45-15 A female infant born with bilateral coronal synostosis and apparent normal growth of her midface. She underwent anterior cranial vault and bilateral superior orbital rim osteotomies with reshaping at 6 months of age as previously described. A, Frontal view soon after birth. B, Superior view preoperatively at 6 months of age. C, Intraoperative lateral view of anterior cranial vault and orbits after osteotomies, reshaping, and fixation of segments. D, Frontal view at 3 years of age. E, Superior view at 1 year of age. Reproduced with permission from Ghali GE et al.⁴⁶ p. 25–7.

advancement. These procedures are usually performed at 6 to 8 months of age. Orbital hypotelorism is corrected by splitting the supraorbital ridge unit vertically in the midline and placing autogenous cranial bone grafts to increase the intraorbital distance. Stabilization is achieved with direct transosseous wires or resorbable microplate fixation. The

microplate fixation is usually placed at the inner surface of the cranial bone. The abnormally shaped bone that has been removed is cut into sections of appropriate shape for the new forehead configuration. The anterior cranial base, anterior cranial vault, and orbit are given a more esthetic shape, and the volume of the anterior cranial vault is increased, which

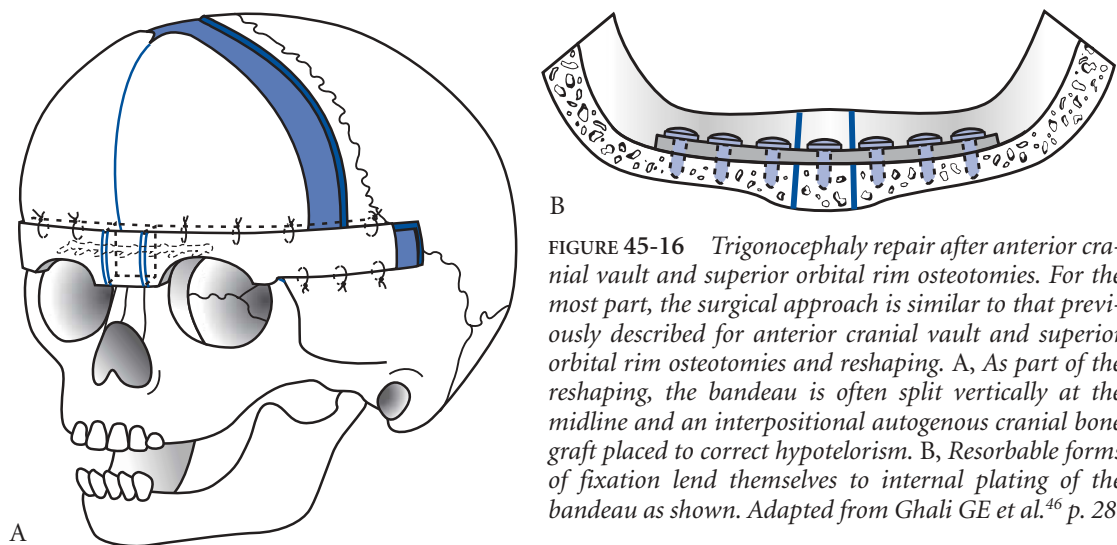


FIGURE 45-16 Trigenocephaly repair after anterior cranial vault and superior orbital rim osteotomies. For the most part, the surgical approach is similar to that previously described for anterior cranial vault and superior orbital rim osteotomies and reshaping. A, As part of the reshaping, the bandeau is often split vertically at the midline and an interpositional autogenous cranial bone graft placed to correct hypotelorism. B, Resorbable forms of fixation lend themselves to internal plating of the bandeau as shown. Adapted from Ghali GE et al.⁴⁶ p. 28.

allows the brain adequate space. Autogenous bone may be taken from the posterior cranium, when required, to enhance frontal reconstruction.

Sagittal Synostosis

Historically, when premature closure of a sagittal suture (Figures 45-18 and 45-19) was recognized in early infancy, most neurosur-

geons believed that simple release of the sagittal suture through a strip craniectomy without simultaneous skull reshaping was adequate treatment.^{4,36,44,45} Our results using this technique have been less than favorable, and a residual cranial vault deformity usually results. If improvements in cranial vault shape are to be achieved, most cases require a formal total cranial vault reshaping at the age of 4 to 8 months. Variations in the degree of the scaphocephalic deformity are common, depending on the extent of sagittal suture stenosis. When the posterior half is fused, the patient is treated in the prone position with the posterior two-thirds of the cranial vault reshaped. When the anterior half is fused, the patient is treated in the supine position with the anterior two-thirds of the cranial vault reshaped, with or without superior orbital rim reshaping. When the entire suture is fused, a combination of

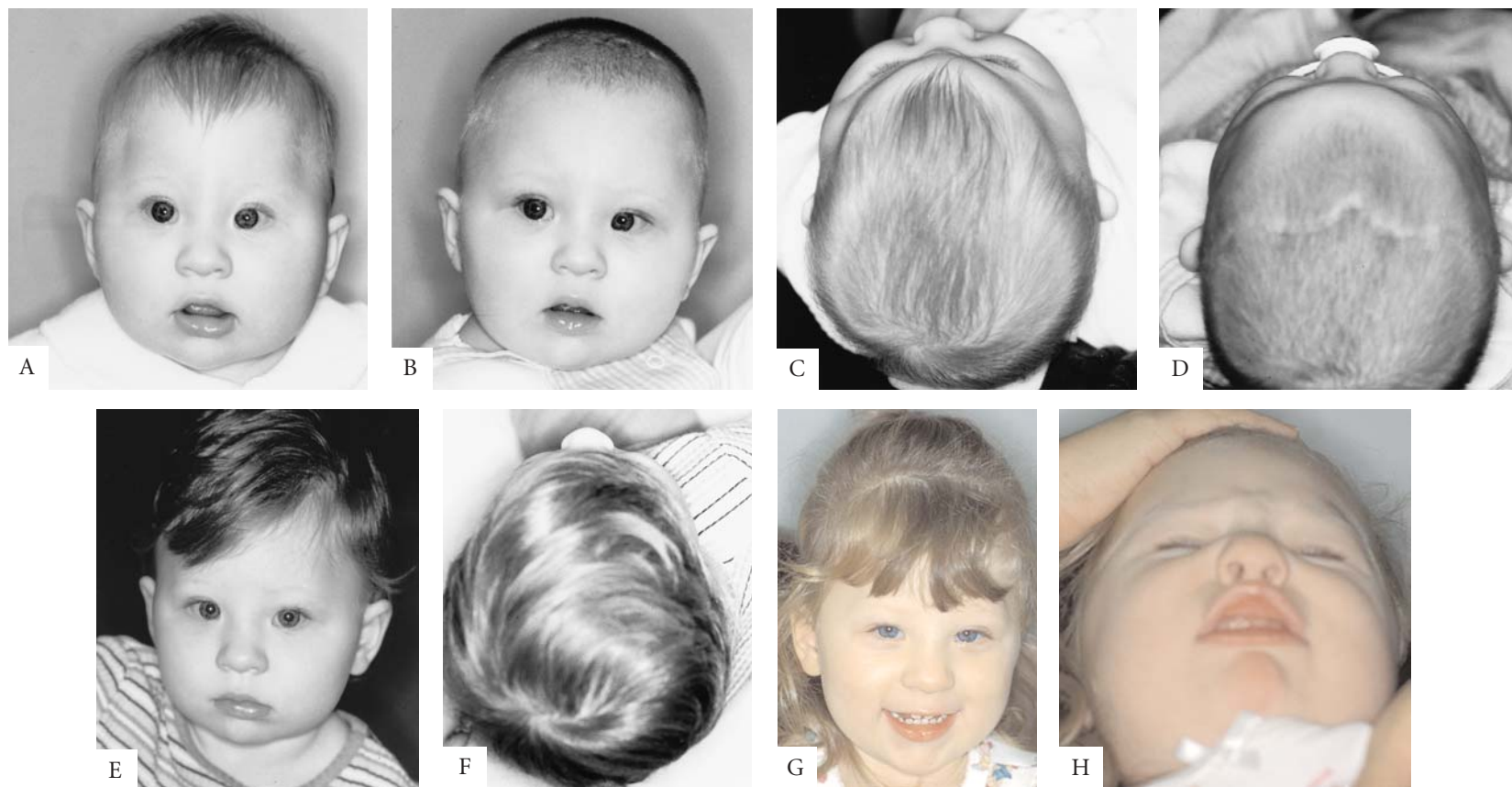


FIGURE 45-17 A 10-month-old girl with metopic synostosis resulting in trigonocephaly. She underwent anterior cranial vault reshaping, bilateral superior orbital rim advancements, and bitemporal widening via barrel-staving osteotomies. A, Frontal view before surgery. B, Frontal view after reconstruction. C, Superior view before surgery. D, Superior view after reconstruction. E, Frontal view at 2 years of age. F, Superior view at 2 years of age. G, Frontal view at 4 years of age. H, Inferior view at 4 years of age. (CONTINUED ON NEXT PAGE)

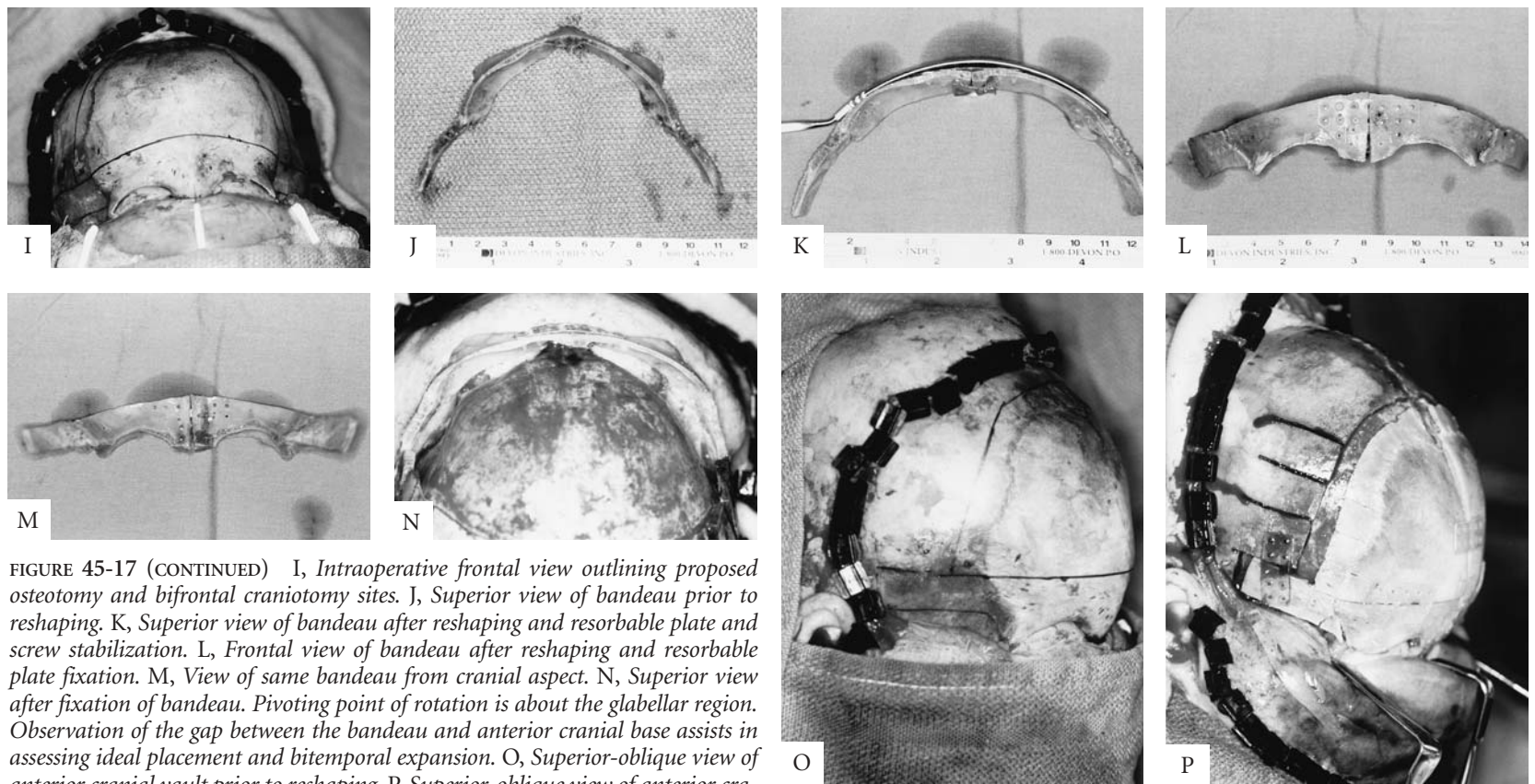


FIGURE 45-17 (CONTINUED) I, Intraoperative frontal view outlining proposed osteotomy and bifrontal craniotomy sites. J, Superior view of bandeau prior to reshaping. K, Superior view of bandeau after reshaping and resorbable plate and screw stabilization. L, Frontal view of bandeau after reshaping and resorbable plate fixation. M, View of same bandeau from cranial aspect. N, Superior view after fixation of bandeau. Pivoting point of rotation is about the glabellar region. Observation of the gap between the bandeau and anterior cranial base assists in assessing ideal placement and bitemporal expansion. O, Superior-oblique view of anterior cranial vault prior to reshaping. P, Superior-oblique view of anterior cranial vault after osteotomies, reshaping, and fixation. Reproduced with permission from Ghali GE et al.⁴⁶ p. 28–34.

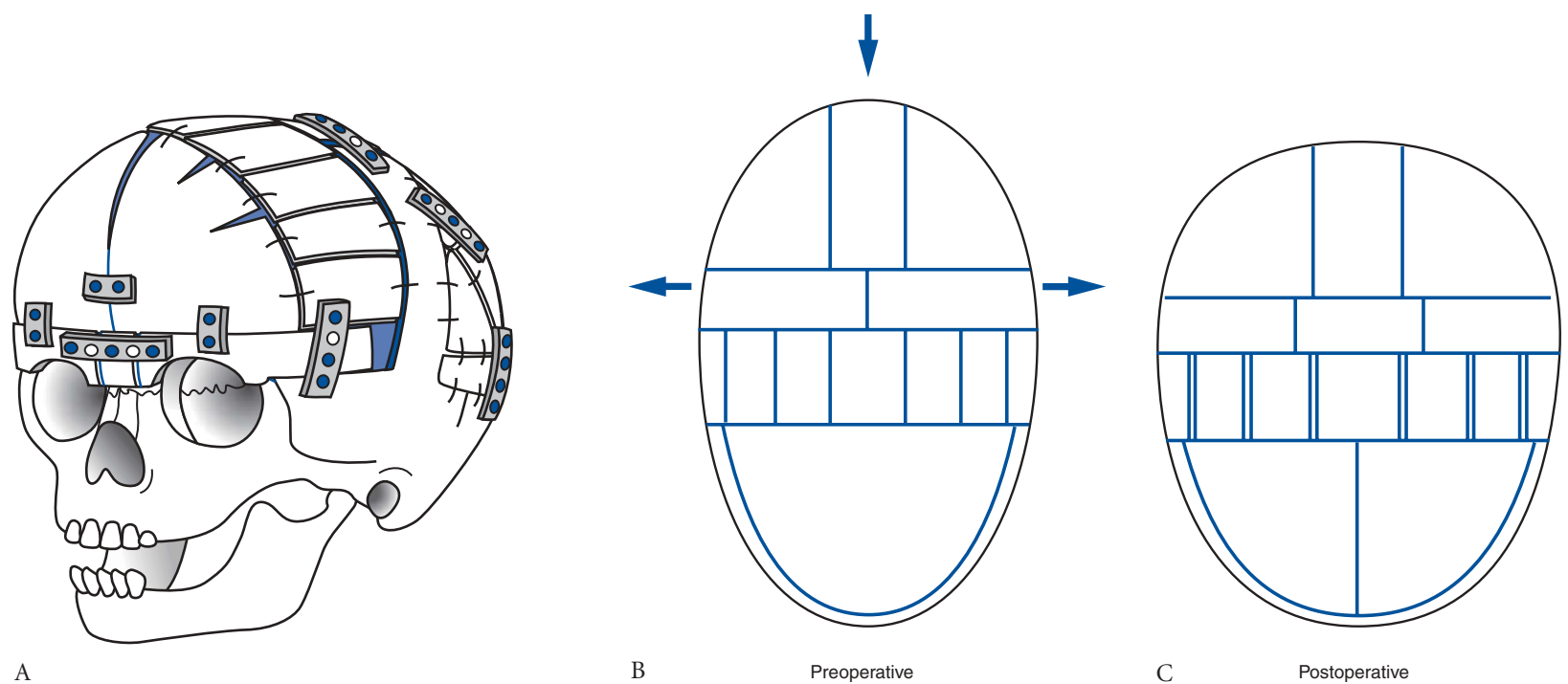


FIGURE 45-18 A child after total cranial vault and upper orbital osteotomies for the treatment of scaphocephaly. A, Forehead is symmetrically tilted back. The occiput is symmetrically tilted forward. The anterior-posterior dimension is thereby shortened and secured via resorbable plates and screws. Barrel-stave cuts are made laterally to widen the transverse dimension or the squamous portion of the temporal plates as osteotomized, interchanged, and stabilized with resorbable plates and screws. Superior view preoperatively (B) and postoperatively (C). Total cranial vault reshaping as well as orbital rim alteration is accomplished to increase the biparietal width and decrease the frontal and occipital prominences. Adapted from Ghali GE et al.⁴⁶ p. 35.

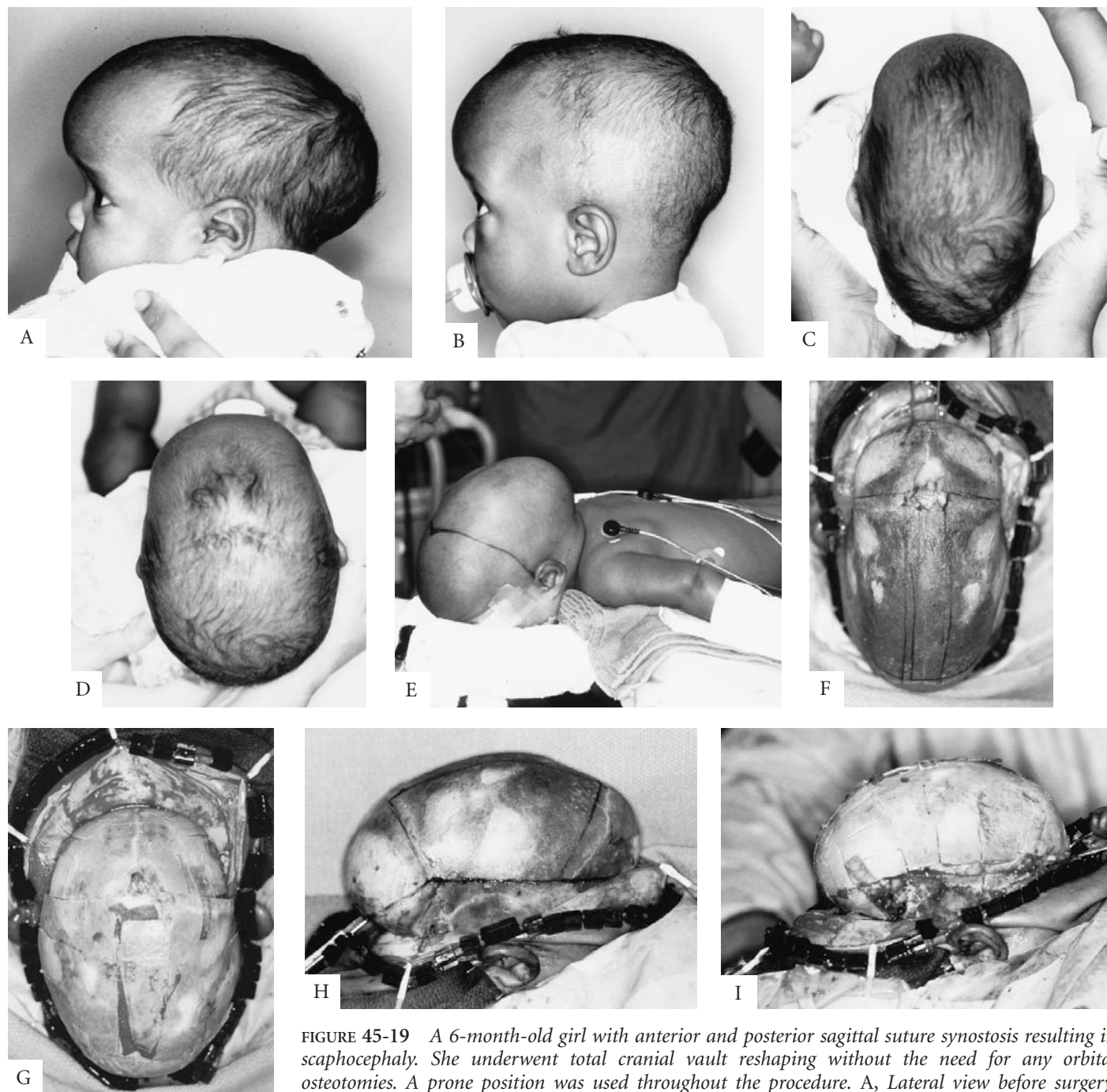


FIGURE 45-19 A 6-month-old girl with anterior and posterior sagittal suture synostosis resulting in scaphocephaly. She underwent total cranial vault reshaping without the need for any orbital osteotomies. A prone position was used throughout the procedure. A, Lateral view before surgery. B, Lateral view after reconstruction. C, Superior view before surgery. D, Superior view after reconstruction. E, Prone positioning is necessary and requires careful protection of both the airway and globes. F, Intraoperative superior view of proposed osteotomy sites for total cranial vault reshaping. G, Intraoperative superior view of the osteotomies, reshaping, and resorbable plate fixation. H, Intraoperative left lateral view prior to reshaping. I, Intraoperative left lateral view after osteotomies, reshaping, and resorbable plate fixation. Reproduced with permission from Ghali GE et al.⁴⁶ p. 36–40.

both approaches may be necessary. Unless a significant concomitant supraorbital deformity exists, we prefer to treat full sagittal suture stenosis (anterior and posterior) at one operative setting in the prone position

via a total cranial vault reshaping. For older children (older than 1 year) or children with a need for upper orbital reconstruction, we prefer the supine position at one operative setting or, rarely, in two stages,

with posterior reconstruction preceding anterior and orbital reconstruction by 4 to 6 months. Other centers have reported good results when routinely staging full sagittal synostosis.

Unilateral Lambdoid Synostosis

Many surgeons consider simple strip craniectomy of the involved suture or partial craniectomy of the region to be adequate treatment. More extensive vault craniectomy and reshaping are generally necessary. If improvements in cranial vault shape are required after 10 to 12 months of age, formal posterior cranial vault reshaping is performed.

Summary

In approximately 1 in 1,000 live births in the United States, an infant has some variant of a craniofacial deformity. If cleft lip and palate deformities are included, the incidence is even greater. Surgical management of these patients has been advocated to occur from the first few weeks after birth until well into the second decade. Many of these patients require multiple, staged procedures that involve movements of the bone and soft tissue from both the intracranial and extracranial approaches. The surgical approach to most of these congenital deformities was radically changed by techniques introduced to the United States by Paul Tessier of France in 1967. From his imaginative intracranial and extracranial approaches, numerous advances have been made that facilitate the biodegradable plating systems, which have improved the management of these complex craniomaxillofacial deformities.

References

- Moss ML. The pathogenesis of premature cranial synostosis in man. *Acta Anat (Basel)* 1959;37:351.
- Zeiger JS, Beaty TH, Hetmanski JB, et al. Genetic and environmental risk factors for sagittal craniosynostosis. *J Craniofac Surg* 2002;13:602–6.
- Brodsky L, Ritter-Schmidt DH, Holt L. Craniofacial anomalies: an inter-disciplinary approach. St. Louis (MO): Mosby Yearbook; 1989.
- Graham JM, de Saxe M, Smith DW. Sagittal craniosynostosis: fetal head constraint as one possible cause. *J Pediatr* 1979;95:747–50.
- Magge SN, Westerveid M, Pruzinsky T, Persing JA. Long-term neuropsychologic effects of sagittal craniosynostosis on child development. *J Craniofac Surg* 2002;13:99–104.
- Marchac D, Renier D. Treatment of craniosynostosis in infancy. *Clin Plast Surg* 1987;14:61–72.
- Cutting C, Grayson B, Bookstein F, et al. Computer-aided planning and evaluation of facial and orthognathic surgery. *Clin Plast Surg* 1986;13:449–62.
- Gault D, Brunelle F, Renier D, Marchac D. The calculation of intracranial volume using CT scans. *Childs Nerv Syst* 1988;4:271–3.
- Lo LJ. Craniofacial computer-assisted surgical planning and simulation. *Clin Plast Surg* 1994;21:501–16.
- Marsh JL, Gado M. The longitudinal orbital CT projection: a versatile image for orbital assessment. *Plast Reconstr Surg* 1983;71:308–17.
- Marsh JL, Vannier MW. Computer-assisted imaging in the diagnosis, management and study of dysmorphic patients. In: Vig KWL, Burdi AR, editors. *Craniofacial morphogenesis and dysmorphogenesis*. Ann Arbor: University of Michigan Press; 1988. p. 109–26.
- Marsh JL, Vannier MW. The “third” dimension in craniofacial surgery. *Plast Reconstr Surg* 1983;71:759–67.
- Marsh JL, Vannier MW. Three-dimensional surface imaging from CT scans for the study of craniofacial dysmorphology. *J Craniofac Genet Dev Biol* 1989;9:61–75.
- Marsh JL, Vannier MW, Stevens WG, et al. Computerized imaging for soft tissue and osseous reconstruction in the head and neck. *Clin Plast Surg* 1985;12:279–91.
- Marsh JL, Vannier MW, Bresina S, Hemmer KM. Application of computer graphics in craniofacial surgery. *Clin Plast Surg* 1986;13:441–8.
- Posnick JC, Bite U, Nakamo P. Comparison of direct and indirect intra-cranial volume measurements. In: *Proceedings of the 6th International Congress on Cleft Palate and Related Craniofacial Anomalies*. June 15–18, 1989.
- Posnick JC. Indirect intracranial volume measurements using CT scans: clinical applications for craniosynostosis. *Plast Reconstr Surg* 1992;89:34–45.
- Vannier MW, Marsh JL, Warren JO. Three dimension CT reconstruction images for craniofacial surgical planning and evaluation. *Radiology* 1984;150:179–84.
- Longacre JJ, Destafano GA, Holmstrand K. The early versus the late reconstruction of congenital hypoplasia of the facial skeleton and skull. *Plast Reconstr Surg* 1961;27:489–504.
- Oakes WJ. Craniosynostosis. In: Serafin D, Geargiade NG, editors. *Pediatric plastic surgery*. St. Louis (MO): C.V. Mosby Co.; 1984. p. 404–39.
- Seymour-Dempsey K, Baumgartner JE, Teichgraeber JF, et al. Molding helmet therapy in the management of sagittal synostosis. *J Craniofac Surg* 2002;13:631–35.
- Sinn DP, Ghali GE, Ortega M. Major craniofacial surgery. In: Levin DL, Morriss FC, editors. *Essentials of pediatric intensive care*. New York: Churchill-Livingstone; 1997. p. 636–43.
- Arndt EM, Travis F, Lefebvre A, Munro IR. Psychological adjustment of 20 patients with Treacher Collins syndrome before and after reconstructive surgery. *Br J Plast Surg* 1987;40:605–9.
- Barden RC, Ford ME, Jensen AG, et al. Effects of craniofacial deformity in infancy on the quality of mother-infant interaction. *Child Dev* 1989;60:819–24.
- Barden RC, Ford ME, Wilhelm W, et al. The physical attractiveness of facially deformed patients before and after craniofacial surgery. *Plast Reconstr Surg* 1988;82:229–35.
- Barden RC, Ford ME, Wilhelm W, et al. Emotional and behavioral reactions to facially deformed patients before and after craniofacial surgery. *Plast Reconstr Surg* 1988;82:409–18.
- Lafebvre A, Travis F, Arndt EM, Munro IR. A psychiatric profile before and after reconstructive surgery in children with Apert’s syndrome. *Br J Plast Surg* 1986;39:510–3.
- Arnaud E, Meneses P, Lajeunie E, et al. Postoperative mental and morphological outcome for nonsyndromic brachycephaly. *J Craniofac Surg* 2002;110:6–12.
- Warschausky S, Kay JB, Buchman S, et al. Health-related quality of life in children with craniofacial anomalies. *J Craniofac Surg* 2002;110:409–14.
- Marchac D. Forehead remodeling for craniosynostosis. In: Converse JM, McCarthy JG, Wood-Smith D, editors. *Symposium on diagnosis and treatment of craniofacial anomalies*. St. Louis (MO): C.V. Mosby Co.; 1979. p. 323.
- Edgerton MT, Jane JA, Berry FA, et al. The feasibility of craniofacial osteotomies in infants and young children. *Scand J Plast Reconstr Surg* 1974;8:164–8.
- Edgerton MT, Jane JA, Berry FA. Craniofacial osteotomies and reconstruction in infants and young children. *Plast Reconstr Surg* 1974;54:13–27.
- McCarthy JG, Epstein F, Sadove M, et al. Early surgery for craniofacial synostosis: an 8-

- year experience. *Plast Reconstr Surg* 1984;73:521–33.
34. Whitaker LA, Barlett SP, Schut L, Bruce D. Craniosynostosis: an analysis of the timing, treatment and complication in 164 patients. *Plast Reconstr Surg* 1987;80:195–212.
 35. Whitaker LA, Schut L, Kerr LP. Early surgery for isolated craniofacial dysostosis. *Plast Reconstr Surg* 1977;60:575–81.
 36. Cohen SR, Holmes RE. Immediate cranial vault reconstruction with bioresorbable plates following endoscopically assisted sagittal synostectomy. *J Craniofac Surg* 2002;13:578–84.
 37. Pietrzak WS. Critical concepts of absorbable internal fixation. *J Craniofac Surg* 2000;11:335–41.
 38. Pietrzak WS, Kumar M, Eppley BL. The influence of temperature on the degradation rate of lactosorb copolymer. *J Craniofac Surg* 2003;14:176–83.
 39. Jane JA, Park TS, Zide BM, et al. Alternative techniques in the treatment of unilateral coronal synostosis. *J Neurosurg* 1984;61:550–6.
 40. Mohr G, Hoffman HJ, Munro IR, et al. Surgical management of unilateral and bilateral coronal craniosynostosis: 21 years of experience. *Neurosurgery* 1978;2:83–92.
 41. Persing JA, Babler WJ, Jane JA, Duckworth PE. Experimental unilateral coronal synostosis in rabbits. *Plast Reconstr Surg* 1986;77:369–77.
 42. Hoffman HJ, Mohr G. Lateral canthal advancement of the supraorbital margins: a new corrective technique in the treatment of coronal synostosis. *J Neurosurg* 1976;45:376–81.
 43. Marchac D, Renier D, Jones BM. Experience with the “floating forehead.” *Br J Plast Surg* 1988;41:1–15.
 44. Shillito J, Matson DD. Craniosynostosis: a review of 519 surgical patients. *Pediatrics* 1968;41:819–53.
 45. Weinzweig J, Baker SB, Whitaker LA, et al. Delayed cranial vault reconstruction for sagittal synostosis in older children: an algorithm for tailoring the reconstructive approach to the craniofacial deformity. *J Craniofac Surg* 2002;110:397–408.
 46. Ghali GE, Sinn DP, Tantipawasasin S. Management of nonsyndromic craniosynostosis. *Atlas Oral Maxillofac Surg Clin N Am* 2002;10:1–41.

Craniofacial Dysostosis Syndromes: Staging of Reconstruction

Jeffrey C. Posnick, DMD, MD

Ramon L. Ruiz, DMD, MD

Paul S. Tiwana, DDS, MD, MS

Cranial sutures are a form of bone articulation in which the margins of the bones are connected by a thin layer of fibrous tissue. The cranial vault is composed of six major sutural areas and several minor sutures, which serve two critical functions during the postnatal period. Initially, the sutures allow head deformation during vaginal delivery as part of the birthing process. Later, during an infant's postnatal development, cranial vault sutures facilitate head expansion to accommodate propulsive brain growth.¹ Only small amounts of pressure (5 mm Hg) from the growing brain are required to stimulate bone deposition at the margins of a cranial bone.^{2,3} Under normal conditions, the brain volume will triple within the first year of life, and by age 2 years, the cranial capacity is four times that at birth.⁴ Under normal circumstances, closure of the cranial vault sutures occurs earlier than closure of the membranous facial bone sutures, which often remain patent until adulthood.

The term *craniosynostosis* is defined as a premature fusion of a cranial vault suture. With rare exception, this is an intrauterine event. A more accurate description of craniosynostosis may be a *congenital absence* of the cranial vault sutures. The result is

fusion of the bones adjacent to the suture and arrested sutural growth of the adjacent bones. The classic theory known as Virchow's law states that premature fusion of a cranial vault suture results in limited development of the skull perpendicular to the fused suture and a compensatory "overgrowth" through the sutures that remain open.⁵ The result is a dysmorphology with characteristics depending on the sutures affected, and potential neurologic consequences related to underlying brain compression. Most forms of craniosynostosis represent random, nonsyndromic malformations limited to the cranial vault and orbital regions. Management typically requires a combined neurosurgical and craniofacial approach for release of the involved suture and reshaping of the dysmorphic skeletal components. For additional discussion of the treatment of nonsyndromic craniosynostosis, see Chapter 45, "Nonsyndromic Craniosynostosis." Craniofacial dysostosis is the term applied to syndromal forms of craniosynostosis. These disorders are characterized by sutural involvement that not only includes the cranial vault but also extends into the skull base and midfacial skeletal structures. Craniofacial dysostosis syndromes have been

described by Carpenter, Apert, Crouzon, Saethre-Chotzen, and Pfeiffer.⁶ Although the cranial vault and cranial base are thought to be the regions of primary involvement, there is also significant impact on midfacial growth and development.^{7,8} In addition to cranial vault dysmorphology, patients with these inherited conditions exhibit a characteristic "total midface" deficiency that is syndrome specific and must be addressed as part of the staged reconstructive approach.

Functional Considerations

Brain Growth and Intracranial Pressure

If the rapid brain growth that normally occurs during infancy is to proceed unhindered, the cranial vault and base sutures must remain open and expand during phases of rapid growth, resulting in marginal ossification. In craniosynostosis, premature fusion of sutures causes limited and abnormal skeletal expansion in the presence of continued brain growth. Depending on the number and location of prematurely fused sutures, the growth of the brain may be restricted.^{2,9-11} In addition, abnormal cranial vault and midfacial morphology occurs as determined by

Virchow's law. If surgical release of the affected sutures and reshaping to restore a more normal intracranial volume and configuration are not performed, decreased cognitive and behavioral function is likely to be the end result.

Elevated intracranial pressure (ICP) is the most serious functional problem associated with premature suture fusion. A "beaten-copper" appearance along the inner table of the cranial vault seen on a plain radiograph or the loss of brain cisternae as observed on a computed tomography (CT) scan may suggest elevated ICP,¹² but these are considered soft radiographic findings.

Intracranial hypertension can be established invasively by means of a bur-hole craniotomy used to place either an epidural or intraparenchymal pressure sensor. Increased ICP is most likely to affect patients with great disparity between brain growth and intracranial capacity and may occur in as many as 42% of untreated children in whom more than one suture is affected.^{2,10,13} Unfortunately, there is no absolute agreement on what levels of ICP are normal at any given age in infancy and early childhood.

The clinical signs and symptoms related to elevated ICP may have a slow onset and be difficult to recognize in the pediatric population. Although standardized CT scans allow for indirect measurement of intracranial volume, it is not yet possible to use these studies to make judgments as to who requires craniotomy for decompression.^{14,15} Careful neurosurgical and pediatric ophthalmologic evaluation are critical components of the data gathering required to formulate a definitive treatment plan in a patient with craniosynostosis.

Vision

Untreated craniosynostosis with elevated ICP will cause papilledema and eventual optic nerve atrophy, resulting in partial or complete blindness. If the orbits are shallow (exorbitism) and the eyes are proptot-

ic (exophthalmos), as occurs in the craniofacial dysostosis syndromes, the cornea may be exposed and abrasions or ulcerations may occur. An eyeball extending outside of a shallow orbit is also at risk of trauma. If the orbits are extremely shallow, herniation of the globe itself may occur, necessitating emergency reduction followed by tarsorrhaphies or urgent orbital decompression.

Some forms of craniofacial dysostosis result in a marked degree of orbital hypertelorism, which may compromise visual acuity and restrict binocular vision. Divergent or convergent nonparalytic strabismus or exotropia occurs frequently and should be considered during the diagnostic evaluation. This may be the result of congenital anomalies of the extraocular muscles themselves. Paralytic or nonparalytic unilateral or bilateral upper eyelid ptosis also occurs with greater frequency with craniofacial dysostosis than in the general population.

Hydrocephalus

Hydrocephalus affects as many as 10% of patients with a craniofacial dysostosis syndrome.¹⁶⁻¹⁹ Although the etiology is often not clear, hydrocephalus may be secondary to a generalized cranial base stenosis with constriction of all the cranial base foramina, which impacts the patient's cerebral venous drainage and cerebrospinal fluid (CSF) flow dynamics. Hydrocephalus may be identified with the help of CT or magnetic resonance imaging (MRI) to document progressively enlarging ventricles. Difficulty exists in interpreting ventricular findings as seen on a CT scan especially when the skull and cranial base are brachycephalic. The skeletal dysmorphology seen in a child with severe cranial dysmorphology related to craniosynostosis may translate into an abnormal ventricular shape that is not necessarily related to abnormal CSF flow. Serial imaging and clinical correlation is indicated, and a great deal of clinical

judgment is often required in making these assessments.

Effects of Midface Deficiency on Airway

All newborn infants are obligate nasal breathers. Many infants born with a craniofacial dysostosis syndrome have moderate to severe hypoplasia of the midface as a component of their malformation. They will have diminished nasal and nasopharyngeal spaces with resulting increased nasal airway resistance (obstruction). The affected child is thus forced to breathe through the mouth. For a newborn infant to ingest food through the mouth requires sucking from a nipple to achieve negative pressure as well as an intact swallowing mechanism. The neonate with severe midface hypoplasia will experience diminished nasal airflow and be unable to accomplish this task and breathe through the nose at the same time.²⁰⁻²³ Complicating this clinical picture may be an elongated and ptotic palate and enlarged tonsils and adenoids. The compromised infant expends significant energy respiring, and this may push the child into a catabolic state (negative nitrogen balance). Failure to thrive results unless either nasogastric tube feeding is instituted or a feeding gastrostomy is placed. Evaluation by a pediatrician, pediatric otolaryngologist, and feeding specialist with craniofacial experience can help distinguish minor feeding difficulties from those requiring more aggressive treatment.

Sleep apnea of either central or obstructive origin may also be present. If the apnea is found to be secondary to upper airway obstruction based on a formal sleep study, a tracheostomy may be indicated. In rare situations, "early" midface advancement is useful to improve the airway and allow for tracheostomy decannulation. Central apnea may occur from poorly treated intracranial hypertension and other contributing factors. If this is the case, the condition may improve by reducing the intracranial

pressure to a normal range through cranio-orbital or posterior cranial vault decompression or expansion.

Dentition and Occlusion

The incidence of dental and oral anomalies is higher among children with craniofacial dysostosis syndromes than in the general population. In Apert syndrome in particular, the palate is high and constricted in width. The incidence of isolated cleft palate in patients with Apert syndrome approaches 30%.¹³ Clefting of the secondary palate may be submucous, incomplete, or complete. Confusion has arisen over whether the oral malformations and absence of teeth that are often characteristic of these conditions are a result of congenital or iatrogenic factors (eg, injury to dental follicles associated with early mid-face surgery). The midfacial hypoplasia seen in the craniofacial dysostosis syndromes often results in limited maxillary alveolar bone to house a full complement of teeth. The result is severe crowding, which often requires serial extractions in order to address the problem. An Angle Class III skeletal relationship in combination with anterior open bite deformity is typical.

Hearing

Hearing deficits are more common among patients with the craniofacial dysostosis syndromes than in the general population.²⁴ In Crouzon syndrome, conductive hearing deficits are common, and atresia of the external auditory canals may also occur. Otitis media is more common in Apert syndrome, although the exact incidence is unknown. Middle ear disease may be related to the presence of a cleft palate that results in eustachian tube dysfunction. Congenital fixation of the stapedial footplate is also believed to be frequent. The possibility of significant hearing loss is paramount in importance and should not be overlooked because of preoccupation with other more easily appreciated craniofacial findings.

Extremity Anomalies

Apert syndrome results in joint fusion and bony and soft tissue syndactyly of the digits of all four limbs.²⁴ These Apert-associated extremity deformities are often symmetric. Partial or complete fusion of the shoulder, elbow, or other joints is common. Broad thumbs, broad great toes, and partial soft tissue syndactyly of the hands may be seen in Pfeiffer syndrome, but these are variable features. Preaxial polysyndactyly of the feet may also be seen in Carpenter syndrome.

Morphologic Considerations

Examination of the patient's entire craniofacial region should be meticulous and systematic. The skeleton and soft tissues are assessed in a standard way to identify all normal and abnormal anatomy. Specific findings tend to occur in particular malformations, but each patient is unique. The achievement of symmetry and normal proportions and the reconstruction of specific esthetic units are essential to forming an unobtrusive face in a child born with a craniofacial dysostosis syndrome.

Frontoforehead Esthetic Unit

The frontoforehead region is dysmorphic in an infant with craniofacial dysostosis.^{25–30} Establishing normal position of the forehead is critical to overall facial symmetry and balance. The forehead may be considered as two separate esthetic components: the supraorbital ridge–lateral orbital rim region and the superior forehead (Figure 46-1A and B).^{31,32} The supraorbital ridge–lateral orbital rim region includes the glabella and supraorbital rim extending inferiorly down each frontozygomatic suture toward the infraorbital rim and posteriorly along each temporoparietal region. The morphology and position of the supraorbital ridge–lateral orbital rim region is a key element of upper facial esthetics. In a normal forehead, at the level of the frontonasal suture, an angle ranging from 90 to 110° is formed by the supraor-

bital ridge and the nasal bones when viewed in profile. Additionally, the eyebrows, overlying the supraorbital ridge, should be anterior to the cornea. When the supraorbital ridge is viewed from above, the rim should arc posteriorly to achieve a gentle 90° angle at the temporal fossa with a center point of the arc at the level of each frontozygomatic suture. The superior forehead component, about 1.0 to 1.5 cm up from the supraorbital rim, should have a gentle posterior curve of about 60°, leveling out at the coronal suture region when seen in profile.

Posterior Cranial Vault Esthetic Unit

Symmetry, form, and the appropriate intracranial volume of the posterior cranial vault are closely linked. Posterior cranial vault flattening may result from either a unilateral or bilateral lambdoidal synostosis, which is rare; previous craniectomy with reossification in a dysmorphic flat shape, which is frequent; or postural molding because of repetitive sleep positioning.³³ A short anterior–posterior cephalic length may be misinterpreted as an anterior cranial vault (forehead) problem when the occipitoparietal (posterior) skull represents the primary region of the deformity. Careful examination of the entire cranial vault is essential to defining the dysmorphic region so that appropriate therapy may be carried out.

Orbitonasozygomatic Esthetic Unit

In craniofacial dysostosis syndromes, the orbitonasozygomatic regional deformity is a reflection of the cranial base malformation. For example, in Crouzon syndrome when bilateral coronal suture synostosis is combined with skull base and midfacial deficiency, the orbitonasozygomatic region will be dysmorphic and consistent with a short (anterior–posterior) and wide (transverse) anterior cranial base.³⁴ In Apert syndrome, the nasal bones, orbits, and zygomas, like

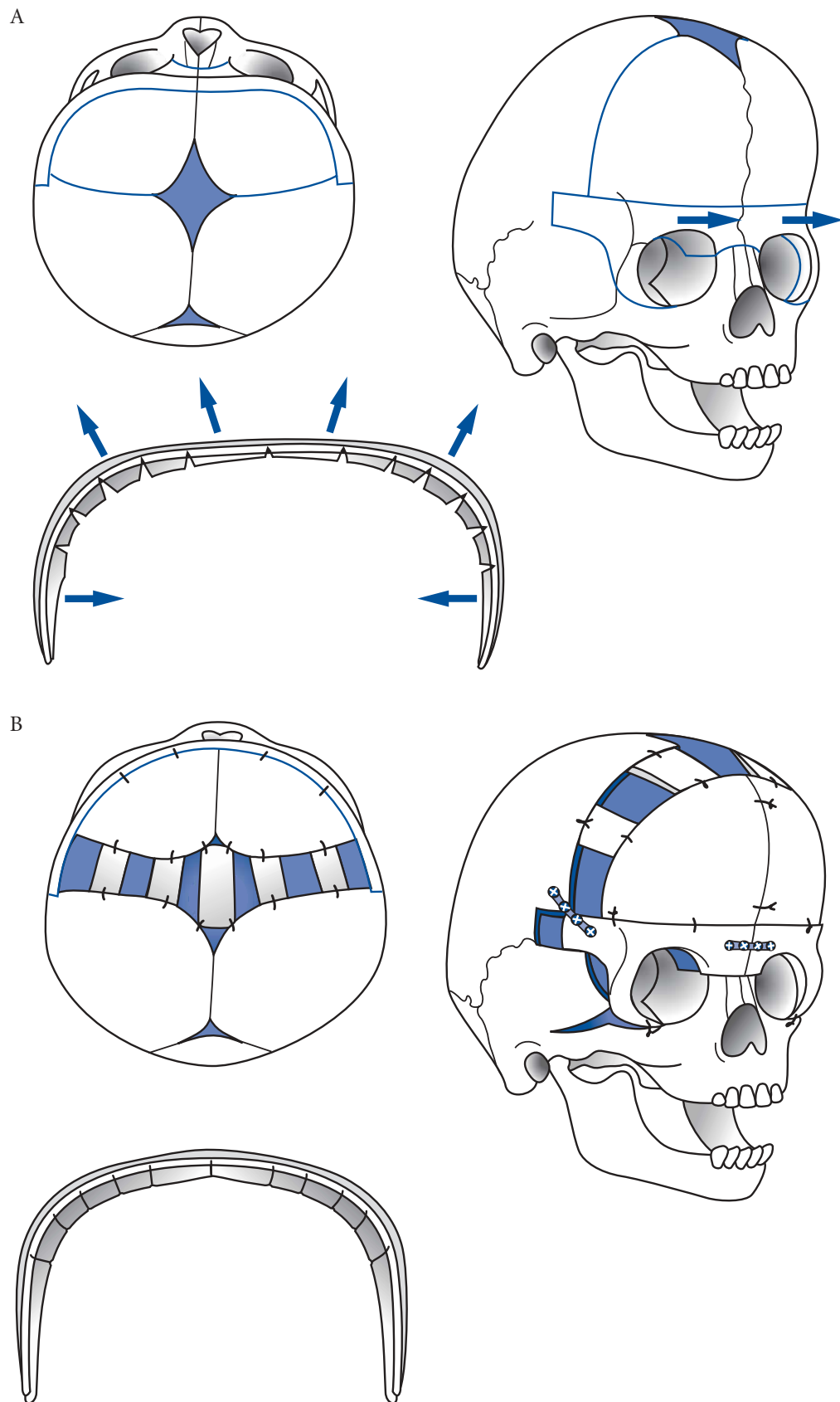


FIGURE 46-1 The craniofacial skeleton of a child with bilateral coronal synostosis before and after anterior cranial vault and three-quarter orbital osteotomies with reshaping. A, Site of osteotomies as indicated. B, After osteotomies and reshaping and fixation of the cranio-orbital regions. Adapted from Posnick JC.⁷⁶

the anterior cranial base, are transversely wide and horizontally short (retruded), resulting in a shallow hyperteloritic upper midface (zygomas, orbits, and nose).³⁴ Advancing the midface without simultaneously addressing the increased transverse width will not adequately correct the dysmorphology.³⁵

Maxillary-Nasal Base Esthetic Unit

In the craniofacial dysostosis patient with midface deficiency, the upper anterior face (nasion to maxillary incisor) is vertically short, and there is a lack of horizontal anterior-posterior (A-P) projection of the midface.^{36,37} These findings may be confirmed with cephalometric analysis that indicates a sella-nasion angle (SNA) below the mean value and a short upper anterior facial height (nasion to anterior nasal spine). The width of the maxilla in the dentoalveolar region is generally constricted with a high arched palate. In order to normalize the maxillonasal base region, multidirectional surgical expansion and reshaping are generally required. The maxillary lip-to-tooth relationship and occlusion are normalized through Le Fort I osteotomy and orthodontic treatment as part of the staged reconstruction.

Quantitative Assessment

A quantitative analysis of measurements taken from CT scans, surface anthropometry, cephalometric analysis, and dental casts is critical to data gathering for evaluation of craniofacial deformities.³⁸⁻⁴³ This analysis will confirm or refute clinical impressions, aid in the treatment planning of intraoperative skeletal movements and reshaping, and provide a framework for objective assessment of immediate and long-term results. These methods of assessment rely on the measurement of linear distances, angles, and proportions based on accurate, reliable, and reproducible anatomic landmarks found to be useful for patient evaluation.

CT Scan Analysis

The use of CT scans has clarified our appreciation of the dysmorphology of a child born with a craniofacial malformation.^{44,45} Accurate standardized points of reference have been identified in the cranio-orbitozygomatic skeleton based on axial CT images.^{42,43} Knowledge of differential facial bone growth patterns and normal measurement values can now be used to improve diagnostic accuracy, assist in the staging of reconstruction by understanding growth vectors, and offer the option of making intraoperative measurements that correlate with the preoperative CT scan measurements and ideal dimensions. This information can effectively guide the surgeon in the reconstruction of an individual with a craniofacial malformation and also allows for accurate postoperative reassessment.

Anthropometric Surface Measurements

Cross-sectional studies of the patterns of postnatal facial growth based on anthropometric surface measurements have been carried out in growing Caucasian children.^{38–41,46} This published material has proven useful in the quantitative evaluation and recognition of discrepancies in postnatal development in the head and face of patients with specific craniofacial syndromes. This is particularly useful when evaluating basic distances, angles, and proportions of the head, face, and orbits in patients affected with craniofacial dysostosis syndromes.

Cephalometric Analysis

Cephalometric radiography, first introduced by Broadbent in 1931, has been traditionally used to study the morphology and patterns of growth of the maxillofacial skeleton.⁴⁷ The large collection of normative data developed allows clinicians to monitor an individual's facial growth. The interpretation of cephalometric radiographs remains useful in the analysis of

facial heights and maxillary, mandibular, and chin positions and their relationships to one another; the cranial base; and the dentition.^{30,36,48,49} The lateral cephalometric radiograph offers an accurate view from the midsagittal plane if the facial skeleton being analyzed is relatively symmetric. Unfortunately, the number of anatomic landmarks that can be identified accurately in the cranio-orbitozygomatic region is limited because of the overlap of structures, which makes predictably locating these anatomic landmarks more difficult.

Surgical Management

Historic Perspectives: The Pioneers

The first recorded surgical approach to craniosynostosis was performed by Lannelongue in 1890⁵⁰ and Lane in 1892,⁵¹ who completed strip craniectomies of the involved sutures. Their aim was to control the problem of brain compression (intracranial hypertension) within a congenitally small cranial vault.

The classic neurosurgical techniques were refined over the ensuing decades and were geared toward resecting the synostotic sutures in the hope that the “released” skull would reshape itself and continue to grow in a normal and symmetric fashion.⁵² Strip craniectomy procedures were supposed to allow for creation of new suture lines at the site of the previous synostosis. With the realization that this goal was not achieved, attempts were made to surgically disassemble the involved cranial vault and then replace the pieces of calvaria as free grafts to shape the cranial vault. Problems with these methods included uncontrolled postoperative skull molding, resulting in reossification in dysmorphic configurations. In some other children, when extensive craniectomies were carried out, permanent skull defects remained.

After World War II, Gillies and Harrison reported experience with an extracranial Le Fort III osteotomy to improve the

anterior projection of the midface in an adult with Crouzon syndrome.⁵³ The early enthusiasm for this technique later turned to discouragement when the patient's facial skeleton relapsed to its preoperative status.

In 1967, Tessier described a new (intracranial–cranial base) approach to the management of Crouzon syndrome.⁵⁴ His landmark presentation and publications were the beginning of modern craniofacial surgery.^{55–63} To overcome the earlier problems encountered by Gillies and Harrison, Tessier developed an innovative basic surgical approach that included new locations for the Le Fort III osteotomy, a combined intracranial–extracranial (cranial base) approach, use of a coronal (skin) incision to expose the upper facial bones, and use of an autogenous bone graft. He also applied an external fixation device to help maintain bony stability until healing had occurred.

The concept of simultaneous suture release for craniosynostosis combined with cranial vault reshaping in infants was initially discussed by Rougerie and colleagues⁶⁴ and later refined by Hoffman and Mohr in 1976.⁶⁵ Whitaker and others proposed a more formal anterior cranial vault and orbital reshaping procedure for unilateral coronal synostosis in 1987,⁶⁶ and then Marchac and colleagues published their experience with the “floating forehead” technique for simultaneous suture release and anterior cranial vault and orbital reshaping to manage bilateral coronal synostosis in infancy.³²

The widespread use of cranial bone as a graft option has virtually eliminated the need for rib and hip grafts when autogenous bone replacement is required in cranio-orbitozygomatic procedures. This represents another of Tessier's contributions to craniofacial surgery that has stood the test of time.

In 1968, Luhr introduced the use of small metal plates and screws to stabilize maxillofacial fractures and then osteotomies.⁶⁷ In current practice, the use of internal plate and screw fixation is the

preferred form of stabilization for the three-dimensional reconstruction of multiple osteotomized bone segments and grafts. The development of resorbable plates and screws as a form of stable fixation continues to evolve as a fixation alternative, especially for use in growing bones and for immobilization of onlay bone grafts.⁴⁷ The reliability of resorbable fixation to withstand the compressive (relapse) forces after total midfacial advancement procedures and the normal loading forces of occlusion during the active bone healing phase leave it a less desirable fixation option for the craniofacial dysostosis patient.

More recently, the intraoperative placement of a distraction device as a method of achieving advancement of the midface in patients with severe forms of craniofacial hypoplasia has been added to the surgeon's armamentarium.⁴⁷ If used, distraction osteogenesis is not applied until after successful completion of standard osteotomies and disimpaction in the operating room. The distraction apparatus is either anchored to the "stable" skeleton internally or externally (through a "halo" head frame) and then to the palatal (intraoral) and infraorbital rims or zygomatic buttresses. Advancement of the "total midface" can then proceed. Once adequate (midface) advancement has been accomplished (on an outpatient basis) over a period of several weeks, the patient is generally returned to the operating room for stabilization and final reconstruction. The final reconstruction may require additional segmental osteotomies, bone grafting, or placement of plate and screw fixation. The "distraction approach" to the midface deformity is a labor-intensive, technique-specific, and relatively crude method of accomplishing horizontal advancement with difficulty in controlling the vertical dimension of the midface and without the ability to alter the transverse deformity or deficiency. In our opinion, the current level of distraction technology leaves it an

adjunctive rather than primary technique. It is most useful when the midfacial hypoplasia is severe to the extent that conventional techniques cannot reliably allow the immediate (in the operating room) desired advancement and when complex vertical and transverse reconstruction is not required.

Philosophy Regarding Timing of Intervention

In considering the timing and type of intervention the experienced surgeon will take several biologic realities into account: the natural course of the malformation (ie, Is the dysmorphology associated with Crouzon syndrome progressively worsening or is it a nonprogressive craniofacial deformity?); the tendency toward growth restriction of an operated bone (esthetic unit) that has not yet reached maturity (ie, we know that operating on a palate of a child born with a cleft in infancy will cause scarring and later result in maxillary hypoplasia in a significant percentage of individuals); and the uncertain relationship between the underlying growing viscera (ie, brain or eyes) and the congenitally affected and surgically altered skeleton (ie, If the cranial vault is not surgically expanded by 1 year of life in a patient with multiple suture synostosis, will brain compression occur?).

In attempting to limit functional impairment and also achieve long-term ideal facial esthetics, an essential question the surgeon must ask is, "During the course of craniofacial development, does the operated-on facial skeletal of the child with craniofacial dysostosis tend to grow abnormally, resulting in further distortions and dysmorphology, or are the initial positive skeletal changes (achieved at operation) maintained during ongoing growth?" Unfortunately, the theory that craniofacial procedures carried out early in infancy will "unlock growth" has not been documented through the scientific method.⁶⁸⁻⁷⁰

Incision Placement

For exposure of the craniofacial skeleton above the Le Fort I level, the approach used is the coronal (skin) incision. This allows for a relatively camouflaged access to the anterior and posterior cranial vault, orbits, nasal dorsum, zygomas, upper maxilla, pterygoid fossa, and temporomandibular joints. For added cosmetic advantage, placement of the coronal incision more posteriorly on the scalp and with postauricular rather than preauricular extensions is useful. When exposure of the maxilla at the Le Fort I level is required, a circumvestibular maxillary intraoral incision is used. Unless complications occur that warrant unusual exposure, no other incisions are required for managing any aspect of the craniofacial dysostosis patient's reconstruction. These incisions (coronal [scalp] and maxillary [circumvestibular]) may be reopened as needed to further complete the patient's staged reconstruction.

Management of Cranial Vault Dead Space

The management of the dead space that results with cranial vault or cranial base expansion is critical to limiting complications. Dead space within the cranial vault after cranial expansion is managed by being gentle to the tissues, achieving good hemostasis, closure of tissue layers, placement of bone grafts, the stable fixation of osteotomy segments, and obliteration (of dead space) with soft tissue flaps or grafts when indicated.

Expansion of the cranial vault with forward advancement of the anterior cranial base, orbits, and midface results in both extradural (retrofrontal) dead space and a communication of the anterior fossa with the nasal cavity.⁷¹ Dead space within the anterior cranial vault and the communication of the frontal fossa with the nasal cavity across the anterior skull base may result in hematoma formation, CSF

leakage, infection, and fistula formation.^{72,73} Management of this expanded space in the anterior cranial fossa following frontofacial or forehead advancement remains controversial. Relatively rapid filling of the expanded intracranial space by the frontal lobes has been documented in infants and young children when the expansion remains in a physiologic range.^{71,74} This observation supports the conservative management of retrofrontal dead space in younger patients. More gradual and less complete filling is thought to occur in older children and adults. If so, this may be particularly troublesome when the anterior fossa dead space communicates directly with the nasal cavity. When possible, closing off the nasal cavity from the cranial fossa at the time of operation is preferred. Insertion of a pericranial flap can help to separate the cavities and at the same time obliterate dead space. The use of fibrin glue to seal the anterior cranial base also provides a temporary repair between the cavities, allowing time for the reepithelialization of the nasal mucosa.⁷⁵ When feasible, after midface advancement the anterior skull base is reconstructed (ie, bone grafts) to facilitate healing across the skull base to limit CSF leakage and prevent fistula formation. Until the torn nasopharyngeal mucosa heals, communication between the nasal cavity and cranial fossa is a potential for leakage (air, fluid, bacteria) and nasocranial fistula formation. To prevent this, postoperative endotracheal intubation may be extended for 3 to 5 days and bilateral nasopharyngeal airways may be placed after extubation. In addition, sinus precautions and restriction of nose blowing further limit reflux (nose to cranial fossa) of air and fluid during the postoperative period. All of these maneuvers are aimed at avoiding a pressure gradient and will facilitate sealing of the intracranial cavity from the upper aerodigestive tract. When anterior cranial vault reconstruction is performed and aerated frontal sinuses

are present, management of the sinus is by either cranialization or obliteration.

When a craniofacial dysostosis patient is to undergo intracranial volume expansion as part of the craniofacial procedure and they also require hydrocephalus management, the potential for problems increases. Complications may arise from excessive CSF drainage (“overshunting”). With overshunting there is decreased brain volume and dead space remains. Fronto-orbital advancement and cranial vault expansion procedures should be carefully staged with ventriculoperitoneal (VP) shunting procedures. Ultimately, the decision regarding the sequencing of shunting procedures is based on neurologic findings and the neurosurgeon’s judgement. In a patient with a VP shunt in place before the surgery, careful neurosurgical evaluation, including CT scanning of the ventricular system, is carried out to confirm that the shunt is functioning appropriately.

Soft Tissue Management

A layered closure of the coronal incision (galea and skin) optimizes healing and limits scar widening. Resuspension of the midface periosteum to the temporalis fascia in a superior and posterior direction facilitates redraping of the soft tissues. Each lateral canthus should be adequately suspended or reattached in a superior–posterior direction to the lateral orbital rim. The use of chromic gut for closure of the scalp skin in children may be used to obviate the need for postoperative suture or staple removal.

Crouzon Syndrome

Primary Cranio-orbital Decompression: Reshaping in Infancy

The initial treatment for Crouzon syndrome generally requires bilateral coronal suture release and simultaneous anterior cranial vault and upper orbital osteotomies with reshaping and advancement (see Figure 46-1).^{76–79} Our preference is to carry

this out when the child is 9 to 11 months of age unless clear signs of increased intracranial pressure are identified earlier in life (Figure 46-2). Reshaping of the upper three-quarters of the orbital rims and supraorbital ridges is geared toward decreasing the bitemporal and anterior cranial base width, with simultaneous horizontal advancement to increase the A-P dimension. This also increases the depth of the upper orbits, with some improvement of eye proptosis. The overlying forehead is then reconstructed according to morphologic needs. A degree of overcorrection is preferred at the level of the supraorbital ridge when the procedure is carried out in infancy. In our opinion, by allowing additional growth to occur (waiting until the child is 9 to 11 months old), the reconstructed cranial vault and upper orbital shape is better maintained with less need for repeat craniotomy procedures but without risking compression of the underlying brain.

The goals at this stage are to provide increased intracranial space in the anterior cranial vault for the brain; to increase the orbital volume, which allows the eyes to be positioned more normally for better protection from exposure; and to improve the morphology of the forehead and upper orbits.

A postauricular coronal (scalp) incision is made, and the anterior scalp flap is elevated along with the temporalis muscle in the subperiosteal plane. Bilateral circumferential periorbital dissection follows, with detachment of the lateral canthi, but with preservation of the medial canthi and nasolacrimal apparatus to the medial orbital walls. The subperiosteal dissection is continued down the lateral and infraorbital rims to include the anterior aspect of the maxilla and zygomatic buttress. The neurosurgeon then completes the craniotomy to remove the dysmorphic anterior cranial vault. With protection of the frontal and temporal lobes of the brain (remaining anterior to each olfactory bulb), safe direct

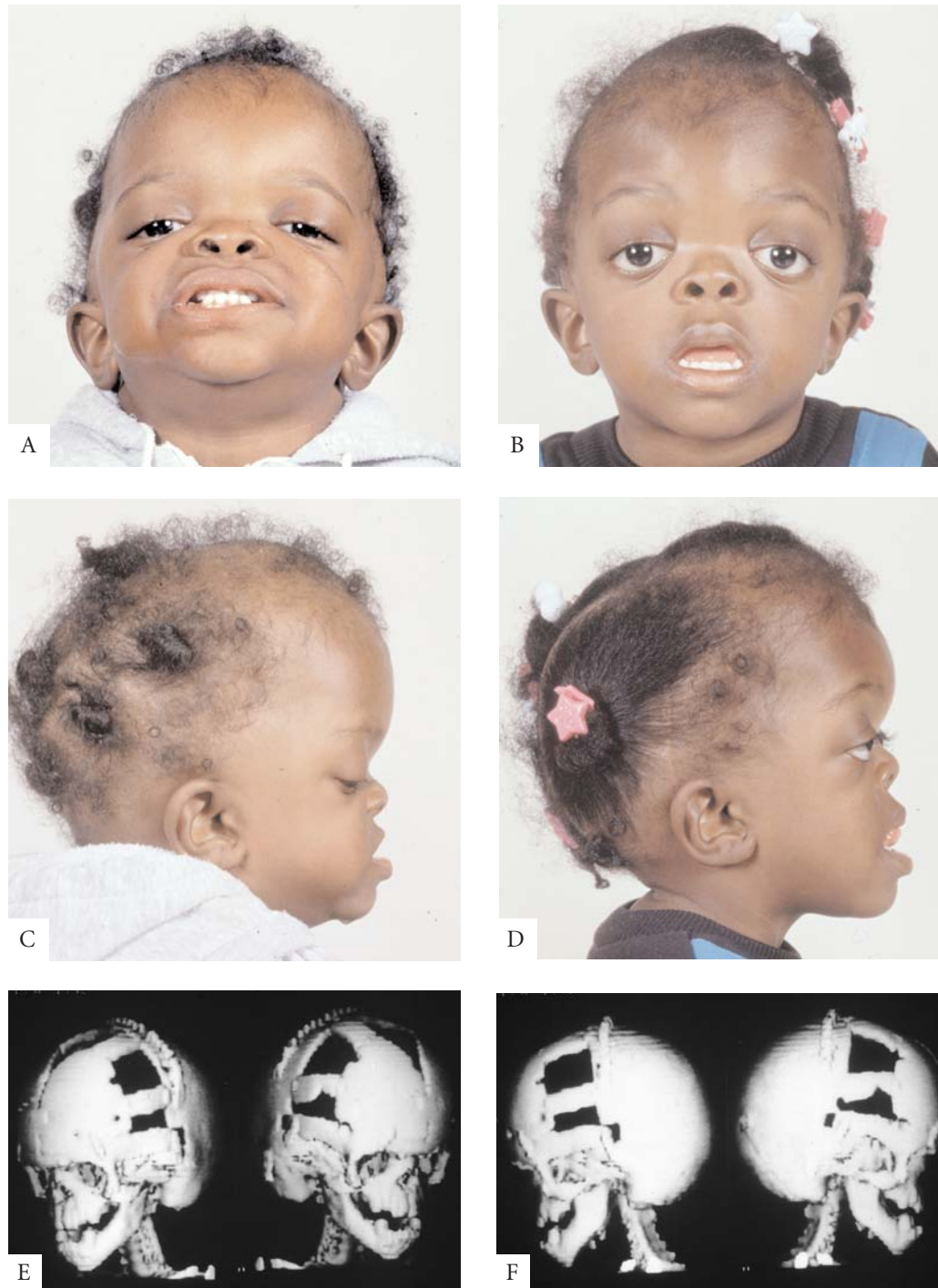


FIGURE 46-2 An 18-month-old girl with brachycephaly and midface deficiency with a mild degree of papilledema was referred for evaluation. She was found to have bilateral coronal synostosis and midface hypoplasia without extremity anomalies. The diagnosis of Crouzon syndrome was made. She underwent cranio-orbital reshaping (see Figure 46-1). Several months later, a ventriculoperitoneal shunt was placed for management of hydrocephalus. Further staged reconstruction will include a total midface advancement procedure later in childhood followed by orthodontic treatment and orthognathic surgery in the early teenage years. A, Frontal view before surgery. B, Frontal view at 3 years of age, 1.5 years after undergoing cranio-orbital decompression and reshaping. C, Profile view before surgery. D, Profile view at 3 years of age, 1.5 years after undergoing first-stage cranio-orbital decompression and reshaping. E and F, Three-dimensional CT scan views of craniofacial skeleton, just 1 week after cranio-orbital reshaping with advancement. Reproduced with permission from Posnick JC. Crouzon syndrome: evaluation and staging of reconstruction. In: Posnick JC, editor. *Craniofacial and maxillofacial surgery in children and young adults*. Philadelphia (PA): W.B. Saunders Co.; 2000. p. 275.

visualization of the anterior cranial base and orbits is possible at the time of orbital osteotomies.

The orbital osteotomies are then completed across the orbital roof and superior aspect of the medial orbital walls, laterally through the lateral orbital walls and inferiorly just into the inferior orbital fissures. The three-quarter orbital osteotomy units, with their tenon extensions, are removed from the field. The orbital units are reshaped and reinserted into a preferred position. Orbital depth is thereby increased, and global proptosis is reduced. Fixation is generally achieved with 28-gauge interosseous wires or suture at each infraorbital rim and with plates and titanium or resorbable screws at the tenon extensions and frontonasal regions.

The removed calvaria is cut into segments, which are placed individually to achieve a more normally configured anterior cranial vault. The goal of reshaping is to narrow the anterior cranial base and orbital width slightly and provide more forward projection and overall normal morphology.

Repeat Craniotomy for Additional Cranial Vault Expansion and Reshaping in Young Children

After the initial suture release, decompression, and reshaping are carried out during infancy, the child is observed clinically at intervals by the craniofacial surgeon, pediatric neurosurgeon, pediatric ophthalmologist, and developmental specialist and undergoes interval CT scanning. Should signs of increased ICP develop, urgent brain decompression with cranial vault expansion and reshaping is performed.⁴⁷ When increased ICP is suspected, the location of brain compression influences for which region of the skull further expansion and reshaping is planned.

If the brain compression is judged to be anterior, then further anterior cranial vault and upper orbital osteotomies with reshaping

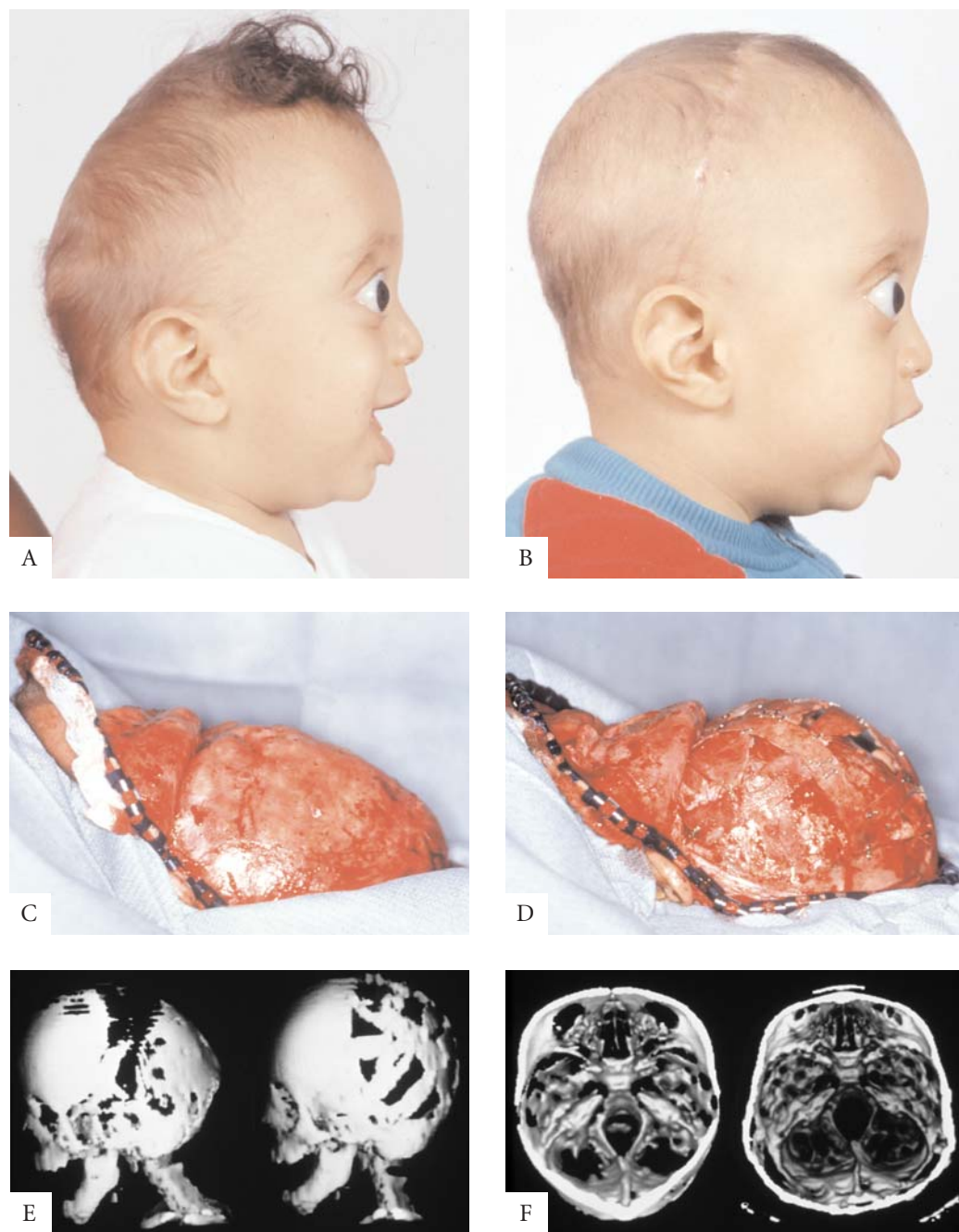


FIGURE 46-3 A child with Crouzon syndrome is shown at 10 months of age. His deformities are characterized by mild bilateral coronal and marked bilateral lambdoid synostosis in combination with midface deficiency. He has diminished intracranial volume, resulting in brain compression. The orbits are shallow with resulting eye proptosis, and the midface is deficient with malocclusion. He is shown before and after undergoing posterior cranial vault decompression and reshaping to expand the intracranial volume. He later underwent placement of a ventriculoperitoneal shunt for management of hydrocephalus. He will require a total midface advancement (monobloc) with further anterior cranial vault reshaping after 5 years of age. This will be followed by orthognathic surgery in combination with orthodontic treatment in the teenage years. A, Profile view before surgery. B, Profile view after posterior cranial vault reconstruction. C, Intraoperative lateral view of cranial vault (patient in prone position) as seen with posterior scalp flap elevated. D, Same intraoperative view after posterior cranial vault decompression, reshaping, and fixation of bone segments with microplates and screws. E, Comparison of three-dimensional CT scan views before and after reconstruction. F, Comparison of three-dimensional CT scan views of cranial base before and after reconstruction. Reproduced with permission from Posnick JC. *The craniofacial dysostosis syndromes: secondary management of craniofacial disorders.* *Clin Plast Surg* 1997;24:429.

ing and advancement are carried out. The technique is similar to that described previously.^{47,78} If the problem is posterior compression, expansion of the posterior cranial vault, with the patient in the prone position, is required (Figure 46-3).

The “repeat” craniotomy carried out for further decompression and reshaping in the child with Crouzon syndrome is often complicated by brittle cortical bone (which lacks a diploic space and contains sharp spicules piercing the dura), the presence of previously placed fixation devices in the operative field (eg, Silastic sheeting, metal clips, stainless steel wires, plates, and screws), and convoluted thin dura compressed against (or herniated into) the inner table of the skull. All of these issues result in a greater potential for dural tears during the calvarectomy than would normally occur during the primary procedure. A greater potential for morbidity should be anticipated when re-elevating the scalp flap, dissecting the dura free of the inner table of the skull and cranial base, and then removing the cranial vault bone.

Management of “Total Midface” Deformity in Childhood

The type of osteotomies selected to manage the “total midface” deficiency or deformity and residual cranial vault dysplasia should depend on the extent and location of the presenting dysmorphology rather than on a fixed approach to the midface malformation.^{47,53–57,78–84} The selection of a monobloc (with or without additional orbital segmentation), facial bipartition (with or without additional orbital segmental osteotomies), or Le Fort III osteotomy to manage the basic horizontal, transverse, and vertical orbital, and upper midface deficiencies or deformities in a patient with Crouzon syndrome depends on the patient’s presenting midface and anterior cranial vault morphology. The observed dysmorphology is dependent on the original malformation, the previous procedures carried out, and the effects of ongoing growth (Figures 46-4 and 46-5).

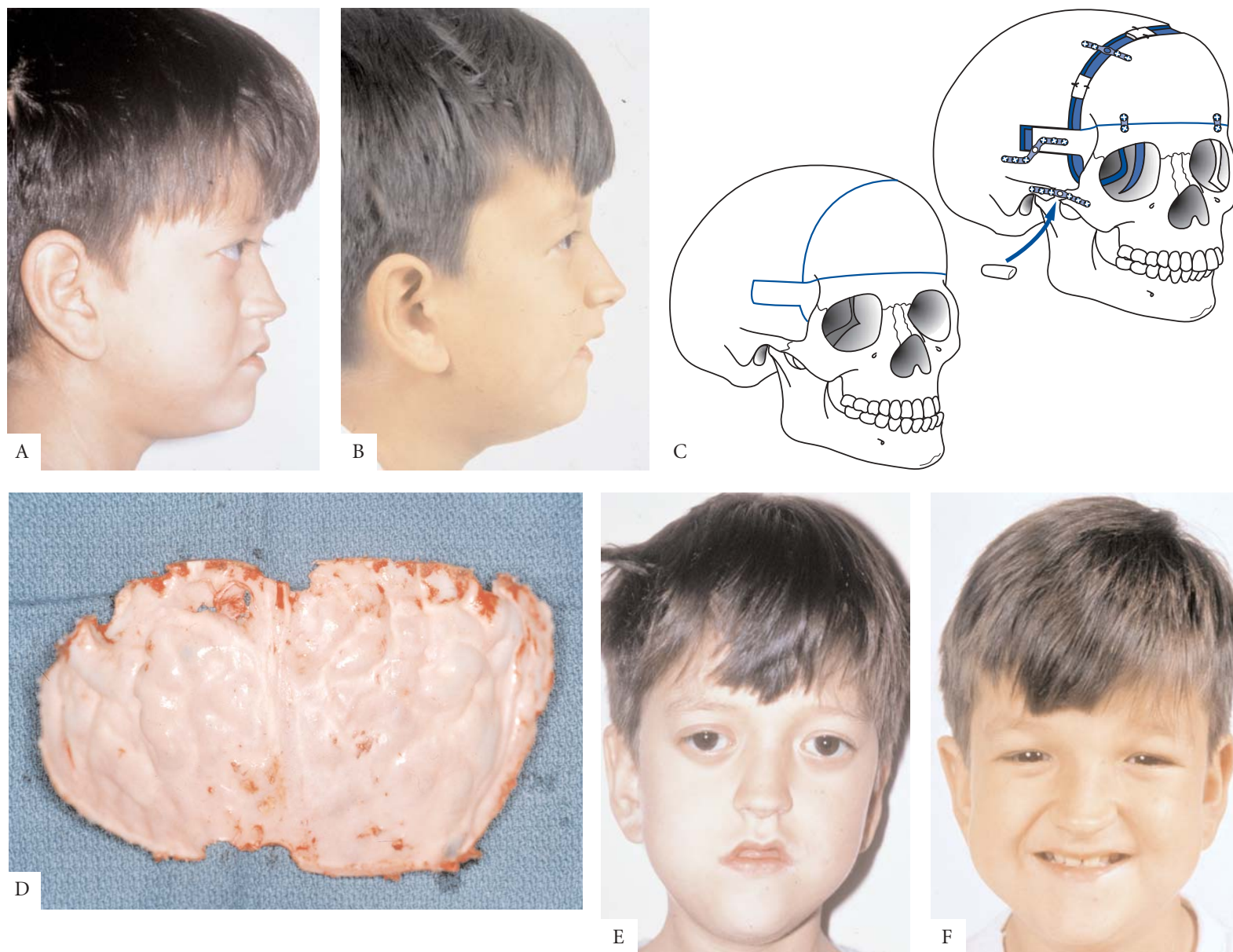


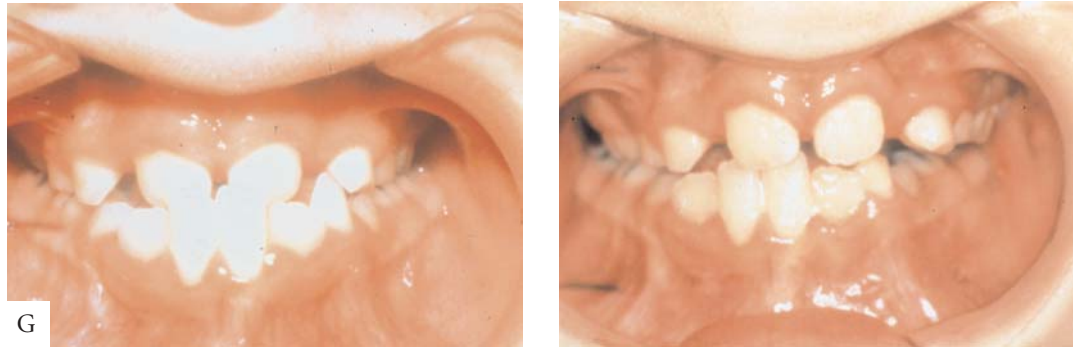
FIGURE 46-4 A child at 8 years of age with Crouzon syndrome who underwent a limited first-stage cranio-orbital procedure at 6 weeks of age. He then underwent anterior cranial vault and monobloc (orbits and midface) osteotomies with advancement. A, Profile view before monobloc procedure. B, Profile view after reconstruction. C, Craniofacial morphology before and after anterior cranial vault and monobloc osteotomies with advancement as carried out. Osteotomy locations indicated. Stabilization with cranial bone grafts and miniplates and screws. D, View of inner surface of frontal bones after bifrontal craniotomy. Compression of brain against inner table has resulted in resorption of the inner skull. This is an indication of long-standing increased intracranial pressure. E, Frontal view before surgery. F, Frontal view after reconstruction. (CONTINUED ON NEXT PAGE)

When evaluating the upper and midface in a child born with Crouzon syndrome, if the supraorbital ridge is in good position when viewed from the sagittal plane (the depth of the upper orbits is adequate), the midface and forehead have a normal arc of rotation in the transverse plane (not concave), and the root of the nose is of normal width (minimal orbital hypertelorism),

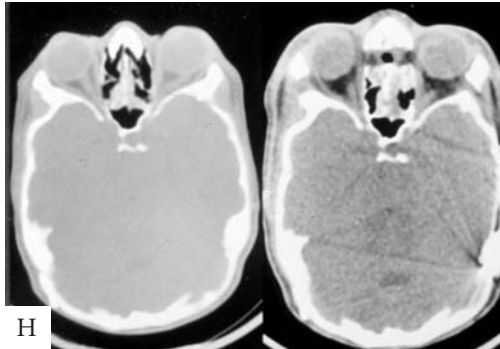
there is little need to reconstruct this region (the forehead and upper orbits) any further. In such patients, the basic residual midface deformity is in the lower half of the orbits, zygomatic buttress, and maxilla. If so, the deformity may be effectively managed using an extracranial Le Fort III osteotomy.

If the supraorbital ridges, anterior cranial base, zygomas, nose, lower orbits, and

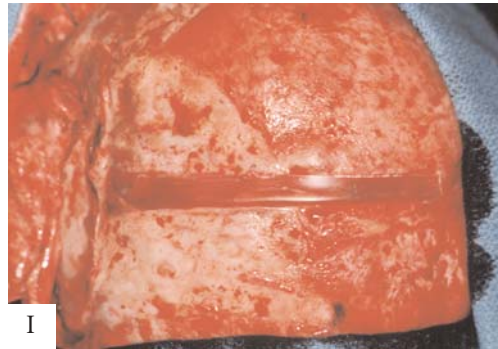maxilla all remain deficient in the sagittal plane (horizontal retrusion), then a monobloc osteotomy is indicated (see Figures 46-4 and 46-5). In these patients, the forehead is generally flat and retruded and will also require reshaping and advancement. If upper midface hypertelorism (increased transverse width) and midface flattening (horizontal retrusion) with loss



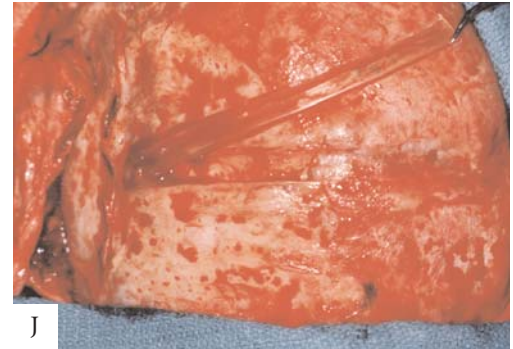
G



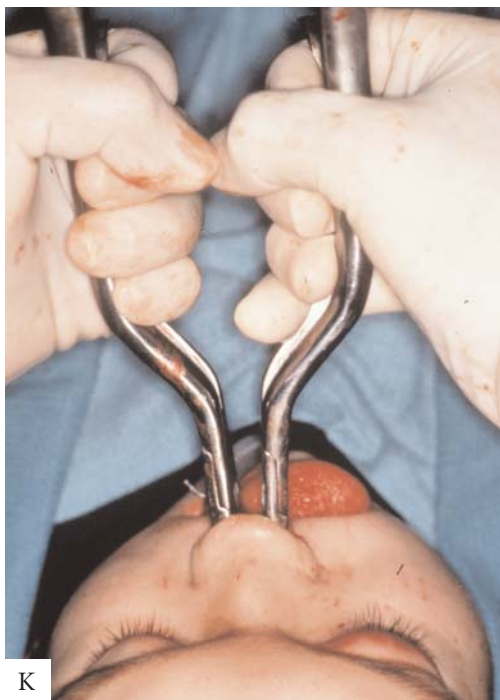
H



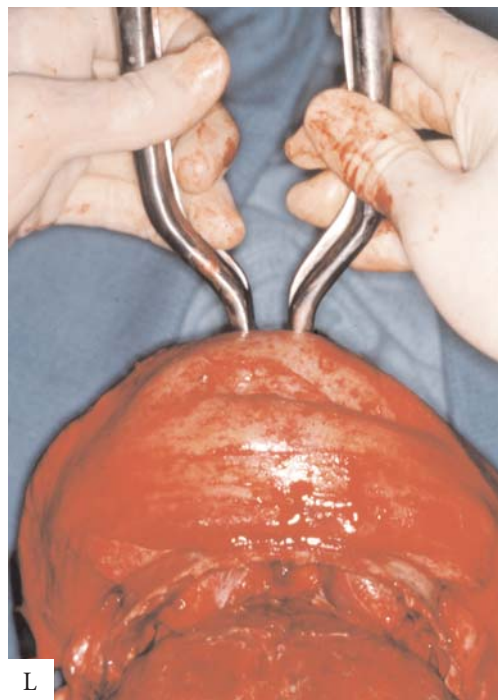
I



J



K



L

FIGURE 46-4 (CONTINUED) G, Occlusal views before and after reconstruction. H, Comparison of axial CT slices through midorbits before and after reconstruction, indicating resulting increased intraorbital depth and decreased proptosis achieved. I, Intraoperative bird's-eye lateral view of cranial vault demonstrating Silastic strip that had been placed by the neurosurgeon when the patient was 2 months of age (8 years earlier). J, Removing the Silastic strip along the sphenoid wing region is difficult due to bone overgrowth. K, Intraoperative view of (Rowe) forceps in nose and mouth after monobloc osteotomy but before disimpaction. L, Same view but with coronal incision turned down, indicating degree of advancement at supraorbital ridge level after disimpaction. (CONTINUED ON NEXT PAGE)

of the normal facial curvature (concave arc) are also present, then the monobloc unit is split vertically in the midline (facial bipartition), a wedge of interorbital (nasal and ethmoidal) bone is removed, and the orbits and zygomas are repositioned medially while the maxilla at the palatal level is

widened. The facial bipartition is rarely required in Crouzon syndrome, but the monobloc is. When a monobloc or facial bipartition osteotomy is carried out as the "total midface" procedure, additional segmentation of the upper and lateral orbits for reconstruction may also be required to

normalize the morphology of the orbital esthetic units.

For most patients, a surgeon's attempt to simultaneously adjust the orbits and idealize the occlusion using the Le Fort III, monobloc, or facial bipartition osteotomy in isolation, without completing a separate

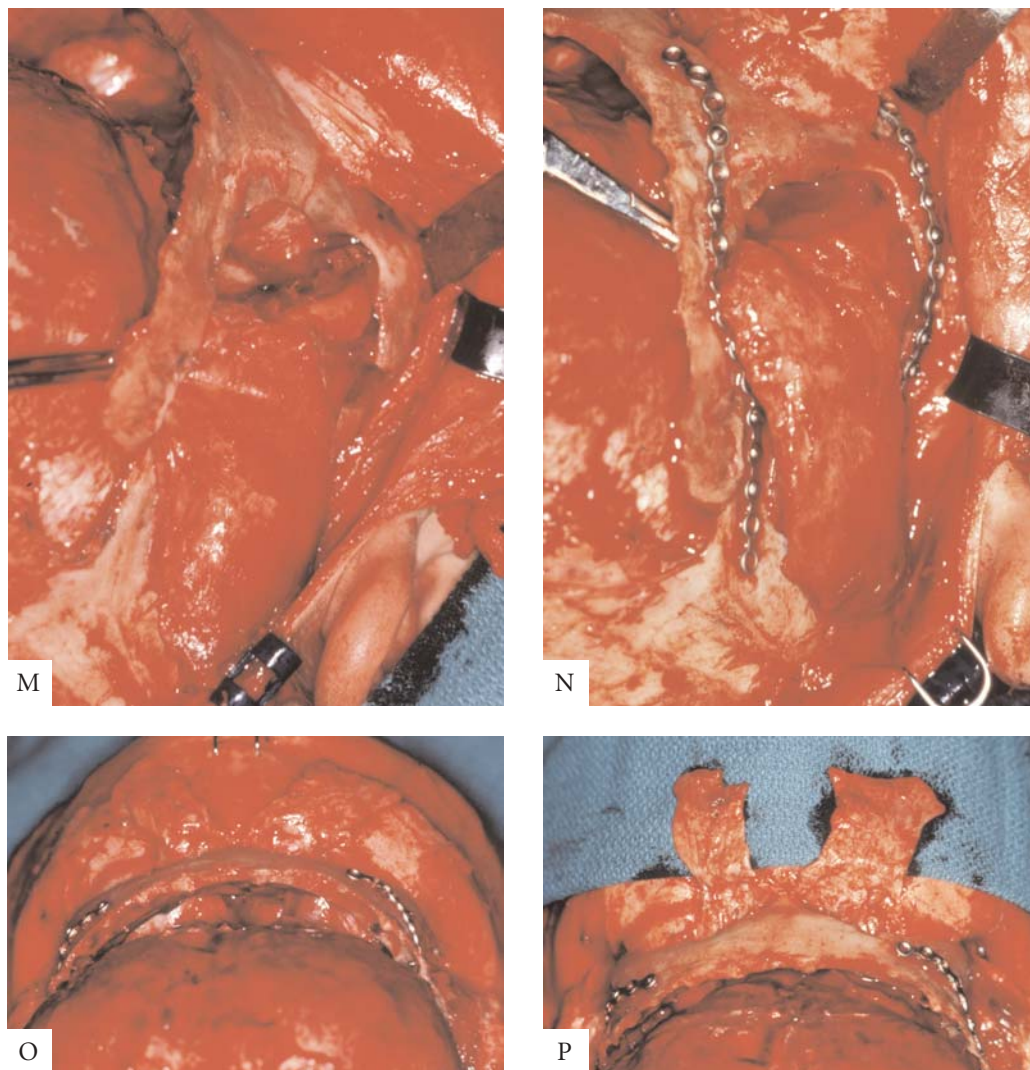


FIGURE 46-4 (CONTINUED) M, Lateral view of zygomatic arch and tenon extension of supraorbital rim after monobloc advancement just before miniplate fixation. N, Same view after miniplate fixation of zygomatic arch and tenon extension. O, Bird's-eye view of stabilized monobloc unit after advancement. There is increased intracranial volume (dead space) in the anterior cranial vault for brain expansion. P, Same view with elevated pericranial flaps, which will be turned in to close the opening between the nose and the anterior cranial base. A, B, D–P reproduced with permission and C adapted from Posnick JC.⁹⁸

Le Fort I osteotomy, is an error in judgment. The degree of horizontal deficiency observed at the orbits and maxillary dentition is rarely uniform. This further segmentation of the midface complex at the Le Fort I level is required to establish normal proportions. If a Le Fort I separation of the total midface complex is not carried out and the surgeon attempts to achieve a positive overbite and overjet at the incisor teeth, over-advancement of the orbits with enophthalmos will occur. The Le Fort I osteotomy is generally not performed at

the time of the total midface procedure. This will await skeletal maturity and then be combined with orthodontic treatment. Until then, an Angle Class III malocclusion will remain.

A major esthetic problem specific to the Le Fort III osteotomy when its indications are less than ideal is the creation of irregular step-offs in the lateral orbital rims. This will occur when even a moderate (Le Fort III) advancement is carried out. These lateral orbital step-offs are unattractive and are visible to the casual observ-

er at conversational distance. Surgical modification performed later is difficult, often with less than ideal esthetic results. Another problem with the Le Fort III osteotomy is the difficulty in judging an ideal orbital depth. A frequent result is either residual proptosis or enophthalmos. Simultaneous correction of orbital hypertelorism or correction of a midface arc-of-rotation problem is not possible with the Le Fort III procedure. Excessive lengthening of the nose, accompanied by flattening of the nasofrontal angle, will also occur if the Le Fort III osteotomy is selected when the skeletal morphology favors a monobloc or facial bipartition procedure. It is not possible to later correct the surgically created vertical elongation of the nose.

Final reconstruction, as discussed above, of the cranial vault deformities and orbital dystopia in Crouzon syndrome can be managed in patients as young as 5 to 7 years of age.⁴⁷ By this age, the cranial vault and orbits normally attain approximately 85 to 90% of their adult size.⁴³ When the upper midface and final cranial vault procedure is carried out at or after this age, the reconstructive objectives are to approximate adult dimensions in the cranio-orbitozygomatic region, with the expectation of a stable result (no longer influenced by growth) once healing has occurred (see Figure 46-4). Psychosocial considerations also support the upper midface and final cranial vault procedure taking place in patients 5 to 7 years of age. When the procedure is carried out at this age, the child may enter the first grade with an opportunity for satisfactory self-esteem. Routine orthognathic surgery will be necessary at the time of skeletal maturity to achieve an ideal occlusion, facial profile, and smile.

Orthognathic Procedures for Definitive Occlusal and Lower Facial Esthetic Reconstruction

Although the mandible has a normal basic growth potential in Crouzon syndrome, the maxilla does not. An Angle Class III

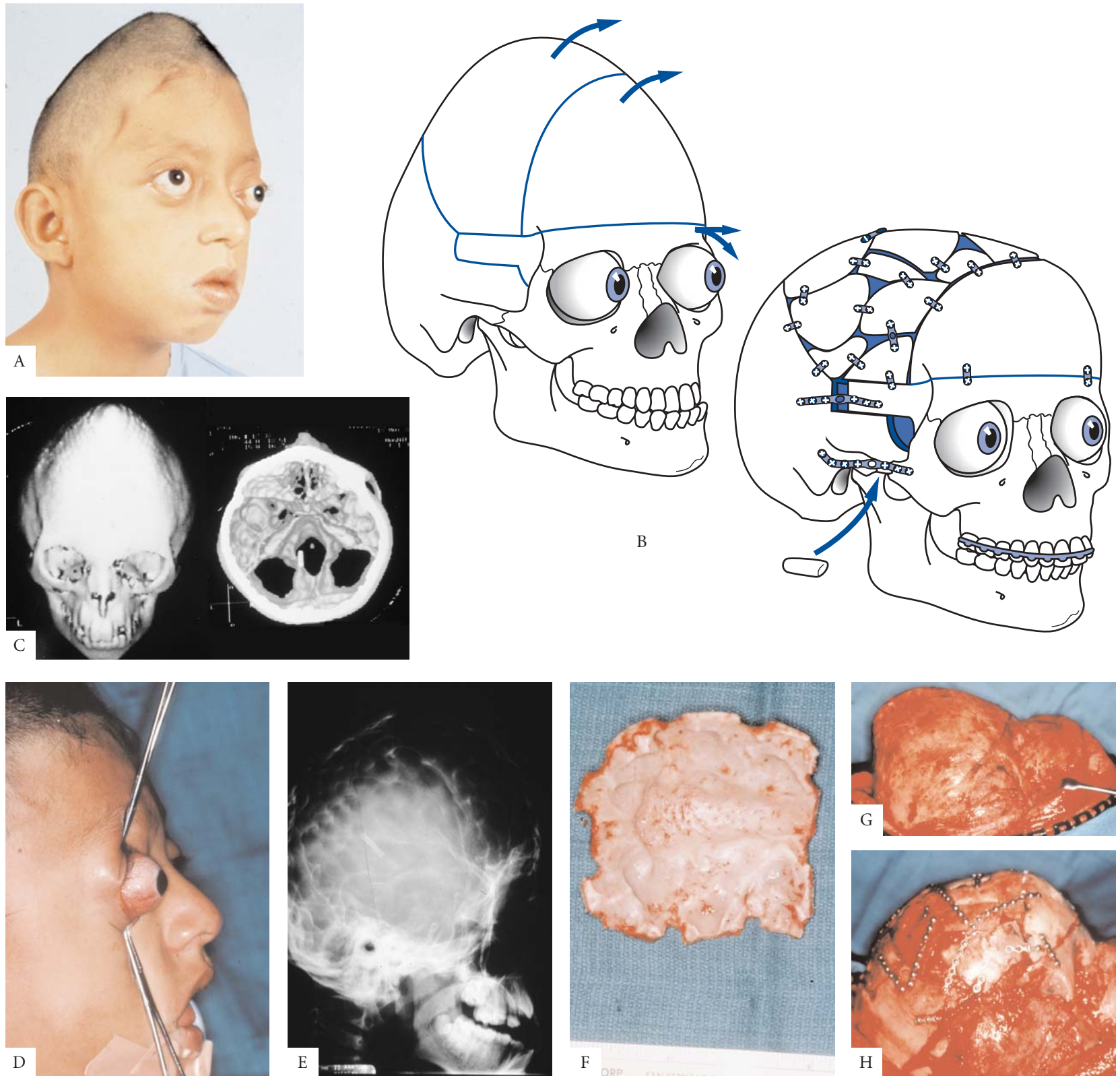


FIGURE 46-5 A 12-year-old boy with unrepaired Crouzon syndrome who underwent total cranial vault and monobloc osteotomies with reshaping and advancement. A, Oblique view prior to surgery. B, The patient's craniofacial morphology before surgery. Osteotomy locations indicated. A second illustration after osteotomies completed with advancement, reshaping, and fixation. C, Three-dimensional CT scan views of cranial vault and cranial base prior to surgery. D, Intraoperative view with forceps placed at orbital rims indicating extent of proptosis. E, Lateral skull radiograph with "fingerprinting" indicating long-standing increased ICP. F, Inner table internal side of frontal bone indicating compression of brain against inner table of skull. G, Intraoperative lateral view of cranial vault and orbits through coronal incision before osteotomies. H, Same view after osteotomies, reshaping and stabilization of bone segments with miniplates and screws. (CONTINUED ON NEXT PAGE)

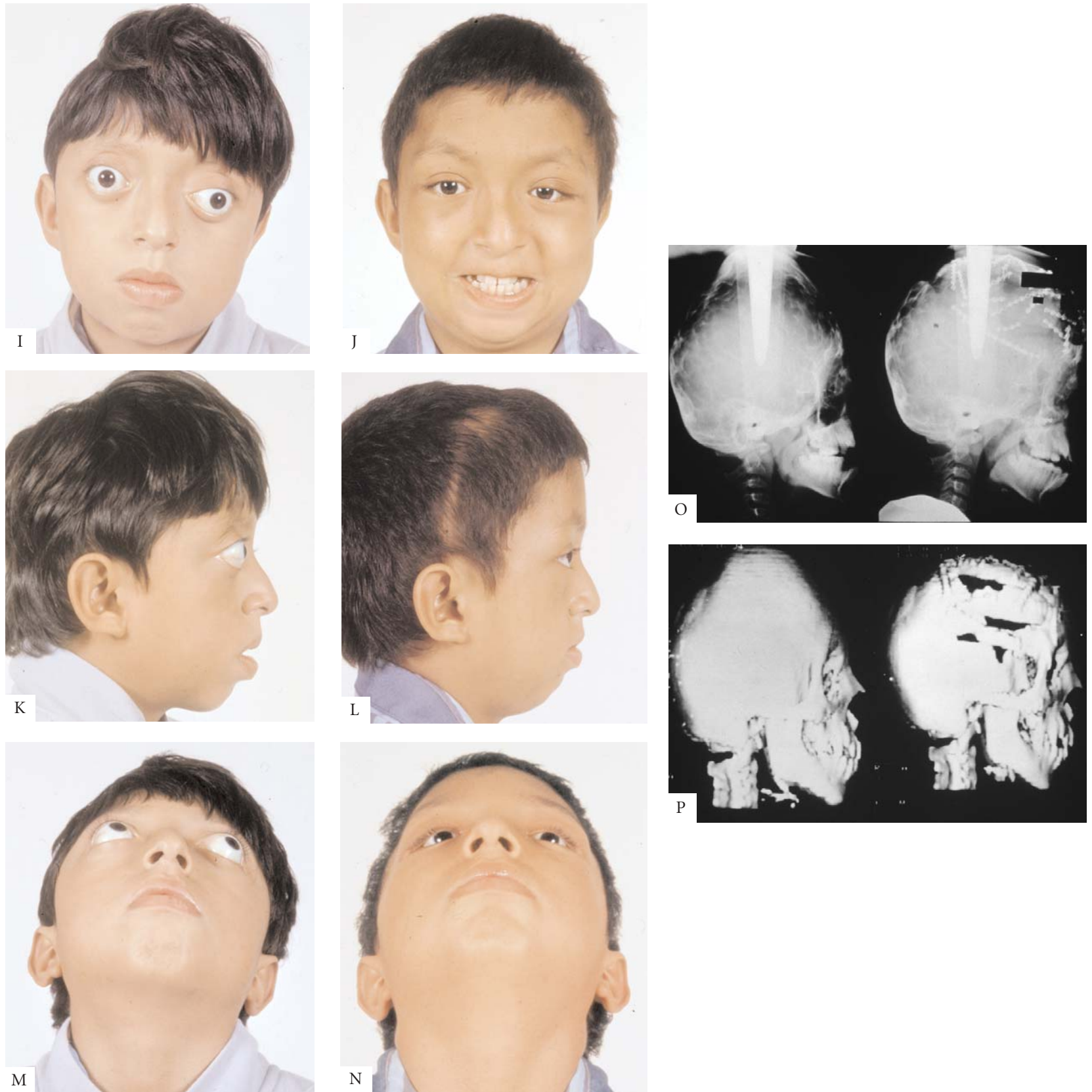


FIGURE 46-5 (CONTINUED) I, Frontal view before surgery. J, Frontal view after reconstruction. K, Profile view before surgery. L, Profile view after reconstruction. M, Worm's-eye view before surgery. N, Worm's-eye view after reconstruction. O, Comparison of lateral cephalometric radiographs before and after reconstruction. P, Comparison of three-dimensional CT scan views before and after reconstruction. A, C–P reproduced with permission and B adapted from Posnick JC.⁹⁸

malocclusion, resulting from maxillary retrusion, with anterior open bite often results. A Le Fort I osteotomy to allow for horizontal advancement, transverse widening, and vertical adjustment is generally required in combination with an osteoplastic genioplasty (vertical reduction and horizontal advancement) to further correct the lower face deformity. Secondary deformities of the mandible should be simultaneously corrected through sagittal split osteotomies. The elective orthognathic surgery is carried out in conjunction with orthodontic treatment planned for completion at the time of early skeletal maturity (approximately 13 to 15 years in girls and 15 to 17 years in boys) (Figure 46-6).

Apert Syndrome

Apert syndrome has previously been classified on the basis of its clinical findings.^{85,86} Postmortem histologic and radiographic studies suggest that skeletal deficiencies in the patient with Apert syndrome result from a cartilage dysplasia at the cranial base, leading to premature fusion of the midline sutures from the occiput to the anterior nasal septum.⁸⁷⁻⁹¹ In addition, a component of the syndrome is four-limb symmetry complex syndactylies of the hands and feet (Figure 46-7). Fusion and malformation of other joints, including the elbows and shoulders, often occur. The soft tissue envelope also varies from that in Crouzon syndrome, with a greater downward slant to the canthi lateral and a distinctive, S-shaped upper eyelid ptosis. The quality of the skin often varies from normal, with acne and hyperhidrosis being prominent features. At the molecular level, one of two fibroblast growth factor receptor 2 (*FGFR2*) mutations involving amino acids (Ser252Trp and Pro253Arg) have been found to cause Apert syndrome in nearly all patients studied.⁹²⁻⁹⁴

Primary Cranio-orbital Decompression: Reshaping in Infancy

The initial craniofacial procedure for Apert syndrome generally requires bilater-

al coronal suture release and anterior cranial vault and upper three-quarter orbital osteotomies to expand the anterior cranial vault and reshape the upper orbits and forehead (see Figure 46-1).^{95,96} Our preference is to carry this out when the child is 9 to 11 months of age, unless signs of increased intracranial pressure are identified earlier in life. The main goals at this stage are to decompress the brain and provide increased space for it in the anterior cranial vault and to increase the orbital volume to decrease globe protrusion. The fronto-orbital surgical technique is similar to that described for Crouzon syndrome (Figure 46-8).

Further Craniotomy for Additional Cranial Vault Expansion and Reshaping in Young Children

As described for Crouzon syndrome, after the initial suture release, decompression, and reshaping carried out during infancy, the child is observed clinically at intervals by the craniofacial surgeon, pediatric neurosurgeon, pediatric ophthalmologist, and developmental pediatrician and undergoes interval CT scanning.^{76,97,98} Should signs of increased ICP develop, further decompression with reshaping of the cranial vault to expand the intracranial volume is performed (Figure 46-9). In Apert syndrome the posterior cranial vault more commonly requires expansion. The technique is similar to that described for Crouzon syndrome.

Management of the “Total Midface” Deformity in Childhood

In Apert syndrome, for almost all patients, facial bipartition osteotomies combined with further cranial vault reshaping permit a more complete correction of the abnormal craniofacial skeleton than can be achieved through other midface procedure options (ie, monobloc or Le Fort III osteotomies). When using the facial bipartition approach, a more normal arc of

rotation of the midface complex is achieved with the midline split. This further reduces the stigmata of the preoperative “flat, wide, and retrusive” facial appearance. The facial bipartition also allows the orbits and zygomatic buttresses as units to shift to the midline (correction of hypertelorism) while the maxillary arch is simultaneously widened. Horizontal advancement of the reassembled midface complex is then achieved to normalize the orbital depth and zygomatic length. The forehead is generally flat, tall, and retruded, with a constricting band just above the supraorbital ridge, giving the impression of bitemporal narrowing. Reshaping of the anterior cranial vault is simultaneously carried out (see Figures 46-8–46-10). See also Figure 46-9H for preoperative craniofacial morphology and planned and completed osteotomies and reshaping. Note that stabilization was achieved with cranial bone grafts and plate and screw fixation. A Le Fort III osteotomy is virtually never adequate for an ideal correction of the residual upper and midface deformity of Apert syndrome.

Orthognathic Procedures for Definitive Occlusal and Lower Facial Esthetic Reconstruction

The mandible has normal basic growth potential in Apert syndrome. The extent of maxillary hypoplasia will result in an Angle Class III malocclusion with severe anterior open-bite deformity. A Le Fort I osteotomy is required to allow for horizontal advancement, transverse widening, and vertical adjustment in combination with an osteoplastic genioplasty to vertically reduce and horizontally advance the chin, often combined with bilateral sagittal split osteotomies of the mandible. The elective orthognathic surgery is carried out in conjunction with detailed orthodontic treatment planned for completion at the time of early skeletal maturity (approximately 13 to 15 years in girls and 15 to 17 years in boys).

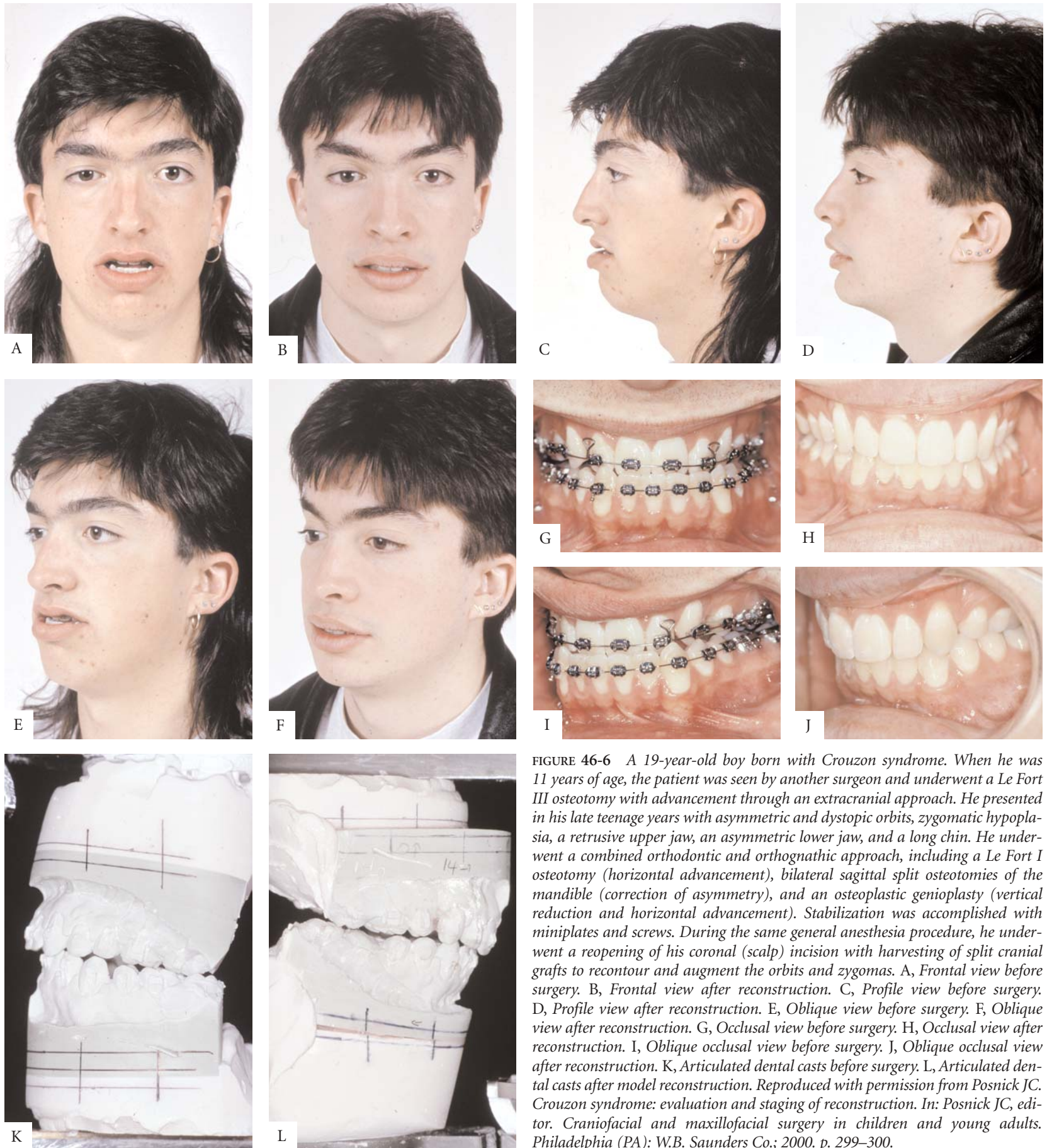


FIGURE 46-6 A 19-year-old boy born with Crouzon syndrome. When he was 11 years of age, the patient was seen by another surgeon and underwent a Le Fort III osteotomy with advancement through an extracranial approach. He presented in his late teenage years with asymmetric and dystopic orbits, zygomatic hypoplasia, a retrusive upper jaw, an asymmetric lower jaw, and a long chin. He underwent a combined orthodontic and orthognathic approach, including a Le Fort I osteotomy (horizontal advancement), bilateral sagittal split osteotomies of the mandible (correction of asymmetry), and an osteoplastic genioplasty (vertical reduction and horizontal advancement). Stabilization was accomplished with miniplates and screws. During the same general anesthesia procedure, he underwent a reopening of his coronal (scalp) incision with harvesting of split cranial grafts to recontour and augment the orbits and zygomas. A, Frontal view before surgery. B, Frontal view after reconstruction. C, Profile view before surgery. D, Profile view after reconstruction. E, Oblique view before surgery. F, Oblique view after reconstruction. G, Occlusal view before surgery. H, Occlusal view after reconstruction. I, Oblique occlusal view before surgery. J, Oblique occlusal view after reconstruction. K, Articulated dental casts before surgery. L, Articulated dental casts after model reconstruction. Reproduced with permission from Posnick JC. Crouzon syndrome: evaluation and staging of reconstruction. In: Posnick JC, editor. *Craniofacial and maxillofacial surgery in children and young adults*. Philadelphia (PA): W.B. Saunders Co.; 2000. p. 299–300.

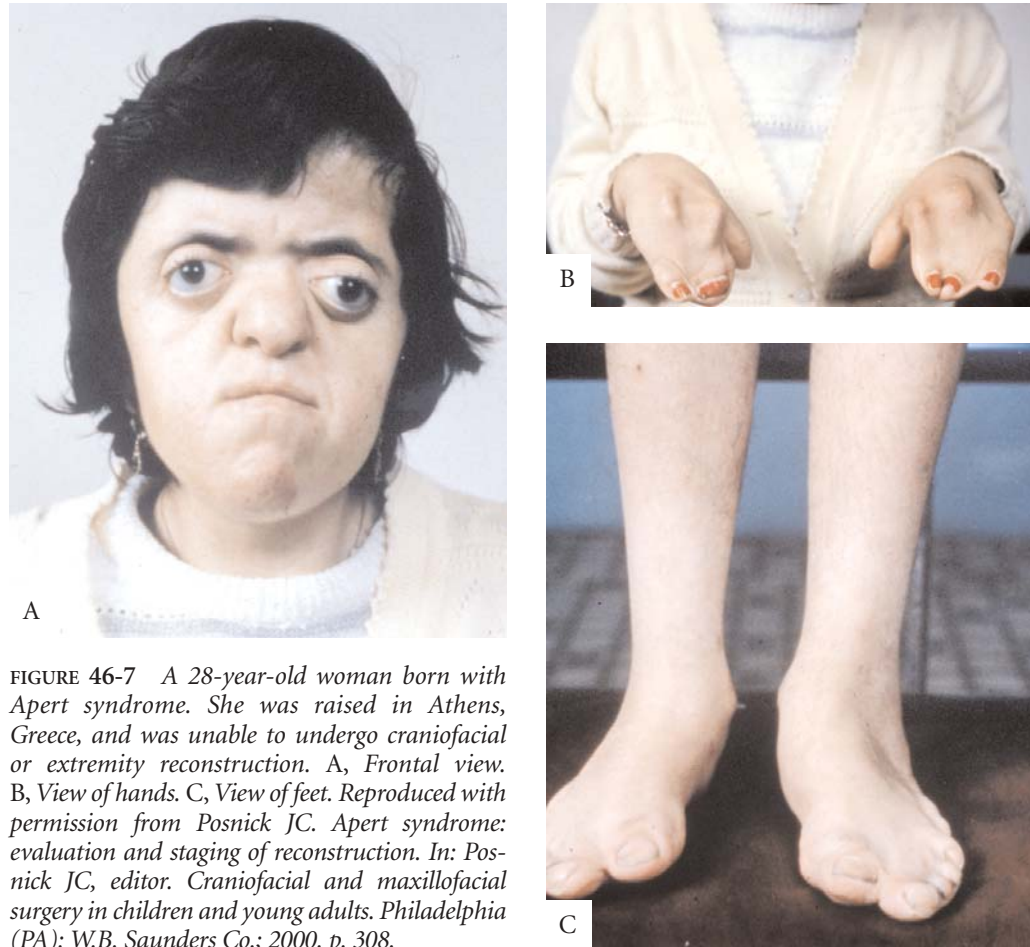


FIGURE 46-7 A 28-year-old woman born with Apert syndrome. She was raised in Athens, Greece, and was unable to undergo craniofacial or extremity reconstruction. A, Frontal view. B, View of hands. C, View of feet. Reproduced with permission from Posnick JC. Apert syndrome: evaluation and staging of reconstruction. In: Posnick JC, editor. Craniofacial and maxillofacial surgery in children and young adults. Philadelphia (PA): W.B. Saunders Co.; 2000. p. 308.

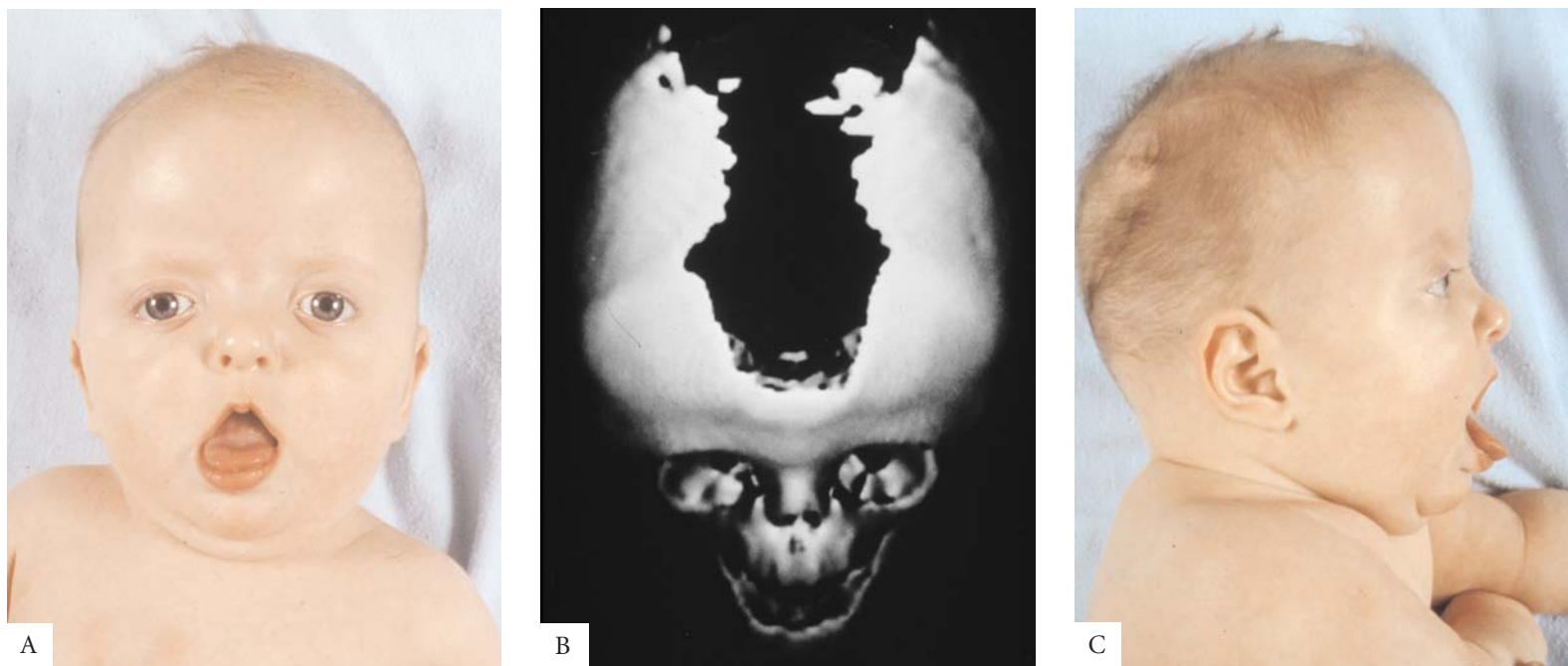


FIGURE 46-8 A 6-month-old girl with Apert syndrome underwent anterior cranial vault and three-quarter orbital osteotomies with reshaping as described (see Figure 46-1). A, Frontal view before surgery. B, Three-dimensional CT scan view of cranial vault before surgery. C, Profile view before surgery. (CONTINUED ON NEXT PAGE)

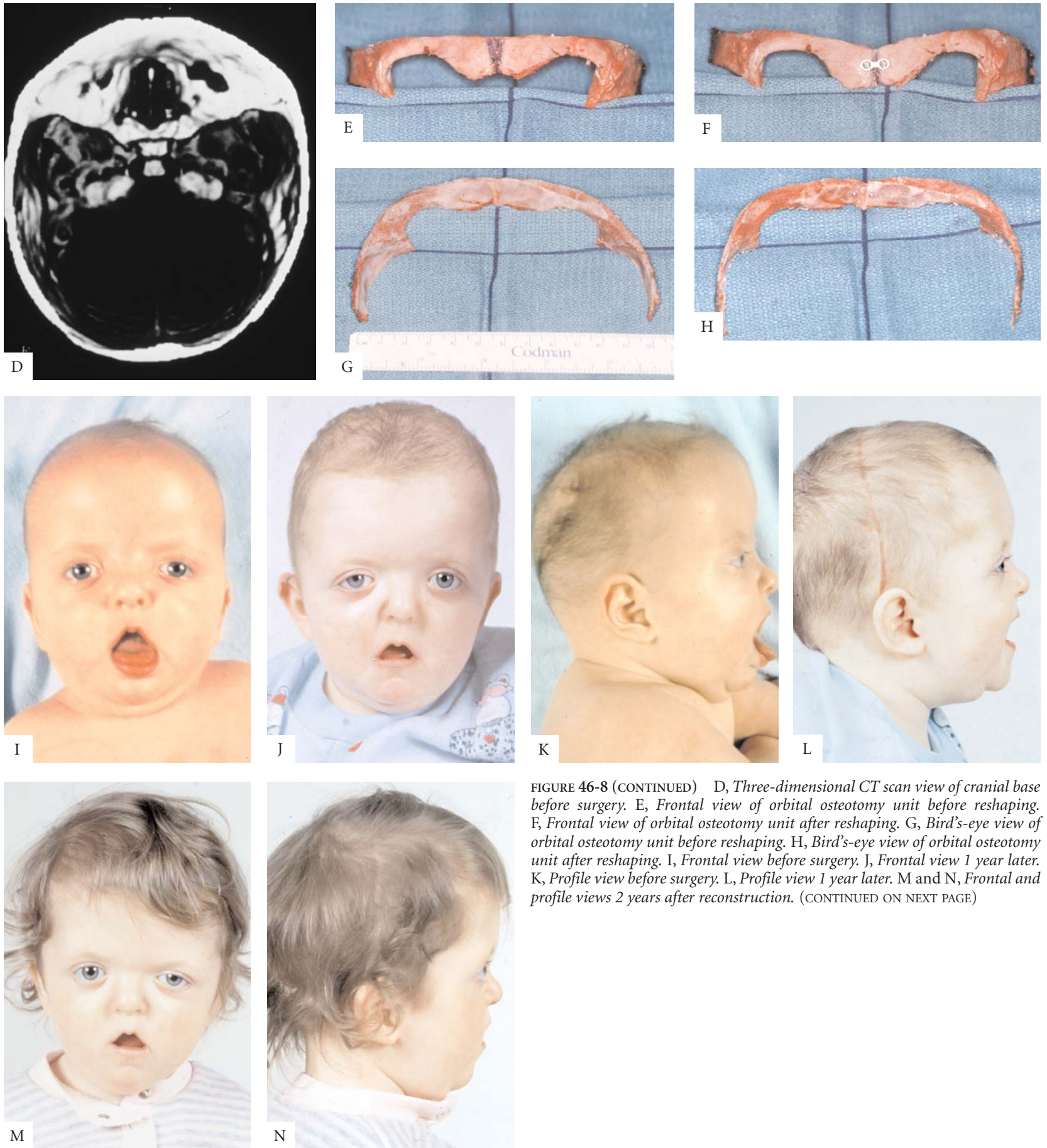


FIGURE 46-8 (CONTINUED) D, Three-dimensional CT scan view of cranial base before surgery. E, Frontal view of orbital osteotomy unit before reshaping. F, Frontal view of orbital osteotomy unit after reshaping. G, Bird's-eye view of orbital osteotomy unit before reshaping. H, Bird's-eye view of orbital osteotomy unit after reshaping. I, Frontal view before surgery. J, Frontal view 1 year later. K, Profile view before surgery. L, Profile view 1 year later. M and N, Frontal and profile views 2 years after reconstruction. (CONTINUED ON NEXT PAGE)

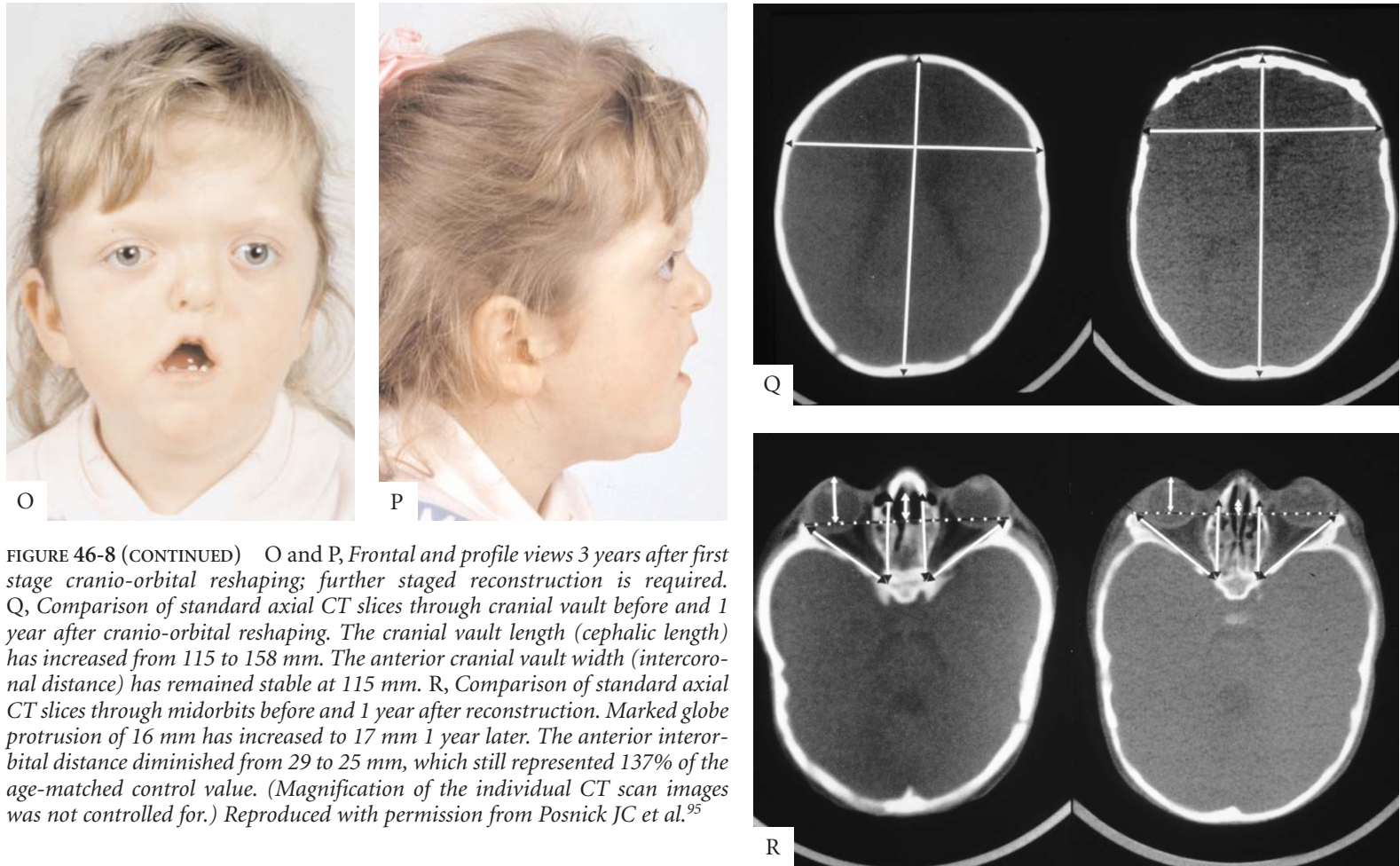


FIGURE 46-8 (CONTINUED) O and P, Frontal and profile views 3 years after first stage cranio-orbital reshaping; further staged reconstruction is required. Q, Comparison of standard axial CT slices through cranial vault before and 1 year after cranio-orbital reshaping. The cranial vault length (cephalic length) has increased from 115 to 158 mm. The anterior cranial vault width (intercoronal distance) has remained stable at 115 mm. R, Comparison of standard axial CT slices through midorbits before and 1 year after reconstruction. Marked globe protrusion of 16 mm has increased to 17 mm 1 year later. The anterior interorbital distance diminished from 29 to 25 mm, which still represented 137% of the age-matched control value. (Magnification of the individual CT scan images was not controlled for.) Reproduced with permission from Posnick JC et al.⁹⁵

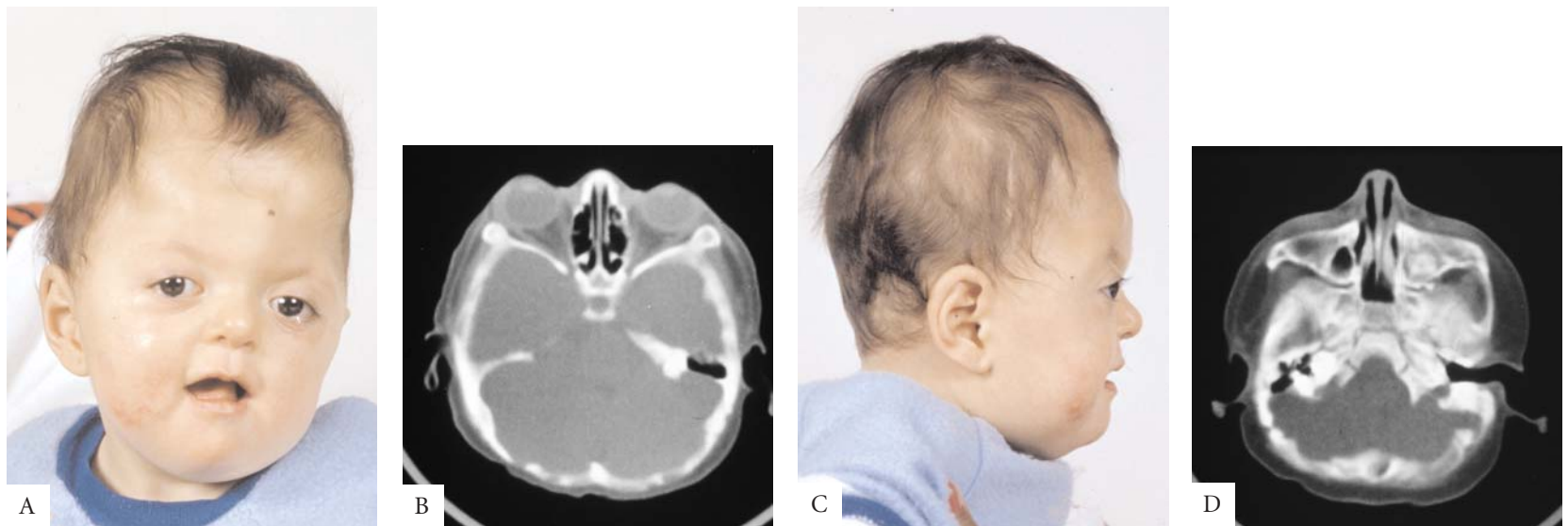


FIGURE 46-9 A child born with Apert syndrome underwent bilateral “lateral canthal advancement” procedures when she was 6 weeks of age, carried out by the neurosurgeon working independently. At 18 months of age, she returned with turricephaly and a constricted anterior cranial vault requiring further cranio-orbital decompression and reshaping. At 5 years of age, she underwent anterior cranial vault and facial bipartition osteotomies with reshaping. As part of her staged reconstruction, she will require orthognathic surgery and orthodontic treatment planned for the teenage years. A, Frontal view at 8 months of age after lateral canthal advancement procedure with residual deformity. B, Axial-sliced CT scan through midorbits indicating dystopia, hypertelorism, and proptosis. C, Lateral view at 8 months of age. D, Axial-sliced CT scan through zygomatic arches indicating midface deficiency. (CONTINUED ON NEXT PAGE)

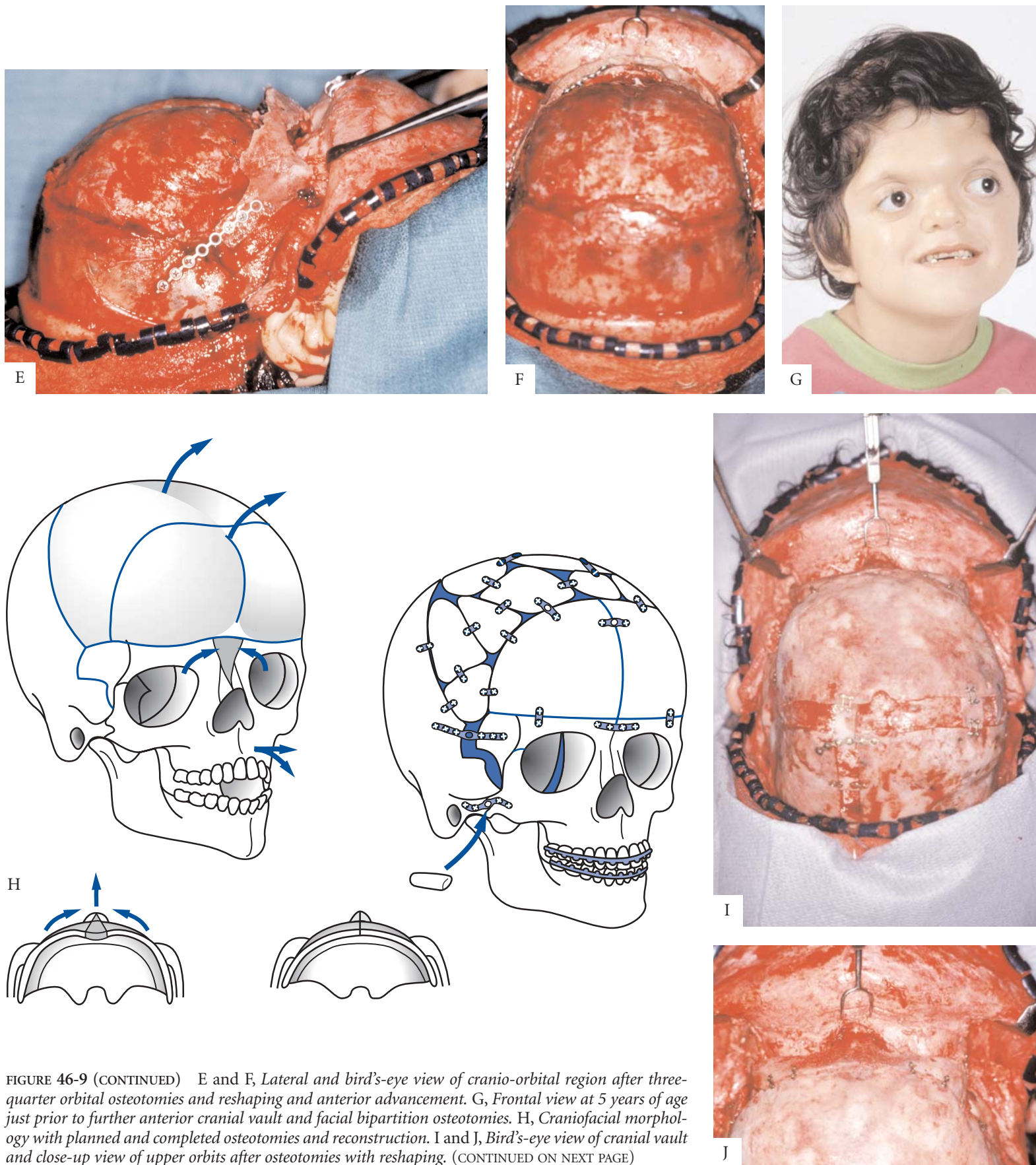


FIGURE 46-9 (CONTINUED) E and F, Lateral and bird's-eye view of cranio-orbital region after three-quarter orbital osteotomies and reshaping and anterior advancement. G, Frontal view at 5 years of age just prior to further anterior cranial vault and facial bipartition osteotomies. H, Craniofacial morphology with planned and completed osteotomies and reconstruction. I and J, Bird's-eye view of cranial vault and close-up view of upper orbits after osteotomies with reshaping. (CONTINUED ON NEXT PAGE)

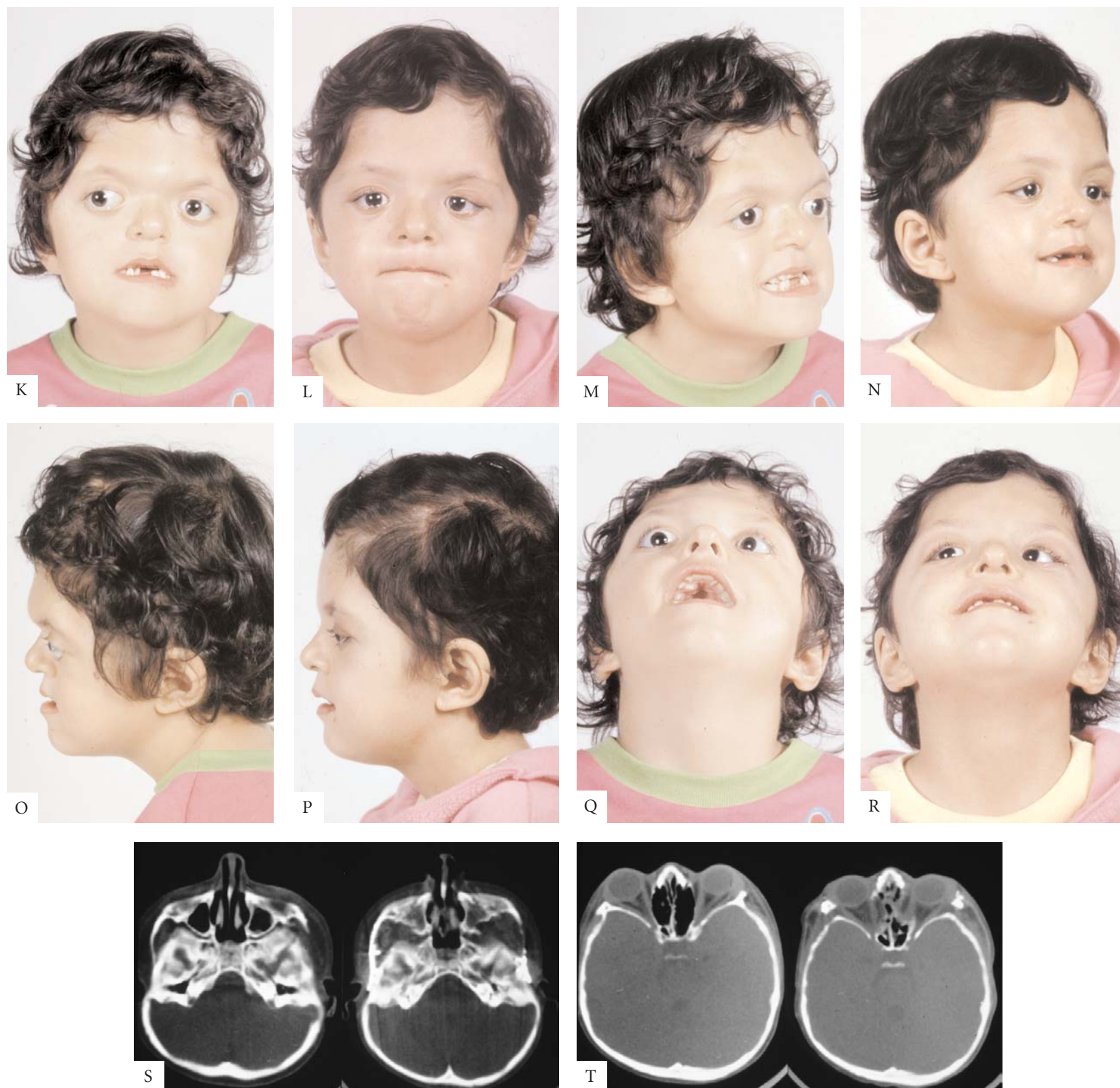


FIGURE 46-9 (CONTINUED) K, Frontal view before surgery. L, Frontal view after facial bipartition reconstruction. M, Oblique view before surgery. N, Oblique view after reconstruction. O, Profile view before surgery. P, Profile view after reconstruction. Q, Worm's-eye view before surgery. R, Worm's-eye view after reconstruction. S, Comparison of axial-sliced CT scans through zygomas before and after reconstruction, indicating a normalization of zygomatic arch length. T, Axial-sliced CT scan views through midorbits before and after reconstruction, indicating correction of orbital hypertelorism and proptosis. (CONTINUED ON NEXT PAGE)

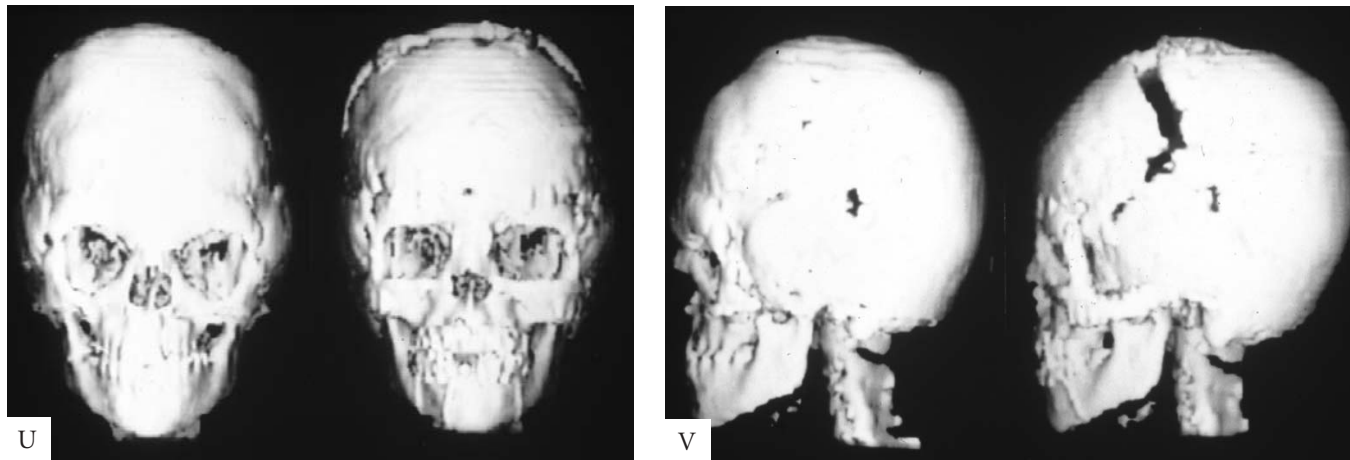


FIGURE 46-9 (CONTINUED) U and V, Comparison of three-dimensional CT scan views of craniofacial region before and after reconstruction, including improved morphology of orbits. A–G, I–V reproduced with permission, and H adapted from Posnick JC. Apert syndrome: evaluation and staging of reconstruction. In: Posnick JC, editor. *Craniofacial and maxillofacial surgery in children and young adults*. Philadelphia (PA): W.B. Saunders Co.; 2000. p. 316.

Pfeiffer Syndrome

In 1964, Pfeiffer described a syndrome consisting of craniosynostosis, broad thumbs, broad great toes, and occasionally partial soft tissue syndactyly of the hands.⁹⁹ This syndrome is known to have an autosomal dominant inheritance pattern with complete penetrance documented in all recorded two- and three-generation pedigrees.¹⁰⁰ Variable expressivity of the cranio-

facial and extremity findings is common (Figures 46-11 and 46-12). Although some authors have found clinical similarities in certain patients with Pfeiffer syndrome, Crouzon syndrome, and Jackson-Weiss syndrome, the three disorders are nosologically distinct.^{47,101} According to Cohen, the phenotypes of the three conditions do not correlate well with the known molecular findings.¹⁰² Patients with these three syn-

dromes may have similar or even identical mutations in exon B of *FGFR2*, yet they breed true within families, an observation that is as yet unexplained by the molecular findings.^{102,103}

Current thinking suggests that Pfeiffer syndrome is heterogeneous because it is caused by a single recurring mutation (Pro252Arg) of *FGFR1* and by several different mutations affecting *FGFR2*.^{104,105}

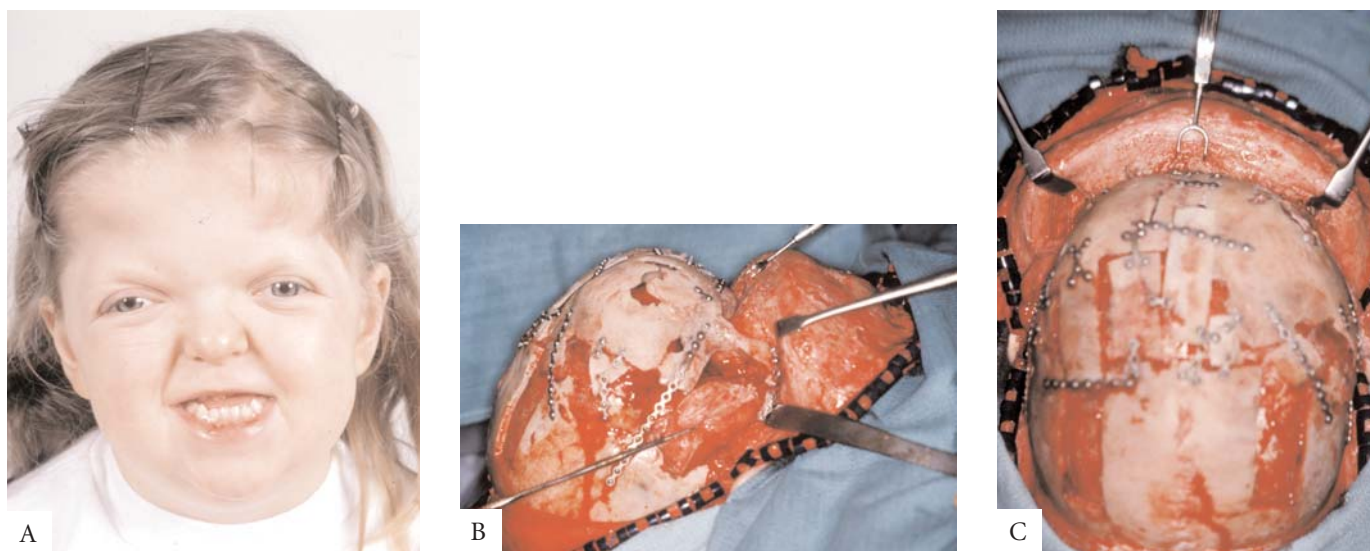


FIGURE 46-10 A 5-year-old girl with Apert syndrome who underwent decompression and forehead and upper orbital reshaping at 6 months of age. She then presented to us with residual deformity requiring cranial vault and facial bipartition osteotomies with reshaping. She will require orthognathic surgery and orthodontic treatment later in the teenage years to complete her reconstruction. A, Frontal view before facial bipartition surgery. B, Intraoperative lateral view of cranial vault and orbits through coronal incision after reshaping. C, Bird's-eye view of cranial vault after osteotomies and reshaping and fixation of bone segments. (CONTINUED ON NEXT PAGE)

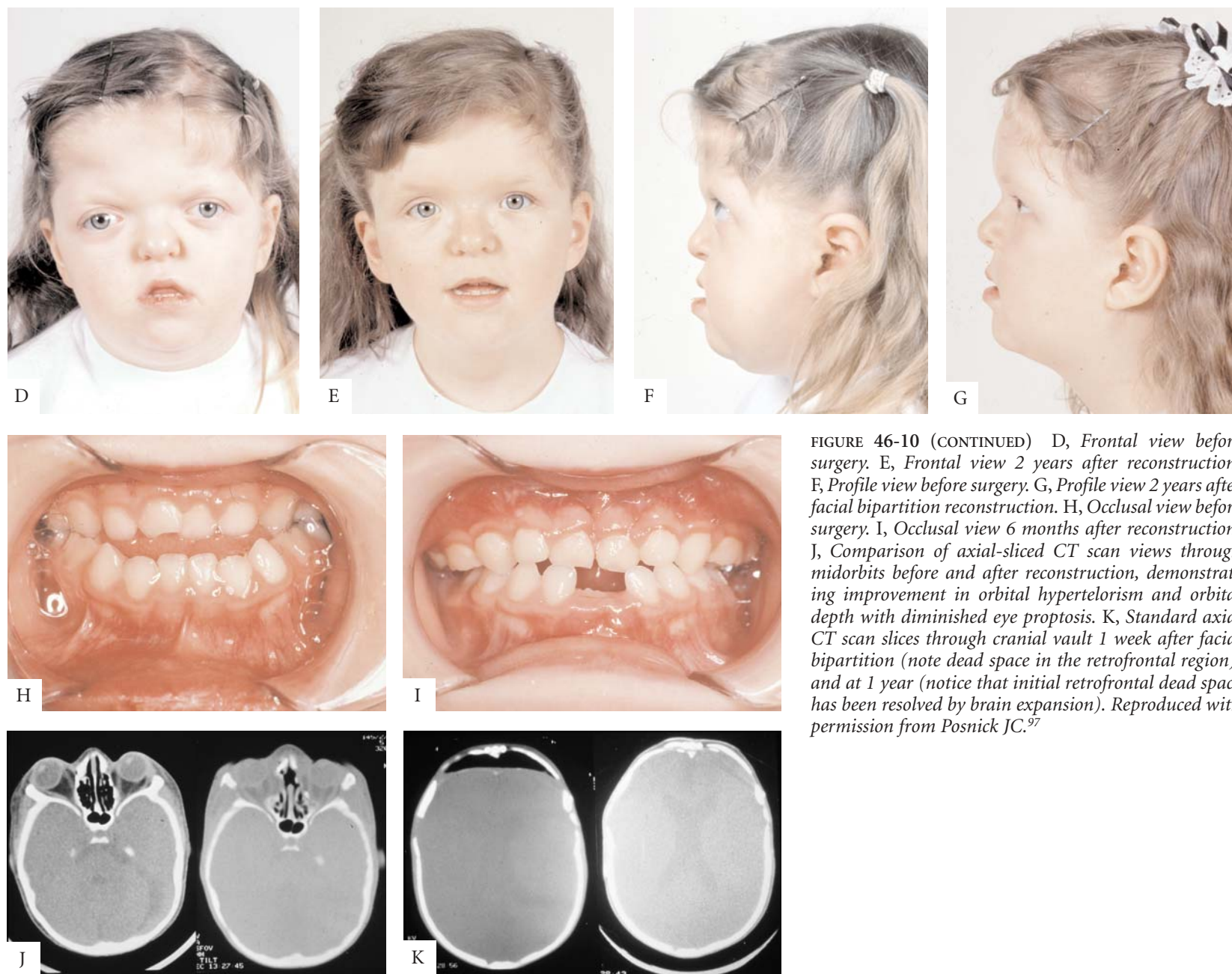


FIGURE 46-10 (CONTINUED) D, Frontal view before surgery. E, Frontal view 2 years after reconstruction. F, Profile view before surgery. G, Profile view 2 years after facial bipartition reconstruction. H, Occlusal view before surgery. I, Occlusal view 6 months after reconstruction. J, Comparison of axial-sliced CT scan views through midorbits before and after reconstruction, demonstrating improvement in orbital hypertelorism and orbital depth with diminished eye proptosis. K, Standard axial CT scan slices through cranial vault 1 week after facial bipartition (note dead space in the retrofrontal region), and at 1 year (notice that initial retrofrontal dead space has been resolved by brain expansion). Reproduced with permission from Posnick JC.⁹⁷

Cohen has reviewed the literature and further subgrouped Pfeiffer syndrome according to clinical features, associated low-frequency anomalies, and outcome. According to Cohen, Type I corresponds to the classic Pfeiffer syndrome and is associated with satisfactory prognosis. The Type II subgroup is associated with the cloverleaf skull anomaly while Type III is not. Both Types II and III have a less favorable outcome, with frequent death in infancy. The Type I variant frequently presents with

bicoronal craniosynostosis and midface involvement. The longitudinal evaluation and staging of reconstruction depend on individual variations but is similar to that described for Crouzon syndrome.

Carpenter Syndrome

Carpenter syndrome is characterized by craniosynostosis often associated with preaxial polysyndactyly of the feet, short fingers with clinodactyly, and variable soft tissue syndactyly, sometimes postaxial ply-

dactyly, and other anomalies such as congenital heart defects, short stature, obesity, and mental deficiency.²⁴ It was first described by Carpenter in 1901 and was later recognized to be an autosomal recessive syndrome. In general, the reconstructive algorithm described for Crouzon syndrome can be followed.

Saethre-Chotzen Syndrome

Saethre-Chotzen syndrome has an autosomal dominant inheritance pattern with

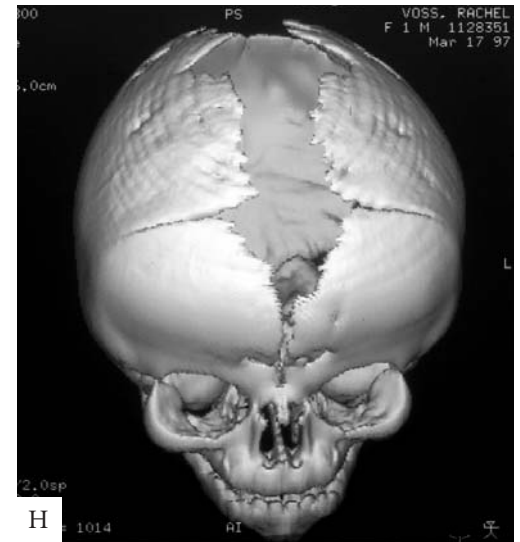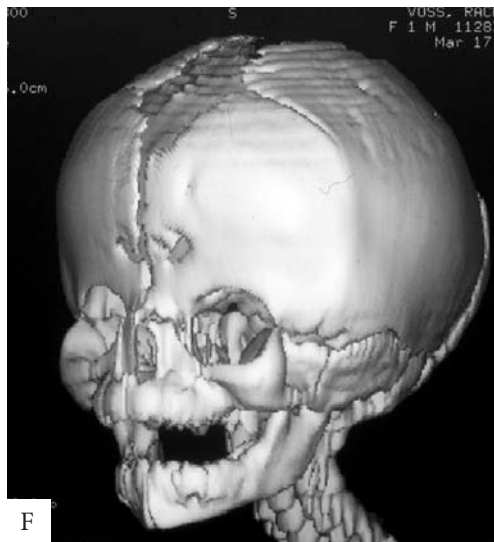
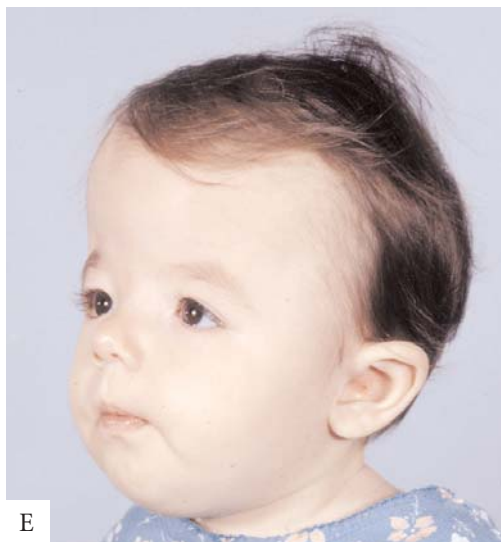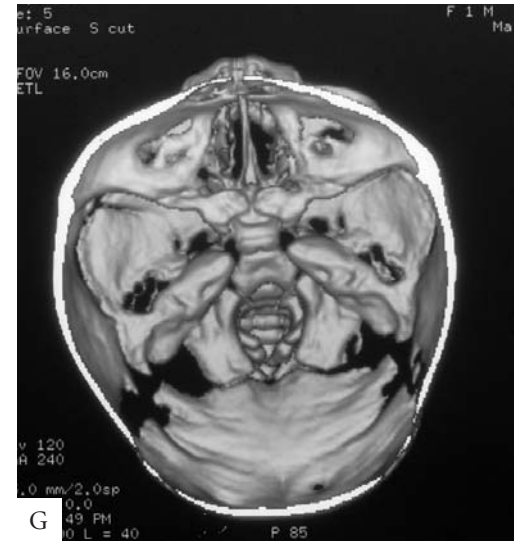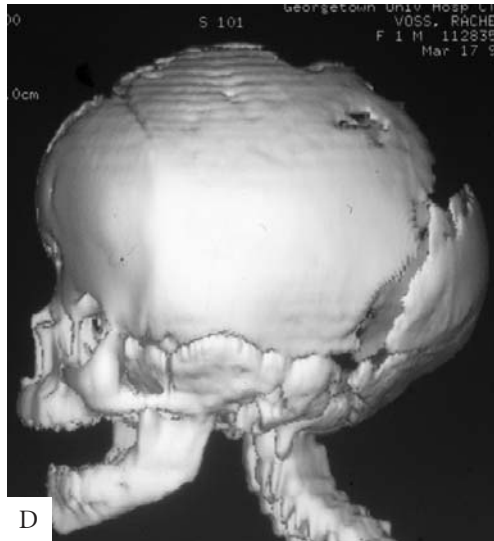


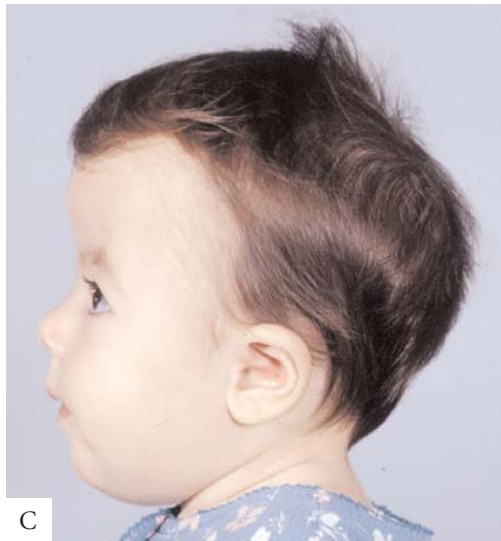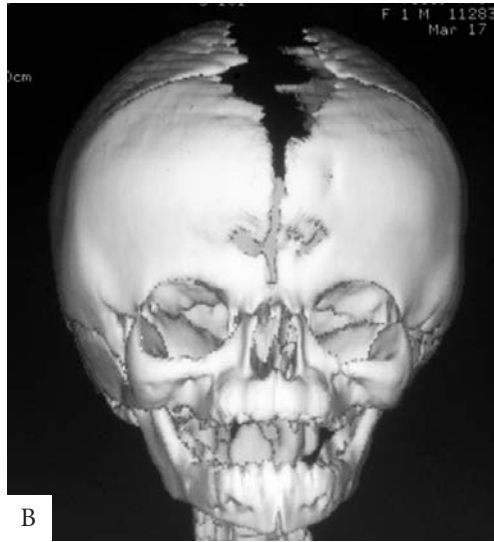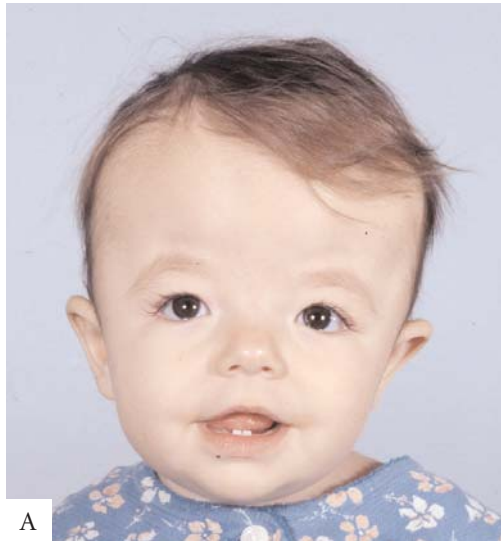FIGURE 46-11 A 2-month-old child born with Pfeiffer syndrome (Type I). She has bilateral coronal synostosis resulting in brachycephaly without suggestion of midface deficiency. A, Frontal view. B, Frontal view of CT scan. C, Profile view. D, Profile view of CT scan. E, Oblique view. F, Oblique view of CT scan. G, Cranial base view of CT scan. H, Craniofacial view of CT scan. Reproduced with permission from Posnick JC. Pfeiffer syndrome: evaluation and staging of reconstruction. In: Posnick JC, editor. Craniofacial and maxillofacial surgery in children and young adults. Philadelphia (PA): W.B. Saunders Co.; 2000. p. 344.

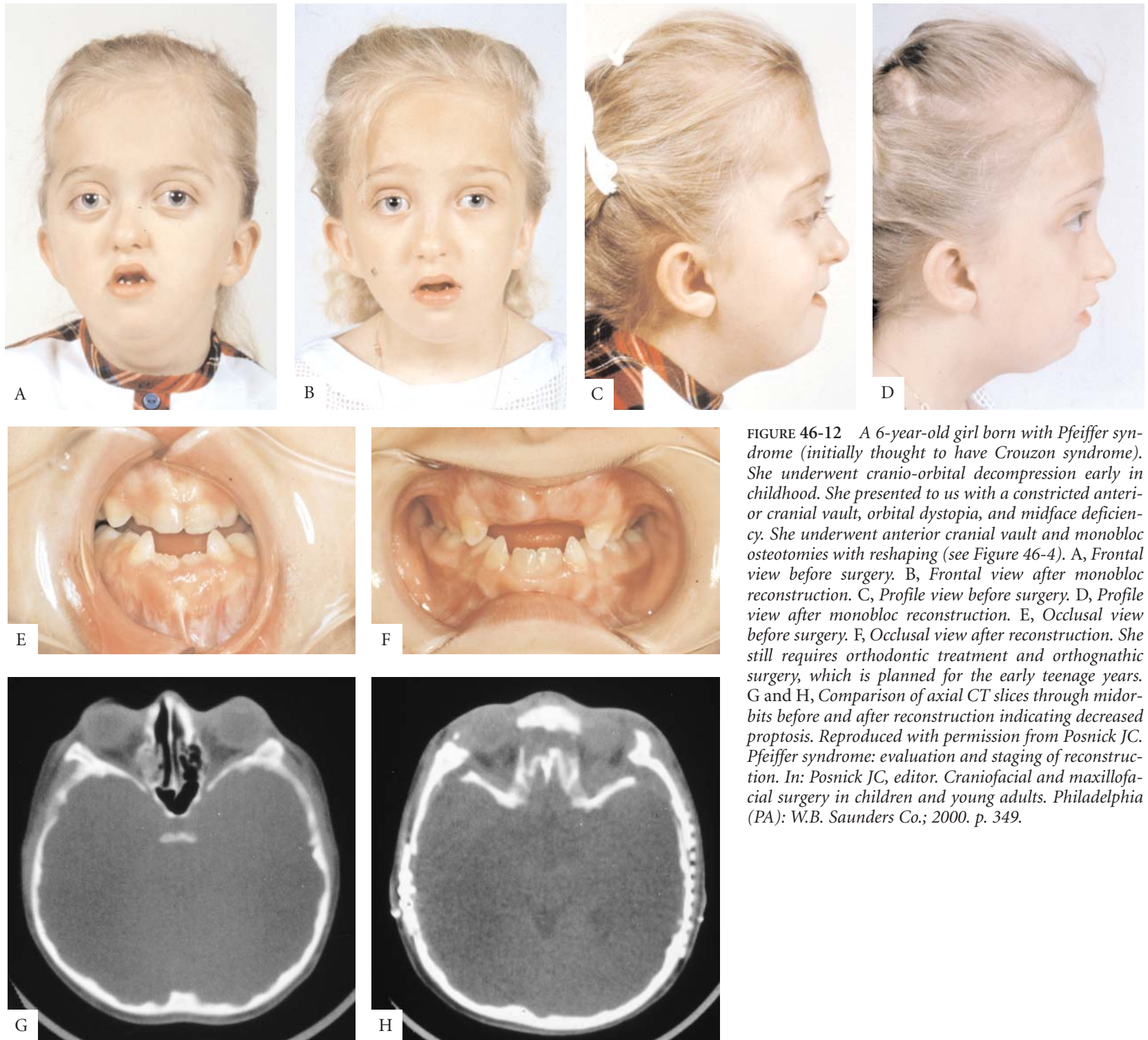


FIGURE 46-12 A 6-year-old girl born with Pfeiffer syndrome (initially thought to have Crouzon syndrome). She underwent cranio-orbital decompression early in childhood. She presented to us with a constricted anterior cranial vault, orbital dystopia, and midface deficiency. She underwent anterior cranial vault and monobloc osteotomies with reshaping (see Figure 46-4). A, Frontal view before surgery. B, Frontal view after monobloc reconstruction. C, Profile view before surgery. D, Profile view after monobloc reconstruction. E, Occlusal view before surgery. F, Occlusal view after reconstruction. She still requires orthodontic treatment and orthognathic surgery, which is planned for the early teenage years. G and H, Comparison of axial CT slices through mid-orbits before and after reconstruction indicating decreased proptosis. Reproduced with permission from Posnick JC. Pfeiffer syndrome: evaluation and staging of reconstruction. In: Posnick JC, editor. *Craniofacial and maxillofacial surgery in children and young adults*. Philadelphia (PA): W.B. Saunders Co.; 2000. p. 349.

a high degree of penetrance and expressivity.¹⁰⁶ Its pattern of malformations may include craniosynostosis, low-set frontal hairline, ptosis of the upper eyelids, facial asymmetry, brachydactyly, partial cutaneous syndactyly, and other skeletal

anomalies. As part of the reconstruction, cranio-orbital reshaping will almost certainly be required and is similar to that described for Crouzon syndrome. Evaluation and management of the total midface deficiency and orthognathic deformities

as described for Crouzon syndrome should be followed.

Cloverleaf Skull Anomaly

Kleeblattschädel anomaly (cloverleaf skull) is a trilobular-shaped skull secondary to

craniosynostosis (Figure 46-13).^{107,108} The cloverleaf skull anomaly is known to be both etiologically and pathogenetically heterogeneous. This anomaly is also non-specific: it may occur as an isolated anomaly or together with other anomalies, making up various syndromes (namely, Apert, Crouzon, Carpenter, Pfeiffer, and Saethre-Chotzen). The extent and timing of anterior cranial vault or upper orbital, posterior cranial vault, and midface reconstruction will be dependent on individual variation in the presenting deformity. In general, the protocol described for Crouzon syndrome can be followed.

Summary

Details of the timing and techniques for correction of the varied forms of craniofacial dysostosis syndromes differ from center to center. However, an essential element of successful rehabilitation is the delivery of care by committed, experienced, and technically skilled clinicians. The combined expertise of an experienced craniofacial surgeon and pediatric neurosurgeon working together to manage the cranio-orbital malformation and the experienced maxillofacial surgeon and orthodontist working together to manage the orthognathic deformity are essential to achieve maximum function and facial esthetics for each patient.

Our preferred approach for management of the craniofacial dysostosis syndromes is to stage the reconstruction to coincide with facial growth patterns, visceral (brain and eye) function, and psychosocial development. Recognition of the need for a staged reconstruction serves to clarify the objectives of each phase of treatment for the craniofacial surgeon, team, and most importantly the patient and patient's family.

By continuing to define our rationale for the timing and extent of surgical intervention and then evaluating both function and esthetic outcomes, we will further

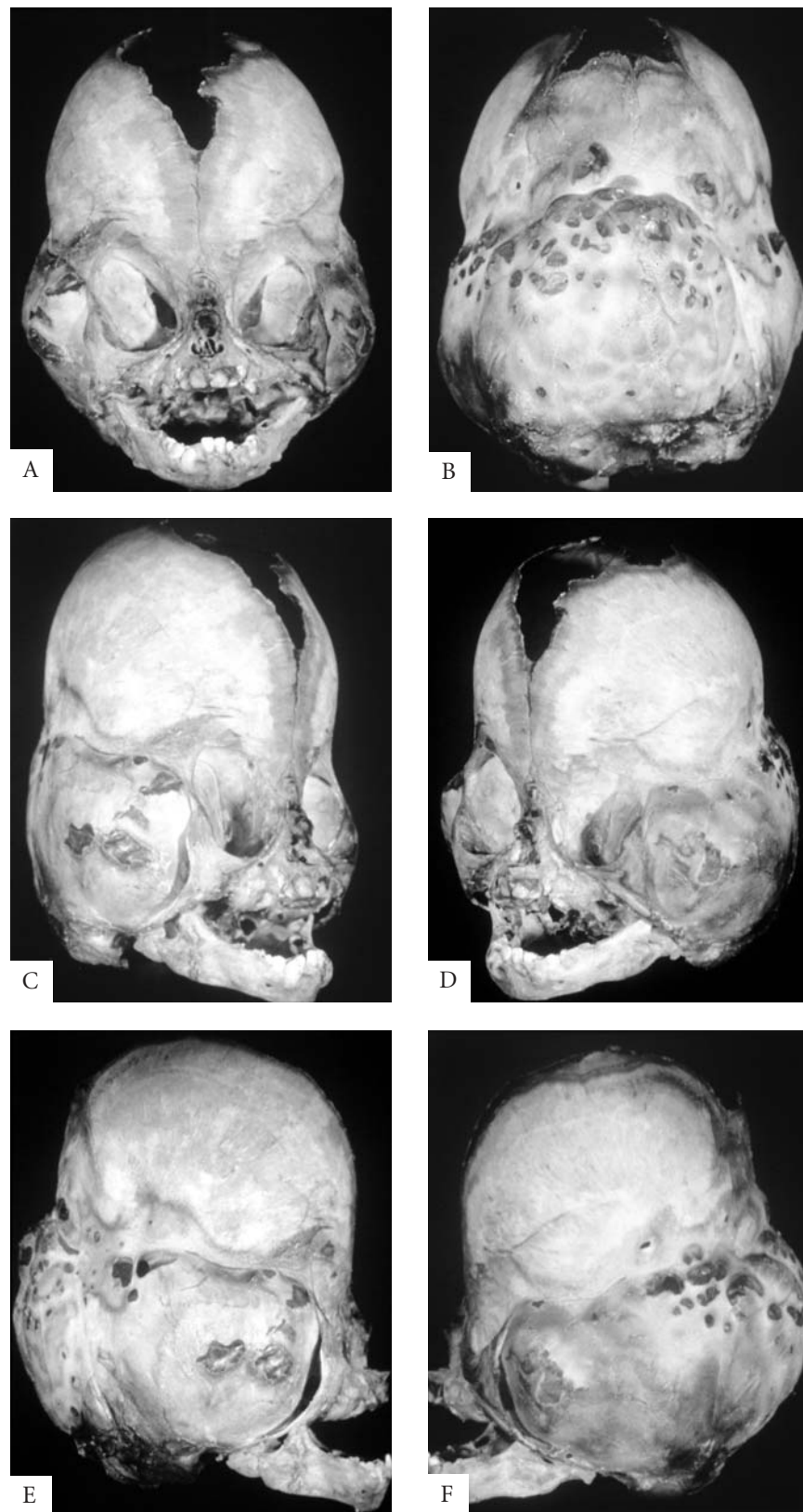


FIGURE 46-13 The craniofacial skeleton of a 6-month-old child born with cloverleaf skull anomaly. He underwent tracheostomy and gastrostomy shortly after birth and died of pneumonia before craniofacial reconstruction could be undertaken. A, Frontal view. B, Posterior view. C, Right oblique view. D, Left oblique view. E, Left profile view. F, Right profile view. Reproduced with permission from *Cloverleaf skull anomalies: evaluation and staging of reconstruction*. In: Posnick JC, editor. *Craniofacial and maxillofacial surgery in children and young adults*. Philadelphia (PA): W.B. Saunders Co.; 2000. p. 364.

improve the quality of life for the many hundreds of children born with syndromal forms of craniosynostosis. Our objective is to see each individual achieve personal success in life without special regard for the original malformation.

References

- Cohen MM Jr. Sutural biology and the correlates of craniosynostosis. *Am J Med Genet* 1993;47:581–616.
- Renier D. Intracranial pressure in craniosynostosis: Pre- and postoperative recordings. Correlation with functional results. In: Persing JA, Jane JA, Edgerton MT, editors. *Scientific foundations and surgical treatment of craniosynostosis*. Baltimore (MD): Williams & Wilkins; 1989. p. 263–9.
- Gault DT, Renier D, Marchac D, Jones BM. Intracranial pressure and intracranial volume in children with craniosynostosis. *Plast Reconstr Surg* 1992;90:230–71.
- Walia HK, Sodhi JS, Gupta BB, et al. Roentgenologic determination of the cranial capacity in the first four years of life. *Ind J Radiol* 1972;26:250.
- Virchow R. *Über den cretinismus, nemetlich in Franken, under uber pathologische: Schadelformen Verk Phys Med Gessellsch Wurszburg* 1851;2:230–71.
- Turvey TA, Gudeman SK. Nonsyndromic craniosynostosis. In: Turvey TA, Vig KWL, Fonseca RJ, editors. *Facial clefts and craniosynostosis: principles and management*. Philadelphia: W.B. Saunders Co.; 1996. p. 596–629.
- Moss ML. The pathogenesis of premature cranial synostosis in man. *Acta Anat (Basal)* 1959;37:351–70.
- Stewart RE, Dixon G, Cohen A. The pathogenesis of premature craniosynostosis in acrocephalosyndactyly (Apert syndrome): a reconsideration. *Plast Reconstr Surg* 1977;59:699–703.
- Pugeaut R. *Le Probleme neuro chirurgical des craniosytenoses*. Cahier Med Lyon 1968;44:3343.
- Renier D, Sainte-Rose C, Marchac D, et al. Intracranial pressure in craniosynostosis. *J Neurosurg* 1982;57:370.
- Siddiqi SN, Posnick JC, Buncic R, et al. The detection and management of intracranial hypertension after initial suture release and decompression for craniofacial dysostosis syndromes. *Neurosurgery* 1995;36:703.
- Turvey TA, Ruiz RL. Craniosynostosis and craniofacial dysostosis. In: Fonseca RJ, Baker SB, Wolford LM, editors. *Oral and maxillofacial surgery*. Philadelphia: W.B. Saunders Co.; 2000. p. 195–220.
- Posnick JC. Craniofacial dysostosis syndromes: a staged reconstructive approach. In: Turvey TA, Vig KWL, Fonseca RJ, editors. *Facial clefts and craniosynostosis: principles and management*. Philadelphia: W.B. Saunders Co.; 1996. p. 630–85.
- Posnick JC. Quantitative computer tomographic scan analysis: normal values and growth patterns. In: Posnick JC, editor. *Craniofacial and maxillofacial surgery in children and young adults*. Philadelphia: W.B. Saunders Co.; 2000. p. 36–54.
- Gault DT, Renier D, Marchac D, et al. Intracranial volume in children with craniosynostosis. *J Craniofac Surg* 1990;1:1.
- Golabi M, Edwards MSB, and Ousterhout DK. Craniosynostosis and hydrocephalus. *Neurosurgery* 1987;21:63.
- Hogan GR, Bauman ML. Hydrocephalus in Apert syndrome. *J Pediatr* 1971;79:782.
- Fishman MA, Hogan GR, Dodge PR. The concurrence of hydrocephalus and craniosynostosis. *J Neurosurg* 1971;34:621.
- Murovic JA, Posnick JC, Drake JM, et al. Hydrocephalus in Apert syndrome: a retrospective review. *Pediatr Neurosurg* 1993;19:151–5.
- Lauritzen C, Lilja J, Jarlstedt J. Airway obstruction and sleep apnea in children with craniofacial anomalies. *Plast Reconstr Surg* 1986;77:1–6.
- Guilleminault C. Obstructive sleep apnea syndrome and its treatment in children: areas of agreement and controversy. *Pediatr Pulmonol* 1987;3:429–36.
- Moore MH. Upper airway obstruction in the syndromal craniosynostoses. *Br J Plast Surg* 1993;46:355–62.
- Drake AF, Sidman JD. Airway management. In: Turvey TA, Vig KWL, Fonseca RJ, editors. *Facial clefts and craniosynostosis: principles and management*. Philadelphia: W.B. Saunders Co.; 1996. p. 174–82.
- Gorlin RJ, Cohen MM Jr, Levin LS. *Syndromes of the head and neck*. 3rd ed. New York: Oxford University Press; 1990. p. 524–5.
- Enlow DH, McNamara JA Jr. The neurocranial basis for facial form and pattern. *Angle Orthod* 1973;43:256–70.
- Kreiborg S. Description of a dry skull with Crouzon syndrome. *Scand J Plast Reconstr Surg* 1982;16:245–53.
- Marsh JL, Gado M. Surgical anatomy of the craniofacial dysostoses: insights from CT scans. *Cleft Palate J* 1982;19:212–21.
- Freide H, Lilja J, Andersson H, Johanson B. Growth of the anterior cranial base after craniotomy in infants with premature synostosis of the coronal suture. *Scand J Plast Reconstr Surg* 1983;17:99–108.
- Marsh JL, Vannier MW. The “third” dimension in craniofacial surgery. *Plast Reconstr Surg* 1983;71:759–67.
- Kreiborg S. Apert and Crouzon syndromes contrasted. Qualitative craniofacial x-ray findings. *J Dent Res* 1985;64:203.
- Marchac D. Radical forehead remodeling for craniosynostosis. *Plast Reconstr Surg* 1978;62:335–8.
- Marchac D, Renier D, Jones BM. Experience with the “floating forehead.” *Br J Plast Surg* 1988;41:1–15.
- Posnick JC. The craniofacial dysostosis syndrome: current reconstructive strategies. *Clin Plast Surg* 1994;21:585–98.
- Carr M, Posnick JC, Pron G, Armstrong D. Cranio-orbito-zygomatic measurements from standard CT scans in unoperated Crouzon and Apert infants: comparison with normal controls. *Cleft Palate Craniofac J* 1992;29:129–36.
- Posnick JC, Al-Qattan MM, Armstrong D. Monobloc and facial bipartition osteotomies: quantitative assessment of presenting deformity and surgical results based on computed tomography scans. *J Oral Maxillofac Surg* 1995;53:358–67.
- Kreiborg S. Crouzon syndrome. A clinical and roentgencephalometric study [thesis (disputats)]. *Scand J Plast Reconstr Surg* 1981;18 Suppl:198.
- Posnick JC, Farkas LG. Anthropometric surface measurements in the analysis of cranio-maxillofacial deformities: normal values and growth trends. In: Posnick JC, editor. *Craniofacial and maxillofacial surgery in children and young adults*. Philadelphia: W.B. Saunders Co.; 2000. p. 55–79.
- Farkas LG, Posnick JC. Growth and development of regional units in the head and face based on anthropometric measurements. *Cleft Palate Craniofac J* 1992;29:301–2.
- Farkas LG, Posnick JC, Hreczko T. Anthropometric growth study of the head. *Cleft Palate Craniofac J* 1992;29:303–7.
- Farkas LG, Posnick JC, Hreczko T. Growth patterns in the orbital region: a morphometric study. *Cleft Palate Craniofac J* 1992;29:315–7.
- Farkas LG, Posnick JC, Hreczko T. Growth patterns of the face: a morphometric study. *Cleft Palate Craniofac J* 1992;29:308–14.
- Waitzman AA, Posnick JC, Armstrong D, Pron GE. Craniofacial skeletal measurements based on computed tomography: part I.

- Accuracy and reproducibility. *Cleft Palate Craniofac J* 1992;29:112-7.
43. Waitzman AA, Posnick JC, Armstrong D, Pron GE. Craniofacial skeletal measurements based on computed tomography. Part II. Normal values and growth trends. *Cleft Palate Craniofac J* 1992;29:118-28.
 44. Vannier MW, Gado M, Marsh JL. Three-dimensional computer graphics for craniofacial surgical planning and evaluation. *Comput Graph* 1983;17:263.
 45. Vannier MW, Pilgram TK, Marsh JL, et al. Craniosynostosis: diagnostic imaging with three-dimensional CT presentation. *AJNR Am J Neuroradiol* 1994;15:1861-9.
 46. Kolar JC, Munro IR, Farkas LG. Patterns of dysmorphology in Crouzon syndrome: an anthropometric study. *Cleft Palate J* 1988;25:235-44.
 47. Posnick JC, Ruiz RL. The craniofacial dysostosis syndromes: current surgical thinking and future directions. *Cleft Palate Craniofac J* 2000;37:433.
 48. Kreiborg S, Pruzansky S. Roentgencephalometric and metallic implant studies in Apert syndrome. Abstract. Presented at the 50th General Session I.A.D.R. 1972. Las Vegas. 298:120[21].
 49. Kreiborg S, Aduss H. Pre and post surgical facial growth in patients with Crouzon and Apert syndromes. *Cleft Palate J* 1986;23(suppl): 78-90.
 50. Lannelongue M. De la craniectomie dans la microcephalie. *Compte Rendu Acad Sci* 1890;110:1382.
 51. Lane LC. Pioneer craniectomy for relief of mental imbecility due to premature sutural closure and microcephalus. *J Am Med Assoc* 1892;18:49.
 52. McCarthy JG, Epstein FJ, Wood-Smith D. Craniosynostosis. In: McCarthy JG, editor. *Plastic Surgery*. Volume 4. Philadelphia: W.B. Saunders Co.; 1990. p. 3013-53.
 53. Gillies H, Harrison SH. Operative correction by osteotomy of recessed malar maxillary compound in case of oxycephaly. *Br J Plast Surg* 1950;3:123.
 54. Tessier P. Osteotomies totales de la face: Syndrome de Crouzon, syndrome D'Apert: Oxycephalies, scaphocephalies, turricephalies. *Ann Chir Plast* 1967;12:273.
 55. Tessier P. The definitive plastic surgical treatment of the severe facial deformities of craniofacial dysostosis: Crouzon and Apert diseases. *Plast Reconstr Surg* 1971;48:419.
 56. Tessier P. Dysostoses cranio-faciales (syndromes de Crouzon et d'Apert): Osteotomies totales de la face. In: *Transactions of the Fourth International Congress of Plastic and Reconstructive Surgery*. Amsterdam: Mosby; 1969. p. 774.
 57. Tessier P. Relationship of craniosynostosis to craniofacial dysostosis and to faciosynostosis: A study with therapeutic implications. *Clin Plast Surg* 1982;9:531.
 58. Tessier P. Autogenous bone grafts taken from the calvarium for facial and cranial applications. *Plast Reconstr Surg* 1971;48:224.
 59. Tessier P. Total osteotomy of the middle third of the face for faciostenosis or for sequelae of the Le Fort III fractures. *Plast Reconstr Surg* 1971;48:533.
 60. Tessier P. Traitement des dysmorphies faciales propres aux dysostoses craniofaciales (DGF), maladies de Crouzon et d'Apert. *Neurochirurgie* 1971;17:295.
 61. Tessier P. Craniofacial surgery in syndromic craniosynostosis: craniosynostosis, diagnosis, evaluation and management. New York: Raven Press; 1986. p. 321.
 62. Tessier P. Recent improvement in the treatment of facial and cranial deformities in Crouzon disease and Apert syndrome. In: *Symposium of Plastic Surgery of the Orbital Region*. St. Louis (MO): C.V. Mosby Co.; 1976. p. 271.
 63. Tessier P. The monobloc frontofacial advancement: Do the pluses outweigh the minuses? [discussion] *Plast Reconstr Surg* 1993;91:988.
 64. Rougerie J, Derome P, Anquez L. Craniostenosis et dysmorphies-cranio-faciales: Principes d'une nouvelle technique de traitement et ses resultats. *Neurochirurgie* 1972;18:429.
 65. Hoffman HJ, Mohr G. Lateral canthal advancement of the supraorbital margin: a new corrective technique in the treatment of coronal synostosis. *J Neurosurg* 1976;45:376.
 66. Whitaker LA, Bartlett SP, Schut L, et al. Craniosynostosis: an analysis of the timing, treatment and complications in 164 consecutive patients. *Plast Reconstr Surg* 1987;80:195.
 67. Luhr HG. Zur Stablen osteosynthese bei unterkieferfrakturen. *Dtsch Zahnertl Z* 1968;23:754.
 68. Kaban LB, Conover M, Mulliken J. Midface position after LeFort III advancement: a long-term follow-up study. *Cleft Palate J* 1986;23(suppl):75-7.
 69. Wolford LM, Cooper RL. Orthognathic surgery in the growing cleft patient and its effect on growth. Abstract. Presented at the American Association of Oral and Maxillofacial Surgeons Annual Scientific Sessions; 1987 Sep; Anaheim (CA): WB Saunders.
 70. Wolford LM, Cooper RL, El Deeb M. Orthognathic surgery in the young cleft patient and the effect on growth. Abstract. Presented at the American Cleft Palate-Craniofacial Association Annual Meeting; 1990 May; St. Louis (MO).
 71. Posnick JC, Al-Qattan MM, Armstrong D. Monobloc and facial bipartition osteotomies reconstruction of craniofacial malformations: a study of extradural dead space. *Plast Reconstr Surg* 1996;97:1118.
 72. Whitaker LA, Munro IR, Sayler KE, et al. Combined report of problems and complications in 793 craniofacial operations. *Plast Reconstr Surg* 1979;64:198.
 73. David DJ, Cooter RD. Craniofacial infections in 10 years of transcranial surgery. *Plast Reconstr Surg* 1987;80:213.
 74. Marsh JL, Galic M, Vannier MW. Surgical correction of craniofacial dysmorphology of Apert syndrome. *Clin Plast Surg* 1991;18:251.
 75. Saltz R, Sierra D, Feldman D, et al. Experimental and clinical applications of fibrin glue. *Plast Reconstr Surg* 1991;88:1005.
 76. Posnick JC. Craniosynostosis: surgical management in infancy. In: Bell WH, editor. *Orthognathic and reconstructive surgery*. Philadelphia: W.B. Saunders Co.; 1992. p. 1839.
 77. Posnick JC. Brachycephaly: bilateral coronal synostosis without midface deficiency. In: Posnick JC, editor. *Craniofacial and maxillofacial surgery in children and young adults*. Philadelphia: W.B. Saunders Co.; 2000. p. 249-68.
 78. Posnick JC. Crouzon syndrome: evaluation and staging of reconstruction. In: Posnick JC, editor. *Craniofacial and maxillofacial surgery in children and young adults*. Philadelphia: W.B. Saunders Co.; 2000. p. 271-307.
 79. Posnick JC, Goldstein JA, Clokie C. Refinements in pterygomaxillary dissociation for total midface osteotomies: instrumentation, technique and CT scan analysis. *Plast Reconstr Surg* 1993;91:167-72.
 80. Murray JE, Swanson LT. Midface osteotomy and advancement for craniosynostosis. *Plast Reconstr Surg* 1968;41:299-306.
 81. Ortiz-Monasterio F, Fuente del Campo A, Carrillo A. Advancement of the orbits and the midface in one piece, combined with frontal repositioning for the correction of Crouzon syndrome. *Plast Reconstr Surg* 1978;61:507-16.
 82. Ortiz-Monasterio F, Fuente del Campo A. Refinements on the monobloc orbitofacial advancement. In: Caronni EP, editor. *Craniofacial surgery*. Boston: Little, Brown; 1985. p. 263.
 83. Hogeman KE, Willmar K. On Le Fort III osteotomy for Crouzon disease in children: report of

- a four year follow-up in one patient. *Scand J Plast Reconstr Surg* 1974;8:169–72.
84. Van der Meulen JC. Medial faciotomy. *Br J Plast Surg* 1979;32:339–42.
85. Cohen MM Jr. An etiologic and nosologic overview of craniosynostosis syndromes. *Birth Defects Orig Artic Ser* 1975;11:137–89.
86. Cohen MM Jr, Kreiborg S. The central nervous system in the Apert syndrome. *Am J Med Genet* 1990;35:36–45.
87. Kreiborg S, Prydsøe U, Dahl E, Fogh-Anderson. Calvarium and cranial base in Apert syndrome: an autopsy report. *Cleft Palate J* 1976;13:296–303.
88. Ousterhout DK, Melsen B. Cranial base deformity in Apert syndrome. *Plast Reconstr Surg* 1982;69:254–63.
89. Kreiborg S, Cohen MM Jr. The infant Apert skull. *Neurosurg Clin North Am* 1991;2:551–4.
90. Cohen MM Jr, Kreiborg S. Skeletal abnormalities in the Apert syndrome. *Am J Med Genet* 1993;47:624–32.
91. Cohen MM Jr, Kreiborg S. The growth pattern in the Apert syndrome. *Clin Genet* 1993;47:617–23.
92. Park WJ, Theda C, Maestri NE, et al. Analysis of phenotypic features and FGFR2 mutations in Apert syndrome. *Am J Hum Genet* 1995;57:321–8.
93. Slaney SE, Oldridge M, Hurst JA, et al. Differential effects of FGFR2 mutations on syndactyly and cleft plate in Apert syndrome. *Am J Med Genet* 1996;58:923–32.
94. Cohen MM Jr. Transforming growth factor β s and fibroblast growth factors and their receptors: role in sutural biology and craniosynostosis. *J Bone Miner Res* 1997;12:322–31.
95. Posnick JC, Lin KY, Jhawar BJ, Armstrong D. Apert syndrome: quantitative assessment in presenting deformity and surgical results after first-stage reconstruction by CT scan. *Plast Reconstr Surg* 1994;93:489–97.
96. Posnick JC. Apert syndrome: evaluation and staging of reconstruction. In: Posnick JC, editor. *Craniofacial and maxillofacial surgery in children and young adults*. Philadelphia: W.B. Saunders Co.; 2000. p. 308–42.
97. Posnick JC. Craniofacial dysostosis: staging of reconstruction and management of the midface deformity. *Neurosurg Clin N Am* 1991;2:683–702.
98. Posnick JC. Craniofacial dysostosis: management of the midface deformity. In: Bell WH, editor. *Orthognathic and reconstructive surgery*. Philadelphia: W.B. Saunders Co.; 1992. p. 1888.
99. Pfeiffer RA. Dominant Erbliche Akrocephalosyndaktylie. *Z Kinderheilkd* 1964;90:301–20.
100. Cohen MM Jr, editor. *Craniosynostosis: diagnosis, evaluation, and management*. New York: Raven Press; 1986.
101. Jabs EW, Li X, Scott AF, et al. Jackson-Weiss and Crouzon syndromes are allelic with mutations in fibroblast growth factor receptor 2. *Nat Genet* 1994;8:275–9.
102. Cohen MM Jr. Pfeiffer syndrome update, clinical subtypes, and guidelines for differential diagnosis. *Am J Med Genet* 1993;45:300–7.
103. Lajeunie E, Ma HW, Bonaventure J, et al. FGFR2 mutations in Pfeiffer syndrome. *Nat Genet* 1995;9:108.
104. Park WJ, Theda C, Maestri NE, et al. Analysis of phenotypic features and FGFR2 mutations in Apert syndrome. *Am J Hum Genet* 1995;57:321–8.
105. Rutland P, Pulley LJ, Reardon W. Identical mutations in the FGFR2 gene cause both Pfeiffer and Crouzon syndrome phenotypes. *Nat Genet* 1995;9:173–6.
106. Paznekas WA, Cunningham ML, Howard TD, et al. Genetic heterogeneity of Saethre-Chotzen syndrome, due to TWIST and FGFR mutations. *Am J Hum Genet* 1998;62:1370–80.
107. Cohen MM Jr. Cloverleaf syndrome update. *Proc Greenwood Gene Center* 1987;6:186–7.
108. Cohen MM Jr. The cloverleaf anomaly: managing extreme cranio-orbito-facio-stenosis [discussion]. *Plast Reconstr Surg* 1993;91:10–4.

Part 7

**TEMPOROMANDIBULAR
JOINT DISEASE**

Anatomy and Pathophysiology of the Temporomandibular Joint

Mark C. Fletcher, DMD, MD

Joseph F. Piccuch, DMD, MD

Stuart E. Lieblich, DMD

Classification

The temporomandibular joint (TMJ) is composed of the temporal bone and the mandible, as well as a specialized dense fibrous structure, the articular disk, several ligaments, and numerous associated muscles. The TMJ is a compound joint that can be classified by anatomic type as well as by function.

Anatomically the TMJ is a diarthrodial joint, which is a discontinuous articulation of two bones permitting freedom of movement that is dictated by associated muscles and limited by ligaments.¹ Its fibrous connective tissue capsule is well

innervated and well vascularized and tightly attached to the bones at the edges of their articulating surfaces. It is also a synovial joint, lined on its inner aspect by a synovial membrane, which secretes synovial fluid. The fluid acts as a joint lubricant and supplies the metabolic and nutritional needs of the nonvascularized internal joint structures.

Functionally the TMJ is a compound joint, composed of four articulating surfaces: the articular facets of the temporal bone and of the mandibular condyle and the superior and inferior surfaces of the articular disk. The articular disk divides

the joint into two compartments. The lower compartment permits hinge motion or rotation and hence is termed *ginglymoid*. The superior compartment permits sliding (or translatory) movements and is therefore called *arthrodial*. Hence the temporomandibular joint as a whole can be termed *ginglymoarthrodial*.

Bony Structures

The articular portion of the temporal bone (Figure 47-1) is composed of three parts. The largest is the articular or mandibular fossa, a concave structure extending from the posterior slope of the articular emi-

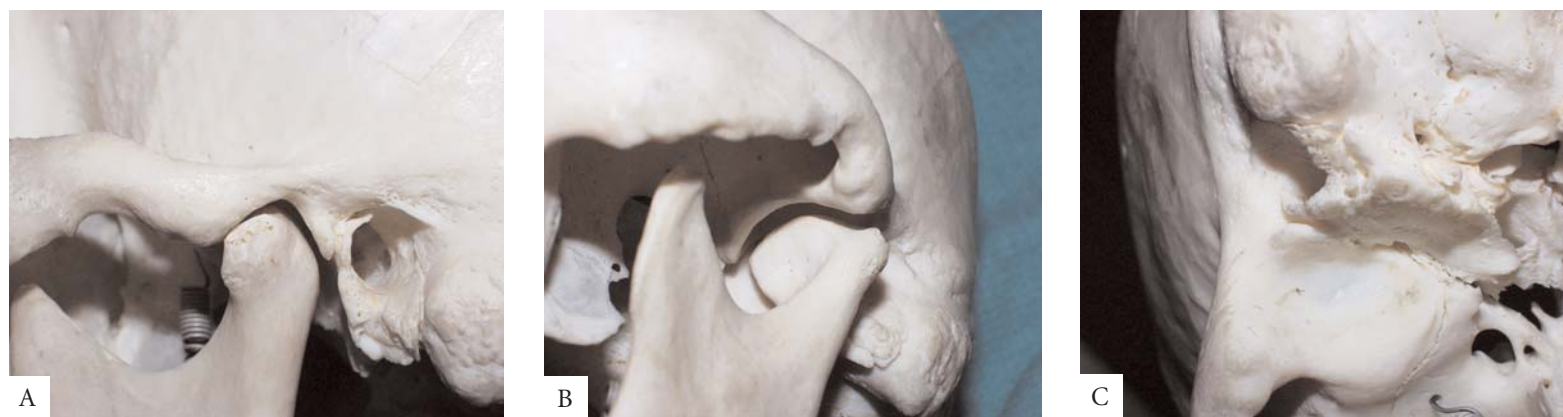

FIGURE 47-1 A, The left temporomandibular joint viewed from the sagittal aspect on a dry skull. B, The left temporomandibular joint viewed from the oblique/coronal aspect on a dry skull. C, The left glenoid fossa and articular eminence.

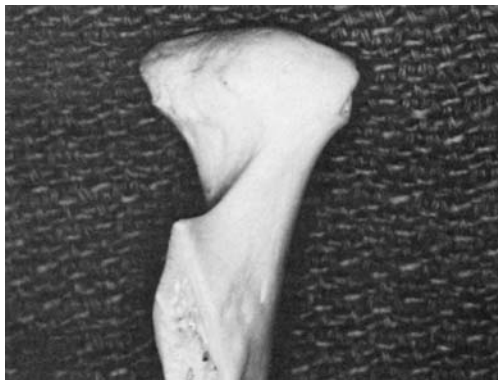

FIGURE 47-2 The mandibular condyle. Reproduced with permission from Piecuch JF, Lieblich SE. *Anatomy and pathology of the temporomandibular joint*. In: Peterson LF, Indresano AT, Marciani RD, Roser SM. *Principles of oral and maxillofacial surgery*. Vol. 3. Philadelphia (PA): J.B. Lippincott Company; 1992. p. 1858.

nence to the postglenoid process, which is a ridge between the fossa and the external acoustic meatus. The surface of the articular fossa is thin and may be translucent on a dry skull. This is not a major stress-bearing area. The second portion, the articular eminence, is a transverse bony prominence that is continuous across the articular surface

mediolaterally. The articular eminence is usually thick and serves as a major functional component of the TMJ. The articular eminence is distinguished from the articular tubercle, a nonarticulating process on the lateral aspect of the zygomatic root of the temporal bone, which serves as a point of attachment of collateral ligaments. The third portion of the articular surface of the temporal bone is the preglenoid plane, a flattened area anterior to the eminence.

The mandible is a U-shaped bone that articulates with the temporal bone by means of the articular surface of its condyles, paired structures forming an approximately 145° to 160° angle to each other. The mandibular condyle (Figure 47-2) is approximately 15 to 20 mm in width and 8 to 10 mm in anteroposterior dimension. The condyle tends to be rounded mediolaterally and convex anteroposteriorly. On its medial aspect just below its articular surface is a prominent depression, the pterygoid fovea, which is the site of attachments of the lateral pterygoid muscle.

Cartilage and Synovium

Lining the inner aspect of all synovial joints, including the TMJ, are two types of tissue: articular cartilage and synovium (Figure 47-3). The space bound by these two structures is termed the *synovial cavity*, which is filled with synovial fluid. The articular surfaces of both the temporal bone and the condyle are covered with dense articular fibrocartilage, a fibrous connective tissue. This fibrocartilage covering has the capacity to regenerate and to remodel under functional stresses. Deep to the fibrocartilage, particularly on the condyle, is a proliferative zone of cells that may develop into either cartilaginous or osseous tissue. Most change resulting from function is seen in this layer.

Articular cartilage is composed of chondrocytes and an intercellular matrix of collagen fibers, water, and a nonfibrous filler material, termed *ground substance*. Chondrocytes are enclosed in otherwise hollow spaces, called lacunae, and are arranged in three layers characterized by different cell shapes (Figure 47-4A). The superficial zone contains small flattened cells with their long axes parallel to the surface.² In the middle zone the cells are larger and rounded and appear in columnar fashion perpendicular to the surface. The deep zone contains the largest cells and is divided by the “tide mark” below which some degree of calcification has occurred. There are few blood vessels in any of these areas, with cartilage being nourished primarily by diffusion from the synovial fluid.

Collagen fibers are arranged in arcades with an interlocking meshwork of fibrils parallel to the articular surface joining together as bundles and descending to their attachment in the calcified cartilage between the tide mark (Figure 47-4B). Functionally these arcades provide a framework for interstitial water and ground substance to resist compressive forces encountered in joint loading. Formed by intramembranous processes the TMJ’s

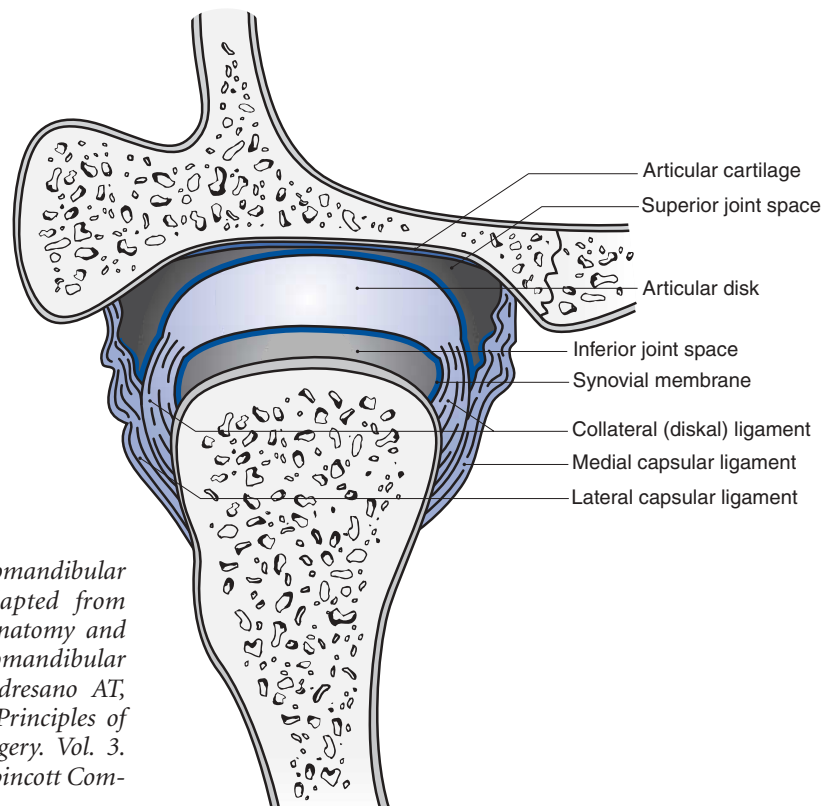


FIGURE 47-3 The temporomandibular joint (coronal view). Adapted from Piecuch JF, Lieblich SE. *Anatomy and pathology of the temporomandibular joint*. In: Peterson LF, Indresano AT, Marciani RD, Roser SM. *Principles of oral and maxillofacial surgery*. Vol. 3. Philadelphia (PA): J.B. Lippincott Company; 1992. p. 1859.

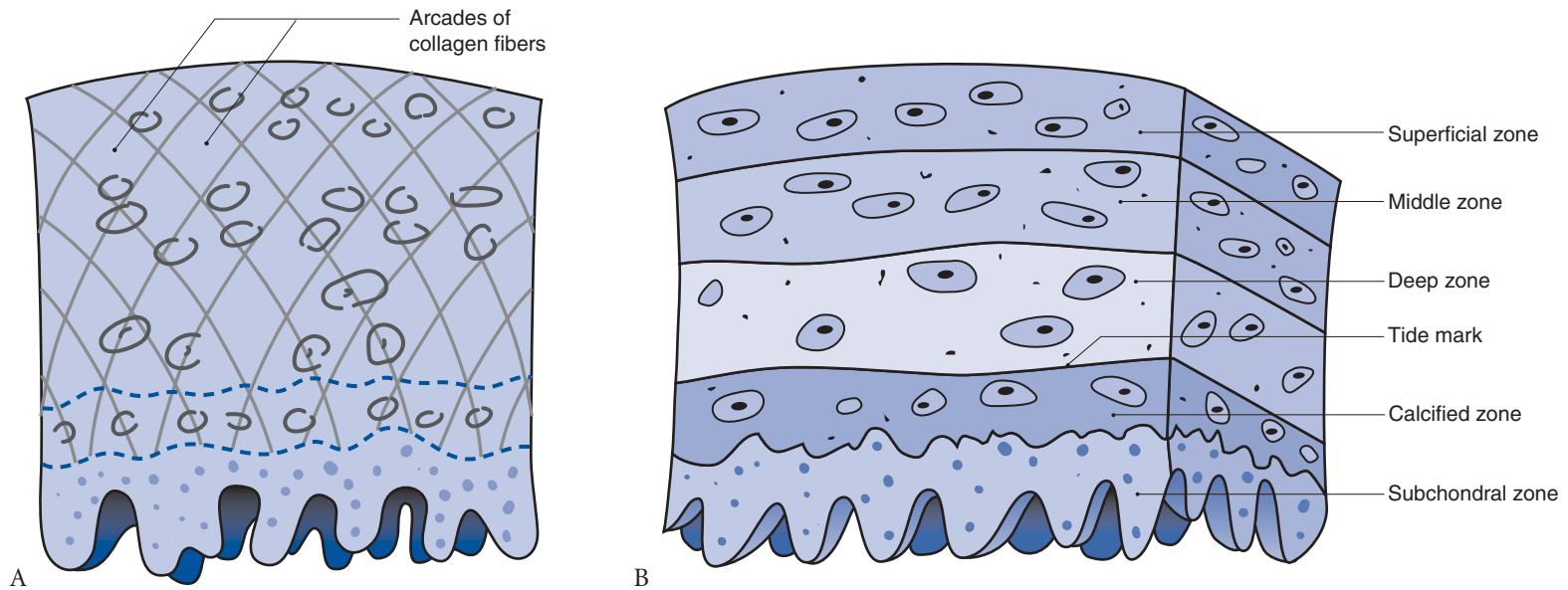


FIGURE 47-4 Articular cartilage. Adapted from Albright JA and Brand RA.²

articular cartilage contains a greater proportion of collagen fibers (fibrocartilage) than other synovial joints, which are covered instead by hyaline cartilage.

The ground substance contains a variety of plasma proteins, glucose, urea, and salts, as well as proteoglycans, which are synthesized by the Golgi apparatus of the chondrocytes. Proteoglycans are macromolecules consisting of a protein core attached to many glycosaminoglycan chains of chondroitin sulfate and keratan sulfate. Proteoglycans play a role in the diffusion of nutrients and metabolic breakdown products. Ground substance permits the entry and release of large quantities of water, an attribute thought to be significant in giving cartilage its characteristic functional elasticity in response to deformation and loading.

Lining the capsular ligament is the synovial membrane, a thin, smooth, richly innervated vascular tissue without an epithelium. Synovial cells, somewhat undifferentiated in appearance, serve both a phagocytic and a secretory function and are thought to be the site of production of hyaluronic acid, a glycosaminoglycan found in synovial fluid. Some synovial cells, particularly those in close approxi-

mation to articular cartilage, are thought to have the capacity to differentiate into chondrocytes. The synovium is capable of rapid and complete regeneration following injury. Recently, synovial cells (as well as chondrocytes and leukocytes) have been the focus of extensive research regarding the production of anabolic and catabolic cytokines within the TMJ.³

Synovial fluid is considered an ultrafiltrate of plasma.² It contains a high concentration of hyaluronic acid, which is thought to be responsible for the fluid's high viscosity. The proteins found in synovial fluid are identical to plasma proteins; however, synovial fluid has a lower total protein content, with a higher percentage of albumin and a lower percentage of α_2 -globulin. Alkaline phosphatase, which may also be present in synovial fluid, is thought to be produced by chondrocytes. Leukocytes are also found in synovial fluid, with the cell count being less than 200 per cubic millimeter and with less than 25% of these cells being polymorphonuclear. Only a small amount of synovial fluid, usually less than 2 mL, is present within the healthy TMJ.

Functions of the synovial fluid include lubrication of the joint, phagocytosis of particulate debris, and nourishment of the

articular cartilage. Joint lubrication is a complex function related to the viscosity of synovial fluid and to the ability of articular cartilage to allow the free passage of water within the pores of its glycosaminoglycan matrix. Application of a loading force to articular cartilage causes a deformation at the location. It has been theorized that water is extruded from the loaded area into the synovial fluid adjacent to the point of contact. The concentration of hyaluronic acid and hence the viscosity of the synovial fluid is greater at the point of load, thus protecting the articular surfaces. As the load passes to adjacent areas the deformation passes on as well, while the original point of contact regains its shape and thickness through the reabsorption of water. Exact mechanisms of flow between articular cartilage and synovial fluid are as yet unclear. Nevertheless the net result is a coefficient of friction for the normally functioning joint—approximately 14 times less than that of a dry joint.

The Articular Disk

The articular disk (Figure 47-5) is composed of dense fibrous connective tissue and is nonvascularized and noninnervated, an adaptation that allows it to resist

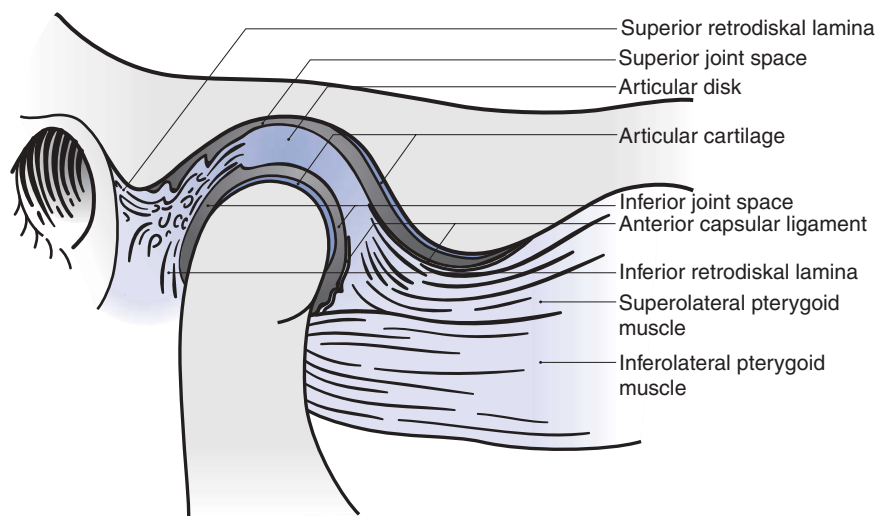


FIGURE 47-5 The temporomandibular joint (lateral view). Adapted from Bell WE.⁴

pressure.⁴ Anatomically the disk can be divided into three general regions as viewed from the lateral perspective: the anterior band, the central intermediate zone, and the posterior band. The thickness of the disk appears to be correlated with the prominence of the eminence. The intermediate zone is thinnest and is generally the area of function between the mandibular condyle and the temporal bone. Despite the designation of separate portions of the articular disk, it is in fact a homogeneous tissue and the bands do not consist of specific anatomic structures. The disk is flexible and adapts to functional demands of the articular surfaces.⁵ The articular disk is attached to the capsular ligament anteriorly, posteriorly, medially, and laterally.⁶ Some fibers of the superior head of the lateral pterygoid muscle insert on the disk at its medial aspect, apparently serving to stabilize the disk to the mandibular condyle during function.

Retrodiskal Tissue

Posteriorly the articular disk blends with a highly vascular, highly innervated structure—the bilaminar zone, which is involved in the production of synovial fluid. The superior aspect of the retrodiskal tissue contains elastic fibers and is termed the *superior retrodiskal lamina*, which attaches to the

tympanic plate and functions as a restraint to disk movement in extreme translatable movements.⁵ The inferior aspect of the retrodiskal tissue, termed the *inferior retrodiskal lamina*, consists of collagen fibers without elastic tissue and functions to connect the articular disk to the posterior margin of the articular surfaces of the condyle. It is thought to serve as a check ligament to prevent extreme rotation of the disk on the condyle in rotational movements.

Ligaments

Ligaments associated with the TMJ are composed of collagen and act predominantly as restraints to motion of the condyle and the disk. Three ligaments—collateral, capsular, and temporomandibular ligaments—are considered functional ligaments because they serve as major anatomic components of the joints. Two other ligaments—sphenomandibular and stylo-mandibular—are considered accessory ligaments because, although they are attached to osseous structures at some distance from the joints, they serve to some degree as passive restraints on mandibular motion.

The collateral (or diskal) ligaments (see Figure 47-3) are short paired structures attaching the disk to the lateral and medial poles of each condyle. Their function is to restrict movement of the disk away from

the condyle, thus allowing smooth synchronous motion of the disk-condyle complex. Although the collateral ligaments permit rotation of the condyle with relation to the disk, their tight attachment forces the disk to accompany the condyle through its translatory range of motion.⁶

The capsular ligament (see Figures 47-3, 47-5, 47-6, and 47-7) encompasses each joint, attaching superiorly to the temporal bone along the border of the mandibular fossa and eminence and inferiorly to the neck of the condyle along the edge of the articular facet. It surrounds the joint spaces and the disk, attaching anteriorly and posteriorly as well as medially and laterally, where it blends with the collateral ligaments. The function of the capsular ligament is to resist medial, lateral, and inferior forces, thereby holding the joint together. It offers resistance to movement of the joint only in the extreme range of motion. A secondary function of the capsular ligament is to contain the synovial fluid within the superior and inferior joint spaces.

The temporomandibular (lateral) ligaments (see Figure 47-7) are located on the lateral aspect of each TMJ.⁵ Unlike the capsular and collateral ligaments, which have medial and lateral components within each

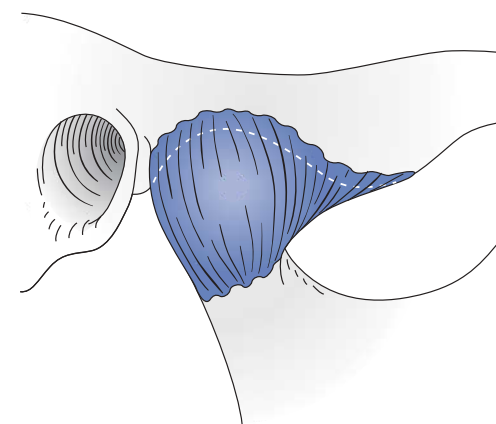


FIGURE 47-6 Capsular ligament (lateral view). Adapted from Piecuch JF, Liebllich SE. *Anatomy and pathology of the temporomandibular joint*. In: Peterson LF, Indresano AT, Marciani RD, Roser SM. *Principles of oral and maxillofacial surgery*. Vol. 3. Philadelphia (PA): J.B. Lippincott Company; 1992. p. 1861.

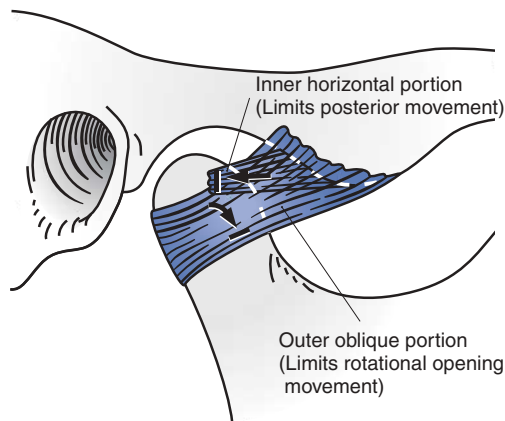


FIGURE 47-7 Temporomandibular joint (lateral aspect). Adapted from Okeson JP.

joint, the temporomandibular ligaments are single structures that function in paired fashion with the corresponding ligament on the opposite TMJ. Each temporomandibular ligament can be separated into two distinct portions, that have different functions.⁶ The outer oblique portion descends from the outer aspect of the articular tubercle of the zygomatic process posteriorly and inferiorly to the outer posterior surface of the condylar neck. It limits the amount of inferior distraction that the condyle may achieve in translatory and rotational movements. The inner horizontal portion also arises from the outer surface of the articular tubercle, just medial to the origin of the outer oblique portion of the ligament, and runs horizontally backward to attach to the lateral pole of the condyle and the posterior aspect of the disk. The function of the inner horizontal portion of the temporomandibular ligament is to limit posterior movement of the condyle, particularly during pivoting movements, such as when the mandible moves laterally in chewing function. This restriction of posterior movement serves to protect the retrodiskal tissue.

The sphenomandibular ligament (Figure 47-8) arises from the spine of the sphenoid bone and descends into the fan-like insertion on the mandibular lingula, as well as on the lower portion of the medial side of the condylar neck.¹ The sphenomandibular ligament serves to some degree

as a point of rotation during activation of the lateral pterygoid muscle, thereby contributing to translation of the mandible.

The stylomandibular ligament (see Figure 47-8) descends from the styloid process to the posterior border of the angle of the mandible and also blends with the fascia of the medial pterygoid muscle. It functions similarly to the sphenomandibular ligament as a point of rotation and also limits excessive protrusion of the mandible.

Vascular Supply and Innervation

The vascular supply of the TMJ arises primarily from branches of the superficial temporal and maxillary arteries posteriorly and the masseteric artery anteriorly. There is a rich plexus of veins in the posterior aspect of the joint associated with the retrodiskal tissues, which alternately fill and empty with protrusive and retrusive movements, respectively, of the condyle-disk complex and which also function in the production of synovial fluid. The nerve supply to the TMJ is predominantly from branches of the auriculotemporal nerve with anterior contributions from the masseteric nerve and the posterior deep temporal nerve.¹ Many of the nerves

to the joint appear to be vasomotor and vasosensory, and they may have a role in the production of synovial fluid.

Musculature

All muscles attached to the mandible influence its movement to some degree. Only the four large muscles that attach to the ramus of the mandible are considered the muscles of mastication; however, a total of 12 muscles actually influence mandibular motion, all of which are bilateral.¹ Muscle pairs may function together for symmetric movements or unilaterally for asymmetric movement. For example, contraction of both lateral pterygoid muscles results in protrusion and depression of the mandible without deviation, whereas contraction of one of the lateral pterygoid muscles results in protrusion and opening with deviation to the opposite side.

Muscles influencing mandibular motion may be divided into two groups by anatomic position. Attaching primarily to the ramus and condylar neck of the mandible is the supramandibular muscle group, consisting of the temporalis, masseter, medial pterygoid, and lateral pterygoid muscles. This group functions predominantly as the elevators of the

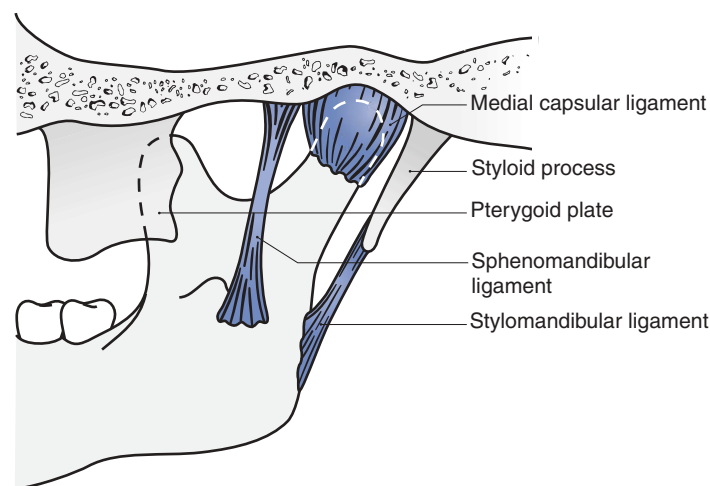


FIGURE 47-8 Temporomandibular ligament (medial view). Adapted from Piecuch JE, Lieblisch SE. *Anatomy and pathology of the temporomandibular joint*. In: Peterson LF, Indresano AT, Marciani RD, Roser SM. *Principles of oral and maxillofacial surgery*. Vol. 3. Philadelphia (PA): J.B. Lippincott Company; 1992. p. 1863.

mandible. The lateral pterygoid does have a depressor function as well.⁷ Attaching to the body and symphyseal area of the mandible and to the hyoid bone is the inframandibular group, which functions as the depressors of the mandible. The inframandibular group includes the four suprahyoid muscles (digastric, geniohyoid, mylohyoid, and stylohyoid) and the four infrahyoid muscles (sternohyoid, omohyoid, sternothyroid, and thyrohyoid). The suprahyoid muscles attach to both the hyoid bone and the mandible and serve to depress the mandible when the hyoid bone is fixed in place. They also elevate the hyoid bone when the mandible is fixed in place. The infrahyoid muscles serve to fix the hyoid bone during depressive movements of the mandible.

Supramandibular Muscle Group

The temporalis muscle (Figure 47-9) is a large fan-shaped muscle taking its origin from the temporal fossa and lateral aspect of the skull, including portions of the parietal, temporal, frontal, and sphenoid bones. Its fibers pass between the zygomatic arch and the skull and insert on the

mandible at the coronoid process and anterior border of the ascending ramus down to the occlusal surface of the mandible, posterior to the third molar tooth.¹ Viewed coronally the temporalis muscle has a bipennate character in that fibers arising from the skull insert on the medial aspect of the coronoid process, whereas fibers arising laterally from the temporalis fascia insert on the lateral aspect of the coronoid process. In an anteroposterior dimension the temporalis muscle consists of three portions: the anterior, whose fibers are vertical; the middle, with oblique fibers; and the posterior portion, with semihorizontal fibers passing forward to bend under the zygomatic arch. The function of the temporalis muscle is to elevate the mandible for closure. It is not a power muscle. In addition contraction of the middle and posterior portions of the temporalis muscle can contribute to retrusive movements of the mandible. To a small degree unilateral contraction of the temporalis assists in deviation of the mandible to the ipsilateral side.

The masseter muscle (Figure 47-10), a short rectangular muscle taking its origin

from the zygomatic arch and inserting on the lateral surface of the mandible, is the most powerful elevator of the mandible and functions to create pressure on the teeth, particularly the molars, in chewing motions. The masseter muscle is composed of two portions, superficial and deep, which are incompletely divided, yet have somewhat different functions. The superficial portion originates from the lower border of the zygomatic bone and the anterior two-thirds of the zygomatic arch and passes inferiorly and posteriorly to insert on the angle of the mandible. The deep head originates from the inner surface of the entire zygomatic arch and on the posterior one-third of the arch from its lower border. The deep fibers pass vertically to insert on the mandible on its lateral aspect above the insertion of the superficial head. The superficial portion in particular has a multipennate appearance with alternating tendinous plates and fleshy bundles of muscle fibers, which serve to increase the power of the muscle. Both the superficial and deep portions of the masseter muscle are powerful elevators of the mandible, but they function independently and reciprocally in other movements. Electromyographic studies show that the deep layer of the masseter is always silent during protrusive movements and always active during forced retrusion, whereas the superficial portion is active during protrusion and silent during retrusion.⁸ Similarly the deep masseter is active in ipsilateral movements but does not function in contralateral movements, whereas the superficial masseter is active during contralateral movements but not in ipsilateral movements.

The medial pterygoid muscle (Figure 47-11) is rectangular and takes its origin from the pterygoid fossa and the internal surface of the lateral plate of the pterygoid process, with some fibers arising from the tuberosity of the maxilla and the palatine bone. Its fibers pass inferiorly and insert on the medial surface of the mandible,

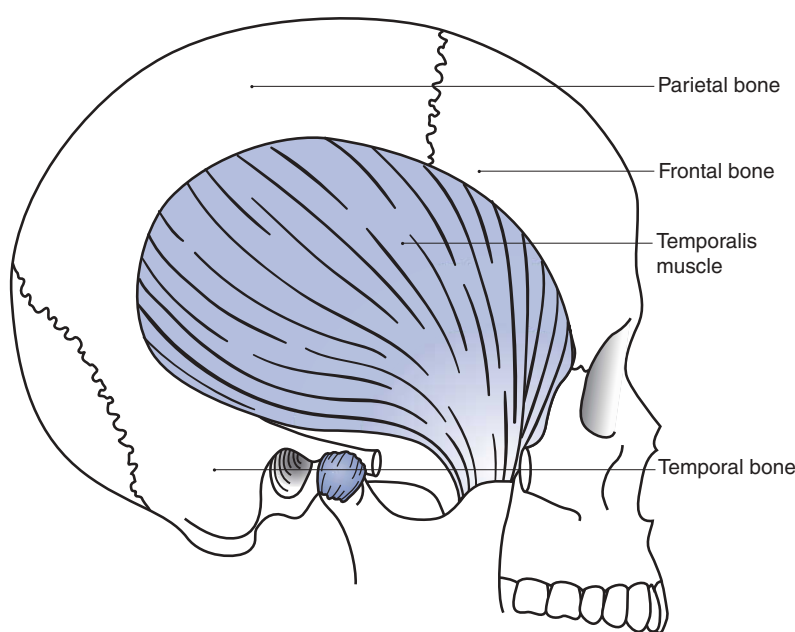


FIGURE 47-9 The temporalis muscle with the zygomatic arch and masseter muscle removed. Adapted from Clemente CD.⁵¹

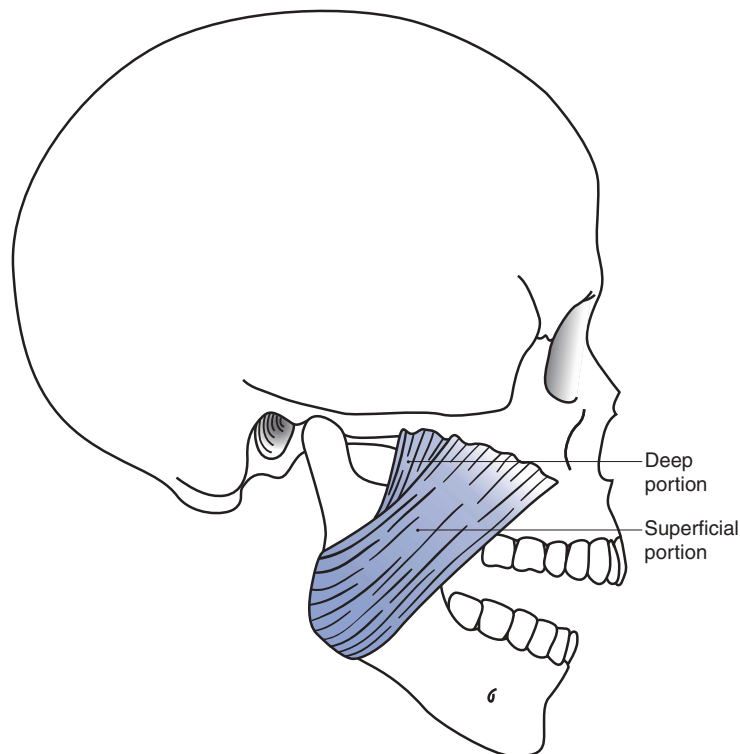


FIGURE 47-10 The masseter muscle. Adapted from Picuch JE, Lieblisch SE. *Anatomy and pathology of the temporomandibular joint*. In: Peterson LF, Indresano AT, Marciani RD, Roser SM. *Principles of oral and maxillofacial surgery*. Vol. 3. Philadelphia (PA): J.B. Lippincott Company; 1992. p. 1865.

inferiorly and posteriorly to the lingual. Like the masseter muscle the medial pterygoid fibers have alternating layers of fleshy and tendinous parts, thereby increasing the power of the muscle. The main function of the medial pterygoid is elevation of the mandible, but it also functions somewhat in unilateral protrusion in a synergism with the lateral pterygoid to promote rotation to the opposite side.

The lateral pterygoid muscle (see Figure 47-11) has two portions that can be considered two functionally distinct muscles. The larger inferior head originates from the lateral surface of the lateral pterygoid plate.⁹ Its fibers pass superiorly and outward to fuse with the fibers of the superior head at the neck of the mandibular condyle, inserting into the pterygoid fovea. The superior head originates from the infratemporal surface of the greater sphenoid wing, and its fibers pass inferiorly, posteriorly, and outward to insert in the superior aspect of the pterygoid

fovea, the articular capsule, and the articular disk at its medial aspect, as well as to the

medial pole of the condyle. Anatomic studies have shown that the majority of the superior head fibers insert into the condyle rather than the disk.

The inferior and superior heads of the lateral pterygoid muscle function independently and reciprocally.^{8,10} The primary function of the inferior head is protrusive and contralateral movement. When the bilateral inferior heads function together, the condyle is pulled forward down the articular eminence, with the disk moving passively with the condylar head. This forward movement of the condyle down the inclined plane of the articular eminence also contributes to opening of the oral cavity. When the inferior head functions unilaterally the resulting medial and protrusive movement of the condyle results in contralateral motion of the mandible. The function of the superior head of the lateral pterygoid muscle is predominantly involved with closing movements of the jaw and with retrusion and ipsilateral movement. A summary of the movements of the lateral pterygoid muscle and the other supramandibular muscles is given in Table 47-1.

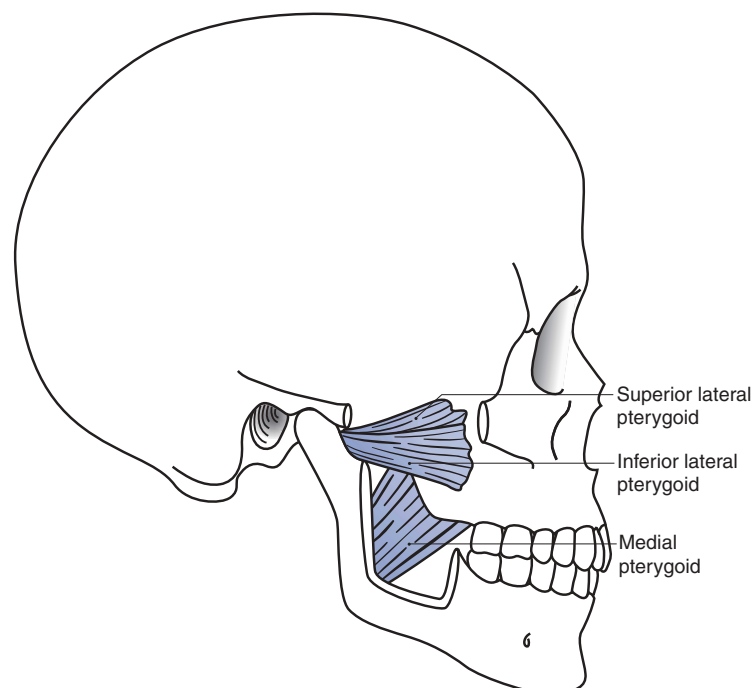


FIGURE 47-11 Medial and lateral pterygoid muscles. Adapted from Clemente CD.⁵¹

Table 47-1 Contributions of the Supramandibular Muscles of Mastication to Movements of the Jaw as Confirmed by Electromyography

<i>Muscles</i>	<i>Movement</i>
Medial pterygoid	Closure, protrusion
Lateral pterygoid (inferior head)	Protrusion, opening contralateral
Lateral pterygoid (superior head)	Retrusion, closure, ipsilateral
Masseter, superficial layer	Protrusion, closure contralateral
Masseter, deep layer	Retrusion, closure ipsilateral
Temporalis, anterior portion	Closure
Temporalis, posterior portion	Retrusion, closure ipsilateral

Adapted from Gay T and Piecuch J.⁸

Inframandibular Muscle Group

The inframandibular muscles can be subdivided into two groups: the suprahyoids and the infrahyoids. The suprahyoid group consists of the digastric, geniohyoid, mylohyoid, and stylohyoid muscles; lies between the mandible and the hyoid bone; and serves to either raise the hyoid bone, if the mandible is fixed in position by the supramandibular group, or depress the mandible, if the hyoid bone is fixed in position by the infrahyoids. The infrahyoid group, consisting of the sternohyoid, omohyoid, sternothyroid, and thyrohyoid muscles, attaches to the hyoid bone superiorly and to the sternum, clavicle, and scapula inferiorly. This group of muscles can either depress the hyoid bone or hold the hyoid bone in position, relative to the trunk, during opening movements of the mandible.

Biomechanics of Temporomandibular Joint Movement

Complex free movements of the mandible are made possible by the relation of four distinct joints that are involved in mandibular movement: the inferior and superior joints—bilaterally. Two types of movement are possible: rotation and translation.

The inferior joints, consisting of the condyle and disk, are responsible for rotation, a hinge-like motion. The center of rotation is considered to be along a horizon-

tal axis passing through both condyles.^{4,5} In theory pure hinge motion of approximately 2.5 cm measured at the incisal edges of the anterior teeth is possible. Nevertheless most mandibular movements are translatory as well, involving a gliding motion between the disk and the temporal fossa, which are the components of the superior joints. The mandible and disk glide together as a unit because they are held together by the collateral ligaments. The maximum forward and lateral movement of the upper joint in translation is approximately 1.5 cm.

All movements of the mandible, whether symmetric or asymmetric, involve close contact of the condyle, disk, and articular eminence. Pure opening, closing, protrusive, and retrusive movements are possible as a result of bilaterally symmetric action of the musculature. Asymmetric movements, such as those seen in chewing, are made possible by unilateral movements of the musculature with different amounts of translation and rotation occurring within the joints on either side.

The positioning of the condyle and disk within the fossa, as well as the constant contact between the condyle, disk, and eminence, is maintained by continuous activity of the muscles of mastication, particularly the supramandibular group. The ligaments associated with the TMJ do not move the joint. Although they can be lengthened by movements of muscles, they do not stretch (ie, do not have an elastic recoil that returns them to a resting position automatically).

Instead the role of the ligaments is that of a passive restriction of movement at the extreme ranges of motion. During normal function rotational and translational movements occur simultaneously, permitting the free range of motion necessary in speaking and chewing.

Pathology of the Temporomandibular Joint

The demand for treatment of temporomandibular joint dysfunction (TMJD) is well known. Most studies estimate the prevalence of clinically significant TMJ-related jaw pain to be at least 5% of the general population. Approximately 2% of the general population seeks treatment for a TMJ-related symptom.^{11,12} TMJD may be the result of muscular hyperfunction or parafunction, and/or underlying primary or secondary degenerative changes within the joint. It is important to note however that no single causative factor leading to TMJD has been unequivocally demonstrated in scientifically based studies.¹³ Classification of TMJD is separated into nonarticular and articular categories and has been eloquently described by de Bont and colleagues.¹³

Nonarticular disorders include muscle disorders such as myofascial dysfunction, muscle spasm (with splinting, pain, and muscle guarding), and myositis. Articular disorders, often accompanied by internal derangement, include noninflammatory and inflammatory arthropathies, growth disorders, and connective tissue disorders. In diagnosing and treating TMJD it is helpful to assess patients with the above classification as a frame of reference Table 47-2. Treatment modalities can vary significantly depending on this classification.

Nonarticular Temporomandibular Disorders

Nonarticular TMJ disorders most commonly manifest as masticatory muscle dysfunction. Approximately one-half or more of all TMJDs are forms of masticatory

Table 47-2 General Classification of Synovial Disorders

<i>Articular Disorders</i>
Noninflammatory arthropathies
Primary osteoarthritis (no clear predisposing factor)
Secondary osteoarthritis (trauma, previous surgery, avascular necrosis)
Mechanical derangements
Bone and cartilage disorders with articular manifestations
Inflammatory arthropathies
Synovitis
Capsulitis
Rheumatoid arthritis
Juvenile rheumatoid arthritis
Seronegative polyarthritis
Ankylosing spondylitis
Psoriatic arthritis
Reactive arthritis (bacterial, viral, fungal)
Growth disorders
Non-neoplastic: developmental (hyperplasia, hypoplasia, dysplasia)
Non-neoplastic: acquired (ie, condylolysis)
Neoplasm
Pseudotumors (synovial chondromatosis)
Benign (chondroma, osteotoma)
Malignant (primary, metastatic)
Diffuse connective tissue disorders
Miscellaneous articular disorders
<i>Nonarticular Disorders</i>
Muscle disorders
Muscle spasm (strain)
Myofascial pain and dysfunction (MPD)
Fibromyalgia
Myotonic dystrophies
Myositis ossificans progressiva
Growth disorders
Adapted from de Bont L et al. ¹³

myalgia.^{14,15} They include such conditions such as acute muscle strain and spasm, myofascial pain and dysfunction (MPD), chronic conditions such as fibromyalgia, and less commonly, myotonic dystrophies and myositis ossificans. They invariably contribute to decreased mandibular range of motion and pain. The important role of

the supramandibular and inframandibular muscle groups on mandibular movement and function is evident in these conditions. Other nonarticular disorders include growth disorders affecting TMJ function and miscellaneous factors such as heterotopic bone formation leading to TMJD.

MPD is most commonly related to masseter or temporalis muscle spasm.¹⁶ Additionally it can involve the pterygoids or any combination of the supramandibular or inframandibular muscle groups. Parafunctional habits such as bruxism and jaw clenching are thought to be the main contributors to MPD and have also been found to be causative in acute closed-lock conditions. The literature is replete with various treatment modalities for MPD. Such treatments include occlusal adjustments (for gross discrepancies), night-guard appliances (for joint unloading, jaw repositioning, and occlusal protection), nonsteroidal anti-inflammatory medications, muscle relaxants, and physical therapy. These treatment modalities, alone or in combination, remain the standard of care for the treatment of nonarticular TMJD, particularly MPD.

Fibromyalgia is a systemic condition marked by poor sleep, generalized pain with absence of localization to joints, and a history of somatization in other organ systems such as irritable bowel syndrome and headaches.¹⁷ It is typically observed in an older population than MPD and has a female predilection. Fibromyalgia is often difficult to differentiate from MPD and is treated in similar fashion; that is, nonsurgically, with anti-inflammatory medications, dietary modifications, home-care techniques, bite appliances, and physical therapy. There appears to be a poorer overall response to the treatment of fibromyalgia when compared with MPD.

Rarely other nonarticular conditions such as myotonic dystrophy and myositis ossificans progressiva can lead to signifi-

cant loss of function and pain in the TMJ region. Myotonic dystrophy is a dominantly inherited multisystem disorder that may affect facial muscles in fully developed disease states.¹⁸ This condition may contribute to atrophy and fibrosis of the supramandibular and inframandibular musculature. Clinically there are a variety of types of myotonic dystrophies. They tend to exert their pathologic effects in similar fashion, sometimes resulting in trismus, loss of function, and pain. Myositis ossificans progressiva is a rare condition resulting in fibrosis of soft tissues after apparent minor trauma. This condition has been reported to affect TMJ function after local trauma, including surgery, and can result in significant loss of mandibular range of motion, trismus, and pain.¹⁹ Soft tissue ossification can sometimes occur after head trauma, severe burns, or neurogenic stimulus. In these cases heterotopic bone formation is observed and can lead to ankylosis in multiple joints throughout the body including the TMJ.²⁰

Articular Temporomandibular Disorders

Noninflammatory articular disorders of the TMJ, the most common of which is osteoarthritis, are often idiopathic. Osteoarthritis can manifest as chondromalacia (softening of the cartilage), temporary or permanent disk displacement, degenerative changes within bone and cartilage often with osteophyte formation and remodeling, fibrosis, or any combination of the above. Noninflammatory articular disorders may also be secondary to trauma, infection, previous surgery, crystal deposition disorders (gout and pseudogout), avascular necrosis, or structural damage to joint cartilage resulting in disk displacement and/or perforation (Figure 47-12). TMJ disk displacement has been categorized through a widely accepted staging system by Wilkes, using such criteria as severity of displacement and chronicity (Table 47-3).²¹

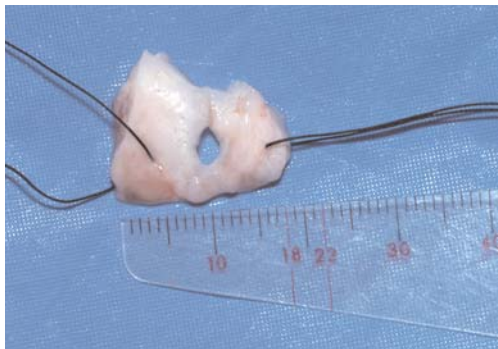


FIGURE 47-12 Perforated disk (Wilkes stage V patient).

Noninflammatory arthropathies are distinctly limited in their amount of overt inflammation and may be clinically silent or focal in nature. Alternatively if the condition becomes more severe, symptoms will ensue. If degenerative changes progress to synovitis, joint effusion (secondary to increased vascular permeability), or capsulitis, it is then considered to have transformed into an inflammatory arthropathy.

Inflammatory arthropathies are primarily due to such conditions as rheumatoid arthritis, juvenile rheumatoid arthritis, ankylosing spondylitis, psoriatic arthritis, or arthritis resulting from infectious causes (see Table 47-2). Secondary causes of inflammatory arthropathies include synovitis, capsulitis, traumatic arthritis, or acute inflamed crystal-induced arthritis, such as gout. As discussed previously non-inflammatory arthropathies can progress to the inflammatory types through increasing concentrations of degradation products within the joint. Degenerative changes resulting in the release of inflammatory mediators have been demonstrated to worsen the degree of tissue destruction and dysfunction within the TMJ. This pathologic inflammatory cascade has been the primary focus of current TMJ research.

The past decade has shed new light on the cause and treatment of articular disorders (mainly, internal derangement) of the TMJ. Gross evaluation of disk position and disk integrity has traditionally been the mainstay of diagnosis and surgical treat-

ment. More recently the physiologic activity of synovial cells, chondrocytes, and inflammatory cells in symptomatic joints have been associated with pathogenesis. This fundamental shift in focus has changed the primary treatment approach from open-joint surgery aimed at restoring the functional anatomy of the TMJ, to less invasive techniques directed toward lysis of adhesions and intracapsular lavage.²² TMJ arthrocentesis and arthroscopy are thought to achieve an alteration in the joint milieu favoring a reduction in symptoms and improved joint function. Open-joint surgery nonetheless may still have a role in severe degenerative disease when preoperative criteria are met and surgery is indicated.

Milam and Schmitz have proposed a variety of molecular biologic mechanisms for TMJD.²³ Synovoid cells, chondrocytes, and inflammatory cells in the TMJ produce a physiologic balance between anabolic and catabolic cytokines.²³ Anabolic cytokines such as insulin-like growth factor-I and transforming growth factor beta are instrumental in the formation of extracellular joint matrix molecules. Collagen, proteoglycans, and glycoproteins are essential in load-bearing joints like the TMJ. Alternatively catabolic cytokines such as interleukin-1 (IL-1), IL-6, and tumor necrosis factor alpha (TNF- α) have been identified with the formation of proteases within the TMJ. These proteases (aspartic, cysteine, serine, and metalloproteases, among others) operate at low and neutral pH to exert their pathologic effects leading to degenerative changes.

Oxidative stress, often found associated with pathologic joints, is thought to contribute to free radical formation in the TMJ. The presence of free radicals has been postulated as an amplifying factor in the activation of cytokines, enzymes, neuropeptides, and arachidonic acid metabolites leading to degenerative joint disease.²⁴ Nitric oxide, a free radical involved in regulating vascular tone, has been observed at higher concentrations in arthritic joints. Nitric oxide has

direct effects on prostaglandin synthesis and cyclooxygenase-2 enzymes leading to synovial inflammation and tissue destruction.²⁵ In a normal functioning joint a delicate balance is maintained between anabolic and catabolic mechanisms. In symptomatic joints catabolic processes have been found to exert greater overall effects thus disrupting the balance between anabolic physiologic maintenance and the negative effects of catabolic cytokines.

TMJ synovial fluid analysis has proven to be an excellent vehicle for evaluating the proposed contribution of cytokines, proteinases, and other catabolites to TMJD. Multiple independent studies support the hypothesis of catabolic imbalance within the joint. Kubota and colleagues demonstrated increased levels of IL-1 β , IL-6, and active matrix metalloproteinases in TMJs with internal derangement and osteoarthritis when compared with control samples.²⁶ This study suggests the presence of elevated concentrations of these cytokines and proteinases serving as potential catabolic markers for cartilage degradation in the human TMJ. Murakami and colleagues reported high concentrations of chondroitin-4 and chondroitin-6 sulfates compared with hyaluronic acid in the TMJ synovial fluid of patients with internal derangement suggesting glycosaminoglycan components as markers of joint pathology.²⁷ Israel and colleagues demonstrated the prevalence of synovitis and osteoarthritis through arthroscopic evaluation in symptomatic TMJs.²⁸ These findings correlated with increased levels of keratan sulfate in the synovial fluid

Table 47-3 Wilkes Classification

Stage I	Early reducing disk displacement
Stage II	Late reducing disk displacement
Stage III	Nonreducing disk displacement: acute/subacute
Stage IV	Nonreducing disk displacement: chronic
Stage V	Nonreducing disk displacement: chronic with osteoarthritis

of these joints suggesting its role as a potential biochemical marker for articular cartilage degradation.²⁸ Recently osteoclastogenesis inhibitory factor/osteoprotegerin (OCIF/OPG), a member of the TNF receptor family, has been studied in synovial fluid samples of TMJD patients.²⁹ Increased osteoclastic activity has been seen histologically in diseased mandibular condyles. Osteoclast differentiation requires cell-to-cell contact between osteoclast progenitors and bone marrow stromal cells. The presence of OCIF/OPG is thought to inhibit osteoclast differentiation by preventing the cell-to-cell contact needed for such activity. Synovial fluid samples in this study demonstrated decreased amounts of OCIF/OPG in osteoarthritic and internally deranged joints suggesting its physiologically important function in healthy joints. Although further investigation of synovial fluid components in TMJD is necessary to formulate definitive conclusions, it continues to shed new light on the pathogenesis and treatment of such disorders.

Treatment of patients with internal derangement of the TMJ typically begins with nonsurgical treatment modalities. Bite appliance therapy, diet modifications, nonsteroidal anti-inflammatory medications, muscle relaxants, moist heat or ice, and physical therapy have been found to be efficacious.³⁰ Surgical intervention is typically employed only after failure of nonsurgical treatment objectives.

A variety of surgical treatment modalities have been used in the treatment of articular TMJD. Arthrocentesis and TMJ arthroscopy have been found to be minimally invasive effective treatments for articular TMJD by decreasing pain and increasing mandibular range of motion. (Surgical techniques for arthroscopy are addressed in Chapter 49, "Temporomandibular Joint Arthrocentesis and Arthroscopy: Rationale and Technique.") Indications for these modalities include, but are not limited to, acute closed-lock degenerative joint disease accompanied by pain and limited range of

motion and joint effusion. Arthrocentesis and arthroscopy have also been reported to be useful in severe, often sudden onset, closed-lock disease due to an anchored or "stuck disk" phenomenon. This proposed phenomenon involves the disk becoming adherent to the glenoid fossa through increased intra-articular friction, with or without the formation of adhesions within the joint. Lysis of adhesions with joint lavage has been reported efficacious in restoring mandibular range of motion and decreasing pain in these clinical scenarios.^{31,32} TMJ arthrocentesis and arthroscopy show promising results using the above criteria of pain symptoms and mandibular range of motion.³³ Based on the pathophysiology discussed in this chapter, a hypothesis explaining the efficacy of joint lavage relates to a proposed alteration in the biochemical constituents of the joint fluid, thus shifting the balance toward anabolic processes while reducing the amount of active catabolites contained within the joint.³⁴

Indications for open arthrotomy include but are not limited to joint ankylosis, the need for reconstruction due to condylar resorption or growth disturbance, history of previous surgery, removal of foreign bodies, neoplasia, trauma, or severe degenerative disease precluding less invasive interventions. (Indications and techniques for open TMJ surgery are addressed more thoroughly in Chapter 50, "Surgery for Internal Derangements of the Temporomandibular Joint," and Chapter 51, "Management of the Patient with End-Stage Temporomandibular Joint Disease.") Open-joint surgery is primarily based on restoration of the functional anatomy of the TMJ when less invasive techniques are not feasible or unsuccessful. Recent data suggest comparable outcomes between open and closed surgery in the TMJ with lower morbidity associated with the latter.³⁵ Open TMJ surgery remains a viable treatment option at the end of the surgical treatment algorithm. New insight into the pathogenesis of TMJD has opened the

door to less invasive (albeit equally effective) treatment options for a large number of TMJD patients.

Infections of the Temporomandibular Joint

Infections of the TMJ are not common. Prompt diagnostic and therapeutic intervention is required when an infection of the TMJ is suspected because joint distention is usually painful and permanent changes in joint function can occur. On examination patients usually exhibit a posterior open bite on the ipsilateral side as a result of the increased joint fluid. The patient will also maintain a posture toward the contralateral side.³⁶ The surface overlying an infected joint is often warm, and fluctuance is occasionally felt.

The bacteria causing an infected joint are usually spread through a hematogenous route. The synovium is vascular and lacks a basement membrane, which permits bloodborne bacteria to gain access to the joint space.³⁷ Joints with underlying arthritic disease tend to be more susceptible to distant infection. Although the source of the bacteria is usually at a distant site, spread from dental infections of maxillary teeth has been reported in which the bacteria are thought to spread through the pterygoid plexus of veins to the joint.³⁸ Direct inoculation of a joint area following a traumatic injury is also possible. Complications of infections of the TMJ include fistula formation, fibrosis or bony ankylosis, temporal bone osteomyelitis, and intracranial abscess formation.

A thorough history and review of systems aids in the diagnosis of acute infectious arthritis of the TMJ. Active infection in adjacent sites, especially the ipsilateral maxillary molars, should be searched for. Other joints must be assessed to determine if they are involved. Initially aspiration of the joint should be considered to both relieve the pain from the joint capsular distention and to help in the identification

of the infecting organism(s). The aspiration is performed by using a 20-gauge or larger needle under sterile conditions. The synovial fluid should be Gram stained and cultured for both aerobic and anaerobic bacteria. Sedation or general anesthesia may be required for the arthrocentesis.

In sexually active adults 60% of general acute infectious arthritis is due to *Neisseria gonorrhoeae*.³⁹ The majority of these patients have a prodrome of malaise, anorexia, headaches, fever, and chills. A few days of migratory arthritis usually precedes the localization of infection in one or two joints. Markowitz and Gerry reported a TMJ involvement rate of 3% in patients with disseminated gonococcal arthritis.⁴⁰ In children under 2 years of age almost 50% of acute infectious arthritis is due to *Haemophilus influenzae*. No reports of TMJ involvement are available. Other gram-positive cocci have been isolated from TMJ infections in all age groups, including staphylococci (particularly in the elderly) and β -hemolytic streptococci. The adherence characteristics of *Staphylococcus aureus* and *Neisseria gonorrhoeae* to synovium account for their prevalence.⁴¹ Thus, the best choice for initial empiric antibiotic therapy for an acute infectious TMJ arthritis is an agent that combines a penicillin with a β -lactamase inhibitor. The combination of ampicillin and sulbactam will cover infections from the staphylococcal and streptococcal groups. Sulbactam, a derivative of penicillin, inactivates bacteria-produced β -lactamase and also has direct bactericidal activity against the *Neisseria* organisms. Therefore, this combination may have an advantage over the combination of a penicillin and clavulanic acid. It should be noted that bacterial resistance has become increasingly more problematic. Reference to up-to-date antibiotic regimens is recommended.

Effective treatment of septic arthritis by oral antibiotics has not been well studied, therefore the parenteral administra-

tion of antibiotics should be used initially.³⁷ Choices include ampicillin and sulbactam (Unasyn) 3 g intravenous (IV) every 6 hours, or clindamycin 600 mg IV every 6 hours in penicillin-allergic patients. A third generation cephalosporin, cefotaxime 6 to 12 g IV per day, could be used for a gram-negative infection in a nonhospitalized patient.³⁷ Tobramycin 3 mg/kg/day in four doses should be considered to treat a possible presence of *Pseudomonas aeruginosa* in infections that develop in hospitalized or immunocompromised patients.

The duration of treatment depends on the clinical response and the organism isolated. Based on information available for treatment of septic arthritis involving *Neisseria gonorrhoeae*, the patient with a septic TMJ could be placed on oral ampicillin or tetracycline after a 2-week course of IV therapy. Reportedly infections involving *Staphylococcus aureus* and gram-negative bacilli require 4 weeks of total therapy, and 2 to 3 weeks of therapy is adequate for streptococci and *Haemophilus* species.⁴² Thus, it appears that a 30-day total course of antibiotic therapy for acute TMJ infection is appropriate.

In addition to culture and sensitivity testing, the aspirate from the infected joint should be submitted for white blood cell (WBC) count and differential, and examined for the presence of crystals and fibrinogen. Fibrinogen is usually present in the synovial fluid of acutely infected joints. Therefore, some of the synovial fluid collected should be placed into a heparinized tube to prevent clotting. It is important to note that ethylenediaminetetraacetic acid (EDTA) interferes with crystal analysis, therefore synovial fluid should not be placed in tubes containing it. The synovial fluid of an inflamed joint commonly contains greater than 2,000 WBC/mm³ (normal < 200 WBC/mm³). Septic joints normally have WBC counts greater than 50,000/mm³. The cells are primarily mononuclear, as opposed to a predominance of polymorphonuclear cells in

infected joint fluid. An exception to this occurs in fungal or mycobacterial joint infections in which the synovial fluid usually contains less than 20,000 WBC/mm³ and shows a greater proportion of mononuclear cells.⁴³

Following the institution of antibiotic therapy, lavage of the joint may be useful. Removing the joint fluid containing the products of the inflammation, reducing the bacterial load within the joint, and relieving the joint distention will usually markedly relieve the patient's symptoms and may also decrease the likelihood of spread to the temporal bone. Murakami and colleagues have reported on the use of the arthroscope for monitoring and treating an acutely infected TMJ.³⁸

Following the resolution of an acute TMJ infection, a program must be started to minimize joint disability and to monitor for recurrence of infection. The acute inflammatory process that accompanies an infection can result in the deposition of fibrinogen and other products, which can predispose the joint toward a fibrous or bony ankylosis. Active range of motion exercises are started as soon as possible to prevent intra-articular adhesions. The patient's range of motion should be documented at weekly intervals. If the range of motion is still limited 1 month following the resolution of the infection, a brisement procedure or an arthroscopic procedure to lyse intra-articular adhesions should be considered. However, before this, extracapsular causes of limited opening, such as masseter muscle trismus, need to be differentiated from intracapsular disorders. Intracapsular restrictions are usually accompanied by restriction of lateral excursions to the contralateral side and deviation on opening. Recurrence of joint infection (of all joints) has been reported to occur at a rate of 10.5%.⁴⁴ Newman noted that infection recurred as long as 1 year following the initial episode.⁴⁴ The patient should be advised of this possibility.

Neoplastic Diseases

Tumors affecting the TMJ area are exceedingly rare. The tissues from which a neoplasm may arise include the synovium, bone, cartilage, and associated musculature. Neoplasms of this region can present with signs and symptoms similar to those occurring with internal derangement (preauricular pain and dysfunction) and thus can result in a delay in the diagnosis. The clinician should be aware of this when treating temporomandibular disorders, especially if the patient fails to respond to traditional therapy.

Benign Tumors

The most common benign bone tumors of the TMJ include the osteoma and condylar enlargement or condylar hypertrophy. Both present signs related to the increase in size of the condyle, a shift in the mandible to the contralateral side, and an ipsilateral open bite. Often the range of motion is decreased as the increased size of the condylar head prevents normal translation. Radiographs, including tomograms and computed tomography scans, should be obtained to delineate the extent of the condylar growth and to determine involvement of the glenoid fossa and associated structures. Radionuclide scans should be performed to determine if the process is still active and bone is being produced. Treatment includes a condylar head resection (partial or complete) for active lesions or a condyloplasty to reduce condylar size and restore the occlusion for nongrowing lesions. Condylar reconstruction is usually not necessary. The disk should be preserved or replaced (if it has been damaged) with a temporalis muscle flap or cartilage graft. Physical therapy is usually required to reduce dysfunction. Postoperative maxillomandibular fixation is not usually necessary, but guiding elastics may be helpful with muscle retraining. An active physical therapy program to reduce joint adhesions prevents permanent restriction of the joint.

Virtually all other benign bone tumors have been reported to occur in the TMJ. These bone tumors behave as they would in other areas of the mandible and therefore should be treated in a similar fashion.

Synovial Tumors

Synovial chondromatosis is the most commonly reported neoplasm of the TMJ synovium. Lustman and Zelster reported a series of 50 cases in which the mean age was 47 years.⁴⁵ This is in contrast to synovial chondromatosis involving other joints, which is more commonly found in the 20- to 30-year-old age group.⁴⁶ Pain and swelling of the preauricular area are the most common initial signs. Depending on the degree of calcification present, radiographs may reveal the presence of loose radiodense bodies within the joint. These loose bodies are formed by metaplastic synovial tissues. Foci of metaplastic synovium detach from the synovial lining and remain viable while suspended in the synovial fluid. While suspended they form a perichondrium and continue to grow and enlarge. Although the reason is unknown this process most frequently occurs in the superior joint space. The loose bodies are composed of cartilage containing multinucleated cells. The presence of cellular atypia and hyperchromatism is common and a careful review of all histologic material removed is necessary to rule out the possibility of chondrosarcoma.

Treatment of synovial chondromatosis involves extirpation of the loose bodies and removal of the synovial lining. Lustman and Zelster reported that a condylectomy was necessary in 13 of 47 cases to gain access to the anteromedial portion of the joint.⁴⁵ The condyle itself is not involved and therefore should only be removed for access. Recurrence of synovial chondromatosis is quite rare and is thought to be caused by an incomplete excision of the original lesions. No cases of TMJ synovial chondromatosis transform-

ing into chondrosarcoma have been reported, although this has been reported in the knee.⁴⁷

Ganglion Cysts

Ganglion cysts have also been reported to occur in association with the TMJ. These are cystic structures that arise subcutaneously in association with the joint capsule or tendon sheaths. Histologic examination of a ganglion reveals a true cyst, containing a mucinous fluid and hyaluronic acid. These lesions present as a preauricular mass and may produce classic "TMJ symptoms," such as pain and limitation of function. The swelling produced by the ganglion in the preauricular region can be confused with a parotid mass. Surgery is indicated to remove the cyst and recurrences have not been reported.⁴⁸

Malignant Tumors

Malignancies of the TMJ are very rare and are usually the result of direct extensions of primary lesions of adjacent structures. Metastatic disease has been reported to involve the TMJ, but is more commonly found in the mandibular angle region. This may be due to the relative paucity of cancellous bone in the condylar head region.⁴⁹ The most common lesions to metastasize to the condyle are adenocarcinomas of the breast, kidney, and lungs. As with benign tumors the early signs of malignant disease of the TMJ are pain and dysfunction. Primary malignancies of the TMJ have been reported as intrinsic tumors of the condylar bone, disk, synovium, and cartilaginous linking. Typically patients with malignancies of the TMJ are older than the usual internal derangement patient. Patients with a history of preexisting malignant disease must undergo a thorough search for metastasis if TMJ symptoms develop. Radionuclide scans may be useful, although the inflammation from chronic synovitis can result in activity localizing in the condyle.⁵⁰ Patients presenting with a fracture of the condyle

without a history of trauma should be suspect for the presence of a malignant lesion in the condyle.

Primary TMJ malignancies require aggressive therapy to prevent intracranial extension of the disease. Radiation, surgery, and chemotherapy are all appropriate means of treatment of diseases in this region. Radiation therapy can also be used for palliation in disseminated disease to control pain from the TMJ region and to prevent pathologic fractures.

References

- DuBrul, EL. *Sicher's oral anatomy*. 7th ed. St. Louis (MO): C.V. Mosby; 1980. p. 146–61, 174–209.
- Albright JA, Brand RA. *The scientific basis of orthopedics*. 2nd ed. Norwalk (CT): Appleton and Lange; 1987. p. 373–86.
- Dijkgraaf LC, Milam SB. Osteoarthritis: histopathology and biochemistry of the TMJ. In: Piecuch JF, editor. *Oral maxillofacial surgery knowledge update*. Vol 3. Rosemont (IL): American Association of Oral and Maxillofacial Surgeons; 2001. p. 5–28.
- Bell WE. *Temporomandibular disorders: classification, diagnosis and management*. 2nd ed. Chicago (IL): Yearbook Medical Publishers; 1986. p. 16–62.
- Okeson JP. *Management of temporomandibular disorders and occlusions*. 2nd ed. St. Louis (MO): C.V. Mosby; 1989. p. 3–26.
- Rayne J. Functional anatomy of the temporomandibular joint. *Br J Oral Maxillofac Surg* 1987;25:92–9.
- Blackwood HJJ. Pathology of the temporomandibular joint. *J Am Dent Assoc* 1969;79:118.
- Gay T, Piecuch J. An electromyographic analysis of jaw movements in man. *Electromyogr Clin Neurophysiol* 1986;26:365–84.
- Carpentier P, Yung JP, Marguelles-Bonnet R, Meunissier M. Insertions of the lateral pterygoid muscle. *J Oral Maxillofac Surg* 1988;46:477–82.
- McNamara JA. The independent functions of the two heads of the lateral pterygoid muscle. *Am J Anat* 1973;138:197–205.
- Goulet JP, Lavigne GJ, Lund JP. Jaw pain prevalence among French speaking Canadians in Quebec and related symptoms of temporomandibular disorders. *J Dent Res* 1995;74:1738–44.
- DeKanter R, Kayser A, Battistuzzi P, et al. Demand and need for treatment of craniomandibular dysfunction in the Dutch adult population. *J Dent Res* 1992;71:1607–12.
- deBont L, Dijkgraaf L, Stegenga B. Epidemiology and natural progression of articular temporomandibular disorders. *Oral Surg Oral Med Oral Pathol Oral Radiol Endod* 1997;83:72–6.
- Marbach JJ, Lipton JA. Treatment of patients with temporomandibular joint and other facial pain by otolaryngologists. *Arch Otolaryngol* 1982;108:102–7.
- List T, Dworkin SF, Harrison R, Huggins K. Research diagnostic criteria/temporomandibular disorders: comparing Swedish and U.S. clinics [abstract]. *J Dent Res* 1996;75(special issue):352.
- Laskin DM. Diagnosis and etiology of myofascial pain and dysfunction. *Oral Maxillofac Surg Clin North Am* 1995;7:73–8.
- Demitrack M. Chronic fatigue syndrome and fibromyalgia dilemmas in diagnosis and clinical management. *Psychiatr Clin North Am* 1998;21:671–92.
- Kiliardis S, Katsaros C. The effects of myotonic dystrophy and Duchenne muscular dystrophy on the orofacial muscles and dentofacial morphology. *Acta Odontol Scand* 1998;56:369–74.
- Steiner M, Gould AR, Kushner GM, et al. Myositis ossificans traumatica of the masseter muscle: review of the literature and report of two additional cases. *Oral Surg Oral Med Oral Pathol Oral Radiol Endod* 1997;84:703–7.
- Rubin M, Cozzi G. Heterotopic ossification of the temporomandibular joint in a burn patient. *J Oral Maxillofac Surg* 1986;44:897–9.
- Wilkes CH. Internal derangement of the temporomandibular joint pathological variations. *Arch Otolaryngol Head Neck Surg* 1989;115:469–77.
- Dolwick MF. Intra-articular disc displacement Part I: its questionable role in temporomandibular joint pathology. *J Oral Maxillofac Surg* 1995;53:1069–72.
- Milam SB, Schmitz JP. Molecular biology of temporomandibular joint disorders: proposed mechanisms of disease. *J Oral Maxillofac Surg* 1995;53:1448–54.
- Milam SB, Zardeneta G, Schmitz JP. Oxidative stress and degenerative temporomandibular joint disease: a proposed hypothesis. *J Oral Maxillofac Surg* 1998;56:214–23.
- Takahashi T, Kondoh T, Ohtani M, et al. Association between arthroscopic diagnosis of osteoarthritis and synovial fluid nitric oxide levels. *Oral Surg Oral Med Oral Pathol Oral Radiol Endod* 1999;88:129–36.
- Kubota E, Kubota T, Matsumoto J, et al. Synovial fluid cytokines and proteases as markers of temporomandibular joint disease. *J Oral Maxillofac Surg* 1998;56:192–8.
- Murakami KI, Shibata T, Kubota E, Maeda H. Intra-articular levels of prostaglandin E2, hyaluronic acid, and chondroitin-4 and -6 sulfates in the temporomandibular joint synovial fluid of patients with internal derangement. *J Oral Maxillofac Surg* 1998;56:199–203.
- Israel HA, Diamond BE, Said-Nejad F, Ratcliffe A. Correlation between arthroscopic diagnosis of osteoarthritis and synovitis of the human temporomandibular joint and keratin sulfate levels in the synovial fluid. *J Oral Maxillofac Surg* 1997;55:210–7.
- Kaneyama K, Segami N, Nishimura M, et al. Osteoclastogenesis inhibitory factor/osteoprotegerin in synovial fluid from patients with temporomandibular disorders. *Int J Oral Maxillofac Surg*. 2003;32:404–7.
- Okeson J. Nonsurgical treatment of internal derangements. *Oral Maxillofac Surg Clin North Am* 1995;7:63–71.
- Nitzan D. The process of lubrication impairment and its involvement in temporomandibular joint disc displacement: a theoretical concept. *J Oral Maxillofac Surg* 2001;59:36–45.
- Rao VM, Liem MD, Farole A, Razik A. Elusive “stuck” disk in the temporomandibular joint: diagnosis with MR imaging. *Radiology* 1993;189:823–7.
- Goudot P, Jaquinet AR, Hugonnet S, et al. Improvement of pain and function after arthroscopy and arthrocentesis of the temporomandibular joint: a comparative study. *J Craniomaxillofac Surg* 2000;28:39–43.
- Zardeneta G, Milam SB, Schmitz JP. Elution of proteins by continuous temporomandibular joint arthrocentesis. *J Oral Maxillofac Surg* 1997;55:709–16.
- Holmlund AB, Axelsson S, Gynther G. A comparison of discectomy and arthroscopic lysis and lavage for the treatment of chronic closed-lock of the temporomandibular joint: a randomized outcome study. *J Oral Maxillofac Surg* 2001;59:972–7.
- Bounds GA, Hopkins R, Sugar A. Septic arthritis of the temporomandibular joint: a problematic diagnosis. *Br J Oral Maxillofac Surg* 1987;25:61–7.
- Simpson ML. Septic arthritis in adults. In: Gustilo RB, Gruminger RP, Tsukayama DT, editors. *Orthopedic infection*. Philadelphia (PA): WB Saunders; 1900. p. 286.

38. Murakami K, Matsumoto K, Iizuka T. Suppurative arthritis of the temporomandibular joint: report of a case with special reference to arthroscopic observations. *J Maxillofac Surg* 1984;12(1):41–5.
39. Parker RH. Acute infectious arthritis. In: Schlossberg D, editor. *Orthopedic infection*. New York (NY): Springer-Verlag; 1988. p. 69–75.
40. Markowitz HA, Gerry RG. Temporomandibular joint disease. *Oral Surg Oral Med Oral Pathol* 1950;3:75–9.
41. Eisenstein BI, Masi AT. Disseminated gonococcal infection and gonococcal arthritis. *Semin Arthritis Rheum* 1988;10:155–9.
42. Smith JW. Infectious arthritis. In: Mandell GL, Douglas RG, Bennett JE, editors. *Principles and practice of infectious diseases*. New York (NY): John Wiley & Sons; 1985. p. 697.
43. Mahowald ML, Messner RP. Chronic infective arthritis. In: Schlossberg D, editor. *Orthopedic infection*. New York (NY): Springer-Verlag; 1988. p. 76–95.
44. Newman JH. Review of septic arthritis throughout the antibiotic era. *Ann Rheum Dis* 1976;35:198–204.
45. Lustman J, Zelster R. Synovial chondromatosis of the temporomandibular joint. *Int J Oral Maxillofac Surg* 1989;18:90–4.
46. Orden A, Laskin DM, Leu D. Chronic preauricular swelling. *J Oral Maxillofac Surg* 1989;47:390–7.
47. King JW, Splut HJ, Fechner RE, Vanderpool DW. Synovial chondrosarcoma of the knee joint. *J Bone Joint Surg* 1967;49:1389–96.
48. Copeland M, Douglas B. Ganglions of the temporomandibular joint. *Plast Reconstr Surg* 1988;69:775–6.
49. Hartman GL, Robertson GR, Sugg WE, et al. Metastatic carcinoma of the mandibular condyle. *J Oral Surg* 1973;31:716–9.
50. Mizukawa JH, Dolwick MF, Johnson RP, et al. Metastatic breast adenocarcinoma of the mandibular condyle. *J Oral Surg* 1980;38:448–9.
51. Clemente CD, editor. *Gray's anatomy of the human body*. 30th ed. Philadelphia (PA): Lea & Febiger; 1985. p. 451.

Nonsurgical Management of Temporomandibular Disorders

Vasiliki Karlis, DMD, MD

Robert Glickman, DMD

Temporomandibular disorder (TMD) is the general term used to describe the manifestation of pain and/or dysfunction of the temporomandibular joint (TMJ) and its associated structures. Up to 5% of the population are affected by TMD, with significantly more frequent and more severe signs and symptoms appearing in women and older adults.^{1,2} The etiology of TMD is presumed to include trauma, parafunctional habits, malocclusion, joint overloading, arthritides, psychological factors, and ergonomic positioning of the head. The impact of psychological factors is difficult to calculate, but approximately 10 to 20% of patients with TMD also manifest some form of psychiatric illness.³ As symptoms of TMD are quite variable and remain exceedingly difficult to attribute exclusively to one or more events (such as the true contribution or extent of involvement of muscles of mastication), the joint itself or psychological factors is best understood in terms of interdependence. When a diagnosis of TMD is suspected or confirmed, therapy should be directed to improve function and reduce pain and discomfort. There is ample literature to suggest that nonsurgical treatment modalities may account for as much as a 74 to 85% favorable response rate in patients with TMD.^{4,5} In one study, Suvinen and colleagues reported that 81% of their

patients showed 50% or greater improvement after conservative physical therapy with a 6-month follow-up, attributing the improvement to a possible placebo-type effect.⁶ Other sources report significant relief in 30 to 60% of patients when under some form of treatment.⁷ Additionally, long-term follow-up studies have suggested that almost all patients with TMD will improve with time, regardless of the type of treatment they may receive.^{4,8-12} Thus, it appears well established in the literature that the majority of patients with TMD achieve some relief of symptoms with nonsurgical therapy. The dilemma for the surgeon is exacerbated by the broad spectrum of results and claims that use a seemingly endless variety of surgical and nonsurgical strategies. Since the extent or severity of symptomatology is apparently unrelated to etiology, and the overwhelming number of symptoms respond to conservative management, the question of whether and how to incorporate surgical and nonsurgical treatment into the care of these patients becomes challenging for the attending physician. There are absolute indications where surgical intervention would be of primary benefit, and the questions would be whether there is still a role for nonsurgical therapy in these patients, and if so, when it should be instituted and for how long.

One approach is to consider the concept of nonsurgical versus surgical therapy misleading and incomplete. There are many times when it is inappropriate to consider surgery. At other times nonsurgical therapy precedes and almost always follows surgical intervention. Therefore, it is essential for the surgeon to have a deep appreciation of the available techniques and their limitations in order to know when and how to properly manage TMDs. The purpose of this chapter will be to delineate those techniques that are adjunctive or discriminating to surgical considerations.

Treatment Considerations

The primary goal in treatment of TMD is to alleviate pain and/or mandibular dysfunction. Pain and alterations in function (ie, mastication and speech) can become quite debilitating, greatly affecting oral health care and diminishing the quality of life for these individuals. Another critical objective relates to patient counseling and education on the predisposing factors for TMD. Depending on the degree of impairment, patients can often be assured that TMD is a benign condition and clinical improvement can be expected with appropriate therapy. However, it is prudent if not incumbent upon the surgeon to inform patients that complete elimination

of symptoms is at times unattainable. Nonsurgical techniques that can decrease unintentional overloading of the masticatory system, eliminate pain, reduce dysfunction, decrease chronicity, and promote healing are essential in all phases of therapy. A patient home care program may prevent further injury and allow for a period of healing. In general patients can be instructed to limit mandibular function, modify habits, avoid stress, and start a home exercise program.⁸

Clicking and popping of the TMJ is quite common in TMD and normal joints. It is difficult to eliminate, usually reoccurs, and there is inconclusive evidence to suggest whether this poses a problem for the patient. There is considerable support that joint sounds without pain or dysfunction should not be treated (Table 48-1).

Once a diagnosis of TMD has been established, frequent follow-up appointments are necessary once therapy is instituted, to determine whether there is any improvement. Initial impressions may require modification after several weeks of therapy, and further diagnostic procedures may be warranted to rule out vascular, neurologic, neoplastic, psychological, or otolaryngologic abnormalities. TMD is a complex disorder that is molded by many interacting factors, and strong consideration should be given to a multidisciplinary approach. The role of the dentist, physical therapist, neurologist, psychologist/psychiatrist, anesthesiologist, and oral and maxillofacial surgeon cannot be understated, and should be key constituents of any facial pain/TMD center. We cannot precisely dictate timing or length of therapy. This must still be determined by the surgeon and based on severity of symp-

Table 48-1 Goals of Nonsurgical Therapy for Temporomandibular Disorders

Alleviate pain
Decrease or eliminate jaw dysfunction
Educate and counsel patients

toms and supporting diagnostic parameters. As with other joints consideration must be given to rule out pathology, decrease inflammation, allow unimpeded joint motion, and restore range of motion. To accomplish this in a ginglymoarthrodial joint that is permanently attached to the opposite side and is intimately involved in oral health is indeed a challenge.

The remainder of this chapter provides basic guidelines for nonsurgical therapeutics. It is not intended to eliminate or preselect adjunctive dental or surgical treatment.

Nonsurgical Therapy

Diet

A soft diet is often overlooked in the management of TMD. A soft diet prevents overloading of the TMJ and decreases muscle activity that may be hyperactive. The extent of time that a patient should be placed on a soft food diet is dependent on the severity of symptoms. Patients should be instructed to cut their food into small pieces and abstain from eating chewy, hard, or crunchy foods. Uncooked vegetables and meats represent examples of foods that should not be eaten by these patients. A strict liquid diet is reserved for those patients experiencing severe TMD symptoms (Table 48-2).

Pharmacotherapy

Medications are often prescribed for managing the symptoms associated with TMD. Patients should understand that these medications may not offer the cure to their problem but can be a valuable adjunctive aid when prescribed as part of a comprehensive program. With pharmacotherapy there is always a danger of drug dependency and abuse, particularly with narcotics and tranquilizers. Since many TMD symptoms are periodic, there is a tendency to prescribe medications on a “take as needed” philosophy. This can provide brief periods of pain relief, but more frequent

Table 48-2 Soft Diet

Decreases muscle activity and loading forces on temporomandibular joints
Controls range of motion—hinge and sliding
Ranges from liquid diet to elimination of hard chewy food; involves cutting food into small pieces
Eliminates gum chewing

pain cycles can result in less effectiveness of the drugs and ultimate overuse or abuse of the medications.¹²⁻¹⁵ The general recommendation is that when pharmacotherapy is employed, the medications should be prescribed at regular intervals for a specific period of time (eg, four times daily for 2 wk). The clinician must always be cognizant of potential personality traits that may contribute to drug dependence or abuse. Other obvious factors are concurrent medical ailments or medications, patient age, occupation, and each patient’s attitude toward pharmacotherapy.

The most common pharmacologic agents used for the management of TMD are analgesics, anti-inflammatory agents, anxiolytic agents, antidepressants, muscle relaxants, antihistamines, and local anesthetics. Analgesics, corticosteroids, and anxiolytics are useful for acute TMD pain. Anti-inflammatory medications and antidepressants are primarily indicated for chronic pain management. Muscle relaxants, nonsteroidal anti-inflammatory drugs (NSAIDs), and local anesthetics can be used for both acute and chronic pain.

Analgesics Analgesic medications are either opiate or nonopiate preparations. Nonopiate analgesics (salicylates and acetaminophen) can be added to the anti-inflammatory regimen to assist in pain relief. The salicylates (ASA) are commonly used in TMD and are the benchmark medications to which other analgesics are usually compared. Salicylates are antipyretic, analgesic, and anti-inflammatory. For

those patients who cannot take aspirin, a nonacetylated aspirin such as choline magnesium trisalicylate or salsalate may be effective. As with all salicylates, however, choline magnesium trisalicylate and salsalate should not be prescribed for children or teenagers with chickenpox, influenza, or flu symptoms or exposure.

Opioid analgesics (oxycodone, propoxyphene, and hydrocodone) should be prescribed only for moderate to severe pain of limited duration, due to the high potential for addiction. These drugs are often administered in conjunction with NSAIDs or acetaminophen (Vicodin, Lortab, Percocet, Darvocet, etc). They act on opioid receptors in the central nervous system, producing analgesia and sedation. Because patients can quickly become dependant on the narcotic analgesics, it is recommended that these drugs not be prescribed for longer than 2 to 3 weeks. Other side effects include constipation secondary to decreased gastric motility.

Anti-inflammatory Medications There are two types of anti-inflammatory medications useful in treating TMD: NSAIDs and corticosteroids (Figure 48-1). Glucocorticosteroids prevent the release of arachidonic acid, a key component of the inflammation cascade. NSAIDs inhibit cyclooxygenase, which inhibits prostaglandin synthesis from arachidonic acid.¹⁶⁻¹⁸

NSAIDs The advantages of NSAIDs in TMD patients are analgesia and their anti-inflammatory properties (Tables 48-3 and 48-4). NSAIDs may offer relief for patients with synovitis, myositis, capsulitis, symptomatic disk displacement, and osteoarthritis.¹⁹ This type of therapy helps alleviate the inflammation, which thereby causes a decrease in pain perception. Side effects include gastric irritation, allergies, and liver dysfunction. An ideal NSAID would be one that has minimal gastric irritation, a quick onset with long-lasting effects, low dosage requirements, is tolerated at high levels,

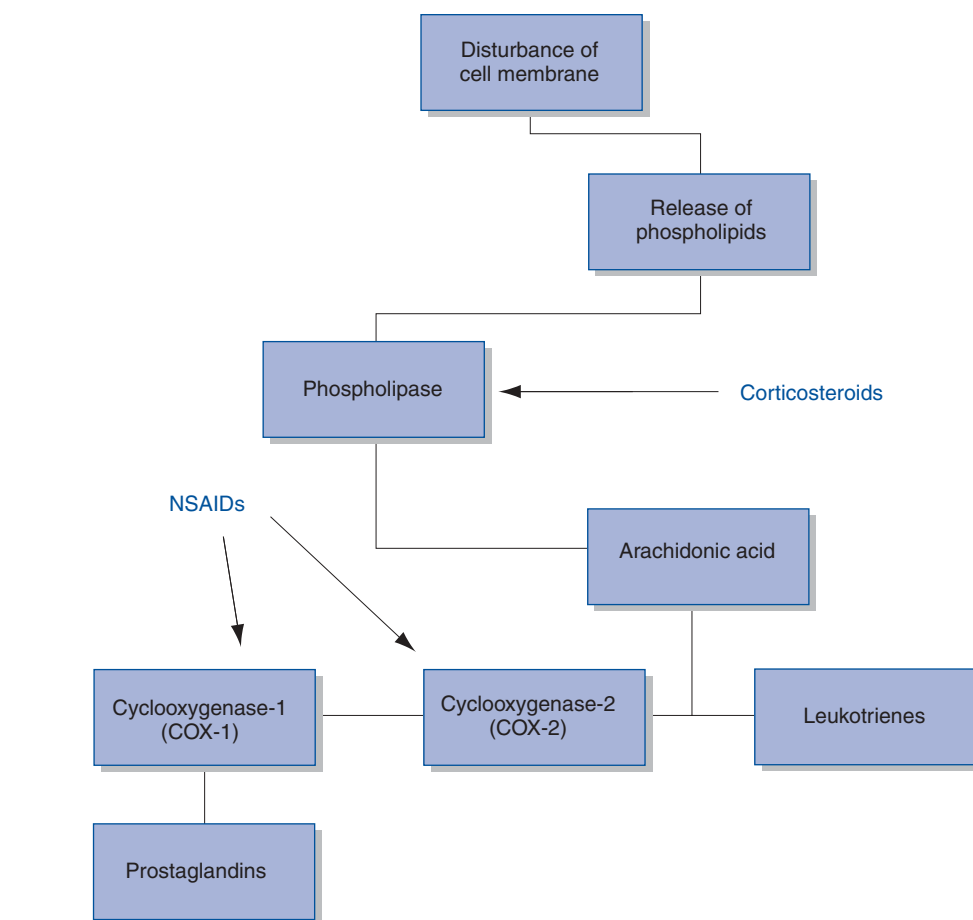


FIGURE 48-1 Inflammation cascade. The corticosteroids prevent the release of arachidonic acid and thereby interrupt most of the inflammation cascade. The NSAIDs inhibit cyclooxygenase, which inhibits prostaglandin synthesis from arachidonic acid. NSAID = nonsteroidal anti-inflammatory drugs.

and is low in cost. NSAIDs are divided into seven groups based on their chemical structure: salicylates (ASA), propionic acids (ibuprofen, naproxen), acetic acids (indomethacin, ketorolac), fenamic acids (meclofenamate), oxicams (piroxicam), and the cyclooxygenase (COX)-2 inhibitors (celecoxib, rofecoxib). The most common NSAIDs used are ibuprofen, diclofenac, and naproxen, but because of purported fewer gastrointestinal (GI) side effects and minimal effect on platelets, COX-2 inhibitors are becoming more popular. Recent studies have found that COX-2, an important inflammatory mediator, is present in the TMJ synovial tissue and fluid of patients with internal derangements. This offers the possibility that the COX-2 inhibitors might be more effective for TMJ

pain and arthralgias than other analgesics.^{20,21} Enteric coating, prodrugs (nabumetone), taking agents after meals or in conjunction with antacids, and taking gastric protective agents (ranitidine and sucralfate) have been reported to reduce the gastric irritation from NSAIDs.²²

Corticosteroids By completely blocking the arachidonic acid cascade, corticosteroids produce a greater anti-inflammatory response than do NSAIDs. Systemic steroids are indicated only for short-term therapy (5 to 7 d) due to their long-term possible complications. Osteoporosis, diabetes, hypertension, electrolyte changes, and clinical Cushing's disease are sequelae of long-term systemic corticosteroid treatment.²³ Steroids have also been directly injected into the TMJ

Category	Generic	Brand	Half-Life (hours)
Salicylates	Acetylsalicylic acid (aspirin)	Bayer	2.5
	Enteric coated	Ecotrin	2.5
	Aspirin with buffering agent	Bufferin	2.5
	Aspirin with caffeine	Anacin	2.5
	Diflunisal	Dolobid	8–12
	Choline magnesium trisalicylate	Trilisate	9–17
	Salsalate	Disalcid	16
Propionic acid	Ibuprofen	Motrin, Advil, Nuprin, Rufen	1.8–2.5
	Fenoprofen	Nalfon	2–3
	Suprofen	Suprol	2–4
	Naproxen	Naprosyn	12–15
	Naproxen sodium	Anaprox	12–15
Acetic acid	Indomethacin	Indocin	4.5–6
	Sulindac	Clinoril	7.8 (16.4)*
	Tolmetin	Tolectin	1–1.5
Fenamic acid	Meclofenamate	Meclomen	2 (3.3)*
	Mefenamic acid	Ponstel	2
Pyrazolones	Phenylbutazone	Butazolidin	84
Oxicam	Piroxicam olamine	Feldene	30–86
COX-2 inhibitors	Celecoxib	Celebrex	11–12
	Rofecoxib	Vioxx	17

*Active metabolite.
Adapted from Syrop SB.²⁵

in an attempt to decrease inflammation or mediate the inflammatory response (ie, following arthroscopy), but long-term or excessive use is associated with condylar hypoplasia by inhibiting osteoblastic activity and increasing loss of calcium in the urine and GI tract.²⁴

Anxiolytics Anxiolytic medications reduce the anxiety, insomnia, and muscle hyperactivity associated with TMD

Minimal gastric irritation
Quick onset with long-lasting effects
Lower dosage
Tolerated at high levels
Low cost

(Tables 48-5 and 48-6). These drugs often help the patient reduce the perception of, or reaction to, stress. Benzodiazepines (diazepam) decrease anxiety, relax skeletal

Generic	Brand	Usual Dosage (mg/d)	Elimination (half-life [h])
Alprazolam	Xanax	0.5–1.5 (ddd)	12–15
Chlordiazepoxide	Librium	15–60 (ddd)	5–30
Diazepam	Valium	2–40 (ddd)	20–50
Flurazepam	Dalmane	30 (at bedtime)	47–100
Lorazepam	Ativan	2–6 (ddd)	10–18
Oxazepam	Serax	30–60 (ddd)	5–15
Prazepam	Verstran	20–40 (ddd)	30–100
Temazepam	Restoril	15–30 (at bedtime)	10–20
Triazolam	Halcion	0.25–0.5 (at bedtime)	1.5–5

ddd = divided daily doses
Adapted from Syrop SB.²⁵

muscle, and cause sedation and may be selected according to their more favorable characteristics (ie, less sedation). The muscle relaxant properties may be used to decrease the effects of bruxism secondary to hyperactivity of muscles of mastication. It is recommended that the benzodiazepines not be used for more than a 2-week period because of the high potential for dependency, although this can be increased up to 3 weeks only at bedtime to control bruxism.¹⁹ Buspar (azaspirodecanedione) is an anxiolytic; however, it does not produce either sedation or muscle relaxation. It may be used to control anxiety in TMD patients without producing drowsiness.

Antihistamines (promethazine and hydroxyzine) antagonize central and peripheral H₁ receptors, and have a sedative effect as well as anxiolytic properties. Antihistamines, unlike the benzodiazepines, do not have the potential for abuse. They can be used more safely in children and the elderly and for the treatment of vertigo and nausea that may accompany TMD.²⁵

Antidepressants Antidepressants include monoamine oxidase inhibitors (MAOIs), tricyclic antidepressants, and selective serotonin reuptake inhibitors (Tables 48-7 and 48-8). They are pre-

Table 48-6 Antianxiety Medications: Benzodiazepines

Bind GABA receptors
 Serotonergic (5-HT) in the amygdala
 Beneficial for treatment of anxiety, insomnia, muscle hypertonicity
 Potential abuse
 Avoid short-acting or high-potency drugs (ie, triazolam, alprazolam, lorazepam)
 Taper gradually to avoid withdrawal, rebound anxiety

GABA = γ -aminobutyric acid; 5-HT = 5-hydroxytryptamine (serotonin).

scribed for chronic pain, headaches, sleep disorders, obsessive-compulsive disorders, and central-mediated pain disorders. The relationship between pain and depression is a challenge and often necessitates treating both simultaneously. Depression in the TMD or chronic pain population is greater than in the general population. Studies report that up to 30% of TMD patients have major depression at the time of presentation for treatment, and up to 74% of patients with chronic TMD have had an episode of major depression.^{26,27}

MAOIs are not routinely prescribed for TMD due to their numerous side effects and dietary restrictions. Benefits of tricyclic antidepressants have been well documented in chronic pain or depression populations and are probably due to analgesic and antidepressant actions. The analgesic properties are independent of the antidepressant effect, which requires higher doses. It has

been shown that low doses of amitriptyline (10 mg) before sleep can have an analgesic effect on chronic pain but have no relationship to the antidepressant actions that require doses up to 20 times greater.²⁸ Tricyclic antidepressants may also help treat nocturnal bruxism and any sleep disturbance associated with TMD.²⁹ Side effects are related to anticholinergic activity causing xerostomia, constipation, blurred vision, and urinary retention. Selective serotonin reuptake inhibitors can also be used for treating the depressed TMD patient. These medications often need to be taken for several months and patients must be counseled appropriately. Fluoxetine (Prozac) may increase bruxism and anxiety and should be carefully monitored.

Muscle Relaxants Centrally acting muscle relaxants (cyclobenzaprine, methocarbamol, and carisoprodol) may be used to relax hyperactive musculature associated with TMD (Tables 48-9–48-11). These relaxants may also act as sedatives, and they are commonly combined with NSAID use. Cyclobenzaprine (Flexeril) has a similar chemical structure to the tricyclic antidepressants and if given over an extended period of time will produce antidepressant and sedative actions as well as the anticholinergic side effects of the tricyclics. Central muscle relaxants can be very effective for acute myofascial pain (ie, trauma).

One peripheral muscle relaxant, baclofen, has been used in myofascial pain but is best reserved for severe muscle spasm or neurogenic pain. Recently botu-

Table 48-8 Antidepressant Medications

Tricyclics are most used and studied for chronic pain and depression
 Monoamine oxidase inhibitors (MAOIs) not first choice due to adverse reactions
 Selective serotonin reuptake inhibitors (SSRIs) such as fluoxetine can increase anxiety and bruxism

linum toxin has been used to treat severe bruxism. By providing muscle relaxation, inflammation of the masseter muscle and TMJ capsule can be reduced.^{30,31}

Local Anesthetics Local anesthetics act on the nerve cell membrane to prevent generation and conduction of impulses (Table 48-12). Local anesthetics can be used as diagnostic blocks intra-articularly and/or intramuscularly to alleviate pain and increase range of motion. For example, injection behind the maxillary tuberosity will permit the lateral pterygoids to be anesthetized, thereby allowing maximal protrusion and retrusion of the mandible. There should be no vasoconstrictor used in conjunction with the anesthesia, as the decrease in blood flow may increase muscular pain. The intrinsic vasodilation effect of the anesthesia may improve perfusion and thereby further alleviate pain. It has been shown that an intra-articular injection of mepivacaine along with physiotherapy in patients with anteriorly displaced disks has yielded favorable results in pain relief and masticatory efficiency.³²

Physical Therapy

There are many factors contributing to limited range of motion. They include muscular pain, anterior disk displacement (closed lock), and fibrotic scar tissue preventing rotation or translational movements. It is well accepted that immobilization has deleterious effects on both joints and muscles.

Table 48-7 Commonly Used Antidepressants

Generic	Brand	Dosage (mg/d)	Side Effects
Amitriptyline	Elavil	10–300	High
Desipramine	Norpramin	50–300	Moderate
Doxepin	Sinequan	25–300	High
Imipramine	Tofranil	20–300	Moderate
Nortriptyline	Pamelor,	25–150	Moderate
	Aventyl	25–150	
Fluoxetine	Prozac	5–20	Moderate

Table 48-9 Commonly Used Muscle Relaxants		
Generic	Brand	Usual Dosage (mg/d; divided doses)
Carisoprodol	Rela, Soma	1,000–1,400
Chlorzoxazone	Paraflex, Parafon Forte D.S.C.	750–3,000
Meprobamate	Miltown, Equanil	1,200–1,600
Methocarbamol	Robaxin	1,500–4,500
Cyclobenzaprine	Flexeril	5–30
Orphenadrine	Norflex, Disipal	150–300
Diazepam	Valium	2–40
Combination Fixed Dosage		
Meprobamate Aspirin	Equagesic	1–2 tablets 3 or 4 times daily
Orphenadrine Aspirin Caffeine	Norgesic	1–2 tablets 3 or 4 times daily

Adapted from Syrop SB.²⁵

Immobilization may cause degenerative changes to the joint surfaces, synovial fluid, and surrounding tissues. Reduced motion also results in rapid muscle fatigue, muscle weakness, and contractures. Synovial fluid generation is reduced or halted when joints are immobile. Additionally it has been observed that the synovial fluid of patients with pain and limited motion often contains inflammatory byproducts. Kaneyama and colleagues listed a variety of cytokines such as interleukin (IL)-1 β , tumor necrosis

factor (TNF)- α , IL-6, and IL-8 in symptomatic joints, not observed in asymptomatic joints.³³ This high level of cytokine activity is believed to be related to the underlying pathogenesis of TMD. Cytokines such as IL-6 and IL-1 β may induce the “inflammatory cascade.” As a result of the release of proteinases, there may be destruction of articular cartilage and bone resorption. Each cytokine has its unique properties, not only affecting the surrounding tissues but also aiding in the release of other

Table 48-10 Central Muscle Relaxants and Their Effects
<i>Central Muscle Relaxants</i>
Carisoprodol (Rela, Soma) Chlorzoxazone (Paraflex) Methocarbamol (Robaxin) Cyclobenzaprine (Flexeril)
<i>Effects</i>
Tranquilizing effects General sedative effect on central nervous system No specific neurotransmitter No effect on skeletal muscle, motor end plate, or nerve fiber

Table 48-11 Peripheral Muscle Relaxants
<i>Peripheral Muscle Relaxants</i>
Baclofen (Lioresal) derivative of GABA that blocks spinal cord contraction reserved for severe muscle spasm, or neurogenic pain Botulinum toxin (Botox) is useful for management of oromandibular dystonia
<i>Effects</i>
Block synaptic transmission at neuromuscular junction Block muscle contraction
GABA = γ -aminobutyric acid.

Table 48-12 Local Anesthetics
Act on nerve cell membrane to prevent generation and conduction of impulses
Diagnostic blocks
Muscle injection treatment to increase range of movement

cytokines.³³ Thus, the role of functional motion and the synovium may be an indeterminate factor in the health of the TMJ (Table 48-13).

Exercise Therapy Physical therapy and exercise are an important part of any TMD program. Mild or acute symptoms can be initially managed with soft diet, jaw rest, heat/ice packs, jaw/tongue posture opening exercises, lateral jaw movements, and passive stretching exercises. Once again the exact sequence of therapy is unknown but is usually based on degree of pain and limitation of function. Further reduction of pain and inflammation may require an office-based physical therapy program. From our experience, ultrasonography,

Table 48-13 Physical Therapy
<i>Home Treatment Program (good for mild acute symptoms)</i>
Soft diet Decrease function Heat/ice packs Jaw/tongue posture opening exercise Lateral jaw movement Control passive motion (ie, Therabite)
<i>Office Treatment (reduction of pain and inflammation)</i>
Ultrasonography Transcutaneous electrical nerve stimulation Range of motion Soft tissue manipulation Trigger point injections Acupuncture (reestablishing proper energy flow by adding electric current or heat to the placed acupuncture needle)

transcutaneous electrical nerve stimulation (TENS), soft tissue manipulation, trigger point injections, and acupuncture have also been advocated as effective in the management of the TMD patient.

Jaw exercise therapy can be described as passive, active, or isometric. Passive jaw exercise allows the patient to manually (or with a device such as Therabite Jaw Motion Rehabilitation System, Atos Medical, Milwaukee, WI, USA) increase interincisal opening (Figure 48-2). Passive jaw exercise has received a great deal of attention recently. Many authors report significant improvement in pain and mobility in the nonsurgical phase of treatment for TMD as well as for the postoperative TMD patients.³⁴⁻³⁷ Passive jaw exercise is also very effective for patients experiencing muscular trismus and myofascial pain dysfunction (MPD). It may be contraindicated in patients with severely displaced disks, due to the possibility of damage to the disk or retrodiskal tissues.

Active exercise using the patient's jaw musculature may be incorporated into a home therapy program. One regimen allows the patient to activate, for example, their suprahyoid muscles (geniohyoid, mylohyoid, digastric, and stylohyoid), thereby inactivating the elevators of the jaw

(medial pterygoid, masseter, temporalis). This may allow for relaxation of hyperactive muscles of mastication and may assist in increasing maximal incisal opening. In the active stretch phase patients are advised to keep their mouth open for several seconds and relax. They are instructed to open until they perceive pain and then advised to hold for several seconds and repeat this exercise several times a day. An active lateral stretch permitting the contralateral lateral pterygoid to be stretched may be accomplished by visualizing themselves in a mirror. In the active protrusion, also performed in front of the mirror, the mandible is protruded forward stretching the lateral pterygoids bilaterally. All active excursions are maintained for several seconds and slowly released.

Isometric exercises have been recommended for patients with severe pain and trismus. There is no movement during this exercise while the depressor muscles are activated, allowing for relaxation of the opposing elevator musculature (medial pterygoids, masseter, temporalis). These exercises are performed by holding the mandible stationary as the muscles are activated isometrically. The lateral pterygoids may also be exercised in a similar isometric fashion.

Mongini describes a three-stage office technique of mandibular manipulation for patients with pain, decreased mobility, and disk displacement without reduction.³⁸ Right and left lateral movements are initiated by the patient. The patient continues the movement while the clinician applies light pressure in the same direction, and in the last stage the mandible is moved to the opposite side with patient assistance.³⁸ Kurita and colleagues described a technique of placing one thumb on the last molar on the affected side while the other hand supports the head in the temporal region.³⁹ The mandible is then moved downward and forward. The patient is instructed to protrude and move their jaw laterally, and open their mouth while the clinician manipulates the jaw. Following this movement the mandible is pushed back so that the condyle is positioned posterosuperiorly in the glenoid fossa. Only 18% of the patients received significant benefit from the manipulation, and the more advanced the displacement, the less the success of the treatment.³⁹ Yuasa and Kurita suggested that physical therapy along with administration of NSAIDs (for a 4-week period) is a more effective way to treat TMJ disk displacement without osseous changes.⁴⁰ Nonetheless, there is no shortage of recommended exercises, and care must be taken to do no harm (Table 48-14).

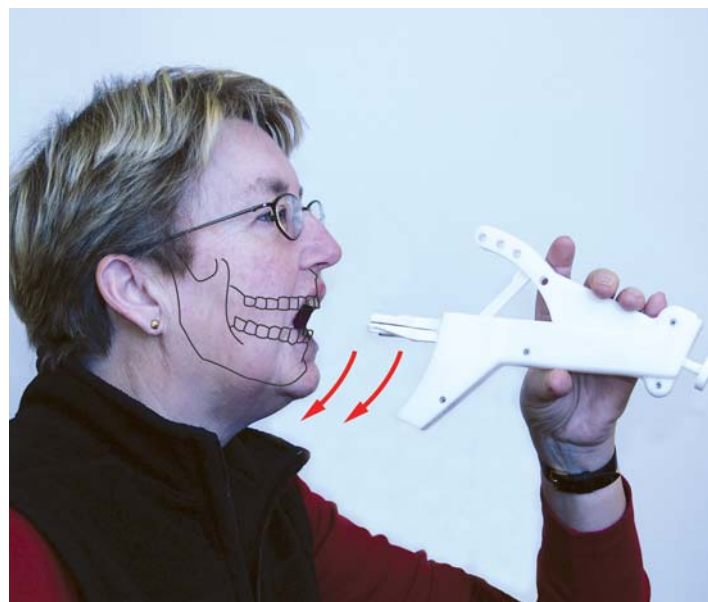

FIGURE 48-2 Patient using passive jaw exercise device to improve interincisal opening and to break any fibrous bands. (This Therabite picture is reproduced with the courtesy and permission of Atos Medical, Milwaukee, WI, USA.)

Table 48-14 Manual Therapy

Soft tissue technique
Massage, relaxation, stimulation, breaking scars, decreasing swelling, stretching
Manipulative therapy—spine realignment
Passive, quick, high-velocity, short-amplitude, thrust that forces the joint beyond its normal end range
Patient has no control; pain relief immediate but short lived

Thermal Agents Thermal agents are often incorporated in the management of TMD. The use of cold and heat can alleviate muscle pain and play an equal role during stretching and strengthening exercises.⁴¹⁻⁴³ Heat therapy has been reported to reduce muscle pain by increasing nerve conduction velocity and local vasodilatation.⁴³ Superficial heat therapy can be implemented with conductive (hot packs, paraffin, whirlpool) or radiant (infrared) agents. The most common types used are a moist hot washcloth, heating pad, or hydrocollator, a pad filled with clay and heated in a water bath to 70° to 88°C. It is wrapped in a towel and placed on the site for 15 to 20 minutes, causing a transient rise in skin temperature to about 42°C. The use of moist heating pads is an effective modality of treatment for myofascial pain associated with TMD.⁴⁴

Cryotherapy is often used as an aid in stretching muscles in an attempt to increase maximal incisor opening limited by pain.⁴¹ The pain perception model described by Melzack and Wall explains why cold therapy stimulates the large A delta fibers (temperature) inhibiting pain, which is stimulated by the small C fibers.⁴³ A physical therapist would place refrigerants on the skin in a sweeping motion followed by stretching of the musculature. Cold therapy should be used with caution because of the potential for increased joint stiffness, contracture, and immobility. Cold can also have analgesic effects after a therapeutic exercise regimen. Ice wrapped in a towel, fluoromethane spray, and reusable ice packs can all be used to deliver cryotherapy to the temporomandibular joint and related muscles. The stretch and spray technique, initially described by Modell and Simons and later modified by Travell and colleagues, is still a mainstay of office physiotherapy.^{41,42} The therapist holds the fluoromethane spray about 30 to 45 cm from the patient and sprays in a sweeping motion multiple times, and this is then followed by stretching exercises.

Possible side effects include frostbite and the potential for joint stiffness. Many therapists follow cryotherapy with moist heat to prevent the muscles from contracting.

Ultrasonography and Phonophoresis

Deep heat can be delivered by ultrasonography or phonophoresis. The ultrasound machine operates above audible frequency sound waves (0.75 to 1.0 MHz), which convert to heat while traveling through soft tissue. The ultrasound machine is applied to the skin along with an acoustic conductive gel, then moved slowly over the affected area in small circular movements. The operator must be careful not to keep the machine in one place for too long as it may cause overheating of the connective tissue, causing structural damage. The deep heat is intended to increase perfusion to the area, decreasing pain and increasing mobility.⁴⁵ Reported effects of ultrasound therapy include altered cell membrane permeability, intracellular fluid absorption, decreased collagen viscosity, vasodilatation, and analgesia. The beneficial effects to joints are reduced capsular contracture, break up of calcium deposits, and decreasing hyaluronic acid viscosity.⁴⁶ Because ultrasonography delivers heat to the deeper structures, it may have some advantage in treating tendonitis, capsulitis, muscle spasm, and tight ligaments.

Phonophoresis is an application of ultrasound heat therapy that incorporates a pad filled with a steroid or anesthetic cream placed over the affected area. As the ultrasound waves are applied, the medications perfuse into the tissues. The most common indication for phonophoresis is synovitis associated with painful jaw hypomobility. Contraindications for the use of ultrasonography and phonophoresis include areas that may have a reduced circulation, fluid-filled organs, eyes, radiation therapy sites, and malignant tissue. Ultrasound therapy should be used with extreme caution over active bone growth centers.⁴⁷

Electrical Stimulation Transcutaneous Electrical Nerve Stimulation TENS has become a viable home therapy in treating TMD. The precise mechanism of action is unknown, but it has been suggested that the gate control theory, counter-irritation, neurohumoral substance release, and peripheral blockade are all involved.⁴⁸ TENS uses a low-voltage electrical current that is designed for sensory counterstimulation in painful disorders. It is used to decrease muscle pain and hyperactivity and for neuromuscular re-education.^{49,50} TENS units are small and portable. Electrodes are placed along dermatomes or over acupuncture and trigger points. The patient can control the settings with variable frequency, amplitude, waveform, width, and pulse mode. Treatment can last several hours. TENS emits an asymmetric biphasic wave of 100 to 500 ms pulse. The efficacy of TENS for analgesia and muscle relaxation in myofascial pain has been documented.⁵¹ Electrode placement is contraindicated over the carotid sinus, transcranially, directly on the spine, on a pregnant womb, or on patients with demand-type pacemakers.⁵²

High-Voltage Stimulation High-voltage stimulation units deliver currents of positive and negative polarity with voltages greater than 100 V, which are delivered in a constant or intermittent pattern. The positive polarity produces vasoconstriction, whereas the negative polarity produces vasodilatation. The positive polarity reduces nerve irritability, and negative polarity enhances it. Negative polarity softens the affected tissue thus decreasing muscle tension. Treatment with high-voltage stimulation has improved jaw mobility and relieved pain intensity in TMD patients.⁵³ It can be used for pain relief, reduction of edema, and neuromuscular stimulation.⁵³

Iontophoresis Iontophoresis transfers ions from a solution through intact skin by

passing a direct current between two electrodes.⁵⁴ Positive ions are transmitted at the cathode, and negative ions are transmitted at the anode. Examples of negatively ionizing drugs are dexamethasone and methylprednisolone. Other drugs used in iontophoresis include lidocaine and salicylates. Iontophoresis was introduced in treating TMD and postherpetic neuralgia in 1982.⁵⁵ It appears to be most effective against inflammation, muscle spasm, and calcium deposits. The deep penetration of the medication aids in the treatment of severe joint inflammation and pain (Table 48-15).

Trigger Points and Muscle Injections A trigger point is an area of hyperirritability in a tissue that, when compressed, is locally tender, hypersensitive, and gives rise to referred pain and tenderness.⁵⁶ Trigger point development may be due to trauma, sustained contraction, or acute strain. When a needle penetrates this area it may cause a twitch response and referred pain.⁵⁶ Injection of local anesthetic agents without epinephrine may cause a temporary anesthesia, which enables the clinician to stretch the muscles in the affected area. A vasodilator effect of the local anesthetic may improve perfusion to the area, thus allowing harmful metabolites which may induce pain to be more readily removed by the vasculature.

Stress-Reduction Techniques

Relaxation and Biofeedback Relaxation and stress-reduction techniques for patients with TMD can be very effective treatment modalities. Various techniques

exist, an example being contracting and releasing skeletal muscles, starting from the feet and moving toward the head and neck region. Patients can also use audiotapes that teach breathing and specific relaxation techniques. Biofeedback techniques incorporate the use of electromyography (EMG) and skin temperature to measure the patient's physiologic function. The information is then conveyed back to the patient by a meter or sound. The patient can gauge their level of relaxation and measure progress accordingly.⁵⁷ The aim is to achieve psychological self-regulation and to monitor the relationship between muscular tension and pain. In a review of the literature Crider and Glaros reported 69% of subjects rated as improved or symptom free following biofeedback and relaxation treatments, whereas only 35% of patients receiving placebo intervention showed any improvement.⁵⁸ Furthermore, on follow-up examination the patients showed no decline from post-treatment levels.⁵⁸ Scott and Gregg advocate that relaxation techniques and EMG feedback can yield good results, especially in patients who are not depressed and have temporomandibular pain for a short period of time.⁵⁹ The chief hurdle is the difficulty to motivate patients in pain (Table 48-16).

Acupressure and Acupuncture Acupressure and acupuncture may be implemented along with other modalities during nonsurgical treatment. Acupuncture uses the relationship between energy flow through meridians, natural elements, and positive and negative life forces. Fine needles

Table 48-16 Behavioral Therapy

Components of Behavioral Therapy

Training the patient to recognize stress, anxiety, and depression
Relaxation training programs
Biofeedback
Self-hypnosis
Meditation
Cognitive therapy

Types of Behavioral Therapy

Psychiatric therapy
Pain clinic treatment (last resort)

are used to reestablish proper energy flow. There are several theories on the mechanism of action of acupuncture and acupressure. The first is the gate control theory, which states that the needle produces a painless stimulation, causing gates to close and preventing signal propagation to the spinal cord.⁶⁰ Other explanations include release of endorphins from the pituitary gland which block pain sensation, promotion of alpha waves (associated with stress reduction and relaxation), and rebalancing the electric ion flow pattern (when disrupted, it may elicit pain).⁶⁰ There are several different acupressure techniques including Jin Shin (two acupressure points held for 30 s to 5 m), Shiatsu (more rapid, held 3 to 10 s), reflexology (acupressure on feet, hands, and ears corresponding to areas of the body), Do-In (self-acupressure and breathing exercises), and G-Jo (acupressure for first aid purposes). Some studies have reported favorable results when these techniques are combined with other modalities (splint therapy), but overall data are limited.^{61,62} These pain therapies can be offered as an alternative to conventional therapy.

Psychotherapy In some cases TMD may be the somatic expression of an underlying psychiatric or psychological disorder such as depression or conversion.^{63,64} The

Table 48-15 Electrical Stimulation

Transcutaneous electrical nerve stimulation
Iontophoresis—direct current to drive drugs into tissue (hydrocortisone, lidocaine, salicylates); good for muscle spasm or inflammation
High-volume stimulation (100 V) (pumping effects of muscle contraction can increase circulation)

clinician should screen for personal or familial history of psychiatric disease, physical or sexual abuse, and substance abuse. Anxiety disorders occur at greater rates in patients with chronic pain.⁶⁵ Once identified these patients should be referred to a psychiatrist and/or psychologist for adjunctive treatment. Psychological treatments include behavioral therapy, cognitive-behavioral therapy, and self-management/support groups. Psychiatric treatments include medications with behavioral therapy. Often as a last resort TMD patients are referred to pain clinics for treatment, whether a psychological component exists or not, often out of frustration.

Occlusal Appliance Therapy

An occlusal appliance is a removable device, usually made of hard acrylic, which is custom fit over the occlusal surfaces of the mandibular or maxillary teeth. The splint is constructed so that there is even occlusal contact with the teeth of the opposing arch in centric and anterior contact only, in lateral and protrusive excursions of the mandible. The physiologic basis of treatment is not well understood but the effectiveness of the occlusal splint has been attributed to a decreased loading on the TMJs and reduction of the neuromuscular reflex activity. Alleviation of bruxism and MPD may be due to the change in vertical dimension, altering the proprioception in the postural position of the mandible.⁶⁶⁻⁶⁸ There are generally two types of appliances: stabilization (flat plane) and anterior repositioning.

Table 48-17 Stabilization Appliance

Stabilizes temporomandibular joints
Redistribution of forces
Relaxation of masticatory muscle
Hard acrylic
Maxillary arch
Wear 24 h (except during meals)

Stabilization (Flat Plane) Appliance A stabilization appliance covers all the teeth in one arch and is indicated to relax the muscles of mastication, aid in joint stability, and protect teeth from bruxism (Table 48-17, Figures 48-3 and 48-4).^{68,69} Additional indications for stabilization appliances may include myalgia, inflammation, and retrodiscitis secondary to trauma. With a stabilization appliance the condyles are placed in the most muscularly stable position while the teeth are contacting evenly and simultaneously.⁷⁰ There must be bilateral equal posterior contacts so that an environment of stable physiologic posture is possible. Canine guidance is created for protrusive and lateral excursions. As the patient's symptoms improve, the splint should be adjusted to maintain even contacts bilaterally. The splint is usually fabricated on the maxillary arch because it covers more tissue, especially with Class II or Class III patients where fabrication of a mandibular appliance can be difficult. On the other hand major advantages of the mandibular stabilization appliance include better speech and less visibility, which may contribute to better patient compliance.⁷⁰ The appliance should be worn 24 hours a day and taken out at mealtimes. Stabilization appliances can be weaned post-TMJ arthroscopy and/or as the patient's symptoms subside.

Major and Nebbe reported effective reduction in headaches and muscle pain using stabilization appliances, but occlusal stabilization appliances have limited value in reducing joint pain.⁷¹ Lundh and colleagues concurred with the fact that the stabilization splints have little value in painful disk displacement without reduction.⁷² Kai and colleagues reported that after treatment with a stabilization occlusal splint of the maxillary arch, clinical signs and symptoms of nonreducing anteriorly displaced disks decreased but osteoarthritic findings increased.⁷³

Anterior Repositioning Appliance The anterior repositioning splint is an interoc-

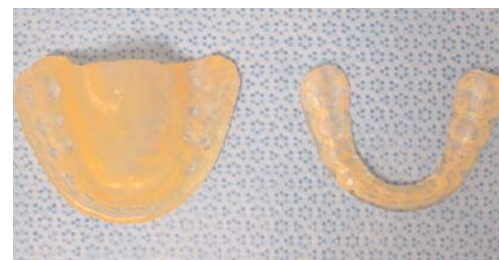

FIGURE 48-3 Stabilization appliance. Hard acrylic full-coverage occlusal splints used for nonsurgical phase of treatment.

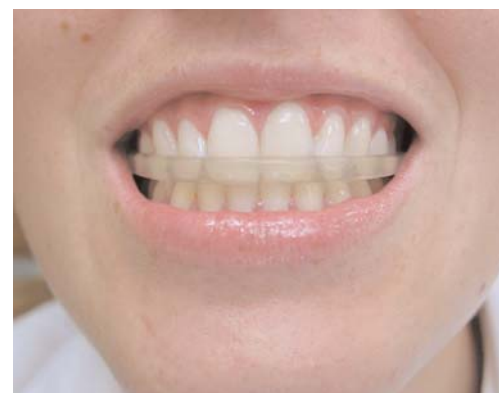

FIGURE 48-4 The stabilization appliance does not change the anterior/posterior jaw position.

clusal appliance that permits the mandible to assume a position more anterior than normal (Table 48-18, Figures 48-5 and 48-6). The purpose of these appliances is to alter the structural condyle-disk-fossa relationship in an effort to decrease joint loading.⁷⁴ Indications for this device are primarily disk derangement disorders. The maxillary appliance is preferred and it is fabricated with a guide ramp that permits the anterior repositioning of the mandible.⁷³ Anterior repositioning appliances are used less frequently because repositioning of the mandible over a period of time can result in irreversible occlusal changes such as posterior open

Table 48-18 Repositioning Appliance

In therapy it attempts to recapture the anterior displaced disk
Need for possible occlusal equilibration and constant adjustment

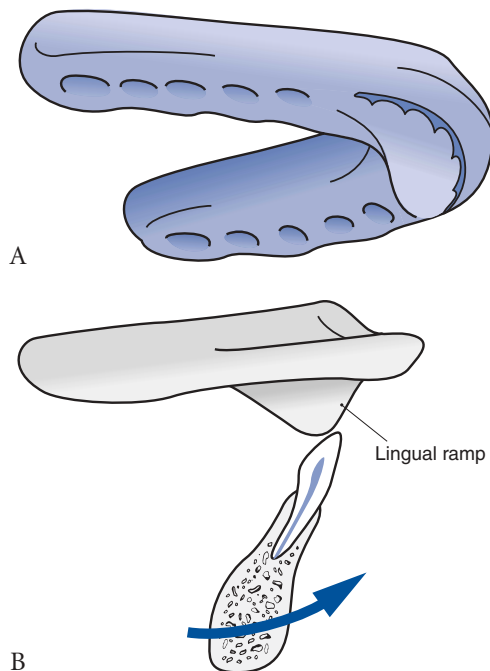


FIGURE 48-5 A, Maxillary repositioning appliance. B, The lingual ramp engages the mandibular incisors and guides the lower jaw forward. A forward repositioner may carry a commitment to restore the patient to a new jaw position. Adapted from Syrop SB. Nonsurgical management of temporomandibular disorders. In: Peterson LJ, Indresano AT, Marciani RD, Roser SM. *Principles of oral and maxillofacial surgery*. Vol. 3. Philadelphia: J.B. Lippincott Company; 1992. p. 1917.

bites, which could require extensive prosthetic rehabilitation.

Occlusal Adjustment There is a limited role for occlusal adjustment or selective grinding in the treatment of TMD.⁷⁵ The purpose of selectively grinding the teeth is

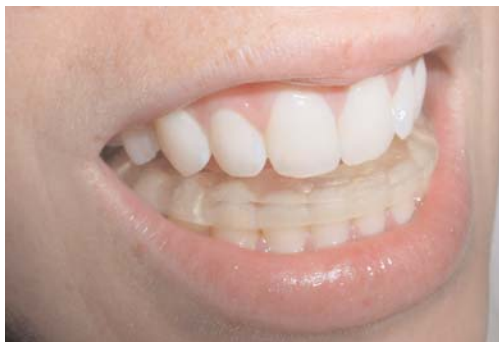

FIGURE 48-6 Repositioning appliance. Hard acrylic repositioning appliance that changes the anterior/posterior jaw position and may require further dental rehabilitation.

to permanently position the dentition into a better occlusion. It is an irreversible process and is best suited for the acute TMD symptoms arising from overcontoured restorations or postorthognathic surgery. In these select cases the occlusal equilibration allows for proper condylar positioning and prevents muscular problems associated with improper interferences.

Causes of Failure

As a singular modality it is very difficult to assess the clinical success or failures of nonsurgical treatments over time. DeLeeuw and colleagues reported long-lasting satisfactory results for patients treated with nonsurgical therapy for internal derangements and osteoarthritis with a 30-year follow-up.⁷⁶ Symptoms such as joint noises persisted, whereas pain and discomfort generally subsided.

There are several possibilities that could explain the cause of failure of nonsurgical therapy for TMDs: incorrect history taking, improper diagnosis and treatment, lack of patient compliance, emotionally debilitated patient, or coexisting morbidities.⁷⁷ When significant symptoms persist after 3 to 6 months of nonsurgical therapy, alternative therapies and/or diagnoses should be considered, including surgery.

Summary

TMD is a complex disorder with common presenting signs and symptoms. In this chapter we have presented nonsurgical strategies used to alleviate the pain and dysfunction associated with the TMJ. Since an exact correlation between diagnosis and treatment is not always possible, success or failure with nonsurgical modalities is not a reliable outcome, even though this therapy may aid in diagnosis and be the first step for most patients. When surgery is indicated or evidence-based, nonsurgical techniques are a crucial adjunct perioperatively, if not forever.

References

- deBont LGM, Kijkgraaf LC, Stegenga B. Epidemiology and natural progression of articular temporomandibular disorders. *Oral Surg Oral Med Oral Pathol Oral Radiol Endod* 1997;83:72–6.
- Carlsson GE. Epidemiology and treatment needed for temporomandibular disorders. *J Orofac Pain* 1999;13:232–7.
- Green CS. Orthodontics and temporomandibular disorders. *Dent Clin North Am* 1988;32(3):529–38.
- Green CS, Laskin DM. Long term evaluation of treatment for myofascial pain dysfunction syndrome: a comparative analysis. *J Am Dent Assoc* 1983; 7:235–8.
- Okeson JP, Hayes DK. Long term results of treatment for temporomandibular disorder: an evaluation by patients. *J Am Dent Assoc* 1986;12:473–8.
- Suvinen TI, Hanes KR, Reade PC. Outcome of therapy in the conservative management of temporomandibular pain dysfunction disorder. *J Oral Rehabil* 1997;24:718–24.
- Gaupp LA, Flinn DE, Weddige RL. Adjunctive treatment techniques. In: Tollinson CD, editor. *Handbook of chronic pain management*. Baltimore (MD): Williams & Wilkins; 1989. p. 174.
- McNeill C, editor. *Temporomandibular disorders: guidelines for classification, assessment and management*. 2nd ed. Chicago (IL): Quintessence Publishing Co.; 1993.
- Mejersjo C, Carlsson GE. Long-term results of treatment for temporomandibular pain-dysfunction. *J Prosthet Dent* 1983;49:805–15.
- Nickerson JW, Boering G. Natural course of osteoarthritis as it relates to internal derangement of the temporomandibular joint. *Oral Maxillofac Surg Clin North Am* 1989;1:27–46.
- Greene CS, Marbach JJ. Epidemiologic studies of mandibular dysfunction: a critical review. *J Prosthet Dent* 1982;48:184–90.
- Okeson JP. *Management of temporomandibular disorders and occlusion*. 2nd ed. St. Louis (MO): C.V. Mosby; 1989.
- Fordyce WE. *Behavior methods for chronic pain and illness*. St. Louis (MO): C.V. Mosby; 1976.
- Black RG. The chronic pain syndrome. *Surg Clin North Am* 1975;55(4):999–1011.
- Fordyce WE. On opioids and treatment targets. *Am Pain Soc Bull* 1991;1:1–13.
- Samuelson B. An elucidation of arachidonic acid cascade. *Drugs* 1987;33 Suppl 1:2–9.
- Simon LS, Mills JA. Non steroidal anti inflammatory drugs and their mechanism of action. *Drugs* 1987;33 Suppl 1:18–27.

18. Insel PA. Analgesic-antipyretics and antiinflammatory agents: drugs employed in the treatment of rheumatoid arthritis and gout. In: Gilman AG, Rall TW, Nies AS, et al., editors. Goodman and Gillman's the pharmacological basis of therapeutics. 8th ed. New York (NY): Pergamon Press; 1990. p. 485–521.
19. Syrop S. Pharmacologic management of myofascial pain and dysfunction. *Oral Maxillofac Surg Clin North Am* 1995;7:87–97.
20. Dimitroulis G, Gremillion HA, Dolwick FM, Walter JH. Temporomandibular disorders. 2. Nonsurgical treatment. *Aust Dent J* 1995;40(6):372–6.
21. Yoshida H, Fukumura S, Fujita M, et al. The expression of cyclo oxygenase-2 in human temporomandibular joint samples: an immunohistochemical study. *J Oral Rehabil* 2002; 29:1146–52.
22. Quinn J, Kent J, Moisc A, Lukiw W. Cyclooxygenase-2 in synovial tissue and fluid of dysfunctional temporomandibular joints with internal derangements. *J Oral Maxillofac Surg* 2000;58:1229–32.
23. Streeten DHP. Corticosteroid therapy, complication and therapeutic indication. *JAMA* 1975;232:1046–59.
24. Cowan J, Moening JE, Bussard DA. Glucocorticoid therapy for myasthenia gravis resulting in resorption of the mandibular condyles. *J Oral Maxillofac Surg* 1995;53:1091–6.
25. Syrop SB. Pharmacological therapy. In: Kaplan AS, Assael LA, editors. Temporomandibular disorders—diagnosis and treatment. Philadelphia (PA): W.B. Saunders; 1991. p. 501–14.
26. Kinney RK, Gatchel RJ, Ellis E, et al. Major psychological disorders in TMD patients: impactions for successful management. *J Am Dent Assoc* 1992;123:49–54.
27. Magni G. On the relationship between chronic pain and depression when there is no organic lesion. *Pain* 1987;31:1–21.
28. Kerrick JM, Fine PG, Lipman AG, Love G. Low dose amitriptyline as an adjunct to opioids for postoperative orthopedic pain: a placebo controlled trial. *Pain* 1993;52:325–30.
29. Brown RS, Bottomley WK. The utilization and mechanism of action of tricyclic antidepressants in the treatment of chronic facial pain: a review of the literature. *Anesth Prog* 1990;37:223–9.
30. Tan E, Janovic J. Treating severe bruxism with botulism toxin. *J Am Dent Assoc* 2000; 131:211–6.
31. Freund B, Schwartz M, Symington JM. Botulism toxin: new treatment for temporomandibular disorders. *Br J Oral Maxillofac Surg* 2000;38:466–71.
32. Guarda NL, Tito R, Beltrame A. Treatment of temporomandibular joint closed lock using intra-articular injection of mepivacaine with immediate resolution durable in time (six month follow-up) [Italian]. *Minerva Stomatol* 2002;51(1–2):21–8.
33. Kaneyama K, Segami N, Nishimura M, et al. Importance of proinflammatory cytokines in synovial fluid from 121 joints with temporomandibular disorders. *Br J Oral Maxillofac Surg* 2002;418–23.
34. Israel H, Syrop S. The important role of motion in the rehabilitation of patients with mandibular hypomobility: a review of the literature. *J Craniomandib Pract* 1993;II(4):298–307.
35. Karlis V, Andreopoulos N, Kinney L, Glickman R. Effectiveness of supervised calibrated exercise therapy on jaw mobility and temporomandibular dysfunction. *J Oral Maxillofac Surg* 1994;52(8 Suppl 2):147.
36. Sebastian MH, Moffet BC. The effect of continuous passive motion on the temporomandibular joint after surgery. *Oral Surg Oral Med Oral Pathol* 1989;67:644–53.
37. Maloney G. Effect of a passive jaw motion device on pain and range of motion in TMD patients not responding to flat plane intraoral appliances. *J Craniomandib Pract* 2002;20(1):55–6.
38. Mongini F. A modified extraoral technique of mandibular manipulation in disk displacement without reduction. *J Craniomandib Pract* 1995;13(1):22–5.
39. Kurita H, Kurashina K, Ohtsuka A. Efficacy of a mandibular manipulation technique in reducing the permanently displaced temporomandibular joint disc. *J Oral Maxillofac Surg* 1999;57:784–7.
40. Yuasa H, Kurita K. Randomized clinical trial of primary treatment for temporomandibular joint disk displacement without reduction and without osseous changes: a combination of NSAIDs and mouth opening exercise versus no treatment. *Oral Surg Oral Med Oral Pathol* 2001;91(6):671–5.
41. Travell JG, Simons DG. Myofascial pain and dysfunction: the trigger point manual. Baltimore (MD): Williams & Wilkins; 1983.
42. Modell W, Travell J, Kraus H. Relief of pain by ethyl chloride spray. *NY State J Med* 1952;52:1550–8.
43. Melzack R, Wall P. Pain mechanisms: a new theory. *Science* 1965;150:971–9.
44. Nelson SJ, Ash MM. An evaluation of a moist heating pad for the treatment of TMJ / muscle pain dysfunction. *Cranio* 1988;6(4):355–9.
45. Vanderwindt D, Vanderheijden G, et al. Ultrasound therapy for musculoskeletal disorder: a systemic review. *Pain* 1999;81(3):257–71.
46. Ziskin MC, Michlovitz SL. Therapeutic ultrasound. In: Michlovitz SL, editor. Thermal agent in rehabilitation. Philadelphia (PA): F.A. Davis Co.; 1990. p. 141–69.
47. Adler RC, Adachi NY. Physical medicine in the management of myofascial pain and dysfunction: medical management of temporomandibular disorders. *Oral Maxillofac Surg Clin North Am* 1995;7(1):99–106.
48. Wolf SL. Neurophysiologic mechanisms in pain modulation: relevance to TENS. In: Manheimer JS, Lampe GN, editors. Clinical transcutaneous electrical nerve stimulation. Philadelphia (PA): F.A. Davis Co.; 1984. p. 41.
49. Clark GT, Adachi NY, Dornan MR. Physical medicine procedures affect temporomandibular disorders: a review. *J Am Dent Assoc* 1990;121:151–61.
50. Mohl ND, Ohrbach RK, Crowe HC, Gross AJ. Devices for the diagnosis and treatment of temporomandibular disorders. Part III. Thermography ultrasound, electrical stimulation and EMG biofeedback. *J Prosthet Dent* 1990;63:472–7.
51. Gold N, Greene CS, Laskin DM. Transcutaneous electrical nerve stimulation therapy for treatment of myofascial pain dysfunction syndrome. *J Dent Res* 1983;62:244.
52. Ersek RA. Transcutaneous electrical neurostimulation. *Clin Orthop* 1977;128:314–24.
53. Eisen AG, Kaufman A, Green CS. Evaluation of physical therapy for MPD syndrome. *J Dent Res* 1984;63(special issue):344, abstract 1561.
54. Lark MR, Gangarosa LP. Iontophoresis: an effective modality for the treatment of inflammatory disorders of the temporomandibular joint and myofascial pain. *J Craniomandib Pract* 1990;8:108–19.
55. Gangarosa LP, Mahan PE. Pharmacologic management of TMJ-MPDS. *Ear Nose Throat J* 1982;61:670.
56. Gerald MJ. Physical medicine modalities and trigger point injections in the management of temporomandibular disorders and assessing treatment outcome. *Oral Surg Oral Med Oral Pathol Oral Radiol Endod* 1997;83(1):118–22.
57. Kaplan AS, Assael LA. Temporomandibular disorders: diagnosis and treatment. Philadelphia (PA): W.B. Saunders Company; 1991. p. 522–5.
58. Crider AB, Glaros AG. A meta-analysis of EMG biofeedback treatment of temporomandibular disorders. *J Orofac Pain* 1999; 13(1):29–37.

59. Scott DS, Gregg JM. Myofacial pain of the temporomandibular joint: a review of the behavioral-relaxation therapies [review]. *Pain* 1980;9(2):231–41.
60. Matsumura WM. Use of acupressure techniques and concepts for nonsurgical management of TMJ disorders. *J Gen Orthod* 1993;4:5–16.
61. Matsumura TM, Ali NM. Evaluation of acupuncture and occlusal splint therapy in the treatment of temporomandibular joint disorders. *Egypt Dent J* 1995;41:1227–32.
62. Berry H, Fernandez L, Bloom B, et al. Clinical study comparing acupuncture, physiotherapy, injection, and oral anti-inflammatory therapy in shoulder cuff lesions. *Curr Med Res Opin* 1980;7:121–6.
63. Rugh JD. Psychological components of pain. *Dent Clin North Am* 1987;31:579–94.
64. Moss RA, Adams HE. The assessment of personality, anxiety and depression in mandibular pain dysfunction subjects. *J Oral Rehabil* 1984;11:233–7.
65. Katon W, Egan K, Miller D. Chronic pain: lifetime psychiatric diagnoses and family history. *Am J Psychiatry* 1985;142:1156–60.
66. Okeson JP, Kemper JT, Moody PM. A study of the use of occlusion splints in the treatment of acute and chronic patients with craniomandibular disorders. *J Prosthet Dent* 1982;48:708–12.
67. Okeson JP, Moody PM, Kemper JT, Haley J. Evaluation of occlusal splint therapy and relaxation procedures in patients with TMJ disorders. *J Am Dent Assoc* 1983;107:420–4.
68. Clark GT. A critical evaluation of orthopedic interocclusal appliance therapy: design, theory and overall effectiveness. *J Am Dent Assoc* 1984;108:359–64.
69. Rugh JD, Harlan J. Nocturnal bruxism and temporomandibular disorders. *Adv Neurol* 1988;49:329–41.
70. Okeson JP. Occlusal appliance therapy. In: Duncan LL, editor. *Management of temporomandibular disorders and occlusion*. 4th ed. Philadelphia (PA): Mosby Publishing; 1998. p. 474–502.
71. Major PW, Nebbe B. Use and effectiveness of splint appliance therapy: review of literature. *J Craniomandib Pract* 1997;15(2):159–66.
72. Lundh H, Per-Lenmart W, Eriksson L, et al. Temporomandibular disk displacement without reduction: treatment with flat occlusal splint versus no treatment. *Oral Surg Oral Med Oral Pathol* 1992;73:655–8.
73. Kai S, Kai H, Tabata O, et al. Long-term outcomes of nonsurgical treatment in nonreducing anteriorly displaced disk of the temporomandibular joint. *Oral Surg Oral Med Oral Pathol* 1998;85:258–67.
74. Moloney F, Howard JA. Internal derangements of the temporomandibular joint. III. Anterior repositioning splint therapy. *Aust Dent J* 1986;31:30–9.
75. Clark GT, Adler RC. A critical evaluation of occlusal therapy. Occlusal adjustment procedures. *J Am Dent Assoc* 1985;110:743–50.
76. DeLeeuw R, Boering G, Stegenga B, et al. Symptoms of temporomandibular joint osteoarthritis and internal derangement 30 years after nonsurgical treatment. *J Craniomandib Pract* 1995;13(2):81–8.
77. Abdel-Fattah RA. Considerations before surgical intervention in management of temporomandibular joint disorders. *J Craniomandib Pract* 1997;15(1):94–5.

Temporomandibular Joint Arthrocentesis and Arthroscopy: Rationale and Technique

Jeffrey J. Moses, DDS

Since the seventh century BC, papyrus images have revealed attempts at temporomandibular disorder (TMD) management through relocation of dislocations. Over a long and arduous route clinicians have sought to relieve the painful dysfunction of this structure through various mechanical, anatomic, and biochemical evaluations and correctional means. Through the relatively recent advances of technology, and partly because of the equivocal successes of historic management outcomes, modern maxillofacial surgeons now have the access to micronized minimally invasive techniques to assist in TMD management. From the diagnostic evidence produced by the thin intra-articular arthroscope and the evaluation of the fluid effudate comes new information turning this era into a valuable epoch of discovery. Successful long-term outcomes from relatively simplified therapeutics have led many surgeons to decrease the incidence of open-joint arthroplasties and their potential negative complication sequelae. While this chapter focuses on the techniques of arthroscopy and arthrocentesis, the current stage of the evolution of treatment philosophies and understanding of these

techniques as applied to the pathophysiology of the discussed temporomandibular joint (TMJ) for successful outcome in patient management are emphasized.

History of Orthopedic Development

The development of biomechanical and optical accesses for the examination of intra-articular structures in the early twentieth century was accomplished by Kenji Tagaki in 1918 by his use of a 7.3 mm diameter pediatric cystoscope allowing him to examine a knee joint.¹ His later development of a 3.5 mm diameter scope made this procedure practical. Of historic significance, in 1921, Bircher published an independent report of the results of his arthroscopic studies of the knee joint using a laparoscope with gaseous distention of the joint space using oxygen or carbon dioxide.² Another report using arthroscopy was published by Kreyscher in 1925, predicting that it would become the definitive diagnostic modality for derangements of the knee.³

Following Tagaki's modification of the cystoscope and diameter reduction to 3.5 mm in the early 1930s and the use of saline for joint distention, several other

pioneers went on to improve arthroscope design and used these in a patient series, publishing their clinical experiences.⁴ Unfortunately, due to the technologic restraints at the time of lack of illumination and having only direct eyepiece visualization with electronic assistance, there was limited acceptance of this method as a valuable diagnostic modality.

A major turning point in the field came in the early 1950s with the recognition that the technologic advances in electronics and optical design could assist in endoscopic equipment development. This was appreciated and used by one of Tagaki's students, Masaki Watanabe. Watanabe and colleagues' design of the no. 21 arthroscope with 100° field of vision and a 6.5 mm diameter using tungsten light illumination and camera attachments turned the direction of this field of interest around.⁵ The work done by Casscells as well as Jackson and Abe built on this foundation clinically, which was credited to Watanabe's performance of the first surgical procedure on the human knee joint in 1955.^{6,7}

Enthused with the potential, Richard O'Conner returned home from a trip to Japan in 1970 and subsequently developed

an operative arthroscope in 1974. He used this to perform a meniscal resection, the results of which he published in 1977.⁸ A generalized instrumentation explosion, coupled with the development of motorized equipment by Lanny Johnson then ensued, which led to further technique developments in arthroscopic managements of intra-articular pathology.⁹ Realizing that these techniques would be best learned in specifically designed courses with hands-on experience, in 1973, John Joyce III and Michael Hardy, an anatomist, organized the first of many courses that developed. This greatly enhanced the spread of this treatment modality throughout the orthopedic community. Many of these early courses were personally overseen by the pioneering experts, including Dr. Watanabe himself.

Development of Temporomandibular Joint Arthroscopy

A major breakthrough for small joint endoscopic access occurred in 1970 with the development of the Watanabe no. 24 Selfoc arthroscope with a 1.7 mm diameter.¹⁰ This was introduced into the TMJ by Masatoshi Ohnishi using a fiberoptic light source and arthroscopic device manufactured by Olympus in the early 1970s. Ohnishi published both the puncture technique and the anatomic findings and later went on to describe the usefulness of this technique for clinical applications in the treatment of TMJ disease in 1980, including photographic documentation of normal anatomy as well as providing early information on traumatic pathology and joint fibrosis.¹¹⁻¹⁴

In 1978 an animal study on rabbits by Hilsabeck and Laskin demonstrated that TMJ arthroscopy was a safe technique that revealed the appearance of intra-articular structures.¹⁵ In 1980 Williams and Laskin went on to introduce pathologic conditions in the rabbit joint and concluded that these could be

diagnosed by the arthroscope.¹⁶ Holmlund and colleagues published similar results in 1986.¹⁷ In 1982 Ken-Ischiro Murakami and Kazumasa Hoshino reported their procedural terminology and arthroscopic anatomy, excellently illustrating the human TMJ with color photography.¹⁸ During a visit to the United States in 1984 Dr. Murakami introduced this concept to Bruce Sanders who, along with Joseph McCain but on separate US coastlines, began to perform the procedures clinically for patients with TMD. Drs. Ronald Kaminishi, Jeffrey Moses, Christopher Davis, as well as others were introduced to the puncture and arthroscopic visualization of the TMJ during this time. Wanting again to develop the training of this technique along the same lines as their orthopedic counterparts, the maxillofacial surgeons sought to develop educational symposia and hands-on training. The first international hands-on course using fresh cadaveric specimens for technique development was initiated by J.J. Moses in late 1985 and continued on through the sponsorship of The Pacific Clinical Research Foundation. Many of the initial surgeons exposed to the modality independently went on to develop a variety of techniques and courses using the communal efforts of the international pioneers at these sessions.

In 1985, with references to the arthroscopic observations, Murakami and Hoshino described histologic cellular characteristics of the inner surfaces of the TMJ.¹⁹ Also in 1985 Holmlund and Helling published their landmark paper on the concept of reproducible puncture sites correlating measurements along the tragal-canthal line.²⁰ These are recommended for surgeons' early learning stages in technique development.²¹

Continued efforts by Murakami and Ono to improve surgical techniques were published in 1986, and McCain presented an abstract at the 1985 Annual Meeting of

the American Association of Oral and Maxillofacial Surgeons (AAOMS) on his investigations.^{22,23} A pivotal work was published in 1987 by Sanders in the treatment of closed lock condition with the surgical application of arthroscopic lysis and lavage over a 2-year period.²⁴

In 1986 the first major didactic symposium on arthroscopy of the TMJ was guided by Drs. Kaminishi and Davis and sponsored by the Southern California Society of Oral and Maxillofacial Surgeons. This started the movement toward academic research and clinical investigations. Notably Dr. Ohnishi provided a demonstration of his puncture technique at this symposium, where many of the pioneers of this group began to prepare themselves for the 1986 meeting of the First Annual Symposium on Arthroscopy of the Temporomandibular Joint led by Dr. McCain, hosted in New York, and sponsored by the Hospital for Joint Diseases. It was at this subsequent meeting that the International Study Group (ISG) for the Advancement of Temporomandibular Joint Arthroscopy was formed. This pioneering group provided many of the national and international liaisons for future collaborations and collective dissemination of information, as well as expertise at the didactic and hands-on cadaveric symposium to follow.

An explosion of papers and presentations on multiple techniques, equipment development, and clinical studies ensued. Partly in an effort to curtail the potential for similar untoward sequelae as has been experienced in the field of open TMJ surgery in the past, the ISG worked together for the development of standards in credentialing, technique workshops, and recording of clinical results and provided clarification criteria for insurance coverage. As a result of much of this work the AAOMS formed an ad hoc committee and issued an official statement regarding TMJ arthroscopy, going on in 1988 to form an adjunctive insurance task force.

Important research over the early years contributed to knowledge showing that although disk position may be indicative of pathologic history, its lack of mobility more closely correlated to pathologic presence.²⁵ Also, the chronicity of the patient's TMD history seemed to lend itself to the development of articular remodeling in the absence of pain and limitation of motion in the postoperative phases.²⁶ Studies aimed at the identification of chemicophysiological markers and mediators were done through joint fluid analysis. It was found that arthroscopic surgery was successful even in Wilkes stage III and stage IV diseases. Recently more work has been done on diskal reshaping procedures as well as arthroscopic functional disectomy through superior-anterior capsular release combined with physical therapy for joint space enlargement.

Technique enhancements still on the horizon include early intervention with injectable joint lubricants like sodium hyaluronate (HA) following initial arthrocentesis or even the use of modified HA as an operating medium or for use as an intra-articular bandage.

Even though arthroscopic surgery is not the panacea for TMJ surgical care, it has proven itself as one of the basic techniques to be mastered by modern oral and maxillofacial surgeons in their complete management armamentarium.

Patient Selection and Evaluation

Although many patients present with pain in and around the TMJ, relatively few are selected for surgery. At the centers working with the Pacific Clinical Research Foundation, manned by teams of dentists, psychologists, physical therapists, and ancillary medical managers, only 10 patients in 400 evaluated actually have intracapsular joint derangements or pathology amenable to invasive procedures.

I have found arthroscopic management to be successful in 8 out of those 10 patients, with only 2 out of the original

400 requiring open surgery. A key to successful outcomes in any surgical care is careful patient selection and perioperative team management.

While patients certainly present with pain originating outside of the joint itself (such as atypical facial pain and neuralgias and some pains related to systemic diseases such as rheumatoid arthritis), for the purposes of this chapter we will limit our discussions to those with intracapsular etiology.

In general one has to screen the patient for the basic premise of pain origin. Is it from within the joint or from the muscles? As always there are etiologic factors affecting both possibilities that need to be identified. The most valuable screening technique comes through a valid history and physical examination that can be fairly succinct.

History

First it is comforting to the patient to address their primary chief complaint. This is done even though it is often secondary to the interest of the surgeon who wants to discover how it originated and what secondary damage has occurred so that corrections can be planned for the patient's condition and to prevent recurrence. This is done by asking the patient to identify the location, onset, and frequency of the pain, in addition to asking what the aggravating factors are and the maneuvers used to relieve the pain. Notice how the patient responds when answering the location question, whether they use a finger pointed to the joint as opposed to a flat hand palm placed on the face. The pointed location tends to lend credibility to capsular-intracapsular joint problems. The character and history of the progression of the joint noise is also helpful, paying close attention to how clicks proceeded to catching and locking, or crepitus. Also ask about the nonsymptomatic side since frequently there may be a history of the same sequence indicating the possibility of

more advanced degenerative disease on that side, which will be evidenced on the radiograph and through the range of mandibular motion examination.

Patients often report pain in the shoulders and neck, headaches, earaches, and feelings of fullness in the ears or dulled hearing. It is important to inquire as to the patient's generalized physical or emotional status regarding recent pregnancy, childbirth, or menopause as well as their condition socially with jobs or family. This frequently adds significant overlay and insight to associated etiology and treatment management.

Positive answers to pointed questions regarding the history of recent or childhood trauma, habits of bruxism or clenching, and medications used, such as those initiating dyskinesia, should be explored. Also, one should inquire into past gnathologic treatments such as prior orthodontic care for closure of open bites, retrognathic treatment with class II elastics or positioners, extensive crown-and-bridge prosthetics, and equilibration for balancing contact occlusal interferences.

Physical Examination

The examination can likewise be fairly concise and takes a close second to the history in importance. The generalized physical examination can follow the focused joint and facial structure examination in order to let the patient know that their chief complaint has been heard, thus giving them more confidence and trust. Clinicians examine the location of pain, skeletofacial form, and the TMJ first followed by the nerve function, muscles, and dentition/occlusion. Initially noting the form of the skeletofacial structures, look for open bites, retrognathism (with or without deep bites), asymmetries of the jaw and facial bones, and pseudobites where the habitual position of the mandible is off of the skeletal position. Careful checking of capsular tenderness as well as palpating and auscultating for

joint sounds, such as reciprocal clicks, pops, catching, and crepitus, all lend valuable information. Be certain to load the affected and nonaffected sides in occlusion to ascertain the effect on the pain as well.

Next generally check sensory nerve function and muscle response to cognitive motor stimulus. The muscle examination naturally follows with observations being made for hypertrophy, asymmetry, and tenderness to palpation. Frequently with longstanding symptoms a cascading of protective muscle splinting will lead to neck and shoulder symptoms. The ears and eyes are checked with notations for later specialist referrals if abnormalities are found or complaints are elicited.

Finally the teeth and occlusion are examined, looking for masked asymmetric skeletal characteristics secondary to orthodontic treatments applied during growth, pseudobite secondary to class II elastics, wear facets and balancing interferences, supraerupted teeth, or loss of posterior support. It is at this point that the mandibular range of motion is measured and observed, and deviations, limitations, or hypermobilities are noted.

Presurgical Diagnostics and Therapeutics

Following the history and physical examination and screening panoramic examination, clinicians usually initiate presurgical conservative therapy. The use of a presurgical orthotic appliance designed to deprogram the habitual occlusion and skeletal positions, as well as provide relief to the muscular splinting and resultant myositis, cannot be overemphasized. This not only assists physical therapists in their assessment and therapeutic care but also provides the surgeon with valuable information as to whether true skeletal asymmetries or open bites are preexisting, which may have been masked by neuromuscular programming through prior clinical care. Usually this is accomplished

with a maxillary splint built with cuspid guidance in order to prevent the dental movement and opening of the interdental spaces produced with clenching or bruxism. If an open bite exists, which would require a mandibular splint due to the undesirable excessive bulk of acrylic on a maxillary splint, the splint should also be designed for lateral disclusion using the bicuspid instead of the cuspid teeth.

The use of the orthotic splint appliance, combined with physical therapy and nonsteroidal anti-inflammatory drugs (NSAIDs), should allow most experienced physical therapists and surgeons to determine whether an intracapsular pathology will be responsive to nonsurgical therapy within a matter of 6 to 8 weeks.

Occasionally the decision is made for therapeutic muscular trigger-point injections or intracapsular superior joint compartment diagnostic blocks of diluted local anesthetic solution in order to segregate pain etiologic foci before proceeding to either arthrocentesis or combined arthroscopic surgery.

Imaging

Traditionally the panoramic view is the first revealing image of the TMJ. Current concepts of management have been expanded through visualization of axially corrected sagittal tomography based on the submental vertex view with the alignment of the x-ray beam along the medial-lateral pole axis of each of the condyles, taken in the open mouth and closed occlusion positions. This is augmented by the coronal views in the protruded occlusion position with the incisors placed edge to edge in order to visualize the medial, lateral, and superior condylar anatomy in relation to the superior condyle's proximity along the functional area of the eminentia. These views can reveal osteophytes, erosions, and remodeling impingements that would otherwise be undetected from other bone imaging techniques.

For the shape, position, mobility, and intrinsic structural integrity of the disk itself, magnetic resonance imaging (MRI) has proven to be extremely reliable.²⁷ Whereas studies have shown that history and clinical examination are reliable for predicting similar MRI diagnosis for anterior disk displacements without reduction, and arthroscopic examinations have been shown to be statistically reliable for disk displacements as well, additional information of disk immobility with normal disk position and diskal structure and integrity loss with myxomatous changes can be ascertained by MRI, proving its overall value and reliability for additional soft tissue information compared with other techniques such as arthrography.^{28,29}

For patients with conditions that are suspect for partial bony ankylosis, which occurs with the advanced disease process associated with repetitive surgery or with a fibrous ankylosis, a computerized axial tomography scan will sometimes provide the best possible information. Whether one chooses to proceed with arthroscopy on basic imaging techniques and the history and physical examination alone or to add more sophisticated imaging to the presurgical diagnostic package is a decision to be made by each clinician who is involved with the individual patient.

Indications and Contraindications

Indications

Early meetings of the International Study Group for the Advancement of TMJ Arthroscopy were convened to formulate international consensus on the various indications and contraindications for TMJ arthroscopy. Resolutions were forwarded for acceptance to the AAOMS, which finalized the position paper on TMJ arthroscopy in 1988.³⁰ This paper separated indications for diagnostic and operative arthroscopy with generalized

examples given of patients in whom disorders were found that were not explained by other means and for which a diagnostic confirmation would affect the patient's care and outcome. It also included indications for diagnostic arthroscopy in order to enhance treatment decisions. Examples include the following:

- Biopsy of suspected lesions or disease
- Confirmation of other diagnostic findings that could warrant surgical intervention
- Unexplained persistent TMJ pain that is nonresponsive to medical therapy

The indications for surgical arthroscopy are matched carefully with the diagnosis before application. Helpful criteria of disease staging should be applied through the combined use of the Wilkes staging classification for internal joint derangement (Table 49-1), which was based on clinical, radiologic, and anatomic divisions, and the Bronstein and Merrill arthroscopic staging of internal joint derangements (Table 49-2) correlated at the time of arthroscopic surgery. Intraoperatively, internal joint surface procedures are applied individually to the significant finding.

Internal joint derangement (IJD) is known to be a preoperative indication for surgical arthroscopy. The AAOMS position paper defines IJD as a disruption of the internal aspects of the TMJ with either diskal displacements or alterations in the normal dynamic motions of the intracapsular elements. This would include adhesions or impingements in the face of even normal disk position. The paper goes on to describe surgical arthroscopy as indicated for joint conditions that constitute a disability for the patient and which are refractory to medical treatments and require structural modification.³⁰

Whereas internal derangements associated with hypomobility due to adhesions, disk immobility, and disk displace-

Table 49-1 Wilkes Staging Classification for Internal Derangement of the Temporomandibular Joint

I. Early Stage
A. Clinical: no significant mechanical symptoms other than early opening reciprocal clicking; no pain or limitation of motion
B. Radiologic: slight forward displacement; good anatomic contour of the disk; negative tomograms
C. Anatomic/pathologic: excellent anatomic form; slight anterior displacement; passive incoordination demonstrable
II. Early/Intermediate Stage
A. Clinical: one or more episodes of pain; beginning major mechanical problems consisting of mid- to late-opening loud clicking, transient catching, and locking
B. Radiologic: slight forward displacement; beginning disk deformity of slight thickening of posterior edge; negative tomograms
C. Anatomic/pathologic: anterior disk displacement; early anatomic disk deformity; good central articulating area
III. Intermediate Stage
A. Clinical: multiple episodes of pain; major mechanical symptoms consisting of locking (intermittent or fully closed), restriction of motion, and difficulty with function
B. Radiologic: anterior disk displacement with significant deformity/prolapse of disk (increased thickening of posterior edge); negative tomograms
C. Anatomic/pathologic: marked anatomic disk deformity with anterior displacement; no hard tissue changes
IV. Intermediate/Late Stage
A. Clinical: slight increase in severity over intermediate stage
B. Radiologic: increase in severity over intermediate stage; positive tomograms showing early to moderate degenerative changes—flattening of eminence; deformed condylar head; sclerosis
C. Anatomic/pathologic: increase in severity over intermediate stage; hard tissue degenerative remodeling of both bearing surfaces (osteophytosis); multiple adhesions in anterior and posterior recesses; no perforation of disk or attachments
V. Late Stage
A. Clinical: crepitus; scraping, grating, grinding symptoms; episodic or continuous pain; chronic restriction of motion; difficulty with function
B. Radiologic: disk or attachment perforation; filling defects; gross anatomic deformity of disk and hard tissues; positive tomograms with essentially degenerative arthritic changes
C. Anatomic/pathologic: gross degenerative changes of disk and hard tissues; perforation of posterior attachment; multiple adhesions; osteophytosis; flattening of condyle and eminence; subcortical cystic formation

Adapted from Bronstein SL and Thomas M.⁷⁹

ments with blockade are likely candidates for structural modifications, those joints with recent trauma, degenerative disease, synovial disease, and even hypermobility are included in the conditions indicated for arthroscopic surgical intervention.

Contraindications

Even though there are relatively few absolute contraindications to joint arthroscopy, it is generally recognized that underlying medical instabilities, overlying skin infections, and risks associated with

Table 49-2 Bronstein and Merrill Arthroscopic Staging of Internal Joint Derangements Correlated with the Wilkes Staging

I. Early Stage	Roofing, 80% (closed position) to 100% (open or protrusive positions); incipient bilaminar zone elongation; normal disk flexure at junction of diskal eminence and superior lamina; normal synovium; incipient loss of articular surface smoothness; normal superior compartment recesses and vascularity
II. Early/Intermediate	Roofing, 50% (closed) to 100% (open or protrusive); bilaminar elongation with decreased flexure; early adhesive synovitis with beginning adhesion formation; slight lateroanterior capsular prolapse
III. Intermediate	Advanced bilaminar elongation with accordion-shaped redundancy and loss of flexure; prominent synovitis; diminished lateral recess; advanced adhesion formation; anterior pseudowall formation in substage B Substage A: Roofing, 5% (closed) to < 15% (open or protrusive); chondromalacia grades I–II (softening, blistering, or furrowing) Substage B: No roofing, more severe anterior recess changes; chondromalacia grades II–III (blistering, furrowing, ulceration, fraying, fibrillation, surface rupture)
IV. Intermediate/Late	Increase over intermediate stage disease; hyalinization of posterior attachment; chondromalacia grades III–IV (ulceration, fraying, furrowing, fibrillation, surface rupture, cratering, bone exposure)
V. Late Stage	Prominent fibrillations on articular surfaces; perforation; retrodiskal hyalinization; false-capsule formation anteriorly; generalized adhesions; advanced synovitis; chondromalacia grade IV (cratering, bone exposure)

Adapted from Bronstein SL and Thomas M.⁷⁹

malignant tumor seeding represent relative contraindications.³¹

Arthroscopic Instrumentation and Anesthesia Consideration

Surgeons performing arthroscopic surgery should be familiar with not only the surgical technique but the supportive electronics and operating room set-up as well. As a guide for the surgeon a recommended schematic of room set-up is shown in Figure 49-1.

Video Monitoring Equipment

Even though the interior surfaces of the joint can be visualized directly via the eyepiece, most arthroscopists prefer to use video electronic enhancement and documentation equipment. A video monitor

and recording device are placed at the head of the patient, easily orienting everyone in attendance to the 12:00 (twelve o'clock) position of the joint with the video camera attached to the arthroscopic eyepiece. A video monitoring cart (Figure 49-2) contains the monitor, light source, and recording units with the cumbersome cords draped on the contralateral side of the patient's head to the surgeon's position. The clear imaging of the joint allows all people involved with the case to clearly participate with interest. This has the additional benefit of allowing them to better anticipate the progress and needs of the surgeon.

Irrigation System

A constant flow of irrigation fluid is essential to providing a clear view of the

joint surfaces through the distention of the potential joint space, as well as for washing blood and debris away from the lens objective. The inflow is attached to the arthroscopic cannula, and an outflow needle is placed elsewhere in the joint space. The diameter of the outflow portal should be of a lesser size than the inflow portal, which allows a slight pressure differential in order to maintain sufficient joint distention.

For routine arthroscopic procedures a 1½ inch 18-gauge short-beveled needle is ideal. If laser débridement is anticipated a second arthroscopic cannula with a stopcock and rubber obturator should be placed so that the outflow volume can be adjusted to the higher flows of irrigation fluid required for the prevention of excessive thermal synovial damage that is possible from the heat generated by the laser photovaporization. Additional benefits of the irrigation include those associated with the therapeutic effects of lavage and arthrocentesis.³²

The components of a simplified approach to an irrigation system include several units of extension tubing with Luer-loc attachments, a 30 mL or 60 mL syringe, a three-way stopcock, the arthroscopic cannula, and a 1½ inch 18-gauge short-beveled needle. For most cases the drainage may be collected in a small basin with the end of the exit tubing taped to the basin's edge, allowing the surgical technician visible evidence that the fluid pushed into the point is equal to that coming back out to prevent extravasation into the peri-articular tissues.

Alternatively for the higher volumes necessary in cases requiring laser-assisted techniques, a pneumatic-assisted compression unit may be used instead of the syringes to provide constant pressure on a 500 mL bag of irrigation solution. This provides a consistent joint distention as well as a cooling flow of solution across the joint surfaces. The outflow in these cases is usually voluminous and is collected in an

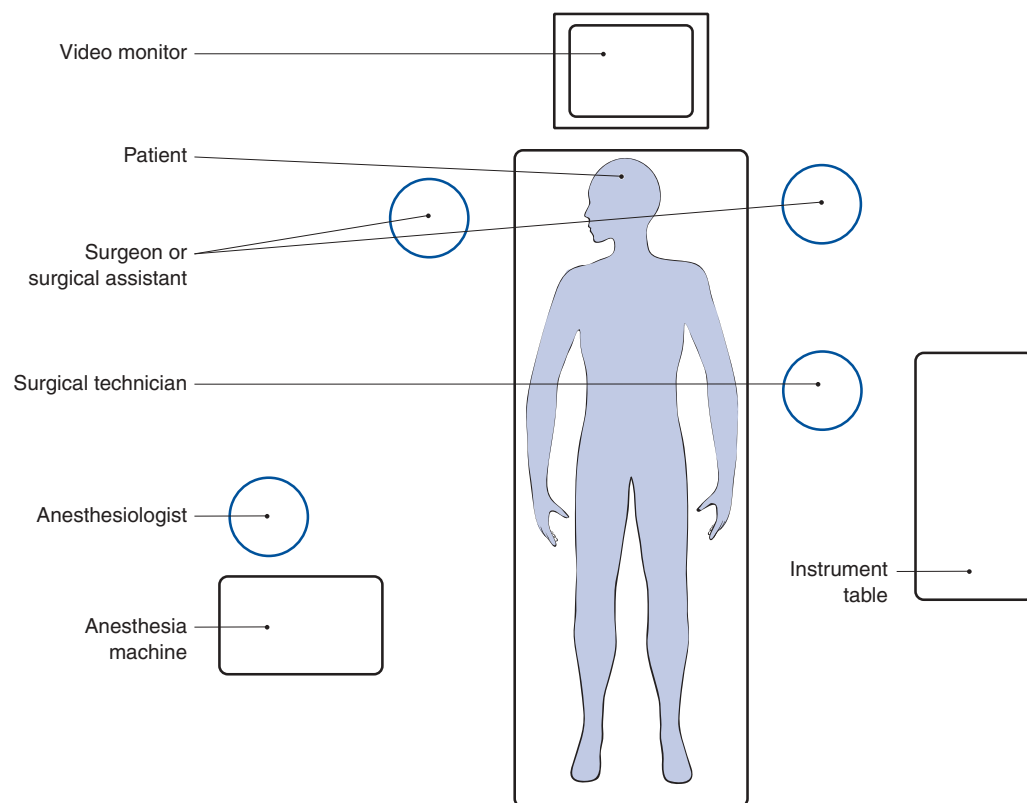


FIGURE 49-1 Position of surgical team and equipment for arthroscopic surgery. The surgeon and surgical assistant may change positions freely without disturbing the positions of the equipment or other persons helping.

orthopedic shoulder arthroscopy bag, which has a drainage portal at the apex.

Arthroscope

The manufacturers use four basic techniques for arthroscope construction. The early design, in 1966, of the rod-lens endoscope by H.H. Hopkins improved the traditional achromatic lens system, which made arthroscopic examination

practical by reducing the diameter of the instrument. By placing at least two different types of glass into the system, secondary advancements made color correction possible. This led to brighter images due to a reduced separation of spaces between the rod lenses when compared with the achromatic focusing lens system, and lessened the likelihood of breakage.⁵

A third advance came with the development of a unique type of glass with a nonuniform refractive index called the Selfoc lens. The characteristic of this gradient-index system is that curved surfaces are not required, and the spacing between the lenses could be eliminated using optional cements which allowed a thinner diameter with brighter images and an equivalent breakage resistance.³³ The glass structure itself provides the focusing power of the system (Figure 49-3).

In the fourth alternative, optical lenses are placed at either end of a fiberoptic

relay, focusing the image along the fiber relay, which transmits the image from the objective to the output ocular lens or eyepiece. These are primarily used in work requiring extreme flexibility such as vascular exploration. However, there are new disposable fiberscopes now available for needle access to the small joint.

No matter whether a rod lens or Selfoc lens is used in arthroscopic surgery, any bending of the lens sheath will produce a dark halo crescent and heralds possible lens damage or fracture.

Visual Fields and Angles

The angle of vision consists of the angle formed extending from the outermost margin of the objective lens to the subject viewed.

The field of vision consists of the three-dimensional circular area within those angles of the angle of vision.

The angle of inclination is commonly termed the direction of view, which can be altered by the lens construct itself. Usual angles of inclination are 10°, 30°, and 70°. Through the careful use of rotation of the angled arthroscope in an arc-like fashion, a wider field of vision can be produced (Figure 49-4).

Another valuable insight into the optical characteristics of the arthroscope is the fact that the field of view will be dimmed by magnification without providing increased resolution. Light transmission is critical in order to keep the image definition clear and is reduced by increasing the angle of inclination from 0° to 70° incrementally.

A good general rule to remember is that as the diameter of the scope decreases and the angle of the scope increases, the apparent field of view and brightness of the image decreases.

There are two ways to overcome these obstacles: (1) through the use of an integrated video arthroscopic system with zoom camera couplers, and (2) through the enhancement of light. Even though a quartz-halogen light may be sufficient for

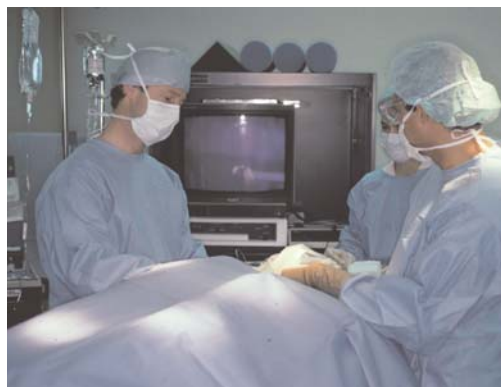

FIGURE 49-2 Video monitoring cart.

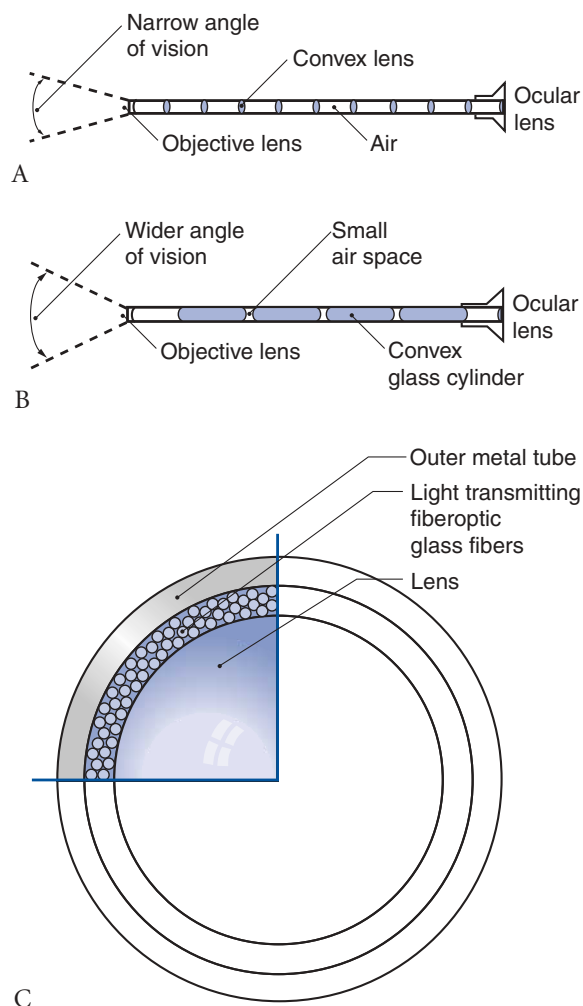


FIGURE 49-3 A, Conventional endoscopic lens system showing the narrow angle of vision. B, Rod-lens system showing the wider angle of vision. C, Cross-sectional representation of endoscope.

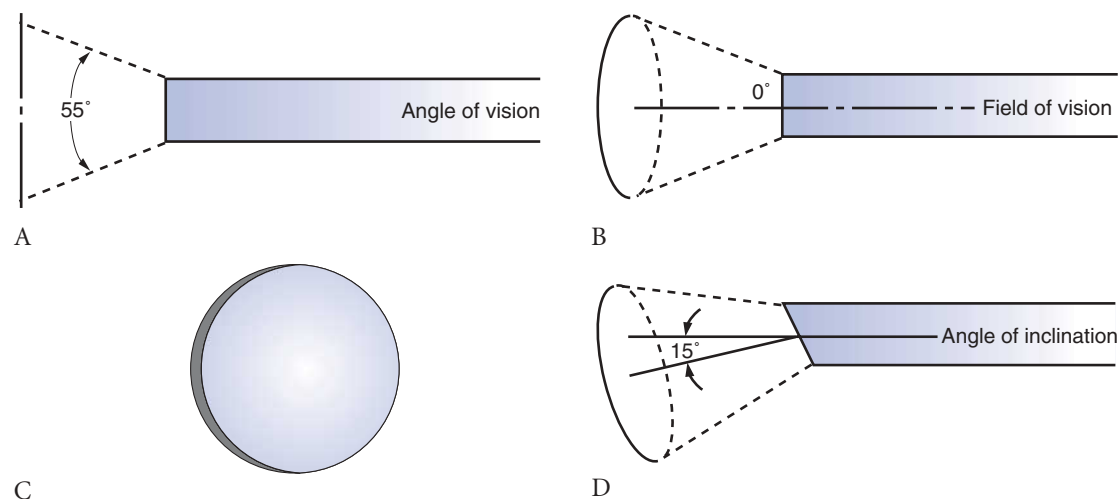


FIGURE 49-4 A, Angle of vision. B, Field of vision. The zero degree angle of inclination gives a straight-ahead view. C, Dark crescent at the edge of the field of vision caused by bending of the arthroscope. D, Angle of inclination (direction of view). Rotation of an arthroscope with an oblique angle of inclination around its axis increases the field of vision.

direct visualization in small joints, video work is greatly improved through the use of a xenon or mercury-xenon arc lamp light source.

The light transmission through the arthroscope is accomplished by the light fibers surrounding the lens system (see Figure 49-3) and is connected at the side of the arthroscope to a fiber light-cord coupler, which, in turn, attaches it to the light source. This light source is usually fitted with an automatic light level adjustment system connected to the camera's console for a feedback loop (Figure 49-5).

Instruments: Cannula, Trocars, Obturators, Elevators

The cannula is a sheath through which either the arthroscope or the instruments may be passed into the joint space repeatedly. A Luer-loc attachment together with stopcock valve is used for inflow where the cannula is housing the arthroscope and used for outflow when on a second cannula that is used for instrumentation access.

Excess outflow can be restricted by partly closing the valve and adding a rubber stopper with a small hole through which the instruments are passed during a triangulation procedure. These cannulae are passed into the joint space after intro-

ducing the sharp trocar into the cannula, which is used to puncture through the skin and joint capsule. The joint capsule is distended with irrigation solution during this maneuver from a needle injection (see section in this chapter "Functional Anatomy and Joint Entry Techniques"). The blunt obturator then replaces the sharp trocar within the cannula as further entry into the joint is accomplished, in order to avoid scuffing of the articular cartilage.

In the superior joint space, after visual confirmation of joint space access has been achieved, the blunt trocar can sometimes be incorrectly used as a release elevator. This can often lead to bending of the cannula and, with repetition, can lead to eventual breakage. It is recommended to use a hardened metal release elevator if further procedures are anticipated (Figure 49-6).

A series of dilation cannulae are also available for enlarging the diameter of the access tube in order to facilitate the use of graspers to remove debris or broken instruments.

Specialized Instruments

A variety of hand and motorized instrumentation is available to the arthroscopic surgeon. The most commonly used are the hooked probe, grasping and biopsy or cutting forceps, scissors, and retrograde (pull) knives. Again, sufficient cannulae diameters to incorporate the grasping forceps after it holds the object are critical in providing a safe and smooth retrieval of the object without having to remove the cannula along with the grasper. This avoids the risk of subcutaneous loss of the object on the way out of the joint space.

Lasers

The use of laser energy in arthroscopic surgery has fought a long battle for acceptance. The carbon dioxide laser proved ineffective for practical reasons relating to the joint insufflation with gasses.^{33,34} The neodymium:yttrium-aluminum-garnet (Nd:YAG) laser was abandoned because it was shown to result in

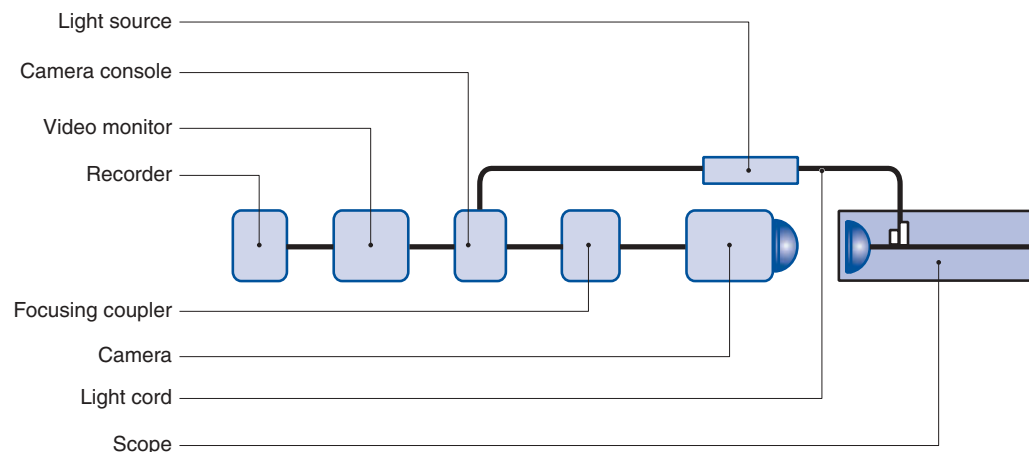


FIGURE 49-5 Schematic of equipment hook-up sequence.

excessive depth of tissue damage.³⁵ However, the holmium:YAG (HO:YAG) laser seems to have won approval within the orthopedic community and has been shown to be effective for the TMJ reduction of synovial and vascular hyperplasias, as well as débridement of fibrous tissues.³⁶ It can be used for the release of the anterior capsule and, in the defocused mode, used for reduction of chondromalacia. Once again generalized synovial damage must be avoided through the use of copious irrigation during the use of laser energy within the joint compartment.

Anesthesia and Medication Considerations

TMJ arthroscopy can be performed in the outpatient or inpatient setting. When local anesthesia alone is used auriculotemporal and intracapsular anesthetic blocks are placed. This technique is usually reserved

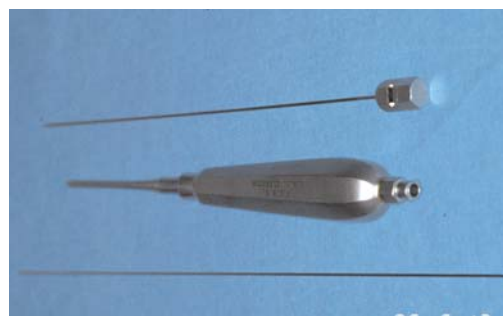


FIGURE 49-6 Moses' release elevator, trocar, and switching stick.

for fine-needle diagnostic arthroscopy. Alternatively it can be performed combined with intravenous sedation for lysis of adhesions as well as eminentia release capsular stretch procedures.

Whereas most surgeons tend to segregate the general anesthesia requirements from the surgical, modern oral and maxillofacial surgeons naturally integrate the two for enhanced outcome. Initially led by requests for controlled hypotension required for beneficial effects during orthognathic surgery, considerations followed that were specific to the arthroscopic surgical arena.

Requests are made for the anesthesiologist to administer certain drugs at the onset of the intravenous (IV) access, as well as muscle relaxants, and even to perform deep extubations at the conclusion of surgery. Injection of methylprednisolone at 125 mg for adults and 40 mg for children is given in order to help stabilize the mast cell membranes to help to inhibit the release of histamines due to tissue injury and to reduce the postoperative edema. Even though postoperative infections are rare, a cephalosporin antibiotic is usually given as well for prophylaxis.

With the anesthesiologist located at the position indicated on Figure 49-1, clear access is given to the surgeons while still affording the anesthesiologist the patient's arm or hand for IV access as needed. Mus-

cle relaxants are given with sufficient length of duration for the entire case in order to allow the surgical assistant better ease of joint mobilization, yielding the surgeon sufficient space for instrumentation.

Even in cases of anticipated short duration it is helpful to explain the requirement for absolute muscular relaxation to the anesthesiologist ahead of time and to allow sufficient postsurgical time for the chemical reversal agents to work adequately for extubation. The surgeon can use this time to organize progress notes or findings and procedural dictation. Also for the more involved cases, a preemergence extubation can help to prevent the Valsalva response to the endotracheal tube and thus limit intra-articular bleeding and hematoma formation.³⁷

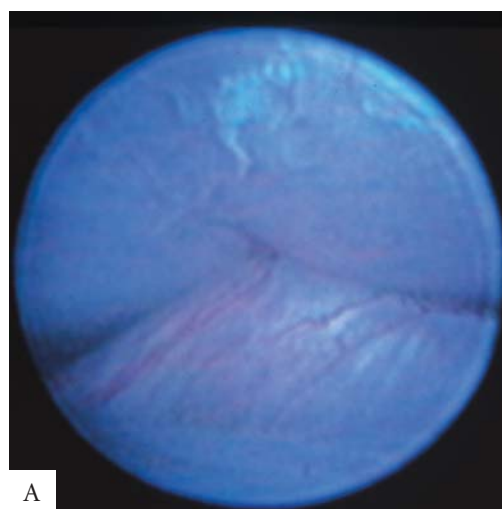
Biomechanics of Articular Pathology and Arthroscopic Management

The etiology of pain in the TMJ diagnosed with IJD is unclear. Certain surgical anatomy of the TMJ is important to understand as it relates to the biomechanics of the functioning joint in order to effectively treat the dysfunctional state of the patient.

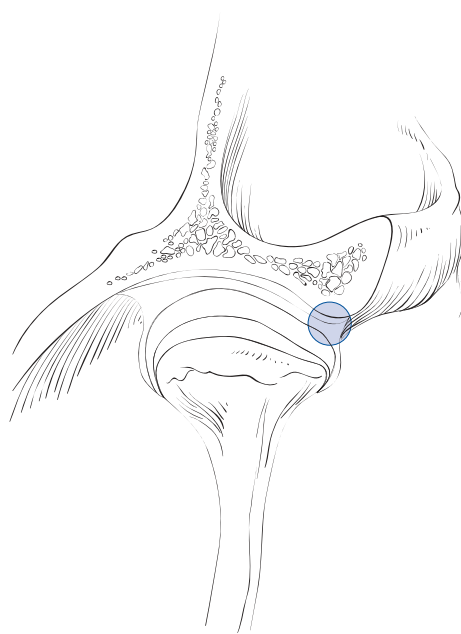
Clinical observations and findings of the synovial lining of the TMJ and correlation of findings of disk perforations, mobility, and blockade also significantly guide the arthroscopic surgeons in their management decisions.

There are many theories regarding TMJ dysfunction. However, the following question arises in almost every discussion: What are the causes of the pain, and why can one joint with disk displacement not hurt whereas another, perhaps with a less serious problem, severely tender?

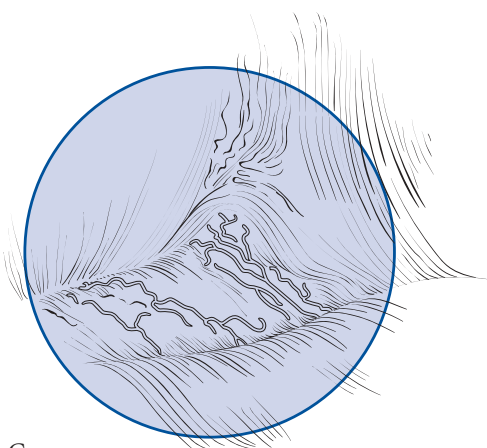
Part of the answer involves the histochemical characteristics of pain mediators within the joint fluid, but the direct and indirect results of inflammation and resulting fibrosis on the capsule, associated tissues, and musculature also play a role in pain symptoms.³⁸



A



B



C

FIGURE 49-7 A, Arthroscopic photograph of endaural view of disk impingement under articular tubercle. Reproduced with permission from Moses JJ.⁴⁷ B, Drawing of location of the endaural view seen in A. C, Drawing of endaural photograph seen in A. B and C adapted from Moses JJ.⁴⁷

A review of studies of similar joint pain and restricted mobility in the shoulder with acromial impingement syndrome shows striking resemblances to observations made on the TMJ (Figure 49-7).³⁹⁻⁴⁵ Additional studies performed

on the basic biomechanics of the TMJ have shown that with jaw rotational mechanics, the linear velocity of rotation (V) will differ between the medial and lateral poles as a consequence of an orthopedic system with two joints func-

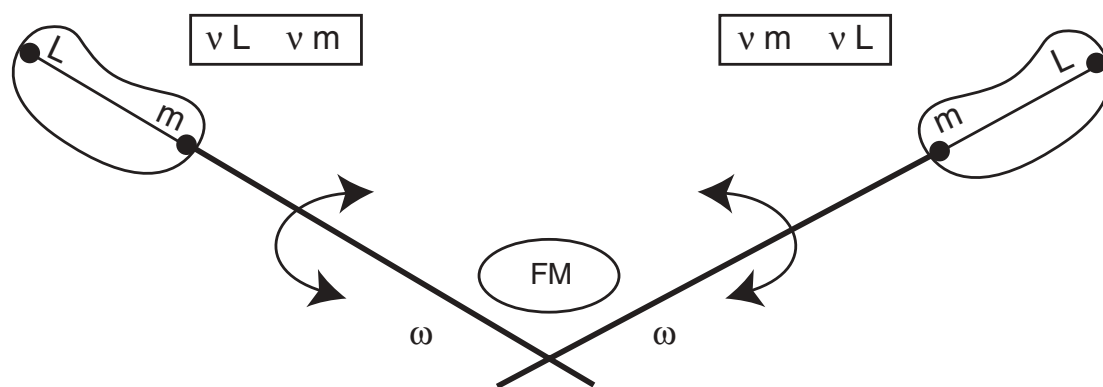


FIGURE 49-8 With jaw rotational mechanics, the linear velocity of rotation (v) will differ between the medial and lateral poles. Given a fixed measurable angular velocity of rotation (r), the velocity of point m (medial pole) will differ from point L (lateral pole). FM = rotational force movement.

tioning simultaneously (Figure 49-8).⁴⁶ An understanding of the force on the load-bearing surfaces with the structural inherent rotational and translational forces and their combined effects on rotational force, moments, torque, and shear, are essential in helping to understand the reasons that lateral condylar pole, eminent, and capsular pathologies are present in higher frequency than at the medial joint location.

This has led to the investigation of the lateral TMJ articulation by coronal MRI and by axial-corrected tomographic laminograms, both taken in the anteroposterior (AP) protruded jaw position performed on patients who had failed nonsurgical efforts to correct TMJ dysfunction and yet did not exhibit classic disk displacement.⁴⁷ These cases were further investigated by direct arthroscopic examinations from the AP view via endaural puncture access. It has become apparent that there is a process of pathology occurring which ranges from seemingly minor capsulitis with proliferative synovial changes to frank degenerative disease with disk/capsular impingements (see Figure 49-7).

Disk displacement actually may occur late in the pathophysiology of internal joint derangement (Table 49-3). Early inflammatory changes, initiated by macrotrauma or microtrauma, may lead to a loss of the lubricating nature of the HA and chondroitin sulfate within the synovial fluid. Capsulitis itself, with the synovium proliferating in an attempt to repair or regenerate damaged intracapsular structures, combines with inflammation and leads to the production of hyaluronidase, which breaks down the HA within the TMJ. A loss of lubrication ensues, leading to increased surface “stickiness,” resulting in capsular fibrosis and relative immobility of the TMJ, especially within the superior joint compartment, on attempted translatory movements of the mandible.

Table 49-3 Progressive Stages of Impingement Lesions

Stage	Diagnosis	Clinical Course	Treatment
I. Inflammation	Acute capsulitis and synovitis	Reversible	NSAIDs, rest, physical therapy, OSA, intracapsular irrigations, and lavage
II. Fibrosis	Chronic adhesive capsulitis, proliferative synovitis, diskal displacement or immobility, synovial plicae	Recurrent pain with activity	Arthroscopic lysis of adhesions, lateral eminencia release and capsular stretch, lavage, physical therapy, OSA
III. Bony remodeling and attachment migration	Diskal displacement or immobility, hyperplastic eminencia tubercle, degenerative joint disease	Progressive disability	Lateral eminencia release, capsular stretch, lateral eminencia osteoplasty, physical therapy, OSA

NSAIDs = nonsteroidal anti-inflammatory drugs; OSA = orthotic splint appliance.

If allowed to mature the adhesions may vascularize and become part of the restrictions (Figure 49-9). On attempted opening, lateral adhesive components can cause incoordination of disk/condyle/eminence dynamics. Strain is placed on the lateral disk attachments as the condyle is forced to begin translation from within the inferior joint compartment. The disk, while relatively immobile in its relationship to the articular eminence, may or may not be displaced at this time (Figure 49-10).

Over a period of time, translation, solely in the inferior joint compartment, may cause a gradually increasing laxity of the lateral disk attachment, allowing the anatomic migration of the disk antero-medially. The patient may also experience a “closed lock,” depending on the morphologic changes within the disk and its ability to form a mechanical obstruction (Figure 49-11).

As the disk slowly migrates forward and medially, movement within the superior joint compartment generally remains

minimal. The inferior joint compartment begins to act as the transitory compartment for the “wide-open” mouth position.

Anterior disk displacement traditionally has been diagnosed via arthrographic studies and now with MRI. A sagittal view may reveal a well-placed disk; however, the MRI coronal view allows diagnosis of medial or lateral disk displacement, as MRI correlative studies on more than 100 arthroscopic confirmations of disk displacement have shown that disks that appeared in normal anatomic position on sagittal views were actually rotated on their condyles with medial displacement (Figure 49-12).

Diagnosis of disk pathologies based on two-dimensional studies can be misleading. In some cases the posterior band almost becomes longitudinally placed anteroposteriorly along the lateral rim of the condyle. This may lead to a “bulging” out of the capsule on coronal MRI (Figure 49-13). In other cases images of a disk more medially displaced may have a “sucked-in” appearance of the lateral capsule on coronal MRI, which is termed lateral capsular prolapse (Figure 49-14). Lateral capsular prolapse may play a role in the development of the lateral impingement phenomenon.

As disk displacement progresses anteromedially the lateral attachment

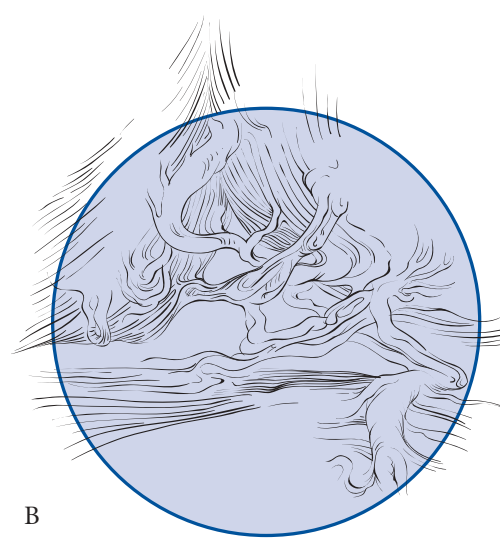
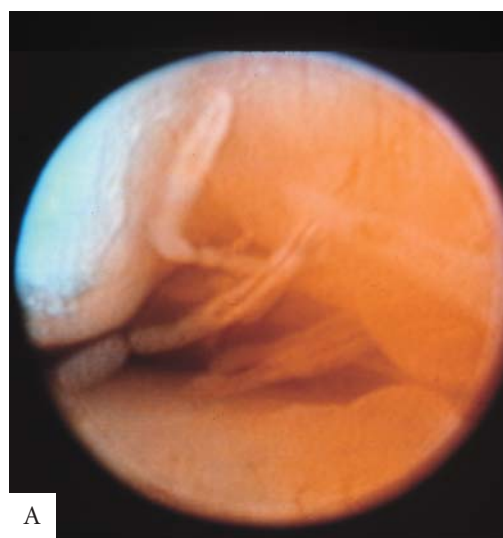


FIGURE 49-9 A, Arthroscopic photograph of endaural view of articular eminence, demonstrating inflamed synovial proliferative tissue and early adhesions. Reproduced with permission from Moses JJ.⁴⁷ B, Drawing of the endaural view seen in A. Location of this tissue is the same as that seen in A. Adapted from Moses JJ.⁴⁷

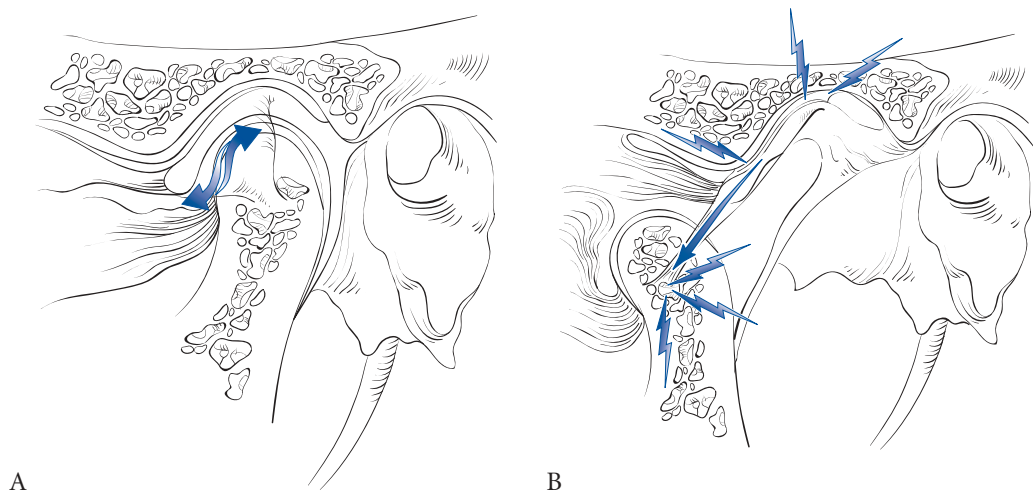


FIGURE 49-10 A, Drawing depicting relative disk immobility after maturation and vascularization of adhesions: translation is forced to occur in the lower compartment. Arrows indicate the movement of the condyle under the immobile disk. B, Eventually there is laxity of the lateral disk attachments and increased translatory movements in the lower joint compartment. Arrow indicates the location of the lateral diskal attachment, which is strained and possibly painful. Adapted from Moses JJ.⁴⁷

migrates forward as a result of the gradual and progressive pull of the condyle, which stretches it during attempted translation in the inferior joint space.^{46–48} The attachment carries with it the bone of the condylar lateral pole, developing the anterior beaking or “lipping” commonly seen in sagittal tomography (Figure 49-15). “Beaking” represents an adaptation of condylar remodeling to forces placed on it rather than a true osteophyte.

If the load is not redistributed, areas of perforation can occur, and further degenerative changes may develop along with adaptive remodeling of both hard and soft tissues (Figure 49-16).⁴⁹ The concept of load distribution is a fundamental biomechanical principle that is crucial to the understanding of joint structure and function. The entire physiologic function of the joint and its associated structures is load distribution, and damage occurs when factors inhibit this function. Dysfunction occurs when metaplasia and adaptive remodeling cannot repair this damage by restructuring load distribution.

A review of arthroscopic cases reveals that the majority of pathologic adhesions

and restricted motion lie within the lateral third of the joint. The soft tissues of the capsule become fibrotic and constricted, with inactivity and/or inflammation restricting mandibular movement. From the endaural arthroscopic approach, viewing anteriorly along the lateral trough of the superior compartment, inflamed synovial proliferation and projection are seen, as well as adhesions binding the disk to the eminence and capsule, leading to restricted mobility and possible pain (see Figure 49-9).

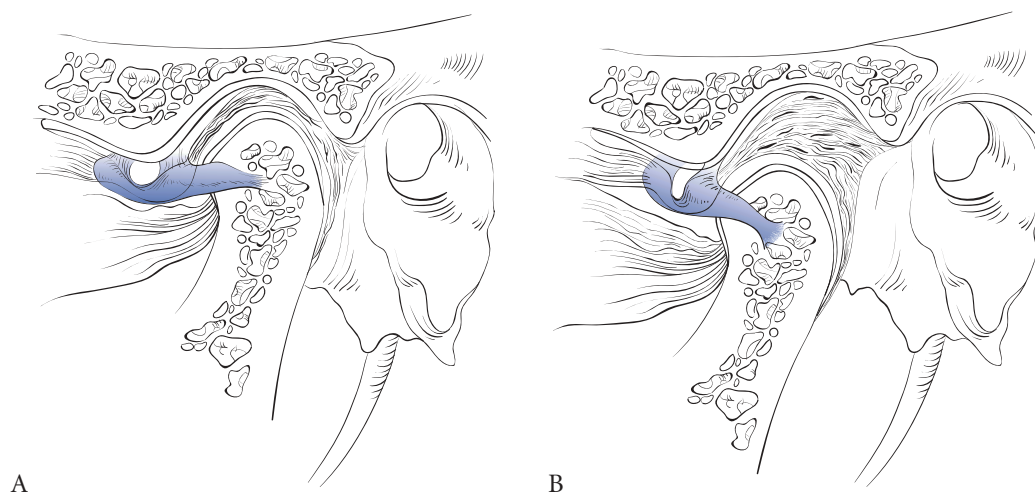


FIGURE 49-11 Disk migration (A) and changes in disk morphology (B) leading to “closed lock.” Superior compartment adhesions restrict translatory movements. Adapted from Moses JJ.⁴⁷

In the advanced stage, areas of lateral condylar resorption, best seen in AP tomograms (Figure 49-17), correlate with the hypertrophic articular tubercles that impinge on the lateral third of the disk (Figure 49-18A–C). If the joint space has diminished with degenerative changes, this becomes especially important as the condyle will articulate more heavily in the lateral area on protrusive and opening movements (Figure 18D and E). In my experience disk perforation occurs most frequently in the lateral posterior bilaminar zone/disk junction correlating with this lateral impingement.

Pain itself is not a disease. “Pain merely halts the function to allow healing. The gradual increase in function allows the programming of mesenchymal cell differentiation.”⁵⁰ The goals of treatment should include decreasing functional load and increasing the capacity of cells to accomplish articular remodeling.

Clinical studies using the lateral eminence release and capsular stretch procedures, combined with routine arthroscopic lysis of adhesions and lavage, have relieved both pain and restricted mandibular mobility in over 92% of patients (see Table 49-3).²⁷ Patients with lateral tubercle impingements on the disk seem to require additional eminoplasty, which gains joint space and

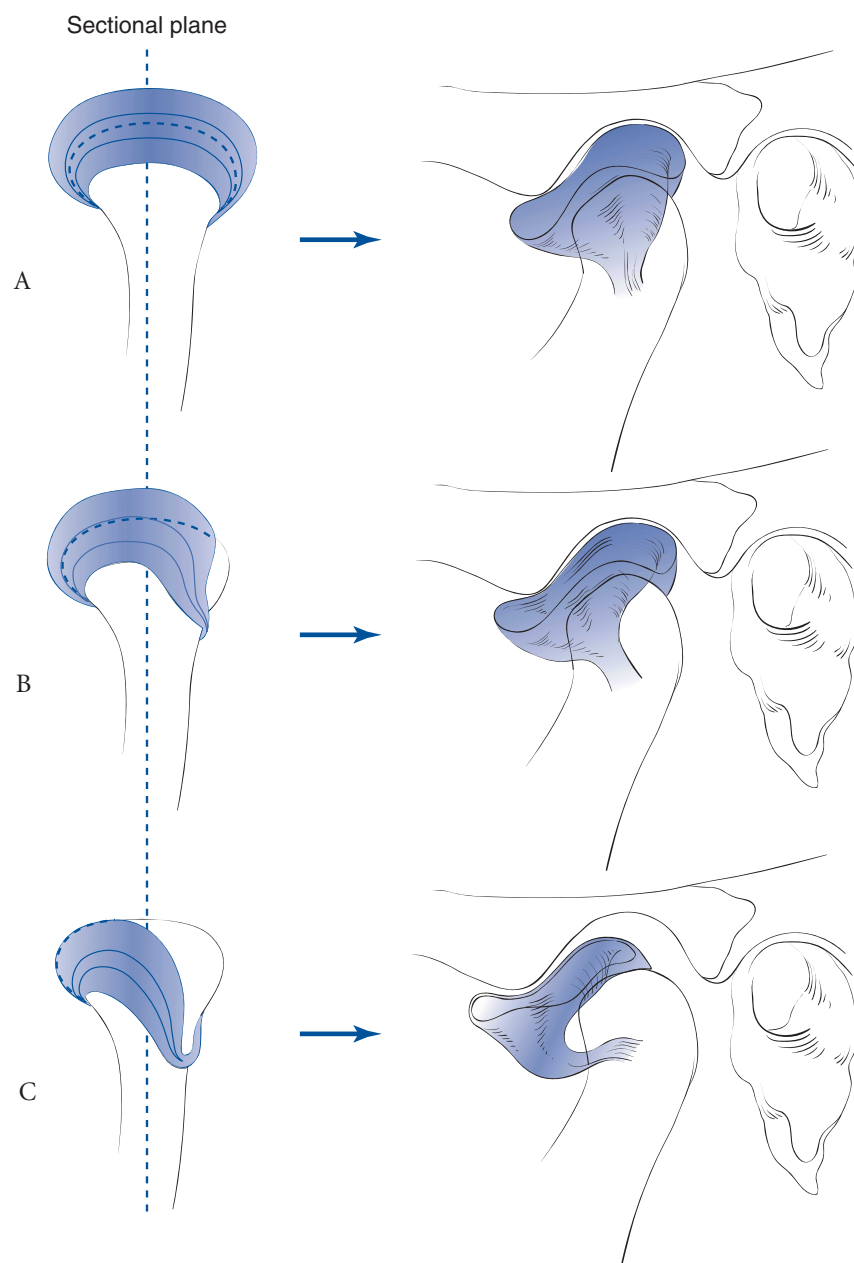


FIGURE 49-12 Disk that appears to be well placed on sagittal imaging (A) actually may be rotated on the condyle with medial displacement (B) and in time may suffer increased laxity of the lateral collateral disk attachments (C). Adapted from Moses JJ.⁴⁷

relieves load concentration from that area (Figure 49-19).⁵¹

MRI analysis study revealed a consistent result of no change in disk position in the closed-mouth status, both before and after arthroscopic surgery in 92 patients.⁵² The study revealed an increase in mobility of the disk following arthroscopic release that was directly correlated with the clinical success of

pain reduction and restoration of normal mandibular function.

The mobilization of tissues within and around the joint, combined with reduction of load concentrations, enhances mesenchymal cell reprogramming, allowing potential formation of pseudodisk articulations and condylar remodeling. Studies are in progress at the present time to investigate whether condylar remodel-

ing occurs long-term following arthroscopic procedures (Figure 49-20).

In a study using standardized tomography, Moses in 1994 showed that disk and capsule mobilizations have effectively restored function with pain reduction, while correlation to chronicity seems to dictate whether or not articular remodeling occurs.²⁶

In certain cases, when the chronicity of the displacement has led to anterior disk displacement, the morphology of the disk can “ball” up and effect a blockade to condylar anterior movements. This phenomenon is termed *obstructive disk blockade*. The traditional approach to this condition’s management is either through open or closed surgical attempts to reshape and reposition the disk or complete disk extirpation.⁵³⁻⁵⁵

An arthroscopic surgical alternative is that consisting of an anterior capsular release performed with either the HO:YAG laser or pull-knife assistance under arthroscopic guidance via triangulation portal access. Care is taken not to violate the pterygoid muscle during this procedure, keeping the dissection on top of this structure. This procedure, termed *anterior capsular release*, allows the opening of the anterior joint compartment for functional remodeling to occur during the postoperative rehabilitation enlarging the space for the disk to move.⁵⁶

Functional Anatomy and Joint Entry Techniques

Over the past 15 years arthroscopy of the TMJ region has gained popularity as both a diagnostic tool and as a therapeutic mode for procedures involving IJD and intracapsular dysfunctional pathology. Although this popularity gave rise to many proposed procedures and techniques, which give the surgeon many choices on which to base their treatments, the fundamentals all remain the same. As the skill of surgeons advances, desired access for visibility and instrumentation has led to the increased use of angled view and alternate entry portals combined with triangulation techniques.

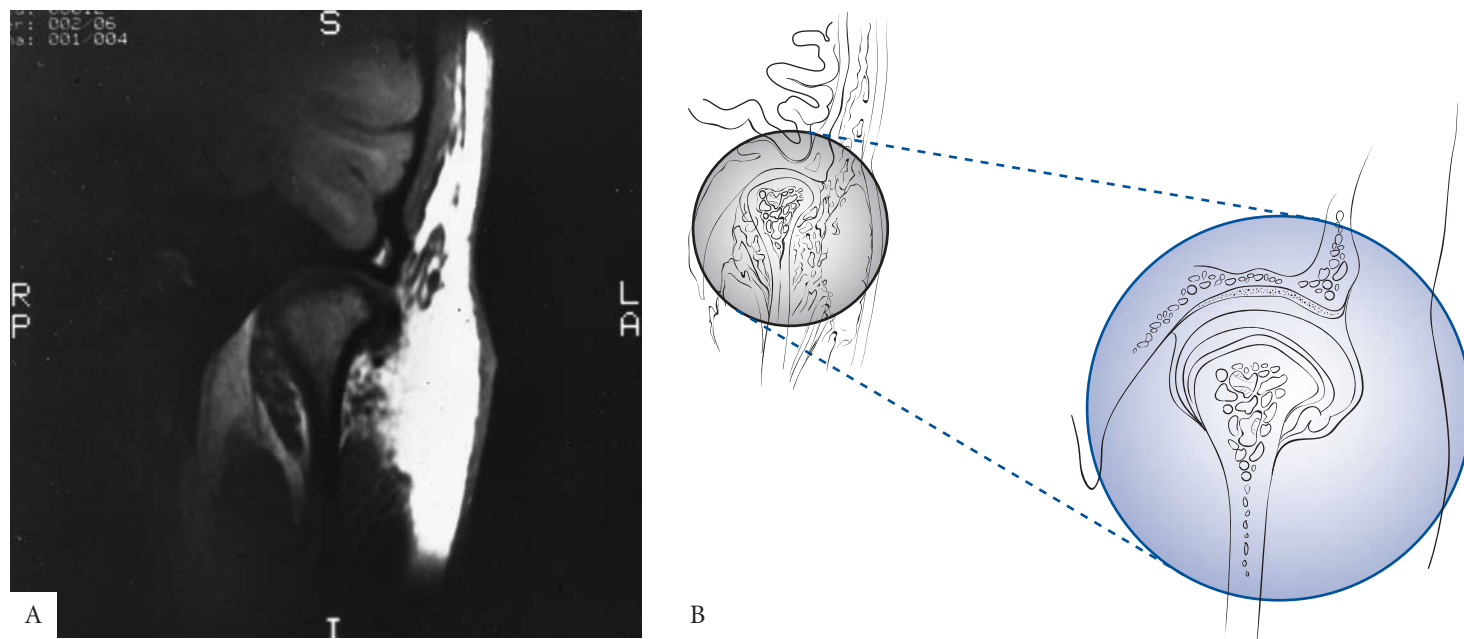


FIGURE 49-13 A, Magnetic resonance image, coronal view, of the temporomandibular joint, demonstrating lateral capsular bulge. Reproduced with permission from Moses JJ.⁴⁷ B, Drawing of the image shown in A. Adapted from Moses JJ.⁴⁷

General Principles

In any arthroscopic surgical procedure involving small joints it is important to adhere to some basic technical points:

1. The joint should remain fully distended, allowing easier trocar puncture
2. The skin should be punctured with a sharp trocar.
3. All intra-articular procedures should be done with care to prevent articular surface damage.
4. Attention should be given to preserve as much healthy synovium as possible in order to enhance its physiologic effects on the joint.
5. The joint space should be kept expanded during instrumentation by a slow infusion irrigation system.

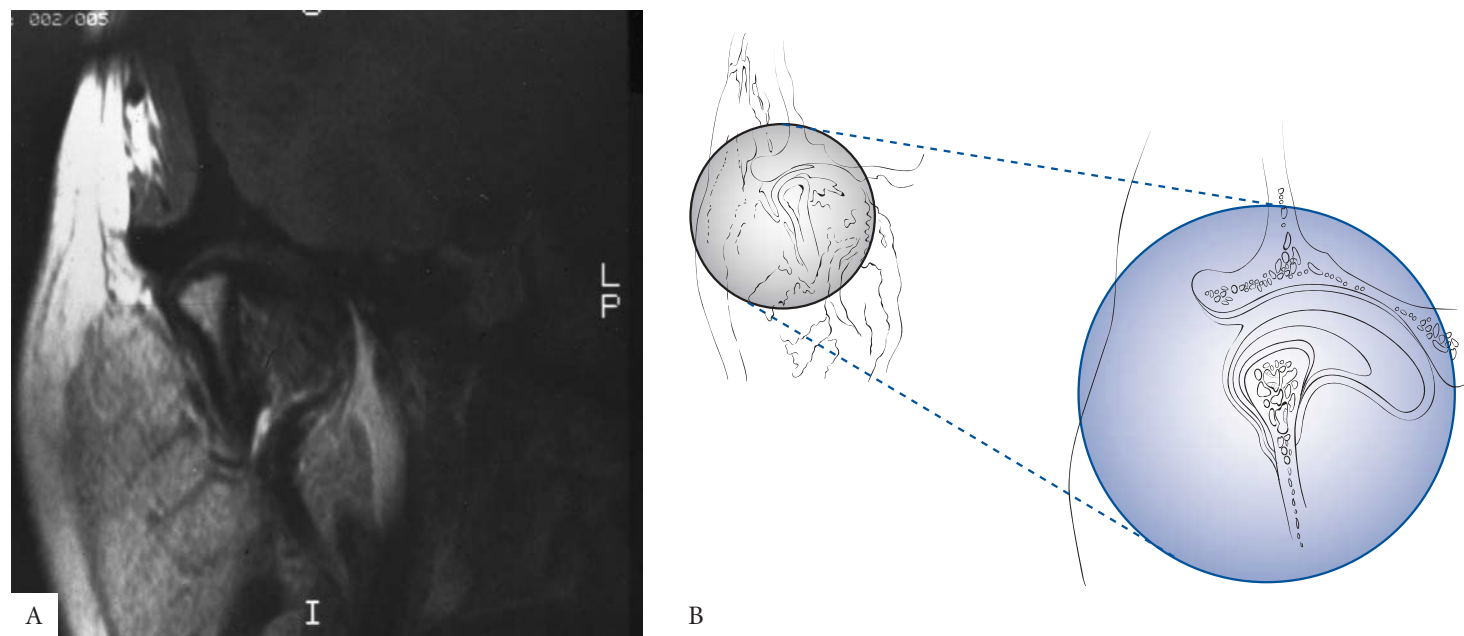


FIGURE 49-14 A, Magnetic resonance image, coronal view, demonstrating lateral capsular concavity and medial diskal displacement. Reproduced with permission from Moses JJ.⁴⁷ B, Drawing of the image shown in A. Adapted from Moses JJ.⁴⁷

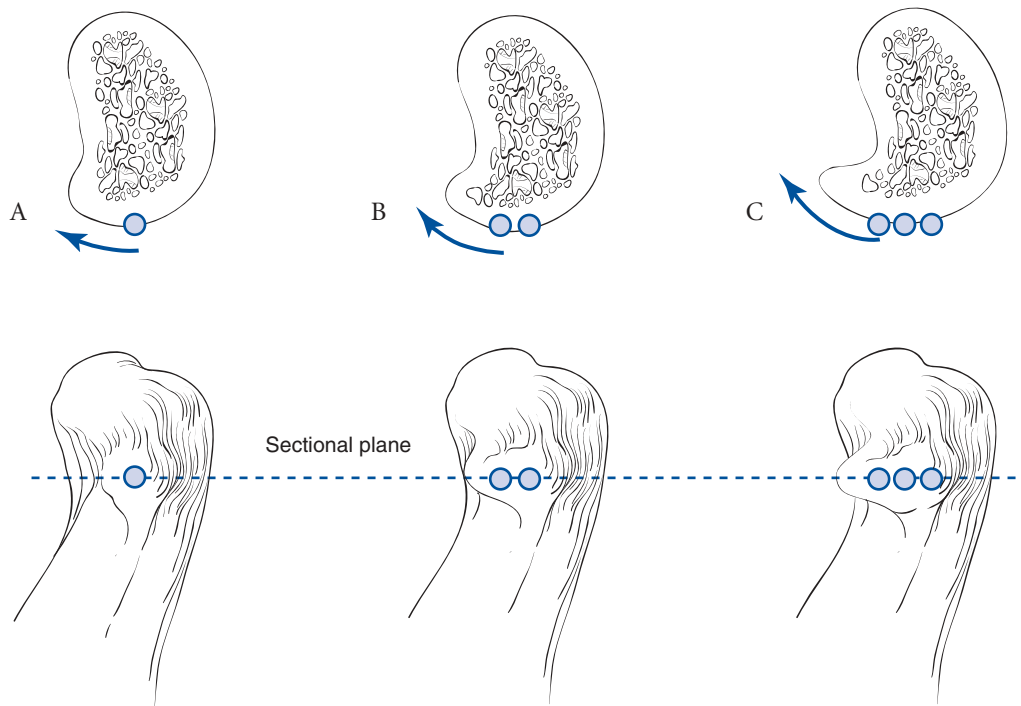


FIGURE 49-15 Drawing depicting progressive development of anterior “beaking” or “lipping” commonly seen on sagittal tomograms. Adapted from Moses JJ.⁴⁷

Puncture Anatomy and Landmarks

The anatomic landmarks relevant for open joint surgery also apply for arthroscopic surgery.

The frontal branch of the facial nerve appears to be the most likely nerve structure to be involved. Whereas Greene and

colleagues reported a mean distance of 22.5 mm from this branch as it crossed the zygomatic arch to the posterior aspect of the tragus with a range of 16 to 29 mm, Al Kayat and Bramley reported the mean distance of 20 mm from its crossing measured to the anterior margin of the bony auditory meatus with a range of 8 to 35 mm.^{57,58}

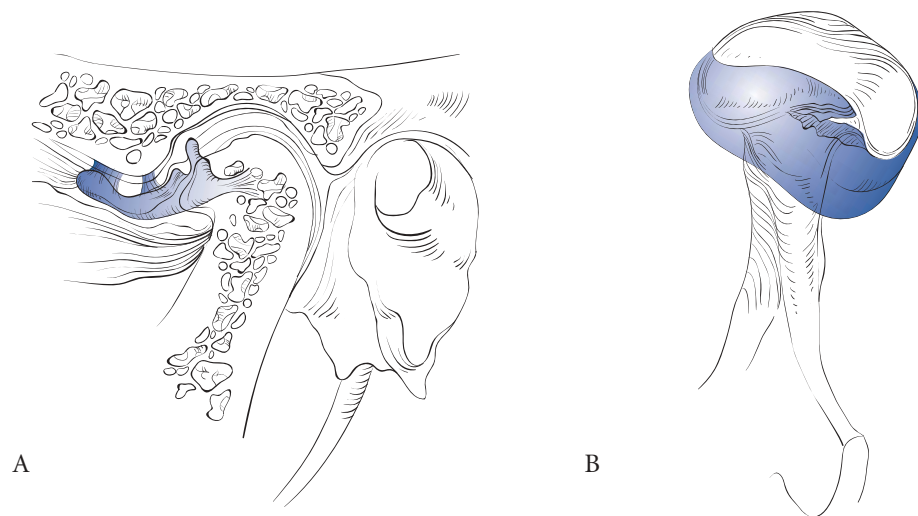


FIGURE 49-16 Further degeneration of hard and soft tissues in response to undistributed load. A, Diskal lateral ligament and bony changes. B, Disk perforation. Adapted from Moses JJ.⁴⁷

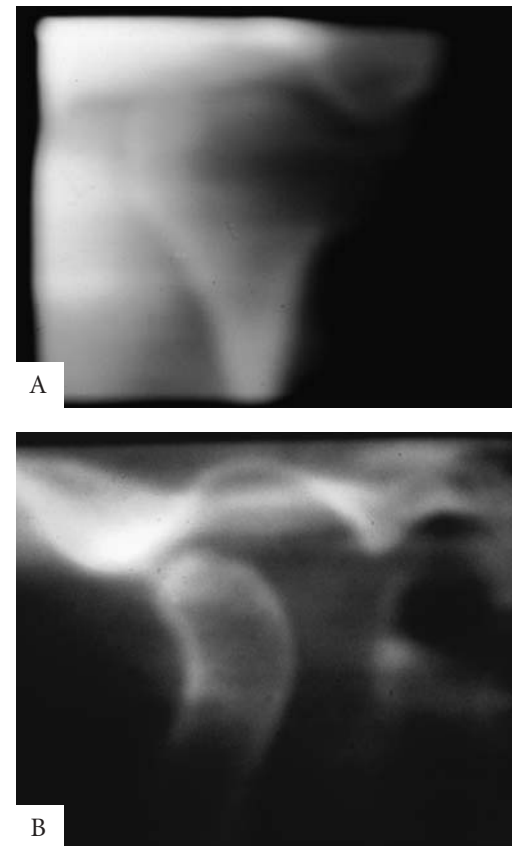


FIGURE 49-17 A, Coronal tomogram taken in slightly protruded position showing bony lateral impingement and prominent articular remodeling of lateral one-third of the condyle. B, Sagittal tomogram of the same temporomandibular joint. Reproduced with permission from Moses JJ.⁴⁷

The tympanic plate was found by Greene and colleagues to be 7 mm anterior to the posterior tragus (range 6 to 9 mm) and perpendicular to the skin at a mean depth of 25.4 mm (range 19 to 32 mm).⁵⁷

Finally, even though the mean distance of the superficial temporal vessels from the posterior aspect of the tragus has been measured at 12.8 mm, there is some variance and this structure occasionally can be vulnerable to puncture lacerations.⁵⁷

There have been reports of cases of arteriovenous fistulas developing as a result of puncture through these structures, requiring subsequent vessel ligations.⁵⁹

An important point to remember during the puncture procedure is the visualization of the directional axis of the trocar angle, which should be anterior

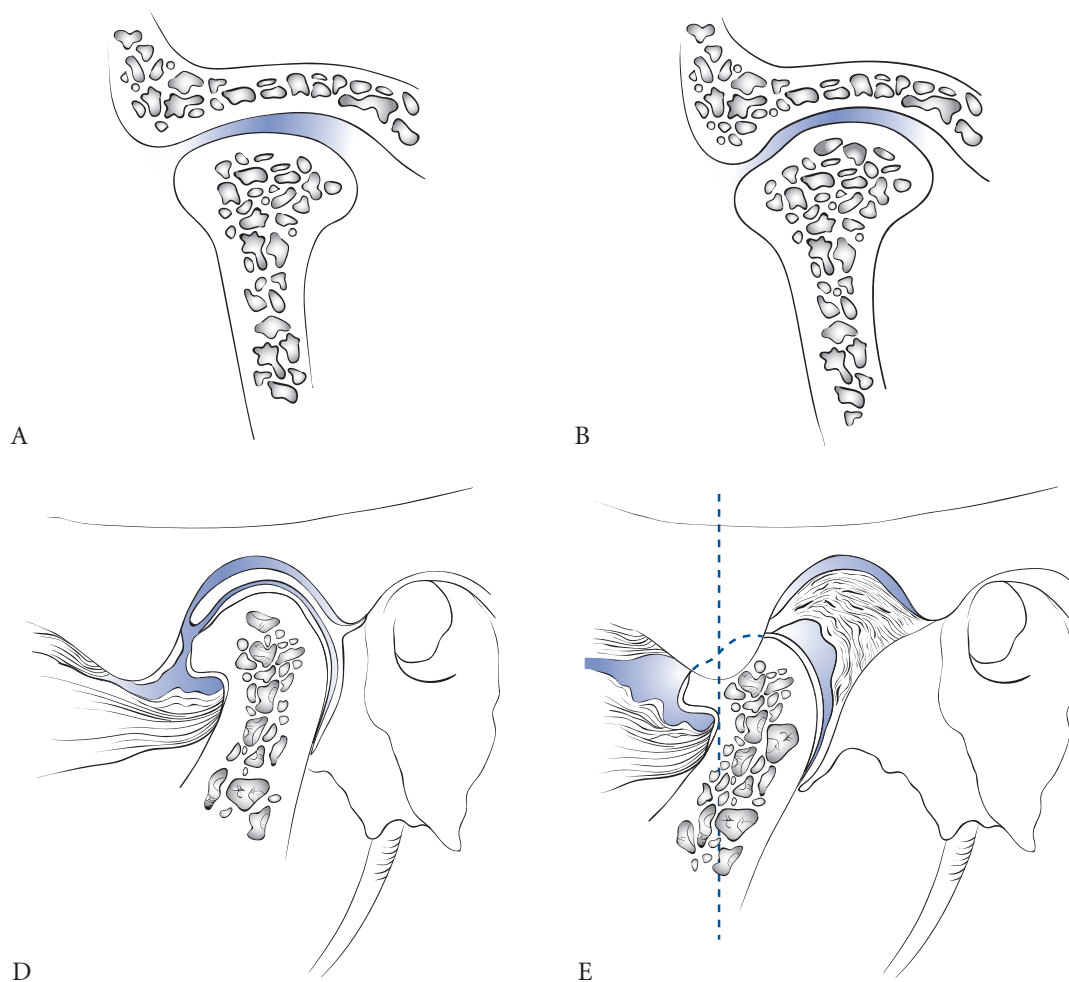


FIGURE 49-18 Drawings showing advanced stages of condylar remodeling and/or resorption. Areas of lateral condylar resorption correlate with hypertrophic articular tubercles (A–C) in response to disk displacement and loss of joint space. D, Sagittal view of degenerative joint closed mouth view. E, Sagittal view of degenerative joint—protruded jaw position. The dashed line sectional plane correlates with the coronal view in C. Degenerative joint with bony changes evident. Adapted from Moses JJ.⁴⁷

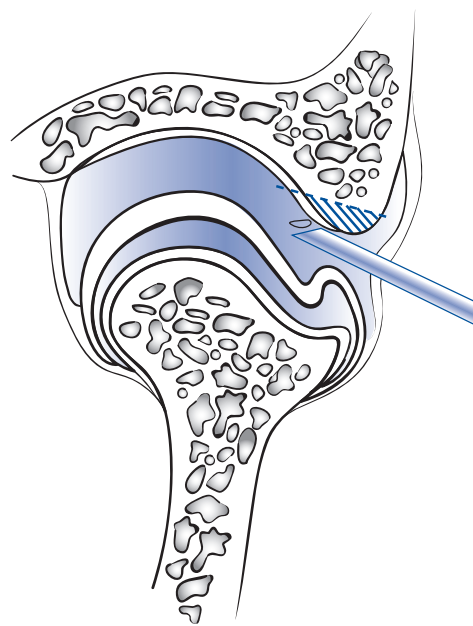


FIGURE 49-19 Drawing showing arthroscopic osteoplasty of hypertrophic articular tubercle. Adapted from Moses JJ.⁴⁷

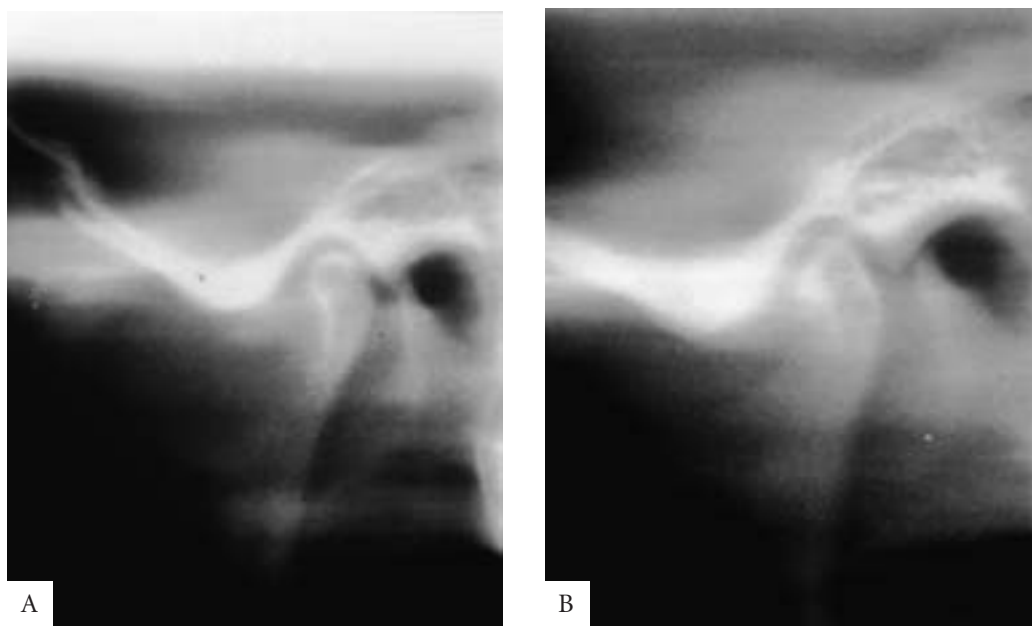


FIGURE 49-20 A, Preoperative sagittal tomogram of a temporomandibular joint (TMJ) with adhesions. B, One-year postoperative sagittal tomogram of same TMJ showing adaptive remodeling following lysis of adhesions and joint lavage. Reproduced with permission from Moses JJ⁴⁷

and superior just above the “finger-palpated” lip of the glenoid fossa and not perpendicular or posteriorly directed in order to avoid middle ear or vessel damage. A frequently overlooked situation leading to a loss of perceived direction is improper head positioning. The head should be turned away from the operator and as flat to the operating table as possible.

Several authors have advocated marking the skin with points measured at 10 mm, 15 mm, and 20 mm along the line drawn from the posterior aspect of the midtragus to the lateral canthus. These positions can be helpful for orientation early in the learning curve for the arthroscopist. After time, however, the size and weight of the patient as well as their age can lead to variations of this.⁶⁰ Experience has shown the initial palpation with the mandibular mobilization by the surgical assistant to be more relevant and valuable than measurements alone.

The surgeon can often palpate the pulse of the superficial temporal vessels and the posterior aspect of the condyle while putting the fingernail side of the surgeon's digit along the inferior lip of the glenoid fossa with the mandible distracted downward and forward by the assistant.

Arthroscopic Approaches

The initial puncture of the TMJ is done with a needle and irrigation solution and is administered for joint distention of the potential space of the superior joint compartment. A detailed description of the initial joint puncture and the superior posterolateral and endaural approaches will follow this overview of the various approaches to the joint compartments (Figure 49-21).

Because many of our radiology imaging procedures cannot accurately visualize early lateral capsular synovial proliferation (see Figure 49-9), capsular herniations (Figure 49-22), or diskal impingements (see Figure 49-7), various approaches to capsular access become important to the arthroscopic surgeon in correctly diagnos-

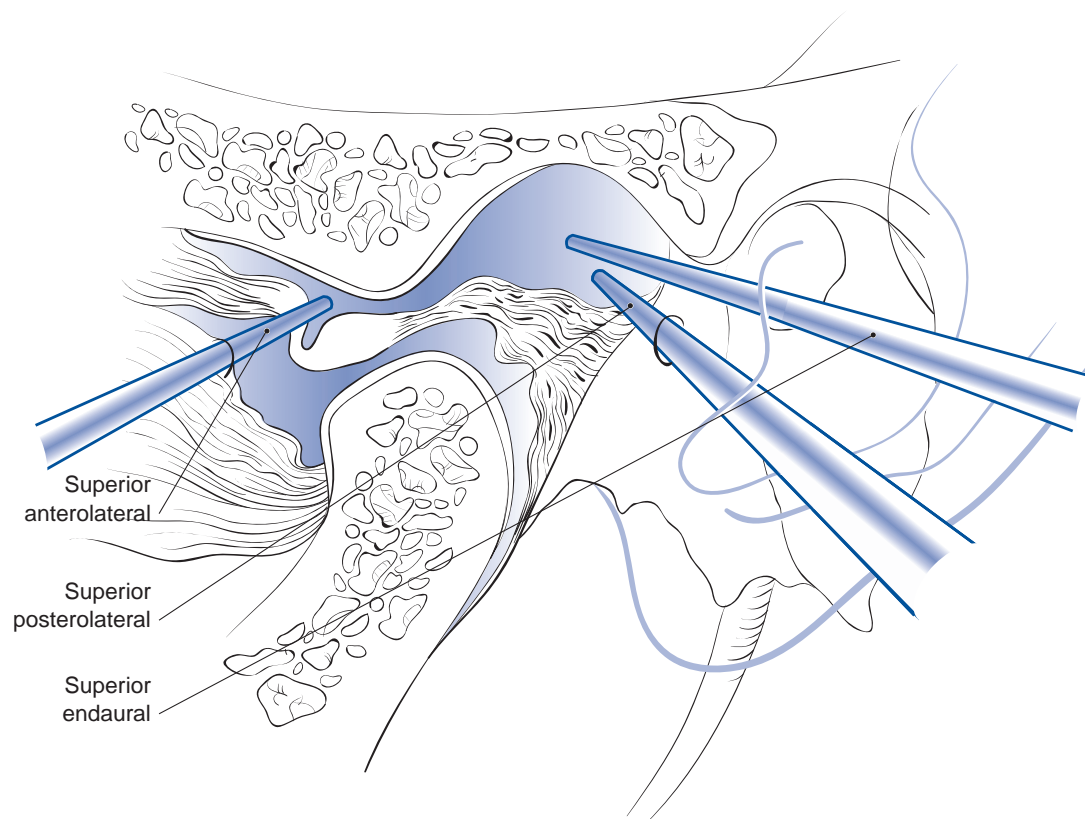


FIGURE 49-21 Arthroscopic approaches to the temporomandibular joint. Adapted from Moses JJ.⁴⁷

ing intra-articular pathologies for the application of treatment modalities.

Superior Posterolateral Approach

In this technique the mandible is distracted downward and forward, producing a triangular depression in the front of the tragus.⁶¹ This depression represents an area bordered superiorly by the glenoid fossa, anteroinferiorly by the dorsal aspect of the condylar head, and posteriorly by the external auditory canal. It is at the roof of this depression, above the gloved fingernail of the surgeon's digit outlining the inferior aspect of the glenoid fossa, that the trocar is inserted. The trocar is directed anterosuperiorly toward the posterior slope of the eminentia. This provides access to the posterosuperior joint space and allows visualization of the superior joint space. The areas that are difficult to visualize are the superoanterior synovial pouch and the medial paradiskal synovial groove.

Inferior Posterolateral Approach

This is a variation of the inferolateral approach, in that the trocar is directed against the lateral posterior surface of the mandibular head.⁶² The inferoposterior synovial pouch and posterior condylar surface can then be examined.

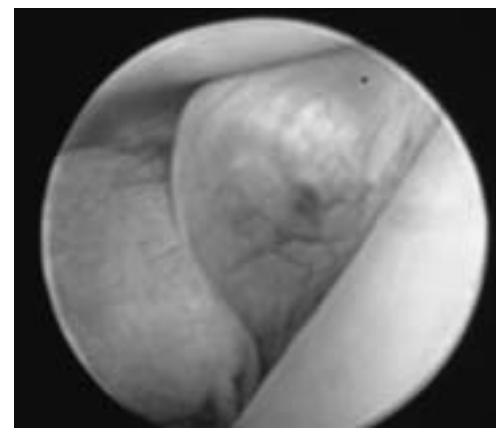


FIGURE 49-22 Capsular herniations noted in the medial wall of a right temporomandibular joint. Reproduced with permission from Moses JJ.⁴⁷

Superior Anterolateral Approach

In this technique the trocar is directed superiorly, posteriorly, and medially along the inferior slope of the articular eminence after first locating the prominence of the lateral articular tubercle as a landmark. The mandibular condyle is distracted inferiorly and positioned posteriorly by the surgical assistant. This approach allows anterosuperior joint compartment instrumentation or visualization.

Inferior Anterolateral Approach

This is a technically more difficult approach than those described above and allows observation of the lower anterior synovial pouch. In this technique the condylar head and articular tubercle are palpated.⁶² The trocar is then inserted at a point anterior to the lateral pole of the condylar head and immediately below the articular tubercle. This places the trocar in the lower anterior synovial pouch, adjacent to the anterior aspect of the condylar head. The technique allows observation of the lower anterior synovial pouch.

Endaural Approach

This access is initiated by a trocar entering the posterosuperior joint space from a point 1 to 1.5 cm medial to the lateral edge of the tragus through the anterior wall of the external auditory meatus. The trocar is directed in an anterosuperior and slightly medial direction toward the posterior slope of the eminentia. This approach provides access and visualization of the posterior superior joint space as well as the medial and lateral paradiskal troughs. Its detailed technique will be covered in this chapter under “Endaural Arthroscopic Approach: Rationale/Technique.”

Joint Distention and Trocar Puncture Technique

The arthroscopic surgical procedures are typically carried out with the patient under general anesthesia via nasal endo-

tracheal intubation and complete neuromuscular relaxation throughout the procedure (Figure 49-23). A 1½ inch 20-gauge short-beveled needle is introduced into the posterior aspect of the superior joint compartment, testing the depth and direction for subsequent trocar/cannula placement. Iced heparinized lactated Ringer’s solution (2000 IU of heparin/L Ringer’s lactate) is administered via a syringe as a joint distension medium (Figure 49-24). To facilitate this maneuver the mandible is distracted downward and forward by the surgical assistant.

The mandibular condyle is then repositioned downward and backward, and a short-beveled 18-gauge outflow needle is attached to the catheter tubing and directed from an anterior lateral approach into the anterior aspect of the superior joint compartment (see Figure 49-24). By slow injection of iced heparinized Ringer’s lactate solution, irrigation of the superior joint compartment should be noted as fluid emerges from the outflow extension tubing. The 20-gauge needle is then removed.

Distention of the capsule is maintained by the slow infusion of the Ringer’s solution temporarily applied to the outflow portal 18-gauge needle prior to trocar puncture. This procedure allows a more distinct feel of the puncture into the joint, which should be done with a sharp trocar. Skin incisions are not required.

Superoposterior Lateral Approach

The sharp trocar is placed into the cannula and, with a fingerstop applied to the cannula grip to prevent inadvertent excessive puncture depth, the trocar is directed into the point above the palpating digit’s fingernail location at the inferior aspect of the glenoid fossa. It is aimed anterosuperiorly toward the posterior slope of the eminentia.

The sharp trocar is then replaced with the blunt obturator and further entry into the joint is executed. The syringe of Ringer’s solution is then removed from the

outflow tubing and connected to the irrigation tubing attached to the arthroscopic cannula stopcock. Bubbles are displaced from the cannula by flushing with irrigation fluid as the arthroscope is placed in the sheath. Examination of the superior joint compartment is then initiated, and systematic examination of the joint is performed prior to further instrumentation.

Lateral Eminentia Release and Capsular Stretch Procedures

Even though these procedures should technically be listed under surgical instrumentation, their importance is assigned not only to therapeutic management but also to the creation of soft tissue mobilization necessary for further joint exploration into the anterosuperior compartment by the endoscope.

Errors in Entry

Occasionally the arthroscopist will encounter difficulty in entry to the superior joint compartment. Most commonly this is due to insufficient joint distention by the irrigation solution. If severe fibrous strands are encountered in a joint not suspected of fibrous ankylosis, the inadvertent positioning of the scope cannula into the retrodiskal tissue is likely to be the cause. In this case removal of the scope from the cannula is recommended, and a repeat process of standardized puncture for superior posterolateral approach with the blunt

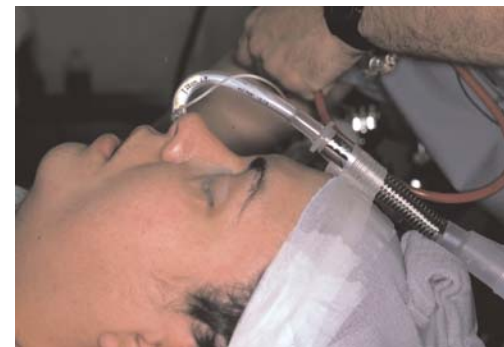

FIGURE 49-23 Example of hair taped on head-wrap and endotracheal tube stabilizer pad. Reproduced with permission from Moses JJ.⁴⁷

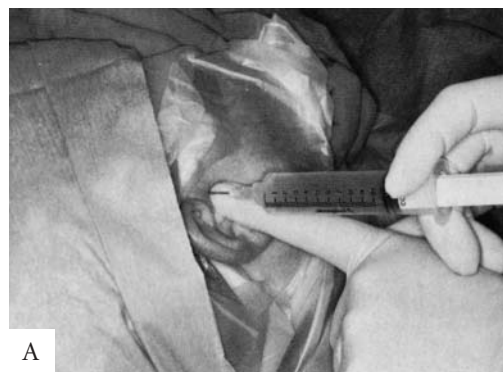
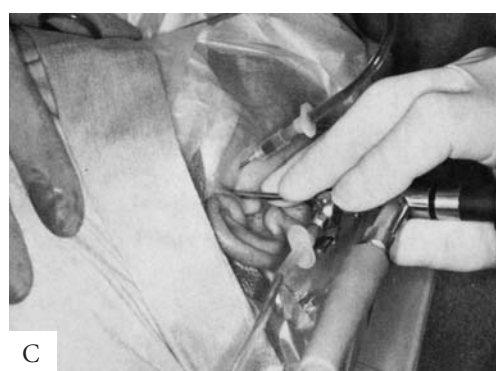
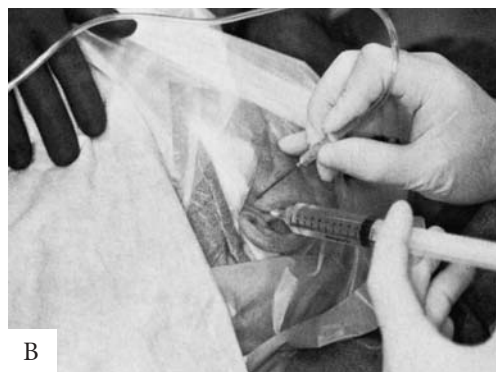FIGURE 49-24 Initial steps in endaural approach. A, Injection of heparinized Ringer's lactate to distend joint. B, Placement of outflow needle in anterolateral aspect of joint. C, Arthroscopic examination of joint via inferolateral approach. Reproduced with permission from Moses JJ.⁴⁷



probe is done. Only after confirmation of actual joint space access is visually achieved through the camera image can further instrumentation be initiated.

Endaural Arthroscopic Approach: Rationale/Technique

Certain limitations have become evident using the traditional posterolateral and anterolateral arthroscopic approaches to the TMJ. This is especially true for visualization of the lateral trough and anterolateral joint space or where access for instrumentation to the medial and lateral paradiskal grooves is required. Clear visualization of those areas is impeded using the currently available 15° angled scopes and lateral portals.⁶³

To solve these visualization and access problems the endaural entry portal provides clear visualization and enhances instrumentation to the medial and, especially, the lateral spaces (Figure 49-25). This new approach also provides better access for the retrieval of loose bodies and broken instruments. Working with the arthroscope in the endaural portals permits access to other portals for instrumentation.

In order to perform this technique a 30° angled arthroscope is recommended, which increases the panoramic visualization of the joint. The off-axis viewing angulation changes as the scope is rotated and permits a more comprehensive examination of the TMJ in areas difficult to examine with conventional 15° arthroscopes. In order to visualize the lateral capsule and attachment areas it is important to obtain

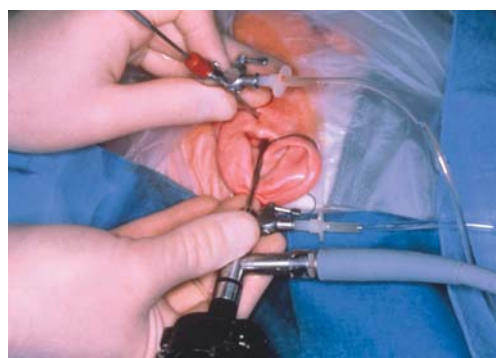


FIGURE 49-25 Clinical view of an arthroscope in the temporomandibular joint that has been placed through the endaural portal. The working portal is now located in the superior posterolateral location. Reproduced with permission from Moses JJ.⁴⁷

an arthroscope that has the visual axis oriented toward the light cord, preventing the impediment of having the light cord forced against the patient's temporal area. Because this is a deviation from the usual manufacturer's product it must be specifically requested during the ordering process.

For the surgeon inexperienced in this technique it is best initially to penetrate the superior joint space from the standard superior posterolateral approach. Once this has been accomplished the arthroscope is then rotated and angled superiorly, posteriorly, and laterally so that the light shines through the anterior wall of the external auditory canal (Figure 49-26). This spot is usually located approximately 1 to 1.5 cm medial to the lateral edge of the tragus in the external auditory canal (Figure 49-27). While the mandible is distracted downward and forward, the anterior wall of the external auditory canal is perforated with the sharp trocar and 30° arthroscopic cannula. The cannula and trocar are angled anterosuperiorly and slightly medially, perpendicular to the posterior slope of the articular eminence. Most important, these instruments enter into the joint above the level of the arthroscope in order to ensure superior compartment puncture (Figure 49-28). Penetration should be carried to a depth of no greater than 1.5 cm using the cannula

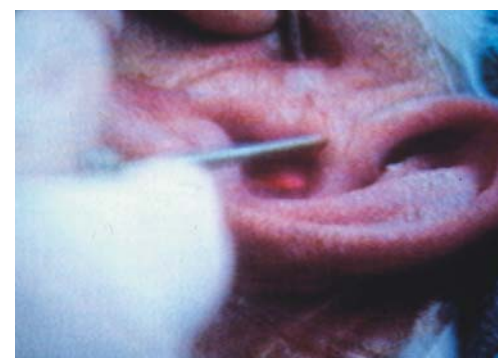

FIGURE 49-26 The arthroscope via the inferolateral portal is angled so that the light from the scope is transilluminated through the tragal cartilage, identifying the site for endaural puncture into the joint. Reproduced with permission from Moses JJ.⁴⁷

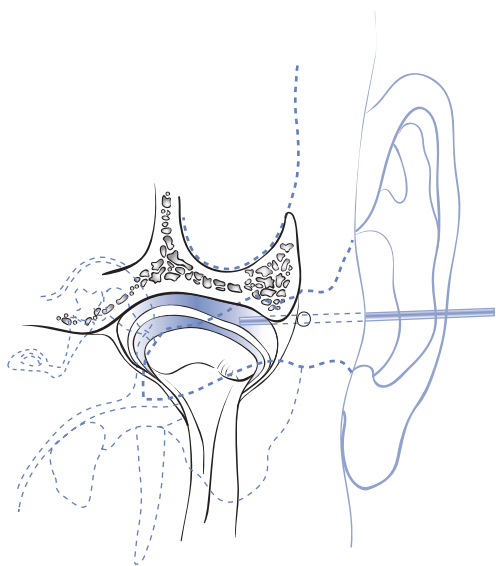


FIGURE 49-27 Diagram indicating approximate site of puncture for the endaural approach. Coronal section is positioned just anterior to the cartilaginous meatus and tragus. Adapted from Moses JJ.⁴⁷

markings as a guide. Visual confirmation of the penetration into the joint space can then be made using the arthroscope, which has been placed in the inferolateral portal. Additional confirmation that the endaural cannula tip lies within the superior joint space can be ascertained when removal of the trocar results in an outflow of irrigation fluid from the endaural cannula. The arthroscope, with the attached fiberoptic cable and inflow tubing, can then be removed from the inferolateral cannula and connected to the endaural cannula. The inferolateral cannula can then be sealed off with a rubber cap to prevent excessive outflow when the TMJ is being irrigated, and the cannula can be used as a working portal while visualization is accomplished via the endaural portal.

By rotating the arthroscope, the medial, lateral, and superior aspects of the TMJ can be examined. This approach is especially helpful in visualizing the anterolateral synovial space, which is difficult to do from either the superior posterolateral or anterolateral portal (Figure 49-29). This technique also allows the superior posterolateral or anterolateral portal to be

used for the instrumentation if necessary (see Figures 49-28 and 49-30).

As skill is acquired, direct puncture through the anterior wall of the external auditory canal into the TMJ can be performed after initial joint distention, without the need for superior posterolateral cannulation. Following the arthroscopic surgical procedure the lateral puncture site receives pressure and round bandage dressings. No sutures are necessary. The endaural puncture is difficult to dress and is left as is. Usually if there is minimal manipulation through this portal, the cartilaginous elastic memory of the canal serves to close the puncture site. A routine otoscopic examination is always made following arthroscopy to visualize the external acoustic meatus and tympanic membrane in order to confirm that no iatrogenic damage has been caused by the procedure.

Perioperative

Preoperative Management

In the preanesthesia holding room several preparatory functions usually help in man-

agement. First, the anesthesiologist assesses the interincisal opening of the patient to determine the extent of the physical blockage versus that of painful restriction. Then, the intravenous line for early administration of the corticosteroid, methylprednisolone, is initiated in order to prepare the patient's mast cell membrane stability which assists in prevention of excessive histamine release on surgical tissue insult. This steroid is followed by an intramuscular injection of 80 mg methylprednisolone acetate at the termination of the case.

Finally, the patient's hair is bundled into a pillowcase and the case is taped to the forehead and nape of the neck with the excess rolled into a "bun" on top of the forehead. This is used to help support the nasoendotracheal tube after intubation (see Figure 49-23). Paper tape is placed along the sideburn hair, holding it up and out of the field. Paper tape with benzoin is used in order to help prevent the "lifting" off of the tape when the surgical prep is applied.

Postoperative Management

Cloth adhesive strips or the ends of cloth bandages are applied to the skin punctures,

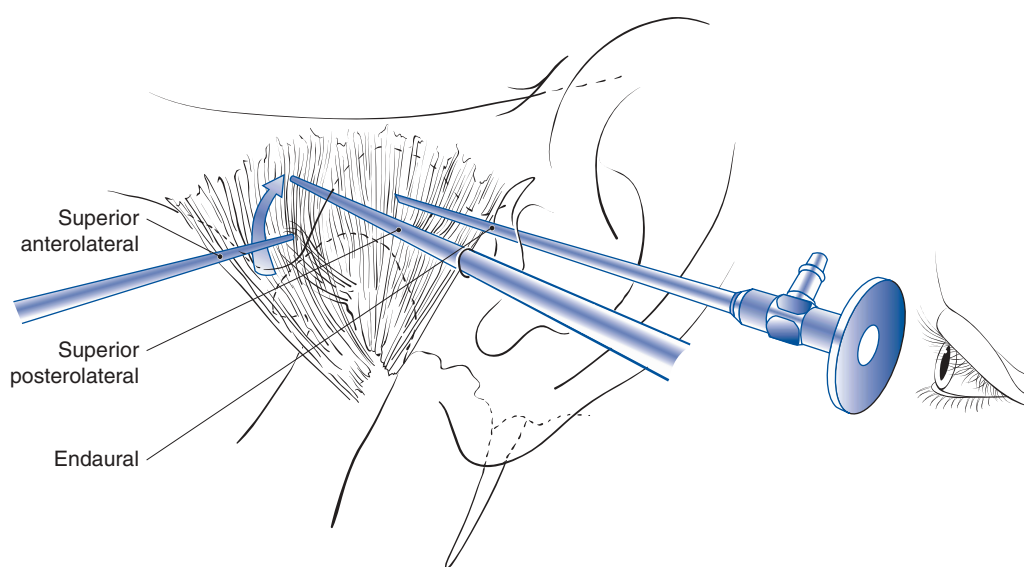


FIGURE 49-28 Diagram of puncture into the temporomandibular joint. The trocar and cannula are directed anterosuperiorly and medially, perpendicular to the posterior slope of the articular eminence and above the inferolateral cannula. The probes, located in either of the working portals, may now be used for the lateral eminence release and the capsular stretch (see arrow). Adapted from Moses JJ.⁴⁷

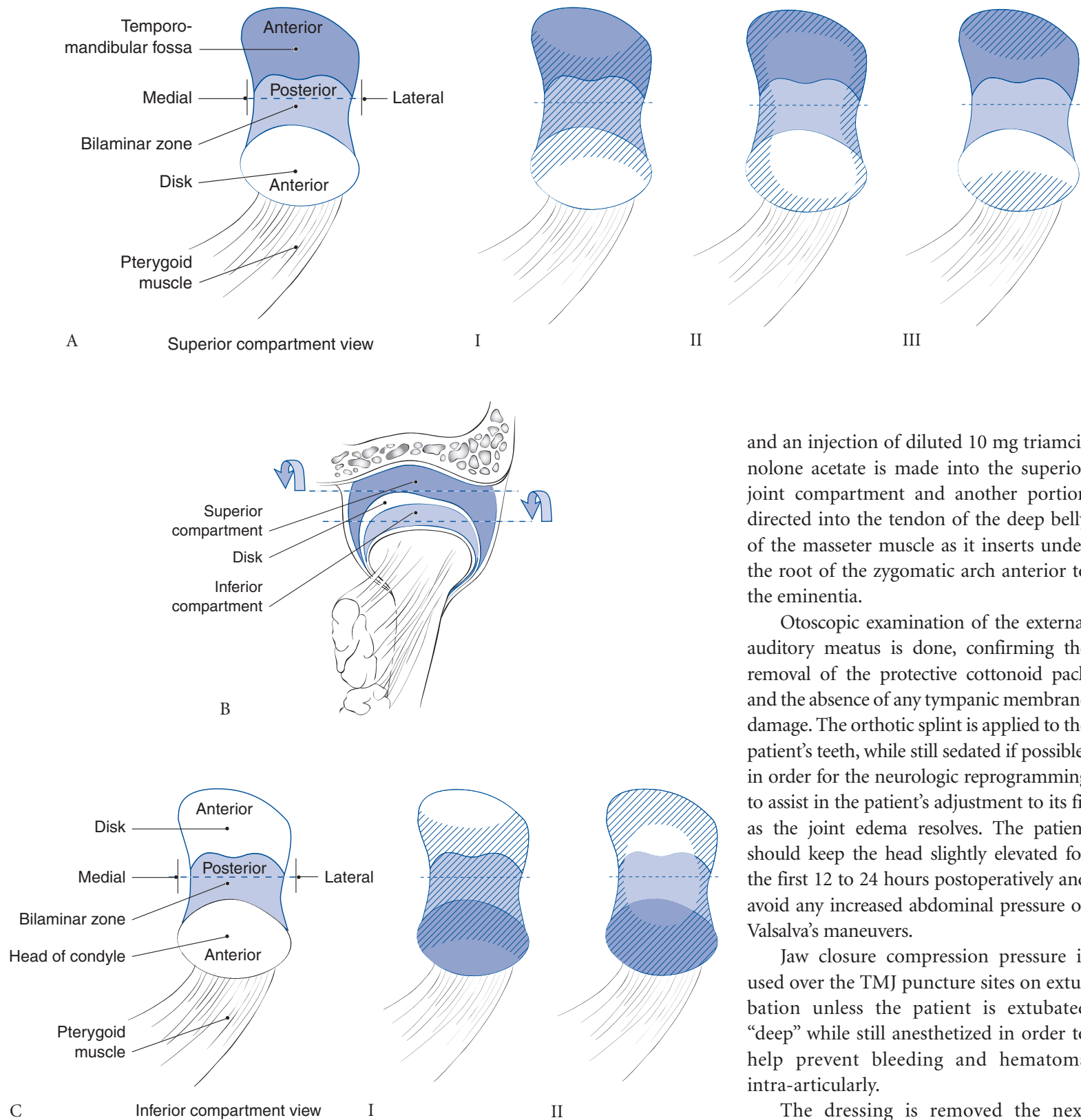


FIGURE 49-29 Visible fields with the various arthroscopic approaches: oriented to the left temporomandibular joint (TMJ) with the roof of the TMJ folded upward. Areas depicted with diagonal lines are difficult to observe arthroscopically. A, Superior compartment, orientation of the sectional planes: I is superior anterolateral area, II is superior posterolateral view, III is inferior anterolateral view. B, Superior and inferior compartment views. C, Inferior compartment, orientation of the sectional planes: I is inferior anterolateral view, II is inferior posterolateral view. Adapted from Moses JJ.⁴⁷

and an injection of diluted 10 mg triamcinolone acetate is made into the superior joint compartment and another portion directed into the tendon of the deep belly of the masseter muscle as it inserts under the root of the zygomatic arch anterior to the eminentia.

Otoscopic examination of the external auditory meatus is done, confirming the removal of the protective cottonoid pack and the absence of any tympanic membrane damage. The orthotic splint is applied to the patient's teeth, while still sedated if possible, in order for the neurologic reprogramming to assist in the patient's adjustment to its fit as the joint edema resolves. The patient should keep the head slightly elevated for the first 12 to 24 hours postoperatively and avoid any increased abdominal pressure or Valsalva's maneuvers.

Jaw closure compression pressure is used over the TMJ puncture sites on extubation unless the patient is extubated "deep" while still anesthetized in order to help prevent bleeding and hematoma intra-articularly.

The dressing is removed the next morning and the adhesive strips are removed. The skin punctures may be washed gently with soapy water and rinsed. They are then coated with a light coat of antibiotic ointment.

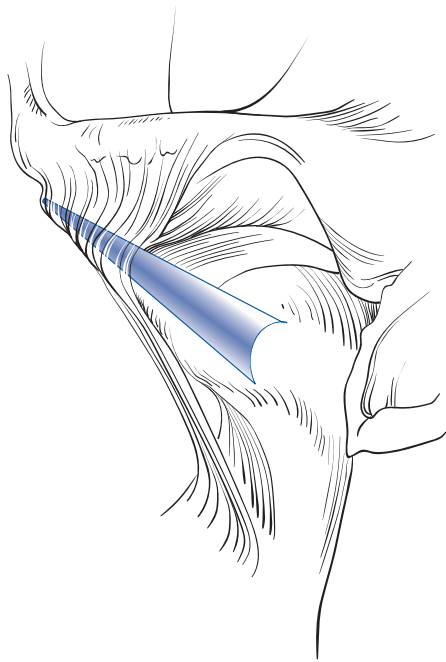


FIGURE 49-30 Diagram showing lateral eminence release. Adapted from Moses JJ.⁴⁷

Postoperative Medications

Routine NSAIDs are given for the postoperative month and muscle relaxants for the first week. Oral cephalosporin following the intraoperative IV bolus of 1 g cephalosporin antibiotics are routinely given for the first week as well. Cortisporin otic suspension eardrops are prescribed for the first 7 to 10 days with 2 drops in the ear canal of the affected side. Narcotic pain medications are rarely, if ever, indicated.

Physical Therapy

Preparatory physical therapy evaluation and management are imperative for a predictable outcome. The patterns for exercise and postoperative mobilization will be well understood and compliance established. Active exercises for the patient consist of opening the jaw, moving it to each side, and protruding the jaw, with each movement performed to the fullest extent ten times and repeated ten times daily for 10 days minimum (Rule of 10's). More important, however, is the passive joint mobilization applied to the patient by the physical therapist. The joint distraction

and mobilization, along with adjunctive therapies, will increase success rates dramatically. This therapy usually can be prescribed with visits three times a week for the first 3 weeks postoperatively, twice a week for the next 2 weeks, and once a week for the next month (Rule of 3-2-1).

Appliance Therapy

An occlusal splint should have been applied postoperatively to deprogram the muscles from periodontal membrane neuromuscular feedback. Occasional skeletofacial deformities of asymmetry or mandibular hypoplasia may be thus revealed, especially in cases where orthodontic elastics have been used during growth and pseudobites have developed.

Sometimes the splint used preoperatively for myositis reduction and other dental attempts for TMJ management may not be applicable for postoperative use following the release of intra-articular pathology. This is explained to the referring clinician as well as the patient, and the new orthotic splint appliance is placed on the patient's teeth on emergence from anesthesia.

The routine use of the splint is dictated by the presence or absence of skeletofacial deformity, muscular symptoms, and the inability to wean off of the device without symptoms. At first the splint is worn full-time (day and night), noting that is especially needed during meals, explaining its similarity to a crutch after knee surgery. If the patient requires orthodontics in preparation for orthognathic surgery, it is usually recommended to maintain the splint on the maxilla while the opposing arch is aligned and leveled and then switch over if necessary to the other arch.

If there is no further concern for either myositis/bruxism control or skeletofacial deformity stabilization, then weaning of the splint from full-time use is indicated. One splint usage routine (Rule of 4's) proven effective is for the patient to wear the splint full-time, including during meals, for 1 month postoperatively until symptoms

and range of motion are normalized. Then weaning takes place over the next 5 months, allowing the patient to reduce wear each month by any selected 4 hours of their choosing, with the exception being the times worn during sleep. This routine yields the final fifth month of wear for nocturnal use only. Many patients wish to maintain the use of the splint at night and a decision can be made at the 6-month postoperative visit, whether this is indicated.

Complications

One might expect there to be a large increase in the complication rate for TMJ arthroscopy when compared with the orthopedic experiences due to the close proximity of many anatomic structures in the head and neck region and their relative complexity of function. At first glance the multicenter retrospective study in 1987 of 2,225 cases showed a global complication rate significantly larger than that reported in a prospective study from orthopedic literature for knees.⁶⁴⁻⁶⁶ The differences in these studies, however, must be measured by the severe limitations of a retrospective design and reliance on surgeon's recall.

One significant conclusion to the multicenter study was that the majority of the complications were perioperative in nature and resolved relatively quickly postoperatively without long-term sequelae. With the learning curve of arthroscopic advancements behind us in this area, the various individual reports of usual and unusual complications have led to a better understanding of prophylactic measures that assist the current surgeon.⁶⁷

Extravasation

Whether or not a mechanical pump or hand-operated syringe is used, extravasation is a continual risk for arthroscopic procedures. Complications include pharyngeal embarrassment of airway requiring overnight hospitalization, periorbital and temporal edema, and transient cranial nerve V and VII effects.⁶⁸ Techniques of

constant inflow-outflow volume monitoring during the procedure with the outflow tubing lifted by taping the end to the edge of a basin help reduce the likelihood of extravasation. Limiting the number of punctures laterally and preventing unnecessary medial capsular wall punctures will keep extravasation down as well.

Procedures should be kept to a minimum duration, and if anterior release procedures are required, they should be done at the end of all the other procedures performed within the joint to help keep the hydraulic distention present and avoid early extravasation limiting operating time.

Neurologic Injury

Nerve injury comprises one of the largest categories of complication reported in the longer retrospective studies.^{64,65} By far the most common are those to the peripheral source of the sensory nerve V and its various branches. While the auriculotemporal branch is most frequently affected, it is commonly transient in its hypoesthesia and usually resolves within 6 months.⁶⁹ The other nerve that is at risk for damage is the inferior alveolar branch which, while usually only transiently affected by extravasation, can be iatrogenically damaged by mandibular angle clamps placed for jaw manipulation.^{70,71} Safer methods of manipulation have been described that use the assistant's hands and thumbs on the teeth for joint positioning or mobilization.⁷² The motor cranial nerve VII (temporozygomatic and masseteric branches) has been reported damaged in arthroscopic procedures, with reporting rates ranging from 0.56% to 4%. The damage typically resolved within 6 months according to reports reviewed.^{64,65,73,74} Management of injury to these motor branches is done postoperatively in a similar fashion to that occurring after open surgery, with artificial tears, eye patching, physical therapy, electrostimulation, and oculo-plastic consultation if needed.

Finally one must constantly be aware of the variation of anatomy present with-

in the TMJ. Rare cases of glenoid fossa defects can result in middle cranial fossae perforation, and more commonly giant cell erosion of bone from previous implant surgery can lead to increased risks of cerebrospinal fluid leakage as well.⁷⁵ Management includes identification, neurosurgical consultations, hospitalization, observation with elevated head and rest, and rarely application of subarachnoid drain placement. Fortunately in most cases the dura seals and the leak resolves.

Vascular

Intraoperative intra-articular hemorrhage as well as retrodiskal hemorrhages can occur with inadvertent medial wall puncture and anterior capsular release. This can sometimes be stopped by the mild hydraulic pressure produced by blocking the outflow portal and allowing inflow pressure to build. If this fails, removal of the instruments and firm compression of the joint, both by shutting the teeth together and lateral compression with gauze overlying the joint capsule, is warranted for a few minutes. Vasoconstrictors may be introduced into the joint space to assist this maneuver.

Another hemorrhagic complication of arthroscopy involves inadvertent puncture or laceration of the overlying vessels on entry. These may include, but are not limited to, superficial temporal artery/vein (A/V), transverse facial A/V, or even the masseteric artery. Very rarely will this event cause such vigorous bleeding as to require intraoperative ligation or subsequent management of an arteriovenous fistula, evidenced by later "whooshing" sounds overlying the joint preauricularly.^{59,65,76} Usually this event can be managed by the application of pressure with gauze overlying the vessel, with the patient's head turned to the opposite side and supported by the operating table headrest, thus allowing continuance of the surgery after homeostasis is achieved.

Intra-articular

The small size of the TMJ and the fact that any joint space is in fact only a potential joint space requires constant hydraulic and mechanical distention in order to negotiate instrumentation safely and without causing unnecessary joint surface scuffing and damage. Entry into the joint space through the capsule may be made with a sharp trocar initially, with the irrigation fluid distending the space, but a blunt trocar should then be used to explore the entry success in order to minimize the possibility of scuffing and damage. Additionally a lateral eminence release and a capsular stretch should be employed early in the procedure to allow easy movements of instruments from the posterior to the anterior recess in order to minimize surface damage and potential instrument breakage.

Instrument Breakage

Due to the minimally invasive nature of arthroscopy and size restraints on the mechanical instruments, metallurgic strengths are sometimes exceeded even with the most careful of techniques. Instrument manufacturers have been encouraged to produce "shear points" within their instruments which, on breakage, keep all of the metallic pieces together. These act as a "fuse" breaker, failing just before the functioning edge of their instrument breaks off into the joint space. Not all manufacturers use this principle, however, and the surgeon must be prepared to retrieve broken instrumentation parts from the joint space, either arthroscopically or via open arthrotomy, thus making it imperative to include this possibility on the operation consent form.

Arthroscopic retrieval can be performed through the use of dilation canulas, which gradually enlarge the access portal to a size sufficient for the grasper or magnetic retriever to hold the broken fragment and come back through the

sheath intact without becoming trapped. If restriction occurs and the sheath has to be removed with the fragment, then there is a strong possibility that the fragment may be lost into the soft tissue between the capsule and the skin. As in standard practice, instrument breakage should require incident reporting.

Otologic

One of the earlier complications of arthroscopic surgery reported was that of injury to the tympanic membrane and the middle ear ossicles and permanent hearing loss.^{73,77} In retrospect it is seen that the anatomic course of the auditory meatus is anterior and medial. This fact, combined with a patient's head position, in anything other than a near-horizontal ear-flat-to-the-table position portends an increased risk of trocar puncture from the posterolateral approach. One must keep constant vigilance to the direction of the entry trocar anteriorly and superomedially *combined* with an awareness of the positioned direction of the patient's head at the onset of surgery.

Other rare otologic events include laceration of the external auditory canal.^{64,65} Treatment usually involves observation, antibiotic drops, or occasional hemostatic control.

More minor events otologically include otitis externa and otitis media, as well as tympanic membrane perforation resulting from too vigorous canal preparation.⁷⁸ Otitis can occur spontaneously postsurgically or from an inadvertent contaminant such as cotton pieces left in the canal.⁷² It is therefore prudent for the surgeon to use an otoscope postoperatively to visualize and dry the canal prior to case conclusion, as well as to prescribe medication such as an antibiotic hydrocortisone suspension for eardrops postoperatively. Patients with nonresolving otologic issues or tympanic membrane damage are referred to an otolaryngology specialist for consultation.

Infection

The low overall infection rate of 1% following arthroscopic surgery of the TMJ follows that of the orthopedic literature.^{64,66} Even the relative contraindication of puncturing through overlying skin infection has had modifications to allow entry into suppurative arthritis with therapeutic benefit and no adverse postoperative dissemination of infection or cellulitis.^{65,75} Although infections are rare, the standard regimen at present for prophylaxis remains at a 1 g bolus of cephalosporin plus oral coverage of cephalosporin 500 mg every 6 hours for 5 days.^{27,68,70} Prophylactic antibiotic corticosteroid eardrops are used for 5 days as well.^{27,68}

Burns

Various procedures using electrocautery and laser have led to concerns regarding adequate protection of tissues to prevent adverse affects. The use of electrocautery within the joint for reduction of inflammatory or granulation tissue can rarely lead to inadvertent contact of the active electrode's end with the metal of the cannula. This can lead to accidental thermal injury.⁷⁹

Additionally, without copious amounts of irrigating solution to flush and cool the synovial lining of the joint, HO:YAG laser débridements can cause thermal damage to these important cells, inhibiting their natural physiologic function of phagocytosis and production of joint lubricants. Not only should the modern arthroscopist have mechanical hand-eye coordination but an awareness of physiologic collateral effects of surgery as well.

Subcutaneous Fat Atrophy

Subcutaneous fat atrophy has been reported both in the literature and in the community anecdotally.³² Triamcinolone is frequently used within the superior joint space postoperatively at the case conclusion and in subsequent visits for management of recurrent fibrosis or ankylosis. Its use in

both the reduction of deep masseter tendonitis by injection and in reduction of capsulitis by iontophoresis is also common. Even though subcutaneous fat atrophy is rare in occurrence, low concentrations and limiting administrations of triamcinolone can be helpful in limiting risk.

Anesthetic Complication

Manipulation of the jaw has been shown to have occasional effects on the carotid body and thus to result in unexpected bradycardia. If such an event is not reversed by relaxing the jaw position, atropine may be administered. Conversely occasionally epinephrine (1:200,000) is administered to assist in hemostasis during arthroscopic surgery *after* the initial examination is complete, so as not to mask the grading of the synovitis. This hemostatic vasoconstrictor may occasionally cause cardiac arrhythmias. Any persistent premature ventricular contractions or ventricular irritabilities may be treated with intravenous lidocaine if indicated.

Outcomes and Discussion

Over the past decade numerous researchers have shown the effectiveness of TMJ arthroscopy, both in the diagnosis and the surgical management of TMJ articulopathies.^{71,80-85}

Although numerous techniques have been developed for both open and arthroscopic surgical management, it would appear that the more complex the procedure applied, the more difficult the postoperative management is, with resulting diminishment of success rates. The overriding factors of similarity for all procedures seem to include the following:

1. Preoperative splint and physical therapy management
2. Release of capsular restrictions, either through incision or blunt obturator release and stretch
3. Release of intra-articular fibrosis and restrictions

4. Application of postoperative physical therapy joint mobilization

The disk position, with the exception of the severely shredded or morphologically obstructed disk, does not appear to affect the patient's outcome of comfort with jaw movements and clinical success.^{25,86} While techniques designed to alter the position of the disk, restrict hypermobility, and the like are certainly sometimes indicated, caution must be taken to rein in the enthusiasm for adding yet more complexity to a system that responds very well to simplicity and is adaptive in its articular remodeling and functional response. Even disks that are perforated and joints with Grades III and IV degeneration respond well to the arthroscopic approach.⁷⁵

Further advancements in arthroscopic techniques and treatment modalities are certainly arising and each advance is weighed with these risk-benefit ratios.

References

1. Tagaki K. Practical experience using Tagaki's arthroscope. *J Jpn Orthop Assoc* 1933;8:132.
2. Bircher E. Die Arthro endoskopie. *Zentralbl Chir* 1921;48:1460.
3. Kreyser P. Semilunar cartilage disease: a plea for early recognition by means of the arthroscope and early treatment of this condition. *IMG* 1925;47:290.
4. Burmann MS, Finkelstein H, Mayer L. Arthroscopy of the knee joint. *J Bone Joint Surg* 1934;16A:225.
5. Watanabe M, Bechtol R, Nottage W. History of arthroscopic surgery. In: Shahriaree H, editor. *O'Connor's textbook of arthroscopic surgery*. Philadelphia (PA): Lippincott; 1984. p. 1–6.
6. Casscells SW. Arthroscopy of the knee joint. *J Bone Joint Surg* 1971;53A:287.
7. Jackson RW, Abe I. The role of arthroscopy in the management of disorders of the knee: an analysis of 200 consecutive examinations. *J Bone Joint Surg* 1972;54B:310.
8. O'Conner RL. *Arthroscopy*. Philadelphia (PA): Lippincott; 1977.
9. Johnson LI. *Arthroscopic surgery: principles and practice*. St. Louis (MO): Mosby; 1986.
10. Watanabe M. *Arthroscopy of small joints*. Tokyo and New York: Igaku-Shoin; 1985.
11. Ohnishi M. Clinical studies on the intra-articular puncture of the temporomandibular joint. *J Jpn Stomat* 1970;37:14.
12. Ohnishi M. Arthroscopy of the temporomandibular joint. *J Jpn Stomat* 1975;42:207.
13. Ohnishi M. Diagnostic application of arthroscope to ankylosis of the temporomandibular joint. *Jpn J Oral Surg* 1976;22:436.
14. Ohnishi M. Clinical application of arthroscopy in temporomandibular joint diseases. *Bull Tokyo Med Dent Univ* 1980;27:141.
15. Hilsabeck RB, Laskin DM. Arthroscopy of the temporomandibular joint of the rabbit. *J Oral Surg* 1978;36:938.
16. Williams RA, Laskin DM. Arthroscopic examination of experimentally induced pathologic conditions of the rabbit temporomandibular joint. *J Oral Surg* 1980;38:652.
17. Holmlund A, Hellsing G, Bang G. Arthroscopy of the rabbit temporomandibular joint. *Int J Oral Maxillofac Surg* 1986;15:170.
18. Murakami K-I, Hoshino K. Regional anatomical nomenclature and arthroscopic terminology in human temporomandibular joints. *Okajimas Folia Anat Jpn* 1982;58:4–6.
19. Murakami K-I, Hoshino K. Histological studies on the inner surfaces of the articular cavities of human temporomandibular joints with special references to arthroscopic observations. *Anat Anz* 1985;160:167.
20. Holmlund A, Hellsing G. Arthroscopy of the temporomandibular joint. *Int J Oral Surg* 1985;14:169.
21. McCain JP. *An illustrated guide to temporomandibular joint arthroscopy*. Andover (MA): Dyonics, Inc.; 1987.
22. Murakami KI, Ono T. Temporomandibular joint arthroscopy by inferolateral approach. *Int J Oral Maxillofac Surg* 1986;15:410.
23. McCain JP. Proceedings of the American Association of Oral and Maxillofacial Surgery TMJ Arthroscopy Symposium Session, Annual Meeting Sept 1985. *J Oral Maxillofac Surg*.
24. Sanders B. Diagnostic and surgical arthroscopy of the temporomandibular joint: clinical experience with 137 procedures over a 2-year period. *J Craniomandib Disord Facial Oral Pain* 1987;1(3):202.
25. Moses JJ, Sartoris D, Glass R, et al. The effect of arthroscopic surgical lysis and lavage of the superior joint space on TMJ disc position and mobility. *J Oral Maxillofac Surg* 1989;47:674–8.
26. Moses JJ, Lo HH. Tomographic changes of the TMJ following arthroscopic surgery with lysis and lavage and eminentia release. *J Orofac Pain* 1994;8:407–12.
27. Moses JJ, Poker ID. TMJ arthroscopic surgery: an analysis of 237 patients. *J Oral Maxillofac Surg* 1989; 47:790–4.
28. Emshoff R, Brandimaier I, Schmid C, et al. Bone marrow edema of the mandibular condyle related to internal derangement, osteoarthritis, and joint effusion. *J Oral Maxillofac Surg* 2003;61(1):35–40.
29. Moses JJ, Salinas E. MRI or arthrographic diagnosis of TMJ internal derangement: correlation comparison study with arthroscopic surgical confirmation. *Oral Surg Oral Med Oral Pathol* 1993;75:268–72.
30. Bronstein SL, Thomas M. *Arthroscopy of the temporomandibular joint*. Philadelphia (PA): W.B. Saunders Co.; 1991. p. 347–50.
31. Shahriaree H. *O'Connor's textbook of arthroscopic surgery*. Philadelphia (PA): J.B. Lippincott; 1984. p. xi, 1, 237.
32. Nitzan DW, Price A. The use of arthrocentesis for the treatment of osteoarthritic temporomandibular joints. *J Oral Maxillofac Surg* 2001;59(10):1154–9.
33. Hopkins H. Optical principles of the endoscope. In: Berci G, editor. *Endoscopy*. New York (NY): Appleton-Century-Crofts; 1976. p. 3–26.
34. Bradrick JP, Eckhauser ML, Indresano AT. Morphologic and histologic changes in canine temporomandibular joint tissues following arthroscopic guided neodymium:YAG laser exposure. *J Oral Maxillofac Surg* 1989;47(11):1177–81.
35. Bradrick JP, Eckhauser ML, Indresano JP. Early response of canine temporomandibular joint tissues to arthroscopically guided neodymium:YAG laser wounds. *J Oral Maxillofac Surg* 1992;50(8):835–42.
36. Hendler BH, Gateno J, Moor P, Sherk HHL. Holmium:YAG laser arthroscopy of the temporomandibular joint. *J Oral Maxillofac Surg* 1992;50(9):931–4.
37. Jones BR, Moses JJ. Anesthesia for temporomandibular joint arthroscopy. *Anesthes Clin North Am* 1989;7(3):693–705.
38. Alstergren P, Kopp S. Prostaglandin E₂ in temporomandibular joint synovial fluid and its relation to pain and inflammatory disorders. *J Oral Maxillofac Surg* 2000;58(2):180–6.
39. Neer CS II. Anterior acromioplasty for the chronic impingement syndrome in the shoulder: a preliminary report. *J Bone Joint Surg* 1972;54A:41.
40. Hawkins RE, Kennedy JC. Impingement syndrome in athletes. *Am J Sports Med* 1980;8:151.
41. Neer CS II. Impingement lesions. *Clin Orthop* 1983;173:70.
42. Pujadas GM. Coracoclavicular ligament syndrome. *J Bone Joint Surg* 1979;52A:136.
43. Post M, Cohen J. Impingement syndrome: a review of late state II and early state III lesions. *Orthop Trans* 1985;9:48.

44. Raggio CL, Warren RF, Sculco T. Surgical treatment of impingement syndrome: 4-year follow-up. *Orthop Trans* 1985;9:48.
45. Backwood HJJ. Arthritis of the mandibular joint. *Br Dental J* 1963;115:317.
46. Kirk WS, Kirk BS. Basic biomechanics for temporomandibular surgeons. Presented at the American Society of TMJ Surgeons' Annual Conference; March 2003; Laguna Beach (CA).
47. Moses JJ. Articular pathology: disc displacement and lateral impingement syndrome. In: Bronstein SC, Thomas M, editors. *Arthroscopy of the temporomandibular joint*. Philadelphia (PA): W.B. Saunders Co.; 1991. p. 249–57.
48. Juniper RP. The pathogenesis and investigation of TMJ dysfunction. *Br J Oral Maxillofac Surg* 1987;25:105–12.
49. Tay David KL. The pathogenesis of disc displacement in the temporomandibular joint: a reassessment of the role of closed-lock positions. *J Gnathol* 1987;6(1).
50. Moffett BC, Johnson LC, McCabe JB, Askew HC. Articular remodeling in the adult human temporomandibular joint. *Am J Anat* 1964;115:119–22.
51. Moses JJ, Topper DC. Use of new arthroscopic joint spreader/stabilizer. *Oral Surg Oral Med Oral Rad J* 1991;71:535–7.
52. Moses JJ, Poker I. Correlation studies of effects of TMJ arthroscopic surgical lysis of superior joint compartment adhesions and lavage. *J Oral Maxillofac Surg* 1989;47:674–8.
53. Kondoh T, Hamada Y, Kamei K, Seto K. Simple disc reshaping surgery for internal derangement of the temporomandibular joint: 5-year follow-up results. *J Oral Maxillofac Surg* 2003;61:41–8.
54. Mazzonetto R, Spagnoli DB. Long-term evaluation of arthroscopic discectomy of the temporomandibular joint using the holmium YAG laser. *J Oral Maxillofac Surg* 2001;59(9):1018–23.
55. Eriksson L, Westesson PL. Discectomy as an effective treatment of temporomandibular joint internal derangement: a 5-year clinical and radiographic follow-up. *J Oral Maxillofac Surg* 2001;59(7):750–8.
56. Moses JJ. TMJ arthroscopic surgery: rationale and technique. *Proceeding of the American Association of Oral and Maxillofacial Surgeons 82nd Annual Meeting*. *J Oral Maxillofac Surg* 2000;58(8).
57. Greene MW, Hacknewy FL, Van Sickles JE. Arthroscopy of the temporomandibular joint: an anatomic perspective. *J Oral Maxillofac Surg* 1989;47:386.
58. Al-Kayat A, Bramley P. A modified preauricular approach to the temporomandibular joint and malar arch. *Br J Oral Surg* 1979;17:91.
59. Moses JJ, Topper DC. Arteriovenous fistula: an unusual complication associated with arthroscopic TMJ surgery. *J Oral Maxillofac Surg* 1990;18:1220–2.
60. Moses JJ, Hosaka H. Pediatric arthroscopic surgery: a case report with special surgical considerations. *J Oral Maxillofac Surg* 1992;7:81–99.
61. Murakami K, Takatoki O. Temporomandibular joint arthroscopy by inferolateral approach. *Int J Oral Surg* 1986;15:410–7.
62. Watanabe M. Arthroscopy of the temporomandibular joint. In: *Arthroscopy of small joints*. New York (NY): Igaku Shoin; 1985.
63. Moses JJ, Poker ID. Temporomandibular joint arthroscopy: the endaural approach. *Int J Oral Maxillofac Surg* 1989;18:347–51.
64. Carter JB, Testa L. Complications of TMJ arthroscopy: a review of 2,225 cases. Review of the 1988 Annual Scientific Sessions abstracts. *J Oral Maxillofac Surg* 1988;46:M14–5.
65. Greene MW, Van Sickles JE. Survey of TMJ arthroscopy in oral and maxillofacial surgery residency programs. *J Oral Maxillofac Surg* 1989;47:574–6.
66. Small NC. Complications in arthroscopic surgery performed by experienced arthroscopists. *J Arthrosc Rel Surg* 1988;4:215–21.
67. Tsuyama M, Kondoh T, Seto K, Fukuda J. Complications of temporomandibular joint arthroscopy: a retrospective analysis of 301 lysis and lavage procedures performed using the triangulation technique. *J Oral Maxillofac Surg* 2000;58(5):500–5.
68. White RD. Retrospective analysis of 100 consecutive surgical arthroscopies of the temporomandibular joint. *J Oral Maxillofac Surg* 1989;47:1014–21.
69. Carter JB, Schwaber MK. Temporomandibular joint arthroscopy: complications and their management. *Oral Maxillofac Surg Clin North Am* 1989;1(1): 185–99.
70. Tarro AW. Arthroscopic diagnosis and surgery of the temporomandibular joint. *J Oral Maxillofac Surg* 1988;46:282–9.
71. Heffez L, Blaustein D. Diagnostic arthroscopy of the temporomandibular joint. I: normal arthroscopic findings. *Oral Surg* 1987;64:653–70.
72. Sanders B. Arthroscopic surgery of the temporomandibular joint: treatment of internal derangement with persistent closed lock. *Oral Surg* 1986;62:361–72.
73. Applebaum EL, Berg LF, Kumar A, et al. Otolgic complications following temporomandibular joint arthroscopy. *Ann Otol Rhinol Laryngol* 1988;97:675–9.
74. Indreasano AT. Arthroscopic surgery of the temporomandibular joint: report of 64 patients with long-term follow-up. *J Oral Maxillofac Surg* 1989;47:439–41.
75. Murakami K, Matsumoto K, Iizuka T. Suppurative arthritis of the temporomandibular joint: report of a case with special reference to arthroscopic observations. *J Maxillofac Surg* 1984;12:41–5.
76. Preisler SA, Koorbusch GF, Olson RAJ. An acquired arteriovenous fistula secondary to temporomandibular joint arthroscopy: report of a case. *J Oral Maxillofac Surg* 1991;49:187–90.
77. Van Sickles JE, Nishioka GJ, Hegewald MD, et al. Middle ear injury resulting from temporomandibular joint arthroscopy. *J Oral Maxillofac Surg* 1987;45:962–5.
78. Tarro AW. Arthroscopic treatment of anterior disc displacement: a preliminary report. *J Oral Maxillofac Surg* 1989;47:353–8.
79. Bronstein SL, Thomas M. *Arthroscopy of the temporomandibular joint*. Philadelphia (PA): W.B. Saunders Co.; 1991. p. 320.
80. Goss AN, Bosanquet AG. Temporomandibular joint arthroscopy. *J Oral Maxillofac Surg* 1986;44:614.
81. Murakami K, Matsuki M, Iizuka T, et al. Diagnostic arthroscopy of the TMJ: differential diagnosis in patients with limited jaw opening. *J Craniomandib Pract* 1986;4:118.
82. Blaustein D, Heffez L. Diagnostic arthroscopy of the temporomandibular joint. II Arthroscopic findings of arthrographically diagnosed disk displacements. *Oral Surg Oral Med Oral Pathol* 1988;65:135.
83. Holmlund A, Helsing G. Arthroscopy of the temporomandibular joint: occurrence and location of osteoarthritis and synovitis in a patient material. *Int J Oral Maxillofac Surg* 1988;17:36.
84. Goss AN, Bosanquet A, Tideman H. The accuracy of temporomandibular joint arthroscopy. *J Craniomaxillofac Surg* 1987;15:99.
85. Uriell P, Bertolucci L, Swaffer C. Physical therapy in the postoperative management of temporomandibular joint surgery. *J Craniomandib Pract* 1989;7:27.
86. Montgomery MT, Van Sickles JE, Thrash WJ, et al. Signs and symptoms, patient satisfaction and meniscal position following arthroscopic TMJ surgery. Paper presented at the 70th Annual Meeting and Scientific Sessions of the American Association of Oral and Maxillofacial Surgeons; 1989 Sep 30; Boston (MA). *J Oral Maxillofac Surg*.

Surgery for Internal Derangements of the Temporomandibular Joint

Leslie B. Heffez, DMD, MS

The chapter on surgery for internal derangements of the temporomandibular joint (TMJ) written for the first edition, published in 1992, has stood the test of time. The surgical procedures described are still being performed today, which is indicative of their acceptance within the surgical community and perhaps of their success. The history of TMJ surgery has paralleled the rise and subsequent all but disappearance of the western cowboy. New surgical techniques that neglected to pay attention to the fundamental underlying symptoms and etiology have been heralded as panaceas, only to rapidly fade into obscurity, leaving a trail of iatrogenia. The new TMJ surgeon must be wary of this past. However, prudence should not lead to avoidance of surgery as a treatment modality.

According to Annandale, Sir Astley Cooper was the first to suspect the existence of altered condyle disk-fossa relations.¹ Later the term *internal derangement* was adopted to describe any pathologic entity that interfered with the smooth function of the TMJ. The term is currently used exclusively to describe alterations in disk-fossa relations. Historically, clinicians have recognized that surgery for internal derangements should be reserved for patients with

pain or dysfunction that is severe and disabling and is refractory to nonsurgical management. These conditions still form the basic indications for surgery. Open surgery of the TMJ for primary disease has undergone a complete metamorphosis as a result of the research and clinical results of surgical arthroscopy. At one time only a handful of surgeons professed the viability of function with a displaced disk and argued against surgical repositioning. Today the tables are reversed, and the majority of surgeons recognize that an internal derangement does not imply an ipso facto need for surgery. Furthermore, the presence of persistent symptoms in light of an internal derangement does not imply that surgical correction is necessary or imminent. Only if the mechanical obstruction is felt to be the primary etiology behind the symptoms is surgery indicated. This philosophy has resulted in a dramatic reduction in the number of open surgical procedures performed. This reduction has, in turn, resulted in dramatically fewer cases deemed to have an iatrogenic pathology; we continue to grapple with the 1980 to 1990 vestiges of such cases.

The chapter begins with sections on criteria for diagnosis and goals for surgical

intervention. A brief discussion of surgical anatomic considerations is followed by a description of the classic surgical approaches to the joint capsule and capsular incisions. A critical review of the history, indications, rationale for performance, and techniques of primary operations of the TMJ is then presented. Numerous references are made to those authors who have fueled the development of surgery for internal derangements. In my discussions I have used the term *posterior attachment* to describe tissue that is an extension of the retrodiskal tissue and inserts onto the posterior aspect of the disk. When the adjective *remodeled* is used to qualify an intra-articular structure, as in *remodeled posterior attachment*, the structure is considered pathologic.

Criteria for Diagnosis

Internal derangements are classically divided into two groups: reducing disk displacements and nonreducing disk displacements. Qualifying descriptors are sometimes included, such as the direction of displacement, degree of displacement, and presence of a perforation. Unfortunately, these large diagnostic rubrics fail to identify the finer stages of the disease

process. Disk morphology and severity of displacement are only gross indicators of the disease process. Although more complicated classifications such as the Wilkes classification exist, the treatments applied to the diagnostic categories have been diverse, rendering specific recommendations ill advised. It suffices to say that an astute clinician must be armed with that rare commodity of common sense rather than a rigid algorithm of treatment modalities. The research and clinical work emanating from arthroscopic trials will, in the future, establish more specific diagnostic criteria for establishing treatment protocols.

In the surgical decision-making process the specific diagnosis is only one piece of information necessary to make the decision to perform surgery. Surgery should be considered when the dysfunction or pain cannot be corrected to a level of patient satisfaction by nonsurgical modalities. Cookbook approaches to the diagnosis and surgical management of internal derangements should not be used. It is important to consider that no dysfunction is identical to another when the surgeon factors into the treatment equation the patient's perception of his or her problem, the effect on daily routine, and the patient psyche. The diagnosis of an internal derangement is achieved predominantly through clinical skills. Imaging of the joint usually is most useful only in the later planning stages of surgery, rather than during the establishment of a working diagnosis. There is the occasional instance in which a diagnostic dilemma exists and magnetic resonance imaging (MRI) is required to elucidate the case.

For the sake of discussion, the condition internal derangement can be identified in three different clinical settings. The first is the occurrence of a primarily functional disturbance. In this condition the chief complaint is functional. The patients may describe a need to perform a special maneuver with the mandible to achieve a wide opening, or they may describe an

annoying terminal jolting associated with closing. Joint pain is typically not chronic and appears to be related to the instability of the condyle-disk relations. Pain occurs with the sudden separation of joint surfaces during disk reduction or displacement. However, pain may not be a feature. Most of these cases demonstrate a reducing disk displacement, in which the disk represents a mobile mechanical obstacle and the condyle is not permanently restricted in its range of motion. Reduction refers to the ability of the condyle to negotiate around the disk. The disk's recoil potential is minimal in the pathologic condition. The inferior surface of the disk is typically bulged and histologically is the site of increased proteoglycan deposition. If pain and dysfunction persist despite treatment of a coexistent parafunctional habit, surgery should be considered. These patients are best managed with open surgery and reduction of the obstructing portions of the articular disk. Diskoplasty, partial discectomy, or full discectomy may be performed, depending on the degree of disk atrophy and deformation. Disk repositioning should be considered only when the disk is minimally deformed and of near-normal length. Clinical indicators for surgical intervention of this condition are rare. Some clinicians prefer to perform arthroscopic disk-stabilizing procedures using suturing or sclerosing techniques.

The second clinical setting in which internal derangements are identified is the condition of closed lock. *Closed lock* refers to an acute or chronic limitation of movement of the condyle owing to an intra-articular disturbance. Patients experiencing closed lock often complain of muscle dysfunction secondary to efforts to reach a baseline mouth opening.

The coexistence of muscle dysfunction and an internal derangement does not imply a relationship. A large segment of the general population have minimal signs and symptoms associated with internal derangements. Careful recording of the chief and

ancillary complaints is imperative, with attention being paid to the details of onset and duration of facial pain and joint noise, timing of symptoms of facial tightness, inability to open or close the mouth, and distribution of headaches. Concomitant sources of pain need to be identified and consultations with neurology, otolaryngology, psychology, or general dentistry, as required, obtained. The history of previous treatment is equally important.

There are usually a number of factors that are considered in the etiology of closed lock, including intracapsular and extracapsular inflammation and adhesions, muscle tension or spasm, disk displacement, synovial fluid viscosity, and reduction in synovial lubrication.

The closed lock phenomenon may resolve spontaneously or gradually over a period of weeks to months. Hence, it is important to evaluate the patient on several visits to effectively note a response to non-steroidal anti-inflammatory agents and muscle relaxants. In the absence of pain, many patients are able to tolerate the restriction in mouth opening, which gradually improves over several months to years.

MRI of the closed lock condition usually demonstrates a displaced disk, with various degrees of deformation. In some patients the disk appears in a normal position but is unable to be displaced down the slope of the eminence. Although not the subject of this chapter, it suffices to say that T1 and T2 (or gradient echo imaging) in sagittal planes is required to delineate intra-articular fluid, interstitial inflammation, and disk morphology. Magnetic resonance images demonstrate that the condyle is unable to displace the disk anterior enough to reach the apex of the eminence or beyond. On fast magnetic resonance or T2 images, inflammatory fluid or increased vascularity appears as a high signal intensity (Figure 50-1).

Adhesions associated with closed lock cannot be definitively identified on an MRI scan. They are suspected when there

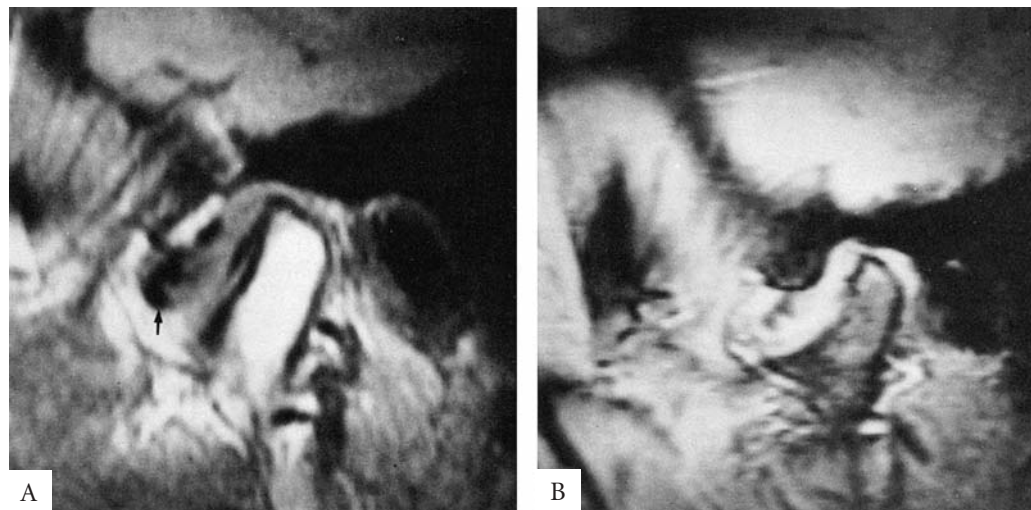


FIGURE 50-1 A, T1-weighted sagittal magnetic resonance image demonstrating a dislocated disk. Note the low signal intensity, which represents a portion of the deformed disk (arrow). B, Fast imaging (GRASS [gradient recalled acquisition in steady state]) of the same section demonstrates the presence of extra-articular and intra-articular fluid or an increase in vascularity in the anterior regions of the joint. These changes may be partly responsible for the closed lock phenomenon.

is a confluence of the low signal intensities of the condyle and glenoid fossa without intervening intermediate signal intensity. Arthrocentesis followed by arthroscopic lysis of superior joint space adhesions, lavage, and manipulation are the treatments of choice for this condition. Open surgical procedures are indicated when arthroscopy has failed to resolve the restriction in opening. The choice of open procedure largely depends on disk anatomy and position.

The third clinical setting is the internal derangement condition of disk displacement that reduces on opening and is associated with persistent preauricular pain refractory to nonsurgical therapy. This is the most difficult of the three conditions to treat and requires long-term therapy with control of parafunctional habits. The clinician must ask whether the pain is occurring from hypermobility caused by contralateral hypomobility, acute or chronic separation of disk surfaces during displacement and reduction, noncompliance with diet restrictions, or persistent parafunctional or work-related habits. There are indications for surgical intervention; however, it is this condition that

carries the greatest peril of being rendered into the painful operated ankylosed joint after several fruitless surgeries.

Arthrocentesis has supplanted arthroscopic surgery as the most successful treatment modality. It should be attempted before performing any open surgical procedure. The type of open procedure is governed by the degree of disk morphology. The key to arthroscopy is to remove the source of the persistent inflammation including the vascular retrodiskal tissue and hyperplastic inflamed synovium.

Goals of Surgery

The general goals of any surgical intervention are to return the patient to a regular diet, with some limitations, and to establish an adequate functional range of motion. Each patient's complaints must be individually analyzed, and specific outcomes set for the operation. Postoperatively the surgeon should evaluate the patient's response to therapy according to whether the patient feels there has been a total eradication, significant reduction, or minimal reduction of his or her complaints, or no change or worsening of the condition. It is unreasonable for the surgeon to evaluate the results

of an operation on the basis of attainment of a finite mouth opening. Many patients are quite satisfied with reductions in their mouth opening as long as their facial pain is relieved. The goals for all surgical procedures should include preservation of articular tissue to permit normalization and regeneration of synovium, and a restoration of the articular relations to permit the joint structures to adapt and function through an adequate range of motion. The remodeled disk is only one element of the degenerative process. Joint function may be asymptomatic and satisfactory in the presence of various types of internal derangement. Thus, surgically returning a displaced disk to the ideal position found in a healthy joint may not be appropriate for an individual patient. To illustrate this point, one would not reposition a disk in a joint in which the articular tissue is so severely damaged that it is incapable of healing. In this situation removing the disk is recommended. Repositioning the disk is recommended in the patient with minimal changes in the joint structures, in whom symptoms have persisted despite nonsurgical and arthroscopic intervention. As indicated above, this condition is indeed rare.

Additional magnetic resonance and arthroscopic information about the structure and function of the joint in health and disease is needed to establish reliable indicators and predictors of surgical outcome.

Surgical Approaches

The classic surgical approaches to the TMJ may be classified as preauricular, endaural, and postauricular. The choice of approach is usually a matter of surgeon's preference and is based on his or her ability and experience. Cosmetic considerations may also influence the choice of approach.

Surgical Anatomic Considerations

Anterior to the auricle, the auricularis anterior and superior muscles overlie the

superficial temporalis fascia and the temporalis fascia. These muscles are incised in the classic preauricular and endaural approaches. The fascia superficial to the muscles is thin and a dull white. This layer is confluent with the galea aponeurotica above and the parotideomasseteric fascia below. The temporalis fascia is a tough fibrous connective tissue structure, substantially thicker than the overlying superficial fascia. It is stark white and extends from the superior temporal line of the temporal bone to the zygomatic arch. The deep surface furnishes one of the origins of the temporalis muscle. Inferiorly, at a variable distance, the fascia splits into two well-defined layers (Figure 50-2). The outer layer attaches to the

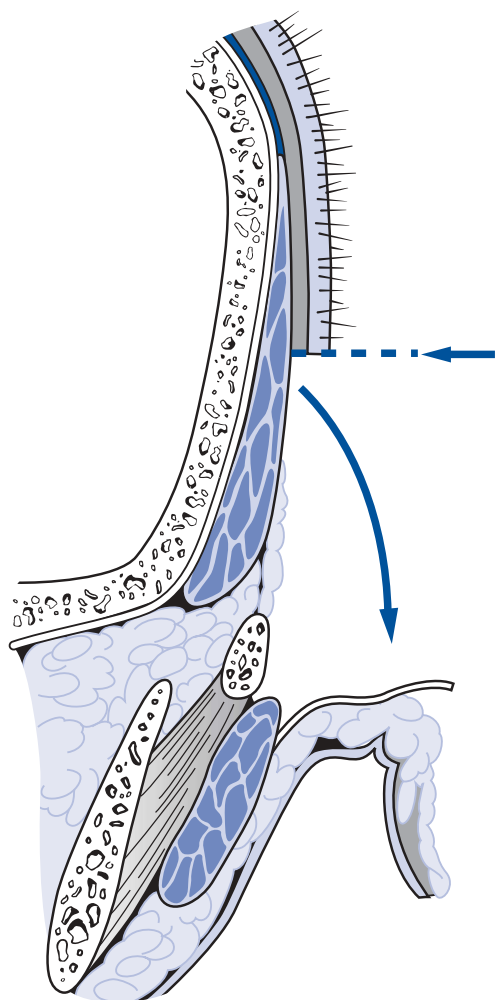


FIGURE 50-2 Coronal section at the level of the zygomatic arch. Two well-defined layers of temporalis fascia are noted (arrows).

lateral margin of the superior border of the zygomatic arch, and the inner layer to the medial margin. A small quantity of fat, the zygomatico-orbital branch of the temporal artery, and zygomaticotemporal branch of the maxillary nerve are located between the fascial layers. The splitting of the fascial layers is most noticeable at the level of the zygomatic arch. Posteriorly, superior to the glenoid fossa, the separation is not as well-defined (Figure 50-3).

The superficial temporal vessels are typically located in the superficial fascia below the auricularis anterior muscle. The vessels are often visible, invested in the superficial fascia without incising the muscle. The superficial temporal vein lies posterior to the artery and the auriculotemporal nerve immediately behind the vessels. The superficial temporal vessels and auriculotemporal nerve appear to take on a horizontal course once the flap is fully developed and reflected anteroinferiorly.²

Numerous authors have studied the facial nerve's anatomic relations to determine clinically applicable landmarks for its main trunk, temporofacial division, and temporal branches. Al-Kayat and Bramley noted that the facial nerve bifurcated into temporofacial and cervicofacial components within 2.3 cm (range 1.5–2.8 cm) inferior to the lowest concavity of the bony external auditory canal and within 3.0 cm (range 2.4–3.5 cm) in an inferoposterior direction from the postglenoid tubercle.³ The temporal nerve branches lie closest to the joint and are the most commonly injured branches during surgery. These nerves are located in a condensation of superficial fascia, temporalis fascia, and periosteum as they cross the zygomatic arch. The most posterior temporal branches lie anteriorly to the postglenoid tubercle. Their location was measured by Al-Kayat and Bramley as 3.5 ± 0.8 cm from the anterior margin of the bony external auditory canal (Figure 50-4).³

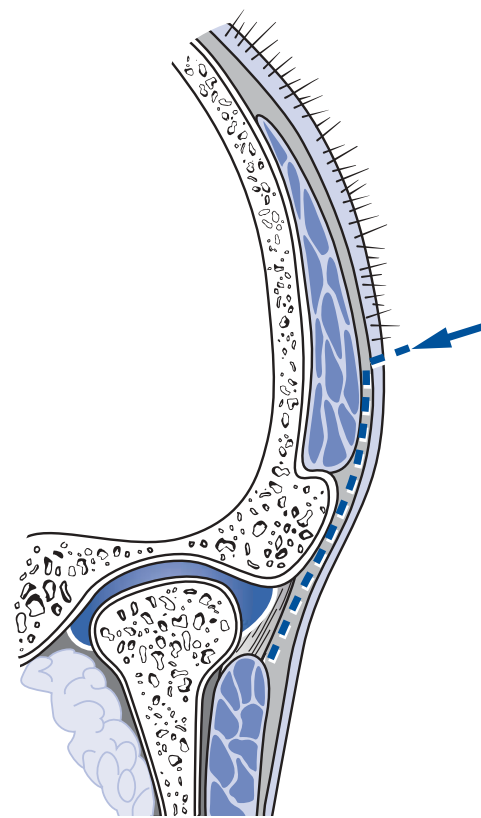


FIGURE 50-3 Coronal section at the level of the glenoid fossa. The splitting of the temporalis fascia is not as well-defined (broken line).

Thus, the two potential sources of facial nerve injury are dissection anterior to the posterior glenoid tubercle where the temporal branches cross the arch, and aggressive retraction at the inferior margin of the flap where the main trunk and temporofacial division are located.

Preauricular Approach

Historically, a myriad of preauricular incisions have been proposed. Many of the earlier designs afforded good access but increased the risk of facial nerve injury and compromised esthetics. The preauricular incisions used today are essentially modifications of the Blair curvilinear or inverted-L incision.⁴ This approach has become the favorite chosen by oral and maxillofacial surgeons. The technique is an incision commencing from within the temporal hairline and extending inferiorly

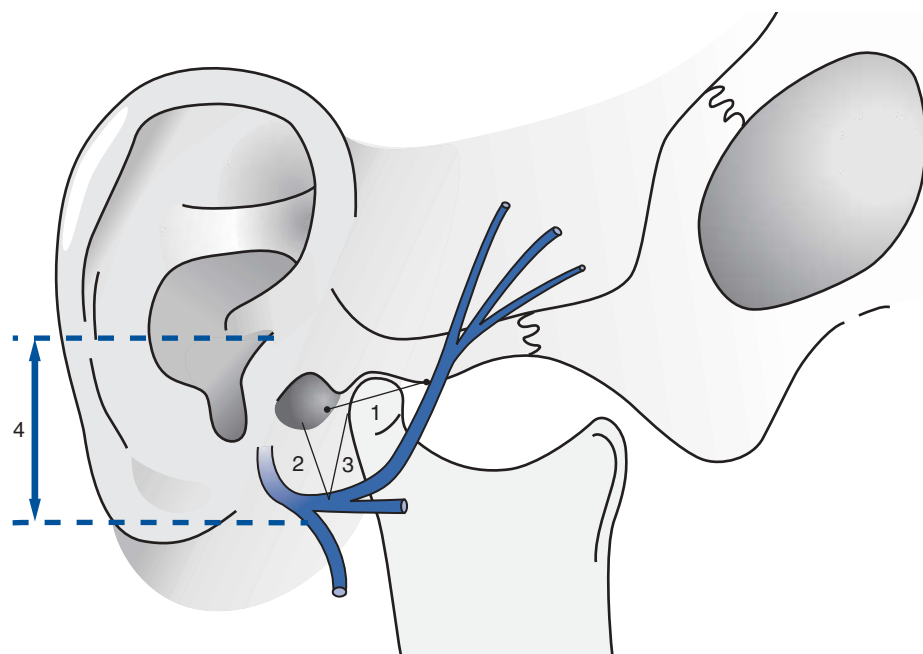


FIGURE 50-4 Landmarks for the location of the temporal branches and main trunk of the facial nerve: (1) the distance between the anterior margin concavity of the meatus to the zygomatic arch (3.5 ± 0.8 cm); (2) the distance between the inferior margin of the meatus to the trunk (2.3 ± 0.28 cm); (3) the distance between the postglenoid tubercle to the main trunk (3.0 ± 0.31 cm); (4) the distance from the tragus to the facial nerve trunk is variable.

into a preauricular crease immediately anterior to the auricle. The exact length and decision to incorporate an anterior temporal extension are governed largely by the nature of the surgical procedure. For some surgeons, the approach for diskectomy requires a smaller incision than that for diskoplasty.

The incision is approximately 3 to 4 cm in length and consists of two limbs: a small superior curved limb (1–2 cm) and an inferior vertical limb anterior to the tragus (variable distance approximately 1–2 cm) (Figure 50-5). The junction of these limbs is the site of attachment of the superior aspect of the helix to the temporal tissue. The extent of the superior limb of the preauricular incision is dictated by the amount of access required, which may not be determined until the dissection has reached the lateral TMJ ligament and capsule. The incision is usually not extended as inferiorly as the lobule of the ear.

The incision should be placed posteriorly to the superficial temporal vessels

and auriculotemporal nerve and within a preauricular crease. The skin and subcutaneous tissues are incised the length of the entire incision. The deeper dissection is begun in the temporal region by sharply dissecting progressively through the auricularis anterior and superficial



FIGURE 50-5 Preauricular incision.

fascial layers to the stark white temporalis fascia (Figure 50-6). A retractor is placed on the anterior flap, and tension is applied in a forward direction. The dissection over the zygomatic arch is addressed. The anatomic layers in this region are usually not clearly defined. There is a condensation of tissues consisting variably of the auricularis interior, superficial fascia, temporalis fascia, periosteum, and occasionally cartilage. This tissue is incised to the level of fibrous connective tissue. A retractor is placed in the incision opposite the tragus, and forward traction is applied to the flap. This results in the definition of a cleft between the perichondrium and cartilage of the external auditory canal and the parotidomasseteric fascia. The perichondrium is followed medially with sharp dissection (Figure 50-7). Care should be exercised not to proceed perpendicularly to the skin surface, as the external auditory canal inclines anteromedially at approximately 45° to the surface. The dissection is continued along the outer surface of the external auditory

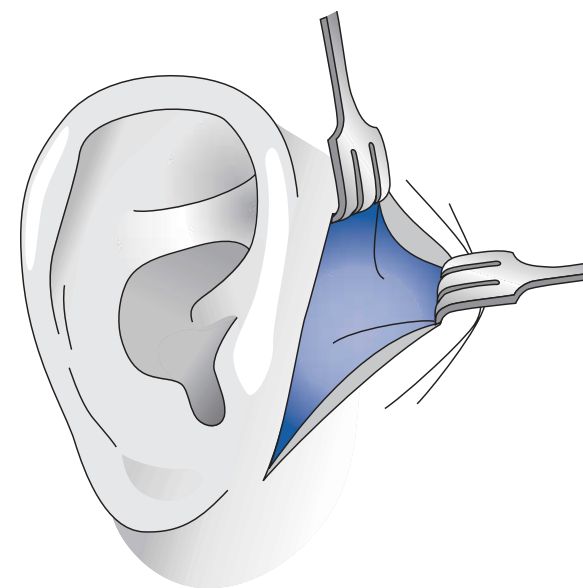


FIGURE 50-6 The preauricular incision has been carried sharply through the skin, subcutaneous tissue, superficial temporal fascia, auricularis anterior and superior, and outer layers of the temporal fascia. The flap is reflected anteroinferiorly, revealing the inner layer of the temporal fascia.

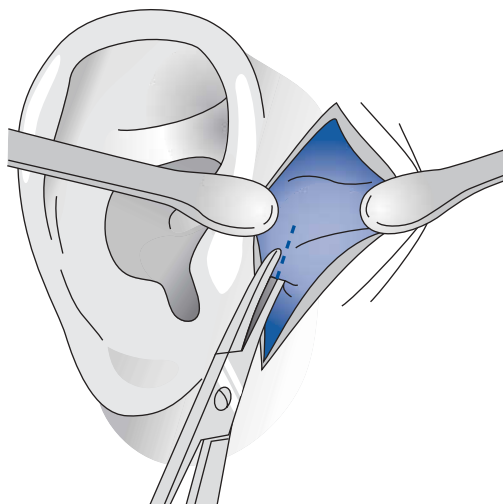


FIGURE 50-7 The parotidomasseteric fascia is sharply dissected from the perichondrium of the external auditory canal (broken line).

canal until the lateral TMJ ligament is reached.

When the condyle and its overlying temporomandibular ligament are palpated, the flap is reflected inferiorly and anteriorly forward with a combination of sharp

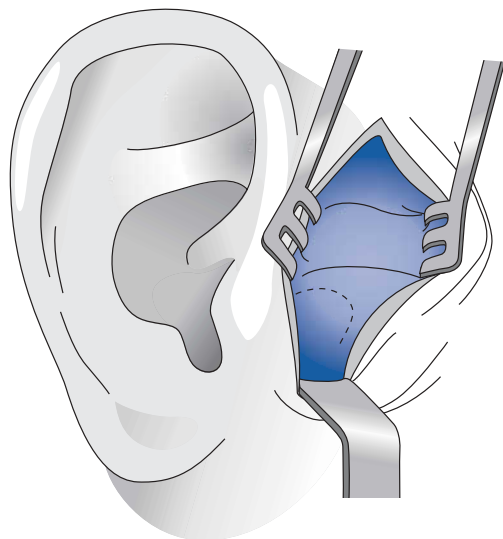

FIGURE 50-8 Retraction is accomplished by using a self-retaining retractor positioned between the external auditory canal and flap and a right-angle retractor at the inferior portion of the flap. The condyle (dotted line) is noted under the lateral TMJ ligament and/or simply the lateral capsule depending on the depth of the reflection.

and blunt dissections. Scissors may be used to cut some fascial attachments to the lateral TMJ ligament. The blades of the scissors are held parallel to the ligament to ensure that the joint is not violated. The flap is reflected as far forward as the midportion of the anterior tubercle. The surgeon can now see the bulging of the lateral pole of the condyle under cover of the lateral ligament and capsule. Gentle manipulation of the jaw to cause movement of the condyle helps to orient the surgeon. The deep surface of the flap and the tissues overlying the zygomatic arch may be touched with a nerve stimulator to ascertain the location of the facial nerve. Retraction is accomplished using a self-retaining retractor (eg, cerebellar Weitlaner or a Dolwick-Reich) placed between the flap and the perichondrium. A small right-angled retractor may be placed at the inferior portion of the flap (Figure 50-8).

Endaural Approach

Rongetti described a modification of Lempert's endaural approach to the mastoid process for surgical improvement of otosclerosis, for approaching the TMJ.^{5,6} The endaural incisions employed today either incorporate the anterior wall of the external auditory canal, or the tragus, or simply the skin overlying the mental aspect of the tragus (Figure 50-9).

The incision begins well within the external auditory meatus at the superior mental wall. At this level the incision is made down to the bone and extended in a curvilinear fashion upward hugging the anterior helix (see Figure 50-9). It becomes less penetrating as it approaches the superior surface, ending at about the level of the inferior tragus. The incision is deepened to the level of the temporalis fascia. The incision is now continued inferiorly, with the knife in continuous contact with the tympanic plate, to make a semi-circular incision to the inferior point of the meatus. The incision is then continued

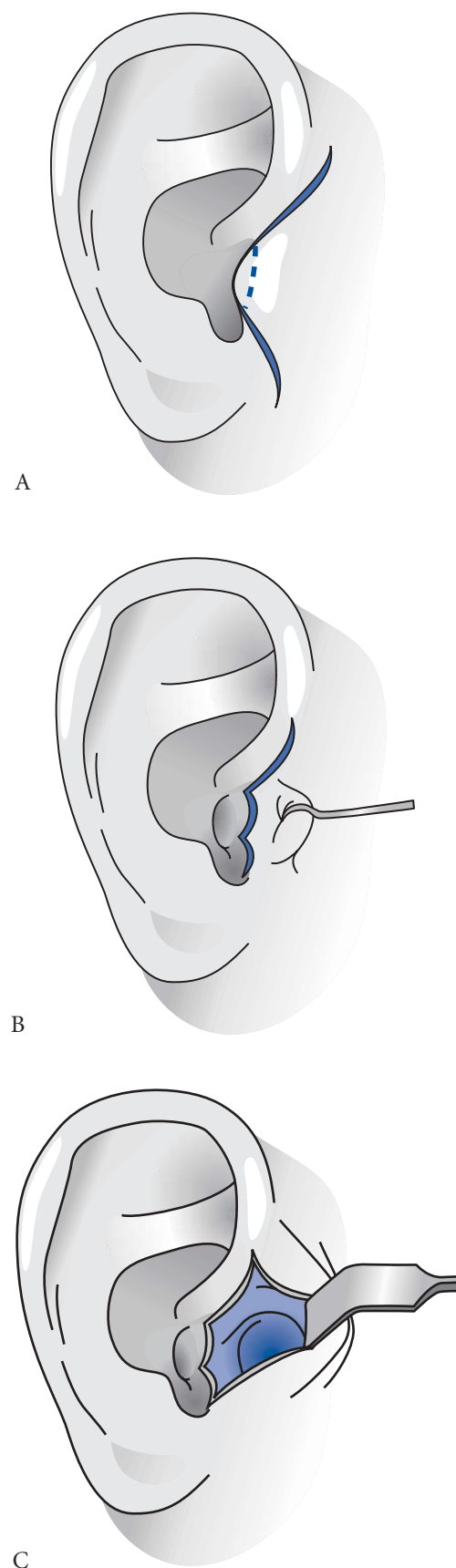


FIGURE 50-9 A–C, Endaural approach according to J. R. Rongetti. Adapted from Rongetti JR.⁵

anteroinferiorly to fall into the incisura intertragica, ending just before it approaches the surface. The application of forward traction on the inner aspect of the tragus assists the surgeon in completing the incision. Sharp dissection is carried deeply for some distance along the perichondrium. The flap is then reflected en masse anteroinferiorly off the lateral capsule and ligament.

The advantages of this incision lie in its excellent access to the lateral and posterior aspects of the joint, good exposure of the anterior aspect, and its esthetic value. The access afforded through this approach is equal to that obtained through the preauricular approach. Disadvantages lie in the potential for perichondritis and an esthetic compromise if tragal projection is lost.

Postauricular Approach

In the postauricular approach the incision is made posterior to the ear and involves the sectioning of the external auditory meatus.⁷ Excellent posterolateral exposure is afforded with this technique. The flap, once reflected, contains the entire auricle and superficial lobe of the parotid gland. A perimeatal approach combining the preauricular and postauricular incisions has also been described.^{8,9}

The incision in the postauricular approach begins near the superior aspect of the external pinna and is extended to the tip of the mastoid process. The superior portion may be extended obliquely into the hairline for additional exposure. The incision is made 3 to 5 mm parallel and posterior to the postauricular flexure (Figure 50-10). The dissection is performed through the posterior auricular muscle to the level of the mastoid fascia, which is contiguous with the temporalis fascia. A combination of blunt and sharp dissections is used to isolate the cartilaginous portion of the external auditory canal. A blunt instrument is placed in the external auditory canal to assist in the




FIGURE 50-10 Postauricular approach. The incision is placed 3 to 5 mm parallel and posterior to the postauricular flexure.

transection of the external auditory canal. The transection may be partial or complete, depending on the need for exposure. The incision should leave 3 to 4 mm of cartilage on the medial aspect to permit adequate reapproximation of the canal (Figure 50-11). This technique helps to prevent meatal stenosis. The incision is carried through the outer layer of the temporalis fascia, continuing inferiorly, reflecting the parotidomasseteric fascia off the zygomatic arch and lateral TMJ ligament (Figure 50-12). A self-retaining retractor is used to maintain exposure. The advantages of the postauricular approach lie in the predictability of the anatomic exposure. Dissection to the joint is rapid with minimal bleeding. The approach offers an alternative for a patient who has had previous procedures in this region. This approach may not be desirable in the patient susceptible to keloid formation, owing to the potential for a keloid to develop in the meatus. Meatal atresia has been reported with this technique.¹⁰ The risk of facial nerve injury is not eliminated. Paresthesia in the area of the posterior aspect of the auricle usually occurs and lasts 3 to 4 months.

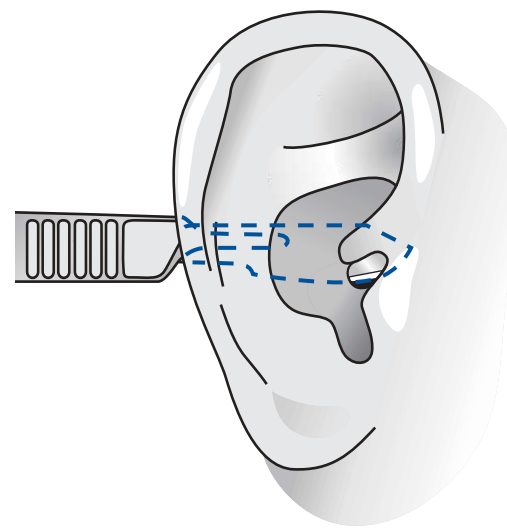


FIGURE 50-11 The external auditory canal is sectioned, leaving 3 to 4 mm of cartilage on the medial aspect to assist reapproximation of the canal.

Capsular Incisions

Horizontal Incision Over the Lateral Rim of the Glenoid Fossa The lateral ligament, capsule, and periosteum are reflected inferiorly en masse. Diskal or posterior attachment connections, or both, to the lateral capsule are dissected sharply with scissors to the level of the condylar neck (Figure 50-13A). Posterior dissection is performed diligently to avoid severing the retrodiskal tissue. This portion of the dissection exposes the superior joint space (Figure 50-13B). A Freer septum elevator

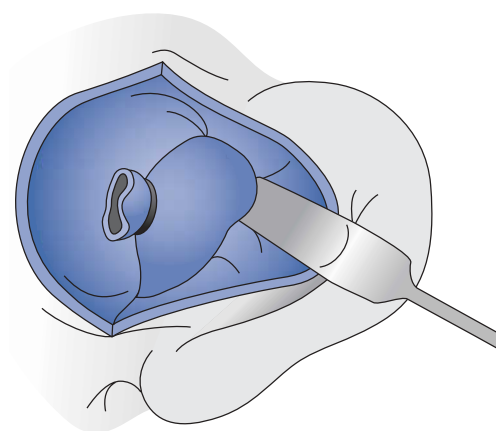


FIGURE 50-12 The external auditory canal has been sectioned and the flap retracted forward.

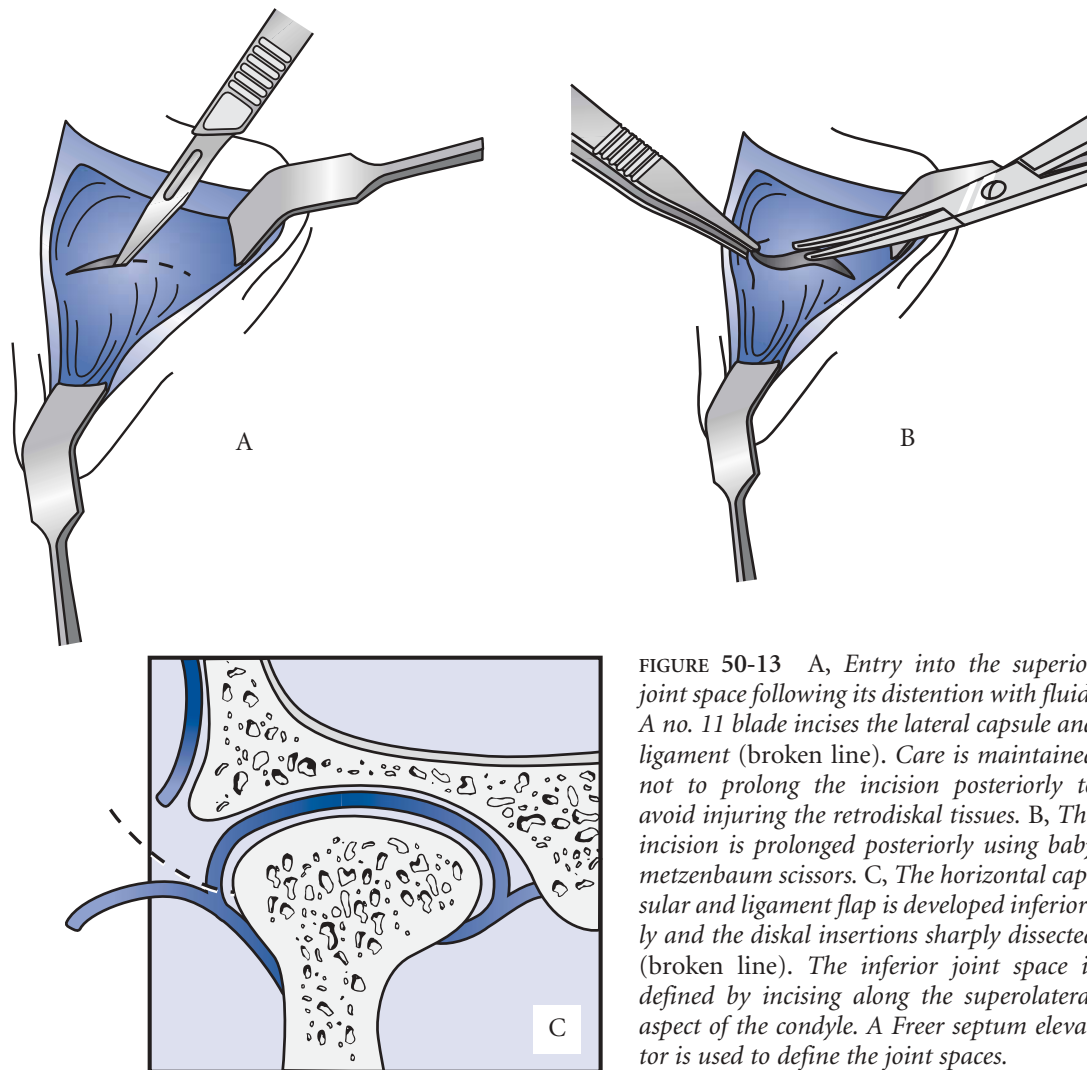


FIGURE 50-13 A, Entry into the superior joint space following its distention with fluid. A no. 11 blade incises the lateral capsule and ligament (broken line). Care is maintained not to prolong the incision posteriorly to avoid injuring the retrodiskal tissues. B, The incision is prolonged posteriorly using baby metzenbaum scissors. C, The horizontal capsular and ligament flap is developed inferiorly and the diskal insertions sharply dissected (broken line). The inferior joint space is defined by incising along the superolateral aspect of the condyle. A Freer septum elevator is used to define the joint spaces.

may be used to define and explore the space. The posterior attachment and disk attachments are then severed sharply at the lateral pole of the condyle from within the developed flap. The Freer septum elevator is used to reflect the posterior attachment and disk superiorly off the head of the condyle to expose the inferior joint space. A periosteal elevator may be used to stretch the capsule and lateral ligament flap outward to form a pocket (Figure 50-13C).

There is a risk of reflecting the fibrous connective tissue that lines the glenoid fossa when this approach is used (Figure 50-14A). The surgeon may form the incorrect assumption that he or she is stripping adhesions from the temporal bone while defining the space. The result may be a

partial or total synovectomy of the superior joint space. Prearthrotomy arthroscopic examinations have alerted clinicians to this error. The ability of the pathologic joint to regenerate this synovium and fibrous connective tissue layer has not been determined.

Horizontal Incision Below the Lateral Rim of the Glenoid Fossa A no. 11 blade may be used to puncture into the superior joint space at the level of the lateral diskocapsular sulcus (Figure 50-14B). The opening is then lengthened anteriorly and posteriorly using sharp-pointed scissors. A dissection technique, similar to that described in the foregoing approach, is used to define the superior joint space. A

dissection is then carried inferiorly removing the attachment of the capsule to the disk and exposing the inferior joint space. There is less risk of injury to the retrodiskal tissue with this approach; the risk to the fibrocartilage is also reduced. This is the approach I favor.

Horizontal Incisions Above and Below the Disk The horizontal approach above and below the disk (Figure 50-14C) leaves some of the capsule and ligament attached to the disk or remodeled retrodiskal tissue.

L-Shaped Incision A horizontal incision is made at or below the lateral rim of the glenoid fossa. The horizontal incision is then joined by either an anterior (Figure 50-14D) or posterior (Figure 50-14E) vertical extension. The posterior vertical incision carries the risk of severing the retrodiskal tissue. The anterior vertical incision should not be placed farther anteriorly than the tubercle to avoid injury to the facial nerve. The capsule and ligament are then reflected either anteroinferiorly or posteroinferiorly.

T-Shaped Incision A horizontal incision is joined by a vertical incision to create a T-shaped incision over the midportion of the glenoid fossa (Figure 50-14F).

Cross-Hair Incision Dissection of the posterior attachment of the lateral ligament and capsule may be tedious with the cross-hair incision (Figure 50-14G).

Open-Sky Incision In the open-sky incision two horizontal incisions are joined by a central vertical incision (Figure 50-14H).

Vertical Incision After a vertical incision is made, the capsular flaps are reflected anteriorly and posteriorly to expose the posterior attachment and disk (Figure 50-14I). Closure of the capsule is often difficult to attain following open surgical procedures. When diagnostic arthroscopy precedes the

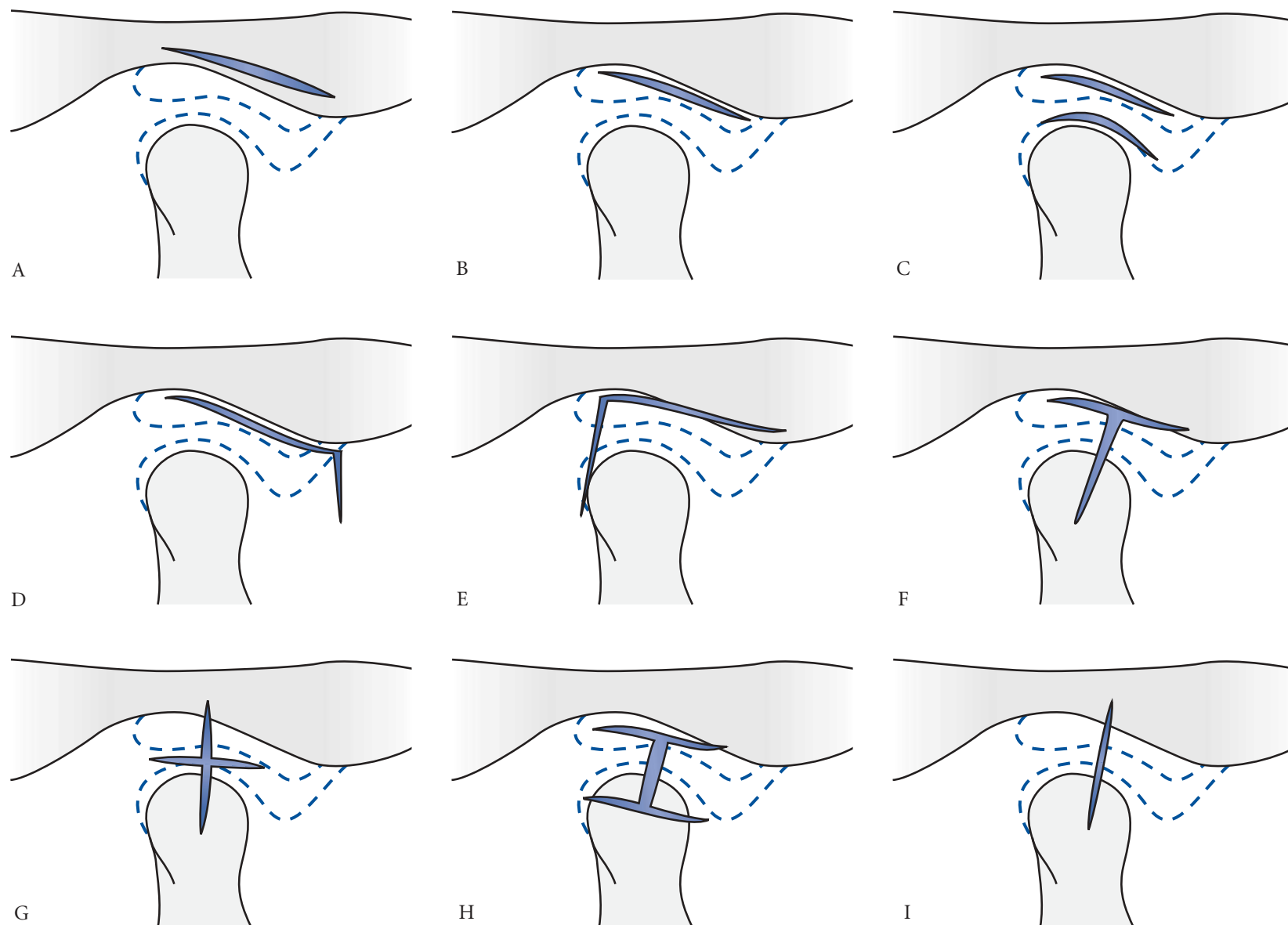


FIGURE 50-14 Capsular incision designs: A, horizontal incision over the lateral rim of the glenoid fossa; B, horizontal incision below the lateral rim of the glenoid fossa; C, horizontal incisions above and below the disk; D and E, L-shaped incision; F, T-shaped incision; G, cross-hair incision; H, open-sky incision; I, vertical incision. The lateral pole of the condyle and lateral aspect of the remodeled posterior attachment (broken lines) are illustrated.

arthrotomy, the inflow and outflow ports violate the capsule, making watertight closure extremely difficult. Support for the lateral ligament can be obtained by raising a temporalis muscle and fascia flap, about 2 cm in length, pedicled inferiorly, and rotated inferiorly over the lateral rim of the glenoid fossa and sutured to the lateral capsular tissue. The pedicle stabilizes the flap but has not been shown to contain nutrient vessels. Closure of the capsule may not be critical to the success of the

discectomy procedure, and in some cases the closure may restrict mandibular motion.^{11,12} However, closure of the capsule and ligament after disk repositioning lends stability to the diskorrhaphy.

Operative Procedures

A concerted comparative evaluation of different surgical techniques is difficult because for many years there was no uniform set of criteria for selection of patients or compilation and evaluation of results.

Criteria and guidelines for disk surgery were initially developed in 1984 by the American Association of Oral and Maxillofacial Surgeons (AAOMS).¹³ The criteria were established through a literature review and consensus. In 1990 a standards and criteria document was published by the AAOMS.¹⁴ The document established indications for surgery, identified markers for favorable and unfavorable results, and outlined risk factors. These publications have laid the groundwork for peer review.

Disk-Repositioning Procedures

The goal of disk-repositioning procedures is to relocate the disk so that its posterior band can be returned to the normal condyle-disk-fossa relationship. Essentially, the repositioning places the posterior band over the superior or superoanterior surface of the condyle. This repositioning is accomplished by one of three procedures: plication in which the remodeled posterior attachment is folded on itself and the lateral tissues are approximated (Figure 50-15); full-thickness excision in which a wedge-shaped portion of the posterior attachment is removed and the lateroposterior tissues are approximated (Figure 50-16); or partial-thickness excision in which the superior lamina of the retrodiskal tissue and posterior attachment are removed, without violation of the inferior joint space, and the lateroposterior tissues are approximated (Figure 50-17).

When the disk displaces, the pathologic changes are not seen uniformly throughout the entire lateromedial extent of the joint. Typically, the medially displaced disk must be rotated posterolaterally to achieve a correct condyle-disk-fossa relation; therefore, a greater amount of tissue is pliated or excised laterally rather than medially. Rarely, the disk may be displaced in the lateral direction, in which event the reverse would be true.

The technical improvements in TMJ arthrography in the 1970s stimulated interest in correcting disturbances in the condyle-disk-fossa relations,¹⁵ and the

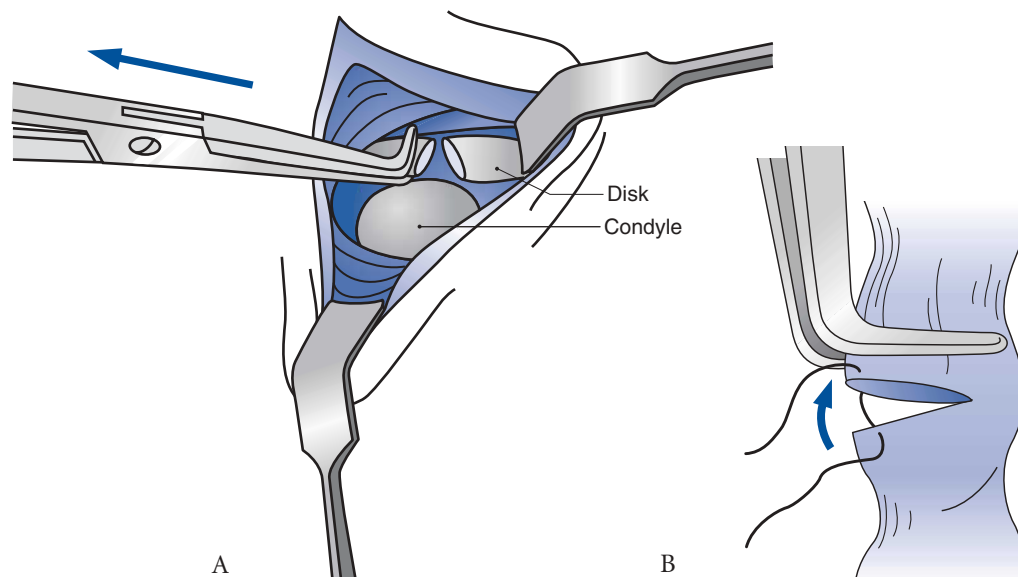


FIGURE 50-16 Disk repositioning achieved through a full-thickness excision of the posterior attachment. Retention of disk position is through sutures placed on posterior and lateral margins. A, A clamp has been placed over the posterior attachment. The arrow represents the direction of pull of the clamp to complete the incision and reveal the condylar surface. B, View from above demonstrating the wedge-shaped resection (arrow indicates the direction of closure).

concept that disk repair procedures were a viable answer to many cases of TMJ dysfunction was re-introduced.¹⁶ Reports on the outcome of disk repair procedures have indicated an 80% or greater success rate.¹⁷⁻¹⁹ The latter assumes an accurate diagnosis has been made. Surgeon diagnostic acumen has evolved with time. Although the results of the procedures may have been good in the 1980s, readers must be cautious as the indications for performing the procedure have changed and hence the outcomes may be misleading given the new subset of surgical candidates.

The histologic basis for performing surgery within vascular retrodiskal tissue was described in animals by Wallace and Laskin and by Zeitler and colleagues.^{20,21} Synoviocytes play an important role in the healing process. Stimulated by inflammation, synoviocytes proliferate and migrate to fill the surgically created gap in the tissues.²²⁻²⁴ The synoviocytes produce ground substance and collagen fibers and phagocytose the debris. The degree of tissue vascularity and the distance from capsular and synovial vasculature have also been described as important factors in the healing process.^{25,26}

Extrapolations to the clinical situation must be made from these results as an animal model for TMJ pathology is lacking. In the human, variable decreases in the vascularity of the remodeled posterior attachment are believed to occur with an increasing duration of displacement and load. The disk-repositioning techniques thus involve a repair in the pathologic remodeled retrodiskal tissue with a variable degree of vascularity. The primary source of nourishment to the repositioned

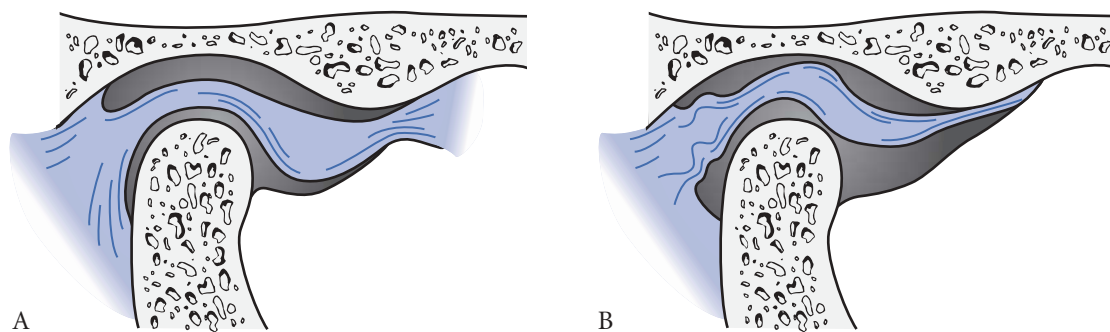


FIGURE 50-15 Disk repositioning achieved through plication of the posterior attachment. Retention of disk position is through sutures to the lateral capsule ligament. A, Preoperative location. B, Postoperative location.

disk appears to be through the synovium on the medial aspect of the disk and posterior recesses of the joint spaces. Thus, a critical aspect of the successful surgical repair in the retrodiskal tissue appears to be the rapid migration of synoviocytes to the area of the surgical repair. Smith and Walters followed up 12 patients for 1 year and reported success suturing tears in the avascular portion of the disk.²⁷ Others, however, have reported that suturing anything but vascularized tissue results in failure of the repair.^{20,28}

With an increasing displacement of the disk, the retrodiskal tissue comes into contact with the condyle and sustains increasing loading. The loading results in decreased vascularity of the retrodiskal tissue. With the reduction in retrodiskal tissue vascularity, this tissue becomes transformed into a pseudodisk. MRI of chronically displaced retrodiskal tissues demonstrates a signal intensity of the tis-

sue that resembles the disk. In fact, radiologists may inaccurately describe a disk fragmentation because only a portion of the displaced disk may display its original signal intensity. The remainder, owing to alterations in the glycoprotein distribution and hence the attraction of water, demonstrate a moderate signal intensity. With increasing displacement of the disk, the superior joint space does not accommodate for the increase in length of the retrodiskal tissue. Rather, the disk undergoes atrophy, deformation (buckling), and absorption into the anterior capsule. These changes can make anatomic repositioning of the disk impossible.

Disk repositioning without diskoplasty is indicated in the following instances:

- There is minimal disk displacement
- The disk is of near-normal length
- The disk structure is near normal (bow-tie)

The rationale behind repositioning is founded on the belief that the disease process is reversible or can be halted by normalizing the position of the disk. In addition, removal of the posterior attachment overlying the condyle is intended to remove a source of localized inflammation. The repositioned disk facilitates movement of the condyle previously blocked by the displaced disk, provides joint stabilization, and improves articular cartilage nutrition and lubrication. Moreover, the rationale is that the workload of the masticatory muscles is reduced when the obstructing disk is repositioned.

Before performing disk-repositioning procedures in patients with satisfactory disk morphology, adequate trials of nonsurgical therapy should be undertaken to determine whether the patient can be made symptom free despite disk displacement. In 1989, reports were published demonstrating, by postarthroscopic MRI, persistent disk displacement despite the resolution of pain and increase in mandibular mobility.^{29,30} These reports,

and the appearance of anterior disk displacement in patients without any history of TMJ symptoms, support the execution of nonsurgical therapy prior to deciding whether it is necessary to perform disk-repositioning surgery.

Deformation of the disk in all planes is an important feature to recognize when planning a repositioning procedure. When a bulge-shaped disk is of appropriate length and can be repositioned, a diskoplasty may be performed to minimize the change in the occlusion.³¹ It has been reported that during function, the fiber arrangement and proteoglycan distribution of the repositioned disk change to those of a normal disk and that diskoplasty therefore would be unnecessary.³² More evidence is still required to substantiate these changes.

In general, the limiting factor to disk repositioning is the degree of lateral disk atrophy or resorption. Despite severe lateral atrophy, the most medial aspect of the disk may have a normal length and shape (Figure 50-18). Disk shortening may preclude disk repositioning without an extensive release of the anterolateral disk attachments, calling into question the procedure of repositioning.

Disk Repositioning and Diskoplasty A rosette-shaped disposable orthopedic meniscus knife, typically used for orthopedic arthroscopic procedures, is used to effect a release of the disk from its most anterior and lateral attachments (Figure 50-19). This is accomplished by gently prodding the knife along the inside perimeter of the capsule (Figure 50-20). As the dissection is performed under cover of the capsule, there is no danger of injuring the facial nerve. Disk mobility is evaluated by applying posterolateral traction with a forceps (Figure 50-21). A DeBakey bulldog vascular clamp is inserted to the medial limit of the posterior attachment and guided posteriorly as far as possible in the glenoid fossa (see Figure 50-20B). The

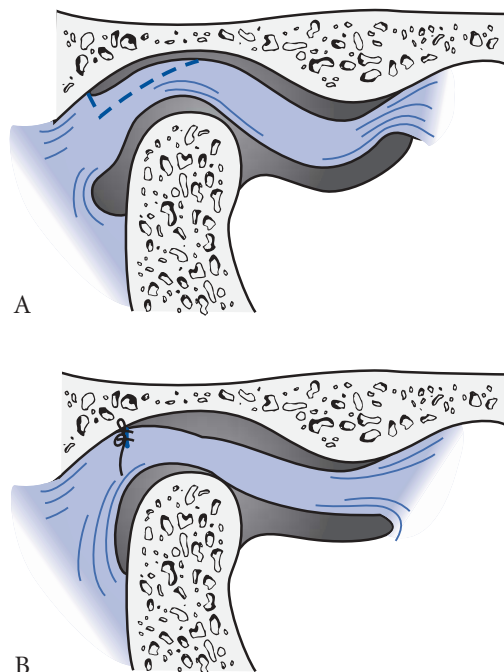


FIGURE 50-17 Disk repositioning achieved through a partial-thickness excision of the superior lamina of the retrodiskal tissue. The inferior joint space is not violated. A, Outline of a partial-thickness excision of the superior lamina. B, Excision is closed, resulting in posterior repositioning of the disk.

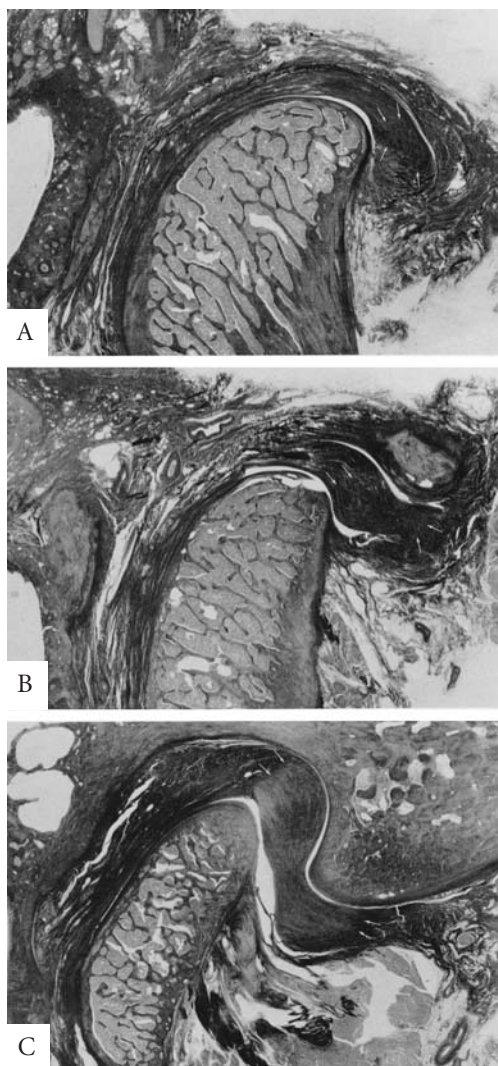


FIGURE 50-18 A series of sagittal histologic sections through a joint, demonstrating partial disk displacement. Note the change in disk length and morphology as one moves from lateral (A) to medial (C) (hematoxylin eosin stain; macroscopic section).

clamp greatly assists in the control of hemorrhage from the retrodiskal tissue, stabilization of the posterior attachment during tissue excision, and stabilization of the posterior attachment during suturing.³³ The design of the instrument minimizes tissue damage. A wedge of remodeled posterior attachment is excised, leaving a 1 mm margin anterior to the beaks of the clamp. This permits suturing of the disk to the retrodiskal tissue without removal of the clamp. Range of motion is then verified. Tissue forceps are used to stabilize and slightly evert the disk so that the infe-

rior surface may be sculpted with meniscus knives (Figure 50-22). The tissue is closed with nonresorbable suture on an S-2 spatula needle (Figure 50-23). Once the disk has been sutured into its new position, its lateral rim is sutured to the lateral capsule ligament.

Operative difficulties with the repositioning techniques include control of hemorrhage from the retrodiskal tissue and access to the medial aspect of the fossa. Bleeding may be controlled by using the DeBakey clamp before sectioning the posterior attachment. Access to the medial aspect of the joint is greatly improved when the anterior attachment is released, permitting the surgeon to draw the disk outward posterolaterally while it remains pedicled to the medial attachment. Interestingly, the problem of access was one of the impetuses for combining disk repositioning with a condylar and/or eminential arthroplasty.

Disk Repositioning and Arthroplasty

Several operators have advocated combining an arthroplasty of the condyle or eminence with disk repositioning.^{16,32,34-36} Arthroplasty reduces the amount of posterolateral repositioning required and therefore permits repositioning of an atrophic disk (Figure 50-24). The current trend, however, is to avoid removal of any normal articular bone since the postoperative healing phase already involves some loss of bone substance, which may be additive and result in occlusal disturbances. In addition, postoperative bleeding from cut bone surfaces into the joint can result in fibrous adhesions of the disk or fibrous/bony ankylosis of the joint.

A 2 to 4 mm condylar-eminence arthroplasty procedure can be performed with rotary or hand instruments. Hand instruments such as fine chisels are preferable to avoid heat generation (Figure 50-25). Bone files should be used judiciously because, once the compact bony layer is interrupted, the trabeculae of bone can be

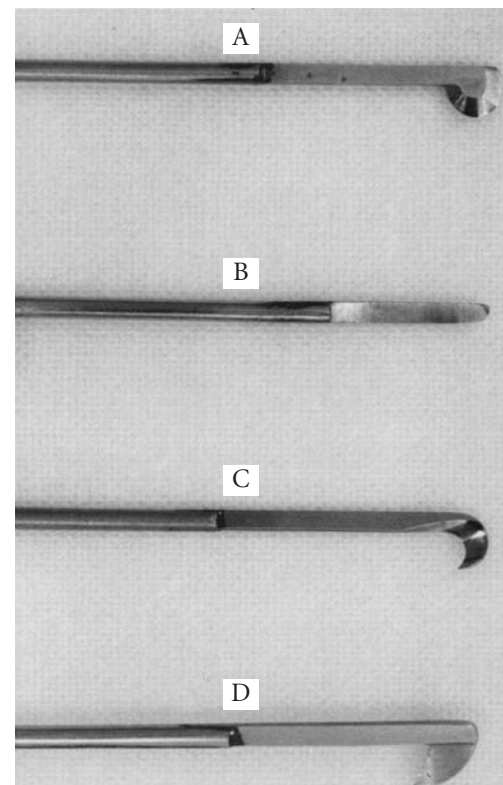


FIGURE 50-19 Orthopedic arthroscopic knives (blade handles are not illustrated): A, rosette mini-meniscus curved; B, curved (right or left available); C, sickle; D, retrograde.

easily and rapidly removed. A periosteal elevator may be used to burnish sharp edges. Care should be exercised not to exaggerate the arthroplasty in the lateral condylar regions while accessing the medial condylar region. In some cases an arthroplasty of the eminence is essentially a lateral tuberculectomy for access and decompression of the anterior recess of the superior joint space (Figure 50-26).^{36,37} Disk repositioning is then performed through the plication or excision technique. The capsule is closed in the customary fashion. Intermaxillary fixation or training elastics are used for 1 to 3 weeks to allow muscular adaptation and dental compensations to occur.

Repair of Perforated Posterior Attachment

Perforations rarely occur within the disk proper but rather within the lateral third of the remodeled posterior attachment.^{38,39}

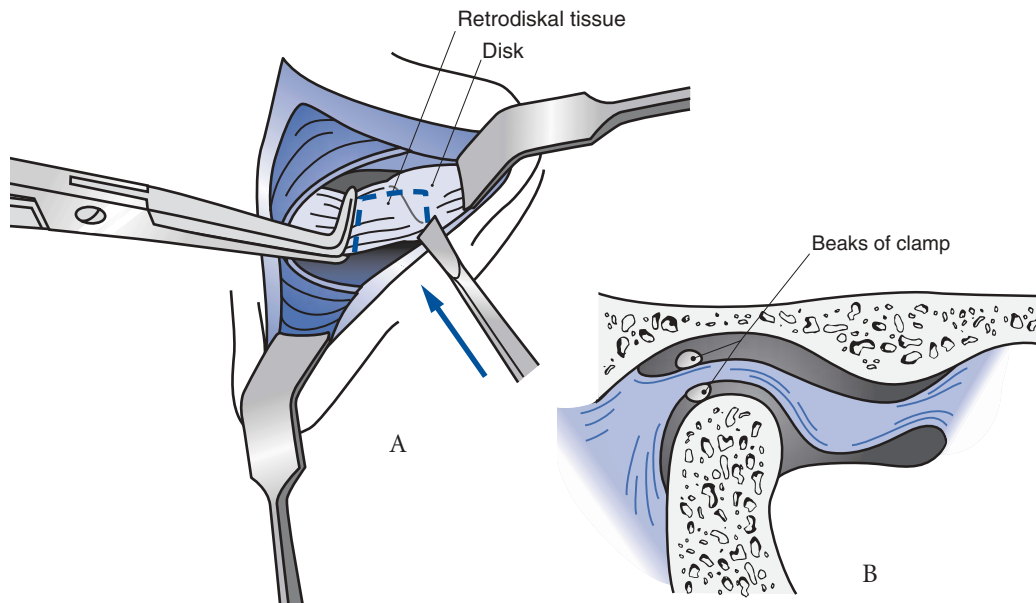


FIGURE 50-20 A, View of partially reducing disk displacement from above and slightly posterior. Note that when the medial portion of the disk is in the normal position, that portion of the disk may be preserved. Note the path of incision of the crescent-shaped mini-meniscus knife (broken line). B, Positioning of the beaks of the DeBakey clamp on retrodiskal tissue.

When the disk is perforated, it may be secondary to a developmental rather than a pathologic process. Condylar overgrowth often occurs in the areas of the perforations; therefore, an arthroplasty is frequently performed in conjunction with the pro-

cedure. The repaired remodeled retrodiskal tissue is intended to maintain the shape of the articular surface and to prevent ankylosis. Repair of a perforation without repositioning the disk is successful only if the disk is atrophied and is not an obstruction to

condylar movement. This procedure is performed rarely and only in those patients refractory to intra-articular steroid injection, arthrocentesis, or arthroscopy.

Management of Small Perforations When primary closure of a small perforation (1–3 mm) is planned, the atrophic displaced disk is repositioned posteriorly to only a minor degree. If the disk is to be fully repositioned, the margins of the perforation should be excised and the posterior attachment on the posterior edge of the disk approximated to the tympanic portion of the retrodiskal tissue. Anterolateral release of the diskal attachments is usually necessary to mobilize the disk posteriorly. The margins of the perforation are oversewn in a straight-line fashion with a nonresorbable material. The repair procedure is often performed in conjunction with an arthroplasty to reduce sharp bony spurs that may be present.

Management of Large Perforations Large perforations are usually grafted after excision of the edges. The disk is not repositioned. In many cases this procedure is a partial diskectomy (Figures 50-27 and 50-

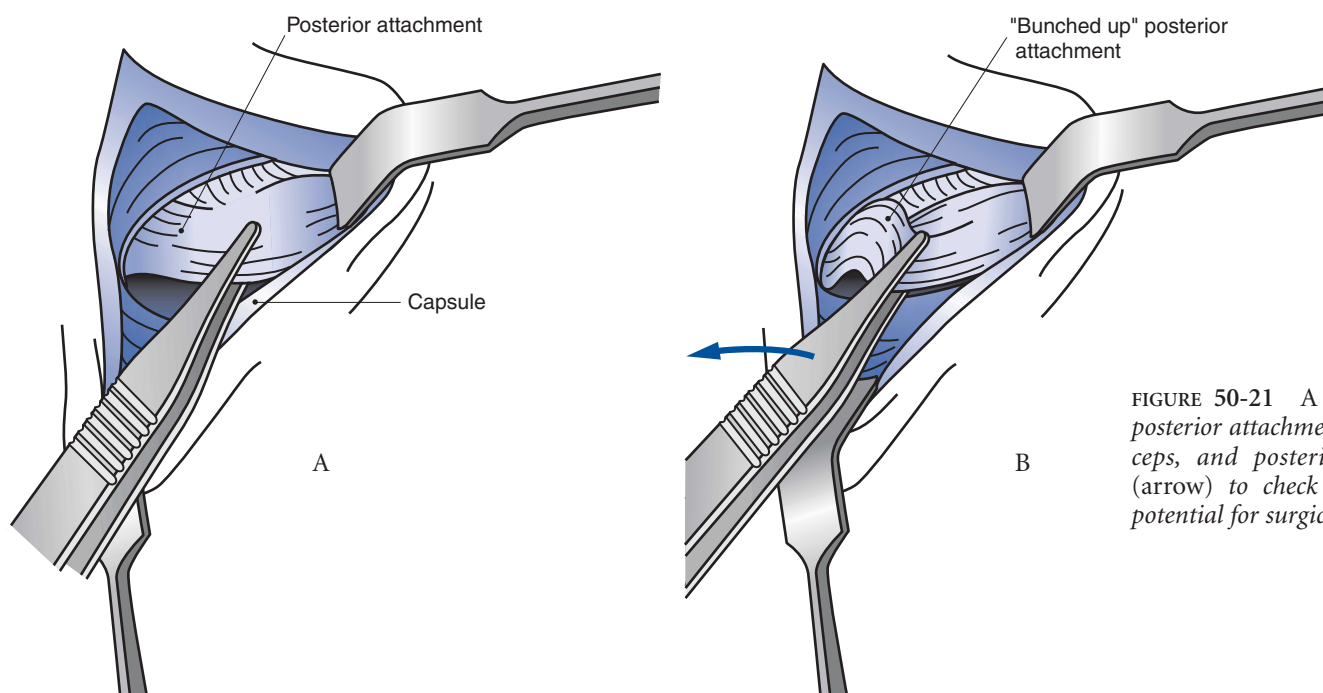


FIGURE 50-21 A and B, The pathologic posterior attachment is grasped with a forceps, and posterior traction is applied (arrow) to check disk mobility and the potential for surgical repositioning.

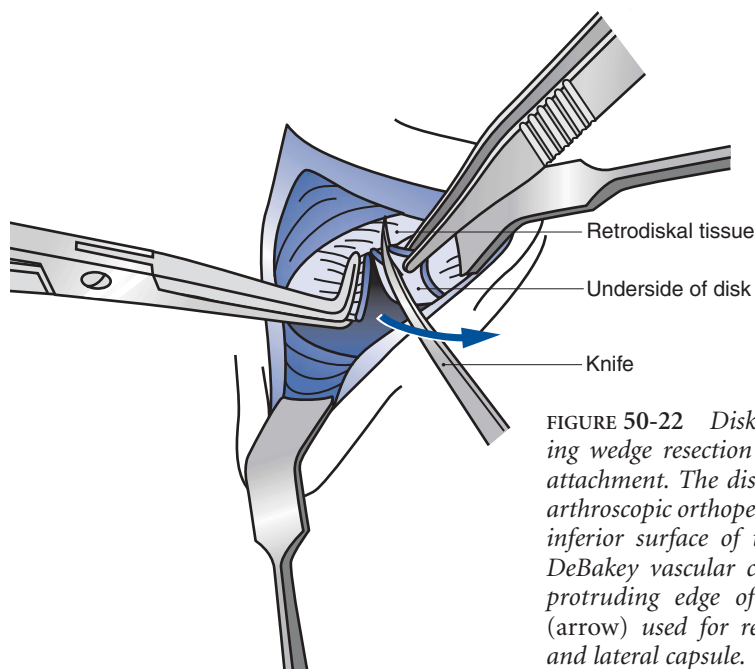


FIGURE 50-22 Diskoplasty is performed following wedge resection of the pathologic posterior attachment. The disk is slightly evened, and an arthroscopic orthopedic knife is used to sculpt the inferior surface of the bulge-shaped disk. The DeBakey vascular clamp is in place. Note the protruding edge of the posterior attachment (arrow) used for reapproximation to the disk and lateral capsule.

28). The graft material is laid over the perforation and posterior attachment. Autografts (dermal) and homografts have been used (Figure 50-29). The free edges of the graft are sutured to the underlying posterior attachment and disk. Typically, medial sutures are difficult to place. A suturing technique using an S-2 spatula or RD-1 needle is recommended.

Disk-Removal Procedures

Partial Diskectomy The partial diskectomy procedure is used to correct partial reducing disk displacement.^{12,40} The goal of the procedure is to excise the pathologic posterior attachment and that portion of the displaced atrophic/resorbed disk that represents an obstruction or is presumed to be responsible for terminal jolting. The portion of the disk that is properly positioned, usually the medial aspect of the disk, is left in place. This procedure was recently re-described under the term *disk reshaping*.⁴¹ Kondoh and colleagues reported a favorable 5-year outcome in their patients.⁴¹ The absence of portions of the TMJ disk may predispose the joint to areas of fibrous or bony ankylosis. The

postoperative import of ankylosis largely depends on the efficacy of physical therapy, the surface area affected, and ability of synovium to regenerate.

The rationale for electing to perform a partial diskectomy rather than a disk repositioning is based on the belief that those factors responsible for the initial disk displacement are often not adequately controlled or identified and thus eventually cause redisplacement of the disk. Usually osseous remodeling changes have occurred to accommodate the change in disk position. Sprinz described the histologic basis for the partial diskectomy procedure.⁴² Surgically created defects within the rabbit meniscus healed uneventfully if the defects

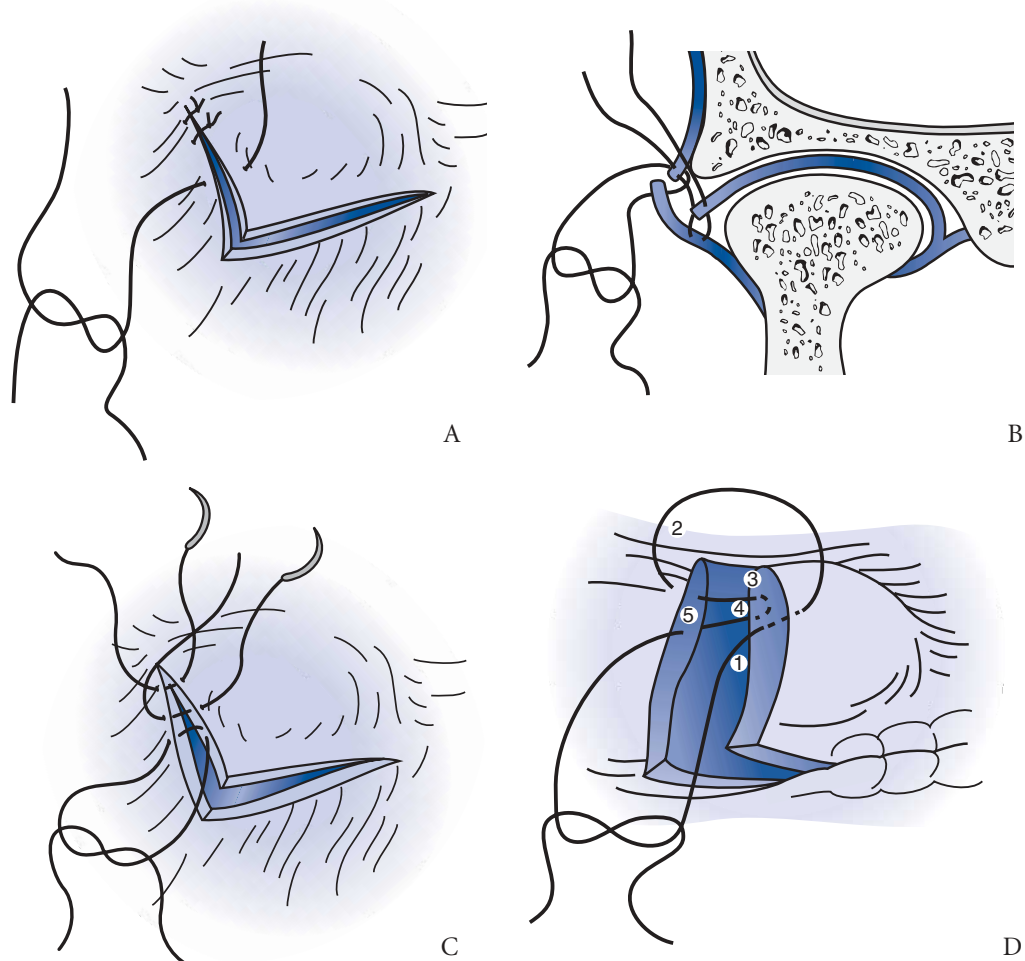


FIGURE 50-23 Disk reapproximation: A, simple posterior and lateral sutures; B, layered closure of the superior and inferior lamina; C, figure-of-8 closure; D, the order of passage of the figure-of-8 suture labeled 1 to 5.

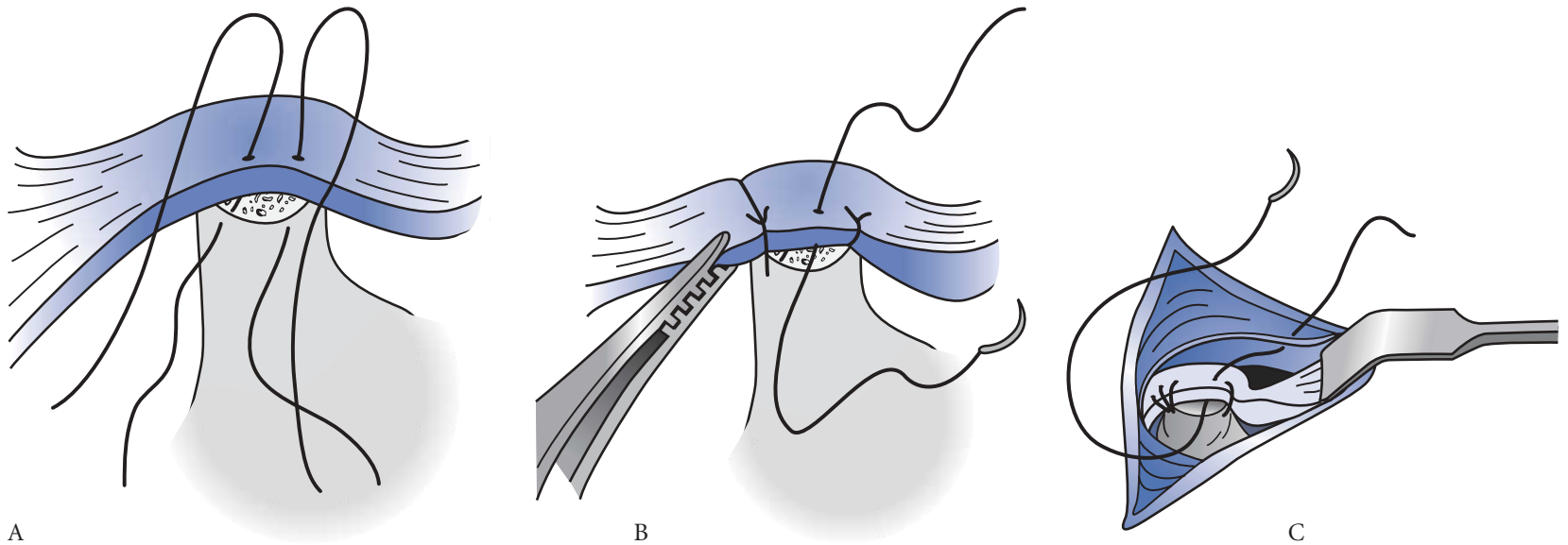


FIGURE 50-24 A–C, Disk repositioning with arthroplasty according to Walker and Kalamchi. The disk is sutured to the condyle stump. Adapted from Walker RV and Kalamchi S.³²

were close to the vascular periphery. In the rabbit knee meniscus subjected to partial meniscectomy, the replacement tissue appeared to be derived from the synovium of the articular capsule.⁴³

Preoperative confirmation of a partial reducing disk using MRI or arthrotomographic images is imperative in deciding whether to perform this procedure. After exposure of the joint spaces, the DeBakey

clamp is inserted to the medial limit of the posterior glenoid fossa. Retrodiskal tissue and displaced portions of the disk are then

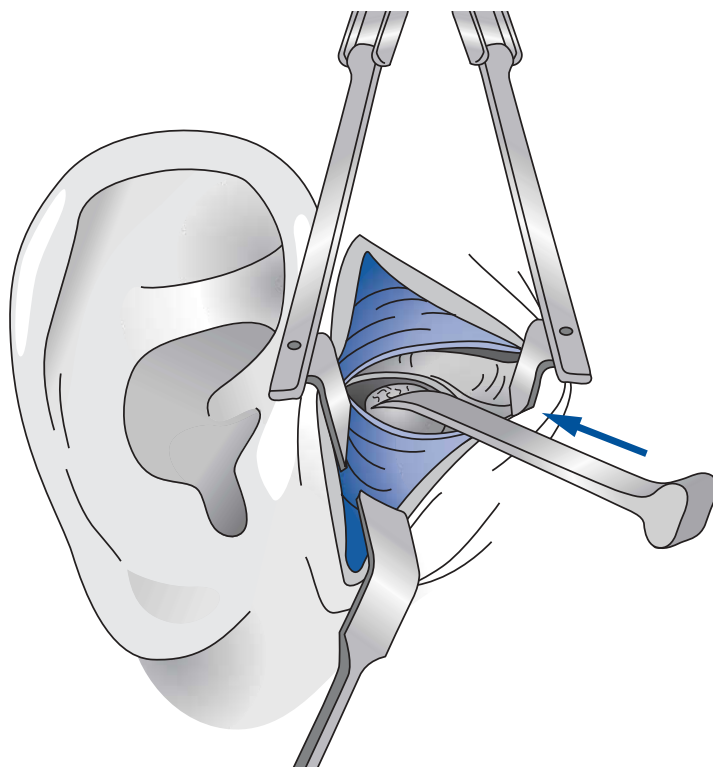


FIGURE 50-25 Condylar arthroplasty using an osteotome. An osteophyte has already been excised. The direction of the osteotome (arrow) is indicated in order to skim the condylar surface. Self-retaining and right-angle retractors are in place.

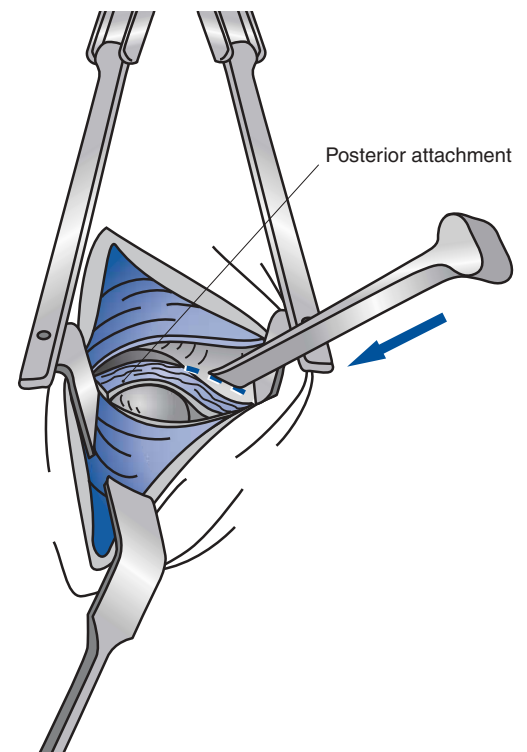


FIGURE 50-26 Lateral tuberclelectomy may be performed to acquire access to the anterior glenoid and eminence regions (broken line indicates bone to be excised and arrow indicates direction of osteotome).

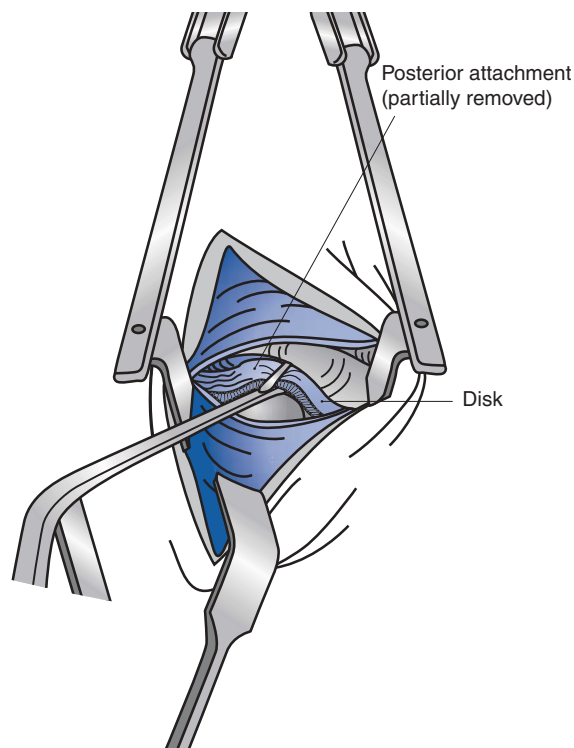


FIGURE 50-27 Partial diskectomy. Midcondylar region is illustrated. Bulge portions of the disk are excised in a piecemeal fashion using otologic basket forceps. Portions of the excised disk partially excised are hatched exposing the remodeled disk in cross-section.

removed in a piecemeal fashion using otologic basket forceps (see Figure 50-27). The tissues are removed until the properly positioned disk is noted. The surgeon may then graft the surgical site with an autologous dermal graft. The graft is sutured to a cuff of tissue left at the circumference of the surgically created perforation (see Figures 50-28 and 50-29). In some cases the surgeon may elect not to graft the artificially created perforation. Capsular and skin closures are accomplished in the customary fashion. Following extirpation of the disk portion in question, joint movement is simulated to ensure that there is smooth condylar movement in lateral and anterior planes. The procedure can produce excellent immediate gratification to the patient and improve joint function. However, complete smooth excision of the inferior aspect of the disk is required to prevent recurrence. A perforation is sometimes intentionally created to

remove the obstacle. The displaced disk is essentially changed to a displaced meniscus. The perforation is rarely problematic for the patient as it is created anterior to the condyle. The perforation repair described earlier is performed over the head of the condyle; such perforations can lead to chronic pain refractory to steroid injection.

Total Diskectomy Total diskectomy is the procedure in which the remodeled posterior attachment and entire disk are excised. It is the most extensively used and reported surgical procedure, having been applied from as early as the 1900s. Total diskectomy has been used to treat the full gamut of internal derangements, without consideration for the degree of displacement of disk morphology, with generally good to excellent results.⁴⁴⁻⁵⁰

Despite the reported successes with diskectomy,⁵¹⁻⁵³ the more sophisticated diskoplasty techniques supplanted the diskectomy during the 1970s to mid-1980s.⁵¹⁻⁵³ In the 1980s diskectomy became popular once again following the introduction of implantable biomaterials that were used as disk replacements.

Diskectomy is indicated in those situations for which disk repositioning is not feasible because of disk atrophy, deformation, or severe degeneration. A joint with an atrophied, deformed, or degenerated disk cannot be rejuvenated because some of the associated pathologic changes—collagen fiber reorientation, increased ground substance, presence of elastic fibers in all disk zones, cartilaginous deposits, and increased vascularity—are irreversible. The goal of surgery is to assist the host to adapt to the pathology at hand by removing the physical impediment to movement and the pathologic posterior attachment.

Bowman studied the results of total diskectomy in 52 patients followed over 3 months to 22 years.¹² Thirty of his patients were studied for 4 years or more. Subsequently, in 1986, Eriksson and West-

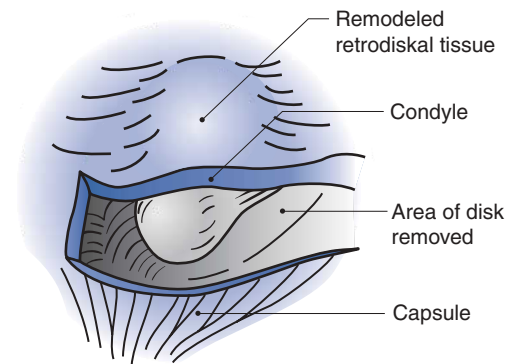


FIGURE 50-28 For repair of a large perforation, a partial diskectomy is performed first. A portion of the disk and the retrodiskal tissue may be retained.

esson reported a follow-up (mean 29 yr) on 15 of Bowman's patients.⁴⁰ Bowman's observations, which have been corroborated by others,^{10,54,55} form the basis of much of the discussion that follows.

Total diskectomy deprives the joint of the posterior attachment and posterior aspect of the remodeled disk. In the diseased state these tissues serve as the shock absorbers for the bony surfaces. The residual "normal" synovium is responsible for the lubrication and nutrition of the articular surfaces. The absence of retrodiskal tissue may interfere with the normal flow and diffusion of synovial fluid.⁵⁶ With diskectomy, the surgeon probably transforms a joint into what more appropriately would be described as two bones in close apposition. As a result, several adaptive changes

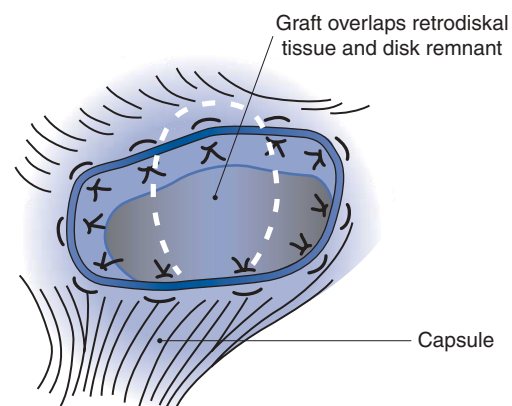


FIGURE 50-29 A dermal graft covers the surgically created perforation. The edges of the graft overlay the disk, retrodiskal tissue, and lateral capsule to assist in suturing.

rapidly occur. These changes are reflected in the manner in which the joint functions and how it appears radiographically. Many clinical examples of such a bony arrangement providing the patient with adequate pain-free function may be drawn from the reconstructive literature.

Clinicians often observe the loss or reduction of gliding motion in the joint with nonreducing disk displacement. In this situation the joint behaves principally as a ginglymoid joint. Initially there is limited translational capability. As healing progresses and osseous remodeling occurs, the rotational (hinge) movement becomes minimal and the gliding motion predominates. The patient must rapidly regain mobility through prescribed physical therapy to prevent the development of ankylosis.

Adult cartilage derives its nutrients solely from synovial fluid. The prolonged contact of bony surfaces following meniscectomy may interfere with diffusion of nutrients from the synovial fluid. The decreased diffusion of nutrients to cartilage may result in the eventual resorption of noncalcified cartilage.

After a diskectomy some masticatory muscle and joint tenderness can be expected for a variable period, extending from several weeks to months. The patient at first favors mastication on the operated side. Later, when healing is advanced, mastication is performed on the nonoperated side. An opening deviation of as much as 8 to 9 mm may occur toward the operated side. The deviation appears to be a normal compensatory function secondary to the loss of posterior attachment and synovium, the change in the joint architecture, and areas of fibrous ankylosis. Counteracting the lateral deviation actively or passively causes pain in the operated joint.

Hypermobility of the nonoperated joint may develop or increase after diskectomy. Limitation of mandibular movement on the operated side appears to be responsible for the hypermobility. The

hypermobility may be responsible for awakening symptoms of a quiescent internal derangement. Capsular tightening procedures have been performed in conjunction with diskectomy to reduce condylar hypermobility (Figure 50-30).⁵⁷⁻⁵⁹ Physical therapy greatly assists the control of the ipsilateral deviation and hence contralateral hypermobility.

Joint crepitations or “snappings” often occur postoperatively. The snappings have been attributed to the condyle rubbing on residual nonextirpated portions of the disk and usually cease after several months. Patients often report an alteration in their bite, although rarely as a major complaint. The thicker the retrodiskal tissue removed, the greater is the anticipated change in occlusion. The sensation of an altered bite usually resolves within a week to several months, with resolution of intra-articular edema, clot retraction, and dental compensations. Occlusal equilibration is rarely indicated.

There is considerable variation in the ability of each patient and joint to adapt to the postdiskectomy state. Individual factors, such as inclination of the eminence, state of preoperative symptoms, loss of molar support, and amount of postoperative remodeling, do not seem to play a substantial role.

Clinicians are often alarmed by the degree of osseous remodeling observed

after a diskectomy. The morphologic and radiologic changes observed in the TMJ concur with those observed in experimental diskectomy.^{41,60} After approximately 1 year the morphologic appearance of the condyle and temporal bone appear similar to those observed in a typical arthroal joint, that is, there are planar (flat) articular surfaces. This is reflected by the manner in which the joint is observed to function. Agerberg and Lundberg described erosion of the articular surfaces and interruptions of the cortical outline on transcranial radiographs.⁶¹ The osseous changes appeared primarily in the lateral and anterior aspects of the joint. The posterior aspects were least affected. Remodeling changes have even been identified in the lateral third of the contralateral (nonoperated) joint.^{62,63} However, this was not confirmed by Bowman.¹² Agerberg and Lundberg concluded that the remodeling process stabilized after 2 years.⁶¹ They used the term *remodeling* and not osteoarthritis to describe the radiographic changes because the osseous changes occurred in the absence of symptoms. The bony changes appear similar to those that are observed longitudinally with chronic disk displacement, suggestive of the same mechanism. The rate of remodeling, however, is accelerated in the postdiskectomy state. A similar observation has been made in the postmeniscectomy human knee joint.⁶⁴

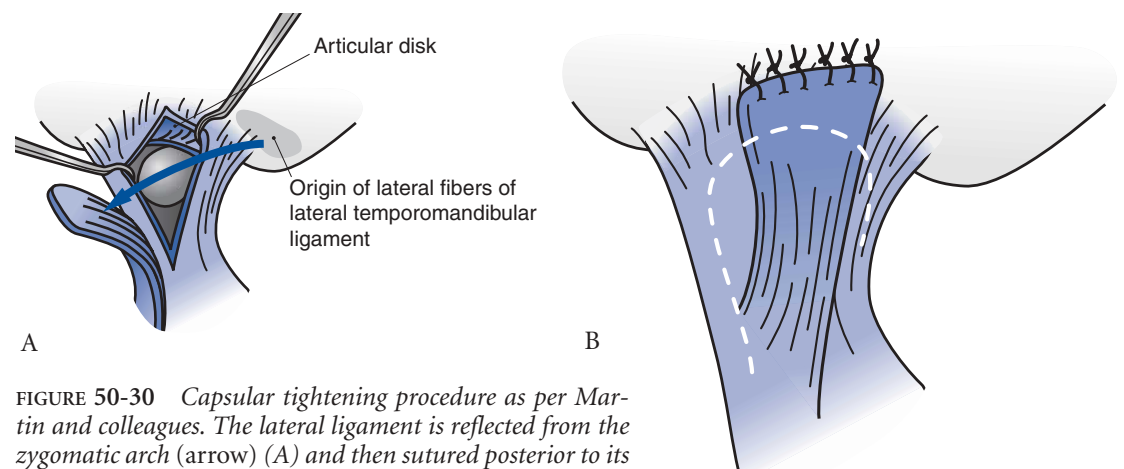


FIGURE 50-30 Capsular tightening procedure as per Martin and colleagues. The lateral ligament is reflected from the zygomatic arch (arrow) (A) and then sutured posterior to its anatomic origin (B). Adapted from Martin BC et al.⁵⁹

Diskectomy without Replacement Disk extirpation is facilitated when the atrophic disk is severed from its anterior and lateral attachments and then retracted laterally and posteriorly to complete the incisions. This approach permits the surgeon to verify the ability of the disk to be repositioned posteriorly before excision. With severe atrophy of the disk, substantial resistance to posterolateral traction is noted. A hemostatic clamp is positioned across the anterior attachment to serve as a guide plane for the knife, which is used to sever the attachment lateromedially (Figure 50-31). As the posterior attachment demonstrates a variable degree of vascularity changes, the DeBakey bulldog vascular clamp or straight mosquito clamp may be applied here before severing the posterior attachment. Next, a hemostat is used to apply outward traction to the tissue to be extir-

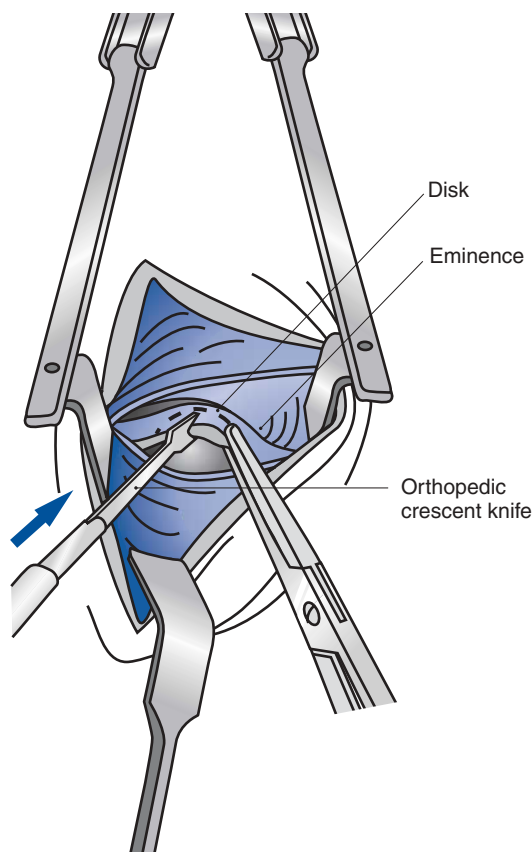


FIGURE 50-31 Total diskectomy. A straight clamp is inserted onto the anterior attachment. A meniscus knife separates the anterior attachment guided by the clamp. The arrow represents the direction of the incision.

pated (Figure 50-32). A meniscus knife is used to sever the medial attachments. When the remodeled posterior attachment and disk are extirpated, the retrodiskal tissue is electrocauterized to control bleeding. Care is taken not to disrupt the fibrous connective tissue lining of the fossa and condyle. The morphology of the condyle and glenoid fossa often prevent excision in one piece. Incomplete excision of the posterior attachment over the lateral pole of the condyle may account for some cases of failure with diskectomy. After the disk and posterior attachment are excised, the surgeon should verify that there is not a significant diaphragm of irregular posterior attachment tissue that remains laterally around the head of the condyle.

With the disk and posterior attachment removed, mandibular range of motion is simulated by manipulating the mandible in lateral and protrusive excursions. Joint noises, characterized as snapping, may indicate a disk remnant. Disk remnants are usually located on the medial aspect of the joint cavity. The surgeon should remove all disk remnants that appear to impede movement.

Disk Replacements

Autogenous, homologous, and alloplastic replacements for the disk have been used following diskectomy to prevent or reduce intra-articular adhesions, osseous remodeling, and recurrent pain. In addition, the interpositional material was believed to decrease joint noises by dissipating loading forces on the osseous surfaces. The effectiveness of interpositional grafts in reducing adhesions, protecting the articular surfaces, and diminishing pain and postdiskectomy joint noise has not been substantiated. The use of these materials is sporadic and according to operator preference.

The dermal graft may be harvested from the buttock, upper lateral thigh, groin, or the inner aspect of the upper extremity. When the thigh is selected as the donor site, a dermatome may be used to

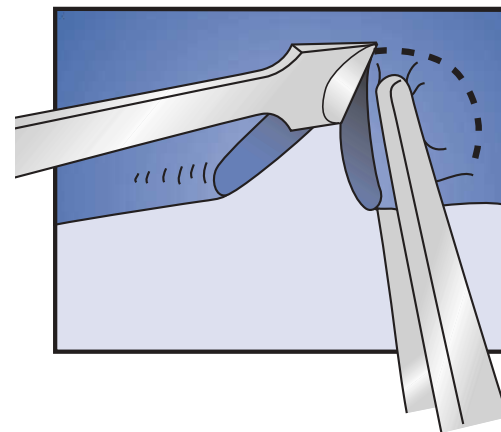


FIGURE 50-32 An arthroscopic knife severs the posterior attachment (broken line), guided by the clamp. The clamp retracts the disk anterolaterally for visibility.

raise the skin (0.30–0.38 mm) and then the dermis (0.46–0.51 mm). The dermatome width should be set to take the dermal graft 20 to 30% larger than is required to compensate for immediate contraction of the graft. Bleeding in the donor site should then be thoroughly controlled to prevent hematoma formation under the skin, which is replaced over the donor site. Adhesive strips may be applied, or the skin edges may be sutured with 5-0 nylon. The surgical site is then dressed with an occlusive dressing. Postoperatively the donor site should be checked for seroma formation during the first 48 hours.

Alternatively, when size requirements are minimal, the graft may be harvested freehand. An elliptic wedge of epidermis and underlying dermis is harvested. The underlying surface of the dermis must be defatted before being implanted. The defatted graft is trimmed and sutured to the retrodiskal tissue and the anterior and lateral capsular attachments.

The dermal graft is believed to function as a framework for the new disk. Vascularization of the graft is probably derived from the joint periphery.^{20,21,28,42} The vascular retrodiskal tissue provides pluripotential cells and synoviocytes to participate in the healing process. Dermal grafts implanted in the primate TMJ were

reported to be viable at postoperative week 36.⁶⁵ The collagen and elastic elements of the dermal graft were reported to persist, whereas the dermal appendages atrophied.^{66,67} Chao and colleagues reported, however, that the dermal grafts were completely repaired by fibrous tissue.⁶⁸

The temporalis muscle has been used as an interpositional material. The flap may be pedicled in a variety of ways, some of which risk the blood supply owing to torsion of the pedicle. Advantages of this technique over a free graft include its stability, owing to its connection at the base (Figure 50-33), its availability at the same surgical site, and its lack of morbidity.

Feinberg and Larsen described a technique that pedicled the posterior temporalis

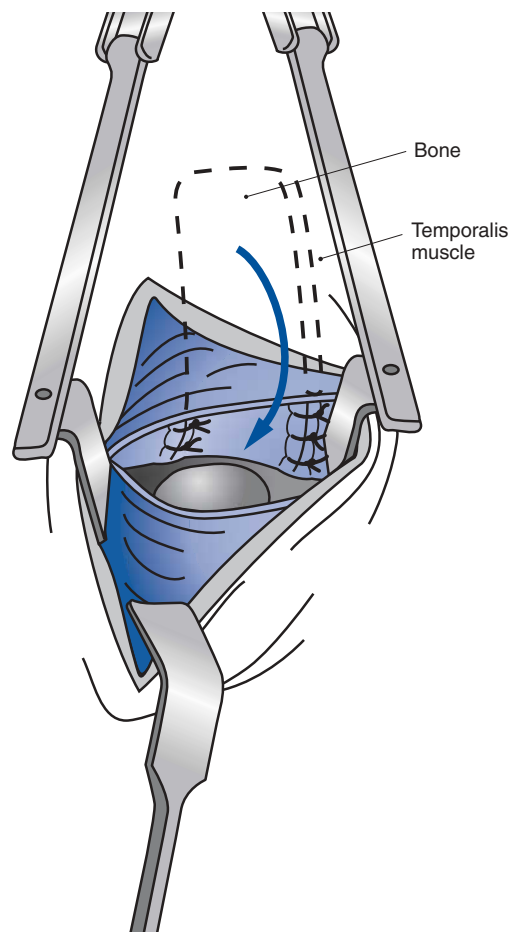


FIGURE 50-33 Disk replacement using temporalis muscle/fascial graft (broken line) pedicled from above the glenoid fossa and rotated inward (arrow). Lateral, anterior, and posterior sutures hold the graft in place.

muscle fibers anteriorly.⁶⁹ A 1 cm-wide paddle is developed above the posterior root of the zygomatic arch. The paddle is elevated and rotated anteriorly and inferiorly around the posterior root of the zygomatic arch. The muscle is then sutured to the retrodiskal tissues (Figure 50-34).

Sanders and Buoncristiani described a technique for using the temporalis myofascial flap for interpositional tissue in TMJ reconstruction.⁷⁰ The shape and size of the flap is outlined by incising posteriorly near the postglenoid spine of the joint through temporalis fascia muscle and periosteum. This incision is extended superiorly near the temporal line. Subperiosteal dissection elevates the amount of flap needed from the temporal bone. A transverse incision is made at the superior portion anteriorly to create a 3 cm-wide flap. The width should be greater than the anteroposterior coverage desired in the joint to allow flap contraction. An anterior incision is made parallel to the posterior incision. The superior aspect of the anterior incision is carried to bone in this thin area of the temporalis. Inferiorly, as the arch is approached, the muscle thickens; therefore, the dissections are not carried completely through muscle to bone. Blunt dissection is carried inferiorly to a point just medial to the arch to permit adequate mobility of the flap. Branches of the temporal artery found in this area are preserved if possible. The length of the flap is usually 5 cm.

The flap is fully reflected off the bone, and resorbable interrupted sutures are placed in several areas on the edge of the flap through fascia, muscle, and the periosteum to keep the layers from separating. Holes are drilled in the bone of the lateral lip of the glenoid fossa posteriorly and anteriorly before placement of the flap into the joint. One suture is placed through bone anteriorly near the eminence, and a second posterior suture is placed near the postglenoid spine. Two additional sutures hold the medial edge to

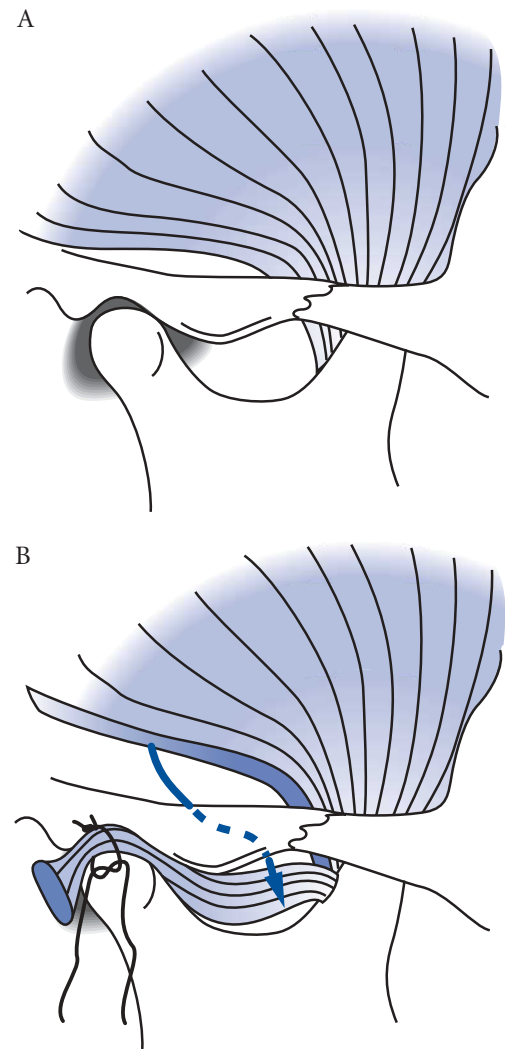


FIGURE 50-34 A and B, Disk replacement using temporalis muscle/fascial graft pedicled anteriorly and rotated anteriorly and inferiorly around (beneath) the posterior root of the zygomatic arch (arrow). The graft is sutured to the retrodiskal tissues.

anterior and posterior medial tissues. These medial sutures are sometimes difficult or impossible to secure, and the sutures through lateral bone are usually adequate to hold the flap in place. A cosmetic temporal defect may result depending on the thickness of tissue harvested.

Autogenous fascia interpositional grafts were described in 1911 for use as interpositional material in gap arthroplasties for ankylosis.^{71,72} The attractiveness of this material lies in its resistance to resorption, response to mechanical stress, and biocompatibility.⁷³⁻⁷⁵

Autogenous conchal cartilage was first used as a disk replacement by Perko, according to Witsenburg and Freihofer.⁷⁶ Cartilage harvested from the cavum conchae results in minimal esthetic compromise. The graft can be tailored to fit the condyle or glenoid fossa. Notably, the quality and thickness of the aural cartilage is variable. In some cases an iatrogenic tear in the cartilage may occur during the harvesting process.

The procedure to obtain chondral cartilage as interpositional material for TMJ reconstruction has been described by Hall and Link.⁷⁷ A 3 to 4 cm postauricular incision is made on the ear a few millimeters lateral to the auriculocephalic sulcus and is carried through to the perichondrium. The middle division of the posterior auricular artery may be encountered and ligated or cauterized. A careful supraperichondral dissection with a fine dissecting scissors exposes the surface of the cartilage. A scalpel is used to cut through the cartilage in the shape of the desired amount of graft, usually 1.5 by 2.5 cm. It is important not to extend to the rim of the antihelix to avoid permanent deformity of the ear. Subperichondral dissection between the skin of the bowl and cartilage permits the cartilage to be removed without tearing it or perforating the skin. The ear is packed with gauze or other material to maintain the shape of the bowl and to apply pressure to the skin. The pressure pack is maintained for 48 hours.

Timmel and Grundschober and Boyne and Stringer reported the use of lyophilized dura in both the porcine and human TMJ.^{78,79} Foreign body reactions were always associated with the material. There was gradual replacement of the material with fibrous connective tissue, although they noted this was not complete by 120 to 130 days. There is increasing resistance among surgeons toward using fresh homologous materials owing to the possibility of transmitting communicable diseases. Relatively recently Creutzfeldt-

Jakob disease has been transmitted to a patient who received lyophilized dura.⁸⁰

In the future surgeons may be able to use tissue explants or biocompatible allogeneic collagen sheets as disk replacements.⁸¹

Alloplastic Materials The requirements for an ideal alloplastic implant are that it be biocompatible, easily secured, adaptable to the variable morphology of the recipient site, and resistant to the compressive and shear forces of the joint. Currently there is no alloplastic material or technique that fulfills all of these requirements. Computer-aided design using three-dimensional computed tomography images of the TMJ may bring us closer to defining the ideal characteristics and design of the various components of the TMJ.

Silicone elastomer is a rarely used implantable material. It is exclusively and rarely used in the TMJ for temporary use, but even in this application it is not free of problems. Its sole reputed advantage is that the material does not incorporate into the surrounding tissues. In the past when it was used as a permanent implant, the material's properties were responsible for its migration through stabilizing wires. Gallagher and Wolford suggested that this lack of stability resulted in the loss of as many as one-third of all implants placed following condylectomy.⁸² Continued loading of silicone elastomer interpositional implants by the condyle has led to fragmentation and foreign body reactions because of its high coefficient of friction and poor wear characteristics under direct function.⁸³ Recognition of the limitation of this material led to the abandonment of the permanent silicone implant elastomer and its subsequent rare use as only a temporary implant replacement.

Implants laminated with a composite of polytetrafluoroethylene (PTFE) and aluminum oxide were used extensively in the early and mid-1980s.^{84,85} The PTFE material's ultraporosity and watability permitted rapid ingrowth of fibrous con-

nective tissue to facilitate anchorage of the prosthesis. The polytef surface on which the condyle interfaced was chosen to provide a smooth surface resistant to shear and compressive forces.

In the mid-1980s reports of problems with the PTFE implant began to surface.⁸⁴ Patients reported pain, swelling, joint crepitus, and limitation of range of motion resistant to conservative management. In such TMJ reconstructions the PTFE implants that were removed demonstrated perforations, shredding, and displacement. Severe osseous remodeling changes, particularly of the condyle, were reported.⁸⁶ Previous reports indicated that the PTFE-carbon implants elicited a severe histiocytic foreign body reaction,⁸⁷ similar to what was being reported as happening in the human TMJ. Because of the growing number of failures with PTFE, in 1990 the Food and Drug Administration formally withdrew the PTFE implant from the market and cautioned that patients should be closely followed up for progressive bony changes using radiographic studies at 6-month intervals.

Temporary Implant Insertion To date only the high-performance polymeric silicone implant has been considered for temporary (retrievable) implant insertion. The paddle-shaped implant is inserted with the neck of the paddle rolled over the zygomatic arch (Figure 50-35). Several tacking sutures are placed to the temporalis fascia. Retrieval is planned for 2 to 6 months postoperatively. As the polymeric silicone material is never incorporated into the host, the implant is easily removed at a second operation under local anesthesia. The fibrous connective tissue that encapsulates the implant is left in place to act theoretically as the permanent layer between the condyle and the fossa. However, at the time of retrieval of the temporary implant, the fibrous connective tissue encapsulation may be incomplete. As a result, this procedure has dropped out of favor.

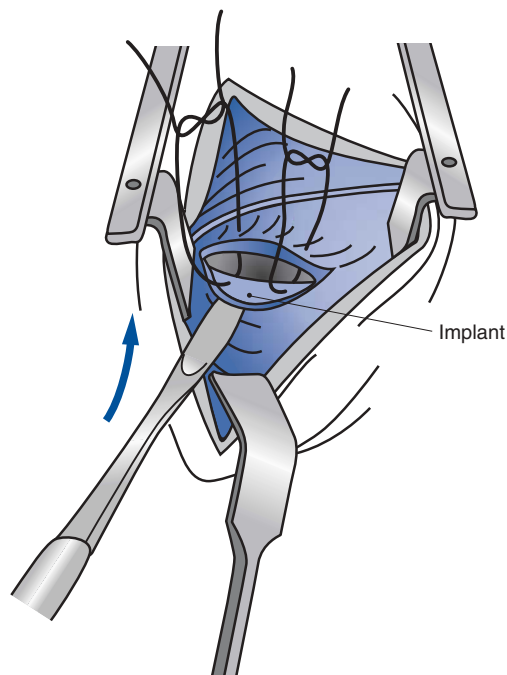


FIGURE 50-35 Temporary (retrievable) polymeric silicone implant inserted. The paddle extension is sutured to the temporalis fascia. A Freer elevator holds the implant in place (arrow) while the sutures are secured.

Condylectomy

Low condylectomy or simply condylectomy is the procedure that is defined as the removal of the entire condylar process. The procedure used to be performed to increase the joint space to alleviate pressure on nerve endings,⁴⁸ but it has largely been abandoned in the surgical repertoire for treatment of internal derangements because of problems of reduced condylar mobility, mandibular deviations, and open bite.

High condylectomy is the removal of only the articular surface of the condyle. The disk is left intact to prevent ankylosis and to promote healing. This contrasted with the radical condylectomy in which the tendon of the lateral pterygoid muscle was released. Only slight mandibular deviation was reported in patients after high condylectomy.⁸⁸⁻⁹⁴

When the condylar or eminence articular surfaces appear intact, most clinicians are reluctant to shave the osseous surfaces. Arthroplasty is performed when the rate

and distribution of bone remodeling have resulted in mechanical interferences.

Condylotomy

The condylotomy procedure is an osteotomy performed through the condylar neck. Campbell, one of the originators of the technique, made the observation that symptoms of TM dysfunction disappeared after condylar fractures.⁹⁵ This led to his application of the closed condylotomy to patients with TMJ symptoms refractory to nonsurgical therapy. The rationale behind its use in treatment of internal derangements was to produce anteromedial displacement of the condyle to change the condyle-disk-fossa relation, increase joint space, shorten the lateral pterygoid muscle, and alter load forces.^{88,96-100}

Originators of the technique performed a closed osteotomy with a Gigli wire saw with the intent of creating an anteromedial fracture dislocation. Intermaxillary fixation was sometimes applied in the immediate postoperative period. Today, when the procedure is performed, the intraoral route used for the vertical mandibular ramus osteotomy is employed.

Postoperative Management

Surgery should reduce painful symptoms to a level that represents little or no concern to the patient. It is important to weigh the contribution of masticatory muscle myalgia to the patient's chief complaint. Although joint surgery can relieve the joint pain, in many cases it may be ineffectual in controlling muscle discomfort. Nonsurgical management of the muscle disorders must continue in many patients after surgery for internal derangements. Joint surgery does not restore the joint to its prepathologic state. The patient should understand that biting force may be reduced and jaw fatigue may become apparent with heavy meals or long conversations. After primary surgery (ie, no previous TMJ surgery), one should strive for the following passive range-of-motion

parameters: maximum interincisal opening of 35 to 40 mm, lateral excursive movements of 4 to 6 mm, and protrusive excursive movements of 4 to 6 mm. However, success should not be measured by the attainment of a finite measurement. A patient's overall success should be measured by the eradication or diminution of the preoperative complaints. Surgery is rarely performed to correct purely functional complaints. Elimination of pain during function is usually the predominant concern for the patient, who is willing to accept some compromise in degree of opening and lateral excursions.

Bite appliances should be used to maintain a stable occlusal relation in the immediate postoperative phase. This is particularly important after disk repositioning. The appliance is frequently adjusted as the edema resolves and disk tissues heal. The patient should be able to return to a normal mechanical diet with minimal dietary restrictions. Restricted foods include such items as French bread, toffee apples, and popcorn. A stable acceptable occlusion should be maintained. Joint sounds may develop or persist, but the asymptomatic sounds should be of minimal concern to the patient.

Postoperative outcomes may be influenced by several factors, including concomitant facial pain from other sources, degenerative bony changes, advanced morphologic changes in the disk, perforation of the posterior attachment, poorly controlled parafunctional habits, malocclusion, psychological overlay, previous TMJ surgery, history of facial nerve paralysis or orofacial numbness, history of infection, or systemic diseases affecting the muscles, ligaments, or bone.¹⁴

Historically, clinicians emphasized restricted joint function after joint surgery. The clinician must balance his desire to rapidly and actively restore a normal range of motion with the capacity of the joint and facial muscles to adapt. Some latitude must be maintained on the part of

the clinician in dealing with a patient's rehabilitation schedule. Care should be exercised in the rehabilitative process of the patient with bilateral joint disease whose operation was unilateral. Diet restrictions are important. Excessive lateral excursive movements to the ipsilateral side may contribute to the exacerbation of contralateral symptoms. There is no cookbook recipe to postoperative management of these patients. Some patients, regardless of the procedure, achieve an acceptable range of motion within 7 to 14 days, with minimal effort on their part. Others need to follow a strict physical therapy regimen. The help of a physical therapist may sometimes be enlisted to regain joint mobility, especially when patient cooperation with a home exercise program is questionable. In general, some light passive opening and protrusion stretching exercises are prescribed four times a day beginning 5 days postoperatively. With disk repair procedures the physical therapy exercises should be more gradual.

Patients should be maintained on a full-liquid to soft diet for the first 2 postoperative weeks. Heat may be applied before and after exercises to improve comfort. Splint therapy is routinely used when a large parafunctional component is present. Some authors advocate using anterior repositioning devices to permit healing of suture sites following disk repositioning. Patients should be encouraged to chew gum after 4 weeks to improve lateral excursive movements.

Complications

Complications may arise immediately (intraoperatively or within 24 hr) or be delayed (> 24 hr).

Transient neuropraxia of the temporal branches of the facial nerve occurs in as many as 20 to 30% of cases. Typically, the injury is of little significance to the patient and resolves within 3 to 6 months. The incidence increases when a separate skin flap is raised.¹⁰¹ Rarely, the zygomatic

branches and, even more rarely, the entire temporofacial division may be injured. Injury to the chorda tympani from aggressive condylar retraction in the medial aspect of the fossa may occur rarely as well. Neuropraxia of the inferior alveolar and, less commonly, the lingual nerves may result from clamp placement for joint manipulation. Auriculotemporal syndrome (gustatory sweating, Frey's syndrome) has been reported as a result of the dissection of the joint.

Hemorrhage from the retrodiskal tissue may interfere with performance of the disk repair. Temporary control may be obtained with seating of the condyle in the glenoid fossa. Electrocautery, injection of epinephrine, or application of hemostatic agents while maintaining the mandible in the closed position may be necessary.

Infections rarely occur. Microorganisms cultured may originate from the skin or external auditory meatus flora. Auriculitis and external otitis are more likely to occur with the postauricular and endaural approaches. To avoid contamination an ear packing is avoided as it frequently becomes dislodged during surgery. In addition, the ear is not suctioned during surgery. When the wound is closed the external auditory canal is irrigated gently with saline via an 18-gauge angiocatheter.

Postoperatively, joint sounds are a frequent occurrence, regardless of the surgery. The sounds following diskectomy may be the loudest. In some patients the sounds may be obtrusive enough to disturb them. The surgeon should delay re-intervention until the patient is reevaluated at 6 to 12 months, as some sounds may become inconsequential to the patient.

Summary

Remarkably good success has been reported with several surgical procedures, which differ in their fundamental approach to the problem and their aggressiveness. Most of these techniques share common denominators: first, a lateral approach to the capsule

and ligament; second, a severing of the posterior attachment-disk attachments to the capsule once the superior joint space is accessed; and, third, a blunt delineation of the joint spaces. Although the capsule and ligament tissues are approximated at the conclusion of the procedure, the patient is encouraged to function on the operated joint. Long before arthroscopic surgery, Toller recognized the importance of mobilizing the condyle-disk-fossa relations to achieve a successful result.¹⁰² He devised the lateral capsular arrangement procedure. It remains to be determined whether disk repositioning, posterior attachment repair, diskectomy, high condylectomy, and even condylotomy derive some or all of their therapeutic benefits through a lateral capsule and ligament release and mobilization of the disk complex. Arthrocentesis and arthroscopic surgical procedures for treatment of the closed lock condition appear to be therapeutic through the same mechanism.¹⁰³

Open surgical approaches to TMJ internal derangements are now relegated to a tertiary line of care following nonsurgical therapy and arthrocentesis/arthroscopy for most conditions. They do, however, have a clear indication for certain mechanical conditions directly attributed to a disk obstruction.

Much of what was written in the previous edition of this chapter has stood the test of time. As we increase our understanding of the pathology, open surgical procedures are being performed for specific well-defined conditions. However, the new TMJ surgeon will never quite appreciate the experience that comes with performance of arthrotomy procedures. Arthroscopy developed as a consequence of this experience. Now, as we regress with progress, arthrocentesis with and without steroid injection, a procedure performed by many surgeons years before the pathology of the joint was even elucidated, has become a mainstay for treatment. This treatment alone has significantly reduced the need to intervene via arthrotomy.

References

- Annandale T. On displacement of the interarticular cartilage of the lower jaw and its treatment by operation. *Lancet* 1887;1:411.
- Warwick R, Williams P, editors. *Gray's anatomy*. 35th ed. Philadelphia: WB Saunders; 1973. p. 1011–5.
- Al-Kayat A, Bramley P. A modified pre-auricular approach to the temporomandibular joint and malar arch. *Br J Oral Surg* 1979;80:17:91.
- Blair VP. Operative treatment of ankylosis of the mandible. *South Surg Gynecol* 1913;26:436.
- Rongetti JR. Meniscectomy—a new approach to the temporomandibular joint. *Arch Otolaryngol* 1954; 60:566–72.
- Lempert J. Improvement of hearing in cases of otosclerosis. *Arch Otolaryngol* 1938; 28:818–23.
- Alexander RW, James RB. Postauricular approach for surgery of the temporomandibular articulation. *J Oral Surg* 1985; 33:346–500.
- Dolwick MF, Kretschmar DP. Morbidity associated with the preauricular and perimeatal approaches to the temporo-mandibular joint. *J Oral Maxillofac Surg* 1982; 40:699–700.
- Eggleston DJ. The perimeatal exposure of the condyle. *J Oral Surg* 1978;36:369–71.
- Husted E. Surgical diseases of the temporomandibular joint. *Acta Odontol Scand* 1956;14:119.
- Bowman K. A new operation for luxation in the temporomandibular joint. *Acta Chir Scand* 1970;136:391.
- Bowman K. Temporomandibular joint arthrosis and its treatment by extirpation of the disc. *Acta Chir Scand* 1947;95 Suppl 118:156.
- American Association of Oral and Maxillofacial Surgeons. 1984 criteria for TMJ meniscus surgery. Chicago: AAOMS; 1984.
- American Association of Oral and Maxillofacial Surgeons. 1990 standards and criteria of surgical procedures. Chicago: AAOMS; 1990.
- Wilkes CH. Structural and functional alterations of the temporomandibular joint. *Northwest Dent* 1978;57:287–94.
- McCarty WL, Farrar WB. Surgery for internal derangements of temporomandibular joint. *J Prosthet Dent* 1979;42:191–6.
- Bronstein SL, Tomasetti BJ, Ryan DE. Internal derangements of the temporomandibular joint: correlation of arthrography with surgical findings. *J Oral Surg* 1981;39:572–84.
- Dolwick MF, Riggs RR. Diagnosis and treatment of internal derangements of the temporomandibular joint. *Dent Clin North Am* 1983;27:561–72.
- Merrill HG. Historical perspectives and comparisons of TMJ surgery for internal derangements and arthropathy. *J Craniomandib Pract* 1986;4:74–85.
- Wallace DW, Laskin DM. Heating of surgical incisions in the disc and retrodiscal tissue of the rabbit temporomandibular joint. *J Oral Maxillofac Surg* 1986;44:965–71.
- Zeitler DL, Olson R, Krizan K, Fonseca R. Healing of meniscus surgery in cynomolgus monkey temporomandibular joints. In: Case reports and outlines of scientific sessions. Proceedings of the 66th Annual Meeting of the AAOMS; New York. September 1984. p. 49.
- Kim JM, Moon MS. The effect of synovectomy upon regeneration of the meniscus in rabbits. *Clin Orthop* 1979;141:287–94.
- Heatley FW. The meniscus—can it be repaired? An experimental investigation in rabbits. *J Bone Joint Surg* 1980;62B:397–402.
- Arnoczky SP, Warren RE. The microvasculature of the meniscus and its response to injury. An experimental study in the dog. *Am J Sports Med* 1983;11:131–41.
- Stingl J. Blood supply of the temporomandibular joint in man. *Folia Morphol* 1965; 13:20–6.
- Satko CR, Blaustein DI. Revascularisation of the rabbit temporomandibular joint after surgical intervention: a histologic and microangiographic study. *J Oral Maxillofac Surg* 1986;44:871–6.
- Smith D, Walters PJ. An alternative to meniscectomy in repair of tears in the temporomandibular meniscus. In: Case reports and outlines of scientific sessions. Proceedings of the 65th Annual Meeting of the AAOMS; 1983 Sept; Las Vegas. 1983.
- Marciani RD, White DK, Traurig H, Roth GI. Healing following condylar shave in the monkey temporomandibular joint. *J Oral Maxillofac Surg* 1988;46: 1071–6.
- Gabler M, Perry H, Schwartz C, et al. Effect of arthroscopic TMJ surgery on articular disk position. Proceedings of the 18th Annual Session of the AADR [special issue]. *J Dent Res* 1989;68:310.
- Montgomery M, Van Sickels J, Harms S, Thrash W. Arthroscopic TMJ surgery. Effects on signs, symptoms and disc position. *J Oral Maxillofac Surg* 1989; 47:1263.
- Heffez L, Jordan S. A classification of temporomandibular joint disk morphology. *Oral Surg* 1988;67:11–9.
- Walker RV, Kalamchi S. A surgical technique for management of internal derangements of the temporomandibular joint. *J Oral Maxillofac Surg* 1987; 45:299–305.
- Saunderson SR, Dolwick MR. Increased hemostasis in temporomandibular joint surgery with the DeBakey clamp. *J Oral Maxillofac Surg* 1983;91:271–2.
- Mercuri LG, Campbell HL, Shanaskin RC. Intraarticular meniscus dysfunction surgery—a preliminary report. *Oral Surg* 1982;54:6.
- Hall MB. Meniscectomy of the displaced temporomandibular joint meniscus without violating the inferior joint space. *J Oral Maxillofac Surg* 1984;42:788–92.
- Weinberg S, Cousens C. Meniscocondylar plication: a modified operation for surgical repositioning of the ectopic temporomandibular joint meniscus. *Oral Surg* 1987;63:393–402.
- Weinberg S. Eminectomy and meniscorrhaphy for internal derangements of the temporomandibular joint. *Oral Surg* 1984;57:241–9.
- Blackwood HJJ. Pathology of the temporomandibular joint. *J Am Dent Assoc* 1969; 79:118–24.
- Isaacson A, Isberg A, Johansson AS, Larson O. Internal derangement of the temporomandibular joint: radiographic and histologic changes associated with severe pain. *J Oral Maxillofac Surg* 1986;44:771–8.
- Eriksson L, Westesson P-L. Discectomy in the treatment of anterior disk displacement of the temporomandibular joint. A clinical and radiological one-year follow-up study. *J Prosthet Dent* 1986;55:106–16.
- Kondoh T, Hamada Y, Kamei K, Seto K. Simple disc reshaping surgery for internal derangement of the temporomandibular joint: 5-year follow-up results. *J Oral Maxillofac Surg* 2003;61:41–8.
- Sprinz R. Further observations on the effect of surgery on the meniscus of the mandibular joint in rabbits. *Arch Oral Biol* 1961; 5:195–201.
- Walmsley R, Bruce J. The early stages of replacement of the semilunar cartilages of the knee in rabbits after operative excision. *J Anat Lond* 1937;72:260.
- Pringle J. Displacement of the mandibular meniscus and its treatment. *Br J Surg* 1918;6:385–9.
- Ashhurst A. Recurrent unilateral subluxation of the mandible excision of the interarticular cartilage in cases of snapping jaw. *Ann Surg* 1921;73:712.
- von Stapelmoehr S. Stir les craquements de l'articulation temporo-maxillaire et les luxations habituelles de la machoire. *Acta Chir Scand* 1929;65:1.

47. Bellinger DH. Internal derangements of the temporomandibular joint. *J Oral Surg* 1952;10:47.
48. Agerberg C, Carlsson CE. Behandlingsresultat efter operativa ingrepp i kakleder. *Sver Tandlak Tidskr* 1969;61:1204.
49. Silver CM. Long-term results of meniscectomy of the temporomandibular joint. *J Craniomandib Pract* 1984;3:46–57.
50. Hall HD. Meniscectomy for damaged discs of the temporomandibular joint. *South Med J* 1985;78:569–72.
51. Poswillo D. The late effects of mandibular condylectomy. *Oral Surg* 1972;33:500–12.
52. Hildebrandt C. Das artikulationsgleichgewicht, ein wort ohne inhalt! *Zahnarztl Rundschau* 1940;43:1592.
53. Staz J. The treatment of disturbances of the temporomandibular joint. *J Dent Assoc S Afr* 1951;6:314.
54. Kiehn CL, Des Prez JD. Meniscectomy for internal derangement of temporomandibular joint. *Br J Plast Surg* 1962;15:199–204.
55. Dingman HO, Moorman WC. Meniscectomy in the treatment of lesions of the temporomandibular joint. *J Oral Surg* 1951;9:214–24.
56. Salter RB, Field P. The effects of continuous compression on living articular cartilage. *J Bone Joint Surg* 1960;42A:31.
57. Morris J. Chronic incurring temporomaxillary subluxation: surgical consideration of snapping jaws with report of successful operative result. *Surg Gynecol Obstet* 1930; 50:983.
58. Gordon SD. Surgery of the temporomandibular joint. *Am J Surg* 1958;95:263–6.
59. Martin BC, Trabue JC, Leech TR. The surgical treatment of chronic derangements of the temporomandibular joint. *Plast Reconstr Surg* 1957;19:131–6.
60. Dubecq XJ. Recherches morphologiques, physiologiques et cliniques sur le menisque mandibulaire: luxation habituelle et craquements temporomaxillaires. *J Med Bordeaux* 1937;114:125.
61. Agerberg C, Lundberg M. Changes in the temporomandibular joint after surgical treatment. A radiologic follow-up study. *Oral Surg* 1971;32:865–75.
62. Prentiss HJ. A preliminary report upon the temporomandibular articulation in the human type. *Dent Cosmos* 1918;6:505.
63. Vaughan HC. A study of the temporomandibular articulation. *J Am Dent Assoc* 1943;19:1501.
64. Collins DH, McElligott TF. Sulphate ($^{35}\text{SO}_4$) uptake by chondrocytes in relation to histological changes in osteoarthritic human articular cartilage. *Ann Rheum Dis* 1960; 19:318–30.
65. Tucker MR, Jacoway JR, White RP Jr. Autogenous dermal grafts for repair of temporomandibular joint disc perforations. *J Oral Maxillofac Surg* 1986;94:781–90.
66. Georgiade N, Altany F, Pickrell K. An experimental and clinical evaluation of autogenous dermal grafts used in the treatment of temporomandibular joint ankylosis. *Plast Reconstr Surg* 1957;19:321–90.
67. Stewart HM, Hann JR, Detomas DC, et al. Histologic fate of dermal grafts following implantation for temporomandibular joint meniscal perforation: a preliminary study. *Oral Surg* 1986;62:481–5.
68. Chao LS, Hinton RJ, Babler WJ, et al. Autogenous dermal graft as a TMJ disc replacement in rabbits. Proceedings of the 18th Annual Session of the AADR [special issue]. *J Dent Res* 1989;68:309.
69. Feinberg SE, Larsen PE. The use of a pedicled temporalis muscle-pericranial flap for replacement of the TMJ disc: preliminary report. *J Oral Maxillofac Surg* 1989; 47:142–6.
70. Sanders B, Buoncristiani RO. Temporomandibular joint arthrotoomy; management of failed cases. *Oral Maxillofac Surg Clin North Am* 1989;1:944.
71. Lewis D, Davis C. Experimental direct transplantation of tendon and fascia. *JAMA* 1911;57:540.
72. Narang R, Dixon RA. Temporomandibular joint arthroplasty with fascia lata. *Oral Surg* 1975;39:45–50.
73. Miller TA. Temporalis fascia grafts for facial and nasal augmentation. *Plast Reconstr Surg* 1988;81:524–33.
74. Kippachne WW, Hunt TK, Jackson DS, et al. Effects of function on grafts of autologous and homologous connective tissue. *Surg Forum* 1961;12:97–9.
75. Kirppachne WV, Hunt TK, Jackson DS, et al. Studies on the effect of stress on transplants of autologous and homologous connective tissue. *Am J Surg* 1962; 104:267–72.
76. Witsenburg B, Freihofer HP. Replacement of the pathological temporomandibular disc using autogenous cartilage of the external ear. *Int J Oral Surg* 1984;13:401–5.
77. Hall HD, Link JJ. Diskectomy alone with ear cartilage in joint reconstruction. *Oral Maxillofac Surg Clin North Am* 1989;2.
78. Timmel R, Grundschober F. The interposition of Lyodura in operations of ankylosis of the temporomandibular joint. An experimental study using pigs. *J Maxillofac Surg* 1982; 10:193–9.
79. Boyne PJ, Stringer DE. Allogeneic freeze-dried dura as meniscus replacement in temporomandibular joint surgery [IADR/AADR abstracts]. *J Dent Res* 1981;64:286.
80. Centers for Disease Control. Possible association between dura mater graft and Creutzfeldt-Jakob disease. *MMWR Morb Mortal Wkly Rep* 1987;Feb:6.
81. Feinberg SE, McDonnell EJ. The use of a collagen sheet as a disc replacement in the rabbit temporomandibular joint. *J Oral Maxillofac Surg* 1995;53:535–42.
82. Gallagher DM, Wolford LM. Comparison of Silastic and Proplast implants in the temporomandibular joint after condylectomy for osteoarthritis. *J Oral Maxillofac Surg* 1985;40:627–30.
83. Dolwick M, Aufdemorte Cornelius TB. Histopathologic findings in internal temporomandibular joint derangements. *IADR Abstr* 1984;265.
84. Turlington EC, Welch SR. Foreign body reaction to Teflon-Proplast fossa implants in TMJ arthroplasty (poster session). In: Annual Scientific Meeting of the AAOMS; New Orleans. Sept 1986.
85. Bronstein SL. Retained alloplastic temporomandibular joint disk implants: a retrospective study. *Oral Surg* 1987;64:135–45.
86. Wade M, Catto D, Florine B. Assessment of Proplast implants and meniscoplasties as TMJ surgical procedures. In: Case reports and outlines of scientific sessions. In: Proceedings of the 68th Annual Meeting of the AAOMS; New Orleans. 1981 Sept. p. 28.
87. Homsy CA, Kent JN, Hinds EC. Materials for oral implantation—biology and functional criteria. *J Am Dent Assoc* 1973; 86:817–32.
88. Christensen RW. Chronic unilateral dislocation of the temporomandibular joint treated surgically by a high condylectomy. *Oral Surg* 1960;13:12–22.
89. James B. The surgical treatment of mandibular joint disorders. *Ann R Coll Surg Engl* 1911;99:310.
90. Cherry CQ, Frew A. High condylectomy for treatment of arthritis of the temporomandibular joint. *J Oral Surg* 1971; 35:285–8.
91. Guralnick W, Kaban LB, Merrill RG. TMJ afflictions. *N Engl J Med* 1975;299:123–9.
92. Dunn MJ, Benza R, Moran D, Sanders J. Temporomandibular joint condylectomy: a technique and postoperative follow-up. *Oral Surg* 1981;51:363–74.
93. Marciani RD, Ziegler RC. Temporomandibular joint surgery: a review of 51 operations. *Oral Surg* 1983;56:472–6.
94. Nespeca JA, Griffin JM Temporomandibular

- joint surgery—a three year study. *J Hawaiian Dent Assoc* 1983;14(2):9–10.
95. Campbell W. Clinical and radiological investigations of the mandibular joints. *Br J Radiol* 1961;38:401–21.
96. Ward TC. Surgery of the mandibular joint. *Ann R Coll Surg Engl* 1961;18:139.
97. Sada V. Experience in surgical treatment of temporomandibular joint arthrosis by the Ward technique. *Trans Cong 1st Int Assoc Oral Surg* 1967;265–7.
98. Tasamen A, Lamberg M. Closed condylotomy in the treatment of osteoarthritis of the temporomandibular joint. *Int J Oral Surg* 1978;7:1–6.
99. Poswillo D. Surgery of the temporomandibular joint. *Oral Rev* 1974;6:87–118.
100. Buckerfeld JP. The applied anatomy of closed condylotomy. *Br J Oral Surg* 1978;15:245–52.
101. Brown RW, Hall AB, Lebowitz MS. Facial nerve injury during TMJ surgery: a comparison of two dissection techniques. In: Case reports and outlines of scientific sessions. *J Oral Maxillofac Surg* 1985;43:20–3.
102. Toller PA. Temporomandibular capsular rearrangement. *Br J Oral Surg* 1074;11:207–12.
103. Nitzan DW, Dolwick MF, Heft MW. Arthroscopic lavage and lysis of the temporomandibular joint: a change in perspective. *J Oral Maxillofac Surg* 1990;48:798–801.

Management of the Patient with End-Stage Temporomandibular Joint Disease

Stephen B. Milam, DDS, PhD

The patient with end-stage temporomandibular joint (TMJ) disease is typically characterized by a protracted history of multiple therapeutic interventions, often including multiple TMJ surgeries. The patient with end-stage TMJ disease commonly suffers from unrelenting pain and severe limitation of jaw movement. In addition, some patients with end-stage TMJ disease may also endure facial deformities, sensory or motor abnormalities, dysfunctional malocclusions, and upper airway compromise. The suffering of these unfortunate individuals is often compounded by their compromised position in managed health care systems and mounting personal debt. Understandably, virtually all patients with end-stage TMJ disease exhibit signs and symptoms of depression, often straining relationships with significant others.

Several factors likely contribute to the evolution of end-stage TMJ disease. The progression of some TMJ disorders may be influenced by variables such as sex (ie, mediated by sex hormones such as estrogen and prolactin), genetic backdrop (eg, predisposition to rheumatoid arthritis is associated with some estrogen receptor polymorphisms), nutritional status, age, and psychological stress (eg, plasma levels of nerve growth factor, an endogenous

peptide implicated in the genesis of some muscular and neurogenic pains, are elevated in humans following psychological stress). In addition, it is clear that many patients with end-stage TMJ disease also suffer from iatrogenic injury.

Currently the prognosis for recovery of the patient with end-stage TMJ disease is extremely poor. Clearly, the best strategy is prevention. How can risks for developing end-stage TMJ disease be reduced?

Basic Elements of Care

Effective management of any TMJ disorder is primarily dependent on three elements of care: an accurate diagnosis, careful patient selection, and effective perioperative patient management (Table 51-1).

An accurate assessment of a patient's condition(s) is an absolute requirement for the selection of an effective treatment. The experienced clinician recognizes that many painful conditions of the head and neck region can mimic a TMJ disorder. For example, it is well known that some masticatory myalgias can produce pain of various qualities (ie, ranging from aching sensations to “stabbing” or “throbbing” pains) that may be felt in the area of one or both TMJs.¹ Furthermore, some of these painful conditions, such as the masticatory myalgias, may also be associated with

restricted jaw movement and may be exacerbated by such movement. Similarities between many painful head and neck disorders with respect to clinical presentation can pose a significant challenge for the clinician to derive an accurate diagnosis. Failure to do so can lead to the initiation of an ineffective and perhaps damaging treatment that may ultimately contribute to clinical anomalies that characterize end-stage TMJ disease.

Proper patient selection is important since, although appropriate surgical objectives and proper technique are obviously significant determinants of treatment outcome, a patient's commitment and ability to perform critical perioperative tasks (eg, regular exercises, nutritional maintenance, abstinence from unhealthy habits) may be the single most important determinant of the outcome of surgical treatment of a TMJ disorder. Therefore, the clinician must accurately assess the patient's willingness

Table 51-1 Basic Elements of Surgical Care

Accurate diagnosis
Careful patient selection
Effective perioperative management
Pain management
Restoration of jaw movement

and ability to comply with an often-difficult perioperative regimen. Depending on the condition, patients who are unwilling or unable to comply with a demanding but essential perioperative regimen may not be viable candidates for the indicated surgery. Failure to recognize this limitation preoperatively often leads to a significantly compromised surgical outcome.

It is also important to delineate realistic objectives of therapy, including surgery, and to recognize the limitations of each approach. Experienced surgeons often reliably achieve TMJ surgical objectives, including excision of neoplastic or diseased tissues, relief of physical obstructions to joint movement, and restoration of important anatomic relationships. However, even the most experienced surgeon may not reliably achieve some treatment objectives such as relief of pain. Clinicians may sometimes recommend treatment by default (eg, other approaches have failed to provide adequate pain relief) without clearly delineated and reliably achieved treatment objectives. Such an approach has significant potential for worsening the patient's overall condition by iatrogenic injury. All recommended treatments should be based on an accurate diagnosis, and a plan based on well-delineated achievable treatment objectives.

Perioperative Management

Patients with end-stage TMJ disease suffer primarily from persistent pain and restricted jaw function. Recent evidence suggests that some persistent pain may result from neuroplastic changes evoked in nociceptive pathways of the central nervous system (CNS) by intense stimulation or nerve injury. There is also strong evidence that these changes may be prevented or significantly obtunded by preemptive techniques that reduce or block CNS responses to surgical stimulation (ie, preemptive analgesia). Two primary goals of perioperative management of the operated TMJ patient are pain control (ie, using

preemptive analgesia techniques) and establishment and maintenance of acceptable joint movements (ie, mandibular range of motion). These goals are not exclusive. Patients who suffer from temporomandibular pain are often noncompliant with recommended jaw exercises that must be performed to achieve and maintain physiologic joint movements.

Pain-Control Strategies

With few exceptions, pain is the primary chief complaint of patients with TMJ disease and is often the principal limiting factor in the patient's willingness to comply with physical therapy designed to restore jaw movements. In addition, patients suffering from persistent pain often exhibit clinical signs of depression. They are often socially withdrawn, and interpersonal relationships with significant others may become compromised. Therefore, effective pain control strategies must be identified, preferably in the preoperative period, and implemented aggressively to ensure an optimum surgical outcome and to sustain an acceptable quality of life for the patient (Table 51-2).

Preemptive Analgesia

Effective postsurgical pain control begins in the operating room. It is now recognized that methods that limit CNS neuronal activation by surgical stimulation may significantly reduce pain in the postsurgical period and may also reduce the liability for the development of some persistent pains. The term *preemptive analgesia* is used to describe methods that apparently reduce postsurgical pain by protecting the CNS from surgical stimulation. The concept is based on recent observations that collectively indicate that nociceptive processing is highly dynamic. Nociception and subsequent pathway sensitization likely involves de novo protein synthesis and even establishment of novel connections by neurons in the affected pathway.²⁻⁴ The old view that nociceptive

Table 51-2 Pain Management

Perioperative
Preemptive analgesic techniques
• Regional anesthesia
• Opioid-based general anesthesia
• Ketamine
• Ketorolac
Immediate postsurgical period
• Regional anesthesia
• Opioids (patient controlled analgesia or scheduled regimens)
• Ketorolac
Long term
Pharmacologic
• Tricyclic antidepressant (eg, amitripty-line)
• Opioids (scheduled dosing)
• GABAergics (eg, baclofen, gabapentin)
• Nonopioid analgesics (for pain associated with inflammation)
Nonpharmacologic
• Regular exercise
• Acupuncture
• Biofeedback
• Transcutaneous electrical nerve stimulation
• Heat/cold packs

GABA = γ -aminobutyric acid.

pathways are merely static conductors of neural signals generated by noxious stimuli appears to be invalid. We now know that gene transcription is induced in stimulated neuronal populations.^{5,6} Some neuropeptides that are translated from these genes may facilitate future neural activities by receptive field expansion or by facilitation of specific interneuronal interactions. The term *neuroplasticity* is often used to refer to the dynamic state of stimulated neural pathways. These, and perhaps other more ominous changes (ie, neuronal death from excessive stimulation), may be fundamental to the development of some chronic pain states. Fortunately, these CNS responses may be significantly attenuated by preemptive analgesic techniques.^{3,7}

Techniques From animal and clinical studies there is evidence that protracted neural responses to painful stimuli can be modified or prevented by the following: (1) neural blockade with local anesthetics,⁸⁻¹⁰ (2) administration of opioids,¹¹⁻¹⁵ (3) administration of *N*-methyl-D-aspartate receptor antagonists (eg, MK801, ketamine, dextrophan),¹⁶⁻¹⁸ or (4) administration of ketorolac, a peripherally and centrally acting nonopioid analgesic.¹⁹⁻²¹ These agents must be administered *prior* to noxious stimulation to prevent CNS changes that may be related to the development of postsurgical pain, and perhaps persistent pain. It is interesting to note that a general anesthetic state does not prevent neuroplastic changes induced by surgical stimulation, unless the general anesthetic technique employs high-dose opioids or ketamine. Neural impulses from surgical stimulation apparently reach the CNS evoking sensitization despite the fact that overt signs of surgical stimulation (ie, patient movement, heart rate, systemic blood pressure) are blocked by general anesthesia. This stimulus-dependent neural sensitization, characterized by receptive field expansion and the “wind-up” phenomenon,^{2,3} has been attributed to postsurgical hyperesthesia and pain.

When regional anesthesia is employed as an adjunct to general anesthesia, there is strong evidence that postoperative pain is significantly reduced, consistent with current models of central sensitization and neuroplasticity. However, to ensure that neural activities induced by surgical stimulation are fully blocked, the surgeon must administer regional anesthesia *prior* to surgical stimulation. If necessary during long procedures, the surgeon should reanesthetize the operative field and not rely solely on a general anesthetic state for CNS protection.

Jebeles and colleagues studied the effects of preemptive regional anesthesia on postsurgical discomfort associated

with tonsillectomy and adenoidectomy performed under general anesthesia.²² Twenty-two children were given either bupivacaine or saline infiltrations in the peritonsillar regions prior to surgical stimulation. For this study postsurgical analgesics were standardized for all subjects and postsurgical pain was assessed over a 10-day period by three dependent measures (ie, constant pain, pain evoked by swallowing a standard volume of water, and the time required to drink 100 mL of water based on the assumption that the rate-limiting factor for this activity is throat pain). All three dependent measures confirmed that subjects given bupivacaine regional anesthesia with general anesthesia experienced significantly less pain over a 10-day postsurgical period compared with the saline-injected group.²² Other studies have provided similar evidence that regional anesthesia, provided prior to surgical stimulation, can significantly reduce pain following craniotomy and bone harvesting from the iliac crest.^{23,24} To date no published papers have documented the efficacy of preemptive regional anesthesia on postoperative pain, or on the subsequent development of chronic pain, in the operated patient with TMJ disease. Nevertheless, existing evidence strongly suggests that the use of regional anesthesia as an adjunct to general anesthesia will significantly reduce postsurgical pain in such a patient.

Opioids administered *prior* to surgical stimulation may also reduce postsurgical hyperesthesia believed to be due to central sensitization. For example, isoflurane or isoflurane and nitrous oxide, administered in a concentration sufficient to suppress cardiovascular responses to surgical stimuli (ie, minimum alveolar concentration that blocks adrenergic responses [MACBAR]), do not inhibit formalin-induced hyperesthesia.²⁵ Formalin injected intradermally provides a potent noxious stimulus that results initially in a volley of neural activity that

sensitizes central nociceptive neurons in the pathway. This observation reinforces previous studies indicating that general anesthesia alone does not offer protection against central sensitization. However, morphine administered *prior* to formalin injection significantly reduces postinjection hyperesthesia in this model.²⁵ In fact, a significant reduction in formalin-induced hyperesthesia was also observed even if morphine was reversed by naloxone shortly after the formalin injection was administered, indicating that even a brief exposure to an opioid prior to noxious stimulation is sufficient to prevent or significantly reduce stimulation-induced hyperesthesia.²⁵ Likewise, alfentanil reduces capsaicin-induced hyperalgesia in human subjects, but only if this agent is administered prior to capsaicin administration.²⁶ Capsaicin is a vanilloid extracted from peppers that is known to selectively stimulate C-fiber neurons expressing the vanilloid receptor (VR-1). Stimulation of C-fiber neurons by capsaicin administration produces receptive field expansion and hyperesthesia by mechanisms that involve central sensitization.³ Notably, alfentanil did not effectively reduce pain scores, flare response, or secondary hyperalgesia when administered *after* an intradermal injection of capsaicin in these human studies.²⁶ These studies highlight the fact that, as is apparent for regional anesthesia, opioids are only optimally effective as modulators of central sensitization and subsequent hyperalgesia if they are administered prior to surgical stimulation.

Ketorolac is a peripherally and centrally acting nonopioid analgesic that is also an effective preemptive analgesic.¹⁹⁻²¹ In a randomized double-blind trial involving 48 patients undergoing ankle fracture surgery, ketorolac 30 mg administered prior to surgical stimulation significantly reduced postsurgical pain relative to the same amount of ketorolac administered after stimulation.²⁰

Preemptive Analgesia and Persistent Pain

Some preemptive analgesia techniques significantly reduce postsurgical pain. There is also evidence that preemptive analgesia may provide some protection against the development of some chronic pain states. Bach and colleagues reported one of the few investigations designed to assess the impact of preemptive analgesia on the evolution of a chronic pain state.²⁷ In this clinical study 25 elderly patients scheduled for a below-the-knee amputation received either treatment with epidural bupivacaine and/or morphine to produce a pain-free state for 3 days prior to surgery, or no pretreatment (control group). All patients subsequently underwent amputation under spinal anesthesia. After 6 months, none of the patients assigned to the presurgery analgesia group experienced phantom limb pain.²⁷ However, 38% of the subjects who did not receive the presurgical pain treatment had phantom limb pain at the 6-month post-amputation period. Furthermore, 27% of these subjects experienced persistent phantom limb pain at the 1-year follow-up period.²⁷

Recommendations It is recommended that, when feasible, an opioid-based or opioid-supplemented general anesthetic technique be employed for TMJ surgery. Also, regional anesthetic should be administered to cover the entire surgical field *prior* to surgical stimulation. During long procedures, the surgical field should be reanesthetized periodically. If there are no contraindications (eg, bleeding concerns), some consideration can also be given to ketorolac administration (ie, 0.5 mg/kg or 30 mg IV) *prior* to surgical stimulation. Finally, postoperative pain should also be well controlled with a combination of regional anesthesia and opioid or ketorolac analgesia. These regimens may significantly reduce postsurgical pain facilitating a shortened convalescence, and may also protect the patient from

CNS responses to surgical stimulation that may be involved in the genesis of some chronic pain states.

Postsurgical Pain Management and Pharmacologic Approaches

Effective pain management permits immediate postsurgery physical therapy by improving patient compliance, which is crucial to the establishment and maintenance of an acceptable mandibular range of motion. Based on the studies cited above, it is reasonable to assume that a continuation of effective pain control beyond the intraoperative period may offer some additional benefits in the prevention of some protracted (ie, chronic) pain states, although this remains a subject for future studies. The most common methods of postsurgical pain management incorporate a combination of opioid and nonopioid analgesics. In some instances other medications (eg, tricyclic antidepressants [TCAs], γ -aminobutyric acid [GABA]-ergics) may also offer significant pain relief for the patient with end-stage TMJ disease. Finally, some patients may benefit from nonpharmacologic approaches (eg, walking 30 min/d for 6d/wk, acupuncture, cold or hot pack applications, hypnosis, meditation, progressive relaxation, biofeedback).that can be used as a substitute for (eg, the medication-intolerant patient) or in tandem with pharmacologic approaches.

Nonopioid Analgesics Nonopioid analgesics, including salicylates (eg, acetylsalicylic acid), *p*-aminophenols (eg, acetaminophen), arylacetic acids (eg, indomethacin), arylpropionic acids (eg, ibuprofen), and keto-enolic acids (eg, piroxicam), are commonly used to manage pain that is associated with inflammation. Nonopioid analgesics block the synthesis of prostaglandins (PGs) from arachidonic acid by the action of cyclooxygenases (COXs) (Figure 51-1). Some PGs (eg, PGE₂) are known to sensitize peripheral nociceptors contributing to the development of hyperalgesia.

Two isoforms of COX are known (COX-1 and COX-2). COX-1 is constantly expressed in most tissues to provide a steady production of PGs that are required for many normal cellular functions.²⁸⁻³⁰ On the other hand, COX-2 is an inducible COX. It is not typically expressed under normal conditions, but, rather, it is synthesized in response to injury accounting for the increased production of PGs associated with inflammation.^{28,31,32} Studies indicate that some PGs (eg, PGE₂) sensitize sensory neurons to stimulation by other biochemicals, including bradykinin and histamine.³³ It is generally felt that PGs play an important role in the genesis of inflammatory pain via this mechanism. PGs, specifically PGE₂, have been detected in lavage fluid or synovial fluid samples obtained from symptomatic human TMJs in concentrations ranging from 0.1 to 3.5 ng/mL.^{34,35} These concentrations are above the dissociation constants for prostanoid receptors (ie, the concentration required for receptor binding) and are therefore physiologic. Nonopioid analgesics are believed to exert their primary effects by inhibiting the synthesis of PGs in peripheral tissues, including the TMJ.

Some nonopioid analgesics may produce analgesia by central mechanisms, perhaps by suppressing COX activity in CNS neurons or adjacent glial cells. An intrathecal administration of acetylsalicylate produced analgesia in humans suffering from late-stage cancer pain.³⁶ Furthermore, central injections of nonopioid analgesics produce antinociception in several animal models of pain.^{37,38} Therefore, it appears that some nonopioid analgesics may relieve some types of pain by both central and peripheral mechanisms.

Side Effects As noted above, it is currently believed that basal levels of PGs are generated under normal circumstances in tissues by the action of COX-1.³⁰ PGs regulate important physiologic processes in several tissues, including gastric

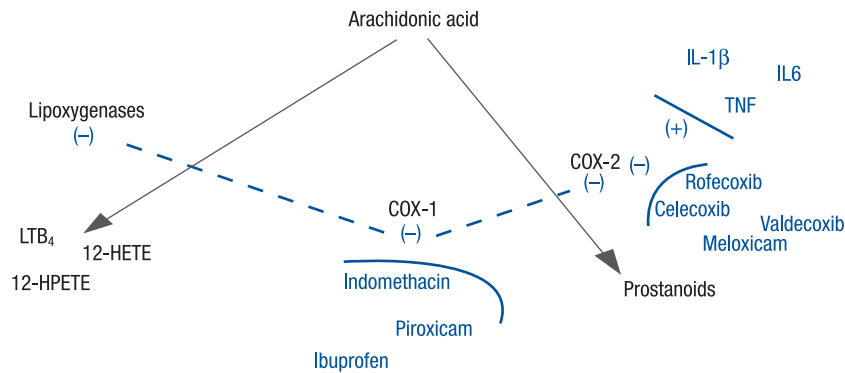


FIGURE 51-1 Proinflammatory molecules derived from arachidonic acid. Proinflammatory prostanoids and leukotrienes (LTs) are derived from arachidonic acid liberated from cell membrane phospholipids by phospholipases. Prostanoids are generated by the actions of cyclooxygenases (COX-1 and COX-2). COX-2 is an inducible form that is synthesized by cells stimulated by molecules produced after injury (eg, interleukin-1 β [IL-1 β], tumor necrosis factor [TNF], IL-6). Leukotrienes are generated by the actions of lipoxygenases. 12-hydroxyeicosatetraenoic acid (12-HETE) and 12-hydroperoxyeicosatetraenoic acid (12-HPETE) may be capable of stimulating nociceptors by direct action (ie, by binding vanilloid receptor 1; see text). Selective COX-2 inhibitors (eg, rofecoxib, celecoxib, meloxicam, and valdecoxib) block the activity of COX-2, thereby reducing prostanoid synthesis under inflammatory conditions. Nonselective COX inhibitors (eg, indomethacin, piroxicam, and ibuprofen) inhibit both COX-1 and COX-2 activities. At higher doses these drugs may also inhibit lipoxygenases.

mucosa, kidney, bone, and cartilage.^{39–44} For example, in the stomach nonopioid analgesic suppression of PG synthesis results in an increase in gastric acid secretion since PGs inhibit this process.³⁹ Also, the secretion of gastric mucus that provides a protective coating of the stomach lining is inhibited by some nonopioid analgesics. These combined effects, in susceptible individuals, can produce gastrointestinal irritation and bleeding. In fact, chronic users of nonopioid analgesics have a threefold greater risk of serious gastrointestinal complications compared with the risk in nonusers.⁴⁵

Selective COX-2 Inhibitors Relatively selective COX-2 inhibitors have been introduced for clinical use in an attempt to reduce systemic side effects associated with chronic nonopioid analgesic consumption. Four relatively selective COX-2 inhibitors are available in the United States at the present time: celecoxib, meloxicam, rofecoxib, and valdecoxib. There has been a general misperception that these agents provide superior analgesia relative to the

traditional nonselective COX inhibitors. However, clinical trials have generally not supported this notion. For example, ibuprofen provides superior analgesia to celecoxib following third molar extraction with a similar side-effect profile.⁴⁶ Therefore, the primary indication for the use of relatively selective COX-2 inhibitors appears to be the control of inflammatory pain in patients with gastrointestinal or renal disorders. However, it should be noted that these agents do not prevent serious gastrointestinal or renal side effects, although the incidence of their occurrence may be relatively low.

Leukotrienes: a Target for Future Therapies Leukotrienes are generated from arachidonic acid by the action of lipoxygenases. Leukotrienes (LTs), particularly LTB₄, are proinflammatory molecules that promote leukocyte chemotaxis, sensitize nociceptors, stimulate free radical production, and promote bone and cartilage destruction. LTB₄ has been detected in lavage fluids obtained from symptomatic human TMJs.³⁴

In addition to well-documented effects on bone and cartilage catabolism, some lipoxygenase products may also play an important role in nociception; they appear to be endogenous analogs of capsaicin.^{47,48} As noted above, the pepper extract capsaicin selectively stimulates nociceptors. The tertiary structures of 12-hydroxyeicosatetraenoic acid and 12-hydroperoxyeicosatetraenoic acid are very similar to that of capsaicin.⁴⁷ Furthermore, these lipoxygenase products are capable of stimulating nociceptors in a concentration-dependent fashion. This evoked activity can be inhibited by antagonists for the primary capsaicin receptor VR-1.⁴⁷ These findings indicate that some lipoxygenase products are capable of directly stimulating nociceptors. By this mechanism, these arachidonic acid products could contribute to inflammatory pain. Therefore, lipoxygenase inhibitors may have significant analgesic properties, in addition to potential inhibitory effects on LT-mediated bone and cartilage catabolism.

Recommendations At the present time the efficacies of nonopioid analgesics employed to manage pain in the patient with end-stage TMJ disease have not been determined. Some nonopioid analgesics to treat arthritic pain are effective. Therefore, one may expect to see beneficial responses to nonopioid analgesics when a significant inflammatory component underlying reported TMJ pain is suspected.

Nonopioid analgesics vary considerably in relative potency. All clinically available nonopioid analgesics suppress PG synthesis to a variable extent (ie, they differ in relative potencies for COX-1 and COX-2 inhibition) in either peripheral or CNS tissues. Some nonopioid analgesics also block LT synthesis in the recommended dose range. LTs, as noted in the previous discussion, can promote potentially detrimental effects in inflamed tissues, and some lipoxygenase products

may be endogenous analgesics. At the present time specific LT inhibitors are not available for clinical use, although compounds have been identified that hold future promise.⁴⁹ Therefore, nonopioid analgesics that inhibit both PG and LT pathways may be preferred.

All nonopioid analgesics achieve synovial fluid concentrations that are above their median effective dose (ED₅₀) following the administration of their recommended oral dose. Therefore, it is difficult to favor one nonopioid analgesic over another in this respect.

Nonopioid analgesics may be indicated when an inflammatory component of the patient's condition is suspected (ie, joint effusion, acute localized pain, local swelling, or acute posterior open bite). Clearly, nonopioid analgesics may offer significant benefits in the postsurgical period, perhaps used in combination with opioids. Given well-documented potentially serious side effects, nonopioid analgesics should be discontinued if a brief trial fails to provide significant clinical benefit or if the patient experiences side effects. If benefits are not apparent after a reasonable trial period (ie, 7–10 d) or if side effects are observed, the drug should be withdrawn. If the nonopioid is found to be effective, it can be continued. However, patients receiving nonopioid analgesics should be monitored on a regular basis for drug side effects. Furthermore, periodic tapered withdrawal trials should be performed to reassess the need for the drug.

Opioids Opioids elicit their physiologic effects via interactions with one or more subclasses of opioid receptors located in the CNS and in peripheral tissues. Three classes of opioid receptor are known to exist, designated μ -opioid receptor (MOR), δ -opioid receptor (DOR), and κ -opioid receptor (KOR). In addition, at least two subclasses of MOR and DOR receptors and four subclasses of the KOR receptor have been identified.^{50,51} Opioids

affect neurons and some non-neural cells such as leukocytes by several mechanisms, including inhibition of cyclic adenosine monophosphate (cAMP) formation, activation of G_o or G_{i/o} proteins, or altered Ca⁺⁺ or K⁺ translocation.^{52–54} Increasing evidence suggests that analgesia may be produced by opioid effects in the CNS, spinal cord, or peripheral tissues. Some types of pain may be refractory to opioid effects. For example, it is generally believed that opioids are ineffective for the relief of neurogenic pain, although there is recent evidence to the contrary.⁵⁵

In animal models of TMJ injury, activation of neurons in multiple areas of trigeminal nuclei can be demonstrated by expression of Fos.⁵⁶ Fos is a transcription factor that regulates the expression of specific genes in all cells including neurons. In neurons Fos expression is used as a measurement of activation and is typically determined using standard immunohistochemical approaches employing monospecific antibodies directed against Fos. Systemically administered morphine significantly reduces Fos expression in the trigeminal nucleus following acute TMJ stimulation in the rat.⁵⁶

Peripheral Mechanisms of Opioid Analgesia

For many years clinicians have been aware of the analgesic effects of peripherally administered opioids. Chase reported that local application of small amounts of morphine was effective in relieving toothache.⁵⁷ Hargreaves and colleagues have recently validated this early observation.⁵⁸ In this latter study endodontic patients diagnosed with acute dental infection were administered morphine (0.4 mg), lidocaine, or saline by intraligamentous injection in a randomized double-blinded fashion. These investigators found that at one-tenth the systemic dose required to relieve dental pain, morphine administered locally (ie, by intraligamentous injection) produced significant pain relief. This supports the belief that opioids can produce

relief of some types of pain by actions in peripheral tissues.

There is additional support for the concept that opioids may provide relief of TMJ pain by peripheral action. In the rat TMJ MOR has been detected at nerve terminals supplying both anterior and posterior synovial tissues, as well as other cell types, presumed to be resident macrophages, mast cells, and endothelial cells.⁵⁹ In other articular joints local injections of opioids can suppress the release of neuropeptides from peripheral nerve terminals supplying the injected joint.⁶⁰ Some neuropeptides, such as substance P and calcitonin gene-related peptide, are proinflammatory and have been detected in nerve terminals supplying the TMJ and in synovial fluid samples recovered from symptomatic TMJs.^{61–64} Release of these neuropeptides into articular tissues can generate a variety of inflammatory responses that may underlie joint pain and disease. The term *neurogenic inflammation* is used to describe this phenomenon. It is speculated that the intra-articular administration of an opioid into the TMJ could inhibit neurogenic inflammation by blocking the release of proinflammatory neuropeptides from stimulated nerve terminals located in the TMJ. Opioids employed in this fashion could be effective “anti-inflammatory” agents if this model is correct.

Despite clinical and animal studies that suggest that peripherally administered opioids produce analgesic responses, studies examining the effects of intra-articular morphine on TMJ pain remain equivocal.^{65–67} In the largest of the three published studies to date, 53 patients diagnosed with unilateral TMJ arthralgia or osteoarthritis were assigned to one of three groups receiving a single intra-articular injection of 1 mg morphine sulfate, 0.1 mg morphine sulfate, or saline.⁶⁷ The dependent measures employed in this study included pain at rest, assessed by a standard visual analog scale, pain at maximum opening, pressure pain

threshold, and mandibular range of motion measurements (ie, maximum vertical opening, lateral and protrusive movements). Significant group differences in pain at maximum opening were not observed until 4 days after the injection in subjects given the 0.1 mg morphine dose. Subjects reported less pain at maximum opening indicating that intra-articular morphine lessened mechanical allodynia (ie, pain with non-noxious mechanical stimulation or movement). However, no dose response was observed (ie, the higher dose of morphine did not produce a similar or greater effect), and pain at rest was not affected by intra-articular morphine. The pressure pain threshold was significantly elevated (ie, more pressure required to produce pain) at the 1-week follow-up period in patients given the 0.1 mg dose of morphine.

Several factors may govern responses to locally administered opioids. Opioids do not produce measurable effects when administered into normal peripheral tissues.⁶⁸⁻⁷⁰ However, when injected into inflamed peripheral tissues, opioids may reduce pain,^{58,71} inhibit plasma extravasation and edema,^{72,73} and alter leukocyte function.^{74,75} Animal studies have demonstrated potent effects of opioids injected into inflamed tissues.⁷⁶ For example, PG-induced hyperalgesia is suppressed by nanomolar concentrations of opioids.⁷⁶ The primary mechanism(s) by which opioids exert their influence in inflamed peripheral tissues is unknown. From previous studies of opioid receptor distribution in the TMJ, it appears that a variety of cells, including neurons, leukocytes, synoviocytes, and endothelial cells, can respond to peripherally administered opioids.⁵⁹ Therefore, it is likely that opioids exert their effects on both neural and non-neural cell populations in inflamed tissue. It is also possible that some inflammatory molecules (eg, bradykinin, PGs) may “sensitize” opioid receptors to opioid stimulation.

Factors Affecting Response to Peripheral and Central Opioids Responses to peripherally administered opioids may be sex dependent. Cai and colleagues examined jaw muscle electromyographic activity in the rat following an injection of glutamate, an algescic amino acid, into the TMJ.⁷⁷ Peripherally applied morphine significantly reduced glutamate-evoked muscle activity in male Sprague-Dawley rats but not when administered to female animals. This observation is consistent with sex-based differences in neural responses following systemically administered opioids. Brainstem neural responses to intense noxious stimulation of the TMJ are obtunded by a prestimulation systemic administration of morphine in male rats to a much greater extent than is observed in female animals.⁵ Morphine is predominantly a MOR agonist. Interestingly, a KOR agonist was found to attenuate brainstem responses to TMJ stimulation in the female to a greater extent than in the male.⁵ These observations indicate that sex hormones may differentially regulate the expression of different opioid receptor types, and that males and females may therefore differ significantly in responses to different opioids (eg, MOR agonists vs KOR agonists). Further research is clearly needed in this area to confirm sex-based differences in opioid receptor expression in the CNS and in peripheral tissues such as the TMJ.

Another factor that may govern responsiveness to opioids is the genetic backdrop of the patient. Polymorphisms of opioid receptor genes could account for some of the variability observed in response to opioids. Polymorphisms are subtle gene mutations that result in the production of a protein, in this case an opioid receptor that differs from native protein with respect to structure and function. Some gene polymorphisms may perturb function of the protein, whereas others may enhance function. Studies are needed to determine whether polymor-

phisms of opioid receptors explain apparent individual differences in clinical response to either peripherally or systemically administered opioids.

Chronic Opioid Therapy Drug dependency or addiction, reinforcing drug-seeking behavior, drug-induced depression, drug tolerance, and fear of government prosecution are frequently cited reasons for avoiding opioids in management protocols for chronic pain patients. Until recently each of these concerns was considered a valid reason for avoiding opioid therapy. However, recent evidence suggests that the risk of addiction may be extremely low in chronic pain patients with no prior history of substance abuse.⁷⁸ Drug use alone does not appear to be the major determinant of addiction. Rather, other factors such as social, psychological, and economic conditions appear to contribute more to addictive behavior.⁷⁹ Psychiatric consultation may be valuable in the identification of individuals with true addictive behavior.

Despite clinical impressions to the contrary, studies have not validated concerns regarding development of opioid tolerance. These data indicate that the analgesic potency of opioids seldom declines over time, unless there is a worsening of the patient’s physical condition.⁸⁰⁻⁸² Furthermore, cross-tolerance is often incomplete in patients who do exhibit signs of opioid tolerance.^{83,84} In these instances switching to another narcotic can produce an analgesic response. Future studies are required to determine the true benefits and risks of protracted opioid therapy to manage persistent pain experienced by the patient with end-stage TMJ disease.

Indications for Opioid Therapy Opioids do not appear to be effective for all types of pain. It is often difficult to determine whether the apparent lack of efficacy observed in some patients is due to this

fact or if the dose administered is simply inadequate. However, a rational approach that can be employed to confirm the analgesic efficacy of opioid therapy for a specific patient is suggested in a study conducted by Dellemijn and Vanneste.⁵⁵ These investigators used an active placebo (diazepam) and an inactive placebo (saline) to demonstrate the analgesic efficacy of an opioid (fentanyl) in patients suffering from neuropathic pain. In this particular study diazepam was no more effective than saline as an analgesic. However, diazepam did produce a sedative effect similar to that produced by fentanyl and was therefore suitable for use as an active placebo. Using this experimental design, the investigators demonstrated the analgesic efficacy of fentanyl for control of neuropathic pain. A similar approach could be employed to determine whether opioid therapy would provide effective analgesia for a particular patient with end-stage TMJ disease. In this way, the clinician could provide a better estimate of the benefit-to-risk ratio of opioid therapy.

As-needed dosing schedules for opioids are avoided. It is preferable to dose opioids on a scheduled basis for optimum control of pain. For example, if the patient indicates that pain is worse in the late morning and afternoon hours, then an adequate loading dose of the opioid should be administered 1 to 2 hours prior to the morning peak pain period with supplemental dosings at 3- to 6-hour intervals depending on the drug. During the titration period patients may be asked to log their pain using a 0 to 10 intensity scale at hourly intervals. Dose adjustments can then be made based on patient reports of pain. Some consideration should be given to the use of long-acting opioids or alternate delivery systems (eg, transdermal, implanted infusion pumps) in those instances when severe protracted pain is controlled by opioid therapy. This approach may be more cost effective and can provide better long-term pain relief.

TCAs Imipramine was the first TCA found to possess analgesic properties.^{85,86} Since that time numerous well-controlled trials have documented pain relieving effects of TCAs.⁸⁷⁻⁹⁰

Mechanism of Antinociception TCAs produce significant analgesia independent of their antidepressant effects. For example, analgesic effects of TCAs are observed in pain patients with normal mood.^{91,92} Furthermore, TCA-induced analgesia is typically observed prior to antidepressant effects and at doses that are generally believed to be too low for any significant antidepressant effect.⁹³⁻⁹⁵

Amitriptyline and imipramine, antidepressants with antinociceptive actions, are potent inhibitors of serotonin reuptake.⁹⁶ Though these agents have no direct effect on norepinephrine reuptake, their metabolites are also potent norepinephrine reuptake inhibitors.⁹⁶ In vivo, these TCAs can be viewed as mixed monoamine reuptake inhibitors (ie, they inhibit the reuptake of both serotonin and norepinephrine).

TCAs enhance the biologic activities of serotonin and norepinephrine by reuptake blockade. Monoamine receptor occupancy is increased by reuptake inhibitors (ie, TCAs) resulting in an antinociceptive effect. There is recent evidence that monoamines may be important modulators of temporomandibular pain.⁹⁷ This is strongly suggested in studies investigating the relative sensitivities of patients who express different versions of the catechol O-methyltransferase (COMT) gene (ie, polymorphisms) to painful masseter muscle stimulation. COMT is an enzyme that regulates noradrenergic neurotransmission by catecholamine metabolism. The gene for COMT exists in a variety of forms created by subtle mutations (ie, polymorphisms). A COMT gene polymorphism exists at codon 158 (a codon is a three-nucleotide deoxyribonucleic acid sequence that encodes a specific amino acid of the encoded protein, in this

instance COMT), where a valine code is substituted by a methionine code. This substitution results in a COMT variant that is three to four times less active than the native COMT. Individuals who are homozygous for this COMT variant report significantly more pain following a hypertonic saline injection of the masseter muscle relative to those individuals who express the normal variant.⁹⁷ Interestingly, these individuals also show a reduction in endogenous opioid responses to this stimulation in discreet regions of the thalamus as assessed by functional magnetic resonance imaging studies.

Efficacy for Relief of Muscular Pain

Amitriptyline significantly reduces the duration and frequency but not the intensity of chronic tension-type headaches.^{89,98} However, selective serotonin reuptake inhibitors do not appear to affect chronic tension-type headaches.⁸⁹ Appropriately controlled clinical studies have also provided evidence that amitriptyline is effective in relieving pain associated with fibromyalgia.⁹⁹⁻¹⁰³ However, sustained clinical improvement occurs in a relatively small percentage of fibromyalgia patients given this agent.

Efficacy for Relief of Neuropathic Pain

As appears to be the case for relief of muscular pain, antidepressants with mixed serotonin and norepinephrine reuptake inhibition (eg, amitriptyline) are more efficacious than relatively selective reuptake blockers (eg, predominant norepinephrine reuptake inhibition by desipramine; predominant serotonin reuptake inhibition by paroxetine or citalopram) with respect to relief of neuropathic pain.^{92,104-108} The efficacy of mixed serotonin and norepinephrine reuptake inhibitors has been demonstrated for various types of neuropathic pain. For example, 53% of patients with neuropathic pain following treatment of breast cancer had a > 50% reduction in pain at a

median daily dose of 50 mg of amitriptyline.¹⁰⁵ Amitriptyline has also been shown to be more effective than placebo for relief of pain associated with diabetic neuropathy, postherpetic neuropathy, and central lesions.^{92,104–108} Some multiply operated patients with end-stage TMJ disease may suffer from neuropathic pains, typically described as “sharp” or “burning,” that likely result from traumatic injury to peripheral neurons during surgery. When this is suspected, it may be appropriate to consider a mixed serotonin and norepinephrine reuptake inhibitor (eg, amitriptyline).

Dosing Recommendations There is a tremendous intersubject variability in the pharmacokinetics of some TCAs. This is believed to be due, in part, to expressed polymorphisms of the sparteine/debrisoquin oxygenase system that governs metabolism of the TCAs.¹⁰⁹ Given the wide intersubject variability in TCA pharmacokinetics, standard-dose regimens may be poorly tolerated or ineffective for a particular individual. Therefore, these drugs should be titrated to effect. It should be also remembered that only 50 to 70% of patients are responders (ie, individuals who experience a desired effect), and often the response to the drug is modest. Although there is a general perception that the analgesic response to TCAs is delayed, studies have actually documented a relatively rapid analgesic response to these agents. In fact, as previously mentioned, measurable antinociceptive effects have been observed after a single dose.⁹⁵ Therefore, an analgesic response should be expected within 1 week of the administration of an effective TCA dose, but a maximum response may not be observed for 4 to 6 weeks.

For most patients amitriptyline is the TCA of choice for pain management in the patient with end-stage TMJ disease. Other TCAs (eg, desipramine) may be less effective for relief of pain owing to their relative

selectivities for monoamine reuptake inhibition. In most instances amitriptyline may be administered as a single dose given at bedtime. An initial dose of 10 to 25 mg is typical for this application. The dose may be increased at 2-week intervals to a range of 10 to 75 mg/d based on subjective pain reports by the patient and drug tolerance. It should be recognized that a therapeutic window has been observed for some TCAs, with maximum analgesic responses typically observed at lower doses.^{110,111} For this reason a ceiling dose of 75 mg (1 mg/kg) amitriptyline for an adult is recommended. If significant pain relief is not observed after trial dosing up to this recommended ceiling, then the agent should be withdrawn by a tapering regimen. If significant pain relief is observed, then the agent should be continued at the effective dose. Periodic tapered withdrawals of the agent are recommended to ascertain the need for continued dosing.

TCAs can usually be administered with few side effects observed at recommended doses. However, side effects including morning sluggishness, urinary retention, weight gain from enhanced appetite, sleep disturbances, and constipation are reported by some patients. Serious side effects, such as cardiac dysrhythmias/myocardial infarction, seizures, stroke, agranulocytosis, and thrombocytopenia, are very rare with low-dose regimens in patients who are not otherwise medically compromised. TCAs should be administered cautiously in patients with a history of cardiovascular disease, seizure disorders, or urinary retention or who concurrently take medications that can influence monoamine activities (eg, antidepressants/antipsychotics, tramadol).

Drug-Induced Bruxism and Jaw Clenching

Patients with end-stage TMJ disease may be subjected to drugs that can exacerbate their condition by induction of focal dystonias leading to increased bruxism or jaw clenching. For example, bilateral masticatory myalgia with TMJ symptoms was ob-

served shortly after the administration of sustained-release bupropion in a 44-year-old man for relief of depression secondary to chronic lower back pain and tension headaches.¹¹² These temporomandibular symptoms developed within 48 hours of a dose adjustment from 150 mg/d of sustained-release bupropion to 300 mg/d. Furthermore, these symptoms resolved completely with withdrawal of the medication. Dystonic reactions to some antipsychotic and antidepressant medications may result from an acute reduction in dopaminergic activity in the brain.^{113,114} Ninety percent of these reactions occur within 3 to 5 days of drug initiation or dose adjustment.¹¹² Selective serotonin reuptake inhibitors (eg, fluoxetine, citalopram, paroxetine, and sertraline) may evoke this response. Ironically, some patients with end-stage TMJ disease are placed on these agents to manage the inevitable depression that occurs in this group of patients. In some of these patients, it is conceivable that the antidepressant could worsen their condition by evoking focal dystonic reactions or bruxism affecting the masticatory and cervical musculature. Such a response could provoke additional muscle pain and may even aggravate a TMJ condition by increasing mechanical loads.

Opioid addiction may be associated with exaggerated oromotor behavior and signs and symptoms of temporomandibular dysfunction. Winocur and colleagues studied 55 individuals who were addicted to opioids and were receiving treatment at a methadone clinic.¹¹⁵ A sex-, age-, and socioeconomic class-matched nonaddict group served as the control in this study. The addicted group exhibited a higher frequency of bruxism and jaw clenching, as well as morning headache, TMJ noises, and masticatory muscle tenderness. It is unclear from this study whether the apparent effects on the stomatognathic system were a direct manifestation of chronic opioid use or a mere reflection of a personality disorder that led to an opioid addiction.

Nevertheless, many patients with end-stage TMJ disease undergo chronic opioid therapy for pain management. In some instances it is possible that induction of focal dystonias in patients with end-stage TMJ disease by opioids could exacerbate their condition, resulting in an escalation in pain that could be confused with opioid tolerance. If this phenomenon is suspected, then a tapered withdrawal of the opioid should be initiated. Contrary to the reaction expected with an opioid-tolerant patient, opioid withdrawal in this instance may provide paradoxical pain relief.

GABAergics GABA is an inhibitory neurotransmitter that has been implicated in nociception modulation.^{116–118} GABA effects are mediated via at least two different types of GABA receptors: GABA_A and GABA_B.^{119,120} A third GABA receptor, GABA_C, may also exist, but its distribution appears to be exclusively restricted to the retina of the eye.¹²¹

GABA_B receptors are inhibitory G-protein coupled receptors that attenuate neural activities.^{120,122} The classic agonist for the GABA_B receptor is baclofen. Baclofen administered either systemically or intrathecally suppresses allodynia and hyperalgesia in animal models of pain.^{123,124} In a clinical study of lower back pain, 30 to 80 mg/d baclofen was found to be superior to placebo as an analgesic.¹²⁵

Gabapentin has been used to reduce pain associated with some neuropathic states including pain that is sympathetically maintained.¹²⁶ Gabapentin appears to elicit this effect by increasing the endogenous synthesis of GABA. Gabapentin's analgesic effects appear to be pain-type specific. In acute pain animal models, gabapentin does not produce analgesia.

Based on available data, it may be reasonable to consider a trial of baclofen (30–80 mg/d) or gabapentin (300–1800 mg/d) for patients with end-stage TMJ disease who may be suffering from a neuropathic component of pain. As previ-

ously mentioned, this might result from previous injury to neurons innervating tissues of the TMJ region. However, given the limited data demonstrating efficacy for temporomandibular pain, particularly in the patient with end-stage TMJ disease, these agents should be reserved for use after other approaches have been tried.

Sympathetically Maintained Pain

Sympathetically maintained pain (SMP), reflex sympathetic dystrophy, causalgia, and most recently complex regional pain syndrome (CRPS) are terms often used by clinicians in reference to a syndrome(s) characterized by continuous burning pain believed to be associated with abnormal nociception affected by activity in the sympathetic nervous system. CRPS typically follows traumatic injury to the affected region. Some multiply operated patients with end-stage TMJ disease with localized tactile or mechanical allodynia and burning pain complaints may be suffering from sympathetically driven pain. However, the incidence of CRPS in patients with end-stage TMJ disease is unknown.

Clinical Presentation Signs or symptoms of CRPS occurring with an incidence of 75% or greater include weakness (95%), pain (93%), altered skin temperature (92%), skin color change (92%), limited range of motion (88%), and hyperesthesia (75%).¹²⁷ Less common findings include edema, altered hair growth, tremor, hyperhidrosis, muscle/skin atrophy, and bone resorption.¹²⁷

The mechanism(s) underlying the development of CRPS is unknown. However, there is emerging evidence that suggests that this condition may result from neuroplastic changes induced by peripheral sensory nerve injury. In animals the sprouting of sympathetic neurons into sensory ganglia (ie, dorsal root ganglia) has been observed after injury to peripheral sensory nerves. This sprouting may be induced by a

neurotrophic substance, known as nerve growth factor (NGF), that is released into injured tissues.^{128–132} A similar response is observed in animals in which NGF is administered intrathecally.¹³² These data are consistent with the belief that CRPS results from an abnormal sympathetic input to sensory ganglia following peripheral sensory nerve injury. This abnormal sympathetic input may be made possible by the development of physical connections between sympathetic neurons and primary afferent sensory neurons. Injury may elicit this abnormal response via molecular intermediates, specifically NGF. Clearly this phenomenon does not occur in all individuals who sustain injuries to sensory peripheral nerves. Future research is needed to confirm this model and to determine risk factors that govern an individual's susceptibility to the development of CRPS.

Treatment Over 25 treatments for CRPS have been reported in the literature.¹³³ The most common therapeutic approach has involved the interruption of sympathetic activity via a stellate ganglion block. An effective stellate ganglion block may produce protracted pain relief (ie, lasting longer than the duration of anesthetic blockade), although this effect is usually transient. Other pharmacologic interventions (eg, phentolamine, prazosin, bretylium, guanethidine, calcitonin, nifedipine, gabapentin) and surgical sympathectomy have also been employed with inconsistent results.¹³³ With new information concerning the molecular events that may underlie the development of CRPS, it is hoped that more effective therapies will be developed in the near future.

Physical Therapy

A primary goal of all therapies directed to the management of the patient with end-stage TMJ disease is to restore normal joint function (ie, joint movement). Patients with end-stage TMJ disease typically exhibit severely restricted jaw move-

ments. Pain and intra-articular fibrosis or fibro-osseous ankylosis often coexist to restrict jaw movement. For this reason, pain management must be effective for optimum patient compliance with prescribed physical therapy.

Passive jaw exercises are effective at improving joint function if they are performed regularly over an extended period of time. Two devices are currently commercially available that facilitate passive motion of the TMJ. Alternatively, passive motion exercises can be performed with simple finger crossover maneuvers or with tongue depressor blades.

A simple but effective protocol incorporating passive motion exercises to increase mandibular movements in the patient with end-stage TMJ disease involves repetitive (10–12 times daily) vertical opening exercises. For these exercises the patient is given a number of tongue depressor blades that, when inserted between the maxillary and mandibular teeth, produce an opening of the jaws that is barely tolerated by the patient. The patient is instructed to apply these tongue depressor blades hourly (8–10 times daily) for 2 to 3 minutes. On the first day of each week, the patient is instructed to increase the total number of tongue depressor blades used by addition of one blade. This approach permits tissues to gradually adapt to advancing jaw movements and is generally well tolerated by the majority of patients with end-stage TMJ disease.

Therapy for Periarticular Ectopic Bone Formation

Periarticular ectopic bone formation is viewed as a significant postsurgical complication with a negative impact on functional outcomes in some patients with end-stage TMJ disease. Ectopic bone may form in adjacent native periarticular tissues or proximate to alloplastic materials used to reconstruct the TMJ. In either instance, periarticular ectopic bone formation is viewed as pathologic since it

typically restricts normal joint movement and may contribute to ongoing pain.

The pathogenesis of periarticular ectopic bone formation is poorly understood. It has been suggested that displaced osteogenic precursor cells are stimulated to form ectopic bone by inflammatory mediators formed in response to surgical insult.¹³⁴ Alternatively, osteoinductive molecules (eg, bone morphogenetic proteins) may be dispersed into periarticular tissues during surgery, resulting in the stimulation of resident pluripotent cells and subsequent ectopic bone synthesis. In addition, there may be other factors, such as genetics, sex hormones, systemic disease (eg, ankylosing spondylitis, Paget's disease), or other local conditions, that could also contribute to the formation of ectopic bone in periarticular tissues of the TMJ.

Two strategies have been employed in an attempt to prevent or minimize periarticular ectopic bone formation in either orthopedic surgery patients or those with TMJ disease. These are low-dose radiation therapy, and nonsteroidal anti-inflammatory drug (NSAID) therapy.

Low-Dose Radiation Therapy Some clinicians have advocated the use of low-dose radiation to prevent or minimize postsurgical fibro-osseous ankylosis of the TMJ.^{135–138} This approach is based on an earlier report indicating that low-dose radiation may be effective at preventing the formation of ectopic bone following hip arthroplasty.¹³⁹ For prevention of periarticular ectopic bone formation of the TMJ, fractionated total doses of 10 to 20 Gy have been used. One study reported that 10 Gy dosing was as effective as higher-dose regimens.¹³⁶

Timing appears to be critical for optimum results from low-dose radiation therapy. It is believed that low-dose radiation therapy elicits its effect on ectopic bone formation by prohibiting the proliferation of pluripotent cells that are precursors to osteoblasts. Therefore, it is rec-

ommended that low-dose radiation therapy be initiated within 4 days of surgery to provide optimum suppression of ectopic bone formation. Although there is some concern that early postsurgical radiation may have a detrimental impact on wound healing, in a recent study of the efficacy of a single dose of 600 cGy administered between postsurgical days 2 and 4 (mean 3.2 d), radiation did not appear to significantly impact wound healing after hip arthroplasty.¹⁴⁰

Radiation therapy was used to prevent ectopic bone formation in the periarticular region of the TMJ in a 53-year-old man.¹³⁷ This individual sustained mandible fractures in an automobile accident and subsequently underwent five operations to correct a TMJ ankylosis suffered as a complication of his injury. Over an 18-year period, the patient suffered from a significant limitation of jaw movement, with reported maximum interincisal movements as low as 6 mm. Following his final TMJ arthroplasty, the patient underwent fractionated cobalt radiation therapy consisting of ten sessions beginning on the first postoperative day. The patient received a total radiation dose of 20 Gy in equal fractions. He apparently tolerated the procedure well without significant complications. At the 3-year follow-up, the patient had sustained a maximum interincisal distance of 25.5 mm.¹³⁷

Schwartz and Kagan provided a report describing a similar beneficial effect of fractionated radiation (ie, 20 Gy in 10 fractions) in a 51-year old man who experienced a zygomatico-coronoid ankylosis following a depressed fracture of the zygomatic arch.¹³⁸ This condition was surgically treated with a 5 mm gap arthroplasty with placement of an intervening sheet of silicone rubber. Postsurgical radiation was initiated 1 week after the operation. At a 19-month follow-up, the patient exhibited a 40 mm maximum interincisal distance. Although the patient initially complained

of xerostomia and had some loss of facial hair, there were no reported lasting ill effects from this treatment.

Experiences with 10 patients suffering from bony ankylosis of the TMJ were reported by Durr and colleagues.¹³⁶ Four men and six women (median age 32.5 yr, range 14–59 yr) with a previous history of TMJ ankylosis underwent TMJ arthroplasties and immediate postsurgical (ie, 1–3 d) radiation therapy consisting of 10 to 11.2 Gy in five fractions over a 5-day period. The median follow-up for this reported case series was 19 months (range 7–31 mo). Only three patients (ie, 30%) were followed up for > 2 years postoperatively. Forty percent of the patients in this series experienced some recurrence of ectopic bone formation as assessed radiographically. A parotitis was identified in 30% of the patients in this series. However, the radiation therapy did not appear to interfere with healing, and there were no other reported complications.

Reid and Cooke have reported the largest case series to date involving postoperative radiation therapy to manage ectopic bone formation of the TMJ in 14 patients with histories of multiple TMJ surgeries.¹³⁵ Each patient underwent TMJ arthroplasty with total joint reconstruction using an alloplastic prosthesis. The majority of these patients received a fractionated 10 Gy radiation dose beginning on the first postoperative day. However, some patients treated early in the series received a fractionated 20 Gy radiation dose. Patients in this series were followed up postoperatively with a mean follow-up of 4.2 years (range 1–9.6 yr). The recurrence rate for ectopic bone formation at the 1-year follow-up was 21%. However, long-term follow-up revealed ectopic bone formation in 75% of the patients seen at 5 years and 100% ($n = 2$) of patients examined at the 9-year follow-up (Figure 51-2). Consistent with earlier reports, no significant persistent side effects of radiation therapy were noted.

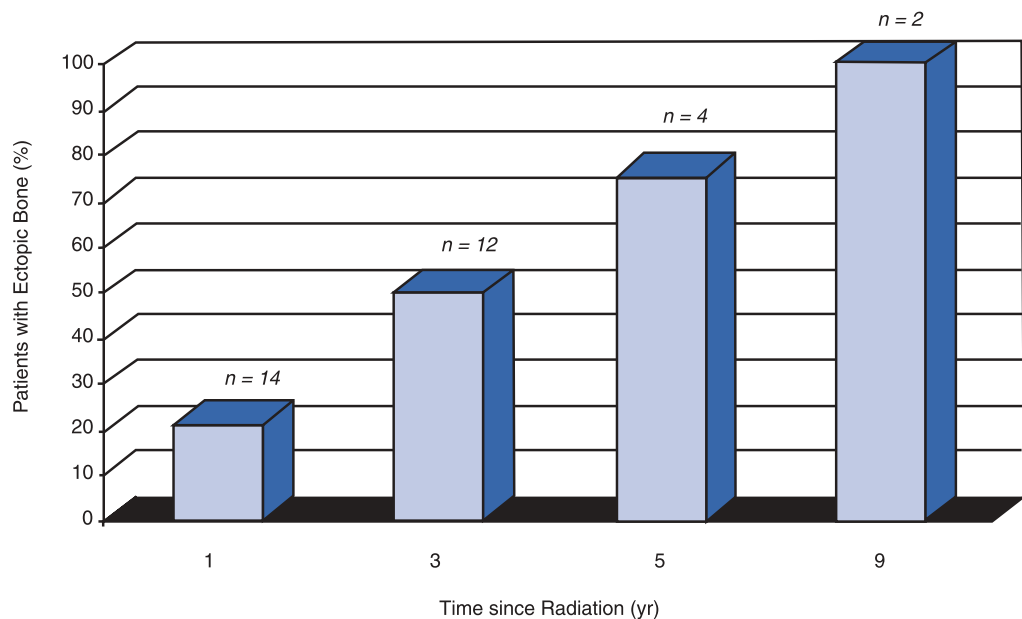


FIGURE 51-2 Recurrence of ectopic bone in patients treated with low-dose radiation. Data adapted from Reid R and Cooke H.¹³⁵

A major concern with the use of low-dose radiation for the treatment of ectopic bone formation in the TMJ area is the potential for induction of neoplasias. Despite the fact that there have been no reported cases of malignant transformation associated with low-dose radiation therapy used to manage periarticular ectopic bone formation in the TMJ area, this concern seems justified based on a report by Ron and colleagues.¹⁴¹ These investigators examined 10,834 patients who had undergone low-dose radiation therapy for the treatment of ringworm infection of the scalp (ie, tinea capitis). All irradiated subjects received treatment (mean radiation dose 1.5 Gy) before the age of 16 years. Controls included 10,834 nonirradiated age- and sex-matched individuals not related to the radiated subjects, serving as a general population control, and 5,392 nonirradiated siblings of the subjects. The subjects were monitored for up to 33 years for the development of benign and malignant neural tumors. Tumors developed in 73 individuals, 60 among irradiated subjects, 8 in the general population control group, and 5 among siblings of irradiated subjects. Overall,

there was a sevenfold increase in neoplasms of the nervous system in individuals who had undergone low-dose radiation therapy. Twenty-four malignant neoplasias were identified in this study, with 18 occurring in irradiated patients, 4 in the general population control group, and 2 in siblings of irradiated subjects. There was a 4.5-fold increase in the incidence of malignant neoplasias in patients who underwent low-dose radiation therapy relative to the control groups. The cumulative risk of developing a neural tumor over a 33-year period was significantly higher in the irradiated group ($0.84 \pm 0.16\%$) than in the controls ($0.09 \pm 0.03\%$). It should be noted that there was a prolonged latency of tumor occurrence (mean 17.6 yr after radiation exposure). From this study it appears that the risk of radiation-associated tumors was highest between 15 and 24 years postradiation. This has significance in light of the fact that the longest published follow-up for any case series reporting the effects low-dose radiation therapy for management of ectopic bone formation in the TMJ area is 9 years (only two patients).¹³⁵ It should be noted that patients receiving radiation

therapy for tinea capitis in this study were significantly younger (< 16 yr old) than the TMJ patients reported in the series cited above. It is possible that the risk of radiation-associated neoplasia may be age dependent. However, this assumption has not yet been validated in appropriately designed studies.

In summary, the evidence supporting the use of low-dose radiation therapy to prevent or minimize ectopic bone formation in periarticular regions of the TMJ is supplied by case summaries that report beneficial effects with 10 to 20 Gy exposures in fractionated doses initiated within 4 days of surgery. However, it should be recognized that definitive studies (ie, appropriately blinded and controlled) have not been reported to date. In the absence of these studies, the true efficacy of this therapy remains obscure. Furthermore, there is evidence that such therapy may pose significant long-term health risks.¹⁴¹

NSAID Therapy Several studies have provided evidence that NSAIDs may be effective retardants of ectopic bone formation.^{140,142-145} The mechanism(s) by which these drugs elicit this effect is currently unknown. However, the effect is believed to be secondary to the ability of these drugs to inhibit prostanoid, and perhaps LT, synthesis associated with normal inflammatory responses to injury.

Kienapfel and colleagues compared the effects of indomethacin, a nonselective COX inhibitor (also capable of inhibiting lipoxygenase), with those of low-dose radiation therapy employed to prevent ectopic bone formation after hip arthroplasty.¹⁴⁰ For this study 154 patients scheduled for hip arthroplasty to treat various degenerative arthritides were randomly assigned to one of three groups: (1) low-dose radiation treatment (600 cGy administered as a single dose between postoperative days 2 and 4); (2) indomethacin treatment (50 mg administered orally twice a day beginning

on postoperative day 1 and continuing until postoperative day 42); or (3) control (no postoperative radiation or NSAID). Patients assigned to the indomethacin treatment group who were either at risk for NSAID-induced gastrointestinal disease or who developed dyspepsia with the therapy were given cimetidine 200 mg (H₂ receptor antagonist) concomitantly.

All subjects enrolled in the study were assessed clinically and radiographically 18 months after surgery.¹⁴⁰ Ectopic bone formation was significantly inhibited by both treatment conditions relative to the control. Furthermore, both treatments were found to be equally effective. Surgical wound secretions were more persistent in the radiated subjects postoperatively, but neither treatment group subsequently exhibited signs of poor wound healing that were significantly different from the control. The incidence of dyspepsia was higher in the indomethacin-treated group, but gastrointestinal bleeding was not detected in this group.

Other NSAIDs have been used to prevent or minimize ectopic bone formation following hip arthroplasty, including ibuprofen, ketorolac, and diclofenac.^{142,143,145} All of these agents are nonselective COX inhibitors (ie, they block by COX-1 and COX-2). At the present time it is not known whether the selective COX-2 inhibitors are effective retardants of ectopic bone formation.

To date there have been no reported studies of NSAID use for the management of ectopic bone formation of the TMJ. Therefore, the efficacy of these agents for this specific application remains to be demonstrated. However, based on the orthopedic surgery literature, it may be prudent to consider NSAID therapy for patients who are at risk for ectopic bone formation following TMJ surgery. The potential gastrointestinal and renal complications associated with this approach should not be underestimated. Patients undergoing NSAID therapy to prevent or

minimize ectopic bone formation should be properly monitored. If indicated, misoprostol or an H₂ receptor antagonist should be administered concomitantly to reduce the potential for serious gastrointestinal complications.

Conclusions

The patient with end-stage TMJ disease is typically afflicted by severe unrelenting pain, restricted jaw function, facial deformity, depression, compromised interpersonal relationships, and financial hardships. Given the complexities involved, these patients pose a significant challenge for the most experienced clinicians. A coordinated team of specialists best provides optimum care. However, in most communities this level of care is not available. The local oral and maxillofacial surgeon is often looked on as the specialist who will manage these complicated cases. For the multiply operated patient with end-stage TMJ disease, few surgical options are viable. In these instances medical management is advised with primary treatment objectives typically being pain management and improvement in jaw movements. When surgery is contemplated, it is imperative that the surgeon complete an accurate assessment of the patient's condition. The surgeon must establish realistic surgical objectives based on this assessment. Finally, the surgeon must exercise good judgment in the selection of patients for surgery. Patients who are incapable or unwilling to comply with demanding but essential postsurgery rehabilitation programs may not be viable candidates for surgery, even when feasible surgical objectives are identified.

References

1. Travell JG, Simons DG. Myofascial pain and dysfunction: the trigger point manual. 1. Baltimore: Williams and Wilkins; 1983.
2. Mendell LM, Wall PD. Response of single dorsal cord cells to peripheral cutaneous unmyelinated fibres. *Nature* 1965;206:97-9.
3. Woolf CJ, King AE. Dynamic alterations in the

- cutaneous mechanoreceptive fields of dorsal horn neurons in the rat spinal cord. *J Neurosci* 1990;10:2717–26.
4. Owens CM, Zhang D, Willis WD. Changes in the response states of primate spinothalamic tract cells caused by mechanical damage of the skin or activation of descending controls. *J Neurophysiol* 1992;67:1509–27.
 5. Bereiter DA. Sex differences in brainstem neural activation after injury to the TMJ region. *Cells Tissues Organs* 2001;169:226–37.
 6. Bereiter DA, Bereiter DF. Morphine and NMDA receptor antagonism reduce *c-fos* expression in spinal trigeminal nucleus produced by acute injury to the TMJ region. *Pain* 2000;85:65–77.
 7. Woolf CJ, Chong MS. Preemptive analgesia—treating postoperative pain by preventing the establishment of central sensitization. *Anesth Analg* 1993;77:362–79.
 8. Giannoni C, White S, Enneking FK, et al. Ropivacaine with or without clonidine improves pediatric tonsillectomy pain. *Arch Otolaryngol Head Neck Surg* 2001;127:1265–70.
 9. Goodwin SA. A review of preemptive analgesia. *J Perianesth Nurs* 1998;13:109–14.
 10. Goldstein FJ. Preemptive analgesia: a research review. *Medsurg Nursing* 1995;4:305–8.
 11. Gilron I, Quirion R,Coderre TJ. Pre- versus post-formalin effects of ketamine or large-dose alfentanil in the rat: discordance between pain behavior and spinal Fos-like immunoreactivity. *Anesth Analg* 1999;89:128–35.
 12. Kelly DJ, Ahmad M, Brull SJ. Preemptive analgesia I: physiological pathways and pharmacological modalities. *Can J Anaesth* 2001;48:1000–10.
 13. Kilickan L, Toker K. The effect of preemptive intravenous morphine on postoperative analgesia and surgical stress response. *Pain* 2001;43:171–5.
 14. Subramaniam B, Pawar DK, Kashyap L. Preemptive analgesia with epidural morphine or morphine and bupivacaine. *Anaesth Intensive Care* 2000;28:392–8.
 15. Chiaretti A, Viola L, Pietrini D, et al. Preemptive analgesia with tramadol and fentanyl in pediatric neurosurgery [discussion]. *Childs Nerv Syst* 2000;16:93–9.
 16. Dickenson AH, Sullivan AF. Evidence for a role of the NMDA receptor in the frequency dependent potentiation of deep rat dorsal horn nociceptive neurones following C fibre stimulation. *Neuropharmacol* 1987;26:1235–8.
 17. Haley JE, Sullivan AF, Dickenson AH. Evidence for spinal N-methyl-D-aspartate receptor involvement in prolonged chemical nociception in the rat. *Brain Res* 1990;518:218–26.
 18. Torrebjork HE, Lundberg LE, LaMotte RH. Central changes in processing of mechanoreceptive input in capsaicin-induced secondary hyperalgesia in humans. *J Physiol* 1992;448:765–80.
 19. Mixer CGR, Hackett TR. Preemptive analgesia in the laparoscopic patient. *Surg Endosc* 1997;11:351–3.
 20. Norman PH, Daley MD, Lindsey RW. Preemptive analgesic effects of ketorolac in ankle fracture surgery [comment]. *Anesthesiology* 2001;94:599–603.
 21. Wittels B, Faure EA, Chavez R, et al. Effective analgesia after bilateral tubal ligation. *Anesth Analg* 1998;87:619–23.
 22. Jebeles JA, Reilly JS, Gutierrez JE, et al. Tonsillectomy and adenoidectomy pain reduction by local bupivacaine infiltration in children. *Int J Pediatr Otorhinolaryngol* 1993;25:149–54.
 23. Honnma T, Imaizumi T, Chiba M, et al. Preemptive analgesia for postoperative pain after frontotemporal craniotomy. *No Shinkei Geka* 2002;30:171–4.
 24. Hoard MA, Bill TJ, Campbell RL. Reduction in morbidity after iliac crest bone harvesting: the concept of preemptive analgesia. *J Craniomaxillofac Surg* 1998;9:448–51.
 25. Abram SE, Yaksh TL. Morphine, but not inhalation anesthesia, blocks post-injury facilitation: the role of preemptive suppression of afferent transmission. *Anesthesiology* 1993;78:713–21.
 26. Wallace MS, Braun J, Schulteis G. Postdelivery of alfentanil and ketamine has no effect on intradermal capsaicin-induced pain and hyperalgesia. *Clin J Pain* 2002;18:373–9.
 27. Bach S, Noreng MF, Tjelliden NU. Phantom limb pain in amputees during the first 12 months following limb amputation, after preoperative lumbar epidural blockade. *Pain* 1988;33:297–301.
 28. Hla T, Ristimaki A, Appleby S, et al. Cyclooxygenase gene expression in inflammation and angiogenesis [review]. *Ann N Y Acad Sci* 1993;696:197–204.
 29. Crofford LJ, Wilder RL, Ristimaki AP, et al. Cyclooxygenase-1 and -2 expression in rheumatoid synovial tissues. Effects of interleukin-1 beta, phorbol ester, and corticosteroids. *J Clin Invest* 1994;93:1095–101.
 30. O'Neill GP, Ford HA. Expression of mRNA for cyclooxygenase-1 and cyclooxygenase-2 in human tissues. *FEBS Lett* 1993;330:156–60.
 31. Hla T, Neilson K. Human cyclooxygenase-2 cDNA. *Proc Natl Acad Sci U S A* 1992;89:7384–8.
 32. Ristimaki A, Garfinkel S, Wessendorf J, et al. Induction of cyclooxygenase-2 by interleukin-1 alpha. Evidence for post-transcriptional regulation. *J Biol Chem* 1994;269:11769–75.
 33. Hua XY, Jinno S, Back SM, et al. Multiple mechanisms for the effects of capsaicin, bradykinin, and nicotine on CGRP release from tracheal afferent nerves: role of prostaglandins, sympathetic nerves, and mast cells. *Neuropharmacol* 1994;33:1147–54.
 34. Quinn JH, Bazan NG. Identification of prostaglandin E2 and leukotriene B4 in the synovial fluid of painful, dysfunctional temporomandibular joints. *J Oral Maxillofac Surg* 1990;48:968–71.
 35. Murakami K-I, Shibata T, Kubota E, et al. Intra-articular levels of prostaglandin E2, hyaluronic acid, and chondroitin-4 and -6 sulfates in the temporomandibular joint synovial fluid of patients with internal derangement. *J Oral Maxillofac Surg* 1998;56:199–203.
 36. Devoghel JC. Small intrathecal doses of lysine-acetylsalicylate relieve intractable pain in man. *J Int Med Res* 1983;11:90–1.
 37. Malmberg AB, Yaksh TL. Antinociceptive actions of spinal nonsteroidal anti-inflammatory agents on the formalin test in the rat. *J Pharmacol Exp Ther* 1992;263:136–46.
 38. Malmberg AB, Yaksh TL. Antinociception produced by spinal delivery of the S and R enantiomers of flurbiprofen in the formalin test. *Eur J Pharmacol* 1994;256:205–9.
 39. Wallace JL. Prostaglandins, NSAIDs, and cytoprotection. *Gastroenterol Clin North Am* 1992;21:631–41.
 40. Clive DM, Stoff JS. Renal syndromes associated with nonsteroidal antiinflammatory drugs. *N Engl J Med* 1984;310:563–72.
 41. Morita I, Suzuki Y, Toriyama K, et al. Induction of cyclooxygenase in osteoblasts and bone metabolism. *Adv Prostaglandin Thromboxane Leukot Res* 1991;21B:839–42.
 42. Bell NH, Hollis BW, Shary JR, et al. Diclofenac sodium inhibits bone resorption in postmenopausal women. *Am J Med* 1994;96:349–53.
 43. Kemick ML, Chin JE, Wuthier RE. Role of prostaglandins in differentiation of growth plate chondrocytes. *Adv Prostaglandin Thromboxane Leukot Res* 1989;19:423–6.
 44. Goldring MB, Sothat E, Elwell JM, et al. Etodolac preserves cartilage-specific phenotype in human chondrocytes: effects on type II collagen synthesis and associated mRNA levels. *Eur J Rheumatol Inflamm* 1990;10:10–21.
 45. Gabriel SE, Jaakkimainen L, Bombardier C.

- Risk of serious gastrointestinal complications related to use of nonsteroidal anti-inflammatory drugs. *Ann Intern Med* 1991;115:787–96.
46. Doyle G, Jayawardena S, Ashraf E, et al. Efficacy and tolerability of nonprescription ibuprofen versus celecoxib for dental pain. *J Clin Pharmacol* 2002;42:912–9.
 47. Hwang SW, Cho H, Kwak J, et al. Direct activation of capsaicin receptors by products of lipoxygenases: endogenous capsaicin-like substances. *Proc Natl Acad Sci U S A* 2000;97:6155–60.
 48. Shin J, Cho H, Hwang SW, et al. Bradykinin-12-lipoxygenase-VR1 signaling pathway for inflammatory hyperalgesia. *Proc Natl Acad Sci U S A* 2002;99:10150–5.
 49. Flynn DL, Belliotti TR, Boctor AM, et al. Styrylpyrazoles, styrylisoxazoles, and styrylisothiazoles. Novel 5-lipoxygenase and cyclooxygenase inhibitors. *J Med Chem* 1991;34:518–25.
 50. Jiang Q, Takemori AE, Sultana M, et al. Differential antagonism of opioid delta antinociception by [D-ala²,Leu⁵,Cys⁶]-enkephalin and naltrindole 5'-isothiocyanate: evidence for delta receptor subtypes. *J Pharmacol Exp Ther* 1991;257:1069–75.
 51. Pasternak GW. Pharmacological mechanisms of opioid. *Clin Neuropharmacol* 1993;16:1–18.
 52. Yoshimura M, North RA. Substantia gelatinosa neurones in vitro hyperpolarized by enkephalin. *Nature* 1983;305:529–30.
 53. Carter BD, Medzihradsky F. G_o mediates the coupling of the mu opioid receptor to adenylyl cyclase in cloned neural cells and brain. *Proc Natl Acad Sci U S A* 1993;90:4062–6.
 54. Grudt TJ, Williams JT. Kappa-opioid receptors increase potassium conductance. *Proc Natl Acad Sci U S A* 1993;90:11429–32.
 55. DelleMijn PLI, Vanneste JAL. Randomized double-blind active-placebo-controlled crossover trial of intravenous fentanyl in neuropathic pain. *Lancet* 1997;349:753–8.
 56. Bereiter DA, Bereiter DF, Ramos M. Vagotomy prevents morphine-induced reduction in Fos-like immunoreactivity in trigeminal spinal nucleus produced after TMJ injury in a sex-dependent manner. *Pain* 2002;96:205–13.
 57. Chase H. Sensitive dentine. *Dent Cosmos* 1867;8:635–7.
 58. Hargreaves KM, Keatin K, Cathers S, et al. Analgesic effects of morphine after PDL injection in endodontic patients. [abstract]. *J Dent Res* 1991;70:445.
 59. Hayashi K, Sugisaiki M, Ota S, et al. mu-Opioid receptor mRNA expression and immunohistochemical localization in the rat temporomandibular joint. *Peptides* 2002;23:889–93.
 60. Yaksh TL. Substance P release from knee joint afferent terminals: modulation by opioids. *Brain Res* 1988;458:319–24.
 61. Ichikawa H, Matsuo S, Wakisaka S, et al. Fine structure of calcitonin gene-related peptide-immunoreactive nerve fibres in the rat temporomandibular joint. *Arch Oral Biol* 1990;35:727–30.
 62. Appलगren A, Appलगren B, Eriksson S, et al. Neuropeptides in temporomandibular joints with rheumatoid arthritis: a clinical study. *Scand J Dent Res* 1991;99:519–21.
 63. Holmlund A, Ekblom A, Hansson P, et al. Concentrations of neuropeptides substance P, neurokinin A, calcitonin gene-related peptide, neuropeptide Y and vasoactive intestinal polypeptide in synovial fluid of the human temporomandibular joint. A correlation with symptoms, signs and arthroscopic findings. *Int J Oral Maxillofac Surg* 1991;20:228–31.
 64. Kido MA, Kiyoshima T, Kondo T, et al. Distribution of substance P and calcitonin gene-related peptide-like immunoreactive nerve fibers in the rat temporomandibular joint. *J Dent Res* 1993;72:592–8.
 65. Bryant CJ, Harrison SD, Hopper C, et al. Use of intra-articular morphine for postoperative analgesia following TMJ arthroscopy. *Br J Oral Maxillofac Surg* 1999;37:391–6.
 66. Furst IM, Kryshatskyj B, Weinberg S. The use of intra-articular opioids and bupivacaine for analgesia following temporomandibular joint arthroscopy: a prospective, randomized trial. *J Oral Maxillofac Surg* 2001;59:979–84.
 67. List T, Tegelberg A, Haraldson T, et al. Intra-articular morphine as analgesic in temporomandibular joint arthralgia/osteoarthritis. *Pain* 2001;94:275–82.
 68. Yuge O, Matsumoto M, Kitahaa L, et al. Direct opioid application to peripheral nerve does not alter compound action potentials. *Anesth Analg* 1985;64: 667–71.
 69. Senami M, Aoki M, Kitahata L, et al. Lack of opiate effects on cat C polymodal nociceptive fibers. *Pain* 1986;27:81–90.
 70. Stein C, Millan M, Shippenberg T, et al. Peripheral effects of fentanyl upon nociception in inflamed tissue of the rat. *Neurosci Lett* 1988;84:225–8.
 71. Stein C, Comisel K, Haimerl E, et al. Analgesic effect of intraarticular morphine after arthroscopic knee surgery. *N Engl J Med* 1991;325:1123–6.
 72. Bartho L, Szolscanyi J. Opiate agonists inhibit neurogenic plasma extravasation in the rat. *Eur J Pharmacol* 1981;73:101–4.
 73. Barber A. Mu- and kappa-opioid receptor agonists produce peripheral inhibition of neurogenic plasma extravasation in rat skin. *Eur J Pharmacol* 1993;236:113–20.
 74. Ruff M, Wahl S, Mergenhagen S, et al. Opiate receptor-mediated chemotaxis for human monocytes. *Neuropeptides* 1985;5:363–366.
 75. Sibinga NES, Goldstein A. Opioid peptides and opioid receptors in cells of the immune system. *Ann Rev Immunol* 1988;6:219–49.
 76. Ferreria S, Nakamura M. Prostaglandin hyperalgesia II: the peripheral analgesic activity of morphine, enkephalins and opioid antagonists. *Prostaglandins* 1979;23:53–60.
 77. Cai BB, Cairns BE, Sessle BJ, et al. Sex-related suppression of reflex jaw muscle activity by peripheral morphine but not GABA. *Neuroreport* 2001;12:3457–60.
 78. Portenoy RK. Chronic opioid therapy for non-malignant pain: from models to practice. *APS J* 1992;1:285–8.
 79. Robins LN, David DH, Nurco DN. How permanent was Vietnam drug addiction? *Am J Public Health* 1974;64:38–43.
 80. Kanner RM, Foley KM. Patterns of narcotic drug use in cancer pain clinic. *Ann N Y Acad Sci* 1981;362:161–72.
 81. Foley KM. Clinical tolerance to opioids. In: Basbaum AI, Bessons JM, editors. *Towards a new pharmacology of pain*. Philadelphia: John Wiley and Sons; 1991. p. 181–197.
 82. Brescia FJ, Portenoy RK, Ryan M. Pain, opioid use and survival in hospitalized patients with advanced cancer. *J Clin Oncol* 1992;10:149–55.
 83. Houde RW. Systemic analgesics and related drugs: narcotic analgesics. In: Bonica JJ, Ventafriddas V, editors. *Advances in pain research and therapy*. Vol. 2. New York: Raven; 1979. p. 263–73.
 84. Inturrisi CE, Foley KM. Narcotic analgesics in the management of pain. In: Kuhar M, Pasternaks GW, editors. *Analgesics: neurochemical, behavioral, and clinical perspectives*. New York: Raven; 1984. p. 257–88.
 85. Kuhn R. Treatment of depressive states with imipramine hydrochloride. *Am J Psychiatry* 1958;115:459–64.
 86. Paoli F, Darcourt G, Corsa P. Note preliminaire sur l'action de l'imipramine dans les etats douloureux. *Rev Neurol* 1960;2:503–4.
 87. Acton J, McKenna JE, Melzack R. Amitriptyline produces analgesia in the formalin pain test. *Exp Neurol* 1992;117:94–6.
 88. Bendtsen L, Jensen R, Olesen J. Amitriptyline, a combined serotonin and noradrenaline reuptake inhibitor, reduces extrareceptive suppression of temporal muscle activity in patients with chronic tension-type headache. *Electroencephalogr Clin Neurophysiol* 1996;101:418–22.

89. Bendtsen L, Jensen R, Olesen J. A non-selective (amitriptyline), but not a selective (citalopram), serotonin reuptake inhibitor is effective in the prophylactic treatment of chronic tension-type headache. *J Neurol Neurosurg Psychiatry* 1996;61:285–90.
90. Brown RS, Bottomley WK. Utilization and mechanism of action of tricyclic antidepressants in the treatment of chronic facial pain: a review of the literature. *Anesth Prog* 1990;37:223–9.
91. Max MB, Zeigler D, Shoaf SE, et al. Effects of a single oral dose of desipramine on postoperative morphine analgesia. *J Pain Symptom Manage* 1992;7:454–62.
92. Max MB, Lynch SA, Muir J, et al. Effects of desipramine, amitriptyline, and fluoxetine on pain in diabetic neuropathy. *N Engl J Med* 1992;326:1250–6.
93. Leijon G, Boivie J. Central post-stroke pain—a controlled trial of amitriptyline and carbamazepine. *Pain* 1989;36:27–36.
94. Kvinesdal B, Molin J, Froland A, et al. Imipramine treatment of painful diabetic neuropathy. *JAMA* 1984;251:1727–30.
95. Coquoz D, Porchet HC, Dayer P. Central analgesic effects of desipramine, fluvoxamine, and moclobemide after single oral dosing: a study in healthy volunteers. *Clin Pharmacol Ther* 1993;54:339–44.
96. Hall H, Ogren SO. Effects of antidepressant drugs on different receptors in the brain. *Eur J Pharmacol* 1981;70:393–407.
97. Zubietta J-K, Heitzeg MM, Smith YR, et al. COMT *val¹⁵⁸met* genotype affects m-opioid neurotransmitter responses to a pain stressor. *Science* 2003;299:1240–3.
98. Gobel H, Hamouz V, Hansen C, et al. Chronic tension-type headache: amitriptyline reduces clinical headache duration and experimental pain sensitivity but does not alter pericranial muscle activity readings. *Pain* 1994;59:241–9.
99. Bryson HM, Wilde MI. Amitriptyline. A review of its pharmacological properties and therapeutic use in chronic pain states. *Drugs Aging* 1996;8:459–76.
100. Godfrey RG. A guide to the understanding and use of tricyclic antidepressants in the overall management of fibromyalgia and other chronic pain syndromes. *Arch Intern Med* 1996;156:1047–52.
101. Goldenberg DL. A review of the role of tricyclic medications in the treatment of fibromyalgia syndrome. *J Rheumatol Suppl* 1989;19:137–9.
102. Goldenberg D, Mayskiy M, Mossey C, et al. A randomized, double-blind crossover trial of fluoxetine and amitriptyline in the treatment of fibromyalgia. *Arthritis Rheum* 1996;39:1852–9.
103. Scudds RA, McCain GA, Rollman GB, et al. Improvements in pain responsiveness in patients with fibrositis after successful treatment with amitriptyline. *J Rheumatol Suppl* 1989;19:98–103.
104. Bowsher D. The effects of pre-emptive treatment of postherpetic neuralgia with amitriptyline: a randomized, double-blind, placebo-controlled trial. *J Pain Symptom Manage* 1997;13:327–31.
105. Eija K, Tiina T, Pertti NJ. Amitriptyline effectively relieves neuropathic pain following treatment of breast cancer. *Pain* 1996;64:293–302.
106. Eisenberg E, Yaari A, Har-Shai Y. Chronic, burning facial pain following cosmetic facial surgery. *Ann Plast Surg* 1996;36:76–9.
107. Jett ME, McGuirk J, Waligora D, et al. The effects of mexiletine, desipramine and fluoxetine in rat models involving central sensitization. *Pain* 1997;69:161–9.
108. McQuay HJ, Tramer M, Nye BA, et al. A systematic review of antidepressants in neuropathic pain. *Pain* 1996;68:217–27.
109. Brosen K, Gram LF. Clinical significance of the sparteine/debrisoquin oxidation polymorphism. *Eur J Clin Pharmacol* 1989;36:537–47.
110. Diamond S, Balters BJ. Chronic tension headache-treated with amitriptyline—a double-blind study. *Headache* 1971;11:110–6.
111. Watson C. Therapeutic window for amitriptyline analgesia. *Can Med Assoc J* 1984;130:105–6.
112. Detweiler MB, Harpold GJ. Bupropion-induced acute dystonia. *Ann Pharmacother* 2002;36:251–4.
113. Miller LG, Jankovic J. Persistent dystonia possibly induced by flecainide. *Mov Disord* 1992;7:62–3.
114. Gerber PE, Lynd LD. Selective serotonin-reuptake inhibitor-induced movement disorders. *Ann Pharmacother* 1998;32:692–8.
115. Winocur E, Gavish A, Volfin G, et al. Oral motor parafunctions among heavy drug addicts and their effects on signs and symptoms of temporomandibular disorders. *J Orofac Pain* 2001;15:56–63.
116. Burt DR, Kamachi GL. GABA_A receptor subtypes: from pharmacology to molecular biology. *FASEB J* 1991;5:2916–23.
117. Goodchild CS, Serrao JM. Intrathecal midazolam in the rat: evidence for spinally mediated analgesia. *Br J Anaesth* 1987;59:1563–70.
118. Crawford ME, Jensen FM, Toftdahl DB, et al. Direct spinal effect of intrathecal and extradural midazolam on visceral noxious stimulation in the rabbit. *Br J Anaesth* 1993;70:642–6.
119. Dunn SMJ, Bateson AN, Martin IL. Molecular neurobiology of the GABA_A receptor. *Int Rev Neurobiol* 1994;36:51–96.
120. Bowery NG. GABA_B receptor pharmacology. *Annu Rev Pharmacol Toxicol* 1993;33:109–47.
121. Djamgoz MBA. Diversity of GABA receptors in the vertebrate outer retina. *Trends Neurosci* 1995;18:118–20.
122. Mott DD, Lewis DV. Bridging the cleft at GABA synapses in the brain. *Int Rev Neurobiol* 1994;36:97–223.
123. Hao JX, Xu XJ, Wiesenfeld-Hallin Z. Allodynia-like effect in rat after ischemic spinal cord injury photochemically induced by laser irradiation. *Pain* 1991;45:175–85.
124. Hao JX, Xu XJ, Yu YX, et al. Baclofen reverses the hypersensitivity of dorsal horn wide dynamic range neurons to mechanical stimulation after transient spinal cord ischemia: implications for a tonic GABAergic inhibitory control of myelinated fiber input. *J Neurophysiol* 1992;68:392–6.
125. Dapas F, Hartman SF, Martinez L, et al. Baclofen for the treatment of acute low-back syndrome: a double-blind comparison with placebo. *Spine* 1985;10:345–9.
126. Mellick LB, Mellick GA. Successful treatment of reflex sympathetic dystrophy with gabapentin. *Am J Emerg Med* 1995;13:96.
127. Veldman PH, Reynen HM, Arntz IE, et al. Signs and symptoms of reflex sympathetic dystrophy: prospective study of 829 patients. *Lancet* 1993;342:1012–6.
128. Jones MG, Munson JB, Thompson SW. A role for nerve growth factor in sympathetic sprouting in rat dorsal root ganglia. *Pain* 1999;79:21–9.
129. McLachlan EM, Hu P. Axonal sprouts containing calcitonin gene-related peptide and substance P form pericellular baskets around large diameter neurons after sciatic nerve transection in the rat. *Neuroscience* 1998;84:961–5.
130. Ramer MS, French GD, Bisby MA. Wallerian degeneration is required for both neuropathic pain and sympathetic sprouting into the DRG. *Pain* 1997;72:71–8.
131. Ramer M, Bisby M. Reduced sympathetic sprouting occurs in dorsal root ganglia after axotomy in mice lacking low-affinity neurotrophin receptor. *Neurosci Lett* 1997;228:9–12.
132. Woolf CJ. Phenotypic modification of primary sensory neurons: the role of nerve growth factor in the production of persistent pain. *Philos Trans R Soc Lond B Biol Sci* 1996;351:441–8.
133. Tanelian DL. Reflex sympathetic dystrophy. A reevaluation of the literature. *Pain Forum* 1996;5:247–56.

134. Puzas JE, Miller MD, Rosier RN. Pathologic bone formation. *Clin Orthop* 1989;245:269–81.
135. Reid R, Cooke H. Postoperative ionizing radiation in the management of heterotopic bone formation in the temporomandibular joint. *J Oral Maxillofac Surg* 1999;57:900–6.
136. Durr ED, Turlington EG, Foote RL. Radiation treatment of heterotopic bone formation in the temporomandibular joint articulation. *Int J Radiat Oncol Biol Phys* 1993;27:863–9.
137. Robinson M, Arnet G. Cobalt radiation to prevent reankylosis after repeated surgical failures: report of case. *J Oral Surg* 1977;35:850–4.
138. Schwartz HC, Kagan AR. Zygomatico-coronoid ankylosis secondary to heterotopic bone formation: combined treatment by surgery and radiation therapy—a case report. *J Maxillofac Surg* 1979;7: 158–61.
139. Coventry MB, Scanlon PW. The use of radiation to discourage ectopic bone. A nine-year study about the hip. *J Bone Joint Surg* 1981;63:201–8.
140. Kienapfel H, Koller M, Wust A, et al. Prevention of heterotopic bone formation after total hip arthroplasty: a prospective randomised study comparing postoperative radiation therapy with indomethacin. *Arch Orthop Trauma Surg* 1999;119:296–302.
141. Ron E, Modan B, Boice JD, et al. Tumors of the brain and nervous system after radiotherapy in childhood. *N Engl J Med* 1988; 319:1033–9.
142. Elmstedt E, Lindholm TS, Nilsson OS, et al. Effect of ibuprofen on heterotopic ossification after hip replacement. *Acta Orthop Scand* 1985;56:25–7.
143. Pritchett JW. Ketorolac prophylaxis against heterotopic ossification after hip replacement. *Clin Orthop* 1995;314:162–5.
144. Sodemann B, Persson PE, Nilsson OS. Prevention of heterotopic ossification by nonsteroid antiinflammatory drugs after total hip arthroplasty. *Clin Orthop* 1988;237:158–63.
145. Wahlstrom O, Risto O, Djerf K, et al. Heterotopic bone formation prevented by diclofenac. Prospective study of 100 hip arthroplasties. *Acta Orthop Scand* 1991; 62:419–21.

Hypomobility and Hypermobility Disorders of the Temporomandibular Joint

Meredith August, DMD, MD

Maria J. Troulis, DDS, MSc

Leonard B. Kaban, DMD, MD

Hypomobility

Etiology

The etiology of mandibular hypomobility is varied, and successful treatment requires an understanding of the underlying disorder. Trauma is the most commonly identified cause, followed by infection (odontogenic, otitis media, and mastoiditis). Various systemic disease states have been associated with hypomobility, including ankylosing spondylitis, rheumatoid arthritis, and other collagen vascular diseases such as scleroderma. Iatrogenic causes have also been identified and include the sequelae of high-dose radiation involving the muscles of mastication, craniotomy procedures, and, uncommonly, orthognathic surgery. Internal temporomandibular joint (TMJ) derangements may also lead to chronic hypomobility problems. Traumatic perinatal events and neuromuscular conditions can result in hypomobility in infancy. In general terms, congenital ankylosis is defined as limited interincisal opening noted at birth with no

known causative factor. Table 52-1 lists the etiologic factors associated with mandibular hypomobility.

Classification

Various classification schemes have been proposed to describe hypomobility.¹⁻³

Trismus is most commonly found in conjunction with spasm of the muscles of mastication. It can be secondary to myofascial pain dysfunction, infection, trauma, tumors, and various medications as well as psychiatric and neurologic factors. Ankylosis may be classified according to location (intra-articular vs extra-articular), type of tissue involved (bony, fibrous, or mixed), and the extent of fusion (complete vs incomplete). True ankylosis is caused by either fibrous or bony fusion of the structures contained within the TMJ capsule and, in its most severe state, is characterized by a bony union of the condyle to the glenoid fossa. True ankylosis has been further classified into subtypes depending on the anatomic positioning of the condyle and the extent of bridging bone. Topazian proposed a

three-stage classification to grade complete ankylosis as follows: stage I, ankylotic bone limited to the condylar process; stage II, ankylotic bone extending to the sigmoid notch; and stage III, ankylotic bone extending to the coronoid process.⁴ Other classification schemes have also been proposed.⁵ However, the utility of these designations in terms of treatment planning is questionable. So-called false ankylosis (pseudoankylosis), in contrast, describes limited mobility based on extra-articular factors such as fibrosis, mechanical obstruction (eg, zygomatic arch fracture), muscle spasm, or other pathologies.

Clinical Presentation

Patients with fibrous or bony ankylosis present with restricted mandibular motion and, depending on the patient's age and the condition's etiology, may have an abnormality in mandibular size and shape. Unilateral pathology in children may result in significant problems with lower facial symmetry. A shortened ramus on the affected side is usually accompanied by a prominent antegonial notch

Table 52-1 Etiologic Factors Associated with Hypomobility of the Mandible**Trismus**

Odontogenic: myofascial pain, malocclusion, erupting teeth
 Infection: pterygomandibular, lateral pharyngeal, temporal
 Trauma: fracture of the mandible, muscle contusion
 Tumors: nasopharyngeal tumors, tumors that invade jaw muscles
 Psychologic: hysteric trismus
 Pharmacologic: phenothiazines
 Neurologic: tetanus

Pseudoankylosis

Depressed zygomatic arch fracture
 Fracture dislocation of the condyle
 Adhesions of the coronoid process
 Hypertrophy of the coronoid process
 Fibrosis of the temporalis muscle
 Myositis ossificans
 Scar contracture following thermal injury
 Tumor of the condyle or coronoid process

True ankylosis

Trauma: intracapsular fracture (child), medial displaced condylar fracture (adult),
 obstetric trauma, intracapsular fibrosis
 Infection: otitis media, suppurative arthritis
 Inflammation: rheumatoid arthritis, Still's disease, ankylosing spondylitis,
 Marie-Strümpell disease, psoriatic arthritis
 Surgical: postoperative complications of temporomandibular joint or orthognathic surgery

noted on radiographs. Such unilateral mandibular growth disturbances have secondary effects on the maxillary occlusal plane and midfacial structures (pyriform rims and bony orbits).

Ankylosis in adults is characterized by limited jaw opening and decreased translation, but the morphologic characteristics found in the growing patient are frequently absent. Loss of condylar structure and mandibular angle prominence is seen in cases caused by rheumatologic disease, specifically scleroderma. An associated anterior open bite is frequently noted with the loss of ramus/condyle height (Figure 52-1). Unilateral cases with a traumatic etiology may result in malocclusion and ipsilateral dental prematurities. A physical examination is helpful in identifying whether the process is bilateral or unilateral and may be suggestive of the etiology.

Imaging Assessment

In addition to the clinical examination, radiographic assessment is critical in evaluating and treating patients with hypomobility disorders. Plain radiographs are limited in delineating the true extent of the deformity. What can be identified with these studies are the presence or absence of a TMJ space, obvious bony abnormalities in the region of the joint, and coronoid hyperplasia. Sanders and colleagues have reported that conventional radiographs underestimate the extent of bony ankylosis and give little information about the anatomy medial to the condyle.⁶ The use of computed tomography (CT) scans (including axial, coronal, and sagittal views with three-dimensional reconstruction) is helpful in fully defining the extent of ankylosis as well as the relationship of the ankylotic mass to important anatomic

structures, especially at the skull base (pterygoid plates, carotid canal, jugular foramen, and foramen spinosum) (Figure 52-2).^{7,8} Often in post-traumatic cases the distance between the maxillary artery and the medial pole of the condyle is reduced—a contrast CT helps to determine this distance. Fusion of the ankylotic mass to the base of the skull can also be appreciated on CT scans. Since adequate treatment requires the removal of the mass in toto, knowledge of this anatomy preoperatively is critical to surgical planning and long-term success.

Magnetic resonance imaging (MRI) has had a great impact on TMJ evaluation, especially regarding the delineation of meniscal position. Diagnosis of fibrous ankylosis is possible with the use of MRI, but the CT scan is superior in demonstrating bony pathology.⁹

Post-traumatic Hypomobility

Trauma is the most common cause of bony and fibrous ankylosis as reported by multiple authors.¹⁰⁻¹² It is hypothesized that the formation of an intra-articular hematoma with subsequent scarring and new bone formation is the common precipitant. Most often, a medially displaced fracture dislocation of the condyle is found. Subsequent hypomobility is of particular concern in growing children in whom the development of hypomobility can have significant impact on facial

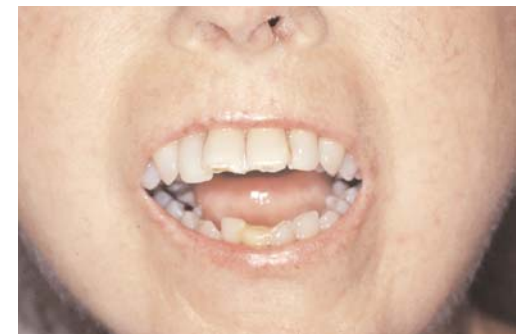

FIGURE 52-1 Patient with systemic sclerosis (scleroderma) demonstrating a limitation in jaw opening and skin changes characterized by perioral furrows and telangiectasia.

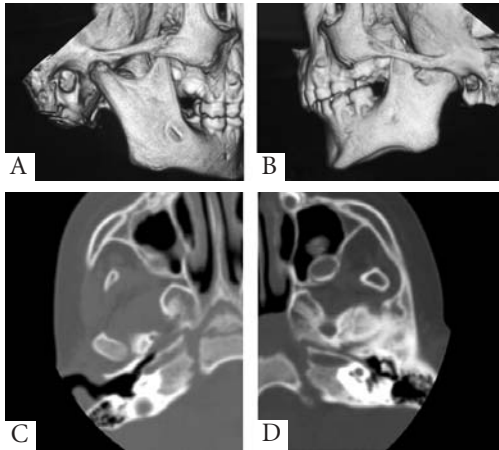


FIGURE 52-2 Three-dimensional (A, B) and axial (C, D) computed tomography scans of a patient with extensive bony ankylosis of the left temporomandibular joint. Note the comparison with the unaffected right side (A, C). Coronoid hyperplasia is also seen on the affected left side (B, D).

growth (Figure 52-3). In addition, resultant hypomobility can lead to speech impairment, difficulty with chewing, poor oral hygiene, limited access to dental care, and possible airway compromise. In large reviews of pediatric facial fractures, the condylar and subcondylar regions were

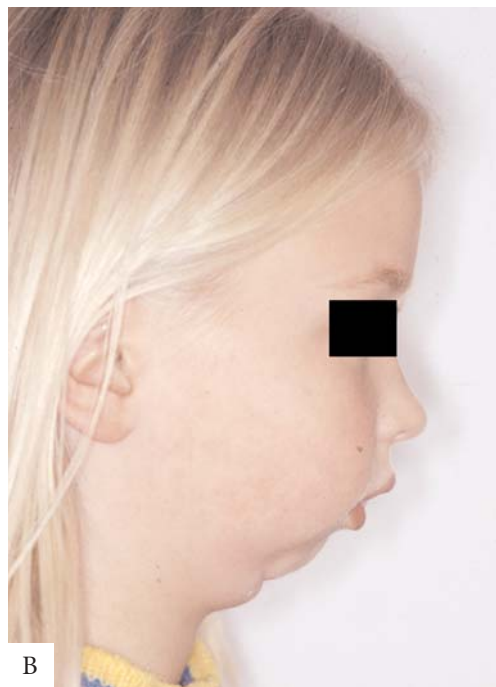
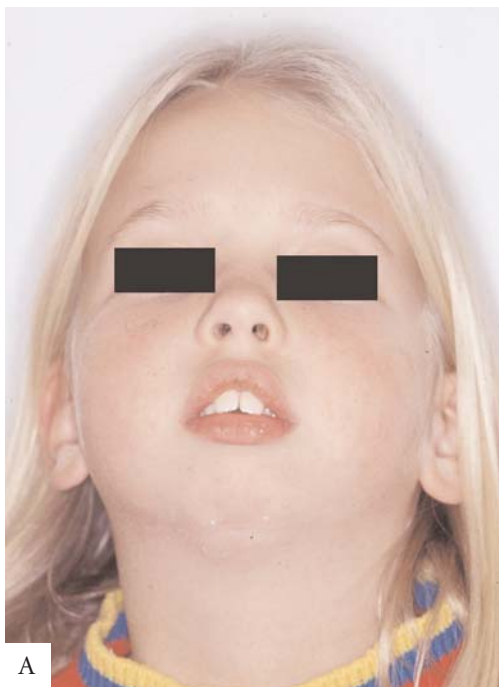
FIGURE 52-3 A and B, Evident mandibular growth disturbance is noted in this child who has had bilateral condylar fractures. Note the submental scar secondary to a laceration sustained at the time of the bony injury.

involved in > 40% of cases.^{13,14} In many cases a direct blow to the chin with transmission of the impact force to the condyles resulted in the fracture. Prolonged immobilization, secondary to treatment with maxillomandibular fixation, splinting, or mechanical obstruction can lead to subsequent ankylosis.

Extra-articular ankylosis can also occur with coronoid fractures and fractures of the zygomatic arch. In both cases the resultant hematoma may calcify, resulting in a fusion of the coronoid process to the zygomatic arch.

Myositis ossificans traumatica (MOT), or fibrodysplasia ossificans circumscripta, is generally associated with a traumatic event or repeated episodes of minor trauma and can result in mandibular hypomobility.^{15,16} The precise mechanism remains to be elucidated but appears to involve fibrous metaplasia and subsequent ossification of both soft tissues and muscle after bleeding and myonecrosis. Histologically, both mature and woven bone can be noted (sometimes in distinct zones), and both

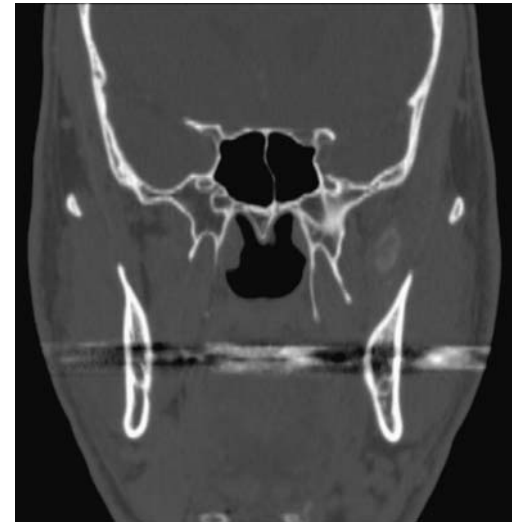


FIGURE 52-4 Computed tomography scan of patient with myositis ossificans traumatica demonstrating a focus of calcification within the medial pterygoid muscle on the left side.

osteoblasts and osteocytes are abundant. MOT is characterized by soft tissue ectopic ossifications and is relatively uncommon in the head and neck regions. Of all reported cases involving the muscles of mastication, the masseter is most commonly affected. MOT involving the medial pterygoid muscle and secondary to local anesthesia injections has also been reported.¹⁷ Diagnosis is confirmed by identification of calcifications within the muscles of mastication on CT scans (Figure 52-4). Minimal response is found with physical therapy and stretching exercises; consequently, surgical treatment is often undertaken to remove the ectopic bone. Other treatment modalities include acetic acid iontophoresis, magnesium therapy, and the use of etidronate sodium.^{18,19} Since repeated relapses and refractory cases are common, the use of multiple treatment modalities may be associated with the best outcome.

Postinfectious Hypomobility

A TMJ infection resulting in hypomobility is most commonly the result of contiguous spread from an odontogenic infection, otitis media, or mastoiditis.^{20, 21} In the era of aggressive antibiotic treatment of infection,

such reported cases are now relatively uncommon. Hematogenous spread of infection has also been reported in association with disease states such as tuberculosis, gonorrhea, and scarlet fever.

Various case series describe deep facial space infections manifesting themselves as hypomobility and often being misdiagnosed at initial presentation.^{22,23} Odontogenic infection is commonly associated with trismus. In such cases associated symptoms (fever, dysphagia) are likely present, and CT scanning is invaluable in determining a diagnosis and in treatment planning. Medial pterygoid abscess formation or fibrosis secondary to hematoma organization can be precipitated by an inferior alveolar nerve block or posterior superior alveolar block. A history of recent dental treatment should suggest this possibility; the use of CT imaging can help delineate the anatomy of the masticator and pharyngeal spaces.

Mass lesions (both benign and malignant) can also result in mandibular hypomobility. Squamous cell carcinoma of the tongue base or tonsillar pillar is often accompanied by trismus. Masses involving the mandibular condyle invariably affect range of motion and need to be included in the differential diagnosis of hypomobility.

Hypomobility following Radiation Therapy

Mandibular hypomobility is a common sequela of the treatment of head and neck malignancies (Figure 52-5). The resultant fibromyositis caused by radiation therapy may exacerbate the postsurgical problems caused by large ablative procedures.²⁴ Goldstein and colleagues reviewed the effects of tumoricidal radiation therapy on restricted mandibular opening and found a linear dose-related effect.²⁵ Mandibular dysfunction increased as the dose to the pterygoid muscles increased. The authors reported diminution in opening with doses as low as 15 Gy. Pow and colleagues reported that 30% of patients treated for

nasopharyngeal carcinoma with high-dose radiation therapy had significant trismus compared with age-matched nonradiated control subjects.²⁶ Radiation therapy for primary tumors of the retromolar trigone was associated with a 12% incidence of long-term trismus. This association, compounded by resultant xerostomia, severely compromises the ability of these patients to maintain oral health.

The efficacy of early interventional physical therapy has been described. Buchbinder and colleagues compared the outcome of unassisted exercise, mechanically assisted exercise with the use of tongue blades, and use of the Therabite System in radiated patients.²⁷ All patients presented with an interincisal opening of < 30 mm. The response to each therapy was recorded every 2 weeks over a 10-week period. All groups showed improvement over the first 4 weeks, but the group using a mechanical exercising device (ie, Therabite System) continued to demonstrate an improvement of maximal interincisal opening (MIO) over the full 10-week period that was significantly greater than that of the other two groups.

Postcraniotomy Hypomobility

Mandibular hypomobility after intracranial surgical procedures is an uncommon yet reported phenomenon.^{28,29} Mechanistically, this problem is secondary to neurosurgical procedures performed through the temporal bone requiring an incision of the temporalis muscle. Subsequent fibrosis of the muscle may then result in limited opening, which is best treated with coronoid resection followed by vigorous physical therapy. The incidence of this problem is not known, but a review by Kawaguchi and colleagues reported limited mouth opening in as many as 33% of patients undergoing frontotemporal craniotomy procedures.³⁰ Although most are self-limiting, persistent hypomobility can severely compromise subsequent airway and anesthesia management in these

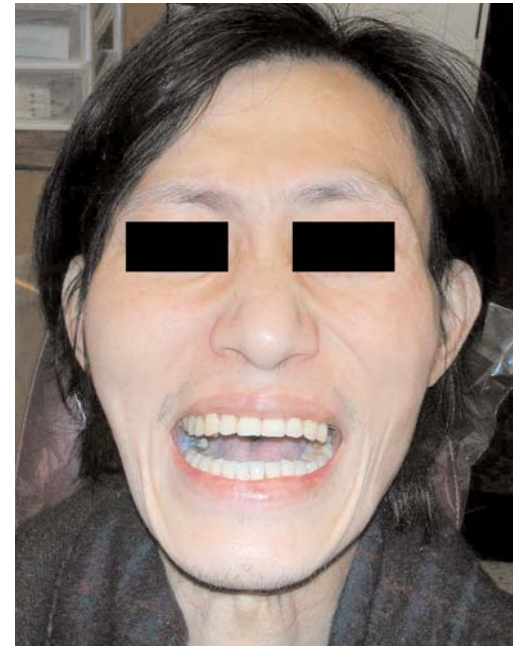

FIGURE 52-5 Patient with a history of high-dose radiation therapy and subsequent reirradiation for recurrence of nasopharyngeal carcinoma. Note the severe temporal atrophy and the limitation in opening.

patients and needs to be recognized. The maximal opening is not improved with the use of muscle relaxants or local or general anesthesia. Patients who have undergone skull base surgery may also manifest severe hypomobility postoperatively. If such surgery requires the dissection of the temporalis muscle inferior to the zygoma, pseudoankylosis of the mandible may be encountered.

Inflammatory and Rheumatologic Causes

Ankylosing spondylitis (Bekhterev's disease) is a chronic and progressive inflammatory condition most commonly affecting the sacroiliac joints and the spine. The male-to-female ratio of incidence is reported to be 2.4:1, and the severity and extension of the disease in male patients is found to be more severe. TMJ involvement in ankylosing spondylitis has been reported in between 1 and 22% of affected individuals and can include severe bony deformation and ankylosis.^{31,32} The most commonly reported radiographic findings in the

condyle and glenoid fossa region include flattening, erosions, sclerosis, osteophytes, subcortical cysts, and bony erosion at the insertion of the masseter (angle of the jaw) and temporalis muscles (coronoid process). One large prospective study evaluating 50 patients with ankylosing spondylitis did not show any correlation between the bony severity noted in the cervical spine and TMJ abnormalities.³³ These authors reported a 22% incidence of TMJ involvement, either clinical or radiographic. Because the majority of patients reported no pain or limitation in function, the radiographic findings included in this study may well have represented early changes in the disease process.

TMJ involvement in rheumatoid arthritis follows the same destructive path as do other joints. Generally, the severity of joint dysfunction is correlated with the stage of rheumatoid arthritis. Radiographically, the most common findings in the condylar region are the following: sclerosis (75%), erosion (50%), and flattening (30%).³⁴ These bony changes commonly result in progressive malocclusion secondary to the loss of ramus/condyle height and subsequent apertognathia. Juvenile rheumatoid arthritis is chronic arthritis diagnosed in childhood before the age of 16 years. It is estimated that > 60% of patients with juvenile rheumatoid arthritis manifest TMJ involvement.³⁵ However, multiple authors point out that despite radiographic and morphologic changes in the joint, a minority of affected children (generally < 25%) report pain with function.^{36,37} Svensson and colleagues report that restricted mouth opening was a more common finding.³⁸ The duration of active disease and a history of pain with function correlate positively with progressive TMJ dysfunction. With active disease in growing children, abnormalities in facial growth, mandibular hypoplasia, and hypomobility are common problems (Figure 52-6).

Scleroderma (progressive systemic sclerosis) is a disorder of unknown etiology affecting multiple organ systems and char-

acterized by abundant fibrosis of the skin, blood vessels, and visceral organs. It is believed that abnormalities in small blood vessels result in the progressive thickening and fibrotic changes noted in affected tissues, particularly those of the gastrointestinal tract, heart, lung, and kidney as well as diffuse skin involvement. Mandibular movement can become severely limited in affected individuals secondary to facial skin fibrosis and atrophy of the muscles of mastication (particularly the masseter and medial pterygoid muscles).³⁹ Bony changes in the mandible are also reported and include severe resorption of the angles, condyles, and coronoid processes (osteolysis).⁴⁰ The bony lesions are believed to be of ischemic origin but may be exacerbated by the tightness of the tissue in the region of the mandibular angles causing pressure resorption as well. In addition to the severe limitation in jaw movement, the small mouth orifice and progressive malocclusion make oral function and access to dental care problematic for these patients.

Hypomobility following Orthognathic Surgery

Hypomobility following orthognathic surgery has been reported by multiple authors and appears to be most commonly associated with the bilateral sagittal split osteotomy.^{41,42} This postoperative limited opening has been commonly attributed to muscle atrophy and soft tissue scar formation. Atrophic muscular changes seem to be exacerbated by prolonged use of maxillo-mandibular fixation, and the advent of rigid internal fixation appears to have limited this problem. Intra-articular pathology (edema, hemorrhage) as well as condylar torque may also result in hypomobility. In such cases rigid internal fixation may predispose to this problem. Van Sickels and colleagues have hypothesized that condylar torque at the time of the bilateral sagittal split osteotomy may cause impingement of the condyle against the disk, causing a mechanical impediment to opening.⁴³

Management of hypomobility after orthognathic surgery depends on the underlying cause. Trauma to the muscles of mastication is best managed postoperatively by vigorous physical therapy protocols. Those patients who fail to improve within the first 3 months need to be carefully evaluated for an intra-articular source of the problem. Edema, bleeding, and fibrosis within the joint space can frequently be managed by arthrocentesis procedures, especially when recognized early. If a mechanical obstruction to opening is suspected, CT is a helpful diagnostic aid. Condylar torque is best treated by reoperation with appropriate positioning of the proximal segment.⁴⁴

General Treatment Considerations

The treatment goal for all hypomobility states is the restoration of normal and comfortable jaw motion and prevention of disease progression. Reversible causes such as muscular hyperactivity or spasm, infectious and inflammatory causes, and medication-induced limitations must be identified and treated. Restoration of function in cases of

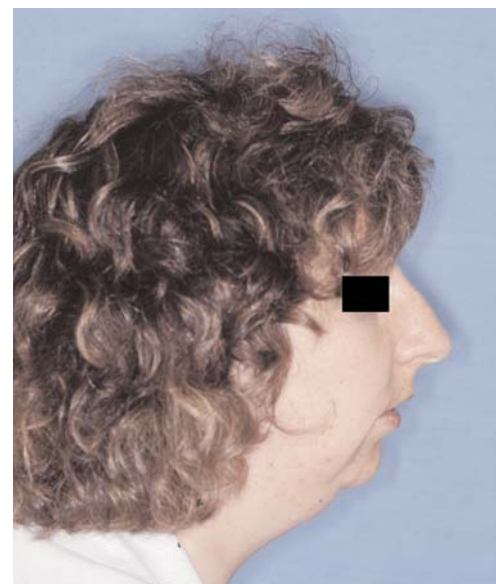

FIGURE 52-6 Adult patient with a history of juvenile rheumatoid arthritis affecting the temporomandibular joints and resulting in a mandibular growth disturbance and hypomobility.

ankylosis can be difficult. Proper treatment requires excision of the involved structures and immediate reconstruction. Many operative techniques have been described in the literature, with varying and often less than satisfactory results. As mentioned above, understanding the etiology and anatomy of the problem is critical and can be greatly aided with CT.

The gap arthroplasty is a procedure that creates a new area of articulation distal to the fused TMJ and ankylotic segment.^{45,46} Advocates of this procedure describe its simplicity. However, the creation of a pseudoarticulation significantly shortens the ramus height, and the procedure is associated with a high degree of reported reankylosis. Development of postoperative malocclusion and a decreased range of motion are the most common problems associated with this procedure as reported by Rajgopal and colleagues.⁴⁷ Because of these limitations, the use of the gap arthroplasty to treat ankylosis has been largely abandoned.

Temporomandibular ankylosis is more commonly treated with complete excision of the ankylotic mass and, if required, by subsequent joint reconstruction. Our protocol for the treatment of ankylosis follows that documented by Kaban and colleagues, a sequential protocol for the treatment of TMJ ankylosis that is based on aggressive resection of the ankylotic mass.⁴⁸ Wide intraoperative exposure is required, and special attention is directed to the medial aspect of the joint to ensure that bony, fibrous, and granulation tissue are completely removed. In addition to this aggressive resection of the bony and fibrous mass, dissection and stripping of the temporalis, masseter, and medial pterygoid muscles followed by ipsilateral coronoidectomy are performed in all cases through the same incision. Long-standing ankylosis frequently results in muscle fibrosis and coronoid hyperplasia. After this resection is completed, the MIO is measured. If it is found to be < 35 mm,

a contralateral coronoidectomy is performed via an intraoral approach to attain the desired level of opening. Because complete resection of the ankylotic mass frequently results in substantial loss of ramus height, subsequent reconstruction must address this fact and attempt to restore occlusion as well as function. Commonly, a temporalis fascia flap and costochondral graft are employed to both line the glenoid fossa and create ramus height. The patient is placed into maxillomandibular fixation following the reconstruction, and the teeth are placed into a prefabricated occlusal splint. Fixation is maintained for approximately 10 days and after release a strict protocol of physiotherapy is employed. Overall results have been excellent with this approach. After 1 year MIO was maintained at > 35 mm in all 18 patients included in the report. Furthermore, absence of pain with function was reported in all but two patients (Figure 52-7).⁴⁸

Recently, the Kaban protocol has been modified to substitute ramus/condyle reconstruction using distraction osteogenesis, when possible, instead of costochondral grafting.⁴⁹ This protocol has the major advantage of eliminating the donor site operation and allowing for immediate vigorous TMJ mobilization. The surgical procedure for the release of the ankylosis is identical to that described above. After the release the jaw is mobilized and the glenoid fossa lined with a temporalis myofascial flap if the native disk is unavailable. The remaining mandibular stump is reshaped to create a narrow and rounded top. A corticotomy is created distally, leaving sufficient bone to serve as a transport disk. The distraction device is secured, the corticotomy completed, and the mobility of the segments tested. Distraction then proceeds at 1 mm/d until the desired length is achieved. The patient begins a program of active jaw motion exercises immediately postoperatively (Figure 52-8).

The use of total joint prostheses has an interesting history in the TMJ. Advocates

describe two major advantages over autogenous reconstruction: (1) the absence of a donor site and (2) the ability of the patient to return to function more quickly. However, multiple complications have been reported—some with devastating consequences for patients.⁵⁰⁻⁵² Foreign body reaction to any alloplast may occur. In its most severe form, extensive bony erosion in the area of the glenoid fossa has been found. Fragmentation of alloplastic material secondary to function with a migration of particles into contiguous tissue and regional lymph nodes has also been reported. Progressive wear may result in a loosening and fracture of the prosthesis. In addition, the lack of growth potential precludes the use of these joint-replacement systems in young children. Recurrent ankylosis after prosthesis placement has also been reported, with periprosthetic calcifications most commonly seen in younger patients.

TMJ reconstruction with a variety of autogenous tissues has been described. When the extent of bony resection does not severely shorten ramus height, autogenous interpositional grafts may be employed. These include skin, temporal muscle, cartilage, and fascia. A recent review by Chossegros and colleagues has demonstrated superior results (defined by the authors as an interincisal opening of 30 mm or greater over a follow-up period of 3 yr) using full-thickness skin grafts and temporalis muscle.⁵³ Various bone grafts (costochondral, sternoclavicular, iliac crest, and metatarsal head) have been used to reconstruct ramus height after the resection of ankylosis. First described in the 1920s, the costochondral graft for TMJ reconstruction was popularized in later years by Poswillo, and MacIntosh and Henny.^{54,55} Autogenous tissue (particularly the costochondral graft) has the advantage of being biologically acceptable and possessing growth and remodeling potentials that make it a particularly attractive reconstructive choice in the growing child. Potential problems with its use include fracture, resorption, donor site

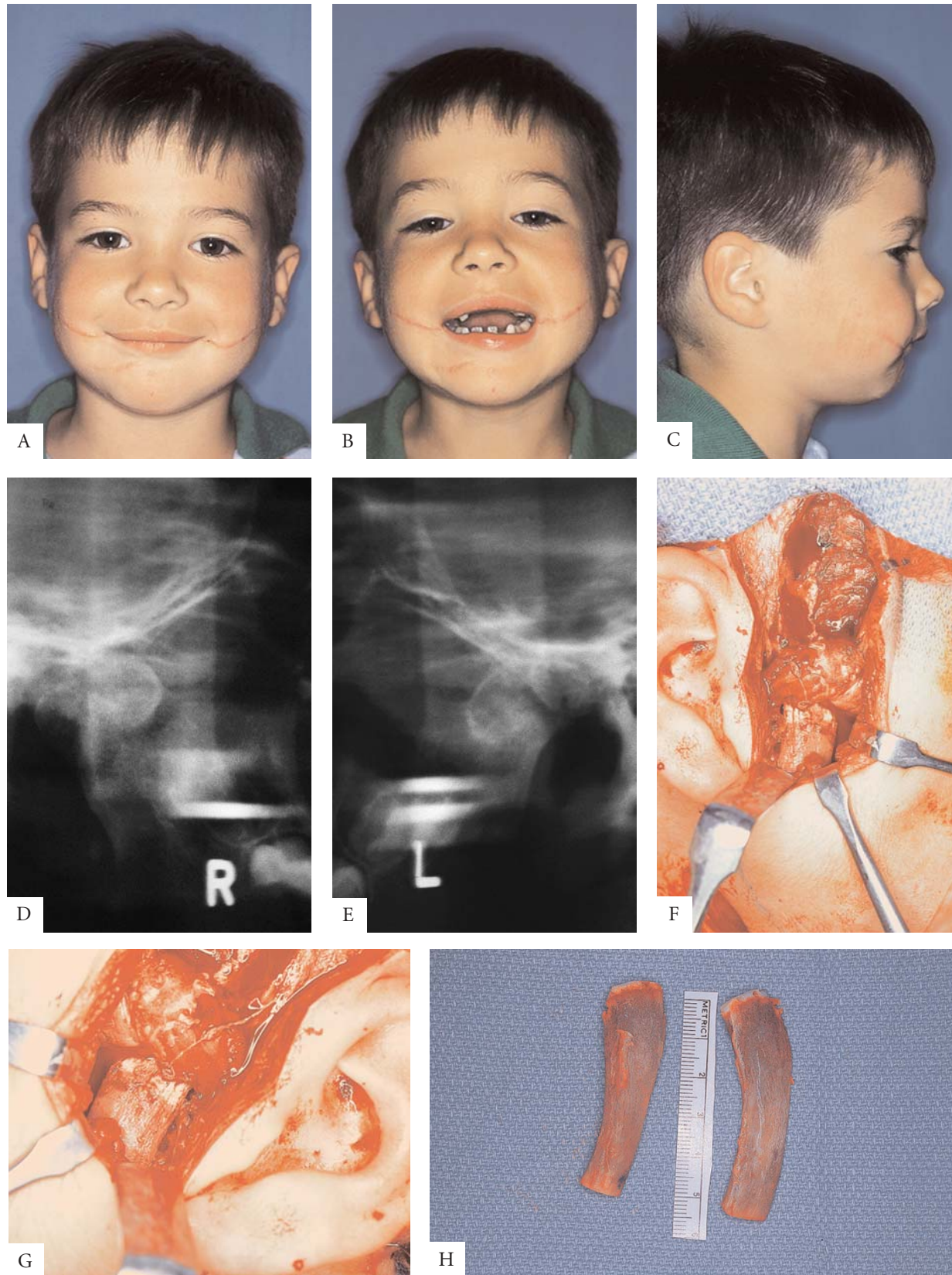


FIGURE 52-7 Three-year-old boy with bilateral bony ankylosis after a motor vehicle accident that also produced bilateral lacerations of the commissures. Frontal photograph (A), frontal maximal incisal opening (B), and lateral photograph (C). Note the limited opening. Right (D) and left (E) panoramic views of the ankylotic masses of the temporomandibular joints (TMJs). Right (F) and left (G) TMJs exposed after the dissection was completed. H, Harvested costochondral grafts with 1–2 mm cartilaginous caps. (CONTINUED ON NEXT PAGE)

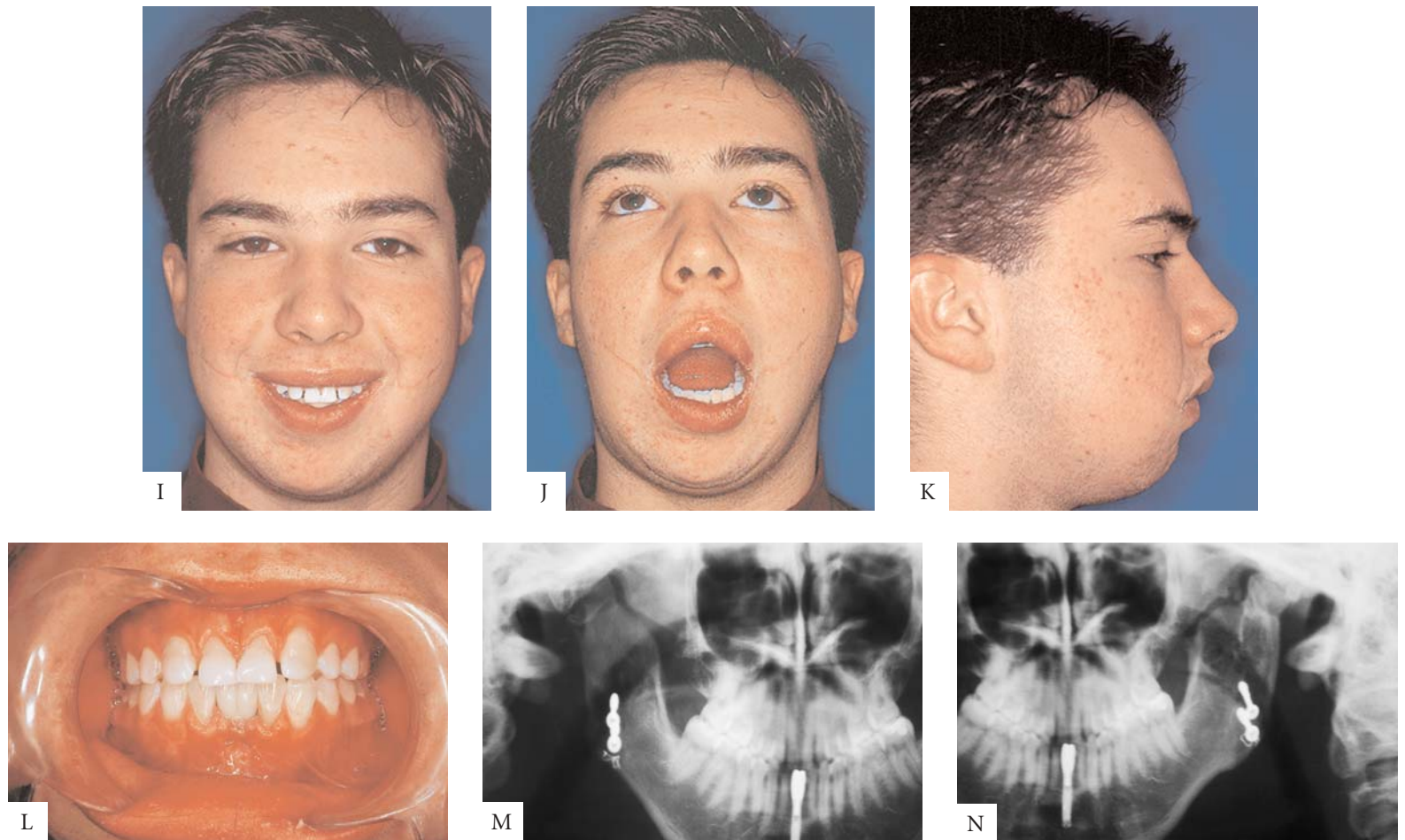


FIGURE 52-7 (CONTINUED) Frontal (I), frontal opening (J), and lateral (K) facial views of the patient 11 years postoperatively. Note maintenance of the normal MIO. L, Intraoral views. Right (M) and left (N) panoramic radiographs show remodeling of the costochondral grafts. Reproduced with permission from Kaban LB. Acquired temporomandibular deformities. In: Kaban LB, Troulis MJ, editors. *Pediatric oral and maxillofacial surgery*. St. Louis (MO): Elsevier; 2004. p. 361–5.

morbidity, recurrence of ankylosis, and a variable growth behavior of the graft in situ.

Complications Associated with Treatment

Various complications have been reported secondary to the treatment of ankylosis. Dolwick and Armstrong caution that a severe limitation of opening can make the palpation of landmarks difficult and increases the surgical risks.⁵⁶ The aggressive bony removal and recontouring that is often required can increase the risk of development of an aural-TMJ fistula if the tympanic plate is displaced posteriorly. In addition, stenosis of the external auditory meatus and subsequent hearing impairment may follow tympanic plate displacement.

Recurrent ankylosis may result from inadequate initial treatment. It most commonly occurs on the medial aspect of the condyle where surgical access is most difficult. Such maneuvers as the postoperative use of nonsteroidal anti-inflammatory drugs and vigorous physical therapy limit problems with recurrent hypomobility.^{57,58}

In pediatric patients treated for ankylosis, the expected outcome may be less sanguine.⁵⁹ The improvement in interincisal opening, despite strict adherence to the above treatment protocol and compliance with physical therapy regimens, is often significantly less than 35 mm. Posnik and Goldstein reviewed the outcome of nine children and demonstrated a mean MIO of 24.8 mm in unilateral cases and

17.5 mm in bilateral cases measured an average of 2 years postoperatively.⁶⁰ The authors caution that improvement in bilateral congenital cases is particularly problematic and may be confounded by the associated neuromuscular and atrophic changes found in these patients.

Peripheral nerve injuries are possible sequelae of all TMJ operations, with the upper branches of the facial nerve being the most vulnerable. Parotid gland injury with subsequent sialocele and fistula formation has also been reported.

As previously described, the costochondral graft is the most commonly used autogenous material for TMJ reconstruction. However, its growth pattern can be unpredictable. Linear overgrowth

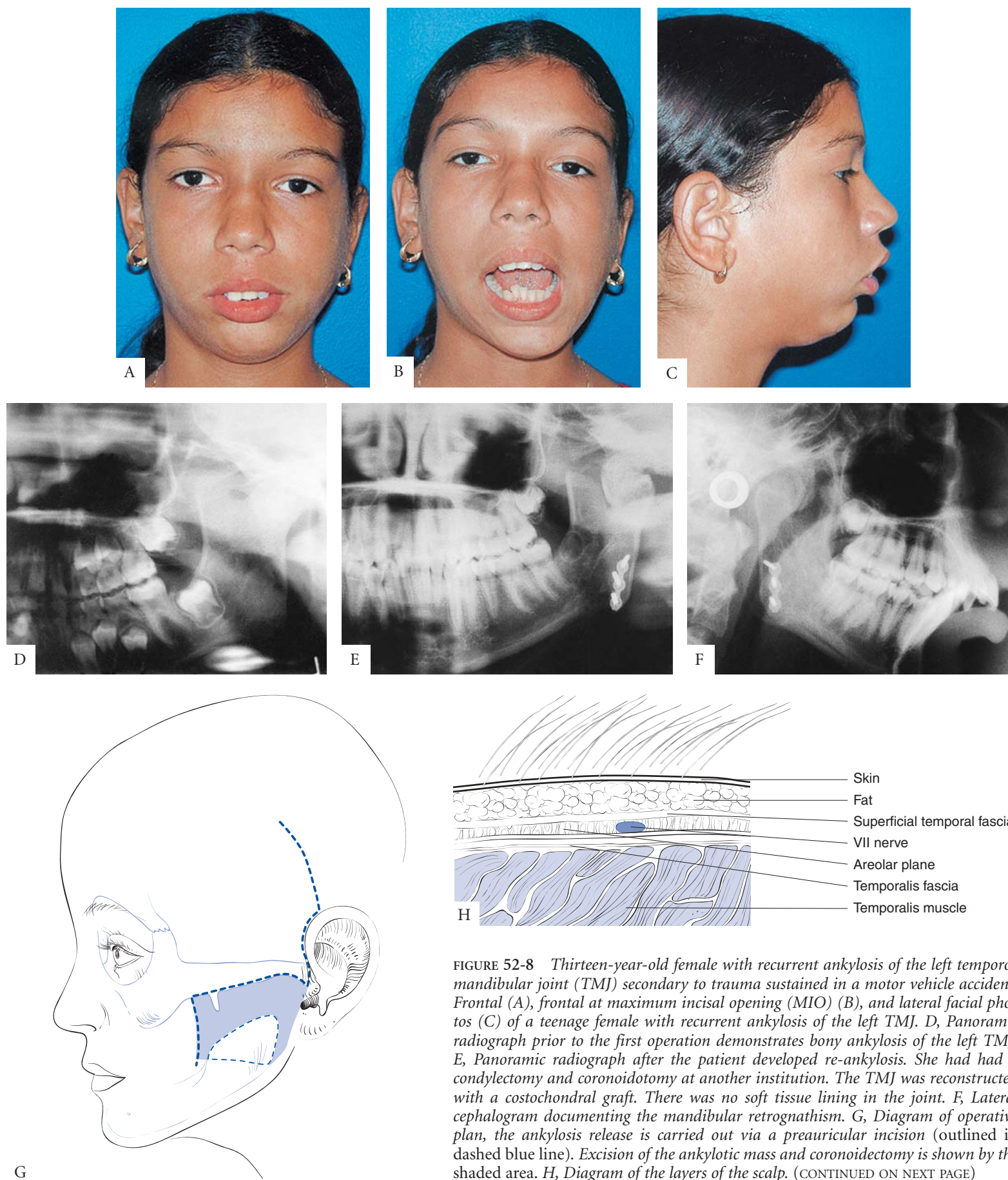


FIGURE 52-8 Thirteen-year-old female with recurrent ankylosis of the left temporomandibular joint (TMJ) secondary to trauma sustained in a motor vehicle accident. Frontal (A), frontal at maximum incisal opening (MIO) (B), and lateral facial photos (C) of a teenage female with recurrent ankylosis of the left TMJ. D, Panoramic radiograph prior to the first operation demonstrates bony ankylosis of the left TMJ. E, Panoramic radiograph after the patient developed re-ankylosis. She had had a condylectomy and coronoidotomy at another institution. The TMJ was reconstructed with a costochondral graft. There was no soft tissue lining in the joint. F, Lateral cephalogram documenting the mandibular retrognathism. G, Diagram of operative plan, the ankylosis release is carried out via a preauricular incision (outlined in dashed blue line). Excision of the ankylotic mass and coronoidectomy is shown by the shaded area. H, Diagram of the layers of the scalp. (CONTINUED ON NEXT PAGE)

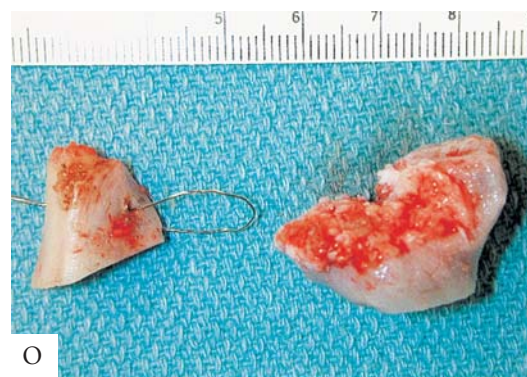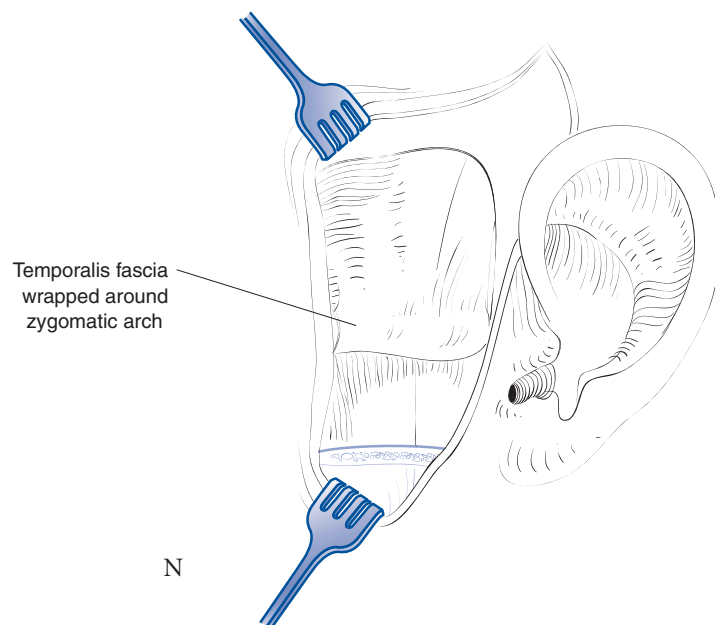
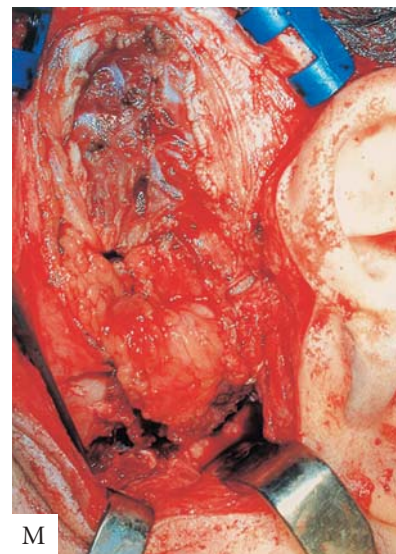
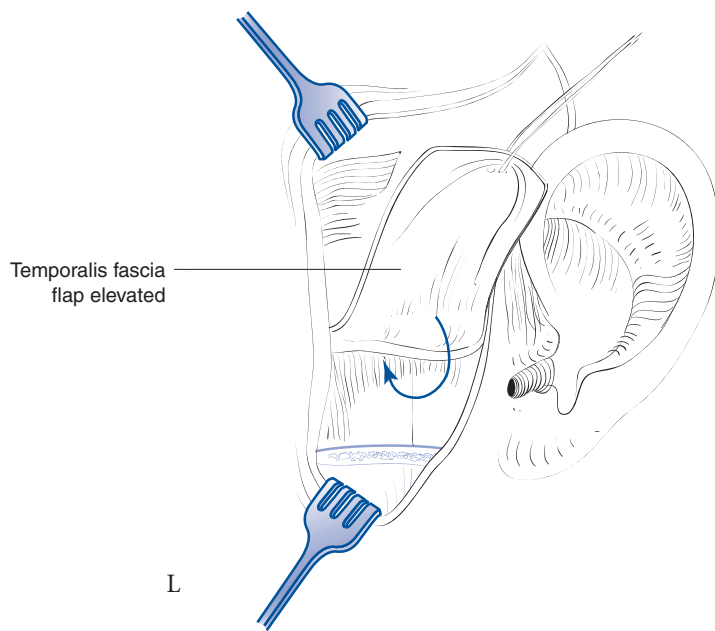
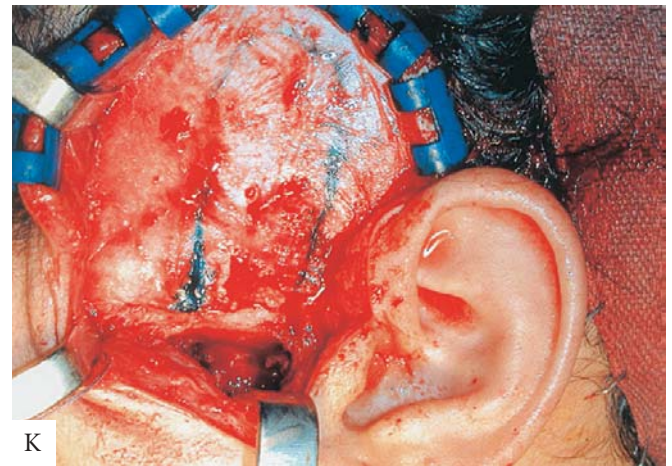
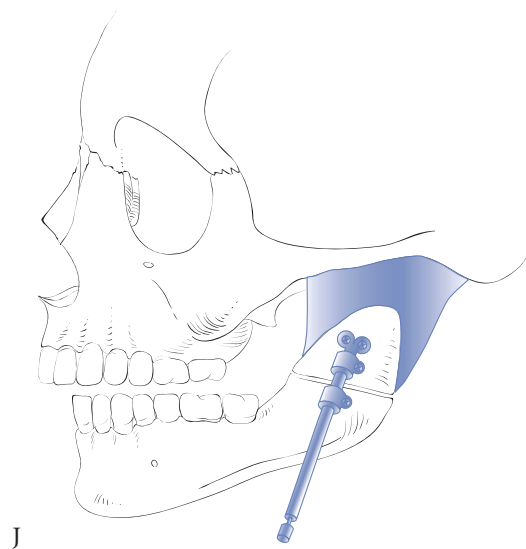
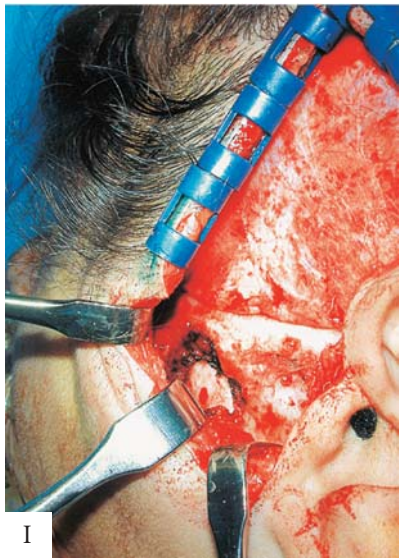


FIGURE 52-8 (CONTINUED) I, Intraoperative view after dissection was completed. Note the bony ankylotic mass and the coronoid process with obliteration of the sigmoid notch. J, Diagram of the bone removed (shaded area) and the proposed reconstruction using a distraction device (Synthes Maxillofacial, Paoli, PA) instead of a costochondral graft. K, Temporalis flap is outlined with malachite green. The flap is dissected and rotated over the arch (L) and sutured in place (M, N). O, Specimen: ankylotic mass and coronoid process. (CONTINUED ON NEXT PAGE)

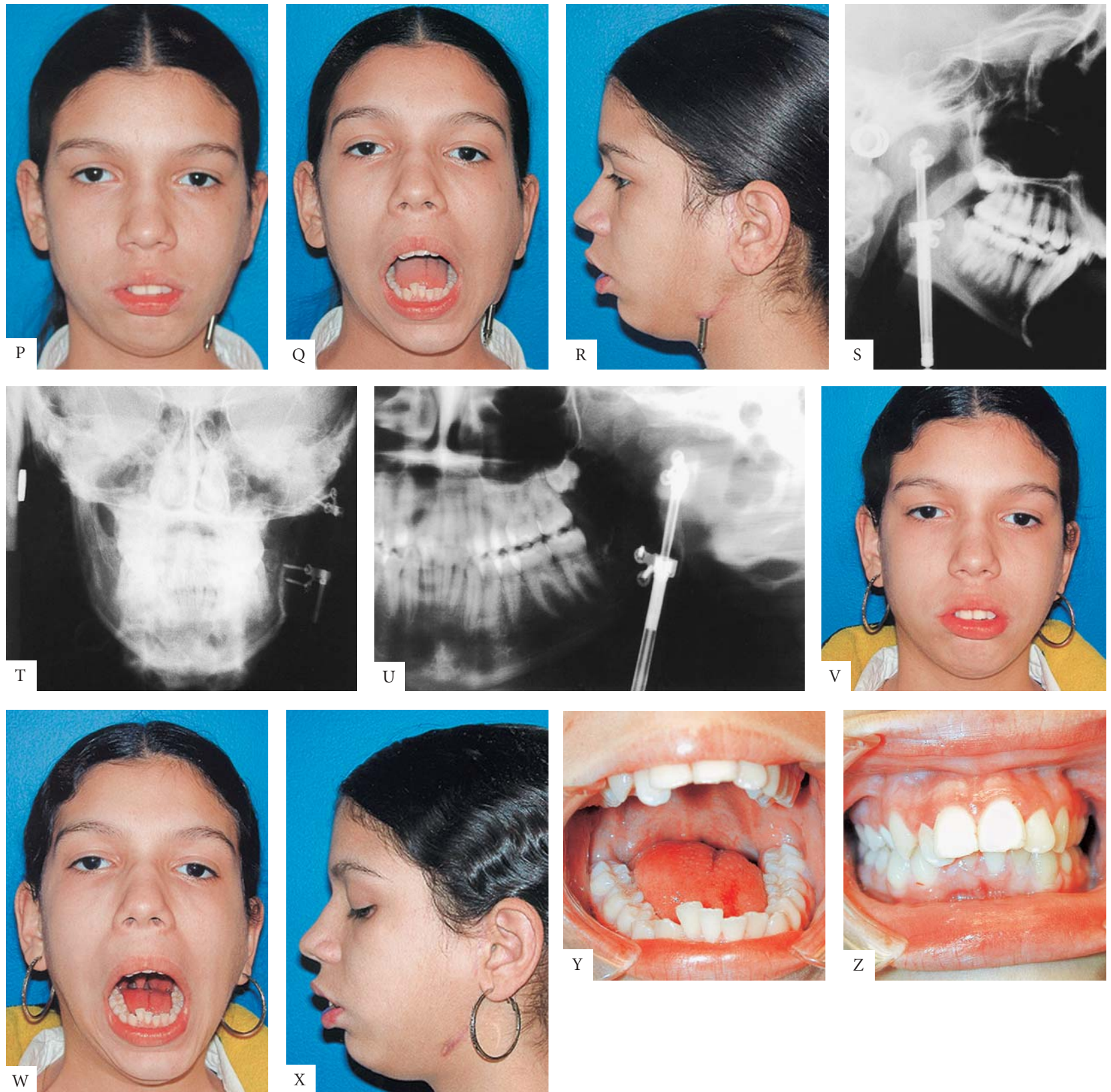

FIGURE 52-8 (CONTINUED) Frontal (P), frontal opening (Q), and lateral (R) photographs at end distraction. The patient was mobilized and started on physical therapy immediately postoperatively. She was comfortable because there was no donor site operation and no period of maxillomandibular fixation. Lateral (S) and anterior-posterior (A-P) (T) designated as cephalogram and panoramic radiograph (U) at the end of distraction osteogenesis demonstrating the lengthened mandibular ramus. Frontal (V), frontal opening (W), and lateral (X) photographs 1 year after completion of treatment. The patient maintained her TMJ motion and will be beginning presurgical orthodontic treatment to correct her preexisting malocclusion. Open (Y) and closed (Z) intraoral views with the patient opening 39 mm at 1 year. (CONTINUED ON NEXT PAGE)

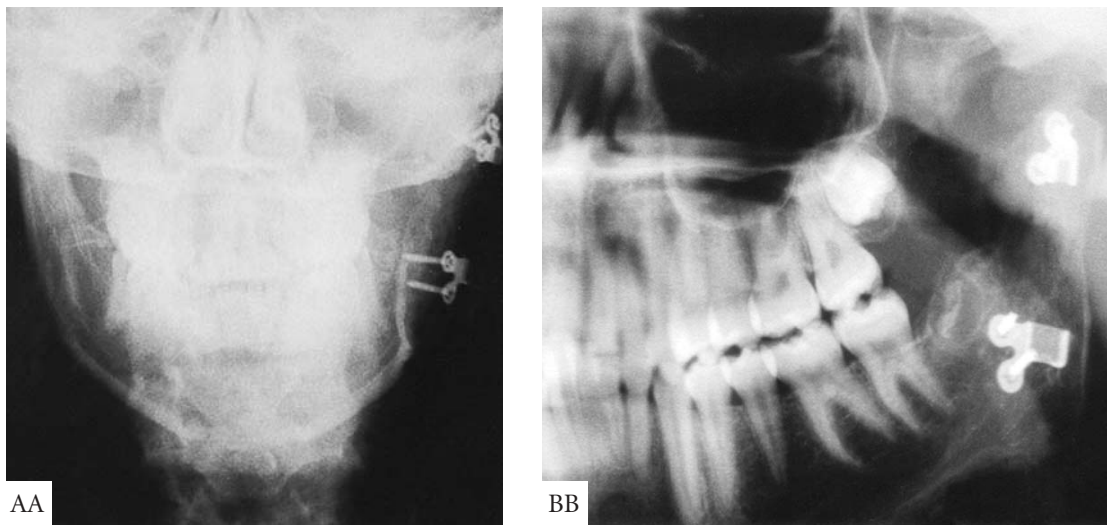


FIGURE 52-8 (CONTINUED) A-P cephalogram (AA) and panoramic radiograph (BB) at 1 year. The ramus lengthening is demonstrated by the space between the retained footplates. A–F, I, K, M and O–BB reproduced with permission and G, H, J, L, N adapted from Kaban LB. *Acquired temporomandibular deformities*. In: Kaban LB, Troulis MJ, editors. *Pediatric oral and maxillofacial surgery*. St. Louis (MO): Elsevier; 2004. p. 354–7.

with the subsequent development of asymmetry and malocclusion has been reported by multiple authors.^{61,62} The frequency is more common in the growing patient. Munro and colleagues reported 2 of 22 cases of considerable linear overgrowth with resultant chin deviation and development of a Class III malocclusion.⁶¹ Perrott and colleagues reported 3 of 26 cases of lateral bony overgrowth (tumor-like overgrowth), with an evident preauricular fullness and subsequent limitation of opening. However, no cases of linear overgrowth were found in that series of patients.⁶²

Postoperative Physical Therapy

Patients with hypomobility disorders require aggressive physical therapy programs, often in conjunction with surgical treatment, to maintain a functional MIO. Various rehabilitation programs have been described in the literature, and approaches include unassisted exercise, tongue-blade and finger-stretch exercises, manual exercisers, and mechanically assisted mandibular motion devices (Figure 52-9). Manipulation under general anesthesia may also be required in refractory or recurrent cases.

Most authors agree that the duration of physical therapy should be prolonged well after a desired MIO is achieved to prevent subsequent relapse.⁶³

Hypermobility

Classification

Mandibular subluxation occurs when there is a momentary inability to close the mouth from a maximally open position. It is defined as a self-reducing partial dislocation of the TMJ, during which the condyle passes anterior to the articular eminence. In distinction, dislocation may be considered a long-lasting inability to close the mouth. Subluxation of the condyle may be an early feature of TMJ pathology in a subset of patients. It is often associated with an abnormally wide opening while eating or yawning. Extended periods of mouth opening (eg, during dental treatment or endotracheal anesthesia) may also precipitate subluxation. Subluxation may occur secondary to acute trauma or following a seizure and is also associated with systemic diseases such as Ehlers-Danlos syndrome and Parkinson's disease.

Etiology

TMJ dislocation is defined as an internal derangement characterized by a condylar position anterior and superior to the articular eminence that is not self-reducing. Recurrent dislocation is a relatively unusual problem. Much like subluxation, the etiology is varied. It is observed most frequently in patients with neurologic and connective tissue disorders, those with TMJ dysfunction, and those being treated with phenothiazines and other neuroleptic agents (Table 52-2).

Extrinsic trauma, especially that sustained while the mouth is open, may result in dislocation. Wide opening of any type as well as capsular laxity may be etiologic. Muscular problems secondary to medication use or neurologic disorders may be associated. The problem may be unilateral or bilateral, and patients generally present with associated muscle spasm and pain.

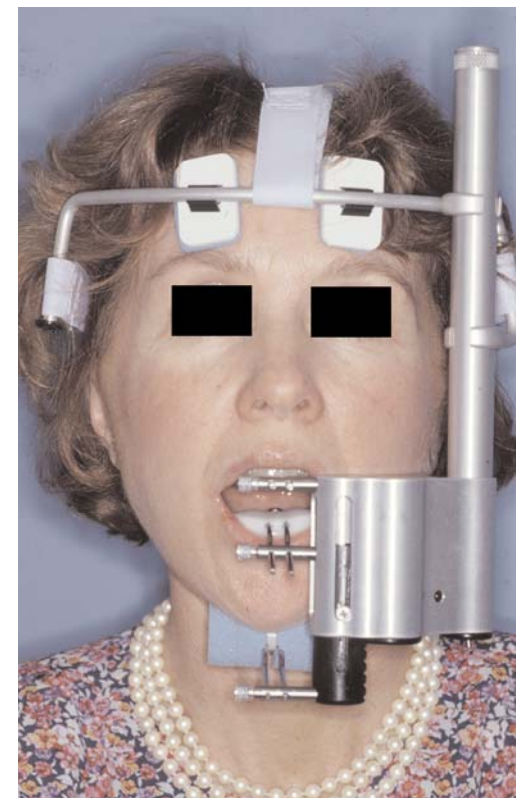


FIGURE 52-9 Photograph demonstrating a continuous passive motion device used in the postoperative management of hypomobility.

Table 52-2 Causes of Hypermobility

Intrinsic trauma: overextension injury
Yawning
Vomiting
Wide biting
Seizure disorder
Extrinsic trauma
Trauma: flexion-extension injury to the mandible, intubation with general anesthesia, endoscopy, dental extractions, forceful hyperextension
Connective tissue disorders: hypermobility syndromes, Ehlers-Danlos syndrome, Marfan syndrome
Miscellaneous causes: internal derangement, dyssynchronous muscle function, contralateral intra-articular obstruction, lost vertical dimension, occlusal discrepancies
Psychogenic: habitual dislocation, tardive dyskinesia
Drug induced: phenothiazines

Treatment Considerations

In the absence of pain, subluxation requires no specific treatment since it is self-reduced by the patient. When associated with wide mouth opening, conscious efforts to avoid this are usually successful at preventing recurrent subluxation. Patients are advised to modify their diets, and dental treatment is done over multiple shorter appointments. The use of bite-blocks during procedures can also be helpful. In cases in which extreme laxity in the joint results in continued problems, surgical intervention may be warranted.

Reduction of mandibular dislocation should be done precipitously before muscle spasm becomes severe and makes the procedure more difficult. Reduction is accomplished by pressing the mandible downward and then backward to relocate the condyle within the glenoid fossa (Figure 52-10). In acute cases this can generally be accomplished without the use of

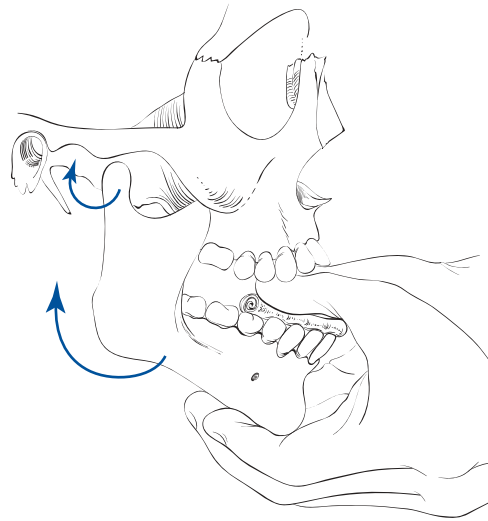


FIGURE 52-10 Bimanual mandibular manipulation in a downward-posterior direction to disengage the condyle from its open-locked position posterior to the articular eminence. Adapted from Rotskoff KS. *Management of hypomobility and hypermobility disorders of the temporomandibular joint*. In: Peterson LJ, Indresano AT, Marciani RD, Roser SM. *Principles of oral and maxillofacial surgery*. Vol. 3. Philadelphia: J.B. Lippincott Company; 1992: p. 2009

anesthesia. In cases of prolonged or chronic dislocation, the use of muscle relaxants and analgesics may be required. If reduction cannot be thus achieved, general anesthesia may be required. After reduction the mandible should be immobilized for several days to allow for capsular repair, muscle rest, and prevention of recurrence.^{64,65}

Chronic dislocation usually requires a more interventional approach. The use of

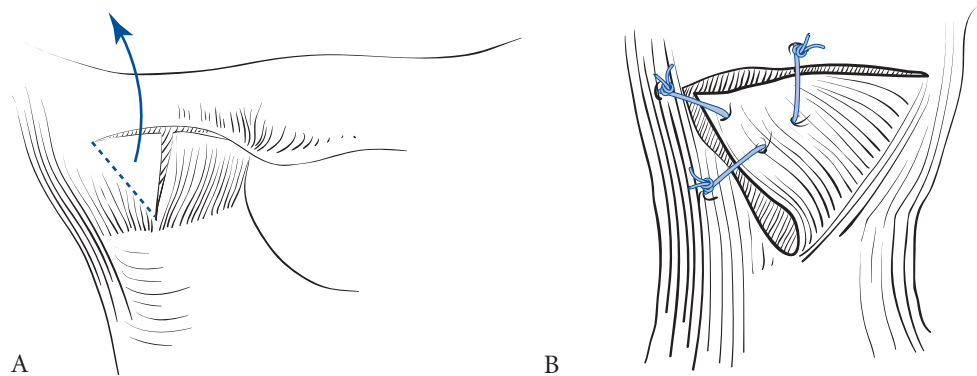


FIGURE 52-11 Capsular plication. The exposed lateral capsule is incised (A) and sutured back on itself (B) to tighten and limit capsular laxity. Adapted from Rotskoff KS. *Management of hypomobility and hypermobility disorders of the temporomandibular joint*. In: Peterson LJ, Indresano AT, Marciani RD, Roser SM. *Principles of oral and maxillofacial surgery*. Vol. 3. Philadelphia: J.B. Lippincott Company; 1992: p. 2010

various sclerosing agents has been described in the past. However, caustic agents can result in progressive damage to other joint structures, and multiple reports of misapplications and complications have resulted in the abandonment of this technique. Surgical treatments of various types are reported. Identification of etiology is important when considering surgical correction. In cases of extreme joint laxity, mechanical tightening may be indicated. Plication procedures involve fastening the condyle to a fixed structure to maintain its position within the glenoid fossa. Certain authors advocate the creation of a mechanical impediment to translation by altering the conformation of the articular eminence. Procedures targeting a decrease in muscle pull can also be effective.

Plication procedures are aimed at limiting mandibular motion and may be accomplished in various ways. Removal of redundant capsular tissue (Figure 52-11) is a relatively simple method for addressing laxity, and a review by MacFarlane reported excellent long-term results.⁶⁶ Plication of the condyle to the temporal bone and of the coronoid process to the zygomatic arch have also been described. Multiple materials have been used for plication procedures, including both resorbable and nonresorbable sutures and wire. Miniplates and surgical anchors have also been used in both the lateral

pole of the condyle and the posterior roof of the zygomatic arch. Wolford and colleagues have described the threading of heavy suture material between the eyelets of the surgical anchors, thereby preventing condylar dislocation.⁶⁷

Mechanical impediments to condylar translation effectively deepen the glenoid fossa. Bone and cartilage grafts (cranial, iliac crest, rib, tibial) have been used for this purpose. Nonautogenous material has also been onlayed to the articular eminence. In 1943 LeClerc and Girald described a procedure for inferior displacement of the zygomatic arch to prevent translation (Figure 52-12).⁶⁸ Access was gained through an extended preauricular incision, and dissection of the zygomatic arch was performed. An oblique osteotomy downward and forward then allowed the arch to be moved inferiorly. Chossegros and colleagues reported excellent success using this technique in 36 patients with chronic and recurrent dislocation.⁵³

The eminectomy procedure was first introduced by Myrhaug in 1951 as a treatment for chronic and habitual dislocation of the condyle.⁶⁹ In addition to the standard open eminectomy, reports describing the use of the arthroscope for this purpose have recently appeared in the literature.⁷⁰ Both procedures involve the removal of a portion of the articular tubercle and eminence to allow the condyle to move freely.

Concerns regarding the use of the eminectomy procedure include the following: hypermobility of the joint with further damage to contiguous tissues; significant and often bothersome TMJ noise (clicking and crepitation) with function; the potential for facial nerve injury; recurrent dislocation; and inadvertent temporal lobe exposure (anatomic variant).⁷¹

Reported success rates of surgery to treat dislocation vary considerably. Recurrent dislocation following standard eminectomy procedures ranges from 7 to 33%.⁷²⁻⁷⁴ Patients with significant ligamentous laxity or predisposing conditions (eg, seizure disorders) are prone to recurrent problems. Arthroscopic eminectomy, owing to technical limitations, prevents the complete removal of the medial aspect of the eminence. The consequence of this in terms of recurrence remains to be elucidated.^{72,73}

If muscular hyperactivity is associated with chronic recurrent dislocation, removal of the insertion of the lateral pterygoid muscle (lateral pterygoid myotomy) may be an effective treatment. Bowman has reported good success with this procedure,⁷⁴ but subsequent animal studies have shown lateral pterygoid electromyographic activity returning to baseline several months after the procedure.⁷⁵ However, the long-term efficacy often attributed to this procedure may be sec-

ondary to scarring anterior to the joint capsule, thereby limiting condylar excursion.⁷⁶

The injection of botulinum toxin type A into the lateral pterygoid muscles has also been proposed as a treatment for chronic and recurrent dislocation of the mandible. Ziegler and colleagues reviewed 21 patients treated in this fashion. Injections were given on a 3-month basis with only 2 of 21 patients suffering further dislocations. No adverse side effects were reported in this series.⁷⁷ Botulinum toxin type A has an associated latency of 1 week, and its duration of action is between 2 and 3 months. Injections should not be done more often than every 12 weeks to avoid the development of antibodies. An injection dose of between 10 and 50 U into the targeted muscle is usually sufficient.

Clark reviewed the use of botulinum toxin for the treatment of mandibular motor disorders, as well as for the treatment of facial spasm, and expanded on the potential side effects of such treatment.⁷⁸ Although local side effects are unusual, the two most common problems encountered were alterations in salivary consistency and an inadvertent weakness of swallowing, speech, and facial muscles. These complications were more commonly reported with lateral pterygoid, soft palate, and tongue injections and were found to be dose dependent.

Summary

This chapter summarizes the spectrum of mobility problems that can affect the TMJ and contiguous structures. The varied etiologic factors associated with hypo- and hypermobility have been reviewed; an understanding of the etiology in each particular case is imperative for appropriate treatment to be rendered. Fortunately, improved imaging techniques, including three-dimensional CT, can be invaluable adjuncts to the history and physical examination. In cases of ankylosis, the extent and nature of the problem is best appreciated with these CT images. Altered anatomy and

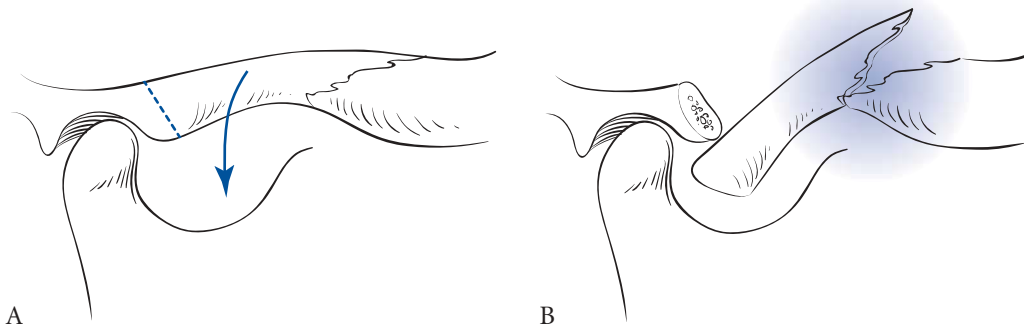


FIGURE 52-12 LeClerc procedure. A, An oblique cut using a fissure bur is created anterior to the articular eminence to decrease the frequency of condylar dislocation by obstructing the path of condylar movement. B, The osteotomized segments of the articular eminence are made to overlap one another. Adapted from Rotskoff KS. Management of hypomobility and hypermobility disorders of the temporomandibular joint. In: Peterson LJ, Indresano AT, Marciani RD, Roser SM. Principles of oral and maxillofacial surgery. Vol. 3. Philadelphia: J.B. Lippincott Company; 1992: p. 2010

the extent of bony bridging can be assessed preoperatively. In addition to operative intervention, long-term success in the management of ankylosis requires aggressive physical therapy programs and longitudinal follow-up.

Hypermobility (both subluxation and dislocation) is similarly reviewed. Again, understanding the causative factors (ligamentous laxity, shallow eminentia, muscular hyperactivity) helps one to focus the treatment planning and to minimize problems with recurrence.

References

- Aggarwal S, Mukhopakhyay S, Berry M, Bhargava S. Bony ankylosis of the temporomandibular joint: a computed tomographic study. *Oral Surg Oral Med Oral Pathol* 1990;69:128–32.
- Chandra P, Dave PK. Temporomandibular joint ankylosis. *Prog Clin Biol Res* 1985;187:449–58.
- El-Mofty S. Ankylosis of the temporomandibular joint. *Oral Surg Oral Med Oral Pathol* 1972;33:650–60.
- Topazian RG. Etiology of ankylosis of the temporomandibular joint: analysis of 44 cases. *J Oral Surg* 1964;22:227–33.
- Adekeye EO. Ankylosis of the mandible; analysis of 76 cases. *J Oral Maxillofac Surg* 1983;41:442–9.
- Sanders R, MacEwan CJ, McCulloch AS. The value of skull radiography in ophthalmology. *Acta Radiol* 1994;35:429–33.
- El-Hakim IE, Metwalli SA. Imaging of temporomandibular joint ankylosis. A new radiographic classification. *Dentomaxillofac Radiol* 2002;31:19–23.
- de Bont LG, van der Kuijl B, Stegenga B, et al. Computed tomography in the differential diagnosis of temporomandibular joint disorders. *Int J Oral Maxillofac Surg* 1993;22:200–9.
- Roberts D, Schenck J, Joseph P. Temporomandibular joint: magnetic resonance imaging. *Radiology* 1985;154:829–30.
- Chidzonga MM. Temporomandibular joint ankylosis: review of thirty-two cases. *Br J Oral Maxillofac Surg* 1999;37:123–6.
- de Burgh JE. Post-traumatic disorders of the jaw joint. *Ann R Coll Surg Engl* 1982;64:29–36.
- Guralnick WC, Kaban LB. Surgical treatment of mandibular hypomobility. *J Oral Surg* 1976;34:343–8.
- Marianowski R, Martins CC, Potard G, et al. Mandibular fractures in children—long term results. *Int J Pediatr Otorhinolaryngol* 2003;67:25–30.
- Zachariades N, Papavassiliou D, Koumoura F. Fractures of the facial skeleton in children. *J Craniomaxillofac Surg* 1990;18:151–3.
- Aoki T, Naito H, Ota Y, Shiiki K. Myositis ossificans traumatica of the masticatory muscles: review of the literature and report of a case. *J Oral Maxillofac Surg* 2002;60:1083–8.
- Parkash H, Goyal M. Myositis ossificans of the medial pterygoid muscle. A cause for temporomandibular joint ankylosis. *Oral Surg Oral Med Oral Pathol* 1992;73:27–8.
- Luchetti W, Cohen RB, Hahr GV, et al. Severe restriction in jaw movement after routine injection of local anesthetic in patients who have fibrodysplasia ossificans progressiva. *Oral Surg Oral Med Oral Pathol Oral Radiol Endod* 1996;81:21–5.
- Wieder DL. Treatment of myositis ossificans with acetic acid iontophoresis. *Phys Ther* 1992;72:133–7.
- Steidl L, Ditmar R. Treatment of soft tissue calcifications with magnesium. *Acta Univ Palacki Olomuc Fac Med* 1991;130:273–87.
- Faerber TH, Ennis RL, Allen GA. Temporomandibular joint ankylosis following mastoiditis; report of a case. *J Oral Maxillofac Surg* 1990;48:866–70.
- Hadlock TA, Ferraro NF, Rahbar R. Acute mastoiditis with temporomandibular joint effusion. *Otolaryngol Head Neck Surg* 2001;125:111–2.
- Cohen SG, Quinn PD. Facial trismus and myofascial pain associated with infectious and malignant disease. *Oral Surg Oral Med Oral Pathol* 1988;65:538–44.
- Leighty SM, Spach DH, Myall RW, Burns JL. Septic arthritis of the temporomandibular joint: review of the literature and report of two cases in children. *Int J Oral Maxillofac Surg* 1993;22:292–7.
- Huang CJ, Chao KS, Tsai J, et al. Cancer of the retromolar trigone: long-term radiation therapy outcome. *Head Neck* 2001;23:758–63.
- Goldstein M, Maxymiw WG, Cummings BJ, Wood RE. The effects of antitumor irradiation on mandibular opening and mobility: a prospective study of 58 patients. *Oral Surg Oral Med Oral Pathol Oral Radiol Endod* 1999;88:365–73.
- Pow EH, McMillan AS, Leung WK, et al. Oral health condition in southern Chinese after radiotherapy for nasopharyngeal carcinoma: extent and nature of the problem. *Oral Dis* 2003;9:196–202.
- Buchbinder D, Currivan RB, Kaplan AJ, Urken ML. Mobilization regimens for the prevention of jaw hypomobility in the radiated patient: a comparison of three techniques. *J Oral Maxillofac Surg* 1993;51:863–7.
- Hollins RR, Moyer DJ, Tu HK. Pseudoankylosis of the mandible after temporal bone attached craniotomy. *Neurosurgery* 1988;22:137–9.
- Nitzan DW, Azaz B, Constantini S. Severe limitation in mouth opening following transtemporal neurosurgical procedures: diagnosis, treatment, and prevention. *J Neurosurg* 1992;76:623–5.
- Kawaguchi M, Sakamoto T, Furuya H, et al. Pseudoankylosis of the mandible after supratentorial craniotomy. *Anesth Analg* 1996;83:731–4.
- Resnick D. Temporomandibular joint involvement in ankylosing spondylitis. *Radiology* 1974;112:587–91.
- Ramos-Remus C, Major P, Gomez-Vargas A, et al. Temporomandibular joint osseous morphology in a consecutive sample of ankylosing spondylitis patients. *Ann Rheum Dis* 1997;56:103–7.
- Locher MC, Felder M, Sailer HF. Involvement of the temporomandibular joints in ankylosing spondylitis (Bechterew's disease). *J Craniomaxillofac Surg* 1996;24:205–13.
- Voog U, Alstergren P, Eliasson S, et al. Inflammatory mediators and radiographic changes in temporomandibular joints of patients with rheumatoid arthritis. *Acta Odontol Scand* 2003;61:57–64.
- Bakke M, Zak M, Jensen BL, et al. Orofacial pain, jaw function and temporomandibular disorders in women with a history of juvenile chronic arthritis or persistent juvenile chronic arthritis. *Oral Surg Oral Med Oral Pathol Oral Radiol Endod* 2001;92:406–14.
- Larheim TA, Hoyeraal HM, Stabrun AE, Haanaes HR. The temporomandibular joint in juvenile rheumatoid arthritis. Radiographic changes related to clinical and laboratory parameters in 100 children. *Scand J Rheumatol* 1982;11:5–12.
- Olson L, Eckerdal O, Hallonsten AL, et al. Craniomandibular function in juvenile chronic arthritis. A clinical and radiographic study. *Swed Dent J* 1991;15:71–83.
- Svensson B, Larsson A, Adell R. The mandibular condyle in the juvenile chronic arthritis patients with mandibular hypoplasia. *Int J Oral Maxillofac Surg* 2001;30:300–5.
- Seifert MH, Steigerwald JC, Cliff MM. Bone resorption of the mandible in progressive systemic sclerosis. *Arthritis Rheum* 1975;18:507–12.
- Haers PE, Sailer HF. Mandibular resorption due to systemic sclerosis. Case report of

- surgical correction of a secondary open bite deformity. *Int J Oral Maxillofac Surg* 1995;24:261–7.
41. Hori M, Okaue M, Hasegawa M, et al. Worsening of pre-existing TMJ dysfunction following sagittal split osteotomy: a study of three cases. *J Oral Sci* 1999;41:133–9.
 42. Feinerman DM, Picuch JF. Long term effects of orthognathic surgery on the temporomandibular joint. Comparison of rigid and nonrigid methods. *Int J Oral Maxillofac Surg* 1995;24:268–72.
 43. Van Sickels JE, Tiner BD, Alder ME. Condylar torque as a possible cause of hypomobility after sagittal split osteotomy: report of three cases. *J Oral Maxillofac Surg* 1997;55:398–402.
 44. Sanders B, Kaminishi R, Buoncristiani R, Davis C. Arthroscopic surgery for treatment of temporomandibular joint hypomobility after mandibular sagittal osteotomy. *Oral Surg Oral Med Oral Pathol* 1990;69:539–41.
 45. Roychoudhury A, Parkash H, Trikha A. Functional restoration by gap arthroplasty in temporomandibular joint ankylosis: a report of 50 cases. *Oral Surg Oral Med Oral Pathol Oral Radiol Endod* 1999;87:166–9.
 46. Sawhney CP. Bony ankylosis of the temporomandibular joint: follow-up of 70 patients treated with arthroplasty and acrylic spacer interposition. *Plast Reconstr Surg* 1986;77:29–40.
 47. Rajgopal A, Banerji PK, Batura V, Sural A. Temporomandibular ankylosis. A report of 15 cases. *J Oral Maxillofac Surg* 1983;11:37–41.
 48. Kaban LB, Perrott DH, Fisher K. A protocol for management of temporomandibular joint ankylosis. *J Oral Maxillofac Surg* 1990;48:1145–51.
 49. Kaban LB. Acquired temporomandibular deformities. In: Kaban LB, Troulis MJ, editors. *Pediatric oral and maxillofacial surgery*. St. Louis: Elsevier; 2004. p. 353–5.
 50. Mercuri LG. The use of alloplastic protheses for temporomandibular joint reconstruction. *J Oral Maxillofac Surg* 2000;58:70–5.
 51. Kent JN, Misiek DJ. Controversies in disc and condyle replacement for partial and total temporomandibular joint reconstruction. In: Worthington P, Evans JR, editors. *Controversies in oral and maxillofacial surgery*. Philadelphia: WB Saunders; 1994. p. 397–435.
 52. Henry CH, Wolford LM. Treatment outcomes for temporomandibular joint reconstruction after Proplast-Teflon implant failure. *J Oral Maxillofac Surg* 1993;51:352–8.
 53. Chossegros C, Guyot L, Cheynet F, et al. Comparison of different materials for interposition arthroplasty in treatment of temporomandibular joint ankylosis surgery: long-term follow-up in 25 cases. *Br J Oral Maxillofac Surg* 1997;35:157–60.
 54. Poswillo DE. Biological temporomandibular joint reconstruction. *Annu Meet Am Inst Oral Biol* 1975;3(7):72–82.
 55. MacIntosh RB, Henny FA. A spectrum of applications of autogenous costochondral grafts. *J Maxillofac Surg* 1977;5:257–67.
 56. Dolwick MF, Armstrong JW. Complications of temporomandibular joint surgery. In: Kaban LB, Pogrel MA, Perrott DH, editors. *Complications in oral and maxillofacial surgery*. Philadelphia: WB Saunders; 1997. p. 89–103.
 57. Topazian RG. Comparison of gap and interpositional arthroplasty in the treatment of TMJ ankylosis. *J Oral Surg* 1966;24:405–9.
 58. Padgett GC, Robinson DW, Stephenson KL. Ankylosis of the temporomandibular joint. *Surgery* 1948;24:426–32.
 59. Oji C. Fractures of the facial skeleton in children: a survey of patients under the age of 11 years. *J Craniomaxillofac Surg* 1998;26:322–5.
 60. Posnick JC, Goldstein JA. Surgical management of temporomandibular joint ankylosis in the pediatric population. *Plast Reconstr Surg* 1993;91:791–8.
 61. Munro IR, Phillips JH, Griffin G. Growth after construction of the temporomandibular joint in children with hemifacial microsomia. *Cleft Palate J* 1989;26:303–11.
 62. Perrott DH, Umeda H, Kaban LB. Costochondral graft construction/reconstruction of the ramus/condyle unit: long-term follow-up. *Int J Oral Maxillofac Surg* 1994;23:321–8.
 63. Friedman MH, Weisberg J, Weber FL. Postsurgical temporomandibular joint hypomobility. Rehabilitation technique. *Oral Surg Oral Med Oral Pathol* 1993;75:24–8.
 64. Caminiti MF, Weinberg S. Chronic mandibular dislocation: the role of non-surgical and surgical treatment. *J Can Dent Assoc* 1998;64:484–91.
 65. Hoard MA, Tadge JP, Gampper TJ, Edlich RE. Traumatic chronic TMJ dislocation: report of an unusual case and discussion of management. *J Craniomaxillofac Trauma* 1998;4:44–7.
 66. MacFarlane WI. Recurrent dislocation of the mandible: treatment of seven cases by a simple surgical method. *Br J Oral Surg* 1977;14:227–9.
 67. Wolford LM, Pitta MC, Mehra P. Mitek anchors for treatment of chronic mandibular dislocation. *Oral Surg Oral Med Oral Pathol Oral Radiol Endod* 2001;92:495–8.
 68. LeClerc G, Girald G. Un nouveau procede de butee dans le traitement chirurgical de la luxation recidivante de la manchoire inferieure. *Mem Acad Chir (Paris)* 1943;69:457–9.
 69. Myrhaug H. A new method of operation for habitual dislocation of the mandible—review of former methods of treatment. *Acta Odontol Scand* 1951;9:247–61.
 70. Sato J, Segami N, Nishimura M, et al. Clinical evaluation of arthroscopic eminoplasty for habitual dislocation of the temporomandibular joint: comparative study with conventional open eminectomy. *Oral Surg Oral Med Oral Pathol Oral Radiol Endod* 2003;95:390–5.
 71. Undt G, Kermer C, Rasse M. Treatment of recurrent mandibular dislocation, part II: eminectomy. *Int J Oral Maxillofac Surg* 1997;26:98–102.
 72. Westwood RM, Fox GL, Tilson HB. Eminectomy for the treatment of recurrent temporomandibular joint dislocation. *J Oral Surg* 1975;33:774–9.
 73. Courtemanche AD, Son-Hing QR. Eminectomy for chronic recurring subluxation of the temporomandibular joint. *Ann Plast Surg* 1979;3:22–5.
 74. Miller GA, Murphy EJ. External pterygoid myotomy for recurrent mandibular dislocation. Review of the literature and report of a case. *Oral Surg Oral Med Oral Pathol* 1976;42:705–16.
 75. Burke RH, McNamara JA Jr. Electromyography after lateral pterygoid myotomy in monkeys. *J Oral Surg* 1979;37:630–6.
 76. Sindet-Pedersen S. Intraoral myotomy of the lateral pterygoid muscle for treatment of recurrent dislocation of the mandibular condyle. *J Oral Maxillofac Surg* 1988;46:445–9.
 77. Ziegler CM, Haag C, Muhling J. Treatment of recurrent temporomandibular joint dislocation with intramuscular botulinum toxin injection. *Clin Oral Invest* 2003;7:52–5.
 78. Clark GT. The management of oromandibular motor disorders and facial spasms with injections of botulinum toxin. *Phys Med Rehabil Clin N Am* 2003;14:727–48.

Part 8

ORTHOGNATHIC SURGERY

Craniofacial Growth and Development: Current Understanding and Clinical Considerations

Peter M. Spalding, DDS, MS, MS

This chapter will provide a summary of the current understanding of prenatal and postnatal craniofacial growth and its relevance for clinical treatment. Although there clearly is awareness of the importance of genetic and environmental influences on craniofacial growth and development, the control and precise biologic mechanisms are not well understood and continue to be fertile areas of investigation. The chapter will review human morphogenesis, prenatal and postnatal growth and development, the factors that influence these phases of growth and development, and the orthopedic and orthodontic clinical considerations that will determine whether surgical intervention will be necessary to achieve optimum cosmetic and functional craniofacial treatment outcomes.

Prenatal Craniofacial Development

Human prenatal development can be conveniently divided into the embryonic period, from fertilization through the eighth week of development, and the fetal period, continuing from the ninth to the fortieth week at birth. The embryonic period is characterized by new tissue differentiation

and organogenesis, whereas the fetal period is distinguished by growth and expansion of the basic structures already formed.

During the first few days following the formation of the single-cell zygote at conception, four mitotic divisions occur to form the 16-cell morula. After entering the uterus the morula develops into a 100-cell blastocyst consisting of an outer (trophoblast) and inner (embryoblast) cell mass. The trophoblast further differentiates to form the placenta and other peripheral embryonic structures, whereas the embryoblast differentiates into the future embryo. At the end of the first week the blastocyst adheres to the uterine endometrium to begin implantation. During the second week the embryoblast forms a bilaminar disk composed of two germ layers: the ectoderm, forming the amniotic cavity floor; and the endoderm, lying beneath and forming the yolk sac floor. Later the ectoderm will form a variety of epidermal structures including dental enamel, oral mucosa and nasal epithelia. The endoderm will later form the pharyngeal epithelium. By the end of the second week the endoderm develops a thickened area called the prechordal plate,

located at the cranial end of the bilaminar disk, that prefaces the development of the head (Figure 53-1).

Embryonic Period

Germ Layer Formation Craniofacial embryogenesis begins during the third week of gestation, when gastrulation and neurulation occur. Gastrulation is the process whereby the bilaminar disk is converted into a trilaminar one with the appearance of the third germ layer, the mesoderm, forming between the other two from ectodermal cell proliferation and differentiation in the caudal area of the disk. The prominence created from this proliferation forms a craniocaudal midline furrow termed the primitive streak. Cell proliferation and differentiation of the cranial end of the primitive streak forms the notochord around which the axial skeleton will form.

Neural Tube Formation Neurulation, occurring at the same time as gastrulation during the third week and continuing through the fourth week, is a process that results in the formation of the neural tube,

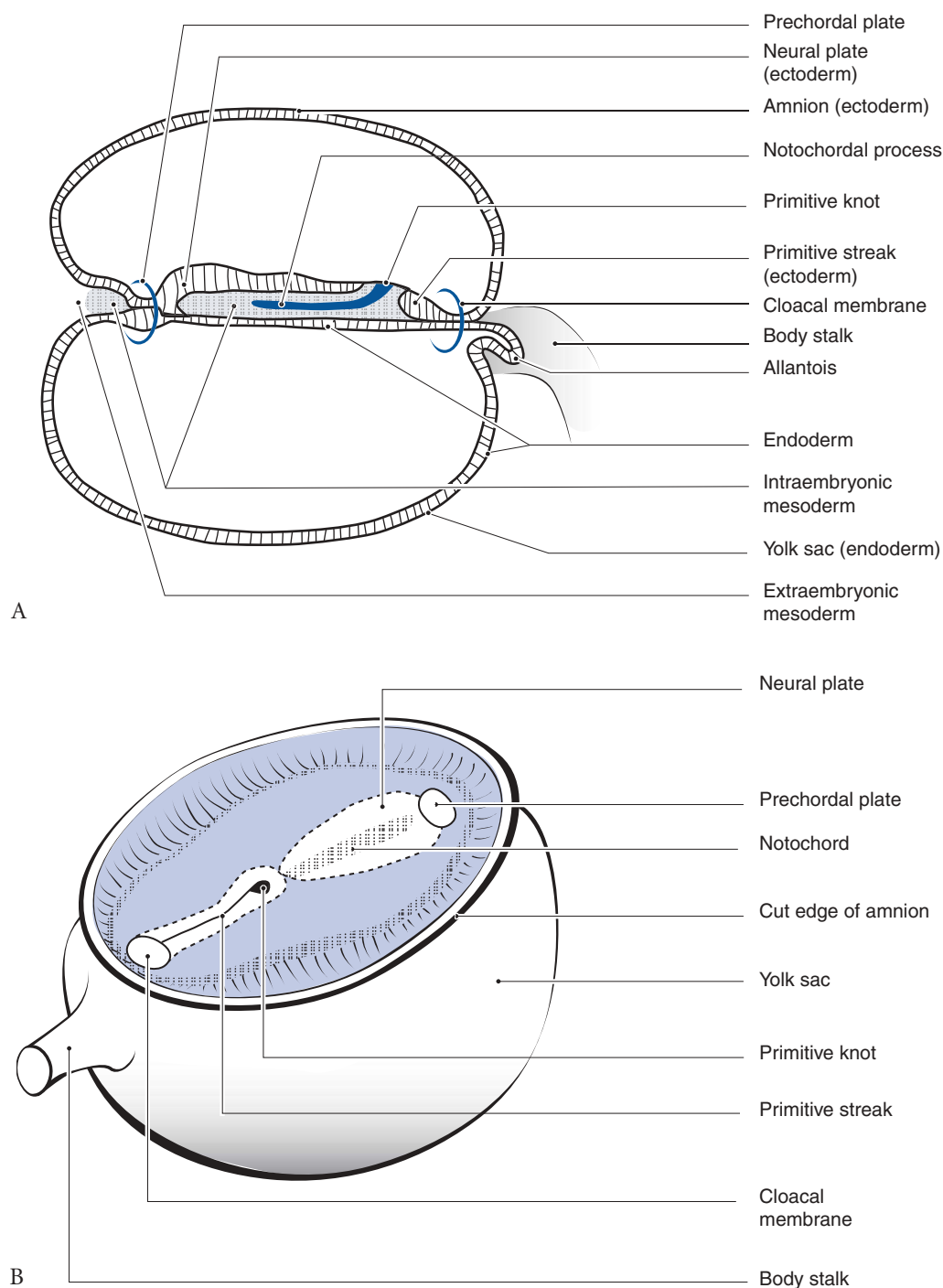


FIGURE 53-1 Embryo 14 days old. A, Longitudinal section showing amnion (above) and yolk sac (below). Adapted from Sperber G. *Craniofacial development*. Hamilton (ON): BC Decker Inc; 2001. p.19. B, Dorsal surface view with the amnion cover removed, showing the embryonic disk. Adapted from Sperber G. *Craniofacial development*. Hamilton (ON): BC Decker Inc; 2001. p.20.

the primordium of the central nervous system. Neurulation is characterized by development of the neural plate from the ectoderm overlying the notochord. As the neural plate grows caudally toward the

primitive streak, the lateral edges of the neural plate rise up to create neural folds, forming the neural groove between them. Mesoderm on either side of the groove develops into paired blocks of tissue called

somites (ultimately 48 somite pairs will develop). In the fourth week the neural folds begin to fuse at the midline in the central part of the embryo, at the level of the fourth to fifth somite, to form the neural tube (Figure 53-2). The neural tube continues to form toward the cranial and caudal ends, completing caudal formation by the time about 20 somite pairs are present. The anterior portion of the neural tube develops into the forebrain, midbrain, and hindbrain. After neural tube closure is complete on day 28, the two hemispheres of the brain begin development, increasing in size to eventually cover the roof of the brain stem. The otic, optic, and olfactory placodes develop in association with the forebrain neuroectoderm.

Cell Population Origin, Migration, and Interaction By the end of the fourth week multipotential neural crest cells arising from the neural folds must translocate or migrate from the dorsal margins of the closing neural tube to specific locations along hyaluronate-rich fibronectin-lined extracellular pathways.¹ The migration of neural crest cells follows a proper sequence and distinct pathways over extensive distances, but there is evidence that the cells have an ability to differentiate into a variety of derivatives (Figure 53-3).² There is growing evidence that neural crest cell differentiation is not predetermined but dependent on their epithelial-mesenchymal cellular interactions with tissues along the route to their final destinations.³ Multiple genes, in particular a class of homeobox-containing transcription factors, affect subpopulations of neural crest cells that help regulate their migration and determine the pattern and position of structures within the pharyngeal arches.⁴ All of the skeletal and connective tissue of the face, with the exception of dental enamel, is derived from neural crest cells, whereas skeletal and connective tissue of the trunk is mesodermal in origin. Many craniofacial malformations are produced from faulty neural crest formation or

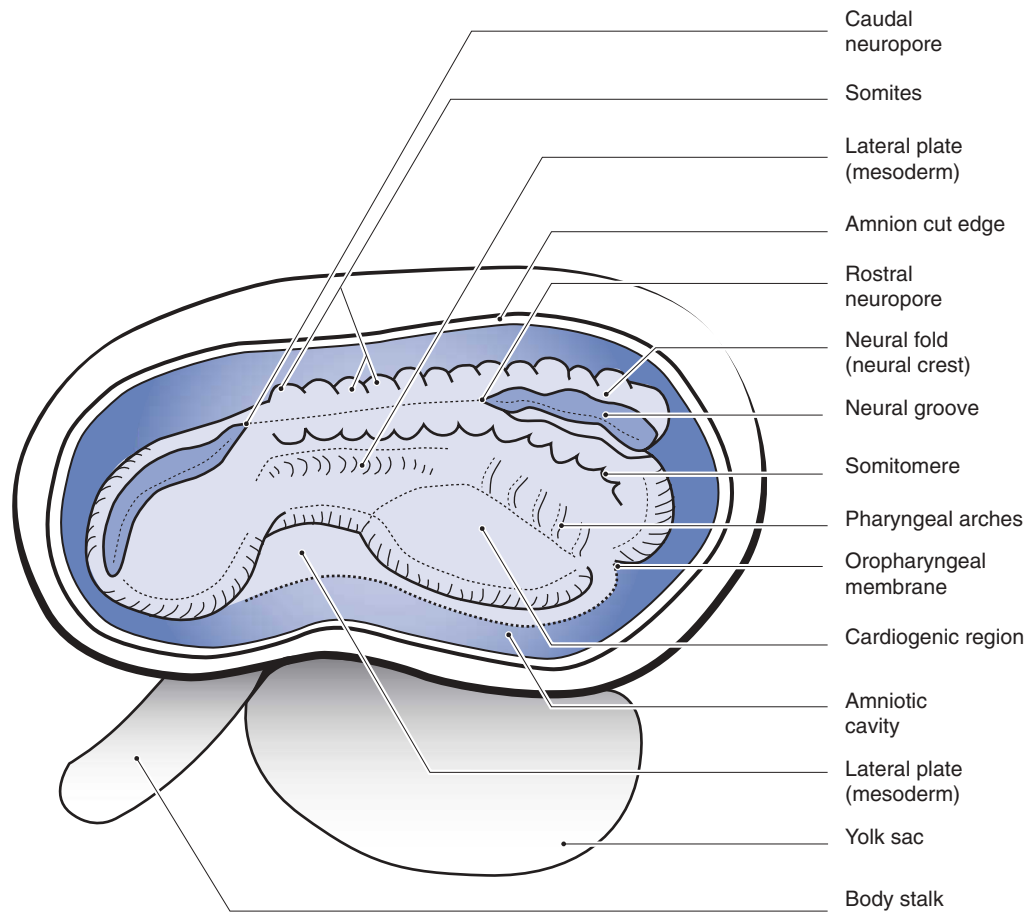


FIGURE 53-2 Longitudinal section of amnion in a 23-day-old embryo illustrating the fusion of neural folds and the initial formation of somites. Adapted from Sperber G. *Craniofacial development*. Hamilton (ON): BC Decker Inc; 2001. p.21.

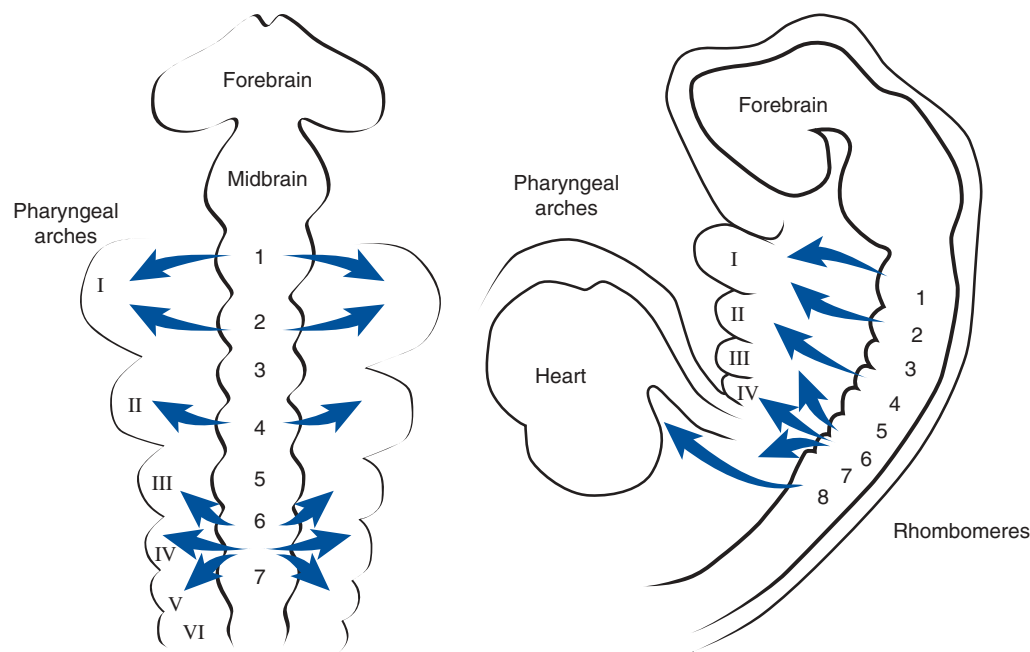


FIGURE 53-3 Illustration of neural crest migration pathways from rhombomeres 1 to 7 to pharyngeal arches I to VI, from dorsal (left) and lateral (right) views. Adapted from Sperber GH. *Pathogenesis and morphogenesis of craniofacial developmental anomalies*. *Ann Acad Med Singapore* 1999;28:708-13.

migration, loss of neural crest cells, or flawed epithelial-mesenchymal interaction during this fourth week of gestation.

Development of Facial Primordia The pharyngeal arches, which give rise to most of the head and neck structures, develop during the fourth week as a result of neural crest migration (Figures 53-3 and 53-4). They consist of four bilaterally paired arches on the ventral external surface of the human embryo. Facial development occurs between the fourth and eighth weeks of gestation. Development of the face begins with five prominences or primordia surrounding the stomatodeum or primitive mouth cavity. The primordia form from the first pair of pharyngeal arches arising from neural crest ectomesenchyme and include the single median frontonasal primordium, the paired maxillary primordia, and the paired mandibular primordia. Recent studies indicate that these facial primordia may be initiated through different morphogenetic mechanisms. They are composed of different neural crest cells, have their outgrowth regulated by different

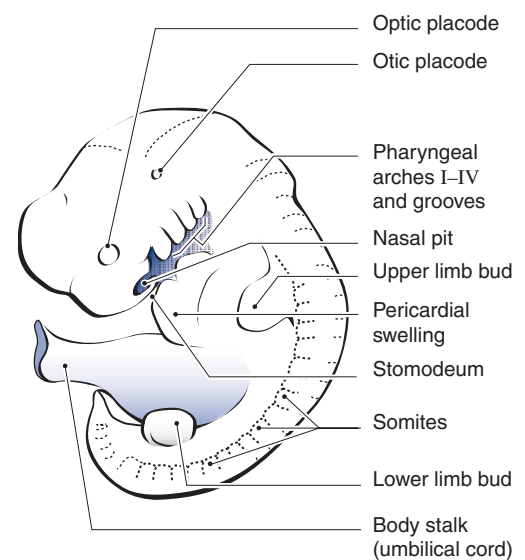


FIGURE 53-4 Lateral view of a 31-day-old embryo showing somites along the back and development of the pharyngeal arches and limb buds. Adapted from Sperber G. *Craniofacial development*. Hamilton (ON): BC Decker Inc; 2001. p. 24.

genes, and have different responses to teratogenic agents.⁵ The facial primordia merge when the epithelium between them breaks down, followed by invasion of the mesenchyme and coalescence of the adjoining prominences (Figure 53-5). Initially the mandibular primordia merge in the midline to form the chin and lower lip. At the same time nasal placodes form in the inferior and lateral portion of the frontonasal primordium. On either side of

these nasal placodes, medial and lateral nasal primordia develop. The medial nasal primordia move toward each other and merge in the midline early in the sixth week, forming the central part of the upper lip and the primary palate, including the maxillary incisors and their surrounding alveolar bone. There still is some controversy regarding the origin of the central part of the upper lip, which some believe is of frontonasal primordial origin.⁶ The

maxillary primordia move medially as well, merging with the lateral and medial nasal primordia during the sixth week, to complete formation of the upper lip. At this same time the maxillary and mandibular primordia merge laterally, determining the width of the mouth. Merging of facial primordia requires disintegration of surface epithelia in order to permit the underlying mesenchymal cells to unite (Figure 53-6). The groove between the primordia is gradually filled out by proliferation of the mesenchyme so that the primordia appear to merge. Facial clefting is a result of failure of epithelial disintegration and lack of merging. Facial primordial growth and merging is dependent on ectodermal-mesenchymal interactions that appear to be regulated by the secreted protein sonic hedgehog (SHH).⁵ Mutations in SHH that prevent its signaling during early neural plate patterning cause midline defects that range from hypotelorism and cleft lip/palate to holoprosencephaly and cyclopia.⁷ There is also evidence that adequate epidermal growth factor receptor signaling is necessary for sufficient secretion of matrix metalloproteinases for normal facial development.⁸ From 5 weeks' gestation to the early part of the fetal period at 9 weeks, there is medial migration of the eyes, assisted by frontal and temporal lobe expansion and greater proliferation of the lateral facial regions relative to the central face, resulting in facial expansion and interocular reduction.

The nasal placodes that formed at about 5 weeks each are separated inferiorly by a nasal groove. With continued proliferation of mesenchyme, the placodes submerge to form the nasal pits, the precursors to the anterior nares. As the nasal pits continue to submerge with the proliferating mesenchyme, they are eventually separated from the stomatodeum by only a thin oronasal membrane. This membrane will rupture at the beginning of the seventh week, forming a continuous nasal and oral cavity.

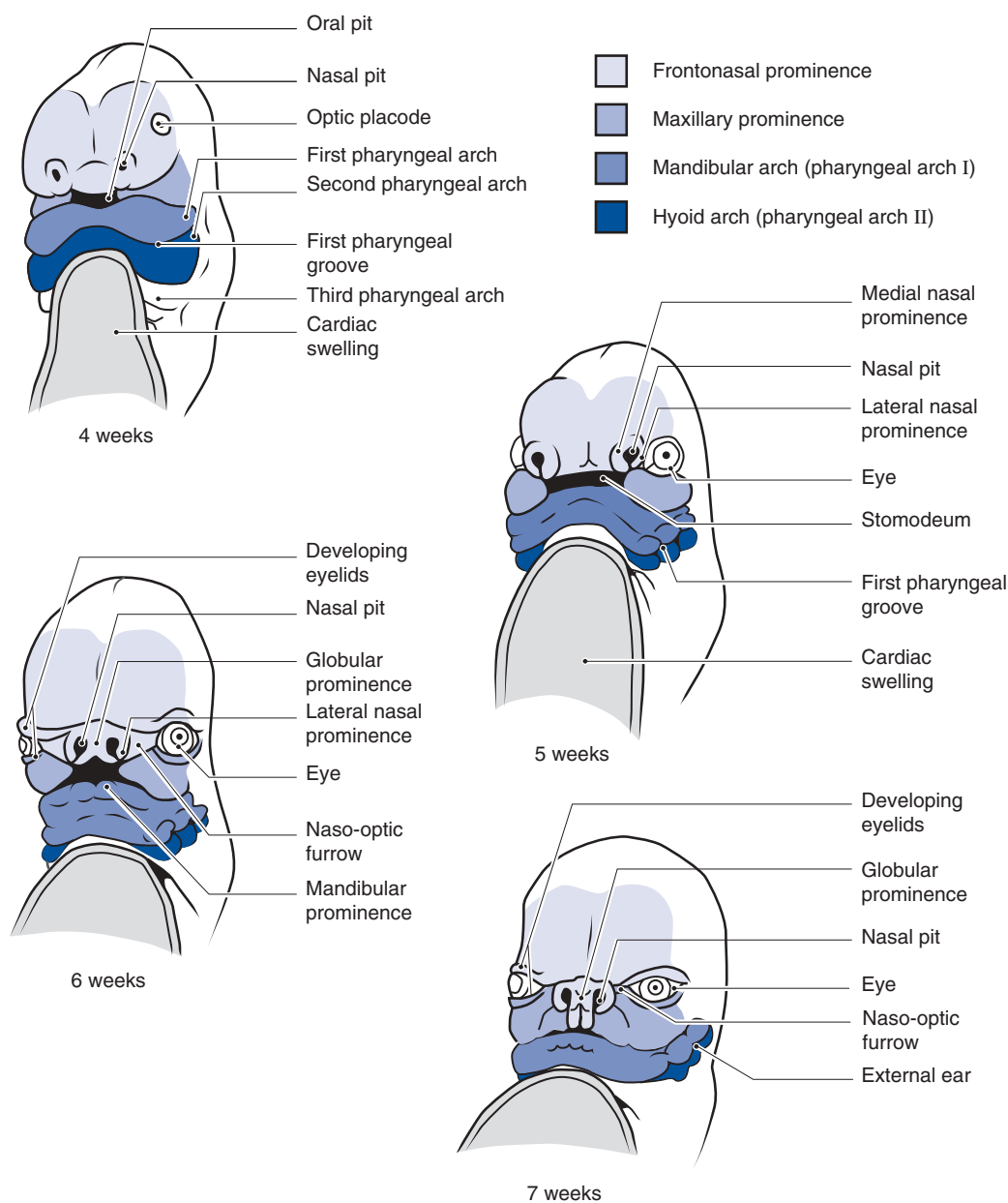


FIGURE 53-5 Frontal view of developing face in 4-, 5-, 6-, and 7-week-old embryos showing the merging of facial primordia (prominences). Adapted from Sperber G. *Craniofacial development*. Hamilton (ON): BC Decker Inc; 2001. p. 32.

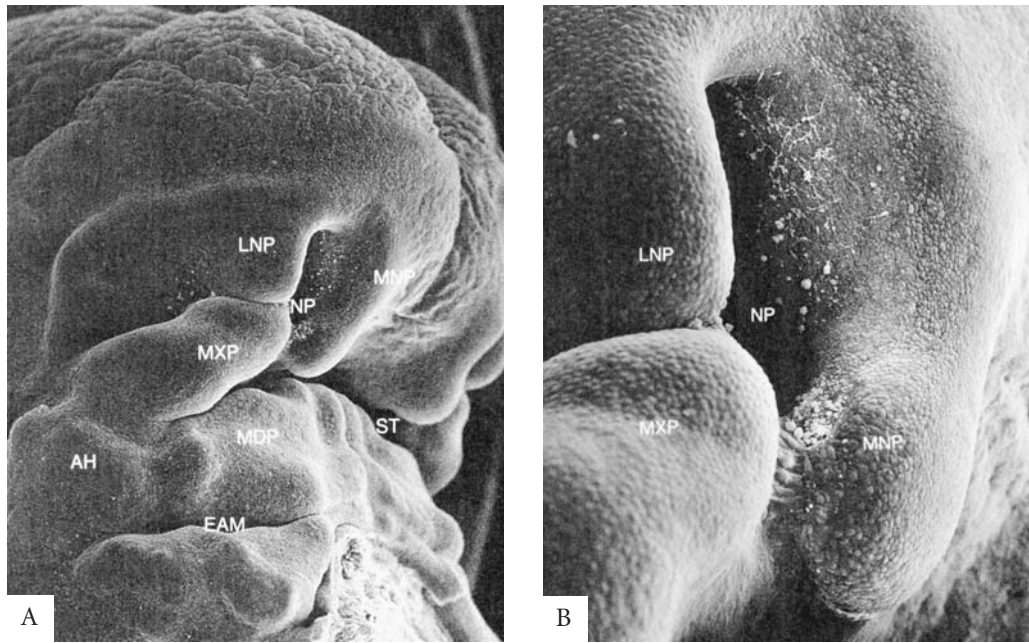


FIGURE 53-6 Scanning electron micrograph of a 41-day-old human embryo. A, Craniofacial region. LNP = right lateral nasal primordium; MNP = right medial nasal primordium; NP = right nasal pit; MXP = right maxillary primordium; AH = right auricular hillock; EAM = right external acoustic meatus; MDP = mandibular prominence; ST = left side of stomodeum. B, Enlarged view, showing the epithelial bridges between the merging right maxillary primordium (MXP) and the right medial nasal primordium (MNP). Failure of these primordia to merge together with the lateral nasal primordium (LNP) results in cleft of the lip. Reproduced with permission from Hinrichsen K. *The early development of morphology and patterns of the face in the human embryo*. In: *Advances in anatomy, embryology and cell biology*. Vol. 98. New York: Springer-Verlag; 1985.

Formation of Neurocranium and Viscerocranium Formation of the craniofacial bones begins with development of the cartilaginous and membranous precursors to the neurocranium and viscerocranium during the latter part of the fifth week of gestation (Figure 53-7). The membranous neurocranium (desmocranium) that will give rise to the flat bones of the calvaria is connective tissue derived from the paraxial mesoderm and neural crest. The cartilaginous neurocranium (chondrocranium) that will form the cranial base is cartilage from neural crest origin. Cartilage maturation occurs in a caudal-rostral sequence. The membranous viscerocranium that will give rise to the maxilla, zygomatic bone, squamous temporal bone, and mandible is derived from the neural crest. The cartilaginous viscerocranium that will form the middle ear ossicles, styloid process of the temporal bone, hyoid bone, and laryngeal cartilages is from neural crest ectoderm.

Endochondral ossification centers occur in the cartilaginous components and intramembranous ossification centers form in the membranous components of the neurocranium and viscerocranium. Osteoblast differentiation with the onset of mineralization results from a rapid angiogenic process with vascular ingrowth closely surrounding the center of ossification. The earliest ossification of the craniofacial bones begins in the seventh and eighth weeks of gestation. There are eventually 110 ossification centers, nearly all of which appear between 6 and 12 weeks' gestation, that develop in the embryo to form 45 bones at birth, which ultimately form 22 bones in the adult.

Ossification The onset of ossification generally follows the chronologic sequence of mandible, maxilla, palatine, cranial base, and cranium, with intermembranous centers usually preceding endochondral

centers.⁹ Ossification of the mandible begins in the mental foramen region. Endochondral ossification of Meckel's cartilage occurs anteriorly to this area and intramembranous ossification occurs posteriorly. The condylar cartilage forms at the posterior end of this intramembranous portion, independently of Meckel's cartilage. Maxillary ossification begins in the area of the infraorbital foramen. Intramembranous ossification occurs anteriorly and posteriorly to this region. The vertical portion of the palatine bone then begins intramembranous ossification in the region of the palatine nerve, followed by ossification of the anterior, then posterior borders of the incisive foramen, spreading through the hard palate from the canine area. Following ossification of the main portion of the mandible and maxilla, during the sixth week of gestation, endochondral ossification of the cranial base occurs in the midline from the foramen magnum to the nasal bone, and intramembranous ossification occurs laterally. Finally intramembranous ossification of the cranial bones follows.

Final Tissue Differentiation Interaction between pharyngeal endoderm and neural crest tissue, followed by oral ectoderm proliferation, produces identifiable odontogenic tissue by the end of 4 weeks' gestation. There are four origin sites of odontogenic epithelium for both the maxillary and mandibular arches, appearing at the end of 5 weeks' gestation. The primary anterior and first molar tooth germs appear at 6 weeks' gestation, followed by development of the primary second molar germs at 7 weeks. Apposition of bone on the alveolar margins of the maxilla and mandible in the presence of developing tooth germs form the initial alveolar processes.

The latest orofacial structure to reach completion at the end of the embryonic period is the secondary palate, developing from the paired lateral palatine shelves of

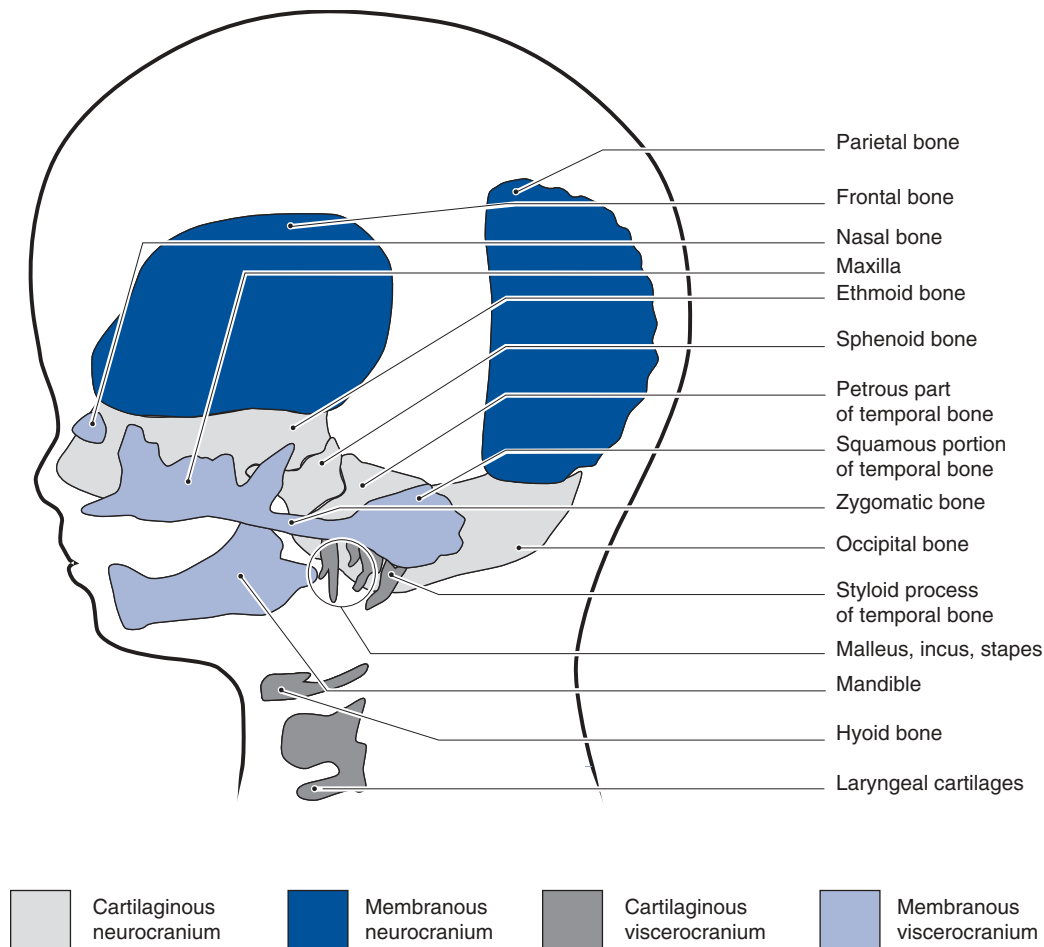


FIGURE 53-7 Lateral view of 20-week-old embryo illustrating initial development of the cartilaginous and membranous neurocranium and viscerocranium. Adapted from Moore KL, Persaud TVN. *The developing human: clinically oriented embryology*. 5th ed. Philadelphia (PA): W.B. Saunders; 1993. p. 361.

the maxilla. These shelves are oriented vertically with the tongue interposed, but the tongue and floor of the oral cavity descend as the nasal chambers expand laterally and inferiorly (Figure 53-8). As this occurs the palatal shelves become elongated and elevate medially toward each other, beginning fusion at the end of the eighth week and completing in the ninth week of gestation. There is evidence that transforming growth factor (TGF)- β 3 is intimately involved in regulating secondary palatal fusion by mediating the breakdown of the midline epithelial seam prior to fusion.¹⁰

Fetal Period

The fetal period begins during the eighth week, at 60 days' gestation, lasting until birth at 40 weeks, and overall somatic

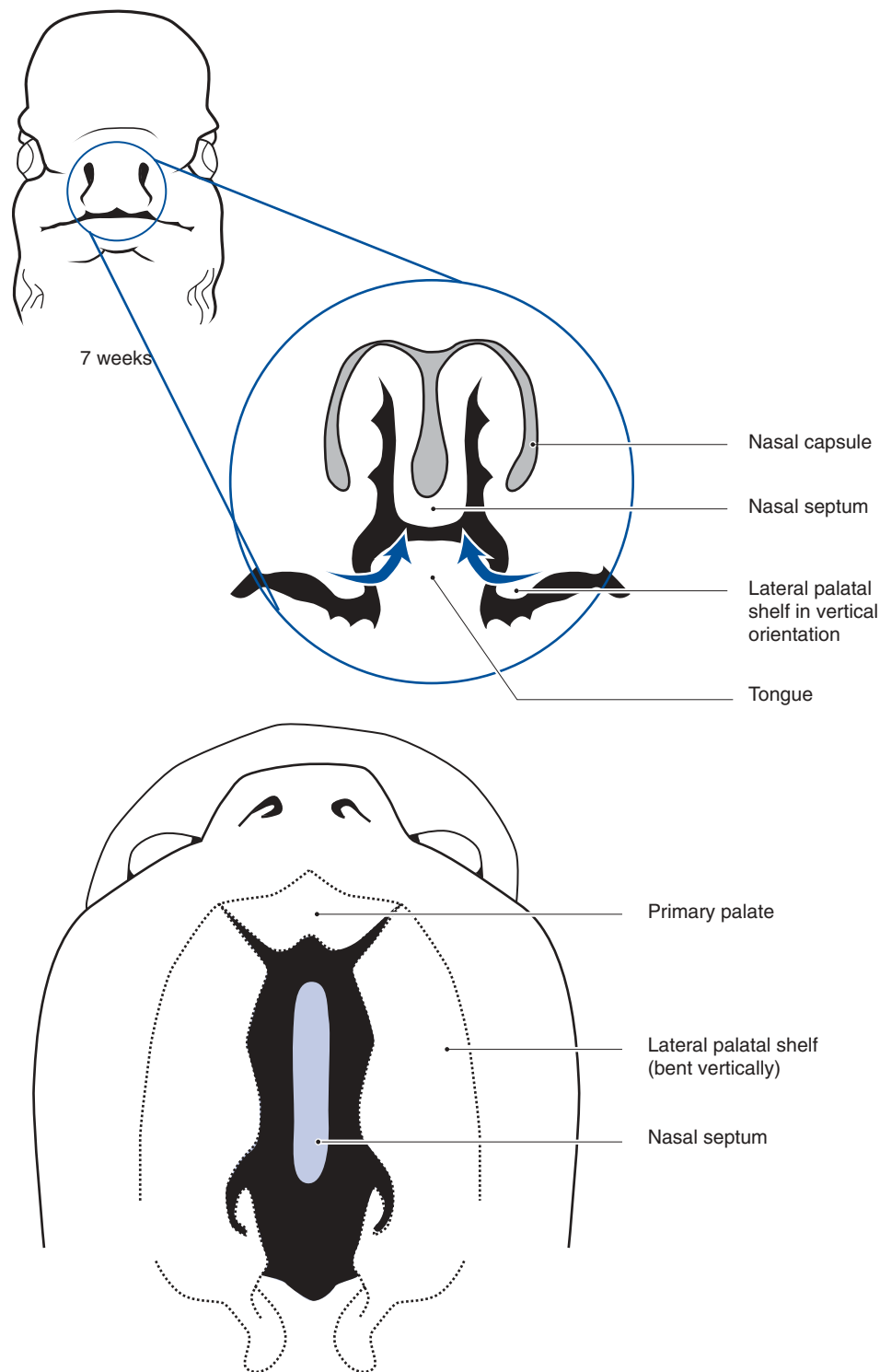
growth follows a cephalocaudal growth gradient (Figure 53-9). There is a prenatal growth spurt between 20 and 30 weeks' gestation with the peak growth velocity at 27 to 28 weeks being approximately 2.5 cm per week. The prenatal spurt in weight is slightly later at 30 to 40 weeks' gestation with a peak at 34 to 36 weeks.¹¹ The rate steadily decreases during the last trimester and continues to decline after birth until adulthood, with two exceptions. The first is a small "midgrowth" spurt that occurs in many children at 6 to 8 years old that has been attributed to increased adrenal secretion of androgenic hormones. The second is a dramatic endocrine mediated "pubertal growth" spurt during adolescence. Growth of the craniofacial complex during the fetal period is characterized by a

constant rate during the second trimester. The craniofacial skeletal components increase more in the anteroposterior dimension than in the vertical or transverse, with the exception of the mandible which increases more in the transverse dimension in order to maintain appropriate articulation.¹²

During the fetal period the neurocranium undergoes precocious development relative to the viscerocranium with earlier brain and neurocranial bone vault growth than facial and masticatory portions of the skull. This results in an early proportional predominance of the neurocranium over the face that only reduces to an 8:1 proportion by birth. The brain nearly doubles in size from 4 months to birth, achieving about 25% of its adult dimension. The formation and maintenance of cranial sutures are regulated by tissue interactions with the underlying dura mater as the brain develops.¹³ A number of growth factors have been identified that regulate cranial bone growth and suture fusion, including TGF- β 1, TGF- β 2, and TGF- β 3, bone morphogenetic protein (BMP)-2, BMP-7, fibroblast growth factor (FGF)-4, insulin-like growth factor (IGF)-I, and SHH.^{14,15} Transcription factors MSX2 and TWIST also play a role in suture development, binding to target effector genes to determine their expression.¹⁶ The eyeballs grow concurrently with the early brain growth, increasing facial expansion and separating the neural and facial skeletons to increase skull height.

The cranial base growth parallels the rapid growth of the cranial vault during the fetal period. The anterior cranial base grows sevenfold while the posterior cranial base increases fivefold. The intraethmoidal and intrasphenoidal synchondroses close before birth.

The ossification centers that begin the formation of the facial bones late in the embryonic period enlarge during the early fetal period until most of the bones have developed into a definitive shape by



A

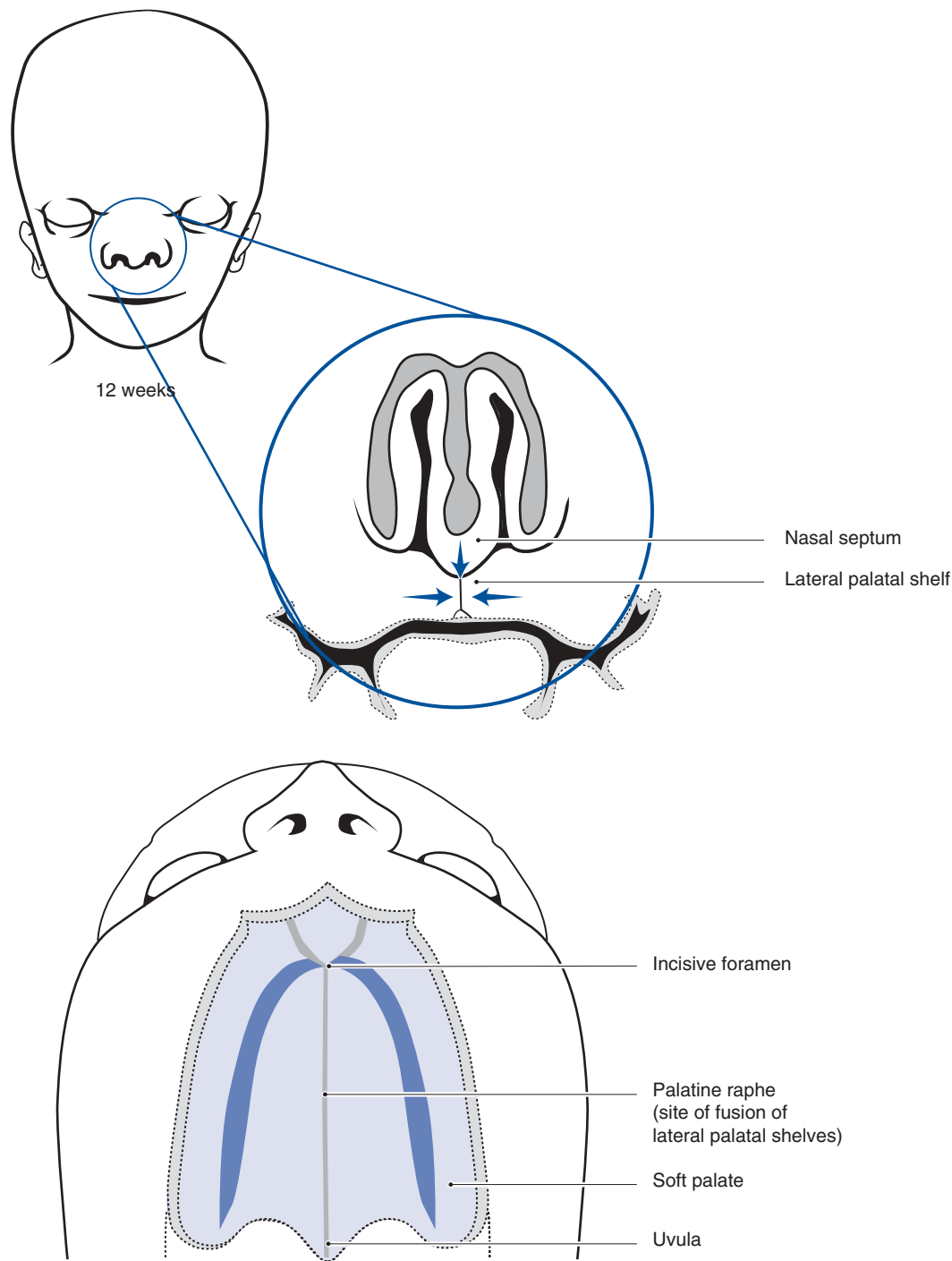
FIGURE 53-8 Frontal view of face, coronal section of the stomodeum, and inferior view of the palate in 7- and 12-week-old embryos. A, Embryo at 7 weeks showing palatal shelves vertically oriented. Adapted from Sperber G. *Craniofacial development*. Hamilton (ON): BC Decker Inc; 2001. p. 41, 114. (CONTINUED ON NEXT PAGE)

14 weeks. At this time they begin to remodel as they continue to grow by intramembranous and/or endochondral ossification. The anterior aspects of the

maxilla, mandible, and zygoma of the fetal and early postnatal face undergo deposition. This early anterior deposition is necessary to permit adequate osseous mass for

the developing tooth buds of the primary and permanent dentitions. Although the tooth germs start to develop as early as 6 weeks' gestation, the onset of dental mineralization does not begin until ossification has occurred. The maxilla demonstrates a rapid height increase associated with dental development.¹⁷ Once the primary teeth have erupted, these same anterior areas undergo resorption rather than deposition to produce the descent of the maxilla with continued growth. Meanwhile the posterior, infraorbital, and lingual surfaces of the maxilla are depository in both fetal and postnatal development. The fetal temporal bone grows faster in height than width while the lateral and inferior margins of the zygomatic bone grow faster than its orbital margin.¹⁷

The paranasal sinuses, including the maxillary, sphenoidal, frontal, and ethmoidal, begin developing at the beginning of the fetal period. Pneumatization begins first with the maxillary sinus, starting at 5 months' gestation. It is proposed that a septomaxillary ligament, attached to the sides and anteroinferior border of the nasal septum and inserted in the nasal spine, transmits septal growth, pulling the maxilla downward. Between the tenth week of gestation and birth, the nasal septum increases its vertical height sevenfold. The nasal septum growth, together with neural growth and facial sutural growth, transposes the maxilla inferiorly and anteriorly. The frontomaxillary, frontonasal, frontozygomatic, frontoethmoidal, and ethmoidolmaxillary sutures grow predominantly in a vertical direction. The temporozygomatic and nasomaxillary sutures contribute most of the anteroposterior change. The intermaxillary and zygomaticomaxillary sutures provide most of the transverse expansion of the face. Overall the middle and lower thirds of the face develop primarily in a downward and slightly forward direction away from the cranial base due to brain development, maxillary and palatine sutural growth, and possibly nasal septum growth.



B

FIGURE 53-8 (CONTINUED) B, Embryo at 12 weeks showing fusion following elevation of palatal shelves. Adapted from Sperber G. *Craniofacial development*. Hamilton (ON): BC Decker Inc; 2001. p. 41, 116.

Although the midsagittal part of the middle face entirely consists of nasal septal cartilage during the fetal period, ossification leaves only a small anterior part of this cartilage remaining postnatally. Currently there is controversy regarding the

role of the nasal septum in postnatal facial growth. Some believe it is limited to a compensatory and biomechanical role, and others believe it serves a more extensive role, particularly in promoting vertical maxillary growth.

Although the mandible is larger than the maxilla during the embryonic period, the mandible approximates the size of the maxilla within the first month of the fetal period. The three secondary cartilages of the mandible do not appear until the tenth and fourteenth weeks of gestation, forming on the lateral and superior aspects of the condylar processes. This secondary type of cartilage differs morphologically from epiphyseal and synchondrosal cartilage.¹⁸ Two of these secondary cartilages forming at the mental protuberance and the coronoid process ossify before birth, leaving only the cartilage on the condylar head as a site of postnatal mandibular endochondral growth. This cartilage never undergoes complete ossification, providing a means for absorbing functional forces and retaining growth potential throughout life. Between the thirteenth and twentieth weeks of gestation, the mandible lags behind the maxilla again while there is a transition from Meckel's cartilage to condylar cartilage as the primary growth site. During the third trimester there is a significant deepening of the corpus in association with the developing dentition. The mandibular ramus growth rate is greater than the growth rate of the mandibular body during this time.¹⁹ At the time of birth the mandible usually is equal in size again to the maxilla, although it is often in a retrognathic position relative to the maxilla.

Development of the permanent tooth germs begins at 16 weeks' gestation, with the first permanent molar germs developing posteriorly from the dental lamina followed by the permanent anterior tooth germs emerging from the lingual side of the primary enamel organs. At birth the primary tooth crowns are still not completely calcified, as the first permanent molars begin to calcify.

Postnatal Craniofacial Development

Skeletal Development

Development and completion of craniofacial growth follow the overall somatic

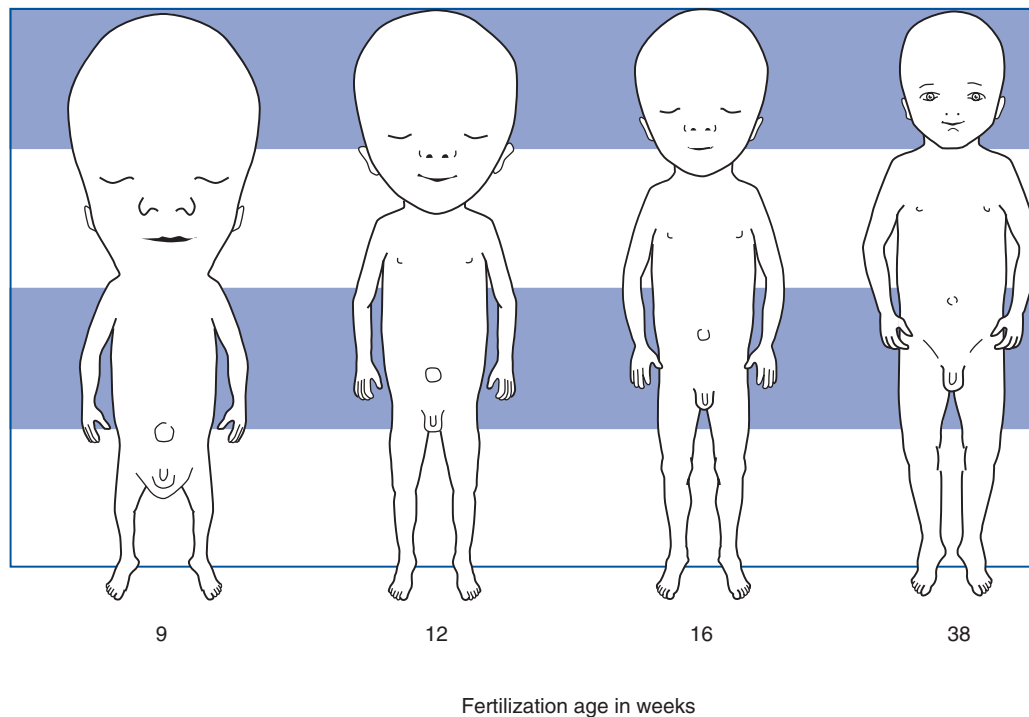


FIGURE 53-9 Changing fetal body proportions with all stages drawn to the same total height. At the start of the fetal period, the head is about half the length of the fetus, and by birth, it is one-quarter the length. Adapted from Moore KL, Persaud TVN. *The developing human: clinically oriented embryology*. 5th ed. Philadelphia (PA): W.B. Saunders; 1993. p. 97.

cephalocaudal growth gradient throughout prenatal and postnatal growth, with cranial vault growth completing before the cranial base, followed by the nasomaxilla and finishing with the mandible. During postnatal growth the neurocranium continues to develop ahead of the viscerocranium (Figure 53-10). It increases from about 30% of its ultimate adult size at the time of birth to 50% by 6 months of age, and 75% by 2 years of age, and nearly 90% by 3 years of age. By 5 years of age, the orbits have reached nearly 80% of their adult size.²⁰ This is why a child of this age appears to have a disproportionately large cranium and eyes. After birth the neurocranium increases about five times in size, whereas the viscerocranium increases about ten times in size. There is also a difference in the amount of postnatal increase in the three dimensions, with the vertical increasing by about 200%, the anteroposterior by somewhat less, and the transverse by the least at approximately

75%. By 10 years of age the neurocranial growth is nearly 95% complete, while facial growth is only about 60% complete.

The craniofacial complex can be divided conveniently into four primary units: the cranial vault, the cranial base, the nasomaxilla, and the mandible. Each of these units has its growth regulated to some extent by both intrinsic and extrinsic

controls. Our understanding of postnatal craniofacial growth has developed in part from cross-sectional anatomic and histologic studies of human cadavers and skeletal material. What has been particularly helpful in supplementing this material is a number of North American longitudinal craniofacial growth records and longitudinal implant (used for stable reference points) studies that were gathered from the 1940s to the mid-1960s before radiation hygiene and human subject research standards became more stringent.²¹

Cranial Vault At birth the cranial bones are separated by sutures with fontanelles where the corners of the bones meet, permitting compression of the skull during the birthing process (Figure 53-11). Postnatal bone growth results in narrowing of the sutures with all of the fontanelles closing within the first 2 years. The pressures exerted by the developing brain determine the size and shape of the cranium. As the brain expands, the pressure creates tension across the sutures and compression against the cranial bones, resulting in intramembranous bone growth by suture and surface apposition. Remodeling of the cranial bones to a flatter shape is necessary to adapt to the expanding surface of the brain. This occurs primarily from endocranial resorption and ectocranial apposition. Although suture apposition

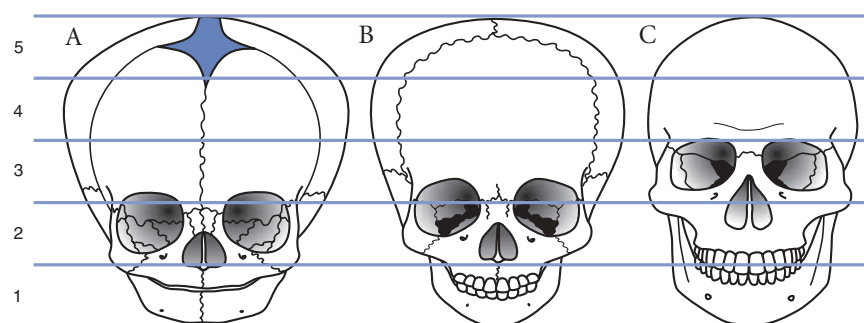


FIGURE 53-10 Changing proportions of the postnatal skull with all stages enlarged to the same skull height and oriented in the Frankfurt horizontal plane with skull height divided into fifths. A, Neonate, showing the viscerocranium representing one-fifth of the total height; B, 3-year-old and C, adult, showing the proportional increase in the height of the viscerocranium relative to the neurocranium. Adapted from Sarnat BG. *Normal and abnormal craniofacial growth. Some experimental and clinical considerations*. *Angle Orthod* 1983;53:263.

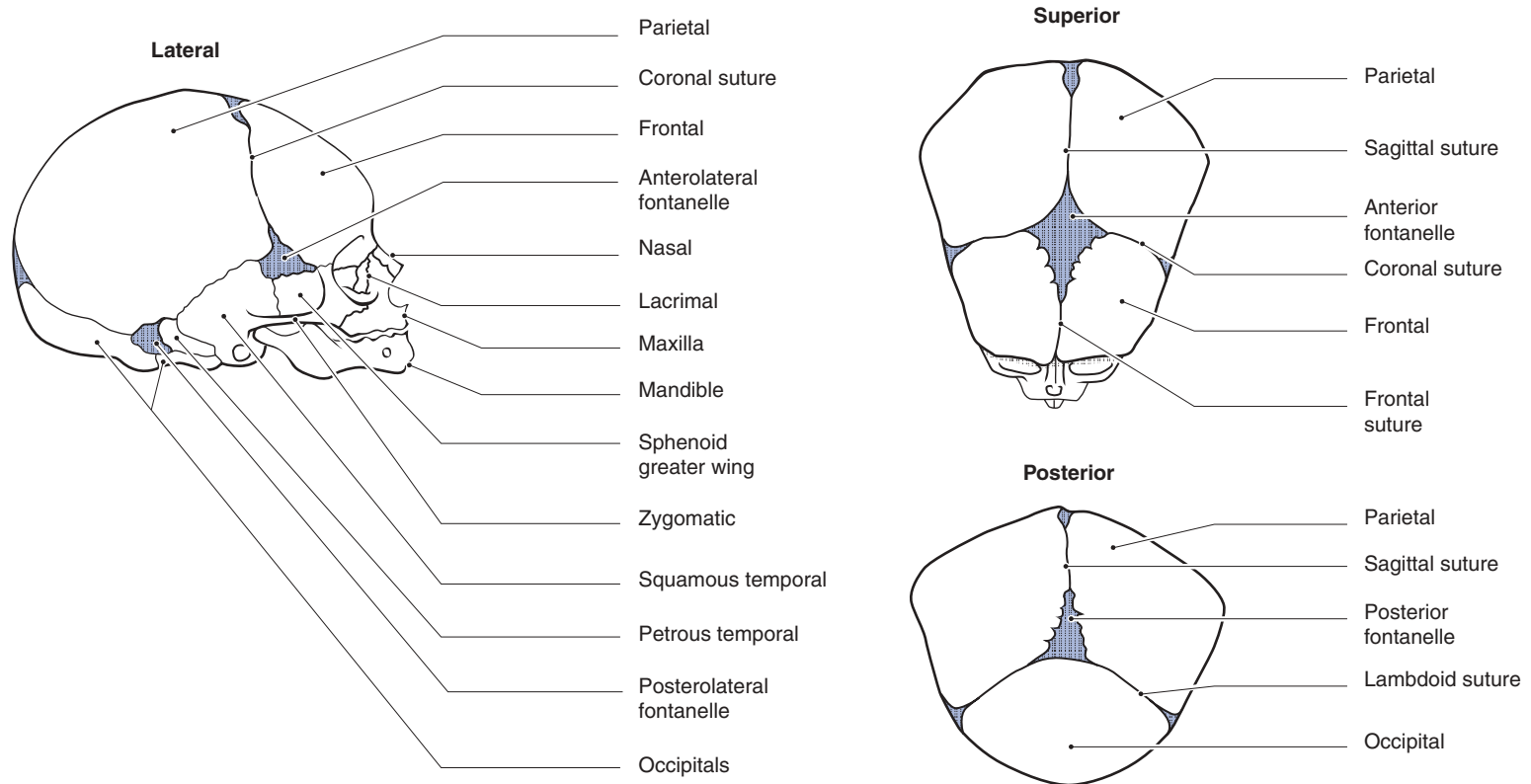


FIGURE 53-11 Fontanelles and sutures of the neonatal skull. Adapted from Sperber G. *Craniofacial development*. Hamilton (ON): BC Decker Inc; 2001. p. 84.

plays a larger role than surface apposition in overall cranial vault capacity, the postnatal shape primarily is determined by extrinsic factors.

By 6 to 7 years of age the inner table of the cranial bones becomes stable due to the cessation of cerebral growth. However, the outer table continues to remodel in response to extracranial muscular forces. The temporal muscles tend to laterally compress the cranium, forming temporal sulci and zygomatic arches. The lateral and posterior cervical muscles insert primarily on the squamous part of the temporal and occipital bones, influencing their shape. Even after attainment of the adult form, the cranial bones continue to thicken during adulthood.

Cranial Base Compared with the other craniofacial units the shape of the cranial base is relatively stable during growth, due likely to its greater intrinsic growth potential. Perhaps more than any other cranio-

facial area, growth of the cranial base is genetically predetermined and influenced the least by functional matrices.^{22,23} However, prenatal brain growth may provide a minor extrinsic influence, causing some flattening of the cranial base, since this does not occur with anencephaly. In addition there is recent evidence that chondral growth of the cranial base can be altered with mechanical forces.²⁴

The anterior cranial base matures earlier than the posterior cranial base with the posterior intraoccipital synchondroses closing during the second and third years postnatally and the anterior intraoccipital synchondroses closing at 3 to 4 years of age (Figure 53-12). The sphenothmoidal synchondrosis closes at about 6 years of age. Although the sphenoccipital synchondrosis is not a main growth site before birth, it provides the greatest contribution to cranial base growth postnatally, delaying fusion until adolescence. The prolonged postnatal growth period of the

spheno-occipital synchondrosis permits posterior growth of the maxilla to provide adequate bone for the developing posterior or permanent teeth and adequate space for the nasopharynx. In addition to endochondral bone growth, intramembranous remodeling of the cranial base occurs, including apposition on the basioccipital bone and anterior margin of the foramen magnum, resulting in continued lengthening of the posterior cranial base even after adolescence. Enlargement of the sella turcica continues postnatally, with the anterior wall stabilizing at about 6 years of age and the posterior wall continuing to resorb until late adolescence.

Nasomaxilla The prenatal precocity of neurocranial growth relative to the face becomes less predominant postnatally. Nevertheless considerable postnatal displacement of the nasomaxilla downward and forward occurs due to continued growth of the brain and cranial base. This

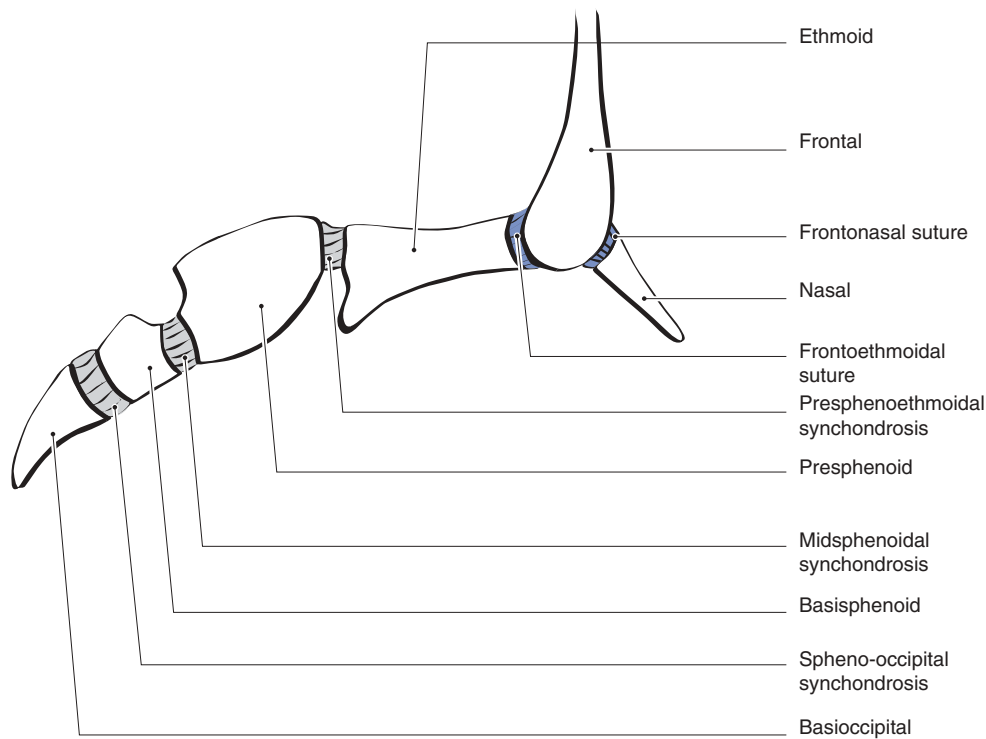
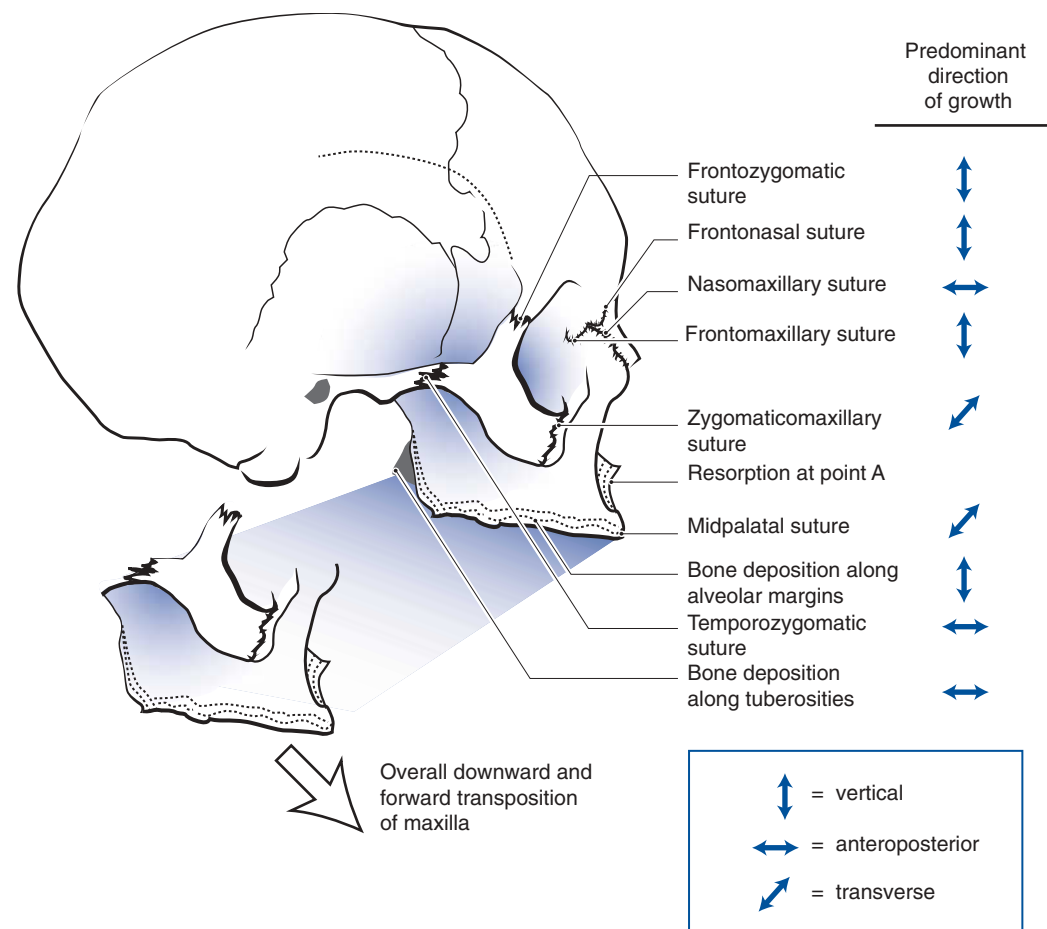


FIGURE 53-12 Midsagittal neonatal cranial base showing sutures and synchondroses. Adapted from Mooney MP, Siegel MI.⁵¹

inferior and anterior maxillary transposition is augmented by the sutural growth between the cranial base and maxilla and growth of the nasal septum. Following birth the vertical growth of the maxilla continues with contributions from the frontomaxillary, frontonasal, frontozygomatic, frontoethmoidal, and ethmoidal-maxillary sutures and possibly the nasal septum (Figure 53-13). The vertical descent of the maxilla is further increased by remodeling with resorption on the nasal surfaces and the simultaneous apposition on the oral surfaces. Anteroposterior growth continues with temporozygomatic and nasomaxillary sutural growth and transverse growth from intermaxillary and zygomaticomaxillary sutures. The resulting downward and forward translation displaces adjacent bones and permits adequate space for the developing nasopharynx and growth at the posterior aspect

FIGURE 53-13 Nasomaxillary intramembranous growth at various sites, resulting in an overall downward and forward transposition of the maxilla relative to the cranial base. Adapted from Sperber G. Craniofacial development. Hamilton (ON): BC Decker Inc; 2001. p. 107.



of the maxilla and maxillary tuberosities to provide adequate space for the development and eruption of the maxillary molars. Following the postnatal growth of the facial sutures, they serve as sites of fibrous union where some remodeling still can take place. In fact a number of cranial and facial sutures are interdigitated but still not fused even beyond 50 years of age.

Growth determinants for postnatal nasomaxillary growth are not well understood and include a variety of intrinsic and extrinsic factors. Passive displacement secondary to brain and cranial base growth, and perhaps nasal septal growth guidance, are the most significant influences on the downward and forward movements of the maxilla after birth until about the seventh postnatal year. From that age through adolescence these influences dramatically decrease as sutural growth and surface intramembranous growth predominate. Maxillary growth also depends to some extent on various functional matrices. The orbits' early response to eyeball growth and their functional movement, the influence of respiration on the nasal cavity, the influence of oral function in determining tuberosity, palatal and alveolar development, and the surrounding facial soft tissues all contribute functional roles in determining growth and remodeling of the nasomaxilla.²⁵

Significant remodeling must occur in order to maintain the general shape of the maxilla as it is displaced downward. As mentioned above, resorption of the nasal side of the maxilla, providing nasal cavity enlargement, occurs concomitantly with apposition on the oral side, resulting in descent of the maxilla. Although secondary pneumatization of the maxillary sinus begins prenatally, it does not occur for the other paranasal sinuses until after birth (first 2 years for ethmoidal and frontal sinuses and 6 to 7 years for sphenoidal sinuses). The vertical growth of the maxillary alveolar process is rapid during dental eruption, surpassing the vertical

descent of the palate threefold. The alveolar development contributes to the depth and width of the palate and vertical height of the face. Considerable resorption of the anterior surface of the maxilla minimizes the overall forward displacement of the maxilla and creates a deeper supra-alveolar concavity while increasing the relative prominence of the anterior nasal spine. Transverse growth occurs by lateral displacement of the maxillary bodies by means of the midpalatal suture and bone resorption on the lateral borders of the nasal cavity. Transverse development of the maxillary alveolar process continues with buccal eruption of the posterior teeth. Growth of the midpalatal suture ends after the first two postnatal years, but the suture remains patent until late adolescence, with fusion usually not being complete until the third decade.

Mandible The mandible has the most delayed growth and the most postnatal growth of all the facial bones. Although usually in a retrognathic position relative to the maxilla at birth, there is rapid postnatal growth that corrects this discrepancy. The right and left bodies of the mandible are still separate at birth, uniting at the midline mental symphysis during the first year of life. The primary sites of mandibular postnatal growth are the endochondral apposition occurring at the condylar cartilages, and the intramembranous apposition on the posterior aspects of the rami and the alveolar ridges (Figure 53-14). Remodeling in the form of resorption of the anterior surface of the condyle, the anterior contours of the ramus, and the inner surface of the mandibular body are integrated with the posterior apposition. The growth of the condylar cartilages contributes most of the total ramus height, whereas growth of alveolar bone contributes about 60% to the mandibular body height.²⁶ Proliferation of condylar cartilage results in superior and posterior growth of the condylar heads, displacing

the mandible downward and forward in concert with the maxilla. Condylar growth appears to involve the sequential involvement of transcription factor SOX9, expressed by chondrocytes, which regulates the synthesis of Type II collagen, Type X collagen secreted as matrix, and vascular endothelial growth factor secreted to regulate the neovascularization of the cartilage.²⁷ At birth the inclination of the mandibular condyles is more horizontal, resulting in a greater increase in length than height. During childhood the inclination becomes more vertical so that condylar growth results in a greater increase in height than length. However, there is great variability in this inclination within the general population, influencing the degree to which the mandibular growth is expressed in a forward anteriorly rotating, as opposed to downward posteriorly rotating, direction. Simultaneous remodeling of the inferior mandibular border tends to reduce the effect of this rotation on facial morphology. Although minimal maxillary growth occurs after about 10 years of age, mandibular growth continues longer, to

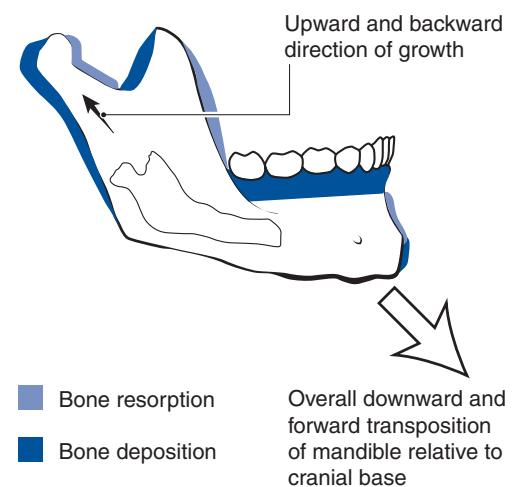


FIGURE 53-14 Mandibular intramembranous and endochondral growth, resulting in an overall downward and forward transposition of the mandible relative to the cranial base. An outline of the fetal mandible is superimposed on the adult mandible for size and shape comparison. Adapted from Sperber G. *Craniofacial development*. Hamilton (ON): BC Decker Inc; 2001. p. 130.

the end of adolescent growth. This differential growth, typically characterized by a peak in the rate of mandibular growth at puberty, usually results in the final correction of the mandibular position relative to the maxilla.

If the cranial base is the craniofacial skeletal unit whose growth is least determined by extrinsic factors, the mandible is the opposite extreme with its growth highly dependent on the postnatal functional demands placed on it. It has a great capacity to adapt to mandibular displacement and accommodate to lingual and labial soft tissue and muscular function. The condylar inclination, dictating the type of mandibular rotation, is determined by these secondary functional influences. The relevant functional matrices include the lateral pterygoid attached to the condylar neck, the growth and function of the tongue, the masticatory muscles attached to the buccal and lingual aspects and to the coronoid process, and the facial soft tissue and musculature, all influencing the ultimate size and shape of the mandible. For this reason the mandible, more than any other part of the craniofacial complex, may have a low intrinsic growth potential that is significantly increased and regulated in response to functional demand.

Dental Development

The alveolar processes contribute a great portion of the vertical height of the lower face. Their development is entirely dependent on the presence and eruption of the primary and permanent dentition. Just as vertical appositional alveolar growth accompanies vertical dental eruption, transverse apposition complements transverse dental eruption. This minor contribution to the transverse dimension of the alveolar processes continues until about 7 years of age, with eruption of the permanent incisors. Further transverse dentoalveolar growth is minimal, occurring with eruption of the premolars and canines. Facial growth and the concomitant

increase in the size of the jaws occur posteriorly, creating additional space for the dentition only in the molar region.

Eruption of the maxillary teeth enhances the vertical dimension of the maxilla with posterior development of the maxillary tuberosities to accommodate the development and eruption of the maxillary posterior teeth. In the mandible, resorption of the anterior ramal borders provides room for the development and eruption of the mandibular posterior teeth. Eruption of the mandibular teeth enhances the vertical growth of the mandible and also contributes to the height of the face. However, compensatory condylar growth must occur to prevent the mandible from rotating posteriorly as the maxilla grows downward and the dentition erupts. Dental emergence into the oral cavity begins at approximately the sixth postnatal month, and the primary dentition is established by 2.5 years of age. The primary incisors begin to exfoliate at 6 to 7 years of age, and the permanent dentition begins to emerge with eruption of the mandibular incisors and first molars. The permanent dentition is established by 12 to 14 years of age except for the eruption of the third molars, contributing to the vertical dimension of the lower face during adolescent growth.

Facial Development

The growth of the facial soft tissue follows the underlying facial bones but is not directly correlated with bone growth. Facial soft tissue is thicker relative to the underlying skeletal tissue in the young child due to subcutaneous fat. This is one of the reasons it is more challenging to assess potential underlying skeletal discrepancies in the young child based only on a clinical appraisal. The thicker soft tissue envelope, together with the relative retrognathic position of the mandible, creates a more convex profile in infancy and early childhood. Lip thickness increases until it reaches a maximum at the end of

the pubertal growth spurt, then decreasing in late teens and adulthood.^{28,29} These later changes, combined with continued forward nasal growth as well as anterior mandibular and chin projection, leave the lips with a more retrusive appearance and the nose and chin with a more prominent appearance. These changes usually create a flatter facial profile in older adolescents and adults. This tendency is even greater on average in males than females, due to the less common presence of subcutaneous fat, combined with more nasal growth and anterior mandibular and chin projection in males.

The facial soft tissue also follows the cephalocaudal growth gradient, with the soft tissue of the lower face growing more in magnitude and duration than the upper face. The vertical length of the upper lip is a smaller proportion of lower face height in the preadolescent, often resulting in lack of resting lip apposition. During and following pubertal growth the upper lip proportion increases with greater vertical lip growth than the underlying vertical skeletal growth, creating a more likely chance of resting lip apposition in adults.³⁰

There is significant growth in the length of the nose during adolescence, influencing the facial balance between the nose, lips, and chin.³¹ In fact the vertical nasal growth is much greater than anteroposterior or transverse nasal growth. Nasal growth during adolescence is primarily limited to cartilage and soft tissue since the nasal bones usually have completed growth earlier. The nasal shape often changes prior to adolescence with the upper nasal dorsum developing superiorly and anteriorly, with the lower nasal dorsum more often following the lower facial growth pattern. In other words, individuals who have a more anterior and superior rotational pattern of lower face growth will exhibit a similar rotation of the lower nasal dorsum. There is some evidence that skeletal Class II jaw relationships usually demonstrate a more prominent nasal

bridge and convex dorsum than balanced jaw relationships.³²

The upper third of the face grows the most rapidly early in life due to brain growth and achieves its ultimate size earliest, finishing most growth by 12 years of age. Orbital height already reaches 55% of its adult height at birth and 94% by 7 years of age.³³ The middle and lower thirds of the face are less affected by brain growth, growing more slowly and for a longer time. Most of the middle third growth is completed later during puberty, with the lower third of the face continuing to grow beyond puberty into adulthood.

In addition to this vertical sequential growth gradient, craniofacial growth does not take place at an equal rate in the three planes of space. The completion of growth follows a sequence where transverse growth finishes first, followed by anteroposterior and finally vertical growth. The face reflects the early transverse neural expansion of the cranium, the early fusion of the mandibular symphysis, and the early growth cessation of the midpalatal suture during the first few years of life. This presents clinically as a disproportionately wide face relative to the height in the infant and young child. As the maxilla and mandible displace and grow downward and forward, the anteroposterior and vertical growth begin to take proportionately greater roles. The growth rate of the maxilla slows down after about 10 years of age, and together with anterior maxillary resorption, reduces the relative anterior projection of the midface. The maxillary length reaches maturity prior to the upper facial height, which is followed by mandibular length and finally ramus height.³⁴ The somewhat retrognathic position of the mandible at birth is usually corrected early in postnatal life. The mandible grows for a longer duration than the maxilla, typically undergoing a growth spurt at puberty. Anteroposterior growth is accompanied and then followed by vertical facial growth, often continuing well beyond puberty, even in to the third and fourth decades.

There are gender differences in facial growth, with males characteristically having volume changes of greater magnitude than females. Females have much less nasal growth on average, with many not even exhibiting a pubertal nasal growth spurt, in contrast to males who characteristically have a nasal growth spurt throughout puberty. Females have earlier soft tissue growth that follows their earlier puberty and they have greater lip thickness at all ages. The flattening of the facial profile during adolescence is less dramatic in females, due in part to their fuller lips, but also due to females having less forward mandibular growth projection and chin growth. Females have on average more late vertical maxillary growth than males. If mandibular growth is not matching these late maxillary changes, the mandible translates downward and backward, resulting in a more convex profile. Not only are male facial volume changes on average greater in magnitude, but the duration of the changes is longer, and there is more predominance of volume increase in the lower third of the face.³⁵ Males are on average more likely to have late mandibular growth that may be beneficial in improving a maxillary protrusion or mandibular retrusion, but is disadvantageous when a mandibular prognathism or maxillary retrusion is present prior to late growth.

Growth and Facial Changes during Adulthood

There has been awareness since the late nineteenth century that human growth continues beyond adolescence, at least until the fourth or fifth decade of life.³⁶ Nevertheless investigators in the mid-twentieth century were surprised to find that facial growth continues into the sixth decade of life.³⁷ More recently it was found that the craniofacial complex remodels throughout adulthood, with thickening of the frontal region of the cranium and a symmetric modest increase in the size of the cranium, cranial base, maxilla, and mandible.^{38,39}

During the past two decades there have been a number of longitudinal craniofacial growth studies that have examined changes during adulthood.⁴⁰⁻⁴⁴ Evaluation of the serial cephalometric radiographs revealed that craniofacial growth continues with increases in both anteroposterior and vertical dimensions at all age levels, similar to the changes seen during adolescence, but of a much lesser magnitude and rate. Females grow less and their craniofacial growth is expressed more vertically with posterior mandibular rotation, whereas males tend to grow with anterior mandibular rotation during adulthood, thereby straightening their profile (Figure 53-15).

Typical lip changes during adulthood include less prominence with decreased thickness and thinning of the vermilion, with male lips continuing to appear more retrusive with age. Female lips generally do not become more retrusive and their lower lip thickness tends to increase slightly. The lips become positioned more inferiorly, resulting in less vertical display of maxillary incisors and less lip separation.⁴⁵ The nose continues to increase in size in all dimensions, but more so in males, with the nasal tip dropping inferiorly.⁴⁶ There is deepening of the nasolabial folds and the oral commissures tend to sag inferiorly. There is more prominence of the pogonion due to continued soft tissue increase, but this is typically limited to males.

The biologic regulator mechanism for initiating and directing craniofacial growth and dental eruption timing, pattern, and rate remains a poorly understood phenomenon. It is clear that it is a complex mechanism, influenced by an intricate interaction of genetic, epigenetic, and local environmental factors.

Factors Influencing Craniofacial Growth

Craniofacial growth is a complex process influenced by both prenatal and postnatal genetic and environmental factors. The principal influence on craniofacial growth

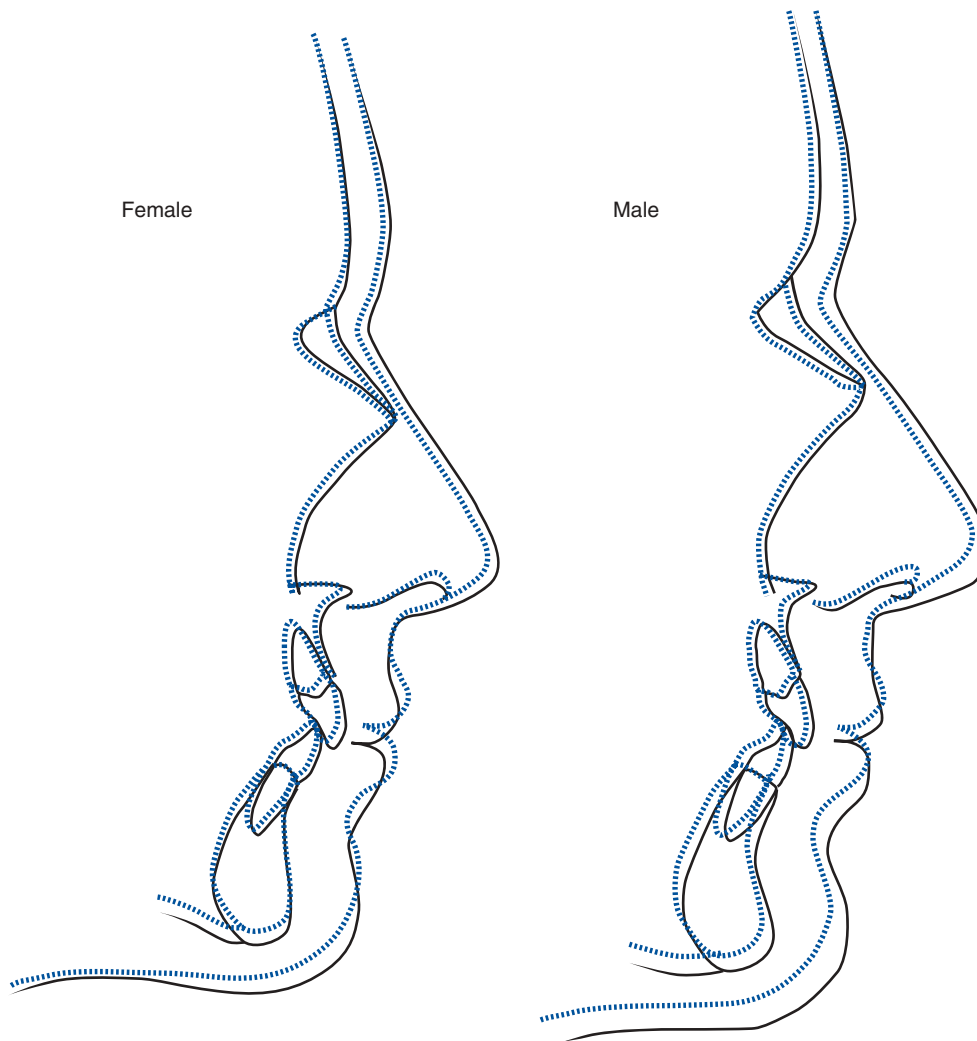


FIGURE 53-15 Composite lateral cephalometric views of female and male showing longitudinal growth changes from young adult (broken line at mean age 17) to middle age adult (solid line at mean age 47 to 51). Note the continued downward and forward skeletal and soft tissue growth with relative flattening of the lips. Adapted from Behrents RG.⁴⁰

and morphogenesis is one of multifactorial genetic control. However, the interaction of this genetic control with environmental factors is a complex one, and it is usually impossible to accurately differentiate between these influences.

Prenatal Factors

Prenatal defects of craniofacial development can be classified conveniently into three categories: (1) malformation—a morphologic defect of an organ, part of an organ, or larger region of the body resulting from an intrinsically abnormal developmental process, which is intrinsically

determined due to the genome or a teratogen, and occurs during the embryonic period; (2) deformation—an abnormal form, shape, or position of a part of the body caused by mechanical forces, which is influenced directly by the fetal environment; and (3) disruption—a morphologic defect of an organ, part of an organ, or a larger region of the body resulting from the extrinsic breakdown of, or an interference with, an originally normal developmental process, which also occurs during the fetal period and may result from intrauterine pressure as well, but can be of metabolic, vascular, and/or teratogenic origin.⁴⁷

Genetic Craniofacial malformations arise from disturbance in morphogenesis as early as the germ layer formation to the final formation of organ systems at the end of the embryonic period. The fourth to eighth weeks' gestation is a particularly critical time because this is the period when neural crest migration is at its most active, the facial primordia and dental laminae are forming, and neurovascular bundles are being generated prior to facial bone ossification. Malformations are caused from chromosome abnormalities or single gene mutations, or are multifactorial (genetic and/or teratogenic) in origin. Growth retardation, premature death, and mental retardation seem to be more frequent in autosomal recessive or X-linked syndromes.⁴⁸ Craniofacial malformations range from acephaly to mild facial defects such as a microform cleft or notching of the lip. Cranial malformations include premature or delayed fusion of the cranial sutures, due to mutations in fibroblast growth factor receptors and the transcription factor MSX2, associated with syndromes such as trisomy 21 and cleidocraniodysostosis or with simply a deformation craniosynostosis.^{49,50} Cranial base malformations usually are related to malformations that affect cartilage growth such as achondroplasia. Apert, Crouzon, and Pfeiffer syndromes involve premature fusion of multiple facial and cranial sutures as well as cranial base synchondroses.⁵¹ Many facial malformations originate from a deficiency, incomplete migration, or failure in cytodifferentiation of neural crest tissue during embryogenesis.⁵² The result is a failure in normal formation of the skeletal and connective tissue portions of the facial primordia. Nasomaxillary malformations include deficiencies and/or absence of facial bones that occur in ectodermal dysplasia or mandibulofacial dysostosis, as well as facial clefts that are associated with over 250 syndromes. The most common craniofacial malformation is unilateral cleft lip,

affecting 1 in 700 to 800 births. Malformations that affect the mandible range from the rare absence (agnathia), to various forms of micrognathia, associated with a number of syndromes, such as mandibulo-facial dysostosis (Treacher Collins syndrome) or Turner syndrome, to macrognathia, associated with hyperpituitarism or hemifacial hypertrophy.

Two more common chromosomal disorders that result in growth retardation are Down syndrome and Turner syndrome, both of which are characterized by short stature and brachycephaly. The protruding tongue typical of Down syndrome usually results in an anterior open bite, whereas a narrow high-arched palate often is seen with Turner syndrome. The Russell-Silver syndrome is a chromosomal disorder characterized by poor fetal and postnatal growth and small triangular facies. Other syndromes associated with prenatal growth retardation include Bloom syndrome, de Lange syndrome, leprechaunism (mutations of the insulin receptor gene), Ellis-van Creveld syndrome, Aarskog syndrome, Rubenstein-Taybi syndrome, Perheentupa syndrome, Dubowitz syndrome, and Johanson Blizard syndrome.⁵³

Single-gene disorders that result in fetal overgrowth include Sotos syndrome, Weaver syndrome, and Beckwith-Wiedemann syndrome. Sotos syndrome includes craniofacial features of macrocephaly, dolichocephaly, a prominent forehead, hypertelorism, prominent ears, high-arched palate, and mandibular prognathism. The Beckwith-Wiedemann syndrome, another example of uniparental disomy, is associated with excessive somatic and specific organ growth (eg, macroglossia) apparently caused by excess IGF-II. In spite of the overgrowth with these disorders that extends from the fetal period into early childhood, both lead to early epiphyseal fusion, resulting in adult short stature. Klinefelter syndrome (XXY) is a chromosomal disorder that leads to postnatal extended growth from pubertal failure, resulting in tall adult stature.

An example of a single-gene growth disorder is achondroplasia, the most common form of human dwarfism, which is autosomal dominant with complete penetrance, involving mutations in the *FGFR3* gene. Since the primary cartilage of the cranial base synchondroses is affected, and not the secondary cartilage of the mandibular condyles, midfacial hypoplasia resulting in a Class III skeletal discrepancy is the usual facial outcome. A single-gene disorder that leads to postnatal overgrowth resulting in tall adult stature is Marfan syndrome.

Environmental Prenatal environmental growth factors are those not directly determined by the genome, including cytoplasmic and extracellular contents in the embryo or fetus and the placenta, influenced by the mother and her interaction with the external environment. Some of these environmental factors may be internal (such as focal embryonic hemorrhages) or external (from maternal malnutrition, metabolic factors, and disease, or exposure to pollutants, chemicals, drugs, infectious agents, or radiation), and may impair normal growth or act as teratogens during either the embryonic or fetal period if the maternal exposure is large or frequent enough (Figure 53-16).

Cytomegalovirus and rubella are examples of pathogens that can cause microcephaly, hydrocephaly, and microphthalmia. Glucocorticoids, phenytoin, ethyl alcohol, tobacco smoke, aspirin, and retinoic acid (a vitamin A metabolite) are examples of an ever-increasing number of substances that are being identified as teratogens, causing cleft lip and palate as well as other craniofacial anomalies.⁵⁴ Teratogens have distinct mechanisms of action and are selective to certain target cells, but the severity of the resulting malformation is variable. It is speculated that the range of phenotypic effects caused by a teratogen is due to factors that include the concentration or method of delivery, the timing and

duration of exposure, variations in susceptibility, and synergistic interactions among teratogenic compounds.⁵⁵ Even in the absence of any detectable malformations, serious long-term physical and mental development can result from drug intake during pregnancy.

When the fetal period begins, environmental factors can still have a profound growth effect on the developing fetus. Maternal malnutrition adversely affects fetal growth.⁵⁶ Maternal diet composition is relevant, with a high-protein diet being associated with increased linear fetal growth and a high-fat diet linked to an increased birth weight. Maternal consumption of alcohol, recreational drugs, or tobacco all have an important negative influence on growth in utero as well as during the first year of life.⁵⁷⁻⁵⁹ Even maternal exposure to passive tobacco smoke reduces fetal growth.⁶⁰ Frequent high maternal noise exposure has been shown to adversely affect prenatal growth, perhaps related to the stress imposed.⁶¹ Maternal pathology such as rubella is particularly detrimental if it occurs in the first trimester, causing a growth deficit with no long-term recovery.⁶²

Intrauterine pressures can result in deformations or disruptions. Intrauterine restrictions can result in mild to severe deformations that can present as mild facial or cranial asymmetry. Some isolated forms of craniosynostosis, causing cranial deformations such as plagiocephaly, may be caused from intrauterine mechanical factors.⁶³ These deformations may resolve after birth with catch-up growth but usually require orthopedic or surgical intervention during infancy. Another deformation is the Robin sequence whereby retrognathia from posterior restraint of the mandible forces the developing tongue into a posterior position, often acting as a mechanical obstruction that prevents elevation of the palatal shelves, resulting in an isolated cleft palate. A disruption is a typically more serious anomaly than a deformation, from the

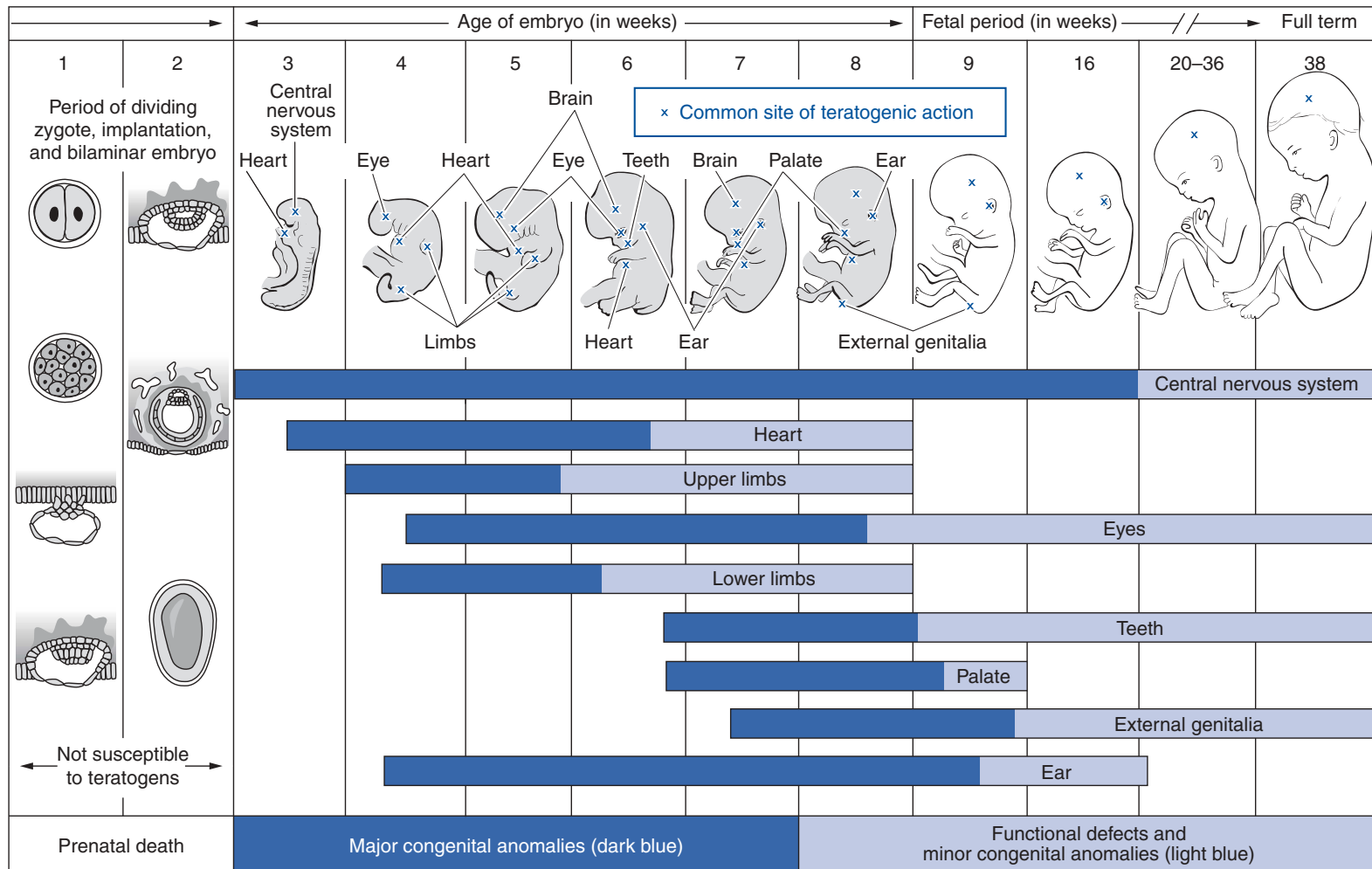


FIGURE 53-16 Susceptibility to teratogens during periods in prenatal human development. During the first two weeks' gestation, damage from the teratogen results in death of the conceptus, or damages only a few cells, allowing recovery by the embryo to develop without birth defects. Dark blue indicates highly sensitive periods when major defects may be produced (eg, amelia, absence of limbs). Light blue indicates less sensitive periods when minor defects may be produced (eg, hypoplastic thumbs). Adapted from Moore KL, Persaud TVN. *The developing human: clinically oriented embryology*. 5th ed. Philadelphia (PA): W.B. Saunders Co.; 1973. p. 156.

standpoint of both treatment and future growth, because it presents as a morphologic and functional defect that requires surgical repair. An example of a disruption is where a strand of torn amnion or amniotic band is swallowed by the fetus, resulting in a facial cleft that is not located at a site of embryonic fusion.

The hormonal regulation of fetal growth is not well understood. Fetal androgens appear to be growth promoters. At midgestation the level of gonadotropin is similar to pubertal levels.⁶⁴ Although there is some evidence that estrogen promotes fetal bone development, there are also data that suggest that it inhibits fetal

growth.^{65,66} There is a marked and progressive increase in prolactin during late gestation. Before 12 weeks' gestation, maternal hypothyroidism can have long-term deleterious effects on hearing and intelligence, but neither maternal nor fetal hypothyroidism has an appreciable effect on fetal length or weight. However, when both conditions are present, linear growth is still unaffected but there is incomplete pulmonary, cardiovascular, and skeletal maturation.⁶⁷ Although poorly understood, insulin appears to have an important role in regulation and promotion of fetal growth. Maternal diabetes increases fetal length and weight, whereas fetal

insulin deficiency results in decreased length and weight at birth.⁶⁸

Although growth hormone (GH) is essential for postnatal growth, growth in utero and probably in the first 2 years of life is largely GH independent.^{69,70} Nevertheless IGF-I and -II play important roles in determining fetal growth, but the specific nature of these roles are not well understood. IGF-II is important in supporting fetal growth during early gestation whereas IGF-I has a greater role during later gestation and especially in postnatal life.⁷¹ The fetal roles of growth factors such as nerve, epidermal, and platelet-derived growth factors also remain unclear. Other

fetal growth factors include hematopoietic growth factors, fibroblast growth factors, vascular endothelial growth factor, and members of the TGF- β family.⁷²

The placenta functions as an additional endocrine organ, providing a secondary source of hypothalamic, pituitary, adrenal, and gonadal hormones and growth factors.⁷³ Placental GH and lactogen can alter the production of maternal IGF-I.⁷¹ Maternal IGF-I in turn affects placental nutrient transport, increasing fetal growth.⁷⁴ Lactogen regulates maternal glucose, amino acid, and lipid metabolism, facilitating nutrient transport to the fetus. Disruption of placental GH or lactogen production can occur from vascular disease, infection, or intrinsic placental abnormalities, impairing fetal growth.⁷⁵

Postnatal Factors

The size of infants in the first months of life is more related to the prenatal environment than parental height. If prenatal factors caused only mild growth attenuation and it occurred during the last trimester, then postnatal catch-up growth is feasible.

An area of craniofacial growth can be differentiated as a growth center or growth site. A growth center is where there is primarily intrinsic genetic growth control with a minimal environmental or functional role. Although a growth site also is controlled to some extent by genetic programming, it is more vulnerable to extrinsic growth control, being dependent more on the functional influence of the surrounding tissues. Cranial base synchondroses, where endochondral ossification of primary cartilage occurs, represent growth centers. The role of the cartilaginous nasal septum as a growth center or site remains controversial. There is a clearer understanding that the endochondral growth of the secondary cartilage of the mandibular condyles acts as a growth site, being greatly influenced by mandibular and soft tissue function. Areas of membranous bone growth resulting from sutural or periosteal

ossification are primarily growth sites and represent the bulk of the remaining craniofacial complex. There are exceptions, such as craniosynostosis, that can be due to an underlying genetic cause. Membranous ossification by sutural and periosteal remodeling is essentially the only type of craniofacial bone growth that occurs after adolescence throughout adulthood.

Genetic Heritability appears to have an effect on somatic growth, from a greater to lesser extent in the following order: skeletal length, skeletal breadth, weight, circumference, and skin folds. By the same token skeletal tissues respond less to changes in the nutritional environment than soft tissues.⁷⁶ The timing and pace of maturation is also genetically controlled to a large degree. The extent to which heredity is the cause of postnatal growth that results in jaw discrepancies is controversial. It appears that the genetic influence is particularly important for excessive mandibular growth and excessive vertical facial growth.^{77,78} It is speculated that probably no more than 50% of facial skeletal variation is due to the genetic component with the remaining half or more due to environmental influence.⁷⁹ Functional forces have a crucial influence in modifying craniofacial bone growth. Although genetic influence is important, the membranous viscerocranium is determined to a great extent by functional influences, with these extrinsic factors having the greatest control over mandibular growth.

Environmental There is a multitude of postnatal environmental factors that interact with genetic control mechanisms, including functional, traumatic, endocrine, nutritional, pathologic, psychological, cultural, and climatic, or seasonal factors.

The functional environment is determined by neuromuscular behavior necessary for survival such as respiration, mas-

tication, deglutition, speech, and posture. However, it is clear that functional influences at rest (ie, postural activity or the presence of a pathologic mass) are much more important than transient muscle contractions and mandibular movement in influencing craniofacial growth.⁸⁰ Chronic pressure alters regional skeletal growth and may be used to improve or correct some craniofacial deformities.⁸¹ Habitual behavior such as non-nutritive sucking and other oral or postural habits also may have an impact on growth if it is present with great enough frequency and duration.^{82,83} Mastication limited to one side for sufficient duration can cause asymmetric mandibular growth.⁸⁴ There is some evidence that diet consistency has an effect on mandibular morphology.^{85,86}

The extent of masticatory muscular and dental development can modify the morphology of skeletal superstructures, including the temporal fossae and sagittal crests, the zygomatic arches, the lateral pterygoid plates, the angular and coronoid processes and rami of the mandible, and parts of the temporomandibular joints.⁸⁷ The size and function of masticatory muscles has been correlated with facial morphology.⁸⁸⁻⁹⁰ Other studies have demonstrated an atrophic effect from muscle denervation.^{91,92} However, it also is clear that external craniofacial bone growth nevertheless can occur in the absence of any muscle function.^{93,94}

Growth deficiency due to neuromuscular deficits can occur in muscle weakness conditions such as muscular dystrophy. The difficulty in returning function to the area makes such conditions particularly resistant to treatment. However, if the muscle is normal, it appears that the normal force range of masticatory muscular function in the general population does not significantly affect facial growth.⁹⁵ Long-term impairment of nasal breathing historically has been viewed as a cause of long face deformity, but this assumption continues to be controversial.⁹⁶ There is

less disagreement about a relationship between nasal obstruction and facial deformity than there is with the extent and duration of mouth breathing necessary to cause a deformity.

Postnatal surgery during infancy for congenital malformations such as cleft lip and palate introduces scarring that is responsible for some midfacial growth attenuation. Typical surgery to close palatal clefts requires that mucoperiosteal flaps be raised and moved medially and posteriorly. This results in denuded bony areas that will heal with the formation of scar tissue bands of variable size and elasticity. This scar tissue usually connects across the maxilla and includes the palatal bones and possibly the pterygoid plates. It is thought that the presence of this scar tissue during postnatal growth compromises midfacial growth.⁹⁷ The longer postnatal surgery can be delayed, the less growth is affected.

Perinatal or postnatal trauma to the craniofacial complex can modify growth if there is limitation of blood supply or mechanical constriction due to scarring. Extensive midfacial trauma can cause midface growth deficiency as a result of the loss of intrinsic nasal septal growth or from a structural collapse that prevents normal morphologic expression of growth.⁹⁸ Untreated burns of the head and neck can cause significant craniofacial dysmorphism.⁹⁹ Neurologic damage may lead to muscle paralysis that can alter craniofacial form due to decreased muscle function. There should be caution when considering early craniofacial reconstructive surgery, since the surgery itself may produce additional scarring that can exacerbate the growth attenuation. There is no evidence that the use of rigid plate fixation for trauma reconstruction causes restrictive growth effects in addition to the trauma alone.¹⁰⁰ With trauma involving the mandible, mandibular function must be maintained, often requiring physical therapy

and the use of a functional appliance. As long as mandibular ankylosis is prevented, surgery should be avoided when treating condylar fractures in children.¹⁰¹

Endocrine disturbances originating from pathology or the environment are among the most potent regulators of postnatal growth. The primary growth promoting hormone, GH, is secreted by the pituitary and regulated by somatostatin and GH-releasing hormone release from the hypothalamus. Studies have demonstrated increased GH secretion throughout the day and night in the newborn. However, IGF-I levels are lower at birth and gradually increase during childhood and into adolescence, indicating an early immaturity in the feedback loop. Although the growth process in utero and in the first months after birth is more nutritionally dependent than GH dependent, this changes during the first year of life, with full GH dependence attained during the second year.⁷⁰ GH has been shown to have a direct stimulatory effect on cartilage growth, whereas IGF-I acts as a secondary stimulatory effector.¹⁰²

Most of our present understanding of the endocrine influence on craniofacial growth has developed from assessing children who have diagnosed endocrine disorders. GH-deficient children have excess subcutaneous fat and overall delayed facial and cranial base development, resulting in infantile, but proportional, facies. Dental development is delayed as well but to a much lesser degree than facial or somatic growth. In contrast the craniofacial growth is disproportionate in an autosomal recessive condition known as Laron syndrome where there is IGF-I deficiency in spite of increased serum GH levels.¹⁰³ There is a normal calvarium with small facial bones, resulting in the forehead appearing large and prominent relative to the small recessed face.¹⁰⁴ This suggests that some areas of the face are more directly affected by GH than IGF-I.

GH excess, usually a consequence of a pituitary adenoma, results in gigantism if it occurs prior to the end of adolescence and presents with overall larger craniofacial dimensions. Acromegaly is the outcome if the GH excess is produced following adolescence, characterized by increased periosteal bone that includes cranial thickening, increased size of the frontal sinuses, prominent supraorbital ridges, and nasal enlargement as well as renewed mandibular condylar cartilage growth, leading to mandibular prognathism.

Hypothyroidism will decrease GH release and results in delayed bone and dental development.¹⁰⁵ The craniofacial outcome of this deficiency differs from GH deficiency primarily by the smaller cranium. Anabolic steroids increase craniofacial growth but may lead to excessive anterior maxillary growth in high doses.¹⁰⁶ Testosterone, GH, and IGF-I accelerate endochondral and intramembranous craniofacial skeletal growth as well as stature height. Estrogen appears to decrease endochondral growth.^{107,108}

Although glucocorticoid production is necessary for normal growth, glucocorticoid therapy in the prepubertal child must be carefully managed to avoid its inhibitory effect on GH and IGF-I production, resulting in short stature.¹⁰⁹ Though there are no clinical studies indicating the effect on craniofacial growth, animal model studies have suggested a retarding effect on mandibular condylar cartilage growth and acceleration in dental eruption.^{110,111}

Poor nutrition, hygiene, and health adversely affect growth. Insufficient caloric and protein intake is the most common cause of growth failure worldwide.¹¹² Growth deficiency from malnutrition is proportional to the severity of the nutritional deficit. Malnutrition is associated with increased GH but decreased production of IGF-I, reallocating calories from anabolic to survival requirements.¹¹³ It is estimated that 55% of the morphologic variation of the cranium is due to nutritional factors.¹¹⁴

Because of the early rapid growth of the brain, the cranium is affected more by infant malnutrition than the rest of the craniofacial complex. The size of the neurocranium decreases in rats subjected to malnutrition.¹¹⁵ A diet deficient in calcium and vitamin D resulted in cranial dimensional changes in rats.¹¹⁶ It is thought that maternal vitamin A deficiency alters endocrine function that causes a disturbance in chondrogenesis, reducing the cranial base.¹¹⁷ Nasomaxillary hypoplasia in humans can be related to maternal vitamin K deficiency induced in rats, causing limited nasal septal cartilage growth.¹¹⁸ Protein malnutrition in rats decreases the length of the skull relative to the width.^{119,120} Voluntary undernutrition has become more common during adolescence, especially with females trying to decrease weight for athletics and those with anxiety about obesity. This may develop into extreme eating disorders such as anorexia or bulimia, which may result in impaired growth, delayed puberty, and osteopenia.¹²¹

Chronic disease such as congenital heart disease, malabsorption syndrome (eg, chronic inflammatory disease, cystic fibrosis, celiac disease), chronic renal or liver disease, chronic anemia, inborn errors of metabolism, chronic infections (eg, tuberculosis, acquired immunodeficiency syndrome), severe asthma, or other chronic pulmonary disease can adversely affect growth.¹²² There are a variety of mechanisms causing the growth deficits from these conditions, including reduced nutritional intake, metabolic disbalance, hypoxia, chronic metabolic acidosis protein loss, and often the treatment for the pathology itself.¹²³ Medications that limit potential growth include chronic adrenal steroid therapy (used for asthma, nephritic syndrome, lupus, and other chronic diseases) and cytostatics (for cancer treatment). Irradiation of the head and face for childhood cancer can result in severe hypoplasia of soft and hard tissues.^{124,125} If cranial irra-

diation is required in cases of leukemia and tumors of the central nervous system, hypothalamic function can be damaged, affecting the release of hypothalamic and pituitary hormones, notably GH.

Chronic psychological trauma, emotional deprivation, or psychosocial stress can have a profound effect on somatic growth, causing a functional and reversible GH deficiency, often mimicking growth disorders that are caused from endocrine or nutritional deficiencies.¹²⁶

Additional less important factors have been shown to have a significant influence on postnatal growth and development. These include climate, altitude, exposure to environmental pollutants, and noise.^{127–130} Future research will increase our understanding of the role that these and other yet unidentified environmental factors play in altering human genetic growth potential.

Orthopedic and Orthodontic Clinical Considerations

Orthopedic Treatment for Growth Modification

Just as our understanding of craniofacial growth is continually evolving, the application of this knowledge to clinical practice is also in a constant state of flux. This application is particularly important in order to determine the appropriate use of growth modification for treatment of craniofacial skeletal discrepancies.

A harmonious esthetic facial appearance and balanced dentoskeletal segments facilitating a functional occlusion are both goals that orthodontists and oral maxillofacial surgeons work to achieve by means of orthodontic treatment combined with orthognathic surgery. However, before a surgical correction is contemplated in a growing patient, a determination should be made if the patient is a candidate for orthopedic treatment that may modify craniofacial growth to improve the skeletal imbalance to a favorable esthetic and func-

tional outcome without the need for orthognathic surgery. It is well known that craniofacial orthopedic devices can generate forces that cause stress in sutures capable of modifying suture growth.¹³¹ As indicated earlier in the chapter, almost 50% of the total cumulative growth of the midface and mandible remains between the ages of 10 years and adulthood, making it possible to have an orthopedic treatment effect on the jaws during this time.

In spite of over a century of clinical experience with orthopedic facial appliances, it remains controversial as to what extent growth can be predictably and permanently modified by orthopedic treatment. Although there is consensus that there is an important genetic influence on the outcome of craniofacial growth, there is a wide range of views regarding the amount in which postnatal factors, particularly orthopedic treatment, influence this outcome. Views range from the belief that orthopedic alteration of jaw relationships is predictable and stable, to the contrasting opinion that facial growth is primarily determined genetically and cannot be significantly altered by orthopedic treatment. The reality is likely to be somewhere between these two extreme views. It has been proposed that the typical range of skeletal malocclusions include individuals with normal gene polymorphisms for signaling molecules and growth factors that attenuate the capacity of tissues and cells to reliably respond to orthopedic treatment.¹³²

The efficacy of craniofacial growth modification has been a controversial subject for more than a century. At the onset of the twentieth century there was universal confidence by the orthodontic profession that forces applied through the dentition to the growing face could effectively treat craniofacial skeletal discrepancies. After the 1920s there was a decline in this conviction by North American orthodontists. With the invention of the cephalostat, more precise skeletal assessment of treatment outcomes became possible during the 1950s. This

resulted in renewed faith in growth modification, with the demonstration of skeletal changes from the use of extraoral force applied with a cervical headgear.

In Europe there was less controversy regarding craniofacial growth modification efficacy throughout the first half of the twentieth century. European orthodontists relied primarily on removable “functional” appliances, designed to provide forces from facial muscles and soft tissue function, for facial orthopedic treatment. The separate philosophical paths taken by European and American orthodontists united in the 1960s, resulting in a more global acceptance of either extraoral (headgear) or intraoral (functional) appliances, or a combination of both to facilitate craniofacial orthopedic treatment. This acceptance gained support and enthusiasm from results of basic research conducted during the 1970s using animal models. Although this enthusiasm reached its peak in the 1980s, it was considerably moderated in the 1990s from clinical experiences and the results of retrospective clinical studies. There remains little argument that some craniofacial growth modification is feasible, but there continues to be controversy over the nature and extent of the skeletal change possible in individual patients as well as the optimal treatment timing and appliance type. In addition a reliable and accurate method of predicting the direction, timing, and magnitude of craniofacial growth for an individual has not been devised.

The aim of craniofacial growth modification is to alter the growth pattern by changing the relationships of the jaws. If the skeletal unit is too large, the aim of the orthopedic treatment is to attenuate or redirect its growth to improve its relationship relative to the opposing jaw. If the jaw is too small, the growth modification treatment is aimed at enhancing or redirecting its growth relative to the larger skeletal unit. Virtually all of the growth modification appliances to date have been “tooth-

borne” to some extent, so that the orthopedic forces applied to the skeletal units also create stress to the teeth that results in some dental movement. Although the goal of craniofacial growth modification is to limit the changes to the skeletal units with minimal movement of the teeth, the reality is that the treatment is a combination of skeletal and dentoalveolar changes.

There is growing evidence that the long-term success of many forms of growth modification requires that the treatment be continued until facial growth is nearly complete, making early treatment a less efficient way to treat many jaw discrepancies. The following discussion will summarize the facial orthopedic options we have for clinical application of our present understanding of craniofacial growth in the three planes of space.

Transverse Orthopedic Treatment Since transverse growth reaches completion earlier than anteroposterior or vertical craniofacial growth, it follows that transverse skeletal problems should be addressed early. The most common transverse skeletal problem is maxillary constriction, which can be treated in the preadolescent child, even as early as during the primary dentition. The most recent federal epidemiologic study, the National Health and Nutrition Estimates Survey (NHANES-III) conducted from 1989 through 1994, indicates the prevalence of posterior crossbite is about 5% of the US population.¹³³ Significant facial or mandibular asymmetry represents about 0.1% of the total population.¹³⁴ Although maxillary orthopedic expansion devices have been used since 1860, they fell out of favor for a few decades prior to the 1940s due to unsubstantiated concerns regarding their safety and effectiveness.¹³⁵ Orthopedic expansion of the maxilla can be achieved with a variety of toothborne appliances (Figure 53-17). These appliances apply moderate to high forces to the teeth that are transmitted as stresses to the

maxilla, primarily distracting the midpalatal sutures but also producing less pronounced stresses to the sphenoid and zygomatic bones and other adjacent structures.¹³⁶ Within days following initial expansion, new bone forms, eventually depositing both perpendicular and parallel to the edges of the expanded sutures.¹³⁷ Although a large amount of the skeletal

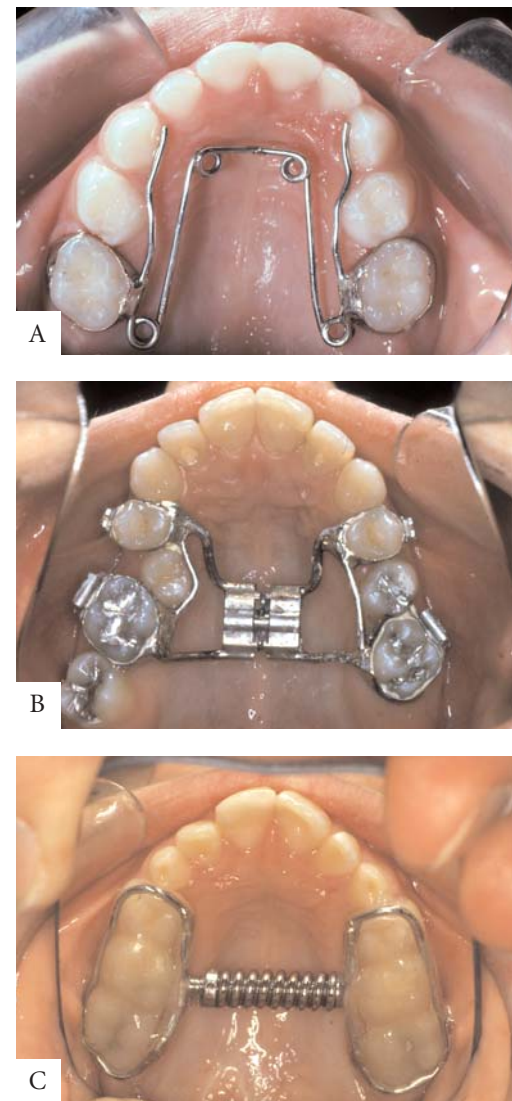


FIGURE 53-17 Types of maxillary orthopedic expansion appliances. A, Quad-helix: An effective skeletal expansion appliance in the primary dentition. B, Banded Hyrax: This traditional jackscrew also can be used as an activation component for an appliance bonded to the maxillary posterior teeth. C, Bonded Minne-expander: This spring-loaded component also can be used as an activation component for an appliance banded to the maxillary posterior teeth.

expansion relapses during retention, overall stability is good if the extent of sutural patency and magnitude of expansion are great enough. A potential additional benefit to improvement in interarch transverse compatibility is an increase in arch perimeter made possible by the maxillary orthopedic expansion.¹³⁸

Although complete fusion of the midpalatal suture usually does not occur until the third postnatal decade, the process leading to fusion is a gradual one, characterized by progressive sutural interdigitation and ossification.¹³⁹ For this reason more effective sutural separation, requiring less force and concomitant dental expansion, is possible in the younger child, especially prior to puberty, during a “phase 1” treatment in the mixed or early permanent dentition. Treatment prior to the pubertal growth velocity peak may result in greater long-term skeletal craniofacial transverse width.¹⁴⁰ Treatment may even be indicated as early as the primary dentition in the presence of a transverse functional shift. This compensatory functional problem can result in asymmetric condylar positioning that may lead to asymmetric mandibular growth and uneven remodeling of the glenoid fossae, possibly resulting in permanent facial asymmetry, even if the constricted maxillary arch is corrected at a later date.¹⁴¹ Maxillary constriction without a transverse functional shift does not carry the same urgency and is conveniently treated closer to the onset of puberty during the early permanent dentition.¹⁴²

Maxillary orthopedic expansion in late adolescent or postadolescent patients should be attempted with caution. Even if skeletal expansion is possible in these older patients, the extent of circum-maxillary sutural patency is limited enough to compromise stability of the treatment outcome. It is appropriate to confirm intermaxillary expansion with an occlusal radiograph in these patients, since the development of a midline diastema may only indicate bending of maxillary bones.

If the expansion is limited to lateral tipping of maxillary posterior teeth, buccal alveolar bone height reduction and gingival recession may occur. It usually is more prudent to consider surgically assisted palatal expansion for late adolescent or postadolescent patients to avoid periodontal compromises and instability.

The expansion appliance can be banded or bonded to the maxillary posterior teeth with a spring-loaded or nonspring-loaded palatal jackscrew that usually is activated by the patient 0.5 mm per day, delivering from 2 to more than 10 pounds of force (this may increase to cumulative loads of 20 pounds or more with multiple activations in the absence of adequate sutural separation). The conventional description for the expansion induced with this appliance is “rapid palatal expansion.” However, it is possible to affect slower expansion with less frequent activations, requiring more active treatment time, but less retention time to ensure sta-

bility.¹⁴³ It is possible to achieve skeletal expansion with simpler appliances such as a W-arch or Quad-helix, provided that the patient is in the primary or very early mixed dentition, when the maxillary sutures are more patent or when a cleft of the hard palate is present (Figure 53-18).

Since all of these expansion appliances are toothborne, unwanted dentoalveolar expansion is an inevitable consequence.^{144,145} An additional undesirable outcome is the long-term loss of about 30% of the skeletal expansion achieved during active treatment due to the rebound of stretched palatal tissues.¹⁴⁶ To compensate for these effects, maxillary expansion should be continued until adequate overexpansion is achieved, usually to the extent that the lingual cusps of the maxillary molars are opposing the buccal cusps of the mandibular molars (Figure 53-19). Once adequate expansion has been accomplished, at least 3 to 6 months of retention is necessary to permit new bone

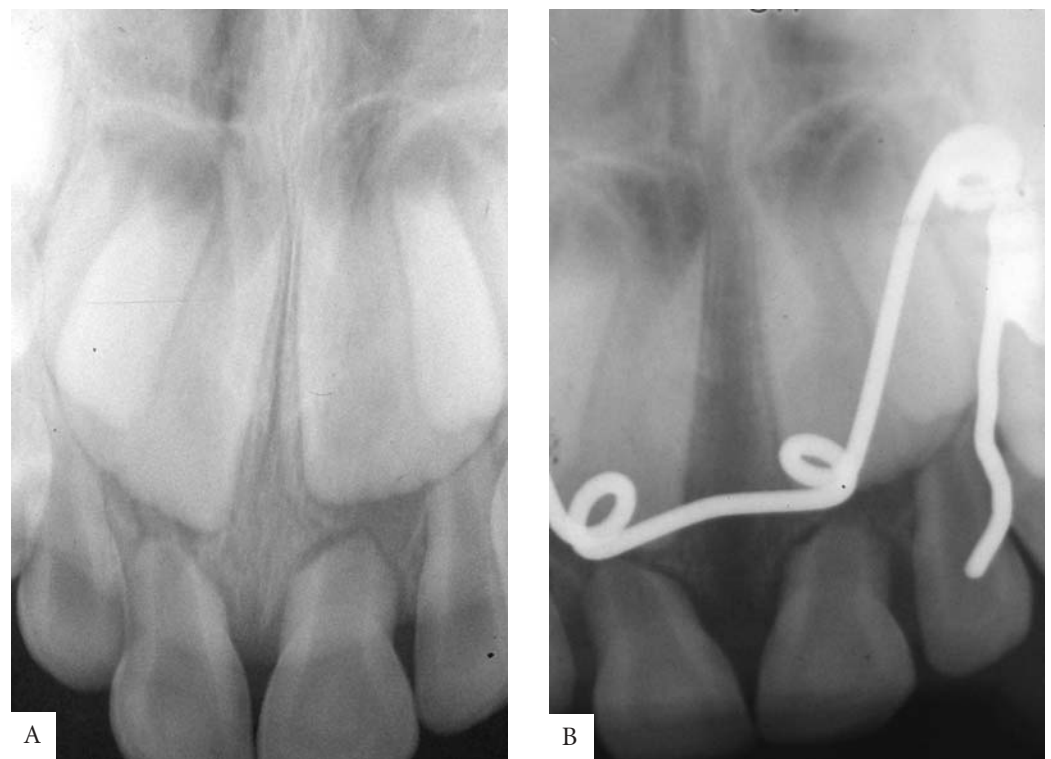


FIGURE 53-18 Intraoral radiographs demonstrating maxillary skeletal expansion with a Quad-helix during the primary dentition. Note the distraction of the midpalatal suture. A, Before expansion. B, After initial expansion.

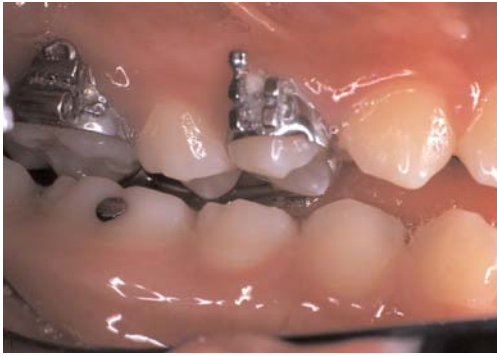

FIGURE 53-19 Maxillary overexpansion to compensate for dentoalveolar expansion and skeletal rebound. Note that the lingual cusps of the maxillary posterior teeth are occluding with the buccal cusps of the mandibular posterior teeth.

to fill in the spaces created by maxillary separation and to permit time for dissipation of reaction forces stored in the facial bones that promote relapse. The overexpansion permits the orthodontist to upright the posterior teeth in their alveolar housing without compromising the transverse occlusal correction following retention. Osseointegrated attachments may hold future promise for a means of expanding the maxilla without buccally tipping posterior teeth (Figure 53-20).¹⁴⁷

A less common transverse skeletal problem than maxillary constriction is asymmetric mandibular deficiency, usually caused from a previous trauma associated

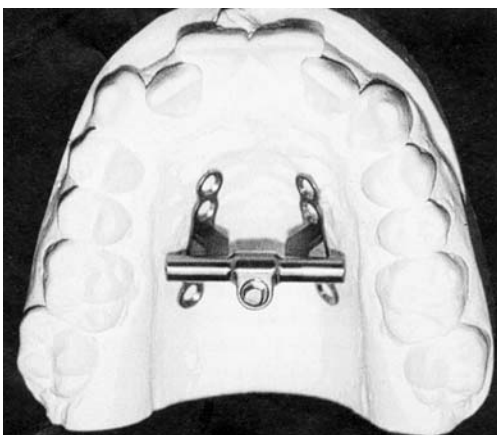


FIGURE 53-20 Palatal distraction appliance. Reproduced with permission from Gerlach KL, Zahl C. Transversal palatal expansion using a palatal distractor. *J Orofac Orthop* 2003; 64:444.

with unilateral mandibular condylar fracture or hemifacial microsomia, a congenital facial asymmetry. In both of these conditions the affected side exhibits growth deficiency relative to the unaffected or normal side, resulting in a mandibular deviation toward the affected side. If left untreated in a growing individual, the alveolar processes compensate with limited eruption of the maxillary posterior teeth on the affected side and excessive eruption of the maxillary posterior teeth on the unaffected side, resulting in an occlusal cant that is higher on the affected side. It is best to start orthopedic treatment with these individuals prior to the pubertal growth spurt, as early as patient compliance will permit. The goal is to maximize the growth expression on the deficient side and minimize dentoalveolar compensation. The orthopedic appliance of choice is an asymmetric “hybrid” functional appliance that is constructed to posture the mandible forward on the affected side, bringing the chin to the midline.¹⁴⁸ Posterior dental eruption is attenuated on the unaffected side with a bite block and eruption is facilitated on the affected side with a buccal shield and the absence of interocclusal acrylic (Figure 53-21). Since untreated mandibular asymmetries of this nature invariably worsen with growth, orthopedic treatment is considered successful if the asymmetry remains stable or improves. Treatment should not continue if progressive asymmetry is apparent in spite of reliable appliance use by the patient.

Anteroposterior Orthopedic Treatment: Class II A Class II skeletal relationship can be the result of a retrusive and/or deficient mandible, a protrusive or vertically excessive maxilla, or a combination of these skeletal problems. The prevalence of this type of malocclusion is about 15 to 20% of the US population, with about 2% severe enough to be considered as handicapping.^{133,134} Prospective clinical studies have supported that early growth modification therapy may lead to an improve-

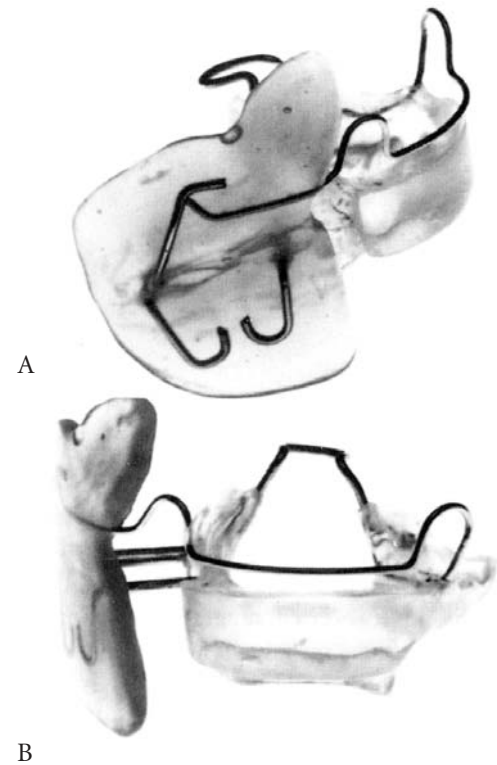


FIGURE 53-21 Asymmetric “hybrid” functional appliance: A, right lateral view; B, frontal view. On the left, unaffected side, posterior dental eruption is restricted with an interocclusal acrylic block. On the right, affected side, the mandible is postured forward and posterior dental eruption is encouraged with a buccal shield and absence of an interocclusal acrylic block. Reproduced with permission from Proffit WR, Fields HW. *Contemporary orthodontics*. 3rd ed. St. Louis (MO): Mosby; 2000. p. 370.

ment in the skeletal Class II malocclusion.^{149–151} It should be kept in mind that regardless of whether orthopedic treatment is attempted during active facial growth, approximately 10% of patients ultimately require orthognathic surgery to fully correct the Class II malocclusion.¹⁵⁰

The headgear has been used as a means of Class II orthopedic treatment in North America since the late nineteenth century (Figure 53-22). An orthopedic force ranging from 16 to more than 32 ounces is delivered using elastic traction from the headgear to a cervical or cranial attachment for 12 to 14 hours per day, usually for 9 to 12 months. Theoretically the force is transmitted in a posterior and

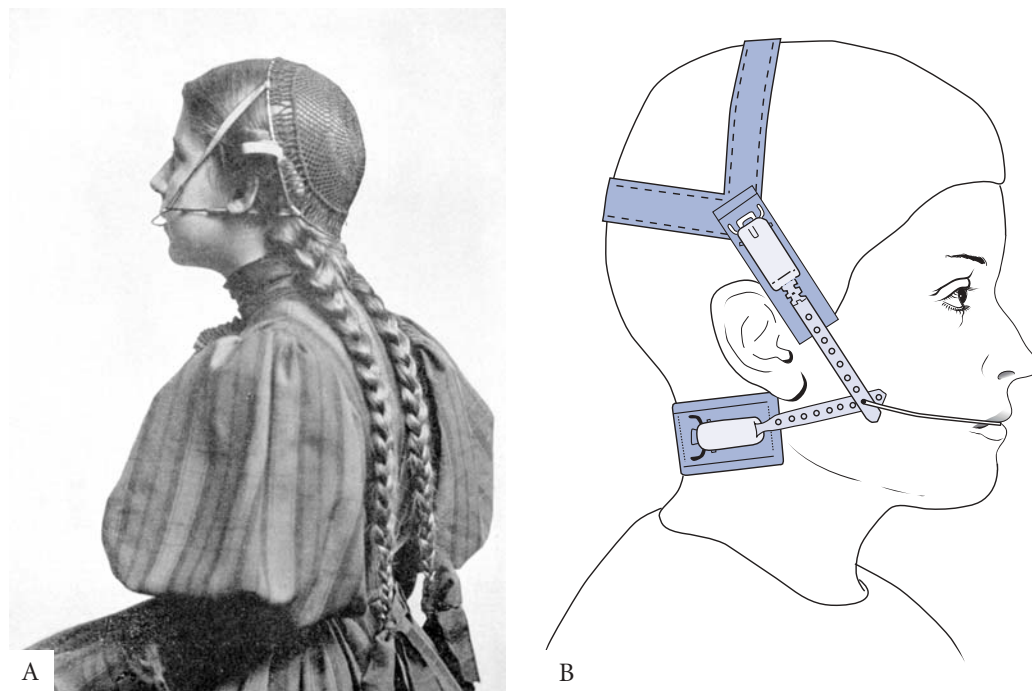


FIGURE 53-22 Headgear, past and present. An orthopedic force is directed posteriorly and superiorly to the maxilla, attenuating circum-maxillary sutural growth. A, Headgear from the late nineteenth century. Reproduced from Angle EH. *Treatment of malocclusion of the teeth*. Philadelphia (PA): S.S. White Dental Manufacturing Co; 1907. p. 234. B, Contemporary headgear. The appliance is fabricated with more durable materials and has additional calibration and safety features but the overall design has changed little in over a century. Adapted from McNamara JA, Brudon WL. *Orthodontics and dentofacial orthopedics*. Ann Arbor (MI): Needham Press, Inc.; 2001. p. 365.

superior direction via the teeth through the maxilla to compress the circum-maxillary sutures, limiting or redirecting maxillary growth. Since the introduction of standardized cephalometric radiographs, many clinical studies have demonstrated that maxillary growth can be altered with the use of the headgear.^{152–170} These clinical data have been supported by primate studies demonstrating that extraoral orthopedic force directed against the maxilla attenuates forward growth and alters bone apposition at the maxillary sutures.^{171–179} There are some studies that suggest that mandibular growth may be enhanced as well. Since the headgear is a toothborne appliance, there is some maxillary dental retraction that accompanies the skeletal change. Another dentoalveolar effect is the attenuation of maxillary molar eruption, resulting in anterior and superior mandibular rotation. There is some support for this being the only clinically rele-

vant skeletal effect.¹⁸⁰ A significant treatment effect usually requires that a headgear be worn 12 to 16 hours per day with a superior and posterior force of one pound or more per side. Human GH and other endocrine factors that promote growth and dental eruption are primarily released during the evening and night.^{181–183} It is fortuitous that this is the only time of day that one can reliably expect an adolescent to wear a headgear. Since it is a removable appliance, few adolescents after the peak of the pubertal growth spurt will reliably wear the appliance.

The alternative orthopedic method for treating a Class II skeletal relationship is the Class II functional appliance, which has been used since the early twentieth century in Europe and since the 1960s in North America. These appliances include the removable toothborne activator, bionator, and twin block, the removable and primarily tissueborne Fränkel (functional

regulator) appliance, or the fixed toothborne Herbst appliance (Figure 53-23). All of these appliances position the mandibular condyles downward and forward away from the glenoid fossae. Theoretically the distracted condylar positions reduce the normal compressive joint pressure on the growing condylar cartilage and the forward mandibular posturing alters muscle tension on the condyles, stimulating or accelerating the endochondral condylar growth more than would normally occur.¹⁸⁴ There is some support from animal studies that a histologic increase in condylar growth can be achieved.^{185–187} However, clinical studies have not confirmed that a greater absolute growth is the long-term treatment outcome.^{149,150} Some retrospective clinical studies have supported the assertion that clinically significant lengthening of the mandible can be achieved with functional appliances.^{188–198} Others have refuted this assertion.^{158,199–217} Much of the skeletal change demonstrated with a functional appliance may result from forces against the maxilla, similar to those applied with a headgear, that are created from the stretched facial muscles and soft tissues attempting to return the postured mandible back to its posterior and superior position.^{158,202,203,208,218–222} Because of the toothborne nature of this appliance, dentoalveolar changes accompany the skeletal changes, including maxillary dental retraction and mandibular dental protrusion.

Clinical studies have demonstrated few differences in treatment outcome when comparing the skeletal response between headgear and functional appliance treatment.^{168,193,223} However, there appears to be more of a maxillary effect with headgears.^{150,158,161,168} There is more of a mandibular effect with functional appliances.^{149,150,168,192,205} Most functional appliances need to be worn for the same daily duration as the headgear (exceptions are the Fränkel and Herbst appliances which

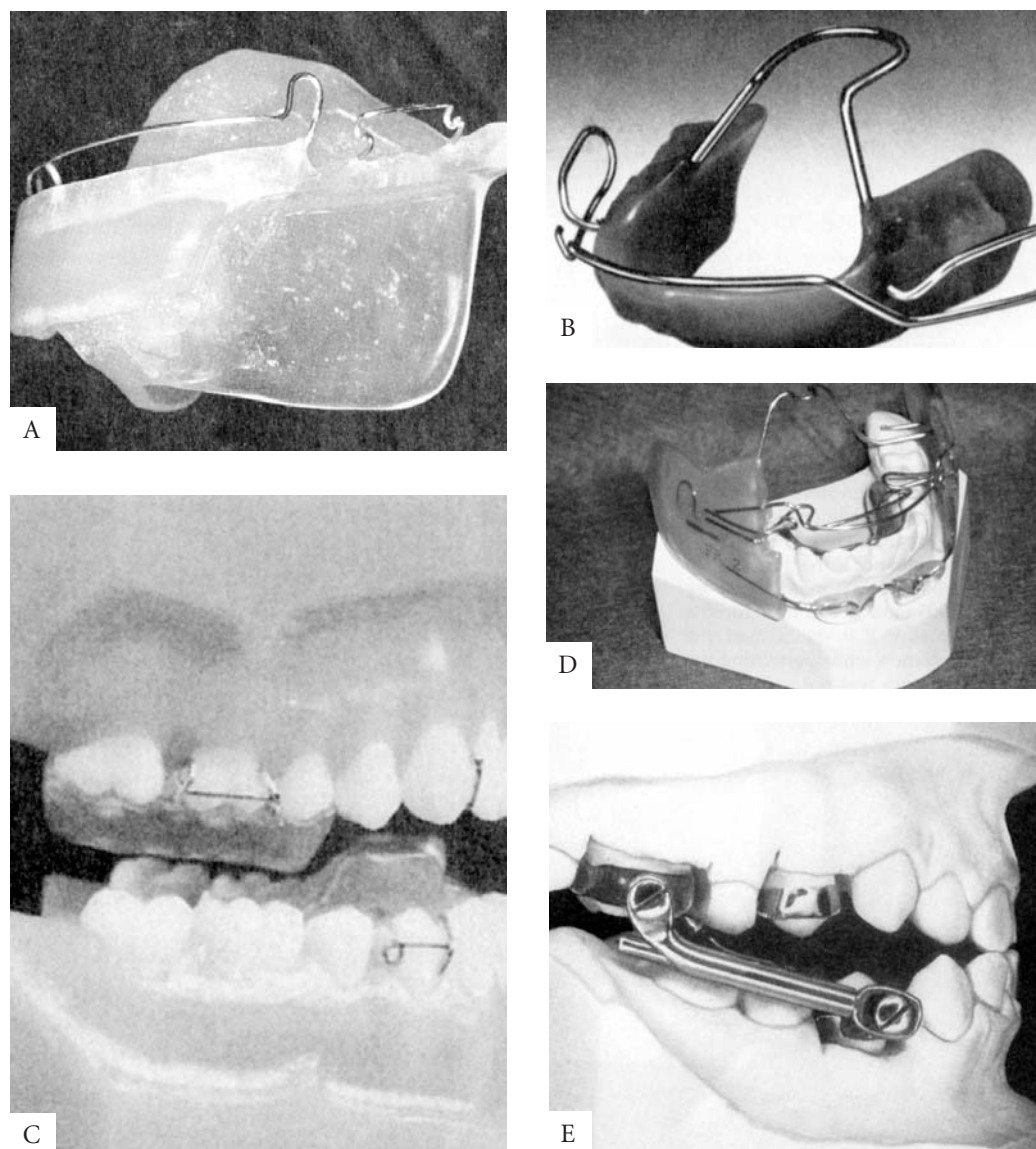


FIGURE 53-23 Class II functional appliances. All of these appliances position the mandible downward and forward, distracting the condyles from the glenoid fossae. This simultaneously creates posterior and superior forces to the maxilla from the facial muscles and soft tissues attempting to return the mandible to its normal position. A, Activator. B, Bionator. C, Twin block. D, Fränkel. E, Fixed Herbst. An alternative is to utilize occlusal acrylic and bond the maxillary portion of the appliance with a removable acrylic splint for the mandibular arch. A, C, and D reproduced with permission from Bishara SE. *Textbook of orthodontics*. Philadelphia (PA): W.B. Saunders; 2001. p. 345. B reproduced with permission from Graber TM, Vanarsdall RL. *Orthodontics: current principles and techniques*, 3rd ed. St. Louis (MO): Mosby; 2000. p. 488. E reproduced with permission from McNamara JA, Brudon WL. *Orthodontics and dentofacial orthopedics*. Ann Arbor (MI): Needham Press, Inc.; 2001. p. 287.

are worn full-time) for a significant treatment effect. Much like the headgear, dependable wear is more realistic during the evening and at night when the most active facial growth and dental eruption usually occur. However, like the headgear, its removable nature prevents it from being

reliably worn by most adolescents after the peak of their pubertal growth spurt.

In the late 1960s, when European and American facial orthopedic philosophies were becoming more fully integrated, a method was introduced in Europe using a headgear in combination with a function-

al appliance (Figure 53-24).^{204,224–227} This approach was intended to provide greater cumulative skeletal growth effects than use of either appliance alone, but this has yet to be demonstrated by clinical studies.

Although there is greater general acceptance that treatment with a headgear or functional appliance may achieve an improved long-term treatment outcome, there continues to be controversy over the optimum treatment time in the growing child. It has already been demonstrated that orthopedic Class II treatment in the very young child, in the primary or early mixed dentition, results in substantial relapse and recurrence of the original facial skeletal pattern by late adolescence.²²⁸ However, there is great debate regarding the efficacy of orthopedic treatment during later mixed dentition as the first phase of a two-phase treatment versus delaying orthopedic treatment until definitive orthodontic treatment during puberty, after the eruption of the permanent dentition. Many orthodontists historically have preferred the earlier first phase since there is substantial potential growth remaining, compliance in wearing the orthopedic appliance often is greater, and the arch space for the remaining erupting dentition may be improved. The advocates for a delayed one-phase treatment have contended that comparable skeletal treatment effects can be achieved during definitive orthodontic treatment, without putting the patient through an unnecessary initial phase.^{229,230} Recent prospective randomized clinical trials have supported this position, demonstrating that early skeletal improvement achieved from these appliances seems to represent accelerated growth and can be used just as effectively later during pubertal growth.^{149–151} They also showed that there was substantial individual growth variability with no reliable predictors for a favorable growth response identified, and early treatment did not reduce the need for dental extraction or orthognathic

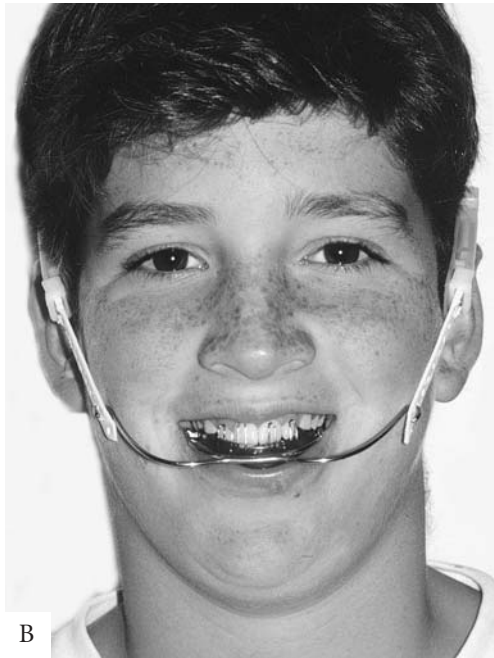
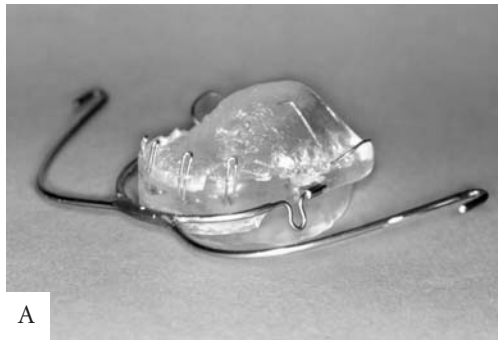

FIGURE 53-24 *Combination headgear and removable functional appliance. The interocclusal acrylic permits the orthopedic force to be transmitted further anteriorly and superiorly through the center of the maxilla. A, Intraoral part of appliance with headgear tubes embedded in the interocclusal acrylic. B, Extraoral part of appliance. Reproduced with permission from Bishara SE. Textbook of orthodontics. Philadelphia (PA): W.B. Saunders; 2001. p. 341.*

surgery during the definitive phase. These studies indicate that there is no adequate additional benefit in treatment outcome to justify the greater burden to the patient, their parents, and the orthodontist, as represented by an early phase that precedes the definitive phase of orthodontic treatment.

It can be concluded from past retrospective and more recent prospective clinical trials that headgear treatment tends to have more of a maxillary restrictive effect whereas functional appliances have more of a mandibular enhancing effect. Either approach can be satisfactory and should be selected on the basis of patient acceptance of the appliance and dentoalveolar side effects (there is more maxillary dental retrusion with headgear and more mandibular protrusion with a functional appliance). It appears that orthopedic treatment during the mixed dentition can only be justified where there is increased trauma risk (due to excessive overjet), sufficient esthetic concern by the patient, or a precocious adolescent growth spurt that substantially precedes dental development. Treatment at an earlier age has been further justified by the argument that there is lack of reliable means of

predicting mandibular growth and that improved cooperation usually is present with the younger patient.²³¹

Although improvement in skeletal discrepancy is expected, the Class II correction usually is due to a combined response of both the dentoalveolar and skeletal segments. Both headgear and Class II functional appliance use can be effective in limiting downward and forward eruption of the maxillary molars. However, the functional appliance tends to promote upward and forward eruption of mandibular molars, which may complement the correction in deep overbite cases but is counterproductive in patients with a long face. Since Class II orthopedic appliances are toothborne, there may be some unwanted dentoalveolar change, including retraction of maxillary anterior teeth and protraction of mandibular anterior teeth. This compensatory change may be undesirable if the skeletal discrepancy ultimately requires orthognathic surgery for correction. With the advent of osseointegrated attachments there may be the future possibility of preventing unwanted dentoalveolar change by attaching a force system directly to these

attachments rather than using toothborne attachments.

Anteroposterior Orthopedic Treatment: Class III A Class III skeletal relationship can be the result of a retrusive and/or deficient maxilla, a large and/or prognathic mandible, or most often, a combination of these skeletal problems. The prevalence of this type of malocclusion is about 3 to 5% of the US population, with about 0.3% severe enough to be considered as handicapping.^{133,134} Since the late nineteenth century, when headgear was being used for Class II skeletal problems, the chin cup was the appliance used for orthopedic treatment of skeletal Class III problems (Figure 53-25). Theoretically an orthopedic force is transmitted to the mandibular condyles, compressing the condylar cartilage and limiting endochondral growth in order to decrease the ultimate length of the mandible.²³² Primate studies suggest that mandibular growth can be limited with heavy full-time forces directed against the condyles.²³³ Full-time wear is unrealistic with humans and most clinical studies have demonstrated that mandibular growth is not restrained, but rather vertically redirected from chin cup wear, resulting in decreased chin prominence at the expense of increased face height.^{234–238} Studies also have suggested that the long-term stability of these changes is poor.^{239,240} Treatment with a chin cup may be an acceptable option for an individual with mandibular excess associated with decreased facial height but is contraindicated where there is a normal or excessive facial height, since the treatment outcome simply would be trading one deformity for another.

Class III functional appliances also have been developed, limiting eruption of mandibular posterior teeth and promoting eruption of maxillary posterior teeth. These functional appliances have few advocates due to their effectiveness being limited to dentoalveolar changes and their inability to promote forward maxillary growth or attenuate mandibular growth.²⁴¹

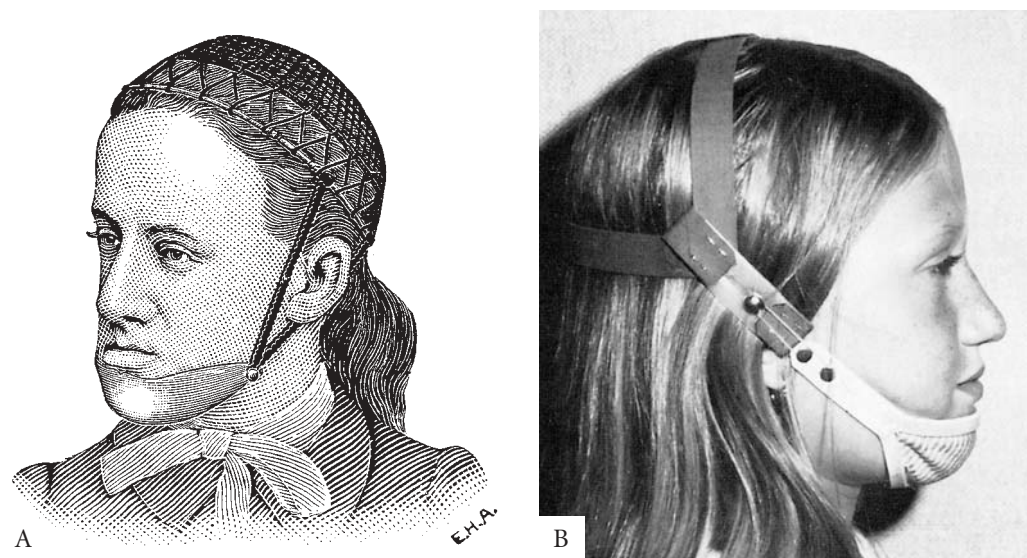


FIGURE 53-25 Class III chin cup appliance. A retractive orthopedic force is directed against the chin posteriorly and superiorly toward the condylar heads. A, Chin cup from the late nineteenth century. Reproduced from Angle EH. *Treatment of malocclusion of the teeth*. Philadelphia (PA): S.S. White Dental Manufacturing Co; 1907. p. 194. B, Contemporary chin cup, with minimal change in design, but fabricated with more comfortable and durable materials. Reproduced with permission from Profit WR, Fields HW. *Contemporary orthodontics*. 3rd ed. St. Louis (MO): Mosby; 2000. p. 271.

Jean Delaire, a French dentist, was responsible for developing the protraction headgear or facemask, the most effective orthopedic appliance for skeletal Class III problems since its introduction in the early 1970s (Figure 53-26).²⁴² Delaire recognized that the offending jaw in many of the skeletal Class III problems was the maxilla, so he departed from the historic focus on the mandible and directed treatment at the retrusive or deficient maxilla. The appliance creates tension in the circum-maxillary sutures with elastics from the maxillary dental arch to a frame that uses the forehead and chin to dissipate the force anteriorly. Primate studies have demonstrated adaptive responses of the sutures to the stress from the distraction forces produced by this appliance.¹³⁷

Depending on the developmental stage and size of the patient, a protractive force ranging from 2 to 4 pounds is applied to the facemask in an anterior and slightly inferior direction relative to the occlusal plane for 12 to 16 hours per day, usually for 6 to 9 months. Clinical studies have demonstrated clinically relevant

maxillary skeletal protraction downward and forward on average with this appliance, with some concomitant protraction of the maxillary teeth due to the tooth-borne nature of the intraoral part of the appliance.^{243–246} However, as with other forms of craniofacial orthopedic treatment, there is substantial variability and an unpredictable patient response to the appliance, ranging from no appreciable skeletal change to about 5 mm anterior maxillary movement.²⁴⁷ It is important to achieve overcorrection of the anterior crossbite and anterior overbite since there is some relapse following discontinuation of treatment.²⁴⁸ Additional effects of maxillary orthopedic protraction often include rotation of the maxilla downward in the posterior and upward in the anterior, downward and backward rotation of the mandible, and retraction of the mandibular incisors due to the reactive posterior force dissipated on the chin. These additional orthopedic and dentoalveolar changes that accompany maxillary skeletal protraction would be contraindicated for a Class III pattern with excessive vertical

development or where mandibular excess is the underlying cause of the problem.²⁴⁹

The timing of facemask therapy usually is recommended for patients in the primary to early mixed dentition (ie, ages 4 to 8), due to the increased patency of the maxillary sutures and compliance with appliance wear at this age.^{250,251} As the patient ages there is more interdigitation and ossification of the sutures, resulting in less skeletal and more dental response to the protraction forces. Nevertheless most clinical studies have found few differences between early and late treatment up until puberty.^{251–254}

The stability of maxillary orthopedic protraction with a facemask is variable and dependent on favorable facial growth following active treatment. However, it is common for the original facial growth pattern to resume after treatment, often resulting in relapse of the skeletal discrepancy. The best overall success rate at the end of adolescent growth cannot be expected to be more than 50%.²⁵⁵ One should expect that about 20% of these patients will ultimately require orthognathic surgery to fully correct the Class III malocclusion.²⁴⁸ The patients who relapse usually have mandibular growth during late adolescence that overwhelms the earlier correction. Long-term efficacy of facemask treatment has not been fully studied.

Class III orthopedic appliances, as with Class II devices, result in dentoalveolar movements that accompany the skeletal changes. Treatment with the facemask causes protraction of maxillary anterior teeth and retraction of mandibular anterior teeth. The development of osseointegrated attachments may make it possible to transmit the orthopedic protraction force to intraoral skeletal attachments that prevent undesirable dentoalveolar changes.²⁵⁶

Vertical Orthopedic Treatment Vertical maxillary excess presents with a maxilla that is inferiorly positioned, resulting in excessive vertical display of maxillary

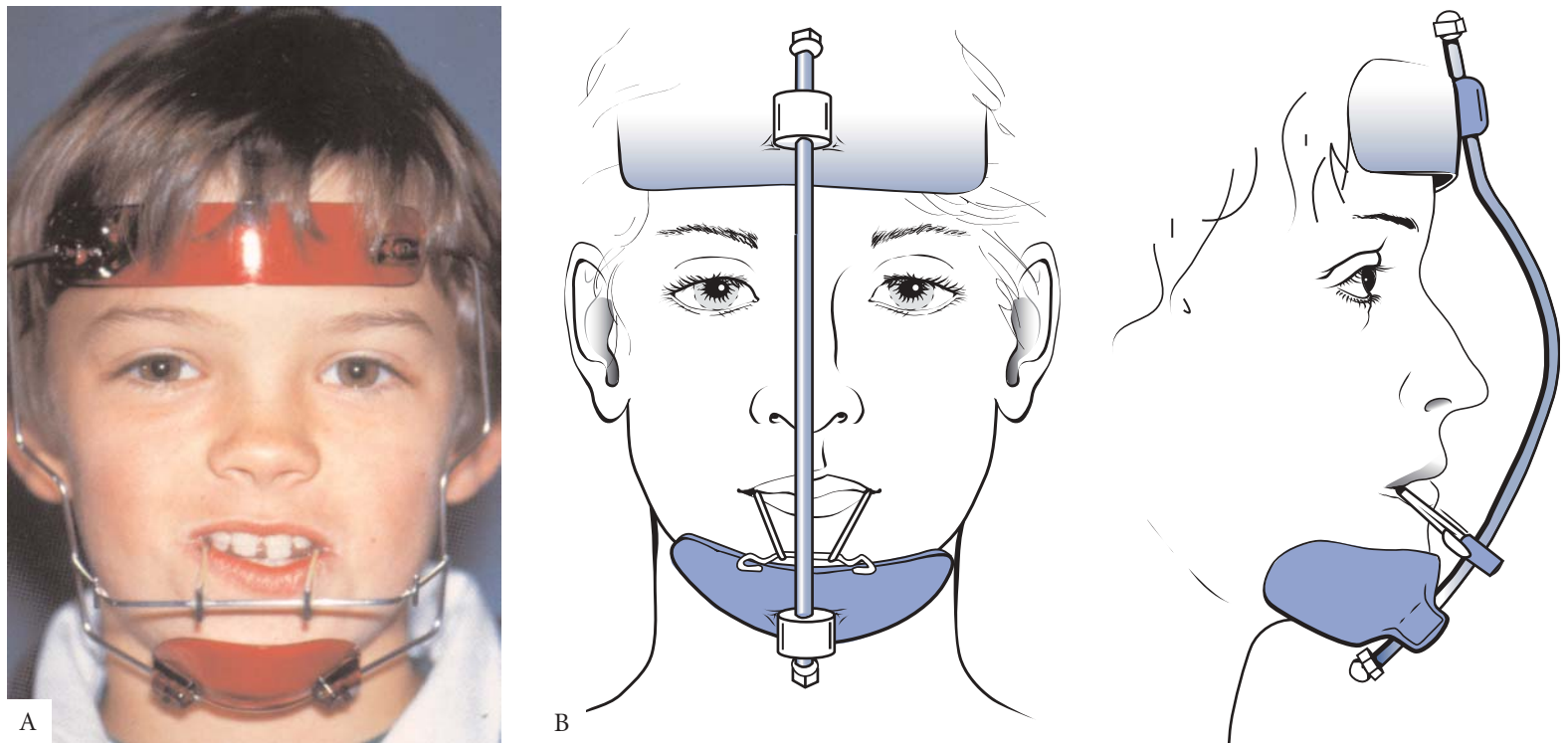


FIGURE 53-26 Class III protraction headgear or facemask. A protractive orthopedic force is directed downward and forward, with the force being dissipated on the forehead and chin, distracting the circum-maxillary sutures to augment anterior maxillary growth. A, Delaire design. Reproduced with permission from Proffit WR, Fields HW. *Contemporary orthodontics*. 3rd ed. St. Louis (MO): Mosby; 2000. p. 516. B, Petit design (frontal and lateral views). Adapted from McNamara JA, Brudon WL. *Orthodontics and dentofacial orthopedics*. Ann Arbor (MI): Needham Press, Inc.; 2001. p. 378.

incisors relative to the upper lip, and downward and backward rotation of the mandible, resulting in an increased mandibular plane angle and lower face height. The prevalence of vertical facial problems is less than 5% of the US population with about 0.3% considered as handicapping.^{133,134}

The orthodontist presently does not have very effective nonsurgical options to manage vertical skeletal problems. Orthopedic treatment strategy is directed at restraining vertical maxillary growth and posterior dental eruption in order to promote anterior and superior mandibular rotation. A high-pull headgear is used to apply a superior intrusive force of 2 to 4 pounds to inhibit eruption of maxillary posterior teeth and compress circum-maxillary sutures to limit the downward development of the maxilla. With exceptional daily (14 to 16 hours) and long-term (throughout adolescent growth)

wear, mandibular growth may be redirected in a more anterior than downward direction, improving a Class II skeletal discrepancy with vertical maxillary excess. However, this is counterproductive when treating vertical maxillary excess with a normal or prognathic mandible, since any decrease in vertical maxillary development would promote anterior mandibular rotation, thereby aggravating the Class III malocclusion. An alternative to the use of high-pull headgear is a removable orthopedic appliance that incorporates interocclusal acrylic bite blocks in order to stretch the facial musculature and soft tissue beyond the normal resting vertical dimension, creating a reactive intrusive force against the mandibular as well as maxillary teeth.^{257,258} As with the high-pull headgear option, exceptional daily and long-term wear is necessary to obtain any appreciable benefit. Repelling magnets have been embedded in the opposing

acrylic bite blocks to accentuate the intrusive force.²⁵⁹⁻²⁶¹ Most of the treatment benefit from this method appears to be limitation of posterior vertical dentoalveolar development rather than any appreciable skeletal effect.²⁶¹⁻²⁶³

A significant treatment effect by either the headgear or interocclusal bite block is rare since it is dependent on the patient wearing the appliance at least 14 to 16 hours per day over a number of years. In fact significant clinical benefit from the use of interocclusal acrylic alone may require closer to 16 to 24 hours per day. As with the Class II orthopedic methods these two methods have been combined into one appliance with the hope that this approach may provide greater cumulative skeletal growth effects than use of either appliance alone.²⁶⁴ In combination with the interocclusal bite block the force transmitted by the headgear can be distributed over all of the teeth

contacting the acrylic, and the force vector can be directed further forward and more vertically, closer to the maxillary center of resistance (see Figure 53-24).

Use of either or both of these orthopedic appliances to treat vertical maxillary excess is particularly challenging since it is impossible to direct the force in a straight vertical manner. Both methods include some posteriorly directed force to the maxilla that is not appropriate unless the maxilla is protrusive as well as inferiorly positioned. It also is counterproductive in a patient with maxillary vertical excess combined with a Class III skeletal relationship. Just as the protraction headgear should not be used with this individual to address the anteroposterior skeletal problem, the high-pull headgear and/or interocclusal bite block are contraindicated in this same clinical situation to address the vertical excess.

No studies to date have been able to demonstrate long-term stability with any nonsurgical orthopedic methods for correcting vertical maxillary excess, with or without an anterior open bite.²⁶⁵ Achieving stability is particularly difficult due to the extended duration of vertical facial growth, often continuing well beyond adolescence.⁴⁰ For a successful outcome orthopedic treatment may have to be extended over a number of years, from the time of the mixed dentition through definitive orthodontic treatment in the permanent dentition, perhaps including a removable orthopedic appliance even during orthodontic retention. This extended treatment makes the vertical plane of space the most difficult to successfully manage by the orthodontist attempting facial growth modification. Osseointegrated attachments hold promise as a means of anchorage to potentially permit more effective treatment of skeletal vertical problems in the future.²⁶⁶

Conclusion Facial orthopedic treatment may be effective in resolving mild to mod-

erate skeletal discrepancies in some patients. An orthopedic phase should be attempted with a specific treatment time frame established in order to assess treatment progress toward successful correction. This time frame must be honored in order to prevent protracted treatment with excessive dental compensations that need to be reversed for surgical correction. The orthodontist attempting growth modification must be mindful of the duration and extent of treatment to prevent excessive length and morbidity of the orthodontic treatment. If significant skeletal improvement is not being achieved within 6 to 8 months of starting orthopedic treatment, the case needs to be reevaluated and the growth modification treatment likely abandoned as a treatment choice.

It has become clear that there is great variability in individual treatment response, even when factoring out wear compliance and duration of treatment. It has not been possible to identify the variables to explain why some patients respond well and some do not demonstrate any significant skeletal improvement with treatment regardless of their facial morphology or the severity of their skeletal discrepancy. It is anticipated that future research will reveal the variables that will enable the clinician to predict treatment response.

It also is expected that research will provide a greater understanding of the nature and extent of facial growth modification possible in individual patients as well as the type of appliance and timing of treatment to achieve the best outcome. The development of intraoral osseointegrated attachments holds promise for a future means of dissipating orthopedic forces to prevent unwanted dentoalveolar changes that presently occur with our toothborne appliances. Analogous attachments are presently undergoing clinical testing for surgically assisted orthopedic movements associated with distraction osteogenesis.^{267,268} Recent and future advances in developmental biology and genomics hold

great promise in increasing our understanding of the molecular and genetic mediators of craniofacial growth.¹³² This understanding will be crucial for us to make constructive modifications of our treatment methods to target these mediators in order to prevent or correct a craniofacial anomaly or developmental deformity.

Orthodontic Camouflage: Orthopedic Consequence versus Surgical Preparation

Orthodontic camouflage, rather than orthognathic surgery, may indeed be an appropriate treatment choice for some mild and moderate skeletal malocclusions in patients who are beyond the pubertal growth spurt. The treatment goal, however, must include a realistic outcome characterized by an acceptable dental and facial esthetic appearance with favorable dental function and occlusion. Since esthetic appearance is subjective in nature, it is essential to have the patient and parent perceptions dictate whether camouflage is a reasonable option.

Most mild and some moderate skeletal Class II malocclusions can be effectively camouflaged with extraction of two maxillary premolars and retraction of maxillary anterior teeth, leaving the posterior teeth in a Class II occlusion. However, these cases should mainly be limited to those that present without significant dental crowding, some protrusion of the maxillary incisors, and where there is not significant maxillary gingival display on smiling. If the maxillary incisors are normally or palatally inclined prior to treatment, orthodontic retraction of these teeth may result in an even poorer esthetic result than the original problem even if the occlusion is acceptable. The unesthetic appearance includes not just the incisor inclination but often an unattractive retrusive upper lip and increased gingival exposure during smiling as well. This is why the recent introduction of palatal implants as orthodontic anchorage, which

provide the opportunity for the orthodontist to retract maxillary incisors even further than was previously possible, is a mixed blessing.

It is more challenging to camouflage Class III than Class II skeletal malocclusions since considerable natural dentoalveolar camouflage (proclined maxillary incisors, lingually inclined mandibular incisors) is often already present prior to treatment. Additional maxillary incisor proclination may be unesthetic, and further lingual inclination of mandibular incisors usually accentuates an already prominent chin. For this reason extraction of mandibular premolars to permit more retraction of mandibular incisors to obtain positive overjet often compromises the esthetic outcome. If interarch tooth size compatibility can be maintained, extraction of one mandibular incisor rather than two premolars may provide an acceptable compromise.

Camouflage of an anterior open bite that is due to maxillary vertical excess has been notoriously unsuccessful in the past. Recently an orthodontic technique for stably extruding anterior teeth has been introduced.²⁶⁹ Unfortunately this only exacerbates the excessive vertical display of maxillary gingiva and anterior teeth.

Summary

The surgeon's understanding of craniofacial growth has an important impact on clinical treatment decisions to alter craniofacial morphology. This understanding is relevant to the appreciation of the role of orthopedic treatment in the prepubertal and pubertal patient to limit or preclude the need for corrective surgery at a later age. Clinically relevant modification of craniofacial growth is possible, but substantial advances will be necessary to elucidate how growth modification can be accomplished in a controlled and predictable manner to achieve an efficacious outcome. Optimal timing and stability of craniofacial surgery are dependent on a thorough appreciation of the sequence, timing, magnitude, and

differential expression of craniofacial growth. The recent dramatic advances in developmental genetics and molecular biology, highlighted by complete mapping of the human genome, usher in a new millennium that promises to bring an explosive increase to our understanding of the complex interactions of the genetic and environmental influences that determine human craniofacial morphogenesis, prenatal development, and postnatal growth. A thorough understanding of these genomic and epigenetic factors will be necessary to determine the best timing and method of clinical intervention to achieve the optimum treatment outcome.

References

- Kontges G, Lumsden A. Rhombencephalic neural crest segmentation is preserved throughout craniofacial ontogeny. *Development* 1996;122:3229–42.
- Bronner-Fraser M, Fraser SE. Application of new technologies to studies of neural crest migration and differentiation. *Am J Med Genet Suppl* 1988;4:23–39.
- Smith I, Thorogood P. Transfilter studies on the mechanism of epithelio-mesenchymal interaction leading to chondrogenic differentiation of neural crest cells. *J Embryol Exp Morphol* 1983;75:165.
- Krumlauf R, Marshall H, Studer M, et al. Hox homeobox genes and regionalisation of the nervous system. *J Neurobiol* 1993;24:1328–40.
- Young DL, Schneider RA, Hu D, Helms JA. Genetic and teratogenic approaches to craniofacial development. *Crit Rev Oral Biol Med* 2000;11:304–17.
- Warbrick JG. The early development of the nasal cavity and upper lip in the human embryo. *J Anat (Lond)* 1960;94:351–62.
- Hu D, Helms JA. The role of sonic hedgehog in normal and abnormal craniofacial morphogenesis. *Development* 1999;126:4873–84.
- Fujino M, Osumi N, Ninomiya Y, et al. Disappearance of epidermal growth factor receptor is essential in the fusion of the nasal epithelium. *Anat Sci Int* 2003;78:25–35.
- Kjaer I. Human prenatal craniofacial development related to brain development under normal and pathologic conditions. *Acta Odontol Scand* 1995;53:135–43.
- Brunet CL, Sharpe PM, Ferguson MW. Inhibition of TGF-beta 3 (but not TGF-beta 1 or TGF-beta 2) activity prevents normal mouse embryonic palate fusion. *Int J Dev Biol* 1995;39:345–55.
- Cameron N. Human growth and development. London: Academic Press, Elsevier Science; 2002. p. 6–7, 85.
- Haupt MI. Growth of the craniofacial complex of the human fetus. *Am J Orthod* 1970;58:373–83.
- Opperman LA, Passarelli RW, Morgan EP, et al. Cranial sutures require tissue interactions with dura mater to resist osseous obliteration in vitro. *J Bone Miner Res* 1995;10:1978–87.
- Roth DA, Gold LI, Han VK, et al. Immunolocalization of transforming growth factor beta 1, beta 2, and beta 3 and insulin-like growth factor 1 in premature cranial suture fusion (see comments). *Plast Reconstr Surg* 1997;99:300–9; discussion 310–6.
- Kim HJ, Rice DP, Kettunen PJ, Thesleff I. FGF-, BMP- and Shh-mediated signaling pathways in the regulation of cranial suture morphogenesis and calvarial bone development. *Development* 1998;125:1241–51.
- Nah H. Suture biology: lessons from molecular genetics of craniosynostosis syndromes. *Clin Orthod Res* 2000;3:37–45.
- Plavcan JM, German RZ. Quantitative evaluation of craniofacial growth in the third trimester human. *Cleft Palate Craniofac J* 1995;32:394–404.
- Rønning O. Basicranial synchondroses and the mandibular condyle in craniofacial growth. *Acta Odontol Scand* 1995;53:162–6.
- Bareggi R, Sandrucci MA, Baldini G, et al. Mandibular growth rates in human fetal development. *Arch Oral Biol* 1995;40:119–25.
- Bentley RP, Sgouros S, Natarajan K, et al. Normal changes in orbital volume during childhood. *J Neurosurg* 2002;96:742–6.
- Hunter WS, Baumrind S, Moyers RE. An inventory of United States and Canadian growth record sets: preliminary report. *Am J Orthod Dentofac Orthop* 1993;103:545–55.
- Copray JC, Jansen HW, Duterloo HS. Growth and growth pressure of mandibular condylar and some primary cartilages of the rat in vitro. *Am J Orthod Dentofac Orthop* 1986;90:19–28.
- Peltomaki T, Kylamarkula S, Vinkka-Puhakka H, et al. Tissue-separating capacity of growth cartilages. *Eur J Orthod* 1997;19:473–81.
- Wang X, Mao JJ. Chondrocyte proliferation of the cranial base cartilage upon in vivo mechanical stresses. *J Dent Res* 2002;81:701–5.
- Kiliaridis S. Masticatory muscle influence on craniofacial growth. *Acta Odontol Scand* 1995;53:196–202.

26. Sarnat BG. Normal and abnormal craniofacial growth. *Angle Orthod* 1983;53:263–89.
27. Rabie ABM, Hägg U. Factors regulating mandibular condylar growth. *Am J Orthod Dentofac Orthop* 2002;122:401–9.
28. Mamandras AH. Linear changes of the maxillary and mandibular lips. *Am J Orthod* 1988;94:405–10.
29. Nanda RS, Meng H, Kapila S, Goorhuis J. Growth changes of the soft tissue profile. *Angle Orthod* 1990;60:177–90.
30. Vig PS, Cohen AM. Vertical growth of the lips: a serial cephalometric study. *Am J Orthod* 1979;75:405–15.
31. Subtelny JD. A longitudinal study of soft tissue facial structures and their profile characteristics defined in relation to underlying skeletal structures. *Am J Orthod* 1959;45:481–507.
32. Chaconas SJ. A statistical evaluation of nasal growth. *Am J Orthod* 1969;56:403–14.
33. Scott JH. Growth of human face. *Proc R Soc Med* 1953;47:91–100.
34. Buschang PH, Baume RM, Nass GG. A craniofacial growth maturity gradient for males and females between 4 and 16 years of age. *Am J Phys Anthropol* 1983;61:373–81.
35. Ferrario VF, Sforza C, Poggio CE, Schmitz JH. Craniofacial growth: a three-dimensional soft-tissue study from 6 years to adulthood. *J Craniofac Genet Dev Biol* 1998;18:138–49.
36. Hrdlička A. Growth during adult life. *Proc Am Phil Soc* 1936;76:847–97.
37. Hooton EA, Dupertuis CW. Age changes and selective survival in Irish males. In: *American Association of Physical Anthropology. Studies in physical anthropology. No. 2.* New York (NY): Wenner-Gren Foundation; 1951. p. 1–130.
38. Israel H. Recent knowledge concerning craniofacial aging. *Angle Orthod* 1973;43:176–84.
39. Lewis AB, Roche AF. Late growth changes in the craniofacial skeleton. *Angle Orthod* 1988;58:127–35.
40. Behrents RG. Growth in the aging craniofacial skeleton. Craniofacial growth monograph series. Monograph 17. Ann Arbor: Center for Human Growth and Development, University of Michigan; 1985.
41. Bishara SE, Treder JE, Jakobsen JR. Facial and dental changes in adulthood. *Am J Orthod Dentofac Orthop* 1994;106:175–86.
42. Formby WA, Nanda RS, Currier GF. Longitudinal changes in the adult facial profile. *Am J Orthod Dentofac Orthop* 1994;105:464–76.
43. West KS, McNamara JA. Changes in the craniofacial complex from adolescence to midadulthood: a cephalometric study. *Am J Orthod Dentofac Orthop* 1999;115:521–32.
44. Akgül AA, Toygar TU. Natural craniofacial changes in the third decade of life: a longitudinal study. *Am J Orthod Dentofac Orthop* 2002;122:512–22.
45. Dickens ST, Sarver DM, Proffit WR. Changes in frontal soft tissue dimensions of the lower face by age and gender. *World J Orthod* 2003;3:313–20.
46. Fanouns N. Aging lips: esthetic analysis and correction. *Facial Plast Surg* 1987;4:179–83.
47. Spranger J, Benirschke K, Hall JG, et al. Errors of morphogenesis: concepts and terms. Recommendations of an international working group. *J Pediatr* 1982;100:160–5.
48. Wilson GN. Genomics of human dysmorphogenesis. *Am J Med Genet* 1992;42:187–96.
49. Jabs EW, Muller U, Li X, et al. A mutation in the homeodomain of the human MSX2 gene in a family affected with autosomal dominant craniosynostosis. 1993;75:443–50.
50. Bellus GA, Gaudenz K, Zackai EH, et al. Identical mutations in three different fibroblast growth factor receptor genes in autosomal dominant craniosynostosis syndromes. *Nat Genet* 1996;14:174–6.
51. Mooney MP, Siegel MI. Understanding craniofacial anomalies: the etiopathogenesis of craniosynostoses and facial clefting. New York (NY): Wiley-Liss, Inc.; 2002.
52. Johnston MC, Bronsky PT. Abnormal craniofacial development: an overview. *Crit Rev Oral Biol Med* 1995;6:368–422.
53. Jones KL. Smith's recognizable patterns of human malformation. Philadelphia (PA): W.B. Saunders; 1988.
54. Shepard TH. Catalog of teratogenic agents. Baltimore (MD): Johns Hopkins University Press; 1995.
55. Gorlin RJ, Cohen MM, Levin LS. Syndromes of the head and neck. New York (NY): Oxford University Press; 1990.
56. Edwards LE, Alton IR, Barrada MI, Hakansen EY. Pregnancy in the underweight woman: course, outcome, and growth patterns of the infant. *Am J Obstet Gynecol* 1979;135:297–302.
57. Abel EL. Consumption of alcohol during pregnancy: a review of effects on growth and development of offspring. *Hum Biol* 1982;54:421–53.
58. Zuckerman B, Frank DA, Hingson R, et al. Effects of maternal marijuana and cocaine use on fetal growth. *N Engl J Med* 1989;320:762–8.
59. Haste FM, Anderson HR, Brooke O, et al. The effects of smoking and drinking on the anthropometric measurements of neonates. *Paediatr Perinatal Epidemiol* 1991;5:83–92.
60. Misra DP, Nguyen RH. Environmental tobacco smoke and low birth weight: a hazard in the workplace. *Environ Health Perspect* 1999;107:897–904.
61. Ando Y, Hattori H. Statistical studies on the effects of intense noise during human fetal life. *J Sound Vibr* 1973;27:101–10.
62. Lejarraga H, Peckham C. Birth weight and subsequent growth of children exposed to congenital rubella in utero. *Arch Dis Child* 1974;49:50–8.
63. Higginbottom MC, Jones KL, James HE. Intrauterine constraint and craniosynostosis. *Neurosurgery* 1980;6:39–44.
64. Gluckman PD. Fetal hypothalamic-pituitary relationships: a review with particular reference to experimental studies of the somatotrophic axis. In: Sizonenko PC, Aubert ML, editors. *Developmental endocrinology. Serono Symposia Publications. Vol 67.* New York (NY): Raven Press; 1990.
65. Abdul-Karim RW, Marshall CD. Influence of maternal oophorectomy on the collagen and calcium contents of fetal bone. *Obstet Gynecol* 1969;34:837–40.
66. Abdul-Karim RW, Nesbitt REL Jr, Drucker MH, Rizk PT. The regulatory effect of estrogens on fetal growth. I. Placental and fetal body weights. *Am J Obstet Gynecol* 1971;109:656–61.
67. de Zegher F, Pernasetti F, Vanhole C, et al. The prenatal role of thyroid hormone evidenced by fetomaternal Pit-1 deficiency. *J Clin Endocrinol Metab* 1995;80:3127–30.
68. Warshaw JB. Intrauterine growth restriction revisited. *Growth Genet Horm* 1992;8:5–8.
69. D'Ercole AJ, Applewhite GT, Underwood LE. Evidence that somatomedins are synthesized by multiple tissues in the fetus. *Dev Biol* 1980;75:315–28.
70. Hindmarsh PC. Endocrinology of growth. In: Cameron N, editor. *Human growth and development.* London: Academic Press, Elsevier Science; 2002. p. 85–101.
71. Evain-Brion D. Hormonal regulation of fetal growth. *Horm Res* 1994;42:207–14.
72. Rotwein P. Peptide growth factors other than insulin-like growth factors or cytokines. In: Degroot LJ, Jameson JL, editors. *Endocrinology.* 4th ed. Philadelphia (PA): W.B. Saunders; 2001. p. 461–76.
73. Siler-Khodr TM. Endocrine and paracrine function of the human placenta. In: Polin RA, Fox WW, editors. *Fetal and neonatal physiology.* 2nd ed. Philadelphia (PA): W.B. Saunders; 1998. p. 89–102.
74. Hall K, Enberg G, Hellem E, et al. Somatomedin levels in pregnancy: longitudinal study in healthy subjects and patients with growth hormone deficiency. *J Clin Endocrinol Metab* 1984;59:587–94.

75. Li Y, Behringer RR. Esx1 is an X chromosome-imprinted regulator of placental development and fetal growth. *Nature Genet* 1998;20:309–11.
76. Towne B, Demerath EW, Czerwinski SA. The genetic epidemiology of growth and development. In: Cameron N, editor. *Human growth and development*. London: Academic Press, Elsevier Science; 2002. p. 103–37.
77. Litton SF, Ackermann LV, Isaacson RJ, Shapiro BL. A genetic study of class III malocclusion. *Am J Orthod* 1970;58:565–77.
78. El-Gheriani AA, Maher BS, El-Gheriani AS, et al. Segregation analysis of mandibular prognathism in Libya. *J Dent Res* 2003;82:523–7.
79. Proffit WR. The development of dentofacial deformity: influences and etiologic factors. In: Proffit WR, White RP, Sarver DM, editors. *Contemporary treatment of dentofacial deformity*. St. Louis (MO): Mosby; 2003. p. 58.
80. Proffit WR. Equilibrium theory revisited. *Angle Orthod* 1978;48:175–86.
81. Buchman SR, Bartlett SP, Wornom IL III, Whitaker LA. The role of pressure on regulation of craniofacial bone growth. *J Craniofac Surg* 1994;5:2–10.
82. Schumacher GH. Factors influencing craniofacial growth. In: *Normal and abnormal bone growth: basic and clinical research*. Alan R. Liss, Inc.; 1985. p. 3–22.
83. Kean MR, Houghton P. The role of function in the development of human craniofacial form: a perspective. *Anat Rec* 1987;218:107–10.
84. Poikela A, Kantomaa T, Pirttiniemi P. Craniofacial growth after a period of unilateral masticatory function in young rabbits. *Eur J Oral Sci* 1997;105:331–7.
85. Bouvier M, Hylander WL. The effect of dietary consistency on gross and histologic morphology in the craniofacial region of young rats. *Am J Anat* 1984;170:117–26.
86. Luca L, Roberto D, Francesca SM, Francesca P. Consistency of diet and its effects on mandibular morphogenesis in the young rat. *Prog Orthod* 2003;4:3–7.
87. Gionhaku N, Lowe AA. Relationship between jaw muscle volume and craniofacial form. *J Dent Res* 1989;68:805–9.
88. Ingervall B, Thilander B. Relation between facial morphology and activity of the masticatory muscles. *J Oral Rehab* 1974;1:131–47.
89. Weijs WA, Hillen B. Relationships between masticatory muscle cross-section and skull shape. *J Dent Res* 1984;63:1154–7.
90. van Spronsen PH, Weijs WA, Valk J, et al. A comparison of jaw muscle cross-sections of long-face and normal adults. *J Dent Res* 1992;71:1279–85.
91. Gardner DE, Luschei ES, Joondeph DR. Alterations in the facial skeleton of the guinea pig following a lesion of the trigeminal motor nucleus. *Am J Orthod* 1980;78:66–80.
92. Wolf G, Koskinen-Moffett L, Kokich V. Migration of craniofacial periosteum in guinea-pigs with unilateral masticatory muscle paralysis. *J Anat* 1985;140:259–68.
93. Hirabayashi S, Harii K, Sakuri A, et al. An experimental study of craniofacial growth in a heterotopic rat head transplant. *Plast Reconstr Surg* 1988;82:236–43.
94. Sakurai A, Hirabayashi S, Harii K, Fukuda O. Experimental studies on complete global brain ischemia using the isohistogenic infantile head transplant model in Lewis rats. *J Reconst Microsurg* 1989;5:145–50.
95. Proffit WR, Fields HW. Occlusal forces in normal and long face children. *J Dent Res* 1983;62:571–4.
96. Vig KW. Nasal obstruction and facial growth: the strength of evidence for clinical assumptions. *Am J Orthod Dentofac Orthop* 1998;113:603–11.
97. Ross RB. The clinical implications of facial growth in cleft lip and palate. *Cleft Palate J* 1970;7:37–47.
98. Moyers RA, McNamara JA. Factors affecting growth of the midface. In: McNamara JA Jr, editor. *Craniofacial growth monograph series*. Monograph 6. Ann Arbor: Center for Human Growth and Development, University of Michigan; 1976. p. 43–59; 169–204; 239–49.
99. Katsaros J, David DJ, Griffin PA, Moore MH. Facial dysmorphology in the neglected paediatric head and neck burn. *Br J Plast Surg* 1990;43:232–5.
100. Laurenzo JE, Canady JW, Zimmerman MB, Smith RJ. Craniofacial growth in rabbits. Effects of midfacial surgical trauma and rigid plate fixation. *Arch Otolaryngol Head Neck Surg* 1995;121:556–61.
101. Proffit WR, White RP, Sarver DM. *Contemporary treatment of dentofacial deformity*. St. Louis (MO): Mosby; 2003. p. 43–51, 587–96.
102. Ohlsson C, Isaksson O, Lindahl A. Clonal analysis of rat tibia growth plate chondrocytes in suspension culture — differential effects of growth hormone and insulin-like growth factor I. *Growth Regul* 1994;4:1–7.
103. Berg MA, Argente J, Chernausk S, et al. Diverse growth hormone receptor gene mutations in Laron syndrome. *Am J Hum Genet* 1993;52:998–1005.
104. Schaefer GB, Rosenbloom AL, Guevara-Aguirre J, et al. Facial morphometry of Ecuadorian patients with growth hormone receptor deficiency. *J Med Genet* 1994;31:635–9.
105. Pirinen S. Endocrine regulation of craniofacial growth. *Acta Odontol Scand* 1995;53:179–85.
106. Barrett RL, Harris EF. Anabolic steroids and craniofacial growth in the rat. *Angle Orthod* 1993;63:289–98.
107. Petrovic A, Stutzmann J, Gasson N. La taille définitive de la mandibule est-elle, comme telle, prédéterminée génétiquement? *Orthod Fr* 1979;50:751–67.
108. Riesenfeld A. Endocrine and biomechanical control of craniofacial growth: an experimental study. *Hum Biol* 1974;46:531–72.
109. Rivkees SA, Danon M, Herrin J. Prednisone dose limitation of growth hormone treatment of steroid-induced growth failure. *J Pediatr* 1994;125:322–5.
110. Maor G, Silberman M. Studies of hormonal regulation of the growth of the craniofacial skeleton. IV. Specific binding sites for glucocorticoids in condylar cartilage and their involvement in the biological effects of glucocorticoids on cartilage cell growth. *J Craniofac Gen Devel Biol* 1986;6:189–202.
111. Teng C-M, Sobkowski J, Johnston L. The effect of cortisone on the eruption rate of root resected incisors in the rat. *Am J Orthod Dentofac Orthop* 1989;95:67–71.
112. Graham GC, Adrianzen T, Rabold J, Mellits ED. Later growth of malnourished children. *Am J Dis Child* 1982;136:348–52.
113. Soliman AT, Hassan AEHI, Aref MK, et al. Serum insulin-like growth factors I and II concentrations and growth hormone and insulin responses to arginine infusion in children with protein-energy malnutrition before and after nutritional rehabilitation. *Pediatr Res* 1986;20:1122–30.
114. Pucciarelli HM. The effects of race, sex, and nutrition on craniofacial differentiation in rats. A multivariate analysis. *Am J Phys Anthropol* 1980;53:359–68.
115. Pucciarelli HM. Growth of the functional components of the rat skull and its alteration by nutritional effects. A multivariate analysis. *Am J Phys Anthropol* 1981;56:33–41.
116. Engstrom C, Linde A, Thilander B. Craniofacial morphology and growth in the rat. Cephalometric analysis of the effects of a low calcium and vitamin D-deficient diet. *J Anat* 1982;134:299–314.
117. Baume LJ, Franquin J-C, Körner WW. The prenatal effect of maternal vitamin A deficiency on the cranial and dental development of the progeny. *Am J Orthod* 1972;62:447–60.
118. Howe AM, Webster WS. Vitamin K — its essential role in craniofacial development. A review of the literature regarding vitamin

- K and craniofacial development. *Aust Dent J* 1994;39:88–92.
119. Li KW. Dietary protein deficiency reduces serum growth hormone and skeletal growth. *J Dent Res* 1995;74:254.
 120. Miller JP, German RZ. Protein malnutrition affects the growth trajectories of the craniofacial skeleton in rats. *J Nutr* 1999;129:2061–9.
 121. Russell GFM. Premenarchal anorexia nervosa and its sequelae. *J Psychiatr Res* 1985; 19:363–9.
 122. Salzer HR, Haschke F, Wimmer M, et al. Growth and nutritional intake of infants with congenital heart disease. *Pediatr Cardiol* 1989;10:17–23.
 123. Cameron N. Human growth and development. London: Academic Press, Elsevier Science; 2002. p. 41.
 124. Berkowitz RJ, Neuman P, Spalding PM, et al. Developmental orofacial deficits associated with multimodal cancer therapy: case report. *Pediatr Dent* 1989;11:227–31.
 125. Cohen SR, Bartlett SP, Whitaker LA. Reconstruction of late craniofacial deformities after irradiation of the head and face during childhood. *Plast Reconstr Surg* 1990;86:229–37.
 126. Powell GF, Brasel JA, Blizzard RM. Emotional deprivation and growth retardation simulating idiopathic hypopituitarism. *N Engl J Med* 1967;276:1271–83.
 127. Bogin B. Patterns of human growth. Cambridge: Cambridge University Press; 1988.
 128. Frisancho AR. Human adaptation and accommodation. Ann Arbor: University of Michigan Press; 1993.
 129. Schell LM, Knutsen KL. Environmental effects on growth. In: Cameron N, editor. Human growth and development. London: Academic Press, Elsevier Science; 2002. p. 165–95.
 130. Schell LM, Norelli RJ. Airport noise exposure and the postnatal growth of children. *Am J Phys Anthropol* 1983;61:473–82.
 131. Mao JJ, Wang X, Kopher RA. Biomechanics of craniofacial sutures: orthopedic implications. *Angle Orthod* 2003;73:128–35.
 132. Carlson DS. Biological rationale for early treatment of dentofacial deformities. *Am J Orthod Dentofac Orthop* 2002;121:554–8.
 133. Brunelle JA, Bhat M, Lipton JA. Prevalence and distribution of selected occlusal characteristics in the US population, 1988–1991. *J Dent Res* 1996;75:706–13.
 134. Proffit WR. The development of dentofacial deformity: influences and etiologic factors. In: Proffit WR, White RP, Sarver DM, editor. Contemporary treatment of dentofacial deformity. St. Louis (MO): Mosby; 2003. p. 23–4.
 135. Haas AJ. Rapid expansion of the maxillary dental arch and nasal cavity by opening the mid-palatal suture. *Angle Orthod* 1961;31:73–90.
 136. Jafari A, Shetty S, Kumar M. Study of stress distribution and displacement of various craniofacial structures following application of transverse orthopedic forces: a three-dimensional FEM study. *Angle Orthod* 2003;73:12–20.
 137. Wagemans PAHM, van de Velde J-P, Kuijpers-Jagtman AM. Sutures and forces: a review. *Am J Orthod Dentofac Orthop* 1988;94:129–41.
 138. McNamara JA. Early intervention in the transverse dimension: is it worth the effort? *Am J Orthod Dentofac Orthop* 2002;121:572–4.
 139. Melsen B, Melsen F. The postnatal development of the palatomaxillary region studied on human autopsy material. *Am J Orthod* 1982;82:329–42.
 140. Baccetti T, Franchi L, Cameron CG, McNamara JA Jr. Treatment timing for rapid maxillary expansion. *Angle Orthod* 2001;71:343–50.
 141. Pirttiniemi P, Kantomaa T, Lahtela P. Relationship between craniofacial and condyle path asymmetry in unilateral cross-bite patients. *Eur J Orthod* 1990;12:408–13.
 142. Revelo B, Fishman LS. Maturational evaluation of ossification of the mid-palatal suture. *Am J Orthod Dentofac Orthop* 1994;105:288–92.
 143. Hicks EP. Slow maxillary expansion: a clinical study of the skeletal vs. dental response to low magnitude force. *Am J Orthod* 1978;73:121–41.
 144. Krebs AA. Expansion of mid palatal suture studied by means of metallic implants. *Acta Odontol Scand* 1959;17:491–501.
 145. Wertz RA. Skeletal and dental changes accompanying rapid midpalatal suture opening. *Am J Orthod* 1970;58:41–66.
 146. Krebs AA. Rapid expansion of mid palatal suture studied by fixed appliance. An implant study over a 7 year period. *Trans Eur Orthod Soc* 1964;141–2.
 147. Mommaerts MY. Transpalatal distraction as a method of maxillary expansion. *Br J Oral Maxillofac Surg* 1999;37:268–72.
 148. Vig PS, Vig KW. Hybrid appliances: a component approach to dentofacial orthopedics. *Am J Orthod* 1986;90:273–85.
 149. Keeling SD, Wheeler TT, King GJ, et al. Antero-posterior skeletal and dental changes after early class II treatment with bionators and headgear. *Am J Orthod Dentofac Orthop* 1998;113:40–50.
 150. Tulloch JFC, Philips C, Proffit WR. Benefit of early class II treatment: progress report of a two-phase randomized clinical trial. *Am J Orthod Dentofac Orthop* 1998;113:62–72.
 151. Ghafari J, Shofer FS, Jacobsson-Hunt U, et al. Headgear versus functional regulator in the early treatment of class II, division I malocclusion: a randomized clinical trial. *Am J Orthod Dentofac Orthop* 1998;113:51–61.
 152. Kloehn S. Guiding alveolar growth and eruption of the teeth to reduce treatment time and produce a more balanced denture and face. *Angle Orthod* 1947;17:10–33.
 153. Poulton DR. Change in class II malocclusions with and without occipital headgear therapy. *Angle Orthod* 1959;29:234–50.
 154. Ricketts RM. The influence of orthodontic treatment in facial growth and development. *Angle Orthod* 1960;30:103–33.
 155. Wieslander L. The effects of orthodontic treatment on the concurrent development of the craniofacial complex. *Am J Orthod* 1963; 49:15–27.
 156. Poulton DR. A three-year survey of class II malocclusions with and without headgear therapy. *Angle Orthod* 1964;34:181–93.
 157. Creekmore TD. Inhibition or stimulation of the vertical growth of facial complex, its significance to treatment. *Angle Orthod* 1967;37:285–97.
 158. Jakobsson SO. Cephalometric evaluation of treatment effect on class II, division I, malocclusions. *Am J Orthod* 1967;53:446–56.
 159. Ringenberg QM, Butts WC. A controlled cephalometric evaluation of single-arch cervical traction therapy. *Am J Orthod* 1970;57:179–85.
 160. Barton JJ. High-pull headgear vs. cervical traction: a cephalometric comparison. *Am J Orthod* 1972;62:517–29.
 161. Wieslander L. The effect of force on craniofacial development. *Am J Orthod* 1974;65:531–8.
 162. Cross JJ. Facial growth: before, during and following orthodontic treatment. *Am J Orthod* 1977;71:68–78.
 163. Melsen B. Effects of cervical anchorage during and after treatment: an implant study. *Am J Orthod* 1978;73:526–40.
 164. Baumrind S, Molthen R, West EE, et al. Mandibular plane changes during maxillary retraction. Part 1 and 2. *Am J Orthod* 1978;74:32–40, 603–20.
 165. Mills CM, Holman RG, Graber TM. Heavy intermittent cervical traction in class II treatment: a longitudinal cephalometric assessment. *Am J Orthod* 1978;74:361–79.
 166. Brown P. A cephalometric evaluation of high-pull molar headgear and facebow neck strap therapy. *Am J Orthod* 1978;74:621–32.
 167. Baumrind S, Molthen R, West EE, Miller DM. Distal displacement of the maxilla and upper first molar. *Am J Orthod* 1979;75:630–40.
 168. Baumrind S, Korn EL, Molthen R, West EE.

- Changes in facial dimensions associated with the use of forces to retract the maxilla. *Am J Orthod* 1981;80:17–30.
169. Howard RD. Skeletal changes with extraoral traction. *Eur J Orthod* 1982;4:197–202.
 170. Firouz M, Zernik J, Nanda R. Dental and orthopedic effects of high-pull headgear in treatment of class II, division 1 malocclusion. *Am J Orthod Dentofac Orthop* 1992;102:197–205.
 171. Sproule WR. Dentofacial changes produced by extraoral cervical traction to the maxilla of the *Macaca mulatta*: a histologic and serial cephalometric study. *Am J Orthod* 1969;56:532–3.
 172. Fredrick DL. Dentofacial changes produced by extraoral cervical traction to the maxilla of the *Macaca mulatta*: a histologic and serial cephalometric study [dissertation]. University of Washington; 1969.
 173. Droschl H. The effect of heavy orthopaedic forces on the maxilla of the growing Siamiri sciureus (squirrel monkey). *Am J Orthod* 1973;63:449–61.
 174. Thompson RW. Extraoral high-pull forces with rigid palatal expansion in the macaca mulatta. *Am J Orthod* 1974;66:302–17.
 175. Elder JR, Tuenge RH. Cephalometric and histologic changes produced by extra-oral high pull traction to the maxilla of *Macaca mulatta*. *Am J Orthod* 1974;66:599–617.
 176. Meldrum RJ. Alterations in the upper facial growth of *Macaca mulatta* resulting from high-pull headgear. *Am J Orthod* 1975; 67:393–411.
 177. Yamamoto J. Effects of extraoral forces in the dentofacial complex of the *Macaca irus*. *J Jpn Orthod* 1975;34:173–97.
 178. Triftshauser R, Walters RD. Cervical retraction of the maxilla in the *Macaca mulatta* monkey. *Angle Orthod* 1976;46:37–46.
 179. Brandt HC, Shapiro PA, Kokich VG. Experimental and postexperimental effects of posteriorly directed extraoral traction in adult *Macaca fascicularis*. *Am J Orthod* 1979;75:301–17.
 180. Dermaut LR, Aelbers CME. Orthopedics in orthodontics: fiction or reality: a review of the literature, Part II. *Am J Orthod Dentofac Orthop* 1996;110:667–71.
 181. Born J, Muth S, Fehm HL. The significance of sleep onset and slow wave sleep for nocturnal release of growth hormone (GH) and cortisol. *Psychoneuroendocrinology* 1988;13:233–43.
 182. Stevenson S, Hunziker EB, Hermann W, et al. Is longitudinal bone growth influenced by diurnal variation in the mitotic activity of chondrocytes of the growth plates? *J Orthop Res* 1990;8:132–5.
 183. Risinger RK, Proffit WR. Continuous overnight observation of human premolar eruption. *Arch Oral Biol* 1996;41:779–89.
 184. Carlson DS. Growth of the temporomandibular joint. In: Zarb GA, Carlsson GE, Sessle B, Mohl ND, editors. *Temporomandibular joint*. 2nd ed. Copenhagen: Munksgaard; 1994. p.128–58.
 185. Petrovic AG. Experimental and cybernetic approaches to the mechanism of action of functional appliances on mandibular growth. In: McNamara JA, Ribbens KA, editors. *Malocclusion and the periodontium*. Craniofacial growth monograph series. Monograph 15. Ann Arbor: Center for Human Growth and Development, University of Michigan; 1984. p. 213–68.
 186. McNamara JA, Bryan FA. Long-term mandibular adaptations to protrusive function in the rhesus monkey (*Macaca mulatta*). *Am J Orthod Dentofac Orthop* 1987; 92:98–108.
 187. Rabie ABM, She TT, Hägg U. Functional appliance therapy accelerates and enhances condylar growth. *Am J Orthod Dentofac Orthop* 2003;123:40–8.
 188. Marshchner JF, Harris JE. Mandibular growth and class II treatment. *Angle Orthod* 1966;36:89–93.
 189. Parkhouse RC. A cephalometric appraisal of cases of Angle's class II, division 1, malocclusion treated by the Andresen appliance. *Dent Pract Dent Rec* 1969;19:425–33.
 190. Woodside DG, Reed RT, Doucet JD, et al. Some effects of activator treatment on the growth rate of the mandible and position of the midface. In: Cook JT, editor. *Transactions of the Third International Orthodontic Congress*. St. Louis (MO): C.V. Mosby Co.; 1975. p. 459–80.
 191. Pancherz H. The effect of continuous bite-jumping on the dentofacial complex: a follow-up study after Herbst appliance treatment of class II malocclusion. *Eur J Orthod* 1981;3:49–60.
 192. Luder HU. Effects of activator treatment — evidence for the occurrence of two different types of reaction. *Eur J Orthod* 1981;3:205–22.
 193. Righellis EG. Treatment effects of Fränkel, activator and extraoral traction appliances. *Angle Orthod* 1983;53:107–21.
 194. Wieslander L. Intensive treatment of severe class II malocclusions with a headgear-Herbst appliance in the early mixed dentition. *Am J Orthod* 1984;86:1–13.
 195. McNamara JA, Bookstein FL, Shaughnessy TG. Skeletal and dental relationships following functional regulator therapy on class II patients. *Am J Orthod* 1985;88:91–110.
 196. Remmer KR, Mamandras AH, Hunter WS, et al. Cephalometric changes associated with treatment using the activator, the Fränkel appliance, and the fixed appliance. *Am J Orthod* 1985;88:363–72.
 197. DeVincenzo JP, Huffer R, Winn MA. A study in human subjects using a new device designed to mimic the protrusive functional appliances used previously in monkeys. *Am J Orthod Dentofac Orthop* 1987;91:213–24.
 198. Jakobsson SO, Paulin G. The influence of activator treatment on skeletal growth in Angle class II: 1 cases. A roentgenocephalometric study. *Eur J Orthod* 1990;12:174–84.
 199. Björk A. The principle of the Andresen method of orthodontic treatment, a discussion based on cephalometric x-ray analysis of treated cases. *Am J Orthod* 1951;37:437–58.
 200. Softley J. Cephalometric changes in seven “post normal” cases treated by the Andresen method. *Dent Rec* 1953;73:485–94.
 201. Björk A. Variability and age changes in overjet and overbite: report from a follow-up study of individuals from 12 to 20 years of age. *Am J Orthod* 1953;39:779–801.
 202. Meach CL. A cephalometric comparison of bony profile changes in class II, division 1 patients treated with extraoral force and functional jaw orthopedics. *Am J Orthod* 1966;52:353–70.
 203. Trayfoot J, Richardson A. Angle class II, division 1, malocclusions treated by the Andresen method. *Br Dent J* 1968;124:516–9.
 204. Hasund A. The use of activators in a system employing fixed appliances. *Trans Eur Orthod Soc* 1969;329–41.
 205. Harvold EP, Vargervik K. Morphogenetic response to activator treatment. *Am J Orthod* 1971;60:478–90.
 206. Stöckli PW, Dietrich UC. Experimental and clinical findings following functional forward displacement of the mandible. *Trans Eur Orthod Soc* 1973;435.
 207. Woodside DG. Some effects of activator treatment on the mandible and the midface. *Trans Eur Orthod Soc* 1973;443–7.
 208. Dietrich UC. Aktivator — mandibuläre Reaktion. *Schweiz Monatsschr Zahnheilkd* 1973;83:1093–104.
 209. Wieslander L, Lagerström L. The effect of activator treatment on class II malocclusions. *Am J Orthod* 1979;75:20–6.
 210. Forsberg CM, Odenrick L. Skeletal and soft tissue response to activator treatment. *Eur J Orthod* 1981;3:247–53.
 211. Calvert FJ. An assessment of Andresen therapy on class II division 1 malocclusion. *Br J Orthod* 1982;9:149–53.
 212. Creekmore TD, Radney LJ. Fränkel appliance

- therapy: orthopedic or orthodontic? *Am J Orthod* 1983;83:89–108.
213. Gianelly AA, Brosnan P, Martignoni M, Bernstein L. Mandibular growth, condyle position, and Fränkel appliance therapy. *Angle Orthod* 1983;53:131–42.
 214. Janson I. Skeletal and dentoalveolar changes in patients treated with a bionator during prepubertal and pubertal growth. In: McNamara JA, Ribbens KA, Howe RP, editors. *Clinical alteration of the growing face. Craniofacial growth monograph series. Monograph 14.* Ann Arbor: Center for Human Growth and Development, University of Michigan; 1983. p. 131–54.
 215. Mills JRE. Clinical control of craniofacial growth: a skeptic viewpoint. In: McNamara JA, Ribbens KA, Howe RP, editors. *Clinical alteration of the growing face. Craniofacial growth monograph series. Monograph 14.* Ann Arbor: Center for Human Growth and Development, University of Michigan; 1983. p. 17–39.
 216. Looi LK, Mills JR. The effect of two contrasting forms of orthodontic treatment on the facial profile. *Am J Orthod* 1986;89:507–17.
 217. Nelson C, Harkness M, Herbisson P. Mandibular changes during functional appliance treatment. *Am J Orthod Dentofac Orthop* 1993;104:153–61.
 218. Moss JP. Cephalometric changes during functional appliance therapy. *Trans Eur Orthod Soc* 1962;327–41.
 219. Evald H, Harvold EP. The effect of activators on maxillary-mandibular growth and relationships. *Am J Orthod* 1967;37:18–25.
 220. Freunthaller P. Cephalometric observations in class II, division 1 malocclusions treated with the activator. *Angle Orthod* 1967;37:18–25.
 221. Hotz R. Application and appliance manipulation of functional forces. *Am J Orthod* 1970;58:459–78.
 222. Ahlgren J, Laurin C. Late results of activator-treatment: a cephalometric study. *Br J Orthod* 1976;3:181–7.
 223. Baumrind S, Korn EL, Isaacson JR, et al. Quantitative analysis of the orthodontic and orthopedic effects of maxillary retraction. *Am J Orthod* 1983;84:384–98.
 224. Teuscher UM. A growth-related concept for skeletal class II treatment. *Am J Orthod* 1978;74:258–75.
 225. Bass NM. Dento-facial orthopaedics in the correction of the class II malocclusion. *Br J Orthod* 1982;9:3–31.
 226. Stöckli PW, Teuscher UM. Combined activator headgear orthopedics. In: Graber TM, Swain BF, editors. *Orthodontics: current principles and techniques.* St. Louis (MO): C.V. Mosby Co.; 1985. p. 405–83.
 227. Lagerström LO, Nielsen IL, Lee R, Isaacson RJ. Dental and skeletal contributions to occlusal correction in patients treated with the high-pull headgear-activator combination. *Am J Orthod Dentofac Orthop* 1990;97:495–504.
 228. Wieslander L. Long-term effect of treatment with the headgear-Herbst appliance in the early mixed dentition. Stability or relapse? *Am J Orthod* 1993;104:319–29.
 229. Pancherz H. The effects, limitations, and long-term dentofacial adaptations to treatment with the Herbst appliance. *Semin Orthod* 1997;3:232–43.
 230. von Bremen J, Pancherz H. Efficiency of early and late class II division 1 treatment. *Am J Orthod Dentofac Orthop* 2002;121:31–7.
 231. Bishara SE. Facial and dental changes in adolescents and their clinical implications. *Angle Orthod* 2000;70:471–83.
 232. Yamada S, Saeki S, Takahashi I, et al. Diurnal variation in the response of the mandible to orthopedic force. *J Dent Res* 2002;81:711–5.
 233. Campbell PM. The dilemma of class III treatment: early or late? *Angle Orthod* 1983;53:175–91.
 234. Thilander B. Chin-cap treatment for Angle. Class III malocclusion: a longitudinal study. *Trans Eur Orthod Soc* 1965;41:311–27.
 235. Vego L. Early orthopedic treatment of cl. II skeletal patterns. *Am J Orthod* 1976;70:59–69.
 236. Graber L. Chin cup therapy for mandibular prognathism. *Am J Orthod* 1977;72:23–41.
 237. Allen RA, Connolly IH, Richardson A. Early treatment of incisor relationship using the chin-cap appliance. *Eur J Orthod* 1993;15:371–6.
 238. Sugawara J, Mitani H. Facial growth of skeletal class III malocclusion and the effects, limitations, and long-term dentofacial adaptations to chin-cap therapy. *Semin Orthod* 1997;3:244–54.
 239. Sakamoto T, Iwase I, Uka A, Nakamura S. A roentgenocephalometric study of skeletal changes during and after chin cap treatment. *Am J Orthod* 1984;85:341–50.
 240. Sugawara J, Asano T, Endo N, Matani H. Long-term effects of chin-cap therapy on skeletal profile in mandibular prognathism. *Am J Orthod* 1990;98:127–33.
 241. Robertson NRG. An examination of treatment changes in children treated with the functional regulator of Fränkel. *Am J Orthod* 1983;83:299–309.
 242. Delaire J. Considérations sur la croissance faciale (en particulier du maxillaire supérieur). *Déductions thérapeutiques. Rev Stomatol* 1971;72:57–76.
 243. Jackson GW, Kokich VG, Shapiro PA. Experimental and postexperimental response to anteriorly directed extraoral force in young *Macaca nemestina*. *Am J Orthod* 1979;75:318–33.
 244. Takada K, Petdachai S, Sakuda M. Changes in dentofacial morphology in skeletal class III children treated by a modified maxillary protraction headgear and a chin cup: a longitudinal cephalometric appraisal. *Eur J Orthod* 1993;15:211–21.
 245. Ngan P, Hagg U, Yiu C, et al. Treatment response to maxillary expansion and protraction. *Eur J Orthod* 1996;18:151–68.
 246. Nartallo-Turley PE, Turley PK. Cephalometric effects of combined palatal expansion and facemask therapy on class III malocclusion. *Angle Orthod* 1998;68:217–24.
 247. Ngan PW, Hagg U, Yiu C, Wei SHY. Treatment response and long-term dentofacial adaptations to maxillary expansion and protraction. *Semin Orthod* 1997;3:255–64.
 248. Williams MD, Sarver DM, Sadowsky PL, Bradley E. Combined rapid maxillary expansion and protraction facemask in the treatment of class III malocclusions in growing children: a prospective long-term study. *Semin Orthod* 1997;3:265–74.
 249. da Silva Filho OG, Magro AC, Capelozza Filho L. Early treatment of the class III malocclusion with rapid maxillary expansion and maxillary protraction. *Am J Orthod* 1998;113:196–203.
 250. Baccetti T, McGill JS, Franchi L. Skeletal effects of early treatment of Class III malocclusion with maxillary expansion and face-mask therapy. *Am J Orthod* 1998;113:333–43.
 251. Kapust AJ, Sinclair PM, Turley PK. Cephalometric effects of face mask/expansion therapy in class III children: a comparison of three age groups. *Am J Orthod Dentofac Orthop* 1998;113:204–12.
 252. Baik HS. Clinical results of the maxillary protraction in Korean children. *Am J Orthod* 1995;108:583–92.
 253. Merwin D, Ngan P, Hagg U, et al. Timing for effective application of anteriorly directed orthopedic force to the maxilla. *Am J Orthod* 1997;112:292–9.
 254. Gallagher RW, Miranda F, Buschang PH. Maxillary protraction: treatment and posttreatment effects. *Am J Orthod* 1998;113:612–9.
 255. Ngan P. Biomechanics of maxillary expansion and protraction in class III patients. *Am J Orthod Dentofac Orthop* 2002;121:582–3.
 256. Smalley WM, Shapiro PA, Hohl TH, et al. Osseointegrated titanium implants for maxillofacial protraction in monkeys. *Am J Orthod Dentofac Orthop* 1988;94:285–95.

257. Woodside DG, Altuna G, Harvold E, et al. Primate experiments in malocclusion and bone induction. *Am J Orthod Dentofac Orthop* 1983;83:460–8.
258. Lundstrom A, Woodside DG. Longitudinal changes in facial type in cases with vertical and horizontal mandibular growth directions. *Eur J Orthod* 1983;5:259–68.
259. Dellinger EL. A clinical assessment of the active vertical corrector — a nonsurgical alternative for skeletal open bite treatment. *Am J Orthod Dentofac Orthop* 1986;89:428–36.
260. Kalra V, Burstone CJ, Nanda R. Effects of a fixed magnetic appliance on the dentofacial complex. *Am J Orthod Dentofac Orthop* 1989;95:467–78.
261. Kuster R, Ingervall B. The effect of treatment of skeletal open bite with two types of bite-blocks. *Eur J Orthod* 1992;14:489–99.
262. Iscan HN, Sarisoy L. Comparison of the effects of passive posterior bite-blocks with different construction bites on the craniofacial and dentoalveolar structures. *Am J Orthod Dentofac Orthop* 1997;112:171–8.
263. Barbre RE, Sinclair PM. A cephalometric evaluation of anterior open bite correction with the magnetic active vertical corrector. *Angle Orthod* 1991;61:93–102.
264. Gallego L, Urbaniak J, Subtelny JD. Adult anterior open bite. *Am J Orthod Dentofac Orthop* 1990;97:522–6.
265. Shapiro PA. Stability of open bite treatment. *Am J Orthod Dentofac Orthop* 2002;121:566–8.
266. Umemori M, Sugawara J, Mitani H, et al. Skeletal anchorage system for open-bite correction. *Am J Orthod Dentofac Orthop* 1998;115:166–74.
267. Sawaki Y, Ohkubo H, Hibi H, Ueda M. Mandibular lengthening by distraction osteogenesis using osseointegrated implants and an intra-oral device: a preliminary report. *J Oral Maxillofac Surg* 1996;54:594–600.
268. Cohen SR. Craniofacial distraction with a modular internal distraction system: evolution of design and surgical techniques. *Plast Reconstr Surg* 1999;103:1592–607.
269. Kim YH, Han UK, Lim DD, Serrano MLP. Stability of anterior open bite correction with multiloop edgewise therapy: a cephalometric follow-up study. *Am J Orthod Dentofac Orthop* 2000;118:43–54.

Database Acquisition and Treatment Planning

Marc B. Ackerman, DMD

David M. Sarver, DMD, MS

Until the turn of the twenty-first century, treatment planning in orthognathic surgery was based primarily on a system of clinical observation, a static set of records (models, radiographs), with the major thrust of treatment being directed toward satisfying lateral cephalometric goals. These goals might include particular measurements (sella-nasion–A point and A point–nasion–B point differences) or analytical norms (Steiner, Ricketts), or even comparison of lateral head film tracings of persons with craniofacial skeletal dysplasia^{1–3} to templates having average skeletal proportions derived from longitudinal growth studies.⁴ The most significant shortcoming of this reliance on the lateral cephalogram as the primary determinant of treatment goal setting is that it did not take into account the resting and dynamic hard–soft tissue relationships, which are the most critical aspects in treatment planning in both orthodontics and orthognathic surgery. Furthermore, cephalometric analysis quantifies dento-skeletal relationships in angular and linear measures, which are not entirely representative of the multidimensional interrelationship of craniofacial parts. That is to say, the integumental soft tissue drape may sometimes be inconsistent with the underlying skeletal framework in a given patient.

Whereas the skeletal framework may be reasonably stable post-adolescence, the soft tissues are more subject to maturational and age-related changes. The cephalometric approach to treatment planning is now considered “Procrustean,” after the story based on Greek mythology. As the story goes, Procrustes was an innkeeper with only one bed. If a traveler was too tall for the bed, Procrustes would cut off the traveler’s feet so that he or she would fit the bed. A traveler who was too short would be stretched on a rack to likewise fit the bed in length. This charming story relates to this chapter in that by applying the same hard tissue cephalometric analysis to all patients, all of our patients end up being crammed into the same bed!

The contemporary approach to the surgical orthodontic treatment of dentofacial deformity will illustrate the use of dentofacial proportionality in the place of applying absolute linear or angular norms to the individual patient. Patient-specific treatment planning will be the focus of this chapter.

Contemporary Orthognathic Treatment Planning

The emphasis in this chapter on orthognathic diagnosis and treatment planning

is intended to lead us into a new era and methodology of patient analysis and treatment goal setting. In modern orthognathic surgery, treatment goals are determined through systematic clinical examination and quantification of the patient’s dentofacial characteristics. Therefore, the purpose of this chapter will be to introduce the reader to a method of systematic dentofacial analysis in all three dimensions with emphasis on both static and dynamic relationships, as well as both functional and esthetic objectives.

Problem-oriented treatment planning has served us very well in the past several decades, by focusing on the problems in need of correction, including the identification of solutions for each problem. The natural progression of problem-oriented treatment planning should now include the identification of favorable attributes as well as the problems. The reason for this next step is the realization that focusing solely on the problems and their solutions may result in a treatment plan which potentially has a negative effect on the positive attributes in that patient. A classic orthodontic example is where the extraction of maxillary premolars in the correction of a skeletal Class II malocclusion, while satisfying functional

and occlusal issues, may result in profile flattening and an unfortunate effect on facial appearance. In the orthognathic arena, a good example is the widening of the alar base secondary to maxillary advancement and/or impaction. The goal of orthognathic treatment is the optimization of negative attributes, while at the same time preserving those attributes that are deemed favorable (Figure 54-1).

This systematic approach to clinical examination of the patient is essential for the development of an optimization-oriented database. All clinically detectable deviations from the optimal range fall into the two broad categories of function and esthetics.

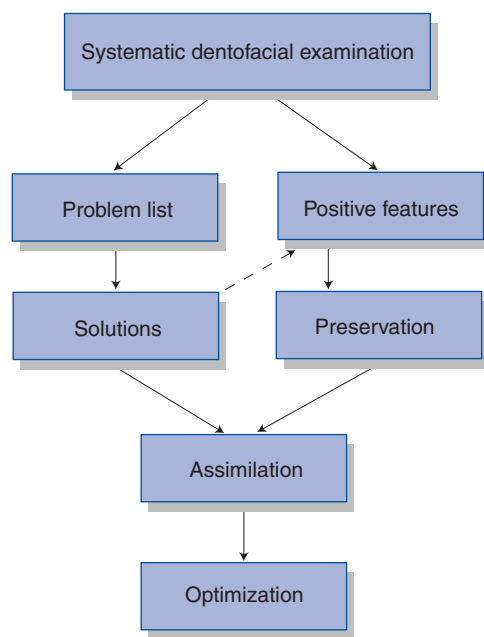


FIGURE 54-1 Contemporary treatment planning flow chart. After the clinical examination and databasing of the quantitative measurements, both problems and positive attributes are identified. Solutions for the problems are identified and the dotted arrow indicates that each potential solution can negatively impact a positive feature. Therefore, the advantage of measuring both problems and positive features permits the clinician to recognize the potential negative impact that any given solution has on the positive attributes. This “decision tree” leads to correction of the problems but also preservation of the positive attributes. The clinician then assimilates all of this information for optimization of treatment.

Function and Dentofacial Deformity

Patients with severe discrepancies in the size and position of their jaws and their teeth often have difficulty in oral function. Certain foods may be difficult to incise and chew. Speech may also be affected by jaw deformity. If the patient cannot bring the tongue and lips into the proper position, it may not be possible to produce a specific sound properly. Besides careful examination of the patient, it is doubtful that diagnostic tests of function that can be carried out in the dental or surgical office are useful. The relationship of temporomandibular (TM) joint problems to severe malocclusion and dentofacial deformities is complex but important. Although there is some evidence that patients with specific types of malocclusion are more susceptible to TM joint problems, the increased risk is relatively small.⁵ In general terms, patients with dentofacial deformity are similar to patients with normal facial proportions in the prevalence of TM joint problems.⁶

Appearance and Dentofacial Deformity

Appearance and dentofacial esthetics can be divided into three subcategories: macroesthetics, miniesthetics, and microesthetics (Figure 54-2). The specific concerns of the patient can be elucidated through open-ended doctor-patient communication and then integrated into the diagnostic decision tree. The surgeon and orthodontist should be sensitive to the patient’s esthetic desires, balancing them against cultural and familial standards. The physical burden of treatment is borne by the patient and must be weighed when determining the extent of surgical intervention. For example, when deciding whether treatment should involve orthodontics alone, orthodontics and orthognathic surgery, or acceptable orthodontic camouflage, the patient should understand the risk-benefit ratio of any given treatment sequence.

Data Collection

Primary data collection begins at the clinical examination and is supplemented with static and dynamic recordings of the patient in three spatial dimensions. Record taking should replicate the functional and esthetic presentation of the patient. Findings from the clinical examination should either be confirmed or challenged by data obtained from the records. The analysis of the clinical database will generate a diagnostic summary and optimized problem list. An emerging soft-tissue paradigm in surgical orthodontic treatment planning has refocused analysis on facial proportionality and balance versus reliance on normative data derived from cephalometrics.⁷ The art of surgical orthodontics rests in the ability to envisage the patient’s desired three-dimensional soft tissue outcome and then retroengineer the dental and skeletal hard tissues to produce such a change. The concept of retroengineering will be explained later in this chapter under technological applications to orthognathic treatment planning.

In today’s clinical environment there are three methods of data collection. The first and most commonly used method includes still photography, study models, and cephalometric radiographs. The second is the use of databasing programs to document direct clinical measurement of the patient’s resting and dynamic relationships. The third involves the use of digital video to record the dynamics of facial movement. This methodology as it currently exists does not dynamically quantify movement. Expect to see greater recognition of the value of this technology, which should lead to research into the quantification of dynamic facial movements.

Conventional Records

Standard orthodontic records have not changed significantly in many years, but contemporary records in surgical orthodontic treatment are changing rapidly.

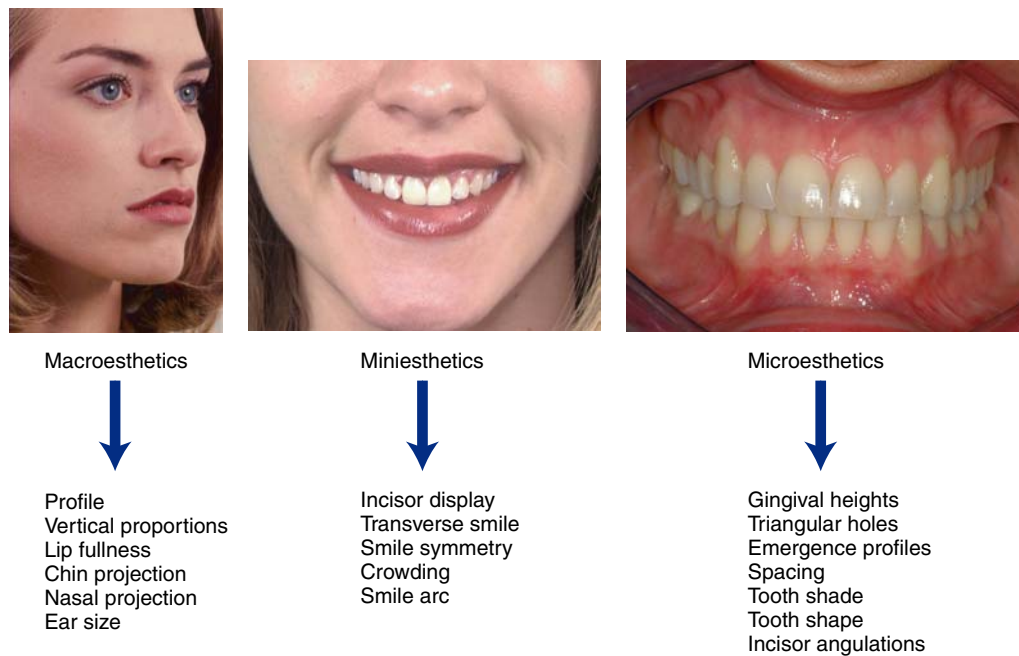


FIGURE 54-2 Recommended subcategories of appearance and esthetics.

Surgical orthodontics demands treating all dimensions of patients. In clinical practice, standard records include film or digital photographs, radiographs, and study models (whether plaster, mounted or unmounted, or electronic models). The facial images, which are universally considered standard records, include frontal at rest, frontal smile, and profile at rest images. Whereas these orientations do provide an adequate amount of diagnostic information, they do not contain all of the information needed for three-dimensional visualization and quantification. Orthognathic surgery requires expansion of the database compared to conventional orthodontic treatment.

The suggested records can be divided into two groups—static and dynamic. The accepted facial photographic recordings should include frontal smile close-up, oblique facial smile, oblique smile close-up, and profile smile.⁸

Direct Measurement as a Biometric Tool

The goal of the clinical examination is to quantitatively assess soft and hard tissue attributes of the dentofacial complex, and

record what elements are satisfactory and which are in need of optimization. Clinical examination procedures vary greatly among practitioners. Measurement should be thorough, systematic, and consistent, thus minimizing the chance that something of importance will be overlooked. We want to avoid the situation where the clinician performs a cursory examination, jotting down brief notes as to abnormalities that are observed without recording any other descriptive data. This practice is often justified by the assumption that most diagnostic decisions can be made from the records after the patient leaves. This is a poor diagnostic technique for several reasons.

First, static records cannot reflect the dynamic relationships that are important in the overall functional assessment of the patient. For example, the simple idea of the relationship of the upper incisor at rest and on smile is not reflected on radiographs or models and is poorly evaluated in photographs. Second, information that may have not looked important enough to write down during a cursory examination may be important later, and thus would be unavailable because it was not recorded.

Third, a thorough and comprehensive examination record that includes normal observations is an accurate medicolegal document. It is hard for an unhappy patient to charge negligence when it is clear that the information was obtained and used. The more thorough and well documented the record is, the more valuable it is if problems arise.

Contemporary clinical examination uses a computer-databasing program to facilitate data entry, and these data are then merged into reports and treatment planning screens or forms.⁹ Each clinical characteristic in the examination has a pop-up menu containing all of the possible descriptions for that particular trait (Figure 54-3). By using a computer interface, the surgeon or orthodontist saves valuable time in both the clinical examination and diagnostic and treatment planning work-up. The information is then stored for recall and analysis, and can even have predefined parameters that identify problematic measurements automatically.

As an example of how this interface facilitates the examination of dynamic hard–soft tissue relationships, we suggest that the following frontal measurements be performed systematically in evaluation of anterior dental display, both at rest and at smile:

- **Philtrum height:** The philtrum height is measured in millimeters from subnasale (the base of the nose at the midline) to the most inferior portion of the upper lip on the vermilion tip beneath the philtral columns. The absolute linear measurement is not particularly important, but what is significant is its relationship to the upper incisor, and the commissures of the mouth. In the adolescent, it is common to find the philtrum height to be shorter than the commissure height, and the difference can be explained in the differential in lip growth with maturation.

FIGURE 54-3 A computer-databasing program facilitates data entry, and these data are then merged into reports and treatment planning screens or forms. Each clinical characteristic in the examination has a pop-up menu containing all of the possible descriptions for that particular trait.

- Commissure height: The commissure height is measured from a line constructed from the alar bases through subspinale, then from the commissures perpendicular to this line.
- Interlabial gap: The interlabial gap is the distance in millimeters between the upper and lower lips, when lip incompetence is present.
- Amount of incisor show at rest: The amount of upper incisor show at rest is

a critical esthetic parameter because one of the inevitable characteristics of an aging tooth-lip relationship is diminished upper incisor show at rest and on smile. For example, an adult patient who displays 3 mm of gingival display on smile and 3 mm of upper incisor at rest should only carefully consider maxillary incisor intrusion or maxillary impaction to reduce gingival display, since reduction in gingival dis-

play also results in diminished incisor show at rest and during conversation (a characteristic of the aging face).

- Amount of incisor display on smile: On smile, patients will either show their entire upper incisor, or only a percentage of the incisor. Measurement of the percentage of incisor display, when combined with the crown height measured next, leads the clinician to decide how much tooth movement is required to attain the appropriate smile for that patient.
- Crown height: The vertical height of the maxillary central incisors in the adult is measured in millimeters and is normally between 9 and 12 mm, with an average of 10.6 mm in males and 9.6 mm in females. The age of the patient is a factor in crown height because of the rate of apical migration in the adolescent.
- Gingival display: There is variability in what is esthetically acceptable for the amount of gingival display on smile, but it is important to always remember the relationship between gingival display and the amount of incisor shown at rest. In broad terms, it is better for a patient to be treated less aggressively in reducing smile gumminess when considering that the aging process will result in a natural diminishment of this characteristic. A gummy smile is often more esthetic than a smile with diminished tooth display.
- Smile arc: The smile arc should be defined as the relationship of the curvature of the incisal edges of the maxillary incisors and canines to the curvature of the lower lip in the posed social smile.^{10,11} The ideal smile arc has the maxillary incisal edge curvature parallel to the curvature of the lower lip upon smile, and the term *consonant* is used to describe this parallel relationship. A *nonconsonant* or flat smile arc is characterized by the

maxillary incisal curvature being flatter than the curvature of the lower lip on smile. The smile arc relationship is not as quantitatively measurable as the other attributes, so the qualitative observation of consonant, flat, or reverse smile arcs is generally cited.

Is it important to measure these above-described characteristics in orthognathic cases? The following case illustrates the significance of resting and dynamic soft tissue measurement, and how surgical or orthodontic treatment planning is determined by direct measurement as much as it is by cephalometric analysis. The role of cephalometrics will be discussed later in this chapter, and the emphasis will be less on static comparisons to norms and more on its coordination with the soft tissue overlay of the face and the use of predictive algorithms to arrive at final macrotreatment decisions.

The patient in Figure 54-4 was a 16-year-old male who presented for an opinion relative to his chief complaint of excessive gingival display on smile, or a “gummy smile” (see Figure 54-4A). He had finished orthodontic treatment about 1 year earlier, and when his mother asked the

orthodontist if something could be done, the orthodontist felt that the only way to improve that smile characteristic was to consider surgical maxillary superior repositioning via Le Fort I osteotomy. A referral to the oral and maxillofacial surgeon was recommended, and maxillary impaction was recommended, but the surgeon felt that he wanted to wait until the patient had reached full physical maturity. The patient’s mother felt further investigation was warranted.

The examination revealed a well-treated orthodontic case with excellent occlusion, and the macrorelations were also quite normal in terms of profile and facial proportion. The anterior tooth-lip relationships were as follows:

- Resting relationships (see Figure 54-4B)
 - Philtrum height: 25 mm
 - Commissure height: 25 mm
 - Maxillary incisor at rest: 2 mm
- Dynamic relationships (see Figure 54-4C)
 - Percentage of maxillary incisor display on smile: 100%
 - Maxillary incisor crown height: 8 mm
 - Gingival display on smile: 4 mm
 - Smile arc: consonant

It is instructive to outline the etiologies of excessive gingival display on smile and characteristics seen with each in order to demonstrate the decision-making process in problem-oriented treatment planning with optimization.

- Vertical maxillary excess: Characterized by a disproportionately long lower facial height, lip incompetence, excessive incisor display at rest, and excessive gingival display on smile
- Short philtrum: The philtrum height shorter than the commissure, excessive incisor display at rest, and a reverse resting upper lip line
- Excessive smile curtain: Excessive animation of the upper lip on smile, displaying more tooth and gingiva than desired
- Short crown height: If the anterior incisor height is short, excessive gingival display may result

In this case, vertical maxillary excess was ruled out because facial proportionality was normal, no lip incompetence was present, and only 2 mm of upper incisor showed at rest. The second possibility, a short philtrum, was ruled out since the philtrum and commissure heights were

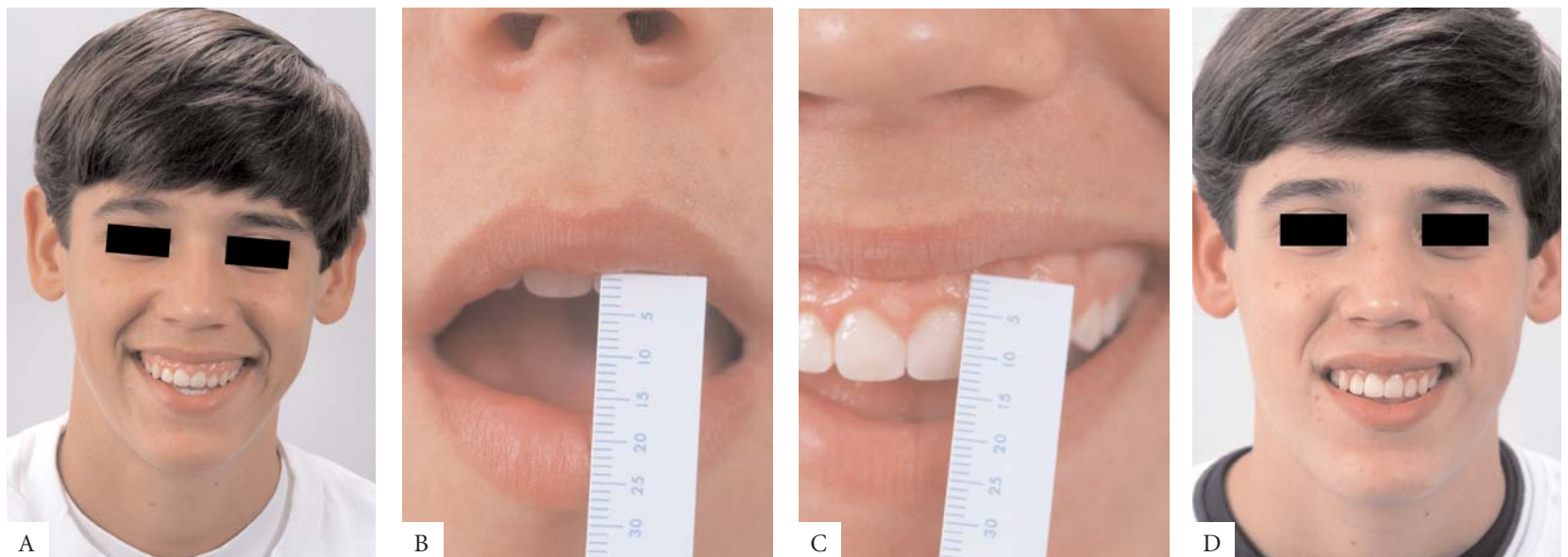

FIGURE 54-4 A–D, Case illustration of direct measurement of lip-tooth-gingival relationships.

the same, and no reverse upper lip resting characteristics were noted. The third possibility, excessive curtain, was eliminated because the vermilion was adequate on smile and the margins of the commissure and philtrum even on posed smile. The fourth possibility, short crown height, was significant since the maxillary incisors measured to be only 8 mm in height.

Therapeutic options to decrease gingival display included maxillary impaction, orthodontic intrusion of maxillary incisors, or periodontal crown lengthening.

- Maxillary impaction: A 4 mm superior repositioning of the maxilla would decrease the gumminess of the smile, but would result in a -2 mm upper incisor show at rest, greatly hastening the aging characteristics of the face and smile.
- Orthodontic intrusion of the maxillary anterior teeth: This would likewise result in reduction of incisor display at rest but would also flatten the already consonant smile arc.
- Periodontal crown lengthening: The increase in anterior crown height decreases the gumminess of the smile (appropriate because the teeth are short), and optimizes treatment by *not* decreasing incisor display at rest and by maintaining the consonant smile arc.

After discussing all these options with the family, the family decided to proceed with the third and recommended option of crown lengthening, with an excellent outcome (see Figure 54-4D).

In summary, this case demonstrates the new direction in dentofacial treatment planning, even though the final result was not an orthognathic treatment plan. This case was selected to make the point that through careful observation and measurement, the appropriate treatment plan was delivered.

Digital Videography

Dynamic recording of patient's facial motion is accomplished with the use of

digital videography.¹² This technology may be used to document and evaluate such characteristics as range of mandibular motion on opening and laterotrusion movements, deviations on opening, smile, and speech. Digital video and computer technology have primarily been used to record anterior tooth display during speech and smiling. Digital videos can be recorded in a standardized fashion with the camera at a fixed distance from the subject. We recommend that these images be taken in a standard format with emphasis on natural head position, so that future analysis and research possibilities may be maximized. We also recommend that video be taken in the frontal, oblique, and lateral dimensions. Clinically, an example of where this technology is most relevant is the patient with an asymmetric smile. The question that arises is whether or not the patient has a dental asymmetry, skeletal asymmetry, or asymmetric movement of the lip curtain during animation. The single smile photograph cannot corroborate the clinical impression gained during the data collection process. The video clip may be reviewed and evaluated during all planning phases of treatment as well as for comparison of the orthognathic treatment effects (Figure 54-5).

Systematic Clinical Examination of Dentofacial Deformity

We have previously discussed the importance of clinical observation and direct measurement of the interaction of hard and soft tissues in planning appropriate combined orthodontic and orthognathic treatments of dentofacial deformity. In this section, we will describe the components of the examination from the macro-, mini-, and microperspectives.

Macroesthetic Examination: Frontal View

The facial areas for macroesthetic examination, as investigated from the frontal view, can be summarized as follows:

- Vertical proportions
 - Facial heights:
 - Lower third
- Transverse proportions
 - Rule of fifths
 - Middle fifth
 - Inner canthi
 - Alar base
 - Medial two-fifths
 - Outer canthi
 - Gonial angles of mandible
 - Outer two-fifths
 - Ear deformity
 - Ear projection
 - Nasal anatomy
 - Alar base
 - Columella
 - Nasal tip
 - Dorsum
- Transverse symmetry
 - Nasal tip to midsagittal plane
 - Maxillary dental midline to midsagittal plane
 - Mandibular dental midline to symphysis
 - Mandibular asymmetry with or without functional shift
 - Maxillomandibular asymmetry
 - Chin asymmetry

The starting point for the macroesthetic examination is the frontal perspective. Transverse and vertical relationships comprise the major components of the frontal examination and analysis. As emphasized in our introduction, the *proportional* relationship of height and width is far more important than absolute values in establishing overall facial type. Faces can be broadly categorized as either mesocephalic, brachycephalic, or dolichocephalic (Figure 54-6).¹³ The differentiation between these facial types has to do with the general proportionality of facial breadth to facial height, with brachycephalic faces being broader and shorter in comparison to the longer and more narrow dolichocephalic faces. Generally, the most attractive faces tend to have common

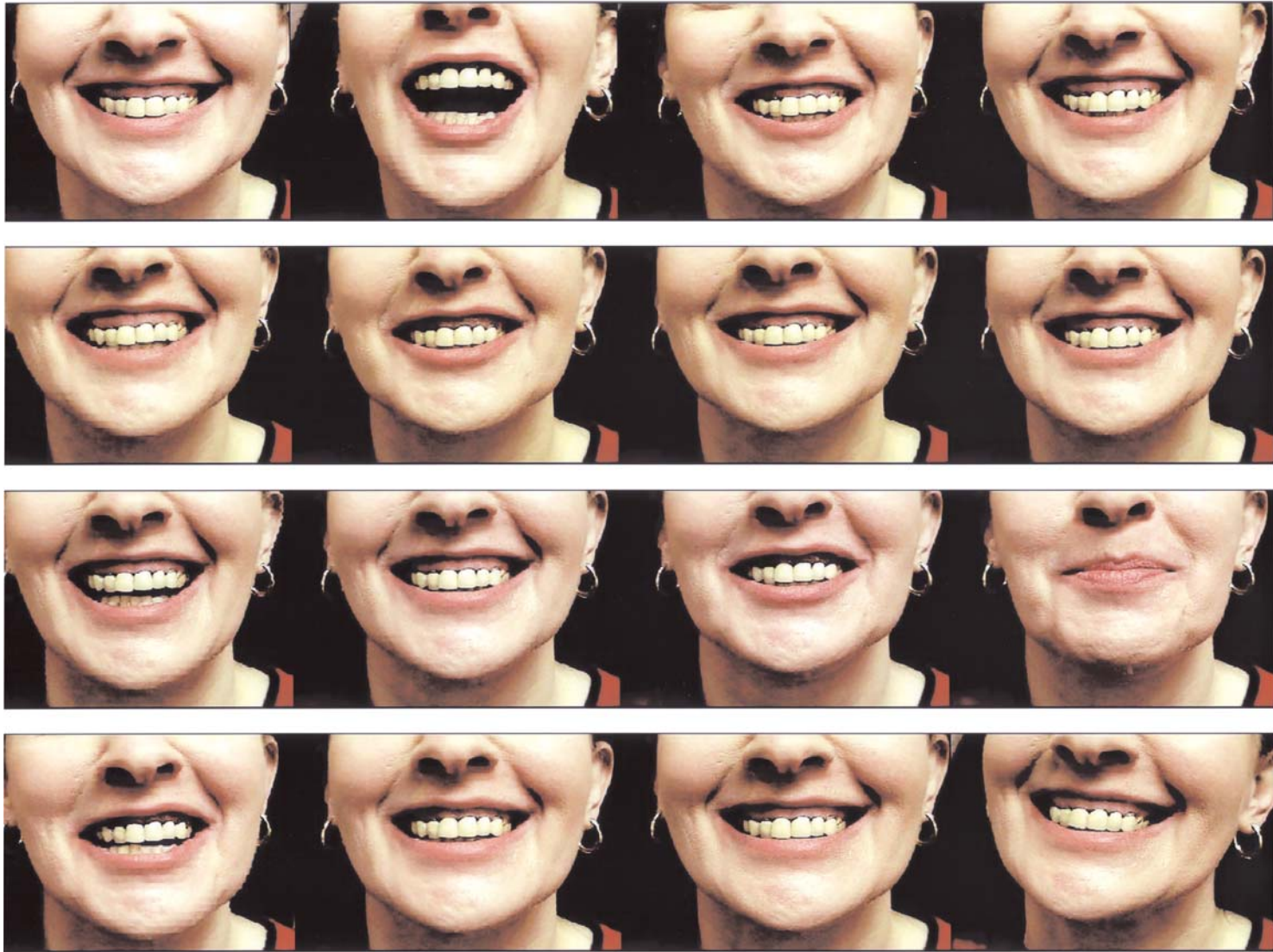


FIGURE 54-5 The video clip may be reviewed and evaluated during all planning phases of treatment as well as for comparison of the orthognathic treatment effects.

proportions and relationships that generally differ from normative values.¹⁴

Vertical Facial Proportions The ideal face is vertically divided into equal thirds by horizontal lines adjacent to the hairline, the nasal base, and menton (Figure 54-7A). Surgical orthodontic treatment is in a large part limited to the lower facial third. Measurement of the upper face is often hindered by the variability in identification of broad landmarks such as the location of the hairline and radix.

We will begin our clinical examination with the evaluation of lower facial height. In the ideal lower third of the

face, the upper lip makes up the upper third, and the lower lip and chin compose the lower two-thirds (Figure 54-7B). Disproportion of the vertical facial thirds may be a result of many dental and skeletal factors, and these proportional relationships may help us define the contributing factors related to vertical dentofacial deformities.

In the following sections, we present case illustrations of orthognathic changes in vertical proportionality.

Short Vertical Proportions The patient in Figure 54-8 presented for correction of her Class II deep bite secondary to her

mandibular deficiency. Her anterior vertical relationships were characterized by a short lower facial third relative to her upper thirds (see Figure 54-8A and B). In addition, the lower third was comprised of a 45:55 vertical relation of the upper lip to lower lip and chin height. Recalling that the ideal proportions of the lower face are one-third upper lip and two-thirds lower lip and chin, the treatment plan was clearly a result of the direct clinical examination rather than any cephalometric standard. Other important clinical measurements entered into the decision process. Differential diagnosis for a short lower facial height included the following:




FIGURE 54-6 A, The mesocephalic facial type is characterized by equal vertical facial thirds. B, The brachycephalic facial type appears square with a diminished lower third. C, The dolichocephalic facial type appears ovoid with an increased lower third.

- Vertical maxillary deficiencies, which are then characterized by the following characteristics:
 - Short lower facial third
 - Diminished maxillary incisor display at rest
 - Diminished incisor display on smile
- Diminished chin height, ascertained through the proportionality in the lower face rather than a linear cephalometric value
- Posterior dental collapse secondary to the loss of posterior dental support

The functional goal of mandibular advancement to correct the Class II dentoskeletal relationship was obvious, but an esthetic adjunctive consideration was a vertical genioplasty to optimize the macroesthetics of her vertical facial thirds. The final diagnosis depended not only on the vertical facial proportionality but on the measurement of the resting tooth-lip relationships as well in order to more clearly define the etiology of the lower facial height. In this

case, our patient displayed 3 mm of maxillary incisor at rest, and all of her maxillary incisor on smile (see Figure 54-8C), which was inconsistent with vertical maxillary

deficiency. Since the chin height was short, the final diagnosis was mandibular deficiency with short chin height. Therefore, the recommended treatment plan was

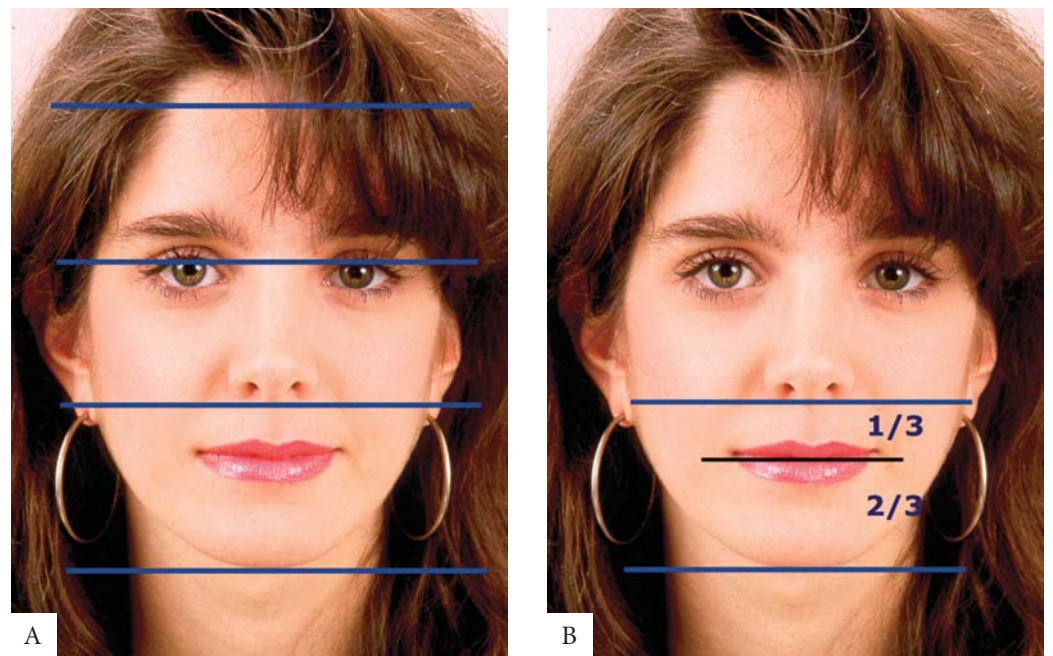


FIGURE 54-7 A, The ideal face is vertically divided into equal thirds by horizontal lines adjacent to the hairline, the nasal base, and menton. B, In the ideal lower third of the face, the upper lip makes up the upper third, and the lower lip and chin compose the lower two-thirds.

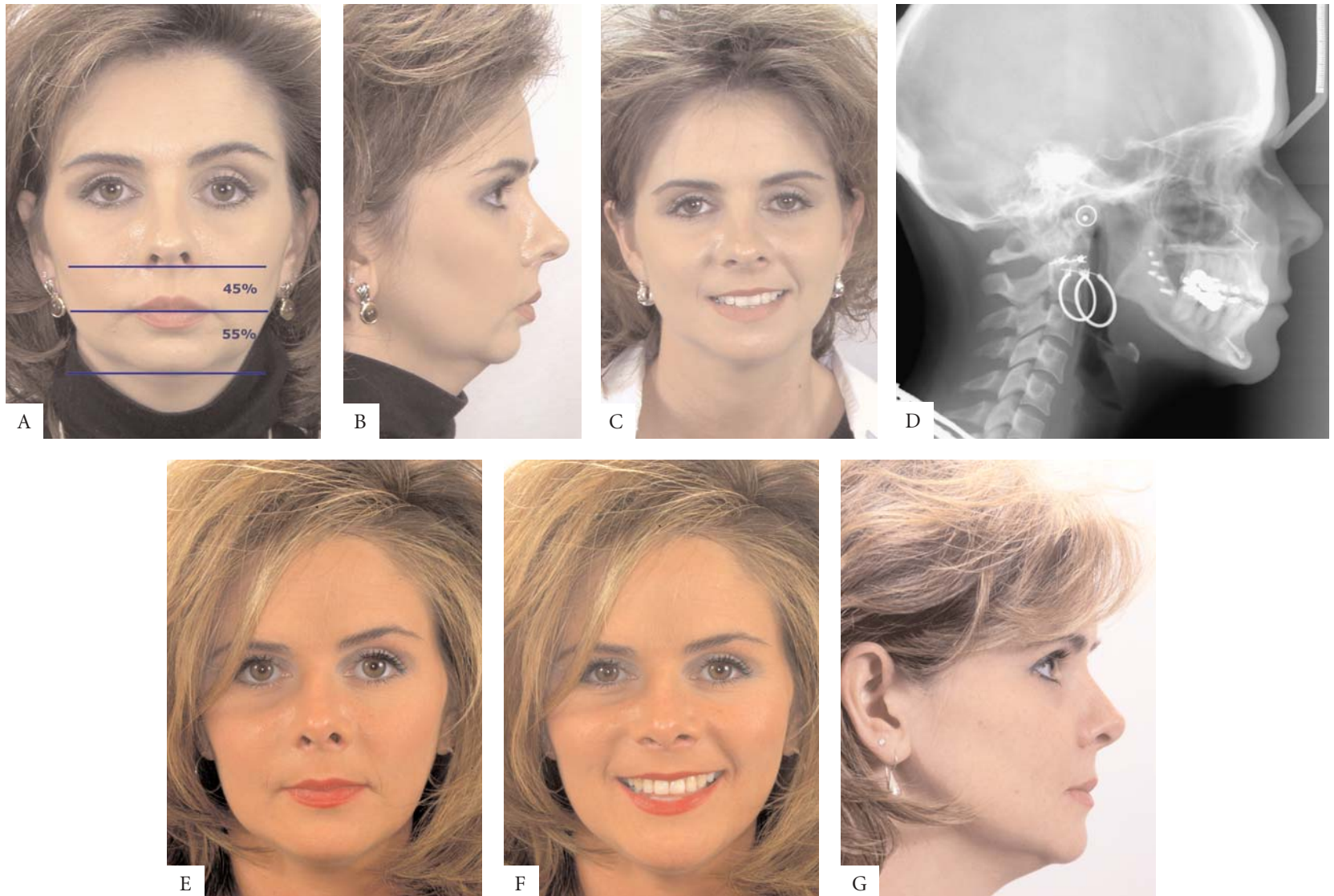

FIGURE 54-8 A, This patient was referred for correction of her Class II deep bite secondary to her mandibular deficiency. B, Evaluation of her anterior vertical relationships was characterized by a short lower facial third relative to her upper thirds. The lower third was comprised of a 45:55 vertical relationship of the upper lip to lower lip and chin height. The ideal proportions of the lower face are one-third upper lip and two-thirds lower lip and chin; thus the treatment plan was derived from the direct clinical examination of this patient rather than any cephalometric standard. C, Our patient displayed 3 mm of maxillary incisor at rest, and all of her maxillary incisors on smile, inconsistent with vertical maxillary deficiency. D, The treatment plan was orthodontic preparation for mandibular advancement and vertical genioplasty. E, The post-treatment frontal view demonstrating balance of the vertical facial thirds. F, The vertical incisor position at smile was maintained, while the lower facial third was vertically augmented. G, The profile view shows improved mandibular projection relative to the upper face, improved chin-neck angle, and improved chin-neck length.

orthodontic preparation for mandibular advancement and vertical genioplasty (see Figure 54-8D) to increase the lower facial height (see Figure 54-8E–G).

Long Vertical Proportions Long lower facial height is due to one of two possibilities: (1) vertical maxillary excess (VME) or (2) excessive chin height. The clinical keys that may be associated with VME are

gummy smile, open bite, lip incompetence, and steep mandibular plane as evidenced by gonial angle form. Excessive chin height is measured from the lower vermilion to the soft tissue menton. The clinical keys that may be associated with excessive chin height are lower facial third disproportionate from the one-third upper lip to two-thirds low lip and chin ratio, and the absence of VME characteristics.

The patient in Figure 54-9A was referred for correction of an anterior open bite and a gummy smile. Our systematic examination revealed the following problem list and characteristics:

- Frontal proportions at rest
 1. Long lower facial third
 2. Disproportion of chin height with the upper lip occupying 25% of the

lower facial third and the lower lip and chin occupying 75% of the lower third of the face

3. Lip incompetence of 5 mm
4. 8 mm of maxillary incisor display at rest
5. Midsymphysis to right 3 mm with no functional shift
6. Lip strain on closure (Figure 54-9B)

Clinical assessment of the frontal resting macroesthetic evaluation: This patient had most of the macrocharacteristics of vertical maxillary excess with a long lower facial height and excessive incisor display at rest. Excessive chin height was also a contributor to the lower facial height disproportion, as is evidenced by the upper lip and chin height clinical proportions.

- Frontal proportions on smile (Figure 54-9C)
 1. 100% of maxillary incisor displayed on smile
 2. Excessive gingival display on smile with 3 mm gingival display at the right cuspid and 5 mm at the left with a transverse cant to the palatal plane
 3. Transverse cant to the maxilla with the left side down 2 mm more than the left

Clinical assessment of the frontal dynamic (smiling) macroesthetic evaluation: A gummy smile was present but with normal incisor crown height. This would exclude cosmetic periodontal crown lengthening as the primary therapeutic choice for improvement of the gummy smile. The asymmetry of the maxilla is in compensation for the mandibular asymmetry, and results in a canted frontal occlusal plane and smile line.

- Oblique at-rest facial observation (Figure 54-9D)
 1. Excessive lower facial height
 2. Lip strain and excessive chin height

3. Flat labiomental sulcus
4. Nasal form judged to be quite adequate

Clinical assessment of the oblique macroesthetic evaluation: The flattened labiomental sulcus was secondary to the excessive lower facial height, lip incompetence, and chin deficiency.

- Oblique smiling facial observation (Figure 54-9E)
 1. No noticeable anteroposterior cant to the maxillary occlusal plane
 2. The smile arc was consonant
 3. The excessive gingival display was also evident on the oblique smile

Clinical assessment from the oblique smiling macroesthetic evaluation: Since the smile arc was consonant, alteration of the palatal plane would not have been indicated either through surgery or orthodontic incisor repositioning.

- Profile evaluation (Figure 54-9F)
 1. Long lower facial third
 2. Long chin height
 3. Flat labiomental sulcus
 4. Lip strain on closure

Clinical assessment of the profile macroesthetic evaluation: As would be expected from the frontal and oblique characteristics, the lateral profile reflected the overall skeletal and dental characteristics of vertical maxillary excess, but the chin deficiency that became evident on the oblique view was clearly demonstrated on the profile view.

The functional problem of the anterior open bite in this nongrowing patient necessitated superior repositioning of the maxilla to correct the functional complaint (Figure 54-9G–K). The exact surgical movements were directed by the clinical examination and measurements. Because the patient had the clinical diag-

nosis of vertical maxillary excess, maxillary impaction was indicated, but some discretionary decisions were needed for appropriate position of the maxilla from the esthetic standpoint. From the frontal dimension, the left side of the maxilla was impacted 2 mm more than the right in order to level the smile line. The differential degree of impaction reflected the degree of the maxillary compensation for the mandibular asymmetry.

Transverse Facial Proportions The assessment of the transverse components of facial width is best described by the rule of fifths.⁹ This method describes the ideal transverse relationships of the face. The face is divided sagittally into five equal parts from helix to helix of the outer ears (Figure 54-10). Each of the segments should be one eye distance in width. Each transverse fifth should be individually examined and then assessed as a complete group.

The middle fifth of the face is delineated by the inner canthus of the eyes. A vertical line from the inner canthus should be coincident with the alar base of the nose. Variation in this facial fifth could be due to transverse deficiencies or excesses in either the inner canthi or alar base. For example, hypertelorism in craniofacial syndromes can create disproportionate transverse facial esthetics.

A vertical line from the outer canthus of the eyes frames the medial three-fifths of the face, which should be coincident with the gonial angles of the mandible. Although disproportion may be very subtle, it is worth noting since our treatments can positively change the shape or relative proportion of the gonial angles.

The outer two-fifths of the face is measured from the lateral canthus to lateral helix of the ear, which represents the width of the ears. Unless this abnormality is part of the chief complaint, prominent ears are often a difficult feature to discuss with the patient because laypeople only recognize its effect on the face in severe cases. However,

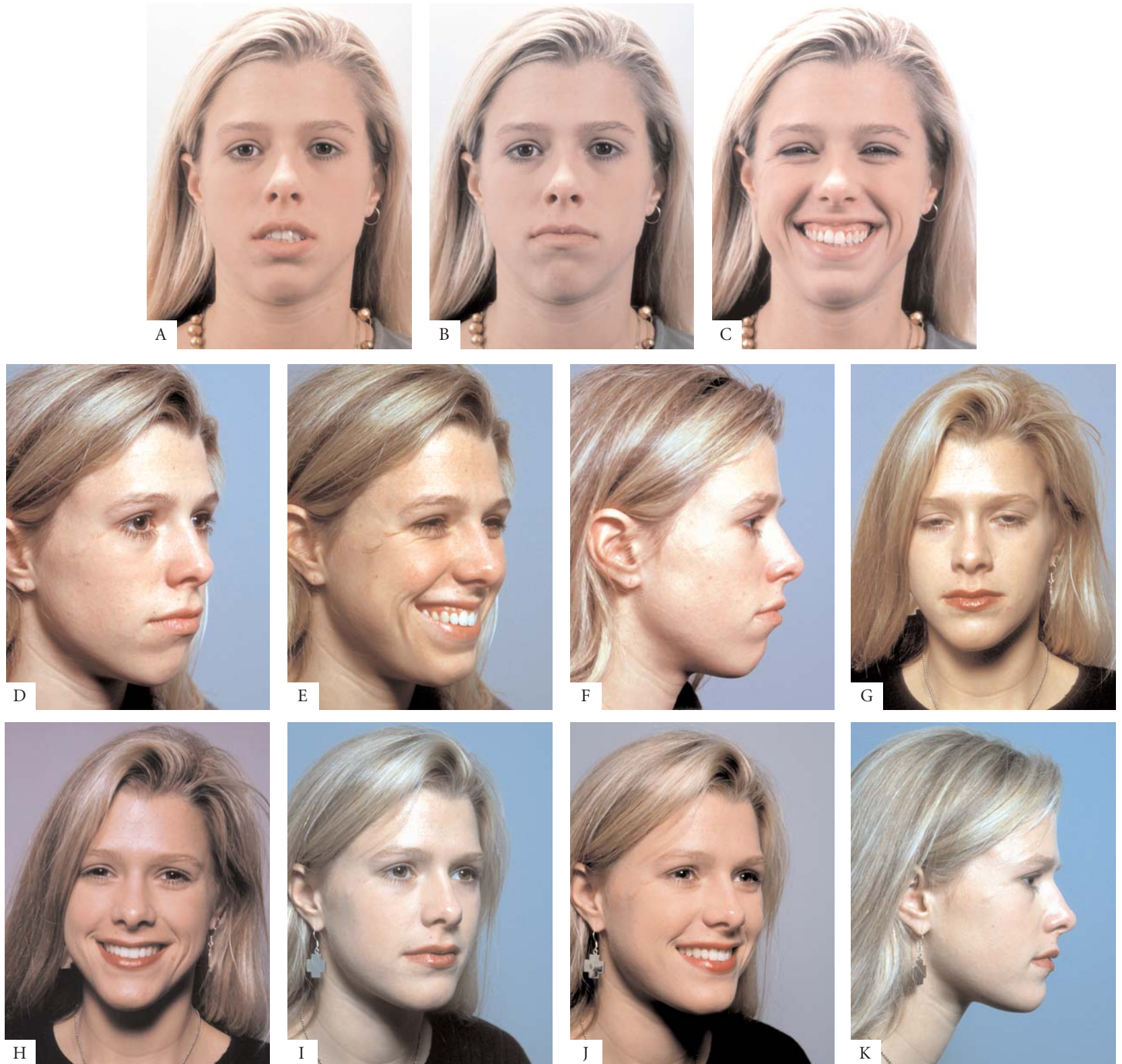

FIGURE 54-9 A, This patient was referred for correction of an anterior open bite and a gummy smile. B, Lip strain on closure. C, Frontal proportions on smile with 100% of maxillary incisor displayed. There was excessive gingival display on smile with 3 mm gingival display at the right cuspid and 5 mm at the left with a transverse cant to the palatal plane. Transverse cant to the maxilla with the left side down 2 mm more than the right. D, Oblique at-rest facial observation with excessive lower facial height, lip strain and excessive chin height, and a flat labiomental sulcus. The nasal form was judged to be quite adequate. E, Oblique smiling facial observation with no noticeable anteroposterior cant to the maxillary occlusal plane. The smile arc was consonant. The excessive gingival display was also evident on the oblique smile. F, Profile evaluation with emphasis on a long lower facial third, long chin height, a flat labiomental sulcus, and lip strain on closure. G–K, The functional problem of the anterior open bite in this nongrowing patient necessitated superior repositioning of the maxilla to correct the functional complaint. The exact surgical movements were obtained from the clinical examination and measurements (see text).




FIGURE 54-10 The face is divided sagittally into five equal parts from helix to helix of the outer ears. The middle fifth of the face is delineated by the inner canthus of the eyes, the inner corner of the eye containing the lacrimal duct. A line from the inner canthus should be coincident with the ala of the base of the nose. A vertical line from the outer canthus of the eyes frames the medial two-fifths of the face, which should be coincident with the gonial angles of the mandible. The outer two-fifths of the face is measured from the lateral canthus to the lateral helix, which represents the width of the ears. Another significant frontal relationship is the midpupillary distance, which should be transversely aligned with the commissures of the mouth.

studies clearly indicate that large ears are judged by laypeople to be one of the most unesthetic features, particularly in males. Otoplastic surgical procedures are relatively atraumatic and can dramatically improve facial appearance. In orthognathic cases in which this disproportion is noted by the clinician, we feel that failure to mention this feature violates informed consent. Therefore, otoplasty should be presented as a treatment option, whether received positively or not. These procedures can be performed on adolescents and adults as is illustrated in Figure 54-11A and B.

Another significant frontal relationship is the midpupillary distance, which



FIGURE 54-11 A, An otoplastic surgical procedure was recommended for this patient's prominent ears. B, The facial transverse fifths were improved, resulting in a dramatic facial improvement.

should be transversely aligned with the commissures of the mouth.¹⁵ Although this is considered the ideal transverse facial proportionality, there is little that can be done therapeutically to correct this disproportion, except in craniofacial synostosis such as Apert syndrome.

Nasal anatomy in the transverse plane should also be assessed through proportionality. The width of the alar base should be approximately the same as the intercanthal distance, which should be the same as the width of an eye. If the intercanthal distance is smaller than an eye width, it is better to keep the nose slightly wider than the intercanthal distance. The width of the alar base is heavily influenced by inherited ethnic characteristics.

Asymmetry of the face is a somewhat natural occurrence. Systematic examination of the patient's facial symmetry should be directly measured in the frontal plane. The following measures compose this portion of the clinical examination.

Nasal Tip to Midsagittal Plane Having the patient elevate the head slightly and then visualizing the nasal tip in relation to the

midsagittal plane provides the best view to evaluate the position of the nasal tip (Figure 54-12). Any deviation of the nasal tip should be noted in relation to the maxillary midline. The clinician should not make the mistake of treating the maxillary midline to a distorted nose. An attempt to obtain the etiology of nasal tip asymmetry is recommended. The

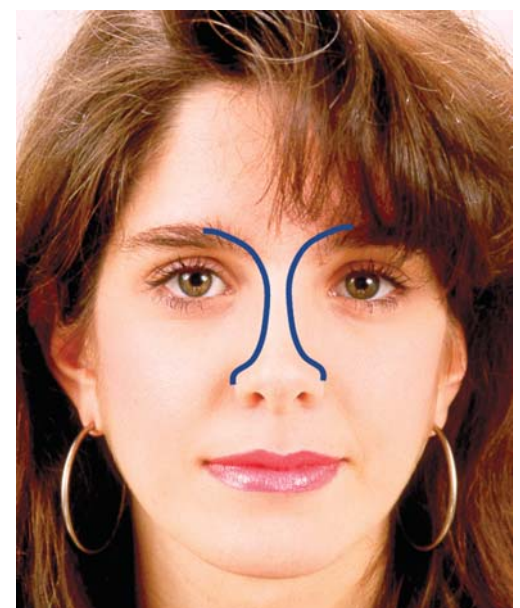

FIGURE 54-12 The "gull in flight" contour of the base of the nose.

patient should be questioned as to any previous history of nasal trauma or nasal surgery for a deviated septum. Patients may then be advised appropriately as to whether this deviation is severe enough to consider correction.

Maxillary Dental Midline to Midsagittal Plane The maxillary dental midline should be recorded relative to the midsagittal plane. A discrepancy could be due to either dental factors or skeletal maxillary rotation. Maxillary rotation is a rarely occurring clinical finding and is usually accompanied by posterior dental crossbite. The dental features of maxillary midline discrepancies will be discussed in both the miniesthetic and microesthetic perspectives.

Mandibular Dental Midline to Midsymphysis The mandibular dental midline to midsymphysis relationship is best visualized by standing behind the patient and then viewing the lower arch from above (Figure 54-13). The patient should open his or her mouth in order for the clinician to view the lower arch and its relationship to the body of the mandible and symphysis. Lower dental midline discrepancies are usually due to tooth related issues such as dental crowding with shifted incisors, premature exfoliation of primary teeth and subsequent space closure in pre-adolescents, congenitally missing teeth, or

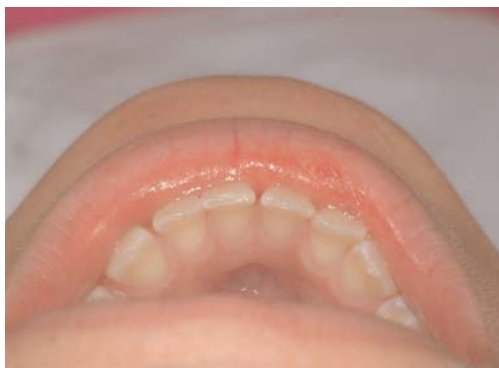

FIGURE 54-13 If the lower dental midline is not coincident with the midsymphysis, it usually indicates a dental shift. However, chin asymmetry should also be considered.

an extracted unilateral tooth. If the lower dental midline is not coincident with the midsymphysis, it usually indicates a dental shift. However, chin asymmetry should also be considered.

Mandibular Asymmetry with or without Functional Shift Mandibular asymmetry is suspected when the midsymphysis is not coincident with the midsagittal plane. An important diagnostic factor is whether a lateral functional shift is present secondary to a functional shift of the mandible due to crossbite. When the patient is manipulated into centric relation, a bilateral, end-to-end crossbite usually is present, and as the patient moves the teeth into full occlusion, the patient must choose a side to move his or her mandible into maximum intercuspation. This lateral shift is indicative not of true mandibular asymmetry but of transverse maxillary deficiency and a resultant functional shift of the mandible.

True mandibular asymmetry is suspected when, in closure into centric relation, no lateral functional shift occurs. The truly asymmetric mandible may be due to an inherited asymmetric facial growth pattern or a result of localized or systemic factors. A thorough history of traumatic injuries and a review of systems of the patient will help ascertain potential etiologies of true mandibular asymmetry.

Chin Asymmetry Facial asymmetry in some cases may be limited to the chin only. If the systematic evaluation of facial symmetry has dental and skeletal midlines and vertical relationships of the maxilla normal and lower facial asymmetry is noted, then the asymmetry may be isolated to the chin. Measurement of the midsymphysis to the midsagittal plane is a logical indicator of chin asymmetry, but the parasymphyseal heights should also be measured when chin asymmetry is suspected (Figure 54-14). The frontal view is recommended, but a view from

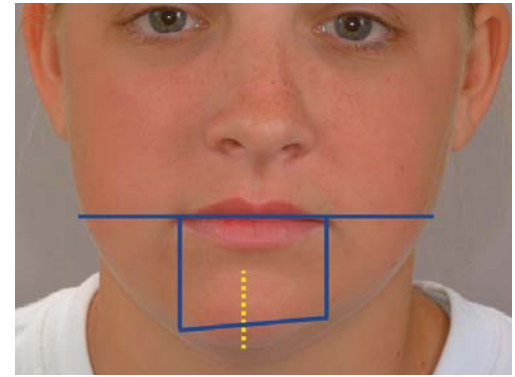


FIGURE 54-14 Measurement of the midsymphysis to the midsagittal plane is a logical indicator of chin asymmetry, but the parasymphyseal heights should also be measured when chin asymmetry is suspected.

the superior facial aspect (much like the evaluation of the mandibular dental midline) with the mouth closed also affords the clinician excellent visualization of the chin to the body of the mandible and the midsymphysis.

Maxillomandibular Asymmetry Mandibular asymmetry is often accompanied by maxillary compensation, which is reflected clinically by a transverse cant of the maxilla. This means that evaluation of mandibular deformity should now include the possibility of maxillomandibular deformity. Transverse tilting of the maxilla may be detectable cephalometrically but is most evident during the macroesthetic examination (Figure 54-15). Clinically, one notes this, for example, as *right maxilla 4 mm more superior than left*. The transverse cant of the maxilla

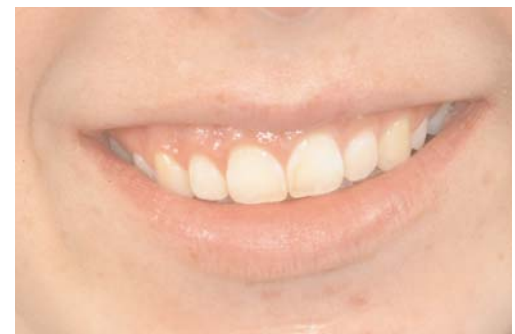

FIGURE 54-15 Transverse tilting of the maxilla may be detectable cephalometrically but is most evident during the macroesthetic examination.

is often determined by the relative difference in gingival show present at the level of the canine moving posterior at smile. Differentiation between the macro- and miniesthetic factors that are related to the transverse cant of the maxilla will be discussed later.

Macroesthetic Examination: Oblique View

The facial areas for macroesthetic examination, as investigated from the oblique view, can be summarized as follows:

- Midfacial
 - Orbital position
 - Nasal form
 - Cheek/zygomatic form
- Lower facial
 - Lip form
 - Philtrum
 - Vermilion
 - Mandibular form
 - Chin projection

The oblique view (Figure 54-16A) in the macroesthetic examination affords the surgeon and orthodontist another perspective for evaluating the facial thirds. With

regard to the upper face, the clinician may view the relative projection of the orbital rim and malar eminence. Orbital and malar retrusion is often seen in craniofacial syndromes. Cheek projection is evaluated in the area of the zygomaticus and malar scaffold. Skin laxity and atrophy of the malar fat pad in this area may actually be a characteristic of aging and therefore seen in the older orthognathic population.¹⁶ This area can be described as deficient, balanced, or prominent. Nasal anatomy, which was described in the frontal examination, may also be characterized in this dimension.

Lip anatomy is also examined in the oblique and lateral views. The philtral area and vermilion of the maxillary lip should be clearly demarcated. The height of the philtrum should be noted as short, balanced, or excessive. Vermilion display should be termed as excessive, balanced, or thin.

The relative projection of the maxilla and mandible can be assessed in the oblique view. Midface deficiency can result in increased nasolabial folding, relaxed upper lip support, and altered columella and nasal tip support.

One of the greatest values of the oblique view is visualization of the body and gonial angle of the mandible as well as the cervicomental area. The patient in Figure 54-16A illustrates a desirable definition of the chin-neck anatomy. The patient in Figure 54-16B has a dolichofacial skeletal pattern with a steeper mandibular plane, not as esthetically pleasing as the previous illustration. The patient in Figure 54-16C demonstrates a brachyfacial pattern with an obtuse cervicomental angle secondary to submental fat deposition.

A characterization of mandibular form is also very important. The oblique view also demonstrates the effects of animation on the appearance of lip and chin projection. The patient in Figure 54-17A and B shows a moderate anterior divergence and facial concavity at rest, but during the smile, animation reveals an increased chin projection with excessive concavity.

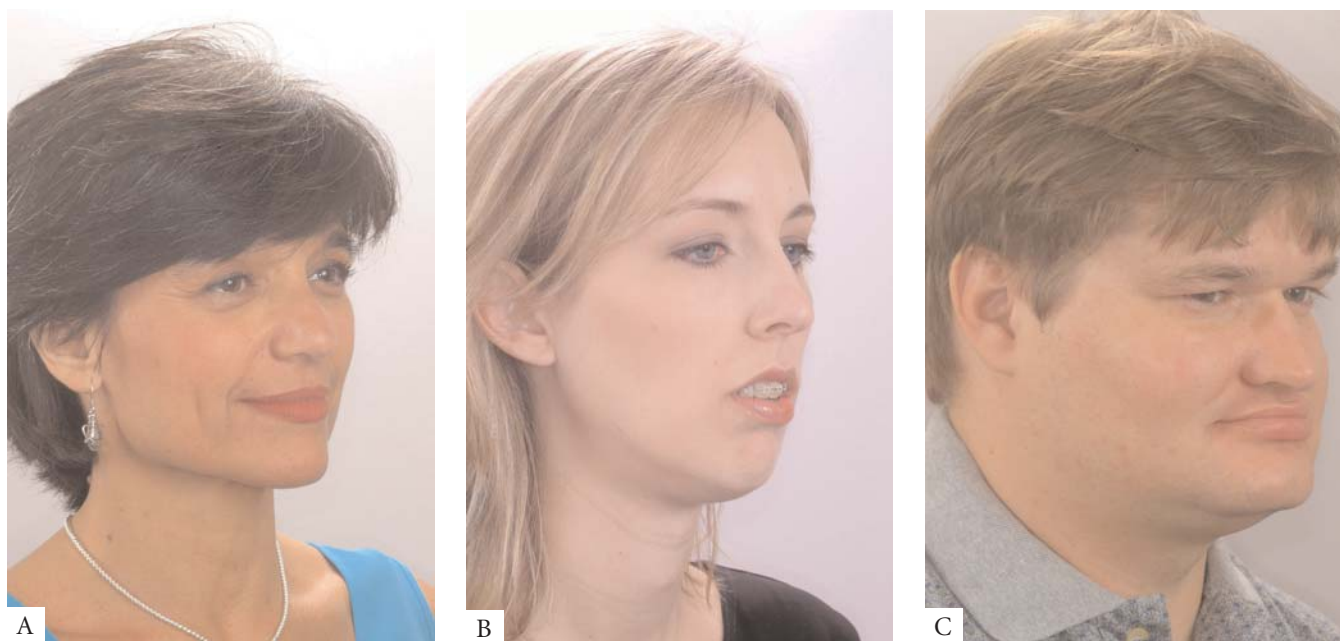

FIGURE 54-16 A, Desirable definition of the chin-neck anatomy. B, A dolichofacial skeletal pattern with a steeper mandibular plane, not as esthetic as the previous illustration. C, A brachyfacial pattern with an obtuse cervicomental angle secondary to submental fat deposition.

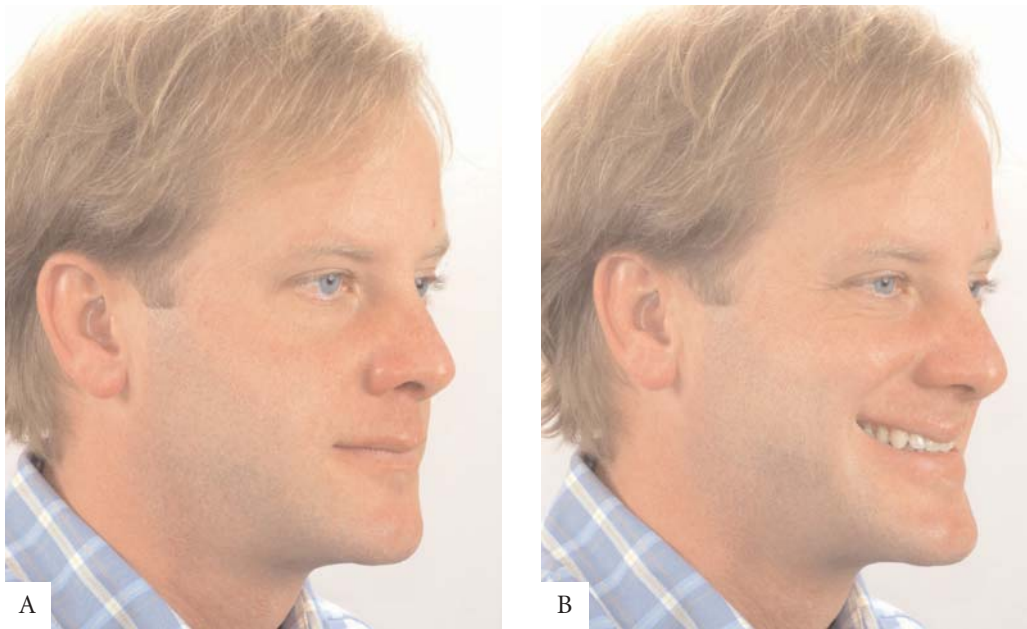


FIGURE 54-17 A, The amount of facial concavity and chin projection at rest is within acceptable limits. B, When this patient animates, an excessive amount of chin projection and facial concavity is revealed.

Macroesthetic Examination: Profile View

The facial areas for macroesthetic examination, as investigated from the profile view, can be summarized as follows:

- Lower facial
 - Maxillomandibular projection or facial divergence
 - Lip form
 - Size
 - Projection
 - Labiomental sulcus
 - Chin projection

The last view in the macroesthetic examination is the profile perspective. Natural head position is essential for accurate evaluation of profile characteristics. The patient should be instructed to look straight ahead and, if possible, into his or her own image in an appropriately placed mirror. The visual axis is what determines “natural head position.” This axis very often, but not always, approximates the Frankfort horizontal plane. The classic vertical facial thirds should also be applied in profile view. An assessment of lower facial deficiency or excess should be noted.

The nasolabial angle describes the inclination of the columella in relation to the upper lip. The nasolabial angle should be in the range of 90 to 120° (Figure 54-18A).¹⁷ The nasolabial angle is determined by several factors: (1) the anteroposterior

position of the maxilla to some degree; (2) the anteroposterior position of the maxillary incisors; (3) vertical position or rotation of the nasal tip, which can result in a more obtuse or acute nasolabial angle; and (4) soft tissue thickness of the maxillary lip that contributes the nasolabial angle, where a thin upper lip favors a flatter angle and a thicker lip favors an acute angle.

The characterization of the lower face in profile (Figure 54-18B) is measured by the relative degree of lip projection, the labiomental sulcus, the chin-neck length, and the chin-neck angle. Maxillary and mandibular sagittal position can be described by means of facial divergence. The lower third of the face is evaluated in reference to the anterior soft tissue point at the glabella. Based on the position of the maxilla and mandible relative to this point, a patient’s profile will be described as straight, convex, or concave, and either anteriorly or posteriorly divergent.

Lip projection is a function of maxillo-mandibular protrusion or retrusion, dental protrusion or retrusion, and/or lip thickness. The description of lip projection

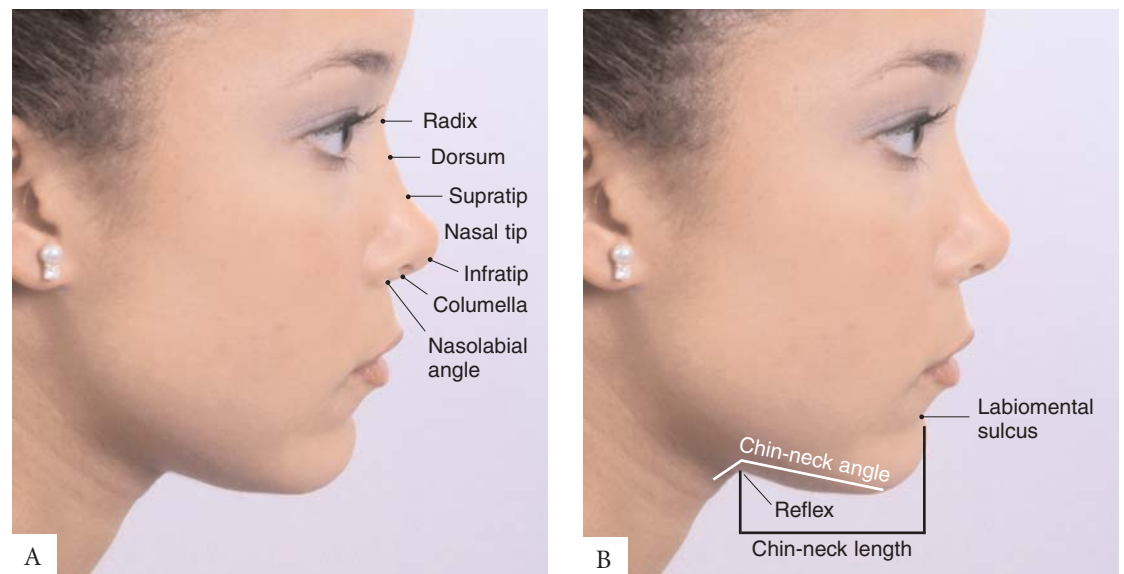


FIGURE 54-18 A, The facial profile view. Superiorly, the radix of the nose is characterized by an unbroken curve that begins in the superior orbital ridge and continues along the lateral nasal wall. The nasal dorsum is made up of both bony and cartilaginous tissues. The nasal tip is described as the most anterior point of the nose, and the supratip is just cephalic to the tip. The columella is the portion of the nose between the base of the nose (subspinale) and the nasal tip. B, The characterization of the lower face in profile is measured by the relative degree of lip projection, the labiomental sulcus, the chin-neck length, and the chin-neck angle.

should include pertinent information from any of the above sources. For example, a patient with lower lip protrusion may be maxillary (midface) deficient with dentoalveolar compensation including flared incisors and a thin maxillary vermilion display, or simply may have a thick lower lip that appears protrusive.

The labiomental sulcus is defined as the fold of soft tissue between the lower lip and the chin and may vary greatly in form and depth. The clinical variables that can affect the labiomental sulcus include (1) lower incisor position, where upright lower incisors tend to result in a shallow labiomental sulcus because of lack of lower lip projection, whereas excessive lower incisor proclination deepens the labiomental sulcus; and (2) vertical height of the lower facial third, which has a direct bearing on chin position and the labiomental sulcus. Diminished lower facial height will usually result in a deeper labiomental sulcus (just as in the overclosed full denture patient), whereas a patient with a long lower facial third has a tendency toward a flat labiomental sulcus.

Chin projection is determined by the amount of anteroposterior bony projection of the anterior, inferior border of the mandible, and the amount of soft tissue that overlays that bony projection. The amount of profile chin projection is measured by the distance from pogonion (or Pg, the most anterior point on the bony chin) to soft tissue pogonion' (or Pg', the most anterior point on the soft tissue profile of the chin) and is not particularly alterable by surgical means. In the adolescent, the amount of chin is directly correlated to the amount of mandibular growth that occurs because the chin point itself is borne on the mandible as it grows anteriorly.

The angle between the lower lip, chin, and R point (the deepest point along the chin-neck contour) should be approximately 90°. An obtuse angle often indicates (1) chin deficiency, (2) lower lip procumbency, (3) excessive submental fat, (4),

retropositioned mandible, and (5) low hyoid bone position.

Another important measure in this area is the chin-neck length and chin-neck angle. The angle, also termed the *cervicomental angle*, has been studied extensively in plastic surgery and orthognathic literature.¹⁸ Studies report that a wide range of normal neck morphology exists, and that the cervicomental angle may vary between 105° and 120°, with gender being a major consideration. Age of the patient must be considered with regard to this area. Soft tissue “sag” due to the loss of skin elasticity during aging is a major cause of change in the cervicomental region. Weight gain is another important factor in the morphology of this area.

Miniesthetic Examination: Frontal View

The facial areas for miniesthetic examination, as investigated from the frontal view, can be summarized as follows:

- Vertical characteristics of the smile
 - Lip-tooth-gingival relationships
 - Gingival display on smile
 - Excessive gingival display on smile
 - Vertical maxillary excess
 - Short philtrum height
 - Excessive curtain
 - Short clinical crown height
 - Upright maxillary incisors
 - Inadequate gingival display on smile
 - Vertical maxillary deficiency
 - Diminished curtain
 - Short clinical crown height
 - Flared maxillary incisors
- Transverse characteristics of the smile
 - Arch form
 - Buccal corridor
 - Cant of the transverse occlusal plane

Vertical Characteristics Lip-Tooth-Gingival Relationships A key feature of vertical facial esthetic characteristics is the

relationship between the incisal edges of the maxillary incisors relative to the lower lip as well as the relationship between the gingival margins of the maxillary incisors relative to the upper lip. The gingival margins of the cuspids should be coincident with the upper lip, and the lateral incisors positioned slightly inferior to the adjacent teeth. It is generally accepted that the gingival margins should be coincident with the upper lip in the social smile. However, this is very much a function of the age of the patient, since children show more teeth at rest and gingival display on smile than do adults.¹⁹

Excessive Gingival Display on Smile

The vertical characteristics of facial miniesthetics impact the relative amount of gingival display at rest and during animation. Gingival display is the amount of “gumminess” of the smile. Measuring the amount of gingival display on smile easily quantitates a “gummy” smile. The decision as to whether the amount of gingival display is an esthetic problem in which treatment is desirable is a personal choice. Orthodontists and oral and maxillofacial surgeons tend to see the “gummy” smile as an unesthetic characteristic, while laypersons attach importance only in the more extreme cases. The use of computerized graphic simulation of the frontal view of the smile is useful in counseling a patient and showing potential treatment changes. The individual is then able to guide the clinician and express opinions about what should and should not be corrected. Computer imaging not only provides the patient with a visual template for treatment but it also provides the clinician with a testing ground for treatment options. The patient in Figure 54-19A exhibits excessive gingival display on smile, secondary to vertical maxillary excess. The diagnosis of vertical maxillary excess is confirmed by the facial characteristics of a long lower facial third, lip incompetence,



FIGURE 54-19 A, This patient exhibits excessive gingival display on smile, secondary to vertical maxillary excess. B, The actual post-treatment outcome.

excessive incisor display at rest, and excessive gingival display on smile. Superior repositioning of the maxilla was performed with excellent facial proportions and smile esthetics (Figure 54-19B).

The patient in Figure 54-20A also exhibited excessive gingival display, but has normal vertical facial proportions. Her incisor crown height, however, is only 8 mm. The etiology of her “gummy” smile is not an orthognathic problem or an orthodontic problem but a cosmetic or periodontal problem. This diagnosis was confirmed and further visualized through computerized image modification (Figure 54-20B and C), simulating the crown-lengthening procedure. Orthodontic intrusion of maxillary incisors would have reduced gingival display but would also have adversely affected the smile arc with concomitant flattening. This case example emphasizes differential diagnosis of gingival display issues and it also emphasizes the optimization of unesthetic facial traits while preserving those positive facial esthetic attributes.

Transverse Characteristics The three transverse characteristics of facial esthetics in the frontal dimension are (1) arch form,

(2) buccal corridor, and (3) the transverse cant of the maxillary occlusal plane.

Arch form plays a pivotal role in the transverse dimension. Recently, much atten-

tion has been focused on using broad square arch forms in orthodontic treatment and orthognathic surgical treatment. In cases in which the arch forms are narrow or collapsed, the smile may also appear narrow and therefore present inadequate transverse smile characteristics. An important consideration in widening a narrow arch form, particularly in the adult, is the axial inclination of the buccal segments. Cases in which the posterior teeth are already flared laterally are not good candidates for dental expansion. Upright premolars and molars allow for a more bodily transverse expansion of the buccal segments in both adolescent and adult patients, but are particularly important in the adult where sutural expansion is less likely. Orthodontic expansion and widening of a collapsed arch form can dramatically improve the appearance of facial esthetics and smile by decreasing the size of the buccal corridors and improving the *transverse smile dimension* (Figure 54-21A and B). The transverse smile dimension

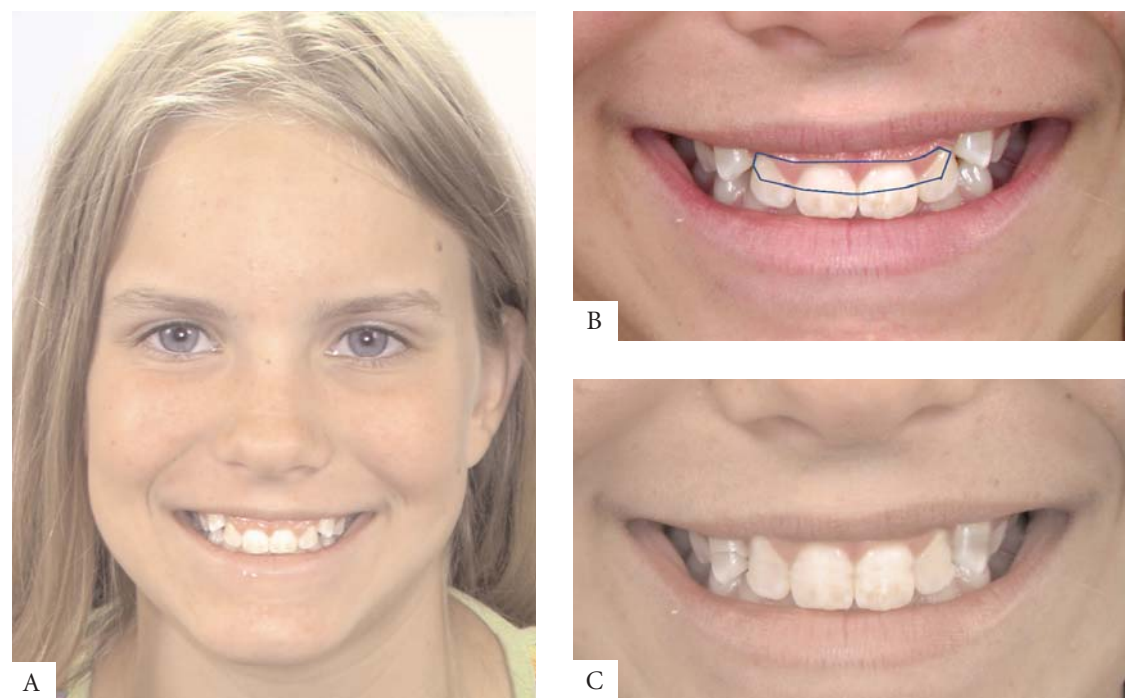

FIGURE 54-20 A, This patient exhibits excessive gingival display, but has normal vertical facial proportions. Her incisor crown height, however, is only 8 mm. The etiology of her “gummy” smile is not an orthognathic problem or an orthodontic problem but a cosmetic or periodontal problem. B and C, This diagnosis was confirmed and further visualized through computerized image modification, simulating the crown-lengthening procedure.

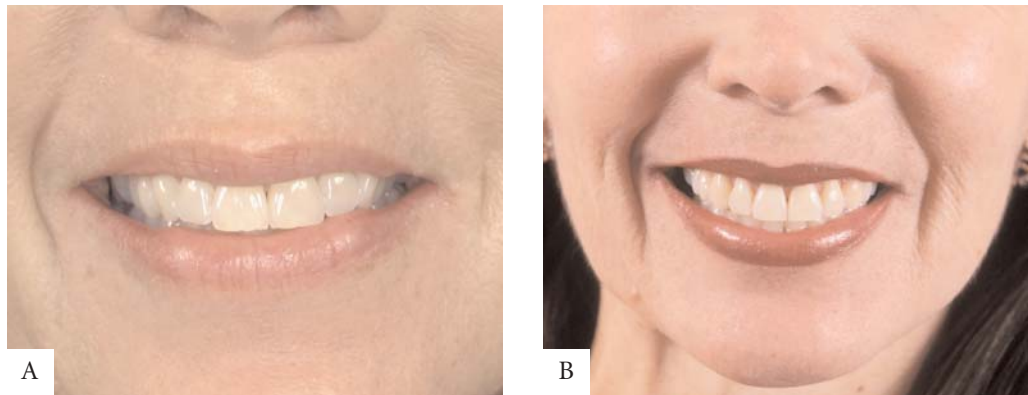


FIGURE 54-21 A, The transverse smile dimension in this patient was characterized by narrow arch form and excessive buccal corridor. In this adult, the axial inclinations of the molars and premolars were favorable for orthodontic expansion. B, The transverse smile dimension after orthodontic treatment.

(and the buccal corridor) is related to the lateral projection of the premolars and the molars into the buccal corridors. The wider the arch form is in the premolar area, the greater would be the portion of the buccal corridor filled.

As alluded to in the previous cases above, arch expansion can have undesirable effects. Expansion of the arch form may fill out the transverse dimension of the smile, but two undesirable side effects may result and careful observation should be made to avoid these side effects wherever possible. First, the buccal corridor can be obliterated and create a “denture”-like smile. Second, when the anterior sweep of the maxillary arch is broadened, the smile arc may be flattened. Although it may not be possible to avoid these undesirable aspects of expansion, the clinician must make a judgment in concert with the patient as to what “trade-offs” are acceptable in the pursuit of the ideal facial esthetic outcome.

The last transverse characteristic of facial esthetics is the transverse cant of the maxillary occlusal plane. Transverse cant of the maxilla can be due to differential eruption and placement of the anterior teeth, and skeletal asymmetry of the skull base and/or mandible resulting in a compensatory cant to the maxilla. Intraoral images or even mounted dental casts do not adequately reflect the relationship of

the maxilla to the smile. Only frontal smile visualization permits the orthodontist to visualize any tooth-related asymmetry transversely.

Smile asymmetry may also be due to soft tissue considerations such as an asymmetric smile curtain. In the asymmetric smile curtain, there is a differential elevation of the upper lip during smile, which gives the illusion of transverse cant to the maxilla. This smile characteristic emphasizes the importance of direct clinical examination in treatment planning the smile, since this soft tissue animation is not visible in a frontal radiograph or reflected in study models. It is not well documented in static photographic images, and is documented best in digital video clips.

Miniesthetic Examination: Oblique View

Miniesthetic examination from the oblique view involves two main areas:

- Orientation of the palatal and occlusal planes
- Smile arc

The oblique view of the smile reveals characteristics of the smile that are not obtainable on the frontal view and certainly not obtainable through any cephalometric analysis. The palatal plane may be canted anteroposteriorly in a number of

orientations. In the most desirable orientation, the occlusal plane is consonant with the curvature of the lower lip on smile (see discussion of *smile arc* below). Deviations from this orientation include a downward cant of the posterior maxilla, upward cant of the anterior maxilla, or variations of both.²⁰ In the initial examination and diagnostic phase of treatment, it is important to visualize the occlusal plane in its relationship to the lower lip.

The *smile arc* should be defined as the relationship of the curvature of the incisal edges of the maxillary incisors, canines, premolars, and molars to the curvature of the lower lip in the posed social smile. The ideal smile arc has the maxillary incisal edge curvature parallel to the curvature of the lower lip upon smile, and the term *consonant* is used to describe this parallel relationship. A *nonconsonant* or flat smile arc is characterized by the maxillary incisal curvature being flatter than the curvature of the lower lip on smile. Early definitions of the smile arc were limited to the curvature of the canines and the incisors to the lower lip on smile because smile evaluation was made on direct frontal view. The visualization of the complete smile arc afforded by the oblique view expands the definition of the smile arc to include the molars and the premolars (Figure 54-22).

Miniesthetic Examination: Profile View

The facial areas for miniesthetic examination, as investigated from the profile view, can be summarized as follows:

- Overjet
- Incisor angulation
 - Upright maxillary incisors
 - Flared maxillary incisors
 - Retroclined mandibular incisors

The two miniesthetic characteristics visualized in the sagittal dimension are overjet and incisor angulation (Figure 54-23). Excessively positive overjet is one of the most



FIGURE 54-22 The smile arc is best visualized in the oblique view, and should be defined as the relationship of the curvature of the incisal edges of the maxillary incisors, canines, premolars, and molars to the curvature of the lower lip in the posed social smile. The 45° view permits visualization of vermilion display, lip fullness, and turgor not readily seen in another view.

recognizable dental traits to the layperson. Adolescents tend to label unflattering names such as “Andy Gump” and “Bucky Beaver” onto children unfortunate enough to have inherited this dentoskeletal pattern. How overjet is orthodontically corrected involves

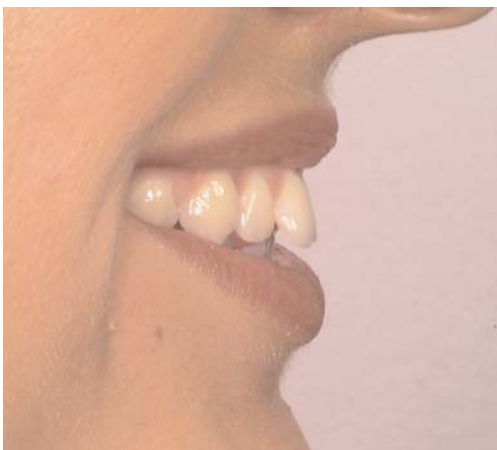

FIGURE 54-23 The two miniesthetic characteristics visualized in the sagittal dimension are overjet and incisor angulation.

macroelements such as jaw patterns and soft tissue elements such as nasal projection. Excessive positive overjet is not as readily perceived in the frontal dimension as it is in the sagittal dimension. Many Class II patterns have very esthetic smiles frontally, but not when the patient’s smile is observed from the side. In Class III patterns, the same phenomenon may be true, in that the smile looks esthetic on frontal smile, but on the oblique or sagittal view, the overall appearance reflects the underlying skeletal pattern and dental compensation. The patient and parents have to decide with the clinician whether this is an acceptable outcome.

The amount of anterior maxillary projection also has great influence on the transverse smile dimension in the frontal view. When the maxilla is retrusive, the wider portion of the dental arch is positioned more posteriorly relative to the anterior oral commissure. This creates the illusion of greater buccal corridor in the frontal dimension. Overall, the sagittal cant of the maxillary occlusal plane in natural head position can influence the smile arc in the frontal dimension, affecting vertical characteristics. A negative cant of this plane will diminish the apposition of the incisal edges of the maxillary anterior teeth to the superior vermilion border of the lower lip at smile.

Dental Examination

The dental component of the clinical examination is the evaluation of any standing periodontal or cariogenic disease process and the assessment of the patient’s occlusion. The areas for dental examination can be summarized as follows:

- Alignment
 - Crowding
 - Spacing
 - Missing or supernumerary teeth
- Anteroposterior
 - Angle classification
 - Overjet
 - Compensation

- Bite depth
 - Anterior
 - Posterior
 - Compensation
- Transverse
 - Compensation
- Functional occlusal issues
 - Missing teeth and sequelae
 - Occlusal interferences and para-function

Intra-arch and interarch relationships are described in the categories of dental alignment, anteroposterior occlusion, and bite depth. Clinically, the patient’s occlusion should be examined both in a static and dynamic sense.

The maxillary and mandibular dental arches are described as either well aligned, crowded, or spaced. The extent of crowding or spacing is usually noted in millimeters. Individual teeth are described by virtue of their spatial position and degree of rotation. Therefore, an incisor could be described as severely rotated and in linguoversion. Any congenitally missing, lost, or supernumerary teeth are noted. A description of teeth that have been severely worn or damaged due to trauma should be included.

In terms of the static occlusion, Angle’s classification of the patient should be recorded. The Angle Class I relationship is such that the mesiobuccal cusp of the maxillary first molar should rest in the buccal groove of the mandibular first molar. The Angle Class II relationship exhibits a more anterior position of the mesiobuccal cusp of the maxillary first molar and the Angle Class III relationship exhibits a more posterior position of the mesiobuccal cusp of the maxillary first molar. The degree of incisor overjet that accompanies an anteroposterior discrepancy should also be noted.

Concepts of Incisor Compensation
Incisor compensation in the sagittal view is very important in planning the presurgical

orthodontics, yet not fully recognized by both orthodontists and surgeons alike. In most cases of skeletal dysplasia, whether in the range of surgical or nonsurgical treatment, dental compensation is a common feature. The forms and expression of this compensation are as complex as the myriad of dentoskeletal problems that exist, but there are common patterns frequently encountered. In the diagnosis and proper treatment of these cases, the primary responsibility of the orthodontist is to recognize these compensations and eliminate or *decompensate* them. The range of which compensations are problematic is not concrete, so the surgeon and the orthodontist must decide how much compensation is acceptable and what is to be done for decompensation. Although we tend to think of these compensations as an anteroposterior consideration (incisor angulation problems), dental compensation can occur in all planes of space.

Class II and Class III Problems The classic pattern of compensation in Class II skeletal patterns is the proclination of the mandibular incisors and retroclination of the maxillary incisors. Conversely,

Class III skeletal dysplasias often feature retroclination of the mandibular incisors and proclination of the maxillary incisors. The orthodontist must recognize these compensations and decide what degree of compensation is acceptable and what requires substantive treatment. For example, if lower incisor flare in the Class II patient is only moderate, what is the value of removing two mandibular premolars to upright the incisors? These decompensation decisions affect the treatment outcome in three basic ways: (1) inadequate incisor positioning can compromise buccal interdigitation; (2) incisor positioning can substantially affect the esthetic outcome; and (3) in certain types of functional problems such as obstructive sleep apnea syndrome, esthetic considerations have a lower priority compared to correction of the functional problem.

The effect of incisor angulation on buccal occlusal relationships was advanced and best expressed by Andrews.²¹ In presurgical preparation for mandibular advancement, maxillary incisors that are not properly flared or mandibular incisors that are left overly

flared may result in the following: (1) insufficient overjet to provide for adequate advancement of the mandible from the esthetic standpoint, and (2) the inability to achieve desired Class I buccal segments because the advanced nature of the lower incisor edge does not permit interdigitation of the buccal segments (Figure 54-24A and B). The appropriate amount of incisor angulation can be determined either through cephalometric investigation or by simply holding study models in a simulated Class I molar relationship.

Vertical Characteristics and Compensations *Bite Depth* The vertical component of the dental examination describes bite depth. A patient's anterior bite depth is the amount of maxillary incisor overbite relative to the mandibular incisors. Therefore, a patient can be described as having an anterior open bite, satisfactory bite (25 to 50% overbite), or an anterior deep bite. The posterior bite depth is usually characterized as being open, satisfactory, or collapsed. The latter is seen when the patient is missing unilateral or bilateral posterior dental units.

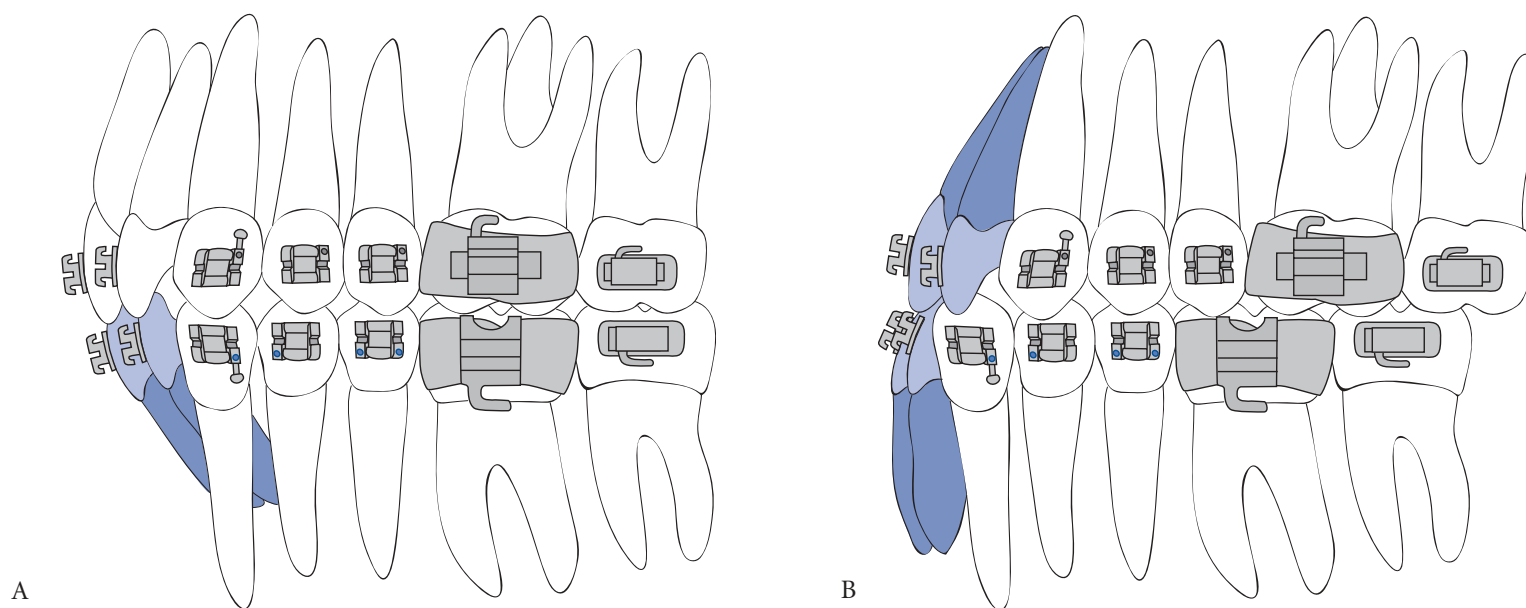


FIGURE 54-24 A, Inadequate decompensation in Class II correction makes Class I buccal segments not attainable because the flared lower incisors do not permit interdigitation of the posterior segments. B, Inadequate decompensation in Class III correction makes Class I buccal segments not attainable because the upright lower incisors or flared maxillary incisors do not permit interdigitation of the posterior segments.

Curve of Spee Dental compensation in the vertical plane has to do with aberrations in the curve of Spee. The curve of Spee is measured by the arc extending from the cusp tips of the incisors posteriorly to the cusp tips of the molars in a sagittal view. Clinically, the study model can be placed on a flat surface and the cusp tips relative to that flat plane will give a rough estimate of the maxillary and mandibular curve of Spee. This is an important diagnostic feature of model analysis in recognizing potential pitfalls that may be encountered during orthodontic preparation for orthognathic surgery. For example, in a patient in whom the anterior segment is significantly superior (greater than 2 mm) to the posterior segment, failure to recognize this occlusal plane differential may result in orthodontic flattening prior to surgery and postsurgical relapse, resulting in anterior open bite.²²

Transverse Compensations The Class II patient often has narrowing of the maxilla in response to the narrower portion of the mandible being placed in the broader portion of the maxillary arch. In the Class III patient, the maxillary posterior segments are often flared buccally in compensation for the wider portion of the mandible being placed into the narrower aspect of the maxilla. By holding the study models in a simulated Class I relationship, these compensations can be easily recognized (Figure 54-25).

Functional Occlusal Issues The last portion of the dental examination relates to dynamics of occlusal function. The clinician should ascertain whether the patient exhibits a discrepancy between maximum intercuspal position and retruded contact position in the anteroposterior dimension. In general, small differences exist in the vast majority of patients. Only large slides should be recorded. If the patient's dentition is mutilated the clinician should note the resultant occlusal compensa-

tions. Any supererupted teeth will create lateral and anteroposterior interferences. A history of bruxism or other parafunctional habits will affect orthodontic appliances and will impact on the type of retention used post-treatment.

Microesthetic Examination

The microesthetic portion of the clinical examination focuses on the morphology of tooth-to-tooth contacts and the surrounding intraoral tissues, summarized as follows:

- Dentogingival relationships
Tooth form/tooth contact/gingival architecture

As a structural unit, the dentogingival complex is defined by the relationship of the teeth to the alveolar bone and surrounding gingival and masticatory mucosa. The factors that influence the appearance of the dentogingival complex are the patient's periodontal status and past history of disease, the proximal and occlusal contacts of the teeth, the shape of the individual teeth, and the type of gingival architecture.

An assessment of the patient's current periodontal status is exceedingly important from an orthodontic and surgical point of view. The clinician should take an accurate dental history in order to ascertain whether the patient has had any periodontal disease and related treatment. Clinically, the teeth should be examined for plaque accumulation and any supragingival calculus. Patients who cannot maintain a satisfactory level of oral hygiene are at risk for gingival inflammation, attachment loss, and caries during presurgical orthodontic treatment. Periapical radiographs combined with a panoramic radiograph will reveal alveolar architecture and any evidence of horizontal or vertical bone loss. Suspected periodontal defects should be probed and the depths recorded. The extent of attachment loss and degree of tooth mobility will influence tooth movement.

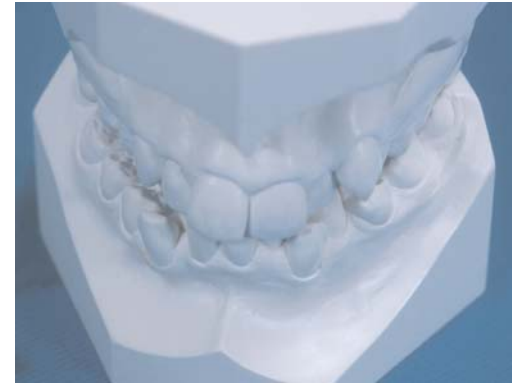

FIGURE 54-25 Transverse problems are first diagnosed by holding the study models together in a simulated Class I relationship. The most commonly found transverse problem is that the maxilla is narrower than the mandible in cases similar to that of this patient who was being evaluated for Class II correction by mandibular advancement.

Surgical treatment planning of the segmental Le Fort I osteotomy should consider gingival architecture in relation to maxillary segmentation. If the incisions are made mesial to the maxillary canines, the patient may lose the interdental papilla in between this tooth and the maxillary lateral incisor. By positioning the incisions distal to the maxillary canines, an obliterated papilla can be more easily camouflaged due to the convexity of the canine.

Computerized Cephalometric Prediction

For computer image prediction, a digital model of the cephalometric tracing must be entered into computer memory. It is important that the radiograph be obtained in natural head position, with the teeth lightly together and in retruded contact position and the lips relaxed. The details of the digital model vary among the several currently available software programs but the similarities are more impressive than the differences. The more points in the digital model, the greater the anatomic fidelity of that model. On the other hand, the more points that are digitized, the more time it takes to perform the digitization process.

A lateral image of the patient's profile, matching the cephalograms as closely as

possible in head position and lip posture, must be captured and entered into the computer program (either directly via digital photography or by scanning a slide). Ideally, the radiograph and profile image would be taken simultaneously, although the hardware arrangement to do this does not yet exist.

The patient in Figure 54-26A presented for correction of a severe Class II dentofacial deformity. After clinical examination and diagnostic records, digital image integration and algorithmic projections are used for consultation with the patient.

After the records are gathered, the next step in the treatment planning is to superimpose the profile image and radiograph, with the hard and soft tissues matched to each other as closely as possible. Most programs use the profile as the major method of image coordination. Once the images are coordinated, any cephalometric analysis can be displayed, although in contemporary surgical planning, the goal of treatment is not what the analysis indicates.

At that point, a “treatment screen” (Figure 54-26B) provides the clinician with “handles” (the blue squares) by which selected sections of hard tissue can be moved (eg, the mandible, the maxilla, or maxillary incisor segment); the procedures similar to the use of templates and manual prediction. In this case illustration, surgical mandibular advancement is being contemplated. Dental compensation is present in the form of flared mandibular incisors, and decompensation is recommended to decompensate the dentition in order to increase the overjet, thus maximizing the magnitude of mandibular advancement. Simulation of lower first premolar extraction and lower incisor retraction is made on the treatment screen; the software applies its imbedded algorithms for profile prediction and creates a new line drawing of the profile (Figure 54-26C) reflecting the expected profile change after incisor decompensation. The algorithms may be ratios based on regressive equations and multiple correla-

tions. They are not the same in all programs: the quality of the algorithms is the major determinant of how well or poorly the predicted profile matches the actual change produced by the treatment. The quantitative table on the right of Figure 54-26C provides to the clinician the measurements of the movements made on screen calibrated to actual movements required clinically to achieve the projected change.

After decompensation movements are simulated, the mandible is advanced on the treatment screen to ideal overjet, and the software then “warps” the original profile image to fit the prediction line drawing, producing an image that conveys much more visual information to the clinician and patient than the line drawing (Figure 54-26D). As treatment is being planned, the amount of change is suggested until, within the limits of possible surgical change, it looks best; it is advantageous to include the patient in this process of adjusting the amount of change to provide an optimal outcome. In this case, a comparison image is generated so the patient may visualize the profile outcome expected with mandibular advancement (Figure 54-26E). The profile was judged to be improved but was still clearly chin deficient. Simulation of chin advancement is then performed (Figure 54-26F), not by using any cephalometric norm or predetermined value, but by simply using the facial outline as a guide. In other words, the chin is moved horizontally and vertically until it meets the approval of the patient. The projected final profile image is depicted in Figure 54-26G. The quantitative table reflects the exact movements in millimeters so that the surgeon and orthodontist have a precise plan for the amount of change needed to produce the desired result seen in Figure 54-26H. Presurgical planning using this methodology should eliminate “on-the-table” estimates of whether or not the patient needs “a bit more chin.” It is ludicrous to make esthetic treatment decisions with the patient under general anesthesia,

horizontal, fully draped, paralyzed, and with a nasal tube in place.

An important consideration is the accuracy of the computer prediction process. Although it is far from perfect (some computer programs are more accurate than others), it is good enough to be clinically useful.²³⁻²⁷ Chin predictions are usually quite accurate and those of the upper lip are reasonably good, whereas predictions of the lower lip can be problematic. As the data on which algorithms are based become more extensive, as different algorithms are applied when vertical and anterior changes occur, and as multiple regression equations replace simple ratios, accuracy can be expected to improve.²⁸

It could be said that in this era of informed consent and bioethical decision-making, the patient should be actively involved in the process of computer prediction and treatment planning. Cultural and familial traits may be important to the patient. Surgeons and orthodontists tend to want to “optimize” all patients to the prevailing esthetic norm, which diminishes any ethnic variation in dentofacial appearance.

Synthesis of an Optimized Problem List

The data derived from the systematic clinical examination and analysis of patient records are synthesized into a diagnostic optimized problem list. Essentially there are two branches in the problem-solving tree: esthetics and function. Thus, the diagnostic problem list should be subdivided into the categories of macroesthetic problems, miniesthetic problems, microesthetic problems, and functional problems. All recognizable problems that are relevant to the patient’s chief complaint should be rank-ordered. Lastly, each problem should be evaluated in terms of its therapeutic modifiability.

Conceptually and operatively, the orthodontist and surgeon have to visualize the desired solution to the specific problem and then assess whether the given solution will negatively impact some other dentofacial

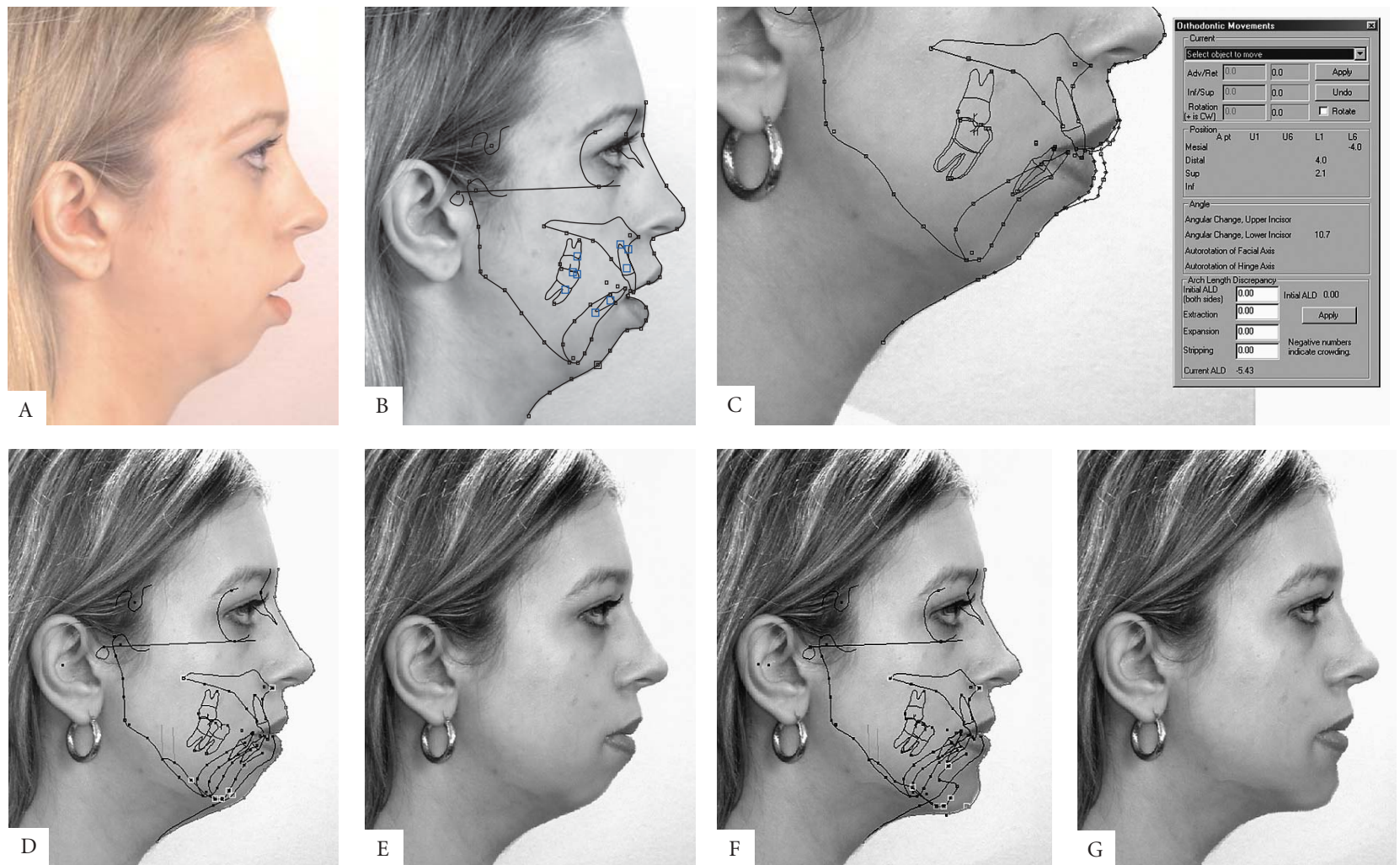
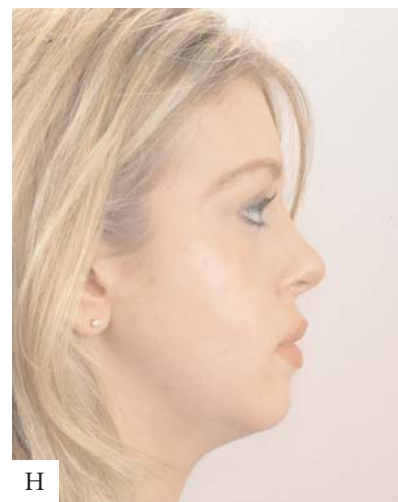

FIGURE 54-26 A, This patient presented for correction of a severe Class II dentofacial deformity. B, A “treatment screen” provides the clinician with “handles” (the blue squares) by which selected sections of hard tissue can be moved (eg, the mandible, the maxilla, or the maxillary incisor segment); the procedures are similar to the use of templates and manual prediction. C, Simulation of lower first premolar extraction and lower incisor retraction is made on the treatment screen. The software applies its imbedded algorithms for profile prediction and creates a new line drawing of the profile reflecting the expected profile change after incisor decompensation. D, After decompensation movements are simulated, the mandible is advanced on the treatment screen to ideal overjet, and the software then “warps” the original profile image to fit the prediction line drawing, producing an image that conveys much more visual information to the clinician and patient than the line drawing. E, In this case, a comparison image is generated so that the patient may visualize the profile outcome expected with mandibular advancement. F, Simulation of chin advancement is then performed, not by using any cephalometric norms or predetermined value, but by simply using the facial outline as a guide. G, The projected final profile image. H, The actual treatment result.



feature at the same time. The concept of facial optimization involves the preservation of as many positive elements as possible, while harmonizing those elements that fall short of the esthetic and functional needs of the patient. The problems that

might exceed the limitations of treatment or perhaps have a poor therapeutic prognosis should be described. Informed consent and bioethical treatment of the surgical patient requires that the clinician explain the risk/benefit considerations of the pro-

posed treatment strategy. The goal of the systematized clinical examination and optimized problem-oriented diagnosis is to record and analyze the data in such a way that the required treatment becomes implicit in the description of the problem.

References

- Jacobson A. The proportionate template as a diagnostic aid. *Am J Orthod* 1979;75:156–72.
- Jacobson A. Orthognathic diagnosis using the proportionate template. *Oral Surg* 1980;238:820.
- Jacobson A, editor. *Radiographic cephalometry: from basics to videoimaging*. Carol Stream (IL): Quintessence Publishing Co.; 1995.
- Broadbent BH Sr, Broadbent BH Jr, Golden WH. *Bolton standards of dentofacial developmental growth*. St. Louis (MO): C.V. Mosby Co.; 1975.
- Sonnesen L, Bakke M, Solow B. Malocclusion traits and symptoms and signs of temporomandibular disorders in children with severe malocclusion. *Eur J Orthod* 1998;10:543–59.
- McNamara JA. Orthodontic treatment and temporomandibular disorders. *Oral Surg Oral Med Oral Pathol Oral Radiol Endod* 1997;83:107–17.
- Sarver DM, Ackerman JL. About face — the re-emerging soft tissue paradigm. *Am J Orthod Dentofacial Orthop* 2000;117:575–6.
- Sarver DM, Ackerman MB. Dynamic smile visualization and quantification: part 1. Evolution of the concept and dynamic records for smile capture. *Am J Orthod Dentofacial Orthop* 2003;124:4–12.
- Sarver DM. *Esthetic orthodontics and orthognathic surgery*. St. Louis (MO): C.V. Mosby Co.; 1997.
- Sarver DM. The smile arc — the importance of incisor position in the dynamic smile. *Am J Orthod Dentofacial Orthop* 2001;120:98–111.
- Ackerman JL, Ackerman MB, Brensinger CM, Landis JR. A morphometric analysis of the posed smile. *Clin Orth Res* 1998;1:1–11.
- Ackerman MB. Digital video as a clinical tool in orthodontics: dynamic smile design in diagnosis and treatment planning. 29th Annual Moyers Symposium on Information Technology and Orthodontic Treatment. Vol 40. Ann Arbor (MI): University of Michigan Press; 2003.
- Farkas LG, Munro JR. *Anthropometric facial proportions in medicine*. Springfield (IL): Charles C. Thomas Publisher Ltd; 1987.
- Peck H, Peck S. A concept of facial esthetics. *Angle Orthod* 1970;40:284–317.
- Mazur A, Mazur J, Keating C. Military rank attainment of a West Point class: effects of cadets' physical features. *Am J Soc* 1984;90:125–50.
- Pessa JA. The potential role of stereolithography in the study of facial aging. *Am J Orthod Dentofacial Orthop* 2001;119:117–20.
- Krugman ME. Photo analysis of the rhinoplasty patient. *J Ear Nose Throat* 1981;60:56–9.
- Sommerville JM, Sperry TP, BeGole EA. Morphology of the submental and neck region. *Int J Adult Orthod* 1988;3:97–106.
- Zachrisson BU. Esthetic factors involved in anterior tooth display and the smile: vertical dimension. *J Clin Orthod* 1998;32:432–45.
- Burstone CJ, Marcotte MR. The treatment occlusal plane. In: *Problem solving in orthodontics: goal-oriented treatment strategies*. Chicago (IL): Quintessence Publishing Co.; 2000. p. 31–50.
- Andrews LF. *Straight wire: the concept and the appliance*. San Diego (CA): L.A. Wells Inc.; 1989.
- Lo FM, Shapiro PA. Effect of presurgical incisor extension on stability of anterior open bite malocclusion treated with orthognathic surgery. *Int J Adult Orthod Orthognath Surg* 1998;13:23–34.
- Sinclair PM, Kilpelainen P, Phillips C, et al. The accuracy of video imaging in orthognathic surgery. *Am J Orthod Dentofacial Orthop* 1995;107:177–85.
- Upton PM, Sadowsky PL, Sarver DM, Heaven TJ. Evaluation of video imaging prediction in combined maxillary and mandibular orthognathic surgery. *Am J Orthod Dentofacial Orthop* 1997;112:656–65.
- Syliangco ST, Sameshima GT, Kaminishi RM, Sinclair PM. Predicting soft tissue changes in mandibular advancement surgery: a comparison of two video imaging systems. *Angle Orthod* 1997;67:337–46.
- Sameshima GT, Kawakami RK, Kaminishi RM, Sinclair PM. Predicting soft tissue changes in maxillary impaction surgery: a comparison of two video imaging systems. *Angle Orthod* 1997;67:346–54.
- Kazandjian S, Sameshima GT, Champlin T, Sinclair PM. Accuracy of video imaging for predicting the soft tissue profile after mandibular set-back surgery. *Am J Orthod Dentofacial Orthop* 1999;115:382–89.
- Peters DG. *Lower lip changes in surgical correction of Class I malocclusion [Master's dissertation]*. Chapel Hill (NC): University of North Carolina; 2001.

Orthodontics for Orthognathic Surgery

Larry M. Wolford, DMD

Eber L. L. Stevao, DDS, PhD

C. Moody Alexander, DDS, MS

Joao Roberto Goncalves, DDS, PhD

Moderate to severe occlusal discrepancies and dentofacial deformities in late adolescents and adults usually require combined orthodontic treatment and orthognathic surgery to obtain optimal, stable, functional, and esthetic results. The basic goals of orthodontics and orthognathic surgery are to (1) satisfy the patients' concerns, (2) establish optimal functional outcomes, and (3) provide good esthetic results. To accomplish this the orthodontist and the oral and maxillofacial (OMF) surgeon must be able to correctly diagnose existing dental and skeletal deformities, establish an appropriate treatment plan, and properly execute the recommended treatment. The orthodontist is limited, to a great extent, by growth, and although the orthodontist can move teeth and, to some degree, the alveolar bone, he or she does not have any appreciable effect on the basal bone of the jaws. The orthodontist's role is to align the teeth relative to the maxillary and mandibular jaws. The OMF surgeon is responsible for surgically repositioning the jaw(s) and associated structures.

It is very important to listen to and understand the patients concerns. Empa-

thetic listening from the first appointment and throughout the treatment will build trust, improve communication, and help provide a quality end result for all parties involved. Comprehensive analysis of the patient and the complete orthodontic records (cephalograms, pantomograms, photographs, dental models) are important for diagnosis and development of the presurgical orthodontic goals. Although detailed analysis of the patient's facial and jaw structures from a clinical and radiographic perspective are vitally important, the focus of this chapter will be the teeth and orthodontic considerations in preparation for orthognathic surgery. Other important factors in diagnosis, treatment planning, and outcomes, such as patient concerns, psychosocial factors, masticatory dysfunction, airway problems, speech difficulties, temporomandibular joint (TMJ) pathologies, and comprehensive orthognathic surgery work-up are discussed elsewhere in this book.

The normal values provided in this chapter are not absolutes for every patient because of individual size, morphologic variances, and racial and ethnic differ-

ences. They are provided as a guide to help the clinician evaluate his or her patient.

Establishing an all-inclusive diagnosis is paramount to developing a comprehensive treatment plan. The orthodontist must determine the orthodontic goals based on the pretreatment findings and on the projected treatment outcome. This chapter will first present orthodontic diagnostic information, followed by orthodontic treatment considerations.

Clinical and Dental Model Diagnosis

From an orthodontic standpoint, in evaluating the occlusion and dental factors, the clinical and dental model analyses correlated with the cephalometric analysis provide the most information for diagnosis and treatment planning. There are 12 basic evaluations that are helpful for these determinations.

1. Arch length: This assessment correlates the mesiodistal widths of the teeth relative to the amount of alveolar bone available and aids in identifying the presence of crowding or

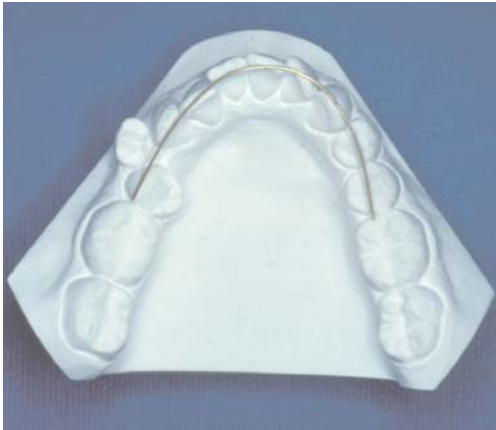

FIGURE 55-1 Arch length assessment correlates the mesiodistal widths of the teeth relative to the amount of alveolar bone available and aids in identifying the presence of crowding or spacing. The curved wire illustrates ideal cuspid and incisor tip position relative to the basal bone.

spacing. This helps determine if teeth need to be extracted or if spaces need to be either created or closed (Figure 55-1). Clinical and dental model assessment correlated to cephalometric analysis will aid in determining arch length requirements. Generally Class II patients will tend to have more crowding in the mandibular arch and less in the maxillary arch, whereas Class III patients may have spacing in the mandibular

arch but a tendency for crowding in the maxillary arch.

2. Tooth-size analysis: This analysis relates the mesiodistal width of the maxillary teeth compared with the mandibular teeth. A tooth-size discrepancy (TSD) causes incompatibility of the dental alignment and can occur in the anterior teeth, premolars, and molars. Approximately 40% of patients with dentofacial deformities will have an anterior TSD affecting the anterior six teeth of the maxillary and mandibular arches (the mandibular arch is commonly too large compared with the maxillary arch), usually due to small maxillary lateral incisors. In such cases proper tooth alignment with all spaces closed often precludes the establishment of a good Class I cuspid-molar relationship with treatment. Instead, a Class II end-on cuspid-molar occlusal relationship may result. Occasionally the maxillary anterior six teeth may be too large for the mandibular anterior teeth, creating an excessive anterior overjet when in a Class I cuspid relationship. Determination of a TSD pretreatment will provide the opportunity to correct the TSD during the presurgical orthodon-

tic phase of treatment. Explaining to the patient, before treatment, that small maxillary lateral incisors may need restorative bonding to maximize the quality esthetic and functional outcome is important, so that the patient is aware from the onset of the time and financial commitment necessary for treatment. The normal mesiodistal widths of each of the permanent teeth are recorded in Tables 55-1 and 55-2. Variations from the norm may create difficulties in the teeth fitting properly.

Bolton's analysis is a method to correlate the widths of the maxillary and mandibular anterior six teeth. Needle-point calipers can be used to measure each individual tooth, and successive holes punched into a tablet for each of the anterior six teeth for each arch. Then a measurement from the first to last holes will give the summation of mesiodistal widths of the anterior six teeth for each arch (Figures 55-2 and 55-3). The summation of the mesiodistal widths of the maxillary anterior six teeth measured at the contact level, divided into the combined width of the mandibular anterior six teeth, yields a value called

Table 55-1 Maxillary Mesiodistal Teeth Diameters

	Central Incisor*	Lateral Incisor*	Cuspids*	First Bicuspid*	Second Bicuspid*	First Molars*	Second Molars*
Males	8.9 (0.59)	6.9 (0.64)	8.0 (0.42)	6.8 (0.47)	6.7 (0.37)	10.6 (0.56)	9.5 (0.71)
Females	8.7 (0.57)	6.8 (0.64)	7.5 (0.36)	6.6 (0.46)	6.5 (0.46)	10.2 (0.58)	8.8 (0.73)

Adapted from Moyers RE et al.² *Measurements in mm (SD).

Table 55-2 Mandibular Mesiodistal Teeth Diameters

	Central Incisor*	Lateral Incisor*	Cuspids*	First Bicuspid*	Second Bicuspid*	First Molars*	Second Molars*
Males	5.5 (0.32)	6.0 (0.37)	7.0 (0.40)	6.9 (0.63)	7.2 (0.47)	10.7 (0.60)	10.0 (0.67)
Females	5.5 (0.34)	5.9 (0.34)	6.6 (0.34)	6.8 (0.70)	7.1 (0.46)	10.3 (0.74)	9.5 (0.59)

Adapted from Moyers RE et al.² *Measurements in mm (SD).

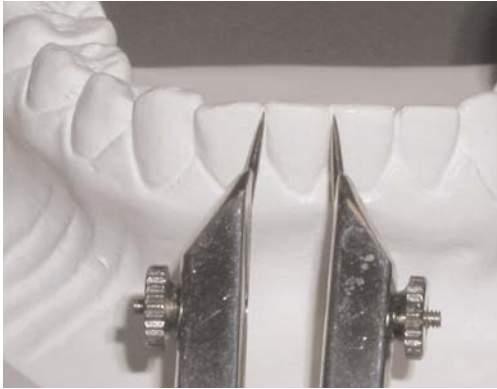

FIGURE 55-2 Bolton's analysis. Needle-point calipers are used to measure each tooth at a contact-point level to aid in tooth-size analysis.

the intermaxillary (Bolton's) index. The average index (percentage) is 77.5 ± 3.5 .¹ A simple conversion of this factor would be to measure the width of the mandibular anterior six teeth and then multiply that sum by 1.3. This results in a calculated ideal maxillary arch width. The difference between the calculated and the actual maxillary arch width values determines the TSD (see Figure 55-3). This evaluation is very helpful in determining presurgical orthodontic and surgical goals. TSDs can also occur in the premolar and molar areas (normally the same maxillary and mandibular teeth are similar in size) where the mandibular teeth may be significantly larger than the maxillary teeth.

The Bolton's analysis is not perfect and functions only as a guide in assessing the tooth-size compatibility of the anterior teeth because it does not take into consideration the labiolingual thickness of the incisors, the axial inclination of the teeth, or the thickness and prominence of the marginal ridges. A thin labiolingual dimension of the maxillary incisors may compensate for small TSDs, but thicker than normal dimensions or prominent marginal ridges may preclude a Class I cuspid relationship




FIGURE 55-3 Bolton's analysis. Successive holes are punched into a tablet for each of the anterior six teeth for each arch. Then measuring from the first hole to the last hole will give the summation of the mesiodistal widths of the anterior six teeth in each arch. Multiplying the summation of the mandibular anterior six teeth (LA) by 1.3 yields the calculated arch width for the maxillary anterior six teeth (UA). Subtracting the actual maxillary anterior arch width from the calculated width yields the tooth-size discrepancy.

even though the Bolton's index is normal. An accurate dental model orthodontic wax set-up may achieve a more accurate assessment.

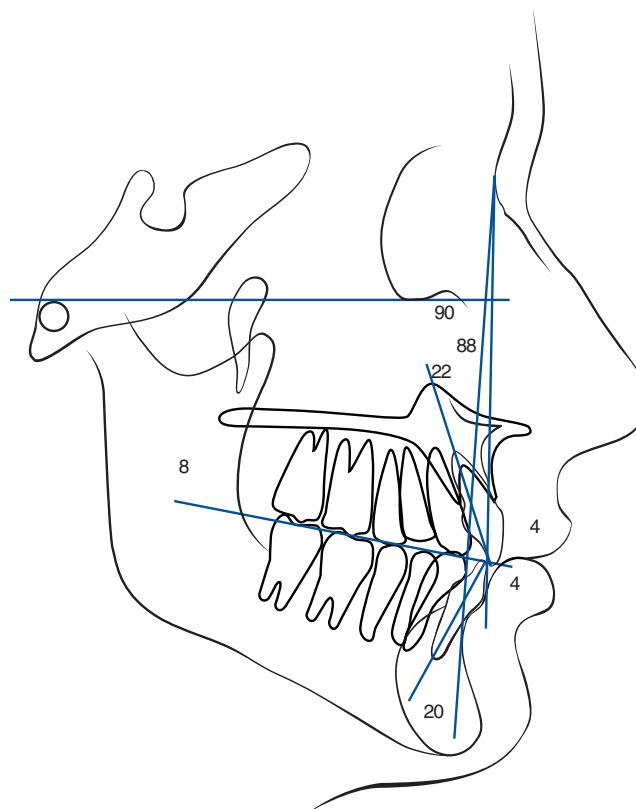


FIGURE 55-4 Cephalometric analysis. Normal maxillary depth angle is $90^\circ \pm 3^\circ$ and mandibular depth is $88^\circ \pm 3^\circ$. Normal occlusal plane angulation is $8^\circ \pm 4^\circ$. Normal maxillary incisor angulation to the nasion point A (NA) line is $22^\circ \pm 2^\circ$ with the labial surface of the incisor being $4 \text{ mm} \pm 2 \text{ mm}$ anterior to the NA line. Normal mandibular incisor angulation to the nasion point B (NB) line is $20^\circ \pm 2^\circ$ with the labial surface of the incisor being $4 \text{ mm} \pm 2 \text{ mm}$ anterior to the NB line.

3. Incisor angulation: This refers to the angulation of the maxillary and mandibular incisors relative to their respective basal bones. The dental models are correlated to the cephalometric analysis and the ideal axial inclination of the incisors determined (Figure 55-4). The incisor angulation analysis contributes to the determination of whether extractions are necessary, spaces need to be created or eliminated, and what mechanics are required to align and level the arches or segments of the arches. The key is to get the incisors in proper position and angulation over basal bone.
4. Arch width analysis: This refers to the evaluation of the intra-arch transverse widths between the maxillary and mandibular arches. The average maxillary and mandibular arch widths for adults are listed in Tables 55-3 and 55-4 (data from University of Michigan Caucasian study).² These averages are only guides and do not account for

patient size, or racial or ethnic differences. However, from a practical standpoint a good way to analyze the arch width is to relate the models to the occlusal position that is to be achieved with the surgical correction and then assess the transverse relationship. For example, if a patient has a Class II occlusion, position the models in a Class I cuspid-molar relation and evaluate the transverse width relationship. Likewise, a patient with a Class III occlusion is evaluated by positioning the models into a Class I cuspid-molar relationship. When a Class II relationship is shifted to a Class I relationship, the maxilla may be narrow and require expansion. In some cases it may be indicated to evaluate the transverse relationship by placing the models into a Class II molar position to determine if a Class I cuspid and Class II molar relationship (this would require maxillary bicuspid extractions) would be best for that particular patient; this may be beneficial when there is significant crowding in the maxillary arch and no crowding in the mandibular arch. Transverse discrepancies will influence the presurgical orthodontics and dictate the surgical procedures required.

- Curve of Spee: This evaluates the vertical position of the anterior teeth compared with the posterior teeth. This assessment can be determined by placing the occlusion of the maxillary dental model on a flat plane; the incisors should be about 1 mm above the flat plane (Figure 55-5A). Placing the occlusion of the mandibular dental model on a flat plane should see the mandibular incisors elevated 1 mm above the midbuccal teeth. A significant accentuated curve of Spee in the maxilla is usually associated with an anterior open bite and a reverse curve associated with an anterior deep bite. An accentuated curve of Spee in the mandible (Figure 55-5B) is commonly associated with an anterior deep bite. Accentuated or reverse curves of Spee will influence whether the curve in each arch requires correction, and if so, whether the correction will be achieved by orthodontics, with or without extractions, opening spaces, or by surgical intervention.
- Cuspid-molar position: This identifies the angle classification and dental interrelationships. It is usually

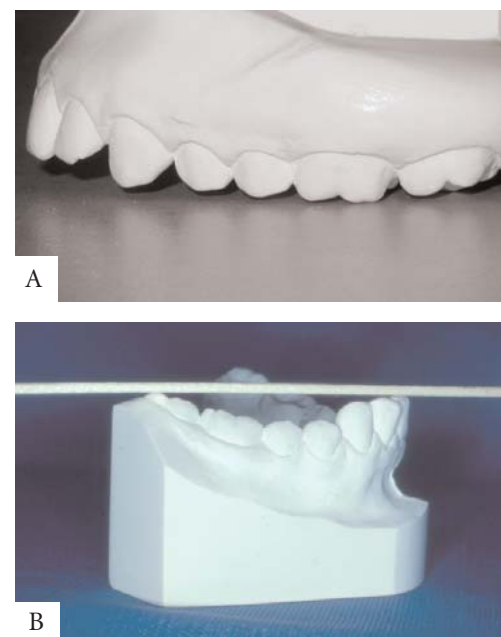


FIGURE 55-5 A, This maxillary arch demonstrates an increased curve of Spee. B, An accentuated (increased) curve of Spee is seen in the mandibular arch.

preferable to have a Class I cuspid-molar relationship as an outcome result; however, a Class II molar relationship is acceptable. A Class III molar relationship is less desirable because the mandibular first molar functions against the maxillary second bicuspid, but it may be indicated in some cases.

Table 55-3 Maxillary Arch Width*

	Cuspids [†]	First Bicuspid [†]	Second Bicuspid [†]	First Molars [†]	Second Molars [†]
Males	32.3 (1.7)	36.7 (2.0)	41.5 (2.5)	47.1 (2.8)	52.3 (3.4)
Females	31.2 (2.45)	34.6 (3.2)	39.3 (2.2)	44.3 (2.3)	49.3 (2.8)

Adapted from Moyers RE et al.²
 *All measurements at centroid.
 †Measurements in mm (SD).

Table 55-4 Mandibular Arch Width*

	Cuspids [†]	First Bicuspid [†]	Second Bicuspid [†]	First Molars [†]	Second Molars [†]
Males	24.8 (1.3)	32.8 (1.5)	37.6 (2.3)	43.0 (2.7)	49.0 (2.3)
Females	23.1 (2.0)	31.8 (1.4)	36.8 (1.3)	41.7 (2.3)	47.2 (2.1)

Adapted from Moyers RE et al.²
 *All measurements at centroid.
 †Measurements in mm (SD).

7. **Tooth arch symmetry:** This compares the left to right side symmetry within each arch. There may be a significant asymmetry within the arch, such as a cuspid on one side being more anteriorly positioned in the arch than the cuspid on the opposite side (Figure 55-6). This problem often occurs with a unilateral missing tooth. Also, vertical asymmetries can occur with individual teeth, sections of the dentoalveolus, or the entire dental arches, creating a cant in the transverse occlusal plane. Correcting these types of conditions may require special orthodontic mechanics, unilateral extraction or opening-up space, asymmetric extractions, and/or surgical procedures.
8. **Curve of Wilson (buccal tooth tipping):** This evaluates the mediolateral position of the occlusal surfaces of the maxillary (Figure 55-7) and mandibular posterior teeth. If the occlusal surfaces of the maxillary or mandibular posterior teeth are tipped too far buccally, it may be difficult to achieve a proper occlusal interdigitation relationship. In the presence of a transverse maxillary deficiency with preexisting increased curve of Wilson and posterior crossbites, it is very difficult, if not impossible, to correct the problem orthodontically, orthopedically, or even with surgically assisted rapid

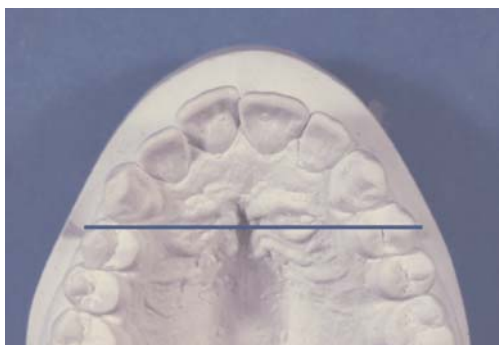


FIGURE 55-6 *Tooth arch symmetry. This model demonstrates that the cuspid on one side of the arch is significantly more anteriorly positioned in the arch compared with the cuspid on the opposite side.*

palatal expansion (SARPE). The curve of Wilson will usually get much worse with these mechanics. In these types of cases surgical expansion by multiple maxillary osteotomies may be indicated to decrease the curve of Wilson.

When the mandibular posterior teeth are tipped buccally, it is often related to macroglossia or habitual tongue posturing. Orthodontic lingual tipping of the posterior teeth is very difficult when macroglossia is present and will likely be unstable. A reduction glossectomy may be indicated before orthodontics in order to permit a more stable orthodontic result.

9. **Missing, broken down, or restored teeth:** These must be identified since they may influence treatment design. If a tooth is nonrestorable and requires extraction, it must be determined if the extraction space requires orthodontic closure or the space maintained for later dental reconstruction. In some cases it may be helpful to maintain the condemned tooth to improve stability during surgical alignment of the jaws or segments thereof, with removal postsurgery. Crowns on previously restored teeth may need to be redone post-orthodontics and -orthognathic surgery, since the crown anatomy may need to be changed for proper occlusion with the new dental relationships. Determination of salvageable teeth and restorative requirements are integral components in the planning and treatment of patients.
10. **Ankylosed teeth:** If undiagnosed, ankylosed teeth can have devastating effects on the presurgical orthodontics. Tooth ankylosis, the fusion of alveolar bone and cementum, results from damage to the periodontal ligament (PDL).

An ankylosed tooth may be identified by failure to move with orthodon-

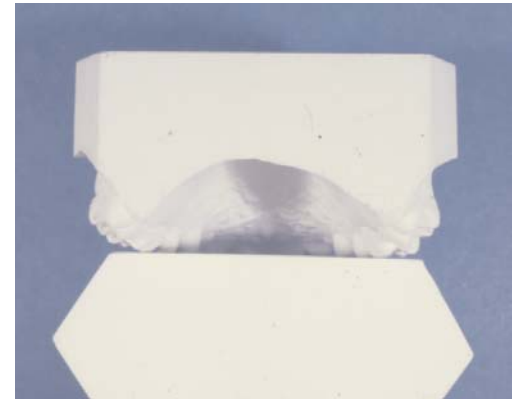


FIGURE 55-7 *Curve of Wilson. This evaluates the mediolateral position of the occlusal surfaces of the maxillary and mandibular posterior teeth.*

tic forces (Figure 55-8), failure of a tooth to erupt, submerged or incomplete tooth eruption (Figure 55-9), or lack of eruption of a tooth compared with adjacent teeth and alveolar bone growth. The most sensitive diagnostic test is percussion, where the ankylosed tooth has a high, clear, solid metallic sound. A normal tooth has a dull sound, being protected by the PDL. However, an erupted tooth with an impacted tooth directly against it will also have a solid sound to percussion. Normal multirrooted teeth present a more solid sound than single-rooted teeth. Therefore, percussion testing should be compared with similar teeth (ie, test bicuspid against bicuspid, molars against molars, using both sides of the arch). An ankylosed tooth lacks

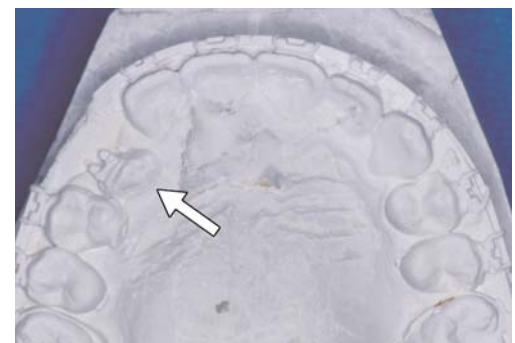

FIGURE 55-8 *This dental model shows a palatally displaced tooth, unresponsive to orthodontic mechanics, indicating probable ankylosis.*

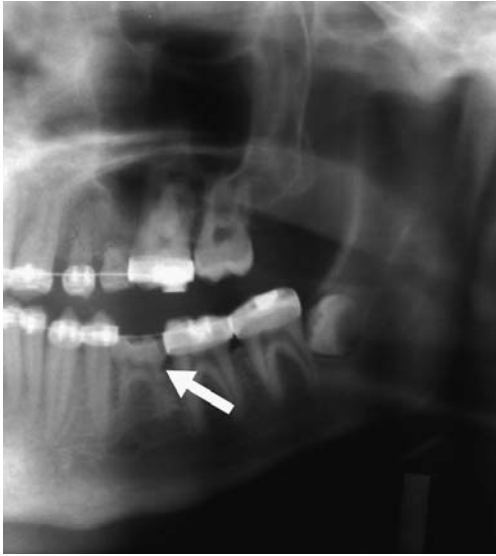

FIGURE 55-9 This pantomogram demonstrates incomplete eruption of a primary tooth without a permanent successor, indicating ankylosis.

mobility. Over 90% of ankylosed teeth are deciduous; most often the second molar followed by the first molar.³ Ankylosed primary teeth are not susceptible to resorption by the follicle of the underlying permanent tooth and may result in its impaction.³

Ankylosed teeth can cause significant problems with jaw growth and development. Early ankylosis results in noneruption or partial eruption, resulting in incomplete development of the alveolar process.⁴ Permanent teeth may be displaced from normal eruption pathways with resulting loss of alveolar bone height. The failure of an ankylosed tooth to erupt may allow adjacent teeth to drift and permit super-eruption of the tooth in the opposing arch. Ankylosed teeth do not respond to orthodontic forces and can create significant orthodontic problems when malaligned and tied into the orthodontic arch wire (Figure 55-10).⁵ The ankylosed tooth functions as an anchor and in active uncontrolled orthodontics, will move adjacent teeth to align with its position, with subsequent development of an occlusal and possibly facial deformity.

11. Periodontal evaluation: This is very important, since preexisting periodontal pathologies could be exacerbated during orthodontic and orthognathic surgical treatments.⁶ Factors that can adversely affect the health and outcome of the periodontal tissues as well as the orthodontics and orthognathic surgery include smoking, excessive consumption of alcohol or caffeine, habitual patterns such as bruxism and clenching, preexisting connective tissue/autoimmune diseases, diabetes, malnutrition, and other diseases that could affect the local tissue blood supply perfusion, and healing. Any pretreatment of acute or chronic periodontal disease should be addressed prior to the orthodontics and surgery. The lack of attached gingiva around the teeth (most commonly seen in the mandibular anterior arch) can cause gingival retraction, loss of bone, and loosening of teeth if orthodontics is initiated and the mandibular incisors are tipped forward (Figure 55-11). Gingival grafting may be indicated prior to orthodontics to provide

attached gingiva so as to prevent these problems. Good communication between the periodontist, orthodontist, and OMF surgeon is of utmost importance.

Orthodontics can help prepare interdental osteotomy sites by tipping the roots of the adjacent teeth away from each other to increase the interosseous space between the roots. There have been a number of studies demonstrating that interdental osteotomies have a minimal effect on the periodontium when they are properly performed.⁷⁻¹¹ Having healthy stable dental tissues to work with during the orthodontics and surgery will maximize the periodontal outcome as well as the overall outcome. The failure to recognize preexisting periodontal pathology, identify risk factors, poor performance of surgery, and/or lack of attention to detail could result in significant periodontal problems as well as other problems that could compromise the final result.

12. Tongue assessment: An enlarged tongue (macroglossia) can cause dentoskeletal

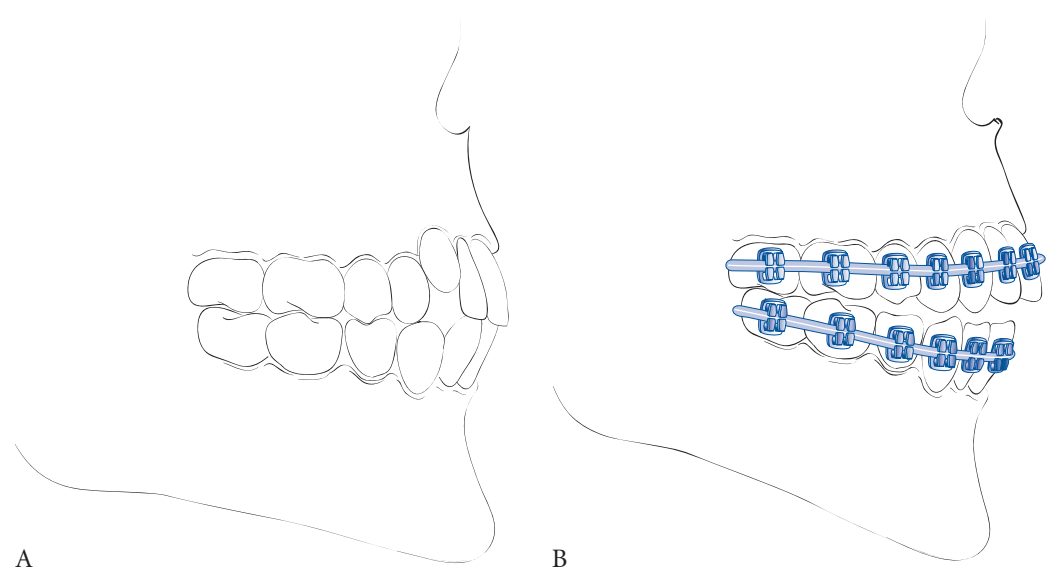


FIGURE 55-10 This illustration depicts a partially submerged ankylosed maxillary cuspid (A). If tied into an active straight arch wire (B), the adjacent teeth will be orthodontically moved toward the ankylosed tooth, resulting in the development of a significant malocclusion.

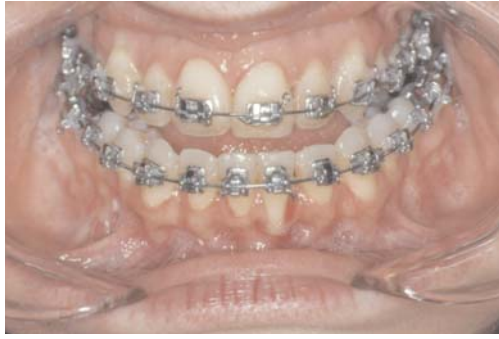

FIGURE 55-11 *Periodontal concerns.* This patient had lack of attached gingiva prior to initiation of orthodontics and was left untreated, causing severe gingival retraction and loss of supporting bone. Gingival grafting should have been performed prior to initiation of orthodontics.

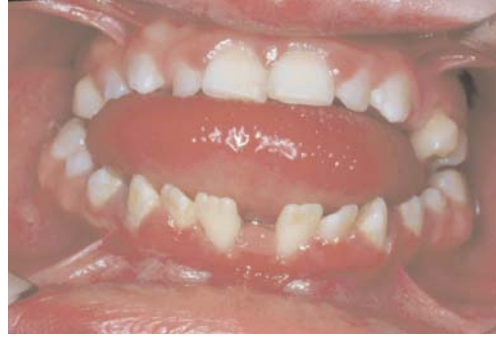

FIGURE 55-12 *Macroglossia.* Some of the clinical features associated with macroglossia include anterior open bite, diastemata between the teeth, accentuated curve of Spee maxillary arch, and reverse curve of Spee mandibular arch.

deformities, instability of orthodontic and orthognathic surgical treatments, and create masticatory, speech, and airway management problems. There are a number of congenital and acquired causes of true macroglossia, including muscular hypertrophy, glandular hyperplasia, hemangioma, lymphangioma, Down syndrome, and Beckwith-Wiedemann syndrome. Acquired factors include acromegaly, myxedema, amyloidosis, tertiary syphilis, cysts or tumors, and neurologic injury.¹² There are specific clinical and cephalometric features that may help the clinician identify the presence or absence of macroglossia, although not all of these features are always present. Specific clinical features include the following (Figure 55-12):

- Grossly enlarged, wide, broad, and flat tongue
- Open bite (anterior or posterior)
- Mandibular prognathism
- Class III malocclusion with or without anterior and posterior crossbite
- Chronic posturing of the tongue between the teeth at rest (rule out habitual posturing of a normal-sized tongue)
- Increased curve of Wilson of maxillary posterior teeth

- Reverse curve of Wilson of mandibular posterior teeth
- Accentuated curve of Spee in the maxillary arch
- Reverse curve of Spee in the mandibular arch
- Increased transverse width of maxillary and mandibular arches
- Diastemata with increased incisor angulation in the mandibular and/or maxillary arches

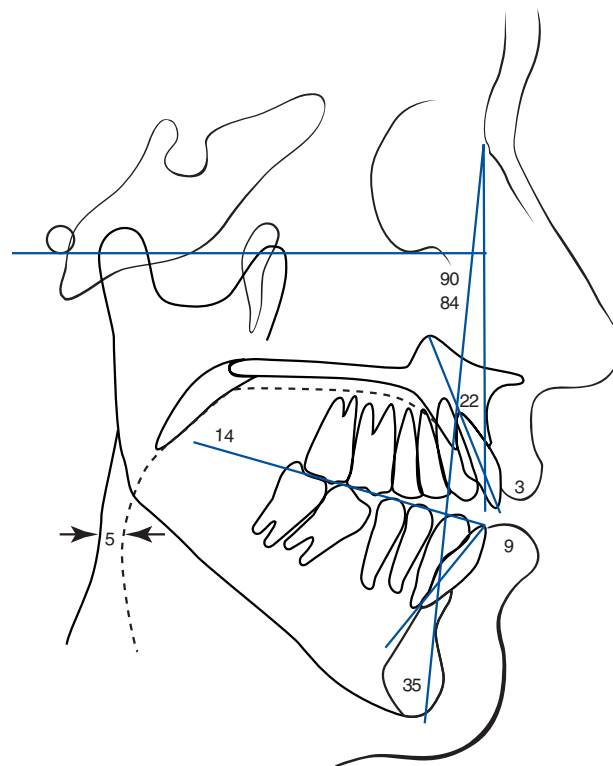


FIGURE 55-13 *Macroglossia.* Cephalometric analysis shows mandibular dentoalveolar protrusion and overangulation of the mandibular anterior teeth. The tongue fills the oral cavity (dotted line) and the oropharyngeal airway is decreased (normal distance from posterior aspect of tongue to posterior pharyngeal wall is 11 mm).

- Crenations (scalloping) on the tongue
- Glossitis (due to excessive mouth breathing)
- Speech articulation disorders
- Asymmetry in the maxillary or mandibular arches associated with an asymmetric tongue
- Difficulty eating and swallowing (severe cases)
- Instability in orthodontic mechanics or orthognathic surgical procedures that in normal circumstances would be stable
- Airway difficulties, such as sleep apnea, secondary to oral or oropharyngeal obstruction
- Drooling

Cephalometric radiographic features commonly seen with macroglossia (Figure 55-13) include the following:

- Tongue filling the oral cavity and extruding through an anterior open bite
- Mandibular dentoalveolar protrusion or bimaxillary dentoalveolar protrusion

- Overangulation of the maxillary and mandibular anterior teeth
- Disproportionately excessive mandibular growth
- Decreased oropharyngeal airway
- Increased gonial angle
- Increased mandibular plane angle
- Increased mandibular occlusal plane angle

Most open bite cases are not related to macroglossia. In fact it has been established that closing open bites with orthognathic surgery will allow a normal tongue (which is a very adaptable organ) to readjust to the altered volume of the oral cavity, with little tendency toward relapse.^{13,14} However, if true macroglossia is present with the open bite, then instability of the orthodontics and orthognathic surgery will likely occur, with a tendency for the open bite to return. Pseudomacroglossia is a condition where the tongue may be normal in size, but it appears large relative to its anatomic interrelationships. This can be created by (1) habitual posturing of the tongue; (2) hypertrophied tonsils and adenoid tissue displacing the tongue forward; (3) low palatal vault, decreasing the oral cavity volume; (4) transverse, vertical, or antero-posterior deficiency of the maxillary and/or mandibular arches decreasing oral cavity volume; and (5) tumors that displace the tongue. Pseudomacroglossia must be distinguished from true macroglossia because the methods of management are different.

Diagnostic List

Before a treatment plan can be properly developed, a diagnostic list of the existing problems is established based on patient concerns, and clinical, radiographic, dental model, and other indicated evaluations. This will include all findings relative to musculoskeletal and dental imbalances, occlusal problems, esthetic concerns, TMJ and/or myofascial pain problems, missing

teeth, crowns, bridges, endodontically treated teeth (these teeth are sometimes ankylosed), periodontal problems, other functional disorders, as well as any other medical factors that may affect treatment outcomes. The treatment plan is formulated from the diagnostic problem list.

Presurgical Orthodontic Goals

The basic presurgical orthodontic goals are as follows:

- Align and position teeth over basal bone
- Avoid excessive intrusion or extrusion of teeth
- Decompensate teeth
- Avoid unstable expansion of the dental arches
- Avoid class II and class III mechanics (unless required for dental decompensation correction in the arches)
- Perform stable and predictable orthodontics

Relative to the position of the maxillary and mandibular incisors, the ideal presurgical orthodontic goals are as follows:

1. Position the long axis of the maxillary central incisors approximately 22° to the nasion point A (NA) line, with the labial surface of the incisors 4 mm anterior to the NA line relative to a normally positioned maxilla and normal occlusal plane angle (see Figure 55-4)
2. Position the long axis of the mandibular central incisors 20° to the nasion point B (NB) line with the labial surface of the incisors 4 mm anterior to that line relative to a normally positioned mandible and normal occlusal plane angle (see Figure 55-4)
3. Satisfy arch length requirements (crowding or spacing)

We have found that using the ideal position of the maxillary and mandibular incisors to the NA and NB lines, respectively (see Figure 55-4), is the most convenient and practical method to establish the presurgical orthodontic goals for the

incisors. However, these presurgical orthodontic goals may be different if the occlusal plane angle is to be altered surgically. Removal of dental compensations is helpful before surgery so that maximum skeletal correction can be achieved. An exact orthodontic treatment plan, including the specific mechanics and anchorage requirements necessary to position the teeth to satisfy the presurgical orthodontic goals, must be developed and executed.

Initial Surgical Treatment Objective

The surgical treatment objective (STO), also known as a prediction tracing, is a two-dimensional visual projection of the changes in osseous, dental, and soft tissues as a result of orthodontics and orthognathic surgical correction of the dentofacial and occlusal deformity. The purpose of the STO is threefold: (1) establish presurgical orthodontic goals, (2) develop an accurate surgical objective that will achieve the best functional and esthetic result, and (3) create a facial profile objective which can be used as a visual aid in consultation with the patient and family members. A prediction tracing of the anticipated presurgical orthodontic dental movements is created by placing an acetate sheet on the original cephalometric tracing and retracing the teeth into the position they will be placed with the presurgical orthodontics, based on the goals and available mechanics (Figure 55-14A). The initial STO is then constructed with the teeth in their presurgical orthodontic final position.

The STO has significant importance in two phases of treatment planning: (1) the initial STO is prepared before treatment to determine the orthodontic and surgical goals; and (2) the final STO is prepared after the presurgical orthodontics are completed but prior to surgery to determine the exact vertical and antero-posterior skeletal and soft tissue movements to be achieved (Figure 55-14B). The

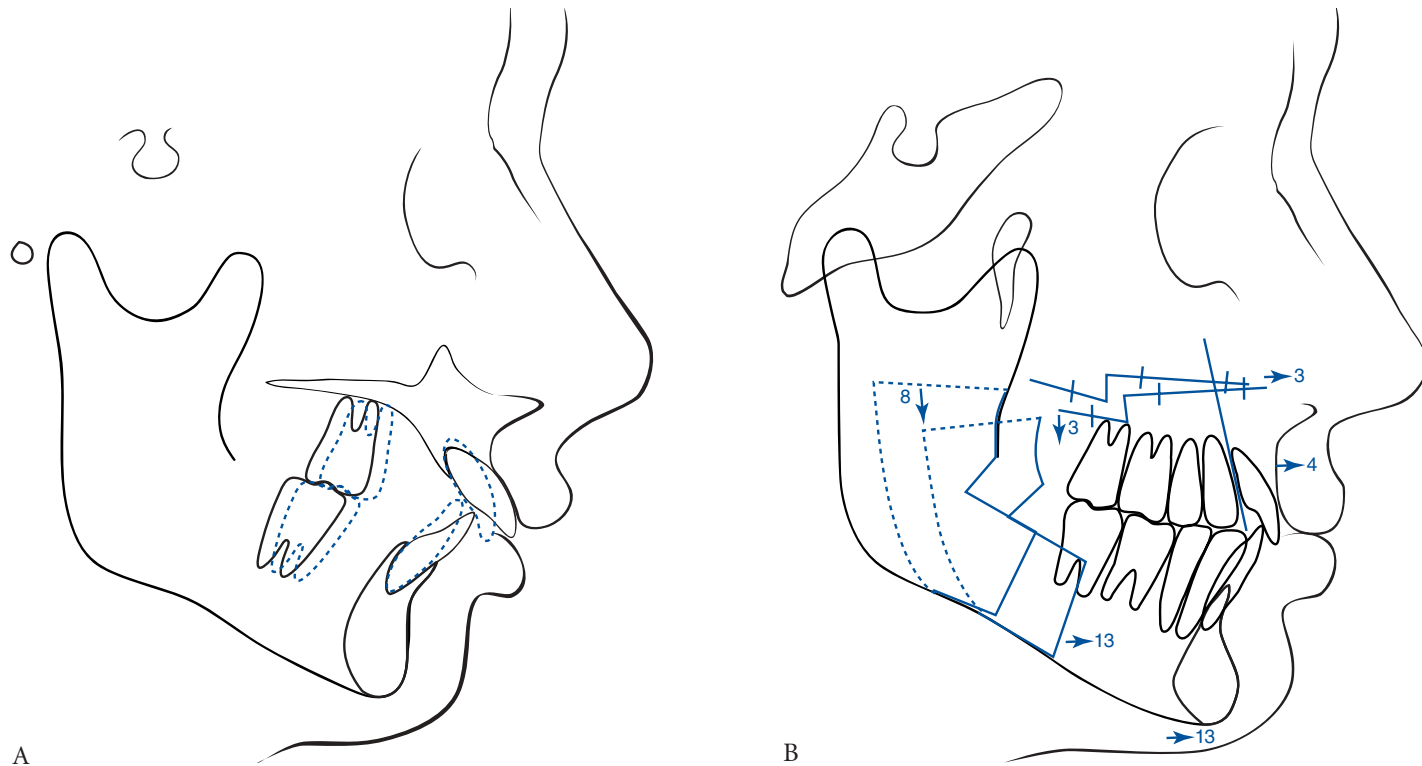


FIGURE 55-14 A, Presurgical orthodontics. The orthodontic movements are traced on the acetate paper overlying the original lateral cephalometric tracing with the teeth in their predetermined, simulated positions. The solid lines, are the original position of the teeth. The dashed lines are the new position of the teeth following simulated extraction of four first bicuspids and orthodontic closure of the spaces. B, Surgical treatment objective (STO). This is an example of a completed final STO which shows the predicted outcome of the presurgical orthodontics and the anticipated surgical treatment. The arrows and numbers indicate the direction and millimeters of movement.

STO is invaluable to the orthodontist and surgeon in establishing treatment objectives and projected results, acting as the *treatment plan blueprint*.

Definitive Interdisciplinary Treatment Plan

The definitive treatment plan is formulated based on the patient's concerns, clinical evaluation, radiographic analysis, dental model evaluation, initial STO, and other relevant evaluations. The general sequencing of the treatment that may be involved is described below.

Dental and Periodontal Treatment

Any indicated periodontal or general dental care related to maintaining teeth or improving dental health should be performed prior to orthodontics and surgical intervention. The objective is to

maintain as many teeth as possible and stabilize the periodontium. Temporary crowns and bridges should be placed where necessary for the orthodontic and surgical phases of the treatment. Permanent crowns, inlays, and bridges should be constructed and inserted after the surgery and orthodontics have been completed. This gives the restorative dentist the opportunity to provide escapement grooves, cuspid protection, and incisal guidance for optimum function and esthetics. Initial periodontal management may include scaling and curettage, eliminating pockets, as well as gingival grafting to provide adequate attached gingiva. Occasionally, in patients with several missing teeth, osseointegrated implant placement prior to orthodontics and orthognathic surgery may provide anchorage for orthodontics and additional dental units

to help in repositioning the jaw structures at surgery.

Presurgical Orthodontics

The orthodontist is responsible for positioning the teeth to the most desirable position over basal bone in preparation for surgery. The development of prescription brackets and straight wire orthodontic techniques has helped simplify orthodontics. Most prescription bracket systems are designed to tip the cuspid roots distally, creating some space between the roots of the lateral incisors and cuspids. In cases requiring segmentalization of the maxilla, this interdental space may be adequate through which to perform interdental osteotomies, but if inadequate, additional room can be created by tipping the lateral incisor roots mesially and the cuspids more distally. Bonded brackets are clean and eliminate interdental spacing problems

created by circumferential bands. Bonded brackets with the currently available resins are quite adequate for orthognathic surgery procedures. However, inaccurate placement of the brackets on the teeth can result in undesired rotations, vertical discrepancies between teeth, malalignment of marginal ridges and labial surfaces of adjacent teeth, and unfavorable root positions. Careful placement of brackets is paramount in helping to achieve high-quality results.

Nickel-titanium or similarly shaped memory arch wires can be advantageous for many orthognathic cases to aid in presurgical orthodontic dental alignment goals. However, there are cases where shape memory wires could be detrimental, such as in an anterior open bite with an accentuated maxillary curve of Spee. The use of nickel-titanium wires or any type of straight wire in these cases can create unstable results such as extrusion of teeth and buccal tipping of the molars as a result of reciprocal forces. Stainless steel wires with compensating bends (Figure 55-15A) or sectional wires (Figure 55-15B) may be a better-controlled mechanical force in these types of cases. The type of arch wire and how long each is left in place is critical and must be carefully monitored by the orthodontist.

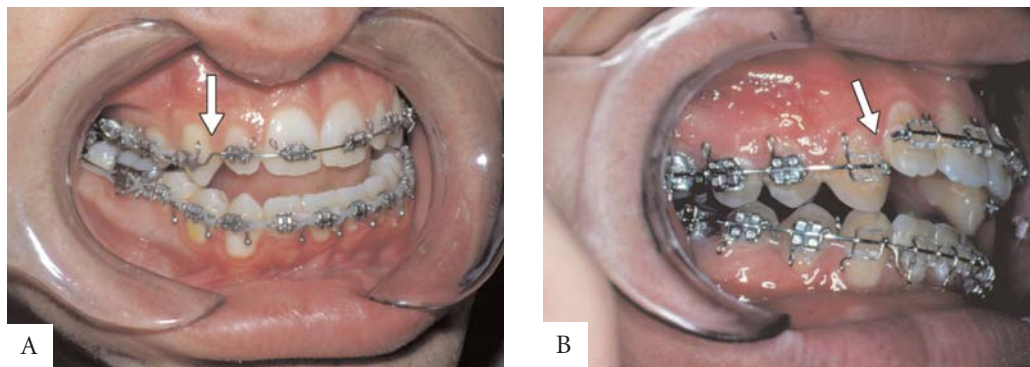


FIGURE 55-15 A, Compensating steps (arrow) have been placed in the orthodontic arch wire so that the anterior teeth are aligned at an elevated level compared with the posterior teeth to eliminate extrusion or intrusion of teeth that may otherwise result in unstable orthodontic movements. B, Sectioning the arch wire (arrow) is another approach to aligning teeth at separate independent levels to avoid extrusion or intrusion of teeth as seen in this maxilla. However, the use of sectional wires may decrease positional control of the teeth adjacent to the ends of the cut wire.

To follow are basic presurgical orthodontic factors that commonly must be addressed in preparing patients for orthognathic surgery.

It is important to avoid interarch class II mechanics (ie, class II elastics, growth appliances, TMJ “disk recapturing” splints, Herbst’s appliances) unless they are specifically required during the presurgical orthodontics (ie, to correct arch asymmetry, decompensate mandibular arch with lingually inclined mandibular incisors). Long-term class II mechanics positions the mandibular condyle downward and forward in the fossa and may allow hypertrophy (thickening) of the TMJ bilaminar tissues (Figure 55-16). This same situation can occur in patients with a “Sunday” bite. In these situations, following surgical mandibular advancement, the bilaminar tissue will slowly thin out over time causing a slow relapse of the mandible toward a Class II relationship. In addition posturing the mandible forward for an extended time could result in foreshortening of the anterior articular disk attachments, increasing the risk of TMJ articular disk displacement postsurgery.

If a patient has been treated with long-term class II mechanics or has a “Sunday” bite, it may be an advantage to use light class III mechanics for a few months presurgery

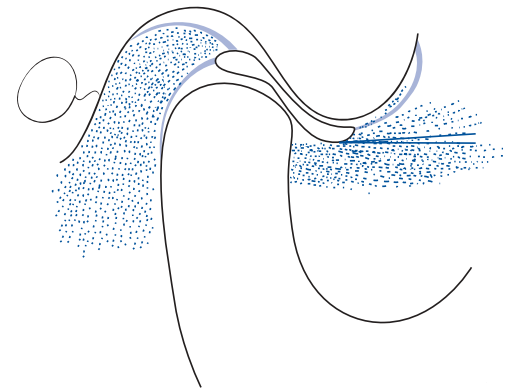


FIGURE 55-16 Use of long-term class II mechanics, anterior repositioning splints, growth devices, or “Sunday” bite relationships can cause hypertrophy of the bilaminar tissue, positioning the condyle downward and forward in the fossa. Postsurgery, particularly with mandibular advancements, this tissue will slowly thin out, and the condyles will move posteriorly in the fossa causing a shift of the mandible and occlusion toward a Class II position.

to eliminate the hypertrophied bilaminar tissue and to decompensate for any unstable orthodontics that may have been created. If the TMJ articular disk does become displaced, it would be better to have that occur before surgery because the articular disk can be surgically repositioned and stabilized with high predictability at the same time as the orthognathic surgery.^{15–18} Attempts to recapture a TMJ displaced disk with splint therapy prior to surgery could be detrimental to the patient relative to outcome stability and pain. In most cases nonsurgical “recapturing” the disk procedures have proved clinically unsuccessful.

Treatment Options for Specific Orthodontic Problems

This section presents specific dental malrelationships and the orthodontic and surgical treatment options for consideration. Comprehensive assessment of the patient and developing treatment objectives will aid in selecting the appropriate treatment.

Adjustment for Tooth-Size Discrepancy

Usually TSDs occur because of small maxillary lateral incisors, making the combined

mesiodistal width of the maxillary anterior six teeth too small to fit properly around the mandibular anterior six teeth, so that when the teeth are properly aligned, an end-on Class II cuspid relationship will result (Figure 55-17). If the Bolton's analysis indicates a significant TSD, presurgical orthodontic adjustments can usually correct the discrepancy and aid in providing a solid Class I cuspid relationship at surgery and in the final outcome. TSDs can also occur in the bicuspid and molars, with the maxillary teeth usually being too small compared with the mandibular teeth. The following are treatment options that can be used to correct TSDs.

Slenderizing Teeth (Interproximal Tooth Size Reduction) This technique reduces the mesiodistal dimension of the involved teeth. Since most TSDs involve larger mandibular anterior teeth compared to the maxillary anterior teeth, slenderizing the mandibular anterior teeth can address the issue (Figure 55-18). Approximately 10 to 12% of the mesiodistal width can be safely removed from each tooth with 50% of the interproximal enamel remaining. Up to 3 mm of reduction can usually be safely achieved in the mandibular anterior

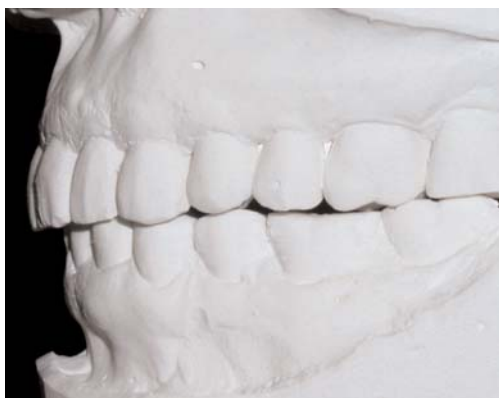

FIGURE 55-17 This patient has well-aligned and leveled teeth in each arch. Maxillary lateral incisors are small creating a tooth-size discrepancy (TSD). Note that with the best possible fit, the patient has an end-on Class II occlusal relationship secondary to the TSD.

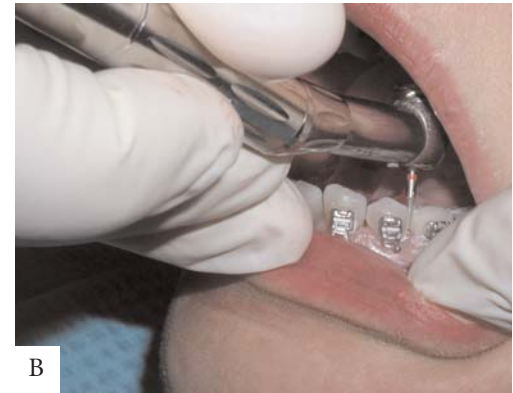
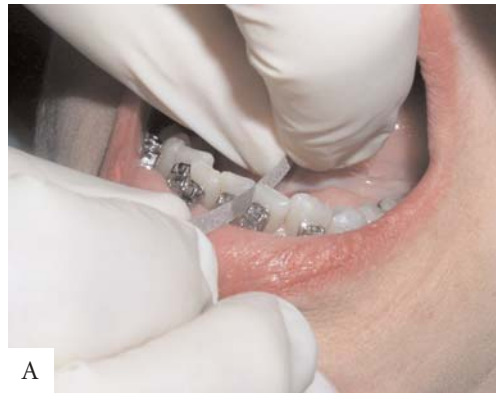
FIGURE 55-18 Mandibular anterior teeth can be slenderized using (A) diamond strip or (B) thin cylindrical diamond bur to reduce the width of the teeth at the contact level. Spacing generated can then be closed with orthodontics.

six teeth. Slenderizing the mandibular anterior teeth is an advantageous procedure, where the maximum width of the incisors is toward the incisor edge, particularly in the presence of crowding and/or overangulation of the mandibular incisors. It is not advantageous if the mandibular anterior teeth are decreased in angulation (lingual inclination), since closing the resultant spaces will further decrease the incisor angulation and may adversely affect esthetics and stability. This technique is not indicated when the contact points are positioned toward the gingiva, as this could result in tissue strangulation with loss of papilla and interdental bone, creating significant periodontal issues. In the rare case where the maxillary teeth are too large for the mandibular teeth, the maxillary teeth can be slenderized, but this is best used when the maxillary teeth are crowded and/or overangulated, and the individual crowns are wider than normal (see Table 55-1).

When TSDs occurs in the bicuspid and/or molar area, slenderizing the mandibular teeth will usually correct the problem, unless the slenderizing will cause excessive retraction of the mandibular anterior teeth. If this appears to be a potential outcome, then careful closure of the spacing by loosening (slipping) posterior anchorage (using mechanics that will

move the posterior teeth forward instead of the anterior teeth backward) may solve the problem. This approach may include class II mechanics to provide forward forces on the posterior teeth or moving one tooth at a time on each side. Dental implants placed adjacent to or posterior to the molars could provide stable anchorage to aid in applying the mechanics necessary to push the posterior teeth forward.

Creating Space In the Arch This can enlarge the circumference of the involved arch. Since TSDs are often related to small maxillary lateral incisors, opening space around the maxillary lateral incisors may be a logical approach. A simple technique involves placement of coil springs between the cuspids and lateral incisors and if needed between the lateral incisors and central incisors to open spaces (Figure 55-19). At the end of treatment the lateral incisors can be built up by bonding, veneers, or crowns. This technique can also be used in the mandibular arch when the mandibular anterior teeth are too small compared to the maxillary anterior teeth. In either arch this technique is most applicable when the teeth are decreased in angulation, since opening space will increase the axial inclination of the incisors. It may not be indicated when the maxillary or mandibular incisors are overangulated or crowded, as

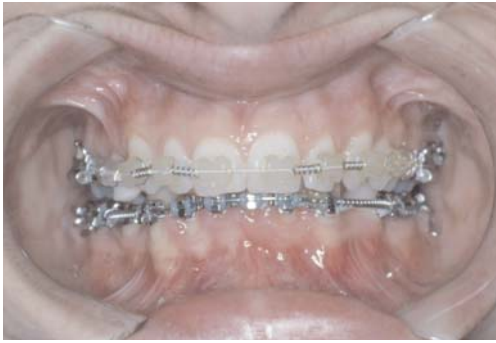

FIGURE 55-19 *Placing coil springs between the maxillary cuspids and lateral incisors as well as the lateral incisors and central incisors can open up spacing around the lateral incisors to correct a tooth-size discrepancy. Post-treatment, the lateral incisors can be built up by bonding, veneers, or crowns.*

the resultant increased angulation may be unstable and cause untoward periodontal changes. However, if there is significant crowding or overangulation of the incisors requiring extraction of bicuspids, during closure of the bicuspid spacing by retraction of the anterior teeth, space could be created around the lateral incisors.

When maxillary incisors are already overangulated, it is not feasible to open spaces during the presurgical orthodontics. In this situation performing interdental osteotomies between the maxillary cuspids and lateral incisors will permit opening space at surgery and the incisors can also be uprighted to decrease their axial angulation. A maximum 3 mm of spacing (1.5 mm on each side) can usually be acquired with this approach.

When the TSD occurs in the bicuspid or molar area, space can be opened around the maxillary bicuspids and/or molars to compensate for the tooth mass deficiency. Bonding, veneers, or crowns can then be placed to eliminate the created space.

Altering Axial Inclination of Incisors This technique can affect the labial circumference of the anterior teeth. Increased axial inclination slightly increases the arch length, and decreased axial inclination slightly decreases it. Application of this technique would result in

increasing the maxillary incisors' angulation above normal and decreasing the mandibular incisors' angulation below normal. This technique can accommodate small TSD differences, but may place the teeth in a compromised position relative to stability and esthetics.

Surgery can alter the axial inclination of the anterior teeth. In the maxillary arch, interdental osteotomies between the lateral incisors and cuspids, and in the mandibular arch anterior subapical osteotomies, will provide a means to alter axial inclination of the incisors.

Altering Mesiodistal Angulation of Maxillary Incisors Tipping the roots of the maxillary central incisors distally away from each other alters the position of the contact points, making the intercontact distance on each tooth slightly wider. This can only be used for small differences. However, it then usually requires recontouring of the distal aspect of the incisor edges and could cause a soft tissue void between the mesial contact points and gingival tissues (“the black triangle”), creating much concern for the patient. This technique is rarely recommended.

Extraction of Mandibular Incisor This technique should only be used for large TSDs (5 mm or more) and only if there is significant crowding and/or significant overangulation of the mandibular incisors. Removing a mandibular incisor usually creates a significant space (the width of the tooth), and closure of that space may significantly decrease the axial inclination of the mandibular incisors. In addition it may cause a decreased transverse width between the cuspids resulting in relative narrowing of both maxillary and mandibular arches. Extraction of a mandibular incisor may produce an increased overjet. If the patient has a good maxillary arch but mandibular crowding and overangulation, large TSD, and an end-on or slight Class III anterior

occlusion, the single mandibular incisor extraction may be the treatment of choice. An alternative in cases with large tooth-size discrepancies would be to slenderize the mandibular anterior teeth and create spacing around the maxillary lateral incisors.

A surgical alternative for a large TSD, when the teeth are not crowded and have good axial angulation, would be to extract the mandibular incisor and perform a vertical osteotomy through the mandible at the extraction site and rotate the segments together to eliminate the extraction space (Figure 55-20). This would prevent further decreased angulation of the incisors with subsequent orthodontics but may narrow the anterior aspect of the mandible.

Correct Overangulated (Proclined) and/or Crowded Maxillary Anterior Teeth

Overangulated and/or crowded maxillary anterior teeth are most commonly seen in patients with maxillary deficiency (hypoplasia). The following treatment methods can be used to correct this type of situation.

Slenderizing and Retraction This technique involves removal of tooth structure at the contact points and is applicable when there is a rare reverse TSD with the maxillary anterior teeth too large for the mandibular anterior teeth. Usually up to 3 mm of tooth structure can be safely removed from the contact area of the maxillary anterior six teeth with a margin of 50% of enamel remaining at the contact areas. However, this could make the maxillary incisors slightly smaller in size unless they are significantly oversized to begin with.

Extraction and Retraction First or second bicuspids can be extracted depending on the amount of crowding, the anchorage requirements, and the amount of retraction of the incisors necessary.

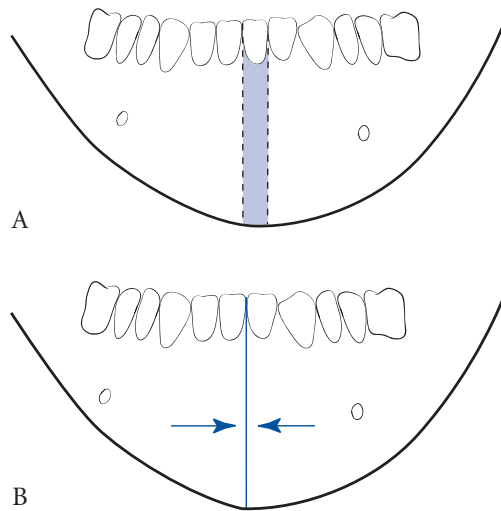


FIGURE 55-20 In the case of a tooth-size discrepancy (TSD) ≥ 5 mm, in the presence of well-aligned teeth in proper angulation, the TSD can be managed by removing a mandibular central incisor and performing a vertical midline osteotomy (A) with closure of that space (B) and stabilization with a bone plate.

Every 1 mm of incisor retraction will require 1 mm of space on each side of the arch. Therefore, if the orthodontic goal is to retract the maxillary incisors by 3 mm, then 6 mm of maxillary arch space will be required to accomplish this. Extracting first bicusps will result in greater incisor retraction, whereas six multirooted posterior dental units (compared to six single-rooted anterior dental units) provide greater posterior anchorage. Extracting second bicusps will result in less incisor retraction, whereas four posterior dental units (compared to eight anterior units) provide less posterior anchorage so that the posterior teeth will move forward a greater amount compared with first bicuspid extractions. The occlusal plane angle will also affect the posterior anchorage. Low occlusal plane angle cases will have greater posterior anchorage stability, even with second bicuspid extraction, than will high occlusal plane angle cases. High occlusal plane angle cases will have less posterior anchorage stability, even with first bicuspid extraction, than low occlusal plane angle cases. These factors are probably

related to bite force influences. The amount of crowding may also influence which teeth to extract.

Distalizing Posterior Teeth This objective can be accomplished using pendulum-type appliances, headgear, class II mechanics, or osseointegrated implants (ie, implants posterior to molars, zygomatic implants, palatal implants, or buccal cortex implants). Distalizing maxillary posterior teeth can be augmented with class II mechanics but should only be used short-term and discontinued several months prior to surgery to minimize postsurgical skeletal relapse potential that can occur with the use of long-term class II mechanics and the subsequent adverse effects on the TMJs. Another option is to distalize one tooth at a time on each side of the arch, beginning with the second molars (2 teeth moved against 12 anchor teeth). Another feasible approach is to use osseointegrated anchors to distalize the maxillary arch, with implants placed in either the zygoma buttress, posterior to second molars, or attached to the buccal cortex. The implants can be left submerged after orthodontic treatment is completed, or could require additional surgery for removal if not removed during the orthognathic surgery.

Anterior Maxillary Segmental Osteotomies This technique permits uprighting of the anterior teeth but will cause the apical base of the segment to shift forward relative to the incisor edges unless teeth are extracted to reposition the incisal edges of the anterior teeth posteriorly. Careful assessment of the profile esthetics is necessary to determine if the patient can esthetically benefit from this change. The interdental osteotomies should be done between the lateral incisors and cuspids as this offers the best control in uprighting the segments (Figure 55-21) and also allows opening of space between the lateral incisors (up to 3 mm with 1.5 mm per side) that can be used for correction of crowding or TSD.

Maxillary Expansion by Orthodontics, Orthopedics (Rapid Palatal Expansion), and Surgically Assisted Rapid Palatal Expansion These techniques will increase arch length and may allow retraction of the anterior teeth. However, they will also increase the curve of Wilson as the transverse width of the maxillary arch increases because the teeth will expand three times as much as the palate expands (Figure 55-22). In addition, with SARPE, the palate moves inferiorly. The expanded arches may not be as orthodontically stable, requiring long-term or permanent retention.

Correct Overangulated (Proclined) and/or Crowded Mandibular Anterior Teeth

Overangulated and/or crowded mandibular teeth occur most often with mandibular deficiency (hypoplasia). The following

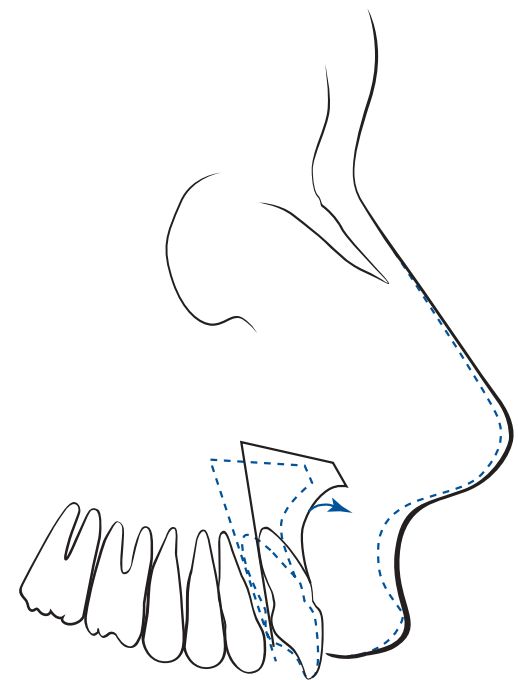


FIGURE 55-21 An anterior maxillary segmental osteotomy can be used to upright the maxillary incisors. However, the dentoalveolus at the apical base will rotate anteriorly if no teeth are extracted. Since this may affect the position of the nose and upper lip, careful evaluation of facial esthetics is necessary to determine if this approach is appropriate. Dashed line represents the original position of the anterior maxilla, and the solid line represents the uprighted segment.

treatment options can be used to correct these types of conditions.

Slenderizing and Retraction This technique involves removal of tooth structure at the contact points and is most applicable when there is a TSD with the mandibular anterior teeth being too large for the maxillary anterior teeth. Up to 3 mm of tooth structure can be safely removed from the contact areas of the mandibular anterior teeth with a margin of 50% of enamel remaining at the contact areas. Subsequent retraction will decrease the axial inclination of the incisors providing that no major crowding is present.

Extraction and Retraction First or second bicuspid can be extracted depending on the degree of angulation, amount of crowding, the anchorage requirements, and the amount of retraction of the incisors necessary. Every 1 mm of incisor

retraction will require 1 mm of space on each side of the arch. Therefore, if the orthodontic goal is to retract the mandibular incisors by 3 mm, then 6 mm of mandibular arch space will be required to accomplish this. Extracting first bicuspid will result in greater incisor retraction, whereas six multirooted posterior dental units (compared with six single-rooted anterior dental units) provide greater posterior anchorage. Extracting the second bicuspid will result in less incisor retraction, whereas four posterior dental units (compared with eight anterior units) provide less posterior anchorage, so that the posterior teeth will move forward a greater amount compared with first bicuspid extractions. The occlusal plane angle will also affect the posterior anchorage. Low occlusal plane angle cases will have greater posterior anchorage stability, even with second bicuspid extraction, than will high occlusal plane angle cases. High occlusal

plane angle cases will have less posterior anchorage stability even with first bicuspid extraction than low angle cases. These factors are probably related to bite force influences. The amount of crowding may also influence which teeth to extract. If there is a large TSD (≥ 5 mm), then extraction of a mandibular incisor could be considered.

Distalize Posterior Teeth The mechanics to accomplish this include intra-arch, inter-arch, extraoral, or implant mechanics. Class III mechanics (ie, elastics, headgear) can be used to distalize the mandibular teeth, but may increase loading on the TMJs and could initiate TMJ problems. Another option is to distalize one tooth at a time on each side of the arch, beginning with the second molars (2 teeth moved against 12 anchor teeth). However, this technique takes a lot of time. The placement of dental implants posterior to the molar teeth or in the posterior buccal cortex could facilitate retraction without appreciably increasing the load to the TMJs.

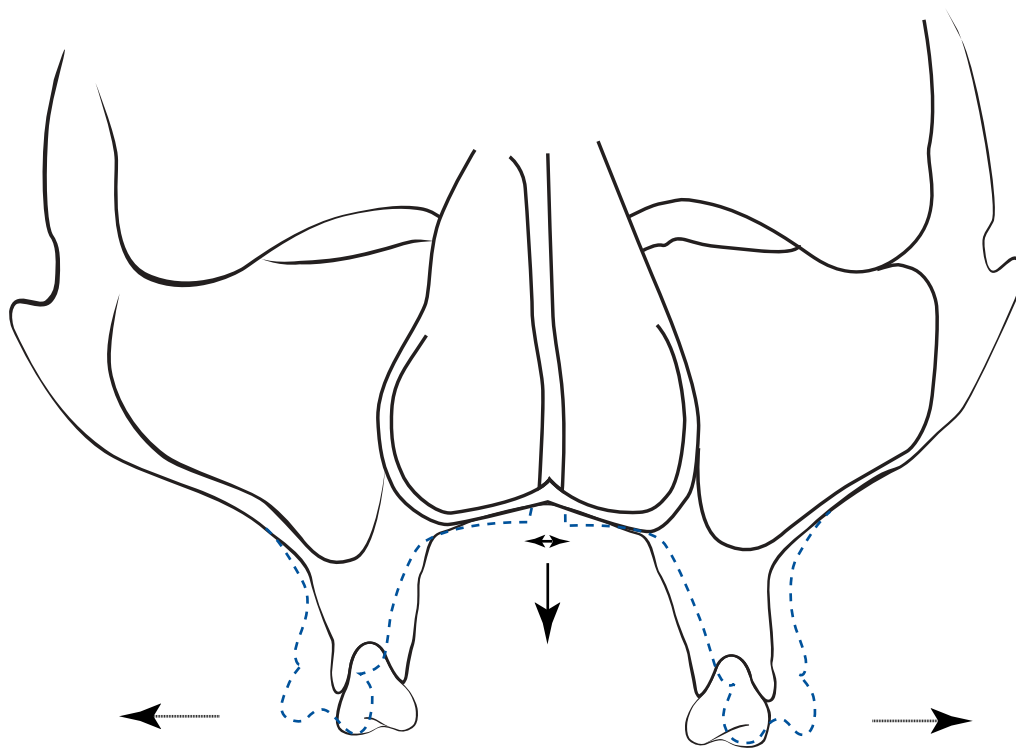


FIGURE 55-22 Maxillary expansion by orthodontics, orthopedics, or surgically assisted rapid palatal expansion (SARPE) will cause an increase of the curve of Wilson. Even with SARPE, the occlusal surface will expand three times as much as the palate will expand, thus increasing the curve of Wilson. The palate will also move inferiorly.

Anterior Mandibular Subapical Osteotomies This technique permits uprighting of the anterior teeth, but will cause the apical base of the segment to shift forward relative to the chin (Figure 55-23), unless teeth are extracted at the time of surgery to reposition the incisal edges of the anterior teeth posteriorly.

Bilateral Mandibular Body Osteotomies This technique will permit uprighting of the anterior teeth and forward rotation of the chin (Figure 55-24), unless teeth are extracted. Without extraction, bilateral body bone grafting will be required to provide bony continuity between the segments and facilitate healing. This technique would only be indicated if the chin is anteroposteriorly deficient before surgery.

Mandibular Symphysis Distraction Osteogenesis This technique, usually performed with a midline vertical osteotomy, will allow expansion of the dentoalveolus and widening of the mandibular arch,

providing room to retract and/or align the teeth. This is an excellent treatment method to gain space for major arch length discrepancies. However, it is done as a prerequisite surgery to achieve the orthodontic goals prior to the major orthognathic surgery. Orthodontic preparation may be necessary prior to performing the midline vertical osteotomy. The roots of the central incisors (or the adjacent teeth, wherever the osteotomy is to be performed) must be tipped away from each other to make room for the interdental osteotomy. This can be accomplished by placing the mesial aspect of the bracket higher than the distal aspect on each of the central incisors. Placing a short segment straight arch wire will then tip the roots distally, creating space to safely perform the vertical interdental osteotomy (Figure 55-25). If a tooth-borne distraction device is used, orthodontic treatment on any other teeth should *not* be initiated until adequate healing of the distraction area has occurred (approximately 4 months from initiation of the distraction). Otherwise it may result in developing dental mobility and orthodontic instability, with the teeth expanding more than the basal bone. This can result in transverse dental

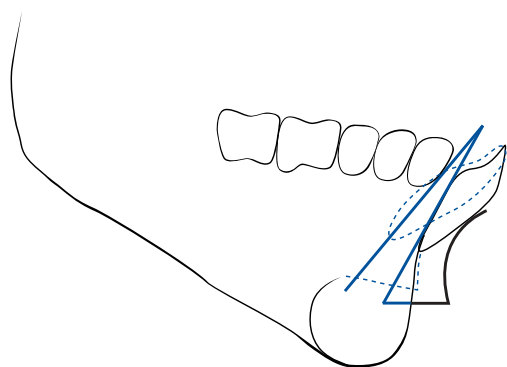


FIGURE 55-23 The anterior mandibular sub-apical osteotomy can be used to upright the mandibular anterior teeth, causing the apical base of the segment to shift forward relative to the chin, if teeth (bicuspid) are not extracted at the time of surgery. This may or may not be a desired outcome. A chin augmentation may be required to achieve optimal esthetics.

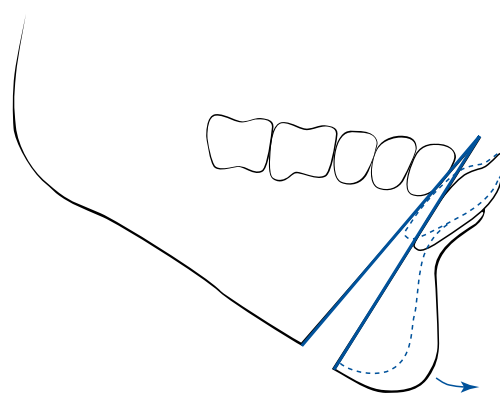


FIGURE 55-24 Bilateral body osteotomies can be used to upright the mandibular anterior teeth, but the chin will rotate forward unless teeth are extracted. A gap created in the mandibular body area will require grafting unless teeth are extracted (first bicuspid) to allow the mandibular anterior teeth to move posteriorly, thus decreasing the forward movement of the chin.

relapse postdistraction with less expansion of the dental arch than desired. Bone-borne devices are not affected by predistraction orthodontics.

Correct Underangulated (Retroclined) Maxillary Incisors

Underangulated maxillary incisors are most commonly seen in Class II Division 2 malocclusions or with missing teeth in the arch. The following approaches can be used to correct this type of condition.

Correct Crowding Crowding of the maxillary anterior teeth can accompany vertically inclined teeth. Therefore, correcting the crowding will increase the incisor angulation.

Open Space In Class I and Class II patients underangulated incisors may be present because of previous extractions (ie, bicuspid), congenitally missing teeth, previous trauma resulting in loss of teeth, or small maxillary anterior teeth (ie, small maxillary lateral incisors). Opening space in the bicuspid areas, if the problem exists there, can correct this problem and provide additional dental units for a more complete occlusal

result. The use of coil springs usually works well for this situation. If the problem is in the lateral incisor area, opening space can help correct the TSD as well as increase the incisor angulation (Figure 55-26).

Interarch Mechanics The use of class III mechanics (ie, elastics) can increase maxillary incisor angulation. However, the class III mechanics can be detrimental by overloading the TMJs.

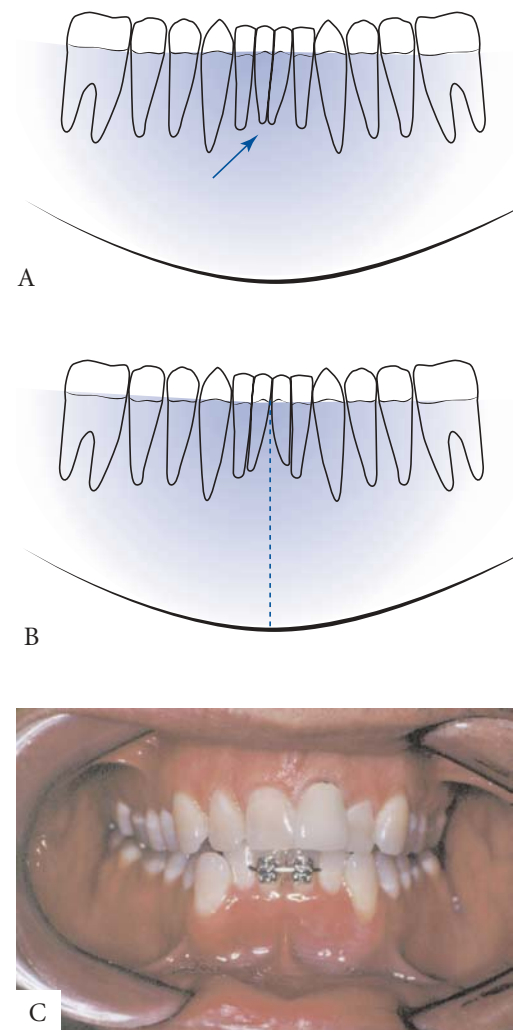


FIGURE 55-25 Mandibular symphysis distraction osteogenesis. A, Often the incisor roots are very close together. B, Space must be created between the roots of teeth adjacent to the intended vertical osteotomy. C, Placing brackets on only the central incisors with the mesial aspect of the brackets higher than the distal aspect on each tooth and placing a short straight wire segment, will tip the roots distally away from each other, creating space to perform the vertical interdental osteotomy.

Interdental Osteotomies An anterior maxillary subapical osteotomy or segmentalized Le Fort I osteotomy will permit rotation of the anterior teeth to increase their angulation. However, significant room must be created between the roots of the adjacent teeth (lateral incisors and cuspids) at the osteotomy areas. Since bone removal between the teeth may be required, there is an increased risk of damage to the adjacent teeth. If the maxilla requires surgical expansion, then segmentalization between the lateral incisors and cuspids will allow the anterior segment to rotate posteriorly between the expanded posterior segments with fewer requirements for bone removal, if required at all.

Correct Underangulated (Retroclined) Mandibular Incisors

Underangulated mandibular incisors are more commonly seen in patients with prognathic mandibles or with missing teeth. The following treatment methods can be used to correct this condition.

Correct Crowding Crowding of the mandibular anterior teeth often accompa-

nies vertically inclined teeth. Therefore, correcting the crowding will increase the incisor angulation.

Open Space In Class I and Class II patients underangulated incisors may be present because of previous extractions, congenitally missing teeth, previous trauma resulting in loss of teeth, or small mandibular teeth. In Class III patients underangulated incisors may be present due to an excessive amount of alveolar bone compared with the size of the teeth. If bicuspid are missing, opening space in the bicuspid areas can correct this problem and provide additional dental units for a more complete occlusal result. The use of coil springs usually works well for this situation (see Figure 55-26).

Occasionally a mandibular incisor may be missing for various reasons. Viable options include opening appropriate space around the remaining three incisors and building up the crowns by bonding, veneers, or crowns. This technique works best if there is a TSD that is less than the width of the missing tooth. However, the maxillary dental midline will be in the center of a mandibular incisor. Another option would be to open space in the area

of the missing tooth and then replace it with a dental implant or bridge. This technique may work best when there is no TSD with a full-size dental replacement.

Interarch Mechanics The use of class II mechanics (ie, elastics, Herbst's appliance) can increase mandibular incisor angulation. However, long-term class II mechanics can be detrimental to outcome stability and results, because of the potential unto-ward effects on the TMJs.

Interdental Osteotomies An anterior subapical osteotomy or bilateral anterior body osteotomies will permit rotation of the anterior teeth to increase their angulation. However, significant room must be created between the roots of the teeth adjacent to the osteotomy areas. Since bone removal between the teeth may be required, there is an increased risk of damage to the adjacent teeth.

Correct Excess Curve of Spee: Maxillary Arch

This condition is most often seen with anterior open-bite situations and high occlusal plane facial types. Careful assessment of the curve of Spee is important because using only orthodontic mechanics to correct this condition may not be very stable. An increased curve of Spee usually makes it difficult to get the occlusion to fit together. The condition can be addressed by the following treatment options.

Extruding Anterior Teeth Conventional orthodontics with straight wire techniques will tend to extrude the anterior teeth, and as a byproduct will tip the molars buccally, increasing the curve of Wilson. These dental changes may be unstable and fraught with relapse potential.

Intruding Midbuccal Teeth This is a very difficult technique, unless high-pull head-gear or osseointegrated implants are used to provide intrusive forces. This would

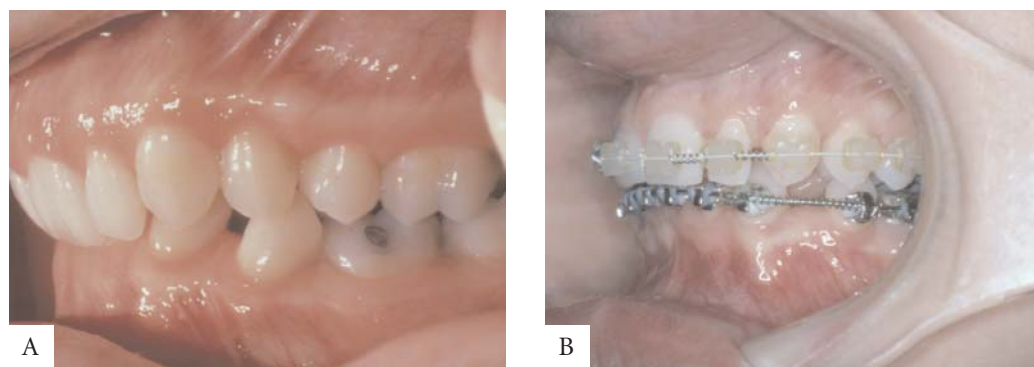


FIGURE 55-26 Coil springs to open space. In some cases, “retroclined” incisors are a result of Division 2 malocclusion, crowding, missing dental units, or small teeth. If there is no significant crowding, spacing can be created by the use of coil springs that will tip the incisors forward. A, Small maxillary lateral incisors and missing mandibular bicuspid. B, The use of coiled springs is demonstrated to open up interdental spaces around the maxillary lateral incisor (to correct for an anterior tooth-size discrepancy) and in the mandibular first bicuspid area (to replace a missing dental unit and increase the angulation of the anterior teeth). The spaces around the maxillary lateral incisor can be eliminated by bonding, veneer, or crown. In the mandibular arch, the space can be eliminated by surgical osteotomy versus replacement of the missing dental unit by crown-and-bridge or osseointegrated implant and crown.

require significant patient compliance and is not a commonly applied procedure.

Extraction and Retraction Extraction of maxillary first or second bicuspid with retraction will usually decrease the curve of Spee, providing the incisors are overangulated to begin with.

Orthodontic, Orthopedic, or Surgically Assisted Rapid Palatal Expansion with Retraction Expansion of the maxillary arch by any of these techniques will increase the arch length and allow some retraction of the anterior teeth. In late adolescence or adulthood, SARPE may provide better stability than the other two techniques. However, note that the curve of Wilson will increase because the expansion at the occlusal level compared with the palate will be a 3:1 ratio.¹⁹

Surgical Correction The maxilla can be orthodontically aligned in segments by aligning the four incisors at a different level, compared with the posterior teeth, to avoid extrusion, intrusion, and buccal tipping of teeth. Placing compensating vertical steps between the lateral incisors and cuspids (see Figure 55-15A) will accomplish alignment at different levels. For some cases the vertical positional difference may occur between the cuspids and bicuspid, or could occur asymmetrically on one side of the arch compared with the other side. The step in the arch would then be made between the appropriate teeth. Another technique to use involves cutting the arch wire into two or more segments and aligning groups of teeth in individual units (see Figure 55-15B). However, it may be more difficult to control rotations and root position, particularly of the teeth adjacent to the ends of the segmented wires, compared with using a continuous wire with compensating vertical steps. The arch can then be leveled surgically with a three-piece maxilla performing osteotomies between the lateral

incisors and cuspids. The three-piece Le Fort I osteotomy, with interdental osteotomies performed between the lateral incisors and cuspids, will permit repositioning of the anterior segment independent of the posterior segments (Figure 55-27). The anterior segment can be reoriented vertically and anteroposteriorly, and the axial inclination of the incisors can be changed to correct the curve of Spee and achieve the best interdigitation of the segments.

Correct Accentuated Curve of Spee: Mandibular Arch

An accentuated curve of Spee in the mandibular arch most often occurs in anterior deep-bite relationships.

Intruding Mandibular Anterior Teeth Intrusion mechanics can predictably inferiorly position mandibular anterior teeth approximately 2 mm. Beyond 2 mm the vertical relapse approaches 60%. With accentuated curves of Spee the contact area of the teeth will be at a different level

where the teeth are more narrow, below the normal contact level. Therefore, for every 1 mm of leveling of the mandibular arch, the mandibular incisor edges will move forward 0.6 mm to 1 mm as the contact points align. Any crowding of the arch will further contribute to flaring of the incisors. Intruding teeth will decrease the anterior mandibular vertical height and must also be taken into consideration so that the anterior mandibular height is not excessively shortened.

Extruding Midbuccal Teeth Extrusion of midbuccal teeth may be more stable than intrusion of anterior teeth. However, this technique is difficult to perform without special considerations. If the patient's malocclusion has the bicuspid and first molars in occlusion, extrusion will be virtually impossible. However, constructing a splint that will open the bite and engage only the mandibular anterior teeth and second molars, with the bicuspid and first molars out of contact with the splint, will permit extrusion

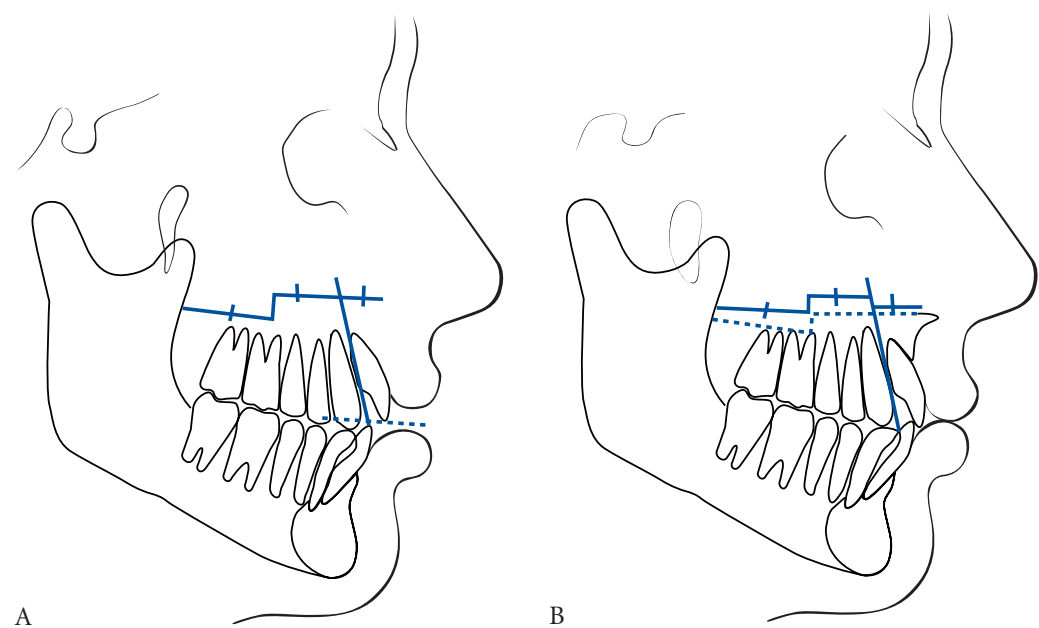


FIGURE 55-27 Surgery for correcting an excessive curve of Spee. A, Aligning the maxilla in segments with the incisors at an elevated level compared with the posterior teeth will permit interdental osteotomies to be performed. B, Surgical leveling of the occlusal plane from a predictability and stability standpoint is superior to orthodontic means alone, particularly when no extractions are performed.

of the midbuccal teeth. Another alternative would be to correct the accentuated curve of Spee after the mandible and occlusion are surgically repositioned, placing the incisors and molars into proper contact, and then extrude the midbuccal teeth postsurgery. With this approach the molars may tip distally and the arch may widen somewhat.

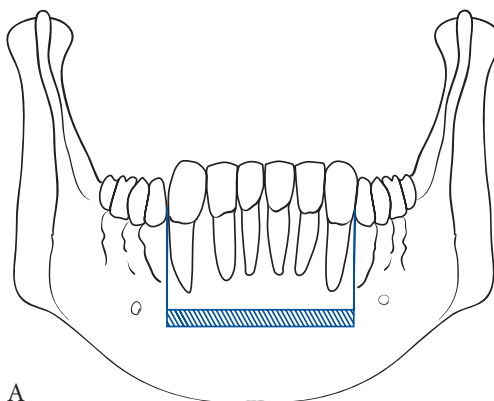
Interdental Osteotomies An anterior subapical osteotomy (Figure 55-28) or bilateral anterior body osteotomies (Figure 55-29) will permit downward repositioning of the anterior teeth, with very stable results when the surgery is properly performed. If the anterior vertical height of the mandible is excessive, then the subapical osteotomy would be indicated since it will shorten the anterior mandibular height by the amount that the incisors are lowered. Bilateral anterior body osteotomies would be indicated when the vertical height of the anterior mandible is normal or less, so that the anterior height remains unaltered while the curve of Spee is corrected.

Correct Reverse Curve of Spee: Maxillary Arch

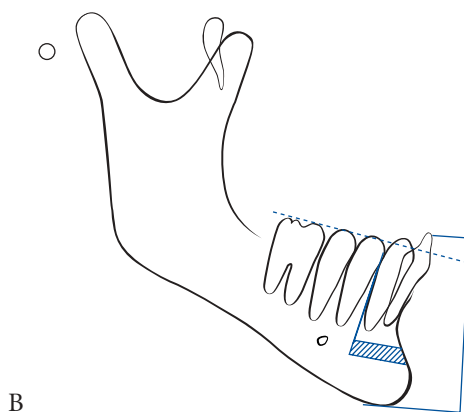
Reverse curves of Spee are more commonly seen in Division 2 malocclusions and in vertical maxillary deficiencies with an anterior deep bite. The maxillary incisors are commonly in a decreased axial inclination. Crowding may or may not be present.

Correct Crowding or Division 2 Relations Eliminating crowding and Division 2 dental positions will tip the incisors forward, increasing the incisor axial angulation and decreasing the reverse curve of Spee. These movements will usually fill out the upper lip, but may decrease the maxillary tooth-to-lip relationship. Maxillary incisors may become intruded with a straight wire technique.

Extruding Midbuccal Teeth This technique is difficult if the midbuccal teeth are

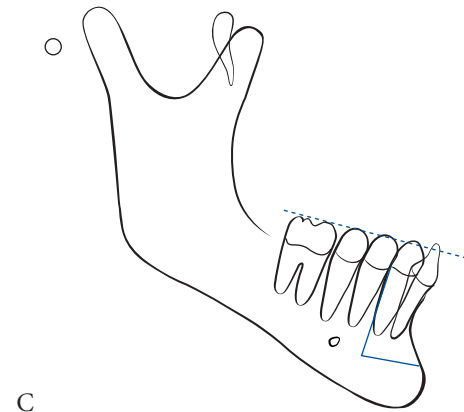


A



B

FIGURE 55-28 Subapical osteotomy correcting an accentuated curve of Spee in the mandibular arch. A, This can be accomplished with a subapical osteotomy composed of two interdental osteotomies and a subapical osteotomy to set the anterior teeth inferiorly. B, C, This is indicated when the anterior mandibular height is greater than normal, as this technique will shorten the anterior mandibular height. This same basic technique can be used to elevate the segment to correct a reverse curve of Spee.



C

in occlusion with mandibular teeth. However, the bite can be opened with a splint that affords contact on only the maxillary second molars and anterior teeth, with the maxillary midbuccal teeth out of contact with the splint. The midbuccal teeth (bicuspid and first molars) can then be extruded into position to improve the curve of Spee.

Open Spaces If the reverse curve of Spee is related to missing teeth or TSDs, then spaces can be opened to aid in increasing the axial inclination of the incisors and decreasing the reverse curve of Spee. These spaces can then be eliminated by bonding, crown and bridge, or dental implants and crowns.

Interdental Osteotomies Multiple maxillary osteotomies can be performed so that the maxilla can be repositioned in segments, enabling leveling of the arch. Presurgical orthodontics should be designed to align

the teeth at different vertical levels to facilitate the surgery and minimize orthodontic relapse potential. It is usually easiest and most applicable to make the osteotomies between the lateral incisors and cuspids. This may particularly be indicated when the maxilla must be repositioned anyway and maxillary expansion is also required. Performing a three-piece segmented maxillary osteotomy will then allow vertical alteration between the anterior and posterior segments to level the curve of Spee.

Correct Reverse Curve of Spee: Mandibular Arch

This condition is most commonly seen in patients with macroglossia, habitual tongue posturing, or tongue thrust, with an associated anterior open bite. The following techniques can be used to correct this type of condition.

Extruding Anterior Teeth Extrusion of anterior teeth may not be very stable long

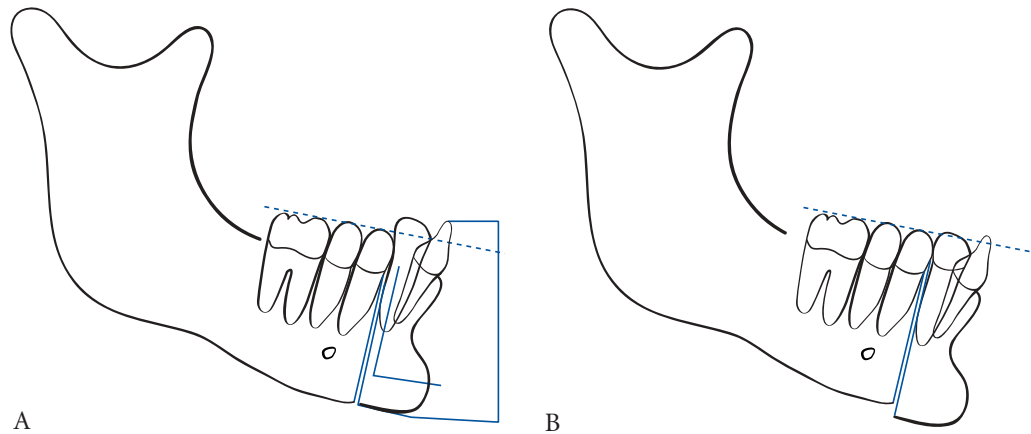


FIGURE 55-29 A, B, Bilateral mandibular body osteotomies will permit leveling of the excessive curve of Spee without shortening the vertical height of the mandible and are indicated when the mandibular anterior dental height is normal or even slightly short vertically. This basic technique can also be used to correct a reverse curve of Spee by elevating the anterior segment.

term, and without permanent retention, could result in re-intrusion and redevelopment of an anterior open bite.

Intrusion of Midbuccal Teeth This is a difficult technique but may be accomplished with osseointegrated implants as anchors. However, it is not known if this would be stable long term.

Extract and Retract If the mandibular incisors are significantly overangulated, with or without crowding, bicuspid extractions can be performed and the incisors retracted, which will decrease the reverse curve of Spee.

Bonding the Mandibular Anteriors This technique can be used to level the arch by building up the incisors, increasing the crown height. However, care must be taken not to exceed a safe crown-root ratio and/or create an esthetic compromise.

Interdental Osteotomies Anterior subapical (see Figure 55-28) or anterior bilateral mandibular body osteotomies (see Figure 55-29) can be used to elevate the anterior teeth. If the anterior mandibular height is short, then the subapical osteotomy can also be used to increase the anterior height of the mandible. If the anterior

mandibular height is normal, then the bilateral anterior body osteotomies will permit elevation of the anterior teeth while maintaining the anterior height of the mandible.

Anteroposterior Arch Asymmetry (Maxilla or Mandible)

Anteroposterior arch asymmetry, when the cuspid on one side of the arch is anterior to the cuspid on the opposite side of the arch, is fairly common in patients with dentofacial deformities. Arch asymmetries can be related to developmental abnormalities, missing teeth, or ankylosed teeth. Dental midlines may not align with the facial midline.

Extract Unilaterally In some cases unilateral extraction and retraction will correct the problem. The decision must be made as to which tooth to extract. Extraction of a first bicuspid will allow greater anterior retraction compared with extracting a second bicuspid. This extraction would only be indicated if there were significant overangulation of the incisors, crowding, and/or significant midline dental shift.

Open Space Unilaterally This technique would be indicated if a tooth is missing,

there is significant decreased angulation of the incisors, and/or the midline is significantly deviated to one side.

Interarch Mechanics This technique can be effectively used by incorporating class II mechanics on one side and class III mechanics on the opposite side. Anterior cross-arch elastics can also be helpful. If only one arch is involved, then maximizing anchorage in the other arch is very important so that an asymmetry does not develop in the normal arch. Osseointegrated implants can be used as anchors to correct asymmetry in an arch without having to use interarch mechanics.

Osteotomies Osteotomies can be used in the maxillary arch by segmentalization of the maxilla and advancing one side more than the other side. Osteotomies in the mandibular arch to correct arch asymmetry can become somewhat complex. Anterior subapical osteotomies with removal of a unilateral tooth can correct some large discrepancies (6 to 9 mm). However, the subapical osteotomy may need to be combined with ramus sagittal split osteotomies and a unilateral or bilateral body osteotomy, with or without extraction, to shift the occlusion into a symmetric position. These types of movements require a high degree of surgical skill, but can provide high-quality outcomes.

Divergence of Roots Adjacent to Interdental Surgical Sites

When interdental osteotomies are planned it may be necessary for the orthodontist to tip the adjacent tooth roots away from the area of the planned osteotomy to prevent damage to the teeth (Figure 55-30). If the roots are too close together, postsurgical periodontal problems may develop with possible loss of interdental bone and teeth. Creating interdental space between the roots significantly improves the margin of safety. This can be easily achieved by selective

bracket placement. For the tooth mesial to the osteotomy, the bracket is slightly rotated so that the mesial aspect of the bracket is positioned slightly more gingivally compared with the distal aspect of the bracket (Figure 55-31). Conversely the distal tooth bracket is positioned so that the distal aspect of the bracket is placed slightly more gingivally compared with the mesial aspect of the bracket. With a straight wire technique the roots will diverge.

Postsurgically, periapical radiography may be necessary for the orthodontist to check for rebonding the adjacent teeth brackets to ensure proper root angulation at completion of treatment.

Extraction Versus Nonextraction

The decision to extract or not to extract can sometimes be difficult. There are a number of factors that may contribute to this determination.

Overangulated Anterior Teeth Excessive over-angulated anterior teeth may require extraction to set the teeth over basal bone. However, if the arch is to be expanded or teeth slenderized for TSD, for example, then extraction may not be necessary.

Crowding This is a common indicator, particularly with major crowding or

overangulated teeth. However, if crowding is mild to moderate, widening of the arch or teeth slenderizing for TSD may eliminate the need for extraction.

Tooth-Size Discrepancy TSDs of significant magnitude may indicate the need for extraction, particularly if the TSD of the anterior mandibular teeth is 5 mm or greater and the mandibular incisors are overangulated and/or crowded, in which case a mandibular incisor extraction could be considered.

Curve of Spee Accentuated curves of Spee in the maxillary arch usually have overangulated maxillary incisors, and reverse curves of Spee in the mandibular arch usually have overangulated mandibular incisors. Extraction of bilateral first or second bicusps and retraction will result in leveling of the arches. However, arch expansion, when indicated, may create enough room so that extractions are not necessary.

Arch Asymmetries With significant anteroposterior arch asymmetries, unilateral or bilateral asymmetric extractions (ie, first bicuspid on one side and a second bicuspid on the opposite side) may be indicated when there is coexisting crowding overangulated incisors, or mid-line shift.

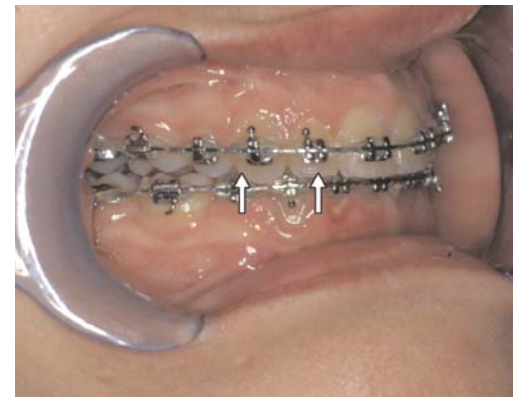


FIGURE 55-31 Selective bracket placement can create adequate interdental space for osteotomies. On the tooth mesial to the osteotomy, slightly rotate the mesial aspect of the bracket gingivally, and on the distal tooth, slightly rotate the distal aspect of the bracket gingivally. A straight wire will then diverge the roots.

Coordination of Maxillary and Mandibular Arch Widths

In some cases transverse arch width discrepancies can be corrected with stable and predictable orthodontic movements, but in other cases orthodontic correction may be very unstable and fraught with relapse. It must be determined whether to correct width problems by orthodontics, orthopedics, SARPE, or surgical expansion. Even with SARPE using a fixed device, the palate only expands approximately one-third the amount of the expansion that occurs at the occlusal level, thus increasing the curve of Wilson.¹⁹ For example, if the maxilla is expanded with SARPE and the expansion at the occlusal level is 6 mm, then the expansion at the palatal level will only be 2 mm (see Figure 55-22). Patients with reverse curves of Wilson in the maxillary arch may benefit more from these techniques, but those with a pretreatment accentuated curve of Wilson may have unfavorable results, with subsequent difficulty getting the buccal cuspids to interdigitate. The following predictable changes will occur with maxillary arch expansion by orthodontic, orthopedic, or SARPE procedures.

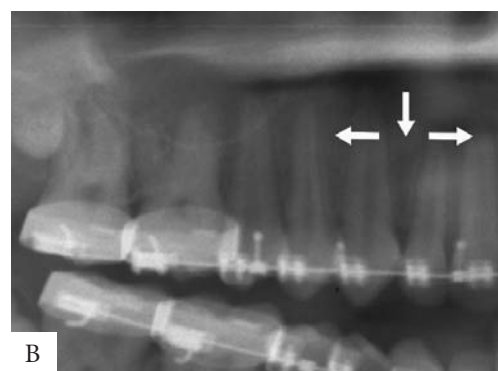
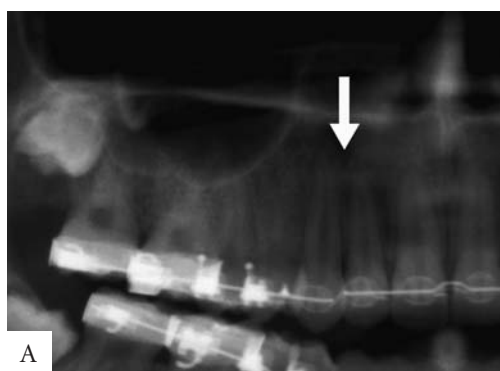

FIGURE 55-30 Interdental osteotomies. A, Pantomogram demonstrating inadequate room between the roots of the lateral incisors and cuspids. Performing osteotomies with roots in this position could result in severe periodontal compromise and possible loss of teeth. B, Adequate spaces for interdental osteotomies can be created by selective bracket placement on the adjacent teeth.

1. The bite may open anteriorly, particularly if the maxillary incisors have significant initial vertical inclination. If the maxillary incisors are overangulated, then the bite may deepen anteriorly as the spacing is closed.
2. Buccal tipping of the maxillary posterior teeth will increase the curve of Wilson, because the lingual cusps will move downward relative to the buccal cusps. This may make it very difficult to properly interdigitate the buccal cusps orthodontically. Therefore, these techniques are not recommended, especially when there is a preexisting accentuated curve of Wilson.
3. Long-term or perhaps permanent retention may be necessary to counterbalance the orthodontic relapse potential seen in a high percentage of these patients.
4. In late adolescent and adult patients, SARPE will likely be necessary to expand the maxilla orthopedically since the midpalatal suture is usually closed.

Surgical expansion of the maxilla at the time of the Le Fort I procedure using multiple segmentation of the maxilla, stabilization with bone plates and palatal or occlusal splints, and hydroxyapatite synthetic bone grafting in the palate and lateral maxillary walls can provide a good outcome. This technique when properly performed is very stable and eliminates the orthodontic relapse potential inherent with the other techniques.

Missing Teeth

Teeth can be missing from the arches for a number of reasons such as congenital absence, uneruption, previous orthodontic extractions, extractions for periodontal or dental pathology, and trauma. In some cases (ie, congenital absence of maxillary lateral incisors, previous inappropriate bicuspid extraction) opening space to accommodate replacement teeth may be indicated. This is most applicable

when the incisors are decreased in angulation without appreciable crowding. If the incisors are already overangulated and/or crowding is present, then opening space orthodontically may be detrimental to stability and periodontal health. In this situation with missing maxillary lateral incisors, the cuspids can be used as lateral incisors, but may require considerable recontouring to esthetically and functionally conform to lateral incisor morphology. Although this cuspid substitution can work well for missing lateral incisors, it is done less frequently now that dental implants are so predictable and successful, thereby allowing the canine to be placed in its normal and more functional position.

When conditions permit, opening space for replacement teeth can be accomplished by appropriate mechanics to achieve the required space. Surgery can also be used to create spacing in some areas. In the mandibular arch, distraction osteogenesis can be used to create space. The missing teeth can then be replaced with dental implants, bridges, or partial dentures for example.

Correction of Rotated Teeth

Bracket placement and arch wire adaptation are the primary keys to correcting rotated teeth and it is usually best to achieve these corrections presurgery. However, if the malrotations do not interfere with the establishment of the desired dentoskeletal relationship, then the rotations can be corrected postsurgery. Severe rotations may require supracrestal fiberotomy to prevent relapse and improve permanent retention. This can often be done at the time of orthognathic surgery.

Management of Ankylosed Teeth

Treatment of ankylosed teeth depends on (1) whether the tooth is primary or permanent, (2) the surrounding dentition, (3) the eruption status, (4) tooth position and orientation, (5) the time of onset and

diagnosis, (6) the age of the patient and, (7) the treatment goals.

Ankylosed Primary Tooth This can impede the development and eruption of the permanent successor. If a primary tooth has a permanent successor, treatment is immediate extraction followed by space maintenance until the permanent tooth erupts. If no permanent successor is present and the primary tooth ankylosis occurs at an early stage in jaw growth and development with submergence of the tooth eminent, treatment includes extraction and space maintenance.²⁰ If the ankylosis occurs late with no permanent successor, the occlusal and proximal contacts can be reestablished with restorative dentistry to provide esthetics and function with perhaps many years of service.²¹

It is important to diagnose and treat the ankylosed tooth before the adolescent growth phase. Retaining an ankylosed tooth during jaw growth leads to arrested development of the alveolar ridge. The severity of alveolar growth loss depends on the amount of facial growth left at the time that the ankylosis occurs. Timing the removal of an ankylosed tooth just at the start of the pubertal phase of adolescent growth may achieve the treatment objective of maintaining alveolar ridge height while allowing the tooth to remain long enough to act as a space maintainer and esthetic temporary.²²

Ankylosed Permanent Tooth An unrecognized ankylosed permanent tooth tied into the arch wire can result in a significant malocclusion (Figure 55-32). There are several ways of treating the permanent ankylosed tooth. If ankylosis of the permanent tooth has an early onset during eruption, the tooth should be luxated, allowing for further eruption.² If repeated luxation proves ineffective, the tooth should be extracted to prevent submergence. If the onset of ankylosis occurs late in the normal eruption pattern, the tooth should be luxated. If the attempt is

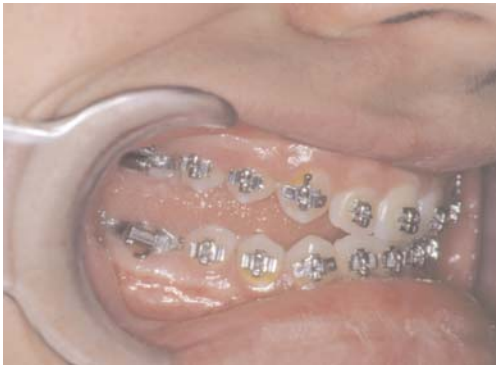

FIGURE 55-32 An ankylosed first molar tied into the arch wire has prevented development of the alveolus and consequently created a significant posterior open bite.

unsuccessful and the tooth does not submerge, it may be vertically restored on growth maturity. A composite build-up or crown can be added to a partially erupted ankylosed tooth to level and align the arch.²¹ A deeply unerupted ankylosed tooth, primary or permanent, may be left undisturbed unless it is infected, alters the alveolar bone growth potential, or constitutes an immediate threat to the occlusion or adjacent teeth, or would impede the placement of an osseointegrated implant.³

Other treatment options include extraction followed by reimplantation, osseointegrated implant, or prosthetic replacement.²³ The patient's developmental age is very important in considering replacing an ankylosed tooth with an osseointegrated implant. The implant will have the same effect on growth of the alveolar ridge as the ankylosed tooth, and therefore should be considered for placement after alveolar growth is essentially complete.²⁴

Proffit suggests surgical luxation of the tooth with extraction forceps disrupting the cementum-bone fusion followed by immediate orthodontic traction to move the tooth into position.²⁰ Luxation involves breaking the bony bridge of ankylosis without damaging the apical nutrient vessels. This procedure forms fibrous inflammation tissue in the reparative process. This tissue forms a false periodontal membrane, and tooth erup-

tion may resume. Orthodontic movement should begin immediately. Complications include possible crown, root, and alveolar fractures, loss of viability and vitality, as well as re-ankylosis. When an ankylosed tooth is impacted, a similar technique can bring an impacted tooth (usually canines) into the arch. Exposure involves surgical uncovering, application of orthodontic bonding, and tension forces applied to direct the tooth into occlusion. However, if the tooth becomes re-ankylosed, the orthodontic forces will intrude adjacent teeth.

Orthodontics for Surgical Management of Ankylosed Teeth Presurgical orthodontics may be indicated to create adequate space (minimum of 2 to 3 mm) between the roots of the adjacent teeth to safely accommodate interdental osteotomies around the ankylosed tooth. Spacing is best assessed with pantomographic or periapical radiographs. The ankylosed tooth is left out of the arch wire, and all other teeth are properly aligned. If orthognathic surgery is required to correct a dentofacial deformity, the orthodontics are performed in the traditional manner, but the ankylosed tooth must remain out of the arch wire, unless it aligns well with one of the dental segments. Following surgery, orthodontic mechanics can be initiated immediately to help get the mobilized dental segment with the ankylosed tooth into the best possible position.

Osteotomy Performing single-tooth osteotomies or sectional-arch osteotomies with mobilization of the segment will permit immediate repositioning of the ankylosed tooth (Figure 55-33), or facilitate repositioning by distraction osteogenesis.

In select cases where an ankylosed primary molar is present, without a successor, a treatment option is to remove the ankylosed tooth and eliminate the extraction space by performing a vertical body osteotomy in conjunction with a mandibular

ramus osteotomy and advance the posterior teeth and mandibular body forward (Figure 55-34). This eliminates the need for osseointegrated implants and extensive dental reconstruction.

Final Presurgical Preparation

As presurgical orthodontic treatment progresses, new diagnostic records (lateral cephalograms, pantomograms, dental models) are taken to determine the feasibility and timing of surgical procedures. This will also aid the orthodontist in identifying specific areas that may need to be addressed in completing the presurgical orthodontic goals (ie, sectional leveling of the arch

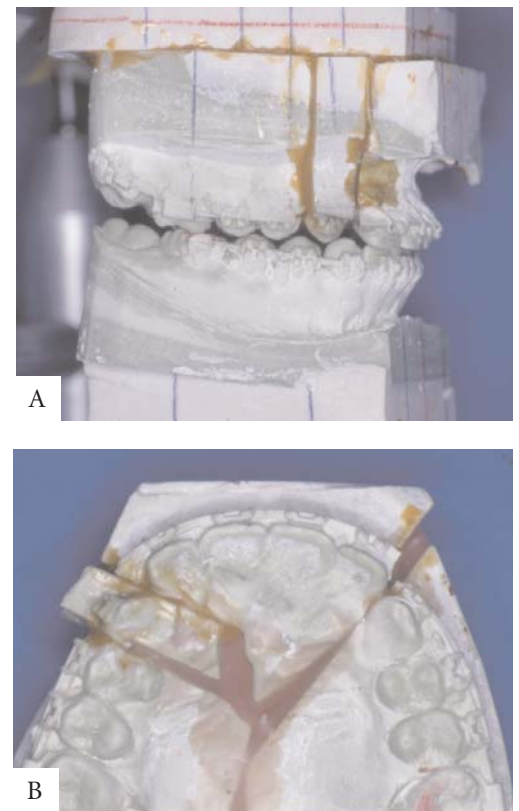


FIGURE 55-33 Single-tooth osteotomies can be performed as isolated cases or they can be performed in combination with multiple maxillary osteotomies to allow individual movement of the dental osseous segments or application of immediate distraction osteogenesis to reposition the tooth properly. The case illustrated had an ankylosed maxillary right cuspid (see Figure 55-8) treated with segmental maxillary osteotomies including a single tooth segment containing the right cuspid (A, B)

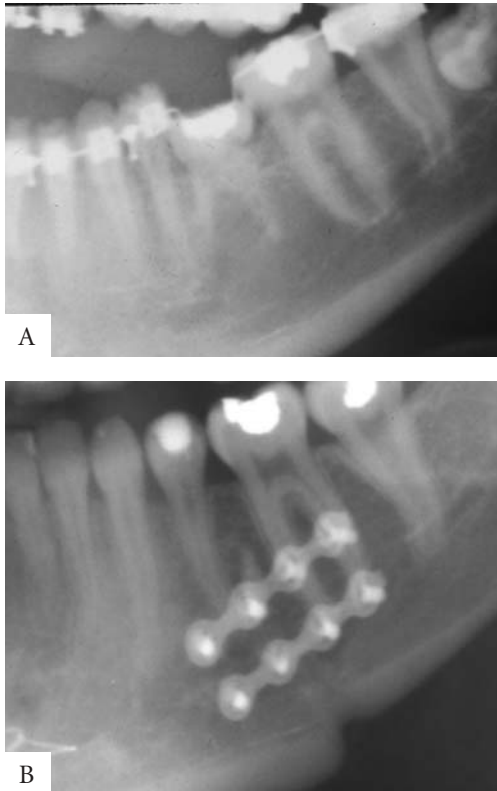


FIGURE 55-34 A, B, An ankylosed submerged primary tooth without a permanent successor can be treated with extraction of the primary tooth as well as a vertical body osteotomy in conjunction with a mandibular ramus sagittal split osteotomy to advance the posterior teeth forward to eliminate the ankylosed tooth and associated space. This eliminates the need for an osseointegrated implant or crown-and-bridge work.

segments, marginal ridge alignment, vertical dental alignment, buccal surface alignment, additional TSD correction).

During surgery the jaws are usually wired together once or twice, as each jaw is independently mobilized and stabilized with rigid fixation. To facilitate wiring the jaws together as well as providing a means of using postsurgical elastics if required, fixtures attached to the brackets or arch wires are usually necessary. Fixtures attached to the brackets are dependent on the manufacturer but may include ball hooks built onto the brackets, T pins, and K hooks, (Figure 55-35). Fixtures attached to the arch wire include crimped-on hooks and soldered pins (Figure 55-36). Hooks built onto the brackets are preferred, followed by the other

hooks placed on the brackets (T pins, K hooks). The least preferred are the hooks on the arch wire. The reason is that if postsurgery elastics are required for an extended time, the elastics and hooks on the arch wire will activate the arch wire, possibly creating unwanted orthodontic forces and movements (ie, tipping the crowns lingually and the roots buccally). This undesirable torquing occurs to a much lesser degree when the hooks are directly on the brackets.

When the maxilla or mandible are to be segmentalized, it may be better for the orthodontist to section the arch wire (see Figure 55-15B) and bend the ends inward at the predetermined osteotomy areas immediately prior to surgery, or the surgeon can cut the wire at surgery.

The best type of arch wire to place prior to surgery is a rectangular stainless steel wire that fills the bracket slot. For example, with an 18 slot, a 17 × 25 gauge wire is recommended, and for a 22 slot, a 21 × 25 gauge wire is indicated. This will help stabilize the individual dental units together as a whole arch or in segments when segmental surgery is required. The final wire should be placed 2 to 3 months prior to surgery.

Postsurgical Orthodontics

In preparation for the postsurgery orthodontic phase of treatment, the surgical stabilizing splint, if used, is usually removed 4 to 6 weeks postsurgery. If the palatal splint design is used and a large maxillary expansion has been performed, the splint can remain for a longer period and the postsurgical orthodontics can be performed around it. The maintenance of the splint will enhance the transverse stability and it can be left in for 2 to 3 months or longer if necessary. It can be made into a removable appliance.

If rigid skeletal fixation is used, active orthodontics involving changing the arch wires can usually resume 4 to 6 weeks postsurgery, when patients are usually comfortable enough to tolerate changing their arch

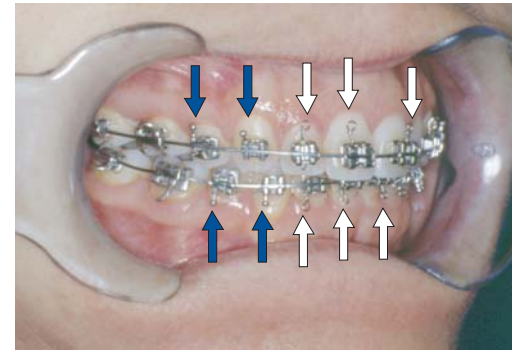


FIGURE 55-35 Orthodontic hooks. Ball hooks built onto the brackets (blue arrows) provide the best stability. Other options include T pins and K hooks (white arrows) or other methods to provide attachments directly on the brackets.

wires. The orthodontist can be fairly aggressive at finishing the occlusion because the osseous segments can still be moved slightly. The teeth move much more rapidly for the first few months postsurgery because there is an increased bony metabolism as a result of the surgery. The orthodontist can therefore accomplish in 1 to 2 weeks what would normally take 4 to 6 weeks to complete. Applying active mechanics at this early postsurgical orthodontic phase of treatment and booking the patient for a routine orthodontic follow-up 4 to 6 weeks later could result in uncontrolled excessive orthodontic movements, resulting in an unfavorable outcome.

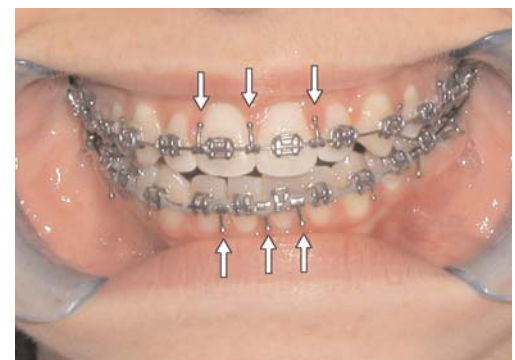


FIGURE 55-36 Soldered pins on the arch wire or crimped hooks (white arrows) onto the arch wire can also be used but are not preferred because the use of postsurgical elastics will activate the arch wire, possibly creating unwanted orthodontic movements.

For most cases the orthodontist should see the patient once a week for the first month, then every 2 weeks for the next 2 months for adjustments so that orthodontic changes can be closely monitored. At the initial appointments root positions are checked, loose brackets and bracket positions are evaluated and corrected, and new arch wires are placed if indicated. Interarch mechanics (ie, class II or III elastics, vertical elastics, and/or cross-arch elastics) can be applied as necessary to finalize the occlusion. Once the initial healing phase is completed (approximately 3 to 4 months postsurgery) and the occlusion is stable, the orthodontic appointment intervals can be extended to the more traditional time frame. The final positioning of the teeth usually takes from 3 to 12 months of postsurgical orthodontic treatment but could be longer depending on the postsurgical orthodontic requirements. Although reasonable stability from surgical healing occurs in approximately 3 to 4 months, the final postsurgical healing phase takes 9 to 12 months.

References

1. Bolton WA. The clinical application of a tooth-size analysis. *Am J Orthod* 1962;48:504–29.
2. Moyers RE, van der Linden FPGM, Riolo ML, McNamara JA. Standards of human occlusal development. The University of Michigan Ann Arbor (MI): The Center for Human Growth and Development; 1976. p. 53–94.
3. Alling CC III, Helfrick JF, Alling RD. Impacted teeth. Philadelphia (PA): WB Saunders Co.; 1993. p. 4.
4. Biederman W. The problem of the ankylosed tooth. In: Spengeman WG, editor. *Dental clinics of North America*. Philadelphia (PA): WB Saunders Co.; 1968. p. 409–24.
5. Jacobs SG. Ankylosis of permanent teeth: a case report and literature review. *Aust Orthod J* 1989;11(1):38–44.
6. Schultes G, Gaggl A, Karcher H. Periodontal disease associated with interdental osteotomies after orthognathic surgery. *J Oral Maxillofac Surg* 1998;56:414–7.
7. Wolford LM. Periodontal disease associated with interdental osteotomies after orthognathic surgery. *J Oral Maxillofac Surg*. 1998;56:417–9.
8. Dorfman HS, Turvey TA. Alterations in osseous crestal height following interdental osteotomies. *Oral Surg Oral Med Oral Pathol* 1979;48:120–5.
9. Shepherd JP. Long-term effects of segmental alveolar osteotomy. *Int J Oral Surg* 1979; 8:327–32.
10. Kwon H, Philstrom B, Waite DE. Effects on the periodontium of vertical bone cutting for segmental osteotomy. *J Oral Maxillofac Surg* 1985;43:953–5.
11. Fox ME, Stephens WF, Wolford LM, el Deeb M. Effects of interdental osteotomies on the periodontal and osseous supporting tissues. *Int J Adult Orthod Orthogn Surg* 1991; 6:39–46.
12. Wolford LM, Cottrell DA. Diagnosis of macroglossia and indications for reduction glossectomy. *Am J Orthod Dentofac Orthop* 1996;110:170–7.
13. Turvey TA, Journot V, Epker BN. Correction of anterior open bite deformity: a study of tongue function, speech changes, and stability. *J Maxillofac Surg* 1976;4:93–101.
14. Wickwire NA, White RP Jr, Proffit WR. The effect of mandibular osteotomy on tongue position. *J Oral Surg* 1972;30:184–90.
15. Wolford LM, Karras S, Mehra P. Concomitant temporomandibular joint and orthognathic surgery: a preliminary report. *J Oral Maxillofac Surg* 2002;60:356–62.
16. Wolford LM, Mehra P, Reiche-Fischel O, et al. Efficacy of high condylectomy for management of condylar hyperplasia. *Am J Orthod Dentofac Orthop* 2002;121:136–51.
17. Mehra P, Wolford LM. The Mitek mini anchor for TMJ disc repositioning: surgical technique and results. *Int J Oral Maxillofac Surg* 2001;30:497–503.
18. Wolford LM, Cardenas L. Idiopathic condylar resorption: diagnosis, treatment protocol, and outcomes. *Am J Orthod Dentofac Orthop* 1999;116:667–76.
19. Schwarz GM, Thrash WJ, Byrd DL, Jacobs JD. Tomographic assessment of nasal septal changes following surgical-orthodontic rapid maxillary expansion. *Am J Orthod* 1985;87(1):39–45.
20. Proffit WR. *Contemporary orthodontics*. St Louis (MO): C.V. Mosby Co.; 1986. p. 191–2, 352.
21. Williams HS, Zwemer, JD, Hoyt DJ. Treating ankylosed primary teeth in adult patients: a case report. *Quintessence Int* 1995;26:161–6.
22. Steiner DR. Timing of extraction of ankylosed teeth to maximize ridge development. *J Endodont* 1997;23:242–5.
23. Geiger AM, Bronsky MJ. Orthodontic management of ankylosed permanent posterior teeth: a clinical report of three cases. *Am J Orthod Dentofac Orthop* 1994;106:543–8.
24. Oesterle LJ. Implant consideration in the growing child. In: Higuchi KW, editor. *Orthodontic applications of osseointegrated implants*. Chicago (IL): Quintessence Publishing Co.; 2000. p. 133–59.

Principles of Mandibular Orthognathic Surgery

Dale S. Bloomquist, DDS, MS

Jessica J. Lee, DDS

The development of mandibular osteotomies for correction of dentofacial deformities closely parallels the advancement of oral and maxillofacial surgery as a specialty more than any other group of surgical techniques. From Hullihen, who in 1849 was the first to describe a mandibular osteotomy, to Obwegeser, who developed the sagittal osteotomy of the vertical ramus, there has been dramatic progress in the techniques of mandibular osteotomies. After Obwegeser's original paper in German, and especially since his description of techniques in the English literature, orthognathic surgery has seen dramatic changes in use as well as refinement of the osteotomies. Although the development of osteotomy techniques is ongoing, it is the purpose of this chapter not only to describe the most commonly used surgical procedures for the mandible but also to emphasize the refinements in technique that have been the result of the most recent clinical as well as basic research.

History

Hullihen corrected a patient with anterior open bite and mandibular dentoalveolar protrusion with an intraoral osteotomy, very similar to what we now describe as an anterior subapical osteotomy (Figure 56-1).¹ His

efforts did not seem to stimulate much interest, for it was almost 50 years later when Angle described a body osteotomy done by V.P. Blair (Figure 56-2A) for a patient with mandibular horizontal excess.^{2,3} This technique, with minor modifications, was advocated until the 1970s. Since then the only major modifications in the body osteotomy that have occurred are a greater emphasis being placed on preserving the inferior alveolar nerve and a switch to an intraoral approach.

The horizontal osteotomy of the vertical ramus popularized by Blair (Figure 56-2B) was accomplished through an extraoral route.⁴ As with many of the early mandibular procedures a horizontal bone cut was made above the lingula and was described for correcting both mandibular horizontal deficiency and horizontal excess. An intraoral technique was not suggested until Ernst discussed his procedure approximately 25 years later.⁵ This method of correcting mandibular deformities was used for almost 60 years, but because of its lack of postoperative stability, it has fallen into disuse.

The subcondylar osteotomy (Figure 56-2C), a form of which was first reported by Limberg as an extraoral technique, has undergone relatively minor refinement to

the intraoral vertical subcondylar osteotomy that is popular today.⁶ There has, however, been a substantial number of osteotomy designs through the vertical ramus that begin in the sigmoid notch, which has led to some confusion in the

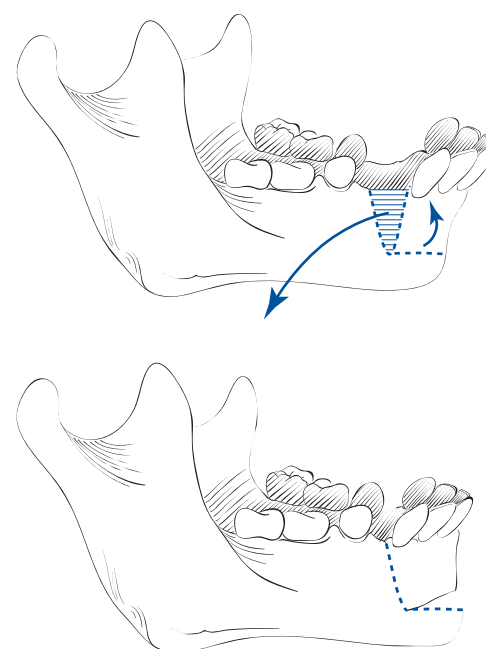


FIGURE 56-1 Hullihen's mandibular subapical osteotomy. Adapted from Bloomquist DS. *Principles of mandibular orthognathic surgery*. In: Peterson LJ, Indresano AT, Marciani RD, Roser SM. *Principles of oral and maxillofacial surgery*. Vol 3. Philadelphia (PA): J.B. Lippincott Company; 1992. p. 1416.

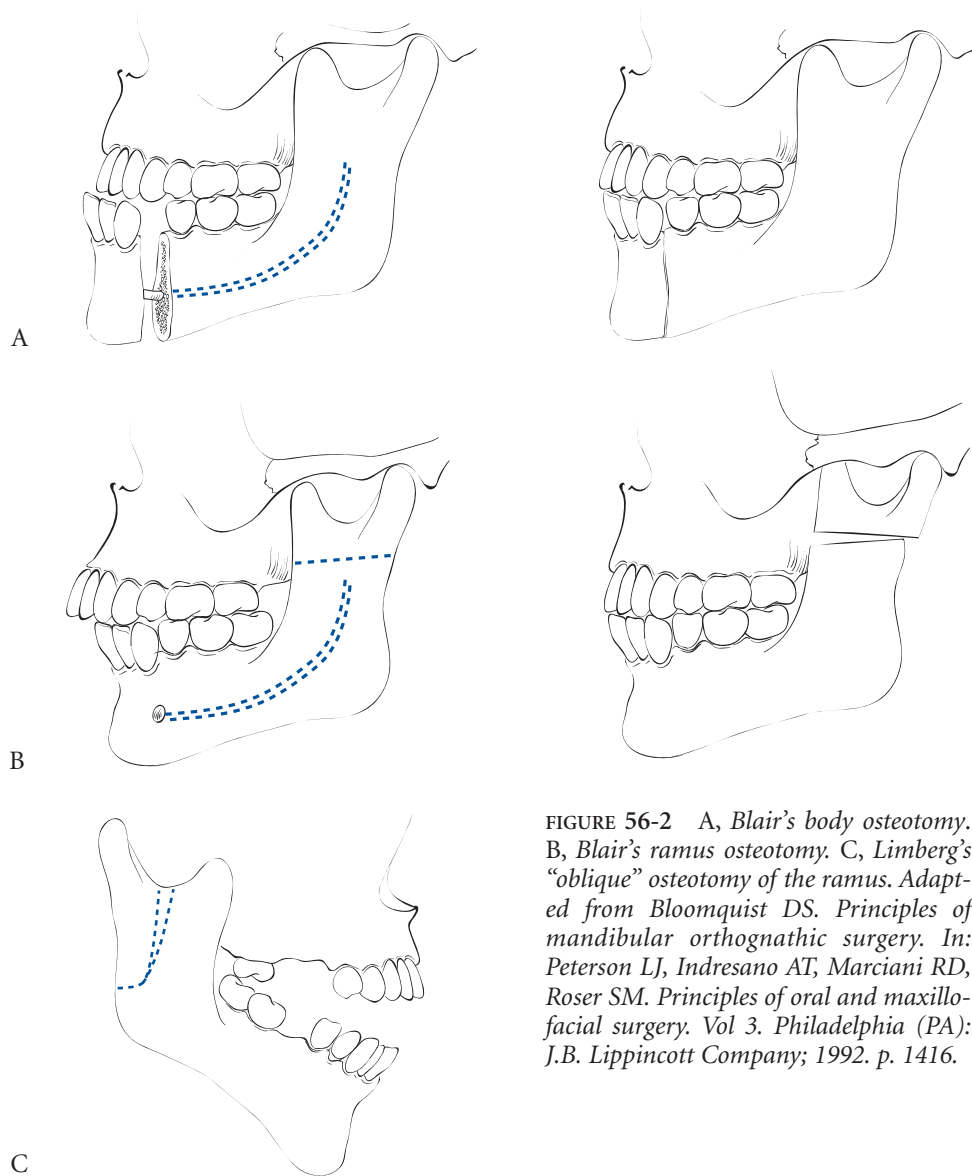


FIGURE 56-2 A, Blair's body osteotomy. B, Blair's ramus osteotomy. C, Limberg's "oblique" osteotomy of the ramus. Adapted from Bloomquist DS. *Principles of mandibular orthognathic surgery*. In: Peterson LJ, Indresano AT, Marciani RD, Roser SM. *Principles of oral and maxillo-facial surgery*. Vol 3. Philadelphia (PA): J.B. Lippincott Company; 1992. p. 1416.

nomenclature of what is a fairly closely related group of osteotomies. The names that have been developed have generally been based on the length and direction of the cuts made in the posterior portion of the vertical ramus. The subcondylar osteotomy was used to describe the condylar neck osteotomies of Kostecka and of Moose.^{7,8} Generally longer cuts that extended to the posterior border above the angle, such as described by Limberg, Thoma, and Robinson, were described as oblique osteotomies.⁵⁻¹⁰ Shira, however, coined the term oblique sliding osteotomy for this particular surgery.¹¹ Finally Caldwell and Letterman described a vertical

osteotomy of the mandibular ramus that included a cut from the sigmoid notch to the inferior border in front of the angle of the mandible.¹² The cut was kept behind the foramen of the mandibular nerve, and a portion of the lateral cortex of the distal fragment was decorticated to allow a larger area of bone contact. Generally these latter two groups of osteotomies are now being called vertical osteotomies, but some semantic differences still persist. Specifically the terms vertical subcondylar osteotomies (VSOs) and vertical ramus osteotomies (VROs) are still used interchangeably in the literature. Primarily this type of osteotomy was designed for correc-

tion of mandibular horizontal excess of mandibular asymmetries, although Robinson described its use with a bone graft for horizontal deficiencies.¹⁰

The intraoral approach to the subcondylar osteotomies is relatively new, having first been described by Moose in 1964.¹³ He approached the condylar neck medially with a straight bur. Winstanley suggested a lateral approach in 1968, but it was not until Hebert and colleagues described the use of a special oscillating saw that this approach became popular.^{14,15}

A variation of the vertical subcondylar osteotomy was suggested by Wassmund in 1927 (Figure 56-3A), which is similar to what is now called the inverted L osteotomy.¹⁶ Pichler and Trauner later suggested the use of bone grafts into the defect left by the advancement of the mandible.¹⁷ Caldwell and colleagues further modified the inverted L by adding a horizontal cut just above the inferior border of the mandible to create what is now called the C osteotomy (Figure 56-3B).¹⁸ The stated advantage of the C osteotomy was that the bone cut design made the use of a bone graft unnecessary. This advantage was further enhanced by the modification suggested by Hayes, with the splitting of the inferior limb sagittally so that more bone contact can be achieved.¹⁹ A further interesting approach to this group of vertical ramus osteotomies done for horizontal mandibular deficiency is the modified L osteotomy described by Fox and Tilson.²⁰ They deleted the superior horizontal cut of the C osteotomy and instead extended the vertical cut to the sigmoid notch. Then the coronoid process was removed and added as a free graft into the defect resulting from the mandibular advancement.

The greatest development in osteotomies of the vertical ramus is the sagittal osteotomy, credited to Obwegeser and Trauner, but generally now used in a fashion modified from the original technique described in 1955.²¹ Lane has been mentioned as the developer of a form of

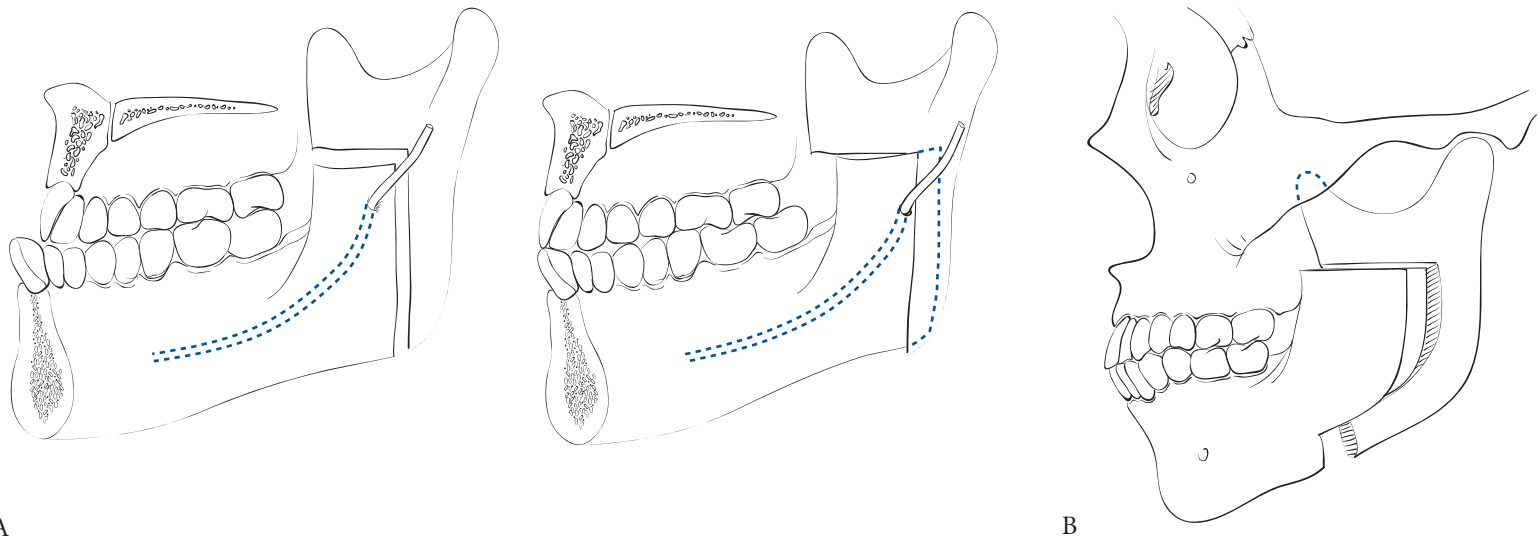


FIGURE 56-3 A, L osteotomy. B, C osteotomy. Adapted from Bloomquist DS. *Principles of mandibular orthognathic surgery*. In: Peterson LJ, Indresano AT, Marciani RD, Roser SM. *Principles of oral and maxillofacial surgery*. Vol 3. Philadelphia (PA): J.B. Lippincott Company; 1992. p. 1417.

the sagittal osteotomy, with parallel horizontal bone cuts made through the medial and lateral cortices of the vertical ramus (Figure 56-4).²² The medial cut was made just above the lingula, with the lateral cut made just below it. This idea was expanded by Schuchardt before being refined and popularized by Obwegeser.²³ The major modifications in the osteotomy design were first made by DalPont with his vertical cut through the lateral cortex as well as the suggestion that the medial horizontal cut be extended only to a point above the

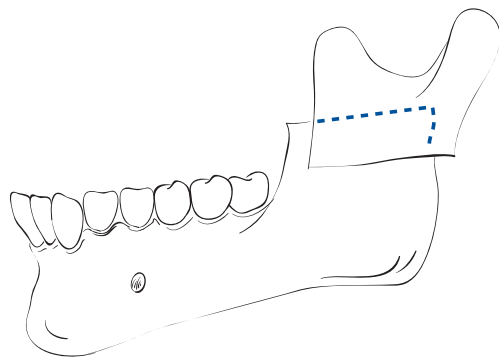


FIGURE 56-4 Lane's osteotomy. Adapted from Bloomquist DS. *Principles of mandibular orthognathic surgery*. In: Peterson LJ, Indresano AT, Marciani RD, Roser SM. *Principles of oral and maxillofacial surgery*. Vol 3. Philadelphia (PA): J.B. Lippincott Company; 1992. p. 1417.

lingula and not to the posterior border (Figure 56-5).²⁴ This latter technique shortens the split posteriorly, and as was further discussed by Hunsuck, decreases the trauma to the overlying soft tissue.²⁵ Many clinicians have offered suggestions for improving the sagittal osteotomy, but the only other major innovation to this technique has been the use of internal rigid fixation. Spiessl suggested the use of screws for fixation of the fragments in the sagittal osteotomy.²⁶ Although wire osseous fixation is still used by some surgeons, rigid internal fixation in some form has become the standard technique for the bilateral sagittal split osteotomy (BSSO).

Osteotomies of the mandibular body do not generally receive the same degree of attention as osteotomies of the vertical ramus, but they have undergone refinements and variations from the original anterior alveolar osteotomies of Hullihen and the body osteotomies of Blair. The first variation of Hullihen's procedure did not appear until 90 years after the original description, when Hofer demonstrated an anterior mandibular alveolar osteotomy to advance anterior teeth in correction of a mandibular dentoalveolar retrusion (Figure 56-6A).²⁷ Kole modified this procedure

by suggesting the use of bone grafts from the mental region to the defect caused by the rotation of the anterior dentoalveolar segment (Figure 56-6B).²⁸ Clinicians now

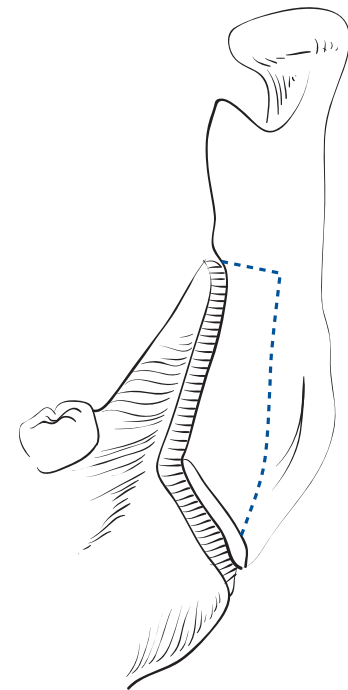
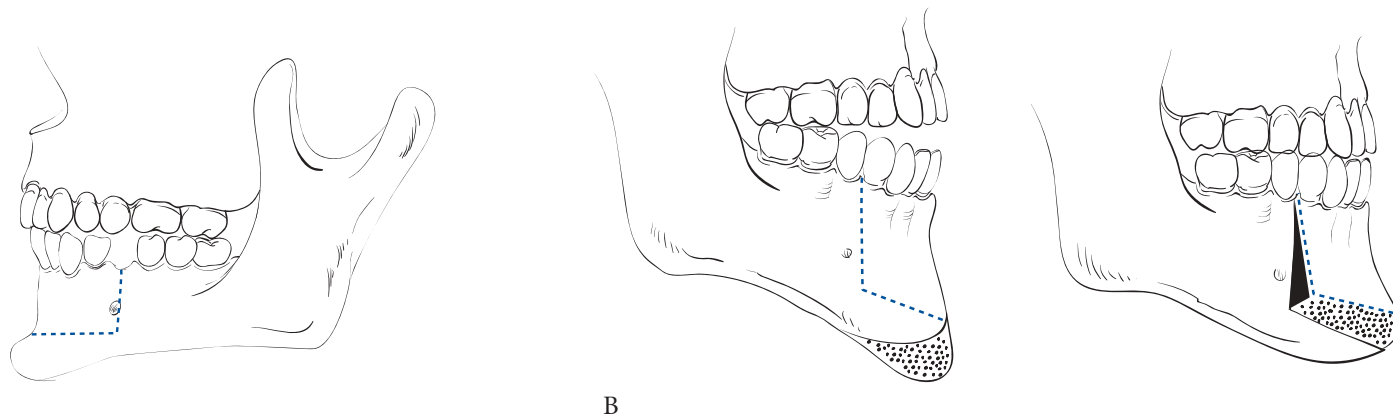


FIGURE 56-5 DalPont's modification of the sagittal osteotomy. Adapted from Bloomquist DS. *Principles of mandibular orthognathic surgery*. In: Peterson LJ, Indresano AT, Marciani RD, Roser SM. *Principles of oral and maxillofacial surgery*. Vol 3. Philadelphia (PA): J.B. Lippincott Company; 1992. p. 1418.



A

B

FIGURE 56-6 A, Hofer's subapical osteotomy. B, Kole's subapical osteotomy. Adapted from Bloomquist DS. *Principles of mandibular orthognathic surgery*. In: Peterson LJ, Indresano AT, Marciani RD, Roser SM. *Principles of oral and maxillofacial surgery*. Vol 3. Philadelphia (PA): J.B. Lippincott Company; 1992. p. 1418.

employing Hofer's osteotomy generally use some form of bone graft in the alveolar defect if significant movement of the fragment is planned. Mandibular alveolar osteotomies have expanded in primarily two ways from Hofer's original procedure. Kent and Hinds initially presented the use of the single-tooth osteotomies of the mandible in 1971, and MacIntosh closely followed with his description of the total mandibular alveolar osteotomy in 1974.^{29,30} This latter procedure continues to be popular, with minor variations being added by other clinicians.

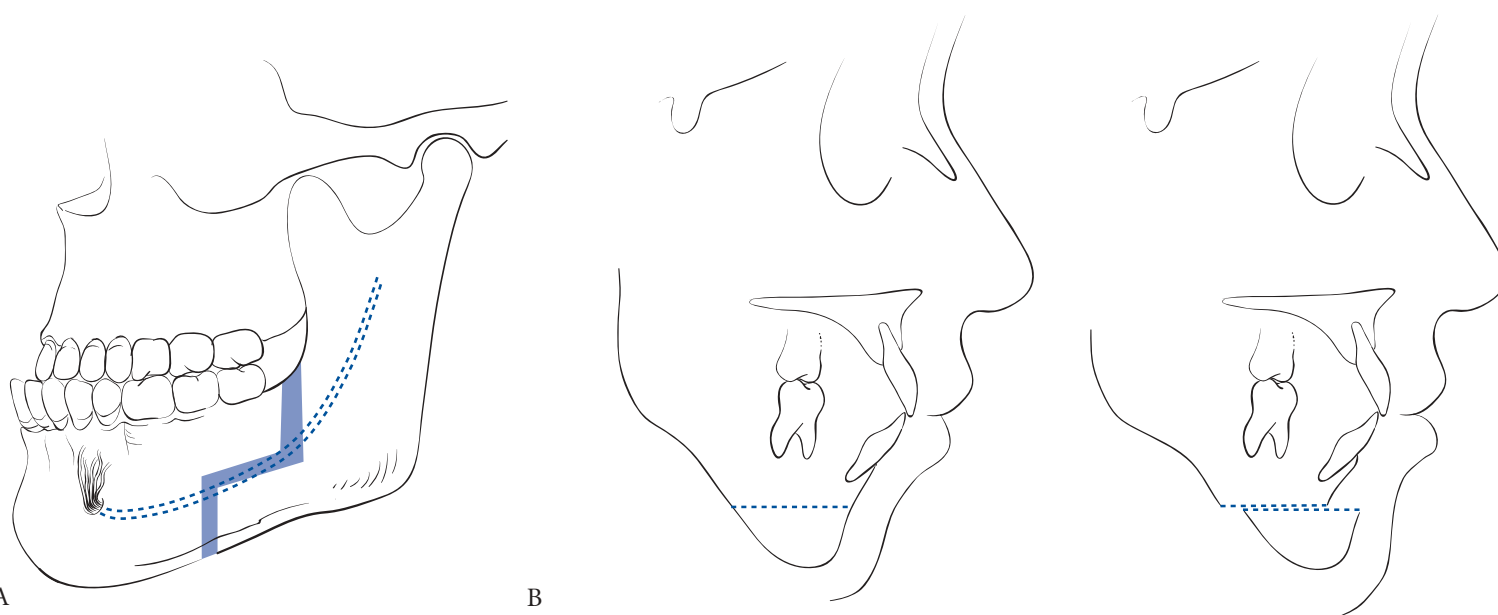
Osteotomies of the body of the mandible have been described in almost every conceivable form, with the most durable advancements being the step osteotomy, initially described by Von Eiselberg in 1906 (Figure 56-7A), and the horizontal osteotomy of the symphysis described by Hofer in 1942 (Figure 56-7B).^{31,32} The step osteotomy was originally described for treatment of mandibular horizontal deficiency, but it has been used in various forms for mandibular horizontal excess as well as asymmetry. The horizontal osteotomy of the symphysis has

also developed a large degree of versatility, with its use in various forms being suggested for almost any skeletal deformity of the bony chin.

Anatomic and Physiologic Considerations of Mandibular Surgeries

Vascular Supply

A major concern with surgery of the facial skeleton is the vascular supply of the bone segments. This was dramatically demonstrated by the explosion of orthognathic



A

B

FIGURE 56-7 A, Von Eiselberg's step osteotomy. B, Hofer's horizontal osteotomy. Adapted from Bloomquist DS. *Principles of mandibular orthognathic surgery*. In: Peterson LJ, Indresano AT, Marciani RD, Roser SM. *Principles of oral and maxillofacial surgery*. Vol 3. Philadelphia (PA): J.B. Lippincott Company; 1992. p. 1419.

surgery in the United States after Bell and Levy's studies of vascular effects of the osteotomies.³³ Although all of the techniques they looked at had been previously used in patients, there had not been any experimental evaluations of the physiologic basis for many of the procedures. Bell and Levy's work demonstrated that blood flow through the mandibular periosteum could easily maintain a sufficient blood supply to the teeth of a mobile segment, even when the labial periosteum was degloved. Blood flow from the periosteum was termed centripetal, to distinguish it from the blood flowing from endosteal vessels outward (centrifugal) that was associated with long bones. Previously clinicians felt that the inferior alveolar artery had a primary role in nourishing the mandible, but Bell and Levy demonstrated that there is also a sufficient blood supply from the surrounding soft tissues, even if the inferior alveolar artery was obstructed. More recent work in animals suggests that the blood supply to the body of the mandible under normal conditions comes almost entirely from the inferior alveolar artery.³⁴ However, when this source is obstructed, the peripheral blood vessels quickly take over for the anterior mandible. The posterior mandibular dentoalveolus, however, does not benefit from this kind of collateral blood supply, which calls into question the safety of posterior mandibular segmental alveolar osteotomies. Zisser and Gattinger showed pulpal necrosis in the molars of horizontal osteotomies done above the inferior alveolar nerve in the body of the mandible of dogs.³⁵

The safety of combined mandibular osteotomies, such as ramal procedures and body osteotomies, has been a concern because of the predominant role of the inferior alveolar artery.³⁶ The fragility of the vascular supply to the mandibular alveolus engenders some concern over the common use of subapical osteotomies. Although their relative safety has been demonstrated by both animal studies and

substantial clinical experience, subapical osteotomies need to be carefully planned to ensure as large a vascular pedicle as possible.^{33,37} Complications, such as pulpal necrosis, soft-tissue defects, and loss of teeth and bone, have demonstrated the delicate nature of the blood supply, especially when attempts at moving small dentoalveolar fragments are made. The effect of aging on the vascular supply to the mandibular body is an area about which very little information is known, particularly whether aging causes a switch from the centrifugal to centripetal blood supply. Bradley has demonstrated an apparent decreasing capacity of the inferior alveolar vessels that occurs with aging, but the impact of this effect on mandibular osteotomies is unknown.³⁸

Osteotomy designs of the vertical ramus have profited by studies of the effect of surgery on vascular supply. The proximal segment of the vertical subsigmoid osteotomy maintains its blood supply through the temporomandibular joint capsule and the attachment of the lateral pterygoid muscle. However, the inferior tip of this fragment has undergone vascular necrosis in experimental studies.³⁹ This led to the suggestion that fewer problems may occur if the cut was made above the angle of the mandible.³⁹

The importance of the periosteal blood supply as well as the endosteal supply in the vertical ramus has been explored by animal research.⁴⁰⁻⁴³ When the medial pterygoid and masseter muscles are stripped, both blood flow and blood supply studies have demonstrated the possibility of avascular necrosis in the proximal segment. Comparisons of extensive muscle stripping of the vertical ramus against preservation of the masseter attachment have demonstrated a significant difference in the vascularity of the inferior portion of the proximal fragment. These studies of blood supply of the vertical ramus may be of value in predicting the vascular effects of the C or L osteotomies. However, resorp-

tion of the proximal fragment has not been reported in these particular bone cuts possibly because of the rarity of their use. However, given the available research, it is wise to minimize the periosteal and muscle attachment stripping on the medial surface of the proximal fragment with either the C or L osteotomy or any of their variations.

The last unanswered question concerning vascular supply in mandibular orthognathic surgery is the determination of a safe distance away from the apex of the teeth to make horizontal bone cuts. Many of the references to this question are based on research done in the maxilla.⁴⁴ From these early animal studies the pulpal blood supply of a tooth should not be affected if a cut was made at least 5 mm away from the apex of the tooth. Zisser and Gattinger, however, saw pulpal changes in dogs with some horizontal cuts that were made 10 mm away from the apex.³⁵ Whether these distances have any relevance to humans is presumptive. Clinically the incidence of tooth devitalization from horizontal subapical osteotomies is extremely low and it can be assumed that, for the most part, 5 mm is a good guideline. A cut made 10 mm from the apices, although allowing a greater safety margin, is often impractical because of other anatomic limitations. The greater distance from the apices of the teeth not only minimizes direct pulpal injury but increases the vascular pedicle to the mobile segment as well.

Nerves

The surgeon working around the face must be constantly aware of the nerve network that exists in this area. Fortunately, on approaching the mandible, these concerns can be narrowed to essentially two major nerves: the marginal mandibular branch of the seventh cranial nerve and the third division of the trigeminal nerve, most frequently one of its branches, the inferior alveolar nerve. The marginal mandibular branch is usually only at risk during extraoral procedures. Although

trauma to this nerve has been reported to have occurred during intraoral approach, it is rare and for the most part appears to be preventable. Avoiding damage to this nerve during extraoral approaches to the mandible is a major surgical goal; in most cases in orthognathic surgery it is achieved because soft tissue anatomy in patients undergoing the surgery has not been disturbed by disease or trauma. The techniques of these approaches are covered elsewhere in these book volumes as well as are the methods for minimizing the risks of damage to the marginal mandibular branch. Damage to the third division of the trigeminal is, however, a much-discussed problem in mandibular surgery. The course of the inferior alveolar nerve into the vertical ramus and then through the body of the mandible makes it extremely susceptible to damage from almost every mandibular surgical procedure. In most cases the surgeon's main goal relative to this nerve is to minimize the trauma because its avoidance is almost impossible. In the past surgeons stressed the importance of looking for and sometimes freeing up the nerve as it either entered or left the mandible before making osteotomies in the areas of the foramina. However, there is a trend toward avoiding this step, unless it is absolutely necessary to make the osteotomy as close to the nerve as possible. The simple act of exposing the nerve seems to increase the chance for postoperative sensory deficiency.

Often the debates on whether one mandibular osteotomy is preferable to another are primarily based on the potential of damaging the inferior alveolar nerve. This has resulted in many clinicians trivializing the damage found following a certain technique. Well-defined standards for both long- and short-term follow-up of nerve damage during mandibular procedures have been discussed⁴⁵; however, in most papers these have not been used to evaluate sensory deficits. In addition very few controlled studies have been published com-

paring procedures; as a result not much can be said in support of any of the differing attempts to minimize nerve damage.

Studies looking at the loss of tooth sensibility from horizontal osteotomies below the dental apices, however, have been quite consistent. Most authors found a relatively high loss of response to pulp testing immediately after osteotomies, especially when teeth are close to a vertical osteotomy.⁴⁶⁻⁴⁸ However, this loss may not correlate with actual loss of tooth vitality and, thus, either tooth loss secondary to an osteotomy or the need for endodontic therapy is very low.

The Muscle

Orthognathic surgery affects muscles in primarily two ways: it changes the length of a muscle or it changes the direction of muscle function. Effects of these changes are still not understood, although various authors have emphasized the importance of controlling muscular changes. The muscles commonly discussed in orthognathic surgery of the mandible have been the muscles of mastication and the suprahyoid group of muscles. Recent interest on the soft tissue effects of facial skeletal surgery has expanded interest to the other facial muscles. This latter group, however, has generally not been discussed relative to mandibular osteotomies, with the possible exception of the effect of the anterior mandibular osteotomies on the attachment of the mentalis muscle. The muscles of mastication, however, have received considerable attention, dating back to the early vertical ramus procedures. Research interest on the effects of altering these muscles concentrated either on their effect on the skeletal changes, especially relapse following mandibular osteotomies, or on the changes in function of these muscles.

Distraction of the superior fragment of a horizontal osteotomy of the vertical ramus following surgery was noted early by surgeons who used this technique.⁴⁹

Evaluation of this procedure following correction of prognathism found a superior movement of the mandible in the gonial region as well as a downward and backward movement at the symphysis. This change, which was attributed to the forces of the pterygomasseteric sling, has received considerable attention, not only in mandibular setbacks done with osteotomies through the vertical ramus but also in mandibular advancements.⁵⁰⁻⁵⁵ The apparent shortening of the vertical ramus has been noted in a number of studies, and in some a correlation has been demonstrated between this change and the posterior movement of the symphysis. The exact reason for the change in the gonion has not been clearly demonstrated. Kohn demonstrated the movement of this point inferoanteriorly in mandibular advancements by way of a measurement he termed the gonial arc (Figure 56-8).⁵⁴ Most investigators feel this represents distraction of the condyle from the fossa, and this

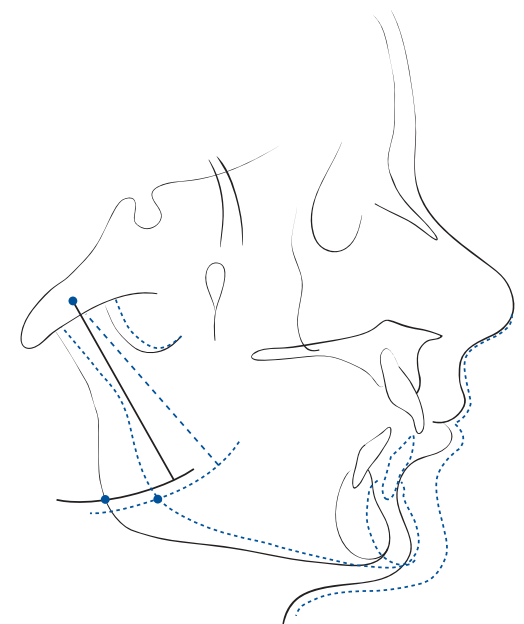


FIGURE 56-8 Gonial arc used for showing condylar position change with a mandibular osteotomy. Adapted from Bloomquist DS. Principles of mandibular orthognathic surgery. In: Peterson LJ, Indresano AT, Marciani RD, Roser SM. Principles of oral and maxillofacial surgery. Vol 3. Philadelphia (PA): J.B. Lippincott Company; 1992. p. 1422.

hypothesis was further supported by the migration of the gonion back during the postoperative period.^{54,55} The long-term postoperative decrease in gonial arc was generally believed to be due to remodeling, especially resorption that occurred at the mandibular angle.^{40,43} Especially in early studies, resorption could have accounted for this change because of the then-accepted technique of completely stripping muscle attachment from the proximal segment. However, in more recent studies in which minimal muscle stripping was done, a similar result has been noted.^{56,57} Will and colleagues noted a condyle distraction followed by an “overshoot” in the resettling of the condyle in the fossa.⁵⁸ This change in condylar position may be due to either displacement of the disk within the joint or compression of the soft tissues of the joint by increased pressures secondary to the muscles of the pterygomasseteric sling.

The rotational change in the proximal segment of a mandibular osteotomy has been implicated in relapse by multiple clinicians who believe that the muscles of the pterygomasseteric sling reassert themselves after the surgery.^{59,60} Therefore, there has been an emphasis on carefully repositioning the proximal segment close to its preoperative position. Unfortunately a correlation between mandibular ramus positioning and relapse in the case of mandibular advancements has never been demonstrated. There have been a few studies that have shown a relation between relapse of mandibular setback surgeries and the position of the vertical ramus.⁶¹ It has been noted in these surgeries that the degree of clockwise rotation of the proximal fragment in a sagittal osteotomy seems to relate to the amount of forward relapse of the distal segment. Franco and colleagues theorized that a stretching of the medial pterygoid muscle as well as the elongation of the anterior fibers of the masseter and temporalis muscles from the clockwise rotation of the proximal seg-

ment both can contribute to relapse in lengthening the muscles of the pterygomasseteric sling.⁶¹ This can result in a change in mandibular position as has been documented by Yellich and colleagues.⁶² The degree to which this is active in orthognathic surgery remains unclear.

The contribution of the suprahyoid muscles to relapse in mandibular advancement surgery is equivocal, with many clinicians claiming an existence of this relationship. Ellis and Carlson demonstrated in monkeys that relieving the suprahyoid muscles from the symphysis of the mandible decreased the amount of relapse when the mandibles were advanced.⁶³ Clinical studies, however, have failed to show a relation between suprahyoid myotomies and relapse.^{64,65} Animal studies have also demonstrated that adaptive changes occur in the connective tissues at the muscle-tendon and tendon-bone interfaces but only with large advancements.⁶⁶

The belief, however unsubstantiated, that muscle pull in some way does affect the stability of mandibular osteotomies has led to a variety of recommendations. Historically the most common method advocated is the attempt at minimizing the change in muscle position and length. The cutting of muscle attachments, such as has been recommended for the suprahyoid group, has the potential for increasing morbidity. Without significant evidence that this is of much value, this additional surgery cannot be justified. However, there has been recognition that muscles and their attachments seem to adapt fairly quickly if the bone is held rigidly for a long enough time.^{66,67} It is important to recognize that intermaxillary dental fixation does not provide a completely stable method of bone fixation, especially if the teeth have been under active orthodontic movement. Additionally the greatest amount of relapse of mandibular osteotomies seems to occur in the first 3 to 6 weeks after surgery. Whatever the causes of the instability during this time there

have been several techniques designed to provide increased stability for this initial period, to improve the stability of mandibular osteotomies. Primarily two techniques have been attempted: external supporting mechanisms and internal rigid fixation. The only external technique that has been of much value has been the wiring technique that has been termed skeletal fixation. With this procedure the bony skeletons are tied to one another, circumventing the periodontal ligaments of the teeth. This has been used with intermaxillary fixation, keeping the mandible immobilized for 6 to 8 weeks (Figure 56-9).^{58,67,68} The alternative procedures of internal rigid fixation techniques using plates or screws will be discussed in the succeeding sections on the osteotomies.

Osteotomy Techniques

Vertical Ramus Osteotomies

Osteotomies in the vertical ramus have been the preferred technique for correcting developmental deformities of the mandible. This preference has increased with closer cooperation between orthodontists and

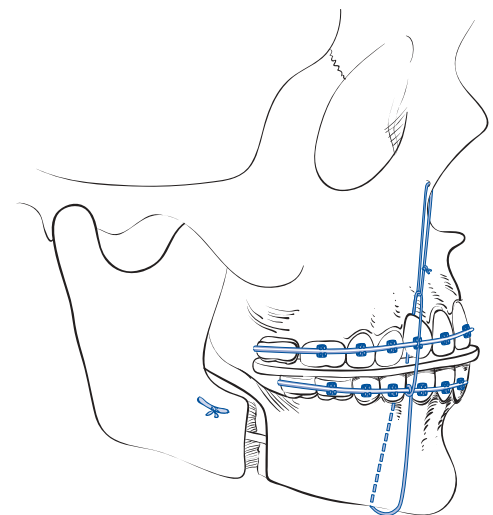


FIGURE 56-9 Skeletal fixation used with maxillo-mandibular fixation or mandibular advancement. Adapted from Bloomquist DS. Principles of mandibular orthognathic surgery. In: Peterson LJ, Indresano AT, Marciani RD, Roser SM. Principles of oral and maxillofacial surgery. Vol 3. Philadelphia (PA): J.B. Lippincott Company; 1992. p. 1423.

surgeons in treating dentofacial deformities. Most of the time the dental arch discrepancies can be orthodontically corrected, leaving the surgeon the responsibility for moving the coordinated dental arch into its new position, as dictated by functional and esthetic demands. Operations in the vertical ramus, therefore, have become almost automatically considered when the dental arch as a unit has to be moved. As previously noted there have been numerous techniques suggested for osteotomies of the ramus, but essentially three different procedures, with minor variations, have been accepted by the surgical community.

Vertical Subcondylar Osteotomies

Osteotomies extending from the sigmoid notch vertically behind the inferior alveolar nerve foramen to the inferior border or angle have had several different names, but generally, the VSOs seem to describe the procedure best (Figure 56-10). This osteotomy was initially done through an extraoral approach but with the development of small oscillating blades with a long shaft, the intraoral route has become preferred.

Indications The VSOs have most commonly been limited to deformities requiring the mandible to be set back for mandibular horizontal excess or to be rotated for mandibular asymmetry. Robinson and Lytle have stated that this osteotomy can be used for mandibular advancement but generally this recommendation was not taken seriously because of the question of stability.⁶⁹ Hall and McKenna revived this indication for minor (2 to 3 mm) advancements.⁷⁰

Techniques When preparing for an intraoral VSO, one needs to closely evaluate the panoramic and lateral head films for the position of the inferior alveolar foramen relative to the posterior border of the mandible. The incision is made in the mucosa from midway up the anterior border of the ramus to the first molar area. The periosteum is reflected laterally to expose the entire ramus, with the exception of the condyle neck and coronoid tip. The posterior and inferior borders can be cleared of periosteum; muscle attachments at the angle are generally difficult to elevate and should be left to ensure blood supply to this area. A special retractor can be placed that

fits around the posterior border and, at the same time, retracts tissue laterally so that an oscillating saw can be used (Figure 56-11A).

The saw chosen should have a rounded blade that is set at an obtuse angle to the long shaft to facilitate the cut. The blade should be used first to score the proposed osteotomy line on the lateral cortex. This line is then closely checked for its position relative to the sigmoid notch, posterior border, and angle. The use of the so-called antilingula has been proposed as the landmark for the mandibular foramen, but has generally fallen into disfavor, both because of the difficulties with its identification and its lack of predictable relation to the foramen.^{12,71,72} The cut should be made no more than 5 to 7 mm anterior to the posterior border at the anticipated level of the foramen, using the retractor as a guide to the posterior border.⁷³ The cut is carried through the medial cortex, starting in the middle of the ramus. It is carried superiorly to the sigmoid notch and then finished at the inferior border (Figure 56-11B). As the cut is completed, antero-lateral tension is kept on the retractor so that the proximal fragment will be brought out laterally. A straight clamp can

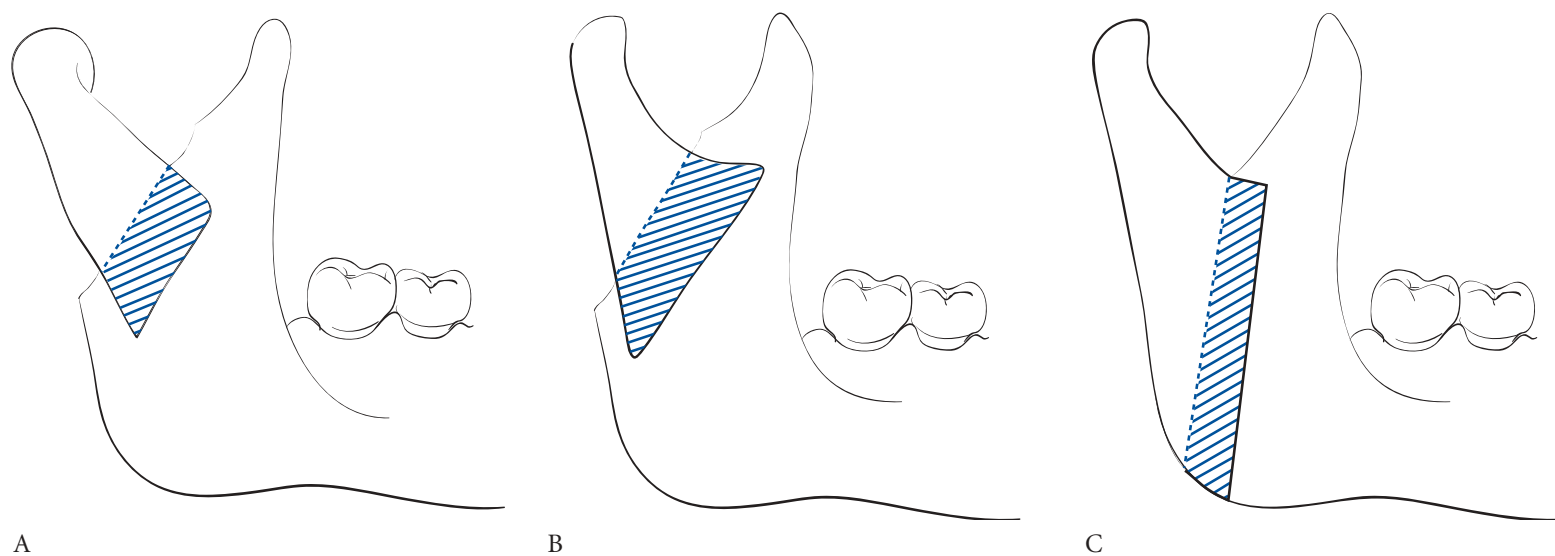


FIGURE 56-10 Different lengths of the osteotomy in the vertical subcondylar osteotomies. Adapted from Bloomquist DS. Principles of mandibular orthognathic surgery. In: Peterson LJ, Indresano AT, Marciani RD, Roser SM. Principles of oral and maxillofacial surgery. Vol 3. Philadelphia (PA): J.B. Lippincott Company; 1992. p. 1423.

be used to rotate the segment laterally after the cut is made and then to stabilize it while periosteum and muscle are stripped from the medial cortex down to the angle (Figure 56-11C). Again a small attachment is left at the angle to ensure a blood supply. This proximal fragment can be held forward and laterally by a small gauze pack while the opposite side is being completed. If the proximal fragment is lost medially, it usually can be brought into the field with the help of a small periosteal elevator that is inserted posteromedially at the level of the sigmoid notch while the distal fragment is being pulled forward. The mandibular dentition is brought into its new position after the completion of both osteotomies, as established by a preformed occlusal splint and stabilized with maxillo-mandibular fixation.

Attention is directed back into the wound and toward the placement and stabilization of the proximal fragment.

Wire osseous fixation is generally not needed, although advocated by some surgeons. Most important is the achievement of as broad a bone contact as possible, without displacing or rotating the condyle. Adjustment of the lateral cortex of the distal fragment may be performed with a straight fissure or small acrylic bur to permit the proximal fragment to lie as flat as possible against the vertical ramus. Care should be taken to ensure that the long axis of the proximal fragment does not differ appreciably from its preoperative position. After a thorough irrigation of the wound the mucosa is closed with a running stitch, using a resorbable suture. No drains or external dressings are placed, and the patient is left in fixation for 6 to 8 weeks. Postsurgical radiographs should be taken as soon as possible to confirm that the condyles have not been displaced. A small amount of forward and downward position of the condyle is common, and this gener-

ally resolves during the period of maxillo-mandibular fixation (Figure 56-12).

Submentovertex radiographs have been suggested to identify divergence of the posterior border. It has been suggested that an angle smaller than 130° produces such a significant surgical problem that this type of patient should be avoided and another technique used. The use of this radiograph as a criterion for choosing this technique has been questioned, but some still feel that it can be pursued to identify the more difficult cases.^{73,74}

A large number of variations of the VSO have come in the osteotomy design. Oblique versions with the cut ending above the angle have been described by many clinicians, with the only apparent benefit being the relative ease in the technique.

Theoretically there should also be less chance of damaging the inferior alveolar nerve, but there has been no study to confirm this benefit. Interestingly the one

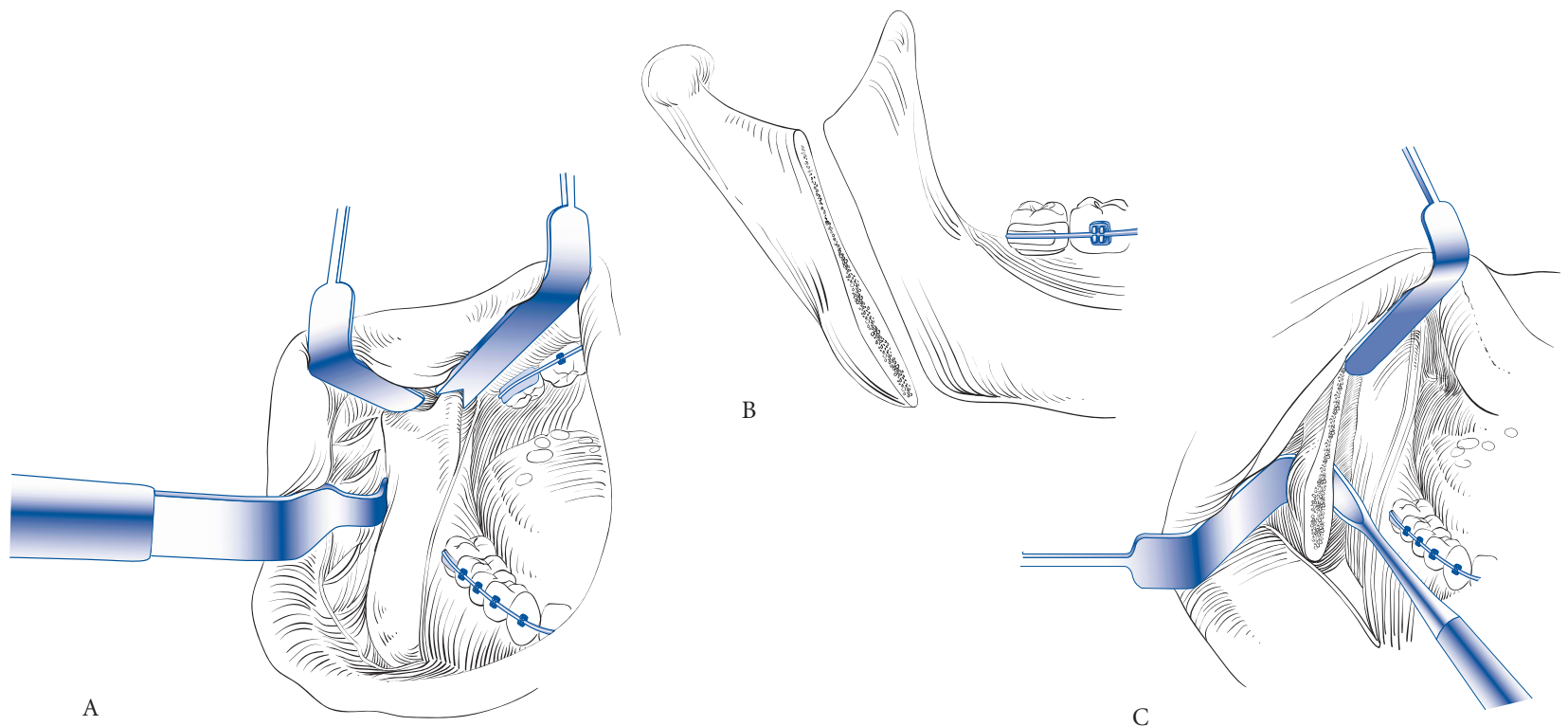


FIGURE 56-11 The intraoral vertical subcondylar osteotomy. A, Exposure. B, Vertical ramus osteotomy. C, Proximal fragment displaced laterally. Adapted from Bloomquist DS. Principles of mandibular orthognathic surgery. In: Peterson LJ, Indresano AT, Marciani RD, Roser SM. Principles of oral and maxillofacial surgery. Vol 3. Philadelphia (PA): J.B. Lippincott Company; 1992. p. 1424.

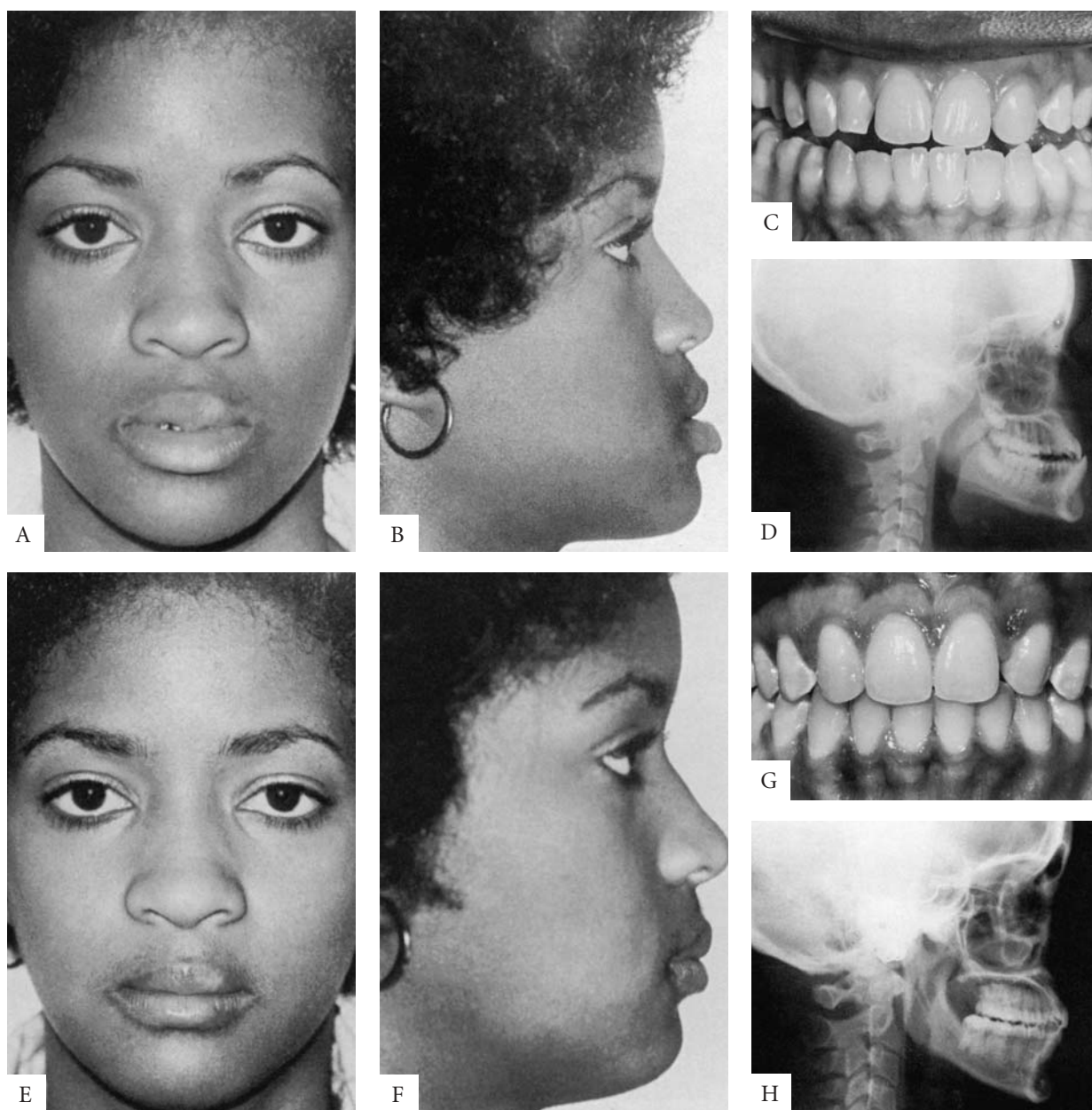


FIGURE 56-12 Patient who was treated with an intraoral VSO for mandibular horizontal excess. A–D, Preoperative photographs and radiograph. E–H, Postoperative photographs and radiograph. Reproduced with permission from Bloomquist DS. *Principles of mandibular orthognathic surgery*. In: Peterson LJ, Indresano AT, Marciani RD, Roser SM. *Principles of oral and maxillofacial surgery*. Vol 3. Philadelphia (PA): J.B. Lippincott Company; 1992. p. 1426.

potential drawback, that of decreased skeletal stability, appears not to be demonstrable.⁷⁵ In contrast with this shorter cut others have recommended that a larger portion of the inferior border be left with the proximal fragment, especially in the larger mandibular setbacks.⁷⁰ This permits a good attachment of the medial pterygoid muscle to be left at the mandibular angle, which has been

claimed to help seat the condyle in the fossa as the patient awakens from anesthesia. This variation, including the use of 8 weeks of fixation, is claimed to decrease one of the problems of the intraoral VSO, specifically that of condylar sag and the resulting open bite that can occur on the release of fixation. Unfortunately no clinical data have been reported that back this claim. The use of osseous wire fixation has

been advocated to ensure the seating of the condyle. Again no study comparing wire osseous fixation with no fixation has shown any advantage for the use of the wire.^{76–78} This may be explicable in the intraoral procedures by the technical difficulties of wire placement. However, Ritzau and colleagues showed in an excellent prospective study that even from an extraoral approach, the position of the

condyle in the fossa is not improved with the use of wire osseous fixation.⁷⁷

The effect of the temporalis on relapse has led to other recommendations that include either stripping the temporalis attachment completely off the coronoid or cutting off the coronoid. The use of this latter coronoidotomy has been recommended by some clinicians for large setbacks, with a few using this modification routinely. The advantage of the coronoidotomy relative to prevention of relapse has not been studied, but the stability of the intraoral vertical subcondylar osteotomy (IVSO) with coronoidotomy, compared with the sagittal split osteotomy of the vertical ramus in mandibular setbacks, has been investigated and the IVSO seemed to be more stable.⁷⁹

The use of the inverted L osteotomy is another way to neutralize the temporalis. This modification of the IVSO requires stripping of the medial periosteum to identify the lingula so that a horizontal cut can be made without increasing the risk of damaging the inferior alveolar nerve. A further modification of the

inverted L osteotomy has been the use of rigid internal fixation. Although technically a difficult surgery it permits the early release from maxillomandibular fixation. Unfortunately there are no long-term studies on the stability of any of the inverted L techniques.

Alternative Techniques The major variation of the described technique is the use of an extraoral approach. The soft tissue incision is similar to that commonly used for an external approach to a fracture of the mandibular angle, with an approximately 4 cm incision made 2 cm below the angle and the inferior border of the mandible (Figure 56-13A). A combination of sharp and blunt dissection is used to get to the inferior border of the mandible. Care is taken to avoid damaging the marginal mandibular branch of the facial nerve. After incising through the periosteum, the bone cuts are similar to those that have been described (Figure 56-13B).

The external approach has been advocated for large mandibular setbacks of

greater than 10 mm, difficult asymmetries, or large vertical moves in patients with unusual facial structure. Except for the risk of the scar, the risks of this technique have been reported as being comparable with the intraoral technique.^{50,80}

Complications Stability Postoperative change in skeletal and dental position following the use of a VSO in the treatment of mandibular horizontal excess has received much attention. Goldstein was the first to use serial cephalograms to evaluate the postoperative change of the mandible after surgical correction of the mandibular prognathism.⁸¹ He noted the anterior relapse that has now been well documented. Poulton and colleagues recommended overcorrecting the mandibular setback by 2 mm to provide for the relapse they noted.⁸² This amount of average relapse has surprisingly remained fairly consistent throughout the history of this technique, even though technical changes in procedures have been made.^{80,83} Stella and colleagues noted that the variation in

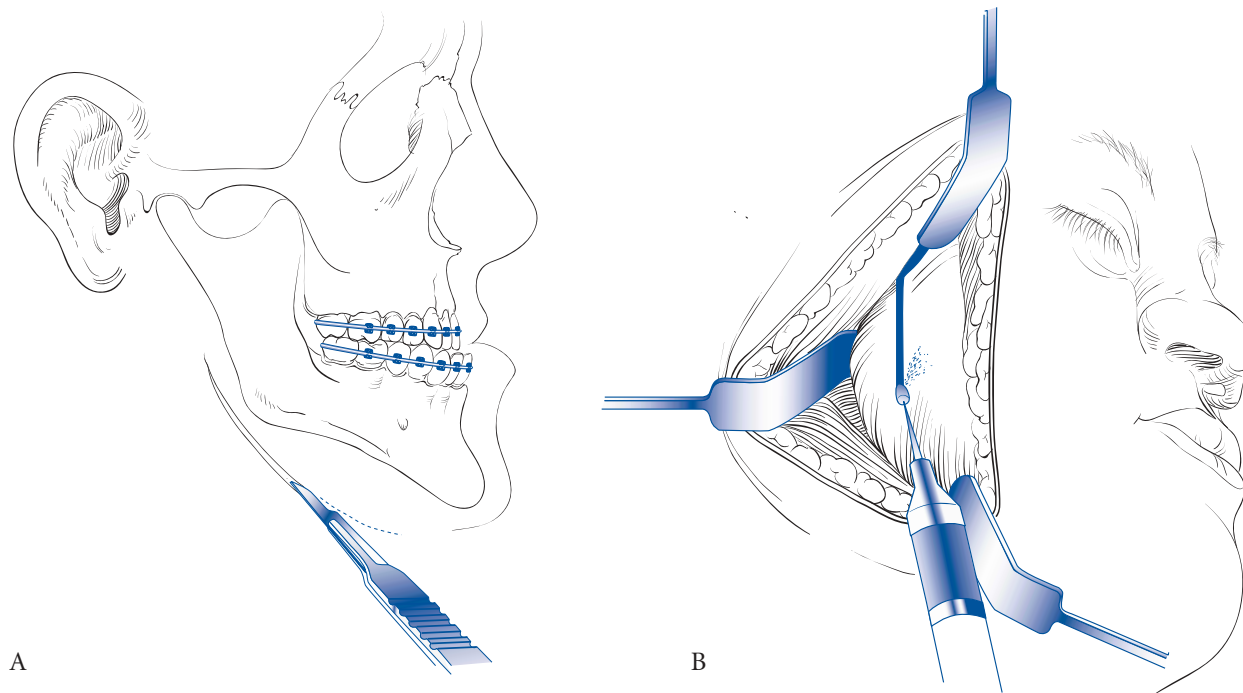


FIGURE 56-13 The extraoral vertical subcondylar osteotomy. Adapted from Bloomquist DS. Principles of mandibular orthognathic surgery. In: Peterson LJ, Indresano AT, Marciani RD, Roser SM. Principles of oral and maxillofacial surgery. Vol 3. Philadelphia (PA): J.B. Lippincott Company; 1992. p. 1428.

the amount of relapse in mandibular setbacks was large and attempts at identifying controllable variables should be made.⁸⁴ They suggested that the proximal fragment rotation affects the short-term pogonion changes, although they did not present any corroborative research. The finding that the pogonion tends to move posteroinferiorly during intermaxillary fixation has been well documented.⁵² This movement, later followed by the anterosuperior “relapse” that occurs after skeletal fixation wires, does seem to stabilize the initial movement but does not affect the long-term relapse.^{50,51,56}

Vertical instability of the VSO develops soon after the release of intermaxillary fixation in many patients. This problem was initially attributed to the “condylar sag” seen on x-ray films taken soon after surgery.⁷³ Although condylar sag may be one cause of relapse, a major contributor seems to be insufficient time of fixation. The VSO is generally not considered an appropriate surgery for correction of anterior open bite. In Scandinavian countries, however, this surgical procedure has been successfully used for patients with mandibular horizontal excess and anterior open bite.⁸⁵

Neural Damage The chance of damaging the marginal mandibular branch of the facial nerve is one of the reasons given by several surgeons for avoiding the extraoral approach to the VSO. This concern, however, seems to be unsubstantiated, in that almost all of the clinicians reporting on the results of this approach have noted very little, if any, motor nerve damage. Damage to the inferior alveolar nerve, however, is a concern in using a VSO. The incidence of trauma to the inferior alveolar nerve at the time of surgery has been reported to vary from being “rare” to occurring 36% of the time.⁷⁰ Long-term sensory defects have also been reported to vary from none to 35%.^{45,86} These apparent discrepancies can be explained by the differences in the sensitivity of the mea-

surement techniques; in addition there is a wide variation in the time after surgery during which the patients were tested. Other variables, such as whether the osteotomy was approached intraorally or extraorally as well as variations in the length of the cut, theoretically could affect the incidence of sensory problems, but comparison studies have not been done. From studies that have been done the incidence of damage to the inferior alveolar nerve is low with the VSO compared with the sagittal osteotomy.^{86,87} The patient, however, should be warned that short-term sensory loss is a definite risk, and permanent neuropathy is possible.

Temporomandibular Joint Dysfunction

There has been interesting literature published on changes in temporomandibular joint function after a VSO. These have included a number of radiographic studies documenting positional change of the condyle relative to the fossa. Radiographically there is an initial downward and forward movement of the condyle, with a subsequent tendency to return to its preoperative position.^{77,78,82} Sometimes a double contour of the condyle appears approximately 6 months postoperatively, which has been attributed to the condyle’s remodeling after the surgery.⁸⁸ Remodeling of the glenoid fossa has also been documented.⁷⁸

In one early review of 100 cases 6 patients were reported to have temporomandibular joint problems at 1 year after surgery.⁸⁹ A form of the VSO has been used to treat patients with temporomandibular pain and dysfunction. It appears that the VSO does not put the temporomandibular joint at any significant risk, and it may in fact be salutary for patients with temporomandibular joint dysfunction.⁹⁰⁻⁹²

Other Complications Among the other reported complications of the VSO, vascular necrosis of the proximal segment

seems to be the most potentially devastating. The maintenance of some muscle attachment to the angles makes this possibility unlikely.

Inverted L and C Ramus Osteotomies

Osteotomy designs in the vertical ramus that include both the condyle and coronoid in the same segment have varied from Blair’s simple horizontal osteotomy to the modified C osteotomy of Hayes. The horizontal osteotomy of the vertical ramus has generally fallen into disuse because of the substantial relapse potential, but many of the remaining suggested variations continue to have treatment value. The two procedures that seem to be the most popular are the inverted L and the C osteotomies. Both are generally approached extraorally, although intraoral variants are possible.⁹³ Clinical studies of either technique are rare, but those that exist seem to demonstrate reasonable success in correcting skeletal deformities with minimal complications.

Indications The C osteotomy is generally reserved for treatment of horizontal mandibular deficiencies, with some authors suggesting that it can be used to close anterior open bite. The inverted L, however, has been used for the correction of most kinds of mandibular horizontal discrepancies, including anterior open bite. Generally advancements of the distal segment with either technique require bone grafting to ensure adequate bone union.

Techniques The basic techniques for an extraoral approach to do a C and inverted L are the same, with the only modification being the inferior horizontal cut in the C osteotomy. For that reason the inverted L will be described first, with various modifications of the C discussed later. The patient is prepared and draped, such that access to both the mouth and the submandibular incision area can occur with-

out contamination of the skin wound by oral organisms. This can be accomplished in a variety of ways, but most surgeons use a plastic drape with adhesive on one edge to separate the two areas. The external drapes should be arranged so that they allow turning of the head for access to the submandibular wounds as well as access to the mouth.

The submandibular incision is made 2 cm below the angle and inferior border of the mandible. The posterior portion is curved superiorly to follow the cervical skin line as well as to improve the access to the entire vertical ramus. Generally the incision is approximately 6 cm in length. Sharp dissection is used down through the platysma, and then blunt dissection is begun to minimize risk to the marginal mandibular branch of the facial nerve. The incision through the pterygo-mandibular sling and periosteum is made along the inferior border and is carried around the angle and up the posterior border about 2 cm. Periosteum and

attachments for the masseter are completely stripped off the lateral cortex of the vertical ramus up to the level of the sigmoid notch. Very little periosteum is stripped off the medial side, especially at the angle, to retain as much blood supply as possible to the proximal fragment. The posterior vertical osteotomy is made at least 7 mm in front of the posterior border and extends to a point of the inferior border just in front of the angle. The horizontal cut is made above the anticipated position of the inferior alveolar foramen (Figure 56-14A). As mentioned above with the VSO it is wise to have a good radiographic view of the ramus so that the position of this foramen can be more accurately located. The study by Reitzik and colleagues of the position of the foramen relative to the lateral landmarks is helpful to review to lessen trauma to the neurovascular bundle.⁷²

Once the cuts are made the medial periosteum may have to be elevated from some of the distal fragment to allow its

advancement. Moist gauze is placed in the wound, and a similar procedure is done on the opposite side. After completion of the second side, drapes are pulled back and shifted such that the oral cavity can be entered to place the mandibular teeth into the new occlusal position and secured with maxillomandibular dental fixation. The surgeons who are involved in the intraoral fixation should change gloves and surgical gowns before the drapes are replaced so that the skin incisions can again be approached. The next step varies depending on the type of mandibular movement that occurred; however, the importance of maintaining the proximal fragment close to its preoperative position remains. If the distal segment is set back, then the proximal segment has to be overlapped laterally (Figure 56-14B). As described with the VSO some adjustments of the lateral cortex of the distal segment may be necessary to permit passive position of the proximal fragment as well as to provide a good area of bone contact. The use of some form of

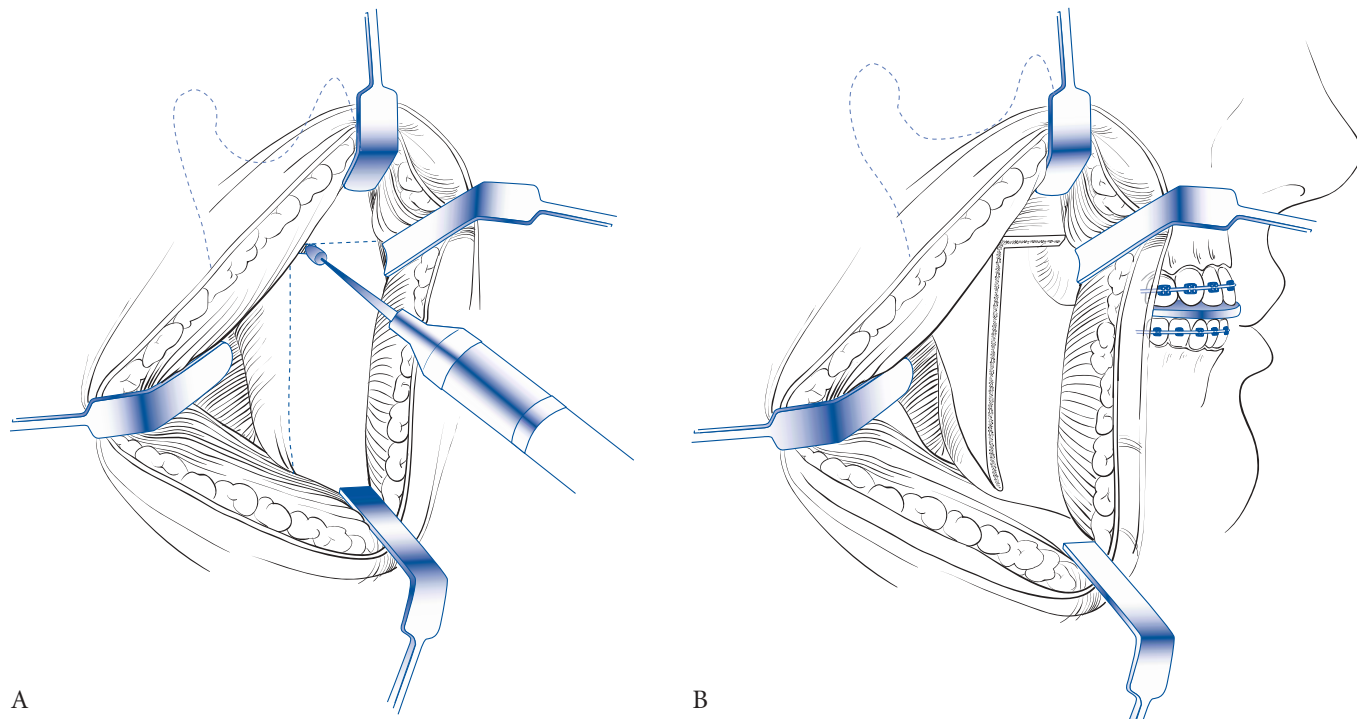


FIGURE 56-14 The extraoral inverted L osteotomy. Adapted from Bloomquist DS. Principles of mandibular orthognathic surgery. In: Peterson LJ, Indresano AT, Marciani RD, Roser SM. Principles of oral and maxillofacial surgery. Vol 3. Philadelphia (PA): J.B. Lippincott Company; 1992. p. 1430.

fixation is generally recommended, although the use of no interosseous fixation has been suggested.⁹³ The type of

osseous fixation varies widely; however, rigid internal fixation with metal plates or mesh secured with screws has become

more popular (Figure 56-15).⁹³ After irrigation the wound is closed in layers by whatever suturing method and material

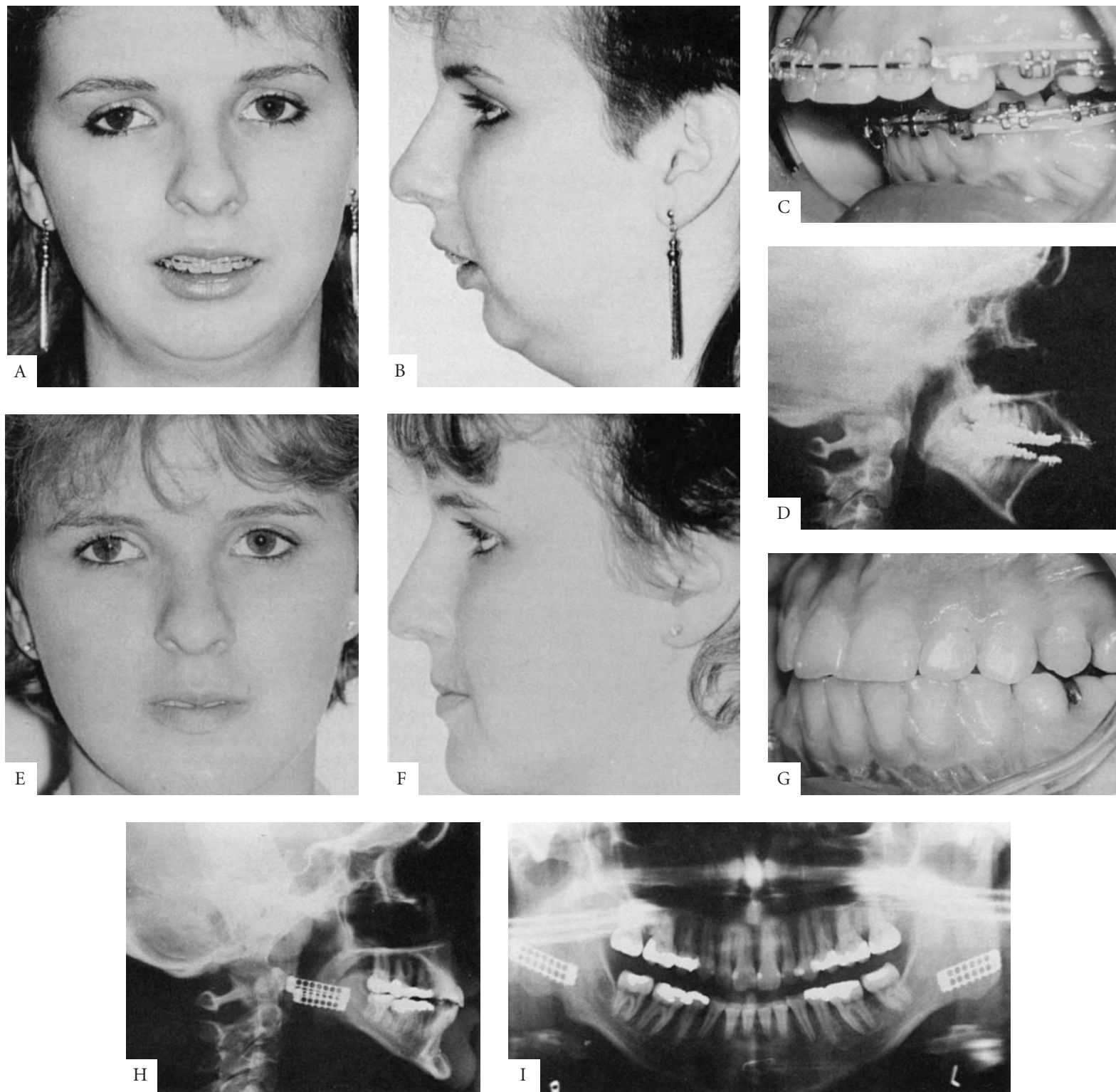


FIGURE 56-15 Patient who was treated with an extraoral inverted L osteotomy (for mandibular horizontal deficiency). A–D, Preoperative photographs and radiograph. E–I, Postoperative photographs and radiograph. Reproduced with permission from Bloomquist DS. Principles of mandibular orthognathic surgery. In: Peterson LJ, Indresano AT, Marciani RD, Roser SM. Principles of oral and maxillofacial surgery. Vol 3. Philadelphia (PA): J.B. Lippincott Company; 1992. p. 1432–3.

the surgeon prefers. Care should be taken to ensure hemostasis as the wound is closed. If there is any concern about hematoma formation a small drain should be placed. External pressure dressings are maintained for 24 to 48 hours. When the bone has been stabilized with wire fixation, maxillomandibular fixation is kept in place for at least 6 weeks and preferably 8 weeks.

Alternative Techniques The most commonly used variation of the previously mentioned technique is the **C** osteotomy. This technique was first described jointly by Caldwell and colleagues in an article reviewing their experiences with what they called a vertical **L** osteotomy.¹⁸ They described a variation of their basic vertical **L** with the addition of a horizontal cut that extended forward from the vertical cut below the inferior alveolar canal (Figure 56-16A). This permitted a larger amount of bone contact when the mandible was advanced. They also realized the problems caused by advancing the coronoid process and recommended either cutting the coronoid loose (coronoidotomy) or including it with the proximal segment (**C** osteotomy). Arcing the inferior cut was suggested to permit increased bone contact as the distal segment was advanced (Figure 56-16B).⁹⁵ Unfortunately the proposed arc cannot always be made since the position of the neurovascular bundle may interfere. Sagittal splitting of the inferior limb of the **C** osteotomy was proposed both to increase the bone contact area when the mandible was advanced and to decrease the problem of “notching” of the inferior border (Figure 56-16C).¹⁹ This latter problem, which is noticeable in some patients, is caused by the defect along the inferior border resulting from the advanced distal segment of the mandible. A further variation used to improve bone healing includes a bone graft taken from the lateral cortex of the distal segment and transferred back into the gap of the midramus area (Figure 56-16D). The coronoid

process has also been recommended as a free graft in to this defect.²⁰

A further major modification of the described techniques is the use of rigid internal fixation.^{94,96,97} The use of vitalium mesh with two screws in each fragment has been demonstrated as being effective, but any rigid plate with screws can be used to permit the early release of maxillo-mandibular dental fixation.

Complications The skeletal stability of the inverted **L** and its modifications,

unlike the VSO, seems to be technique-sensitive to the type of fixation used. Like stability studies for almost all aspects of orthognathic surgery, controlled clinical studies are nonexistent, and the comparison of techniques by a single institution, if reported, lacks sufficient numbers of patients to make valid conclusions. Farrell and Kent looked at inverted **L** and **C** osteotomies and reported skeletal relapse similar to what had been reported for the BSSO.⁹³ However, because there were different criteria for the use of these two

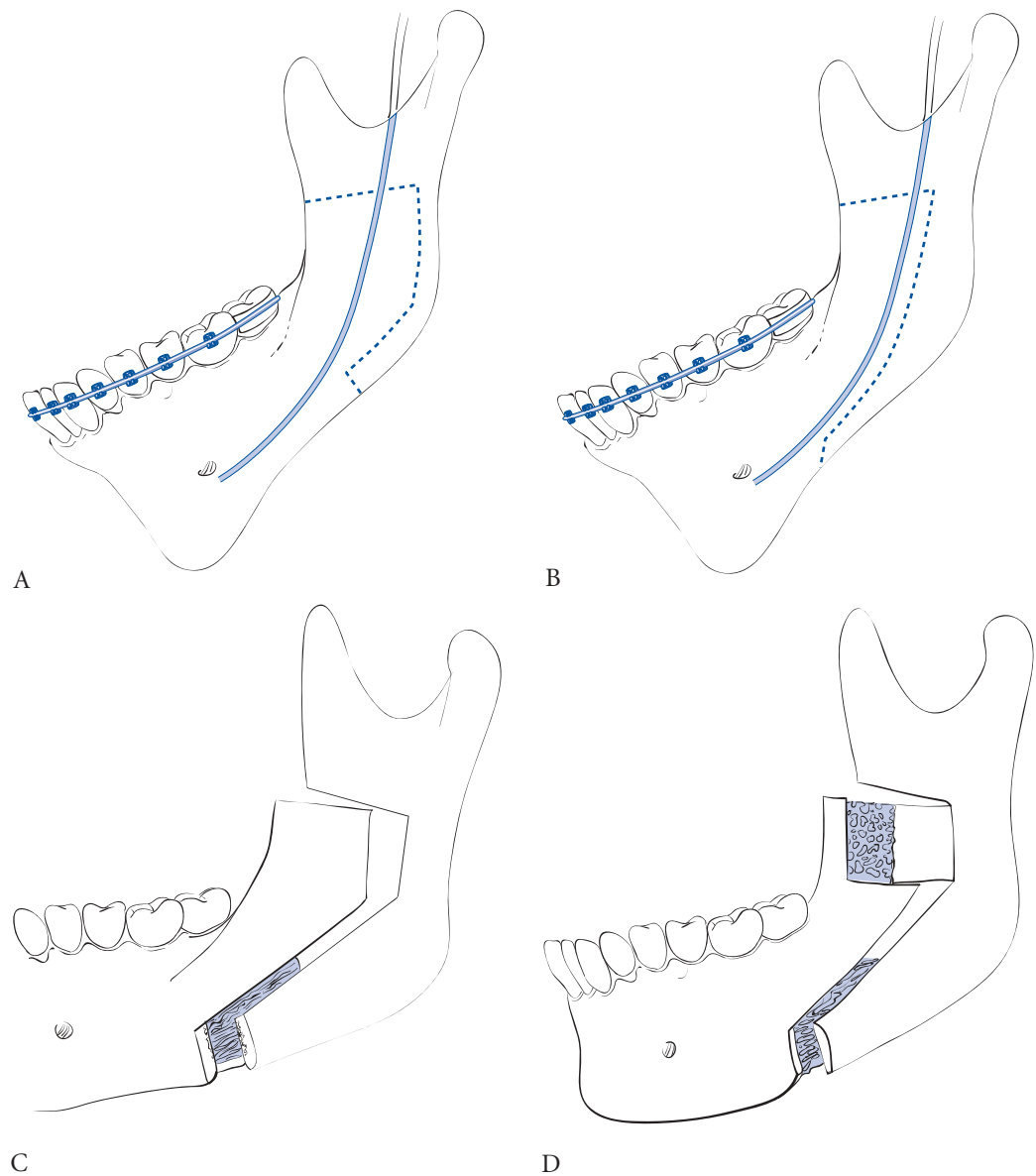


FIGURE 56-16 Different forms of the **C** osteotomy. Adapted from Bloomquist DS. Principles of mandibular orthognathic surgery. In: Peterson LJ, Indresano AT, Marciani RD, Roser SM. Principles of oral and maxillofacial surgery. Vol 3. Philadelphia (PA): J.B. Lippincott Company; 1992. p. 1434.

types of osteotomies, comparisons between them are questionable. Greebe and Tuinzing compared the stability of mandibular advancement by way of an inverted L or a BSSO.⁹⁸ With only a few patients they did not show any difference between the groups, but they did claim that skeletal relapse was dependent on the ratio of posterior facial height to anterior facial height. The largest studies of the stability of the inverted L included the use of rigid internal fixation in patients who had the mandible advanced. These seem to demonstrate that the use of rigid fixation for this type of procedure is more stable than simple maxillomandibular fixation.^{96,97} However, statements relative to stability of mandibular setbacks or the closure of open bites cannot be made, although a few authors seem to advocate these skeletal deformities as indications for the use of the inverted L osteotomy.^{96,99}

The incidence of facial nerve damage has not been mentioned in any review of these techniques, although it can be inferred to be quite low, given the reports for the external approach to the VSO. The incidence of damage to the inferior alveolar nerve should be higher than the extraoral VSO because of the horizontal portions of the osteotomy, but Reitzik and colleagues reported only a 6% incidence of permanent anesthesia with inverted L osteotomies.⁹⁶ The incidence of unsightly scars, which many clinicians claim deters them from using this approach, is unknown with this group of osteotomies.

Bilateral Sagittal Split Osteotomy of the Vertical Ramus

The BSSO of the vertical ramus has in a relatively short time become the predominant orthognathic procedure of the mandible. Schuchardt is generally given credit for the use of an intraoral approach to what some call the “step” osteotomy of the vertical ramus.²³ Specifically he described parallel horizontal cuts through the cortex of the vertical ramus, the medial

cut being placed above the lingula and a lateral cut being made about 1 cm below that. A split was then made between these two cortices, and the distal segment could then be advanced or set back. Lane evidently described a very similar procedure earlier, but it probably was done extraorally (see Figure 56-4).²² The singular credit for improving on this osteotomy, as well as being its strongest advocate, belongs to Obwegeser, who together with Trauner in 1955 described a sagittal split of the vertical ramus.²¹ This intraoral technique included the medial horizontal cut above the lingula, but the lateral horizontal cut was lower than Schuchardt’s and extended to a point just above the angle, at least 25 mm below the lingual cortical cut (Figure 56-17A). A wide-splitting osteotome was then used to obtain a split between the cortices, with care taken to preserve the inferior alveolar nerve and vascular bundle. This procedure was later slightly modified by Obwegeser by angling the lateral cut more toward the inferior border of the mandible (Figure 56-17B). The major modifications still in use today were suggested by DalPont.²⁴ The change commonly attributed to DalPont is the vertical cut through the lateral cortex behind the second molar. But he also suggested the use of

a medial cut that extends just past the lingula so that the posterior split would occur in the mylohyoid groove instead of back at the inferior border. Multiple other modifications have been suggested, but surprisingly the present-day osteotomy remains very similar to that initially described by Obwegeser and DalPont.

Indications The BSSO has been advocated for almost every possible move that includes the entire horizontal ramus of the mandible.

Technique This osteotomy has had multiple variations suggested, as would be expected for such a popular procedure, but many of them are based on a surgeon’s individual preference, and their effect on the outcome of the osteotomy is questionable. Therefore, only the basic procedures to be followed will be outlined, as well as the significant modifications that have been shown to affect the outcome or seem to have a good theoretical basis.

The incision is started on the anterior portion of the vertical ramus, midway between the occlusal planes. It is carried downward through the middle of the retro-molar fossa to a point about 5 mm behind the second (or in some cases third) molar.

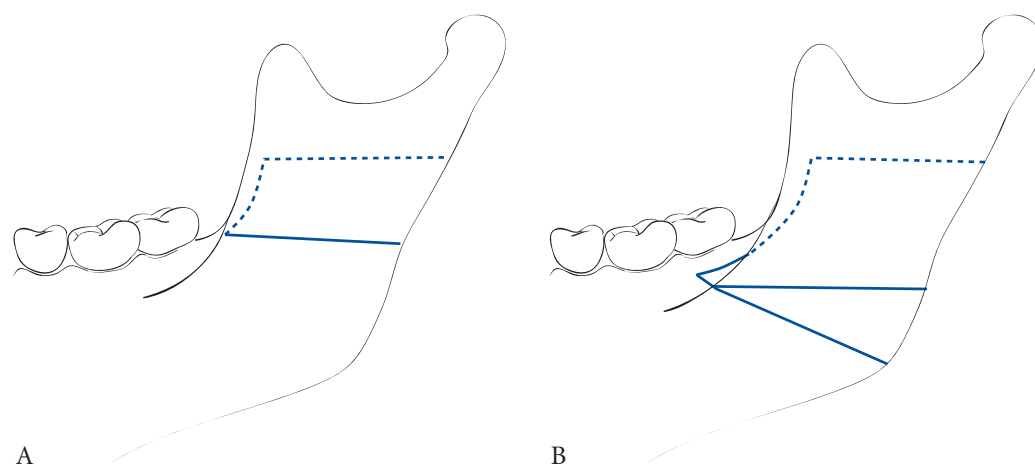


FIGURE 56-17 Obwegeser’s osteotomies of the ramus. A, Original cortical cuts. B, Later lateral cortex cuts. Adapted from Bloomquist DS. *Principles of mandibular orthognathic surgery*. In: Peterson LJ, Indresano AT, Marciani RD, Roser SM. *Principles of oral and maxillofacial surgery*. Vol 3. Philadelphia (PA): J.B. Lippincott Company; 1992. p. 1435.

Then the incisions wind laterally and forward to a point distal of the first molar (Figure 56-18A). The incision should be kept lateral enough to allow easy closure of the wound with the teeth in fixation. The periosteum is reflected to expose the lateral cortex to the mandible down to the inferior border. The exposure should be limited posteriorly to maximize the blood supply to the proximal fragment; this usually means the exposure ends at about the antegonial notch. A lateral channel retractor can be placed at this time to assist in retraction as the periosteum is elevated from the retro-molar area up the anterior border of the vertical ramus. Special periosteal strippers have been developed to assist this portion of the surgery. The attachment of the temporalis muscle can be tenacious, but it has to be removed to at least the level of the sigmoid notch to ensure adequate access for the medial cut. Most times this means stripping about a centimeter of the temporalis attachment off the anterior border of the coronoid. The periosteum is then elevated from the medial surface of the vertical ramus, starting at about the level of the sigmoid notch and extending back to the medial flare at the start of the condylar neck. Inferiorly the medial cortex is exposed to the lingula, with care being used to minimize trauma to the inferior alveolar nerve as it exits behind and below this point. The periosteal elevation can be extended inferoanteriorly along the internal oblique line to the distal of the second molar to allow better exposure of the osteotomy site. A variety of retractors are available for the protection of the medial soft tissue and nerve, but it is wise to choose one that permits as much visualization as possible while at the same time protecting the soft tissue (Figure 56-18B). Excessive medial retraction should not be done in order to minimize neural damage. It should be noted that no attempt is made to carry the exposure to the posterior border of the vertical ramus.

The osteotomy is started by making a horizontal bone cut through the medial

cortex of the vertical ramus that extends from a point just posterior to and above the lingula to the anterior border. Anteriorly the cut is made about halfway through the ramus, but in the concavity above and behind the lingula it should be shallow to allow the posterior medial split to initiate in the mylohyoid groove (Figure 56-18C). Sometimes it is helpful to use a large round or acrylic bur to remove bone from the internal oblique ridge so that the depth of this concavity can be visualized. Occasionally at the level of this horizontal cut there is no significant cancellous bone to delineate the cortices. Here the use of a half thickness of the ramus is the most practical guideline for judging the depth of this cut.

The vertical cut through the buccal cortex is generally made just distal to the second molar and extends from the inferior border superiorly to the external oblique ridge. Sometimes the mandible is thin and the external oblique ridge ends at the distal buccal aspect of the second molar. In this case the superior aspect of the vertical cut should be posterolateral enough so that the roots of the second molar are not placed at risk. The cut should be as close to perpendicular to the inferior border as possible and extended just into cancellous bone. Caution must be used such that the cut is not taken any deeper because the inferior alveolar nerve can be just medial to the cortex.

The vertical and horizontal cortical cuts are connected, starting superiorly at the anterior border of vertical ramus and continuing down just inside the external oblique ridge to the vertical cut (Figure 56-18D). Again the cut is made into cancellous bone, when at all possible, with the superior part of this connection being as deep as possible, especially if there is no cancellous bone present. This will minimize the chance of an inadvertent fracture of the medial cortex. Difficulty is encountered often if a third molar is present and has been scheduled to be removed at the

time of surgery. It is generally wise to plan for the mandibular third molars to be removed well in advance of the sagittal osteotomy since they can make the surgery more difficult. Experienced surgeons can remove the tooth and obtain a successful split, but almost all try to avoid this situation because it may increase the risk of an unplanned buccal or lingual cortical plate fracture and can make rigid fixation with the use of screws more difficult.

Techniques vary widely in how the split is accomplished. The method to be described is an attempt to be as universal as possible. First, steps are taken to ensure that the limits of the split occur as defined by the horizontal and vertical bone cuts. A narrow (4 mm) thin osteotome is driven along the horizontal cut and directed so that it cuts through the medial cortex above and behind the lingula. It is also used to ensure that the split at the base of the vertical cut is started through the midpoint of the inferior border. Many surgeons also use this type of thin osteotome to “step” along the connecting cut to help ensure that the split stays close to the lateral bone cortex. Traditionally wide-wedging osteotomes have been used to slowly complete the split. More often today a special spreading instrument is used along with a smaller osteotome to allow more control of the split. Generally the movement is initiated along the vertical cut and carefully extended posteriorly. The fine osteotome can be used to keep the split close to the lateral cortex. If the nerve is encountered it is carefully separated from the proximal fragment. The split along the inferior border can be difficult to control, and the judicious use of a thin osteotome will assist in this area. Finally as the posterior split through the medial cortex is made care should be used to prevent the split from continuing behind the mylohyoid fossa and starting up the neck of the condyle. The speed of the split often varies, depending on the elasticity of the bone. In older patients, in

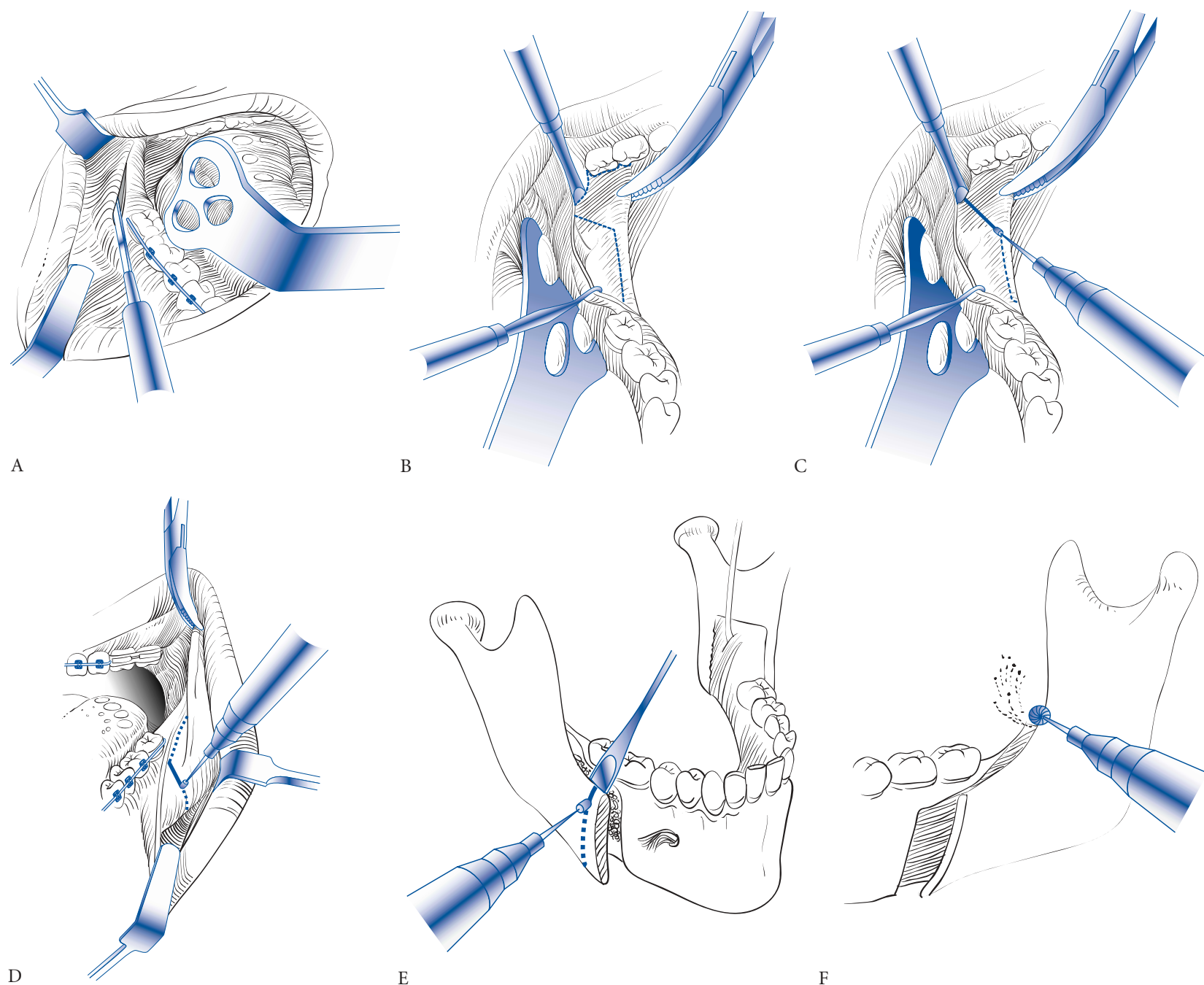


FIGURE 56-18 The bilateral sagittal split osteotomy. A, Incision. B and C, Medial exposure and horizontal cut. D, Vertical cut. E, Bone removal for setback. F, Bone removal for large adjustments. Adapted from Bloomquist DS. *Principles of mandibular orthognathic surgery*. In: Peterson LJ, Indresano AT, Marciani RD, Roser SM. *Principles of oral and maxillofacial surgery*. Vol 3. Philadelphia (PA): J.B. Lippincott Company; 1992. p. 1436–7.

whom the bone is not as elastic, the split can occur very suddenly. Preventing inappropriate fractures is dependent on the care used not only in making the cortical bone cuts but also in ensuring that the splits occur as planned at the posterior aspect of the horizontal cut and along the inferior border.

Periosteum of the muscle attachment of the medial pterygoid is stripped off the proximal fragment to permit freedom of movement between the two fragments. If the mandibular teeth are scheduled to be moved posteriorly, either on one side when correcting an asymmetry or bilaterally for correction of horizontal mandibular

excess, an appropriate amount of bone is removed at this time from the anterior edge of the proximal fragment. The amount of removal can be based on model surgery or on the prediction tracings. On large setbacks, bone will need to be removed from the anterior edge of the vertical ramus to prevent this area from interfering with

the patient's ability to clean the mandibular second molars (Figure 56-18E). Conversely in large advancements, bone sometimes has to be removed from the remaining portion of the anterior border of the vertical ramus of the distal segment just anterior to the lingula, to prevent encroachment of the segment against the tuberosity (Figure 56-18F). After the opposite side is split the mandible is moved into its new position and stabilized by maxillomandibular fixation. It is preferable that an occlusal splint be used to ensure accurate position of the mandible relative to the maxilla, based on the presurgical model surgery. It is rare that teeth occlude well enough that a splint is not needed.

The placement of osseous fixation is made at this point. As multiple techniques are possible, different options will be described in the following section "Alternative Techniques." After placement of osseous fixation, if rigid fixation is used, the maxillomandibular fixation is released, allowing the occlusion to be checked. The wounds are thoroughly irrigated and closed with the use of a resorbable running suture. No drains or external dressings are generally necessary (Figure 56-19).

Alternative Techniques There are many variations to the foregoing technique. In this section only the major ones will be discussed. The design of the osteotomy itself is an area that has received much attention, with each of these variations generally representing an attempt to decrease the incidence of one or more complications. There is very little supportive research for any of the modifications. Obwegeser was responsible for two variations, the first being his original design, in which the buccal cut was horizontal and parallel to the lingual cut through the cortex of the vertical ramus (see Figure 56-17A). This original technique was modified by making the lateral cortical cut at an angle to the medial cut so that the posterior portion of the osteotomy ended just above the angle (see Figure 56-17B).¹⁰⁰

A popular modification of DalPont's vertical osteotomy is the continuation of this cut completely through the inferior border, which, according to its advocates, made the split easier.⁵⁹ This technique, however, makes the use of rigid fixation with screws difficult.¹⁰¹ A few modifications have been suggested for the connecting cut, with the primary goal of allowing

better control of the proximal fragment. These modifications appear to be primarily personal preferences as there is no evidence that these changes improve the success of the procedure.

A major area of variation for the sagittal split osteotomy of the vertical ramus occurs in the use, or nonuse, of osseous fixation.^{21,25,102,103} The original Obwegeser technique used wire through the superior lateral and medial cortices.¹⁰⁴ This technique, with minor variation, became the standard for the sagittal osteotomy until screw fixation became popular.⁵⁹ The use of circummandibular wire and inferior border wires have also been suggested as possibly better ways of controlling the proximal fragment.¹⁰⁵ No evidence exists that any of these wire techniques have an advantage for minimizing complications.²⁶

Spiessl introduced the concept of using screws for the "rigid internal fixation" of the sagittal osteotomy.²⁶ Following its introduction in 1974 there was a slow acceptance of this method of osseous fixation. Currently there is little debate on the advantages of using rigid internal fixation. However, there exists a wide variety of methods and materials used. Initially the use of three 2.7 mm

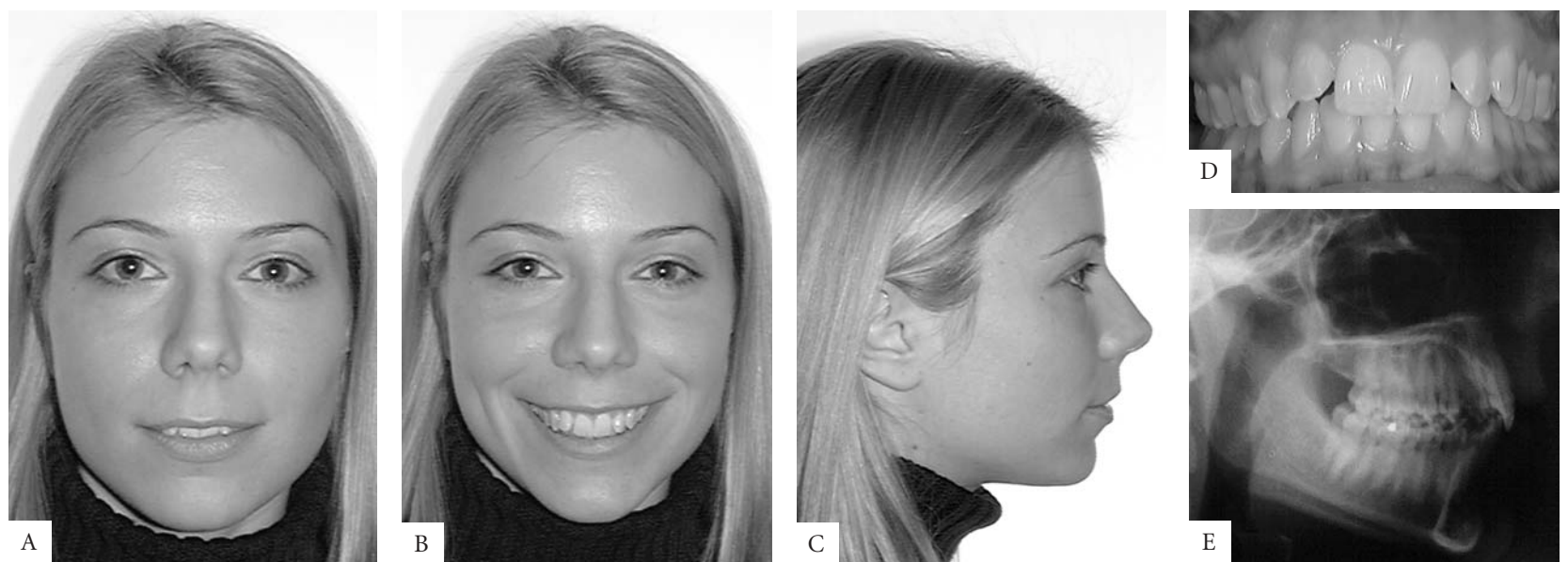

FIGURE 56-19 Patient who was treated with bilateral sagittal split osteotomies (for mandibular horizontal deficiency). A–E, Preoperative photographs and head radiograph. (CONTINUED ON NEXT PAGE)

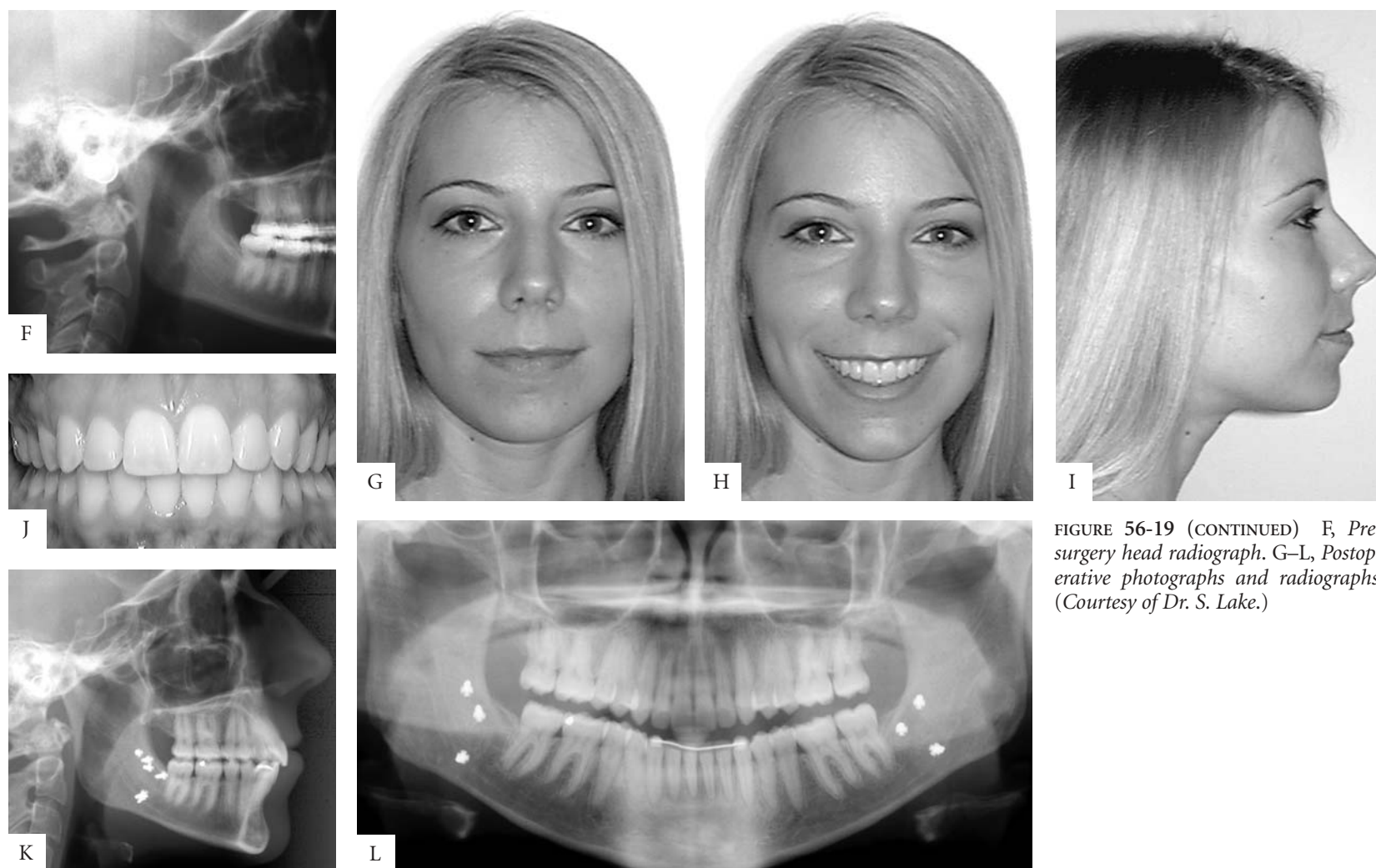


FIGURE 56-19 (CONTINUED) F, Pre-surgery head radiograph. G-L, Postoperative photographs and radiographs. (Courtesy of Dr. S. Lake.)

“lag” screws on each side was advocated. A lag screw is placed by drilling a “guiding” hole with a larger drill through the lateral cortex, followed by a smaller hole through the medial cortex that is threaded with the use of a tap. Lag screws are then used to fix the proximal fragment tightly to the distal fragment. Compression across the osteotomy site is felt to be important to speed the healing of the osteotomy as well as to ensure the stability of the mandible. Concern exists that compression may cause increased nerve damage and displacement of the condyles, with subsequent temporomandibular joint dysfunction.^{106,107} An alternative technique, the position screw or bicortical screw, in which both cortices are tapped, has been advocated for stabilizing osteotomy segments.¹⁰⁰ This technique permits mainte-

nance of the gaps that may occur between the proximal and distal fragments, with no effort being made to compress the two segments together. Standardization of techniques does not exist in rigid fixation of the sagittal osteotomy as there are differences in screw sizes, number of screws, materials used, and whether plates are used across the osteotomy sites. Most of the research in the United States has centered on the use of three screws that are 2 mm in diameter. Direct comparisons of differing rigid fixation techniques are rare and do not demonstrate that any one technique is an advantage.¹⁰⁸⁻¹¹⁰ One exception was noted by Fujioka and colleagues, who found that there was more rotation through the osteotomy sites in patients with monocortical plate and screw fixation.¹¹¹

The use of resorbable screws has been a recent addition to fixation techniques. First attempted in Finland, the screws are made from polyglycolic acid using different manufacturing techniques and formulas. Development of these self-reinforced polylactic/polyglycolic polymers that have reliable strength to withstand forces of mastication have made their use possible in orthognathic surgery. The obvious advantage of resorbable fixation is to obviate the need for future hardware removal, which has become important with patient concerns over the potential risks of any kind of permanent implants. The key features that are crucial in its application in orthognathic surgery are the material’s rigidity and strength with an ability to resorb in a timely fashion. A few small studies have shown

apparent stability of these resorbable implants comparable to the metallic fixation; however, some inherent problems with material handling and early fixation failures have been reported.¹¹²⁻¹¹⁴ Suuronen and colleagues reported on the use of poly-L-lactic acid (PLLA) screws for fixation in BSSO, with no apparent malocclusion or skeletal relapse.¹¹² Harada and Enomoto and later Ferretti and Reyneke compared titanium and resorbable screws and noted no difference in healing between two groups and no statistically significant difference in skeletal relapse.^{113,114} However, Harada and Enomoto's patients were placed in maxillomandibular fixation for a period ranging from 9 to 14 days following surgery.¹¹² Kallela and colleagues used self-reinforced PLLA (SR-PLLA) screws for mandibular osteotomies and no maxillo-mandibular fixation was used postoperatively.¹¹⁵ Mean advancement was 4.57 mm at B point, and the mean relapse was 17%. In their 2-year follow-up study in 1999, the authors reported osteolytic changes seen around the resorbable screws in 27% of cases, and the screw canals remained as radiolucent shadows without bony filling. Turvey and colleagues reported their experience with resorbable fixation for 194 osteotomies of the maxilla and/or mandible.¹¹⁶ Forty-three of the patients had a sagittal osteotomy with 2 mm screws placed on each side for fixation. They reported only one infection at a sagittal osteotomy site and one patient who exhibited abnormal masticatory pressures that resulted in loosening of the fixation. Acceptance of the routine use of resorbable fixation with the sagittal split is going to require long-term evaluations with well-designed studies comparing these materials to the metal hardware. The major potential risk of permanent metal fixation is the possibility of bone remodeling, causing the hardware to become noticeable and possibly irritating to the patient. Although not reported in the literature oral and maxillofacial surgeons have had experience

with patients returning to have plates and screws removed simply because these implants have become noticeable. This problem has to be weighed against the still unexplored or unknown side effects of the resorbable materials. A good example of these unknowns is the precise time needed for total resorption and degradation of PLLA in human tissues, which is reported to range anywhere from 90 days to 5 years. Surgeons are going to have to closely follow the literature to determine the practicality of these new materials.

An interesting suggested modification in the BSSO technique is the purposeful changing of the rotational position of the proximal fragment to control the direction of mandibular growth. It has generally been recommended that the proximal segment be maintained as close as possible to its preoperative position. O'Ryan and Epker have further suggested that rotating the proximal fragment in a growing patient can change the vector of condylar growth and, thereby, influence the final mandibular position.¹¹⁷ Studies have failed to support this contention.¹¹⁸ Also there is concern in using a sagittal osteotomy in growing children, especially those requiring long advancement. Huang and Ross demonstrated what they felt to be a stoppage in mandibular growth and condylar resorption in growing patients in whom sagittal osteotomies were performed.¹¹⁹ Whether this was a problem of the techniques used or a problem with performing surgery in such a young group of patients is unknown, but this effect has not been noted in any further literature.

A final modification of the BSSO is the concomitant use of a midsymphysal osteotomy to allow for correction of width discrepancies in the dental arch. Although this procedure could be used with any of the ramal osteotomies, it has only been described with the sagittal osteotomies. First mentioned by Bell, it has become more practical with the use of rigid internal fixation.¹²⁰ A single four-hole plate across the

bone cut, along with an intact orthodontic arch wire, provides sufficient stability.¹²¹ Concerns of adverse effects on the temporomandibular joint and the periodontium were also shown to be insignificant.¹²²

Complications Stability The stability of the sagittal osteotomy of the vertical ramus is the most studied complication in orthognathic surgery. Since the relapse patterns differ between mandibular advancements and setbacks, their particular causes most likely differ; however, many of the principles in preventing relapse may be the same. Whereas much of the research on mandibular advancement has been done in the United States, mandibular prognathism has generally received the greatest interest in the Scandinavian countries and the Far East. This highlights one of the major problems for surgeons attempting to decide on which techniques to use to minimize postoperative skeletal change. There are large variations in research techniques as well as surgical approaches that exist not only between surgical centers in different countries but also within the same country. Fortunately there is enough corroboration in the literature that some general statements can be made.

One of the most important findings made in the stability of mandibular osteotomies was that intermaxillary fixation does not prevent postoperative skeletal change. Although this is true of any type of mandibular osteotomy, it was first recognized in the evaluation of mandibular sagittal osteotomies. It is generally felt that soft tissue pressures and muscle pull are the major factors influencing relapse, especially in mandibular advancement.^{52,53,122} However, early attempts at minimizing these effects, such as suprahyoid myotomies and external supportive devices, have not been shown to be effective.⁶⁴ Internal support techniques, however, have been shown to be effective. Before rigid fixation screws and plates were used,

a type of internal support called skeletal fixation was shown to be effective in decreasing the down and back relapse pattern of mandibular advancements.⁶⁴ This fixation was usually used in addition to maxillomandibular fixation and consists of wires running from the piriform rim to circummandibular wires placed in the cuspid or molar areas (see Figure 56-9). Interestingly, Van Sickles noted a decrease in relapse in patients with large advancements when skeletal fixation was combined with rigid internal screw fixation.¹²³

Other possible causes of relapse that have been implicated are patient's age, preoperative mandibular plane steepness, rotational position of the proximal fragment, amount of distal segment advancement, and the displacement of condyle from the fossa. The effect of mandibular plane steepness is somewhat controversial because of variable results reported in the literature, most of which looked at patients who had wire osseous fixation with intermaxillary fixation. Mobarak and colleagues did clearly find decreased stability in patients with steep mandibular plane angles when rigid internal fixation was used.¹²⁴ Of the remaining variables only the last two appear to be definitively supported by clinical studies as being important. In their multicenter study, Schendel and Epker found that displacement of the condyle from the fossa was a significant predictor of relapse.⁶⁴ This was further confirmed by Lake and colleagues, who also showed the relation between the amount of advancement and the amount of relapse.⁵⁵

The final area that has been considered as possibly affecting relapse in both mandibular advancement and setback is the rigidity of the fixation across the osteotomy site. Early investigators felt that fixation across the osteotomy site may hinder the normal repositioning of the condyle in the fossa that occurs during maxillomandibular fixation.¹⁰³ Later studies showed that wire osteosynthesis was superior to no osseous fixation in frag-

ment position, and the incidence of relapse was less.¹⁰² However, the search for a superior osseous wiring technique that would decrease relapse has not been successful, with most studies that looked at osseous wiring techniques being very consistent in finding a mean relapse of approximately 30%. The large range of individual relapses that does exist has led many surgeons to believe that there are multiple factors that influence relapse.

The use of rigid internal fixation techniques has become the preferred method for minimizing skeletal relapse in the BSSO. Spiessl together with Schmoker and colleagues first discussed the advantages of lag screws in mandibular sagittal split osteotomies. Their initial study of skeletal stability looked at mandibular setbacks, comparing the use of three 2.7 mm screws against wire fixation and one or two screws.¹²⁵ It was not until 1985 that Van Sickles and Flanary showed evidence that a similar rigid fixation technique provided increased stability in mandibular advancements.¹²⁶ Furthermore larger and longer studies have clearly shown the stability of using three bicortical screws for fixation of the sagittal osteotomy.¹²⁷⁻¹³⁰ These studies have reported a mean relapse rate of between 0 and 8%. The majority of studies comparing rigid internal fixation techniques against the use of wire osseous fixation have also confirmed a significant difference in stability between the techniques.¹³¹⁻¹³⁵ Interestingly the only clinical study that evaluated the stability of osseous wire fixation versus rigid screw fixation on patients treated at the same center seemed to show a comparable long-term stability.¹³⁶ This study, however, reported an unusually high stability of the wire osseous fixation group and did nothing to dispute the stability of the screw fixation. The number of screws may very well influence the stability, although only Spiessl's original study demonstrated a difference.

Another common method for rigid internal fixation of the BSSO is the use of

miniplates with monocortical screws. Generally 2 mm systems are used with two screws placed on either side of the osteotomy.¹³⁷⁻¹⁴⁰ Questions remain over the minimum number of screws necessary to prevent relapse and whether more or larger screws will improve stability in longer advancements. It has been shown that a single 2 mm screw does not seem to increase mandibular stability over wire osseous fixation, and thus it could be argued, in light of the previously reviewed research, that an increase in number or size of screws can result in more osseous stability.^{130,141}

Nerve Damage The possibility of damage to the inferior alveolar nerve during the sagittal osteotomy has been well known since the technique was first described, but surprisingly the problem was minimized by early surgeons. Kole first mentioned a high incidence of sensory problems immediately after surgery for patients with sagittal osteotomies, but most clinicians claimed a very low incidence of long-term problems.^{142,143} Walter and Gregg, during an objective study of sensory problems, noted a large incidence of long-term problems.⁴⁵ Since this first definitive study there has continued to be a variety of reported instances of both immediate postsurgical as well as chronic sensory disturbances.

Westermarck and colleagues evaluated 496 sagittal osteotomies for possible correlations between neurosensory dysfunction and other variables, such as the age of the patient, mandibular movement, type of split technique and fixation, degree of intraoperative nerve encounter, and surgical skill.¹⁴⁴ Nerve dysfunction developed in 40% of the cases. The patient's age had a significant influence on the recovery of the neurosensory function as well as the severity of neurosensory disturbance. Intraoperative nerve encounter and nerve manipulation as well as surgical experience were also reported to have an effect on nerve dysfunction. Other variables had

no significant effects on the incidence of neurosensory dysfunction. Ylikontiola and colleagues also found a statistically significant positive correlation between subjective neurosensory loss and the patient's age and, in addition, magnitude of mandibular movement and degree of manipulation of the nerve.¹⁴⁵

A number of other clinical researchers have noted a significant relation between the patient's age and nerve recovery. This finding was noted early on by MacIntosh, who emphasized that he does not use this osteotomy for patients over age 40 years.¹⁴⁶ The only other interesting correlation was made by Van Sickels and colleagues who reported that patients with a concurrent genioplasty had a greater loss of sensation initially.¹⁴⁷ Unfortunately the wide variation in measurement protocols makes comparisons of these various reports difficult. This also makes difficult the evaluation of techniques that have been suggested to decrease the incidence of nerve damage.

White and colleagues pointed out that damage to the inferior alveolar nerve most likely occurs either during the medial retraction of the soft tissues and the nerve as it enters the canal or during the vertical bone cut.¹⁴⁸ Guernsey and DeChamplain felt that damage occurred during the splitting of the mandible and reported the problem of parts of the nerve staying in the proximal fragment after the split.¹⁴⁹ This has led some surgeons to recommend the use of a small flat (spatula) osteotome during the split, instead of the wide-splitting osteotome.¹⁵⁰ The fine osteotome is malleted carefully along the lateral cortex and cancellous bone junction. The nerve is exposed less often during the split by this technique, and consequently it has been assumed that this results in less sensory disturbances.^{151,152} Unfortunately this technique has not been directly compared with any other, and the comparison of the occurrence of sensory disturbance between reports is impossible. Yoshida and colleagues and later Yamamoto and colleagues,

found that nerves that were close to the lateral cortex, as determined by radiographs, were more likely to have severe sensory alteration after surgery.^{152,153} The deficits were also more likely to be present 1 year after surgery when the marrow space between the mandibular canal and the external cortical bone was 0.8 mm or less. Some authors feel that by making the vertical cut in the lateral cortex more posterior, a lower incidence of sensory problems occurs.^{152,154} This has not been substantiated in comparison studies.

Another possible cause of sensory loss to the nerve may be due to the sharp bone irregularities of the proximal fragment or to compression of the nerve when the proximal fragment is positioned and fixed.^{155,156} A round or acrylic bur can be used to remove any bone spicules as well as to widen and deepen the canal in the proximal fragment to prevent this effect. Care must be taken when working around the nerve so that instruments used during the osteotomy do not themselves cause direct damage. This concern was heightened with the use of screw fixation. Paulis and Steinhauser noted slightly higher incidences of long-term sensory loss in patients with rigid screw fixation compared with simple osseous fixation but statistics were not used and the significance of their numbers is highly suspect.¹⁵⁷ Nishioka and colleagues did a comprehensive study involving sensory loss after the use of screw fixation and found the incidence of inferior alveolar sensory loss to be high but well within the range of sensory loss reported by other well-designed objective studies.¹⁵⁸ Subsequently the effect of type of fixation on the neurosensory functional outcome was extensively studied by a number of authors using different methods of clinical testing.¹⁵⁹⁻¹⁶² Brush stroke detection was diminished to a greater extent in the rigid fixation group compared with the wire fixation group from 8 weeks through 2 years postoperatively; however, monofilament detection

did not show significant difference between types of fixation throughout the 2-year follow-up.¹⁵⁹ Despite a great number of studies on neurosensory disturbance following orthognathic surgery, the severity of inferior alveolar nerve injury is difficult to compare across different studies since there is lack of standardization as to which neurosensory tests were used, ways the tests were performed, and how the results were interpreted. Certain neurosensory tests are more sensitive in detecting sensory nerve deficit than others. Tests that evaluate patients' abilities to discriminate direction have been shown to be more sensitive indicators of trigeminal neurosensory impairment than other tests such as light touch detection. Westermarck and colleagues used visual analog scale, light touch perception, and temperature testing and concluded that there is a good positive correlation with nerve dysfunction.¹⁶⁰ Alternatively, Chen and colleagues compared three methods of assessing neurosensory disturbance following BSSO: two-point discrimination, pressure-pain thresholds, and perceived sensation changes in specific facial regions.¹⁶¹ The two-point discrimination test was consistent with patients' self-ratings of neurosensory problems using facial maps, but the pressure-pain test was the least sensitive to neurosensory changes. The frequency of the inferior alveolar nerve disturbance ranged from 10 to 94% depending on the test method and the test site used. In a well-controlled study by Nakagawa and colleagues, the occurrence of a long-lasting postoperative trigeminal sensory hypoesthesia was found to be dependent on the nerve involvement at the bone split interface, the manner of fixation, or the intraoperative handling of the tissue surrounding the nerve.¹⁶²

Although the neurosensory function of the inferior alveolar nerve following sagittal split osteotomy has received a great deal of attention, very few studies have documented the incidence of lingual nerve

dysfunction. Jacks and colleagues retrospectively reviewed the patient-reported incidence, duration, and perceived deficit associated with lingual nerve function.¹⁶³ In the BSSO patients 19% reported lingual nerve sensory changes of whom 69% reported a resolution of symptoms within a year and 88% reported altered daily activities. When compared with the inferior alveolar nerve, lingual nerve sensory changes occurred much less frequently and resolved more frequently and sooner, but they were associated with greater perceived deficits in patients' daily activities. Zuniga and colleagues were the first to report on studies performed to assess the effect of lingual nerve injury and repair on human taste perception.¹⁶⁴ Gent and colleagues later examined perceived taste intensity and taste quality identification on localized regions of the tongue after orthognathic surgery.¹⁶⁵ Lingual nerve function in taste perception was diminished at 1 to 2 months after surgery, likely due to impaired chorda tympani nerve function, but it improved by 6 to 9 months after surgery.

Temporomandibular Joint Dysfunction

The incidence of temporomandibular joint dysfunction will be considered in two ways: first, the incidence of temporomandibular joint symptoms that are present after surgery compared with preoperative findings; and second, the change in mandibular range of motion. The latter may obviously not be related to temporomandibular joint dysfunction; on the other hand it has to be considered if evaluating the effects of the surgery on the temporomandibular joint. Unfortunately very few authors related these two areas when they reported on the effect of the sagittal osteotomy. Another factor that must be taken into account in evaluating the effects on the temporomandibular joint in any recent orthognathic surgery is the possible contribution of the orthodontics as provided in conjunction with the

surgery. There is still debate on how much orthodontics itself may help or cause temporomandibular joint dysfunction.

Similar to sensory loss the potential of the sagittal osteotomy causing temporomandibular joint dysfunction was recognized early in its use.²⁴ Reporting of the incidence of temporomandibular joint problems, however, has been highly variable, with most authors recording only the postoperative complaint without any reference to the preoperative condition. Some of the first reviews that did look at pre- and postoperative temporomandibular joint symptoms seemed to imply an increase in joint noises, but not in pain, following the sagittal osteotomy.^{56,166,167} The use of rigid screw fixation was felt by some to cause an increase in temporomandibular joint problems.¹⁶⁸ This concern was highlighted by radiographic findings of condylar changes that occurred with rigid screw fixation. Kundert and Hadjianghelou demonstrated that this tendency occurred with both wires and screws but was greater with rigid fixation than with a wire osseous fixation technique.¹⁰⁶ In neither study was there a discussion of whether these changes had any clinical consequences. Hackney and colleagues found in their study of patients, in whom bicortical screw fixation with mandibular sagittal split was used for mandibular advancements, that little change in condylar position occurred, and there was no significant effect of the surgery on temporomandibular joint symptoms.¹⁶⁹ Paulis and Steinhauser compared preoperative and postoperative temporomandibular joint symptoms in two large groups who had either rigid screw fixation or wire osseous fixation of sagittal osteotomies.¹⁵⁷ They could find no difference in postoperative incidence between the two groups and in fact found a notable decrease in temporomandibular joint pain in both groups. The possibility that the sagittal osteotomy may benefit many patients with temporomandibular joint

symptoms was suggested by Martis and Karabouta.^{170,171} He reported that only 11% of the patients who had temporomandibular joint symptoms before surgery had any symptoms after, whereas about 4% of the asymptomatic patients had problems after surgery. These results were better than but consistent with a study of all types of orthognathic surgery patients, which showed an improvement in a large percentage of patients, with relatively small risk for the asymptomatic patient.¹⁷²

There is, surprisingly, a body of evidence in the literature that sagittal split osteotomy may have a beneficial effect on preexisting temporomandibular joint dysfunction. It is generally believed that temporomandibular joint dysfunction is found at a higher incidence in Class II patients compared with patients with Class I and III malocclusions. The use of the sagittal split osteotomy as an alternative to the mandibular condylotomy to treat patients with painful temporomandibular joint dysfunction has been proposed by some authors.¹⁷³ They suggest repositioning the proximal segment and increasing the joint space, both of which are thought to have an unloading effect on the highly innervated retrodiskal tissues. However, this is controversial and there has not been adequate research to confirm this impression.

Debate on rigid versus wire fixation relative to their effects on the temporomandibular joint has led to a number of studies. Most have shown that there is no significant difference in the incidence of temporomandibular joint symptoms between patients who have received rigid fixation versus wire osteosynthesis during sagittal split osteotomies.¹⁷⁴ Feinerman and Piecuch compared the temporomandibular joint outcomes of the miniplate with monocortical screw group versus the superior border wire fixation with maxillomandibular fixation group.¹⁷⁵ They found no demonstrable long-term differences between the two groups with respect to mandibular vertical opening,

crepitation, and temporomandibular joint pain. In fact masticatory muscle pain and temporomandibular joint clicking improved with rigid fixation and worsened with nonrigid fixation.

The only negative report on the effects of BSSOs on the temporomandibular joint was submitted by Wolford and colleagues.¹⁷⁶ They evaluated changes in temporomandibular joint dysfunction in patients with presurgical temporomandibular joint internal derangement as well as the long-term stability of patients who underwent orthognathic surgery. Unlike other clinicians they observed the appearance of new or an aggravation of existing temporomandibular joint symptoms in a group of patients who were an average of 14 months postsurgery. Therefore, the authors recommended that surgical correction of preexisting temporomandibular joint pathology be considered, either preceding or simultaneous with the orthognathic surgery. In summary it appears that there is a low risk of worsening temporomandibular joint symptoms in patients who do have some form of temporomandibular joint dysfunction when using the BSSO. Conversely this osteotomy may result in improved symptoms in a greater number of patients. Unfortunately methods of predicting this outcome in individual patients have not been developed.

Mechanical displacement of the condyle out of its correct position has been implicated as a significant factor in postsurgical skeletal relapse after sagittal split osteotomy. For this reason, as well as in an attempt to minimize temporomandibular joint problems, a great deal of interest has been focused by early investigators on the issues of condylar position after sagittal split osteotomy.¹⁷⁷ There have been a myriad of technical notes on how to maintain the preoperative condylar position and use of different condylar repositioning devices, based on anecdotal reports of individual surgeon's experiences. Harris and colleagues examined fac-

tors influencing condylar position after sagittal split osteotomy fixed with rigid fixation.¹⁷⁸ The amount of advancement did not correlate with condylar displacement. Condyle angulation and superior-inferior movement did correlate somewhat with the amount of advancement. In addition Van Sickels and colleagues found that the condylar position was slightly different with rigid fixation versus wire osteosynthesis beyond 8 weeks postoperatively, but the ultimate position of the condyle was not different.¹⁷⁹ They found, as have many others, that the final condylar position was posterior and superior after a mandibular advancement. Renzi and colleagues specifically examined Class III patients without preoperative temporomandibular joint dysfunction; half of the patient population was treated with a condylar positioning device whereas the other half of patients was treated with manual control of condylar position.¹⁸⁰ The condylar repositioning device did not prevent the changes in condyle positions in all cases. Neither group had any skeletal or occlusal relapse or postsurgical temporomandibular joint dysfunction. However, the incidence of new onset of temporomandibular joint dysfunction in healthy individuals following orthognathic surgery is known to be low as previously mentioned, and this study only included patients without preoperative temporomandibular joint symptoms. Therefore, it is not surprising that the patients did not develop any postsurgical temporomandibular joint dysfunction. The clinical implication of condylar position in the healthy versus the preexisting temporomandibular joint dysfunction groups may be different; therefore, the true clinical significance of condylar position in exacerbation of temporomandibular joint symptoms remains an enigma.

Computed tomography (CT) has enabled clinicians to assess and quantify condylar position changes in three planes of space. Alder and colleagues reported

that changes in condylar position occurred in all planes of space, but the most common postoperative condyle position was more lateral with increased condyle angle, the coronoid process was higher, and the condyle was again reported to be more superior and posterior in the fossa.¹⁸¹ Rebellato and colleagues found in their study group that there was increased superior postsurgical movement of the condyles with increasing magnitudes of surgical advancement of the mandible.¹⁸²

Magnetic resonance imaging (MRI) has revolutionized the examination of the temporomandibular joint, in that it allows not only the evaluation of condylar position but also provides information on the disk. Gaggl and colleagues reported clinical and MRI findings of the temporomandibular joint in Class II patients, preoperatively and 3 months postoperatively.¹⁸³ Clinically patients had improvements in joint pain and abnormal joint sounds such as clicking. The MRI showed displacement of the disk in 38 of the 50 joints preoperatively and in 28 postoperatively. No correlation was made between the change in disk position and improvement in temporomandibular joint symptoms, which is consistent with other MRI studies. Ueki and colleagues made interesting comparisons of the condylar and disk positions after BSSO and intraoral vertical ramus osteotomy (IVRO) and correlated these findings with temporomandibular joint symptoms postoperatively.¹⁸⁴ Fewer or no temporomandibular joint symptoms were reported by 88% of the patients who underwent IVRO and by 66% of patients who underwent BSSO. MRI study showed no change in anterior disk displacement after BSSO; however, improvement was seen in 44% of patients who underwent IVRO, at least in the early postsurgical period.

The effect of the sagittal osteotomy of the vertical ramus on mandibular range of motion has been extensively studied. Whereas Stacy found that patients who underwent mandibular setbacks with

maxillomandibular fixation generally returned to presurgical limits within 9 months following surgery without any physical therapy, other authors have found very different results.¹⁸⁵ Storum and Bell found that without active physical therapy after the release of maxillomandibular fixation there was a decrease in the patient's ability to achieve preoperative opening when compared with patients who had an active rehabilitation program.¹⁸⁶ This latter study is consistent with most clinicians' experience, and some form of active physical therapy is recommended after release from maxillomandibular fixation. However, there is some evidence that rigid internal fixation that permits mandibular movement soon after surgery may result in a more rapid return to preoperative mandibular movement.¹⁸⁷ Nishimura and colleagues found that final postoperative mouth opening was not significantly influenced by the type of fixation.¹⁸⁸

A final poorly understood temporomandibular joint complication is spontaneous resorption of condyles following sagittal osteotomies.¹⁸⁹ This is a process that may be different from standard relapse with the abnormal resorption being seen primarily in a specific group of patients—young females who have had a history of temporomandibular joint dysfunction before surgery and have undergone a mandibular advancement. Remodeling of the condyles is now accepted to occur after sagittal osteotomies, but fortunately only rarely has this condylar resorption resulted in significant clinical changes. Cutbirth and colleagues evaluated long-term condylar resorption after mandibular advancement stabilized with bicortical screws.¹⁹⁰ Large advancement and preoperative temporomandibular joint symptoms significantly correlated with long-term postoperative condylar resorption at the mean follow-up of 3 years. The amount of vertical resorption did not directly correlate with the amount of relapse seen between 6 to 8 weeks and

long term. Surprisingly there was an improvement in temporomandibular joint symptoms for the group as a whole and even among the group who developed condylar resorption. It should be noted, however, that it is often difficult to draw a line between normal condylar remodeling and condylar resorption. In the Cutbirth study, the authors arbitrarily established a parameter of less than 10% loss of height of the condyle to be considered as "normal remodeling."¹⁹⁰ Attempts to delineate the normal versus pathologic process are difficult, and may lead to an underestimation of the number of condylar resorptions that may occur.

Hoppenreijns and colleagues evaluated the long-term treatment results of 26 patients (23 women and 3 men) who developed progressive condylar resorption following orthognathic surgery.¹⁹¹ The preoperative condylar configuration was noted in patients with deep bites to have more resorption on the superior aspect of the condyle, whereas patients with anterior or open bites had resorption on the superior and anterior surfaces of the condyle. Thirteen patients were managed without surgery after the diagnosis of condylar resorption, and only 3 patients had Class I occlusion at the end of treatment. Thirteen patients underwent a second surgical correction, with 7 patients having satisfactory occlusal results. Four of the patients had relapse with a stable occlusion not requiring further treatment, and 2 patients had complete relapse requiring a third surgical procedure. It was suggested that without surgical intervention after condylar resorption, further resorption ceased after approximately 2 years. The authors speculated that either the mechanical loading during or after BSSO and/or the impediment of blood flow to the condylar segment and the temporomandibular joint capsule may play a role in the condylar resorption. However, the etiology for this process is still unclear, but it does seem to be self-limiting and the resulting

dental skeletal deformity can usually be successfully treated with further mandibular surgery.

Miscellaneous Complications A wide variety of other complications have been reported following the sagittal split osteotomy of the mandibular ramus. Early reviews of complications from this procedure noted some trouble with excess blood loss, postoperative airway compromise, large aseptic bone loss, and facial nerve damage. Greater experience and better instrumentation seem to have dramatically decreased the incidence of these problems. Bleeding is generally easily managed by direct or indirect pressure over the bleeding soft tissue and vessels. Lanigan and colleagues, reporting on a questionnaire sent to a large number of oral and maxillofacial surgeons, found only 21 cases of significant bleeding following mandibular osteotomies.¹⁹² Suspected sources of bleeding included the inferior alveolar artery, facial artery, maxillary artery, and retromandibular vein. Management primarily included direct pressure packing or ligation of the vessel via the open wound. Extraoral approaches to gain access to the facial or external carotid artery can be ineffective due to the collateral circulation. Angiography with embolization is considered appropriate in cases of acute persistent postoperative arterial bleeding.

One group of problems that seems to persist is the inappropriate fracture in the proximal segment or the posterior lingual aspect of the distal segment. Good surgical technique minimizes these problems, and care used during the split is worth the effort, as correcting a "bad" split can be difficult. Fortunately the use of screws and plates does improve the chance of obtaining a satisfactory result, in light of an unexpected fracture, with minimum further morbidity to the patient.¹⁹³ It has been felt that one of the major risk factors predisposing to buccal cortex fracture is the pres-

ence of impacted third molars. Precious and colleagues retrospectively reviewed two groups of patients: one group with retained impacted third molars removed during BSSO and the other group with third molars having been removed at least 6 months before BSSO.¹⁹⁴ There was a 1.9% incidence of unfavorable fractures, and the majority of fractures occurred with the group who had the third molars removed at least 6 months before the BSSO. Mehra and colleagues reported 2.2% unfavorable fractures in 500 procedures.¹⁹⁵ They noted a larger percentage of unfavorable fractures in the patients with retained third molars (3.2% vs 1.2%). This finding is consistent with that of Reyneke and colleagues who found that the presence of unerupted third molars increased the degree of difficulty of BSSO, and all 4 (out of 139 patients) unfavorable fractures occurred in those patients with unerupted third molars present at the time of surgery.¹⁹⁶ Ideally third molars should be extracted at least 6 (preferably 9) months prior to the mandibular osteotomy, both to minimize unfavorable fractures and to allow optimal bony healing, especially when using internal rigid fixation.

Airway patency has become an area of concern to some clinicians, especially in the cases where the mandible is set back. Riley and colleagues reported two patients who were surgically treated for prognathism and later developed sleep apnea.¹⁹⁷ Kawamata and colleagues studied patients with mandibular prognathism who were treated with either sagittal split osteotomy or IVRO for mandibular setback.¹⁹⁸ Using three-dimensional CT images they quantified the airway space after surgery and found that the lateral and frontal widths of the pharyngeal airway had decreased by 23% and 11%, respectively. This reduction in airway dimension did not resolve at 1 year after surgery. However, in the longer postoperative period, a visible recovery of pharyngeal width was seen in some cases. These findings of the decreased airways sec-

ondary to mandibular setback have been confirmed by other investigators. Noteworthy, however, is that only one of these clinical studies had a reported incidence of a patient developing sleep apnea following orthognathic surgery. Therefore one should be cognizant of any physiologic and medical etiologic factors that may have contributed to the emergence of sleep apnea symptoms, rather than simply using the measurement of the posterior airway space following mandibular osteotomies as the sole means of predicting a new onset of sleep apnea disorders.

In general, the risk of infection seems to be low with the BSSO. In their clinical review of 700 consecutive cases of mandibular osteotomies, Bouwman and colleagues reported that screw removal due to infection was performed in 2.8% of cases.¹⁹⁹ Screw loosening occurred in the first postoperative week, which resulted in an occlusal discrepancy in four patients. Fifteen sides required one or more screws to be removed as a result of infection. In a large study of complications in orthognathic surgery, Acebal-Bianco and colleagues reported 36 infections out of 802 mandibular osteotomies (0.05%), but only 5 patients had hardware removed due to infections.²⁰⁰

Horizontal Ramus Osteotomies

Since Blair's first description of his osteotomy of the horizontal ramus, there have been a variety of osteotomy designs documented. Initially the surgeons used extraoral, or a combination of extraoral and intraoral techniques, but since the early 1950s the advocated approaches have primarily been intraoral. It is difficult to choose a representative technique for the body osteotomies because of the wide variations described as well as the relative infrequency of these techniques. Of the described procedures, the step osteotomy will be reviewed because of its versatility and its apparent common use in some centers.

Indications The largest limitation of body osteotomies is that the osteotomy has to be made through the dental alveolus and, thus, edentulous spaces are usually required. Because these osteotomies are made in front of the pterygomasseteric sling, some surgeons feel that the results are more stable and, therefore, prefer body osteotomies in the treatment of prognathism when there are already edentulous spaces. Other unusual mandibular abnormalities, such as asymmetries, may also be treated more appropriately with one of these forms of osteotomy.

With the step osteotomy the surgeon has to be concerned about the horizontal component of the "step," which often has to be made between the inferior alveolar nerve and the apices of the teeth. Sufficient room should therefore be available for this cut, unless the surgeon plans to externalize part of the inferior alveolar nerve so that the cut can be made at the level of or below the canal.

Technique An incision is made 4 to 5 mm below the level of the attached gingiva (enough tissue is left superiorly to permit later suturing) and is carried forward at this level until the cuspid, where it can be dropped down 5 mm and extended forward to the midline (Figure 56-20A). The periosteum is elevated inferiorly until the mental foramen is located and then the remainder of the periosteum is stripped to expose the area of the osteotomy. The attached gingiva is also carefully elevated in the area of the dental alveolar cut so that it can be protected during the osteotomy.

The vertical cut through the alveolus is made with either a saw or bur. A finger should be kept on the lingula to prevent the power instrument from penetrating the mucosa. When the surgical plan includes a mandibular setback, a block of bone needs to be removed to permit this movement. The distance between the parallel cuts necessary to remove the bone should be as close as possible to the planned setback, as

determined by the model surgery. The vertical cuts are taken inferiorly to the level of the planned horizontal cut, which would be at least 5 mm below the dental apices. The inferior vertical cuts are then made, again using parallel cuts as necessary for a setback of the distal fragment. Finally the horizontal cut is made, preferably by a saw, to minimize bone removal and endangerment of the apices or the inferior alveolar nerve (Figure 56-20B).

The distal segment is related to the proximal segment with an occlusal splint and fixed with maxillomandibular fixation. If the mandible is set back any distance a wedge of attached tissue over the alveolar vertical osteotomy needs to be removed to permit the setback. This wedge should be narrower than the planned movement to allow tight mucosal contact. This eliminates the need for suturing in this area, which is often difficult, if not impossible. Osseous wire fixation can be placed at the inferior border or, if a rigid fixation technique is desired, straight four-holed plates with

monocortical screws can be placed above and below the nerve. With a rigid fixation technique the maxillomandibular wires can be cut and the segment's stability and position are checked before closure of the wound. The surgical sites are thoroughly irrigated and the mucosa is then closed with a resorbable suture. Maxillomandibular fixation, if used, is maintained for 6 to 8 weeks (Figure 56-21).

Alternative Techniques There are multiple variations of body osteotomies. Generally the mucosal approaches are similar, although some surgeons prefer to make a cervical incision posterior to the mental foramen and then carry it below the attached tissue in the anterior symphyseal region. This approach unfortunately presents some difficulty in wound closure, especially if maxillomandibular fixation is chosen.

One of the most difficult variations in the surgical approach occurs when there is a need for visualization or exteriorization

of the inferior alveolar nerve, if an osteotomy is planned through the canal. The easiest method for this is similar to that described by Epker.²⁰¹

After the lateral surface of the mandible is exposed in the area of the planned osteotomies, parallel horizontal cortical cuts are made on either side of the anticipated route of the nerve. These cuts are extended beyond either side of the planned osteotomy, sufficient to permit adequate approach to the nerve, as well as to permit enough freedom of the nerve during stretching or compression that will occur with the planned segment movements. Perpendicular cuts are made just through the cortex at about 1 cm intervals (Figure 56-22). Starting with the forward cuts a thin sharp 4 mm osteotome is carefully used to start a cleavage line through the cancellous bone, preferably just below the cortex. As each individual section is broken away the medial aspect of the fragment needs to be checked to ensure that a nerve is not still attached to it. After all the small lateral cor-

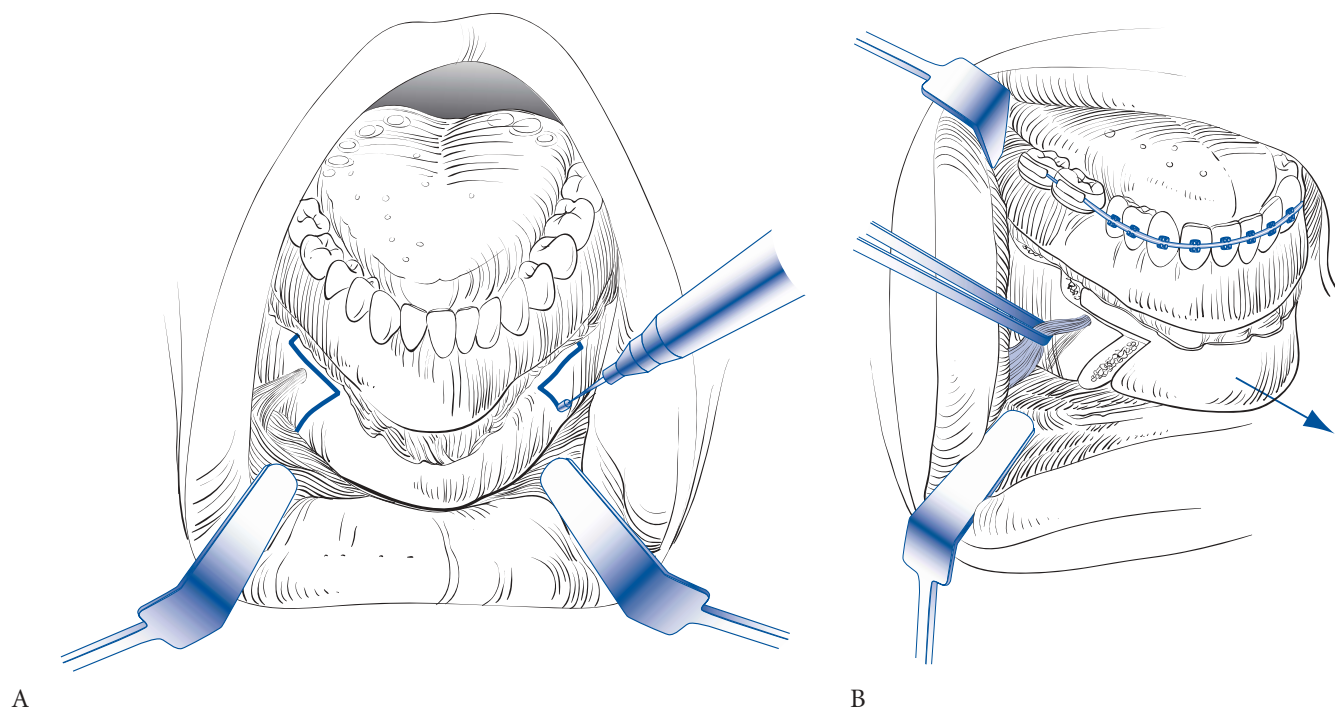


FIGURE 56-20 The step osteotomy. Adapted from Bloomquist DS. Principles of mandibular orthognathic surgery. In: Peterson LJ, Indresano AT, Marciani RD, Roser SM. Principles of oral and maxillofacial surgery. Vol 3. Philadelphia (PA): J.B. Lippincott Company; 1992. p. 1444.

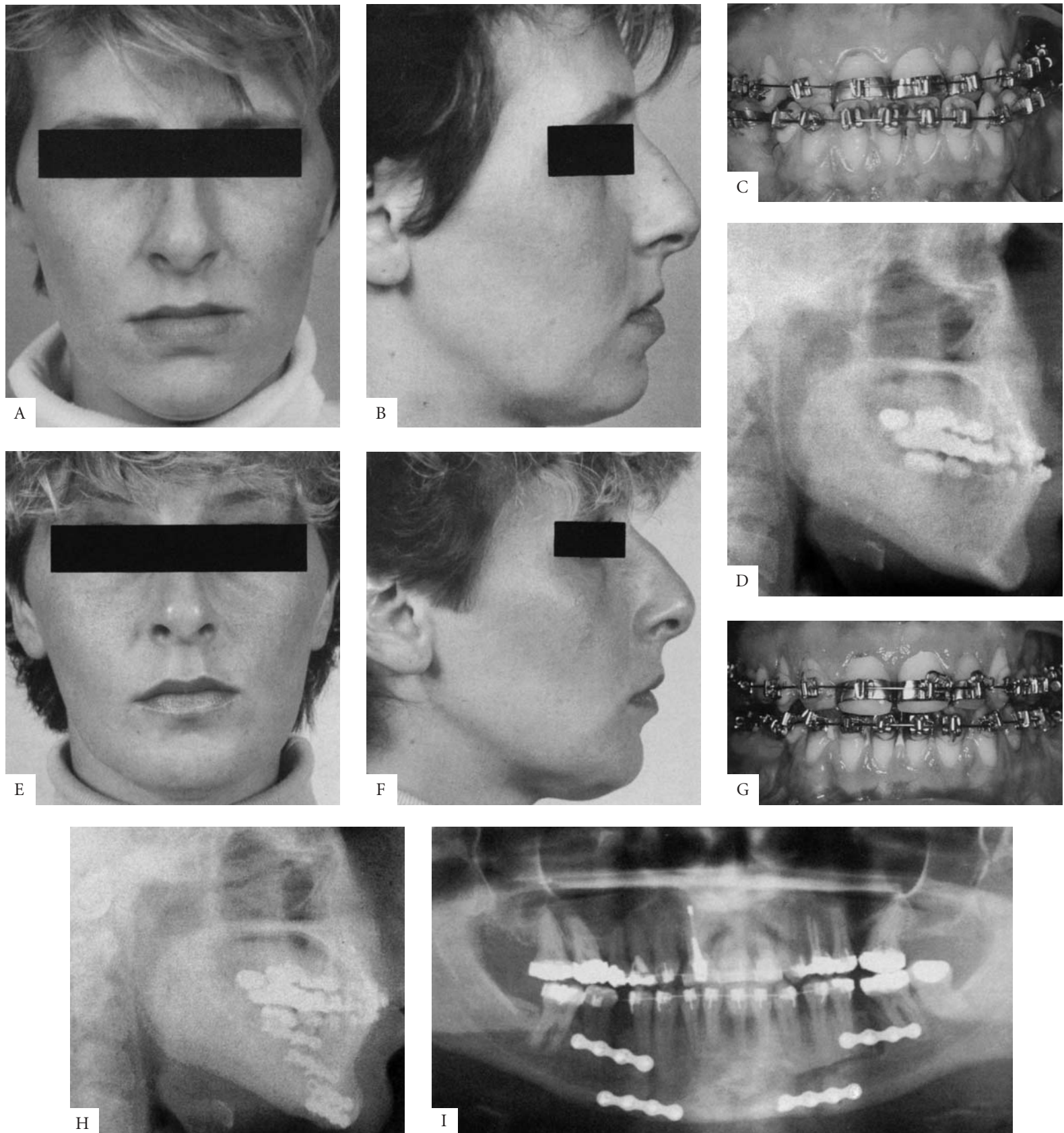


FIGURE 56-21 Patient who was treated with a step osteotomy for mandibular horizontal excess. A–D, Preoperative photographs and radiograph. E–I, Postoperative photographs and radiographs. Reproduced with permission from Bloomquist DS. Principles of mandibular orthognathic surgery. In: Peterson LJ, Indresano AT, Marciani RD, Roser SM. Principles of oral and maxillofacial surgery. Vol 3. Philadelphia (PA): J.B. Lippincott Company; 1992. p. 1446–7.

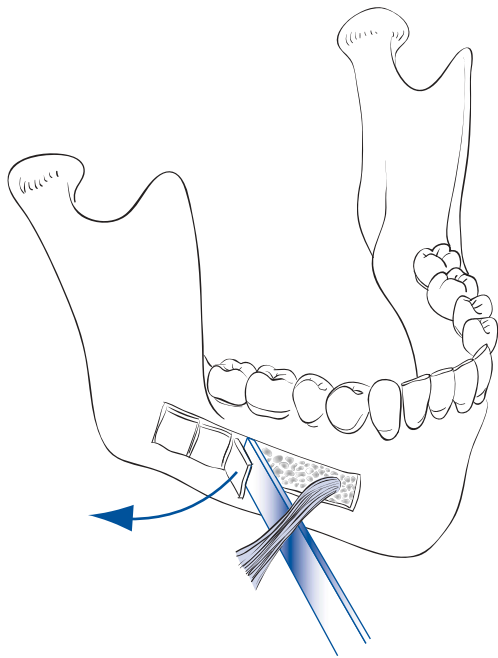


FIGURE 56-22 Decortication for exposure of the inferior alveolar nerve and vessels. Adapted from Bloomquist DS. *Principles of mandibular orthognathic surgery*. In: Peterson LJ, Indresano AT, Marciani RD, Roser SM. *Principles of oral and maxillofacial surgery*. Vol 3. Philadelphia (PA): J.B. Lippincott Company; 1992. p. 1448.

tical segments have been removed, often the nerve has been exposed and judicious use of a small surgical curette is all that is needed to remove any bone spicules over the nerve as well as carefully lift the nerve out of its canal. If cancellous bone is still covering the nerve, then a medium-sized round bur can be used to carefully remove the overlying bone. A small periosteal elevator or a surgical curette can be positioned in the lateral aspect of the canal when the nerve is exposed and the thin bur used to remove the remaining overlying bone. Following the visualization or exteriorization of the nerve the osteotomies can proceed as planned.

Although primarily used for distal fragment setback, the step osteotomy can be used for advancement. To accomplish that, a horizontal incision has to be made on the lingual side of the alveolus, posterior to the vertical alveolar bone cut. The mucoperiosteum below this cut can then be elevated to allow it to be stretched with the advance-

ment. The lateral incision is designed to permit the labial tissue to be pulled lingually, without tension, so that soft tissue closure can be done. Bone grafts are generally used in the gaps created by the advancements, especially in the alveolar area, where prostheses may later be placed.

Sagittal osteotomies of the horizontal ramus have been described with either an extraoral or intraoral approach possible.^{202,203} In the intraoral approach the lingual exposure has to be increased to make the vertical cortical cut. This generally requires that the incision on the lingual side of the teeth be brought forward, close to the midline, so that retraction may occur without endangering the surrounding soft tissue. The advantage of this type of osteotomy is that it allows the use of rigid internal fixation with bicortical screws, and generally a bone graft is not needed if the distal segment is advanced.

Complications Reports of body osteotomies in the literature include mostly case histories; hence, there are few series reporting an incidence of complications. The wide variety of techniques makes it impossible to make any definitive statements about body osteotomies. Therefore, this section will be primarily limited to the listing of the reported complications, many of which can be anticipated simply from the knowledge of the anatomy of the area.

Stability One of the primary reasons given by surgeons for using a body procedure is the stability of the technique. Sandor and colleagues looked at relapse of the step osteotomy and found it to be very stable.²⁰⁴ Most other authors have not strictly analyzed the results but claim a good long-term stability with their particular technique.^{205,206}

Neural Complications Those studies that include reports of the incidence or duration of neurosensory damage report a high recovery ratio.^{205,206} Unfortunately

these studies are of questionable value because of the inadequate testing method. It can be expected, however, that immediate postoperative sensory loss will be present after any of the body osteotomies, especially those that require visualization or exteriorization of the nerve. The incidence of devitalization of teeth on either side of the osteotomy, or of those teeth above the horizontal cut of the step osteotomy, is unknown, although it is probably similar to those reported with mandibular subapical osteotomies.

The increased potential of nonunion in body osteotomies has been discussed, but the incidence is unknown. The possibility of this occurring is probably very low if, as has been suggested, care is used in osteotomy design to ensure sufficient bone contact as well as in the provision of adequate fixation.

The possibility of periodontal defects does exist for osteotomies made close to the teeth where the surrounding soft tissue pedicle may be injured. As has been noted earlier the possibility of this occurring in midline osteotomies is low, but whether this can be related to other parts of the dental alveolus is doubtful.²⁰⁷

Subapical Osteotomies

There are essentially three types of mandibular subapical osteotomies: the anterior subapical, the posterior subapical, and the total alveolar osteotomy. Each has a place in orthognathic surgery and, therefore, the indications and techniques of each shall be described individually. Their complications are similar; accordingly they will be discussed together in one section.

Anterior Subapical Osteotomy *Indications* The subapical osteotomy has historically been popular because of its versatility, and it has been used to move the anterior mandibular teeth and alveolus in almost every conceivable direction. The biggest concern of surgeons in this procedure is the potential of damaging teeth and, therefore,

space must be present or made to permit a safe vertical cut in the dental alveolus.

Procedure If necessary, teeth are removed to permit the osteotomies or to provide space for the planned alveolar movement. The incision is started about 1 cm behind the planned vertical osteotomy and is carried forward about 4 to 5 mm below the attached tissue until reaching the cuspid, at which time it can be dropped down and carried to the midline to connect with an opposing incision. Periosteum is elevated, exposing the lateral cortex of the mandible, with care being used around the mental foramen as well as some attachments being left at the inferior border to ensure stability of the soft tissue chin. The attached tissue at the planned vertical osteotomy site needs to be elevated, and if posterior movement of the segment is anticipated, some of this tissue may have to be removed. As mentioned with the step osteotomy the width of the tissue removed should be less than the planned posterior movement to ensure adequate soft tissue contact.

The vertical osteotomies are made using parallel cuts when the posterior movement of the segment is planned. Good preoperative radiologic evaluation and planning will minimize the chance of

damage to the inferior alveolar nerve. Most anterior subapical osteotomies are designed to include the cuspids and the incisors, which generally place the vertical cuts anterior to the mental foramen. Difficulties arise if the planned osteotomy includes extraction of the first bicuspid or if the cut is planned behind this point. The importance of being able to make the horizontal cut at least 5 mm below the teeth apices cannot be overemphasized. Not only the vitality of the teeth but the whole segment is affected by the level of the horizontal cut. If parallel horizontal cuts are planned to move the anterior segment apically, the superior cut is made first. The inferior cut is then made, and the segment of bone is removed without overly manipulating the dental alveolar segment and increasing the likelihood of injuring the soft tissue pedicle (Figure 56-23A). Beveling of the cut from anterior to posteroinferior will minimize the amount of bone to be removed and increase the size of the lingual pedicle. Usually, on trying to position the mobile dental alveolar segment to the rest of the mandible, further bone interferences are found. These exist primarily on the lingual cortex of the vertical cuts and care must be used in the rotation of the mobile segment to access this cortex. If possible a

retractor should be placed between the bone and the thin lingual mucosa to minimize the soft tissue trauma.

After ensuring a good fit in the surgical splint the segment is stabilized by either wiring the splint to the teeth individually (Figure 56-23B) or by circumferential mandibular wires that can be combined with intermaxillary fixation. Osseous wires or plates with monocortical screws are rarely needed for stability but can be used if desired. Bone gaps caused by movement of the segment, especially by vertical movement necessary for the closure of an anterior open bite, should be grafted. The use of cortical bone from the symphysis, as advocated by Kole, has been popular because many patients with an anterior open bite have the long anterior face which can be improved by removal of the bone (Figure 56-23C).²⁸ The surgical site is then irrigated thoroughly and closed with resorbable sutures.

Posterior Subapical Osteotomy Indications The posterior subapical osteotomy has few indications, especially if orthodontics are available to the patient. Primarily it can be used as a correction of supereruption of posterior mandibular teeth or ankylosis of one or more posterior teeth. Abnormal buccal or lingual posi-

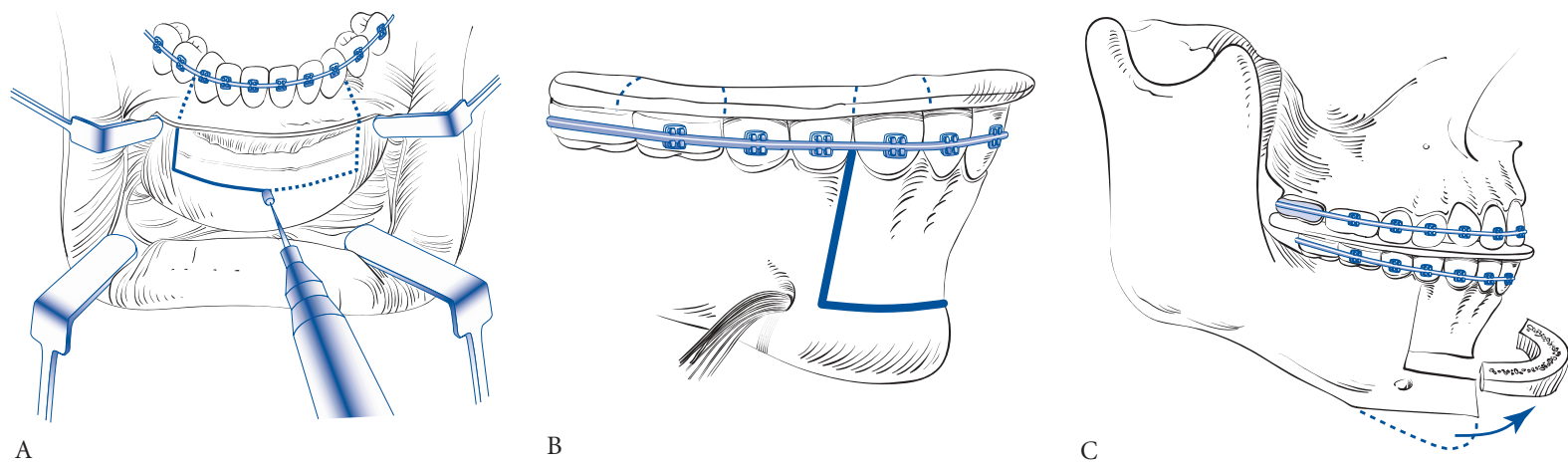


FIGURE 56-23 The anterior subapical osteotomy. A, Osteotomy. B, Occlusal splint. C, Bone graft from chin for correction of anterior open bite (Kole). Adapted from Bloomquist DS. Principles of mandibular orthognathic surgery. In: Peterson LJ, Indresano AT, Marciani RD, Roser SM. Principles of oral and maxillofacial surgery. Vol 3. Philadelphia (PA): J.B. Lippincott Company; 1992. p. 1450.

tion of these teeth can also be improved on when orthodontics is not feasible.²⁰⁸

Technique The following technique is that of Peterson, who first described this osteotomy.²⁰⁸ This procedure can be done under local anesthesia with sedation as well as with general anesthesia. An incision is started 3 to 4 mm laterally to the attached gingiva, beginning at the anterior border of the vertical ramus. This incision is made down into the bone and is carried forward to the cuspid. Periosteum is stripped superiorly and inferiorly sufficiently to expose the lateral cortex for the planned osteotomies (Figure 56-24). The osteotomy is outlined with a bur, based on the preoperative radiographic analysis of the length of the roots and the position of the nerve. The vertical cuts are made first through both cortices with a fine osteotome or thin saws. The horizontal cut is carried only through the buccal cortex, and a thick splitting osteotome is used to complete the osteotomy. Care is taken to

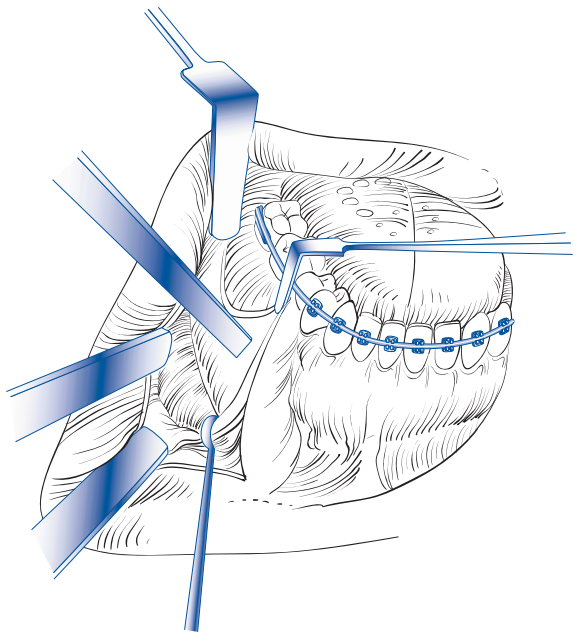


FIGURE 56-24 The posterior subapical osteotomy. Adapted from Bloomquist DS. Principles of mandibular orthognathic surgery. In: Peterson LJ, Indresano AT, Marciani RD, Roser SM. Principles of oral and maxillo-facial surgery. Vol 3. Philadelphia (PA): J.B. Lippincott Company; 1992. p. 1451.

ensure that the nerve is not caught in the mobile segment and that appropriate bone adjustments are made to permit the planned movement. The segment is positioned and stabilized with an acrylic splint and wire. Grafting is used if a bone gap remains. The mucosa is closed with a running resorbable suture.

Alternative Techniques Major modification of the foregoing technique would be appropriate if insufficient distance lay between the dental apices and the inferior alveolar nerve. In that situation the nerve can be externalized, as described previously, and a horizontal cut made through the canal. Periapical radiographs taken intraoperatively after the buccal horizontal cut will ensure that the osteotomies lie safely away from the teeth and nerve. This latter technique has been found to be useful, as a good visual angle is difficult with the posterior teeth. Also, with either of these techniques, the horizontal cut can be taken safely through the lingual cortex, which does away with the unpredictability of the lingual cortical fracture.

Total Alveolar Osteotomy

Indications The total mandibular alveolar osteotomy, first described by MacIntosh and Carlotti, has limited application but can prove valuable in mandibular dental alveolar protrusion or retrusion.²⁰⁹ It has also been advocated for the closure of anterior open bite when used with a bone graft.

Technique An incision is started on the external oblique ridge of the base of the vertical ramus. The incision is carried down to bone and extends forward 4 to 5 mm below the attached gingiva. The incision can drop lower as the canine is passed and meets the contralateral incision at the midline. The periosteum is elevated to expose the lateral cortex, with care

used around the mental nerve, as well as leaving some attachment at the inferior border of the symphysis for the soft tissue chin. The vertical cut posterior to the last molar is made first and is taken down to the level of the planned horizontal osteotomy. As with the step osteotomies the horizontal cut needs to be well placed, based on periapical radiographs. If this cut cannot be made safely between the dental apices and the inferior alveolar nerve, then the nerve needs to be exteriorized or the cut placed below the nerve (Figure 56-25A). The horizontal cut can then be placed low enough to be away from dental apices as well as allowing a good vascular pedicle to the dental alveolus. The angle of the horizontal cut can be made to facilitate the segment movement; for instance, a flat cut permits the straight advancement of the segment without changing mandibular height, at the same time maintaining a large area of bone contact.

The mobile segment is related to the maxilla with an acrylic occlusal splint and intermaxillary fixation. Osseous fixation is achieved, with the lateral cortical wires being placed in the first bicuspid area. As with correction of an anterior open bite any bone gaps created are filled with graft material. The wound is thoroughly irrigated and closed with resorbable suture.

Technique Variations Booth and colleagues suggested a variation of the total mandibular subapical osteotomy that combines the sagittal split osteotomy of the vertical ramus with the total mandibular alveolar osteotomy (Figure 56-25B).²¹⁰ This modification has a number of advantages over the original technique. First the osteotomy is made below the inferior alveolar nerve, thereby decreasing the risk of damaging the inferior alveolar nerve and the apices of the teeth, at the same time preserving much of the vascular supply to the mobile segment. Also the sagittal part of the osteotomy allows a larger bone contact area to assist in healing.

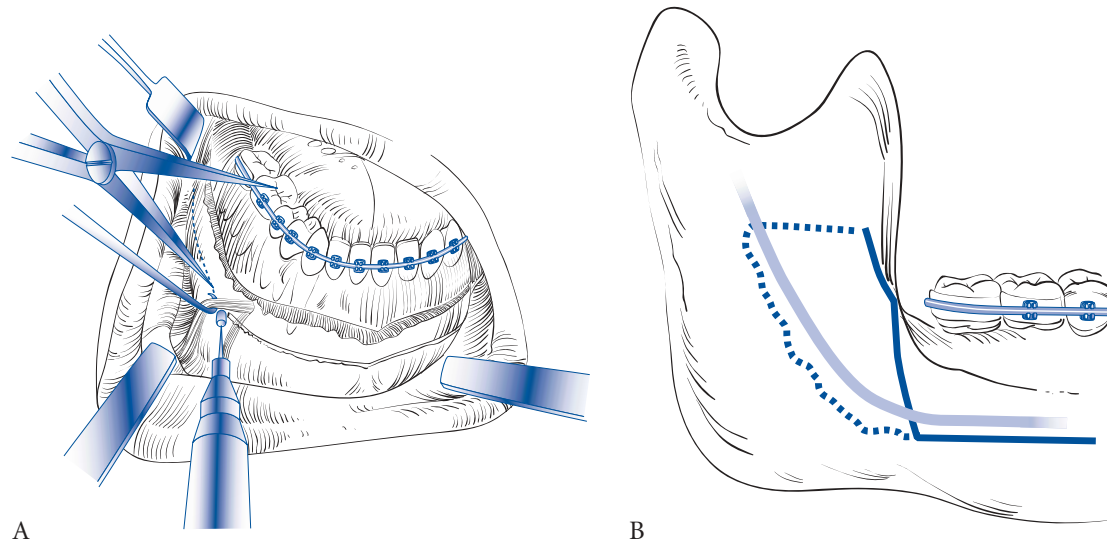


FIGURE 56-25 A and B, Variations of the total mandibular alveolar osteotomy. Adapted from Bloomquist DS. *Principles of mandibular orthognathic surgery*. In: Peterson LJ, Indresano AT, Marciani RD, Roser SM. *Principles of oral and maxillofacial surgery*. Vol 3. Philadelphia (PA): J.B. Lippincott Company; 1992. p. 1451.

The total mandibular alveolar osteotomy can also be divided into interdental segments to correct axial inclination of teeth or to close the edentulous area. These modifications are not easily done with Booth's osteotomy but can be valuable as a variation of the original procedure.

Complications The complications of all mandibular alveolar osteotomies will be considered together because of their similarities. Stability is often mentioned as one of the advantages of any of the alveolar osteotomies because of the minimal soft tissue forces generally placed on these areas. Unfortunately there have been very few studies to document this claim. Those that have been done question the stability of these segmental osteotomies. Theisen and Guernsey evaluated six patients who had anterior subapical osteotomies.²¹¹ At 1 year after surgery, an average of 1 mm of movement of incisors was noted on lateral cephalograms. In contrast Kloosterman evaluated a much larger group and found a 30% recurrence of open bite after anterior maxillary osteotomies.⁴⁸

Unlike segment stability, neurologic and vascular complications have received a lot of

attention. Most of this evaluation has been directed at pulpal changes and not at peripheral inferior alveolar sensory loss or avascular bone loss. Both of these latter problems are recognized complications of mandibular subapical osteotomies, but there are no clinical studies noting their incidence.^{28,36} Many authors report some incidence of sensory change of the lip but claim there have been no permanent problems; normal sensation returns in about 3 months.^{209,211,212}

Clinical and animal studies of the effect of mandibular osteotomies on the pulp are numerous.^{35,37,39,40} An early animal study did not note many vascular changes when a lingual vascular pedicle was maintained.³³ However, all subsequent studies have noted a significant decrease in blood flow, especially to the dental pulp.²¹³ Histologic studies of dental pulp after subapical osteotomies reveal some pulpal necrosis in most teeth.^{35,214} Whether this is of clinical importance is questionable, as there were relatively few teeth in clinical series that required endodontics or that needed to be extracted.^{47,48} It is likely that some pulpal necrosis occurs in greater numbers of teeth than are clinically obvious.²¹⁵ The only way the pulpal changes

have been assessed clinically is with "vitality testing." A change in pulpal nerve sensation obviously may not be related to a decrease in pulpal vascularity. However, the rate of recovery of sensory loss seems to give some measure of the trauma to the teeth. Early clinical studies seem to show that teeth in mandibular alveolar osteotomies fare better than their maxillary counterparts.²¹⁶ More recent and larger studies, however, have demonstrated the reverse.^{47,48} One report found that approximately 40% of the teeth in the repositioned segment remain unreactive at 1 year.⁴⁷ This high incidence of pulpal trauma was attributed to technical errors during surgeries. The incidence of teeth requiring endodontics range from 1.5 to 10%. The teeth at greatest risk for damage are those in the mobile segment next to a vertical osteotomy. The teeth immediately posterior to the vertical cut are approximately equal in risk to the teeth in the center of the mobile segment.

Periodontal problems have been briefly mentioned by authors reviewing mandibular alveolar osteotomies.^{48,211} The incidence and quantitative evaluations of soft and hard tissue loss have not been done,

although individual cases of significant interdental bone loss have been noted. Periodontal problems are seen less frequently when the vertical cuts are made in extraction sites than when the cuts are attempted between teeth without extraction.⁴⁸

Horizontal Osteotomy of the Symphysis

The horizontal osteotomy of the symphysis differs very little from that originally described by Hofer, except that the procedure is done intraorally.³² The versatility of this procedure for skeletal deformities of the chin is impressive.

Indications This osteotomy with minor variations can be used to improve almost every conceivable skeletal abnormality of the chin. The technique is primarily used only for esthetic reasons. Therefore, its use depends on the patient's concern about appearance of this area of the face. Often the surgeon has to bring to the patient's attention the need for a genioplasty when other facial osteotomies are planned because of the impact that these osteotomies will have on chin prominence. The indications, there-

fore, are often made apparent by comprehensive treatment planning by the surgeon.

Technique The horizontal osteotomy of the symphysis is often done in conjunction with other major osteotomies and, thus, is frequently accomplished under a general anesthetic. However, it can be performed as a separate procedure on an outpatient basis under sedation and local anesthesia.

The mucosal incision is made on the labial side of the vestibule at about 1 cm above its depth and extends posteriorly to the first bicuspid. This incision is carried just below the mucosa to the depth of the vestibule and then angled directly to the labial cortex through the mentalis muscle (Figure 56-26A). Periosteum is elevated inferiorly to a point just below the intended level of osteotomy. Laterally the periosteum is elevated to the mental foramen and then extended posteroinferiorly to the inferior mandibular border. The extent of the posterior cortical exposure is generally determined by the position of the mental foramen and the vertical height of the mandible in this area. In many cases this means that it will end in about the first molar area.

No attempt is generally made to expose the mental nerve by releasing the soft tissue around it, primarily because the nerve can be small and friable, making inadvertent severing possible. The periosteal elevation behind the foramen is minimized to just that needed for placement of a narrow retractor and the saw blade or bur.

It is helpful at this point to inscribe a vertical mark (or marks) into the bone across the planned osteotomy site so that the transverse position of the inferior fragment can be more easily oriented after the osteotomy. The osteotomy cut is then made with a reciprocating saw (Figure 56-26B). The length and angle of the horizontal cut can have profound effects on postsurgical results. Further osteotomies or osteoplasties are made after mobilization of the lower segment. The stabilization of the segment in its new position can be made with cortical wires, circummandibular wires, or plates and screws. The wound is irrigated and closed in two layers (muscle and mucosa) with resorbable suture. Tape placed across the lip and chin is maintained for 24 to 48 hours to minimize hematoma formation as well as to help support the suture lines. Patients should be instructed not to pull their lip to minimize dehiscence of the wound.

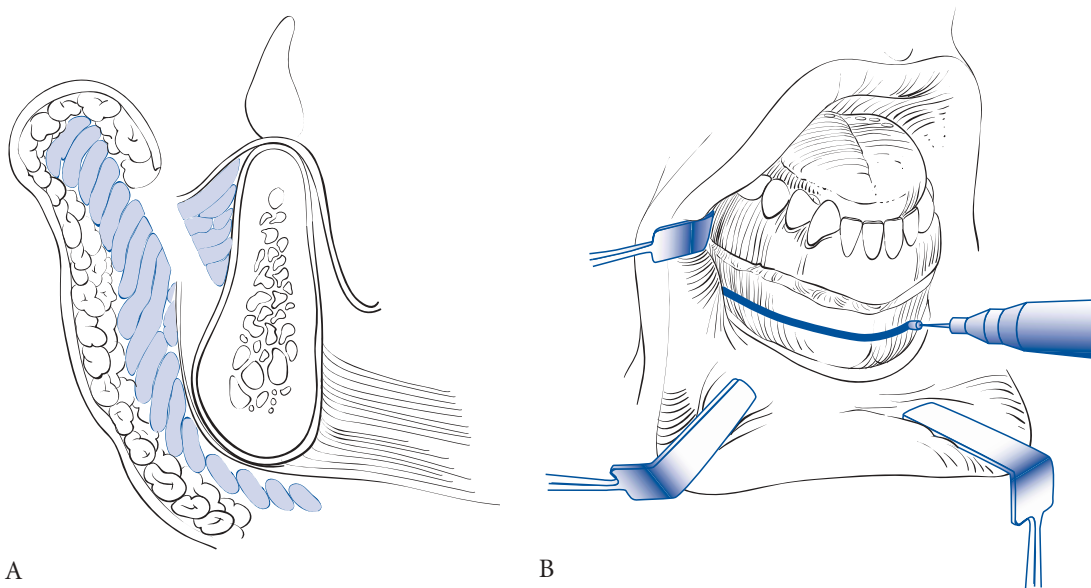


FIGURE 56-26 The surgical approach for the horizontal osteotomy. A, Soft tissue approach. B, Osteotomy. Adapted from Bloomquist DS. *Principles of mandibular orthognathic surgery*. In: Peterson LJ, Indresano AT, Marciani RD, Roser SM. *Principles of oral and maxillofacial surgery*. Vol 3. Philadelphia (PA): J.B. Lippincott Company; 1992. p. 1453.

Alternative Techniques The primary technique differences for the horizontal osteotomy center on the osteotomy design, and these design differences depend on the symphyseal deformity that is being corrected. Obwegeser concentrated on correction of horizontal deficiency of the chin when he described the basic procedure (Figure 56-27A).¹⁰⁰ He suggested that a midsagittal osteotomy of the inferior fragment may be helpful in preventing the prominence of the posterior ends of the fragment, relative to the body of the mandible, as the fragment is advanced (Figure 56-27B). A narrower chin point can also be obtained by taking a wedge of bone out from the lingual aspect of this cut (Figure 56-27C). The length of

the cut posteriorly has important esthetic consequences. Most notably larger advancements require a larger cut to the first or second molar region. This permits a smoother line to the inferior border of the mandible. Overlapping an advanced inferior fragment on the lateral cortex of the symphysis allows both an increase in horizontal prominence as well as a decrease in the anterior mandibular

vertical height (Figure 56-27D).²¹⁷ Larger advancements of the inferior fragment can be obtained by double or triple osteotomies, rotation of the fragment combined with a graft at the posterior gap, and bone graft between the symphysis and the fragment (Figure 56-27E–G).^{218,219}

Horizontal chin excess is traditionally treated by moving the inferior fragment

posteriorly.²²⁰ Depending on the angle of the cut this will also increase facial height. Sometimes when this is done it is necessary to remove the posterior ends of the inferior fragment to prevent unsightly protrusions from the inferior border of the mandible (Figure 56-27H). When the patient has normal facial height, the plane of the osteotomy should parallel the Frankfort

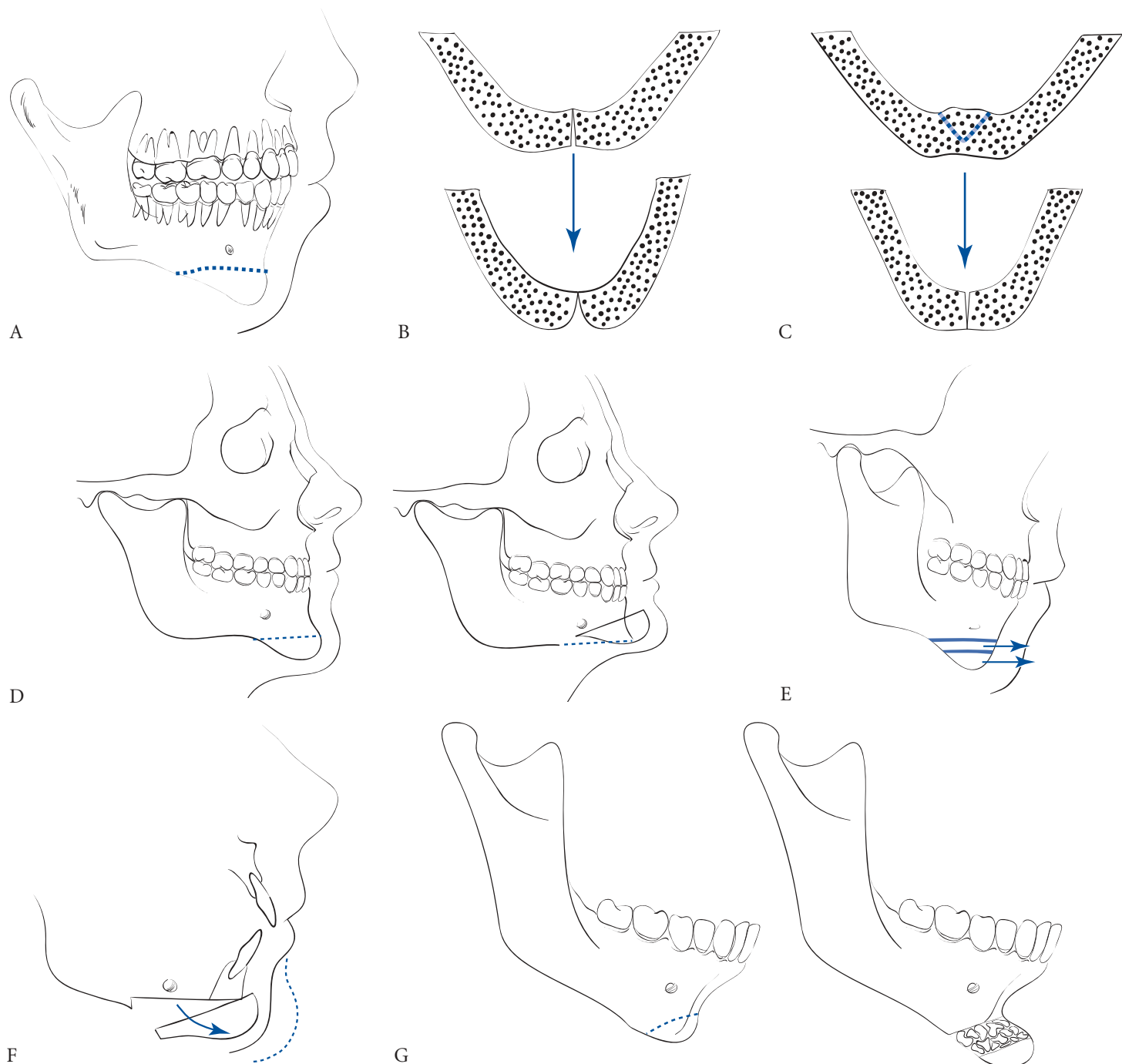


FIGURE 56-27 A–G, Various forms of the horizontal osteotomy. (CONTINUED ON NEXT PAGE)

horizontal or natural head position, if at all possible. The anterior chin projection can be reduced by using parallel or V-shaped osteotomies cut in a more vertical plane, with the middle segment removed (Figure 56-27I).

Vertical symphyseal excess can be reduced by removing the middle segment of bone when the plane of two parallel osteotomies is more horizontal

(Figure 56-27J). These cuts, however, do not always need to be parallel and in fact should be designed to fit the particular structural problem. This design also permits the correction of a mild horizontal deficiency that is combined with a mild vertical excess (Figure 56-27K). This skeletal problem can also be corrected by making a single osteotomy more vertical and moving the segment anteriorly and

forward (Figure 56-27L). Vertical symphyseal deficiency can be handled only by some type of interpositional material, with either bone grafts or implants (Figure 56-27M). Even the use of plates alone to hold the fragment in a lower position has been suggested (Figures 56-28 and 56-29).

The use of wires, screws, or plate and screws for the fixation of the inferior frag-

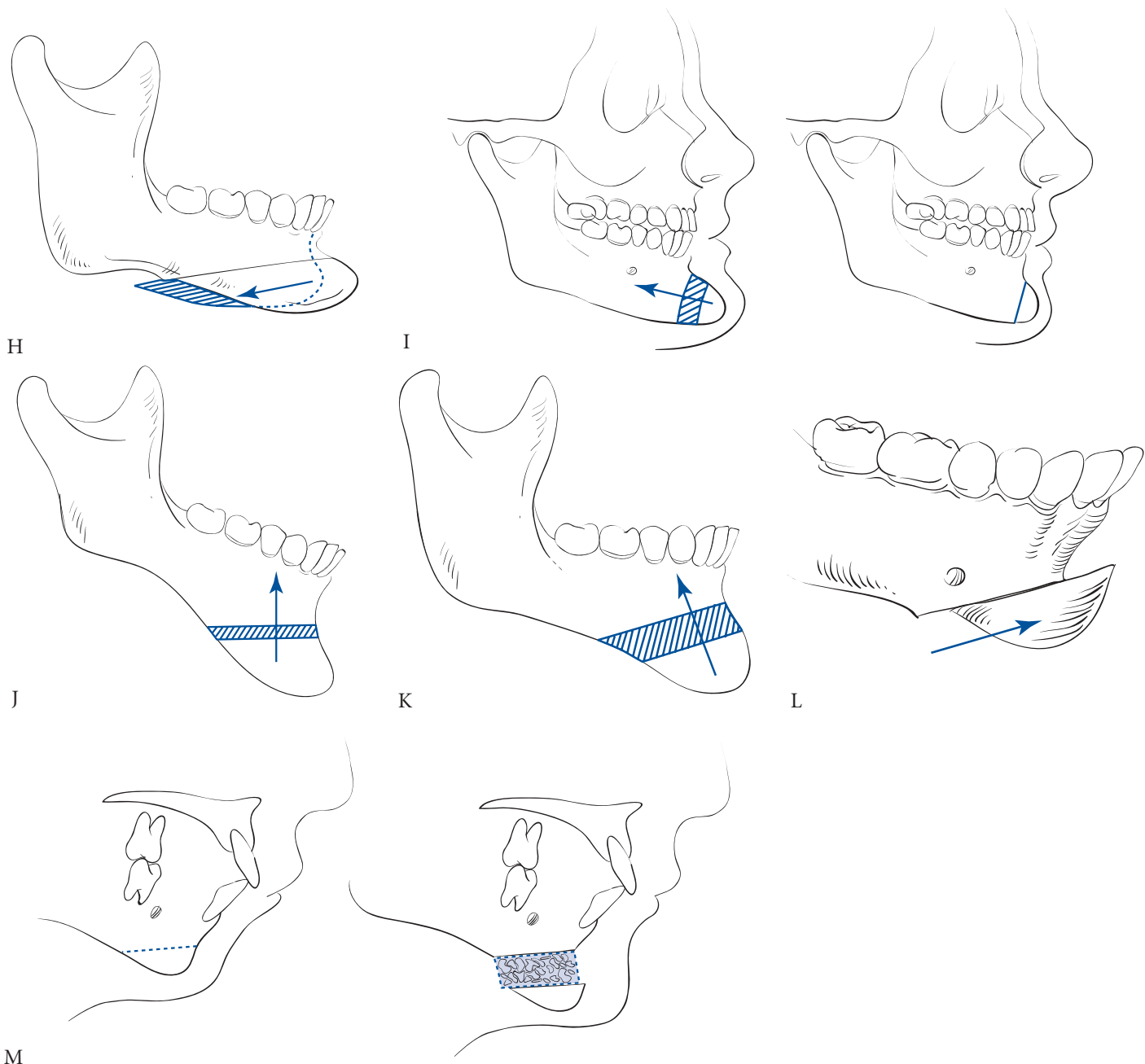


FIGURE 56-27 (CONTINUED) H–M, Various forms of the horizontal osteotomy. Adapted from Bloomquist DS. *Principles of mandibular orthognathic surgery*. In: Peterson LJ, Indresano AT, Marciani RD, Roser SM. *Principles of oral and maxillofacial surgery*. Vol 3. Philadelphia (PA): J.B. Lippincott Company; 1992. p. 1454–5.

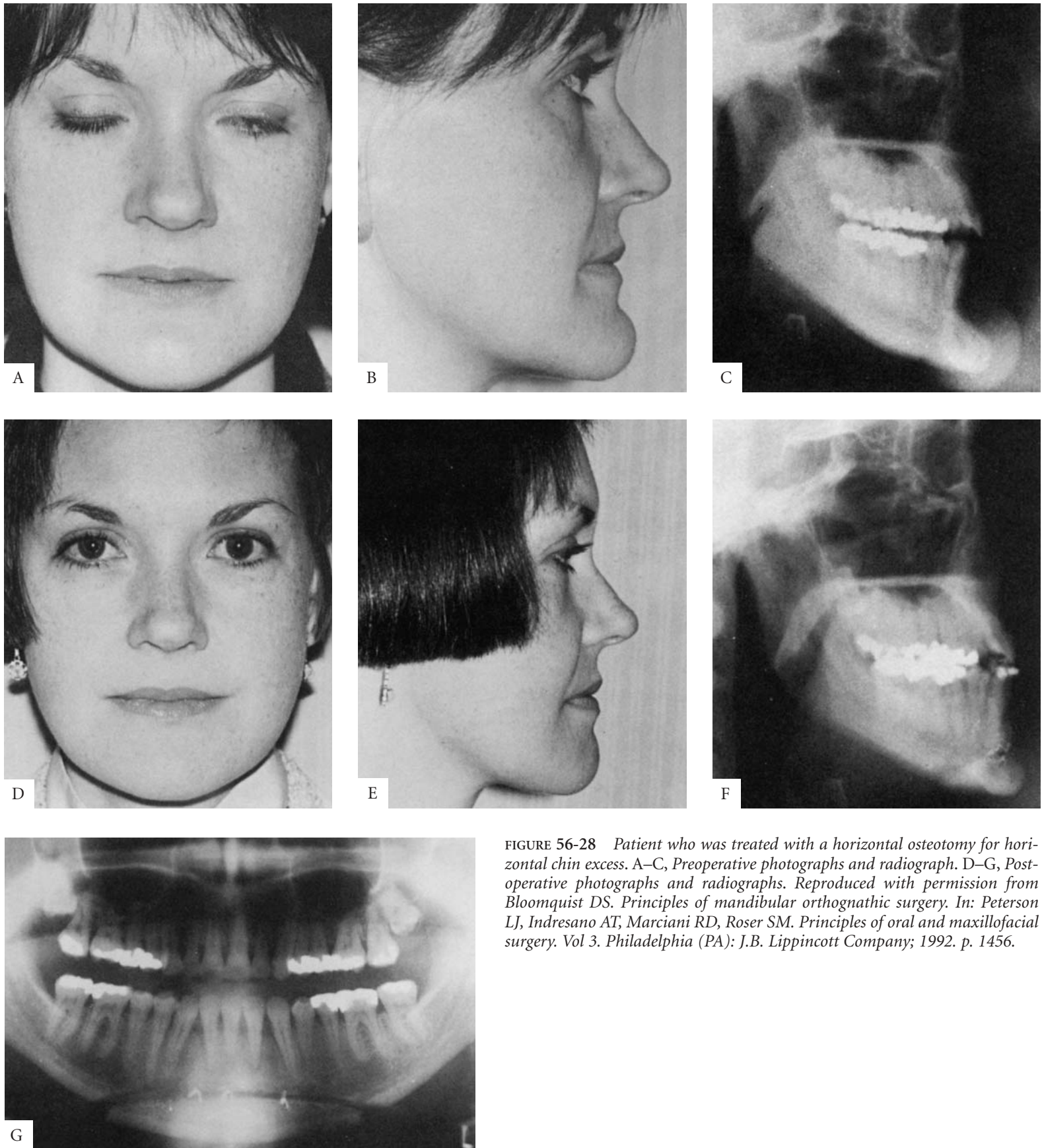


FIGURE 56-28 Patient who was treated with a horizontal osteotomy for horizontal chin excess. A–C, Preoperative photographs and radiograph. D–G, Postoperative photographs and radiographs. Reproduced with permission from Bloomquist DS. Principles of mandibular orthognathic surgery. In: Peterson LJ, Indresano AT, Marciani RD, Roser SM. Principles of oral and maxillofacial surgery. Vol 3. Philadelphia (PA): J.B. Lippincott Company; 1992. p. 1456.

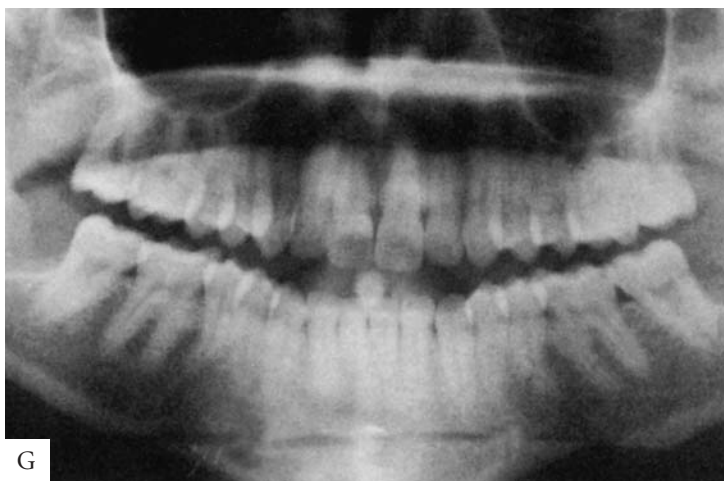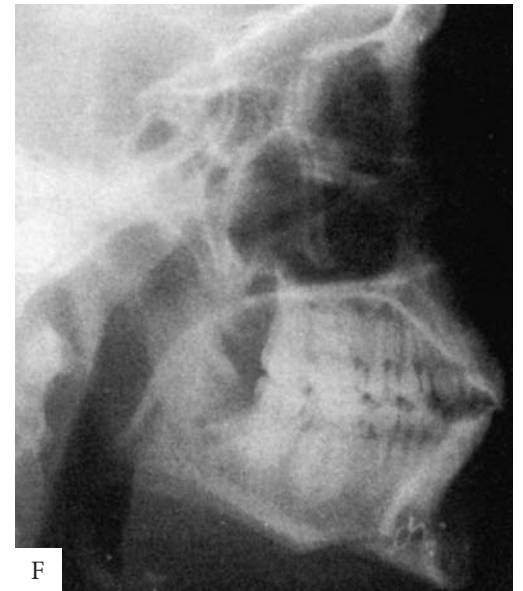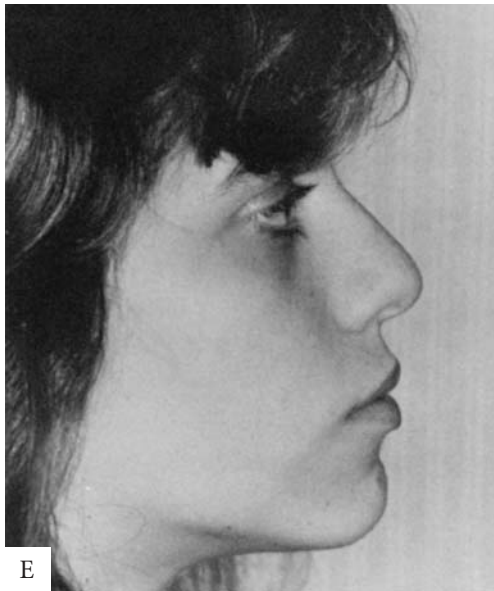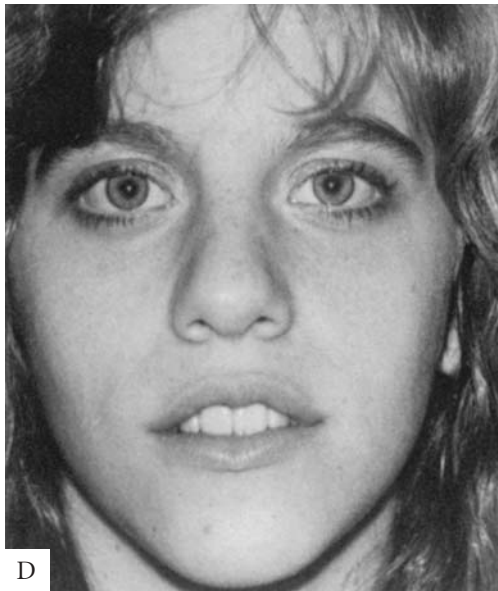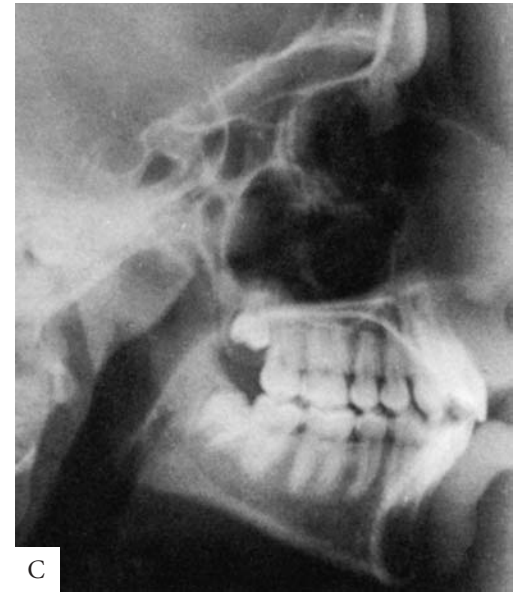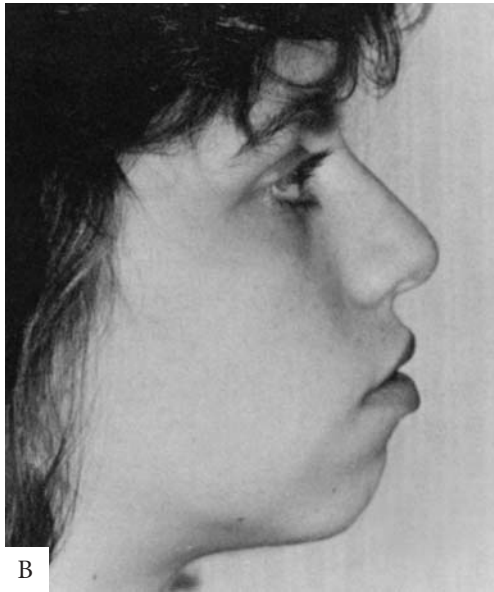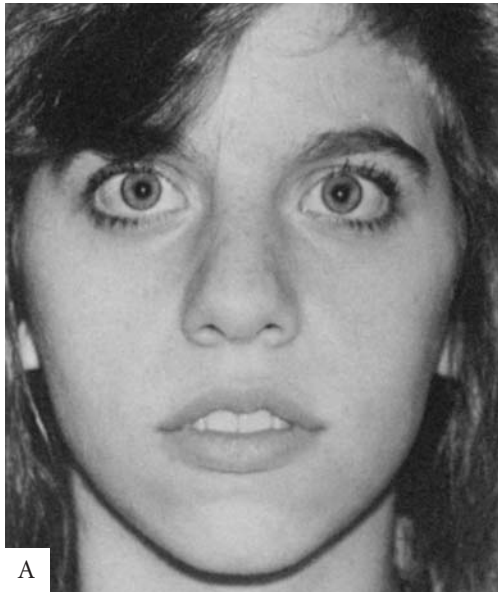


FIGURE 56-29 Patient was treated with a horizontal osteotomy for horizontal chin deficiency. A–C, Preoperative photographs and radiograph. D–G, Postoperative photographs and radiographs. Reproduced with permission from Bloomquist DS. Principles of mandibular orthognathic surgery. In: Peterson LJ, Indresano AT, Marciani RD, Roser SM. Principles of oral and maxillofacial surgery. Vol 3. Philadelphia (PA): J.B. Lippincott Company; 1992. p. 1457.

ment is still common. Precious and colleagues evaluated the changes that occur as the bone remodels following a horizontal osteotomy.²²¹ They recommended that the fixation take into account these changes, especially the positioning of rigid fixation such as plates. Plates along the superior border of the inferior fragment may become noticeable to the patient as the bone remodels.

Complications The incidence of postoperative problems after a horizontal osteotomy of the symphysis is rarely mentioned. This may be because genioplasties are frequently done in conjunction with other osteotomies, which makes the attribution of various complications difficult. Most of the literature concerning genioplasties concentrates on the soft tissue response to the skeletal movement.

Reports of relapse after genioplasties are sparse and conflicting. Some clinicians report that there is essentially no relapse after a genioplasty, with a rounding of the sharp corners of the advanced segment occurring with time.^{222–225} These studies, however, follow patients for only up to 1 year. Two other studies with follow-up of at least 1 year do seem to show some instability of the skeletal advancement.^{226,227} The mean relapse with a genial advancement varies widely (2.6 to 30%). The one seemingly consistent finding is that much of the skeletal relapse occurs within the first year. As with stability studies of other osteotomies there exists a large variation in individual relapse, and no attempt has been made to identify the causes. However, there are probably many factors involved, including the magnitude of advancement. There have been no studies in the stability of this surgery in correction of other symphyseal deformities. Martinez and colleagues found that regeneration of the cortical thickness of the symphysis was significantly better in patients younger than 15 years of age.²²⁴ They suggested that this may be beneficial if

further surgical advancement of the chin is to be considered.

The predictable possibility of sensory loss from this procedure has not been adequately evaluated. In one study it was noted that postsurgical sensory loss was found in all patients but was temporary, with normal sensation returning within 12 months.²²⁸ Another study reported a 3.5% long-term incidence of sensory deficits following genioplasties. Other complications such as bone loss and infections have been reported, but small samples preclude any definitive statements on incidence.²²⁹

References

- Hullihen SP. Case of elongation of the under jaw and distortion of the face and neck, caused by a burn, successfully treated. *Am J Dent Sci* 1849;9:157.
- Angle EH. Double resection of the lower maxilla. *Dent Cosmos* 1889;40:635.
- Blair VP. Report of a case of double resection for the correction of protrusion of the mandible. *Dent Cosmos* 1906;48:817.
- Blair VP. Operations on the jaw bone and face. *Surg Gynecol Obstet* 1907;4:67.
- Ernst F. Progenie. In: Kirshhner M, Nordmann O, editors. *Die Chirurgie*. IV. Berlin, Germany: Urban & Schwarzenberg; 1927. p. 802.
- Limberg A. Treatment of open-bite by means of plastic oblique osteotomy of the ascending rami of the mandible.. *Dent Cosmos* 1925;67:1191.
- Kostecka P. A contribution to the surgical treatment of open-bite. *Int J Orthod* 1934; 28:1082.
- Moose SM. Surgical correction of mandibular prognathism by intra-oral subcondylar osteotomy. *Br J Oral Surg* 1964;39:172.
- Thoma KH. Surgical treatment of the deformities of the jaws. *Am J Orthod* 1946;32:333.
- Robinson M. Prognathism corrected by open vertical subcondylotomy. *J Oral Surg* 1958; 16:215.
- Thoma KH. Oblique osteotomy of mandibular ramus — special technique for correction of various types of facial defects and malocclusion. *Oral Surg* 1961;14 Suppl 1:23.
- Caldwell JB, Letterman GS. Vertical osteotomy in the mandibular rami for correction of prognathism. *J Oral Surg* 1954;12:185.
- Moose SM. Surgical correction of mandibular prognathism by intraoral subcondylar osteotomy. *J Oral Surg Anesth Hosp D Serv* 1964;22:197.
- Winstanley RP. Subcondylar osteotomy of the mandible and the intraoral approach. *Br J Oral Surg* 1968;6:134.
- Hebert JM, Kent JN, Hinds EC. Correction of prognathism by an intraoral vertical subcondylar osteotomy. *J Oral Surg* 1970;28:651.
- Wassmund M. *Frakturen und luxationen des gesichtsschadels*. 1927.
- Pichler H, Trauner R. *Lehrbuch der mund- und kieferchirurgie*. Wien, Vienna;1948.
- Caldwell JB, Hayward JR, Lister RL. Correction of mandibular retrognathia by vertical L osteotomy: a new technique. *J Oral Surg* 1968;26:259.
- Hayes PA. Correction of retrognathia by modified “C” osteotomy of the ramus and sagittal osteotomy of the mandibular body. *Oral Surg* 1973;31:682.
- Fox GL, Tilson HB. Mandibular retrognathia: a review of the literature and selected cases. *J Oral Surg* 1976;34:53.
- Obwegeser H, Trauner R. Zur operationstechnik bei der progenie und anderen unterkieferanomalien. *Dtsch Zahn Mund Kieferheilkd* 1955;23:H1–2.
- Hensel GC. The surgical correction of mandibular protrusion, retraction, and fractures of the ascending rami. *Int J Orthodont Oral Surg* 1937;23:814.
- Schuchardt K. Ein beitrag zur chirurgischen kieferorthopadie unter berucksichtigung ihrer bedeutung fur die behandlung angeborener and erworbener kieferdeformaten Uei soldaten. *Dtsch Zahn Mund Kieferheilkd* 1942;9:73.
- DalPont G. Retromolar osteotomy for the correction of prognathism. *J Oral Surg Anesth Hosp D Serv* 1961;19:42.
- Hunsuck EE. Modified intraoral sagittal splitting technique for correction of mandibular prognathism. *J Oral Surg* 1968;26:250.
- Spiessl B. Ostoesynthese abei sagittaler osteotomie nach Obwegeser/dal Pont. *Fortschr Kiefer Gesichtschir* 1974;18:145.
- Hofer O. Die vertikale osteotomie zur verlangerung des einseitig verkurzten aufsteigenden unterkieferastes. *Atschr Stomatol* 1936;34:826.
- Kole H. Surgical operations on the alveolar ridge to correct occlusal abnormalities. *Oral Surg Oral Med Oral Pathol* 1959;12:277.
- Kent JN, Hinds EC. Management of dental facial deformities by anterior alveolar surgery. *J Oral Surg* 1971;29:13.
- MacIntosh RB. Total mandibular alveolar osteotomy: encouraging experiences with an infrequently indicated procedure. *J Maxillofac Surg* 1974;2:210.
- Von Eiselberg A. Uber plastik bei ektropium

- des unterkeifers (progenie). *Klin Wochenschr* 1906;19:1505.
32. Hofer O. Operation der prognathie und mikrogenie. *Dtsch Zahn Mund Kieferheilkd* 1942;9:121.
 33. Bell WH, Levy BM. Revascularization and bone healing after anterior mandibular osteotomy. *J Oral Surg* 1970;28:196.
 34. Hellem S, Ostrup LT. Normal and retrograde blood supply to the body of the mandible in the dog. *Int J Oral Surg* 1981;10:31.
 35. Zisser G, Gattinger B. Histologic investigation of pulpal changes following maxillary and mandibular alveolar osteotomies in the dog. *J Oral Surg* 1982;40:322.
 36. Epker BN. Vascular considerations in orthognathic surgery. *Oral Surg* 1984;57:467.
 37. Boc T, Peterson L. Revascularization after posterior mandibular alveolar osteotomy. *J Oral Surg* 1981;39:177.
 38. Bradley JC. Age changes in the vascular supply of the mandible. *Br Dent J* 1972;132:142.
 39. Bell WH, Kennedy JW III. Biological basis for vertical ramus osteotomies — a study of bone healing and revascularization in adult rhesus monkeys. *J Oral Surg* 1976;34:215.
 40. Grammer FC, Meyer MW, Richter KJ. A radioisotope study of the vascular response to sagittal split osteotomy of the mandibular ramus. *J Oral Surg* 1974;32:578.
 41. Bell WH, Schendel SA. Biologic basis for modification of the sagittal ramus split operation. *J Oral Surg* 1977;35:362.
 42. Path MG, Nelson RL, Morgan PR, Meyer MW. Blood flow changes after sagittal split of the mandibular ramus. *J Oral Surg* 1977;35:98.
 43. Grammer FC, Carpenter AM. A quantitative histologic study of tissue responses to ramal sagittal splitting procedures. *J Oral Surg* 1979;37:482.
 44. Bell WH. Revascularization and bone healing after anterior maxillary osteotomy: a study using adult rhesus monkeys. *J Oral Surg* 1969;27:249.
 45. Walter JM, Gregg JM. Analysis of postsurgical neurologic alteration in the trigeminal nerve. *J Oral Surg* 1979;37:410.
 46. Hutchinson D, MacGregor AJ. Tooth survival following various methods of sub-apical osteotomy. *Int J Oral Surg* 1972;1:181.
 47. Pepersack WJ. Tooth vitality after alveolar segmental osteotomy. *J Maxillofac Surg* 1973;1:85.
 48. Kloosterman J. Kole's osteotomy: a follow-up study. *J Maxillofac Surg* 1985;13:59.
 49. Ridell A, Soremark R, Lundberg M. Positional changes of the mandible after surgical correction of mandibular protrusion by horizontal osteotomy of the rami. *Acta Odontol Scand* 1971;29:123.
 50. Tornes K, Wisth PJ. Stability after vertical subcondylar ramus osteotomy for correction of mandibular prognathism. *Int J Oral Maxillofac Surg* 1988;17:242.
 51. Astrand P, Ridell A. Positional changes of the mandible and upper and lower anterior teeth after oblique sliding osteotomy of the mandibular rami. *Scand J Plast Reconstr Surg* 1973;7:120.
 52. Poulton DR, Ware WH. Surgical-orthodontic treatment of severe mandibular retrusion. *Am J Orthod* 1971;58:244.
 53. Poulton DR, Ware WH. Surgical-orthodontic treatment of severe mandibular retrusion (part II). *Am J Orthod* 1973;63:237.
 54. Kohn MW. Analysis of relapse after mandibular advancement surgery. *J Oral Surg* 1978;36:676.
 55. Lake SL, McNeill RNA, Little RM, West RA. Surgical mandibular advancement: a cephalometric analysis of treatment response. *Am J Orthod* 1981;80:376.
 56. Smith GC, Moloney FB, West RA. Mandibular advancement surgery: a study of the lower border wiring technique for osteosynthesis. *Oral Surg* 1985;60:461.
 57. Komiri E, Aigase K, Sugisaki M, Tanabe H. Skeletal fixation versus skeletal relapse. *Am J Orthod Dentofac Orthop* 1987;92:412.
 58. Will LA, Joondeph DR, Hold TH, West RA. Condylar position following mandibular advancement: its relationship to relapse. *J Oral Maxillofac Surg* 1984;42:578.
 59. Epker BN. Modifications in the sagittal osteotomy of the mandible. *J Oral Surg* 1977;35:157.
 60. Komiri E, Aigase K, Sugisaki M. Cause of early skeletal relapse after mandibular setback. *Am J Orthod Dentofac Orthop* 1989;95:29.
 61. Franco JE, Van Sickels JE, Thrash WJ. Factors contributing to relapse in rigidly fixed mandibular setbacks. *J Oral Maxillofac Surg* 1989;47:451.
 62. Yellich GM, McNamara JA, Ungerleider JC. Muscular and mandibular adaptation after lengthening, detachment, and reattachment of the masseter muscle. *J Oral Surg* 1981;39:656.
 63. Ellis E III, Carlson DS. Stability two years after mandibular advancement with and without suprahyoid myotomy: an experimental study. *J Oral Maxillofac Surg* 1983;41:426.
 64. Schendel SA, Epker BN. Results after mandibular advancement surgery: an analysis of 87 cases. *J Oral Surg* 1980;38:265.
 65. Bhatia SN, Yant B, Behbehani I, Harris M. Nature of relapse after surgical mandibular advancement. *Br J Orthod* 1985;12:58.
 66. Reynolds ST, Ellis E III, Carlson DS. Adaptation of the suprahyoid muscle complex to large mandibular advancements. *J Oral Maxillofac Surg* 1988;46:1077.
 67. Ellis E III, Reynolds S, Carlson DS. Stability of the mandible following advancement: a comparison of three postsurgical fixation techniques. *Am J Orthod Dentofac Orthop* 1988;94:38.
 68. Ellis E III, Gallo JW. Relapse following mandibular advancement with dental plus skeletal maxillomandibular fixation. *J Oral Maxillofac Surg* 1986;44:509.
 69. Robinson M, Lytle JJ. Micrognathism corrected by vertical osteotomies of the rami without bone grafts. *Oral Surg Oral Med Oral Pathol* 1962;15:641.
 70. Hall HD, McKenna SJ. Further refinement and evaluation of intraoral vertical ramus osteotomy. *J Oral Maxillofac Surg* 1987;45:684.
 71. Bereni B. Open subcondylar osteotomy in the treatment of mandibular deformities. *Int J Oral Surg* 1973;2:81.
 72. Reitzik M, Griffiths RR, Mirels H. Surgical anatomy of the ascending ramus of the mandible. *Br J Oral Surg* 1976;14:150.
 73. Hall HD, Chase DC, Payor LG. Evaluation and refinement of the intraoral vertical subcondylar osteotomy. *J Oral Surg* 1975;33:333.
 74. Massey GB, Chase DC, Thomas PM, Kohn MW. Intraoral oblique osteotomy of the mandibular ramus. *J Oral Surg* 1974;32:755.
 75. Tornes K. Osteotomy length and postoperative stability in vertical subcondylar ramus osteotomy. *Acta Odontol Stand* 1989;47:81.
 76. Sund G, Eckerdal O, Astrand P. Changes in the temporomandibular joint after oblique osteotomy of the mandibular rami: a longitudinal radiological study. *J Maxillofac Surg* 1983;11:81.
 77. Ritza M, Wenzel A, Williams S. Changes in condyle position after bilateral vertical ramus osteotomy with and without osteosynthesis. *Am J Orthod Dentofac Orthop* 1989;96:507.
 78. Sund G, Eckerdal O, Astrand P. Skeletal remodeling in the temporomandibular joint after oblique sliding osteotomy of the mandibular rami. *Int J Oral Maxillofac Surg* 1986;15:233.
 79. Proffit WR, Phillips C, Denn C IV, Turvey TA. Stability after surgical-orthodontic correction of skeletal class III malocclusion. I: Mandibular setback. *Int J Adult Orthodont Orthognath Surg* 1991;6:7.
 80. Nystrom E, Rosenquist J, Astrand P, Nordin T. Intraoral or extraoral approach in oblique sliding osteotomy of the mandibular ramus. *J Maxillofac Surg* 1984;12:277.
 81. Goldstein A. Appraisal of results of surgical

- correction of class III malocclusions. *Angle Orthod* 1974;17(3-4):59.
82. Poulton DR, Taylor RC, Ware WH. Cephalometric x-ray evaluation of the vertical osteotomy correction of mandibular prognathism. *Oral Surg Oral Med Oral Pathol* 1963;16:807.
 83. Morrill LR, Baumrind S, Miller D. Surgical correction of mandibular prognathism. *Am J Orthod* 1974;65:503.
 84. Stella JP, Astrand P, Epker BN. Patterns and etiology of relapse after correction of class III open bite via subcondylar ramus osteotomy. *Int J Adult Orthod Orthogn Surg* 1986;1:191.
 85. Kahnberg KE, Widmark G. Surgical treatment of the open bite deformity: surgical correction of combined mandibular prognathism and open bite by oblique sliding osteotomy of the mandibular rami. *Int J Oral Maxillofac Surg* 1988;17:45.
 86. Zaytoun HS, Phillips C, Terry BC. Long-term neurosensory deficits following transoral vertical ramus and sagittal split osteotomies for mandibular prognathism. *J Oral Maxillofac Surg* 1986;44:193.
 87. Wang JH, Waite DE. Vertical osteotomy vs sagittal split osteotomy of the mandibular ramus: comparison of operative and postoperative factors. *J Oral Surg* 1975;33:596.
 88. Hollender L, Ridell A. Radiography of the temporomandibular joint after oblique sliding osteotomy of the mandibular rami. *Scand J Dent Res* 1974;82:466.
 89. Egyedi P, Houwing M, Juten E. The oblique subcondylar osteotomy: report of results of 100 cases. *J Oral Surg* 1981;39:871.
 90. Bell WH, Yamaguchi Y, Poor MR. Treatment of temporomandibular joint dysfunction by intraoral vertical ramus osteotomy. *Int J Adult Orthod Orthogn Surg* 1990;5:9.
 91. Upton LG, Sullivan SM. Modified condylectomies for management of mandibular prognathism and temporomandibular joint internal derangement. *Clin Orthod* 1990; 24:697.
 92. Hu J, Wang D, Zou S. Effects of mandibular setback on the temporomandibular joint: a comparison of oblique and sagittal split ramus osteotomy. 2000;58:375.
 93. Farrell CD, Kent JN. Evaluation of the surgical stability of 20 cases of inverted-L and C osteotomies. *J Oral Surg* 1977;3:239.
 94. Reitzik M. Mandibular advancement surgery: stability following a modified fixation technique. *J Oral Surg* 1980;38:893.
 95. Hawkinson RT. Retrognathia correction by means of an arcing osteotomy in the ascending ramus. *J Prosthet Dent* 1968; 20:77.
 96. Reitzik M, Barer PC, Wainwright WM, Lim B. The surgical treatment of skeletal anterior open-bite deformities with rigid internal fixation in the mandible. *Am J Orthod Dentofac Orthop* 1990;97:52.
 97. Barer PC, Wallen TR, McNeill RW, Reitzik M. Stability of mandibular advancement osteotomy using rigid internal fixation. *Am J Orthod Dentofac Orthop* 1987;92:403.
 98. Greebe RB, Tuinzing DR. Mandibular advancement procedures: predictable stability and relapse. *Oral Surg* 1984;57:13.
 99. Dattilo DJ, Braun TW, Sotereanos GC. The inverted L osteotomy for treatment of skeletal open-bite deformities. *J Oral Maxillofac Surg* 1985;43:440.
 100. Obwegeser H. The surgical correction of mandibular prognathism and retrognathia with consideration of genioplasty. *Oral Surg* 1957;10:681.
 101. Jeter TS, Van Sickels JE, Dolwick MR. Modified techniques for internal fixation of sagittal ramus osteotomies. *J Oral Maxillofac Surg* 1984;42:270.
 102. Sandor GKB, Stoelinga PJW, Tideman H, Leenen RJ. The role of the intraosseous osteosynthesis wire in sagittal split osteotomies for mandibular advancement. *J Oral Maxillofac Surg* 1984;42:231.
 103. Isaacson RJ, Kopytov OS, Bevis RR, Waite DE. Movement of the proximal and distal segments after mandibular ramus osteotomies. *J Oral Surg* 1978;36:263.
 104. Obwegeser H. The indications for surgical correction of mandibular deformity by the sagittal splitting technique. *Br J Oral Surg* 1962;1:157.
 105. Booth DF. Control of the proximal segment by lower border wiring in the sagittal split osteotomy. *J Maxillofac Surg* 1981;9:126.
 106. Kundert M, Hadjiangelou O. Condylar displacement after sagittal splitting of the mandibular rami: a short term radiographic study. *J Maxillofac Surg* 1980;8:278.
 107. Spitzer W, Rettinger C, Sitzman F. Computerized tomography examination for the detection of positional changes in the temporomandibular joint after ramus osteotomies with screw fixation. *J Maxillofac Surg* 1984;12:139.
 108. Watzke IM, Tucker MR, Turvey TA. Lag screw versus position screw techniques for rigid internal fixation of sagittal osteotomies: a comparison of stability. *Int J Adult Orthod Orthogn Surg* 1991;6:19.
 109. Bloomqvist JE, Isaksson S. Skeletal stability after mandibular advancement: a comparison of two rigid internal fixation techniques. *J Oral Maxillofac Surg* 1994;52:1133.
 110. Bloomqvist JE, Ahlborg G, Isaksson S, Svartz K. A comparison of skeletal stability after mandibular advancement and use of two rigid internal fixation techniques. *J Oral Maxillofac Surg* 1997;55:568.
 111. Fujioka M, Fujii T, Hirano A. Comparative study of mandibular stability after sagittal split osteotomies: bicortical versus monocortical osteosynthesis. *Cleft Palate Craniofac J* 2000;37:551.
 112. Suuronen R, Laine P, Pohjonen T, Lindqvist C. Sagittal ramus osteotomies fixed with biodegradable screws: a preliminary report. *J Oral Maxillofac Surg* 1994;52:715.
 113. Harada K, Enomoto S. Stability after surgical correction of mandibular prognathism using the sagittal split ramus osteotomy and fixation with poly-L-lactic acid (PLLA) screws. *J Oral Maxillofac Surg* 1997;55:464.
 114. Ferretti C, Reyneke JP. Mandibular sagittal split osteotomies fixed with biodegradable or titanium screws: a prospective, comparative study of postoperative stability. *Oral Surg Oral Med Oral Pathol Oral Radiol Endod* 2002;93:534.
 115. Kallela I, Laine P, Suuronen R, et al. Skeletal stability following mandibular advancement and rigid fixation with polylactide biodegradable screws. *Int J Oral Maxillofac Surg* 1998;27:3.
 116. Turvey TA, Bell RB, Tejera TJ, Proffit WR. The use of self-reinforced biodegradable bone plates and screws in orthognathic surgery. *J Oral Maxillofac Surg* 2002;60:59.
 117. O'Ryan F, Epker BN. Deliberate surgical control of mandibular growth: 1. A biomechanical theory. *Oral Surg* 1982;53:2.
 118. Killiany DM, Johnston LE Jr. Surgical control of mandibular growth: test of a recent biomechanical hypothesis. *Oral Surg* 1986;62:500.
 119. Huang CS, Ross RB. Surgical advancement of the retrognathic mandible in growing children. *Am J Orthod* 1982;82:89.
 120. Bell WH. Augmentation of the nasomaxillary and nasolabial regions. *Oral Surg Oral Med Oral Pathol* 1976;41:691.
 121. Alexander C, Bloomqvist D, Wallen T. Stability of mandibular constriction with a symphyseal osteotomy. *Am J Orthod Dentofac Orthop* 1993;103:15.
 122. McNeill RW, Hooley JR, Sundberg RJ. Skeletal relapse during intermaxillary fixation. *J Oral Surg* 1973;31:212.
 123. Van Sickels JE. A comparative study of bicortical screws and suspension wires versus bicortical screws in large mandibular advancements. *J Oral Maxillofac Surg* 1991;49:1293.
 124. Mobarak KA, Espeland L, Rogstad O, Lyberg T.

- Mandibular advancement surgery in high-angle and low-angle class II patients: different long-term skeletal responses. *Am J Orthod Dentofac Orthop* 2001;119:368.
125. Schmoker R, Speissl B, Gensheimer T. Functionally stable osteosynthesis and simulography in sagittal osteotomy of the ascending ramus: a comparative clinical study. *Schweiz Monatsschr Zahnheilkd* 1976;86:582.
 126. Van Sickels JE, Flanary CM. Stability associated with mandibular advancement treated by rigid osseous fixation. *J Oral Maxillofac Surg* 1985;43:338.
 127. Van Sickels JE, Larsen AJ, Thrash WJ. Relapse after rigid fixation of mandibular advancement. *J Oral Maxillofac Surg* 1986;44:698.
 128. Van Sickels JE, Larsen AJ, Thrash WJ. A retrospective study of relapse in rigidly fixated sagittal split osteotomies: contributing factors. *Am J Orthod Dentofac Orthop* 1988;93:413.
 129. Caskey RT, Turpin DL, Bloomquist DS. Stability of mandibular lengthening using bicortical screw fixation. *Am J Orthod Dentofac Orthop* 1989;96:320.
 130. Knaup CA, Wallen TW, Bloomquist DS. Linear and rotational changes in large mandibular advancements using three or four fixation screws. *Int J Adult Orthod Orthogn Surg* 1993;8:245.
 131. Douma E, Kufnec MM, Moshiri F. A comparative study of stability after mandibular advancement surgery. *Am J Orthod Dentofac Orthop* 1991;100:141.
 132. Mommaerts MY. Lag screw versus wire osteosynthesis in mandibular advancement. *Int J Adult Orthod Orthogn Surg* 1991;6:153.
 133. Moenning JE, Bussard DA, Lapp TH, Garrison BT. A comparison of relapse in bilateral sagittal split osteotomies for mandibular advancement: rigid internal fixation (screws) versus inferior border wiring with anterior skeletal fixation. *Int J Adult Orthod Orthogn Surg* 1990;5:175.
 134. Berger JL, Pangrazio-Kulbersh V, Bacchus SN, Kasczynski R. Stability of bilateral sagittal split ramus osteotomy: rigid fixation versus transosseous wiring. *Am J Orthod Dentofac Orthop* 2000;118:397.
 135. Dolce C, Hatch JP, Van Sickels JE, Rugh JD. Rigid versus wire fixation for mandibular advancement: skeletal and dental changes after 5 years. *Am J Orthod Dentofac Orthop* 2002;121:610.
 136. Watzke IM, Turvey TA, Phillips C, Proffit WR. Stability of mandibular advancement after sagittal osteotomy with screw or wire fixation: a comparative study. *J Oral Maxillofac Surg* 1990;48:101.
 137. Rubens BC, Stoelinga PJW, Blijdorp PA, et al. Skeletal stability following sagittal split osteotomy using monocortical miniplate internal fixation. *Int J Oral Maxillofac Surg* 1985;17:371.
 138. Lee J, Piecuch JE. The sagittal ramus osteotomy. Stability of fixation with internal miniplates. *Int J Oral Maxillofac Surg* 1992;21:326.
 139. Abeloos J, Le Clercq C, Neyt L. Skeletal stability following miniplate fixation after bilateral sagittal split osteotomy for mandibular advancement. *J Oral Maxillofac Surg* 1993;51:366.
 140. Scheerlinck JP, Stoelinga PJ, Blijdorp PA, et al. Sagittal split advancement osteotomies stabilized with miniplate fixation. A 2–5 year follow-up. *Int J Oral Maxillofac Surg* 1994;23:127.
 141. Bloomquist D. The use of a single lag screw in the mandibular sagittal osteotomy. Presentation at the AAO-ASOMFS Conference on Surgical Orthodontics; 1983; New Orleans, LA.
 142. Kole H. Results, experience, and problems in the operative treatment of anomalies with reverse overbite (mandibular protrusion). *Oral Surg* 1965;19:427.
 143. Behrman SJ. Complications of sagittal osteotomy of the mandibular ramus. *J Oral Surg* 1972;30:554.
 144. Westermark SA, Bystedt H, von Konow L. Inferior alveolar nerve function after sagittal split osteotomy of the mandible: correlation with degree of intraoperative nerve encounter and other variables in 496 operations. *Br J Oral Maxillofac Surg* 1998;36:429.
 145. Ylikontiola L, Kinnunen J, Laukkanen P, Oikarinen K. Prediction of recovery from neurosensory deficit after bilateral sagittal split osteotomy. *Oral Surg Oral Med Oral Pathol Oral Radiol Endod* 2000;90:275.
 146. MacIntosh RB. Experience with the sagittal osteotomy of the mandibular ramus: a 13-year review. *J Maxillofac Surg* 1981;8:151.
 147. Van Sickels JE, Hatch JP, Dolce C, et al. Effects of age, amount of advancement, and genioplasty on neurosensory disturbance after a bilateral sagittal split osteotomy. *J Oral Maxillofac Surg* 2002;60:1012.
 148. White RP, Peters PB, Costich ER, Page HL Jr. Evaluation of sagittal split-ramus osteotomy in 17 patients. *J Oral Surg* 1969;27:851.
 149. Guernsey LH, DeChamplain RW. Sequelae and complications of the intraoral sagittal osteotomy in the mandibular rami. *Oral Surg* 1971;32:176.
 150. Fiamminghi L, Aversa C. Lesions of the inferior alveolar nerve in sagittal osteotomy of the ramus: experimental study. *J Maxillofac Surg* 1979;7:125.
 151. Brusati R, Fiamminghi L, Sesenna E, Gazzotti A. Functional disturbance of the inferior alveolar nerve after sagittal osteotomy of the mandibular ramus: operating technique for prevention. *J Maxillofac Surg* 1981;9:123.
 152. Yoshida T, Nagamine T, Kobayashi T, et al. Impairment of the inferior alveolar nerve after sagittal split osteotomy. *J Craniomaxillofac Surg* 1989;17:271.
 153. Yamamoto R, Nakamura A, Ohno K, Michi KI. Relationship of the mandibular canal to the lateral cortex of the mandibular ramus as a factor in the development of neurosensory disturbance after bilateral sagittal split osteotomy. *J Oral Maxillofac Surg* 2002;60:490.
 154. Freihofer HP Jr. Probleme der behandlung der progenie durch sagittler spaltung der aufsteigenden unterkieferaste. *Schweiz Monatsschr Zahnheilkd* 1976;86:679.
 155. Wolford LM, Bennett MA, Rafferty CG. Modification of the mandibular ramus sagittal split osteotomy. *Oral Surg Oral Med Oral Pathol* 1987;64:146.
 156. Converse JM. Surgical treatment of facial injuries. In: Kazanjian VH, Converse JM, editors. *Surgical treatment of facial injuries*. Baltimore (MD): Williams & Wilkins; 1974.
 157. Paulis GW, Steinhauser EW. A comparative study of wire osteosynthesis versus bone screws in the treatment of mandibular prognathism. *Oral Surg* 1982;54:2.
 158. Nishioka GJ, Zysset ME, Van Sickels JE. Neurosensory disturbance with rigid fixation of the bilateral sagittal split osteotomy. *J Oral Maxillofac Surg* 1987;45:20.
 159. Lemke RR, Rugh JD, Van Sickels J, Bays RA, Clark GM. Neurosensory differences after wire and rigid fixation in patients with mandibular advancement. *J Oral Maxillofac Surg* 2000;58:1354.
 160. Westermark A, Englesson L, Bongehiellm U. Neurosensory function after sagittal split osteotomy of the mandible: a comparison between subjective evaluation and objective assessment. *Int J Adult Orthod Orthogn Surg* 1999;14:268.
 161. Chen N, Neal CE, Lingenbrink P, et al. Neurosensory changes following orthognathic surgery. *Int J Adult Orthod Orthogn Surg* 1999;14:259.
 162. Nakagawa K, Ueki K, Takasuka S, et al. Somatosensory-evoked potential to evaluate the trigeminal nerve after sagittal split osteotomy. *Oral Surg Oral Med Oral Pathol Oral Radiol Endod* 2001;91:146.
 163. Jacks SC, Zuniga JR, Turvey TA, Schalit C. A retrospective analysis of lingual nerve sensory changes after mandibular bilateral

- sagittal split osteotomy. *J Oral Maxillofac Surg* 1998;56:700.
164. Zuniga Jr, Chen N, Phillips CL. Chemosensory and somatosensory regeneration after lingual nerve repair in humans. *J Oral Maxillofac Surg* 1997;55:2.
 165. Gent JF, Shafer DM, Frank ME. The effect of orthognathic surgery on taste function on the palate and tongue. *J Oral Maxillofac Surg* 2003;61:766.
 166. Freihofer HPM Jr, Petresevic D. Late results after advancing the mandible by sagittal splitting of the rami. *J Maxillofac Surg* 1975;3:250.
 167. O’Ryan F, Epker BN. Surgical orthodontics and the temporomandibular joint II: mandibular advancement via modified sagittal split ramus osteotomies. *Am J Orthod* 1983;83:418.
 168. Buckley MJ, Tulloch JFC, White RP, Tucker MR. Complications of orthognathic surgery: a comparison between wire fixation and rigid internal fixation. *Int J Adult Orthod Orthogn Surg* 1989;4:69.
 169. Hackney FL, Van Sickels JE, Nummikoski PV. Condylar displacement and temporomandibular joint dysfunction following bilateral sagittal split osteotomy and rigid fixation. *J Oral Maxillofac Surg* 1989;47:223.
 170. Martis CS. Complications after mandibular sagittal split osteotomy. *J Oral Maxillofac Surg* 1984;42:101.
 171. Karabouta I, Martis C. The TMJ dysfunction syndrome before and after sagittal split osteotomy of the rami. *J Maxillofac Surg* 1985;13:185.
 172. Kerstens HCJ, Tuinzing DB, van der Kwast WAM. Temporomandibular joint symptoms in orthognathic surgery. *J Craniomaxillofac Surg* 1989;17:215.
 173. Pruitt JW, Moenning JE, Lapp TH, Bussard DA. Treatment of painful temporomandibular joint dysfunction with the sagittal split ramus osteotomy. *J Oral Maxillofac Surg* 2002;60:996.
 174. Flynn B, Brown DT, Lapp TH, et al. A comparative study of temporomandibular symptoms following mandibular advancement by bilateral sagittal split osteotomies: rigid versus nonrigid fixation. *Oral Surg Oral Med Oral Pathol* 1990;70:372.
 175. Feinerman DM, Picuch JF. Long-term effects of orthognathic surgery on the temporomandibular joint: comparison of rigid and nonrigid fixation methods. *Int J Oral Maxillofac Surg* 1995;24:268.
 176. Wolford LM, Reiche-Fischel U, Mehra P. Changes in temporomandibular joint dysfunction after orthognathic surgery. *J Oral Maxillofac Surg* 2003;61:655.
 177. Lühr HG. The significance of condylar position using rigid fixation in orthognathic surgery. *Clin Plast Surg* 1989;16:147.
 178. Harris MD, Van Sickels JE, Alder M. Factors influencing condylar position after the bilateral sagittal split osteotomy fixed with bicortical screws. *J Oral Maxillofac Surg* 1999;57:650.
 179. Van Sickels JE, Tiner BD, Keeling SD, et al. Condylar position with rigid fixation versus wire osteosynthesis of a sagittal split advancement. *J Oral Maxillofac Surg* 1999;57:31.
 180. Renzi G, Becelli R, Di Paolo C, Iannetti G. Indications to the use of condylar repositioning devices in the surgical treatment of dental-skeletal class III. *J Oral Maxillofac Surg* 2003;61:304.
 181. Alder ME, Deahl ST, Matteson SR, et al. Short-term changes of condylar position after sagittal split osteotomy for mandibular advancement. *Oral Surg Oral Med Oral Pathol Oral Radiol Endod* 1999;87:159.
 182. Rebellato J, Lindauer SJ, Sheats RD, Isaacson RJ. Condylar positional changes after mandibular advancement surgery with rigid internal fixation. *Am J Orthod Dentofac Orthop* 1999;116:93.
 183. Gaggli A, Schultes G, Santler G, et al. Clinical and magnetic resonance findings in the temporomandibular joints of patients before and after orthognathic surgery. *Br J Oral Maxillofac Surg* 1999;37:41.
 184. Ueki K, Marukawa K, Nakagawa K, Yamamoto E. Condylar and temporomandibular joint disc positions after mandibular osteotomy for prognathism. *J Oral Maxillofac Surg* 2002;60:1424.
 185. Stacy GC. Recovery of oral opening following sagittal ramus osteotomy for mandibular prognathism. *J Oral Maxillofac Surg* 1987;45:487.
 186. Storum KA, Bell WH. The effect of physical rehabilitation on mandibular function after ramus osteotomies. *J Oral Maxillofac Surg* 1986;44:94.
 187. Aragon SB, Van Sickels JE. Mandibular range of motion with rigid/non-rigid fixation. *Oral Surg Oral Med Oral Pathol* 1987;63:408.
 188. Nishimura A, Sakurada S, Iwase M, Nagumo M. Positional changes in the mandibular condyle and amount of mouth opening after sagittal split ramus osteotomy with rigid or nonrigid osteosynthesis. *J Oral Maxillofac Surg* 1997;55:672.
 189. Phillips RM, Bell WH. Atrophy of mandibular condyles after sagittal ramus split osteotomy: report of case. *J Oral Surg* 1978;36:45.
 190. Cutbirth M, Van Sickels JE, Thrash WJ. Condylar resorption after bicortical screw fixation of mandibular advancement. *J Oral Maxillofac Surg* 1998;56:178.
 191. Hoppenreijns TJ, Stoelinga PJ, Grace KL, Robben CM. Long-term evaluation of patients with progressive condylar resorption following orthognathic surgery. *Int J Oral Maxillofac Surg* 1999;28:411.
 192. Lanigan DT, Hey J, West RA. Hemorrhage following mandibular osteotomies: a report of 21 cases. *J Oral Maxillofac Surg* 1991;49:713.
 193. Tucker MR, Ochs MW. Use of rigid internal fixation for management of intraoperative complications of mandibular sagittal split osteotomy. *Int J Adult Orthod Orthogn Surg* 1988;2:71.
 194. Precious DS, Lung KE, Rynn BR, Goodday RH. Presence of impacted teeth as a determining factor of unfavorable splits in 1256 sagittal-split osteotomies. *Oral Surg Oral Med Oral Pathol Oral Radiol Endod* 1998;85:362.
 195. Mehra P, Castro V, Freitas RZ, Wolford LM. Complications of the mandibular sagittal split ramus osteotomy associated with the presence or absence of third molars. *J Oral Maxillofac Surg* 2001;59:854.
 196. Reyneke JP, Tsakiris P, Becker P. Age as a factor in the complication rate after removal of unerupted/impacted third molars at the time of mandibular sagittal split osteotomy. *J Oral Maxillofac Surg* 2002;60:654.
 197. Riley RW, Powell NB, Guillemineault C, Ware W. Obstructive sleep apnea syndrome following surgery for mandibular prognathism. *J Oral Maxillofac Surg* 1987;45:450.
 198. Kawamata A, Fujishita M, Arijii Y, Arijii E. Three-dimensional computed tomographic evaluation of morphologic airway changes after mandibular setback osteotomy for prognathism. *Oral Surg Oral Med Oral Pathol Oral Radiol Endod* 2000;89:278.
 199. Bouwman JPB, Husak A, Putnam GD, et al. Screw fixation following bilateral sagittal ramus osteotomy for mandibular advancement: complications in 700 consecutive cases. *Br J Oral Maxillofac Surg* 1995;33:231.
 200. Acebal-Bianco F, Vuylsteke PL, Mommaerts MY, De Clercq CA. Perioperative complications in corrective facial orthopedic surgery: a 5-year retrospective study. *J Oral Maxillofac Surg* 2000;58:754.
 201. Epker BN. Dentofacial deformities. In: *Integrated orthodontic and surgical correction*. St Louis (MO): C.V. Mosby; 1986.
 202. Beke AL, Yahner VB. Surgical correction of overbite and overjet with sagittal osteotomy of the mandibular horizontal ramus: report of case. *J Oral Surg* 1969;27:358.

203. Bloomquist DS. Mandibular body sagittal osteotomy in the correction of malunited edentulous mandibular fractures. *J Maxillofac Surg* 1982;10:18.
204. Sandor GK, Stoelinga PJ, Tideman H. Reappraisal of the mandibular step osteotomy. *J Oral Maxillofac Surg* 1982;40:78.
205. Keller EE, Hill AJ Jr, Sather AH. Orthognathic surgery: review of mandibular body procedures. *Mayo Clin Proc* 1976;51:117.
206. Nakajima T, Kajikawa Y, Ueda K, Hanada K. Sliding osteotomy in the mandibular body for correction of prognathism. *J Oral Surg* 1978;36:361.
207. Kavanaugh SH. Maxillary midline split surgery [dissertation]. Department of Orthodontics, University of Washington; 1985.
208. Peterson LJ. Posterior mandibular segmental alveolar osteotomy. *J Oral Surg* 1978;36:454.
209. MacIntosh RB, Carlotti AE. Total mandibular alveolar osteotomy in the management of skeletal (infantile) apertognathia. *J Oral Surg* 1975;33:921.
210. Booth DF, Dietz V, Gianelly AA. Correction of class III malocclusion by combined sagittal ramus and subapical body osteotomy. *J Oral Surg* 1976;34:630.
211. Theisen FC, Guernsey LH. Postoperative sequelae after anterior segmental osteotomies. *Oral Surg Oral Med Oral Pathol* 1976;41:139.
212. Pangrazio-Kulbersh V, MacIntosh RB. Total mandibular alveolar osteotomy: an alternative choice to other surgical procedures. *Am J Orthod* 1985;87:319.
213. Meyer MW, Cavanaugh GD. Blood flow changes after orthognathic surgery: maxillary and mandibular subapical osteotomy. *J Oral Surg* 1976;34:495.
214. Banks P. Pulp changes after anterior mandibular subapical osteotomy in a primate model. *J Maxillofac Surg* 1977;5:39.
215. Scheideman GB, Kawamura H, Finn RA, Bell WH. Wound healing after anterior and posterior subapical osteotomy. *J Oral Maxillofac Surg* 1985;43:408.
216. Johnson JV, Hinds EC. Evaluation of teeth vitality after subapical osteotomy. *J Oral Surg* 1969;27:256.
217. Converse JM, Wood-Smith D. Horizontal osteotomy of the mandible. *Plast Reconstr Surg* 1964;34:464.
218. Neuner O. Correction of mandibular deformities. *Oral Surg Oral Med Oral Pathol* 1973;36:779.
219. Fitzpatrick B. Reconstruction of the chin in cosmetic surgery (genioplasty). *Oral Surg* 1975;39:522.
220. Hinds EC, Kent JN. Genioplasty: the versatility of horizontal osteotomy. *J Oral Surg* 1969;27:690.
221. Precious DS, Armstrong JE, Morais D. Anatomic placement of fixation devices in genioplasty. *Oral Surg Oral Med Oral Pathol* 1992;73:2.
222. Scheideman GB, Legan HL, Bell WH. Soft tissue changes with combined mandibular setback and advancement genioplasty. *J Oral Surg* 1981;39:505.
223. Gallagher DM, Bell WH, Storum KA. Soft tissue changes associated with advancement genioplasty performed concomitantly with superior repositioning of the maxilla. *J Oral Maxillofac Surg* 1984;42:238.
224. Martinez JT, Turvey TA, Proffitt WR. Osseous remodeling after inferior border osteotomy for chin augmentation: an indication for early surgery. *J Oral Maxillofac Surg* 1999;57:1175.
225. Talebzadeh N, Pogrel MA. Long-term hard and soft tissue relapse rate after genioplasty. *Oral Surg Oral Med Oral Pathol Oral Radiol Endod* 2001;91:153.
226. Fitzpatrick BN. Genioplasty with reference to resorption and the hinge sliding osteotomy. *Int J Oral Surg* 1974;3:247.
227. McDonnell JP, McNeill RW, West RA. Advancement genioplasty: a retrospective cephalometric analysis of osseous and soft tissue changes. *J Oral Surg* 1977;35:640.
228. Hohl TH, Epker BN. Microgenia: a study of treatment results, with surgical recommendations. *Oral Surg Oral Med Oral Pathol* 1976;41:545.
229. Nishioka GJ, Mason M, Van Sickels JE. Neurosensory disturbance associated with the anterior mandibular horizontal osteotomy. *J Oral Maxillofac Surg* 1988;46:107.

Maxillary Orthognathic Surgery

Vincent J. Perciaccante, DDS

Robert A. Bays, DDS

History

Orthognathic surgery of the maxilla was first described in 1859 by von Langenbeck for the removal of nasopharyngeal polyps.¹ The first American report of a maxillary osteotomy was by Cheever in 1867 for the treatment of complete nasal obstruction secondary to recurrent epistaxis for which a right hemimaxillary down-fracture was used.² Over the next 70 years numerous authors described osteotomy techniques that mobilized the entire maxilla for the treatment of pathologic processes.

In 1901 Le Fort published his classic description of the natural planes of maxillary fracture.³ In 1927 Wassmund first described the Le Fort I osteotomy for the correction of midface deformities.⁴ However, total mobilization of the maxilla with immediate repositioning was not performed until 1934 by Axhausen.⁵ Separation of the pterygomaxillary junction was advocated by Schuchardt in 1942.⁶ Moore and Ward in 1949 recommended horizontal transection of the pterygoid plates for advancement.⁷ Willmar reported on over 40 cases treated this way and of severe bleeding in most, thereby abandoning this procedure in favor of separation at the pterygomaxillary junction.⁸ Most of these techniques simply mobilized the maxilla to one degree or another, and then placed orthopedic forces on it to achieve the

desired repositioning—a sort of unintentional distraction osteogenesis. These methods were associated with high levels of relapse.

In 1965 Obwegeser suggested complete mobilization of the maxilla so that repositioning could be accomplished without tension.⁹ This proved to be a major advance in stabilization, as documented by Hogemann and Willmar, de Haller, and Perko, respectively.^{10–12}

Anterior segmentalization of the maxilla was also addressed in the early descriptions, including those by Wassmund, by Cohn-Stock, and by Spanier.^{4,13,14} Again, complete mobilization of the maxilla with vascular compromise was avoided, and multiple segments contributed to poor stability. Cupar, Kole, and Wunderer, respectively, reported more direct surgical access to these procedures with improved mobilization and maintenance of blood supply.^{15–18} Posterior segmentalization of the maxilla was used by Schuchardt but it had limited stability also owing to incomplete mobilization.¹⁹ Kufner improved on this technique by completely mobilizing the osteotomized segment prior to repositioning.²⁰ Logically, anterior and posterior segmental osteotomies were combined to accomplish total maxillary alveolar osteotomy for repositioning and segmental manipulation simultaneously.^{21,22} Several forms of total maxillary osteotomies

were described by Cupar, Converse and Shapiro, and Kole, respectively.^{15,23,24} Willmar further established the stability of the Le Fort I osteotomy, and Bell and colleagues documented the overall superiority of the total down-fracture Le Fort I osteotomy for segmental and one-piece maxillary osteotomy.^{8,25} Bone grafting to enhance stabilization was advocated by Cupar, Gillies and Rowe, and Obwegeser, respectively, who first advocated grafting in the pterygomaxillary fissure.^{15,16,26,27} Interestingly, Willmar did not find a difference in stability with and without bone grafting in nonclefted cases.⁸

Early descriptions of the rigid fixation of maxillary osteotomies were published by Michelet and colleagues in 1973, Horster in 1980, Drommer and Luhr in 1981, and Luyk and Ward-Booth in 1985.^{28–31} Since that time, many methods have been advocated for the rigid fixation of maxillary osteotomies. These have included bone plates, metallic mesh, pins, the rigid adjustable pin (RAP) system, and resorbable fixation.^{32–34} Since these landmark papers, volumes have been written regarding a wide variety of technical factors, many of which reflect operator preference.

Basic Principles

Maxillary deformities may manifest in any of the three planes of space: sagittal, axial, and coronal. Patients displaying abnormal

facial anatomy often exhibit elements of maxillary and mandibular deformities. Therefore, the clinician must recognize and be prepared to treat maxillary and midface deformities. Subjectively, patients with maxillary deformities often describe their problem in terms of the relative mandibular appearance. Patient expectations clearly demonstrate the importance of the chin in patient satisfaction.³⁵ This perceptual preoccupation with apparent mandibular excess or deficiency in the absence of a significant absolute mandibular abnormality may necessitate extensive consultation and guidance from the surgeon to assist the patient in recognition of the contribution made by the midface and maxilla to overall facial appearance. Similarly the patient may relate the importance of nasal prominence or deficiency in describing his or her chief complaint.

Scrutiny of physical characteristics, model surgery, and cephalometric analysis with prediction tracings will assist in obtaining a satisfactory treatment plan. These important diagnostic and treatment planning modalities are discussed extensively elsewhere in the text; however, model surgery is the most valuable tool in preparing for orthognathic correction of skeletal facial deformities. While model surgery is essential for immediate preoperative surgical simulation and splint construction, it may be even more important in early treatment planning. Prior to any orthodontic or surgical treatment, model surgery is the best method to determine the postoperative position of the *mandible* as well as the maxilla. No cephalometric prediction (computer generated or hand drawn) or photographic manipulation can reveal all of the three-dimensional and occlusal information gleaned from accurate model surgery. In the pretreatment state the teeth may not fit together perfectly during this preliminary model surgery, but orthodontics can be simulated to permit an accurate projection of the specific movements required of the maxilla and

mandible to achieve the desired results. The model measurements made at the time of this exercise should be exactly the same as those used for the actual preoperative model surgery (see below). Pretreatment model surgery is essential when contemplating maxillary surgery alone and very useful when planning two-jaw surgery. Pretreatment model surgery permits the *three-dimensional* evaluation of the maxilla and the mandible, whether the mandible is autorotated without surgery or also osteotomized.

Model Surgery, Reference Marks, and Intraoperative Positioning

The purposes of preoperative model surgery are to (1) mark the models to facilitate three-dimensional measurement of the pre- and postoperative positioning; (2) place the jaw models into the desired positions based on all of the database including three-dimensional clinical assessment (the most important), radiographic analysis, model studies and patient desires; (3) evaluate the feasibility of the planned surgical moves using the measurements and make necessary adjustments; (4) determine the vertical change that will be achieved at the time of surgery in such a way that it can be accurately duplicated intraoperatively; and (5) construct the surgical splint(s).

The following method has been used successfully for over 20 years by the senior author (RAB). The technique is based on three simple principles:

1. A measurement is made from a point above the osteotomy to a point below it at model surgery and intraoperatively. After the maxilla is moved the same superior point is used but the point on the maxilla has been moved along a predetermined plane. This creates a triangle defined by one superior point and two inferior points (pre- and postoperatively). This triangle can

be measured accurately on models and on the patient at surgery.

2. Central incisor vertical measurements can be made directly on the models.
3. If the measurements made on the models and at surgery have the same pre- and postoperative *differences*, the incisor vertical will be correct.

Centric relation mounted models are marked to record all possible surgical movements anteriorly and posteriorly (Figure 57-1). For the purpose of illustration Figure 57-1A and B demonstrate the measurements that are necessary for intraoperative control of the vertical position of the maxilla. The vertical measurements at the maxillary canines and first molars are the critical ones for use intraoperatively (see Figure 57-1C). The bilateral vertical measurements must be made from stable points on the top of the mounting ring, not just anywhere along the mounting ring (points A and P) to cusp tips. Gingival cuffs will be used intraoperatively (Figure 57-2) on the canines (point B) and first molars (point C). The maxillary model is then moved to the desired position, including vertical. The measurement of the vertical position of the incisor is made by placing the Boley gauge flat on the top of the mounting ring (parallel to the Frankfort horizontal) to the tip of the incisor (see Figure 57-1D). This vertical measurement of the maxillary central incisor is constantly controlled while the maxilla is positioned in all other planes of space (see Figure 57-2A). After the maxillary model has been fixed in the proper position, an imaginary triangle is created by points A, B, and B' and by points P, C, and C'. The lines A-B and P-C are the preoperative vertical values and the lines A-B' and P-C' are the hypotenuses of the triangles and the postoperative vertical values (see Figure 57-2B). The *differences* between lines A-B and A-B' and lines P-C and P-C' are the important values. The absolute numbers are not.

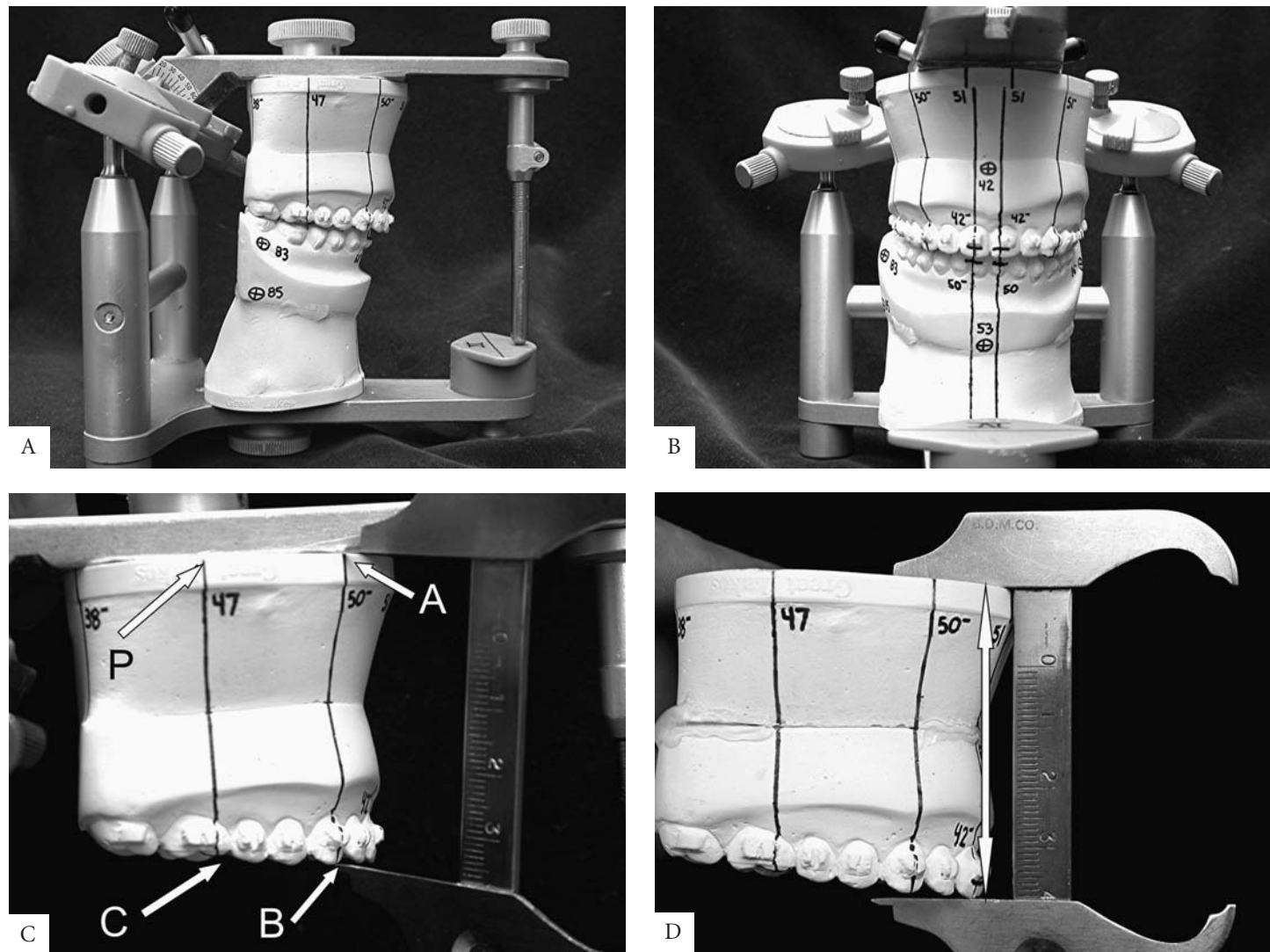


FIGURE 57-1 A, Mounted models marked for orthognathic surgery with vertical preoperative values recorded. B, Frontal view shows midline markings that can be seen on either side of the pin when it is placed. C, Straight-line measurements are made from points A to B and points P to C on each side. D, Maxillary central incisor is measured perpendicular to the Frankfort horizontal, which is from the top of the mounting ring. (Note: This is not a straight point-to-point measurement, but a perpendicular to Frankfort one.)

Intraoperatively marks are made above the proposed osteotomy sites in the piriform rims and the first molar/butress areas (points A and P) (see Figure 57-2C). Measurements are made from point A to the gingival cuff of the canine (point B) and from point P to the first molar (point C). The gingival cuffs are used because the cusps will be hidden under the splint and the brackets may come loose during surgery. During maxillary positioning, lines A–B' and P–C' can be measured until the *difference* between lines A–B and A–B' and lines P–C and P–C' are as predicted by

the models (see Figures 57-2D and E). When this is accomplished the anterior vertical changes of the central incisors will be as they were on the models, so that no direct measurement of incisors is necessary. Usually the maxilla is repositioned anteroposteriorly and sometimes mediolaterally as it is moving vertically. This method of measurement is especially important when large anteroposterior or mediolateral moves are included.

Our experience and that of others has shown that external reference marks add nothing to the accuracy of vertical maxil-

lary positioning if the internal reference method is as outlined above.^{36,37}

Surgical Anatomy

Osseous Structures

The body of the maxilla contains the maxillary sinus in its entirety, except rarely when the apex extends into the zygomatic bone.³⁸ The anterior surface of the maxilla is the anterolateral wall of the sinus. The infraorbital foramen is located at variable distances below the inferior orbital rim. Continuing inferiorly is the

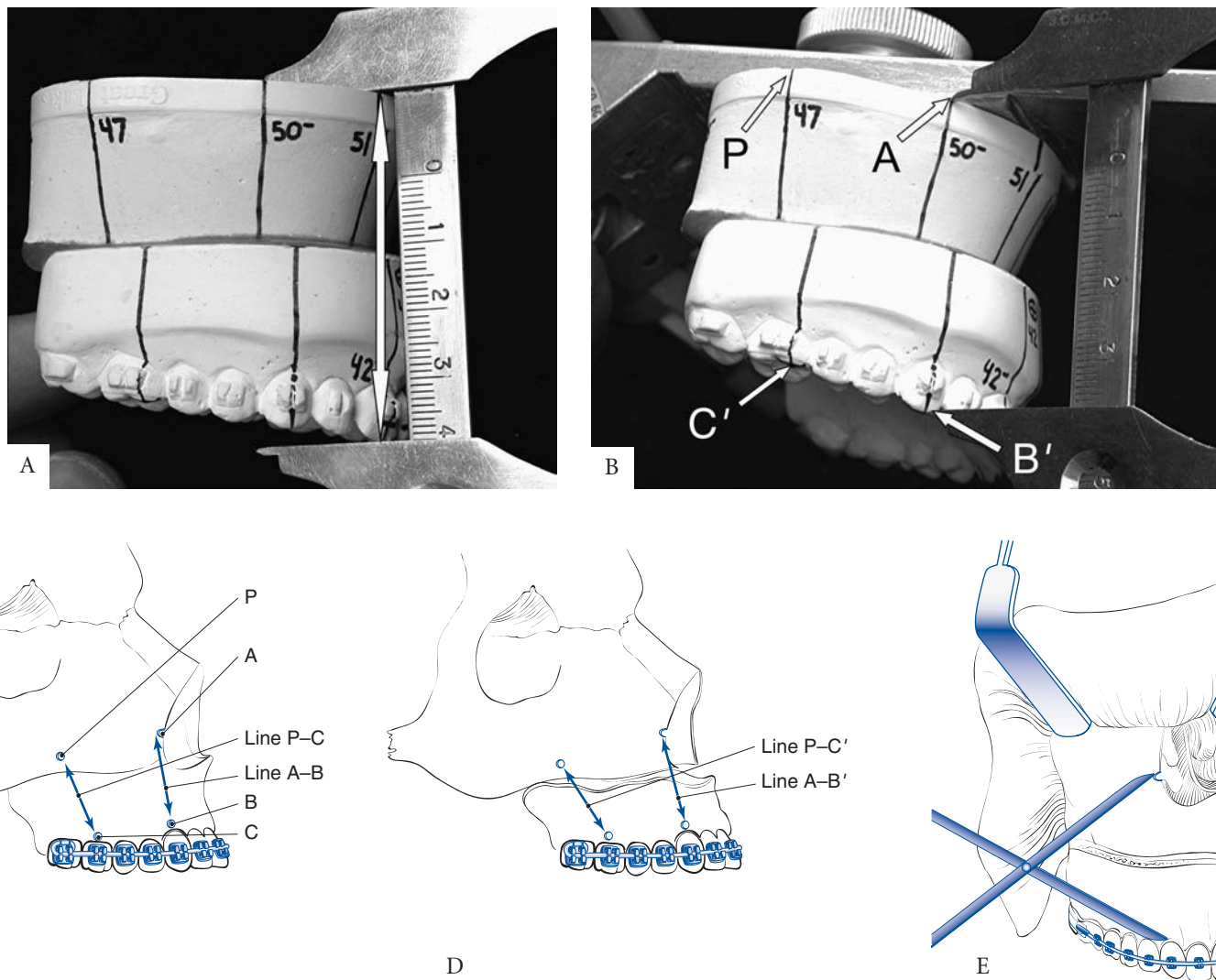


FIGURE 57-2 A, Maxillary model has been moved into desired position including vertical. Maxillary incisor is again measured perpendicular to the Frankfort horizontal (ie, from the top of the mounting ring). B, Straight line measurements are made from points A to B' and P to C' bilaterally. C, At surgery, slots are made in the piriform rim and holes in the buttress to simulate points A and P bilaterally. The gingival cuffs of the canines and first molars represent points B and C. D, Following mobilization of the maxilla it is placed so that the differences between lines A-B and A-B' are the same as they were on the models. Lines P-C and P-C' can be used similarly. Note: If this is done precisely, the vertical change at the central incisors will be the same as it was on the models so that there is no need to make a direct measurement of the centrals. E, Illustration of measurement method at surgery.

canine fossa lateral to the canine tooth. The anterior alveolar process of each maxilla surrounds the piriform aperture, and they unite in the midline to form the anterior nasal spine. This bony spine is the most anterior and inferior attachment for the mobile anterior cartilaginous nasal septum. An elevated sharp crest at the junction of the anterior and nasal surfaces of the maxilla, which forms the nasal floor, inclines this structure superiorly at the aperture. The body of the maxilla and its frontal process

form the superolateral boundary of the piriform aperture as a thin edge of bone (Figure 57-3).

In the midline the nasal crest of the maxilla articulates with the septal or quadrangular cartilage and vomer.^{39,40} The septal cartilage rests in a central groove, which extends posterior to the anterior nasal spine. This articulation is flexible but strengthened by the perichondrium-periosteum continuity and interposed connective tissue. In the midline at the junction of the maxilla and the premaxilla is the incisive fossa, which

typically presents the openings of four canals through which the nasopalatine arteries and nerves are conducted.

The palate is formed by the palatine process of the two maxillas and the horizontal lamina of the palatine bones.⁴¹ The transverse suture between the maxilla and palatine bones lies roughly 1 cm anterior to the posterior margin of the hard palate. At its lateral extent the suture widens into the greater palatine foramen, which is approximately 1 cm posteromedial to the second molar (Figure 57-4).

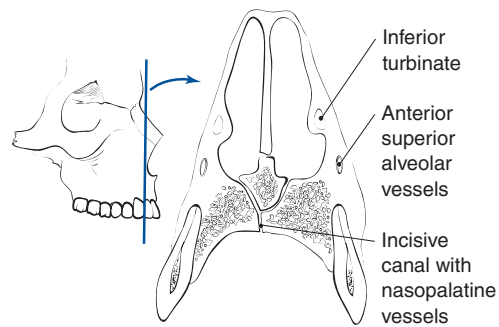


FIGURE 57-3 Cross-sectional anatomy of the maxilla at the piriform rim.

The greater palatine canal is formed similarly between the perpendicular laminae of the palatine and maxillary bones, which form the inferior lateral nasal wall. The inferior nasal concha also articulates with the maxillary and palatine components of the lateral nasal wall.

Posterolaterally the maxillary tuberosity is behind the third molar. Above this tuberosity the posterior superior alveolar foramina may be observed through which the nerves and vessels emerge. The pyramidal process of the palatine bone unites the two pterygoid plates of the sphenoid bone with each other and to the maxilla. The pterygomaxillary junction, formed by the palatine bone, ends superiorly in the pterygomaxillary fissure leading into the pterygopalatine fossa.^{42,43} The foramen rotundum enters the posterior wall of the pterygopalatine fossa and the pterygoid or vidian canal. Medially the sphenopalatine foramen leads to the lateral nasal cavity posterior to the middle nasal concha of the ethmoid bone. Anteriorly the infraorbital and zygomatic nerves and infraorbital vessels run in the infraorbital canal, and inferiorly the descending palatine artery and greater palatine nerves course within the greater palatine canal.

Vascular Structures

Although numerous texts describe the anatomy of the intact maxilla, several aspects of maxillary blood flow remain in doubt following maxillary osteotomy.

The Le Fort I maxillary osteotomy had been performed for over 100 years before Bell first identified the exact nature of blood vessels in the osteotomized maxilla, which provided information regarding the viability to the pedicled maxilla.^{44,45} It was obvious that even though the direct blood supply to the maxillary teeth and periodontium was interrupted, collateral circulation existed to perfuse the dental pulp and surrounding structures (Figures 57-5 and 57-6). This same circulation was also responsible for the survival of the rest of the maxilla; however, the exact nature of the various factors affecting maxillary perfusion is still not well documented or understood. Bell's studies revealed that saving the descending palatine arteries made little difference, indicating that a collateral vasculature existed, probably from the soft palate, which was adequate for maxillary perfusion. The down-fractured maxilla has a rich blood supply via the ascending pharyngeal artery and the ascending palatine branch of the facial artery.⁴⁶

Bell also verified the revascularization of anterior maxillary osteotomies using the microangiographic technique.⁴⁵ Brusati and Bottoli performed revascularization studies similar to those of Bell and found quite different results.⁴⁷ They found

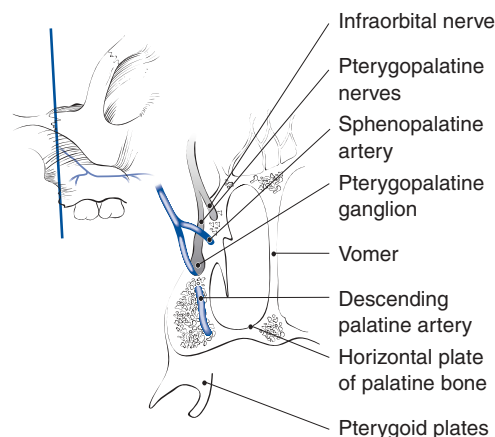


FIGURE 57-4 Cross-sectional anatomy at the pterygomaxillary junction. Note the position of the greater palatine foramen and perpendicular plate of the palatine bone.

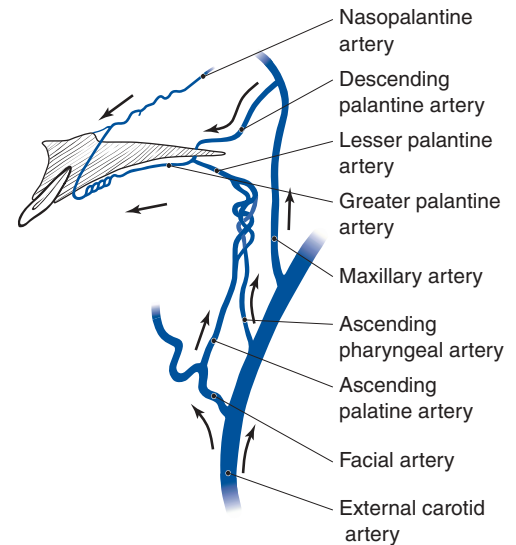


FIGURE 57-5 Pathway of the ascending palatine, ascending pharyngeal, and descending palatine arteries as they continue into the greater palatine arteries.

the tunneling technique to be superior in maintaining the blood supply, especially to the pulpal tissues, when compared with the labial pedicled anterior maxillary procedures.^{17,18} This was just the opposite from the findings of Bell.⁴⁵ A possible explanation for this discrepancy is that Bell used monkeys whereas Brusati and Bottoli used dogs, which they claimed possess a more similar maxillary vasculature to that of the human.⁴⁸ The clinical significance of these differences is not clear to this day.

Revascularization does not necessarily represent blood flow, and therefore Nelson and colleagues used a radioactive microsphere technique to evaluate maxillary blood flow.⁴⁹ Unfortunately several variables were present in this study that make interpretation difficult. In none of the above-mentioned studies were the maxillas moved to a new position, which may represent the largest insult to the blood supply at the time of actual maxillary osteotomy. Additionally, in Nelson's study, severance of the descending palatine vessels was inadvertent and no ligation was performed.⁴⁹ This allowed bleeding to occur through the lacerated vessels and prevented a pressure head

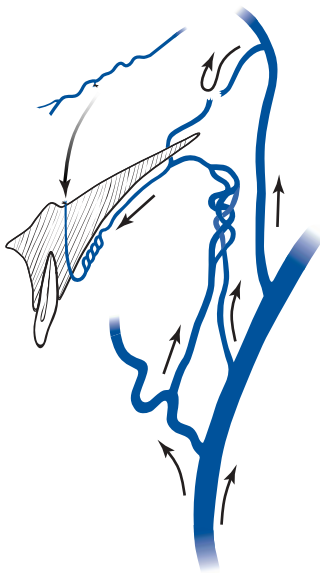


FIGURE 57-6 Soft palatal, ascending pharyngeal, and ascending palatal vessels anastomose with the greater palatine artery. Major vessels have been sectioned and tied. The arrows signify direction of blood flow.

from developing to maintain distal flow to the anterior maxilla. Also there were large differences in the preoperative microspheres values between animals such that postoperative comparisons were impossible. In other studies involving anterior maxillary osteotomies, Nelson and colleagues found no significant differences among three different techniques that were similar to the ones described by Brusati and Bottoli, plus a third procedure using only a palatal pedicle.^{47,50} Although no statistical difference was seen, the palatal flap seemed to be slightly superior to the others. Again the same problems existed with this study as before, rendering conclusions impossible.

Soft Tissue Envelope of the Maxilla

The midfacial superficial fascia or subcutaneous tissue contains a variable amount of adipose tissue with the muscles of facial expression in its deep layer. This is tightly bound to bone except adjacent to the buccal fat pad and in the lower eyelids. Hollinshead divided the mimetic or facial muscles into five chief groups concerning the mouth, nose, orbit, ear, and scalp.⁴² Of concern to the present discussion are the

muscles of the mouth and nose, which are innervated at their posterior inferior aspect by the facial nerve. They insert into the skin and most arise from periosteum of the facial skeleton.

The upper oral group of muscles radiates from their insertions near the corner of the labial commissure. From a horizontal to vertical orientation and inferior to superior the risorius, zygomaticus major and minor, and the levators (levator labii superioris alaeque nasi) insert and blend with the skin and orbicularis oris. The risorius does not arise from bone but originates from the superficial fascia over the parotid gland. The risorius, zygomaticus major, and zygomaticus minor elevate and retract the corner of the mouth and upper lip laterally. The superficial levator muscles and a third deeper one, the levator anguli oris, elevate the lateral upper lip. In addition the levator labii superioris alaeque nasi attaches to the skin and greater alar cartilage of the nose, thus lifting the ala and widening the naris.

The orbicularis oris is composed of many multidirectional fiber groups that blend with other surrounding facial muscles, encircle the mouth, originate from periosteum covering the roots of the canine teeth, insert laterally at the corner of the mouth, and pass at right angles to the encircling sphincter fillers connecting skin to labial mucosa. This diverse muscle draws the lips together, purses the lips, presses the lips against the teeth, and pulls the corners of the lips inward.

The buccinator arises from the mandible and maxilla and the pterygomandibular raphe, by which it is separated from the superior pharyngeal constrictor. The fibers pass forward and slightly inferiorly to blend with the orbicularis oris and attach to the mucosa and skin of the labial region. The buccinator flattens the cheek against the teeth.

Both Lightoller and Nairn place emphasis on the modiolus, which is the point at the lateral aspect and just superi-

or to the corner of the mouth where muscles of the oral group of the mimetic muscles converge.^{51,52} The orbicularis oris and buccinator joined at the modiolus form a continuous muscular sheet on either side of the midline. The zygomaticus major, levator anguli oris, and depressor anguli oris (as a group referred to as “modiolar stays”) immobilize the modiolus in any position. Additionally the marginal and peripheral parts of the orbicularis oris muscle are distinguished. The peripheral aspect of the muscle lies parallel with the inner labial mucosal surface, and the marginal part curls outward following the vermilion surface. As tension is expressed in the orbicularis oris, the marginal aspect of the muscle is thought to straighten and decrease vermilion exposure, thereby pulling the upper and lower lips toward each other and against the dentition.

The nasal group of facial muscles dilates and compresses the nares. The nasalis arises from the maxilla lateral and inferior to the ala. The transverse portion unites with the contralateral muscle over the dorsum of the nose. The alar part inserts into the greater alar cartilage. Thus, the two parts compress and dilate the nasal apertures respectively. The depressor septi muscle lies beneath the orbicularis oris and attaches to the base of the columella and posterior ala. Its action narrows the naris. The posterior and anterior dilator muscles are intrinsic muscles of the nose that course from the alar cartilages to the margin of the pads. The nasal mucoperiosteum is firmly fixed to the elevated piriform rim above the floor of the nose, to the lateral margin of the nasal aperture and the anterior nasal spine. The premaxillary wings that flare laterally from the anterior midline nasal crest provide an irregular attachment of the mucoperiosteum along the inferoanterior nasal floor.

The palate is covered by mucosa firmly adherent to the periosteum and containing mucous minor salivary glands. The mucosa is thin in the central palate and

thickens toward the alveolar process. The palatine crest is a transverse elevation at the posterior border of the horizontal plate of the palatine bone that gives attachment to the tensor veli palatini muscle. The larger lateral pterygoid plate is the origin of the inferior head of the lateral and the medial pterygoid muscles. A small part of the medial pterygoid also arises from the maxillary tuberosity. The tensor veli palatini muscle curves around the hamulus, which is the inferior end of the medial pterygoid plate. From the hamulus the tensor muscle of the palate enters the soft palatal tissues. The tensor aponeurosis is an adherent connective tissue sheath continuous with the periosteum, which covers the posterior hard palate attaching laterally to the submucosal layer of the pharynx and the tensor veli palatini tendon.

Surgical Techniques

Soft Tissue Incision and Surgical Exposure of the Maxilla

Exposure of the anterior, lateral, and pterygomaxillary regions is most commonly achieved by incising horizontally through the buccolabial mucoperiosteum above the attached gingival margin at the level of the maxillary teeth apices (Figure 57-7A). The vestibular incision courses from the first molar to the contralateral first molar (Figure 57-7B). The parotid papilla is identified and retracted superolaterally during completion of the incision posteriorly. The incision can be made with electrocautery or steel as there have been no studies performed that show a difference between the two. After initial penetration of the mucosa the natural tendency to cut more superiorly with deeper penetration must be avoided. This is particularly important in the incisor area, as this would carry one into the nasal cavity.

The superior tissues are reflected subperiosteally, first at the piriform aperture margins (Figure 57-7C). Progressively more superior exposure lateral to the nasal

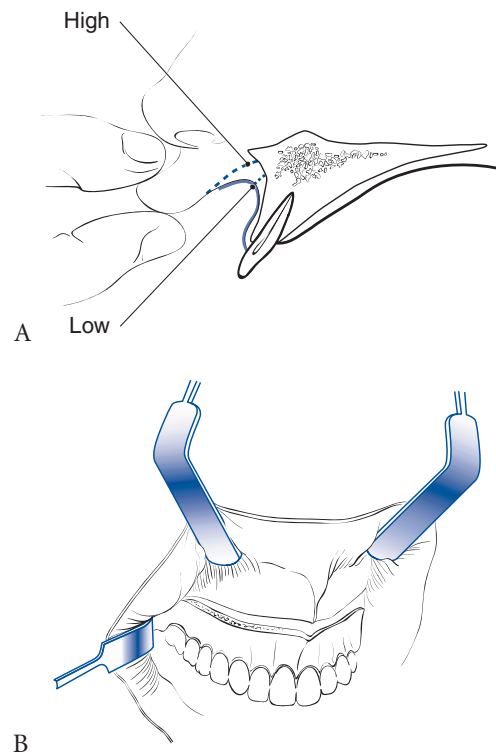


FIGURE 57-7 A, The soft tissue incision for maxillary surgery. B, The circumvestibular incision extends from the area of the first molar to the same location on the opposite side. C, The nasal mucosa is elevated beginning on the superolateral surface of the piriform rim.

aperture will expose the infraorbital nerve exiting from its foramen. Posterior reflection proceeding from the delineated infraorbital foramen reveals the zygomaticomaxillary suture, zygomatic buttress, and the most anterior aspect of the zygomatic arch. Inferiorly, with subperiosteal tunneling, the lateral aspect of the maxillary tuberosity and its junction with palatine bone and pterygoid plates of the sphenoid bone are identified. Care should be taken to direct this subperiosteal dissection inferiorly, toward the mucogingival junction, as it is carried back toward the pterygomaxillary fissure, to avoid vascular structures. Meticulous maintenance of the subperiosteal plane of dissection will prevent troublesome exposure of buccal fat pad tissue, which impairs visualization and retraction of soft tissue during subsequent osseous surgery. A retractor with a curvilinear end is placed in the pterygomaxillary junction to facilitate exposure. Attention should be paid to the placement of this retractor, as it too can be responsible for periosteal rents and exposure of the buccal fat.

Tissues inferior to the horizontal incision are elevated minimally. In areas of interdental osteotomies for segmentalization of the maxillary arch the inferior attached gingiva and periosteum are elevated conservatively, with a Woodson elevator, while retraction laterally is provided by skin hooks (Figure 57-8A). Since the alveolar osteotomy will be accomplished with thin osteotomes, osseous exposure requirements at the alveolar crest level are minimal.

When intersegmental movement will be great and may result in tearing of the gingival papilla, an alternative approach to the interdental region may be used. Additionally a wider exposure of alveolar bone is frequently needed when an osteotomy is to be performed in an edentulous or extraction space. In these situations a vertical mucosal incision at the line angle, one-tooth distant from the osteotomy site (Figure 57-8B), will facilitate wider exposure for osseous procedures. This incision should be used only when an anterior labial pedicle is maintained to maximize the labial vascular pedicle during multisegmental osteotomy.

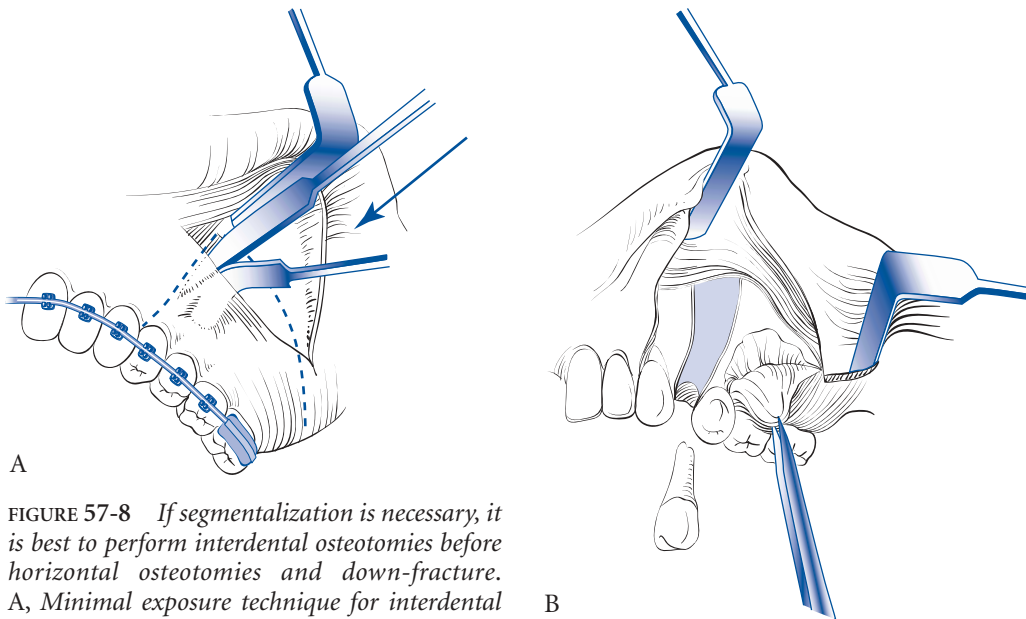


FIGURE 57-8 If segmentalization is necessary, it is best to perform interdentary osteotomies before horizontal osteotomies and down-fracture. A, Minimal exposure technique for interdentary osteotomies. B, Vertical incision for interdentary osteotomies.

For one-, two-, and most routine three-piece maxillary osteotomies, a circumvestibular incision with minimal interdentary exposure is preferred. For three-piece maxillary osteotomies that involve exceptionally wide expansion or extreme changes at the interdentary site, four-piece maxillary osteotomies, and osteotomies in some ex-cleft patients, soft tissue incisions can be modified from second molar to first premolar to maintain an anterior labial pedicle (Figure 57-9). A midline vertical incision is placed to gain access to the midline of the maxilla.

Once the labial incisions are completed the nasal mucoperiosteum is elevated to complete soft tissue exposure of the osseous surgical site (see Figure 57-7C). Initial establishment of a subperiosteal dissection plane is imperative for completion of nasal tissue dissection without disruption of mucoperiosteal integrity. Because the nasal cavity is more voluminous inside the piriform rim than at the piriform aperture, the elevator should be held at an oblique angle to the surrounding maxillary bone adjacent to the nasal aperture. While maintaining the elevator tip against bone, the mucoperiosteum is

reflected from the nasal floor, lateral nasal wall, and nasal crest of the maxilla. The dissection should continue superiorly for a centimeter up the vertical nasal walls to prevent tearing during osteotomy or down-fracture of the maxilla, particularly at the superior reflections of the nasal floor medially and laterally. The anteroposterior depth of this soft tissue dissection is approximately 15 to 20 mm. The remaining posterior soft tissue is reflected more precisely after initial down-fracture of the maxilla.

Osseous Surgery

After recording the reference measurements as outlined earlier (see Figure 57-2), the osteotomy is performed. The design of the osteotomy will depend on the maxillary movement desired. Regardless of the design of the osteotomy the measurement marks are used as illustrated in Figure 57-2. Initially the basic horizontal osteotomy will be discussed and then alterations will be described for specific situations. *Segmentalization* of the maxilla may be necessary in certain cases. Specifics of this procedure will be discussed at the end of the basic horizontal technique. The lateral

maxillary osteotomy (Figure 57-10) is started at the greatest convexity of the zygomatic buttress because that is the easiest starting surface for the reciprocating saw. It is advanced anteriorly through the lateral piriform rim below the inferior turbinate while the nasal mucoperiosteum is retracted and protected using a periosteal elevator. For the basic maxillary osteotomy this horizontal osteotomy is parallel to the maxillary arch wire approximately coincident with the cut performed previously during model surgery. After the anterior osteotomy is completed, it is continued posteriorly by tapering inferiorly toward the pterygomaxillary junction. A thin reciprocating saw blade and copious irrigation are used for this osseous cut. The most posterior centimeter or so of the lateral wall can be cut with the same saw, but from inside out (Figure 57-11).

Next a nasal septal osteotome is directed slightly downward and posterior (Figure 57-12) beginning just above the anterior nasal spine while the anterior nasal mucoperiosteum is retracted. Proceeding posteriorly the osteotome is carefully maintained in the midline. The tendency toward superior deviation while separating the cartilaginous and vomerine septum from the nasal crest of the maxilla

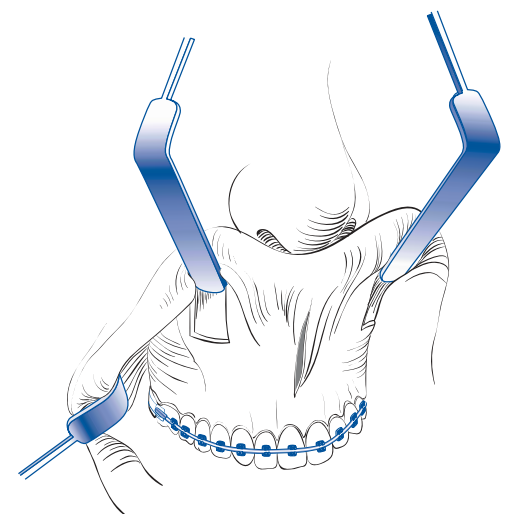


FIGURE 57-9 Bilateral vestibular incisions are made from the first premolar to the second molar; shown with a midline vertical incision.

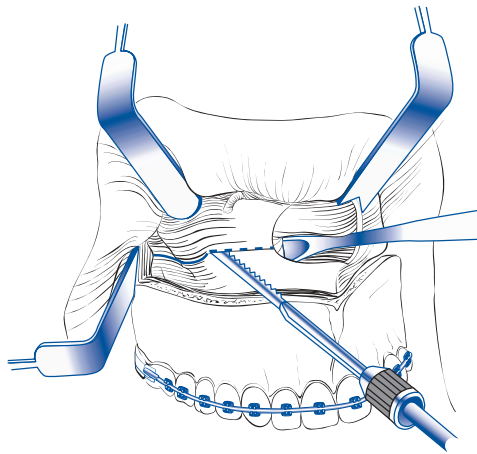


FIGURE 57-10 Lateral wall osteotomy is begun at greatest convexity of the buttress and brought forward to the piriform rim with a periosteal elevator protecting the nasal mucosa and the endotracheal tube.

necessitates maintenance of a slight downward inclination of the septal osteotome. The lateral nasal wall is severed using a thin osteotome directed posteriorly while medial retraction of the nasal mucoperiosteum is accomplished with a periosteal elevator. The osteotome is gently malleted posteriorly for a distance of approximately 20 mm to avoid premature injury to the descending palatine neurovascular bundle that resides in the lateral posterior nasal wall.

After the above osteotomies have been performed, the pterygoid plates are separated from the maxillary tuberosity (Figure 57-13) using a small sharp curved osteotome. This instrument is preferred over the traditional thick pterygomaxillary osteotome because the thin cutting edge limits fracture and promotes precise division of this bony junction.⁵³ The tip of the osteotome is directed as anteriorly, inferiorly, and medially as the tunneled buccal soft tissue allows. A finger placed palatal and posterior to the maxillary tuberosity will facilitate early verification of the complete separation of bone while avoiding trauma to the palatal vascular pedicle. The authors prefer to have this instrument sharpened before each case.

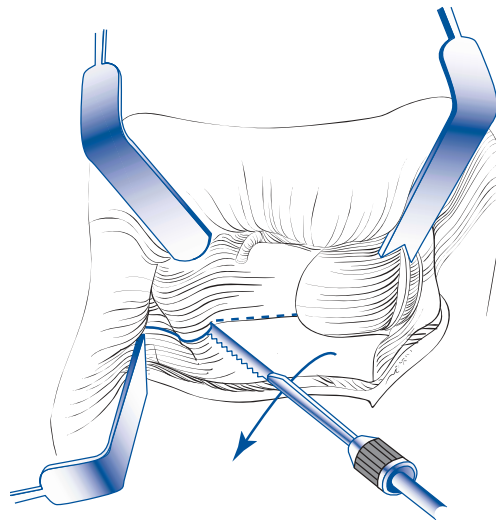


FIGURE 57-11 The saw is then turned inside out and the osteotomy from the buttress to the pterygomaxillary junction is made angling downward as it goes posteriorly.

Downward pressure is placed on the anterior maxilla using the sharp hooks of a Senn retractor to facilitate initial downfracture of the maxilla (Figure 57-14). If moderate pressure does not result in mobilization of the inferior segment, the completeness of the above osteotomies must be suspect. The cement spatula osteotome is used to ensure complete bony severance of the anterior lateral nasal wall and zygomaticomaxillary portions of the osteotomy. The curved osteotome is again placed into the pterygomaxillary junction, malleted gently, and then torqued to mobilize the maxilla. If no significant movement is detected, then the

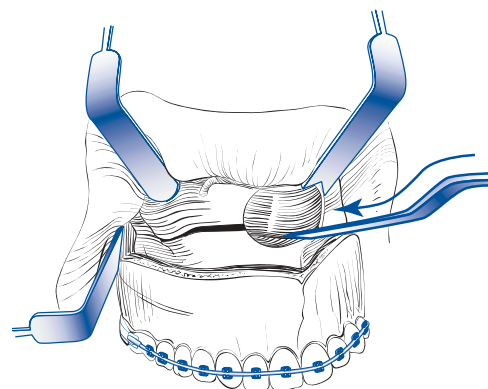


FIGURE 57-12 Separation of the nasal septum from the septal crest of the maxilla with a special osteotome.

osteotome may be stepped slightly superiorly, directed anteriorly, and malleted until the separation is complete.

When mobility occurs the nasal mucoperiosteum is elevated progressively more posteriorly until the posterior edge of the hard palate is encountered (see Figure 57-14). Portions of the pterygoid plates or perpendicular process of the palatine bone that resist fracture may be completely separated from the maxilla using an osteotome under direct visualization (Figure 57-15). The descending palatine neurovascular bundle is isolated, ligated, and divided.

Significant movement of the posterior maxilla can cause tensile forces on the descending palatine neurovascular components. Superior repositioning of the maxilla may also compress the exposed vessels and nerve between the inferior and superior osseous segments. Severe postoperative bleeding after Le Fort I maxillary osteotomy has been reported.⁵⁴⁻⁵⁷ Attempts to preserve the neurovascular bundle may increase this possibility. Ligation and division of this structure has been shown to have no deleterious influence on perfusion or neurosensory function.^{58,59} The bone of the perpendicular plate of the palatine bone surrounding the neurovascular bundle is

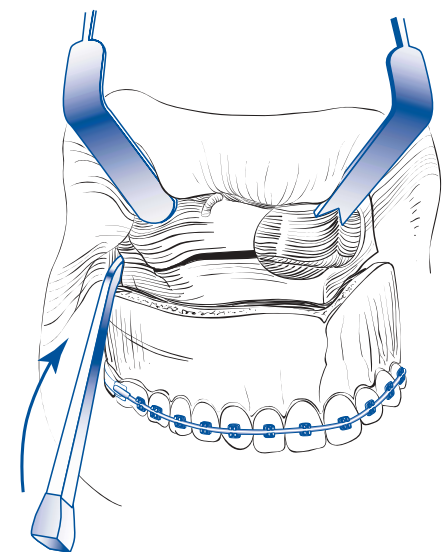


FIGURE 57-13 Pterygomaxillary separation with a small sharp curved osteotome directed medially.

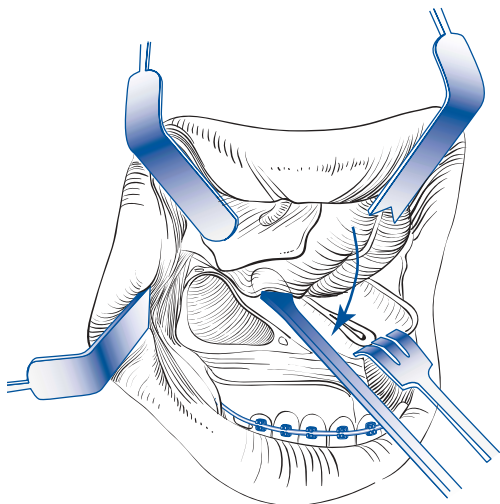


FIGURE 57-14 Down-fracture is accomplished with a sharp-toothed Senn retractor, with simultaneous elevation of nasal mucoperiosteum.

carefully removed using a Woodson elevator, burs, and rongeurs, and the neurovascular bundle is ligated and divided (see Figure 57-15). After down-fracture, complete mobilization of the maxilla is the next objective. A J stripper normally used for periosteal elevation in sagittal osteotomies engages the posterior border of the midline nasal floor at the posterior nasal spine (Figure 57-16), and anterolateral pressure is

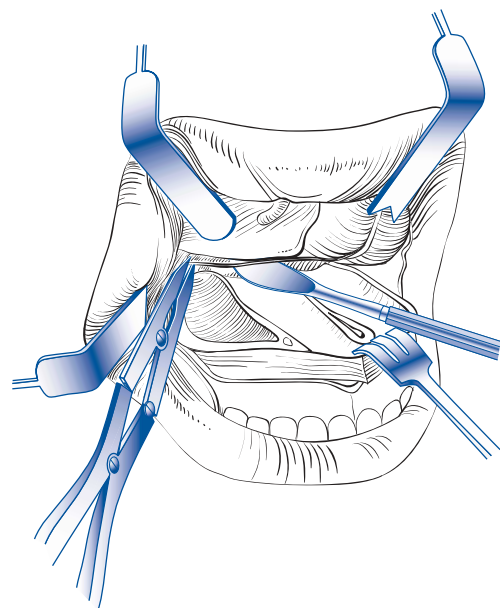


FIGURE 57-15 Complete removal of bone around the perpendicular plate of palatine bone. The descending palatine artery is isolated, ligated, and divided.

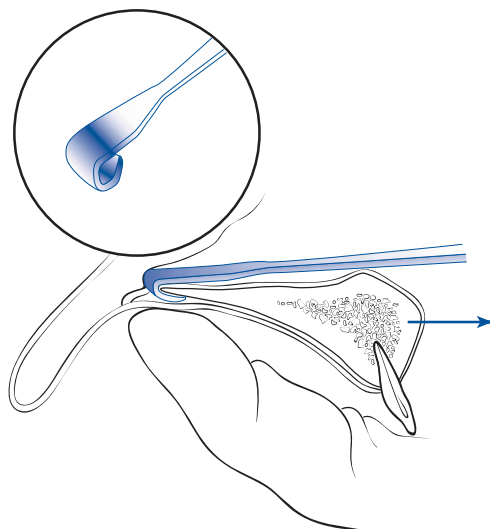


FIGURE 57-16 Mobilization of the maxilla with a J stripper.

exerted to progressively increase mobility of the maxilla. The goal of these maneuvers is to move the maxilla into the approximate final position with only gentle digital pressure. After mobilization from the cranial base is completed, a reassessment of the surgical move is considered. Based on the movement planned any possible bony interferences posterior to the second molar must be removed before application of maxillomandibular fixation (MMF). When all possible interferences posterior to the second molar have been removed, the maxilla is wired to the mandible with the occlusal splint interposed.

We prefer to have the patient completely paralyzed during the period of maxillary positioning. Condylar positioning while rotating the maxilla and mandible is paramount to success. The physiologic position of the condyles is thought to be a superoanterior orientation relative to the glenoid fossae against the posterior slopes of the articular eminences, with the disk interposed between the condyle and the fossa. The surgeon must position the condyles of the maxillomandibular complex in this upward and forward direction prior to autorotation (Figure 57-17). The importance of this stage of the surgery cannot be overesti-

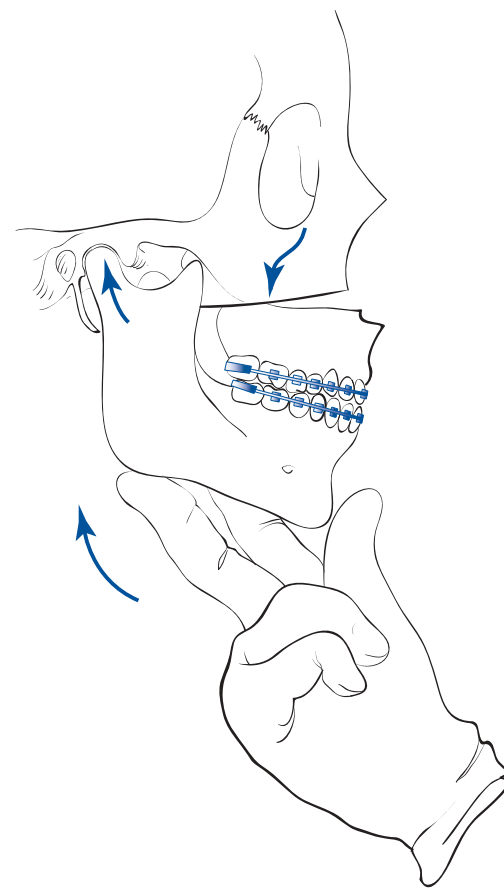


FIGURE 57-17 Manual positioning of the maxillomandibular complex with condyles seated. Note the posterior pivot point that must be removed.

ated. The most likely points of unrecognized bony interferences are in the areas of the pterygoid plates, the maxillary tuberosities, and the perpendicular plate of the palatine bone. It is quite possible to rotate the maxillomandibular complex inappropriately while being unaware of a premature pivot point in these posterior bony areas (Figure 57-18A). This will result in Class II open bite discrepancy once the patient is released from MMF. If a significant period of MMF or training elastics is used postoperatively, this discrepancy may not become apparent for weeks or months (Figure 57-18B). Once these posterior interferences have been removed, the surgeon continues to rotate the entire complex around the temporomandibular joints until the appropriate vertical relationship is achieved as described above. The cartilaginous sep-

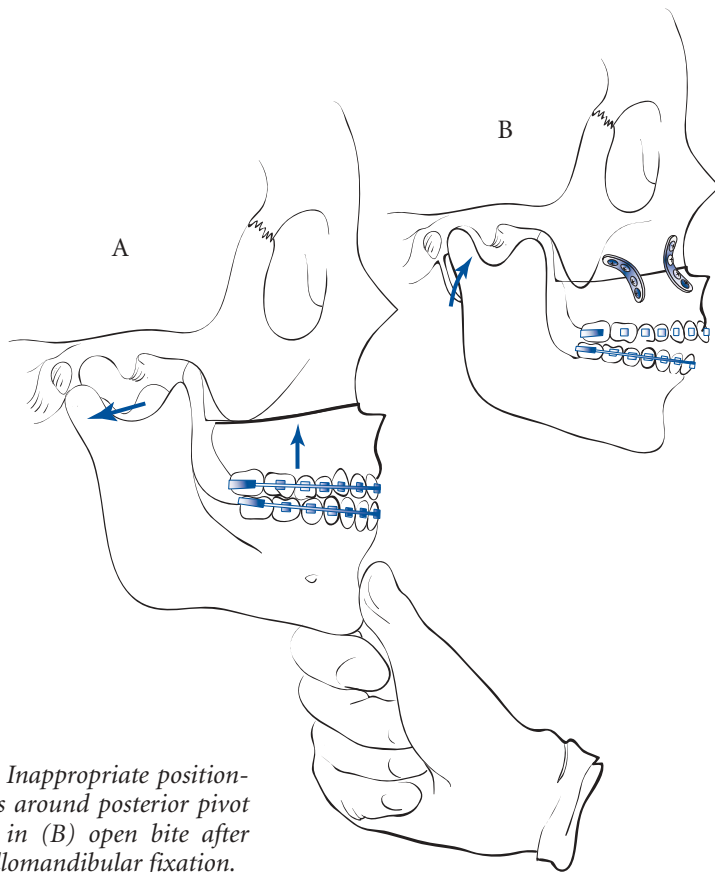


FIGURE 57-18 A, *Inappropriate positioning of the condyles around posterior pivot points will result in (B) open bite after release from maxillomandibular fixation.*

tum and vomer as well as the nasal crest of the maxilla are reduced in height equal to the planned movement of the maxilla. This may entail a submucous resection of the cartilaginous nasal septum to prevent buckling of the septum from pressure as the maxilla is repositioned. A groove can be fashioned in the midline of the nasal floor to accommodate the recontoured septum.

A portion of the inferior edge of the cartilaginous septum should be removed. The tendency is to remove too little because of the irregular inferior contact between septum and maxilla. Even if the maxilla is inferiorly positioned, buckling of the septum may occur because the cartilaginous septum extends anterior and inferior to the anterior nasal spine and therefore can be buckled as the maxilla moves forward even if there is some downward movement (Figure 57-19). All of the maxillary positioning has been pre-determined by the model surgery and

splint construction, except for the vertical. As the maxilla is rotated upward around the condyles, bone is only removed at the point of contact, not a full wedge (Figure

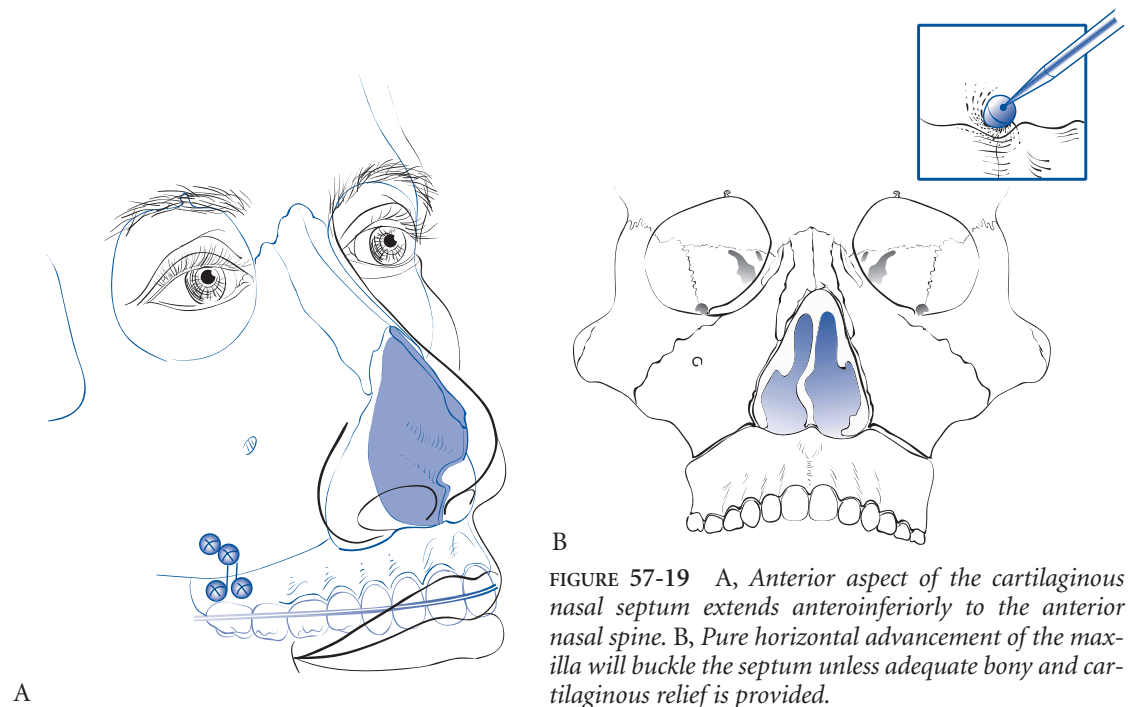


FIGURE 57-19 A, *Anterior aspect of the cartilaginous nasal septum extends anteroinferiorly to the anterior nasal spine. B, Pure horizontal advancement of the maxilla will buckle the septum unless adequate bony and cartilaginous relief is provided.*

57-20). This facilitates ideal bone-to-bone contact and avoids large gaps in between. Once the desired vertical relationship has been achieved based on the measurements described above, the maxilla should be fixed in position with internal rigid fixation. Sequentially eliminating only interfering osseous structures ensures optimal bone contact. This method is preferred over a wedge osteotomy.⁶⁰ Maxillo-mandibular fixation is removed and the mandible is rotated into the splint while held to the maxilla. If the occlusion is correct, the splint is removed and not left in place postoperatively.

Variations in the above basic osteotomy design may enhance osseous contact, facilitate bone graft placement, or aid fixation device application, and result in improved stability of the superiorly, inferiorly, or anteriorly repositioned maxilla. These variations will be described below as they apply to specific maxillary movements. To prevent septal deviation despite adequate bone and cartilage removal, it is often desirable to suture the nasal septum to the anterior nasal spine. This is done by drilling a hole through the anterior nasal spine and passing a 1-0 polyglycolic acid

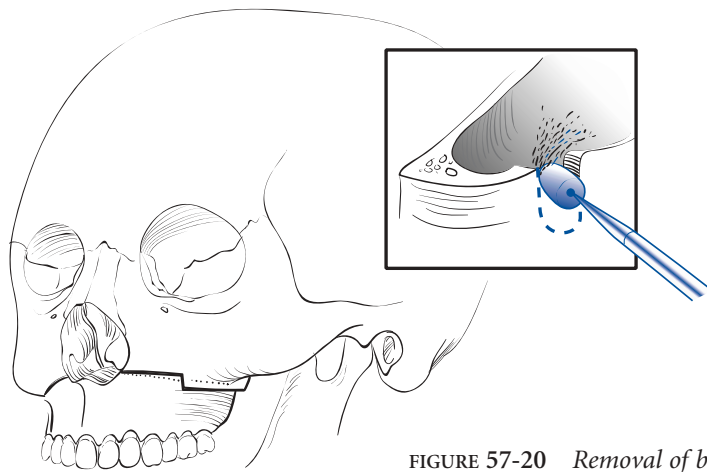
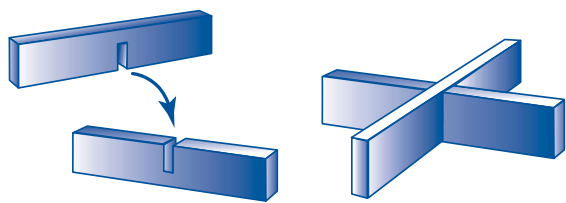


FIGURE 57-20 Removal of bony walls and slotting of the contact points.



suture through the hole and then through the cartilaginous septum (Figure 57-21). This will also prevent postoperative displacement of the septum during extubation or in the Post-anesthesia Care Unit.

Segmentalization

A wide range of permutations may be undertaken if segmentalization is needed. Three-piece maxillary osteotomy is perhaps the most common. The decisions regarding which of the many options will be used are made by pretreatment and preoperative model surgery. The need for extractions is also determined at this stage. If no extractions are necessary, interdental osteotomies can be safely made between parallel roots of the canines and laterals or canines and premolars. If extractions are decided on by the coordinated efforts of orthodontist and surgeon, they may be done early in treatment or during the osteotomy. A complete discussion of the indications and considerations that influence these decisions is covered elsewhere in this book. However, if there are no specific orthodontic reasons to extract teeth, it has been our experience that it is rarely necessary to extract just for the purpose of

surgery. The most common need for segmentalization is to widen the maxilla and adjust the angulations of the posterior maxillary segments. If the anterior six maxillary teeth fit well with the lower anterior teeth, the interdental osteotomy is performed between the canine and premolar teeth. This places the potential for a periodontal defect at the interdental osteotomy site more posteriorly in the mouth. But if the canines need to be widened along with the posterior seg-

ments, the interdental osteotomy is placed between canine and lateral incisor teeth. We prefer to make this osteotomy with a thin cement spatula osteotome while palpating palatally. The standard circumvestibular incision can be made with conservative tunneling from the incision inferiorly to the alveolar crest on the buccal surface of the maxilla. The osteotome is malletted through until palpated under the palatal mucosa (see Figure 57-8A). With care the osteotomy can be carried superiorly to the level of the horizontal maxillary osteotomy and medially to the horizontal surface of the palate. This should be done before any of the other maxillary osteotomies are done because the maxilla must be stable at the time of malleting. If teeth are to be extracted at the time of osteotomy, an alternative to tunneling is to lay a flap into the gingival sulcus for better access (see Figure 57-8B). However, if this is done, it is recommended that an anterior pedicle be retained for blood supply (see Figure 57-9).

Segmentalization using this or any other technique is more difficult when significantly altered osteotomy designs are used, such as high Le Fort I, II, or III. When the Z osteotomies (see below) are used, interdental segmentalization between canines and laterals is feasible, but more difficult if attempted between canines and premolars.

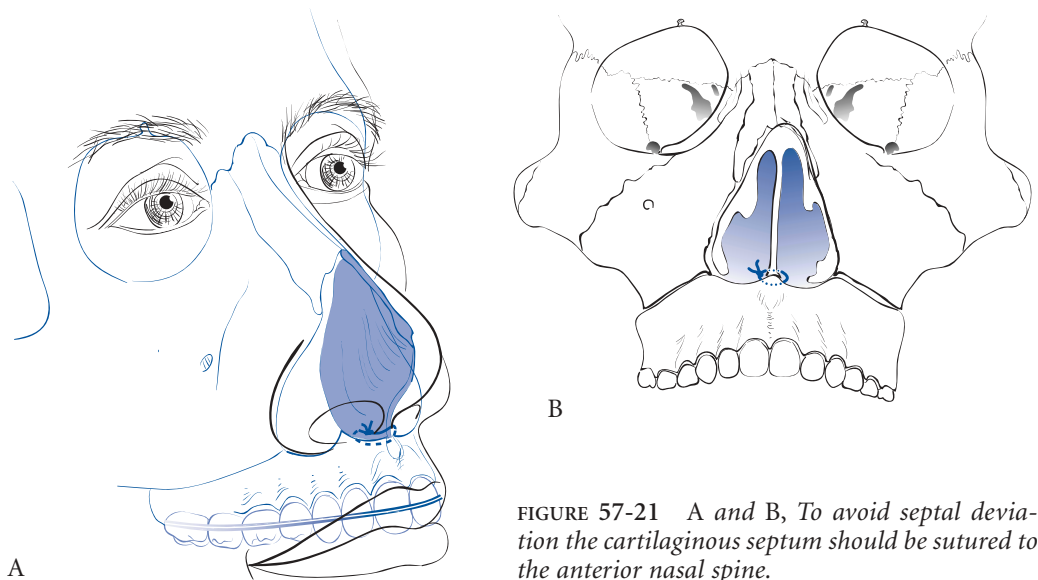


FIGURE 57-21 A and B, To avoid septal deviation the cartilaginous septum should be sutured to the anterior nasal spine.

Following the down-fracture and full mobilization of the maxilla, the remainder of the segmentalization can be performed. The palatal soft tissue is very thin in the midline and the bone is very thick, but the opposite is true 6 to 8 mm lateral to the midline. For that reason two parasagittal osteotomies are made along the floor of the nose using a bur with a rounded tip, such as a Steiger bur (Figure 57-22). The parasagittal cuts are joined with the interdental ones to free the three dentoalveolar segments. If any significant torquing of the anterior segment is to be done, the two parasagittal cuts must be joined across the midline so that there are three dentoalveolar segments and one midpalatal bony fragment. In two-piece osteotomies the two parasagittal cuts are joined with the interdental cut between the central incisors at the incisive canal.

The orthodontic arch wire is cut at the interdental osteotomy sites, and the segments are mobilized appropriately. The segments are wired to the preformed surgical splint. If bone grafting is needed on the palate it must be done before the maxilla is positioned and stabilized vertically. Interdental and buccal bone grafting can be done just before closure of the

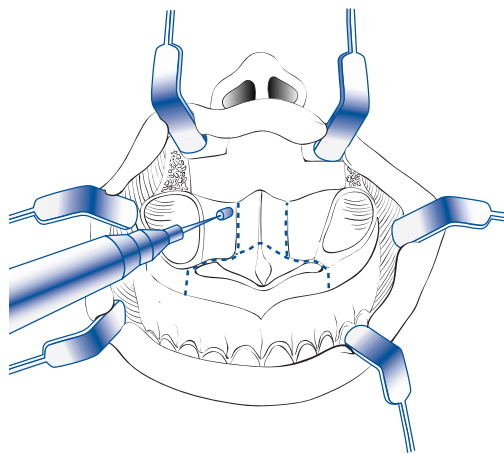


FIGURE 57-22 Following down-fracture the maxilla is segmentalized with a rounded end cutting bur such as a Steiger bur by making two parasagittal cuts that join across the midline and connect with the interdental osteotomies.

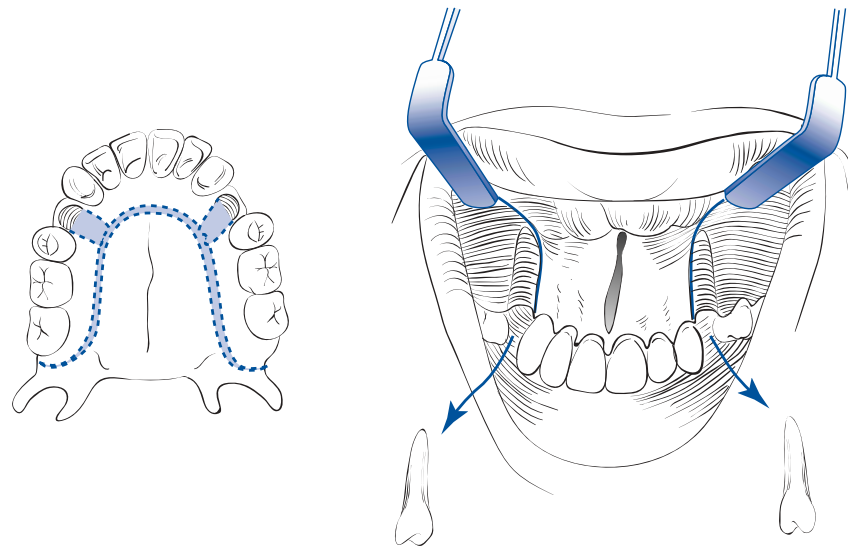


FIGURE 57-23 The traditional method of gaining access for total maxillary alveolar osteotomy was to make vertical incisions bilaterally. This technique can be used for other segmental osteotomies.

soft tissue wounds. Following splint fixation the orthodontic arch wire can be luted back together with quick curing acrylic if necessary. This avoids the time-consuming practice of tying in a preformed surgical arch wire.

If two-piece maxillary osteotomy is to be performed in the midline, we still prefer to use two parasagittal osteotomies that are brought together at the incisive canal. The interdental osteotomy is also performed with a cement spatula osteotome before the other osteotomies. Four-piece maxillary osteotomy is practically never indicated with a competent orthodontic set-up. If it is attempted, a tunneling technique is recommended in which an anterior pedicle of mucoperiosteum is retained to assist in the perfusion of the anterior segments.

The length of time that the splint is left in place depends on the amount and type of movements made by the various segments. The range of time the splint is left in place would be 3 weeks for smaller movements and up to 8 weeks for greater expansion. The patient is returned to the orthodontist immediately after removal of the splint for fabrication of the appropriate retention and resumption of orthodontic treatment.

Finally if large interdental bone removal is necessary to close large extraction spaces, access may be needed on the palate, especially in the midline. In this case we prefer to retain an anterior labial mucoperiosteal pedicle with a small midline vertical incision to access the anterior nasal spine (Figures 57-23 and 57-24). This allows for a midline palatal incision and conservative circumferential incisions to access the palatal bone removal.

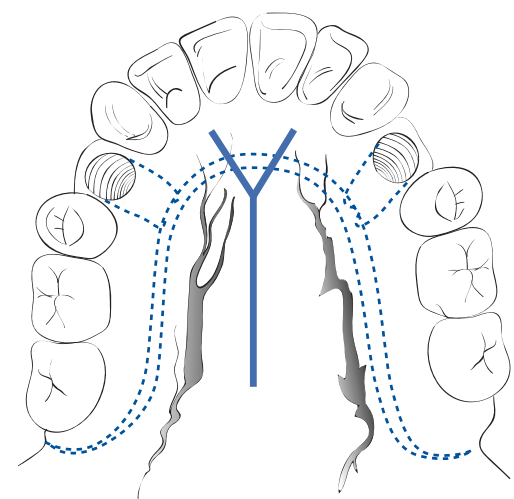


FIGURE 57-24 The traditional total maxillary alveolar osteotomy midline palatal incision with a Y at the anterior aspect can be used with caution.

Superior Repositioning

Lateral maxillary wedge osteotomy prior to maxillary repositioning often leaves large gaps between the bony interfaces as the maxilla is moved superiorly.⁶⁰ Shifting, tilting, or advancing the maxilla may reduce bone-to-bone contact. Sequential removal of osseous contacts avoids this needless loss of bone and provides more secure contact between the maxilla and the cranial base (see Figure 57-20). Therefore, only one horizontal osteotomy is made and no bone is removed until MMF is established and vertical repositioning is begun.

With MMF in place the maxilla and mandible are moved through the arc of rotation as dictated by the seated mandibular condyle (see Figures 57-17 and 57-18). The areas of bone contact can now be seen as the maxilla is positioned superiorly. Just enough bone is removed at the contact points to permit the superior repositioning planned. In many cases this will result in the formation of slots or grooves in the zygomatic buttress wall or elsewhere along the maxillary wall (see Figure 57-20). One must be careful that the grooves do not inhibit the free rotational movement of the maxillo-mandibular complex. This technique is particularly valuable when the maxilla is being shifted laterally or torqued in a transverse direction, which makes prediction of an osteotomy difficult. The maxilla is rigidly fixed and the MMF removed, the mandible autorotated into occlusion, and correct maxillary position confirmed.

Anterior Repositioning

The traditional Le Fort I osteotomy is inclined inferiorly from anterior to posterior in order to avoid the relatively large maxillary cuspid tooth root and placement of the cut inferior to the lateral extent of the zygomatic buttress. The resultant inclined plane may be problematic if this does not coincide with the desired movements.

A variety of straight, stepped, and Z osteotomies can be designed to accommodate the planned moves (Figures 57-25–57-28).^{61–65} If grafting (Figure 57-29) is desirable, the steps or Z osteotomies provide much better grafting sites than the pterygomaxillary fissure.

Inferior Repositioning

Inferior repositioning of the maxilla offers a special challenge in orthognathic surgery because there is a great relapse tendency.^{66–69} Various mechanisms have been advocated for stabilization and fixation of the maxilla after inferior repositioning. There have been a variety of techniques used to stabilize the inferior positioned maxilla, including suspension wires, interosseous wires, bone plates, Steinmann pins, Wessberg pins, and RAPs.^{33,62,65,70–72}

Stabilization of the inferiorly repositioned maxilla may not require bone grafting from a distant site if a series of slanted Z or step osteotomies are used (see Figure 57-25).^{61,65} The angulations of the osteotomies are planned so that the maxilla will slide down the incline plane of the cuts, maintaining bone contact as it is repositioned anteriorly and inferiorly. Depending on the inclination of the anterior versus posterior osteotomies, the max-

illa may be positioned more anteriorly or more inferiorly (see Figures 57-26–57-28).

Most surgeons prefer to use bone grafts and rigid fixation to stabilize the maxilla that has been inferiorly repositioned and has no bone-to-bone contact. Grafts can be secured with bone screws or plates if sufficient bone is available or with wire (see Figure 57-29). Candidates for inferior maxillary repositioning often have paper-thin maxillary bone. Internal rigid fixation with interosseous metal plates is the stabilization method of choice; however, occasionally insufficient bone is available adjacent to the osteotomy sites. In these cases the RAP system can be a crucial alternative (Figure 57-30). The application of this system has been described elsewhere.⁶⁵

Posterior Repositioning

Posteriorly repositioning the maxilla must be approached cautiously due to resultant loss of upper labial and paranasal osseous support for the overlying soft tissue. If the osteotomy is carried through the pterygomaxillary junction, bone must be removed either from the pterygoid plates (with great caution) or the maxillary tuberosity. An alternative is to direct the osteotomy through the maxillary

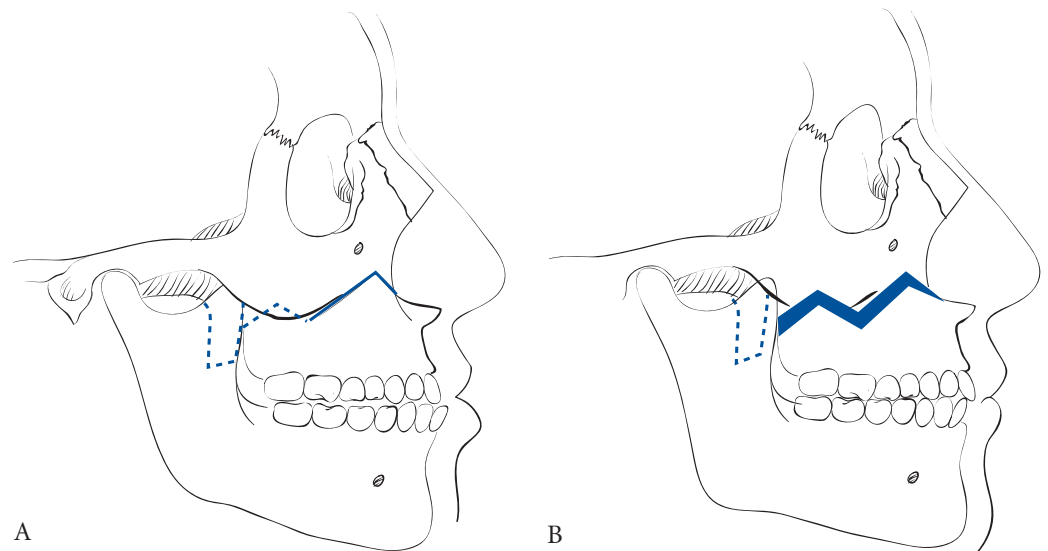


FIGURE 57-25 A, A Z-shaped osteotomy can be designed in the lateral walls of the piriform rims and the buttresses so that the maxilla may be moved downward and forward (B) without loss of all bony contact.

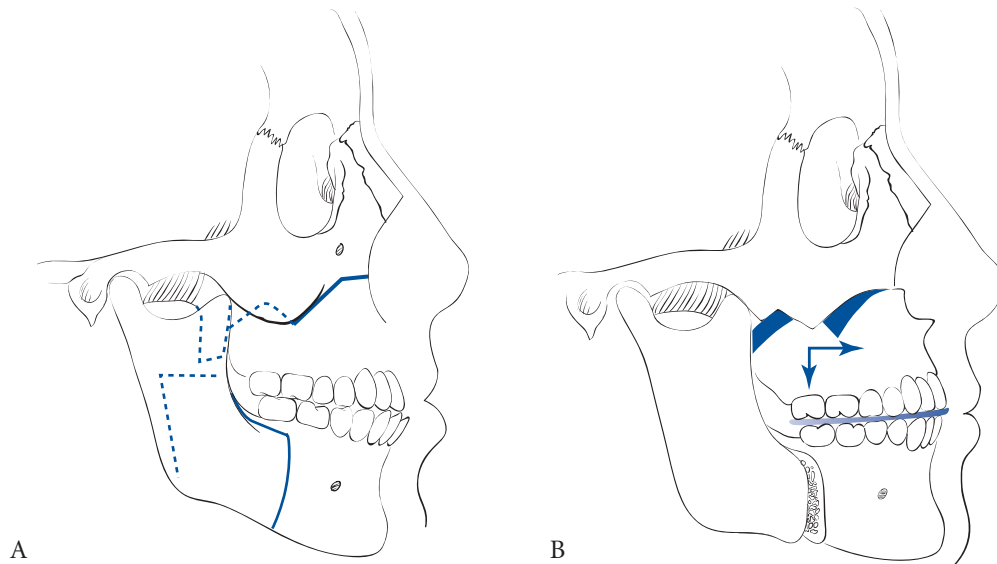


FIGURE 57-26 A, A Z osteotomy with the posterior cut steeper than the anterior one to increase posterior facial height and to (B) rotate the maxilla downward and forward with adjustment to the occlusal plane.

tuberosity just posterior to the second molar.^{73,74} This will leave tuberosity bone attached to the pterygoid plates, which can be more safely removed. Dangers of the technique include damage to the greater palatine artery distal to its anastomosis with the lesser palatine.

Maxillary horizontal excess may also be addressed by anterior maxillary osteotomy when extractions are indicated or edentulous sites are present. These techniques are discussed in detail later in this chapter.

Stable Fixation for Maxillary Osteotomies

Rigid internal fixation with bone plates and screws has become the standard for maxillary stabilization. Although this technique has eliminated many of the early postoperative stability concerns, the technique is less forgiving than wire fixation. Therefore, intraoperative positioning is even more important. A wide variety of plating systems and sizes are available. Each surgeon will discover his or her preference, but 2.0 mm four-hole plates are used in most cases (Figure 57-31). These will require a little more effort for adaptation than lighter ones, but with

practice can be used just as accurately and with more stability. When used, these plates virtually eliminate postoperative plate fracture or mobility.

Specific Procedures

Total Maxillary Alveolar Osteotomy

The total maxillary alveolar osteotomy was designed to avoid some of the problems seen with the Le Fort I down-fracture

technique; however, it did not fare any better.⁷⁵ Purported advantages including improved nasal airway, improved stability due to better bony contact, improved ability to widen the maxilla, and better maxillary perfusion have not been realized.⁷⁵⁻⁸¹ In several thousand maxillary osteotomies over the past 20 years, we have not found a need for this procedure.

Anterior Maxillary Osteotomy

Numerous techniques have been used to accomplish the anterior maxillary osteotomy. The three major techniques involve the use of one of three vascular pedicles: labial (Figure 57-32), palatal (Figure 57-33), and a combination of these with vertical incisions in both (Figure 57-34). All of these can be successful, and when done properly have few complications; however, what scant literature exists would indicate that the palatal pedicle provides the best vascularity.⁵⁰

Anterior maxillary osteotomies are generally used to treat horizontal maxillary excess when the posterior occlusion is correct or correctable by mandibular surgery. Commonly, anterior maxillary osteotomy with premolar extractions is used for bimaxillary protrusion in which both the anterior maxilla and the anterior mandible are to be retracted (Figure

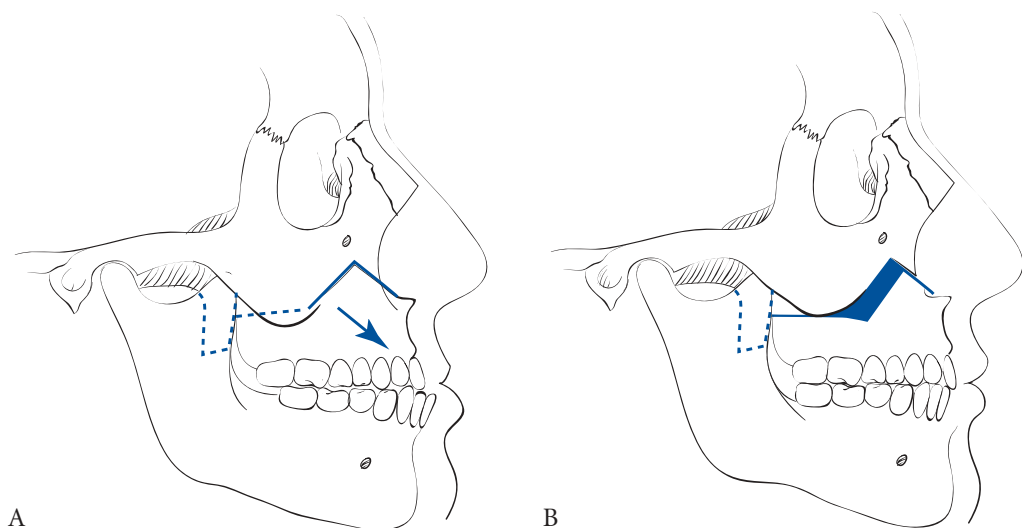


FIGURE 57-27 A, A Z osteotomy with the posterior cut shallower than the anterior one to increase anterior facial height and to (B) rotate the maxilla down in the front and adjust the occlusal plane to a steeper angle.

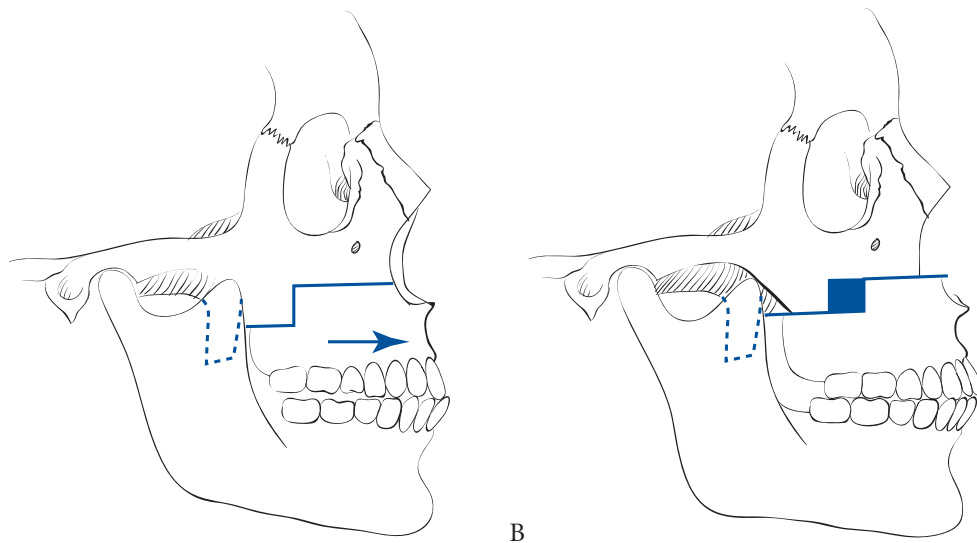


FIGURE 57-28 An alternative method for advancement is to create a step (A) in the buttress and place a bone graft (B) in the step after repositioning.

57-35). These procedures are also used for correction of anterior open bite. Occasionally anterior maxillary osteotomy may be coupled with mandibular advancement and anterior mandibular segmental surgery in patients with a severe curve of Spee.

Sequencing the work-up when both jaws are involved requires imagination, because the surgical procedures need to be done systematically so that the surgeon never loses orientation. There are two possible scenarios: (1) the posterior occlusion is not going to be changed because the posterior maxillary and mandibular teeth need not be moved, or (2) mandibular surgery will be performed thereby correcting the posterior occlusion. This is a crucial difference because if the posterior occlusion is *not* going to be changed by surgery, then the models must be mounted in *centric occlusion*, not centric relation. If the posterior occlusion will be altered by mandibular surgery, then a new centric relation will be established by the surgery and model surgery can be done as usual. In the first case the maxillary anterior model is cut and repositioned to the best relationship against the uncut mandible in centric occlusion and the remaining maxillary dentition, and then a splint is constructed.

If mandibular surgery is to be done, two mandibular models are mounted, one mandibular model is cut, and the other is left intact to preserve the intermediate phase. The anterior maxilla and the mandible are cut and repositioned together to the final position and a final splint is made. The cut maxilla can then be articulated with the uncut mandible to establish the intermediate position and a second (intermediate) splint is made. The final splint will be wired to the maxilla for a postoperative period so there must be a separate intermediate splint that articu-

lates with the final splint and the mandibular teeth.

Particularly in segmental surgery the model surgery should simulate the actual surgery to provide a clear understanding of the three-dimensional movements necessary to the proper performance of the surgical procedure. Measurement marks should be made at the level of the interproximal spaces and the root tips. Marks should also be made on the palate at the root tips and the maxillary midline. If widening is to occur, transpalatal marks should also be used. The use of intermediate splints in segmental cases is a little different from their use in total arch cases. Since the posterior maxilla is not mobilized, the anterior maxillary positioning is more difficult and can be deceiving. For example, the anterior maxilla can fit into the splint and appear ideal until the mandible is rotated into occlusion. If the mandible does not arc into the ideal occlusion, it is possible that the anterior maxilla is tipped superiorly or inferiorly and must be adjusted. For this reason the mandible should not be wired into MMF but left free to rotate into the maxilla. At surgery, if the mandible is held into intermaxillary fixation during the fixation process for the anterior maxilla, it is possible to pull the condyles out of the fossae

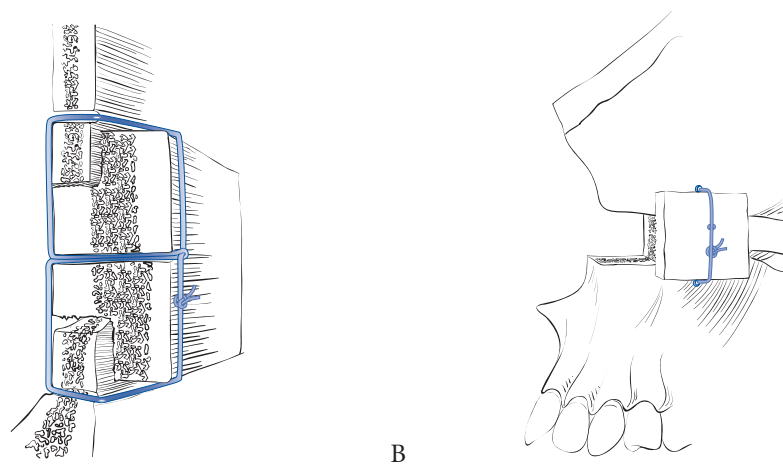
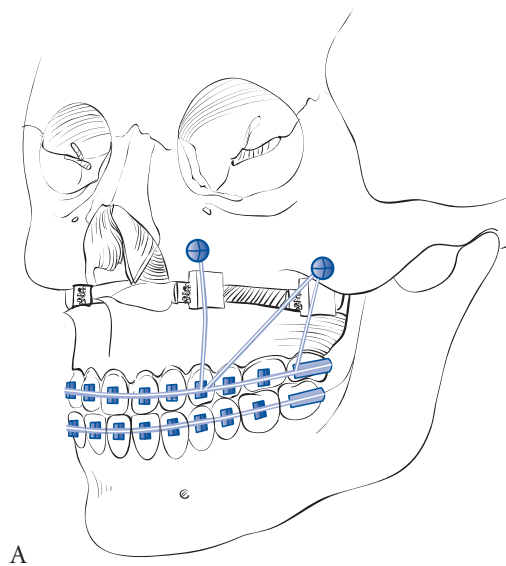
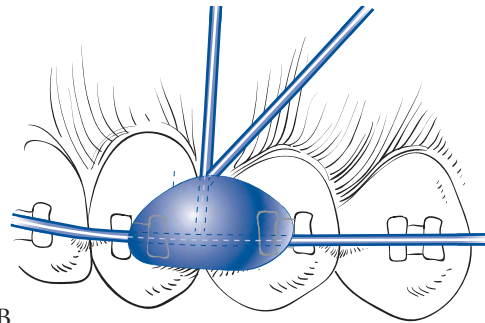


FIGURE 57-29 A, A single hole is placed in the middle of the bone graft and a loop of 28-gauge stainless steel wire is placed through the hole from inside out. The two ends are divided, with one placed through the superior cranial base wall and the other through the inferior maxillary segment. Finally one end is passed through the loop and twisted to the other, much like an Ivy loop. B, Bone graft shown in place.



A

FIGURE 57-30 A, Rigid adjustable pin system. A 0.045 inch orthodontic wire is fabricated on a skull preoperatively and adapted to the newly positioned maxilla intraoperatively so that the wire lies passively, close to the orthodontic appliances or arch bars. B, The acrylic cements the junction of the wire and the orthodontic appliances; the end of the wire is also covered.



B

with a resultant malocclusion. Therefore, the splint must be ligated to the posterior maxilla first, and the anterior maxilla is then brought into the splint and ligated. If the mandible rotates into the desired occlusion, then the maxilla can be considered to be in the correct place and fixed accordingly. If mandibular surgery is required, it can be initiated at this time.

The choice of surgical technique is made on the basis of access and the areas that will be most difficult to visualize intraoperatively. For example, in cases of open bite in which no teeth are to be

extracted, the anterior segment will be rotated clockwise downward after interdental osteotomies. Access to the interdental area, the midline of the palate, and the anterior nasal spine is not as critical as it is with other surgical movements. This procedure can be done with a circumvestibular incision or with bilateral horizontal incisions in the canine-molar regions and a vertical incision in the midline between the central incisors. On the other hand, if first premolars are to be extracted or have already been, and the anterior maxilla is to be retracted several millimeters, access to

the midpalatal area is essential. The Wunderer technique, in which the palatal soft tissue is elevated posteriorly, gives great access to the palatal bony tissue, but care must be taken to preserve the labial soft tissue pedicle.¹⁸ However, if superior repositioning is required, the access to the junction of the anterior nasal spine and the nasal septum is poor. A vertical incision can be made over the anterior nasal spine, but since this labial flap represents the total blood supply to the anterior maxilla, it is not recommended.

Our choice of procedures for most anterior maxillary osteotomies is a hybrid (see Figure 57-34). The labial incisions are made laterally as per Wunderer with a vertical midline incision to permit access to the anterior nasal spine–nasal septum. However, in place of a full palatal flap, circumdental incisions are made around the necks of the teeth on either side of the interdental osteotomies and a midline incision is made over the midpalatal suture with a small anterior Y if necessary. The Y should be anterior to the interdental bone cut and be as conservative as possible.

Fixation of anterior maxillary osteotomies is as varied as the surgical techniques.⁸² Orthodontic arch wires and cast splints represent two of the extremes

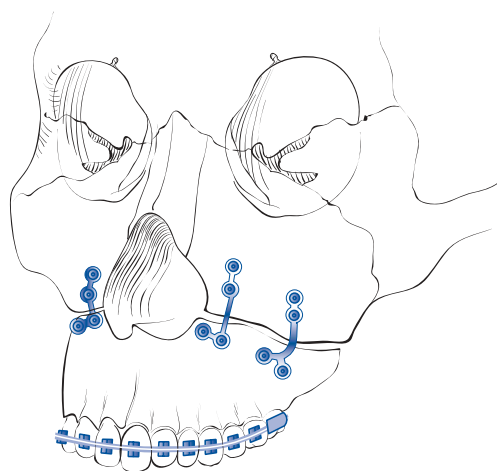


FIGURE 57-31 Bone plating encompasses a wide variety of plates and screws, ranging from very rigid to very malleable. Generally 2.0 mm plates are used in the piriform rims and either 2.0 or 1.5 mm plates in the buttresses.

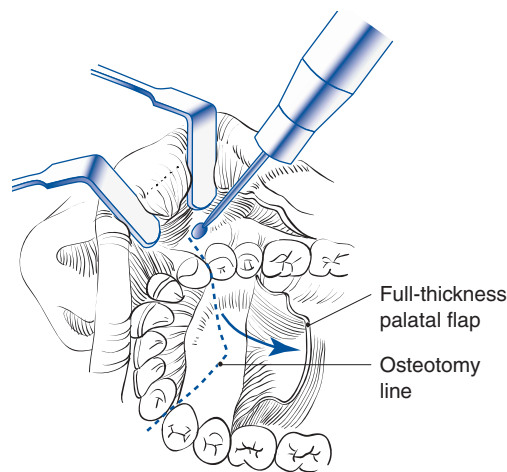


FIGURE 57-32 Labial pedicle for anterior maxillary osteotomy; the palate is flapped open.

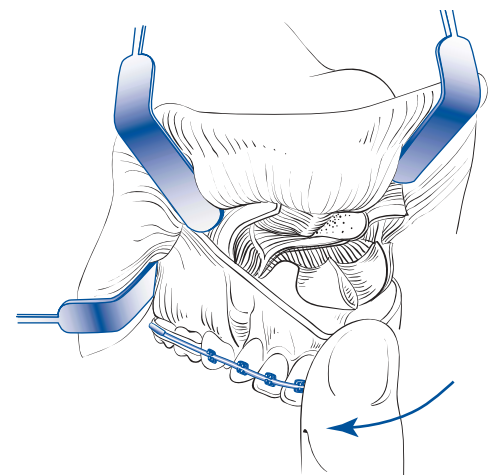


FIGURE 57-33 Palatal pedicle for anterior maxillary osteotomy is created with a horizontal labial incision.

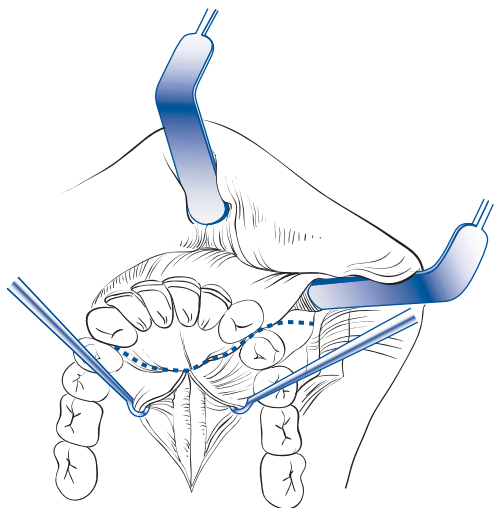


FIGURE 57-34 A combination of labial and palatal pedicles can be used for an anterior maxillary osteotomy without extractions.

in techniques used for fixation. Orthodontic appliances, if they are in place, are the handiest to use at least for part of the fixation. However, supplemental fixation may be desirable. An occlusal splint, with skeletal wire in the anterior nasal spine, is helpful in such cases, especially if tension on the free segment is expected. Small plates and screws can be carefully used to fixate the segment. Arch bars have been used and in certain cases may be appropriate, but a lower level of precision can be expected.

The most important guideline is that, at the time of surgery, the anterior maxilla must be mobile enough so that it does not require any significant pressure to move it into the desired position. Fixation can then be instituted by one of the many methods that will hold the segment in the proper position throughout the healing period. Maxillomandibular fixation is almost never required.

Posterior Maxillary Osteotomy

The posterior maxillary osteotomy and its modifications are rarely indicated today.^{19,22,83-88} If open bite or transverse expansion is needed, the Le Fort I down-fracture is much easier, quicker, and more predictable. Posterior maxillary osteotomy is usually indicated as a preprosthetic pro-

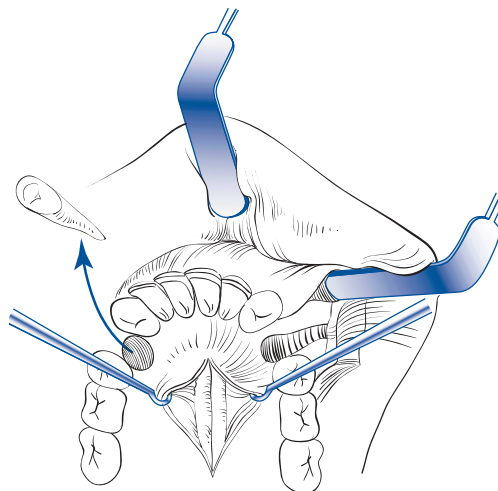


FIGURE 57-35 Anterior maxillary osteotomy with first premolars extracted corrects maxillary excess, bimaxillary protrusion, and anterior open bite.

cedure to correct hypereruption of a posterior maxillary dentoalveolar segment. Meticulous model surgery is essential to visualizing the three-dimensional movements and in anticipating osseous interference of the segment. Periapical radiographs are useful for evaluating planned interdental and supra-apical osteotomy sites. Once again the models should be mounted in centric occlusion, not centric relation, unless the mandible is also going to be operated on.

Outpatient anesthesia can be used for isolated posterior segmental procedures. A high palatal vault permits palatal osteotomy transantrally beneath the nasal floor. The soft tissue incision is made horizontally in the maxillary buccal vestibule from the anticipated anterior interdental osteotomy site to the second molar (Figure 57-36). Mucoperiosteal dissection beneath the superior aspect of the incision exposes the lateral maxilla. The pterygomaxillary region is exposed and soft tissue retracted in a tunneling dissection. At the anterior interdental osteotomy site, conservative tunneling of the periosteum exposes the full vertical extent of the dentoalveolus. After retraction of the soft tissue with skin hooks and right-angle retractors, the buccal interdental osteotomy can be outlined

with a small fissure bur in a rotary hand-piece or can be directly completed with a thin cement spatula osteotome.

A horizontal osteotomy is made approximately 5 mm above the roots of the teeth and connected with the anterior interdental cut (see Figure 57-36). The vertical interdental osteotomy should be completed first so that the segment is not mobile while using interdental osteotomes. The palatal osteotomy is accomplished with a small sharp curved osteotome directed at the juncture of the vertical alveolus and horizontal palatal shelf. The surgeon places a finger in the palatal mucosa to detect complete osseous sectioning while minimizing palatal mucosal trauma (Figure 57-37A and B). In cases with high palatal vaults the transantral cut is completed along the entire anteroposterior extent of the planned palatal osteotomy (see Figure 57-37B), except in the area of the descending palatal neurovascular bundle. Next the pterygomaxillary junction is separated with a chisel using a technique similar to that for a total maxillary osteotomy. Patients with low flat palatal vaults are more easily osteotomized through the nasal floor (Figure 57-37C).

The posterior dentoalveolar segment is down-fractured using digital pressure. Anticipated osseous interference may be

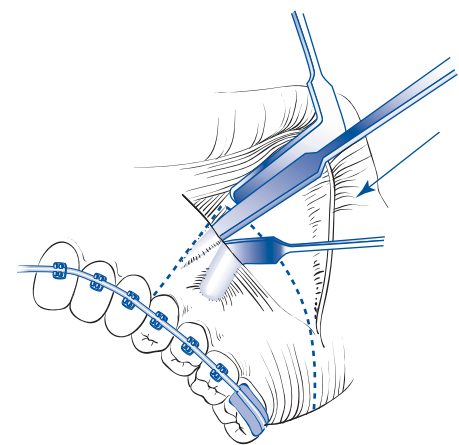


FIGURE 57-36 Posterior maxillary osteotomy. Horizontal vestibular incision with tunneling access to the interdental papilla. The dashed line marks horizontal and interdental osteotomies.

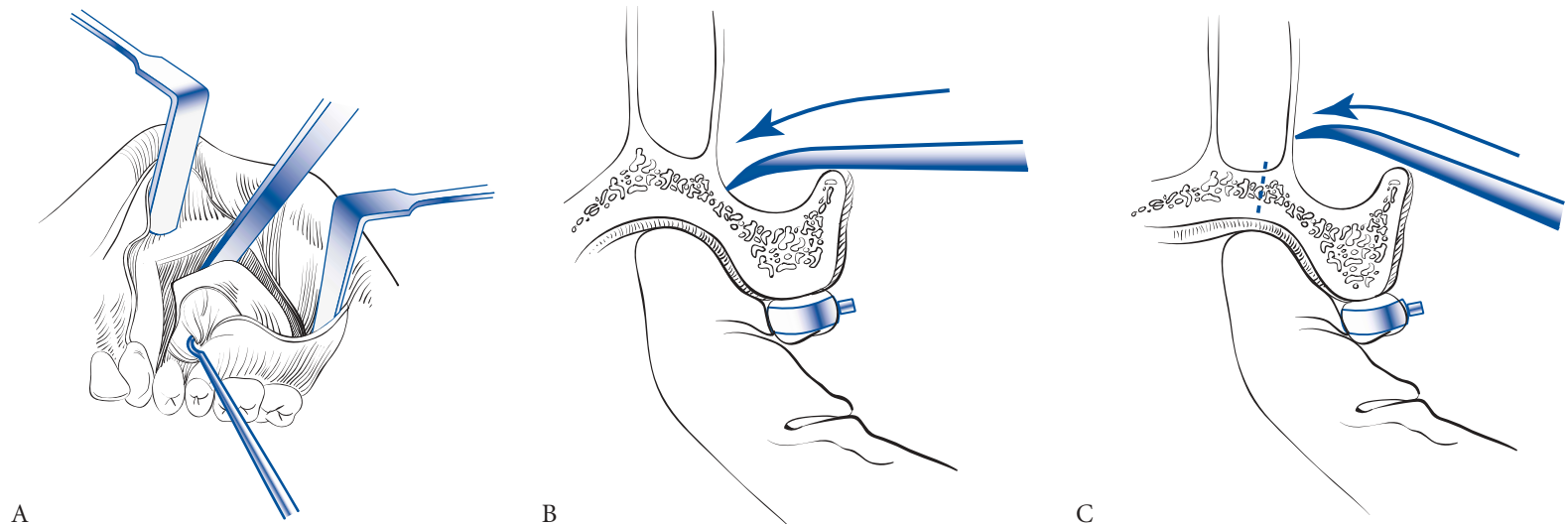


FIGURE 57-37 A, Transantral osteotomy is made at the junction of the horizontal palate and vertical alveolar process. B, Approach for deep vaulted palates. C, Approach for flat shallow palates.

removed using a bur or rongeur. Previously inaccessible medial and posterior walls of the mobile segment are addressed following mobilization and displacement of the posterior segment. Bone removal at the perpendicular plate of the palatine bone and mobilization should continue until the segment can be repositioned with minimal digital force (Figure 57-38). Final contouring is accomplished while holding the splint on the stable portion of the maxilla. The mandible is rotated into its dictated occluding position to ensure that no distortion of the splint has occurred. A slightly thicker splint and transpalatal acrylic or wire reinforcement will add rigidity to prevent inadvertent distortion of the posterior extension of the splint. The segment is ligated to the splint.

The repositioned posterior maxillary segment may be fixated with interosseous wire, suspension wire, stable pin fixation, or bone plates. Osseous grafts are rarely required but may be obtained from local regional sites. Additional stability is attained by luting the orthodontic arch wire back together with quick curing acrylic or by placing a rectangular arch wire across the interdental osteotomy site. Intermaxillary fixation is not required.

If the posterior segment is to be repositioned laterally or medially to any extent, added access is necessary. A midline palatal incision may be made and the palatal tissue reflected laterally (Figure 57-39). Careful dissection ensures the integrity of the greater palatine vasculature. This approach gives access to the sinus and nasal cavity. If the palatal vault is high, the osteotomy is usually carried through the sinus (see Figure 57-37B). If the alveolus is short and the palatal vault shallow, the osteotomy usually crosses the medial sinus wall and passes through the floor of the nose (see Figure 57-37C).

Surgically Assisted Rapid Palatal Expansion: History

The concept of correcting maxillary transverse width discrepancies originated in the United States in 1860 by Angell, who reported it in *Dental Cosmos*. Angell described a widening of the maxillary dental arch by opening the midpalatal suture.⁸⁹ The concept fell into disuse by American practitioners by the early 1900s. Haas re-introduced the concept in 1961 with rapid palatal expansion (RPE, also referred to as rapid maxillary expansion), appliances that effectively corrected arch width discrepancies.⁹⁰ In growing

children nonsurgical RPE results in opening of the midpalatal suture, but stability has been questioned. Timms and Moss, Haas, and Isaacson and Ingram have shown orthodontic RPE to result in alveolar bending, periodontal membrane compression, lateral tooth displacement, and tooth extrusion.⁹¹⁻⁹³ For those reasons Haas believed that overexpansion was very important. Even

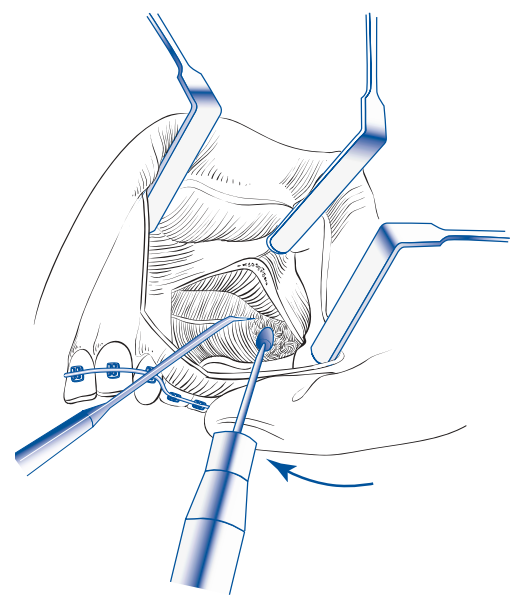


FIGURE 57-38 Bone is removed at the perpendicular plate of the palatine bone using a transantral approach.

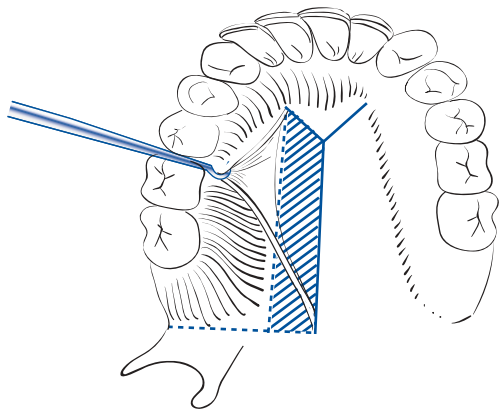


FIGURE 57-39 A midline palatal incision gives access for the removal of bone as the posterior maxillary segment is moved medially.

with 50% overexpansion, nonsurgical RPE has been associated with relapse and subsequent failure in adults, but has been relatively successful in children and adolescents.^{91–93}

Although historically the midpalatal suture was thought to be the area of resistance to expansion, Isaacson and Ingram have shown that the major site of resistance is not the midpalatal suture but the remaining maxillary articulations.⁹³ Lines as well as Bell and Epker demonstrated that increased facial skeletal resistance to expansion was at the zygomaticotemporal, zygomaticofrontal, and zygomaticomaxillary sutures.^{94,95} Wertz theorized that the resistance was due to the zygomatic arches.⁹⁶ Identification of these areas of resistance in the craniofacial skeleton stimulated the development of various maxillary osteotomies to expand the maxilla in conjunction with orthodontic appliances.⁹⁶ Published surgical techniques report the removal of the bony resistance of the maxilla in order to symmetrically expand the hemimaxillas with short-term orthopedic forces.^{94,95,97–101} Lehman and colleagues have also demonstrated expansion with an RPE appliance.⁹⁷ Kennedy and colleagues reported a significant increase in the amount of lateral movement in animals that had osteotomies prior to orthodontic RPE.⁹⁸

Reported results vary with technique and the timing of placement of an active orthopedic expansion device, but all note the expansion to be more stable than orthodontic RPE alone.

The role of surgery with RPE is to release the areas of resistance in the maxillas before RPE. Whether RPE will be done alone or in conjunction with surgery will depend on the patient's age and the condition of the midpalatal suture, but not the maxillomandibular relation. Lines found surgically assisted rapid palatal expansion (SARPE) to be extremely valuable in young patients (growing children) exhibiting maxillary collapse, maxillary retrusion, and pseudo-Class III malocclusions.⁹⁴

SARPE is distraction osteogenesis of the maxilla in a transverse plane. The benefits of its use are gradual callous distraction that allows the soft tissues to accommodate, and greater long-term stability.

When maxillary expansion and total maxillary osteotomy are needed, two treatment regimens are possible: SARPE as a first stage followed by a one-piece maxillary osteotomy at a later date or multiple-piece maxillary osteotomy in the normal orthognathic sequence. The four factors that must be considered when determining which method is preferred are arch length discrepancy, arch morphology, vertical dimension, and ectopic eruption of posterior teeth.

Arch Length Discrepancy In cases of arch length deficiency, a SARPE increases arch circumference sufficiently, especially in the anterior, to permit alignment of crowded teeth and avoid extraction of premolars or excessive tipping of incisors. SARPE is also beneficial when minimal changes in the sagittal dimension are necessary because of the nasolabial angle and lip-to-tooth considerations.

Arch Morphology The majority of cases of transverse deficiency characteristically exhibit a narrow tapering arch form with

the discrepancy pronounced in the canine region. To achieve a functional occlusion, the intercanine width must be increased and the anterior segment flattened for a normal elliptical arch morphology. If nonextraction orthodontic therapy is desired, a SARPE is the treatment of choice. A three- or four-piece segmental maxillary surgical procedure may be less ideal, particularly because of potential periodontal problems and possible vascular compromise.

If the discrepancy is minimal and extraction of the first premolars is desired, a three-piece segmental maxillary procedure is indicated, but only after the canines are orthodontically moved posteriorly to provide an increased width. The inherent problem is relapse of the buccally displaced canines. This procedure is indicated if there is no transverse discrepancy in the canine region but significant constriction in the premolar-molar region.

Vertical Dimension The vertical dimension is of particular concern in patients who exhibit anterior open bites. Segmental orthodontics is suggested, with no attempt to level the arch, using a three- or four-piece maxillary procedure to level the arch and at the same time correct the bilateral absolute transverse maxillary deficiency.

Ectopic Eruption of One or Two Posterior Teeth If ectopic eruption is serious enough that it cannot be treated with orthodontic therapy, a segmental osteotomy with expansion may be done.

The stability of SARPE has been reported.^{99,102} In one reported study on long-term stability of SARPE, the surgical results remained stable with only 6.4 to 7.5% relapse in the canine, premolar, and molar regions.⁹⁹ This stability exceeds that of multiple-piece Le Fort osteotomies.^{100,102}

Surgically Assisted Rapid Palatal Expansion: Surgical Technique

Bilateral mucoperiosteal incisions are made from the piriform rims to zygomatic

buttresses (Figure 57-40A). Bilateral osteotomies are then made from the piriform rims to low in the pterygomaxillary junction (see Figure 57-40A). A simple anteroposterior osteotomy from the piriform rim to the pterygomaxillary junction is suggested for SARPE. More complicated designs appear to be advantageous in two-dimensional drawings, but in fact are meaningless when applied to three-dimensional geometric structures such as the maxilla.¹⁰³ The theory put forth by Betts and colleagues shows a sloped cut from the piriform to the buttress.¹⁰³ The supposition is that as the maxilla is expanded, it will “ride down” this slope. This concept appears valid in a two-dimensional drawing; however, three-dimensionally, if the osteotomy is made flat from lateral to medial, as expansion occurs, then the bone at the piriform slides laterally over the flat surface lateral to it and the bone of the buttress slides laterally over the flat surface lateral to it. Therefore, if the lateral maxillary wall saw cuts are made straight in perpendicular to the midsagittal plane from lateral to medial, then the angulation of the cut from anterior to posterior does not affect the vertical position of the segments as they are expanded. This can be easily demonstrated on a dry skull.

Osteotomies are made of the anterior 1.5 cm of the lateral nasal wall because this is the thickest portion of the anterior nasal wall. Separation of the hemimaxillas is performed by driving a spatula osteotome between the central incisors parallel to the palate for approximately 1 to 1.5 cm (Figure 57-40B–D). The expansion device is turned until separation is noted between the central incisor teeth (Figure 57-41). Both segments are mobilized by prying until equal mobility is seen bilaterally. Mobilization is continued until approximately 1.5 to 2.0 mm is opened between central incisors.

Some authors recommend a subtotal Le Fort I osteotomy with a horizontal

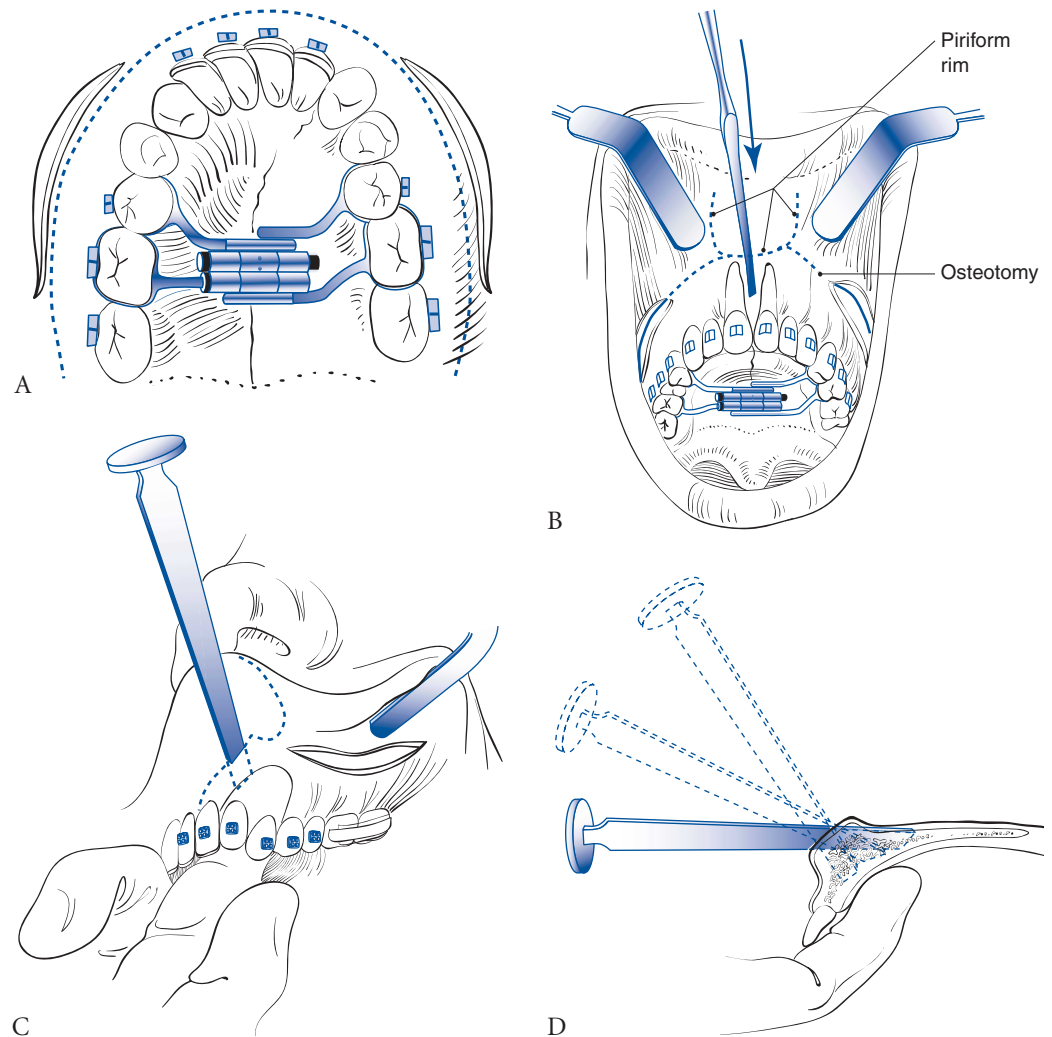


FIGURE 57-40 Surgically assisted rapid palatal expansion. A, Bilateral horizontal mucoperiosteal incisions are made, followed by bilateral osteotomies from the piriform rims to pterygomaxillary junctions. B–D, Division of hemimaxillae is accomplished by inserting an osteotome in the midline.

osteotomy, vertical midline osteotomy, and pterygoid and septal separation.¹⁰³ Shetty and colleagues demonstrated, with a photoelastic model, that the mid-palatal and pterygomaxillary articulations were the primary anatomic sites of resistance to expansion forces.¹⁰⁴ The article by Shetty and colleagues in 1994 report performing only incomplete cuts of the lateral maxillary wall, from second bicuspid to second molar. It is unclear whether these findings would be as significant with complete cuts from the piriform to the pterygomaxillary fissure. Need for separation of the pterygomaxillary junction is therefore a point of debate. However, since our results have

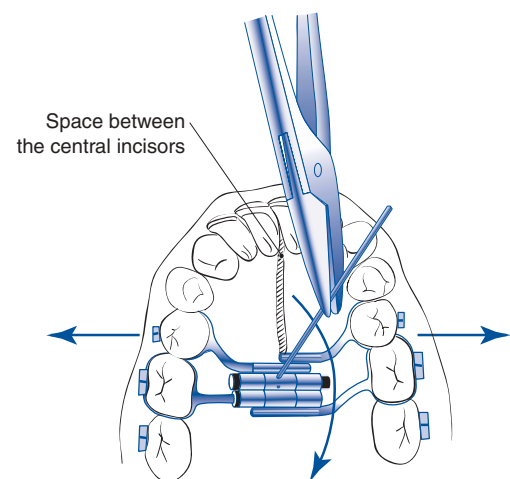


FIGURE 57-41 Surgically assisted rapid palatal expansion. Expansion device is turned to separate hemimaxillas.

shown minimal relapse without pterygo-maxillary disjunction, we do not perform this maneuver in most cases.⁹⁹

If two sources of potential hemorrhage (manipulation of the pterygomaxillary junction and separation of the nasal septum from the nasal crest of the maxilla) are avoided, this procedure can be done as an office-based procedure, on an outpatient basis, and under intravenous sedation. Steroids are routinely used but antibiotics are not necessary. A 5-day postoperative rest period is observed, after which the expansion appliance is turned according to specific instructions until the desired expansion is achieved.

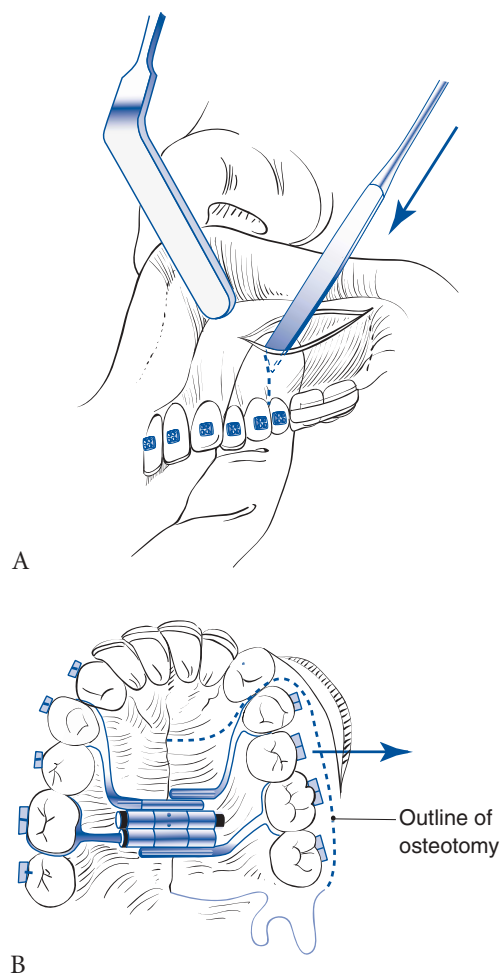


FIGURE 57-42 Unilateral surgically assisted rapid palatal expansion. A, Osteotomy is driven to midpalatal suture. B, Horizontal osteotomy is completed in the same manner as bilateral osteotomy.

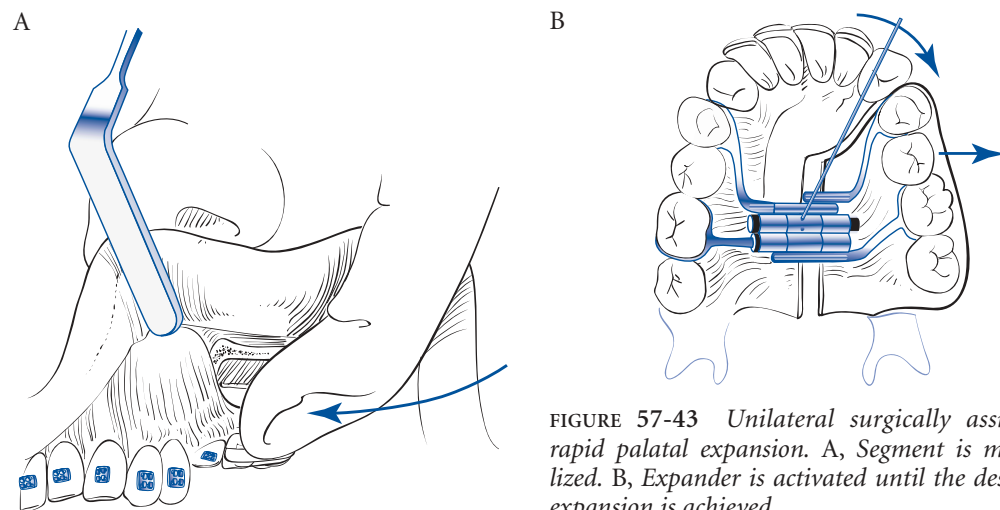


FIGURE 57-43 Unilateral surgically assisted rapid palatal expansion. A, Segment is mobilized. B, Expander is activated until the desired expansion is achieved.

Unilateral SARPE can be achieved by completing a vertical interdental osteotomy between the appropriate teeth and connecting that with a horizontal osteotomy extending posteriorly to the pterygomaxillary junction. If the entire hemimaxilla is to be mobilized, it is performed in the same way as described for a bilateral case, only unilaterally. If a widening of only the posterior part of the hemimaxilla

is desired, the interdental osteotomy must be completed all the way to the midline suture (Figure 57-42). The segment is mobilized (Figure 57-43A) and expanded in the same manner as the bilateral procedure (Figure 57-43B).

Zygomatic Osteotomy

In patients with severe midface deficiency it may be favorable to enhance the prominence

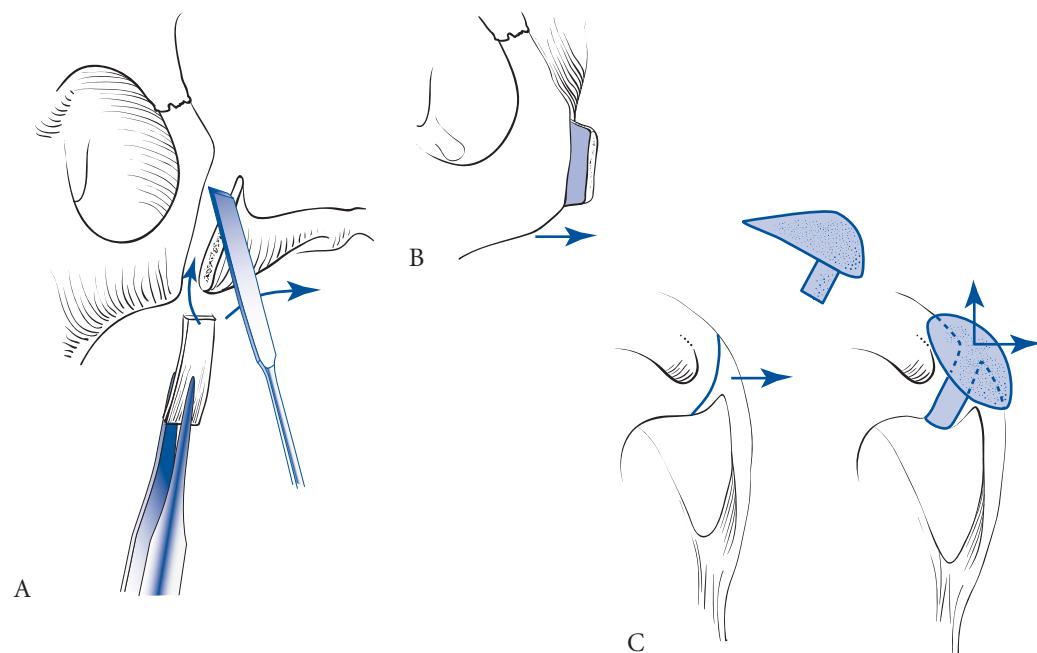


FIGURE 57-44 Zygomatic osteotomy. A, Parasagittal vertical osteotomy cuts through the root of the zygoma. B, With out-fracturing and placement of graft material for transverse augmentation of the malar eminence. C, Mushroom-shaped graft placement for anteroposterior and transverse augmentation of the malar eminence.

of the zygomas. Also, esthetically, high cheekbones have always been popular, and with a growing public awareness of surgical capabilities an increasing demand has surfaced for procedures to enhance this area. Numerous methods have been developed to augment the malar eminences, most involving grafts or implants. Autologous grafts are disappointing because of resorption and the need for a donor site. Allogeneic transplants such as lyophilized cartilage have been used with some success but are prone to migration. Presently our choice for malar augmentation is with alloplastic implants (porous polyethylene).

However, when alloplasts are contraindicated, the zygomatic osteotomy may be useful. The zygomatic osteotomy is approached through an intraoral incision. A reciprocating saw is used to make a parasagittal osteotomy through the zygoma just adjacent to the root of the structure (Figure 57-44A and B). This is done as close to the lateral orbital rim as possible. The zygoma is out-fractured gently so that an interpositional material can be placed to hold it in position. The interpositional material can be stabilized in any traditional method, since it is not difficult to fixate this area. This technique does not give anterior projection unless the interpositional material is fashioned to project forward (Figure 57-44C).

Modified Le Fort Osteotomies

Osteotomies that extend the traditional Le Fort I have been called by many names including modified Le Fort I, II, III; high Le Fort I; and pyramidal, middle, intermediary, quadrangular, and maxillary-malar-infraorbital osteotomies (Figure 57-45A–C). We have used them all and have described them previously.¹⁰⁵ This group of osteotomies is severely limited regarding expansion, and rotational and torquing movements. Therefore, with the success of porous polyethylene implants to the malar, infraorbital, lateral orbital, and paranasal regions, we rarely see a need for these more invasive osteotomies (Figure 57-46A–C).

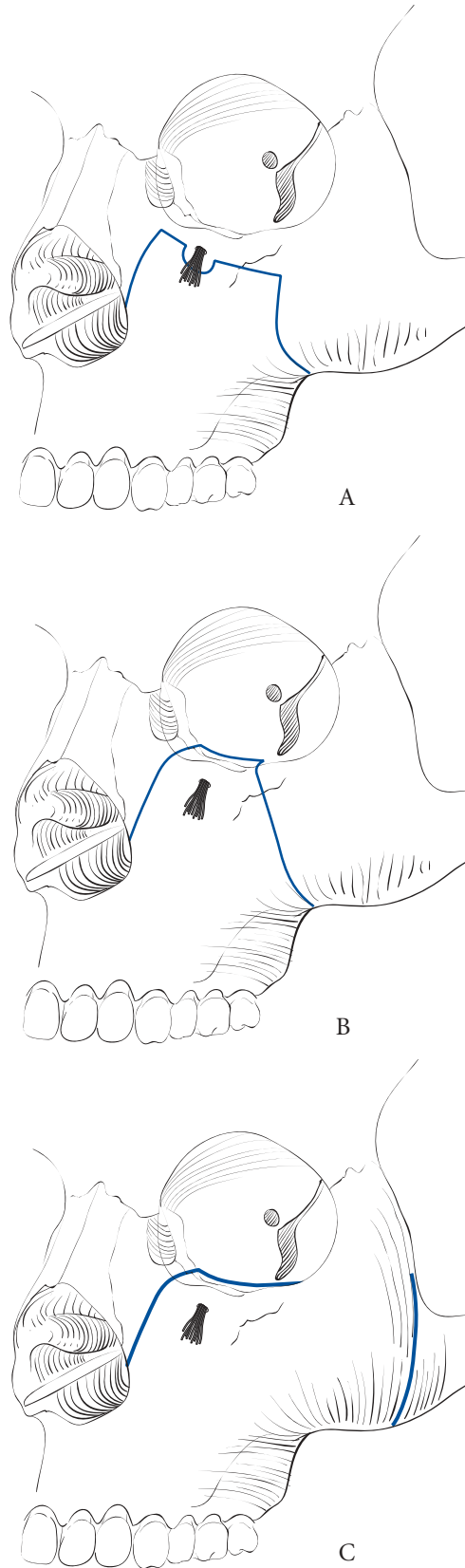


FIGURE 57-45 Modified Le Fort I osteotomy. A, High Le Fort I below the infraorbital rims. B, Quadrangular Le Fort I extending into the orbital floor. C, Quadrangular Le Fort I including the lateral orbital rim and zygoma.

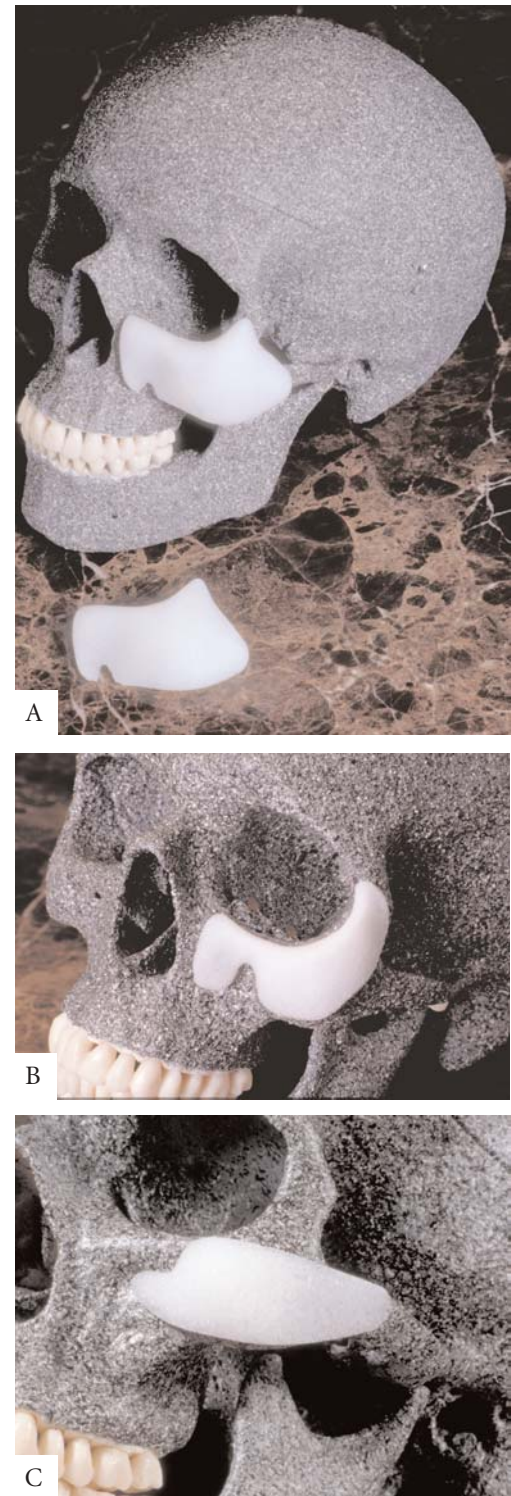


FIGURE 57-46 Porous polyethelene implants. A, Infraorbital augmentation with the zygoma. B, Infraorbital augmentation with the zygoma and lateral orbital rim. C, Zygoma augmentation.

References

1. von Langenbeck B. Beitrage zur Osteoplastik. In: Goschen A, editor. Die osteoplastische Resektion des Oberkiefers. Deutsche Klinik. Berlin: Reimer; 1859.
2. Cheever D. Naso-pharyngeal polpus, attached to the basilar process of occipital and body of the sphenoid bone successfully removed by a section, displacement, and subsequent replacement and reunion of the superior maxillary bone. *Boston Med Surg* 1867;8:162.
3. Le Fort R. Fractures de la machoire superieure. *Rev Chir* 1901;4:360.
4. Wassmund M. Frakturen und Lurationen des Gesichtsschadels. Berlin; 1927.
5. Axhausen G. Zur Behandlung veralteter desloziert verheilte Oberkieferbrunche. *Dtsch Zahn Mund Kieferheilkd* 1934;1:334.
6. Schuchardt D. Ein Beitrag zur chirurgischen Kieferorthopadie unter Berucksichtigung ihrer Bedertung fur die Behandlung angeborener und erworbener Kieferdeformaten bei Soldaten. *Dtsch Zahn Mund Kieferheilkd* 1942;9:73.
7. Moore F, Ward F. Complications and sequelae of untreated fractures of the facial bones and their treatment. *Plast Surg* 1949;1:262.
8. Willmar K. On Le Fort I osteotomy; A follow-up study of 106 operated patients with maxillo-facial deformity. *Scand J Plast Reconstr Surg* 1974;12 (Suppl 12):1-68.
9. Obwegeser H. Eingriffe an Oberkiefer zur Korrektur des progenen. Vol 75. *Zahnheilk*; 1965, p. 356.
10. Hogemann K, Willmar K. Die Vorverlagerung des Oberkiefers zur Korrektur von Gebisanomalien. In: Schuchardt K, editors. *Gesichtschir* Hrsg. Stuttgart: Thieme; 1967.
11. deHaller C. Ergebnisse ders operativin Vorbringens des Oberkiefers; 1969.
12. Perko M. Maxillary sinus and surgical movement of maxilla. *Int J Oral Surg* 1972; 1:177-84.
13. Cohn-Stock G. Die Chirugische-Immediatre-Julierung der Kiefer speziell die Chirurgische Behandlung der Prognathie. *Vjschr Zahnheilk (Berlin)* 1921;37:320.
14. Spanier F. Prognathie-Operationen Z zahnarytl. *Orthop Munchen* 1932;24:76.
15. Cupar I. Die Chirurgische Behandlung der Formund Stellungsveranderungen des Oberkiefers. *Ost Z Stomat* 1954;51:565.
16. Cupar I. Die Chirurgische Behandlung def Formund Stellungsveranderungen des Oberkiefers. *Buss Sc Cons Acad RPF Yougosl* 1955;2:60.
17. Kole H. Surgical operations on the alveolar ridge to correct occlusal abnormalities. *Oral Surg* 1959;12:277.
18. Wunderer S. Erfahrungen mit der operativen Behandlung hochgradiger Prognathien. *Dtsch Zahn Mund Kieferheilkd* 1963;39:451.
19. Schuchardt K. Experiences with the surgical treatment of deformities of the jaws: prognathia, micrognathia and open bite. In: Wallace AG, editor. *Second Congress of International Society of Plastic Surgeons*. Vol 73. London: E & S Livingstone; 1959.
20. Kufner J. Experience with a modified procedure for correction of open bite. In: Walker RV, editor. *Transactions of the Third International Conference on Oral Surgery*. Vol 18. London: E & S Livingstone; 1970.
21. West RA, McNeill RW. Maxillary alveolar hyperplasia, diagnosis and treatment planning. *J Maxillofac Surg* 1975;3:239-50.
22. Bell WH. Correction of skeletal type of anterior open bite. *J Oral Surg* 1971; 29:706-14.
23. Converse J, Shapiro H. Treatment of developmental malformation of the jaws. *Plast Reconstr Surg* 1952; 10:473.
24. Kole H. In: Reischenback, Kole, Brueckel, eds. *Chir Kieferorthopadie*. Leipzig: Barth, 1965.
25. Bell WH, Fonseca RJ, Kennedy JW, Levy BM. Bone healing and revascularization after total maxillary osteotomy. *J Oral Surg* 1975; 33:253-60.
26. Gillies J, Rowe N. L'osteotomie du maxillaire superieur envisagee essentiellement dans les cas de bec-de-lievre totale. *Rev Stomat* 1954;55:545.
27. Obwegeser HL. Surgical correction of small or retrodisplaced maxillae. The "dish-face" deformity. *Plast Reconstr Surg* 1969; 43:351-65.
28. Michelet FX, Deymes J, Dessus B. Osteosynthesis with miniaturized screwed plates in maxillo-facial surgery. *J Maxillofac Surg* 1973;1(2):79-84.
29. Horster W. Experience with functionally stable plate osteosynthesis after forward displacement of the upper jaw. *J Maxillofac Surg* 1980;8(3):176-81.
30. Drommer R, Luhr HG. The stabilization of osteotomized maxillary segments with Luhr mini-plates in secondary cleft surgery. *J Maxillofac Surg* 1981;9:166-9.
31. Luyk NH, Ward-Booth RP. The stability of Le Fort I advancement osteotomies using bone plates without bone grafts. *J Maxillofac Surg* 1985;13(6):250-3.
32. Edwards RC, Kiely KD. Resorbable fixation of Le Fort I osteotomies. *J Craniofac Surg* 1998;9(3):210-4.
33. Bays RA. Rigid stabilization system for maxillary osteotomies. *J Oral Maxillofac Surg* 1985;43:60-3.
34. Stringer DE, Boyne PJ. Modification of the maxillary step osteotomy and stabilization with titanium mesh. *J Oral Maxillofac Surg* 1986;44:487-8.
35. Olson RE, Laskin DM. Expectations of patients from orthognathic surgery. *J Oral Surg* 1980;38:283-5.
36. Ong TK, Banks RJ, Hildreth AJ. Surgical accuracy in Le Fort I maxillary osteotomies. *Br J Oral Maxillofac Surg* 2001;39:96-102.
37. Renzi G, Carboni A, Perugini M, Becelli R. Intraoperative measurement of maxillary repositioning in a series of 30 patients with maxillomandibular vertical asymmetries. *Int J Adult Orthodon Orthognath Surg* 2002;17(2):111-5.
38. Schaeffer J. The sinus maxillaires and its relations in the embryo, child and adult man. *Am J Anat* 1910b;10:313.
39. Klaff D. The surgical anatomy of the antero caudal portion of the nasal septum: a study of the area of the premaxilla. *Laryngoscope* 1956;66:995.
40. Cottle M, Loring RM, Fischer GG, Gaynon IE. The maxilla-premaxilla approach to extensive nasal septum surgery. *Arch Otolaryngol* 1958;68:301.
41. Hollinshead W. *Anatomy for surgeons*. 3rd ed. Philadelphia (PA): Harper and Row; 1982.
42. Hollinshead W. *Textbook of anatomy*. 3rd ed. Hagerstown (MD): Harper and Row; 1974.
43. Sewall E. Surgical removal of the sphenopalatine ganglion. *Ann Otol Rhinol Laryngol* 1937;46:79.
44. Bell WH. Le Fort I osteotomy for correction of maxillary deformities. *J Oral Surg* 1975; 33:12-26.
45. Bell WH. Revascularization and bone healing after anterior maxillary osteotomy: a study using adult rhesus monkeys. *J Oral Surg* 1969;27:249-55.
46. Siebert JW, Angrigiani C, McCarthy JG, Longaker MT. Blood supply of the Le Fort I maxillary segment: an anatomic study. *Plast Reconstr Surg* 1997;100:843-51.
47. Brusati R, Bottoli V. Maxillary anterior segmentary osteotomy: experimental research on vascular supply of osteotomised segment. *Fortschritte der Kiefer- und Gesichtschirurgie* 1974;18:90-3.
48. Miller M, Christensen G, Evan H. *Anatomy of the dog*. Philadelphia (PA): WB Saunders; 1964.
49. Nelson RL, Path MG, Ogle RG, et al. Quantitation of blood flow after Le Fort I osteotomy. *J Oral Surg* 1977;35:10-6.
50. Nelson RL, Path MG, Ogle RG, et al. Quantitation of blood flow after anterior maxillary

- osteotomy: investigation of three surgical approaches. *J Oral Surg* 1978; 36:106–11.
51. Lightoller G. Facial muscles *J Anat* (Lond) 1925;60:1.
 52. Nairn RI. The circumoral musculature: structure and function. *Br Dent J* 1975;138:49–56.
 53. Robinson PP, Hendy CW. Pterygoid plate fractures caused by the Le Fort I osteotomy. *Br J Oral Maxillofac Surg* 1986;24:198–202.
 54. Lanigan DT, West RA. Management of postoperative hemorrhage following the Le Fort I maxillary osteotomy. *J Oral Maxillofac Surg* 1984;42:367–75.
 55. Hemmig SB, Johnson RS, Ferraro N. Management of a ruptured pseudoaneurysm of the sphenopalatine artery following a LeFort I osteotomy. *J Oral Maxillofac Surg* 1987; 45:533–6.
 56. Solomons NB, Blumgart R. Severe late-onset epistaxis following Le Fort I osteotomy: angiographic localization and embolization. *J Laryngol Otol* 1988;102:260–3.
 57. Newhouse RF, Schow SR, Kraut RA, Price JC. Life-threatening hemorrhage from a Le Fort I osteotomy. *J Oral Maxillofac Surg* 1982;40:117–9.
 58. Dodson TB, Bays RA, Neuenschwander MC. Maxillary perfusion during Le Fort I osteotomy after ligation of the descending palatine artery [comment]. *J Oral Maxillofac Surg* 1997;55(1):51–5.
 59. Bouloux GF, Bays RA. Neurosensory recovery after ligation of the descending palatine neurovascular bundle during Le Fort I osteotomy. *J Oral Maxillofac Surg* 2000;58(8):841–5; discussion, 846.
 60. Bell WH, Proffit WP. Maxillary Excess. In: Bell WH, Proffit WP, White RP, eds. *Surgical correction of dentofacial deformities. Vol I.* Philadelphia (PA): WB Saunders; 1980. p. 234–441
 61. Reyneke JP, Masureik CJ. Treatment of maxillary deficiency by a Le Fort I downsliding technique. *J Oral Maxillofac Surg* 1985;43:914–6.
 62. Bennett MA, Wolford LM. The maxillary step osteotomy and Steinmann pin stabilization. *J Oral Maxillofac Surg* 1985;43:307–11.
 63. Kaminishi RM, Davis WH, Hochwald DA, Nelson N. Improved maxillary stability with modified Lefort I technique. *J Oral Maxillofac Surg* 1983;41(3):203–5.
 64. Stringer DE, Boyne PJ. Modification of the maxillary step osteotomy and stabilization with titanium mesh. *J Oral Maxillofac Surg* 1986;4:487–8.
 65. Bays RA. Maxillary osteotomies utilizing the rigid adjustable pin (RAP) system: a review of 31 clinical cases. *Int J Adult Orthodont Orthognath Surg* 1986;1:275–97.
 66. Hedemark A, Freihofer HP Jr. The behaviour of the maxilla in vertical movements after Le Fort I osteotomy. *J Maxillofac Surg* 1978;6:244–9.
 67. Epker BN, Fish LC, Paulus PJ. The surgical-orthodontic correction of maxillary deficiency. *Oral Surg Oral Med Oral Pathol* 1978;46:171–205.
 68. Wolford LM, Hilliard FW. The surgical-orthodontic correction of vertical dentofacial deformities. *J Oral Surg* 1981;39:883–97.
 69. Freihofer HP Jr. Results of osteotomies of the facial skeleton in adolescence. *J Maxillofac Surg* 1977;5:267–97.
 70. Bell WH, Jacobs JD, Quejada JG. Simultaneous repositioning of the maxilla, mandible, and chin. Treatment planning and analysis of soft tissues. *Am J Orthod* 1986;89:28–50.
 71. Persson G, Hellem S, Nord PG. Bone-plates for stabilizing Le Fort I osteotomies. *J Maxillofac Surg* 1986;14:69–73.
 72. Wessberg GA, Epker BN. Intraoral skeletal fixation appliance. *J Oral Maxillofac Surg* 1982;40:827–9.
 73. Dupont C, Ciaburro TH, Prevost Y. Simplifying the Le Fort I type of maxillary osteotomy. *Plast Reconstr Surg* 1974;54:142–7.
 74. Trimble LD, Tideman H, Stoelinga PJ. A modification of the pterygoid plate separation in low-level maxillary osteotomies. *J Oral Maxillofac Surg* 1983;41:544–6.
 75. Wolford LM, Epker BN. The combined anterior and posterior maxillary osteotomy: a new technique. *J Oral Surg* 1975;33:842–51.
 76. Hooley J, West R. Vertical repositioning of total maxillary alveolus to compensate for “short upper lip.” *Second Congress of the Europe Association for Maxillofacial Surgery; 1974.* [abstract]
 77. Guenther TA, Sather AH, Kern EB. The effect of Le Fort I maxillary impaction on nasal airway resistance. *Am J Orthod* 1984;85:308–15.
 78. Turvey TA, Hall DJ, Warren DW. Alterations in nasal airway resistance following superior repositioning of the maxilla. *Am J Orthod* 1984;85(2):109–14.
 79. Warren DW. A quantitative technique for assessing nasal airway impairment. *Am J Orthod* 1984;86:306–14.
 80. Walker DA, Turvey TA, Warren DW. Alterations in nasal respiration and nasal airway size following superior repositioning of the maxilla. *J Oral Maxillofac Surg* 1988;46:276–81.
 81. Moloney F, West RA, McNeill RW. Surgical correction of vertical maxillary excess: a re-evaluation. *J Maxillofac Surg* 1982;10:84–91.
 82. Bays RA, Fonseca RJ, Turvey TA. Single arch stabilization devices for segmental orthognathic surgery. *Oral Surg Oral Med Oral Pathol* 1978;46:467–76.
 83. West RA, Epker BN. Posterior maxillary surgery its place in the treatment of dentofacial deformities. *J Oral Surg* 1972;30:562–3.
 84. Sailer HF. [Routine methods in orthodontic surgery]. *Revue d Orthopedie Dento-Faciale* 1982;16:307–26.
 85. Merville LC, Princ G. Postero-lateral expansion osteotomy of maxilla. A case report. *J Craniomaxillofacial Surg* 1987;15:20–3.
 86. Bell WH, Turvey TA. Surgical correction of posterior crossbite. *J Oral Surg* 1974; 32:811–22.
 87. Perko M. [Late surgical correction of tooth malpositions and jaw abnormalities in patients with clefts]. *SSO: Schweizerische Monatsschrift fur Zahnheilkunde* 1969;79:179–213.
 88. Moloney F, Stoelinga PJ, Tideman H. The posterior segmental maxillary osteotomy: recent applications. *J Oral Maxillofac Surg* 1984;42:771–81.
 89. Angell EH. Treatment of irregularities of the permanent adult tooth. *Dent Cosmos* 1860;1:540.
 90. Haas A. Rapid expansion of the maxillary dental arch and nasal cavity by opening the mid palatal structure. *Angle Orthod* 1961;31:73.
 91. Timms DJ, Moss JP. A histological investigation into the effects of rapid maxillary expansion on the teeth and their supporting tissues. *Transact Europ Orthod Soc* 1971:263–7.
 92. Haas AJ. Long-term posttreatment evaluation of rapid palatal expansion. *Angle Orthod* 1980;50:189–217.
 93. Isaacson R, Ingram A. Forces produced by rapid maxillary expansion: forces present during treatment. *Angle Orthod* 1964;34:256.
 94. Lines PA. Adult rapid maxillary expansion with corticotomy. *Am J Orthod* 1975;67:44–56.
 95. Bell WH, Epker BN. Surgical-orthodontic expansion of the maxilla. *Am J Orthod* 1976;70:517–28.
 96. Wertz RA. Skeletal and dental changes accompanying rapid midpalatal suture opening. *Am J Orthod* 1970;58:41–66.
 97. Lehman JA Jr, Haas AJ, Haas DG. Surgical orthodontic correction of transverse maxillary deficiency: a simplified approach. *Plast Reconstr Surg* 1984;73:62–8.
 98. Kennedy JW III, Bell WH, Kimbrough OL, James WB. Osteotomy as an adjunct to rapid maxillary expansion. *Am J Orthod* 1976;70:123–37.
 99. Bays RA, Greco JM. Surgically assisted rapid palatal expansion: an outpatient technique with long-term stability. *J Oral Maxillofac Surg* 1992;50(2):110–3; discussion 114–5.
 100. Phillips C, Medland WH, Fields HW Jr.

- Stability of surgical maxillary expansion. *Int J Adult Orthod Orthognath Surg* 1992;7(3):139–46.
101. Stephens C. An examination of the long-term stability of surgical-orthodontic maxillary expansion [dissertation]. Columbus (OH): Ohio State University; 1986.
102. Pogrel MA, Kaban LB, Vargervik K, Baumrind S. Surgically assisted rapid maxillary expansion in adults. *Int J Adult Orthod Orthognath Surg* 1992;7(1):37–41.
103. Betts NJ, Vanarsdall RL, Barber HD, et al. Diagnosis and treatment of transverse maxillary deficiency. *Int J Adult Orthod Orthognath Surg* 1995;10(2):75–96.
104. Shetty V, Caridad JM, Caputo AA, Chaconas SJ. Biomechanical rationale for surgical-orthodontic expansion of the adult maxilla. *J Oral Maxillofac Surg* 1994;52(7):742–9; discussion 750–1.
105. Bays RA, Timmis DP, Hegtvedt AK. Maxillary orthognathic surgery. In: Peterson LJ, et al, editors. *Principles of oral and maxillofacial surgery*. Philadelphia (PA): J. B. Lippincott; 1992. p. 1349–414.

Management of Facial Asymmetry

Peter D. Waite, MPH, DDS, MD

Scott D. Urban, DMD, MD

In the 1960s surgical treatment of orthognathic deformities developed when satisfactory results were unobtainable by orthodontics alone. Mild cases of jaw deformities and malocclusion can sometimes be camouflaged by dental treatment and growth modification.¹ Severe malocclusion is often beyond the envelope of orthodontic treatment; therefore, surgical procedures of the maxilla and mandible have been developed. Just as some malocclusions are beyond orthodontics alone, some orthognathic deformities are beyond surgery directed at a single jaw, that is, the maxilla or the mandible. Although a single osteotomy might improve function and esthetics, bimaxillary surgery or double-jaw surgery is often indicated for large anteroposterior discrepancies, open bite, and most asymmetries.²⁻⁵ As orthognathic surgery has been refined, it has become evident that some problems are beyond treatment of a single jaw. The novice might assume that single-jaw surgery is better—simple and less complicated—but the final outcome is often a compromise and unstable. Bimaxillary surgery allows a much greater degree of flexibility with regard to three-dimensional treatment.

In the 1960s and 1970s surgeons attempted to limit orthognathic surgery to one jaw, usually the mandible. Ramus osteotomies with maxillary osteotomies were complex, technically difficult, time consuming, unstable, and associated with

higher morbidity.⁶ It is impossible to correct a canted maxilla without adjusting the mandibular plane of occlusion. Even simple midline discrepancies resulting from unilateral tooth loss can be quickly improved by mild rotational changes in the facial skeleton.

This chapter focuses on the unique nature of asymmetric orthognathic deformities as an indication for bimaxillary surgery, which is really nothing more than a combination of two procedures. The most important aspect of bimaxillary surgery is not the ability to do simultaneous maxillary and mandibular procedures, but to understand the indications and treatment plan and how to maintain a stable reference during surgery.

Little has been written on orthognathic asymmetries as an indication for bimaxillary surgery. Poor treatment planning and poor surgical reference are common mistakes. Asymmetries require three-dimensional changes and complex skeletal movements with adjunctive soft tissue symmetry. The current discussion includes etiology amenable to orthognathic procedures, diagnostic imaging, treatment planning, and surgery.

Facial symmetry has a high correlation with attractiveness. Even a slight asymmetry is quickly noticed by the human eye. Greater degrees of asymmetry are correlated with clinical depression, neurosis, inferiority complex, poor self-esteem, and gen-

eral poor-quality-of-life health problems.⁷ Mandibular asymmetry is a significant dysfunction and difficult to correct.

Etiology

There are multiple causes of mandibular and facial asymmetry, but the differential can be separated into three classes: congenital, developmental, and acquired.^{8,9} *Congenital* anomalies are conditions acquired during in utero development and can be further subdivided into malformations, deformities, and disruptions. Malformations are the result of an intrinsically abnormal developmental process in embryogenesis. Unilateral cleft lip is an example of a malformation.⁹ Deformities are an abnormal form or position of a part of the body caused by a nondisruptive mechanical force during the fetal period.⁹ Mandibular deformation may result from a prolonged sharply laterally flexed position of the head with the shoulder pressed against the mandible during late intrauterine growth. Disruptions are morphologic defects resulting from a breakdown of an otherwise normal developmental process.⁹ Rare facial clefting and limb amputation from an amniotic band are good examples of disruption.⁹ *Developmental* anomalies are conditions arising during postuterine growth through adulthood. *Acquired* anomalies are conditions arising from either trauma or pathology.

Congenital Anomalies

Hemifacial Microsomia

Hemifacial microsomia (HFM) is a craniofacial malformation of the first and second branchial arches presenting with asymmetric unilateral or bilateral hypoplasia of the orbit(s), maxilla, mandible, ear, cranial nerves, and soft tissue (Figure 58-1).¹⁰ Current evidence supports the theory that hemifacial microsomia results from a defect in the proliferation and migration of embryonic neural crest cells.^{11,12} Other theories have included hemorrhage of the stapedial artery during fetal development, which ultimately leads to impaired unilateral facial growth.^{13,14} However, the true etiologic factors still remain unknown.

Two important factors need to be considered in the treatment planning of HFM: (1) the facial growth potential and/or restriction and its effect on surrounding structures and (2) the degree of hypoplasia involving the glenoid fossa, mandibular condyle, and ramus unit.^{15,16} Classifying the extent of the HFM deformity

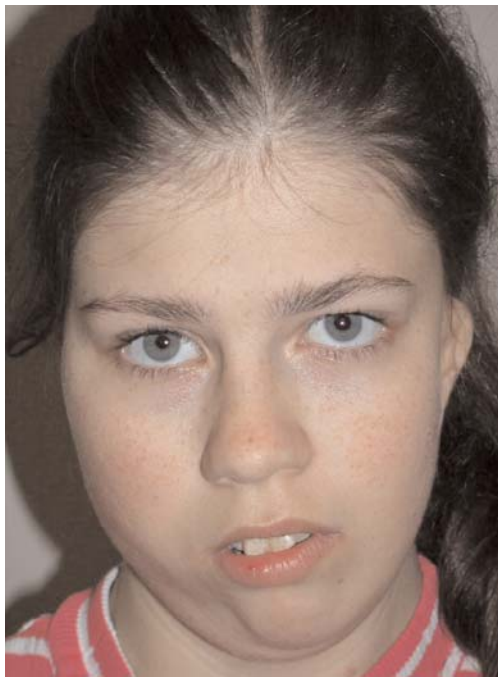

FIGURE 58-1 A 16-year-old female with mild hemifacial microsomia type I. Note the canted maxilla, dental deviation, and facial asymmetry.

can provide clarity in determining ideal reconstruction and accurate prognosis. The Pruzansky HFM classification,¹⁷ modified by Kaban and colleagues,¹⁸ currently provides a clinically useful framework to help guide the treatment plan based on the presence or absence of critical structures.^{18,19}

HFM type I deformity can be summarized as a generalized mild hypoplastic state involving the muscles of mastication, the glenoid fossa, and the mandibular condyle and ramus unit. The temporomandibular joint (TMJ) functions with normal rotation and restricted translation. Patients present with mild mandibular retrognathia and facial asymmetry. Because there is satisfactory TMJ occlusal function and mild dysmorphology, surgical therapy is usually not indicated.

HFM type IIA deformity involves a hypoplastic cone-shaped condylar head. The condyle is located medial and anterior to a hypoplastic glenoid fossa. TMJ function is often satisfactory. Again, surgical intervention of the TMJ is usually not indicated.

HFM type IIB deformity involves a moderate to severe hypoplasia of the glenoid fossa, condyle, and mandibular ramus. Unlike the type IIA deformity, these patients have no articulation between the temporal bone and a condyle. However, manual manipulation reveals a posterior “stop” of the condyle contacting the glenoid fossa.²⁰

A patient with HFM type III has a complete absence of the mandibular ramus and condyle. No manual condylar seating or posterior stop is present. These patients present with severe mandibular dysmorphology and often require TMJ surgical reconstruction (Figure 58-2).²⁰

The treatment of HFM is controversial. The treatment philosophy of interceptive orthodontics and surgical treatment in growing children is based upon the theory that HFM is a progressive deformity.¹⁵ Conversely, a treatment protocol based on

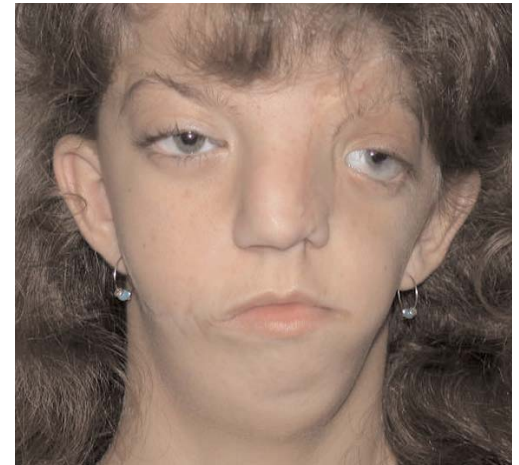


FIGURE 58-2 A 14-year-old female with severe hemifacial microsomia type III, which is associated with facial clefting and a total absence of condyle.

the theory that HFM is not progressive in nature is well described by Posnick.¹⁶

Cleft Lip and Cleft Palate

Patients with a cleft lip and cleft palate often present with a bilateral or unilateral midface deficiency resulting in augmentation and involving the paranasal, nasal, infraorbital, and zygomatic regions as well as the occlusal level.²¹ However, the degree and location of maxillofacial growth deficiency in children with clefts is largely dependent on the location and type of cleft lip/cleft palate repair and the age of the child at the time of repair.²²⁻²⁴ Most studies show that children with a repaired cleft lip/cleft palate have decreased vertical and horizontal maxillary growth and decreased vertical growth of the ramus and steep mandibular plane angle.²⁵⁻²⁷ Ross has shown that approximately 25% of patients with a repaired cleft lip or cleft palate have a midface deficiency and class III malocclusion that require skeletal surgery.²⁸

Plagiocephaly

Plagiocephaly is derived from the Greek word *plagios*, which refers to the twisted shape of the skull when viewed cranially-caudally. The etiology is often a unilateral synostosis of the coronal or lambdoid

suture. Unilateral synostosis of the coronal suture results in an asymmetric parallelogram-shaped forehead and brow. The affected side is flattened, and the contralateral side may show compensatory bulging or bossing. In addition, synostosis of the coronal suture often indirectly affects the lower facial morphology. The root of the nose is deviated to the involved side, and the chin is often deviated to the side opposite of the flattened forehead. The mandible is normally developed but may exhibit secondary dysmorphology.^{29,30}

Congenital Hemifacial Hyperplasia

Congenital hemifacial hyperplasia is a rare unilateral enlargement of the craniofacial soft and/or bony tissues. Although the term *hemihypertrophy* has commonly been used, it is inappropriate because the condition refers to hemihyperplasia.³¹ Pollock and colleagues have hypothesized that the reason for the asymmetric facial development is abnormal neural crest migration.³² Yoshimoto and colleagues have found increased proliferative activity of osteoblasts in a patient with congenital hemifacial hyperplasia and have hypothesized that fibroblast growth factor and its receptor signal transduction axis in osteoblasts may be selectively involved, leading to the progression of hemifacial overgrowth.³³

Developmental Anomalies

Intrinsic Jaw-Growth Deformities

Facial Hemiatrophy Facial hemiatrophy (Parry-Romberg syndrome) is characterized by a progressive unilateral facial loss of skin, soft tissues, cartilage, and bony tissue (Figure 58-3). Usually, the left side is affected rather than the right. Associated abnormalities include jacksonian epilepsy, cutaneous dyspigmentations, and ipsilateral alopecia.³¹

The syndrome usually starts during the first two decades of life and completes progression within 2 to 15 years.^{34–36} The etiology of facial hemiatrophy remains largely unknown, but associations with Lyme disease, ablation of the superior cervical sympathetic ganglia, localized scleroderma, Rasmussen encephalitis, and systemic lupus erythematosus have been found.^{37–41} Alterations in the peripheral trophic sympathetic system is one of the more emphasized theories.³¹ Treatments have included silicone injections, alloplastic implants, microfat injections, and microvascular free tissue transfer.^{42–44}

Hemimandibular Hyperplasia/Elongation Another condition resulting in facial asymmetry is hemimandibular hyperplasia. Hemimandibular hyperplasia is characterized by a diffuse enlargement of the condyle, the condylar neck, and the mandibular ramus and body.⁴⁵ In 1986 Obwegeser and Makek described the deformity as hemimandibular hyper-

plasia or hemimandibular elongation.⁴⁶ In 1996 Chen and colleagues proposed that all cases of hemimandibular hyperplasia and hemimandibular elongation actually represent variations of condylar overgrowth.⁴⁷ They proposed that if condylar overgrowth is not arrested, it can progress into hemimandibular hyperplasia and hemimandibular elongation. In spite of the differences in nomenclature, no etiologic factor has been established. Condylar growth patterns can be evaluated by serial clinical comparisons, cephalometric tracings, and bone scanning with technetium 99m phosphate. However, no ideal method has been found to assess whether condylar overgrowth is “inactive.” Therapy is guided by the patient’s age and condylar growth activity. Treatment modalities have ranged from condylectomy to orthopedic maxillary management. However, strong consideration should be given to refraining from surgery until growth activity has ceased.⁴⁵

Secondary Growth Deformities

Sternocleidomastoid torticollis is a condition thought to result from a birth trauma–induced hematoma of the sternocleidomastoid muscle that fibroses over time and leads to muscular contraction. However, the precise etiologic factors are still considered unknown. If the condition is not corrected with proper physiotherapy for the neck/sternocleidomastoid muscle or surgical therapy, malformed facial development may occur ipsilateral to the side affected by the torticollis.^{48,49}

Duchenne’s muscular dystrophy and cerebral palsy often result in areas of decreased muscle tone, which can affect the development of facial morphology by limiting the amount of bone formation at sites of muscle attachment and function. Consequently, facial asymmetry/dysmorphology can be a finding with Duchenne’s muscular dystrophy and cerebral palsy.⁵⁰



FIGURE 58-3 *Right facial hemiatrophy (Parry-Romberg syndrome). At the time this photograph was taken, the patient had undergone skin and bone grafting.*

Acquired Facial Asymmetries

Condylar Trauma

A frequent cause of facial asymmetry in the growing child is trauma to the mandibular condyle (Figures 58-4 and 58-5).⁵¹ Trauma-induced injury to the condyle can lead to a hemarthrosis, which can result in scarring and restricted translation of the condyle. Proffit and Turvey described this as a functional ankylosis or soft tissue extracapsular ankylosis.⁵² Bony ankylosis of the condyle to the skull base can also occur from an intracapsular hemarthrosis.

Consequently, traumatic-induced scarring or bony ankylosis of the TMJ can result in relative degrees of restricted skeletal growth. In other words, the greater the degree of translational restriction, the greater the facial deformity. Thus, a frequently entertained question is whether open reduction and internal fixation of the condylar fracture are required to stabilize the condylar cartilaginous growth center. Studies in immature primates and children have revealed that the displaced condylar segment undergoes resorption and that a new condyle and the overlying cartilage are regenerated. Thus, there is nothing intrinsically important about the condylar head tissue as a mandibular




FIGURE 58-4 This adult male sustained a fracture of the condyle as a teenager resulting in abnormal growth.

growth center. Because the condylar head in children is generated spontaneously, the necessity of open reduction and internal fixation of the displaced condylar segment is eliminated. Moreover, the resulting scar and possible soft tissue and hard tissue restriction from open reduction could outweigh the benefits of surgical and anatomic condylar alignment. Thus, open reduction of condylar fractures in children should be avoided.⁵²⁻⁵⁴

Juvenile Idiopathic Arthritis

Facial asymmetry can be a finding in patients affected with juvenile idiopathic arthritis (JIA) of the TMJ.⁵⁵ JIA is a disease characterized by chronic inflammation of one or more joints affecting children up to the age of 18 years. The TMJ is frequently involved and can lead to facial growth disturbance including facial asymmetry.⁵⁵ TMJ involvement can be asymmetrical or asymptomatic and may not be evident clinically.^{56,57} However, symptomatic TMJ involvement may not be associated with facial growth disturbances, and, conversely, facial growth disturbance may be present without TMJ symptoms.⁵⁶

Both polyarticular- and pauciarticular-onset JIA have been found to have a negative impact on the form, function, and esthetics of the face; however, the effects are more pronounced with polyarticular JIA.^{58,59} Characteristic facial features of patients with JIA include a small mandible, Class II malocclusion, and anterior open bite. Patients with polyarticular JIA with TMJ involvement tend to have small short faces with underdeveloped mandibles.⁶⁰

Currently there is no effective therapeutic means to eliminate the progression of the disease and its effect on facial development; however, methotrexate therapy has been shown to minimize TMJ destruction and craniofacial dysmorphology in patients affected with polyarticular JIA.⁶¹ Corticosteroids have been used in the treatment of JIA, but their therapeutic value is still controversial.

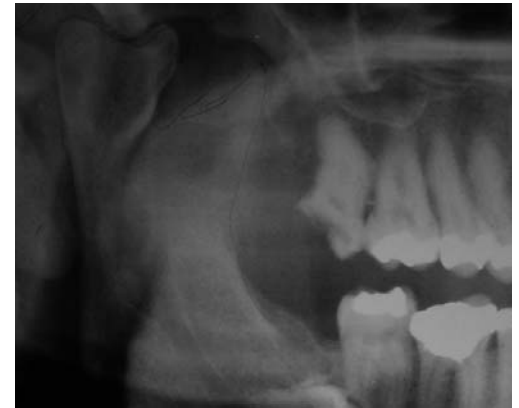

FIGURE 58-5 Panoramic radiograph of the patient in Figure 58-4 demonstrates condylar asymmetry.

Degenerative Joint Disease

Degenerative joint disease (DJD) is considered an end-stage result of progressive internal derangement of the TMJ. Usually, patients have bilateral involvement of the TMJ; however, unilateral involvement is not uncommon. The “wear and tear” effect of DJD on the TMJ results in condylar-glenoid erosion and decreased condylar ramus height. Clinically, patients often present with increasing preauricular crepitus, a limited mandibular range of motion, pain, and an anterior or open bite.⁶²

Clinical Assessment

Principles

The method of evaluating the patient with a dental facial condition begins with ascertaining the patient's chief complaint. Then, as the medical history of the present illness unfolds, the answers to pertinent questions regarding a history of facial trauma, arthritis, and congenital malformations, for example, are obtained.

A physical examination of the head and neck should include the following⁶³:

1. Visual inspection of the entire face including facial subunits for symmetry
2. Palpation of the face to differentiate between soft and hard tissue defects

3. Comparison of dental and facial midlines with each other and with the central facial axis
4. Inspection for gonial angle symmetry and differences in antegonial notching
5. Analysis of the relationship between the upper lip and the maxillary central incisors
6. Inspection for malocclusion, occlusal canting, inclination of anterior teeth, dental crowning, open bites, maximal interincisal opening, and mandibular deviation with opening
7. Examination of the TMJ function

After the patient's chief complaint, history of present illness, past medical history, physical examination, radiographs and articulator mounted diagnostic casts have been obtained and evaluated, a problem list and corresponding treatment plan can then be constructed.

Radiography

Panoramic Radiographs The panoramic radiograph can provide information regarding the relative height of the mandibular condyle and ramus. Degenerative changes or asymmetric morphology can be identified with a comparative vertical measurement of the condylar head apex to the sigmoid notch base, and the sigmoid notch base to the mandibular angle.⁶³

Posteroanterior Cephalometric Radiographs The posteroanterior cephalometric radiograph enables one to understand the extent of the deformity relative to the cranial base. By tracing soft and hard tissue features and then placing a true vertical and horizontal midline axis, one can visualize deviations of the dental and skeletal midline, occlusal cants, and vertical asymmetries.⁶³

Lateral Cephalometric Radiographs A lateral cephalometric radiograph can provide clues of vertical differences by the

lack of superimposition (eg, two separate radiographic mandibular inferior borders). However, to determine the relative significance of the differences in dentofacial superimposition, one must know whether the external auditory canals are level with the patient's natural head position. Only a single cephalometric ear rod should be used if the patient's auditory canals are not level.⁶³

Computed Tomography

Computed tomography (CT) can provide two-dimensional localized views of the facial skeleton, or it can be developed further into three-dimensional views that can provide excellent detail necessary for the proper diagnosis and treatment of a complex facial dysmorphism (Figure 58-6).

Stereolithographic Modeling

Three-dimensional CT scans can provide information to allow the fabrication of an actual three-dimensional skeletal model. These models can help one make surgical predictions; however, because of their expense, these models are mainly used for complex dentofacial and craniofacial deformities.⁶⁴

Technetium 99m Phosphate Bone Scans

Radionuclide skeletal scintigraphy has been shown to be a sensitive technique for identifying mandibular overgrowth in the patient with a facial deformity. However, scan findings are nonspecific and may be the result of a variety of bone and soft tissue abnormalities, including soft and hard tissue carcinomas, sarcomas, metastatic disease, hematologic disease, infections, inflammatory states, metabolic diseases, and trauma.⁶⁵ In patients with facial asymmetry mandibular overgrowth, nucleotide uptake is not symmetric bilaterally. In these cases, patients present with an increased nucleotide activity on the affected side. However, caution must be taken when evaluating an area of

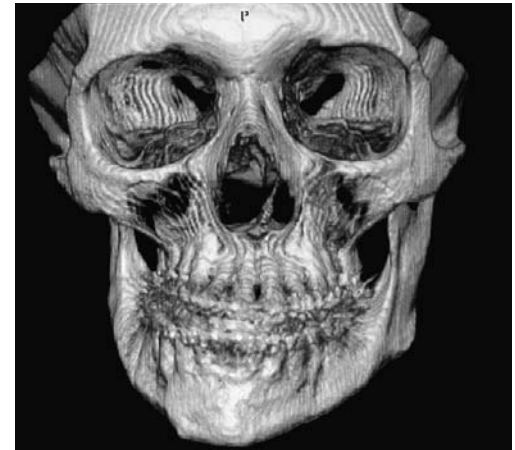

FIGURE 58-6 Three-dimensional computed tomographic scan of asymmetric skull.

increased uptake not to mistake condylar overgrowth for other conditions (ie, arthritis, TMJ disorders, trauma) that can mimic nucleotide uptake activity.⁶⁶ Additional techniques of fusing single-photon emission CT images to high-resolution structural CT images have been shown to provide a further precise anatomic delineation of bone activity.⁶⁷

Surgical Treatment

Asymmetry may not always be obvious to the patient and family. Correct treatment begins with proper diagnosis. One should evaluate the face in all dimensions, carefully analyzing vertical and horizontal dimensions corresponding to facial subunits. Failure of the surgeon to recognize asymmetry until after surgery is often viewed by the patient as an excuse for poor treatment. In general, treatment planning of facial asymmetry is much the same as for any orthognathic case, except that more emphasis is placed on the frontal view.

Cephalometrics may be grossly inaccurate owing to ear rod positioning. Posteroanterior cephalometric radiographs are good simple screening tools but, standard computerized CT scans are much more accurate. CT data can be converted by computer-aided design/computer-aided manufacturing (CAD/CAM) imaging into an actual acrylic model. This

model can be used for model surgery, implant fabrication, and distraction osteogenesis design.

Ultimately, the clinical examination is the most important diagnostic tool. Body posture, mannerisms, and hairstyle hide facial asymmetry and may mislead the treatment plan.

In a University of North Carolina study of 495 patients with facial asymmetry, the mandible was most often affected. Upper facial asymmetry was found only in 5%, but a chin deviation was present in 75% of all cases. Chin deviation is most often to the left, indicating a tendency for increased right-sided growth.⁶⁸ People notice chin deviation.

Delayed Treatment

Treatment of asymmetry in preadolescent children is extremely complex, and the results are not always predictable. Studies of growth modification with functional appliance have been problematic because of a various treatment designs with poor treatment group composition, poor control group composition, and difficulties with randomization. The topic is often discussed in orthodontic pediatric textbooks. Although noninvasive techniques do not harm the patient, most craniofacial asymmetry syndromes, condylar deformities, and traumatic injuries at an early age do require surgery. Bite-block therapy can be helpful in controlling the plane of occlusion but rarely prevents surgery. Bite-block therapy is mainly directed as an intervention for secondary growth deformities.

Maintenance of TMJ Function

Mild asymmetry in a growing patient with functional condyles should receive early interceptive orthodontics, and the patient should be allowed to finish growing before surgery is performed. Jaw movement is important following condylar fracture. Physical therapy and rehabilitation stimulates condylar and mandibular growth. Poor function results in a more asymmet-

ric mandible and secondary skull base. Asymmetry of the skull base correlates with maxillary midface asymmetry.

Post-traumatic mandibular hyperplasia is less frequently seen than growth retardation. Mandibular hyperplasia is usually apparent after adolescent growth, whereas delayed growth is often present early in life. Regardless of the true etiology, it is important to establish a surgical treatment plan with the most esthetic, functional, and stable result. Orthognathic asymmetries should be treated after growth is complete, and often require combined maxillary and mandibular surgery.

Orthodontic Considerations

Human facial symmetry has long been a critical factor for attractiveness. It is also well documented that true symmetry is not normal.^{69,70}

For the average orthodontic patient, minor asymmetries become a concern only as an esthetic issue. Severe asymmetries often result in crossbite, malocclusion, cheek biting, poor mastication, condylar dysfunction, myositis, tendonitis, and chronic pain. From a diagnostic standpoint, patients with asymmetries differ from the typical orthodontic patient in several ways. The clinical examination and records should generate enough information to accurately diagnose and formulate the best possible treatment plan. This includes multiple photographs, lateral and posteroanterior cephalometric radiographs, and face-bow-mounted dental models.⁶²⁻⁷¹

Facial structures may be evaluated against a grid formed by the midsagittal plane and several perpendicular lines, according to the area being evaluated (eg, interpupillary, subnasal, stomion). A tongue blade or Fox plane can be used to determine whether a cant is present in the occlusal plane. Unilateral vertical maxillary excess and mandibular asymmetries are usually associated with an occlusal plane

cant.⁶³ This is why most asymmetries cannot be treated with single-jaw surgery.

Typical orthodontic diagnostic records rely heavily on a profile view. The lateral approach comes from the traditional diagnosis based on cephalometric radiographs; however, patients are more aware of their esthetic presentation from the frontal view. Additional diagnostic records may include a posteroanterior cephalometric radiograph, a submentovertex radiograph, and an accurate face-bow transfer with casts mounted on a semiadjustable articulator.⁶⁵⁻⁷³

The orthodontic management of patients with asymmetries does not differ a great deal from that for a typical orthognathic patient. Good communication and a team approach during all phases of treatment are essential. Once the diagnosis and treatment plan are established, the presurgical orthodontic phase is initiated. Basic principles of presurgical orthodontics must be observed. All tooth movements that may compromise stability must be avoided, especially if the intended movement may be more easily accomplished with the movement of a bony segment during surgery, that is, transverse expansion. Dentoalveolar decompensation in the upper arch must take into account the postsurgical position of the upper incisor. Maxillary anteroposterior movements as well as posterior impactions have the greatest effect on the upper incisors with regard to anteroposterior positioning and torque, respectively. Dentoalveolar decompensations in the lower arch must observe the anatomic limits of the symphysis. One must observe that the morphogenetic pattern of patients with maxillomandibular discrepancies results in specific abnormal bony architectures. It is for this reason that cephalometric norms should not be used. There should be no compromise in the presurgical orthodontic treatment plan as it would severely limit the overall outcome. Do not hesitate to extract teeth if necessary. Impressions and early model

surgery are helpful and confirm that the presurgical goals are correct and/or have been achieved. Common problems include improper buccal root torque in the upper arch, improper arch coordination (especially when anteroposterior movements are planned), and a lack of overjet (which would hinder placement of buccal segments in an ideal Class I occlusion).

The decision to extract teeth is often difficult. The first question that must be asked is whether there is severe crowding. The answer is based primarily on the planned position for the upper and lower incisors well positioned in basal bone. The upper incisors' relationships to the sella-nasion (SN) (104°), palatal plane (104°), and nasion-A point (NA) line (4 mm and 22°) are good indicators of whether these teeth need to be decompensated. It must be kept in mind that posterior impaction of the maxilla decreases the torque of the upper incisors. In addition, large unilateral vertical changes such as impaction downgrafting on one side also swing and rotate the midlines of the maxillary teeth. However, when this is anticipated, the upper incisors should be maintained slightly proclined. As a surgical objective, the position of the upper incisor and that of a point relative to the nasion perpendicularly can be used as reasonable cephalometric references. Therefore, dental crowding and the desired position for the upper incisors within basal bone of the maxilla ultimately determine the need for extractions. Upper second bicuspid are the teeth of choice for extraction when minimal incisor decompensation is required. Maxillary first bicuspid are extracted when the upper incisors require greater degrees of decompensation, such as in Class III malocclusions.

If mild crowding is present (up to 4 mm) and no dentoalveolar decompensation is needed, a nonextraction approach is acceptable, and some interproximal reduction may be required. If decompensation of the incisors is required, the

cephalometric correction must be factored into the crowding assessment. For every 3° of change in the angle between the lower incisor and the mandibular plane, one must add or subtract 2.5 mm to the measured clinical crowding. In patients with Class II malocclusion, cephalometric correction most often adds to the clinical crowding since the lower incisor typically requires more upright positioning. In patients with Class III malocclusion, cephalometric correction usually alleviates crowding. In other words, cephalometric correction takes into account the goals for the lower incisor in the crowding assessment; moreover, it helps one decide which teeth should be extracted. When the measured crowding in the lower arch is moderate (5–9 mm), second bicuspid should be extracted. The result is the alignment and complete closure of the extraction sites. This should be achieved with the lower incisor in the ideal position. When crowding is severe (> 10 mm) after cephalometric correction, first bicuspid should be extracted to allow alignment and proper positioning of the lower incisor. The rationale is as follows: When two bicuspid are extracted, an average of 14 mm of space is created. If the total crowding is 10 mm including cephalometric correction, then 4 mm of space are left. These 4 mm are used by forward movement of the posterior teeth as lost anchorage during the alignment and retraction of the lower anterior tooth.

Maximum decompensation is often required with minimal clinical crowding, therefore requiring that the first bicuspid be extracted. If crowding exceeds 14 mm, extractions alone are not sufficient to alleviate crowding and achieve an ideal position for the lower incisors. Interproximal reduction may help to create another 3 to 4 mm of space.

Patients with hyperdivergent faces with an asymmetry require differential maxillary impaction. Such cases need a flattening of the curve of Spee on both

arches prior to surgery. The curve of Spee is often different from left to right. Flattening this curve allows for maximum intercuspation to be achieved between the anterior teeth and bicuspid, with minimum posterior open bites. If the posterior maxilla is intentionally overimpacted when relapse is expected, the result is a posterior open bite, and no vertical elastics are placed distal to the bicuspid for the first 8 weeks after surgery. Intercuspation should be accomplished. In the patient with facial asymmetry, one side may be more open than the other. It is usually the hypoplastic side that remains slightly open, and teeth can be extruded postsurgically. An open bite of 2 mm is acceptable and sometimes desirable as settling and some relapse occur after surgery. After surgery no orthodontic forces should be in the direction of the potential surgical relapse.

Patients with hypodivergent asymmetric faces typically require mandibular advancement and an increase of the lower anterior facial height. The original malocclusion is often characterized by an excessive overbite, overjet, and curve of Spee. The upper curve of Spee should be flattened and the ideal position of the upper incisors achieved. The degree of curve of Spee may be different from side to side. No attempt should be made to level the lower curve of Spee because forward movement of the mandible to an ideal overbite and overjet automatically increases the lower facial height. If the lower mandibular plane angle has been maintained during advancement, this may result in a posterior open bite at the bicuspid or molars. The interocclusal space leads to leveling of the mandibular curve of Spee with minimal effort after surgery. A flexible braided wire is used in the lower arch as vertical intercuspation elastics are applied to extrude the lower posterior teeth. A class II or class III vector may be incorporated to achieve optimal occlusion. The upper arch should be stabilized by a heavy rectangular wire. Postsurgical orthodontic procedures

usually are completed within 6 to 8 months of surgery if all other phases of treatment are successful. Vertical elastics may be directed by the orthodontist depending on the occlusion and the unique differences of the hyperplastic or hypoplastic side of the face. Severe orthognathic asymmetries are often difficult from an orthodontic standpoint owing to the presence of unilateral differences of a hyperplastic presentation and a contralateral hypoplastic dental compensation.

Surgical Approach and Techniques

In rare cases asymmetries may be treated in a single jaw. Generally, asymmetric growth causes compensation in the teeth, alveolus, and other jaw. Furthermore, this compensation is different from side to side and requires slightly different orthodontic mechanics. Facial asymmetry may be improved esthetically by an inferior border ostectomy, augmentation, and genioplasty. The esthetic impact of asymmetry involves both hard and soft tissue. The zygoma and periorbital and nasal structures may be asymmetric. Even adjacent soft tissues, such as the salivary glands, muscles, and adipose tissue, can be different in quantity from side to side. The patient should be well informed regarding the limitations and surgical expectations. Rarely can asymmetric deformities be corrected completely.

Most patients notice horizontal or transverse discrepancies more often than vertical asymmetries. Maxillary dental midline, chin, and nasal deviations are obvious clinically. Facial length is less apparent. In severe cases, such as hemifacial microsomia or other syndromes, soft tissue augmentation and even free vascularized tissue may be necessary.

The oral and maxillofacial surgeon should make a note of minor anatomic asymmetry. Orbital, nasal, and upper lip position; maxillary midline; smile arch; amount of gingival show per side; cheek

mass; dimples; mandibular dental midlines; mandibular deviations on opening; TMJ articulation; translation; gonial angles; and cervical anatomy should be documented. The surgical procedure should be selected based on the etiology and a concern for stability. For example, when correcting a maxillary cant, vertical impaction is more stable than is vertical downgrafting. Often the discrepancy can be corrected by a combination of both impaction and downgrafting. Severe asymmetries with a short ramus height may require an extraoral inverted L osteotomy with bone grafting. This technique releases the mandibular sling and provides good access to the hypotrophic ramus, excellent bone grafting access, and accurate rigid fixation. Vertical changes of < 6 to 8 mm may be treated by intraoral sagittal split osteotomies. Rotational movements of the mandible produce proximal segment flaring on the advancing side and ramus collapse on the other. Proximal segment flaring may require modification (see Chapter 56, "Principles of Mandibular Orthognathic Surgery."). Some surgeons prefer a vertical oblique ramus osteotomy combined with a unilateral sagittal split ramus osteotomy. This combination surgery usually requires intermaxillary fixation, which may be beneficial in asymmetric cases. With current techniques, monocortical plate fixation can be achieved with a vertical ramus osteotomy. On the other hand, intermaxillary fixation is often necessary and even beneficial because alignment of the segments with rigid fixation is not always possible and the soft tissue pulls back to the original asymmetric position. A treatment plan should be established with an accurate clinical examination, cephalometric analysis, and model surgery. The surgical procedure should be executed efficiently, deftly, and with minimal morbidity. The aforementioned issues of relapse, stability, and mode of fixation should be established prior to surgery and discussed with the patient.

The first, and perhaps most important, treatment plan decision the surgeon encounters involves the upper incisor position. The choice of maxillary incisor position is key and essentially determines the three-dimensional position of everything else. The surgeon must correct maxillary incisor midlines, proclination, occlusal plane, smile arch, dental/gingival show, and lip support. An intermediate splint can be valuable in positioning the maxilla, assuming an accurate face-bow transfer and model surgery have been performed. One should not be a slave to an intermediate splint for it is only one method of aligning the asymmetry. Surgical experience and appreciation of esthetic symmetry are often more valuable.

The maxilla must be placed in the proper and most symmetric position. Consider the occlusion in relation to the unsplit mandible and ask yourself, Does that look reasonable according to the treatment plan? The maxillary position can best be measured using a combination of an external pin, Fox plane, lip position, and internal reference marks. The intermediate splint helps one place and hold the maxilla in the correct position during rigid fixation. The concept of an intermediate splint is based on proper condylar position. Functional condylar position in an awake upright person is not the same as it is in a supine paralyzed patient. Furthermore, asymmetric problems often originate from abnormal condylar (TMJ) disorders. Many patients with facial asymmetry do not have symmetric condylar rotation and therefore exhibit a great deal of muscular compensation with posturing. If an intermediate splint does not seem to position the maxilla properly in all three dimensions, the surgeon should consider other references for facial symmetry. Nothing can replace surgical experience. The mandible is usually cut first but is not split until after maxillary surgery and fixation. This prevents excessive force on the new maxillary position and seems to

expedite the process. Some surgeons complete and fixate the mandibular osteotomy before maxillary surgery. This requires a predetermination of both mandibular and maxillary positions.

Mandibular ramus surgery is often difficult in cases of asymmetry because the ramus and body of the mandible are deformed and hypoplastic and the range of motion limited. Limited surgical access and a smaller soft tissue envelope create a difficult challenge. If the mandible is cut first but not split, the osteotomies are made and a moist sponge is placed while the maxillary surgery is completed. The mandible is later split and moved to the proper position with the maxilla and held in the proper occlusion by an occlusal wafer or splint with intermaxillary fixation. Rigid fixation of the mandible can be achieved with either bicortical position screws or monocortical plates, assuming the condylar position is correct. In large horizontal rotations of the mandible, bicortical screws cannot be placed as true compression screws (lag screws) without torquing the condyle. Modifications of the lingual cortical plate and selective grinding of the bone can be helpful in increasing the bony apposition. In most cases monocortical plates seem to provide adequate stability without compression of the nerve or torquing of the condyle.

Surgical mobilization is a key point in bimaxillary surgery. The mandible and maxilla should be free enough to be positioned passively without pulling the soft tissue. This is a significant point to be considered because the positioning can create a tight masseteric sling and limited periosteal tissue. If the segments are “stretched” into position, one cannot expect long-term stability. A balance between an excessive stripping of the vascularity and a restricted connective tissue envelope must be achieved. Therefore, in cases of severe hypoplastic asymmetry with only rudimentary condyle, one should consider condylar reconstruction

or extraoral procedures of the ramus. In some situations distraction osteogenesis may even be helpful in growing more bone and essentially expanding tissue.

Adjunctive simultaneous soft tissue procedures can be considered after successful positioning of the maxillo-mandibular dental component by secure rigid fixation. Alignment of the chin, nose, and malar complex should be performed after the functional anatomy of the maxilla and mandible is established. Simultaneous surgery has multiple advantages, but may not always be feasible.

The following case is an example of a patient with facial asymmetry resulting from trauma who required combination maxillary and mandibular surgery (Figure 58-7). She was a 20-year-old female with a chief complaint of difficulty eating and chewing; she had chronic myofascial pain and masticatory dysfunction. She had sustained a jaw fracture as a young child and had not received treatment. The young lady experienced gradual facial asymmetry and sought orthodontic treatment. Such a case cannot be treated properly with orthodontics alone; neither can it be corrected in a single jaw.

Her physical examination revealed a healthy young woman in no acute distress but with an obvious facial deformity.

The basal view often better demonstrates the deformity, as does having the patient bite on a tongue blade (Figure 58-8). She was normocephalic (although she had a short face), asymmetric, and had deviation of the jaw to her right (Figure 58-9). The TMJ articulated and translated well without clicking or popping. The maximum incisal opening was 56 mm, with a deviation to the right. The mandibular midline was 7 mm to the right, the overjet was 5 mm, the overbite was 2 mm, and there was excessive lower dental show. She had a right buccal crossbite, an anterior crossbite, maxillary hypoplasia, a canted maxilla, and a short mandibular condyle (Figure 58-10).

The presurgical work-up included a three-dimensional CT scan, cephalometric and panoramic radiography, and face-bow mounting for an accurate intermediate splint and model surgery (Figures 58-11–58-13). The Erickson table was used to measure the vertical change and to fabricate an intermediate splint to assist in positioning the maxilla from the stable mandible (Figures 58-14 and 58-15). The surgical plan was a Le Fort I advancement of 3 to 4 mm and a downgrafting of 4 to 5 mm on the right side (Figure 58-16). The osteotomy gap was bone grafted with

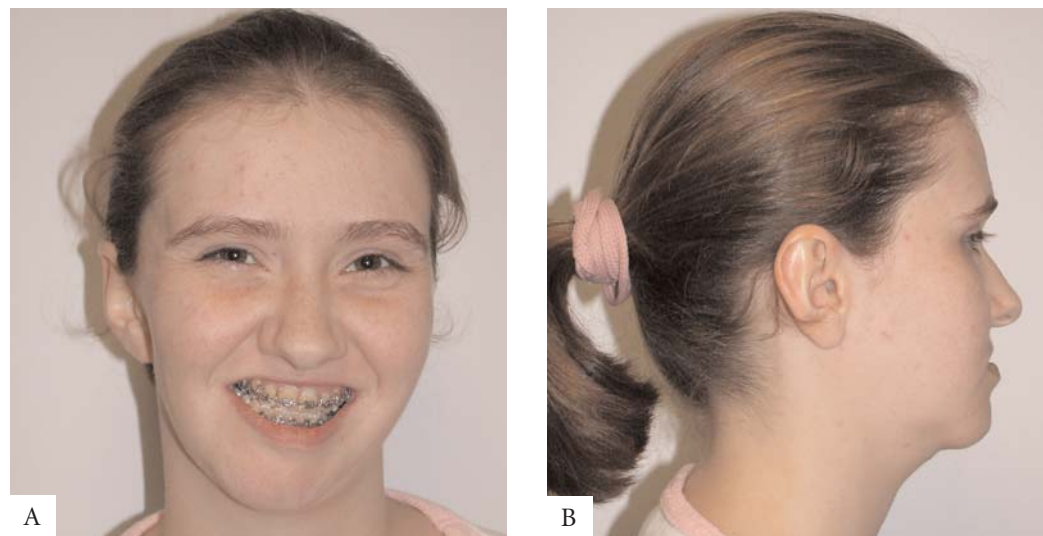

FIGURE 58-7 A, Frontal view with a full smile. B, Later profile shows a midface deficiency and relative mandibular prognathism in spite of the old mandible fracture.

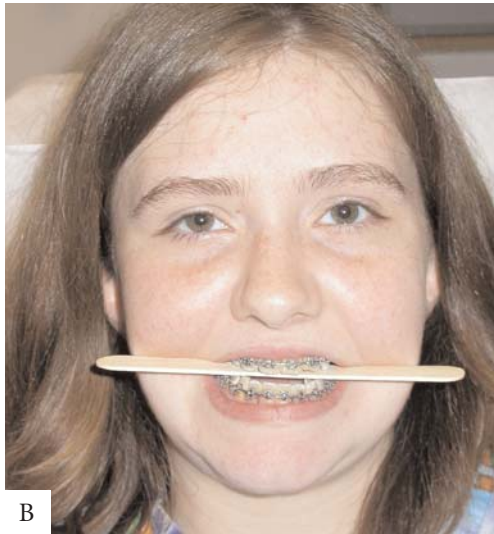
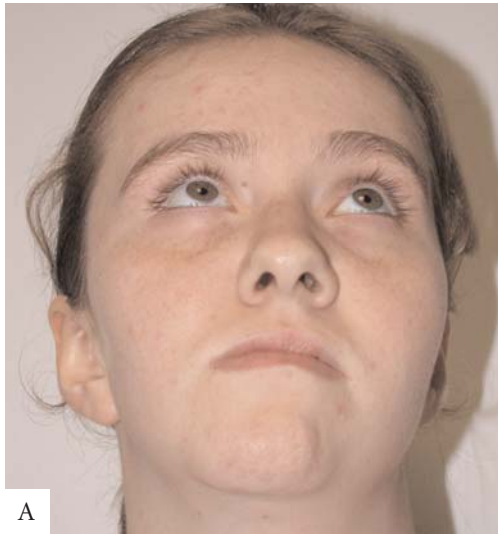
FIGURE 58-8 A, Basal view shows facial asymmetry and a chin deviation to the right. B, Clinical photograph of a tongue blade demonstrating the canted occlusal plane in relation to the orbital rim.

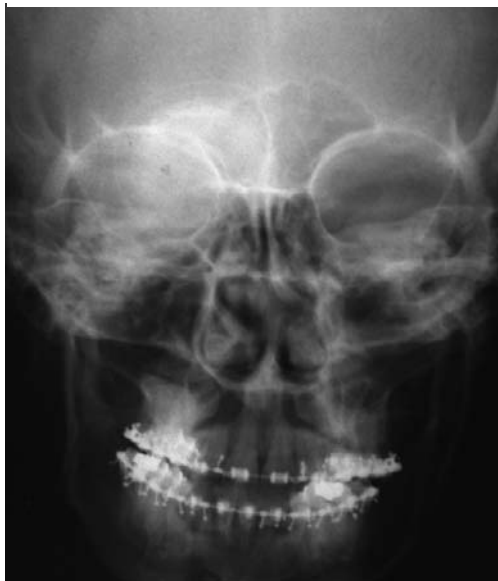

FIGURE 58-9 Cephalometric view showing a short right facial height.

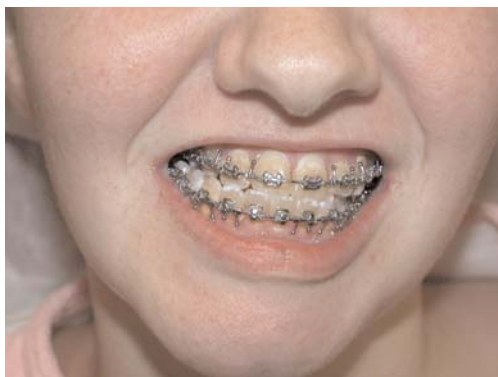

FIGURE 58-10 Clinical analysis of the teeth demonstrates an asymmetry and midline discrepancy.

banked tibial bone that was mortised and fixated. This was determined with a model surgery to level the cant of the maxilla. A Steinmann pin was placed at the nasal bone for an external vertical reference. This technique is valuable in establishing the correct facial dimension. In addition, a Fox occlusal plane was used to evaluate the leveling of the maxilla in relation to the infraorbital rims during surgery (Figure 58-17). Multiple methods of evaluating symmetry are helpful in achieving a good result. Intermediate splints, internal/external reference marks,

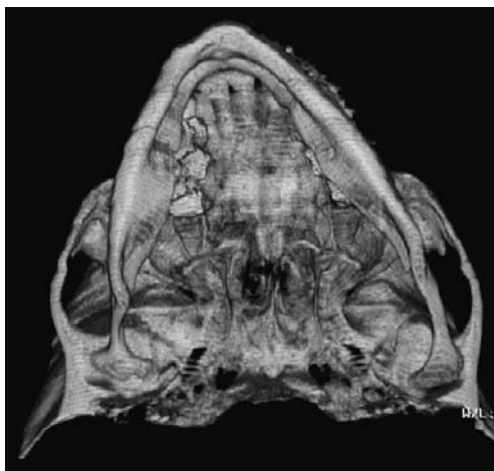

FIGURE 58-11 This three-dimensional computed tomogram clearly identifies the asymmetry.

and careful clinical inspection from different perspectives are all valuable surgical skills in simultaneous jaw surgery for the patient with facial asymmetry. The unsplit mandible is also a key reference for determining the change in maxillary position. In this case, after the maxilla was correctly positioned and leveled, the mandible was split and set to the plane of occlusion. A bilateral sagittal split osteotomy of the mandible was cut prior to the Le Fort I procedure but was not split. This seems to be a common sequence for most surgeons. Consideration was given to a vertical oblique osteotomy on the left, but the rotation seemed favorable and the fixation more stable. Most patients with facial asymmetry are hypoplastic and need lower facial advancement not reduction. A horizontal geniotomy was performed to advance the chin point 4 mm and level the deviation. After the orthognathic phase of surgery, the tube was switched to the mouth by the transpharyngeal route. This technique is efficient and is commonly used for simultaneous rhinoplasty. A standard internal rhinoplasty was performed to narrow the nose, refine the tip, and reduce the dorsum. Often facial asymmetry affects multiple facial subunits. The nose may appear asymmetric or deviated in relation to the mouth and chin. Great

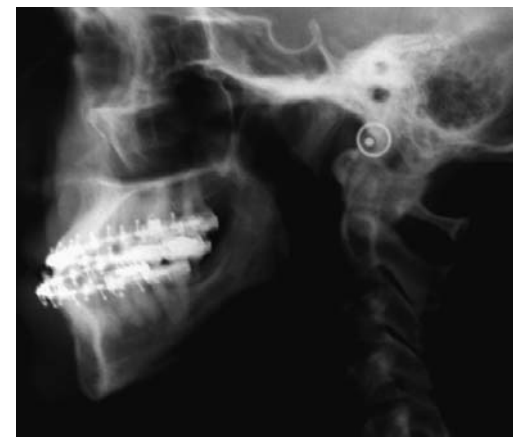

FIGURE 58-12 Lateral cephalometric view appears to show a prognathic jaw even though there is a history of a condylar fracture.

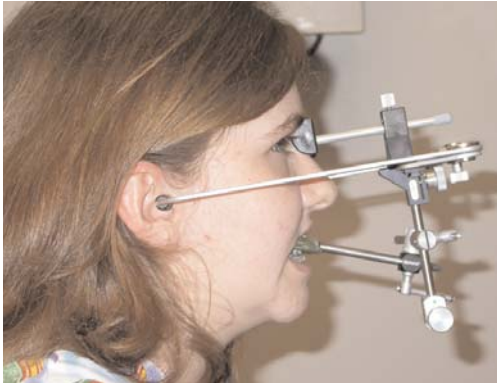

FIGURE 58-13 A face-bow transfer is valuable but sometimes difficult in cases of severe asymmetry owing to an abnormal external auditory canal.

attention must be given to creating middle face symmetry.

At 3 months the postoperative results were satisfactory and the patient was very happy (Figure 58-18). The occlusion was well aligned and finishing orthodontics were completed without difficulty. This case demonstrates well the principles discussed above.

An example of mild developmental asymmetry is demonstrated in the follow-




FIGURE 58-14 Mounted dental models on an Erickson platform with reference marks help one determine the amount of change and fabrication of an intermediate splint. Note the amount of midline discrepancy.

ing case. Such a case can be challenging for the orthodontist/surgical team because the orthodontic preparation may be different for right and left sides; the asymmetry is mild and it is tempting to undertreat the problem with single-jaw surgery. This patient was a 17-year-old female with an open bite and right laterognathia. She had posterior vertical maxillary excess mild crowding, Class III molar relation, dento-facial asymmetry, and a pseudomandibular prognathism (Figures 58–19 58–22). She complained of lip incompetence, difficulty chewing and biting food, nasal obstruction, and xerostomia. Her father had a history of mandibular prognathism and orthognathic surgery.

This patient denied previous trauma to her facial bones. The orbital rims were symmetric, but the right ear was slightly lower. The TMJs articulated well, and there was no myofascial pain. The mandibular midline was 4 mm to the right, as was the chin. She had 4 to 5 mm of gingival show with a high smile. There was no overjet and 4 mm of open bite. She had a mild transverse deficiency of the posterior maxilla.

The treatment plan began with an extraction of teeth no. 1, 16, 17, 18, 32, 4, 13, 21, and 28 prior to presurgical orthodontics. Orthodontics was performed to level alignment and to decompensate in



FIGURE 58-15 Lateral view of mounted models.

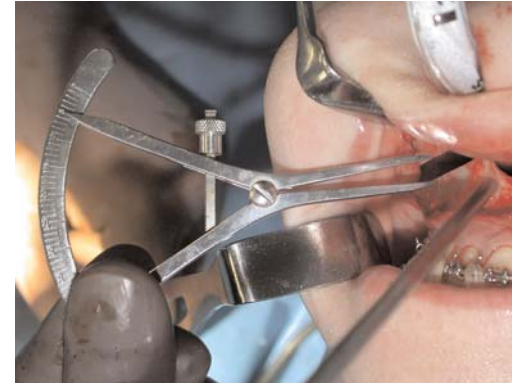

FIGURE 58-16 Intraoperative measurement confirms the treatment plan and correct positioning as determined by the intermediate splint.

preparation for a two-piece Le Fort I osteotomy, bilateral sagittal osteotomy, genioplasty, and rhinoplasty. Presurgical records included surgical mounted models, a face-bow transfer, and detailed radiographs. A CT scan was not obtained.

A sagittal split osteotomy was cut but not split until after the maxilla was positioned. The maxilla was impacted 4 mm posteriorly and widened by a segmental osteotomy between the central incisors. An intermediate splint was used to

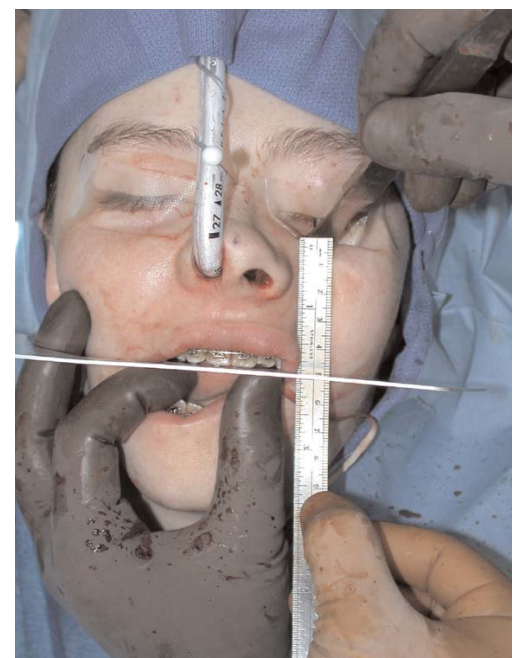

FIGURE 58-17 A prosthetic Fox plane can be used as a final reference to evaluate the leveling of the maxilla in reference to the infraorbital rim.

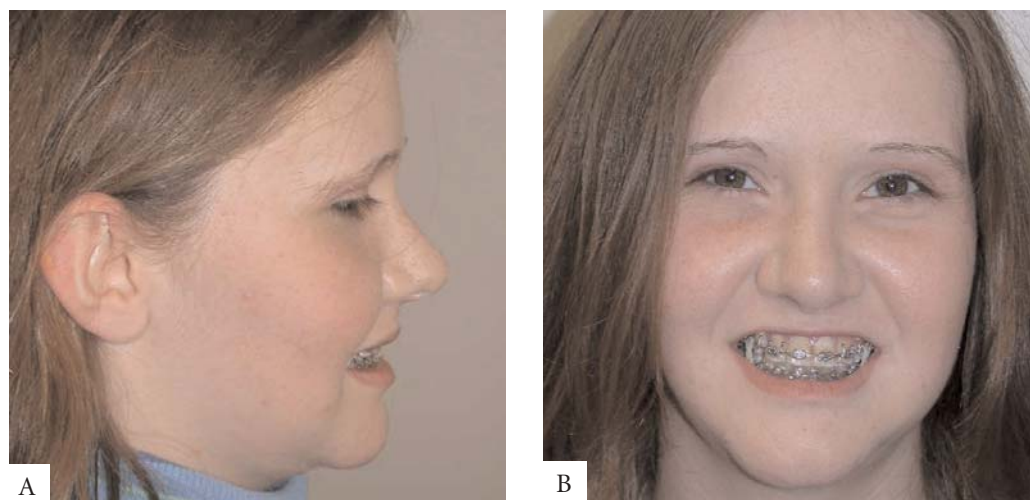


FIGURE 58-18 A, Postoperative lateral view with animation. B, Postoperative frontal view with animation.

position the maxilla. The maxilla was rigidly fixated with a resorbable mesh. Internal and external references were used to properly position the maxilla, as were the predetermined intermediate splint and model surgery. The mandible was then completed and rotated slightly by the sagittal split osteotomy. The chin point was moved to the left and advanced with a horizontal genioplasty. The endotracheal tube was changed to the oral route, and rhinoplasty performed to improve facial harmony and symmetry. The surgery was performed without complications.

The postoperative course was without complications. At 1 month the splint was

removed and the occlusion was satisfactory (Figures 58-23 and 58-24). At 1 year the patient's occlusion was good, the open bite stable, and facial symmetry excellent (Figures 58-25–58-28).

Summary

Correction of orthognathic deformities often requires surgery of both the maxilla and the mandible. Combining osteotomies of the maxilla and the mandible is more complicated than single-jaw surgery and is perhaps associated with increased morbidity, but the surgical options and results are better. Double-jaw surgery does *not* result in twice the morbidity of single-jaw

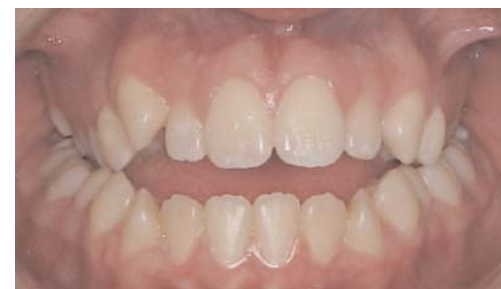

FIGURE 58-20 The frontal view of dentition demonstrates an open bite and midline asymmetry.

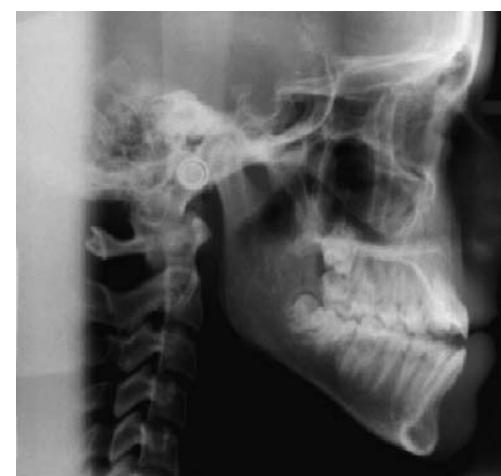

FIGURE 58-21 Initial cephalometric radiograph.

surgery. The indications for bimaxillary surgery are severe deformities untreatable in one jaw, deformities of both jaws, unfavorable movement prone to relapse, and complex three-dimensional movements for which single-jaw surgery would be a functional/cosmetic compromise. Dentofacial asymmetry may develop from a primary cause but presents with secondary compensation in the hard and soft tissues of the face. Such asymmetry is a good indication for bimaxillary surgery.

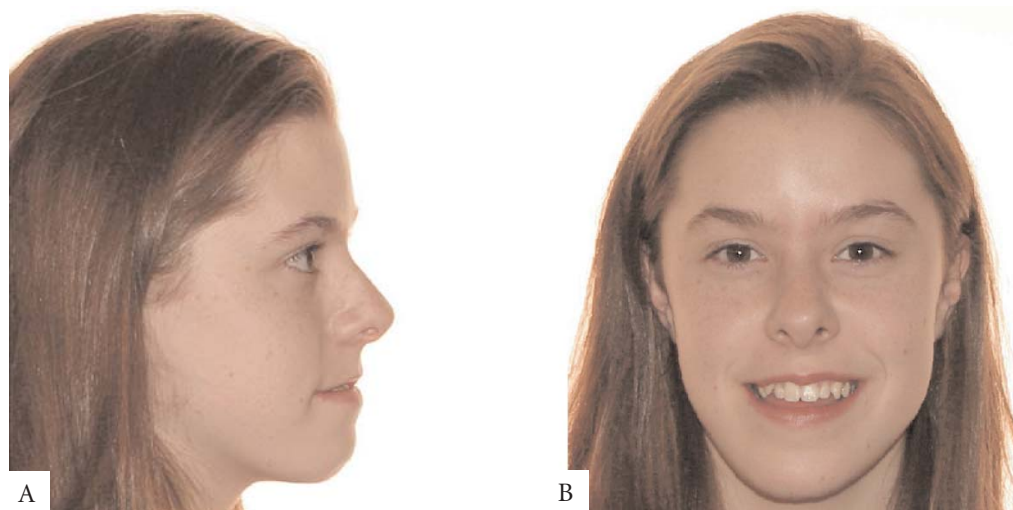

FIGURE 58-19 A, Initial lateral profile. B, Initial frontal view with smile.

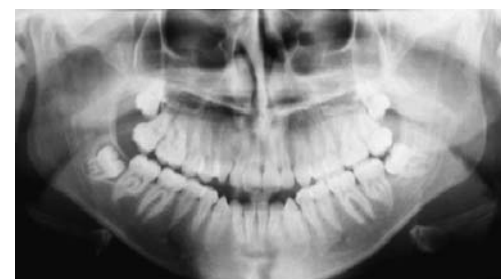

FIGURE 58-22 Initial panoramic radiograph.

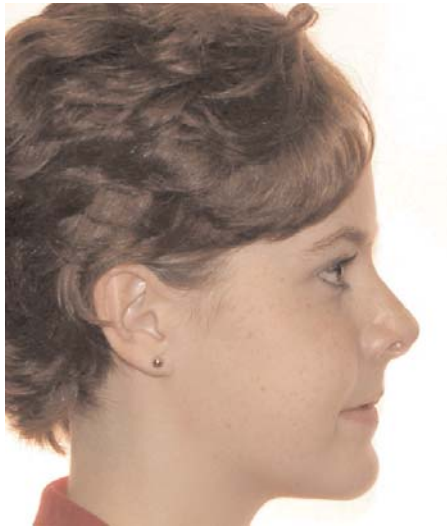

FIGURE 58-23 Postsurgical lateral profile.



FIGURE 58-24 Postsurgical frontal photograph with smile.

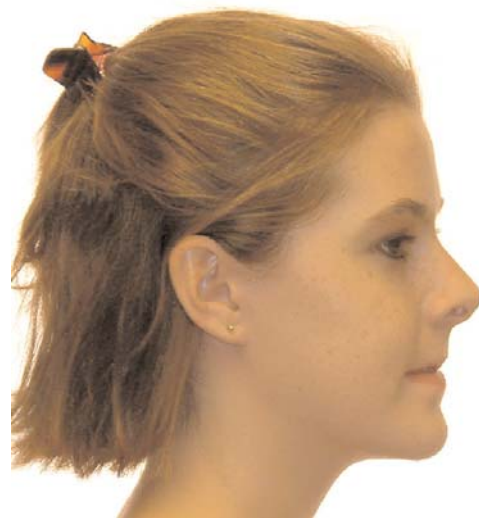

FIGURE 58-25 Final profile after surgery.



FIGURE 58-26 Final frontal view with smile after surgery. Note the facial symmetry.

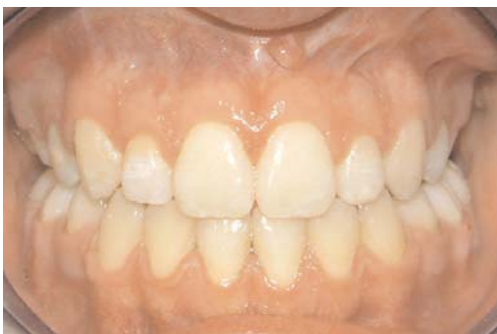

FIGURE 58-27 Frontal view of occlusion after surgery.

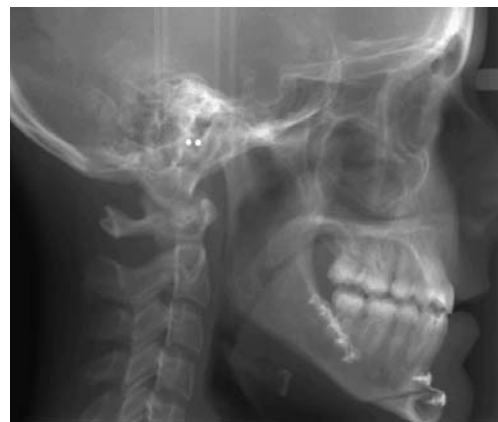

FIGURE 58-28 Cephalometric radiograph taken 1 year after surgery.

Current surgical techniques have reduced the morbidity and length of stay in the hospital and have improved the outcome. This chapter presented combined maxillary and mandibular osteotomies with a special emphasis on asymmetries as an indication. The concept of comprehensive facial analysis and treatment was represented in the cases demonstrated. If correction of mild asymmetries is attempted with single-jaw surgery, the results are suboptimal and disappointing.

Acknowledgment

We would like to thank Dr. Andre Ferreira for orthodontic support.

References

1. Proffit W, White R, Savers D. Contemporary treatment of dentofacial deformity. St. Louis (MO): Mosby; 2003.
2. Bell WH, Condit CL. Surgical-orthodontic correction of adult bimaxillary protrusion. *J Oral Surg* 1970; 28:578–90.
3. Connole PW, Small EW. Combined maxillary and mandibular osteotomies: discussion of three cases. *J Oral Surg* 1971;29:572–8.
4. Epker BN, Wolford LM. Middle third face osteotomies: their use in the correction of acquired and developmental dentofacial and craniofacial deformities. *J Oral Surg* 1975;33:491–514.
5. Turvey TA. Simultaneous mobilization of the maxilla and mandible: surgical technique and results. *J Oral Maxillofac Surg* 1981;40:96–9.
6. Gross BD, James AB. The surgical sequence of combined total maxillary and mandibular osteotomies. *J Oral Surg* 1978;36:513–22.
7. Shackelford TK, Larsen RJ. Facial asymmetry as an indicator of psychological, emotional, physiological distress. *J Pers Soc Psychol* 1997;72:456–66.
8. Cohen MM Jr. The child with multiple birth defects. New York: Raven Press; 1982.
9. Cohen MM. Perspectives on craniofacial asymmetry 1. The biology of asymmetry. *Int J Oral Maxillofac Surg* 1995;24:2–7.
10. Gorlin RJ, Cohen MM, Levin LS. Syndromes of the head and neck. 3rd ed. New York: Oxford University Press; 1990.
11. Johnston MC, Bronsky PT. Prenatal craniofacial development: new insights on normal and abnormal mechanisms. *Crit Rev Oral Biol Med* 1995;6:368–422.
12. Seow WK, Urban S, Vafaie N, Shusterman S.

- Morphometric analysis of the primary and permanent dentitions in hemifacial microsomia: a controlled study. *J Dent Res* 1998;77:27–38.
13. Poswillo DE. The pathogenesis of the first and second branchial arch syndrome. *Oral Surg Oral Med Oral Pathol* 1975;35:302–27.
 14. Poswillo DE. Hemorrhage in development of the face. *Birth Defects* 1975;11:61.
 15. Kearns GJ, Padwa BL, Kaban LB. Hemifacial microsomia: the disorder and its surgical management. In: Booth PW, Schendel SA, editors. *Maxillofacial surgery*. St. Louis: Churchill Livingstone; 1999. p. 917–42.
 16. Posnick JC. Hemifacial microsomia: evaluation and treatment. In: *Craniofacial and maxillofacial surgery in children and young adults*. Philadelphia: WB Saunders; 1999. p. 419–45.
 17. Pruzansky S. Not all dwarfed mandibles are alike. *Birth Defects* 1969;1:120.
 18. Kaban LB, Moses MH, Mulliken JB. Surgical correction of hemifacial microsomia in the growing child. *Plast Reconstr Surg* 1988;82:9–19.
 19. Cousley RR, Calvert ML. Current concepts in the understanding and management of hemifacial microsomia. *Br J Plast Surg* 1997;50:536–51.
 20. Vargervik K, Hoffman W, Kaban LB. Comprehensive surgical and orthodontic management of hemifacial microsomia. In: Turvey TA, Vig KW, Fonseca RJ, editors. *Facial clefts and craniosynostosis: principles and management*. Philadelphia: WB Saunders; 1996. p. 537–64.
 21. Stella JP, Chaisresoahurnpon N, Epker BN. Diagnostic criteria for midface deficiency [abstract]. *Cleft Palate-Craniofacial Association* 1993;182:6.
 22. Johnson GP. Craniofacial analysis of patients with complete clefts of the lip and palate. *Cleft Palate J* 1980; 17:17–23.
 23. Fonseca RJ, Turvey TA, Wolford LM. Orthognathic surgery on the cleft patient. In: Fonseca RJ, Baker SB, Wolford LM, editors. *Oral and maxillofacial surgery: cleft/craniofacial/cosmetic surgery*. Vol 6. Philadelphia (PA): WB Saunders; 2000. p. 87–146.
 24. Bishara SE. Cephalometric evaluation of facial growth in operated and non-operated individuals with isolated clefts of the palate. *Cleft Palate J* 1973;10:239–46.
 25. Bardach J. The influence of cleft repair on facial growth. *Cleft Palate J* 1990;27:76–8.
 26. Shaw WC, Dahl E, Asher-McDade C, et al. A six-center international study of treatment outcome in patients with clefts of the lip and palate. Part 5. General discussion and conclusions. *Cleft Palate Craniofac J* 1992;29:413–8.
 27. Semb G. A study of facial growth in patients with unilateral cleft lip and palate treated by Oslo CLP team. *Cleft Palate Craniofac J* 1991;28:1–21.
 28. Ross RB. Treatment variables affecting facial growth in complete unilateral cleft lip and palate. *Cleft Palate J* 1987;24:5–77.
 29. Shin JH, Persing J. Asymmetric skull shapes: diagnostic and therapeutic consideration. *J Craniofacial Surg* 2003;14:696–9.
 30. Kane AA, Lo LJ, Vannier MW, Marsh JL. Mandibular dysmorphology in unicoronal synostosis and plagiocephaly without synostosis. *Cleft Palate Craniofac J* 1996; 33:418–23.
 31. Cohen MM. Perspectives on craniofacial asymmetry. IV Hemi-asymmetries. *Int J Oral Maxillofac Surg* 1995;24:134–41.
 32. Pollock RA, Newman MH, Burdi AR, Condit DP. Congenital hemifacial hyperplasia: an embryonic hypothesis and case report. *Cleft Palate J* 1985;22:173–84.
 33. Yoshimoto H, Yano H, Kobayushi K, et al. Increased proliferative activity of osteoblasts in congenital hemifacial hypertrophy. *Plast Reconstr Surg* 1998;102:1605–10.
 34. Parry CH. Collections from unpublished papers. Vol 1. London: Underwood; 1825.
 35. Romberg MH. Trophoneurosen. In: *Klinische Ergebnisse*. Berlin: A. Forstner; 1846. p. 75–81.
 36. Stone J. Parry-Romberg syndrome: a global survey of 205 patients using the Internet. *Neurology* 2003;61:674–6.
 37. Shah JR, Juhasz C, Kupsky WJ, et al. Rasmussen encephalitis associated with Parry-Romberg syndrome. *Neurology* 2003;61:395–7.
 38. Stern HS, Elliott LF, Beegle PH. Progressive hemifacial atrophy associated with Lyme disease. *Plast Reconstr Surg* 1992; 90:479–83.
 39. Moss ML, Crikelair GF. Progressive facial hemiatrophy following cervical sympathectomy in the rat. *Arch Oral Biol* 1959;1:254–8.
 40. Rees TD. Facial atrophy. *Clin Plast Surg* 1976;3:637–46.
 41. Roddi R, Riggio E, Gilbert PM, et al. Progressive hemifacial atrophy in a patient with lupus erythematosus. *Plast Reconstr Surg* 1994;93:1067–72.
 42. Franz FP, Blocksma R, Brudage SR, et al. Massive injection of liquid silicone for hemifacial atrophy. *Ann Plast Surg* 1988;20:140–5.
 43. Roddi R, Riggio E, Gilbert PM, et al. Clinical evaluation of techniques used in the surgical treatment of progressive hemifacial atrophy. *Craniofacial Surg* 1994;22:23–32.
 44. Pisarek W. Reconstruction of craniofacial microsomia and hemifacial atrophy with free latissimus dorsi flap. *Acta Chir Plast* 1988;30:194–201.
 45. Marchetti C, Cocchi R, Gentile L, Bianchi A. Hemimandibular hyperplasia: treatment strategies. *J Craniofac Surg* 2000;11:46–53.
 46. Obwegeser HL, Makek MS. Hemimandibular hyperplasia—hemimandibular elongation. *J Maxillofac Surg* 1986;14:183–208.
 47. Chen YR, Bendov-Samuel RL, Huang CS. Hemimandibular hyperplasia. *Plast Reconstr Surg* 1996;97:730–7.
 48. Stassen LF, Kerwala CJ. New surgical technique for the correction of congenital muscular torticollis (wry neck). *Br J Oral Maxillofac Surg* 2000;38:142–7.
 49. Chen CE, Ko JY. Surgical treatment of muscular torticollis for patients above 6 years of age. *Arch Orthop Trauma Surg* 2000;120:149–51.
 50. Kiliaridis S, Katsaros C. The effects of myotonic dystrophy and Duchenne muscular dystrophy on the orofacial muscles and dental facial morphology. *Acta Odontol Scand* 1998;56:369–74.
 51. Proffit WR, Vig KW, Turvey TA. Fractures of the mandible condyle: frequently an unsuspected cause of facial asymmetry. *Am J Orthod* 1980;78:1–24.
 52. Proffit WR, Turvey TA. Dentofacial asymmetry. In: Proffit WR, White RP, Sarver DM, editors. *Contemporary treatment of dentofacial deformity*. St. Louis: Mosby; 2003. p. 574–644.
 53. Demianczuk AN, Verchere C, Phillips JH. The effect on facial growth of pediatric mandibular fractures. *J Craniofac Surg* 1999;10:323–8.
 54. Pirttiniemi PM. Associations of mandibular and facial asymmetries—a review. *Am J Orthod Dentofacial Orthop* 1994;106:191–200.
 55. Stabrun AE. Impaired mandibular growth and micrognathic development in children with juvenile rheumatoid arthritis. *Eur J Orthod* 1991;13:423–34.
 56. Bazan MT. An overview of juvenile rheumatoid arthritis. *J Pedod* 1981;6:68–76.
 57. Kjellberg H, Fasth A, Kiliaridis S, et al. Craniofacial structure in children with juvenile rheumatoid arthritis compared with healthy children with ideal or postnormal occlusion. *Am J Orthod Dentofacial Orthop* 1995;107:67–78.
 58. Mericle PM, Wilson VK, Moore TL, et al. Effects of polyarticular and pauciarticular onset juvenile rheumatoid arthritis on facial and mandibular growth. *J Rheumatol* 1996;23(1):159–65.
 59. Stabrun AE, Larheim TA, Hoyeraal HM, Rosler M. Reduced mandibular dimensions and

- asymmetry in juvenile rheumatoid arthritis pathologic factors. *Arthritis Rheum* 1988;31:602–11.
60. Walton AG, Welburg RR, Thomason JM, Foster HE. Oral health and juvenile idiopathic arthritis: a review. *Rheumatology* 2000; 39:550–5.
 61. Ince DO, Ince A, Moore TL. Effect of methotrexate on the TM joint and facial morphology in juvenile rheumatoid arthritis patients. *Am J Orthod Dentofacial Orthop* 2000;118:75–83.
 62. Schellhas KP, Piper MA, Omlie MR. Facial skeletal remodeling due to temporomandibular joint degeneration: an imaging study of 100 patients. *Cranio* 1992; 10:248–59.
 63. Hegtvedt AK. Diagnosis and management of facial asymmetry. In: *Principles of oral and maxillofacial surgery*. Philadelphia: JB Lippincott Company; 1992. p. 1400–14.
 64. Sailer HF, Haers PE, Zollikofer CP, et al. The value of stereolithographic models for preoperative diagnosis of craniofacial deformities and planning of surgical corrections. *Int J Oral Maxillofac Surg* 1998;27:327–33.
 65. O'Mara RE. Role of bone scanning in dental and maxillofacial disorders. In: Freeman M, Weissman HS, editors. *Nuclear medicine annual*. New York: Raven Press; 1985. p. 265–84.
 66. O'Mara RE. Scintigraphy of the facial skeleton. *Oral Maxillofac Surg Clin North Am* 1992;4:51–60.
 67. Strumas N, Antonyshyn O, Caldwell CB, Mainprize J. Multimodality imaging for precise localization of craniofacial osteomyelitis. *J Craniofac Surg* 2003;14:215–9.
 68. Severt TR, Proffit WR. The prevalence of facial asymmetry in the dentofacial deformities population at the University of North Carolina. *Int J Adult Orthodon Orthognath Surg* 1997;12:171–6.
 69. Peck S, Peck L. Skeletal asymmetry in esthetically pleasing faces. *Angle Orthod* 1991; 61(1):43–8.
 70. Burk PH. Stereophotogrammetric measurement of normal asymmetry in children. *Hum Biol* 1971;43:536–48.
 71. Sutton PR. Lateral facial asymmetry methods of assessment. *Angle Orthod* 1968;38(1):82–92.
 72. Cheney EA. Dentofacial asymmetry and their clinical significance. *Am J Orthod* 1961; 47:814–29.
 73. Harvold E. Cleft lip and palate: morphologic studies of facial skeleton. *Am J Orthod* 1954;40:493–506.

Soft Tissue Changes Associated with Orthognathic Surgery

Norman J. Betts, DDS, MS

Sean P. Edwards, DDS, MD

While few patients and clinicians question the functional benefits of orthognathic surgery, the esthetic results that accompany surgery of the bony foundation of the face are equally powerful, if not more so. It is therefore incumbent upon the surgeon to include a component of soft tissue changes in the surgical treatment plan while working to achieve a stable, functional dentoskeletal unit.

Fundamental to such treatment planning is a sound knowledge of the behavior of the soft tissues of the face in response to both orthodontic and surgical changes. Close collaboration between surgeon and orthodontist is essential for this to occur.

The soft tissue response to orthognathic surgery will be discussed in this chapter. In addition, the surgical procedures and techniques used to control the soft tissue changes will be presented and evaluated in order to help the surgeon understand, control, and maximize the beneficial aspects of the facial soft tissue response to surgery.

Historical Perspective

The orthodontic literature contains the origins of predicting changes in the soft tissues of the face following the treatment of dentofacial deformities. Orthognathic

surgery initially was used to correct skeletofacial deformities and the resultant functional problems, often at the expense of the facial soft tissue esthetics. In time, a greater concern for the esthetic aspects of surgery developed, such that facial soft tissue prediction became an integral part of preoperative planning and postoperative outcome assessment.

Early studies produced average ratios, which related designated hard and soft tissue landmarks. The ratios were of use for predicting the response of the soft tissues to various skeletal and dental changes. These ratios are averages, however, and investigators realized that individual variability was significant. It was surmised that facial soft tissue response to orthodontics and surgery was multifactorial in nature. As a result, more elaborate statistical analyses were employed, with varying degrees of success, to elucidate the factors governing the soft tissue response to surgery. Consequently, prediction equations were developed that would help in preoperative surgical planning and postoperative outcome assessment.

Recently, much emphasis has been placed on developing procedures that assist the surgeon in controlling the soft tissue response to surgery. By using procedures

such as the alar cinch suture and V-Y closure, the surgeon can minimize or eliminate unesthetic soft tissue changes and may optimize positive esthetic changes.

Facial Esthetics in Society

Physical appearance is critically important in our society.¹⁻³ Perception of oneself and the perceptions of others are both essential to self-esteem. The most significant aspect of one's self-image is facial appearance. As a result, dentofacial and skeletofacial deformities have a significant psychological and social impact on those afflicted. Further, the correction of these deformities can have an equally significant impact on self-esteem and personality.

General Considerations

Much has been written about soft tissue changes associated with orthognathic surgery, and each paper has its strengths and weaknesses. Variation in design, heterogeneity of study design, surgical technique, and patient populations do not allow for direct comparison. To make some objective comparisons between methodologically different studies, we identified a set of characteristics for the theoretically ideal study of the soft tissue changes associated with orthognathic

surgery (Table 59-1). These criteria should help the reader to evaluate individual investigations. This technique for assessing the previous literature is helpful and should be considered for use in other areas of scientific investigation.⁴

Most of the studies dealing with this subject provide ratios of soft to hard tissue movement. Ratios are averages. Averages apply well to groups but often fail to account for individual variation within the group. Further, these ratios only describe the relationship of two specific points. It is highly improbable that consistently accurate predictions of soft tissue change can be accomplished with only simple correlations. The complex behavior of the facial soft tissue drape is much more realistically described by the interaction of several factors within the skeletal framework. This

may explain some of the extreme variability that many authors have encountered.⁵⁻⁹ At best, ratios serve to give a general appreciation of the expected outcome.⁹ Some authors have stated that ratios are just as efficacious in predicting the soft tissue response to osseous surgery as multiple regression and stepwise regression analysis.^{6,9} This may be a result of several factors such as lack of inclusion of important variables (eg, the method of soft tissue closure and osseous contouring) into their database; a mixed sample population (race, age, or sex); small numbers of patients; or inability to limit the sample to specific vectors of osseous movement.^{4,6,8,9}

Recent investigations have shown improved predictive ability when patients were grouped by vector-specific movements of the osseous segments.^{4,10}

Orthodontic Considerations

Tooth position and alveolar morphology result from the sum of applied forces during their development. These applied forces derive from the cheeks, lips, and tongue and parafunctional habits. Obviously, skeletal imbalances are accompanied by soft tissue imbalances. The result is dental compensation for skeletal malocclusions. Orthodontic correction of these compensatory changes will often result in a worsening of the malocclusion preoperatively, and the jaw-to-jaw discrepancy will appear clinically more severe.^{11,12} Thus, initial treatment planning should consider these changes, and final surgical treatment plans should be based on records obtained as close to surgery as possible. When evaluating ratio studies, it becomes apparent that the position of the incisor teeth does not always accurately reflect the osseous movement. This is because of postoperative orthodontic tooth movement. The molar teeth or bony landmarks such as the anterior nasal spine (ANS) undergo less postoperative change and may more accurately describe the osseous surgical movement. Therefore, these landmarks should produce a more accurate ratio or prediction.⁹

Cephalometric Considerations

The use of a standardized cephalometric technique is essential to the study of this subject. The components of a standardized cephalometric technique are using the same cephalometer, with the same source-object and object-film distances, and positioning the patient in a natural head position with the teeth in centric relation and soft tissues in repose. The cephalogram obtained from the standardized cephalometric technique must allow visualization of the complete soft tissue profile. Relaxation of the soft tissues may be difficult to produce and reproduce. Relaxed lip posture is especially difficult to achieve in patients with excessive interlabial gap. Straining to close the gap by contracting the mentalis muscles flattens

Table 59-1 Theoretical Ideal Characteristics of a Study to Investigate the Soft Tissue Changes Associated with Orthognathic Surgery

1. Prospective
2. Adequate sample size
3. Randomized treatments (if treatments differ within the sample)
4. Nongrowing patients
5. No previous trauma to the osseous structures of the face
6. Exclusion of patients with congenital defects or syndromes (eg, cleft patients)
7. Elimination of the confounding effects of pre- and postoperative orthodontic tooth movement
8. Constant presence or absence of orthodontic appliances
9. Same cephalostat used for all cephalograms with identical source-subject and subject-film distances
10. Soft tissues in repose for all cephalograms
11. Superimposition of cephalograms on the nearest osseous structure not affected by surgery or on a stable reference line
12. Use of a tracing template to assist in landmark identification
13. Evaluation of both profile and full facial soft tissue changes, or 3-D analysis
14. No concomitant or prior soft tissue surgery
15. Exclusion of segmental surgical procedures
16. One vector of movement (or grouped in study)
17. No concomitant osseous surgery on another portion of the facial skeleton
18. Homogeneity of the soft tissue incisions and closure techniques
19. No hard tissue contouring (eg, recontouring of ANS)
20. Use of rigid osseous fixation
21. Uniform follow-up intervals
22. Follow-up time of at least 6 months (1 year is preferable)
23. Error analysis of measurement and landmark identification

ANS = anterior nasal spine.
Adapted from Betts et al.⁴

the labiomental fold and distorts the overall contour of the chin. It is important that patients be instructed to keep their lips in repose for the cephalogram.¹³

To minimize measurement error during cephalometric analysis, landmarks or planes approximating the structures being evaluated must be superimposed. This superimposition should be on landmarks not modified or changed during the surgical procedure.^{9,14} Another contributing factor to measurement error is orthodontic tooth movement between the times of comparison. Orthodontic changes can be minimized by obtaining the preoperative cephalogram within a month of the planned surgical procedure,^{6,9} and performing minimal postoperative orthodontics.⁹ Also, the presence, or absence, of orthodontic appliances must be constant during the study period. The presence of orthodontic appliances influences lip posture, and their placement or removal will change the soft tissue drape.⁴

Landmark identification is simplified and becomes more accurate when templates are used.^{9,10,14} This is especially valid for soft tissue landmarks.¹¹ Soft tissue landmarks are often arbitrary and located on gently curving contours. These landmarks can therefore move vertically over the surface of the tissue after surgically induced change.^{8,12} If tracing templates are used, these points can be more accurately located.

Soft Tissue Considerations

The ability to predict the hard and soft tissue changes prior to an orthognathic surgical procedure is critical to the treatment planning process. With the refinement of surgical procedures and the advent of rigid fixation techniques, the surgeon is able to accurately reposition and retain the osseous components in a planned position. However, the change in soft tissue morphology after combined orthodontic and surgical therapy depends on several

factors. These include surgical procedure,^{6,15–19} method of wound closure,^{6,9,15,16,18,19} the new spatial arrangement of the skeletal and dental elements,¹⁹ the adaptive qualities of the soft tissues,¹⁹ growth,^{17,20} orthodontic vectors of tooth movement,^{17,19} lip thickness,^{5,6,17,21–23} lip tonus,⁹ lip area, lip contact (competence), lip strength, interlabial gap, amount of overjet, amount of fatty tissue and musculature, and postoperative edema.¹⁷

Because of swelling, tissue redistribution, and functional adaptation, long-term follow-up is needed to assess soft tissue changes after surgical procedures. Most authors suggest that the soft tissues stabilize after 6 months.^{15,17,19,21,22} Others suggest that at least 12 months are required.^{11,24} Hack and colleagues found evidence of continued soft tissue settling several years after surgery.²⁵ Surgical technique and method of wound closure have been shown to affect soft tissue relationships.^{6,9,15,16,18,19,26–28} For example, the horizontal incision in the upper labial vestibule commonly used to gain access to the maxilla for the Le Fort I osteotomy causes shortening of the lip with loss of vermilion and a decrease in lip thickness,¹⁶ whereas vertical incisions with a tunneling approach and palatal flap for the same surgical procedure show minimal postoperative lip changes.¹⁹ Betts and colleagues, investigating the soft tissue response to maxillary surgery, noted that soft tissue changes may be more affected by the type and position of the soft tissue incision and methods used in closure than by the surgically induced hard tissue change.⁴

Changes in facial esthetics and occlusion following orthognathic surgery depend highly on the stability achieved following surgery. Simply put, the soft tissue will mirror changes in the bony foundation should skeletal relapse occur.

Many authors have shown that thin lips move more predictably than thick lips.^{5,6,10,17,22,23} Two theories have been advanced to explain this discovery. First, the actual bulk of a thick lip may have a

tendency to absorb a large amount of bony advancement without a perceptible change in soft tissue contour. Second, “dead space” under the lip may absorb the first portion of a bony advancement before the soft tissue is affected (eg, with severe maxillary retrognathia).^{5,6,10,17,22,23}

The general trend noted in the literature is that the horizontal changes in the soft tissues are often predictable, whereas the vertical changes are unpredictable. This may be because of smaller movements in the vertical plane and the use of soft and hard tissue landmarks better suited for horizontal assessment. Also, hard tissue change is less predictable and less stable in the vertical dimension.

The cephalometric landmarks shown in Figure 59-1 will be used to describe the relationships between the soft and hard tissue changes presented in the rest of this chapter.

Orthodontic Incisor Retraction

Most orthodontic changes will be reflected in changes in the position and posture of the lips. Early studies in the orthodontic literature stressed that the soft tissue profile was closely related to skeletal and dental structures.²⁹ More recent work has demonstrated that a direct relationship between hard and soft tissue changes may not always exist.^{20,30} Simply put, the position of the lips is not solely determined by tooth position. The effects of growth and development, large ANB angle (angle formed by A point, nasion, and B point), positional relationship of the upper incisor on the lower lip (overbite and overjet), and adipose tissue are other factors that confuse the issue and may contribute to the great individual variability observed.^{14,31}

The changes in the soft tissues associated with orthodontic incisor movements are seen in Table 59-2.

Review of the literature indicates that with incisor retraction, the upper lip rotates backward around subnasale,¹⁸ with an associated reduction in the prominence of the lips relative to their adjacent sulci.³²

Also, upper lip thickness increases with maxillary incisor retraction (1 mm with 3 mm of incisor retraction,³³ 1 mm with 1.5 mm of incisor retraction³⁴). Correlation analysis discloses that upper lip response is related not only to the upper incisor retraction, but also to lower incisor movement, mandibular rotation, and the position of the lower lip.

The lower lip moves less predictably with retraction of the incisors than does the upper lip.³² Several theories have been advanced to explain this phenomenon. Hershey has theorized that this is because the lower lip is much more self-supporting

and not as dependent upon underlying incisor support.³² Other investigators feel that this is explained by combined upper and lower incisor effects on the lower-lip positioning (note the $-1:1$ effect of upper incisor retraction to lower-lip retraction).³⁵ They feel that the upper teeth, not the lower, establish the curve of the lower lip. Therefore, if the upper incisor is retracted more than the lower incisor, the lower lip may displace more posteriorly than the lower incisor ($-1.56:1$,³⁵ $-1.22:1$ ³²). Another theory is that many factors contribute to the final position of the lower lip. This theory is supported by

correlation analysis, which indicates that mandibular rotation had a greater influence on lower lip response than did incisor movement. Stepwise regression analysis lends further support to this theory by revealing a complex interaction between dental movement, mandibular rotation, and the perioral soft tissues, as well as a complex relationship within the soft tissues themselves.

Maxillary Surgical Procedures

Most soft tissue change after Le Fort I surgery is manifested in the nasal and labial structures.³⁶⁻³⁸

Nasal Structures

Movement of the maxilla affects the lower aspect of the nasal dorsum.^{5,6,21,36-39} The general trend is a widening of the alar base in all patients regardless of the vector of maxillary movement. An associated shortening of the columellar height, alar height and nasal tip projection has been observed, and the nasolabial angle decreases or remains constant in most cases (Figure 59-2).⁴

Different movements of the maxilla have distinct effects on the nasal and labial morphology (Table 59-3). Superior repositioning of the maxilla causes elevation of the nasal tip,^{40,41} widening of the alar bases,^{4,41} and a decrease in the nasolabial angle.⁴⁰ Inferior maxillary repositioning produces loss of nasal tip support, downward movement of the columella and alar bases, thinning of the lip, and an increase in the nasolabial angle. Anterior repositioning of the maxilla has a profound effect on the nose and upper lip, resulting in advancement of the upper lip, subnasale and pronasale, thinning of the lip,¹⁶ widening of the alar bases, and an increase in the supratip break if the ANS is left intact.^{8,36-38} The nasal tip advances approximately one-half the distance of subnasale.²¹ This may be a result of widening at the alar base, which reduces nasal tip protrusion.⁴

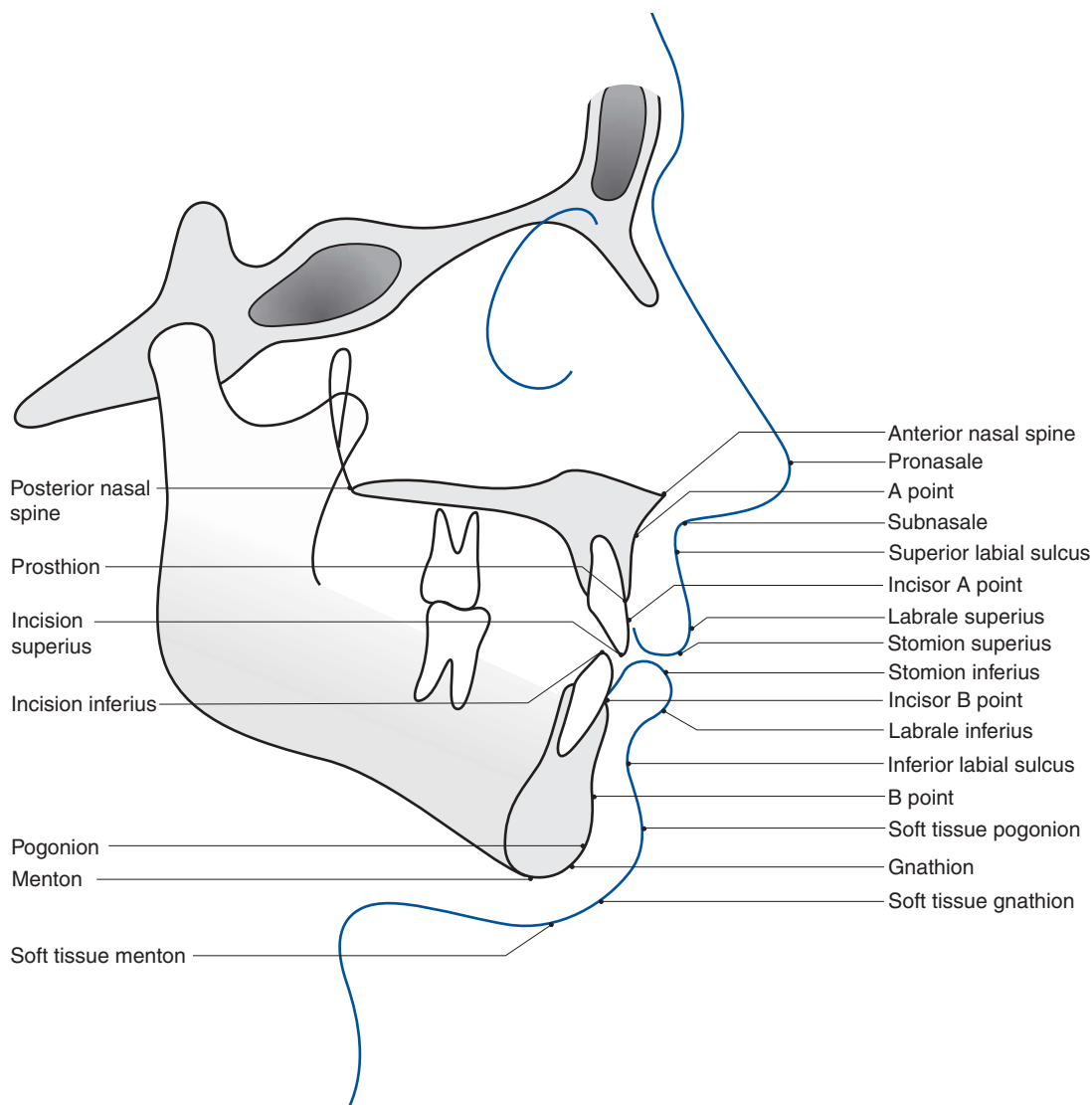


FIGURE 59-1 The hard and soft tissue cephalometric landmarks used for the evaluation of the hard and soft tissue changes associated with orthognathic surgical procedures. These landmarks are referenced in Table 59-2. Adapted from Betts NJ et al.⁴

Table 59-2 Soft Tissue Changes Associated with Orthodontic Tooth Movement

Anatomic Structure	Ratio	Orthodontic Movement	Author
Superior sulcus (H)	-0.89:1	Upper incisor retraction	
Upper lip (H)	-0.87:1	Upper incisor retraction	
Lower sulcus (H)	-0.87:1	Lower incisor retraction	
Lower lip (H)	-0.93:1	Lower incisor retraction	
Lower lip (H)	-0.82:1	Upper incisor retraction	Bloom ^{*14}
Upper lip (H)	-0.34:1	Upper incisor retraction	
Lower lip (H)	-1.56:1	Lower incisor retraction	
Lower lip (H)	-1:1	Upper incisor retraction	Rudee ^{*35}
Upper, lower lips (H)	±0.75-0.9:1	Incisor protrusion or retraction	Robinson et al ^{*61}
Upper lip (H)	-0.5:1	Ls: Ia Upper incisor retraction	
Lower lip (H)	-1.22:1	Li: Ib Lower incisor retraction	Hershey, Smith ⁷
Upper lip (H), increased nasolabial angle, no nasal change	-0.5:1	Maxillary incisor retraction	Proffit, Epker ¹⁸
Upper lip (H)	-0.63:1	Ls: Upper incisor retraction	Rains, Nanda ¹⁰¹ Attarzadeh, Adenwalla ³¹
Upper lip (H)	-0.4:1	Ls: Upper incisor retraction	
Lower lip (H)	-0.7:1	Li: Upper incisor retraction	Yogosawa ¹⁰²
Upper lip (H)	-0.44:1	Ls: Upper incisor retraction	
Lower lip (H)	-1.2:1	Li: Lower incisor retraction	Kasai ¹⁰³

*Includes growing patients.
H = horizontal; Ia = incisor A point; Ib = incisor B point; Li = labrale inferius; Ls = labrale superius.

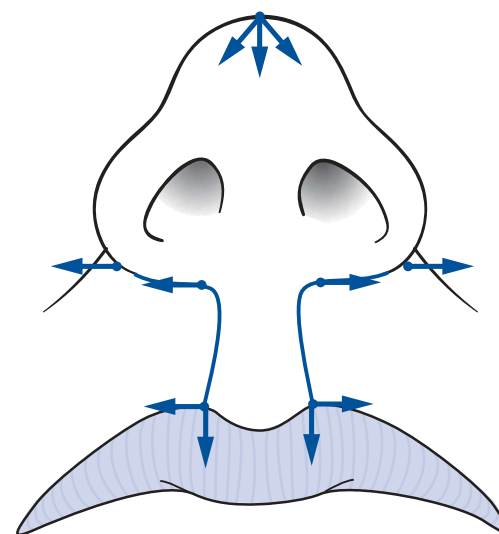


FIGURE 59-2 The general trends of postsurgical changes in the nasal and labial soft tissues expressed in a nonvector format (the arrows are not specific for length, but are specific for direction). Generally, the alar base of the nose widened and the nasal tip decreased in height in relation to the adjacent soft tissues. The philtral columns of the lip widened and became longer, and the nasolabial angle decreased. Adapted from Betts NJ. Changes in the nasal and labial soft tissues after surgical repositioning of the maxilla. [master's thesis] Ann Arbor (MI): University of Michigan; 1990.

Preoperative alar-base width of the nose is important in final postsurgical outcome. Narrow noses were observed to widen more at the alar base than did broad noses.^{4,26} Important nasal changes have been documented as a result of rotation of the maxilla.^{9,42} A counterclockwise rotation of the occlusal plane raises the nasal tip, while a clockwise rotation of the occlusal plane decreases the superior movement of nasal tip.^{6,42}

Labial Structure

Maxillary surgery has a significant impact on upper lip morphology and position. The upper lip is attached to the nose and this prevents a 1:1 soft tissue change.⁴³ The upper lip widens and lengthens at the philtral columns after maxillary surgery.⁴ Shortening of the upper lip with a loss of exposed vermilion can occur if a V-Y closure technique is not employed at the time of surgery.^{16,28}

Anterior Segmental Repositioning

The soft tissue changes associated with the maxillary segmental setback osteotomy include an increase in the nasolabial angle because of posterior lip rotation around subnasale,⁴³⁻⁴⁶ lengthening of the upper lip, decrease in interlabial gap,⁴⁶ and uncurling and retraction of the lower lip with associated decrease in the depth of the inferior labial sulcus (Table 59-4).⁴⁵

Table 59-3 Nasal Effects of Maxillary Surgery

Direction Maxillary Movement	Alar Bases	Nasal Tip	Supratip Depression	Dorsal Hump	Nasolabial Angle
Superior	Increase	Increase	Increase	Decrease	Decrease
Anterior	Increase*	Increase*	Increase*	Decrease	Decrease
Inferior	Inferior	Decrease	Decrease	Increase	Increase
Posterior	None	Decrease	Decrease	Increase	Increase

*Indicates a greater magnitude of change.
Adapted from O'Ryan F, Schendel S. Nasal anatomy and maxillary surgery. III. Surgical techniques for correction of nasal deformities in patients undergoing maxillary surgery. Int J Adult Orthodon Orthognath Surg 1989;4:157.

Table 59-4 Soft Tissue Changes Associated with Anterior Segmental Setback Osteotomy

Anatomic Structure	Ratio	Landmarks	Author(s)
Increased nasolabial angle			
Upper lip (H)	-0.68:1	Ls: Ia	Bell, Dann ⁶⁹
Upper lip (H)	-0.5:1	Ls: Is	Lines, Steinhauer ⁴³
Upper lip (H), increased nasolabial angle	-0.67:1		
Lower lip (H)	-0.3:1		Proffit, Epker ¹⁸
Upper lip (H)	-0.43:1	Ls: Is	
Nasolabial angle	12.2°	Increase	Lew, et al ⁴⁶

H = horizontal; Ia = incisor A point; Is = incision superius; Ls = labrale superius.

Anterior Repositioning

Maxillary anterior repositioning has the greatest effect on the nose and upper lip. This movement precipitates advancement of the upper lip, subnasale, and nose,^{6,36-38} slight shortening of the upper lip, thinning of the lip (approximately 2 mm),^{10,36-38,47} widening of the alar bases,³⁶⁻³⁸ and a deepening of the supratip depression if the ANS is left intact.^{21,23,36-38,48} A progressive increase in the horizontal soft tissue displacement is seen from the tip of the nose to the free end of the upper lip.³⁷ A concomitant decrease in nasolabial angle is observed with only slight changes in the lower lip.^{5,18} Leaving the ANS intact has a favorable effect on the forward displacement of the upper lip and especially the base of the nose (subnasale).²⁴ The ratios derived from previous investigations can be found in Table 59-5.

A significant difference between the ratio of horizontal change of upper incisor to vermilion border of the upper lip in previous studies (0.6:1)^{6,21,22} compared with the ratio reported by Carlotti and colleagues (0.9:1)⁴⁸ is a result of the use of the alar cinch suture and V-Y closure during the surgical procedure. The ratio reduces with larger advancements because of soft tissue stretching.⁴⁸ If the ANS is left intact, the nasolabial angle may remain relatively unchanged. The nasal tip rises slightly so subnasale migrates forward along with the upper lip.¹⁵

Superior Repositioning

Superior repositioning of the maxilla causes elevation of the nasal tip,^{21,36-38} widening of the alar bases (2–4 mm),^{23,26,36-38} and a decrease in the nasolabial angle (Table 59-6).³⁶⁻³⁸ These nasal changes occur without change in angulation of the upper lip.^{6,8} The upper lip closely follows the movement of the maxillary incisor in the horizontal plane. The lip follows superiorly approximately 40% of the vertical maxillary change. This lip shortening is accentuated with combined anterior and superior maxillary movements.²³ The amount of vertical soft tissue change increases progressively from the nasal tip to stomion superius, with loss of vermilion if a V-Y closure is not used.^{6,8} However, Phillips found that the vermilion border of the upper and lower lips decreased slightly in the lateral portion of the lip, even with a V-Y closure.²⁶ Interestingly, when superimposition is done on maxillary landmarks, the soft tissues of the lip migrate downward in relation to the maxilla. This may be because of the connection of the upper lip to the nose.^{6,8}

Inferior Repositioning

Maxillary inferior repositioning produces loss of nasal tip support, downward repositioning of the columella and alar bases, thinning of the lip, and an increase in the nasolabial angle.³⁶⁻³⁸ Lengthening and thinning of the upper lip is also observed.¹⁸

Posterior Repositioning

Maxillary setback procedures result in loss of nasal tip support because of posterior movement of the ANS and the bony support area around the piriform aperture.³⁷ The lip rotates posteriorly and superiorly about subnasale with increasing nasolabial angle^{8,49} and thickens slightly (Table 59-7).⁴⁹

Multidirectional Maxillary Movements

Most maxillary movements are multidirectional (anterior and superior, anterior and inferior, posterior and superior, posterior and inferior, etc). The expected soft tissue changes would be a combination of the expected changes from the pure vectors of movement (Figures 59-3–59-5).

Mandibular Surgical Procedures

Generally the soft tissues of the mandible follow the hard tissues closely. The exception is the lower lip. Because of its contact with the upper incisor and upper lip, its movement is often variable and unpredictable.

Anterior Segmental Posterior Repositioning

The lower lip follows the lower incisor posteriorly, which causes a flattening of the labiomental fold. There is less posterior displacement of the soft tissues as the chin is approached. No effective change is observed at the chin (Table 59-8).⁴³

Anterior Repositioning

The soft tissue changes associated with mandibular advancement surgery are limited to the structures below the superior labial sulcus. There is little change in the upper lip^{43,50-52} and none above the ANS.⁵³ The lower lip advancement is variable, and the lip often lengthens.⁵³ The lower labial sulcus and chin adhere to the bony structure of the mandible. Consequently, they follow the underlying osseous tissues closely, advancing more than the lower lip does (Figure 59-6). This leads to an opening of the labiomental

Table 59-5 Soft Tissue Changes Associated with Maxillary Advancement

Anatomic Structure	Ratio	Landmarks	Author(s)
Upper lip (H)	0.67:1	Ls: Is Cleft pts. removed ANS	Lines, Steinhauser ⁴³
Upper lip (H)	0.5:1	Ls: Is	
Upper lip (V)	0.3:1	Ls: Is	
Nasolabial angle	-1.2°:1	Nasolabial angle: Is	
Nasal tip (H)	0.28:1	Pn: Is	Dann, et al ⁵
Nasal base (H)	0.57:1	Sn: A pt.	
Upper lip (H)	0.56:1	Ls: Is cleft pts	Freihofer ²²
Nasal base (H)	0.57:1	Sn: A pt.	
Nasal tip (H)	0.28:1	Pn: A pt. cleft pts	Freihofer ²¹
Upper lip (H)	0.5:1		Proffit, Epker ¹⁸
Nasal tip (H)	0.17:1	Pn: Ia	
Upper lip (H)	0.5:1	Ls: Is	Radney, Jacobs ⁸
Nasal tip (H)	0.17:1	Pn: Ia	
Nasal base (H)	0.24:1	Sn: Ia	
Upper labial sulcus (H)	0.52:1	SLS: Ia	
Upper lip (H)	0.62:1	Ls: Ia	Mansour, et al ⁶
Upper lip (H)	0.5:1	Ss: A pt.	
Upper lip (V)	-0.3:1	Ss: A pt.	Bundgaard, et al ⁴²
Upper labial sulcus (H)	0.8:1	SLS: A pt., alar cinch, V-Y closure	
Upper lip (H)	0.9:1	Ls: Is	Carlotti, et al ⁴⁸
Upper lip (H)	0.82:1	Ls: Is	
Upper lip (V)	-0.32:1	Ss: Is	
Nasal base (H)	0.51:1	Sn: A pt.	Rosen ²³
Nasal base (H)	0.3:1	Sn: A pt. (thick lip)	
Nasal base (H)	0.46:1	Sn: A pt. (thin lip)	Stella, et al ¹⁰
Upper lip (middle) (H)	1:1	3-D analysis	McChance, et al ^{104,105}
Nasal base	1.25:1	3-D analysis	
Subnasale	0.63:1	Sn: A pt. cleft pts	Ewing, Ross ⁷⁸
Upper lip (H)	0.66:1	SLS: Is	
Nasal tip	0.36:1	Pn: Is	
Upper lip (H)	0.91:1	SLS: Is	
Upper labial sulcus (H)	0.38:1	SLS: A pt	
Nasal base (H)	0.60:1	Sn: ANS	Hack et al ²⁵
Upper Lip (H)	0.74	Ls: Is	
Upper labial sulcus (H)	0.76:1	SLS: A pt	Lin, Kerr ¹⁰⁶
Upper lip (H)	0.65:1	Ls: Is	Rosenberg, et al ²⁷

A pt. = A point; ANS = anterior nasal spine; H = horizontal; Ia = incisor A point; Is = incision superius; Ls = labrale
Pn = pronasale; SLS = superior labial sulcus; Sn = subnasale; Ss = stomion superius; V = vertical.

fold. As with maxillary and genial surgeries, the vertical changes are variable.

A correlation between the vertical change in menton and the angle and depth of the labiomental fold has been elucidated. As menton moves caudally, the angle opens and the depth decreases.⁵⁰

Facial height is also affected by mandibular advancement. In low-angle, Angle Class II cases, facial height increases slightly with advancement, but in high-angle, Angle Class II cases, a large increase in facial height occurs with advancement. Further, soft tissue changes may be more

pronounced with advancements in low-angle cases (Table 59-9).⁵⁴

The position of the lower lip is affected by the upper incisor, the lower incisor, and its contact with the upper lip. The anterosuperior position of the upper one-half of the lower lip touches the upper incisor in Angle Class II, non-open-bite cases and is usually folded forward. As the mandible is advanced, the chin and lower labial sulcus come forward, but the superior portion of the lower lip does not, since it was already folded forward by its contact with the upper incisor. This causes an opening of the labiomental fold and may explain why the ratio of advancement at labrale inferius to the incisor inferius is reduced.^{18,43,53} Consequently during treatment planning, the lower lip must be righted to a relatively normal position before it is advanced in order to approximate its true postsurgical position.

Dolce and colleagues, with 2 years of follow-up, suggest that these changes are more stable when rigid fixation techniques are employed.⁵⁵ Long-term, more horizontal relapse can be expected at the level of the lip and the lower labial sulcus than at the level of pogonion.⁵⁶ As Johnston⁵⁷ and Mobarak⁵⁴ point out, the lack of correlation between surgical hard tissue movements and the soft tissue changes long-term make prediction of lasting changes difficult to predict.

Posterior Repositioning

Mandibular setback surgery has no effects on subnasale or the tissues superior to subnasale. However, a slight posterior displacement of the upper lip, with lengthening,^{18,58,59} and a slight increase in the nasolabial angle is observed.⁶⁰ The soft tissues follow the mandible posteriorly, with the chin following most closely, followed by the inferior labial sulcus and the lower lip. The lower lip shortens, becomes more protrusive by curling out, and the labiomental fold deepens and becomes more acute (Figure 59-7).^{7,58-60} Vertical changes of the soft tissues of the lips are related to hard tissue vertical changes. During

Table 59-6 Soft Tissue Changes Associated with Maxillary Impaction

Anatomic Structure	Ratio	Landmarks	Author(s)
Upper lip (V)	-0.38:1	Ls: Is vertical	
Upper lip (V)	-0.51:1	Ls: Is maxillary excess	Schendel, et al ⁴⁹
Upper lip (V)	-0.4:1	Ls: Is bimaxillary protrusion	
Upper lip (V)	-0.3:1	Ss: Is	
Upper labial sulcus (V)	-0.25:1	Ls: Is	
Nose (V)	-0.2:1	SLS: Is	
Nose (V)	-0.16:1	Sn: Is	
Upper labial sulcus (H)	0.76:1	Pn: Is (ANS removed)	Radney, Jacobs ⁸
Upper lip (H)	0.89:1	SLS: Ia	
Nose (V)	-0.15:1	Ls: Ia	
Nasal base (V)	-0.28:1	Pn: Pr	
Upper lip (V)	-0.31:1	Sn: Pr	
Upper lip (V)	-0.42:1	Ls:Pr	
Upper labial sulcus (V)	0.12:1	SLS: Is	Mansour, et al ⁶
Upper lip (V)	-0.06:1	SLS: ANS	
Upper lip (V)	-0.41:1	Ls: ANS	
Upper lip (V)	1.33:1	Ss: ANS	Sakima, Sachdeva ⁹
Upper lip (V)		Ss: A pt (V-Y closure)	Rosenberg, et al ²⁷
Full face evaluation			
Greatest alar width	Average = 3.4mm	Full facial photographs	
Alar base width	Average = 2.7mm		
Decreased vermillion more lateral	Average 1 mm	V-Y closure	Phillips, et al ²⁶
Upper lip (middle) (H)	1:1	3-D analysis	McChance, et al ^{104,105}
Alar Base (H)	1.25:1	3-D analysis	
Nasal base (V)	0.29:1	Sn: ANS	Hack, et al ²⁵
Upper labial sulcus (V)	0.54:1	SLS: A pt	
Upper lip (V)	0.72:1	SLS: Is	

A pt. = A point; ANS = anterior nasal spine; H = horizontal; Ia = incisor A point; Is = incision superius; Ls = labrale superius; Me = menton; Pn = pronasale; Pr = prosthion; SLS = superior labial sulcus; Sn = subnasale; Ss = stomion superius; V=vertical.

superior mandibular repositioning, the lower lip becomes shorter, protrusive, and smaller

in area. In contrast, with inferior mandibular repositioning, the lower lip becomes longer

Table 59-7 Soft Tissue Changes Associated with Maxillary Setback

Anatomic Structure	Ratio	Landmarks	Author(s)
Upper lip (H)	-0.76:1	Ls: Incisor	
Upper lip (H)	-0.66:1	Ls: Incisor vertical maxillary excess	Schendel et al ⁴⁹
Upper lip (H)	-0.67:1	Ls: Incisor bimaxillary protrusion	
Upper labial sulcus (H)	-0.33:1	Ls: Is	
Nose (H)	-0.33:1	SLS: Is	
Nasolabial angle	Increase	Sn: Is	Radney, Jacobs ⁸

H = horizontal; Is = incision superius; LS = labrale superius; SLS = superior labial sulcus; Sn = subnasale.

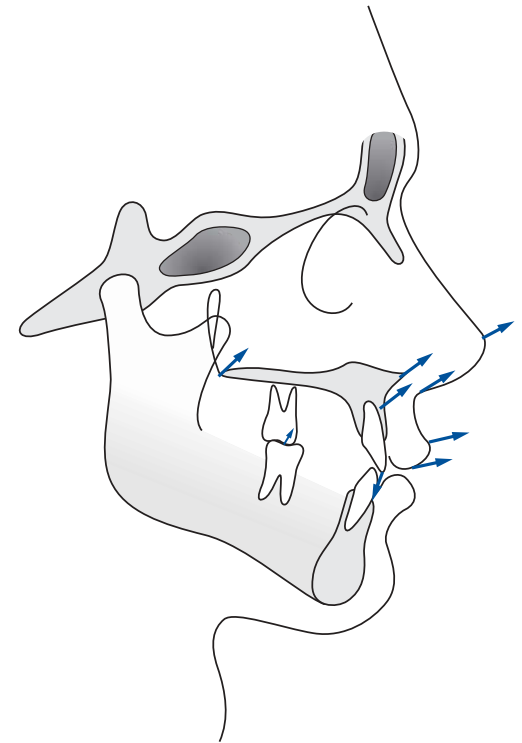


FIGURE 59-3 The average hard and soft tissue changes of the advancement, impaction group in vector format (arrows depict mean direction and mean amount of change). Note that the nasal tip elevates slightly, but subnasale advances more, effectively decreasing nasal tip protrusion. Adapted from Betts NJ. Changes in the nasal and labial soft tissues after surgical repositioning of the maxilla [master's thesis]. University of Michigan; 1990.

with increased area.⁶¹ The vertical soft tissue changes correlate poorly with hard tissue movements (Table 59-10).⁶¹ As with mandibular advancements, long-term soft tissue changes have been found to correlate relatively poorly with the initial surgical bony changes, though in the short term they do change predictably.⁶²

Autorotation

During autorotation of the mandible, the soft tissues follow the osseous landmarks on approximately a 1:1 basis,^{6,8} except the lower lip, which falls slightly lingual to the arc of rotation.^{6,8,15} A slight increase in the labiomental angle is often observed,⁶ as is a slight thickening of the lips as the vertical facial height decreases (Table 59-11).⁴³

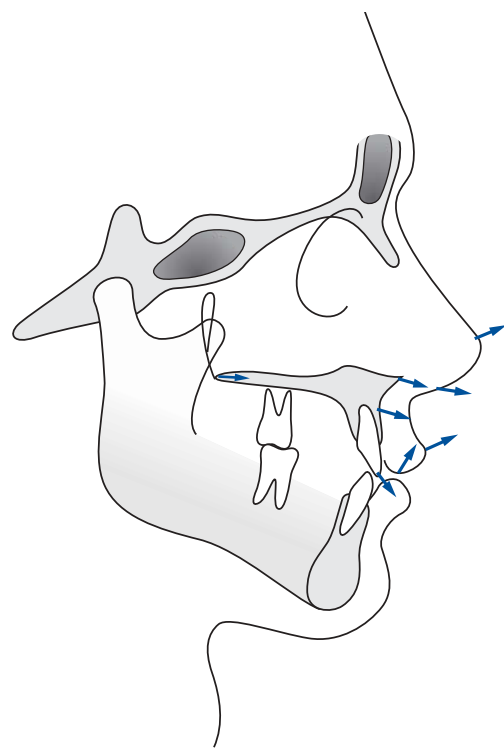


FIGURE 59-4 The average hard and soft tissue changes of the advancement, downgraft group in vector format (arrows depict mean direction and mean amount of change). Note that the nasal tip elevates slightly, but subnasale advances more, effectively decreasing the nasal tip protrusion. Adapted from Betts NJ. Changes in the nasal and labial soft tissues after surgical repositioning of the maxilla [master's thesis]. Ann Arbor (MI): University of Michigan; 1990.

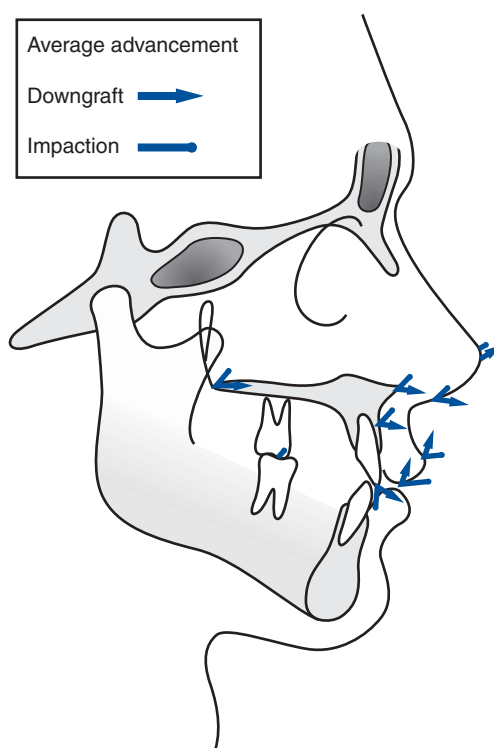


FIGURE 59-5 Overlay of average hard and soft tissue changes of advancement, impaction and advancement, downgraft in vector format. Average advancement (see legend above) as defined by the mean direction and mean amount of change, is indicated by arrows (downgraft) and lines with dots (impaction). Note that subnasale moves in the direction of the anterior nasal spine and A point. Adapted from Betts NJ. Changes in the nasal and labial soft tissues after surgical repositioning of the maxilla [master's thesis] Ann Arbor (MI): University of Michigan; 1990.

Genial Segment Surgical Procedures

The symphysis has been exposed both intraorally and extraorally for osteotomy of the inferior border of the mandible to advance, retract, widen, narrow, lengthen, or shorten the chin.⁴⁵ The majority of change seen after genioplasty is in the soft tissue of the chin, and less effect is seen in the labial sulcus and lower lip.⁶³ Early studies describing the soft tissue changes associated with genial surgery had several problems. They included few cases, related short-term results, and superimposed the cephalograms on the cranial base. Superimposition of the cephalograms should occur on the areas of the mandible not changed with surgery,^{13,64,65} because concomitant maxillary and mandibular

surgery may invalidate chin measurements calculated from superimpositions on the cranial base.⁶⁶⁻⁶⁸

Anterior Repositioning: Bony

Early attempts at advancement genioplasty used nonpedicled free grafts or onlay bone

grafts. However, these procedures were later abandoned because of excessive resorption and poor predictability. Consequently, the surgical emphasis shifted to the horizontal osteotomy of the anterior mandible.

At first a degloving incision was used to expose the anterior mandible.^{67,69,70} However, several investigators demonstrated that minimal soft tissue stripping gave a more predictable hard and soft tissue response because of less bone resorption of the advanced segment.^{13,45,65,66,71,72} No bony remodeling of gnathion or menton was observed. However, bone resorption could be demonstrated near the osteotomy (the anterosuperior and posteroinferior aspects of the advanced genial segment).^{66,67,69,70,72-74} Bony apposition occurred at B point and the inferior border osteotomy (Figure 59-8).⁶⁷ These same studies demonstrated that when the technique of minimal soft tissue stripping was used, the soft tissues followed the hard tissues closely without chin droop.^{13,45,65,66,68} There was also a small but negligible effect on the labiomental sulcus,^{66,68} an increase in submental length, an improved relationship of lower lip to tooth,⁶⁶ less soft tissue thinning,⁶⁸ and an improved neck-chin angle.

The soft tissue changes following horizontal advancement genioplasty depend on the magnitude and direction of the positional change of the genial segment, the design of the mucosal and osseous incisions, the amount of soft tissue stripping, and other concomitant jaw movements (Table 59-12).^{13,66,67,69,70}

Table 59-8 Soft Tissue Changes Associated with Mandibular Anterior Segmental Osteotomy

Anatomic Structure	Ratio	Landmarks	Author(s)
Lower lip (H)	-0.75:1	Li: Ii	Lines and Steinhauser ⁴³
Lower lip (H)	-0.67:1		
Chin (H)	No change		Proffit, Epker ¹⁸
Lower lip (H)	-0.71:1	Li: Ii	Lew et al ⁴⁶

H = horizontal; Ii = incision inferius; Li = labrale inferius.

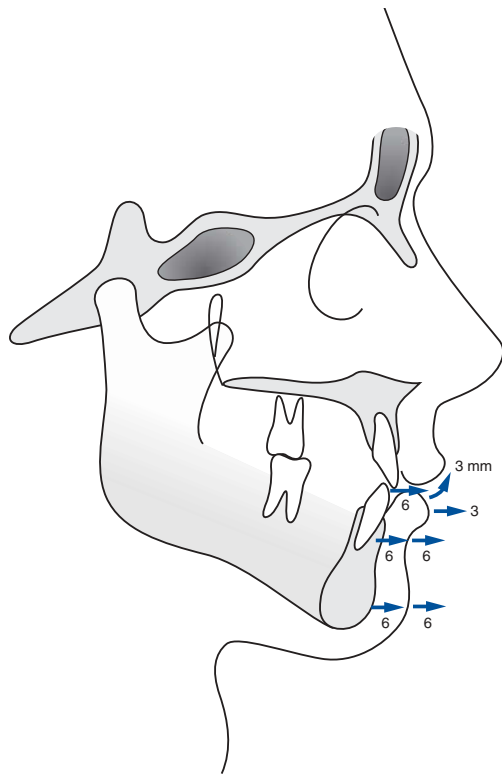


FIGURE 59-6 Overlay of average hard and soft tissue changes of mandibular advancement in vector format. Generally the soft tissues follow the bony movements in a 1:1 ratio. Adapted from Betts NJ, Dowd KF. Soft tissue changes associated with orthognathic surgery. *Atlas Oral Maxillofac Surg Clin North Am* 2000;8:13–38.

The advantages of osseous genial surgery are preservation of the normal chin contour,⁷⁵ improved predictability of the soft tissue response,⁴⁵ stability,^{45,68} versatility,⁴⁵ and preservation of blood supply to osteotomized segments.⁷⁵

Those patients who had both vertical reduction and advancement genioplasties showed slightly larger soft tissue advancement than those who had advancement genioplasty only (0.93:1 vs 0.81:1). This may be explained by bunching of the soft tissues. When the soft tissues are bunched (vertical reduction more than advancement), the soft tissues advance more than when the soft tissues are stretched (advancement only).^{66,76}

Tulasne suggested that the overlapping bone flap genioplasty gives a more natural contour to the lower face and a better balance between the lower lip, chin, and submental

Table 59-9 Soft Tissue Changes Associated with Mandibular Advancement

Anatomic Structure	Ratio	Landmarks	Author(s)
Lower lip (H)	0.62:1	Li: Ii	Lines, Steihauser ⁴³
Chin (H)	1:1	Pgs: Gn	
Lower lip (H)	0.85:1	Li: Ii	Talbot ⁵¹
Lower labial sulcus	1.01:1	ILS: B pt.	
Chin (H)	1.04:1	Pgs: Pg	Proffit, Epker ¹⁸
Lower lip (H)	0.75:1		
Chin (H)	1:1		Quast, et al ¹¹
Lower lip (H)	0.38:1	Li: Ii	
Lower labial sulcus (H)	0.97:1	ILS: B pt.	Mommaerts, Marxer ⁵⁰
Chin (H)	0.97:1	Pgs: Pg	
Chin (H)	0.97:1	Gns: Gn	Hernandez-Orsini et al ¹¹³
Chin (H)	0.87:1	Mes: Me	
Lower lip (H)	0.56:1	Li: Ii	Dermaut, De Smit ⁵³
Lower labial sulcus	1.06:1	ILS: B pt.	
Chin (H)	1.03:1	Pgs: Pg	McChance ^{104,105}
Chin (V)	0.93:1	Mes: Me	
Upper lip (H)	-0.02:1	Ls: Ii	Thuer, et al ⁵²
Lower lip (H)	0.43:1	Li: Ii	
Lower labial sulcus (H)	0.93:1	ILS: B pt.	Keeling, et al ⁵⁶
Chin (H)	0.94:1	Pgs: Pg	
Chin (H)	0.95:1	Gns: Gn	Ewing, Ross ⁷⁸
Chin (H)	0.97:1	Mes: Me	
Lower lip (H)	0.26:1	Li: Ii	Mobarak, et al ⁶²
Lower labial sulcus (H)	1.19:1	ILS: B pt.	
Chin (H)	1.1:1	Pgs: Pg	Ewing, Ross ⁷⁸
Lower lip (H)	1.25:1	3-D analysis	
Chin (H)	1.25:1	3-D analysis	Ewing, Ross ⁷⁸
Lower lip (H)	0.66:1	Li: Ii	
Lower labial sulcus (H)	0.88:1	ILS: B pt.	Ewing, Ross ⁷⁸
Chin (H)	1:1	Pgs: Pg	
Lower lip (H)	0.88:1	ILS: B pt.	Ewing, Ross ⁷⁸
Chin (H)	1:1	Pgs: Pg	
Lower lip (H)	0.8:1	Li: Ii	Ewing, Ross ⁷⁸
Lower labial sulcus (H)	1:1	ILS: B pt.	
Chin (H)	1:1	Pgs: Pg	Ewing, Ross ⁷⁸
Lower lip (H)	0.6:1	Li: Ii (all faces)	
Lower labial sulcus (H)	0.86-0.95:1	ILS: B pt.	Ewing, Ross ⁷⁸
Chin (H)	1-1.1:1	Pgs: Pg	
Menton	0.92-1.04:1	Mes: Me	Mobarak, et al ⁶²

B pt. = B point; Gn = gnathion; Gns = soft tissue gnathion; H = horizontal; Ii = incision inferius; ILS = inferior labial sulcus; Li = labrale inferius; Ls = Labrale superius; Me = menton; Mes = soft tissue menton; Pg = pogonion; Pgs = soft tissue pogonion; V = vertical.

region than does the sliding genioplasty associated with a wedge osteotomy.⁷⁷ However, it is associated with a large amount of bony resorption, especially in adolescent patients.

Predictions of lower and genial soft tissue changes when a genioplasty is added

to a mandibular advancement are notoriously variable.⁷⁸ However, the use of rigid internal fixation for the mandibular advancement makes the soft tissue changes in the chin and lip more durable in the long term.⁵⁵

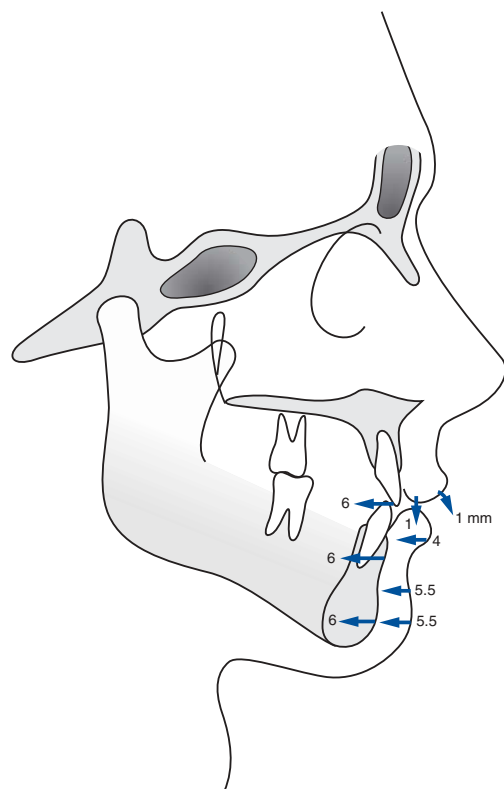


FIGURE 59-7 Overlay of average hard and soft tissue changes of mandibular setback in vector format. The soft tissues of pogonion and B point move more predictably than labrale inferius. Adapted from Betts NJ, Dowd KF. Soft tissue changes associated with orthognathic surgery. *Atlas Oral Maxillofac Surg Clin North Am* 2000;8:13–38.

Table 59-10 Soft Tissue Changes Associated with Mandibular Setback

Anatomic Structure	Ratio	Landmarks	Author(s)
Lower lip (H)	-0.69:1	Li: Pg	
Lower labial sulcus (H)	-0.93:1	ILS: Pg	Aaronson ⁶⁰
Lower labial sulcus (H)	approx. -1:1	ILS: B pt.	
Chin (H)	approx. -1:1	Pgs: Pg	Robinson et al ⁶¹
Upper lip (H)	-0.2:1	Ls: Li	
Lower lip (H)	-0.75:1	Li: Li	
Chin (H)	-1:1	Pgs: Gn	Lines, Steinhauser ⁴³
Upper lip (H)	-0.2:1	Ls: Pg	
Lower lip (H)	-0.6:1	Li: Pg	
Chin (H)	-0.9:1	Pgs: Pg	Hershey, Smith ⁷
Upper lip (H)	-0.2:1		
Lower lip (H)	-0.75–0.8:1		
Chin (H)	-1:1		Proffit, Epker ¹⁸
Lower lip (H)	-0.93:1	Li: Li	
Lower labial sulcus (H)	-0.03:1	ILS: B pt	
Chin (H)	-0.91:1	Pgs: Pg	Gjorup, Athanasiou ¹¹⁰
Lower Lip (H)	-1:1	3-D analysis	McChance et al ^{104, 105}
Chin (H)	-1:1	3-D analysis	
Upper lip (H)	-0.32:1	Ls: Pg	
Lower lip (H)	-0.80:1	Li: Pg	
Chin (H)	-0.83:1	Pgs: Pg	Gaggl et al ¹¹¹
Lower lip (H)	-0.5:1	Li: Pg	Enacar et al ¹¹²
Lower lip (H)	-1.02:1	Li: Li	
Lower labial sulcus (H)	-1.09:1	ILS: B pt.	
Chin (H)	-1.04:1	Pgs: Pg	Mobarak et al ⁶²

B pt. = B point; Gn = gnathion; H = horizontal; Li = incision inferius; ILS = inferior labial sulcus; Li = labrale inferius; Ls = labrale superius; Pg = pogonion; Pgs = soft tissue pogonion.

Anterior Repositioning: Alloplastic

Early attempts at advancement genioplasty included the use of alloplastic implants. Unfortunately, long-term follow-up revealed several unforeseen complications. For this reason, advancement genioplasty with alloplastic implants has fallen out of favor. The disadvantages of alloplastic materials include resorption or deformation of the underlying symphyseal bone with possible devitalization of the mandibular anterior teeth,^{12,18,47,79–81} migration of the implant,^{45,69,79} extrusion of the implant,⁷⁹ infection (especially with Proplast),^{45,69} and a less predictable soft tissue to hard tissue ratio.^{45,69} In addition, alloplastic materials do not address excessive or reduced chin height.⁶⁹ Newer materials have been developed that reduce the incidence of these

Table 59-11 Soft Tissue Changes Associated with Mandibular Autorotation

Anatomic Structure	Ratio	Landmarks	Author(s)
Chin (V)	-0.8:1	Pgs: Gn	Lines, Steinhauser ⁴³
Chin (H)	1:1		
Lower labial sulcus	1:1	ILS: B pt.	
Chin (H)	1:1	Pgs: Pg	Radney, Jacobs ⁸
Lower lip (H)	0.75:1	Li: Li	
Lower labial sulcus (H)	0.9:1	ILS: B pt.	
Chin (H)	0.86:1	Pgs: Pg	
Lower lip (V)	-0.93:1	Si: Is	
Chin (V)	-1.2:1	Mes: Me	Mansour et al ⁶
Lower lip (V)	-1.03:1	Si: Me	
Lower lip (V)	-1.48:1*	Li: Me	
Inferior labial sulcus (V)	-1.05:1	ILS: Me	
Inferior labial sulcus (H)	0.61:1	ILS: Me	
Chin (H)	0.79:1	Pgs: Me	
Chin (V)	-0.98:1	Pgs: Me	Sakima Sachdeva ⁹

*May represent uprighting of the lower lip due to a loss of contact with the upper incisor.
B pt. = B point; H = horizontal; ILS = inferior labial sulcus; Li = incision inferius; Li = labrale inferius; Gn = gnathion; Me = menton; Mes = soft tissue menton; Pg = pogonion; Pgs = soft tissue pogonion; Si = stomion inferius; V = vertical.

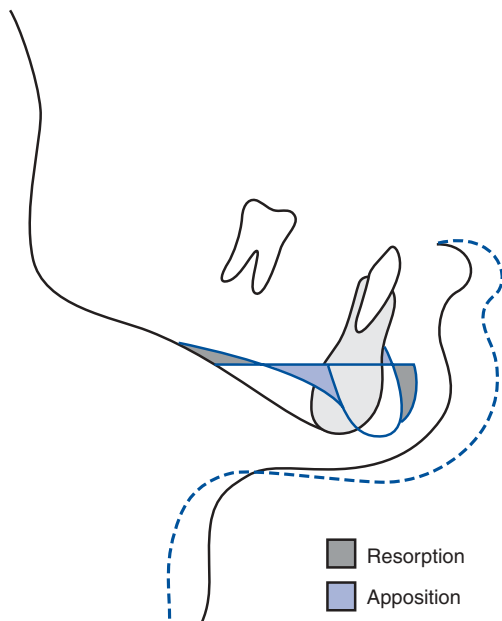


FIGURE 59-8 Osseous resorption at pogonion and deposition at menton. Adapted from Polido WD, Bell WH. Long-term osseous and soft tissue changes after large chin advancements. *J Cranio-maxillofac Surg* 1993;21:54–9.

complications, making alloplastic augmentation a more viable option.

If alloplastic implants are used they should be placed subperiosteally, low on the inferior border below the mentalis muscle, and over dense cortical bone. See Table 59-13 for soft tissue changes with alloplastic chin implants. Alloplastic implants should not be used in the correction of severe deformities but can be used in patients with a mild to moderate deformity.^{13,47,80} A periodic radiographic examination of the implant is recommended to monitor bony resorption.^{47,81}

Posterior Repositioning

Early attempts at reducing horizontal excess of the genial segment of the mandible by bony recontouring caused very little improvement of the soft tissue profile.⁶⁴ This technique has been abandoned. The soft tissue changes associated with setback genioplasty are less well correlated with the hard tissue movements than during advancement genioplasty (Table 59-14).

Table 59-12 Soft Tissue Changes Associated with Advancement Genioplasty			
Anatomic Structure	Ratio	Landmarks	Author(s)
Chin (H)	0.57:1	Pgs: Pg Ant. Sliding	Bell, Dann ⁶⁹
Chin (H)	0.75:1	Pgs: Pg H (some Multistep)	McDonnel et al ⁶⁷
Chin (H)	0.67:1		Proffit, Epker ¹⁸
Chin (H)	approx. 1:1	H with broad soft tissue pedicle IVRO setback	Bell ¹⁴
Lip (H)	0.44:1	Li: Pg H	Busquets, Sassouni ⁶³
Chin (H)	0.83:1	Pgs: Pg (some with osteotomy)	
Chin (H)	0.97:1	Pgs: Pg H with broad pedicle (IVRO setback)	Scheideman ⁶⁸
Chin (H)	0.85:1	H with broad pedicle	Bell, Gallagher ⁴⁵
Chin (H)	0.81:1	Pgs: Pg Advancement only, H sliding with broad pedicle	
Chin (H)	0.93:1	Pgs: Pg Advancement and vertical reduction, H sliding with broad pedicle, maxillary impaction	Gallagher et al ⁶⁶
Chin (H)	0.7:1	H	Epker, Fish ¹⁰⁷
Chin (H)	0.73:1	Pgs: Pg Overlapping, bone flap	Tulasne ⁷⁵
Chin (H)	0.97:1	Pgs: Pg H with broad pedicle	Park et al ⁶⁵
Chin (H)	1:1	Pgs: Pg	Krekmanov, Kahnberg ⁷²
Chin (H)	1.1:1	Pgs: Pg, BSSO+GP	Ewing, Ross ⁷⁸
Chin (H)	0.83:1	Pgs: Pg, H with broad pedicle and large advancements	Polido, Bell ¹⁰⁸

BSSO + GP = bilateral sagittal split osteotomy + genioplasty; H = horizontal; IVRO = intraoral vertical ramus osteotomy; Li = labrale inferius; Pg = pogonion; Pgs = soft tissue pogonion.

Reduction genioplasty is contraindicated in a patient with minimal or no labio-mental fold. Flattening of the chin and elimination of the labiomenal fold will

Table 59-13 Soft Tissue Changes Associated with Alloplastic Chin Implants			
Anatomic Structure	Ratio	Landmarks	Author(s)
Chin (H)	0.6:1	Pgs: Pg Silicone (unstable and cause resorption)	Bell, Dann ⁶⁹
Chin (H)	0.9:1	Pgs: Pg Proplast (resorption)	Dann, Epker ⁷⁹
Chin (H)	1:1		Proffit, Epker ¹⁸

H = horizontal; Pg = pogonion; Pgs = soft tissue pogonion.

Table 59-14 Soft Tissue Changes Associated with Setback Genioplasty

Anatomic Structure	Ratio	Landmarks	Author(s)
Chin (H)	-0.33:1	Pgs: Pg ant. recontouring degloving dissection	Hohl, Epker ⁶⁷
Chin (H)	-0.75:1	Interpositional	Wessberg et al ¹⁰⁹
Chin (H)	-0.58:1	Pgs: Pg H with broad pedicle	Bell ¹³
Chin (H)	-0.50:1	Pgs: Pg	Krekmanov, Kahnberg ⁷²

H = horizontal; sulcus; PG = pogonion; Pg ant. = pogonion anterior; Pgs = soft tissue pogonion.

result.⁸² It is also important to realize that setback genioplasty will make undesirable changes in the neck-chin proportion. In a patient with a poor neck-chin proportion, this procedure is contraindicated.

Vertical Repositioning: Superior and Inferior

The soft tissues follow the hard tissues very closely in augmentation genioplasty. However, this is not the case for vertical reduction (inferior border osteotomy or sandwich osteotomy) genioplasty (Table 59-15).

Special Circumstances

Distraction Osteogenesis

Since its first use in the human mandible by McCarthy and colleagues, this surgical technique has exploded in popularity.⁸³ Its use does not lend itself well to soft tissue predictions of the sort used for orthognathic surgery for various reasons, and few efforts have been made in this regard. Difficulties derive from the fact that most patients are still growing when subjected to the technique, that the principle of gradual distraction of a bone is probably accompanied by a component of soft tissue growth, so-called distraction histogenesis, and that very little is known about the dimensional stability of these bony changes. Efforts in this regard have examined soft tissue profile changes associated with maxillary distraction.^{84,85}

However, the technique allows for real-time adjustment of the change within the context of desired occlusion for most

applications, thereby not requiring precise predictions as for conventional orthognathic surgery. The topic will be of great interest, and the stability of the changes only more so as its use for the treatment of obstructive sleep apnea in adults becomes more prevalent.

Overall, the changes observed are comparable to those for maxillary advancement via the Le Fort I osteotomy with a decrease in midfacial concavity, increases in nasal tip projection, advancement of the lip, and closing of the nasolabial angle (Table 59-16).^{84,85}

Bimaxillary Advancement Surgery for Obstructive Sleep Apnea

The 5-year incidence of obstructive sleep apnea (OSA) in adult populations in the United States has been estimated to be

7.5% for moderately severe cases and 16% for less severe cases.⁸⁶ While orthognathic surgery has traditionally been applied to correct stomatognathic deformities and dysfunction, it also has been shown to be a powerful tool in correcting obstructive sleep apnea.^{87,88}

Little work has been done to describe the facial changes associated with this surgery, which differs from traditional orthognathic surgery in several ways. Patients presenting for maxillomandibular advancement surgery for OSA tend to be older, in their fourth and fifth decades of life.⁸⁹ They tend to be obese and have a thicker, laxer soft tissue envelope with which to “absorb” these bony changes. They will often present without skeletal imbalances that we traditionally seek to correct. Further, advancements of this sort are generally larger than those seen in the typical orthognathic surgery population, usually ranging from 10 to 12 mm. The goals of this surgery are very different. Here we seek to maximize the skeletal advancement to the benefit of the airway but often to the detriment of the soft tissue profile. Treatment planning then aims to minimize any untoward changes to the profile. Most patients seem to approve or be neutral with respect to their facial changes.⁹⁰ Prognathic patients are more likely to disapprove of

Table 59-15 Soft Tissue Changes Associated with Vertical Augmentation or Reduction Genioplasty

Anatomic Structure	Ratio	Landmarks	Author(s)
Augmentation			
Chin (V)	1:1	Interpositional	Wessberg et al ¹⁰⁹
Reduction			
Chin (V)	-0.25:1	Mes: Me, Inferior border, osteotomy, degloving dissection	Hohl, Epker ⁶⁴
Chin (V)	-0.26:1	Pgs: Pg H with broad pedicle	Park et al ⁶⁵
Chin (V)	-0.35:1	Mes: Me	Krekmanov, Kahnberg ⁷²
Chin (V)	-0.40:1	Mes: Me	Ewing, Ross ⁷⁸

H = horizontal; Me = menton; Mes = soft tissue menton; Pg = pogonion; Pgs = soft tissue pogonion; V = vertical.

Table 59-16 Soft Tissue Changes Associated with Maxillary Distraction Osteogenesis*

Anatomic Structure	Ratio	Landmarks	Author(s)
Nasal tip	0.53:1	Pn: ANS	Ko et al ⁸⁵
Superior labial sulcus (H)	0.96:1	SLS: A pt.	
Upper lip (H)	0.8:1	Ls: Is	
Nasal advancement	0.57:1	Pn: ANS	Harada et al ⁸⁴
Superior labial sulcus (H)	0.83:1	Sn: ANS	
Upper lip	0.71:1	Ls: ANS	

*All cleft patients.
A pt. = A point; ANS = anterior nasal spine; H = horizontal; Is = incision superius; Ls = labrale superius; Pn = pronasale; SLS = superior labial sulcus; Sn = subnasale.

their new profile.⁹⁰ Adjunctive measures such as ANS reshaping may help minimize upper lip and nasal tip rotation, but little can be done to minimize the effects of surgery at the chin (Table 59-17).

In terms of ratios of change in this population, only one study has been reported to date.⁹¹ This overall lack of data does not permit a comparison to traditional orthognathic changes.

Poor Surgical Esthetic Results and Techniques of Soft Tissue Control

Maxilla

The secondary soft tissue changes found with maxillary surgery include widening of the alar bases,^{36-38,48,92} upturning of the nasal tip, flattening and thinning of the upper lip,^{19,36-38,48,92} downturning of the commissures of the mouth,^{36-38,48,92} and opening of the nasolabial angle. These changes are similar to those found in the aging face and are generally perceived as unesthetic.³⁶⁻³⁸ Other potentially unesthetic changes include loss of normal lip pout and a decrease in visible vermilion.^{19,48,92}

Several investigators have suggested that the etiology of these soft tissue changes is attributable to three factors: (1) elevation of the periosteum and muscle attachments adjacent to the nose without adequate replacement, (2) postsurgical edema, and (3) increased bony support in advancement cases.^{24,41}

The importance of muscle repositioning following superior repositioning of the maxilla was stressed by many investigators.^{24,48,92,93} They state that the muscles detached during stripping of the periosteum required for maxillary surgery shorten and retract laterally. The muscles reattach in this position if they are not reapproximated at the time of surgery. The lateral movement of the muscles and subcutaneous tissues causes the alar base to flare and the upper lip to thin.

The loss of visible vermilion may be a result of other causes. These include a rolling under of the vermilion of the upper lip secondary to an incision made high in the vestibule with associated scarring and retraction^{24,48,92} and inclusion of large amounts of tissue during closure.²⁴ This loss of vermilion is especially unattractive in those individuals with already thin lips⁴⁰ and is more pronounced with posterior and superior repositioning of the maxilla.

Postsurgical widening of the alar base after the maxillary Le Fort I procedure may be a favorable outcome in a patient with vertical maxillary hyperplasia and thin slit-like nares.¹⁵ However, if a wide preoperative alar base is present, these same changes become undesirable,^{24,41} especially with anterior or superior repositioning of the maxilla⁹⁴ (Figure 59-9A–D). Before techniques to control nasal width were developed, Bell and Proffit suggested that at the time of preoperative assessment, patients with a wide nose be warned that a rhinoplasty may be indicated.⁴⁰

Techniques to Control the Soft Tissues

To control the soft tissue changes associated with maxillary surgery, the surgeon must first be aware of any preexisting deformity, the anticipated soft tissue adaptation to the surgical procedure being planned, and the importance of the effects of orofacial muscles on form, function, and esthetics. Once this has occurred the soft tissues can be manipulated to advantage by the surgeon.^{4,93}

Several surgical techniques have been suggested to help control the detrimental soft tissue changes associated with maxillary surgery. They include the V-Y closure, the alar cinch suture, a combination of the alar cinch suture and the V-Y closure, contouring of the ANS, septum reduction, and the double V-Y closure.

Table 59-17 Soft Tissue Changes Associated with Maxillomandibular Advancement for OSA

Anatomic Structure	Ratio	Landmarks	Author(s)
Nasal tip (H)	0.16:1	Pn: Is	Louis et al ⁹¹
Superior labial sulcus (H)	0.39:1	Sn: Is	
Upper lip (H)	0.80:1	SLS: Is	
Nasal tip (V)	0.16:1	Pn: Is	
Superior labial sulcus (V)	0.16:1	Sn: Is	
Upper lip (V)	0.16:1	SLS: Is	

H = horizontal; Is = incision superius; Pn = pronasale; SLS = superior labial sulcus; Sn = subnasale; V = vertical.

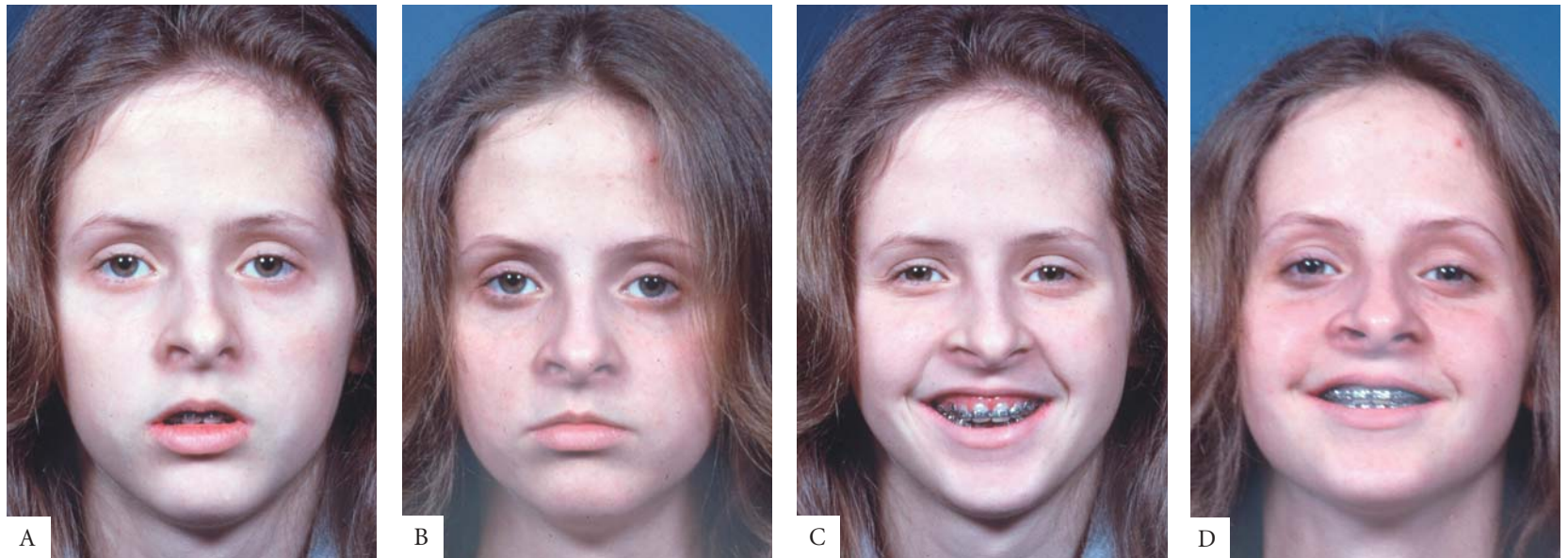

FIGURE 59-9 Unesthetic widening of the alar base and downturning of the corners of the mouth in a patient with an already wide nose. This patient was treated with a maxillary procedure without an alar cinch or V-Y closure. A, Preoperative full facial view. B, Postoperative full facial view. C, Preoperative smiling full facial view. D, Postoperative smiling full facial view. Reproduced with permission from Betts NJ, Fonseca RJ. *Soft tissue changes associated with orthognathic surgery*. In: Bell WH, editor. *Modern practice in orthognathic and reconstructive surgery*. Vol 3. Philadelphia (PA): W.B. Saunders; 1992. p. 2197.

V-Y Closure There is always an antero-posterior thinning of the upper lip (especially with maxillary advancement) and a loss of vermilion (especially with maxillary impaction) unless a V-Y closure is used (Figure 59-10A–C).

The upper lip, when closed in a V-Y fashion, follows the hard tissues forward at more nearly a 1:1 ratio, with prevention of upper lip thinning and loss of the vermilion.^{10,15,48,93}

The V-Y closure is accomplished during closure of the maxillary vestibular incision.

The mid portion of the incision is identified and retracted anteriorly with a single skin hook. One centimeter of the incision is closed in an anteroposterior direction. Using a separate suture mucosa, periosteum and interposed muscular tissue is engaged by the needle

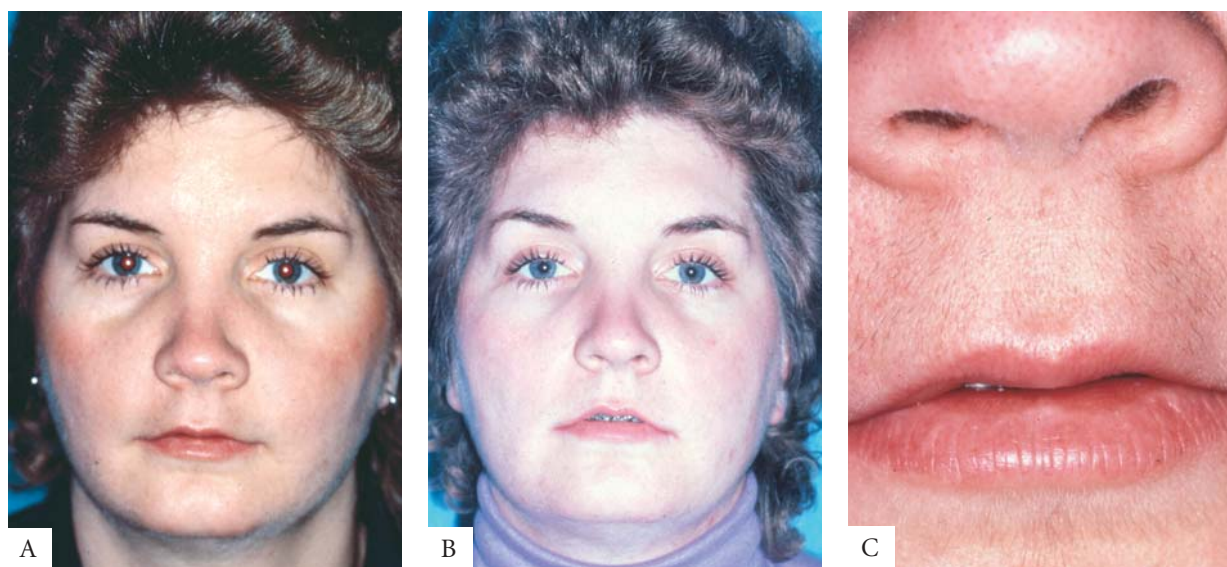

FIGURE 59-10 Unfavorable change in the vermilion of the upper lip following maxillary impaction surgery in a patient with a preexisting thin vermilion. A, Preoperative state. Note preexisting minimal vermilion exposure. B, Postoperative state. C, Close-up view of the postoperative state. Note that the loss of vermilion is more pronounced in the lateral portions of the lip than in the medial portion. Reproduced with permission from Betts NJ, Fonseca RJ. *Soft tissue changes associated with orthognathic surgery*. In: Bell WH, editor. *Modern practice in orthognathic and reconstructive surgery*. Vol 3. Philadelphia (PA): W.B. Saunders; 1992. p. 2198.

on either side of the incision and sutured in a continuous fashion. The superior aspect of the incision is gradually advanced toward the midline by taking smaller bites of tissue in the upper margin of the incision and larger bites in the lower margin (Figure 59-11A and B). Both sides of the incision are closed in a similar fashion to the midline suture. Often, following this type of closure, the lip will look rather full and short in the midline. Within the next several days, the lip will lengthen and become more normal in appearance.⁹³

Alar Cinch Collins and Epker identified patients who may develop undesirable nasal esthetic changes as those who have normal or wide frontonasal esthetics prior to surgery and will undergo a superior or anterior surgical repositioning of the maxilla.⁹⁴ These observations led to the development of techniques designed to control the alar base width after maxillary surgery. Bell and Proffit described adjunctive techniques to ensure an esthetic reconstruction of the alar base in maxillary impaction cases.⁴⁰ These included (1) reduction of the anterior extent of the piriform rim, (2) reduction of the ANS, and (3) trimming of the height of the anterior nasal floor. A different technique for correcting the flat and flaring nose was described by Millard.⁹⁵ This served as a model for the later development of the alar cinch techniques.⁹⁴ The original cinch suture was passed from the fibroadipose tissue on one side of the alar base to the other and was tied to a predetermined width (Figure 59-12A–E).

This technique was then modified to a figure-eight suture that was passed from lateral to medial, catching the fibroadipose tissue of the alar base (Figure 59-12F–H).^{24,41} Schendel and Delarre suggest that the suture should be passed not through the fibroadipose tissue but through the transverse nasalis muscles of the nose.⁹²

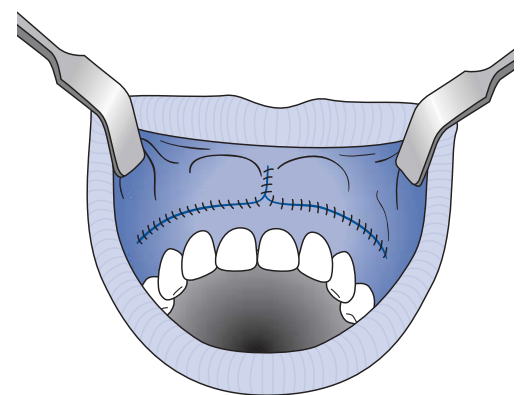
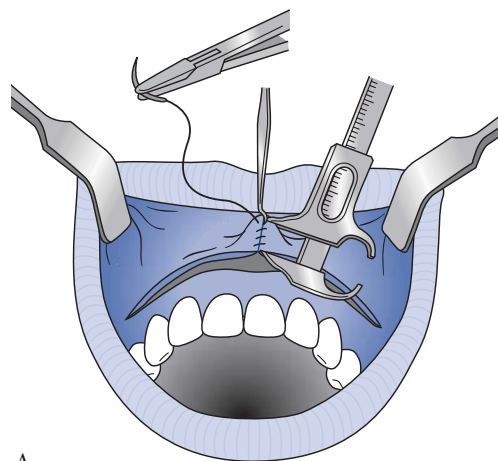
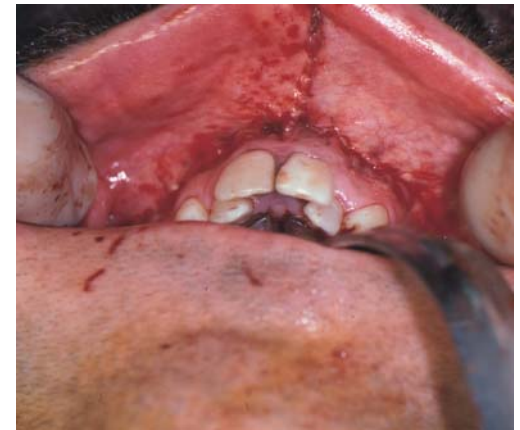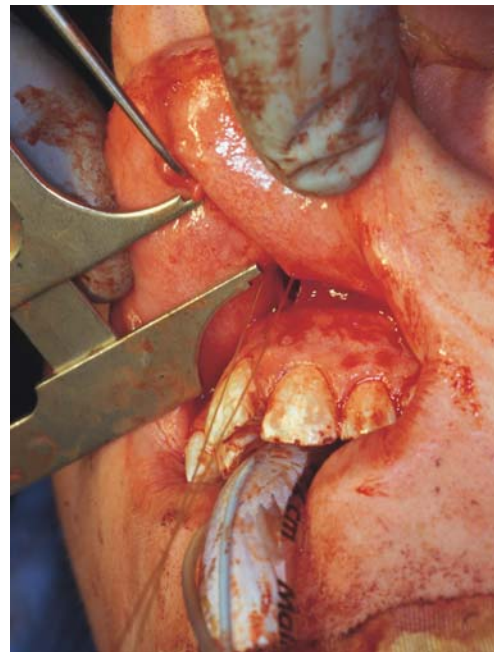
Past observations have suggested that the alar cinch suture does not control the alar base width^{4,96} and may even cause fur-

ther widening of the alar base. Subsequently, another technique of alar cinch suturing was suggested. In this technique, a hole is placed in the ANS and the suture is passed through the soft tissues at the base of the nose and back to the ANS bilaterally and individually tied (Figure 59-12I–L).¹⁵

A measurement of the greatest alar width must be taken on the patient and

recorded in the chart preoperatively. This number should be available during surgery so that reference to it can be made at the time of nasolabial muscle reconstruction.

Combination of Alar Cinch and V-Y Closure Several investigators indicated that the best control of the alar base in patients having maxillary superior or anterior repositioning could be achieved by using the V-Y closure and the alar cinch suture together.^{15,36–38,41,92,93} Their objective was to quantify the alar base width changes with and without the alar base cinch suture. All patients had a V-Y closure. They



A

B

FIGURE 59-11 A, The V-Y closure is accomplished during closure of the maxillary vestibular incision. The midportion of the incision is identified and retracted anteriorly with a single skin hook. One centimeter of the incision is closed in an anteroposterior direction. B, Using a separate suture mucosa, periosteum and interposed muscular tissue are engaged by the needle on either side of the incision and sutured in a continuous fashion. The superior aspect of the incision is gradually advanced toward the midline by taking smaller bites of tissue in the upper margin of the incision and larger bites in the lower margin. Both sides of the incision are closed in similar fashion to the midline suture. Photographs reproduced with permission and illustrations adapted from Milles M, Betts NJ. Techniques to preserve or modify lip form during orthognathic surgery. *Atlas Oral Maxillofac Surg Clin North Am* 2000;8:71–9.

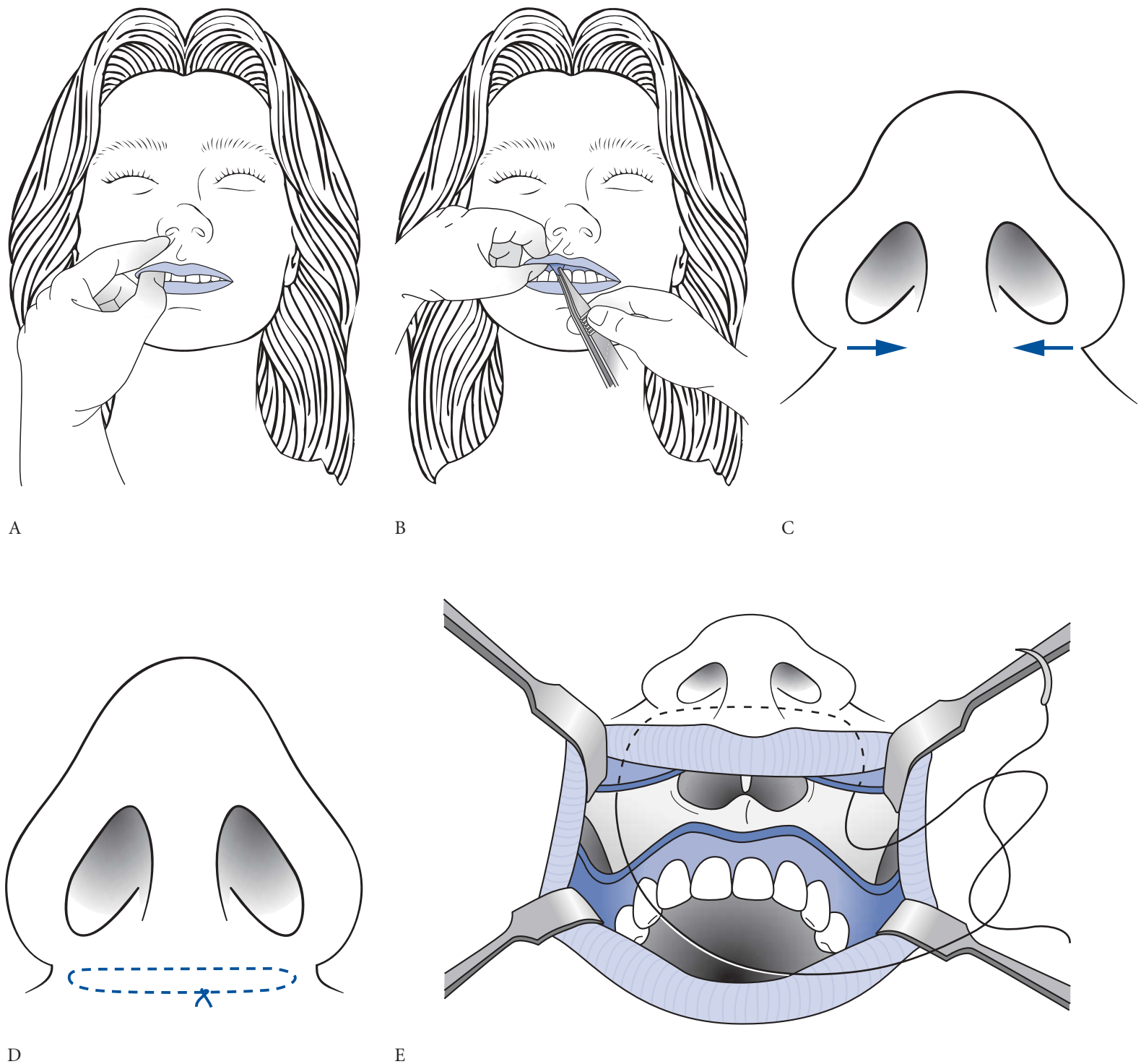


FIGURE 59-12 A, Alar base cinch suture. The upper lip is grasped between the forefinger and thumb, with the forefinger placed directly on the junction of the ala with the face. B, The lip is inverted and the tissue lying over the forefinger is grasped with a forceps. The lip is released and the tissue grasped in the forceps is manipulated to ensure that the alar base moves properly. If appropriate movement is not observed, the process must be repeated until correct needle placement is ensured. C–E, A nonresorbable suture (ie, 2-0 Prolene) is passed from the fibroadipose tissue (or transverse nasalis muscle) on one side of the alar base to the other and is tied to a predetermined width. (CONTINUED ON NEXT PAGE)

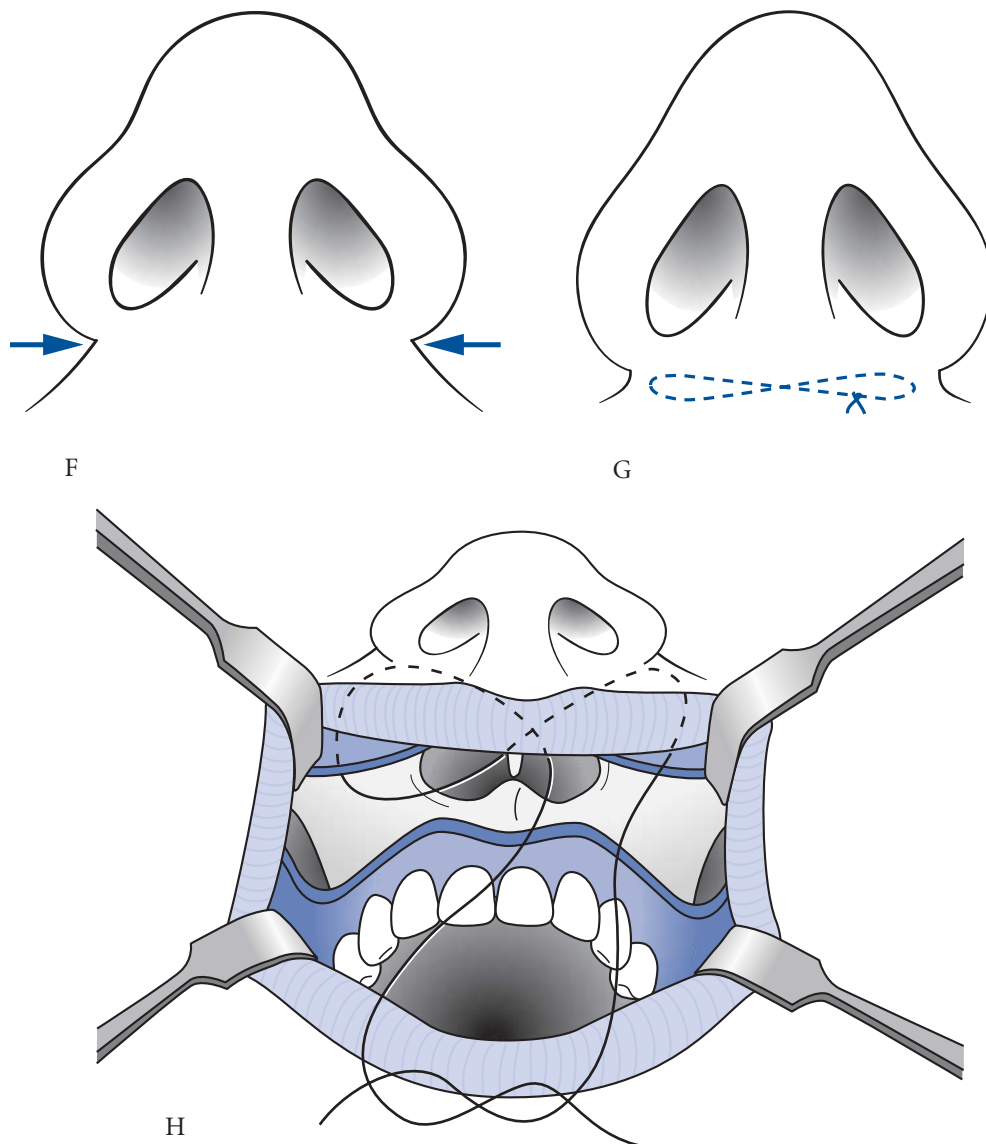


FIGURE 59-12 (CONTINUED) F–H, The figure-eight alar cinch suture technique. Following the initial steps described above, the suture is passed in a lateral to medial direction through the fibroadipose tissue on one side, and in the identical fashion (lateral to medial direction) on the other side of the nose. It is then tied in the midline to a predetermined width. (CONTINUED ON NEXT PAGE)

found that the alar bases widened in all patients and widening was lessened when the alar cinch suture was used. The alar base widened an average of 2.9% with the alar cinch suture and 10.8% without it.⁴¹

The effects of simultaneous placement of an alar cinch suture and a V-Y closure are successfully repositioning the lip muscles in a predictable manner,⁹³ preventing shortening of the lip in impaction cases,^{41,93} maintaining the normal lip pout,⁹³ preventing loss of vermilion,^{41,48,93}

maintaining the anteroposterior thickness of the lip,⁴¹ decreasing the widening of the alar base,^{41,48,93} and preventing drooping of the corners of the mouth⁹³ (Figure 59-13A–E). The ability of the figure of eight alar cinch suture combined with a V-Y advancement closure to reconstruct the patient to their preoperative soft tissue state was recently demonstrated in a prospective investigation with long-term follow-up. This study was performed in a surgical model (surgically assisted maxil-

lary expansion) that stressed the soft tissue closure technique and did not confound the soft tissue changes with vertical or anteroposterior vectors of maxillary movement. A figure-eight alar cinch suture combined with a V-Y advancement closure predictably reconstructed the patient's preoperative soft tissue state. Suturing the alar bases independently to the nasal septum (combined with a V-Y closure) was less effective but still superior to a V-Y closure alone.⁹⁷

Contouring the ANS Reduction of the ANS is indicated in patients undergoing large advancements or impactions of the maxilla who already have good nasal tip projection (Figure 59-14).²¹ The hard tissue changes in the position of the ANS affect primarily the soft tissue landmarks subnasale and pronasale.⁴

This technique should not be used in patients who have poor preoperative nasal tip projection. The nasal tip will rise if the ANS is left intact when advancing or impacting the maxilla. ANS reduction is also contraindicated in patients who are having a maxillary setback procedure. The result could lead to a “polybeak” deformity or drooping of the columella (Figure 59-15A–D).

Septoplasty The cartilaginous nasal septum should be reduced during maxillary impactions of greater than 3 mm to prevent postoperative deviation or buckling of the septum.^{40,46} This is done by reflecting the septal perichondrium and removing the appropriate amount of cartilage from the inferior aspect of the nasal septum with a scissor or scalpel blade (Figure 59-16A and B). The same amount of septum should be removed as the maxilla is impacted. This technique can be combined with reduction of the maxillary nasal crest. Prudence must be exercised as overreduction of the septum can result in either a saddle nose deformity or a polybeak deformity depending on the location of the excessive cartilage resection.¹⁵

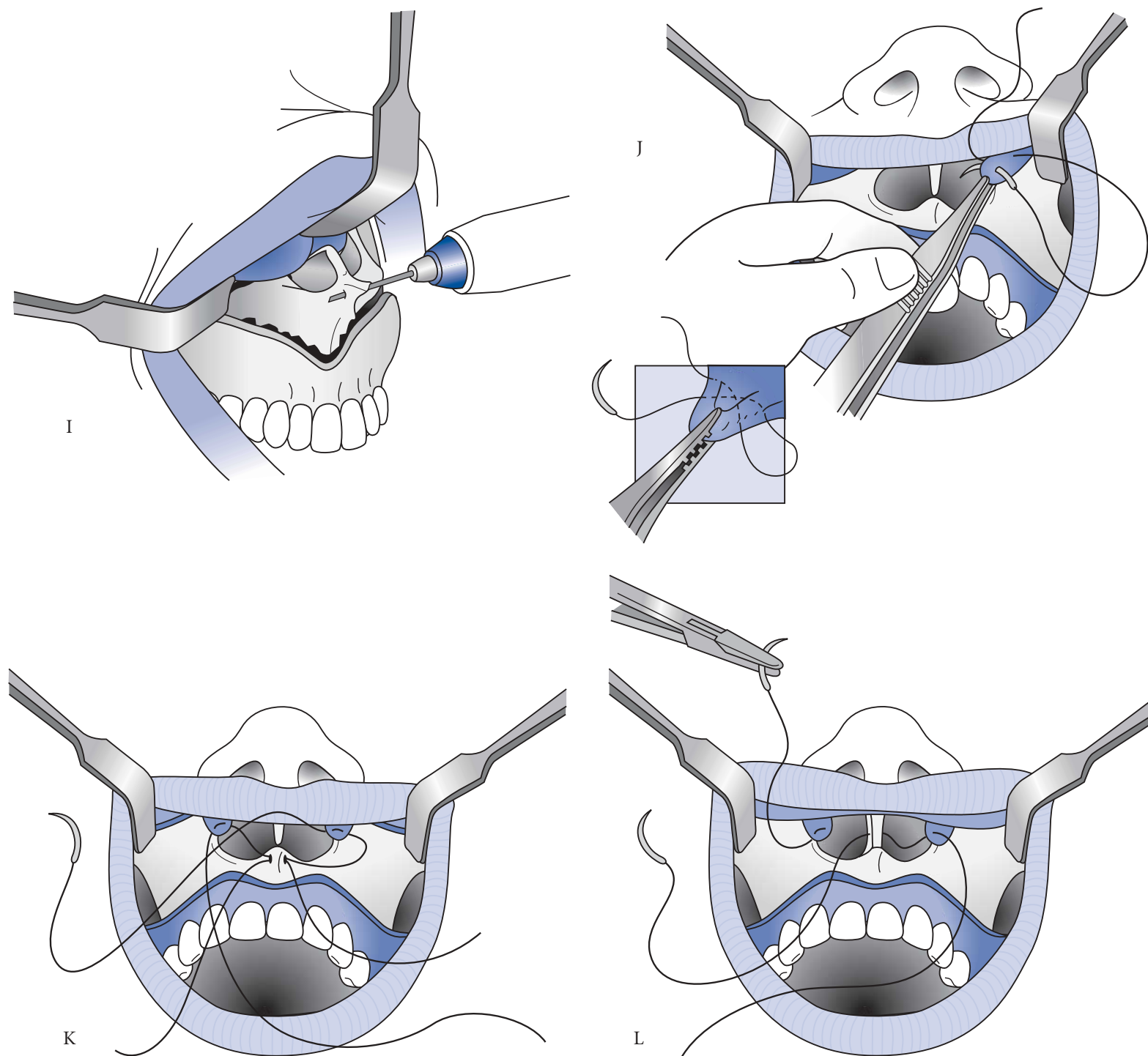


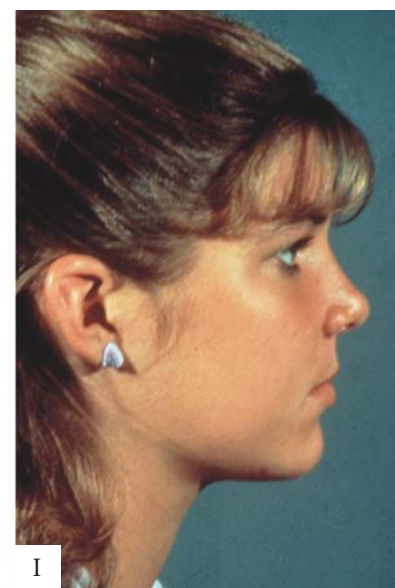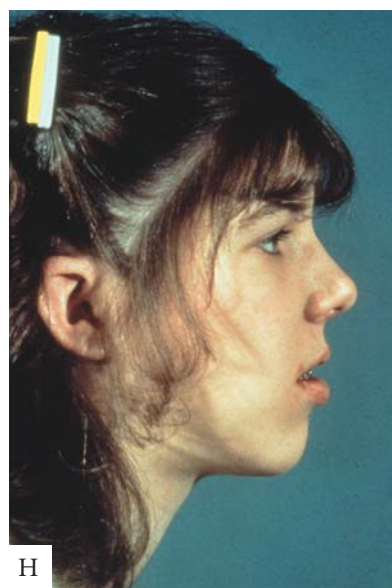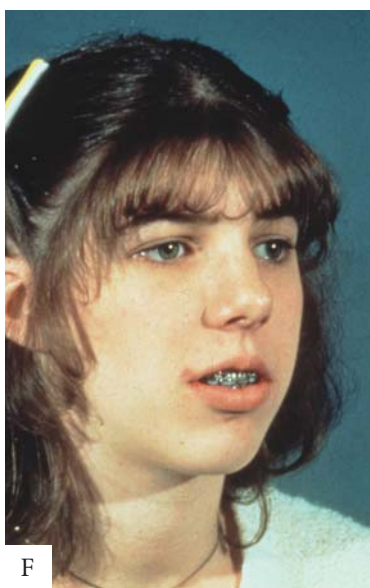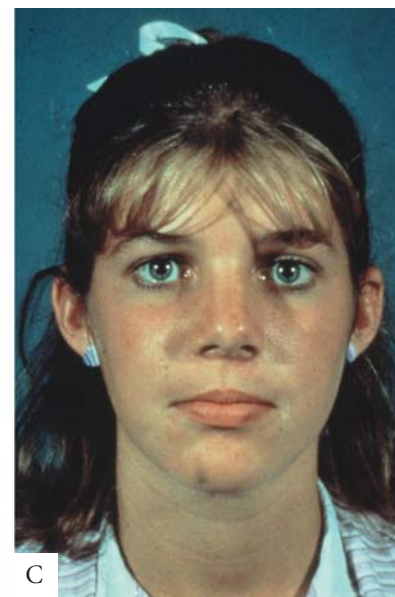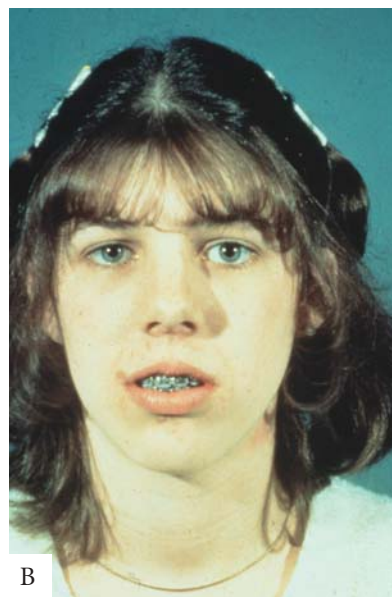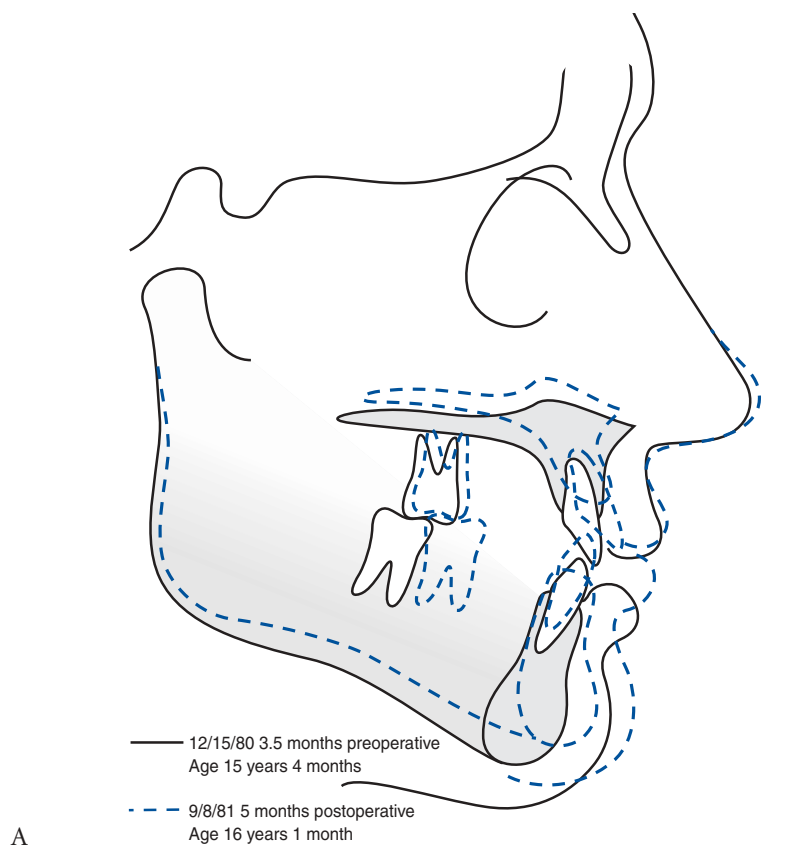
FIGURE 59-12 (CONTINUED) I–K, The dual-suture alar cinch technique. Before identifying the appropriate tissues described above, a hole is drilled in the ANS. Individual sutures are placed through the fibroadipose tissues, then through the hole below ANS and tied to a predetermined width for each nostril. L, Modification of this technique. Instead of the sutures being placed through the ANS, the individual sutures are passed through the anterior caudal septum. Adapted from Betts NJ. Techniques to control nasal features. *Atlas Oral Maxillofac Surg Clin North Am* 2000;8:53–69.

Double V-Y Closure The double V-Y closure was first proposed by Lassus for thickening of the thin lip (Figure 59-17A and B).⁹⁸ Hackney and colleagues com-

pared muscle reorientation using an alar cinch suture in conjunction with a simple closure technique, a single V-Y closure technique, and a double V-Y closure tech-

nique.⁹⁹ They observed that all three methods of closure yielded a significant increase in alar base width, and the double V-Y closure preserved the vermilion

FIGURE 59-13 Favorable soft tissue changes after maxillary impaction surgery and mandibular autorotation in a patient with an already wide alar base by use of an alar cinch suture and a V-Y closure. A, Data from pre- and postoperative cephalograms. Patient 3.5 months preoperation at age 15 years, 4 months (solid line); patient at age 16 years, 1 month postoperation (dotted line). B, Pre- and C, postoperative full facial views. D, Pre- and E, postoperative smiling full facial views. F, Pre- and G, postoperative three-quarter views. H, Pre- and I, postoperative profiles. A adapted from and B–I reproduced with permission from Betts NJ, Fonseca RJ. Soft tissue changes associated with orthognathic surgery. In: Bell WH, editor. *Modern practice in orthognathic and reconstructive surgery*. Vol 3. Philadelphia (PA): W.B. Saunders; 1992. p. 2171–2209.



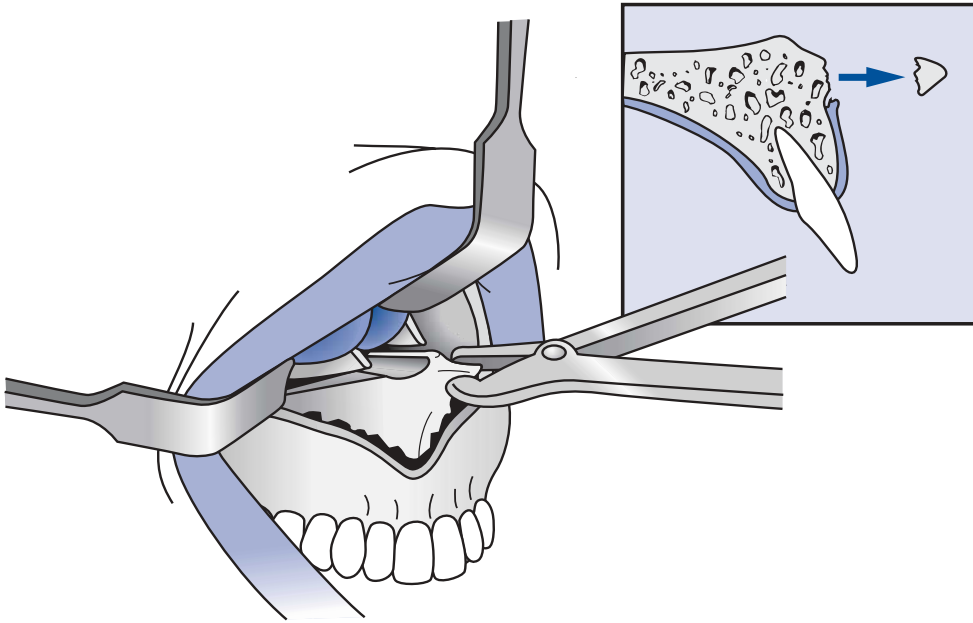


FIGURE 59-14 Reduction of the anterior nasal spine during a maxillary osteotomy. This procedure is indicated in patients undergoing large advancements or impactions of the maxilla who already have good nasal tip projection. This procedure is contraindicated in patients who have poor preoperative nasal tip projection or are having a maxillary setback procedure. Adapted from Betts NJ. *Techniques to control nasal features. Atlas Oral Maxillofac Surg Clin North Am* 2000;8:53–69.

(especially in the lateral portion of the lip) with less variability than with the other two techniques of closure. The true

indication for this procedure is the patient who preoperatively has a thin lateral vermillion.¹⁰⁰

Mandible

When contemplating a mandibular setback osteotomy the surgeon must carefully assess the patient's submentocervical morphology. If a patient has a short submental length and poor submentocervical proportion, mandibular setback may worsen this, resulting in a "double chin." If this complication is a possibility, the surgeon may elect to combine the mandibular setback procedure with an advancement genioplasty or submentocervical liposuction (if adipose tissue is present).

Chin

Incorrect planning, vestibular scarring, excessive detachment of soft tissue from the chin, suprahyoid myotomy, improper closure of the soft tissue incision, hematoma formation, genial remodeling, and excessive bone resorption may compromise the results of chin surgery.⁶⁶

Bone resorption is related to the amount of soft tissue dissection and therefore is more pronounced in nonpedicled genioplasties.⁶⁹ Adolescent patients also have more bone resorption after genioplasty procedures.⁷⁷

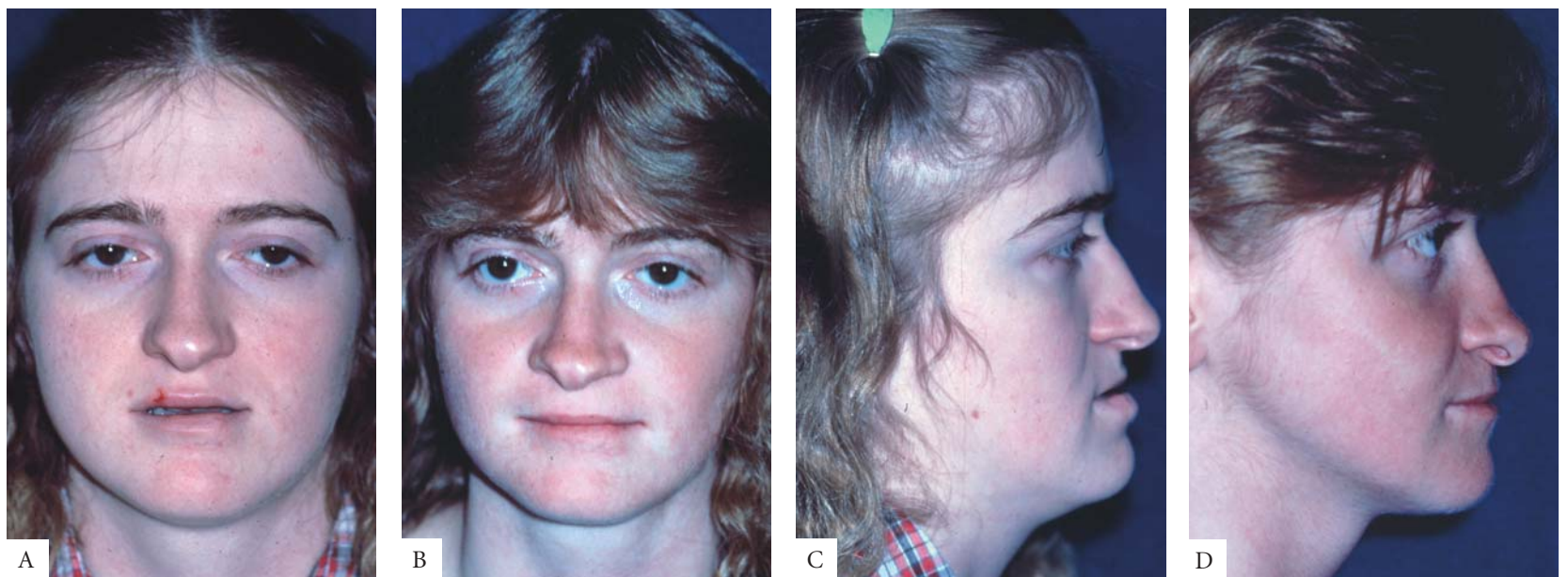

FIGURE 59-15 Poor esthetic outcome in a patient who had overzealous reduction of anterior nasal spine (ANS) after a maxillary advancement procedure. A, Preoperative full facial view. B, Postoperative full facial view. C, Preoperative profile view. D, Postoperative profile view. Reproduced with permission from Betts NJ, Fonseca RJ. *Soft tissue changes associated with orthognathic surgery. In: Bell WH, editor. Modern practice in orthognathic and reconstructive surgery. Vol 3. Philadelphia (PA): W.B. Saunders; 1992. p 2201.*

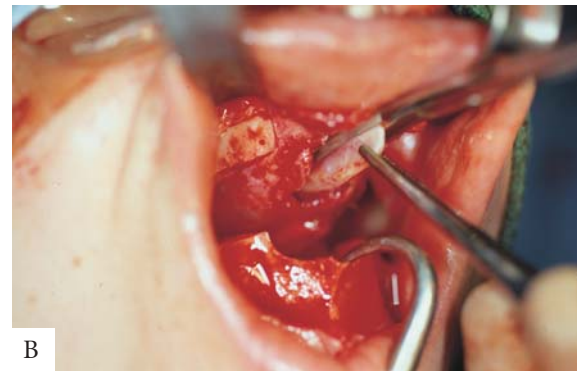
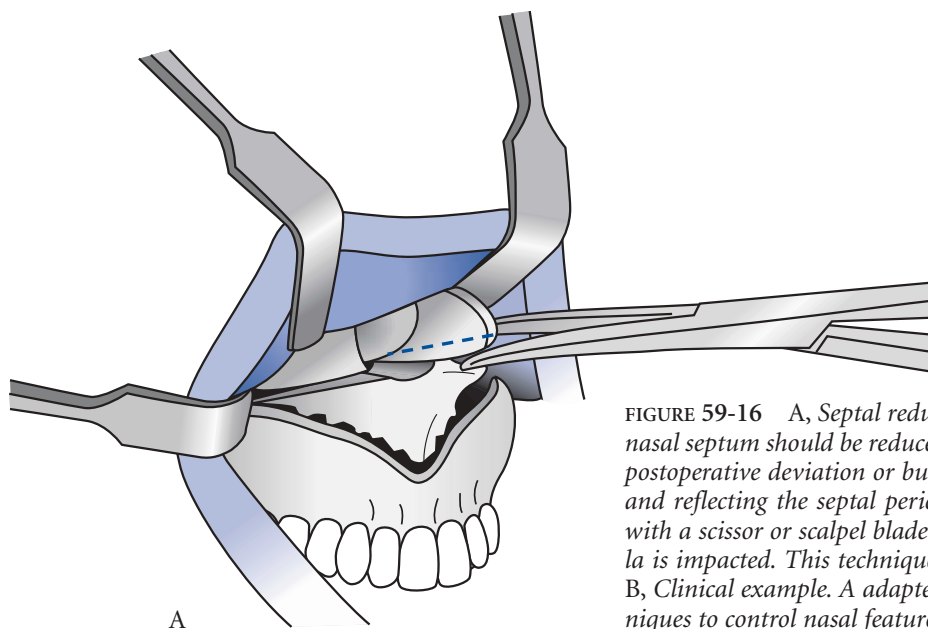


FIGURE 59-16 A, Septal reduction during maxillary impaction osteotomy. The cartilaginous nasal septum should be reduced during maxillary impactions of greater than 3 mm to prevent postoperative deviation or buckling of the septum. This is done by incising the nasal mucosa and reflecting the septal perichondrium and removing the appropriate amount of cartilage with a scissor or scalpel blade. The same amount of septum should be removed as the maxilla is impacted. This technique can be combined with reduction of the maxillary nasal crest. B, Clinical example. A adapted from and B reproduced with permission from Betts NJ. *Techniques to control nasal features. Atlas Oral Maxillofac Surg Clin North Am 2000;8:53–69.*

Chin ptosis or “witch’s chin” (Figure 59-18A–C) is an unesthetic complication secondary to the degloving dissection of the chin or to lack of reattachment of the mentalis muscle at the time of surgery. This may lead to an inferior tissue slide causing excess interlabial incompetence and exposure of the lower teeth secondary to lower lip ptosis and redundant tissue in the submental area.^{45,68,70}

Several investigators have demonstrated that using a procedure that minimizes soft tissue stripping may produce a more predictable hard and soft tissue response in the osteotomized segment.^{44,45,65,66,68,71} Therefore, the surgeon should attempt to maintain as much soft tissue pedicle on the labial and lingual aspects of the mandible as possible. In addition to a predictable soft to hard tissue ratio, preserva-

tion of the soft tissue pedicle ensures a greater blood supply to the osteotomized segment, less bony resorption, and a decreased risk of infection.^{64,71}

During closure, the mentalis muscles must be reapproximated to prevent ptosis of the chin. An incision out into the unattached tissues of the lip can help prevent postoperative wound dehiscence and facilitate muscle reapproximation.

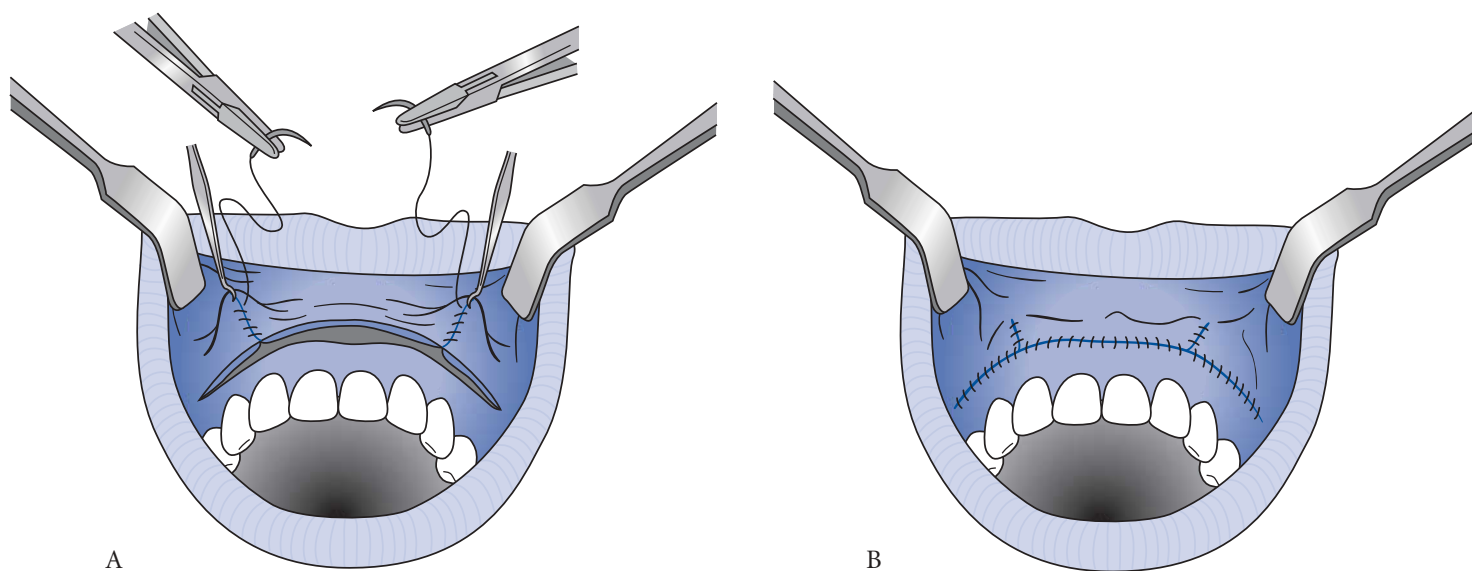


FIGURE 59-17 A, Double V-Y advancement closure showing initial retraction and closure of anterior components of vestibular incision. B, Closure completed. Adapted from Milles M, Betts NJ. *Techniques to preserve or modify lip form during orthognathic surgery. Atlas Oral Maxillofac Surg Clin North Am 2000;8:71–9.*

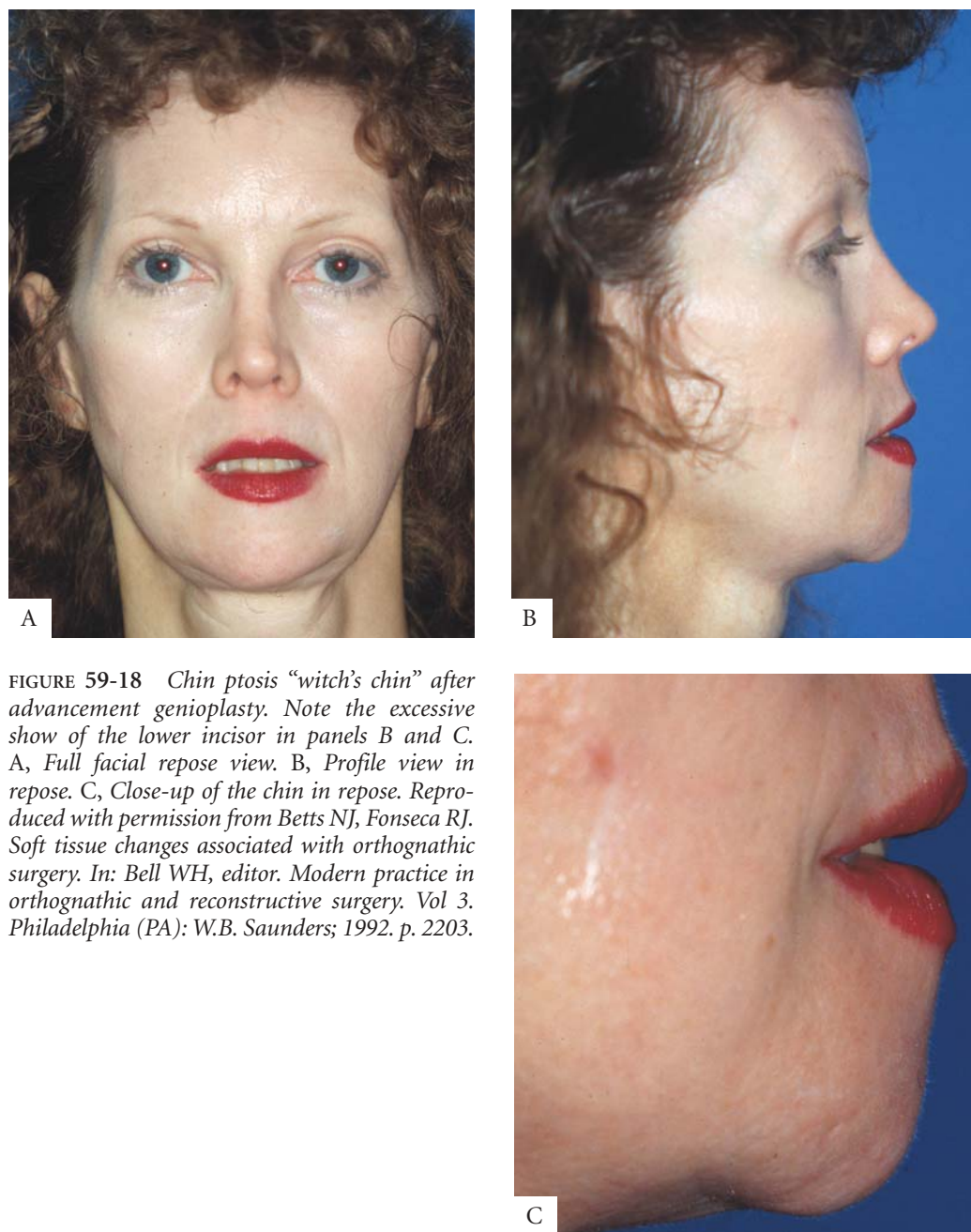

FIGURE 59-18 Chin ptosis “witch’s chin” after advancement genioplasty. Note the excessive show of the lower incisor in panels B and C. A, Full facial repose view. B, Profile view in repose. C, Close-up of the chin in repose. Reproduced with permission from Betts NJ, Fonseca RJ. *Soft tissue changes associated with orthognathic surgery*. In: Bell WH, editor. *Modern practice in orthognathic and reconstructive surgery*. Vol 3. Philadelphia (PA): W.B. Saunders; 1992. p. 2203.

A chin dressing fabricated from elastic tape should be placed at the end of the surgical procedure to stabilize the soft tissues and prevent hematoma formation. These dressings are typically worn for 5 to 7 days postoperatively.

Secondary Revision of Poor Surgical Results

The best method of treatment for a poor soft tissue outcome is prevention. The deformity should be recognized, the soft

tissue effects of the surgical procedure should be anticipated, and the correct interceptive procedures instituted. However, if a secondary procedure is required, the same techniques described in the preceding sections can be used. Revision surgery is more difficult than control of the soft tissues at the time the original surgery because of scarring and change in normal anatomic relationships.^{24,45} Rosen suggests that these secondary procedures be attempted only after the final soft tis-

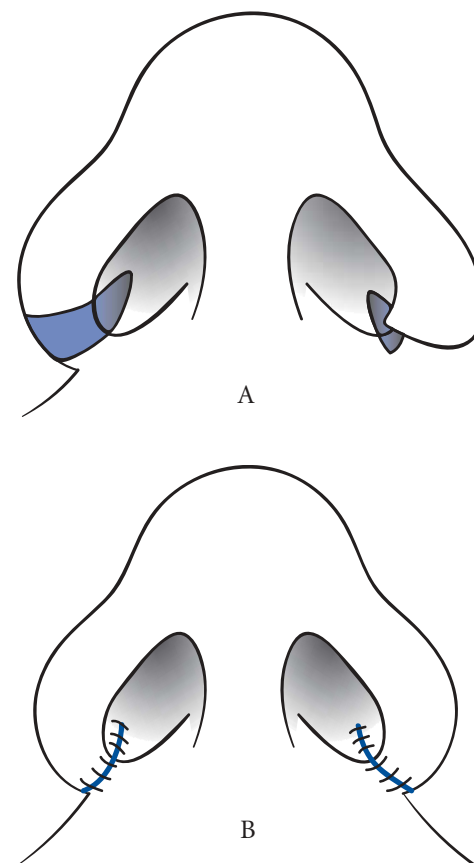


FIGURE 59-19 Bilateral alar base wedge resections. A, Resected area of the alar base. B, The nostril area following suturing demonstrating narrowing of the width of the nostrils and nasal base. Adapted from Betts NJ. *Techniques to control nasal features*. *Atlas Oral Maxillofac Surg Clin North Am* 2000;8:53–69.

sue drape has been established and the residual defect has been identified.²³

Other procedures for revising a poor surgical outcome are submental lipectomy, nasal wedge resection (Weir excisions) (Figure 59-19),²³ and rhinoplasty.

References

1. Dion KE, Berscheid E, Walster E. What is beautiful is good. *J Pers Soc Psychol* 1972;24:285.
2. Kalik M. Toward an interdisciplinary psychology of appearance. *Psychiatry* 1977;41:243.
3. Mathes E. The effects of physical attractiveness and anxiety on heterosexual attraction over a series of five encounters. *J Marriage Fam* 1975;37:769.
4. Betts NJ, Fonseca R, Vig P, et al. Changes in nasal and labial soft tissues after surgical repositioning of the maxilla. *Int J Adult Orthodont Orthognath Surg* 1993;8:7–23.

5. Dann JJ, Fonseca R, Bell WH. Soft tissue changes associated with total maxillary advancement: a preliminary study. *J Oral Surg* 1976;34:19–23.
6. Mansour S, Burstone C, Legan H. An evaluation of soft tissue changes resulting from LeFort I maxillary surgery. *Am J Orthod* 1983;84:37–47.
7. Hershey HG, Smith L. Soft tissue profile change associated with surgical correction of the prognathic mandible. *Am J Orthod* 1974;65:483–503.
8. Radney LJ, Jacobs J. Soft-tissue changes associated with surgical total maxillary intrusion. *Am J Orthod* 1981;80:191–212.
9. Sakima T, Sachdeva R. Soft tissue response to Le Fort I maxillary impaction surgery. *Int J Adult Orthodon Orthognath Surg* 1987;4:221–31.
10. Stella JP, Streater M, Epker BN, Sinn DP. Predictability of upper lip soft tissue changes with maxillary advancement. *J Oral Maxillofac Surg* 1989;47:697–703.
11. Quast DC, Biggerstaff R, Haley JV. The short-term and long-term soft-tissue profile changes accompanying mandibular advancement surgery. *Am J Orthod* 1983;84:29–36.
12. Robinson M. Bone resorption under plastic chin implants. *J Oral Surg* 1969;27:116–8.
13. Bell W. Correction of mandibular prognathism by mandibular setback and advancement genioplasty. *Int J Oral Surg* 1981;10:221–9.
14. Bloom L. Perioral profile changes in orthodontic treatment. *Am J Orthod* 1961;47:371.
15. Waite P. Simultaneous orthognathic surgery and rhinoplasty. *Oral Maxillofac Surg Clin North Am* 1990;2:339–50.
16. Ingersoll SK, Peterson L, Weinstein S. Influence of horizontal incision on upper lip morphology [abstract 360]. *J Dent Res* 1982; 61:218.
17. O'Reilly M. Integumental profile changes after surgical orthodontic correction of bimaxillary dentoalveolar protrusion in black patients. *Am J Orthod Dentofacial Orthop* 1989;96:242–8.
18. Proffit WR, Epker B. Treatment planning for dentofacial deformities. In: Bell WH, White RP, editors. *Surgical correction of dentofacial deformities*. Philadelphia: WB Saunders; 1980. p. 183–7.
19. Tomlak DJ, Picuch J, Weinstein S. Morphologic analysis of upper lip area following maxillary osteotomy via the tunneling approach. *Am J Orthod* 1984;85:488–93.
20. Subtelny J. A longitudinal study of the soft tissue facial structures and their profile characteristics, defined in relation to underlying skeletal structures. *Am J Orthod* 1959;45:481.
21. Freihofer HJ. Changes in nasal profile after maxillary advancement in cleft and non-cleft patients. *J Maxillofac Surg* 1977;5:20–7.
22. Freihofer HJ. The lip profile after correction of retromaxillism in cleft and noncleft patients. *J Maxillofac Surg* 1976;4:136–41.
23. Rosen H. Lip-nasal aesthetics following LeFort I osteotomy. *Plast Reconstr Surg* 1988; 81:171–82.
24. Wolford L. Lip-nasal aesthetics following LeFort I osteotomy [discussion]. *Plast Reconstr Surg* 1988;81:180.
25. Hack GA, de Molvan Otterloo J, Nanda R. Long-term stability and prediction of soft tissue changes after LeFort I surgery. *Am J Orthod Dentofacial Orthoped* 1993;104:544–55.
26. Phillips C, Devereux J, Camilla Tulloch JE, et al. Full face soft tissue response to surgical maxillary intrusion. *Int J Adult Orthodon Orthognath Surg* 1986;1:299–304.
27. Rosenburg A, Muradin M, van der Bilt A. Nasolabial esthetics after Le Fort I osteotomy and V-Y closure: A statistical evaluation. *Int J Adult Orthodon Orthognath Surg* 2002;17:29–39.
28. Filho HN, Goncales ES, Berrentin-Felix G, et al. Evaluation of facial soft tissues following surgically assisted expansion associated with the simple V-Y suture. *Int J Adult Orthodon Orthognath Surg* 2002;17:89–97.
29. Reidel R. An analysis of dentofacial relationships. *Am J Orthod* 1957;43:103.
30. Burstone C. Integumental contour and extension patterns. *Angle Orthod* 1959;29:93.
31. Attarzadeh F, Adenwalla T. Soft tissue profile changes concurrent with orthodontic treatment. *Int J Orthod* 1990;28:9–16.
32. Hershey H. Incisor tooth retraction and subsequent profile change in postadolescent female patients. *Am J Orthod* 1972;61:45.
33. Moss JP, McCance A, Fright WR, et al. A three dimensional soft tissue analysis of fifteen patients with class II division malocclusions after bimaxillary surgery. *Am J Orthodon Dentofacial Orthoped* 1994;105:430–7.
34. Anderson JP, Joondeph D, Turpin DL. A cephalometric study of profile changes in orthodontically treated cases ten years out of retention. *Angle Orthod* 1973;43:324.
35. Rudee D. Proportional profile changes concurrent with orthodontic therapy. *Am J Orthod* 1964;50:421.
36. O'Ryan F, Schendel S. Nasal anatomy and maxillary surgery. I. Esthetic and anatomic principles. *Int J Adult Orthodon Orthognath Surgery* 1989;4:27–37.
37. O'Ryan F, Schendel S. Nasal anatomy and maxillary surgery. II. Unfavorable nasolabial esthetics following the LeFort I osteotomy. *Int J Adult Orthodon Orthognath Surg* 1989;4:75–84.
38. O'Ryan F, Schendel S. Nasal anatomy and maxillary surgery. III. Surgical techniques for correction of nasal deformities in patients undergoing maxillary surgery. *Int J Adult Orthodon Orthognath Surg* 1989;4:157–74.
39. Proffit WR, Epker B, Ackerman JL. Systematic description of dentofacial deformities: the database. In: Bell WH, White RP, editors. *Surgical correction of dentofacial deformities*. Philadelphia: WB Saunders; 1980. p. 114–22.
40. Bell WH, Proffit W. Esthetic effects of maxillary osteotomy. In: Bell WH, White RP, editors. *Surgical correction of dentofacial deformities*. Philadelphia: WB Saunders; 1980. p. 368–70.
41. Guymon M, Crosby D, Wolford LM. The alar base cinch suture to control nasal width in maxillary osteotomies. *Int J Adult Orthodon Orthognath Surg* 1988;3:89–95.
42. Bundgaard M, Melson B, Terp S. Changes during and following total maxillary osteotomy (LeFort I procedure): a cephalometric study. *Eur J Orthod* 1986;8:21–29.
43. Lines PA, Steinhauser E. Soft tissue changes in relationship to movement of hard tissue structures in orthognathic surgery: a preliminary report. *Journal of Oral Surgery* 1974;32:891–6.
44. Bell WH, Brammer J, McBride KL, et al. Reduction genioplasty: surgical techniques and soft tissue changes. *Oral Surg Oral Med Oral Pathol Oral Radiol Endod* 1981; 51:471–7.
45. Bell WH, Gallagher D. The versatility of the genioplasty using a broad pedicle. *J Oral Maxillofac Surg* 1983;41:763–9.
46. Lew KKK, Loh F, Yeo JF. Profile changes following anterior subapical osteotomy in Chinese adults with bimaxillary protrusion. *Int J Adult Orthodon Orthognath Surg* 1989;4:189–96.
47. Freidland JA, Cocciano P, Converse JM. Retrospective cephalometric analysis of mandibular bone absorption under silicone rubber chin implants. *Plast Reconstr Surg* 1976;57:144–51.
48. Carlotti AE Jr, Ashaffensburg P, Schendel SA. Facial changes associated with surgical advancement of the lip and maxilla. *J Oral Maxillofac Surg* 1986;44:593–6.
49. Schendel SA, Eisenfeld J, Bell WH, et al. Superior repositioning of the maxilla: stability and soft tissue osseous relations. *Am J Orthod* 1976;70:663–74.
50. Mommaerts MY, Marxer H. A cephalometric analysis of the long-term, soft tissue profile changes which accompany the advance-

- ment of the mandible by sagittal split ramus osteotomy. *J Craniomaxillofac Surg* 1987;15:127–31.
51. Talbott J. Soft tissue response to mandibular advancement surgery [master's thesis]. Lexington (KY): University of Kentucky; 1975.
 52. Thuer U, Ingervall B, Vuillemin T. Stability and effect on the soft tissue profile of mandibular advancement with sagittal split osteotomy and rigid internal fixation. *Int J Adult Orthodon Orthognath Surg* 1994;9:175–85.
 53. Dermaut LR, De Smit A. Effects of sagittal split advancement osteotomy on facial profiles. *Eur J Orthod* 1989;11:366–74.
 54. Mobarak KA, Espeland L, Krogstad O, Lyberg T. Soft tissue profile changes following mandibular advancement surgery: predictability and long term outcome. *Am J Orthod Dentofacial Orthop* 2001;119:368–81.
 55. Dolce C, Johnson P, Van Sickels JE, et al. Maintenance of soft tissue changes after rigid versus wire fixation for mandibular advancement, with and without genioplasty. *Oral Surg Oral Med Oral Pathol Oral Radiol Endod* 2001;92:142–9.
 56. Keeling SD, Labanc J, Van Sickels JE, et al. Skeletal change at surgery as a predictor of long-term soft tissue profile change after mandibular advancement. *J Oral Maxillofac Surg* 1996;54:134–44.
 57. Johnston L. Discussion: skeletal change at surgery as a predictor of long-term soft tissue profile change after mandibular advancement. *J Oral Maxillofac Surg* 1996;54:145–6.
 58. Weinstein S, Harris E, Archer SY. Lip morphology and area changes associated with surgical correction of mandibular prognathism. *J Oral Rehabil* 1982;9:335–54.
 59. Fromm B, Lundberg M. The soft-tissue facial profile before and after surgical correction of mandibular protrusion. *Acta Odontol Scand* 1970;28:157–77.
 60. Aaronson S. A cephalometric investigation of the surgical correction of mandibular prognathism. *Angle Orthod* 1967;379:251.
 61. Robinson SW, Speidel T, Isaacson RJ, et al. Soft tissue profile change produced by reduction of mandibular prognathism. *Angle Orthod* 1972;42:227.
 62. Mobarak KA, Krogstad O, Espeland L, Lyberg T. Factors influencing the predictability of soft tissue profile changes following mandibular setback surgery. *Angle Orthod* 2001;71:216–27.
 63. Busquets CJ, Sassouni V. Changes in the integumental profile of the chin and lower lip after genioplasty. *J Oral Surg* 1981;39:499–504.
 64. Hohl TH, Epker B. Macrogenia: a study of treatment results, with surgical recommendations. *Oral Surg Oral Med Oral Pathol Oral Radiol Endod* 1976;41:545–67.
 65. Park HS, Ellis E, Fonseca RJ, et al. A retrospective study of advancement genioplasty. *Oral Surg Oral Med Oral Pathol Oral Radiol Endod* 1989;67:481–9.
 66. Gallagher DM, Bell W, Storum KA. Soft tissue changes associated with advancement genioplasty performed concomitantly with superior repositioning of the maxilla. *J Oral Maxillofac Surg* 1984;42:238–42.
 67. McDonnell JP, McNeill R, West RA. Advancement genioplasty: a retrospective cephalometric analysis of osseous and soft tissue changes. *J Oral Surg* 1977;35:640.
 68. Scheideman GB, Legan H, Bell WH. Soft tissue changes with combined mandibular setback and advancement genioplasty. *J Oral Surg* 1981;39:505–9.
 69. Bell WH, Dann J III. Correction of dentofacial deformities by surgery in the anterior part of the jaws: a study of stability and soft tissue changes. *Am J Orthod* 1973;64:162–87.
 70. Trauner RT, Obwegeser H. The surgical correction of mandibular prognathism and retrognathia with consideration of genioplasty. Part I. Surgical procedures to correct mandibular prognathism and reshaping of the chin. *Oral Surg Oral Med Oral Pathol Oral Radiol Endod* 1957;10:667.
 71. Ellis E, DeChow P, McNamara JA Jr, et al. Advancement genioplasty with and without soft tissue pedicle: an experimental investigation. *J Oral Maxillofac Surg* 1984;42:637–45.
 72. Krekmanov L, Kahnberg K. Soft tissue response to genioplasty procedures. *Br J Oral Maxillofac Surg* 1992;30:87–91.
 73. Precious D, Armstrong JE, Morais D. Anatomic placement of fixation devices in genioplasty. *Oral Surg Oral Med Oral Pathol Oral Radiol Endod* 1992;73:2–8.
 74. Ayoub AF, Stirrups D, Moos KF. Evaluation of changes following advancement genioplasty using finite element analysis. *Br J Oral Maxillofac Surg* 1993;31:217–22.
 75. Converse JM, Wood-Smith D. Horizontal osteotomy of the mandible. *Plast Reconstr Surg* 1964;34:464.
 76. Van Sickels JE, Tiner BD, Jones DL. Hard and soft tissue predictability with advancement genioplasties. *Oral Surg Oral Med Oral Pathol Oral Radiol Endod* 1994;77:218–21.
 77. Tulasne J. The overlapping bone flap genioplasty. *J Craniomaxillofac Surg* 1987;15:214–21.
 78. Ewing M, Ross R. Soft tissue response to mandibular advancement and genioplasty. *Am J Orthod Dentofacial Orthoped* 1992;101:550–5.
 79. Dann JJ, Epker B. Proplast genioplasty: A retrospective study with treatment recommendations. *Angle Orthod* 1977;47:173–85.
 80. Peled IJ, Wexler M, Ticher S, et al. Mandibular resorption from silicone chin implants in children. *J Oral Maxillofac Surg* 1986;44:346–8.
 81. Robinson M. Bone resorption under plastic chin implants. *Arch Otolaryngol* 1972;95:30.
 82. Bailey LJ, Collie F, White RP. Long-term soft tissue changes after orthognathic surgery. *Int J Adult Orthodon Orthognath Surg* 1996;11:7–18.
 83. McCarthy JG, Schreiber J, Karp NS, et al. Lengthening of the human mandible by gradual distraction. *Plast Reconstr Surg* 1992;89:1–8.
 84. Harada K, Baba Y, Ohyama K, Omura K. Soft tissue profile changes of the midface in patients with cleft lip and palate following maxillary distraction osteogenesis: a preliminary study. *Oral Surg Oral Med Oral Pathol Oral Radiol Endod* 2002;94:673–7.
 85. Ko EW, Figueroa A, Polley J. Soft tissue profile changes after maxillary advancement with distraction osteogenesis by use of a rigid external distraction device: a 1 year follow up. *J Oral Maxillofac Surg* 2000;58:959–69.
 86. Tishler PV, Larkin E, Schlutler MD, Redline S. Incidence of sleep-disordered breathing in an urban adult population: the relative importance of risk factors in the development of sleep-disordered breathing. *J Am Med Assoc* 2003;289:2230–7.
 87. Riley RW, Powell N, Guilleminault C. Obstructive sleep apnea syndrome: a review of 306 consecutively treated surgical patients. *Otolaryngol Head Neck Surg* 1993;108:117–25.
 88. Waite PD, Wooten V, Lachner J, et al. Maxillo-mandibular advancement surgery in 23 patients with obstructive sleep apnea syndrome. *J Oral Maxillofac Surg* 1989;47:1256–61.
 89. Young T, Palta M, Dempsey J, et al. The occurrence of sleep-disordered breathing among middle-aged adults. *N Engl J Med* 1993;328:1230–5.
 90. Li KK, Riley R, Powell NB, Guilleminault C. Patient's perception of the facial appearance after maxillomandibular advancement for obstructive sleep apnea syndrome. *J Oral Maxillofac Surg* 2001;59:377–80.
 91. Louis PJ, Austin R, Waite PD, Matthews CS. Soft tissue changes of the upper lip associated with maxillary advancement in obstructive sleep apnea patients. *J Oral Maxillofac Surg* 2001;59:151–6.
 92. Schendel SA, Delaire J. Facial muscles: form, function, and reconstruction in dentofacial deformities. In: Bell WH, White RP, editors. *Surgical correction of dentofacial*

- deformities. Philadelphia: WB Saunders; 1980. p. 259–80.
93. Schendel SA, Williamson L. Muscle reorientation following superior repositioning of the maxilla. *J Oral Maxillofac Surg* 1983;41:235–40.
94. Collins PC, Epker B. The alar base cinch: a technique for prevention of alar base flaring secondary to maxillary surgery. *Oral Surg Oral Med Oral Pathol Oral Radiol Endod* 1982;53:549–53.
95. Millard D. The alar cinch for the flat flaring nose. *Plast Reconstr Surg* 1980;65:669–72.
96. Mack JA, Vizuetta J, LaBanc J, et al. Three dimensional changes of the upper lip and nose following maxillary superior repositioning. Proceedings of the 68th Annual Meeting, American Association of Oral and Maxillofacial Surgeons. New Orleans (LA): WB Saunders;1986.
97. Betts NJ, Dalrymple D, Francioni SE. Two different alar cinch suturing techniques following surgically assisted rapid maxillary expansion (1 year data). *J Oral Maxillofac Surg* 1995;53 Suppl 4:82.
98. Lassus C. Thickening the thin lips. *Plast Reconstr Surg* 1981;68:950–2.
99. Hackney FL, Nishioka G, Van Sickels JE. Frontal soft tissue morphology with double V-Y closure following LeFort I osteotomy. *J Oral Maxillofac Surg* 1988;46:850–6.
100. Hackney FL, Timmis D, Van Sickels JE. Esthetic evaluation of frontal labial morphology after double V-Y closure following LeFort I osteotomy. *J Oral Maxillofac Surg* 1989;47:1277–80.
101. Rains MD, Nanda R. Soft-tissue changes associated with maxillary incisor intrusion. *Am J Orthod* 1982;81:481–8.
102. Yogosawa F. Predicting soft tissue profile changes concurrent with orthodontic treatment. *Angle Orthod* 1990;60:199–206.
103. Kasai K. Soft tissue adaptability to hard tissues in facial profiles. *Am J Orthod Dentofac Orthop* 1998;113:674–84.
104. McCance AM, Moss JP, Fright WR, et al. A three-dimensional soft tissue analysis of 16 skeletal class III patients following bimaxillary surgery. *Br J Oral Maxillofac Surg* 1992;30:221–7.
105. Mchance AM, Moss JP, Fright WR, et al. A three-dimensional analysis of soft and hard tissue changes following bimaxillary orthognathic surgery in skeletal class III patients. *Br J Oral Maxillofac Surg* 1992;30:305–11.
106. Lin SS, Kerr JS. Soft and hard tissue changes in class III patients treated by bimaxillary surgery. *Eur J Orthod* 1998;20:25–33.
107. Epker BN, Fish LC. Definitive immediate presurgical planning. In: Epker BN, Fish LC, editors. *Dentofacial deformities: integrated orthodontic and surgical correction*. Vol. 1 St. Louis: CV Mosby; 1986. p. 103–27.
108. Polido WD, Bell WH. Long-term osseous and soft tissue changes after large chin advancements. *J Craniomaxillofac Surg* 1993; 21:54–9.
109. Wessberg GA, Wolford LM, Epker BN. Interpositional genioplasty for the short face. *J Oral Surg* 1980;38:584–90.
110. Gjorup H, Athanasiou AE. Soft tissues and dentoskeletal profile changes associated with mandibular setback osteotomy. *Am J Orthod Dentofac Orthop* 1991;100: 312–23.
111. Gaggl A, Schultes G, Karcher H. Changes in soft tissue profile after sagittal split ramus osteotomy and repositioning of the mandible. *J Oral Maxillofac Surg* 1999; 52:542–6.
112. Enacar A, Taner T, Toroglus S. Analysis of soft tissue profile changes associated with mandibular setback and double jaw surgeries. *Int J Adult Orthod Orthognath Surg* 1999;14:27–35.
113. Hernandez-Orsini R, Jacobson A, Sarver DM, et al. Short-term and long-term soft tissue profile changes after mandibular advancements using rigid fixation techniques. *Int J Adult Orthod Orthognath Surg* 1989; 4:209–18

Prevention and Management of Complications in Orthognathic Surgery

Joseph E. Van Sickels, DDS

Complications of orthognathic surgery can be divided into several broad and overlapping categories. Whether surgery of the maxilla or mandible is done, regional anatomy, amount of movement, number of segments needed, and type of fixation employed all influence the types of problems observed. Difficulties encountered can fall into one or more of the following areas: vascular, neural, infectious, fracture management, occlusal changes, joint dysfunction, dental, and miscellaneous complications.

The approach to complications used in this chapter is divided into two areas: prevention and management. Prevention can be summarized as preoperative evaluation and treatment planning. Many of the less than desired results can be traced to errors in preoperative clinical examination, models, or records. Patients with unusual anatomy may dictate departure from established treatment modalities, but their care should be planned in advance.

Vascular Complications

Hemorrhage in the Maxilla

Acute Injuries Severe hemorrhage has been documented with maxillary and mandibular surgery and can have both

immediate and secondary effects.¹⁻⁷ Massive hemorrhage is rare whether acutely or in the postoperative period, but is possible with maxillary surgery. The vessels most at risk of injury during maxillary surgery are the internal maxillary artery, the posterior superior alveolar artery, and the greater palatine artery.

Massive blood loss can occur secondary to injury to the internal carotid artery and the internal jugular vein. When fracturing the pterygoid plates it is possible to fracture the base of the skull by vigorously manipulating chisels or directing chisels against the plates.^{8,9} This can result in direct or indirect damage to major vessels in the neck or skull. When approaching maxillary surgery one should remember that vessels may be directly injured during osteotome placement or indirectly through shattering the pterygoid plates. Efforts should be made to properly direct osteotomes in the pterygoid plates and to down-fracture the maxilla without excessive force. If the maxilla is extremely difficult to mobilize, the posterior cut may be directed into the tuberosity and away from the pterygoid plates (Figure 60-1).¹⁰ Patients who are undergoing a maxillary osteotomy to correct malposition of their maxilla following trauma may present special considera-

tions. The previous midface trauma may have resulted in fractures at the base of the skull. Manipulations to mobilize the maxilla may result in the osteotomy following the previous fracture lines.

Generally when brisk bleeding is encountered during surgery, the osteotomy should be completed, the maxilla down-fractured, and the site assessed for the bleeding source. Alternatively, the region may need to be packed to control blood loss, and then the osteotomy completed. The best opportunity to identify a

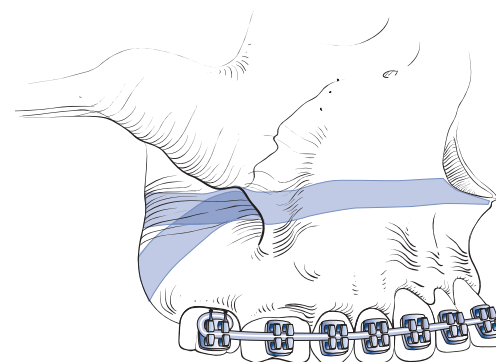


FIGURE 60-1 The posterior cut is directed into the tuberosity behind the second molar when the maxilla is difficult to mobilize. Adapted from Van Sickels JE, Tucker MR. *Prevention and management of complications in orthognathic surgery*. In: Peterson LJ, Indresano AT, Marciani RD, Roser SM. *Principles of oral and maxillofacial surgery*. Vol. 3. Philadelphia (PA): JB Lippincott Company; 1992. p. 1466.

bleeding vessel is when it is first cut. Ligature clips are applied or electrocautery is used if the vessel is easily seen. When hemorrhage obscures the field, packing followed by attempts to directly occlude the vessel should be attempted. The last option is to pack resorbable materials in the region under pressure, with tamponade of the bleeding source.

The carotid artery may be susceptible to both direct and indirect insult during the operation. Thrombosis of the internal carotid artery after orthognathic surgery may occur because of excessive extension of the head and neck.¹¹ Mortality associated with thrombosis of the internal carotid has been estimated at 40%, with an additional 52% of the patients being left with a serious neurologic deficit. Extension of the head and neck serves to stretch and partially fix the carotid artery against the cervical vertebrae, and contralateral rotation of the head results in further stretch of the artery. Positioning the patient in this manner places the internal carotid at risk for direct or indirect trauma.

Delayed Hemorrhage Delayed hemorrhage following a Le Fort I maxillary osteotomy may occur as early as the night of surgery to as late as 9 days postoperatively. The vessels most frequently involved are the greater palatine artery, the internal maxillary, and the pterygoid venous plexus of veins.⁶

Suggestions to reduce this type of injury include careful placement and orientation of the pterygomaxillary osteotome in the suture and angling the osteotomy inferior from the zygomaticomaxillary crest toward the pterygoid plates.¹² The mean distance from the most inferior junction of the maxilla and the pterygoid plates to the internal maxillary artery in the pterygopalatine fossa is 25 mm. With an average length of an osteotome of 15 mm, assuming normal anatomy, the margin of safety to separate

the entire pterygomaxillary junction is 10 mm. However, patients with dentofacial and craniofacial anomalies can have anatomic variation from these normative data. The internal maxillary artery and its branches are most vulnerable to damage in their course through the pterygopalatine fossa and fissure when the maxillary tuberosity is separated from the pterygoid plates with an osteotome.

The posterior superior alveolar and the greater palatine arteries may be severed during the Le Fort I procedure because they lie in the bony walls, although the posterior superior alveolar artery is not thought to present a significant problem for bleeding. It is generally recommended that the greater palatine arteries be preserved by gently removing bone that surrounds the vessels (Figure 60-2). However, if bleeding is encountered, the vessel should be ligated rather than letting it retract and bleed. Preserving the vessels maximizes the blood supply to segmented

maxilla and minimizes neural deficits to the palate.

There are several treatment options for the patient with postoperative hemorrhage after maxillary surgery, and they vary with the degree and severity of the bleeding. The most obvious sign of this type of problem is hemorrhage coming from both nares.³ When a patient is initially seen with postoperative bleeding, intermaxillary fixation (IMF), if present, should be removed. The patient's general physical status should be assessed and appropriate bleeding and coagulation studies ordered. Abnormal parameters warrant correction and possible consultations. With a good light source present, the nose should be suctioned to reveal whether a bleeding site is arterial or venous in nature. If adequate assessment is not possible, the nose should be anesthetized and decongested with a local anesthetic and a vasoconstrictor. Local anesthetic injections in the nose and

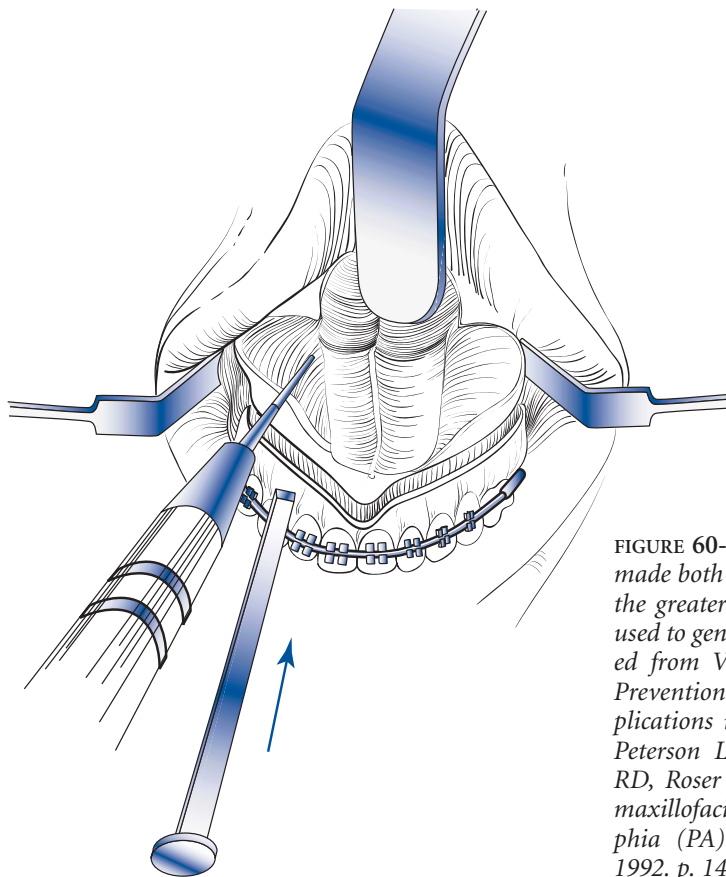


FIGURE 60-2 Using a bur, a groove is made both medially and laterally up to the greater palatine artery. A chisel is used to gently fracture the bone. Adapted from Van Sickels JE, Tucker MR. Prevention and management of complications in orthognathic surgery. In: Peterson LJ, Indresano AT, Marciani RD, Roser SM. Principles of oral and maxillofacial surgery. Vol. 3. Philadelphia (PA): JB Lippincott Company; 1992. p. 1466.

around the greater palatine foramen are helpful in stopping or slowing postoperative hemorrhage.

If the bleeding is minor in nature, it may be possible to treat the patient with bed rest. Anterior and posterior packing for 3 to 5 days combined with bed rest can be used for recurrent bleeding or for a patient not responding to initial therapy. For a patient who does not respond to these therapies or in whom the bleeding is severe or persistent, exploration of the surgical site and direct ligation or packing of problematic regions is suggested. An angiogram may be necessary. Additional operative techniques may be employed depending on clinical examination or angiographic findings. These include packing of the maxillary sinus and angiographic embolization of the specific vessel. Ligation of the external carotid artery might be considered in extreme emergencies; however, with collateral circulation, bleeding may still occur after this vessel is ligated.

Hemorrhage in the Mandible

Vascular Injury As with maxillary surgery, major vessels can be injured with mandibular procedures. Occlusion of the internal carotid has been described following a sagittal split osteotomy.¹³ Major central nervous system morbidity can occur following this injury.

Vascular injuries are due to indirect trauma either through forceful placement of a retractor placed on the lingual surface of the ramus of the mandible or the use of a mallet and chisel on the medial aspect of the mandible. Medical and surgical management of carotid artery thrombosis is beyond the scope of this text. Prevention is relatively easy. Placement of retractors and chisels on the medial posterior aspect of the mandible should be used with caution. It is preferable to limit dissection and subsequent chisel placement just distal to the lingula.

Hemorrhage with Sagittal Split Osteotomy Early reports noted numerous incidences of excessive bleeding with the sagittal split osteotomy.¹⁴ Vessels injured were the internal maxillary artery, the facial artery, and the inferior alveolar artery. These injuries were attributed to inexperience, excessive tissue stripping, and lack of sophisticated instrumentation. Excessive hemorrhage remains a problem with the sagittal split osteotomy although to a much lesser degree. In a series of 256 sagittal osteotomies the incidence of hemorrhage was 1.2% (3 cases).¹⁵ This included 2 cases of injury to the inferior alveolar artery and 1 to the anterior facial artery.

Hemorrhage occurring secondary to vascular injury on the medial or lateral aspects of the mandible with a sagittal split osteotomy can be controlled in a number of ways. The simplest involves packing, clamping, or injecting epinephrine (1:100,000) into vessel walls. Caution should be used when applying electrocautery in close proximity to the inferior alveolar nerve. When necessary, bipolar cautery is suggested. Extraoral dissections to control bleeding sources are seldom necessary.

Hemorrhage with Other Ramal Procedures In a study of the intraoral vertical subcondylar osteotomies there was a low incidence of damage to the maxillary artery.¹⁶ The masseteric artery may be injured by carrying a saw cut too far into the sigmoid notch. The inferior alveolar artery may also be injured with a vertical subcondylar osteotomy, which is usually caused by bringing the vertical cut of the ramus too far anteriorly to the posterior border of the mandible.

Access to the bleeding vessel is difficult given the approach. Fortunately in most instances, intraoperative bleeding along the ramal cut or in the sigmoid notch can be controlled by tamponade. Late sequelae such as an aneurysm may require embolization.

Loss of Vascularity

Segmental Procedures The results of vascular compromise vary between maxillary and mandibular procedures. Complications, ranging from fibrosis of pulpal tissues and periodontal defects to loss of segments, tend to increase with the number of segments. The most frequent cause of complications associated with the maxilla is interruption of the blood supply.¹⁷ Additional causes may include lack of segment stabilization, patient factors, inadequate preoperative evaluations, poor follow-up, and multiple segments.¹⁷ Patients who are heavy smokers or who have other systemic reasons for small vessel disease may mandate an altered treatment plan.

Several suggestions have been proposed to avoid vascular complications with segmental procedures. Preoperative planning to ensure adequate space between teeth, model surgery that minimizes the amount of bone removed, and careful examination of periapical radiographs prior to surgery are part of the planning that goes on prior to arriving in the operating room. Intraoperative management includes careful cutting between segments and the use of chisels and irrigated burs to complete cuts. These steps will minimize the amount of heat generated and decrease the chance of creating bone or tooth defects. Release of soft tissue adjacent to osteotomy sites and gentle mobilization of segments to avoid tearing and cutting of flaps is essential. Splints with palatal bars used for stabilization should not impinge on the palatal pedicle that serves as the major blood supply to maxillary segments. Special considerations must be given to the patient who has had previous palatal surgery or multiple segmental procedures or is a cleft palate patient. In these instances standard flap designs may not be adequate.

Complications such as periodontal defects, pulpal necrosis, and delayed union

are more commonly seen in the anterior region of the mandible but may be associated with any segmental operation. Mandibular segmental procedures require detailed planning of soft tissue incisions and careful elevation of soft tissue pedicles. In order to minimize intraoperative complications, the vascular supply to involved segments must be optimized by designing as large a flap as possible to the involved segment, maintaining maximal soft tissue attachment to the segment to be mobilized, avoiding stripping the lingual mucoperiosteal pedicle, and making the bony cut as apical as possible to include as much muscle as possible.

Aseptic Necrosis Major loss of soft and hard tissue of the maxilla is rare and is most often due to a compromised blood supply. This can be caused by a kinked pedicle in the palate or tearing of flaps. Isolated cases of loss of the entire maxilla or segments have been reported (Figure 60-3).¹⁷ More subtle complications secondary to vascular

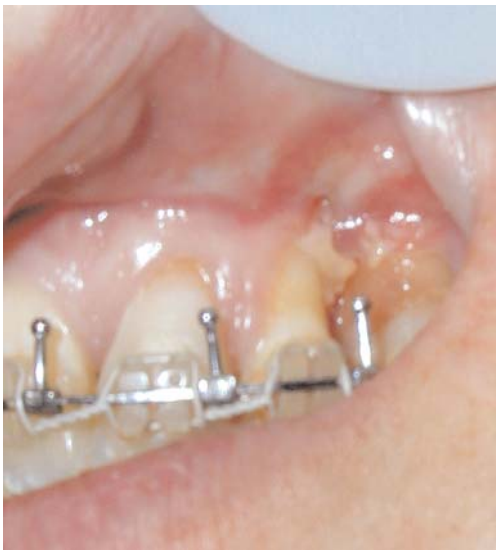

FIGURE 60-3 Necrosis of the soft and hard tissues has occurred in the left lateral/cuspid region after a Le Fort I osteotomy. Adapted from Van Sickels JE, Tucker MR. *Prevention and management of complications in orthognathic surgery*. In: Peterson LJ, Indresano AT, Marciani RD, Roser SM. *Principles of oral and maxillofacial surgery*. Vol. 3. Philadelphia (PA): JB Lippincott Company; 1992. p. 1468.

compromise range from flattening of the papilla and loss of the gingiva to periodontal defects in areas of osteotomy cuts.

Aseptic vascular necrosis of the proximal segment with a sagittal split osteotomy has been attributed to excessive stripping of the segments.¹⁸ Loss of bone secondary to aseptic necrosis has resulted in disfigurement of patients. As early as 1974 Grammer and colleagues noted in animals the death of large areas of bone in the proximal fragment secondary to elevation of the mucoperiosteal pedicle.¹⁹ They proposed that devitalized bone usually revascularized. However, when revascularization does not occur, a substantial loss of bone from the mandibular ramus can occur, especially in the gonial angle region. In 1977 Epker presented modifications of the sagittal split and discussed a technique in which the amount of dissection of the masseter was greatly decreased.²⁰ Adoption of this technique has greatly minimized the incidence of avascular necrosis after a sagittal split osteotomy. Rigid fixation of segments, which allows early revascularization, has also minimized the incidence of aseptic necrosis.

Early publications suggested that an advancement genioplasty could be done successfully by repositioning the lower border of the mandible as a free graft. However, when this is done, resorption of the advanced segment occurs to varying degrees and results in slight to almost complete loss of the genial segment. Leaving the lingual and the buccal pedicles intact minimizes resorption and gives a more predictable chin contour. Therefore, efforts should be made to preserve the largest pedicle possible. Large genial advancements may mandate more release of lingual soft tissue to achieve the desired results. However, with an adequate labial pedicle and rigid fixation, bone loss should not be appreciable.

The intraoral vertical subcondylar osteotomy is the mandibular procedure where the proximal segment is at most risk

due to release of periosteal attachments. One study reported 2 out of 42 patients with necrosis of the distal tip of the proximal segment.²¹ The surgical technique involved stripping the entire lateral and medial surfaces of the mandible up to the mandibular neck. With more recent modifications of the technique where a pedicle of medial pterygoid muscle attached to the posterior and medial aspect of the proximal segment is maintained, necrosis of the proximal tip has not been a problem.²²

Nonunion or Delayed Union of the Maxilla

Nonunion of the maxilla may be due to both local and systemic factors. The blood supply may be compromised by poor surgical planning or may be questionable because of previous surgery, as in cleft palate patients. Scarring in large advancements may make it difficult to passively reposition a maxilla. Patients may have parafunctional activity or excessive bite forces. In those patients in whom the maxilla has been moved superior and posterior, there may be insufficient bone interface to allow healing. Patients with systemic conditions that interfere with healing, such as diabetes and smoking, require individual case planning to minimize complications.

When an unstable maxilla is anticipated, bone plates may be combined with auxiliary forms of stabilization. In most cases this includes skeletal wires and a period of IMF from 1 to 6 weeks. With inferior positioning of the maxilla, bone plates and bone grafts can be combined with adjustable pins (Figure 60-4). When these are used the patient is not kept in IMF for more than 1 week. Bone gaps greater than 5 mm should be grafted. If the maxilla has good bone contacts in multiple regions, isolated defects may be filled with alloplastic material. Large bone gaps in multiple regions require autogenous grafts.

After surgery the major sign of a problem is mobility of the maxilla when the

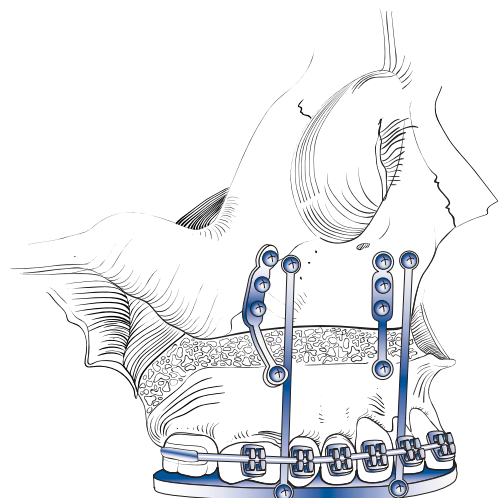


FIGURE 60-4 The maxilla is inferiorly positioned using bone grafts, plates, and adjustable pins. Adapted from Van Sickels JE, Tucker MR. *Prevention and management of complications in orthognathic surgery*. In: Peterson LJ, Indresano AT, Marciani RD, Roser SM. *Principles of oral and maxillofacial surgery*. Vol. 3. Philadelphia (PA): JB Lippincott Company; 1992. p. 1469.

patient occludes. Treatment of a mobile maxilla may be divided into early and late management. The use of IMF is controversial. If the patient is not in fixation a short period of fixation may help. On the other hand, if the patient is in IMF, removing it may allow consolidation. This is particularly important in the patient who has parafunctional activities. Additionally, flat plane splints may be used to distribute occlusal force more evenly. For minor problems selective occlusal equilibration may resolve premature contacts, contributing to movement of the maxilla. Patients should be placed on a soft diet. Heavy elastics should be discontinued, because with function they put intermittent strong forces on the maxilla. For patients with posterior relapse, light short class III elastics can help prevent further movement and may allow osseous consolidation. However, all elastics must be used judiciously as they may aggravate a problem. If a patient ends up with a minor Class III malocclusion, it is usually easier to manage than a nonunion maxilla.

Late management involves returning the patient to surgery for autogenous bone grafting and very rigid stabilization of the maxilla. This would include large bone plates, bone grafts, auxiliary techniques, and possibly alloplastic materials. Reoperation should be approached aggressively by completely mobilizing the maxilla and removing fibrous tissue.

Nonunion or Delayed Union of the Mandible

Nonunion or delayed union of the mandible may be due to avascular necrosis, insufficient bone contact, instability of the fixation appliances, or instability of bone fragments. It has been seen with sagittal split and vertical subcondylar osteotomies.

Vertical ramal osteotomies have special considerations, not only because a great deal of tissue may be stripped from the segments but also because the fragments may not lie in close apposition or be stabilized. Any large parafunctional movement of the jaws or trauma in the early phases after surgery may lead to nonunion (Figure 60-5).

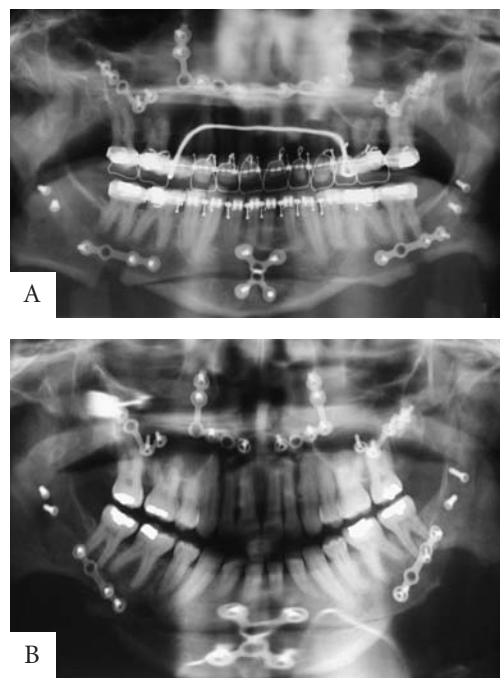


FIGURE 60-5 A and B, Patient whose plates gave way 2 weeks after surgery when vigorous manipulation of her jaw was attempted.

Large advancements are of a greater concern than small advancements. For advancements of greater than 7 mm, additional plates may be needed to maintain stability (Figure 60-6). Alternatively, skeletal wires and a brief period of IMF have been shown to give increased stability.²³

Delayed union of a sagittal split osteotomy can be treated by a period of IMF. Alternatively, the patient may need a second operation and additional plates or screws. Nonunion mandible following a vertical subcondylar osteotomy may be more of a problem with edentulous patients or when a very short vertical cut is used (Figure 60-7). A second operation, approaching the fragment from an extraoral approach to align and rigidly fix it, may be necessary.

Dental and Periodontal Injuries

Dental and periodontal injuries can be secondary to both vascular and nonvascular

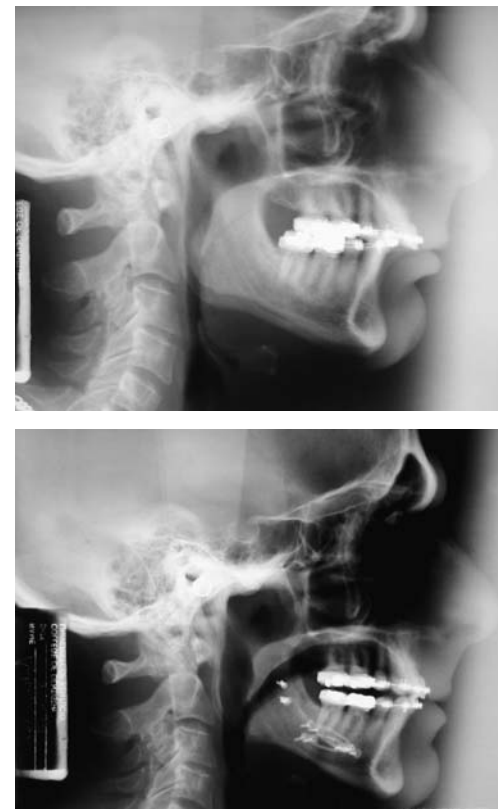

FIGURE 60-6 Large advancement of the mandible with monocortical plates and bicortical screws.

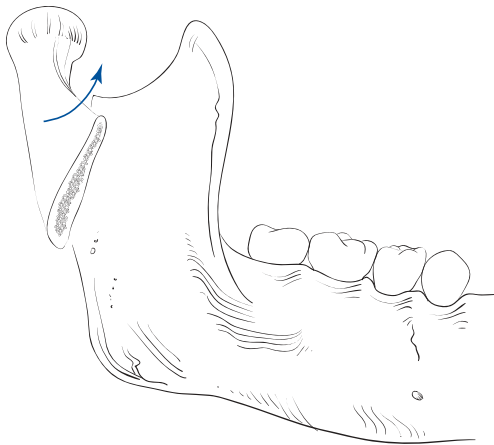


FIGURE 60-7 Severe condylar rotation is common with a short subcondylar osteotomy. Adapted from Van Sickels JE, Tucker MR. *Prevention and management of complications in orthognathic Surgery*. In: Peterson LJ, Indresano AT, Marciani RD, Roser SM. *Principles of oral and maxillofacial surgery*. Vol. 3. Philadelphia (PA): JB Lippincott Company; 1992. p. 1470.

causes and are most frequently related to planning or technical errors made at the time of surgery (Figure 60-8). Segmental procedures in the maxilla and mandible may cause a number of problems, including cut teeth, loss of teeth, need for postoperative root canals, and periodontal defects.

Preoperative orthodontic mechanics can be used to maximize a space between root apices in a planned osteotomy site.

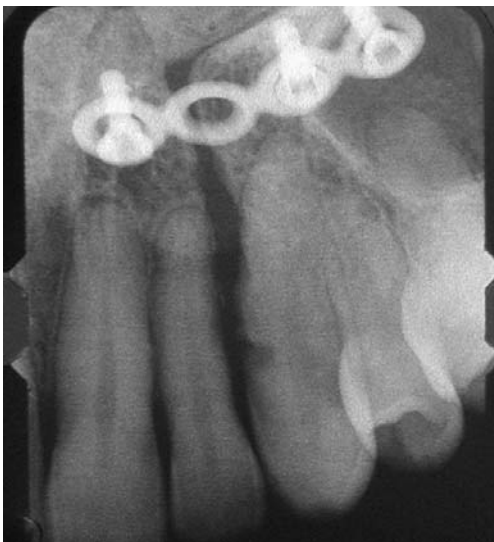

FIGURE 60-8 Injured root surface adjacent to an interdental cut.

Periapical radiographs should be studied to note the direction of the root apices. A minimum space of 3 mm is advocated when placing osteotomy cuts between teeth, and 5 mm is recommended above the apices to avoid injury to pulp.²⁴ Precise model surgery can greatly reduce the frequency of dentoalveolar injury. Surgery should be planned so that a minimal amount of bone is removed between segments. Manipulation and prying of segments should be done toward the apices of the teeth rather than at the gingival margin to minimize tears in the mucosa and subsequent periodontal defects. Segments should be tipped apart whenever possible. Copious irrigation of fine fissure burs should be used when cutting through the outer cortex in the maxilla. This is followed by gentle and progressive chisel placement in the region to separate the segments. When a bony palatal island is used, release of tissue should occur under the island rather than from the alveolar segments. After segments are gently separated, small amounts of bone may be judiciously removed. When larger wedges of bone are planned for removal, always remove less bone than was planned. When segments do not fit together, they can be gently trimmed. Defects seen following excessive removal of bone usually fill with scar tissue.

In the mandible it is necessary to cut both the buccal and lingual plates, leaving only a small amount of lingual cortical plate near the cervical portion of teeth to be separated by a chisel. Use of saws is recommended to cut through the mandible, with careful palpation on the lingual surface. Owing to the dense lingual cortex, chisels are much more dangerous in the mandible than in the maxilla where they could shatter the lingual cortex or tear the lingual pedicle region. For these reasons chisels should be used cautiously following a saw cut, and segments should be pried apart with minimal tapping through to the lingual surface.

Fistulas

Postoperative fistulas in the oronasal and oroantral regions generally result from soft tissue injury at the time of surgery. Fistulas have been reported with isolated segmental as well as total maxillary osteotomies.²⁵ This may occur as a result of rotary instruments, saws, or osteotomies that perforate the palatal mucosa at the time the segmental osteotomies are completed. Impingement of soft tissue in the segmental osteotomy site during segment repositioning and fixation may also result in tissue necrosis and fistula formation. Tearing of palatal mucosa at the time of attempted tissue stretching may also result in non-healing defects. This is most common when a bony osteotomy is made in the midline of the maxilla while attempting to stretch the midpalatal tissue (Figure 60-9).

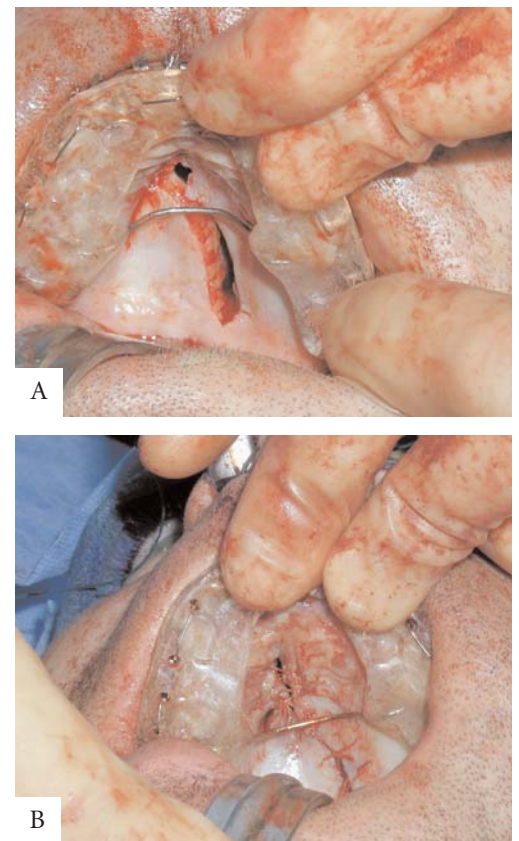


FIGURE 60-9 A, Oronasal communication has been created during a Le Fort I osteotomy with palatal sectioning. B, Sutures placed at the time of surgery, with good oral hygiene, resulted in spontaneous closure at 8 weeks.

Careful soft tissue manipulation at the time of surgery in an attempt to prevent tissue perforation is the best method for prevention of fistula formation. When expansion is needed, the palatal mucosa can be incised with two parallel incisions just medial to the greater palatine foramen; bony separation then occurs in the midpalatal area.²⁵ The tissue can stretch and expand in an area well away from the bony separation. An alternative technique involves making parasagittal cuts in the nasal floor immediately adjacent to the lateral nasal wall. The osteotomy can thus be made over tissue that is thicker and somewhat more elastic.²⁶ If a small tear is noted following a bony cut, care should be taken to release the palatal tissue from above prior to expansion of segments.

When a fistula is noted postoperatively, several measures can be pursued that may allow the fistula to close spontaneously. Preventing sinus or nasal infections is essential. This includes antibiotic therapy, decongestants, and nasal drainage. Construction of an appliance that will obturate the fistula without placing pressure on the overlying tissue will generally help in closure by reducing food contamination. Careful attention must be given to the construction of any appliance used to obturate a fistula in the immediate postoperative period. Excess pressure on the palatal mucosa may result in decreased vascularity, resulting in further loss of soft tissue and associated bone. If local measures, appropriate medical therapy, and fistula obturation have been unsuccessful, surgical closure of the fistula will be required.

When considering closure of a fistula, it is important to ensure that at least 6 months have elapsed to allow for revascularization of the maxillary segment. Carefully managed fistulas will continue to close for 8 to 12 weeks. If this therapy is not successful, a soft tissue flap should be raised from an area farthest from segments with the least potential for decreased vascularity. Timing varies, but the maxilla

should be revascularized by 6 months. If a large segment of the maxilla was involved in the initial hypovascular state, distant flaps should be considered. Choices include a buccal fat pad or a tongue flap, among others.

Management of Tissue after Vascular Compromise

Doppler flowmetry of the maxillary gingiva can be used to detect subtle decreases in the maxillary gingival blood flow following a Le Fort I osteotomy.²⁷ However, its use is limited to clinical studies at the present time. Clinically, blanched followed by cyanotic attached gingiva and adjacent free mucosa are early indications of vascular compromise following orthognathic surgery.²⁸ The overlying tissue can be an indicator of bony involvement. Three scenarios are possible: loss of vascularity to the soft tissue, whereupon the bone is perfused; loss of vascularity to the bone, whereupon soft tissue is perfused; and loss of vascularity to both the bone and soft tissue. If cyanosis is noted in the immediate postoperative period (hours to days after surgery), IMF, if present, should be released and the mouth inspected for kinked or constricted tissue. Splints must be carefully evaluated to identify areas of pressure on soft tissue by the appliance. If removal of IMF and relief or removal of splints is not helpful or the tissue is already necrotic, then supportive care is necessary to attempt to minimize the amount of bone loss. Loss of the soft tissue and exposure of the underlying bone is often what occurs. In severe cases this should be treated as an intraoral free graft. Meticulous irrigation should be performed several times a day with or without packing of the wound. Like all graft tissues it must be absolutely secure. Stability will allow some degree of revascularization. Hyperbaric oxygen therapy may be helpful to minimize bone loss while promoting neovascularization.

Reconstruction will vary and depend on the size of the resultant defect.

Nerve Injury

Sensory Injuries in the Maxilla

Sensory injuries in the maxilla have not been as thoroughly studied as those seen with mandibular surgery. With a carefully placed circumvestibular incision combined with gentle retraction, nerve injury is inconsequential and limited to the terminal branches of the infraorbital nerve. Recovery of sensation to the lip, cheeks, and nose usually occurs within 2 to 8 weeks.

Paresthesias secondary to damage of the sensory nerve supply to the teeth and mucosa are more common. Decreased sensation to the mucosa is transient and normal sensation commonly returns within 6 to 12 months. Although this is usually the case, patients will occasionally have permanent numbness intraorally on the palate and buccal gingiva. This is annoying, particularly if on the palate, as it can be burned by hot food. To preserve sensation to the palate, some authors feel that the greater palatine neurovascular bundle should be preserved.²⁸

Failure of the teeth to respond to stimulation may also be temporary. However, permanent loss of response to electrical, hot, or cold stimulation is not unusual, and does not necessarily represent a tooth that needs endodontic therapy. The clinician must differentiate a nonvital tooth from one that does not respond to stimulation but has an intact blood supply. A tooth that shows periapical radiolucency on radiographs or a fistula upon examination is a candidate for root canal therapy.

Sensory Injuries in the Mandible

Sagittal Split Osteotomy Transections of the inferior alveolar nerve can occur during a sagittal split osteotomy.²⁹ The most likely time for this to occur is during the splitting process. When the segments are

being separated, care should be taken to visualize the nerve. If the nerve is in the distal segment or encased in cortical bone, appropriate steps should be taken to release it. This may be as simple as releasing the nerve with an elevator from a medullar bone, or it may require additional bone cuts to release it from cortical bone. One study suggested that low body height of the patient and inferior position of the nerve may increase the risk for injury.²⁹ Repair of the nerve with one or more sutures placed in the epineurium has been recommended.³⁰ However, one large series had a 3.5% incidence of transection of the inferior alveolar nerve, which was anterior to or in the third molar region in all instances.¹⁵ Nerve endings were approximated in 9 patients by positioning the segments but not suturing them. The length of follow-up for these patients was 2 to 5 years, and all of the patients had some return of sensation to the normal inferior alveolar nerve distribution. Whether this represented regeneration or new growth from the cervical plexus is unknown.

If the transection occurs at the vertical bony cut, immediate repair may be difficult. To expose more of the nerve in the distal segment a second cut anterior to the first is necessary. When excessive tension is present, the nerve may have to be exposed distally to the mental foramen to allow a tension-free repair. The need for such an extensive procedure needs to be weighed against other goals to be achieved with the surgery.

Injury to the inferior alveolar nerve in the absence of a transection is frequently associated with sagittal splitting of the mandibular ramus. Risk factors for an increased amount of neurosensory disturbance include the age of the patient, whether they have a genioplasty, and the amount of advancement.^{31,32} Multiple techniques have been suggested to prevent these injuries, including osteotomy design, chisel placement, dissection technique, decompression of the lateral fragment,

and steroid use. Vigorous medial retraction may cause the inferior alveolar nerve to be compressed against the lingula and decrease intraoperative nerve conduction.^{29,33} Retraction on the medial aspect of the mandible should be done carefully to avoid compression nerve injuries. The best place to make the lateral (vertical) cut is in the first and second molar region where the cortex is the thickest, the mandible is the thickest, and the nerve is furthest from the lateral cortex.^{15,34} Other suggestions have been made to prevent nerve injuries based on clinical experience, but no controlled studies have been done to prove whether one way is preferable to another.

Injury to the lingual nerve during a sagittal split osteotomy can occur but it is unusual.^{35,36} The course of the lingual nerve near the medial surface of the mandible varies; therefore, any dissection on the lingual aspect of the mandible in the third molar region may temporarily or permanently injure this nerve.³⁷ As with inferior alveolar nerve injuries, lingual nerve injuries should be carefully followed and documented. If the nerve is visualized and has been transected, it should be repaired at the time of surgery.

Other Ramal Procedures Although vertical or oblique ramal osteotomies are frequently suggested as alternatives to a sagittal split osteotomy for horizontal mandibular excess, these procedures may also cause permanent injury to the inferior alveolar nerve. The incidence of permanent paresthesia following an intraoral vertical subcondylar osteotomy has ranged from 9 to 11%.^{38,39} Endoscopic approaches to the ramus may have a different incidence of nerve injury, but experience with these techniques is limited.⁴⁰ The precise mechanism of injury to the inferior alveolar nerve is unclear and steps to prevent this complication require further study. The saw blade should follow the posterior border of the ramus until it reaches a point

well above the antelinguar bulge on the lateral aspect of the mandible. Postoperative anesthesia should be carefully followed.

Motor Nerve Injury

Injury to the facial nerve is much more common with extraoral approaches than with intraoral surgery. However, there have been multiple reports of facial nerve injuries with sagittal split and vertical subcondylar osteotomies.⁴¹⁻⁴⁴ In one series that studied 1,747 cases of sagittal splits, the incidence was 0.26%.⁴³ The degree of injury varies from partial to total paralysis and is often seen following a setback of the mandible, but has been seen with a mandibular advancement.⁴² The possible causes of injury are impingement of the nerve when the distal segment was moved back, fracture of the styloid process and subsequent displacement, and introduction of retractors behind the ascending ramus with impingement of the nerve. Most of the reported cases occurred with mandibular setbacks without use of the Hunsuck modification.⁴⁵ The most likely cause of nerve injury is pressure on the nerve trunk, either by the distal segment or by retractors placed behind the mandible (Figure 60-10). To prevent this problem a medial/lingual split should be just distal to the inferior alveolar nerve when a sagittal split is used to set back the mandible. If a medial split extends to the posterior border, bone should be removed proximal to the lingula. Unfortunately the magnitude of setbacks causing this problem is unknown and probably varies with individuals. Care should be taken when retractors are placed behind the mandible on all ramus osteotomies.

When a facial paralysis occurs after surgery, there are a number of electrical tests that can be used to determine the depth of injury and subsequent therapy. Electroneurography, a study of peripheral nerve conduction, or electromyography, which is the detection and evaluation of electrical potentials from muscles,

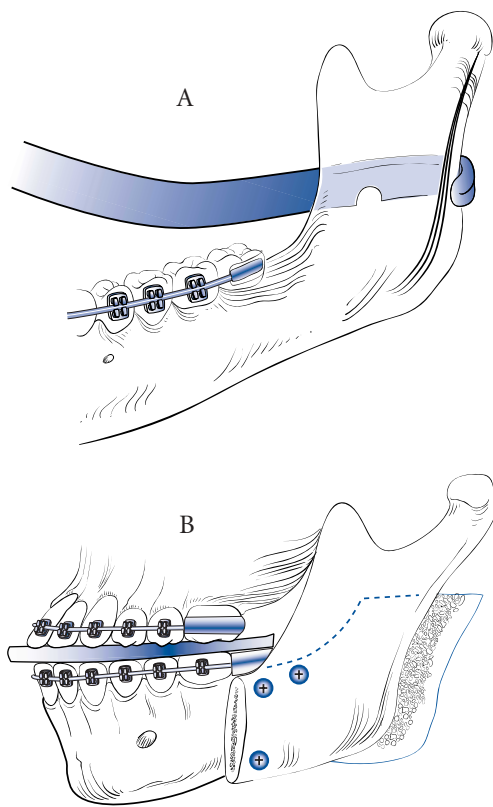


FIGURE 60-10 Two possible causes of facial nerve injury with a sagittal split osteotomy. A, Retraction on the medial behind the ramus. B, Extension of the distal segment beyond the proximal segment. Adapted from Van Sickels JE, Tucker MR. *Prevention and management of complications in orthognathic surgery*. In: Peterson LJ, Indresano AT, Marciani RD, Roser SM. *Principles of oral and maxillofacial surgery*. Vol. 3. Philadelphia (PA): JB Lippincott Company; 1992. p. 1473.

can be used.^{46,47} It is important to distinguish between an injury that causes segmental demyelination and one that causes wallerian degeneration. With axonal interruption the ability to transmit an impulse is lost over a period of 5 to 7 days. When axonal degeneration occurs, the prognosis for complete recovery is poor. When this is noted, surgical exploration should be considered to rule out a laceration of the nerve. As long as the axon remains intact at the site of blockage, the nerve will continue to respond to stimulation distal to the blockage even though paralysis is present. Evoked eletromyography (EEMG), a test in which

the degree of muscle twitch elicited is recorded, has been used as a prognostic test.⁴⁸ If the response to EEMG remains greater than 25% at 5 days, the injury is mild and the prognosis is good.⁴⁸

Clinical management of the patient during the paralysis can vary depending on the nerve branches and the type of nerve injury involved. When the patient has difficulty achieving eyelid closure, an eye patch and methylcellulose eye drops may be useful. Physical therapy such as heat, facial massage, and facial exercise performed twice a day have been suggested. Facial cream should be massaged into the skin around the eyes and mouth and over the midface, ideally using an electric vibrator. Exercises may consist of having the patient stand in front of a mirror to watch his or her face while raising the eyebrows, blowing the cheeks, and grinning. Even though no facial movement may be noted, intact nerve fibers will be activated and the exercise will help to maintain muscle tone. Electrical and mechanical stimulation may maintain muscle tone. Steroids had been given orally, intramuscularly, and intravenously for facial nerve paralysis.

Nasal and Sinus Considerations

Alterations in Nasal Form: Septum

Repositioning of the maxilla requires manipulation of nasal components and the maxillary sinus. As a result of these manipulations, alterations can occur with the internal nasal anatomy including position of the turbinates, nasal septum, and nasal valve. Adverse effects of maxillary osteotomies on the alar bases, nasal tip, supratip depression, and upper lip may result in an unesthetic postoperative facial appearance.⁴⁹⁻⁵¹

The maxillary septum may be deviated prior to surgery, at the time of surgery, or during extubation. Hence the septum should be inspected prior to surgery and

at the time of surgery. During a Le Fort I maxillary surgery it is possible to align the septum at its inferior anterior caudal end. At surgery the septum is disarticulated from the entire maxilla. In particular, with impaction, the maxilla will encroach on the presurgical dimension of the nasal septum. Because of this movement, attention must be given to the positioning of the septum at the time of surgery. Failure to do so may result in septal deviation and obstruction, or in abnormal positioning of the columella and nasal tip.⁵⁰ There are several techniques for superior repositioning, including resection of an appropriate portion of the inferior aspect of the nasal septum or creating a groove in the superior aspect of the maxilla. In segmental osteotomies, creating a bony island with parasagittal palatal cuts may eliminate posterior superior pressure. However, it will not eliminate pressure from the anterior portion of the maxilla on the septum.

When septal deviation is recognized postoperatively, three choices for management should be considered (Figure 60-11). These include immediate manipulation, reoperation, or septoplasty at a later time. If appropriate management of the nasal septum was accomplished at the time of surgery but the nasal septum appears to be asymmetric, manipulation with an instrument placed within the nose on each side of the base of the nasal septum may allow for repositioning in the midline position (see Figure 60-11B and C). If rigid fixation has been used and the patient has no airway difficulties, short-term packing may be considered. If septal deviation is due to intraoperative management or if postoperative manipulation poses difficulty, immediate reoperation with further septal surgery may be indicated. If none of the previous approaches seems acceptable, and the patient does not have significant airway difficulty, the deviation can be reevaluated at a later date with consideration for a septoplasty through standard techniques.

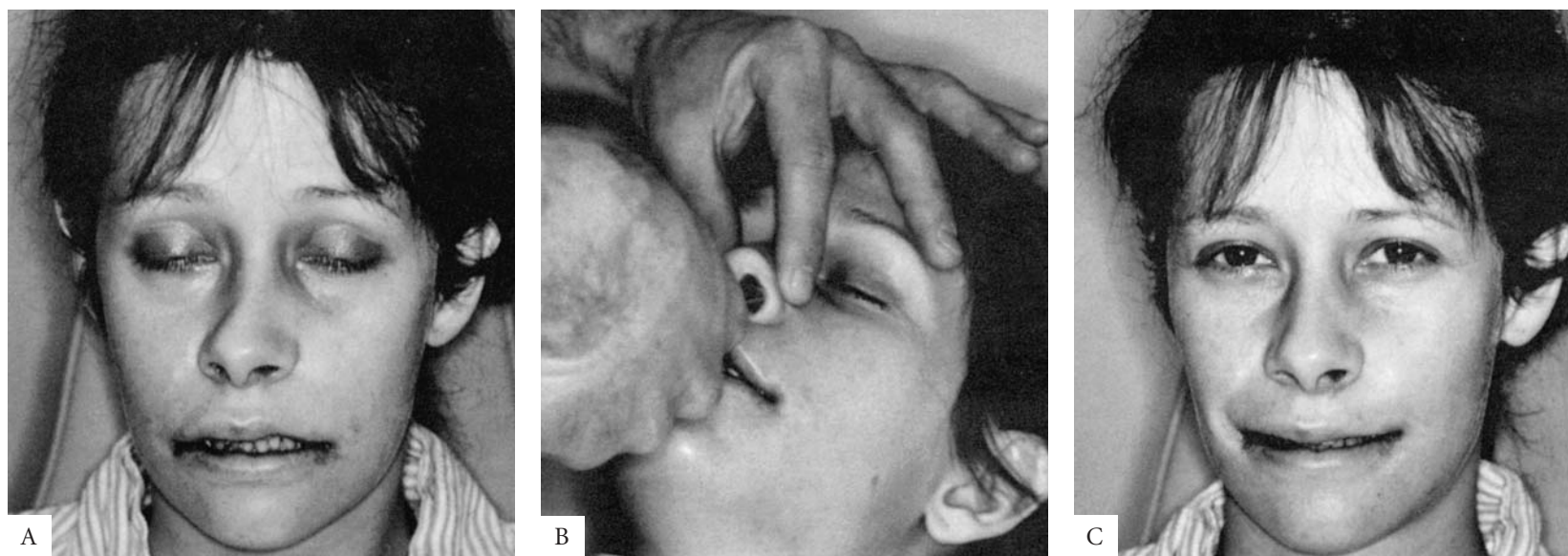


FIGURE 60-11 A, Deviated septum initially after surgery. B, Manipulation. C, After manipulation.. Reproduced with permission from Van Sickels JE, Tucker MR. Prevention and management of complications in orthognathic surgery. In: Peterson LJ, Indresano AT, Marciani RD, Roser SM. Principles of oral and maxillofacial surgery. Vol. 3. Philadelphia (PA): JB Lippincott Company; 1992. p. 1475.

Alterations in Nasal Form: Nasal Valve

An area of concern in maxillary surgery is alteration in internal nasal anatomy, nasal airway resistance, and breathing patterns as a result of maxillary surgery. Expansion of the maxilla with surgery has shown little change in the nasal airway. Some patients remain obligatory mouth breathers even after expansion.⁵² Of greater concern is the possibility that superiorly repositioning the maxilla may decrease the nasal airway. Several studies have documented that the reverse is true.^{53–55} Superior maxillary repositioning appears to increase nasal cross-sectional area, decrease nasal airway resistance, and increase nasal breathing. The explanation for this decrease in nasal airway resistance is most likely related to alteration in configuration of the nasal valve area.^{53–55} The nasal valve is formed by the nasal septum, the floor of the nose, the soft tissue on the lateral aspect of the nose, and the caudal end of the upper lateral nasal cartilage. The increase in alar base width that results from elevating the soft tissues to expose the maxilla causes a slight widen-

ing of the nasal valve and thus reduces nasal airway resistance. Because this valve is at the smallest cross-sectional area of the nose, alterations in this area are likely to have a significant effect on nasal breathing whereas changes in much larger intranasal areas have little effect. This same phenomenon has been demonstrated in patients with cleft palates.⁵⁶

Alterations in Nasal Form: Alar Base

In addition to the internal nasal changes, there are facial esthetic changes that may result from maxillary surgery. Failure to properly manage the nasal septum, paranasal musculature, and labial mucosa may result in undesirable facial esthetic results. Adverse changes in nasal and perioral configuration following maxillary surgery may include excessive alar base widening, increased prominence of the alar groove, upturning of the nasal tip (with an obtuse nasolabial angle), flattening and thinning of the upper lip, and downturning of the labial commissures.⁵⁰ These complications may also be compounded by internal deviation of the nasal septum or asymmetric posi-

tioning of the columella and nasal tip due to septal deviation. These types of problems are difficult to manage and are best treated by prevention. The need to control alar base width and the necessity of reconstruction of paranasal and perioral musculature have been previously described.⁴⁹

Postoperative Sinus Symptoms

Postoperative complications related to the maxillary sinuses are primarily limited to infection, inadequate drainage, and open fistulas. Although many patients experience drainage and some sinus symptoms in the immediate postoperative period, true perioperative infections of the sinus area and long-term sinusitis are rare.^{57,58} Between 2 and 6 months after surgery there will be normalization of the bony and soft tissue structures in over 55% of the patients.⁵⁸ However, at 6 months, 30% of the patients will show some latent mucosal borderline swelling.⁵⁸

Despite the rarity of infections there are several potential causes of infections in the maxillary sinus area. The formation and retention of large blood clots in the sinus cavity is an obvious source of infec-

tion. Preoperative antibiotic prophylaxis with subsequent antibiotic levels present in the clot will help reduce infections from this source. Other potential causes of infection in the sinus are preexisting disease, dental infection secondary to trauma to the teeth, soft tissue ischemia and avascularity, and debris within the sinus. Foreign objects such as wires, bone plates, or screws are rarely, if ever, the isolated cause of a sinus infection and do not appear to cause a significant increase in the incidence of infection after maxillary surgery.⁵⁷

Preoperative assessment of patients presenting for maxillary surgery should include a history and clinical examination, with careful attention to symptoms of any existing maxillary sinus infection. Evaluation of preoperative radiographs may provide some information regarding sinus pathology. Postoperative management of sinus infections should include appropriate antibiotic therapy verified by culture and sensitivity, decongestants, intranasal vasoconstrictors, and irrigation of patent fistulas if present. Generally sinus drainage can be managed within 10 to 14 days with these techniques. When a sinus infection is refractory to medical treatment, sinusoscopy should be considered. These patients should be managed in a manner similar to treatment for patients who have not had surgery.

Unanticipated Mandibular Osteotomy Fractures

Fragment Management

Fragment management, or more appropriately intraoperative management of unusual fragments, is a problem seen more frequently with mandibular procedures, especially sagittal split osteotomy. Additional segments may occur on either the proximal or distal fragments. The incidence of unfavorable fractures with a bilateral sagittal split is 1.9 to 2.2% with a slightly higher incidence when the third molars are present.^{59,60}

These fractures may be in either the proximal or distal segment.

Intraoperative management of an inadequate split is that separation of the proximal and distal segments must first be completed. Intraoral management is the rule. A small or large fragment may have been fractured. Management will vary depending on the size and location of the fragment. It must first be determined where the fracture deviated from the desired split. Often it is necessary to remove the free segment to get access to the remaining mandible. Using a saw or a bur the intact mandible or segments are grooved so that a sagittal split can occur along the original planned lines. Chisels are used to complete the desired split. The key to management is to orient oneself to what is left. Once the split is successfully completed, the distal segment is advanced to its desired position. The position and size of the remaining fragments may make positioning of the condyle difficult. Segments are sequentially stabilized to the remaining fragments. An extraoral approach may be an option, but is usually not necessary. The following examples will illustrate management of various fractures.

Proximal Segment, Mandible Intact

The difficulty in managing segments depends on the location and size of the fractured pieces. A fragment may shear off the lateral aspect of the mandible, leaving the mandible intact. Whenever a buccal fragment shears off, the usual cause is an inadequate bone cut on the inferior border on the lateral vertical cut. The split must then be completed. This can be done by making a deep groove on the inferior border and connecting it with the previous groove coming down the external oblique ridge. By gently prying and, when necessary, cutting bone, the segments will be separated as originally planned. Placing the distal segment in occlusion, the free fragment should be stabilized with screws and

plates. In Figure 60-12 a buccal fragment has been fractured. The main portion of the mandible was intact before completion of the split. The segment is stabilized with a plate and screw osteosynthesis, as shown in Figure 60-13. Condylar position is not difficult to establish when a proximal segment is large enough to be positioned and overlapped with the distal segment in its new position. Bicortical screws can be used between the areas of contact of the two segments. With a small free fragment (as depicted) it is frequently easier to place a plate on it out of the mouth and then reattach it to the proximal segment.

Proximal Segment Split Complete

When the fragment occurs more superiorly, or there is a large advancement, such that there is no contact between the proximal and distal segments when placed into occlusion (Figure 60-14), a different approach must be taken. The condyle and coronoid are in one piece, simulating a horizontal osteotomy of the mandible,

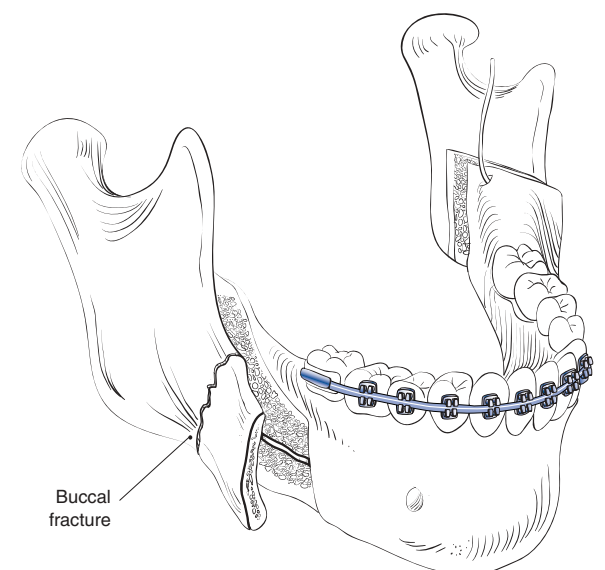


FIGURE 60-12 Buccal segment, fractured off. Adapted from Van Sickels JE, Tucker MR. *Prevention and management of complications in orthognathic surgery*. In: Peterson LJ, Indresano AT, Marciani RD, Roser SM. *Principles of oral and maxillofacial surgery*. Vol. 3. Philadelphia (PA): JB Lippincott Company; 1992. p. 1477.

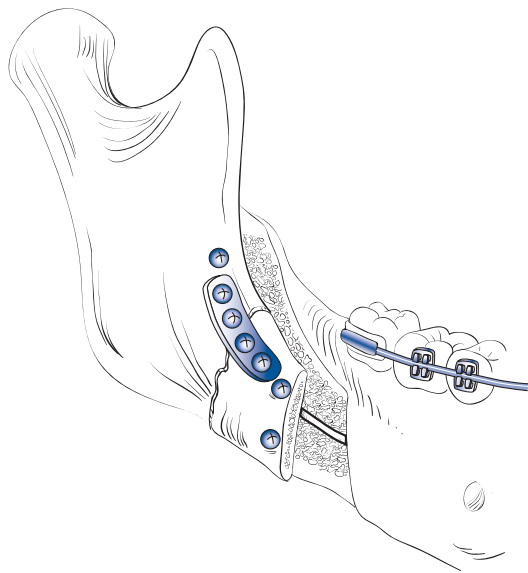


FIGURE 60-13 A four-hole or larger plate is used to stabilize the free fragment to the proximal segment. Additional bicortical screws are placed to ensure stability of the complex. Adapted from Van Sickels JE, Tucker MR. *Prevention and management of complications in orthognathic surgery*. In: Peterson LJ, Indresano AT, Marciani RD, Roser SM. *Principles of oral and maxillofacial surgery*. Vol. 3. Philadelphia (PA): JB Lippincott Company; 1992. p. 1478.

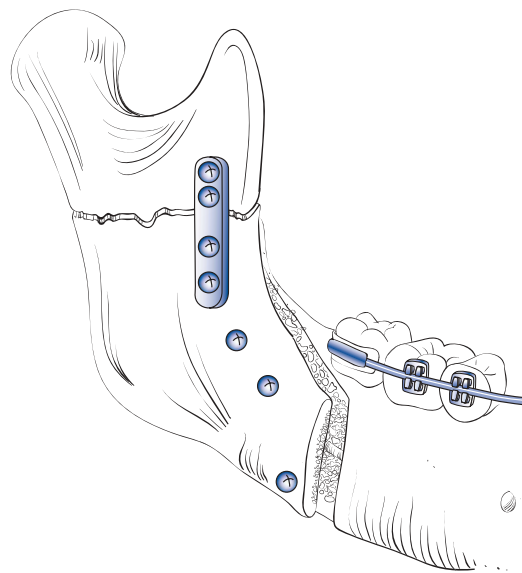


FIGURE 60-15 A plate has been placed on the ascending ramus with additional bicortical screws placed between the proximal and distal segments. Adapted from Van Sickels JE, Tucker MR. *Prevention and management of complications in orthognathic surgery*. In: Peterson LJ, Indresano AT, Marciani RD, Roser SM. *Principles of oral and maxillofacial surgery*. Vol. 3. Philadelphia (PA): JB Lippincott Company; 1992. p. 1478.

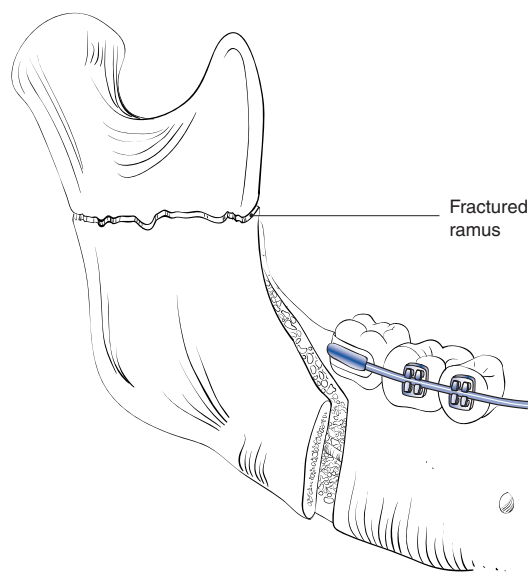


FIGURE 60-14 The proximal fragment has a high or horizontal fracture. Adapted from Van Sickels JE, Tucker MR. *Prevention and management of complications in orthognathic surgery*. In: Peterson LJ, Indresano AT, Marciani RD, Roser SM. *Principles of oral and maxillofacial surgery*. Vol. 3. Philadelphia (PA): JB Lippincott Company; 1992. p. 1478.

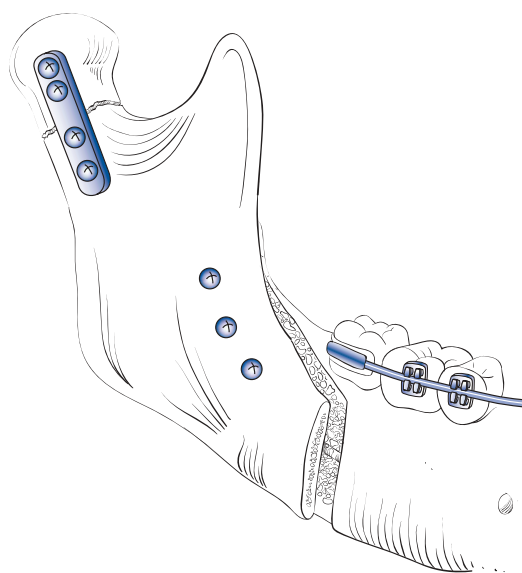


FIGURE 60-16 A plate is used on the condylar segment with additional screws placed to stabilize the free fragment to the distal segment. Adapted from Van Sickels JE, Tucker MR. *Prevention and management of complications in orthognathic surgery*. In: Peterson LJ, Indresano AT, Marciani RD, Roser SM. *Principles of oral and maxillofacial surgery*. Vol. 3. Philadelphia (PA): JB Lippincott Company; 1992. p. 1479.

with or without the angle as a separate fragment. Control of the condylar position is much more difficult. The large fragment that was sheared off should have a plate placed on it outside the mouth. It should be re-inserted and connected to the proximal segment (Figure 60-15). This usually requires two percutaneous incisions. Having done this the proximal segment is easier to manage and it can be united with the distal segment in its new position. This can be done with a series of plates or bicortical screws. Control of condylar position may be established by posterior, superior, and vertical pressure on the reunited proximal segment, followed by clamp placement prior to placement of bicortical screws, or by the use of a clamp on the coronoid process to stabilize the proximal fragment before screw placement.

The last case scenario is a fracture of the condyle with the coronoid and angle in a separate fragment. Here one must plate the condyle to the advanced reunited distal segment and use screws in other parts where there is overlap (Figure 60-16). Correct condylar positioning is extremely difficult to achieve in this environment. Through percutaneous incisions a plate is placed on the condyle. Using the plate as a handle, holes are drilled in the distal fragment and screws placed.

Lingual Segment Fracture

Fortunately, fractures of the lingual fragment occur less frequently than fractures of the buccal fragment. The underlying cause is frequently an impacted third molar or it may be secondary to wedging too high on the medial aspect of the mandible (Figure 60-17). To prevent this type of fracture it is wise to have third molars removed at least 9 months prior to surgery. When an unwanted fracture occurs, the split must be completed along the original planned osteotomy lines. As the free segment is not in the way when the split is completed, it is frequently possible

to leave substantial vascular pedicle attached to it. The distal segment is placed into occlusion. The free fragment is manipulated to an anterior position and is fixed to the proximal segment by one or more bicortical screws. One or more plates or titanium mesh may be placed across the osteotomy site (Figure 60-18).

Excessive Lateral Displacement

Excessive lateral displacement can occur during a vertical subcondylar osteotomy. Depending on the geometry of the move, the proximal fragment or condylar segment may be displaced laterally or medially. The usual position is lateral to the main body of the mandible. Even with moderate flaring there is considerable remodeling possible and this is usually not a problem. Occasionally the proximal segment will be flared excessively. This can be remedied intraoperatively by removing a second wedge at the sigmoid notch region (Figure

60-19). Care must be taken in this region because the masseteric branch or the maxillary artery itself can be injured.

If excessive flaring is noted postoperatively, the segment may be manually repositioned, but if this does not succeed, reoperation is necessary.

Medial Displacement

In some cases of asymmetry the rotation may be such that the condylar fragment may be placed medially. Whether this will increase the incidence of nerve injury is unknown. Medial displacement rarely causes problems. A conceivable patient complaint is irritation of the pharynx. If this happens the medial fragment needs to be contoured or removed.

Proximal Segment Rotation

Lack of control of the proximal segment with a sagittal split osteotomy can have several effects that are both esthetic and

functional. Postoperation muscular pull is such that the proximal segment is pulled anterior and superior while the distal fragment is pulled posterior and inferior (Figure 60-20). Anterior superior rotation of the proximal segment may result in an unpleasant cosmetic result by flattening of the gonial angle and notching the inferior border of the mandible anterior to the angle. This causes a bulge in the cheek secondary to the position of the proximal fragment. The type of osteosynthesis used has been shown to affect the position of the fragment during surgery and in the initial postoperative period.⁶¹

Ideal management of a rotated proximal segment is prevention. Several positioning appliances have been presented to control the proximal segment during surgery.⁶²⁻⁶⁴ Rigid fixation used without positioning appliances has shown minimal rotation of the proximal segment with surgery.⁶¹ However, there is a tendency to

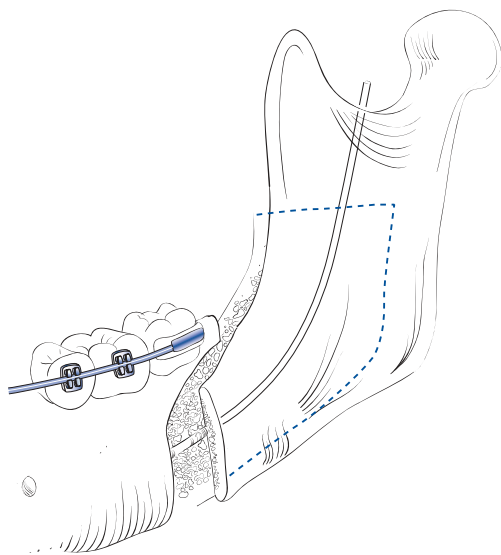


FIGURE 60-17 A lingual split (distal segment) has occurred in the third molar region. Adapted from Van Sickels JE, Tucker MR. Prevention and management of complications in orthognathic surgery. In: Peterson LJ, Indresano AT, Marciani RD, Roser SM. Principles of oral and maxillofacial surgery. Vol. 3. Philadelphia (PA): JB Lippincott Company; 1992. p. 1479.

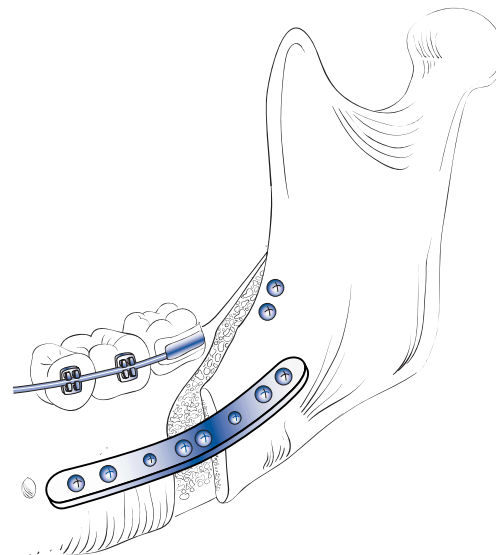


FIGURE 60-18 Two bicortical screws are used to stabilize the free segment to the proximal segment. A plate can be used to stabilize the proximal segment to the distal fragment. Adapted from Van Sickels JE, Tucker MR. Prevention and management of complications in orthognathic surgery. In: Peterson LJ, Indresano AT, Marciani RD, Roser SM. Principles of oral and maxillofacial surgery. Vol. 3. Philadelphia (PA): JB Lippincott Company; 1992. p. 1480.

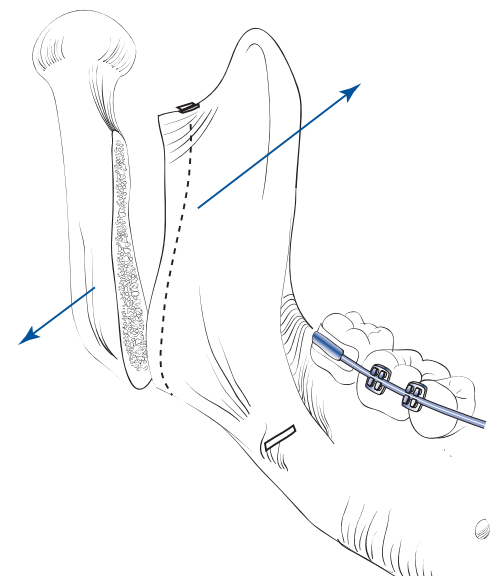


FIGURE 60-19 Excessive flaring caused by bone contact at the sigmoid notch. This can be resolved by removing a wedge from the distal segment. Adapted from Van Sickels JE, Tucker MR. Prevention and management of complications in orthognathic surgery. In: Peterson LJ, Indresano AT, Marciani RD, Roser SM. Principles of oral and maxillofacial surgery. Vol. 3. Philadelphia (PA): JB Lippincott Company; 1992. p. 1481.

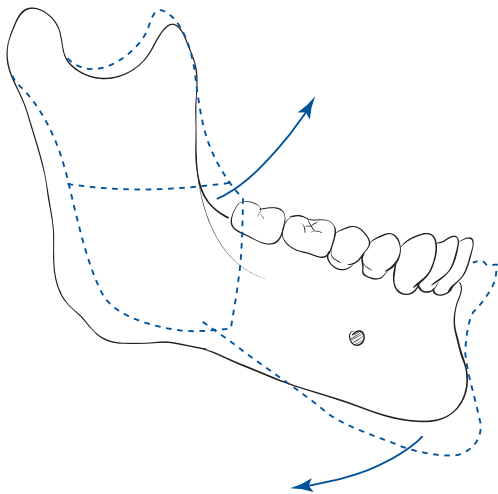


FIGURE 60-20 Pull of the muscles of mastication on the proximal and distal segments. Adapted from Van Sickels JE, Tucker MR. *Prevention and management of complications in orthognathic surgery*. In: Peterson LJ, Indresano AT, Marciani RD, Roser SM. *Principles of oral and maxillofacial surgery*. Vol. 3. Philadelphia (PA): JB Lippincott Company; 1992. p. 1481.

rotate the proximal segment medially and superiorly with large advancements.⁶⁵ This can result in an unesthetic effect for the patient, especially if there was any discrepancy in the height of the ramus prior to surgery (Figure 60-21). To date, the amount of rotation that will cause clinically significant decreases in muscle efficiency and unesthetic facial changes is unknown.

Excessive rotation of the proximal segment should be evaluated as to whether there are functional (decreased bite force, hypomobility) or esthetic (loss of the gonial angle) problems, or both. An

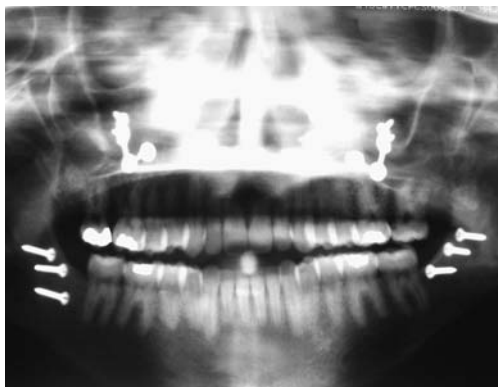


FIGURE 60-21 Radiograph of short ramus.

esthetic problem seen in a patient with acceptable occlusal results may be treated by the use of an alloplastic implant. If the patient has an occlusal problem with esthetic considerations, the sagittal split can be redone (Figure 60-22). When these are combined with decrease in bite force and hypomobility, then reoperation must be combined with a vigorous postoperative physiotherapy program.

Most patients demonstrate decreased maxillomandibular opening compared with their preoperative state. The most dramatic decreases are seen after bilateral sagittal split osteotomies.⁶² Temporomandibular mobility must be restored by postoperative physiotherapy. Ellis examined the range of mandibular motion after a sagittal advancement osteotomy in monkeys, when either IMF or rigid osseous fixation was used.⁶⁶ Animals that did not undergo IMF maintained a greater range of motion in the early postsurgical period and obtained preoperative mobility by 12 weeks postoperatively. Animals that underwent 6 weeks of IMF showed significant decreases in range of motion when compared to the rigid fixation group at each time period post-surgery. Several clinical studies have shown that whether IMF or rigid fixation is used, with postoperative physiotherapy, a normal or near-normal range of motion will return by 2 years after surgery.^{61,67}

There are several potential causes of hypomobility in patients undergoing orthognathic surgery. Scar tissue induced

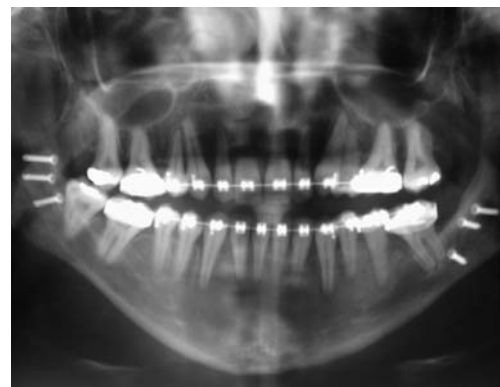

FIGURE 60-22 Occlusal discrepancy.

by the surgery plays a major role. However, immobilization can compound the effects of surgical dissection and have adverse effects on the muscles, joints, and connective tissues. Immobilization by itself induces atrophy with a marked decrease in muscle fiber diameter. This problem may be compounded if the muscle is immobilized in a shortened position. In addition, following IMF, a series of degenerative changes occur in articular cartilage and synovial membranes.

Techniques that eliminate or minimize immobilization will probably decrease postsurgical hypomobility. Despite this it is strongly suggested that all patients have routine presurgical evaluation of muscle and joint function and a systematic rehabilitation regimen as part of their postsurgical program. Mandibular ramal procedures are potentially the most harmful to the surrounding tissue of the jaws. Mandibular advancements, in particular, are susceptible to postoperative hypomobility. If rigid fixation is used, mild self-directed physiotherapy beginning 1 to 2 weeks after surgery may suffice, consisting of instructions on active and passive exercises. When a patient's progress is limited or when surgery has been associated with longer periods of IMF, then more vigorous physical therapy is needed. If this is unsuccessful, intra-articular pathology may be responsible for the problem and additional steps may need to be taken to restore a normal range of motion.⁶⁸

Temporomandibular Joint Dysfunction

Short-Term Disorders

Joint dysfunction in patients undergoing orthognathic surgery deserves careful preoperative examination. A number of patients presenting for orthognathic surgery will have muscular temporomandibular dysfunction.⁶⁹⁻⁷¹ Although a small percentage of patients will develop

symptoms with surgery, the large majority will improve. Achieving a better functional relationship can help temporomandibular symptoms, but orthognathic surgery should not be offered as a cure for these problems. After surgery patients may have acute or gradual increases in temporomandibular symptoms. Acute exacerbations may be treated with anti-inflammatory medications and physical therapy. Gradual increases or chronic manifestations of temporomandibular problems are managed with standard protocols for these patients. Concern exists that with rigid fixation there will be a higher incidence of temporomandibular dysfunction compared with the use of wire osteosynthesis. Studies that have compared these two populations have not borne out these assumptions.^{67,70}

Long-Term Disorders

Condylar resorption has been noted with and without orthognathic surgery. The cause of delayed relapse may be secondary to a number of factors including preexisting internal derangements. The role that surgery may play in these unusual cases is unknown. The incidence of condylar resorption or progressive condylar resorption ranges from 5 to 10% of the patients who undergo orthognathic surgery.⁷²⁻⁷⁷ Patients who need large advancement of the mandible and who have preoperative temporomandibular symptoms are more likely to have this problem than those who have smaller advancements and no symptoms.^{72,74} Condylar resorption has been noted 12 to 17 months after surgery.⁷⁶ Management includes splint therapy, with a possible role for medications.^{76,77} Secondary surgery is unpredictable, with additional resorption possible in as many as 50% of cases.⁷⁶

Unanticipated Maxillary Fractures

Whereas several reports have discussed management of additional fragments with

mandibular osteotomies, little attention has been directed to maxillary surgery. With modified cuts of the maxilla, the bone leading to the zygomatic buttress (wing) may be thin and fractured (Figure 60-23). Management can be accomplished by using a plate to span the gap and then re-inserting the fragment (Figure 60-24).

Over- or underimpaction of the maxilla can occur at the time of surgery. This can be avoided with an external reference. One choice is to place a pin at nasion at the beginning of surgery. Intraoperative measurements will ensure that the maxilla is at the appropriate position at the end of surgery.⁷⁸ When the maxilla is under impacted, very few options exist. Plates, if present, may be removed and an attempt made to impact the maxilla with suspension wires in an outpatient environment. However, it is unlikely that this procedure will achieve the desired results. When the maxilla is overimpacted, it can rarely be successfully treated by multiple vertical elastics used in the early postoperative

period. If unsuccessful, then a reoperation should be considered.

Postoperative Occlusal Discrepancies

Occlusal abnormalities may be related to a number of factors either in the preoperative, intraoperative, or postoperative phase of patient management. A review of cases of maxillary surgery suggests that the majority of discrepancies between what was desired and what was obtained can be traced to inaccurate preoperative records.⁷⁹

Open Bites

Surgical Causes

Anterior open bites after surgery may be due to the technical difficulties seen with both the maxilla and mandible at the time of surgery. With the maxilla these include posterior interferences that are not recognized when the patient is in IMF. If the maxilla is fixed with condyles that are dislocated out of the glenoid fossa, when the

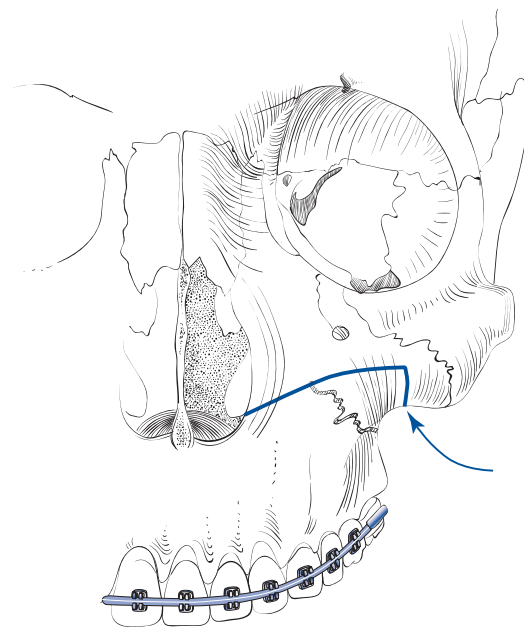


FIGURE 60-23 “Wing” of the maxilla fractured off. Adapted from Van Sickels JE, Tucker MR. Prevention and management of complications in orthognathic surgery. In: Peterson LJ, Indresano AT, Marciani RD, Roser SM. Principles of oral and maxillofacial surgery. Vol. 3. Philadelphia (PA): JB Lippincott Company; 1992. p. 1483.

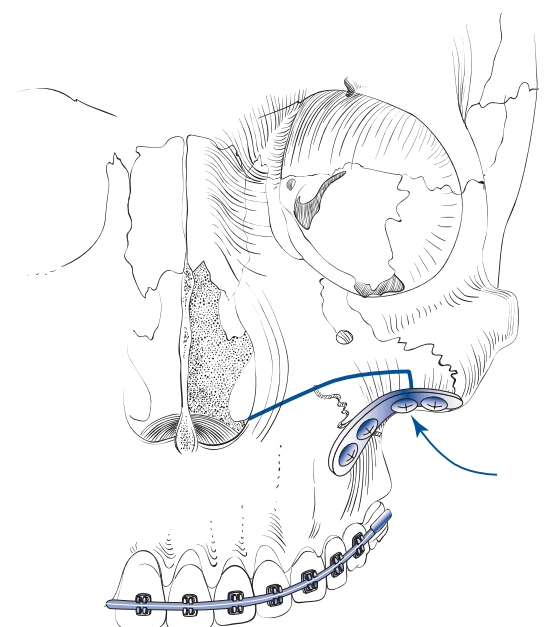


FIGURE 60-24 Plate spans the gap; bone segment lies under the plate. Adapted from Van Sickels JE, Tucker MR. Prevention and management of complications in orthognathic surgery. In: Peterson LJ, Indresano AT, Marciani RD, Roser SM. Principles of oral and maxillofacial surgery. Vol. 3. Philadelphia (PA): JB Lippincott Company; 1992. p. 1483.

patient is taken out of fixation, the occlusal discrepancy is usually recognized. Occasionally, however, it is not recognized until the next day. Depending on the severity of an open bite, the patient may have to be taken back to the operating room.

Open bites that occur after orthodontic appliances have been removed may be due to relapse of surgically or orthodontically treated transverse discrepancies. Surgical and orthodontic correction of severe transverse discrepancies have been noted to be unstable.⁸⁰ When relapse of the transverse discrepancy occurs, it is usually manifested by an anterior open bite. Management of late discrepancy will depend on its severity.

Dental or Orthopedic Causes

Open bites have been noted to recur years after treatment with both orthodontics and surgery.^{80,81} Stability of orthodontic therapy varies depending on the orthodontic techniques used to treat an open bite.⁸² Rotation of incisors that are flared with closure of an open bite may be no more problematic than for other tooth movements. When extrusion of teeth has occurred with orthodontic mechanics, the results are less predictable. Why this occurs is somewhat controversial. Extrusion may have increased sensitivity to external factors, such as the tongue and circumoral musculature. Lack of stability or recurrence of the open bite is therefore felt to be secondary to the continued presence of etiologic factors and failure of biologic adaptation. Measures taken to correct these problems may include orthodontic cribs or surgical techniques such as partial glossectomies.

Relapse of the Mandible

Relapse of the mandible following a bilateral sagittal split has been well documented in the literature, especially with larger advancements.⁸³⁻⁸⁶ However, occlusal discrepancies can occur secondary to several reasons. Many of these occlusal discrepan-

cies can be traced to the technical aspects of rigid fixation. Occlusal changes seen with rigid fixation may be secondary to condylar torque, condylar sag, or incorrect placement of the fragments at the time of surgery. This may result in anterior or posterior open bites or lateral shifts. Severe discrepancies may need to have a second operation. Minor discrepancies can be treated by early aggressive orthodontics. Posterior open bites of less than 3 mm can be treated with vertical elastics or orthodontic mechanics. Larger posterior open bites may have to be reoperated, with removal of the screws and replacement with either screws or wires. Anterior open bites represent failure to properly place the condyle or instability at the osteotomy site. IMF with anterior elastic traction may prevent reoperation when the cause is instability at the osteotomy site.

The preferred time to initiate therapy is as soon after surgery as the discrepancy is noted. Removal of the screws or plates in an outpatient environment at 3 weeks, coupled with elastic therapy, can sometimes correct some postoperative malocclusions. Failure to place the condyle in the fossa, either unilaterally or bilaterally, needs evaluation as to whether orthodontic therapy can correct the problem or if the surgery needs to be repeated. A lateral shift of the occlusion where the midline is off to one side is usually due to condylar torque at the time of surgery. When placing a clamp between the proximal and distal segments, the proximal segment should be observed for shifts or torque of the segment. If seen the fragments may need to be contoured or the clamp repositioned. After surgery a shift in the midlines secondary to torque of the segments may be treated by orthodontics or by reoperation. Small shifts of 1 mm or less can be managed by orthodontic mechanics. Larger ones may need a second surgery.

Relapse of a skeletal Class III occlusal condition upon release of IMF has been noted.⁸⁷⁻⁸⁹ Several authors believe this can

be caused by pushing the proximal fragment back during surgery. With the release of IMF the mandible rotates forward. To prevent this problem it has been suggested that the inferior border of the proximal and distal segments be aligned and that the medial sling be released.⁸⁸ Others disagree and feel that clockwise rotation of the proximal segment is not responsible for the relapse.⁸⁹ Additionally, the use of a monocortical plate on the proximal segment may provide a more stable result than that seen with bicortical screws (Figure 60-25). When this occlusal discrepancy is seen after surgery, short class III elastics can correct the problem if it is small. If the discrepancy is greater than 3 to 4 mm, a second operation is necessary.

Anterior Open Bite

As discussed above, an anterior open bite may be seen after a bilateral sagittal split osteotomy (Figure 60-26). This is usually due to a failure of the screws and/or plates placed at the time of fixation, or technical difficulties incurred at the time of splitting the segments with resulting edema in the joints which resolves with time. However, an anterior open bite is much more commonly seen in patients following an intraoral vertical ramus osteotomy upon

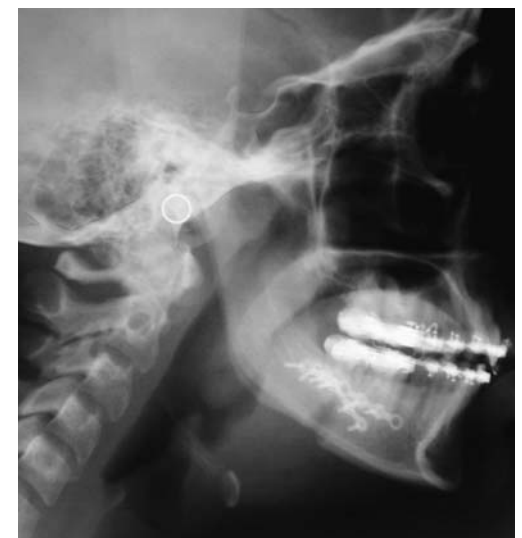

FIGURE 60-25 Monocortical plate on the buccal surface of the proximal and distal segments.

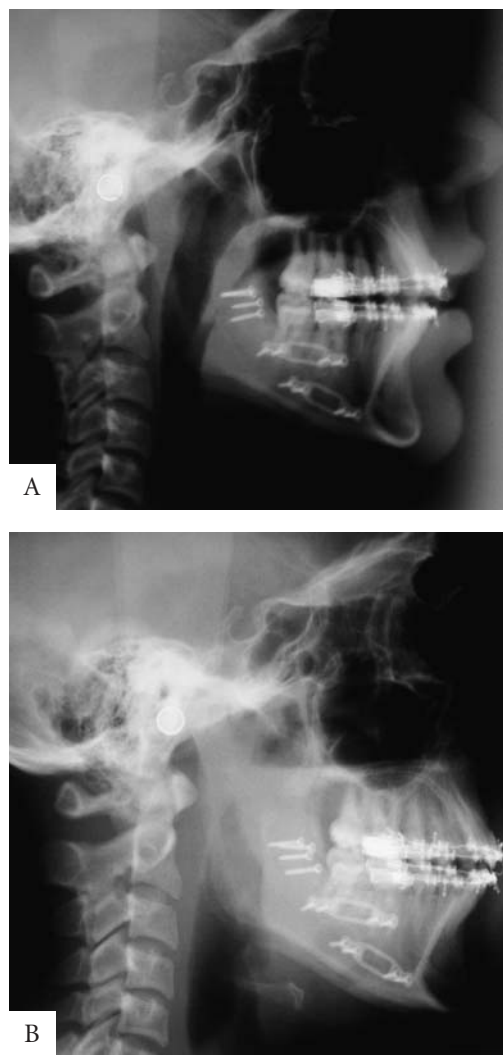


FIGURE 60-26 Open bite following a bilateral sagittal split. A, At 24 hours. B, After 1 week.

release of IMF.^{90,91} Suggestions to prevent this problem from occurring include removing the coronoid process, placing skeletal wires, or using modified cuts of the ramus and 8 weeks of IMF.⁹¹ Postoperative elastics have been used for 2 to 6 weeks when open bites have been noted.

Miscellaneous Occurrences

Endotracheal tubes have occasionally been cut during maxillary surgery. In some instances patients needed to be reintubated; in others packing around the endotracheal tube is sufficient.

Alar rim injuries are due to pressure on the rim from the nasotracheal tube. Care should be taken when wrapping the

head so that there is no pressure on the tip of the nose or the forehead or ears.

Emphysema in the cervical and facial regions has been noted after a variety of procedures that are unrelated to orthognathic surgery. However, there are several reports of air in the soft tissues of the head, neck, and chest following Le Fort I osteotomies.⁹² Subcutaneous emphysema of the cheeks is probably due to forceful blowing of the nose, which allows air into the surrounding tissues through the maxillary sinus. Forceful coughing can allow air to pass into the retropharyngeal space and into the mediastinum. Alternatively, rupture of a perivascular bleb or traumatic introduction of air through the cervical fascia is possible. Subcutaneous emphysema can be managed by observation, heat, and antibiotics. Therapy for pneumo-mediastinum consists of close observation, cardiac monitoring, intravenous fluids, and antibiotics. Chest tubes or drainage of the mediastinum may be necessary. Supplemental oxygen as well as pulmonary physiotherapy should be used.

Epiphora

Epiphora may be seen following a maxillary osteotomy and is frequently due to swelling of the nasal mucosa. Alternatively, the nasolacrimal duct may be injured when a concomitant turbinectomy is performed with an osteotomy. This is especially true if the bone cut along the medial wall of the sinus is high. Such tearing is infrequent and transient. Careful dissection and osteotomies around the medial aspect of the piriform aperture may decrease the incidence of this finding. Persistent tearing that does not decrease after 3 weeks may need to be addressed by a dacryocystorhinostomy.

Auriculotemporal Syndrome

The auriculotemporal syndrome, gustatory sweating, or Frey's syndrome is an unusual complication mainly of parotid surgery. After an injury to the auriculotemporal

nerve, the symptoms are believed to be caused by a misdirected regeneration of parasympathetic fibers to denervated sweat glands. A number of authors have reported it occurring after extraoral vertical ramus osteotomies and bilateral sagittal split osteotomies.⁹³⁻⁹⁶ Patients' symptoms occurred 3 months to 3 years after surgery.

Mild cases in which the patient may only have symptoms with spicy foods should be observed, because the symptoms may decrease with time. A variety of treatments have been suggested for more severe symptoms, including topical scopolamine and insertion of fascia lata or acellular human dermis matrix under the skin.⁹⁷ Topical scopolamine has a series of undesirable side effects. Recently there have been reports of the use of botulinum toxin as a successful treatment for this problem.^{98,99}

Facial Scars

Although attempts are made to camouflage extraoral site incisions, unattractive facial scarring occasionally occurs. Egyedi and colleagues noted 6 undesirable scars in a group of 100 patients with extraoral incisions.¹⁰⁰ The criteria they used to determine what was attractive or unattractive are unknown. Percutaneous incisions of 2 to 4 mm seldom leave significant scars. More problematic is when the skin sticks to the underlying muscles. Scar revisions are usually able to improve on an existing scar. Intraoral management with the right instruments may obviate the need for most skin incisions.

Salivary Injuries

Injuries to the parotid gland can occur with extraoral procedures. Painless swelling, parotid sialoceles, and fistulas have been seen in the first week after surgery.¹⁰¹ The treatment of sialoceles or salivary fistulas may include antisialogogues, pressure dressings, and aspiration from a nondependent point. Sialography is not recommended in the acute phases of these injuries, because it may

create a fistula or increase its size. Resolution of a sialocele should be seen within 1 month with nonsurgical therapies. Failure of these more conservative therapies may be followed by more extensive surgical procedures.

References

- Panula K, Finne K, Oikarinen K. Incidence of complications and problems related to orthognathic surgery: a review of 655 patients. *J Oral Maxillofac Surg* 2001; 59:1128–36.
- Bradley JP, Elahi M, Kawamoto HK. Delayed presentation of pseudoaneurysm after Le Fort I osteotomy. *J Craniofac Surg* 2002; 13:746–50.
- Lanigan DT, West RA. Management of postoperative hemorrhage following the Le Fort I maxillary osteotomy. *J Oral Maxillofac Surg* 1984;42:367–75.
- Lanigan DT, Hey JH, West RA. Major vascular complications of orthognathic surgery: hemorrhage associated with Le Fort I osteotomies. *J Oral Maxillofac Surg* 1990;48:561–73.
- Lanigan DT, Hey JH, West RA. Major vascular complications of orthognathic surgery: false aneurysms and arteriovenous fistulas following orthognathic surgery. *J Oral Maxillofac Surg* 1991;49:571–7.
- Tiner BD, Van Sickels JE, Schmitz JP. Life threatening, delayed hemorrhage after Le Fort I osteotomy requiring surgical intervention: report of two cases. *J Oral Maxillofac Surg* 1997;55:91–3.
- Lanigan DT, Hey J, West RA. Hemorrhage following mandibular osteotomies: a report of 21 cases. *J Oral Maxillofac Surg* 1991; 49:713–24.
- Giroto JA, Davidson J, Wheatly M, et al. Blindness as a complication of Le Fort osteotomies: role of atypical fracture patterns and distortion of the optic canal. *Plast Reconstr Surg* 1998;102:1409–21.
- Lanigan DT, Tubman DE. Carotid-cavernous fistula following Le Fort I osteotomy. *J Oral Maxillofac Surg* 1987;45:969–75.
- Lanigan DT, Loewy J. Postoperative computed tomography scan study of the pterygomaxillary separation during the Le Fort I osteotomy using a micro-oscillating saw. *J Oral Maxillofac Surg* 1995;53:1161–6.
- Brady SC, Courtemanche AD, Steinbok P. Carotid artery thrombosis after elective mandibular and maxillary osteotomies. *Ann Plast Surg* 1981;6:121–6.
- Turvey TA, Fonseca RJ. The anatomy of the internal maxillary artery in the pterygopalatine fossa: its relationship to maxillary surgery. *J Oral Surg* 1980;38:92–5.
- Sanni KS, Campbell RL, Rosner MJ, Goyne WB. Internal carotid artery occlusion following mandibular osteotomy. *J Oral Maxillofac Surg* 1984;42:394–9.
- Behrman SJ. Complications of sagittal osteotomy of the mandibular ramus. *J Oral Surg* 1972;30:554–61.
- Turvey TA. Intraoperative complications of sagittal osteotomy of the mandibular ramus: incidence and management. *J Oral Maxillofac Surg* 1985;43:504–9.
- Tuinzing DB, Greebe RB. Complications related to the intraoral vertical ramus osteotomy. *Int J Oral Surg* 1985;14:319–24.
- Lanigan DT, Hey JH, West RA. Aseptic necrosis following maxillary osteotomies: report of 36 cases. *J Oral Maxillofac Surg* 1990; 48:142–56.
- Lanigan DT, West RA. Aseptic necrosis of the mandible: report of two cases. *J Oral Maxillofac Surg* 1990;48:296–300.
- Grammer FC, Meyer MW, Richter KJ. A radioisotope study of the vascular response to sagittal split osteotomy of the mandibular ramus. *J Oral Surg* 1974;32:578–82.
- Epker BN. Modifications in the sagittal osteotomy of the mandible. *J Oral Surg* 1977;35:157–9.
- Hall HD, Chase DC, Payor LG. Evaluation and refinement of the intraoral vertical subcondylar osteotomy. *J Oral Surg* 1975;33:333–41.
- Hall HD, McKenna SJ. Further refinement and evaluation of the intraoral vertical subcondylar osteotomy. *J Oral Maxillofac Surg* 1987;45:684–8.
- Van Sickels JE. A comparative study of bicortical screws and suspension versus bicortical screws in large mandibular advancements. *J Oral Maxillofac Surg* 1991;49:1293–8.
- Dorfman HS, Turvey TA. Alterations in osseous crestal height following interdental osteotomies. *Oral Surg Oral Med Oral Pathol* 1979;48:120–5.
- Wolford LM, Rieche-Fischel O, Mehara P. Soft tissue healing after parasagittal palatal incisions in segmental maxillary surgery: a review of 311 patients. *J Oral Maxillofac Surg* 2002;60:20–5.
- Turvey TA. Management of the nasal apparatus in maxillary surgery. *J Oral Surg* 1980; 38:331–5.
- Dodson TB, Bays RA, Neuenschwander MC. Maxillary perfusion during Le Fort I osteotomy after ligation of the descending palatine artery. *J Oral Maxillofac Surg* 1997;55:51–5.
- Epker BN. Vascular considerations in orthognathic surgery. II Maxillary osteotomies. *Oral Surg Oral Med Oral Pathol* 1984;57:473–8.
- Teerijoki-Oksa T, Jaaskelainen SK, Forssell H, et al. Risk factors of nerve injury during a mandibular sagittal split osteotomy. *Int J Oral Maxillofac Surg* 2002; 31:33–9.
- Ziccardi VB, Assael LA. Mechanism of trigeminal nerve injuries. *Atlas Oral Maxillofac Surg Clin North Am* 2001;9:1–11.
- Van Sickels JE, Hatch JP, Dolce C, et al. Effects of age, amount of advancement, and genioplasty on neurosensory disturbance after a bilateral sagittal split osteotomy. *J Oral Maxillofac Surg* 2002;60:1012–7.
- Gianni AB, D'Orto O, Biglioli F, et al. Neurosensory alterations of the inferior alveolar and mental nerve after genioplasty alone or associated with sagittal osteotomy of the mandibular ramus. *J Craniomaxillofac Surg* 2002;30:295–303.
- Jones DL, Wolford LM. Intraoperative recording of trigeminal evoked potential during orthognathic surgery. *Int J Adult Orthodon Orthognath Surg* 1990;5:163–74.
- Rajchel J, Ellis E III, Fonseca RJ. The anatomic location of the mandibular canal: its relationship to the sagittal ramus osteotomy. *Int J Adult Orthodon Orthognath Surg* 1986;1:37–47.
- Schendel SA, Epker BN. Results after mandibular advancement surgery: an analysis of 87 cases. *J Oral Surg* 1980;38:265–82.
- Jacks SC, Zuniga JR, Turvey TA, Schalit C. A retrospective analysis of lingual nerve sensory changes after mandibular bilateral sagittal split. *J Oral Maxillofac Surg* 1998;56:700–4.
- Miloro M, Halkias LE, Slone HW, Chakeres DW. Assessment of the lingual nerve in the third molar region using magnetic resonance imaging. *J Oral Maxillofac Surg* 1997;55:134–7.
- Karas ND, Boyd SB, Sinn DP. Recovery of neurosensory function following orthognathic surgery. *J Oral Maxillofac Surg* 1990; 48:124–34.
- Westermarck A, Bystedt H, von Konow L. Inferior alveolar nerve function after mandibular osteotomies. *Br J Oral Maxillofac Surg* 1998;36:425–8.
- Troulis MJ, Kaban LB. Endoscopic approach to the ramus/condyle unit: clinical applications. *J Oral Maxillofac Surg* 2001;59:503–9.
- Sakashita H, Miiyata M, Miyamoto H, Miyaji Y. Peripheral facial palsy after sagittal split ramus osteotomy for setback of the mandible. A case report. *Int J Oral Maxillofac Surg* 1996;25:182–3.

42. Piecuch JF, Lewis RA. Facial nerve injury as a complication of sagittal split ramus osteotomy. *J Oral Maxillofac Surg* 1982;40:309–10.
43. de Vries K, Devriese PP, Hovinga J, van den Akker HP. Facial palsy after sagittal split osteotomies. A survey of 1747 sagittal split osteotomies. *J Craniomaxillofac Surg* 1993;21:50–3.
44. Motamedi MH. Transient temporal nerve palsy after intraoral subcondylar ramus osteotomy. *J Oral Maxillofac Surg* 1997;55:527–8.
45. Hunsuck EE. A modified intraoral sagittal splitting technique for correction of mandibular prognathism. *J Oral Maxillofac Surg* 1968;26:250–3.
46. Chow LC, Tam RC, Li MF. Use of electroneurography as a prognostic indicator of Bell's palsy in Chinese patients. *Otol Neurotol* 2002;23:598–601.
47. Gutmann L. Pearls and pitfalls in the use of electromyography and nerve conduction studies. *Semin Neurol* 2003;23:77–82.
48. May M, Klein SR, Blumenthal F. Evoked electromyography and idiopathic facial paralysis. *Otolaryngol Head Neck Surg* 1983;91:678–85.
49. O'Ryan F, Schendel S. Nasal anatomy and maxillary surgery. I. Esthetic and anatomic principles. *Int J Adult Orthodon Orthognath Surg* 1989;4:27–37.
50. O'Ryan F, Schendel S. Nasal anatomy and maxillary surgery. II. Unfavorable nasolabial esthetics following Le Fort I osteotomy. *Int J Adult Orthodon Orthognath Surg* 1989;4:75–84.
51. O'Ryan F, Carlotti A. Nasal anatomy and maxillary surgery. III. Surgical techniques for correction of nasal deformities in patients undergoing maxillary surgery. *Int J Adult Orthodon Orthognath Surg* 1989;4:157–74.
52. Warren DW, Hershey HG, Turvey TA, et al. The nasal airway following maxillary expansion. *Am J Orthod Dentofac Orthoped* 1987;91:111–6.
53. Walker DA, Turvey TA, Warren DW. Alterations in nasal respiration and nasal airway size following superior repositioning of the maxilla. *J Oral Maxillofac Surg* 1988;46:276–81.
54. Erbe M, Lehotay M, Gode U, et al. Nasal airway changes after Le Fort I impaction and advancement: anatomical and functional findings. *Int J Oral Maxillofac Surg* 2001;30:123–9.
55. Kunkel M, Hochban W. The influence of maxillary osteotomy on nasal airway patency and geometry. *Mund Kiefer Gesichtschir* 1997;1:194–8.
56. Gotzfried HF, Masing H. Improvement of nasal breathing in cleft patients following mid-face osteotomy. *Int J Oral Maxillofac Surg* 1988;17:41–4.
57. Bell CS, Thrash WJ, Zysset MK. Incidence of maxillary sinusitis following Le Fort I maxillary osteotomy. *J Oral Maxillofac Surg* 1986;44:100–3.
58. Kahnberg KE, Engstrom H. Recovery of maxillary sinus and tooth sensibility after Le Fort I osteotomy. *Br J Oral Maxillofac Surg* 1987;25:68–73.
59. Mehra P, Castro V, Freitas RZ, Wolford LM. Complications of the mandibular sagittal ramus osteotomy associated with the presence or absence of third molars. *J Oral Maxillofac Surg* 2001;59:854–8.
60. Precious DS, Lung KE, Pynn BR, Goodday RH. Presence of impacted teeth as a determining factor of unfavorable splits in 1256 sagittal split osteotomies. *Oral Surg Oral Med Oral Pathol Oral Radiol Endod* 1998;85:362–5.
61. Hatch JP, Van Sickels JE, Rugh JD, et al. Mandibular range of motion after bilateral sagittal split ramus osteotomy with wire osteosynthesis or rigid fixation. *Oral Surg Oral Med Oral Pathol Oral Radiol Endod* 2001;91:274–80.
62. Ellis E III. Condylar positioning devices for orthognathic surgery. Are they necessary? *J Oral Maxillofac Surg* 1994;52:536–52.
63. Helm G, Stepke MT. Maintenance of the preoperative condyle position in orthognathic surgery. *J Craniomaxillofac Surg* 1997;25:34–8.
64. Merten HA, Halling F. A new condylar positioning technique in orthognathic surgery. Technical note. *J Craniomaxillofac Surg* 1992;20:310–2.
65. Harris MD, Van Sickels JE, Alder M. Factors influencing condylar position after the bilateral sagittal split osteotomy fixed with bicortical screws. *J Oral Maxillofac Surg* 1999;57:650–4.
66. Ellis E III. Mobility of the mandible following mandibular advancement and maxillo-mandibular or rigid internal fixation: an experimental investigation in *Macaca mulatta*. *J Oral Maxillofac Surg* 1988;46:118–23.
67. Feinerman DM, Piecuch JF. Long-term effects of orthognathic surgery on the temporomandibular joint: comparison of rigid and non-rigid fixation methods. *Int J Oral Maxillofac Surg* 1995;24:268–72.
68. Van Sickels JE, Tiner BD, Alder ME. Condylar torque as a possible cause of hypomobility after sagittal split osteotomy. Report of three cases. *J Oral Maxillofac Surg* 1997;55:398–402.
69. De Boever AL, Keeling SD, Hilsenbeck S, et al. Signs of temporomandibular disorders in patients with horizontal mandibular deficiency. *J Orofac Pain* 1996;10:21–7.
70. Rodrigues-Garcia RC, Sakai S, Rugh JD, et al. Effects of major class II occlusal correction on temporomandibular signs and symptoms. *J Orofac Pain* 1998;12:185–92.
71. Panula K, Somppi M, Finne K, Oikarinen K. Effects of orthognathic surgery on temporomandibular joint dysfunction. A controlled prospective 4 year follow-up study. *Int J Oral Maxillofac Surg* 2000;29:183–7.
72. Cutbirth M, Van Sickels JE, Thrash WJ. Condylar resorption after bicortical screw fixation of mandibular advancement. *J Oral Maxillofac Surg* 1998;56:178–82.
73. Hwang SJ, Haers PE, Zimmermann A, et al. Surgical risk factors for condylar resorption after orthognathic surgery. *Oral Surg Oral Med Oral Pathol Endod* 2000;89:542–52.
74. Scheerlinck JP, Stoeltinga PJ, Blijdorp PA, et al. Sagittal split advancement osteotomies stabilized with miniplates. A 2–5 year follow-up. *Int J Oral Maxillofac Surg* 1994;23:127–31.
75. Hoppenreijts TJ, Freihofer HP, Stoeltinga PJ, et al. Condylar remodeling and resorption after Le Fort I and bimaxillary osteotomies in patients with anterior open bite. A clinical and radiological study. *Int J Oral Maxillofac Surg* 1998;27:81–91.
76. Hoppenreijts TJ, Stoeltinga PJ, Grace KL, Robben CM. Long-term evaluation of patients with progressive condylar resorption following orthognathic surgery. *Int J Oral Maxillofac Surg* 1999;28:411–8.
77. Arnett GW, Milam SB, Gottesman L. Progressive mandibular retrusion-idiopathic condylar resorption. Part II. *Am J Orthod Dentofac Orthop* 1996;110:117–27.
78. Nishioka GJ, Van Sickels JE. Modified external reference measurement technique for vertical positioning of the maxilla. *Oral Surg Oral Med Oral Pathol* 1987;64:22–3.
79. Jacobson R, Sarver DM. The predictability of maxillary repositioning in Le Fort I orthognathic surgery. *Am J Orthod Dentofac Orthop* 2002;122:142–54.
80. Profitt WR, Turvey TA, Phillips C. Orthognathic surgery: a hierarchy of stability. *Int J Adult Orthodon Orthognath Surg* 1996;11:191–204.
81. Burford D, Noar JH. The causes, diagnosis and treatment of anterior open bite. *Dent Update* 2003;30:235–41.
82. Beane RA. Nonsurgical management of the anterior open bite: a review of options. *Semin Orthod* 1999;5:275–83.
83. Dolce C, Van Sickels JE, Bays RA, Rugh JD. Skeletal stability after mandibular advancement with rigid versus wire fixation. *J Oral Maxillofac Surg* 2000;58:1219–8.
84. Dolce C, Hatch JP, Van Sickels JE, Rugh JD.

- Rigid versus wire fixation for mandibular advancement skeletal and dental changes after 5 years. *Am J Orthod Dentofac Orthop* 2002;121:638–49.
85. Blomqvist JE, Ahlborg G, Isaksson S, Svartz K. A comparison of skeletal stability after mandibular advancement and use of two rigid internal fixation techniques. *J Oral Maxillofac Surg* 1997;55:568–74.
86. Moenning JE, Bussard DA, Lapp TH, Garrison BT. Comparison of relapse in bilateral sagittal split osteotomies for mandibular advancement: rigid internal fixation (screws) versus inferior border wires with anterior skeletal fixation. *Int J Adult Orthodon Orthognath Surg* 1990;5:175–82.
87. Proffit WR, Phillips C, Turvey TA. Stability after surgical-orthodontic corrective of skeletal Class III malocclusion. 3. Combined maxillary and mandibular procedures. *Int J Adult Orthodon Orthognath Surg* 1991;6:211–25.
88. Franco JE, Van Sickels JE, Thrash WJ. Factors contributing to relapse in rigidly fixed mandibular setbacks. *J Oral Maxillofac Surg* 1989;47:451–6.
89. Costa F, Robiony M, Sembronio S, et al. Stability of skeletal Class III malocclusion after combined maxillary and mandibular procedures. *Int J Adult Orthodon Orthognath Surg* 2001;16:179–92.
90. Proffit WR, Phillips C, Dann C IV, Turvey TA. Stability after surgical orthodontic correction of skeletal Class III malocclusion. I. Mandibular setback. *Int J Adult Orthodon Orthognath Surg* 1991;6:7–18.
91. Tornes K, Wisth PJ. Stability after vertical subcondylar ramus osteotomy for correction of mandibular prognathism. *Int J Oral Maxillofac Surg* 1988;17:242–8.
92. Nannini V, Sachs SA. Mediastinal emphysema following Le Fort I osteotomy: report of a case. *Oral Surg Oral Med Oral Pathol* 1986;62:508–9.
93. Berrios RJ, Quinn PD. Frey's syndrome: a complication after orthognathic surgery. *Int J Adult Orthodon Orthogn Surg* 1986;1:219–24.
94. Kopp WK. Auriculotemporal syndrome secondary to vertical sliding osteotomy of the mandibular rami: report of a case. *J Oral Surg* 1968;26:295–6.
95. Tuinzing DB, van der Kwast WA. Frey's syndrome. A complication after sagittal splitting of the mandible. *Int J Oral Surg* 1982;11:197–200.
96. Guerrissi J, Stoyannoff J. Atypical Frey syndrome as a complication of Obwegeser osteotomy. *J Craniofac Surg* 1998;9:543–7.
97. Sinha UK, Saddat D, Doherty CM, Rice DH. Use of AlloDerm implant to prevent Frey syndrome after parotidectomy. *Arch Facial Plast Surg* 2003;5:109–12.
98. Eckardt A, Kuettner C. Treatment of gustatory sweating (Frey's syndrome) with botulinum toxin A. *Head Neck* 2003;25:624–8.
99. Restivo DA, Lanza S, Patti F, et al. Improvement of diabetic autonomic gustatory sweating by botulinum toxin type A. *Neurology* 2002;59:1971–3.
100. Egyedi P, Houwing M, Juten E. The oblique subcondylar osteotomy: report of results of 100 cases. *J Oral Surg* 1981;39:871–3.
101. Dierks EJ, Granite EL. Parotid sialocele and fistula after mandibular osteotomy. *J Oral Surg* 1977;35:299–300.

Orthognathic Surgery in the Patient with Cleft Palate

Timothy A. Turvey, DDS

Ramon L. Ruiz, DMD, MD

Katherine W. L. Vig, BDS, MS, D Orth

Bernard J. Costello, DMD, MD

The estimated incidence of orofacial clefts involving the lip and palate in the United States is approximately 1 to 2 per 1,000 births or approximately 1 in 700 live births.¹ The average cost of rehabilitation of a child born with an oral cleft is estimated at approximately \$100,000 (US). The occurrence rate of infants born with a cleft lip and/or palate is influenced by race and gender, and the cost varies by the number of procedures and interventions performed.

Care for an infant born with an orofacial cleft begins with primary surgical repair of the lip followed by the palate and continues in defined and appropriate stages to late adolescence, at which point public funding is usually discontinued. The burden of care assumed by the patient and family in the indirect costs of time off from work/school and transportation by the caregiver is not to be underestimated, and it is often inadequately equated with the financial or direct costs of treatment.

The interdisciplinary approach to the management of patients with a cleft lip and/or palate and other craniofacial anomalies requires careful coordination and communication; a cleft palate team establishes a patient-centered approach

that follows critical pathways.²⁻⁵ The timing and sequencing of care is critical because of the interaction of facial growth with the development of the dentition. Clefts of the maxilla, especially the unilateral cleft lip and palate, are associated with a skeletal maxillary deficiency in the transverse, anteroposterior, and vertical dimensions. The dysmorphology in all three dimensions has been attributed to scar tissue following the primary repair of the lip during the first 6 months of life and the palatal repair, which is performed typically at 12 to 18 months. Clefts of the maxilla, both unilateral and bilateral, have been considered to have an intrinsic growth deficiency of skeletal, soft tissue, and dental components. However, in those children who have unrepaired clefts early in childhood, relatively normal occlusal relationships are established compared with those relationships in children who are surgically repaired in the first 2 years of life. This latter group is characterized by anterior and posterior dental crossbites, midface sagittal deficiency, and associated vertical overclosure.⁶ Because the cleft involves the dentoalveolus and occurs owing to the lack of fusion of the primary

palate during embryogenesis, the dental lamina may also be involved, with consequences of extra teeth such as supernumerary teeth, malformed and misplaced teeth, or an absence of teeth in the cleft site. Normal biologic variation is the result of phenotypic variation, which allows one individual to be distinguished from another by facial appearance. Therefore, dental malocclusions may occur on all skeletal patterns, but in the population with a cleft lip and palate, the pathogenesis of clefting is superimposed on the individuals' inherited facial pattern. Additionally, facial clefts are associated with over 300 syndromic conditions,^{7,8} so a patient may have syndromic or nonsyndromic facial cleft; this distinction and diagnosis is confirmed by the geneticist on the team.

Asymmetry is a typical facial characteristic and is one of the stigmas associated with unilateral orofacial clefts. Cleft patients typically express concerns about their facial appearance, but they also have problems with communication because their speech is affected. This is partially because the velopharyngeal mechanism is inadequate to close off the oropharynx from the nasopharynx,

resulting in hypernasality and a lack of intelligibility of the phonetic components.

The severity of the skeletal aspect of the malocclusion and facial asymmetry determines the surgical/orthodontic approach. Mild discrepancies may be camouflaged by the orthodontic dentoalveolar compensation. However, during adolescence the compensation for the skeletal discrepancy may be outgrown; orthognathic surgery is the treatment of choice for patients in their late teens. Because growth prediction is not an exact science, an anterior crossbite corrected in the mixed dentition frequently reestablishes following the pubertal growth spurt and adolescent growth.

The purpose of this chapter is to discuss the surgical and orthodontic correction of the cleft in dysmorphic faces. The focus is on patients with cleft lip and palate who would benefit from bone grafts in the early mixed dentition, and maxillary advancement with contour bone grafting in adolescence when growth of the nasomaxillary complex has stabilized. The successful correction of these secondary skeletal deformities frequently requires treatment protocols that include orthognathic surgery in conjunction with the final phase of orthodontic treatment. Patients with a cleft lip and palate benefit from staged and coordinated procedures to achieve optimal results. These include bone-graft construction of the cleft maxilla and palate in the mixed dentition phase of development, and orthognathic surgery to correct the midface deficiency in adolescence. These procedures are designed to be only stages in the process of reconstruction and rehabilitation.

Timing and Sequencing of Bone Grafting the Cleft Maxilla and Palate

An understanding of craniofacial growth and development is critical in timing both surgical and orthodontic interventions. In bone grafting, dental development is more

important than is the chronologic age of the patient. The decision for determining orthodontic expansion to detect the dental crossbite, as a presurgical phase of orthodontics, depends on the root development of the unerupted canine. If the lateral incisor is developing on the posterior side of the cleft, a bone graft needs to be performed early to allow eruption to the cleft site. Seminal papers defined the age for secondary alveolar bone grafting, which is now a well-accepted procedure after primary lip and palate repair.^{9,10} They divided the timing into early, 2 to 5 years of age; intermediate, 6 to 15 years of age; and late, 16 years to adult. A retrospective interdisciplinary study reported the outcome of bone grafts to the cleft maxilla relative to radiographic and periodontal parameters; as well, it stated that the closure of fistulas and the eruption of the canine through the bone-graft site suggested high success in age-appropriate patients.¹¹ A longitudinal retrospective study provided evidence for the timing and sequencing of the surgical and orthodontic treatment, using cancellous bone harvested from the iliac crest and the stage of development of the unerupted canine, typically between 9 and 11 years of age.¹² Contemporary opinion considers this intermediate time frame to have the greatest benefits and the least risk in compromising midface skeletal and dental growth and development.

Benefits of bone grafting include the following:

- Bone is provided into which the unerupted teeth adjacent to the cleft may erupt or be moved orthodontically. The timing and sequencing of the bone graft is determined by the position of the teeth adjacent to the cleft, their root development, and their stage of eruption, rather than the chronologic age of the patient.
- Supernumerary or malformed teeth may be removed at the time of the surgical placement of the bone graft

into the cleft site. Patent oronasal fistulas either in the palate or the nasolabial vestibule are closed. Fistula closure is achieved by using a three-layered closure technique with the grafted bone sandwiched between the two soft tissue planes.

- The grafted bone provides support and elevation of the alar base in the defect and improves nasal and lip symmetry.
- Because there is continuity of the maxilla, the restorative dentist has the opportunity to provide a more esthetic and hygienic prosthetic replacement, even if teeth are missing. The placement of implants into bone grafts is successful and is a contemporary alternative to a bridge or removable appliance.
- In repaired bilateral clefts of the lip and palate, the placement of bone grafts bilaterally in the cleft sites stabilizes the premaxilla while providing bone into which the adjacent unerupted teeth may erupt.

Through efforts to determine the optimal timing of treatment, several controversies have arisen related to the age of the patient, the type of bone graft, the site from which the graft is harvested, and the optimal timing of orthodontic expansion of the maxilla in relation to the surgical placement of the bone graft.¹²

The surgical technique for bone grafting the cleft maxilla and palate involves a three-layered closure with autogenous cancellous bone graft sandwiched between the nasal floor and the oral mucosa. An incision is made around the cleft to preserve the fixed gingiva to circumscribe the fistula (Figure 61-1). The tissue is then elevated from the bone on both sides of the cleft in the subperiosteal plane to the level of the anterior nasal spine and the lateral piriform rim. The tissue is elevated, inverted, and sutured to form a reconstructed nasal floor (Figure 61-2). Fresh cancellous

bone is then condensed in the cleft defect and over the hypoplastic bone edges of the cleft (Figure 61-3). Oral tissue is either rotated or advanced to close over the bone grafts (Figures 61-4–61-6).

Timing of Midface Advancement Surgery in Adolescents

Biologic and psychosocial concerns govern the decision for the timing of surgical maxillary advancement. It is always prudent to delay surgery of the nasomaxillary complex until growth has stabilized and the peak velocity of somatic growth has passed. This improves the predictability and long-term stability of treatment and reduces the risk that surgical-orthodontic correction will be outgrown. The optimal time for surgical correction of the skeletal discrepancy is when the patient is physically and psychologically prepared. Patients need to appreciate the relevance of facial growth and development and the consequences if surgical correction is

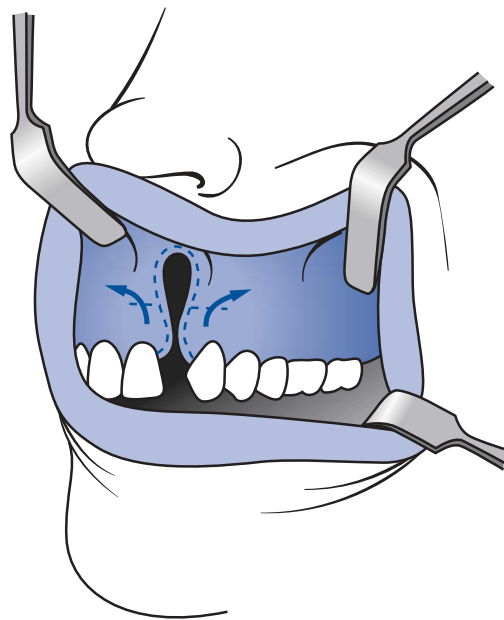


FIGURE 61-1 Outline of the incision to prepare the cleft site for bone grafting. The fixed gingival tissues are preserved and sutured back. Adapted from Turvey TA, Vig KWL, Fonseca RJ. *Surgical management*. In: *Facial clefts and craniosynostosis: principles and management*. Philadelphia (PA): W.B. Saunders Company; 1996. p. 412.

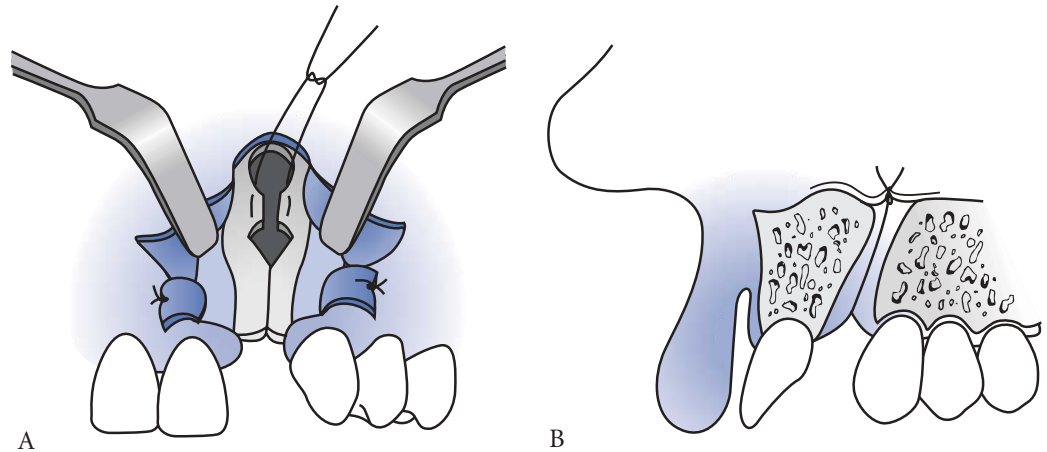


FIGURE 61-2 A, The tissues lining the cleft are elevated to the nasal cavity to construct a floor. B, Closure of the nasal lining is accomplished with a horizontal mattress suture to evert the edges toward the nasal side. Adapted from Turvey TA, Vig KWL, Fonseca RJ. *Surgical management*. In: *Facial clefts and craniosynostosis: principles and management*. Philadelphia (PA): W.B. Saunders Company; 1996. p. 413.

undertaken prior to maturation. Another biologic consideration regarding the timing of surgery is the eruption of the permanent dentition. Delaying surgery until the canine and second molars have erupted minimizes the risk of endodontic requirements and displacement of the second molars. Third molars can usually be removed at the time of maxillary surgery, and their presence should not be a major concern. Patients, parents, and treating doctors participate in the decision regarding when to proceed with surgery; the approach should be patient centered and evidence based with regard to the risks, costs, and benefits. Patient autonomy in the decision should be given the highest priority in orthognathic surgery. This requires that patients be in late adolescence to understand the consequences of the decision and be able to rationalize the expectations for the outcome.

Adolescents are under enormous pressures to conform to their peers. At no other time in life is an individual exposed to concerns about their self-image and physical attractiveness with such additional pressure of peer criticism of appearance differences. Many adolescent patients with clefts are subjected to ridicule about their facial appearance, and

this is accompanied by low self-esteem and impaired socialization. Social withdrawal is another issue resulting from the pressures felt by adolescents, especially those with facial disfigurement. Although counseling can help, the patient must still

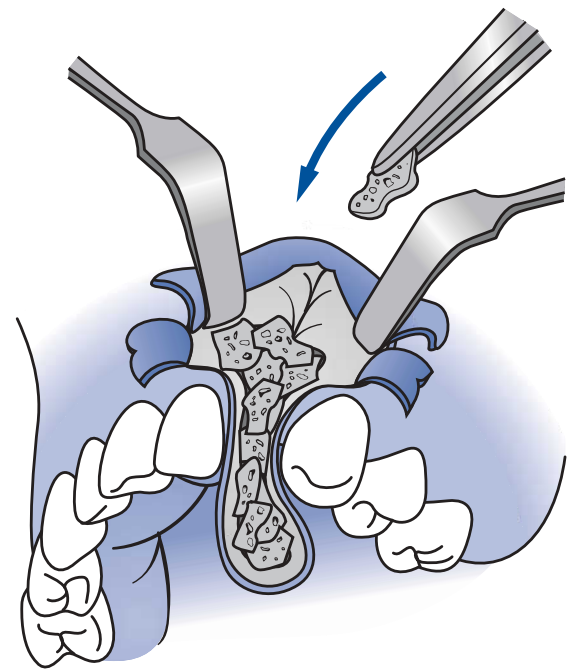


FIGURE 61-3 Cancellous bone particles packed into the defect must extend from the nasal rim to the alveolar crest. Adapted from Turvey TA, Vig KWL, Fonseca RJ. *Surgical management*. In: *Facial clefts and craniosynostosis: principles and management*. Philadelphia: W.B. Saunders Company; 1996. p. 415.

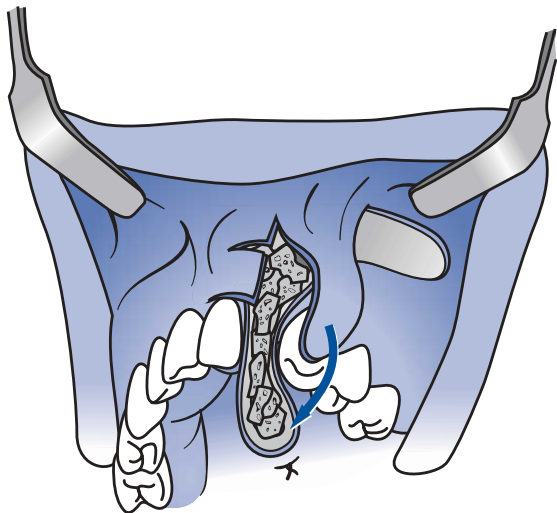


FIGURE 61-4 A buccal mucosal flap is elevated, maintaining a wide and thick anterior base. The flap is then rotated to cover the defect. Adapted from Turvey TA, Vig KWL, Fonseca RJ. *Surgical management*. In: *Facial clefts and craniosynostosis: principles and management*. Philadelphia (PA): W.B. Saunders Company; 1996. p. 417.

cope with the disfigurement; however, this may be improved with surgery.

Improving facial appearance by addressing the skeletal disproportion often

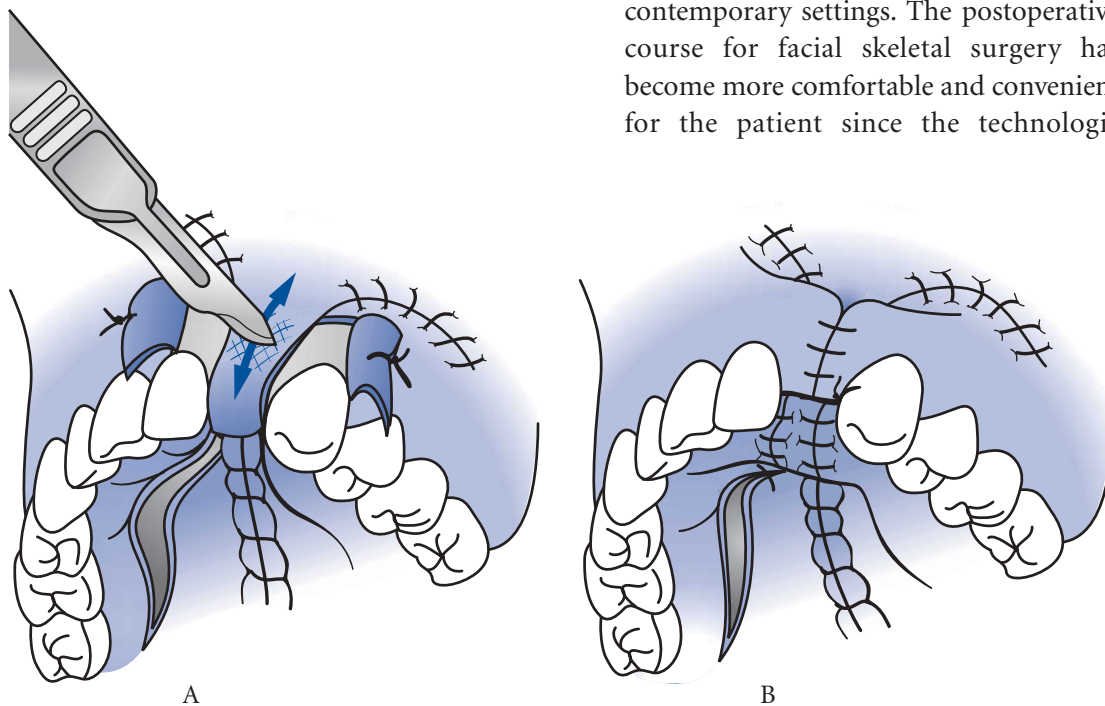


FIGURE 61-5 A, The rotated flap is de-epithelialized in the areas where the fixed flaps will lie. B, The fixed gingiva is then secured to the flap and around the margins of the teeth. Adapted from Turvey TA, Vig KWL, Fonseca RJ. *Surgical management*. In: *Facial clefts and craniosynostosis: principles and management*. Philadelphia (PA): W.B. Saunders Company; 1996. p. 417.

results in dramatic and complementary changes. Patients typically perceive these changes positively—the changes send a clear message that someone cares about them and is sensitive to their concerns. An improvement in self-concept and image in patients with a cleft lip and/or palate usually follows surgical correction of the mid-face deficiency and skeletal disproportion. Patients' perception of their quality of life is an important consideration and should not be overlooked in the timing of surgery. However, care should be taken in the psychosocial assessment to identify unrealistic expectations and to recognize those patients who use the stigmas as an excuse for dependency. Identification of these individuals prior to surgery is not easy; interdisciplinary management should include the involvement of a psychologist on the cleft palate team.

The decision to proceed with surgery prior to maturation may result in additional surgery being needed once growth is complete. This need is tempered by the reduced morbidity of repeat surgeries in contemporary settings. The postoperative course for facial skeletal surgery has become more comfortable and convenient for the patient since the technologic

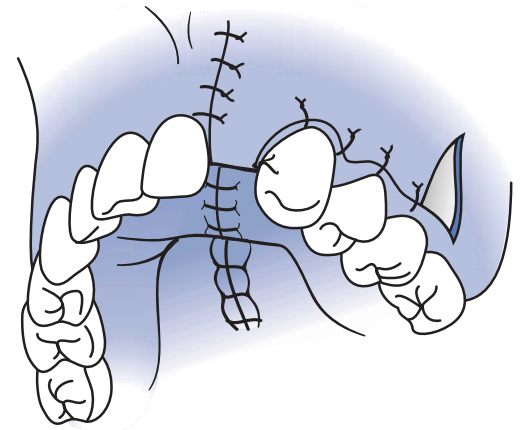


FIGURE 61-6 A sliding buccal gingival flap is elevated from around the teeth and advanced forward, leaving the posterior defect to granulate. Adapted from Turvey TA, Vig KWL, Fonseca RJ. *Surgical management*. In: *Facial clefts and craniosynostosis: principles and management*. Philadelphia (PA): W.B. Saunders Company; 1996. p. 419.

advancements of bone plates and screws have essentially replaced the need for intermaxillary fixation. The contemporary use of steroids and antibiotics has controlled swelling and infection, and alternatives to homologous blood transfusion (autologous blood banking and the use of recombinant erythropoietin) are effectively employed. Impatient surgeons or orthodontists should not rationalize early skeletal surgery prior to maturation for their own convenience. Final decisions regarding the timing of surgery should recognize the wishes of patients and parents, and the orthodontists and surgeons should provide the information needed to make an informed decision.

Presurgical Counseling

Patients born with a congenital facial malformation are psychologically different from those patients with acquired dentofacial deformities, who tend to be more prone to neuroticism.¹³ Patients with a cleft have had their problem since birth and have adapted to multiple changes from their previous surgical procedures. Many patients with orofacial clefts have experienced the disappointment of previous

surgical soft tissue revisions that were expected to erase the scar on the lip and correct the nasal asymmetry. However, unrealistic expectations of skeletal surgery should be identified before the surgical intervention, and the patient should be referred for counseling.

Skeletal surgery does not erase the lip scar, but it does provide an opportunity to improve the skeletal support for the soft tissue drape. It can help improve the symmetry of the lip and nasal base and also support the nasal tip. Skeletal support may reduce the stigmas of midface deficiency associated with the cleft defect so that soft tissue revisions may not be needed or desired. The scar commonly falls on a flat unsupported position of the lip and becomes obvious. Often, appropriate skeletal support moves the scar to an area of greater curvature, which reflects light differently and results in a less conspicuous scar. Therefore, patients should be counseled that the skeletal surgery sets the stage for future definitive lip and nasal revisions.

Orthognathic Surgery for the Cleft Patient

In contemporary cleft team settings, most patients with clefts of the maxilla undergo bone grafting at a developmentally appropriate time in the mixed dentition stage. When midface advancement surgery is planned later in adolescence, it is a relatively straightforward procedure. For those patients who have not benefited from previous bone grafts, the situation is more complex. In both circumstances the general principles of flap design for maxillary advancement, ensuring adequate perfusion to the mobilized maxilla, are of paramount importance. A cleft maxilla differs because of the absence of tissues, and multiple surgical procedures are needed to repair and close defects. Perfusion of the mobilized maxilla is dependent on vessels coming from the overlying soft tissues, predominantly the palatal tissues. In cleft patients this tissue is commonly scarred and fibrot-

ic; therefore, care must be exercised when designing the incision to perform the osteotomy. With few exceptions, almost all patients can be treated with a Le Fort I osteotomy via the circumvestibular incision and a down-fracture approach. For those with severe palatal scarring, who have previously undergone an island palatal repair, and those with bilateral clefts of the maxilla, an anterior buccal pedicle should be left on the mobilized maxilla to maintain adequate perfusion. Technically, this is a more challenging operation.

The circumvestibular incision is made from the zygomaticomaxillary buttress to the opposite side, high in the mucobuccal fold (Figure 61-7). Subperiosteal dissection exposes the entire lateral wall of the maxilla from the nose to the pterygoid plate and from the alveolus, above the roots of the teeth, to the inferior orbital rim. The broad exposure permits excellent visualization of all osteotomies. At the time of mobilization, this incision permits the maxilla to be down-fractured and entirely pedicled to the palatal tissues and the remaining buccal tissues below the incision. Good visualization and ease of mobilization are the major advantages of this approach. Hemorrhage control is performed with direct visualization, usually by the ligation of vessels.

When an anterior buccal pedicle remains, the operation is technically more difficult (Figure 61-8). Visualization is reduced, and mobilization by down-fracturing is not possible. Mobilization of the midface is achieved by in-fracturing, combined with anterior traction. For most patients with a cleft palate, the area of greatest resistance to mobilization of the maxilla is the vertical portion of the palatine bone, located in the posteromedial aspect of the maxillary sinus. The bone is thick and access is limited, especially when down-fracturing is not possible. Compounding this is the presence of the greater palatine vessels, which descend from the sphenopalatine fossa to the pos-

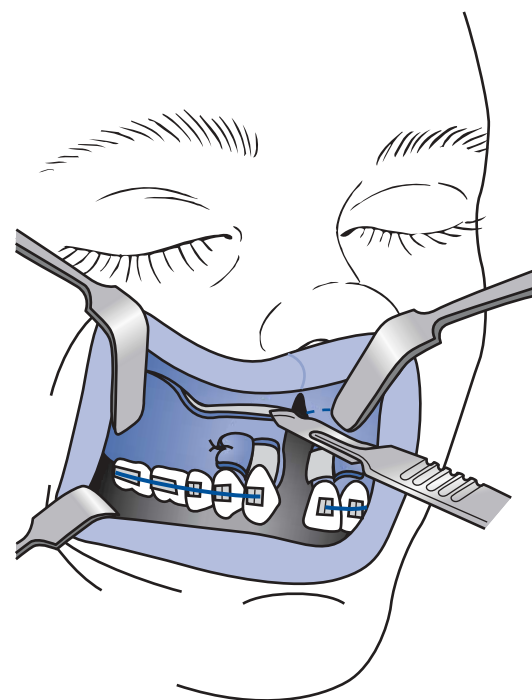


FIGURE 61-7 A circumvestibular incision is used when a Le Fort I down-fracture is performed. The incision is made high on the zygomaticomaxillary buttress to ensure adequate perfusion to the anterior maxilla. Note that the attached gingiva around the teeth on both sides of the cleft is reflected and preserved. The remaining tissue lining the cleft walls is later incised and reflected palatally or buccally, depending on where it is needed for closure (see Figure 61-11B). Adapted from Turvey TA et al.¹⁵

terior maxilla (Figure 61-9). The vessels, which run through the canal in this bone, are prone to rupture during mobilization. Hemorrhage control is limited—packing and the use of a vasoconstrictor (epinephrine 1:100,000) are usually effective.

The surgical technique employed for both of these approaches has been described in detail previously, and interested readers are referred to more detailed sources.¹⁴

Residual oronasal fistulas are common in patients whose maxillas have not been bone grafted previously. An incision design should permit simultaneous closure of oronasal fistulas. Of key importance is the construction of a nasal floor, which is created by using the tissues lining the fistulas (Figures 61-10–61-12).

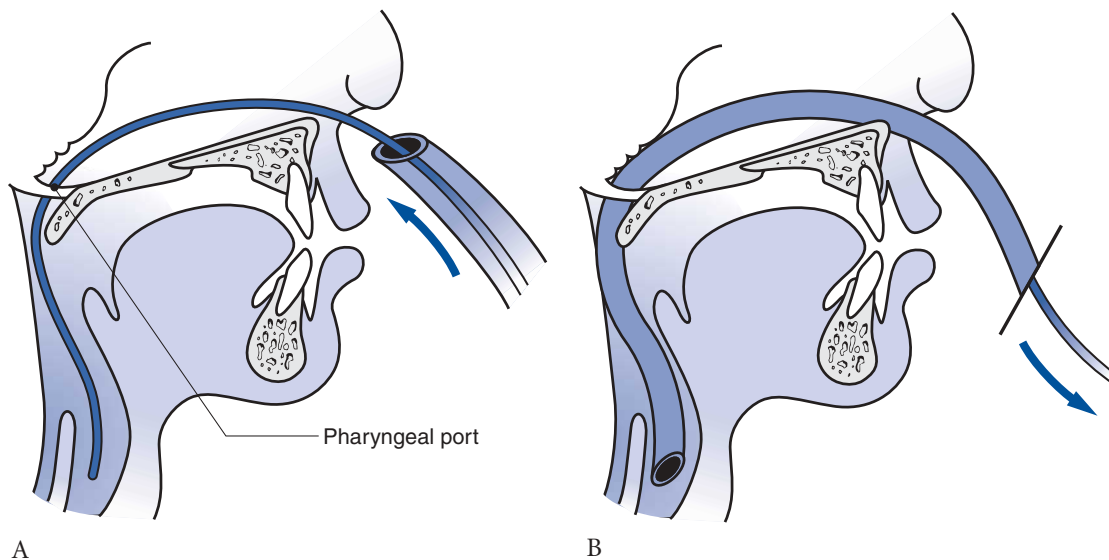


FIGURE 61-8 A and B, A catheter passed nasally through the velopharyngeal ports serves to guide the nasoendotracheal tube past the pharyngeal flap. Adapted from Turvey TA et al.¹⁵

Creativity and care are the important elements in surgery to correct midface deficiency in patients with clefts. Since the skeleton is always asymmetric in cleft patients, it is crucial that the osteotomy is designed for maximum improvement of esthetics (Figure 61-13). If an adequate

improvement cannot be obtained by an osteotomy alone, only bone grafting to enhance skeletal support and shape should be considered. Sometimes even subtle differences between osteotomy designs on the cleft side reflect positive soft tissue changes.

Adequate mobilization is a key factor for success when performing midface osteotomies in the presence of a cleft. The scarring and thickness of bone (particularly in the vertical part of the palatine bone) are two major obstacles. The posteromedial aspect of the maxillary sinus is unusually thick in cleft patients, and it must be cut or fractured to permit adequate mobilization. This is usually accomplished with a small osteotomy tapped along the lateral nasal walls (see Figure 61-9). Failure to weaken these structures prior to mobilization may result in an unfavorable fracture extending to the skull base or orbit. Blindness has been reported following Le Fort I osteotomies in cleft patients, and an inadvertent fracture in this area is the suspected cause.¹⁵ If excessive forces are required to mobilize the maxilla, repeated use of the osteotomy to further weaken the structure is advisable prior to beginning mobilization.

It is often tempting to segment the maxilla of patients with a cleft to improve

occlusal relationships. However, segmenting the maxilla in this population should be undertaken with caution, considering the compromised vascularity and scarring of the tissues. Accepting posterior cross-bites and other occlusal compromises may be judicious, rather than risking necrosis of a segmental osteotomy. A contemporary goal of cleft care is to eliminate and/or reduce the need for prosthetic management. Closing dental spaces with segmental osteotomies is an effective way to achieve this goal. Additionally, this maneuver results in more soft tissue availability to create an intact nasal lining. Although opening the space with segmental osteotomies is possible, it requires bone grafts and a rotation of soft tissues to close the defects. Except in extreme salvage circumstances, dental space opening should be avoided (Figures 61-14 and 61-15).

Bone Grafting with Maxillary Advancement

There are three important reasons to use bone grafts in patients with a cleft when performing midface advancement. First,

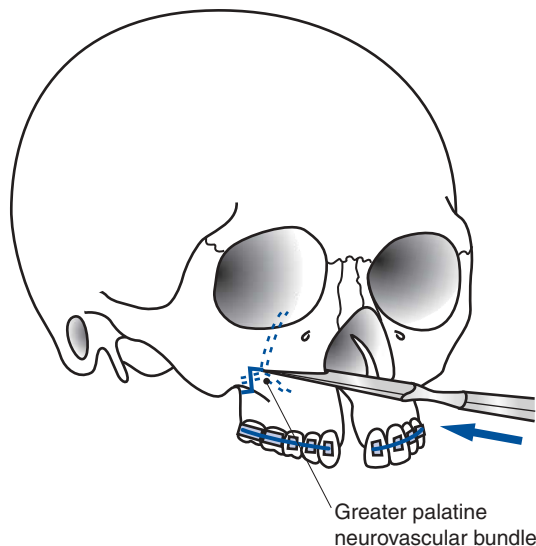


FIGURE 61-9 A small osteotome is tapped through the lateral nasal wall posteriorly toward the perpendicular part of the palatal bone. At this point the resistance increases because this part of the lateral nasal wall thickens. The greater palatine neurovascular bundle descends through this region and is at risk. Adapted from Turvey TA et al.¹⁵

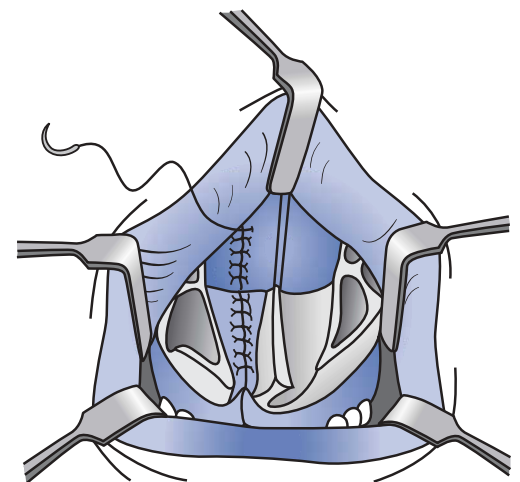
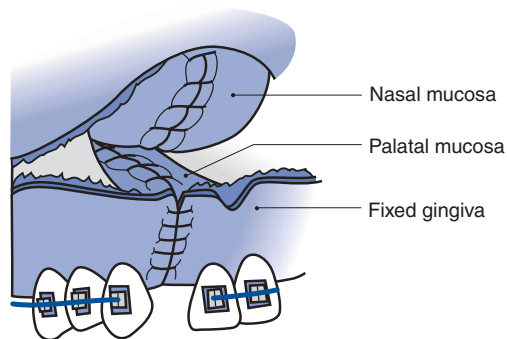
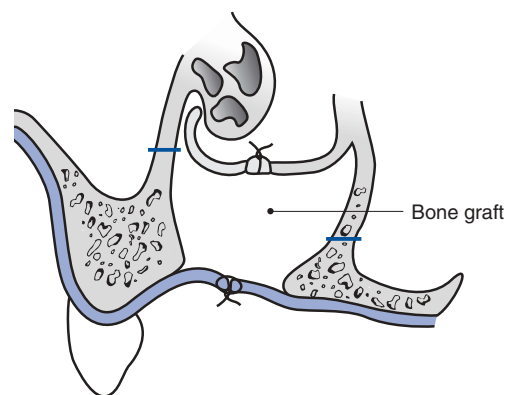


FIGURE 61-10 The mucosa lining the cleft alveolar region is elevated from the nasal side and pushed orally, where it is sutured on both the palatal and buccal sides. The bone edges of the cleft must be adequately exposed for successful reconstruction. The nasal mucosa is also closed primarily. Adapted from Turvey TA et al.¹⁵



A



B

FIGURE 61-11 A, Buccal view demonstrating the tissues lining the cleft elevated, pushed orally, and sutured on the oral side. B, Deeper view into the cleft demonstrating the closure of the oral and nasal tissues and the pocket for the bone graft. Adapted from Turvey TA et al.¹⁵

the bone graft can be wedged into the defects in the lateral maxillary walls; this helps to maintain the position of the maxilla during healing. Second, the bone graft also encourages bone healing and reduces the risks of fibrous union. The third reason to use bone grafts in midface advancement is to contour the middle face. In patients with a cleft, the midface is not just retruded, it is also malformed. Thus, altering the skeletal morphology is important for esthetic enhancement. Augmentation of the cheek projection, infraorbital regions, paranasal regions, nasal bridge, or chin is commonly employed at the time of midface advancement. These maneuvers are helpful and easily performed at the time of surgery, and their importance should not be underestimated.

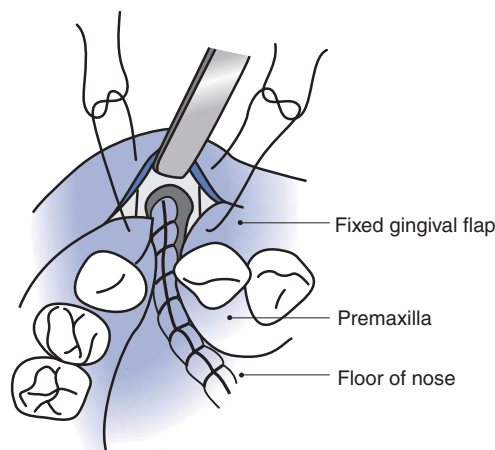


FIGURE 61-12 The nasal floor is constructed with tissues lining the cleft that are mobilized superiorly and sutured. Adapted from Turvey TA et al.¹⁵

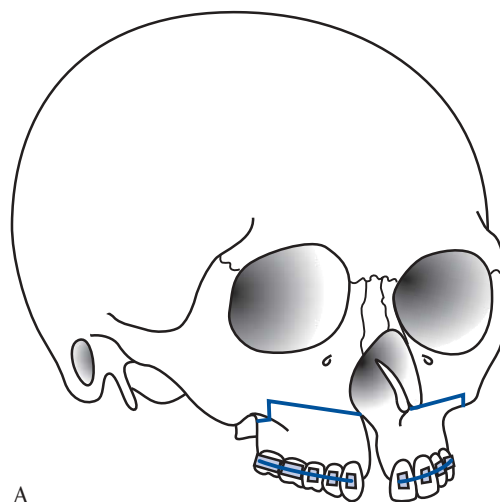
The choice of bone-graft material for use in cleft surgery is always fresh autogenous bone. Cancellous bone or cortico-cancellous blocks are generally reserved for filling defects in the alveolus or lateral

maxillary walls. The authors' preference for bone grafts to contour the middle face is split-thickness calvaria. For the chin a pedicled bone graft from the inferior border of the mandible is always employed.

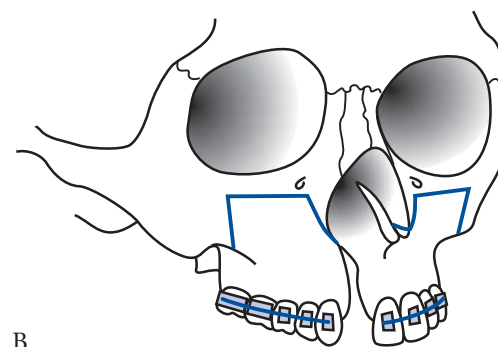
Bone Grafting of the Cleft Maxilla and Palate

Cancellous grafts can generally be condensed into cleft defects and are self-retained. Block grafts or onlay grafts should always be secured with a screw to promote healing, reduce resorption, and the risk of infection.

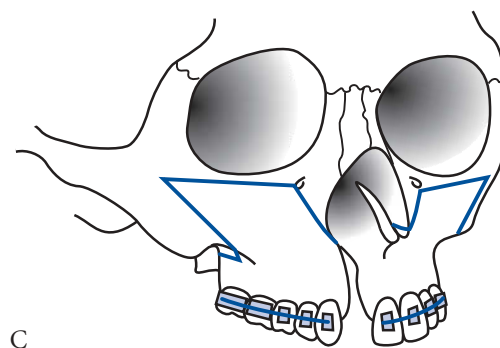
There are multiple bone donor sources, including the ilium, cranium, tibia, mandible, and ribs. Although harvesting bone requires more surgical time and has associated morbidity, the predictability of the result easily justifies its use. There is no autogenous bone substitute that has the same success in patients with a cleft as does fresh autogenous bone. The morbidity of



A



B



C

FIGURE 61-13 The design of the lateral maxillary osteotomy is determined by the patient's esthetic needs. A, The classic low-level cut. B, A higher-level cut approaching the infraorbital rims. C, A modification used when enhancement of the cheek prominence is desired. When the options shown in Figures B and C are used, there is risk of fracturing these buttresses because the bone is thin. Repair is possible with microplates. Adapted from Turvey TA et al.¹⁵

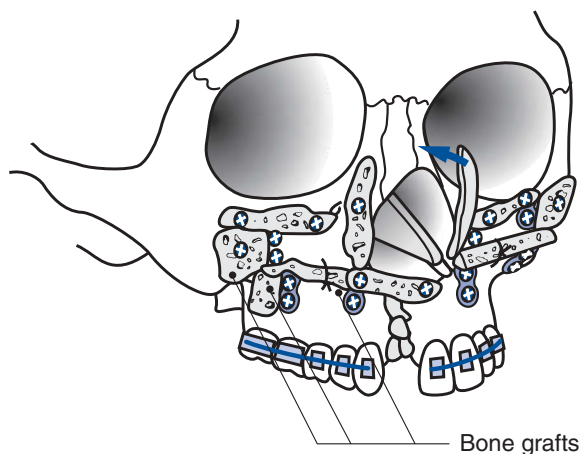


FIGURE 61-14 Onlay bone grafts are positioned and secured with screws. Wires are occasionally necessary to prevent displacement of the inlaid bone grafts into the sinus. Adapted from Turvey TA et al.¹⁵

bone harvest can be reduced with a good surgical technique and should not be an excuse for using bone alternatives.

Stabilizing the Operated Maxilla

The development of more rigid fixation devices permits improvement of results of

cleft skeletal surgery. Originally, stainless steel plates and screws and, later, titanium systems were used instead of the traditional stainless steel wires to secure the position of the maxilla. The many benefits of using more rigid fixation include a reduced time for intermaxillary fixation and better assurance of the position of the midface during healing. A single disadvantage of the use of metallic bone plates and screws is a reduced ability to manipulate tooth-bearing segments with elastic traction during the postoperative period to correct the occlusal result.

Velopharyngeal Considerations

One of the complexities of the cleft malformation involves the function of the velopharyngeal sphincter. Under normal circumstances, sealing the nasal cavity from the oral cavity occurs by a simultaneous elevation of the soft palate and contraction of the lateral pharyngeal walls to produce closure of the nasopharynx from the oral cavity. In many patients with a

repaired cleft palate, the velopharyngeal mechanism is fragile and the patient has learned to overcome a short or scarred immobile palate by compensating and recruiting adjacent structures. Passavant's bar (a hypertrophy of tissue in the posterior pharyngeal wall) is a result of a compensatory effort that many patients with a cleft develop to overcome the deficit and inadequacy of velar movement.

Forward displacement of the maxilla in patients without a cleft is well tolerated, and these patients have adequate compensatory reserve to overcome the change in position of soft palate. A minority of patients with a cleft are not able to tolerate even small degrees of maxillary displacement, and the velopharyngeal function may deteriorate, affecting the patient's speech and communication ability.¹⁶ This potential risk should be evaluated before maxillary-advancement surgery, and patients should be appropriately counseled. In patients with a cleft, the occurrence of velopharyngeal inadequacy following midface advancement is infrequent and additional surgical procedures are usually unnecessary. Almost all patients with a cleft experience hypernasality immediately following surgery. Fortunately, this gradually resolves with time, and most patients return to their baseline speech by 6 months after surgery. It is prudent to delay subsequent surgery to reduce nasality for at least 6 months following maxillary advancement. This allows natural compensation to occur and permits bone healing to proceed without introducing more scarring, which may contribute to relapse.¹⁷

An interesting observation in some patients with pharyngeal flaps who do not have velopharyngeal adequacy prior to midface advancement is an improvement of nasal speech after surgery. Although sibilant distortions secondary to malocclusion are expected to improve, reduction of hypernasality after maxillary advancement is paradoxical. The explanation of this occurrence is the altered dynamics of the sphincter that result after

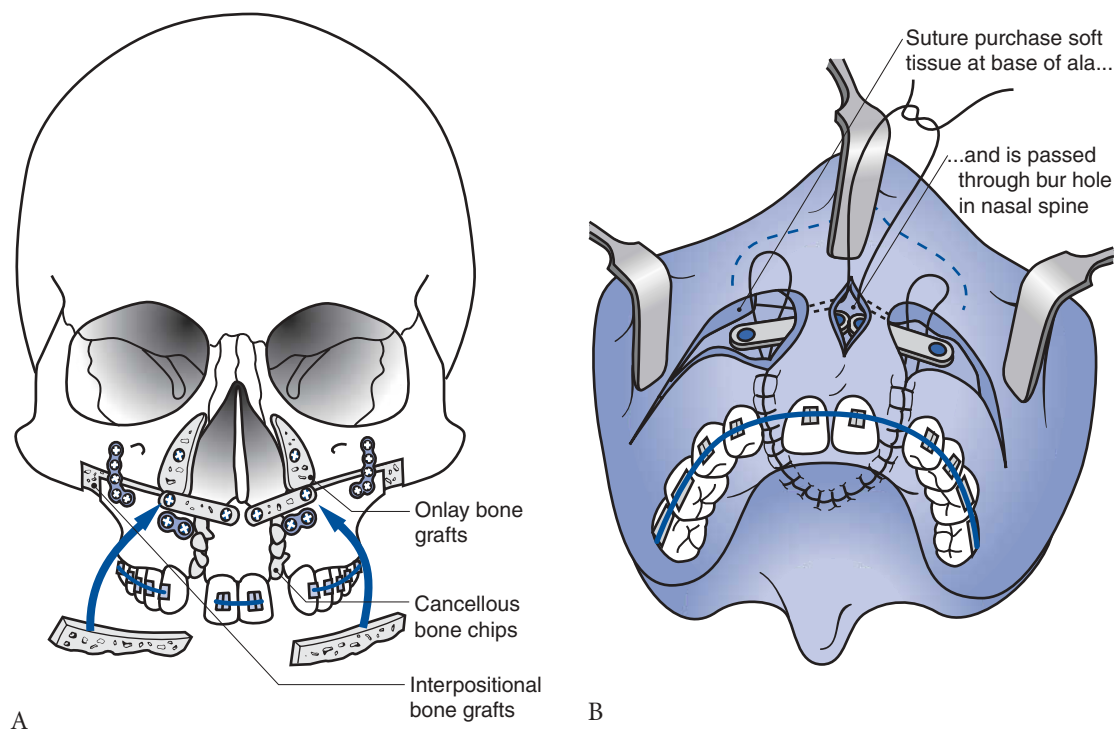


FIGURE 61-15 A and B, The premaxilla is secured with bone grafts, which are used to construct the inferior piriform rim. These grafts are tunneled under the buccal flaps and screwed to the nasal spine anteriorly and to the lateral maxilla posteriorly. Adapted from Turvey TA et al.¹⁵

surgery. Apparently, stretching the flap and its positional change improve the dynamics of the velopharyngeal mechanism so that improved speech occurs in some patients. This observation is not predictable, and patients must be cautioned appropriately.

When a pharyngeal flap is in place and maxillary advancement is undertaken, the flap should be removed only if it does not permit adequate mobilization of the maxilla. When the flap is in place, nasal intubation can be difficult; the anesthesiologist must be prepared to use endoscopic assistance with endotracheal tube insertion (see Figure 61-8).

References

- Murray JC, Daack-Hirsh S, Buetow KH, et al. Clinical and epidemiological studies of the cleft lip and palate in the Philippines. *Cleft Palate Craniofac J* 1997;34:7–10.
- Christensen K. Methodological issues in epidemiological studies in oral clefts. In: Wyszynski D, editor. *Cleft lip and palate*. Oxford: Oxford University Press; 2002.
- Lidral AC, Vig KWL. The role of the orthodontist in the management of cleft lip and palate. In: Wyszynski D, editor. *Cleft lip and palate*. Oxford: Oxford University Press; 2002.
- Washington Department of Health. *Cleft lip and palate: critical elements of care*. Washington: Washington Department of Health; 1997.
- American Cleft Palate–Craniofacial Association. Parameters for the evaluation of treatment of patients with cleft lip/palate or other craniofacial anomalies. *Cleft Palate Craniofac J* 1993;30 Suppl:4.
- Mars M, Houston WJB. A preliminary study of facial growth and morphology in unoperated male unilateral cleft lip and palate subjects over 13 years of age. *Cleft Palate J* 1990;27:7–10.
- Cohen MM Jr. Syndromes with cleft lip and palate. *Cleft Palate J* 1978;15:306–28.
- Cohen MM Jr, Bankier A. Syndrome delineation involving orofacial clefting. *Cleft Palate J* 1991;28:119–20.
- Boyne PJ, Sands NR. Secondary bone grafting of alveolar and palatal clefts. *J Oral Surg* 1972;30:87.
- Boyne PJ, Sands NR. Combined orthodontic-surgical interaction in the management of residual palato-alveolar cleft defects. *Am J Orthod* 1976;70:21.
- Turvey TA, Vig KWL, Moriarty J, Hoke J. Delayed bone grafting in the cleft maxilla and palate: a retrospective multidisciplinary analysis. *Am J Orthod* 1984;86:244–56.
- Bergland O, Semb G, Abyholm FE. Elimination of the residual alveolar cleft by secondary bone grafting and subsequent orthodontic treatment. *Cleft Palate J* 1986;23:175.
- Phillips C, Proffit WR. Psychosocial aspects of dentofacial deformity and its treatment. In: Proffit WR, White RP, Sarver DM. *Contemporary treatment of dentofacial deformity*. St. Louis (MO): Mosby; 2003. p. 70–91.
- Vig KWL, Turvey TA, Fonseca RJ. Orthodontic and surgical considerations in bone grafting in the cleft maxilla and palate. In: *Facial clefts and craniosynostosis: principles and management*. Philadelphia (PA): W.B. Saunders; 1996.
- Turvey TA, Vig KWL, Fonseca RJ. Maxillary advancement and contouring in the presence of cleft lip and palate. In: *Facial clefts and craniosynostosis: principles and management*. Philadelphia (PA): W.B. Saunders; 1996.
- Lo LJ, Huen KF, Chen YR. Blindness as a complication of LeFort I osteotomy for maxillary disimpaction. *Plast Reconstr Surg* 2002;109:688–98.
- Mason RA, Turvey TA, Warren DW. Speech considerations with maxillary advancement procedures. *J Oral Surg* 1980;38:752.

Distraction Osteogenesis

Suzanne U. Stucki-McCormick, MS, DDS

Distraction osteogenesis (DO), a useful technique to generate bone and soft tissue, can be applied to craniofacial reconstruction, including orthognathic surgery, cleft lip and palate reconstruction, a new mandibular condyle regeneration, a dentoalveolar unit reconstruction for dental implants and transport DO for discontinuity defects.

Regardless of the surgical site, adherence to the following basic Ilizarov principles is the key to surgical success¹:

1. Osteotomy of the bone site with minimal periosteal stripping
2. Latency period: 3, 5, or 7 days, depending on the surgical site
3. Distraction rate: 1.0 mm per day (0.5–2.0 mm)
4. Distraction rhythm: continuous force application is best, yet device activation bid is more practical and allows for better patient compliance
5. Consolidation: until a cortical outline can be seen radiographically across the distraction gap, usually 6 weeks

The distraction technique involves creating an osteotomy in an area adjacent to an area of bone deficiency. Applying slow tension forces separates the bony edges, which creates a regenerate chamber from which the new bone and soft tissues are formed (Figure 62-1). This regenerate chamber may be large and wide, with abundant blood supply from the overlying

muscle and skin, as in mandibular distraction. Conversely, the distraction gap may be small, with thin mucosal coverage, as in dentoalveolar distraction for dental implants. The local periosteal blood supply and the size of the distraction segment influence the treatment plan decisions; in fact, for small bone segment distraction, the rate of distraction may need to decrease to 0.5 to 0.7 mm per day. However, for sagittal distraction of the mandible whereby the bone segments overlap, the distraction rate should increase to 2.0 mm per day. I recommend modifying the Ilizarov principles in each individual, based on the size of the distraction bone segment and the regional blood supply (Table 62-1).

Initially, the regenerate chamber is filled with a fibrous matrix that ossifies from the periphery centrally.² The distraction gap shape and the resultant new DO bone are influenced by the vector of distraction and the rate of distraction. Altering the vector of distraction during active DO will correspondingly alter the three-dimensional shape of the regenerate chamber and the resultant new DO bone (Figure 62-2). If the distraction rate is too rapid, then the regenerate chamber will be hourglass shaped, and the new DO bone will be thinned centrally.

The osteotomy location can affect the shape of the regenerate chamber and the final new bone. If the osteotomy is created in an area of thin bone stock, then the

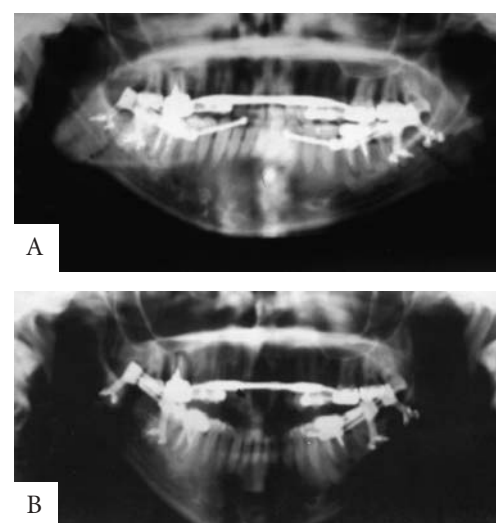


FIGURE 62-1 During the distraction process the bony edges of the osteotomy (A) are separated slowly over time to create an initial radiolucent regenerate chamber (B), which has the size and shape of the native bone.

regenerate chamber will thin and assume the shape of the native bone. In treatment planning and during surgery, it may be necessary to adjust the osteotomy site, placing the bone cut in an area of maximum bone thickness to create a large and robust regenerate chamber (Figure 62-3).

Until the distraction gap ossifies completely, the regenerate chamber is influenced by the local muscle pull. As distraction proceeds, the regenerate chamber becomes enlarged and is filled initially with a weak fibrous matrix. Simultaneously, the local muscles that are attached to the DO site are stretched. The stretched

Table 62-1 Distraction Protocol

Distraction	Latency (d)	Rate (total) (mm/d)	Rhythm
Mandible	5	1.0	bid
Maxilla	5	1.0	bid
Alveolus/implant	5–7	0.5–0.7–1.0	bid
Transport	5–7	1.0	bid
Condyle: transport	5–7	1.0	tid, qid
Mandible: children	3–5	1.0–2.0	bid
Mandible: sagittal	5–7	2.0	bid
Transport: neck dissection	7–10	0.5–1.0	bid
Transport: XRT	7–10	0.5	bid

bid = twice a day; qid = four times a day; tid = three times a day; XRT = external beam radiation therapy.

muscles tend to return to their original sarcomeric length, pulling on the regenerate chamber and on the intervening immature bone matrix, causing an alteration of the vector of DO and displacement of the distraction segment in the direction of the muscle (Figure 62-4). This effect is most noticeable by the action of the temporalis and the mylohyoid musculature. Vector control maneuvers, including the use of surgical guides, orthodontic appliances, and interim partial dentures with a portal for DO device access, help to maintain and adjust the vector of distraction.³

Clinicians may use the fibrous matrix nature of the regenerate chamber to their

advantage to mold the regenerate into the proper orientation and location, including distraction of a segment outside the normal anatomic periosteal plane. Specifically, clinicians may mold the regenerate at any time in the distraction process—during active DO and at the end of DO.

During active distraction, the regenerate is molded by altering the vector of the distractor. Some DO devices have mechanical hinges that allow the clinician to adjust

the vector of distraction. This is done easily in an office setting, often using local anesthesia, if necessary. If performing a significant (≥ 3 mm) molding move or vector change, then I recommend that a short (1 to 3 days) latency is observed prior to commencing with the distraction protocol. This allows for healing of the disrupted microvasculature and osteoid matrix within the regenerate chamber that the vector change produced. A longer latency (2 to 4 days) is recommended if the bone segment is small, as in dentoalveolar distraction for dental implants.

Perform regenerate molding at the end of active distraction to help guide the end of active distraction to help guide the bone segment into its final position.⁴ After only 3 weeks of consolidation, remove the distractor prematurely, and reposition the segment to its final position. Use traction orthodontic elastics to guide the segment to its final position and to hold the segment in this position until final ossification occurs. At the time of device removal, however, the segment may be repositioned

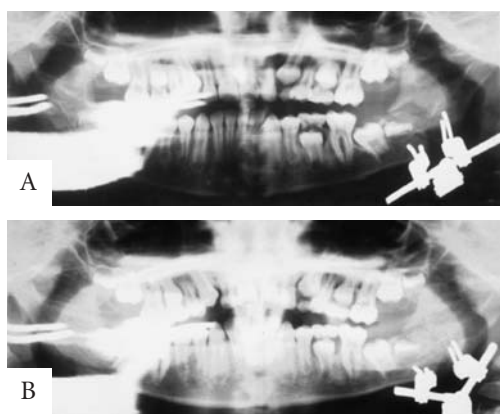


FIGURE 62-2 Initially the distraction vector is linear (A). Once 5 mm of regenerate chamber has been created, the distractor can be adjusted, altering the vector of distraction, which correspondingly alters the three-dimensional shape of the new bone (B).

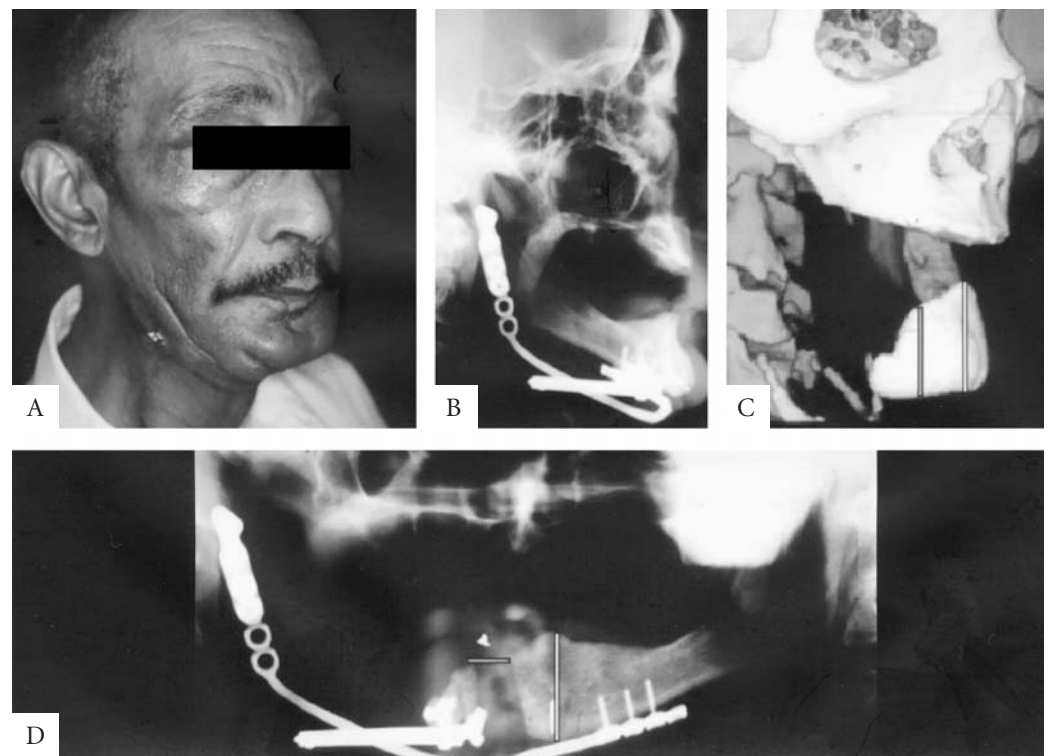


FIGURE 62-3 For transport distraction to create a new mandible (A, B), the osteotomy should be placed in an area of maximal bone stock (C, D) to create a robust regenerate chamber.

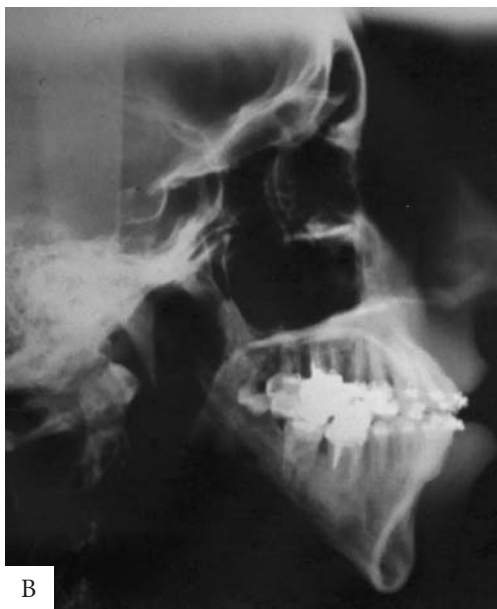
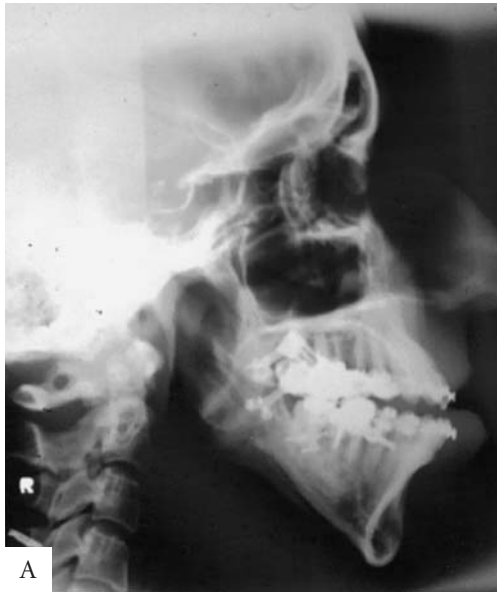
FIGURE 62-4 During the final stages of distraction osteogenesis, the weak regenerate chamber is under the influence of local muscle pull. A, Here the mylohyoid created an open bite, which was counteracted by orthodontic elastics. B, Using callous manipulation with orthodontic elastics, the open bite was closed.

manually and held in place with rigid fixation plates and screws.

Perform “dancing” of the distraction segment if a discrepancy occurs in planned distraction amounts, such as bilateral mandibular advancement for asymmetries.⁵ Initially, both segments are advanced at the planned distraction rate.

When the larger, less asymmetric side reaches its final position, the segment becomes the dancing side, advancing the DO segment in the morning then turning it back the same amount in the evening. In the meantime, the lesser more asymmetric segment continues to be advanced at the planned rate until it catches up with the contralateral side. Carry out any final adjustments to the mandibular positioning when the asymmetry has been corrected by advancing or dancing the two sides as needed (Figure 62-5).

As with orthognathic surgery, treatment planning for distraction osteogenesis includes predicting the amount and trajectory of the planned bone movement. Although the DO device may be activated 1.0 mm per day, this does not translate to 1.0 mm of bone advancement per day. The amount of actual bone movement is always less than the distance that is indicated on the distraction device, therefore the clinician monitors the patient’s progress closely, including radiographs.

The surgical approach and technique are similar to orthognathic surgery. When locating and positioning the bone cut, also consider the placement and orientation of the distraction device. Mark the planned osteotomy. Then, create a corticotomy, verifying the ability to place the distractor in the proper orientation. Make the screw fixation holes for the distraction device, and remove the device. The corticotomy is then converted atraumatically to an osteotomy, and the distraction device is fixated into place. The device is activated to ensure impedance-free advancement of the distraction segments.⁶ Remove any bony interferences, and return the device to its closed neutral position. Prior to initial device orientation and placement, activate the distractor 1.0 to 2.0 mm. Thus, after the osteotomy and the device are secured into place, the DO device can be “closed” 1.0 to 2.0 mm, reducing and minimizing the initial distraction gap created by the bone cut.

Mandibular Distraction

For patients with craniofacial microsomia, mandibular distraction of the affected side is a useful technique for generating both bone and soft tissue. The surgical approach is similar to a sagittal osteotomy. Create a bone cut in the ramus of the mandible on the affected side above the lingua along the ramus to the posterior border of the mandible above the gonial angle. Position the distractor, and convert the corticotomy to an osteotomy, after which the distraction device is secured. Intraoral distractors are preferred to external devices to decrease scarring. Compared with a completely submerged device, DO devices in which the distraction mechanism is intraoral yet extramucosal allow the clinician to monitor the distractor directly without the need for radiographs. In addition, removal of the device is facilitated if the distraction mechanism is extramucosal. The vector of distraction is calculated based on the trajectory of the bone segment and on the local anatomy, including bone stock, tooth buds and/or roots, and position of the inferior alveolar nerve. Achieve chin point correction by vertical distraction of the ramus (Figure 62-6).⁷

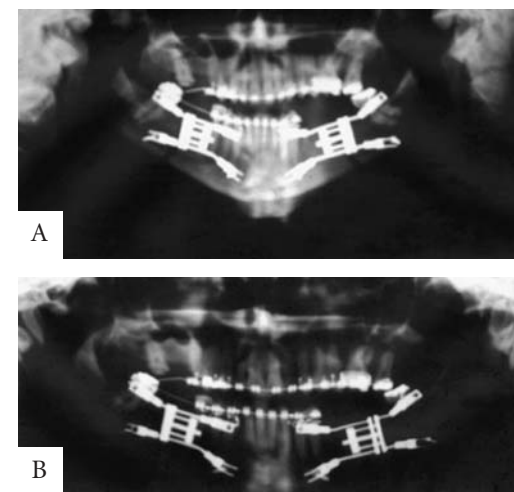


FIGURE 62-5 To correct asymmetry the devices are initially distracted by the same amount (A), then using “disk dancing,” the regenerate chamber can be advanced or returned to bring the segment into proper position (B).

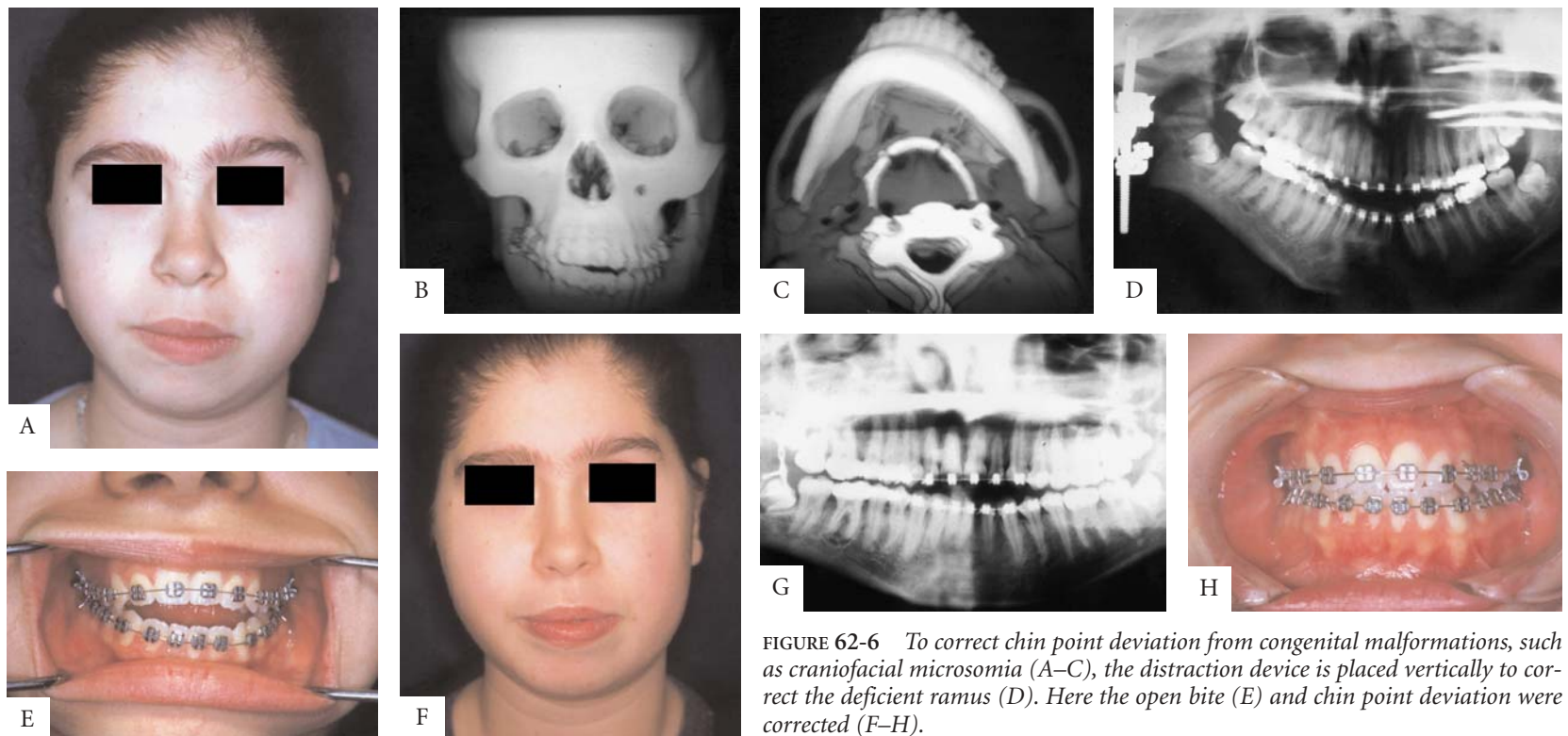


FIGURE 62-6 To correct chin point deviation from congenital malformations, such as craniofacial microsomia (A–C), the distraction device is placed vertically to correct the deficient ramus (D). Here the open bite (E) and chin point deviation were corrected (F–H).

The distraction process continues 1.0 mm per day until the mandibular asymmetry is corrected. I recommend age-dependant overcorrection to compensate for the decreased growth potential of the genetically affected side.⁸ Remove the distractor when a cortical outline can be seen radiographically (Figure 62-7). Perform mandibular distraction for all Pruzansky-Mulliken classifications of craniofacial microsomia (Figure 62-8).⁹

Mandibular distraction plays a unique role for infants with airway compromise, as a consequence of micrognathia.^{10,11} Early distraction of the body of the mandible bilaterally has shown promise for improving airway volume and in decreasing airway resistance, leading to early decannulation or avoidance of a tracheotomy.^{12,13}

For large mandibular advancements or for patients with a history of temporomandibular joint disorders, DO is a useful treatment alternative. Use a modification of the classic sagittal split technique for such cases.⁵ As the proximal and distal segments overlap, the distraction rate is increased to

2.0 mm per day (0.5 mm qid [4 times a day]). Further, create a groove in the superior aspect of the horizontal bone cut above the lingual to allow for impedance-free rotation of the proximal segment during DO (Figure 62-9). Ideally, the distractors are placed parallel to the midsagittal plane of the mandible, although this is not always achieved.^{14,15} Class II orthodontic elastics are placed to “unload” the temporomandibular joint. At the time of surgery, place a maxillary occlusal surgical guide that extends to one-half of the occlusal surface of the maxillary second molar, with the final occlusion indexed. As distraction proceeds, guide the mandible into the proper occlusion using light elastics. Sagittal distraction of the mandible appears to provide condylar axis stability and has minimal deleterious effects on the temporomandibular joint.⁵

Mandibular Widening

DO, a useful tool to create space for severe mandibular crowding, is often combined with maxillary transverse widening and surgically assisted palatal

expansion (Figure 62-10).¹⁶ For the mandible, make a vestibular incision similar to a genioplasty, approach the mandible, and score the planned osteotomy site. Create the osteotomy in the corpus of the mandible with a bur or a saw. Perform the interdental osteotomy with fine chisels in a tunneling technique, reducing the periosteal stripping, being careful to avoid encroaching on or injuring the periodontal ligament of the teeth in the osteotomy line. The tissue type in the osteotomy site is the template for DO. Consequently, if the osteotomy is positioned completely in the bone, bone will be created. If the osteotomy encroaches on periodontal ligament tissues, the distraction gap fills with bone and moderate amounts of periodontal ligament-like tissues, leading to a pseudo-union.¹⁷ For the central incisors that are extremely crowded, carry out the interdental osteotomy laterally between less crowded teeth; namely, the lateral incisor and the cuspid. Create a horizontal step 5 mm below the roots of the incisor teeth, and make the main osteotomy of corpus of mental region vertically in the midline.

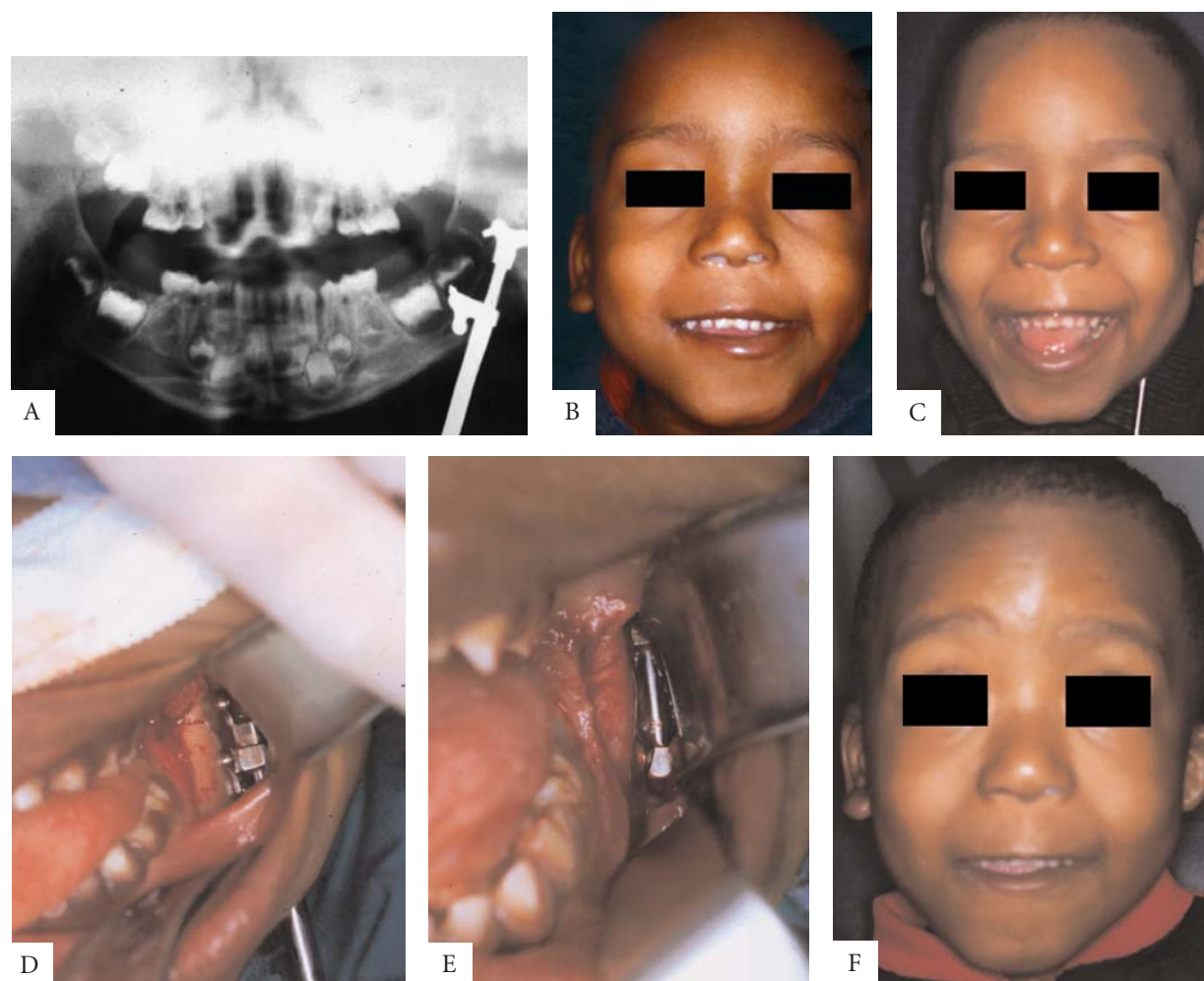


FIGURE 62-7 The distractor is advanced until the deformity is corrected (A–C). Initially, osteotomy (D) produces a radiolucent regenerate chamber (A) that ossifies with time (E), at which point the distractor is removed (F).

The distractor of choice is placed. Most distractors are tooth and bone borne. Distractors that are solely bone borne tend to produce a V-shaped regenerate chamber, with more widening at the level of the alveolus and less widening at the level of the inferior border.

After a 5- to 7-day latency, distraction proceeds at 1.0 mm per day. Be sure to apply slow incremental distraction forces; DO forces generated during mandibular widening may translate to the mandibular condyle.¹⁸ Minimal in nature, these forces cause mild adaptive bony changes that are well tolerated. Nevertheless, monitor patients closely for any complaints of preauricular pain or limitation of motion, which would indicate altering the 1.0 mm per day DO protocol from

0.5 mm twice daily to 0.25 mm four times daily device activation.

After DO, the surgeon may place a plastic pontic tooth in the gap between the central incisors to stabilize the teeth and to prevent their central migration.¹⁹ To prevent migration of the teeth into the DO gap, include these teeth in the orthodontic arc wire, with the possible placement of a light spring. Remove the distractor once a cortical outline can be seen on the radiograph. Place a lingual arch to help stabilize the new transverse dimension.

Simultaneous Maxillary and Mandibular Distraction

Patients who have craniofacial microsomia often have maxillary hypoplasia and a concomitant occlusal cant toward the

affected side. Using mandibular DO during the primary or mixed dentition phase often autocorrects the maxillary occlusal cant (Figure 62-11). If the maxillary molar teeth are present in full occlusion or if the patient is in permanent dentition, then a concomitant maxillary distraction, along with the mandibular distraction, may be indicated.^{20,21} The surgeon performs a corticotomy at the Le Fort I level, including pterygoid disjunction, taking care to avoid the unerrupted tooth buds or roots during the bone cut. The maxilla is loosened but not down-fractured. Orthodontic elastics (8 oz) are then applied bilaterally, with increased elastic traction on the affected side to guide the maxilla to its proper orientation during the DO process (Figure 62-12). Elastic traction that results in max-

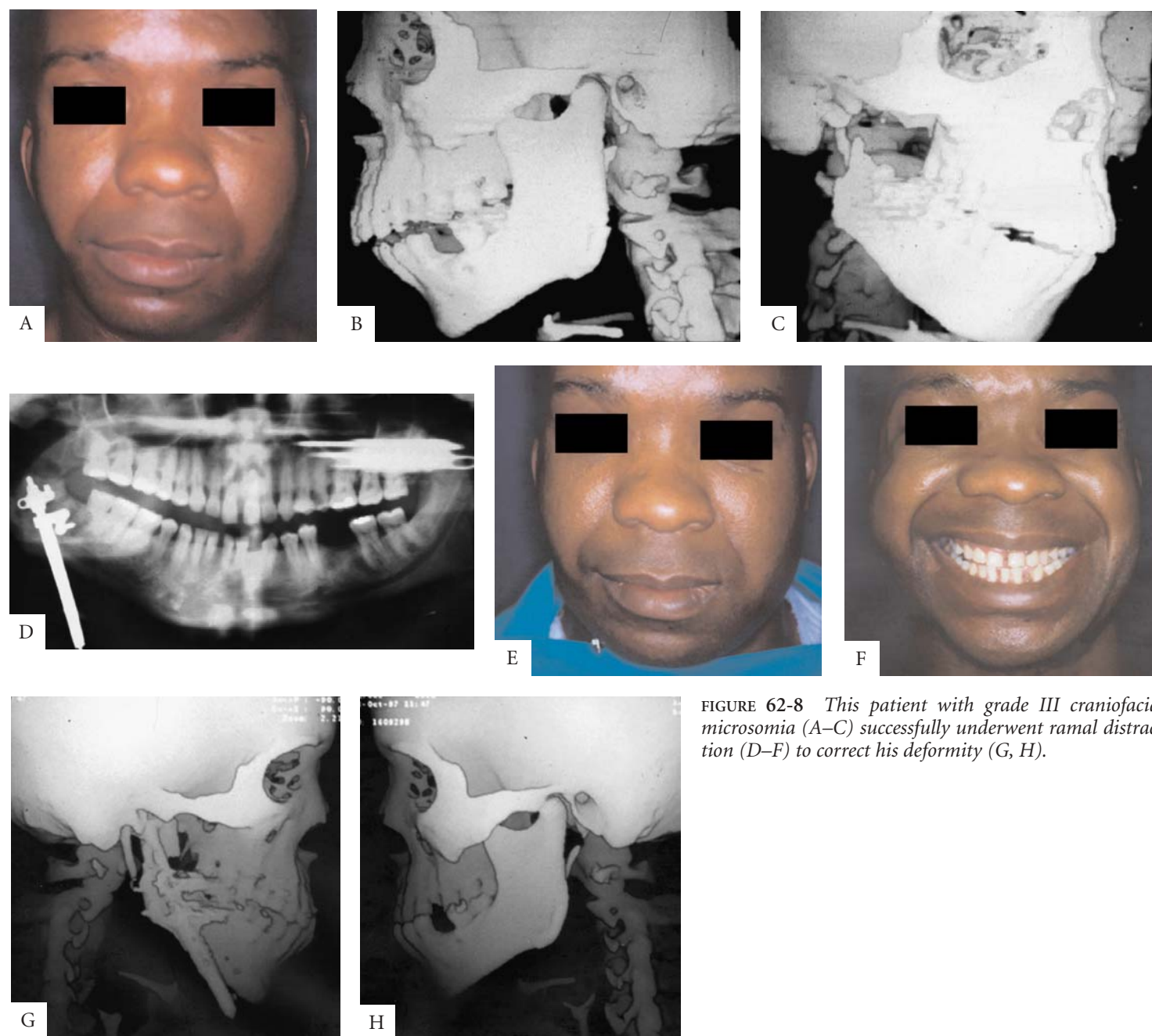

FIGURE 62-8 This patient with grade III craniofacial microsomia (A–C) successfully underwent ramal distraction (D–F) to correct his deformity (G, H).

illomandibular fixation (MMF) is not required to guide the maxilla along with the mandible during DO.²²

Maxillary Distraction

Likewise, use DO for maxillary advancement. This technique is especially useful for patients with large advancements or in patients postpalatoplasty for cleft lip and palate whose scarring causes inadequate tissue or difficulty in moving the maxilla.^{23,24} The surgical approach is sim-

ilar to conventional orthognathic surgery, with the osteotomy at the Le Fort I level. The maxilla is freed but not completely down-fractured. If the maxilla is inadvertently completely down-fractured, then loosely place a suspension suture (2-0 polydioxanone suture) in the bone across the bone gap at the level of the first molar tooth and the zygomatic buttress to help stabilize and prevent inferior tipping of the posterior maxilla. The distractors are pre-bent to

facilitate device placement. The zygomatic buttress region is a good point for device fixation. Ideal trajectory would locate the two distractors that are parallel to each other and the midsagittal plane. Achieving this congruity is much more difficult in the maxilla owing to local anatomy, device design, and location of the osteotomy, limiting device placement and orientation. Ensure that the resultant moment arm of the two distractors will not cancel each other as the distractors

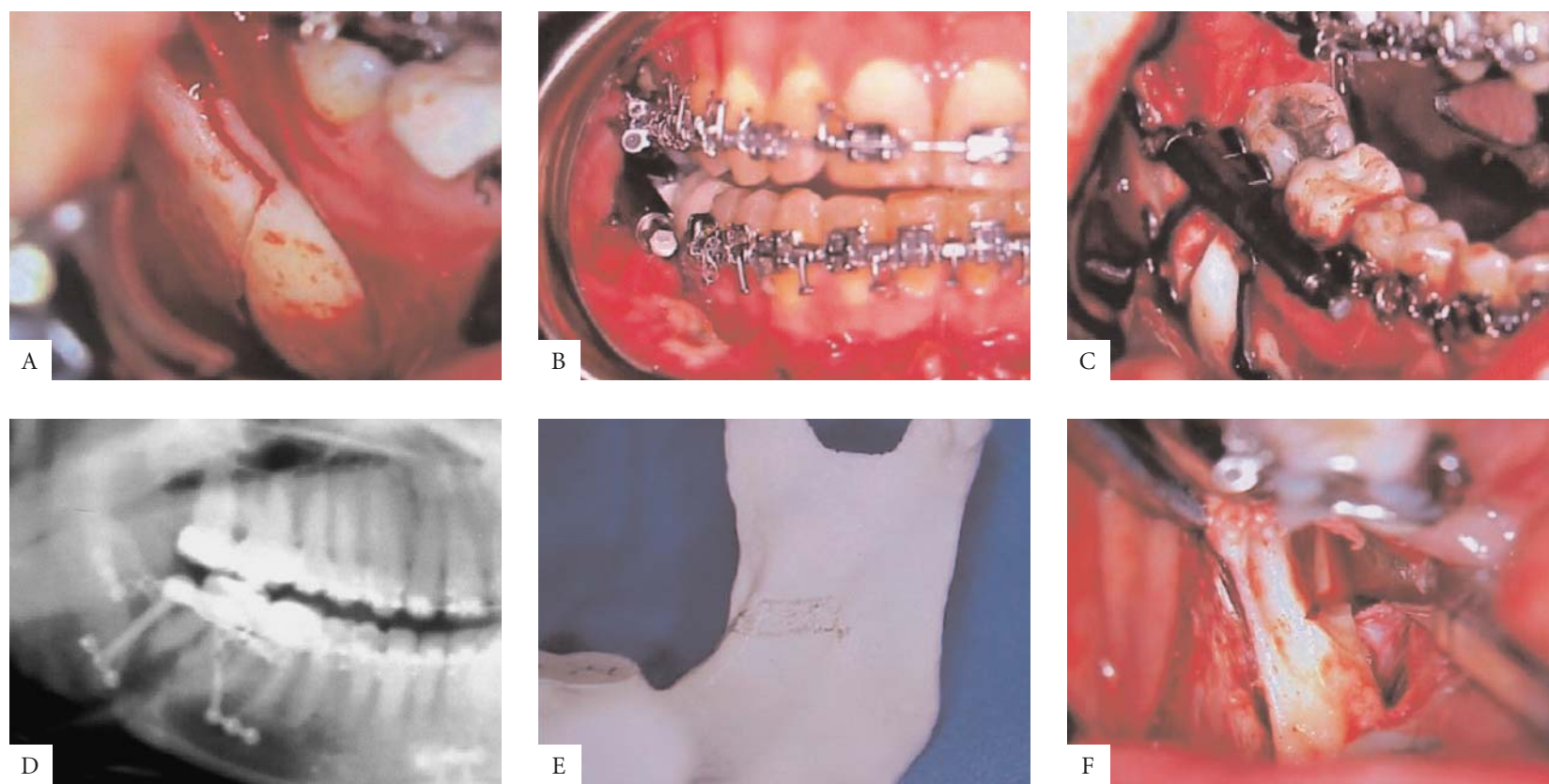


FIGURE 62-9 A–D, Classic sagittal split osteotomy technique can be modified to allow for mandibular advancement. E, F, The horizontal bone cut is modified to allow for impedance-free advancement during distraction osteogenesis. (Courtesy of Dr. J.J. Moses.)

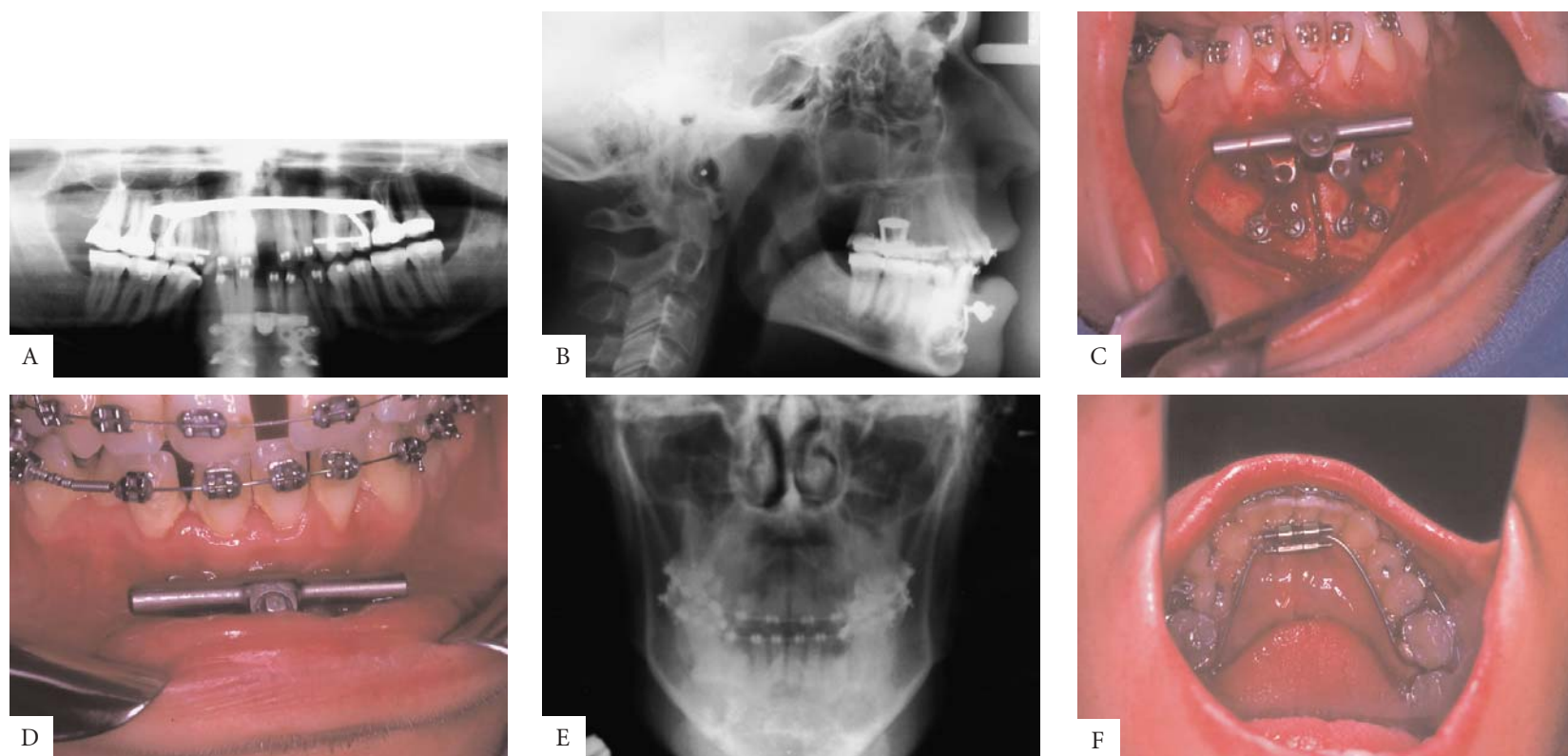


FIGURE 62-10 A, B, Patients with narrow arch forms and dental crowding are aided using mandibular widening as well as surgically assisted maxillary expansion. C, D, Bone-borne devices can be placed into the vestibule. E, F, The resultant increase in transverse dimension can be stabilized with a lingual orthodontic appliance.

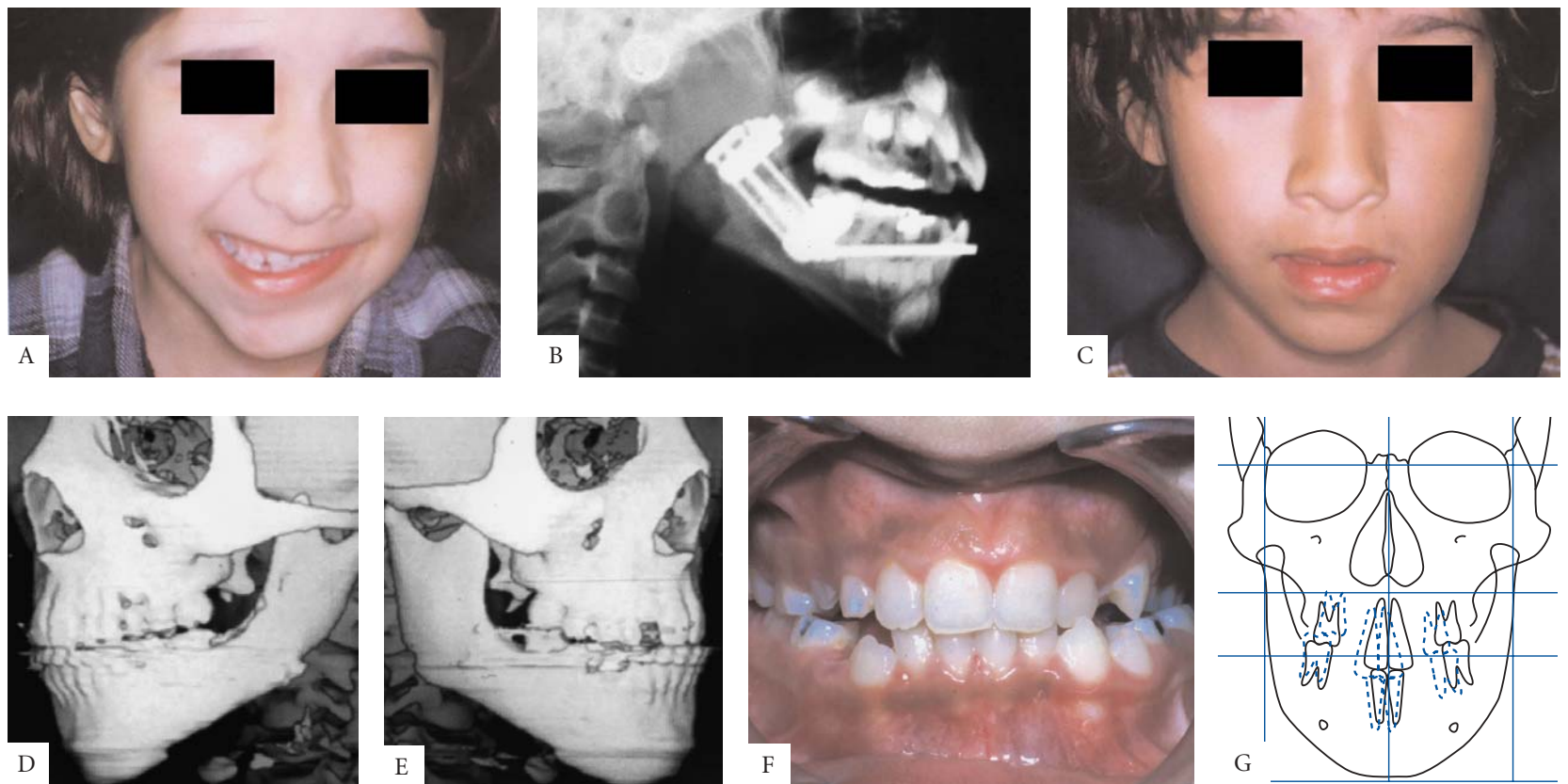


FIGURE 62-11 This patient in mixed dentition with significant occlusal cant (A) underwent mandibular distraction using a submerged device (B) to correct the deformity (C). The neomandible (D) mimics the native mandible (E) in size and form. The mandible was overcorrected with the dental midline distracted one-half tooth toward the contralateral side (F). The maxillary occlusal cant was autocorrected as the mandible was placed in the proper position and with the eruption of the permanent teeth (G).

reach their maximal length. Use anterior traction elastics to guide the maxilla to its proper position. Put an intravenous tubing that is cut to size over the two ends of the distraction device activation rods to prevent lip ulcers (Figure 62-13).

Expanding the soft tissue envelope is often the rate-limiting step in large maxillary advancements. In these patients (> 8 to 10 mm advancement) or for those who have palatal scarring, the use of an external halo frame is indicated. Although a bit cumbersome and unsightly, the external frame can produce significant and dramatic maxillary advancements (Figure 62-14). The surgery is similar to conventional orthognathic surgery. Perform a high Le Fort or stepped osteotomy, if indicated. Secure the device below the height of contour of the skull; otherwise, the halo may dislodge vertically.

Active DO requires careful observation, as the center of rotation of the maxilla is at the level of the roots of the maxillary first molar.²⁵ Left unchecked, the maxilla will be distracted anteriorly and superiorly, creating an open-bite malocclusion. Using the external halo frame, adjust the arms vertically to allow the maxilla to advance in a downward and forward vector. Similarly, to allow for correction of a maxillary asymmetry, the arms of the halo device can be differentially activated (ie, 0.5 mm on one side and 1.0 mm per day on the other (see Figure 62-14). Once the ossification of the distraction site is complete (ie, until the maxilla is stable to palpation, usually in 5 to 6 weeks or when radiographic evidence of a cortical outline is seen), the halo device is removed in the office without the need for rigid fixation of the maxilla. Occasionally, prior to complete ossification of the site, the patient

may request to have the halo removed. The device is removed with concomitant placement of rigid fixation plates.

Maxillary Segmental Distraction

In patients who have a wide alveolar cleft, perform a segmental osteotomy in the lesser segment, advancing it via distraction to close the alveolar defect.²⁶ The bone cut is usually located between the bicuspid and the molar teeth of the lesser segment (Figure 62-15). In the same way, place the bone cut in the greater segment between the incisor and the cuspid teeth to distract the gap closed from either one or two directions. Use of orthodontic appliances and the arch wire allows the distraction segment to follow the curvature of the maxillary arch. During post-distraction, place an orthodontic spring on the arch wire, paralleling the regenerate chamber to

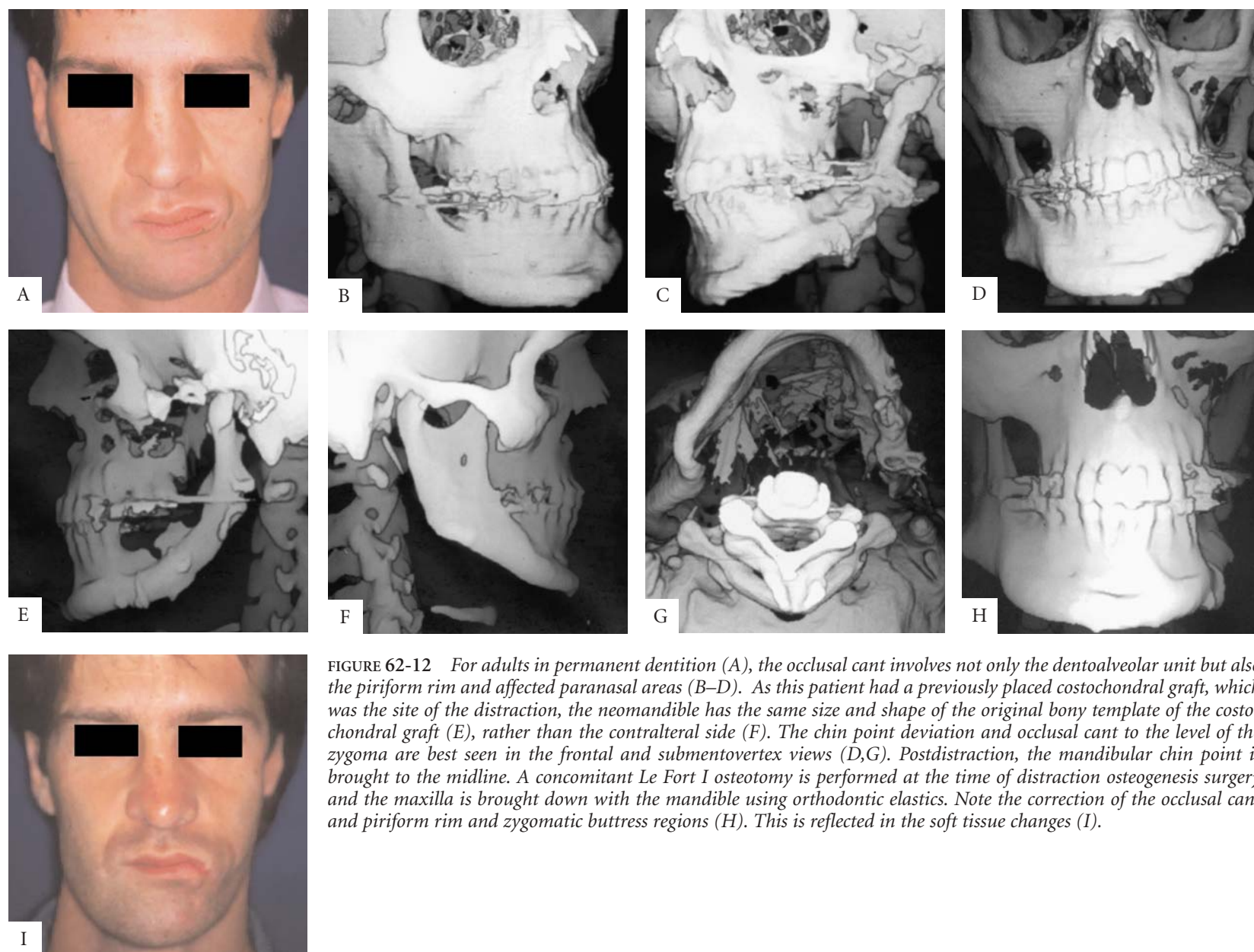


FIGURE 62-12 For adults in permanent dentition (A), the occlusal cant involves not only the dentoalveolar unit but also the piriform rim and affected paranasal areas (B–D). As this patient had a previously placed costochondral graft, which was the site of the distraction, the neomandible has the same size and shape of the original bony template of the costochondral graft (E), rather than the contralateral side (F). The chin point deviation and occlusal cant to the level of the zygoma are best seen in the frontal and submentovertex views (D,G). Postdistraction, the mandibular chin point is brought to the midline. A concomitant Le Fort I osteotomy is performed at the time of distraction osteogenesis surgery and the maxilla is brought down with the mandible using orthodontic elastics. Note the correction of the occlusal cant and piriform rim and zygomatic buttress regions (H). This is reflected in the soft tissue changes (I).

help hold the segment in proper orientation. In 1 to 2 weeks after distraction ossification, move the bicuspid and cuspid teeth orthodontically back to their correct position into the ossified DO bone, leaving the anterior dentoalveolar unit for implant reconstruction or for final periosteoplasty and smaller bone graft, if indicated. This segmental distraction is a form of transport DO.

For patients who have congenital agenesis of the premaxilla or who experience traumatic loss of the dentoalveolar unit,

anterior maxillary segmental distraction is indicated (Figure 62-16). Use tunneling techniques to perform the anterior osteotomy, making the horizontal bone cut parallel to the occlusal plane to facilitate segment advancement along a horizontal vector (Figure 62-17). Bilateral distractors are placed, and distraction proceeds after a 5-day latency at a rate of 1.0 mm per day. Anterior traction elastics aid in the forward thrust of the segment. The distractors are removed once a bony outline can be seen radiographically and

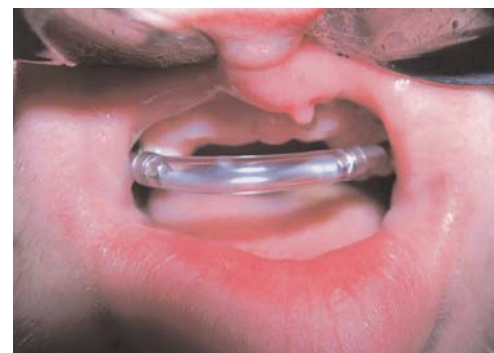


FIGURE 62-13 An intravenous tubing can be placed over the free end of maxillary distractors to avoid lip ulcers. The tubing is removed to activate the device then reapplied.

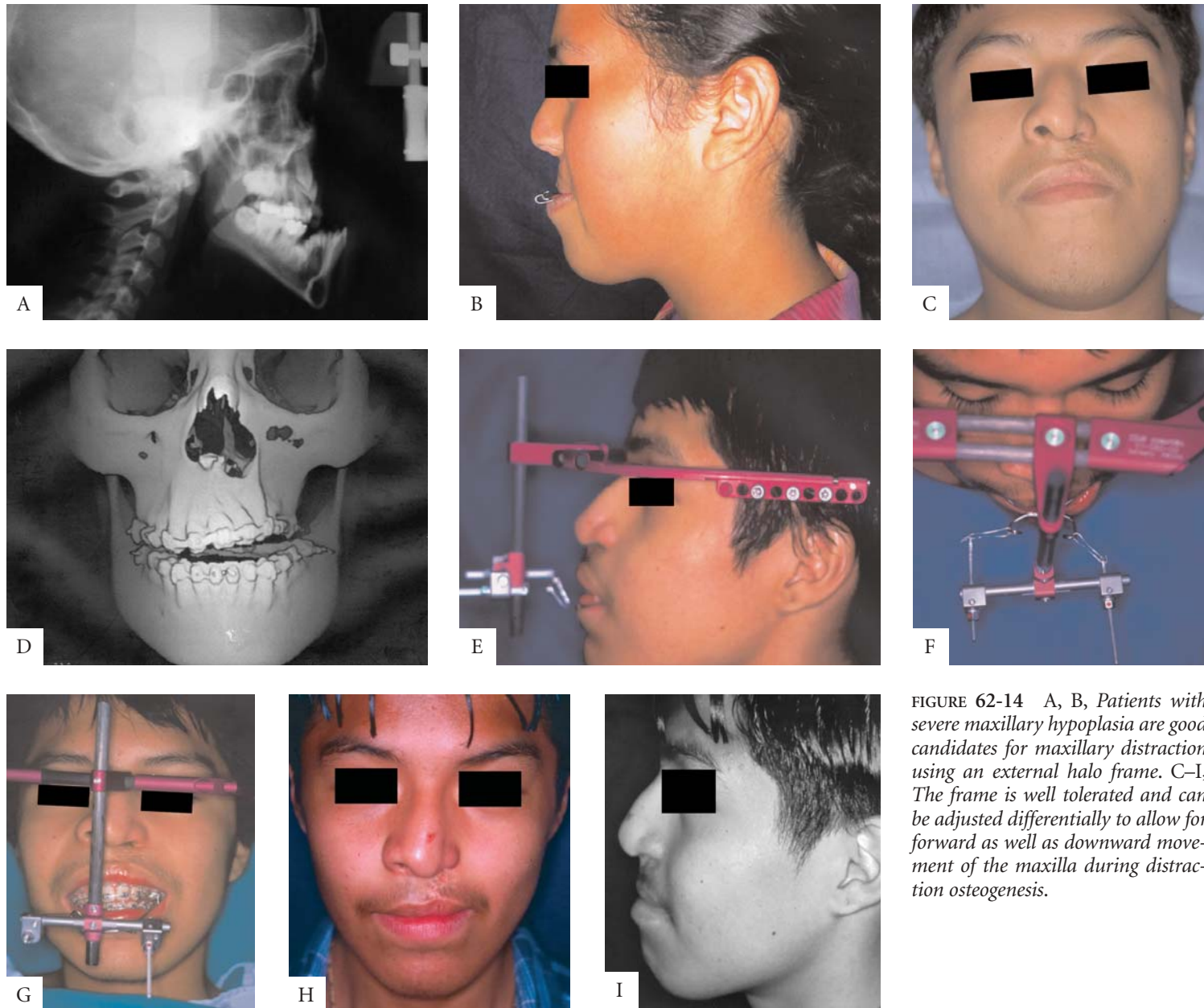


FIGURE 62-14 A, B, Patients with severe maxillary hypoplasia are good candidates for maxillary distraction using an external halo frame. C-I, The frame is well tolerated and can be adjusted differentially to allow for forward as well as downward movement of the maxilla during distraction osteogenesis.

once the segment is stable. The distractors can be removed prior to complete ossification (3 to 4 weeks) to mold the regenerate or at the patient's request. Position rigid fixation plates at the time of device removal. Resorbable rigid fixation plates are useful for this purpose; the site will ultimately undergo dental implant reconstruction.

Transport Distraction Osteogenesis

The power of DO is that both bone and soft tissues are regenerated. Transport distraction

involves creating a transport disk in the bone stump, adjacent to a discontinuity defect or a resection site. The transport disk is then advanced 1.0 mm per day as the distraction gap increases in size to span the discontinuity defect (Figure 62-18).²⁷ The resultant regenerate chamber will have the same size and shape of the transport disk. Careful treatment planning is necessary to plan the site of the osteotomy, thus determining the shape of transport disk and regenerate (Figure 62-19). Occasionally, a tooth may need to be sacrificed to allow for osteotomy placement in an optimal position.

Both external and submerged devices have been used for transport DO. Three points of fixation are required for transport DO: (1) in the proximal stump, (2) in the distal site, and (3) in the transport disk. Use a rigid fixation plate as a substitute for the three points of fixation along with a conventional distractor. The rigid fixation plate also acts as a guide for the transport disk during distraction (see Figure 62-18). Once the transport disk reaches the docking site, the segment is held in neutral fixation until a cortical outline is seen in the regenerate. At the time of

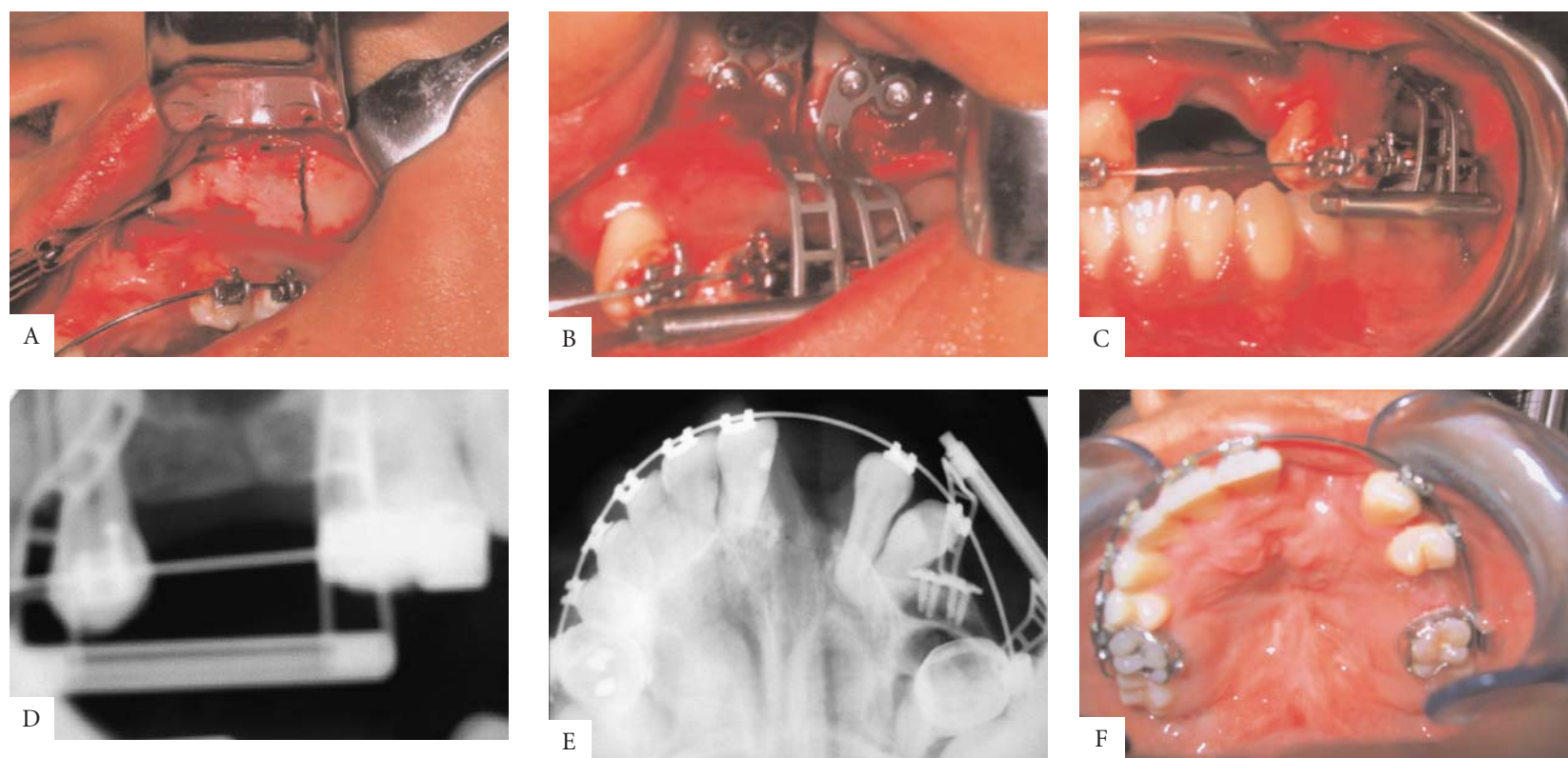


FIGURE 62-15 Segmental distraction can be performed for focal bone and soft tissue deficiencies such as alveolar cleft defects. A–C, The bone cut is made between the molar and bicuspid teeth and the orthodontic wire acts as a guide during distraction osteogenesis. D–F, A new dentoalveolar unit is formed and the cuspid and bicuspid teeth can be moved back into proper position orthodontically post-distraction osteogenesis.

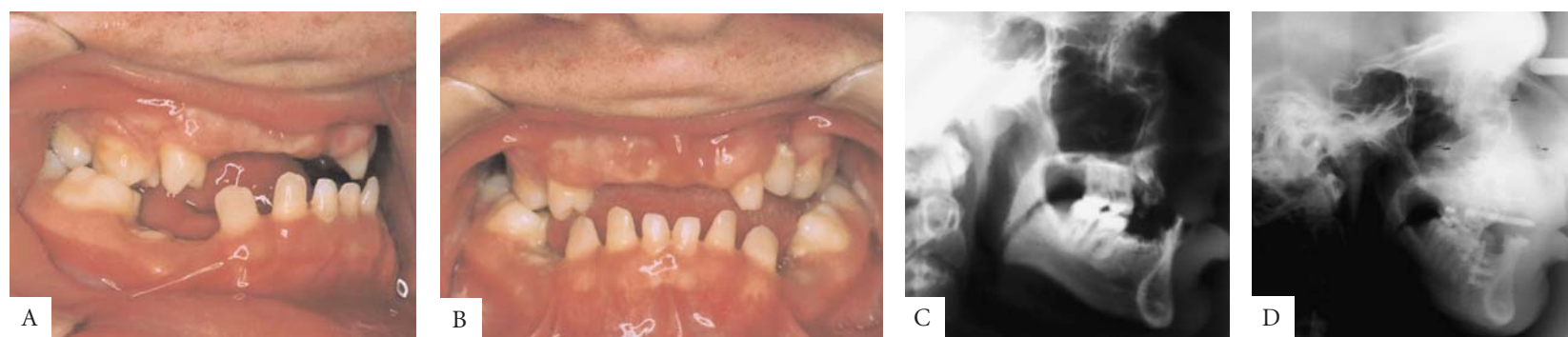


FIGURE 62-16 Patients with anterior maxillary congenital deformities including anodontia (A, B) are treated with anterior segmental maxillary distraction osteogenesis (DO) and concomitant posterior mandibular DO widening (C, D).

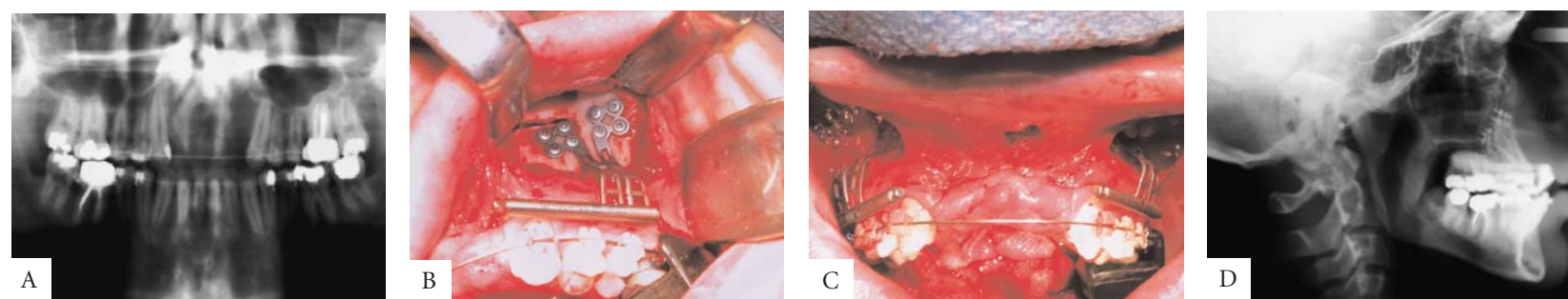


FIGURE 62-17 A, Patients with traumatic avulsion of the premaxillary segment can be treated with segmental anterior distraction osteogenesis. B, The bone cut is made parallel to the occlusal plane and the distractors placed via a tunneling technique (Courtesy of KLS Martin L.P., Jacksonville, FL). C, D, A flat plane occlusal splint is inserted to allow for impedance-free maxillary advancement.

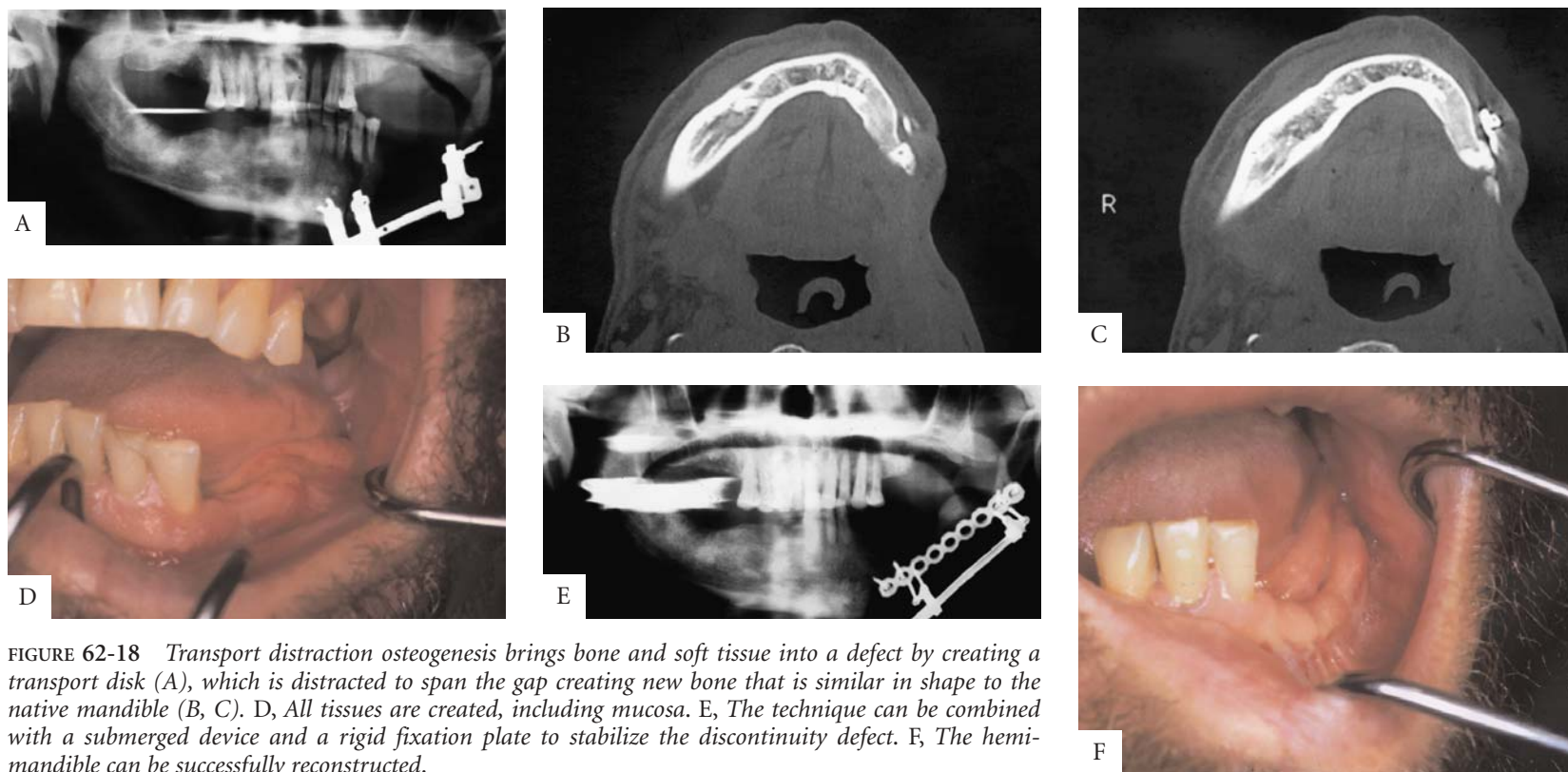


FIGURE 62-18 Transport distraction osteogenesis brings bone and soft tissue into a defect by creating a transport disk (A), which is distracted to span the gap creating new bone that is similar in shape to the native mandible (B, C). D, All tissues are created, including mucosa. E, The technique can be combined with a submerged device and a rigid fixation plate to stabilize the discontinuity defect. F, The hemimandible can be successfully reconstructed.

distractor removal, the surgeon may need to position a small bone graft between the transport disk and the docking site because the transport disk becomes rounded and encased with a fibrocartilagenous cap. Obtaining osseous union necessitates removal of this intervening fibrocartilagenous cap.

During active DO, monitor the patient closely to rule out soft tissue dehiscence. Occasionally the leading edge of the transport disk can migrate through the soft tissue. The suggested local wound-care measures include antibiotics and antimicrobial mouth rinses. A blood supply that is compromised (eg, a patient status post-radiation therapy) indicates disk dancing until the dehiscence site closes.

Symphyseal reconstruction can be difficult because the regenerate chamber tends to assume a straight line, rather than follow and maintain the curvilinear shape.²⁸ Use molding devices, including an intraoral surgical guide, to facilitate and maintain the shape of the regenerate chamber (see Figure 62-19).²⁹ Viewed

from above, the dentoalveolar unit assumes an arcuate form. Viewed from below, the mandible assumes five lines: two body regions, two parsymphyseal regions, and one symphyseal region. Thus, plan for five linear distraction vectors to reconstruct the mandible (Figure 62-20).

One alternative treatment plan calls for the creation of a large transport disk (1.5 to 3.0 cm) advanced in a linear fashion until the junction of the next linear segment.²⁸ The disk is held in neutral fixation for a few days or weeks until early ossification occurs. Subsequently, the disk is divided into two segments, with one-half of the original transport disk held in place to the reconstruction plate. The other one-half becomes a new transport disk reoriented in the proper vector, which, after a 3- to 5-day latency, is advanced by distraction in the new trajectory (see Figure 62-20).

Transport distraction has been used successfully either in primary reconstruction at the time of bone resection or in secondary reconstruction. For primary

reconstruction, the devices are placed at the time of resection. If a concomitant neck dissection is done, then the latency period should be increased to 7 days. For secondary reconstruction, limited surgical dissection is advocated. As the soft tissue bed may be heavily scarred, the distraction rhythm may need to be altered to four times a day rather than twice a day to allow incremental stretching of the overlying soft tissues. Tension within the overlying soft tissue may cause daily “relapse” by

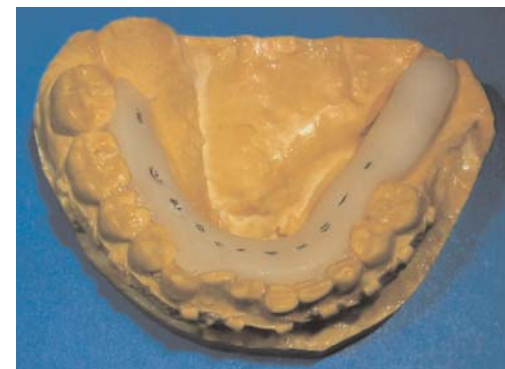


FIGURE 62-19 Surgical guides can be fabricated to help maintain the curvilinear shape of the regenerate during transport distraction osteogenesis.

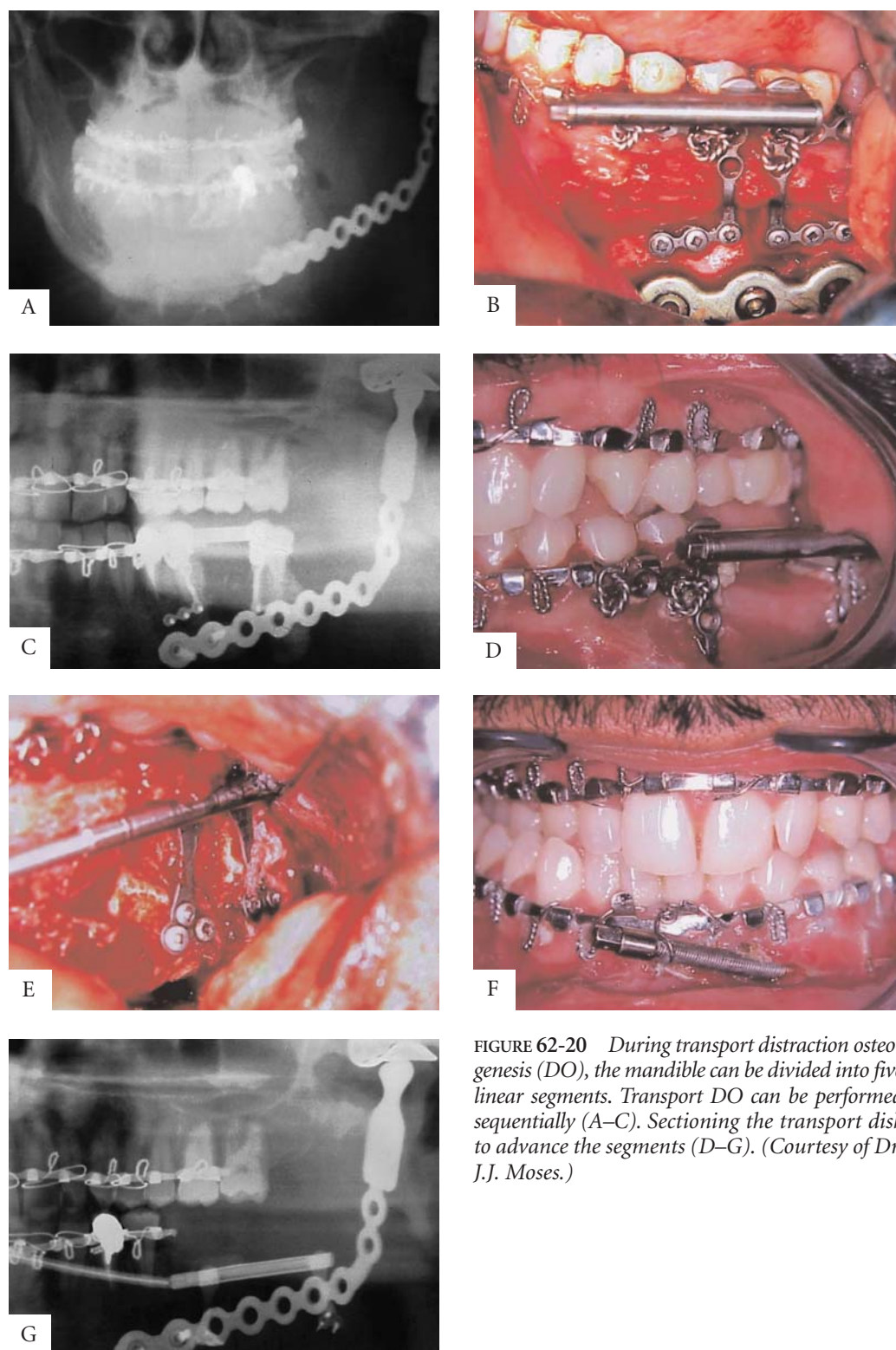


FIGURE 62-20 During transport distraction osteogenesis (DO), the mandible can be divided into five linear segments. Transport DO can be performed sequentially (A–C). Sectioning the transport disk to advance the segments (D–G). (Courtesy of Dr. J.J. Moses.)

exerting a counterforce on the transport disk. Transport DO has been used to successfully create a neomandible in patients who have had post-resection radiation therapy.^{30,31} Although predistraction

hyperbaric oxygen therapy is appropriate, it is not mandatory. During active distraction, neovascularization has occurred.³² Use transport DO to reconstruct a neomandible without hyperbaric oxygen ther-

apy. The distraction rate is reduced to 0.5 mm per day, and the overlying soft tissues are carefully monitored.

DO can be used in conjunction with conventional reconstructive techniques (eg, microvascular flaps). One concern, however, is that the donor bone, such as a fibula, may not have the ideal form post-mandibular reconstruction for implant placement and prosthetic reconstruction. Use distraction as a secondary technique to obtain ideal height and width for implant reconstruction.³³ The technique is similar to that for DO of an atrophic mandible for dental implants.

Transport Distraction to Generate a Neocondyle

During transport DO, the transport disk becomes rounded and covered by a fibrocartilagenous cap. This cap is removed to ensure osseous continuity in mandibular reconstruction. Use this fibrocartilagenous cap to reconstruct a neocondyle.^{34–36} Create a reverse L osteotomy in the ramus of the mandible from the sigmoid notch behind the lingua to 1.0 to 1.5 cm above the inferior border of the mandible (Figure 62-21). The distractor is oriented vertically, almost parallel to the posterior border of the ramus, to guide the transport disk into the fossa, creating a neocondyle. In the same way, the segment can be overdistracted to increase posterior vertical ramal height and to reestablish the gonial angle. For bilateral cases, a coronoidectomy prevents rotation of the proximal segment from temporalis muscle pull during the DO process.

In patients who have bony ankylosis, carry out a gap arthroplasty concomitantly with the distraction surgery (Figure 62-22). As the neocondyle assumes the form of the fossa, it is important to surgically shape the new fossa well in all three planes of space during the gap arthroplasty portion of the procedure. Distraction is initiated after a 5-day latency period and proceeds until the transport disk reaches the glenoid fossa.

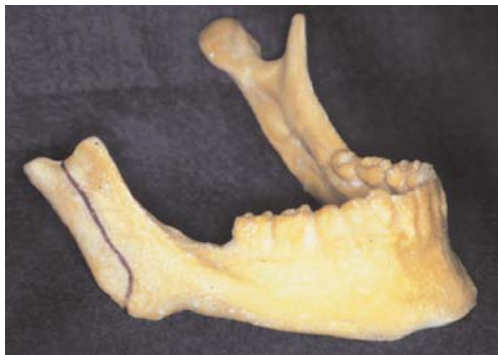

FIGURE 62-21 A reverse L osteotomy is performed in the ramus of the mandible for condylar transport distraction osteogenesis.

The patient will remark that they can feel pressure as the articulation of the condyle and fossa is reestablished. This is confirmed radiographically. The DO device is held in neutral fixation until a cortical outline is viewed in the regenerate chamber near the angle of the mandible.

Patients with condylar resorption (idiopathic, degenerative, and rheumatoid arthritis) experience a loss of posterior vertical height and an anterior open bite as a consequence of the resorptive process of the condyle. The slow applica-

tion of force over time via DO to generate new bone is ideally suited to patients requiring mandibular advancement who have a history of temporomandibular joint involvement. Using the same osteotomy, the ramus is over distracted, creating an edge-to-edge Class III profile (Figure 62-23). Remove the distractors after 3 weeks of osseous consolidation, and mold the regenerate using orthodontic elastics to rotate the mandible counter clockwise and to close the open bite. Elastic maxillomandibular fixation is not required to mold the regenerate. Insert a maxillary splint to decrease the load on the temporomandibular joints. Likewise, instruct patients to wear the molding elastics in intervals, allowing other time intervals for free mandibular movement (ie, 4 hours in elastics and 3 hours off). Monitor patients closely, and if the patient complains of preauricular discomfort or limitation of motion, adjust the regenerate molding protocol.

Regardless of the etiology, all patients undergoing condylar transport DO are in active physical therapy during the entire DO

process and are also instructed about at-home physical therapy exercises. Success of the transport DO technique to create a neocondyle depends on mandibular motion.

Alveolar Distraction Osteogenesis for Dental Implants

Bone grafting techniques for alveolar ridge reconstruction prior to dental implant reconstruction are well established. For cases requiring greater than 4 to 5 mm, apply vertical height augmentation, or if the overlying soft tissue may not support osseous augmentation, alveolar DO is a useful treatment alternative.³⁷⁻³⁹

Carry out a vestibular incision to approach the site. Minimal periosteal stripping is advocated as the transport disk is small. Carefully create the bone cut, using a saw or bur for the horizontal cut, and use chisels at the alveolar crest, sparing the lingual or palatal periosteum. The distractor is adapted to the site. Apply the distractor to the outer cortical surface of the regenerate chamber or place with a central activation pin extending transosseously (Figure 62-24). Once placed, activate the distractor

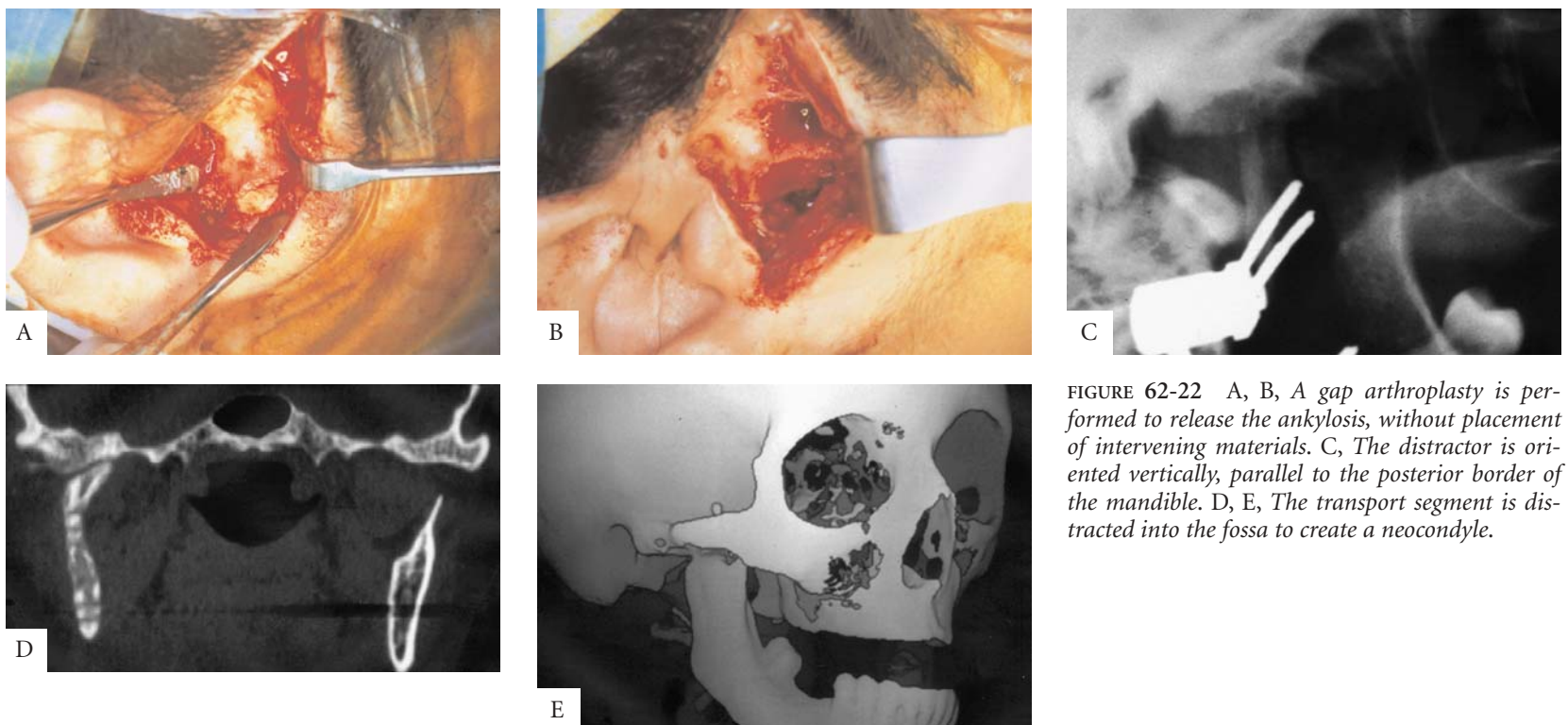


FIGURE 62-22 A, B, A gap arthroplasty is performed to release the ankylosis, without placement of intervening materials. C, The distractor is oriented vertically, parallel to the posterior border of the mandible. D, E, The transport segment is distracted into the fossa to create a neocondyle.

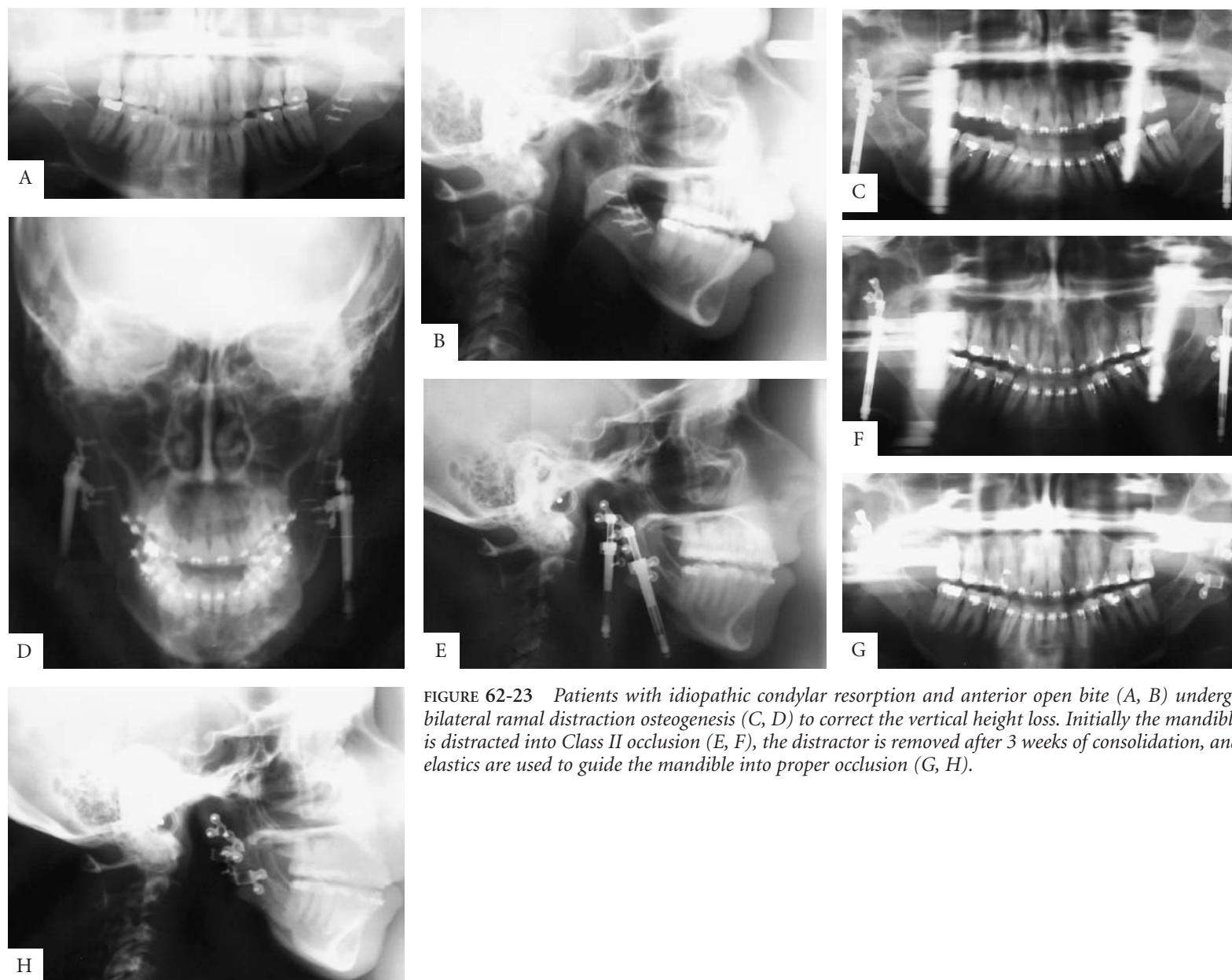


FIGURE 62-23 Patients with idiopathic condylar resorption and anterior open bite (A, B) undergo bilateral ramal distraction osteogenesis (C, D) to correct the vertical height loss. Initially the mandible is distracted into Class II occlusion (E, F), the distractor is removed after 3 weeks of consolidation, and elastics are used to guide the mandible into proper occlusion (G, H).

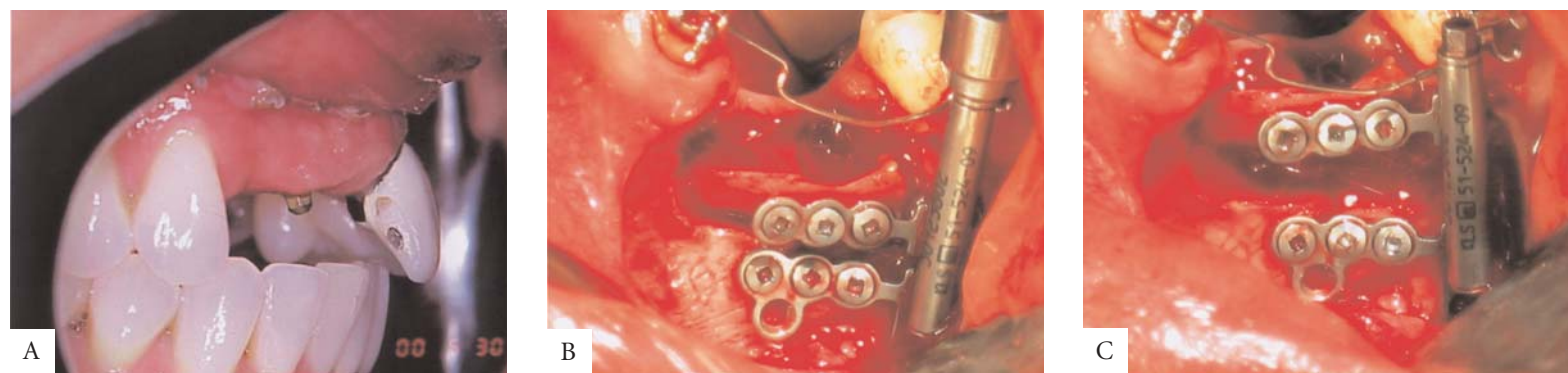


FIGURE 62-24 Alveolar distractors are interosseous (A) or extraosseous (B). C, After device application the distractor is activated to ensure impedance-free movement of the segment. The transport disk is then returned to the closed position.

to check for impedance-free movement of the distraction segment. Remove any bony interferences. The wound is closed and after a 3- to 5-day latency, the distractor is activated up to 0.7 to 1.0 mm per day. The distraction disk is small; thus, a rate of 0.5 to 0.7 mm per day is advocated if the blood supply to the segment is compromised. Distraction proceeds until the desired amount of bone is obtained. Often the segment is overdistracted to a position above the alveolar crest of the adjacent teeth. During implant placement, the excess crestal bone can be sculpted and contoured using a periodontal bur that produces an esthetic implant site. The segment is held in place to allow for ossification. Some authors recommend 8 weeks of ossification, whereas others recommend 12 weeks prior to implant placement.^{37,39} Initially, the regenerate chamber is radiolucent. This decreases with time, but the regenerate chamber will continue to be less radio-

dense for up to 1 year post-distraction. Applying platelet rich plasma (PRP) into the distraction gap at the time of initial distraction surgery may increase DO bone ossification.⁴⁰

Both interosseous and extraosseous distraction devices work well; however, they have some drawbacks. Devices placed on the outer cortical surface may cause slight buccal resorption of the outer cortex, requiring a “patch graft” at the time of device removal. Placing a guided bone regeneration (GBR) membrane next to the bone below the distraction device will also act to decrease this buccal resorption.⁴¹ Devices that are placed transosseously result in fibrous tissue in-growth around the central distraction pin. This tissue is removed at the time of the device removal but can limit immediate implant placement. Dental implants may be placed at the time of distractor removal or at 1 month later. Second-stage implant place-

ment allows the soft tissues to mature and facilitates treatment planning for ideal implant placement. Place implants to span the regenerate chamber, including a portion of the distal osteotomy site.

Vector control is paramount with small-segment distraction, such as DO for dental implants. The small bone segments are under local muscle pull, especially the mylohyoid. Vector control devices, including orthodontic appliances and interim treatment partials with an access hole for the DO device activation rod, are useful to help guide the distractor into place (Figure 62-25). Callus manipulation as previously described may be performed under local anesthesia to re-direct the proper path of distraction. New alveolar DO devices that incorporate hinges allow the clinician to redirect the vector during active distraction (Figure 62-26).^{42,43}

Local osseous anatomy can influence distraction device placement. The fixation plates of an extraosseous device may require bending to make the distraction pin more vertical and to optimize the ideal vector. Placing the device flush directly on the bone surface can direct the bone segment in an inappropriate direction, as is the case with the atrophic anterior maxilla and mandible (Figure 62-27). Similarly, to ensure proper device trajectory, the central pin hole of an intraosseous device may require angling more buccally than along the central axis of the alveolus. The fixation plates may need altering that takes into account the local anatomy, including the mental nerve and piriform rim regions. In fact, place the extraosseous device in a cantilever fashion with the central portion of the device offset (Figure 62-28).

Knife-edge ridges can be a difficult problem. Distracting the alveolus in a straight vertical direction will produce an increase in height but a narrow bone stock. Perform differential distraction by performing the lingual cut incompletely, allowing the lingual site to act as a “hinge.”^{44,45} The

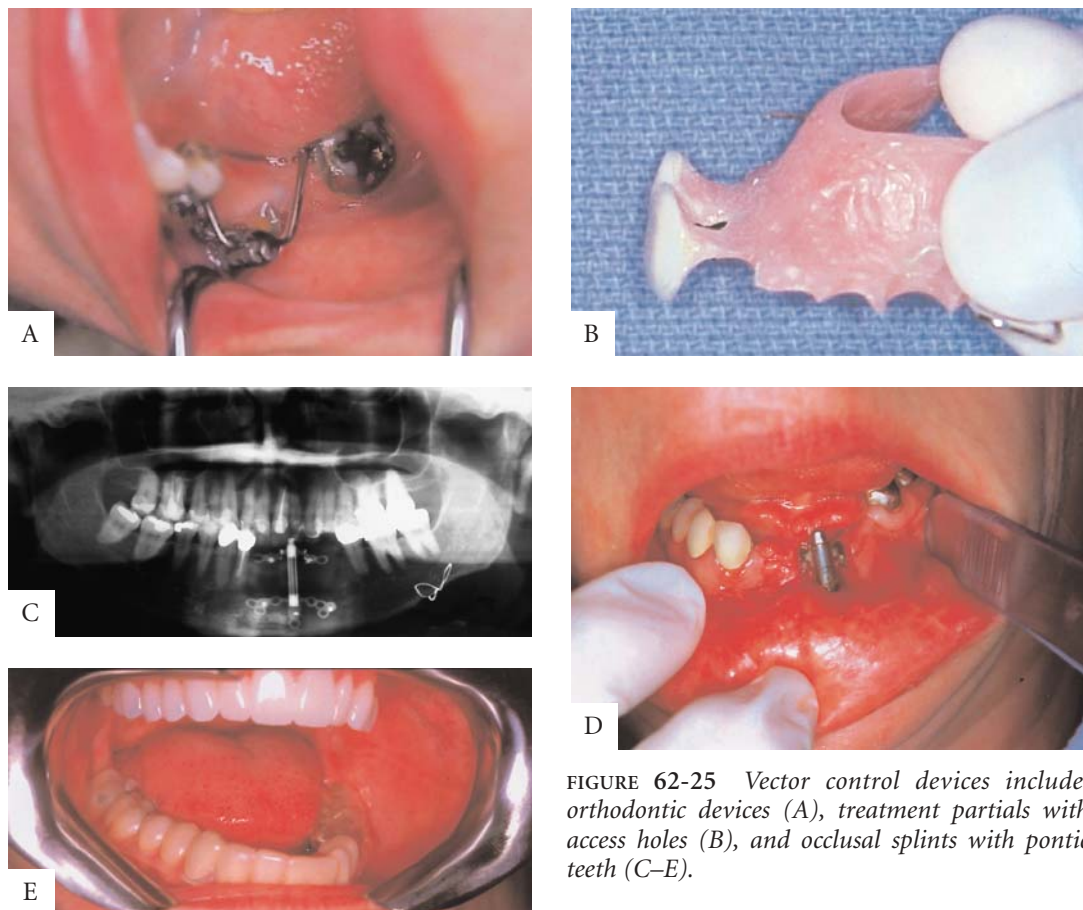


FIGURE 62-25 Vector control devices include: orthodontic devices (A), treatment partials with access holes (B), and occlusal splints with pontic teeth (C–E).

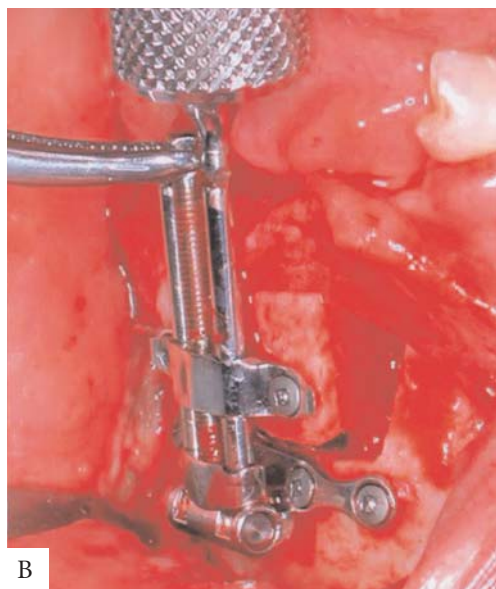
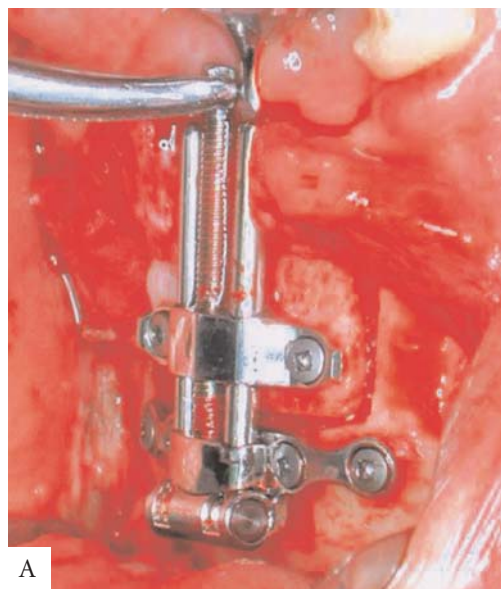


FIGURE 62-26 A and B, Alveolar distraction devices with internal hinges allow for vector adjustment during active distraction osteogenesis. (Courtesy of Dr. M. Robinoy.)

device is placed, and distraction proceeds as usual. The hinge motion allows the buccal wall to be initially distracted differentially more than the lingual; specifically, the buccal site “opens” to create a flat crestal surface suitable for implants (Figure 62-29).

Posterior saddle deformities of the mandible are also problematic. The curve of Spee dictates that straight vertical distraction results in generating more bone in the retromolar region. To alleviate this

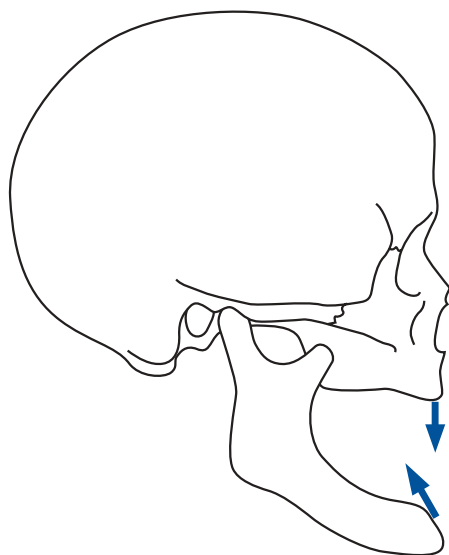


FIGURE 62-27 Placing the extraosseous distractor flush on the native bone will produce a poor trajectory to the vector.

problem, make an L-shaped bone cut adjacent to the remaining teeth, and use a monocortical miniplate to fixate the posterior-most portion on the bone cut (Figure

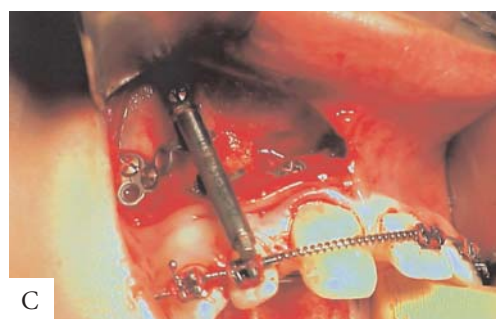
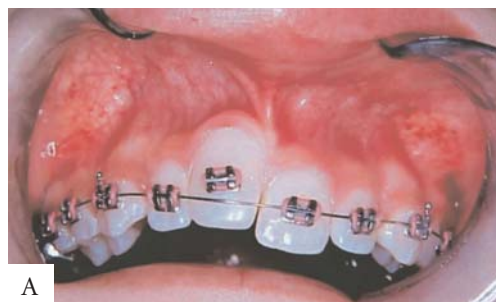

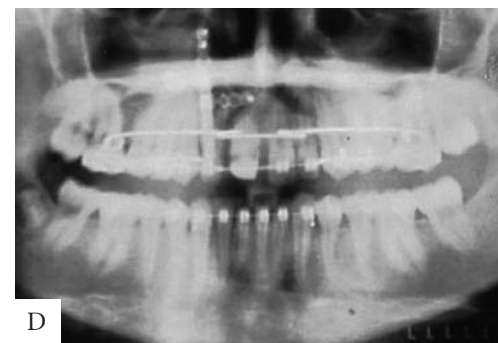
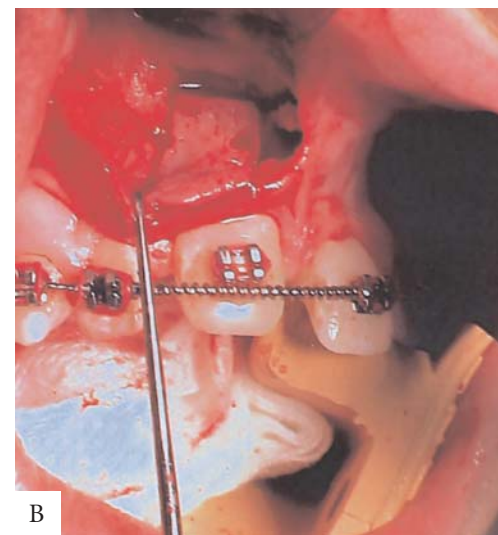
FIGURE 62-28 A, Distraction osteogenesis (DO) was performed prior to extraction of this malpositioned, ankylosed, previously hopelessly avulsed tooth. B, DO prior to extraction facilitated proper crestal bone and gingival height. C, D, The DO device is placed lateral to the transport disk in a cantilever fashion to optimize bone stock for device placement.

62-30).^{45,46} Distraction proceeds with the anterior portion of the distraction segment rotating and hinging around the distal fixation plate to differentially increase the anterior region.

Use distraction to reconstruct atrophic edentulous maxillas and mandibles. The technique is the same. One device is placed in the midline, and the vector is adjusted to distract the bone segment up and buccally. To avoid fracture of the atrophic mandible, modify the bone cut to a trapezoidal shape. Rounding the internal corners of the osteotomy eliminates local inherent stresses, which have been associated with mandibular fractures.⁴⁷ For severely atrophic cases, place a reconstruction plate, in conjunction with the distraction devices, at the time of the osteotomy.⁴⁸

Complications

Most complications associated with the distraction technique are iatrogenic and



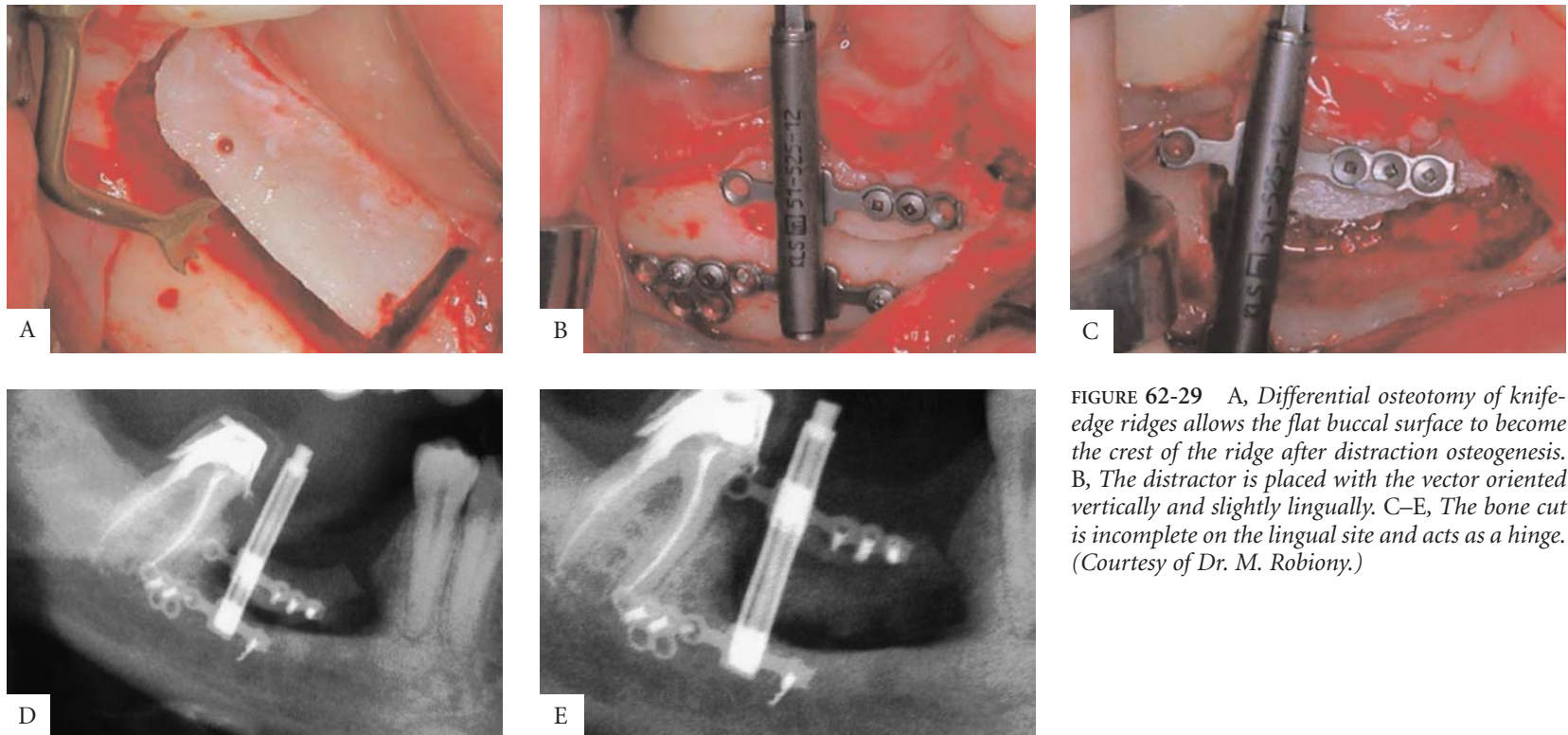


FIGURE 62-29 A, Differential osteotomy of knife-edge ridges allows the flat buccal surface to become the crest of the ridge after distraction osteogenesis. B, The distractor is placed with the vector oriented vertically and slightly lingually. C–E, The bone cut is incomplete on the lingual site and acts as a hinge. (Courtesy of Dr. M. Robiony.)

easily managed.^{49,50} Inaccurate planning may lead to poor vector trajectory of the bone segments. Molding the regenerate can alleviate this problem. Careful follow-

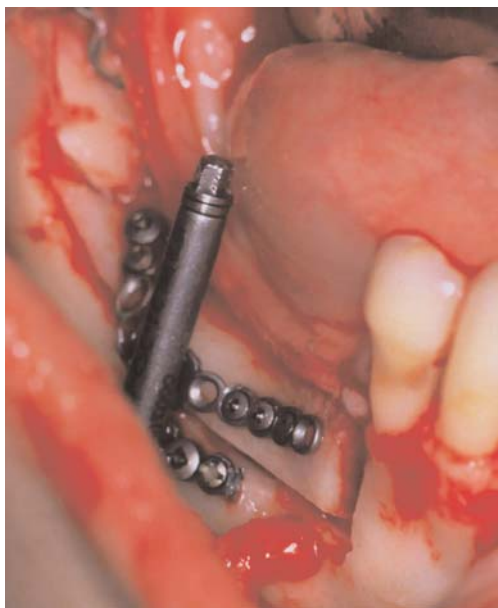


FIGURE 62-30 For posterior mandibular saddle deformities, an L-shaped osteotomy is performed in the alveolus with a monocortical miniplate placed at the distal tip acting as a hinge. (Courtesy of Dr. G. Milessi.)

up is mandatory during the entire distraction process, including the time of post-distraction ossification. During this latter time period, the regenerate chamber is fully extended and is most under the influence of local muscle pull. Also, the period of post-distraction ossification is the best time to easily mold the regenerate.

Wound dehiscence problems can occur. Local wound care, including antibiotics and antimicrobial mouth rinses, alleviates this problem. Disk dancing can be performed to allow the local wound site to heal after which DO can begin. Occasionally, however, the distractor fixation screw heads become visible, but this is not a concern. Overdistraction of the segment can compensate for potential crestal bone loss from screw-head exposure.

References

1. Ilizarov GA. The principles of the Ilizarov method. *Bull Hosp Joint Dis* 1988;48:1–16.
2. Karp NS, McCarthy JG, Schreiber JS, et al. Membranous bone lengthening: a serial histologic study. *Ann Plas Surg* 1992;29:2.
3. Herford A, Audia F, Stucki-McCormick SU. Alveolar distraction osteogenesis and vector control—a preliminary report. In: Arnaud E, Diner PA, editors. *Proceedings 3rd International Meeting on Craniofacial DO*; 2001 Jun 14–16; Paris, France. Bologna (IT): Monduzzi; 2001.
4. Hoffmeister B, Marcks CH, Wolff KP. The floating bone concept in intraoral distraction. *J Craniomaxillofac Surg* 1998;26 Suppl 1:76–81.
5. Moses JJ. Sagittal distraction of the mandible: a technique for nerve preservation and condylar axis stability. *Proceedings 4th International Congress of Osteogenesis of the Facial Skeleton*; 2003 Jul 2–5; Paris, France. Bologna (IT): Monduzzi; 2003.
6. Watzinger F, Wanschitz F, Rasse M, et al. Computer-aided surgery in distraction osteogenesis of the maxilla and mandible. *Int J Oral Maxillofac Surg* 1999;28:171–5.
7. McCarthy JG, Stelnicki EJ, Grayson BH. Distraction osteogenesis of the mandible: a ten-year experience. *Semin Orthod* 1999;1:3–8.
8. Grayson BH, Stucki-McCormick SU, Santiago PE. Vector of device placement and trajectory of mandibular distraction. *J Craniofac Surg* 1998;8:473–80.
9. Stucki-McCormick SU, Fox R, Mizrahi R. Distraction osteogenesis for congenital mandibular deformities. *Atlas Oral Maxillofac Surg Clin North Am* 1999;7:85–110.
10. Perlyn CA, Schmelzer RE, Sutera SP, et al. Effect of distraction osteogenesis of the

- mandible on upper airway volume and resistance in children with micrognathia. *Plast Reconstr Surg* 2002;109:1809–18.
11. Denny A, Kalantarian B. Mandibular distraction in neonates: a strategy to avoid tracheostomy. *Plast Reconstr Surg* 2002;109:896–904.
 12. Woodson BT, Hanson PR, Melugin MB, Gama AA. Sequential upper airway changes during mandibular distraction for obstructive sleep apnea. *Otolaryngol Head Neck Surg* 2003;128:142–4.
 13. Smith KS. Pediatric sleep apnea and treatment with distraction osteogenesis. *Ann R Australas Coll Dent Surg* 2000;15:163–7.
 14. Cope JB, Yamashita J, Healy S, et al. Force level and strain patterns during bilateral mandibular osteodistraction. *J Oral Maxillofac Surg* 2000;58:171–89.
 15. Cope JB, Samchukov ML, Cherkashin AM, et al. Biomechanics of mandibular distractor orientation: an animal model analysis. *J Oral Maxillofac Surg* 1999;57:952–64.
 16. Contasti G, Guerrero C, Rodriguez AM, Legan HL. Mandibular widening by distraction osteogenesis. *J Clin Orthod* 2001;35:165–73.
 17. Bell WH, Gonzalez M, Samchukov ML, Guerrero CA. Intraoral widening and lengthening of the mandible in baboons by distraction osteogenesis. *J Oral Maxillofac Surg* 1999;57:548–63.
 18. Kewitt GF, Van Sickels JE. Long-term effect of mandibular midline distraction osteogenesis on the status of the temporomandibular joint, teeth, periodontal structures, and neurosensory function. *J Oral Maxillofac Surg* 1999;57:1419–26.
 19. Guerrero CA, Bell WH, Contasti GI, Rodriguez AM. Intraoral mandibular distraction osteogenesis. *Semin Orthod* 1999;5:35–40.
 20. Molina F. Combined maxillary and mandibular distraction osteogenesis. *Semin Orthod* 1999;5:41–5.
 21. Padwa BL, Kearns GJ, Todd R, et al. Simultaneous maxillary and mandibular distraction osteogenesis with a semiburied device. *Int J Oral Maxillofac Surg* 1999;28:2–8.
 22. Moses JJ, Vega L. Sagittal distraction of the mandible. In: Arnaud E, Diner PA, editors. *Proceedings 3rd International Meeting on Craniofacial DO*; 2001 Jun 14–16; Paris France. Italy. Bologna (IT): Monduzzi;2001.
 23. Polley JW, Figueroa AA. Rigid external distraction: its application in cleft maxillary deformities. *Plast Reconstr Surg* 1998;102:1360–74.
 24. Cohen SR. Midface distraction. *Semin Orthod* 1999;5:52–8.
 25. Ahn JG, Figueroa AA, Braun S, Polley JW. Biomechanical considerations in distraction of the osteotomized dentomaxillary complex. *Am J Orthod Dentofacial Orthop* 1999;116:264–70.
 26. Liou EJ, Chen PK, Huang CS, Chen YR. Interdental distraction osteogenesis and rapid orthodontic tooth movement: a novel approach to approximate a wide alveolar cleft or bony defect. *Plast Reconstr Surg* 2000;105:1262–72.
 27. Costantino PD, Buchbinder D. Mandibular distraction osteogenesis: types, applications, and indications. *J Craniofac Surg* 1996;7:404–7.
 28. Guerrero CA, Gonzalez M. Intraoral bone transport by distraction osteogenesis in mandibular reconstruction. In: Arnaud E, Diner PA, editors. *Proceedings 4th International Congress of Osteogenesis of the Facial Skeleton*; 2003 Jul 2–5; Paris, France. Bologna (IT): Monduzzi; 2003.
 29. Herford AS. Use of a plate guided distraction device for transport distraction osteogenesis of the mandible. In: Arnaud E, Diner PA, editors. *Proceedings 4th International Congress of Osteogenesis of the Facial Skeleton*; 2003 Jul 2–5; Paris, France. Bologna (IT): Monduzzi; 2003.
 30. Stucki-McCormick SU, Fox R, Mizrahi R, Erickson M. Transport distraction: mandibular reconstruction. *Atlas Oral Maxillofac Surg Clin North Am* 1999;7:65–84.
 31. Gantous A, Phillips JH, Catton P, Holmberg D. Distraction osteogenesis in the irradiated canine mandible. *Plast Reconstr Surg* 1994;93:164–8.
 32. Aronson J. Temporal and special increases in blood flow during distraction osteogenesis. *Clin Orthop Rel Res* 1994;301:124–31.
 33. Klesper B, Lazar F, Siessegger M, et al. Vertical distraction osteogenesis of fibula transplants for mandibular reconstruction – a preliminary study. *J Craniomaxillofac Surg* 2002;30:280–5.
 34. McCarthy JG, Stelnicki EJ, Mehrara BJ, Longaker MT. Distraction osteogenesis of the craniofacial skeleton. *Plast Reconstr Surg* 2001;107:1812–27.
 35. Stucki-McCormick SU, Fox RM, Mizrahi RD. Reconstruction of a neocondyle using transport distraction osteogenesis. *Semin Orthod* 1999;5:59–63.
 36. Piero C, Alessandro A, Giorgio S, et al. Combined surgical therapy of temporomandibular joint ankylosis and secondary deformity using intraoral distraction. *J Craniofac Surg* 2002;13:401–10.
 37. Chin M. Distraction osteogenesis for dental implants. *Atlas Oral Maxillofac Surg Clin North Am* 1999;7:41–63.
 38. Jensen OT, Cockrell R, Kuhike L, Reed C. Anterior maxillary alveolar distraction osteogenesis: a prospective 5-year clinical study. *Int J Oral Maxillofac Implants* 2002;17:52–68.
 39. Block MS, Gardiner D, Almerico B, Neal C. Loaded hydroxylapatite-coated implants and uncoated titanium-threaded implants in distracted dog alveolar ridges. *Oral Surg Oral Med Oral Pathol Oral Radiol Endod* 2000;89:676–85.
 40. Robiony M, Polini F, Costa F, Politi M. Osteogenesis distraction and platelet-rich plasma for bone restoration of the severely atrophic mandible: preliminary results. *J Oral Maxillofac Surg* 2002;60:630–5.
 41. Millisi W, Millisi-Schobel G. Alveolar distraction osteogenesis of the mandible. In: Arnaud E, Diner PA, editors. *Proceedings 4th International Congress of Osteogenesis of the Facial Skeleton*; 2003 Jul 2–5; Paris, France. Bologna (IT): Monduzzi; 2003.
 42. Zechner W, Bernhart T, Zauza K, et al. Multi-dimensional osteodistraction for correction of implant malposition in edentulous segments. *Clin Oral Implants Res* 2001;12:531–8.
 43. Stucki-McCormick SU, Moses JJ, Robinson R, et al. Alveolar distraction devices. In: Jensen, editor. *Alveolar distraction osteogenesis*. Carol Stream (IL): Quintessence Publishing Co. Inc; 2002. p. 41–58.
 44. Chin M. Alveolar distraction osteogenesis with endosseous devices in 175 cases. In: Arnaud E, Diner PA, editors. *Proceedings 3rd International Meeting on Craniofacial DO*; 2001 Jun 14–16; Paris, France. Bologna (IT): Monduzzi; 2001.
 45. Stucki-McCormick SU, Moses JJ. Vertical alveolar distraction of the posterior mandible. In: Jensen, editor. *Alveolar distraction osteogenesis*. Carol Stream (IL): Quintessence Publishing Co.; 2002. p. 89–94.
 46. Millesi G, Klug C, Millesi W, et al. Vertical distraction osteogenesis in the mandible combined with L-shaped osteotomy and guided bone regeneration. *Cranio-maxillo-facial distraction*. Graz (AU): University of Graz; 2002.
 47. Hidding J, Lazar F, Zoller JE. The Cologne concept on vertical distraction osteogenesis. In: Arnaud E, Diner PA, editors. *Proceedings 3rd International Meeting on Craniofacial DO*; 2001 Jun 14–16; Paris, France. Bologna (IT): Monduzzi; 2001.
 48. Hidding J, Lazar F, Zoller JE. Initial outcome of vertical distraction osteogenesis of the atrophic alveolar ridge. *Mund Kiefer Gesichtschir* 1999;3 Suppl 1:79–83.
 49. Garcia AG, Martin MS, Vila PG, Maceiras JL. Minor complications arising in alveolar distraction osteogenesis. *J Oral Maxillofac Surg* 2002;60:496–501.
 50. Grayson BH, Santiago PE. Treatment planning and biomechanics of distraction osteogenesis from an orthodontic perspective. *Semin Orthod* 1999;5:9–24.

Surgical and Nonsurgical Management of Obstructive Sleep Apnea

B. D. Tiner, DDS, MD

Peter D. Waite, MPH, DDS, MD

Sleep and dreaming have been sources of mystery and fascination since biblical times. Sleep consists of inevitably recurring episodes of readily reversible relative disengagement from sensory and motor interaction with the environment.¹ The function of sleep remains a mystery, and only in recent years has there been research into specific symptom complexes and causes of sleep disorders. In 1979 the Association of Sleep Disorders Center and the Association for the Psychophysiological Study of Sleep published the first classification of sleep and arousal disorders.²

Modern sleep research became possible in 1924 when Hans Berger, a German psychiatrist, described the recording of human electroencephalography.³ Loomis and colleagues in 1935 published a quantitative description of the four levels of sleep based on electroencephalogram (EEG) characteristics.^{4,5} The historic discovery of a cyclic phase of sleep characterized by rapid conjugate eye movements was made by Aserinsky and Kleitman in 1953.⁶ Subsequent studies confirmed this to be a very active phase of sleep that correlated closely with dreaming.⁷

Normal Sleep Stages

Normal sleep architecture includes both quiet sleep (nonrapid eye movement [non-REM] sleep) and active sleep (rapid eye

movement [REM] sleep). Non-REM sleep consists of four stages which are based largely on the original criteria of Loomis and colleagues.^{4,5} Stage 2 predominates and comprises 45 to 50% of total sleep time. The four stages of non-REM sleep represent progressively deeper sleep marked by the increasing appearance of high-amplitude slow waves in stages 3 and 4, which are collectively known as delta sleep. Non-REM sleep is characterized by a general slowing of all levels of activity. Progression through all four stages of non-REM sleep usually occurs rapidly after sleep onset. REM sleep occurs after non-REM sleep has been established, and the first REM period normally occurs after 70 to 90 minutes of non-REM sleep. The average duration of a period of REM sleep is about 20 minutes. The initial REM period of the night is usually very brief, but subsequent REM periods become longer. During an average night of REM/non-REM cycle progression, 4 to 6 REM periods normally occur at intervals of 60 to 90 minutes. REM sleep occupies about 20 to 25% of total sleep time in a healthy young adult. REM sleep EEG patterns look very similar to those seen during the wakeful state. Generalized skeletal muscle atonia (except for the ocular muscles) and absence of reflexive activity are other features unique to REM sleep. Marked physiologic changes also

occur during REM sleep. Temperature, blood flow, and oxygen use in the brain are increased. Heart rate, blood pressure, and respiration show dramatic fluctuations and increase in average rate.

During sleep the control of respiration is influenced by two systems: the metabolic control system and the behavioral control system.⁸ The influences of hypoxia and hypercarbia on ventilation are the predominant components of the metabolic control system of respiration. This system predominantly controls respiration during non-REM sleep. The behavioral control system governs respiration during voluntary activities, such as swallowing or speaking, and may suppress the ventilatory response to metabolic stimuli. During REM sleep, the effects of hypoxia and hypercarbia on ventilation are much less than during non-REM sleep, and the behavioral control system may predominate. With a blunted response to hypoxia and hypercarbia, irregular respirations, and decreased skeletal muscle tone of the upper airway muscles during REM sleep, an episode of partial or complete airway obstruction with apnea or hypopnea may occur.

Sleep Apnea Syndrome

The sleep apnea syndrome is a disorder characterized by abnormal breathing in

sleep and sleep fragmentation. At least 30 episodes of apnea occur during 7 hours of nocturnal sleep in these patients. Apnea is defined as the cessation of airflow from the nostrils and mouth for at least 10 seconds. These apneic episodes can result in hypoxemia, hypercarbia, systemic and pulmonary hypertension, polycythemia, cor pulmonale, bradycardia, and cardiac dysrhythmias. Sudden death has occurred in patients with sleep apnea. Throughout the night the alternating episodes of apnea and arousal from sleep may occur as frequently as 400 to 600 times, with each typical apnea episode lasting 15 to 60 seconds. These episodes can amount to as much as 50% of a night's sleep. The frequent disruption results in symptoms similar to sleep deprivation. These include excessive daytime sleepiness, fatigue, depression, personality changes, and impotence. These dysfunctional symptoms are common primary complaints and are often the reason people seek treatment.

Epidemiologic data suggest that sleep apnea syndrome may be quite common, particularly in its milder forms. In fact, obstructive sleep apnea is the second most common sleep disorder, insomnia being the most common. A 1993 Sleep Commission Report estimated that 20 million Americans have sleep apnea, with the majority being undiagnosed and untreated.⁹ The exact prevalence is unknown, but sleep apnea syndrome may affect up to 2 to 3% of adult males.⁸ In certain populations the prevalence may be as high as 10%. Most patients are diagnosed after age 40, but sleep apnea can occur at any age. There is a strong male predilection, with men outnumbering women by up to 8 to 1 until menopause. This implies a hormonal influence. The cost for diagnosis and treatment of this sleep disorder accounts for over \$50 million (US) in hospital bills each year. Overall, sleep disorders and sleepiness cost the United States economy a minimum of \$15.9 billion (US) in direct costs each year.¹⁰

Classification

Central sleep apnea, obstructive sleep apnea, and mixed sleep apnea are the variations of apnea that occur in the syndrome. In central sleep apnea, respiratory muscle activity ceases simultaneously with airflow at the mouth and nostrils.¹¹ This disorder is found in patients with central nervous system (CNS) insufficiency that affects the outflow of neural output from the respiratory center to the diaphragm and other muscles of respiration. CNS disorders associated with central sleep apnea include brainstem neoplasms, brainstem infarctions, bulbar encephalitis, bulbar poliomyelitis, spinal surgery, cervical cordotomy, and primary idiopathic hypoventilation.

Patients with central sleep apnea have been treated with some success by using respiratory-stimulating drugs such as theophylline, progesterone, and acetazolamide. In severe central apnea, modalities of treatment have included phrenic nerve pacemaker implantation to ensure regular respiration during sleep and nocturnal mechanical ventilation with a negative pressure ventilator for more severe cases. There are no simple and convenient methods of treatment for mild central apnea.

The most common type of sleep apnea by far is obstructive. This is characterized by sleep-induced obstruction of the upper airway that results in cessation of airflow with preservation of respiratory effort, respiratory center drive, and diaphragmatic contraction.¹¹

Mixed sleep apnea is a combination of central and obstructive apnea. This pattern begins with an episode of central apnea with no airflow detectable at the mouth and nostrils and no respiratory muscle activity. The pattern ends with an episode of obstructive apnea with only cessation of airflow at the mouth and nostrils.¹¹

Differential Diagnosis

Profound hypersomnolence is a characteristic feature of both sleep apnea and nar-

colepsy; hence, they are often confused. However, unlike sleep apnea, narcolepsy affects both sexes equally, with most patients experiencing the onset of symptoms around or shortly before puberty.¹² The first symptom to appear with narcolepsy is usually excessive daytime somnolence (EDS). The sleep attacks can range from mild to severe and are characterized by the sudden onset of overwhelming sleepiness that lasts 30 seconds to 20 minutes. Following brief naps, the narcoleptic usually feels refreshed and relatively free from disturbing symptoms for up to 2 hours. Serious accidents, marital discord, and the inability to hold jobs frequently result from these sleep attacks. Another feature of narcolepsy is the abrupt loss of muscle control (cataplexy). Attacks can be particularly disabling, because they are characteristically precipitated by emotional experiences such as laughter, anger, or excitement. Additional associated symptoms of narcolepsy include sleep paralysis and hypnagogic hallucinations. Sleep paralysis is the skeletal muscle atonia of REM sleep persisting into the awake state. Hypnagogic hallucinations are REM sleep imagery occurring while falling asleep. Patients are sometimes misdiagnosed as schizophrenic if hypnagogic hallucinations are prominent.

Diagnosis of narcolepsy is made by documenting sleep-onset REM periods during a nocturnal polysomnography.¹² In normal sleep REM sleep is usually not seen until about 70 to 90 minutes into sleep. The clinical features of narcolepsy probably represent abnormal manifestations of REM sleep.

Treatment modalities for narcolepsy include behavioral therapies, CNS stimulants, tricyclic antidepressants, or monoamine oxidase inhibitors (only in resistant cases) and L-tryptophan.¹³

Other disorders that may be confused with sleep apnea syndrome include sleep-related abnormal swallowing syndrome, gastroesophageal reflux, depression, alcohol or drug dependence, and sleep-related nocturnal myoclonus.

History of Obstructive Sleep Apnea Syndrome

Obstructive sleep apnea has a remarkably short history considering the incidence and disabling symptoms of the syndrome. Burwell and colleagues published the first description of the syndrome in 1956.¹⁴ Their report compared an obese, somnolent, polycythemic patient with the sleepy red-faced boy, Joe, in the Charles Dickens novel *The Posthumous Papers of the Pickwick Club* (1837). However, Burwell and colleagues did not link their patient's excessive daytime sleepiness to nocturnal sleep fragmentation. In 1966, Gastaut and colleagues were the first investigators to demonstrate repeated apneas in pickwickian patients during sleep.¹⁵ They correctly attributed the excessive daytime somnolence in these patients to nocturnal sleep fragmentation caused by repeated apneas.

The misdiagnosis of narcolepsy in patients with sleep apnea and the general skepticism of excessive daytime somnolence as a valid clinical sign are the two main reasons sleep apnea syndrome was overlooked for so long.

Clinical Manifestations

Sleep apnea patients present with a variety of symptoms and clinical manifestations. Patients with obstructive sleep apnea most often complain of EDS. The patients may experience serious social, economic, and emotional problems from the EDS associated with this disorder. The uncontrollable desire to sleep may predispose the patients to occupational or automobile accidents.

Almost all patients or their bed partners give a history of heavy, loud snoring which has usually been present for several years before the EDS was noted. The snoring is produced from the passage of air through the oropharynx causing vibrations of the soft palate. Typically the snoring is interrupted periodically by

apneic episodes that last 30 to 90 seconds. Bed partners usually describe an episode in which the snoring stops and the patient seems to stop breathing for a period of time. A loud snort followed by a hyperventilation usually signals an end to the apneic episode.

Other common presenting complaints are morning headaches and nausea that result from the hypercarbia which develops with the hypoventilatory episodes. Depression, personality changes, and intellectual deterioration may also develop.

The systemic hypertension that is a common finding in obstructive sleep apnea may be related to the catecholamine release triggered by the systemic hypoxemia. In more advanced severe cases, pulmonary hypertension, polycythemia, and cor pulmonale may develop and become life threatening. However, most patients do not manifest these disturbances because their ventilation during wakeful periods is sufficient to prevent these complications of chronic hypoxia.

A prominent sinus dysrhythmia is commonly associated with the apneic episodes. The extent of bradycardia is directly proportional to the severity of the oxygen desaturation. The greatest degree of cardiac slowing occurs in obstructive apneas in which a Müller maneuver is performed. Increased vagal efferent tone mediates the bradycardia.

The development of severe and life-threatening medical complications from the apneic events clearly depends on the frequency, duration, and degree of hypoxemia and associated hypertensive response.

Physical Findings

A major feature of obstructive sleep apnea is obesity. The increased body weight correlates with increased frequency of apnea and the severity of hypoxemia. However, the morbidly obese, somnolent, hyperventilating patient with cor pulmonale represents only a small number of sleep apnea patients. Lower BMI (body mass index)

patients with obstructive sleep apnea often have more abnormal cephalometrics than obese people.^{16,17}

Obstruction can occur at a number of points in the airway. Physical examination of these patients may reveal hypertrophy of the tonsils or adenoids, retrognathia, micrognathia, macroglossia, deviation of the nasal septum, a thick short neck, or tumors in the nasopharynx or hypopharynx. Both primary and secondary medical conditions are associated with obstructive sleep apnea, owing to their effects on the upper airway anatomy. These may include temporomandibular joint disorders, myxedema, goiter, acromegaly, and lymphoma.

Most patients with classic obstructive sleep apnea have no identifiable craniofacial anomaly. However, there does appear to be a significant subpopulation of sleep apnea patients with craniofacial anomalies.^{18,19} Lowe and colleagues found several alterations in craniofacial form in subjects with obstructive sleep apnea that may reduce the dimensions of the upper airway and subsequently impair stability of the upper airway.²⁰ A sample of 25 adult male patients with moderate to severe obstructive sleep apnea showed a posteriorly positioned maxilla and mandible, a steep occlusal plane, overerupted maxillary and mandibular teeth, proclined incisors, a steep mandibular plane, a large gonial angle, increased upper and lower facial heights, a posteriorly placed pharyngeal wall, and an anterior open bite in association with a long tongue.²⁰ Bacon and colleagues evaluated 32 patients with sleep apnea by cephalometry and demonstrated an anteroposterior shortening of the cranial base, a posterior facial compression with narrowing of the pharyngeal airway, and an increased lower facial height.¹⁸ Rivlin and colleagues reported on nine obstructive sleep apnea patients with posterior displacement of the mandible.²¹ The number of apneas correlated with the total posterior displacement.²¹

Diagnosis

Physical Examination

A diagnostic evaluation includes a thorough history and physical examination, fiberoptic endoscopy, radiologic evaluation, and polysomnography. Little additional information can be gained from routine laboratory tests. Except in severe cases, pulmonary function tests, electrocardiogram (ECG), arterial blood gases, and chest radiographs are often normal during wakefulness in sleep apnea patients.

Other diagnostic tests that may aid in evaluating sleep apnea patients include a complete blood count (CBC), serum electrolytes, and thyroid function tests. Secondary polycythemia may be revealed by a CBC, and nocturnal carbon dioxide retention may be reflected by increased bicarbonate levels. Hypothyroidism, a contributing cause of sleep apnea, may be identified from thyroid function studies.

After a complete history is obtained from the patient and his or her bed partner, a complete clinical examination of the mouth, nasal, pharyngeal, and laryngeal areas is performed. The emphasis of the clinical examination should be the identification of anatomic abnormalities that may contribute to or produce obstruction during sleep. The nose is examined for a deviated nasal septum and enlargement of the turbinates. Micrognathia, retrognathia, and macroglossia may be noted in examination of the oral cavity. Occasionally masses or tumors in the nasopharynx or hypopharynx may be noted. In the pharynx, adenotonsillary hypertrophy, a long soft palate, a large base of the tongue, and excess pharyngeal mucosa are potential causes of obstruction. The larynx is examined for vocal cord webs and paralysis of the vocal cords. Obstructive sleep apnea patients may present with any combination of these anatomic abnormalities.

After topically anesthetizing the nasal cavity and pharynx, a fiberoptic endo-

scope is introduced through the nose. In sequential fashion the nasopharynx, oropharynx, hypopharynx, and larynx are examined. The appearance and position of the soft palate, base of tongue, and lateral pharyngeal walls are evaluated. Changes in the position of the base of the tongue such as forward movement with protrusion of the mandible are noted. The appearance of the pharyngeal airway and degree of pharyngeal wall collapse is noted while the patient performs a modified Müller maneuver. To accomplish this maneuver the patient attempts to inspire with the mouth and nose closed. Increased negative pressure in the pharynx will demonstrate the point of collapse.

Cephalometric Examination

A lateral cephalogram is routinely obtained in the radiologic evaluation of sleep apnea patients (Figure 63-1). Cephalometric analysis is performed to identify any skeletal and soft tissue abnormalities that may exist. The advantages of cephalometry are its easy access, low cost, and minimal radiation exposure. However, it should be recognized that there are obvious limitations of evaluating a three-dimensional area with a two-dimensional lateral cephalometry.

Mandibular or maxillary position can be evaluated by a number of methods including the SNA and SNB angles. Patients with skeletal deficiencies are more likely to have obstruction at the base of the tongue or at the level of the soft palate. Riley and colleagues determined that obstructive sleep apnea patients had an inferiorly positioned hyoid bone, a longer-than-normal soft palate, and a narrowing at the base of the tongue.^{22,23} The position of the hyoid bone is determined by drawing a perpendicular line from the mandibular plane (MP) through the hyoid bone (H). The mean MP-H distance for normal subjects is 15.4 ± 3 mm (see Figure 63-1). The position of the hyoid bone is important because it serves as a central anchor for the muscles of the tongue and thereby partly deter-

mines tongue position. Soft palate length is measured from a line drawn from posterior nasal spine (PNS) to the tip of the soft palate shadow (P). The mean PNS-P distance in normal subjects is 37 ± 3 mm. Posterior airway space is determined by a line drawn from point B through the gonion (Go) intersecting the base of the tongue and the posterior pharyngeal wall. Figure 63-2 demonstrates change in posterior airway spaces following maxillomandibular advancement. Mean posterior airway space in normal subjects was determined to be 11 ± 1 mm. Lower face height is measured from the anterior nasal spine (ANS) to the menton (Me). There is no absolute value for this measurement in obstructive sleep apnea patients. However, some studies have

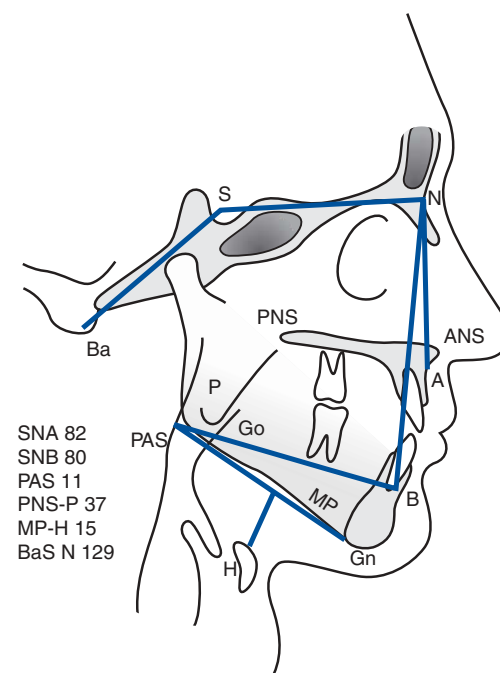


FIGURE 63-1 Cephalometric screening used for initial evaluation of patients with obstructive sleep apnea syndrome. A = A point; ANS = anterior nasal spine; B = B point; Ba = basion; Gn = gnathion; Go = gonion; H = hyoid; MP = mandibular plane; N = nasion; P = palate; PAS = posterior airway space; PNS = posterior nasal spine; S = sella; SNA = sella-nasion–A point; SNB = sella-nasion–B point. Adapted from Tiner BD, Waite, PD. *Surgical and nonsurgical management of obstructive sleep apnea*. In: Peterson LJ, Indresano AT, Marciani RD, Roser SM. *Principles of oral and maxillofacial surgery*. Vol. 3. Philadelphia (PA): J.B. Lippincott Company; 1992. p. 1535.

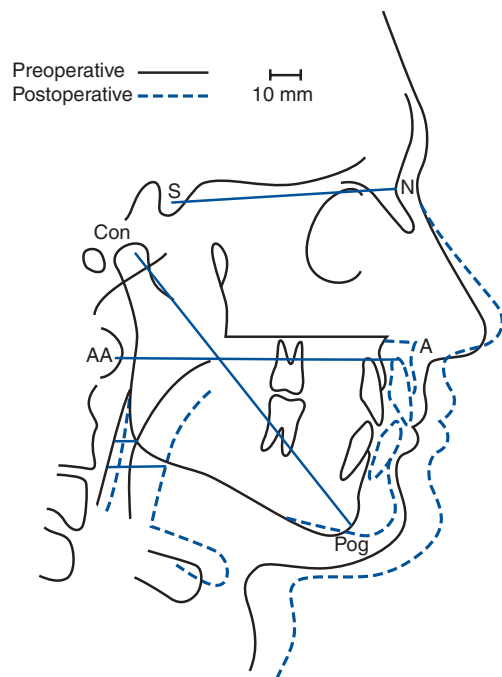


FIGURE 63-2 Change in posterior airway space following maxillary and mandibular advancement. A = A point; AA = anterior edge of atlas; Con = condylion; N = nasion; Pog = Pogonion; S = sella. Adapted from Tiner BD, Waite, PD. *Surgical and nonsurgical management of obstructive sleep apnea*. In: Peterson LJ, Indresano AT, Marciani RD, Roser SM. *Principles of oral and maxillofacial surgery*. Vol. 3. Philadelphia (PA): J.B. Lippincott Company; 1992. p. 1536.

shown an increased lower face height and a shortened cranial base with obstructive sleep apnea patients.¹⁸

Computed Tomography

Computed tomography (CT) is an alternative to cephalometry and has been used to provide a quantitative assessment of the upper airway at various levels. With three-dimensional CT reconstructions, Lowe and colleagues found obstructive sleep apnea patients with larger tongue surface areas and smaller airway surface areas.²⁴ Haponik and colleagues found significantly decreased cross-sectional areas of the nasopharynx, oropharynx, and hypopharynx in obstructive sleep apnea patients when compared with control subjects by using CT scanning.²⁵ Some authorities feel that the airway can only be assessed by a CT scan. However, Riley and colleagues compared patients who

had three-dimensional CT scans and found a statistically significant correlation between the posterior airway space (PAS) measured on the lateral cephalogram and the volume of the pharyngeal airway measured on CT scans.^{23,26} Waite and Villos demonstrated by helical CT analysis that maxillomandibular advancement increases both anteroposterior and lateral dimension of the airway at all levels from nasopharynx to hyoid.²⁷ Many studies are currently being done to determine the effects of patient position and changes in airway. A cephalogram and a CT scan are static evaluations at a fixed time of a dynamic system and they should be viewed as only part of the overall evaluation of the patient.

Polysomnography

Nocturnal polysomnography remains the gold standard for establishing the diagnosis of sleep apnea, quantitating its severity, and determining the success of treatment modalities. The study is performed in a sleep laboratory and the patient's sleep is monitored overnight. At least 4 hours of total sleep time must be recorded for a diagnostic study. The components of the polysomnogram include the EEG, electrooculogram (EOG), electromyogram (EMG), and electrocardiogram (ECG, lead V₂). Sleep staging and architecture are determined by the EEG, EOG, and EMG tracings. Potentially lethal cardiac dysrhythmias are detected by the ECG. Oxygen saturation is measured by ear oximetry. A 5% or greater decrease in arterial oxygen saturation from baseline is significant during episodes of apnea or hypopnea. Respiratory effort and breathing pattern are measured using respiratory inductive plethysmography or by measuring intrathoracic pressure changes with an esophageal balloon catheter. The distinction between an episode of central apnea and obstructive apnea is made by correlating airflow at the nose and mouth with movement of the abdominal and thoracic respiratory muscles. Central apnea occurs

if both airflow and respiratory muscle movement stop simultaneously. An episode of obstructive apnea occurs when airflow at the mouth and nose ceases but respiratory muscles in the abdomen and thorax continue to move dysfunctionally.

Of particular interest are the number of respiratory events (apneas and hypopneas), the number of oxygen desaturations below 90%, and the lowest oxygen desaturation. The respiratory disturbance index (RDI) can be calculated from these data:

$$\text{RDI} = \frac{\text{Apneas} + \text{Hypopneas}}{\text{Total sleep time}} \times 60$$

An RDI greater than 5 is considered abnormal and an RDI greater than 20 is considered clinically significant, because EDS usually does not occur below this level. Obstructive sleep apnea also becomes clinically significant when oxygen desaturation events fall below 85%.

Site of Obstruction

Following a complete presurgical evaluation, each patient is grouped according to the site of obstruction: type I, oropharynx; type II, oropharynx and hypopharynx; type III, hypopharynx. In a review of 40 obstructive sleep apnea patients, Riley and colleagues found the majority of patients had a type II obstruction (soft palate and base of tongue).²⁸

The mandible, base of tongue, hyoid, and pharyngeal wall are intimately related by their muscular and ligamentous attachments. The mandible is related to the base of the tongue by the genioglossus muscle. The tongue, through multiple muscular and connective tissue attachments, is related to the hyoid bone and to the mandible in such a way that retraction of the mandible results in a narrowing of the airway and posterior movement of the tongue. Compensatory mechanisms exist in non-sleep apneic patients to prevent occlusion of the airway. However, in sleep apneic patients, these mechanisms do not exist or are unable to compensate adequately.

Obstruction of the upper airway is primarily prevented by the action of the pharyngeal dilating muscles contracting in phase with respiration. Reduced muscle tone is normal and prominent during REM sleep. However, obstructive sleep apnea patients may have a significant reduction in muscle activity during non-REM sleep so that the pharynx becomes narrower and airway resistance increases. In patients with abnormal skeletal development the reduction in size of the resting airway may predispose them to upper airway obstruction during sleep.

The patency of the upper airway is determined by a balance between the pharyngeal musculature and the negative oropharyngeal pressures that are generated from resistance to airflow in the nasopharynx. Because the airway of obstructive sleep apnea patients is unstable even at rest, any structural narrowing of the airway will eventually hinder the muscular component of the balance. Collapse of the airway in obstructive sleep apnea is primarily a result of high intraluminal negative pressures associated with hypotonic pharyngeal wall musculature and disproportionate anatomy in either the oropharynx or hypopharynx or both. Disproportionate anatomy includes any combination of large base of tongue, long soft palate, narrow mandibular arch, shallow palatal arch, or retrognathic mandible.

Medical Treatment

Once the diagnosis has been confirmed, the treatment approach for sleep apnea is determined by the severity of the physiologic derangements and the predominant type of apnea. Regardless of the predominant type of apnea present, all patients should be cautioned that certain drugs may precipitate or exacerbate obstructive sleep apnea. Alcohol and other central nervous system depressants have been shown to aggravate sleep apnea and even to precipitate apnea and oxygen desaturations in normal persons.²⁹

Weight loss and nasal continuous positive airway pressure are the initial modes of therapy that should be initiated in obese patients with moderate obstructive sleep apnea. A study of 16 patients who lost an average of 20 kg showed fewer apneas, reduced oxygen desaturations, and less daytime sleepiness than a control group of patients who did not lose weight.³⁰ Many patients can relate weight gain in preceding years to an increase in severity of their obstructive sleep apnea symptoms. Unfortunately weight loss by dietary measures is seldom sustained, and obstructive sleep apnea symptoms recur with weight gain. Riley and colleagues found that 47 of 50 obstructive sleep apnea patients who were between 20 and 100% overweight at the time of diagnosis had regained all the weight they had initially lost 5 to 7 years later.³¹

The role of oxygen therapy in the treatment of sleep apnea is controversial. In a study by Motta and Guilleminault, the administration of oxygen increased the duration of apneic episodes and led to worsening of acidosis and hypercarbia during both REM and non-REM sleep.³² It is unknown how many of their patients had chronic obstructive lung disease. Other studies have shown that supplemental oxygen therapy consistently reduced the severity of oxygen desaturation and decreased the frequency of apnea.^{33,34}

The combined experience of these reports suggests that oxygen therapy limited to a flow rate of 2 L/min can be used safely in most obstructive sleep apnea patients and will produce beneficial effects on respiration. The dangers of profound hypoxemia are greater than the concerns of prolonged apnea, acidosis, and hypercarbia. The effects of oxygen therapy on a patient with severe airway obstruction or chronic respiratory acidosis should be monitored with oximetry or polysomnography.

Several drugs have been used in the treatment of obstructive sleep apnea syn-

drome with variable results. The carbonic anhydrase inhibitor acetazolamide stimulates respiration by producing a metabolic acidosis. This drug reduced the number of apneas and decreased the severity of oxygen desaturations in a group of patients with central sleep apnea.³⁵ However, in several cases, acetazolamide given to patients with mild obstructive sleep apnea produced more frequent obstructive apneas of longer duration.³⁶ Therefore, acetazolamide is probably not indicated in the management of obstructive sleep apnea syndrome.

Some patients with obstructive sleep apnea benefit from the respiratory stimulant effect of progesterone, especially those with the obesity-hypoventilation syndrome.³⁷⁻⁴⁰ Progesterone increases alveolar ventilation and improves oxygenation, but its effect on frequency of apnea is limited. Major side effects that limit its long-term use include decreased libido, alopecia, and impotence.

The tricyclic antidepressant protriptyline is the most effective and best studied drug for the treatment of obstructive sleep apnea.⁴¹ In a study of 12 patients, Smith and colleagues showed a reduction in apnea frequency and oxygen desaturation during non-REM sleep, in addition to a decrease in REM sleep.⁴² Protriptyline produces its beneficial effect by a preferential stimulation of upper airway muscle tone and by decreasing the percentage of time spent in REM sleep, thereby reducing the more severe REM-related apneas. Anticholinergic side effects such as dry mouth, constipation, urinary retention, and impotence are frequent and limit its use.

Oral Appliances

The use of a variety of prosthetic devices is another approach to treatment. The nasopharynx and the posterior tongue are the two anatomic areas of concern. Insertion of a nasopharyngeal airway has been used to prevent upper airway occlusion at the level of the soft palate.⁴³ The American Sleep Disorders Association recommends

that oral appliances may be used in patients with primary snoring, mild obstructive sleep apnea, or in patients with moderate to severe obstructive sleep apnea who refuse or are intolerant of nasal continuous positive airway pressure. The Food and Drug Administration has granted market clearance for 32 oral appliances for snoring but only 14 of these have received market clearance for treatment of snoring and obstructive sleep apnea (Table 63-1).⁴⁴ Common side effects of oral appliance therapy include excessive salivation, xerostomia, soft tissue irritations, transient discomfort of the teeth and temporomandibular joint (TMJ), and temporary minor occlusal changes. Uncommon, more serious complications include permanent occlusal changes and significant TMJ discomfort.

Removable anterior repositioning splints have been used somewhat successfully to temporarily advance the mandible while passively bringing the tongue forward with it.⁴⁴⁻⁴⁶ The optimal amount of forward movement is between 50 and 75% of the patient's maximum protrusive distance. An important design feature of these devices is that the appliance must maintain the mandible in the forward position while the patient is asleep. Bear

and Priest used a mandibular anterior repositioning splint to determine whether surgical advancement of the mandible would have any lasting and positive effect on a patient's obstructive sleep apnea.⁴⁷

A tongue-retaining device (TRD) that pulls the tongue forward without moving the mandible forward has also been used successfully in some patients with mild to moderate obstructive sleep apnea.^{48,49} The TRD functions by placing the tongue into a cup or bubble positioned between the anterior teeth. Surface adhesion holds the tongue in place and the appliance requires that the patient's jaw remains partially open. One disadvantage of the TRD is that the tongue is not always held forward because surface tension of the tongue in the bubble is lost after a time. The TRD and mandibular anterior repositioning splints both force nasal breathing, which can be difficult for patients with inadequate nasal airways.

Arguably, the most researched oral appliance is the Klearway titratable appliance developed by Alan Lowe, DMD, PhD, at the University of British Columbia, Canada. It features a maxillary and mandibular component connected with an adjustable screw mechanism (Figure 63-3). The components

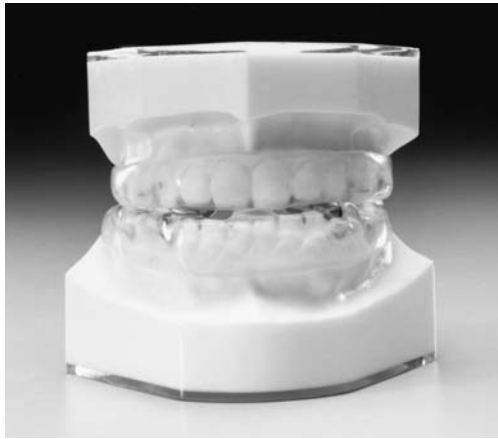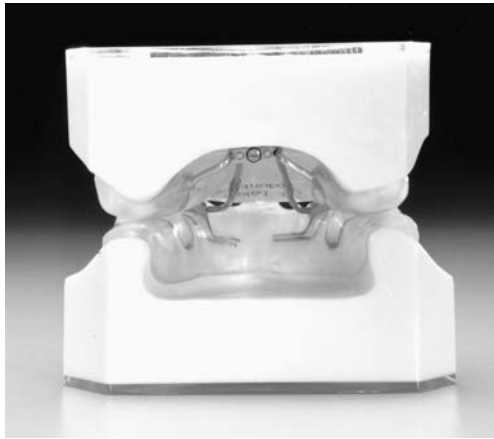are made of a thermoactive acrylic resin that is slightly soft at body temperatures and very compliant at high temperatures. This property decreases major tooth discomfort and considerably increases retention in those patients who have lost a significant number of teeth. A unique feature of the Klearway appliance is that it permits both lateral (1 to 3 mm) and vertical (1 to 5 mm) jaw movement during sleep which reduces the risk of TMJ and jaw muscle discomfort. This movement also facilitates oral breathing in patients with nasal airway obstruction. The screw mechanism of the appliance allows for an 11 mm anterior movement of the mandible with a total of 44 incremental steps of 0.25 mm. In a study of 38 patients with moderate to severe obstructive sleep apnea by Lowe and colleagues, the Klearway appliance reduced the RDI to less than 15 per hour in 80% of the moderate group and in 61% of the severe group.⁵⁰ The Klearway appliance is marketed worldwide by Great Lakes Orthodontic Ltd., Tonawanda, NY, USA.

Another commonly used and effective oral appliance is the Herbst appliance, which is an anterior mandibular positioning device. It consists of two full-coverage clear acrylic components snapped onto the maxillary and mandibular teeth connected with two rod and tube attachments that allow vertical opening, protrusion, limited lateral movement, and no retrusive movement. It is used only at night and advances the mandible 5 to 7 mm or at least 75% of the patient's maximum protrusive distance. A study by Clark and colleagues on 24 patients with mild to severe obstructive sleep apnea patients using the Herbst appliance showed a significant improvement in the RDI after 4 months of appliance use in 58% of the subjects on the post-appliance polysomnogram.⁵¹

Another disadvantage of oral appliances is the need to wear them nightly. As with any device, compliance has been shown to be a problem with oral appliances. If appliance therapy is successful,

Table 63-1 Food and Drug Administration Approved Oral Appliances for the Treatment of Obstructive Sleep Apnea

<i>Appliances</i>	<i>Manufacturer</i>
Adjustable PM Positioner	Jonathan A. Parker, DDS
Elastic Mandibular Advancement, Triation (EMA-T)	Frantz Design, Inc.
Elastic Mandibular Advancement	Frantz Design, Inc.
Elastomeric Sleep Appliance	Village Park Orthodontics
Equalizer Airway Device	Sleep Renewal Inc.
Herbst	Orthodontics, SUNY at Buffalo
Klearway	Great Lakes Orthodontics, Ltd.
NAPA	Great Lakes Orthodontics, Ltd.
OSAP	Snorefree, Inc.
PM Positioner	Jonathan A. Parker, DDS
Silencer	Silent Knights Ventures, Inc.
Sleep-In Bone Screw System	Influence Inc.
SNOAR Open Airway Appliance	Kent J. Toone, DDS
Thornton Oral Appliance	W. Keith Thornton, DDS

FIGURE 63-3 *Klearway oral appliance.*

further treatment options may include mandibular advancement surgery to achieve the same forward tongue position on a permanent basis.

Continuous Positive Airway Pressure

Continuous positive airway pressure (CPAP) through the nose has been shown to be quite successful in treating a broad range of obstructive sleep apnea patients and is presently the most successful nonsurgical treatment.⁵²⁻⁵⁴ The nasal CPAP is administered while the patient is asleep by means of a tight-fitting mask that is connected to a compressor. A CPAP of 7 to 15 cm of water acts as a pneumatic splint of the upper airway and prevents passive collapse of soft tissues during respiration. Stimulation of mechanoreceptors of the genioglossus muscle leading to increased airway tone has also been suggested as a mechanism of action. Sullivan and colleagues were the first to report the successful treatment of sleep apnea with nasal CPAP in 1981.⁵⁵ In most cases this therapy is effective in eliminating apneas and hypopneas, improving arterial oxygen saturations, reducing or eliminating excessive daytime sleepiness, and eliminating sleep disruption and fragmentation. CPAP may be combined with surgery and weight loss, or it may be used as a sole form of therapy. Although initially recommended for short-term relief of sleep apnea, the use

of nasal CPAP for long-term care of patients has increased over the past few years. In recent years bilevel positive airway pressure (Bi-PAP) systems that allow independent regulation of inspiratory and expiratory pressures and the newest modification in CPAP systems, Auto-CPAP, have been used to more effectively treat obstructive sleep apnea and increase tolerance and compliance.^{56,57} Auto-CPAP units adjust the CPAP throughout the night rather than delivering one fixed pressure. Optimal CPAP is delivered to the patient adjusting for positional changes, alcohol or sedative effects, sleep-state-dependent changes (REM vs non-REM), and the effects of upper airway infections or congestion. Bi-PAP (\$2,500) and Auto-CPAP (\$1,600) systems are more expensive than traditional CPAP (\$600 to \$800) systems.

Despite the uniform success of this therapy, patient compliance remains a problem. Compliance rates at 12 months have been reported as low as 54%.⁵⁸ The average nightly use of CPAP is 4.8 hours and the rate of use is usually determined in the first week of use. Overall approximately one-third of patients love CPAP, one-third struggle with CPAP but eventually tolerate it, and one-third hate CPAP and never use it. Patient dissatisfaction results from nasal dryness and congestion, sore throat, dryness of the skin and eyes, claustrophobia, and the inability to tolerate the noise, dis-

comfort, or mask. Careful patient selection and follow-up are essential if nasal CPAP is selected as a treatment modality.

Surgical Treatment

Surgery has been the primary form of therapy for obstructive sleep apnea. To be successful the surgical procedure must either bypass the obstructive area or prevent collapse of the soft tissues in the upper airway at the obstruction. Many patients and surgeons tend to view surgical treatment of obstructive sleep apnea as a quick and permanent cure. However, a clear definition of what constitutes a cure is lacking in the literature. This problem often makes a determination of the efficacy of individual surgical procedures difficult. Only objective data obtained from a postoperative polysomnogram can be accepted as proof of efficacy for surgical procedures. Currently the procedures used in the surgical treatment of obstructive sleep apnea include tracheostomy, nasal surgery, uvulopalatopharyngoplasty, and several orthognathic surgical procedures. Selection of the individual procedure is determined by the severity of the sleep apnea, the presence of a maxillofacial skeletal deficiency, the site of the obstructive segment, and the presence of morbid obesity.

Tracheostomy

Tracheostomy was the first efficacious surgical procedure for treating obstructive sleep apnea, performed by Kuhlo and colleagues in 1969.⁵⁹ It is almost 100% curative in relieving the signs and symptoms of obstructive sleep apnea because it bypasses all the potential obstructive sites in the upper airway. After tracheostomy there is a rapid and striking reduction in daytime somnolence and a marked improvement in sleep architecture due to a major reduction in the frequency of arousals. Sinus dysrhythmias, bradycardia, pulmonary hypertension, hypoxemia, and apnea all improve dramatically with the procedure. Tracheostomy

clearly is an effective surgical treatment for patients with obstructive apnea.

The disadvantages of a permanent tracheostomy can have a devastating effect on sleep apnea patients. Almost all patients experience psychological depression from the social and medical problems associated with a lifelong tracheostomy. The tracheostomy leaves the patient esthetically disfigured and exposes the patient to common local complications such as bleeding, infection, pain, and granulation tissue formation. Patients are also at increased risk for the more serious complications of tracheal stenosis or erosion into an adjacent blood vessel. Because of these disadvantages and complications, a permanent tracheostomy should be reserved for severe cases of obstructive sleep apnea with significant cardiovascular symptoms. Simmons and colleagues have suggested that tracheostomy should be the primary therapy for all patients who spend substantial time in severe oxygen desaturations below 50% and for those who have life-threatening cardiac dysrhythmias during sleep apnea.⁶⁰ Tracheostomy may also be used as an interim treatment until adjunctive procedures to reconstruct the upper airway are completed.

Nasal Surgery

Significant obstruction in the nasal cavity has been shown to cause excessive daytime sleepiness, sleep fragmentation, hypopneas, and periodic breathing during sleep.⁶¹ In most patients with moderate to severe obstructive sleep apnea, nasal obstruction is not the major contributing factor. The obstruction may be due to a deviated nasal septum, nasal polyps, or enlargement of the turbinates. In these patients septoplasty, nasal polypectomy, or turbinectomies are usually helpful only as adjunctive surgical procedures in the treatment of obstructive sleep apnea. Unless the obstruction in the nasal cavity is severe, surgical correction usually will not yield any significant improvement on a repeat polysomnography.

Uvulopalatopharyngoplasty

The oropharynx and soft palate can cause significant airway obstruction during sleep. At least 10% of persons over the age of 40 years snore regularly and significantly. Loud and intermittent snoring is found in almost all patients with obstructive sleep apnea. In many cases habitual snoring is present for many years before sleep apnea is diagnosed. Ikematsu followed a large number of habitual snorers over several years and found that 91% of these patients had decreased oropharyngeal dimensions and longer soft palates and uvulas than normal subjects.⁶² He was able to eliminate their snoring by surgically excising the excessive soft tissue in the palatal folds and partially excising the uvula.

With minor modifications, Simmons and colleagues and Fujita and colleagues popularized the uvulopalatopharyngoplasty (UPPP) for the treatment of obstructive sleep apnea.^{60,63} The procedure was designed to eliminate oropharyngeal obstruction by performing a tonsillectomy and adenoidectomy, excising the uvula, removing redundant lateral pharyngeal wall mucosa, and resecting 8 to 15 mm along the posterior margin of the soft palate.

The surgical technique of UPPP varies to some degree by patient and surgeon, but the basic goal is to shorten the palate and widen the posterior airway space (Figure 63-4). A mucosal incision is created with electrocautery on the anterior surface of the soft palate. The dissection is frequently carried laterally to include the palatine tonsil. The tonsillar bed is coagulated and hemostasis achieved. Palatal muscle is excised and mucosa from the nasopharynx is pulled forward for primary closure. Multiple interrupted resorbable sutures are placed. If the tonsil is removed, the mucosa of the anterior fauces pillar is closed to the posterior fauces pillar. This attempt to remove redundant pharyngeal

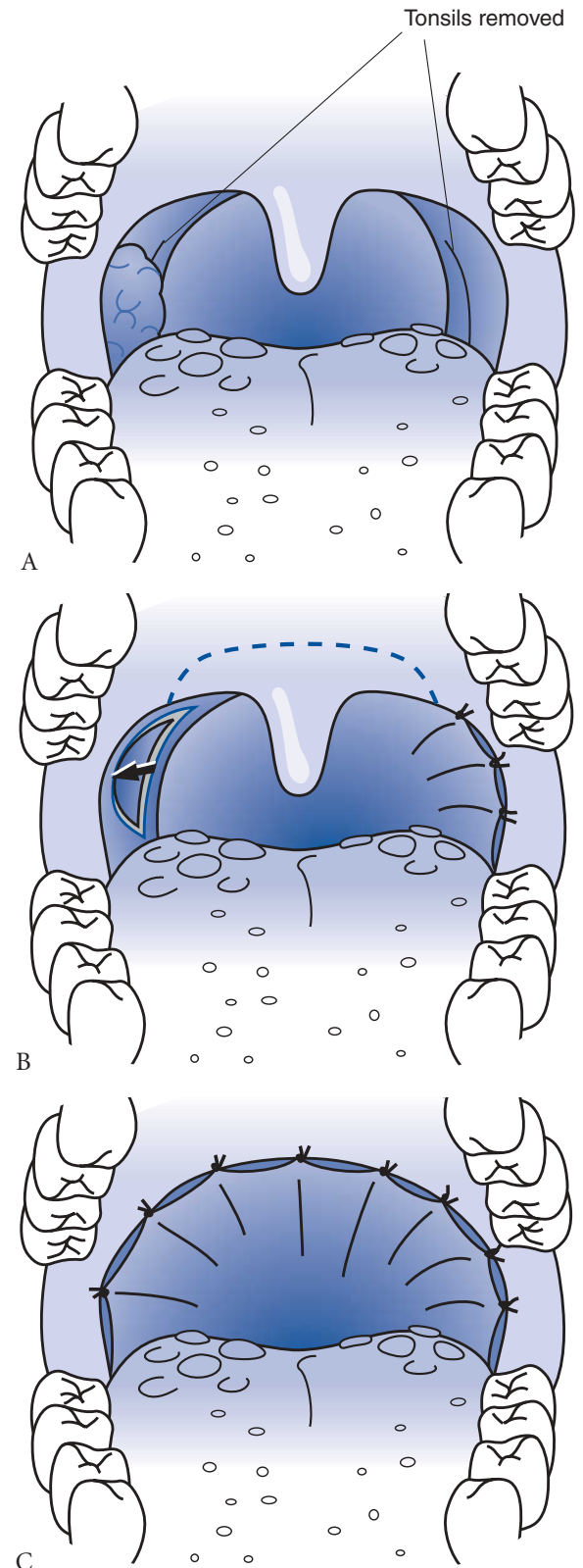


FIGURE 63-4 A–C, Uvulopalatopharyngoplasty. Tonsils and uvula are removed and the anterior pillar is closed to the posterior pillar. Adapted from Tiner BD, Waite, PD. *Surgical and nonsurgical management of obstructive sleep apnea*. In: Peterson LJ, Indresano AT, Marciani RD, Roser SM. *Principles of oral and maxillofacial surgery*. Vol. 3. Philadelphia (PA): J.B. Lippincott Company; 1992. p. 1540.

tissue and stretch or tighten the posterior pharyngeal wall results in constriction. In addition, frequently by shortening the soft palate, the width of the soft palate is thickened, as demonstrated cephalometrically. Lymphoid tissue from the tonsillar fossa can be removed separately or in conjunction with the uvula (Figure 63-5). The amount of velum to be excised is determined by the location of palatal competence and closure of the nasopharynx. These can be estimated or identified during nasopharyngoscopy. Palatal incompetence can occur but usually is of minimal concern if the patient swallows carefully. Pain with swallowing usually lasts for several weeks.

UPPP results in symptomatic improvement in the patient and eliminates habitual snoring in almost all cases. However, reports show that significant objective improvement on the postoperative polysomnogram ranges only from 41 to 66%.^{58,60,64,65} This procedure only eliminates the obstruction at the level of the soft palate and does not address obstructions occurring in the hypopharyngeal and base

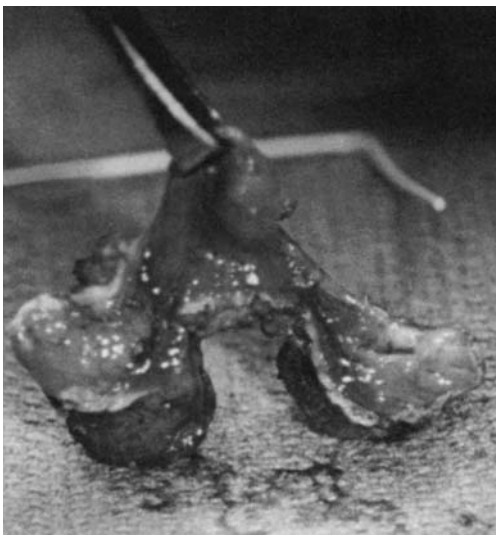


FIGURE 63-5 Surgical specimen of tonsils and uvula. Reproduced with permission from Tiner BD, Waite, PD. Surgical and nonsurgical management of obstructive sleep apnea. In: Peterson LJ, Indresano AT, Marciani RD, Roser SM. Principles of oral and maxillofacial surgery. Vol. 3. Philadelphia (PA): J.B. Lippincott Company; 1992. p. 1541.

of tongue areas. Many patients have more than one site of obstruction. If UPPP is performed when the presurgical evaluation demonstrates obstruction localized to the soft palate–tonsil area, then the success rate of the surgical procedure approaches 90% treating obstructive sleep apnea.^{23,26}

Complications from UPPP are related to changes in palatal function. Permanent velopharyngeal incompetence occurs in approximately 5% of patients and is more common during the first 2 months postoperatively. Patients experience occasional reflux of liquids into the nose and mild nasal air escape during speech. However, hypernasal speech and changes in the quality of the patient’s speech are usually not seen. Simmons and colleagues reported a 5 to 10% rate of minor wound infections that resolved with antibiotics.⁶⁴ Palatal stenosis is definitely a risk with this operation and occurs in about 1% of patients. It occurs more frequently with excessive resections of the posterior tonsillar pillars and injudicious use of electrocautery. Postoperative pain after UPPP is significant, and narcotic analgesia should be used with caution to prevent sedation-induced exacerbation of obstructive sleep apnea. Postsurgical deaths have resulted from the combination of pharyngeal edema and narcotic use.

Laser-Assisted Uvulopalatoplasty

In the late 1980s Dr. Yves-Victor Kamami (Paris, France) designed a procedure to reshape and recontour the soft palate under local anesthesia with a CO₂ laser to treat snoring and selected patients with obstructive sleep apnea syndrome.⁶⁶ He originally named the procedure “laser resection of the palatopharynx” or LRPP. Initially the procedure was accomplished in four or five sessions spaced at monthly intervals. Over time the procedure evolved into a one-stage technique for most patients. It consisted of two paramedian vertical incisions placed lateral to the uvula extending up toward the junction of the

hard and soft palates for 2 to 3 cm. A second horizontal incision was placed just under the roof of the uvula leaving a small uvula to prevent centripetal scar formation. Over a 5-year period, Kamami treated 63 obstructive sleep apnea patients with this technique. The RDI was reduced by more than 50% in 55 patients that were classified as successful responders. The RDI improved from 41.5 to 16.9 for the average responder, and for the entire group the average RDI improved from 41.3 to 20.3.

In the early 1990s in the United States, Dr. Yosef Krespi modified the procedure and renamed it “laser-assisted uvulopalatoplasty” or LAUP. He initially used the procedure to treat loud habitual snoring. In a study of 280 patients treated in the office under local anesthesia, 84% were cured with an average of 2.7 sessions.⁶⁷ Overall results for obstructive sleep apnea patients treated with LAUP are far less encouraging, with an average successful surgical response of 52.2%.⁶⁸ Based on these findings the current main indications for LAUP include loud habitual snoring, upper airway resistance syndrome, and mild obstructive sleep apnea (apnea index < 20). All snoring patients who elect to undergo LAUP should be evaluated for obstructive sleep apnea preoperatively and again postoperatively if obstructive sleep apnea was previously diagnosed. If not, then the patient and surgeon may be lulled into a false sense of security by eliminating the snoring without eliminating the undiagnosed obstructive sleep apnea, potentially increasing patient morbidity and mortality.⁶⁹

The most common complication following LAUP is a moderate to severe sore throat. Patients experience pain 8 to 10 days after surgery and reach their peak pain intensity on the fourth or fifth postoperative day. Pain control is achieved with oral analgesics and anesthetic gels. The risk for velopharyngeal insufficiency is low since the procedure is frequently done in stages and the surgeon has the opportunity to evaluate speech and soft palate function

after each session. Patients are also at low risk for bleeding and infection. The great majority of patients can eat, drink, and speak almost immediately and can resume full activities the following day.

Orthognathic Surgery Procedures

Various orthognathic surgical procedures have been described for the treatment of obstructive sleep apnea. The majority of patients have airway obstruction at the level of the soft palate and at the base of the tongue (type II obstruction). Orthognathic surgical procedures can change the size of the airway in several regions. Mandibular advancement and genial advancement probably work by changing the position of the mandible and hyoid bone with subsequent effects on the genioglossus and hyoglossus muscles. Obstructive sleep apnea patients with identifiable craniofacial anomalies can clearly benefit from a variety of these procedures.

Mandibular Advancement Total mandibular advancement was the first orthognathic surgical procedure used in the treatment of obstructive sleep apnea. Kuo and colleagues in 1979 and Bear and Priest in 1980 reported complete reversal of sleep apnea symptoms in patients with horizontal mandibular deficiency treated by mandibular advancement.^{47,70} More recently Alvarez and colleagues reported the successful treatment of an edentulous patient with sleep apnea by mandibular and genial advancement.⁷¹

A bilateral sagittal ramus osteotomy is usually the procedure of choice for total mandibular advancement. The amount of advancement is determined preoperatively from the orthognathic surgery database. Adjunctive orthodontic treatment is frequently necessary to obtain the desired occlusion and to eliminate dental compensations that would otherwise limit the amount of advancement. After advancement with the standard surgical technique, the fragments are rigidly fixed with screws or bone

plates. For large advancements of 7 mm or more, long-term stability is enhanced with a 5- to 7-day course of maxillo-mandibular fixation and skeletal suspension wires. In advancements of 6 mm or less, maxillomandibular fixation is usually not necessary.

The exact reason for how mandibular advancement improves obstructive sleep apnea is not clearly known, but the suspected effect is the pulling of the tongue forward off the pharyngeal wall. This effect is created by anteriorly moving the insertion of the genioglossus and geniohyoid muscles. If this were the only factor, then anterior chin procedures would be equally effective as total mandibular procedures. Variations of geniostomies have been designed to maximally pull the tongue muscles forward.

Genial Advancement A rectangular osteotomy apical to the teeth but maintaining the inferior border of the mandible allows the genial tubercles with their muscular attachments to be maximally advanced with minimal cosmetic change (Figure 63-6). A modified vestibular mucosal incision is made in the anterior mandible. Periosteum is reflected down to the inferior border. An oscillating saw is used to make parallel horizontal cuts that include the genial tubercle. The osteotomy is designed in a shape similar to a drawer so that it can be pulled outward with the genial muscles. The bone must be broad enough cuspid to cuspid to be rotated 90° and set on top of the buccal cortex. The outer cortical and cancellous bone of the rectangle can then be removed and the inner cortex rigidly fixed with bone screws. Any hemorrhage from the cancellous bone should be controlled.

This procedure does not change the esthetic chin or advance the anterior belly of the digastric muscle, which may be helpful in suspending the hyoid. In contrast to this procedure a horizontal sliding geniostomy does advance the genial tubercles and the anterior belly of the digastric muscle.

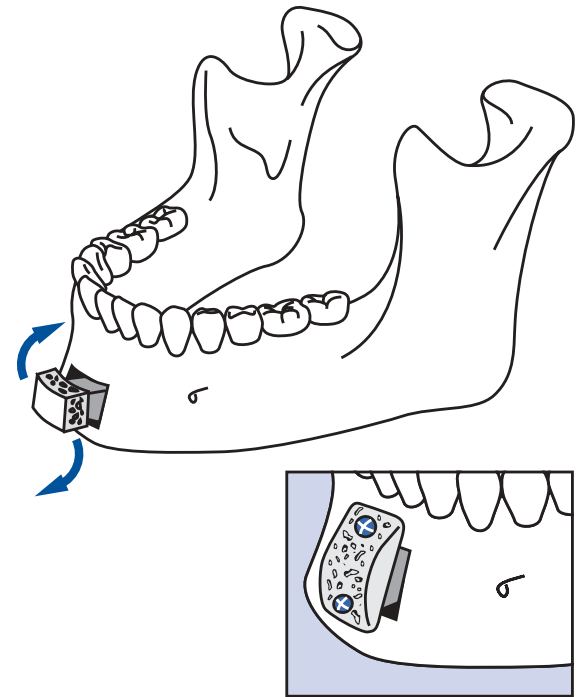


FIGURE 63-6 Genial tubercle advancement. The outer table of symphysis is removed and the inner table is secured with 2 mm screws. Adapted from Tiner BD, Waite, PD. *Surgical and nonsurgical management of obstructive sleep apnea*. In: Peterson LJ, Indresano AT, Marciani RD, Roser SM. *Principles of oral and maxillo-facial surgery*. Vol. 3. Philadelphia (PA): J.B. Lippincott Company; 1992. p. 1542.

Genial Advancement with Hyoid Myotomy and Suspension In 1984 Riley and colleagues described an alternative technique in which an inferior mandibular osteotomy and an associated hyoid myotomy and suspension were used in the treatment of obstructive sleep apnea (Figure 63-7).⁷² This technique is similar to a horizontal mandibular osteotomy, which is commonly used for advancement genioplasty. The osteotomy is designed to include the genial tubercle on the inner cortex of the anterior mandible where the genioglossus muscle attaches. Repositioning the anteroinferior segment of the mandible forward with the attached genioglossus muscle theoretically pulls the tongue forward and improves the hypopharyngeal airway. In conjunction with the osteotomy, the body and greater cornu of the hyoid are isolated

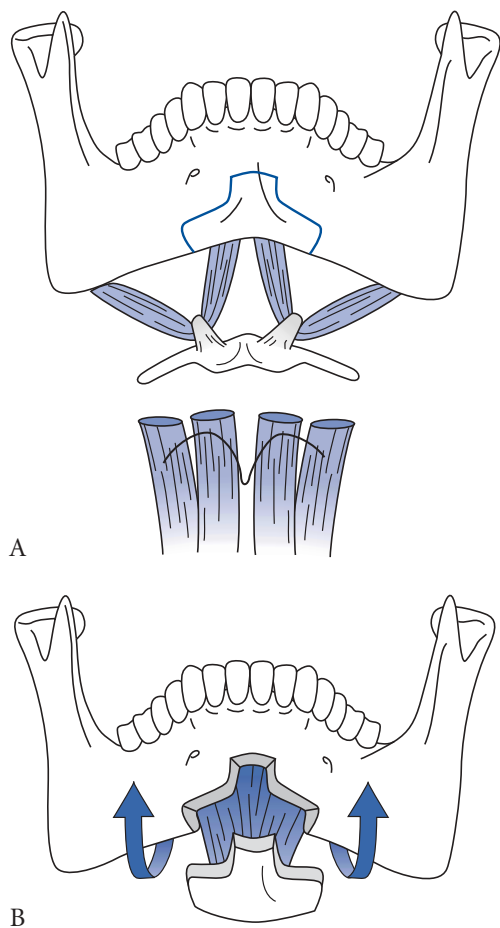


FIGURE 63-7 Inferior mandibular osteotomy and hyoid myotomy. A, Omohyoid, sternohyoid, and thyrohyoid muscles released (see Figure 63-8 for more detail on muscular relationships). B, Inferior segment is advanced anteriorly and locked on the anterior mandible. Adapted from Tiner BD, Waite, PD. *Surgical and nonsurgical management of obstructive sleep apnea*. In: Peterson LJ, Indresano AT, Marciani RD, Roser SM. *Principles of oral and maxillofacial surgery*. Vol. 3. Philadelphia (PA): J.B. Lippincott Company; 1992. p. 1543.

through a submental incision. The infrahyoid muscles are transected, taking care to remain on the hyoid bone at all times to avoid injury to the superior laryngeal nerves (see Figure 63-7A). This allows the hyoid bone to be pulled anteriorly and superiorly. Strips of fascia or nonresorbable suture are passed around the body of the hyoid and attached to the intact portion of the anterior mandible to complete the hyoid suspension.

In 1989 Riley and colleagues published a review of 55 patients with obstructive

sleep apnea who were treated with inferior mandibular osteotomy and hyoid suspension.⁷³ Forty-two patients had obstruction at both the oropharynx and hypopharynx and received concomitant UPPP and inferior mandibular osteotomy with hyoid myotomy and suspension. The remaining 6 patients were determined to have obstruction localized to the base of the tongue and underwent the osteotomy and hyoid suspension only. All patients were reevaluated 6 months following surgery by polysomnography. Thirty-seven patients (67%) were considered to be responders to surgery based on the polysomnogram results. Genioglossus advancement ranged from 8 to 18 mm with a mean of 13 mm. All responders to surgery showed significant improvement in their RDI and oxygen desaturation events. Eighteen patients (33%) were considered nonresponders and failed to show significant improvement by polysomnography. The presence of preexisting chronic obstructive pulmonary disease was found to be a determining factor in increasing the risk of failure.

In 1994 Riley and colleagues reported on a new modified technique for hyoid suspension that fixed the hyoid to the thyroid cartilage instead of the anterior margin of the mandible.⁷⁴ When this modified technique was performed with inferior mandibular osteotomy, in lieu of the original hyoid suspension technique, the surgical response rate (with or without UPPP) was raised to 79.2%. The 5 nonresponders in this study of 24 patients achieved postoperative RDI values close to levels at which they would have been considered surgical responders.

Long-term follow-up of these patients has shown that the indication for this procedure is limited. Patients with normal pulmonary function, normal skeletal mandibular development, the absence of obesity, and moderate obstructive sleep apnea are candidates for treatment with inferior mandibular osteotomy with hyoid myotomy and suspension.

The most serious reported complication from a hyoid suspension has been severe aspiration in one patient, in which the thyrohyoid membrane was totally sectioned.²⁸ Other complications have included wound infections, transient sensory disturbances of the mental nerve, and mandibular fracture. An advantage to hyoid suspension is that it circumvents the need for maxillomandibular fixation and does not affect the occlusion.

Maxillomandibular Advancement Combined advancement of the maxilla and mandible with or without hyoid suspension is the most recent and efficacious surgical procedure for the treatment of obstructive sleep apnea. The surgical technique includes a standard Le Fort I osteotomy in combination with a mandibular sagittal split osteotomy for advancement of the maxilla and mandible. A concomitant inferior mandibular osteotomy with or without hyoid myotomy and suspension, as previously described, is also performed. This surgery may result in a significant facial change, which is most often favorable (Figures 63-8 and 63-9). Several authors have described the use of maxillomandibular advancement (MMA) in treating large series of obstructive sleep apnea patients.⁷⁵⁻⁸⁰ In a series of 23 patients, Waite and colleagues performed a high sliding horizontal geniotomy without the hyoid myotomy and suspension.⁷⁵ All patients were reevaluated by polysomnography at 6 weeks postoperatively. The surgical success with MMA was 65% based on a postsurgical RDI of less than 10. Riley and colleagues reported the largest series of obstructive sleep apnea patients treated with MMA in which 98% (89 of 91) were successfully treated based on a postoperative RDI of less than 20 with at least a 50% reduction in the RDI compared to the preoperative study.⁷⁶ It should be noted that 67 of the 91 patients (74%) did not receive phase 1 therapy based on their two-phase protocol for reconstruction of the upper

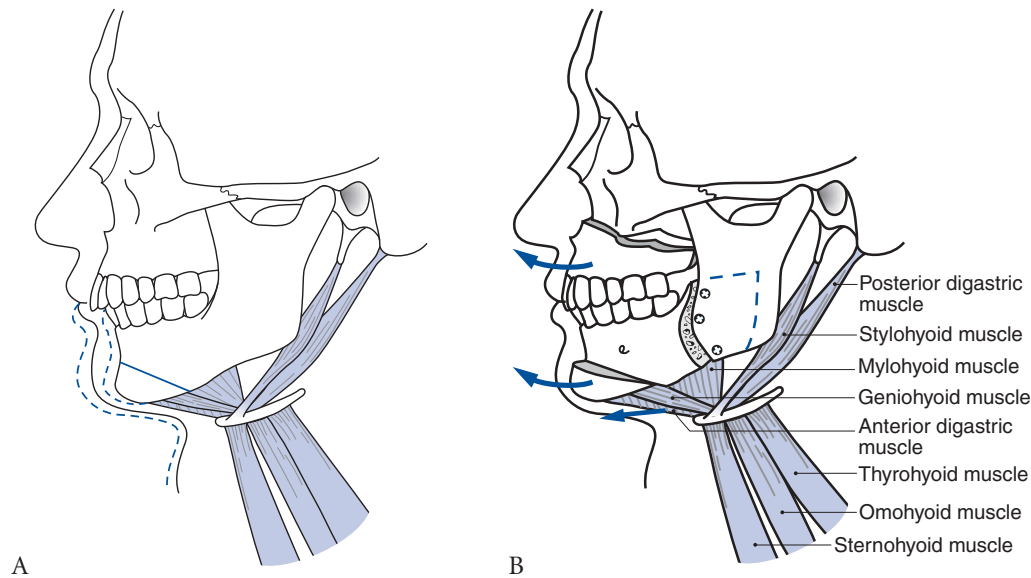


FIGURE 63-8 Schematic drawings of preoperative (A) and postoperative (B) two-jaw advancement, genial advancement, and hyoid suspension. Adapted from Tiner BD, Waite, PD. *Surgical and nonsurgical management of obstructive sleep apnea*. In: Peterson LJ, Indresano AT, Marciani RD, Roser SM. *Principles of oral and maxillofacial surgery*. Vol. 3. Philadelphia (PA): J.B. Lippincott Company; 1992. p. 1544.

airway. Despite this, the MMA was labeled a phase 2 procedure. In 1997, Hochban and colleagues reported a 98% success rate on 38 obstructive sleep apnea patients consecutively treated with a 10 mm MMA as the primary surgery, without any adjunctive procedures.⁷⁷ Their criteria for success were based on the more rigid postoperative RDI of less than 10. Patient selection for MMA was based on subjective symptoms of excessive daytime sleepiness, an RDI of greater than 20, and specific craniofacial characteristics determined cephalometrically. Only 2 patients who were morbidly obese were treated surgically. Based on their excellent results the authors concluded that a stepwise algorithm of staged surgical procedures was not justified. In a series of 50 obstructive sleep apnea patients consecutively treated with MMA, Prinsell reported a 100% success rate based on a postoperative RDI of less than 15, an apnea index (AI) of less than 5, or a reduction in the RDI and AI of greater than 60%.⁷⁸ In this series occasional concomitant nonpharyngeal procedures and an anterior interior mandibular osteotomy were accomplished with the MMA as a sin-

gle-stage operation. In 1999 Lee and colleagues proposed a three-stage protocol for the surgical treatment of obstructive sleep apnea patients.⁷⁹ All 35 patients in their series had type II obstruction with collapse at the oropharyngeal and hypopharyngeal areas. Stage 1 reconstruction consisted of a UPPP and inferior sagittal osteotomy with genioglossus muscle advancement, or an anterior mandibular osteotomy. If stage 1 was unsuccessful, then patients advanced to stage 2, which consisted of MMA with rigid fixation. A hyoid myotomy and suspension was the sole component of stage 3 reconstruction. Based on postoperative polysomnography, 69% (24 of 35) were considered surgical responders based on an RDI of less than 20. Of the 11 stage 1 failures, 3 elected to proceed to stage 2 reconstruction with MMA. All patients who underwent MMA had a postoperative RDI of less than 10, indicating a 100% response rate. No patient required stage 3 reconstruction. Bettega and colleagues treated 51 consecutive obstructive sleep apnea patients according to the Stanford two-step surgical procedure.⁸⁰ Forty-four patients had phase 1 surgery with a success

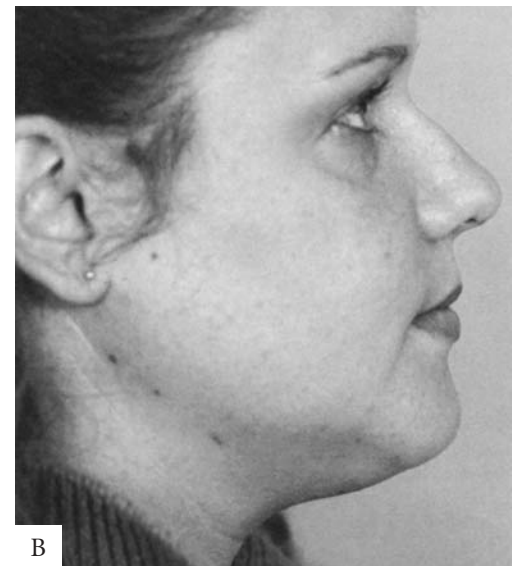
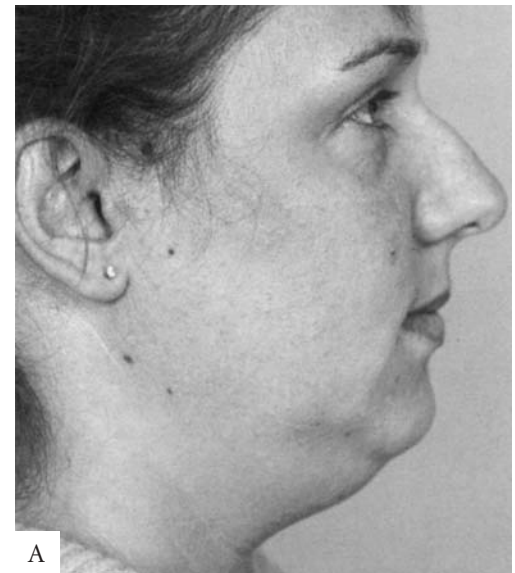

FIGURE 63-9 Preoperative (A) and postoperative (B) photographs of a patient with obstructive sleep apnea syndrome who underwent two-jaw surgery with a genial advancement. Reproduced with permission from Tiner BD, Waite, PD. *Surgical and nonsurgical management of obstructive sleep apnea*. In: Peterson LJ, Indresano AT, Marciani RD, Roser SM. *Principles of oral and maxillofacial surgery*. Vol. 3. Philadelphia (PA): J.B. Lippincott Company; 1992. p. 1545.

rate of 22.7% (10 of 44). Twenty patients underwent MMA as part of phase 2 in the protocol. Of these, 75% (15 of 20) were considered to be surgical responders based on a postoperative RDI of less than 15 and at least a 50% reduction in the RDI. Of the 5 failures, 3 had postoperative RDIs of less than 20.

The PAS consistently increases with maxillomandibular advancement. However, there is no direct relationship between the gain in PAS and the remission of sleep apnea. MMA is effective for patients who have obstruction at the base of the tongue. This surgical treatment is the most efficacious procedure for expanding the pharyngeal airway and improving or eliminating obstructive sleep apnea. It remains the best current alternative to tracheostomy.⁸¹ Indications for this procedure include severe mandibular deficiency (SNB < 74°), morbid obesity, severe obstructive sleep apnea (RDI > 50, oxygen desaturations < 70%), hypopharyngeal narrowing, and failure of other forms of treatment.⁸² The success rate of MMA appears to increase when adjunctive procedures such as UPPP, partial glossectomy, septoplasty, or turbinectomies are included in the treatment plan. This lends support to the theory that most obstructive sleep apnea patients have multiple levels of obstruction.

Adjunctive orthodontic therapy is usually indicated in patients selected for MMA. Presurgical orthodontics improves the postoperative occlusion and eliminates pre-existing dental compensations that would otherwise limit the amount of advancement. Maximum advancement of the facial skeleton and maintenance of a functional occlusion and acceptable esthetics are the goals of surgical-orthodontic correction.

The osteotomies are rigidly fixed with miniplates and bicortical screws (Figure 63-10). With large advancements (> 7 mm), skeleton suspension wires and a short course of maxillomandibular fixation (1 wk) can be used to reduce surgical relapse. Potential complications of MMA include surgical relapse, non-union, bleeding, malocclusion, infection, unfavorable changes in facial appearance, and permanent or temporary sensory disturbances of the inferior alveolar and infraorbital nerves.

The long-term skeletal stability of MMA has been shown to be quite good.

Louis and colleagues showed a mean relapse of 0.9 ± 1.8 mm among 20 maxillary advancement patients who underwent MMA for obstructive sleep apnea.⁸³ The mean follow-up period was 18.5 months (range 6 to 29 mo). When the patients were divided into three groups reflecting small (6 mm or less), medium (7 to 9 mm), and large (10 mm or more) advancements, there was no statistical difference in the measured relapse among the groups. Rigid fixation was achieved with four miniplates and no bone grafts were used in any of the maxillary advancements. Nimkarn and colleagues reported on 19 obstructive sleep apnea patients who underwent MMA with simultaneous genioplasty and found relatively stable long-term (> 12 mo) surgical stability of the maxilla and mandible.⁸⁴ Maxillary and mandibular advancement was stable over the long term in both the vertical and horizontal planes. With the exception of gonion in the vertical plane, there was no statistically significant correlation between the amount of surgical advancement and the amount of postsurgical instability.

Mandibular Setbacks In a small number of patients, a mandibular setback procedure can be the initiating factor in the development of obstructive sleep apnea. Riley and associates reported on two women who developed obstructive sleep apnea syndrome after mandibular osteotomies for correction of Class III malocclusion and skeletal prognathism.⁸⁵ Neither patient had any symptoms of sleep apnea prior to surgery. Postoperatively both patients began to snore loudly. Evaluation by polysomnography confirmed the presence of obstructive sleep apnea syndrome. A comparative examination of the preoperative and postoperative lateral cephalograms of each patient showed a more inferiorly positioned hyoid bone and a narrowing of the pharyngeal airway as a result of the mandibular setback procedure.

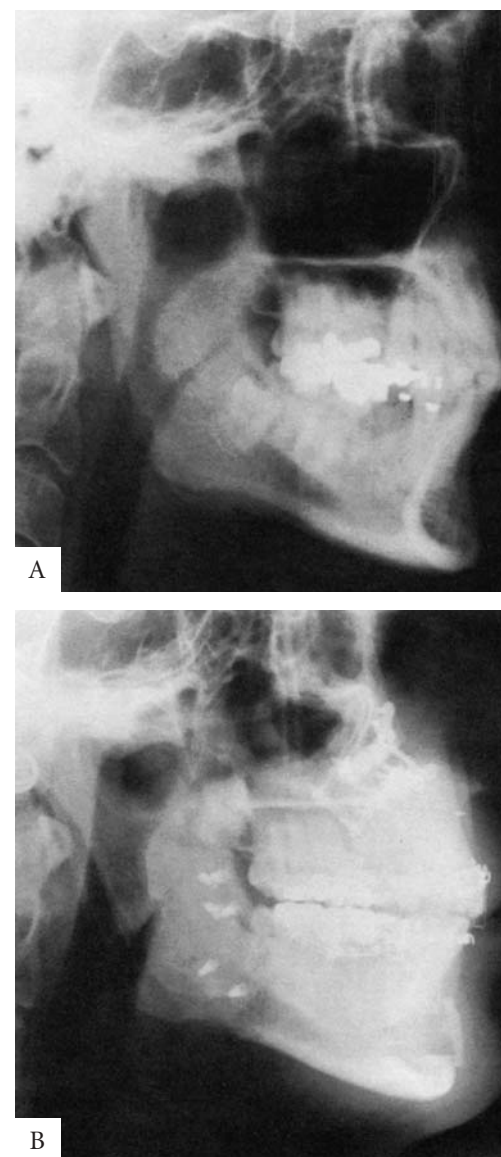


FIGURE 63-10 Preoperative (A) and postoperative (B) radiographs of a two-jaw surgery and genial tubercle advancement for sleep apnea. Reproduced with permission from Tiner BD, Waite, PD. *Surgical and nonsurgical management of obstructive sleep apnea*. In: Peterson LJ, Indresano AT, Marciani RD, Roser SM. *Principles of oral and maxillofacial surgery*. Vol. 3. Philadelphia (PA): J.B. Lippincott Company; 1992. p. 1546.

In an attempt to identify those patients potentially at risk for obstructive sleep apnea, all patients who are planned for mandibular setback procedures should be questioned preoperatively and postoperatively about the presence or absence of snoring, excessive daytime sleepiness, or observed apneas during sleep. Although the vast majority of patients who undergo

Table 63-2 Results of Maxillomandibular Advancement for Obstructive Sleep Apnea

Results	RDI	Desaturation*	No. of Patients	Percent of Total
Excellent	≤ 10	0	20	28.2
Good	≤ 10	≤ 20	26	36.6
Satisfactory	≤ 10	> 20	15	21.1
Poor	> 20	> 20	10	14.1

Maxillomandibular advancement surgery results for 71 obstructive sleep apnea syndrome patients classified by polysomnography.
RDI = respiratory disturbance index.
*Number of oxygen desaturations below 90%.

mandibular setbacks are able to adapt to the changes in the skeletal and muscular apparatus, there is a subset of patients who may be at risk for developing overt signs of obstructive sleep apnea following mandibular setbacks.

Summary

Because the obstructive sleep apnea syndrome is a complex disorder, the type of treatment selected should be tailored to the individual patient based on the relative risks and benefits of the therapy and the severity of the disease. Although a subset of the patients who present with obstructive sleep apnea have an identifiable craniofacial anomaly, care must be used in choosing a simple mechanistic therapy. The success of the chosen therapy should be evaluated both subjectively and objectively. There is no clear agreement on what constitutes a cure of sleep apnea. Most authors use the RDI in assessing severity of disease and success of treatment. However, all agree that the potentially significant physiologic consequences that can be life threatening result from hypoxemia. In some cases patients after treatment have no oxygen desaturations below 90%, but in terms of RDI they are considered not cured and are deemed treatment failures.

A more reasonable approach would be to define the concept of success in terms of excellent, good, fair, and poor and to avoid using the term "cured" in assessing treatment outcomes. These terms could be quantitatively approached assigning low-

est oxygen desaturation and RDI parameters to each one. In Table 63-2 the results of 71 patients treated by maxillomandibular advancement are assessed by these criteria. In managing patients with severe sleep apnea, a "cure" is seldom achieved with a single surgical or medical treatment (tracheostomies excluded). However, maxillomandibular advancement may significantly improve a patient to the point that nonsurgical therapies are more efficacious, if needed at all.

References

- Schmidt HS. Disorders of sleep and arousal. In: Gregory I, Smeltzer DJ, editors. *Psychiatry essentials of clinical practice*. Boston (MA): Little, Brown & Co.; 1983. p. 343.
- Association of Sleep Disorders Center. *Diagnostic classification of sleep and arousal disorders*. 1st ed. Prepared by the Sleep Disorders Classification Committee. *Sleep* 1979;2:1.
- Berger H. Uber das elektrenkephalogramm des menschen. *Arch Psychiatr Nervenkr* 1929;87:527.
- Loomis AL, Harvey EN, Hobart GA. Potential rhythms of the cerebral cortex during sleep. *Science* 1935;81:597.
- Loomis AL, Harvey EN, Hobart GA. Further observations on the potential rhythms of the cerebral cortex during sleep. *Science* 1935;82:199.
- Aserinsky E, Kleitman N. Regularly occurring periods of eye motility and concomitant phenomena during sleep. *Science* 1953;118:273.
- Freeman FR. *Sleep research: a critical review*. Springfield (IL): Charles C. Thomas; 1972.
- Waldhorn RE. Sleep apnea syndrome. *Am Fam Physician* 1985;32:149.
- National Commission on Sleep Disorders Research. *Wake up America: a national sleep alert*. Washington (DC): Government Printing Office; 1993.
- Sher AE. Treating obstructive sleep apnea syndrome: a complex task [editorial]. *West J Med* 1995;162:170-2.
- Bornstein SK. Respiration during sleep: polysomnography. In: Guilleminault C, editor. *Sleep and waking disorders: indications and techniques*. Menlo Park (CA): Addison-Wesley; 1982. p. 183.
- Baker TL. Introduction to sleep and sleep disorders. *Med Clin North Am* 1985;69:1123.
- Roth B. *Narcolepsy and hypersomnia*. Basel: S. Karger AG; 1980.
- Burwell CS, Rubin ED, Whaley RD, et al. Extreme obesity associated with alveolar hypoventilation: a pickwickian syndrome. *Am J Med* 1956;21:811.
- Gastaut H, Tassinari CA, Duron B. Polygraphic study of the episodic diurnal and nocturnal (hypnic and respiratory) manifestations of the pickwick syndrome. *Brain Res* 1966;2:167.
- Partinen M, Quera-Salva MA, Jamieson A. Obstructive sleep apnea and cephalometric roentgenograms: the role of anatomic upper airway abnormalities in the definition of abnormal breathing during sleep. *Chest* 1988;93:1199-205.
- Tsuchiya M, Lowe AA, Pae EK, Fleetham JA. Obstructive sleep apnea subtypes by cluster analysis. *Am J Orthod Dentofacial Orthop* 1992;101:533-42.
- Bacon WH, Krieger J, Turlot J-C, Stierle JL. Craniofacial characteristics in patients with obstructive sleep apnea syndrome. *Cleft Palate J* 1988;25:374.
- Lyberg T, Kogstad O, Ojupesland G. Cephalometric analysis in patients with obstructive sleep apnea syndrome. *J Laryngol Otol* 1989;103:287.
- Lowe AA, Santamaria JD, Fleetham JA, Price C. Facial morphology and obstructive sleep apnea. *Am J Orthod* 1986;90:484.
- Rivlin J, Hofstein V, Kalbfleisch J, et al. Upper airway morphology in patients with idiopathic obstructive sleep apnea. *Am Rev Respir Dis* 1984;129:355.
- Riley R, Guilleminault C, Herran J, Powell N. Cephalometric analyses and flow-volume loops in obstructive sleep apnea patients. *Sleep* 1983;6:303.
- Riley R, Guilleminault C, Powell N, Simmons FB. Palatopharyngoplasty failure, cephalometric roentgenograms, and obstructive sleep apnea. *Otolaryngol Head Neck Surg* 1985;93:240.
- Lowe AA, Gionhaku N, Takeuchi K, Fleetham JA. Three-dimensional CT reconstruction

- of tongue and airway in adult subjects with obstructive sleep apnea. *Am J Orthod Dentofacial Orthop* 1986;90:364.
25. Haponik EF, Smith PL, Bohlman ME, et al. Computerized tomography in obstructive sleep apnea. *Am Rev Respir Dis* 1983;127:221.
 26. Riley RW, Powell N, Guilleminault C. Current surgical concepts for treating obstructive sleep apnea syndrome. *J Oral Maxillofac Surg* 1987;45:149.
 27. Waite RD, Villos G. Surgical changes of posterior airway spaces in obstructive sleep apnea. *Oral Maxillofac Surg Clin North Am* 2002;August.
 28. Riley RW, Powell NB, Guilleminault C. Maxillary, mandibular, and hyoid advancement for treatment of obstructive sleep apnea: a review of 40 patients. *J Oral Maxillofac Surg* 1990;48:20.
 29. Wiggins RV, Schmidt-Nowara WW. Treatment of the obstructive sleep apnea syndrome. *West J Med* 1987;147:561.
 30. Smith PL, Gold AR, Meyers DA. Weight Loss in mild to moderately obese patients with obstructive sleep apnea. *Ann Intern Med* 1985;103:850.
 31. Riley RW, Powell NB, Guilleminault C, Ninomucia G. Maxillary, mandibular, hyoid advancement: an alternative to tracheostomy in obstructive sleep apnea syndrome. *Otolaryngol Head Neck Surg* 1986;94:584.
 32. Motta J, Guilleminault C. Effects of oxygen administration in sleep-induced apneas. In: Guilleminault C, Dement WC, editors. *Sleep apnea syndrome*. New York (NY): Alan R. Liss; 1978. p. 137.
 33. Martin RJ, Sanders MH, Gray BA, et al. Acute and long-term ventilatory effects of hyperoxia in the adult sleep apnea syndrome. *Am Rev Respir Dis* 1982;125:175.
 34. Smith PL, Haponik EF, Bleecker ER. The effects of oxygen in patients with sleep apnea. *Am Rev Respir Dis* 1984;130:958.
 35. White DP, Zwillich CW, Pickett CK, et al. Central sleep apnea: improvement with acetazolamide therapy. *Arch Intern Med* 1982;142:1816.
 36. Sharp JT, Druz WS, D'Souza V, et al. Effect of metabolic acidosis upon sleep apnea. *Chest* 1985;87:619.
 37. Lyons HA, Huang CT. Therapeutic use of progesterone in alveolar hypoventilation associated with obesity. *Am J Med* 1968;44:881.
 38. Sutton FD, Zwillich CW, Creagh CE, et al. Progesterone for outpatient treatment of pickwickian syndrome. *Ann Intern Med* 1975;83:476.
 39. Orr WC, Imes MK, Martin RJ. Progesterone therapy in obese patients with sleep apnea. *Arch Intern Med* 1979;139:109.
 40. Strohl KP, Hensley MJ, Saunders NA, et al. Progesterone administration and progressive sleep apneas. *JAMA* 1981;245:1230.
 41. Brownell LG, West P, Sweatman P, et al. Protriptyline in obstructive sleep apnea: a double-blind trial. *N Engl J Med* 1982;307:1037.
 42. Smith PL, Haponik EF, Allen RP, et al. The effects of protriptyline in sleep-disordered breathing. *Am Rev Respir Dis* 1983;127:8.
 43. Afzelius LE, Elmquist D, Hougaard K, et al. Sleep apnea syndrome: an alternative to tracheostomy. *Laryngoscope* 1981;91:285.
 44. Lowe AA. Oral appliances for sleep breathing disorders. In: Kryger M, Roth T, Dement W, editors. *Principles and practice of sleep medicine*. 3rd ed. Philadelphia (PA): W.B. Saunders Co.; 2000. p. 929–31.
 45. Clark GT. Management of obstructive sleep apnea with dental appliances. *Calif Dent Assoc J* 1988;16:26.
 46. Soll BA, George PT. Treatment of obstructive sleep apnea with a nocturnal airway-patency appliance. *New Engl J Med* 1985;313:386.
 47. Bear SE, Priest JH. Sleep apnea syndrome: correction with surgical advancement of the mandible. *J Oral Surg* 1980;38:543.
 48. Cartwright RD, Samelson CF. The effects of a nonsurgical treatment for obstructive sleep apnea: the tongue-retaining device. *JAMA* 1982;248:705.
 49. Clark GT, Nakano M. Dental appliances for the treatment of obstructive sleep apnea. *J Am Dent Assoc* 1989;118:611.
 50. Lowe AA, Sjöholm CF, Ryan JA, et al. Treatment, airway and compliance effects of a titratable oral appliance. *Sleep* 2000;23:172–8.
 51. Clark GT, Arand D, Chung E, Tong D. Effect of anterior mandibular positioning on obstructive sleep apnea. *Am Rev Respir Dis* 1993;147:624–9.
 52. Sullivan CE, Issa FG, Berthon-Jones M, et al. Home treatment of obstructive sleep apnea with continuous positive airway pressure applied through a nose-mask. *Bull Eur Physiopathol Respir* 1984;20:49.
 53. Issa FG, Sullivan CE. The immediate effects of continuous positive airway pressure treatment on sleep pattern in patients with obstructive sleep apnea syndrome. *Electroencephalogr Clin Neurophysiol* 1986;63:10.
 54. Klein M, Reynolds LG. Relief of sleep-related oropharyngeal airway obstruction by continuous insufflation of the pharynx. *Lancet* 1986;1:935.
 55. Sullivan CE, Issa FG, Berthon-Jones M, et al. Reversal of obstructive sleep apnea by continuous positive airway pressure applied through the nares. *Lancet* 1981;1:862.
 56. Laursen SB, Dreijer B, Hemmingsen C, Jacobsen E. Bi-level positive airway pressure treatment of obstructive sleep apnea syndrome. *Respiration* 1998;65:114–9.
 57. Meurice J, Marc I, Series F. Efficacy of auto-CPAP in the treatment of obstructive sleep apnea/hypopnea syndrome. *Am J Respir Crit Care Med* 1996;153:794–8.
 58. Katsantonis GP, Schweitzer PK, Branham GH, et al. Management of obstructive sleep apnea: comparison of various treatment modalities. *Laryngoscope* 1988;98:304.
 59. Kuhlo W, Doll E, Franck MD. Erfolgreiche Behandlung eines pickwick-syndroms durch eine dauertrachealkanüle. *Dtsch Med Wochenschr* 1969;94:1286.
 60. Simmons FB, Guilleminault C, Silvestri R. Snoring, and some obstructive sleep apnea, can be cured by oropharyngeal surgery. *Arch Otolaryngol* 1983;109:503.
 61. Heimer D, Scharf S, Lieberman A, et al. Sleep apnea syndrome treated by repair of deviated nasal septum. *Chest* 1983;84:184.
 62. Ikematsu T. Study of snoring, 4th report: therapy. *J Jap Otorhinolaryngol* 1964;64:434.
 63. Fujita S, Conway W, Zorick F, et al. Surgical correction of anatomic abnormalities in obstructive sleep apnea syndrome: uvulopalatopharyngoplasty. *Otolaryngol Head Neck Surg* 1981;89:923.
 64. Simmons FB, Guilleminault C, Miles LE. The palatopharyngoplasty operation for snoring and sleep apnea: an interim report. *Otolaryngol Head Neck Surg* 1984;92:375.
 65. Guilleminault C, Hayes B, Smith L, et al. Palatopharyngoplasty in obstructive sleep apnea syndrome. *Bull Eur Physiopathol Res* 1983;19:595.
 66. Kamami YV. Outpatient treatment of sleep apnea syndrome with CO₂ laser: laser-assisted UPPP. *J Otolaryngol* 1994;23:395–8.
 67. Krespi YP, Pearlman SJ, Keidar A. Laser-assisted uvula-palatoplasty for snoring. *J Otolaryngol* 1994;23: 328–34.
 68. Terris DJ, Wang MZ. Laser-assisted uvulopalatoplasty in mild obstructive sleep apnea. *Arch Otolaryngol Head Neck Surg* 1998;124:718–20.
 69. Sher AE. Update on upper airway surgery for obstructive sleep apnea. *Curr Opin Pulm Med* 1995;1:504–11.
 70. Kuo PC, West RA, Bloomquist DS, et al. The effect of mandibular osteotomy in three patients with hypersomnia sleep apnea. *Oral Surg* 1979;48:385.
 71. Alvarez CM, Lessin ME, Gross PD. Mandibular advancement combined with horizontal

- advancement genioplasty for the treatment of obstructive sleep apnea in an edentulous patient. *Oral Surg* 1987;64:402.
72. Riley R, Guilleminault C, Powell N, et al. Mandibular osteotomy and hyoid bone advancement for obstructive sleep apnea: a case report. *Sleep* 1984;7:79.
 73. Riley RW, Powell NB, Guilleminault C. Inferior mandibular osteotomy and hyoid myotomy suspension for obstructive sleep apnea: a review of 55 patients. *J Oral Maxillofac Surg* 1989;47:159.
 74. Riley RW, Powell NB, Guilleminault C. Obstructive sleep apnea and the hyoid: a revised surgical procedure. *Otolaryngol Head Neck Surg* 1994;111:717–21.
 75. Waite PD, Wooten V, Lachner J, et al. Maxillomandibular advancement surgery in 23 patients with obstructive sleep apnea syndrome. *J Oral Maxillofac Surg* 1989;47:1256.
 76. Riley RW, Powell NB, Guilleminault C. Obstructive sleep apnea syndrome: a review of 306 consecutively treated surgical patients. *Otolaryngol Head Neck Surg* 1993;108:117–25.
 77. Hochban W, Conradt R, Brandenburg U, et al. Surgical maxillofacial treatment of obstructive sleep apnea. *Plast Reconstr Surg* 1997;99:619–26.
 78. Prinsell JR. Maxillomandibular advancement surgery in a site-specific treatment approach for obstructive sleep apnea in 50 consecutive patients. *Chest* 1999;116:1519–29.
 79. Lee NR, Givens CD, Wilson J, Robins RB. Staged surgical treatment of obstructive sleep apnea syndrome: a review of 35 patients. *J Oral Maxillofac Surg* 1999;57:382–5.
 80. Bettega G, Pepin JL, Veale D, et al. Obstructive sleep apnea syndrome fifty-one consecutive patients treated by maxillofacial surgery. *Am J Respir Crit Care Med* 2000;162:641–9.
 81. Riley RW, Powell NB, Guilleminault C. Obstructive sleep apnea syndrome: a surgical protocol for dynamic upper airway reconstruction. *J Oral Maxillofac Surg* 1993;51:742–7.
 82. Prinsell JR. Maxillomandibular advancement surgery for obstructive sleep apnea syndrome. *J Am Dent Assoc* 2002;133:1489–97.
 83. Louis PJ, Waite PD, Austin RB. Long-term skeletal stability after rigid fixation of Lefort I osteotomies with advancements. *Int J Oral Maxillofac Surg* 1993;22: 82–6.
 84. Nimkarn Y, Miles PG, Waite PD. Maxillomandibular advancement surgery in obstructive sleep apnea syndrome patients: long-term surgical stability. *J Oral Maxillofac Surg* 1995;53:1414–8.
 85. Riley RW, Powell NB, Guilleminault C, Ware W. Obstructive sleep apnea syndrome following surgery for mandibular prognathism. *J Oral Maxillofac Surg* 1987;45:450–2.

Part 9

FACIAL ESTHETIC SURGERY

Blepharoplasty

Heidi L. Jarecki, MD

Mark J. Lucarelli, MD

Bradley N. Lemke, MD

Current blepharoplasty techniques were at least two thousand years in the making. Reports from as early as AD 25 to 35, such as *De Re Medica* by Roman encyclopedist and philosopher Aulus Cornelius, demonstrated appreciation of upper eyelid skin excision in the treatment of upper eyelid disorders.¹ Early descriptions of surgery involving eyelid reconstruction by Carl Ferdinand von Graefe, often regarded as the founder of modern plastic surgery, in 1818, and Johann Karl George Fricke, a student of von Graefe's, in 1829, represent the first reported uses of the term blepharoplasty.^{1,2} A.W. Sichel first accurately described "herniated orbital fat" in 1844.¹ Sidney Fox originated the term dermatochalasis in 1952 to describe age-associated excess in eyelid skin.²

Cosmetic surgery was not embraced until the early twentieth century when Charles Conrad Miller penned the first book dedicated to cosmetic surgery in 1907 entitled *Cosmetic Surgery: The Correction of Featural Imperfections*.¹ Shortly thereafter Frederick Kolle published a text on plastic and cosmetic surgery in which he detailed the value of preoperative eyelid skin marking to determine the proper amount to excise during surgery.² The value of preoperative and postoperative photography was introduced in 1926 by Parisian A. Suzanne Noël, one of the first

female pioneers in cosmetic surgery.² These landmark contributions spawned current blepharoplasty techniques, which continue to be further refined and optimized to achieve superior functional and cosmetic results.

Blepharoplasty is frequently performed either as an adjunctive procedure or as a freestanding operation. A 2002 American Academy of Cosmetic Surgery (AACS) survey reported 27,503 blepharoplasty surgeries performed by AACS members, making blepharoplasty the tenth most frequently performed cosmetic procedure in the United States (K. Rybarczyk, personal communication, January 2003). Common indications for blepharoplasty are dermatochalasis, blepharochalasis, orbital septum weakness with resultant fat pad herniation, hypertrophic orbicularis oculi muscle, eyelid laxity with malposition, and other adnexal abnormalities (ie, herniated lacrimal gland, varicose veins, eyelid skin lesions). Dermatochalasis is simply an excess of eyelid skin, often the result of age- or ultraviolet (UV)-associated decreases in collagen and changes in elasticity and composition of the dermis and epidermis.³ Recurrent angioedema of the eyelid results in characteristic laxity, fullness, and episodic edema known as blepharochalasis. Acquired blepharoptosis indicates a drooping eyelid that usually

results from disinsertion of the aponeurotic insertion of the levator palpebrae superioris into the upper eyelid. Blepharoptosis may be present in the setting of dermatochalasis or blepharochalasis. Orbital septal weakness is evident when "bulges," which represent herniation of orbital fat, are present in the eyelids. A hypertrophic orbicularis oculi muscle presents as a horizontal prominence of the lower eyelid immediately beneath the palpebral margin. Eyelid laxity may manifest as ectropion, canthal angle alterations, and epiphora.

The ensuing chapter is intended as a survey of important information for the blepharoplasty surgeon to consider. On completion of the chapter the surgeon should understand pertinent anatomy, be able to identify good blepharoplasty candidates, be capable of developing a surgical plan, and understand the major complications and how to avoid them. This information should serve as a springboard to direct the surgeon in routes of appropriate inquiry.

Anatomy

A thorough understanding of the topography of the upper two-thirds of the face is requisite for successful eyelid surgery. Eyelids should not be viewed in isolation but rather in context of the relationship to the eyebrow above and midface below.

Forehead and Eyebrow

Understanding the normal or idealized brow position is important during evaluation for blepharoplasty.^{4,5} In general men tend to have lower flatter brows at the level of the superior orbital rim. The typical female brow rests 1 cm above the superior orbital rim and peaks between the lateral corneal limbus and lateral commissure, creating a higher and gently arched appearance. Figures 64-1 and 64-2 demonstrate the typical position of the female and male brow, respectively, in youth. Women frequently alter eyebrow position and shape by epilating eyebrow hair so as to approximate the more idealized arched brow.

The eyebrow provides vertical support to the upper eyelid, contributing to the architecture of the eyelid. Eyebrow position is significantly influenced by the elevators and depressors of the brow as well as underlying connective tissue attachments. The frontalis muscle, which originates within the galea aponeurotica, is the main elevator of the eyebrow. The corrugator supercilii, depressor supercilii, procerus, and orbicularis oculi depress the medial brow, whereas the orbicularis muscle is the main lateral brow depressor. Corrugator contraction compresses the medial eyebrows toward the midline with slight depression, forming vertical or oblique

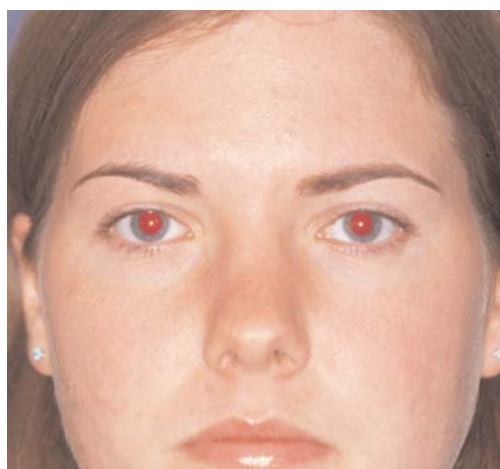


FIGURE 64-1 Typical female brow position. Note the relationship of the brow relative to the superior orbital rim.

glabellar furrows. Contraction of the procerus depresses the glabella, creating horizontal rhytids across the dorsum of the nose. Depressor supercilii contraction causes medial eyebrow depression and formation of oblique glabellar furrows. At its insertion point into the eyebrow the frontalis muscle interdigitates with the orbicularis oculi muscle.

Beneath the frontalis lies the eyebrow fat pad, a structure composed of loose fibrous septae with fat-filled interseptate spaces. The eyebrow fat pad is continuous inferiorly with the filmy areolar posterior orbicularis fascia on the undersurface of the orbicularis muscle.⁶ On the underside of the eyebrow fat pad, dense connective tissue attachments fasten the superficial muscle plane to the supraorbital ridge, thereby supporting the medial one-half to two-thirds of the eyebrow.⁶ Similar attachments for the lateral third of the brow are lacking, thus explaining the preferential ptosis of the temporal brow with aging.⁶ In addition the elevating frontalis muscle does not extend to the lateral-most portion of the eyebrow, further contributing to temporal brow ptosis.

The eyebrow provides vertical support to the anterior upper eyelid structures below, therefore ptosis of the eyebrow increases the amount of apparent upper eyelid dermatochalasis may result in excessive eyelid skin removal, further exacerbation of inferior brow displacement, and an inability to close the eyelids. With mild temporal brow ptosis as the only brow position abnormality, more eyelid skin can be removed laterally during blepharoplasty to provide a satisfactory result. With more severe eyebrow and forehead ptosis, consideration of eyebrow and forehead lifting is important.

Midface

Comprising the area from the inferior orbital rim to the mouth, the midface pos-

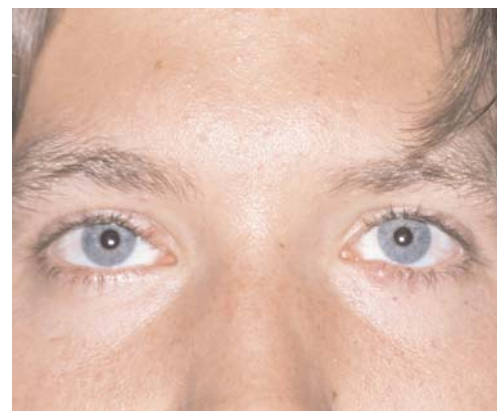

FIGURE 64-2 Typical male brow position. Note that relative to the female brow the male brow position is lower and flatter.

sesses structures and landmarks important to the planning of a successful lower lid blepharoplasty. Nasojugal and malar folds separate the thin lower eyelid skin from the thicker skin of the cheek. The superficial musculoaponeurotic system (SMAS) is a fibrous fascial network interconnecting the muscles of facial expression, which acts as a force distributor of facial muscle contractions to the skin to allow for facial expression.⁷ The SMAS divides the subcutaneous fat into two layers and possesses fibrous septae connecting to the dermis. The orbitomalar and zygomatic ligaments provide connections between the periosteum and dermis.^{8,9}

In youth the eyelid cheek contour is a smooth single convexity from the tarsus inferiorly to the cheek. With age numerous soft tissue and skeletal changes occur in the eyelid and midface. The orbital septum weakens permitting orbital fat prolapse, orbital rim exposure, and a prominence of the cheek. Inferolateral aging-associated descent of the orbicularis oculi muscle can also disrupt the eyelid cheek contour.¹⁰ Descent of the malar fat pad contributes substantially to midfacial ptosis.^{11,12} Anatomic studies demonstrate attenuation or abnormal inferior displacement of the subcutaneous insertions of the orbitomalar, masseteric cutaneous, and zygomatic ligaments in the setting of midfacial

ptosis.^{12,13} Important changes of the maxilla, as described by Pessa and colleagues, also contribute to midfacial aging.^{14,15}

Ocular Adnexa

The eyelid margin is traditionally divided into anterior and posterior lamellae. The anterior lamella is composed of the skin, orbicularis oculi muscle, muscle of Riolan, and glands of Zeis and Moll, whereas the posterior lamella is composed of the palpebral conjunctiva, tarsal plates, and associated meibomian glands. A cross-section of the upper and lower eyelid structures demonstrates the composition of the anterior and posterior lamellae (Figure 64-3). The anterior and posterior lamellae are divided by the orbital septum, a structure occasionally referred to as the middle lamella.

Eyelid Skin Thickness Eyelid skin possesses a minimal subcutaneous fibroadipose layer and an attenuated dermis, contributing to its status as the thinnest skin in the body. Subcutaneous fat is completely absent in the pretarsal area. An abrupt transition to thicker skin with a correspondingly more dense fibroadipose layer is encountered near the orbital rim. Care must be taken to minimize surgical incisions laterally beyond the thin eyelid skin as scar appearance may markedly differ. The eyelid skin of Asians tends to be slightly thicker than that of Caucasians primarily due to a thicker dermis and subcutaneous fat.¹⁶

Aging Skin Changes Aging skin changes, such as pigmentary aberrations (dyschromia) and wrinkling (rhytids), result from a combination of UV-induced photodamage, mechanical forces from gravity, and facial muscle contraction and altered chemical environment.³ Decreases in the synthesis of Type I collagen have been demonstrated in aged human eyelid skin.¹⁷

Eyelid Topography Fissure Heights, Upper Eyelid Crease The adult vertical interpalpebral fissure measures 9 to 12 mm,

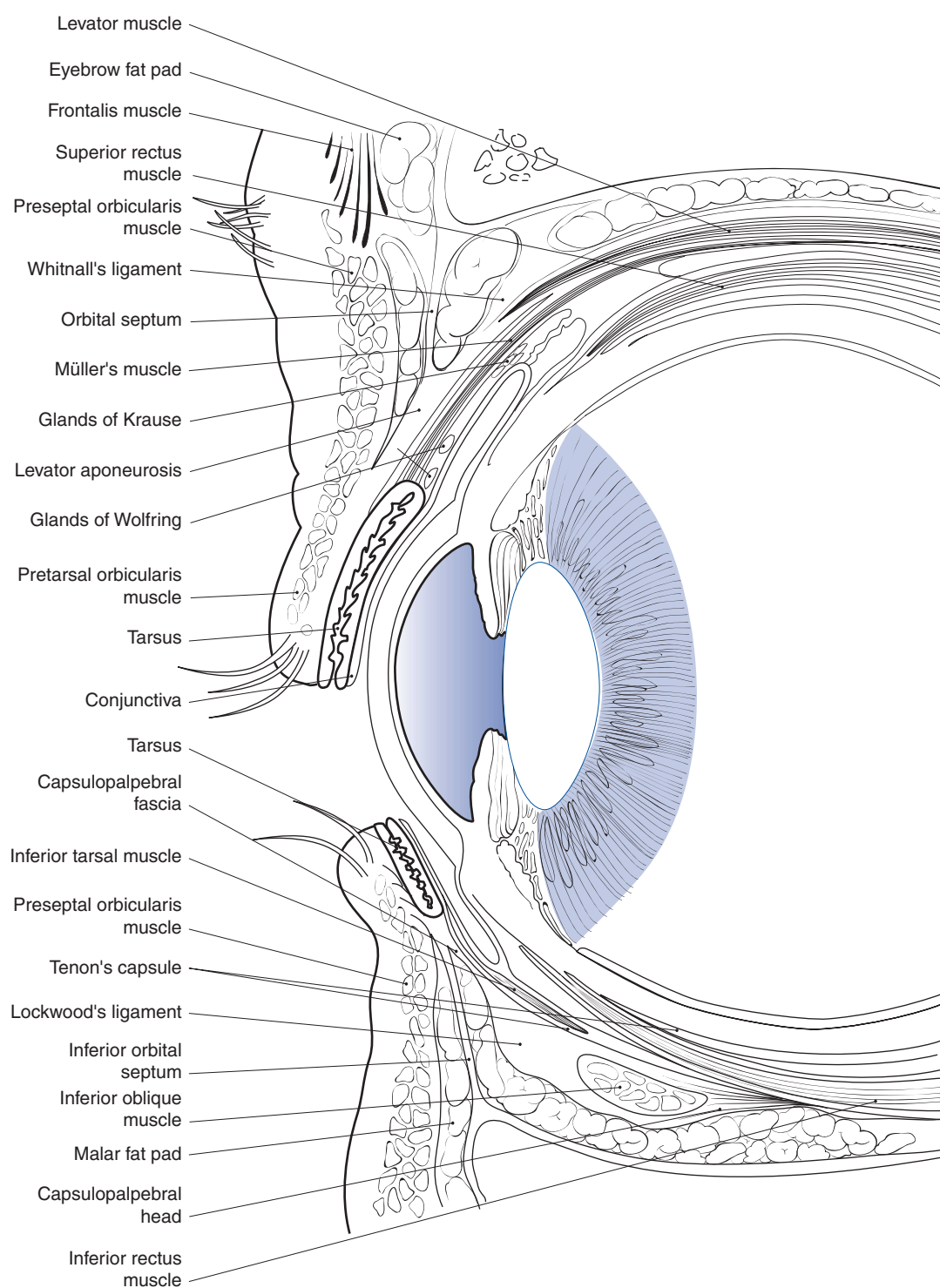


FIGURE 64-3 Cross-sectional view of the structures composing the upper and lower eyelid. Adapted from Kikkawa DO and Lemke BN.⁴¹

whereas the horizontal interpalpebral fissure is 28 to 30 mm. With age the horizontal fissure shortens by approximately 10%.¹⁸ The lateral canthal angle lies 1 to 2 mm superior to the medial canthal angle,

giving the youthful eye a subtle lateral inclination. The apex of the upper eyelid margin rests slightly nasal to the pupil at the level of limbus in children and 1.0 to 2.0 mm below the limbus in adults, yielding

a margin reflex distance of 4 to 5 mm. The lower eyelid margin peaks inferiorly directly beneath the pupil. Figure 64-4 demonstrates the normal upper and lower eyelid position. As depicted in Figure 64-5 dermal and conjoined fascia attachments of the levator palpebrae superioris aponeurosis form the upper eyelid crease, an important anatomic and surgical landmark often used as an incision site.^{6,19,20} Position of the upper eyelid crease varies with age, gender, and, to some degree, ethnicity.²¹ The youthful eyelid crease is approximately one-third of the distance from the eyelid margin to the lower edge of the brow.²² Elevation of the upper eyelid crease may signify disinsertion or attenuation of the levator muscle attachments due to age-related lipid infiltration. Concomitant upper lid blepharoptosis is commonly present in the setting of an elevated upper lid crease. In general upper eyelid creases in Caucasian females are 9 to 10 mm above the upper lid margin, whereas in Caucasian males they are 7 to 8 mm above the upper lid border. A cross-sectional study demonstrated upper lid crease heights lower than traditionally purported values, although small sample size and variation in measuring technique may account for the inconsistency.²¹ Upper eyelid crease position in African Americans has not been documented extensively in the literature, although clinical experience suggests a position similar to that found in Caucasians.

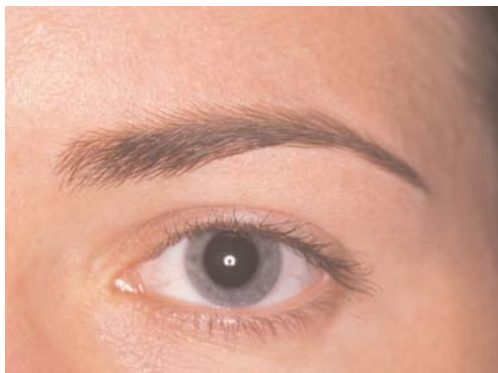

FIGURE 64-4 Normal position of the upper and lower eyelids.

Asian Upper Eyelid In individuals of Asian ethnicity three main variations of upper eyelid crease anatomy exist: single eyelid, low eyelid crease (inside-fold type of crease), and double eyelid with lid crease parallel to lid margin (Figure 64-6).^{16,23-25} In patients with a single eyelid or low eyelid crease the levator aponeurosis fuses with the orbital septum near the eyelid margin below the supratarsal border, creating an essentially absent or low upper lid crease.¹⁶ In the Asian double eyelid the level of fusion of the orbital septum with the levator aponeurosis is higher than in the Asian single eyelid.¹⁶ Aside from the orbital

septum fusion site, thicker fat layers and a lower primary insertion of the levator aponeurosis to the upper eyelid skin contribute to the characteristic topography of the Asian eyelid.

Lower Eyelid Crease The lower eyelid crease, formed by connective tissue fibers extending anteriorly from the capsulopalpebral fascia into the subcutaneous tissues, is less prominent than its upper eyelid counterpart and is often most noticeable in children.²⁶ The lower lid crease begins medially 4 to 5 mm inferior to the lower lid margin and slopes inferiorly as it proceeds laterally.

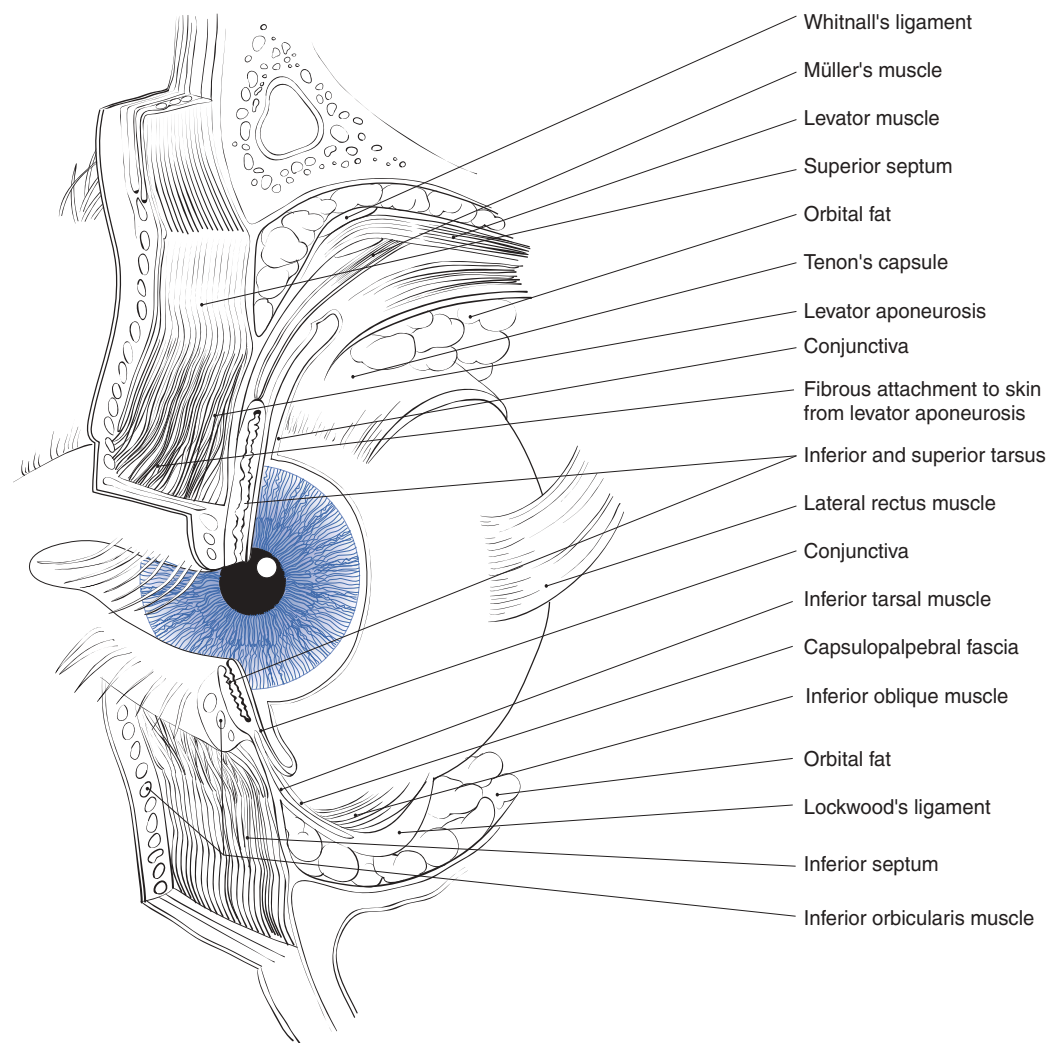


FIGURE 64-5 Cross-sectional view of the dermal and conjoined fascial attachments of the levator aponeurosis responsible for lid crease formation. Adapted from Lemke BN and Lucarelli MJ.¹¹¹

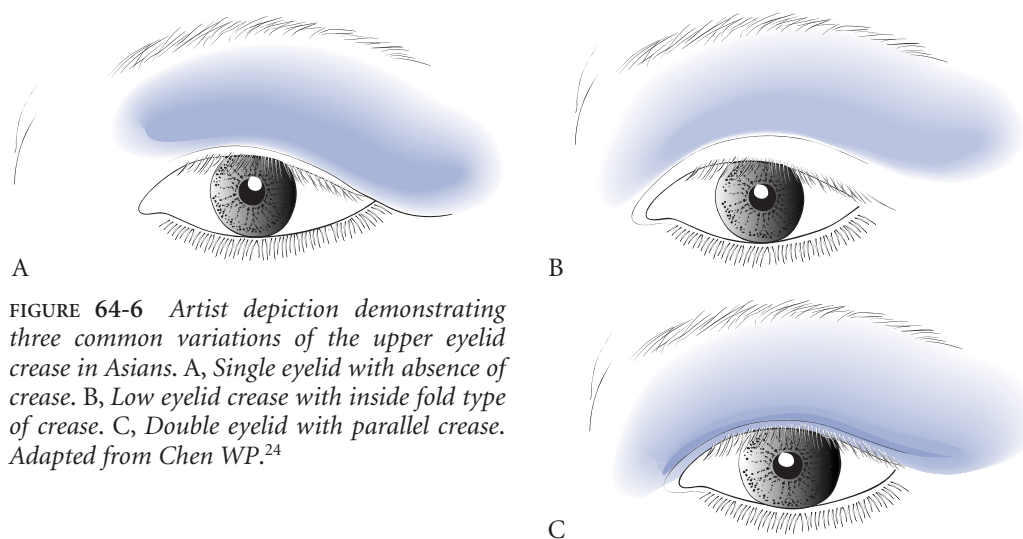


FIGURE 64-6 Artist depiction demonstrating three common variations of the upper eyelid crease in Asians. A, Single eyelid with absence of crease. B, Low eyelid crease with inside fold type of crease. C, Double eyelid with parallel crease. Adapted from Chen WP.²⁴

Eyelid Connective Tissue **Orbital Septum**

The orbital septum, an anatomic boundary between the eyelids and orbit, is a multilaminar layer of dense connective tissue arising from the arcus marginalis, a thickened white fibrous line on the periosteum of the bony orbital margin.²⁷ The orbital septum forms the anterior boundary of the orbit. Medially the septum splits to cover the posterior aspect of Horner's muscle and adhere to the lacrimal fascia, inserting on the posterior lacrimal crest and anterior lacrimal crest, respectively. Laterally the septum inserts anteriorly on the lateral canthal ligament and posteriorly on Whitnall's tubercle of the lateral orbital rim. In the upper eyelid the orbital septum joins the levator aponeurosis 2 to 5 mm above the superior tarsal

border.²⁷ In the lower lid the septum fuses with the inferior tarsal border after joining the lower lid retractors 4 to 5 mm inferior to the tarsus.²⁶ A cadaver demonstration with artist's depiction of the orbital septum is shown in Figure 64-7. Orbital septal strength varies among individuals and with age. Attenuation of the septum allows for anterior orbital fat prolapse.

Tarsus Composed of dense fibrous tissue the tarsal plates contribute structural integrity to the eyelids. Approximately 1.0 to 1.5 mm thick the tarsal plates measure approximately 25 mm in length and range from 10 to 12 mm in height in the upper lid and 3 to 5 mm in the lower lid, with no difference noted between gen-

ders.²⁸ The tarsal plates taper convexly medially and laterally to conform to the globe (Figure 64-8). Within the tarsal plates are the meibomian glands, holocrine sebaceous glands responsible for the lipid layer of the tear film. The meibomian glands are branched acinar glands with long central ducts opening at the eyelid margin just posterior to the gray line. There are approximately 25 glands in the upper eyelid and 20 in the lower eyelid.

Medial and Lateral Canthal Ligaments

The medial and lateral tarsal borders are firmly attached to the orbital rims via the fibrous medial and lateral canthal ligaments, respectively (see Figure 64-8). The medial canthal ligament is more complex anatomically due to its often tripartite attachment as well as its relationship with the lacrimal system. The anterior arm inserts onto the maxillary bone, anterosuperior to the lacrimal crest. The posterior arm attaches to the posterior lacrimal crest in a fanlike fashion and may partially fuse with the posterior surface of the lacrimal sac. The superior arm inserts onto the orbital process of the frontal bone, contributing to the formation of the lacrimal sac fossa roof.²⁹ The lateral canthal ligament inserts on the zygomatic bone at Whitnall's tubercle 1.5 mm inside the lateral

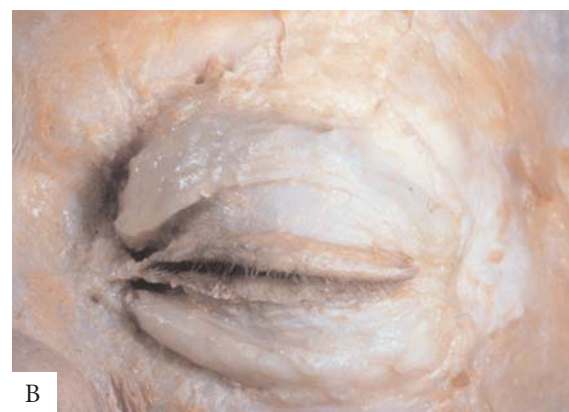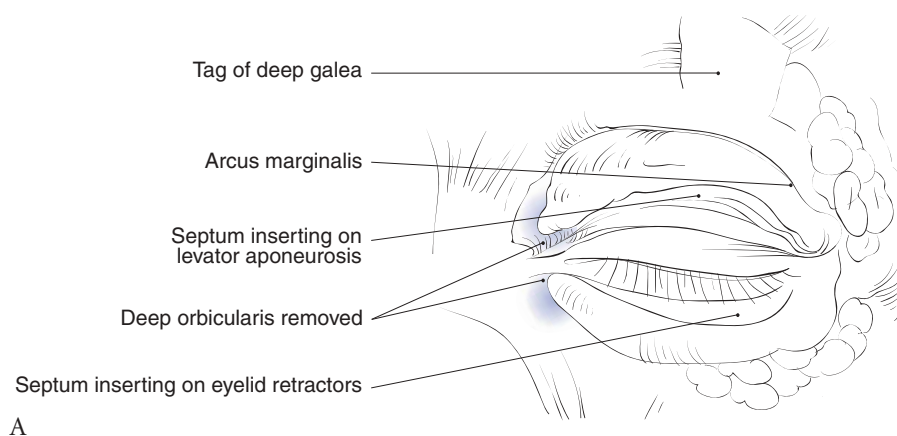


FIGURE 64-7 A and B, Cadaver demonstration of the orbital septum after removal of the forehead and eyelid musculature. A adapted from and B reproduced with permission from Lemke BN and Della Rocca RC.¹¹²

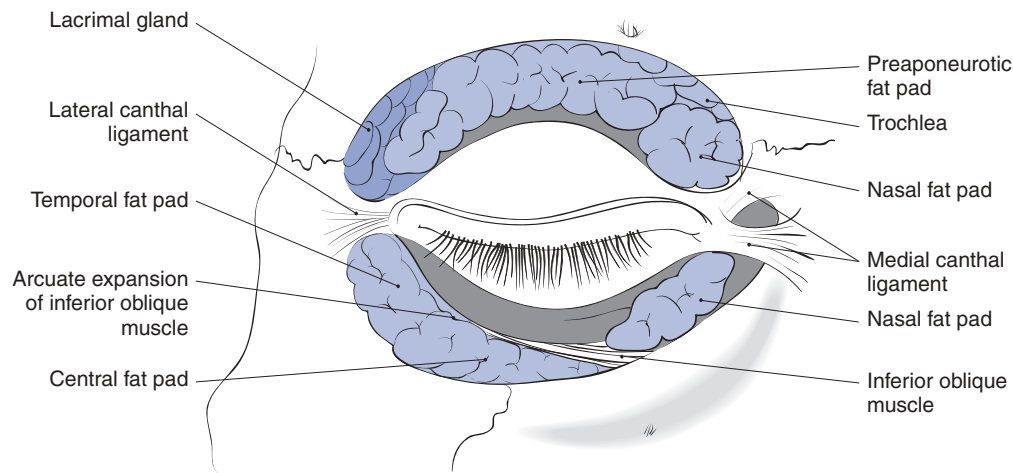


FIGURE 64-8 Skeletonized anterior view of tarsus, canthal ligaments, and fat pads. The medial canthal ligament possesses a complex tripartite attachment. Adapted from Kikkawa DO and Lemke BN.⁴¹

orbital rim and serves as both a stabilizer of the lids and a mobilizer of the lateral canthal angle via attachments to the lateral rectus check ligaments.^{30,31} Whitnall's tubercle is a key surgical landmark as it is the site of lateral lid attachment when performing a canthopexy. Approximately 2 mm of temporal movement of the lateral canthal angle is afforded on lateral gaze due to the fusion of the lateral rectus check ligaments with the lateral canthal ligament.³⁰

Whitnall's Superior Transverse Ligament

The junction of the levator muscle and levator aponeurosis is encircled by a transverse fibrous condensation known as Whitnall's superior transverse ligament, a supporter of the superior anterior eyelid. Although originally thought to serve as a check ligament for the levator, Whitnall's ligament has also been postulated to function as a suspender providing vertical support for the orbit (Figure 64-9).^{32,33} Whitnall's ligament inserts superomedially within the orbit on the frontal bone behind the trochlea and superolaterally near the frontozygomatic suture after attaching to the posterior fibers of the lacrimal gland capsule.³⁴ During ptosis surgery Whitnall's ligament is a key landmark, often corresponding to the transition from levator muscle to aponeurosis.

Lockwood's Ligament The lower lid counterpart to Whitnall's ligament is Lockwood's ligament, a product of the conjoined fascia of the inferior rectus and inferior oblique. Inserting on the medial and lateral canthal ligaments as well as the bony orbital rim, Lockwood's ligament serves as a suspensory sling for the inferior anterior orbit. Lockwood's ligament is strongest anterior to the inferior oblique muscle.²⁶

Eyelid Musculature *Orbicularis Oculi*

Part of the anterior lamella of the upper

eyelid, the orbicularis oculi is a ring-shaped superficial sphincter muscle that can be thought of in three concentric portions: pretarsal, preseptal, and orbital. Figure 64-10 demonstrates the orbicularis oculi muscle in the setting of the superficial facial muscles. Adherent to the tarsus the pretarsal orbicularis requires sharp dissection for isolation. Posterior to the preseptal orbicularis, a thin fibrofatty inferior extension of the eyebrow fat pad, the postorbicularis fascia facilitates dissection of the preseptal orbicularis from the orbital septum. The peripheral-most orbital orbicularis covers the orbital rims. Together the pretarsal and preseptal orbicularis comprise the palpebral orbicularis, responsible for reflexive eyelid closure. The clinical implication of the palpebral orbicularis' function is evident in the postoperative period when the reflexive blink response is temporarily decreased as a result of preseptal orbicularis removal in the blepharoplasty skin muscle flap. The patient must be reminded to blink fully and frequently during postoperative healing to adequately moisten the cornea. Orbital orbicularis contraction produces forceful voluntary eyelid closure. The orbicularis has firm attachments to under-

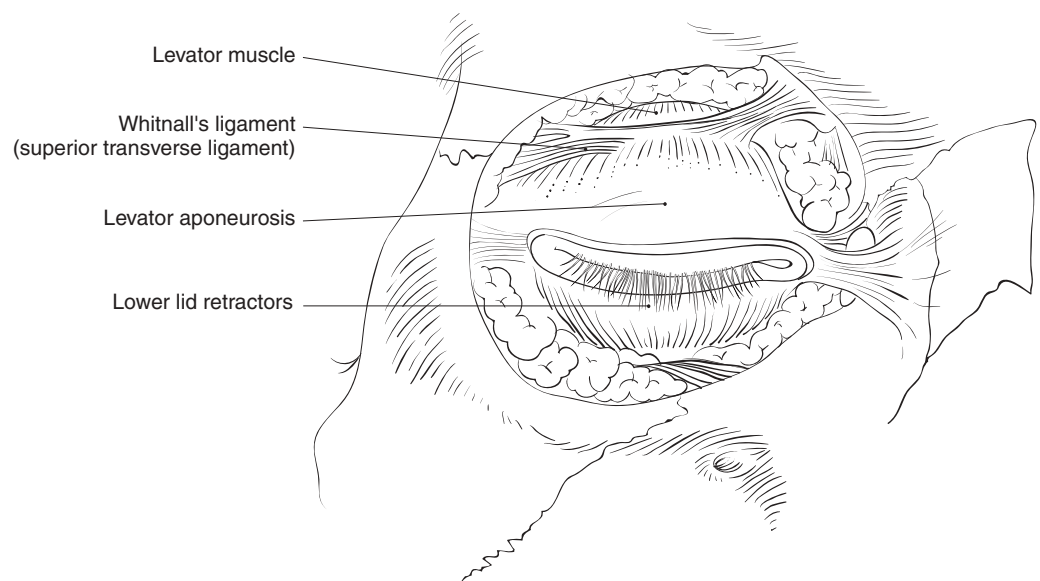


FIGURE 64-9 Whitnall's ligament of the eyelid, levator palpebrae superioris, and the lower eyelid retractors. Adapted from Nerad JA.⁷⁶

lying structures at the lateral palpebral raphe, medial canthal region, and upper and lower eyelid retractor insertions. The muscle of Riolan, a small portion of the orbicularis separated from the pretarsal orbicularis fibers by the cilia, creates the gray line of the lid margin. The lacrimal (Horner-Duverney) muscle, formed by the deep pretarsal head of the orbicularis as it inserts on the posterior lacrimal crest and lacrimal fascia, is thought to play a role in lacrimal outflow, although the exact nature of its function is controversial.³⁵ Contraction of the lacrimal muscle results in medial and posterior movement of the lower eyelid with the blink.

Levator Palpebrae Superioris The levator palpebrae superioris, the main retractor of the upper eyelid, arises from the lesser wing of the sphenoid deep in the bony orbit, coursing anteriorly above the superior rectus muscle and forming an aponeurosis with several important bony, dermal, and tarsal attachments. As mentioned above, the dermal and conjoined fascial attachments of the levator aponeurosis are responsible for the superior lid crease location (see Figure 64-9).^{19,20}

Müller's Muscle Müller's muscle, a sympathetically innervated minor retractor of the upper lid arising from the undersurface of the levator palpebrae superioris muscle, inserts into the superior tarsal border. Shortening of this muscle from the posterior aspect may be performed as an adjunct ptosis repair during blepharoplasty.³⁶⁻³⁸ Approximately 2 mm of upper lid lift are provided by contraction of Müller's muscle, practically evidenced by the mild upper lid lift experienced with a rush of sympathetic excitation (ie, during the fight-or-flight response).

Lower Eyelid Retractors The lower lid counterparts of the levator and Müller's muscles are the capsulopalpebral fascia and the inferior tarsal muscle, the retractors

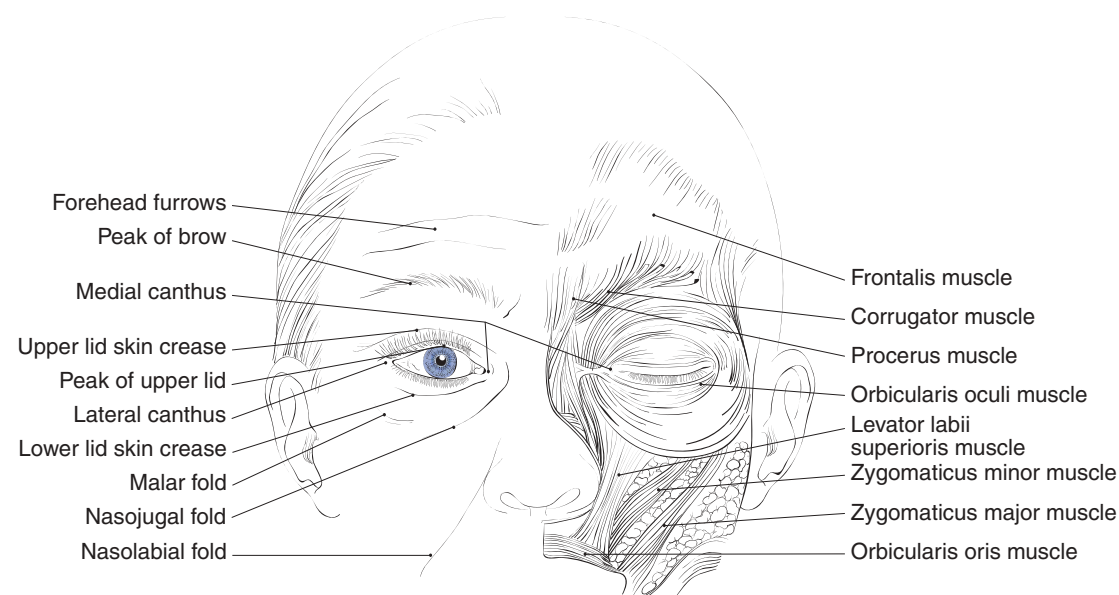


FIGURE 64-10 Selected musculature of the eyelid. Orbicularis oculi in the setting of the superficial facial muscles. Adapted from Nerad JA.⁷⁶

tors of the lower lid (see Figure 64-9). The terminal fibers of the inferior rectus muscle give rise to a fibrous extension known as the capsulopalpebral head of the inferior rectus which splits to encompass the inferior oblique muscle, forming the inferior tarsal muscle and the capsulopalpebral fascia.²⁶ These layers fuse anterior to the inferior oblique muscle, forming Lockwood's suspensory ligament, the analog to Whitnall's ligament of the upper lid. Continuing anteriorly the lower lid retractors insert on Tenon's fascia, the inferior tarsal border, and the orbital septum at a level 4 to 5 mm below the tarsal border.

Eyelid Fat Pads **Orbital Relations** In the anterior orbit, distinct fat compartments can be identified, although the majority of the anterior orbital fat pads remain continuous with posterior orbital fat (Figure 64-11).³⁹ This continuity prompted concern that excessive traction on orbital fat was responsible for orbital hemorrhage complicating blepharoplasty with fat removal.⁴⁰ Most surgeons implicate faulty hemostasis of fat pads, rather than traction, as the cause of postblepharoplasty orbital hemorrhage. Careful hemostasis is essential when performing eyelid fat removal.

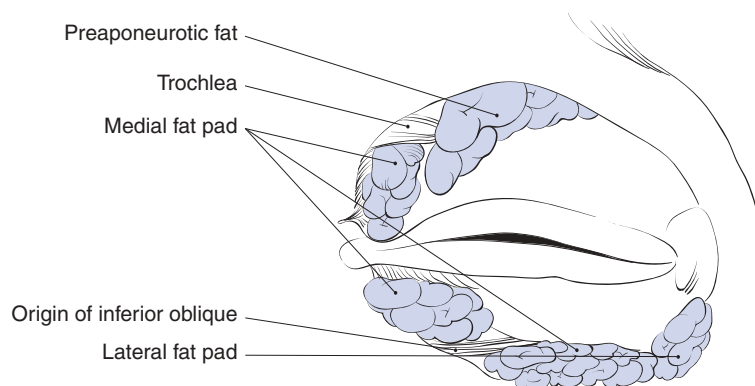


FIGURE 64-11 Artist rendition of the eyelid fat pad. Adapted from Lemke BN and Della Rocca RC.¹¹²

Aging Changes In the youthful face, orbital fat is held in check by a hearty orbital septum. Weakening of the septum associated with aging, chronic allergic swelling, or medical problems resulting in fluid retention (ie, hypo- or hyperthyroidism) may permit anterior prolapse of orbital fat, resulting in steatoblepharon. Aging may also cause atrophy of eyelid fat, creating a superior sulcus deformity. Dietary deficiency alone, however, has not been shown to result in orbital fat loss.⁴¹

Upper Eyelid Fat Pads The upper eyelid contains central and medial fat pockets anterior to the levator muscle and aponeurosis. Immediately posterior to the orbital septum lies the yellow central or preaponeurotic fat, which is not continuous with posterior orbital fat. Medially and inferior to the trochlea is the firmer and more pale fibrous medial fat pad.³⁹ Manipulation of the medial fat pad often requires placement of additional anesthesia into the fat pad itself, as more superficial anesthesia will not adequately infiltrate this structure. Laterally the superior anterior orbit houses the lacrimal gland. Orbital fat does not herniate in the lateral upper eyelid. Care must be taken to avoid removal of lacrimal tissue when fat pad excision is intended. Inspecting for color difference between the pink lacrimal gland and yellow fat is helpful in differentiation. Note that lacrimal gland prolapse may occur as an involutional change or in association with thyroid orbitopathy, making the position of the gland more anterior than usual.

Lower Eyelid Fat Pads The lower lid contains medial, central, and lateral fat pads, which may prolapse separately. Between the medial and central compartments resides the arcuate expansion of the inferior oblique muscle. Care must be taken to avoid damage to the inferior oblique muscle during lower lid blepharoplasty as vertical or torsional diplopia will result.

Eyelid Vasculature Arteries The eyelid vascular supply is rich, allowing for excellent healing and infection resistance, while mandating the surgeon to be cognizant of vascular relationships to avoid excessive bleeding. Both internal and external carotid arteries contribute to eyelid blood supply via the ophthalmic artery and the facial and infraorbital arteries, respectively (Figure 64-12). The facial artery becomes the angular artery in the medial canthal region and then perforates the orbital septum to anastomose with branches of the ophthalmic artery medial and anterior to the lacrimal sac. Arising from the maxillary artery the infraorbital artery travels within the infraorbital sulcus and canal to emerge from the infraorbital foramen and aid in arterial supply of the lower lid. The ophthalmic artery terminates in the lacrimal, frontal, supraorbital, supratrochlear, and nasal arteries.

Several anastomotic networks, known as arcades, exist in the eyelids. The peripheral arcade of the upper lid lies superior to the tarsus and directly anterior to Müller's muscle, supplying the superior aspect of the upper lid and superior conjunctival

fornix. The marginal arcades of the upper and lower lids lie 2 to 4 mm from the eyelid margin, directly anterior to the tarsi. A peripheral arcade may be present in the lower lid, although it is less well developed.⁴¹

Veins The eyelid venous supply possesses deep and superficial anastomoses. The facial vein, the principal vein of the eyelids, forms a deep anastomosis with the superior ophthalmic vein via the supraorbital vein and a second deep anastomosis with the deep pterygoid plexus via the deep facial vein. Both anastomoses are potential routes for cavernous sinus spread of superficial infection.

Lymphatics Recent anatomic studies demonstrate the lymphatic system of the upper and lower eyelids to consist of superficial subcutaneous and deep pre-tarsal plexuses.⁴² Using lymphoscintigraphy to characterize drainage pathways, parotid lymph node drainage from the upper eyelid, medial canthus, and lateral lower eyelid was shown.⁴³ Similar studies demonstrated medial and central lower

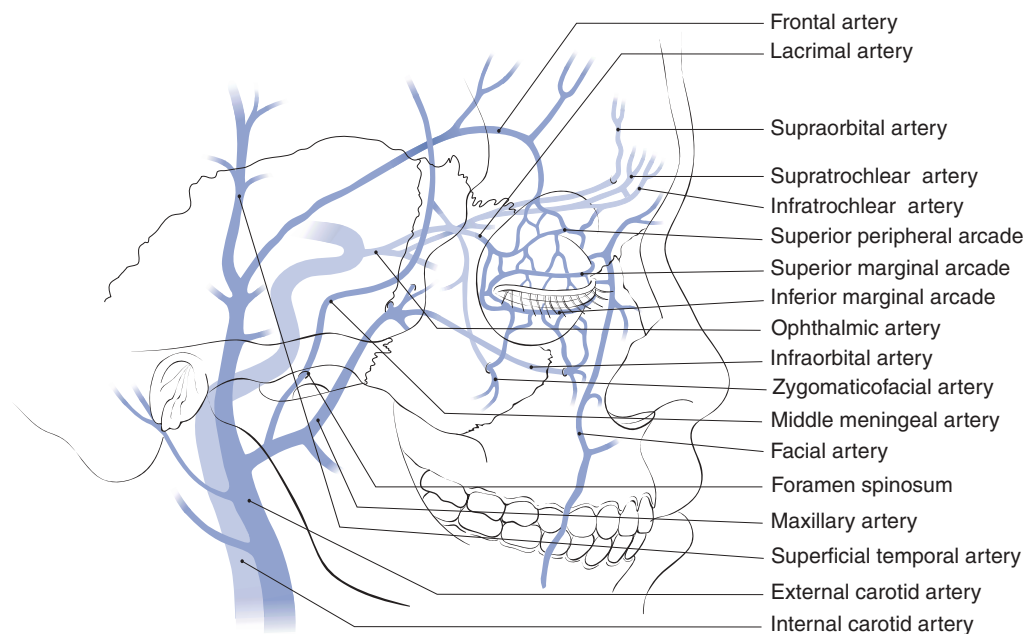


FIGURE 64-12 Orbital arterial blood is supplied from both internal and external carotid arteries. Adapted from Kikkawa DO and Lemke BN.⁴¹

eyelid drainage to the submandibular lymph nodes and a dual drainage of the central upper eyelid to both submandibular and parotid nodes.⁴³

Innervation Motor Cranial nerve VII, the facial nerve, supplies motor innervation for all the facial muscles (Figure 64-13). The facial nerve arises from the pons, eventually dividing into temporal, zygomatic, buccal, mandibular, and cervical branches. The temporal branch innervates both frontalis and orbicularis oculi, whereas the zygomatic and buccal divisions also contribute in an overlapping fashion to innervation of the orbicularis oculi.⁴⁴

The levator palpebrae superioris receives motor innervation from the terminal branches of the superior division of cranial nerve III, the oculomotor nerve, which travels within the muscle cone and enters the superior rectus inferiorly 15 mm from the orbital apex and subsequently enters the levator. Müller's muscle is sympathetically innervated by postganglionic fibers that arise in the superior cervical ganglion, enters the cavernous sinus surrounding the internal carotid artery, and subsequently joins nerve branches to enter the orbit.

Sensory Sensory innervation of the eyelids is via the ophthalmic and maxillary divisions of the trigeminal nerve (cranial nerve V), which give rise to the lacrimal, frontal, and nasociliary nerves, and the infraorbital, zygomatic, sphenopalatine, and posterosuperior alveolar nerves, respectively (Figure 64-14). The lacrimal nerve courses superotemporally to supply the lacrimal gland, conjunctiva, and lateral upper lid and send an anastomotic branch to the zygomaticotemporal nerve. The frontal nerve divides into supraorbital and supratrochlear branches near the orbital rim. The supraorbital nerve exits the orbit via a notch or foramen in the superior orbital rim to provide sensation for the majority of the forehead and scalp. The

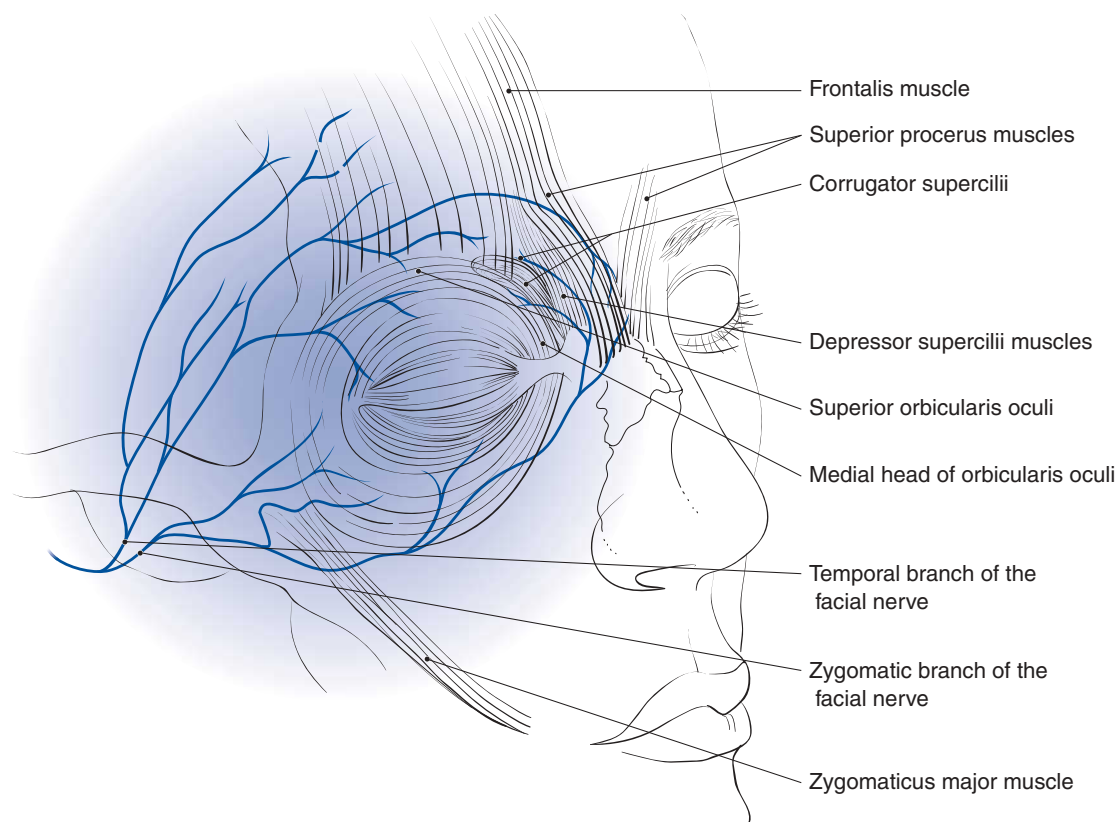


FIGURE 64-13 Anatomy of cranial nerve VII, the source of motor innervation for the face. Adapted from Knize DM.¹¹³

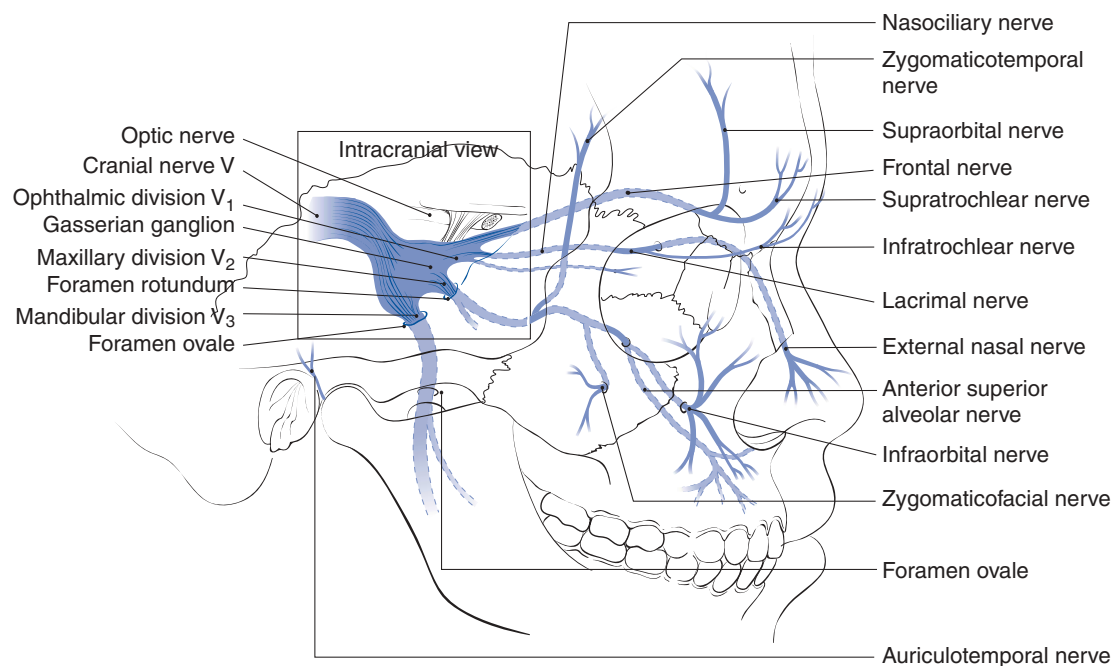


FIGURE 64-14 Cranial nerves V₁ and V₂ supply sensory innervation to the periorbital region. Adapted from Kikkawa DO and Lemke BN.⁴¹

supratrochlear nerve, exiting the orbit lateral to the corrugator muscle, conveys sensory input from the bridge of the nose and

medial aspect of the upper eyelid and forehead.^{45,46} The nasociliary nerve gives rise to the anterior and posterior ethmoidal

nerve, the long ciliary nerves to the globe, and a sensory root to the ciliary ganglion and terminates as the sensory root to the infratrochlear nerve.⁴¹ Emerging from the infraorbital foramen the infraorbital nerve supplies the skin and conjunctiva of the lower eyelid, nasal skin and septum, and upper lip skin and mucosa via the inferior palpebral, lateral nasal, and superior labial nerve terminal branches, respectively. The zygomatic nerve divides into the zygomaticofacial and zygomaticotemporal nerves. The former travels along the inferolateral orbit, traversing the zygomaticofacial foramen before innervating the cheek skin, whereas the latter exits the orbit to the temporal fossa and supplies the lateral forehead.

Lacrimal System and Tear Film Composition *Lacrimal Glands* The lacrimal gland, incompletely divided by the lateral horn of the levator into orbital and palpebral lobes, lies in a shallow depression of the superotemporal frontal bone. In the superior and inferior conjunctival fornices are the accessory lacrimal glands of Krause and Wolfring.

Lacrimal Drainage System The lacrimal drainage system is diagrammed in Figure 64-15. The upper and lower lid puncta lie 8 and 10 mm lateral to the tear sac, respectively, and are normally well apposed to the globe. Initially vertical for 2 mm the canaliculi make a 90° turn and travel 8 mm within the orbicularis muscle just beneath the lid margin to join, forming the common canaliculus. The common canaliculus then joins the lacrimal sac, which is found within the bony lacrimal fossa. Ten percent of the population lacks a common canaliculus, and the canaliculi simply lead to the lacrimal sac. The nasolacrimal duct drains beneath the inferior turbinate into the inferior meatus.

Tear Film Composition The precorneal tear film is comprised of three layers:

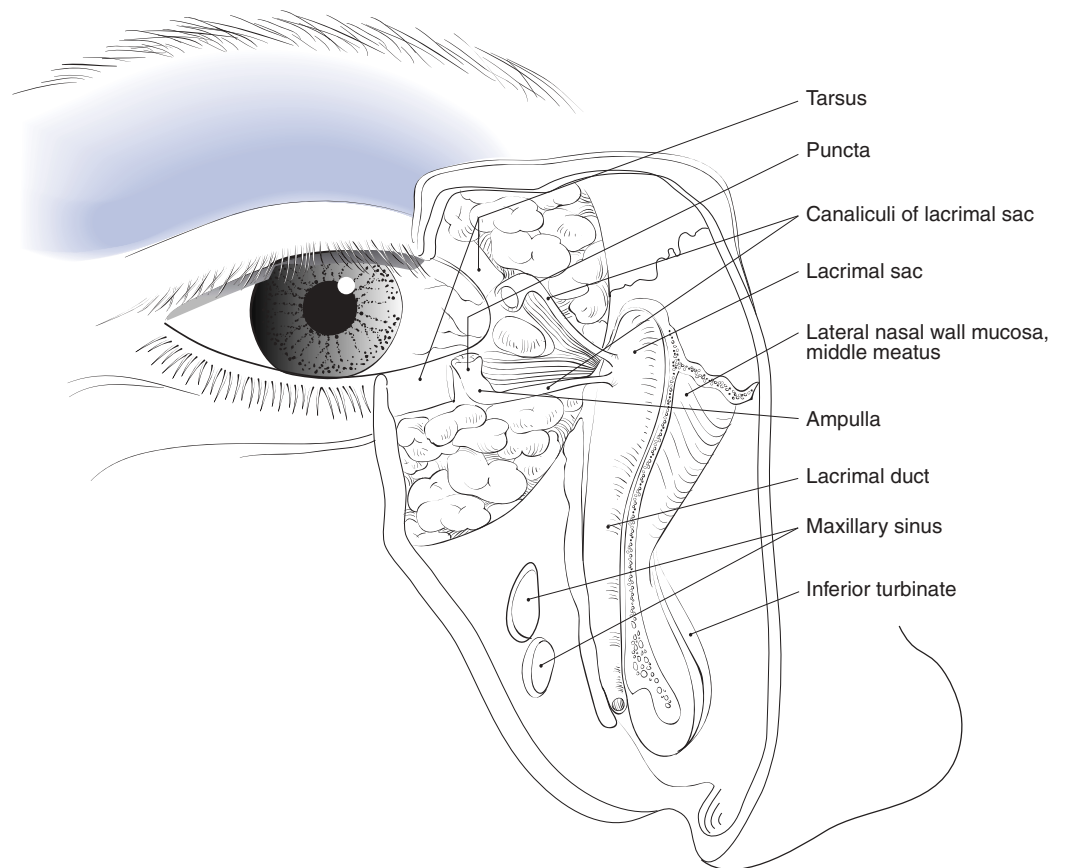


FIGURE 64-15 The lacrimal system of the eyelid. Adapted from Lemke BN and Lucarelli MJ.¹¹¹

mucin, aqueous, and lipid. The inner mucin layer, produced by conjunctival goblet cells, stabilizes the tear film while lubricating the corneal surface. Accessory and main lacrimal glands account for the middle aqueous layer, the thickest portion of the tear film. The most superficial lipid layer, secreted by the meibomian glands and glands of Zeis and Moll, further stabilizes the tear film and prevents evaporation. Reflex tearing prompted by emotion or an ocular irritant is produced by the main lacrimal gland. Deficiency of any component of the tear film leads to dry eye symptoms.

The tear layer must be regularly redistributed by the eyelid blink mechanism to maintain ocular surface comfort and integrity. Postoperative lessening of the magnitude and frequency of the blink may temporarily elicit dry eye symptoms in predisposed individuals. Blepharitis, conjunctivitis, and corneal irritation symp-

toms are also amplified by this temporary postblepharoplasty eyelid dyskinesia.

Patient Evaluation: History

Eliciting the Chief Concern

Whether primarily cosmetic or functional, patient selection for blepharoplasty requires careful consideration of history elements, physical features, and patient expectations as well as investigation into potential clinical pitfalls. The blepharoplasty surgeon must thoroughly explore the goals of the patient. Patients needing a functional blepharoplasty owing to severe dermatochalasis often describe frontal headache or fatigue from frontalis contraction, impairment of superior visual field, or a need to raise the chin or use manual elevation of the brow or lids to enhance vision. Symptoms are frequently exacerbated by fatigue and are generally worse in the evening (ie, while reading in downgaze

before bedtime). Patients may relate needing to raise their lid skin to see better. Patients seeking cosmetic blepharoplasty may lament they “look tired all the time” or describe a sagging change in their lid and eyebrow position compared with the lid and brow position of their youth. Documentation of lid effect on patient quality of life is valuable. Information on the impact on occupation, hobbies, driving, and other activities of daily living is essential both for better understanding of the patient’s goals and for third party reimbursement.

The patient is encouraged to demonstrate the problem areas while looking at a handheld mirror. Patients are also asked to bring old photographs that reveal eyebrow position at an earlier age. Asian blepharoplasty candidates are encouraged to present photographs demonstrating the desired upper eyelid crease type. Some surgeons use computer modeling programs to illustrate possible results to patients. An immediate demonstration of the effect of eyebrow elevation or the impact of aging can be achieved through use of digital photography of the patient with comparison to prior photographs.

In functional and cosmetic patients, especially in the latter group, expectations must be well defined. Ideal cosmetic candidates can describe which physical parameters they find problematic. It is helpful to have the patient point out, either in a mirror or a photograph, the objectionable features. Vague complaints or withdrawal from the decision-making process often predict inadequate understanding and unrealistic expectations. The issues under discussion should be those of the surgical candidate, not issues generated by others. An open patient-physician relationship and thorough dialogue remain key building blocks to a successful surgical outcome.

Important History Elements

Historic questions on the initial evaluation are designed to clarify the patient’s issues while identifying factors that can alter

treatment or contraindicate blepharoplasty. A complete past ocular history, including documentation of contact lens use or intolerance, tearing abnormalities, dry eye history, and previous surgery, as well as a thorough past medical history are necessary. Any history of dry eye symptoms, such as ocular scratchiness, blurred vision, foreign body sensation, or pain, should be investigated, as blepharoplasty may aggravate these symptoms. Ophthalmology consultation should be considered. Epiphora, ocular irritation with ambient wind, or current use of artificial tears all raise the possibility of postoperative dry eye symptoms. Keratoconjunctivitis sicca or cicatricial conjunctival disease should make the surgeon wary of proceeding with blepharoplasty.

Prior facial, and especially lid and brow, surgeries should be discussed. If upper eyelid blepharoplasty has been previously performed and the patient complains of a persistent skin fold, evaluate the eyebrow position to rule out forehead ptosis. Similarly the appearance of medial fat pad fullness can be mimicked by medial eyebrow ptosis. A descended eyebrow fat pad or a prolapsed lacrimal gland may also be mistaken by the patient as “residual upper eyelid fat” for which a secondary upper lid procedure is sought. The patient is shown their upper eyelid appearance with the forehead supported in the normal position. If a significant effect is noted the patient must compromise on the final blepharoplasty result or accept concomitant forehead lifting. Previously performed lower blepharoplasty may leave the patient desiring more fat removal, treatment of an accentuated nasojugal fold, skin laxity or deformity, eyelid malposition, or a lateral canthal deformity. A surgeon performing a transcutaneous lower blepharoplasty reenters the muscle later with an increased risk of postoperative lid retraction.

Although rare with blepharoplasty given the thin nature of the eyelid skin, the possibility of hypertrophic scar formation

should be discussed, especially with higher Fitzpatrick skin types.⁴⁷ The possibility of pigmentary change of the surgical wound should also be addressed. Any history of periocular trauma should be explored as to the timing and nature of the injury.

Clinical course and physiologic stability should be documented in patients with thyroid eye disease, as eyelid retraction associated with thyroid ophthalmopathy may worsen after poorly executed blepharoplasty. Eyelid retraction, eyelid edema, and any herniated fat measurements in patients with thyroid disease should be stable for at least 6 months prior to consideration of surgery.⁴⁸ Excessive proptosis in patients with thyroid eye disease is generally treated with orbital decompression prior to any eyelid surgery. Patients with thyroid orbitopathy often exhibit persistent eyelid fat herniation, eyebrow fat pad hypertrophy, and a glabellar grimace (Figure 64-16).

A full medication history should be documented, especially the use of aspirin, nonsteroidal anti-inflammatory medications, anticoagulants, homeopathic herbal

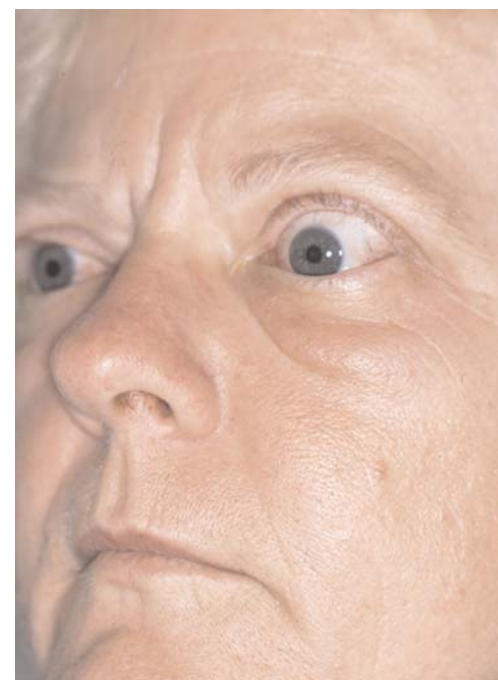

FIGURE 64-16 Patient displaying features characteristic of thyroid orbitopathy.

preparations, and vitamin E, as patients will need to discontinue these medicines preoperatively for 1 to 2 weeks. Warfarin is generally held for 4 days preoperatively. Inquiry regarding cigarette, alcohol, and illicit drug use should be made as the former may influence skin quality and healing and the latter two may affect the patient's ability to complete postoperative care.

Physical Examination

The preoperative physical examination of a patient requesting blepharoplasty focuses on eyelid function (ocular protection, tear film distribution, and clearance of the visual axis) as well as structure and regional anatomy that may necessitate adjunctive procedures for a superior result.

The Eyebrow Examination of the forehead and eyebrow seeks to define brow position as a contributor to apparent upper lid skin redundancy. Findings may be demonstrated to the patient with a mirror. Eyebrow position below the supraorbital rim yields a T-type configuration to the nasal-eyebrow angle, whereas the youthful female brow position creates a Y-type nasal-eyebrow angle configuration.⁴⁶ Measuring the distance from the central inferior eyebrow to the inferior corneal limbus while the patient is in primary gaze can aid in identification of patients with brow ptosis. A value less than 22 mm, especially in women, may warrant consideration of brow elevation as an adjunctive procedure.⁴⁸ Quantitative grading of brow ptosis can be obtained by placing a millimeter ruler vertically over the eyebrow and measuring the difference in millimeters between current location and ideal position when the eyebrow is elevated by the clinician's finger. Performing the measurement over the medial, central, and lateral brow is beneficial to quantify brow ptosis, which is often segmental. Adjunctive brow elevation must be considered if more than mild brow ptosis is present.

Upper Eyelid The skin quantity, quality, and resilience are important in determining the amount of skin to excise and use of adjunctive procedures. With the patient's eyes closed and gentle elevation of the brow to smooth out the upper eyelid skin, an objective measurement of the amount of eyelid skin can be obtained. Generally 18 to 21 mm of eyelid skin is retained during upper lid blepharoplasty.⁴ Eyelid skin should be examined for dermatopathology (ie, eczema), inflammation, pigmentary inconsistencies, and prior surgical scars. Any suspicious skin lesions suggestive of neoplasia should be documented and dealt with prior to surgery. Rhytids should be assessed. Orbital fat herniation, manifested as lid fullness, can be appreciated in the medial and central upper lid by palpation. Fullness in the lateral upper lid may signify lacrimal gland prolapse, which may necessitate repositioning during blepharoplasty.

The upper eyelid crease is identified by gently lifting the eyebrow and asking the patient to look down, then slightly up, and then down again while inspecting upper lid skin for a dynamic crease that retracts with slight upgaze. Static eyelid skin creases may or may not reflect this dynamic infolding produced by levator muscle activity. The distance from the central upper lid crease to the upper lid margin is normally 9 to 11 mm in women and 7 to 8 mm in men, except for the aforementioned variation in Asian eyelid crease location. Greater values than expected may indicate levator aponeurosis disinsertion and possible blepharoptosis. Lesser values may indicate preaponeurotic fat pad incursion into the pretarsal space. Lid crease reformation may be considered when desired.

It is critical that the upper eyelid position, evaluated with the forehead relaxed, be assessed preoperatively in the blepharoplasty candidate and that the measurements be recorded in the chart. The margin reflex distance (MRD), the distance from the middle of the pupil to the upper

lid margin, is determined by shining a penlight in the patient's eyes to obtain a pupillary light reflex while the patient is in primary gaze. Should the patient's upper lid ptosis preclude visualization of the light reflex, the lid should be raised until the reflex is seen and the number of millimeters of lift needed is recorded as a negative value. A normal MRD is 4 to 4.5 mm (Figure 64-17). Care must be taken to distinguish between genuine lid ptosis and severe dermatochalasis wherein the draped skin obscures the light reflex. An MRD greater than 5.5 mm and superior scleral show are indicative of upper lid retraction. Investigation of possible thyroid disease should be considered. Upper eyelid position with the eyelids gently closed should be inspected for lagophthalmos (incomplete lid closure), which may herald dry eye symptoms if greater than 2 mm. Special attention to lagophthalmos is warranted in patients who have undergone prior blepharoplasty.

Levator palpebrae superioris function is key to upper lid position and should be objectively measured. While holding a vertical millimeter ruler lateral to the greatest diameter of the palpebral fissure, the upper lid margin is measured in extreme downgaze and extreme upgaze. Care must be taken to immobilize the brow so as to avoid the influence of frontalis recruitment. Repeating the measurement several times is useful to obtain an average, which is recorded. Lid lag, evidenced by lack of

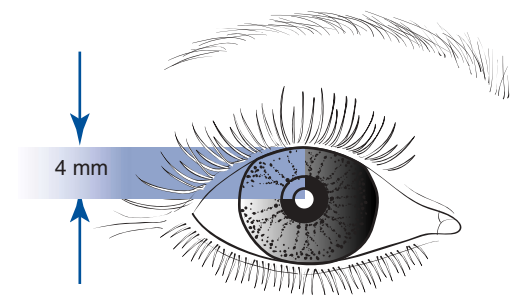


FIGURE 64-17 The margin reflex distance measures the distance between the center of the pupil and the margin of the upper eyelid. Adapted from Putterman AM.⁴⁸

smooth pursuit of the upper lid margin with the superior corneal limbus while the patient moves from upgaze to downgaze, can alert the examiner to possible thyroid disease. The presence of excessive upper lid laxity, upper lash ptosis, and papillary conjunctivitis in a patient with ocular irritation and injection suggests floppy eyelid syndrome. Lash ptosis is an altered trajectory of the lashes whereby cilia project inferiorly rather than anterosuperiorly. If floppy eyelid syndrome is suspected, examination findings will confirm abnormally easy distraction of the upper lid off the ocular surface. Horizontal tightening of the upper eyelids, performed by lateral shortening and re-insertion of a tarsal strip within the orbital rim, may be indicated.

The eyelid margin should be inspected. Evidence of blepharitis, such as collarettes along the lashes, thickened lid margins, and plugged meibomian glands, should be noted and lid hygiene (ie, warm washcloth soaks with gentle baby shampoo eyelid cleansing) prescribed to resolve the blepharitis prior to surgery.

Lower Eyelid Careful skin examination is equally as important in the lower eyelid area as in the upper lid. Rhytids, especially “crow’s feet,” should be noted, as prominence may necessitate adjunctive topical retinoic acid, chemical peels, laser resurfacing, and botulinum toxin A injections. Assessing for extra lower lid skin is best performed in upgaze. The pinch test uses an angled forceps, such as a Brown-Adson, to grasp a redundant fold of lower lid skin without altering lid position while the patient is in upgaze with his or her mouth open (to allow for maximal necessary excursion of lower lid skin). The amount of skin grasped approximates the amount to excise. Orbital fat prolapse is noted in the medial, central, and lateral lower lid. Facile differentiation of orbital fat from edema is achieved by gentle ballottement of the upper eyelid; fat herniation will result in distinct anterior movement of the

fullness whereas edema will not. Hypertrophied orbicularis muscle is most prominent when the patient smiles.

Lower lid position can be quickly assessed by examining the lower eyelid margin position relative to the inferior corneoscleral limbus. Any inferior scleral show in primary gaze is objectively measured from the inferior corneoscleral limbus to the lower eyelid margin, or using the margin reflex distance-2 (MRD₂), the distance from the pupillary light reflex to the lower lid margin in primary gaze. Together the MRD and MRD₂ compose the palpebral fissure height. Normally the lower lid rests at or slightly above the inferior corneal limbus. An increased MRD₂ raises concern of lower lid retraction from thyroid ophthalmopathy, lower lid laxity, mechanical forces, or cicatricial causes. A hypoplastic maxilla causing decreased prominence of the inferior orbital rim may contribute to postoperative susceptibility to lower lid retraction and ectropion.

Abnormal lower lid position and rounding of the lateral canthal angle often result from lower lid laxity. Laxity is assessed by distraction and the snap-back test. By gently grasping the lower lid centrally, the lid is distracted off the globe anteriorly. Normal distraction is less than 6 mm. Greater distraction suggests laxity. To perform the snap-back test the lower lid is pulled inferiorly and released while the patient refrains from blinking. A normal lid returns to the globe quickly with one or fewer blinks. A lax lid requires several blinks to resume its former position and may remain inferiorly displaced and everted, indicating ectropion. Laxity of the lateral canthal tendon is the most common cause of lower lid laxity. The ability to displace the punctum greater than 2 mm laterally indicates laxity of the medial canthal tendon.⁴⁹ Lower lid horizontal tightening procedures should be performed at the time of blepharoplasty surgery for the lax lower lid to prevent postoperative ectropion and recreate the

youthful, slightly elevated, well-defined lateral canthal angle.

Midface Architecture Midfacial ptosis, festoons, and malar mounds are important aspects to note on evaluation, as separate procedures are necessary to address these concerns. Midfacial ptosis encompasses a host of changes caused by attenuation of the subcutaneous portions of the orbitomalar, masseteric cutaneous, and zygomatic ligaments, including soft tissue inferior migration of the lower eyelid structures, cheek, and midface, as well as concomitant prominence of the nasolabial fold (Figure 64-18).¹² When attenuation of the lower lid orbicularis oculi and laxity of orbicularis attachments to deep fascia develop, the orbicularis may sag or form redundant folds known as festoons.⁵⁰ Several levels of festoons have been described including pretarsal, preseptal, orbital, and malar, and composition varies to include one or more of the following: skin, muscle, suborbicularis fat,

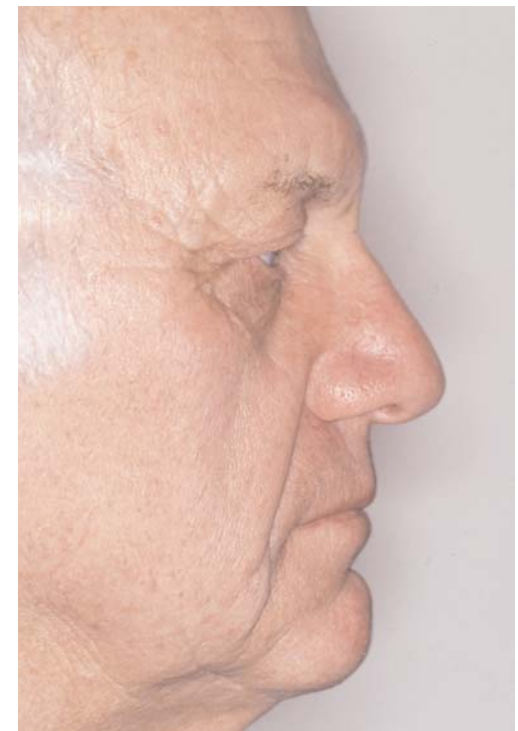


FIGURE 64-18 Profile of a patient with descent of the cheek prominence characteristic of midfacial ptosis.

and herniated orbital fat.⁵⁰ Malar mounds, projections of skin and fat in the area of the malar eminence, are areas of altered inferior orbital orbicularis fibers that allow abnormal communication between subdermal and suborbicularis fat.⁵⁰ Malar mounds often prove challenging to resolve.

Lacrimal Secretion and Ocular Surface Evaluation Dry eye symptoms are frequent following blepharoplasty, and preoperative evaluation of the lacrimal system may direct surgical intervention and patient education, thereby avoiding significant morbidity. The tear meniscus, tear break-up time, Schirmer testing, and/ or fluorescein corneal staining are often used. The tear meniscus may be measured using a thin cross-sectional beam of light of a slit lamp biomicroscope focused on the patient's lower lid. The beam height is changed to match the height of the tear meniscus on the lower lid. Normal values are approximately 0.2 to 0.3 mm. The tear break-up time test requires instillation of 2% fluorescein dye on the cornea and examination with a cobalt blue light. The patient is asked to blink once and then refrain from blinking. Any loss of the tear film continuity (evidenced as a streaky dry spot and color change from green to blue) in less than 10 seconds is considered abnormal. The tear break-up test measures tear stability, which is largely due to the lipid component of the tear film. The Schirmer tests, the gold standards for lacrimal testing, quantify the aqueous tear secretory component. After blotting the inferior cul de sac and palpebral conjunctiva, a bent filter paper strip (ie, a Schirmer strip), is placed in the lateral third of the lower eyelid with the strip notch at the eyelid margin such that the strip proceeds anteriorly. The room lights are dimmed to avoid reflex tearing. The strip is removed after 5 minutes and the amount of strip wetting measured. Topical anesthesia is

generally used in the basic secretion test, which indicates basal tear secretion. The normal value is approximately 15 mm. Tear hyposecretion is indicated with 5 to 10 mm of wetting and less than 5 mm suggests dry eye. Interpalpebral corneal and conjunctival staining with fluorescein (Figure 64-19) is characteristic of keratitis sicca, while inferior corneal staining suggests exposure keratopathy or blepharitis.^{51,52} The extent of evaluation for dry eye varies among surgeons and often from patient to patient with the same surgeon.⁵³ There is controversy in the literature regarding the most appropriate evaluation, although the general consensus is that historic and physical examination elements suggestive of dry eye warrant more thorough evaluation and an especially conservative blepharoplasty.⁵⁴⁻⁵⁶ Patient education should stress the role of ocular lubrication.

One of the important ocular surface protective mechanisms is the Bell's phenomenon, or the normal "rolling back" of the eyes with lid closure. This may be tested by asking the patient to tightly close their eyes while the examiner manually opens the lids to assess corneal position. A poor Bell's phenomenon indicates a risk of postoperative corneal exposure and irritation.

Corneal sensation is another key aspect of ocular surface protection. It may be tested by touching a wisp of cotton to the peripheral cornea while the patient is in upgaze. A blink response is normal. Patients who wear contact lenses or who have undergone refractive surgery may have decreased corneal sensation.⁵⁷⁻⁵⁹ Individuals seeking cosmetic corneal surgery often seek cosmetic blepharoplasty.

Ocular Motility Evaluation Diplopia may result spontaneously after blepharoplasty or be due to iatrogenic injury of the superior or inferior oblique muscles. A baseline evaluation of extraocular motility is therefore warranted. Using a muscle light or the examiner's finger, the patient is

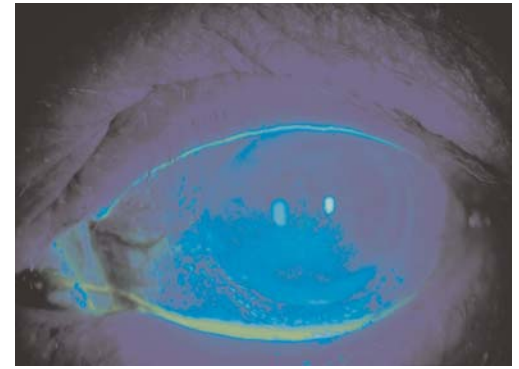


FIGURE 64-19 Punctate staining of the cornea typical of keratitis sicca.

directed to look in the nine positions of gaze: superotemporal, superior, superonasal, lateral, medial, inferotemporal, inferior, inferonasal, and straight ahead. Any ocular motility deviations should be evaluated prior to surgery. Patients with thyroid ophthalmopathy having impaired ocular motility are generally recommended to have their strabismus surgery prior to any eyelid surgery.

Visual Acuity A vital sign of ocular function, the best-corrected visual acuity of both eyes, should be documented prior to surgery. If visual acuity is subnormal, ophthalmologic evaluation is especially important. In addition postoperative visual complaints can be more accurately assessed when the baseline visual acuity has been recorded. Visual decline postoperatively may be wrongly attributed to blepharoplasty if preoperative visual acuity has not been documented.

Ancillary Studies

Both visual field testing and photography aid in demonstrating preoperative changes in visual function and appearance. Visual field testing is necessary for patients wishing to determine insurance benefits for surgery.

Visual Field Evaluation Peripheral visual field testing is performed to document visual field loss, usually of the superior field, due to upper eyelid dermatochalasis

or blepharoptosis. Several different perimeters may be used, such as the automated Humphrey or manually operated Goldmann perimeter or tangent screen. Perimetry is performed with the patient's eyelid unaltered and repeated with the eyelid skin or ptotic lid elevated.

Photographic Documentation Preoperative photography is key when performing eyelid surgery. Documentation of preoperative appearance serves as a benchmark from which postoperative change can be determined and is a valuable reference when initially unforeseen postoperative complications arise. Minimum photographs recommended include frontal primary, upgaze and downgaze, and lateral views. Discussion of photographic specifics is beyond the scope of this chapter and the reader is referred to alternate texts for a more complete discourse.⁶⁰

Anesthesia

The majority of blepharoplasty surgery is performed in an outpatient surgical environment or an office procedure room, under local anesthesia, with or without intravenous sedation. Oral anxiolytics such as diazepam are often employed when intravenous sedation is not used. Adjunctive procedures performed at the time of blepharoplasty may warrant general endotracheal anesthesia, and the anesthesia and sedation needs may vary on an individual basis.

The blepharoplasty surgeon should be familiar with topical and local infiltrative anesthesia options. Commonly used topical ocular anesthetics include the ester-type compounds, proparacaine (0.5%) and tetracaine (0.5%). Commonly used local infiltrative anesthesia choices are all amides and include lidocaine (0.5 to 2.0%), mepivacaine (1 to 2%), and bupivacaine (0.25 to 0.75%). Lidocaine and mepivacaine have an onset of action from 3 to 6 minutes and a comparable duration of action (120 minutes) when epinephrine

is mixed with lidocaine. Bupivacaine has a slower onset of action (10 minutes) and a longer duration of action (8 to 12 hours). Epinephrine is added to promote hemostasis through vasoconstriction and slow absorption, thereby prolonging duration of the anesthetic and increasing the maximum safe anesthetic dosage. No additional therapeutic benefit is gained by adding concentrations of epinephrine greater than 1:100,000. A mixture of 2% lidocaine with 1:100,000 epinephrine and 0.5% bupivacaine with epinephrine allows for rapid onset of prolonged anesthesia. Overdose toxicity of the amide-type anesthetics manifests as mild hypertension and tachycardia, lightheadedness, mild agitation, and confusion. Severe toxicity is marked by seizures, coma, respiratory depression, bradycardia, ventricular dysrhythmias, and asystole. Maximal doses based on milligram per kilogram and total daily dose are 7 mg/kg and 500 mg for lidocaine with epinephrine, 4.5 mg/kg and 300 mg for lidocaine without epinephrine, and 7 mg/kg and 1,000 mg for mepivacaine. Bupivacaine daily dose should not exceed 175 mg and maximal daily dose with epinephrine is 225 mg.

Hyaluronidase, an enzyme that degrades the polysaccharide hyaluronic acid, may be added to local anesthetics to aid in anesthetic diffusion and tissue permeability. Duration of anesthetic action is decreased when hyaluronidase is used concomitantly.

Sodium bicarbonate has been advocated as a local anesthetic adjunct to reduce the discomfort associated with anesthetic infiltration.⁶¹ A base, sodium bicarbonate, partially neutralizes the acidic nature of local anesthetics with epinephrine, thereby decreasing the irritation that the acidic anesthetic pH induces.

Anesthesia injection is performed from the temporal aspect with the needle bevel up. Keeping the needle as parallel as possible to the eyelid skin and carefully stabilizing the patient's head during injection

guard against inadvertent globe penetration. Injection sites are placed within the skin area to be excised, thereby allowing removal of the occasionally produced microhematomas. Milking the injected fluid medially aids in minimizing the number of sites injected. Injection depth is at the level of the orbicularis muscle.

Upper Eyelid Blepharoplasty

Preoperative Concerns

On the day of surgery, review of the surgical plan and examination of the patient in an upright position are helpful.

Once in the operating room, skin incision lines are marked with a methylene blue surgical marking pen prior to skin preparation or immediately thereafter. The former has the advantage of allowing full view of the patient's face during the marking process and providing several minutes of anesthesia infiltration while the surgeon is scrubbing for the surgery and the patient is being draped. Injection prior to surgical marking is not recommended unless the surgeon waits for the injected volume to diffuse as the injected volume may influence placement of surgical marks. The patient's periocular area should be thoroughly prepared with a 5% povidone-iodine or pHisoHex solution. Care should be taken to not allow pHisoHex solution to contact the corneal or conjunctival surfaces. Irrigate the ocular surface well if contact occurs. Care must be taken to avoid removing the surgical marking during preparation if marking is performed prior to the prep. Topical ocular anesthesia drops (ie, proparacaine or tetracaine) are instilled onto the ocular surface and a protective corneal contact may be inserted.

Surgical marking requires that the patient be supine with the surgeon intermittently elevating the brow manually so as to flatten any redundant upper eyelid skin. If the brow is not elevated, erroneously high surgical marking may result. Special care is

taken to provide vertical traction on the pretarsal skin to remove any redundancy as the inferior incision is designed. The initial surgical mark extends from the punctum to the lateral canthus and lies along the upper eyelid crease or where the intended lid crease will be. The location of the upper eyelid crease should be measured with calipers to confirm proper placement of the inferior aspect of the incision. In women the initial surgical mark is generally 8.5 to 10 mm above the superior lid margin centrally. The corresponding value in men is 7 to 8 mm. The crease may be designed 0.5 mm lower than ultimately desired as vertical traction will stretch the skin somewhat and provide desired lash eversion. Surgical marking in the Asian patient varies from these values and will be discussed below. The superior surgical mark is placed next. Approximately 18 to 21 mm of upper eyelid skin should be left after the intended skin is removed. Care should be taken to avoid confusing epilated inferior eyebrow skin for true eyelid skin. Excessive skin removal will result in difficulty with eyelid closure and impair ocular surface protection. Excessive skin removal might also preclude future correction of eyebrow or forehead ptosis. The upper and lower surgical marks are connected in a curvilinear manner (Figure 64-20). To test the adequacy of lid skin remaining, the upper and lower marks should be approximated using a pinching technique with forceps. The forceps should grasp all excessive skin without altering the closed eyelid margin. Slight elevation of the eyelashes with the pinch may be desired. Any opening of the lids during medial, central, and lateral pinch assessment should warrant modification of intended incision lines.

Local anesthesia is next injected subcutaneously into the skin intended for removal. Gentle pressure may be used to diffuse the injected fluid.

Excision of the Skin-Muscle Flap After sufficient anesthesia infiltration has

occurred and a corneal protector has been placed on the operative eye if desired, the eyelid skin is held taut for the incision. Careful traction perpendicular to the incision site can be provided by the surgical assistant. A no. 15 Bard-Parker blade, straight iris scissors, carbon dioxide (CO₂) laser, electrosurgical microdissection needle, or radiosurgical unit is used to incise the skin and orbicularis muscle along the previously placed surgical marks.

The skin-muscle flap is next dissected off the orbital septum by elevating the lateral aspect of the flap superiorly with forceps while the assistant provides perpendicular traction at the superior and inferior margins of the flap. A gentle painting motion is used, with care to avoid violating the orbital septum. The edges of the flap should be angled at approximately 45° to avoid a bulky muscular ridge when the edges are reapproximated during closure. Angulation of the edge is especially important temporally where the muscle layer is thicker. Hemostasis should be achieved with cautery after flap dissection and, if no fat excision is planned, the skin can be closed at this point.

Fat Debulking Upward traction is used to lift the orbital septum prior to opening the septum in the superomedial aspect with Westcott scissors, electrosurgical microdissection needle, or CO₂ laser. The septal opening is extended laterally to comprise the full width of the flap. The herniated orbital fat pads should be evident medially and centrally. Color as well as location can be helpful in differentiation, as the medial fat pad is a more pale lemon color as opposed to the brighter yellow central fat pad. The connective tissue capsule overlying the medial fat pad is opened. Gentle ballottement of the globe through the upper lid aids in herniating the fat through the incised capsule. The medial fat pad may require additional anesthetic injection to facilitate comfort during manipulation. The fat is gently grasped

with straight forceps and teased out, then clamped at the base exiting the capsule. Cautery is used to separate the fat from the clamp. Care should be taken to achieve excellent fat pad hemostasis as postoperative bleeding may contribute to the rare but vision-threatening complication of orbital hemorrhage. Herniation of the central or preaponeurotic fat pad is addressed in a similar fashion by incising the overlying capsule, teasing out the fat, and clamping and cauterizing the herniated fat.

Over the last decade emphasis has been placed on removing less fat during both upper and lower blepharoplasty. In male blepharoplasty patients, fat excision should be especially judicious as the superior sulcus in men is generally more full than in women and excessive fat excision may feminize appearance by creating an unnaturally hollow-appearing superior sulcus. With a bilateral upper eyelid blepharoplasty, attention should be directed toward leaving rather than resecting symmetric amounts of fat. Alternatively fat may be thermally sculpted to improve the eyelid contour.

Lacrimal Gland Prolapse A fullness to the lateral upper eyelid may suggest prolapse of the orbital lobe of the lacrimal gland, which is seen as a pink to tan firm lobulated structure intraoperatively after the septum is opened. Care should be taken not to resect lacrimal gland tissue as postoperative dry eye may result. Repositing the prolapsed lacrimal gland in the lacrimal gland fossa should be easily achieved. Difficulty in repositing may suggest a neoplastic or infiltrative process and warrant a biopsy. A double-armed 5-0 polypropylene suture may be used to refixate the prolapsed gland to the orbital roof periosteum.^{62,63}

Eyelid Crease Reformation and Skin Closure Reformation of the upper eyelid crease seeks to establish a connection between the levator aponeurosis and the orbicularis oculi muscle. In most instances

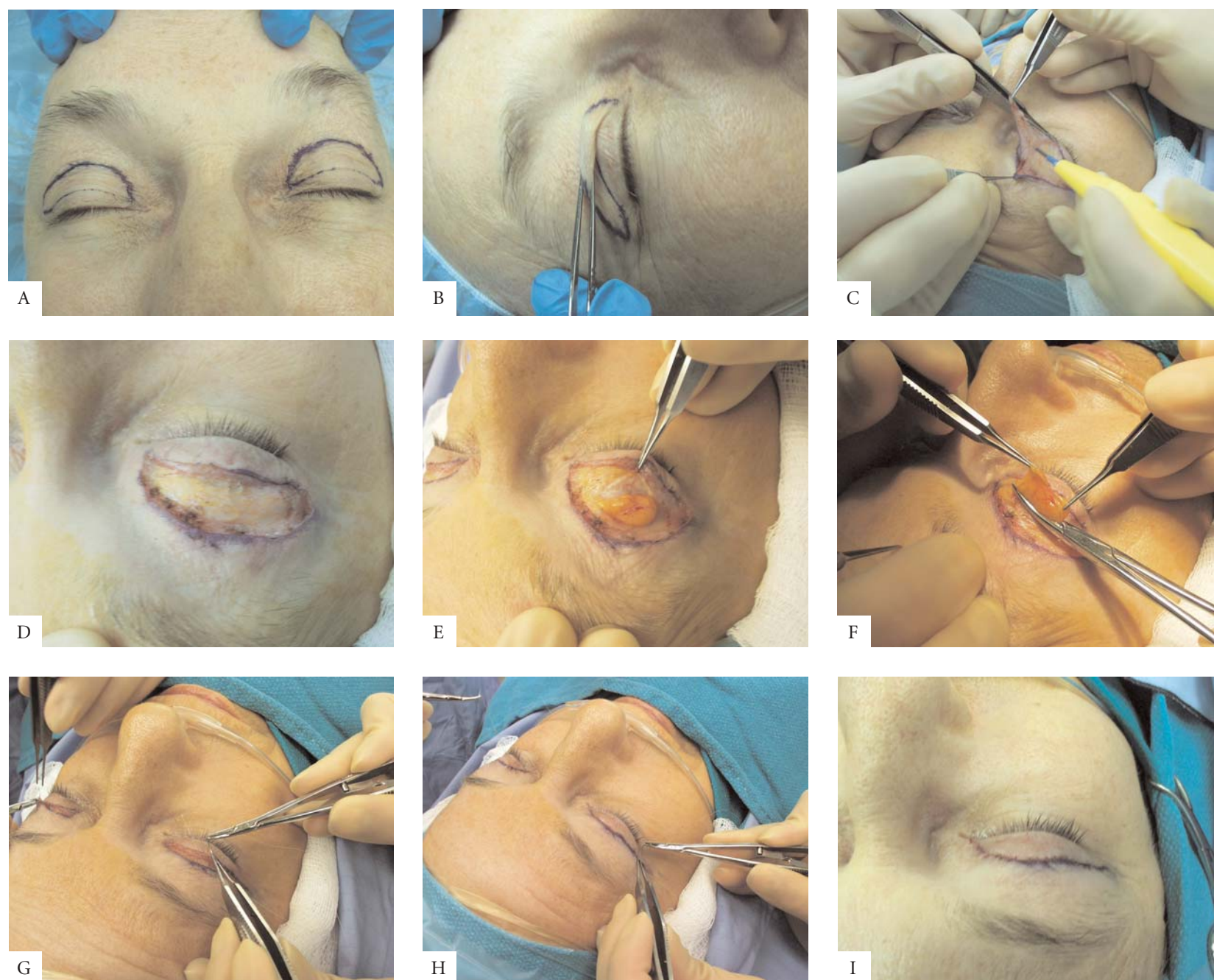


FIGURE 64-20 A, Upper eyelid transcutaneous blepharoplasty. Surgical marking. B, Pinching technique to assess adequacy of amount of remaining lid skin. C, Dissection of the skin-muscle flap. D, Completion of skin-muscle flap dissection showing intact orbital septum. E, Opening of the orbital septum. F, Fat pad debulking. G, Closure of the orbicularis. H, Closure of the skin. I, Completed result.

the inferior tissues are sufficiently adherent posteriorly such that a lid reformation suture may not be required. Prior to eyelid crease reformation, meticulous hemostasis should again be checked. Reformation is performed using buried interrupted sutures with an intermediate duration absorbable suture (ie, polyglactin) passed through both upper and lower orbicularis edges and the

levator aponeurosis at the level of the top of the tarsus. Care should be taken to achieve symmetric upper lid creases bilaterally.

The orbicularis is next approximated with several buried interrupted sutures of 7-0 polyglactin or a similar suture material. Placement of these interrupted sutures should allow facile reunion of the upper eyelid skin edges with a smooth contour.

Redundant skin causing cutaneous standing defects should be excised using Burow's triangle technique. The skin is closed using 6-0 fast-absorbing gut suture in a running fashion, beginning medially and progressing laterally. Alternative suture options for skin closure include nylon, polypropylene, or silk, although sutures that are not absorbable require removal approximately 5 to 7 days

postoperatively. Greater duration of suture retention is required if CO₂ laser resurfacing is performed concomitantly with blepharoplasty. Skin closure sutures should have only minimal tension. Recent evidence suggests the tissue adhesive octyl-2-cyanoacrylate is a viable alternative to sutures.⁶⁴ Several key steps of transcutaneous upper eyelid blepharoplasty are shown in Figure 64-20.

Transconjunctival Upper Lid Blepharoplasty Reserved for patients with isolated medial fat pad herniation and minimal or no wrinkling of the upper eyelid skin is the transconjunctival approach, which is relatively new.^{65,66} The transconjunctival approach is a valuable one for patients in whom a noticeable scar would be unavoidable with the transdermal approach (ie, young patients), patients who have residual medial fat pad prominence after traditional upper lid blepharoplasty, or as an adjunct to a brow lift and periorbital laser for periorbital rhytids. Patients with severe blepharoptosis, dermatochalasis or prominent upper lid asymmetry are not candidates for this approach.⁶⁵

After instilling tetracaine on the corner of the operative eye a corneal protective lens is inserted. Local anesthesia is next injected into the medial aspect of the upper fornix. A Desmarres retractor is used to expose the upper lid palpebral conjunctiva. An incision is made 3 to 4 mm above the upper tarsal margin, and medial dissection toward the contralateral parietal bone is carried out using angled scissors. Once the connective tissue of the medial fat pad is opened the fat protrudes outward. The fat is next gently grasped, clamped, and cauterized at the excision base. When fat excision is complete the lid is released without closure of the incision site.^{65,67}

Asian Upper Eyelid Blepharoplasty Originally described in 1896 by the Japanese physician M. Mikamo, the double eyelid procedure creates a superior palpebral crease in Asian patients with single eye-

lids.⁶⁸ This frequently performed cosmetic procedure seeks to create a defined crease parallel to the eyelid margin or an arcing crease that begins at the medial canthal area and gradually fans away from the lid margin laterally.⁶⁹ Consideration of the patient's facial features should guide surgical planning of the lid crease.⁷⁰ Because lid crease asymmetry is the most frequent complication, careful surgical planning and marking are critical to ensure proper crease placement.⁷¹

The patient is prepared in the manner described for a transcutaneous blepharoplasty. The lower surgical mark, which indicates the final desired crease location, should be 5 to 8 mm from the ciliary margin, thereby approximating the superior tarsal margin.²⁴ Vertical tarsal height can be ascertained by lid eversion. The lower surgical mark shape depends on whether a parallel or arcing crease is planned.²⁴ The amount of skin excised, as determined by the superior surgical mark, should be conservative. The skin-muscle flap is next dissected. A suborbicularis fat pad may be encountered, which can be carefully excised to reveal the orbital septum.¹⁶ The orbital septum is next gently opened to allow for any necessary preaponeurotic fat pad treatment and to access the levator aponeurosis. Two options are frequently employed for lid crease creation, which requires an adhesion between the skin and levator aponeurosis. Direct suturing of the pretarsal orbicularis to the levator aponeurosis is accomplished via multiple small interrupted sutures that incorporate bites of the levator aponeurosis and the pretarsal orbicularis in the area of the desired final lid crease. A running suture would then be used to close the skin. Alternatively the skin edges can be directly sutured to the levator aponeurosis by picking up the lower skin edge, incorporating a small bite of levator aponeurosis in the desired crease location, and finishing by passing through the upper skin

edge. Placing several such sutures can fix the crease location and the remainder of the skin incision can be closed using sutures performed in a running fashion.²⁴ Figure 64-21 depicts the latter variation in Asian eyelid crease reformation.

Lower Eyelid Blepharoplasty

Selection of Approach Blepharoplasty of the lower eyelid can be approached via an anterior transcutaneous or a posterior transconjunctival approach depending on the abnormalities to be addressed. The traditional transcutaneous route provides excellent visualization of lower lid fat pads and allows for excision of excessive skin, hypertrophic orbicularis muscle, and herniating fat. The risk of lower lid malposition, however, is not insignificant using an

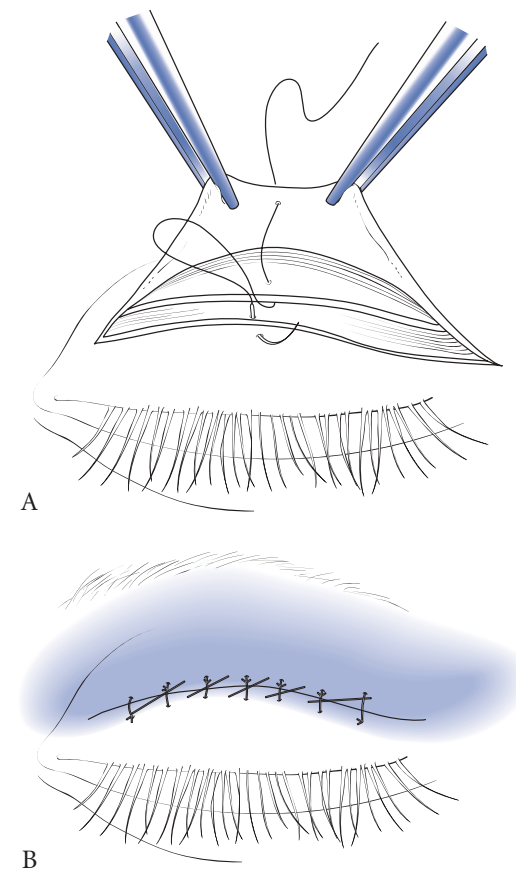


FIGURE 64-21 Asian lid crease reformation. A, Direct suturing of the orbicularis to the levator aponeurosis. B, A continuous suture is used to approximate wound edges. Adapted from Chen WP.²⁴

anterior approach. The transconjunctival approach carries a significantly lower risk of postoperative lower lid malposition and does not create an external scar. The transconjunctival approach is ideal in the setting of isolated fat herniation with minimal skin redundancy. The darkly pigmented patient predisposed to altered pigmentation or scar formation may also be a good transconjunctival blepharoplasty candidate. Patients with thyroid eye disease, who are prone to lower eyelid retraction, are potential posterior blepharoplasty candidates provided enough lid laxity is present to allow conjunctival access. Adjunctive procedures such as chemical peels, CO₂ laser skin resurfacing, or pinch skin excision are commonly performed in association with transconjunctival lower lid blepharoplasty. These adjunctive procedures have expanded the lower lid pathologies successfully treated by the transconjunctival approach to include most patients.⁷²

Presence of lower eyelid laxity calls for an adjunctive horizontal lower lid tightening procedure at the time of lower eyelid blepharoplasty. Failure to perform such a procedure heightens the risk of lower lid retraction, lateral canthal abnormalities, and inferior scleral show.

Transcutaneous Approach An infraciliary surgical mark is drawn approximately 1.5 mm beneath and parallel to the lower lash line extending from the punctum to the lateral canthus. Temporal to the lateral canthus the mark is continued laterally within a preexisting “laugh line” for approximately 5 mm. Care should be taken to avoid an inferiorly sloping termination of the incision as an unnatural surgical scar will result. Subcutaneous anesthesia is next injected and the patient is prepared for surgery in a similar manner to that described for upper eyelid blepharoplasty.

A no. 15 Bard-Parker blade, CO₂ laser, microdissection needle, or other incising instrument is used to make the skin incision. A 4-0 silk traction suture

may be placed through the skin, orbicularis, and superficial tarsus to aid in upward displacement of the lower eyelid. Subcutaneous dissection is carried out taking care to minimize trauma to the pretarsal orbicularis. Next the orbicularis is incised below the inferior tarsal border with Westcott scissors or other appropriate instrument for the full length of the incision. A skin and muscle flap is dissected inferiorly toward the orbital rim. Excellent hemostasis should be obtained with judicious use of cautery. The orbital septum is next opened with Westcott scissors where it overlies the lower eyelid fat pads. The fat pad capsules are subsequently incised beginning with the lateral fat pad, which is the more difficult compartment to visualize. Gentle ballottement of the globe is used to aid in fat prolapse. The herniated fat is grasped, clamped, and excised. Meticulous hemostasis of fat is essential to avoid retrobulbar hemorrhage. Conservative fat resection is recommended, as over-resection results in a hollow appearance rather than a youthful one. The central and medial fat pads are debulked as needed in a similar fashion. Fat removal is compared bilaterally for symmetry.

A horizontal tightening procedure is indicated in nearly all cases of anterior approach lower lid blepharoplasty. The lateral tarsal strip procedure is a secure time-honored method of resuspending the lower eyelid but requires opening of the lateral commissure.⁷³ Alternative procedures addressing lower lid laxity include suspension of the lateral retinaculum and canthal-sparing lateral canthopexy.^{74,75}

The skin and muscle flap are draped over the edge of the lid margin while the lid is not held in traction and the patient is looking upward and opening his or her mouth. These latter maneuvers simulate the lower eyelid's maximally extended position and aid in preventing excessive skin removal.⁷² The redundant skin and muscle flap is drawn superolaterally,

marked with a surgical marking pen, and subsequently excised. A conservative approach to skin and muscle excision is crucial to prevent postoperative lower lid malposition. Rarely should more than 2 to 3 mm of the skin muscle flap be excised in total.⁷² Special care should be taken to avoid creating lateral canthal rounding by not removing excessive skin laterally. Suturing the muscle flap to the zygomatic periosteum prior to excision of excess skin and orbicularis muscle may provide better appreciation of final tissue location and permit modifications prior to permanent tissue alteration. If hypertrophic orbicularis was earlier noted, a strip of orbicularis muscle should be excised in the affected area prior to closure of the skin. The muscle is later closed with interrupted buried absorbable suture (ie, 7-0 polyglactin). Alternatively, should greater support be desired, the muscle may be anchored to the zygomatic periosteum, if not already performed. The skin is closed with a running 6-0 fast-absorbing gut suture proceeding from the medial to lateral aspect. Figure 64-22 demonstrates several of the important aspects of transcutaneous lower eyelid blepharoplasty.

Transconjunctival Approach Formal marking is not performed for transconjunctival lower eyelid blepharoplasty, although marking the herniating fat pads may be of benefit.⁷⁶ Topical anesthesia is instilled onto the ocular surface and a corneal protective contact is inserted. Local anesthesia is injected subcutaneously in the central lower lid just beneath the lashes and into each fat pad. The skin is next prepared with 5% povidone-iodine or pHisoHex as in the previously described fashion.

The inferior palpebral conjunctiva is exposed using a Desmarres retractor or a 4-0 silk traction suture placed through the skin, orbicularis, and superficial tarsus in the central lower eyelid. The traction suture may be placed through the

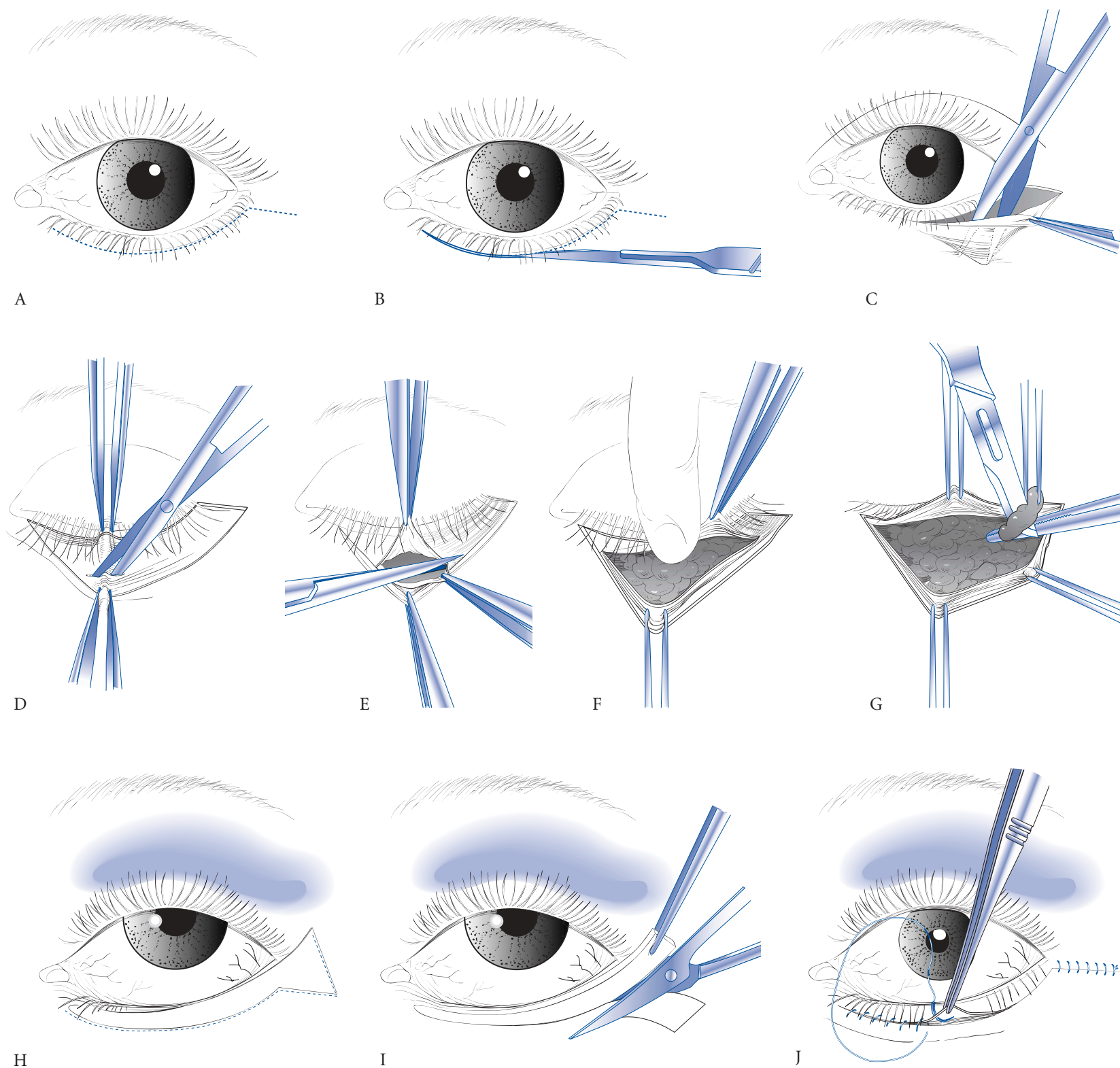


FIGURE 64-22 Transcutaneous lower eyelid blepharoplasty. A, Surgical marking. B, Skin incision along previously placed surgical marks. C, Subcutaneous dissection. D, Orbicularis incision beneath the inferior tarsal border. E, Extension of orbicularis incision to achieve full length of skin incision. F, Gentle globe ballotement to expose herniated fat after orbital septal incision. G, Herniated fat treatment after incision of overlying fat pad capsule. H, Determination of redundant skin and orbicularis. I, Excision of redundant tissue. J, Skin closure after orbicularis fixation and orbicularis closure. Adapted from Putterman AM.⁴⁸

inferior conjunctiva and lower lid retractors and fixed superiorly to aid in exposure. An incision through the conjunctiva and the lower eyelid retractors is made approximately halfway from the inferior border of tarsus and the inferior fornix. The incision is extended medially beneath the punctum and laterally nearly to the lateral canthus. The lower lid is next retracted anteriorly and inferiorly to facilitate isolation of the three fat pads, which are further defined by blunt dissection through the capsulopalpebral fascia. The inferior oblique muscle should be identified between the central and medial fat pads. Care should be taken to avoid aggressive or sharp dissection that may induce injury to the muscle. Fat removal or sculpting is next performed beginning with the lateral fat pad. As described above gentle ballottement of the globe aids in orbital fat prolapse. The herniating fat is carefully grasped and excised. Some surgeons favor clamping the fat during excision. Meticulous hemostasis is essential during fat pad excision. After fat pad debulking the anterior border of the fat pads should be flush with the inferior orbital rim. Overzealous fat pad excision risks a postoperative hollow appearance.

The superior traction suture is removed prior to closing the conjunctiva. Complete hemostasis should be confirmed before closure is attempted. The conjunctiva and lower eyelid retractors are reapproximated with two or three buried interrupted sutures of 6-0 or 7-0 polyglactin or other suture. Several important aspects of transconjunctival lower eyelid blepharoplasty are demonstrated in Figure 64-23.

Skin Pinch Excision Transconjunctival lower lid blepharoplasty does not address excess lower lid skin, making skin pinch excision a useful adjunct for small amounts of excess lower lid skin. Significant excessive lower lid skin is identified using the aforementioned pinch test. Local anesthesia is next injected and the pinch

test is performed again, taking care to place the tine of the forceps within a pre-existing skin fold and create a pinched off ridge of tissue to be removed. The redundant skin is then excised using curved scissors. The skin is closed using 6-0 fast-absorbing gut suture in a running fashion.

Lateral Canthopexy A time-honored procedure for lateral canthopexy is the lateral strip procedure, which entails determining the amount of horizontal excess of lower eyelid (part of which is used as the tarsal strip), dividing the lower lid of the strip at the gray line, and removing the anterior lamella, conjunctiva, cilia, and lid margin-associated glands.⁷³ Desired lower lid position is determined and a suture on a semicircular needle is used to fasten the tarsal strip to the periosteum inside the lateral orbital rim at a level to yield the optimal postoperative lower lid location and apposition of lower eyelid to the globe. A canthal reformation suture is passed through the gray line of the upper eyelid and the tarsal strip to recreate the lateral canthal angle. The orbicularis is closed using buried interrupted absorbable suture. Fast-absorbing gut suture is used to close the skin.

Midfacial Rejuvenation Standard lower eyelid blepharoplasty does not address midfacial aging changes often present in the blepharoplasty patient. Hamra proposed an arcus marginalis release procedure to recreate the contour of the youthful lower lid and cheek.⁷⁷ The procedure entails creating a skin-muscle flap, incision of the arcus marginalis at the orbital rim, and removal of a portion of the inferior orbital septum, with subsequent reposition and fixation of the orbital fat over the orbital rim.⁷⁷ A transconjunctival approach to the arcus marginalis with similar transposition of orbital fat has recently been advocated.⁷⁸ Elevation of the soft tissue of the midface by suture plication using transcuta-

neous, subperiosteal, transconjunctival, and supraperiosteal routes has also been described.^{79,80}

Steinsapir recently reported the use of a hand-carved expanded polytetrafluoroethylene orbital rim as both a site for resuspension of the midfacial soft tissues and a mechanism to compensate for lost midface volume.⁸¹

Postoperative Management

Postoperative instructions seek to limit edema and ecchymosis and prevent postoperative bleeding.

Ice-cold compresses are placed over the operative site immediately on arrival in the postoperative recovery area. These compresses should be used continuously for 36 to 48 hours after the procedure with cessation only for dining and bathroom breaks. After 48 hours warm compresses may be used for comfort and to hasten resolution of edema. Up to 4 weeks should be allowed for resolution of bruising, although the majority of patients note limited discoloration beyond 1 week. Complete resolution of edema may require several weeks.

During the first 48 to 72 hours minimal physical activity is recommended. Patients should remain supine with approximately 30 degrees of head elevation provided by pillows or a recliner. Walking and low impact activities can be resumed after postoperative days 2 to 3, although refraining from strenuous physical activity for the first week postoperatively is strongly recommended. During weeks 2 and 3, activity may gradually be increased. In general most patients require 1 to 2 weeks off from work including the operative day. For patients with physically intense occupations, longer time away is required.

Application of a combination antibiotic and steroid ointment to any dermal incision site is recommended. Keeping the absorbable sutures moist allows for their timely dissolution. A typical schedule includes three times per day application for

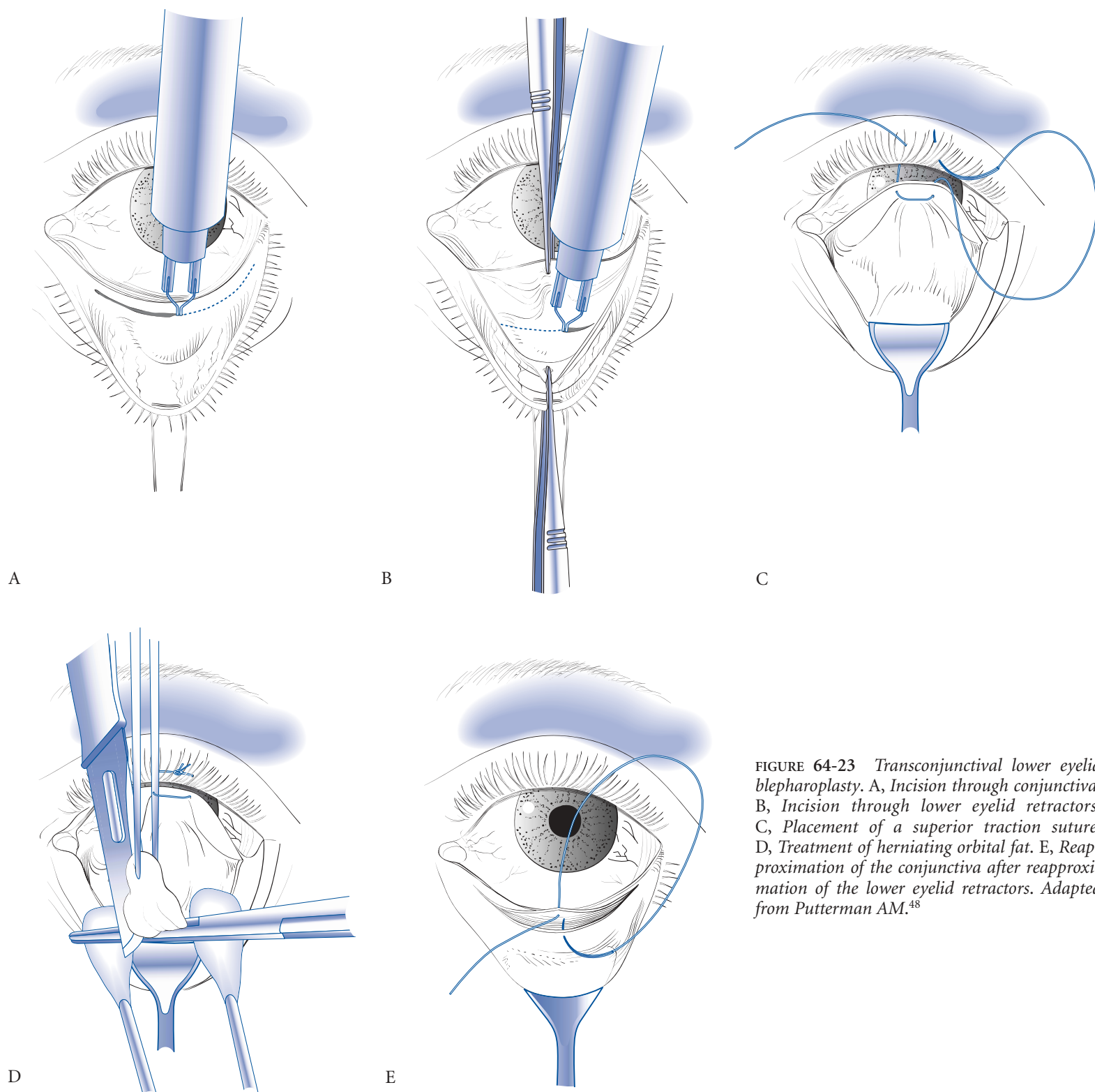


FIGURE 64-23 Transconjunctival lower eyelid blepharoplasty. A, Incision through conjunctiva. B, Incision through lower eyelid retractors. C, Placement of a superior traction suture. D, Treatment of herniating orbital fat. E, Reapproximation of the conjunctiva after reapproximation of the lower eyelid retractors. Adapted from Putterman AM.⁴⁸

the first week, with taper to twice daily application in the second week and application four times daily in the third week. Transconjunctival incision sites should be lubricated with an antibiotic ointment in a

similar schedule. Application of makeup to the incision sites should be deferred 1 week.

Postoperative pain is usually not a significant concern. Nonetheless a prescription for several tablets of a low potency

opioid and acetaminophen combination analgesic may be provided. Acetaminophen should be sufficient for the majority of patients. Routine aspirin and nonsteroidal anti-inflammatory drug use

can be resumed several days postoperatively. Warfarin may be restarted on the day after surgery. Excessive postoperative discomfort should be investigated as it may herald an orbital hemorrhage or other complications.

The patient is advised to trim short loose absorbable skin sutures. Care should be taken to avoid rubbing the incisions or vertically stressing the incisions with digital traction when attempting to open the eyes. The buried absorbable sutures may occasionally be palpated postoperatively as small nodules along the incision for as long as 5 to 6 weeks. Occasionally these buried sutures may surface and require trimming.

Follow-up evaluation 1 week postoperatively is typical, with additional visits scheduled as needed. Postoperative photography is typically obtained approximately 4 months after the procedure.

Management of Complications

Complications following blepharoplasty are either cosmetic, functional, or vision-threatening. The majority of complications can be readily prevented by clear preoperative communication, careful preoperative and intraoperative measurements, and meticulous surgical technique. Prior to pursuing surgery all the major possible complications should be discussed with the patient.

Complications of Upper Eyelid Blepharoplasty

Inadequate Skin Excision A common postoperative cosmetic concern, inadequate skin excision manifests as a second fold superior to the upper eyelid crease. Previously unrecognized eyebrow ptosis may contribute to the appearance of excess skin, especially laterally, and should therefore be assessed. When a true excess of upper lid skin is present, careful additional resection of skin and orbicularis is indicated. In general revision blepharoplasty should be delayed for several months to allow resolution of edema.

Excessive Skin Excision Overzealous removal of upper eyelid skin may result in cosmetic as well as functional concerns. Patients may describe a tight sensation in their lids, demonstrate lagophthalmos, or display symptoms and signs of exposure keratitis. Like most complications, excessive skin excision is best prevented as subsequent management is challenging. Lid massage, consisting of vigorous downward massage on the anterior tarsal surface, instituted 1 to 2 weeks postoperatively, can resolve mild cases. The patient is advised to blink fully and use artificial tears during the day and ophthalmic ointment at night. More significant over-resection of skin may require full-thickness skin grafting, commonly performed after 6 months to allow for more complete wound healing. Retroauricular skin is frequently used as a graft site for eyelid reconstruction. Care must be taken to properly thin the graft. If possible the graft placement should be superior to the lid incision to lessen cosmetic impact.

Lid Crease Asymmetry Raising an inferior lid crease is easier than lowering an excessively high crease; therefore, unless the higher crease is abnormally elevated, the lower crease should be raised to achieve symmetry. Removing a crescent of skin and muscle above the low crease, with care to make the inferior edge (the new location of the lid crease) symmetric with the opposite crease, lysing any attachments inferior to the new crease location, and closing the ellipse by incorporating several stitches through the levator aponeurosis recreates the new lid crease.⁴⁸

High Lid Creases Successfully lowering an excessively high lid crease is difficult. The adhesions forming the current lid crease must be interrupted and an incision made for the new crease closed by suture bites through the levator aponeurosis and the new incision wound edges. In some cases orbicularis muscle transposition

from above can prevent the original skin crease adherence to the underlying fibrous tissue. A fat graft between the orbital septum and levator aponeurosis may be required to prevent adhesions.⁸²

Excessive Fat Removal A deep medial concavity or superior sulcus results from aggressive medial fat removal. Injection of autogenous fat or dermal fat grafting has been attempted to augment an excessively hollow superior sulcus. Careful conservative fat excision is warranted to avoid superior sulcus syndrome, especially in males, as creation of a deep sulcus feminizes the eyelid.

Wound Dehiscence Wound dehiscence is best handled by resuturing the eyelid if the area of dehiscence is greater than several millimeters in length. Small areas of dehiscence can be allowed to granulate if granulation does not impair final scar cosmesis. If re-approximation is performed the wound bed should be scraped free of granulation tissue and the edges trimmed to expose fresh tissue prior to the second closure. Surgical closure should include adequate muscular closure to minimize this complication.

Suture Milia Suture milia are small cystic epithelial inclusions occurring at suture entrance points into the skin. Common and temporary, suture milia appear approximately 1 week postoperatively and disappear over the ensuing months. Hot compresses may hasten milia resolution. Alternatively a large bore needle or scissors can be used to create an opening in the cyst to aid in healing.

Postoperative Ptosis Injury to the levator aponeurosis through direct intraoperative trauma or from stretching by postoperative hematoma may result in postoperative ptosis.⁸³ Recent anatomic dissections evidencing terminal branches of the superior division of the oculomotor nerve far anterior in the levator palpebrae superioris

muscle prompted speculation that infiltrating local anesthetics affecting these end branches may induce transient ptosis.⁸⁴ Mild postoperative ptosis (2 mm or less) from eyelid edema can be observed for spontaneous resolution. Poor levator function or severe ptosis warrants timely surgical exploration, as the fibrotic phase of healing will complicate repair. Surgical correction of prolonged ptosis can be accomplished with a conjunctival Müllerectomy, or external levator repair in mild cases, and levator aponeurosis advancement in more extensive cases.

Dry Eye Symptoms Dry eye symptoms are a frequent complication of blepharoplasty due to altered lid function and decreased spontaneous blink rate and magnitude. Topical artificial tears and lubricating ointment are often sufficient for symptom control, although punctal occlusion may be warranted in the setting of more severe dry eye symptoms. Punctal occlusion at the time of blepharoplasty in patients with dry eye syndrome may be of some benefit in decreasing postoperative exacerbation of symptoms.⁸⁵

Diplopia Injury to the superior oblique tendon or trochlea, although uncommon, has been described following upper blepharoplasty with medial fat excision.^{86,87} Poor visualization during cautery or dissection was implicated during reported cases.^{86,87} Recent anatomic dissections confirm a consistent relationship between the trochlea and superior orbital foramen and the superior oblique tendon and the frontozygomatic suture.⁸⁸ Direct visualization during cautery and dissection coupled with familiarity of associated anatomy decreases the risk of tendon or trochlear damage.

Bleeding Intraoperative and postoperative bleeding can be vision-threatening complications. Patients should be instructed to discontinue aspirin, nonsteroidal anti-inflammatory drugs, and

other platelet-impairing medications 1 to 2 weeks preoperatively. Warfarin is generally withheld 4 days preoperatively. Intraoperative bleeding often results from the orbicularis muscle. Recent evidence suggests a prominent arterial branch, which pierces the orbital septum and levator aponeurosis at the upper aspect of the tarsus, may account for excessive bleeding if damaged when the septum is opened for fat excision.⁸⁹

Aside from causing significant ecchymosis, insufficient hemostasis can result in retrobulbar hemorrhage or hematoma and concomitant loss of vision.^{90,91} Many patients will describe a small degree of bruising and swelling postoperatively, often beginning after a sneeze, cough, or in the setting of hypertension. Significant pain, proptosis, marked upper lid swelling, restricted extraocular motions, and/or any decrease in vision raises suspicion for a retrobulbar hemorrhage, a true emergency requiring immediate bedside wound release with or without a lateral canthotomy and cantholysis, hyperosmotic agents, and systemic corticosteroids.

Hematoma presents with severe ecchymosis and eyelid edema. Visual compromise may be present if the lids are tense. Since compression of the globe and optic nerve is of concern, intraocular pressure (IOP) should be measured. If no visual deterioration or increase in IOP is found, conservative management with ice-cold compresses can be used. Visual compromise or increased IOP may necessitate a return to the operating room to reopen the incision site, evacuate any clots, and address the source of bleeding.

Vision Loss Most cases of vision loss after blepharoplasty are due to hemorrhage or hematoma formation with resultant optic nerve damage or central retinal artery occlusion.^{90,92} Angle-closure glaucoma following blepharoplasty has also been reported.⁹³ Instructing patients to monitor their vision and promptly

responding to all patient reports of excessive pain best detect these complications.

Complications of Lower Eyelid Blepharoplasty

Lower Eyelid Retraction Eyelid malposition after lower lid blepharoplasty has several etiologies: excessive anterior lamella removal, scarring of the orbital septum, inadequate treatment of lower eyelid laxity, or hematoma-associated fibrosis. Delayed lower eyelid retraction resulting from scarring of the orbital septum is largely associated with the anterior approach to lower eyelid blepharoplasty. A posterior approach avoiding incision of the orbital septum has been demonstrated to minimize lower eyelid retraction.⁹⁴ Lower eyelid retraction is a more frequent complication in patients with shallow orbits and prominent eyes.

Initial treatment of lower eyelid retraction varies with extent and duration of altered lid position. Early identification of retraction warrants conservative treatment such as vigorous upward massage, placement of temporary traction sutures, or a temporary tarsorrhaphy suture.⁹⁵ Postoperative edema may contribute to early postoperative retraction, emphasizing the importance of a period of watchful waiting and conservative therapy.

Persistent retraction resistant to conservative measures can be treated with septal scar tissue lysis and lateral canthopexy. Scar lysis is accomplished by dissection between the orbicularis and septum via an incision associated with a lateral canthotomy.⁹⁶ Lateral canthopexy is usually performed using the lateral tarsal strip approach as described previously.⁷³ Temporary suspension of the lower eyelid to the brow has been proposed to provide further upward traction.⁹⁶

Severe lower eyelid retraction may necessitate posterior lamella extension with a hard palate mucosal or ear cartilage graft, often with a horizontal tightening

procedure.^{96–99} The palpebral conjunctiva and lower eyelid retractors are incised and recessed. Through a palpebral conjunctival incision inferior to the lower tarsal border, the orbicularis is exposed and the graft sutured inferior to the tarsus in the recipient bed.

Lower Eyelid Ectropion Often symptomatic due to drying of the exposed conjunctiva, lower lid ectropion may exist alone or in combination with lower lid retraction. If previously unappreciated lid laxity is present, horizontal tightening is performed as previously described. A deficit of anterior lamella is addressed using a full-thickness skin graft harvested from the upper eyelid or retroauricular area. Grafts must be sized larger than the ideal final size to accommodate postoperative contracture.

Inadequate Fat Removal Further excision of lower eyelid fat should be addressed through a posterior approach to avoid excessive cutaneous scar formation and lower lid malposition. Often the lateral lower eyelid fat pad is implicated.

Excessive Fat Removal A tear trough deformity, the lower lid analog to the upper lid superior sulcus syndrome, describes a prominent inferior orbital rim and nasojugal fold that may result from aggressive lower lid fat removal. Injection of autologous fat into the deformity, particularly directed at the underlying musculature, has been attempted to address the tear trough deformity.^{100,101} Eyelid fibrosis with decreased mobility is associated with excessive fat removal and multiple surgical interventions.

Diplopia Diplopia may result after both transcutaneous and transconjunctival lower lid blepharoplasty due to direct and indirect injury of the inferior oblique and inferior rectus.^{87,102} Inferior oblique injury should be suspected in patients

complaining of vertical diplopia increasing in gaze contralateral to the operated eye. Recent anatomic dissections demonstrate a consistent relationship between the inferior oblique muscle and the inferior orbital rim, infraorbital foramen, and supraorbital notch.¹⁰³ Precise anatomic knowledge coupled with avoidance of an excessively inferior conjunctival incision and care when treating prolapsed fat are recommended to avoid extraocular muscle injury.

Bleeding As previously discussed with complications of upper lid blepharoplasty, hemostasis is critical in blepharoplasty to avoid postoperative retrobulbar hemorrhage and hematoma formation.

Vision Loss Causes of vision loss after lower eyelid blepharoplasty are similar to those described with upper eyelid blepharoplasty.

Adjunctive Procedures

Chemical Peeling

Chemical peeling, or chemexfoliation, involves using a chemical agent to wound the epidermis and dermis, thereby evoking an inflammatory healing response that acts to improve skin texture. The level of the peel is dictated by the depth of penetration, nature of destruction, and inflammatory response. A variety of agents may be employed, most commonly trichloroacetic acid (TCA), glycolic acid, or phenol, and the concentration of the chemical agent varies depending on the depth of peel desired.¹⁰⁴ In general more severe rhytids or skin texture problems require a deeper peel to achieve the desired effect. Medium-depth TCA chemexfoliation in conjunction with transconjunctival lower eyelid blepharoplasty has been demonstrated to achieve excellent results in improving lower eyelid skin appearance.¹⁰⁵

Evaluating a blepharoplasty patient for chemexfoliation requires additional

appreciation of skin pigmentation, often using the Fitzpatrick skin pigment type classification, inquiry into history of herpes simplex infection, and knowledge of the patient's need to return to social activities.⁴⁷ Previous herpes infections may require prophylaxis with antiviral agents. Patients with higher Fitzpatrick skin types, extensive sun exposure, or diffuse freckling may have unacceptable scarring, hypopigmentation, or noticeable demarcation borders of treated skin and hence should be considered with caution.¹⁰⁶

Chemexfoliation relies on even application of the peeling agent to the intended treatment area. Pretreatment of the treatment area with retinoic acid can be performed to enhance uptake. Any skin oil or greases will impair even chemical treatment, making careful soap and water skin cleansing and acetone degreasing crucial to a successful peel. Chemical peeling should follow completion of blepharoplasty surgery. The peel is applied to the skin using sturdy cotton-tipped applicators, with care taken to achieve symmetric application, avoid inadvertent corneal application, and treat more lightly those areas with the thinnest skin (ie, medial canthal and pretarsal skin). Initially a white frost becomes apparent after chemical application, which gives way to deep erythema. Cold compresses to the treated area after the skin has dried may decrease discomfort. A bland lubricating ointment should be applied to treated skin prior to the patient leaving the postoperative recovery area. Postoperative care for patients undergoing chemical peel requires twice to four times daily mild soap cleansing, gentle patting to dry, and ointment re-application until all treated skin has reepithelialized. Sun exposure, which may cause skin burning and hyperpigmentation, should be avoided meticulously by wearing a hat and dark sunglasses during the first month. Careful sunscreen application is advised thereafter.

Complications of chemexfoliation include pigmentary change, scarring or

other textural changes, corneal damage, lid position abnormalities, infection, prolonged erythema, acne, and cold sensitivity.

Laser Skin Resurfacing

Laser skin resurfacing employs a CO₂ or erbium laser to thermally remove a defined layer of dermal tissue and shrink collagen, prompting improved skin appearance through collagen contraction, new collagen formation, and remodeling and epidermal growth. The number of passes taken determines the depth of treatment. Laser resurfacing is ideal for patients with minimally pigmented skin who seek improvement of skin with photodamage or acne scarring.¹⁰⁷ Adjunctive CO₂ laser resurfacing of the lower eyelid in conjunction with transconjunctival lower lid blepharoplasty has been demonstrated to successfully address lower eyelid wrinkling that may result from transconjunctival blepharoplasty alone.¹⁰⁸ When compared to a phenol chemical peel, CO₂ laser resurfacing was found to be equally as efficacious in diminishing rhytids in thin-skinned facial areas and more effective at improving texture in thicker glandular facial areas.¹⁰⁹ The erbium:yttrium-aluminum-garnet (YAG) laser has been recently introduced as an alternative method of laser skin resurfacing.

History and physical elements to be explored are similar to those described for patients being evaluated for chemexfoliation. Additionally past use of isotretinoin (accutane) should be obtained, as the drug-induced elimination of glandular architecture contraindicates laser resurfacing for the subsequent 1 to 2 years following drug discontinuation.¹¹⁰ Prior to undergoing laser resurfacing, patients predisposed to hyperpigmentation are typically treated for several weeks with a skin bleaching agent. Prophylactic antivirals and antibiotics are also commonly employed.

Surgical marking plays a critical role in successful laser resurfacing by providing a

roadmap to direct treatment application. After carefully marking all significant rhytids, general anesthesia or monitored sedation coupled with proper local or regional nerve block anesthesia is achieved. Resurfacing is performed using laser settings determined by the area of interest. Resurfacing is carried out methodically, taking care to wipe the ablated tissue away prior to re-treatment to avoid excessive heat absorbance in any given location. Generally one or two passes with lower power are performed on periocular skin.¹¹⁰ Color change indicates depth of treatment, progressing from pink to orange to yellow-orange to yellow-white as more passes are made or more energy is used per pass. Excessive treatment risks hypertrophic scarring. After procedure completion the skin is irrigated, gently patted dry, and a dry occlusive or wet dressing is applied. Many surgeons have abandoned occlusive dressings in favor of simply keeping the face well lubricated with a bland lubricant such as petroleum jelly. Dilute vinegar and water soaks are favored by many for cleansing. Dressings are changed daily with additional lubrication ointment applied until reepithelialization occurs, generally after 10 to 14 days. Antibiotic ointment is occasionally used; however, the risk of inducing allergies to the applied antibiotic has lessened the frequency of this practice. Ice packs are used postoperatively to reduce edema. Complications are similar to chemexfoliation.

References

1. Katzen LB. The history of cosmetic oculoplastic surgery. In: Putterman AM, editor. *Cosmetic oculoplastic surgery: eyelid, forehead, and facial techniques*. 3rd ed. Philadelphia (PA): W.B. Saunders; 1999. p. 3–10.
2. Albert DM, Edwards DD. *The history of ophthalmology*. Cambridge (MA): Blackwell Science; 1996.
3. Glogau RG. Physiologic and structural changes associated with aging skin. *Dermatol Clin* 1997;15:555–9.
4. Flowers RS. Blepharoplasty. In: Courtiss EH, editor. *Male aesthetic surgery*. St. Louis (MO): Mosby; 1982.
5. Freund RM, Nolan WB 3rd. Correlation

- between brow lift outcomes and aesthetic ideals for eyebrow height and shape in females. *Plast Reconstr Surg* 1996;97:1343–8.
6. Lemke BN, Stasior OG. The anatomy of eyebrow ptosis. *Arch Ophthalmol* 1982;100:981–6.
7. Mitz V, Peyronie M. The superficial musculoaponeurotic system (SMAS) in the parotid and cheek area. *Plast Reconstr Surg* 1976;58:80–8.
8. Kikkawa DO, Lemke BN, Dortzbach RK. Relations of the superficial musculoaponeurotic system to the orbit and characterization of the orbitomalar ligament. *Ophthalm Plast Reconstr Surg* 1996;12:77–88.
9. Furnas DW. The retaining ligaments of the cheek. *Plast Reconstr Surg* 1989;83:11–6.
10. Hamra ST. Repositioning the orbicularis oculi muscle in the composite rhytidectomy [comment]. *Plast Reconstr Surg* 1992;90:14–22.
11. Owsley JQ. Lifting the malar fat pad for correction of prominent nasolabial folds [comment]. *Plast Reconstr Surg* 1993;91:463–74; discussion 75–6.
12. Lucarelli MJ, Khwarg SI, Lemke BN, et al. The anatomy of midfacial ptosis. *Ophthalm Plast Reconstr Surg* 2000;16:7–22.
13. Ozdemir R, Kilinc H, Unlu RE, et al. Anatomico-histologic study of the retaining ligaments of the face and use in face lift: retaining ligament correction and SMAS plication. *Plast Reconstr Surg* 2002; 110:1134–47; discussion 1148–9.
14. Pessa JE, Zadoo VP, Mutimer KL, et al. Relative maxillary retrusion as a natural consequence of aging: combining skeletal and soft-tissue changes into an integrated model of midfacial aging. *Plast Reconstr Surg* 1998;102:205–12.
15. Pessa JE, Desvigne LD, Lambros VS, et al. Changes in ocular globe-to-orbital rim position with age: implications for aesthetic blepharoplasty of the lower eyelids. *Aesthet Plast Surg* 1999;23:337–42.
16. Jeong S, Lemke BN, Dortzbach RK, et al. The Asian upper eyelid: an anatomical study with comparison to the Caucasian eyelid. *Arch Ophthalmol* 1999;117:907–12.
17. DeBacker CM, Putterman AM, Zhou L, et al. Age-related changes in type-I collagen synthesis in human eyelid skin. *Ophthalm Plast Reconstr Surg* 1998;14:13–6.
18. van den Bosch WA, Leenders I, Mulder P. Topographic anatomy of the eyelids, and the effects of sex and age. *Br J Ophthalmol* 1999;83:347–52.
19. Siegel R. Surgical anatomy of the upper eyelid fascia. *Ann Plast Surg* 1984;13:263–73.
20. Stasior GO, Lemke BN, Wallow IH, Dortzbach RK. Levator aponeurosis elastic fiber

- network. *Ophthalmol Plast Reconstr Surg* 1993;9:1–10.
21. Cartwright MJ, Kurumety UR, Nelson CC, et al. Measurements of upper eyelid and eyebrow dimensions in healthy white individuals. *Am J Ophthalmol* 1994;117:231–4.
 22. Shorr N, Cohen MS. Cosmetic blepharoplasty. *Ophthalmol Clin North Am* 1991;4:17–33.
 23. Han MH, Kwon ST. A statistical study of upper eyelids of Korean young women. *Korean J Plast Surg* 1992;19:930–5.
 24. Chen WP. Upper blepharoplasty in the Asian patient. In: Putterman AM, editor. *Cosmetic oculoplastic surgery: eyelid, forehead, and facial techniques*. 3rd ed. Philadelphia (PA): W.B. Saunders; 1999. p. 101–12.
 25. Chen WP. Asian blepharoplasty. Update on anatomy and techniques. *Ophthalmol Plast Reconstr Surg* 1987;3:135–40.
 26. Hawes MJ, Dortzbach RK. The microscopic anatomy of the lower eyelid retractors. *Arch Ophthalmol* 1982;100:1313–8.
 27. Meyer DR, Linberg JV, Wobig JL, McCormick SA. Anatomy of the orbital septum and associated eyelid connective tissues. Implications for ptosis surgery [comment]. *Ophthalmol Plast Reconstr Surg* 1991;7:104–13.
 28. Wesley RE, McCord CD Jr, Jones NA. Height of the tarsus of the lower eyelid. *Am J Ophthalmol* 1980; 90:102–5.
 29. Anderson RL. Medial canthal tendon branches out. *Arch Ophthalmol* 1977;95:2051–2.
 30. Gionia VM, Linberg JV, McCormick SA. The anatomy of the lateral canthal tendon. *Arch Ophthalmol* 1987;105:529–32.
 31. Whitnall SE. *The anatomy of the human orbit and accessory organs of vision*. London, England: Oxford University Press; 1932.
 32. Whitnall SE. On a ligament acting as a check to the action of the levator palpebrae superioris muscle. *J Anat Physiol* 1910;14:131.
 33. Goldberg RA, Wu JC, Jesmanowicz A, Hyde JS. Eyelid anatomy revisited. Dynamic high-resolution magnetic resonance images of Whitnall's ligament and upper eyelid structures with the use of a surface coil [comment]. *Arch Ophthalmol* 1992;110:1598–600.
 34. Codere F, Tucker NA, Renaldi B. The anatomy of Whitnall ligament. *Ophthalmology* 1995;102:2016–9.
 35. Lucarelli MJ, Dartt DA, Cook BE Jr, et al. The lacrimal system. In: Kaufman PL, editor. *Adler's physiology of the eye*. 10th ed. St. Louis (MO): Mosby; 2003. p. 723.
 36. Putterman AM, Urist MJ. Muller's muscle-conjunctival resection ptosis procedure. *Ophthalmol Surg* 1978;9:27–32.
 37. Dresner SC. Further modifications of the Muller's muscle-conjunctival resection procedure for blepharoptosis. *Ophthalmol Plast Reconstr Surg* 1991;7:114–22.
 38. Brown MS, Putterman AM. The effect of upper blepharoplasty on eyelid position when performed concomitantly with Muller muscle-conjunctival resection. *Ophthalmol Plast Reconstr Surg* 2000;16:94–100.
 39. Sires BS, Lemke BN, Dortzbach RK, Gonnering RS. Characterization of human orbital fat and connective tissue. *Ophthalmol Plast Reconstr Surg* 1998;14:403–14.
 40. Sutcliffe T, Baylis HI, Fett D. Bleeding in cosmetic blepharoplasty: an anatomical approach. *Ophthalmol Plast Reconstr Surg* 1985;1:107–13.
 41. Kikkawa DO, Lemke BN. Orbital and eyelid anatomy. In: Dortzbach RK, editor. *Ophthalmic plastic surgery: prevention and management of complications*. New York (NY): Raven Press; 1994. p. 1–29.
 42. Cook BE Jr, Lucarelli MJ, Lemke BN, et al. Eyelid lymphatics I: histochemical comparisons between the monkey and human. *Ophthalmol Plast Reconstr Surg* 2002;18:18–23.
 43. Cook BE Jr, Lucarelli MJ, Lemke BN, et al. Eyelid lymphatics II: a search for drainage patterns in the monkey and correlations with human lymphatics. *Ophthalmol Plast Reconstr Surg* 2002;18:99–106.
 44. Knize DM. Muscles that act on glabellar skin: a closer look. *Plast Reconstr Surg* 2000; 105:350–61.
 45. Knize DM. A study of the supraorbital nerve. *Plast Reconstr Surg* 1995;96:564–9.
 46. Tarbet KJ, Lemke BN. Clinical anatomy of the upper face. *Int Ophthalmol Clin* 1997; 37:11–28.
 47. Fitzpatrick TB. The validity and practicality of sun-reactive skin types I through VI. *Arch Dermatol* 1988;124:869–71.
 48. Putterman AM, editor. *Cosmetic oculoplastic surgery: eyelid, forehead, and facial techniques*. 3rd ed. Philadelphia (PA): W.B. Saunders; 1999.
 49. Fante RG, Elnor VM. Transcaruncular approach to medial canthal tendon plication for lower eyelid laxity. *Ophthalmol Plast Reconstr Surg* 2001;17:16–27.
 50. Furnas DW. Festoons, mounds, and bags of the eyelids and cheek. *Clin Plast Surg* 1993; 20:367–85.
 51. van Bijsterveld OP. Diagnostic tests in the Sicca syndrome. *Arch Ophthalmol* 1969;82:10–4.
 52. Hurwitz JJ. *The lacrimal system*. Philadelphia (PA): Lippincott-Raven; 1996.
 53. McKinney P, Byun M. The value of tear film breakup and Schirmer's tests in preoperative blepharoplasty evaluation. *Plast Reconstr Surg* 1999;104:566–9; discussion 570–3.
 54. Tarbet KJ. Ophthalmic evaluation should be a preoperative requirement prior to blepharoplasty [comment]. *Arch Otolaryngol Head Neck Surg* 2001;127:723.
 55. Pastorek N. Preoperative ophthalmic evaluation is a personal choice [comment]. *Arch Otolaryngol Head Neck Surg* 2001;127:724.
 56. Burke AJ, Wang T. Should formal ophthalmologic evaluation be a preoperative requirement prior to blepharoplasty? [comment] *Arch Otolaryngol Head Neck Surg* 2001; 127:719–22.
 57. Murphy PJ, Patel S, Marshall J. The effect of long-term, daily contact lens wear on corneal sensitivity. *Cornea* 2001;20:264–9.
 58. Patel S, Perez-Santonja JJ, Alio JL, Murphy PJ. Corneal sensitivity and some properties of the tear film after laser in situ keratomileusis. *J Refract Surg* 2001;17:17–24.
 59. Chuck RS, Quiros PA, Perez AC, McDonnell PJ. Corneal sensation after laser in situ keratomileusis [comment]. *J Cataract Refract Surg* 2000;26:337–9.
 60. Silver B. Photographing the blepharoplasty patient. In: Putterman AM, editor. *Cosmetic oculoplastic surgery eyelid, forehead, and facial techniques*. 3rd ed. Philadelphia (PA): W.B. Saunders; 1999. p. 39–46.
 61. Steinbrook RA, Hughes N, Fanciullo G, et al. Effects of alkalinization of lidocaine on the pain of skin infiltration and intravenous catheterization. *J Clin Anesth* 1993;5:456–8.
 62. Petrelli RL. The treatment of lacrimal gland prolapse in blepharoplasty. *Ophthalmol Plast Reconstr Surg* 1988;4:139–42.
 63. Leone CR. Treatment of a prolapsed lacrimal gland. In: Putterman AM, editor. *Cosmetic oculoplastic surgery eyelid, forehead, and facial techniques*. 3rd ed. Philadelphia (PA): W.B. Saunders; 1999. p. 169–78.
 64. Greene D, Koch RJ, Goode RL. Efficacy of octyl-2-cyanoacrylate tissue glue in blepharoplasty. A prospective controlled study of wound-healing characteristics. *Arch Facial Plast Surg* 1999;1:292–6.
 65. Januszkiewicz JS, Nahai F. Transconjunctival upper blepharoplasty [comment]. *Plast Reconstr Surg* 1999;103:1015–8; discussion 1019.
 66. Guerra AB, Berger A 3rd, Black EB 3rd, et al. The bare area of the upper conjunctiva: a closer look at the anatomy of transconjunctival upper blepharoplasty. *Plast Reconstr Surg* 2003;111:1717–22.
 67. Guerra AB, Metzinger SE, Black EB 3rd. Transconjunctival upper blepharoplasty: a safe and effective addition to facial rejuvenation techniques. *Ann Plast Surg* 2002; 48:528–33.

68. Mikamo M. Plastic operation of the eyelid. *J Chugaii Jishimpo* 1896;17:1197.
69. Zubiri JS. Correction of the Oriental eyelid. *Clin Plast Surg* 1981;8:725–37.
70. Kikkawa DO, Kim JW. Asian blepharoplasty. *Int Ophthalmol Clin* 1997;37:193–204.
71. Weng CJ, Noordhoff MS. Complications of Oriental blepharoplasty. *Plast Reconstr Surg* 1989;83:622–8.
72. Kikkawa DO, Kim JW. Lower-eyelid blepharoplasty. *Int Ophthalmol Clin* 1997;37:163–78.
73. Anderson RL, Gordy DD. The tarsal strip procedure. *Arch Ophthalmol* 1979;97:2192–6.
74. Fagien S. Algorithm for canthoplasty: the lateral retinacular suspension: a simplified suture canthopexy [comment]. *Plast Reconstr Surg* 1999;103:2042–53; discussion 2054–8.
75. Lemke BN, Cook BE Jr, Lucarelli MJ. Canthus-sparing ectropion repair. *Ophthal Plast Reconstr Surg* 2001;17:161–8.
76. Nerad JA. The requisites in ophthalmology: oculoplastic surgery. St. Louis (MO): Mosby; 2001.
77. Hamra ST. Arcus marginalis release and orbital fat preservation in midface rejuvenation [comment]. *Plast Reconstr Surg* 1995;96:354–62.
78. Goldberg RA. Transconjunctival orbital fat repositioning: transposition of orbital fat pedicles into a subperiosteal pocket. *Plast Reconstr Surg* 2000;105: 743–8; discussion 749–51.
79. Hester TR, Codner MA, McCord CD, et al. Evolution of technique of the direct transblepharoplasty approach for the correction of lower lid and midfacial aging: maximizing results and minimizing complications in a 5-year experience. *Plast Reconstr Surg* 2000;105:393–406.
80. Freeman MS. Transconjunctival sub-orbicularis oculi fat (SOOF) pad lift blepharoplasty: a new technique for the effacement of nasojugal deformity [comment]. *Arch Facial Plast Surg* 2000;2:16–21.
81. Steinsapir KD. Aesthetic and restorative midface lifting with hand-carved, expanded polytetrafluoroethylene orbital rim implants. *Plast Reconstr Surg* 2003;111:1727–37; discussion 1738–41.
82. Shorr N, Christenbury JD, Goldberg RA. Free autogenous “pearl fat” grafts to the eyelids. *Ophthal Plast Reconstr Surg* 1988;4:37–40.
83. Baylis HI, Sutcliffe T, Fett DR. Levator injury during blepharoplasty. *Arch Ophthalmol* 1984;102:570–1.
84. Hwang K, Lee DK, Chung IH, Lee SI. Patterns of oculomotor nerve distribution to the levator palpebrae superioris muscle, and correlation to temporary ptosis after blepharoplasty. *Ann Plast Surg* 2001;47:381–4.
85. Becker BB. Punctal occlusion and blepharoplasty in patients with dry eye syndrome. *Arch Otolaryngol Head Neck Surg* 1991;117:789–91.
86. Wesley RE, Pollard ZF, McCord CD Jr. Superior oblique paresis after blepharoplasty. *Plast Reconstr Surg* 1980;66:283–6.
87. Harley RD, Nelson LB, Flanagan JC, Calhoun JH. Ocular motility disturbances following cosmetic blepharoplasty. *Arch Ophthalmol* 1986;104:542–4.
88. Wilhelmi BJ, Mowlavi A, Neumeister MW. Upper blepharoplasty with bony anatomical landmarks to avoid injury to trochlea and superior oblique muscle tendon with fat resection. *Plast Reconstr Surg* 2001;108:2137–40; discussion 2141–2.
89. Hwang K, Kim BG, Kim YJ, Chung IH. Lateral septoaponeurotic artery: source of bleeding in blepharoplasty performed in Asians. *Ann Plast Surg* 2003;50:156–9.
90. Cruz AA, Ando A, Monteiro CA, Elias J Jr. Delayed retrobulbar hematoma after blepharoplasty. *Ophthal Plast Reconstr Surg* 2001;17:126–30.
91. Mahaffey PJ, Wallace AF. Blindness following cosmetic blepharoplasty: a review. *Br J Plast Surg* 1986;39:213–21.
92. Kelly PW, May DR. Central retinal artery occlusion following cosmetic blepharoplasty. *Br J Ophthalmol* 1980;64:918–22.
93. Gayton JL, Ledford JK. Angle closure glaucoma following a combined blepharoplasty and ectropion repair. *Ophthal Plast Reconstr Surg* 1992;8:176–7.
94. Goldberg RA, Lessner AM, Shorr N, Baylis HI. The transconjunctival approach to the orbital floor and orbital fat. A prospective study. *Ophthal Plast Reconstr Surg* 1990;6:241–6.
95. Rosenberg GJ. Temporary tarsorrhaphy suture to prevent or treat scleral show and ectropion secondary to laser resurfacing or laser blepharoplasty. *Plast Reconstr Surg* 2000;106:721–5; discussion 726–7.
96. Baylis HI, Goldberg RA, Groth MJ. Complications of lower blepharoplasty. In: Putterman AM, editor. *Cosmetic oculoplastic surgery: eyelid, forehead, and facial techniques*. 3rd ed. Philadelphia (PA): W.B. Saunders; 1999. p. 429–56.
97. Cohen MS, Shorr N. Eyelid reconstruction with hard palate mucosa grafts [comment]. *Ophthal Plast Reconstr Surg* 1992;8:183–95.
98. Patel BC, Patipa M, Anderson RL, McLeish W. Management of postblepharoplasty lower eyelid retraction with hard palate grafts and lateral tarsal strip. *Plast Reconstr Surg* 1997;99:1251–60.
99. Shorr N, Fallor MK. “Madame Butterfly” procedure: combined cheek and lateral canthal suspension procedure for post-blepharoplasty, “round eye,” and lower eyelid retraction. *Ophthal Plast Reconstr Surg* 1985;1:229–35.
100. Klein AW, Wexler P, Carruthers A, Carruthers J. Treatment of facial furrows and rhytides. *Dermatol Clin* 1997;15:595–607.
101. Rose JJ Jr, Lemke BN, Lucarelli MJ, et al. Anatomy of facial recipient sites for autologous fat transfer. *Am J Cosmet Surg* 2003;20:17–25.
102. Ghabrial R, Lisman RD, Kane MA, et al. Diplopia following transconjunctival blepharoplasty. *Plast Reconstr Surg* 1998;102:1219–25.
103. Mowlavi A, Neumeister MW, Wilhelmi BJ. Lower blepharoplasty using bony anatomical landmarks to identify and avoid injury to the inferior oblique muscle. *Plast Reconstr Surg* 2002;110:1318–22; discussion 1323–4.
104. Coleman WP 3rd. Dermal peels. *Dermatol Clin* 2001;19:405–11.
105. Gilbert SE. Transconjunctival blepharoplasty with chemoexfoliation. *Ann Plast Surg* 1996;37:24–9.
106. Goldberg RA, Joshi AR, McCann JD, Shorr N. Management of severe cicatricial entropion using shared mucosal grafts. *Arch Ophthalmol* 1999;117:1255–9.
107. Fitzpatrick RE. CO₂ laser resurfacing. *Dermatol Clin* 2001;19:443–51.
108. Carter SR, Seiff SR, Choo PH, Vallabhanath P. Lower eyelid CO₂ laser rejuvenation: a randomized, prospective clinical study. *Ophthalmology* 2001;108:437–41.
109. Langsdon PR, Milburn M, Yarber R. Comparison of the laser and phenol chemical peel in facial skin resurfacing. *Arch Otolaryngol Head Neck Surg* 2000;126:1195–9.
110. Millman AL. Eyelid and facial laser skin resurfacing. In: Putterman AM, editor. *Cosmetic oculoplastic surgery: eyelid, forehead, and facial techniques*. 3rd ed. Philadelphia (PA): W. B. Saunders; 1999. p. 355–66.
111. Lemke BN, Lucarelli MJ. Anatomy of the ocular adnexa, orbit and related facial structures. In: Nesi FA, Lisman RD, Levine MR, editors. *Smith’s ophthalmic plastic and reconstructive surgery*. St. Louis (MO): Mosby; 1998. p. 3–78.
112. Lemke BN, Della Rocca RC. Surgery of the eyelids and orbit: an anatomical approach. East Norwalk (CT): Appleton & Lange; 1990.
113. Knize DM, editor. *The forehead and temporal fossa anatomy and technique*. Philadelphia (PA): Lippincott; 2001. p. 39.

Basic Principles of Rhinoplasty

James Koehler, DDS, MD

Peter D. Waite, MPH, DDS, MD

For many cosmetic surgeons rhinoplasty is one of the most challenging surgical procedures. A clear understanding of nasal anatomy is critical in order to provide an esthetic result that does not compromise nasal function. Developing a pattern of analysis of the nose is vital for proper diagnosis and for determining the most appropriate treatment plan. Numerous rhinoplastic techniques have been described. Some surgeons favor an endonasal approach whereas others believe that an external approach is more desirable. Each surgeon must become familiar with all technique options in order to address the wide variety of challenges of rhinoplasty surgery.

The goal of this chapter is to give a broad overview of the diagnosis and treatment of nasal deformities. It is by no means exhaustive since multiple textbook volumes have been written on this subject. The reader should gain an understanding of nasal anatomy and determine how to systematically analyze the nose. Both endonasal and external rhinoplasty will be described.

Nasal Anatomy

A clear understanding of nasal anatomy is important to successfully perform nasal procedures and decrease the incidence of complications.

Surface Anatomy

The terms used to describe the surface anatomy of the nose are important in

nasal form analysis and for treatment plan formulation (Table 65-1). For descriptive purposes the spatial relationships are described as cephalic, caudal, dorsal, basal, anterior, posterior, superior, and inferior (Figure 65-1).

Skin and Soft Tissue

The soft tissue that overlies the bone and cartilage may influence the final result of rhinoplasty. The thickness of the skin will determine how it will re-drape after performing a rhinoplasty. The skin thickness varies along the dorsum of the

nose. The skin is fairly thick and mobile in the region of the nasion. It quickly thins over the nasal dorsum and is generally thinnest and most mobile in the mid-dorsal region (rhinion). In the distal third of the nose the skin tends to be more thick and adherent and has an increased sebaceous content.

A patient with thin skin will show dramatic changes with alteration of the underlying bone and cartilage, and this limits room for error since little is camouflaged by the thickness of the skin. Conversely for thick-skinned individuals more

Table 65-1 Surface Anatomy of the Nose

Glabella: the most forward projecting point of the forehead in the midline at the level of the supraorbital ridges
Radix: the junction between the frontal bone and the dorsum of the nose
Rhinion: the anterior tip at the end of the suture of the nasal bones
Dorsum: the anterior surface of the nose formed by the nasal bones and the upper lateral cartilages
Supratip break: the slight depression in the nasal profile at the point where the nasal dorsum joins the lobule of the nasal tip
Infratip lobule: the portion of the tip lobule that is found between the tip-defining points and the columellar-lobular angle
Tip-defining points: there are four tip defining points, which include the supratip break, the columellar-lobular angle, and the most projected area on each side of the nasal tip formed by the lower lateral cartilages
Alar sidewall: the rounded eminence forming the lateral nostril wall
Alar-facial junction: the depressed groove formed on the face where the ala joins the face
Columella: the skin that separates the nostrils at the base of the nose

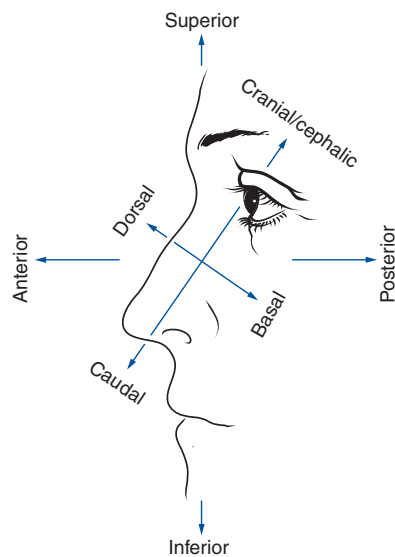


FIGURE 65-1 *Spatial descriptors.* In describing the relationship of one anatomic unit to another many terms are used. The standard relationships are anterior, posterior, superior, and inferior. The nose is also described in terms of dorsal, basal, caudal, and cranial (or cephalic) positions. Adapted from Austermann K. *Rhinoplasty: planning techniques and complications.* In: Booth PW, Hausamen JE, editors. *Maxillofacial surgery.* New York: Churchill Livingstone; 1999. p. 1378.

aggressive sculpturing of the nasal skeleton must be performed in order to effect significant changes. Although thick skin may mask imperfections it does not redrape as well and can result in underlying fibrosis and formation of a polybeak deformity (supratip scarring). Better results are possible with thin-skinned patients, however the margin for error is smaller. The surgeon must sometimes modify the technique depending on the type of skin of the patient.

Superficial Musculoaponeurotic System and Nasal Musculature

The muscles of the nose are encased in the nasal superficial musculoaponeurotic system (SMAS). This is a fibromuscular layer that separates the skin and subcutaneous tissue from the nasal cartilage and bone. The SMAS of the nose is in continuity with the SMAS of the face. During rhinoplastic surgery the dissection is performed

beneath the SMAS. Violating the SMAS will often result in increased bleeding, scarring, and postoperative edema.

The muscles of the nose can be divided into four categories: the elevators, the depressors, the compressors, and the dilators (Figure 65-2). The muscles of significance are the paired depressor septi nasi. These muscles can result in drooping of the nasal tip during smiling. This added tension on the nasal tip must be recognized preoperatively and addressed by resection in order to achieve a cosmetic result.¹

Blood Supply

There is a rich blood supply to the subdermal vascular plexus of the nose that arises from branches of both the internal and external carotid arteries. The blood supply from the internal carotid artery that supplies the external nose includes the dorsal nasal artery and the external nasal artery. The dorsal nasal artery is a branch of the ophthalmic artery. The

external nasal artery is a branch of the anterior ethmoid artery.

The external nose is also supplied by branches of the facial artery and the internal maxillary artery, which originate from the external carotid artery. The facial artery branches include the angular artery, lateral nasal artery, alar artery, septal artery, and superior labial artery (Figure 65-3).

The internal nose is supplied by the internal and external carotid branches. The ophthalmic artery, a branch of the internal carotid, branches into the anterior and posterior ethmoidal arteries. The anterior ethmoidal artery supplies the anterosuperior part of the septum and the lateral nasal wall. The posterior ethmoidal artery supplies the septum, lateral nasal wall, and the superior turbinate.²

The internal maxillary artery branches include the sphenopalatine artery and the greater palatine artery. The sphenopalatine artery supplies most of the posterior part of the nasal septum, lateral wall of the

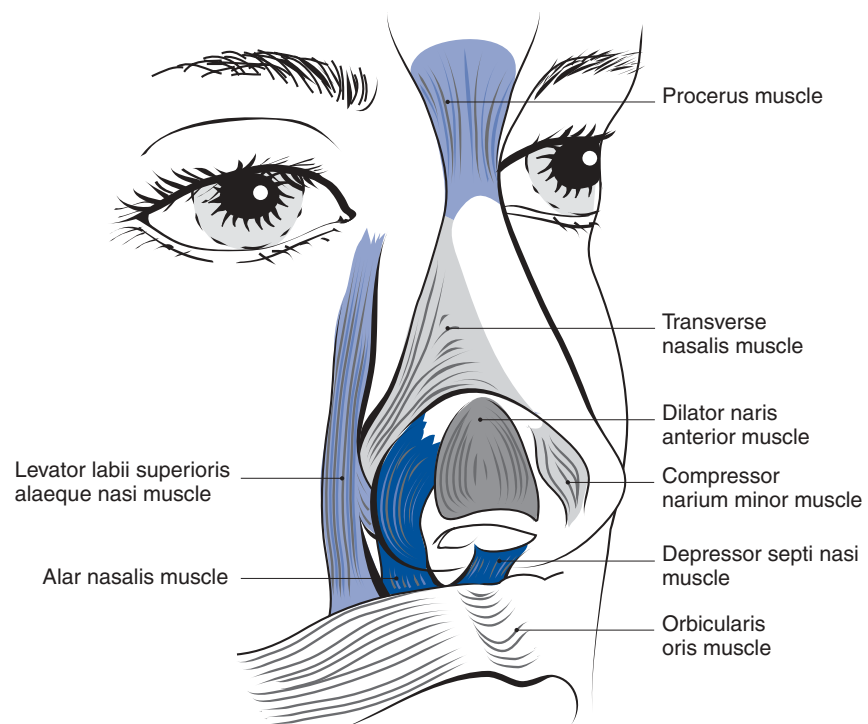


FIGURE 65-2 *Nasal musculature.* The muscles of the nose are grouped into the elevators (light blue), the depressors (dark blue), the compressors (light gray), and the dilators (dark gray). Adapted from Jewett B. *Anatomic considerations.* In: Baker SR, editor. *Principles of nasal reconstruction.* St. Louis (MO):Mosby; 2002. p. 17.

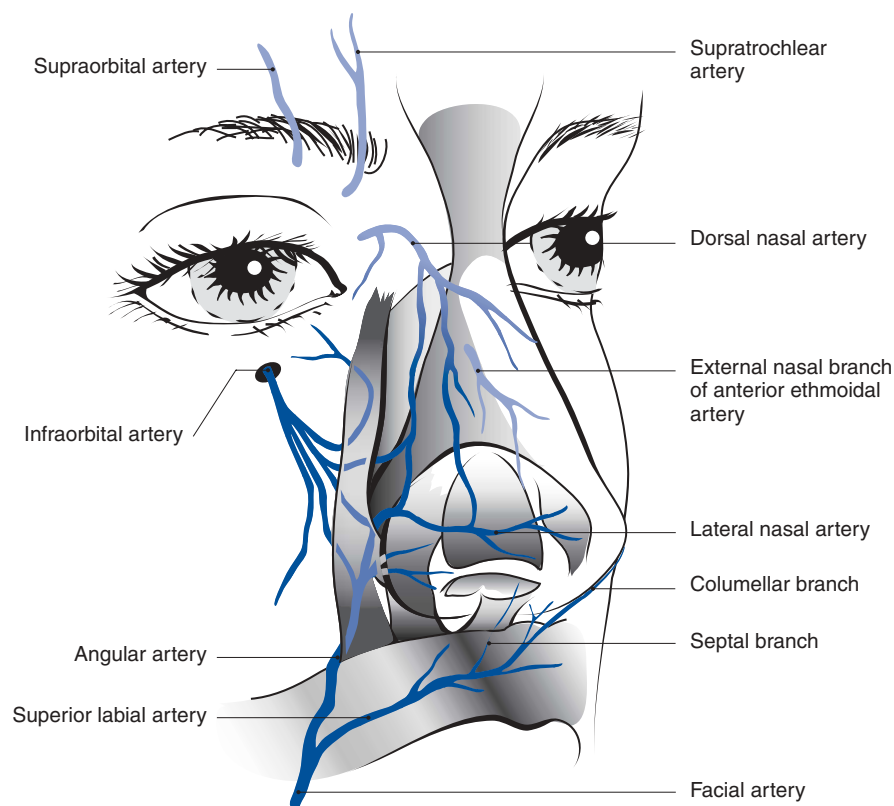


FIGURE 65-3 Arteries of the external nose. The arterial supply of the external nose comes from branches of the external carotid artery (dark blue) and the internal carotid artery (light blue). Adapted from Jewett B. *Anatomic considerations*. In: Baker SR, editor. *Principles of nasal reconstruction*. St. Louis (MO): Mosby; 2002. p. 18.

nose, roof, and part of the nasal floor. The greater palatine artery supplies a portion of the anterior and inferior portion of the nasal septum (Figure 65-4).²

The surgically significant area for internal nasal bleeding is known as Kiesselbach's plexus (also termed Little's area). This is the area in the anteroinferior part of the nasal septum which is a common site of epistaxis. It is where the sphenopalatine, greater palatine, superior labial artery, and anterior ethmoid arteries anastomose (Figure 65-5).² The venous drainage of the nose is primarily from the facial and ophthalmic veins.

One concern during nasal surgery is the possibility of compromised blood flow to the nasal tip if the surgeon performs an external rhinoplasty. The blood supply to the nasal tip has been analyzed by lymphoscintigraphic studies, cadaver dissections, and histologic sections.^{3,4} The

conclusion is that the primary blood supply to the nasal tip comes from the bilateral lateral nasal arteries that course in a plane superficial to the alar cartilages in the subdermal plexus approximately 2 to 3 mm above the alar groove. Thus a columellar incision does not compromise tip blood supply. Also there are no significant veins and minimal lymphatics in the columellar region.^{3,4} Some surgeons believe that external rhinoplasty remains more edematous for longer postoperative periods than an endonasal rhinoplasty.

Bone and Cartilage

The structure of the nose consists of the paired nasal bones as well as the frontal process of the maxilla. The bone is thickest near the junction with the frontal bone and tapers as it joins with the upper lateral cartilages.

The upper lateral cartilages are in intimate contact with the nasal bones and underlie the nasal bones for approximately 6 to 8 mm. The connection between the

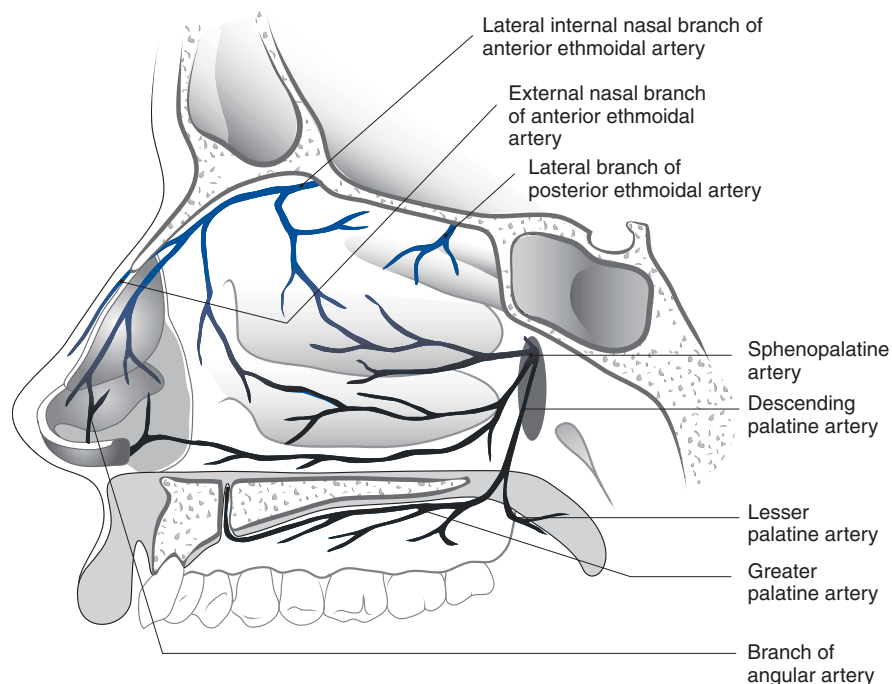


FIGURE 65-4 Arteries of the lateral nasal wall. The arterial supply of the lateral nasal wall arises from branches of the external carotid artery (black) and the internal carotid artery (blue). Adapted from Jewett B. *Anatomic considerations*. In: Baker SR, editor. *Principles of nasal reconstruction*. St. Louis (MO): Mosby; 2002. p. 23.

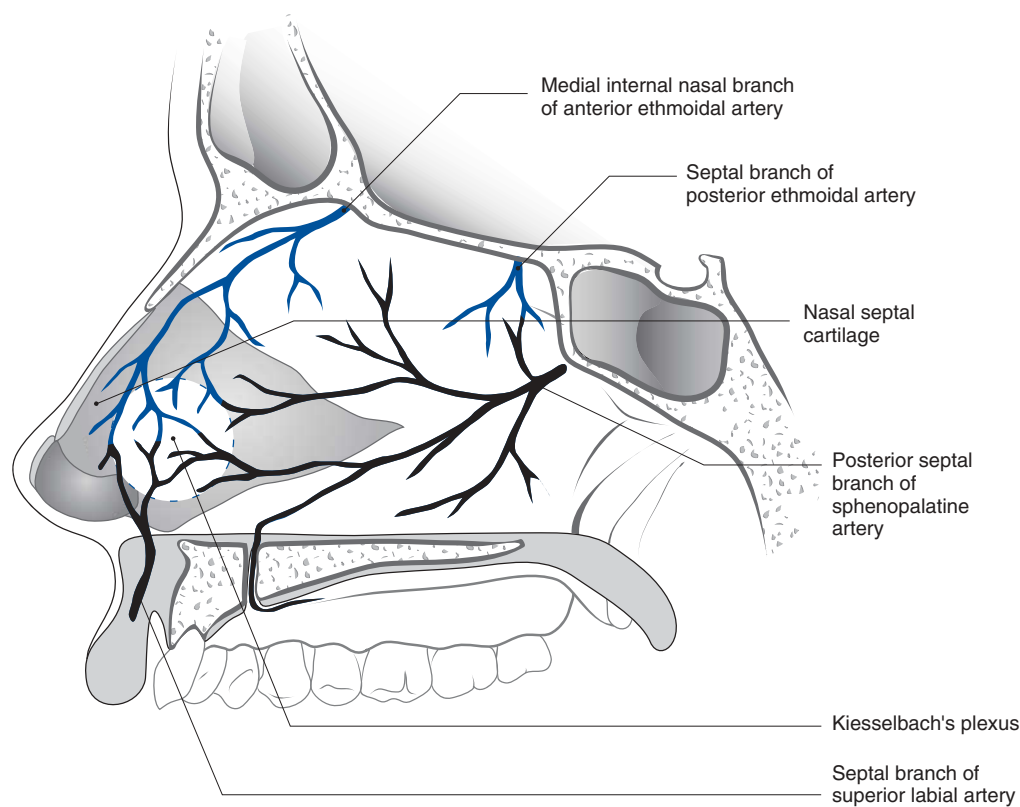


FIGURE 65-5 Arteries of the nasal septum. The arterial supply of the nasal septum arises from branches of the external carotid artery (black) and the internal carotid artery (blue). Kiesselbach's plexus is formed by the sphenopalatine artery, greater palatine artery, superior labial artery, and anterior ethmoid arteries. It is a common site of epistaxis. Adapted from Jewett B. *Anatomic considerations*. In: Baker SR, editor. *Principles of nasal reconstruction*. St. Louis (MO): Mosby; 2002. p. 23.

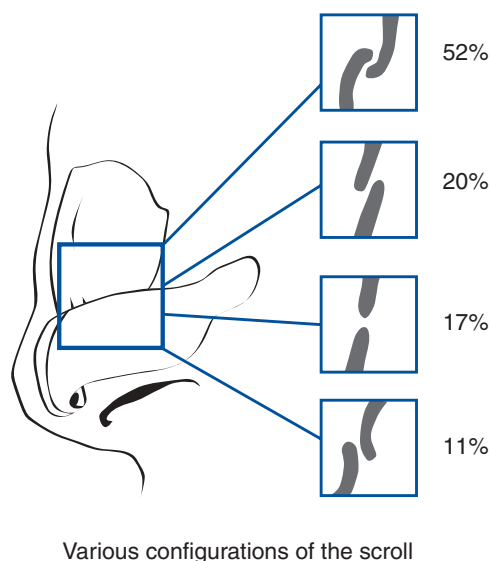


FIGURE 65-6 Configurations of the scroll. The relationship of the upper lateral and lower lateral cartilages is termed the scroll. Anatomic studies have identified four common configurations: interlocked (52%), overlapping (20%), end to end (17%), and opposed (11%). Adapted from Lam SM and Williams EF III.⁵

nasal bones and upper lateral cartilages should not be violated since this may disrupt the internal nasal valve causing nasal obstruction and asymmetry. The internal nasal valve is formed by the junction of the upper lateral cartilages and the nasal septum.

The lower lateral cartilages comprise the lower third of the nose and connect to the upper lateral cartilages in a union described as the scroll. There are various configurations of the scroll.^{5,6} The scroll is described as interlocked (52%), overlapping (20%), end to end (17%), or opposed (11%) (Figure 65-6). The scroll provides significant support to the nasal tip. When performing an endonasal rhinoplasty this area is violated by the intercartilaginous incision (Figures 65-7–65-9). The lower lateral cartilage is divided into medial and lateral crura. The medial crura are in intimate contact with the nasal septum and

provide tip support. The lateral crura extend superiorly and form dense fibroareolar tissue attachments with the pyriform aperture. The intermediate crus is the diverging of the medial crus before turning to become the lateral crus proper. The highest point of the intermediate crus is an important surgical landmark known as the tip-defining point (Figure 65-10).

The nasal septum is formed by both bone and cartilage. The ethmoid and vomer provide bony support posteriorly. The quadrangular cartilage provides support anteriorly (Figure 65-11).

Support for the nasal tip is classified into major and minor divisions. The major tip support comes from the size, shape, and strength of the lower lateral cartilages, the attachment of the medial crura of the lower lateral cartilage to the caudal septum, and the fibrous attachment of the lower lateral cartilage to the upper lateral cartilage. The minor tip support comes from the nasal spine, the membranous septum, the cartilaginous dorsum, the sesamoid complexes, the interdomal ligaments, and the alar attachments to the skin (Table 65-2).⁵

Nerves

The sensory nerve supply to the skin of the external nose is supplied by the ophthalmic and maxillary divisions of the

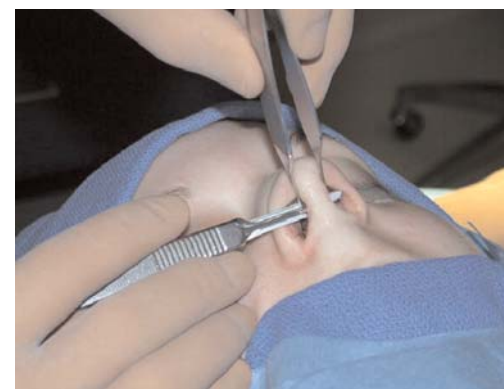

FIGURE 65-7 Partial transfixion. The partial transfixion incision through the membranous septum and short of the medial crural foot pads.

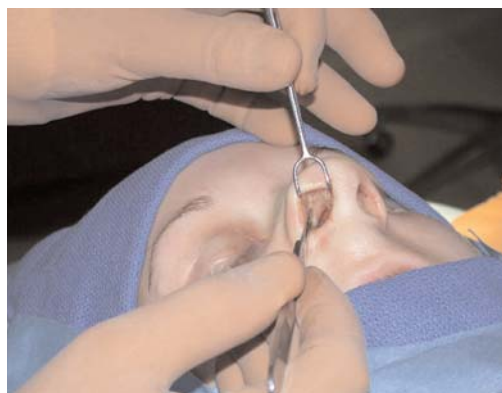

FIGURE 65-8 Intercartilaginous incision. The intercartilaginous incision, between the upper and lower cartilage, allows access to the nasal dorsum. Note the incision does not violate the nasal valve.

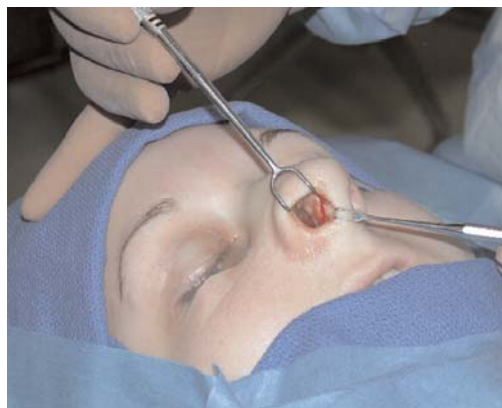

FIGURE 65-9 Connecting intercartilaginous and partial transfixion incisions. The intercartilaginous incision extends along the upper edge of the lateral crus to connect with the transfixion incision. This will provide access for a septoplasty during internal rhinoplasty.

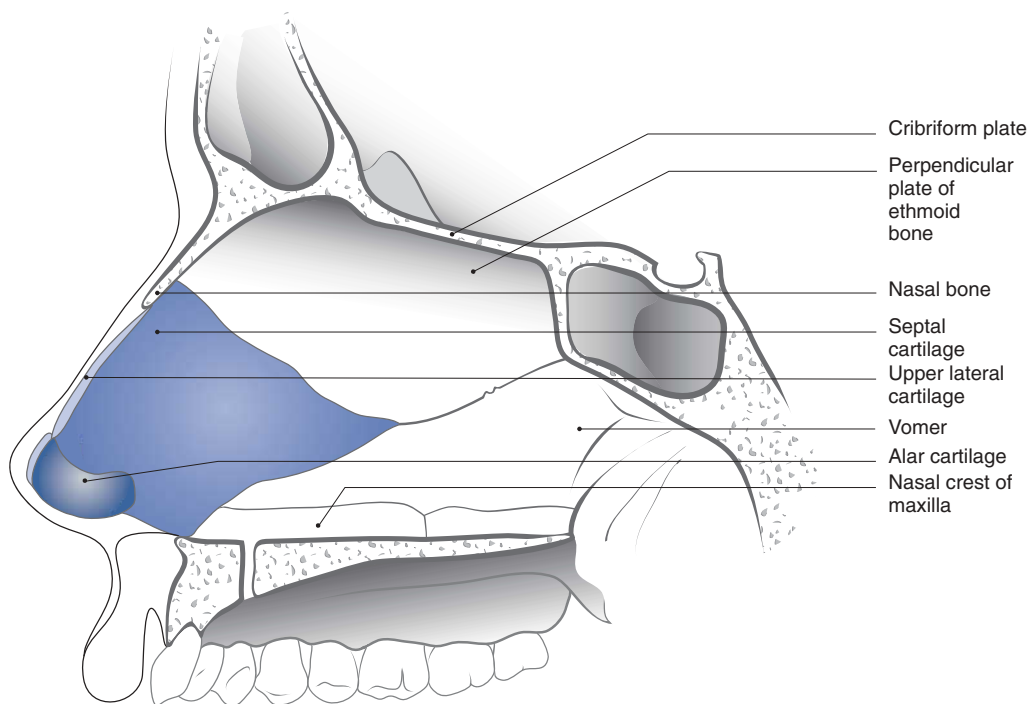


FIGURE 65-11 Anatomy of the nasal septum. The nasal septum is composed of the perpendicular plate of the ethmoid, the vomer, and the quadrangular cartilage. Adapted from Jewett B. *Anatomic considerations*. In: Baker SR, editor. *Principles of nasal reconstruction*. St. Louis (MO): Mosby; 2002. p. 22.

trigeminal nerve. Branches of the supra-trochlear and infratrochlear nerves supply the skin in the region of the radix and rhinion. The lower half of the nose is supplied by the infraorbital nerve and the external nasal branch of the anterior ethmoidal nerve (a branch of the nasociliary nerve that arises from the ophthalmic branch of the trigeminal nerve) (Figure 65-12).

The main sensory nerve supply to the nasal septum comes from the internal nasal nerve (a branch of the anterior ethmoidal nerve) and the nasopalatine nerve (Figure 65-13). The lateral nasal wall sensation is supplied by the anterior ethmoidal nerve, branches of the pterygopalatine ganglion, branches of the greater palatine nerve, the infraorbital nerve, and the anterior superior alveolar nerve.

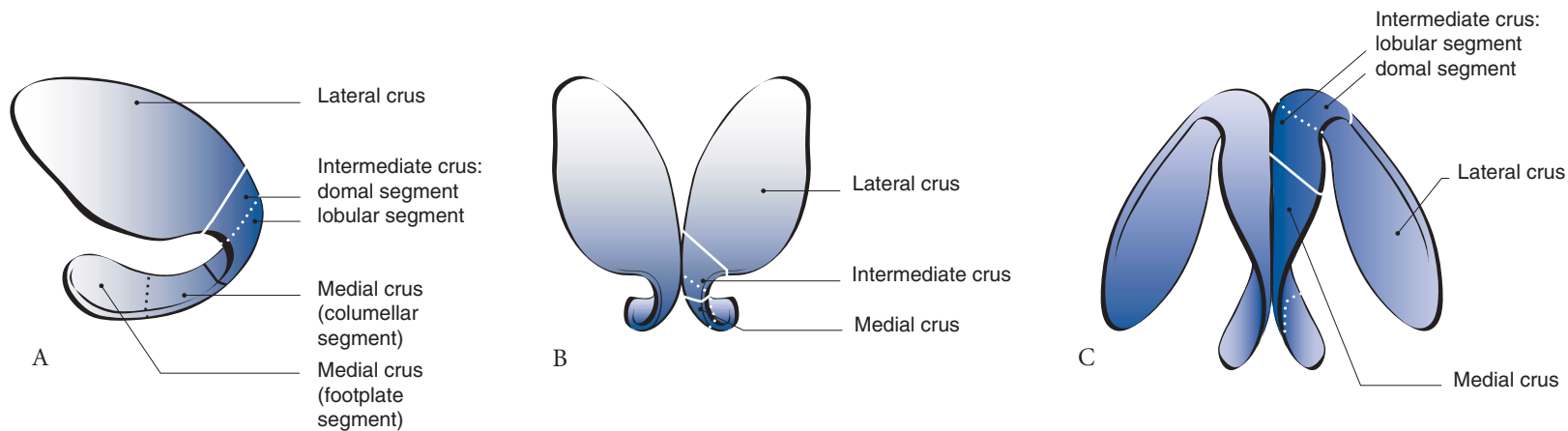


FIGURE 65-10 A–C, Anatomy of the lower lateral cartilages. The lower lateral cartilages are often described as having a lateral crus, medial crus, and an intermediate crus. The intermediate crus is the most projected portion of the lower lateral cartilages and these form two of the tip-defining points seen on nasal tip analysis. Adapted from Jewett B. *Anatomic considerations*. In: Baker SR, editor. *Principles of nasal reconstruction*. St. Louis (MO): Mosby; 2002. p. 21.

Table 65-2 Tip Support Mechanisms

The three major tip support mechanisms include

1. The size, shape, and strength of the lower lateral cartilages
2. The attachment of the medial crura to the caudal septum
3. The attachment of the lower lateral cartilages to the upper lateral cartilages

The minor tip support mechanisms include

1. The interdomal ligament
2. The sesamoid complex extending the support of the lateral crura to the piriform aperture
3. The attachment of the alar cartilages to the overlying skin
4. Cartilaginous septal dorsum
5. Nasal spine
6. The membranous septum

Parasympathetic innervation is derived from branches of the pterygopalatine ganglion which are derived from cranial nerve VII. Some sympathetic branches reach the nasal cavity via the nasociliary nerve.^{2,7}

Nasal Valve

The airflow through the nose is regulated by the internal and external nasal valves. The external nasal valve is comprised of the lower lateral cartilage and the nasal septum and floor. Collapse of the external nasal valve can sometimes be noted when the nares become occluded on even gentle inspiration. This problem is seen in patients with narrow nostrils, a projecting nasal tip, and thin alar sidewalls. External nasal valve collapse is usually seen in patients who have had previous rhinoplasty surgery and excessive trimming of the cephalic portion of the lower lateral cartilages. It is also seen with increased age and in facial nerve paralysis. The external nasal valve collapse can be corrected by deprojecting the overprojected nose, realigning the lateral crura into a more caudal orientation, and placing alar batten grafts to provide structural support and prevent collapse.⁸

The internal nasal valve is formed by the junction of the septum with the upper lateral cartilages. The angle formed should be a minimum of 10° to 15° to maintain

patency. Deviation of the nasal septum or separation of the upper lateral cartilages from the nasal bones can lead to obstruction. This problem is also seen after rhinoplasty if the patient has had weakening of the upper and lower lateral cartilages. These patients often have a pinched

appearance in the supra-alar region. The Cottle test is used to evaluate obstruction at the internal valve by using a finger to distract the check and lateral wall of the nose thereby opening the valve. If nasal airflow is dramatically improved, then the internal valve may require correction. These patients often have symptomatic relief by the use of external taping devices. Surgical correction involves the placement of spreader grafts between the septum and upper lateral cartilages to increase the angle at this junction.⁸⁻¹⁰

Cosmetic Evaluation

The cosmetic evaluation begins in the same way as with any examination, by eliciting the chief complaint of the patient. The patient should be given a mirror and cotton-tipped applicator to point out specific cosmetic concerns. Following this a thorough medical history should be obtained. Specific attention should be directed toward

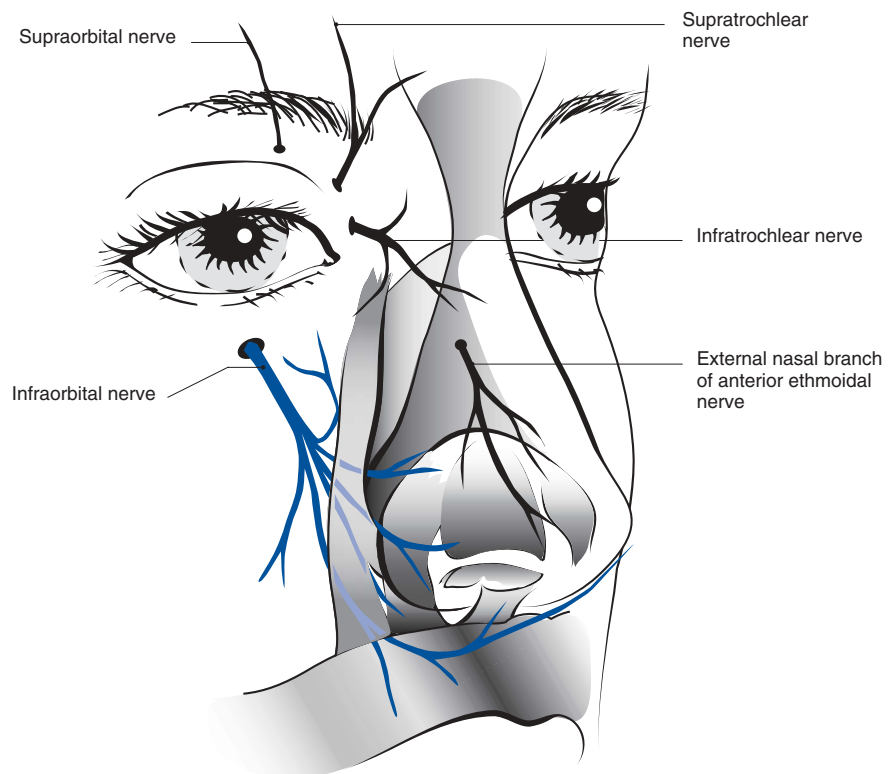


FIGURE 65-12 Sensory nerves of the external nose. The sensory innervation of the nose is derived from the V₁ (ophthalmic; colored black) and from V₂ (maxillary; colored blue) divisions of the trigeminal nerve. Adapted from Jewett B. *Anatomic considerations*. In: Baker SR, editor. *Principles of nasal reconstruction*. St. Louis (MO): Mosby; 2002. p. 19.

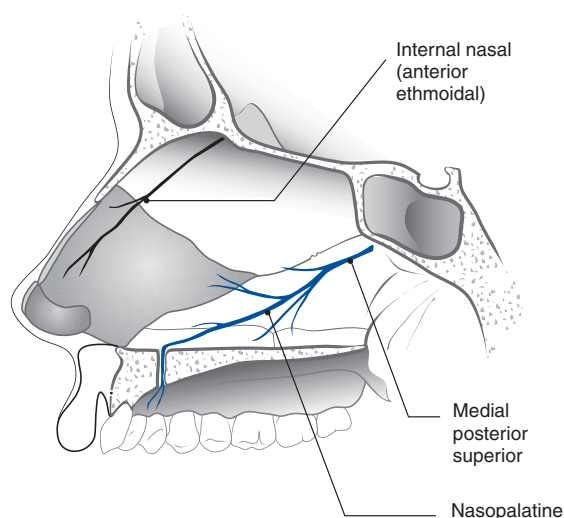


FIGURE 65-13 Sensory nerves of the nasal septum. The main sensory nerve supply comes from the internal nasal nerve (a branch of the anterior ethmoidal nerve V_1 (black) and the nasopalatine nerve V_2 (blue). Adapted from Jewett B. *Anatomic considerations*. In: Baker SR, editor. *Principles of nasal reconstruction*. St. Louis (MO): Mosby; 2002. p. 19.

obtaining a history of nasal trauma, nasal obstruction, previous nasal surgery, and medications (including over-the-counter and herbal medications).

Psychiatric Stability

In addition to analyzing the nose the surgeon needs to assess if the patient is psychologically prepared for a cosmetic procedure. Patients should have realistic expectations and motivations. A patient who is internally motivated (eg, wishes to improve their self-esteem) to have the procedure is a better candidate than one who desires the procedure for external reasons (eg, spouse wants them to have it done).^{11,12}

The surgeon should beware of patients who are indecisive, rude, uncooperative, depressed, have unrealistic expectations, or have significant personality disorders because they may never be satisfied. Other warning signs of poor patients are those who overly flatter, are talkative, consider themselves to be a very important patient, have minimal or no deformity, are surgeon shoppers, price hagglers, or involved in litigation. Most importantly, do not operate on a patient that you do not like.¹¹⁻¹⁴

General Facial Analysis

Prior to performing a specific analysis of the nose, a global assessment of the face

and its proportions should be done. Refer to Chapter 54, “Database Acquisition and Treatment Planning,” for additional information on facial analysis in orthognathic surgery.

Nasal Analysis

The nasal examination should be performed in a systematic manner so that the proper diagnosis is attained (Figures 65-14 and 65-15).

General Assessment

Skin

The skin should be assessed for its thickness, mobility, and sebaceous gland content. Any pigmentations or scars should also be noted. Thick skin does not re-drape well after rhinoplasty.

Symmetry

Any gross asymmetries in all views should be noted.

Lateral View Nasofrontal Angle The nasofrontal angle is defined as the angle formed from lines that are tangential to the glabella and the nasal dorsum and intersect through the radix as seen on a profile view. The normal angle is between 125° and 135° (Figure 65-16).

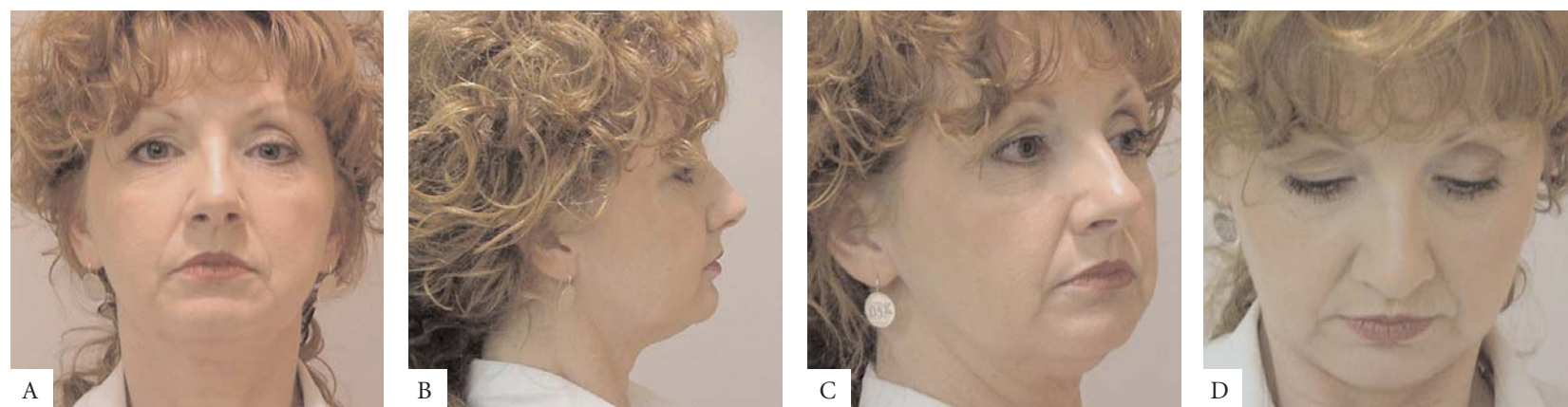

FIGURE 65-14 Preoperative rhinoplasty. A, Preoperative frontal view shows the width of the nose and alar base. B, Preoperative lateral view shows the nasal profile and dorsum in relation to the nasofrontal angle and nasolabial angle. C, Preoperative three-quarter, or oblique view, is most natural and often revealing for harmony of the orbital rims and gull wings that flow into the nasal dorsum. D, Preoperative basal view is either taken from above or below the patient and is a good view of tip and base morphology.

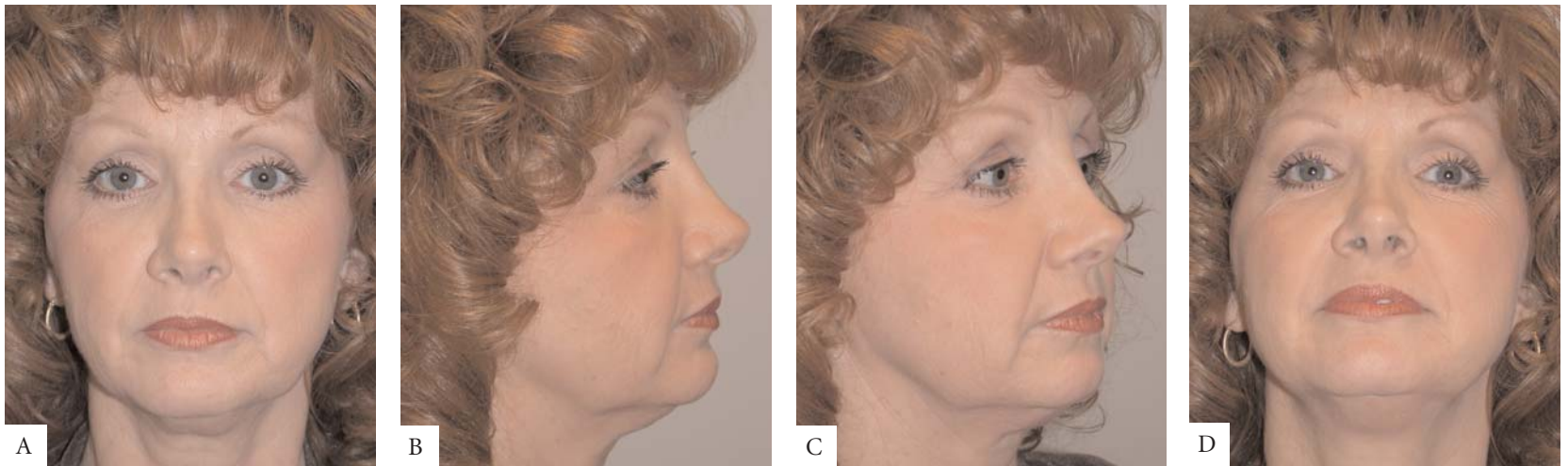

FIGURE 65-15 Postoperative rhinoplasty. A, Postoperative frontal view shows the change in the width of the nose. This is the patient's most critical analysis. B, Postoperative lateral view shows the change in dorsal reduction and tip position. C, Postoperative three-quarter, or oblique view, demonstrates the symmetry and graceful balance of the nose with the face. D, Postoperative basal view shows the width of the nose and any tip deviation from the dorsal midline.

The position of the radix should then be assessed in terms of its anteroposterior and vertical positions from a profile view. The radix should lie in a vertical plane

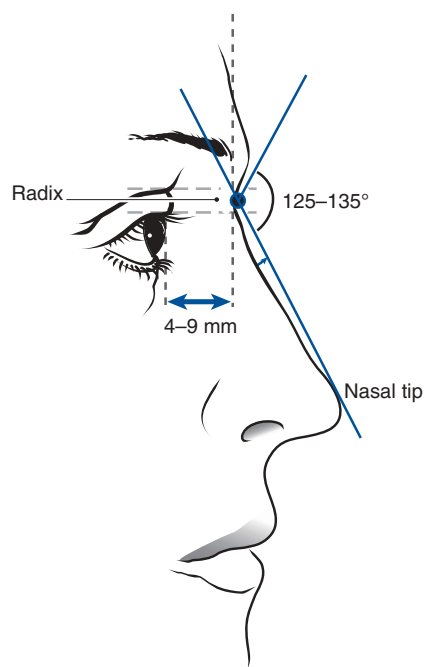


FIGURE 65-16 Position of the nasal dorsum and radix. The nasal dorsum is typically 2 mm behind a line drawn from the radix to nasal tip in women. In men the nasal dorsum typically lies on this line. The radix should lie between the upper eyelid margin and the supratarsal folds in a vertical plane and approximately 4 to 9 mm anterior to the corneal plane. Adapted from Austermann, K., *Rhinoplasty: planning techniques and complications*. In: Booth PW, Hausamen JE, editors. *Maxillofacial surgery*. New York: Churchill Livingstone; 1999. p. 1380.

somewhere between the lash line and the supratarsal folds. In addition it should be 4 to 9 mm anterior to the corneal plane (see Figure 65-16).

Nasal Dorsum In women the nasal dorsum should lie approximately 2 mm posterior to a line drawn from the radix to the nasal tip. In males the nasal dorsum should lie on this line or slightly in front of it (see Figure 65-16).

The length of the nose (radix to tip) can be measured clinically or on photographs taken during the initial examination. The ideal nasal length should approximate the distance from stomion to menton if the lower facial height is proportionate to the middle facial height (glabella to subnasale). If the lower face height is not proportionate it is best to estimate the nasal length as 0.67 times the middle facial height.

Nasal Tip Definition The nose should have four tip defining points which when drawn on the nose in the frontal view appear as two equilateral triangles (Figure 65-17). These points include the supratip break, the columellar-lobular angle, and the two tip-defining points (the most projected portion of the nasal tip)

Nasal Tip Projection Nasal tip projection can be defined as the distance that the tip (pronasale) projects anterior in the facial plane.¹⁵ Perception of nasal tip projection can be influenced by many factors: upper lip length, nasolabial angle, nasofrontal angle, dorsal hump, and

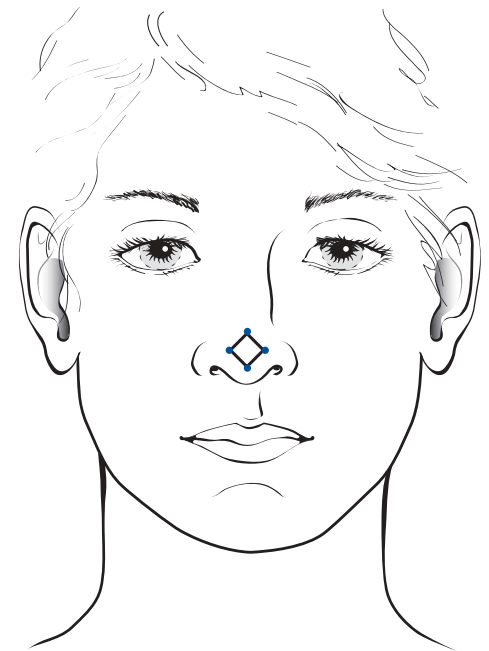


FIGURE 65-17 Nasal tip-defining points. A nose should have four tip-defining points. These are defined by the supratip, columellar-lobular angle, and the tip-defining points of each intermediate crus of the lower lateral cartilages.

chin projection. There are several methods to determine if the nasal tip projection is adequate. Most cosmetic rhinoplasty procedures are designed to preserve tip projection.

The simplest method to remember is Simons' method, which states that the lip-to-tip ratio is 1:1. Essentially the length of the upper lip (from subnasale to labrale superioris) should equal the nasal projection (measured from subnasale to pronasale). This method may be invalid because of the wide variation in lip lengths.¹⁶

The Goode method is another way of determining nasal projection. Using the Goode method a line is drawn from the radix to the nasal tip. A second line is drawn from the radix to the alar columellar junction. A third line is drawn perpendicular to this and passes through the nasal tip. Goode's analysis states that if the nasofrontal angle is between 36° and 40°, then the length of the perpendicular line passing through the nasal tip should be 0.55 to 0.6 of the length of the nasal dorsum (Figure 65-18).¹⁶

Rohrich describes another technique of assessing nasal tip projection. If the nasal dorsal length is appropriate, the tip projection should be 0.67 times the ideal nasal length. The ideal nasal length should be equal to the distance from stomion to menton or 1.6 times the distance from the nasal tip to stomion. The tip projection is measured from the alar facial junction to the nasal tip.¹⁷ This method is subject to a great deal of facial variation.

Additionally a vertical line drawn from the most projected portion of the upper lip should divide the nose in two equal halves between the alar facial groove and the nasal tip. If the anterior portion is greater than 60%, then the nose is likely to be overprojected (Figure 65-19).¹⁷

Nasal tip Rotation The nasal tip rotation is evaluated by the nasolabial angle and the columellar-lobular angle. Nasolabial angle is defined as the angle formed by lines that are tangential to the columella of the nose

and the philtrum of the lip and intersect at the subnasale. In women this should be approximately 95° to 110°, whereas in men this should be 90° to 95°. Lip position may be dependent on tooth position. The columellar-lobular angle is defined as the angle formed by the intersection of a line tangential to the columella and a line tangential to the infratip lobule. This angle is normally between 30° and 45°.

Tip Support The strength of the cartilage in the tip of the nose is apparent when one presses on the tip. A nose with poor support may require cartilaginous struts to counteract the inherently weakened tip from the rhinoplasty. The effect of facial animation should also be noted. Some patients have overactive depressor septi nasi muscles, which result in a drooping nasal tip on smiling. The columella show on a lateral view should be 3 to 4 mm below the inferior alar rim.¹³

Frontal View Width of Nasal Dorsum

The width of the nasal body and tip should be approximately 80% of the alar base width. This is assuming that the alar base is in proper anatomic proportions. The alar base width should approximate the intercanthal distance. If the width of the nasal dorsum is significantly greater than 80%, then lateral nasal osteotomies should be considered. The eyebrows should gracefully flow into the nasal dorsum analogous to a gull wing in flight.

The alar rims and columella should also be a gently curving line that appears as a bird in flight.

Alar Width The alar base width should approximate the intercanthal distance. Seldom is the nasal width less than the intercanthal dimension.

Basal View From a basal view the columella-to-lobule ratio should be 2:1. Nostril size and shape should also be noted. An esthetic nostril is teardrop

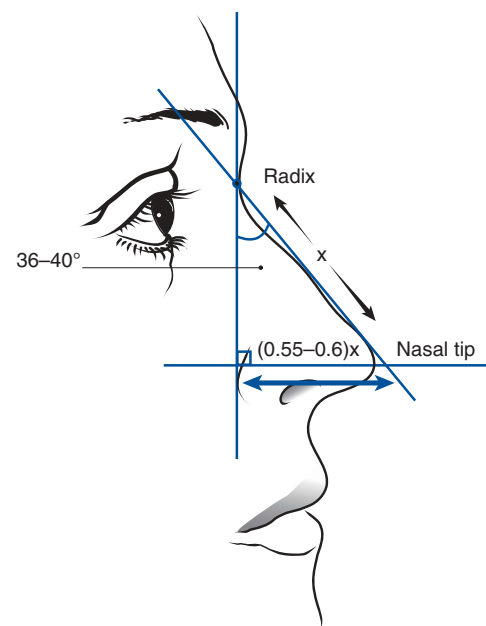


FIGURE 65-18 Goode method of nasal projection. This method is sometimes used to determine adequacy of nasal projection. If the nasofrontal angle is between 36° to 40°, then the length of a perpendicular line through the nasal tip should be 0.55 to 0.6 the length of the nasal dorsum. x = nasal length. Adapted from Austermann, K., *Rhinoplasty: planning techniques and complications*. In: Booth PW, Hausamen JE, editors. *Maxillofacial surgery*. New York: Churchill Livingstone; 1999. p. 1380.

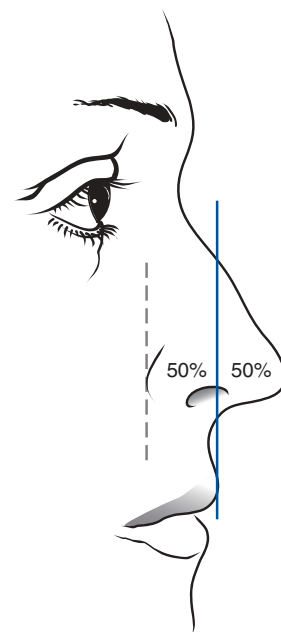


FIGURE 65-19 Nasal projection. A vertical line through the most projected part of the upper lip should divide the nose into two equal parts. If the nasal tip comprises > 60%, then the nose may be overprojected.

shaped, but there is a great amount of ethnic variation (Figure 65-20).

Oblique View The oblique view is most natural and sometimes more revealing than standard photographs. It demonstrates the flow of subunits and facial harmony. The three-quarters view is how we usually see each other in routine interaction.

Functional Considerations

Although the patient desires cosmetic correction of their nose, the functional significance of the nose should be closely considered. Nasal airflow through both the internal and external nasal valves should be evaluated. The septum should be evaluated for deviation and perforations. The septum is often a good site for harvesting autogenous cartilage for grafting. The turbinates should be evaluated for hypertrophy. Rhinoscopy with a nasal speculum can be performed both before and after the administration of a topical decongestant.

Photographs

The examination is not complete without standardized facial photographs. The standard facial photographs should include frontal, right, and left lateral views; right and left oblique views; and a high and low basal view. Close-up views are taken if warranted. The photographs are beneficial from a medicolegal standpoint, and they also allow the surgeon to

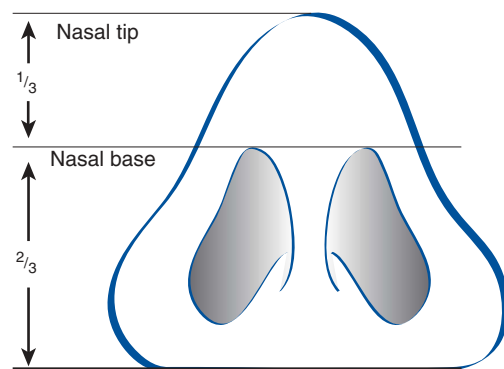


FIGURE 65-20 *Columella-to-lobule ratio.* The columella-to-lobule ratio should be 2:1.

study the nose in more detail and to develop a surgical plan.

Anesthesia

Proper anesthesia of the nose is important to ensure minimal distortion of the tissues as well as to provide adequate hemostasis. Prior to injecting the nose, cottonoids or cotton-tipped applicators soaked in 4% cocaine or oxymetazoline are placed in each nostril to constrict the mucous membranes of the turbinates. If the rhinoplasty is to be performed under sedation, then cocaine is preferred because of its anesthetic properties. If the procedure is performed under general anesthesia, then oxymetazoline is sufficient.

Three cottonoids are placed in each nostril: one along the middle turbinate, one along the superior nasal vault, and one along the inferomedial septum.

Local anesthesia is achieved with 2% lidocaine with 1:100,000 epinephrine. In an endonasal rhinoplasty the following areas are injected:

- 0.5 cc deposited at the junction of each upper and lower lateral cartilage (intercartilaginous area)
- 0.5 cc deposited in the region of each marginal incision
- 3 cc along the nasal dorsum and lateral nasal bones (hugging periosteum)
- 1 cc along the nasal septum
- 0.5 cc at each alar base
- 1 cc at each infraorbital nerve
- 1 cc at the nasal tip

For external rhinoplasty the following additional area is injected:

- 1 cc to the columella

Incisions/Sequencing

There are multiple incision techniques used to gain access to the cartilage and bone support of the nose.

Complete Transfixion

This incision provides access to the caudal septum, medial crura, and nasal spine.

The incision is made with a no. 15 blade, beginning just caudal to the superior caudal end of the nasal septum. The incision extends inferiorly through the membranous septum, following the cephalic margin of the medial crura (see Figures 65-7 and 65-21A). It results in ptosis and deprojection of the nose.

Partial Transfixion

This incision is similar to the complete transfixion incision except that it stops at the level of the medial footpads of the lower lateral cartilages. The advantage of this incision is that the attachments of the medial footpads of the lower lateral cartilages to the caudal septum are not disrupted (see Figures 65-7 and 65-21B).

Hemitransfixion

This incision is a complete transfixion incision that is performed on only one side of the membranous septum. It does not traverse both mucosal surfaces and therefore some attachments of the medial crura to the caudal septum are maintained. Access to the nasal septum is good with this incision; however, delivery of the lower lateral cartilage on the side opposite to the incision is difficult (see Figures 65-7 and 65-21C).

Killian Incision

This incision is seldom used in rhinoplasty. It is a useful incision to gain access to the nasal septum if only a septoplasty is to be performed. The incision is made several millimeters cephalad to the caudal edge of the septum. It can be extended onto the nasal floor if needed.

Intercartilaginous Incision

This incision is made at the junction of the upper and lower lateral cartilages. The nare is elevated superiorly with a double skin hook. A no. 15 blade should pass below the lower lateral cartilage and above the upper lateral cartilages. This incision is typically made after a transfixion incision. The intercartilaginous incision is then

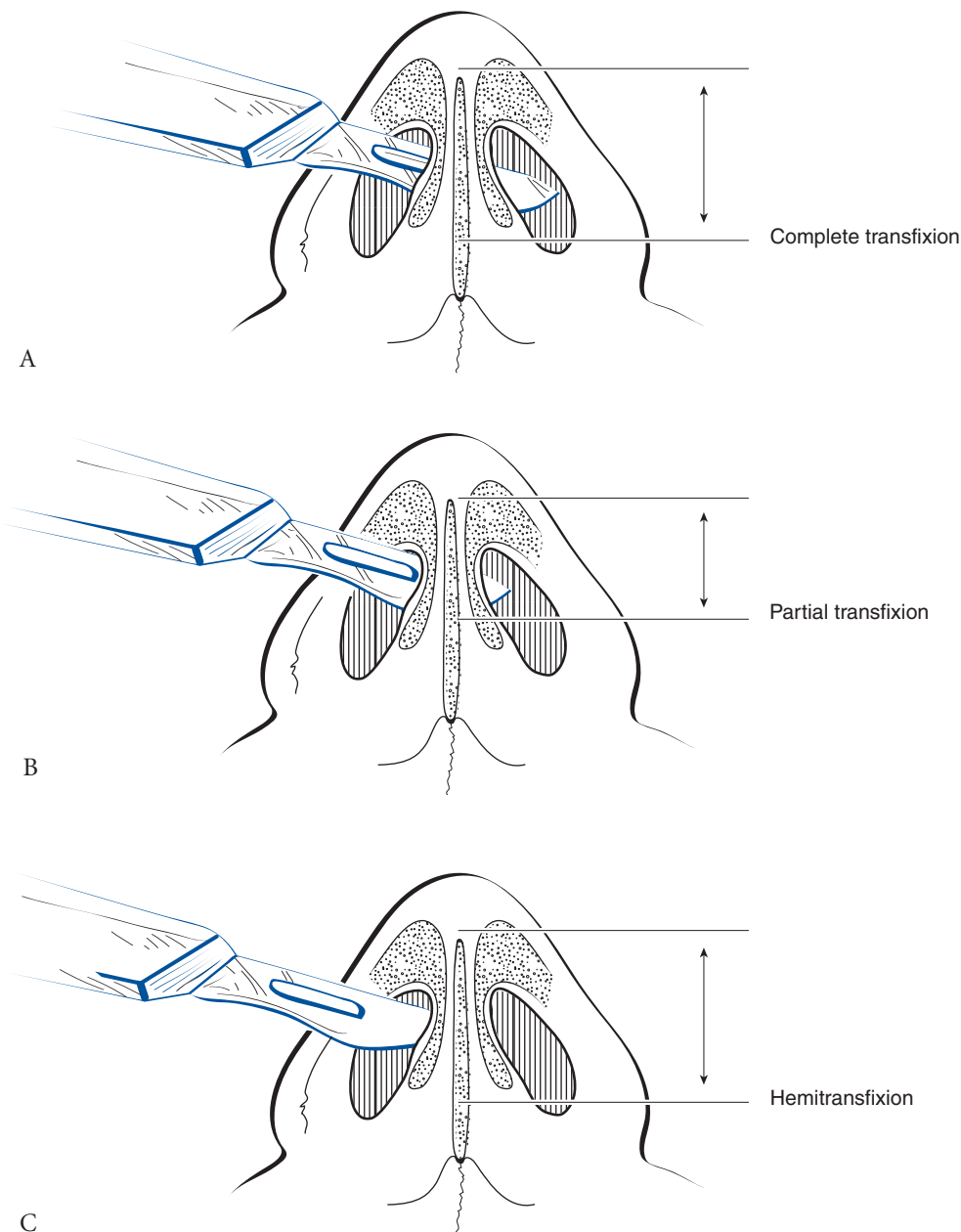


FIGURE 65-21 Transfixion incisions. A, A complete transfixion incision is made caudal to both the medial crura and through the membranous septum. B, A partial transfixion incision is similar except the incision stops short of the medial foot pads of the medial crura. C, A hemitransfixion incision is a complete transfixion incision that is performed only on one side, therefore the other medial crura and footpad is not violated.

connected to the transfixion incision (see Figures 65-8, 65-9, and 65-22).

Intracartilaginous Incision

This incision is made through both the vestibular nasal mucosa and a portion of the lower lateral cartilages. This incision is similar to the intercartilaginous incision except that it is made 3 to 5 mm posterior

to the junction of the upper and lower lateral cartilages. This incision in effect performs a complete cephalic strip of the lower lateral cartilages without the need for delivering the cartilage. The disadvantage is that the lower lateral cartilage is not directly visualized and it may therefore be difficult to achieve symmetry between the right and left sides.

Rim/Marginal Incision

This incision parallels the caudal edges of the lower lateral cartilages. The incision is used in combination with an intercartilaginous incision in an endonasal rhinoplasty. The two incisions allow the lower lateral cartilage to be delivered and visualized. This allows the surgeon to more accurately trim the cartilage if needed. In an open rhinoplasty this incision is combined with a transcolumellar incision in order to gain access to the lower lateral cartilage and nasal dorsum (Figure 65-23).

Transcolumellar Incision

This incision is made through the thinnest portion of the columella at a level just superior to the flaring of the medial crura. The incision can be made with a notched V in the center of the columella or as a “stair step.” This will break up the scar and assist in closure. This incision is connected with a marginal incision bilaterally for open rhinoplasty (see Figure 65-23).

The two principle techniques are the endonasal and external rhinoplasty. Each of these techniques will be described in general terms, in the order in which the authors perform them. Other surgeons may perform the sequence in a different order (Tables 65-3 and 65-4).

Septoplasty

In rhinoplasty surgery there are several reasons to access the nasal septum: (1) to correct nasal airflow obstruction, (2) to assist in the correction of asymmetries, and (3) to harvest cartilage for tip grafting.

Access to the nasal septum in an endonasal approach is through a partial-transfixion incision, which is connected to bilateral intercartilaginous incisions. The partial-transfixion incision can be extended to the nasal floor on the side on which the septoplasty is to be performed. After completing the incisions the caudal aspect of the nasal septum is exposed by dissecting the mucoperichondrium from one

FIGURE 65-22 Intercartilaginous incisions. The intercartilaginous incision is made at the junction of the upper and lower lateral cartilages. The blade should pass below the lower lateral and above the upper lateral cartilage. Adapted from Alexander R. *Fundamental terms, considerations, and approaches in rhinoplasty*. In: Waite PD, editor. *Atlas of the oral and maxillofacial surgery clinics of North America: rhinoplasty*. Philadelphia (PA): W.B. Saunders; 1995. p. 19.

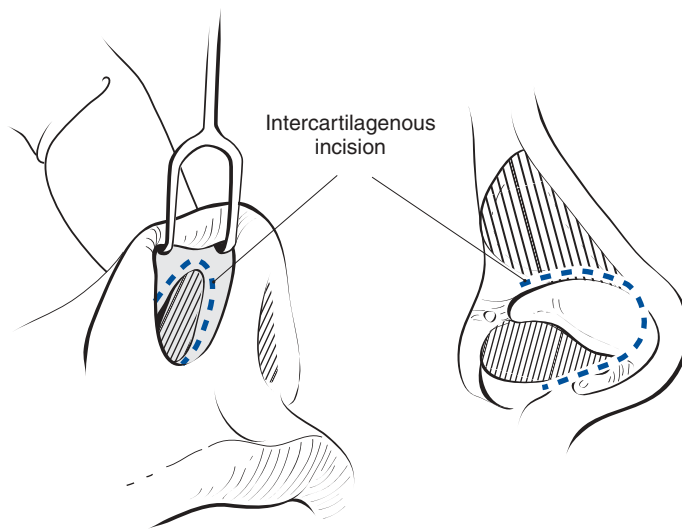
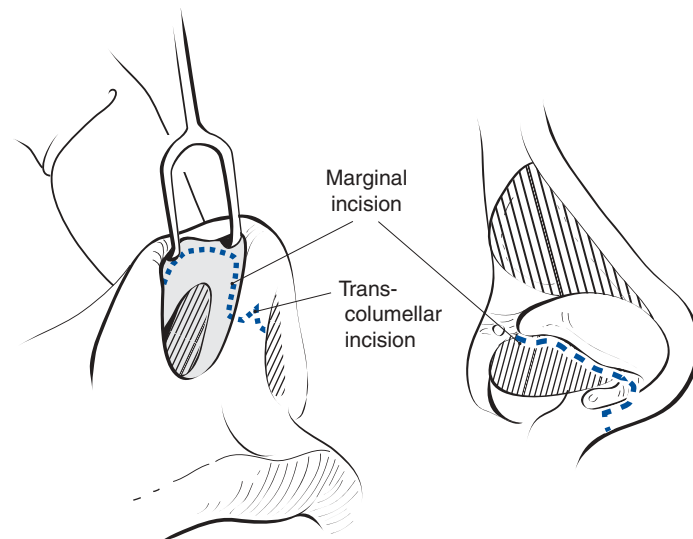


FIGURE 65-23 Marginal incision. This incision is made parallel to the caudal edge of the lower lateral cartilage. This incision can be combined with bilateral intercartilaginous incisions for a cartilage delivery technique in endonasal rhinoplasty or combined with a transcolumellar incision for an external rhinoplasty. Adapted from Alexander R. *Fundamental terms, considerations, and approaches in rhinoplasty*. In: Waite PD, editor. *Atlas of the oral and maxillofacial surgery clinics of North America: rhinoplasty*. Philadelphia (PA): W.B. Saunders; 1995. p. 19.



side. Two tunnels will be developed, one superior and the other inferior, which will ultimately be joined so that wide exposure of the septum is obtained.¹⁸ Initially sharp dissection is done with a no. 15 blade or scissors to expose a portion of the caudal septum. The perichondrium is gently scored using a no. 15 blade. A dental amalgam condenser is then used in a sweeping motion to develop a plane between the perichondrium and the nasal septum (Figure 65-24). Once this plane of dissection is started a Freer or Cottle elevator can be used to complete the septal envelope (Figure 65-25). The mucoperichondrium is

tightly bound at the junction of the septum and the maxillary crest.

Once the septum is exposed it can be treated in four ways: (1) resection, (2) morselization, (3) segmental transection, and (4) swinging door flaps.¹⁸ Submucosal resection allows a significant portion of cartilage to be harvested for grafting. At least 1 cm should be maintained superiorly and anteriorly in an L-shaped configuration to provide support for the nose (Figure 65-26). In order to resect the cartilage a Cottle elevator is used to cut the cartilage. Fomon scissors may be used to make the superior and inferior cuts

Table 65-3 Surgical Sequence for Endonasal Rhinoplasty

The general sequence is

1. Local anesthesia
2. Partial transfixion incision (see Figure 65-7)
3. Intercartilaginous incision (join with partial transfixion) (see Figures 65-8, 65-9, 65-21, and 65-22)
4. Septoplasty (if needed) (see Figures 65-24 and 65-25)
5. Dorsal reduction (see Figures 65-28–65-30)
6. Lateral nasal osteotomies (see Figure 65-31)
7. Marginal incision (see Figure 65-23)
8. Delivery of lower lateral cartilages (see Figure 65-37)
9. Tip modification (ie, cephalic strips/cartilage grafting/suture techniques)
10. Alar base modification (see Figure 65-41)
11. Closure, taping, and splinting

Table 65-4 Surgical Sequence for External Rhinoplasty

The general sequence is

1. Local anesthesia
2. Bilateral marginal incisions (see Figure 65-23)
3. Columellar incision (see Figure 65-23)
4. Skeletonization of upper and lower lateral cartilages and nasal dorsum
5. Dorsal reduction
6. Dome division if access is needed to the septum for septoplasty or graft harvest
7. Septoplasty (if needed)
8. Turbinate reduction
9. Lateral nasal osteotomies
10. Tip modification (ie, cephalic strips/cartilage grafting/suture techniques)
11. Alar base modification
12. Closure, taping, and splinting

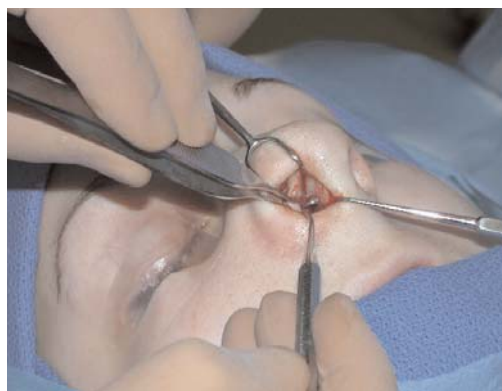

FIGURE 65-24 Identifying perichondrium. The perichondrium is elevated with a dental amalgam condenser. One will notice a slight blue-gray cartilage and a distinct plane of dissection.

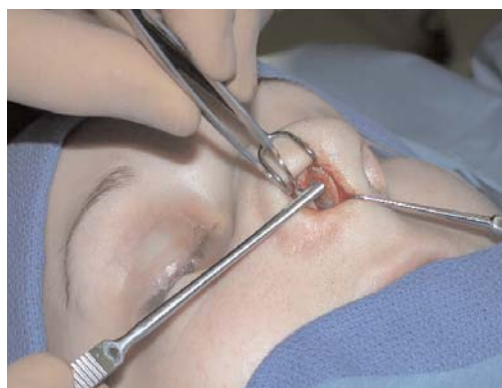

FIGURE 65-25 Elevation of mucoperichondrium. The Cottle elevator is specifically designed to elevate the nasal envelope without perforation.

through the bony septum. The cartilage can also be removed with a Ballenger swivel blade. If no cartilage is needed for the rhinoplasty, the resected cartilage can be morselized and replaced. Morselization can be performed in situ. Another technique for aligning the septum is through a segmental transection. In this technique the mucoperichondrium is elevated on one side of the septum. Cross-hatching with a no. 15 blade is performed to weaken the cartilage (Figure 65-27). The mucoperichondrium on the other side of the septum provides support. 4-0 gut mattress sutures can be positioned through the septum to assist in realignment. A septal splint is placed for 1 week. Finally a swinging door type flap can be used to reposition a large segment of flat cartilage

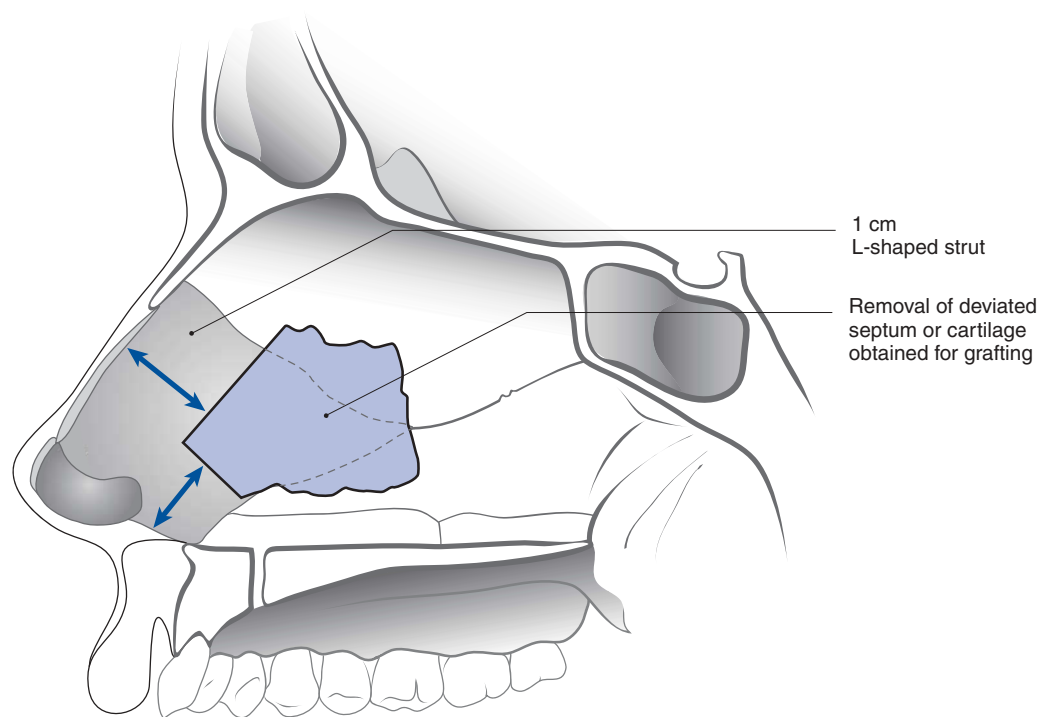


FIGURE 65-26 Resection of cartilage/bone from the nasal septum. This may be done to harvest cartilage for grafting procedures or for removal of grossly deviated septum. It is important to maintain 1 cm dorsally and caudally for nasal support.

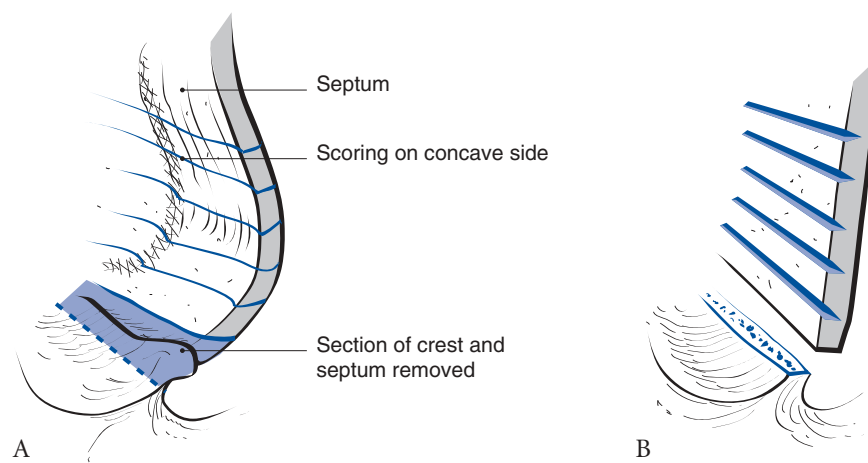


FIGURE 65-27 Septal repositioning. A deviated nasal septum can be repositioned by removing the obstruction inferiorly (A) and cross-hatching the cartilage to allow the deviated portion to be repositioned (B). Adapted from Robinson RC. *Functional septorhinoplasty*. In: Waite PD, editor. *Atlas of the oral and maxillofacial surgery clinics of North America: rhinoplasty*. Philadelphia (PA): W.B. Saunders; 1995. p. 35.

that is improperly angulated. The mucoperichondrium is elevated on one side. Through and through incisions are made on either side of the deviated cartilage. The cartilage is also separated from the maxillary crest so that it can hinge into a more normal position. Septal splints may

be required for 1 week. In all septal procedures a 4-0 gut on a straight needle is routinely used to perform a mattress suture through the septum and mucosa. This decreases the likelihood of a septal hematoma formation and circumvents the need for nasal packs.

Tears in the septal mucosa are not uncommon. However, it is not problematic as long as the tears are only on one side of the septum. Unilateral tears require no elaborate closure. If the tear is through and through, at least one side should be closed. This is best done with a 5-0 chromic gut suture.

Turbinectomy

Although the focus of this chapter is the cosmetic rhinoplasty, some mention needs to be made on maintaining function. Inferior turbinate hypertrophy is a problem that can result in nasal obstruction after cosmetic rhinoplasty, if the problem is not recognized preoperatively. Hypertrophy of the inferior turbinates is the most common cause of nasal airway obstruction.^{19,20} Hypertrophy can be caused by numerous factors. Most commonly it is related to allergic symptoms. Hypertrophy caused by allergy should be managed medically with antihistamines and topical corticosteroids. If this fails, then surgical management can be considered.²¹ In cases of a deviated nasal septum the turbinate on the side at which the nasal passage is enlarged can become hypertrophic with time. In patients with anatomic enlargement of the turbinate, the problem needs to be recognized so that the nasal passage does not become obstructed when the septum is straightened.

Management of inferior turbinate hypertrophy is controversial and outside the scope of this chapter. The surgical procedures used to treat this problem have included corticosteroid injection, turbinate out-fracture, electrocautery, cryosurgery, laser reduction, partial turbinate resection, total turbinate resection, submucous turbinate resection, and vidian neurectomy.²⁰⁻²⁴ Each of these procedures has various advantages and disadvantages and the procedure chosen depends on the patient. The most common complications from turbinate surgery are hemorrhage, atrophic rhinitis, and ozena.

Nasal Dorsum

Reduction

One of the most dramatic changes that can be achieved in rhinoplasty surgery is correction of a dorsal hump. There are many ways to remove the hump. Some surgeons use a scalpel and osteotome, whereas others use rasps, and a few use power rasps. The authors recommend to first incise the cartilaginous convexity below the nasal bones and then to use a Rubin osteotome to remove the bony hump (Figures 65-28–65-31). Care must be taken to keep the osteotome directed superficially, since it can deflect downward and result in over-reduction. After removing the gross hump, sequential

rasping can be used for refinement. After removal of any significant dorsal hump, the patient is left with an open roof deformity. This must be closed with lateral nasal osteotomies (see Figure 65-31).

Augmentation

Augmentation is indicated when there has been excessive reduction from previous rhinoplasty or from a post-traumatic defect. Several techniques are used to augment the nasal dorsum.

Autogenous Augmentation In the setting of acute trauma, cranial bone grafts can be used to provide support. These are cantilevered off the frontal bone with a miniplate. The graft must be properly

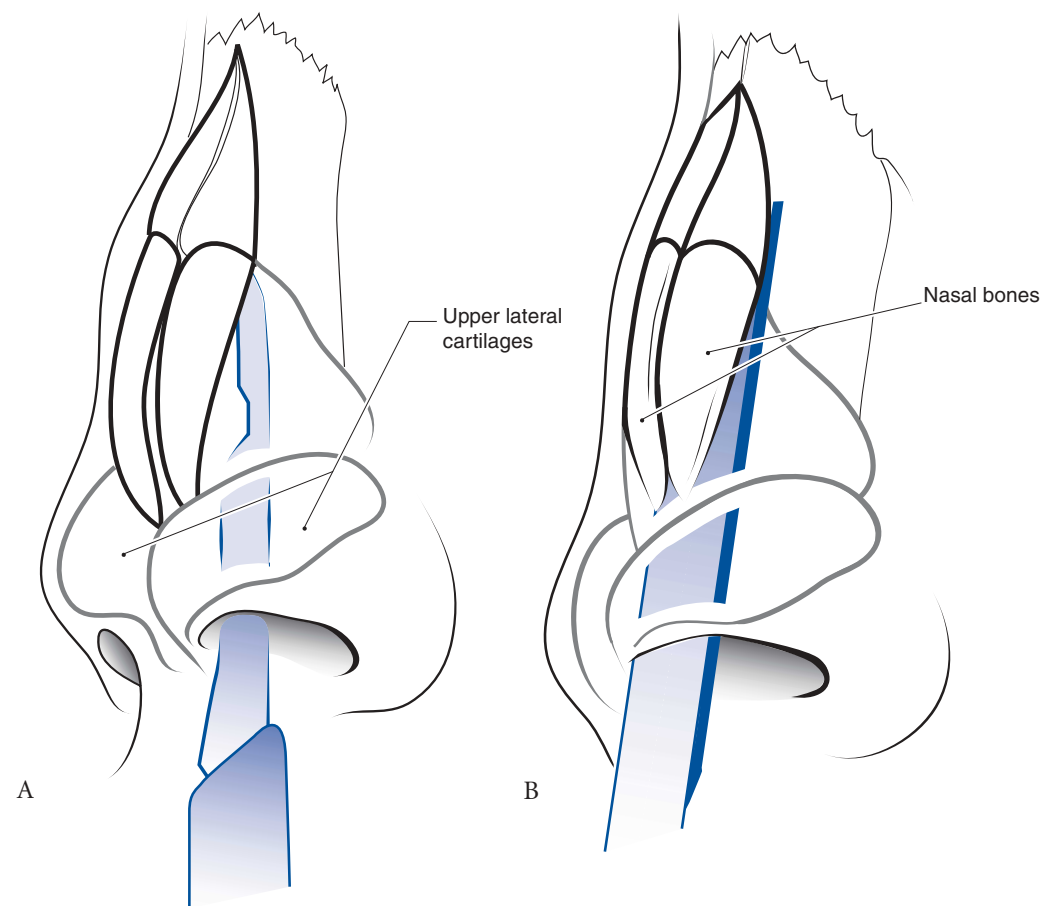


FIGURE 65-28 Removal of a dorsal hump. A, The dorsal hump is removed by first using a scalpel to incise through the upper lateral cartilages. B, Next, a Rubin osteotome is used to reduce the bony prominence. Care is needed to keep the osteotome from being directed too far posteriorly thereby over-reducing the dorsum. Adapted from Austermann, K., *Rhinoplasty: planning techniques and complications*. In: Booth PW, Hausamen JE, editors. *Maxillofacial surgery*. New York: Churchill Livingstone; 1999. p. 1389.

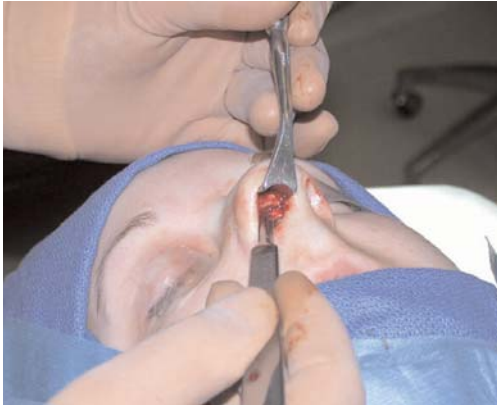

FIGURE 65-29 Dorsal reduction. An Aufrecht retractor lifts the dorsal drape and can protect the skin during hump reduction. A no. 15 blade is used to incise the cartilaginous dorsum. Working through this incision, an osteotome or rasp is used to reduce the bone of the dorsum.

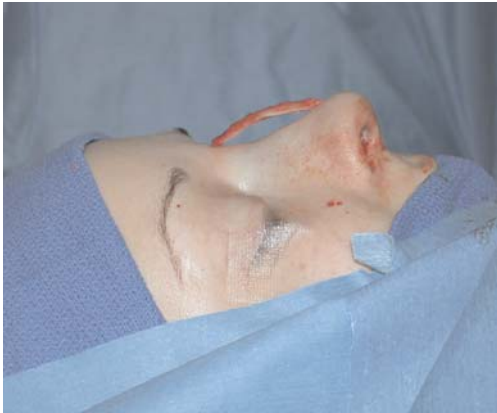

FIGURE 65-30 Dorsal reduction. The dorsum should be about two-thirds of the cartilage and one-third of the bone.

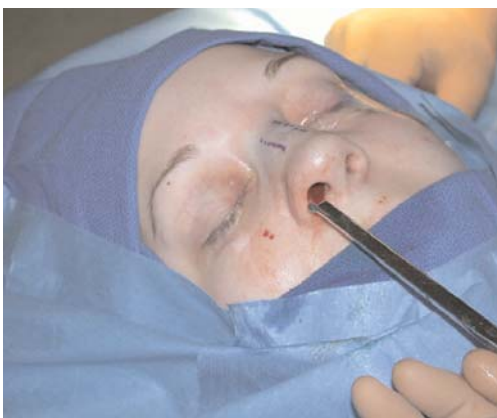

FIGURE 65-31 Lateral nasal osteotomies. Removal of a large dorsal hump will often leave a flat open roof deformity, and this can be reduced by lateral nasal osteotomies with an invert chisel, saw, or rasp.

shaped so that it provides support but does not distort the shape of the nose.^{25–27} Rib cartilage can also be harvested for augmentation of the nasal dorsum. Silicone sizers can be used to estimate the size and shape of graft needed. Once the graft is harvested, a 0.035 inch K-wire can be placed in the center of the graft to stabilize it. Rib grafts have a tendency to distort with time and the K-wire may help limit this tendency.²⁸

For a less aggressive augmentation, autogenous cartilage harvested from the nasal septum can be used. This can be layered and sutured together. It is then placed through traditional rhinoplasty incisions.^{29–31}

Alloplastic Augmentation Another technique is to use cadaveric dermis along the nasal dorsum. The advantage here is that no harvesting is required and the material is pliable. However, the resorption of this material is unpredictable. Other implantable materials include silicone and expanded polytetrafluoroethylene (ePTFE) implants. These can be contoured to the appropriate size intraoperatively. The issue with implants is that the grafts can extrude or become infected. Meticulous placement is essential.^{31–34}

Osteotomies

Osteotomies are performed after the nasal reduction has been performed. The purposes of lateral nasal osteotomies include reduction of the open nasal roof, correction of deviated nasal bones, and narrowing of a wide nasal base (see Figure 65-31).

There are two principal types of nasal osteotomy: lateral and medial. The lateral nasal osteotomy can be performed at different levels. It typically begins low on the piriform rim and can end either high or low in its relationship to the nasal bones. Thus the osteotomy is often termed as a low-to-low osteotomy or a low-to-high osteotomy. These osteotomies can be performed via an internal or external tech-

nique. Regardless of which technique is used, limited periosteal dissection is favored so that support is provided to the nasal bones. Medial osteotomies are seldom needed but can be used to obtain a controlled fracture in patients with thick nasal bones or when a low-to-low technique is used. Also, regardless of the osteotomy technique, the osteotomies should not be carried above the intercanthal line. The bone above this point becomes much thicker and mobilization becomes difficult. Care should be taken when performing medial osteotomies, since the thicker portion of the nasal bone can be included in the lateral osteotomy segment and result in widening of the upper nasal dorsum. This is termed a rocker deformity.

Lateral nasal osteotomies are not always required to close an open roof deformity after dorsal hump reduction. Some surgeons believe it is better to place spreader grafts in those patients with short nasal bones so that compromise of the internal nasal valve does not occur. If an osteotomy is performed in a patient with shorter nasal bones, then a low-to-high technique is preferred.

Nasal Tip

Understanding the mechanisms of nasal tip support is critical when performing rhinoplasty. The surgeon must understand both the desired and undesired changes that occur from the surgical approach or technique.³⁵

The three major tip support mechanisms include the following:

1. The size, shape, and strength of the lower lateral cartilages
2. The attachment of the medial crura to the caudal septum
3. The attachment of the lower lateral cartilages to the upper lateral cartilages

The minor tip support mechanisms include the following:

1. The interdomal ligament
2. The sesamoid complex, extending the support of the lateral crura to the piriform aperture
3. The attachment of the alar cartilages to the overlying skin
4. The cartilaginous septal dorsum
5. The nasal spine
6. The membranous septum^{36,37}

Certain surgical procedures can affect tip support. For example a complete transfixion incision will disrupt the fibrous attachments of the caudal septum to the medial crura thus leaving little support for the nasal tip. Suturing techniques and cartilage strut grafts may be necessary to reestablish support if this incision is performed. Intercartilaginous incisions, which are useful to gain access to the nasal dorsum, interrupt the ligamentous connections of the upper and lower lateral cartilages. This can result in cephalic tip rotation, which may or may not be desirable. A cephalic strip procedure creates even further disruption and rotation of the lower lateral cartilages. Most often tip rhinoplasty is designed to refine and decrease the tip lobule while maintaining or even increasing rotation and projection.

The cartilaginous support of the nasal tip is often described in terms of a tripod concept.^{38,39} The medial crura of both the lower lateral cartilages together form one strut of the tripod, and each of the lateral crura of the lower lateral cartilages forms a strut. By selectively shortening or lengthening any of these struts, the tip position can be altered.

The tip position changes are referred to in terms of both projection and rotation. Tip projection is the distance from the tip of the nose to the alar-facial junction. Increasing tip projection is one of the most difficult procedures to perform in rhinoplasty surgery. Nasal tip projection can be increased by both grafting and non-grafting techniques.

Tip Projection *Increasing Tip Projection* Nongrafting techniques to increase nasal projection include the following:

1. Suturing of divergent medial crura: For this technique to be effective there must be diverging medial crura. Intervening soft tissue may require excision prior to suturing with mattress sutures.⁴⁰
2. Lateral crural steal: The lower lateral cartilage is skeletonized and the lateral crura cartilages are sutured with a mattress suture so that the lateral crura now contributes to the medial crura (Figure 65-32). This results in increased projection and some rotation as well.^{41,42}

Grafting techniques to increase projection include the following:

1. Collumellar strut: This technique involves the placement of a strut of septal cartilage between the feet of the medial crura and abutted against the nasal spine. The medial crura are elevated superiorly with double skin hooks and the cartilage strut is sutured to the medial crura via mattress sutures. Only a minor amount of tip projection can be increased with this method.
2. Peck graft: This is an onlay graft in the region of the nasal tip. Layers of cartilage are placed in the domal region to
3. Umbrella graft: This technique involves the creation of a cartilaginous structure that resembles the appearance of an umbrella. It is useful when both tip projection and support of weak medial crura are required. The umbrella graft is constructed from harvested septal, ear, or rib cartilage. It is then sutured in position so that the “handle” of the umbrella is between the medial crura and the “canopy” of the umbrella rests atop the dome. The canopy portion can be modified to incorporate the Peck graft technique by stacking layers of cartilage (Figure 65-34).⁴³
4. Shield graft: This graft was first described by Sheen.³⁰ A piece of septal cartilage is shaped to form a trapezoidal configuration measuring 6 to 8 mm superiorly and 5 mm inferiorly. The graft is usually 10 to 12 mm long and is beveled so that the corners are blunted. The graft is placed in a pocket through an endonasal approach or sutured in position via an open approach. The superior and lateral aspect of the graft forms the tip-defining points (Figure 65-35).³⁰

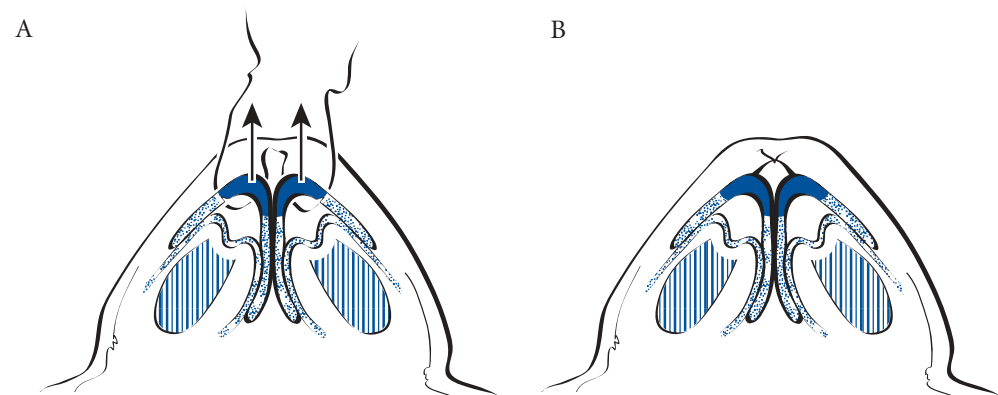


FIGURE 65-32 *Lateral crural steal.* A, B, A horizontal mattress suture is placed in the lateral crura in order to increase nasal projection and narrow the nasal tip. Adapted from Taylor CO. *Surgery of the nasal tip.* In: Waite PD, editor. *Atlas of the oral and maxillofacial surgery clinics of North America: rhinoplasty.* Philadelphia (PA): W.B. Saunders; 1995. p. 61.

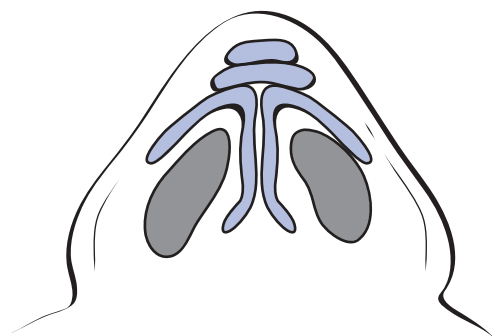


FIGURE 65-33 Peck graft. This involves the placement of layers of cartilage grafts in the region of the nasal tip to increase nasal projection. Adapted from Taylor CO. *Surgery of the nasal tip*. In: Waite PD, editor. *Atlas of the oral and maxillofacial surgery clinics of North America: rhinoplasty*. Philadelphia (PA): W.B. Saunders; 1995. p. 62.

Decreasing Tip Projection Decreasing tip projection involves reduction of the tip supporting mechanisms. Achieving acceptable results when decreasing projection can be difficult since nasal definition can be lost.⁴⁴ If the nasal projection needs to be decreased, be certain to first confirm that the problem is not the result of an optical illusion caused by a low radix position. If the problem is a low radix, then a dorsal radix graft is the appropriate treatment.

Methods to decrease projection include the following:

1. Complete transfixion incision: As discussed above, a complete transfixion incision will decrease tip support. Intercartilaginous incisions or cephalic strips will also weaken the tip support but will increase tip rotation.
2. Lower the septal angle: If the septum is providing significant support for the nasal tip, then the septal angle must be lowered. This is done by excision of a portion of the caudal septum. Additionally the medial crura can be separated from the caudal septum to decrease projection.
3. Crural excision: To dramatically decrease tip projection the medial and lateral crura may need to be sectioned, overlapped, and sutured into a new position with less projection. This technique maintains the natural shape of the tip at the domes (Figure 65-36). Excision of a segment cartilage in the domes and suturing them back together can be done, but it will change the shape of the nasal tip.

Sometimes, after decreasing the nasal projection, the patient may have flaring of the ala and increased infratip columellar show. This can be treated with an alar base resection but should be used judiciously.

Tip Rotation Increasing Tip Rotation Understanding the tripod concept and tip supporting mechanisms is important when determining which of the following methods to use to increase tip rotation.

1. Removal of dorsal hump: A subtle way to increase rotation of the tip is to reduce a dorsal hump if present.
2. Resection of the caudal septum: A small triangular piece of caudal septum can be removed. The base of this triangular shape is at the nasal dorsum.
3. Cephalic strips from lower lateral cartilages: A complete strip of cephalic cartilage from the lower lateral cartilages will result in increased tip rotation. Even an intercartilaginous incision will result in some tip rotation (Figure 65-37).
4. Shorten the lateral crura
5. Shield graft: A shield graft gives the illusion of increased tip rotation.
6. Augmentation of premaxilla: Placement of cartilage or ePTFE in the premaxilla region below the anterior nasal spine will also give the illusion of increased tip rotation.

Decreasing Tip Rotation Decreasing tip rotation is done by two methods:

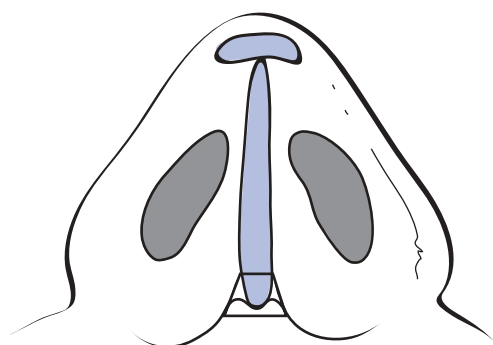


FIGURE 65-34 Umbrella graft. This is essentially a columellar strut graft placed between the medial crura, combined with a tip graft. This technique improves support of the medial crura as well as increases nasal projection. Adapted from Taylor CO. *Surgery of the nasal tip*. In: Waite PD, editor. *Atlas of the oral and maxillofacial surgery clinics of North America: rhinoplasty*. Philadelphia (PA): W.B. Saunders; 1995. p. 61.

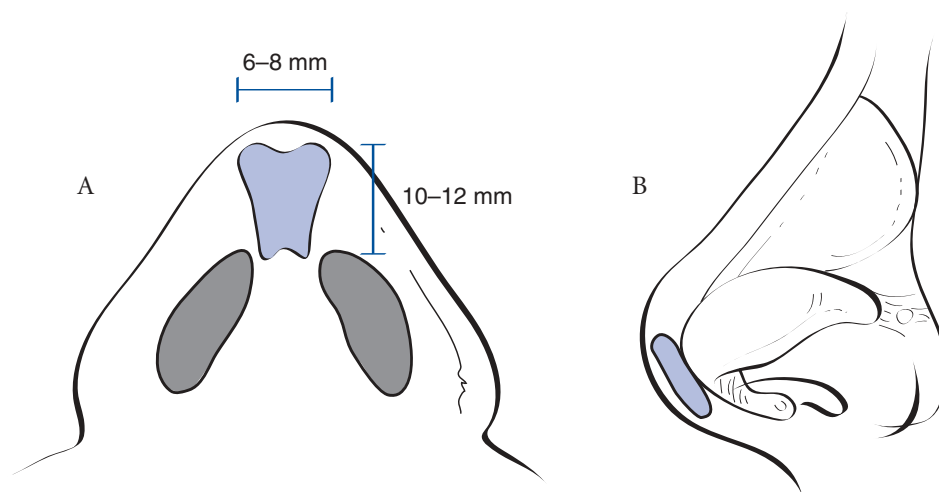


FIGURE 65-35 Shield graft. A, B, This is a grafting technique used to redefine the tip-defining points of the nose. The graft is typically 6 to 8 mm wide superiorly, 5 mm wide inferiorly, and 10 to 12 mm long. Adapted from Taylor CO. *Surgery of the nasal tip*. In: Waite PD, editor. *Atlas of the oral and maxillofacial surgery clinics of North America: rhinoplasty*. Philadelphia (PA): W.B. Saunders; 1995. p. 62.

1. Trim the caudal septum near the anterior nasal spine
2. Augment the nasal dorsum: this creates the illusion of decreased tip rotation.

Tip Shape In addition to changing the tip position, the tip shape must also be considered. Historically changes to the nasal tip were performed by selective cartilage excision and reapproximation. The Goldman tip is an example of such a technique. The current trend is to preserve and re-orient existing cartilage and place cartilaginous grafts if required.⁴⁵ Excessive grafting can be unpredictable in the long run.

Although cartilage preservation is emphasized there is still sometimes a need to remove cartilage. There are three principal techniques of cartilage excision in the nasal tip region: a complete strip technique, a weakened complete strip technique, and an interrupted strip technique. A greater

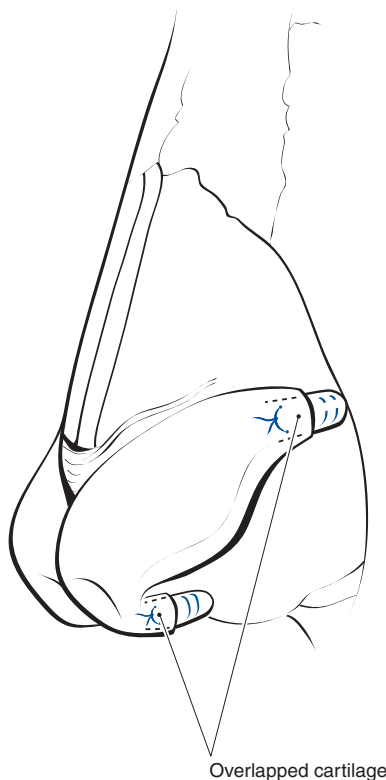

FIGURE 65-36 Crural excision. This is used when the nasal tip needs dramatic deprojection. A portion of the lateral crura is excised and the ends are sutured back together.

resection generally results in more dramatic tip narrowing and rotation.

Complete strip techniques involve the removal of a complete piece of cartilage from the cephalic end of the lower lateral cartilages (see Figures 65-37 and 65-38). This procedure is thought to be more stable since it leaves an intact strip of the inferior border of the lower lateral cartilage. Aggressive resection can result in loss of tip support, alar notching, alar retraction, and the appearance of increased columellar show. Most surgeons feel that a minimum width of 6 mm is required to maintain the structural integrity of the lower lateral cartilage.

The weakened complete strip technique involves the removal of a complete cephalic strip followed by weakening of the cartilage by selective morselization of the medial and lateral crura with a scalpel blade.

An interrupted strip involves division of the lateral crura from the dome (Figure 65-39). This technique provides greater rotation than a complete strip but can also result in complications, including loss of tip support, alar notching, and alar retraction. In addition the nasal tip can develop a pinched appearance. The classic Goldman tip is an example of an interrupted strip

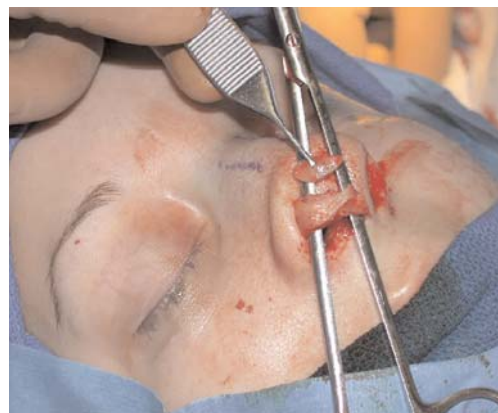

FIGURE 65-37 Delivery of lower lateral cartilage. The lower lateral cartilage is best delivered by a marginal incision or exposed through an open rhinoplasty for direct visualization and surgical manipulation. Tip refinement is improved in this case by complete tip reduction to reduce the volume of the tip.

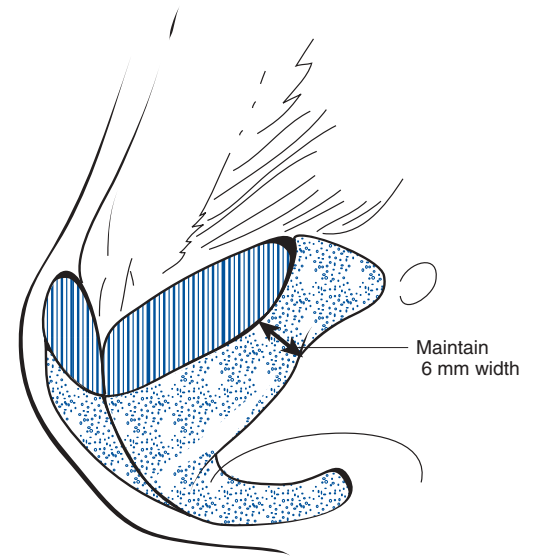


FIGURE 65-38 Complete strip technique. This involves the excision of a strip of cartilage on the cephalic portion of the lower lateral cartilage. This will result in increased tip rotation. It is important to maintain a minimum of 6 mm width of cartilage for structural support of the nose. Adapted from Taylor CO. *Surgery of the nasal tip*. In: Waite PD, editor. *Atlas of the oral and maxillofacial surgery clinics of North America: rhinoplasty*. Philadelphia (PA): W.B. Saunders; 1995. p. 58.

technique (Figure 65-40). In this technique the lateral crura are divided lateral to the tip-defining points. The medial segments are sutured together, which results initially in increased tip projection. The lateral crural segments are left alone as independent units. This procedure is no longer commonly used because of problems with tip asymmetry, pinched appearance of the nasal tip, and long-term tip ptosis.

For patients with a broad nasal tip, transdomal suturing techniques are often used to narrow the tip. Volume reduction is performed first if needed by cartilage excision as described above. Next, excision of excessive interdomal soft tissue is performed. A 4-0 polydioxanone transdomal suture is placed in a horizontal mattress fashion to narrow and re-orient the alar cartilages. The advantage of this technique is that the suturing can be done multiple times until the surgeon is satisfied with the result. Additionally the long-term results of this technique have been favorable.⁴⁶⁻⁴⁸

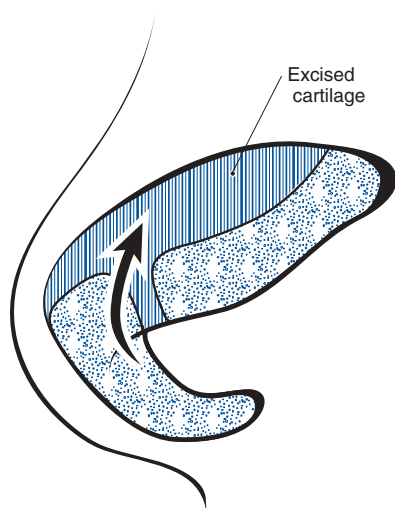


FIGURE 65-39 *Interrupted strip technique.* This is similar to the complete strip except the remaining cartilage is also divided in a vertical fashion. This allows for even greater tip rotation, as indicated by the arrow; however, it can result in a pinched nasal tip and functional problems. The cartilage can be weakened by scoring it in a vertical fashion and this is termed a weakened complete strip technique. Adapted from Taylor CO. *Surgery of the nasal tip.* In: Waite PD, editor. *Atlas of the oral and maxillofacial surgery clinics of North America: rhinoplasty.* Philadelphia (PA): W.B. Saunders; 1995. p. 59.

Nasal Base Alar Reduction

The alar base should approximate the intercanthal distance and be no more than 1 to 2 mm wider than this. The nostrils should have a symmetric appearance. Asymmetry of the nostril is often due to a deviated nasal septum and this should be reevaluated prior to consideration of an alar base resection.

The primary procedure to reduce the alar base width is an alar base resection. Alar modification is often considered in cases where the nose has to be deprojected or to balance the anatomy in certain ethnic types. It is mandatory to be conservative when performing alar reduction since it is difficult to correct an over-reduction. If there is any doubt, the surgeon should delay the alar base reduction until a later date.⁴⁹

The procedure is performed by excising a small wedge of vestibular mucosa

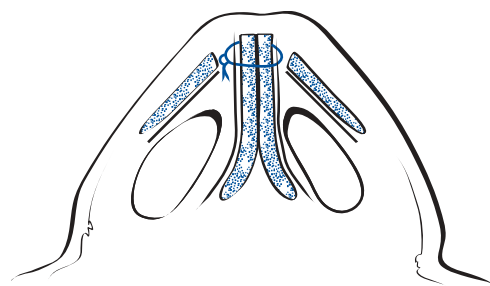


FIGURE 65-40 *Goldman tip.* This is an interrupted strip technique in which the lateral crura are divided lateral to the tip-defining points. The medial segments are then sutured together to increase nasal tip projection and to narrow the nasal tip. Adapted from Willis AE, Costa LE. *Surgical management of the nasal base.* In: Waite PD, editor. *Atlas of the oral and maxillofacial surgery clinics of North America: rhinoplasty.* Philadelphia (PA): W.B. Saunders; 1995. p. 61.

and skin. The angulation can be adjusted so that greater reduction of the outer perimeter of the ala is reduced and only limited reduction of the internal perimeter is performed.⁴⁹ The excision should be conservative and will rarely be greater than 3 mm in width (Figure 65-41).

Postoperative Management

After performing the rhinoplasty the surgeon must decide whether intranasal stents or packing is necessary. We generally do not place nasal packing. If the septum requires additional support during healing, then silicone stents are placed. These stents are also used if there are mucosal tears or if a turbinectomy was performed. The stents help reduce the incidence of synechiae formation. The stents are secured to each other by a 3-0 silk suture passed through the columella and are typically left in place for 1 week.

Next the nasal dorsum is splinted. Benzoin or mastisol is painted on the nasal dorsum and $\frac{1}{4}$ inch brown paper tape is applied. After placement of the tape the splint is applied. A metal Denver splint or thermoplastic splint is contoured and applied. Additional paper tape can be placed over the splint.

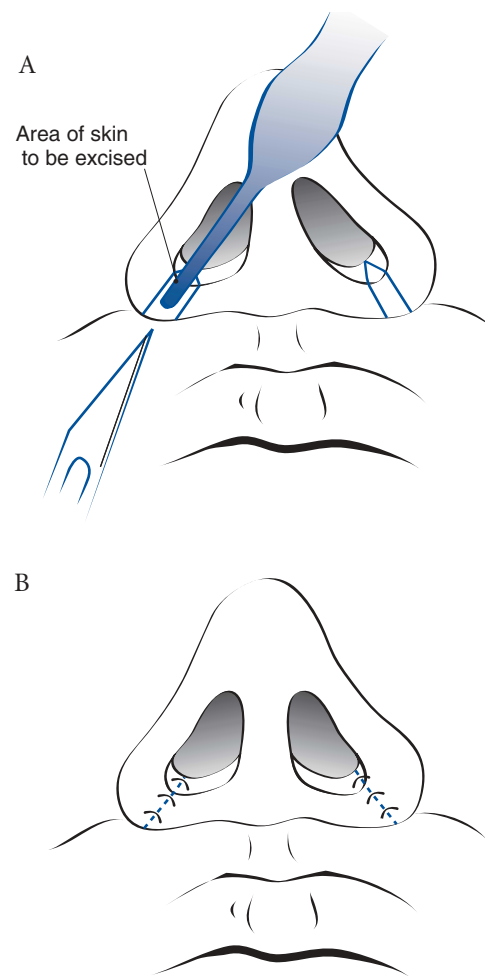


FIGURE 65-41 *Alar base reduction (Weir's excision).* A, This is used to narrow an overly wide nostril. B, A small amount of vestibular mucosa and skin is excised and sutured together. The excision is usually 1 to 2 mm wide

References

1. Rohrich RJ, Huyn B, Muzaffar AR, et al. Importance of the depressor septi nasi muscle in rhinoplasty: anatomic study and clinical application. *Plast Reconstr Surg* 2000;105:376-83; discussion 384-8.
2. Hollinshead W. *Anatomy for surgeons: the head and neck.* 3rd ed. Philadelphia (PA): Lippincott-Raven; 1982.
3. Rohrich RJ, Muzaffar AR, Gunter JP. Nasal tip blood supply: confirming the safety of the transcolumellar incision in rhinoplasty. *Plast Reconstr Surg* 2000;106:1640-1.
4. Toriumi DM, Mueller R, Grosch T, et al. Vascular anatomy of the nose and the external rhinoplasty approach. *Arch Otolaryngol Head Neck Surg* 1996;122:24-34.
5. Lam SM, Williams LE. Anatomic considerations in aesthetic rhinoplasty. *Facial Plast Surg* 2002;18:209-14.

6. Dion MC, Jafek BW, Tobin CE. The anatomy of the nose. External support. *Arch Otolaryngol* 1978;104:145–50.
7. Janfaza P, Nadol JB, Galla R, et al. *Surgical anatomy of the head and neck*. 1st ed. Philadelphia (PA): Lippincott Williams & Wilkins; 2001. p. 908.
8. Toriumi DM, Josen J, Weinberger M, et al. Use of alar batten grafts for correction of nasal valve collapse. *Arch Otolaryngol Head Neck Surg* 1997;123:802–8.
9. Sheen JH. Spreader graft: a method of reconstructing the roof of the middle nasal vault following rhinoplasty. *Plast Reconstr Surg* 1984;73:230–9.
10. Gunter JP, Rohrich DR, William P. Dallas rhinoplasty. 1st ed. Vol 1. St. Louis (MO): Quality Medical Publishing, Inc.; 2002. p. 654–656.
11. Correa AJ, Sykes JM, Ries WR. Considerations before rhinoplasty. *Otolaryngol Clin North Am* 1999;32:7–14.
12. Meyer L, Jacobsson S. The predictive validity of psychosocial factors for patients' acceptance of rhinoplasty. *Ann Plast Surg* 1986;17:513–20.
13. Tardy ME Jr, Dayan S, Hecht D. Preoperative rhinoplasty: evaluation and analysis. *Otolaryngol Clin North Am* 2002;35:1–27,v.
14. Rohrich RJ. The who, what, when, and why of cosmetic surgery: do our patients need a preoperative psychiatric evaluation? *Plast Reconstr Surg* 2000;106:1605–7.
15. Petroff MA, McCollough EG, Hom D, et al. Nasal tip projection. Quantitative changes following rhinoplasty. *Arch Otolaryngol Head Neck Surg* 1991;117:783–8.
16. Crumley RL, Lanser M. Quantitative analysis of nasal tip projection. *Laryngoscope* 1988;98:202–8.
17. Gunter JP, Rohrich DR, William P. Dallas rhinoplasty. 1st ed. Vol 1. St. Louis (MO): Quality Medical Publishing, Inc.; 2002. p. 65.
18. Gunter JP, Rohrich RJ. Management of the deviated nose. The importance of septal reconstruction. *Clin Plast Surg* 1988; 15:43–55.
19. Courtiss EH, Goldwyn RM, O'Brien JJ. Resection of obstructing inferior nasal turbinates. *Plast Reconstr Surg* 1978;62:249–57.
20. Pollock RA, Rohrich RJ. Inferior turbinate surgery: an adjunct to successful treatment of nasal obstruction in 408 patients. *Plast Reconstr Surg* 1984;74:227–36.
21. Jackson LE, Koch RJ. Controversies in the management of inferior turbinate hypertrophy: a comprehensive review. *Plast Reconstr Surg* 1999;103:300–12.
22. Mabry RL. Intranasal steroids in rhinology: the changing role of intratubinal injection. *Ear Nose Throat J* 1994;73:242–6.
23. Rohrich RJ, Kreuger JK, Adams WP Jr, et al. Rationale for submucous resection of hypertrophied inferior turbinates in rhinoplasty: an evolution. *Plast Reconstr Surg* 2001;108:536–44; discussion 545–6.
24. Elwany S, Harrison R. Inferior turbinectomy: comparison of four techniques. *J Laryngol Otol* 1990;104:206–9.
25. Posnick JC, Seagle MB, Armstrong D. Nasal reconstruction with full-thickness cranial bone grafts and rigid internal skeleton fixation through a coronal incision. *Plast Reconstr Surg* 1990;86:894–902; discussion 903–4.
26. Jackson IT, Choi HY, Clay R, et al. Long-term follow-up of cranial bone graft in dorsal nasal augmentation. *Plast Reconstr Surg* 1998;102:1869–73.
27. Celik M, Tuncer S. Nasal reconstruction using both cranial bone and ear cartilage. *Plast Reconstr Surg* 2000;105:1624–7.
28. Gunter JP, Clark CP, Friedman RM. Internal stabilization of autogenous rib cartilage grafts in rhinoplasty: a barrier to cartilage warping. *Plast Reconstr Surg* 1997;100:161–9.
29. Sancho BV, Molina AR. Use of septal cartilage homografts in rhinoplasty. *Aesthetic Plast Surg* 2000;24:357–63.
30. Sheen JH. Achieving more nasal tip projection by the use of a small autogenous vomer or septal cartilage graft. A preliminary report. *Plast Reconstr Surg* 1975;56:35–40.
31. Toriumi DM. Autogenous grafts are worth the extra time. *Arch Otolaryngol Head Neck Surg* 2000;126:562–4.
32. Parker Porter J. Grafts in rhinoplasty: alloplastic vs. autogenous. *Arch Otolaryngol Head Neck Surg* 2000;126:558–61.
33. Adamson PA. Grafts in rhinoplasty: autogenous grafts are superior to alloplastic. *Arch Otolaryngol Head Neck Surg* 2000; 126:561–2.
34. Romo T 3rd, Sclafani AP, Jacono AA. Nasal reconstruction using porous polyethylene implants. *Facial Plast Surg* 2000;16:55–61.
35. Adams WP Jr, Rohrich RJ, Hollier LH, et al. Anatomic basis and clinical implications for nasal tip support in open versus closed rhinoplasty. *Plast Reconstr Surg* 1999;103: 255–61; discussion 262–4.
36. Tardy ME Jr, Cheng EY, Jernstrom V. Misadventures in nasal tip surgery. Analysis and repair. *Otolaryngol Clin North Am* 1987;20:797–823.
37. Thomas JR, Tardy ME Jr. Complications of rhinoplasty. *Ear Nose Throat J* 1986;65:19–34.
38. McCollough EG, Mangat D. Systematic approach to correction of the nasal tip in rhinoplasty. *Arch Otolaryngol* 1981;107:12–6.
39. Anderson JR. New approach to rhinoplasty. A five-year reappraisal. *Arch Otolaryngol* 1971;93:284–91.
40. Tebbetts JB. Shaping and positioning the nasal tip without structural disruption: a new, systematic approach. *Plast Reconstr Surg* 1994;94:61–77.
41. Foda HM, Kridel RW. Lateral crural steal and lateral crural overlay: an objective evaluation. *Arch Otolaryngol Head Neck Surg* 1999;125:1365–70.
42. Kridel RW, Konior RJ, Shumrick KA, et al. Advances in nasal tip surgery. The lateral crural steal. *Arch Otolaryngol Head Neck Surg* 1989;115:1206–12.
43. Mavili ME, Safak T. Use of umbrella graft for nasal tip projection. *Aesthetic Plast Surg* 1993;17:163–6.
44. Tardy ME Jr, Walter MA, Patt BS. The overprojecting nose: anatomic component analysis and repair. *Facial Plast Surg* 1993;9:306–16.
45. Tebbetts JB. Rethinking the logic and techniques of primary tip rhinoplasty: a perspective of the evolution of surgery of the nasal tip. *Otolaryngol Clin North Am* 1999;32:741–54.
46. Tardy ME Jr, Patt BS, Walter MA. Transdomal suture refinement of the nasal tip: long-term outcomes. *Facial Plast Surg* 1993; 9:275–84.
47. Daniel RK. Rhinoplasty: a simplified, three-stitch, open tip suture technique. Part I: primary rhinoplasty. *Plast Reconstr Surg* 1999;103:1491–502.
48. Daniel RK. Rhinoplasty: a simplified, three-stitch, open tip suture technique. Part II: secondary rhinoplasty. *Plast Reconstr Surg* 1999;103:1503–12.
49. Tardy ME Jr, Patt BS, Walter MA. Alar reduction and sculpture: anatomic concepts. *Facial Plast Surg* 1993;9:295–305.

Rhytidectomy

G. E. Ghali, DDS, MD

T. William Evans, DDS, MD

Face-lifting has received significant attention over the past several decades owing to increasing patient demands for a more youthful appearance. The face undergoes harmonious changes in the facial skeleton, deep soft tissue elements, and skin texture during the aging process. Dissection of cadavers has identified facial ligaments, muscle expansions, and dissection planes that give us a better understanding of facial aging and rejuvenation. Perhaps more importantly, it has also been the catalyst for the evolution of a variety of face-lifting techniques. The goal of facial rejuvenation should be to address all components of aging, leaving the patient with a younger-appearing face and a long-lasting result. If this is accomplished, the patient's face and neck will continue to age harmoniously.¹

Critical evaluation of early techniques and a clear understanding of surgical anatomy have provided insight into the perils and pitfalls of surgical rejuvenation of the face and have resulted in the complexity of various rhytidectomy techniques. Today rhytidectomy is one of the most frequently performed esthetic surgical procedures in the United States.

There are numerous techniques currently used for performing face-lifts but no general agreement as to which of these techniques is most effective²; facial esthetic surgeons have discussed the advantages and disadvantages of superficial and deep

face-lifts for many years. A clear consensus is difficult because patient variables such as past medical history, anatomy, genetic background, social history (eg, smoking, alcohol), motivation to have esthetic surgery, and environment make it virtually impossible to perform a blinded long-term prospective clinical study. Evaluation of facial esthetic surgery is also difficult because most procedures yield satisfactory results initially, often producing enough improvement to be accepted as a good result.

History

Although doubt still exists as to who performed the first face-lift, most authorities date the procedure to the early part of the twentieth century.³⁻¹³ Historically, rhytidectomy procedures may be divided into three main categories: skin excision, subcutaneous undermining, and superficial musculoaponeurotic system (SMAS) manipulation. Early rhytidectomy procedures were limited to skin excision and wound closure without any appreciable subcutaneous undermining.^{3,4,8-10,14} Beginning in the late 1920s, the conventional face-lift operation, consisting of skin dissection with subcutaneous undermining, was established.¹³

The subcutaneous rhytidectomy was the preferred technique for many years. A small amount of subcutaneous tissue is elevated with the skin and is simply redraped, leaving the patient with less

redundancy. However, this technique does not address underlying skeletal deformities, ptotic deep soft tissue structures, or changes in skin texture. Therefore, it usually results in a more unnatural look and increases the likelihood of complications, particularly skin slough.

In an attempt to improve the results obtained with the subcutaneous face-lift, several clinicians described techniques to correct platysmal banding and submental lipomatosis.¹⁵⁻¹⁸ The third historic category came with the advent of SMAS manipulation. Multiple surgeons have described various techniques involving the SMAS and platysma to enhance cervicofacial rhytidectomy.^{1,19-35} In 1974 Skoog described a procedure based on surgical anatomy.¹⁹ At that time the subdermal plane was accepted by most to be the anatomic limit for face-lifting and rejuvenation. Skoog's technique redraped the skin and platysma together, leaving the patient with a more youthful jaw line.

Subsequently Mitz and Peyronie's description of the SMAS provided an anatomic basis for restoration of the face.²¹ Hamra (initially with the deep-plane and later with the composite rhytidectomy) and, later, Owsley (with the multiplanar/multivector approach) modified and improved Skoog's technique by performing a more complete release of the nasolabial fold.^{35,36} Ramirez showed that after subperiosteal release, the soft tissues of the

cheek, forehead, jowls, lateral canthus, and eyebrows can be restored to their youthful relationship with the underlying skeleton.³⁷ Finally, Watson and colleagues described a technique similar to that of Owsley but combined it with laser resurfacing.³⁸ This technique involved a larger plane of subdermal or subcutaneous undermining than that described by Hamra.

Four generations of rhytidectomy techniques are recognized (Table 66-1).³⁹ Current literature has popularized more complex procedures including the deep-plane and composite rhytidectomies.^{1,34,35} These methods have incorporated multiplanar dissections and craniofacial techniques in an attempt to gain better control of the midface soft tissues. Whether these techniques provide longer-lasting results remains to be shown.^{1,34,35,39-42} Multiple authors have cautioned that the more complex deep-plane and composite rhytidectomies typically carry increased morbidity.^{1,40,41,43-49}

Patient Evaluation

When a rhytidectomy is being contemplated, the treatment requirements of the surgeon must be balanced with the desires of the patient (Table 66-2).⁵⁰ These requirements are critical for proper patient selection. The patient evaluation must include general medical and psychological considerations in addition to physical facial features. Neglect of any aspect of the patient evaluation can lead to future problems.⁵¹

Table 66-1 Generations of Rhytidectomy

I	Subcutaneous dissection only with variable skin undermining
II	Subcutaneous dissection + SMAS plication or imbrication
III	Subcutaneous dissection + SMAS plication or imbrication + deep midface section dissection
IV	Composite dissection

SMAS = superficial musculoaponeurotic system.

Table 66-2 Rhytidectomy Requirements

Patient	Surgeon
Minimal morbidity risk	Safe and predictably consistent outcomes
Long-lasting results	Reasonable operative time
Quick recovery	Reasonable cost to patients
Affordable	Reasonable postoperative recovery period
Performed on outpatient basis; will be ambulatory	Adaptable for revision procedures
	Teachable to residents and fellows

A thorough medical evaluation must be completed prior to surgery. Medical illnesses such as diabetes, hypertension, hypothyroidism, and asthma must be appropriately treated and controlled preoperatively. Medical evaluation is essential for detecting conditions that may adversely affect a patient's ability to tolerate an anesthetic or that may compromise the final surgical result. Appropriate consultations regarding cardiovascular disease, pulmonary disease, coagulopathies, and other active medical problems should be obtained preoperatively. Current medication profiles should be elicited, including aspirin and aspirin-containing compounds, nonsteroidal anti-inflammatory drugs, and herbal drugs, as well as high doses of vitamin E. Examination of prior surgical incisions, such as those resulting from previous thyroidectomies or parotidectomies, is useful in evaluating the wound-healing capacity.

Tobacco and alcohol use, as well as the use of illicit substances, may increase the incidence of surgical complications. Cigarette smoking, diabetes mellitus, and previous head and neck radiation therapy may also impede healing and should be recognized preoperatively. Patients should be told that cigarette smoking significantly increases the likelihood of skin flap necrosis, poor healing, and unsightly scars.^{52,53} Studies have demonstrated a 12-fold greater risk of skin slough in smokers compared with that in nonsmokers.^{52,53} Animal studies involving skin flap experiments have also supported this conclusion.⁵²⁻⁵⁷

A review of the patient's psychological history should focus on motivation for surgery and outcome expectations. Patients seeking surgery based on recent emotional events or with unrealistic expectations should be further counseled and the procedure postponed or cancelled.^{58,59}

The goal of face-lifting is to correct anatomic changes to the face and neck that have occurred as a result of the normal aging process. Patients considered for rhytidectomy present with various degrees of age-related alterations to the facial soft tissues. Ideally, face-lift candidates are 45 to 55 years of age, are in good health, are of normal weight, possess a good bone structure, and possess a thin neck and a deep cervicomental angle. Physical examination of the patient includes a detailed regional evaluation of the face. A face-lift is capable of correcting specific anatomic regions, and a complete and detailed description of the patient's physical characteristics is important. A systematic evaluation allows the surgeon to assess the areas that can be improved with an isolated rhytidectomy and to determine whether other ancillary procedures will be beneficial. Additionally, a detailed regional evaluation provides an opportunity for the surgeon and the patient to understand the limitations of the rhytidectomy; the surgeon can refer to the evaluation when explaining the expected outcome.

Evaluation of the upper facial one-third includes the forehead and upper and lower eyelids. In general, these areas are not affected by the standard rhytidectomy

and are therefore not addressed in this review. Evaluation of the middle facial one-third includes the face and ears. The quality of the skin should be noted, including thickness, redundancy, previous scarring, fine or coarse rhytids, and the location of the hairline. Patients with significant elastosis or actinic damage do not obtain and retain the same quality of results as do patients possessing good skin quality. Assessment of the ear lobe shape and position is critical, and any deviations from normality should be pointed out to the patient preoperatively. Documentation of the nasolabial folds, including length, depth, and symmetry, as well as an assessment of the degree of jowls should be noted. Presence of perioral rhytids is important because they are not corrected with rhytidectomy procedures.

The evaluation of the lower facial one-third includes the chin, jaw line, and neck. A useful preoperative classification of the neck for cervicofacial rhytidectomy divides the neck profile into six distinct classes (Table 66-3).⁶⁰ Using this classification, the clinician can identify each patient's specific abnormality and choose the most appropriate procedure for optimal results (Figure 66-1). Skin redundancy, platysmal banding, cervicomental angle, and submental fat accumulation are important to note in this region. Additionally, the degree of ptosis of the submandibular glands should be assessed and recorded at this time.

Preoperative photographs provide invaluable medicolegal documentation as well as an opportunity to review patient characteristics before and during surgery. The surgeon should obtain the photographs of the full face in repose and smiling, right and left profiles, and right and left three-quarter views. Close-ups of the forehead, eyebrows, and periorbital and perioral regions should be taken, depending on the particular deformity.

An essential component of the patient evaluation includes the preoperative visit.

Table 66-3 Dedo Classification of Facial Profiles

Classification	Comments
I. Normal	Well-defined cervicomental angle Good muscle tone No submental fat
II. Cervical skin laxity	Obtuse cervicomental angle owing to relaxed skin
III. Submental fat accumulation	Requires submental lipectomy
IV. Platysma muscle banding	Requires muscle clipping, plication, or imbrication
V. Retrognathia/microgenia	Requires genioplasty or orthognathic surgery
VI. Low hyoid	Difficult to alter Important to inform patient of limitation

Adapted from Dedo DD.⁶⁰

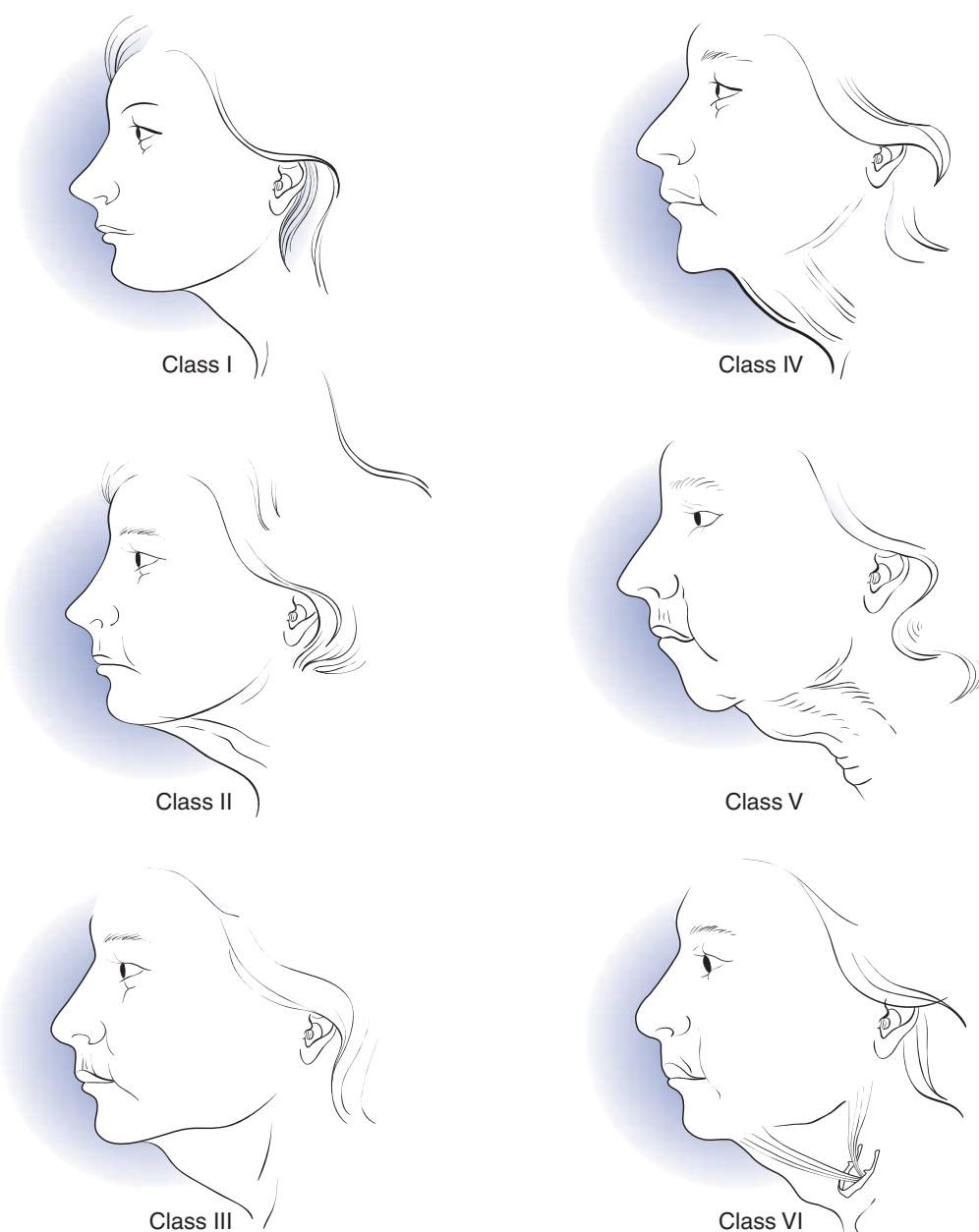


FIGURE 66-1 Six classes of facial profiles by Dedo. Adapted from Dedo DD.⁶⁰

It is an excellent opportunity to educate the patient regarding various aspects of the procedure, postoperative care, and expectations. It is wise to review any and all patient instructions during the preoperative visit including medications, skin cleaning, and makeup. Patients must discontinue all aspirin-containing compounds, nonsteroidal anti-inflammatory medications, and vitamin E at least 2 weeks prior to surgery. Germicidal shampoo and skin cleaners are used several days before the scheduled date of the procedure to reduce bacterial counts. The patient should wash his or her hair and face and remove all makeup the night before surgery. A written copy of postoperative instructions should be given to and reviewed with the patient (Appendix).

A description of the expected convalescence is appropriate during the preoperative visit. In general, 10 to 14 days is a reasonable time period to wait for ecchymosis to resolve sufficiently to allow camouflage with makeup. Patients should not expect to return to work or social activities before this time. They should be educated regarding expectations in the early postoperative period since those unaware of the slow evolution of results will quickly become frustrated. It should be clearly explained that appearance will continue to improve over a period of several months.

Surgical Technique

Superficial-Plane Rhytidectomy

Once appropriate monitors are placed and the patient is adequately sedated, proposed incision lines and anticipated areas of undermining are marked with a skin marker while the patient is seated in an upright position. The face, neck, and hair are prepped with an appropriate antiseptic surgical scrub. Skin preparations should include the full length of the planned incision and all exposed skin within the surgical field.

Our preference is to perform rhytidectomies under local anesthesia with appropriate sedation and analgesia. Suitable agents include intravenous fentanyl, midazolam, ketamine, and/or propofol. Local anesthesia is provided along the incision line with a 2% lidocaine solution with 1:100,000 epinephrine via a dental syringe. Hydrodissection is performed within the planned plane of dissection with a tumescent anesthetic technique (Figure 66-2).⁶¹⁻⁶⁶

Although multiple techniques exist for mixing the tumescent solution, our preference is to mix 20 mL of a 2% lidocaine with 180 mL of normal saline, creating a solution of 0.2% lidocaine with a 1:1,000,000 epinephrine concentration. This mixture is administered through four trocar sites: temporal, infralobular, mastoid, and submental (Figure 66-3). The solution is deposited subcutaneously in the supraSMAS plane.

Hydrodissection should extend 1 cm beyond the proposed undermining mark that delineates the anticipated extent of flap

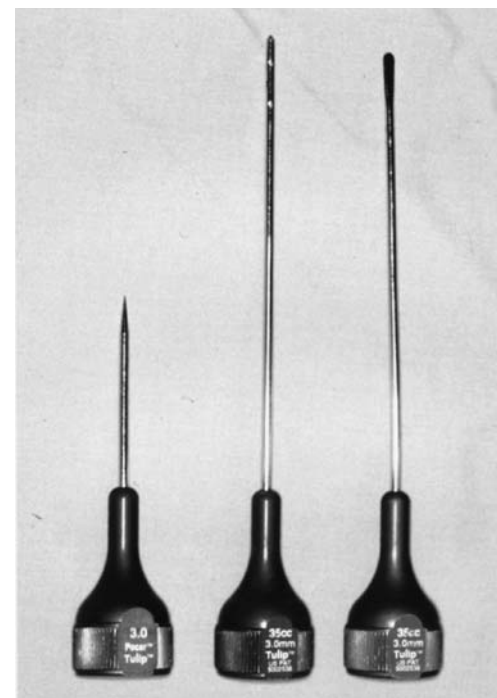
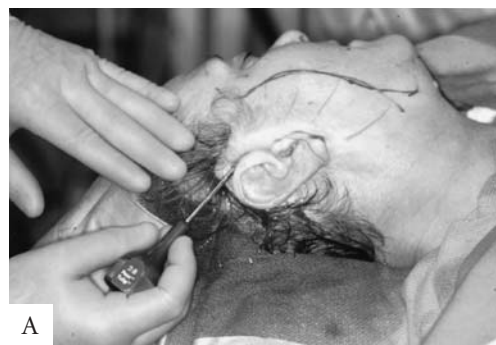
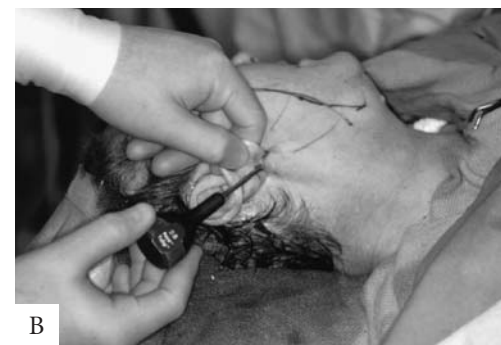
FIGURE 66-2 From left to right: *procar/trocar, infiltrator, and dissector* used for the tumescent technique.

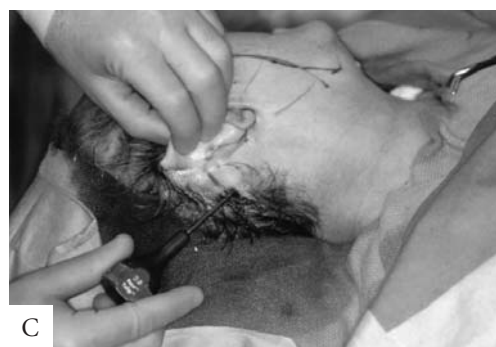development. Approximately 75 mL of the tumescent anesthetic solution is deposited per side, with an additional 50 mL deposited



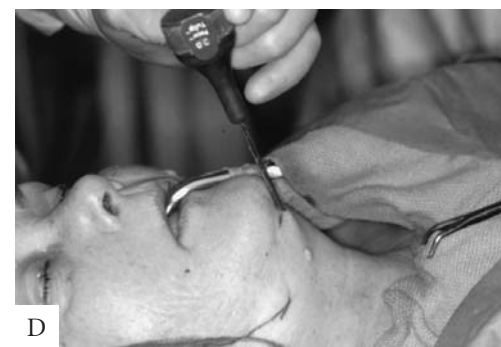A



B



C



D

FIGURE 66-3 Four trocar sites are typically used: A, *temporal*; B, *infralobular*; C, *mastoid*; D, *submental*.

in the submental region. The anesthetic is allowed to work for 8 to 10 minutes before proceeding. Typically, the contralateral side is not infiltrated until just prior to initiating closure on the first side.

Following deposition of the anesthetic solution, blunt cannula dissection of the cervicofacial and submental regions is performed. The cervicofacial dissection is generally performed without suction (Figure 66-4), whereas the submental dissection is performed under suction (Figure 66-5). The submental dissection, using the blunt cannula, is accomplished prior to the initiation of the cervicofacial dissection. As previously mentioned, the planned incisions should be marked with the patient seated in an upright position,

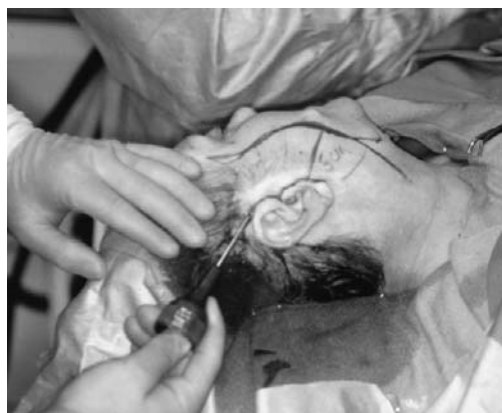

FIGURE 66-4 Cervicofacial dissection in the supra-SMAS (superficial musculoaponeurotic system) plane without suction.

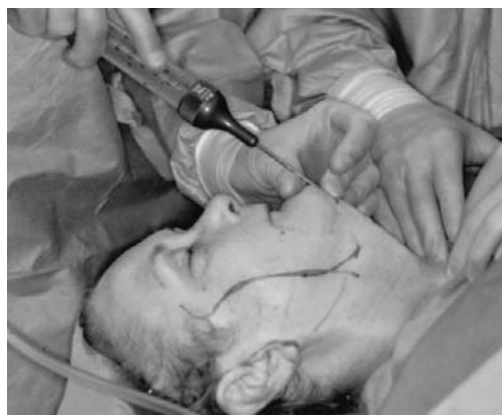

FIGURE 66-5 Submental dissection in the supraplatysmal plane under suction.

and prior to administration of the local anesthetic, to prevent distortion of local anatomy. There are numerous modifications of the standard face-lift incision, but several general principles should be followed closely.⁶⁷⁻⁷⁰

It is not necessary to shave the hair in the incision area. If necessary, the hair may be braided along the proposed incision, with the temporal extension placed no more than 2 cm within the hair and parallel to the hairline. Some surgeons recommend a pretrichial incision to prevent the posterosuperior migration of the temporal line.

The incision should be extended inferiorly toward the root of the helix, anterior to the curve of the crus helicis, following the margin of the tragus, and proceed anteriorly just above the base of the incisura intertragica (Figure 66-6). Preservation of the incisura helps to prevent distortion of the tragus postoperatively, providing a more esthetic scar. The incision curves inferiorly 1 to 2 mm below the junction of the lobule with the cheek, rising superiorly onto the back of the conchal bowl approximately 3 to 5 mm and reaching the level of the postauricular sulcus or superior crus of the antihelix. The incision is then directed posteroinferiorly approximately 4 to 5 cm into the scalp of the retromastoid region (Figure 66-7).

If significant cervical skin redundancy is noted, the incision may parallel the posterior hairline for several centimeters before being directed into the hair-bearing skin. This maneuver can prevent a step deformity in the posterior hairline when significant cervical skin is excised. Care must be taken to maintain approximately a 90° angle at the reflection of the posterior flap to prevent skin slough at the tip of the flap.

Several considerations for incision design are important in the male patient.^{18,71} In the temporal region the planned incision is affected by the patient's hair pattern. Individuals with thick temporal hair can tolerate a standard incision. Those with thinning hair,

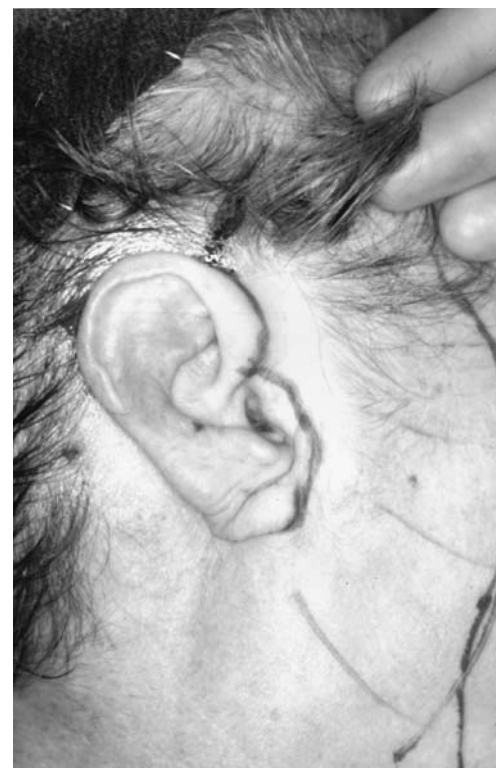

FIGURE 66-6 Temporal, preauricular, and infralobular components of the typical rhytidectomy incision.

temporal recession, or significant male pattern baldness require a modification of the incision design.

In the preauricular region, the male sideburn must be taken into consideration and the non-hair-bearing skin anterior to the ear must be left intact to prevent an unnatural appearance. Therefore, the incision should extend in a linear fashion, following a natural skin crease adjacent and parallel to the sideburn. This is in contrast to the curved incision used in female patients.

Last, the posterior extension of the incision is placed along the margin of the postauricular hairline. Although this placement has the potential to be slightly more noticeable, the importance of preventing posterior displacement or a step deformity to the hairline must be taken into account. A final consideration in the male patient is the inevitable transfer of hair-bearing skin into the postauricular region or into the ear canal itself.

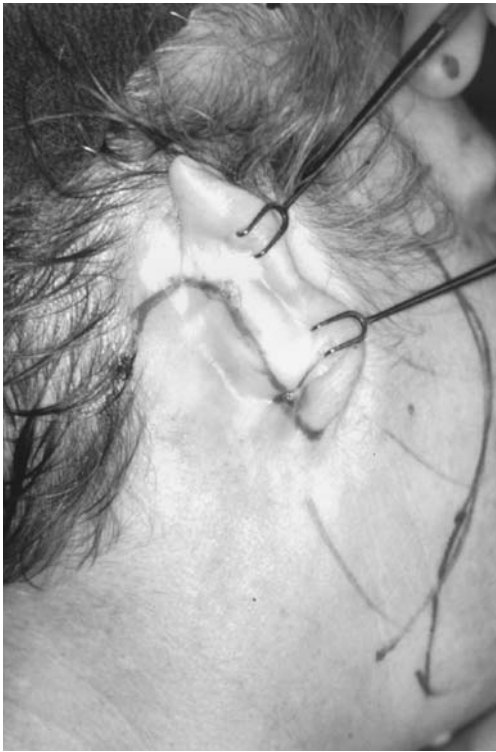

FIGURE 66-7 Postauricular and mastoid components of the typical rhytidectomy incision.

Management of the cervical region, if indicated, is begun with the placement of a transverse incision in a submental skin crease as an extension of the submental trocar puncture (Figure 66-8). This incision should not be placed in the dominant crease of the “double-chinned” deformity, as scarring may result during the healing process and accentuate the crease. The incision should be approximately 2 cm in

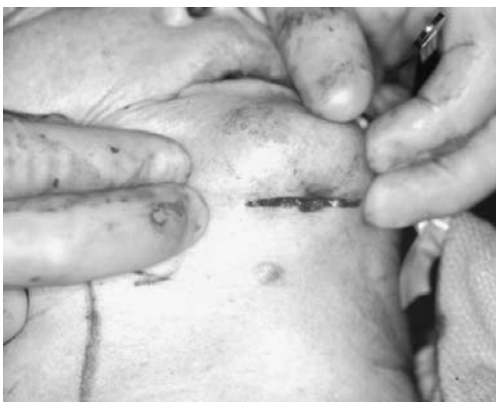

FIGURE 66-8 Submental incision placed to address platysmal banding.

length and placed just inferior to the dominant crease.

Dissection in the submental region proceeds in a subcutaneous plane and joins the lateral subcutaneous neck planes subsequent to the submental dissection. Excess subcutaneous fat may be excised with sharp scissors or a cannula, if indicated. Lipectomy in the submental region should be done cautiously. Overly enthusiastic removal of fat in this region can lead to an atrophic appearance of the cervical facial tissues or a “cobra” neck deformity.¹⁷

Next, the anterior borders of the platysma bands are identified, and excess subcutaneous tissue is removed. The medial borders should be released along their deep surface from the submental region inferiorly to the level of the thyroid

cartilage. The medial borders are then repositioned in the midline, and any overlapping tissue is excised. Plication of the medial platysma borders proceeds from the submental region to the level of the thyroid cartilage with a 2-0 slow-resorbing suture (Figure 66-9).

A horizontal myotomy of the inferior aspect of the platysma may be beneficial in accentuating the cervicomental angle and relieving tension along the anterior surface of the neck. Partial horizontal transection is frequently all that is required and can be performed with sharp scissors at the inferior-most aspect of the dissection of the medial borders. If complete transection is indicated, the lateral aspect of the platysma can be excised through the lateral neck face-lift flap.^{25,28,72,73}

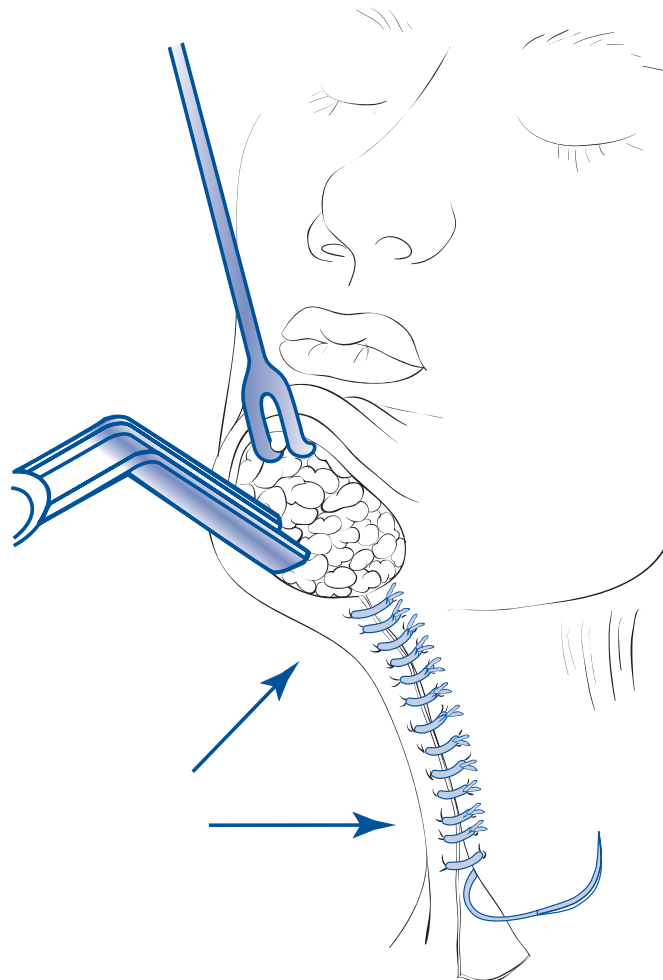


FIGURE 66-9 Platysmal plication accomplished.

Flap Development Flap development is initiated by undermining 1 cm along the entire length of the face-lift incision. This is accomplished in a subdermal plane with a blade or sharp scissors, using skin hooks for retraction (Figure 66-10). On the underside of the flap, maintain approximately 3 to 4 mm of subcutaneous fat to preserve the subdermal vasculature.

In the temporal region, the depth of the flap should be carried through the temporoparietal fascia (subgaleal) down to the loose areolar tissue overlying the deep temporal fascia. Dissection in this plane creates a thicker flap, providing increased protection from any ischemic injury that would damage hair follicles and create subsequent alopecia. The temporal dissection is extended in this plane using a combination of blunt and sharp dissection.

Blunt-tipped scissors should be used in a push-cutting motion into the residual tunnels that were developed secondary to the previous blunt cannula dissection (Figure 66-11). Rees T-clamps are used for countertraction and aid in the dissection. Undermining in this plane can be safely carried superiorly to the level of the lateral canthus.

At this point the dissection is carried inferiorly and medially across the cheek in the subcutaneous plane. This zone of transition from the sub-SMAS (deep to the temporoparietal fascia) to the subcutaneous plane of dissection corresponds to

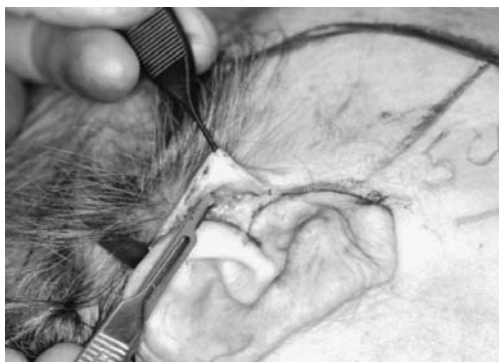

FIGURE 66-10 Flap development initiated by 1 cm undermining via a blade or sharp dissection scissors.

the mesotemporalis that contains the superficial temporal artery and the frontal branch of the facial nerve.⁷⁴⁻⁷⁶ The facial nerve is located anterior and inferior to the frontal branch of the superficial temporal artery, so preservation of this vessel during dissection helps to protect this important nerve.

The extent of undermining necessary depends on the patient. Younger patients without excessive laxity of the skin require only 4 to 5 cm of undermining, but older patients with redundant tissue and severe jowling may require undermining to within 1 cm of the oral commissure. When platysma banding is present, the cervical dissection is carried inferiorly to the level of the thyroid cartilage and should communicate with the dissection from the contralateral side.

In the postauricular region, the flap should be developed in the subcutaneous plane below the ear lobe to protect the great auricular nerve. This nerve is the one most commonly injured during rhytidectomy procedures (Figure 66-12).⁷⁷⁻⁷⁹ The great auricular nerve runs just deep to the superficial fascia overlying the sternocleidomastoid muscle and supplies sensation below and behind the ear. With the head turned 45° toward the contralateral side, the great auricular nerve consistently crosses the middle of the sternocleidomastoid muscle at a level 6.5 cm below the caudal edge of the bony external auditory canal (Erb's point).⁷⁹ Maintaining subcutaneous dissection below the ear lobe helps protect the great auricular nerve, but above the level of the ear lobe, the greater auricular is not at risk and dissection may be carried deeper.⁸⁰ Meticulous hemostasis is then accomplished with bipolar cautery. Overzealous use of electrocautery should be avoided on the skin-flap side to reduce the risk of ischemic injury and flap necrosis.

Next, the underlying SMAS in the cheek region is manipulated. Many of the age-related changes in the facial region are due to ptosis of the underlying fat. Correc-

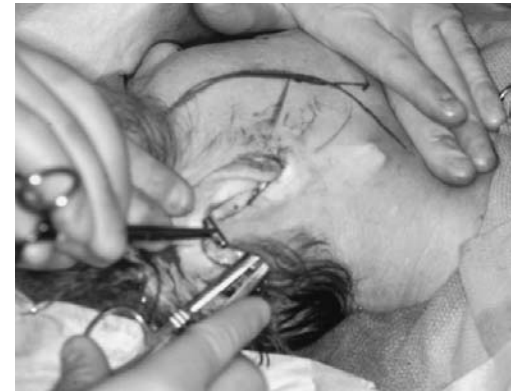

FIGURE 66-11 Scissors are used in a push-cutting motion with the tips up.

tion of these changes is best obtained by repositioning this tissue along direction lines (vectors) different from those used for the skin flap. Independent bidirectional suspension of the SMAS and the skin flap reposition the ptotic facial tissues, providing longer-lasting results and reducing an unnatural appearance.

SMAS manipulation can be by plication, imbrication, or a combination of these techniques; there are proponents of each method. *Plication* is a technique whereby the SMAS is folded upon itself to obtain the desired repositioning, and *imbrication* is a technique in which the SMAS is incised or excised so that the distal portion is repositioned to overlap the proximal tissue (Figure 66-13).

SMAS plication is accomplished with a 2-0 slow-resorbing suture on a tapered

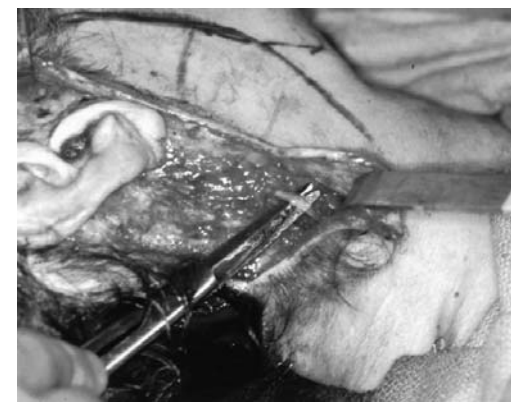

FIGURE 66-12 Great auricular nerve demonstrated.

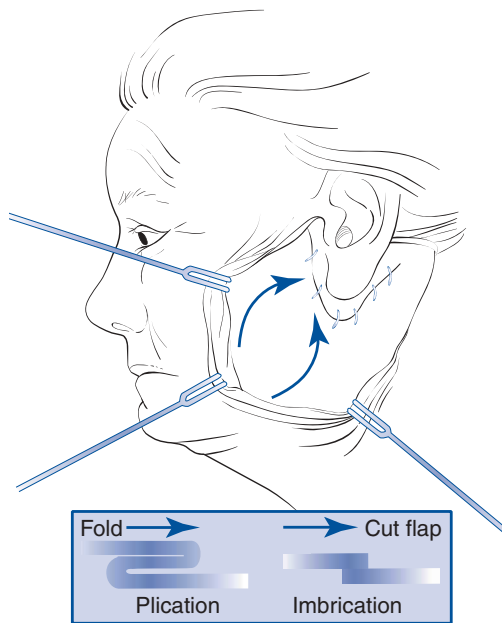


FIGURE 66-13 Illustration of plication versus imbrication.

needle (Figure 66-14). All knots are buried to prevent irritation to the skin flap or palpability. Two key sutures are placed initially, with the first extending from the fascia overlying the angle of the mandible to the fascia immediately inferior to the tragus. The second suture is placed from the fascia lateral to the oral commissure to the fascia immediately superior to the tragus. Several additional sutures may be placed, if needed, in the preauricular and postauricular areas. This suture placement provides a posterosuperior repositioning of the ptotic tissues.

Imbrication requires elevation of a sub-SMAS flap. An incision is made horizontal-

ly just inferior to the zygomatic arch and vertically posterior to the angle of the mandible. Landmarks for the incision include the zygomatic arch, tragus, platysma muscle, and the mandible (Figure 66-15). The horizontal incision is made approximately 1 cm below and parallel to the zygomatic arch to prevent damage to the frontal branch of the facial nerve. The middle portion of the tragus may be used as a reference for staying below the zygomatic arch.

The incision is carried forward 2 to 3 cm. The vertical incision descends inferiorly along the posterior border of the platysma several centimeters below the angle of the mandible. It is important to keep the incision posterior to the angle of the mandible to prevent damage to the marginal mandibular branch of the facial nerve. The SMAS is then elevated for 2 to 3 cm in a sub-SMAS plane (Figure 66-16). The flap is redraped posterosuperiorly and sutured using the technique previously described for plication.

Redraping of the skin flap is performed with the patient's head in a neutral position. Extension or flexion of the neck influences the amount of skin excised and may adversely affect the outcome. Key suspension staples or sutures are placed prior to trimming the skin flap. In general, the skin flap is redraped in a posterosuperior direction with an emphasis on the posterior direction. The majority of the needed superior suspension is accomplished by SMAS

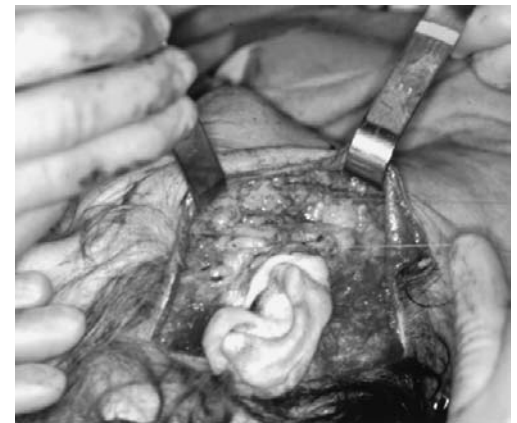

FIGURE 66-16 Following superficial musculo-aponeurotic system flap elevation, 2-0 resorbable suture on a tapered needle is used for buried knots to secure the imbrication.

manipulation. Care should be taken to prevent a misdirection of facial rhytids and a distortion of the temporal hairline. Careful assessment of appearance should be made prior to suturing the flap in place.⁸¹

The first key skin-suspension suture (or staple) is placed in the temporal region just above the ear. The flap is then grasped, and the appropriate vector is determined and held in place while the flap is trimmed and the staple placed. The second staple is placed in the postauricular region at the most posterior and superior aspect of the flap. Careful attention should be given to proper inset of the ear. In a nonoperated ear, the long axis of the ear lobe hangs 10 to 15° posterior to the long axis of the ear proper. This relationship must be maintained to prevent obvious deformities of the ear.

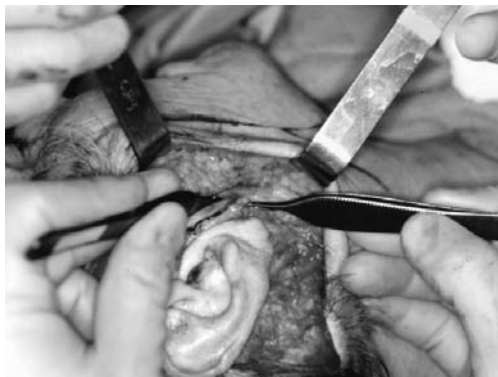

FIGURE 66-14 The area of plication is assessed.

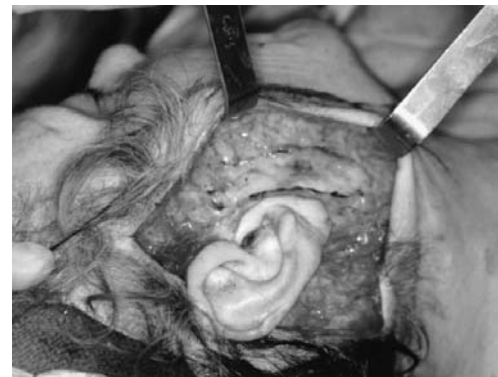

FIGURE 66-15 The area of proposed resection in preparation for imbrication is marked.

Skin Closure Trimming of excess skin is performed with a blade or Iris scissors (Figure 66-17). It is important to be aware of the amount of skin to be excised in the temporal region to prevent distortion of the hairline. The distance from the lateral canthus to the anterior margin of the temporal hairline should be recorded preoperatively to serve as a reference for skin excision. Skin closure in the hair-bearing scalp (ie, temporal and mastoid regions) is performed with subdermal 3-0 resorbable sutures. Staples may be

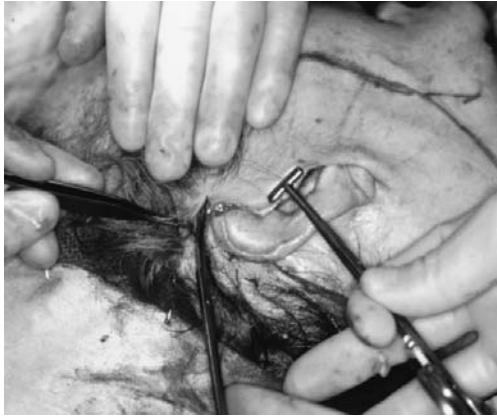


FIGURE 66-17 Following the placement of key staples, flap trimming is accomplished with a blade or Iris scissors.

used to approximate skin margins of the temporal and mastoid scalp. Our preference is to provide a layered closure to minimize tension on the most superficial aspect of the skin.⁸¹ The immediate postauricular region is closed with a 4-0 plain gut suture, without the need for deep sutures. In the preauricular region, a 4-0 resorbable suture is placed followed by approximation of the skin edges with a 6-0 or 7-0 nylon running suture. The deep layers of the submental incision are closed with 4-0 resorbable suture, and 6-0 nylon is used for the skin edges.

The decision of whether to place drains must be made on an individual basis, depending on how much oozing or edema is present. In our experience drains are rarely needed. Antibacterial ointment and gauze dressings should be placed along the incision lines. Gauze is also placed preauricularly and postauricularly as well as in the submental region. The entire face should then be wrapped, taking care to prevent excessive tightness of the dressing as it can lead to ischemia of the flaps (Figure 66-18). Additionally, the appropriate positioning of the ears under the dressing should be noted. Dressings should not be manipulated for evaluation until the first postoperative day. Most complications in rhytidectomy occur early in the postoperative period (ie, 24–36 h); close follow-up is therefore essential.^{82–85} Some surgeons prefer to use

no dressings postoperatively.⁸⁶ The degree of edema and ecchymosis postoperatively is frequently underestimated and can be quite shocking to the patient, despite the surgeon's best attempts to educate him or her. The patient's hair should be gently cleansed and rinsed for additional comfort. Incision lines should be cleansed daily with a 1:1 solution of hydrogen peroxide and water. Antibacterial ointment should be used until all sutures are removed.

The preauricular sutures are removed after 4 to 5 days, as are the staples in the temporal and mastoid regions after 10 days. Patients should be instructed not to wash their hair until all sutures have been removed and then to wash only gently with baby shampoo. Written suggestions for the avoidance of ultraviolet light and high heat from hair dryers and for the use of sunblock and incision massage should be given to the patient and repeated orally in the early postoperative visits. The effects of the procedure are still striking for years after surgery (Figures 66-19 and 66-20).

Deep-Plane Rhytidectomy

After the induction of general anesthesia and intubation, 3 cc of sterile methylene blue is introduced through each parotid duct to stain the parotid glands. This allows for confident and safe dissection and is an excellent teaching aid.

The circle of knowledge and caution (CKC) is then drawn on both cheeks (Figure 66-21). This is a circle of required precise knowledge of facial anatomy needed by both experienced and inexperienced surgeons performing face-lifts. Point A, representing the origin of the zygomatic major muscle, is measured along a line from the lateral canthus to the tragon, 2 cm posterior and 2.5 cm inferior to the lateral canthus. Point B, representing the perforating branch of the transverse facial artery, is measured 3 cm posterior and 3.5 cm inferior to the lateral canthus. A circle is drawn with point A as the center

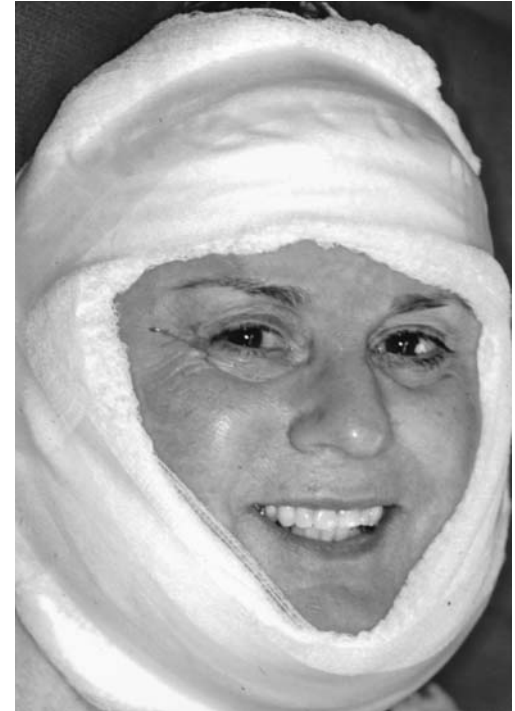

FIGURE 66-18 Typical face-lift dressing immediately postoperatively.

and the radius being the distance between points A and B. Obviously, these measurements are not exact in every patient.

The CKC represents the most complex area of anatomy and the most dangerous area in terms of risk in a deeper-plane face-lift procedure. The perforating branch of the transverse facial artery that is accompanied by a small sensory branch of the zygomaticofacial nerve is the "caution sign." If the artery is severed during the sub-SMAS dissection, it gives a bloody warning to the surgeon that the CKC is near; with careful dissection in the known area of this artery, preservation can be accomplished but is not mandatory in nonsmokers. Safe entrance into the CKC is from superior to this perforating branch over the origin of the zygomatic major muscle through the zygomatic osteocutaneous ligament. If this is followed, the surgeon will never encounter the zygomatic branch of the facial nerve and only occasionally will encounter the branch of the zygomatic branch that enters the deep aspect of the superior third of the zygomatic major muscle.

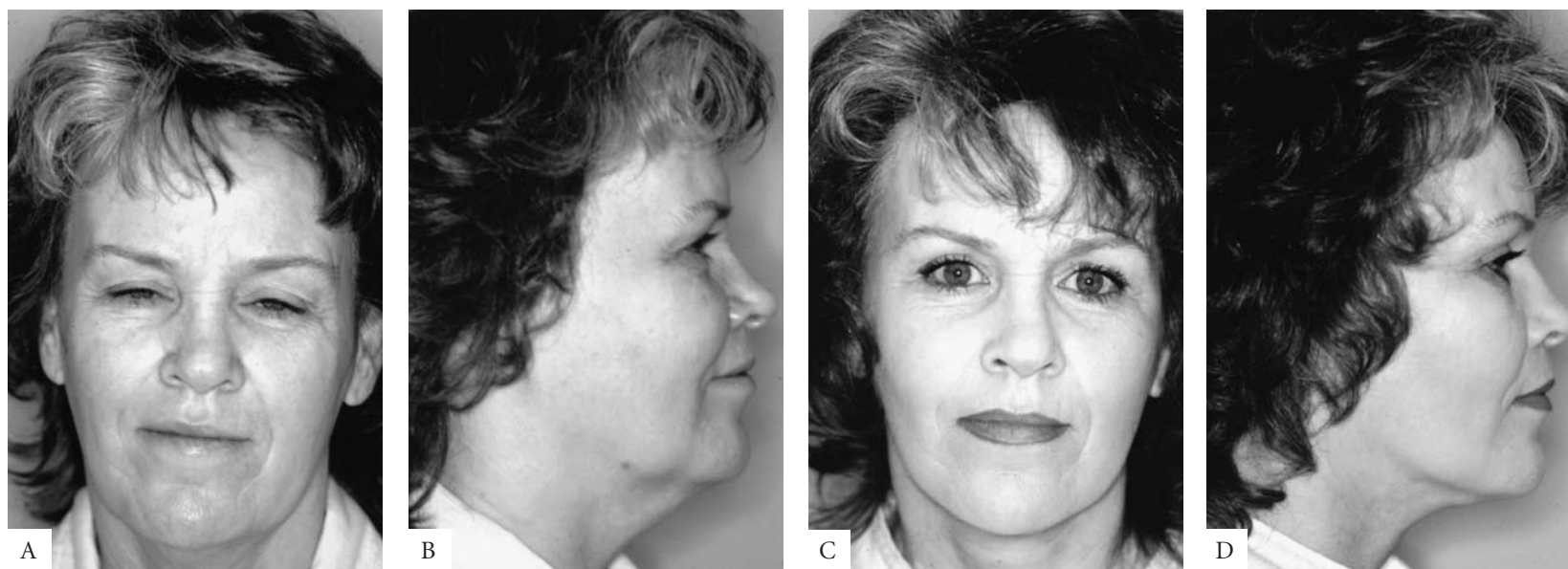

FIGURE 66-19 Typical result achieved with a superficial-plane rhytidectomy including superficial musculoaponeurotic system imbrication: A and B, preoperative photographs; C and D, photographs taken 2 years postoperatively.

The contents of the CKC are the perforating branch of the transverse facial artery, the zygomatic osteocutaneous ligaments, the infraorbital osteocutaneous ligaments, the superior portion of the masseteric fascicutaneous ligaments, the origins of the zygomaticus muscles, the inferolateral portion of the orbicularis oculi muscle, the zygomatic branch of the facial nerve and its branch to the deep aspect of the superior third of the zygomaticus major muscle, the occasionally present inferior palpebral branch of the facial nerve to the orbicularis oculi muscle, and possibly the parotid duct.

Xylocaine 2% with epinephrine 1:50,000 is instilled only in the area of the planned incision, not under the skin flap or the SMAS flap. Since an endoscopic brow lift is usually performed simultaneously with this deep-plane technique, an incision, as drawn in Figure 66-22, is usually preferred in both females and males. We prefer the pretragal incision unless a female patient specifically requests a retrotragal incision. Incisions in the sideburn and in the posterior hair edge are significantly beveled to allow hair growth through the resultant scar.

Preauricular subcutaneous dissection is performed to a level superficial to the lateral part of the orbital portion of the orbicularis oculi, which interrupts the fibrous septa in the superficial fat layer that cause crow's-feet rhytids and also interrupts the fibrous septa of the zygomatic osteocutaneous ligaments and masseteric fascicutaneous ligaments. The subcutaneous dissection proceeds 2 cm posterior to the oral commissure and extends just inferior to the lower border of the mandible, where the previously performed cervical subcutaneous dissection is encountered. This subcutaneous dissection is not taken to the melonolabial groove to allow the SMAS–malar fat pad–skin complex to remain intact. Postauricular subcutaneous dissection is performed superficial to the sternocleidomastoid-investing fascia to the level of the cricoid cartilage and anterior in the neck to the previously performed cervicoplasty subcutaneous dissection superficial to the investing superficial fascia of the platysma muscle. The posterior border of this dissection is the anterior border of the trapezius muscle (Figure 66-23). The subcutaneous dissection is significantly

reduced in smokers and patients with other microvascular disease, and this may compromise the natural postoperative result. In smokers the perforating branch of the transverse facial artery is not interrupted in either the subcutaneous or sub-SMAS planes and is maintained for perfusion of the skin flap border.

The SMAS incision is marked posterior to anterior along the inferior border of the zygomatic arch until the origin of the posterior border of the superficial head of the masseter muscle is palpated (the zygomatic arch descends to meet zygomatic buttress). The marking is then directed toward the pupil extending over the orbital portion of the orbicularis oculi muscle and fascia to the level of the inferior orbital rim. The preauricular SMAS marking is 1 cm anterior and parallel to the skin incision (Figure 66-24). At the lobule of the ear, the SMAS marking turns posteriorly 10° and extends to the level of the cricoid cartilage (extent of neck dissection) parallel and anterior to the posterior border of the platysma muscle.

The SMAS incision is made through the vascular orbicularis oculi muscle with cautery; then a scalpel is used to

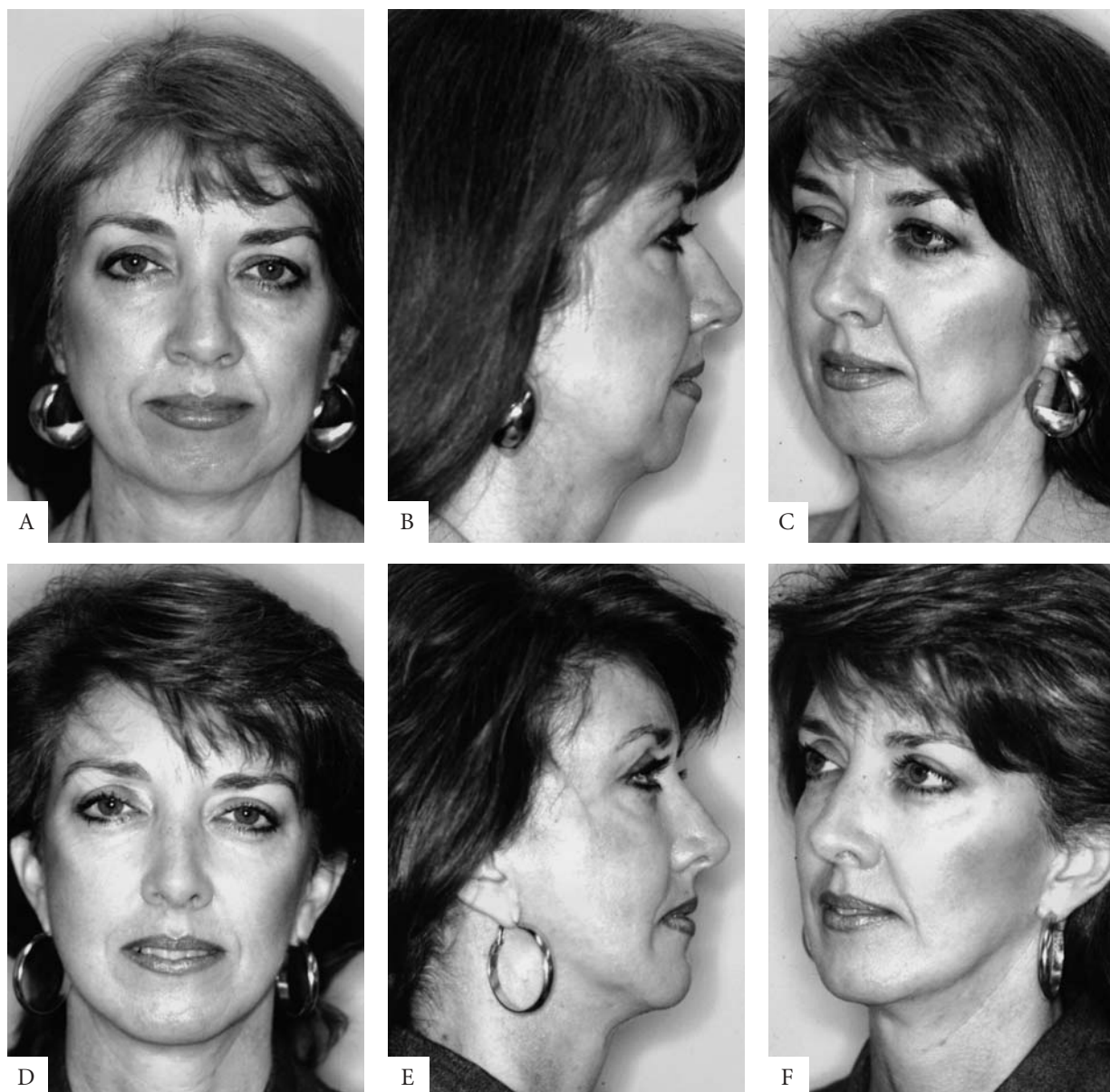

FIGURE 66-20 Rhytidectomy procedures often complement various skeletal or orthognathic procedures. This patient had a superficial rhytidectomy, rhinoplasty, and augmentation genioplasty. A–C, Preoperative views; D–F, 2½ years postoperatively.

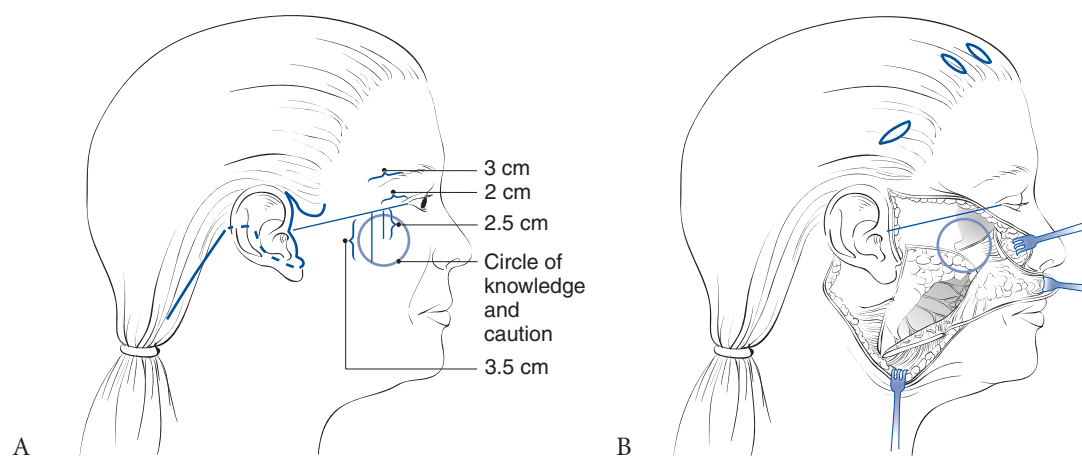


FIGURE 66-21 A, The circle of knowledge and caution (CKC) is constructed by measuring 2 cm and 3 cm from the lateral canthus along a line from the lateral canthus to the tragus. From these respective points, 2.5 cm and 3.5 cm inferior is the origin of the zygomaticus major muscle and the perforating branch of the transverse facial artery. The circle is drawn with the origin of the zygomaticus major as the center, and the radius is the distance from this point to the perforating branch of the transverse facial artery. B, CKC transposed over the extended multiplanar multivector face-lift dissection.

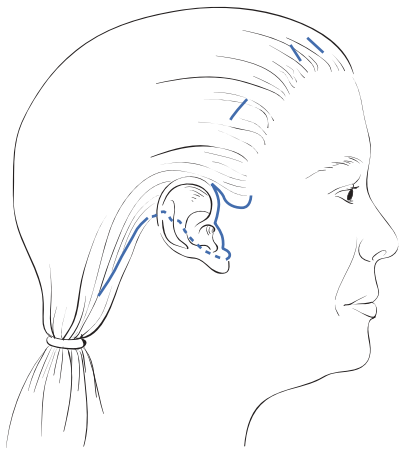


FIGURE 66-22 Face-lift skin incision (pretragal).

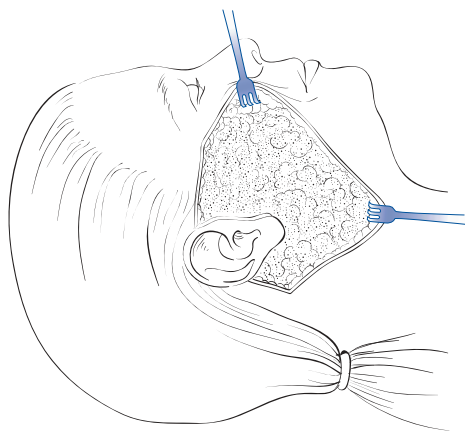


FIGURE 66-23 Subcutaneous dissection (sideburn and postauricular hair clipped, not shaved).

continue the incision to approximately 2 cm below the ear lobe. Scissor dissection to protect the great auricular nerve and the external jugular vein completes the SMAS incision in the neck to the level of the cricoid cartilage.

SMAS flap elevation is started with a scalpel at the posterosuperior edge, and sharp dissection exposes the sub-SMAS fat at the superior pole of the parotid gland that protects the frontal branch of the facial nerve. Continued inferior sharp dissection exposes the parotid fascia seen easily because of the blue-stained parotid gland. The CKC area is dissected last, after the rest of the entire SMAS flap is mobilized (Figure 66-25).

As previously described, there is strict adherence between the SMAS aponeurosis and the parotid fascia, and sharp dissection is required to separate the SMAS from the parotid fascia. This same adherence from scarring after SMAS repositioning is what helps give this deeper-plane technique long-term stability. A SMAS incision anterior to the parotid fascia does not give this benefit, and more dependence is placed on the sutures.

Once the anterior edge of the blue-stained parotid gland is seen or the dissection becomes much easier because of fatty/areolar tissue, sharp dissection is stopped. The remainder of the sub-SMAS flap dissection, except for the CKC area, can be achieved with blunt scissor dissection, remaining just deep to the facial SMAS and the neck platysma fascia. The deep fat layer is areolar and more fatty, allowing blunt dissection over the masseteric fascicutaneous ligaments and deep to the platysma fascia in the neck to join the previously performed cervicoplasty dissection. The area over the posterior portion of the submandibular gland is gently bluntly dissected. The only exception to this is in the area of the platysma cutaneous ligaments, where sharp dissection is required. Care is taken around the angle of the mandible to remain just deep to the neck platysma fascia to remain clear of the marginal mandibular branch of the facial nerve, which is rarely seen. Multiple cervical branches of the facial nerve perforating the deep fasciae that penetrate the deep surface of the platysma muscle are visualized in the neck, and vertical blunt scissor dissection preserves them.

The CKC area is next addressed. The caution sign is the perforating branch of the transverse facial artery (Figure 66-26). Once this is encountered, sharp sub-SMAS dissection with scissors is directed superior to this vessel, through the zygomatic ligaments until the origin of the zygomatic major muscle is visualized (Figure 66-

27). Dissection is continued over and parallel to the zygomaticus muscles deep to the superficial leaf of investing superficial facial fascia (SMAS) of the zygomaticus muscles and deep to the anterior portion of the divided orbicularis oculi muscle and its investing fascia (SMAS) for about half the length of the zygomaticus muscles (Figure 66-28). This dissection is safe if it remains superficial to the zygomaticus muscles and deep to the cut anterior edge

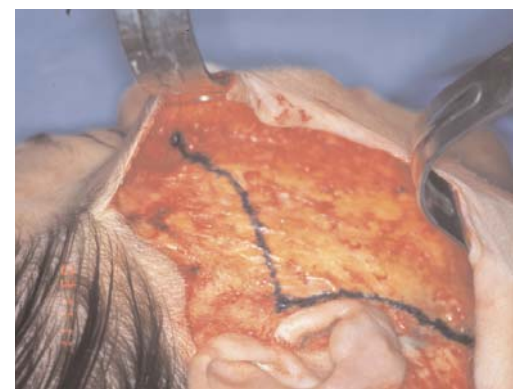

FIGURE 66-24 Marking for right-sided superficial musculoaponeurotic system incision. The anterosuperior portion of the mark is directed toward the right pupil, not the lateral canthus.

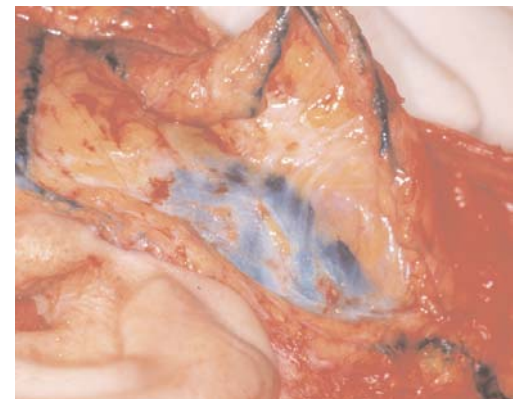


FIGURE 66-25 The initial sharp dissection of the right-sided superficial musculoaponeurotic system (SMAS) flap, separating the SMAS from sub-SMAS fat superior to the superior pole of the methylene blue-stained parotid gland, and the SMAS from the parotid fascia over the methylene blue-stained parotid gland. The appearance of sub-SMAS fat and the outline of the anterior border of the parotid gland determine the end of sharp dissection and the start of blunt dissection between the SMAS and masseteric fascia.

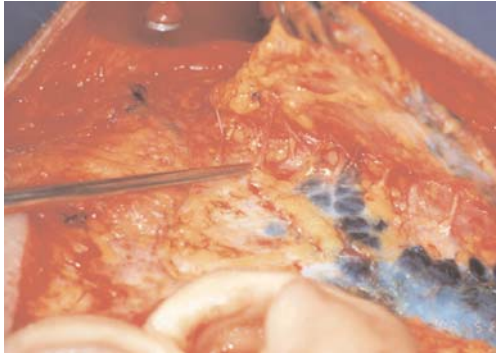


FIGURE 66-26 Right-sided sub-SMAS (*superficial musculoaponeurotic system*) dissection with the instrument pointing to the perforating branch of the transverse facial artery—the start of the circle of knowledge and caution.

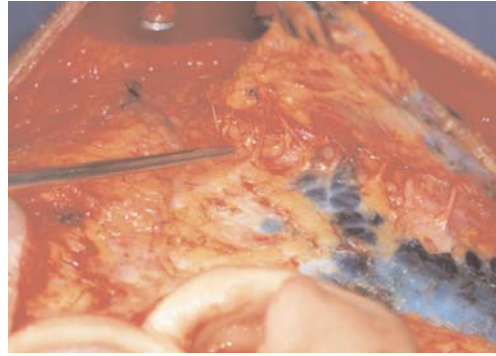


FIGURE 66-27 Right-sided sub-SMAS (*superficial musculoaponeurotic system*) dissection with a clamp grasping portions of the zygomatic osteocutaneous ligaments, which will be interrupted to uncover and visualize the origin of the zygomaticus major muscle.

of the orbicularis oculi muscle. Dissection is continued through the zygomatic osteocutaneous ligaments and the infraorbital osteocutaneous ligaments (often to the nose) (Figure 66-29) and carefully through the superior masseteric fasci-cutaneous ligaments until the SMAS flap, which includes the ptotic malar fat pad, is freely mobilized (Figure 66-30). If more mobilization is required (rarely occurs), blunt dissection is accomplished cautiously through the masseteric fasci-cutaneous ligaments to the anteroinferior insertion of the masseter muscle exposing the buccal fat pad, the peripheral branches of the zygomatic and buccal branches of the facial nerve, and the facial vessels.

Moderate superoposterior traction is placed on the passively mobile SMAS flap, a back cut is made at the superoposterior point, and a key 2-0 slow-resorbing suture is used to fix the SMAS flap to the immobile superoposterior SMAS. The appropriate amount of superior SMAS flap is then excised along with a pie-shaped section of SMAS/orbital portion of the orbicularis oculi muscle. This section is then re-approximated with 2-0 slow-resorbing suture in a superoposterior vector elevating the midface, relocating any prolapsed infraorbital fat, and improving the lower eyelid/cheek junction (along with the pre-

vious interruption of the infraorbital osteocutaneous ligaments). The superior SMAS flap is then sutured with a 2-0 slow-resorbing suture in a vertical vector to elevate the lower face and jowl.

Moderate posterosuperior traction is then placed on the SMAS flap in a direction parallel and slightly superior to the inferior border of the mandible, a back cut is made, and another key 2-0 slow-resorbing suture is placed to fix this SMAS flap to the stout parotid cutaneous ligaments to define the inferior border of the mandible. Mild posterior traction is placed on the neck SMAS (platysma), the excess is excised, and the mobile neck SMAS flap is sutured to the

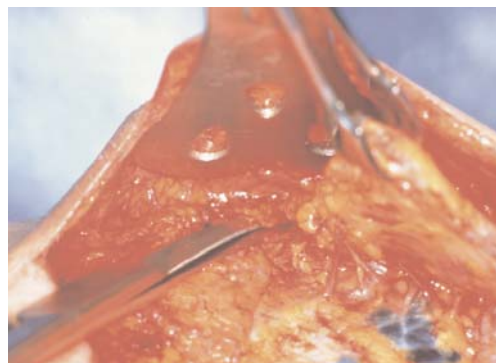


FIGURE 66-28 Right-sided subsuperficial fascia dissection superficial to the zygomaticus major muscle for approximately half the length of the muscle.

posterior immobile neck SMAS. Moderate posterior traction is placed on the preauricular SMAS flap, the excess is excised, and the mobile SMAS flap is sutured to the posterior immobile SMAS (Figure 66-31). The SMAS is reapproximated to maintain the integrity of the SMAS/mimetic muscles complex to allow natural animation. Stability is obtained by having the resultant scarring of the SMAS complex in close relationship with the natural facial fascial tissue adherence areas. The vectors of traction are opposite the vectors of aging, with excess SMAS being removed that should be approximately equal to the amount of tissue ptosis present before surgery (Figure 66-32).

Excessive traction on the anterosuperior portion of the SMAS flap will flatten the melonasolabial groove completely giving an unnatural result. Sufficient repositioning of the malar fat pad to rejuvenate, not obliterate, the melonasolabial groove is desired. Rarely, dissection deep to the malar fat pad but superficial to the facial mimetic muscles is required to mobilize the malar fat pad sufficiently, and the malar fat pad is elevated and independently sutured to the SMAS.⁸⁷⁻⁹⁰ The skin is then redraped along a slightly superoposterior vector, and a cut is made to free the ear lobe. The skin flap is then elevated, and any bleeders are coagulated. The area of surgery is irrigated well

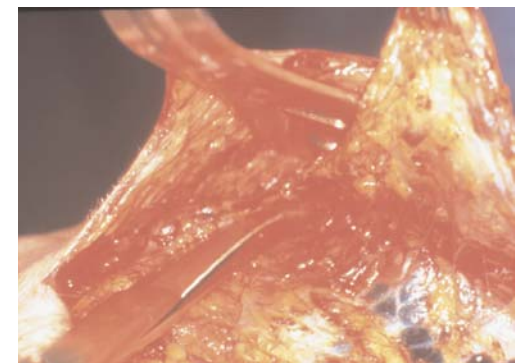
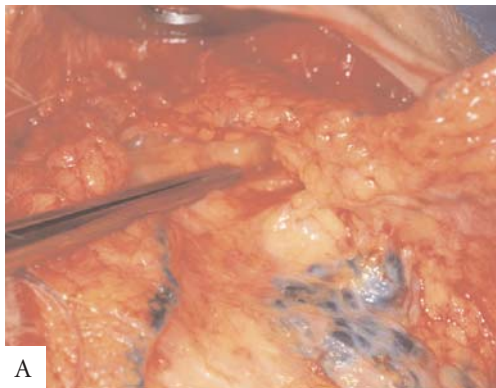
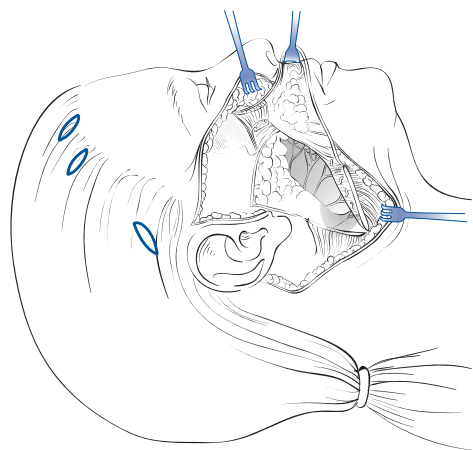


FIGURE 66-29 Right-sided suborbicularis oculi muscle/SMAS (*superficial musculoaponeurotic system*) dissection in the suborbicularis oculi fat to interrupt the infraorbital osteocutaneous ligaments, often as far medial as the nose.



A



B

FIGURE 66-30 A, Right-sided complete mobilization of superficial musculoaponeurotic system flap. The instrument is pointing to the zygomaticus minor muscle. The cut edge of the orbicularis oculi muscle invested by superficial fascia and fat can be seen. B, Illustration of the anatomy in Figure A.

with saline, and both the SMAS and the undersurface of the skin flap are dried with sponges. Fibrin glue is sprayed in all areas, and the skin flap is appropriately positioned. Compression without movement is applied for 5 minutes.

Excess skin is carefully excised and closure is performed with 5-0 polyglactin 910 sutures in the subcutaneous layer, dermal adhesive on the preauricular skin incision, and 5-0 fast-absorbing gut suture in the postauricular skin incisions. No drains are used. Cotton is placed over the areas of surgery, and moderate pressure is applied for 8 to 12 hours with facial and occipital pressure bands. The dressing is intended to prevent abnormal facial and neck movement during the first 8 to 12 hours of the postoperative period.

Summary

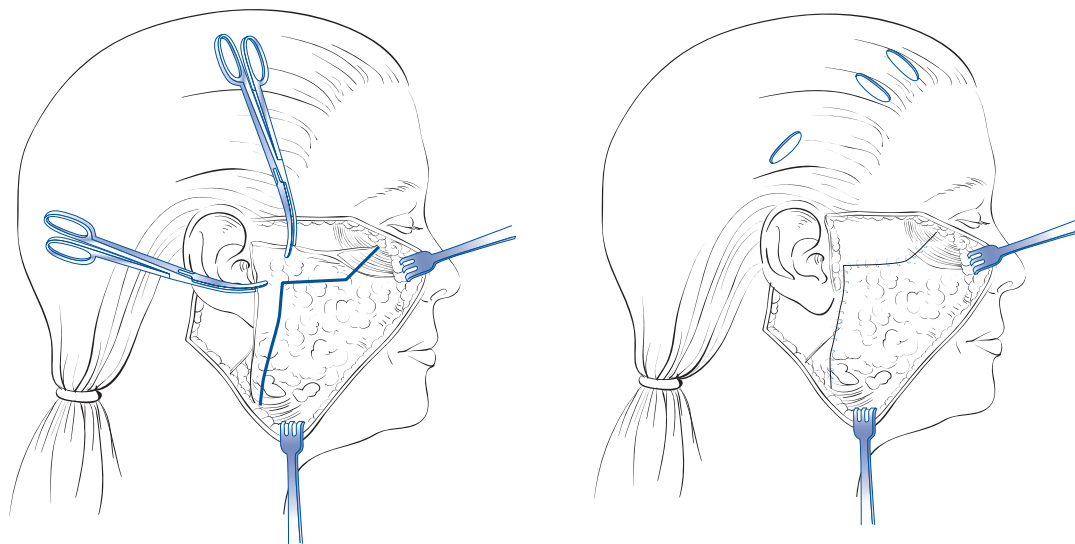
Over the past two decades, numerous rhytidectomy techniques have been described to improve the results of facial rejuvenation. When contemplating facial rejuvenation surgery, the treatment requirements of the surgeon must be balanced with the desires of the patient. These requirements are critical in defining the advantages of one technique of face-lifting over the other. As we prepare our patients for esthetic

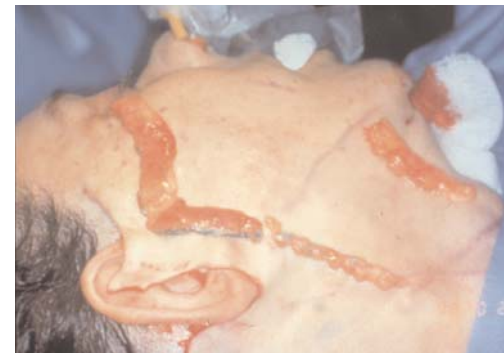

FIGURE 66-32 The amount of facial and neck superficial musculoaponeurotic system (SMAS; including the central neck SMAS from cervicoplasty) removed in a typical extended multiplanar multivector face-lift. Notice the passive redraping of the skin.

surgery, we must consider all the variables discussed and individualize each treatment plan. Not all patients should undergo a deep-plane face-lift; however, many will benefit from release of the retaining ligaments and a repositioning of tissues in multiple vectors.

In the realm of oral and maxillofacial surgery, the rhytidectomy procedure finds great application as an adjunct to traditional skeletal surgery. It seeks to reverse the effects of gravity and relaxation of the facial skin and fascia by resuspending the facial units and eliminating excess skin and subcutaneous tissue. Although a wide variety of



A

B

FIGURE 66-31 A and B, Moderate traction is placed on the superficial musculoaponeurotic system (SMAS) flap, the excess SMAS is excised after the superoposterior key suture is placed, and the SMAS flap is sutured in the appropriate vectors to the fixed SMAS.

techniques are reported for face-lifting, we have attempted to provide a broad overview of the superficial-plane rhytidectomy and deep multiplanar techniques. These techniques are both efficacious and safe. By tailoring the approach to the specific needs of each patient, based on a thorough knowledge of surgical anatomy, the maxillofacial surgeon should achieve consistently good results with minimum morbidity.

References

- Hamra ST. Composite rhytidectomy. *Plast Reconstr Surg* 1992;90:1–13.
- Miller TA. Face-lift: which technique? *Plast Reconstr Surg* 1997;100:501.
- Joseph J. Hangewangenplastik (Melomio-plastik). *Dtsch Med Wochenschr* 1921;47:287.
- Lexer E. Die Gesamte Wiederherstellungschirurgie. Vol 2. Leipzig: JA Barth; 1931.
- Rogers BO. A brief history of cosmetic surgery. *Surg Clin North Am* 1971;51:265–88.
- Rogers BO. The development of aesthetic plastic surgery: a history. *Aesthet Plast Surg* 1976;1:3.
- Rogers BO. A chronologic history of cosmetic surgery. *Bull NY Acad Med* 1977;47:265–302.
- Passot R. La chirurgie esthetique des rides du visage. *Presse Med* 1919;27:258.
- Bourguet J. La disparition chirurgicale des rides du visage. *Bull Acad Med (Paris)* 1919;82:183.
- Bettman AG. Plastic and cosmetic surgery of the face. *Northwest Med* 1920;19:205.
- Kolle FS. Plastic and cosmetic. New York: Appleton; 1911. p. 116–7.
- Miller CC. Semilunar excision of the skin at the outer canthus for the eradication of crow's feet. *Am J Dermatol* 1907;11:483.
- Barnes H. Truth and fallacies of face peeling and face lifting. *Med J Reconstr* 1927;126:86.
- Hollander E. Cosmetic surgery. In: Joseph M, editor. *Handbuch der Kosmetik*. Leipzig: Verlag von Veit; 1912.
- Aufricht G. Surgery for excess skin of the face and neck. In: Wallace EB, editor. *Transaction of the International Society of Plastic Surgeons*. Second Congress. London: Livingstone; 1960. p. 495–502.
- Adamson JE, Horton CE, Crawford HH. The surgical correction of the "turkey gobbler" deformity. *Plast Reconstr Surg* 1964;34:598–605.
- Millard DR, Pigott RW, Hedo A. Submandibular lipectomy. *Plast Reconstr Surg* 1968;41:513–22.
- Baker TJ, Gordon HL. Rhytidectomy in males. *Plast Reconstr Surg* 1969;44:219–22.
- Skoog T. Plastic surgery—new methods and refinements. Philadelphia: WB Saunders; 1974.
- Guerro-Santos J, Espaillat L, Morales F. Muscular lift in cervical rhytidoplasty. *Plast Reconstr Surg* 1974;54:127–30.
- Mitz V, Peyronie M. The superficial musculoaponeurotic system (SMAS) in the parotid and cheek area. *Plast Reconstr Surg* 1976;58:80–8.
- Owsley JQ. Platysma-fascial rhytidectomy: a preliminary report. *Plast Reconstr Surg* 1977;60:843–50.
- Owsley JQ. SMAS-platysma face lift. *Plast Reconstr Surg* 1983;71:573–6.
- Connell BF. Cervical lifts: the value of platysma muscle flaps. *Ann Plast Surg* 1978;1:32–43.
- Connell BF. Contouring the neck in rhytidectomy by lipectomy and a muscle sling. *Plast Reconstr Surg* 1978;61:376–83.
- Gerro-Santos J. The role of the platysma muscle in rhytidoplasty. *Clin Plast Surg* 1978;5:29–49.
- Guerro-Santos J. Surgical correction of the fatty fallen neck. *Ann Plast Surg* 1979;2:389–96.
- Aston SJ. Platysma muscle in rhytidoplasty. *Ann Plast Surg* 1979;3:529–39.
- Lemmon ML, Hamra ST. Skoog rhytidectomy: a five year experience with 577 patients. *Plast Reconstr Surg* 1980;65:283–97.
- Lemmon ML. Superficial fascia rhytidectomy. A restoration of the SMAS with control of the cervicomental angle. *Clin Plast Surg* 1983;10:449–78.
- Kaye BL. The extended neck lift: the "bottom line." *Plast Reconstr Surg* 1980;65:429–35.
- Kaye BL. The extended face-lift with ancillary procedures. *Ann Plast Surg* 1981;6:335–46.
- Teimourian B. Face and neck suction-assisted lipectomy associated with rhytidectomy. *Plast Reconstr Surg* 1983;72:627–33.
- Hamra ST. The tri-plane facelift dissection. *Ann Plast Surg* 1984;12:268–74.
- Hamra ST. The deep-plane rhytidectomy. *Plast Reconstr Surg* 1990;86:51–61.
- Owsley JQ. Lifting the malar fat pad for correction of prominent nasolabial folds. *Plast Reconstr Surg* 1993;91:463–74.
- Ramirez OM. The subperiosteal rhytidectomy: the third-generation facelift. *Ann Plast Surg* 1998;28:218–32.
- Watson SW, Stone TL, Sinn DP. The four dimensional rhytidoplasty. *Am J Cosmet Surg* 2001;18:5–13.
- Duffy MJ, Friedland JA. The superficial-plane rhytidectomy revisited. *Plast Reconstr Surg* 1994;93:1392–403.
- Psillakis JM, Rumley TO, Camargos A. Subperiosteal approach as an improved concept for correction of the aging face. *Plast Reconstr Surg* 1988;82:383–94.
- De la Plaza R, Valiente E, Arroyo JM. Supraperiosteal lifting of the upper two-thirds of the face. *Br J Plast Surg* 1991;44:325–32.
- Ramirez OM, Maillard GF, Musolas A. The extended subperiosteal facelift: a definitive soft-tissue remodeling for facial rejuvenation. *Plast Reconstr Surg* 1991;88:227–36.
- Keller GS. KTP laser rhytidectomy. *Facial Plast Surg Clin North Am* 1993;1:157.
- Beeson WH. Extended posterior rhytidectomy. *Facial Plast Surg Clin North Am* 1993;1:215.
- Binder WJ. A comprehensive approach for aesthetic contouring of the midface in rhytidectomy. *Facial Plast Surg Clin North Am* 1993;1:253.
- Rubin LR, Simpson RL. The new deep plane face lift dissections versus the old superficial techniques: a comparison of neurologic complications [editorial]. *Plast Reconstr Surg* 1996;97:1461–5.
- Baker DC. Deep dissection rhytidectomy: a plea for caution [editorial]. *Plast Reconstr Surg* 1994;93:1498–9.
- Adamson PA, Moran ML. Complications of cervicofacial rhytidectomy. *Facial Plast Surg Clin North Am* 1993;1:133–42.
- Kaye BL. The superficial-plane rhytidectomy revisited [discussion]. *Plast Reconstr Surg* 1994;93:1404–5.
- Ghali GE, Smith BR. A case for superficial rhytidectomy. *J Oral Maxillofac Surg* 1998;56:349–51.
- Baker TJ. Patient selection and psychological evaluation. *Clin Plast Surg* 1978;5:3–14.
- Rees TD, Liverett DM, Guy CL. The effect of cigarette smoking on skin-flap survival in the facelift patient. *Plast Reconstr Surg* 1984;73:911–3.
- Webster RC, Kazda G, Hamden US, et al. Cigarette smoking and facelift: conservative versus wide undermining. *Plast Reconstr Surg* 1986;77:596–604.
- Lawrence WT, Murphy RC, Robson MC, et al. The detrimental effect of cigarette smoking on flap survival: an experimental study in the rat. *Br J Plast Surg* 1984;37:216–9.
- Kaufman T, Eichenlaub EH, Levin M, et al. Tobacco smoking: impairment of the experimental flap survival. *Ann Plast Surg* 1984;13:468–72.
- Craig S, Rees TD. The effects of smoking on experimental skin flaps in hamsters. *Plast Reconstr Surg* 1985;78:842–6.
- Nolen J, Jenkins RA, Kurihara K, et al. The acute effects of cigarette smoke exposure on experimental skin flaps. *Plast Reconstr Surg* 1985;75:544–51.

58. Edgerton MT, Webb WL, Slaughter R, et al. Surgical results and psychosocial changes following rhytidectomy. *Plast Reconstr Surg* 1964;33:503–21.
59. Goin MK, Burgoyne RW, Goin JM, et al. Prospective psychologic study of 50 female facelift patients. *Plast Reconstr Surg* 1980;65:436–42.
60. Dedo DD. A preoperative classification of the neck for cervicofacial rhytidectomy. *Laryngoscope* 1980; 90:1894–6.
61. Schoen SA, Taylor CO, Owsley TG. Tumescent technique in cervicofacial rhytidectomy. *J Oral Maxillofac Surg* 1994;52:344–7.
62. Klein JA. The tumescent technique for liposuction surgery. *Am J Cosmet Surg* 1987;4:263.
63. Lillis PJ. Liposuction surgery under local anesthesia: limited blood loss and minimal lidocaine absorption. *J Dermatol Surg Oncol* 1988;14:1145–8.
64. Klein JA. Tumescent technique for regional anesthesia permits lidocaine doses of 35 mg/kg for liposuction: peak plasma lidocaine levels are diminished and delayed 12 hours. *J Dermatol Surg Oncol* 1990;16:248–63.
65. Klein JA. The tumescent technique anesthesia and modified liposuction technique. *Dermatol Clin* 1990;8:425–37.
66. Lillis PJ. The tumescent technique for liposuction surgery. *Dermatol Clin* 1990;8:439–50.
67. Talamas I. A nondeforming rhytidectomy incision. *Aesthetic Plast Surg* 1999;23:228–32.
68. Stuzin JM, Baker TJ, Baker TM. Refinements in face lifting: enhanced facial contour using Vicryl mesh incorporated into SMAS fixation. *Plast Reconstr Surg* 2000;105:290–301.
69. Knize DM. Periauricular facelift incisions and the auricular anchor. *Plast Reconstr Surg* 1999;104:1508–20.
70. Little JW. Hiding the posterior scar in rhytidectomy: the omega incision. *Plast Reconstr Surg* 1999;104:259–72.
71. Baker DC, Aston SJ, Guy CL, et al. The male rhytidectomy. *Plast Reconstr Surg* 1977;60:514–22.
72. Peterson R. The role of the platysma muscle in cervical lifts. In: *Symposium on surgery of the aging face*. St. Louis: Mosby; 1978. p. 115–24.
73. Connell BF. Contouring the neck in rhytidectomy by lipectomy and a muscle sling. *Plast Reconstr Surg* 1978;61:376–83.
74. Aston SJ. Platysma muscle in rhytidoplasty. *Ann Plast Surg* 1979;3:529–39.
75. McKinney P, Tresley GE. The “maxi-SMAS”: management of the platysma bands in rhytidectomy. *Ann Plast Surg* 1984;12:260–7.
76. Baker DC, Conley J. Avoiding facial nerve injuries in rhytidectomy. *Anatomical variation and pitfalls*. *Plast Reconstr Surg* 1979;64:781–95.
77. Liebman EP, Webster RC, Berger AS, et al. The frontalis nerve in the temporal brow lift. *Arch Otolaryngol* 1982;108:232–5.
78. Stuzin JM, Wagstrom L, Kawamoto HK, et al. Anatomy of the frontal branch of the facial nerve: the significance of the temporal fat pad. *Plast Reconstr Surg* 1989;83:265–71.
79. McKinney P, Katrana DJ. Prevention of injury to the greater auricular nerve during rhytidectomy. *Plast Reconstr Surg* 1980; 66:675–9.
80. McKinney P, Gottlieb J. The relationship of the great auricular nerve to the superficial musculoaponeurotic system. *Ann Plast Surg* 1985;14:310–4.
81. Webster RC, Smith RC, Karolow WW, et al. Comparison of SMAS plication with SMAS imbrication in face-lifting. *Laryngoscope* 1982;92:901–12.
82. Webster R, Smith R, Hall B. Facelift—better results with safer surgery of the head and neck. In: Ward P, Berman W, editors. *Plastic and reconstructive surgery of the head and neck*. St. Louis: CV Mosby; 1984. p. 321–3.
83. Gordon HL. Rhytidectomy. *Clin Plast Surg* 1978; 5:97–107.
84. Baker DC. Complications of cervicofacial rhytidectomy. *Clin Plast Surg* 1983; 10:543–62.
85. Rees TD, Baker DC. Complications of aesthetic facial surgery. In: Conley J, editor. *Complications of head and neck surgery*. Philadelphia: WB Saunders; 1980.
86. Aston SJ. Problems and complications in platysma-SMAS cervicofacial rhytidectomy. In: Kaye B, Gradinger G, editors. *Symposium on problems and complications in aesthetic plastic surgery of the face*. St. Louis: CV Mosby; 1983.
87. Owsley JQ. Lifting the malar fat pad correction of prominent nasolabial folds. *Plast Reconstr Surg* 1994;93:463–74.
88. Owsley JQ. Elevation of the malar fat pad superficial to the orbicularis oculi muscle for correction of prominent nasolabial folds. *Clin Plast Surg* 1995;22:2.
89. Owsley JQ, Weibel TJ. Multiple vector face-lift: SMAS-platysma rotation flap plus midface malar fat pad suspension. *Oper Tech Plast Reconstr Surg* 1995;2:99–107.
90. Forrest CR, Phillips JH, Bell A, Gruss JS. The biomechanical effects of deep tissue support as related to brow and facelift procedures. *Plast Reconstr Surg* 1991;88:427–32.

APPENDIX Postoperative Rhytidectomy Instructions

Immediately upon Arriving Home

- Head elevation: Lie down with your head and back elevated on two pillows. You must sleep in this position for 1 week.
- Dressings: Do not remove bandages. These will be removed at the office on your first postsurgery visit.
- Ice packs: Place ice packs (ice in freezer bags or packages of frozen peas) over the cheek areas on and off over a period of 24 hours. *Do not* put ice on after 24 hours unless you are told to do so.
- Swelling: Ice packs will keep swelling and bruising to a minimum.
- Bruising: Bruising often lasts 7 to 14 days.
- Medication: Take pain medication *only if needed* and with food or crackers.
- Diet: Upon arriving home from surgery, begin with clear liquids until fully awake; then begin regular food intake with soft foods.
- Suture care: Keep all sutures clean with a peroxide-water solution. Keep sutures covered with antibiotic ointment at all times. Clean three to five times per day.

One Day or More after Surgery

- Moist heat: Ice packs are to be discontinued 24 hours after surgery. *Wait 12 hours*; then you may begin moist heat. Use a moist washcloth between an electric heating pad and your face. Do not use heat continuously; for example, use for 30 minutes and then off for 30 minutes. *Do not* set the heating pad higher than *medium* at any time, regardless of how cool it feels to you.
- Activity: Stay up as much as possible. Avoid bending over or lifting heavy objects for 1 week. Strenuous activities should be limited for 2 to 3 weeks.
- Work: Most people plan to return to work in 2 weeks. This depends on how you feel about being seen with bruising. Most of the bruising can be masked with makeup if you prefer to return earlier.
- Makeup: Cosmetics may be applied on the sixth day. Ask about special coverup products for bruising. Mint green coverstick followed by a flesh-tone foundation will cover most bruises.
- Bathing: You may bathe or shower, but keep the bandages dry. When bandages are removed, gently wash the facial areas.
- Hair care: You may wash your hair on the fifth day after surgery. *Do not bend over* to wash your hair; this may cause bleeding or swelling to occur. Use medium heat on your hair dryer. High heat or hot rollers should not be used for 7 to 10 days. You may use color on your hair in 3 weeks.
- Diet: Eat regular but soft meals. You will need to take vitamins and minerals to help with the healing. We will be glad to give you vitamin and mineral information.
- Sun: Protect your facial skin from excessive sun exposure for 1 month after surgery.

Please report any of the following to our office:

- Excessive pain or bleeding
- Itching or rash around stitches
- Oral temperature > 100°F (37.8°C)
- Excessive swelling/bruising, fatigue, or depression

Forehead and Brow Procedures

Angelo Cuzalina, MD, DDS

Upper facial cosmetic surgery has enjoyed an unprecedented increase in popularity over the past decade. The yearning of baby boomers to look and feel rejuvenated has led to new endoscopic techniques aimed at creating a more youthful and natural appearance with shorter recovery periods than existed in past decades.¹⁻³ The ultimate goal of improving a person's appearance remains unchanged. Society shapes our views of what looks attractive, and no mathematic formula can ever be used to determine an ideal eyebrow position (Figure 67-1). Each individual has his or her own unique perception of facial beauty. For most people the upper face and eyes impart more emotion than does any other part of the human body; it is clear that rejuvenation of this vital area can provide an esthetically pleasing result.

Esthetic concerns of the forehead and brow regions of the face affect a wide range of age groups. Unlike the standard lower face and neck rhytidectomy, which more commonly affects patients after the age of 45 years, cosmetic concerns in the upper third of the face may be evident for patients in their twenties and thirties owing to genetic predisposition. The forehead and brow area must be entirely evaluated for a wide range of interlacing diagnoses. Matching the problem(s) to the ideal rejuvenation technique(s) is essential for maximum esthetic benefits. Thinning skin and laxity owing to age and gravity

encompass only a portion of the forehead and brow dilemmas that must be addressed when planning rejuvenation procedures (Figure 67-2).

The aging process typically leads to forehead and brow ptosis on almost every patient; however, it is important to distinguish whether the ptosis in the forehead and brow region is owing to problems with brow position, upper eyelid laxity, or a combination of the two (Figure 67-3). Other problems such as dynamic lines caused by muscle activity in the glabellar

region, variable hairline patterns, bony abnormalities, and asymmetries, as well as skin texture itself, also must be assessed in relation to each other. Achieving the patient's desired expectation depends not only on sound surgical skill and judgment, it also depends critically on communication between the surgeon and patient. Truthful disclosure of what can reasonably be attained is prudent and helps to prevent patient dissatisfaction.

Rejuvenation of the upper third of the face is one of the most rewarding and



FIGURE 67-1 Three different types of esthetically pleasing foreheads and eyebrow position. The tail of the eyebrow is located along the alar-canthal line. The greatest brow arch is seen in the lateral third between the lateral limbus and canthus of the eye. The outer half of the brow is “ideally” located 5 to 10 mm above the orbital rim in females.

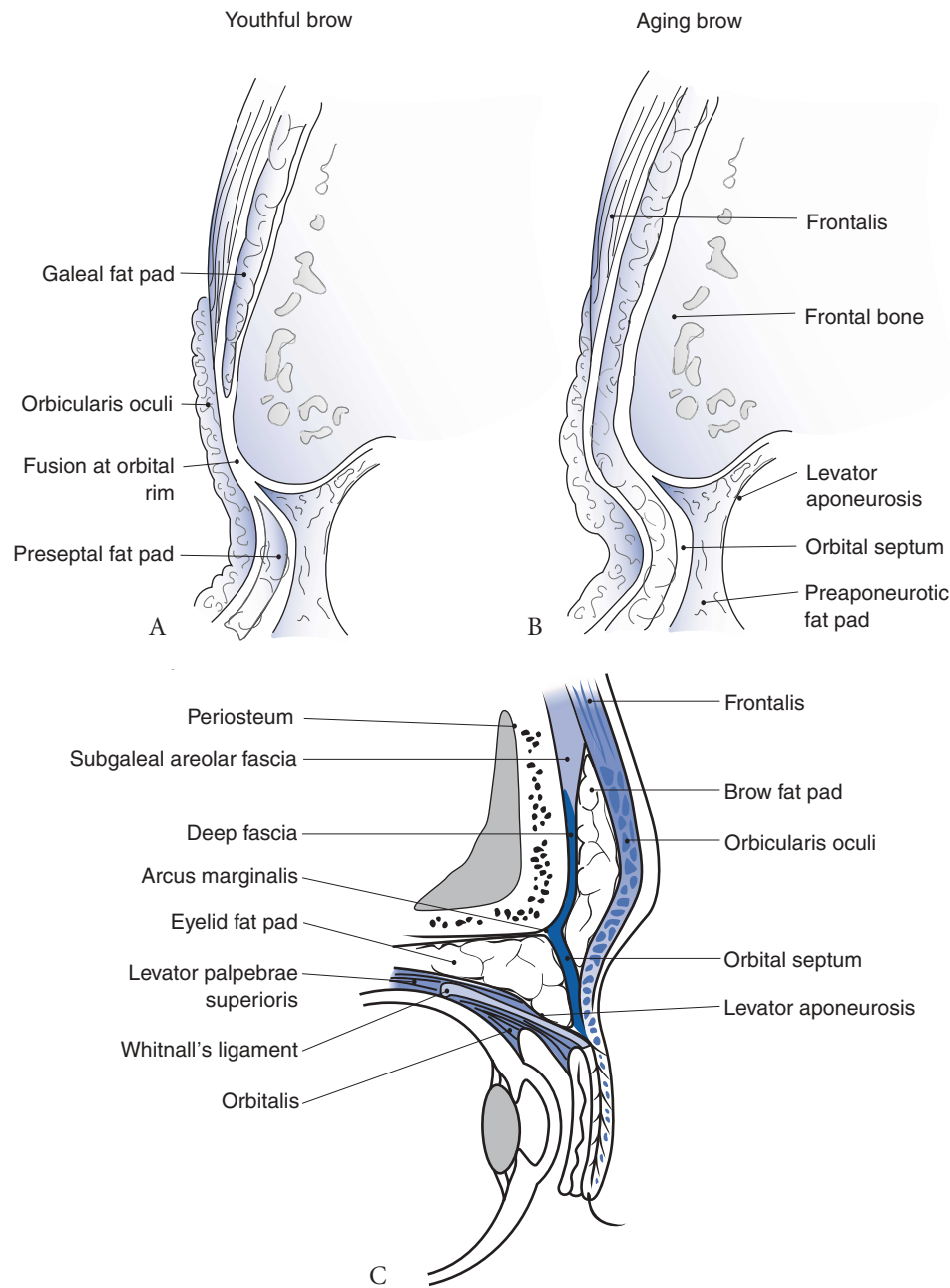


FIGURE 67-2 A, The youthful brow is elevated proportionately and has densely adherent periorbital fascia and muscle. B, Brow descent owing to aging and the associated loss of fascial integrity, along with orbital fat prolapse. C, Cross-section of the brow near the mid-pupillary position.

fulfilling procedures a surgeon can offer to select patients. Specific elevation and correction of lateral hooding can be appear natural and still impart a tremendous improvement in the patient's overall beauty and youthful appearance (Figure 67-4). The goal of this chapter is to review the upper third of facial anatomy specific to forehead and brow rejuvenation techniques and to discuss a variety of the most

common techniques for rejuvenating the forehead and brow region.

Anatomic and Esthetic Considerations

It is generally accepted that a youthful forehead is roughly one-third of the overall facial height.⁴⁻⁹ Essentially, the distance from the hairline to the glabella is equal to the distance from the glabella to the point

at the base of the columella or subnasale (Figure 67-5). A youthful-appearing eyebrow is different for men and women. The female eyebrow should be arched with the highest point of the brow on a sagittal line from the lateral canthus.^{10,11} The entire brow itself should be above the orbital rim. In general the medial brow of the female is located ideally 1 to 3 mm above the orbital rim and the lateral third of the brow 5 to 10 mm above the rim.¹² This is in contrast to a typical male eyebrow that should lie at or only slightly above the orbital rim in a more horizontal or uniform arch fashion (Figure 67-6). Elevating the lateral third of the male eyebrow disproportionately more than the remaining brow will create a feminine appearance.

The detailed anatomy of individual areas has been well described in the literature and often relates to the specific procedure being performed.¹³⁻²⁵ Therefore, the following anatomic discussion is simplified by separating the specific regions into bony landmarks, muscle and fascial anatomy, vessel and nerve anatomy, and specific endoscopic anatomy, and each anatomic region is addressed individually as it relates to specific surgical procedures.

Bony Landmarks

Bony landmarks of the forehead and brow region can be focused all around the frontal bone, which makes up the highest percentage of the upper third of the face. The connections (suture lines such as the nasofrontal, zygomaticofrontal, and coronal) are important landmarks because they can be clinically relevant for limits of dissection and can help surgeons determine their location during dissection. For instance, the zygomaticofrontal suture line is an ideal location to end most basic brow lift dissections (Figure 67-7). Additional dissection can be performed if midface lifting is also planned or if the patient desires more elevation at the lateral canthal region. Overaggressive dissection here in many patients can create an unnatural

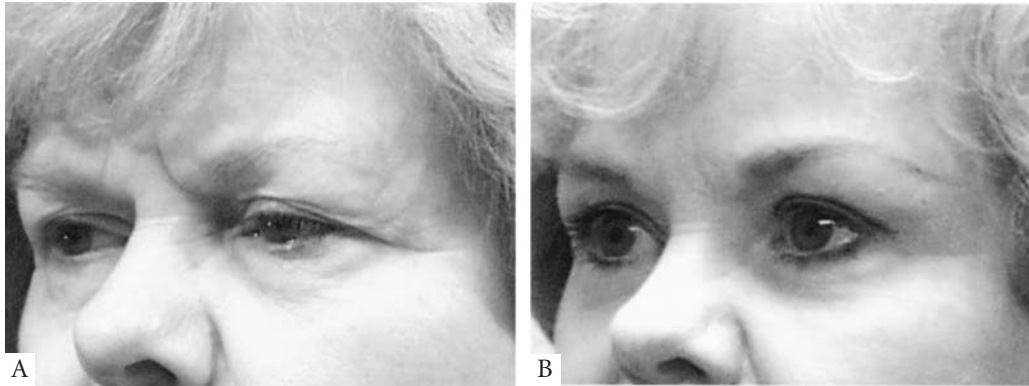


FIGURE 67-3 A, Rejuvenation of the upper third of the face must address whether the problem is limited to brow ptosis, eyelid ptosis, or a combination of both, as seen in the patient on the left. Skin texture must also be evaluated. B, This photograph was taken 1 month after a coronal brow lift, upper blepharoplasties, and full-face laser resurfacing.

cat's-eye appearance, particularly if too much tissue is elevated medially along the suture line and lateral canthus. Likewise, the nasofrontal suture line is a nice landmark to note during dissection for a few reasons. First, dissection usually needs to proceed only a few millimeters below this suture level onto the nasal bones for adequate release. Second, the paired procerus muscles can be identified here and transection performed if required. Third, depending on the level of horizontal transection in this area, the nasofrontal angle point of takeoff can be altered slightly if desired. Last, nasal tip rotation can be achieved if wanted, especially with significant dissection below the nasofrontal suture line.

Another general bony landmark is the orbital rim, which limits inferior dissection but must be well visualized and free of periosteal attachments to lift the brow and brow fat pads for long-term results. Important muscle and fascial attachments are also located at the level of the orbital rim medially and laterally. The tenacious temporal fusion line (zone of fixation) that exists along the temporal ridge must be identified during dissection.^{26,27} It is also important to know its location preoperatively so that proper incision placement can be made to facilitate a clean dissection endoscopically (Figure 67-8).

Bony thickness varies in different areas of the skull. In addition, venous lakes present on the inside surface of the skull tend to be more centralized around the sagittal suture line. If bone tunnels or screws are planned for fixation purposes, the midline should be avoided, if possible, because of the sagittal sinus as well as higher-density venous lakes in this area (Figure 67-9). Thickness does increase

posteriorly near the occiput, but screw or bone tunnel fixation here is more challenging and is not required. Caution must be taken also to avoid lateral placement because of thinness of the lateral skull and the middle meningeal arteries. Knowledge of average thickness for a given location and internal anatomy indicates that the safest location for bone tunnels or screws is located along a parasagittal line approximately at the midpupil or lateral limbus line and just anterior to the coronal suture (see Figure 67-9).

Muscle and Fascial Anatomy

Paired muscles of the forehead and brow region are often thought of as elevators and depressors. Although several depressor muscles can pull the brow down or obliquely, the only true elevator of the forehead, the frontalis, moves upward to raise the brow. This movement, along with some static tone, maintains brow position but also can lead to horizontal creases over time. The frontalis originates from the deep galeal plane (galea aponeurotica that

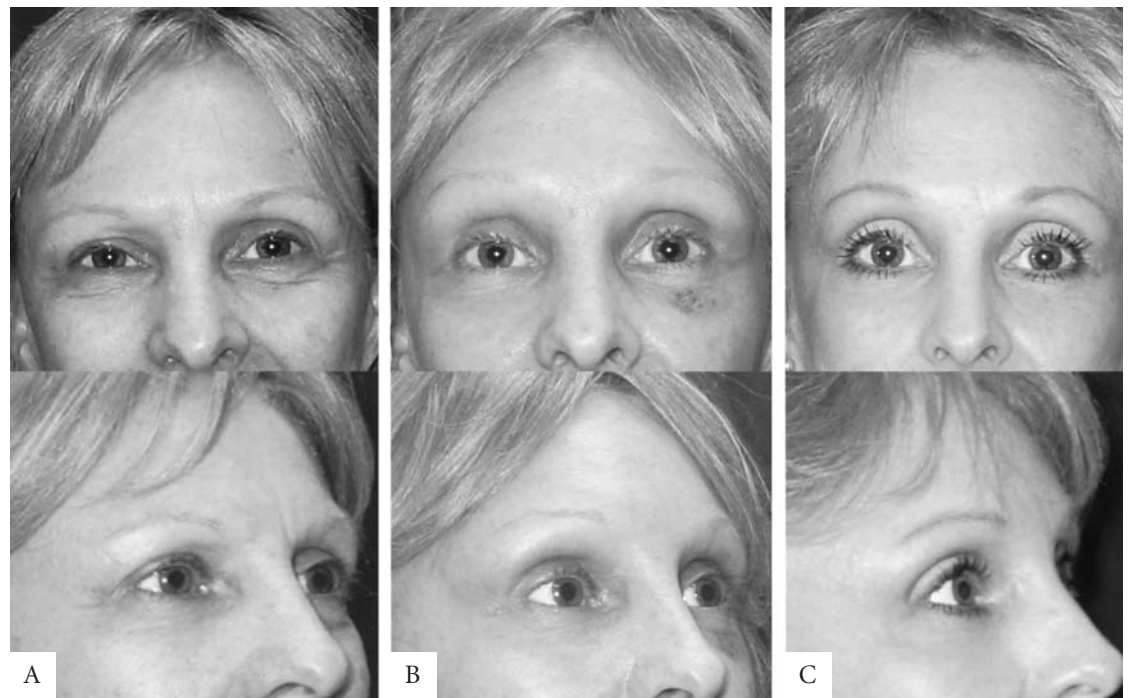

FIGURE 67-4 A, Preoperative view of patient with classic lateral hooding brow ptosis and only "pseudo" upper eyelid laxity or ptosis. B, One week following endoscopic forehead and brow lift only. (Slight overcorrection is noted in this early period.) C, Correction of lateral hooding with isolated brow lift after 1 month.

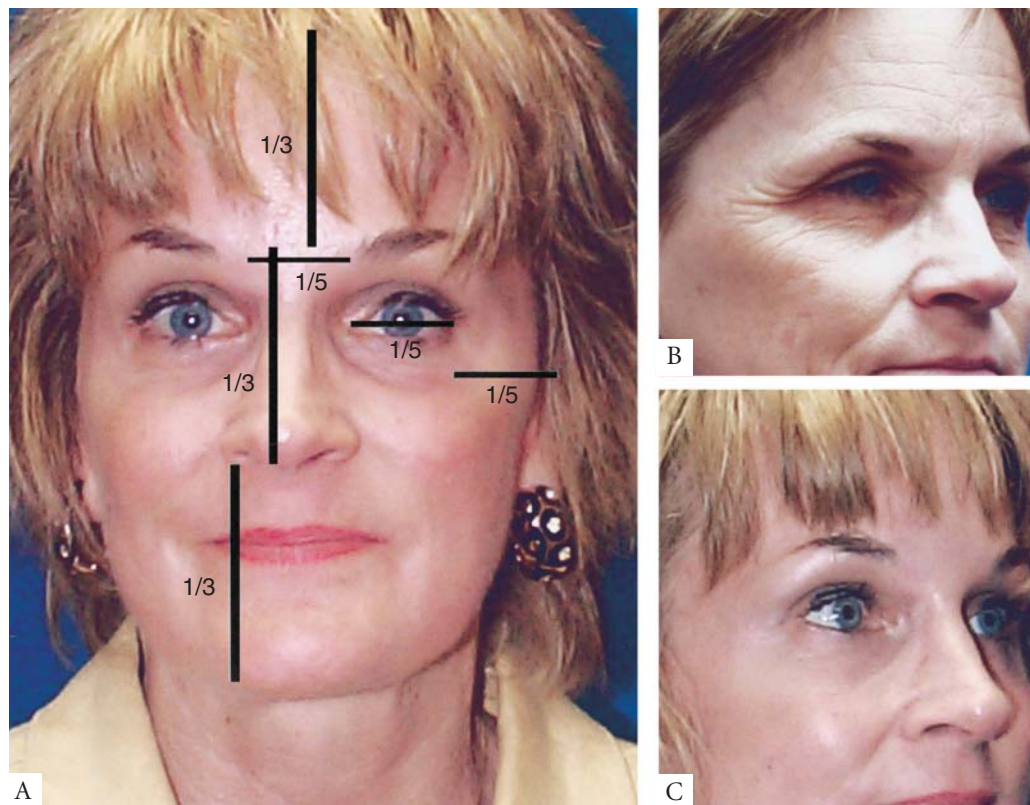


FIGURE 67-5 A, Example of ideal facial proportions based on vertical facial thirds and horizontal proportions approximately the width of the eye or one-fifth of the facial width. B, Preoperative. C, Six weeks following endoscopic forehead and brow lift along with laser skin resurfacing.

connects to the occipitalis posteriorly). It inserts into the orbital portion of the orbicularis oculi, which inserts into the dermis immediately below the eyebrow. Its lateral extension fuses into the dense collection of fascia almost 1 cm wide, called the zone of adherence, which extends along the superior temporal line and ends inferiorly just above the zygomaticofrontal suture.

The fascial attachments, known as the orbital ligament (see Figure 67-7), are the inferior termination point of the zone of adherence near the orbital rim where connective tissue fibers of the temporoparietal fascia are fixated to the bone at the superolateral orbital rim (Figure 67-10). Lateral and posterior along a near horizontal line from the orbital ligament is the orbicularis-temporal ligament, which is the transverse fusion zone of fibers from the lateral orbicularis, the temporoparietal fascia, and the tempo-

ralis fascia. These are important clinical anatomic areas because freeing the zones of adherence is necessary to achieve long-term results with lift procedures. However, care is required in this region to avoid overzealous stretching and injury to the facial nerve.

The acronym *SCALP* applies for the standard layers in the forehead: skin, subcutaneous tissue, *a*poneurosis (the thick galeal fascia), loose areolar (subgaleal) plane, and *p*erosteum²⁸⁻³⁰; however, the galeal fascia fuses into the frontalis muscle and its midline fascial attachments at this level. This allows a sliding movement over the scalp with contraction of the muscle. The frontalis and galea together can also be thought of as an extension of the temporoparietal fascia in the temporal region as well as the superficial musculoaponeurotic system (SMAS) below the level of the zygomatic arch.³¹⁻³³ The temporoparietal fascia appears somewhat loose or spongy clinically and houses the temporal nerve within its undersurface.

Many other paired forehead and brow muscles thought of as depressors are present along the brow to facilitate facial expression.³⁴⁻⁴¹ The two most well known are the procerus and the corrugator supercilii, which are present in the glabella (Figure 67-11). The procerus muscles are paired superiorly but fuse inferiorly into one muscle belly that originates from the nasal bones and cartilage. Superiorly procerus fibers insert into medial frontalis and the overlying dermis. The procerus is responsible for depression and frowning in the midline, which often creates a horizontal crease (“bunny lines”) across

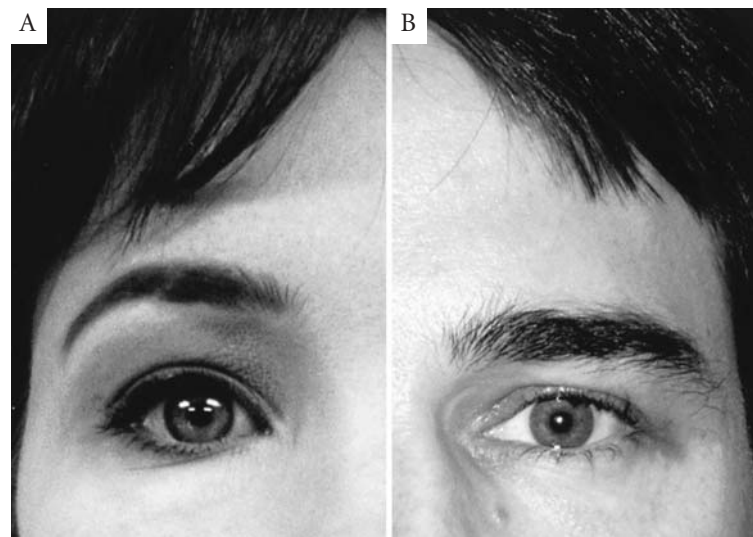

FIGURE 67-6 A, Female brow shown with a nicely accentuated arch in the lateral third well above the orbital rim. B, The average male brow position is level with the orbital rim with a symmetric arch form.

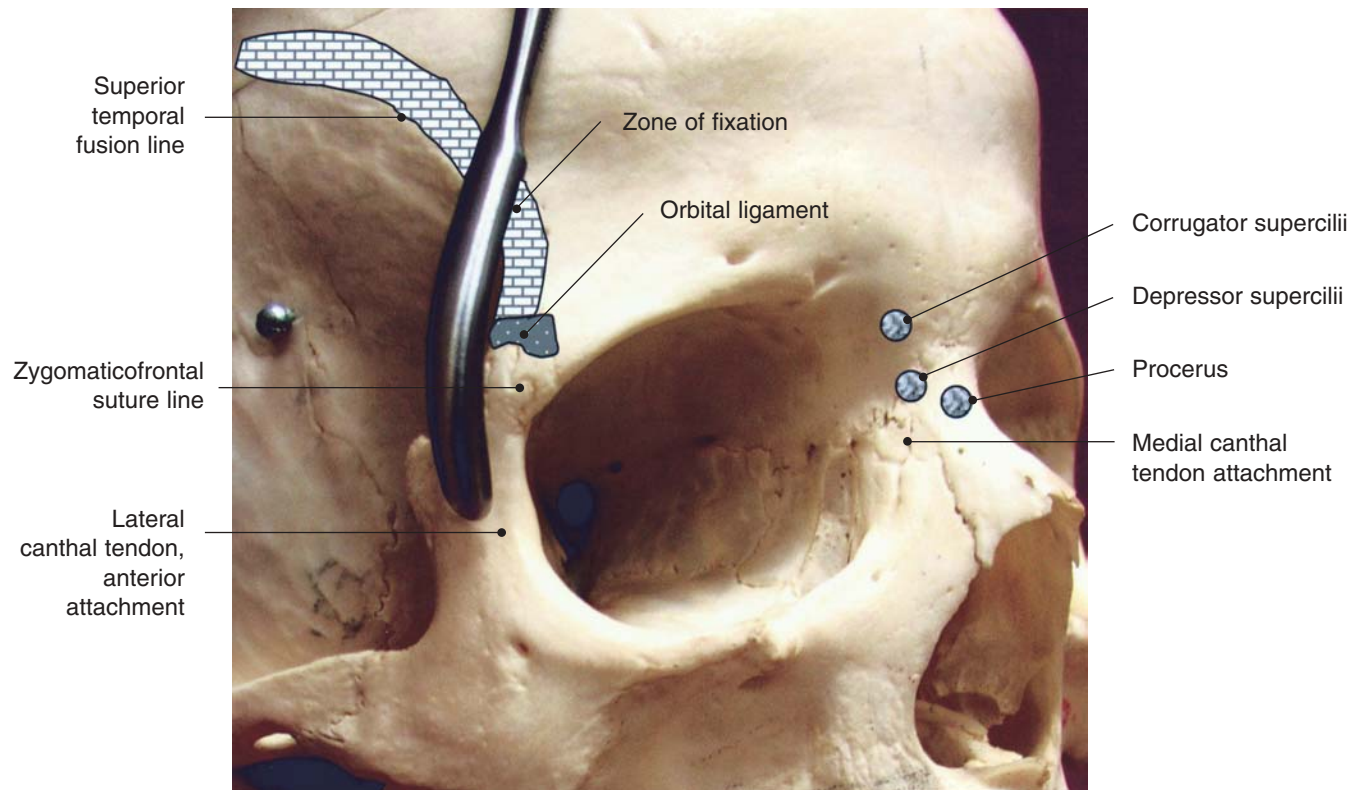


FIGURE 67-7 Periosteal elevator shown at a more aggressive level of dissection to elevate the lateral canthus slightly, if desired. Fascial and muscle attachments are labeled. Elevation at this level detaches only the superficial layer of the lateral canthal tendon. (The deep portion of the lateral canthus is 5 mm within the orbital rim attached to Whitnall's tubercle.)

the upper portion of the nose. The corrugator supercilii are depressors that act obliquely across the glabella and produce the classic vertical lines seen when squinting (Figure 67-12). The corrugator originates from the frontal bone just above the nasal bones and inserts in the dermis of the medial brow. The corrugator has two heads, the oblique and the transverse, which act to pull the medial brow in respective locations. Together the paired procerus muscles and corrugator are the main depressors of the medial brow and are the most common muscles treated with botulinum toxin type A to help alleviate frown lines in the glabella. These same two muscles are also most often transected during a brow or forehead lift to achieve a smoother and longer-lasting result (Figure 67-13).

Another depressor muscle of importance is the depressor supercilii, which originates on the frontal process of the

maxilla just below the corrugator supercilii and inserts in the medial frontalis fibers and dermis just above the medial brow. Because it lies superficial to the corrugator, it can be easily paralyzed inadvertently by botulinum toxin. It is also

important to note because it lies behind the corrugator and can be transected by aggressive dissection through the corrugator during a brow lift. Although patients with a very low medial brow position may occasionally benefit from this

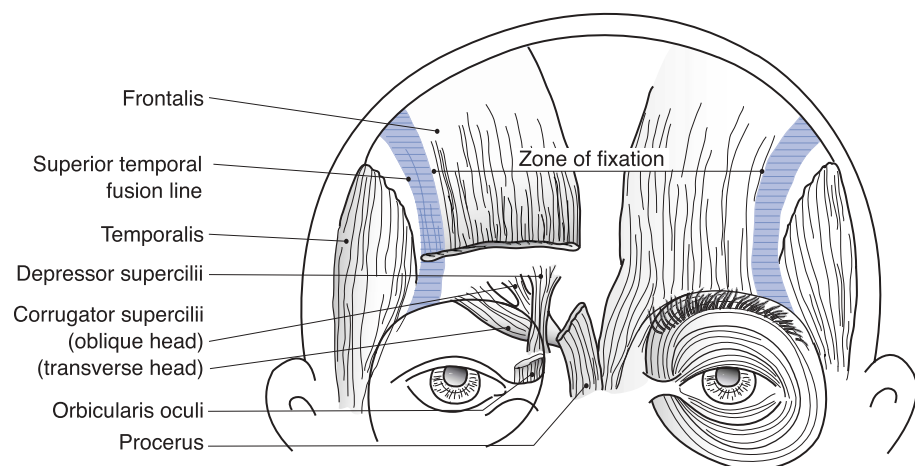


FIGURE 67-8 Cutaway portions of the frontalis muscles, procerus, and orbicularis oculi on one side demonstrate the relationship to the deeper depressors of the brow (corrugator supercilii and depressor supercilii). The zone of fixation (in blue) runs medial to the superior temporal fusion line.

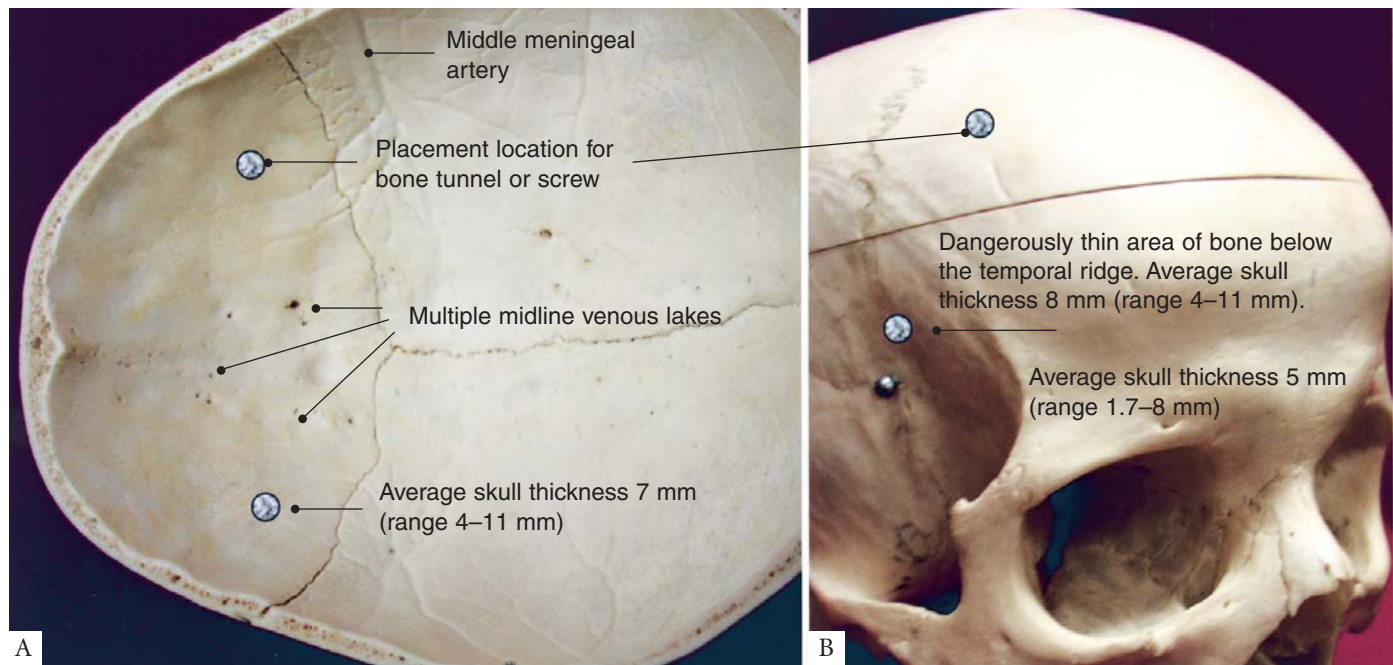


FIGURE 67-9 A, Inside view of the calvarium of the skull demonstrating the high density of venous lakes near the midline and associated structures. B, Illustration of the ideal location placement for bone screws or tunnels based on ideal vector of lift and anatomic limitations.

maneuver, it often gives rise to over-elevation of the medial brow following surgery, which causes the patient to look somewhat surprised (Figure 67-14). Superficial to the depressor supercillii is the orbital portion of the orbicularis oculi that inserts into portions of the adjacent depressors, the superficial sur-

face of the inferior frontalis, as well as the dermis below the brow.^{42,43} The orbital portion of the orbicularis muscle originates in part from the medial canthal tendon and adjacent bone. Deep to all the depressors is the galeal fat pad, which lies immediately below the transverse head of the corrugator and helps in identification

of muscular landmarks.⁴⁴ The galeal fat is usually exposed clinically instantly after transection through the periosteum along the orbital rim (Figure 67-15).

Finally, paired temporalis muscles are located in each temporal fossa, where they originate and then insert on the coronoid process of the mandible. The importance of these muscles during upper facial rejuvenation chiefly pertains to their overlying fascia, which can be used to delineate surgical planes and aid in fixation. The spongy temporoparietal fascia is superficial to the dense and shiny white temporalis fascia. The temporalis fascia adheres to the temporalis muscles below and splits into a superficial and deep layer in the lower half of the fossa. For consistency, the superficial layer of deep temporalis fascia (which really describes only that portion of deep temporalis fascia at the level of the split and below) is subsequently referred to simply as temporalis fascia. In essence, this term will be used to describe any of this deep thick fascial layer that is seen clinically from the temporal crest down to the zygomatic arch (Figure 67-16).

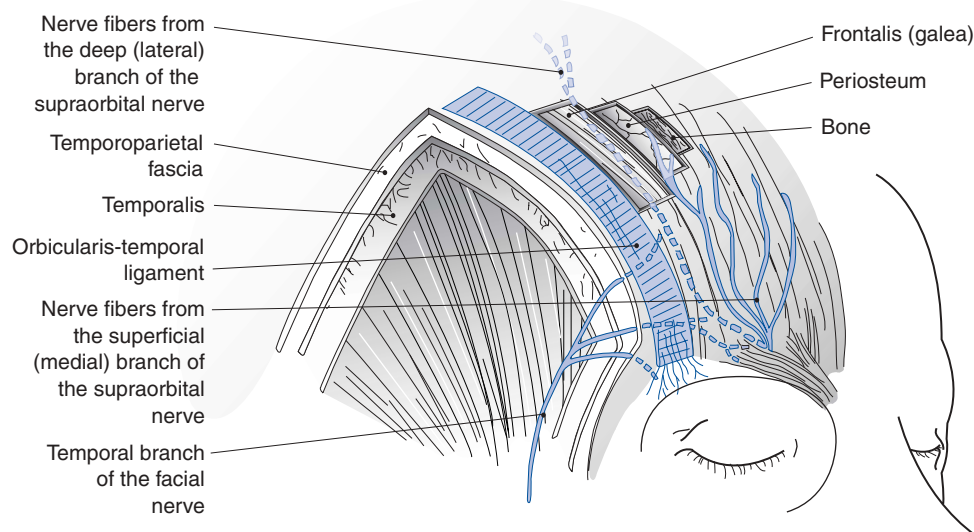


FIGURE 67-10 Layers of fascia are seen on each side of the zone of fixation (in blue). The layers must be elevated and connected to a uniform sliding plane surgically to achieve pleasing and long-lasting brow lift results, while not damaging the associated motor and sensory nerves.

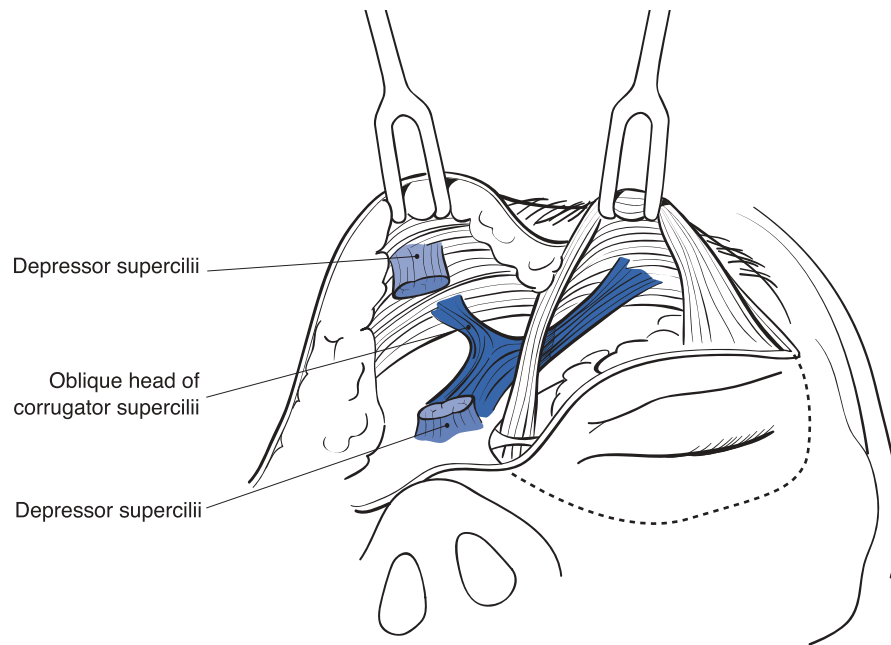


FIGURE 67-11 The oblique and transverse heads of the corrugator supercilii are seen behind the stump of the depressor supercilii. Both heads of the corrugator muscles and the orbicularis oculi insert into the dermis below the brow.

One method of fixation during brow lifting is the use of suture to fixate the temporoparietal fascia from below a skin incision to the dense and adherent temporalis fascia above the incision to elevate the lateral brow. Some surgeons advocate removing a window of temporalis fascia and exposing the underlying temporalis muscle in hopes of creating

scarification in this region and improving fixation longevity.¹²

Vessel and Nerve Anatomy

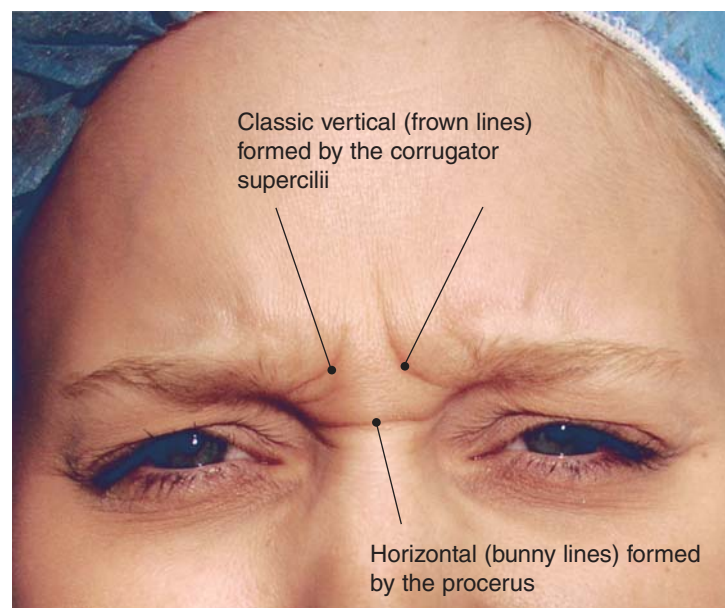
Blood supply to the upper face and scalp is plentiful and comes from multiple sources. Several major vessels of the upper face originate from the external carotid artery including the superficial temporal

artery and the facial artery. These give rise to the blood supply in the medial canthal region via the angular artery and in the lateral canthal region by way of the frontal or anterior branch of the superficial temporal artery. The internal carotid artery gives way to the middle meningeal artery and the ophthalmic artery. The ophthalmic artery then gives rise to the supraorbital and supratrochlear arteries, which exit their respective foramina and supply the majority of the forehead and midscalp with blood. The terminal arterial branches of the upper face have major anastomoses with adjacent vessels.

Venous drainage of the upper face follows the respective arterial supply but can be somewhat more variable. However, one particular vein, known as the sentinel vein (medial zygomaticotemporal vein), runs perpendicular through the temporalis fascia connecting the superficial and middle temporal veins (Figure 67-17).⁴⁵ The sentinel vein can most often be found approximately 1 cm lateral or posterior to the zygomaticofrontal suture line. It is clinically significant during endoscopic procedures because, if injured, it can result in impaired field visualization and significant bruising.

Nerve supply parallels arterial supply to some degree. The supratrochlear and supraorbital nerves, which are responsible for the majority of sensation in the forehead, exit via the same foramina or general location as do the supraorbital and supratrochlear blood vessels. The sensory nerves originate from the first division of the trigeminal nerve. The supraorbital nerve has two divisions after exiting its foramen: the deep (or lateral) division supplies the more lateral and posterior portion of the forehead and scalp, and the superficial (or medial) division pierces the frontalis and runs superficially to the muscle, supplying sensation to the forehead along the midpupil line (Figure 67-18). The location of the supraorbital nerve's exit is relatively consistent. The supraor-

FIGURE 67-12 Frown lines of the glabella are produced by the actions of the corrugator supercilii to produce the classic vertical wrinkles, whereas the actions of the more vertically arranged fibers of the procerus muscle produce the horizontal wrinkles seen across the bridge of the nose.



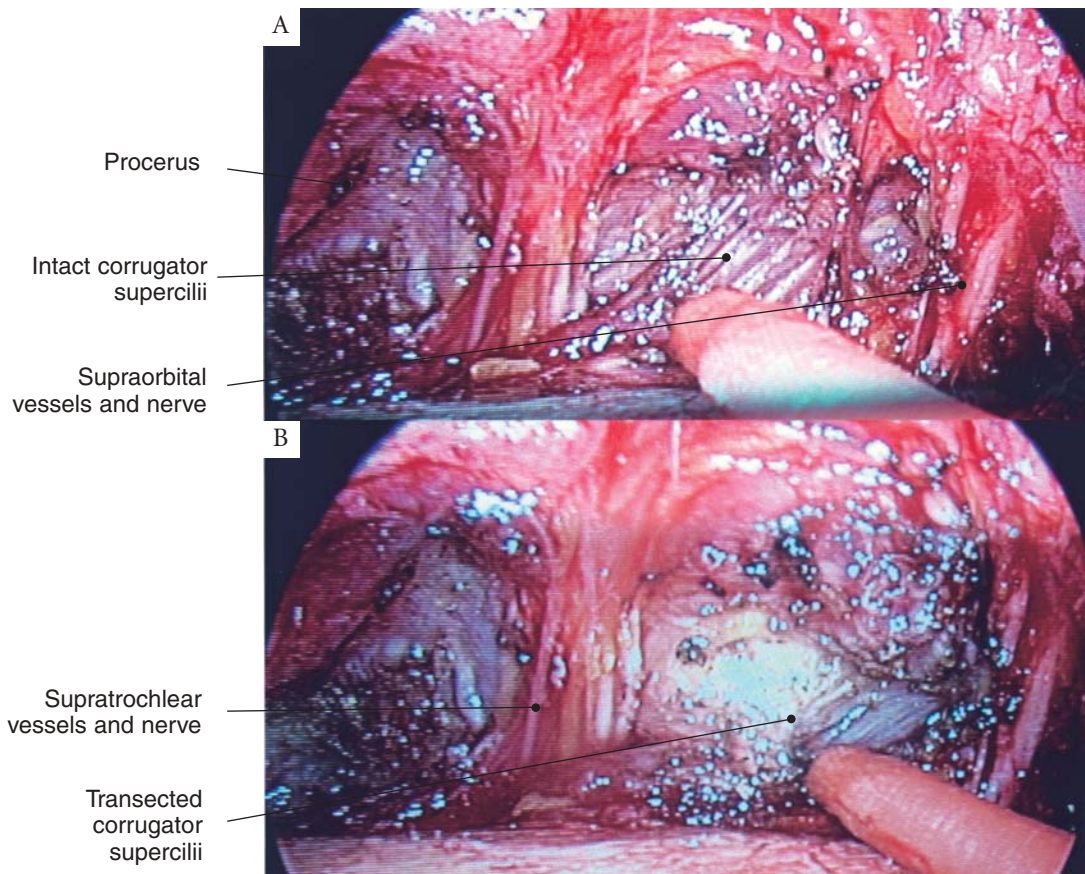


FIGURE 67-13 Endoscopic views of the right side of the forehead. Location of the corrugator supercilii relative to the supraorbital nerve (A) immediately before it is transected with a needle-tip cauterium (B). Following transection through the belly of the corrugator supercilii.

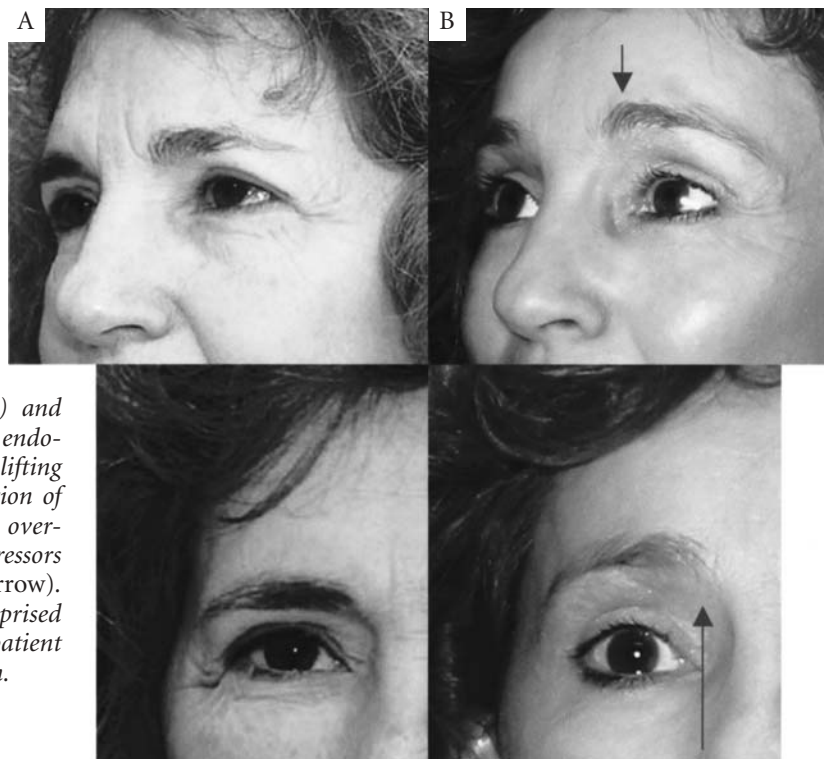

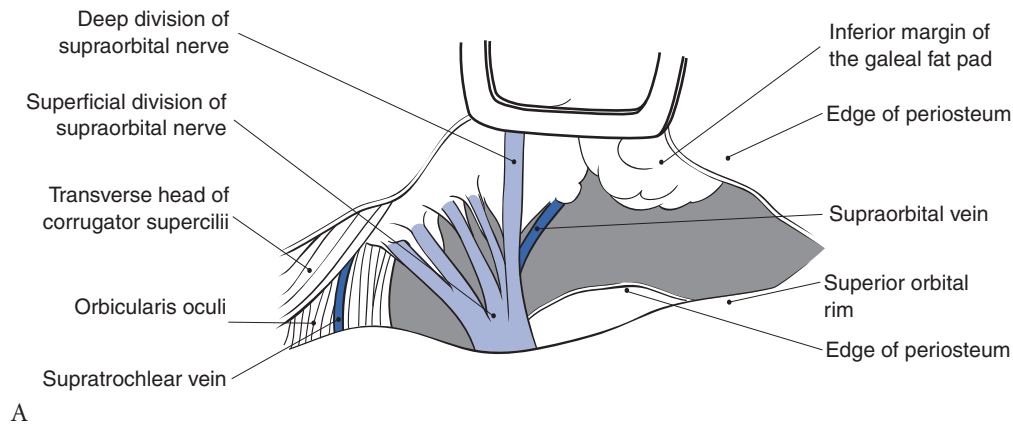
FIGURE 67-14 Before (A) and after (B) photos following endoscopic forehead and brow lifting demonstrating good elevation of the lateral hooding but over-resection of the medial depressors in the area indicated (arrow). This can result in a surprised look, especially when the patient elevates the brow, as shown.

bital foramen or notch is typically found within 1 mm of a line drawn in a sagittal plane tangential to the medial limbus (Figure 67-19).⁴⁶ The deep division has been known to exit as often as 10% from another foramen that can be as high as 1.5 cm above the orbital rim.

The supratrochlear nerves exit from around the orbital rim at an average of 9 mm medial to the exit of the supraorbital nerve.⁴⁶ The nerves supply sensation to the midforehead with some overlap from the supraorbital nerves. Infratrochlear nerves, also from division one of the trigeminal nerve, exit just below the supratrochlear nerves around the medial orbital rim to supply sensation to the upper nose and medial orbit. Zygomaticofrontal and zygomaticotemporal nerves are from the second division of the trigeminal nerve. They exit their respective small foramina and supply sensation to the lateral orbit and temporal regions of the face.

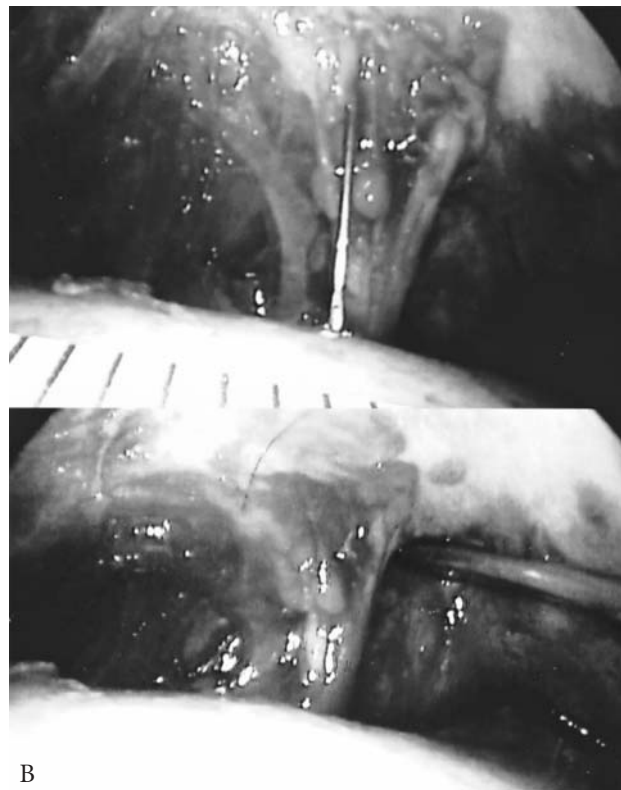
The facial nerve supplies motor innervation to the forehead and glabella.⁴⁷⁻⁵¹ The frontal (or temporal) branch of the facial nerve supplies the frontalis muscle, the superior portion of the orbicularis oculi, the superior portion of the procerus, and the transverse head of the corrugator supercilii. The zygomatic branch of the facial nerve supplies the medial head of the orbicularis oculi, the oblique head of the corrugator supercilii, the inferior portion of the procerus, and the depressor supercilii (Figure 67-20).

The auriculotemporal nerve, from the third division of the trigeminal nerve, supplies sensation in front of the ear to the temporal skin above the zygomatic arch and along the course of the superficial artery. It may be confused clinically during a face-lift with the frontal branch of the facial nerve. It can, however, be distinguished from the facial motor nerve because it runs within 1 cm anterior to the tragus of the ear and parallel to the superficial temporal artery. The much more significant frontal branch of the facial nerve



A

FIGURE 67-15 A, Right-sided forehead landmarks. B, Endoscopic view of the right supraorbital nerve and vessels. The first view is seen with a 27-gauge needle over the nerve trunk after it is placed through the skin of the brow level with the patient's medial limbus (iris).



B

runs an average of 2 cm anterior to the tragus when crossing the zygomatic arch. The temporal branch of the facial nerve crosses the arch at an oblique angle at an average of 2 cm posterior to the orbital rim. The depth of the temporal nerve is just below the SMAS at the arch and below the temporoparietal fascia immediately above the arch. The frontal (temporal) branch usually has divided into two rami at the level of the arch and has at least four branches by the time it reaches the level of the eyebrow.

Endoscopic Anatomy

Initial dissection must be performed to gain adequate space for the endoscopic equipment. This early dissection is performed in the posterior forehead and temporal regions; endoscopy-guided dissection is used for the last 2 cm above the orbital rim and zygomatic arch. Elevation of the deep tissues in this "safe zone" is essentially performed blindly through each of the small scalp incisions. Incisions and specific tissue release and fixation

techniques are highly variable among surgeons.⁵²⁻⁵⁹ I prefer to dissect within a completely subperiosteal plane medially to the temporal crest and in the plane immediately above the temporalis fascia below the temporal line on each side. Subperiosteal dissection in the lateral forehead helps to avoid injury to the deep or lateral division of the supraorbital nerve, which runs in the subgaleal plane near the zone of fixation. Some surgeons begin their dissection in a subgaleal plane in the posterior scalp.^{59,60} Regardless, a space is created in the safer posterior areas of the scalp to allow room for placement of an endoscope, which aids dissection in the more risky areas of the forehead.

The first anatomic landmark the surgeon must consider is the zone of fixation along the superior temporal crest. Its inferior edge is found near the superior lateral orbital rim. A convergence of fibers from the periosteum, galea, temporalis, and temporoparietal fascia interlace and fuse to form the zone of adherence, much in the same way the layers of tissue planes come together at the level of the zygomatic arch. The zone of fixation can be elevated bluntly at the hairline level and a couple of centimeters below, but as the surgeon approaches the lateral brow beginning approximately 2 cm above brow level, use of an endoscope aids dissection. At this point the ligament has branches of the temporal nerve within it, and care must be taken to remain against the bone and temporalis fascia below to avoid nerve injury. Another fibrous attachment, the orbicularis-temporal ligament, is also present here and contains motor nerve fibers (see Figure 67-17); it is the decussation of fibers from the temporoparietal fascia and of the temporal fascia that extends laterally from the orbital ligament. The zone of adherence becomes even more tenacious as the orbital ligament (see Figure 67-7) at the orbital rim level is approached. Slow meticulous dissection is required at this point to avoid nerve injury as well as injury to the sentinel

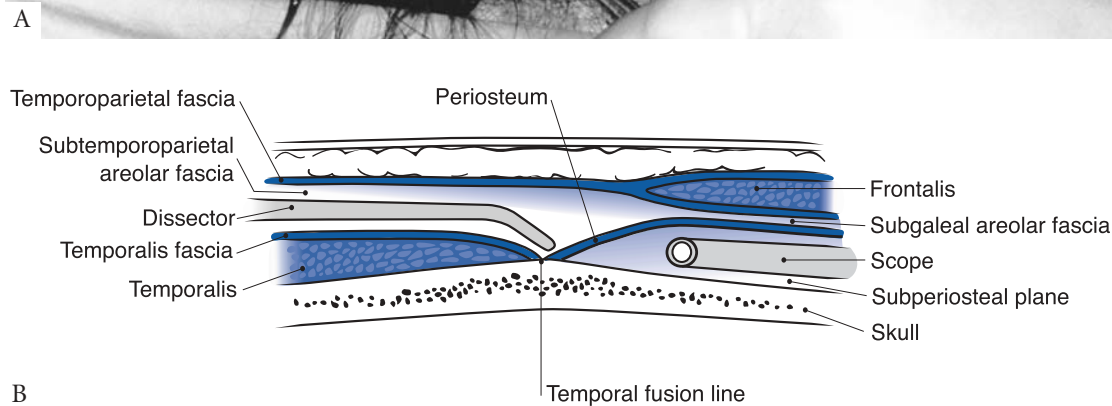
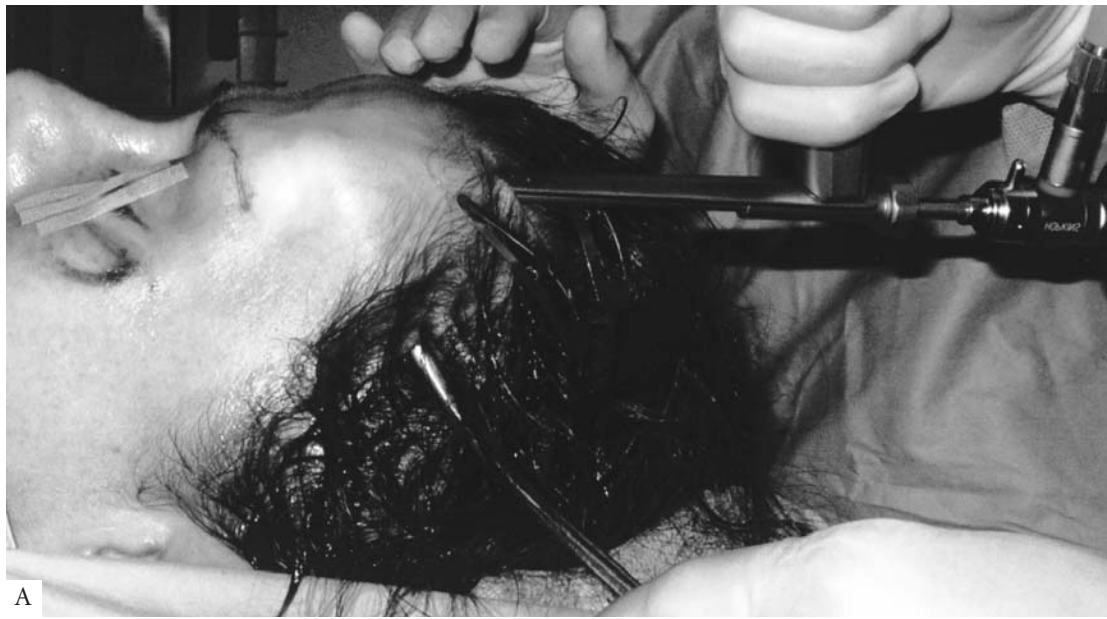

FIGURE 67-16 A and B, Endoscopic dissection must connect the tissue planes on each side of the temporal crest. Various approaches may be used as long as the anatomic planes seen above are sufficiently understood to allow proper tissue release, a clean endoscopic view, and protection of the facial nerve.

vein that is located within the orbicularis-temporal ligament approximately 1 cm laterally to the zygomaticofrontal suture. Careful dissection exposes an intact sentinel vein that can be seen piercing through the temporal fascia at a perpendicular angle and entering the temporoparietal fascia above (see Figure 67-17).

Dissection above the orbital rims in the subperiosteal plane should expose the entire superior orbital rim from each zygomaticofrontal suture. The curvature of the rims should be visualized so that transection through the periosteum can be made at the level of the rims. The nasofrontal suture may not always be seen but can be felt by the periosteal elevator used to lift tissue. When transecting through the

periosteum across the entire orbital rim, subgaleal fat is often encountered initially, except when the transection is directly

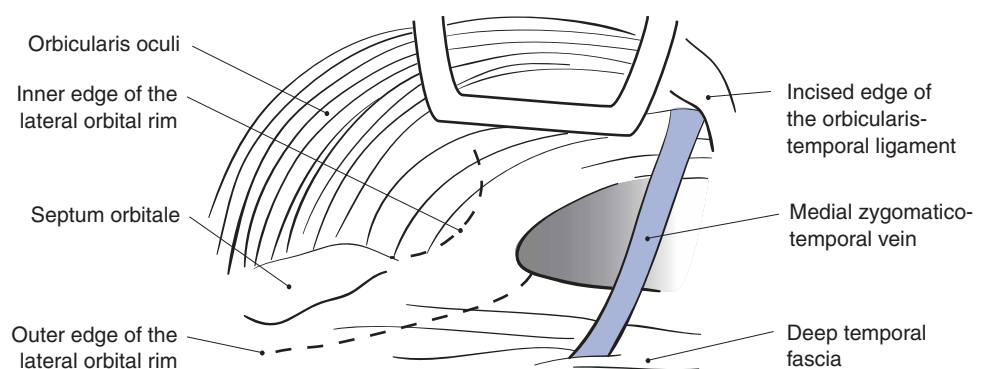


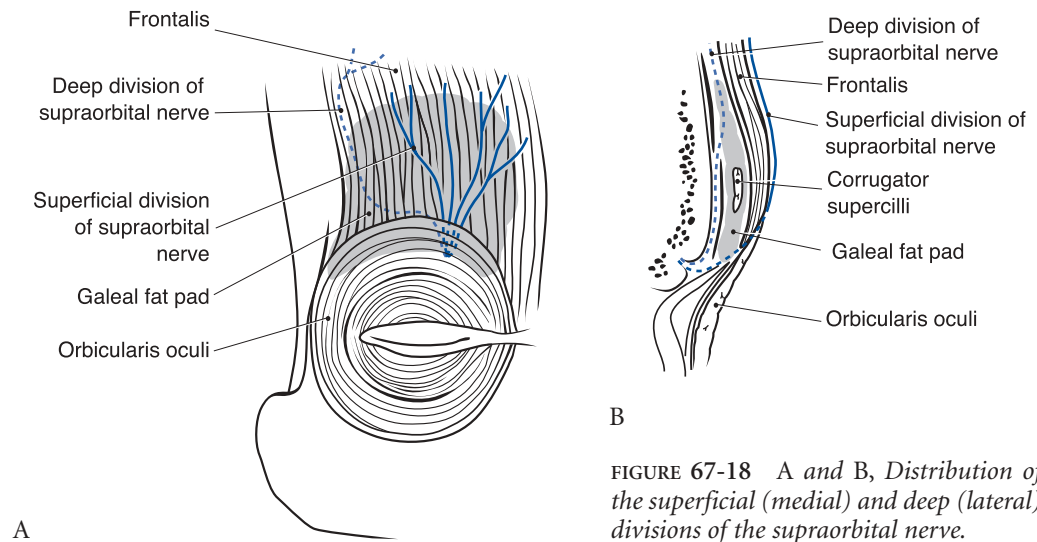
FIGURE 67-17 Dissection below the patient's right temporal crest is shown with release of the orbicularis-temporal ligament. The medial zygomaticotemporal (sentinel) vein seen here pierces the temporalis fascia approximately 1 cm posterior to the zygomaticofrontal suture line.

behind the supraorbital nerve at the rim level where the deep (or lateral) division of the nerve is closely adherent to periosteum (see Figure 67-15). Preoperatively marking a point on the brow at a level tangential to the medial limbus iris helps the surgeon to easily identify the location of the supraorbital vessels and nerves.⁴⁶ Dissection through the periosteum in this region should be performed slowly and superficially to avoid injury to these structures. The transverse head of the corrugator supercilii is seen at the orbital rim level behind the supraorbital vessels and nerves. The corrugator supercilii can be carefully transected or partially excised.⁶¹ Medially, the oblique head of the corrugator is encountered, and by a transection through this portion of muscle, the supratrochlear nerve and depressor supercilii muscle may be seen and protected from injury. Medially, in the glabella, the procerus muscle, which is variable in thickness, is seen. Care should be taken to avoid overaggressive muscle resection in thin patients as this can result in an atrophic defect in the glabella. Deeper dissection toward the skin level under the brow will lead to the orbicularis oculi but is typically not necessary to gain the desired effect (except with regard to the lateral orbicularis, where limited transection may improve lateral brow elevation).^{62,63} Also, one or more incisions through the periosteum at higher levels

under the frontalis muscle in the midline can be performed but is only required if deep horizontal lines are present.⁶⁴ It is more important to gain complete release of the retaining lateral ligaments, transection of those muscles causing glabellar lines, and adequate separation of the periosteum along the orbital rim to get the elevation of brow and forehead tissues for the most pleasing and long-term esthetic result.⁶⁵⁻⁷⁵

Preoperative Evaluation and Surgical Preparation

Determining whether a patient will benefit from a brow or forehead lift and which procedure will work best is critical to avoid disappointing the patient. Commonly the novice surgeon notices only horizontal forehead lines as an indication for a brow lift. Unfortunately, this is much less of a problem for most patients than is a low lateral brow position (hooding) or glabellar crease (see Figure 67-3). As discussed above, the ideal female brow position is above the orbital rim at a level that varies among individuals. An average distance of 5 to 10 mm of brow elevation above the rim in the lateral third generally looks most pleasing. Men require a straight-up elevation of the entire brow to avoid feminizing their appearance by overelevation of the lateral brow. In addition, men may benefit more from a standard upper blepharoplasty and local transpalpebral brow lift if the brow ptosis is minimal. As with any cosmetic surgery, a decision regarding the risks and benefits must be made and must conform to the patient's desires. Patient education is required so that they know the risks as well as what can *realistically* be achieved (Figure 67-21). Even with fairly aggressive muscle resection and forehead elevation, patients often form new dynamic lines in the upper face following surgery. Lateral crow's-feet owing to the action of the orbicularis oculi when smiling may appear improved following a brow lift since the muscle is unfolded. However,



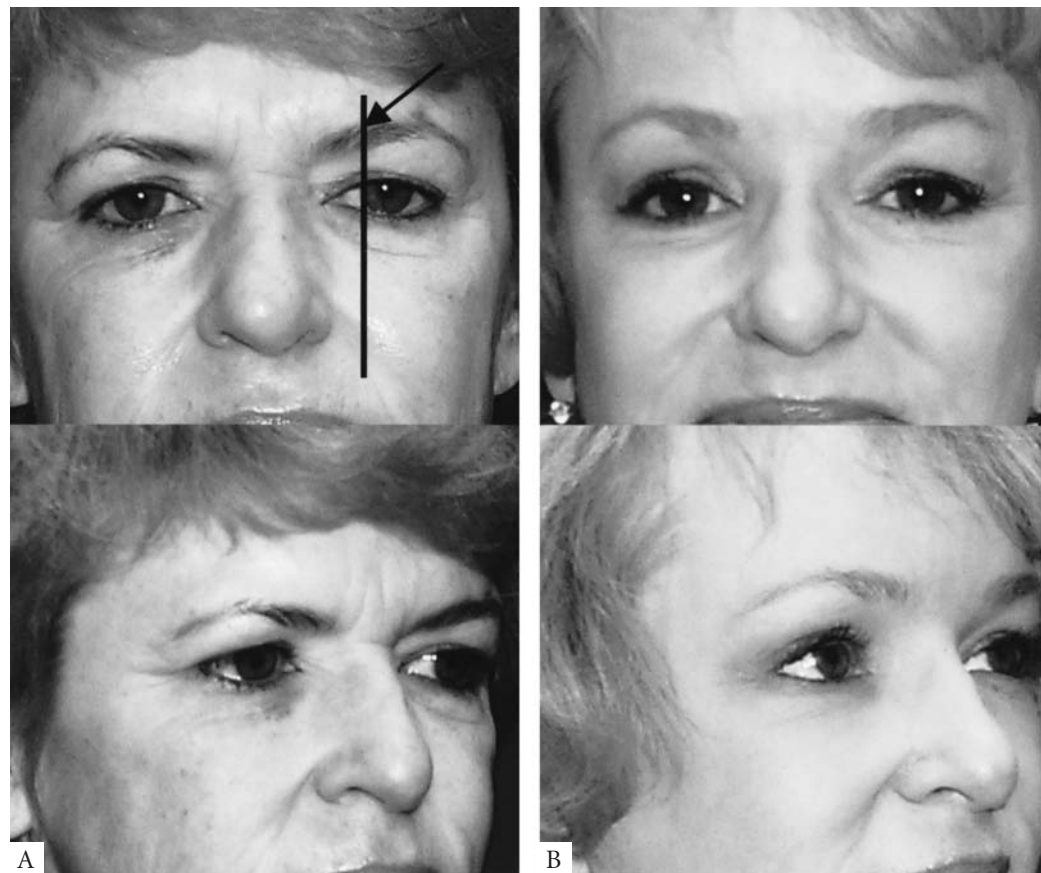A

B

FIGURE 67-18 A and B, Distribution of the superficial (medial) and deep (lateral) divisions of the supraorbital nerve.

they are not completely eliminated by brow lifting alone, and the patient must understand that botulinum toxin therapy may be required to treat these particular lines on an ongoing basis.⁷⁶

In addition to lines on the forehead, lines in the glabella, brow ptosis, and the condition of the patient's skin must also be evaluated. Intrinsic skin and collagen damage from the effects of sun, age, and smoking



A

B

FIGURE 67-19 A, Preoperative photograph demonstrating the location of the supraorbital vessels by a line drawn vertically from the medial iris. B, One and a half years following an endoscopic forehead and brow lift. No blepharoplasty was ever performed.

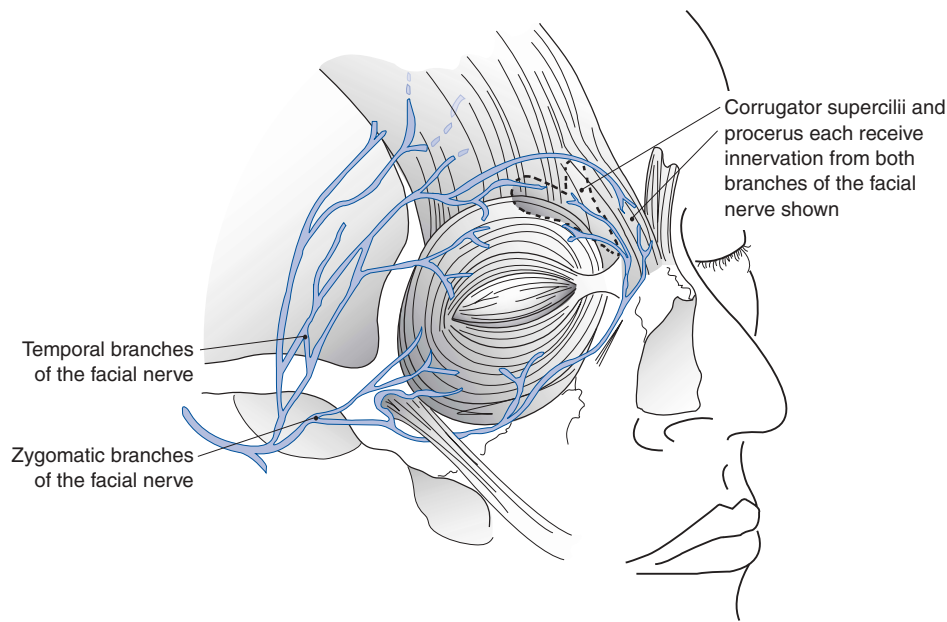


FIGURE 67-20 Motor nerve supply to the forehead depressor muscle comes from both the temporal and zygomatic branches of the facial nerve.

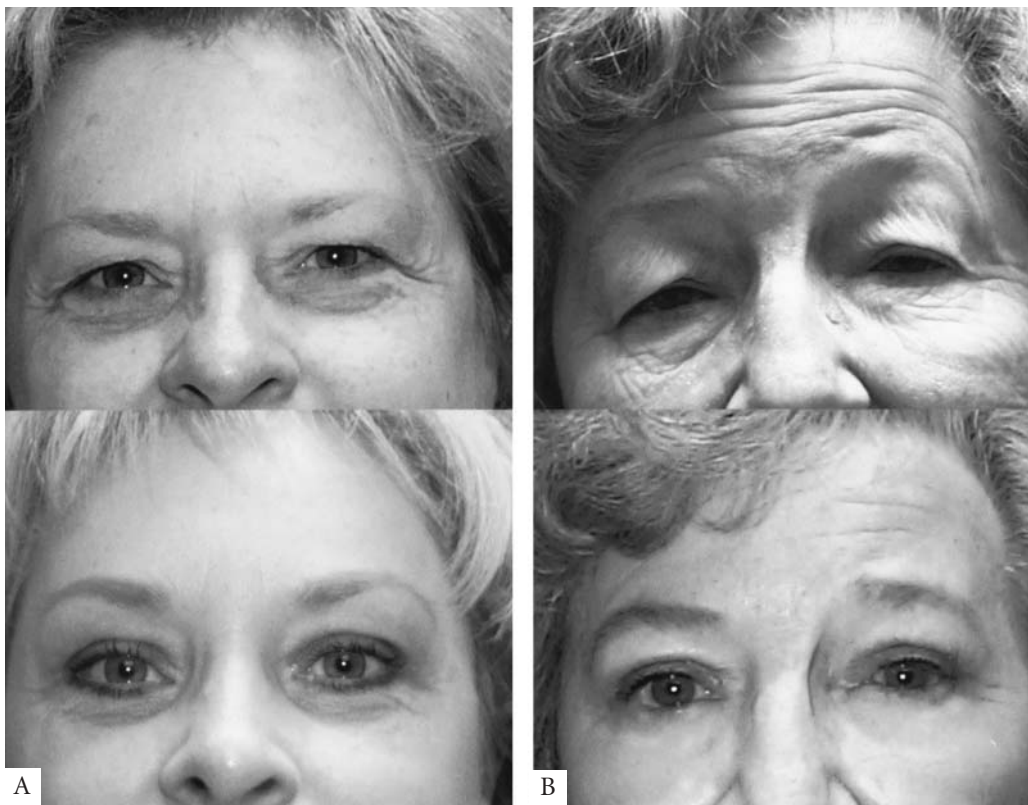

FIGURE 67-21 A, Because of both brow ptosis and upper eyelid laxity, the patient shown required upper blepharoplasties as well as endoscopic forehead and brow lifting to achieve the results she desired. B, The patient is shown before and after only blepharoplasty and full-face laser skin resurfacing. She has multiple problems including asymmetry of the brows owing to a blepharospasm on the left side, eyelid asymmetry and severe laxity, pseudoelevation of the brows owing to frontalis compensation for severe eyelid ptosis, and severe actinic skin damage. She is not a good candidate for simultaneous brow lifting since a change in brow position will likely occur following the removal of the eyelid ptosis. She is a good candidate for botulinum toxin therapy on her left side.

are not treated by lifting alone. Topical skin care (eg, retinoic acid, microdermabrasion, pulsed-light therapy, sunblocks) along with possible surgical resurfacing must be considered.⁷⁷⁻⁷⁹ In general the forehead can be treated safely with chemical peels or laser skin resurfacing into the dermal level simultaneously with brow-lifting procedures, provided the lifting is performed with a subgaleal or subperiosteal technique rather than a subcutaneous one. Finally, bony irregularities or hypertrophic bony orbital rims can be evaluated for treatment by means of a cephalometric radiograph or computed tomography (CT) scan as required. Bony contouring can be performed on a limited basis endoscopically, but a major reduction for significant bone hypertrophy such as a frontal boss is best treated with an open (coronal) approach. The amount of bone reduction is limited by the pneumatization of the frontal sinus, which is best evaluated by CT. Although treatment planning for placement of bone tunnels does not require a preoperative CT, a standard cephalometric radiograph may help to reassure the surgeon regarding the thickness of corticocancellous bone available.

As with any surgical procedure, appropriate preoperative laboratory and other indicated tests must be performed. Written instruction are given to the patient regarding pre- and postoperative care, including instructions for shampooing hair with antibacterial soap or other antiseptic shampoo and avoidance of the use of hair spray or other hair products immediately prior to surgery. The patient should be thoroughly instructed on the critical need to avoid all medications that may cause platelet dysfunction 10 days prior to surgery (including aspirin and other non-steroidal anti-inflammatory drugs, vitamin E, and many over-the-counter herbal supplements). Endoscopic techniques require a very dry operating field that necessitates strict avoidance of these medications as well as proper preoperative injection of vasoconstrictive agents.

Prior to anesthesia, photos are taken and the patient is marked while awake and sitting up. Following the introduction of general anesthesia or intravenous sedation, the patient is prepped and carefully injected with local anesthetic with epinephrine. I prefer to use a local anesthetic with 1:100,000 epinephrine along the entire orbital rim, and a tumescent anesthesia solution (250 cc of normal saline mixed with 1 cc of 1:1,000 epinephrine and 20 cc of 2% lidocaine) in the remaining upper forehead, temple, and posterior scalp. Careful injection in the desired tissue planes helps to avoid the formation of a hematoma during the injection and allows for a nearly bloodless procedure. Minor shaving of hair along the marked incision lines is performed if desired immediately prior to the final preparation and draping of the area.

Coronal Forehead and Brow Lift

Still one of the most common approaches for forehead and brow lifting, the classic coronal lift involves an incision across the entire forehead from ear to ear, staying well behind the hairline.^{80–88} Dissection is typically in the subgaleal or subperiosteal plane and then connects to the subtemporoparietal plane laterally. This gives great exposure of the entire orbital rims for bony osteoplasty, if required, and treatment of muscles that require resection including the depressors (corrugator and procerus) as well as the frontalis. Heavy horizontal forehead creases can be addressed with this technique either by way of midline myotomies or minor midline thinning of the frontalis. Major resection of the frontalis should be avoided to prevent postoperative irregularities and strange facial expressions during frontalis movement. The lateral frontalis should be avoided to prevent nerve damage, ptosis, and other irregularities.

Regrettably, the coronal lift also has the disadvantages of a long incision and a significant elevation of the hairline.

Patients with a high hairline are not good candidates for this technique since a significant amount of scalp excision is required. Many surgeons believe this scalp excision is a reasonable trade-off because they feel that the technique gives a more lasting approach than do newer endoscopic techniques. If performed correctly, the endoscopic technique can be as long lasting and possibly more precise than open brow-lifting techniques. Care must be taken with the coronal lift to avoid elevating the medial brow too much and creating a very high hairline. Roughly, to gain 1 cm of brow elevation, 1.5 to 2 cm of scalp must be excised with this technique. The amount of tissue excised is not a precise determinant of the amount of brow elevation obtained. Scoring of the underlying fascia and muscle resection can cause the tissue to stretch oddly, making prediction of the exact brow elevation difficult.

The benefits of the coronal lift include great exposure and relatively easy dissection. It can also be used to extend the procedure into a deep-plane face-lift by dissection over the zygomatic arches and onto the zygoma and masseter. This much more aggressive lift gives excellent elevation of the midface but greatly increases postoperative edema and the potential for motor nerve damage. The extended technique should only be attempted by an experienced surgeon,^{89–93} and careful consideration should be given to alternative treatments. Comparatively, the basic coronal lift is an easier procedure for the novice surgeon. When selecting this tried-and-true method, one should take into account the disadvantages, including the lengthy scar and possible hair loss, significant scalp anesthesia, and a significantly elevated hairline.

Trichophytic or Pretrichial Forehead and Brow Lift

Although trichophytic and pretrichial lifts are sometimes thought to be the same procedure, the *pretrichial* lift actually involves

an incision in front of the hairline. With this procedure, hair does not grow anterior to the incision, leaving a visible scar in front of the hairline. In contrast, in the *trichophytic* lift, although still at the frontal hairline, the incision is placed just behind the hairline. This incision is beveled so that follicles in front of the initial skin incision survive and hair grows anterior to the incision to better camouflage the resulting scar. It should be noted that many surgeons use these terms interchangeably. Even better than the trichophytic lift is the irregular trichophytic hairline, which not only employs a beveled incision but creates a wavy pattern along the hairline for a more natural postoperative appearance compared with a straight-line scar.

Regardless of the specific incision design, the ultimate advantages of the trichophytic forehead and brow lift include great exposure (similar to that with the coronal approach) and the ability to lower a high forehead. Unlike the classic coronal lift, bare forehead skin is excised from the hairline. Also, lateral incisions and dissection are usually limited with this technique unless required. Incision design can even improve hair thinning in the temporoparietal areas by excising the area of hair loss and bringing forward areas of dense hair-bearing scalp. The posterior scalp and hairline can be brought forward to lower a high forehead by almost any amount. The more lowering that is desired, the more posterior is the dissection and release. Limited or no posterior dissection can be performed if the hairline is to remain at the same level.

The forward dissection is the technique that varies the most among surgeons. A totally subperiosteal technique versus a subgaleal technique is an option. A subcutaneous technique has recently become more popular, particularly when the depressors in the lower brow do not require treatment.⁹⁴ Staying superficial to the frontalis breaks the dermal insertions that create deep horizontal rhytids. The subcutaneous lift is occasionally combined

with deep dissection to treat glabellar lines as well as horizontal lines in the forehead.

Overall, the trichophytic technique of forehead and brow lifting is an invaluable tool for any surgeon performing facial cosmetic surgery. When a patient presents with a high forehead and low brow position, the trichophytic approach is the procedure of choice to correct both problems. The main disadvantage is the potential for a visible incision despite best efforts. All prospective patients considering this technique must be informed of the chance that there may be a visible scar at the hairline. Surprisingly, when presented with the potential problems and given the choice, many patients prefer to undergo an endoscopic approach with a slight elevation in hairline rather than risk a visible hairline scar. Still, the patient with an extremely high hairline is often thrilled with the lower hairline obtainable only with the trichophytic approach. Attention to detail and gentle soft tissue management are essential to attaining a natural hairline and hidden scar with this popular technique.

Endoscopic Forehead and Brow Lift

Early attempts at endoscopic surgery began over a century ago with Nietzsche's description of a crude cystoscope. A few decades ago endoscopic surgery progressed through use in upper gastrointestinal

examinations and then intra-abdominal surgery. However, facial endoscopic cosmetic surgery did not blossom until the early 1990s. Over the past decade the endoscopic forehead and brow lift procedure has been considered by many to be the state-of-the-art technique for upper facial rejuvenation.⁹⁵⁻⁹⁷ It is versatile and can be combined with many other procedures. The most noted benefits of the endoscopic technique are the smaller scars hidden in the hairline and selective brow elevation without the need for removal of any hair or skin (Figure 67-22).

The technique involves several incisions placed strategically behind the hairline to gain access for early blunt dissection and insertion of the endoscope and tissue retractor. Other incisions can be used as ports for dissecting tools such as periosteal elevators, electrocautery, lasers, tissue graspers, and suction instruments. Among surgeons a variety of incision (port) designs are used. Fixation points are usually placed at these incision sites; therefore, I prefer five separate 2.5 cm long incisions placed for easy access but mostly for ideal fixation placement. Each of the five incisions begins approximately 1 cm posterior to the hairline. One is placed in the midline in the sagittal plane and two in the parasagittal plane tangential to the lateral third of the brow (where maximum lift is typically desired in females). This same

incision can be moved slightly medially in male patients to give a more even brow elevation. The midline incision plus the two parasagittal incisions are aligned vertically to avoid unnecessary transection of sensory nerves originating from the supra-orbital nerves below. The two parasagittal incisions are placed medial to the temporal crest to gain access to skull bone rather than the more lateral temporalis fascia. Bone is the strongest fixation tissue available and ideally should be used thus.⁹⁸⁻¹⁰⁰

It is important to access the subperiosteal plane easily for a clean future endoscopic view. Accidental placement of the parasagittal incisions too far laterally over the zone of fixation or temporalis muscle makes pocket development difficult and obscures future endoscopic visualization. Moreover, the parasagittal incisions are located in a thick area of the frontal bone where there is a low density of venous lakes. Placing the incision here helps to prevent accidental intracranial injury during bone tunnel creation or placement of bone screws.

Lastly, two temporal incisions are made, one on each side of the head, for direct access to the thick temporal fascia. These incisions are placed perpendicular to the desired elevation vector from the lateral canthal region. Coincidentally, the temporal incision parallels the course of the temporal branch of the facial nerve

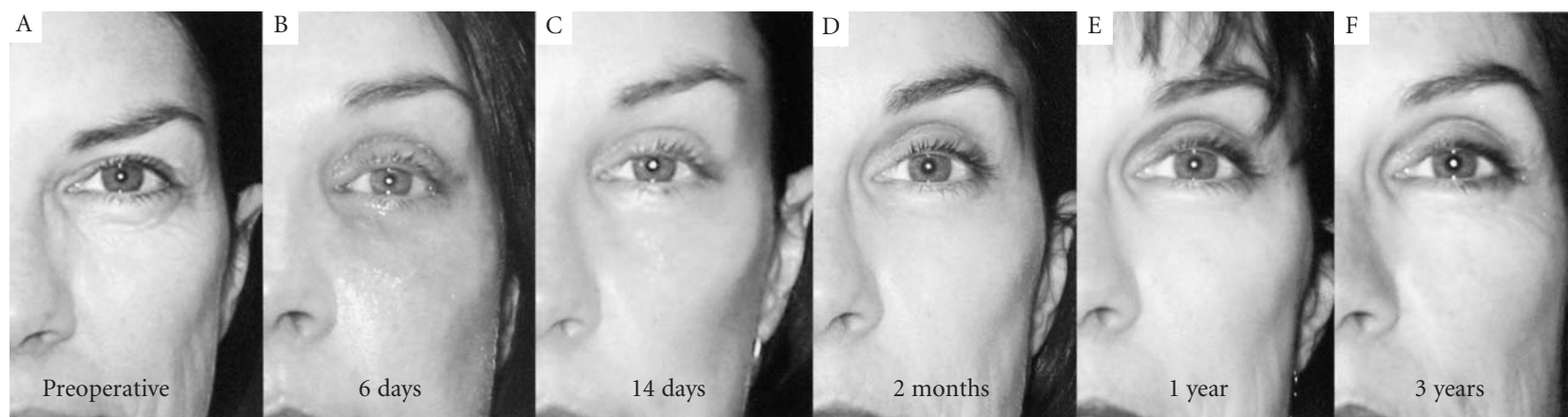


FIGURE 67-22 A to F, Sequential appearance following endoscopic forehead and brow lifting (eyelid and skin resurfacing procedures were also performed). Slight overelevation of the brow is noted for 6 days after surgery, as expected. The brow position remains very stable from 2 weeks to 3 years after the surgery.

that is located 2 to 3 cm inferior to this incision. It also parallels the superficial temporal artery and vein. Arranging the three medial incisions on a vertical axis and the two temporal incisions in an oblique position to parallel the nerve and blood supply in each area can reduce interference with sensation and vascular supply to the scalp.

Dissection is performed through the above incisions down through periosteum medial to the temporal crest and down to temporalis fascia lateral to the crest. Some surgeons may elect to use a subgaleal rather than subperiosteal placement of the incision medially. Total subperiosteal dissection medial to the temporal lines rather than subgaleal dissection leads to better fixation and long-term stabilization (see Figure 67-22).

Blunt and blind dissection can be carried out after reaching the subperiosteal and subtemporoparietal planes through the five incisions. Finger dissection and long curved endoscopic periosteal elevators are used to lift the tissue anteriorly to a point 2 cm above the orbital rims and zygomatic arch. Posteriorly blunt dissection should elevate the temporal tissues a few centimeters behind the ear, where the temporal fossa becomes self-limiting. The subperiosteal dissection above needs to elevate the scalp at least 10 cm posteriorly but can extend as far back as the lambdoid suture. Once these areas are freed, a connection can be made from the temporal region to the subperiosteal dissection through the upper portion of the zone of fixation at the temporal crest by finger dissection (Figure 67-23). Blind release of the more inferior portion of the temporal line where the facial nerve crosses should be avoided. Endoscope-guided dissection here helps to prevent nerve injury. Using finger dissection the upper zone of fixation is broken through proceeding from the temporal incision toward the medial scalp, rather than vice versa, to prevent creation of a false tunnel in the spongy or

foamy temporoparietal fascia. False tunnels along the temporal crest create problems when the endoscope is inserted through the parasagittal port to visualize the lateral forehead; the tunnels force the placement of the endoscope in a more superficial plane within the temporoparietal fascia, which greatly increases the chance of nerve injury. Therefore, it is critical to stay firmly against the periosteum and the temporalis fascia when initially elevating the scalp and forehead.

Following blunt elevation of the scalp from each incision for complete flap elevation, the endoscope is normally inserted through one of the three more medial incisions. Poor initial blunt dissection makes the initial endoscopic dissection feel very tight, and care must be taken not to perforate the skin by excessive retraction. Medial dissection over the nasofrontal suture and orbital rims is per-

formed under direct endoscopic vision with a curved and smooth elevator to avoid inadvertent tearing of the periosteum. The periosteum may be thin in some patients, in whom a straighter elevator may be used to transect the periosteum at the level of the rim (arcus marginalis). However, the entire rolled edge of the orbital rim must be visualized before proceeding with periosteal incision (Figure 67-24). Typically the periosteum is more precisely incised with a needle-tip cautery or laser set at low power. The supraorbital nerves and vessels as described earlier are at a level tangential to the medial limbus and are immediately behind (superficial to) the periosteum from the internal endoscopic view.^{46,101} This necessitates meticulous cautery dissection here to avoid injury to these structures (see Figure 67-24). Suction placed by an assistant from another port is required to maintain

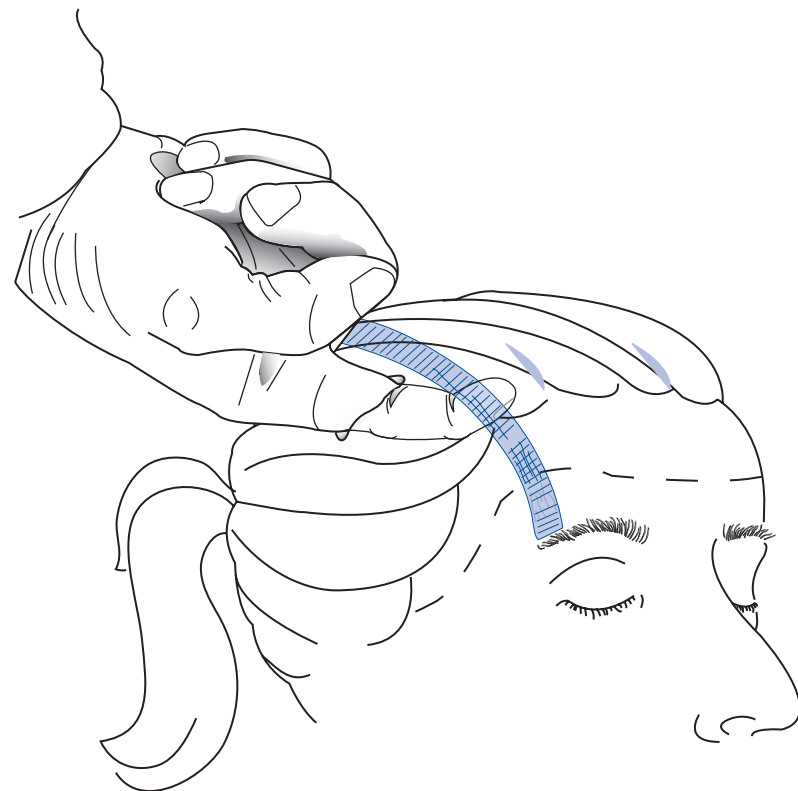


FIGURE 67-23 Blind finger dissection is performed initially, avoiding overzealous dissection inferiorly. Dissection proceeds from the subtemporoparietal plane laterally to the already elevated subperiosteal plane medially. The opposite direction of elevation (medial to lateral) may produce false tunnels in the temporoparietal tissue, which impair future endoscopic vision.

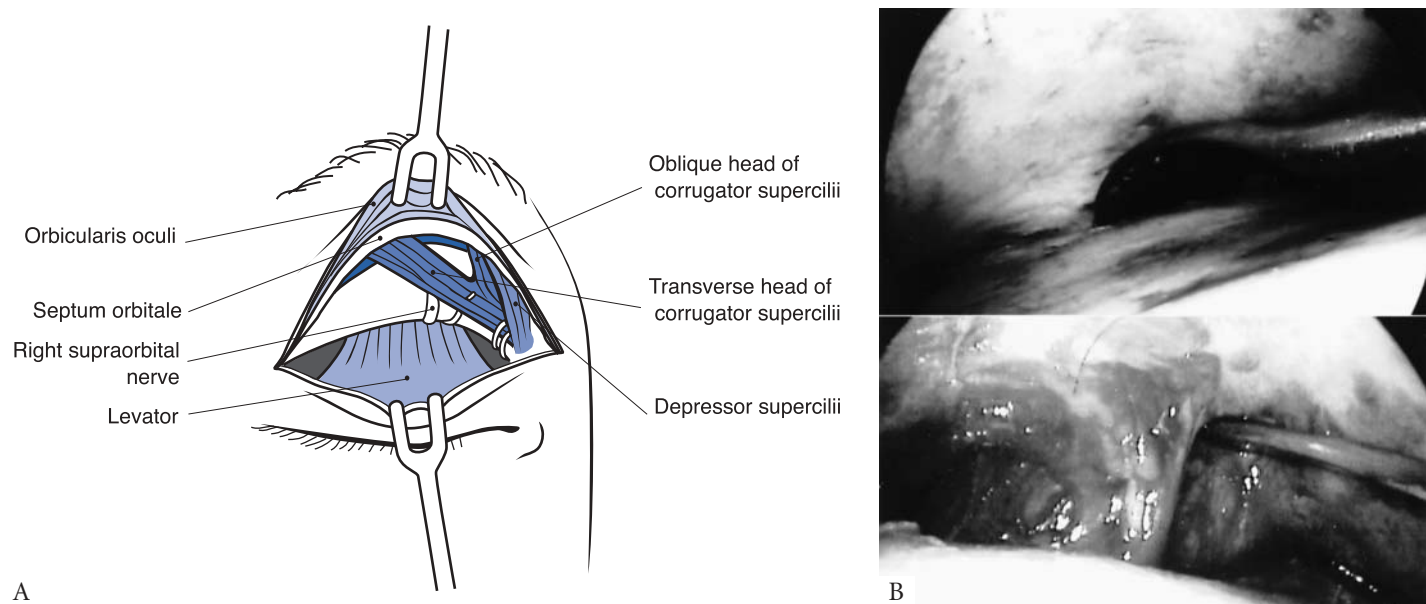


FIGURE 67-24 A, This line drawing demonstrates the orbital rim and local depressor muscle as seen from a transblepharoplasty incision. B, Endoscopic photographs show the rolled border of orbital rim prior to periosteal release in the first view and the supraorbital nerve and vein in the next view after excising through the periosteum.

a clear view when using cautery or laser. Temporal incisions work well for suction ports during dissection over the rims since the endoscope and cautery take up most of the room through any of the middle three incision sites. With clear and near bloodless dissection at this point, transection can be performed through the corrugator supercilii and procerus. If unwanted bleeding is encountered and cannot be controlled easily with pinpoint accurate cautery, then pressure should be applied externally over the rim until improved visualization allows for control of bleeding without nerve damage.

Vertical rhytids in the glabella created by the corrugators can be improved greatly by transection through these muscles. Likewise, horizontal glabellar lines are treated by transection of the procerus muscle that creates these particular facial wrinkles. Some surgeons advocate more aggressive surgical avulsion of these muscles with endoscopic biopsy forceps. Aggressive muscle removal may lead to a more permanent treatment of glabellar lines compared with isolated transection only, but should be avoided in most cases owing to an increased risk of significant postoperative

irregularities and abnormal facial expression. As a rule, patients prefer a more natural appearance with some minor return of frown lines to risking a bizarre facial expression and glabellar depression.

Once the periosteum is completely freed across the orbital rims and appropriate muscles have been treated, the cut periosteal edges are spread apart (periosteal elevators work well for this) by at least 1 cm to aid the release at the arcus marginalis. This allows significant and long-term brow elevation. Next the lateral orbital rim must be exposed in the subperiosteal plane after careful release below the zone of fixation and orbital ligament. Dissection along the anterior and inferior aspects of the temporal crest must be performed cautiously to avoid temporal nerve injury. Overzealous retraction of the dense tissue here that contains the nerve can result in nerve damage. Staying snugly against periosteum and the temporalis fascia helps to prevent nerve damage and produces a much cleaner dissection. Slowly creating a distinct plane of dissection down to the zygomaticofrontal suture line and avoiding excess retraction helps to prevent unwanted bleeding from the sen-

tinel vein (zygomaticotemporal vein), which needs not be sacrificed for a standard endoscopic forehead and brow lift.

Dissection for a standard endoscopic brow lift should not proceed all the way to the zygomatic arch but should stop approximately 1 cm above this level. If an extended midface lift is planned and there is a desire to elevate tissue over the zygomatic arch itself, then dissection must go below the superficial layer of deep temporal fascia just above the arch. Abbreviated midface lifts performed simultaneously with endoscopic brow lifts may simply stay in the subperiosteal plane along the lateral orbital rim and avoid the more risky full-arch release. The beauty of the classic endoscopic brow lift is its versatility and the ease with which additional procedures can be combined simultaneously with this elegant cosmetic surgery. For instance, the temporal incision of an endoscopic forehead lift can easily be extended inferiorly to meet up with the preauricular incision from a standard lower face-lift. Also, midface lifting (with intraoral dissection) can connect the intraoral subperiosteal dissection over the zygoma to the subperiosteal plane from the endoscopic brow lift

through a tunnel near the lateral orbital rim (Figure 67-25).

After all dissection is complete, appropriate elevation and fixation is required (Figure 67-26). Many techniques have been described such as tissue suture only, bone screws and plates, resorbable screws, bone tunnels, local skin excision, temporalis muscle exposure for added scarification, tissue glue, and tight head wraps.¹⁰² Regardless of any specific fixation technique, the key to long-term fixation is adequate lower forehead tissue release during endoscopic dissection. Failure to adequately release internal tissue results in a relapse of brow ptosis, even with heavy fixation and the appearance of a “nice” lift during surgery.

Once complete internal release of the forehead is obtained, the specific lifting vectors must be determined for the most pleasing esthetic effect. The lateral third of the female brow is elevated to the greatest extent, which is up to 1 cm above the orbital rim. The medial brow should be only slightly above the rim level and

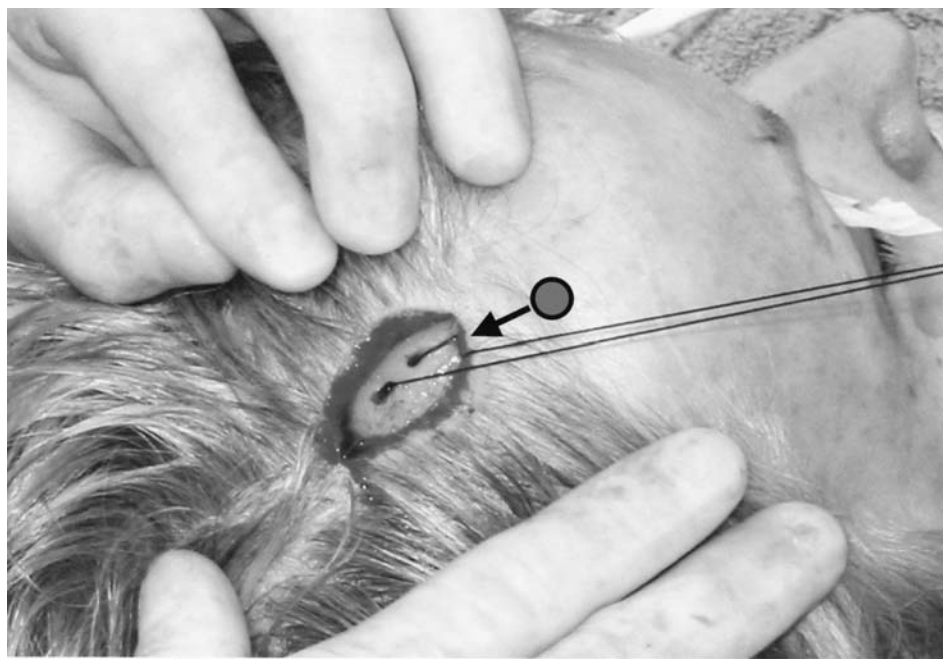


FIGURE 67-26 Example of bone tunnel fixation shown at the site of the right parasagittal incision. The anterior circle represents the position of suture placement through the galea, which elevates the lateral brow toward the bone tunnel.

definitely below the middle and lateral brow levels to avoid a surprised or bewildered expression (see Figure 67-14). Typically the glabellar region is elevated on

its own without the need for midline fixation, which helps to avoid overelevation medially. The lateral third of the brow is lifted straight up and fixated at the level of the hairline. The galeal tissue is typically secured to bone at this point, while the lateral brow is held at the desired height or 1 to 2 mm above the desired level.¹² Very little relapse occurs with proper technique and averages only 1 to 2 mm after 2 weeks. Measurements can also be made with clear circular templates from the pupil to brow to help improve symmetry. The brow position remains very stable following this early recovery period (see Figure 67-22). A question remains as to the time required for complete fixation of the periosteum. Some animal studies suggest a full 12 weeks are required for what is termed *full histologic periosteal refixation*.¹⁰³ However, there is clinical evidence suggesting adequate fixation occurs in as little as 7 days. An example is the common fixation technique used by many surgeons who place a single transcutaneous bone screw at each parasagittal incision, which is removed

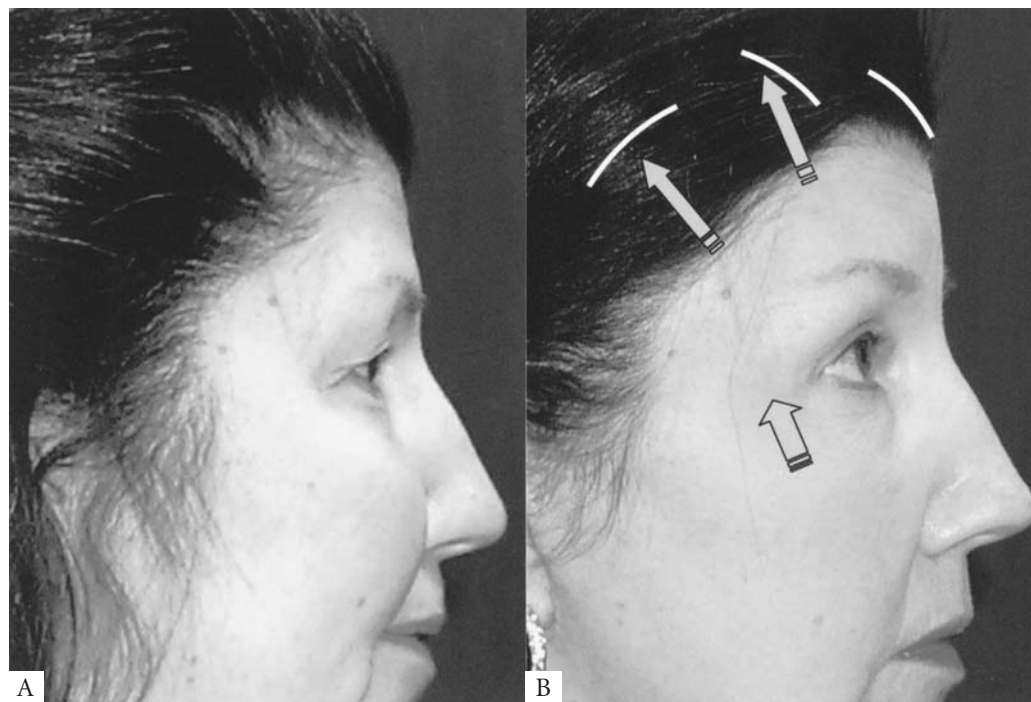

FIGURE 67-25 Views before (A) and after (B) an endoscopic forehead, brow, and midface lift. Arrows represent vectors of lift. Fixation is performed at the level of the hairline through the temporal and parasagittal incisions shown.

after only 1 week. The 1-week fixation technique has been used with success for many years. It has been suggested that longer bony fixation may provide longer-term retention and less early relapse that some have considered normal. The key to long-term fixation seems for now to be determined usually by proper tissue dissection and release.

Although there are many fixation techniques, the use of bone tunnels at the parasagittal incisions appears to be one of the best methods for fixing the galea and periosteum near the hairline to a bone tunnel created posteriorly under the incision using a single heavy suture (see Figure 67-26). Fixation of the lateral tail of the brow is performed at each temporal incision, where an isolated heavy suture pliates the temporoparietal fascia in a posterior and superior vector to the thick temporalis fascia. Optional creation of a small window of exposed temporalis muscle in this area may aid in internal scar formation and fixation. The vector of lift at this outer tail of the brow follows a line drawn at an angle from the outer nasal ala that passes just beside the lateral canthus (see Figure 67-25).

Final closure of the hair-bearing scalp incisions can be performed with skin staples only with excellent scar formation since no skin is excised and no pressure exists at the incision sites. Redundant tissue (forehead skin) created by an average of 1 cm of brow elevation is easily distributed evenly over the posterior 15 to 20 cm of elevated scalp, which essentially absorbs or redistributes this excess tissue with few to no signs of bunching. Because of this phenomenon, the endoscopic forehead and brow lift tends to elevate the hairline only a very small amount compared with the open skin excising coronal technique.

Interestingly, in a survey performed in 1998 of American Society of Plastic Surgeons members, of the total 6,951 brow lifts performed by 570 members who

returned the questionnaire, 3,534 involved a coronal technique and incision and 3,417 were performed endoscopically. The most noted difference was the higher risk of hair loss with the coronal technique; however, both techniques enjoyed very low overall complication rates.

Direct Brow Lift

The direct brow lift involves excision of an ellipse of skin adjacent to and just above the eyebrow (Figure 67-27). A beveled incision is used to parallel the hair follicles of the brow or so that some follicles remain at the base of the bevel to grow later above the scar. The dissection remains in the subcutaneous plane to avoid muscle or nerve injury.

Advantages of the direct brow lift are that it is a simple procedure (with an easy two-layer closure), it can be performed under local anesthesia, and it can treat brow position asymmetries. It remains a

good alternative technique that may be an excellent option for an elderly patient who has severe brow ptosis and heavy wrinkles but cannot tolerate more extensive surgery and would benefit from a short procedure under local anesthesia. The main disadvantage is the potentially visible scar immediately above the brow.

Midforehead and Brow Lift

Incisions made in the middle or upper forehead regions have similar advantages and disadvantages to the direct brow lift.¹⁰⁴⁻¹⁰⁷ The incisions are made on each side of the forehead in an elliptical fashion so that the resulting scar follows a horizontal line already present in the forehead. Although this is probably the least used of all the techniques described, it may be a practical alternative for the elderly patient with thin eyebrows and deep horizontal rhytids who requires a short procedure under local anesthesia.

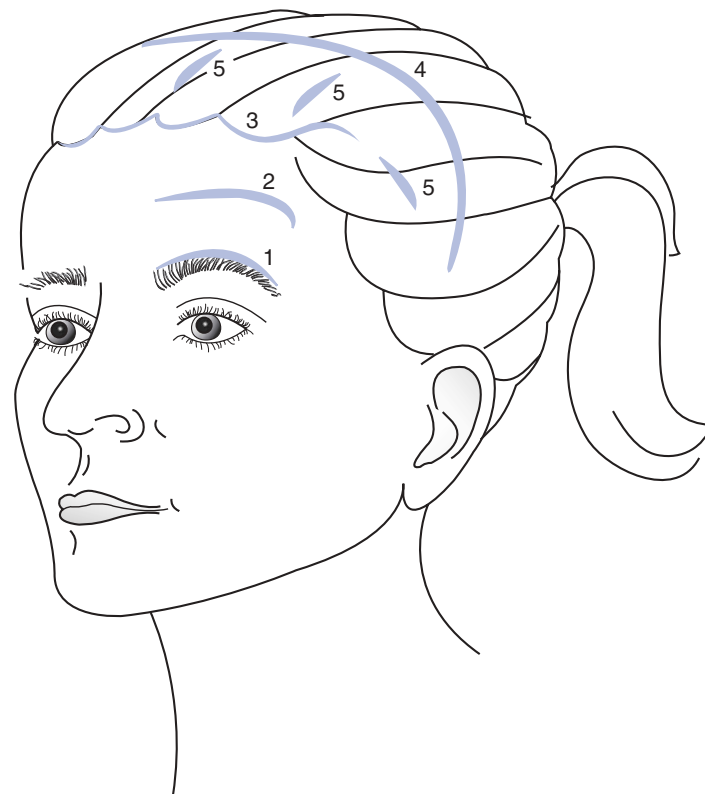


FIGURE 67-27 Representative incisions for typical brow-lifting procedures: (1) direct brow lift, (2) midforehead lift, (3) trichophytic brow lift, (4) coronal brow lift, and (5) endoscopic brow lift.

Transpalpebral and Other Local Brow Procedures

There has been a significant increase in the movement toward minimally invasive techniques to perform cosmetic surgery. New techniques for forehead and brow rejuvenation fill the literature and offer potentially exciting methods to gain esthetic improvement with less risk than with current procedures. A few such procedures include lateral brow lifting with temporal incisions only, denervation techniques through small punctures around the brow, and direct approaches through an upper blepharoplasty incision. It should be noted that although procedures such as making small punctures to destroy medial portions of facial nerve innervating medial depressors may seem minimally invasive, they are certainly not without risk.

Many of the “minimally invasive” procedures take advantage of the proximity of the local depressor muscle. For instance, the transpalpebral or transblepharoplasty approach for forehead rejuvenation gains access to the local depressors through an upper eyelid incision.¹⁰⁸ Dissection through this incision involves a short distance to the corrugator supercilii, the procerus, and depressor supercilii of the glabella, which can each be selectively transected from this incision to reduced unwanted wrinkles and elevate the medial brow (see Figure 67-11). Likewise, the orbicularis can be incised and subperiosteal dissection performed above the orbital rim to elevate the lateral brow through this same local incision. Suture plication of the periosteum above the rim may further elevate the lateral brow.

Another adjunctive technique in the upper third of the face is that of fat grafting in areas of age-related fat atrophy. Fat can essentially be grafted anywhere; however, caution is required in the glabellar region where occasional local necrosis can occur from fat infiltration. This also

occurs occasionally after collagen injections in the same region.¹⁰⁹ There are a great number of alternative techniques, and each must be evaluated for safety, efficacy, and longevity on an individual basis.

Botulinum Toxin–Assisted Brow Lift

Botulinum toxin has been used for nearly two decades to improve the esthetic appearance of the upper third of the face by reducing wrinkles of the forehead (horizontal lines), glabella (frown and bunny lines), and lateral orbital crow’s-feet (laugh lines).¹¹⁰ More recently it has been used specifically to elevate certain regions of the brow to obtain a “chemical brow lift.”¹¹¹ The depressor muscles are paralyzed with botulinum toxin not only to reduce the wrinkles they create but also to allow the frontalis muscle to elevate the brow farther because of the decrease in muscular antagonism. By decreasing the tone and downward pull of the orbicularis immediately below the brow, the lateral third of the eyebrow elevates approximately 2 to 4 mm from the result of botulinum toxin placed in the upper crow’s-feet area. Such treatment of depressor muscles in the glabellar region can help elevate the medial brow. Of course, as with surgical brow lifting, overcorrection in the medial brow may result in an abnormal facial expression.

Dosages used vary with individuals. Botox comes in a 100-unit vial to be mixed with 1 to 10 cc normal saline. The more dilute solutions (6–10 cc/100 units) begin to lose efficacy and can distort the tissue, whereas high concentration mixtures (1–2 cc/100 units) may be wasteful and imprecise. Regardless of dilution, it is the total dosage in units of botulinum toxin and its proper placement that determine the outcome. For most individuals 5 to 10 units is all that is required for each lateral crow’s-foot region. However, the larger muscles of the glabella (procerus and corrugators) require at least 15 units of the toxin and up

to 50 units for maximum results. Appropriate dosage in the glabella is the most variable. Treatment of horizontal forehead lines typically requires between 15 and 25 units. It should be noted that simultaneous treatment of horizontal forehead lines from the frontalis may decrease or eliminate brow elevation that otherwise may have been created by botulinum toxin treatment of the depressor muscles. Moreover, excessive toxin treatment of horizontal lines close to the eyebrows (within 1 cm) should often be avoided owing to the risk of true ptosis of the forehead, brow, and upper eyelids.

Botulinum toxin has also been recommended to aid long-term stability of the surgical forehead and brow lift. The theory involved is that control of the downward pull of the depressors (by temporarily paralyzing them chemically) gives the periosteum time to attach securely in an elevated position. The injection can be done during surgery but there is an increased risk of eyelid ptosis and an unwanted delay since botulinum toxin typically takes 3 to 5 days to take full effect. Therefore, ideally botulinum toxin is injected 1 to 2 weeks prior to surgery. Regardless of any benefit this may give to long-term surgical fixation, the resulting reduction in wrinkles of the forehead and glabella and in crow’s-feet is almost always popular with patients, even though the results last for only 3 to 6 months.

Adjunctive Procedures: Skin Care and Micropigmentation

A variety of procedures can be used for the superficial treatment of poor skin texture and are covered more completely in Chapter 69, “Skin Rejuvenation Procedures.” For complete rejuvenation of the upper third of the face, skin resurfacing techniques may be required to address aging problems, especially those related to sun exposure, that cannot be adequately treated with lifting methods alone.

Prior to any resurfacing procedure such as laser skin resurfacing, chemical

peels, or dermabrasion, the patient should be treated with topical skin medications to decrease the risk of scarring and pigment problems. Retinoic acid–type preparations used for ideally 6 weeks prior to resurfacing and 4% hydroquinone for patients with darker skin tones (Fitzpatrick 3 or higher) are two possibilities (see Chapter 69, “Skin Rejuvenation Procedures”). Simultaneous resurfacing procedures can be accomplished with brow lifting provided the surgical plane of dissection is subperiosteal or subgaleal and not subcutaneous.

Another adjunctive procedure growing in popularity is medical micropigmentation. The use of new skin pigments that do not contain iron oxide has improved the appearance of tattoos placed to enhance a thin eyebrow or as permanently applied eyeliner. The ink is relatively permanent but often requires touch-ups owing to some fading over the first 3 to 5 years. Patients who have poor hand motor skills can greatly benefit from this procedure. A certified technician under a doctor’s supervision usually performs the micropigmentation. However, consultation with a surgeon prior to micropigmentation is important since placement of a permanent brow tattoo in a more elevated position may create problems if the patient desires a surgical brow lift later. Therefore, if a patient is seeking brow lifting in addition to the micropigmentation, it is advisable to perform the surgical brow lift prior to the permanent makeup if feasible.

Postoperative Care

Following surgical forehead and brow lifting, a compression bandage is applied using a material such as Coban or Coflex. The pressure helps to limit edema and hematoma formation while possibly improving fixation. Typically a drain is not required if a very dry field has been maintained. The patient should be instructed to limit activity and to use cold compresses over the eyes and brows. Head elevation is also recommended for the first several

days. Avoidance of antiplatelet drugs preoperatively, a careful surgical technique, and the immediate postoperative use of cold compresses, elevation, and limited strenuous activity significantly decrease postoperative healing time.

The relatively snug postoperative dressing may be removed on postoperative day 1 to visually inspect the surgical site for any problems. A less constrictive Velcro-type head wrap can then be used to allow patient comfort and easy removal for showering. Patients are allowed to gently shampoo their hair after 24 hours but must be cautioned to avoid water pressure directly over any incision sites. Each incision is then cleaned twice a day with a dilute peroxide solution, and a thin layer of antibiotic ointment is applied for the first week. Staples are removed at the end of 1 week. Chemical treatments of hair such as “perms” should be delayed for at least 2 weeks to avoid possible hair loss as a reaction to the harsh chemicals. Hot curling irons or other similar devices must be used with caution since areas of scalp anesthesia may be present for months and can predispose a patient to an accidental self-inflicted burn.

Complications

Fortunately, major complications are rare with properly performed forehead and brow rejuvenation procedures. Good patient selection, diligent preoperative planning, meticulous surgical technique, and thorough postoperative care are all required to help limit the chance for complications.^{112–115} Minor complications can always occur despite a surgeon’s best efforts. No matter how minor the problem, the patient must be treated with concern and compassion. Typically patients who undergo cosmetic surgery are expecting to look better as soon as possible and are not always as tolerant of perioperative problems as are trauma patients. Extensive edema and ecchymoses are not normally considered complications but may war-

rant appropriate reassurance and even simple suggestions to hasten recovery when feasible. Suggestions regarding makeup from a well-trained staff member may greatly improve a postoperative patient’s mood when shown how to better hide persistent erythema or ecchymosis.

True complications include poor scar appearance, wound dehiscence, hematoma, skin sloughs or perforations, asymmetries, sensory disturbances, facial paralysis, eyelid ptosis, corneal abrasions, dry eye syndrome, hair loss (alopecia), infection, relapse, irregular facial expressions, and contour irregularities. Of all these potential problems, permanent facial paralysis and major tissue loss are the most devastating. Fortunately, these particular complications are rare (< 0.3%, which is less than that for a standard lower face-lift). Regardless, it is critical to know the precise anatomy and to avoid improper or excessive retraction, overzealous cautery, and overthinning of the flaps when transecting the depressors. In addition, hematomas must be diagnosed and treated without delay.

Some problems such as corneal abrasions can be very concerning to the patient owing to the severe pain and can be nearly eliminated by proper technique and perioperative attention to detail. For instance, an eye lubricant should always be used. Also, thought should be given to the placement of temporary tape strips, such as Steri-Strips, over the eyelids or a tarsorrhaphy suture to help prevent inadvertent scratching of the cornea by gauze or tubing, for example, during the procedure (see Figure 67-16). All severe pain requires immediate evaluation, and suspected abrasion should be treated by appropriate ophthalmic drops for pain and patching of the affected eye for 12 to 24 hours. Appropriate ophthalmologic consultation is required for persistent or uncontrollable eye pain, persistent dry-eye symptoms, or unusual changes in vision. Minor blurred vision for the first 12 hours is not unusual owing to chemosis and use of ophthalmic ointments.

Alopecia and sensory disturbances can be bothersome to the patient and often are not permanent. The problem is the inability to predict whether the numbness a patient has will partially, fully, or not go away, and just how soon it might be alleviated. With proper technique, an endoscopic forehead and brow lift has a high rate of sensory nerve recovery, but full recovery may take several months and require patient reassurance. Although exact numbers are not known, empiric observation of the last 150 endoscopic brow lifts that I have performed suggests that sensory disturbances are an occasional early concern but an unusual complaint after 6 to 12 months. Alopecia, on the other hand, is a significant concern, especially if it persists longer than 6 to 12 months. Hair may return after an average 4- to 8-month dormancy period of the hair follicle. However, excessive tension on the flaps, rough handling of wound margins, or excessive use of cautery near follicles may lead to permanent hair loss that requires treatment.¹¹⁶

Proper planning, technique, and postoperative care helps to reduce the incidence of complications. Immediate and appropriate treatment along with sincere concern for the patient's well-being should help to reduce the chance of the situation worsening or patient being dissatisfied.

Summary and Conclusions

An explosion in the number of rejuvenation techniques for the upper face in the past decade, led by the use of endoscopes and botulinum toxin, has revolutionized the treatment of aging in this area. Cosmetic surgery treatment of the upper third of the face is frequently an essential component for complete facial rejuvenation. Procedures are highly variable and can offer improvement to both young and old. Matching the problems to the ideal rejuvenation techniques is essential for maximum esthetic benefits. Even the best surgical technique can result in inadequate or even poor results if improper patient

selection or incorrect diagnoses are made; for this reason, the forehead and brow area must be evaluated critically for a wide range of interlacing diagnoses.

Specific skin problems vary with a patient's age and sex, but gravity remains consistent and nonselective; therefore, the only issues regarding the occurrence of brow ptosis are when it will occur and how severe it will be. Wrinkles are also inevitable but may be dynamic or static in nature. Thanks to botulinum toxin, the previously difficult treatment of dynamic upper facial lines can be effected at low risk with a simple injection. The common and consistent finding of brow ptosis, especially in the lateral third of the brow, may now be selectively treated endoscopically to achieve a more youthful appearance. Society's idea of beauty at any one moment in time will ultimately help to guide the patient and surgeon to choose where the brow should be placed as opposed to merely raising it higher. True rejuvenation is likely more complex and involves multiple modalities and even tissue replacement such as fat grafting. Only time and persistence will prove what best restores youth to the upper face.

Facial cosmetic surgery continues to rise in popularity exponentially. The aging population wants to feel and look more youthful but nonetheless demands to remain natural looking. Today's discerning patient is often very knowledgeable on the subject of their cosmetic surgery options and may insist on a specific technique. The advice of a well-trained surgeon and diagnostician may make or break the ultimate result and prevent a cosmetic disaster. It is vital that the surgeon refuse to perform treatment that is not in the best interest of the patient. Cosmetic surgery is a luxury and is an optional procedure, no matter how much of an emergency it seems to the patient. At the end of the day, it is the surgeon's responsibility to provide the patient with the best and safest options available to achieve realistic goals.

References

- Ramirez OM. Endoscopic techniques in facial rejuvenation. An overview. Part 1. *Aesthetic Plast Surg* 1994;8:141-147.
- Isse NG. Endoscopic facial rejuvenation. Endo-forehead, the functional lift. *Case reports. Aesthetic Plast Surg* 1994;18:21-9.
- Tessier P. Ridectomie frontale. [Lifting frontale.] *Gaz Méd Fr* 1968;75:55-65.
- Becker FF, Johnson CM. Surgical treatment of the upper third of the aging face. In: Cummings CW, Fredrickson JM, Harker LA, editors. *Otolaryngology-head and neck surgery*. St. Louis: Mosby; 1986. p. 475.
- Zide BM, Jelks GW. *Surgical anatomy of the orbit*. New York: Raven Press; 1985.
- Fagien S. Eyebrow analysis after blepharoplasty in patients with brow ptosis. *Ophthal Plast Reconstr Surg* 1992;8:210.
- Ellis DAF, Ward D. The aging face. *J Otolaryngol* 1986; 15:217-23.
- Johnson JD, Hadley RC. The aging face. In: Converse JM, editor. *Reconstructive plastic surgery*. Philadelphia: WB Saunders; 1964. p. 1306-42.
- Powell H, Humphreys B. *Proportions of the aesthetic face*. New York: Thieme-Stratton; 1984.
- Huntley HE. *The divine proportion*. New York: Dover; 1970.
- Rickets RM. Divine proportion of facial aesthetics. *Clin Plast Surg* 1982;9:401.
- Evans TW. Browlift. *Atlas of Oral Maxillofac Surg Clin North Am* 1998;6:111-33.
- Ellis DAF, Bakala CD. Anatomy of the motor innervation of the corrugator supercilii muscle: clinical significance and development of a new surgical technique for frowning. *J Otolaryngol* 1998;27:222-7.
- Larrabee WF, Mahielski KH. *Surgical anatomy of the face*. New York: Raven Press; 1993.
- Gonzalez-Ulloa M. Facial wrinkles, integral elimination. *Plast Reconstr Surg* 1962;29:658.
- Bostwick J, Eaves F, Nahai F. *Endoscopic plastic surgery*. St. Louis: Quality Medical Publishers; 1995.
- Hiatt JL, Gartner LP. In: Gardner J, editor. *Textbook of head and neck anatomy*. 2nd ed. Baltimore: Williams and Wilkins; 1987. p. 156-245, 373-45.
- Hamas RS. Reducing the subconscious frown by endoscopic resection of the corrugator muscles. *Aesthetic Plast Surg* 1995;19:21-5.
- Salasche SJ, Bernstein G, Senkarik. *Surgical anatomy of the skin*. Appleton & Lange; 1988.
- Edwards BF. Bilateral neurotomy for the frontalis hypermotility. *Plast Reconstr Surg* 1957;19:341-4.

21. Ellis DAF, Masri H. The effect of facial animation on the aging upper half of the face. *Arch Otolaryngol Head Neck Surg* 1989;115:710-2.
22. Brennan HG. The forehead lift. *Otolaryngol Clin North Am* 1980;13:209.
23. Rafaty FM, Brennan HG. Current concepts in brow pexy. *Arch Otolaryngol Head Neck Surg* 1983;109:152.
24. Rafaty FM, Goode RL. The browlift operation in a man. *Arch Otolaryngol Head Neck Surg* 1978;104:69.
25. Rafaty FM, Goode RL, Fee WE. The browlift operation. *Arch Otolaryngol Head Neck Surg* 1975;101:467.
26. Knize DM. Reassessment of the coronal incision and subgaleal dissection for forehead-plasty. *Plast Reconstr Surg* 1998;102:478.
27. Grant JCB, editor. *Grant's atlas of anatomy*. 6th ed. Baltimore: Williams & Wilkins, 1972.
28. Tolhurst DE, Carstens MH, Greco RJ, et al. The surgical anatomy of the scalp. *Plast Reconstr Surg* 1991;87:603.
29. Tremolada C, Candiani P, Signorini M, et al. The surgical anatomy of the subcutaneous fascial system of the scalp. *Ann Plast Surg* 1994;32:8.
30. Carstens MH, Greco RJ, Hurwitz DJ, et al. Clinical applications of the subgaleal fascia. *Plast Reconstr Surg* 1991;87:615.
31. Waite PD, Cuzalina LA. Rhytidectomy. In: Fonseca RJ, editor. *Oral and maxillofacial surgery: cleft/craniofacial/cosmetic surgery*. Vol 6. Philadelphia (PA): WB Saunders Co; 1998. p. 365-81.
32. Tobin HA, Cuzalina LA, Tharanon W, Sinn DP. The biplane face lift: an opportunistic approach. *J Oral Maxillofac Surg* 2000; 58:76-85.
33. Tobin HA, Cuzalina LA. SMAS surgery versus deep-plane rhytidectomy. In: Pensak ML, editor. *Controversies in otolaryngology*. New York: Thieme; 2001. p. 148-55.
34. Knize DM. Transpalpebral approach to the corrugator supercilii and procerus muscles. *Plast Reconstr Surg* 1995;95:52-60.
35. Aiache AE. Transblepharoplasty brow-lift. Presented at the American Society of Aesthetic Plastic Surgery; 1995 May; San Francisco, CA.
36. Boyd B, Caminer D, Moon HK. Innervation of the procerus and corrugator muscles and its significance in facial surgery. Paper presented at the annual meeting of the ASPRS; 1997 September; San Francisco, CA.
37. Knize DM. A study of the supraorbital nerve. *Plast Reconstr Surg* 1997;99:1224.
38. Knize DM. Muscles that act on glabellar skin: a closer look. *Plast Reconstr Surg* 2000; 105:350.
39. Netter FM. *Atlas of human anatomy*. Summit (NJ): Ciba-Geigy; 1989.
40. Knize DM. An anatomically based study of the mechanism of eyebrow ptosis. *Plast Reconstr Surg* 1996;97:1321.
41. De la Plaza R, De la Cruz L. A new concept in blepharoplasty. *Aesthet Plast Surg* 1996; 20:221.
42. Lemke BN, Stasior OG. The anatomy of eyebrow ptosis. *Arch Ophthalmol* 1982;100:981.
43. Meyer DR, Linberg JV, Wobig JL, et al. Anatomy of the orbital septum and associated eyelid connective tissues. *Ophthalm Plast Reconstr Surg* 1991;7:104.
44. Aiache AE, Ramirez OM. The suborbicularis oculi fat pads: an anatomic and clinical study. *Plast Reconstr Surg* 1995;95:37.
45. Trinei FA, Januszkiewicz J, Nahai F. The sentinel vein: an important reference point for surgery in the temporal region. *Plast Reconstr Surg* 1998;101:27.
46. Cuzalina LA, Holmes J. A simple and reliable landmark for identification of the supra-orbital nerve in surgery of the forehead: an in vivo anatomical study. *J Oral Maxillofac Surg* 2003.[Submitted]
47. Gosain AK, Sewall SR, Yousif NJ. The temporal branch of the temporal nerve: how reliably can we predict its path? *Plast Reconstr Surg* 1997;99:1224.
48. Ellis E, Zide MF, editors. *Surgical approaches to the facial skeleton*. Baltimore: Williams & Wilkins; 1995. p. 59-169
49. Liebman E, Webster R, Berger A, et al. The frontalis nerve in the temporal brow lift. *Arch Otolaryngol Head Neck Surg* 1982; 108:232-35.
50. Furnas DW. Landmarks for the trunk and the temporofacial division of the facial nerve. *Br J Surg* 1965; 52:694.
51. Correia P, Zani R. Surgical anatomy of the facial nerve as related to ancillary operations in rhytidoplasty. *Plast Reconstr Surg* 1973;52:549-52.
52. Isse NG. Endoscopic forehead lift. *Clin Plast Surg* 1995; 22:661.
53. Isse NG. The endoscopic approach to forehead and brow lifting. *Aesthetic Plast Surg* 1998;18.
54. Vasconez LO, Core GB, Gamboa-Bobadilla M, et al. Endoscopic techniques in coronal brow lifting. *Plast Reconstr Surg* 1994;94:788.
55. Morselli PG. Fixation for forehead endoscopic lifting: a simple, easy, no-cost procedure. *Plast Reconstr Surg* 1996 97:1309.
56. Marchac D, Ascherman J, Arnaud E. Fibrin glue fixation in forehead endoscopy: evaluation of our experience with 206 cases. *Plast Reconstr Surg* 1997;100:704.
57. Hoeing JF. Rigid anchoring of the forehead to the frontal bone in endoscopic facelifting: a new technique. *Aesthetic Plast Surg* 1996;20:213.
58. De la Fuente A, Santamaria AB. Facial rejuvenation: a combined conventional and endoscopic assisted lift. *Aesthetic Plast Surg* 1996;20:471.
59. Isse NG. Endoscopic forehead lift, evolution and update. *Clin Plast Surg* 1995;2:661.
60. Adamson PA, Johnson CM, Anderson JR, et al. The forehead lift: a review. *Arch Otolaryngol Head Neck Surg* 1985;111:325-9.
61. Liang M, Narayanan K. Endoscopic oblation of the frontalis and corrugator muscles: a clinical study. *Plast Surg Forum* 1992; XV:54.
62. Su CT. Technique for division and suspension of the orbicularis oculi muscle. *Clin Plast Surg* 1981;8:673.
63. Byrd HS, Andochick SE. The deep temporal lift: a multiplanar lateral brow, temporal, and upper face lift. *Plast Reconstr Surg* 1996;97:928.
64. Kerth JD, Triumi DM. Management of the aging forehead. *Arch Otolaryngol Head Neck Surg* 1990;116:1137-42.
65. Chierici G, Miller A. Experimental study of muscle reattachment following surgical detachment. *J Oral Maxillofac Surg* 1984;42:485.
66. Ramirez OM. Endoscopic subperiosteal browlift and facelift. *Clin Plast Surg* 1995; 22:639-60.
67. Tobin HA. The extended subperiosteal coronal lift. *Am J Cosmet Surg* 1993;10:47-57.
68. Psillakis JM, Rummley TO, Camargos A. Subperiosteal approach in an improved concept for correction of the aging face. *Plast Reconstr Surg* 1988;82:383-92.
69. Maillard GF, Cornette de St Cyr B, Schefflan M. The subperiosteal bicoronal approach to total face lifting: the SMAS-deep musculoaponeurotic system. *Aesthetic Plast Surg* 1991;15:285-91.
70. Ramirez OM. Endoscopic techniques in facial rejuvenation: an overview. *Aesthetic Plast Surg* 1994;18:141-371.
71. Daniel RK, Ramirez OM. Endoscopic assisted aesthetic surgery. *Aesthetic Plast Surg* 1994;14:18-20.
72. Toledo LS. Facial rejuvenation: technique and rationale. In: Fodar P, Isse N, editors. *Endoscopically assisted aesthetic plastic surgery*. St. Louis: Mosby; 1996. p. 91-105.
73. Psillakis JM. Subperiosteal approach for surgical rejuvenation of the upper face. In: Psillakis J, editor. *Deep face-lifting techniques*. New York: Thieme; 1994. p. 51-63.
74. Hinderer UT. The sub SMAS and subperiosteal

- rhytidectomy of the forehead and middle third of the face: a new approach to the aging face. *Facial Plast Surg Clin North Am* 1992;8(1):18–32.
75. Dempsey PD, ONeal RM, Izenberg PH. Subperiosteal brow and midface lifts. *Aesthetic Plast Surg* 1995; 19:59–68.
 76. Blitzer A, Brin MF, Keen MS, et al. Botulinum toxin for the treatment of hyperfunctional lines of the face. *Arch Otolaryngol Head Neck Surg* 1993;119:1018–22.
 77. Ruess WR, Owsley JQ. The anatomy of the skin and fascial layers of the face in aesthetic surgery. *Clin Plast Surg* 1987;14:677–82.
 78. McCollough EG, Langsdon PR. Dermabrasion and chemical peel. New York: Thieme; 1998.
 79. Buzzell RA. Effects of solar radiation on the skin. *Otolaryngol Clin North Am* 1993;26:1–11.
 80. Ortiz-Monasterio FG, Olmedo A. The coronal incision in rhytidectomy: the brow lift. *Clin Plast Surg* 1978;5:167.
 81. Ellenbogen R. Transcoronal eyebrow lift with concomitant upper blepharoplasty. *Plast Reconstr Surg* 1983; 71:490.
 82. Wojtanowski MH. Bicoronal forehead lift. *Aesthetic Plast Surg* 1994;18:33.
 83. Abul-Hassan HS, Van Drasek Ascher G, Acland RD. Surgical anatomy and blood supply for the fascial layers of the temporal regions. *Plast Reconstr Surg* 1986;77:17.
 84. Stuzin JM, Wagstrom L, Kawamoto HK, et al. Anatomy of the frontal branch of the facial nerve: the significance of the temporal fat pad. *Plast Reconstr Surg* 1989;83:265.
 85. Savani A. Physiopathology of the aging face. In: Psillakis JM, editor. *Deep face-lifting techniques*. New York: Thieme; 1994. p. 11–23.
 86. De la Plaza R, Valiente E, Arroya JM. Supraperiosteal lifting of the upper two thirds of the face. *Br J Plast Surg* 1991;4:325–32.
 87. Wassef M. Superficial fascial and muscular layers in the face and neck: a histologic study. *Aesthetic Plast Surg* 1987;11:171.
 88. Tirkanits B, Daniel RK. The biplanar forehead lift. *Aesthetic Plast Surg* 1990;14:111.
 89. Ramirez OM, Maillard GF, Musolas A. The extended subperiosteal face lift: a definitive soft-tissue remodeling for facial rejuvenation. *Plast Reconstr Surg* 1991; 88:227–36.
 90. Psillakis JM. Embryology and anatomy review of the superficial fascia or SMAS. In: Psillakis JM, editor. *Deep face-lifting techniques*. New York: Thieme; 1994. p. 1–11.
 91. Bosse JP, Papillon J, editors. *Surgical anatomy of the SMAS at the malar region*. In: *Transactions of the Ninth International Congress of Plastic and Reconstructive Surgery*. New York: McGraw-Hill; 1987.
 92. Owsley JQ. *Aesthetic facial surgery*. Philadelphia: WB Saunders; 1994.
 93. Yousif NJ, Mendelson BC. Anatomy of the mid-face. *Clin Plast Surg* 1995;22:227–41.
 94. Guyuron B, Davies B. Subcutaneous anterior hairline forehead rhytidectomy. *Aesthetic Plast Surg* 1988;12:77.
 95. Aiache AE. Endoscopic face-lift. *Aesthetic Plast Surg* 1994;18:275.
 96. Ramirez OM. Endoscopic forehead and face-lift: step-by-step. *Open Tech Plast Reconstr Surg* 1995;2:116–26.
 97. Matarasso A, Terino EO. Forehead-brow rhytidoplasty: reassessing the goals. *Plast Reconstr Surg* 1994; 93:1378.
 98. Newman JP, LaFerriere KA, Koch RJ, et al. Transcalvarial suture fixation for endoscopic brow and forehead lifts. *Arch Otolaryngol Head Neck Surg* 1997;123:313.
 99. Kim SK. Endoscopic forehead scalp flap fixation with K-wire. *Aesthetic Plast Surg* 1996;20:217.
 100. Pakkanen M, Salisbury AV, Ersek RA. Biodegradable positive fixation for endoscopic browlift. *Plast Reconstr Surg* 1996;98:1087.
 101. Knize DM. A study of the supraorbital nerve. *Plast Reconstr Surg* 1995;96:564.
 102. Loomis MG. Endoscopic brow fixation without bolsters or miniscrews. *Plast Reconstr Surg* 1996;98:373.
 103. Dyer WK, Yung RT. Botulinum toxin-assisted brow lift. In: Larrabee WF, Thomas JR, editors. *Facial plastic surgery clinics of North America: rejuvenation of the upper face*. Vol 8, Number 3. Pennsylvania: W.B. Saunders Company; 2000. p. 343–54.
 104. Brennan HG, Rafty FM. Midforehead incisions in treatment of the aging face. *Arch Otolaryngol Head Neck Surg* 1982;108:732–4.
 105. Johnson CM, Waldman SR. Midforehead lift. *Arch Otolaryngol Head Neck Surg* 1983;109:155–9.
 106. Cook TA, Brownrigg PJ, Wang TD, et al. The versatile midforehead browlift. *Arch Otolaryngol Head Neck Surg* 1989;115:163.
 107. Johnson CM, Walman SR. Midforehead lift. *Arch Otolaryngol Head Neck Surg* 1983;109:155.
 108. Guyuron B, Michelow BJ, Thomas T. Corrugator supercilii muscle resection through a blepharoplasty incision. *Plast Reconstr Surg* 1995;95:691–6.
 109. Stegman SJ, Chu S, Armstrong RC. Adverse reactions to bovine collagen implant: clinical and histologic features. *J Dermatol Surg Oncol* 1988;14:39–47.
 110. Keen MS, Khosh MM. The role of botulinum toxin A in facial plastic surgery. In: Willet JM, editor. *Facial plastic surgery*. Upper Saddle River (NJ): Prentice Hall; 1997. p. 323–9.
 111. Frankel AS, Kamer FM. Chemical browlift. *Arch Otolaryngol Head Neck Surg* 1998;124:321.
 112. Beeson WH, McCollough EG. Complications of the forehead lift. *Ear Nose Throat J* 1985;64:27.
 113. Connell BF, Lambros VS, Neurohr GH. The forehead lift: techniques to avoid complications and produce optimal results. *Aesthetic Plast Surg* 1989;13:217.
 114. Matarasso A. Endoscopic assisted forehead-brow rhytidoplasty: theory and practice. *Aesthetic Plast Surg* 1995;19:141.
 115. Daniel RK, Tirkantis B. Endoscopic forehead lift, aesthetics and analysis. *Clin Plast Surg* 1995;22:605–18.
 116. Mayer TG, Fleming RW. Management of alopecia. In: Cummings CW, Fredrickson JM, Harker LA, et al, editors. *Otolaryngology—head neck surgery*. St. Louis: Mosby; 1986. p. 429.

Liposculpting Procedures

Milan J. Jugan, DMD

Liposculpting procedures in oral and maxillofacial surgery have been described in the literature since the 1930s; however, since the introduction of blunt cannula liposuction in the late 1970s, the theories, techniques, and indications for fat removal and transfer have evolved tremendously. Excisional techniques of fat removal used for treating most patients with localized submental lipodystrophy yielded variable results, scarring, and high complication rates. In the cervicofacial region the closed liposuction technique has proven to be an excellent technique for the removal of submental fat and, in addition, has provided a simplified technique with relatively few complications. Also, improved techniques for harvesting, preparing, and injecting fat to augment facial defects or create a more youthful appearance have been developed and are demonstrating long-term success. This chapter discusses a wide range of facial liposculpting procedures to include cervicofacial liposuction, autologous fat transfer, and the use of these techniques as adjunctive procedures to facilitate orthognathic, reconstructive, and maxillofacial cosmetic surgery procedures.

Cervicofacial Liposuction

History

Sculpting the body by removing localized fat deposits has been well documented in the literature for almost a century. Early

excisional body-sculpting techniques included direct lipectomy and open instrument curettage.¹ These techniques were also used in an attempt to remove fat and sculpt the regions of the face and neck. Maliniak described submental fat removal and neck contouring with the excision of redundant tissue in the early 1930s.² Two decades later Davis reported using curettes to remove fat through a small submental incision.³ Our modern techniques of cervicofacial liposuction in oral and maxillofacial surgery can be traced to the pioneering work of four surgeons. Schrudde introduced a technique called *lipexeresis* in 1972.⁴ Modifying a uterine cannula, he described a procedure by which he tunneled in the subcutaneous fat and removed fat particles by suction. In the 1980s Illouz defined several principles for the successful treatment of localized lipodystrophy.⁵ His technique of *lipolysis* is accomplished by injecting a mixture of saline and hyaluronidase solution into the surgical site, causing fat cells to rupture. He theorized that this rupturing of fat cells would make their removal by suction cannulas more efficient. Fournier developed the closed syringe technique, using small-diameter cannulas with an attached plastic syringe to generate the necessary negative pressure.⁶ Finally, Klein developed the tumescent technique, a safe and effective procedure used by most surgeons today.⁷ His technique uses large volumes of dilute

epinephrine solution with or without lidocaine. Although the benefit of a large-volume fat removal without creating an electrolyte imbalance is not generally a concern for the oral and maxillofacial surgeon, the reduction in blood loss, decrease in postoperative ecchymosis, and decreased need for compression garment wear all benefit the cervicofacial liposuction patient.

Indications

Cervicofacial suction-assisted lipectomy is mainly used to correct or improve the body-contour irregularities caused by localized fat deposits in the head and neck region. Specifically, those localized fat deposits that tend to be resistant to dieting and exercise tend to respond favorably. In addition to its use as an esthetic procedure, the techniques mastered in cervicofacial liposuction may be used to facilitate flap elevation, defat pedicled flaps, and remove benign lipomas.^{8,9}

In the maxillofacial region liposuction is most effective in contouring the submental, submandibular, and jowl regions of the face. These areas tend to be easily accessible to the liposuction cannulas for removal of the fat deposits and are also amenable to compression garment placement to facilitate recontouring of the regions. Various authors have also suggested the use of liposuction to contour and smooth deep nasolabial folds and to

remove buccal fat pads to recontour full cheeks.^{10,11} In my experience, nasolabial folds are more predictably managed with augmentation procedures (fat injection) than with fat removal. In addition, removal of buccal fat pads may create a hollowing of the buccal region, owing to progressive fat atrophy with aging, and an unnatural noncosmetic-appearing midface.

Patient Evaluation

Successful cervicofacial liposuction requires careful patient selection and a clear diagnosis of the pathologic entity desired to be modified. The patient's skin tone, skeletal configuration, muscular support of the neck, and body habitus should all be evaluated.

The ideal candidate is a woman of average weight and good skin elasticity, who demonstrates localized adipose accumulations that do not correspond to the patient's overall body habitus. If a patient has recently undergone significant weight loss, she should be advised that the ideal time for cervicofacial liposuction procedures is after 6 months of stable weight management. Patients who are generally overweight respond poorly to liposuction procedures and should be treated with caution. If the operating surgeon decides to proceed, these patients should be at the lower end of their usual weight range to obtain maximum benefit from the proposed surgery. In general, women are excellent candidates for cervicofacial liposuction, probably owing to their thinner less sebaceous skin, which tends to contract in a more predictable fashion over the reduced subcutaneous fat.

Skin elasticity should be evaluated in all patients undergoing cervicofacial liposuction. Patients should have sufficient skin elasticity to facilitate smooth and uniform redraping of skin over the recontoured fat and muscle. Those patients with skin excess or extremely lax or inelastic skin may achieve suboptimal results such as postoperative sagging and should be

counseled on the benefit of adjunctive skin-tightening procedures to achieve the desired results.¹²

Finally, those patients with obtuse cervicofacial angles, in addition to fat accumulation, may require deeper plane procedures to achieve an acceptable cosmetic improvement. Patients with platysmal decussation may benefit from platysmal plication in addition to liposuction to achieve a more youthful-appearing cervicofacial region. In those patients with platysmal ptosis and an obtuse cervicofacial angle, liposuction alone leads to less-than-optimal results. These patients are best approached with liposuction in combination with suture suspension to lift the platysma and recreate the cervicofacial angle.¹³

Instrumentation

For the most part, relatively little equipment is required to perform cervicofacial liposuction. Various companies manufacture a host of devices; however, the basic equipment remains a suction device and aspiration cannulas.

Cannula design has changed since the description of the procedure by Illouz.⁵ A variety of lengths, diameters, and tip designs are available to the surgeon, and the cannula should be chosen according to the procedure being performed. The length of the cannula may vary depending on the specific surgical goal. A short cannula may be chosen to access only the submental region, but a longer cannula or second surgical incision may be needed to work at the angle of the mandible. In general, a 25 to 30 cm length is sufficient for most surgeries in the head and neck region.

Cannula diameter affects the volume of fat removed. It is important to remember that the amount of tissue that can be removed with a pass of the cannula depends on the diameter of the cannula lumen and the suction pressure. Therefore, under an equal amount of pressure, a larger-diameter cannula lumen removes

more fat than does a cannula of smaller diameter. If the goal of surgery is to rapidly remove a large amount of excess adipose tissue, then a larger-diameter cannula is chosen. If the goal is to accurately remove a small amount of fat with more control, then a smaller diameter is chosen. A cannula diameter of 2 to 6 mm is generally used in cervicofacial liposuction procedures.

Finally, tip design is evaluated. Most importantly, the cannula should have a smooth tip and aperture opening. Fat is drawn into the cannula lumen through the aperture opening by the vacuum from the suction unit and then avulsed by the back-and-forth movement of the cannula. Neurovascular structures are pushed aside by a blunt smooth tip. Sharp edges will cut and shave, placing surrounding blood vessels and nerves at greater risk for injury. Damage to these structures may result in alterations to sensation, seroma, hematoma, or necrosis of overlying skin. Again, the goals of the surgery are important when choosing a tip design. A narrow cannula with round tips may be used for the precise removal of small fatty deposits. Flat spatula cannulas are more commonly used in open procedures to defat flaps because an effective seal may be maintained with the underlying tissue bed.

In general, cannula design should be selected to facilitate the goal of the surgical procedure, and a variety of designs should be available to provide the patient with an optimum outcome. Figures 68-1 to 68-3 show examples of various cannula designs available for cervicofacial liposculpting procedures.

The suction device provides the vacuum to the aspiration cannula for removal of the fat deposits. This negative pressure may be generated via a hand-held syringe, wall suction, or commercially available suction unit. Hand-held syringe devices are good for use in the head and neck region owing to their low cost, portability, and ease of handling. They provide an efficient technique for precise contouring of

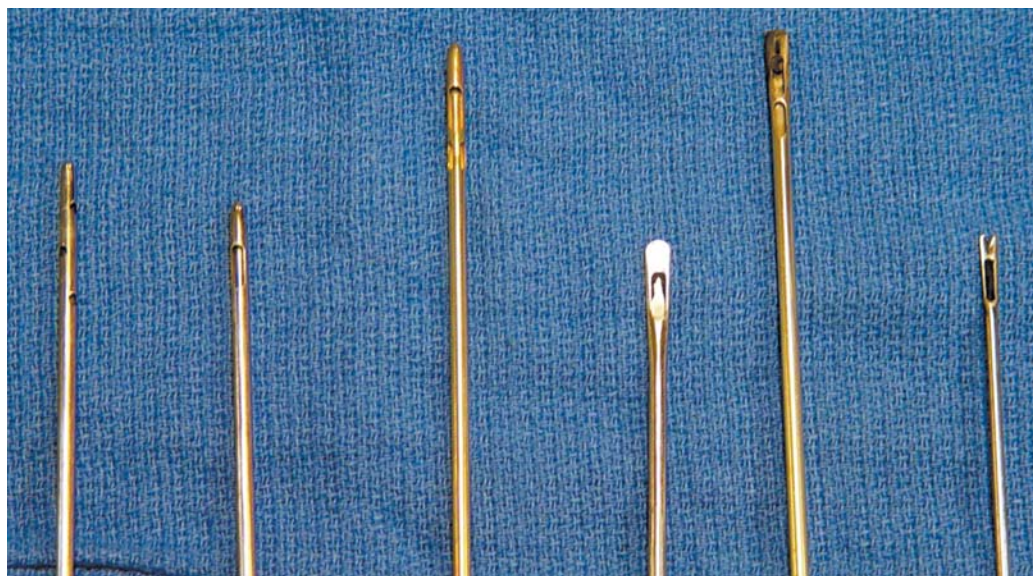


FIGURE 68-1 Various designs of cannula tip available for syringe liposuction systems.

irregularities secondary to cervicofacial adiposity.⁶ The negative pressure is generated by placing 5 cc of tumescent solution into the cannula-syringe unit, placing the cannula working port beneath the flap, and pulling back on the plunger to create the vacuum. When the plunger is pulled back to the fullest extent, it is possible to obtain 1 atm of negative pressure. Various plunger locks are manufactured to hold the plunger in position during the operation. A disadvantage of this system is the loss of vacuum that occurs if tissue contact is lost.

Wall suction and commercially available suction units are useful for closed and open liposuction techniques. They provide continuous vacuum and are most useful for removing large amounts of fat or defating a flap.

A final consideration for choosing a suction device is the ability to vary the amount of negative pressure through the cannula. Whereas 1 atm of negative pressure is ideal for liposuction procedures, 0.5 atm of negative pressure is more appropriate to harvest fat for fat-injection techniques.

Anesthesia

Liposculpting procedures may be performed in various settings from an office or surgicenter to a main operating room.

Although some patients may desire general anesthesia, the vast majority of cervicofacial procedures may be performed with local anesthesia and intravenous sedation.

The tumescent technique of superficial liposuction, published by Jeffery Klein in 1987,⁷ has become the standard against which all other techniques are compared. It is distinct from other liposuction techniques in that the entire procedure can be performed under local anesthesia only if the surgeon so desires. Most importantly for the patient, the tumescent technique provides excellent anesthesia and out-

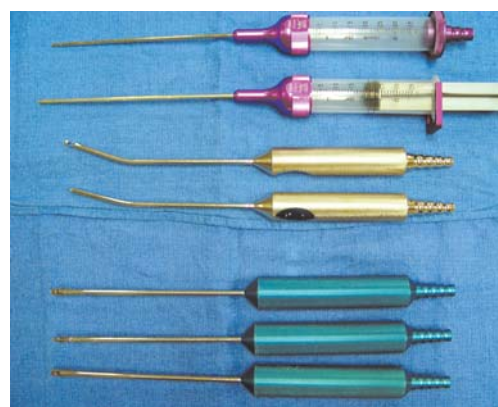


FIGURE 68-2 Examples of various cannulas available for cervicofacial liposculpting procedures. Note the differences in cannula length, diameter, tip design, and ability for use with a syringe or suction aspiration system.

standing hemostasis. To understand Klein's tumescent technique, one needs to review the wet technique of Illouz.⁵ Illouz injected hypotonic saline, lidocaine, epinephrine, and hyaluronidase into the liposuction site, attempting to cause lysis of fat cells and improve fat extraction. With the wet technique, excessive blood loss remained a significant risk. Large cannulas were used to remove as much fat as possible in the shortest amount of time. Postoperatively, bruising was extensive and patients wore compressive garments for several weeks. Klein's technique for the head and neck advocates the use of a local anesthetic solution containing normal saline, 0.1% lidocaine, epinephrine at a concentration of 1:1,000,000, and bicarbonate. Table 68-1 provides concentration data on several mixtures of tumescent solution that I use. Klein also demonstrated that a large amount of lidocaine could be injected into the superficial fat compartments without a large increase in serum lidocaine levels since aspiration of the infiltrate and fat were being performed.⁷ In general, 50 to 100 cc of Klein's solution are used in the cervicofacial region for liposuction procedures.

In 1997 the American Academy of Cosmetic Surgery published its *Guidelines for Liposuction Surgery* and stated, "The tumescent infiltration (technique) has been shown over the last 9 years to be the safest for liposuction and lipocontouring, with the fastest recovery time and least complications for the patient."¹⁴

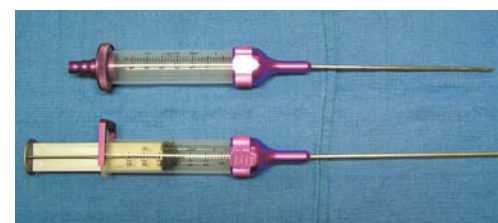

FIGURE 68-3 Syringe liposuction system set up for standard syringe liposuction and adaptation to a suction aspiration system. This system is particularly useful for collecting harvested fat in the syringe.

Table 68-1 Tumescent Solution Concentration Data

Component	Solution A*	Solution B†	Solution C‡
Lidocaine (1%)	50 cc (500 mg); 0.05%	100 cc (1,000 mg); 0.1%	150 cc (1,500 mg); 0.15%
Epinephrine (1:1,000)	0.5 cc (0.5 mg); 1:2,000,000	1.0 cc (1.0 mg); 1:1,000,000	1.5 cc (1.5 mg); 1:666,666
Bicarbonate (1 mEq/mL)	10 cc; 10 mEq/L	10 cc; 10 mEq/L	10 cc; 10 mEq/L
Normal saline	1,000 mL	1,000 mL	1,000 mL

*Solution A is used for patients undergoing liposculpting procedures for the first time.
†Solution B is used for revision liposculpting procedures.
‡Solution C is used for liposuction-assisted rhytidectomy procedures and fat harvesting.

Although the tumescent technique will continue to evolve with research and evolution of equipment, it certainly has proven to be a safe and effective therapy for cervicofacial liposuction.

Technique

The goal of cervicofacial liposuction is to create a smooth and regular contour of the head and neck regions by the precise removal of localized fat deposits while minimizing external scarring. To that end, the patient must be educated on the risks and benefits of the procedure. A preoperative consultation should be performed that includes adequate photodocumentation of the patient's preoperative condition. Informed consent for liposuction surgery and sedation must be reviewed and obtained. Appendix A shows a sample consent form for a cervicofacial liposuction procedure. The patient's medical history should be reviewed for any contraindications to surgery and to determine any potentially modifiable factors (eg, use of nonsteroidal anti-inflammatory drugs or herbal medications, and smoking).

On the day of surgery the patient is marked up in the sitting position, and the areas of proposed fat removal are reviewed and verified with the patient. Various other anatomic structures may be marked up depending on the surgeon's preference, but I recommend marking the inferior border of the mandible, sternocleidomastoid muscle, and the top of the thyroid cartilage, as well as the proposed surgical incisions.

All skin incisions should be large enough to accommodate placement of the aspirating cannulas. Incisions that are too large leave an unsightly scar when healed, and incisions that are too small may be damaged by friction from the back-and-forth motion of the cannula. The submental and submandibular areas may be liposuctioned using a single incision in the submental crease. The jowl area may be best approached from an incision in the posterior earlobe crease. A small incision in the nasal vestibule area may allow access to facial adiposity not adequately removed through the previously described incisions.

The patient is placed in a modified semi-Fowler position, monitors are placed, and supplemental oxygen is delivered. Intravenous sedation is then titrated to the level desired by the operating surgeon. Local anesthetic is infiltrated into the incision sites, and an incision is made through the dermis. A small pocket is then created within the superficial fat plane between the dermis and the platysma or superficial musculoaponeurotic system (SMAS). Tumescent liposuction solution is then infiltrated into this space via an infiltrating cannula. Care is taken to remain in the compartment of superficial fat above the platysma muscle. The cannula is advanced in a plane parallel to the skin surface and is easily palpable during the infiltration process. The cannula is advanced in a systematic manner throughout the area to be treated, and the solution is injected as the cannula is being with-

drawn. In the average patient, 100 to 150 cc of solution is deposited in the plane of dissection. The area is then to remain undisturbed by instrumentation for 10 to 15 minutes, allowing for maximum vasoconstriction and providing excellent local anesthesia. Effective placement of the tumescent solution will result in blanching of the overlying skin owing to the vasoconstrictive effects of the solution.

After 10 to 15 minutes, an operating cannula is placed into the incision site, and the process of suction-free pretunneling is begun throughout the surgical site. When the operating cannula is inserted, care must be taken to ensure that the aperture opening is directed away from the skin. If facing the skin, the aperture may cause damage to the subdermal plexus, resulting in an increase in postoperative complications and the potential for postoperative epidermal ridge formation. Pretunneling is performed by systematically passing the cannula back and forth through the fat deposits, with care being taken to remain within the superficial fat compartment. Although not mandatory, pretunneling defines the appropriate surgical plane, breaks up fat cells, and aids in the extraction of fat cell content.

Following pretunneling the cannula is connected to the suction device. Fat is removed from the desired areas by directing the cannula through the pretunneled area in the same systematic manner used initially. Again, care is taken to ensure that the aperture opening is directed away from the skin and that the cannula remains in

the proper plane of dissection. A superficial plane may be maintained by tenting the skin away from the deep tissues with the tip of the cannula and by palpating the cannula through the skin using the nonoperating hand. Fat is extracted from the superficial fat compartment until the desired contour is achieved. Once the main area of adiposity is reduced, the cannula is carried slightly beyond the margins of the original dissection to feather out the edges of the operative site and to reduce the potential for contour irregularities. The site should be inspected frequently to avoid overcorrection. Direct palpation is the most accurate method to assess the amount of fat removed. The skin should be pinched and rolled between the thumb and index finger. The skin should feel loose, with a thin layer of adipose tissue remaining on the undersurface of the dermis. In most cases the surgeon removes between 20 and 100 cc of fat in the cervicofacial region. Additional contouring may be required following the submental approach; in this case posterior earlobe crease incisions may be used to overlap the dissection areas. The same sequence of pretunneling, inspection, and fat removal is used to optimize the final contour enhancement for the patient.

Following completion of the liposuction, residual blood, tumescent fluid, and fat particles are expressed from the space. The incision sites are closed using a 5-0 or 6-0 monofilament suture such as nylon or polypropylene. The wounds are then covered with an antibiotic ointment and dressings. A light pressure dressing is placed to reduce tissue edema and to immobilize and reshape the skin over the recontoured area. Although multiple regimens for compression exist, I instruct patients to wear the compression garment continuously for 7 days and then only at night for an additional 7 days. Appendix B shows an example of postoperative instructions for patients undergoing cervicofacial liposuction.

Complications

Postoperative complications associated with cervicofacial liposuction are rare. Since liposuction of the head and neck region usually involves the removal of < 100 cc of fat from a limited area, the complications associated with whole-body liposuction procedures, such as significant blood loss, rapid fluid shifts, hypotension, shock, and death, are not seen.

Infections following cervicofacial liposuction occur in < 0.2% of cases,¹⁵ and a low rate should be expected with adherence to strict sterile procedure. Since cervicofacial liposuction is a sterile procedure, antibiotics are not required. However, literature suggests that they are commonly used as a prophylactic measure by many surgeons.¹⁶

Hematomas and seromas are rarely seen. Compression garment wear limits the potential for this complication. Small hematomas or seromas are generally managed by needle aspiration and extended wear of a compression garment until completely resolved.

Contour irregularities are probably the most common postoperative complication. They may be treated based on the etiology of formation. Those complications related to excess skin (sagging) should be treated with a skin-tightening procedure. Irregularities of the underlying muscle (platysmal ptosis or platysmal decussation) should be corrected by a procedure designed to correct muscular problems. Both of the above-mentioned complications are the result of poor patient selection and diagnosis. Contour irregularities owing to inadequate fat removal may be corrected with further liposculpting procedures; however, overaggressive removal of fat may be more difficult to correct.

Injuries to the branches of the facial nerve or the greater auricular nerve are rare and may be avoided by adhering to the appropriate technique and ensuring that dissection is in the correct surgical plane. If facial nerve injury does occur,

monitoring and early referral to an appropriate specialist is indicated.

Liposuction as an Adjunctive Procedure

Orthognathic Surgery

Orthognathic surgical procedures have long been recognized as a means to manipulate the esthetics of the face. Hard tissues of the facial skeleton are manipulated by osteoplasty, osteotomy, and skeletal implants to modify a patient's appearance. However, the skin and subcutaneous tissues do play a role in determining a portion of facial esthetics, particularly in the cervicomental region. Those orthognathic procedures that affect the position of the mandible also affect the esthetics of the submental and neck region. For instance, a patient undergoing a mandibular setback procedure may have an esthetic cervicomental angle prior to the procedure but have lax submental tissue following the procedure. This modification of an adjacent esthetic subunit of the head and neck underscores the need for a total facial analysis of our orthognathic patients prior to the initiation of surgical treatment. In the case of liposculpting procedures, a patient's submental, jowl, and neck regions may be treated with cervicofacial liposuction in conjunction with orthognathic surgery to better define the inferior border of the mandible, remove unesthetic submental fat deposits, or assist in tightening lax submental tissues to establish an acceptable cervicomental angle. An important limitation to consider with this type of combined treatment is the etiology of the original craniofacial defect being treated. In those patients with severely hypoplastic mandibles, a deficiency in cervicomental skin and muscle may also exist. In such a case cervicofacial liposuction would not be a benefit in recreating an esthetic cervicomental angle. Figure 68-4 demonstrates reconstruction of the cervicomental region in a patient undergoing combined orthognathic and liposculpting procedures.

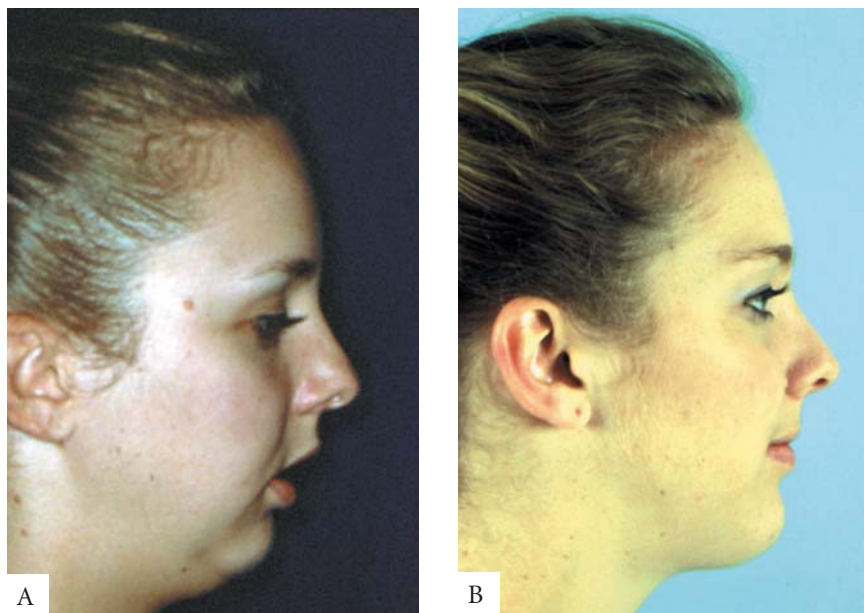

FIGURE 68-4 This patient underwent orthognathic surgery consisting of a segmental Le Fort I osteotomy with impaction, bilateral sagittal split ramus osteotomies, advancement genioplasty, and cervicofacial liposuction. A, Preoperative view. B, Postoperative view. Note the esthetic appearance of the cervicomental angle.

Chin Augmentation Cervicofacial liposuction may be performed in conjunction with chin augmentation or advancement genioplasty if the patient exhibits a hypoplastic genial process. The combination of procedures enhances the results that the patient would receive from liposuction alone.¹⁷ The advancement genioplasty or chin augmentation improves the final result by accentuating the depth of the cervicomental angle. In many cases a chin implant may be placed using the same incision through which the liposuction was performed by slightly increasing the size of the incision to accommodate the chin implant. Advancement genioplasty may be performed through an intraoral incision, with closure occurring prior to the start of liposuction; this allows the field to be cleared of all contaminated instruments and provides the surgeons with the opportunity to change their gloves.

Liposuction-Assisted Rhytidectomy

Liposuction may be used to enhance the results of rhytidectomy (face-lift) when

significant submental adiposity exists. Both open and closed liposuction techniques may be used. Three main areas may be addressed with the liposuction technique. First, the technique of pretunneling may assist the surgeon in elevating the facial flap. The blunt-tipped cannula may be passed easily through the subcutaneous fat layer to assist in the dissection and limit the potential for damage to the subdermal plexus. Second, following elevation of the flap, the spatula cannula may be used to defat the SMAS layer and the posterior aspect of the platysma. This maneuver helps to better identify the surgical plane and to limit the potential for postoperative contour irregularities. Any fat that may be associated with excessive jowls may be eliminated from overlying the SMAS at this time. Finally, liposuction may be used in the neck and submental areas to eliminate fatty deposits and potentiate the appropriate redraping of the neck and facial skin. It is important to remember that liposuction provides only an adjunct to rhytidectomy and that SMAS suspension with skin excision must still be per-

formed. Figure 68-5 illustrates a case in which a patient underwent liposuction-assisted rhytidectomy.

Autologous Fat Transfer

History

Autologous fat transfer for soft tissue augmentation or reconstruction continues to be viewed with guarded acceptance by surgeons throughout the world. Many surgeons are able to obtain predictable results, a fact that has spurred continued interest in the concept of fat transfer. In addition, many practitioners now feel that the loss of fat volume in the face may lead to premature aging and a less-than-cosmetic appearance. As a result, there has been a resurgence in the acceptance of fat-injection techniques. The technique itself was first introduced by Neuber in 1893, when he used a free fat graft from the upper extremity to reconstruct a periorbital defect.¹⁸ His data seemed to suggest that smaller grafts were more successful in that they had a greater chance for long-term survival. Building on this knowledge, Verderame in 1909 advocated overcorrection of defects to the significant amount of graft resorption associated with autologous fat transfer.¹⁹ It is important to realize that these studies involved sharply dissected fat grafts with defined clinical margins for vascular ingrowth and not bluntly dissected fat from liposuction harvest procedures. Research continued into sharply dissected autologous fat grafts with several human studies by Peer in the 1950s.^{20,21} He sharply dissected fat from the abdomens of 13 individuals and divided the fat into two equal grafts. One graft was inserted in entirety, whereas the other graft was sharply subdivided into multiple smaller pieces. His studies demonstrated that the greatest damage to the graft occurred at the cut margins and that the grafts that were cut into smaller pieces retained less of their volume. Although this would seem to be contradictory to

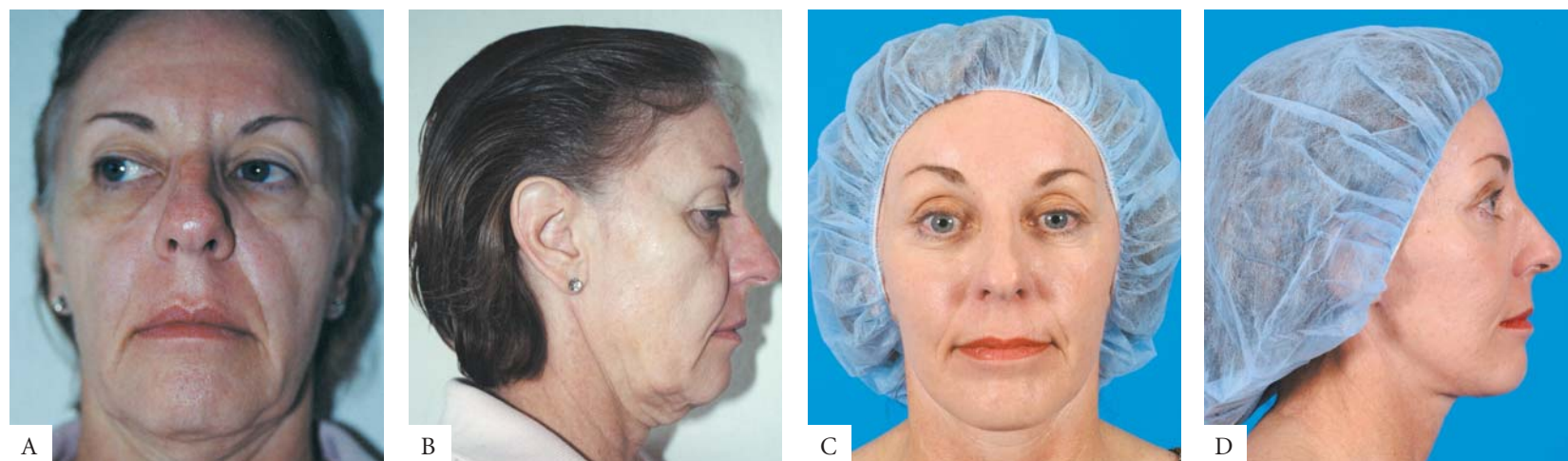

FIGURE 68-5 This patient underwent a cervicofacial liposuction-assisted rhytidectomy. A and B, Preoperative frontal and lateral views. C and D, Postoperative frontal and lateral views. Note the excellent definition of the inferior border of the mandible and the esthetic appearance of the cervicomental angle.

earlier research demonstrating greater graft volume survival in smaller grafts, the contradiction relates to the surgical damage created by the sectioning of a larger graft into smaller portions versus the harvesting of a smaller graft initially.

Blunt lipectomy with autologous fat grafting by injection has recently become popular owing to the relative ease of the procedure. Illouz first wrote about the grafting of liposuctioned fat in 1986,²² and others have published multiple positive reports of the technique based on clinical experience^{23–25}; however, little scientific information on the validity of this technique has become available until recently. Fournier and Otteni studied histologically the damage to lipocytes following their extraction by blunt cannula liposuction and noted no damage to the cells.¹⁶ It is important to note that these studies were carried out using large-diameter cannulas, not the smaller-diameter cannulas used today. More recently Carpaneda demonstrated that the aspirated material retrieved following liposuction consists of adipose cells, collagen fibers, vessels, nerves, ruptured cells, inflammatory proteins, proteases, and lipogenic enzymes.²⁶ Campbell and colleagues studied adipocyte glucose oxidation and lipid synthesis following suction extraction and injection through needles of varying sizes.

Their research showed that the smaller-diameter needles were associated with increasing cell damage.²⁷ More current research focuses on limiting damage to cells on extraction and providing an appropriate environment for cell survival during transfer. Various techniques involve the use of platelet gel, enriched tissue culture medium, and albumin to promote the survival of fat cells and maintain the volume of the grafted tissue.^{28–30}

Autologous Fat Injection

The technique for autologous fat transfer by injection varies with the provider. As demonstrated by the limited literature review previously presented, there are multiple theories and techniques associated with fat transfer. The following technique has been used over a period of years, providing predictable cosmetic results for many patients.

As with cervicofacial liposuction, the appropriate preoperative consultation, medical evaluation, photodocumentation, and informed consent procedures are necessary for all patients. Patients should identify the defect that they desire to be corrected or describe the cosmetic enhancement that they wish to be achieved by autologous fat transfer. Prominent nasolabial or melolabial folds, prominent nasojugal grooving, and atrophic lips are all cosmetic deformi-

ties that lend themselves to correction by autologous fat injection. At the preoperative appointment, a site for fat harvest is chosen. Acceptable sites include the abdomen, lateral thigh, and buttocks.

On the day of surgery, the area to receive fat augmentation is clearly marked and confirmed with the patient. The procedure may be carried out under local anesthesia, but I prefer the use of light conscious sedation and local anesthesia for enhanced patient comfort. The technique previously described for tumescent liposuction is followed for harvesting fat, with one exception. Research indicates that fat cell damage is reduced when lower vacuum pressures are used. In this case 0.5 atm of vacuum pressure is advocated for the harvest of fat to be re-injected. Once the fat is harvested, it is moved to a sterile back table for preparation. The area of harvest is cleaned, excess tumescent solution and debris are expressed, and the wound is closed. The area is then covered with a compressive garment.

At our institution fat to be injected is then processed through a centrifuge at 3400 rpm for 3 minutes to separate viable fat cells from damaged cells and blood products. Following processing, the undesired materials are decanted from the viable fat cells, which are then transferred to an injection syringe.

Fat is transferred into the desired tissue location with a 14-gauge injection cannula and a high-pressure injection device, as demonstrated in Figure 68-6. It is important to remember that the fat should be injected with two to three passes of the cannula in various planes. Theoretically, multiple passes provide an increased surface area for vascular ingrowth leading to increased graft volume survival. Figure 68-7 shows a patient receiving an autologous fat graft to the lips during a rhytidectomy procedure. The grafting cannula is then removed and the area cleaned. There is no need to suture closed the injection sites.

Dermal Fat Grafts

First introduced by Neuber in 1893,¹⁸ dermal fat grafts are used for a variety of reconstructive and cosmetic techniques. In the maxillofacial region a variety of soft tissue deficit reconstructions have been performed using dermal fat grafts, including soft tissue enhancement of hemifacial atrophy patients, reconstruction following radical parotidectomy, repair of gunshot wounds, and various cosmetic augmentation procedures. Peer demonstrated less resorption in dermal fat grafts than with free fat grafting, although he still reported a 50% loss of weight and volume of the grafted fat at 1 year.²⁰ Research by Longacre and by Neumann,^{31,32} who both used pedicled dermal fat grafts for reconstructive procedures, achieved excellent results

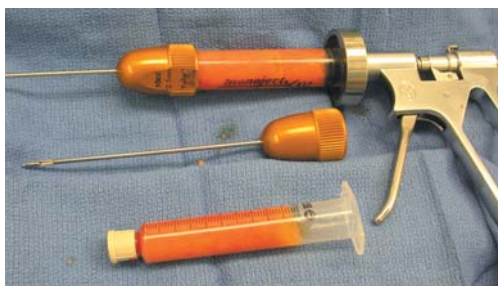

FIGURE 68-6 Autologous fat prepared for injection transfer. The high-pressure injection device is loaded with a 10 cc syringe of graft material. Two injection cannulas are available for use.

with retention of fat and postulated that the pedicled blood supply accounted for the reduction in overall fat resorption. Although these grafts do provide a reliable result, they should only be selected for smaller defects of the maxillofacial region. For larger defects microvascular transfer of skin and muscle provides a more predictable and stable cosmetic result.

The technique for obtaining a dermal fat graft is well described. A site for harvesting the graft is selected that has thick but relatively hairless skin. Two techniques for accessing the dermis and fat are generally accepted. The first employs a split-thickness skin graft (0.036 to 0.041 cm), which is lifted to expose the underlying dermis. Sharp excision of the dermal fat graft with a knife is then performed. Care must be taken to ensure that the fat remains attached to the dermis. Figure 68-8 shows a dermal fat graft harvested for soft tissue reconstruction. Once the graft is removed, local hemorrhage is controlled, and the area is closed. The second newer technique involves de-epithelialization of the skin with a CO₂ laser. This technique is extremely helpful in managing a specific area, as in an island or a pedicled flap, and in facilitating an elliptic area of de-epithelialization to allow for straight-line closure. The CO₂ laser is set at 10 W of power with a 1 to 2 mm spot size, and the area to be de-epithelialized is then systematically lasered. When the area has been completed, the area is débrided with a wet sponge. Often, two or three passes with the laser are needed to completely de-epithelialize the area. Care must be taken to limit the thermal damage to the underlying dermis and fat. Once the de-epithelialization is completed, the dermis and fat are harvested with a knife, local hemorrhage is controlled, and the area is closed.

Complications

As with cervicofacial liposuction, the complications associated with the transfer of autologous fat are limited. Primarily, mis-

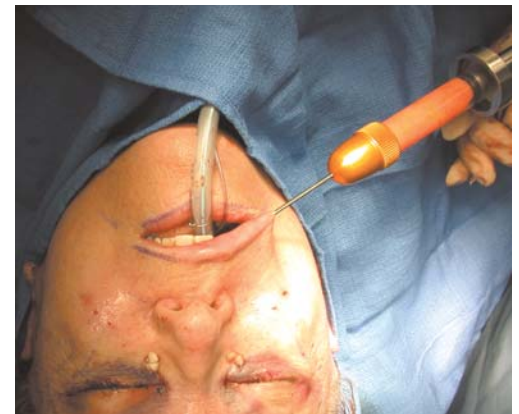

FIGURE 68-7 Injection of autologous fat grafts into the lip during a rhytidectomy procedure.

placement of the graft, infection, and loss of significant graft volume are worthy of mention. Grafts are generally overcontoured to account for the loss of graft volume during the healing phase. Since the location of graft volume loss is difficult to predict, the potential for graft misplacement exists. Should residual fat remain in an area where it is not desired, the remaining graft may be removed by local suction lipectomy with a syringe and a small cannula. Infection of the graft site is possible if meticulous sterile technique is not followed. I advocate the use of prophylactic antibiotics for all patients undergoing autologous fat transfer. Finally, loss of significant fat volume may occur leading to patient dissatisfaction and irregular or unacceptable contour. Since fat-volume retention seems to be related to a number of variables, patients should be counseled concerning the potential need for multiple

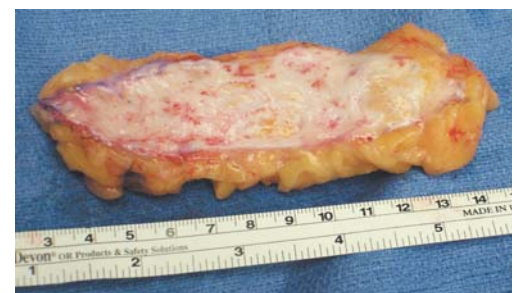

FIGURE 68-8 Example of a dermal fat graft harvested for soft tissue reconstruction.

grafting procedures to achieve the final result. Our experience indicates that most patients achieve their expected results with two or three grafting procedures.

Summary

Liposculpting procedures of the cervicofacial region provide patients with a simple and predictable means for improving their facial esthetics. The procedures have been described in the scientific literature for over 100 years and have been performed safely by many oral and maxillofacial surgeons. Cervicofacial liposculpting techniques can also be used to enhance the results of orthognathic surgery and other more involved maxillofacial cosmetic surgery procedures. With the advent of the tumescent liposuction technique, small-diameter cannulas, and the syringe suction technique, the procedures are easily and safely performed in the modern oral and maxillofacial surgery office environment. Autologous fat-transfer techniques for facial reconstruction and maxillofacial esthetic surgery have also found a place in the contemporary oral and maxillofacial surgery practice.

The views expressed in this chapter are those of the author and do not represent the official policy or position of the Department of the Navy, Department of Defense, or US Government.

References

- Fischer G. The evolution of liposculpture. *Am J Cosmet Surg* 1997;14:231–8.
- Maliniak JW. Is the surgical restoration of the aged face justified? *Med J Rec* 1932;135:321–2.
- Davis AD. Obligations in the consideration of myeloplasties. *J Int Surg* 1955;24:568–73.
- Schrudde J. Lipexeresis in the correction of local adiposity. In: *First Congress of International Society of Aesthetic Plastic Surgery*. Rio de Janeiro; 1972.
- Illouz YG. Body contouring by lipolysis: a 5-year experience with over 3000 cases. *Plast Reconstr Surg* 1983;72:591–7.
- Fournier P. Chance and lipoextraction: thoughts and progress in lipoplasty (reduction and augmentation). *Am J Cosmet Surg* 1988;5:249–51.
- Klein JA. The tumescent technique for liposuction surgery. *Am J Cosmet Surg* 1987;4:263–7.
- Field LM. Adjunctive liposurgical debulking and flap dissection in neck reconstruction. *J Dermatol Surg Oncol* 1986;12:917–20.
- Hallock GG. Liposuction for debulking free flaps. *J Reconstr Microsurg* 1986;2:235–9.
- Newmann J, Nguyen A, Anderson R. Liposuction of the buccal fat pad. *Am J Cosmet Surg* 1986;3:1–9.
- Teimourian B. Suction lipectomy of the face and neck. *Facial Plast Surg* 1986;4:35–41.
- Courtiss EH. Suction lipectomy of the neck. *Plast Reconstr Surg* 1985;76:882–9.
- Giampapa VC, DiBernardo BE. Neck contouring with suture suspension and liposuction: an alternative for the early rhytidectomy candidate. *Aesthetic Plast Surg* 1995;19:217–23.
- American Academy of Cosmetic Surgery. 1997 guidelines for liposuction surgery. *Am J Cosmet Surg* 1997;14:387–95.
- Newman J, Dolsky RL. Evaluation of 5,458 cases of liposuction surgery. *Am J Cosmet Surg* 1984;1:25–34.
- Fournier PF, Otteni FM. Lipodissection in body sculpting: the dry procedure. *Plast Reconstr Surg* 1983;72:598–609.
- Newman J, Dolsky RL, Mai ST. Submental liposuction extraction with hard chin augmentation. *Arch Otolaryngol* 1984;110:454–7.
- Neuber F. Fat grafting. *Chir Kongr Verh Dtsch Ges Chir* 1893;22:66–71.
- Verderame H. Uber Fett transplantation bei adharenten knochennarben am orbitalrand. *Klin Monatshefte Augenheilkd* 1909;47:433–7.
- Peer LA. Loss of weight and volume in human fat grafts. *Plast Reconstr Surg* 1950;5:217–30.
- Peer LA. The neglected free fat graft. *Plast Reconstr Surg* 1956;18:233–50.
- Illouz YG. The fat cell “graft”: a new technique to fill depressions. *Plast Reconstr Surg* 1986;78:122–3.
- Bircoll M, Novak BH. Autologous fat transplantation employing liposuction techniques. *Ann Plast Surg* 1987;18:327–9.
- Chajchir A, Benzaquen I. Fat-grafting injection for soft tissue augmentation. *Plast Reconstr Surg* 1989;12:921–34.
- Teimourian B. Repair of soft-tissue contour deficit by means of semiliquid fat graft. *Plast Reconstr Surg* 1986;78:123–4.
- Carpaneda CA. Study of aspirated adipose tissue. *Aesthetic Plast Surg* 1996;20:399–402.
- Campbell GL, Laudenslager N, Newman J. The effect of mechanical stress on adipocyte morphology and metabolism. *Am J Cosmet Surg* 1987;4:89–97.
- Fulton JE. Stabilization of fat transfer to the breast with autologous platelet gel. *Int J Cosmet Surg* 1999;7:6. 273–9.
- Har-Shai Y, Lindenbaum ES, Gamliel-Lazarovich A, et al. An integrated approach for increasing the survival of autologous fat grafts in the treatment of contour defects. *Plast Reconstr Surg* 1999;104:945–54.
- Kaminski MV Jr, Wolosewick JJ, Smith J. Preservation of interstitial colloid: a critical factor in fat transfer. *Oral Maxillofac Surg Clin North Am* 2000;12:4. 631–9.
- Longacre JJ. Use of local pedicle flaps for reconstruction of breast after subtotal or total mastectomy. *Plast Reconstr Surg* 1953;11:380–403.
- Neumann CG. The use of large buried pedicled flaps of dermis and fat, clinical and pathological evaluation of hemiatrophy. *Plast Reconstr Surg* 1953;11:315–32.

Appendix A

INFORMED CONSENT FOR SUCTION-ASSISTED LIPECTOMY (SURGICAL AND SUCTION-ASSISTED FAT REDUCTION)*

I hereby authorize Dr. _____ and staff to perform the following procedure:

and to administer the anesthetic I have chosen, which is () local anesthetic, () intravenous sedation, () or general anesthetic.

Other treatment options: _____

Please initial each paragraph after reading. If you have any questions, please ask your doctor *before* initialing.

Liposuction

I hereby acknowledge that the following has been explained to me and that I have had an opportunity to ask questions.

- _____ 1. Suction-assisted lipectomy is the technique to remove a localized collection of fat beneath the skin.
- _____ 2. I understand the purpose of the surgery is to treat and attempt to correct the appearance of localized areas on my body.
- _____ 3. I have been completely candid and honest with my surgeon regarding my motivation for undergoing a lipectomy, realizing that a new appearance does not guarantee an improved life.
- _____ 4. I understand that if I am an active smoker I must cease smoking at least 2 weeks prior to surgery. Failure to follow this instruction can have dramatic effects on the success of the surgery.
- _____ 5. It has been explained to me that suction-assisted lipectomy is not a substitute for weight reduction that can ordinarily be obtained by dieting and exercise and that it is not a cure for obesity. It is a surgical technique suitable for selected patients.
- _____ 6. I hereby acknowledge that I have attempted to accurately provide Dr. _____ and/or his staff with an accurate medical history, realizing that withholding certain information may adversely affect my diagnosis and the final result of the surgery.
- _____ 7. It has been explained to me that my physical condition may require surgical lipectomy, in which excess skin and fat may be removed instead of or in addition to suction-assisted lipectomy.

Surgical Considerations

- _____ 1. The technique of liposuction has been explained to me. I have been told that suction-assisted lipectomy may be performed under local anesthesia or, in selected cases, with the use of intravenous sedation or a general anesthetic. The procedure begins with small incisions approximately 1 cm long. The doctor will then insert a blunt-ended tubular instrument (catheter) into the area of the incision and then, using suction, extract the deposits of fat. I have been advised that additional incisions may be necessary to gain adequate access to all areas of unwanted fat deposits.

Postoperative Considerations

- _____ 1. The incisions will be closed with small sutures. Generally, the scars are small. However, I have been advised that in some cases scarring may be unpredictable and a second procedure may be required to reduce the scarring.
- _____ 2. Following the surgery I have been told that a snug dressing of elastic gauze may be applied to the entire area to help the skin conform smoothly to the shape of the underlying tissue. This pressure-type bandage is generally worn for about 2 weeks. Some bruising and swelling may persist for several weeks after the operation. Some postoperative pain can be expected, and medication will be prescribed to provide some relief.
- _____ 3. I have been advised and acknowledge that there is no guarantee that the procedure will improve my appearance. Patients react differently depending upon age and health. Some individuals have less skin elasticity and may require additional procedures to remove or tighten excess skin. Further, some people have skin that tends to wrinkle more than do others. To assist in healing, strenuous physical activity such as aerobics or physical labor must be avoided during the first week postoperatively.

Risks and Complications

Dr. _____ has explained to me there are certain inherent and potential risks in any treatment plan or procedure and that, in this specific instance, such operative risks include but are not limited to the following:

- _____ 1. There is a possibility that a second surgery/procedure will need to be performed in the event the doctor encounters an abundance of excess fat.
- _____ 2. Ordinarily, liposuction of the face and neck does not require blood transfusions. However, all patients respond differently. I have been told that there is a possibility that a blood transfusion will be performed, and I have been advised of my rights regarding autologous blood (self and family transfusions).
- _____ 3. The surgery will involve areas of certain cranial or facial nerves. Damage to the nerves can result in numbness, which is usually temporary. However, in rare cases the numbness can be permanent. Additionally, there is a risk of damage to nerves that affect motor function. For example, there may be an inability to purse the lips. The condition is usually temporary; however, in rare conditions it can be permanent.
- _____ 4. It is possible that after fat removal the overlying skin will not be smooth; rather, it may have a “washboard” appearance. A second liposuction procedure or other cosmetic surgery may be necessary to correct this condition.
- _____ 5. In the event that fat is to be removed from the cheek area, I have been advised that a change in facial tone occurs in some cases. The condition is usually temporary; however, on rare occasions this condition can be permanent.

- ___ 6. Any surgery involves the risk of infection requiring antibiotic treatment. Most cases resolve without complication; however, in rare situations treatment of a serious infection may require hospitalization.
- ___ 7. There is a possibility of localized collections of blood in areas of fat removal. Secondary procedures to remove the blood may be required.

Anesthesia

In the event that I am to receive intravenous or general anesthesia, I understand and agree that I am not to have had and/or have not had anything to eat or drink for 8 hours before my surgery. **FAILURE TO FOLLOW THIS INSTRUCTION MAY BE LIFE THREATENING!**

- ___ 1. I consent to the administration of () local anesthetic, () intravenous sedation, or () general anesthetic, having first had the risks and benefits of each explained to me.
- ___ 2. I have been made aware that certain medications, drugs, anesthetics, and prescriptions that I may be given can cause drowsiness, incoordination, and a lack of awareness, which may be worsened by the use of alcohol and other drugs. I have been advised not to operate any vehicle or hazardous machinery and not to return to work while taking such medications, or until I am fully recovered from the effects of the same. I understand this recovery may take up to 24 hours or more after I have taken the last dose of medications. If I am given sedative medication during my surgery, I agree to have a responsible adult drive me home and accompany me until I am fully recovered from the effects of the sedation.
- ___ 3. I understand that certain anesthetics can cause bodily injury and death.

No Guarantee of Treatment Results

- ___ 1. No guarantee or assurance has been given to me that the proposed treatment will be curative and/or successful to my complete satisfaction. Owing to individual patient differences, there may exist a risk of failure or relapse, my condition may worsen, or selective re-treatment may be required in spite of care provided.
- ___ 2. I have had an opportunity to discuss with Dr. _____ my past medical and health history including any serious problems and/or injuries and have fully informed him of the same.
- ___ 3. I agree to cooperate fully with the recommendations of Dr. _____ while I am under his care, realizing that any lack of such cooperation can result in less-than-optimal results or may be life threatening.
- ___ 4. If any unforeseen condition should arise in the procedure of the operation calling for the doctor's judgment regarding procedures in addition to or different from those now contemplated, I request and authorize the doctor to provide the appropriate service.

Miscellaneous

- ___ 1. I request the disposal by authorities of this medical facility of any tissues or parts that it may be necessary to remove.
- ___ 2. I understand that photographs and movies may be taken of this operation and that they may be viewed by various personnel undergoing training or indoctrination at this or other facilities. I consent to the taking of such pictures and observation of the operation by authorized personnel, subject to the following conditions:
- A. My name and my family's name are not to be used to identify said pictures.
- B. Said pictures are to be used only for purposes of medical/dental study or research.

For Female Patients

I have advised Dr. _____ as to whether I am currently using birth control pills. I have been advised and informed that certain antibiotics and some pain medications may neutralize the therapeutic effect of birth control pills allowing for conception and resulting in pregnancy. I agree to consult with my family physician to initiate additional forms of mechanical birth control during the period of my treatment with Dr. _____ and until I am advised by my physician that I can return to using birth control pills exclusively.

I have had an opportunity to have my questions answered, and I certify that I understand the English language.

Patient's (or legal guardian's) signature

Date/Time

Witness's signature

Date

Counseling Physician/Dentist: I have counseled this patient as to the nature of the proposed procedure(s), attendant risks involved, and expected results, as described above.

Counseling physician/dentist's signature

Appendix B

POSTOPERATIVE INSTRUCTIONS FOR FACIAL LIPOSUCTION*

Please read your instructions carefully and call us if you have any questions.

Swelling and a large amount of discoloration are normal following liposuction surgery. The following instructions are designed to help you minimize discomfort after surgery.

Position

Elevate your head and back using several pillows or use a recliner chair with the head at a 45° angle. It is important that you do so for *1 to 2 days* after your surgery. Lay on your back, rather than on your side or stomach.

Ice

Ice may be used over the surgical area for the first *24 hours* around the clock, as directed (leaving it off for eating and performing hygiene).

Activity

During your *first day* after surgery, stay up as much as possible. You should sit, stand, or walk around rather than remain in bed. However, you should rest when you become tired. Avoid bending or lifting more than 2.5 kg during the first week. You may do *passive exercises only!* Stay away from any activity that raises the pressure in your face for *2 weeks* as excessive pressure may cause a severe bleed. Avoid excessive talking and extreme facial movements (which may increase bleeding/bruising).

Diet

- Day of surgery, postoperatively: Start with clear cool fluids when these are tolerated, advance to warm (*not hot!*) fluids and very soft foods only, such as soups, dairy products, and applesauce.
- From the second day after surgery until your next office visit: Eat warm soft foods or cool foods—foods that do not require a lot of chewing. Also, make sure you are drinking lots of fluids during your postoperative recovery, at least eight 250 mL glasses a day for about 3 weeks. *This is very important!*
- One week after surgery: Resume your regular diet.

Medication

Pain medication: Take one dose when you arrive at home, then as needed every *4 to 6 hours* for discomfort or pain.

Caution: Do not drive or operate dangerous machinery while taking narcotic pain medication. Do not drink alcohol while taking pain medication or antibiotics.

Heat

Begin using moist heat on the second postoperative day. A moist towel should be placed between the skin and the heat source. Do not use heat continuously, only for *20 minutes four times per day* for a *2-week period*.

Sun Exposure

Protect the facial skin from excessive sun exposure for 1 month after surgery. Use a sunblock that is SPF 15 or higher. Wear a hat.

Sports

Do not participate in swimming, gym activities, or strenuous activities for *1 week*. Do not dive or ski for *2 months*. Passive exercise such as walking is permitted.

Acetylsalicylic Acid

The use of acetylsalicylic acid (Aspirin or medications containing ASA) should be avoided for *10 days* prior to surgery. Take acetaminophen (Tylenol) for headaches and minor pain.

Smoking

Smoking should be stopped at least *2 weeks* prior to surgery. Smoking impairs circulation, and good circulation is needed for proper healing. An adequate blood supply leads to a good surgical result for you.

Bruising/Swelling

Bruising and swelling are to be expected. Bruising is usually gone in 7 to 10 days. The swelling takes a while longer to subside.

Bleeding

If the dressing or elastic support is quite bloodstained, this should be reported to the doctor *immediately!*

Dressings

A compression dressing must be worn continuously for 1 week; it may be removed for short periods of time and then reapplied. Leave this on *24 hours a day for the first week*, and then mainly wear the support dressing at night.

Bathing

You may bathe in the tub or shower, and shampoo your hair during the *first day* after surgery. Use mild soaps and shampoos to avoid irritation.

Shaving

Resume shaving when swelling subsides and the area is not too tender.

Care of Your Incisions

Supplies needed: bacitracin ointment, 1/2 oz; cotton-tip applicators (eg, Q-Tips)

1. Use cotton-tip applicators and warm water to clean all blood and material from the cuts. *Do not* leave any crusts or blood on the stitched areas. Repeat a minimum of four to five times per day.
2. Cover *all* cuts and abrasions with ointment—do not allow *any* areas to dry out or scab over.
3. Do not apply any bandages or other materials to the surgical area unless otherwise instructed.

Follow-Up Appointments

Please check off postoperative appointments as they are kept:

1 to 2 days _____ 5 days _____ 2 weeks _____
2 months _____ 6 months _____

Final Note

Faithful adherence to the preoperative and postoperative instructions will not only help to minimize swelling, pain, and discomfort, but will also aid in achieving an excellent surgical result. If you do have problems, don't hesitate to contact our office for assistance.

Please report any of the following to our office:

- Excessive bleeding
- Sudden swelling
- Any itching, rash, or reaction to any of the medications
- Temperature above 101°F (38.3°C) (taken orally)

*Adapted from a form by the Oral and Maxillofacial Surgery Clinic, Naval Medical Center, San Diego, CA.

Skin Rejuvenation Procedures

Gary D. Monheit, MD

The pursuit of youth and beauty has become a hallmark of the baby-boomer generation, which has now advanced to midlife and beyond. The distinct increase in an older population due to newer medical and technological advancements and career development has brought a larger healthy population interested in cosmetic procedures. This mid-age population has remained active in the workforce and now demands “no downtime” procedures for skin rejuvenation that will maintain their appearance for work and pleasure. This has encouraged the development of new lasers, new fillers, botulinum toxin, cosmeceuticals, and many other innovations that have reduced the downtime and increased the safety of our cosmetic facial rejuvenation procedures. Anyone interested in providing facial cosmetic procedures and surgery needs to become familiar with all the procedures now available.

Aging of the skin is the combined result of both intrinsic factors and extrinsic external influences from the environment. Intrinsic aging is the roles that genetics plays in relation to chronologic age. These include alteration of skeletal mass and proportion, atrophy and redistribution of subcutaneous fat, increased laxity of underlying fascia and musculature, and skin changes characterized by thinning and atrophy. Most intrinsic factors cannot be prevented, but rejuvenative changes can be made with cosmeceutical agents and resurfacing procedures.

Extrinsic factors are preventable environmental influences leading to premature aging of the skin, including ultraviolet (UV) exposure, smoking, chemicals, and gravity. UV exposure is the primary environmental factor, preferentially affecting those with a lighter skin color. The mechanism includes the production of UV-inducing oxygenated fine radiants that have been shown to invite a cascade of molecular events leading to the production of collagen-degrading enzymes. This creates the characteristic features of photoaging, including rough texture, atrophy, fine and coarse wrinkles, and sallow and leathery appearance with dyschromia.¹

In the evaluation of the patient with photoaging, equal emphasis must be placed on prevention as well as treatment. Agents available range from cosmeceutical topical agents to filling agents that include resurfacing devices such as chemical peels, ablative resurfacing lasers, and dermabrasion. An initial consultation is performed to determine which of these tools is best for the patient based on severity and diversity of the condition.

Methods to evaluate photoaging include the Glogau classification of wrinkles. It classifies patients into one of four groups based on degree of severity (Table 69-1). Category I patients are young, with “no wrinkles” and minimal photoaging and are best managed with cosmeceutical agents and superficial resurfacing proce-

dures such as light chemical peels and microdermabrasion. Category II patients are in their thirties, with early to moderate signs of photoaging and characterized by wrinkles in motion. Category III patients have moderate to advanced photoaging with static wrinkles requiring more significant ablative resurfacing techniques. Category IV patients are the oldest, with more severe photoaging changes and wrinkles

Table 69-1 Glogau’s Classification of Photoaging

Group I: Mild (typically age 28–35 years)
A. Little wrinkling or scarring
B. No keratoses
C. Requires little or no makeup
Group II: Moderate (age 35–50 years)
A. Early wrinkling; mild scarring
B. Sallow color with early actinic keratoses
C. Little makeup
Group III: Advanced (age 50–65 years)
A. Persistent wrinkling or moderate acne scarring
B. Discoloration with telangiectasias and actinic keratoses
C. Wears makeup always
Group IV: Severe (age 60–75 years)
A. Wrinkling; photoaging, gravitational, and dynamic
B. Actinic keratoses with or without skin cancer or severe acne scars
C. Wears makeup with poor coverage

significant enough to justify deep resurfacing and other surgical techniques.²

Ablative resurfacing injures the skin in a controlled fashion to a specific depth, encouraging the growth of new and improved skin. These methods include chemical peeling, dermabrasion, and laser resurfacing. Skin resurfacing techniques are divided into superficial, medium depth, and deep, relating to the level of injury (Figure 69-1). The deeper procedures are restricted to the face since other body areas do not have the healing capacity to rejuvenate new skin after such an injury. Care must also be taken with the neck, which may scar with medium-depth or deep injury.³

Table 69-2 presents a useful classification system for categorizing skin resurfacing methods. It is based on the objective data collected by Stegman, who correlated strengths of trichloroacetic acid (TCA) by biopsy of depth of tissue destruction and then new collagen rejuvenation.⁴ Thus superficial, medium depth, and deep resurfacing correlates modalities of peeling, dermabrasion, and laser to common denominators; namely, inflammation and injury.⁴

A useful method of assessing skin-related photoaging is the Monheit-Fulton

index (Table 69-3). This system categorizes the visual changes in photoaging skin and quantitates the amount to guide the physician with appropriate therapy. The system combines age-related textural and lesional changes into a numeric system that will predict how aggressive a physician should be in using superficial, medium-depth, and deep resurfacing procedures.⁵

Medical Care of Photoaging Skin

The basis of all rejuvenative therapy involves using sunscreen protection and cosmeceutical preparations that will help reverse photoaging changes. These products include sunscreens, retinoids, hydroxy acids, antioxidants, and bleaching agents as needed.

Ultraviolet damage is caused by both UVB (290 to 320 nm) and UVA (320 to 400 nm). Both the burning rays of UVB and the more deeply penetrant UVA cause problems of photocarcinogenesis and photoaging of the dermis. Most sunscreens provide adequate protection against the burning effects of UVB but deliver only partial protection against UVA. Sunscreens are divided into chemical and physical blockers. The chemical

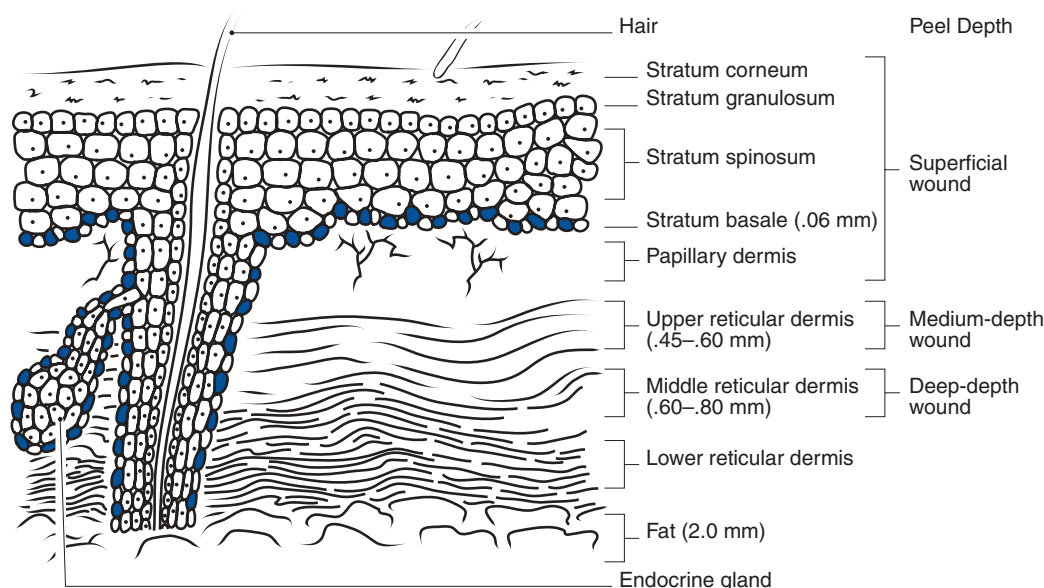


FIGURE 69-1 Cross-section of skin with superficial, medium, and deep wound areas.

Table 69-2 Classification of Ablative Skin Resurfacing Methods*

Superficial: Very Light†

Low-potency formulations of glycolic acid or other alpha-hydroxy acid
10–20% TCA (weight-to-volume formulation)
Jessner's solution (see Table 69-3)
Tretinoin
Salicylic acid
Microdermabrasion

Superficial: Light†

70% glycolic acid
Jessner's solution
25–30% TCA
Solid CO₂ slush
Microdermabrasion

Medium-Depth

88% phenol
35–40% TCA
Jessner's–35% TCA
70% glycolic acid–35% TCA
Solid CO₂–35% TCA
Conservative manual dermasanding
Erbium:YAG laser resurfacing
Conservative CO₂ laser resurfacing

Deep

Unoccluded or occluded Baker-Gordon phenol peel
TCA in concentrations > 50%
Wire brush or diamond fraise dermabrasion
Aggressive manual dermasanding
Manual dermasanding or motorized dermabrasion after a medium-depth peel
Aggressive erbium:YAG laser resurfacing
CO₂ laser resurfacing
Combination erbium:YAG/CO₂ laser resurfacing

CO₂ = carbon dioxide; TCA = trichloroacetic acid; YAG = yttrium-aluminum-garnet.

*Although this classification represents an oversimplification, because the depth of injury actually varies somewhat along a continuum for each different type of resurfacing procedure, it is helpful when discussing the various options with a patient.

†Techniques for ablative laser resurfacing of superficial depth have been developed but are probably impractical.

Table 69-3 Monheit-Fulton Index of Photoaging Skin						
Texture Changes		Points				Score
Wrinkles—dynamic (% of potential lines)	1 < 25%	2 < 50%	3 < 75%	4 < 100%	_____	
Wrinkles—photoaging (% of potential lines)	1 < 25%	2 < 50%	3 < 75%	4 < 100%	_____	
Cross-hatched lines—fine lines (% of potential lines)	1 < 10%	2 < 20%	3 < 40%	4 < 60%	_____	
Sallow color and dyschromia	1 Dull	2 Yellow	3 Brown	4 Black	_____	
Leathery appearance	1	2	3	4	_____	
Crinkly (thin and parchment)	1	2	3	4	_____	
Pebbly (deep whitish nodules) (% of face)	2 < 25%	4 < 50%	6 < 75%	8 < 100%	_____	
Pore no. and size	2 < 25%	4 < 50%	6 < 75%	8 < 100%	_____	
Lesions		Points				Score
Freckles—mottled skin (no. present)	1 < 10	2 < 25	3 < 50	4 < 100	_____	
Lentigenes (dark/irregular) and SKs (size)	2 < 5 mm	4 < 10 mm	6 < 15 mm	8 < 20 mm	_____	
Telangiectasias—erythema flush (no. present)	1 < 5	2 < 10	3 < 15	4 > 15	_____	
Actinic keratoses and seborrheic keratoses (no. present)	2 < 5	4 < 10	6 < 15	8 > 15	_____	
Skin cancers (no. present— now or by history)	2 1 ca	4 2 ca	6 3 ca	8 > 4 ca	_____	
Senile comedones (in cheekbone area)	1 < 5	2 < 10	3 < 20	4 > 20	_____	
Total Score					_____	
Corresponding Rejuvenation Program						
Score	Needs					
1–6	Skin-care program with tretinoin, glycolic acid peels					
7–11	Same plus Jessner’s peel; pigmented lesion laser and/or vascular laser					
12–16	Same plus medium peel—Jessner’s–TCA peel; skin fillers and/or botulinum toxin					
17 or more	Above plus laser resurfacing					
Staff Signature	Date	Patient Signature	Date			

screens include oxybenzone, para-aminobenzoic acid, and octyl methoxycinnamate. The physical blockers nowadays are transparent micronized formulations of titanium dioxide and afford more complete UVA and UVB protection.⁶

Topical retinoids have a direct effect on epidermal cell proliferation and dermal collagen growth. They have demonstrated significant effects on photoaging skin including dyschromias, epidermal growths, and fine wrinkle lines. The Federal Drug Administration has approved topical retinoids for the treatment of aging and photodamaged skin in the form of tretinoin cream (0.05% or 0.02%) and most recently tazarotene cream 0.1%. Use of a retinoid with a sunscreen is basic in skin care for photoaging skin problems. It is also used prior to resurfacing procedures to enhance the epidermal and dermal regenerative effect after resurfacing injury.⁷

Hydroxy acids have become a part of skin care programs for their effect on thinning the stratum corneum and decreasing epidermal cell cohesion. This has a regenerative effect on epidermal cell kinetics, giving the skin texture a plumper rejuvenative appearance. There is little definitive evidence that topical alpha-hydroxy acids have an effect on dermal collagen per se.⁸

Topical antioxidants have shown an effect in retarding the reactive oxygen species created by ultraviolet damage. Vitamin C (ascorbic acid) has been shown to be a potent scavenger of free oxygen radicals. Topical products have shown activity in the experimental mode but clinical efficacy as of yet is anecdotal. Vitamin E is a lipid-soluble antioxidant that has become popular in topical form, but little true objective data are present to document its effect on photoaging skin.⁹

Chemical Peeling

Chemical peeling remains one of the most popular choices for both patient and physician. In comparison to some of the newer options available, chemical peels have a

long-standing safety and efficacy record, are performed with ease, are low in cost, and have a relatively quick recovery time. Various acidic and basic compounds are used to produce a controlled skin injury and are classified as superficial, medium-depth, and deep peeling agents according to their level of penetration, destruction, and inflammation (see Table 69-2). In general superficial peels cause epidermal injury and occasionally extend into the papillary dermis, medium-depth peels cause injury through the papillary dermis to the upper reticular dermis, and deep peels cause injury to the midreticular dermis.⁴

Prior to the application of peeling solutions the surgeon must vigorously cleanse the skin surface to remove residual oils, debris, and excess stratum corneum. The face is initially scrubbed with 4" × 4" gauze pads containing 0.25% Irgasan (Septisol solution; Calgon Vestal Laboratories, St. Louis, MO, USA), then rinsed with water and dried. Because of the defatting and degreasing properties of acetone, gauze pads moistened in an acetone preparation are then used to cleanse the skin even further. The importance of cleansing in the peeling procedure cannot be overemphasized. A thorough and evenly distributed cleansing and degreasing of the face assures uniform penetration of the peeling solution and leads to an even result without skip areas (Figure 69-2).¹⁰

The effect of a chemical peel is dependent upon the agent used, its concentration, and the techniques employed before and during its application. Each wounding agent used in peels has unique chemical properties and causes a specific pattern of injury to the skin.³ It is important for the physician using these solutions to be familiar with their cutaneous effects and proper methods of application to ensure correct depth of injury. The marketplace has been flooded with numerous proprietary formulations of these peeling agents, with each product claiming

unique advantages. These products are often expensive and have not been unequivocally shown to be safer or more effective than the conventional solutions. The following sections will therefore focus on the specific chemical agents that are actively responsible for producing the various patterns of injury.

Superficial Chemical Peeling

Superficial chemical peels are indicated in the management of acne and its postinflammatory erythema, mild photoaging (Glogau I and II), epidermal growths such as lentiginos and keratoses, as well as melasma and other pigmentary dyschromias. Multiple peels on a repeated basis are usually necessary to obtain optimal results. The frequency of peels and degree of exposure to the peeling agent may be increased gradually as necessary. Results are enhanced by medical or cosmoceutical therapy.¹¹ All superficial chemical peels share the advantages of only mild stinging and burning during application as well as minimal time needed for recovery. They are a part of office-based procedures.¹²

Superficial chemical peels are divided into two varieties; very light and light (see Table 69-2). With very light peels the injury is usually limited to the stratum corneum and only creates exfoliation, but the injury may extend into the stratum granulosum. The agents used for these peels include low potency formulations of glycolic acid, 10 to 20% TCA, Jessner's solution (Table 69-4), tretinoin, and salicylic acid. Light peels injure the entire epidermis down to the basal layer, stimulating the regeneration of a fresh new epithelium. Agents used for light peels include 70% glycolic acid, 25 to 35% TCA, Jessner's solution, and solid carbon dioxide (CO₂) slush.¹³ During the application of superficial peeling agents, there may be mild stinging followed by a level I frosting, defined as the appearance of erythema and streaky whitening on the surface (Figure 69-3).

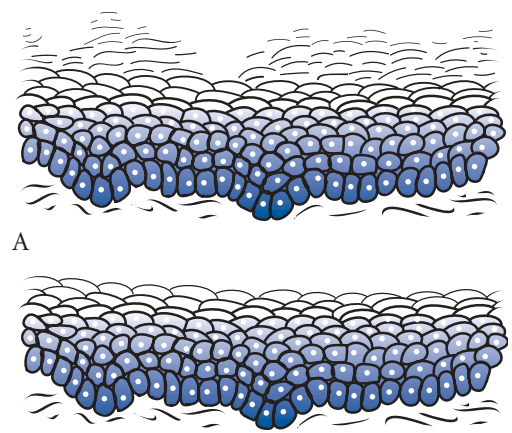


FIGURE 69-2 A, Irregular surface. B, Clean regular surface.

Alpha-hydroxy acid (AHA) peeling agents have been used widely in skin rejuvenation programs since the early 1990s. The depth of injury is determined by the specific AHA used, its pH, the concentration of free acid, the volume applied to the skin, and the duration of contact or time that the agent is left on the skin before neutralization.⁸ In low concentrations (20 to 30%), AHAs have been shown to decrease the cohesion of corneocytes at the junction of the stratum corneum and the stratum granulosum, whereas higher concentrations (up to 70%) are associated with complete epidermolysis. Weekly or biweekly applications of 40 to 70% unbuffered glycolic acid with cotton swabs, a sable brush, or 2" × 2" gauze pads have been used most often for acne, mild photoaging, and melasma.⁸ The time of application is critical for glycolic acid, as it must be rinsed off with water or neutralized with 5% sodium bicarbonate after 2 to 4 minutes.

Application of 10 to 20% TCA with either a saturated 2" × 2" gauze pad or

Table 69-4 Jessner's Solution (Combes' Formula)

Resorcinol, 14 g
Salicylic acid, 14 g
85% lactic acid, 14 g
95% ethanol (q.s.a.d.), 100 mL

q.s.a.d. = quantum satis ad ("up to sufficient quantity").

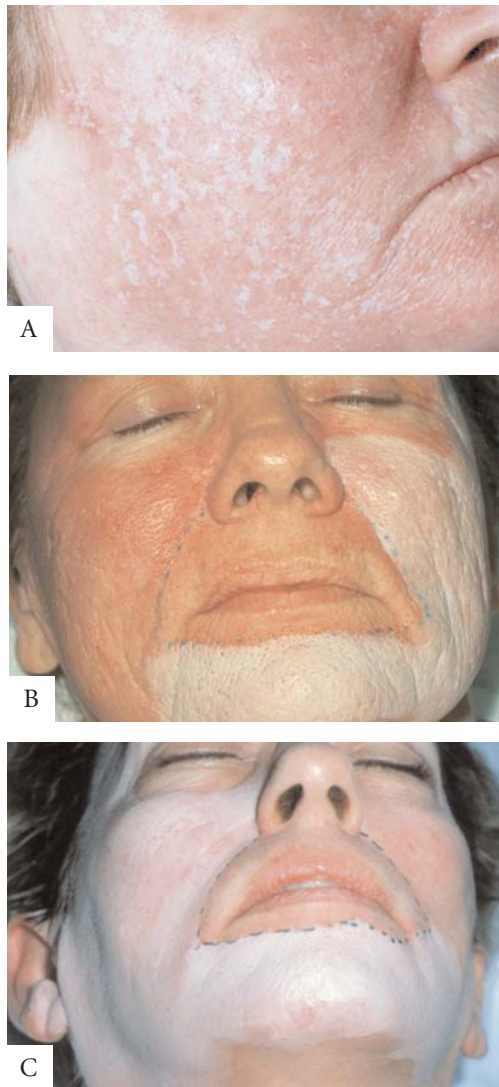


FIGURE 69-3 A, Level I frosting as found with light chemical peeling; erythema with streaky frosting. B, Level II—erythema with diffuse white frosting. C, Level III—solid white enamel frosting.

sable brush produces erythema and a very light frost within 15 to 45 seconds. The depth of penetration of the peeling solution is related to the number of coats applied; thus, deeper penetration and injury can occur with overcoating. Ideally, a level I frosting is obtained with superficial TCA peels. Protein precipitation results and leads to exfoliation without vesiculation. Concentrations of TCA up to 35% can also be used alone as a superficial peeling agent but may create an injury that extends partially into the upper dermis.¹³

Jessner's solution is a combination of keratolytic ingredients that have been used for over 100 years in the treatment of inflammatory and comedonal acne as well as hyperkeratotic skin disorders (see Table 69-4). Jessner's solution has intense keratolytic activity, initially causing loss of corneocyte cohesion within the stratum corneum and subsequently creating intercellular and intracellular edema within the upper epidermis if application is continued.¹⁴ The mode of application for the Jessner's peel is similar to that of the 10 to 20% TCA peel. The clinical end point of treatment is erythema and blotchy frosting. It is a good repetitive peel for photoaging skin because of its inflammatory effects. The peel can be repeated every 2 weeks.

Salicylic acid, a beta-hydroxy acid that is one of the ingredients in Jessner's solution, can also be used alone in superficial chemical peeling.¹⁵ It is a preferred therapy for comedonal acne as it is lipophilic and concentrates in the pilosebaceous apparatus. It is quite effective as an adjunctive therapy for open and closed comedones and resolving post-acne erythema (Figure 69-4). It is also a peel of choice for melasma and pigmentary dyschromia because it has minimal inflammatory action. Used repeatedly it has the least risk of postinflammatory hyperpigmentation. Superficial peeling for abnormal pigmentation is combined with skin care and topical retinoids, a bleaching product (hydroquinone, including 4 to 8%), and an adequate sunscreen.¹⁶

Prior to the initial treatment with a superficial peel, both patient and physician must understand the limitations, especially on photoaging, to avoid future disappointment. The effect of repetitive superficial chemical peels never approaches the beneficial effect obtained with a single medium-depth or deep peel, in that the improvements in photoaged skin following superficial peels are usually subtle because there is little to no effect on the

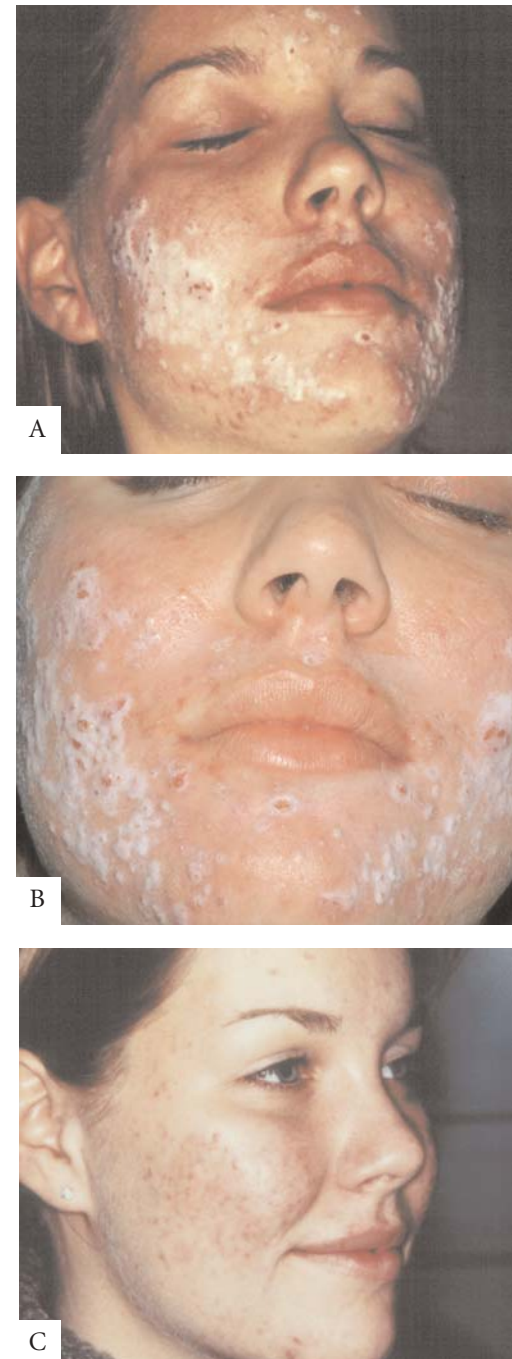


FIGURE 69-4 Salicylic acid peels are effective for the treatment of acne and comedones. Repetitive treatment over 6 weeks with acne treatment will hasten resolution of the condition. A, Pretreatment, active acne. B, Perifollicular frosting seen with salicylic acid, a lipophilic chemical. C, Post-treatment result 6 weeks later.

dermis. Nevertheless their ease of use and minimal downtime makes these “lunchtime” peels rewarding for patients with realistic expectations and are a favorite among the busy baby boomers.

Medium-Depth Chemical Peeling

Medium-depth chemical peels consist of controlled damage through the epidermis and papillary dermis, with variable extension to the upper reticular dermis. During the 3 months postoperatively, there is increased collagen production with expansion of the papillary dermis and the development of a mid-dermal band of thick elastic-staining fibers.⁴ These changes correlate with continued clinical improvement during this time.

For many years 40 to 50% TCA was the prototypical medium-depth peeling agent because of its ability to ameliorate fine wrinkles, actinic changes, and preneoplasia. TCA as a single agent for medium-depth peeling has fallen out of favor because of the high risk of complications, especially scarring and pigmentary alterations, when used in strengths approaching 50% and higher.¹⁷ Today most medium-depth chemical peels are performed using 35% TCA in combination with either Jessner's solution, 70% glycolic acid, or solid CO₂ as a "priming" agent (Table 69-5). These combination peels have been found to be as effective as 50% TCA alone but with fewer risks. The level of penetration is better controlled with these combination peels, thereby avoiding scarring seen with higher concentrations of TCA.

Brody developed the use of solid CO₂ to freeze the skin prior to the application of 35% TCA.¹⁸ This causes complete epidermal necrosis and significant dermal edema, thereby allowing deeper penetration of the

TCA in selected areas.¹⁰ Monheit then described a combination medium-depth peel in which Jessner's solution is applied, followed by 35% TCA.¹⁴ Similarly, Coleman and Futrell have demonstrated the use of 70% glycolic acid prior to the application of 35% TCA for medium-depth peeling.¹⁹ Jessner's solution and glycolic acid both appear to effectively weaken the epidermal barrier and allow deeper, more uniform, and more controlled penetration of the 35% TCA.

Current indications for medium-depth chemical peeling include Glogau level II or moderate photoaging, epidermal lesions such as actinic keratoses, pigmentary dyschromias, and mild acne scarring, as well as blending of the effects of deeper resurfacing procedures. The most popular of the medium-depth peels for facial rejuvenation is the Jessner's–35% TCA peel, with other combination peels being used less frequently. This peel has been widely accepted because of its broad range of uses, the large number of people in whom it is indicated, its ease of modification according to the situation, and its excellent safety profile. It is not a "lunchtime" treatment, however, and should be considered a surgical procedure requiring preoperative consideration and preparation, operative sedation, and after-care for 1 week or more.

The Jessner's–35% TCA peel is particularly useful for the improvement of mild to moderate photoaging. (Figure 69-5). It freshens sallow atrophic skin and softens fine rhytids with minimal risk of textural

or pigmentary complications (see Figure 69-5). Collagen remodeling occurs for as long as 3 to 4 months postoperatively, during which there is continued improvement in texture and rhytids. When used in conjunction with a retinoid, bleaching agent, and sunscreens, a single Jessner's–35% TCA peel lessens pigmentary dyschromias and lentiginos more effectively than do repetitive superficial peels (Figure 69-6). Epidermal growths such as actinic keratoses also respond well to this peel. In fact the Jessner's–35% TCA peel has been found to be as effective as topical 5-fluorouracil chemotherapy in removing both grossly visible and clinically undetectable actinic keratoses but has the added advantages of lower morbidity and greater improvement in associated photoaging (Figure 69-7).²⁰

This peel is also useful to blend the effects of other resurfacing procedures with the surrounding skin. Patients who undergo laser resurfacing, deep chemical peeling, or dermabrasion to a localized area such as the periorbital or perioral region often develop a sharp line of demarcation between the treated and untreated skin. This is because the surrounding photoaging skin has significant dyschromia and textural aging. The treated skin may appear hypopigmented (also known as pseudohypopigmentation) in comparison to the untreated skin. A Jessner's–35% TCA peel performed on the adjacent untreated skin helps to blend the treated area into its surroundings. For example, a patient with advanced photoaging in the periorbital region and moderate photoaging on the remaining face may desire CO₂ laser resurfacing only around the eyes. In this patient, medium-depth chemical peeling of the areas not treated with the laser would improve the photoaging in these regions and avoid a line of demarcation.²¹ It is important to note that when used in combination with other resurfacing procedures such as laser irradiation or dermabrasion, the peel should be performed first, in order to

Table 69-5 Agents Used for Medium-Depth Chemical Peeling

Agent	Comment
40–50% TCA	Not recommended
Combination 35% TCA–solid CO ₂ (Brody)	The most potent combination
Combination 35% TCA–Jessner's (Monheit)	The most popular combination
Combination 35% TCA–70% glycolic acid (Coleman)	An effective combination
88% phenol	Rarely used

CO₂ = carbon dioxide; TCA = trichloroacetic acid.

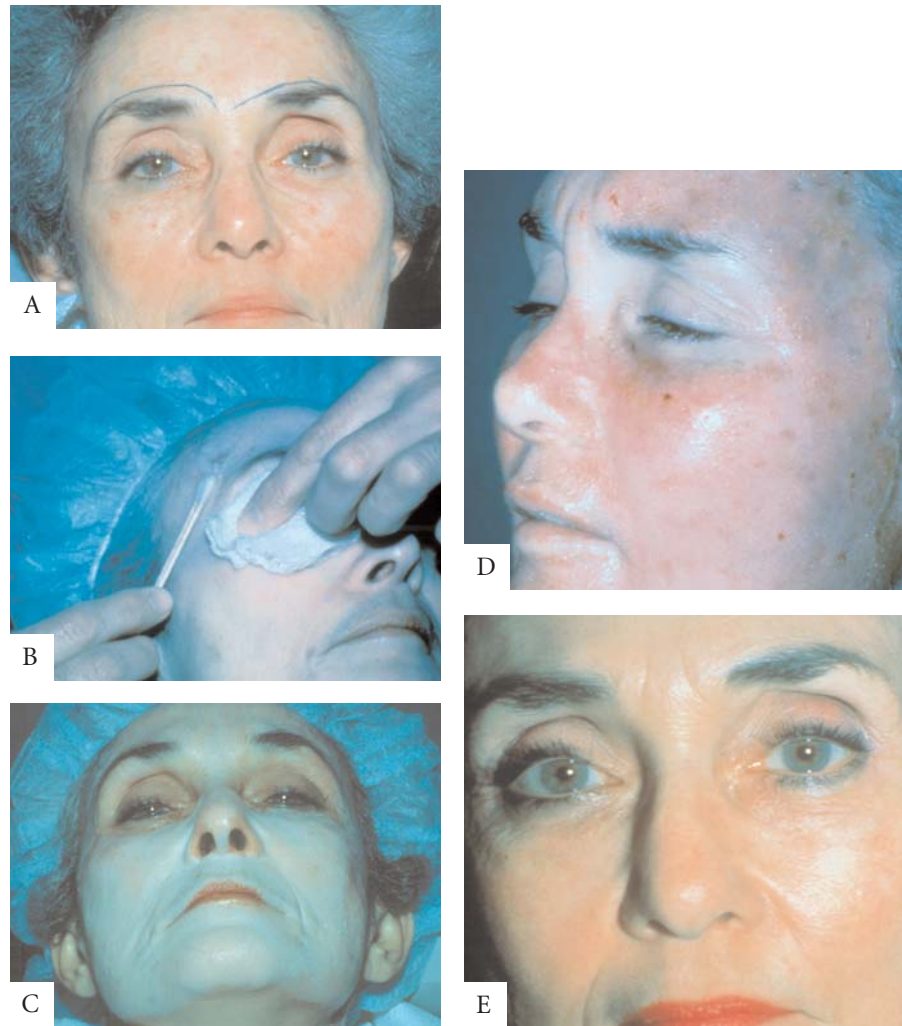

FIGURE 69-5 Medium-depth chemical peel used to treat moderate photoaging skin. A, Preoperative photograph demonstrating epidermal growths with aging textural changes. B, Application of 35% trichloroacetic acid directly after Jessner's solution. C, White enamel frosting (level III) from 35% trichloroacetic acid. D, Desquamation and inflammation 4 days after peel. E, Final results 6 months later.

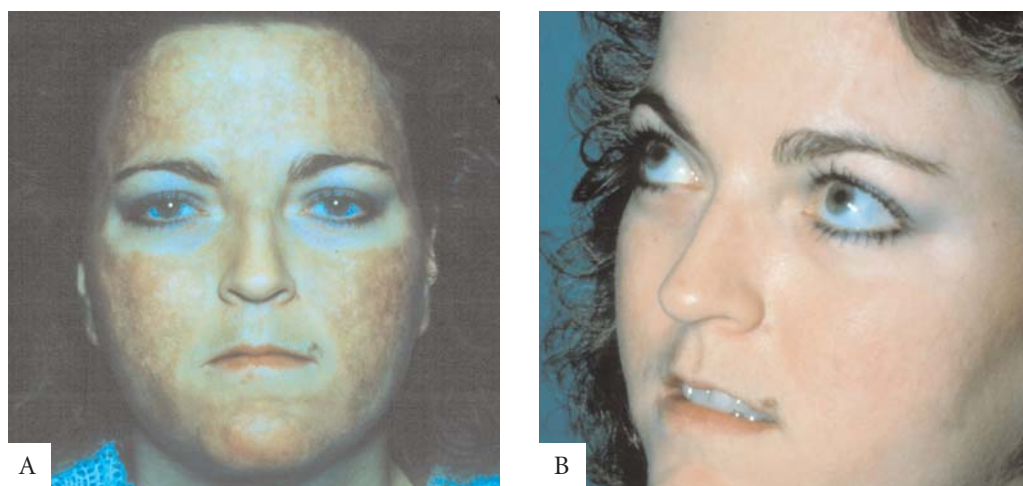

FIGURE 69-6 Postinflammatory hyperpigmentation unresponsive to topical agents (hydroquinone and tretinoin) and superficial chemical peeling. Full response to medium-depth chemical peel and topical agents. A, Preoperative. B, Six weeks postoperative.

avoid accidental application of the peeling agent onto previously abraded areas of skin (Figure 69-8).

Using either cotton-tipped applicators or 2" × 2" gauze pads, a single even coat of Jessner's solution is applied first to the forehead, followed by the cheeks, nose, and chin, and lastly, the eyelids. Proper application of Jessner's solution causes minimal discomfort and creates a faint frost within a background of mild erythema (level I). After a 1- to 2-minute wait for the Jessner's solution to completely dry, 35% TCA is then applied evenly with one to four cotton-tipped applicators (Figure 69-9). The effectiveness of this peel is directly dependent on the depth of penetration of the peeling solutions, and this depth is a function of the adequacy of degreasing and the amount of both solutions applied. The use of cotton swabs, particularly for the application of TCA, is advantageous because it allows the surgeon to easily vary the amount of solution applied according to the patient's specific needs. The amount of TCA delivered to the skin surface is determined by the number of applicators used, their degree of saturation, the amount of pressure applied to the skin surface, and the duration of their contact with the skin. Four moist cotton-tipped applicators are applied in broad strokes over the forehead and on the medial cheeks. Two mildly soaked cotton-tipped applicators can be used across the lips and chin, and one damp cotton-tipped applicator on the eyelids. The depth of penetration and completion of the peel reaction can be monitored by the level of frosting. A full combination Jessner's–35% TCA peel should obtain a level II to III frosting. One should never overcoat TCA on a level III frosting, as the injury may be pushed to a level that can cause complications (ie, pigmentation or scarring).

Anatomic areas of the face are peeled with TCA sequentially from the forehead to temple to cheeks and finally to the lips

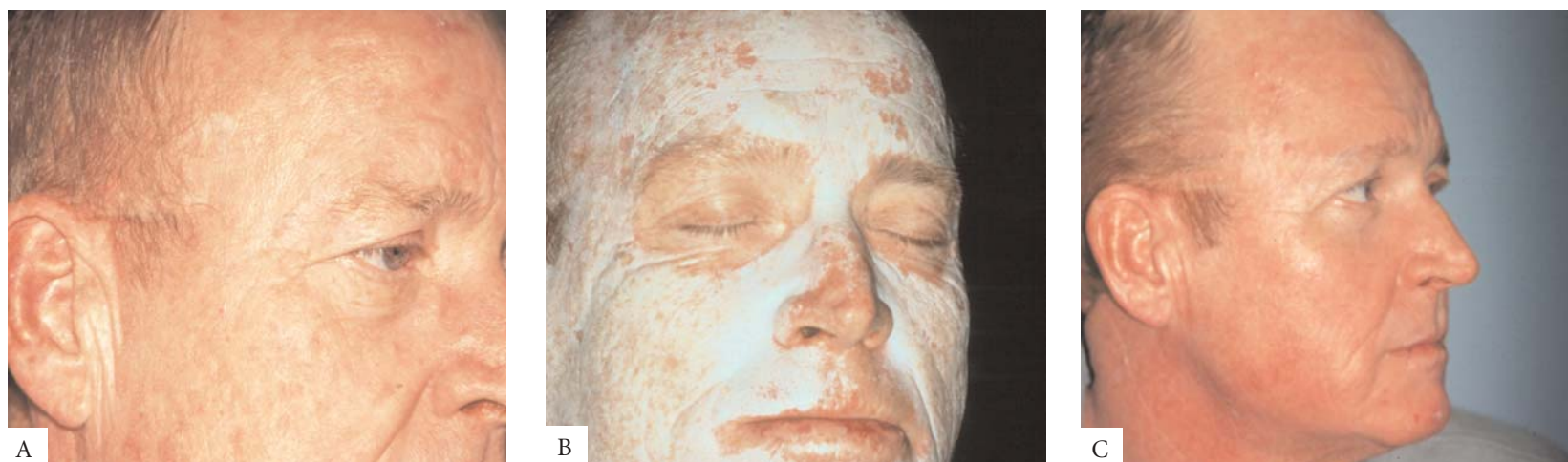

FIGURE 69-7 Medium-depth chemical peel for treatment of diffuse actinic keratoses and photoaging. The Jessner's–35% TCA peel was used as a single treatment, with healing in 8 days. A, Preoperative. B, Frosting after trichloroacetic acid. C, One month postoperative.

and eyelids. Careful feathering of the solution into the hairline and around the rim of the jaw and brow conceals the demarcation line between peeled and nonpeeled skin. Areas of wrinkled skin are stretched taut with the help of an assistant to allow even application of the solution into the folds and troughs. This technique is particularly helpful on the skin of the upper and lower lips. For perioral rhytids, TCA is applied with the wood portion of a cotton-tipped applicator and extended onto the vermilion border (see Figure 69-9D).

Eyelid skin must be treated delicately and carefully to avoid overapplication and to prevent exposure of the eyes to TCA solution.²² The patient should be positioned with the head elevated at 30 degrees, and excess peel solution on the cotton tip should be squeezed out so that the applicator is semidry. With the eyes closed a single applicator is rolled gently from the periorbital skin onto the upper eyelid skin without going beyond the moveable lid. Another semidry applicator is then rolled onto the lower eyelid skin within 2 to 3 mm of the lid margin while the patient is looking superiorly. Excess peel solution should never be left on the lids because it can roll into the eyes, and tears should be immediately dried with a cotton-tipped applicator

because they may pull the solution into the eye by capillary action.

The white frost from the TCA application appears on the treated area within 30 seconds to 2 minutes (see Figure 69-5C). This response is representative of keratocoagulation and indicates that the TCA's physiologic reaction is complete. TCA

takes longer to frost than phenol preparations but a shorter period of time than the superficial peeling agents. The desired endpoint in medium-depth peeling is level II to level III frosting (Table 69-6). Level II frosting is defined as a white-coated frosting with a background of erythema (see Figure 69-3B).

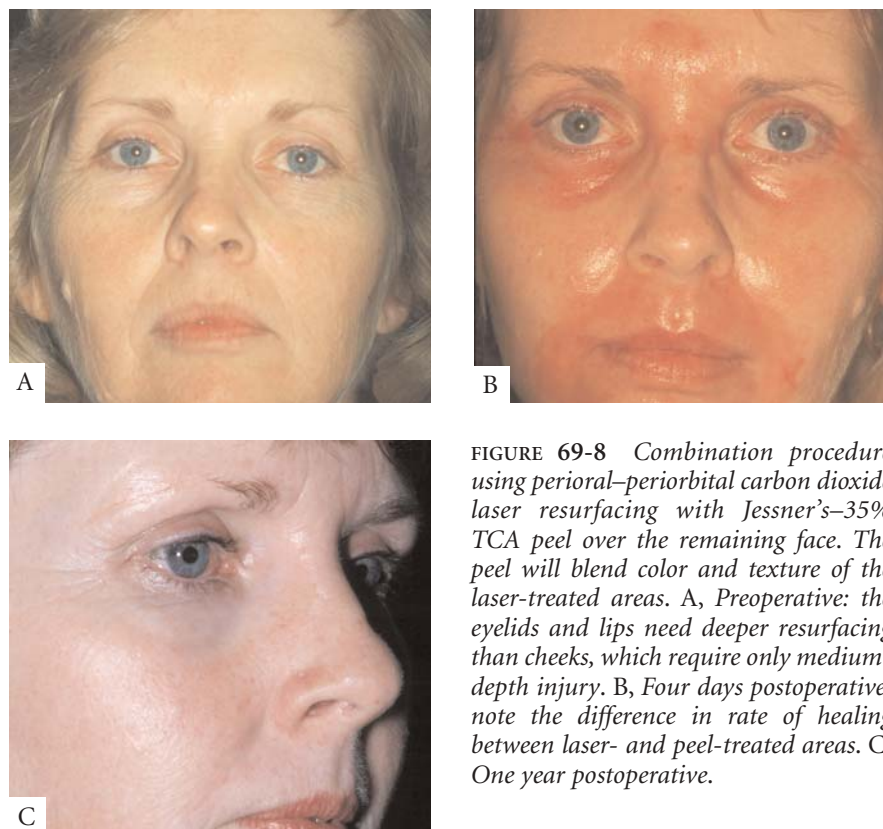

FIGURE 69-8 Combination procedure using perioral–periorbital carbon dioxide laser resurfacing with Jessner's–35% TCA peel over the remaining face. The peel will blend color and texture of the laser-treated areas. A, Preoperative: the eyelids and lips need deeper resurfacing than cheeks, which require only medium-depth injury. B, Four days postoperative: note the difference in rate of healing between laser- and peel-treated areas. C, One year postoperative.

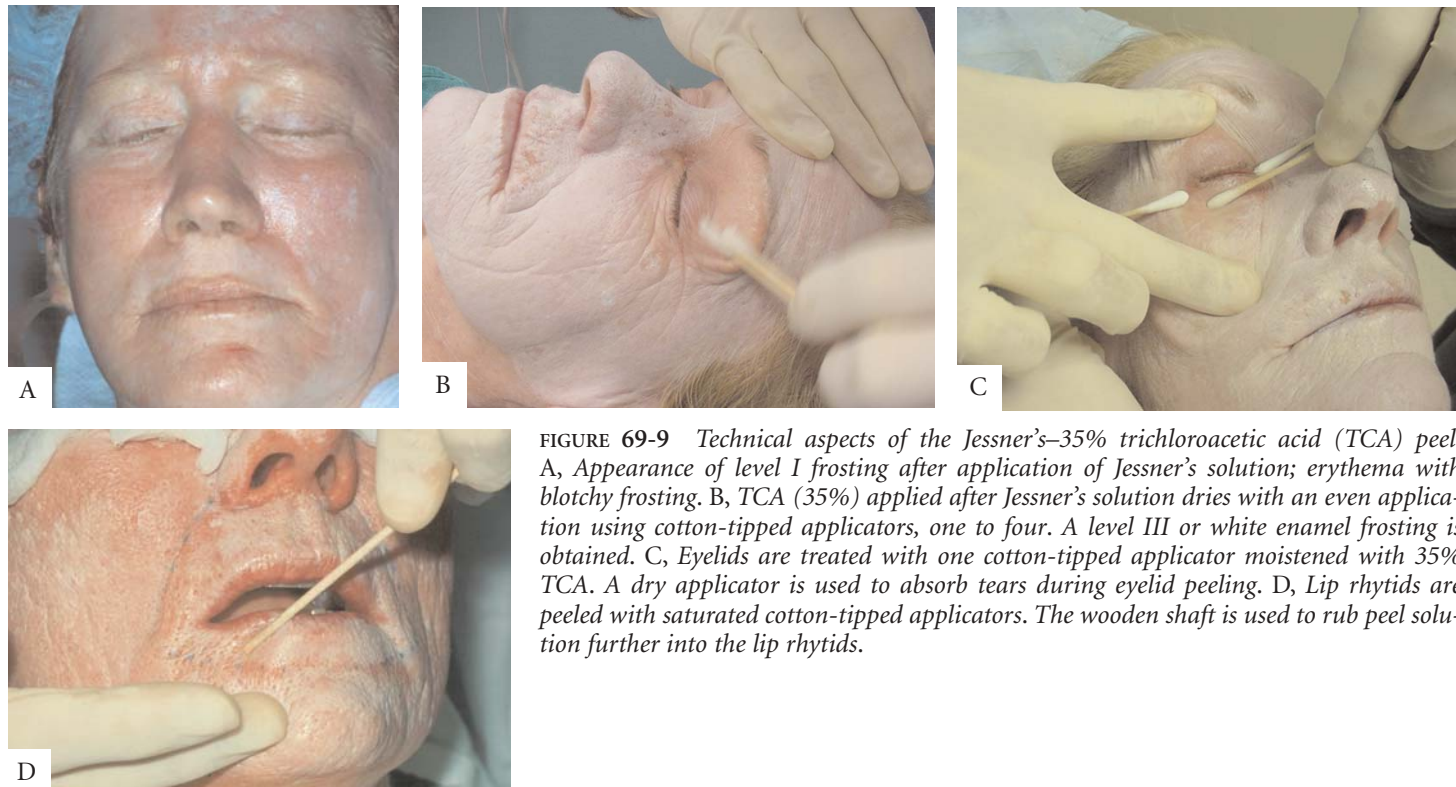


FIGURE 69-9 Technical aspects of the Jessner's-35% trichloroacetic acid (TCA) peel. A, Appearance of level I frosting after application of Jessner's solution; erythema with blotchy frosting. B, TCA (35%) applied after Jessner's solution dries with an even application using cotton-tipped applicators, one to four. A level III or white enamel frosting is obtained. C, Eyelids are treated with one cotton-tipped applicator moistened with 35% TCA. A dry applicator is used to absorb tears during eyelid peeling. D, Lip rhytids are peeled with saturated cotton-tipped applicators. The wooden shaft is used to rub peel solution further into the lip rhytids.

Level III frosting, which is associated with penetration to the reticular dermis, is a solid white enamel frosting with no background of erythema (see Figure 69-5C). A deeper level III frosting should be restricted only to areas of thick skin and heavy actinic damage. Most medium-depth chemical peels achieve a level II frosting, and this is especially important over the eyelids and areas of sensitive skin. Areas with a greater tendency to form scars, such as the zygomatic arch, the bony prominences of the jawline, and chin, should receive no greater than level II frosting.

Before re-treating an area with inadequate frosting, the surgeon should wait at least 3 to 4 minutes after the application of TCA to ensure that frosting has reached its peak. Each cosmetic unit is then assessed, and areas of incomplete or uneven frosting are carefully re-treated with a thin application of TCA. Additional applications of TCA increase the depth of penetration as well as the risk of complications, so one

should apply more solution only to the underfrosted areas.

Although there is an immediate burning sensation as the peel solution is applied, the discomfort begins to subside as frosting occurs and resolves fully by the time of discharge. This peel can be performed with light sedation such as

- Diazepam 10 mg orally
- Meperidine 50 mg intramuscularly
- Hydroxyzine 25 mg intramuscularly

After the skin is cooled with saline the patient will remain comfortable throughout the postoperative period. Cool saline compresses offer symptomatic relief at the conclusion of the peel. Unlike the compresses in glycolic acid peels, the saline following a TCA peel simply provides relief and does not “neutralize” the acid.

Deep Chemical Peeling

Patients with more extreme photoaging skin may require deep chemical peeling, motorized dermabrasion, or laser resurfac-

ing to improve their greater degree of skin damage. As discussed with medium-depth peels, deep chemical peeling leads to production of new collagen and ground substance, down to a level in proportion with the depth of the peel. The peeling agent of choice is the Baker-Gordon phenol peel.

The Baker-Gordon peel uses phenol in a formulation that permits deep penetration into the dermis, deeper than full-strength phenol.²³ The Baker-Gordon formula consists of Septisol solution, croton oil, and tap water added to a solution of phenol, reducing its concentration to 50% or 55% (Table 69-7). The mixture of

Table 69-6 Grades of Frosting with Trichloroacetic Acid Peels

Grade	Visual Finding
I	Erythema with streaky frosting
II	White frosting with visible erythema
III	White enamel frosting, no erythema

Table 69-7 The Baker-Gordon Formula

88% liquid phenol (USP), 3 mL
Tap water, 2 mL
Septisol liquid soap, 8 drops
Croton oil, 3 drops

USP = United States Pharmacopeia.

ingredients is freshly prepared and must be stirred vigorously prior to application due to its poor miscibility. The liquid soap, Septisol, is a surfactant that reduces skin tension, allowing a more even penetration. Croton oil is a vesicant epidermolytic agent that enhances phenol absorption. Recent investigations into the effects of this peel using varying concentrations of both phenol and croton oil have suggested that the procedure's efficacy is more related to the amount of croton oil than phenol.^{24,25}

There are two main variations in deep chemical peeling with the Baker-Gordon phenol formula: occluded and unoccluded. Occlusion of the peeling solution with tape is thought to increase its penetration and extend the injury into the midreticular dermis. This technique is particularly helpful for deeply lined "weather-beaten" faces but should be used only by experienced surgeons because of the higher risk of complications.²⁶ The unoccluded technique as modified by McCollough and Langsdon involves a more vigorous cleansing of the skin and the application of more peel solution.²⁷ This may enhance the efficacy of the solution but without penetration as deeply as in an occluded peel. In the hands of a skilled and knowledgeable surgeon both methods are safe and reliable in rejuvenating advanced to severe photoaged skin. Deep chemical peeling can significantly improve or even eliminate deep furrows as well as other textural and pigmentary irregularities associated with severe photoaging (Figure 69-10). A remarkable degree of improvement is the expected result of deep chemical peeling when performed properly on carefully selected patients.

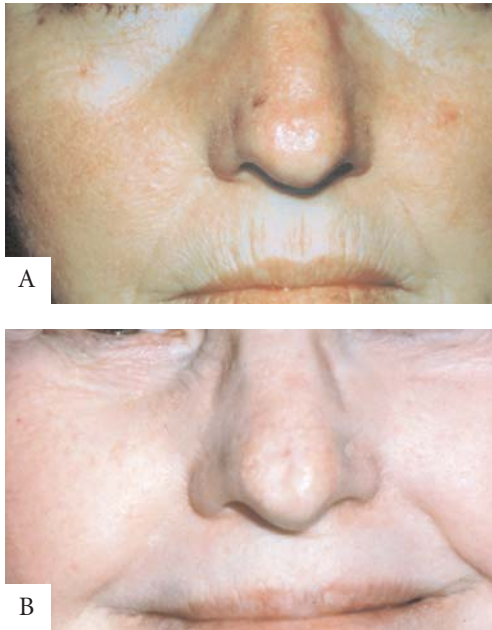


FIGURE 69-10 Advanced photoaging of perioral rhytids treated with Baker-Gordon phenol peel. A, Preoperative photograph, demonstrating perioral rhytides, textural and pigmentary changes with epidermal growths. B, Postoperative photograph, 2 years later. Note the phenol peel maintains correction for many years.

The patient undergoing deep chemical peeling must understand and be willing to accept the significant risk of complications and the increased degree of morbidity. The most notable complications include scarring, textural changes such as "alabaster skin" or "plastic skin," and pigmentary disturbances. It is not uncommon for patients to experience postoperative erythema that can take many months to resolve and that may be followed by variable hypopigmentation (Figure 69-11). Male patients and patients with darker complexions are less favorable candidates for deep chemical peeling since the hypopigmentation is less easily camouflaged. Since phenol is cardiotoxic, preoperative evaluation includes a complete blood count, liver function tests, serum urea nitrogen and creatinine and electrolyte determinations, and a baseline electrocardiogram. Any patient who has a history of cardiac arrhythmias or who is taking a medication known to precipitate

arrhythmias should not undergo a full-face Baker-Gordon phenol peel. Patients with a history of hepatic or renal disease are also poor candidates.

Compared with medium-depth and superficial peeling, the Baker-Gordon phenol peel is a time-consuming procedure and must be performed only in a properly equipped facility. The required waiting period after the treatment of each cosmetic unit limits the rate of cutaneous absorption, thereby preventing the serum levels of phenol from reaching a dangerous peak during the procedure. Intravenous hydration with 1 L of lactated Ringer's solution before the procedure and another liter during the peel also promotes phenol excretion and prevents toxicity. Continuous electrocardiography, pulse oximetry, and blood pressure monitoring are mandatory during the entire perioperative period. Any abnormalities, such as a premature ventricular contraction or premature atrial contraction, necessitate abrupt stoppage of the procedure and careful evaluation for toxicity.²⁸ Oxygen is supplemented throughout the procedure as some physicians feel that it has a protective effect against cardiac arrhythmias.

After thorough cleansing and degreasing of the skin, the chemical agent is applied sequentially to six esthetic units: forehead, perioral region, right cheek, left cheek, nose, and periorbital region. There is a 15-minute time interval between the

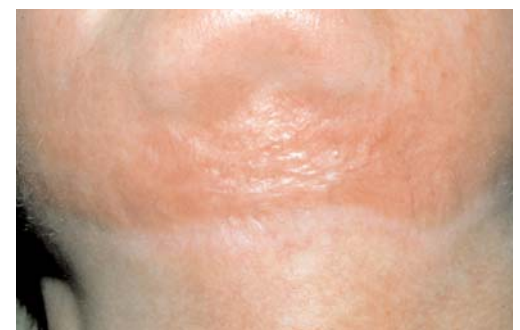

FIGURE 69-11 Complications from Baker-Gordon phenol peel with prolonged nonhealing, resulting in hypopigmentation and marbled scarring.

treatment of each cosmetic area, allowing 60 to 90 minutes for the entire procedure. Cotton-tipped applicators are used with a similar technique as discussed with the medium-depth Jessner's–35% TCA peel, though less solution is used because frosting occurs very rapidly (Figure 69-12). Occlusion of the peel can be accomplished with strips of waterproof zinc oxide tape (eg, 0.5 inch Curity tape) to each cosmetic unit just after the phenol is applied. Care is exercised to extend the peel slightly beyond the mandibular rim to conceal the demarcation between treated and untreated skin. The last esthetic unit, the periorbital skin, is treated cautiously and conservatively to avoid overpenetration which can lead to ectropion or scarring. It is important to remember that diluting a phenol compound with water may increase its penetration, so mineral oil rather than water should be used to flush the eyes if contact occurs.

Application of the peeling agent creates an immediate burning sensation, which lasts for 15 to 20 seconds, subsides for 20 minutes, and then returns for the next 6 to 8 hours. Ice packs may be applied as necessary for patient comfort. Narcotics are usually prescribed on discharge for adequate pain control. Systemic steroids are also administered by some surgeons to lessen the inflammatory response. For untaped peels, petrolatum is applied and a biosynthetic dressing can be used for the first 24 hours.

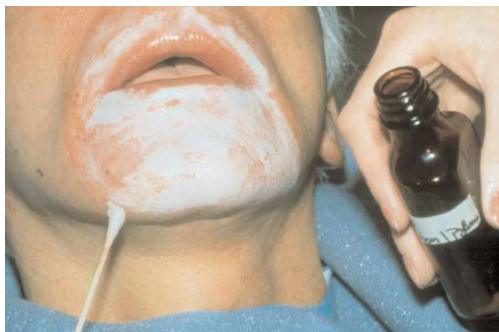


FIGURE 69-12 Rapid frosting from small amounts of Baker-Gordon phenol solution applied with cotton-tipped applicators.

Mechanical Resurfacing Procedures

During the past five decades, dermabrasion using a rotating abrasive surface attached to a power-driven hand engine has been considered a premier skin resurfacing procedure for facial scars. It has generally been regarded as a deep resurfacing modality based on its depth of injury and its prolonged healing time. The original descriptions of modern dermabrasion involved the use of a wire brush, which remains in use today.^{29,30} In 1957 the diamond fraise was introduced and became the preferred instrument for dermabrasion by some surgeons because it is less aggressive and more forgiving than the wire brush.³¹ Recently there has been a resurgence of interest in manual dermasanding which allows for more deliberate and controlled skin planing and microdermabrasion.^{32,33}

Microdermabrasion

Microdermabrasion is considered superficial because it removes the stratum corneum and outer epidermis. Its classification as light or very light in comparison to the other superficial resurfacing procedures depends on the techniques and aggressiveness of the operator. The microdermabrasion unit's handpiece is a closed system, which propels aluminum oxide crystals at the skin at high speeds and simultaneously removes them with suction. These units were developed commercially in the mid-1990s and are currently in widespread use in both physicians' offices and nonmedical esthetic spas. Microdermabrasion may be indicated for acneiform conditions, pigmentary dyschromias, and as a "lunchtime" procedure for facial rejuvenation in all skin types.^{34,35} Both the patient and physician must understand that the degree of objective improvement with microdermabrasion may be limited. This is a repetitive procedure performed every 2 weeks along with appropriate cosmeceutical agents.

Ideal candidates for microdermabrasion typically are young patients who desire limited facial rejuvenation without "downtime" and thus must have realistic expectations of the limited anticipated results. Patients often report that their skin has a smoother texture and that cosmetics are easier to apply and blend in with their skin more easily (Figure 69-13). Although the role of microdermabrasion in facial rejuvenation has grown dramatically since these units were developed, the scientific data to justify their use has been lacking.

Manual Dermasanding

Manual dermasanding involves abrading the skin by hand using silicon carbide sandpaper or wallscreen commercially available at any hardware store. Its classification as a wounding agent is entirely dependent on the type of paper used, the force applied by the surgeon, and the duration of contact with the skin. Although it can be used to produce a wound as deep as with wire brush dermabrasion or several passes with a pulsed CO₂ laser, manual dermasanding is probably most commonly used as a medium-depth or "minimally deep" resurfacing modality (Table 69-8).

Manual dermasanding is most often used for resurfacing localized regions to minimize the appearance of a scar or to

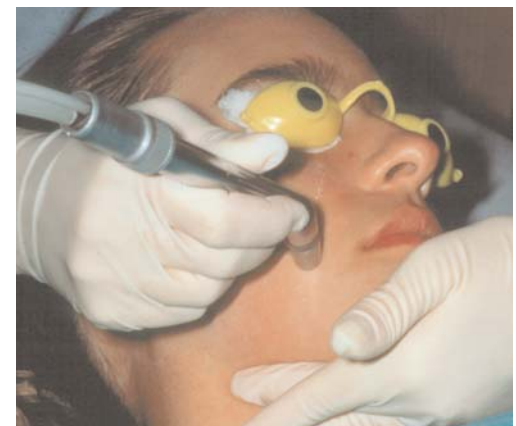

FIGURE 69-13 Microdermabrasion: aluminum oxide crystals are propelled at high speeds within a closed system and removed with suction.

Table 69-8 Advantages of Manual Dermasanding over Motorized Dermabrasion

Greater control over depth of injury, particularly on the lips and orbital rims
Blending of abraded areas into adjacent unabraded areas accomplished more easily and with better results
Lower cost and greater simplicity of instrumentation and set-up
No risk of aerosolizing infectious particles
Possibly lower incidence of postinflammatory hypopigmentation ^{37,38}

blend or enhance the effects of a medium-depth chemical peel or a combination procedure.³⁶ It can be used following CO₂ laser resurfacing to feather the transition into hair-bearing areas that are inaccessible to the laser. Manual dermasanding of the eyebrows and hairline and gentle abrasion of the upper neck at the inferior aspect of the laser-irradiated zone are all effective at minimizing lines of demarcation between treated and untreated skin (Figure 69-14). It can also be useful immediately after laser resurfacing for stubborn rhytids, particularly in the perioral region. Manual dermasanding can improve the outcome by producing a slightly greater depth of injury in a controlled fashion where further thermal injury would be risky. It will also remove adherent necrotic debris and thermal damage, thus speeding up the healing process. Similarly a medium-depth chemical peel can be immediately followed by manual dermasanding on the more troublesome areas to enhance the results and also along the borders of the peeled skin to blend the effects. Our clinical

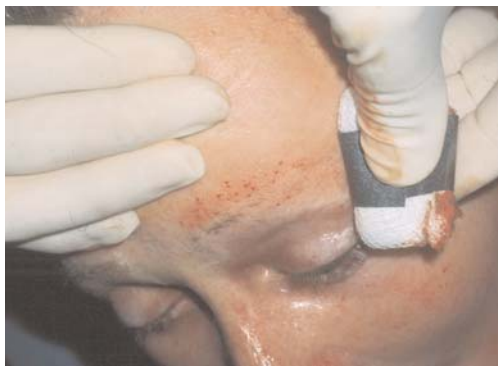

FIGURE 69-14 Manual dermasanding using 320-grit silicone carbide sandpaper to blend carbon dioxide laser resurfacing into the eyebrow area.

experience suggests that dermasanding after a Jessners–35% TCA peel may yield impressive postoperative results that approach those seen with either motorized dermabrasion or CO₂ laser resurfacing in patients with photoaging skin. (Figure 69-15). This combination is particularly helpful in patients who may not tolerate the greater degree of sedation often necessary with CO₂ laser resurfacing.

The necessary materials for manual dermasanding include silicon carbide sandpaper or wallscreen. Both may be purchased in a variety of grades: fine grade (no. 400), medium grade (nos. 220–320), and coarse grade (no. 180). The sandpaper is easy to use because of its flexibility and is easily cut into smaller pieces, which can be steam autoclaved. A 1.5" × 3" piece of sterilized sandpaper is wrapped around either the barrel of a 3 mL syringe or a rolled-up 2" × 2" gauze pad and moistened with saline or a soap-free cleanser for lubrication. A 1% solution of lidocaine with epinephrine may be used instead if additional anesthesia is necessary. Both back-and-forth and circular motions are used to gradually abrade the skin layer-by-layer until the hills and valleys are softened or adjacent areas are blended to the desired degree. Coarse grades may be used initially for “debulking,” followed by finer grades later in the procedure. The fine grade is used to blend delicate areas of skin, such as around the eyelids. At the completion of the procedure the dark-colored silicon carbide particles remaining on the skin surface should be rinsed off because there is a theoretical risk of their becoming implanted.

Motorized Dermabrasion

Some of the units most commonly used today are the Bell hand engine (Bell International, Burlingame, CA), the AEV-12 hand engine (Ellis International, Madison, NJ), and the Osada surgical hand-piece (Osada, Inc., Los Angeles, CA). A topical refrigerant spray (Frigiderm, Frigiderm Corp., Costa Mesa, CA) is used to produce anesthesia and to harden the skin as it is abraded. The spray immobilizes the topographic features so that there is no distortion by the pressure of the abrasive instrument.

The two abrasive instruments most often employed with these units are the wire brush and the diamond fraise. The wire brush has numerous small-caliber stainless steel wires that project circumferentially from the curved side of a cylindrical hub. A diamond fraise consists of a stainless steel cylinder to which industrial-grade diamonds are bonded to create the abrasive surface. As compared with wire brush instruments, diamond fraises are manufactured with a greater variety in shape, width of abrasive surface, wheel diameter, and coarseness of grit. The wire brush is more aggressive and cuts more quickly and more deeply into the skin with each stroke, thereby posing a greater risk of injury and requiring more skill to operate. Although the diamond fraise is generally safer and more forgiving, it may not yield the degree of improvement possible with the wire brush, especially for more stubborn conditions such as deep acne scarring (Figure 69-16).

Because dermabrasion with either instrument is highly technique-dependent and its learning curve is steep, there may be considerable variability in the clinical results obtained by different operators. It is very important for beginning dermabraders to attain thorough hands-on instruction from an experienced operator in order to be adequately trained. The proper techniques for motorized

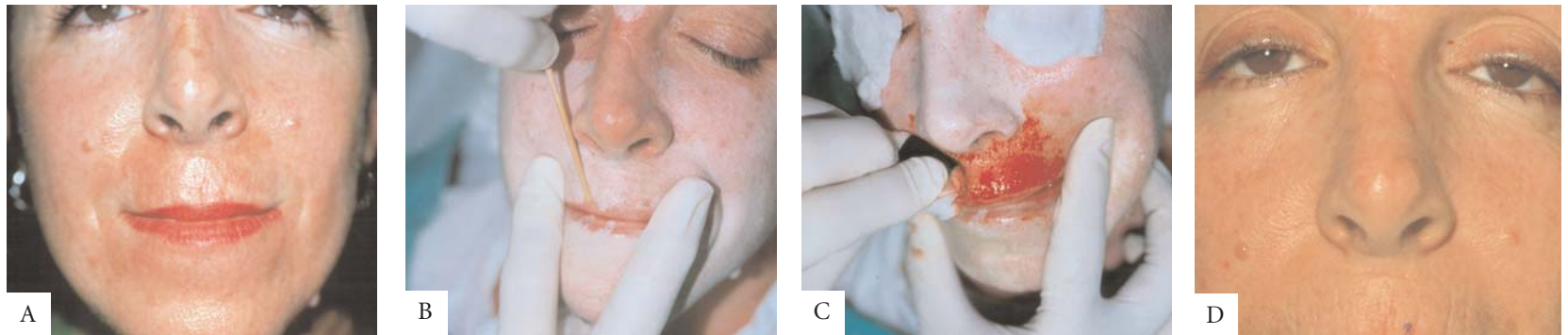


FIGURE 69-15 Medium-depth chemical peel with manual dermasanding for photoaging skin. A, Preoperative: moderate photoaging of face with more advanced perioral rhagades. B, Jessner's—35% trichloroacetic acid peel applied over face including the perioral area. C, Manual dermasanding to the perioral skin to bloody points. D, One-month postoperative photograph revealing improvement in all areas.

dermabrasion have also been the subject of comprehensive reviews in the literature.^{37–39} Careful evaluation of the depth of injury throughout the procedure is critical to ensure sufficient depth for optimal results without penetrating beyond the desired level and risking scarring. Because of the potential for aerosolization of infectious particles during dermabrasion, appropriate precautions are mandatory to protect the operating room staff.

Moderate to severe acne scarring is the most notable indication for dermabrasion, as laser resurfacing has yielded variable results and chemical peeling is generally disappointing (Table 69-9). Dermabrasion selectively planes off the “hilltops” that surround the atrophic “valleys,” whereas chemical peeling and lasers produce an injury of equivalent depth in both areas (Figure 69-17).

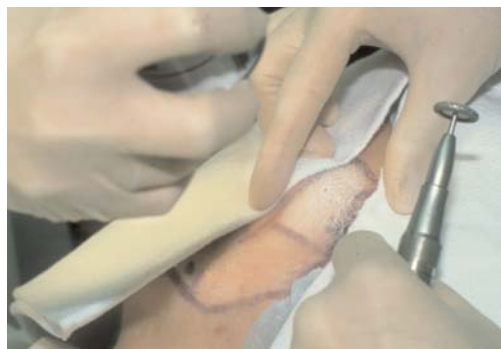

FIGURE 69-16 Mechanical dermabrasion is performed with a diamond fraise over rigid skin cooled with a topical refrigerant spray.

The use of CO₂ lasers has revolutionized resurfacing techniques for photoaging skin. Because of the varying properties of lasers, the physician must be thoroughly familiar with the physics, technology, and operating geometry of the laser. Whether or not the laser is pulsed, continuous, or computer scanned impacts the physiologic response. The level of destruction is different for each laser; thus, the physician should be familiar with the laser of choice. For reliable vaporization of skin layers, a pulsed laser with a computer-generated scanner (CPG) makes the procedure safer. Each pass destroys 75 to 100 μm of tissue with a zone of thermal damage below. Thus, two to three passes with an ultra-pulse CO₂ laser is maximal for rejuvenation of photodamaged skin—a deep resurfacing technique. The zone of thermal damage causes collagen shrinkage or contraction, which is a unique characteristic for CO₂

laser resurfacing. This gives an added benefit to wrinkle treatment that is not found with either dermabrasion or chemical peeling. This is especially true with perioral and periorbital wrinkled skin.

CO₂ laser resurfacing requires anesthesia: either general operative anesthesia or tumescent local anesthesia for the entire face. Laser safety precautions are needed to prevent laser fire or laser injury to the employees, the unprotected skin, the teeth, or even the endotracheal tube for general anesthesia. These must be protected with appropriate laser-resistant materials: eye shields, teeth guards, and appropriate laser-resistant endotracheal tube wrapping. Using the CPG the operator must remember that the pulse overlap for a chosen pattern size and shape is set so that each pattern is made to touch yet not overlap. The density is an important parameter in determining laser beam intensity. One

Table 69-9 Conditions for Which Motorized Dermabrasion May Be the Preferred Resurfacing Modality

Acne scarring
Surgical or traumatic scars
Benign neoplastic processes (multiple trichoepitheliomas, syringomas, adenoma sebaceum)
Malignant and premalignant neoplastic processes (skin cancer treatment and prevention in basal cell nevus syndrome and xeroderma pigmentosum as well as management of extensive carcinoma in situ)
Extensive epidermal lesions such as epidermal nevi
Decorative or traumatic tattoos unresponsive to the pigmented lesion lasers
Rhinophyma

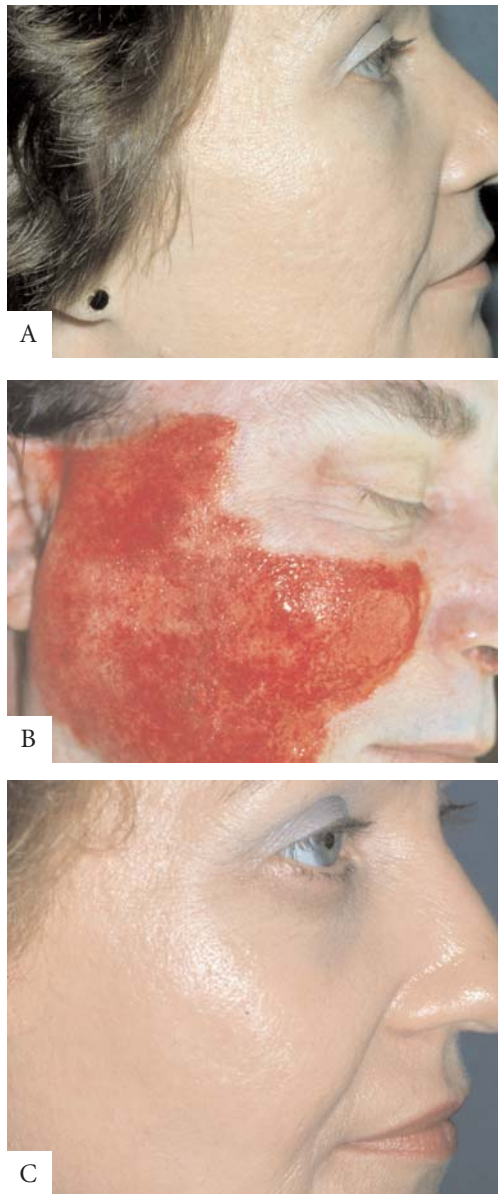


FIGURE 69-17 Full-face dermabrasion performed for acne scars. A, Preoperative: shallow and atrophic scars most amenable to dermabrasion. B, Postoperative dermabrasion prior to biosynthetic dressing. C, Three months postoperative.

should not go above a density of 6 with facial resurfacing. Each pass should cover the face fully, vaporizing the tissue to ash and debris, which is wiped off between each pass. The visual end point is a mauve or slightly yellow discoloration indicating denaturation of dermal collagen. Further passes cause deeper dermal scarring. Special care must be taken over scar-prone areas such as the bony prominences of the chin, jawline, malar ridge, and forehead.

The eyelid is treated more conservatively as collagen can precipitate an ectropion, with or without scar. The lips are treated with two to three passes but not over the vermilion line as this can flatten the lip in an unesthetic manner. Bordered facial creases such as the jawline and neck should be blended with light chemical peeling and minimal dermasanding to soften the demarcations of treated and untreated photoaging neck skin.

Of equal importance to the operative technique is proper postoperative wound care. Partial thickness skin wounds heal fastest when kept at or near 100% humidity or occlusive or semi-occlusive dressings. Nonstick pads and hydrogels are changed daily to remove coagulation debris and necrotic tissue. This is important to prevent secondary wound infection with resultant scarring. My usual postoperative program is 4 to 5 days of biologic hydration, changed daily, followed by 5 days of 0.25% acetic acid soaks (1 teaspoon white vinegar in 1 pint of warm water) four times a day followed by occlusive ointments such as petrolatum ointment or eucerin cream. After 10 days, the patient is usually ready for light cleansers and creams and a mild topical steroid cream for erythematous areas (Table 69-10).

Full makeup can be used with sunscreen after 2 weeks. Sunscreen with strong sun avoidance should be adhered to for 2 to 3 months to prevent postlaser hyperpigmentation.

Herpes simplex infection can occur during the healing period following medium-depth or deep ablative injury. Antiviral prophylaxis should begin during the operative session and continue beyond reepithelialization, 10 to 14 days. If infection occurs, punctate vesicles occur with pain and full treatment therapy should be carried out to prevent scarring.

Delayed wound healing may be a sign of bacterial infection, or resurfacing too deep to heal normally. It should be treated with biologic dressings, appropriate

Table 69-10 Avoiding Complications Postoperatively for Skin Resurfacing

<p>Use proper occlusive wound care, and monitor daily.</p> <p>Watch for pain; it may indicate herpes simplex virus infection.</p> <p>Watch and treat early bacterial and fungal infection.</p> <p>Evaluate closely and follow areas of poor healing.</p> <p>Treat prolonged erythema or early scarring early and vigorously.</p>
--

antibiotics, and cortisones as indicated. The diligent physician must watch his or her patients carefully during the postoperative course to catch these complications early and prescribe appropriate treatment. This will prevent the permanent complications of pigmentation changes and scarring.

Conclusions

The general public has a renewed interest in skin rejuvenation. Although there are many techniques presently available, it is up to the cosmetic physician to match the appropriate tool with the patient's needs, to give proper benefit with the least risk. These tools call for special training and experience, and as one gains further knowledge and skill, these procedures generally occupy a rewarding part of one's practice.

References

- Leyden JJ. Photodamage: an overview. *Skin Allergy News* 2003;Suppl:3-4.
- Glogau RG. Chemical peeling and aging skin. *J Geriatr Dermatol* 1994;2(1):30-5.
- Monheit GD, Chastain MA. Chemical peels in facial rejuvenation: non-surgical modalities. *Facial Plast Surg Clin North Am* 2001;9(2):243.
- Stegman SJ. A comparative histologic study of the effects of three peeling agents and dermabrasion on normal and sun-damaged skin. *Aesthetic Plast Surg* 1982;6:123-5.
- Monheit GD. Consultation for photoaging skin, presented at the American Academy of Dermatology Annual Meeting; 1999 March 20; New Orleans, LA.

6. Lowe, NJ. Textbook of facial rejuvenation. London: Martin Danitz; 2002. p. 3–11.
7. Kligman, AM. Topical retinoic acid (tretinoin) for photoaging: conceptions and misperceptions. *Cutis* 1996;57:142–4.
8. Moy LS, Murad H, Moy RL. Glycolic acid peels for the treatment of wrinkles and photoaging. *J Dermatol Surg Oncol* 1993;19:243–6.
9. Draelos, ZD. Topical agents used in association with cosmetic surgery. *Semin Cutan Med Surg* 1999;18(2):112–8.
10. Monheit GD. Skin preparation: an essential step before chemical peeling or laser resurfacing. *Cosmet Dermatol* 1996;9(9):13–4.
11. Rubin M. Manual of chemical peels. Philadelphia (PA): Lippincott; 1995. p. 50–67.
12. Clark CP. Office-based skin care and superficial peels: the scientific rationale. *Plast Reconstr Surg* 1999;104:854–64; discussion 65–6.
13. Brody HJ. Chemical peeling. St. Louis (MO): Mosby; 1992. p. 59–60.
14. Monheit GD. The Jessner's + TCA peel: a medium depth chemical peel. *J Dermatol Surg Oncol* 1989;15:945–50.
15. Kligman D, Kligman AM. Salicylic acid peels for the treatment of photoaging. *Dermatol Surg* 1998;24:325–8.
16. Monheit, GD. Chemical peeling for pigmentary dyschromias. *Cosmet Dermatol* 1995;8(5):10–5.
17. Brody HJ, Hailey CW. Medium-depth chemical peeling of the skin: a variation of superficial chemosurgery. *J Dermatol Surg Oncol* 1986;12:1268–75.
18. Brody HJ. Variations and comparisons in medium depth chemical peeling. *J Dermatol Surg Oncol* 1989;15:953–63.
19. Coleman WP, Futrell JM. The glycolic acid trichloroacetic acid peel. *J Dermatol Surg Oncol* 1994;20:76–80.
20. Witheiler DD, Lawrence N, Cox SE, et al. Long-term efficacy and safety of Jessner's solution and 35% trichloroacetic acid vs 5% fluorouracil in the treatment of widespread facial actinic keratoses. *Dermatol Surg* 1997;23:191–6.
21. Monheit GD. The Jessner's-TCA peel. *Facial Plast Surg Clin North Am* 1994;2:21–7.
22. Morrow DM. Chemical peeling of eyelids and periorbital area. *J Dermatol Surg Oncol* 1992;18:102–10.
23. Baker, TS, Gordon HL. Chemical face peeling. In: *Surgical rejuvenation of the face*. St. Louis (MO): C.V. Mosby; 1986. p. 230–2.
24. Hetter GP. An examination of the phenol-croton oil peel: Part I. Dissecting the formula. *Plast Reconstr Surg* 2000;105:227–39; discussion 49–51.
25. Hetter GP. An examination of the phenol-croton oil peel: part IV. Face peel results with different concentrations of phenol and croton oil. *Plast Reconstr Surg* 2000;105:1061–83; discussion 84–7.
26. Alt T. Occluded Baker/Gordon chemical peel. Review and update. *J Dermatol Surg Oncol* 1989;15:980–93.
27. McCollough EG, Langsdon PR. Chemical peeling with phenol. In: Roenigk H, Roenigk R, editors. *Dermatologic surgery: principles and practice*. New York (NY): Marcel Dekker; 1989. p. 997–1016.
28. Beeson WH. The importance of cardiac monitoring in superficial and deep chemical peeling. *J Dermatol Surg Oncol* 1987;13:949–50.
29. Burks JW. Abrasive removal of scars. *South Med J* 1955;48:452–9.
30. Kurtin A. Corrective surgical planing of the skin. *Arch Dermatol Syphil* 1953;68:389–97.
31. Alt TH. Facial dermabrasion: advantages of the diamond fraise technique. *J Dermatol Surg Oncol* 1987;13:618–24.
32. Harris DR, Noodleman FR. Combining manual dermasanding with low strength trichloroacetic acid to improve actinically injured skin. *J Dermatol Surg Oncol* 1994;20:436–42.
33. Chiarello SE. Tumescant dermasanding with cryospraying. A new wrinkle on the treatment of rhytids. *Dermatol Surg* 1996;22:601–10.
34. Bernard RW, Beran SJ, Rusin L. Microdermabrasion in clinical practice. *Clin Plast Surg* 2000;27:571–7.
35. Warmuth IP, Echt A, Scarborough DA, Bisaccia E. Microdermabrasion: a new rejuvenation treatment option. *Cosmet Dermatol* 1999;12:7–10.
36. Zisser M, Kaplan B, Moy RL. Surgical pearl: manual dermabrasion. *J Am Acad Dermatol* 1995;33:105–6.
37. Yarborough JM. Dermabrasion by wire brush. *J Dermatol Surg Oncol* 1987;13:610–5.
38. Alt TH. Technical aids for dermabrasion. *J Dermatol Surg Oncol* 1987;13:638–48.
39. Yarborough JM, Coleman WP, Lawrence N. Wire brush dermabrasion. In: Coleman WP, Lawrence N, editors. *Skin resurfacing*. Baltimore (MD): Williams & Wilkins; 1998.

Alloplastic Esthetic Facial Augmentation

Bruce N. Epker, DDS, MSD, PhD

Alloplastic esthetic facial augmentation of the chin, mandibular angles and inferior borders, skeletal nasal base, and cheeks is the standard of care, as opposed to autogenous augmentation. A variety of approved alloplastic facial implants are available to the surgeon. In general, marketed implants are proven nontoxic, noncarcinogenic, and nonantigenic, and they are inert in body fluids.¹⁻³ Moreover, the optimal material is user friendly; it is easily modified, maintains the desired shape, is not mobile, and is cost effective.

No single implant possesses all of these optimal properties, yet some are clearly closer to these ideals than others. The more commonly employed esthetic facial implants, which most closely achieve these ideals, include porous polyethylene, silicone, and polytetrafluoroethylene (PTFE) and high-density polyethylene. It is not the intent of this article to compare and contrast these facial implant materials as they are all approved and acceptable and each is espoused by different surgeons as the preferred material for cosmetic esthetic facial augmentation.

To achieve predictable and successful results with alloplastic esthetic facial augmentation, special attention to the differential diagnoses established via a detailed patient evaluation,⁴⁻¹¹ meticu-

lous surgical technique, proper modification, and placement of the implant are essential. Accordingly, this chapter emphasizes and details these aspects of esthetic facial augmentation.

An additional item discussed herein is still controversial—the use of antibiotics with surgery for alloplastic facial augmentation. A recent survey of surgeons revealed a spectrum of opinions. Approximately 30% of surgeons use no antibiotics or intravenous antibiotics only during surgery. About an additional 30% continue antibiotics for 1 to 3 days postoperatively, and 40% use them for 4 to 7 days postoperatively.¹² Unfortunately, the incidence of infection with the various regimens is not available; however, the overall incidence is very low. I use a single intraoperative dose of intravenous antibiotics at the commencement of surgery; generally, I use cephalosporin regardless of whether an extraoral or intraoral approach is taken.^{13,14}

Finally, alloplastic nasal augmentation is not discussed here as, in general, I prefer autogenous materials for this purpose.

The Chin

Alloplastic chin augmentation is generally reserved for the patient who has lax and/or redundant soft tissues or who is undergoing simultaneous neck surgery, such as

cervicofacial liposuction, platysma plication, or rhytidoplasty. When this approach is used, special care is directed to evaluating for a tapered chin appearance or “marionette grooves,” which frequently exist in the older patient population. Many commercially available alloplastic chin implants *do not* provide adequate lateral augmentation and posterior extension in the parasymphysis regions to correct these problems. Therefore, the modification or selection of a properly sized and shaped alloplastic implant is important.

Preoperative planning consists of a systematic sequential esthetic clinical evaluation and a lateral cephalometric evaluation to determine the specific shape and magnitude of the augmentation.

Chin augmentation has long been an esthetic adjunct to numerous orthognathic, craniofacial, and cosmetic procedures. Various authors have proposed and extolled the advantages of their “modifications” of this basic operation, but, despite its widespread application, its esthetic demands and results are not yet well specified.¹⁵⁻¹⁷

This procedure is planned to achieve specific esthetic objectives:

- Frontally, a well-defined smooth inferior border of the mandible that separates the lower third of the face from

the neck proper is important for good esthetics. A lack of this distinct border detracts from good chin-neck esthetics. A posteriorly well-extended implant and proper inferior placement, at the inferior mandibular border, help to achieve this objective.

- The esthetically attractive chin is balanced in width with the other facial features, especially the bizygomatic and bigonial facial widths. Many individuals with recessed chins also have dolichocephalic facial features, or what has been described as the “pointed chin” or “witch’s chin.” When this condition exists and is not deliberately modified, augmentation of the chin often results in an accentuation of the existing pointed chin. In persons with this facial structure, augmentation of the chin should be accomplished by *enhanced lateral augmentation*. This is accomplished by modifying standard chin implants as described in the surgical technique discussion to follow.
- The esthetically attractive chin has no evidence of parasymphyseal depressions or grooves. These soft tissue marionette grooves may exist independently of or in concert with the pointed chin. This condition is accentuated in most older individuals. When these grooves exist, special attention is given to lateral or parasymphyseal augmentation, similar to that used to improve the pointed chin.
- The esthetics of anteroposterior chin position is determined by evaluating the cephalometric values: NB:Pog, A:Pog, and subnasale perpendicular. The normal relations of these are as follows: NB:Pog line has the lower incisor tip and bony chin prominence on a 2:1 to 1:1 relationship. Line A:Pog has the tip of the lower incisor on or 1 to 2 mm posteriorly positioned. The soft-tissue chin is 4 mm distal to SN perpendicular. These values are used to determine the optimal relationship of the hard

and soft tissues of the chin relative to lower incisor position, lower lip, and upper lip. Two qualifiers regarding esthetic anteroposterior chin augmentation are important in the context of the proposed cephalometric treatment planning. First, *do not* advance the bony chin beyond the anterior position of the lower incisor as determined by the NB:Pog and A:Pog criteria, even when subnasale perpendicular soft tissue values suggest otherwise. Second, in older individuals, often those undergoing cervicofacial liposuction, rhytidoplasty, or both, anteroposterior augmentation of the chin to its “ideal” hard and soft tissue values generally results in an excessive amount of chin projection *in the eyes of the patient*. This is perhaps because the individual has had the deficient condition for so many years that he or she has become accustomed to it.

In sum, before performing esthetic chin augmentation, consider all of these criteria and *do not* rely primarily on achieving the ideal anteroposterior chin position; otherwise, the esthetic results in a significant number of patients will fall short of the desired results.¹⁸

This procedure is most often performed under local anesthesia with sedation, along with other procedures such as blepharoplasty, rhinoplasty, cervicofacial liposuction, and rhytidoplasty.

With a surgical marking pen, the true chin and neck midlines are marked to aid subsequently in precise implant positioning; also, the planned submental incision is marked.¹⁹ When this procedure is being performed under local anesthesia with sedation, bilateral inferior alveolar nerve blocks are given with 2% lidocaine with 1:100,000 epinephrine. Next, the submental area where the incision is to be made and the entire area to be undermined subperiosteally are infiltrated with about 7 to 10 cc of local anesthetic with epinephrine.

Seven to 10 minutes are allowed to pass after infiltration of the local anesthetic.

The implant is to be placed through a submental incision of about 5 cm, made just distal to the normal submental crease. When the incision is made in the naturally occurring submental crease, it can accentuate this crease and cause an unesthetic dimpling in that area. The incision is made through the skin and subcutaneous tissue, and hemostasis is obtained with needle-point diathermy. The incision is then carried directly down to the inferior border of the mandible and through the periosteum with diathermy cutting.

After identification and exposure of the inferior border of the mandible, a subperiosteal dissection is completed along the entire inferior aspect of the mandibular symphysis, *well posterior* on each side to the region of the gonial notch. Following exposure of the inferior border, the subperiosteal dissection is carried superiorly beginning anteriorly. Laterally it is extended superiorly only enough to allow the mental neurovascular bundles to be identified and visualized. No attempt is made to expose them extensively because doing so increases the potential for neurosensory defects to the lower lip and chin.

An extended preformed implant is generally selected, one that is configured in such a way that it extends posteriorly into the molar region.^{8,17,19} In patients with a tapered (pointed) chin or marionette grooves, the selected implant is modified. The selected implant is 2 to 4 mm greater in the anteroposterior dimension than the desired anteroposterior augmentation.¹⁹ This dimension is reduced at surgery and, in essence, accentuates the parasymphysis augmentation to improve the pointed chin or parasymphysis depressions. These alterations are made to provide a more lateral (parasymphysis) augmentation than is available in most preformed alloplastic chin implants (Figure 70-1).

After trial insertion of the implant, the surgeon determines the need for addition-

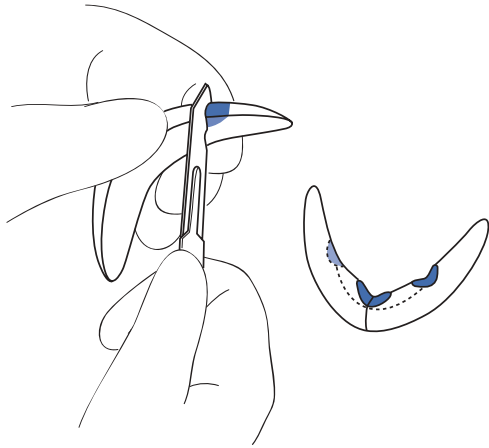


FIGURE 70-1 Reduction of the anteroposterior thickness effects a rounding of the chin and visibly changes a pointed chin into a more rounded one. Adapted from Epker BN.¹⁹ p. 27.

al adaptations in either the implant or the subperiosteal dissection to ensure that it rests passively on the lateral and inferior borders of the mandible. The mental neurovascular bundles are visualized during the trial insertion to make certain that the implant does not encroach on them. If this does occur, these areas are marked in situ on the implant, and the implant is removed and these areas relieved.

On completion of all adaptations, two holes are drilled through the implant and outer cortex of the underlying bone. The implant midline and marked facial midline are checked, and the implant is then stabilized with titanium screws to prevent inadvertent early postoperative displacement and to avoid mobility of the implant. If the implant is porous, it is vacuum impregnated with an antibiotic solution before it is definitively stabilized into position.

The incision is closed in layers with 4-0 polyglactin 910 platysma muscle sutures, 4-0 chromic gut subcutaneous sutures, and 5-0 braided polyester or monofilament nylon skin sutures. Antibiotic ointment and a perforated film absorbent dressing (Telfa) are placed over the incision, and a multiple-layered 1.25 cm tape dressing is placed to reduce edema and or hematoma formation. The dressing is left in place for

48 hours. When additional neck surgery is done, as is frequently the case with this procedure, a more extensive neck pressure dressing may be placed. Generally, intraoperative antibiotics are used and no postoperative antibiotics given.

Sutures are removed on the fifth postoperative day, and after 7 to 10 days any areas of irregularity caused by edema or hematoma are treated by deep massage and heat. No other special treatment is needed.

Complications that occur with this procedure vary and are generally minimal.¹⁸

The patient seen in Figure 70-2 is shown before and after alloplastic chin augmentation, emphasizing lateral parasymphysis augmentation to reduce the pointed appearance of the chin and the marionette grooves.

Mandibular Angle and Inferior Border

A well-defined mandibular angle and inferior mandibular border are important to an esthetically pleasing face. Indeed, *proper definition in this region is the very basis of visually separating the face from the neck*, thereby making them distinct from one another. When this area is not well defined, the face and neck become confluent and unattractive. Accordingly, in selected individuals esthetic augmentation of the mandibular angles and inferior mandibular borders is to be considered.¹⁹

The differential diagnosis of poor definition of the angle and inferior mandibular borders is important; one must consider whether it results from abnormal skeletal support, cervicofacial lipomatosis, soft tissue redundancy, or a combination of these conditions

A routine clinical evaluation via multidirectional observation and palpation can readily allow the surgeon to diagnose cervicofacial lipomatosis and/or soft tissue redundancy. A standard lateral cephalometric evaluation of the mandibular plane angle is used to determine the presence and degree of an underlying skeletal sup-

port abnormality. The normal mandibular plane angle (FH:Go-Gn) is 24°. One then draws the normal inferior border line angle. This in essence represents the newly to be constructed inferior mandibular border and allows the surgeon to determine the specifics of vertical and anteroposterior implant design.

The vertical linear distance between the two mandibular planes (the patient's and the constructed normal) in the gonial angle is measured. This distance is the amount of vertical change in the angle that would be indicated to create ideal skeletal support. Generally, the older the patient, the less one augments this area all the way to the ideal. The lateral superior height is measured so that it extends to above the midramus. Anteroposteriorly the mental foramen is generally the limiting extent of the implant. Finally, frontal face esthetics is evaluated to determine the approximate desired lateral width of the implant in the angle-ramus area. In the esthetically pleasing face, the mandibular angle area is medial to the zygomatic area so that the face tapers slightly from the zygomatic area.

When soft tissue conditions coexist with the defined underlying skeletal abnormalities, correction of the skeletal deformity may produce significant improvements in the associated soft tissue conditions. Finally, when identifiable skeletal and major associated soft tissue problems coexist, the skeletal surgery described herein can be done either primarily or simultaneously with liposuction or rhytidoplasty; however, I prefer to perform the face- and neck-lift secondarily.

Once the above data are established, a preformed porous polyethylene implant is selected and appropriately modified at surgery as discussed in the surgical technique section to follow.²⁰⁻²³

Surgery can be performed with general anesthesia or intravenous sedation and local anesthesia.¹⁹ Inferior alveolar nerve blocks are given bilaterally. In addition, a 2% local anesthetic containing 1:200,000

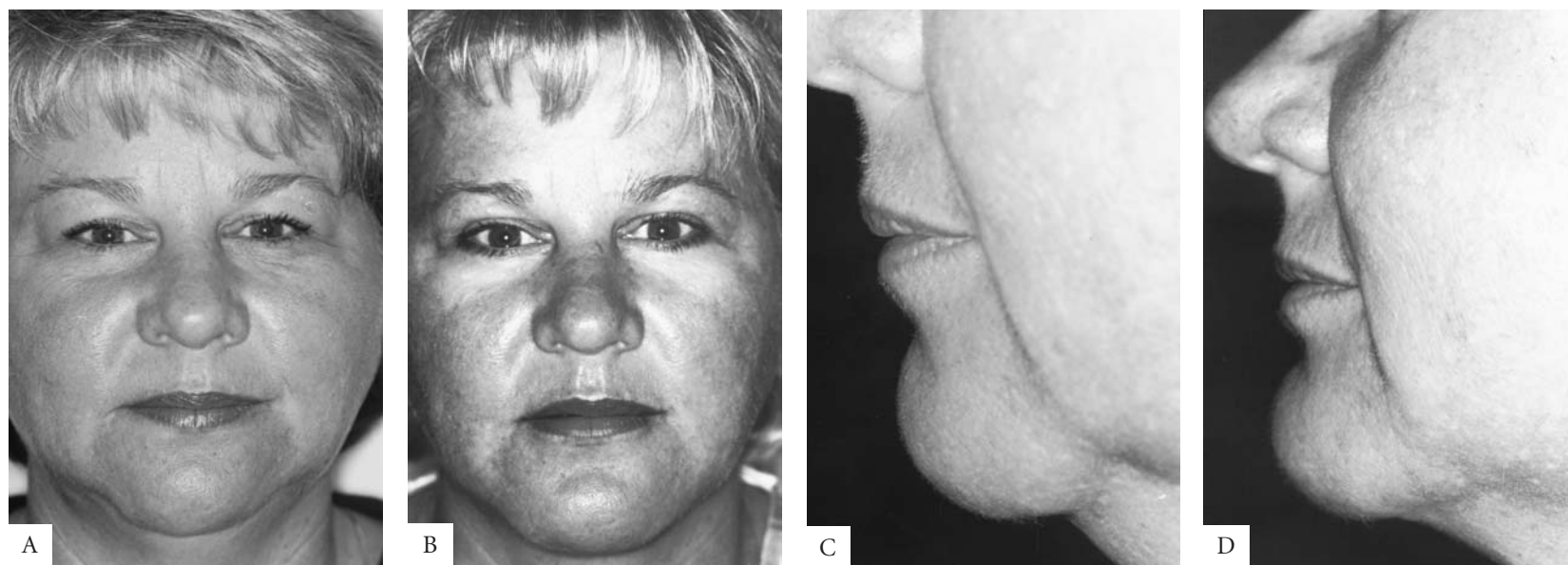


FIGURE 70-2 Preoperative (A and C) and postoperative (B and D) photographs of a patient who underwent chin augmentation to reduce a pointed chin appearance illustrating more lateral augmentations.

epinephrine is infiltrated bilaterally just lateral to the mandible from midramus to the angle and along the entire lateral aspect of the mandibular body to the region of the mental neurovascular bundle. Approximately 10 cc of local anesthetic is infiltrated on each side. The surgical procedure is begun about 7 to 10 minutes after injection of the local anesthetic.

The incision is begun posterolaterally, just anterior to the bulge of the fat pad, midway down to the depth of the sulcus. This incision is made through the mucosa, buccinator, and periosteum, anteriorly to the region of the canine tooth; however, as one proceeds anteriorly into the premolar region, the incision is initially carried only through the mucosa to avoid inadvertently transecting the mental neurovascular bundle.

After the mental neurovascular bundle is exposed, the remainder of the dissection is done entirely in the subperiosteal tissue plane. This begins anteriorly with deliberate mobilization of the tissues around the mental neurovascular bundle, carrying the dissection inferiorly subposteriorly to the inferior border of the mandible. The dissection is next carried posteriorly to the angle of the mandible, while the masseter

muscle is elevated superiorly about half way up the ascending mandibular ramus. No attempt is made to penetrate the periosteum at the inferior and posterior borders of the mandible.

In the region of the mandibular angle and along the posterior border, a J-shaped periosteal elevator is used to complete the subperiosteal dissection (Figure 70-3).

Once the lateral body and ascending ramus of the mandible are exposed in the subperiosteal tissue plane, the periosteum can be opened with finger dissection at the inferior aspect, as necessary for adequate relaxation.

My preferred augmentation material is porous polyethylene, which is available in several preformed sizes and shapes. The approximate size and shape of the implant should be determined previously, as discussed in the previous section. On the basis of the measurements, the preformed implant is modified during the actual surgical procedure. After the initial modifications, before a try-in placement, the implant is vacuum impregnated with an antibiotic solution. This is achieved by placing the implant into a 60 or 90 cc syringe in which the antibiotic solution is present, inserting the plunger of the

syringe and evacuating all air, and repeatedly withdrawing the plunger forcefully while holding a finger over the end of the syringe. This removes the air from the porous implant and replaces it with the concentrated antibiotic solution. The procedure requires considerable effort and pressure, often taking a few minutes. When this process reaches its end point, the implant sinks in the solution.

The initial try-in is then done. Additional modifications are often necessary, such as notching the implant in the region of the mental neurovascular bundle and molding it slightly into a curved

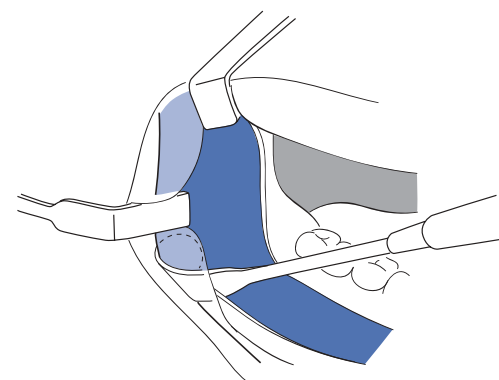


FIGURE 70-3 Use of a J-shaped elevator to remove the tenacious angle muscle attachments. Adapted from Epker BN.¹⁹ p. 84.

configuration to adapt it more precisely to the lateral aspect of the ramus and body of the mandible. To bend the implant, it is placed in sterile hot saline; this removes its original memory and allows it to be readily molded.

The implant is inserted into position. Once inserted and its inferior and posterior aspects “locked” beneath the posterior and inferior borders of the mandible, the implant is inspected for any final adaptations. At this point the implant is removed, placed back into the antibiotic, and the wound packed.

The identical dissection is then completed on the opposite side, and before insertion of the second implant, the same basic modifications are made to a second implant so that the implants are virtual mirror images of one another. This assumes that the patient has a symmetric deformity in this area. When asymmetry exists, it is identified and recorded preoperatively, and the modification of the implants for independent shaping of the right and left sides is done preoperatively.

After completion of the dissection on the second side and the try-in of the second implant, both implants are ready for final insertion. The implants are irrigated free of blood and debris and vacuum impregnated again with the antibiotic solution. One or two monocortical titanium screws are placed to stabilize the implant (Figure 70-4).

The implant is inserted on one side first, and the incision is closed in two layers. The first layer is the periosteal and buccinator muscle, which is closed with 3-0 chromic sutures. Then, with a running 3-0 chromic horizontal mattress suture, the mucosal layer is closed. Interrupted sutures are finally placed as needed to effect a watertight closure of the incision. After completion of closure on one side, the second antibiotic-impregnated implant is placed into the opposite side, and the stabilization and layered closure are completed.

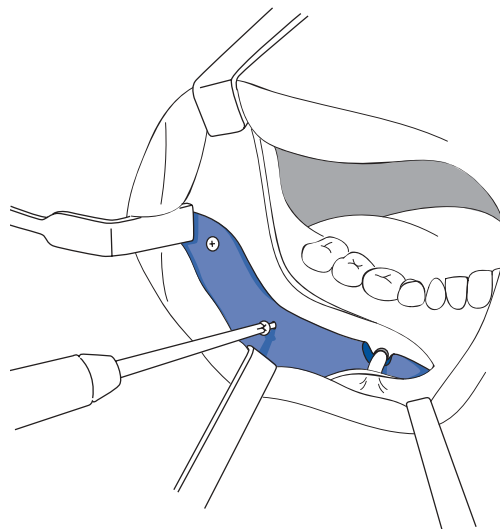


FIGURE 70-4 Stabilization of the implant with monocortical titanium screws. Adapted from Epker BN.¹⁹ p. 89.

A multilayered 1.25 cm tape dressing is placed so that the tape extends from the cheek area well inferiorly into the neck, thereby applying primarily lateral pressure to this area to minimize postoperative edema and hematoma. When this dressing is applied, it is placed so that the pressure is directly applied laterally. This dressing is left in place for 48 hours. On removal of the tape dressing, the patient is instructed to use heat to decrease the swelling.

Postoperatively the patient is placed on a clear liquid diet for the first 24 hours and then advanced to a full liquid diet for 4 to 5 days. After this time, he or she may begin a mechanical soft diet for 10 to 14 days until the intraoral incision lines are completely healed. After approximately 2 weeks, the implants are self-stabilized by fibrous soft tissue ingrowth, and the incisions are completely healed; at this time unlimited physical activity is permitted.

At the 2-week period patients generally have some limitation in the range of mandibular motion because of the surgery and its sequelae. Accordingly, they are placed on a regimen of active jaw exercises, three times a day for approximately 5 minutes each. These exercises consist of maximum interincisal opening, protrusion, and clenching. Generally, within 7 to

14 days asymptomatic full range of mandibular motion is obtained.

This procedure is designed to accentuate and normalize the mandibular angle and inferior mandibular border to set the lower third of the face off clearly from the neck, making each into a discrete esthetic unit. Additionally, this procedure effects some tightening of the overlying soft tissues, affecting a “mini face-lift” in individuals who have slight skin laxity and/or mild jowls (Figure 70-5). The procedure is often done in concert with other orthognathic, reconstructive, and cosmetic facial procedures.

Skeletal Nasal Base

The indication for skeletal nasal base augmentation is based on a clinical esthetic facial evaluation in individuals who are not Class III maxillary deficient. This condition is frequently associated with inherent nasal deformities.^{19–24} The typical clinical esthetic findings are outlined below.

Frontally the alar base width is highly variable but most often is somewhat narrow, and the upper lip vermilion is often deficient or exhibits a “gullwing” appearance. Moreover, the patient has deficiency in the paranasal areas, as opposed to prominent soft tissue nasolabial folds (Figure 70-6A). In profile, flat to concave paranasal anatomy and a groove ratio of nasal tip–subnasale to subnasale–alar is approximately 1:1 instead of the normal 2:1. In addition, the following most often coexist: a relatively prominent nose, poor nasal tip projection, unesthetic nasal tip rotation (droop), and lack of a supratip break (Figure 70-6B).²⁵

Anatomically, the skeletal nasal base is the area that, in part, determines paranasal fullness, alar base position, nasal tip support, *relative* nasal prominence, and internal nasal valve (liminal valve) function. Accordingly, the esthetics of these areas depends on but is not totally determined by the underlying skeletal anatomy.

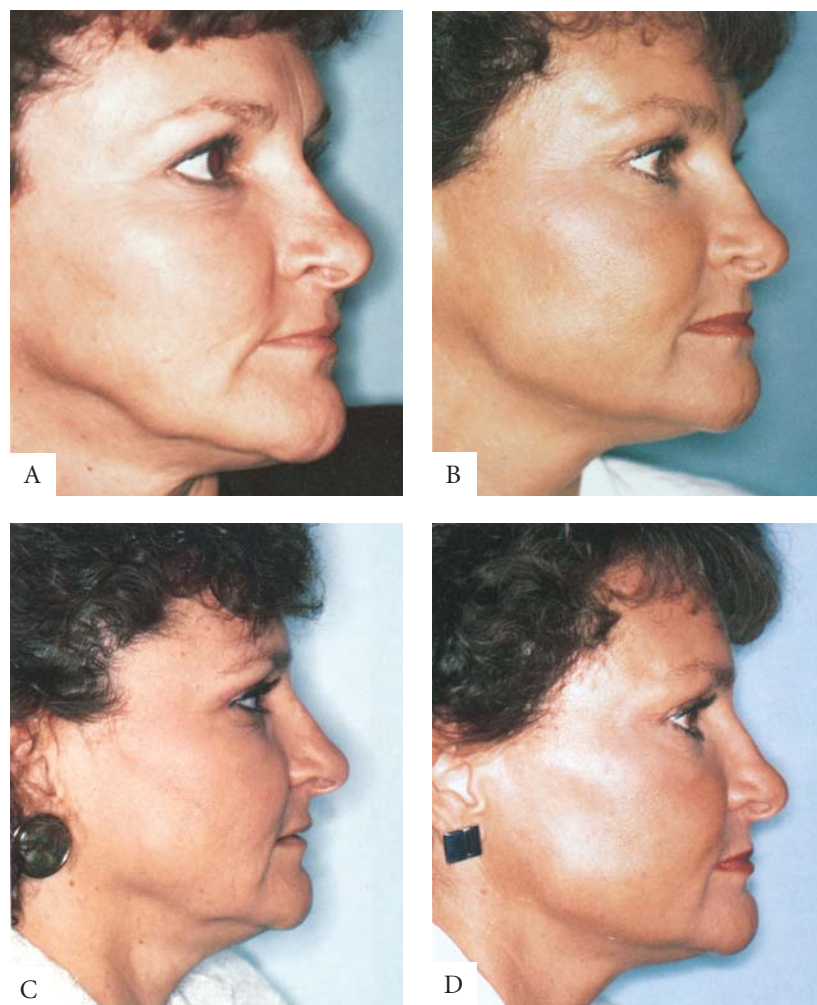

FIGURE 70-5 Preoperative (A and C) and postoperative (B and D) photographs of a patient who underwent mandibular angle-inferior border augmentation. Note the tightening of soft tissues with a reduction of the laxity, especially in the jowl. Reproduced with permission from Epker BN.¹⁹ p. 94.

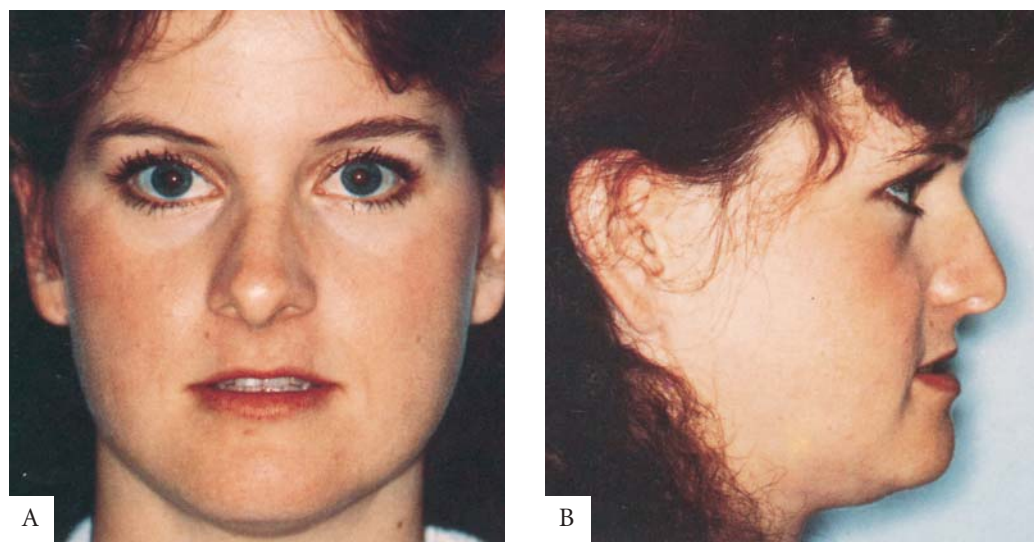

FIGURE 70-6 A and B, Patient with a Class I occlusion and classic features of skeletal nasal base deficiency. Reproduced with permission from Epker BN.¹⁹ p. 116.

The cephalometric analysis may or may not exhibit evidence of maxillary deficiency in the presence of a Class I occlusion. This is true because these cephalometric values have traditionally been determined by measures around a point that may not be deficient. However, the piriform rims per se, as well as the immediate adjacent areas of the maxilla, are deficient. Unfortunately, these areas are not amenable to measurement or evaluation with conventional lateral cephalometrics.

Individuals to be considered for skeletal nasal base augmentation are those with *isolated skeletal nasal base deficiency* who possess a functional Class I relationship and are not candidates for orthognathic surgical consideration. In some individuals, in whom a skeletal Class III deformity exists in the mandible and is corrected with an osteotomy to set back the mandible, the skeletal nasal base deficiency can be simultaneously corrected by skeletal nasal base augmentation.²⁴ Finally, this procedure is indicated in certain individuals who present for rhinoplasty and/or septorhinoplasty.²⁵

Two approaches to the surgery are used, depending on the severity of the deficiency as determined by the clinical findings: a limited approach and an extended approach. The limited approach is used when the magnitude of augmentation planned is minimal (2–3 g of hydroxylapatite per side). In such individuals the alar base width is generally normal, and in profile the nasal size, tip projection, and a supratip area are essentially normal. This approach *does not* noticeably affect the upper lip vermilion exposure.

Conversely, the extended approach permits alar base width adjustment and control of upper lip vermilion exposure (increased exposure). Also, since it is used for larger augmentations (4–6 g per side), it effects a relative decrease in nasal size, increasing the tip projection and supratip break.

The procedure can be readily performed under either general or local anes-

thetia with or without sedation. Before injection of the local anesthetic, the alar base width is measured and an esthetic determination is made as to its most desirable postoperative width. About 10 minutes before initiation of the actual surgery, the infraorbital nerves are blocked bilaterally, and 10 cc of 2% lidocaine with 1:200,000 epinephrine is infiltrated from the zygomatic-alveolar crest area on one side to the same area on the opposite side, up into the region of the frontal process of the maxilla. When the limited augmentation is to be done, about 2 to 3 g of hydroxylapatite are used on each side, as opposed to 4 to 6 g for the extended augmentations.

The limited approach is achieved through two vestibular incisions. On each side a diagonal incision is made from the piriform rim area in the depth of the vestibule down to the level of the attached gingiva in the canine region. This incision is carried directly down to bone. The anterior maxilla is then subperiosteally exposed so that the surgeon can visualize the piriform rim of the nose medially and extended superiorly and laterally by the desired amount (Figure 70-7). The augmentation material is perhaps most easily delivered by means of the syringe technique. About

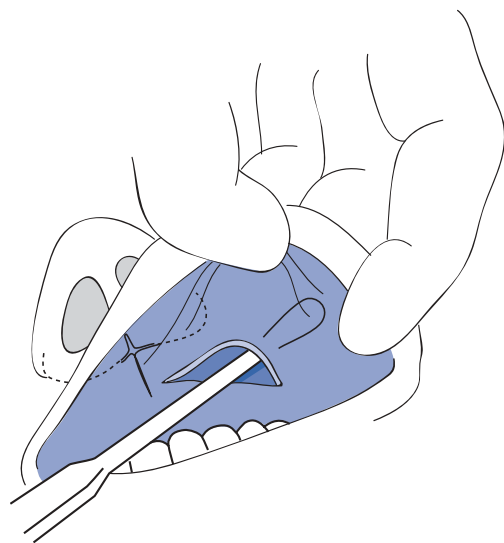


FIGURE 70-7 When less augmentation is necessary, the limited incision approach is used. Adapted from Epker BN.¹⁹ p. 126.

2 to 3 g of nonresorbable hydroxylapatite is mixed with sterile saline and a collagen hemostatic and placed into a 3 cc syringe that has had the delivery end cut off.¹³ Closure is performed with running 3-0 chromic horizontal mattress sutures. No dressings are placed. Gentle external massage is done to ensure symmetry.

For the extended augmentation approach, a standard horizontal incision is made in the depth of the maxillary vestibule from the second premolar area on one side to the same area on the opposite side. This incision is carried directly down to bone, and the entire anterior maxilla is exposed subperiosteally. The exposure extends posteriorly only to the anterior aspect of the zygomatic alveolar crest, then superiorly to expose the infraorbital nerve and medially above the nerve onto the infraorbital rim. The lateral and inferior region of the bony piriform rim is exposed including the anterior nasal spine. The periosteum in this region is carefully mobilized over the piriform rim and into the nasal cavity for about 5 mm. In this phase of the subperiosteal dissection, care is exercised not to tear the periosteum and enter the nasal cavity. When this occurs it is best to suture this communication to avoid possible postoperative infection.

Before augmentation, sutures are placed to control the alar base width. A hole is drilled in the anterior nasal spine. Depending on the predetermined esthetic desires for alar base width changes, these sutures are variably tightened to control the alar base width at its presurgical width, permit it to widen, or allow it to somewhat narrow. This latter objective is seldom indicated in this condition because the alar base width is most often narrow, and the patient generally benefits from some controlled degree of alar base widening. However, when this area is not controlled with alar base retention sutures as described, it widens unpredictably and often excessively. Two separate 2-0 slowly resorbable sutures are placed through a single hole drilled

through the anterior nasal spine region. Next, the upper lip is grasped, and the forefinger is placed facially, precisely over the inferior alar rim while the lip vestibule is retracted with the intraorally placed thumb. With toothed forceps the area in the vestibular incision directly adjacent to the everted alar rim is firmly grasped. This tissue is a combination of the fibroareolar extension of the lower lateral cartilage and the lateral nasalis muscle; occasionally, a small sesamoid accessory of cartilaginous component is noted (Figure 70-8). When the proper tissue is grasped and the lip released from the fingers while maintaining the tissue grasped with forceps, the alar base is readily advanced medially toward the columella; the alar base is then observed and measured facially. Sometimes several attempts at grasping the proper tissue with the forceps must be made to identify the tissue that permits virtually unrestricted medial movement of the alar base. For the alar base cinch procedure to be effective, the proper tissue in this area must be identified bilaterally to effect symmetric control of the alar bases.

Once the proper tissue is identified, while it is maintained in the forceps, a Burnell or figure-of-eight tendon-type suture is placed with a 2-0 polyfilament slowly absorbable suture. A separate suture is passed through each side first and the needle left attached to the suture (Figure 70-9). Then each needle is passed

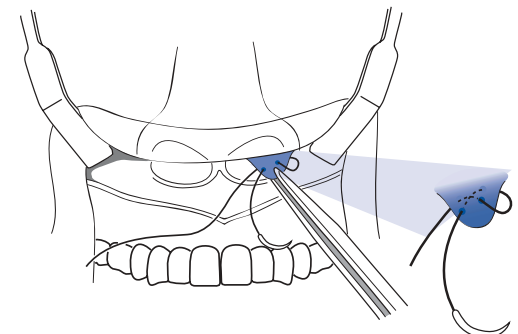


FIGURE 70-8 Alar cinch with attention to proper tissue selection and suture technique. Adapted from Epker BN.¹⁹ p. 123.

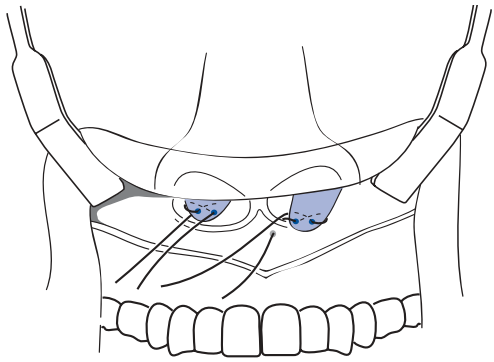


FIGURE 70-9 Independent suturing of each side to anterior nasal spine. Adapted from Epker BN.¹⁹ p. 124.

through the hole placed in the anterior nasal spine. These sutures are later tied after the actual augmentation.

The skeletal nasal base augmentation is performed with a nonabsorbable mixture of particulate hydroxylapatite and a hemostatic collagen preparation, moistened with sterile saline. Only enough collagen hemostatic material is used to form a dough mass that does not flow.

Generally, between 8 and 12 g of hydroxylapatite are used in the extended approach, depending on the relative severity of the skeletal nasal base deficiency. The mixture is separated into two equal portions so that equal augmentation is attained on both sides. After placement, it is molded with a periosteal elevator to conform it to the underlying bone. Most often this material is extended superiorly to the infraorbital nerve and often more medially to the infraorbital rim. Care is taken not to place much of the material into the region of the frontal process of the maxilla because this unesthetically widens the nose. Once the implants are placed bilaterally, equally and symmetrically adapted, and contoured to create facial symmetry, the incision is closed.

First, the alar base sutures are tied. Each suture is independently hand tied while that side's alar base width is observed (measured) facially. As a general principle, the alar base should be narrowed 2 mm more than desired because some widening tends to occur postopera-

tively. Next, the vestibular incision is closed with deliberate attention to control of the upper lip fullness and the amount of exposed vermilion. Often, after the alar base cinch sutures are tied, the labial mucosa is somewhat tethered superiorly and must be undermined in the region of the alar base cinch suture. This is important to avoid reduction of the upper lip's vermilion exposure with the subsequent vestibular closure.

When there is no desire to alter the preexisting upper lip esthetics, the mucosal portion of the incision is closed in the usual V-Y fashion, with the vertical extent of the Y being about 10 to 15 mm. This basically avoids reduction in exposure of the upper lip vermilion (Figure 70-10).

More often, it is desirable to increase the exposure of the upper lip vermilion, especially when the preoperative lip has gullwing characteristics. In these instances an extended closure is done, requiring extensive undermining of the upper lip mucosa. While the lip is retracted with a single skin hook placed precisely in the midline and with a retractor placed laterally, undermining of the lip mucosa is performed with small scissors. The extent of the mucosal undermining is determined by the desired esthetic changes in the upper lip. When maximal increased exposure of the upper lip vermilion is wanted, as is the case with a gullwing upper lip appearance, extensive undermining is achieved anteriorly almost to the wet line of the lip and an equivalent amount posteriorly. When this undermining is completed, it is critical that the surgeon be able to pass the scissors freely from one side to the other, demonstrating a continuous pocket. Next, the horizontal vestibular limbs are closed with interrupted or continuous 45° angled sutures to reduce tension and further advance the mucosa.

When the extensive mucosal undermining is done with a V-Y closure, a dental cotton roll coated with an antibiotic ointment is inserted into the depth of the

labial vestibule in the midline, and tape is placed tightly over the lip to maintain pressure. The tape is extended inferiorly over the lip mucosa. When this is not done, considerable lymphedema occurs in the midline of the upper lip. The cotton roll and tape dressing are left in place for 48 hours and then removed. Similarly, layered tape dressings are applied to the paranasal regions and maintained for 48 hours. Cold is applied to the face during this time.

After surgery and the removal of the dressing, the patient must maintain a liquid to very soft diet for 7 to 10 days until the vestibular incision is well healed. After 3 to 4 days he or she is instructed to begin forceful lip exercises to further reduce edema. At this time, when the edema is resolving, the surgeon gently palpates the paranasal areas to ensure symmetry. The implanted material can be gently molded for about 5 to 7 days before it assumes a solid state without flow properties.

The limited exposure approach is done primarily to reduce mild paranasal depressions (Figure 70-11). The extended procedure produces esthetic changes consistent with improved frontal face esthetics,

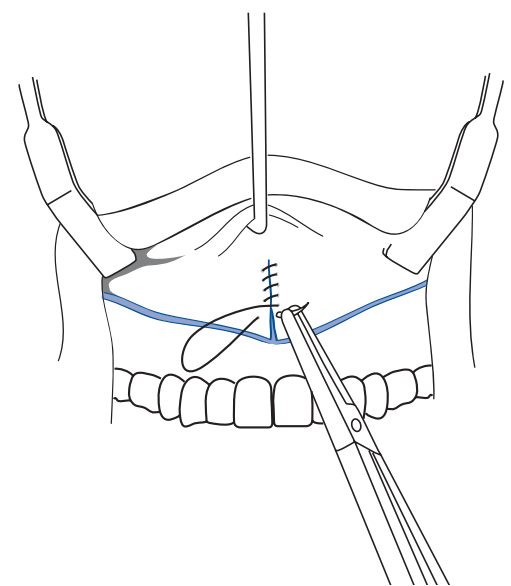


FIGURE 70-10 V-Y closure is done to enhance exposure of upper lip vermilion. Adapted from Epker BN.¹⁹ p. 127.

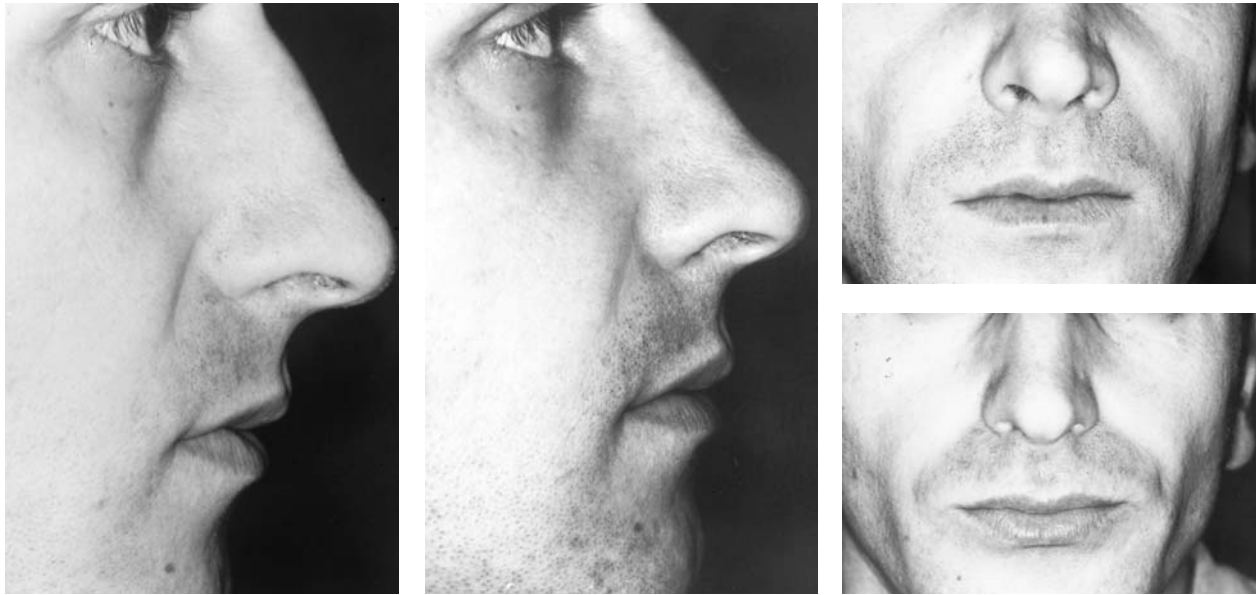

FIGURE 70-11 The limited exposure can be performed without significant effects on the nose or upper lip.

including improved upper lip fullness, increased exposure of the upper lip vermilion, improved balance of the alar base width with the remainder of the facial features, and decreased prominence of the nasolabial folds. In profile the concave-to-flat paranasal region becomes normally convex. Prominence of the nose is decreased, nasal tip projection is improved, often with the creation of a supratip break, and some cephalic rotation of the nasal tip is achieved (Figure 70-12). This extended procedure is frequently

used with other skeletal/soft tissue cosmetic maxillofacial procedures, especially rhinoplasty.

The Cheek

Esthetic cheek augmentation may be indicated as an isolated esthetic maxillofacial surgical procedure or be performed in concert with other skeletal/soft tissue facial esthetic surgeries.²⁶⁻³⁵ As with the other procedures discussed in this chapter, this statement implies that the patient both *possesses* the deformity (albeit to highly

variable degrees) and *desires* enhancement. Moreover, it must be appreciated that three patients with the same degree of anatomic deformity may each desire different degrees of augmentation, much the same as occurs with breast augmentation.

Esthetic cheek augmentation is indicated in individuals who frontally exhibit poor lateral cheek projection (bizygomatic width) in relation to the bigonial and bitemporal widths. Many such patients *appear* to exhibit vertically long faces, even though they do not possess any of the

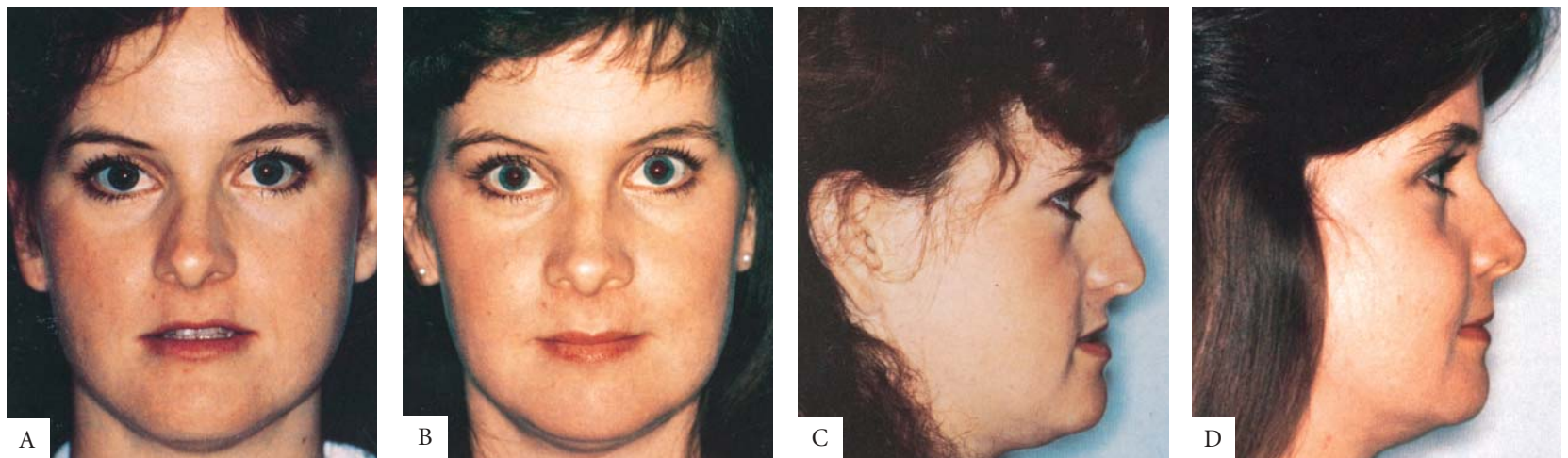

FIGURE 70-12 Preoperative (A and C) postoperative (B and D) appearances after an extended approach with an alar cinch and a V-Y augmentation of the upper lip. Reproduced with permission from Epker BN.¹⁹ p. 130-1.

objective criteria of the long-face syndrome. This is because of the abnormal facial length-to-width relationships caused by the abnormal narrow bizygomatic width. Similarly, poor cheek projection is noted in the three-quarter oblique view. In profile these same individuals possess variable degrees of inadequate cheek and/or lateral infraorbital rim projection.^{19,25}

A detailed systematic esthetic examination of this area is performed because the evaluation of this area of the face must be multidirectional. Esthetic judgments made exclusively from a single view are incomplete with respect to the specificity of the deficiency.

Frontally the area of maximum cheek prominence is located about 10 mm lateral and 15 mm to 20 mm inferior to the lateral canthus. The cheek prominence is positioned more laterally than the mandibular angle. The bizygomatic width of the esthetically attractive face is the widest dimension of the face, with the bitemporal width and bigonial widths following. Silver has defined a malar prominence triangle, which very closely locates the malar prominence to this same location.²⁶

From the profile perspective, the cheek prominence and infraorbital rim in the esthetically attractive individual are situated so that the infraorbital rim is about equally projected with the anterior-most projection of the globe, and the cheek prominence is located several millimeters anterior to the globe. This relationship results in the cheek area being *clearly convex* in its configuration, as opposed to flat or concave.

Most analyses of the malar prominence that have been described in the literature are from the three-quarters view. These include Hinderer's, Wilkinson's, Powell and colleagues', and Prendergast and Schoenrock's methods.³⁶⁻³⁹ These methods result in highly variable ideal locations for the malar prominence, both vertically and laterally. Specifically, Hinderer's method is too nonspecific, Wilkin-

son's locates the prominence quite inferiorly, and Prendergast and Schoenrock's locates it medially. Powell and colleagues' analysis is comparable with the frontal view values recommended by the author. In the three-quarters oblique esthetic assessment, the esthetically attractive contralateral cheek prominence extends well beyond a line from the lateral commissure of the mouth to the lateral canthus. Its most prominent location is about 15 to 20 mm beneath the lateral canthus.

The basal view simply supplements the findings from the other perspectives and also reveals both the true lateral and, to a lesser degree, anterior projections of the cheeks. This view is important to best determine the symmetry of the cheeks.

The surgeon must not only evaluate the cheek prominence proper but also the buccal area because excessive fullness in the buccal region can lead the surgeon to the erroneous *impression* that cheek deficiency exists. When cheek deficiency and buccal fullness coexist, the surgeon must exercise caution with respect to whether and how much cheek augmentation versus buccal fat pad reduction is to be performed.

A mark is made on the face in the ideal region of the cheek eminence, 10 mm lateral and 15 to 20 mm inferior to the lateral canthus. This mark aids in the proper superoinferior and lateral positioning of the cheek implant. Similarly, it helps in *predetermining* the desired lateral and anteroposterior thickness of the cheek augmentation. It is important to create a gentle convex surface curvature beginning in the infraorbital area and extending inferiorly 15 to 20 mm. In concert with this marking, a tangent from the soft tissue gonial angle to this region is constructed with a ruler to "estimate" the desired lateral projection as determined by the criteria previously discussed.

The procedure can be readily performed under either general anesthesia supplemented with a local anesthetic with 1:200,000 epinephrine, or local

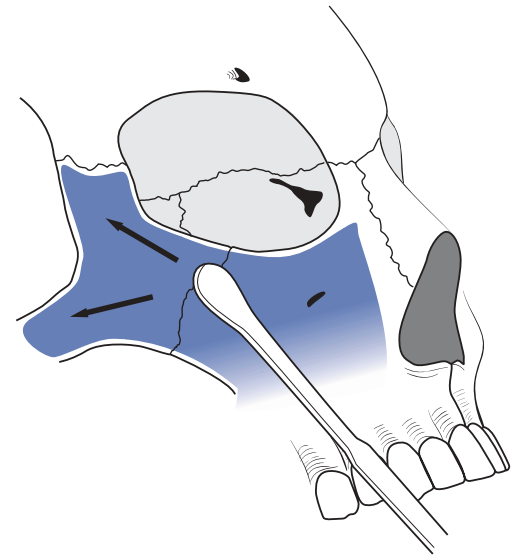


FIGURE 70-13 Extent of undermining for the placement of a cheek implant. Adapted from Epker BN.¹⁹ p. 147.

anesthesia and sedation. About 10 minutes before surgery the infraorbital nerves are blocked bilaterally with a few cubic centimeters of 2% lidocaine with 1:200,000 epinephrine. A few minutes later the entire maxillary vestibule is infiltrated transorally with approximately 10 cc of the same agent, from the zygomatic-alveolar crest area on one side to the same area on the opposite side. In addition, the subperiosteal dissection extends laterally along the zygomatic arch.

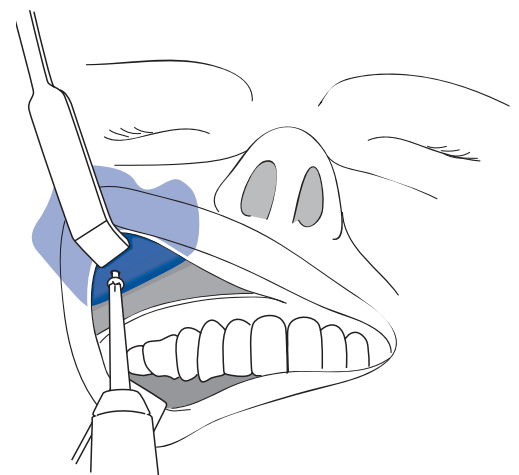


FIGURE 70-14 Symmetric and good stabilization of the right and left cheek implants is best achieved with screw fixation. Adapted from Epker BN.¹⁹ p. 152.

A horizontal vestibular incision is made with diathermy in the depth of the vestibule from the canine region distally to that of the molars. This incision is carried tangentially down to bone, and the entire malar area is sequentially exposed subperiosteally. This exposure extends superiorly to the infraorbital nerve and then medially above the nerve to expose the infraorbital rim. Next, the superior and lateral extents of this subperiosteal dissection are completed. Superiorly, lateral to the infraorbital nerve, the lateral infraorbital rim is exposed. The subperiosteal dissection is

then extended along the lateral aspect of the zygomatic arch posteriorly. The dissection must be liberal enough to create an adequate “pocket” into which the implant can be placed *passively* (Figure 70-13).

Once the subperiosteal dissection is completed, the predetermined desired size and shape of the implant is adapted for a try-in. Currently a large number of different-shaped cheek implants exist, constructed from various materials. Moreover, variable techniques and even locations for their placement are espoused. I currently prefer porous polyethylene implants because they

do not have complete memory, are readily modifiable at surgery, are porous (resulting in tissue ingrowth and self-stabilization), and are able to be optimally molded after heating in sterile hot saline. When porous polyethylene is used, it is vacuum impregnated with an antibiotic as described above. Careful adaptation of the preformed implants is necessary to obtain optimal results.

After initial trial the implant is revised with a surgical blade and/or heating to mold it to the underlying bone. The need for any additional adjustments

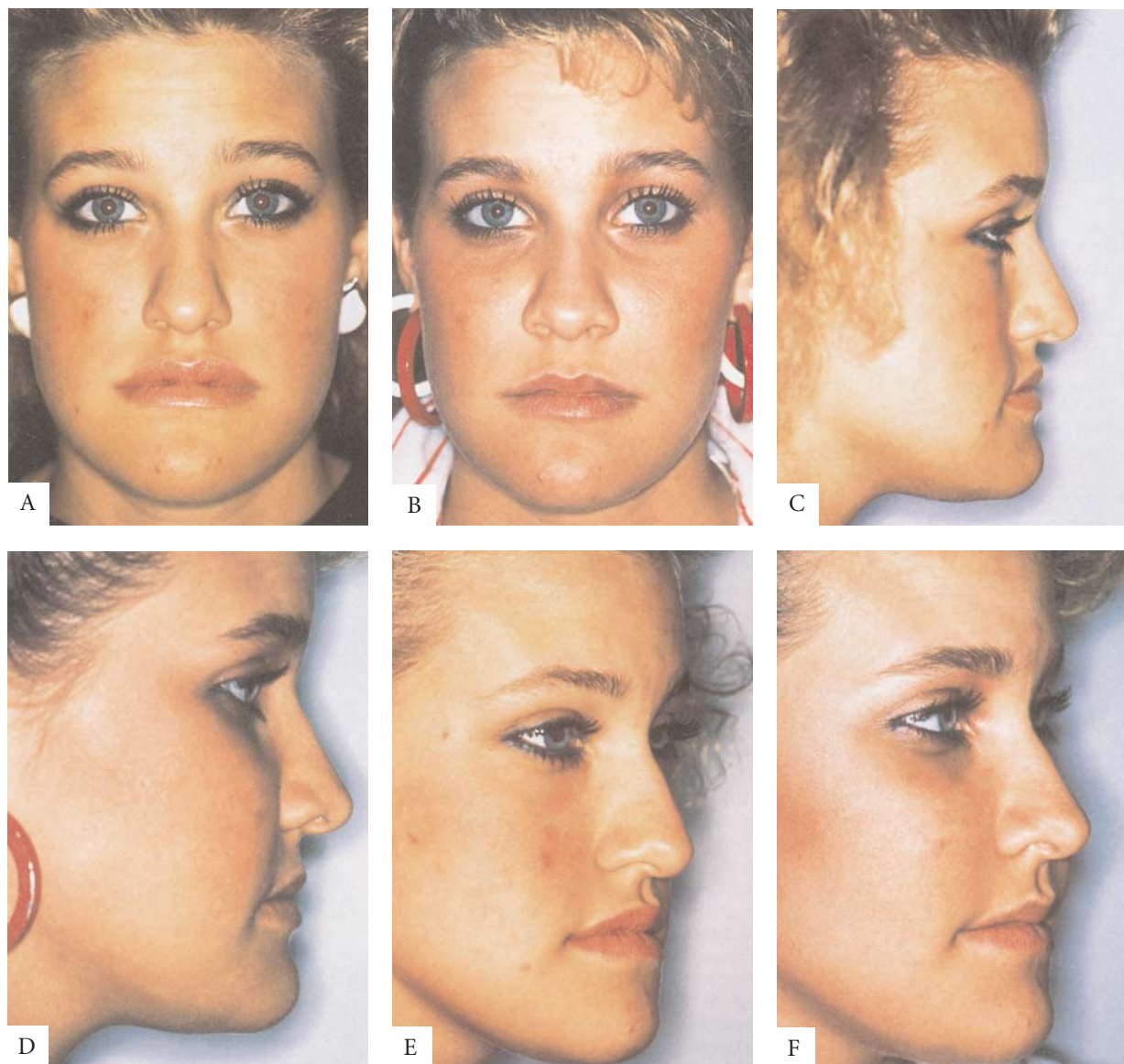

FIGURE 70-15 Preoperative (A, C, and E) and postoperative (B, D, and F) appearances of a patient who underwent a cheek augmentation. Reproduced with permission from Epker BN.¹⁹ p. 156–7.

is determined at this time while the implant is held in its proper position, visualized through the incision, and facially palpated.

After the final adjustments are completed on the first side, the contralateral implant is modified to be a mirror image so that perfect right-to-left symmetry is achieved, unless the patient possesses some asymmetry. The identical vestibular incision and subperiosteal dissection is then carried out on the opposite side.

The implants are then both rinsed in the antibiotic solution, placed carefully into their proper location, and stabilized with one or two titanium screws. It is essential that the positioning and stabilization of the right and left cheek implants be precisely symmetric and that they exhibit no tendency to rotate or displace. If either of the latter is evident on one or both sides, a second screw is placed to prevent this movement (Figure 70-14).

Any asymmetry or instability of one or both implants at the termination of surgery will become clinically evident after resolution of the edema following surgery; *this is the most frequent cause for postoperative patient concern after this procedure.*

The vestibular incision is closed with a single-layered 3-0 plain horizontal mattress gut suture. A layered tape dressing is applied for 48 hours. After removal of the dressing the patient maintains a liquid to very soft diet for 7 to 10 days until the vestibular incisions are well healed. After complete healing of the vestibular incisions, the patient is instructed to begin vigorous lip exercises to expedite resolution of residual edema and to improve natural lip motion.

This procedure may be performed independently or in concert with other skeletal/soft tissue esthetic maxillofacial procedures as described in the introductory section of this chapter. The results obtained with this procedure can be predictable and esthetically impressive (Figure 70-15).

Summary

Alloplastic facial augmentation has become a standard of care. Careful preoperative detailed systematic esthetic evaluations permit the various areas of the face to be augmented precisely.

References

1. Yaremchuk MJ, Rubin JP, Posnick JC, et al. Implantable materials in facial aesthetic and reconstructive surgery: biocompatibility and clinical application. *J Craniofac Surg* 1996;7:473-84.
2. Rubin JP, Yaremchuk MJ. Complications and toxicities of implantable biomaterials used in facial reconstructive and aesthetic surgery; a comprehensive review of the literature. *Plast Reconstr Surg* 1997;100:1336-45.
3. Silver FH, Maas CS. Biology of synthetic facial implant materials. *Facial Plastic Surg Clin North Am* 1994;2:241-53.
4. Singh S, Baker JL. Use of expanded tetrafluoroethylene in aesthetic surgery of the face. *Clin Plast Surg* 2000;27:579-93.
5. Levine B, Berman WE. The current status of expanded polytetrafluoroethylene (Gore-Tex) in facial plastic surgery. *Ear Nose Throat J* 1995;74:681-84.
6. Frodel JL, Lee S. The use of high-density polyethylene implants in facial deformities. *Arch Otolaryngol Head Neck Surg* 1998;124:1219-23.
7. Spector M, Flemming WR, Sauer BW, et al. Early tissue infiltrate in porous polyethylene implants into bone: a scanning EM study. *J Biomed Mater Res* 1975;9:537-45.
8. Wellisz T, et al. Characteristics of tissue response to MedPor porous polyethylene implants in the human face. *J Long-Term Effects MedPor Implant* 1993;3:223-35.
9. Karras SC, Wolford LM. Augmentation genioplasty with hard tissue replacement implants. *J Oral Maxillofac Surg* 1998;56:549-52.
10. Pearson DC, Sherris DA. Resorption beneath Silastic mandibular implants. *Arch Otolaryngol Head Neck Surg* 1999;1:261-4.
11. Vuyk HD. Augmentation mentoplasty with solid silicone. *Clin Otolaryngol* 1996;21:106-18.
12. Perrotti JD, Castor SA, Perez PC, Zins JE. Antibiotic use in esthetic surgery: a national survey and literature review. *Plast Reconstr Surg* 2002;15:1685-93.
13. Holz G, Novotny-Lenhard J, Kinzig M, Soergel F. Single dose antibiotic prophylaxis in maxillofacial surgery. *Chemotherapy* 1994;40:65-9.
14. Sylaidas P. Postoperative infection following clean facial surgery. *Clin Plast Surg* 1997;39:341-5.
15. Shaber EP. Vertical interpositional augmentation genioplasty with porous polyethylene. *Int J Oral Maxillofac Surg* 1987;16:678-84.
16. Zeller SD, Hiatt WR, Moore DL, Fain DW. Use of preform hydroxylapatite blocks for grafting in genioplasty procedures. *Int J Oral Maxillofac Surg* 1986;15:665-8.
17. Choe KS, Stucki-McCormick SV. Chin augmentation. *Facial Plastic Surg Clin North Am* 2000;16:45-54.
18. Scaccia FJ, Allphine AL, Stepnick DW, et al. Complications of augmentation mentoplasty. A review of 11,095 cases. *Int J Aesthet Rest Surg* 1983;1:3-8.
19. Epker BN. *Esthetic maxillofacial surgery*. Philadelphia: Lea & Febiger; 1994.
20. Themistocles G, Salvatore MA, Sotereanos GC, et al. Alloplastic augmentation of the mandible angle. *J Oral Maxillofac Surg* 1996;54:1417-23.
21. Ousterhout DK. Mandibular angle augmentation and reduction. *Clin Plast Surg* 1991;18:153-9.
22. Alache AE. Mandibular angle implants. *Aesthet Plast Surg* 1992;16:349-54.
23. Bikhazi HB, Antwerp RV. The use of Medpor in cosmetic and reconstructive surgery: experimental and clinical evidence. *Plast Reconstr Surg* 1990;6:271-33.
24. Epker BN, Fish LC, Stella, J, et al. Dentofacial deformities: an integrated orthodontic-surgical approach. St. Louis: D.V. Mosby Co; 1998.
25. Epker BN. Correction of the skeletal nasal base in rhinoplasty. *J Oral Maxillofac Surg* 1991;49:938-43.
26. Silver WE. The use of alloplastic materials in contouring the face. *Facial Plast Surg* 1986;3:81-98.
27. Binder WJ. Submalar augmentation. An alternative to face-lift surgery. *Arch Otolaryngol Head Neck Surg* 1989;115:797-803.
28. Brennan GH. Augmentation malarplasty. *Arch Otolaryngol Head Neck Surg* 1982;108:441-5.
29. Giampapa VG. Aesthetic recontouring of the midfacial skeleton: a regional approach. *Am J Cosmet Surg* 1988;4:583-8.
30. Marble HB Jr, Alexander JM. A precise technique for restoration of bony facial contour deficiencies with silicone rubber implants: report of cases. *J Oral Surg* 1972;30:737-41.
31. O'Quinn B, Thomas JR. The role of Silastic in malar augmentation. *Facial Plast Surg* 1986;3:99-105.
32. Tobin HA. Malar augmentation as an adjunct

- to facial cosmetic surgery. *Am J Cosmet Surg* 1986;3:3-13.
33. Whitaker L. Aesthetic augmentation of the malar-midface structures. *Plast Reconstr Surg* 1987;80:337-44.
34. Mladick RA. Alloplastic cheek augmentation. *Clin Plast Surg* 1991;18:29-38.
35. Robiony M, Costa F, Demitri V, Politi M. Simultaneous malaroplasty with porous polyethylene implants and orthognathic surgery for correction of malar deficiency. *J Oral Maxillofac Surg* 1998;56:734-41.
36. Hinderer UT. Malar implants for improvement of facial appearance. *Plast Reconstr Surg* 1975;56:157-65.
37. Wilkinson TS. Complications in esthetic malar augmentation. *Plast Reconstr Surg* 1983;71:643-7.
38. Powell NB, Riley RW, Laub DR. A new approach to evaluation and surgery on the malar complex. *Ann Plast Surg* 1988;20:206-14.
39. Prendergast M, Schoenrock LD. Malar augmentation. *Arch Otolaryngol Head Neck Surg* 1989;115:964-9.

Otoplastic Surgery for the Protruding Ear

Todd G. Owsley, DDS, MD

Auricular deformities, in particular prominent or protruding ears, are a common congenital anomaly, affecting nearly 5 % of the Caucasian population.¹ Congenital in nature, children are most likely to suffer the consequences of the deformity in the form of ridicule by their peers. Protruding ears, commonly referred to as *prominauris*, can be predictably treated for children prior to entering grade school, and thus help the children avoid the emotional trauma caused from the ridicule. Otoplastic surgery is primarily performed on children and can be a valuable service for the patient and satisfying for the surgeon.

It is important for the surgeon to understand the history of various surgical techniques to develop a predictable and successful technique to address the problem of protruding ears. Dieffenbach (1845) is credited with the first otoplastic technique to correct a prominent auricle.² Ely, in 1881, authored the first case report describing correction of prominent ears in a 12-year-old boy who was being teased at school.³ Since that report, over 180 surgical techniques have been described in the literature for the correction of protruding ears.

When clinically evaluating the facial complex, the ears are often overlooked. If protruding ears are present, reduction otoplasty as an adjunctive or isolated procedure can be performed predictably

and often with satisfying results. A thorough understanding of the embryology and development of the human auricle along with the resultant external anatomy of the ear are of paramount importance in developing a predictable and stable technique to deal with the common auricular deformities.

Embryology of the Auricle

Malformations of the auricle are common, occurring in 1 out of 12,500 births.⁴ They can occur alone or in combination with a syndrome affecting the head and neck structures. The embryogenesis of the auricle exemplifies in miniature the precise and logical progression so characteristic of the developing human form. The external ear development during the third to twelfth weeks of embryonic life is complex. The precursors to the auricle present in days 36 to 38 of intrauterine life, developing first from the first branchial groove where the first (mandibular) and second (hyoid) branchial arches are present (Figure 71-1). Both arches give rise to the auricular hillocks often referred to as the auricular tubercles of His.⁴ Numbers 1, 2, and 3 arise from the caudal border of the mandibular arch, while numbers 4, 5, and 6 are formed from the cephalic border of the hyoid arch. The auricular hillocks present in their most prominent and characteristic form by

intrauterine day 41. During this same stage, the groove between the mandibular and hyoid arches (hyomandibular groove) widens and deepens by the increased growth of the hillocks. This groove eventually forms the external auditory canal and concha. By day 43 to 45, the hillocks have migrated and coalesced to form the auricle.⁴ During this union, the mesenchyme of the hyoid arch increases substantially relative to the mandibular arch to contribute 85% of the external adult ear. Hillocks 2 and 3 from the mandibular arch lose their individuality and fuse to form the helical crus. Later, hillocks 4 and 5 from the hyoid arch merge and alter their configuration as they give rise to the helix and antihelical fold. Hillock 1 remains prominent and becomes the tragus, and hillock 6 becomes the antitragus.⁴

Surgical Anatomy

The majority of the growth of the pinna is completed by an early age. The average child has 85% ear development by 3 years of age. The ear is nearly fully grown by the age of 7 to 8 years. The ear height continues to grow into adulthood, but the width and distance of the ear from the scalp changes little after 10 years of age. It is important to note that each individual's ears often vary in size and shape.⁵ The average adult ear is approximately 6.5 cm

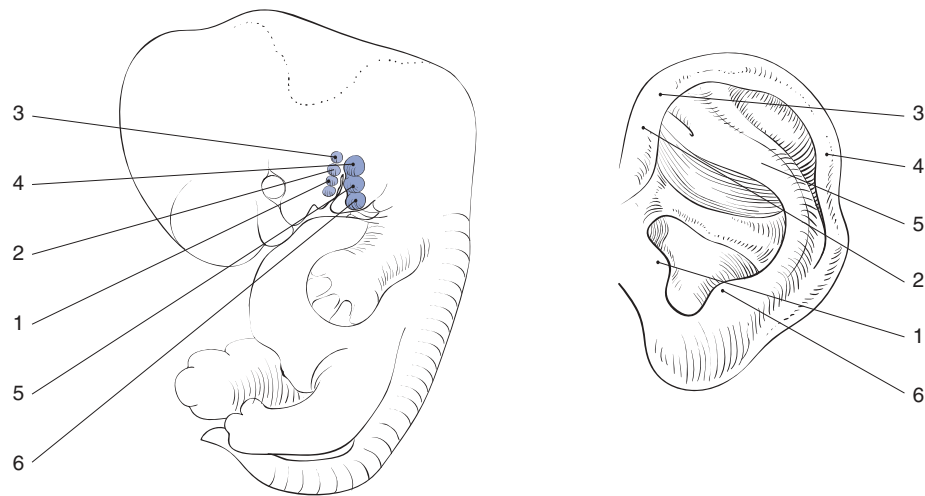


FIGURE 71-1 Development of the auricle from the first and second branchial arches. The numbers in the left diagram correspond with the structures in the right diagram. Adapted from Owsley T. *Otoplastic surgery for the protruding ear*. In: Fonseca RJ, editor. *Oral and maxillofacial surgery*. Vol. 6. Philadelphia (PA): W.B. Saunders; 2000. p. 408-18.

in length and 3.5 cm in width. In the normal ear, the auricle lies between horizontal lines drawn from the upper rim of the orbit and the nasal spine. The normal posterior wall of the conchal bowl is set at an angle of approximately 90° to the mastoid.⁶ A second 90° angle is formed as the antihelical fold and is called the scaphoconchal angle. These two angles in combination with the curvature of the helix set the auricle adjacent to the scalp at approximately 25 to 35° and is called the auriculocephalic angle (Figure 71-2).⁷ In otoplastic surgery, when correcting prominent ears, there are three important anatomical pearls that can be used intraoperatively to assess the final result. The helical rim should be seen just lateral to the most lateral presence of the antihelix from the frontal view. The distance measured between the helical rim and the mastoid area is slightly less than 2 cm. Finally, the distance between the skull and the uppermost aspect of the helix is approximately 1 cm (Figure 71-3A and B).

The auricular cartilage is a unique and delicate structure that is intricately shaped with multiple elevations and depressions providing both skeletal support and form to the adult ear. The cartilage of the auri-

cle is a single piece of yellow (elastic) fibrocartilage with a complicated relief on the anterior, concave side and a smooth, posterior convex side. Cartilage thickness is fairly uniform throughout. The cartilage is covered on both surfaces by a thin, firm, adherent layer of perichondrium. The anterior lateral surface of the cartilage is covered with a fine, thin skin, closely adherent to the cartilaginous framework. Subcutaneous fat is practically nonexistent, but a diffuse subdermal vascular plane exists which supports flap viability.⁸ The posterior surface of the cartilage framework is draped with a less adherent skin that contains two layers of fat and a larger subdermal plexus of arteries, veins, and nerves.

A helical border terminates anteriorly in a crus, commonly called the radix, which lies almost horizontally above the external auditory meatus. The antihelix crowning the posterior conchal wall separates and diverges into both a superior and anterior crus enclosing the triangular fossa. Between the helix and the antihelix lies a long, deep furrow called the scaphoid fossa. The conchal cavity, composed of the cymba (superior) and cavum (inferior) concha, arises from the floor, which is

approximately 8 mm deeper than the overlying tragus and antitragus. The inferior tip of the helical cartilage is referred to as the cauda or tail. Extending from this inferiorly is the lobule, hanging devoid of skeleton (Figure 71-4A and B).

Blood Supply

The arterial blood supply to the ear is derived principally from two main branches of the external carotid artery: superficial temporal artery and posterior auricular artery. The superficial temporal artery emerges from the parotid capsule, 1 cm in front of the ear deep to the veins and below the anterior auricular muscle. It gives off the superior, medial, and inferior branches supplying the anterior and anterolateral surface of the auricle (Figure 71-5A). The posterior surface is dominantly supplied by the posterior auricular artery which travels parallel to the postauricular crease upwards crossing below the great auricular nerve and under the posterior auricular muscle. Awareness of this relationship is important to avoid damage to the artery or nerve during surgery. The posterior auricular artery gives off three

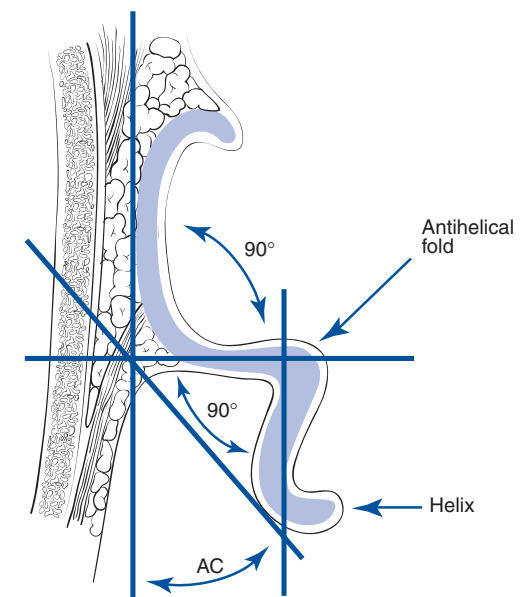


FIGURE 71-2 An axial section at the level of the helical crus demonstrates the ideal auriculocephalic angle (AC) of 30° . Adapted from Tanzer RC.²⁰

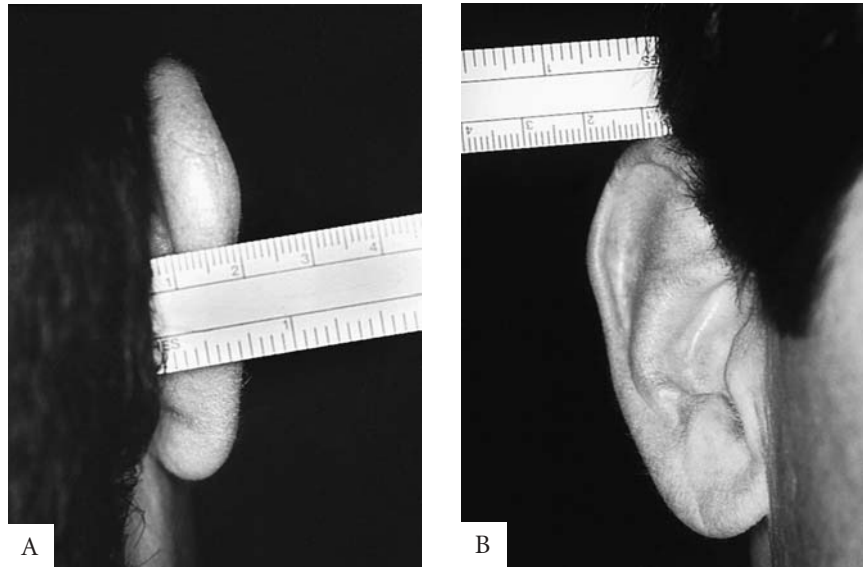


FIGURE 71-3 A, B, Anatomic “pearls,” useful intraoperatively. Reproduced with permission from Owsley T. *Otoplastic surgery for the protruding ear*. In: Fonseca RJ, editor. *Oral and maxillofacial surgery*. Vol. 6. Philadelphia (PA): W.B. Saunders; 2000. p. 408–18.

branches: superior, medial, and inferior, providing a greater volume of blood to the postauricular ear than its anterior counterparts. These same vessels perforate the auricular cartilage over a large surface of the anterior ear and anastomose with the branches of the superficial temporal artery. The external ears have a tremendous blood supply, allowing multiple surgical approaches or salvage of the ear following traumatic avulsion.

Venous drainage of the ear via the complementary veins is into the external jugular vein. Lymphatic drainage is into three surrounding areas via the complex and extensive fine network of lymphatic vessels.

Nerve Supply

The sensory nerve supply is primarily from the anterior and posterior branches of the great auricular nerve. The nerve is an important surgical landmark traveling 8 mm posterior to the postauricular crease. When dissecting in this area, care must be taken to avoid damage to the nerve which can result in near complete anesthesia to the ear. Less important contributions of sensation are made by the auriculotemporal and lesser occipital

nerves to the conchal cavity and external auditory meatus (Figure 71-5B). Regional anesthesia of the auricle is readily accomplished by instilling anesthetic solution along its base anteriorly and posteriorly. Supplemental anesthesia may be needed at the posterior wall of the external auditory meatus supplied by the auricular branches of the vagus nerve (Arnold’s nerve).

Deformities

Ear deformities are common and variable due to the complex embryologic

engineering that takes place in the development of the auricle as described previously. Many classification systems of ear deformities have been attempted. Tanzer classifies congenital ear defects, correlating embryologic development with a surgical approach for correction of the deformity.⁹ Marx has a well accepted classification system subdividing microtia into three groups according to severity.¹⁰ Rogers simplifies classification of congenital ear defects, dividing them into four groups according to various stages of arrested development: microtia, lop ear, cup ear, and protruding ear.⁶ In this chapter addressing the prominent ear, the term *protruding* is used as a general term to refer to any ear that is more prominent than is considered “normal.” It is beyond the scope of this chapter to classify other congenital abnormalities and their correction.

Protruding Ear

In patients with protruding ears, there are two major deformities that individually or in combination account for the majority of the abnormalities. There are several lesser deformities seen that can accentuate the abnormality as well. The most common seen is a poorly developed antihelical fold which can involve both the superior and anterior crura. This eliminates a defi-

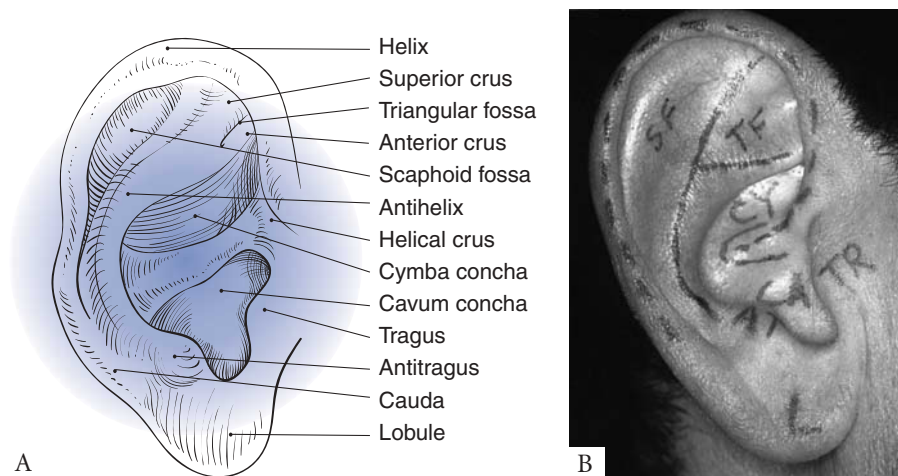


FIGURE 71-4 A, B, Anatomy of the external ear.

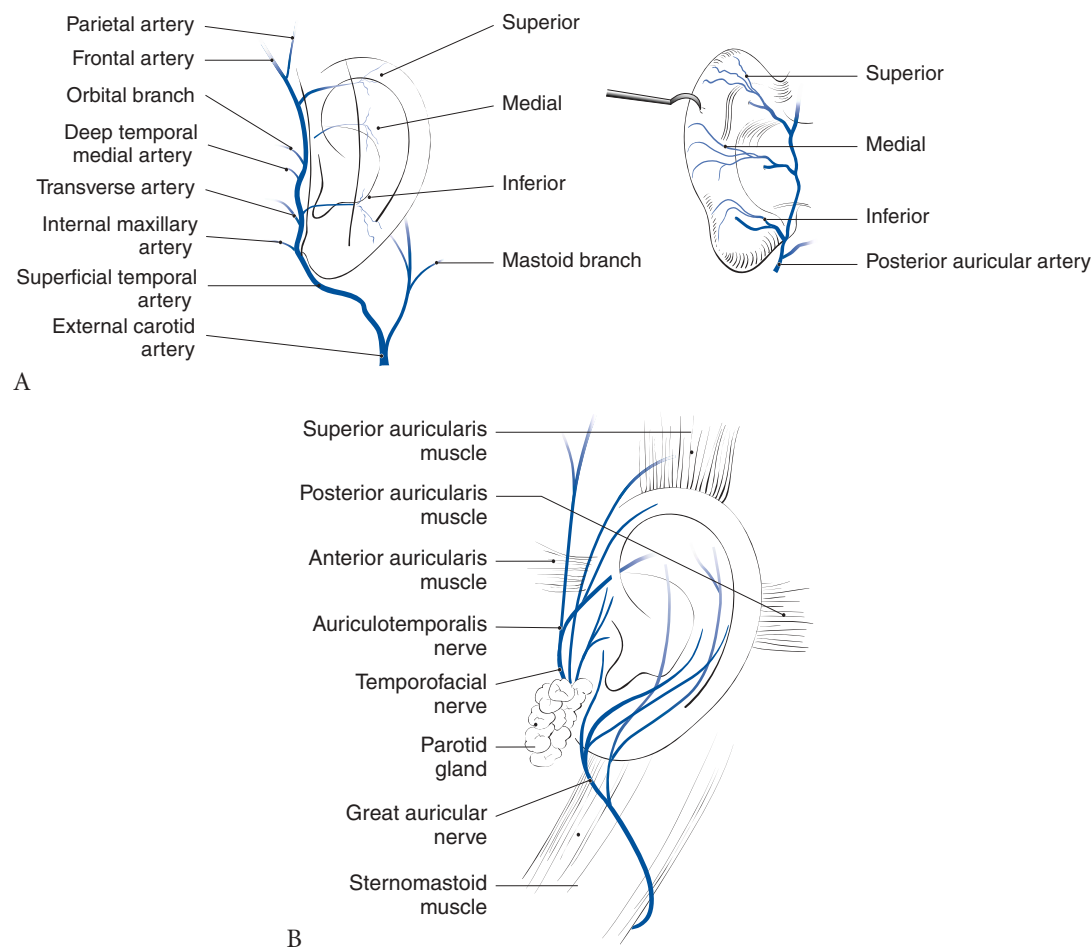


FIGURE 71-5 A, Arterial blood supply. B, Nerve supply. Adapted from Owsley T. *Otoplastic surgery for the protruding ear*. In: Fonseca RJ, editor. *Oral and maxillofacial surgery*. Vol. 6. Philadelphia (PA): WB Saunders; 2000. p. 408–18.

nition between the conchal cavity and scapha resulting in the lateral projection of the upper portion of the helix. The second abnormality seen is the formation of excessive conchal cartilage, in particular the posterior conchal wall. This causes significant protrusion of the auricle. It is not uncommon to recognize some degree of both abnormalities present producing the protruding auricle.

Other potential deformities are a protruding earlobe, irregularities along the helix including an unrolled margin of the helical rim and more recently described an anteriomedially displaced insertion of the postauricular muscle. Of importance, this deformity is often bilateral and can be associated with ossicular deformities and a hearing deficit.¹¹

Obviously, precise recognition of the cause or causes of the protruding ear is crucial in formulating the surgical technique to be employed in correction of the abnormality.

Surgical Correction

Perhaps the most important indication for surgical correction of prominent ears is to eliminate the psychosocial effects that the ear defect produces. Macgregor and others have well documented the irreversible social and psychological consequences that facial anomalies, especially the ears, can inflict.¹² The ridicule by peers begins as early as age 4 to 5 years during development, this leads to problems with social adjustment, self-image

deficit, and ultimately behavioral disorders. Therefore, most patients present at an early age for surgical correction. Most surgeons agree that surgical correction of the ear can be performed safely between 4 years of age and the beginning of school attendance to avoid the ridicule, becoming one of the most common elective procedures performed in young children. Adults also present to correct a lifelong cosmetic defect.

Surgical Techniques

Many otoplasty techniques described in the surgical literature are similar and have evolved over an 80-year experience. Many techniques only address the conchal hypertrophy without mention of the antihelical fold. The described techniques generally can be subdivided into a “suture-only” technique, cartilage splitting or weakening technique, or a combination of the two.

Furnas (1968) described his suture-only technique for the correction of the prominent ear deformity.¹³ This technique consisted of a postauricular approach, removing the skin, connective tissue, and vestigial posterior auricular muscle and its ligament down to the underlying mastoid fascia. A total of 2 to 3 nonresorbable sutures are placed through conchal cartilage and mastoid fascia and tightened to the new desired retracted position of the ears. This remains a commonly used technique to set back the ears in patients with conchal hypertrophy alone. Problems associated with this technique have been relapse secondary to the cartilaginous memory, a shallow conchal bowl, and irregularities created in folding the conchal floor. Another difficult problem seen is displacing the conchal bowl anteriorly, creating narrowing of the external auditory canal.

The Converse-Wood-Smith technique is used to correct and create an antihelical fold using a cartilage cutting and suture method.¹⁴ Several full thickness

cuts through cartilage are placed in the scaphoid fossa. The cartilage is then folded on itself, described as “tubing,” and permanent horizontal mattress sutures are placed forming the new antihelical fold. Additionally, if excessive conchal cartilage is present, it can be addressed with a cartilage incision added at the rim of the bowl to reduce the bowl and retract the ear. A new antihelical fold is formed, however, typically with sharp cartilaginous ridges seen through the thin anterior auricular skin.

This chapter will describe two techniques that address the two fundamental abnormalities in protruding ears and have

produced consistent, satisfying cosmetic results, and have essentially eliminated the fear of relapse. The Davis method addresses the protruding ear caused by a hypertrophic posterior wall of the conchal bowl. The Mustarde method is used to create a new antihelical fold (Figure 71-6).

The refinement of other abnormalities such as the prominent earlobe will also be discussed.

Davis Method

The Davis method, for the correction of conchal hypertrophy, is a cartilage excision technique performed in a step-wise fashion.^{8,15}

1. Marking the cartilage excision: Initially, the area of cartilage to be removed is marked on the skin of the anterior surface of the conchal bowl. Methylene blue transfixion tattoos are preferred and demonstrated to mark the posterior surface of the conchal cavity. The line lies just below the lower crus border, carries forward into the cymbal fossa, and continues around as an “arrowhead” to preserve a well-defined, helical radix. The tracing should continue forward against the posterior edge of the external auditory canal. From that location, it curves posteriorly

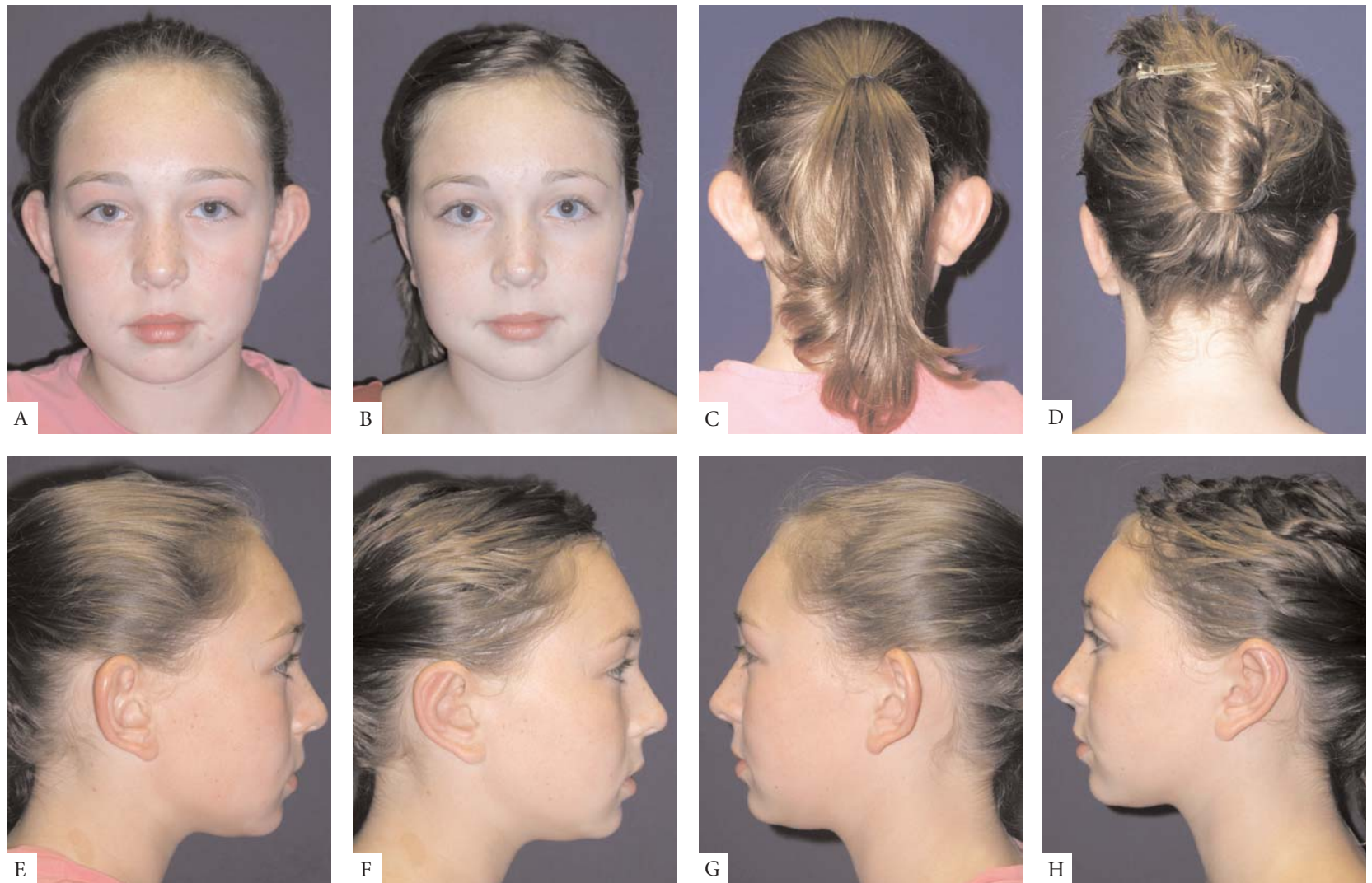

FIGURE 71-6 A–D, Preoperative and postoperative photographs of an 11-year-old girl who presented for correction of protruding ears. Her diagnosis was a combination of conchal hypertrophy and lack of antihelical fold formation bilaterally. The Davis and Mustarde techniques were used on both ears. E–H, Lateral views of both ears demonstrating a natural-appearing, new antihelical fold and a deepened conchal bowl.

into the cavum concha, continuing onto the posterior conchal wall, leaving 8 mm of posterior conchal wall height measured from the conchal scaphal junction. This should complete the circle which should appear “kidney bean” shaped including the entire conchal bowl. The exact height of the posterior wall is important and must be measured for each case individually (Figure 71-7A–C).

2. Removal of skin and cartilage: Prior to beginning the actual surgical procedure, local anesthesia is used for hydrodissection of the tightly adhered anterior auricular skin along the conchal bowl. This simplifies the dissection of cartilage from the overlying skin. The concha is exposed through a postauricular elliptical skin excision. The width of the ellipse is only to remove the predicted excess skin that is produced with ear repositioning. The closure of the incision should be passive. This area is predisposed to hypertrophic or keloidal scarring when closed under tension. Once having removed the postauricular skin, the conchal cartilage is visualized along with the previously placed tattoo marks. The marks are used as a guide for incising through the cartilage, taking care to avoid perforation of the anterior skin. The dissection is then carried onto the anterior conchal cartilage surface subperichondrially. The hydrodissection along with a small, sharp Freer elevator allows separation between the skin and cartilage. The cartilage is then removed which includes the entire conchal bowl with the exception of the 8 mm left along the posterior conchal wall. The ear is then placed passively onto the mastoid surface, and the new projection of the helical rim is observed and carefully measured. Any defective prominence can be revised with further cartilage removal. The postauricular muscle

and underlying connective tissue are removed down to the underlying mastoid fascia to allow for passive skin draping of the conchal floor, producing a natural-appearing, deepened conchal bowl. Any excessive postauricular skin can be removed at this time (Figures 71-7D–F).

3. Ear fixation: The ear is fixed in its new position with 3 to 4 mattress transfixion sutures of 3-0 silk that perforate the skin anteriorly, anchor deeply into the postauricular muscle stump, and pass back through the anterior skin. The mattress sutures are then gently tied over a dental cotton roll, moistened with a triple antibiotic ointment, which has been placed into the cymbal and caval fossa, making sure to place one end of the cotton roll into the external auditory canal to avoid postoperative stenosis. The sutures and cotton roll hold the ear in place during healing, stretch and flatten the skin uniformly over the conchal floor, and give depth to the conchal bowl. The postauricular incision is then closed in a running fashion with a resorbable suture, leaving a small opening inferiorly for drainage. The cotton roll dressing is left in place for a minimum of two weeks for optimal healing (Figures 71-7G–I)

Mustarde Method

The Mustarde method, first described in 1959, is indicated for the prominent ear with a poorly formed or lack of an antihelical fold.¹⁶ This cartilage weakening technique relies on precisely placed horizontal mattress sutures, creating a new antihelical fold. It is rarely performed alone and used commonly in combination with the Davis method described above.

1. Antihelical fold markings: The scapha is folded back against the underlying scalp by applying digital pressure on the superior helical rim,

which creates an antihelical fold. The crest of the fold is marked with a surgical marker. To prepare for placement of the mattress sutures, marks are placed parallel to the crest at least 7 mm apart to avoid creating too narrow of a fold. The lateral marks placed on the skin are transferred to the underlying cartilage with a hypodermic needle dipped in methylene blue (Figures 71-8A and B).

2. Dissection and cartilage weakening: Local anesthetic solution is infiltrated along the scaphal fossa beneath the anterior auricular skin, hydrodissecting the skin from the underlying cartilage. This is to facilitate the anterior dissection and mattress suture placement. The postauricular skin is then removed in an identical fashion as described with the Davis method. Once having identified the marks placed on the posterior surface of the scaphoid cartilage, a Freer elevator is passed through a small horizontal incision created through the cartilage at the most inferior aspect of the new antihelical fold. The anterior auricular skin is then dissected from the underlying cartilage corresponding to the crest of the new antihelical fold. Through the tunnel dissected along the anterior surface of the cartilage, the body of the new antihelical fold is weakened to facilitate folding and remove the inherent memory. Many methods have been described, however cartilage weakening can be performed adequately using a Brown-Adson forceps, a nasal rasp, or a dermabrader with a small diamond fraise (Figures 71-8C–E).
3. Suture placement: Nonresorbable, horizontal mattress sutures (4-0 Mersilene) are placed. The sutures are all placed through the medial perichondrium, cartilage, and lateral perichondrium, being careful not to include the anterior skin. The sutures should be

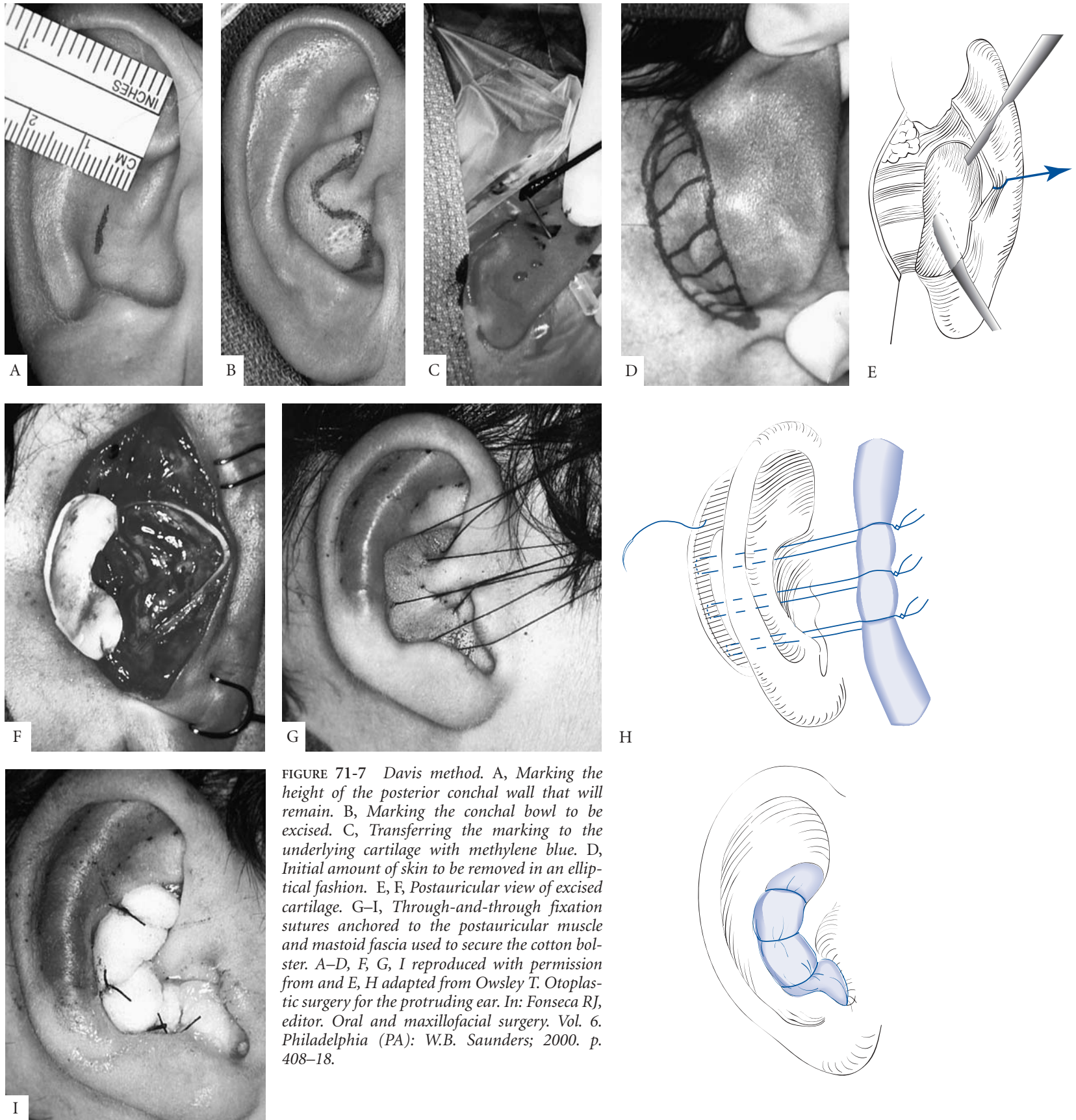


FIGURE 71-7 Davis method. A, Marking the height of the posterior conchal wall that will remain. B, Marking the conchal bowl to be excised. C, Transferring the marking to the underlying cartilage with methylene blue. D, Initial amount of skin to be removed in an elliptical fashion. E, F, Postauricular view of excised cartilage. G–I, Through-and-through fixation sutures anchored to the postauricular muscle and mastoid fascia used to secure the cotton bolster. A–D, F, G, I reproduced with permission from and E, H adapted from Owsley T. *Otoplastic surgery for the protruding ear*. In: Fonseca RJ, editor. *Oral and maxillofacial surgery*. Vol. 6. Philadelphia (PA): W.B. Saunders; 2000. p. 408–18.

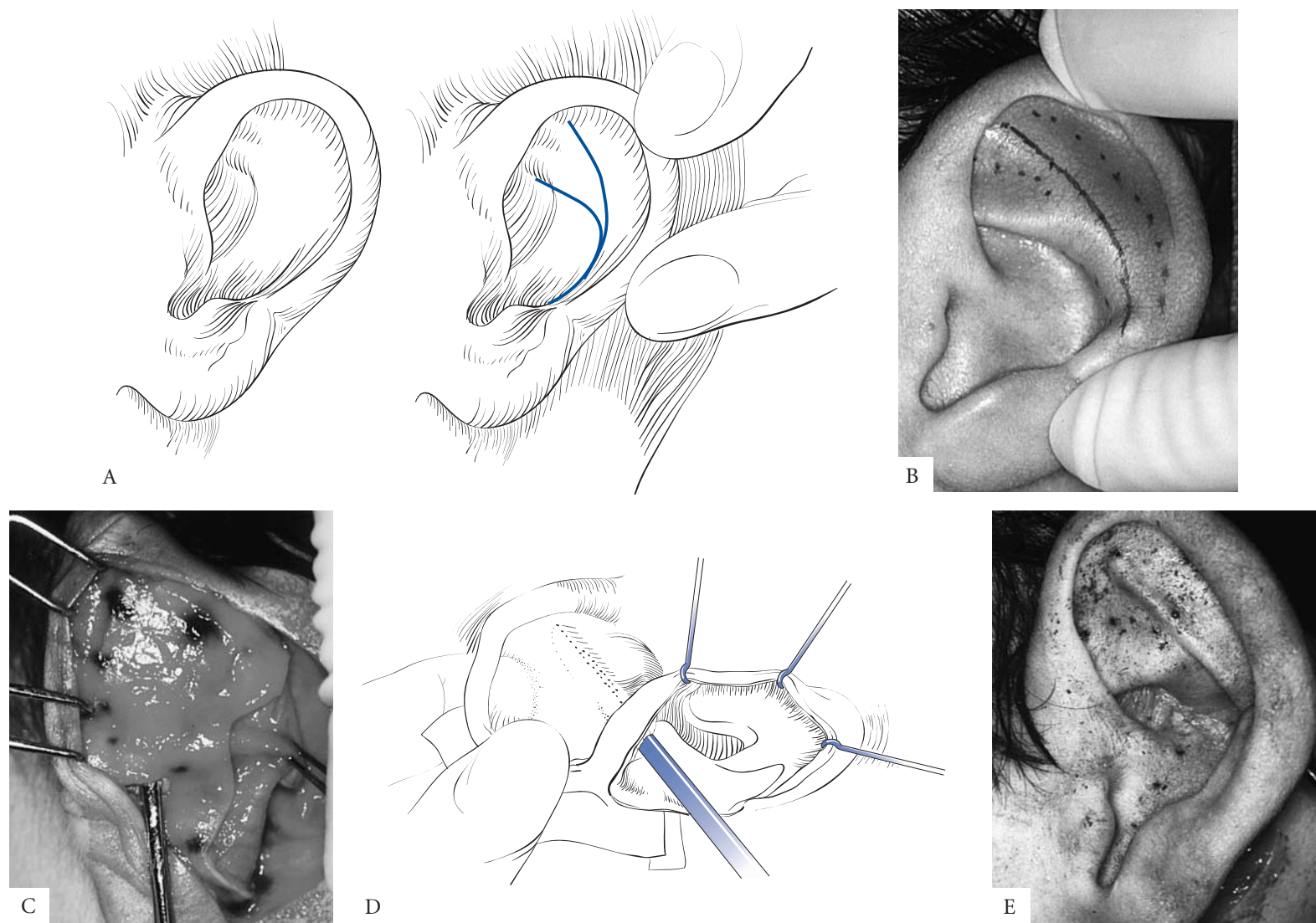


FIGURE 71-8 Marking of skin to correct protruding lobule Mustarde technique. A and B, Creating and marking the desired antihelical fold by folding back the helix with digital pressure. Lines, parallel to the crest of the fold, are marked and transferred to the underlying cartilage and used for suture placement. C–E, Dissection of the scaphoid fossa beneath the anterior skin for weakening and creation of the desired antihelical fold. (CONTINUED ON NEXT PAGE)

placed perpendicularly across the antihelical fold, so that upon tightening, a well-rounded, antihelical fold will be created. The sutures are tightened under direct observation and adjusted accordingly to form the new antihelical fold (Figures 71-8F and G).

4. Dressing: The dressing is important and is placed to provide adequate pressure to obliterate dead space and avoid a postoperative hematoma formation. A carefully layered dressing is placed over the anterior and opposing posterior surfaces of the scaphoid region with a quarter-inch petrolatum

gauze, followed by 4 x 4 inch fluffs, held secure with a pressure-type facial dressing (Figures 71-8H and I).

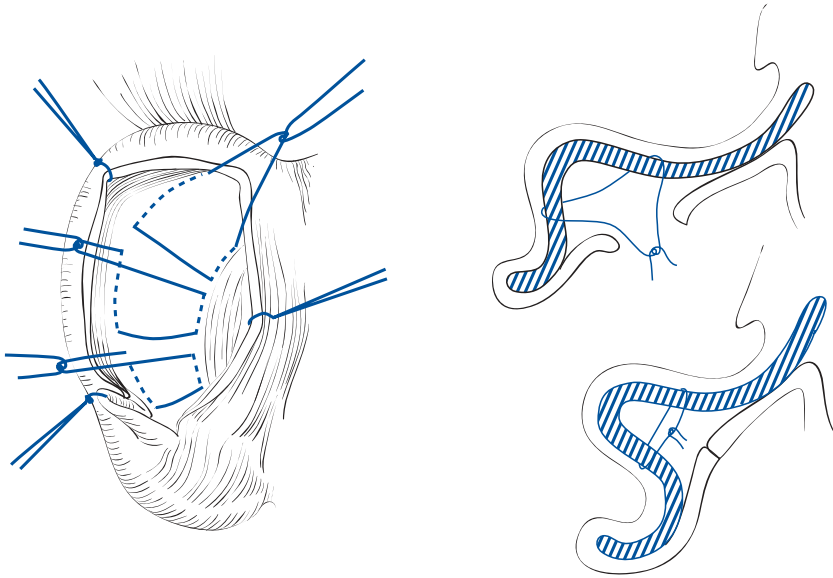
Correction of the Protruding Earlobe

A protruding earlobe often accompanies a protruding ear. If so, it must be identified and corrected simultaneously. If the lobule of the ear protrudes, an extension of the posterior auricular incision is drawn with a surgical marker in the shape of a V onto the earlobe. Finger pressure on the freshly marked lobe, compressing it to the mas-

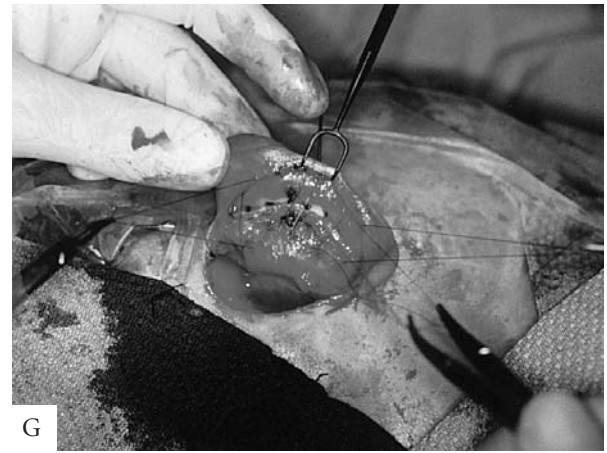teroid skin, produces a mirror image imprint forming a W-shaped (fish tail) portion of skin to be excised. After this portion is excised and hemostasis achieved, closure is accomplished with a 4-0 plain gut suture. The two V-shaped incisions are brought together reducing the protruded state of the lobule (Figure 71-9A and B).¹⁴

Complications

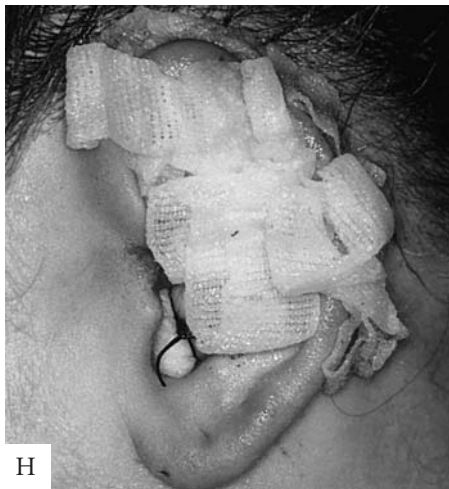The incidence of complications after reduction otoplasty is quite low.¹⁷ The major complications to be avoided are infection and keloid formation. Immediate



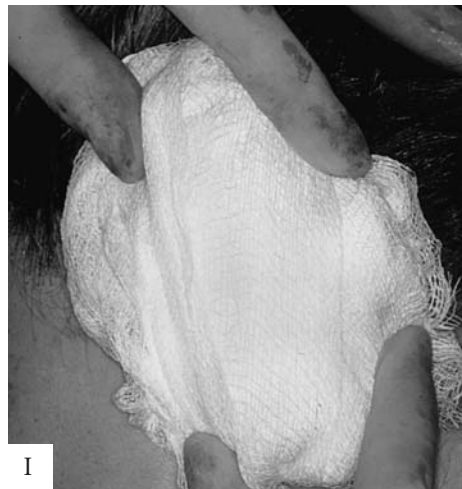F



G



H



I

FIGURE 71-8 (CONTINUED) F and G, Placement of the horizontal mattress sutures to create a new antihelical fold. H and I, Placement of petrolatum gauze and fluffs as an important pressure dressing. B, C, E, G–I reproduced with permission from and A, D, F adapted from Owsley T. *Otoplastic surgery for the protruding ear*. In: Fonseca RJ, editor. *Oral and maxillofacial surgery*. Vol. 6. Philadelphia (PA): W.B. Saunders; 2000. p. 408–18.

complications include pressure necrosis from an overly tight dressing and hematoma formation. Delayed or long term complications include hypertrophic or keloid scar formation, recurrence of the ear deformity, neurosensory deficits, and unesthetic results.

Hematoma

Postoperative hematoma formation, with an incidence of 2 to 4 %, is the most common problem that requires immediate and aggressive intervention.¹⁷ It is most often related to inadequate hemostasis achieved at the time of surgery. Other factors in hematoma formation include an overly tight wound closure without drainage at the base

of the wound, postoperative trauma, hypertension, and a preexisting bleeding dyscrasia. Persistent pain beneath the dressing or significant bleeding through and around the dressing suggests hematoma formation and demands prompt inspection. The presence of a hematoma is indicated by a tense and bluish swelling beneath the auricular skin, most often in the retroauricular space. Management includes suture removal, blood clot evacuation, hemostasis, and reclosure of the wound with a large pressure dressing reapplied. Large doses of antibiotics are advisable to prevent perichondritis. If this problem remains untreated, it can result in fibrosis, perichondritis, and cauliflower ear deformity.

Perichondritis

Wound infection in otoplasty occurs in the early postoperative period and is usually a sequela to an undetected or inadequately treated hematoma. Symptoms include pain, erythema, fever, and discharge that may or may not be present. Treatment includes high doses of antibiotics following appropriate wound cultures. Common bacteria include *Staphylococcus aureus*, *Escherichia coli*, and *Pseudomonas aeruginosa*. Adequate drainage is achieved by opening all sutures and carefully irrigating necrotic debris from the wound. All correction sutures must be removed and the cosmetic deformity addressed at a later

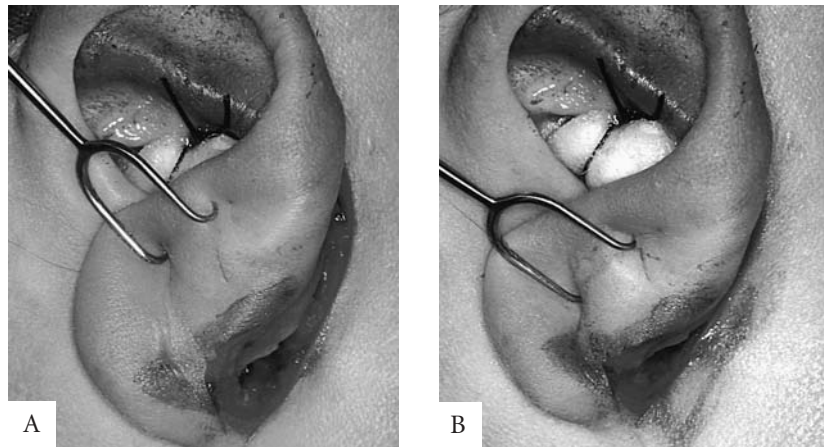


FIGURE 71-9 A, B Marking of skin to correct protruding lobule. Areas marked are excised in “fishtail” fashion and closed. Reproduced with permission from Owsley T. *Otoplastic surgery for the protruding ear*. In: Fonseca RJ, editor. *Oral and maxillofacial surgery*. Vol. 6. Philadelphia (PA): W.B. Saunders; 2000. p. 408–18.

date. The complication can be devastating, causing massive cartilage destruction with a severe deformity resulting, even with aggressive therapy. Prophylactic antibiotics have not been scientifically proven to be beneficial, but are often used in the preoperative and postoperative period to avoid this devastating complication.

Keloid and Hypertrophic Scar Formation

The closure line of the skin incision in the postauricular region is susceptible to scar formation, especially closed under tension. It is most commonly seen in younger patients and patients with deeply pigmented skin. Keloid formation, one of the most frustrating of all postoperative complications, requires aggressive therapy. In the early stages of keloid formation, intralesional triamcinolone acetonide is injected weekly until regression or significant improvement is evident. Most hypertrophic scars improve with steroid infiltration, but some keloids can progress into significant unesthetic lesions. Low dose radiation, although potentially dangerous, may provide the only effective means of control of some keloids. The more advanced lesions require surgical excision combined with radiation and delayed skin grafting of the irradiated area, with final

aid from intralesional triamcinolone. The risk can be minimized by ensuring that the skin incision is closed passively.

Esthetic Complications

Inadequate correction of the ear deformity is the most common untoward result of otoplasty, often more obvious to the surgeon than to the patient. Calder and Nassan described at least one complication or residual deformity in 16.6% of all the patients who underwent otoplasty using all techniques.¹⁸ Recurrence of the ear deformity is a more common complication of reduction otoplasty, but is less likely to happen after excising a portion of the cartilage as well as a segment of skin, as described in the Davis method. Depending on sutures alone for achieving correction carries a greater risk of recurrence.

Telephone Ear Deformity

Telephone ear deformity occurs when the root of the helix and the ear lobule remain protruded while the middle half, or third, of the ear is set back against the head. This is more common in a large ear with a wide scapha. The incidence has been reported to be 3%.¹⁹ Reverse telephone ear reveals a pronounced conchal bowl with respect to the lower and upper poles. These deformi-

ties can be avoided by carefully checking the position of the helical root, the upper helical rim, and the lobule at the completion of surgery.

Scapha Buckling

Scapha buckling or a transverse fold can develop in the Mustarde technique. This deformity can be avoided by placing the horizontal mattress sutures closer together where the scapha is widest, combined with adequate anterior scoring or weakening.

Narrowed Meatus

A constricted external auditory meatus can occur if the conchal bowl is rotated anteriorly in setting the ear back in any technique in which the conchal bowl is not excised. This problem is eliminated in the Davis method in which the floor of the conchal bowl is excised. Care must also be taken in placing the inferior end of the cotton roll bolster dressing into the external auditory canal to avoid stenosis.

Summary

Reduction otoplasty carries few complications and can provide satisfying results for both the patient and surgeon in the majority of cases. As in all cosmetic procedures, proper patient selection is imperative. Accurate preoperative assessment of the individual deformities and the appropriate choice of a surgical correction will minimize unfavorable esthetic results. The single greatest cause of an unfavorable result in this procedure is inaccurate diagnosis.

The surgeon must understand the normal external anatomy of the ear and learn to recognize the pathological characteristics of the abnormal ear. Having accurately assessed the deformity, the surgeon needs to be familiar with the various surgical approaches available to correct them. Finally, it is important to have a working knowledge of the potential complications of otoplasty and their prevention and treatment.

References

1. Ellis DA, Keohone JD. A simplified approach to otoplasty. *J Otolaryngol* 1992;21:66.
2. Deiffenbach JF. Die operative chirurgie. Leipzig (FA): Brockhaus; 1845. Cited by Tanzer RC. Deformities of the auricle. In: Converse JM, editor. *Plastic and reconstructive surgery*. 2nd ed. Philadelphia (PA): W.B. Saunders; 1997. p. 1710.
3. Ely ET. An operation for prominence of the auricles. *Arch Ophthalmol Otolaryngol* 1881;10:97.
4. Karmody CS, Annino DJ Jr. Embryology and anomalies of the external ear. *Facial Plast Surg* 1995;11:251–6.
5. Strenstrom SJ. Cosmetic deformities of the ears. In: Grabb W, Smith JW, editors. *Plastic surgery*. Boston (MA): Little Brown and Co.; 1968. p. 595.
6. Rogers BO. Microtic, lop, cup and protruding ears: four directly inheritable deformities? *Plast Reconstr Surg* 1968;41:208.
7. Allison GR. Anatomy of the external ear. *Clin Plast Surg* 1978;5:419–22.
8. Davis JE. *Aesthetics and reconstructive otoplasty*. New York (NY): Springer-Verlag; 1987. p. 77–87.
9. Tanzer RC. Congenital deformities. Deformities of the auricle. In: Converse JM, editor. *Reconstructive plastic surgery*. 2nd ed. Philadelphia (PA): W.B. Saunders; 1997. p. 1671.
10. Marx H. Die Missbildungen des Ohres. Sekundäre Ohrmissbildungen. In: Handke F, Lubarsch O, editors. *Hanbush der speziellen pathologischen Anatomie und Histologie*. Vol 12. Berlin: Springer-Verlag; 1926. p. 697.
11. Guyuron B, DeLuca L. Ear projection and the posterior auricular muscle insertion. *Plast Reconstr Surg* 1997;100:457–60.
12. Macgregor FC. Ear deformities: social and psychological implications. *Clin Plast Surg* 1978;5(3).
13. Furnas DW. Correction of prominent ears by concha-mastoid sutures. *Plast Reconstr Surg* 1968;42:189–93.
14. Converse SM, Wood-Smith D. Corrective and reconstructive surgery in deformities of the auricle. In: Papasella MM, Shumrick DA, editors. *Otolaryngology*. Vol 3: head and neck. Philadelphia (PA): W.B. Saunders Co.; 1973. p. 500–27.
15. Davis JE. Prominent ears. *Clin Plast Surg* 1978;5(3).
16. Mustarde JC. The correction of prominent ears using simple mattress sutures. *Br J Plast Surg* 1963;5:170.
17. Adamson PA, Strecker HD. Otoplasty techniques. *Facial Plast Surg* 1995;11:284–300.
18. Calder JC, Nassan A. Morbidity of otoplasty: a review of 562 consecutive cases. *Br J Plast Surg* 1994; 47:170–4.
19. Lavy J, Sterns M. Otoplasty: techniques, results and complications – a review. *Clin Otolaryngol* 1997;22: 390–3.
20. Tanzer RC. Congenital deformities. In: Converse J, editor. *Reconstructive plastic surgery*. Vol 4. 2nd ed. Philadelphia (PA): WB Saunders; 1977.
21. Davis JE. Anatomy of the ear. In: Stark R, editor. *Surgery of the head and neck*. New York (NY): Churchill Livingstone; 1987.

