

## ORIGINAL ARTICLE

COMPARISON OF TWO INTRACANAL MEDICAMENTS IN  
RESOLUTION OF APICAL RADIO LUCENCY

Amna Riaz, Anser Maxood, Saeeda Abdullah, Kiran Saba, Shahab Ud Din, Shahreen Zahid\*

Department of Operative Dentistry, Pakistan Institute of Medical Sciences, Shaheed Zulfiqar Ali Bhutto Medical University, Islamabad,

\*National University of Medical Sciences, Rawalpindi-Pakistan

**Background:** As a gold standard, calcium hydroxide has always been used as a root canal medicament against root canal pathogens but its combination with chlorhexidine is not being employed in routine despite its documented efficacy and results. The objective of the study is to compare calcium hydroxide and combination of calcium hydroxide with 2% CHX on the basis of radiographic evidence of resolution of periapical radiolucency when they are used as an interappointment dressing /intracanal medicament for 14 days. **Method:** A total of 60 patients of either gender was included in the study. The age range was 15–60 years with the radiographic evidence of radiolucency of 2–4 mm in size. Both maxillary and mandibular teeth till first molar were selected. Teeth with previous endodontic treatment mentally handicapped and terminally ill patients were excluded. Selected patients were placed randomly into Group 1 (calcium hydroxide alone) and in Group 2 (calcium hydroxide in combination with 2% chlorhexidine gel). Obturation and permanent filling was done at 14<sup>th</sup> day. The patient was recalled after 90 days of obturation and a radiograph was taken. Final outcome was measured at the end of 90<sup>th</sup> day of obturation. **Results:** The mean of percentage reduction in size of apical radiolucency at 3 months was 91.03% for group 1 and 97.26% for group 2 with *p*-value 0.13 (not significant). The results suggested equivalent results after medication with 2% chlorhexidine with calcium hydroxide but 2% chlorhexidine still showed better results than the group without CHX in terms of healing. **Conclusion:** This study concluded that calcium hydroxide in combination with 2% chlorhexidine as intracanal medicament results in better resolution of periapical radiolucency in terms of percentage resolution of periapical radiolucency.

**Keywords:** Root canal treatment; Calcium hydroxide; Chlorhexidine

**Citation:** Riaz A, Maxood A, Abdullah S, SbabK, Ud-Din S, Zahid S. Comparison of two intracanal medicaments in resolution of apical radiolucency. J Ayub Med Coll Abbottabad 2018;30(3):320–4

## INTRODUCTION

The endodontic pathologies most of the times are caused by the direct or indirect interaction of bacteria.<sup>1</sup> The pulp gets pathologically involved due to open dentinal tubules, exposure of pulp due to caries or trauma, apical foramen and lateral canals as well as the bacteria from the blood stream.<sup>2</sup> As a result of the interaction of the microorganisms and their by-products with mediators of inflammation in the pulpal tissue numerous irritants harbour in the root canal system. Release of these irritants from infected root canals into peri-radicular tissues is the major cause of peri-radicular lesions.<sup>3</sup>

Eradication of infection from the root canal requires access to the pulp chamber and root canal, canal instrumentation and irrigation, interim root canal medication and finally filling of root canal.<sup>3</sup> In necrotic teeth with acute apical periodontitis, incidence of inter-appointment pain increases as number of root canal microbes increases.<sup>4</sup> Much attention should be given to complete debridement with adjunctive use of canal medication to eliminate chances of inter-appointment pain.<sup>5</sup>

Intracanal medicaments have long been used to augment the mechanical procedure. Literature

shows that mechanical debridement alone is not sufficient to decrease inter-appointment pain and recommends use of intracanal medicament.<sup>6</sup> Use of intracanal medicaments during the inter-appointment period has been widely used to reduce remaining bacteria in the root canal system, and to retard the growth of new bacteria thus reducing the risks of inflammation in peri-radicular tissues.<sup>7,8</sup>

Ca(OH)<sub>2</sub> is the most commonly used intracanal medicament for multiple appointment root canal treatment. During the past decade chlorhexidine has received much attention as root canal irrigant and intracanal medication.<sup>9</sup> This study was aimed to compare the Ca(OH)<sub>2</sub> alone and Ca(OH)<sub>2</sub> in combination with 2% CHX gel in mean time of healing of apical radiolucency. This study will therefore, help in recommending whether intracanal medicaments such as chlorhexidine should be used in combination with calcium hydroxide in routine endodontic therapy.

## MATERIAL AND METHODS

This Randomized controlled trial was carried out from January to June 2016. Approval was taken from local ethical committee. Total 60 patients of either

gender, reporting to Department of Operative Dentistry, Pakistan Institute of Medical Sciences, Islamabad (SZABMU), were selected. Sample size was calculated by taking level of significance as 5% and power of study as 80%. The age range was 15–60, years with radiographic evidence of radiolucency of 2–4 mm in size. Both maxillary and mandibular teeth till first molar were included. Teeth with previous endodontic treatment mentally handicapped and terminally ill patients were excluded.

Informed, written consent and history was taken from each patient. Clinical examination and pulp vitality tests were done. A total of 60 patients were included in study and divided into two groups of 30 each. Each patient was assigned a computer-generated list of random numbers with a randomization ratio of 1:1 produced by random allocation software (version 1.0, May 2004). So that Group 1=30 and Group 2=30.

All the endodontic treatment was performed by one researcher. At the first visit a preoperative radiograph was taken to check for apical radiolucency. Tooth was anesthetized with local anaesthesia using 2% Lidocain with 1:100,000 epinephrine for patient comfort before starting the treatment. Teeth were isolated using rubber dam. Initial caries was excavated and an access cavity was prepared using round bur. Coronal shaping and flaring was carried out with slow speed GG drills (Dentsply). Pulpectomy was done following which working length was determined using #15 stainless steel file. Canals were prepared at correct working length accordingly using crown down technique. Canal instrumentation was performed using manual files and master apical file #30–40 was established for molars and #40–60 for premolars and incisors. Throughout the procedure the canals were washed and flushed with 5.0 ml of 5.25% NaOCl. After completion of canal instrumentation all canals were irrigated with NaOCl and then dried with sterile absorbent paper points.

Lentulo-spiral was used to fill all canals in Group I with Calcium hydroxide powder (Roth international ltd) mixed with saline in a ratio 1:1. In group II a paste made of calcium hydroxide with 2% chlorhexidine (Techno Dent Russia) in ratio 1:1, was placed in the canals.

GROUP 1: Ca(OH)<sub>2</sub>.

GROUP2: Ca(OH)<sub>2</sub> +2% CHX.

Access cavity was sealed with cotton and interim restoration.

Patients were recalled after 14 days for second appointment. The intracanal medicament was removed from the canals using Head storm files with circumferential filing; canals were irrigated with NaOCl and dried again and then obturated with Gutta

Percha (Dentsply) using lateral condensation method and sealed coronally with GIC (Fuji) filling material. Patients were recalled after 30 days for a permanent restoration with Amalgam for posterior teeth and composite for anterior and a radiograph was taken. The patients were recalled after 90 days of obturation and a radiograph was taken. The preoperative radiograph taken at the 1<sup>st</sup> visit was compared with radiograph taken after 90 days to check for resolution of apical radiolucency. The percentage change was calculated between the radiographs taken at first visit and at three months. All radiographs were taken using a paralleling device XCP (Dentsply) to ensure same orientation every time. Final outcome was measured at the end of 90<sup>th</sup> day of obturation.

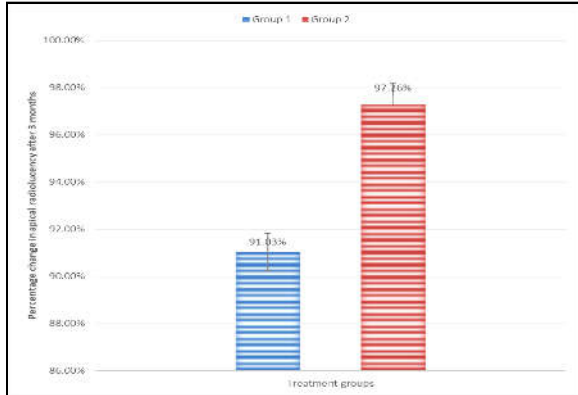
Data was entered and analysed using SPSS version 23. Descriptive statistics were calculated for both qualitative and quantitative variables. For quantitative variables, (percentage healing of apical radiolucency) mean and Standard Deviation was calculated. For qualitative variables (Gender and type of tooth) frequency and percentage were calculated. One-way ANOVA was used to compare mean percentage reduction in periapical radiolucency in two groups. *p*-value was  $\geq 0.05$  was considered significant.

## RESULTS

The study was carried out in sixty patients who consented to be part of the trial. Thirty patients in each group, Group1 and Group 2, the list of demographics of each group tooth type are given. (Table-2).

Age range in this study was from 15 to 60 years with mean age of 37.86±8.51years. The mean age of patients in group 1 was 37.23±8.39 years and in group 2 was 38.10±8.78years. Majority of the patients 32 (53.33%) were between 30 to 45 years of age. Out of 60 patients, 41 (68.33%) were females and 19 (31.67%) were males with female to male ratio of 2:1.

The mean of percentage change in size of apical radiolucency at 3 months was 91.03% (SD±17.3) for Group 1 and 97.26% (SD±9.0) for Group 2 with *p* value 0.13 which was not significant (Figure-1, Table-1). No abnormal clinical findings were recorded in either group at the 3 months follow-up examination. In Group I out of 30 cases, 6 cases still had a persistent apical radiolucency with slight change in size. while in Group 2 the number of cases with persistent radiolucency was 3 only. No attempt was made to equalize the number of multirrooted teeth in both groups. Although multirrooted teeth with apical radiolucency have a reduced probability of absolute elimination of apical periodontitis as compared to teeth having single roots.<sup>2</sup> Fortunately, the number of teeth in each group was reasonably evenly distributed (Table-2)



**Figure-1: The mean of percentage change in size of apical radiolucency.**

**Table-1: Mean and standard deviation of percentage healing in group 1 and group 2.**

	n	Mean	SD	Std. Error
Ca(OH) <sub>2</sub>	30	91.0333	17.32068	3.71003
Ca(OH) <sub>2</sub> Chx	30	97.2667	9.05513	1.65323
Total	60	94.1500	15.91058	2.05405

**Table-2: Percentage of distribution of teeth in both groups according to tooth type.**

GROUP	ANTERIOR n (%)	PREMOLARS n (%)	MOLARS n (%)
Group I	6(20.0%)	11(36.6%)	13(43.3%)
Group II	5(16.6%)	13(43.3%)	14(46.6%)

**DISCUSSION**

Many clinical investigations have been carried out to date to find absolute intracanal medication by using several combinations such as camphorated paramonochorophenol, chlorhexidine, iodine potassium iodine, erythromycin and clindamycin or tetracycline with Ca(OH)<sub>2</sub>.<sup>10</sup> The addition of chlorhexidene to calcium hydroxide is supported by several studies.<sup>11</sup> In our study, we have compared Ca(OH)<sub>2</sub> and Ca(OH)<sub>2</sub> in combination with 2% CHX gel in percentage reduction in size of apical radiolucency.

The outcome results relied basically on the radiographic interpretation, the specificity of radiographs to identify absence of apical radiolucency is poor, therefore the outcome reported might only be considered a relative estimate of actual healing. However radiographic assessment has been used exclusively in all endodontic outcome studies, it remains the standard in daily clinical practice.<sup>12</sup> In our study the change in size of apical radiolucency was measured and the difference was measured. The percentage change was calculated between the radiographs taken at first visit and at three months.

The expectation that teeth with interappointment 2% CHX+ Ca(OH)<sub>2</sub> paste (Group 2) would result in improved healing compared to Ca(OH)<sub>2</sub> paste (Group 1) was not supported by our

results. In Group 1 out of 30 cases, 6 cases still had a persistent apical radiolucency with slight change in size. While in Group 2 the number of cases with persistent radiolucency was 3 only. The persistence of the apical radiolucency could be attributed to procedural error or a faulty seal of tooth. Since the type of teeth included in the study was also different (incisors, premolars and molars) the healing of apical periodontitis in single canal and multi-canal tooth is also different.<sup>2</sup>

According to a study conducted by Creg Trevit *et al*, complete healing of teeth with apical periodontitis has been reported in range of 73–86%. In group in which calcium hydroxide was used healing was in reported at 9.00+0.71 and it was found to be 12.26+0.91 ( $p \leq 0.05$ ) for chlorhexadiene.<sup>8</sup> Our study showed comparable results with 91.03% healing in Group 1 and 97.26% in Group 2. Several studies support the use of 2% CHX because of its activity against root canal microbes,<sup>13,14</sup> which is in agreement of the findings of the present study.

The mechanism of action of the combined use of Ca(OH)<sub>2</sub> and 2% CHX may be attributed to liberation of active oxides, which is highly efficient in combating against endotoxins.<sup>15</sup> On the contrary, another study did not reveal any differences between Ca(OH)<sub>2</sub> pastes with or without 2% CHX gel to eradicate root canal toxins. These differences in the results of both studies can be attributed to difference in methodology (study design and period of use of medicament).<sup>16</sup> We used the combination of Ca(OH)<sub>2</sub> and 2% CHX for 14 days as interappointment dressing followed by obturation. Since our study was *in vivo* the teeth were not extracted for histological sections to observe the elimination of endotoxin.

According to one study the combination of Ca(OH)<sub>2</sub> with saline and CHX was tested against microbes. The results showed the combination with CHX gel showed better activity against microbes as compared to saline.<sup>17</sup> *E. faecalis* is most commonly found bacteria in root canal. In another study Ca(OH)<sub>2</sub> was used against *E. faecalis* and was found to be ineffective however the combination of Ca(OH)<sub>2</sub> with CHX resulted in remarkable reduction in *E. faecalis* in detin.<sup>18</sup> Other studies also support this combination Ca(OH)<sub>2</sub> and CHX in combating *E. Faecalis*.<sup>19,20</sup> In our study although the intracanal cultures were not done but since the healing of apical periodontitis is associated to reduction in bacterial counts and according to our results the percentage healing of Group 2 was almost 97% it can be inferred that the combination of Ca(OH)<sub>2</sub> with CHX is effective in eliminating the canal bacteria.

As an intracanal medication, Ca(OH)<sub>2</sub> was found to be as effective as 1% CHX in decreasing load of *Enterococcus (E.) faecalis* at 3 and 8 days, whereas at

14 days, the efficiency was found to be less than the other test periods.<sup>21</sup> The intracanal medication was used for a period of 14 days in both the groups in our study which showed favourable results in terms of healing in both the study groups.

The basic requirement for an intracanal medicament is to be non-toxic. The use of a 2% CHX as a periodontal wash was non-irritant to the gums, suggesting its safety for intraoral use.<sup>22</sup> Therefore, these properties make 2% CHX gel a suitable combination with CH as an intracanal medication.<sup>23</sup>

Another parameter that needs consideration with use of intracanal medicament is its interaction with the apical seal. Study carried out by Wuerch *et al* confirmed that the apical seal is not effected by the combination of Ca(OH)<sub>2</sub> with CHX as an intracanal medication for 2 weeks.<sup>21</sup> In another study the paste made of Ca(OH)<sub>2</sub> with 2% CHX gel can be used routinely without disturbing the ability of obturation material to seal the root canal.<sup>24</sup> Since this parameter was not evaluated in our study as a separate variable, it can be said on basis of the above mentioned studies that the seal of obturating material was not affected in both the study groups.

This study has a few limitations. Since we were unable to cultivate the root canal bacteria, nothing can be said about the percentage elimination of canal bacteria with certainty. Secondly the sample size could be increased to authenticate the results. Calculation of healing at different time intervals could help us calculate the mean time of healing.

## CONCLUSION

This study concluded that Group 2 resulted in better healing and reduction of size of apical radiolucency to Group 1. It can be suggested that calcium hydroxide in combination with 2% chlorhexidine can be used as a primary intracanal medicament. The healing of apical periodontitis is associated to reduction in intracanal bacterial load. Thus, it can be said that the combination of calcium hydroxide with 2% chlorhexidine results in better elimination of canal microbes.

## AUTHORS' CONTRIBUTION

AR: Data collection, interpretation, write up, data analysis. AM: Topic selection and supervision. SA: Conceptualization of study design. KS: Data collection and data analysis. S: Proof reading and review. SZ: Data Analysis. BB: Literature search.

## REFERENCES

1. Ahmed I, Howlader M. Non-surgical Management of Endodontic Periradicular Pathosis - A Clinical Research. Bangabandhu Sheikh Mujib Med Univ J 2006;1(1):22-8.
2. Penesis VA, Fitzgerald PI, Fayyad MI, Wenckus CS, beGole EA, Johnson BR. Outcome of one-visit and two-visit endodontic treatment of necrotic teeth with apical

- periodontitis: a randomized controlled trial with one-year evaluation. J Endod 2008;34(3):251-7.
3. Vaghela DJ, Kandaswamy D, Venkateshabu N, Jamini N, Ganesh A. Disinfection of dental tubules with two different formulations of calcium hydroxide as compared to 2% chlorhexidine: as intracanal medicaments against *Enterococcus faecalis* and *Candida albicans*: an in vitro study. J Conserv Dent 2011;14(2):182-6.
4. Dall AQ, Jouhar R, Ahmed NA. Comparison of Inter-appointment Pain between Ledermix and no intracanal medicament in acute apical periodontitis. J Liaquat Univ Med Health Sci 2011;10:106-11.
5. Fulzele P, Baliga S, Thosar N, Pradhan D. Evaluation of calcium ion, hydroxyl ion release and pH levels in various calciumhydroxide based intracanal medicaments: an in vitro study. Contemp Clin Dent 2011;2(4):291-5.
6. Abbott PV. Endodontics - Current and future. J Conserv Dent 2012;15(3):202-5.
7. Mohammadi Z, Shalavi S. Is chlorhexidine ideal vehicle for calcium hydroxide: a microbiologic view. Iran Endod J 2012;7(3):115-22.
8. Tervit C, Paquette L, Basrani B, Friedman S. Proportion of healed teeth with apical periodontitis medicated with two percent chlorhexidine gluconate liquid: a case-series study. J Endod 2009;35(9):1182-5.
9. Ng Y, Mann V, Gulabivala K. A prospective study of the factors affecting outcomes of nonsurgical root canal treatment: part I: periapical health. Int J Endod 2011;44(7):583-9.
10. De Souza-Filho FJ, Soares Ade J, Vianna ME, Zaia AA, Ferraz CC, Gomes BP. Antimicrobial effect and pH of chlorhexidine gel and calcium hydroxide alone and associated with other materials. Braz Dental J 2008;19(1):28-33.
11. Signoretti FGC, Gomes BP, Montagner F, Barrichello Tosello F, Jacinto RC. Influence of 2% chlorhexidine gel on calcium hydroxide ionic dissociation and its ability of reducing endotoxin. Oral Surg Oral Med Oral Pathol Oral Radiol Endod 2011;111(5):653-8.
12. Ferraz CCR, Gomes BP, Zaia AA, Teixeira FB, Souza-Filho FJ. In vitro assessment of the antimicrobial action and mechanical ability of chlorhexidine gel as an endodontic irrigant. J Endod 2001;27(7):452-5.
13. Gomes BP, Vianna ME, Senna NT, Zaia AA, Ferraz CC, de Souza-Filho FJ. In vitro evaluation of the antimicrobial activity of calcium hydroxide combined with chlorhexidine gel used as intracanal medicament. Oral Surg Oral Med Oral Pathol Oral Radiol Endod 2006;102(4):544-50.
14. Gomes BP, Souza SF, Ferraz CC, Teixeira FB, Zaia AA, Valdrighi L, *et al*. Effectiveness of 2% chlorhexidine gel and calcium hydroxide against *Enterococcus faecalis* in bovine root dentine in vitro. Int Endod J 2003;36(4):267-75.
15. Yeung SY, Huang CS, Chan CP, Lin CP, Lin HN, Lee PH, *et al*. Antioxidant and pro-oxidant properties of chlorhexidine and interaction with calcium hydroxide solutions. Int Endod J 2007;40(11):837-44.
16. Vianna ME, Horz HP, Conrads G, Zaia AA, Souza-Filho FJ, Gomez BPPA. Effect of root canal procedures on endotoxins and endodontic pathogens. Oral Microbiol Immunol 2007;22(6):411-8.
17. Sirén EK, Haapasalo MP, Waltimo TM, Orstavik D. In vitro antibacterial effect of calcium hydroxide combined with chlorhexidine or iodine potassium iodine on *Enterococcus faecalis*. Eur J Oral Sci 2004;112(4):326-31.
18. Ercan E, Dalli M, Dulgergil CT. In vitro assessment of the effectiveness of chlorhexidine gel and calcium hydroxide paste with chlorhexidine against *Enterococcus faecalis* and *Candida albicans*. Oral Surg Oral Med Oral Pathol Oral Radiol Endod 2006;102(2):27-31.

19. Zerella JA, Fouad AF, Spangberg LS. Effectiveness of a calcium hydroxide and chlorhexidine digluconate mixture as disinfectant during retreatment of failed endodontic cases. *Oral Surg Oral Med Oral Pathol Oral Radiol Endod* 2005;100(6):756–61.
20. Almyroudi A, Mackenzie D, McHugh S, Saunders WP. The effectiveness of various disinfectants used as endodontic intracanal medications: an in vitro study. *J Endod* 2002;28(3):163–7.
21. Southard SR, Drisko CL, Killoy WJ, Cobb CM, Tira DE. The effect of 2% chlorhexidine digluconate irrigation on clinical parameters and the level of *Bacteroides gingivalis* in periodontal pockets. *J Periodontol* 1989;60(6):302–9.
22. Wuerch RMW, Apicella MJ, Mines P, Yancich PJ, Pashley DH. Effect of 2% chlorhexidine gel as an intracanal medication on the apical seal of the root-canal system. *J Endod* 2004;30(11):788–91.
23. Kontakiotis EG, Tsatsoulis IN, Papanakou SI, Tzanetakis GN. Effect of 2% chlorhexidine gel mixed with calcium hydroxide as an intracanal medication on sealing ability of permanent root canal filling: a 6-month follow-up. *J Endod* 2008;34(7):866–70.
24. Estrela C, Bueno MR, Leles CR, Azevedo B, Azevedo J. Accuracy of cone beam computed tomography and panoramic and periapical radiography for detection of apical periodontitis. *J Endod* 2008;34(3):273–9.

*Received: 12 June, 2017*

*Revised: 21 November, 2017*

*Accepted: 14 January, 2018*

**Address for Correspondence:**

**Amna Riaz**, Department of Operative Dentistry, Pakistan Institute of Medical Sciences, Islamabad-Pakistan

**Email:** riaz.amna84@gmail.com