


## Chapter 49 – Total Laryngectomy

David E. Eibling

Of the approximately 12,000 new cases of carcinoma of the larynx discovered each year in the United States, slightly more than one half are initially seen in an advanced stage and are not suitable for endoscopic excision or conservation laryngeal surgery. The most important factor leading to early diagnosis of laryngeal cancer is recognition by the patient and primary caregiver that a sore throat or abnormal voice may indicate a risk for carcinoma of the larynx, particularly in patients with the risk factors of tobacco and alcohol use. Further improvement in the control rate of laryngeal carcinoma will require earlier recognition of the need for laryngoscopy in symptomatic patients. The American Academy of Otolaryngology–Head and Neck Surgery Foundation has established a web-based educational program for primary care providers to assist in these educational efforts, of which hoarseness is one module ([www.entlink.net/education/cool](http://www.entlink.net/education/cool); accessed 15 April 2005).

### PATIENT SELECTION

Total laryngectomy is required when alternative means of controlling the cancer are not feasible. This includes patients who have fixation of the vocal cord or cancer that has spread out of the endolarynx by invasion of cartilage, base of the tongue, or hypopharynx.[1] Radiation or chemoradiation therapy is inadequate in the management of locally advanced cancer, especially with cartilage invasion, and surgical salvage is required in a significant number of patients treated with this modality.[2]

Over the past several decades the paradigm has shifted significantly in that patients with cancer that would have required total laryngectomy in the past can now be offered laryngeal preservation—either surgically with conservation partial laryngectomy or transoral endoscopic CO<sub>2</sub> laser excision, as described in previous chapters, or through protocols combining chemotherapy and radiotherapy. Some patients with cancer that would be amenable to conservation laryngeal surgery are not candidates as a result of underlying medical conditions, usually pulmonary. Because total laryngectomy separates the airway from the digestive tract, aspiration is eliminated, which often leads to improvement in preoperative pulmonary status for patients unable to tolerate aspiration.

### Organ Preservation with Chemoradiation Therapy

Locally advanced cancer cannot usually be cured with radiation alone, and most centers report rates of less than 50%. [2] The addition of chemotherapy, either neoadjuvant or concurrent, increases the probability of cure to approximately that of surgical excision if surgical salvage is performed expeditiously for persistent disease. Long-term disease-free survival rates for T3 and T4 cancers are similar for either surgery or chemoradiation protocols, with about two thirds of the latter group succeeding in retaining their larynx.[3–5] *Functional* organ preservation remains elusive for many of these patients, however, because of the swallowing dysfunction or aspiration that accompanies successful treatment of these larger tumors such that many of these patients will have a permanent tracheotomy and percutaneous endoscopic gastrostomy despite cure of their cancer. Others will require total laryngectomy as a result of radionecrosis of the larynx or recurrent cancer.[6,7] Difficulty recognizing recurrent or persistent cancer because of edema and submucosal location of recurrence may result in delayed diagnosis of recurrence. Newer imaging modalities with positron emission tomography (PET)-computed tomography (CT) scanning may reduce this risk somewhat,[8] but the optimal utility of PET-CT in monitoring this patient group is still unknown. Some patients ultimately require laryngectomy for the management of pain and aspiration secondary to laryngeal dysfunction after completion of therapy. Although cost is often quoted as a factor, there is little significant difference in cost between surgery and organ preservation. A recent report analyzing cost indicated that organ preservation protocols actually cost approximately 10% *more* than surgical extirpation and postoperative radiotherapy.[9]

The final decision must be customized for each patient. Organ preservation carries with it a degree of uncertainty regarding the status of the retained larynx, a higher risk for significant dysphagia, and an increased risk of aspiration but avoids the presence of a stoma and facilitates nearly normal speech. Each patient must be counseled regarding the options and educated sufficiently to take an active role in decision making. Surgeons who undertake to direct the management of patients with advanced laryngeal cancer must be cognizant of the nuances of surgical as well as organ-sparing paradigms of therapy to optimally counsel and manage patients seeking their care.

Total laryngectomy is the standard against which all other forms of therapy for laryngeal cancer must be measured

because total laryngectomy is highly effective in managing glottic, subglottic, and supraglottic carcinoma.<sup>[10]</sup> Total laryngectomy is an integral part of laryngopharyngectomy and is required for advanced hypopharyngeal cancer. Cancer confined to the glottis tends to remain localized; hence, total laryngectomy alone will achieve cure in the vast majority of cases staged T3 or less. Once cancer has extended outside the glottis by extension through cartilage either into the soft tissue of the neck, into the subglottis, or into the supraglottic tissues (transglottic), extirpation of all disease is more challenging.

## Neck Dissection

The glottis, in direct contradistinction to the supraglottis, is relatively devoid of lymphatics. Cervical metastases are rare if the cancer is confined to the true vocal cord. As a result, routine elective neck dissection is not required for T1 or T2 glottic cancer. However, all supraglottic cancers, hypopharyngeal cancers, and T3 or T4 glottic cancers are more likely to have clinically apparent or occult regional metastatic disease. Bilateral neck dissection is required for all supraglottic cancers, all hypopharyngeal cancers that involve the medial wall, and cancer of the anterior commissure with cartilage invasion. Cancer that originates in the subglottis or is glottic with extension more than 2 cm subglottically has a high propensity to involve the paratracheal nodes. Tumor deposits in these nodes are thought to be responsible for the high incidence of stomal recurrence in patients with tumors that exhibit subglottic extension.<sup>[11,12]</sup> As a result, removal of the ipsilateral thyroid lobe and adjacent paratracheal nodes is routine for tumors with subglottic extension.

Adjuvant radiotherapy is warranted in all patients with hypopharyngeal cancer, those with more than two positive nodes or extracapsular spread on pathologic examination of the neck specimens, patients with greater than 2 cm of subglottic extension, and those with positive paratracheal lymph nodes. In patients with primary cancer of the subglottis or subglottic extension or with positive paratracheal lymph nodes, the radiotherapist must be specifically directed to treat the area of the stoma and the upper mediastinum to prevent stomal recurrence. These regions are not routinely included in postoperative adjuvant radiation therapy of the neck because irradiation of the stoma and trachea can result in severe tracheitis.

## PREOPERATIVE PLANNING

All patients with cancer of the larynx require careful preoperative evaluation, which must include a search for a second cancer of the upper aerodigestive tract, esophagus, or lung; assessment of the patient's general medical condition; and evaluation of the cancer by direct laryngoscopy and biopsy for verification of histology. Imaging studies are helpful in the staging of larger cancers by identifying involvement of the laryngeal framework, the paraglottic space, and the neck.<sup>[8,11]</sup> Minimal benefit is derived from radiographic imaging in early vocal cord carcinoma. Current wisdom suggests that high-resolution CT scanning is more beneficial than magnetic resonance imaging (MRI) in the evaluation of advanced malignancies; however, this may change in coming years as the resolution of MRI and other modalities improves. PET scanning is not helpful in the evaluation of primary glottic cancer but is useful in identifying metastatic disease in the neck or second primary lung cancer and may become standard in future years. Preoperative chest radiography is mandatory because almost all these patients have a significant smoking history and a certain percentage will demonstrate the presence of a simultaneous cancer of the lung. CT scanning of the chest is warranted to further evaluate abnormalities noted on chest radiography and may be beneficial in the evaluation of all patients with laryngeal cancer. Glottic cancer with vocal cord paralysis may represent advanced-stage laryngeal cancer or two primary cancers with recurrent laryngeal nerve involvement by metastatic lung cancer. Assessment of the patient's general medical condition, particularly pulmonary reserve, is necessary to select the optimal treatment modality. Total laryngectomy is the treatment of choice if the patient has impaired pulmonary status, even if the tumor may be amenable to a surgical organ preservation procedure.

Preoperative endoscopy under general anesthesia should be carried out in all patients, not only to assess the size and extent of the primary cancer and to obtain tissue for biopsy but also to search for second primary cancers. Careful examination of the oral cavity, base of the tongue, piriform sinuses, and esophagus is warranted. The routine use of bronchoscopy has been somewhat controversial; however, some surgeons routinely perform flexible fiberoptic bronchoscopy with washings to assist in identifying patients with a second primary cancer of the lung. Bronchoscopy should certainly be carried out when imaging studies suggest a simultaneous bronchogenic carcinoma.

Selection of the appropriate treatment modality is the most difficult responsibility in the management of these patients. Patients should be counseled regarding surgical and nonsurgical options. It is inappropriate to insist that patients undergo one specific form of therapy, particularly when acceptable cure rates can be obtained by other options. Surgeons must be aware of their own biases and strive to present a balanced and informed set of options to the patient and family. Usually, frank discussion with the patient will result in a clear decision regarding the treatment modality most beneficial for the individual patient.

Patients must be counseled regarding the risk of continued smoking, which has been demonstrated to result not only in an increased incidence of second primary cancer and risk of recurrence but also in a reduction in the

probability of cure by radiotherapy.<sup>[13]</sup> Enrollment in a smoking cessation program and the use of transdermal nicotine replacement, as well as the administration of bupropion, may be helpful. Frank discussion with the patient and family may assist in reducing or eliminating dependence on tobacco. Unfortunately, smoking remains a problem in many patients, even those who have undergone total laryngectomy. Development of a second primary cancer in the lung and esophagus, particularly in patients who continue to smoke after radiotherapy or partial laryngectomy, remains a serious problem and is a common cause of death in patients treated successfully for their initial primary cancer.

## TECHNIQUE

The steps for total laryngectomy are listed in Table 49-1.

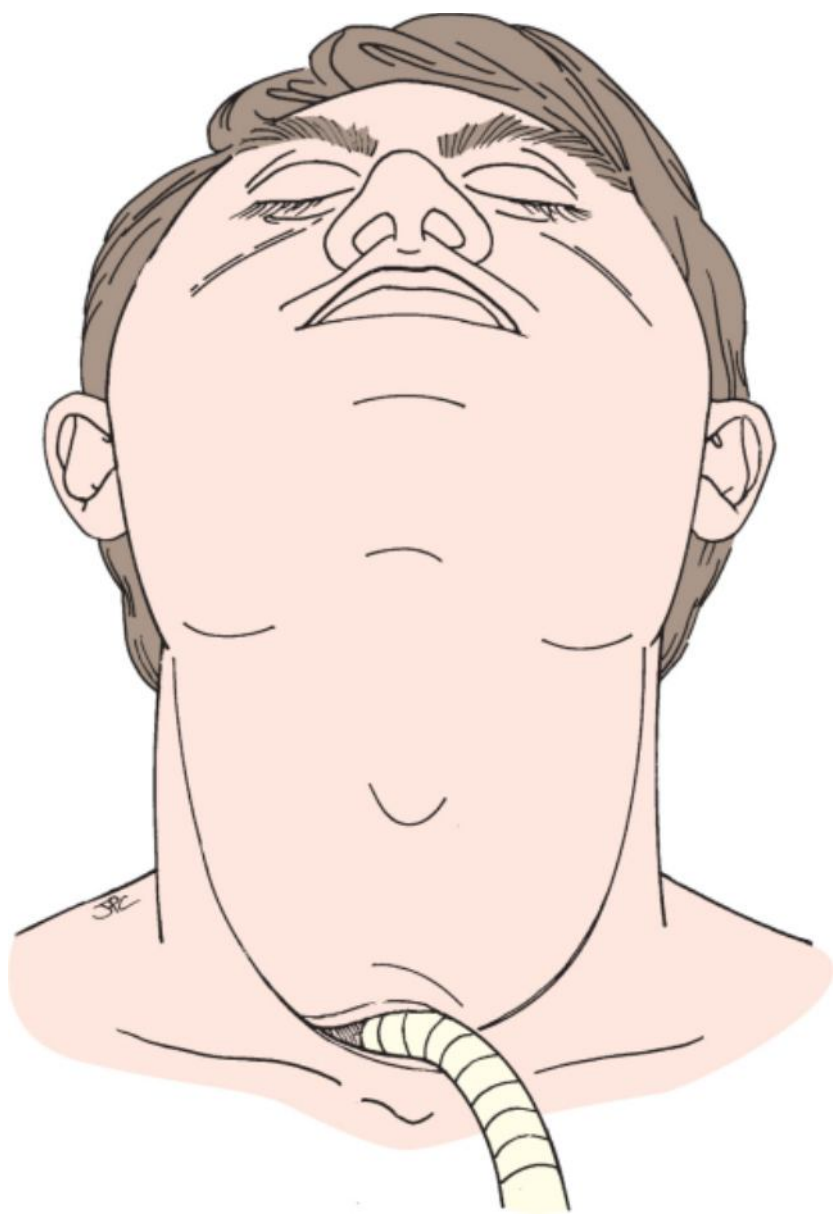
**Table 49-1 -- STEPS IN TOTAL LARYNGECTOMY**

Administer perioperative antibiotics
Perform a tracheostomy
Make an apron flap incision
Perform a subplatysmal dissection of the flap
Divide the fascia and anterior jugular veins
Expose the sternocleidomastoid muscle and dissect the "outer tunnels"
Incise the strap muscles and elevate them off the thyroid gland
Divide the thyroid isthmus and free the thyroid lobes
Dissect the inner tunnels
Divide the superior laryngeal artery, vein, and nerve
Expose and free the body and greater cornu of the hyoid bone
Rotate the larynx and divide the constrictor muscles
Free the piriform mucosa and superior cornu of thyroid cartilage
Divide the trachea and identify the party wall
Open the pharynx through the vallecula, piriform sinus, or postcricoid mucosa
Excise the tumor under direct vision with adequate margins (<1 cm) while preserving as much piriform sinus mucosa as possible
Examine the specimen and select sites for frozen section determination of margins
Insert and secure the nasogastric tube
Close the pharynx via a vertical, horizontal, or T closure with an inverting suture
Do not close the constrictors. Irrigate the wound and test the pharynx for leaks
Create a permanent tracheostoma with pie-crust sutures while remembering to bevel the trachea and "walk the skin" to prevent stomal stenosis
Close the skin over suction drains

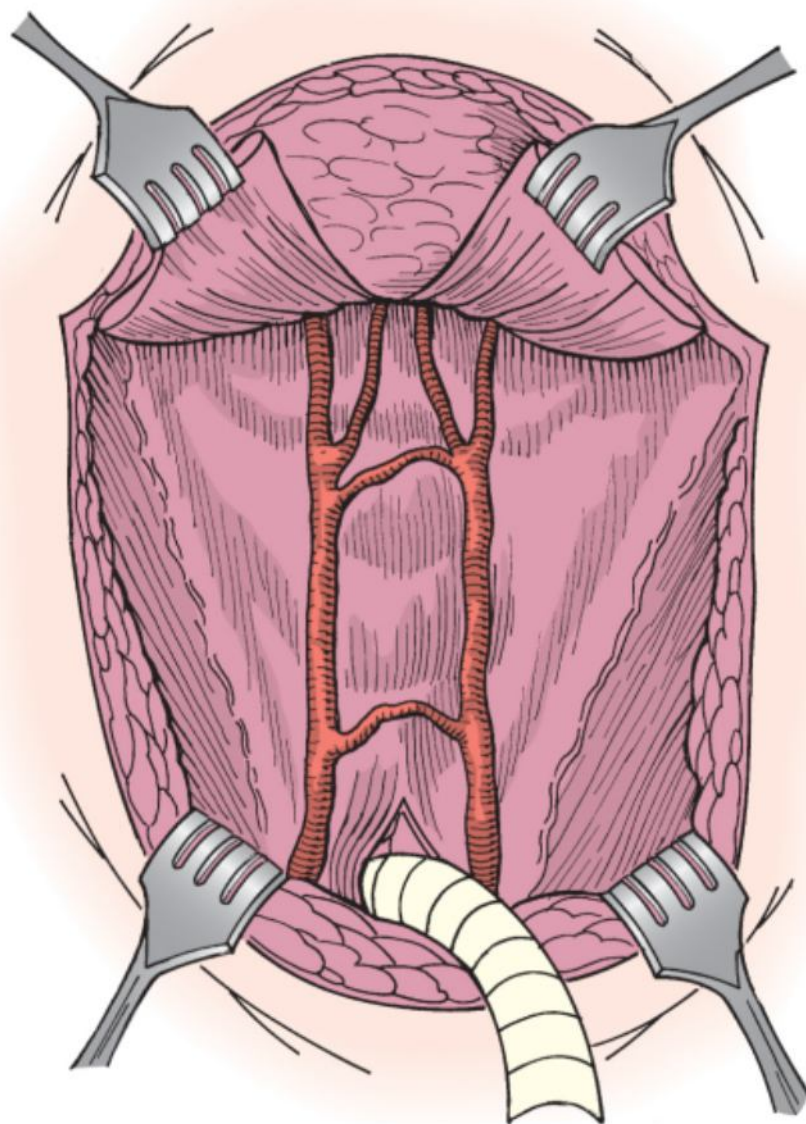
As in any surgical procedure in which the upper aerodigestive tract is entered through the neck, antibiotics are administered perioperatively. Antibiotics must be administered before initiation of the surgical procedure and continued for 24 hours postoperatively. There is probably no need to continue antibiotics past 24 hours, and the antibiotic must cover gram-positive organisms, as well as anaerobes, essentially normal oral flora.

The patient is anesthetized, a tracheotomy is performed, and an endotracheal tube is placed in the stoma. Care must be taken to perform the tracheotomy at an adequate distance inferior to the cancer if there is significant subglottic extension. It may be necessary to perform the tracheotomy under local anesthesia in patients with large obstructing tumors in whom induction of general anesthesia and endotracheal intubation cannot be accomplished safely.

An apron incision is outlined (Fig. 49-1) such that the tracheostomy incision is incorporated. If neck dissection is to be performed in continuity with the laryngectomy, the apron incision can be extended laterally as a utility incision to gain access to the contents of the neck. Subplatysmal skin flaps are elevated to above the level of the hyoid bone for exposure of both sternocleidomastoid muscles (Fig. 49-2).

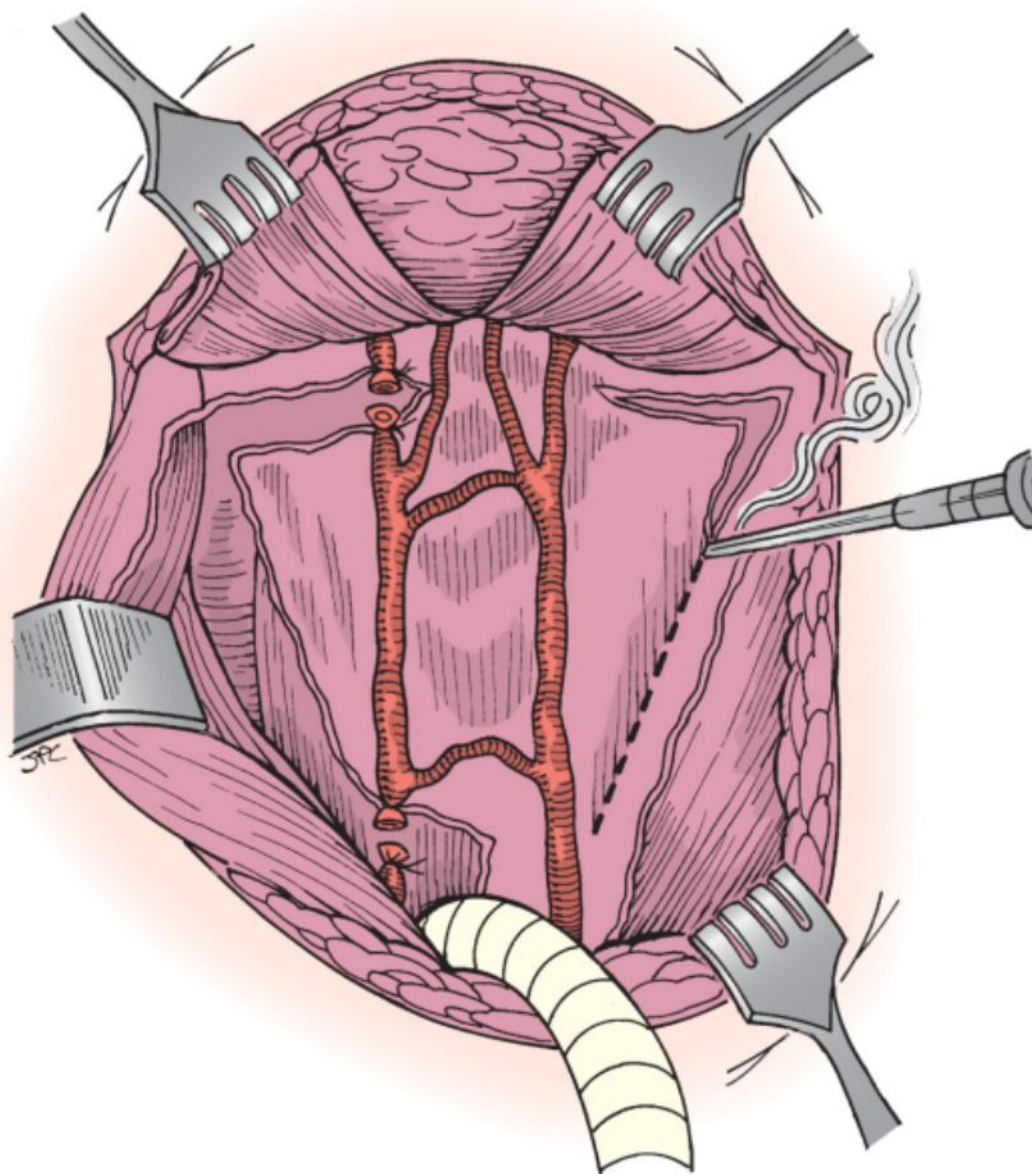


**Figure 49-1** Apron incision for total laryngectomy.

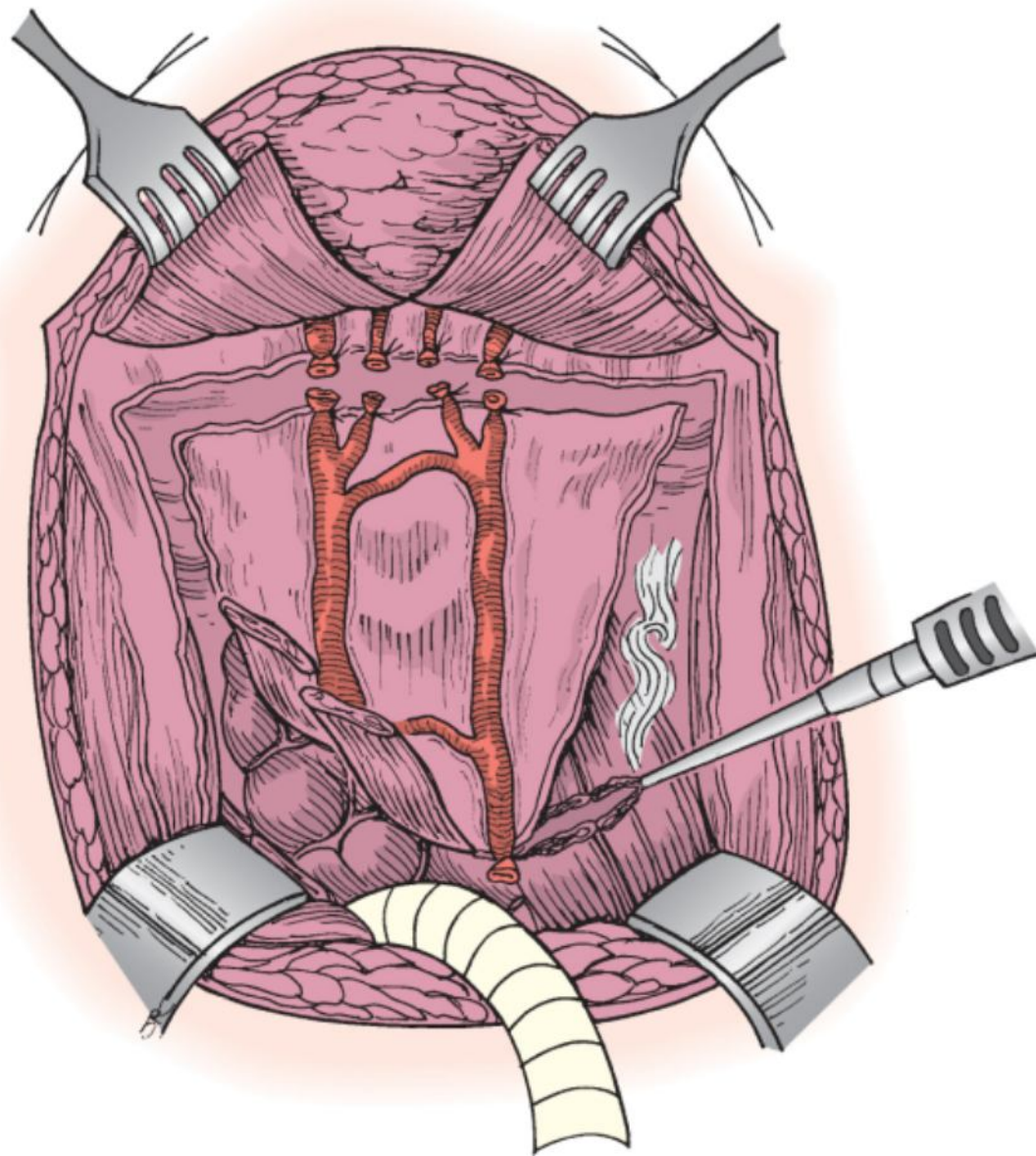


**Figure 49-2** Elevated apron incision.

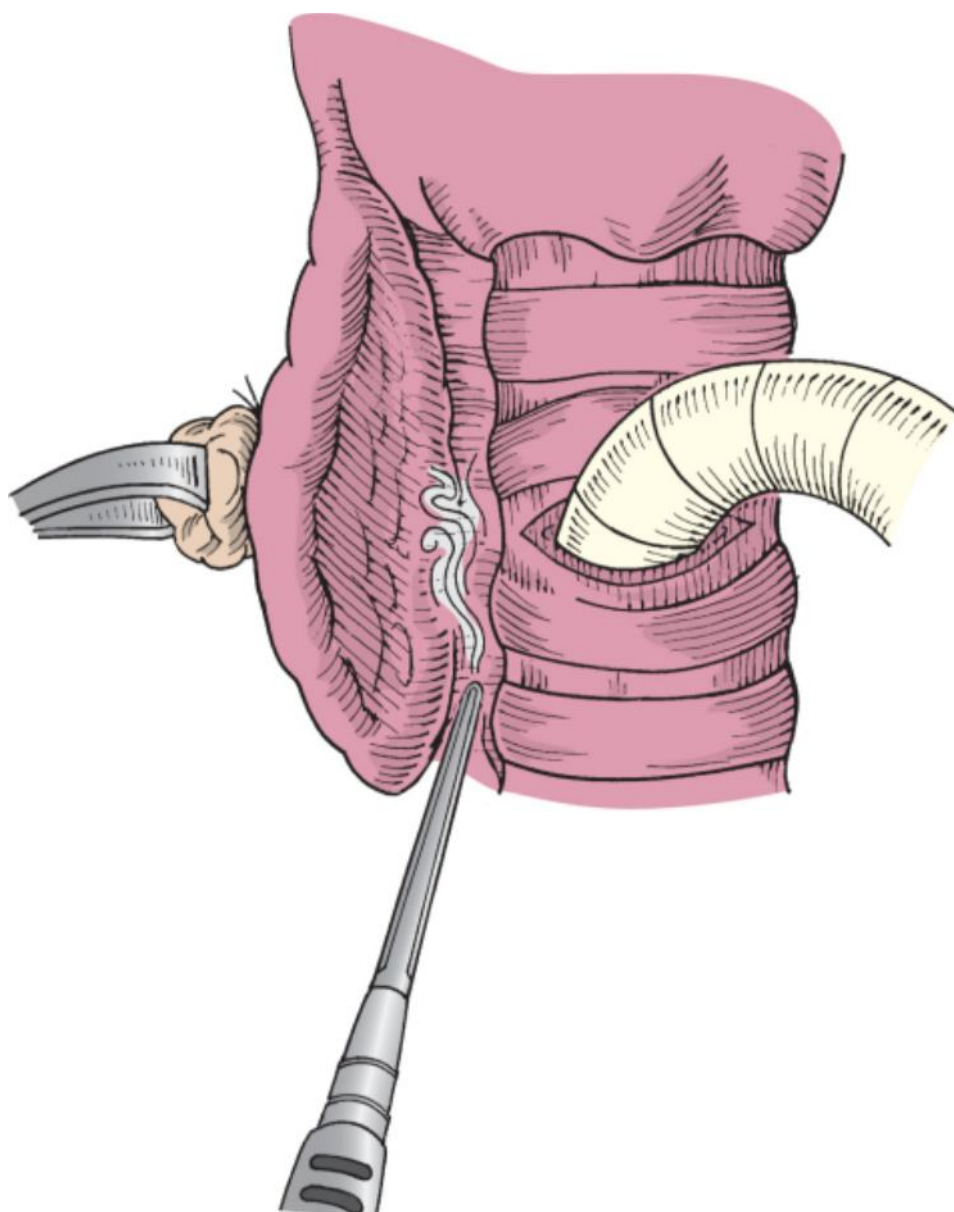
The cervical fascia is divided over the sternocleidomastoid muscles, and the incisions are connected inferiorly and superiorly. It will be necessary at this stage to divide and ligate the anterior jugular veins. “Outer tunnels” are bluntly dissected between the sternocleidomastoid muscle and the strap muscles on either side to free the medial contents of the neck (Fig. 49-3). The strap muscles are divided, usually at about the level of the tracheotomy stoma (Fig. 49-4). They are elevated superiorly and medially to gain access to the thyroid gland. The thyroid isthmus is divided (if not done at the time of the tracheotomy), and the contralateral thyroid lobe is freed from its attachment to the trachea (Fig. 49-5). The ipsilateral thyroid lobe is left attached and removed with the specimen. Electrocautery is effective in reducing the bleeding commonly encountered at this step. The “deep tunnel” between the carotid sheath and the larynx is dissected bluntly along the prevertebral fascia. By dissecting superiorly to the level of the greater cornu of the hyoid bone, the superior laryngeal bundle is encountered and should be ligated.



**Figure 49-3** Incision of the fascia over the sternocleidomastoid muscle and over the hyoid bone with the development of “outer tunnels” deep to the sternocleidomastoid muscle (right side).



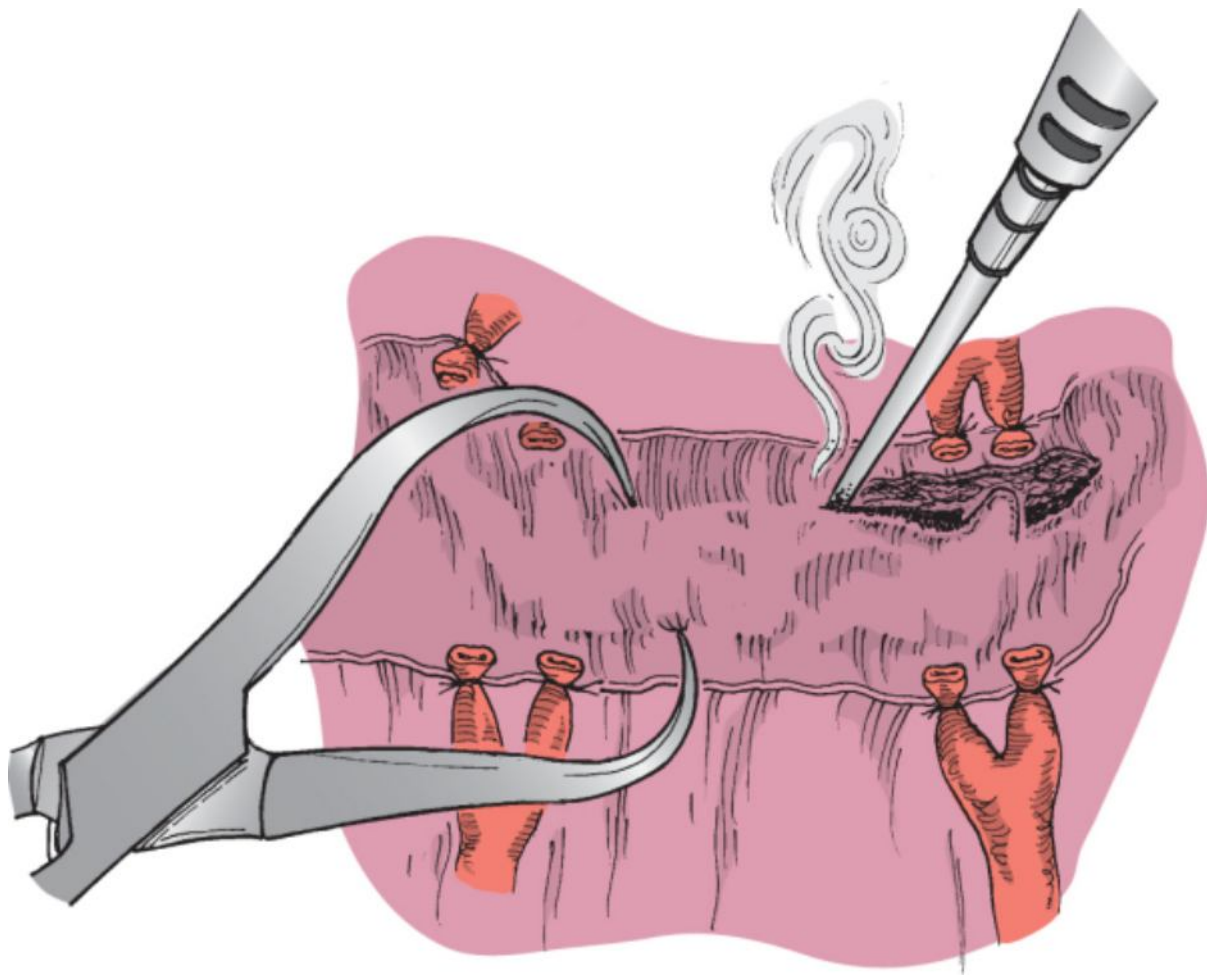
**Figure 49-4** Division of the strap muscles.



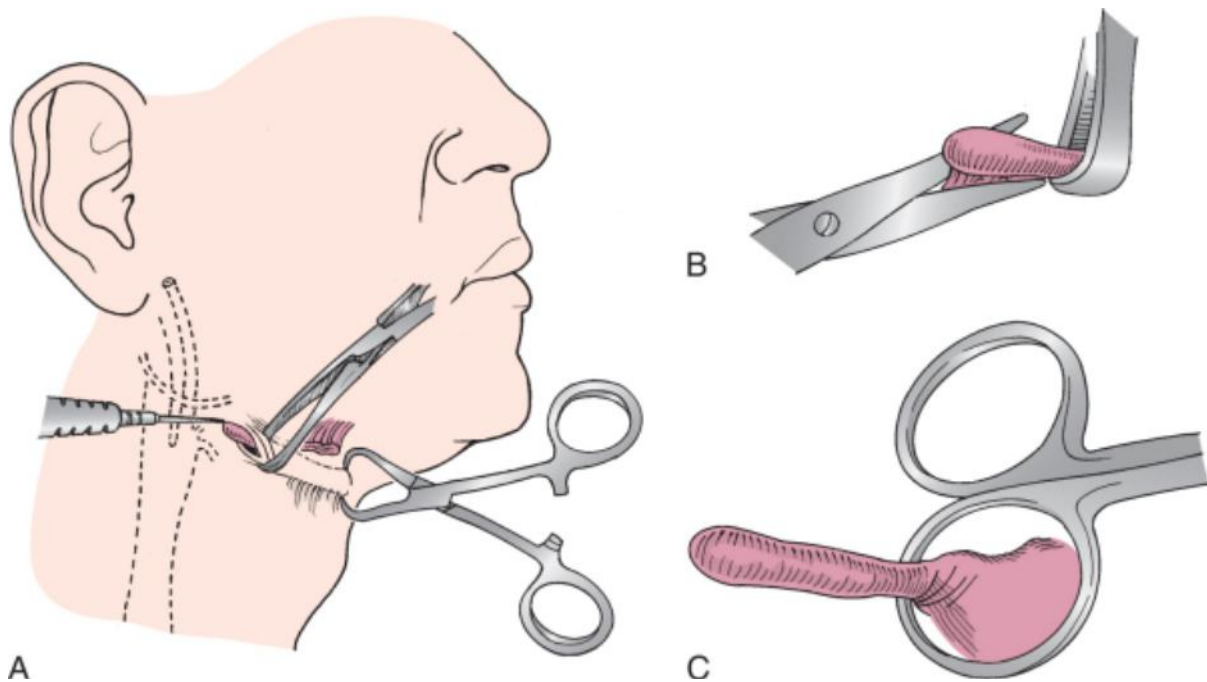
**Figure 49-5** Separation of the thyroid lobe from the trachea. Electrocautery is effective in reducing bleeding.

The hyoid bone is exposed in the midline and grasped with a towel clip (Fig. 49-6). The suprahyoid muscles are divided, and the hyoid bone is left attached to the thyrohyoid membrane and the strap muscles. When the central portion of the hyoid bone has been released, it is grasped with a towel clip and retracted anteriorly to gain exposure of the lateral cornua. The lateral cornu is grasped with an Allis clamp and pulled away from the hypoglossal nerve and lingual artery. The ligament and its attachments are divided to free the cornu. It is important at this stage to stay on bone to avoid injury to the hypoglossal nerve and lingual artery (Fig. 49-7).



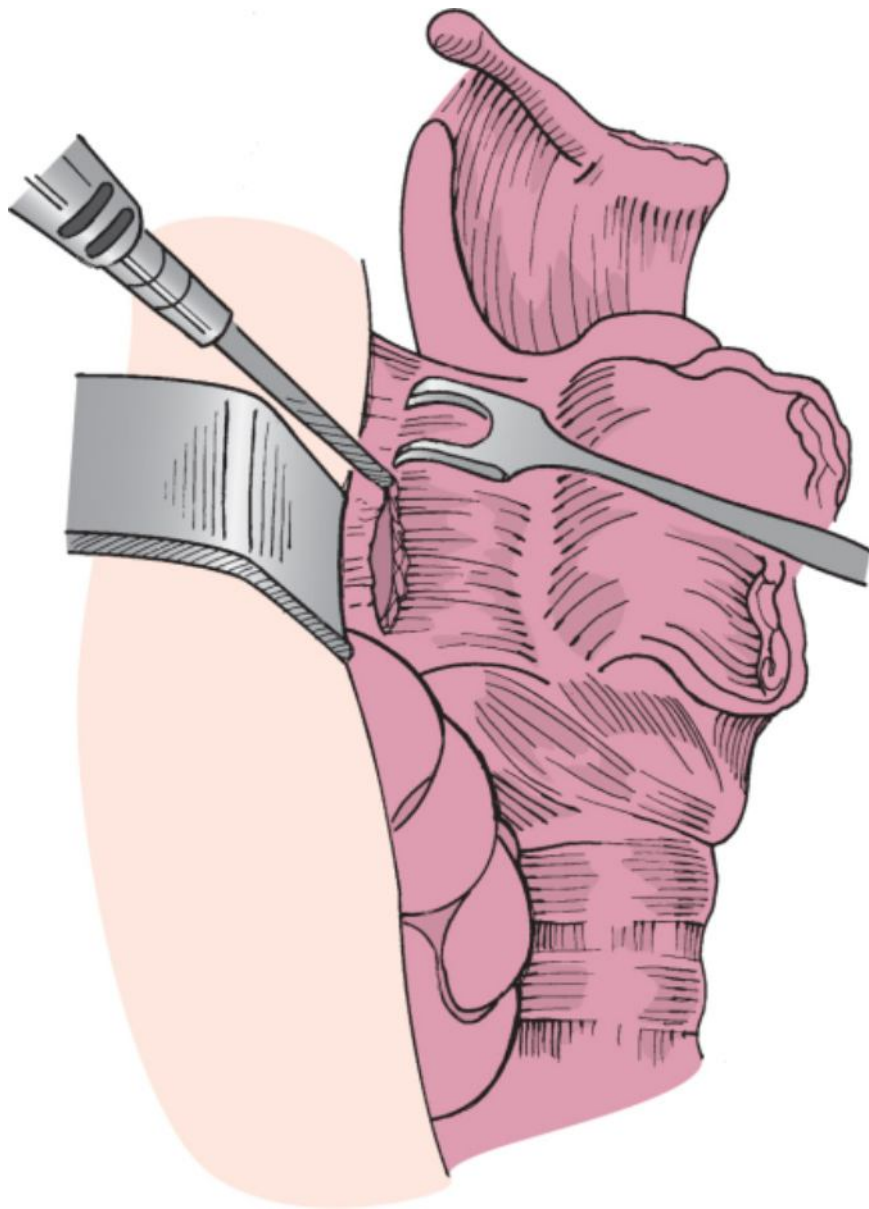


**Figure 49-6** The hyoid bone is grasped with a towel clip and the suprahyoid muscles dissected from bone via electrocautery.

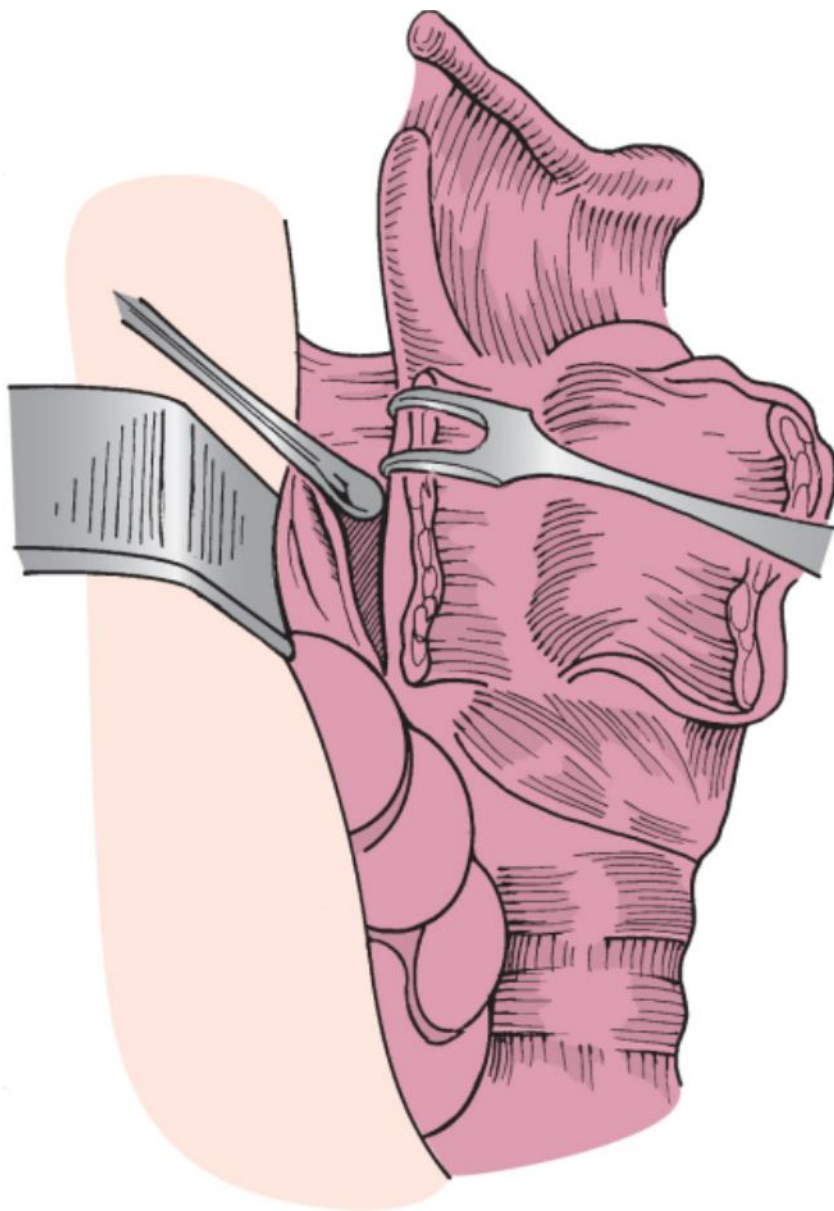


**Figure 49-7** Freeing the greater cornu of the hyoid bone. Care must be taken to keep the dissection on the undersurface of the hyoid to avoid injury to the lingual artery and hypoglossal nerve. This is done by retracting the lateral cornu with an Allis clamp and exposing the tip of the hyoid (A), incising immediately deep to the cornu with scissors (B), and bluntly dissecting the bone from the piriform sinus wall with the handle of the scissors (C).

The larynx is rotated by placing a hook under the lateral aspect of the ala. The constrictor muscles are then incised along the lateral border of the thyroid cartilage (Fig. 49-8). Piriform mucosa is bluntly elevated from the undersurface of the thyroid ala (Fig. 49-9) (unless there is ipsilateral involvement of the piriform sinus mucosa by cancer). This maneuver will assist in preserving mucosa needed for closure of the pharynx and is particularly important if the contralateral piriform mucosa must be sacrificed.

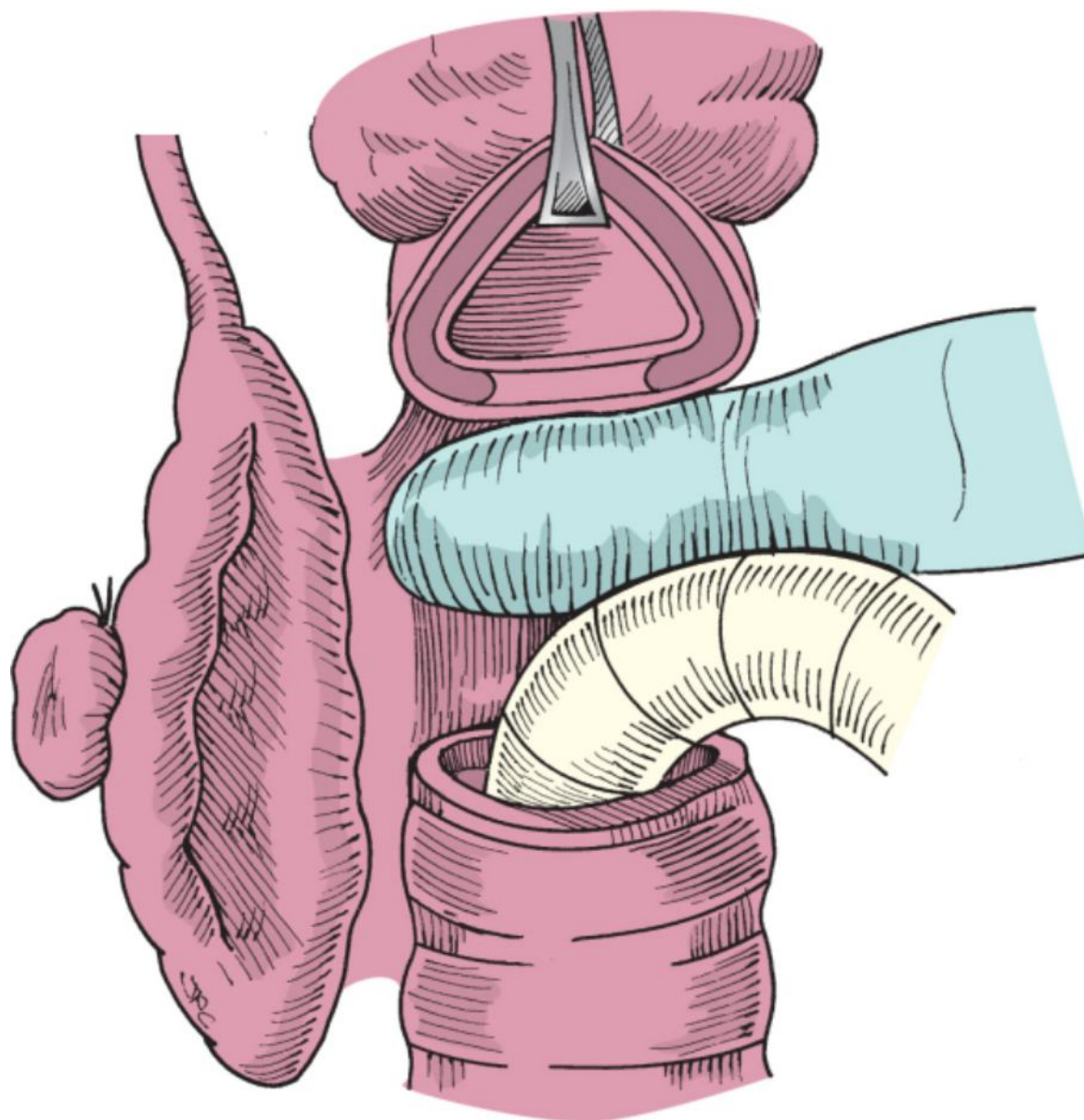


**Figure 49-8** Lateral rotation of the larynx to assist in incising the inferior constrictor muscle along the lateral margin to the thyroid ala.



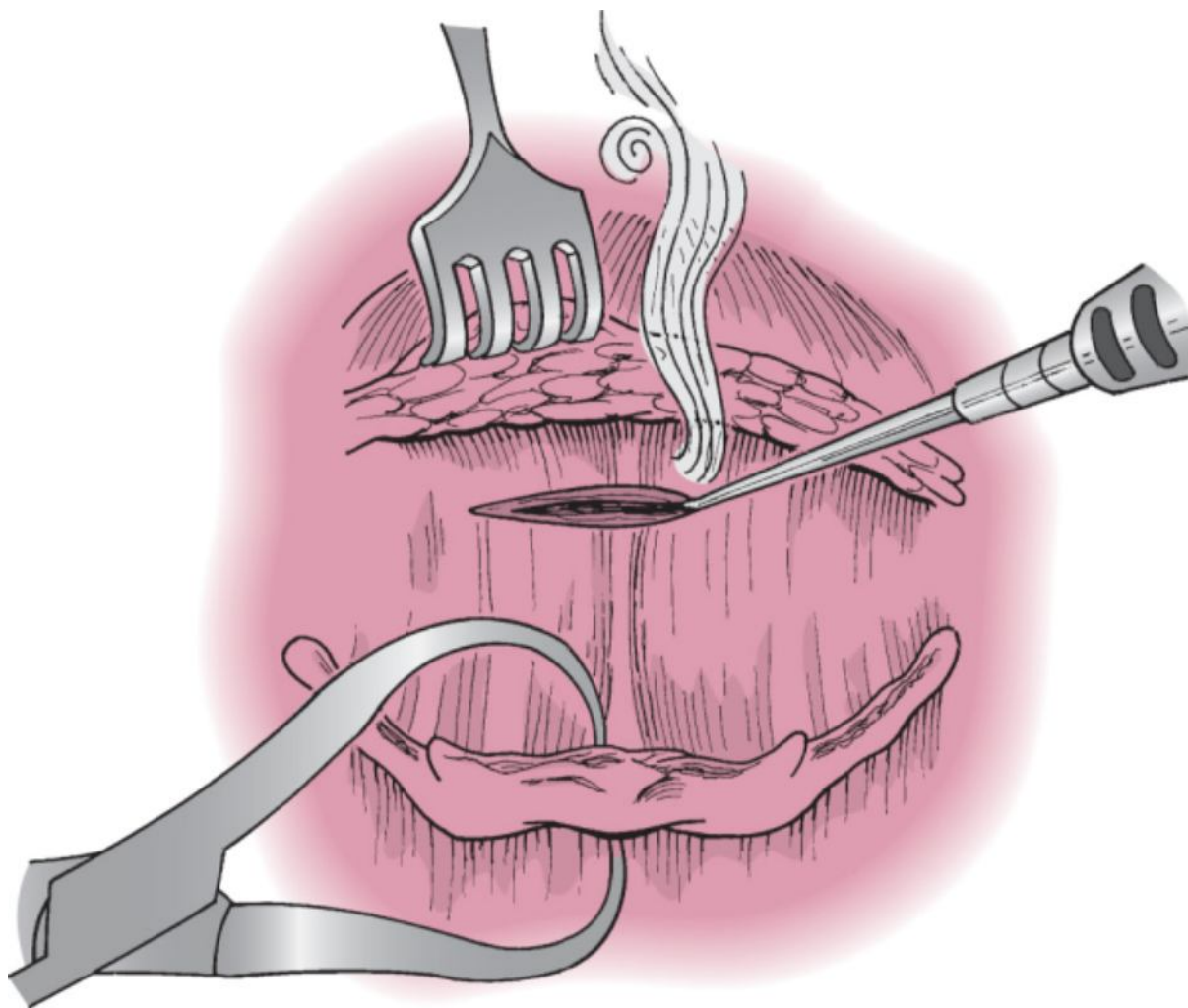
**Figure 49-9** Elevation of the piriform mucosa to assist in preserving the mucosa. This step is key to ensure that adequate mucosa is preserved for closure of the pharynx.

The trachea is divided, and the posterior wall of the trachea is separated from the cervical esophagus. Blunt dissection superiorly will free the larynx up to the level of the postcricoid mucosa (Fig. 49-10). The larynx is now freed except for its attachments to the pharyngeal mucosa.

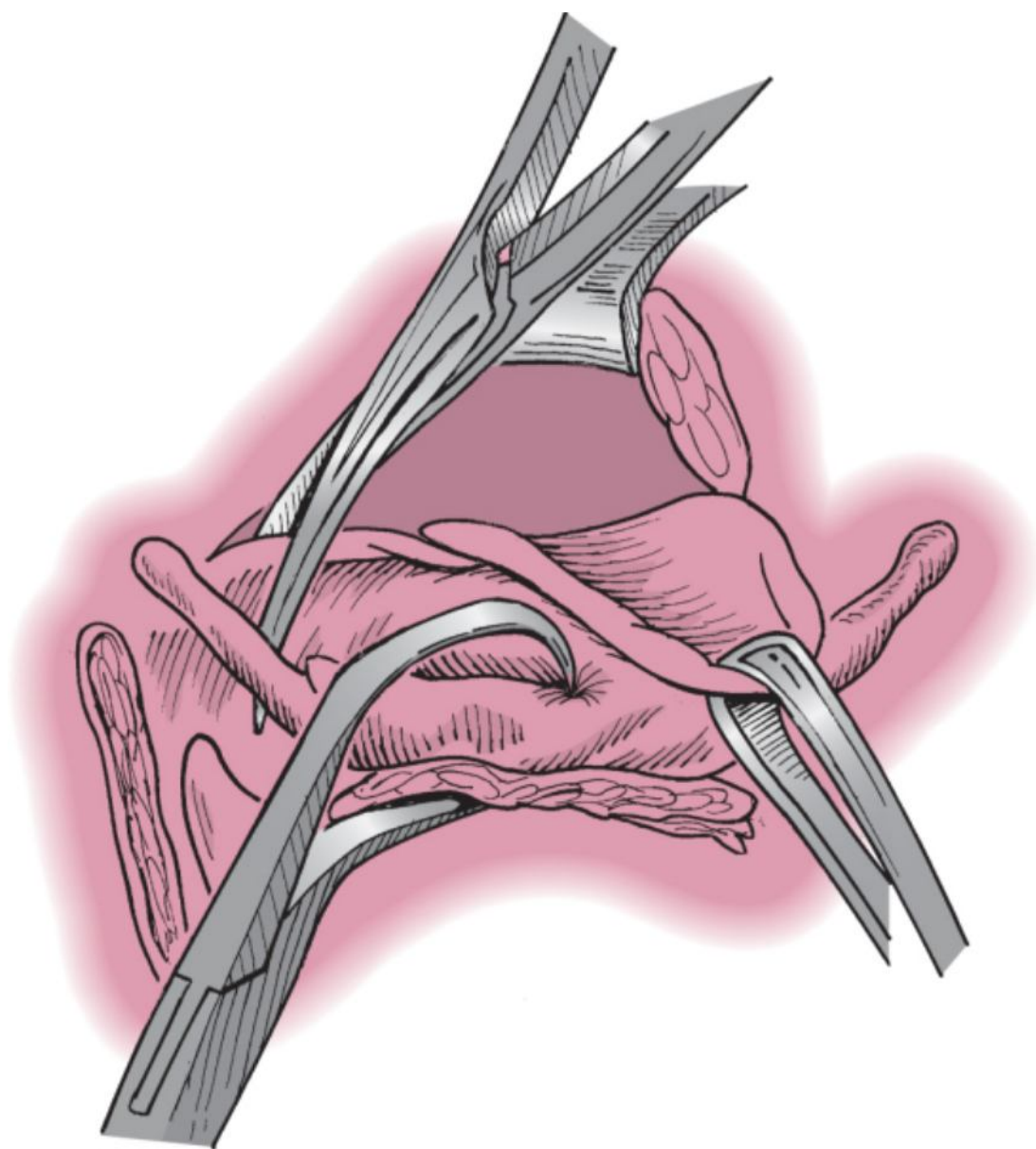


**Figure 49-10** Division of the posterior wall of the trachea and dissection to the postcricoid region. The most difficult part of this dissection is identification of the correct plane of dissection. Once the correct plane is identified, the dissection is easily performed with a finger.

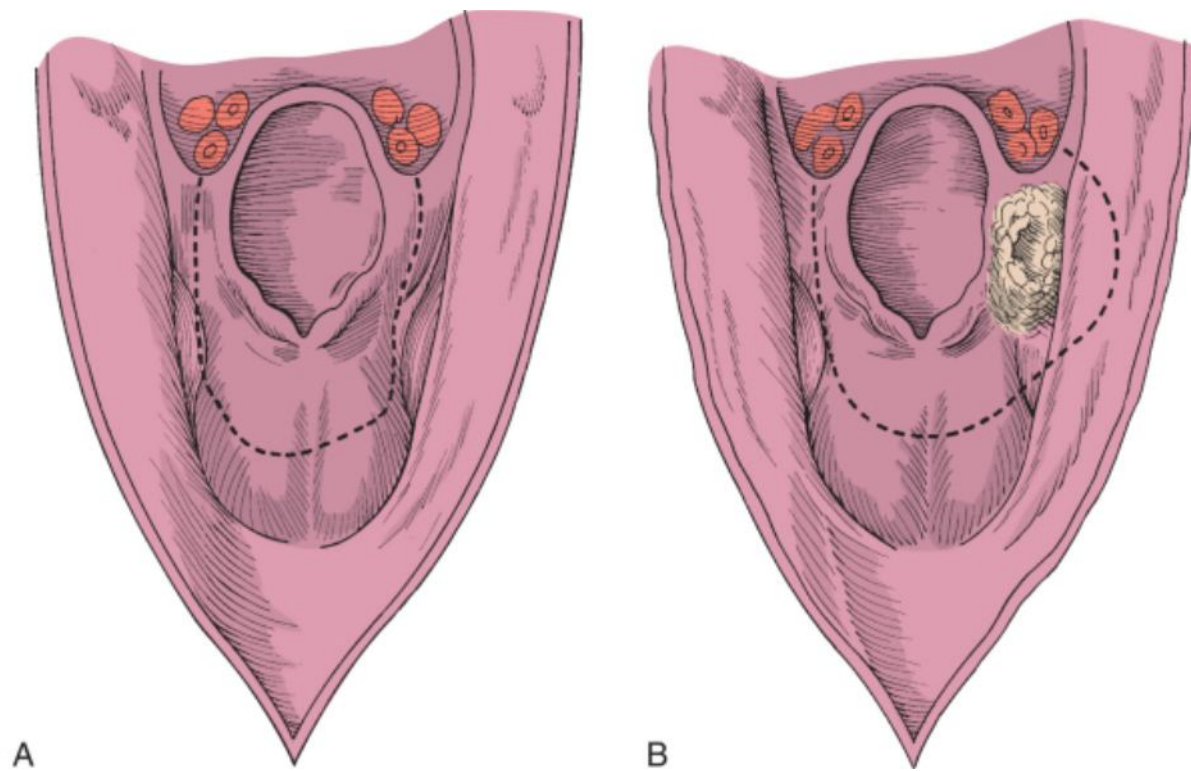
The pharynx can be entered in one of several ways. Ideally, the surgeon is familiar with several choices and selects one distant to the site of the tumor to afford maximal exposure and provide direct visualization of the cancer. Unless involved by tumor, the most expeditious approach is to enter through the vallecula. The hyoepiglottic ligament is identified by dissecting posteriorly from the hyoid (Fig. 49-11). By following this ligament posteriorly under the tongue musculature, the epiglottis can be identified and grasped with an Allis clamp and the mucosa incised to enter the vallecula. It is useful for the surgeon to put on a headlight at this time and move to the head of the table. With scissors and careful visualization of the mucosal surfaces, the larynx can be examined in detail and resected while taking care to ensure preservation of uninvolved pharyngeal mucosa to allow adequate mucosa for later closure (Figs. 49-12 to 49-14). This technique conserves maximal pharyngeal mucosa for closure (Figs. 49-13B and 49-14). It is critical that hypopharyngeal cancers be accurately assessed preoperatively to ensure that adequate mucosa will remain for pharyngeal closure. The specimen is resected and submitted for pathologic evaluation (Fig. 49-15). It is unnecessary to obtain frozen sections because adequate margins are the purpose of this operation.



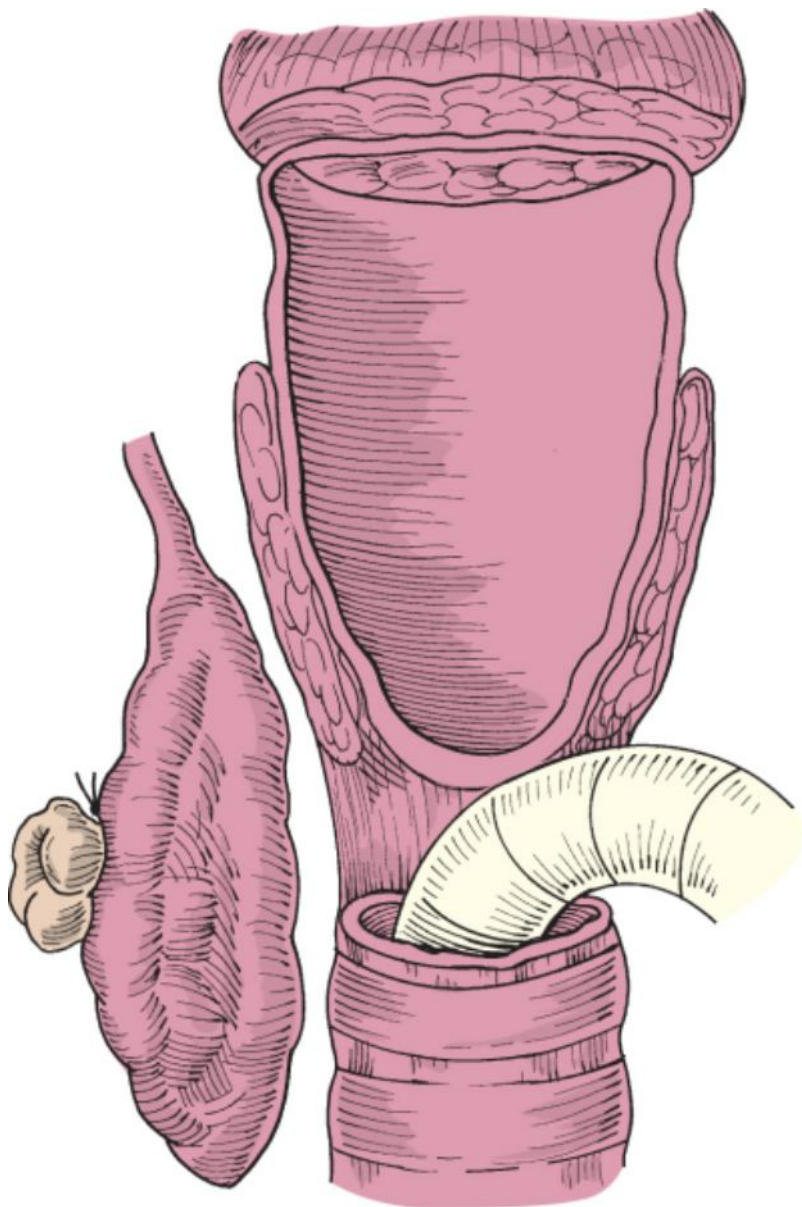
**Figure 49-11** Identification of the epiglottis is eased by following the hyoepiglottic ligament. With adequate retraction, the epiglottis is exposed and the pharynx is opened into the vallecula. This is usually farther from the hyoid bone than would be suspected.



**Figure 49-12** Excision of the larynx is begun by incising the pharyngoepiglottic fold while staying just lateral to the aryepiglottic fold. The outside scissors blade will be medial to the hyoid and the thyroid ala.

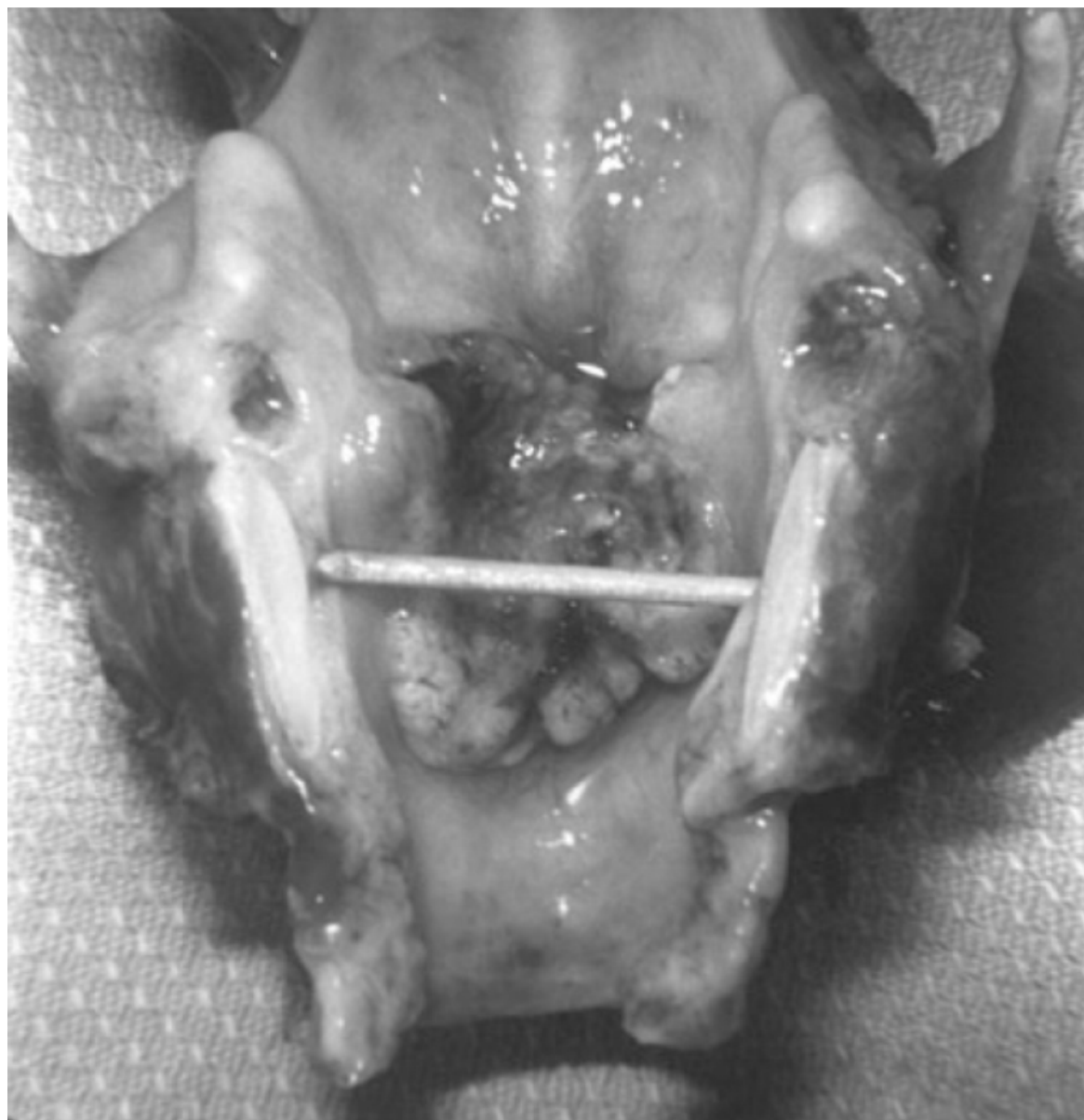

**Figure 49-13** A and B, Mucosal cuts for excision of the larynx, with care taken to preserve as much of the piriform mucosa as feasible. The piriform mucosa must be sacrificed if the cancer extends over the aryepiglottic fold or is within the piriform sinus (B).



**Figure 49-14** Defect after removal of the larynx. Note the preservation of the piriform sinus mucosa.

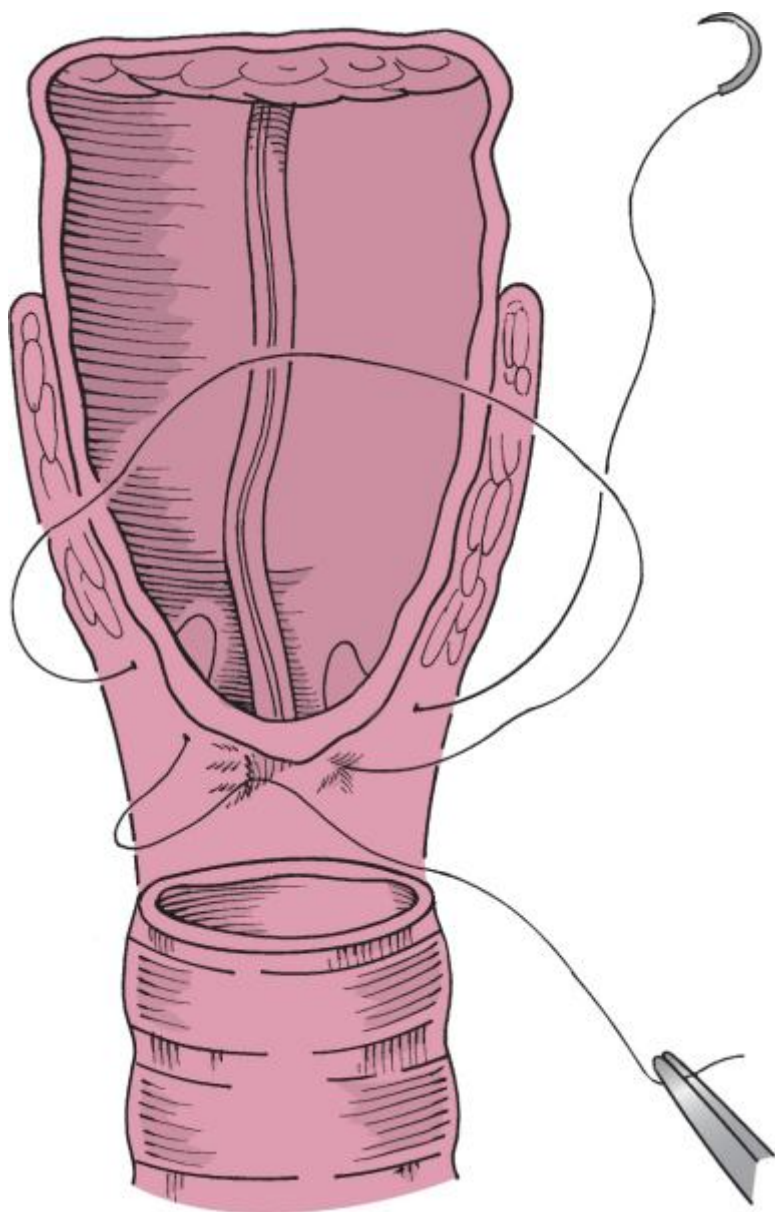




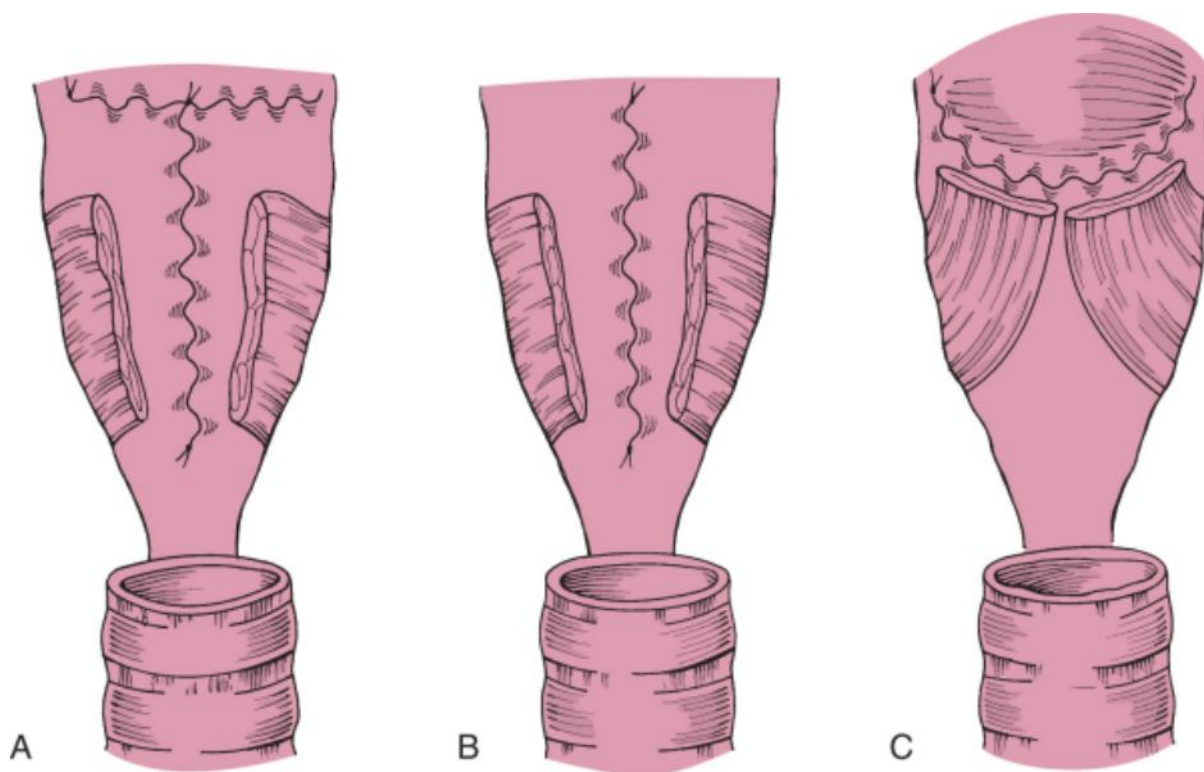
**Figure 49-15** Laryngeal specimen opened to show transglottic cancer. The cancer is crossing the anterior commissure from superior to inferior.

After hemostasis is obtained, a nasogastric tube is inserted through the nose, brought out into the pharynx, and passed into the esophagus and secured. If a tracheoesophageal puncture is planned, it is performed at this time, as described in Chapter 50. Care must be taken during tracheoesophageal puncture to ensure that the tract does not communicate with the neck but passes directly through the posterior wall of the trachea into the esophagus. Some surgeons routinely denervate the pharyngeal muscles or perform a myotomy by dividing the constrictor muscles along the posterior aspect of the pharynx to assist in postoperative voicing.

The type of closure will often be dictated by the amount of remaining piriform sinus mucosa. The pharyngeal mucosa is closed with running inverting suture (Fig. 49-16), usually in a  $\Gamma$ , vertical, or horizontal fashion (Fig. 49-17). The suturing technique is critical, and more than one individual should be observing each suture to ensure that the mucosa is inverted. Reinforcing sutures may be used; however, the constrictor muscles should *not be closed* because this will contribute to postoperative dysphagia and difficulty with voicing if speech rehabilitation with a tracheoesophageal puncture is used.

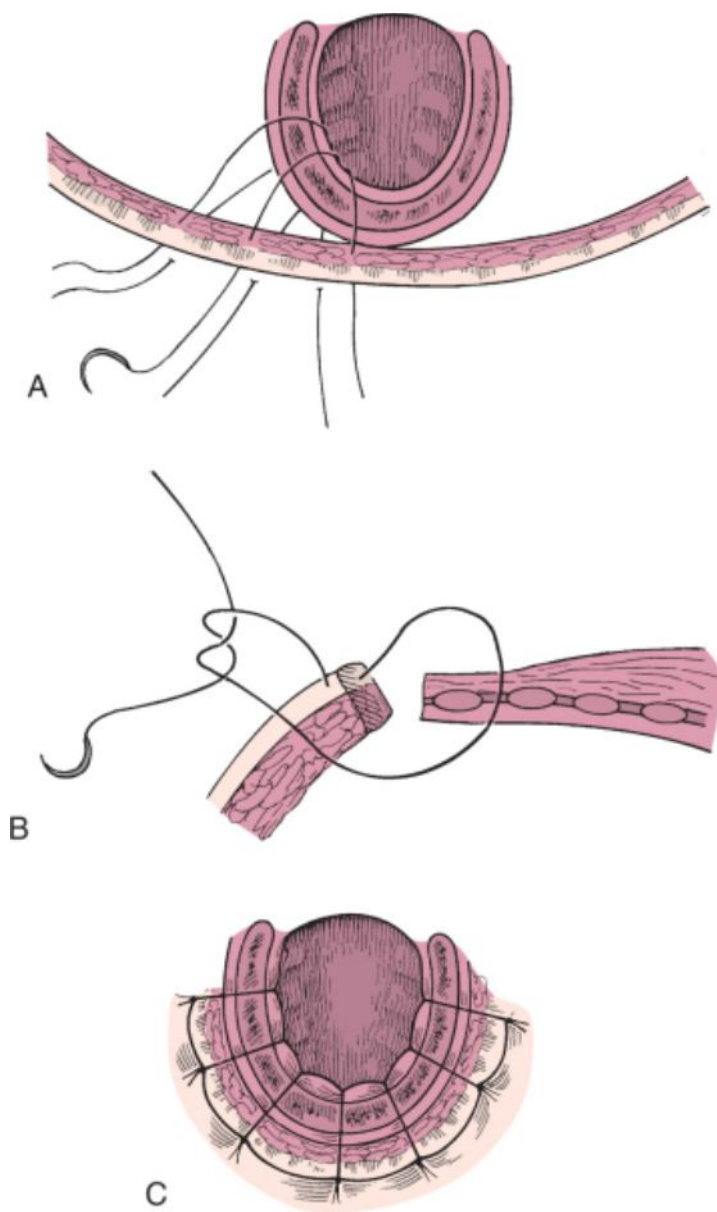


**Figure 49-16** Closure of the pharynx with detail of the suturing technique. Mucosal edges must be inverted or a fistula will develop.



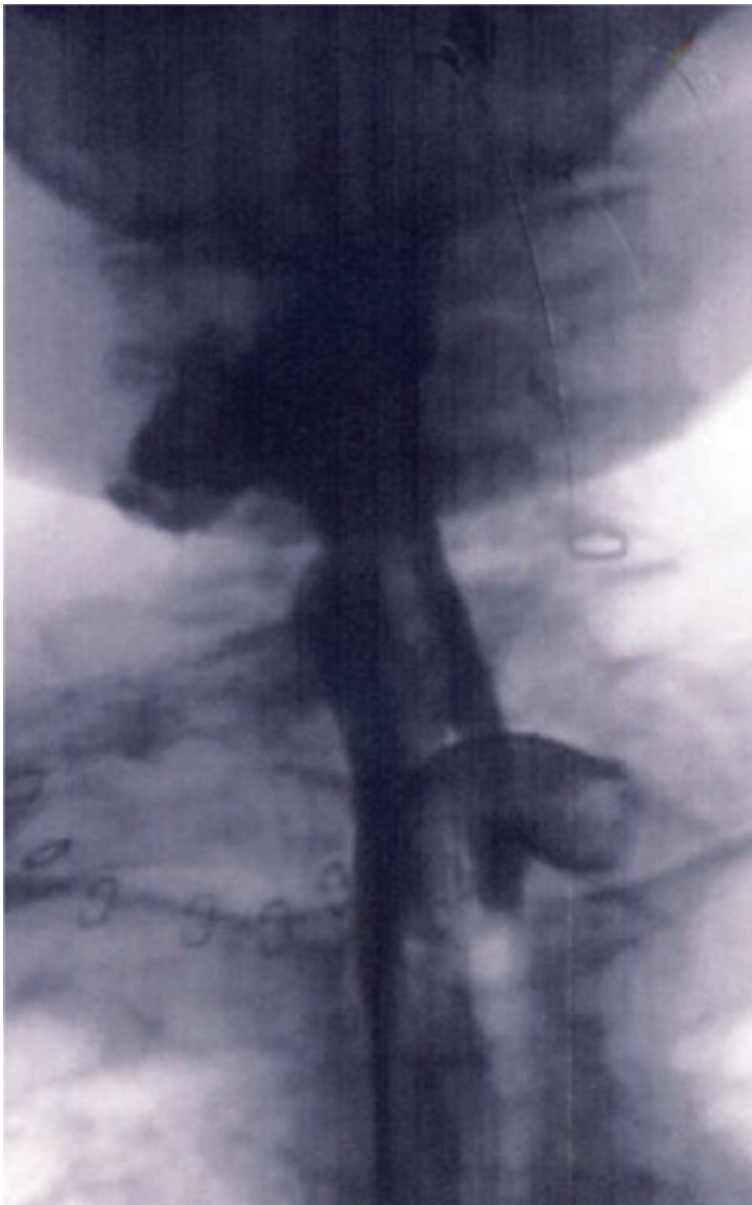
**Figure 49-17** Three types of pharyngeal closure. A T closure (A) is most common, although the T is technically difficult and prone to leakage. Vertical (B) or horizontal (C) closure can be performed if adequate mucosa is preserved, and these closures may be preferable.

The wound is irrigated, and the stoma is created by half-mattress sutures (Fig. 49-18). Stoma stenosis can be prevented by beveling the tracheal incision and advancing skin by taking larger bites on the skin side than on the tracheal side during closure. Hemovac suction drains are used. The neck incision should not be closed until the stoma has been created, and then the neck incision can be closed in the typical manner with absorbable deep sutures and skin staples. A dressing is applied and secured to assist in coapting the skin flaps. The anode tube is removed and a cuffed tracheostomy tube inserted. We generally use a no. 8 cuffed tracheostomy tube that is changed to an uncuffed laryngectomy tube after several days.



**Figure 49-18** Creation of the stoma with half-mattress sutures. **A**, The skin flaps are “walked” medially to ensure adequate stomal diameter by taking wider “bites” of skin than of trachea with each suture. **B**, Detail of a half-mattress suture. This technique pulls skin over the tracheal edge to cover cartilage. **C**, Stomal closure. In actuality, the half mattress sutures pull the skin over the exposed tracheal rings.

The patient is fed by nasogastric tube when bowel sounds are heard. After the appropriate period, usually about 7 days, the nasogastric tube is removed and the patient is maintained on a liquid diet. Patients who have previously undergone radiotherapy or in whom the pharyngeal closure is difficult or who demonstrate erythema of the flap with or without fever are studied with an esophagogram before initiating an oral diet. Identification of a sinus tract is an indication to delay the oral diet and continue tube feeding until it is clear that a fistula or a sinus tract is not present (Fig. 49-19).



**Figure 49-19** Barium swallow in a patient who has undergone total laryngectomy with a small pharyngeal leak. If small, it may respond to conservative treatment and not progress to a pharyngocutaneous fistula.

#### PEARLS

- Not every patient is best served by total laryngectomy. Discussion with the patient will usually lead to a clear understanding of the patient's preferences for therapy.
- Conservation laryngeal procedures require that the tumor and the patient both be amenable to the planned procedure. Do not perform conservation horizontal procedures on patients in whom aspiration will be a problem.
- Extension beyond the larynx to the subglottis, base of the tongue, and hypopharynx increases the chance of leaving persistent tumor behind. Frozen section evaluation of surgical margins is necessary.
- A carefully performed pharyngeal closure is key to avoiding a postoperative fistula.
- A tracheotomy under local anesthesia may be necessary in patients with a large obstructive laryngeal cancer.

#### PITFALLS

- The most common pitfall in the surgical management of laryngeal carcinoma is failure to accurately stage the tumor and thereby make an inappropriate choice of therapy. Repeat endoscopy just before the procedure is helpful, particularly when the patient has undergone diagnostic endoscopy and biopsy elsewhere.

- Failure to administer perioperative antibiotics will result in an unacceptable rate of wound infection in patients in whom the upper aerodigestive tract is opened. Each surgeon must establish a system—or confirm that a system exists—to ensure that antibiotics are administered at the right time and in the right dose.
- Continued soilage of the wound with oropharyngeal secretions as a result of technical error during pharyngeal closure is the most common cause of postoperative wound infection and pharyngocutaneous fistula.
- Failure to accurately close the pharynx can result in the development of a fistula. This complication can be prevented by meticulous attention to detail during closure of the pharynx. The closure must be performed without tension and with careful inversion of the mucosa. Adequate wound drainage is necessary to prevent accumulation of fluid, which acts as a culture medium for wound infections.

Copyright © 2009 [Elsevier](#) Inc. All rights reserved. Read our Terms and Conditions of Use and our Privacy Policy.  
For problems or suggestions concerning this service, please contact: [online.help@elsevier.com](mailto:online.help@elsevier.com)