

Flexibook




Pocket Atlas of Sectional Anatomy

Computed Tomography and
Magnetic Resonance Imaging

T. B. Moeller
E. Reif

Volume III:
Spine, Extremities, Joints

basic sciences



Thieme



Pocket Atlas of Sectional Anatomy

Computer Tomography
and Magnetic Resonance Imaging

Volume 3
Spine, Extremities, Joints

Torsten B. Moeller, MD
Department of Radiology
Caritas Hospital
Dillingen, Germany

Emil Reif, MD
Department of Radiology
Caritas Hospital
Dillingen, Germany

485 Illustrations

Thieme
Stuttgart · New York

Library of Congress Cataloging-in-Publication Data is available from the publisher.

Translator: Barbara Herzberger, MD,
Munich, Germany

Illustrator: Barbara Gay, Stuttgart, Germany

© 2007 Georg Thieme Verlag,
Rüdigerstrasse 14, 70469 Stuttgart, Germany
<http://www.thieme.de>
Thieme New York, 333 Seventh Avenue,
New York, NY 10001, USA
<http://www.thieme.com>

Cover design: Thieme Marketing
Typesetting by Primustype Hurler,
Notzingen
Printed in Germany by Appl, Wemding

10-ISBN 3-13-143171-7 (GTV)
13-ISBN 978-3-13-143171-4 (GTV)
10-ISBN 1-58890-566-7 (TNY)
13-ISBN 978-1-58890-566-6 (TNY)

1 2 3 4 5 6

Important note: Medicine is an ever-changing science undergoing continual development. Research and clinical experience are continually expanding our knowledge, in particular our knowledge of proper treatment and drug therapy. Insofar as this book mentions any dosage or application, readers may rest assured that the authors, editors, and publishers have made every effort to ensure that such references are in accordance with the **state of knowledge at the time of production of the book.**

Nevertheless, this does not involve, imply, or express any guarantee or responsibility on the part of the publishers in respect to any dosage instructions and forms of applications stated in the book.

Every user is requested to examine carefully the manufacturers' leaflets accompanying each drug and to check, if necessary in consultation with a physician or specialist, whether the dosage schedules mentioned therein or the contraindications stated by the manufacturers differ from the statements made in the present book. Such examination is particularly important with drugs that are either rarely used or have been newly released on the market. Every dosage schedule or every form of application used is entirely at the user's own risk and responsibility. The authors and publishers request every user to report to the publishers any discrepancies or inaccuracies noticed. If errors in this work are found after publication, errata will be posted at www.thieme.com on the product description page. Some of the product names, patents, and registered designs referred to in this book are in fact registered trademarks or proprietary names even though specific reference to this fact is not always made in the text. Therefore, the appearance of a name without designation as proprietary is not to be construed as a representation by the publisher that it is in the public domain.

This book, including all parts thereof, is legally protected by copyright. Any use, exploitation, or commercialization outside the narrow limits set by copyright legislation, without the publisher's consent, is illegal and liable to prosecution. This applies in particular to photostat reproduction, copying, mimeographing, preparation of microfilms, and electronic data processing and storage.

For my American relatives

**Bernie and Arlene, Bryan, Nancy,
Rick and Bill, Shirley, Mike, Michael,
Austin and Amanda, Audrey, Mike,
Kristin and Katelyn, Claudia, Dale,
Bryan, Jamie, and Meghan**

Preface

Magnetic resonance imaging (MRI) of the musculoskeletal system is an established and important component in the diagnosis of diseases of the joints, soft tissues, bones, and bone marrow. We are therefore pleased to collect together images of the joints and the spinal column in a separate volume on the musculoskeletal system. Demonstrating the growing importance of new developments in MRI in recent years, with ever-increasing resolution, many images were acquired with 3-tesla units. We are deeply grateful to the manufacturers, Siemens and Philips, for making this possible.

We believe that colored atlases are the ideal medium to represent the highly detailed images achieved nowadays with improved resolution techniques. Volume 3 of the *Pocket Atlas of Sectional Anatomy* provides a color illustration facing each magnetic resonance image, as in the preceding volumes on the skull, thorax, and abdomen. To ensure the greatest possible precision in details, we still produce these illustrations ourselves. Each is accompanied by a sectional image and an orientation aid. Uniform color schemes ensure optimal clarity, as similar structures, such as arteries, veins, nerves, tendons, etc., are consistently represented in the same color. Individual muscle groups are represented uniformly, but differentiated from other muscle groups, so that classification is possible even when numerous groups of muscles are shown in the same image. Maximal lucidity prevails even in highly detailed representations. This is made possible by the high quality of the production and printing process that are characteristic of Thieme International.

Our special thanks go to our radiology assistants, Silke Köhl, Sabine Mattil, Stephanie Müller, Heike Philippi, Brigitte Schild, Petra Weber, and Tanja Breunig, and also to Birgit Reuter and Marion Hellinger from the Siemens Manufacturing Center, for providing these images. We are deeply grateful to our medical colleagues Sigrid Roth and, especially, Simone Zenner, for their intensive discussions and helpful suggestions.

Torsten B. Moeller
Emil Reif

Contents

Upper Extremity	1
Arm, Axial	2
Shoulder, Coronal	62
Shoulder, Sagittal	74
Elbow, Coronal	84
Elbow, Sagittal	90
Hand, Coronal	98
Hand, Sagittal	106
Lower Extremity	115
Leg, Axial	116
Hip, Coronal	180
Hip, Sagittal	190
Knee, Coronal	200
Knee, Sagittal	212
Foot, Coronal	232
Foot, Sagittal	254
Spine	263
Spine, Sagittal	264
Cervical Spine, Sagittal	266
Cervical Spine, Coronal	272
Cervical Spine, Axial	278
Thoracic Spine, Sagittal	288
Thoracic Spine, Axial	294
Lumbar Spine, Sagittal	296
Lumbar Spine, Coronal	304
Lumbar Spine, Axial	310
Bibliography	316
Index	318

 Arteries Nerves Veins Bones Fatty tissue Cartilage Tendon Disk, labrum etc. Fluid**Muscles of Trunk:**

Serratus anterior

Omohyoid

Trapezius

Subclavius

Intercostal

**Muscles of Shoulder:**

Deltoid

Infraspinatus

Pectoralis major and pectoralis minor

Subscapularis

Coracobrachialis

Latissimus dorsi

Dorsal Muscles of Lower Arm:

Supinator

Extensor pollicis longus and brevis

Extensor indicis

Muscles of Hand:

Dorsal and palmar interosseous

Lumbrical

**Volar Muscles of Upper Arm:**

Biceps brachii

Brachialis

**Dorsal Muscles of Upper Arm:**

Triceps brachii

Anconeus

**Dorsal Muscles of Lower Arm****(superficial layer):**

Extensor digitorum

Extensor digiti minimi

Extensor carpi ulnaris

**Radial Muscles of Lower Arm:**

Brachioradialis

Extensor carpi radialis longus

Extensor carpi radialis brevis


**Volar Muscles of Lower Arm (superficial layer):**

Pronator teres

Flexor digitorum superficialis

Flexor carpi radialis and flexor carpi ulnaris

Palmaris longus and palmaris brevis

**Volar Muscles of Lower Arm (deep layer):**

Flexor digitorum profundus

Flexor pollicis longus

Pronator quadratus

**Muscles of Little (Fifth) Finger:**

Abductor digiti minimi

Flexor digiti minimi brevis

Opponens digiti minimi

**Muscles of Thumb:**

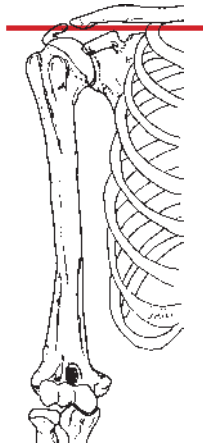
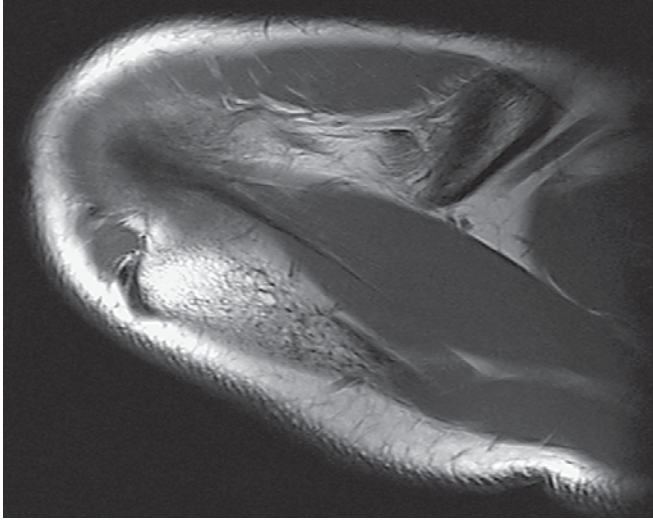
Abductor pollicis longus

and abductor pollicis brevis

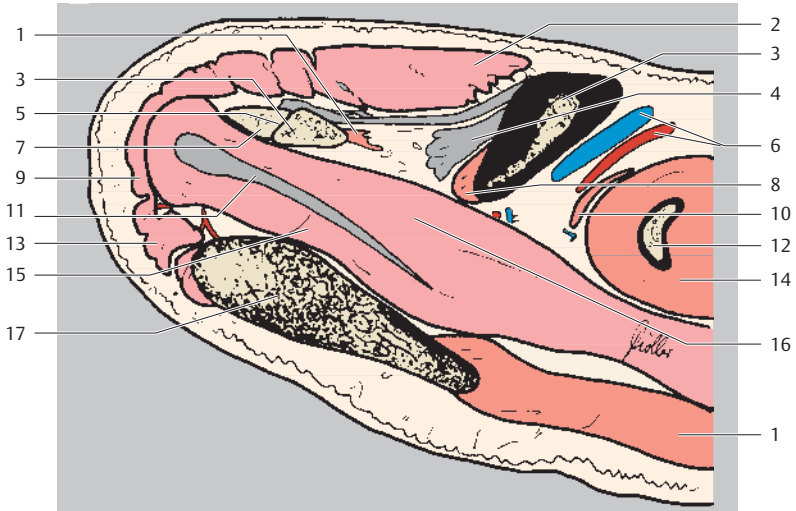
Opponens pollicis

Flexor pollicis brevis

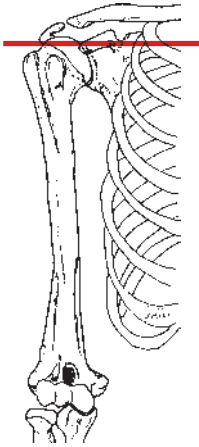
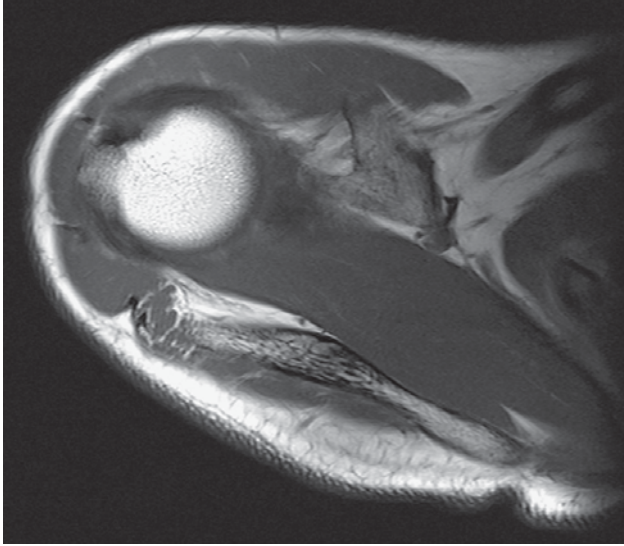
Adductor pollicis



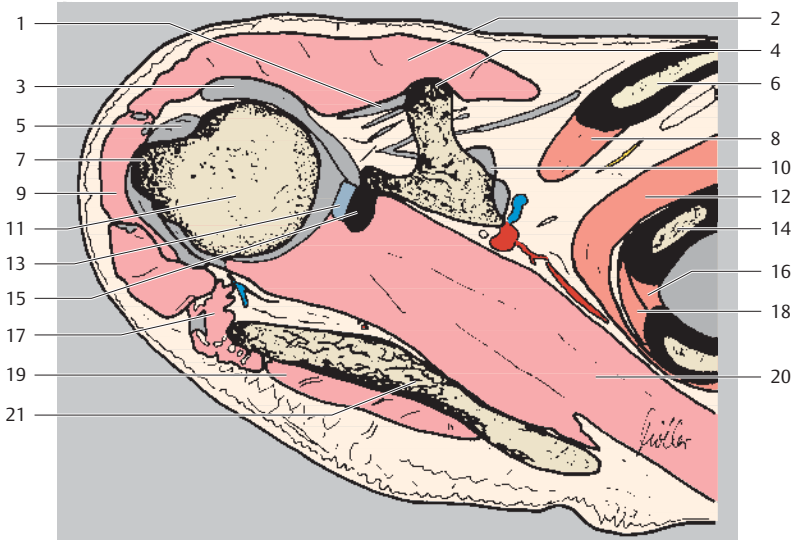
Ventral
Lateral Medial
Dorsal



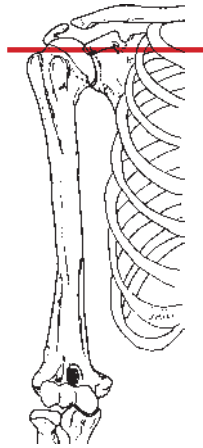
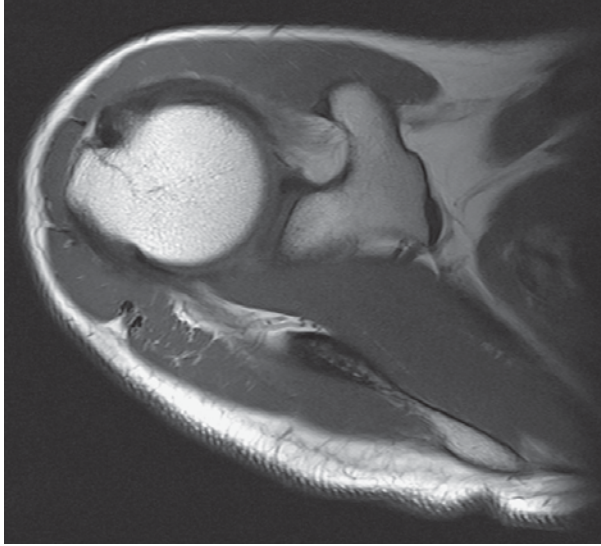
- | | |
|------------------------------------|--|
| 1 Trapezius muscle | 11 Supraspinatus muscle (central tendon) |
| 2 Deltoid muscle (clavicular part) | 12 Rib |
| 3 Clavicle | 13 Deltoid muscle (spinal part) |
| 4 Coracoclavicular ligament | 14 Serratus anterior muscle |
| 5 Acromioclavicular joint | 15 Supraspinatus muscle (dorsal ligament) |
| 6 Suprascapular artery and vein | 16 Supraspinatus muscle (ventral ligament) |
| 7 Acromion | 17 Spine of scapula |
| 8 Subclavius muscle | |
| 9 Deltoid muscle (acromial part) | |
| 10 Omohyoid muscle | |



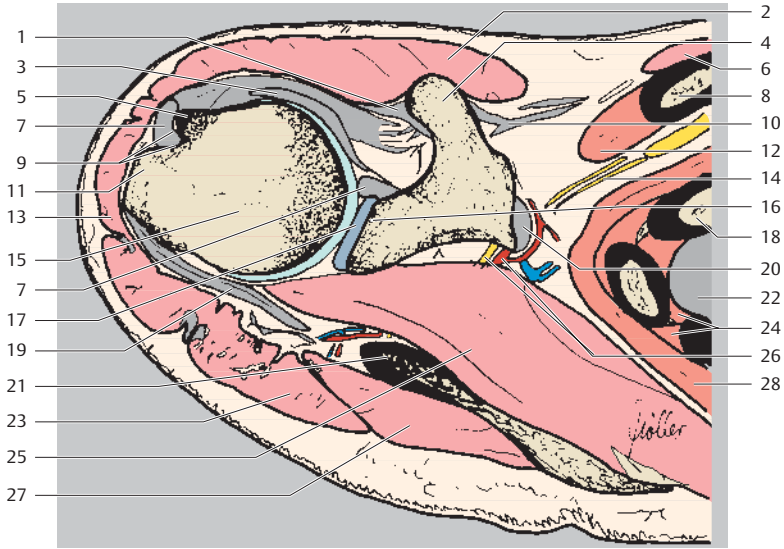
Ventral
Lateral Medial
Dorsal



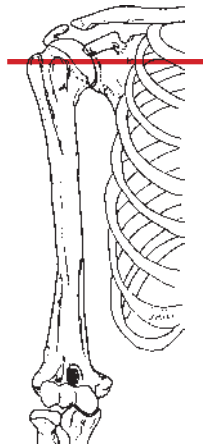
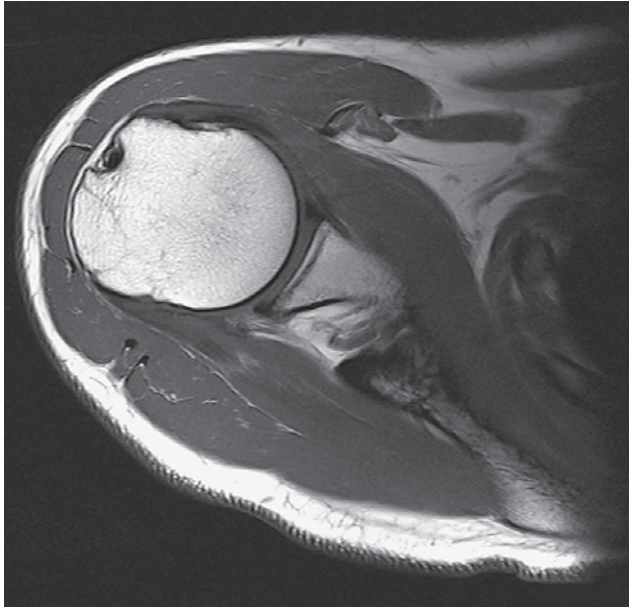
- | | |
|------------------------------------|---------------------------------|
| 1 Coracohumeral ligament | 12 Serratus anterior muscle |
| 2 Deltoid muscle (clavicular part) | 13 Superior glenoid labrum |
| 3 Middle glenohumeral ligament | 14 Rib |
| 4 Coracoid process | 15 Glenoid |
| 5 Supraspinatus muscle (tendon) | 16 Internal intercostal muscle |
| 6 Clavicle | 17 Deltoid muscle (spinal part) |
| 7 Humerus (greater tubercle) | 18 External intercostal muscle |
| 8 Subclavius muscle | 19 Infraspinatus muscle |
| 9 Deltoid muscle (acromial part) | 20 Supraspinatus muscle |
| 10 Coracoclavicular ligament | 21 Spine of scapula |
| 11 Head of humerus | |



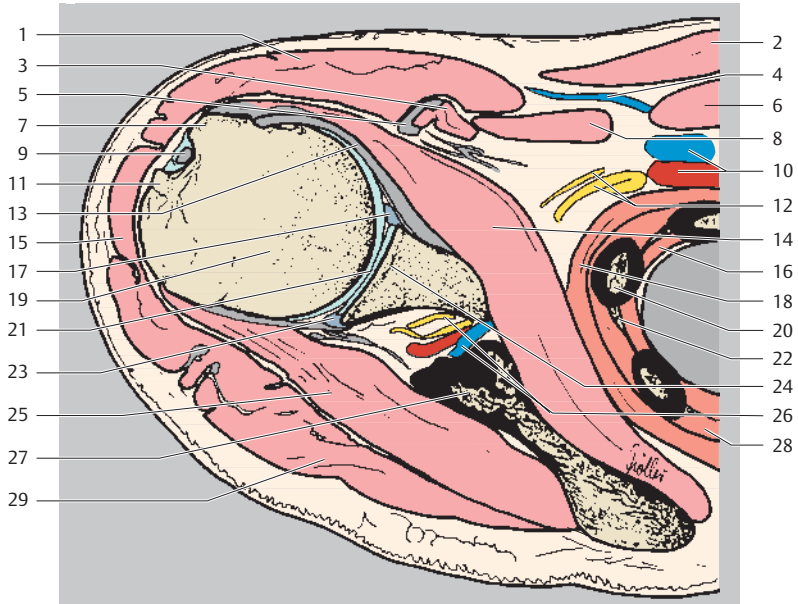
Ventral
Lateral Medial
Dorsal



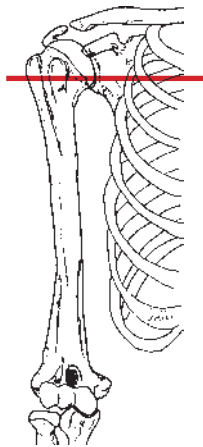
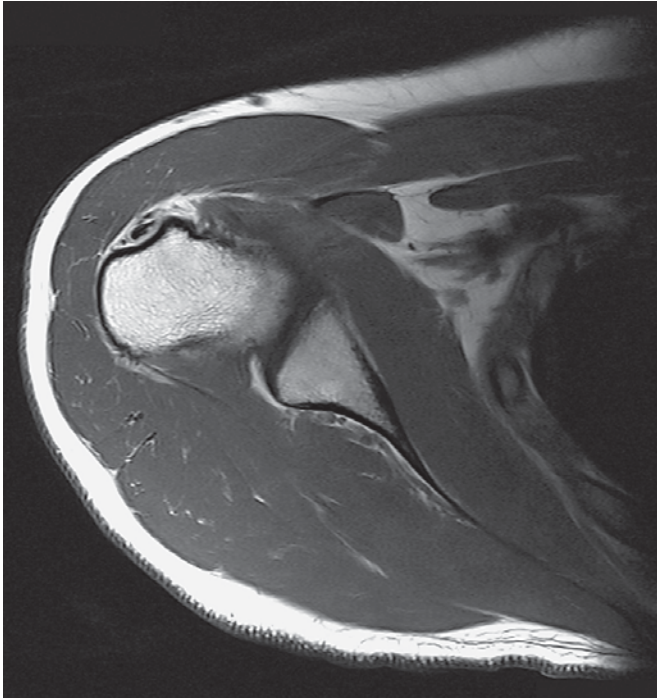
- | | |
|---|--|
| 1 Coracohumeral ligament | 15 Head of humerus |
| 2 Deltoid muscle (clavicular part) | 16 Glenoid |
| 3 Middle glenohumeral ligament | 17 Superior glenoid labrum |
| 4 Coracoid process | 18 Rib |
| 5 Humerus (lesser tubercle) | 19 Infraspinatus muscle (tendon attachment) |
| 6 Pectoralis major muscle | 20 Coracoclavicular ligament |
| 7 Biceps brachii muscle (long head, tendon) | 21 Spine of scapula |
| 8 Clavicle | 22 Lung |
| 9 Intertubercular sulcus (bicipital groove) | 23 Deltoid muscle (spinal part) |
| 10 Pectoralis minor muscle (tendon) | 24 Internal and external intercostal muscles |
| 11 Humerus (greater tubercle) | 25 Supraspinatus muscle |
| 12 Subclavius muscle | 26 Suprascapular artery and vein |
| 13 Deltoid muscle (acromial part) | 27 Infraspinatus muscle |
| 14 Brachial plexus | 28 Serratus anterior muscle |



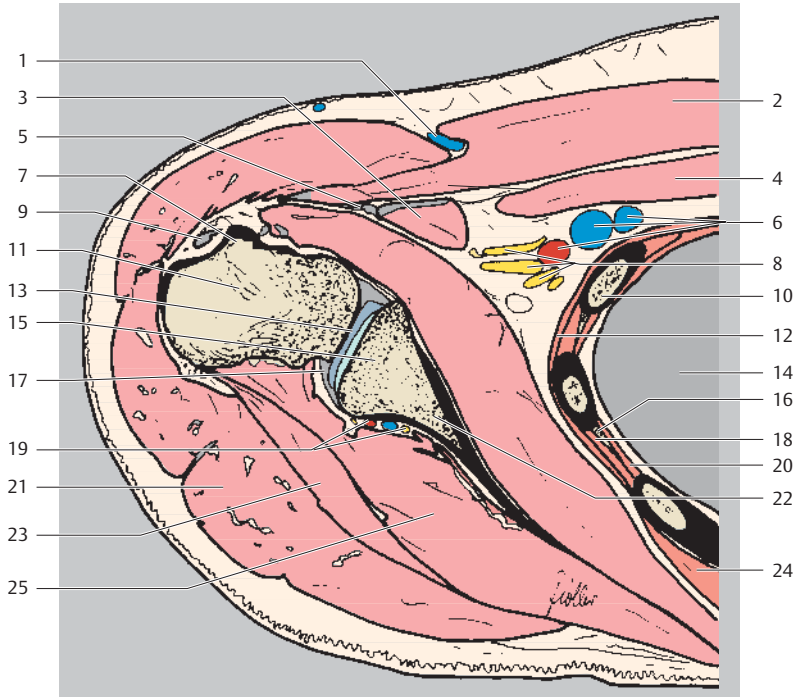
Ventral
Lateral Medial
Dorsal



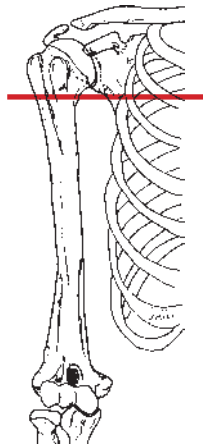
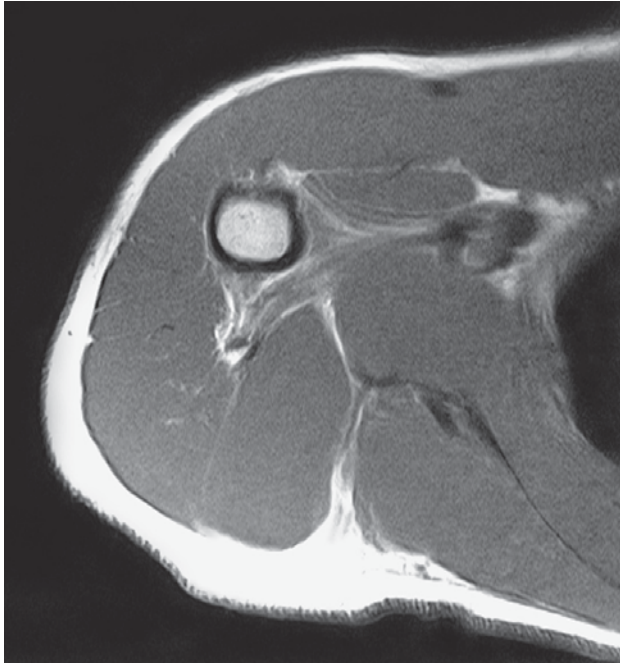- | | |
|--|--|
| 1 Deltoid muscle (clavicular part) | 14 Subscapularis muscle |
| 2 Pectoralis major muscle | 15 Deltoid muscle (acromial part) |
| 3 Coracobrachialis muscle (+ tendon) | 16 Internal intercostal muscle |
| 4 Cephalic vein | 17 Anterior glenoid labrum |
| 5 Biceps brachii muscle (short head, tendon) | 18 Serratus anterior muscle |
| 6 Subclavius muscle | 19 Head of humerus |
| 7 Humerus (lesser tubercle) | 20 Rib |
| 8 Pectoralis minor muscle | 21 Humeroscapular joint |
| 9 Biceps brachii muscle (long head, tendon) | 22 Intercostal artery, vein, and nerve |
| 10 Axillary artery and vein | 23 Posterior glenoid labrum |
| 11 Humerus (greater tubercle) | 24 Glenoid |
| 12 Brachial plexus and subscapular nerve | 25 Infraspinatus muscle |
| 13 Middle glenohumeral ligament | 26 Suprascapular artery, vein, and nerve |
| | 27 Scapula |
| | 28 External intercostal muscle |
| | 29 Deltoid muscle (spinal part) |



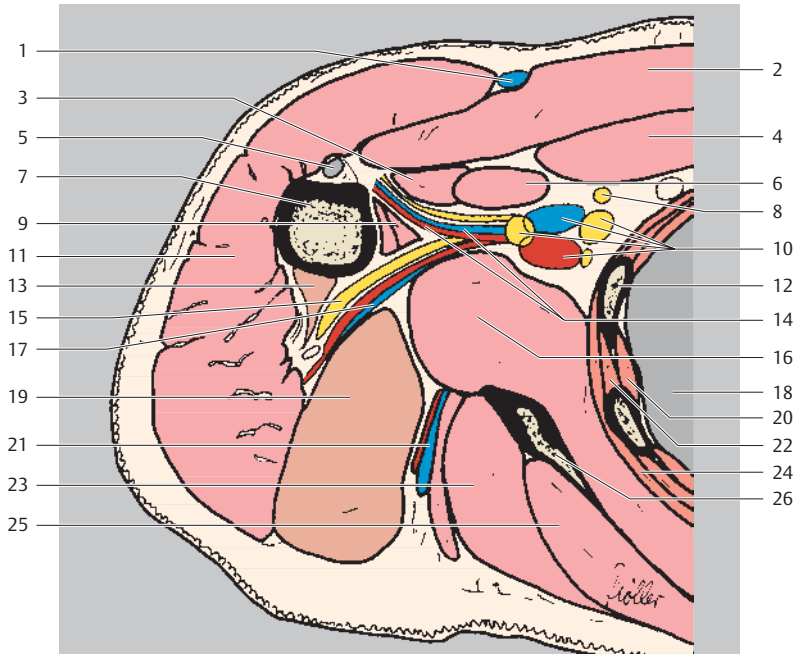
Ventral
Lateral Medial
Dorsal



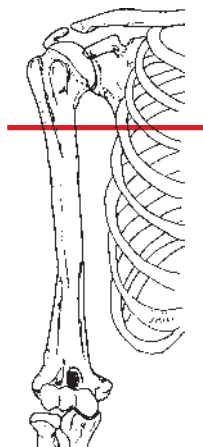
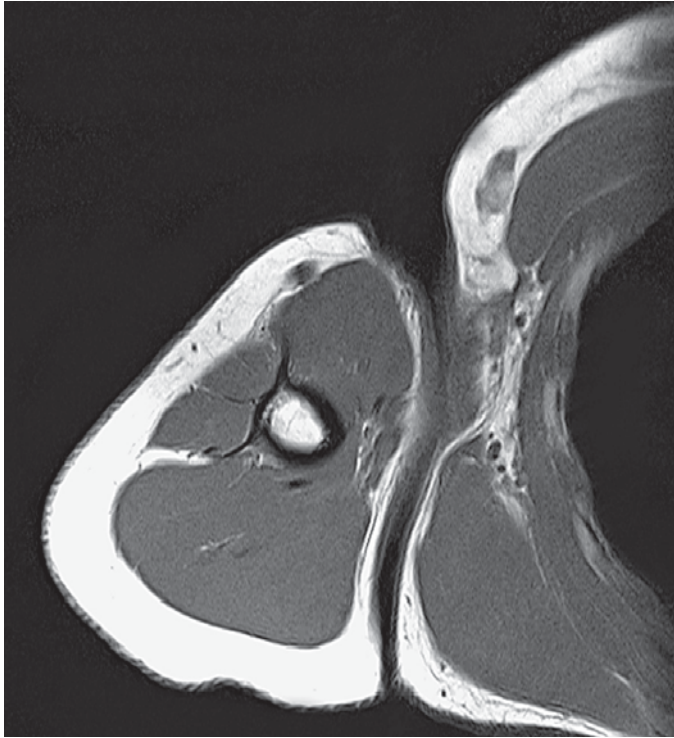- | | |
|---|--|
| 1 Cephalic vein | 12 Serratus anterior muscle |
| 2 Pectoralis major muscle | 13 Inferior glenoid labrum |
| 3 Coracobrachialis muscle
(+ tendon) | 14 Lung |
| 4 Pectoralis minor muscle | 15 Glenoid |
| 5 Biceps brachii muscle (short
head, tendon) | 16 Intercostal artery, vein, and nerve |
| 6 Axillary artery and vein | 17 Joint capsule |
| 7 Humerus (lesser tubercle) | 18 External intercostal muscle |
| 8 Brachial plexus | 19 Suprascapular artery, vein, and nerve |
| 9 Biceps brachii muscle (long
head, tendon) | 20 Internal intercostal muscle |
| 10 Rib | 21 Deltoid muscle |
| 11 Humerus | 22 Scapula |
| | 23 Teres minor muscle |
| | 24 Serratus posterior muscle |
| | 25 Infraspinatus muscle |



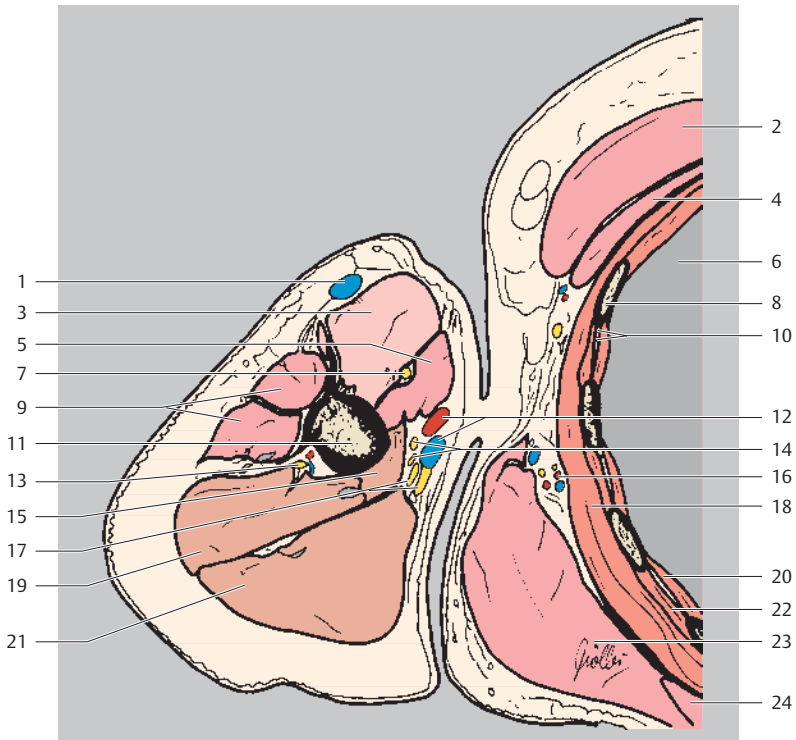
Ventral
Lateral Medial
Dorsal



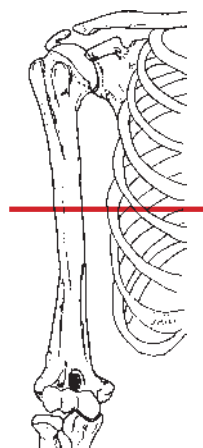
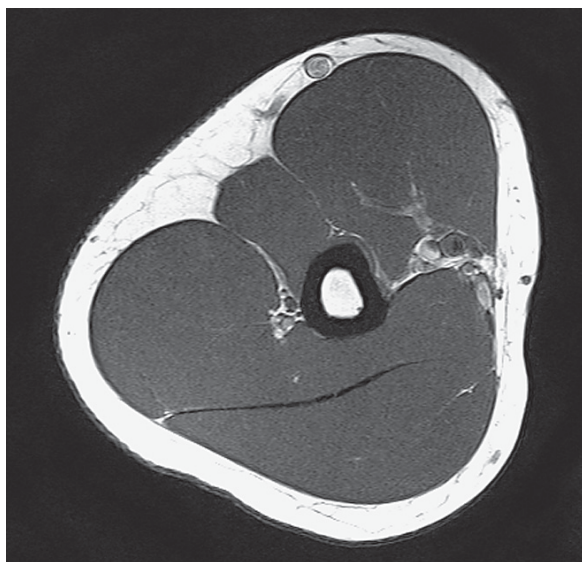- | | |
|--|---|
| 1 Cephalic vein | 14 Anterior circumflex humeral artery and vein |
| 2 Pectoralis major muscle | 15 Axillary nerve |
| 3 Biceps brachii muscle (short head, tendon) | 16 Subscapularis muscle |
| 4 Pectoralis minor muscle | 17 Posterior circumflex humeral artery and vein |
| 5 Biceps brachii muscle (long head, tendon) | 18 Lung |
| 6 Coracobrachialis muscle | 19 Triceps brachii muscle (long head) |
| 7 Humerus | 20 Internal intercostal muscle and innermost intercostal muscle |
| 8 Long thoracic nerve | 21 Circumflex scapular artery |
| 9 Latissimus dorsi muscle and teres major muscle | 22 External intercostal muscle |
| 10 Axillary artery and vein and brachial plexus | 23 Teres minor muscle |
| 11 Deltoid muscle | 24 Serratus anterior muscle |
| 12 Rib | 25 Infraspinatus muscle |
| 13 Triceps brachii muscle (lateral head) | 26 Scapula |



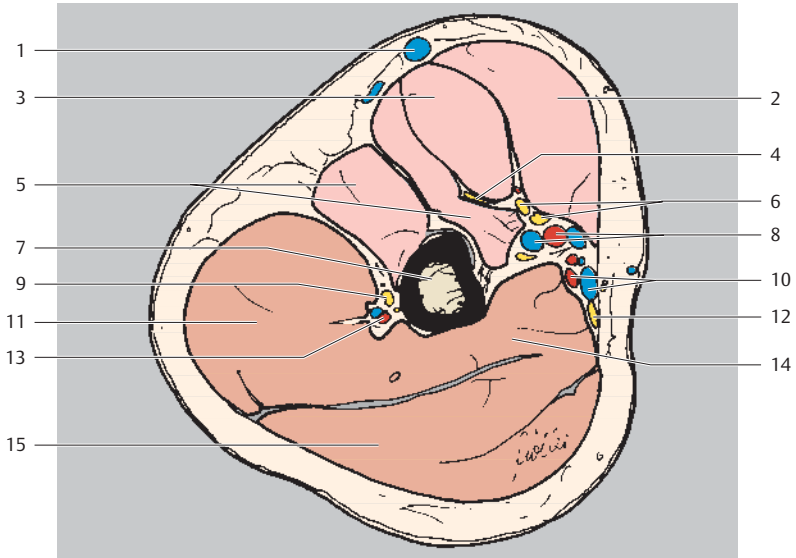
Ventral
Lateral Medial
Dorsal



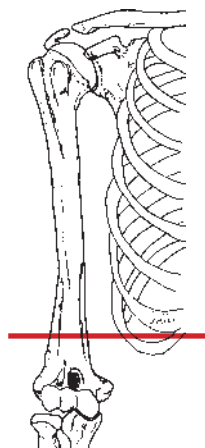
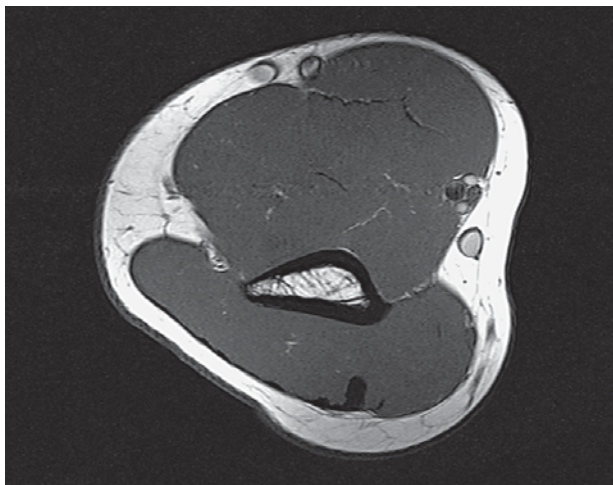
- | | |
|--|---|
| 1 Cephalic vein | 14 Median nerve |
| 2 Pectoralis major muscle | 15 Triceps brachii muscle (medial head) |
| 3 Biceps brachii muscle | 16 Thoracodorsal artery and nerve |
| 4 Pectoralis minor muscle | 17 Ulnar nerve |
| 5 Coracobrachialis muscle | 18 Serratus anterior muscle |
| 6 Lung | 19 Triceps brachii muscle (lateral head) |
| 7 Musculocutaneous nerve | 20 Internal and innermost intercostal muscles |
| 8 Rib | 21 Triceps brachii muscle (lateral head) |
| 9 Deltoid muscle | 22 External intercostal muscle |
| 10 Intercostal artery, vein, and nerve | 23 Teres major muscle and latissimus dorsi muscle |
| 11 Humerus (shaft) | 24 Infraspinatus muscle |
| 12 Brachial artery and vein | |
| 13 Radial nerve | |



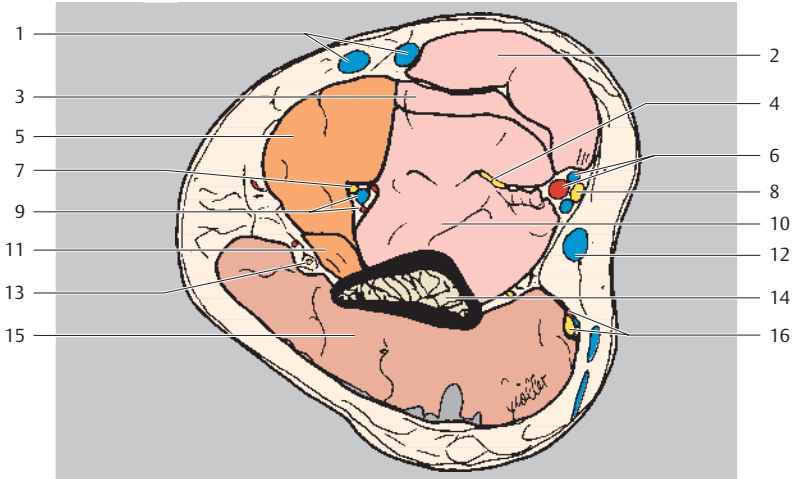
Ventral
Lateral Medial
Dorsal



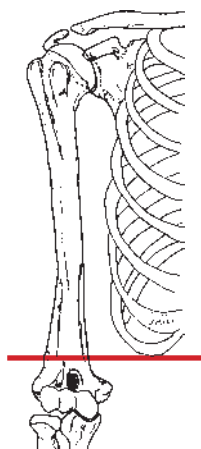
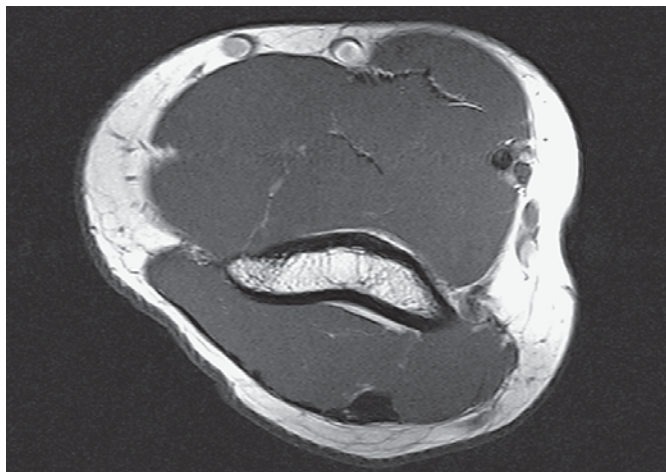
- | | |
|--------------------------------------|--|
| 1 Cephalic vein | 8 Brachial artery and vein |
| 2 Biceps brachii muscle (short head) | 9 Radial nerve |
| 3 Biceps brachii muscle (long head) | 10 Basilic vein |
| 4 Musculocutaneous nerve | 11 Triceps brachii muscle (lateral head) |
| 5 Brachial muscle | 12 Ulnar nerve |
| 6 Median nerve | 13 Deep brachial artery and vein |
| 7 Humerus (shaft) | 14 Triceps brachii muscle (medial head) |
| | 15 Triceps brachii muscle (long head) |



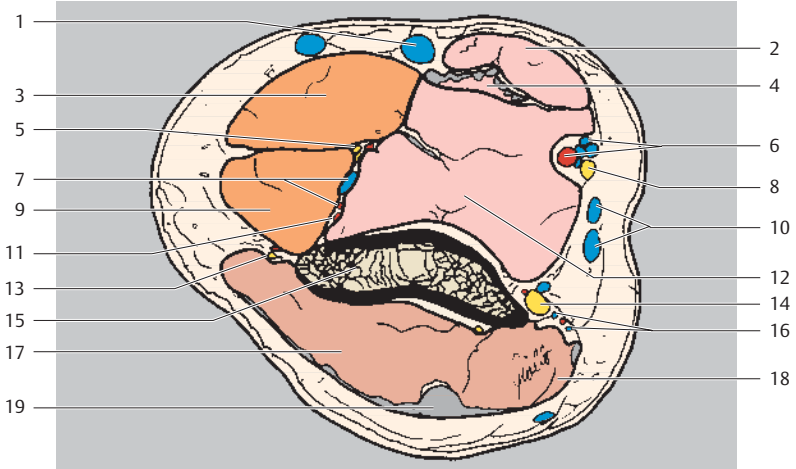
Ventral
Lateral Medial
Dorsal



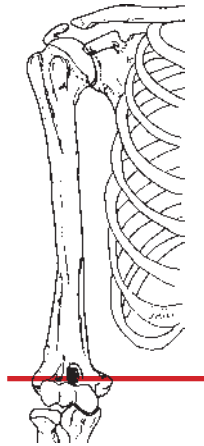
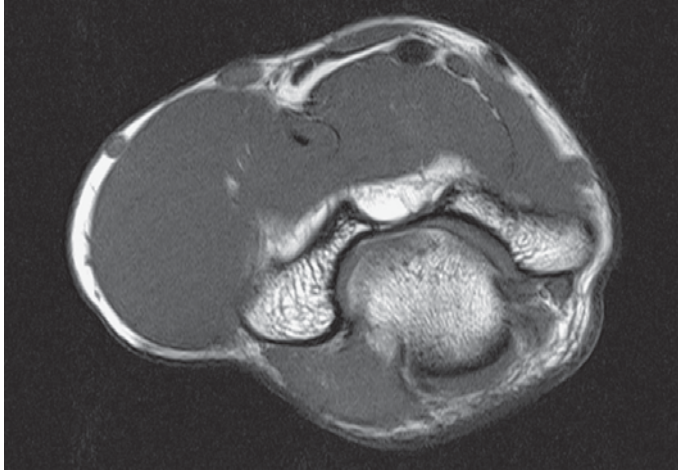
- | | |
|--------------------------------------|--|
| 1 Cephalic vein | 8 Median nerve |
| 2 Biceps brachii muscle (short head) | 9 Deep brachial artery and vein |
| 3 Biceps brachii muscle (long head) | 10 Brachialis muscle |
| 4 Musculocutaneous nerve | 11 Extensor carpi radialis longus muscle |
| 5 Brachioradialis muscle | 12 Basilic vein |
| 6 Brachial artery and vein | 13 Posterior cutaneous nerve of forearm |
| 7 Radial nerve | 14 Humerus (shaft) |
| | 15 Triceps brachii muscle |
| | 16 Ulnar nerve, artery, and vein |



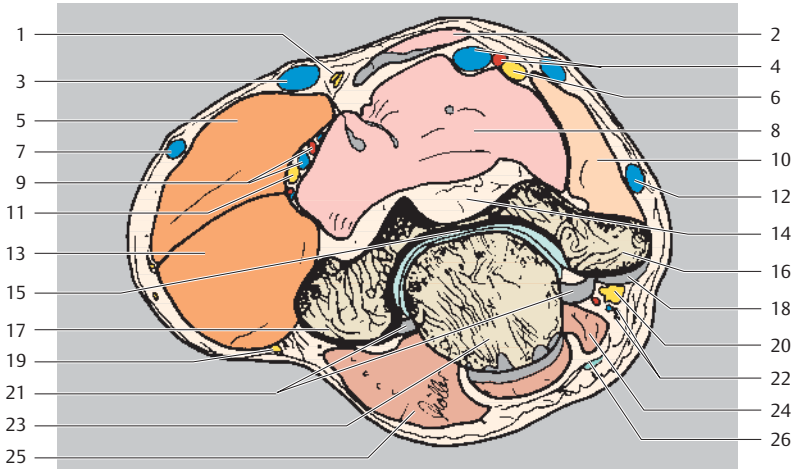
Ventral
Lateral Medial
Dorsal



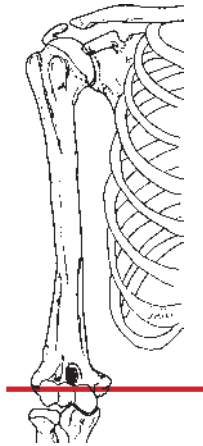
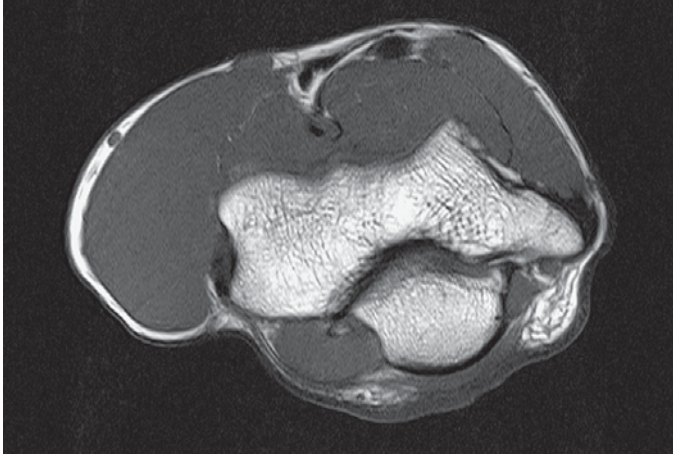
- | | |
|--|--|
| 1 Cephalic vein | 10 Basilic vein |
| 2 Biceps brachii muscle (short head) | 11 Medial collateral artery |
| 3 Brachioradialis muscle | 12 Brachialis muscle |
| 4 Biceps brachii muscle (long head and tendon) | 13 Posterior cutaneous nerve of forearm |
| 5 Radial nerve | 14 Ulnar nerve |
| 6 Brachial artery and vein | 15 Humerus (shaft) |
| 7 Deep brachial artery and nerve | 16 Ulnar artery and vein |
| 8 Median nerve | 17 Triceps brachii muscle (lateral head) |
| 9 Extensor carpi radialis longus muscle | 18 Triceps brachii muscle (medial head) |
| | 19 Triceps brachii muscle (tendon) |



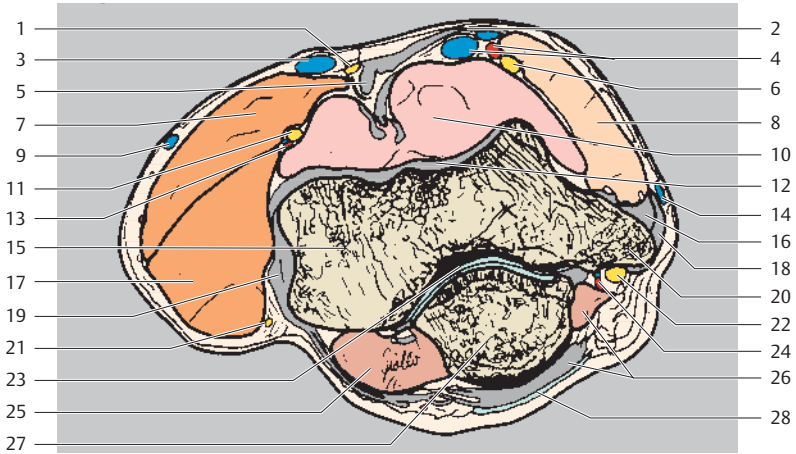
Ventral
Lateral Medial
Dorsal



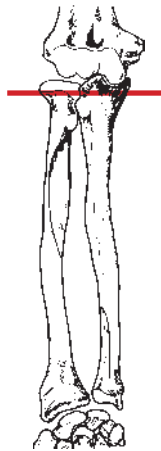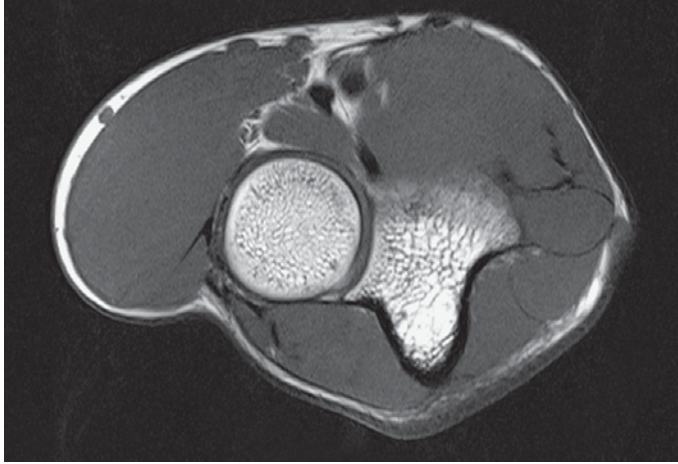
- | | |
|--|---|
| 1 Cutaneous nerve of forearm | 15 Humeroulnar joint |
| 2 Biceps brachii muscle (+ tendon) | 16 Medial epicondyle of humerus |
| 3 Median cubital vein | 17 Lateral epicondyle of humerus |
| 4 Brachial artery and vein | 18 Tendon attachment of ventral superficial muscles of forearm and collateral ligaments |
| 5 Brachioradialis muscle | 19 Posterior cutaneous nerve of forearm (radial nerve) |
| 6 Median nerve | 20 Ulnar nerve |
| 7 Cephalic vein | 21 Joint capsule |
| 8 Brachialis muscle | 22 Superior collateral ulnar artery and nerve |
| 9 Collateral radial artery and vein | 23 Olecranon |
| 10 Pronator teres muscle | 24 Triceps brachii muscle (+ tendon) |
| 11 Radial nerve | 25 Anconeus muscle |
| 12 Basilic vein | 26 Subcutaneous olecranon bursa |
| 13 Extensor carpi radialis longus muscle | |
| 14 Olecranon fossa | |



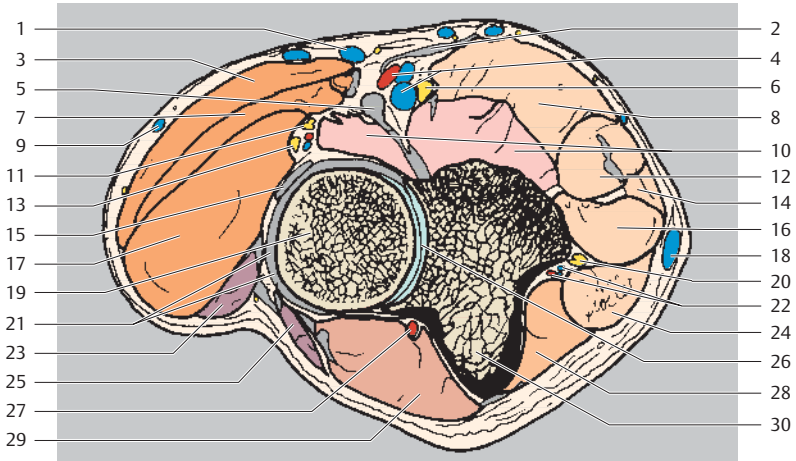
Ventral
Lateral Medial
Dorsal



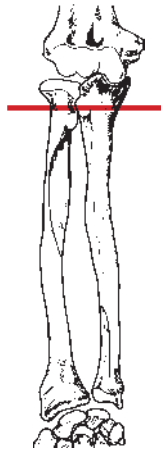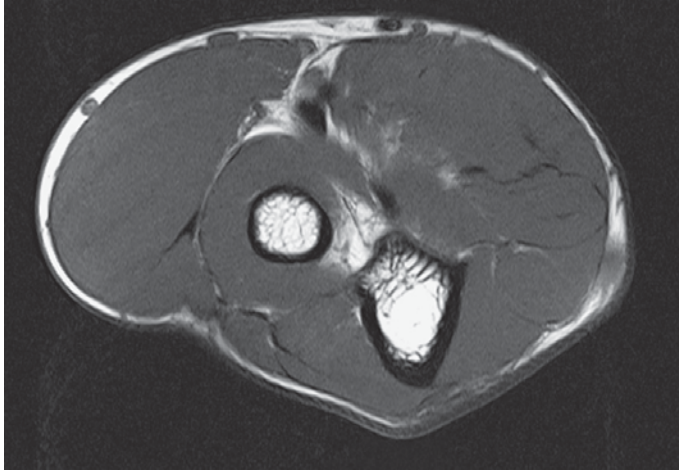
- | | |
|---|--|
| 1 Cutaneous nerve of forearm | 17 Extensor carpi radialis longus muscle |
| 2 Bicipital aponeurosis | 18 Palmaris longus muscle (tendon attachment) |
| 3 Median cubital artery | 19 Lateral collateral ligament |
| 4 Brachial artery and vein | 20 Medial epicondyle of humerus |
| 5 Biceps brachii muscle (tendon) | 21 Posterior cutaneous nerve of forearm (radial nerve) |
| 6 Median nerve | 22 Ulnar nerve |
| 7 Brachioradialis muscle | 23 Humeroulnar joint |
| 8 Pronator teres muscle | 24 Superior collateral ulnar artery and vein |
| 9 Cephalic vein | 25 Anconeus muscle |
| 10 Brachialis muscle (+ tendon) | 26 Triceps brachii muscle (+ tendon) |
| 11 Radial nerve | 27 Olecranon |
| 12 Articular capsule of elbow | 28 Subcutaneous olecranon bursa |
| 13 Radial collateral artery and vein | |
| 14 Basilic vein | |
| 15 Capitulum of humerus | |
| 16 Flexor carpi radialis muscle (tendon attachment) | |



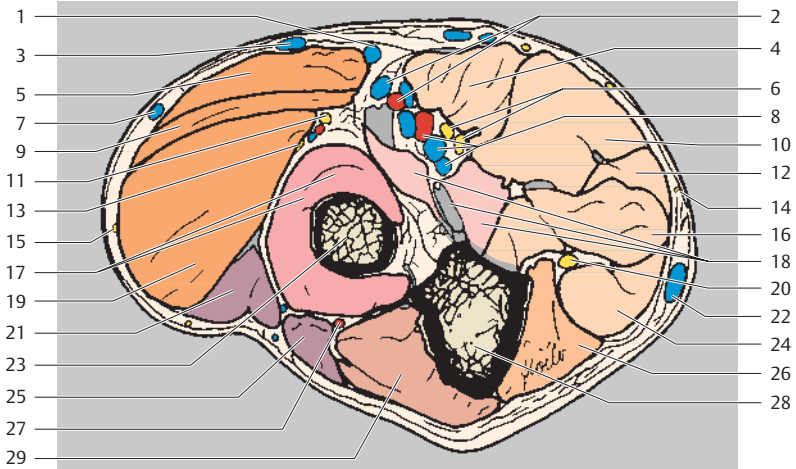
Ventral
Radial □ Ulnar
Dorsal



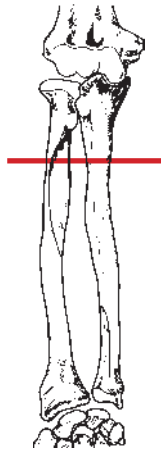
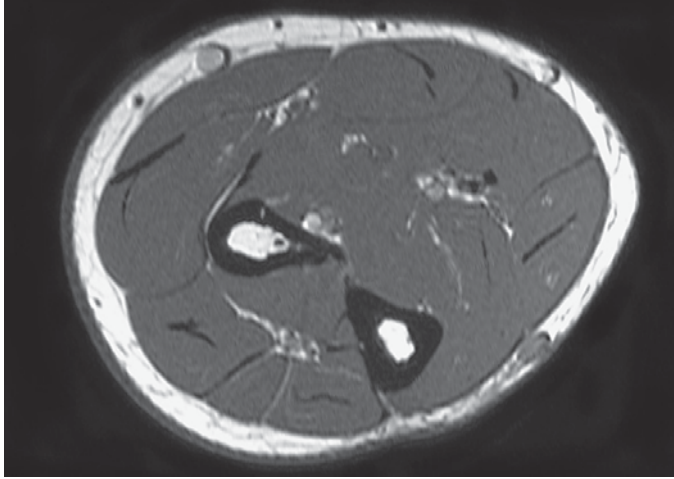
- | | |
|---|--|
| 1 Median cubital vein | 16 Flexor digitorum superficialis muscle |
| 2 Bicipital aponeurosis | 17 Extensor carpi radialis brevis muscle |
| 3 Brachioradialis muscle | 18 Basilic vein |
| 4 Brachial artery and vein | 19 Head of radius |
| 5 Biceps brachii muscle (tendon) | 20 Ulnar nerve |
| 6 Median nerve | 21 Annular ligament |
| 7 Extensor carpi radialis longus muscle | 22 Superior ulnar collateral artery and vein |
| 8 Pronator teres muscle | 23 Extensor digitorum muscle |
| 9 Cephalic vein | 24 Flexor carpi ulnaris muscle |
| 10 Brachial muscle (+ tendon) | 25 Extensor carpi ulnaris muscle |
| 11 Radial nerve (superficial branch) | 26 Proximal radioulnar joint |
| 12 Flexor carpi radialis muscle | 27 Recurrent interosseous artery |
| 13 Radial nerve (deep branch) | 28 Flexor digitorum profundus muscle |
| 14 Palmaris longus muscle | 29 Anconeus muscle |
| 15 Supinator muscle (tendon) | 30 Ulna |



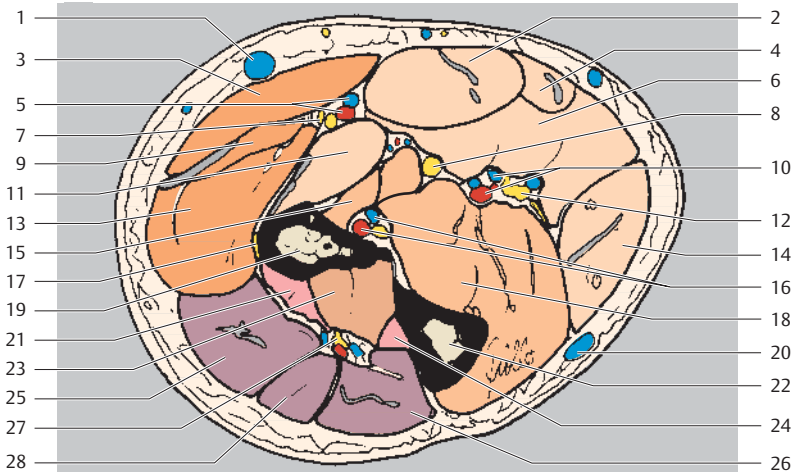
Ventral
Radial Ulnar
Dorsal



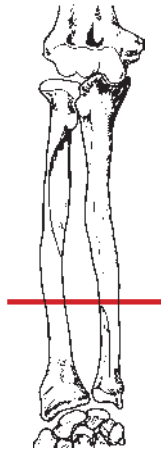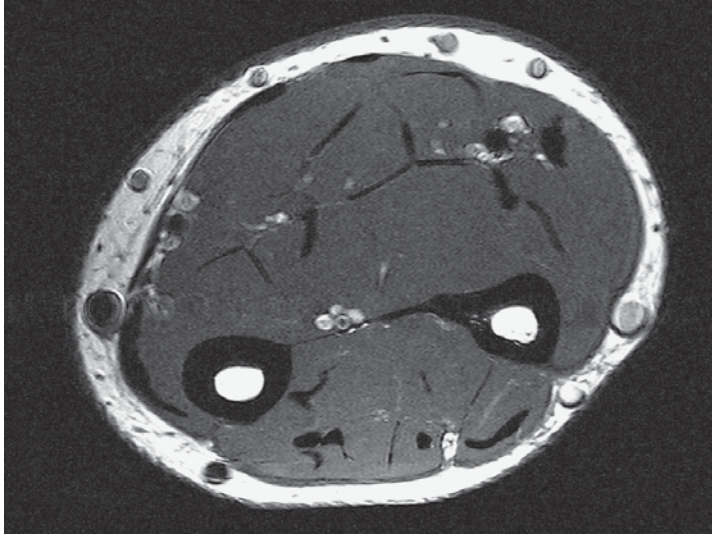
- | | |
|---|--|
| 1 Deep median cubital vein | 15 Posterior cutaneous nerve of forearm |
| 2 Radial artery and vein | 16 Flexor digitorum superficialis muscle |
| 3 Accessory cephalic vein | 17 Supinator muscle |
| 4 Pronator teres muscle | 18 Brachialis muscle (+ tendon attachment) |
| 5 Brachioradialis muscle | 19 Extensor carpi radialis brevis muscle |
| 6 Median nerve | 20 Ulnar nerve |
| 7 Cephalic vein | 21 Extensor digitorum muscle |
| 8 Ulnar artery and vein | 22 Basilic vein |
| 9 Extensor carpi radialis longus muscle | 23 Radius |
| 10 Flexor carpi radialis muscle | 24 Flexor carpi ulnaris muscle |
| 11 Radial nerve (superficial branch) | 25 Extensor carpi ulnaris muscle |
| 12 Palmaris longus muscle | 26 Flexor digitorum profundus muscle |
| 13 Radial nerve (deep branch) | 27 Recurrent interosseous artery and vein |
| 14 Medial cutaneous nerve of forearm | 28 Ulna |
| | 29 Anconeus muscle |



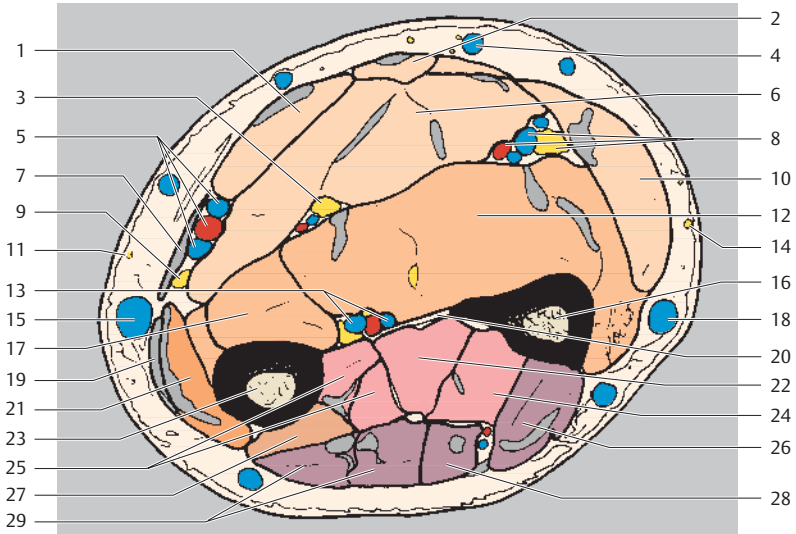
Ventral
Radial Ulnar
Dorsal



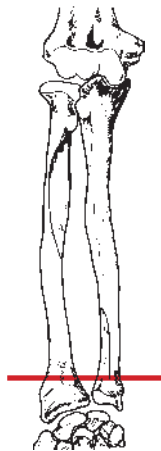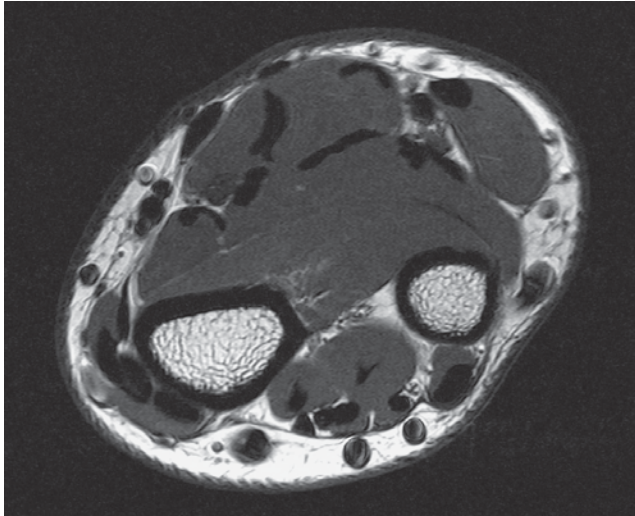
- | | | | |
|----|--|----|--|
| 1 | Median cubital vein | 14 | Flexor carpi ulnaris muscle |
| 2 | Flexor carpi radialis muscle | 15 | Flexor pollicis longus muscle |
| 3 | Brachioradialis muscle | 16 | Posterior interosseous artery, vein, and nerve |
| 4 | Palmaris longus muscle | 17 | Radial nerve (deep branch) |
| 5 | Radial artery and vein | 18 | Flexor digitorum profundus muscle |
| 6 | Flexor digitorum superficialis muscle | 19 | Radius |
| 7 | Radial nerve (superficial branch) | 20 | Cephalic vein |
| 8 | Median nerve | 21 | Supinator muscle |
| 9 | Extensor carpi radialis longus muscle (+ tendon) | 22 | Ulna |
| 10 | Ulnar artery and vein | 23 | Abductor pollicis longus muscle |
| 11 | Pronator teres muscle | 24 | Extensor pollicis longus muscle |
| 12 | Ulnar nerve | 25 | Extensor digitorum muscle |
| 13 | Extensor carpi radialis brevis muscle | 26 | Extensor carpi ulnaris muscle |
| | | 27 | Posterior interosseous artery, vein, and nerve |
| | | 28 | Extensor digiti minimi muscle |



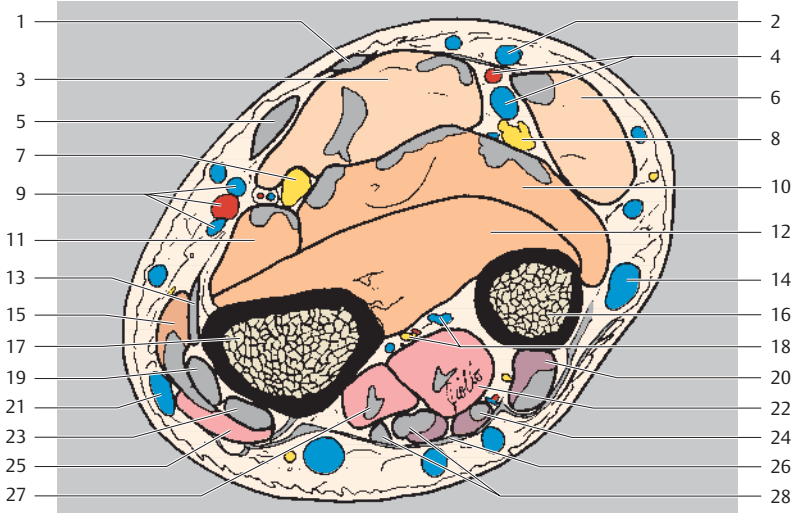
Ventral
Radial Ulnar
Dorsal



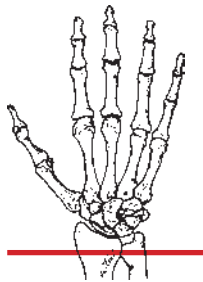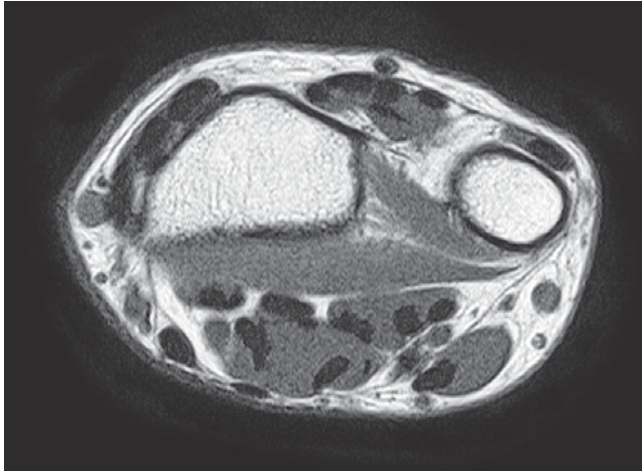
- | | |
|--|---|
| 1 Flexor carpi radialis muscle | 14 Lateral cutaneous nerve of forearm |
| 2 Palmaris longus muscle | 15 Cephalic vein |
| 3 Median nerve | 16 Ulna |
| 4 Median basilic vein | 17 Flexor pollicis longus muscle |
| 5 Radial artery and veins | 18 Basilic vein |
| 6 Flexor digitorum superficialis muscle | 19 Extensor carpi radialis longus muscle (tendon) |
| 7 Brachioradialis muscle (tendon) | 20 Interosseous membrane of forearm |
| 8 Ulnar artery, vein, and nerve | 21 Extensor carpi radialis brevis muscle (+ tendon) |
| 9 Radial nerve (superficial branch) | 22 Extensor pollicis longus muscle |
| 10 Flexor carpi ulnaris muscle | 23 Radius |
| 11 Posterior cutaneous nerve of forearm | 24 Extensor indicis muscle |
| 12 Flexor digitorum profundus muscle | 25 Extensor pollicis brevis muscle |
| 13 Anterior interosseous artery, vein, and nerve | 26 Extensor carpi ulnaris muscle |
| | 27 Abductor pollicis longus muscle |
| | 28 Extensor digiti minimi muscle |
| | 29 Extensor digitorum muscle |



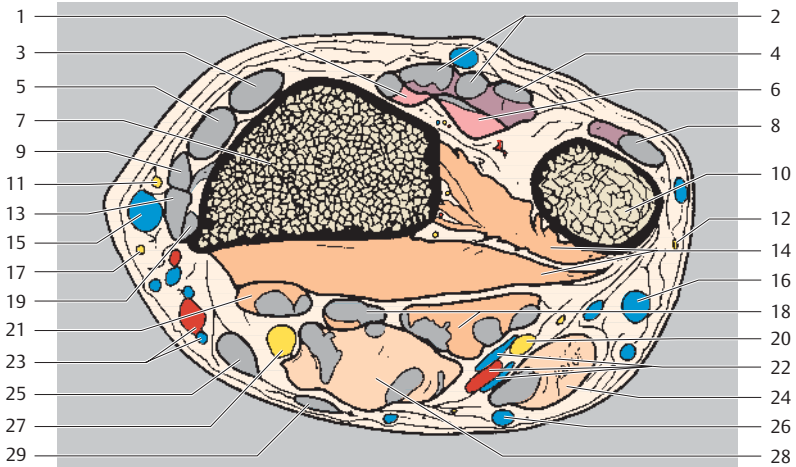
Ventral
Radial Ulnar
Dorsal



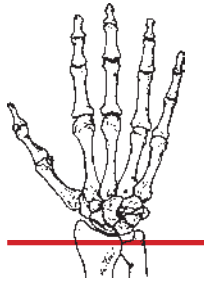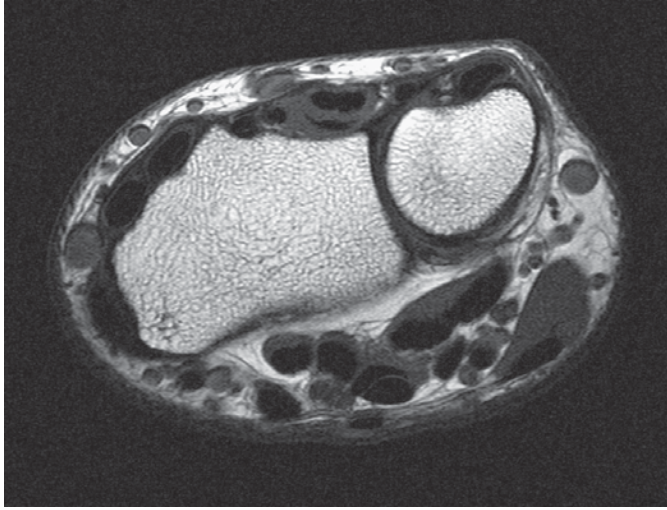
- | | | | |
|----|---------------------------------------|----|--|
| 1 | Palmaris longus muscle (tendon) | 15 | Abductor pollicis longus muscle (+ - tendon) |
| 2 | Subcutaneous vein | 16 | Ulna |
| 3 | Flexor digitorum superficialis muscle | 17 | Radius |
| 4 | Ulnar artery and vein | 18 | Anterior interosseous artery, vein, and nerve |
| 5 | Flexor carpi radialis muscle (tendon) | 19 | Extensor carpi radialis longus muscle (tendon) |
| 6 | Flexor carpi ulnaris muscle | 20 | Extensor carpi ulnaris muscle |
| 7 | Median nerve | 21 | Cephalic vein |
| 8 | Ulnar nerve | 22 | Extensor indicis muscle |
| 9 | Radial artery and veins | 23 | Extensor carpi radialis brevis muscle (tendon) |
| 10 | Flexor digitorum profundus muscle | 24 | Extensor digiti minimi muscle |
| 11 | Flexor pollicis longus muscle | 25 | Extensor pollicis brevis muscle |
| 12 | Pronator quadratus muscle | 26 | Extensor retinaculum |
| 13 | Brachioradialis muscle | 27 | Extensor pollicis longus muscle |
| 14 | Basilic vein | 28 | Extensor digitorum muscle (+ tendon) |



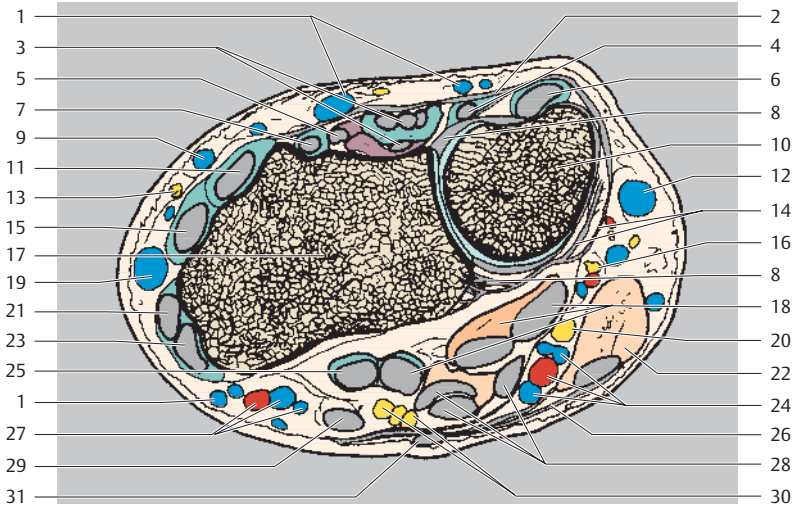
Dorsal
Radial Ulnar
Palmar



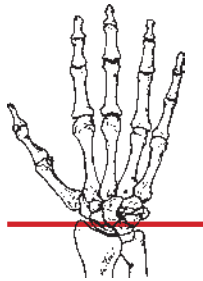
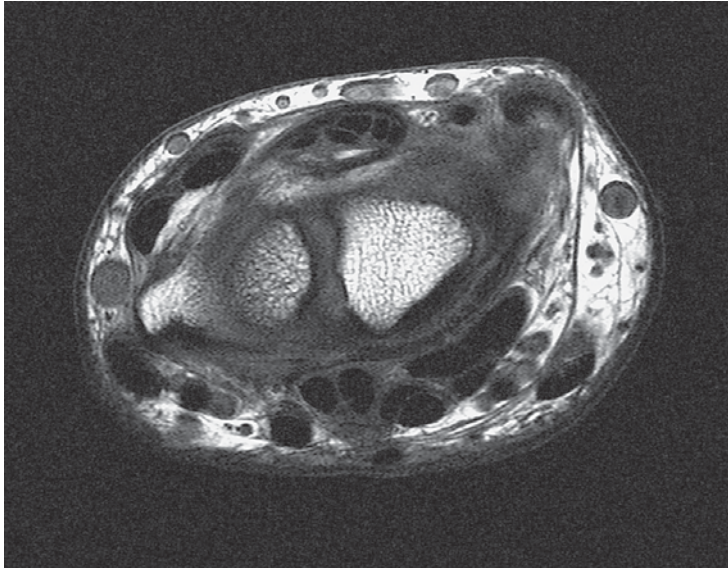
- | | |
|--|---|
| 1 Extensor pollicis longus muscle | 13 Abductor pollicis longus muscle (tendon) |
| 2 Extensor digitorum muscle | 14 Pronator quadratus muscle |
| 3 Extensor carpi radialis brevis muscle (tendon) | 15 Cephalic vein |
| 4 Extensor digiti minimi muscle | 16 Basilic vein |
| 5 Extensor carpi radialis longus muscle (tendon) | 17 Lateral cutaneous nerve of forearm |
| 6 Extensor indicis muscle | 18 Flexor digitorum profundus muscle |
| 7 Radius | 19 Brachioradialis muscle (tendon) |
| 8 Extensor carpi ulnaris muscle | 20 Ulnar nerve |
| 9 Extensor pollicis brevis muscle (tendon) | 21 Flexor pollicis longus muscle |
| 10 Ulna | 22 Ulnar artery and veins |
| 11 Radial nerve (superficial branch) | 23 Radial artery and veins |
| 12 Lateral cutaneous nerve of forearm | 24 Flexor carpi ulnaris muscle |
| | 25 Flexor carpi radialis muscle (tendon) |
| | 26 Subcutaneous vein |
| | 27 Median nerve |
| | 28 Flexor digitorum superficialis muscle |
| | 29 Palmaris longus muscle |



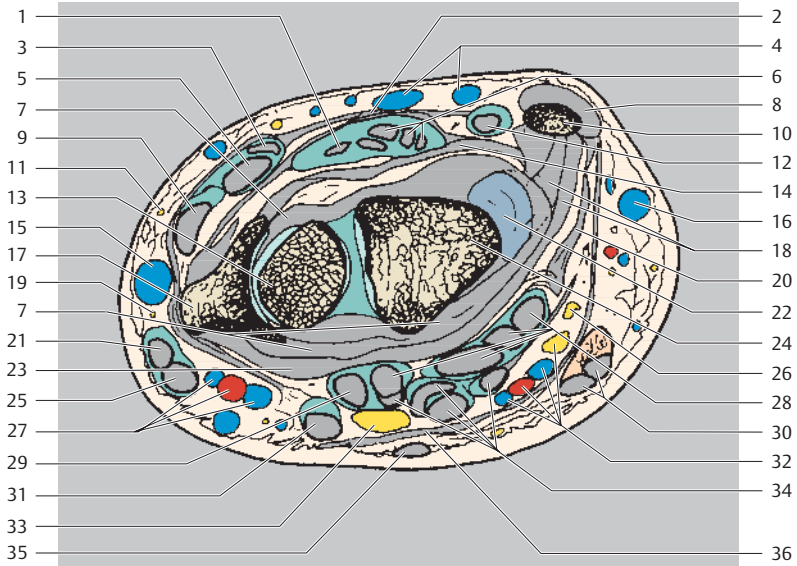
Dorsal
Radial Ulnar
Palmar



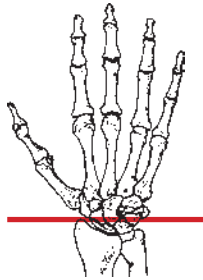
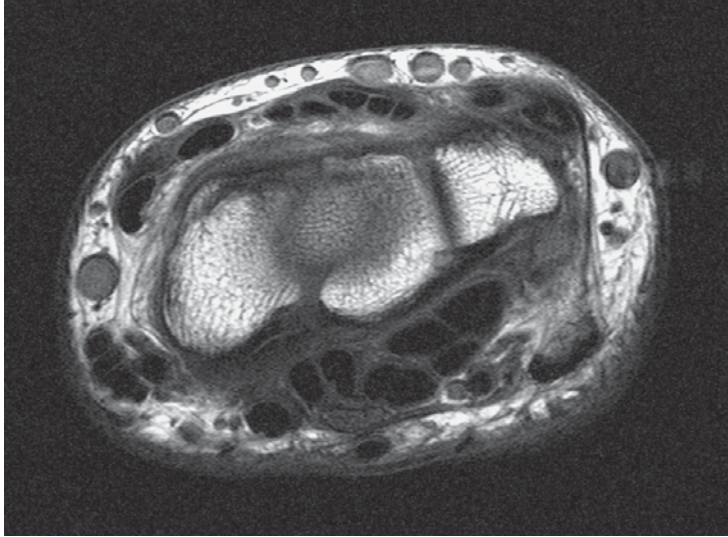
- | | |
|---|---|
| 1 Subcutaneous vein | 15 Extensor carpi radialis longus muscle (tendon) |
| 2 Extensor retinaculum | 16 Ulnar nerve (dorsal branch) |
| 3 Extensor digitorum muscle | 17 Radius |
| 4 Extensor digiti minimi muscle (tendon) | 18 Flexor digitorum profundus muscle |
| 5 Extensor indicis muscle (tendon) | 19 Cephalic vein |
| 6 Extensor carpi ulnaris muscle (tendon) | 20 Ulnar nerve |
| 7 Extensor pollicis longus muscle (tendon) | 21 Extensor pollicis brevis muscle (tendon) |
| 8 Joint capsule | 22 Flexor carpi ulnaris muscle |
| 9 Accessory cephalic vein | 23 Abductor pollicis longus muscle (tendon) |
| 10 Ulna | 24 Ulnar artery and veins |
| 11 Extensor carpi radialis brevis muscle (tendon) | 25 Flexor pollicis longus muscle |
| 12 Basilic vein | 26 Antebrachial fascia |
| 13 Radial nerve (superficial branch) | 27 Radial artery and veins |
| 14 Palmar ulnocarpal ligament | 28 Flexor digitorum superficialis muscle |
| | 29 Flexor carpi radialis muscle (tendon) |
| | 30 Median nerve |
| | 31 Palmaris longus muscle |



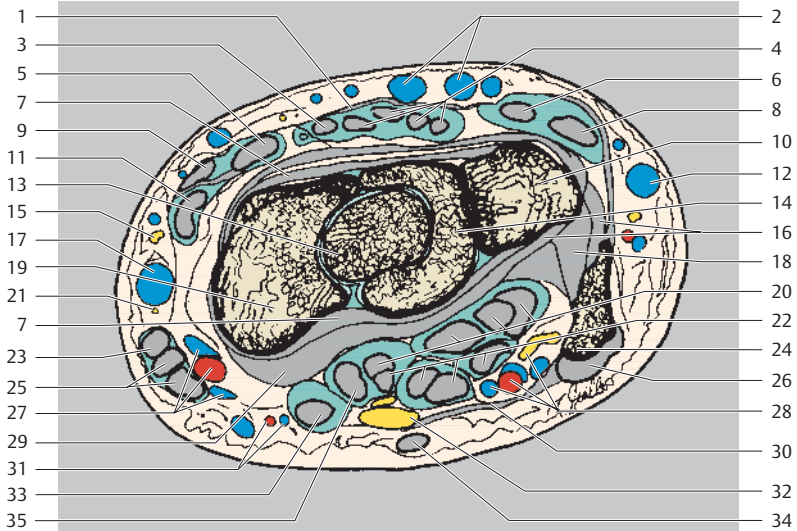
Dorsal
Radial Ulnar
Palmar



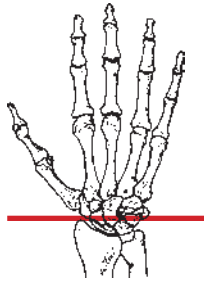
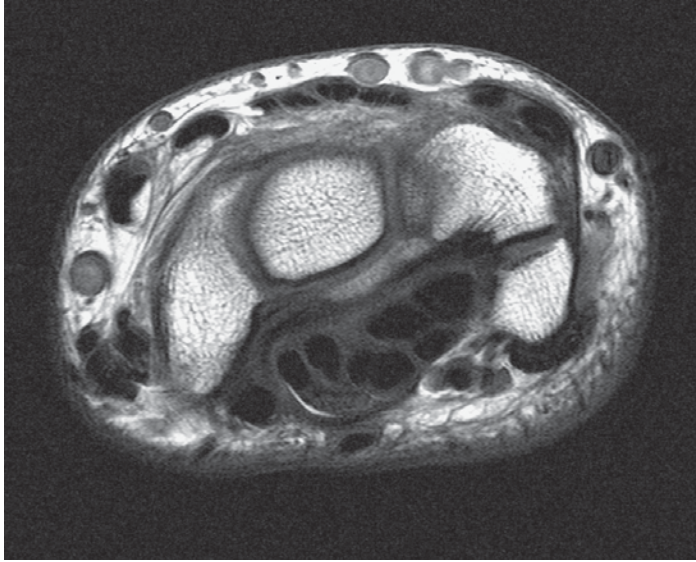
- | | |
|--|--|
| 1 Extensor indicis muscle (tendon) | 18 Palmar ulnocarpal ligament |
| 2 Extensor retinaculum | 19 Radial nerve (superficial branch) |
| 3 Extensor pollicis longus muscle (tendon) | 20 Ulnar collateral ligament of wrist joint |
| 4 Subcutaneous vein | 21 Extensor pollicis brevis muscle (tendon) |
| 5 Extensor carpi radialis brevis muscle (tendon) | 22 Triangular fibrocartilage |
| 6 Extensor digitorum muscle (tendon) | 23 Palmar radiocarpal ligament |
| 7 Joint capsule | 24 Lunate |
| 8 Extensor carpi ulnaris muscle (tendon) | 25 Abductor pollicis longus muscle (tendon) |
| 9 Extensor carpi radialis longus muscle (tendon) | 26 Ulnar nerve (dorsal branch) |
| 10 Ulna (styloid process) | 27 Radial artery and veins |
| 11 Posterior cutaneous nerve of forearm (radial nerve) | 28 Flexor digitorum profundus muscle (tendons) |
| 12 Extensor digiti minimi muscle (tendon) | 29 Flexor pollicis longus muscle |
| 13 Scaphoid | 30 Flexor carpi ulnaris muscle |
| 14 Dorsal radiocarpal ligament | 31 Flexor carpi radialis muscle (tendon) |
| 15 Cephalic vein | 32 Ulnar nerve, artery, and veins |
| 16 Basilic vein | 33 Median nerve |
| 17 Radius | 34 Flexor digitorum superficialis muscle (tendons) |
| | 35 Palmaris longus muscle |
| | 36 Flexor retinaculum |



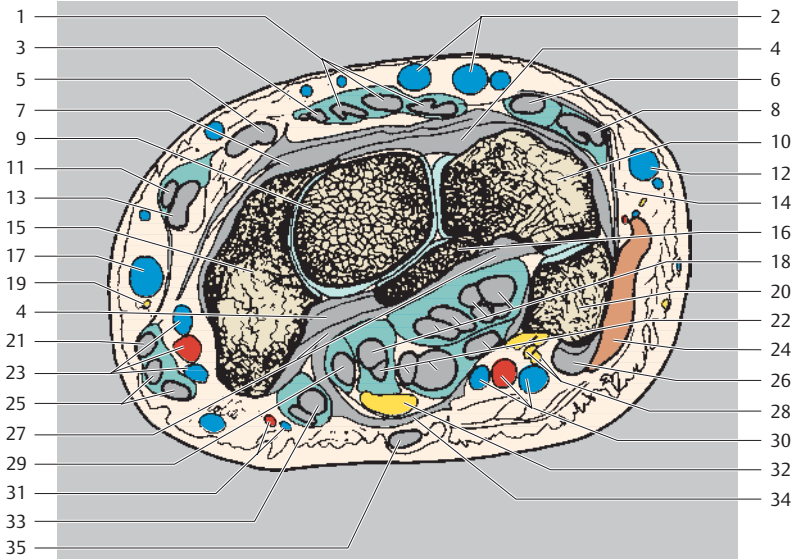
Dorsal
Radial Ulnar
Palmar



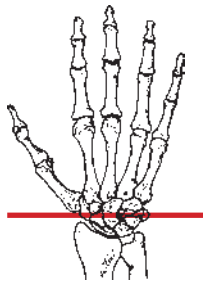
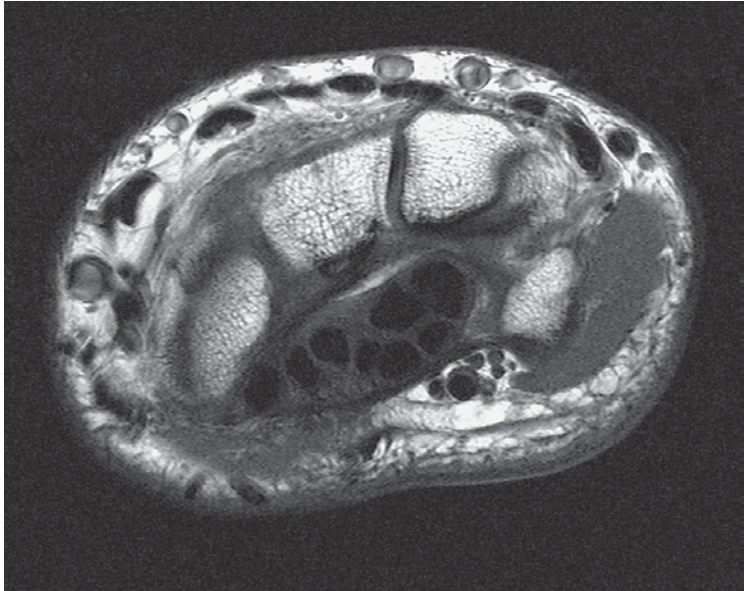
- | | |
|--|--|
| 1 Extensor retinaculum | 18 Palmar intercarpal ligament |
| 2 Subcutaneous vein | 19 Scaphoid |
| 3 Extensor indicis muscle (tendon) | 20 Flexor digitorum profundus muscle (tendons) |
| 4 Extensor digitorum muscle (tendons) | 21 Radial nerve (superficial branch) |
| 5 Extensor carpi radialis brevis muscle (tendon) | 22 Flexor digitorum superficialis muscle (tendons) |
| 6 Extensor digiti minimi muscle (tendon) | 23 Extensor pollicis brevis muscle (tendon) |
| 7 Joint capsule | 24 Pisiform |
| 8 Extensor carpi ulnaris muscle (tendon) | 25 Abductor pollicis longus muscle (tendon) |
| 9 Extensor pollicis longus muscle (tendon) | 26 Flexor carpi ulnaris muscle (tendon attachment) |
| 10 Triquetrum | 27 Radial artery and veins |
| 11 Extensor carpi radialis longus muscle (tendon) | 28 Ulnar nerve, artery, and veins |
| 12 Basilic vein | 29 Ulnar radiocarpal ligament |
| 13 Capitate | 30 Flexor retinaculum |
| 14 Lunate | 31 Superficial palmar branch of radial artery and vein |
| 15 Posterior cutaneous nerve of forearm (radial nerve) | 32 Median nerve |
| 16 Palmar ulnocarpal ligament | 33 Flexor carpi radialis muscle (tendon) |
| 17 Cephalic vein | 34 Palmaris longus muscle |
| | 35 Flexor pollicis longus muscle |



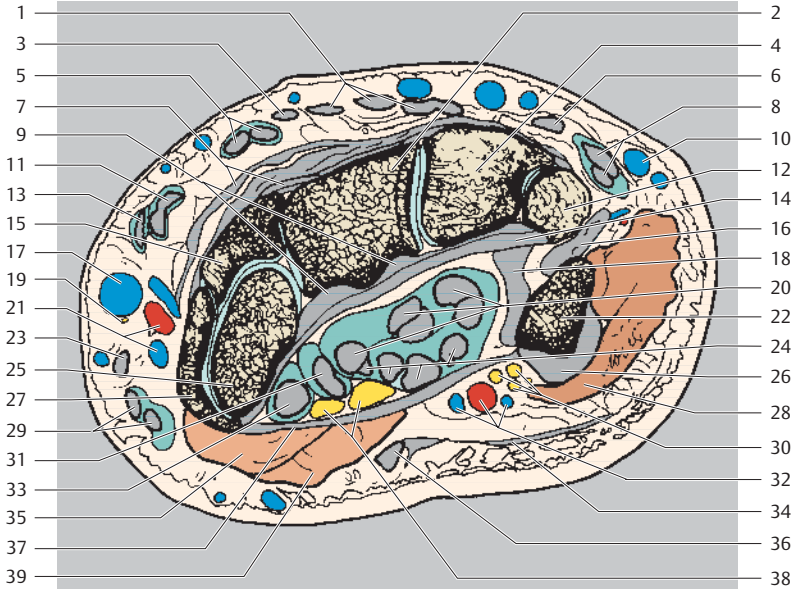
Dorsal
Radial Ulnar
Palmar



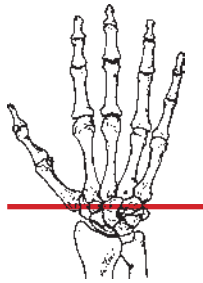
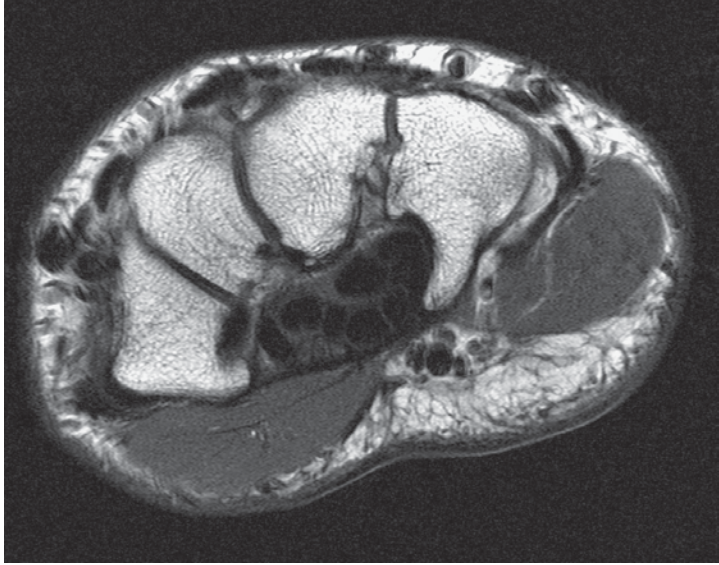
- | | |
|---|--|
| 1 Extensor digitorum muscle (tendons) | 18 Flexor digitorum profundus muscle (tendons) |
| 2 Subcutaneous vein | 19 Radial nerve (superficial branch) |
| 3 Extensor indicis muscle (tendon) | 20 Pisiform |
| 4 Joint capsule | 21 Extensor pollicis brevis muscle (tendon) |
| 5 Extensor carpi radialis brevis muscle (tendon) | 22 Flexor digitorum superficialis muscle (tendons) |
| 6 Extensor digiti minimi muscle (tendon) | 23 Radial artery and veins |
| 7 Dorsal intercarpal ligament | 24 Abductor digiti minimi muscle |
| 8 Extensor carpi ulnaris muscle (tendon) | 25 Abductor pollicis longus muscle (tendon) |
| 9 Capitate | 26 Flexor carpi ulnaris muscle |
| 10 Triquetrum | 27 Palmar radiocarpal ligament |
| 11 Extensor pollicis longus muscle (tendon) | 28 Ulnar nerve |
| 12 Basilic vein | 29 Flexor pollicis longus muscle |
| 13 Extensor carpi radialis longus muscle (tendon) | 30 Ulnar artery and veins |
| 14 Palmar ulnocarpal ligament | 31 Superficial palmar branch of radial artery and vein |
| 15 Scaphoid | 32 Median nerve |
| 16 Lunate | 33 Flexor carpi radialis muscle (tendon) |
| 17 Cephalic vein | 34 Flexor retinaculum |
| | 35 Palmaris longus muscle |



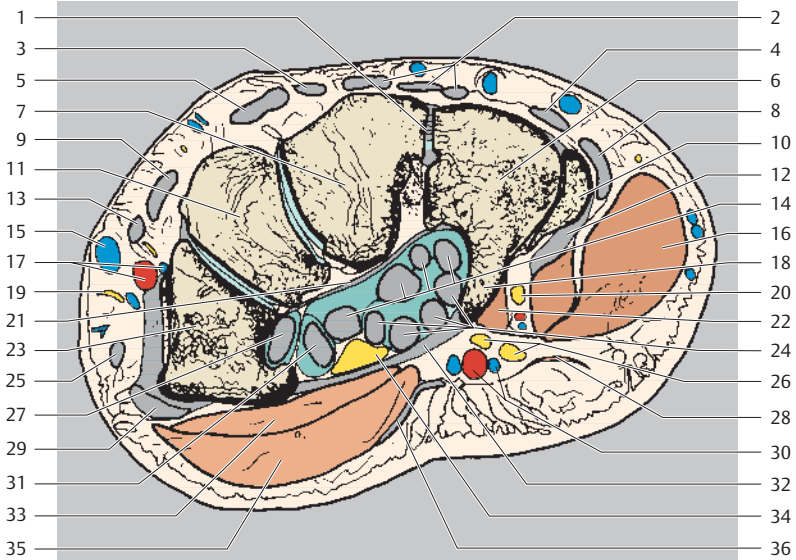
Dorsal
Radial Ulnar
Palmar



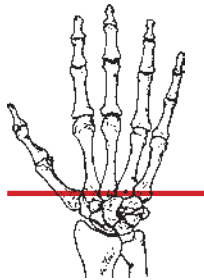
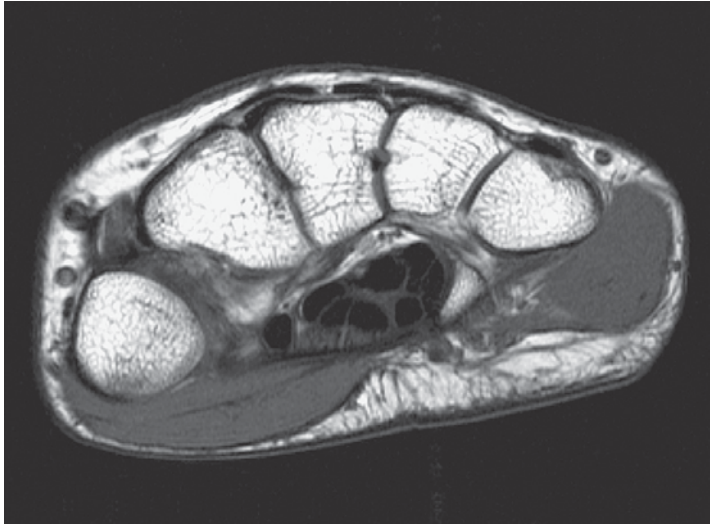
- | | |
|---|--|
| 1 Extensor digitorum muscle (tendons) | 19 Radial nerve (superficial branch) |
| 2 Capitate | 20 Flexor digitorum profundus muscle (tendons) |
| 3 Extensor indicis muscle (tendon) | 21 Radial artery and veins |
| 4 Hamate | 22 Pisiform |
| 5 Extensor carpi radialis brevis muscle (tendon) | 23 Extensor pollicis brevis muscle (tendon) |
| 6 Extensor digiti minimi muscle (tendon) | 24 Flexor digitorum superficialis muscle (tendons) |
| 7 Dorsal intercarpal ligament | 25 Scaphoid |
| 8 Extensor carpi ulnaris muscle (tendon) | 26 Flexor carpi ulnaris muscle (tendon) |
| 9 Joint capsule | 27 Trapezium |
| 10 Basilic vein | 28 Abductor digiti minimi muscle |
| 11 Extensor carpi radialis longus muscle (tendon) | 29 Abductor pollicis longus muscle (tendon) |
| 12 Triquetrum | 30 Ulnar nerve |
| 13 Extensor pollicis longus muscle (tendon) | 31 Flexor pollicis longus muscle (tendon) |
| 14 Palmar intercarpal ligament | 32 Ulnar artery and veins |
| 15 Trapezoid | 33 Flexor carpi radialis muscle (tendon) |
| 16 Pisometacarpal ligament | 34 Palmaris brevis muscle (tendon) |
| 17 Cephalic vein | 35 Opponens pollicis muscle |
| 18 Pisohamate ligament | 36 Palmaris longus muscle (tendon) |
| | 37 Flexor retinaculum |
| | 38 Median nerve |
| | 39 Abductor pollicis brevis muscle |



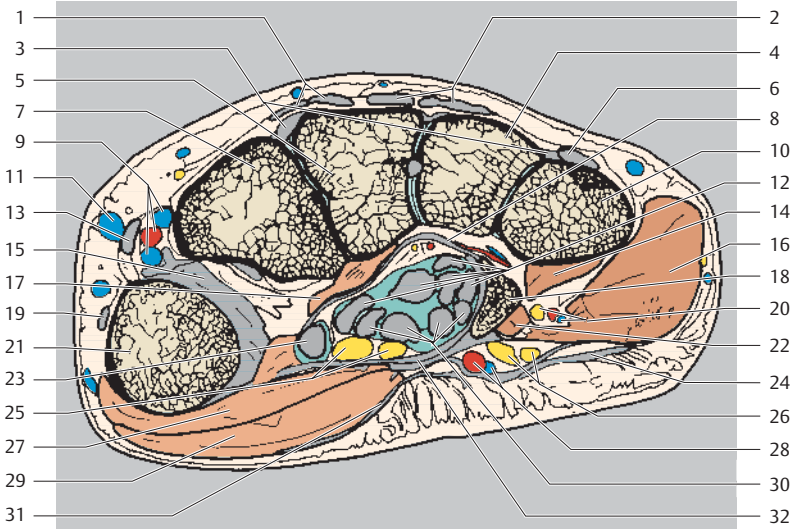
Dorsal
Radial Ulnar
Palmar



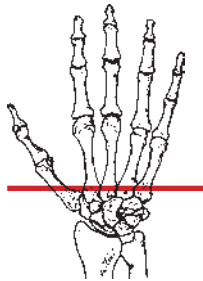
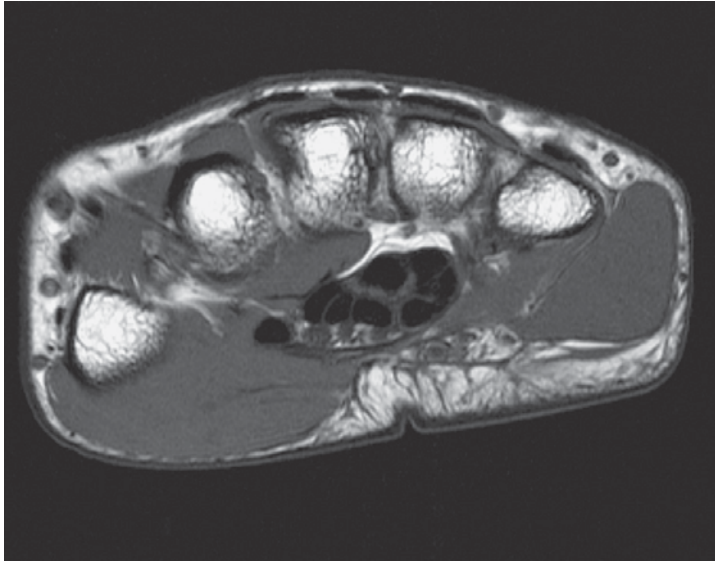
- | | |
|--|--|
| 1 Intercarpal (capitohamate) joint | 16 Abductor digiti minimi muscle |
| 2 Extensor digitorum muscle (tendons) | 17 Radial artery and veins |
| 3 Extensor indicis muscle (tendon) | 18 Hook of hamate |
| 4 Extensor digiti minimi muscle (tendon) | 19 Radial nerve (superficial branch) |
| 5 Extensor carpi radialis brevis muscle (tendon) | 20 Ulnar nerve (deep branch) |
| 6 Hamate | 21 Palmar intercarpal ligament |
| 7 Capitate | 22 Flexor digiti minimi muscle |
| 8 Extensor carpi ulnaris muscle (tendon) | 23 Trapezium |
| 9 Extensor carpi radialis longus muscle (tendon) | 24 Flexor digitorum superficialis muscle (tendons) |
| 10 Metacarpal V (base) | 25 Extensor pollicis brevis muscle (tendon) |
| 11 Trapezoid | 26 Ulnar nerve |
| 12 Pisometacarpal ligament | 27 Flexor carpi radialis muscle (tendon) |
| 13 Extensor pollicis longus muscle (tendon) | 28 Palmaris brevis muscle |
| 14 Flexor digitorum profundus muscle (tendons) | 29 Flexor pollicis longus muscle |
| 15 Cephalic vein | 30 Ulnar artery and veins |
| | 31 Abductor pollicis longus muscle (tendon) |
| | 32 Flexor retinaculum |
| | 33 Opponens pollicis muscle |
| | 34 Median nerve |
| | 35 Abductor pollicis brevis muscle |
| | 36 Palmar aponeurosis |



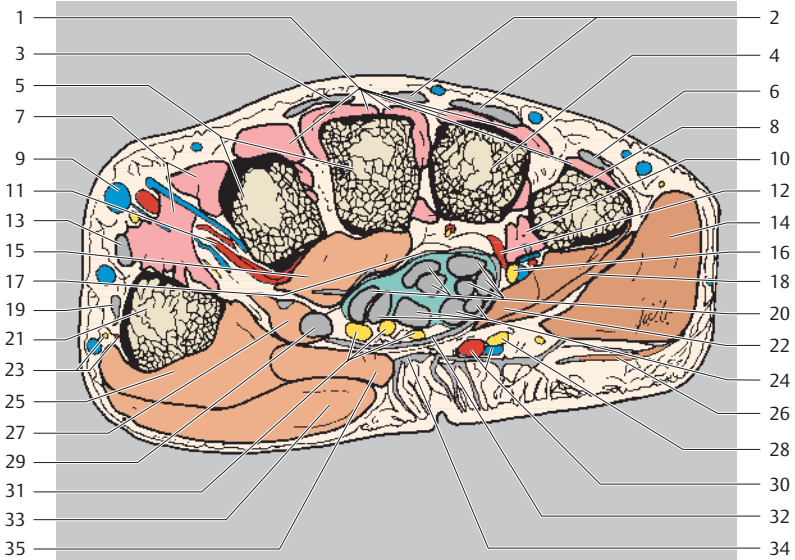
Dorsal
Radial Ulnar
Palmar



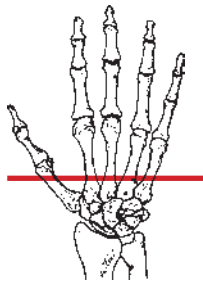
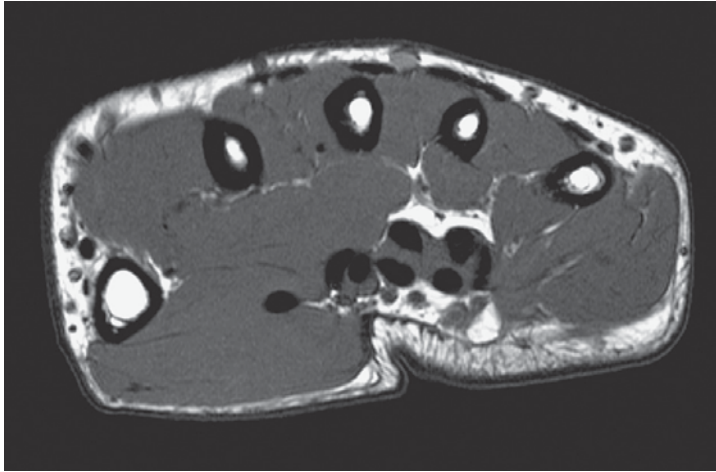
- | | |
|--|--|
| 1 Extensor indicis muscle (tendon) | 17 Adductor pollicis muscle (oblique head) |
| 2 Extensor digitorum muscle (tendons) | 18 Hamate (hook) |
| 3 Dorsal metacarpal ligament | 19 Extensor pollicis brevis muscle (tendon) |
| 4 Metacarpal IV (base) | 20 Ulnar nerve, artery, and vein (deep branch) |
| 5 Metacarpal III (base) | 21 Metacarpal I (base) |
| 6 Extensor digiti minimi muscle (tendon) | 22 Flexor digiti minimi muscle |
| 7 Metacarpal II (base) | 23 Flexor pollicis longus muscle (tendon) |
| 8 Palmar intercarpal ligament | 24 Palmaris brevis muscle |
| 9 Radial artery and veins | 25 Median nerve |
| 10 Metacarpal V (base) | 26 Ulnar nerve |
| 11 Cephalic vein | 27 Opponens pollicis muscle |
| 12 Flexor digitorum profundus muscle (tendons) | 28 Ulnar artery and vein |
| 13 Extensor pollicis longus muscle (tendon) | 29 Abductor pollicis brevis muscle |
| 14 Opponens digiti minimi muscle | 30 Flexor digitorum superficialis muscle (tendons) |
| 15 Joint capsule | 31 Palmar aponeurosis |
| 16 Abductor digiti minimi muscle | 32 Flexor retinaculum |



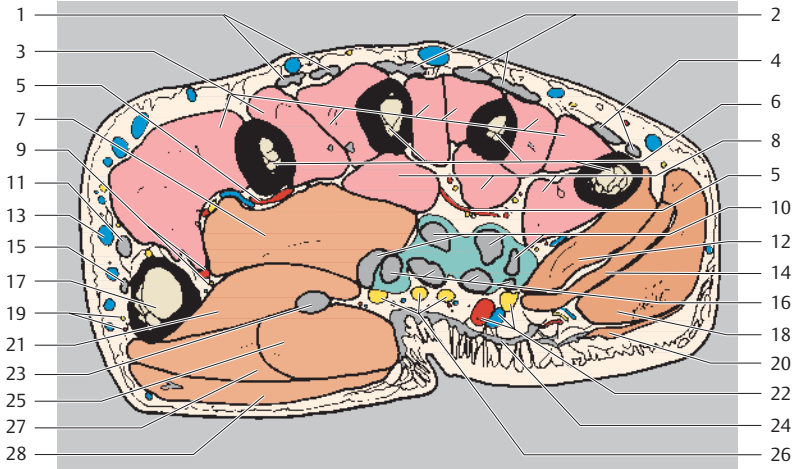
Dorsal
Radial Ulnar
Palmar



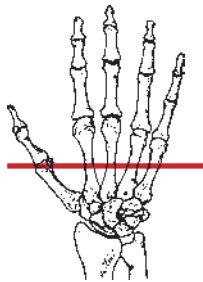
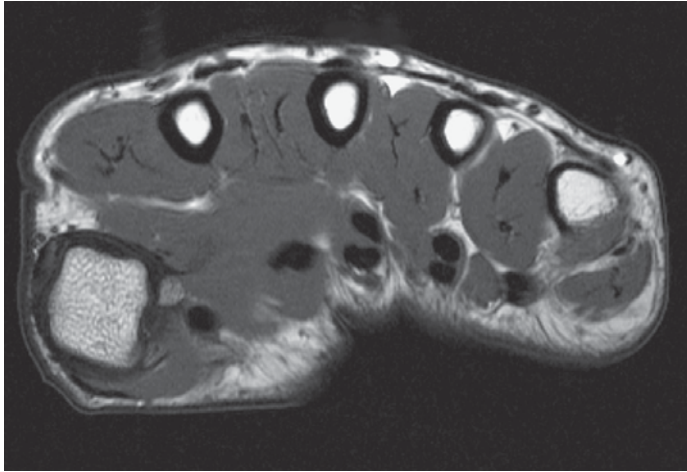
- | | |
|--|---|
| 1 Dorsal interosseous muscles | 18 Flexor digiti minimi muscle |
| 2 Extensor digitorum muscle (tendons) | 19 Extensor pollicis brevis muscle (tendon) |
| 3 Extensor indicis muscle (tendon) | 20 Flexor digitorum profundus muscle (tendons) |
| 4 Metacarpal IV (base) | 21 Metacarpal I (head) |
| 5 Metacarpals II and III (bases) | 22 Opponens digiti minimi muscle |
| 6 Extensor digiti minimi muscle (tendon) | 23 Dorsal nerve and artery of thumb |
| 7 Dorsal interosseous muscle I | 24 Flexor digitorum superficialis muscle (tendons) |
| 8 Metacarpal V | 25 Opponens pollicis muscle |
| 9 Cephalic vein | 26 Palmaris brevis muscle |
| 10 Palmar interosseous muscles | 27 Flexor pollicis brevis muscle (deep head) |
| 11 Deep palmar arch (from radial artery) | 28 Ulnar nerve |
| 12 Deep palmar arch (from deep ulnar artery) | 29 Flexor pollicis longus muscle (tendon) |
| 13 Extensor pollicis longus muscle (tendon) | 30 Ulnar artery and veins |
| 14 Abductor digiti minimi muscle | 31 Median nerve |
| 15 Adductor pollicis muscle (oblique head) | 32 Flexor retinaculum |
| 16 Ulnar nerve (deep branch) | 33 Abductor pollicis brevis muscle |
| 17 Palmar intercarpal ligament | 34 Palmar aponeurosis |
| | 35 Flexor pollicis brevis muscle (superficial head) |



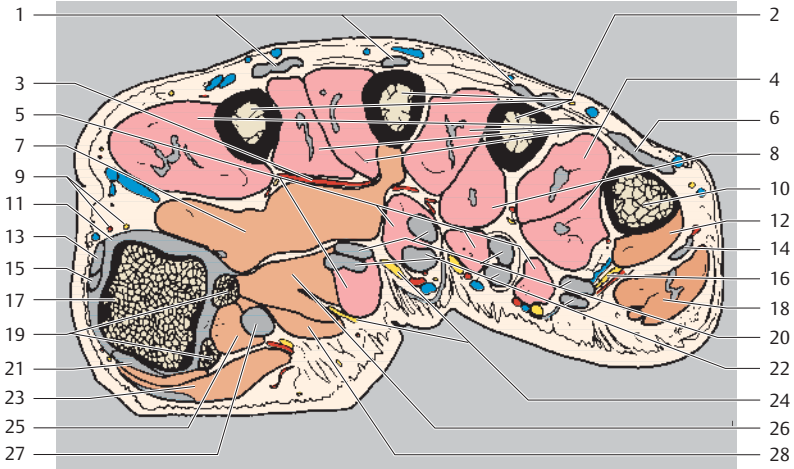
Dorsal
Radial Ulnar
Palmar



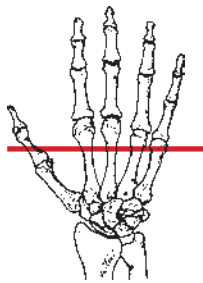
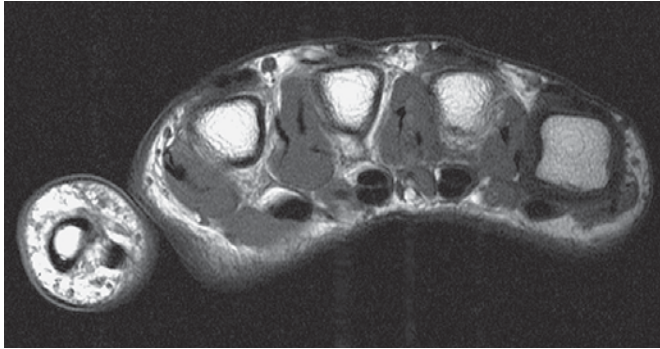
- | | |
|--|---|
| 1 Extensor indicis muscle (tendon) | 15 Extensor pollicis brevis muscle (tendon) |
| 2 Extensor digitorum muscle (tendons) | 16 Flexor digitorum superficialis muscle (tendons) |
| 3 Dorsal interosseous muscles | 17 Metacarpal I (shaft) |
| 4 Extensor digiti minimi muscle (tendon) | 18 Abductor digiti minimi muscle |
| 5 Deep palmar arch | 19 Dorsal digital artery and nerve of thumb |
| 6 Metacarpals II-V (shafts) | 20 Palmaris brevis muscle |
| 7 Adductor pollicis muscle (oblique head) | 21 Flexor pollicis brevis muscle (deep head) |
| 8 Palmar interosseous muscles | 22 Ulnar nerve, artery, and vein |
| 9 Princeps pollicis artery and palmar digital nerve (of thumb) | 23 Flexor pollicis brevis muscle (superficial head) |
| 10 Flexor digitorum profundus muscle (tendons) | 24 Palmar aponeurosis |
| 11 Extensor pollicis longus muscle (tendon) | 25 Flexor pollicis brevis muscle (superficial head) |
| 12 Opponens digiti minimi muscle | 26 Median nerve |
| 13 Cephalic vein (of thumb) | 27 Opponens pollicis muscle |
| 14 Flexor digiti minimi brevis muscle | 28 Abductor pollicis brevis muscle |



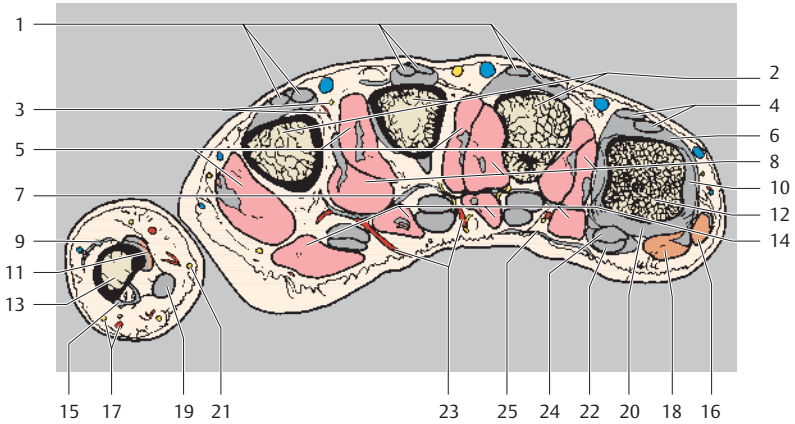
Dorsal
Radial Ulnar
Palmar



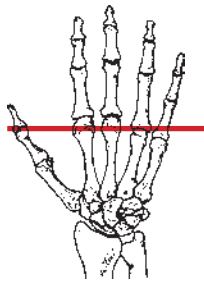
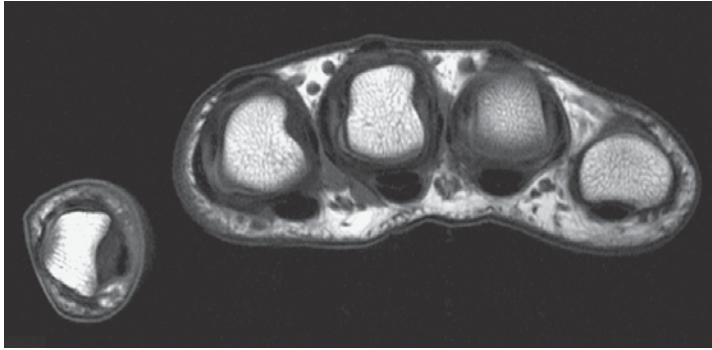
- | | |
|--|---|
| 1 Extensor digitorum muscle (tendons) | 15 Extensor pollicis brevis muscle (tendon) |
| 2 Metacarpals II-IV (shafts) | 16 Ulnar nerve (superficial branch) |
| 3 Deep palmar arch | 17 Metacarpal I (head) |
| 4 Dorsal interosseous muscles | 18 Abductor digiti minimi muscle |
| 5 Lumbrical muscles | 19 Sesamoid bones |
| 6 Extensor digiti minimi muscle (tendon) | 20 Flexor digitorum profundus muscle (tendons) |
| 7 Adductor pollicis muscle (transverse head) | 21 Opponens pollicis muscle (+ tendon attachment) |
| 8 Palmar interosseous muscles | 22 Flexor digitorum superficialis muscle (tendons) |
| 9 Dorsal digital nerve and artery of thumb | 23 Abductor pollicis brevis muscle |
| 10 Metacarpal V (head) | 24 Common palmar digital nerves of median nerve |
| 11 Collateral ligament | 25 Flexor pollicis brevis muscle (superficial head) |
| 12 Opponens digiti minimi muscle (tendon) | 26 Adductor pollicis muscle (oblique head) |
| 13 Extensor pollicis brevis muscle (tendon) | 27 Flexor pollicis longus muscle (tendon) |
| 14 Flexor digiti minimi brevis muscle | 28 Flexor pollicis brevis muscle (deep head) |



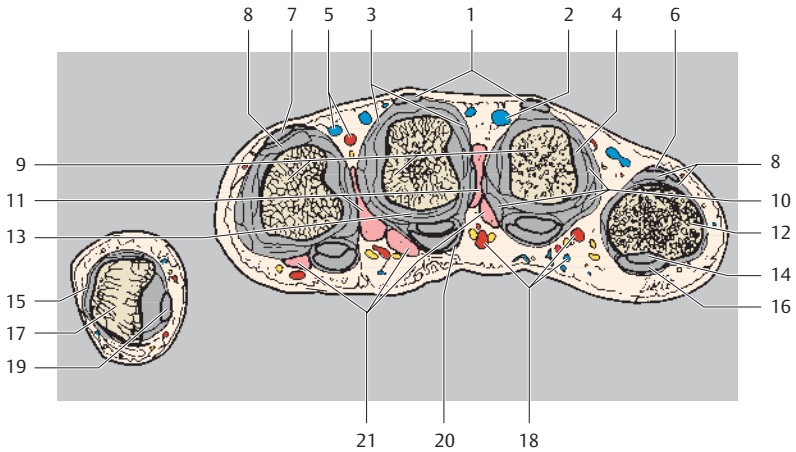
Dorsal
Radial Ulnar
Palmar



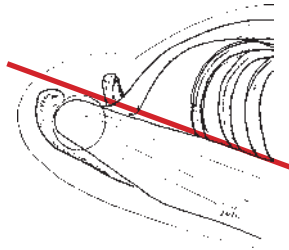
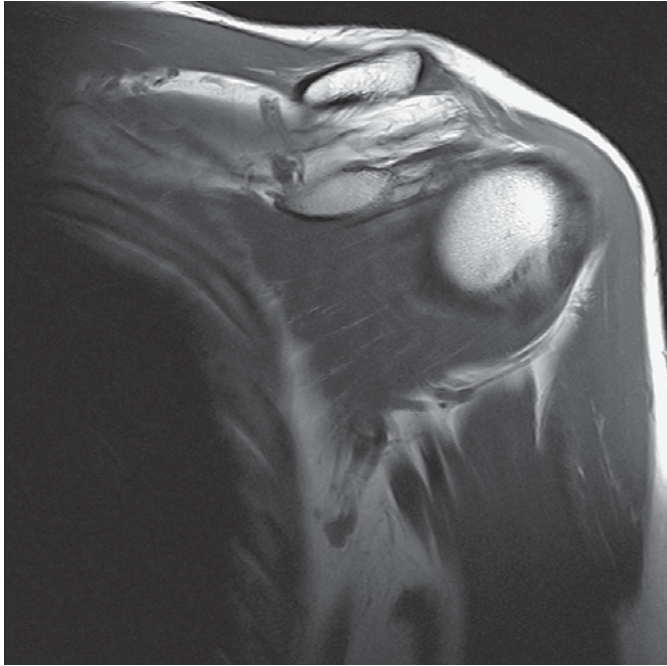
- | | |
|---|--|
| 1 Extensor digitorum muscle (tendons) | 15 Flexor pollicis brevis muscle and abductor pollicis brevis muscle (tendon attachment) |
| 2 Metacarpals II-IV (shafts) | 16 Abductor digiti minimi muscle |
| 3 Dorsal digital artery and nerve | 17 Dorsal digital nerve and artery of thumb |
| 4 Extensor digiti minimi muscle (tendon) | 18 Flexor digiti minimi brevis muscle |
| 5 Dorsal interosseous muscles | 19 Flexor pollicis longus muscle (tendon) |
| 6 Dorsal (extensor) expansion | 20 Palmar ligament |
| 7 Deep transverse metacarpal ligament | 21 Palmar digital artery and nerve of thumb |
| 8 Palmar interosseous muscles | 22 Flexor digitorum superficialis muscle (tendons) |
| 9 Extensor pollicis muscle (aponeurosis) | 23 Palmar digital arteries and nerves |
| 10 Collateral ligament | 24 Flexor digitorum profundus muscle (tendons) |
| 11 Adductor pollicis muscle (tendon attachment) | 25 Palmar aponeurosis with longitudinal fasciculi |
| 12 Metacarpal V (head) | |
| 13 First proximal phalanx | |
| 14 Lumbrical muscles | |



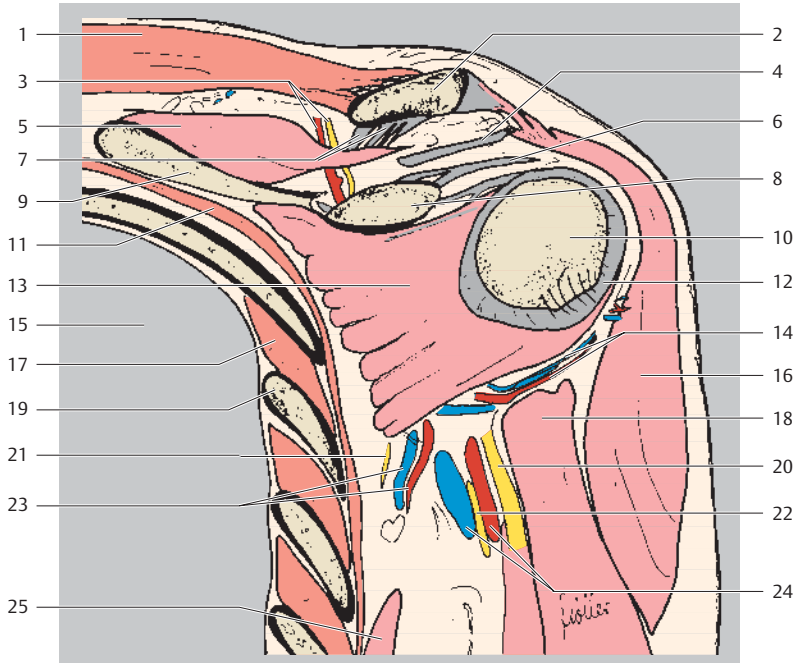
Dorsal
Radial Ulnar
Palmar



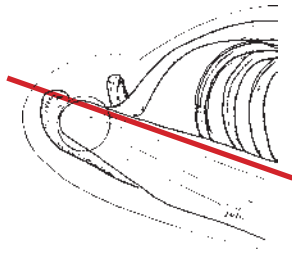
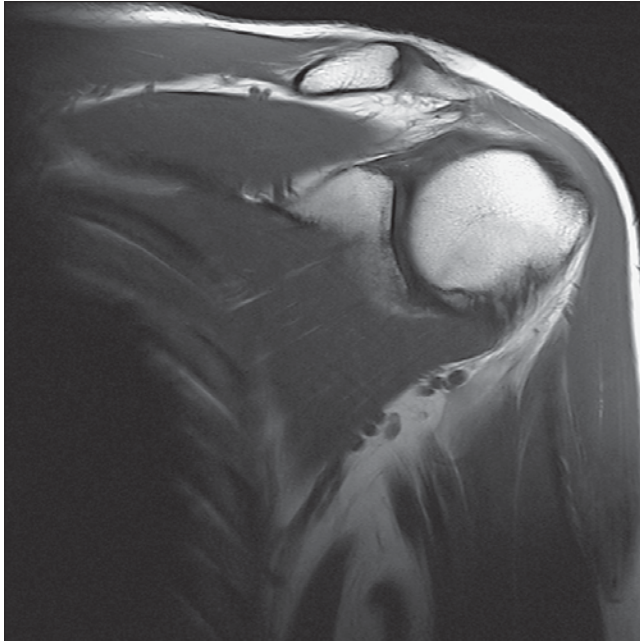
- | | |
|--|---|
| 1 Extensor digitorum muscle (tendons) | 11 Interosseous muscle |
| 2 Dorsal digital vein | 12 Proximal phalanx V (base) |
| 3 Sagittal ligament | 13 Palmar ligament |
| 4 Collateral ligament | 14 Flexor digitorum profundus muscle (tendons) |
| 5 Dorsal digital artery and nerve | 15 Extensor pollicis muscle (aponeurosis) |
| 6 Extensor digiti minimi muscle (tendon) | 16 Flexor digitorum superficialis muscle (tendon) |
| 7 Extensor indicis muscle (tendon) | 17 Proximal phalanx I |
| 8 Dorsal (extensor) expansion ("dorsal aponeurosis") | 18 Palmar digital arteries and nerves |
| 9 Metacarpals (shafts) | 19 Flexor pollicis longus muscle (tendon) |
| 10 Interosseous muscle (tendon) | 20 Annular ligament |
| | 21 Lumbrical muscle |



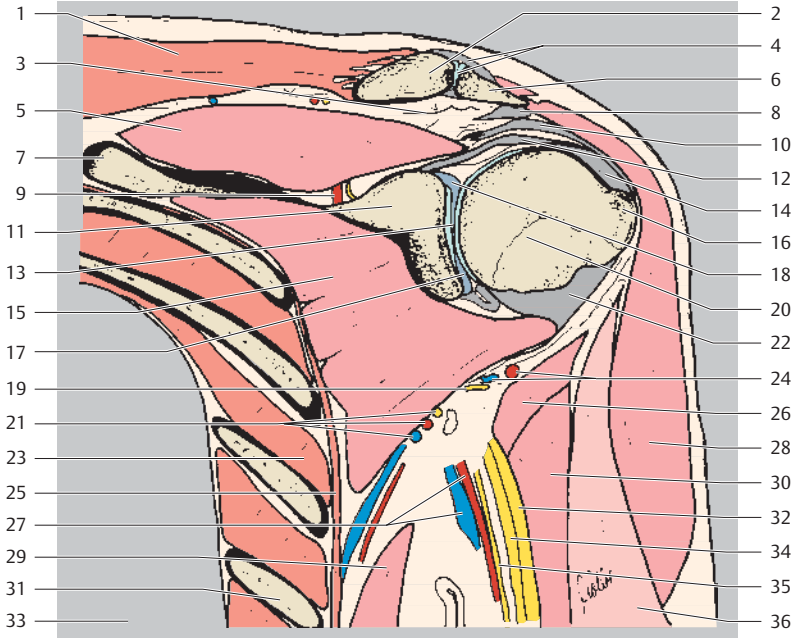
Cranial
Medial Lateral
Caudal



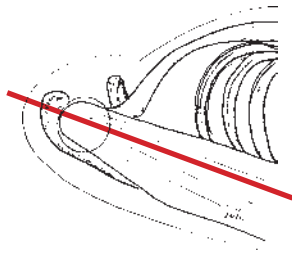
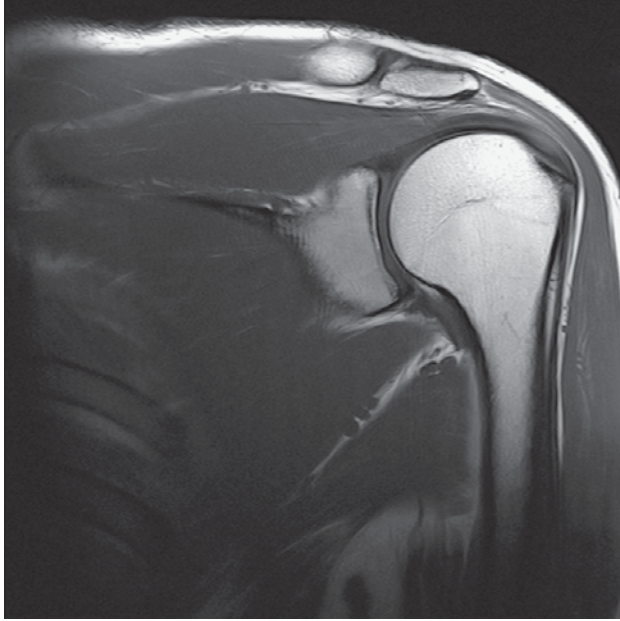
- | | |
|---------------------------------|--|
| 1 Trapezius muscle | 14 Anterior circumflex humeral artery and vein |
| 2 Clavicle | 15 Lung |
| 3 Suprascapular artery and vein | 16 Deltoid muscle |
| 4 Coracoacromial ligament | 17 Intercostal muscle |
| 5 Supraspinatus muscle | 18 Coracobrachialis muscle |
| 6 Coracohumeral ligament | 19 Rib |
| 7 Coracoclavicular ligament | 20 Radial nerve |
| 8 Coracoid process | 21 Thoracodorsal nerve |
| 9 Scapula (superior border) | 22 Median nerve |
| 10 Humerus (head) | 23 Suprascapular artery and vein |
| 11 Serratus anterior muscle | 24 Brachial artery and vein |
| 12 Joint capsule | 25 Latissimus dorsi muscle |
| 13 Subscapularis muscle | |



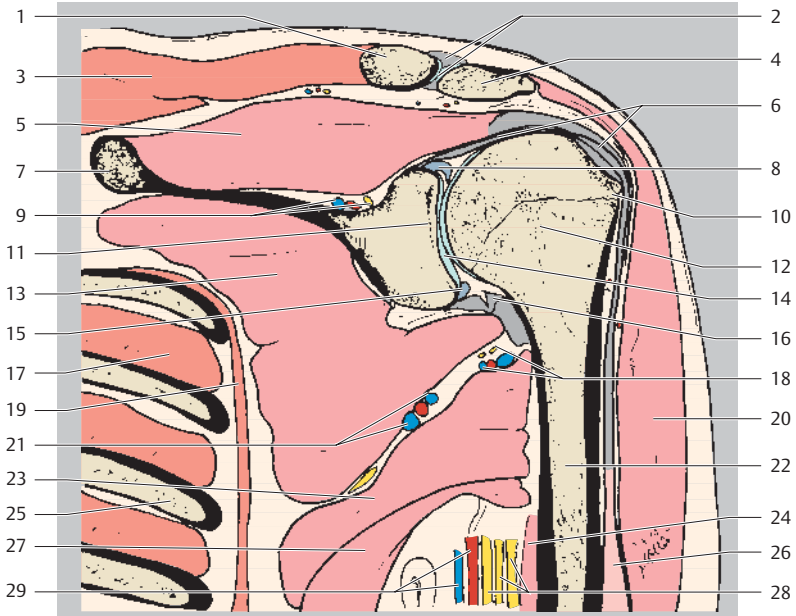
Cranial
Medial Lateral
Caudal



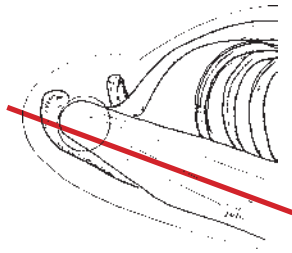
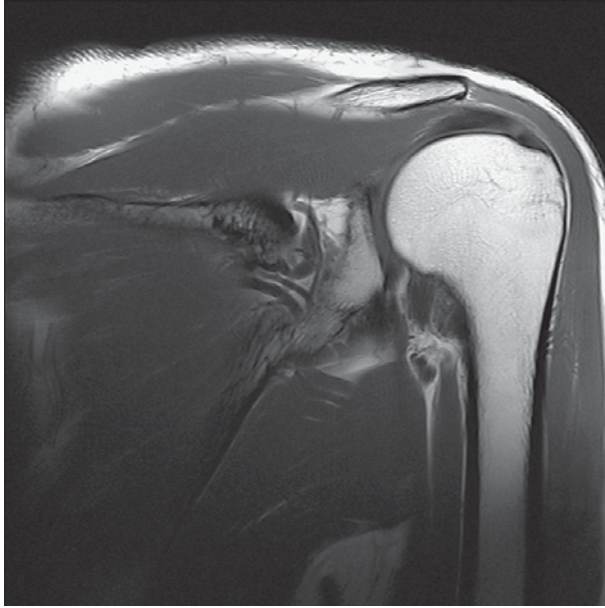
- | | |
|--|---|
| 1 Trapezius muscle | 18 Glenoid labrum (superior) |
| 2 Clavicle | 19 Axillary nerve |
| 3 Subacromial bursa | 20 Humerus (head) |
| 4 Acromioclavicular joint and acromioclavicular ligament | 21 Subscapular artery, vein, and nerve |
| 5 Supraspinatus muscle | 22 Glenohumeral ligament |
| 6 Acromion | 23 Intercostal muscle |
| 7 Scapula | 24 Posterior circumflex humeral artery and vein |
| 8 Coracoacromial ligament | 25 Serratus anterior muscle |
| 9 Suprascapular artery and vein | 26 Teres major muscle |
| 10 Coracohumeral ligament | 27 Axillary artery and vein |
| 11 Glenoid | 28 Deltoid muscle |
| 12 Biceps brachii muscle (long head, tendon) | 29 Latissimus dorsi muscle |
| 13 Glenohumeral joint | 30 Coracobrachialis muscle |
| 14 Supraspinatus muscle (tendon attachment) | 31 Rib |
| 15 Subscapularis muscle | 32 Radial nerve |
| 16 Greater tubercle | 33 Lung |
| 17 Glenoid labrum (inferior) | 34 Median nerve |
| | 35 Ulnar nerve |
| | 36 Biceps muscle (long head) |



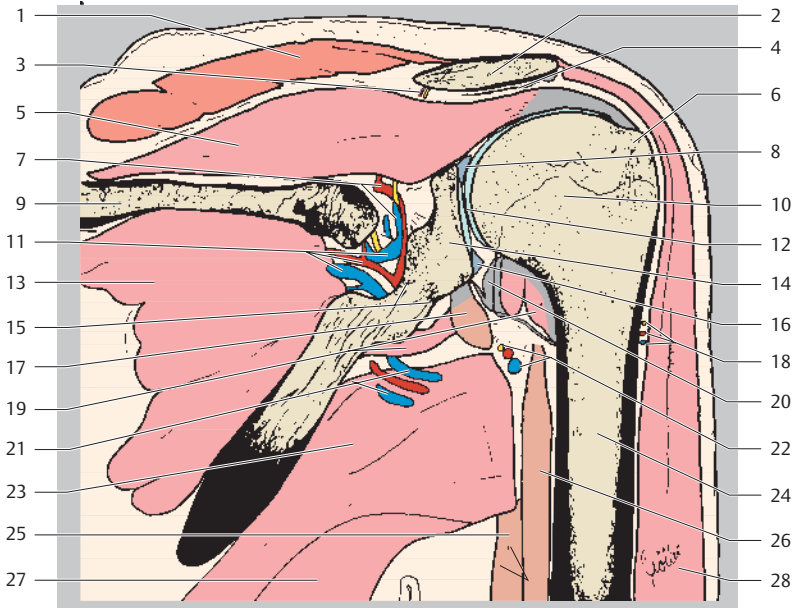
Cranial
Medial Lateral
Caudal



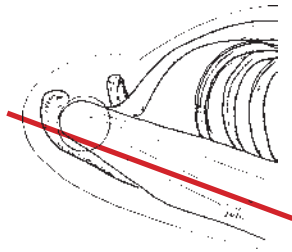
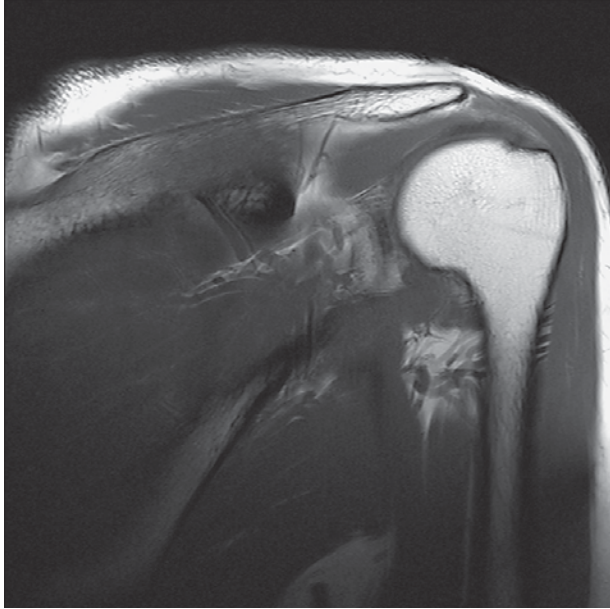
- | | |
|--|--|
| 1 Clavicle | 15 Glenoid labrum (inferior) |
| 2 Acromioclavicular joint and acromioclavicular ligament | 16 Axillary recess |
| 3 Trapezius muscle | 17 Intercostal muscle |
| 4 Acromion | 18 Posterior circumflex humeral artery and vein and axillary nerve |
| 5 Supraspinatus muscle | 19 Serratus anterior muscle |
| 6 Biceps brachii muscle (long head, tendon) | 20 Deltoid muscle |
| 7 Scapula | 21 Subscapular artery and vein |
| 8 Glenoid labrum (superior) | 22 Humerus (shaft) |
| 9 Suprascapular artery, vein, and nerve | 23 Teres major muscle |
| 10 Greater tubercle | 25 Rib |
| 11 Glenoid | 26 Biceps brachii muscle (long head) |
| 12 Humerus (head) | 27 Latissimus dorsi muscle |
| 13 Subscapularis muscle | 28 Ulnar, medial, and radial nerves |
| 14 Glenohumeral joint | 29 Brachial artery and vein |



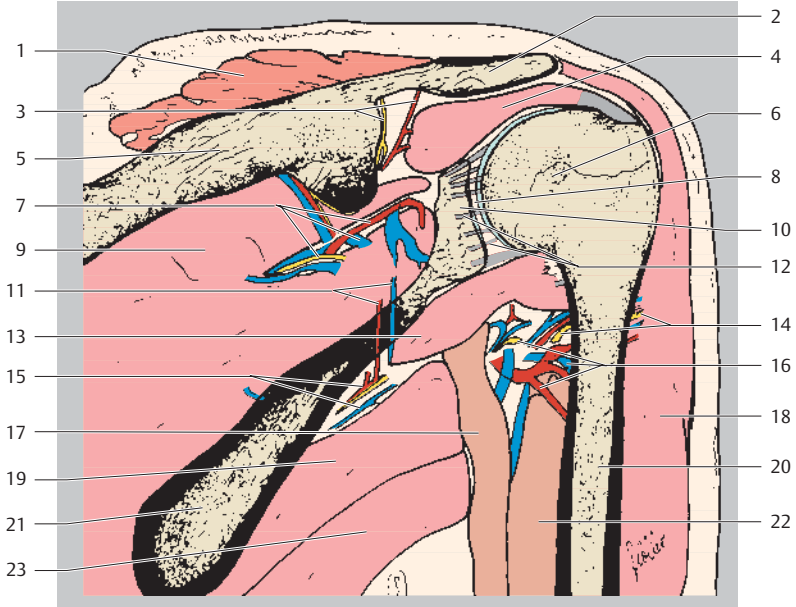
Cranial
Medial Lateral
Caudal



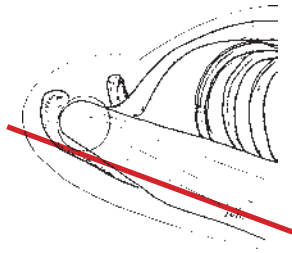
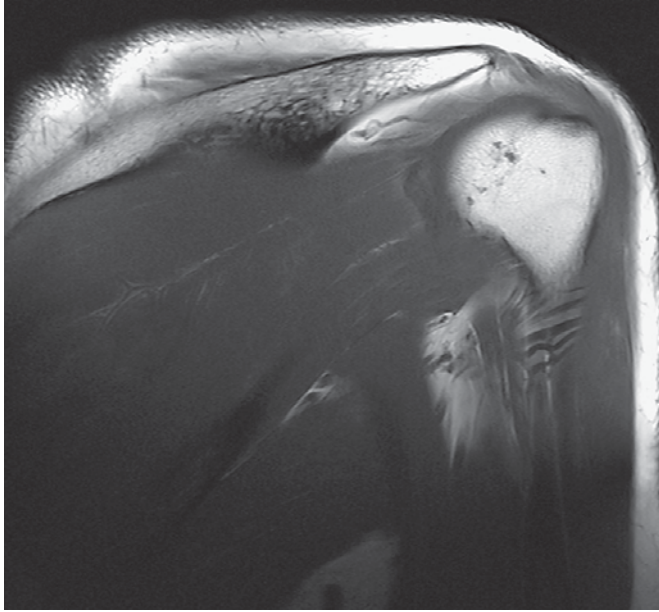
- | | |
|---|--|
| 1 Trapezius muscle | 16 Glenoid labrum (inferior) |
| 2 Acromion | 17 Triceps brachii muscle (long head, tendon attachment) |
| 3 Suprascapular artery and vein (acromial branch) | 18 Posterior circumflex humeral artery and vein and axillary nerve (muscular branches) |
| 4 Subacromial bursa | 19 Teres minor muscle |
| 5 Supraspinatus muscle | 20 Axillary recess |
| 6 Lesser tubercle | 21 Subscapular artery and vein |
| 7 Suprascapular artery, vein, and nerve | 22 Posterior circumflex humeral artery and vein and axillary nerve |
| 8 Glenoid labrum (superior) | 23 Teres major muscle |
| 9 Scapula | 24 Humerus (shaft) |
| 10 Humerus (head) | 25 Triceps brachii muscle (long head) |
| 11 Circumflex scapular artery and vein | 26 Triceps brachii muscle (lateral head) |
| 12 Glenohumeral joint | 27 Latissimus dorsi muscle |
| 13 Infraspinatus muscle | 28 Deltoid muscle |
| 14 Glenoid | |
| 15 Neck of scapula | |



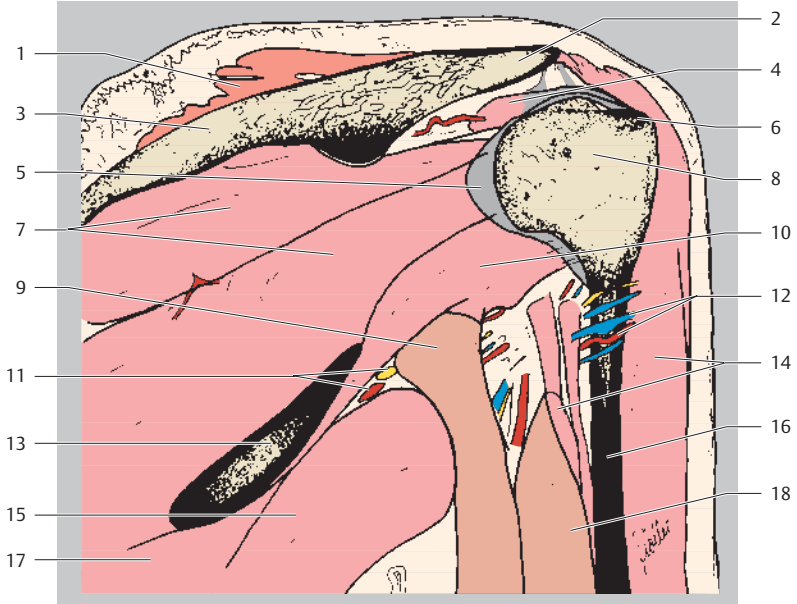
Cranial
Medial Lateral
Caudal



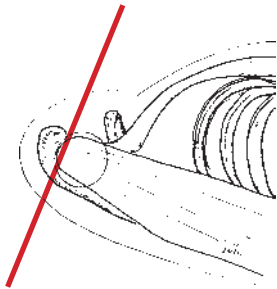
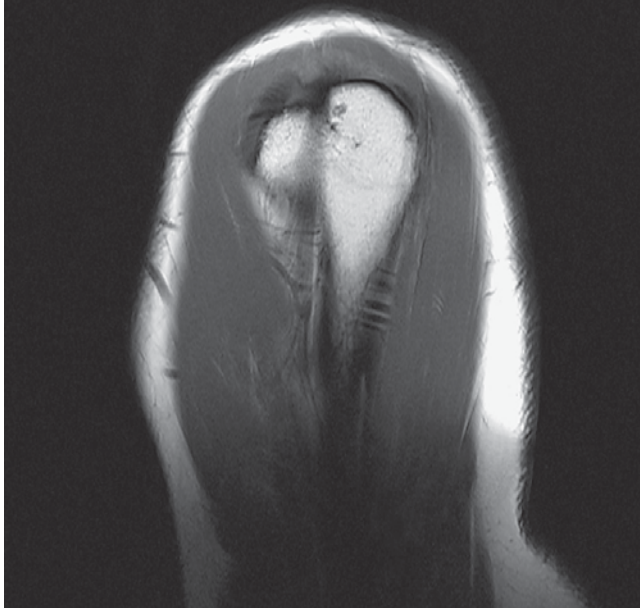
- | | |
|---|--|
| 1 Trapezius muscle | 13 Teres minor muscle |
| 2 Acromion | 14 Posterior circumflex humeral artery and vein and axillary nerve (muscular branches) |
| 3 Subscapular artery, vein, and nerve (acromial branch) | 15 Subscapular artery and vein |
| 4 Supraspinatus muscle | 16 Posterior circumflex humeral artery and vein and axillary nerve |
| 5 Spine of scapula | 17 Triceps brachii muscle (long head) |
| 6 Humerus (head) | 18 Deltoid muscle |
| 7 Scapular artery, vein, and nerve | 19 Teres major muscle |
| 8 Glenohumeral joint | 20 Humerus (shaft) |
| 9 Infraspinatus muscle | 21 Scapula |
| 10 Glenoid | 22 Triceps brachii muscle (lateral head) |
| 11 Circumflex scapular artery and vein | 23 Latissimus dorsi muscle |
| 12 Joint capsule | |



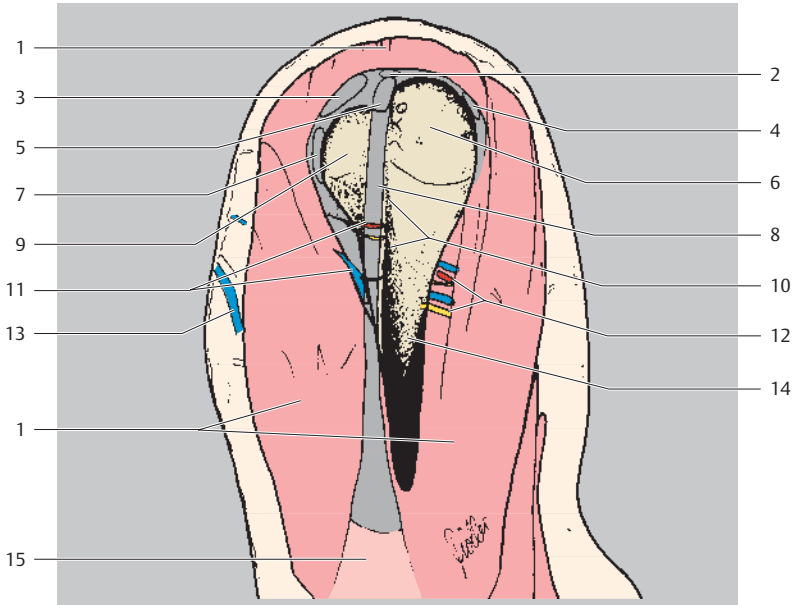
Cranial
Medial Lateral
Caudal



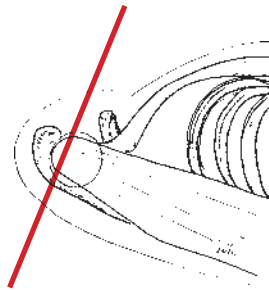
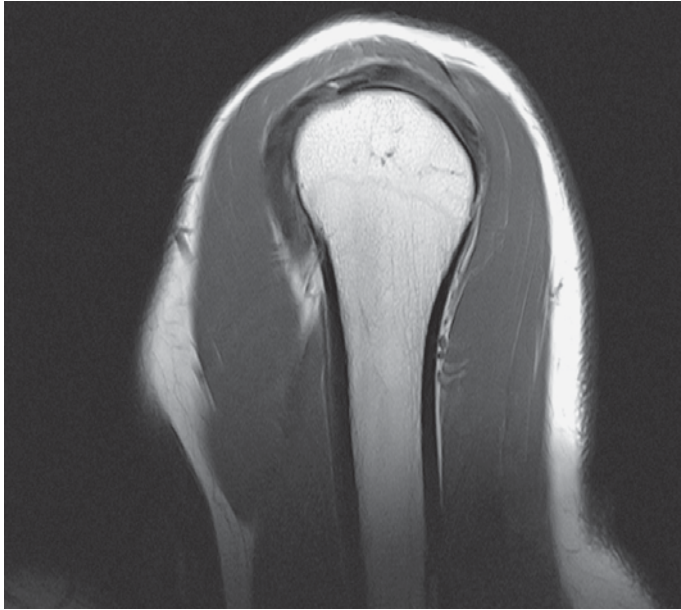
- | | |
|--------------------------------------|--|
| 1 Trapezius muscle | 10 Teres minor muscle |
| 2 Acromion | 11 Subscapular artery and vein |
| 3 Spine of scapula | 12 Posterior circumflex humeral artery and vein and axillary nerve |
| 4 Supraspinatus muscle | 13 Scapula |
| 5 Joint capsule | 14 Deltoid muscle |
| 6 Lesser tubercle | 15 Teres major muscle |
| 7 Infraspinatus muscle | 16 Humerus (shaft) |
| 8 Humerus (head) | 17 Latissimus dorsi muscle |
| 9 Triceps brachii muscle (long head) | 18 Triceps brachii muscle (lateral head) |



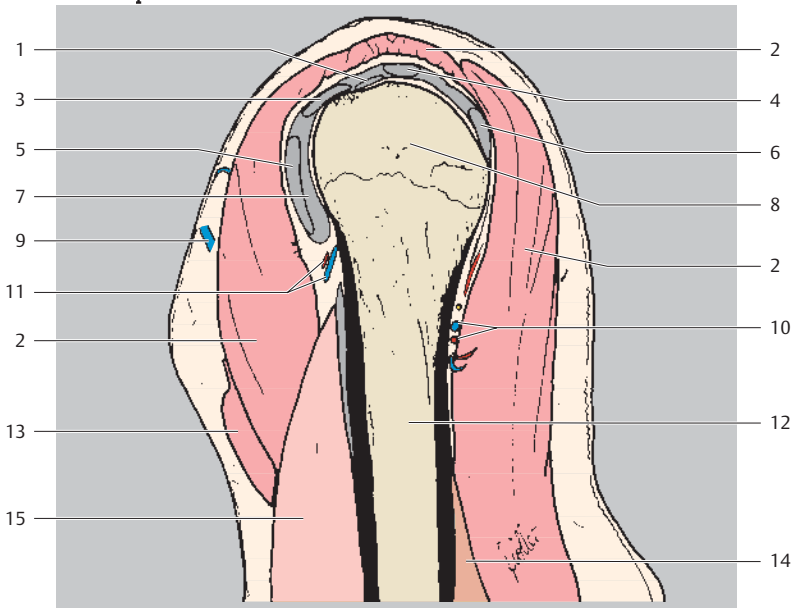
Cranial
Ventral Dorsal
Caudal



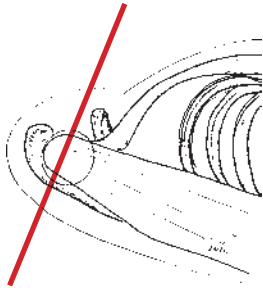
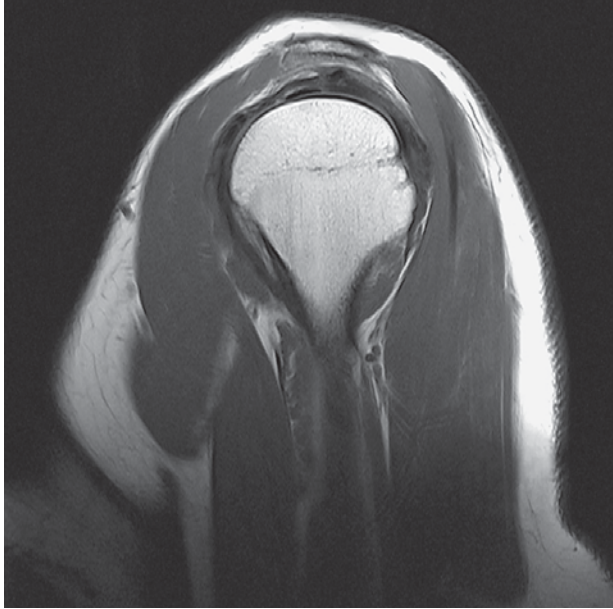
- | | |
|---|---|
| 1 Deltoid muscle (acromial part) | 9 Lesser tubercle |
| 2 Supraspinatus muscle (tendon) | 10 Crest of greater tubercle |
| 3 Glenohumeral ligament (superior) | 11 Anterior circumflex humeral artery and vein |
| 4 Infraspinatus muscle (tendon) | 12 Posterior circumflex humeral artery and vein |
| 5 Intertubercular sulcus (bicipital groove) | 13 Cephalic vein |
| 6 Lesser tubercle | 14 Humerus (shaft) |
| 7 Glenohumeral ligament (middle) | 15 Biceps brachii muscle (long head) |
| 8 Biceps brachii muscle (long head, tendon) | |



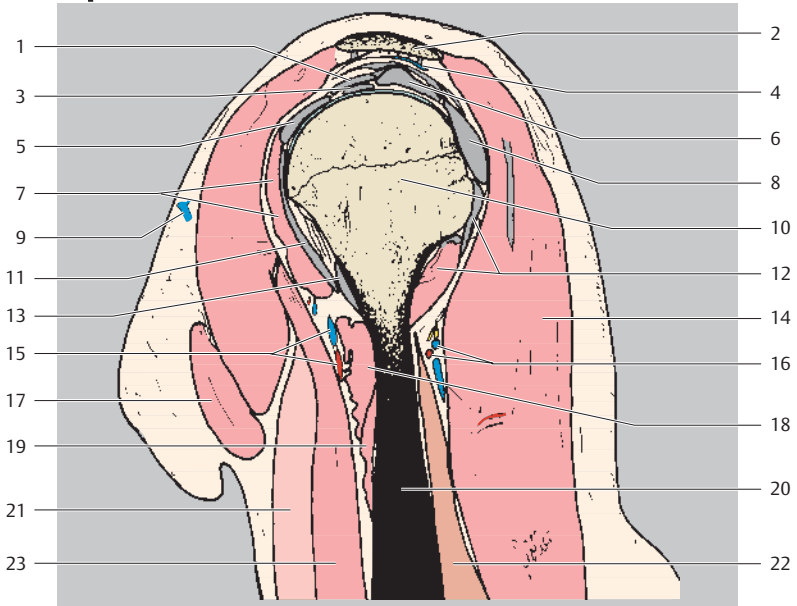
Cranial
Ventral Dorsal
Caudal



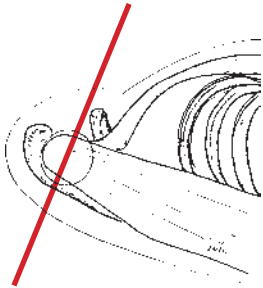
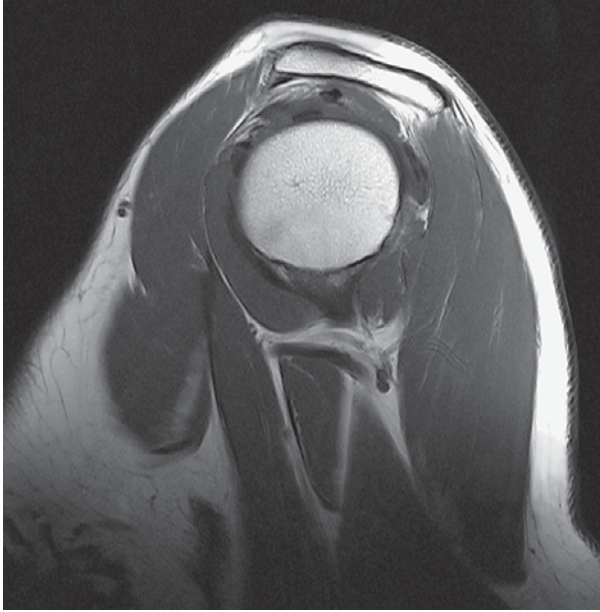
- | | |
|---|---|
| 1 Biceps brachii muscle (long head, tendon) | 8 Humerus (head) |
| 2 Deltoid muscle (acromial part) | 9 Cephalic vein |
| 3 Glenohumeral ligament (superior) | 10 Posterior circumflex humeral artery and vein |
| 4 Supraspinatus muscle (tendon) | 11 Anterior circumflex humeral artery and vein |
| 5 Glenohumeral ligament (middle) | 12 Humerus (shaft) |
| 6 Infraspinatus muscle (tendon) | 13 Pectoralis major muscle |
| 7 Joint capsule | 14 Triceps brachii muscle (medial head) |
| | 15 Biceps brachii muscle (long head) |



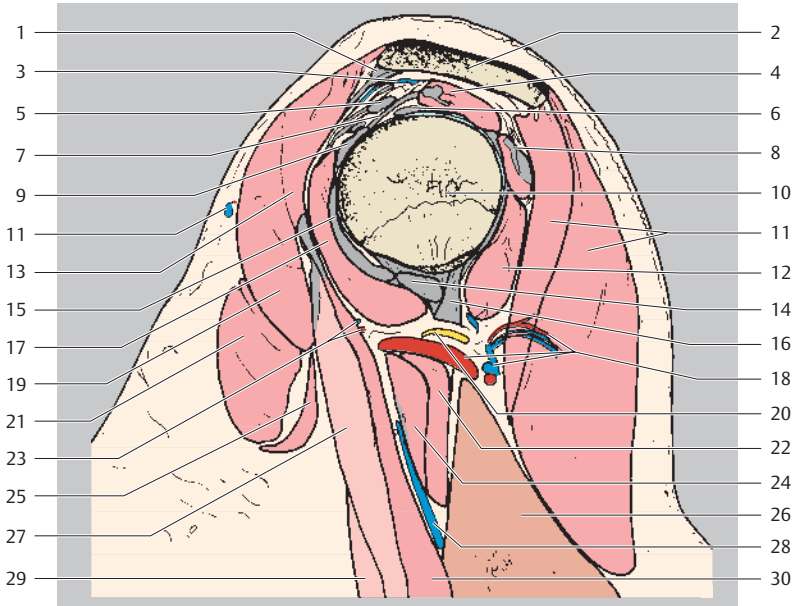
Cranial
Ventral Dorsal
Caudal



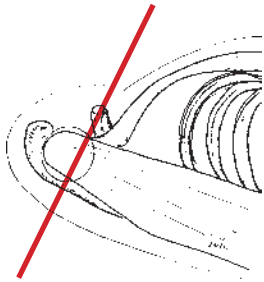
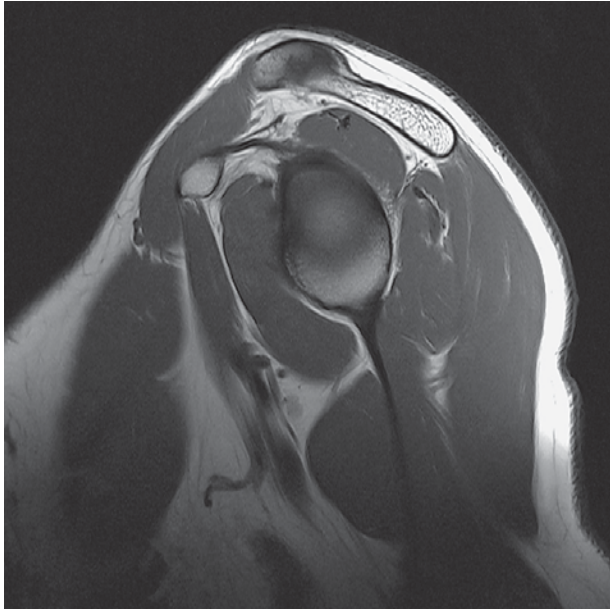
- | | |
|---|---|
| 1 Transverse humeral ligament | 13 Glenohumeral ligament (inferior) |
| 2 Acromion | 14 Deltoid muscle (acromial part) |
| 3 Biceps brachii muscle (long head, tendon) | 15 Anterior circumflex humeral artery and vein |
| 4 Subdeltoid bursa | 16 Posterior circumflex humeral artery and vein |
| 5 Glenohumeral ligament (superior) | 17 Pectoralis major muscle |
| 6 Supraspinatus muscle (tendon) | 18 Latissimus dorsi muscle |
| 7 Subscapularis muscle | 19 Teres major muscle |
| 8 Infraspinatus muscle (tendon) | 20 Humerus (shaft) |
| 9 Cephalic vein | 21 Biceps brachii muscle (long head) |
| 10 Humerus (head) | 22 Triceps brachii muscle (medial head) |
| 11 Glenohumeral ligament (middle) | 23 Coracobrachial muscle |
| 12 Teres minor muscle (+ tendon attachment) | |



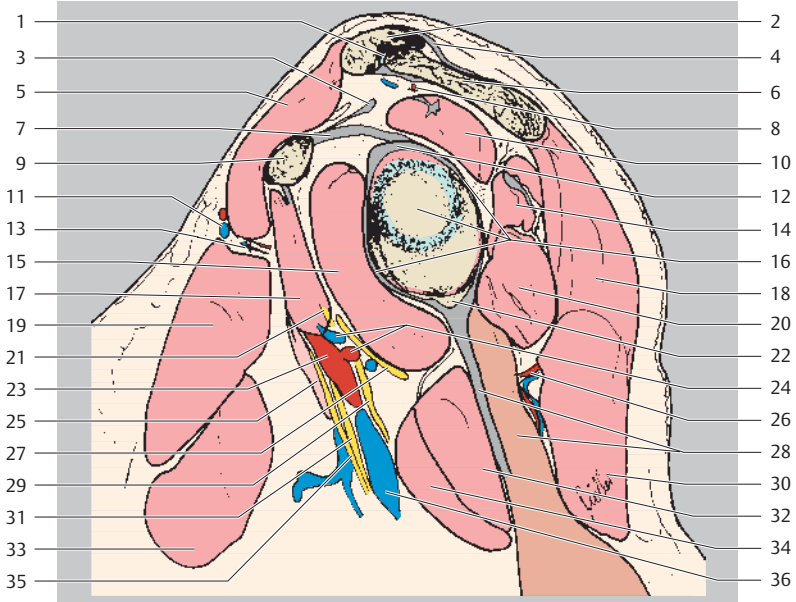
Cranial
Ventral Dorsal
Caudal



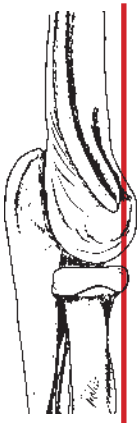
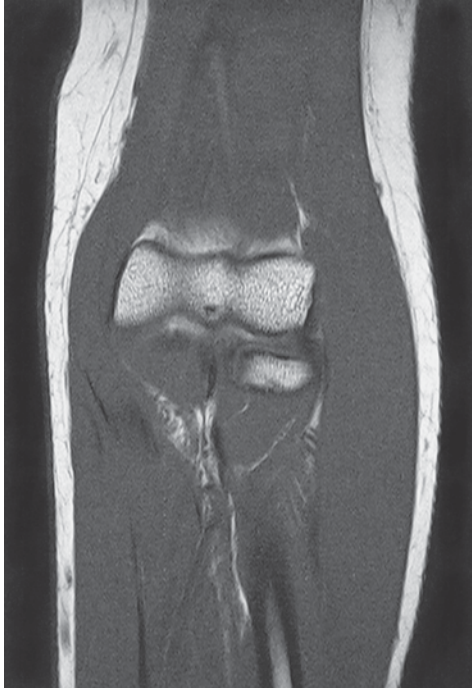
- | | |
|---|---|
| 1 Coracoacromial ligament | 16 Teres major muscle (tendon) |
| 2 Acromion | 17 Subscapularis muscle |
| 3 Subacromial bursa | 18 Posterior circumflex humeral artery and vein + muscular branches |
| 4 Supraspinatus muscle (+ tendon) | 19 Deltoid muscle (clavicular part) |
| 5 Coracohumeral ligament | 20 Axillary nerve |
| 6 Biceps brachii muscle (long head, tendon) | 21 Pectoralis major muscle |
| 7 Transverse humeral ligament | 22 Teres major muscle |
| 8 Infraspinatus muscle (+ tendon) | 23 Anterior circumflex humeral artery and vein |
| 9 Superior glenohumeral ligament | 24 Latissimus dorsi muscle |
| 10 Humerus (head) | 25 Pectoralis minor muscle |
| 11 Cephalic vein | 26 Triceps brachii muscle (long head) |
| 12 Teres minor muscle | 27 Biceps brachii muscle (short head + tendon) |
| 13 Deltoid muscle (acromial part) | 28 Basilic vein |
| 14 Inferior glenohumeral ligament | 29 Biceps brachii muscle (long head) |
| 15 Middle glenohumeral ligament | 30 Coracobrachialis muscle |



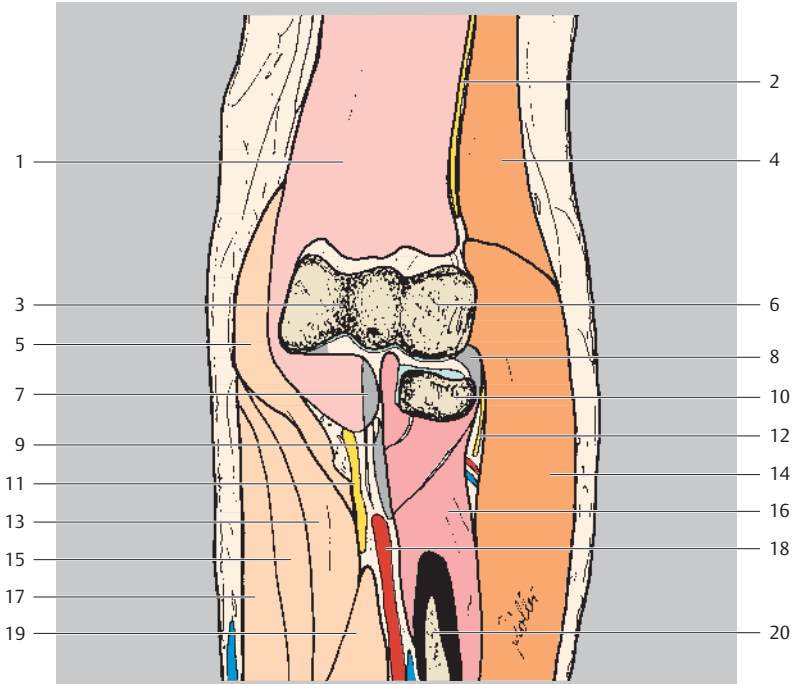
Cranial
Ventral Dorsal
Caudal



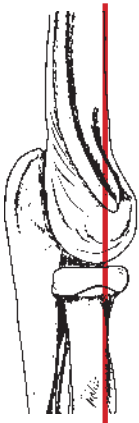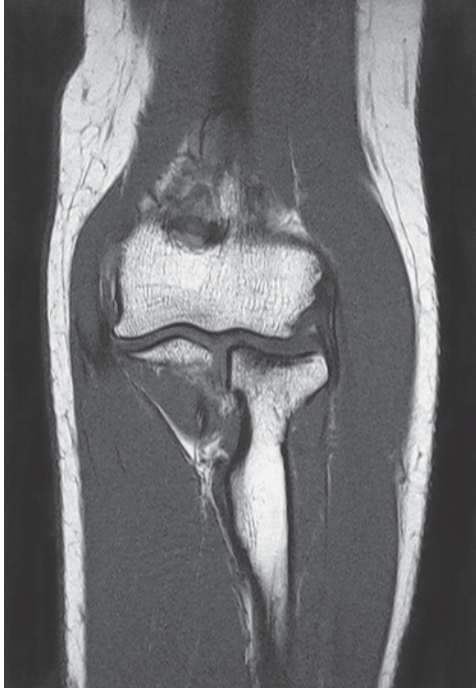- | | |
|---|---|
| 1 Acromioclavicular joint | 18 Deltoid muscle (acromial part) |
| 2 Clavicle | 19 Pectoralis major muscle |
| 3 Coracoacromial ligament | 20 Teres major muscle |
| 4 Acromioclavicular ligament | 21 Musculocutaneous nerve |
| 5 Deltoid muscle (clavicular part) | 22 Infraglenoid tubercle |
| 6 Acromion | 23 Brachial artery |
| 7 Coracohumeral ligament | 24 Posterior circumflex humeral artery and vein |
| 8 Thoracoacromial artery (acromial branch) | 25 Biceps brachii muscle (short head) |
| 9 Coracoid process | 26 Posterior circumflex humeral artery and vein (muscular branches) |
| 10 Supraspinatus muscle (+ tendon) | 27 Axillary nerve |
| 11 Cephalic vein | 28 Triceps brachii muscle (long head + tendon) |
| 12 Biceps brachii muscle (long head, tendon attachment) | 29 Radial nerve |
| 13 Thoracoacromial artery (deltoid branch) | 30 Deltoid muscle (spinal part) |
| 14 Infraspinatus muscle (+ tendon) | 31 Ulnar nerve |
| 15 Subscapularis muscle | 32 Teres major muscle |
| 16 Glenohumeral joint and joint capsule | 33 Pectoralis minor muscle |
| 17 Coracobrachialis muscle | 34 Latissimus dorsi muscle |
| | 35 Median nerve |
| | 36 Brachial vein |



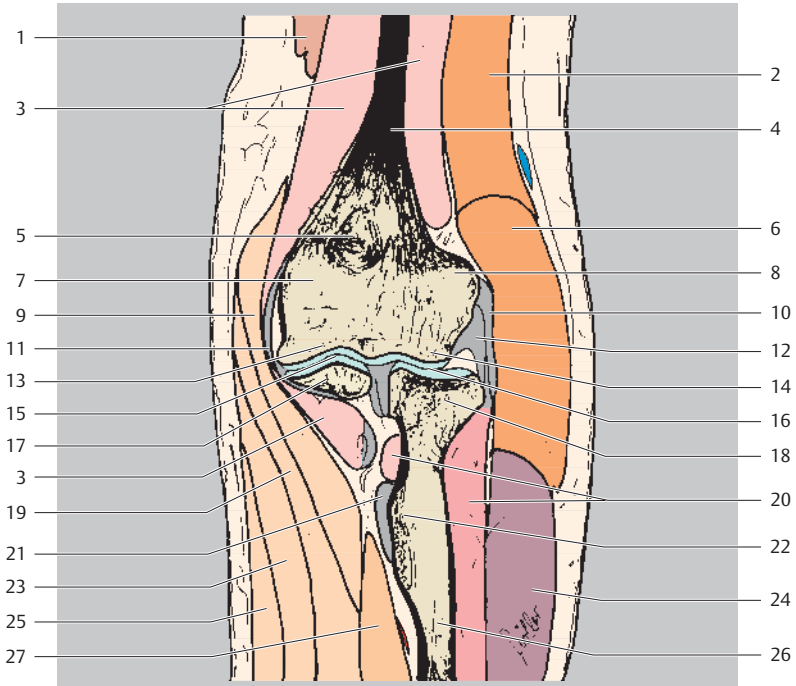
Proximal
Ulnar □ Radial
Medial Lateral
Distal



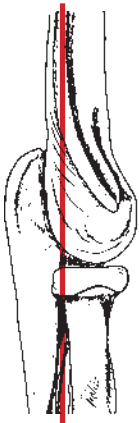
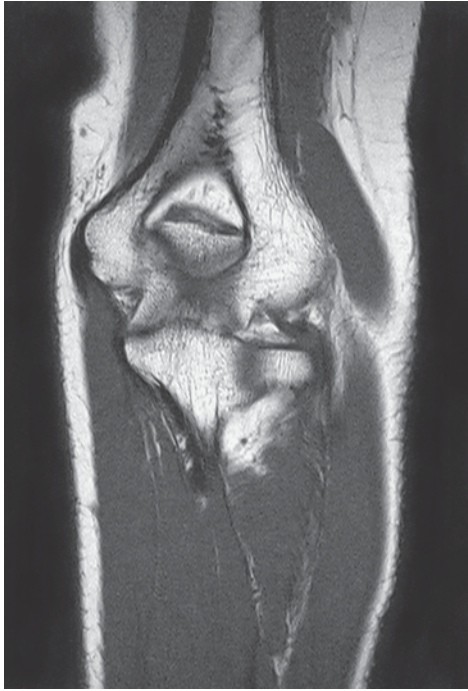- | | |
|--|--|
| 1 Brachialis muscle | 11 Median nerve |
| 2 Radial nerve | 12 Radial nerve (deep branch) |
| 3 Trochlea of humerus | 13 Flexor carpi radialis muscle |
| 4 Brachioradialis muscle | 14 Extensor carpi radialis longus and brevis muscles |
| 5 Pronator teres muscle | 15 Palmaris longus muscle |
| 6 Capitulum of humerus | 16 Supinator muscle |
| 7 Brachialis muscle (tendon) | 17 Flexor carpi ulnaris muscle |
| 8 Annular ligament and radial collateral ligament of wrist joint | 18 Interosseous artery and vein |
| 9 Biceps brachii muscle (tendon) | 19 Flexor digitorum profundus muscle |
| 10 Radius (head) | 20 Radius (shaft) |



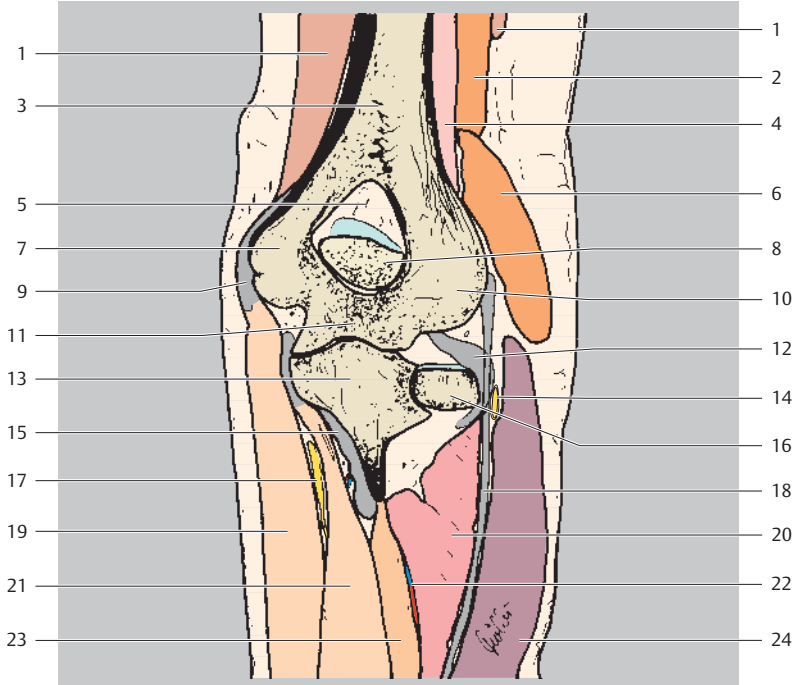
Proximal
Ulnar □ Radial
Medial Lateral
Distal



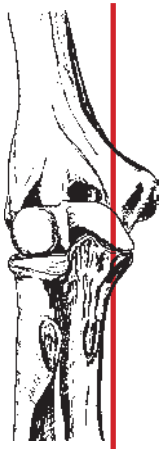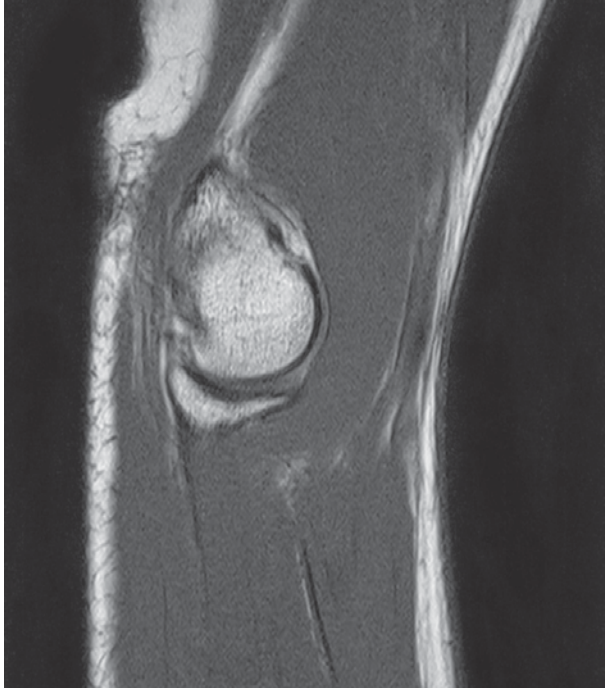- | | | | |
|----|---------------------------------------|----|---------------------------------------|
| 1 | Triceps brachii muscle | 14 | Capitulum of humerus |
| 2 | Brachioradialis muscle | 15 | Humeroulnar joint |
| 3 | Brachialis muscle | 16 | Humeroradial joint |
| 4 | Humerus (shaft) | 17 | Ulna (coronoid process) |
| 5 | Coronoid fossa | 18 | Radius (head) |
| 6 | Extensor carpi radialis longus muscle | 19 | Flexor carpi radialis muscle |
| 7 | Medial epicondyle | 20 | Supinator muscle |
| 8 | Lateral epicondyle | 21 | Biceps brachii muscle (tendon) |
| 9 | Pronator teres muscle | 22 | Radial tuberosity |
| 10 | Common extensor tendons (attachment) | 23 | Palmaris longus muscle |
| 11 | Medial collateral ligament | 24 | Extensor digitorum muscle |
| 12 | Radial collateral ligament | 25 | Flexor digitorum superficialis muscle |
| 13 | Trochlea of humerus | 26 | Radius (head) |
| | | 27 | Flexor digitorum profundus muscle |



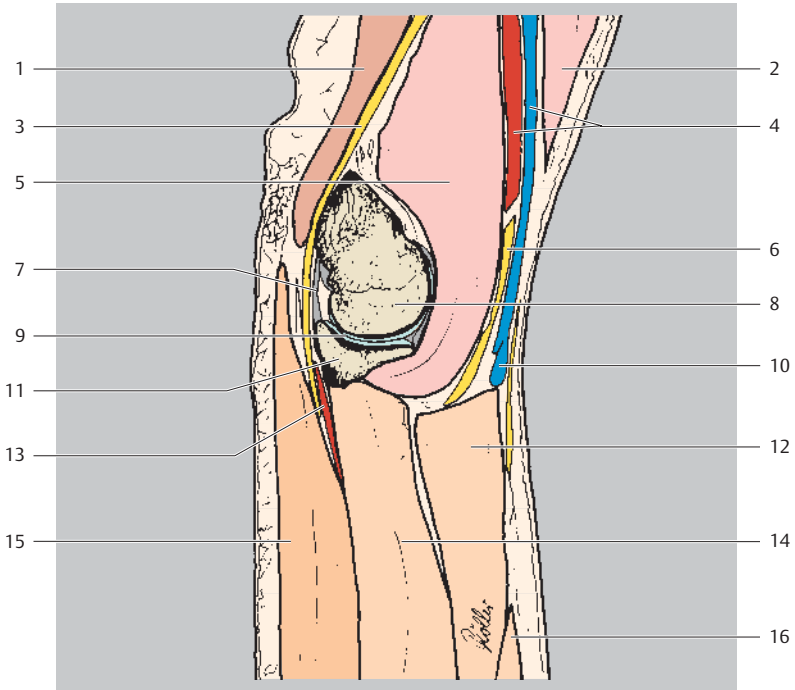
Proximal
Ulnar □ Radial
Medial Lateral
Distal



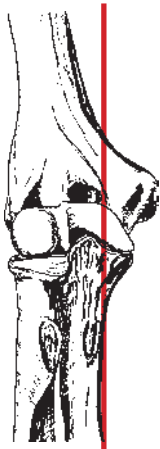
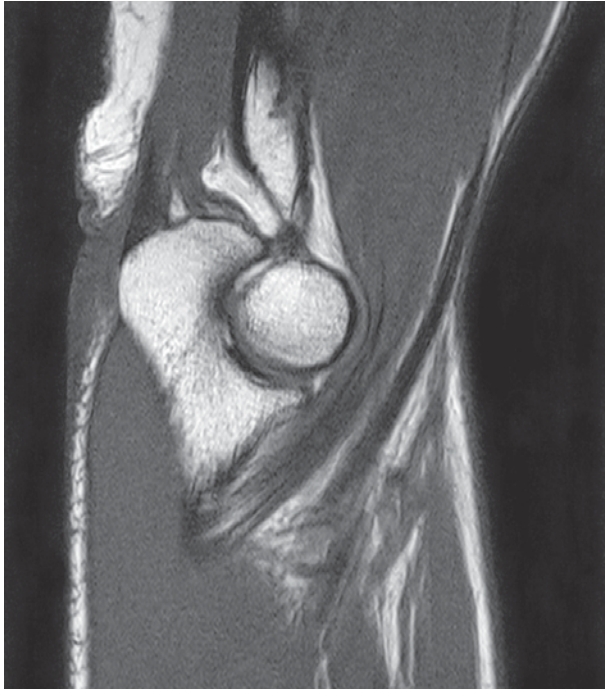
- | | | | |
|----|---------------------------------------|----|---------------------------------------|
| 1 | Triceps brachii muscle | 12 | Annular ligament |
| 2 | Brachioradialis muscle | 13 | Ulna (coronoid process) |
| 3 | Humerus (shaft) | 14 | Radial nerve (deep branch) |
| 4 | Brachialis muscle | 15 | Brachialis muscle (tendon attachment) |
| 5 | Olecranon fossa (posterior fat body) | 16 | Radius (head) |
| 6 | Extensor carpi radialis longus muscle | 17 | Ulnar nerve |
| 7 | Medial epicondyle | 18 | Common extensor tendons |
| 8 | Olecranon | 19 | Flexor carpi ulnaris muscle |
| 9 | Common flexor tendons (attachment) | 20 | Supinator muscle |
| 10 | Lateral epicondyle | 21 | Flexor digitorum superficialis muscle |
| 11 | Trochlea of humerus | 22 | Common interosseous artery and vein |
| | | 23 | Flexor digitorum profundus muscle |
| | | 24 | Extensor digitorum muscle |



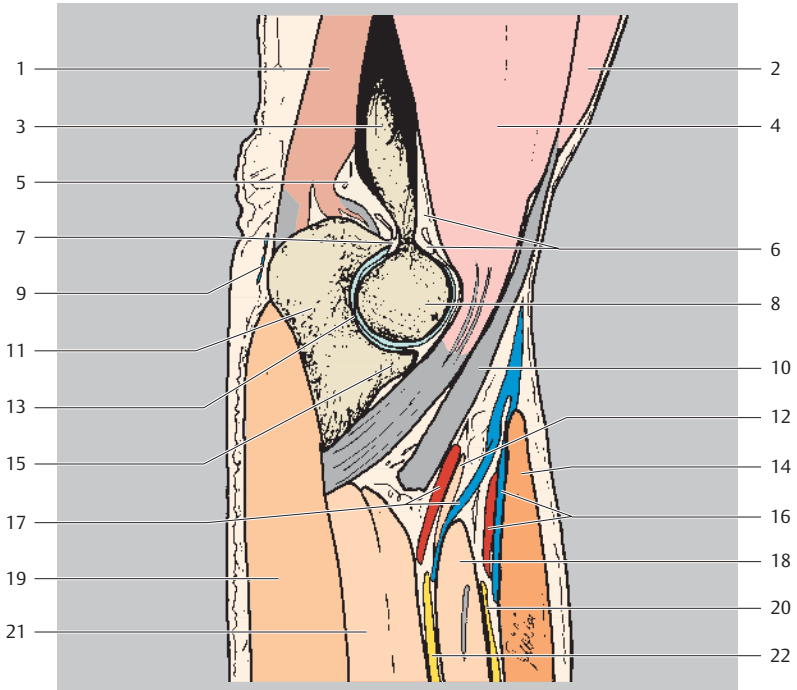
Proximal
Dorsal Ventral
Distal



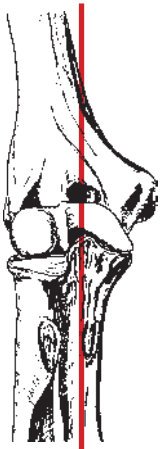
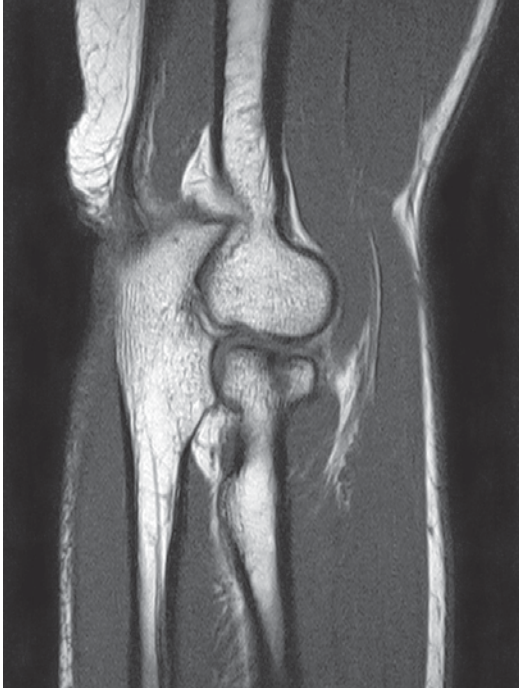- | | | | |
|---|--|----|---------------------------------------|
| 1 | Triceps brachii muscle | 8 | Humerus (trochlea) |
| 2 | Biceps brachii muscle | 9 | Humeroulnar joint |
| 3 | Ulnar nerve | 10 | Median cubital vein |
| 4 | Brachial artery and nerve | 11 | Olecranon |
| 5 | Brachialis muscle | 12 | Pronator teres muscle |
| 6 | Median nerve | 13 | Ulnar recurrent artery |
| 7 | Collateral ulnar ligament, posterior part (+ posterior capsule of the elbow joint) | 14 | Flexor digitorum superficialis muscle |
| | | 15 | Flexor digitorum profundus muscle |
| | | 16 | Flexor carpi radialis muscle |



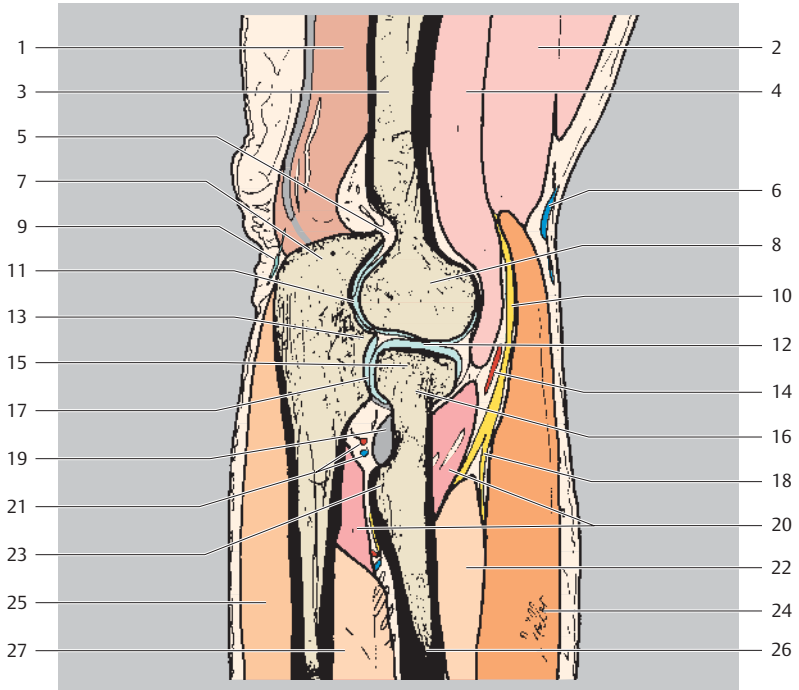
Proximal
Dorsal Ventral
Distal



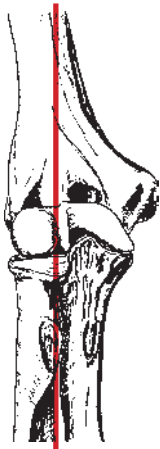
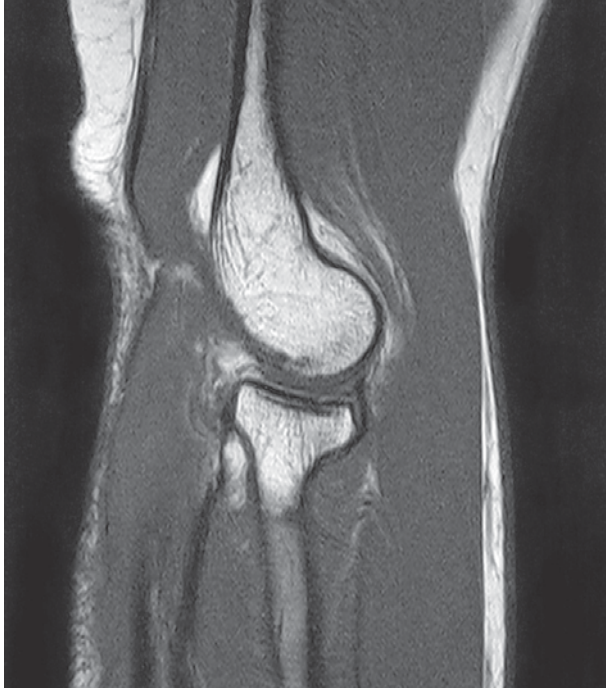- | | | | |
|----|--------------------------------------|----|---------------------------------------|
| 1 | Triceps brachii muscle | 12 | Pronator teres muscle (ulnar head) |
| 2 | Biceps brachii muscle | 13 | Trochlear notch |
| 3 | Humerus | 14 | Brachioradialis muscle |
| 4 | Brachialis muscle | 15 | Coronoid process |
| 5 | Posterior fat body of elbow | 16 | Radial artery and vein |
| 6 | Anterior fat body and coronoid fossa | 17 | Ulnar artery and vein |
| 7 | Olecranon fossa | 18 | Pronator teres muscle |
| 8 | Humerus (trochlea) | 19 | Flexor digitorum profundus muscle |
| 9 | Olecranon bursa | 20 | Radial nerve |
| 10 | Biceps muscle (tendon) | 21 | Flexor digitorum superficialis muscle |
| 11 | Olecranon | 22 | Median nerve |



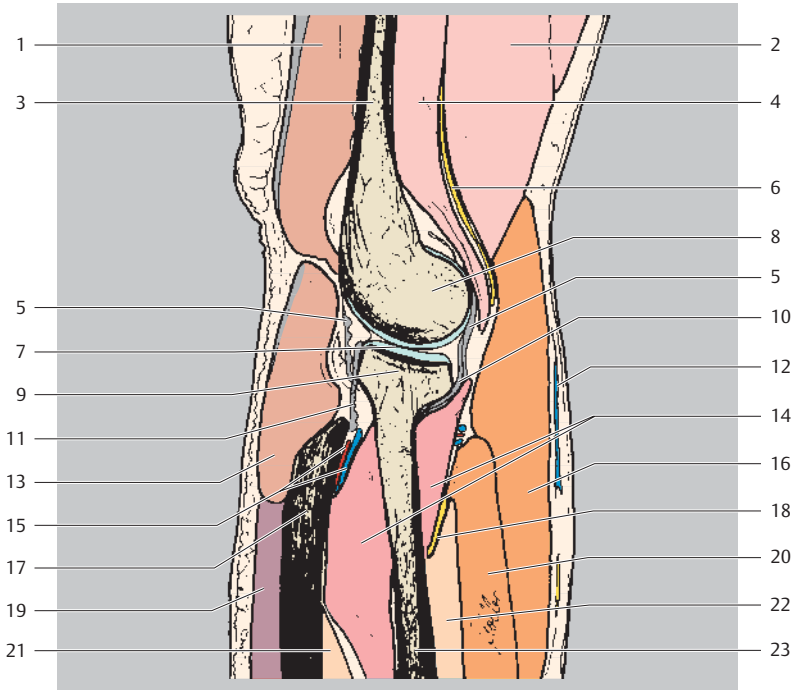
Proximal
Dorsal Ventral
Distal



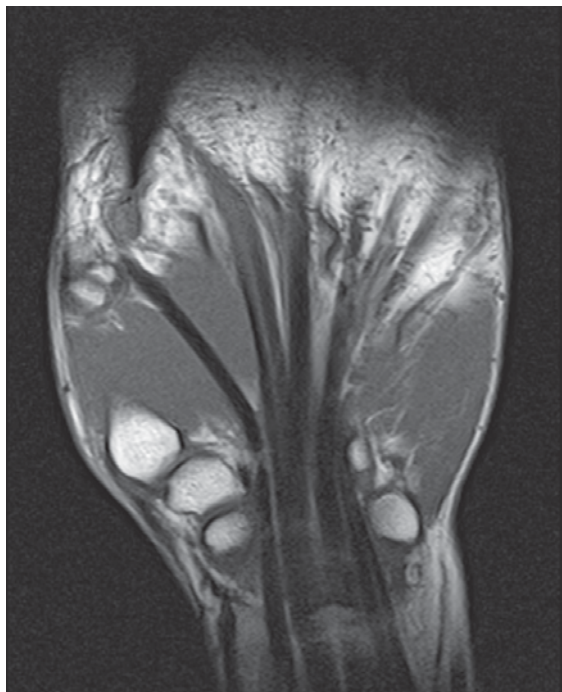- | | |
|----------------------------|--|
| 1 Triceps brachii muscle | 15 Radius (head) |
| 2 Biceps brachii muscle | 16 Radius (neck) |
| 3 Humerus (shaft) | 17 Proximal radioulnar joint |
| 4 Brachialis muscle | 18 Radial nerve (superficial branch) |
| 5 Olecranon fossa | 19 Biceps muscle (tendon attachment) |
| 6 Cephalic vein | 20 Supinator muscle |
| 7 Olecranon | 21 Interosseous artery and vein |
| 8 Humerus (capitulum) | 22 Flexor digitorum superficialis muscle |
| 9 Olecranon bursa | 23 Radial tuberosity |
| 10 Radial nerve | 24 Brachioradialis muscle |
| 11 Trochlear notch | 25 Flexor digitorum profundus muscle |
| 12 Humeroradial joint | 26 Radius (shaft) |
| 13 Coronoid process | 27 Pronator teres muscle (ulnar head) |
| 14 Profunda brachii artery | |



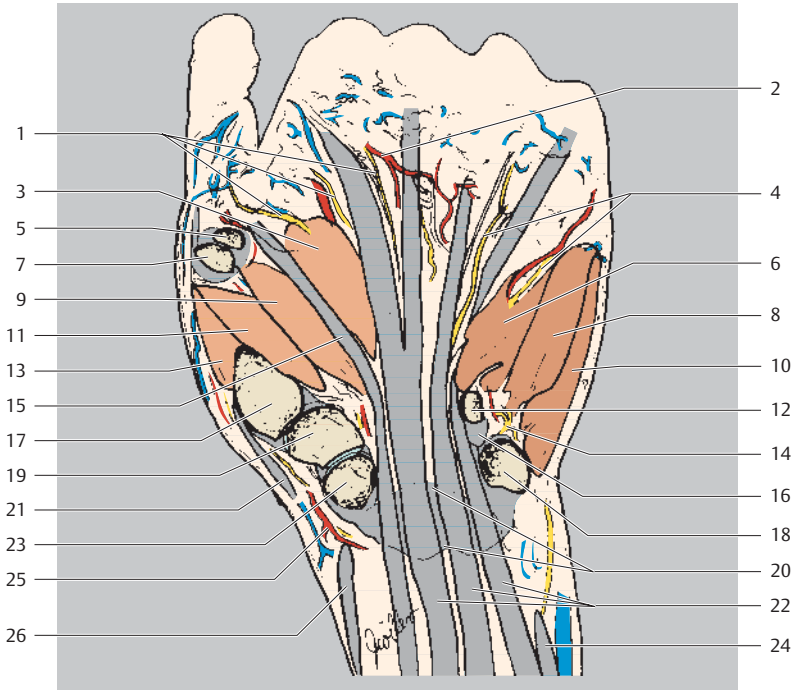
Proximal
Dorsal Ventral
Distal



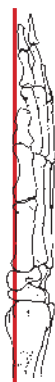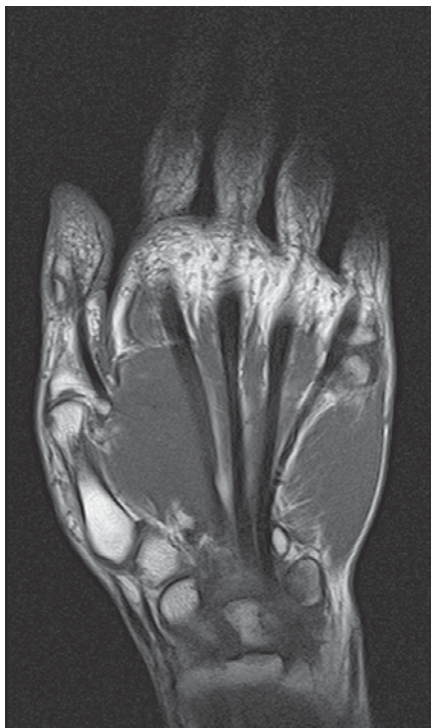
- | | | | |
|----|----------------------------|----|---|
| 1 | Triceps brachii muscle | 13 | Anconeus muscle |
| 2 | Biceps brachii muscle | 14 | Supinator muscle |
| 3 | Humerus (shaft) | 15 | Interosseous artery and vein |
| 4 | Brachialis muscle | 16 | Brachioradialis muscle |
| 5 | Joint capsule | 17 | Ulna (shaft) |
| 6 | Radial nerve | 18 | Radial nerve (deep branch) |
| 7 | Humeroradial joint | 19 | Extensor carpi ulnaris muscle |
| 8 | Humerus (capitulum) | 20 | Extensor carpi radialis longus muscle |
| 9 | Radius (head) | 21 | Pronator teres muscle (ulnar head) |
| 10 | Anular ligament of radius | 22 | Flexor digitorum superficialis muscle (radial head) |
| 11 | Radial collateral ligament | 23 | Radius (shaft) |
| 12 | Cephalic vein | | |



Distal
Radial Ulnar
Proximal

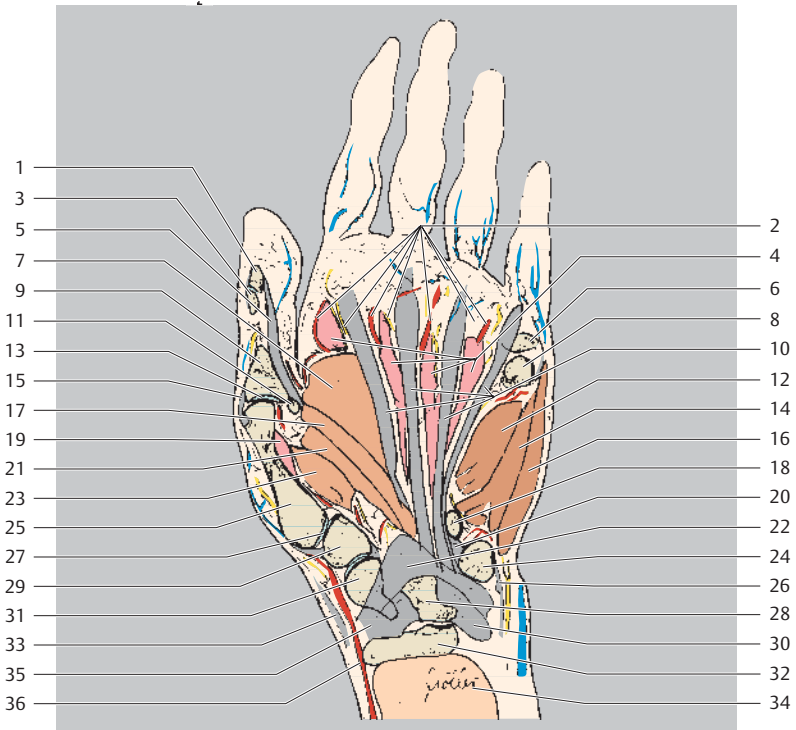


- | | |
|--|--|
| 1 Proper palmar digital nerves (of median nerve) | 14 Ulnar nerve (deep branch) |
| 2 Proper palmar digital arteries | 15 Flexor pollicis longus muscle (tendon) |
| 3 Adductor pollicis muscle (transverse head) | 16 Pisohamate ligament |
| 4 Proper palmar digital nerves (of ulnar nerve) | 17 Metacarpal I (base) |
| 5 Proximal phalanx I (base) | 18 Pisiform |
| 6 Opponens digiti minimi muscle | 19 Trapezium |
| 7 Metacarpal I (head) | 20 Palmar radiocarpal ligament |
| 8 Flexor digiti minimi muscle | 21 Abductor pollicis longus muscle (tendon attachment) |
| 9 Flexor pollicis brevis muscle (deep head) | 22 Flexor digitorum profundus muscle (tendons) |
| 10 Abductor digiti minimi muscle | 23 Scaphoid |
| 11 Abductor pollicis muscle | 24 Flexor carpi ulnaris muscle |
| 12 Hamate (hook) | 25 Radial artery (superficial palmar branch) |
| 13 Opponens pollicis muscle | 26 Brachioradialis muscle (tendon) |

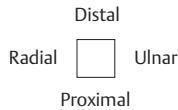
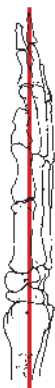
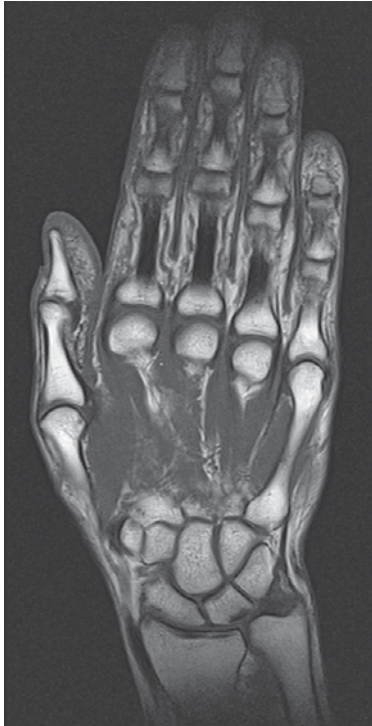
Distal
 Radial Ulnar
 Proximal

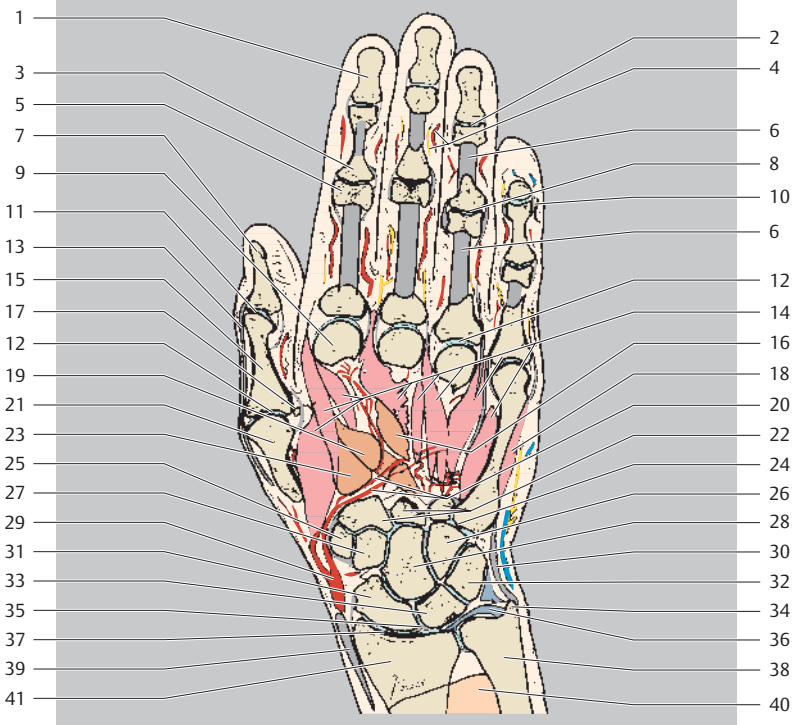
- 1 Distal phalanx I
- 2 Proper palmar digital arteries and nerves
- 3 Proximal phalanx I (head)
- 4 Lumbrical muscles



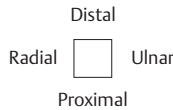
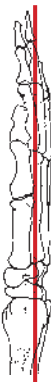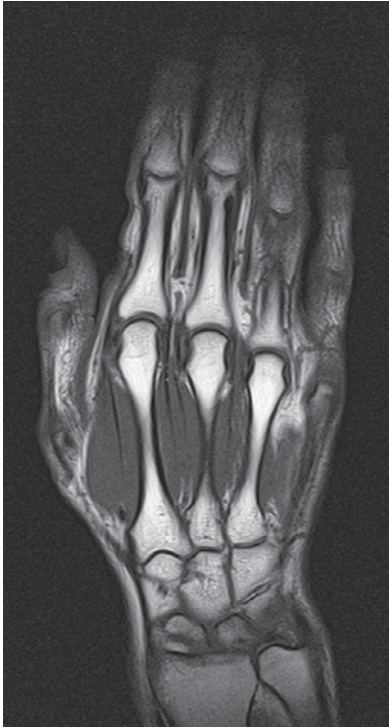- | | |
|--|---|
| 5 Flexor pollicis longus muscle (tendon) | 20 Pisohamate ligament |
| 6 Proximal phalanx V (base) | 21 Flexor pollicis brevis muscle |
| 7 Adductor pollicis muscle (transverse head) | 22 Radiate carpal ligament |
| 8 Metacarpal V (head) | 23 Opponens pollicis muscle |
| 9 Proximal phalanx I (base) | 24 Pisiform |
| 10 Flexor digitorum profundus muscle (tendons) | 25 Metacarpal I |
| 11 Sesamoid bone | 26 Ulnar collateral ligament of wrist joint |
| 12 Opponens digiti minimi muscle | 27 Carpometacarpal joint I |
| 13 Metacarpophalangeal joint I | 28 Lunate |
| 14 Flexor digiti minimi muscle | 29 Trapezium |
| 15 Joint capsule | 30 Palmar ulnocarpal ligament |
| 16 Abductor digiti minimi muscle | 31 Scaphoid |
| 17 Adductor pollicis muscle (oblique head) | 32 Radius |
| 18 Hamate (hook) | 33 Extensor pollicis brevis muscle |
| 19 Interosseus muscle | 34 Pronator quadratus muscle |
| | 35 Palmar radiocarpal ligament |
| | 36 Radial artery |



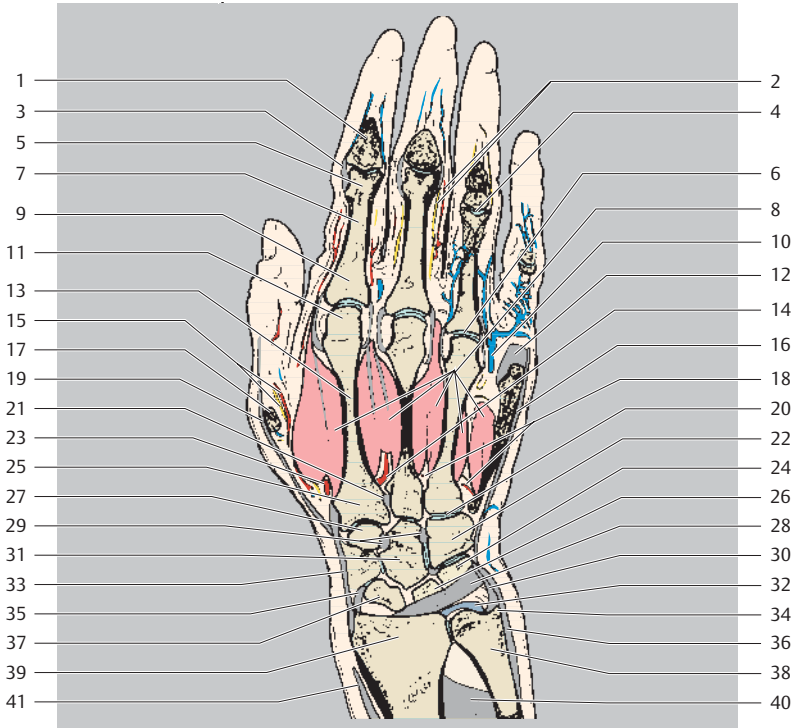
- 1 Distal phalanx 2
- 2 Distal interphalangeal joint
- 3 Middle phalanx (base)
- 4 Proper palmar digital nerves and arteries
- 5 Proximal phalanx (head)
- 6 Flexor digitorum muscle (tendon)
- 7 Distal phalanx 1
- 8 Proximal interphalangeal joint
- 9 Metacarpal II (head)



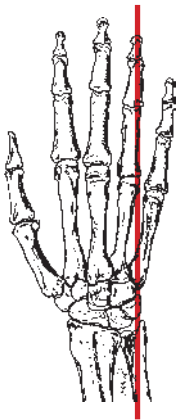
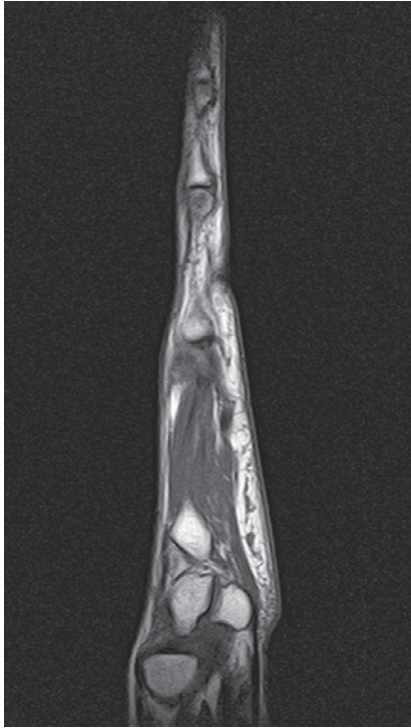
- | | |
|---|---|
| 10 Collateral ligament | 25 Trapezium |
| 11 Interphalangeal joint I | 26 Hamate |
| 12 Metacarpophalangeal joint | 27 Trapezoid |
| 13 Extensor pollicis longus muscle (tendon) | 28 Capitate |
| 14 Interosseous muscles | 29 Radial artery |
| 15 Proximal phalanx I | 30 Ulnar collateral ligament of wrist joint |
| 16 Adductor pollicis muscle (transverse head) | 31 Scaphoid |
| 17 Sesamoid bone | 32 Triquetrum |
| 18 Abductor digiti minimi muscle | 33 Lunate |
| 19 Adductor pollicis muscle (oblique head) | 34 Ulnar styloid process |
| 20 Deep palmar arch and palmar carpal arch | 35 Interosseous ligament (scapholunate) (TFC) |
| 21 Metacarpal I (head) | 36 Triangular fibrocartilage complex (TFC) |
| 22 Metacarpals (bases) | 37 Wrist joint |
| 23 Flexor pollicis brevis muscle | 38 Ulna |
| 24 Carpometacarpal joint | 39 Brachioradialis muscle (tendon) |
| | 40 Pronator quadratus muscle |
| | 41 Radius |



- 1 Middle phalanx (base)
- 2 Dorsal digital arteries and nerves
- 3 Collateral ligament
- 4 Proximal interphalangeal joint
- 5 Proximal phalanx (head)
- 6 Metacarpophalangeal joint
- 7 Proximal phalanx (shaft)
- 8 Interosseous muscles
- 9 Proximal phalanx (base)
- 10 Dorsal metacarpal vein
- 11 Metacarpal (head)

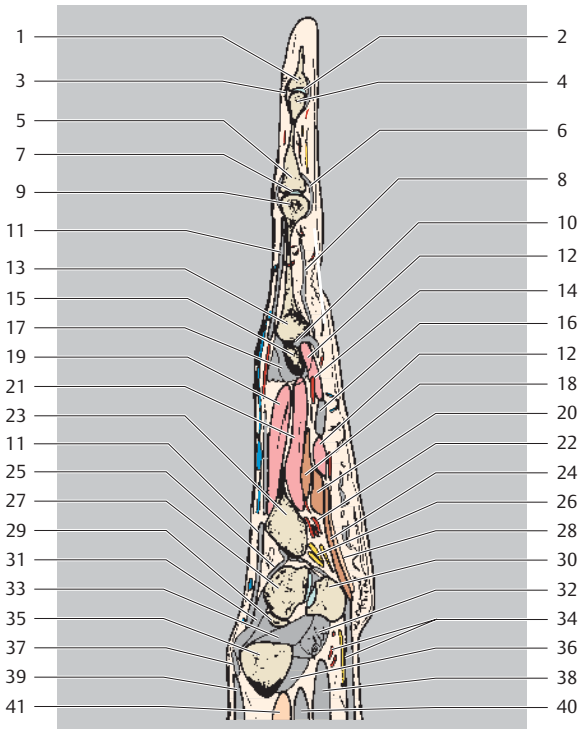


- | | |
|--|---|
| 12 Joint capsule | 26 Lunate |
| 13 Metacarpal (shaft) | 27 Trapezoid |
| 14 Dorsal metacarpal arteries | 28 Dorsal radiocarpal ligament |
| 15 Dorsal metacarpal artery and nerve of thumb | 29 Interosseous intercarpal ligament |
| 16 Extensor digitorum muscle (tendon) | 30 Ulnar collateral ligament of wrist joint |
| 17 Metacarpal I (head) | 31 Capitate |
| 18 Dorsal metacarpal arteries (perforating branches) | 32 Ulnar articular disk |
| 19 Extensor pollicis longus muscle (tendon) | 33 Extensor carpi radialis longus muscle (tendon) |
| 20 Carpometacarpal joint | 34 Styloid process of ulna |
| 21 Interosseous metacarpal ligaments | 35 Radial collateral ligament of wrist joint |
| 22 Hamate | 36 Extensor carpi ulnaris muscle (tendon) |
| 23 Radial artery (dorsal carpal branch) | 37 Scaphoid |
| 24 Triquetrum | 38 Ulna |
| 25 Metacarpal II (base) | 39 Radius |
| | 40 Interosseous membrane |
| | 41 Brachioradialis muscle (tendon) |

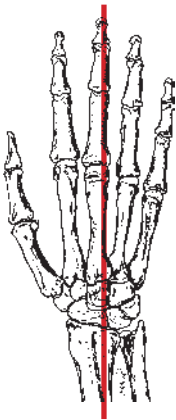
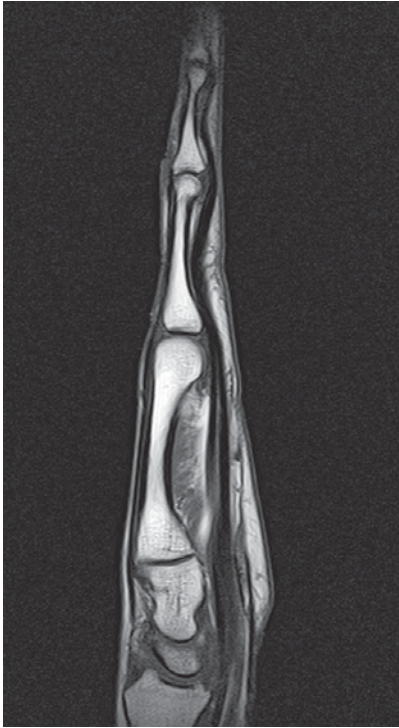

Distal
 Dorsal Palmar
 Proximal

- 1 Distal phalanx
- 2 Distal interphalangeal joint
- 3 Joint capsule
- 4 Middle phalanx (head)
- 5 Middle phalanx (base)
- 6 Palmar collateral ligament
- 7 Proximal interphalangeal joint
- 8 Flexor digitorum muscle (tendon)
- 9 Proximal phalanx (head)
- 10 Metacarpophalangeal joint
- 11 Extensor digitorum muscle (tendon)

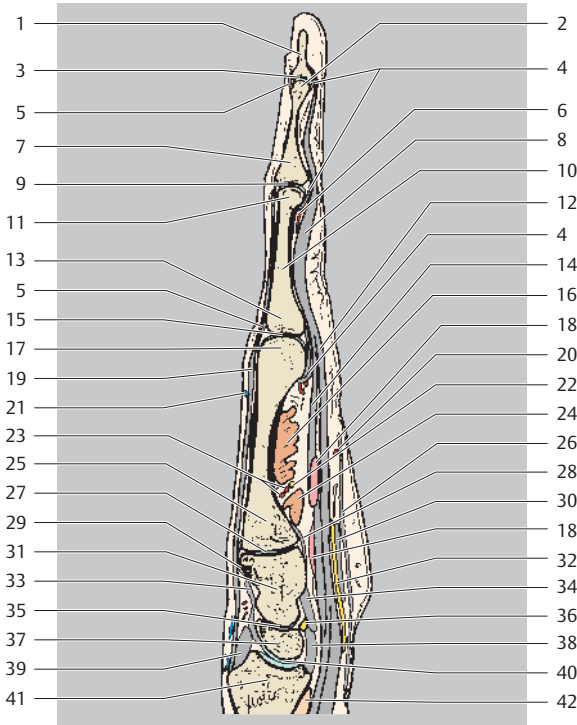


- | | | | |
|----|--|----|---|
| 12 | Lumbrical muscles | 27 | Triquetrum |
| 13 | Proximal phalanx (base) | 28 | Palmaris brevis muscle |
| 14 | Palmar metacarpal artery | 29 | Lunate |
| 15 | Metacarpal (head) | 30 | Pisiform |
| 16 | Flexor digiti minimi muscle (tendon) | 31 | Dorsal radiocarpal ligament |
| 17 | Collateral ligament and attachment of interosseous muscles | 32 | Palmar ulnocarpal ligament |
| 18 | Opponens digiti minimi muscle | 33 | Triangular fibrocartilage complex (+ disk equivalent) |
| 19 | Dorsal interosseous muscle | 34 | Ulnar artery and nerve |
| 20 | Flexor digiti minimi brevis muscle | 35 | Ulna |
| 21 | Palmar interosseous muscle | 36 | Palmar radioulnar ligament |
| 22 | Deep palmar arch | 37 | Dorsal radioulnar ligament |
| 23 | Metacarpal V (base) | 38 | Flexor digitorum profundus muscle (tendon) |
| 24 | Abductor digiti minimi muscle | 39 | Extensor carpi ulnaris muscle |
| 25 | Dorsal carpometacarpal ligament | 40 | Extensor digitorum superficialis muscle (tendon) |
| 26 | Ulnar nerve (deep branch) | 41 | Pronator quadratus muscle |

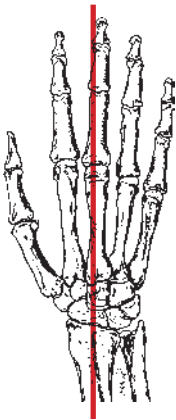
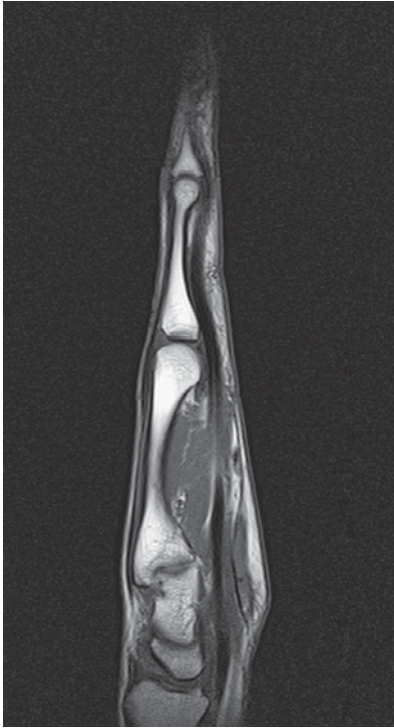


Distal
Dorsal Palmar
Proximal

- 1 Distal phalanx
- 2 Middle phalanx (head)
- 3 Distal interphalangeal joint
- 4 Palmar ligament
- 5 Joint capsule
- 6 Palmar digital artery
- 7 Middle phalanx (base)
- 8 Flexor digitorum muscle (tendon)
- 9 Proximal interphalangeal joint

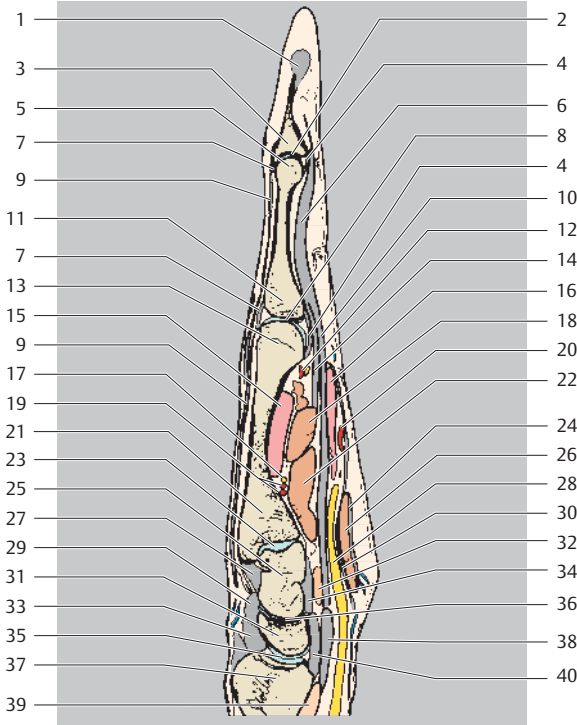


- | | |
|---|---------------------------------------|
| 10 Proximal phalanx (shaft) | 25 Metacarpal (base) |
| 11 Proximal phalanx (head) | 26 Palmar aponeurosis |
| 12 Flexor digitorum superficialis muscle (tendon) | 27 Carpometacarpal joint |
| 13 Proximal phalanx (base) | 28 Palmar carpometacarpal ligament |
| 14 Flexor digitorum profundus muscle (tendon) | 29 Dorsal carpometacarpal ligament |
| 15 Metacarpophalangeal joint | 30 Flexor retinaculum |
| 16 Adductor pollicis muscle (transverse head) | 31 Capitate |
| 17 Metacarpal (head) | 32 Median nerve |
| 18 Lumbrical muscles | 33 Dorsal intercarpal ligament |
| 19 Extensor digitorum muscle (tendon) | 34 Palmar intercarpal ligament |
| 20 Superficial palmar arch | 35 Intercarpal (scaphocapitate) joint |
| 21 Palmar digital vein | 36 Lunate |
| 22 Ulnar nerve (deep branch) | 37 Scaphoid |
| 23 Deep palmar arch | 38 Palmar radiocarpal ligament |
| 24 Adductor pollicis muscle (deep head) | 39 Dorsal radiocarpal ligament |
| | 40 Wrist joint |
| | 41 Radius |
| | 42 Pronator quadratus muscle |

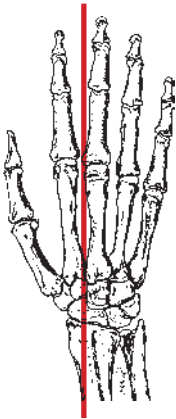
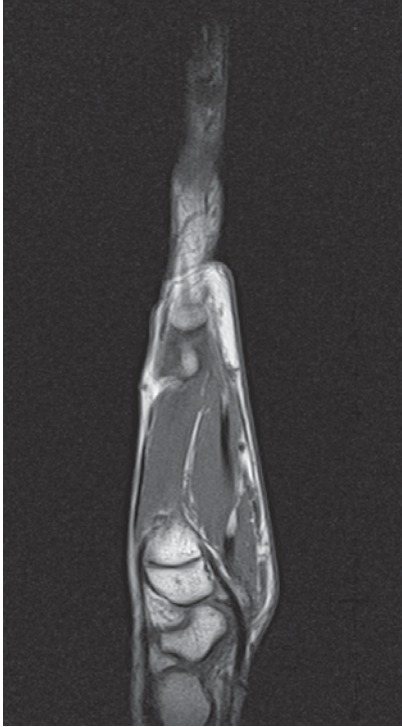


Distal
Dorsal Palmar
Proximal

- 1 Collateral ligament (distal interphalangeal joint)
- 2 Proximal interphalangeal joint
- 3 Middle phalanx (base)
- 4 Palmar ligament
- 5 Proximal phalanx (head)
- 6 Flexor digitorum muscle (tendon)

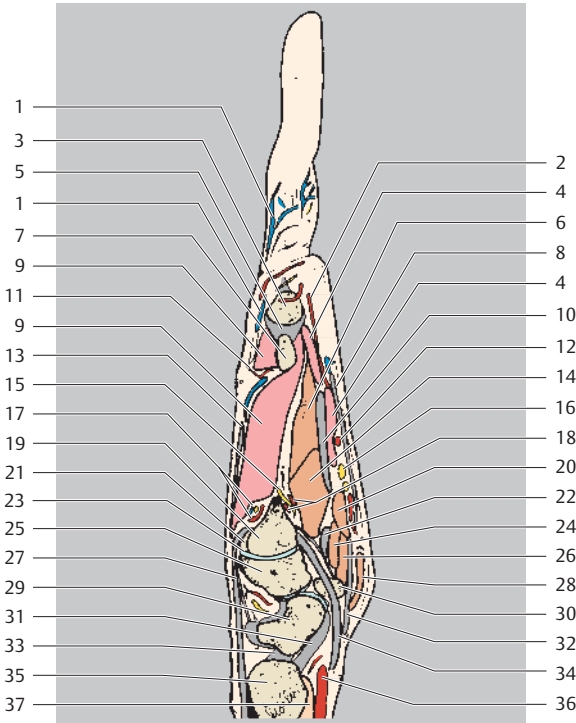


- | | |
|---|--|
| 7 Joint capsule | 22 Adductor pollicis muscle (oblique head) |
| 8 Metacarpophalangeal joint | 23 Carpometacarpal joint |
| 9 Extensor digitorum muscle (tendon) | 24 Palmar aponeurosis |
| 10 Flexor digitorum superficialis muscle (tendon) | 25 Capitate |
| 11 Proximal phalanx (base) | 26 Abductor pollicis brevis muscle |
| 12 Common palmar arteries | 27 Dorsal carpometacarpal ligament |
| 13 Metacarpal (head) | 28 Median nerve |
| 14 Flexor digitorum profundus muscle (tendon) | 29 Dorsal intercarpal ligament |
| 15 Interosseous muscle | 30 Flexor retinaculum |
| 16 Lumbrical muscles | 31 Scaphoid |
| 17 Ulnar nerve (deep branch) | 32 Flexor pollicis muscle (deep head) |
| 18 Adductor pollicis muscle (transverse head) | 33 Dorsal radiocarpal ligament |
| 19 Deep palmar arch | 34 Palmar intercarpal ligament |
| 20 Superficial palmar arch | 35 Radiocarpal joint |
| 21 Metacarpal (base) | 36 Intercarpal (scaphocapitate) joint |
| | 37 Radius |
| | 38 Flexor pollicis longus muscle |
| | 39 Pronator quadratus muscle |
| | 40 Palmar radiocarpal ligament |













Distal
 Dorsal Palmar
 Proximal


- 1 Dorsal digital vein
- 2 Common palmar digital artery
- 3 Proximal phalanx (base)
- 4 Lumbrical muscles
- 5 Collateral ligament (metacarpophalangeal joint)
- 6 Adductor pollicis muscle (transverse head)
- 7 Metacarpal (head)
- 8 Palmar aponeurosis




- | | |
|---|--|
| 9 Interosseus muscle | 22 Flexor pollicis longus muscle (tendon) |
| 10 Flexor digitorum muscle (tendon) | 23 Carpometacarpal joint |
| 11 Dorsal digital artery | 24 Flexor pollicis brevis muscle (deep head) |
| 12 Superficial palmar arch | 25 Trapezoid |
| 13 Extensor digitorum muscle (tendon) | 26 Opponens pollicis muscle |
| 14 Adductor pollicis muscle (oblique head) | 27 Extensor carpi radialis brevis muscle |
| 15 Ulnar nerve (deep branch) | 28 Abductor pollicis brevis muscle |
| 16 Common palmar digital nerve (of median nerve) | 29 Scaphoid |
| 17 Dorsal digital arteries and nerves | 30 Hamate (hook) |
| 18 Deep palmar arch | 31 Palmar radiocarpal ligament |
| 19 Metacarpal II (base) | 32 Flexor retinaculum |
| 20 Flexor pollicis brevis muscle (superficial head) | 33 Radial collateral ligament of wrist joint |
| 21 Metacarpal III (base) | 34 Flexor carpi radialis muscle |
| | 35 Radius |
| | 36 Radial artery |
| | 37 Pronator quadratus muscle |

	Arteries
	Nerves
	Veins
	Bones
	Fatty tissue
	Cartilage
	Tendon
	Meniscus, labrum etc.
	Fluid
	Intestine


Hip and Thigh Muscles:

	Sartorius
	Tensor fasciae latae
	Iliacus
	Iliopsoas
	Psoas
	Gluteus maximus, medius and minimus
	Rectus abdominis
	External and internal oblique muscle of abdomen
	Piriformis
	Gemellus muscles
	Quadratus femoris
	Obturator internus
	Semitendinosus
	Semimembranosus
	Biceps femoris





Adductors:

	Obturator externus
	Pectineus
	Adductor longus, brevis, and magnus
	Gracilis



Quadriceps:

	Rectus femoris
	Vastus lateralis, medialis, and intermedius
	Popliteus


Leg Muscles:

	Extensor group
	Tibialis anterior
	Extensor digitorum longus
	Extensor hallucis longus
	Peroneus group:
	Peroneus brevis (fibularis brevis)
	Peroneus longus (fibularis longus)
	Flexor group:
	Tibialis posterior
	Flexor digitorum longus
	Flexor hallucis longus
	Triceps surae:
	Gastrocnemius
	Soleus
	Plantaris


Muscles of Foot

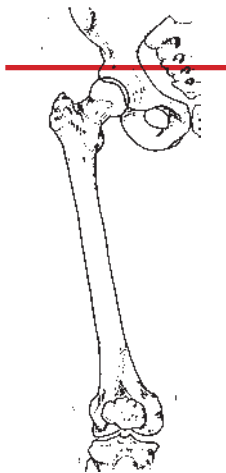
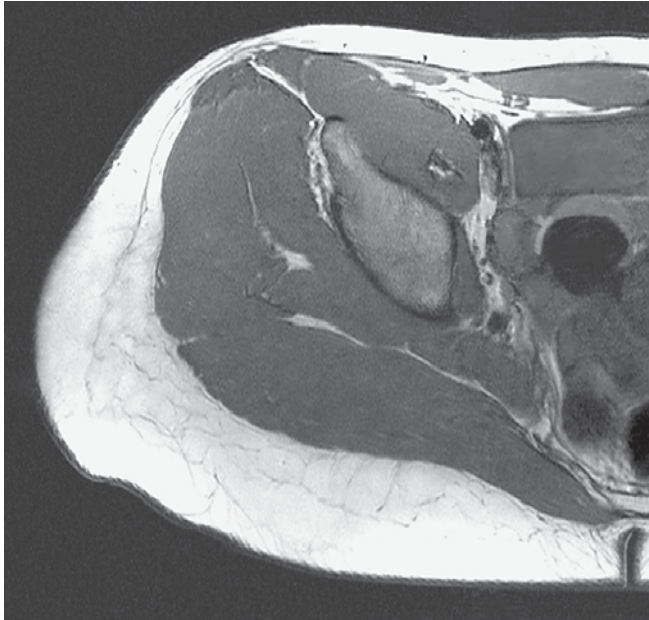
	Extensor digitorum brevis
	Extensor hallucis brevis
	Dorsal and plantar interosseous
	Flexor digitorum brevis
	Quadratus plantae
	Lumbricales

Muscles of Big Toe:

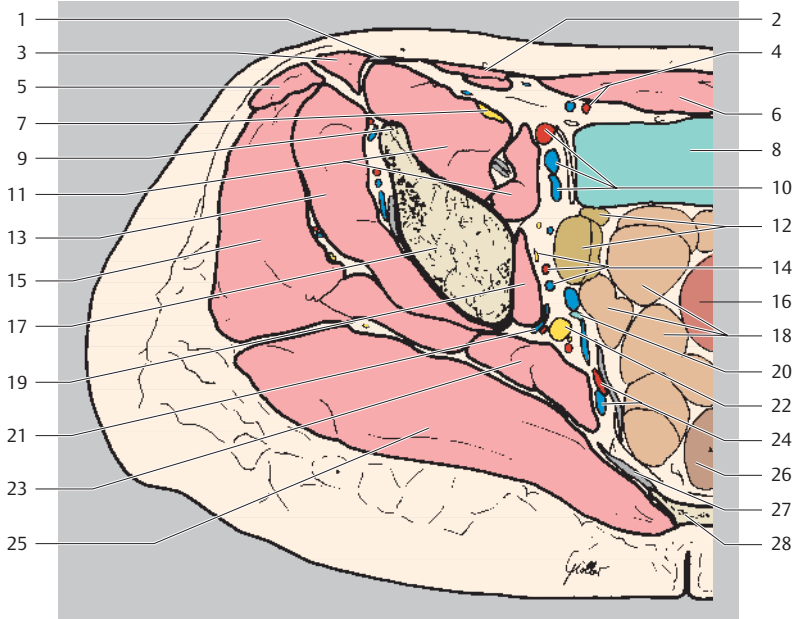
	Flexor hallucis brevis
	Abductor hallucis
	Adductor hallucis

Muscles of Little (Fifth) Toe:

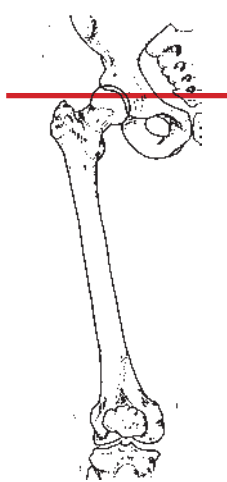
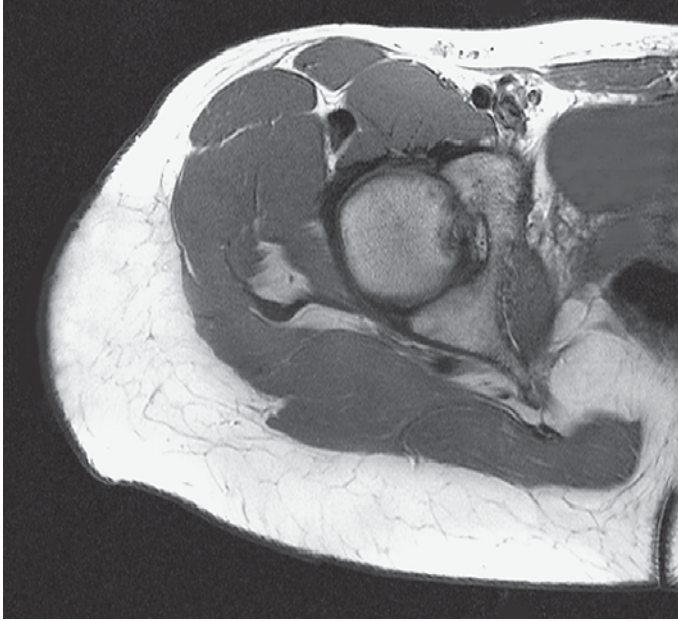
	Abductor digiti minimi
	Flexor digiti minimi
	Opponens digiti minimi



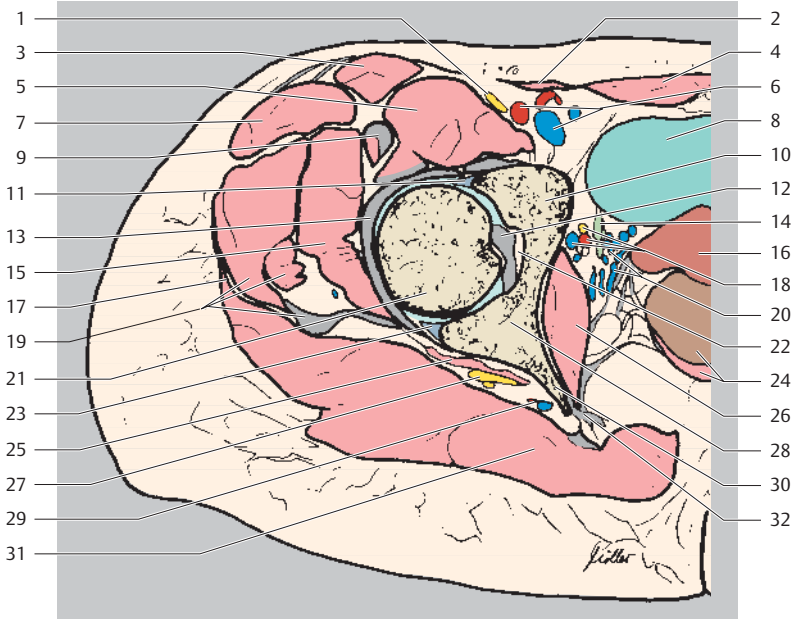
Ventral
Lateral Medial
Dorsal



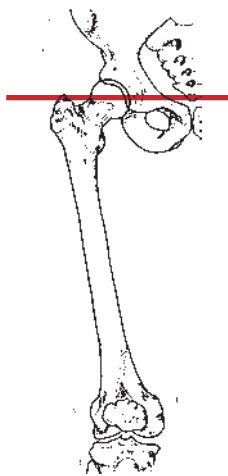
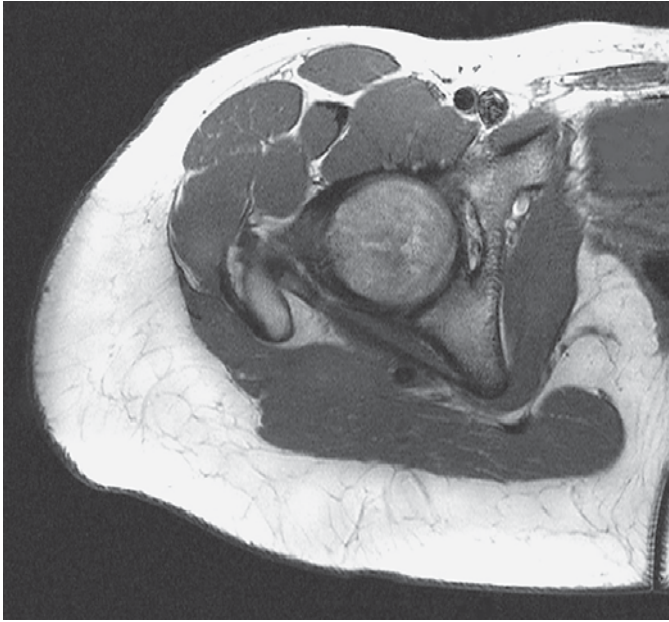
- | | |
|---|--------------------------------------|
| 1 Inguinal ligament | 14 Obturator artery, vein, and nerve |
| 2 Internal oblique abdominal muscle + transverse abdominal muscle | 15 Gluteus medius muscle |
| 3 Sartorius muscle | 16 Uterus |
| 4 Inferior epigastric artery and vein | 17 Ilium |
| 5 Tensor fasciae latae muscle | 18 Small intestine |
| 6 Rectus abdominis muscle | 19 Obturator internus muscle |
| 7 Femoral nerve | 20 Ureter |
| 8 Urinary bladder | 21 Superior gluteal artery and vein |
| 9 Inferior anterior iliac spine | 22 Lumbosacral plexus |
| 10 External iliac artery and veins | 23 Piriformis muscle |
| 11 Iliopsoas muscle | 24 Internal iliac artery and vein |
| 12 Ovary and uterine tube | 25 Gluteus maximus muscle |
| 13 Gluteus minimus muscle | 26 Rectum |
| | 27 Sacrotuberous ligament |
| | 28 Sacrum |



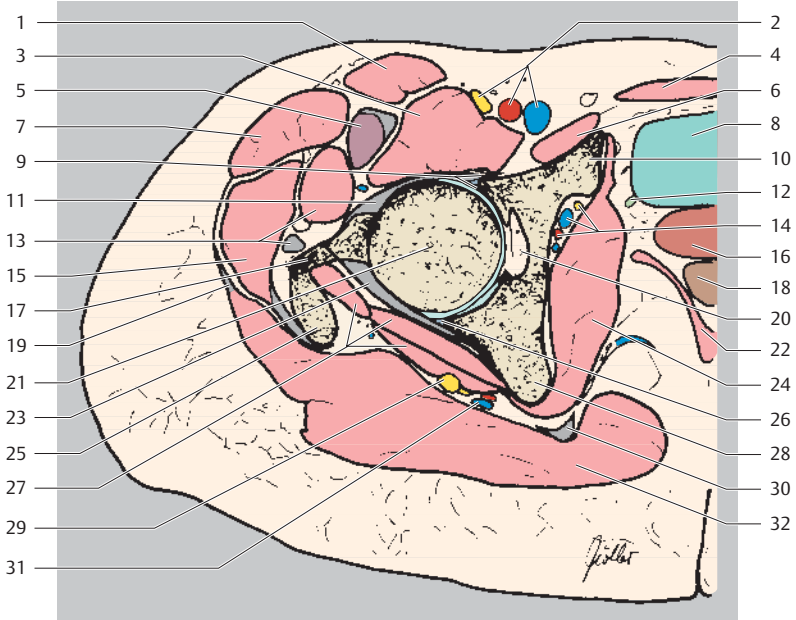
Ventral
Lateral Medial
Dorsal



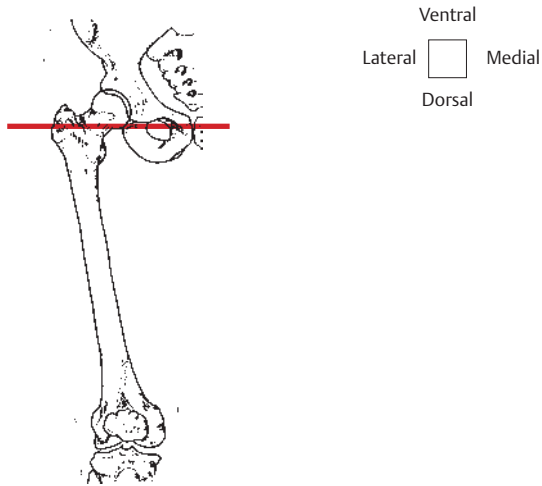
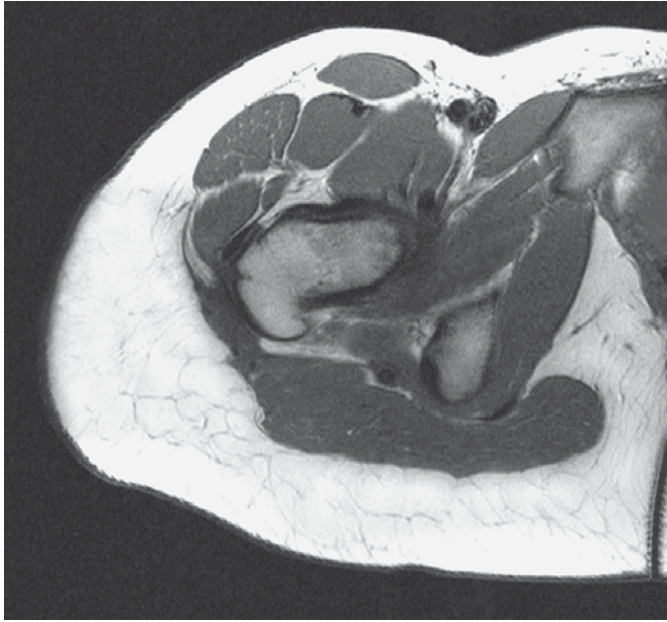
- | | |
|---|--------------------------------------|
| 1 Femoral nerve | 16 Uterus |
| 2 Internal oblique abdominal muscle + transverse abdominal muscle | 17 Head of femur |
| 3 Sartorius muscle | 18 Obturator artery, vein, and nerve |
| 4 Rectus abdominis muscle | 19 Iliotibial tract |
| 5 Iliopsoas muscle | 20 Uterine venous plexus |
| 6 External iliac artery and vein | 21 Gluteus medius muscle (+ tendon) |
| 7 Tensor fasciae latae muscle | 22 Acetabular fossa |
| 8 Urinary bladder | 23 Posterior glenoid labrum |
| 9 Rectus femoris muscle (tendon) | 24 Rectum and levator ani muscle |
| 10 Pubis (superior ramus) | 25 Piriformis muscle |
| 11 Anterior glenoid labrum | 26 Obturator internus muscle |
| 12 Ligament of head of femur | 27 Sciatic nerve |
| 13 Iliofemoral ligament | 28 Ischium |
| 14 Ureter | 29 Superior gluteal artery and vein |
| 15 Gluteus minimus muscle | 30 Ischial spine |
| | 31 Gluteus maximus muscle |
| | 32 Sacrotuberous ligament |

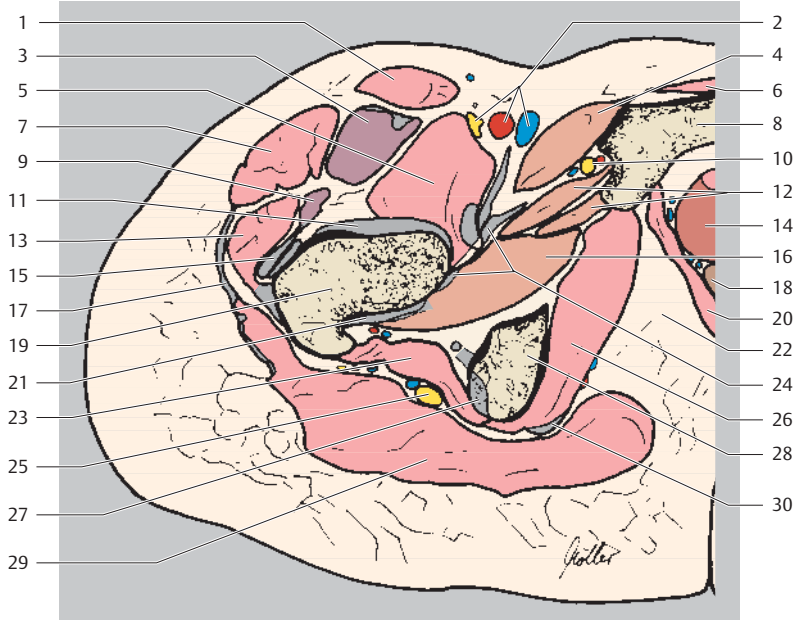


Ventral
Lateral Medial
Dorsal

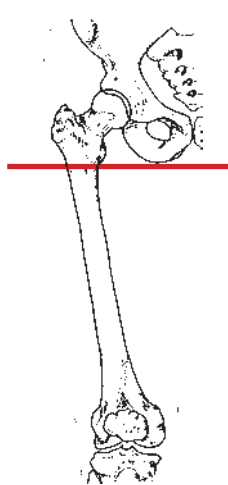
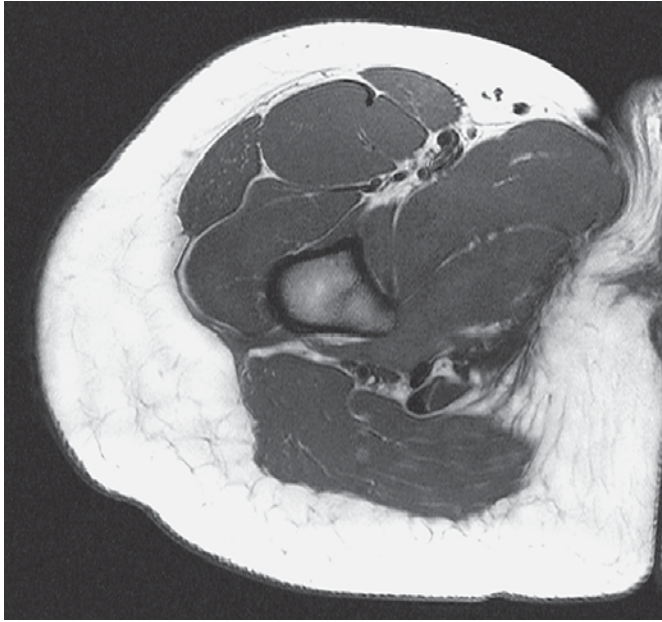


- | | |
|---|--|
| 1 Sartorius muscle | 16 Vagina |
| 2 Femoral artery, vein, and nerve | 17 Neck of femur |
| 3 Iliopsoas muscle | 18 Rectum |
| 4 Rectus abdominis muscle | 19 Iliotibial tract |
| 5 Rectus femoris muscle
(+ tendon) | 20 Acetabular fossa |
| 6 Pectineus muscle | 21 Head of femur |
| 7 Tensor fasciae latae muscle | 22 Levator ani muscle |
| 8 Urinary bladder | 23 Ischiofemoral ligament and
ligamentous capsule |
| 9 Anterior glenoid labrum | 24 Obturator internus muscle |
| 10 Pubis (superior ramus) | 25 Great trochanter |
| 11 Iliofemoral ligament | 26 Posterior glenoid labrum |
| 12 Ureter | 27 Gemellus inferior muscle |
| 13 Gluteus minimus muscle | 28 Ischium |
| 14 Obturator artery, vein, and
nerve | 29 Sciatic nerve |
| 15 Gluteus medius muscle
(+ tendon) | 30 Sacrotuberous ligament |
| | 31 Superior gluteal artery and nerve |
| | 32 Gluteus maximus muscle |

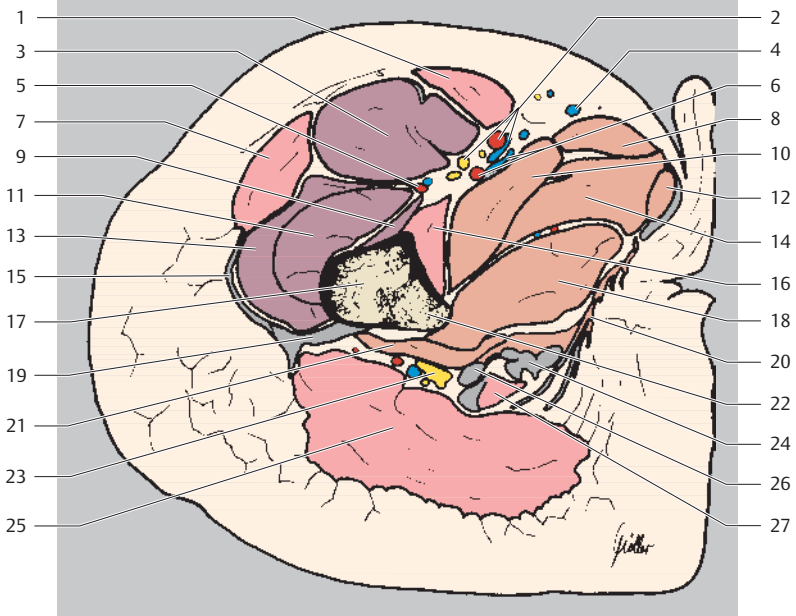




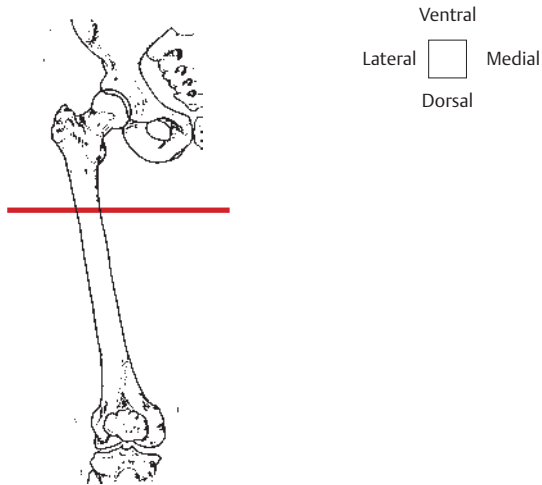
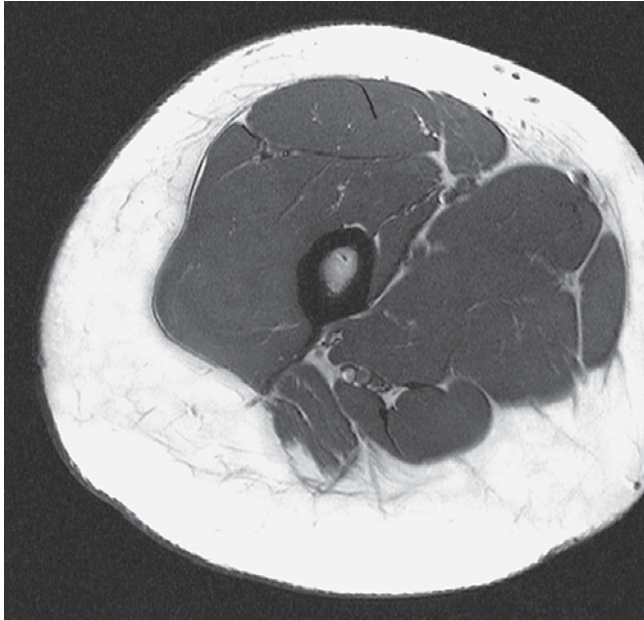- | | |
|--------------------------------------|--|
| 1 Sartorius muscle | 15 Gluteus minimus muscle (+ tendon) |
| 2 Femoral artery, vein, and nerve | 16 Obturator externus muscle |
| 3 Rectus femoris muscle (+ tendon) | 17 Iliotibial tract |
| 4 Pectineus muscle | 18 Rectum |
| 5 Iliopsoas muscle | 19 Femur |
| 6 Rectus abdominis muscle | 20 Levator ani muscle |
| 7 Tensor fasciae latae muscle | 21 Ischiofemoral ligament |
| 8 Pubis (inferior ramus) | 22 Ischiorectal fossa |
| 9 Vastus lateralis muscle | 23 Quadratus femoris muscle |
| 10 Obturator nerve (anterior branch) | 24 Pubofemoral ligament |
| 11 Iliofemoral ligament | 25 Sciatic nerve |
| 12 Adductor brevis muscle | 26 Obturator internus muscle |
| 13 Gluteus medius muscle (+ tendon) | 27 Tendon attachment of dorsal thigh muscles |
| 14 Vagina and urethra | 28 Ischial tuberosity |
| | 29 Gluteus maximus muscle |
| | 30 Sacrotuberous ligament |

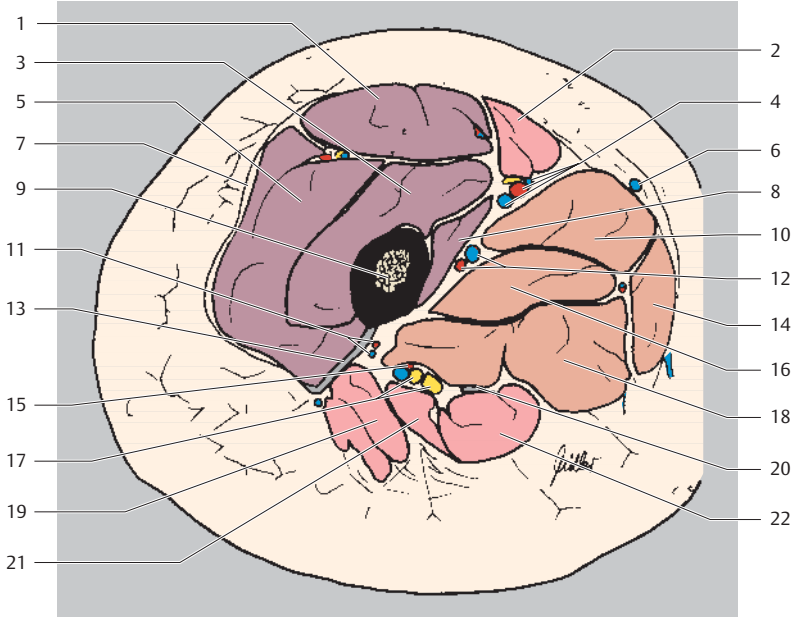


Ventral
Lateral Medial
Dorsal

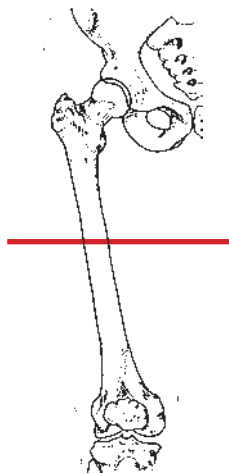
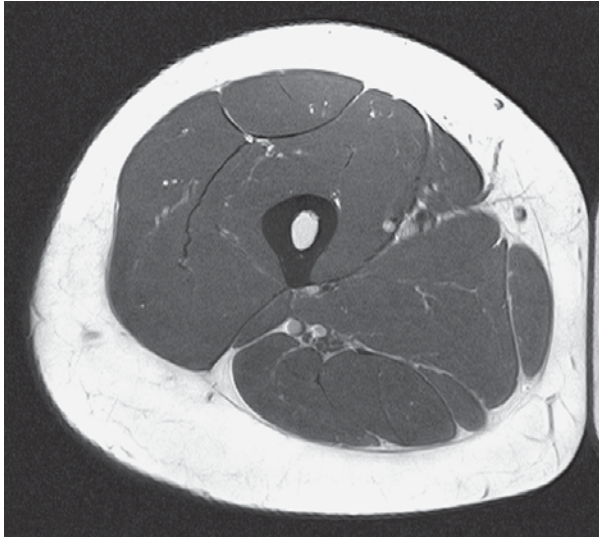


- | | |
|--------------------------------------|---|
| 1 Sartorius muscle | 14 Adductor brevis muscle |
| 2 Femoral artery, vein, and nerve | 15 Iliotibial tract |
| 3 Rectus femoris muscle | 16 Iliopsoas muscle |
| 4 Great saphenous vein | 17 Femur |
| 5 Circumflex femoral artery and vein | 18 Adductor magnus muscle |
| 6 Deep femoral artery and vein | 19 Lateral femoral intermuscular septum |
| 7 Tensor fasciae latae muscle | 20 Obturator internus muscle |
| 8 Adductor longus muscle | 21 Quadratus femoris muscle |
| 9 Vastus medialis muscle | 22 Lesser trochanter |
| 10 Pectineus muscle | 23 Sciatic nerve |
| 11 Vastus intermedius muscle | 24 Semimembranosus muscle (tendon) |
| 12 Gracilis muscle | 25 Gluteus maximus muscle |
| 13 Vastus lateralis muscle | 26 Biceps femoris muscle (tendon) |
| | 27 Semitendinosus muscle (tendon) |

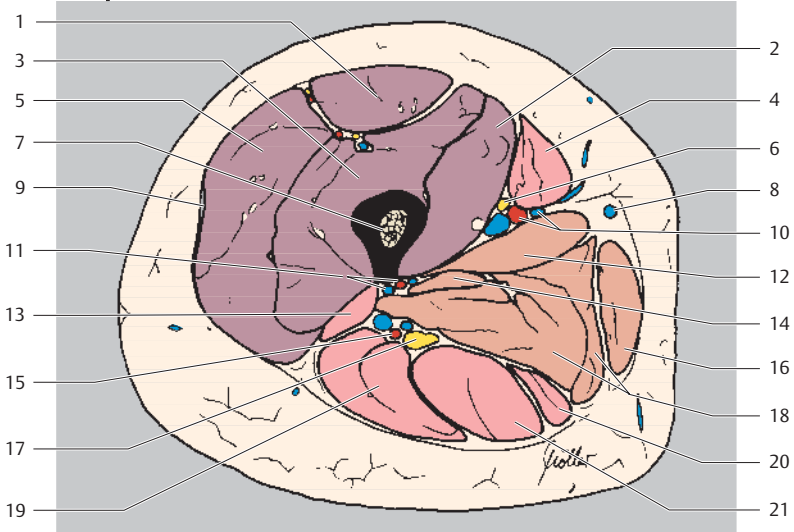




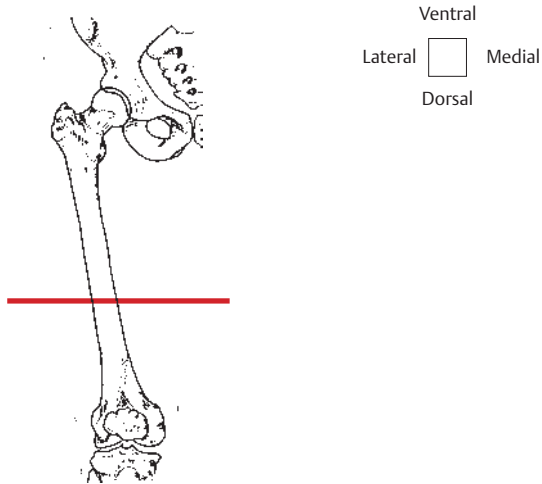
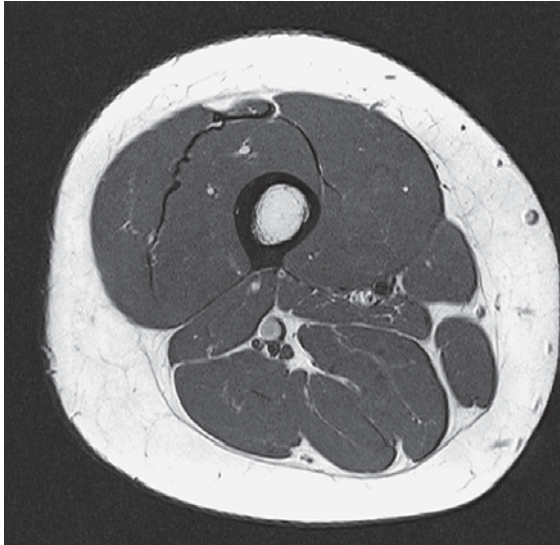
- | | |
|---|---|
| 1 Rectus femoris muscle | 12 Deep artery and vein of thigh |
| 2 Sartorius muscle | 13 Lateral femoral intermuscular septum |
| 3 Vastus intermedius muscle | 14 Gracilis muscle |
| 4 Femoral artery, vein, and nerve | 15 Artery and vein to sciatic nerve |
| 5 Vastus lateralis muscle | 16 Adductor brevis muscle |
| 6 Great saphenous vein | 17 Sciatic nerve |
| 7 Iliotibial tract | 18 Adductor magnus muscle |
| 8 Vastus medialis muscle | 19 Gluteus maximus muscle |
| 9 Femur | 20 Semimembranosus muscle (tendon) |
| 10 Adductor longus muscle | 21 Biceps femoris muscle |
| 11 Perforating artery of deep artery of thigh | 22 Semitendinosus muscle |

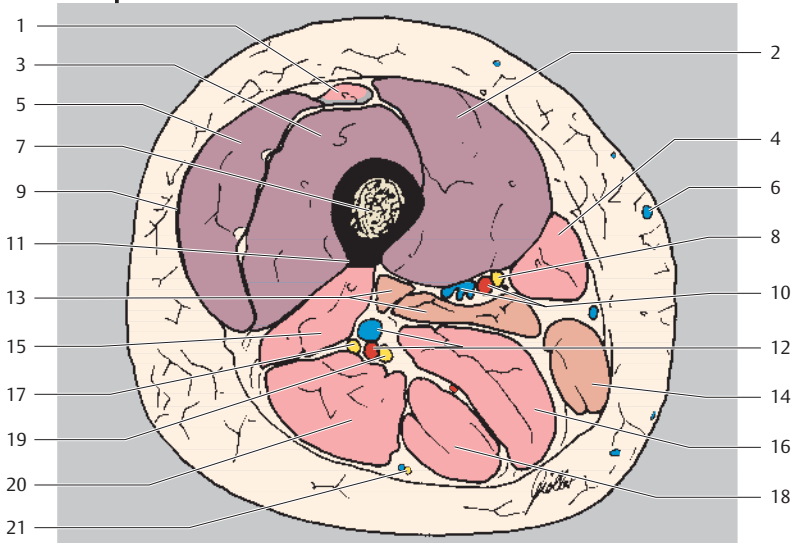


Ventral
Lateral Medial
Dorsal

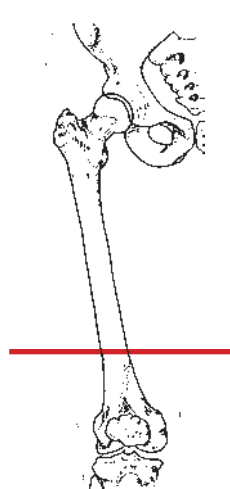
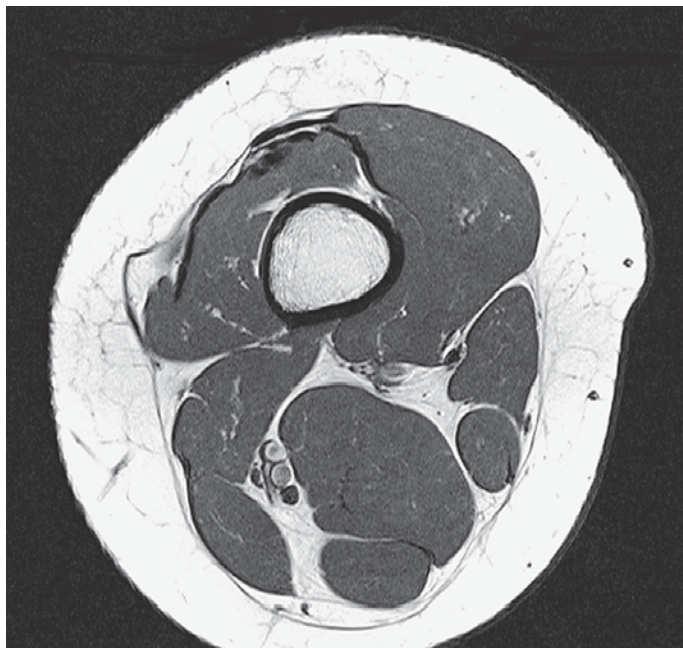


- | | |
|----------------------------------|---------------------------------------|
| 1 Rectus femoris muscle | 12 Adductor longus muscle |
| 2 Vastus medialis muscle | 13 Biceps femoris muscle (short head) |
| 3 Vastus intermedius muscle | 14 Adductor brevis muscle |
| 4 Sartorius muscle | 15 Artery to sciatic nerve |
| 5 Vastus lateralis muscle | 16 Gracilis muscle |
| 6 Saphenous nerve | 17 Sciatic nerve |
| 7 Femur | 18 Adductor magnus muscle |
| 8 Great saphenous vein | 19 Biceps femoris muscle (long head) |
| 9 Iliotibial tract | 20 Semimembranosus muscle |
| 10 Femoral artery and vein | 21 Semitendinosus muscle |
| 11 Deep artery and vein of thigh | |

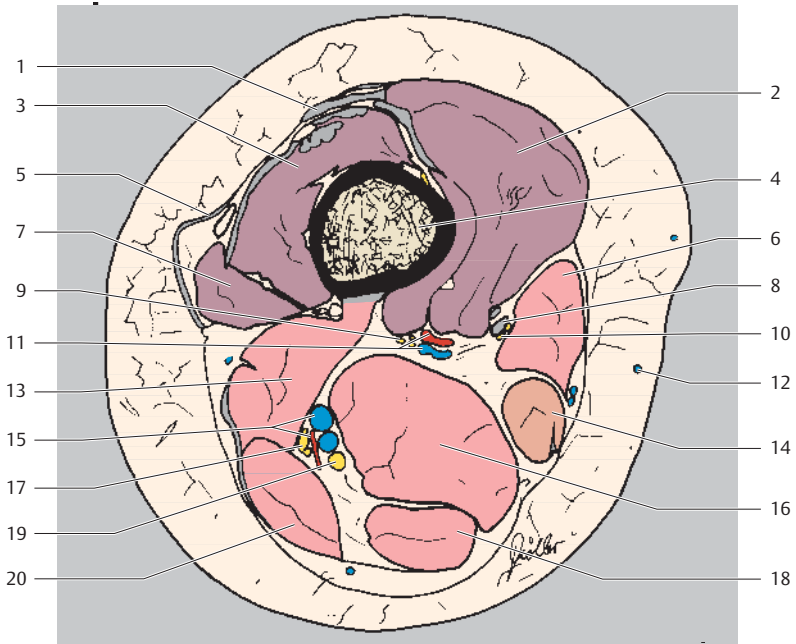




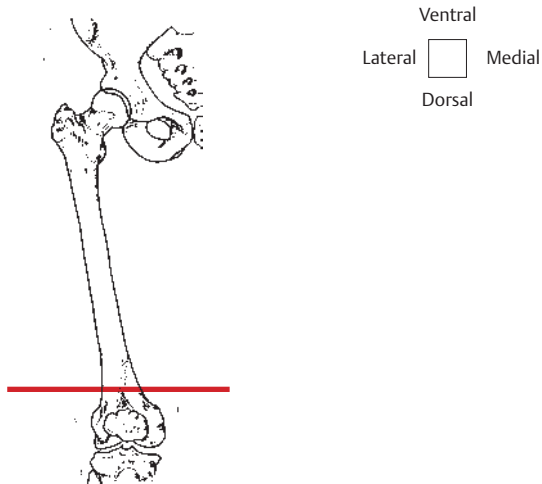
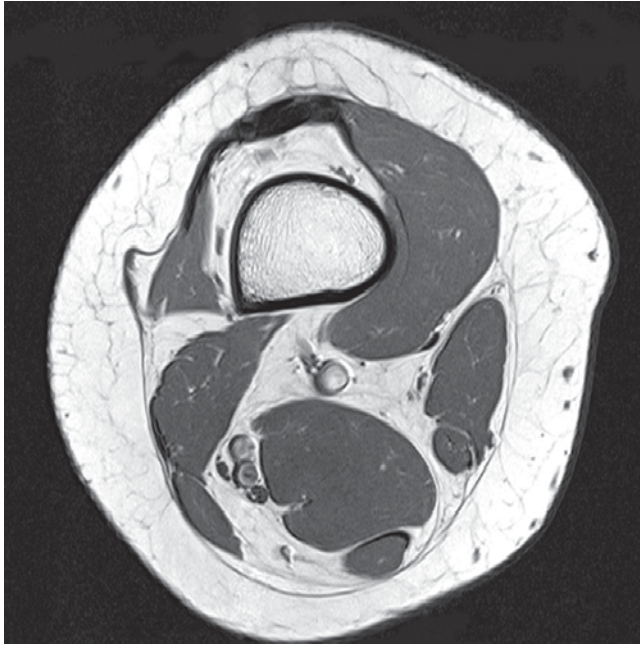
- | | |
|------------------------------------|---|
| 1 Rectus femoris muscle (+ tendon) | 12 Perforating artery and vein of deep artery and vein of thigh |
| 2 Vastus medialis muscle | 13 Adductor magnus muscle |
| 3 Vastus intermedius muscle | 14 Gracilis muscle |
| 4 Sartorius muscle | 15 Biceps femoris muscle (short head) |
| 5 Vastus lateralis muscle | 16 Semimembranosus muscle |
| 6 Great saphenous vein | 17 Common fibular (peroneal) nerve |
| 7 Femur | 18 Semitendinosus muscle |
| 8 Saphenous nerve | 19 Tibial nerve |
| 9 Iliotibial tract | 20 Biceps femoris muscle (long head) |
| 10 Femoral artery and vein | 21 Posterior femoral cutaneous nerve |
| 11 Linea aspera | |

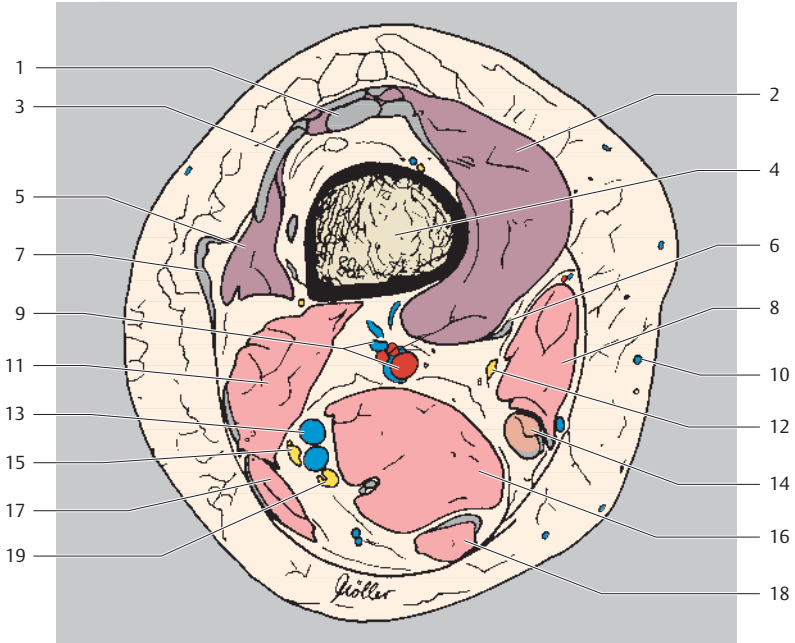


Ventral
Lateral Medial
Dorsal

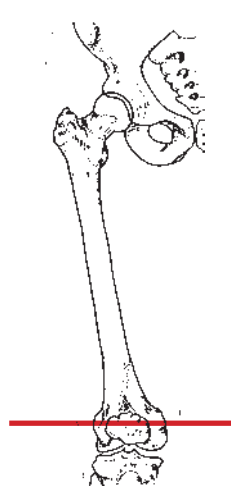
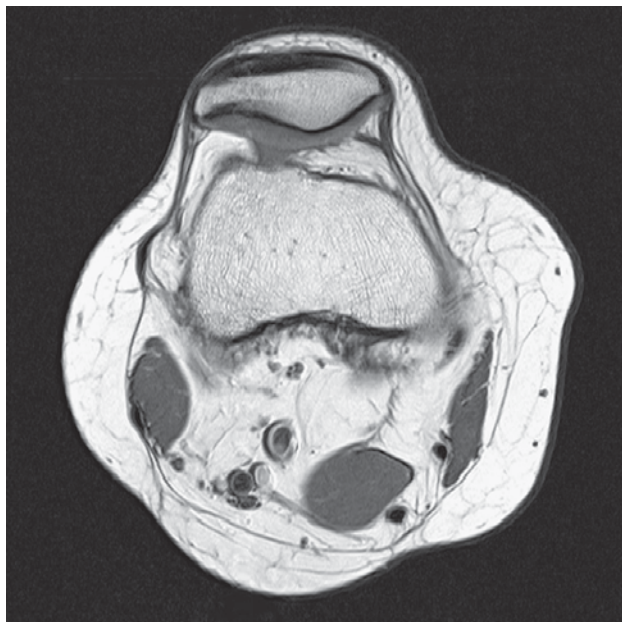

- | | |
|------------------------------------|---|
| 1 Rectus femoris muscle (tendon) | 11 Femoral artery and vein |
| 2 Vastus medialis muscle | 12 Great saphenous vein |
| 3 Vastus intermedius muscle | 13 Biceps femoris muscle (short head) |
| 4 Femur | 14 Gracilis muscle |
| 5 Iliotibial tract | 15 Perforating artery and vein of deep artery and vein of thigh |
| 6 Sartorius muscle | 16 Semimembranosus muscle |
| 7 Vastus lateralis muscle | 17 Common fibular (peroneal) nerve |
| 8 Adductor magnus muscle (tendon) | 18 Semitendinosus muscle |
| 9 Muscular branch of femoral nerve | 19 Tibial nerve |
| 10 Saphenous nerve | 20 Biceps femoris muscle (long head) |

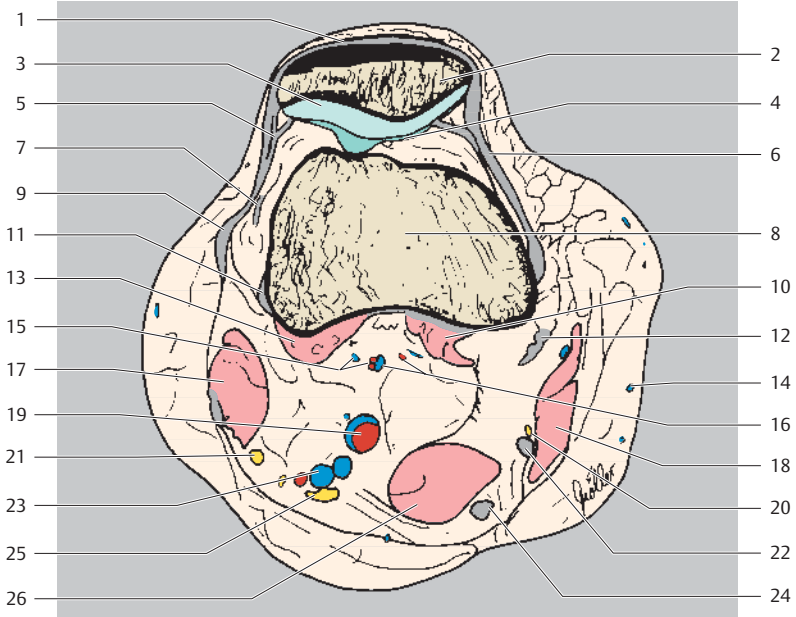




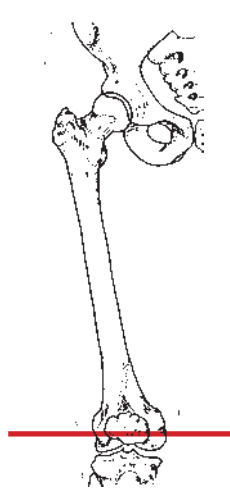
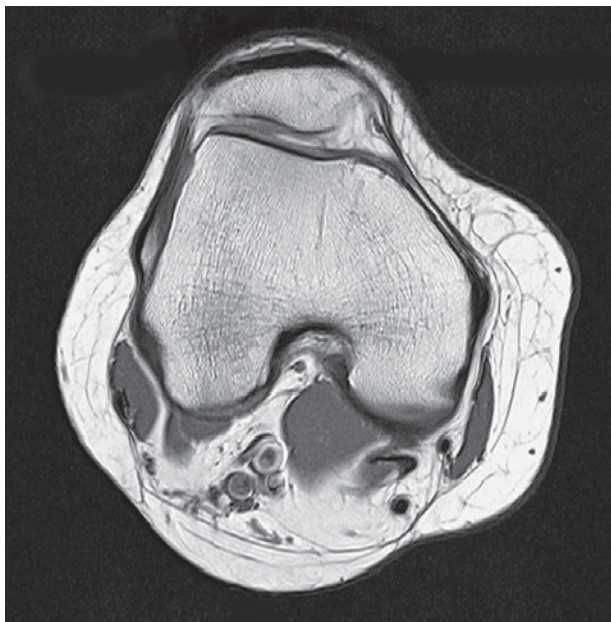- | | |
|--|---|
| 1 Rectus femoris muscle (tendon) | 10 Great saphenous vein |
| 2 Vastus medialis muscle | 11 Biceps femoris muscle (short head) |
| 3 Vastus intermedius muscle (+ tendon) | 12 Saphenous nerve |
| 4 Femur | 13 Perforating vein of deep vein of thigh |
| 5 Vastus lateralis muscle | 14 Gracilis muscle |
| 6 Adductor magnus muscle (tendon) | 15 Common fibular (peroneal) nerve |
| 7 Iliotibial tract | 16 Semimembranosus muscle |
| 8 Sartorius muscle | 17 Biceps femoris muscle (long head) |
| 9 Femoral artery and vein | 18 Semitendinosus muscle |
| | 19 Tibial nerve |



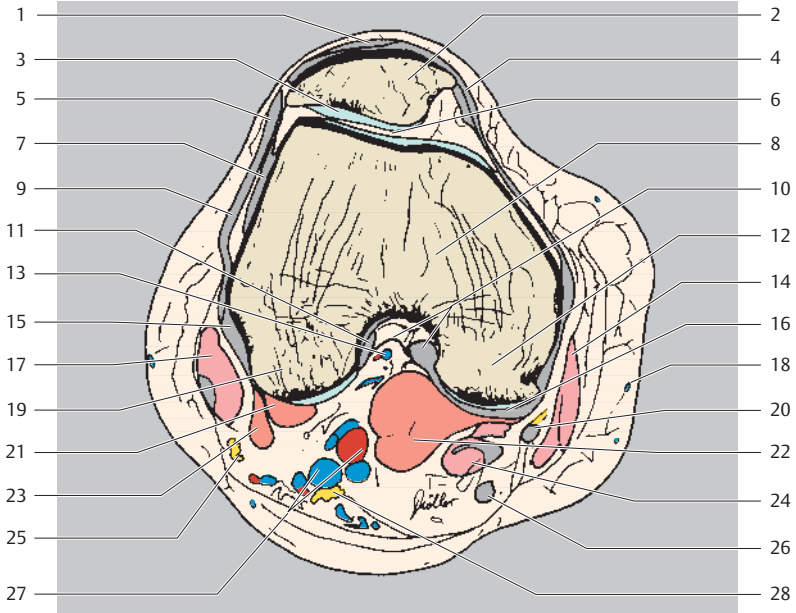Ventral
Lateral Medial
Dorsal



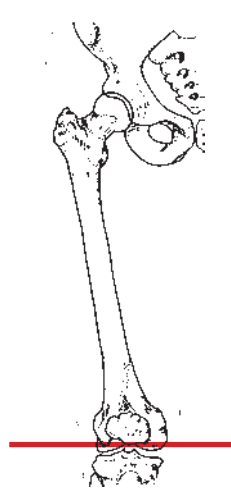
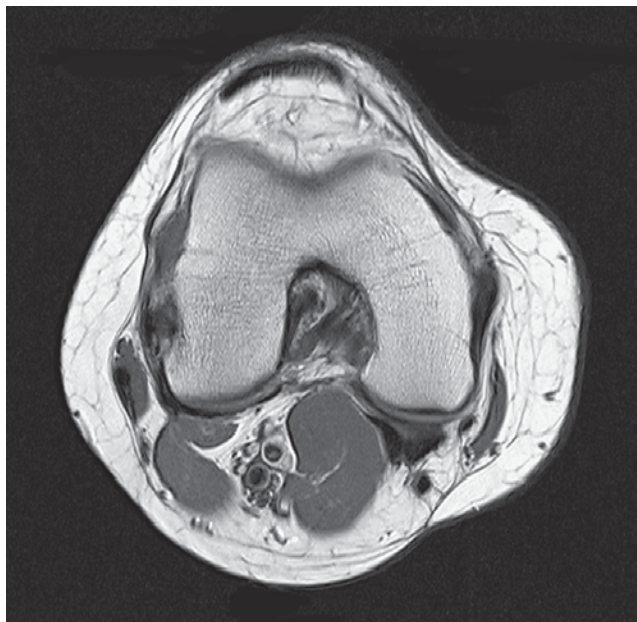
- | | |
|---|---|
| 1 Patellar ligament | 14 Great saphenous vein |
| 2 Patella | 15 Superior lateral genicular artery and vein |
| 3 Retropatellar cartilage | 16 Superior medial genicular artery and vein |
| 4 Femoropatellar joint | 17 Biceps femoris muscle (+ tendon) |
| 5 Lateral patellar retinaculum | 18 Sartorius muscle |
| 6 Medial patellar retinaculum | 19 Femoral artery and vein |
| 7 Vastus lateralis muscle (tendon) | 20 Saphenous nerve |
| 8 Femur | 21 Common fibular (peroneal) nerve |
| 9 Iliotibial tract | 22 Gracilis muscle (tendon) |
| 10 Gastrocnemius muscle (medial head, tendon) | 23 Perforating artery of deep artery of thigh |
| 11 Popliteus muscle (tendon) | 24 Semimembranosus muscle |
| 12 Adductor magnus muscle (tendon) | 25 Tibial nerve |
| 13 Gastrocnemius muscle (lateral head) | 26 Semitendinosus muscle |



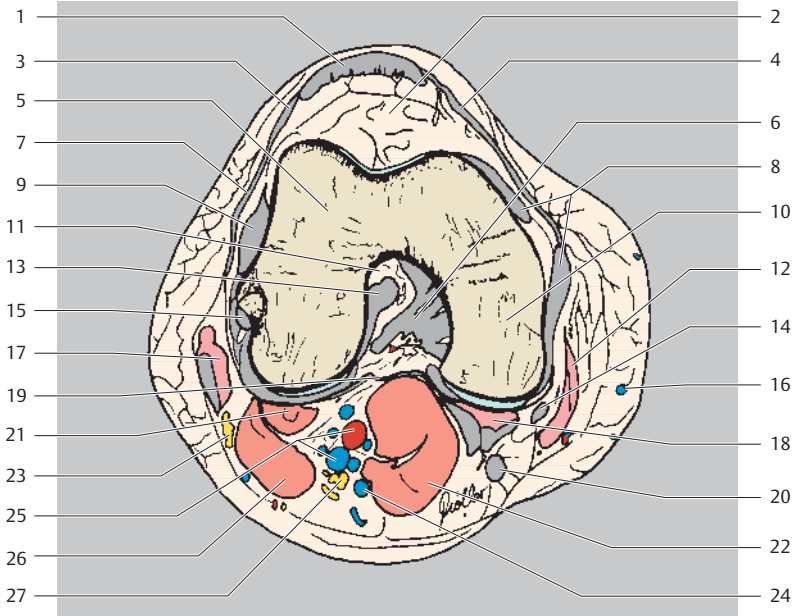
Ventral
Lateral Medial
Dorsal



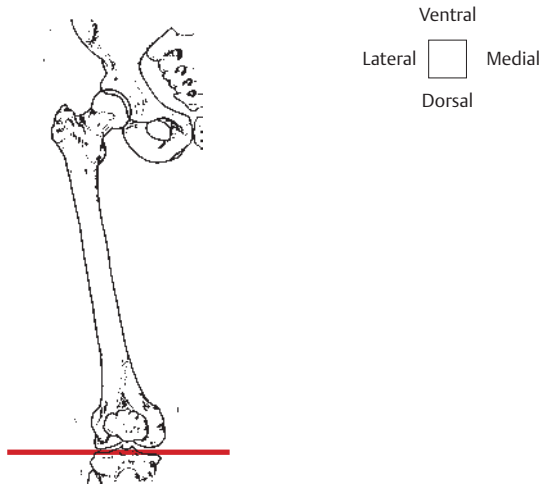
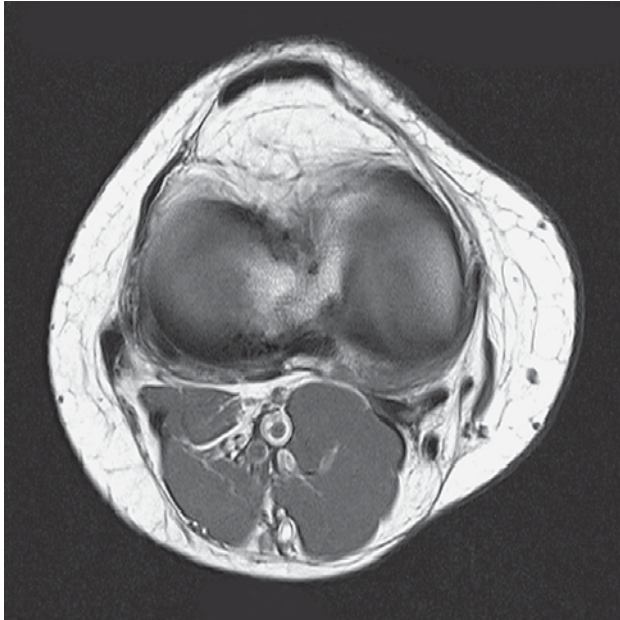
- | | |
|---|---|
| 1 Patellar ligament | 15 Popliteus muscle (tendon) |
| 2 Patella | 16 Joint capsule and oblique popliteal ligament |
| 3 Retropatellar cartilage | 17 Biceps femoris muscle (+ tendon) |
| 4 Medial patellar retinaculum | 18 Great saphenous vein |
| 5 Lateral patellar retinaculum | 19 Medial femoral condyle |
| 6 Femoropatellar joint | 20 Gracilis muscle (tendon) |
| 7 Lateral collateral ligament | 21 Plantaris muscle |
| 8 Femur | 22 Gastrocnemius muscle (medial head) |
| 9 Iliotibial tract | 23 Gastrocnemius muscle (lateral head) |
| 10 Joint capsule and posterior cruciate ligament (attachment) | 24 Semimembranosus muscle (+ tendon) |
| 11 Anterior cruciate ligament (attachment) | 25 Common fibular (peroneal) nerve |
| 12 Medial femoral condyle | 26 Semitendinosus muscle (tendon) |
| 13 Middle genicular artery | 27 Femoral artery and vein |
| 14 Sartorius muscle | 28 Tibial nerve |

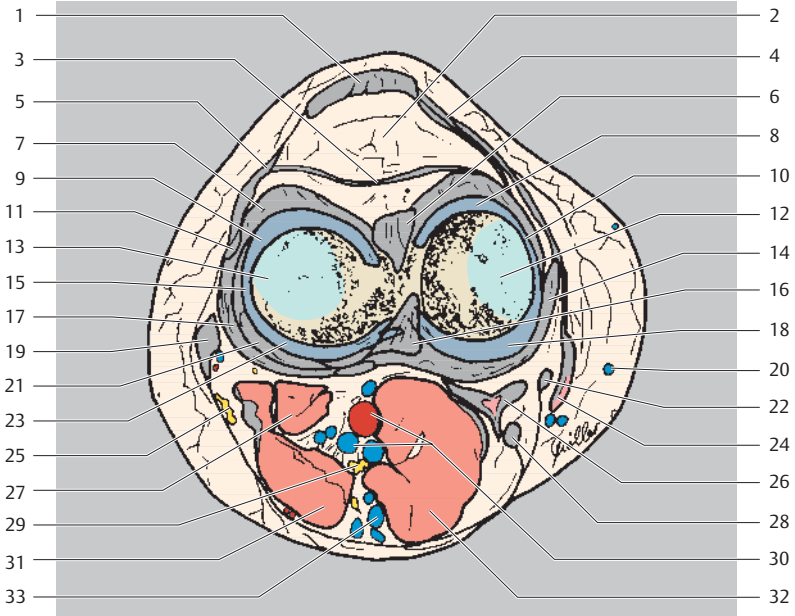


Ventral
Lateral Medial
Dorsal

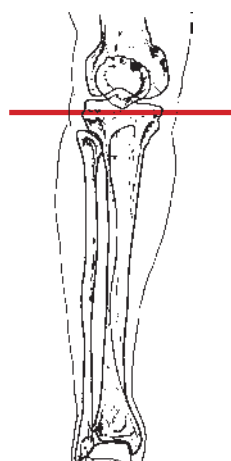
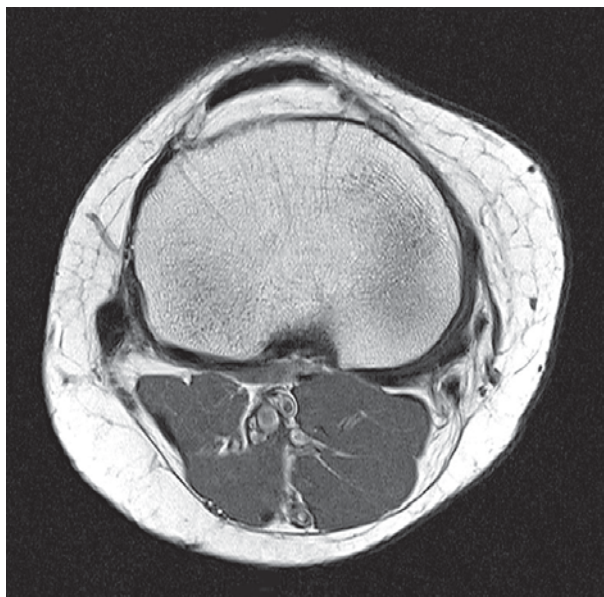


- | | |
|--------------------------------|---|
| 1 Patellar ligament | 15 Popliteus muscle (tendon) |
| 2 Infrapatellar fat body | 16 Great saphenous vein |
| 3 Lateral patellar retinaculum | 17 Biceps femoris muscle (+ tendon) |
| 4 Medial patellar retinaculum | 18 Semimembranosus muscle (+ tendon) |
| 5 Lateral femoral condyle | 19 Oblique popliteal ligament and joint capsule |
| 6 Posterior cruciate ligament | 20 Semitendinosus muscle (tendon) |
| 7 Iliotibial tract | 21 Plantaris muscle |
| 8 Medial collateral ligament | 22 Gastrocnemius muscle (medial head) |
| 9 Lateral collateral ligament | 23 Common fibular (peroneal) nerve |
| 10 Medial femoral condyle | 24 Popliteal vein |
| 11 Intercondylar fossa | 25 Femoral artery and vein |
| 12 Sartorius muscle | 26 Gastrocnemius muscle (lateral head) |
| 13 Anterior cruciate ligament | 27 Tibial nerve |
| 14 Gracilis muscle (tendon) | |

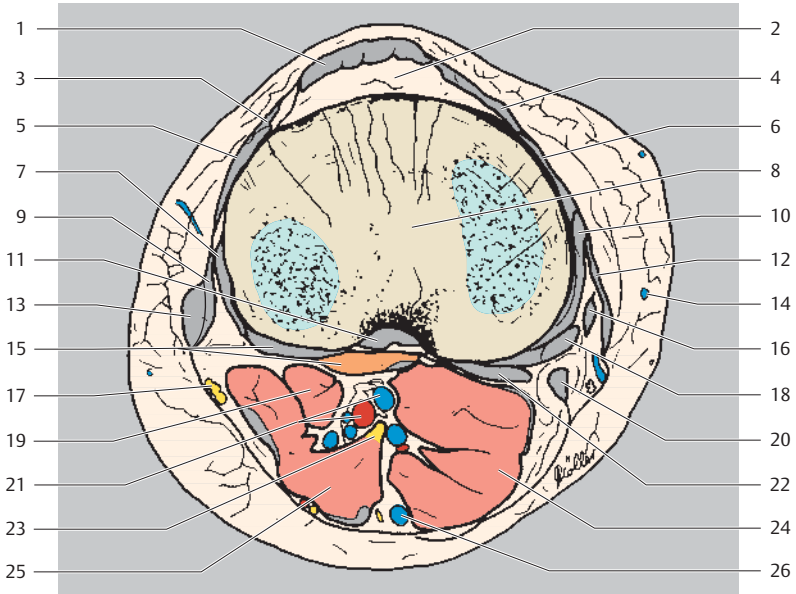




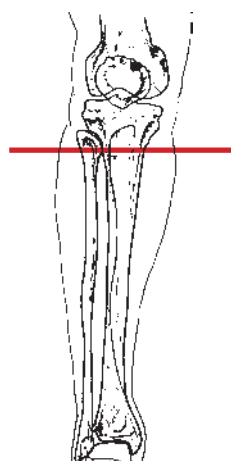
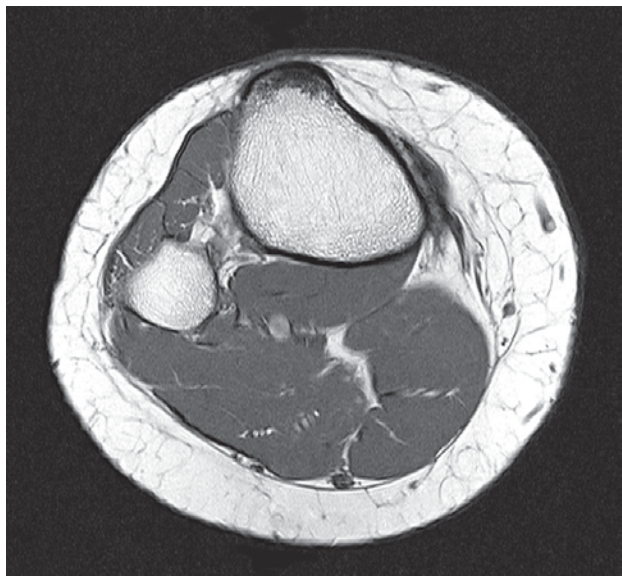
- | | |
|---|--|
| 1 Patellar ligament | 16 Posterior cruciate ligament |
| 2 Infrapatellar fat body | 17 Lateral collateral ligament |
| 3 Transverse patellar retinaculum | 18 Medial meniscus (posterior horn) |
| 4 Medial patellar retinaculum | 19 Biceps femoris muscle (tendon) |
| 5 Lateral patellar retinaculum | 20 Great saphenous vein |
| 6 Anterior cruciate ligament | 21 Popliteus muscle (tendon) |
| 7 Joint capsule | 22 Gracilis muscle (tendon) |
| 8 Medial meniscus (anterior horn) | 23 Lateral meniscus (posterior horn) |
| 9 Lateral meniscus (anterior horn) | 24 Sartorius muscle (+ tendon) |
| 10 Medial meniscus (intermediate part) | 25 Common fibular (peroneal) nerve |
| 11 Iliotibial tract | 26 Semimembranosus muscle (+ tendon) |
| 12 Medial femoral condyle with joint cartilage | 27 Plantaris muscle |
| 13 Lateral femoral condyle with joint cartilage | 28 Semitendinosus muscle (tendon) |
| 14 Lateral collateral ligament | 29 Tibial nerve |
| 15 Lateral meniscus (intermediate portion) | 30 Femoral artery and vein |
| | 31 Gastrocnemius muscle (lateral head, tendon) |
| | 32 Gastrocnemius muscle (medial head, tendon) |
| | 33 Popliteal vein |



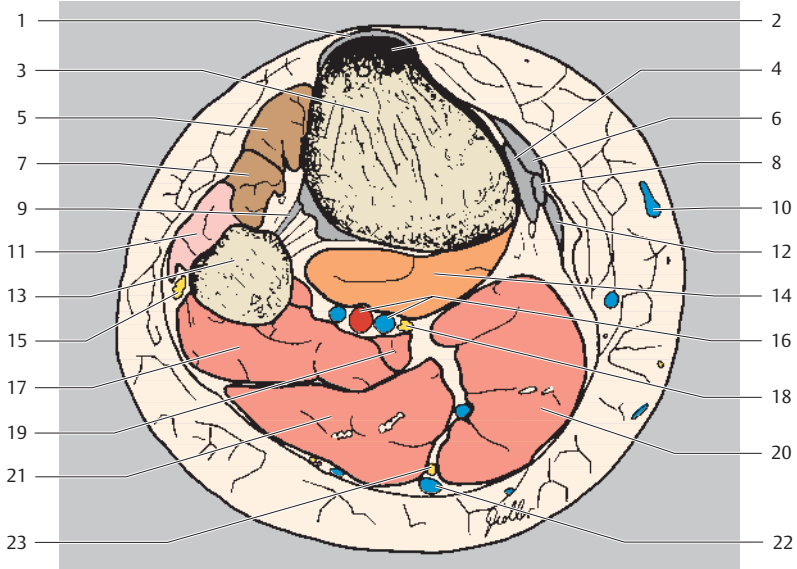
Anterior
Ventral
Lateral Medial
Dorsal
Posterior



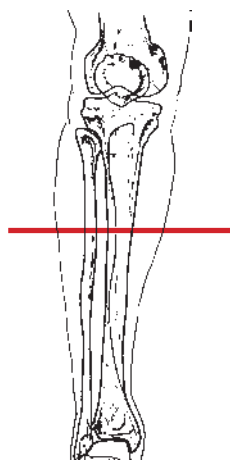
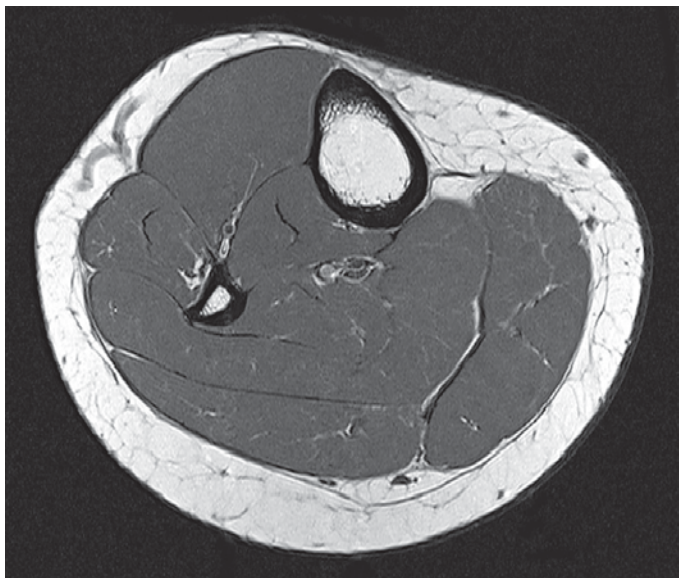- | | |
|-----------------------------------|---|
| 1 Patellar ligament | 16 Gracilis muscle (tendon) |
| 2 Infrapatellar fat body | 17 Common fibular (peroneal) nerve |
| 3 Lateral patellar retinaculum | 18 Semimembranosus muscle (+ tendon) |
| 4 Medial patellar retinaculum | 19 Plantaris muscle |
| 5 Iliotibial tract | 20 Semitendinosus muscle (tendon) |
| 6 Joint capsule | 21 Femoral artery and vein |
| 7 Lateral collateral ligament | 22 Oblique popliteal ligament and joint capsule |
| 8 Head of tibia | 23 Tibial nerve |
| 9 Fibular collateral ligament | 24 Gastrocnemius muscle (medial head, tendon) |
| 10 Medial ligament | 25 Gastrocnemius muscle (lateral head, tendon) |
| 11 Posterior cruciate ligament | 26 Popliteal vein |
| 12 Sartorius muscle (tendon) | |
| 13 Biceps femoris muscle (tendon) | |
| 14 Great saphenous vein | |
| 15 Popliteus muscle (+ tendon) | |



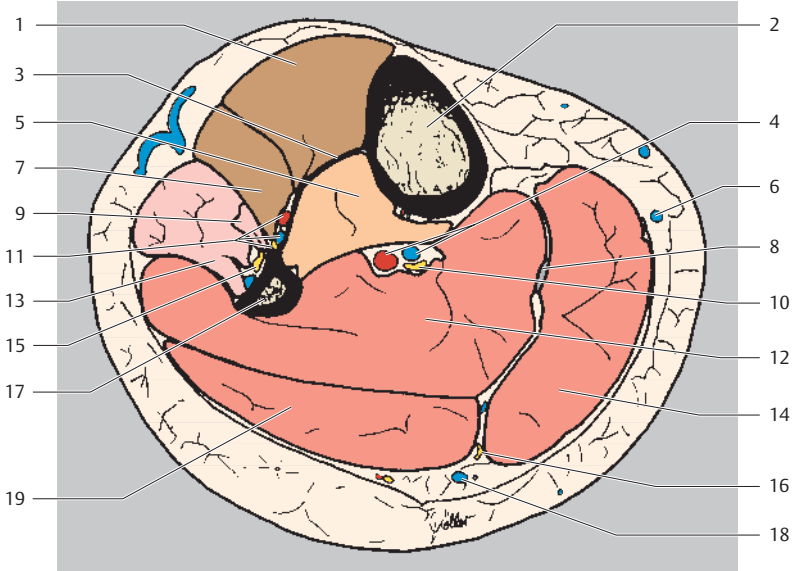
Anterior
Lateral Medial
Posterior



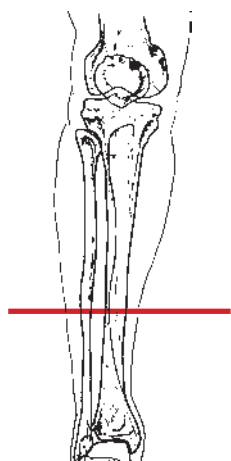
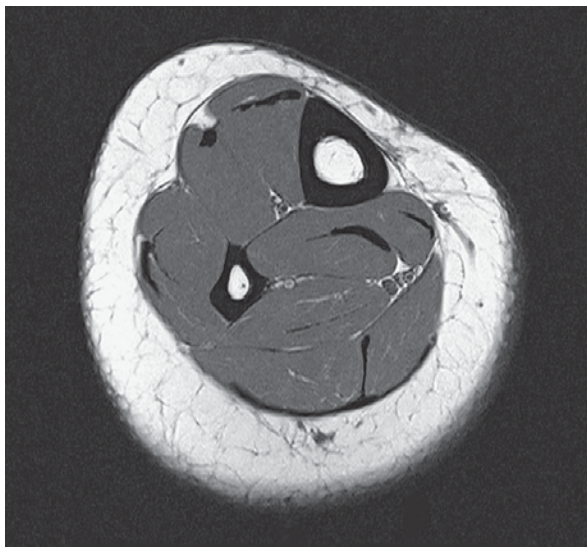
- | | |
|---------------------------------------|--|
| 1 Patellar ligament | 12 Semitendinosus muscle (tendon) |
| 2 Tibial tuberosity | 13 Head of fibula |
| 3 Tibia | 14 Popliteus muscle |
| 4 Medial patellar retinaculum | 15 Common fibular (peroneal) nerve |
| 5 Anterior tibial muscle | 16 Femoral artery and vein |
| 6 Sartorius muscle (tendon) | 17 Soleus muscle |
| 7 Extensor digitorum longus muscle | 18 Tibial nerve |
| 8 Gracilis muscle (tendon) | 19 Plantaris muscle |
| 9 Interosseous membrane of leg | 20 Gastrocnemius muscle (medial head) |
| 10 Great saphenous vein | 21 Gastrocnemius muscle (lateral head) |
| 11 Peroneus (fibularis) longus muscle | 22 Popliteal vein |
| | 23 Medial sural cutaneous nerve |



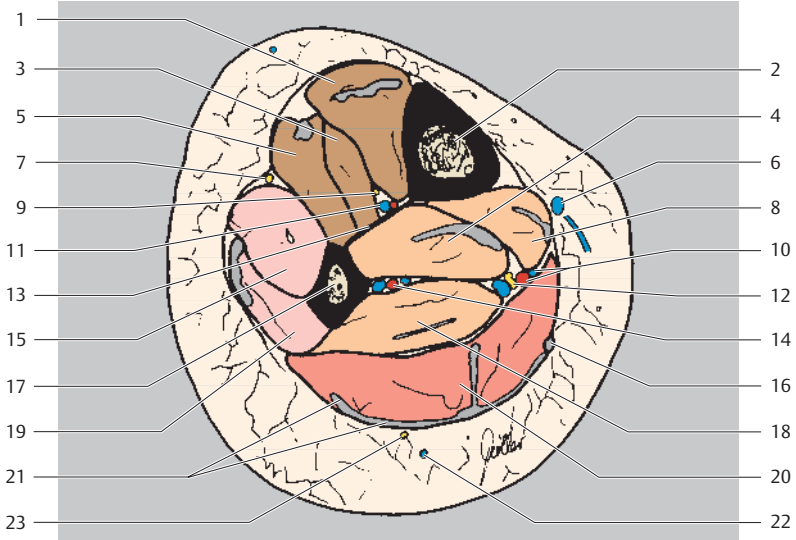
Anterior
Lateral Medial
Posterior



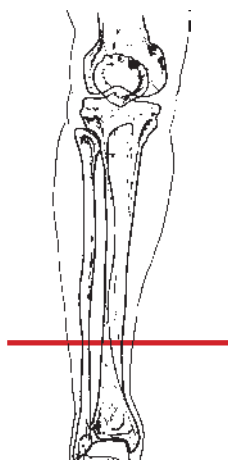
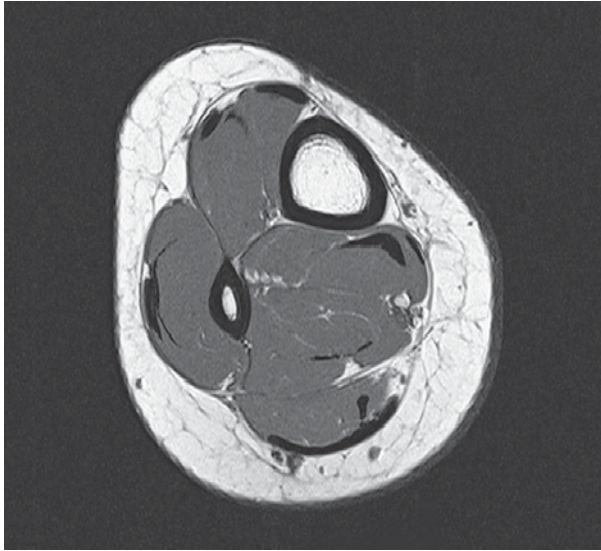
- | | |
|--------------------------------------|--|
| 1 Tibialis anterior muscle | 10 Tibial nerve |
| 2 Tibia | 11 Anterior tibial artery and vein and deep fibular (peroneal) nerve |
| 3 Interosseous membrane of leg | 12 Soleus muscle |
| 4 Femoral artery and vein | 13 Peroneus (fibularis) longus muscle |
| 5 Tibialis posterior muscle | 14 Gastrocnemius muscle (medial head) |
| 6 Great saphenous vein | 15 Superficial fibular (peroneal) nerve |
| 7 Extensor digitorum longus muscle | 16 Medial sural cutaneous nerve |
| 8 Plantaris muscle (tendon) | 17 Fibula |
| 9 Peroneus (fibularis) brevis muscle | 18 Small saphenous vein |
| | 19 Gastrocnemius muscle (lateral head) |



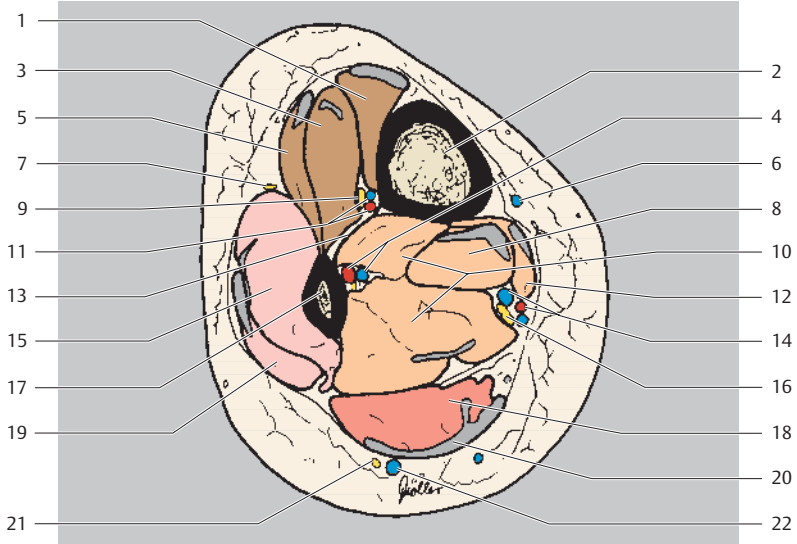
Anterior
Lateral Medial
Posterior



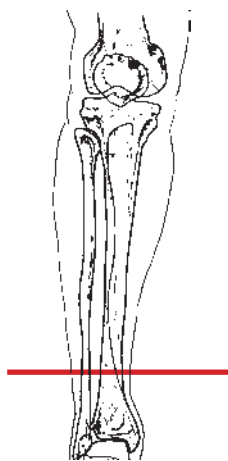
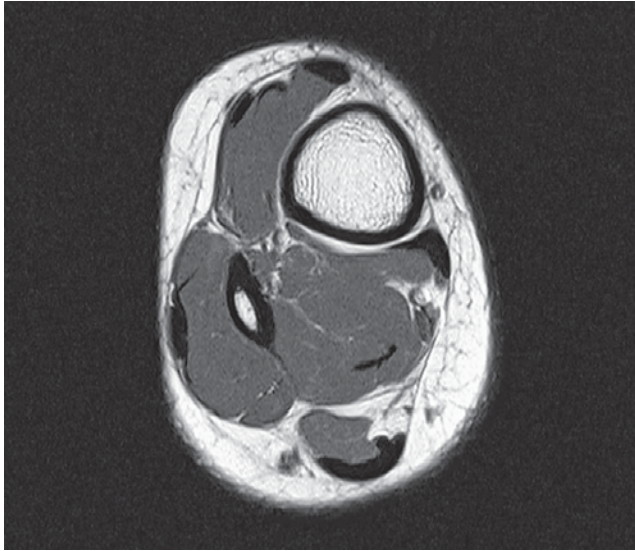
- | | |
|---|--|
| 1 Tibialis anterior muscle (+ tendon) | 11 Anterior tibial artery and vein |
| 2 Tibia | 12 Tibial nerve |
| 3 Extensor hallucis longus muscle | 13 Interosseous membrane of leg |
| 4 Tibialis posterior muscle | 14 Fibular (peroneal) artery and vein |
| 5 Extensor digitorum longus muscle (+ tendon) | 15 Peroneus (fibularis) brevis muscle |
| 6 Great saphenous vein | 16 Plantaris muscle (tendon) |
| 7 Superficial fibular (peroneal) nerve | 17 Fibula |
| 8 Flexor digitorum longus muscle (+ tendon) | 18 Flexor hallucis longus muscle |
| 9 Deep fibular (peroneal) nerve | 19 Peroneus (fibularis) longus muscle (+ tendon) |
| 10 Posterior tibial artery and vein | 20 Soleus muscle |
| | 21 Gastrocnemius muscle (tendon) |
| | 22 Small saphenous vein |
| | 23 Medial sural cutaneous nerve |



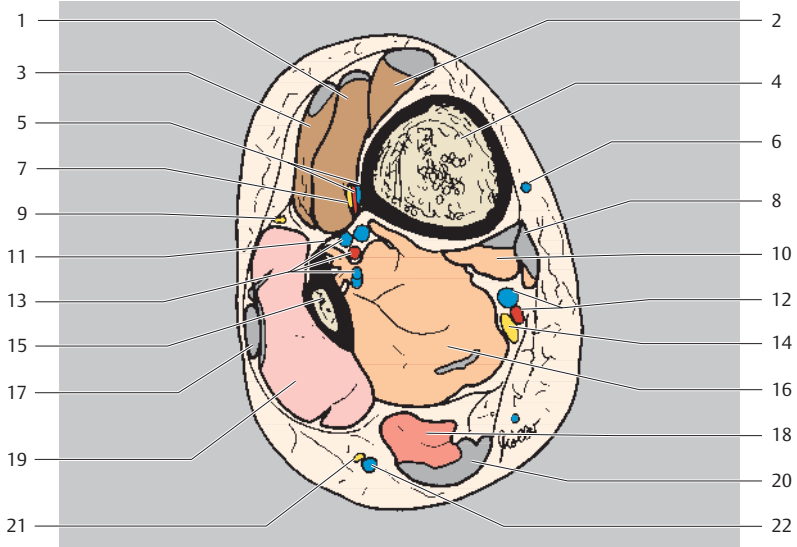
Anterior
Lateral Medial
Posterior



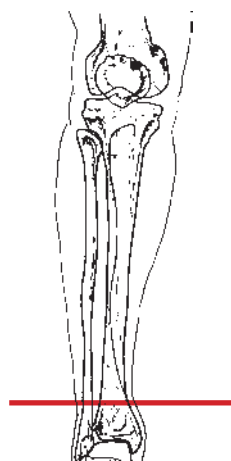
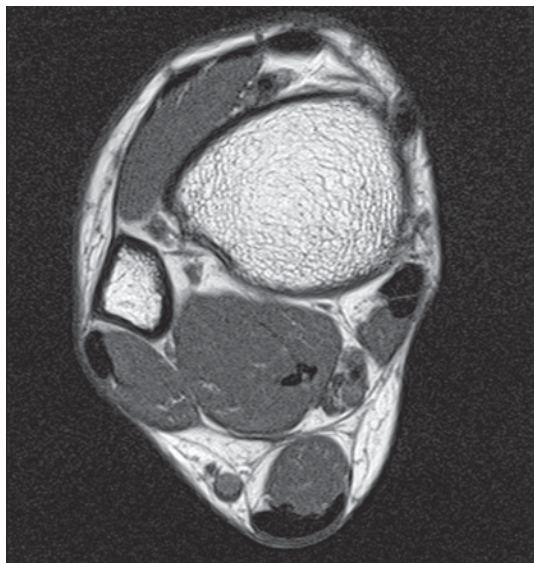
- | | | | |
|----|---|----|---|
| 1 | Tibialis anterior muscle (+ tendon) | 11 | Anterior tibial artery and vein |
| 2 | Tibia | 12 | Flexor digitorum longus muscle (+ tendon) |
| 3 | Extensor hallucis longus muscle | 13 | Interosseous membrane of leg |
| 4 | Fibular (peroneal) artery and vein | 14 | Posterior tibial artery and vein |
| 5 | Extensor digitorum longus muscle (+ tendon) | 15 | Peroneus (fibularis) brevis muscle |
| 6 | Great saphenous vein | 16 | Tibial nerve |
| 7 | Superficial fibular (peroneal) nerve | 17 | Fibula |
| 8 | Tibialis posterior muscle (+ tendon) | 18 | Soleus muscle |
| 9 | Deep fibular (peroneal) nerve | 19 | Peroneus (fibularis) longus muscle (+ tendon) |
| 10 | Flexor hallucis longus muscle | 20 | Gastrocnemius muscle (tendon, + tendon of plantaris muscle) |
| | | 21 | Sural nerve |
| | | 22 | Small saphenous vein |



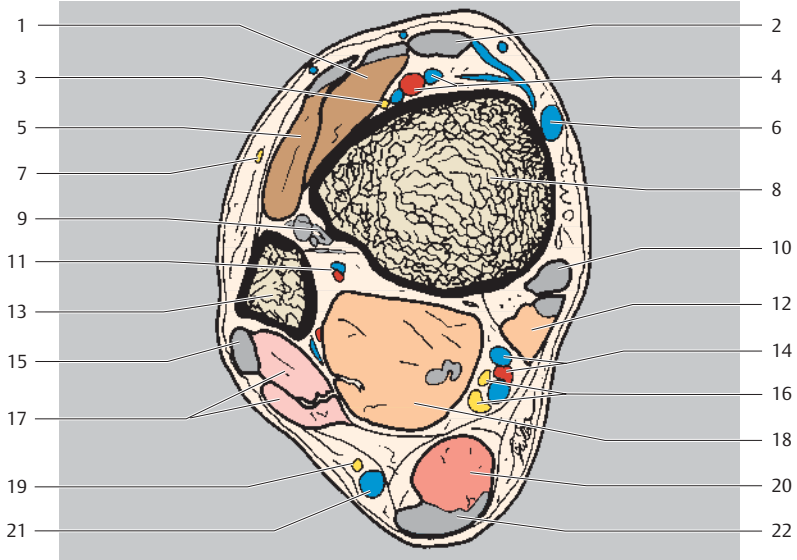
Anterior
Lateral Medial
Posterior



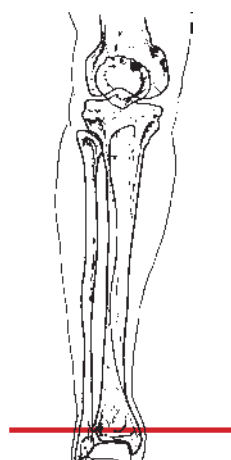
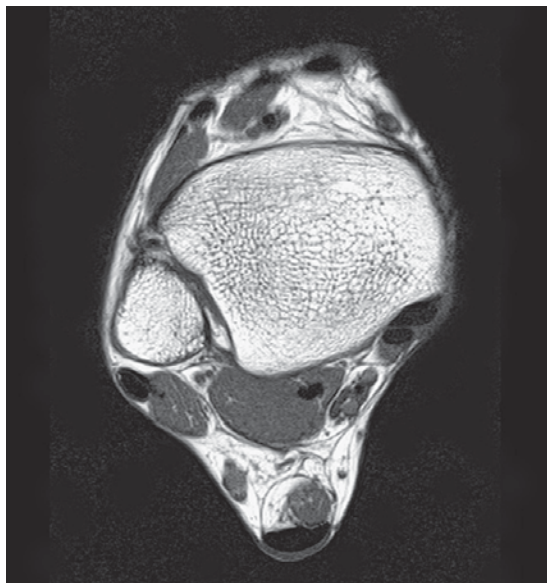
- | | |
|---|--|
| 1 Extensor hallucis longus muscle (+ tendon) | 11 Interosseous membrane of leg |
| 2 Tibialis anterior muscle (+ tendon) | 12 Posterior tibial artery and vein |
| 3 Extensor digitorum longus muscle (+ tendon) | 13 Fibular (peroneal) artery and veins |
| 4 Tibia | 14 Tibial nerve |
| 5 Anterior tibial artery and vein | 15 Fibula |
| 6 Great saphenous vein | 16 Flexor hallucis longus muscle |
| 7 Deep fibular (peroneal) nerve | 17 Peroneus (fibularis) longus muscle (tendon) |
| 8 Flexor digitorum longus muscle (+ tendon) | 18 Soleus muscle |
| 9 Superficial fibular (peroneal) nerve | 19 Peroneus (fibularis) brevis muscle |
| 10 Tibialis posterior muscle (+ tendon) | 20 Gastrocnemius muscle (tendon, + tendon of plantaris muscle) |
| | 21 Sural nerve |
| | 22 Small saphenous vein |



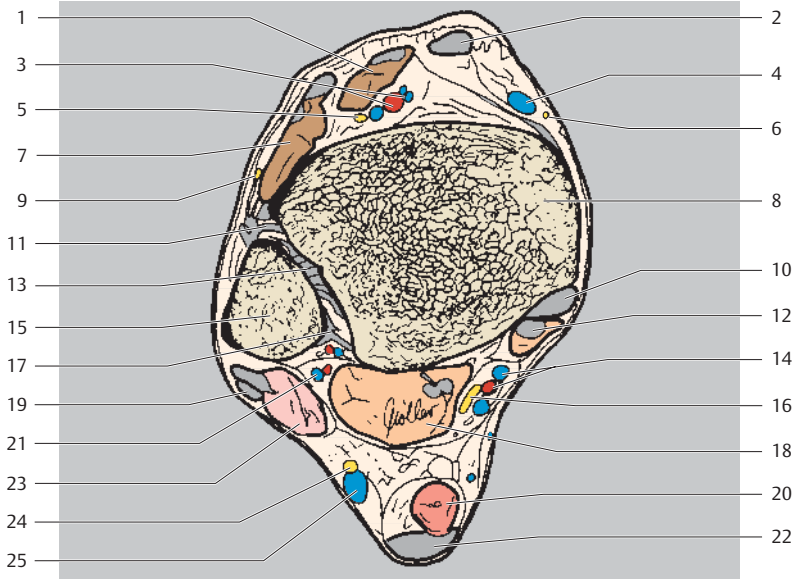
Anterior
Lateral Medial
Posterior



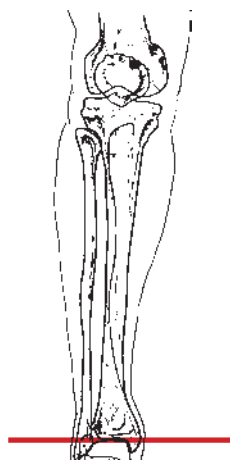
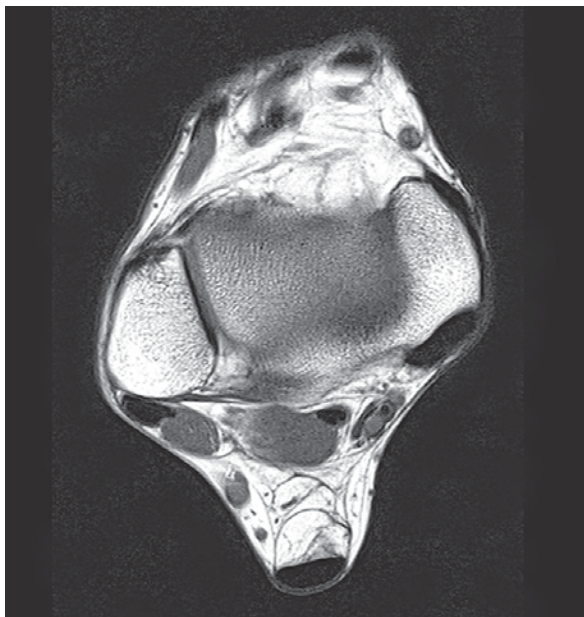
- | | |
|---|---|
| 1 Extensor hallucis longus muscle (+ tendon) | 11 Fibular (peroneal) artery and vein |
| 2 Tibialis anterior muscle (tendon) | 12 Flexor digitorum longus muscle (+ tendon) |
| 3 Deep fibular (peroneal) nerve | 13 Fibula |
| 4 Anterior tibial artery and vein | 14 Posterior tibial artery and vein |
| 5 Extensor digitorum longus muscle (+ tendon) | 15 Peroneus (fibularis) longus muscle (tendon) |
| 6 Great saphenous vein | 16 Tibial nerve |
| 7 Superficial fibular (peroneal) nerve | 17 Peroneus (fibularis) brevis muscle |
| 8 Tibia | 18 Flexor hallucis longus muscle |
| 9 Interosseous membrane of leg | 19 Sural nerve |
| 10 Tibialis posterior muscle (tendon) | 20 Soleus muscle |
| | 21 Small saphenous vein |
| | 22 Tendons of triceps surae and plantaris muscles |



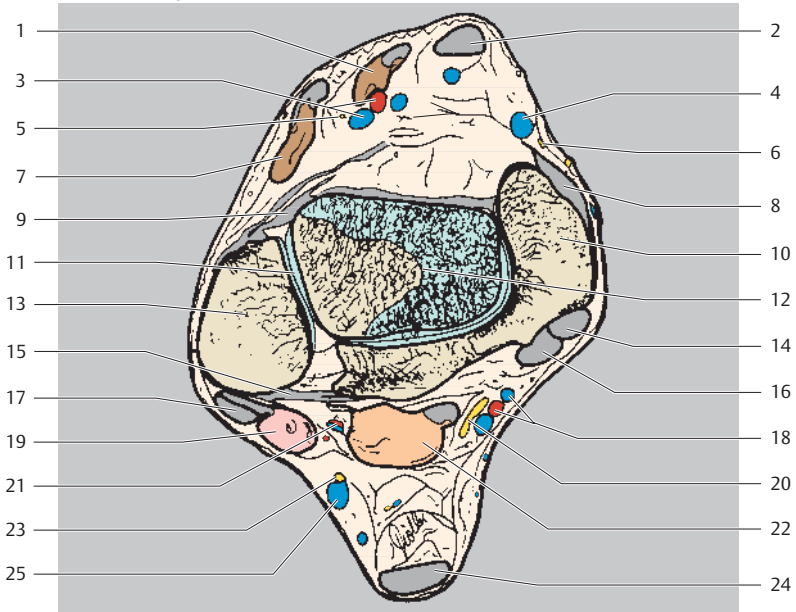
Anterior
Lateral Medial
Posterior



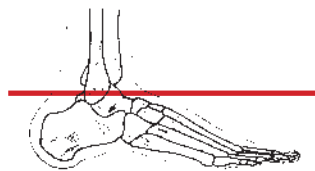
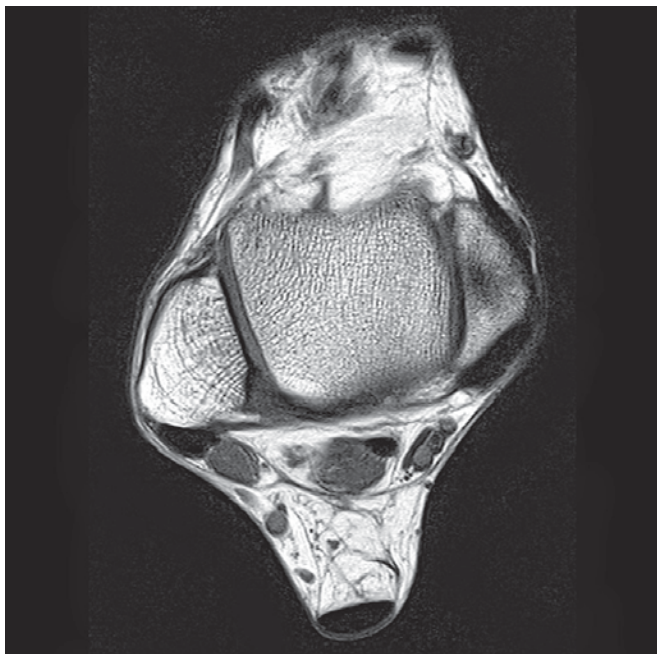
- | | |
|---|---|
| 1 Extensor hallucis longus muscle (+ tendon) | 13 Inferior tibiofibular joint |
| 2 Tibialis anterior muscle (tendon) | 14 Posterior tibial artery and vein |
| 3 Anterior tibial artery and vein | 15 Fibula |
| 4 Great saphenous vein | 16 Tibial nerve |
| 5 Deep fibular (peroneal) nerve | 17 Posterior tibiofibular ligament |
| 6 Saphenous nerve | 18 Flexor hallucis longus muscle (+ tendon) |
| 7 Extensor digitorum longus muscle (+ tendon) | 19 Peroneus (fibularis) longus muscle (tendon) |
| 8 Tibia | 20 Soleus muscle |
| 9 Superficial fibular (peroneal) nerve | 21 Fibular (peroneal) artery and vein |
| 10 Tibialis posterior muscle (tendon) | 22 Tendons of triceps surae and plantaris muscles |
| 11 Anterior tibiofibular ligament | 23 Peroneus (fibularis) brevis muscle (+ tendon) |
| 12 Flexor digitorum longus muscle (+ tendon) | 24 Sural nerve |
| | 25 Small saphenous vein |



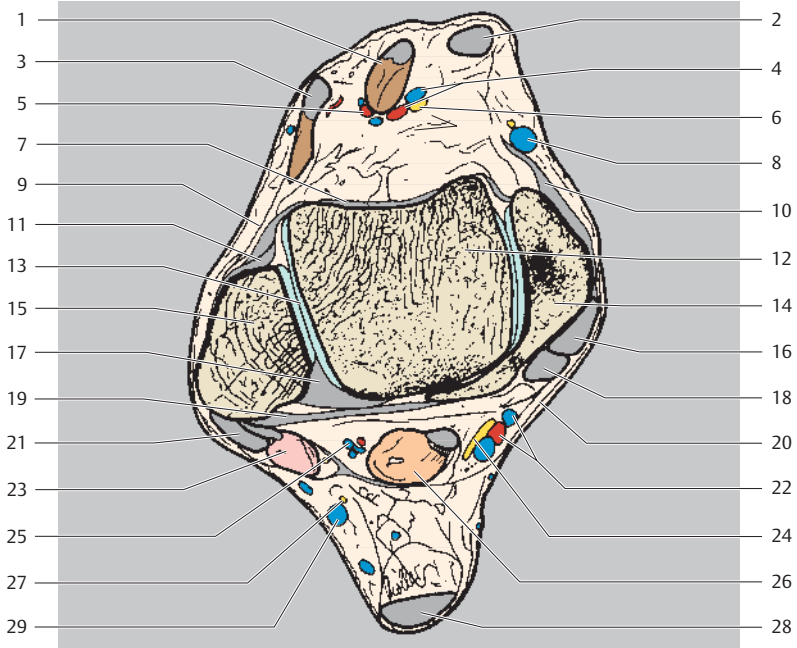
Anterior
Lateral Medial
Posterior



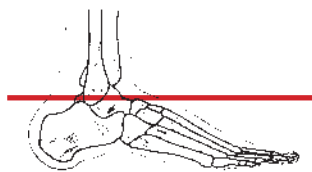
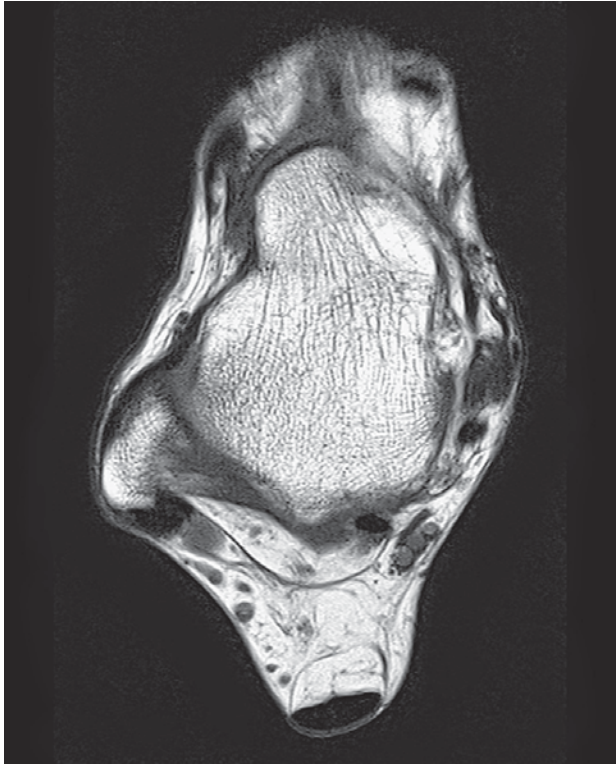- | | |
|---|---|
| 1 Extensor hallucis longus muscle (+ tendon) | 14 Tibialis posterior muscle (tendon) |
| 2 Tibialis anterior muscle (tendon) | 15 Posterior tibiofibular ligament |
| 3 Anterior tibial artery and vein | 16 Flexor digitorum longus muscle (tendon) |
| 4 Great saphenous vein | 17 Peroneus (fibularis) longus muscle (tendon) |
| 5 Deep fibular (peroneal) nerve | 18 Posterior tibial artery and vein |
| 6 Saphenous nerve | 19 Peroneus (fibularis) brevis muscle (+ tendon) |
| 7 Extensor digitorum longus muscle (+ tendon) | 20 Tibial nerve |
| 8 Deltoid ligament (tibionavicular and anterior tibiotalar parts) | 21 Fibular (peroneal) artery and vein |
| 9 Anterior tibiofibular ligament | 22 Flexor hallucis longus muscle (+ tendon) |
| 10 Medial malleolus (tibia) | 23 Sural nerve |
| 11 Tibiofibular syndesmosis | 24 Tendons of triceps surae muscle and plantaris muscle |
| 12 Talocrural joint | 25 Small saphenous vein |
| 13 Lateral malleolus (fibula) | |



Anterior
Lateral Medial
Posterior

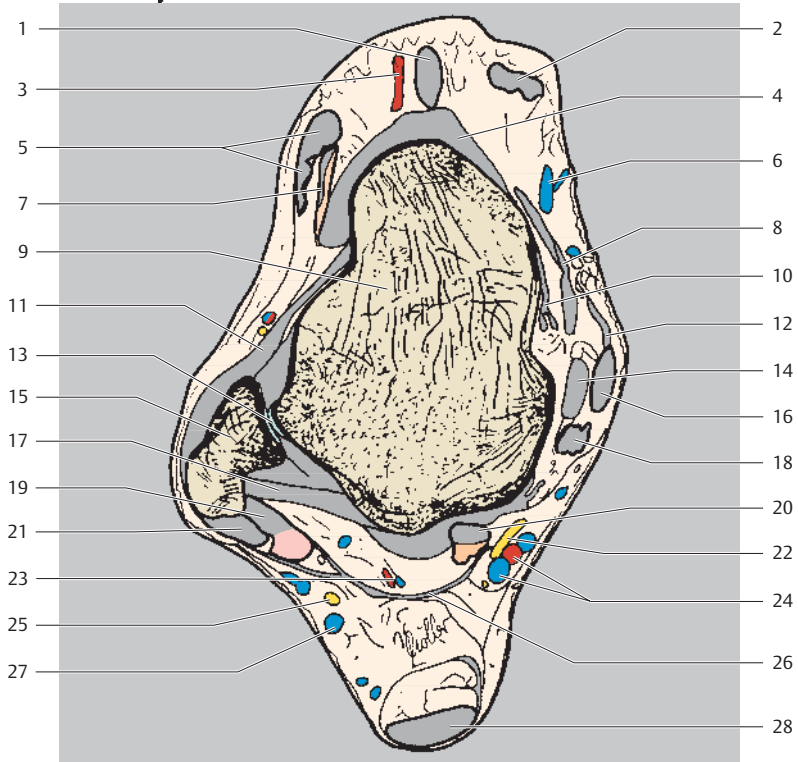


- | | |
|--|--|
| 1 Extensor hallucis longus muscle (tendon) | 15 Lateral malleolus (fibula) |
| 2 Tibialis anterior muscle (tendon) | 16 Tibialis posterior muscle (tendon) |
| 3 Extensor digitorum longus muscle (tendon) | 17 Posterior talofibular ligament |
| 4 Dorsalis pedis artery | 18 Flexor digitorum longus muscle (tendon) |
| 5 Lateral tarsal artery | 19 Posterior tibiofibular ligament |
| 6 Deep fibular nerve | 20 Flexor retinaculum |
| 7 Dorsal talonavicular ligament and joint capsule | 21 Peroneus (fibularis) longus muscle (tendon) |
| 8 Great saphenous vein | 22 Posterior tibial artery and vein (+ tendon) |
| 9 Extensor retinaculum | 23 Peroneus (fibular) brevis muscle (+ tendon) |
| 10 Deltoid ligament (tibionavicular and anterior tibiotalar parts) | 24 Tibial nerve |
| 11 Anterior talofibular ligament | 25 Fibular (peroneal) artery and vein (+ tendon) |
| 12 Talus | 26 Flexor hallucis longus muscle |
| 13 Talocrural joint | 27 Sural nerve |
| 14 Medial malleolus (tibia) | 28 Achilles' tendon (calcaneal tendon) |
| | 29 Small saphenous vein |

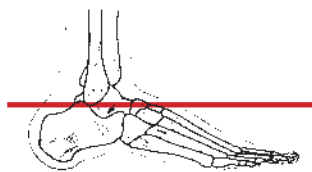
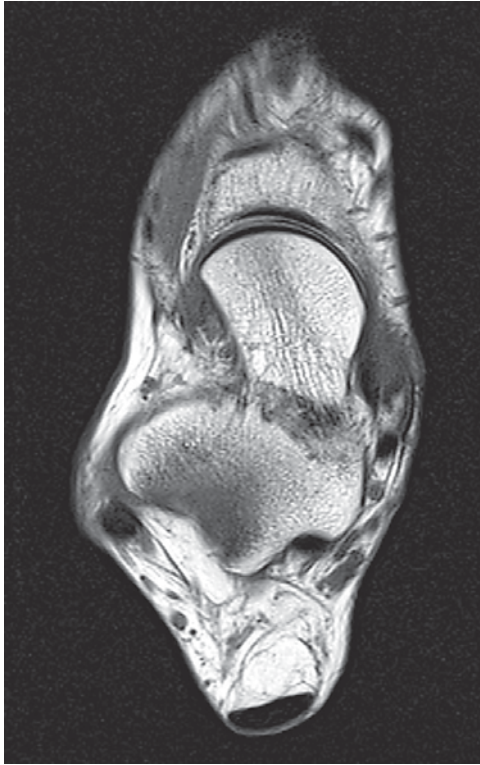


Anterior
Lateral Medial
Posterior

- 1 Extensor hallucis longus muscle (tendon)
- 2 Tibialis anterior muscle (tendon)
- 3 Dorsalis pedis artery
- 4 Dorsal talonavicular ligament
- 5 Extensor digitorum longus muscle (+ tendon)

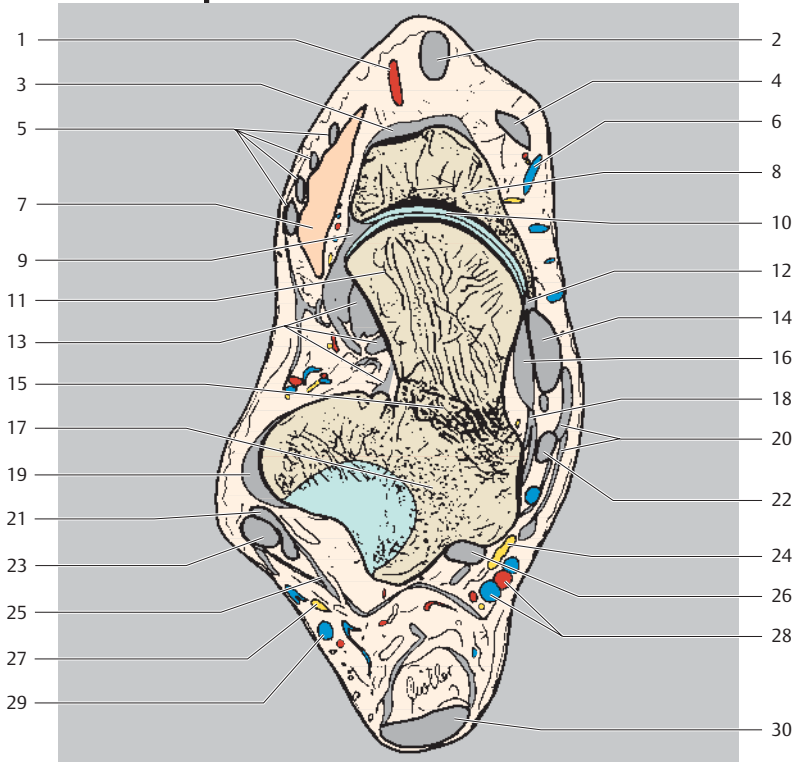


- | | | | |
|----|--|----|---|
| 6 | Great saphenous vein | 17 | Posterior talofibular ligament |
| 7 | Extensor digitorum brevis muscle (+ tendon) | 18 | Flexor digitorum longus muscle (tendon) |
| 8 | Deltoid ligament (tibionavicular part) | 19 | Peroneus (fibularis) brevis muscle (+ tendon) |
| 9 | Talus | 20 | Flexor hallucis longus muscle (+ tendon) |
| 10 | Deltoid ligament (anterior tibiotalar part) | 21 | Peroneus (fibularis) longus muscle (tendon) |
| 11 | Anterior talofibular ligament | 22 | Tibial nerve |
| 12 | Flexor retinaculum | 23 | Fibular (peroneal) artery and vein |
| 13 | Talocrural joint | 24 | Posterior tibial artery and vein |
| 14 | Deltoid ligament (posterior tibiotalar part) | 25 | Sural nerve |
| 15 | Lateral malleolus (fibula) | 26 | Superior peroneal retinaculum |
| 16 | Tibialis posterior muscle (tendon) | 27 | Small saphenous vein |
| | | 28 | Achilles' tendon (calcaneal tendon) |

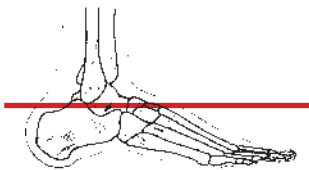
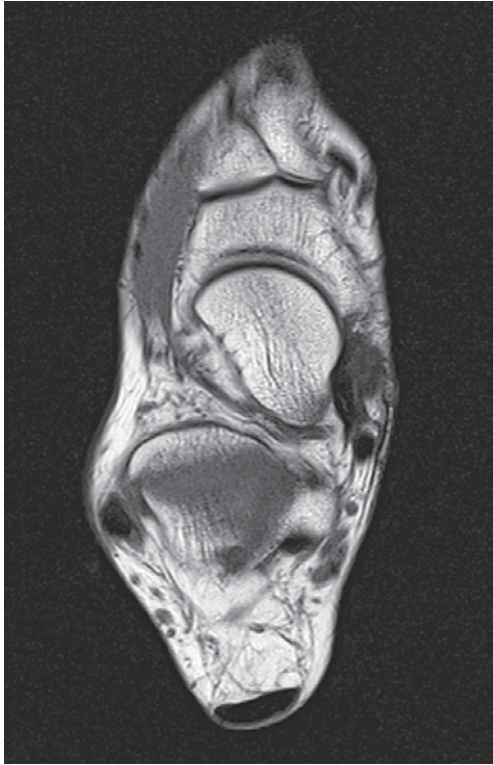


Anterior
Lateral Medial
Posterior

- 1 Dorsalis pedis artery
- 2 Extensor hallucis longus muscle (tendon)
- 3 Dorsal tarsal ligaments
- 4 Tibialis anterior muscle (tendon)
- 5 Extensor digitorum longus muscle (tendon)
- 6 Great saphenous vein

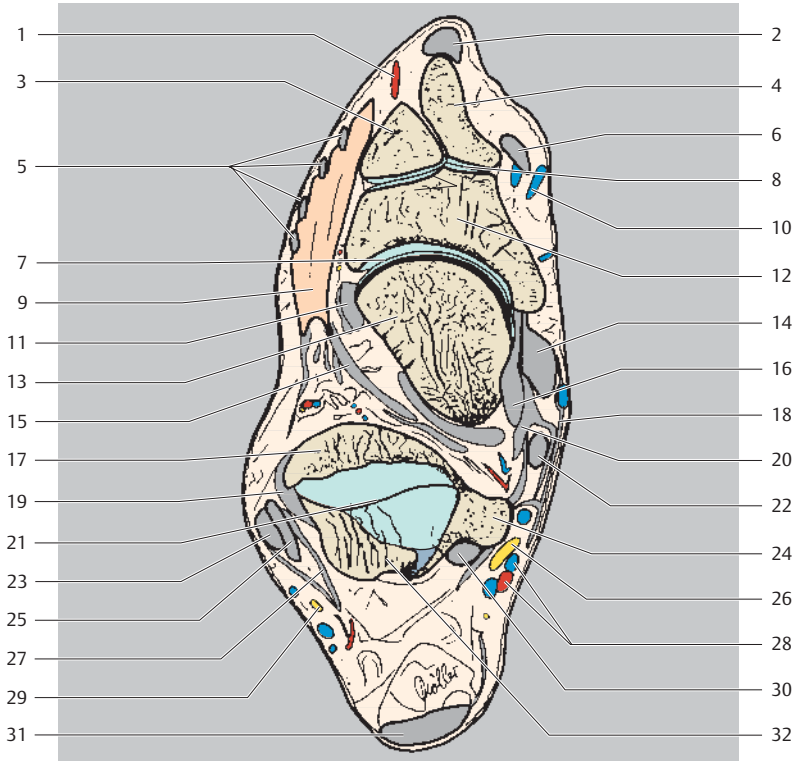


- | | |
|---|--|
| 7 Extensor digitorum brevis muscle | 19 Calcaneofibular ligament |
| 8 Navicular | 20 Flexor retinaculum |
| 9 Dorsal talonavicular ligament | 21 Peroneus (fibularis) brevis muscle (tendon) |
| 10 Talonavicular joint | 22 Flexor digitorum longus muscle (tendon) |
| 11 Head of talus | 23 Peroneus (fibularis) longus muscle (tendon) |
| 12 Deltoid ligament (tibionavicular part) | 24 Tibial nerve |
| 13 Interosseous talocalcaneal ligament | 25 Superior fibular (peroneal) retinaculum |
| 14 Tibialis posterior muscle (tendon) | 26 Flexor hallucis longus muscle (tendon) |
| 15 Neck of talus | 27 Sural nerve |
| 16 Deltoid ligament (tibio calcaneal part) | 28 Posterior tibial artery and vein |
| 17 Talus (body) | 29 Small saphenous vein |
| 18 Deltoid ligament (posterior tibiotalar part) | 30 Achilles' tendon (calcaneal tendon) |

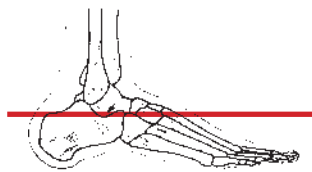
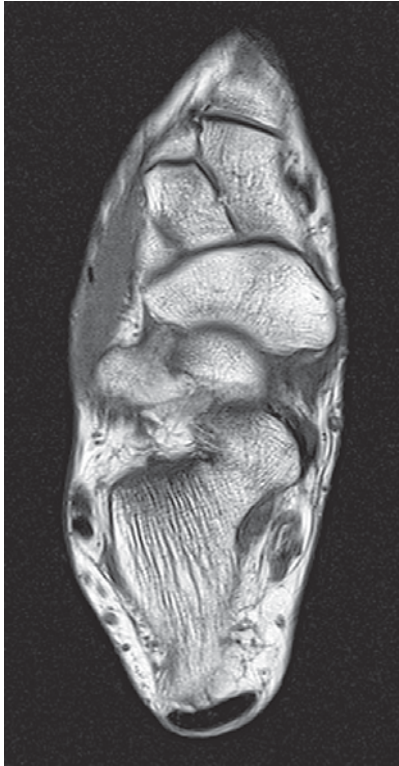

Anterior
Lateral Medial
Posterior

- 1 Dorsalis pedis artery
- 2 Extensor hallucis longus muscle (tendon)
- 3 Intermediate cuneiform
- 4 Medial cuneiform
- 5 Extensor digitorum longus muscle (tendons)

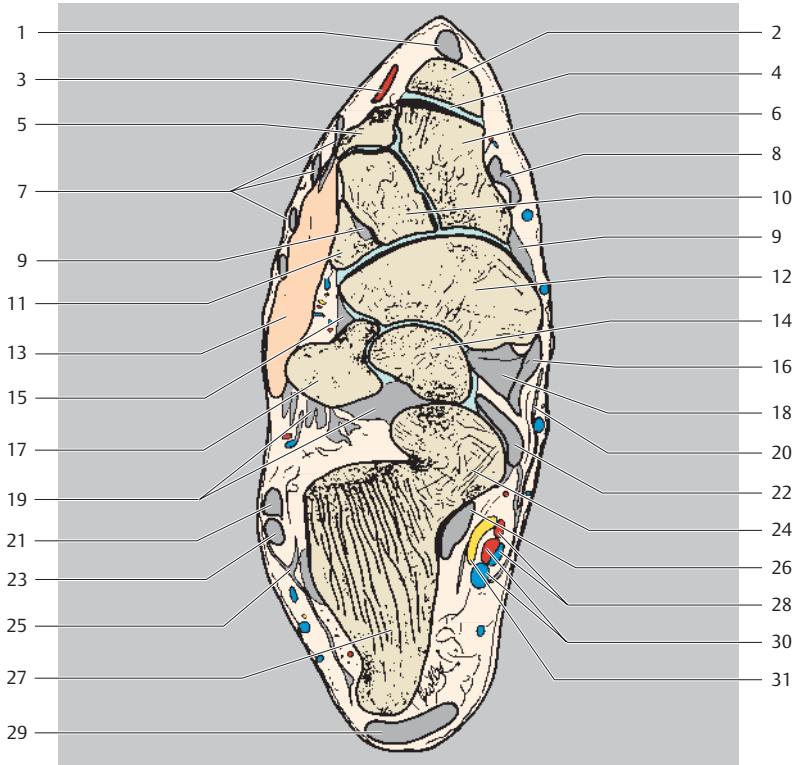


- | | | | |
|----|---|----|---|
| 6 | Tibialis anterior muscle | 19 | Calcaneofibular ligament |
| 7 | Talonavicular joint | 20 | Talocalcaneal ligament (medial) |
| 8 | Cuneonavicular joint | 21 | Subtalar (talocalcaneal) joint |
| 9 | Extensor digitorum brevis muscle | 22 | Flexor digitorum longus muscle (tendon) |
| 10 | Great saphenous vein | 23 | Peroneus (fibularis) longus muscle (tendon) |
| 11 | Bifurcate ligament | 24 | Talus (posterior process) |
| 12 | Navicular | 25 | Peroneus (fibularis) brevis muscle (tendon) |
| 13 | Talus (head) | 26 | Tibial nerve |
| 14 | Tibialis posterior muscle (tendon) | 27 | Peroneal retinaculum |
| 15 | Interosseous talocalcaneal ligament | 28 | Posterior tibial artery and vein |
| 16 | Deltoid ligament (tibio-calcaneal and tibio-navicular part) | 29 | Dorsal lateral cutaneous nerve |
| 17 | Talus (body) | 30 | Flexor hallucis longus muscle (tendon) |
| 18 | Flexor retinaculum | 31 | Achilles' tendon (calcaneal tendon) |
| | | 32 | Calcaneus |

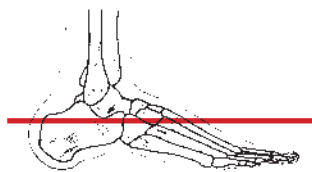
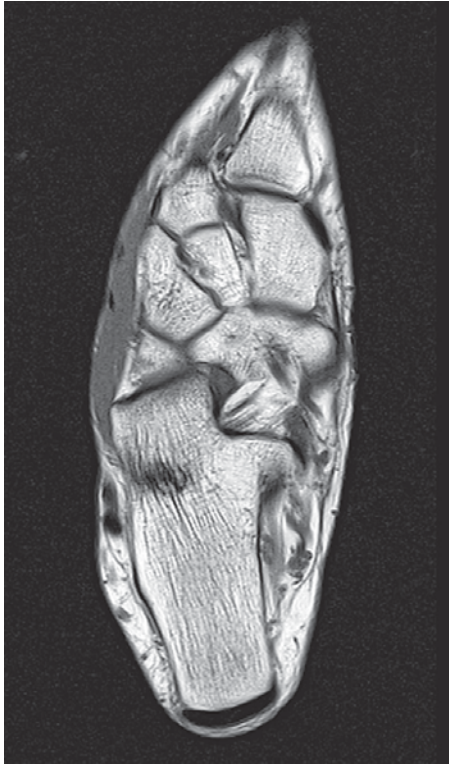

Anterior
Lateral Medial
Posterior

- 1 Extensor hallucis longus muscle (tendon)
- 2 Metatarsal I (base)
- 3 Dorsalis pedis artery
- 4 First tarsometatarsal joint
- 5 Metatarsal II (base)
- 6 Medial cuneiform

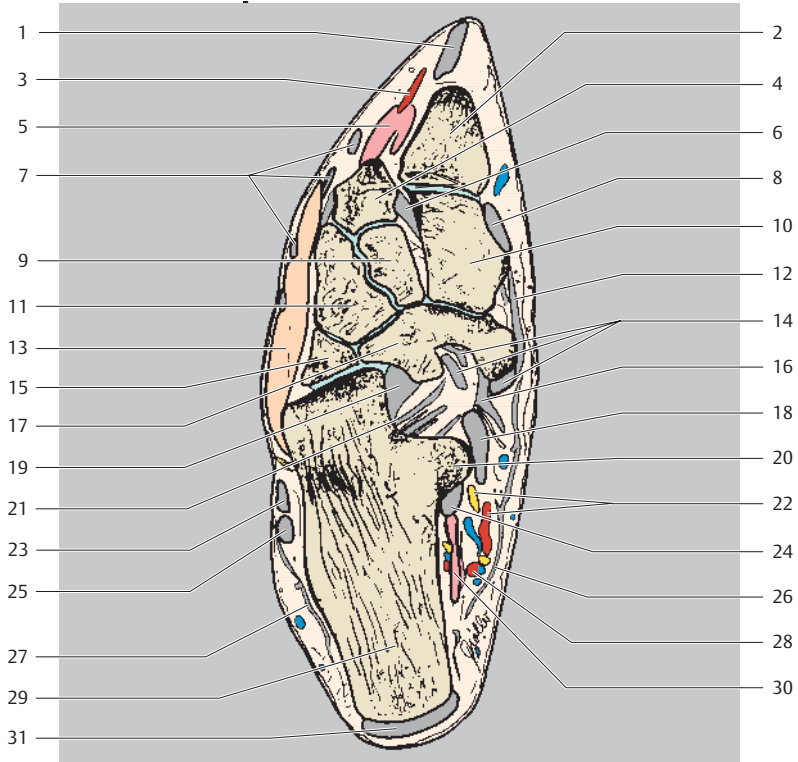


- | | |
|--|--|
| 7 Extensor digitorum longus muscle (tendons) | 19 Interosseous talocalcaneal ligament |
| 8 Tibialis anterior muscle (tendon) | 20 Flexor retinaculum |
| 9 Dorsal tarsal ligaments | 21 Peroneus (fibularis) brevis muscle (tendon) |
| 10 Intermediate cuneiform | 22 Flexor digitorum longus muscle (tendon) |
| 11 Lateral cuneiform | 23 Peroneus (fibularis) longus muscle (tendon) |
| 12 Navicular | 24 Calcaneus (talar shelf) |
| 13 Extensor digitorum brevis muscle | 25 Peroneal retinaculum |
| 14 Talus (head) | 26 Flexor hallucis longus muscle (tendon) |
| 15 Bifurcate ligament | 27 Calcaneal tuberosity |
| 16 Deltoid ligament (tibionavicular part) | 28 Medial plantar artery and vein |
| 17 Calcaneus | 29 Achilles' tendon (calcaneal tendon) |
| 18 Tibialis posterior muscle (tendon) | 30 Lateral plantar artery and vein |
| | 31 Tibial nerve |

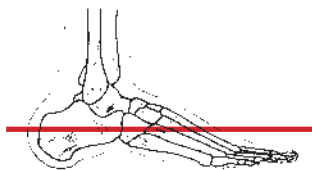
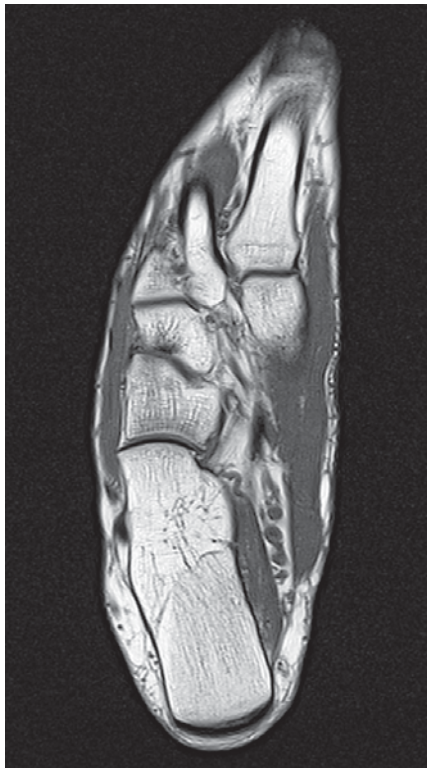

Anterior
 Lateral Medial
 Posterior

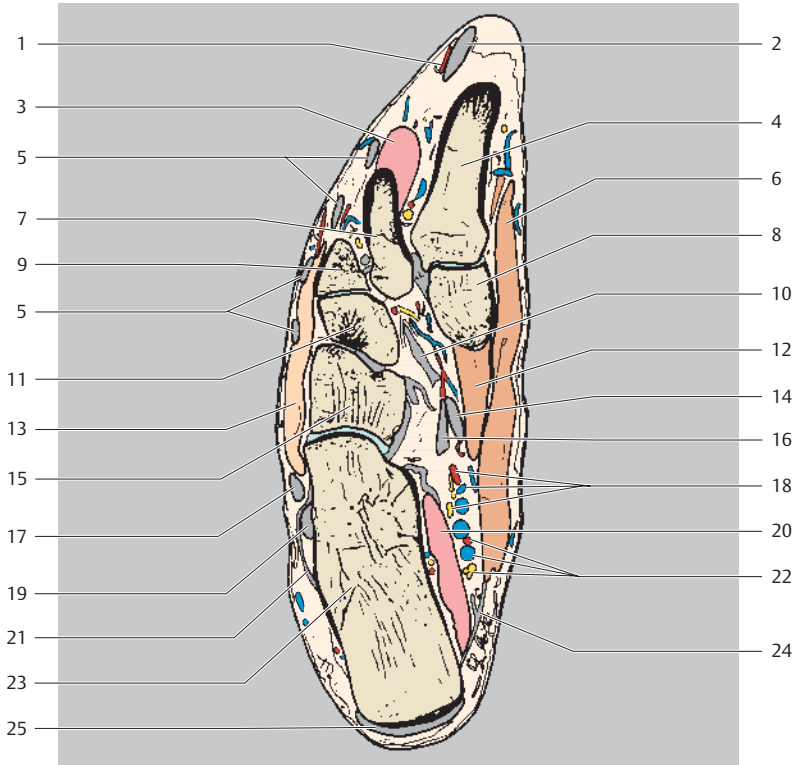
- 1 Extensor hallucis longus muscle (tendon)
- 2 Metatarsal I (base)
- 3 Dorsalis pedis artery
- 4 Metatarsal II (base)
- 5 Dorsal interosseous muscles
- 6 Interosseous cuneometatarsal ligaments
- 7 Extensor digitorum longus muscle (tendons)



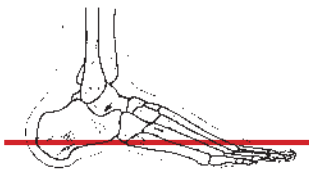
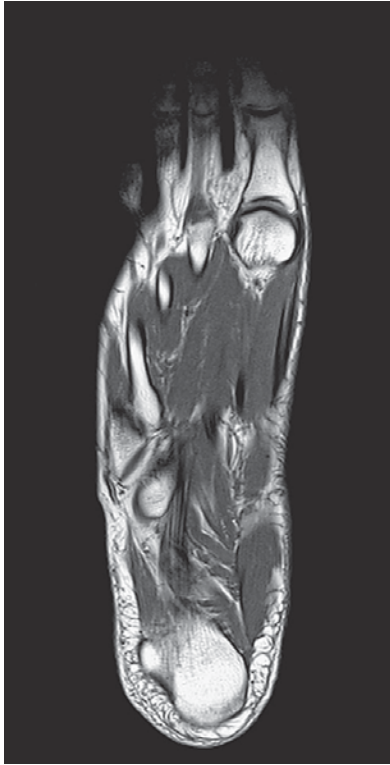
- | | |
|---|--|
| 8 Tibialis anterior muscle (tendon) | 20 Calcaneus (talar shelf) |
| 9 Intermediate cuneiform | 21 Long plantar ligament |
| 10 Medial cuneiform | 22 Medial plantar artery and vein |
| 11 Lateral cuneiform | 23 Peroneus (fibularis) brevis muscle (tendon) |
| 12 Dorsal tarsal ligaments | 24 Flexor hallucis longus muscle (tendon) |
| 13 Extensor digitorum brevis muscle | 25 Peroneus (fibularis) longus muscle (tendon) |
| 14 Tibialis posterior muscle (tendon) | 26 Flexor retinaculum |
| 15 Cuboid | 27 Peroneal retinaculum |
| 16 Spring ligament (plantar calcaneonavicular ligament) | 28 Lateral plantar artery and vein |
| 17 Navicular | 29 Calcaneus (calcaneal tuberosity) |
| 18 Flexor digitorum longus muscle (tendon) | 30 Quadratus plantae muscle |
| 19 Spring ligament (plantar calcaneonavicular ligament) | 31 Achilles' tendon (calcaneal tendon) |



Anterior
Lateral Medial
Posterior

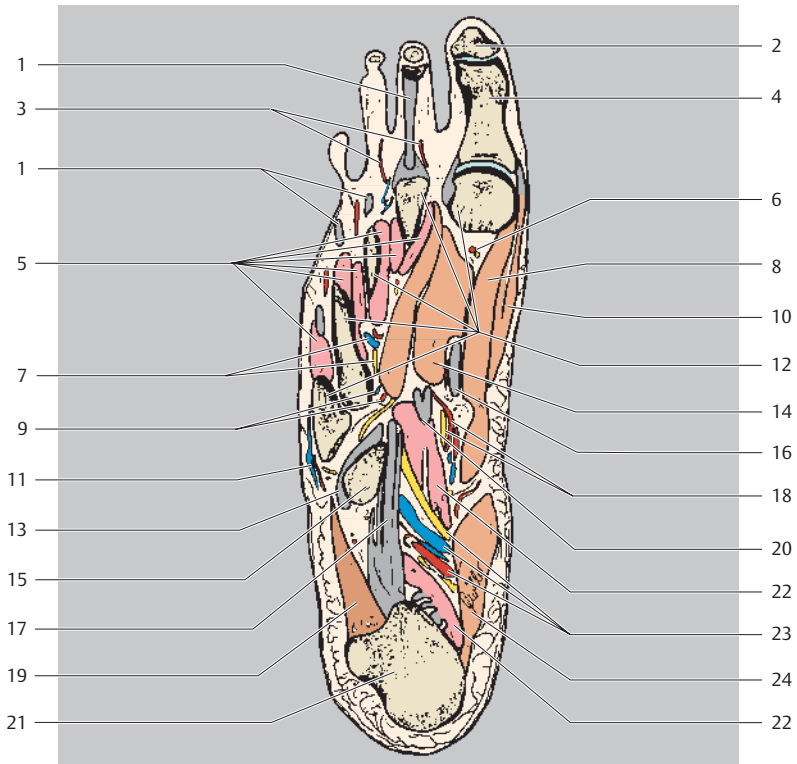


- | | |
|--|---|
| 1 Dorsalis pedis artery | 14 Flexor hallucis longus muscle (tendon) |
| 2 Extensor hallucis longus muscle (tendon) | 15 Cuboid |
| 3 Dorsal interosseous muscles | 16 Flexor digitorum longus muscle (tendon) |
| 4 Metatarsal I (base) | 17 Peroneus (fibularis) brevis muscle (tendon) |
| 5 Extensor digitorum longus muscle (tendons) | 18 Medial plantar artery, vein, and nerve |
| 6 Abductor hallucis muscle | 19 Peroneus (fibularis) brevis muscle (tendon) |
| 7 Metatarsal II (base) | 20 Quadratus plantae muscle |
| 8 Medial cuneiform | 21 Inferior fibular (peroneal) retinaculum |
| 9 Metatarsal III (base) | 22 Lateral plantar artery, vein, and nerve |
| 10 Tibialis posterior muscle (tendon) | 23 Calcaneus |
| 11 Lateral cuneiform | 24 Flexor retinaculum |
| 12 Flexor hallucis brevis muscle | 25 Achilles' tendon (calcaneal tendon) (attachment) |
| 13 Extensor digitorum brevis muscle | |

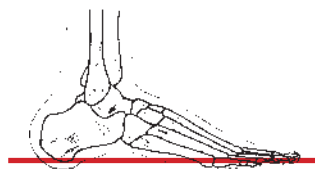
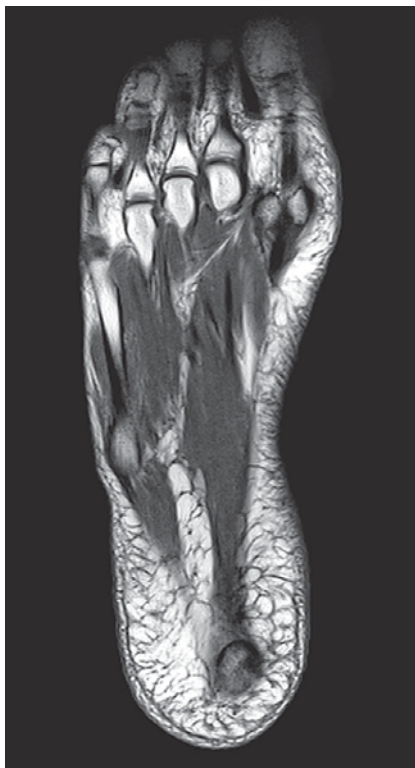

Anterior
Lateral Medial
Posterior

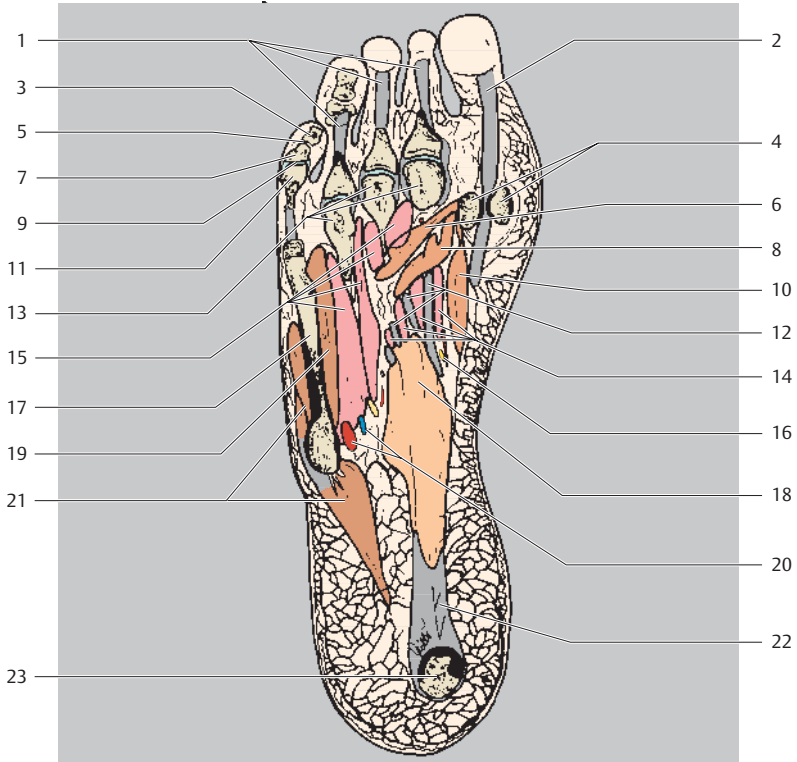
- 1 Extensor digitorum longus muscle (tendon)
- 2 Distal phalanx I
- 3 Plantar digital arteries
- 4 Proximal phalanx I
- 5 Dorsal and plantar interosseous muscles



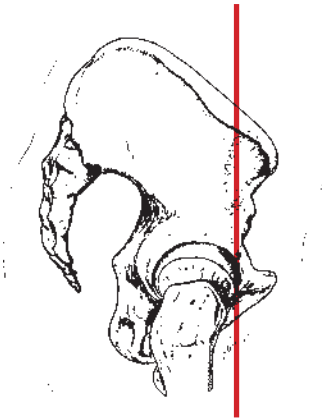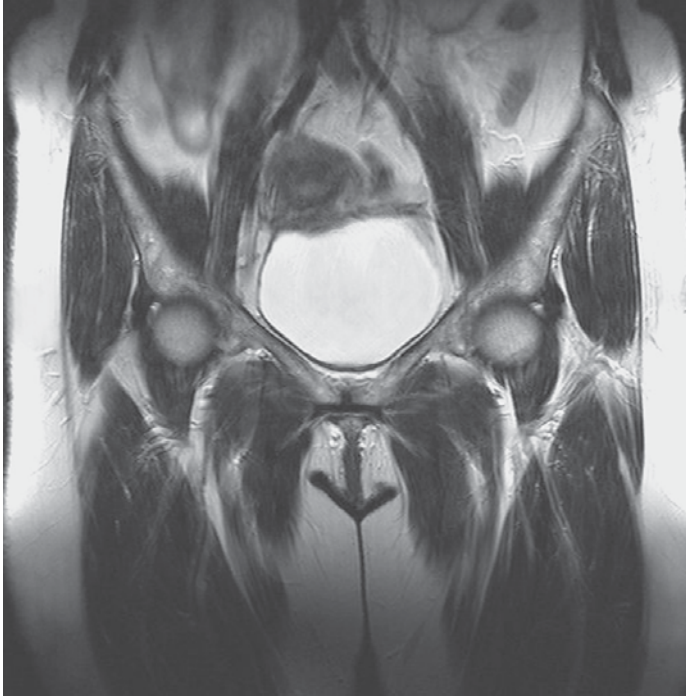
- | | | | |
|----|--|----|---|
| 6 | Plantar metatarsal artery and vein | 15 | Cuboid |
| 7 | Lateral plantar artery and vein (superficial branch) | 16 | Flexor hallucis longus muscle (tendon) |
| 8 | Flexor hallucis brevis muscle (medial head) | 17 | Long plantar ligament |
| 9 | Lateral plantar artery and vein (deep branch) | 18 | Medial plantar artery, vein, and nerve |
| 10 | Abductor hallucis muscle (tendon) | 19 | Abductor digiti minimi muscle |
| 11 | Fifth plantar digital artery, vein, and nerve | 20 | Flexor digitorum longus muscle (tendon) |
| 12 | Metatarsals | 21 | Calcaneus (calcaneal tuberosity) |
| 13 | Peroneus (fibularis) longus muscle (tendon) | 22 | Quadratus plantae muscle |
| 14 | Flexor hallucis brevis muscle (lateral head) | 23 | Lateral plantar artery, vein, and nerve |
| | | 24 | Abductor hallucis muscle |



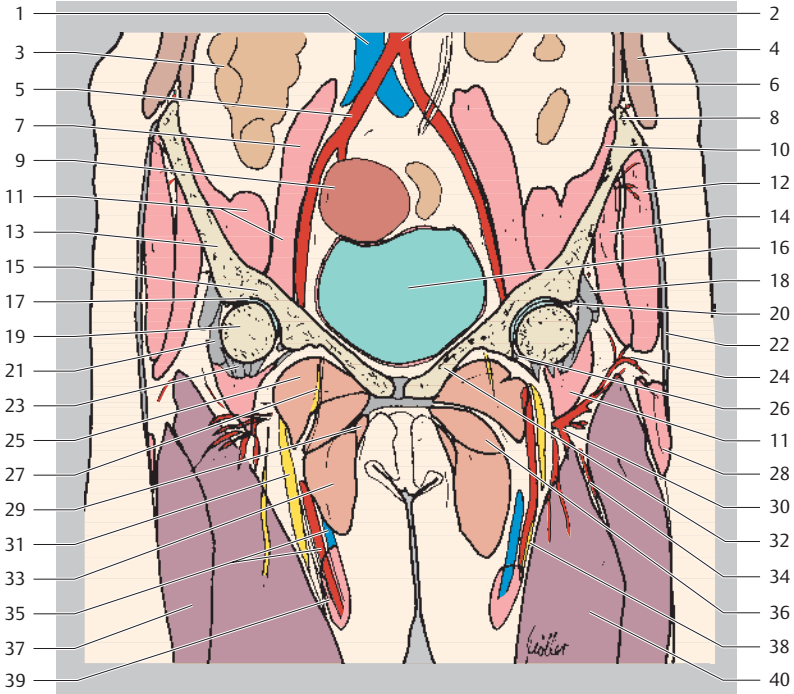
Anterior
Lateral Medial
Posterior



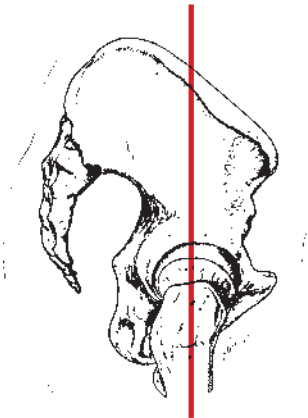
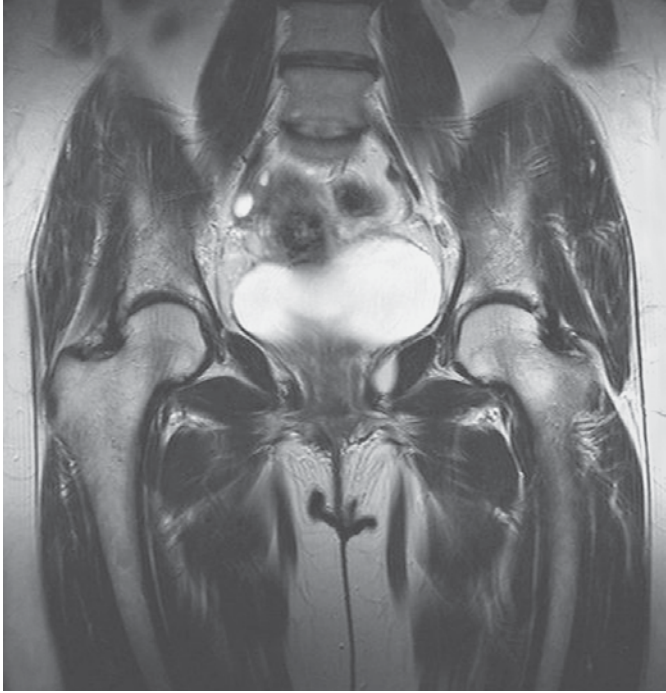
- | | |
|--|---|
| 1 Flexores digitorum muscles (tendons) | 11 Proximal phalanx V |
| 2 Flexor hallucis longus muscle (tendon) | 12 Flexor digitorum longus muscle (tendons) |
| 3 Distal phalanx V | 13 Metatarsal bones (heads) |
| 4 Sesamoid bones | 14 Lumbrical muscles |
| 5 Fifth distal interphalangeal joint (DIP) | 15 Dorsal and plantar interossei muscles |
| 6 Adductor hallucis muscle (transverse head) | 16 Medial plantar artery, vein, and nerve (deep branch) |
| 7 Medial phalanx V | 17 Metatarsal V |
| 8 Adductor hallucis muscle (oblique head) | 18 Flexor digitorum brevis muscle |
| 9 Fifth proximal interphalangeal joint (PIP) | 19 Flexor digiti minimi brevis muscle |
| 10 Flexor hallucis brevis muscle | 20 Lateral plantar artery and vein |
| | 21 Abductor digiti minimi muscle |
| | 22 Plantar aponeurosis |
| | 23 Calcaneus (calcaneal tuberosity) |



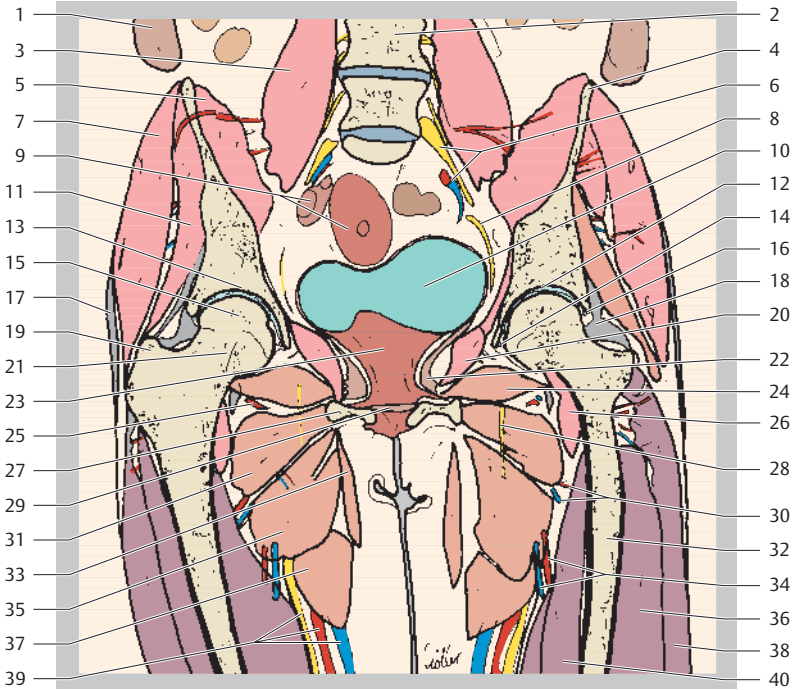
- 1 Inferior vena cava
- 2 Aorta (bifurcation)
- 3 Small intestine
- 4 Internal oblique muscle of abdomen
- 5 (Right) common iliac artery
- 6 Transversus abdominis muscle



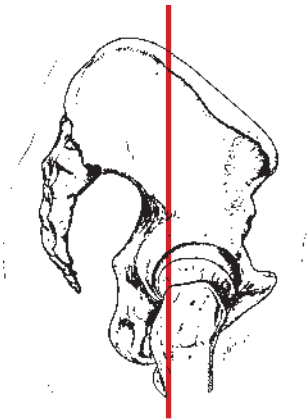
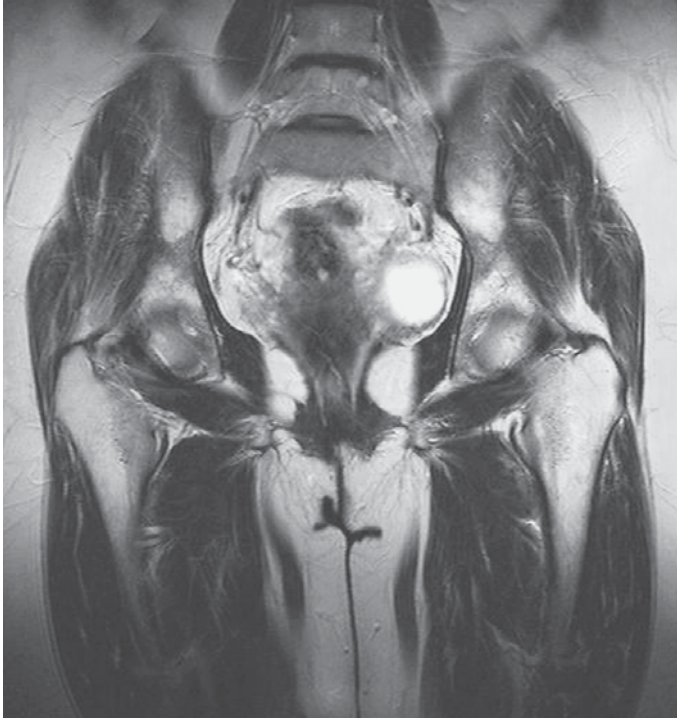- | | |
|---|--|
| 7 Psoas muscle | 24 Lateral circumflex femoral artery (ascending branch) |
| 8 Anterior superior iliac spine | 25 Pectineus muscle |
| 9 Uterus | 26 Inferior glenoid labrum |
| 10 Iliac muscle | 27 Obturator nerve |
| 11 Iliopsoas muscle | 28 Tensor fasciae latae muscle |
| 12 Gluteus medius muscle | 29 Gracilis muscle |
| 13 Ilium | 30 Deep artery of thigh |
| 14 Gluteus minimus muscle | 31 Femoral nerve |
| 15 Roof of acetabulum | 32 Pubis |
| 16 Urinary bladder | 33 Adductor longus muscle |
| 17 Hip joint | 34 Lateral circumflex femoral artery (descending branch) |
| 18 Rectus femoris muscle (tendon) | 35 (Superficial) Femoral artery and vein |
| 19 Head of femur | 36 Adductor brevis muscle |
| 20 Superior glenoid labrum | 37 Vastus lateralis muscle |
| 21 Iliofemoral ligament (transverse part) | 38 Saphenous nerve |
| 22 Iliotibial tract | 39 Sartorius muscle |
| 23 Iliofemoral ligament (descending part) | 40 Vastus intermedius muscle |



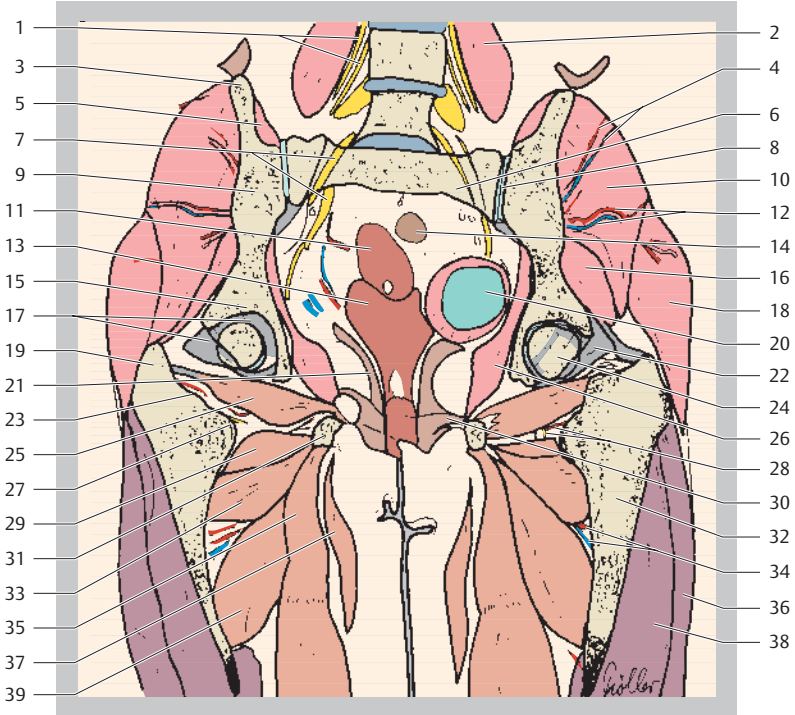
- 1 External oblique and internal oblique muscles of abdomen
- 2 Fourth lumbar vertebra
- 3 Psoas muscle
- 4 Anterior superior iliac spine
- 5 Iliacus muscle



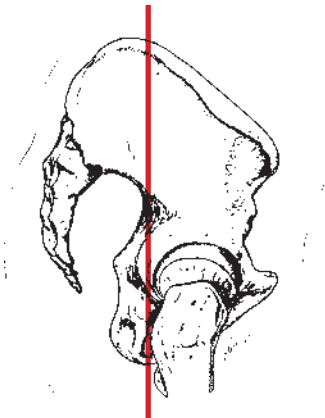
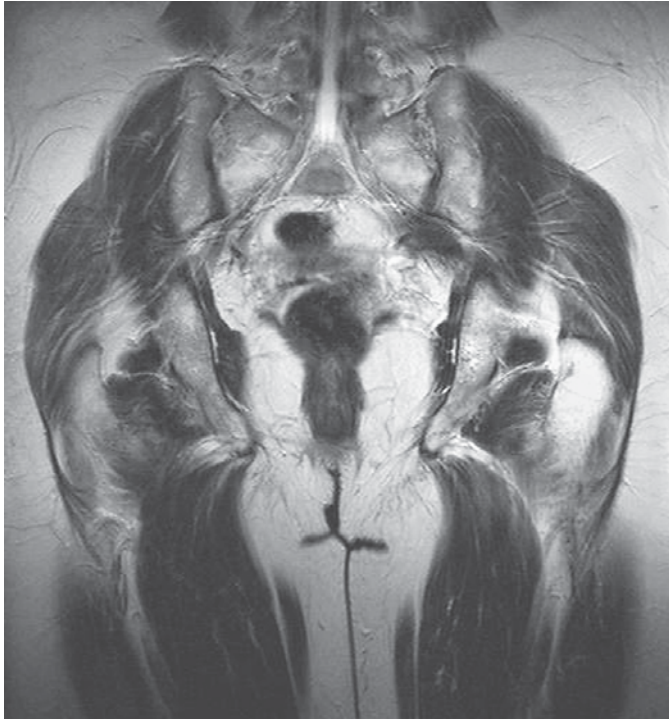
- | | |
|---|---|
| 6 Sacral plexus and (left) internal iliac artery and vein | 25 Medial circumflex femoral artery |
| 7 Gluteus medius muscle | 26 Iliopsoas muscle |
| 8 Obturator nerve | 27 Pubis |
| 9 Ovary and uterus | 28 Obturator nerve |
| 10 Urinary bladder | 29 Deep transverse perineal muscle |
| 11 Gluteus minimus muscle | 30 Lateral circumflex femoral artery and vein (descending branch) and femoral nerve (anterior cutaneous branch) |
| 12 Hip joint | 31 Pectineus muscle |
| 13 Roof of acetabulum | 32 Femur (shaft) |
| 14 Inferior glenoid labrum | 33 Gracilis muscle |
| 15 Head of femur | 34 Deep artery and vein of thigh |
| 16 Superior glenoid labrum | 35 Adductor brevis muscle |
| 17 Iliotibial tract | 36 Vastus intermedius muscle |
| 18 Iliofemoral ligament | 37 Adductor longus muscle |
| 19 Greater trochanter | 38 Vastus lateralis muscle |
| 20 Obturator internus muscle | 39 (Superficial) Femoral artery, vein, and saphenous nerve |
| 21 Femur (neck) | 40 Vastus medialis muscle |
| 22 Levator ani muscle | |
| 23 Vagina | |
| 24 Obturator externus muscle | |

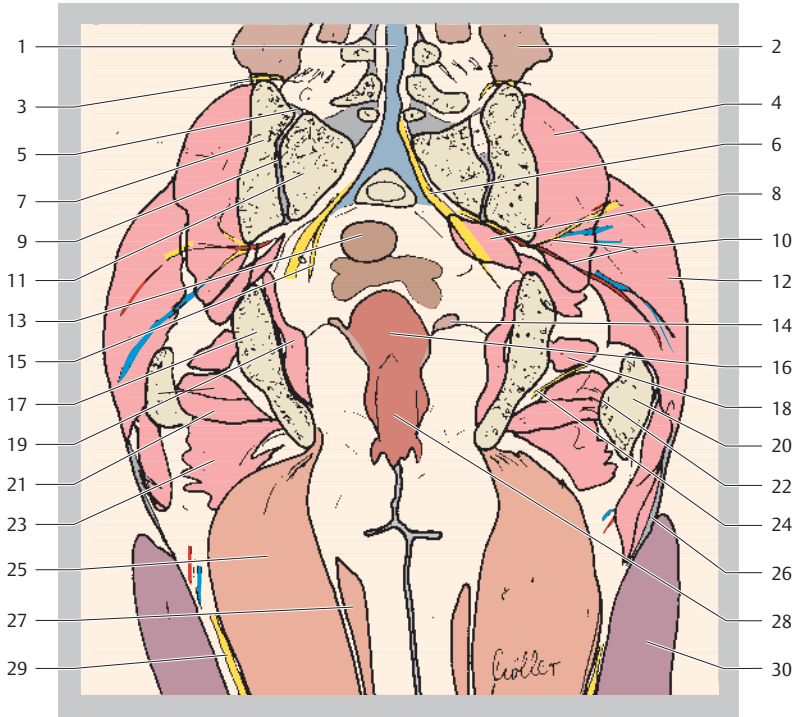


- 1 Lumbar plexus
- 2 Psoas muscle
- 3 Iliac crest
- 4 Superior gluteal artery and vein
- 5 Iliacus muscle

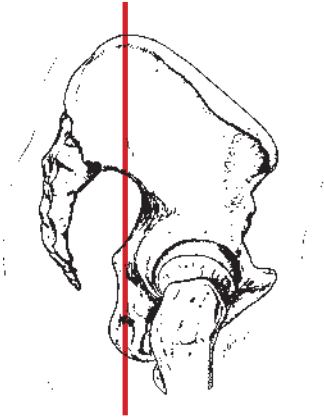
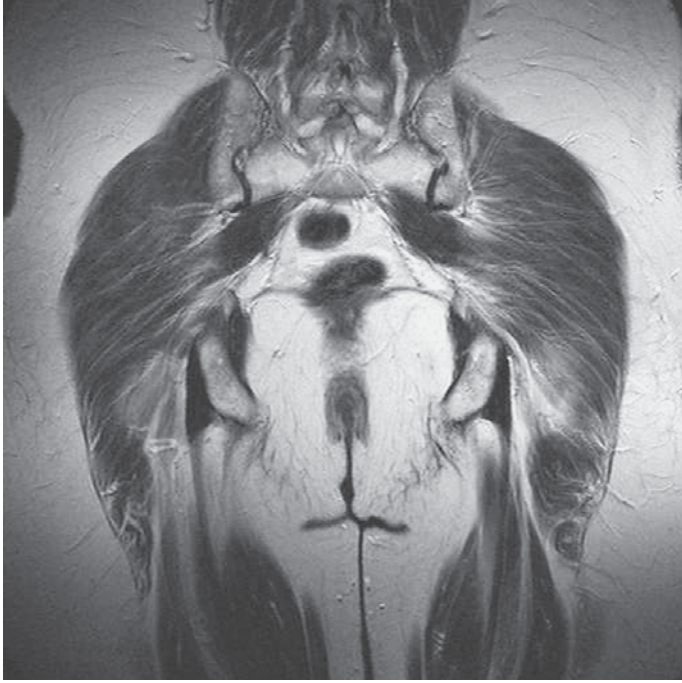

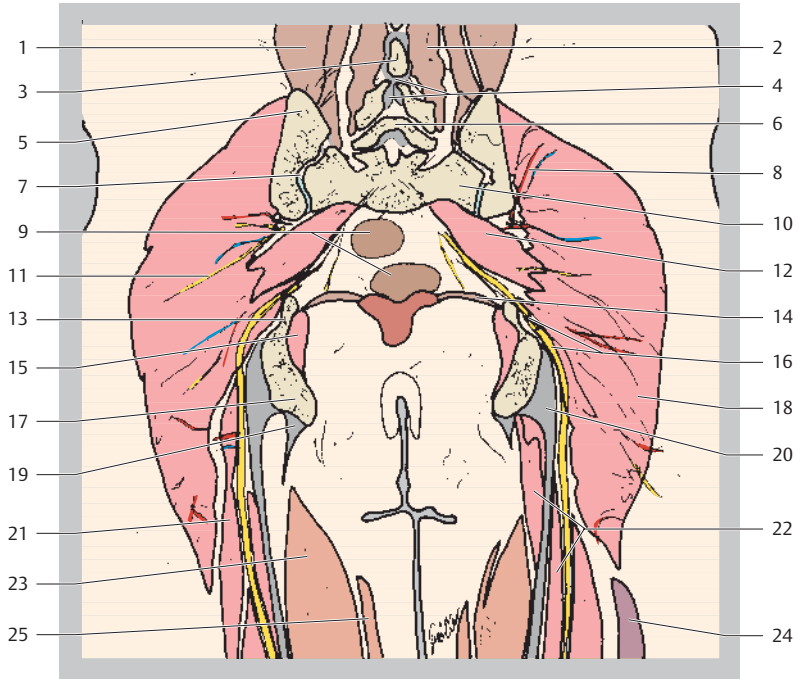
- | | |
|-------------------------------------|--|
| 6 Sacrum | 24 Head of femur |
| 7 Sacral plexus | 25 Obturator externus muscle |
| 8 Sacroiliac joint | 26 Obturator internus muscle |
| 9 Ilium | 27 Lesser trochanter |
| 10 Gluteus medius muscle | 28 Medial circumflex femoral artery and vein |
| 11 Uterus | 29 Adductor minimus muscle |
| 12 Inferior gluteal artery and vein | 30 Transversus perinei profundus muscle |
| 13 Vagina | 31 Pubis (inferior ramus) |
| 14 Sigmoid colon | 32 Femur (shaft) |
| 15 Roof of acetabulum | 33 Adductor brevis muscle |
| 16 Gluteus minimus muscle | 34 Deep femoral artery and vein |
| 17 Zona orbicularis | 35 Adductor magnus muscle |
| 18 Gluteus maximus muscle | 36 Vastus lateralis muscle |
| 19 Greater trochanter | 37 Gracilis muscle |
| 20 Urinary bladder | 38 Vastus intermedius muscle |
| 21 Levator ani muscle | 39 Adductor brevis muscle |
| 22 Ischiofemoral ligament | |
| 23 Intertrochanteric crest | |



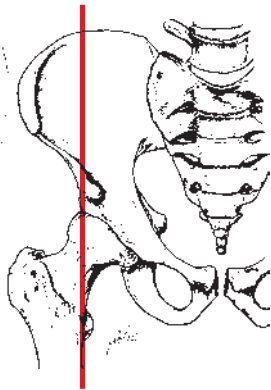
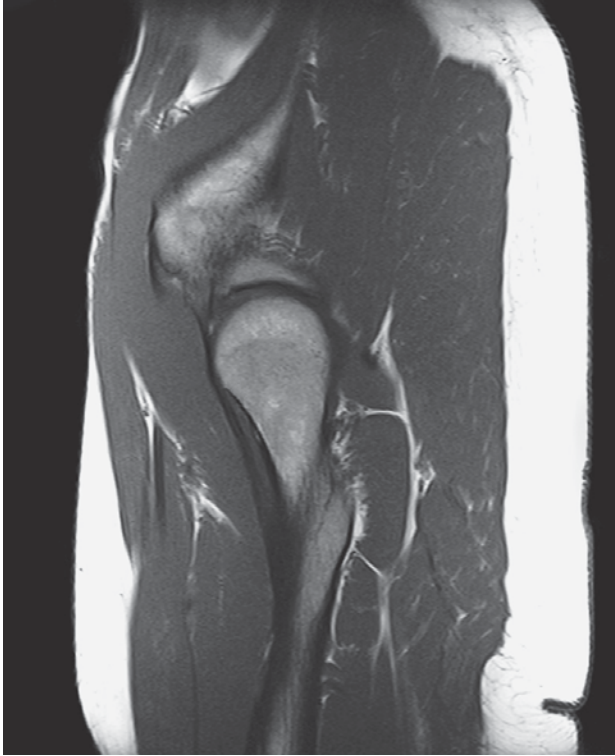
- | | |
|--|------------------------------|
| 1 Spinal canal | 15 Pudendal nerve |
| 2 External oblique and internal oblique muscles of abdomen | 16 Uterus |
| 3 Superior clunial nerves | 17 Ischium |
| 4 Gluteus medius muscle | 18 Gemellus superior muscle |
| 5 Sacroiliac ligament | 19 Obturator internus muscle |
| 6 Sciatic nerve | 20 Greater trochanter |
| 7 Ilium | 21 Gemellus inferior muscle |
| 8 Piriformis muscle | 22 Intertrochanteric crest |
| 9 Sacroiliac joint | 23 Quadratus femoris muscle |
| 10 Inferior gluteal artery, vein, and nerve | 24 Muscular nerve |
| 11 Sacrum (lateral mass) | 25 Adductor magnus muscle |
| 12 Gluteus maximus muscle | 26 Iliotibial tract |
| 13 Sigmoid colon | 27 Gracilis muscle |
| 14 Levator ani muscle | 28 Vagina |
| | 29 Sciatic nerve |
| | 30 Vastus lateralis muscle |

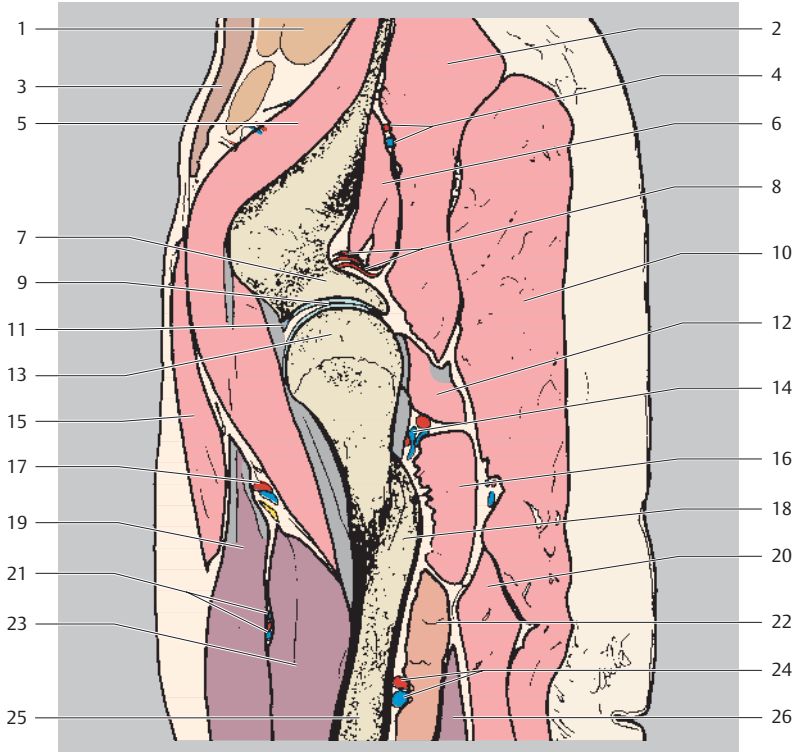




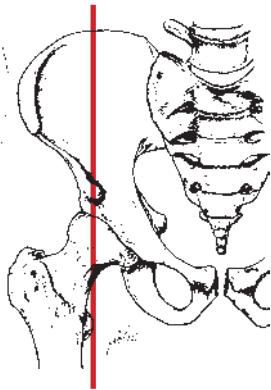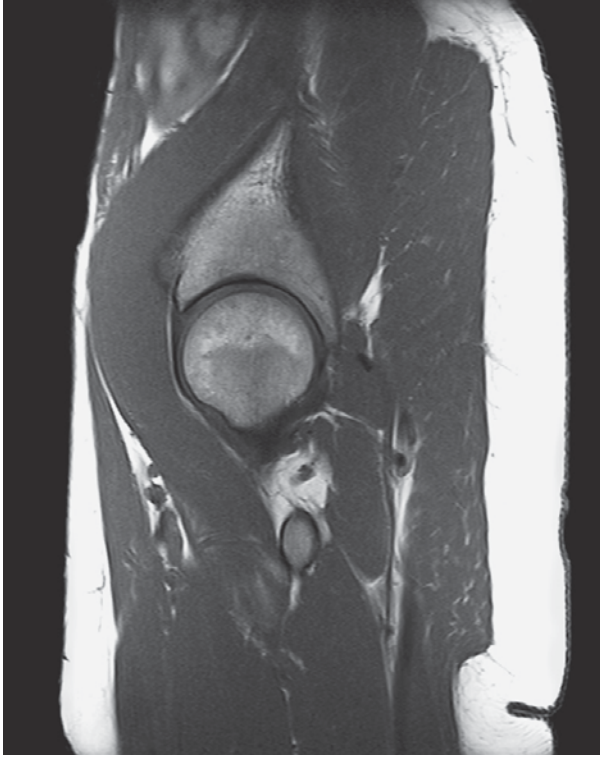- | | |
|---|---|
| 1 Iliocostalis lumborum muscle | 14 Levator ani muscle |
| 2 Multifidus muscle | 15 Obturator internus muscle |
| 3 Spinous process | 16 Sciatic nerve |
| 4 Interspinous ligament | 17 Ischial tuberosity |
| 5 Ilium | 18 Gluteus maximus muscle |
| 6 Vertebral arch | 19 Adductor magnus muscle (attachment) |
| 7 Sacroiliac joint | 20 Semitendinosus and biceps femoris muscles (common tendon attachment) |
| 8 Superior gluteal artery, vein, and nerve | 21 Biceps femoris muscle (long head) |
| 9 Rectum | 22 Semitendinosus muscle |
| 10 Sacrum (lateral mass) | 23 Adductor magnus muscle |
| 11 Inferior gluteal artery, vein, and nerve | 24 Vastus lateralis muscle |
| 12 Piriformis muscle | 25 Gracilis muscle |
| 13 Ischial spine | |



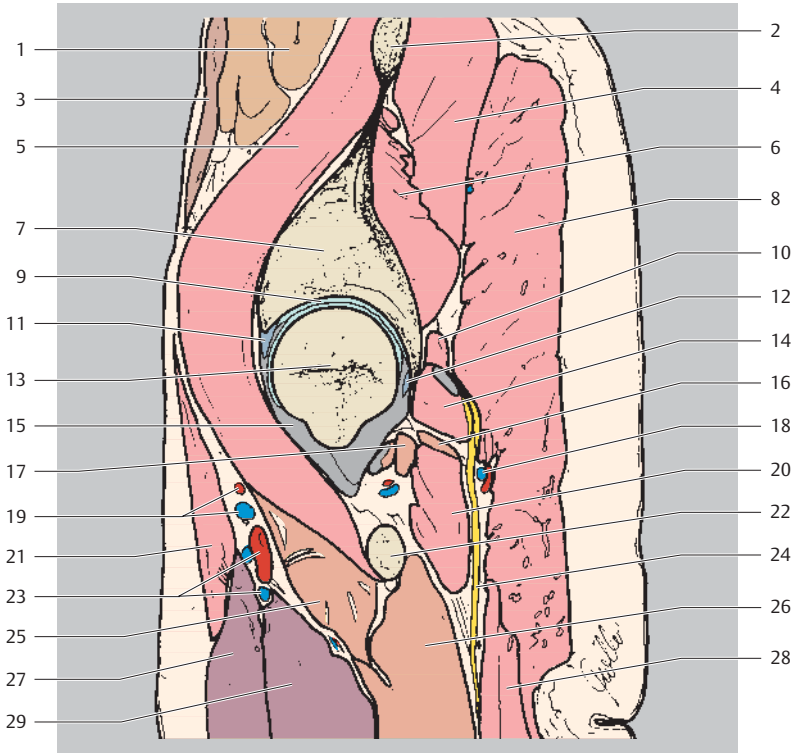
Proximal
Ventral Dorsal
Distal



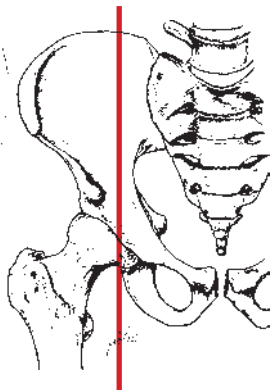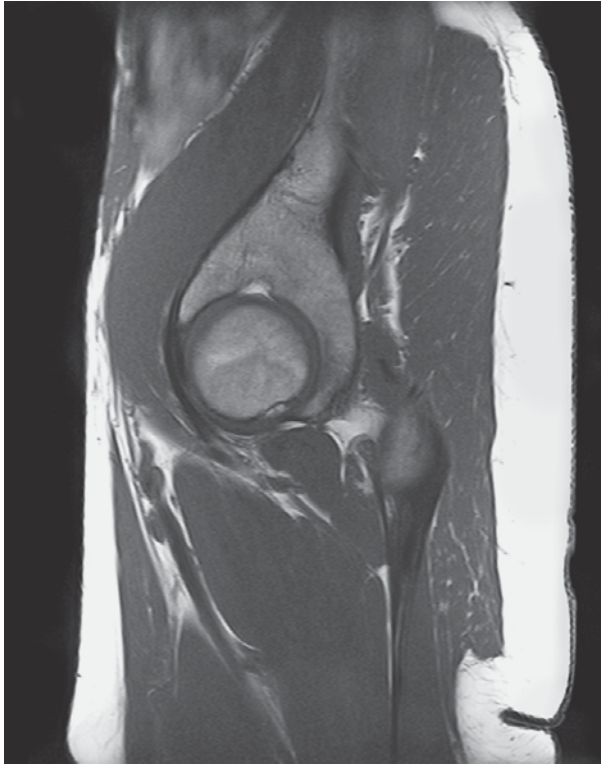- | | |
|---|--|
| 1 Small intestine | 14 Medial circumflex femoral artery |
| 2 Gluteus medius muscle | 15 Sartorius muscle |
| 3 Rectus abdominis muscle | 16 Quadratus femoris muscle |
| 4 Superior gluteal artery and vein | 17 Lateral circumflex femoral artery (ascending branch) |
| 5 Iliopsoas muscle | 18 Lesser trochanter |
| 6 Gluteus minimus muscle | 19 Rectus femoris muscle |
| 7 Ilium (roof of acetabulum) | 20 Biceps femoris muscle (long head) |
| 8 Superficial circumflex iliac artery | 21 Lateral circumflex femoral artery (descending branch) |
| 9 Hip joint | 22 Adductor magnus muscle |
| 10 Gluteus maximus muscle | 23 Vastus intermedius muscle |
| 11 Superior glenoid labrum | 24 Perforating artery |
| 12 Obturator internus muscle and gemellus muscles | 25 Femur (shaft) |
| 13 Femur (head) | 26 Vastus lateralis muscle |



Proximal
Ventral Dorsal
Distal

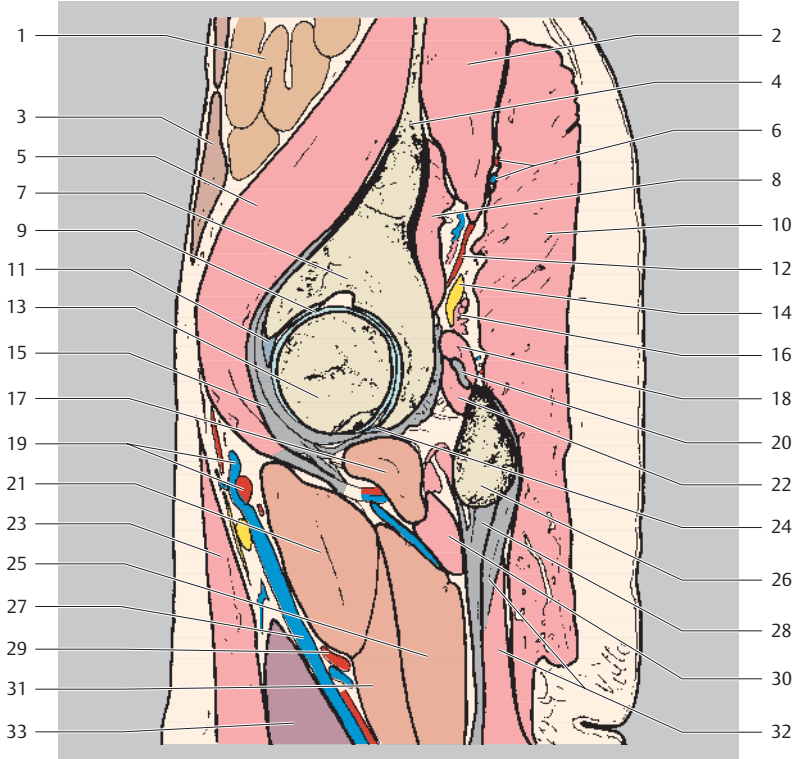


- | | |
|---|--|
| 1 Small intestine | 16 Adductor minimus muscle |
| 2 Ilium | 17 Obturator externus muscle |
| 3 Rectus abdominis muscle | 18 Inferior gluteal artery and vein |
| 4 Gluteus medius muscle | 19 Lateral circumflex femoral artery (ascending branch) |
| 5 Iliopsoas muscle | 20 Quadratus femoris muscle |
| 6 Gluteus minimus muscle | 21 Sartorius muscle |
| 7 Ilium (roof of acetabulum) | 22 Lesser trochanter |
| 8 Gluteus maximus muscle | 23 Lateral circumflex femoral artery (descending branch) |
| 9 Hip joint | 24 Sciatic nerve |
| 10 Piriformis muscle | 25 Pectineus muscle |
| 11 Superior glenoid labrum | 26 Adductor magnus muscle |
| 12 Inferior glenoid labrum | 27 Rectus femoris muscle |
| 13 Femur (head) | 28 Biceps femoris muscle |
| 14 Obturator internus muscle and gemellus muscles | 29 Vastus medialis muscle |
| 15 Joint capsule | |

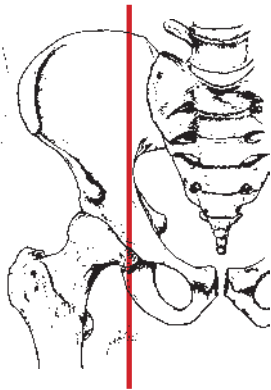
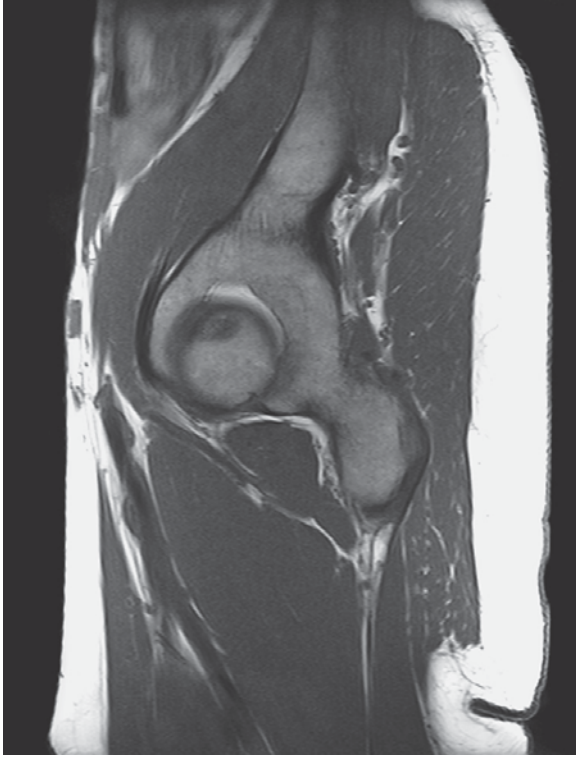

Proximal
Ventral Dorsal
Distal

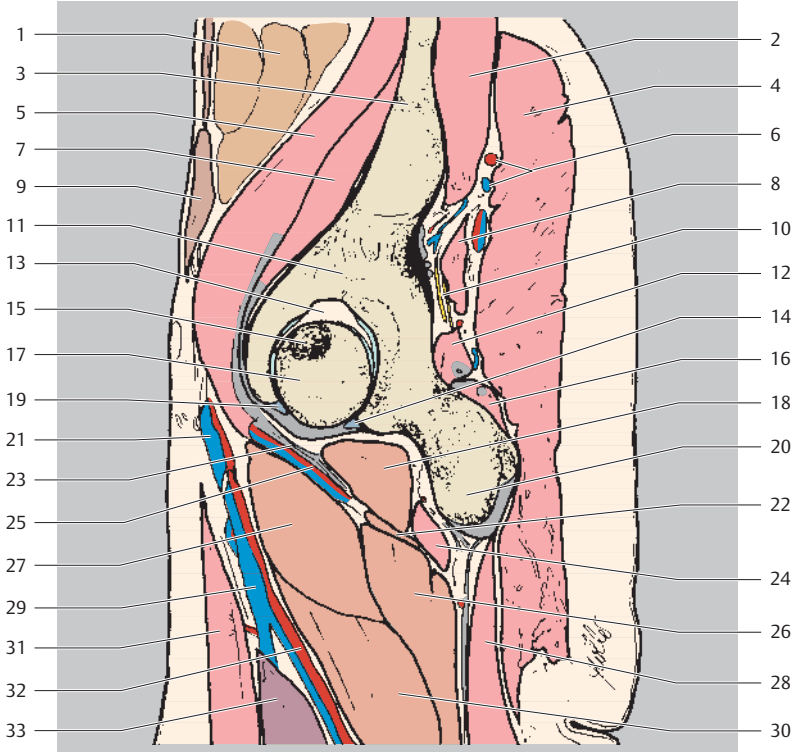
- 1 Small intestine
- 2 Gluteus medius muscle
- 3 Rectus abdominis muscle
- 4 Ilium



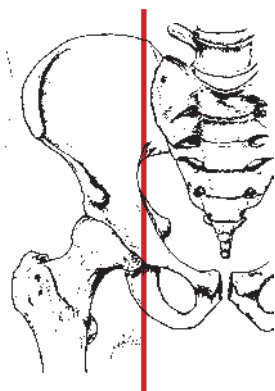
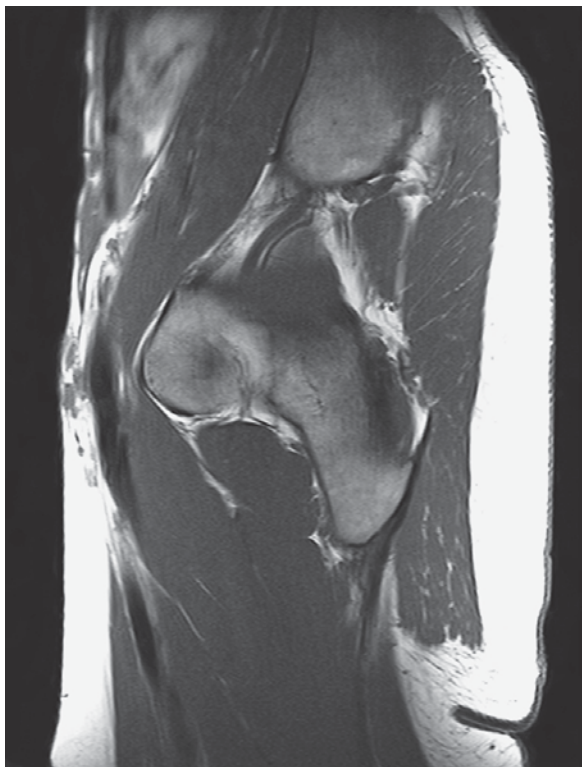- | | |
|---|---|
| 5 Iliopsoas muscle | 19 Lateral circumflex femoris artery (ascending branch) |
| 6 Superior gluteal artery, vein, and nerve | 20 Obturator internus muscle (tendon) |
| 7 Ilium (roof of acetabulum) | 21 Pectineus muscle |
| 8 Gluteus minimus muscle | 22 Gemellus inferior muscle |
| 9 Hip joint | 23 Sartorius muscle |
| 10 Gluteus maximus muscle | 24 Inferior glenoid labrum |
| 11 Superior glenoid labrum | 25 Adductor magnus muscle |
| 12 Superior gluteal artery and vein, inferior gluteal nerve | 26 Ischium |
| 13 Femur (head) | 27 Deep artery and vein of thigh |
| 14 Sciatic nerve | 28 Semimembranosus and semitendinosus muscles (tendon attachment) |
| 15 Joint capsule | 29 Perforating arteries |
| 16 Piriformis | 30 Quadratus femoris muscle |
| 17 Obturator externus | 31 Adductor brevis muscle |
| 18 Obturator internus and gemellus muscles | 32 Biceps femoris muscle (+ tendon) |
| | 33 Vastus medialis muscle |



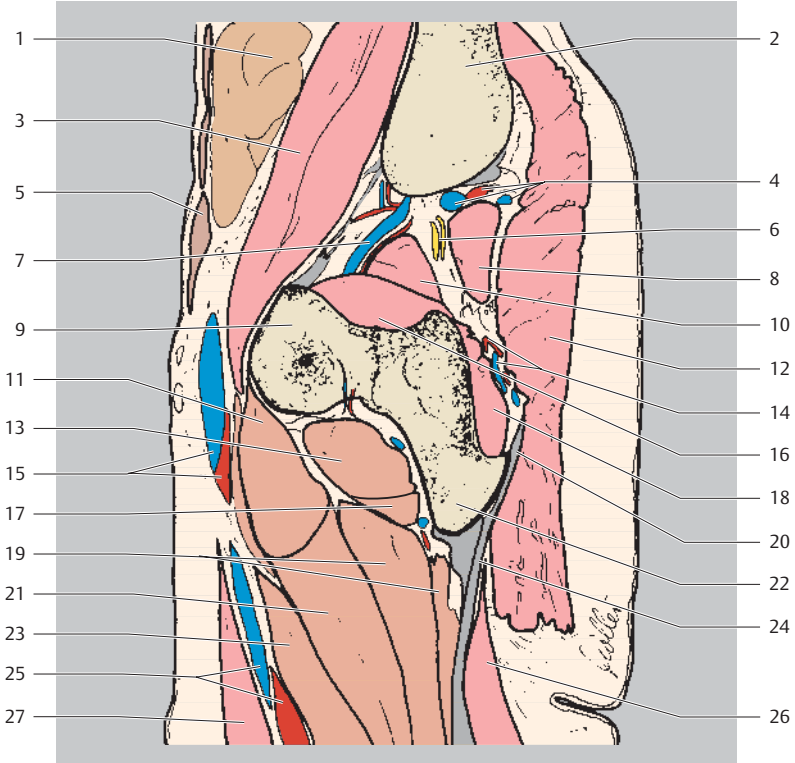
Proximal
Ventral Dorsal
Distal



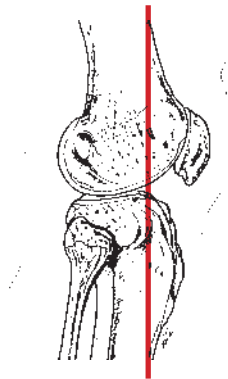
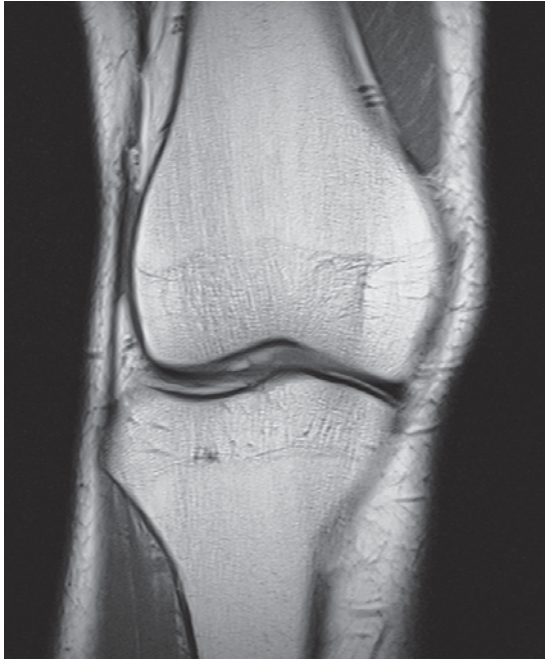- | | |
|--|---|
| 1 Small intestine | 18 Obturator externus muscle |
| 2 Gluteus medius muscle | 19 Superior glenoid labrum |
| 3 Ilium | 20 Ischium |
| 4 Gluteus maximus muscle | 21 Lateral circumflex femoral artery and vein |
| 5 Psoas muscle | 22 Adductor minimus muscle |
| 6 Superior gluteal artery, vein, and nerve | 23 Ischiofemoral ligament |
| 7 Iliacus muscle | 24 Quadratus femoris muscle |
| 8 Piriformis muscle | 25 Lateral circumflex femoral artery |
| 9 Rectus abdominis muscle | 26 Adductor magnus muscle |
| 10 Sciatic nerve | 27 Pectineus muscle |
| 11 Ilium (roof of acetabulum) | 28 Biceps femoris muscle |
| 12 Gemellus superior muscle | 29 (Superficial) Femoral artery and vein |
| 13 Acetabular fossa | 30 Adductor brevis muscle |
| 14 Inferior glenoid labrum | 31 Sartorius muscle |
| 15 Fovea | 32 Deep artery and vein of thigh |
| 16 Gemellus inferior muscle | 33 Vastus medialis muscle |
| 17 Femur (head) | |



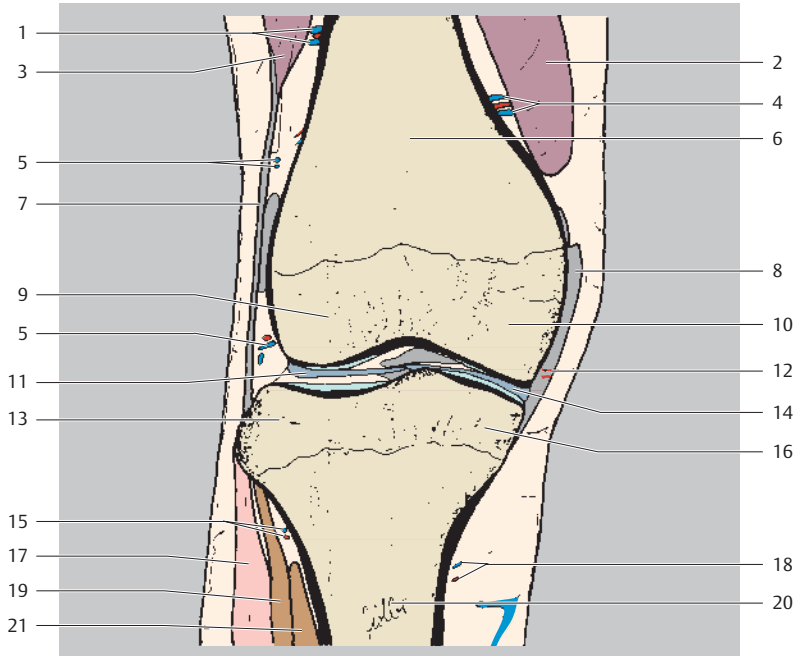
Proximal
Ventral Dorsal
Distal



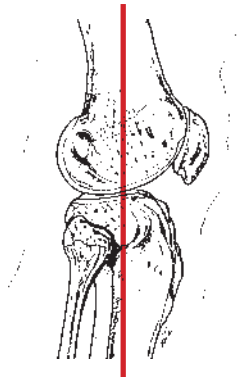
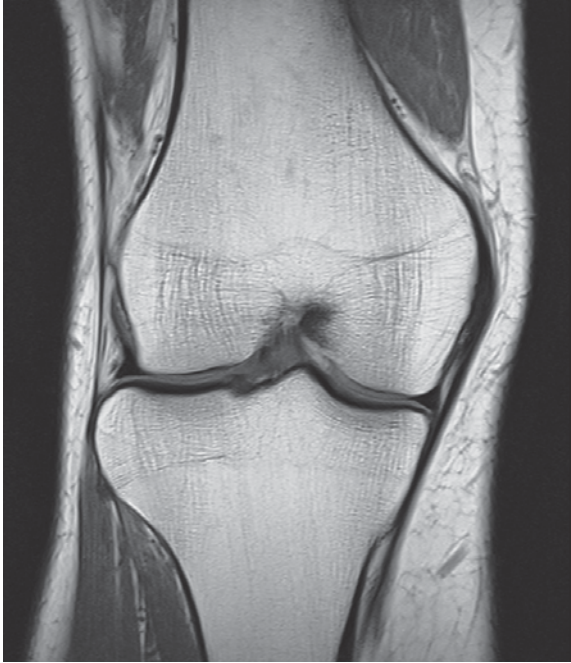- | | |
|--|--|
| 1 Small intestine | 15 Femoral artery and vein |
| 2 Ilium | 16 Obturator internus muscle |
| 3 Iliopsoas muscle | 17 Adductor minimus muscle |
| 4 Superior gluteal artery, vein, and nerve | 18 Gemellus inferior muscle |
| 5 Rectus abdominis muscle | 19 Adductor magnus muscle |
| 6 Sciatic nerve | 20 Sacrotuberous ligament |
| 7 Internal iliac artery and vein | 21 Adductor brevis muscle |
| 8 Piriformis muscle | 22 Ischial tuberosity |
| 9 Ilium (joint socket) | 23 Adductor longus muscle |
| 10 Gemellus superior muscle | 24 Biceps femoris muscle (common tendon) |
| 11 Pectineus muscle | 25 (Superficial) Femoral artery and vein |
| 12 Gluteus maximus muscle | 26 Biceps femoris muscle |
| 13 Obturator externus muscle | 27 Sartorius muscle |
| 14 Inferior gluteal artery and nerve | |



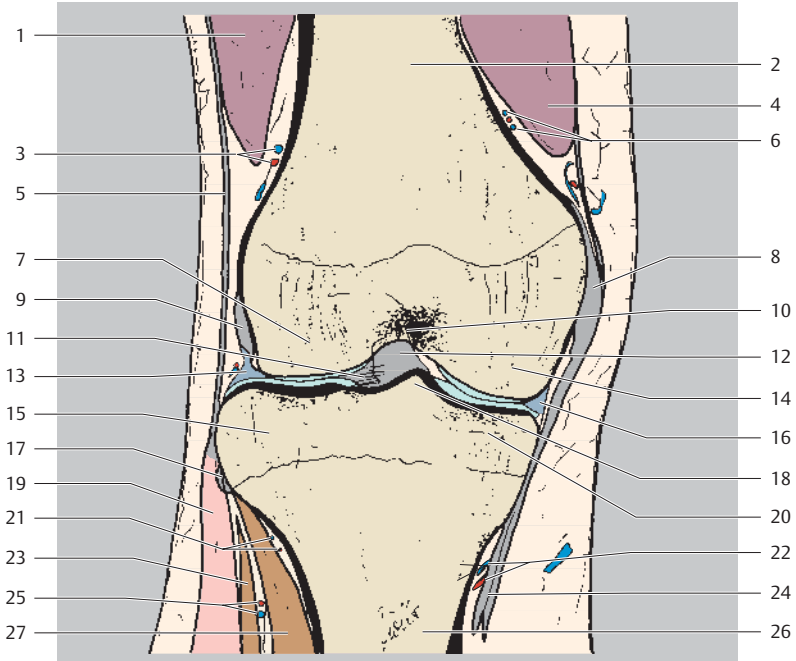
Proximal
Lateral Medial
Distal



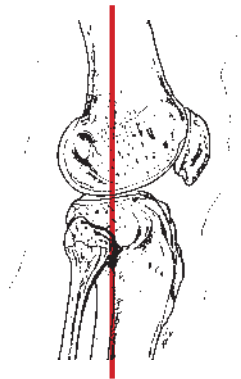
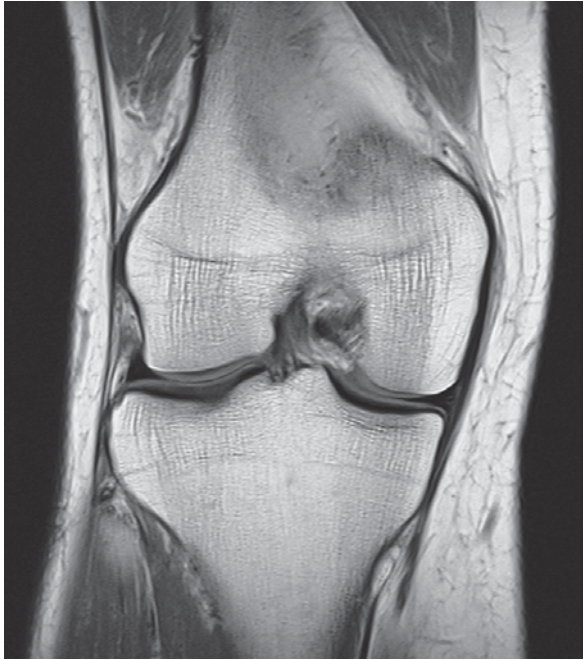- | | |
|-------------------------------------|---|
| 1 Superior lateral genicular artery | 11 Lateral meniscus (anterior horn) |
| 2 Vastus medialis muscle | 12 Descending genicular vein (articular branches) |
| 3 Vastus lateralis muscle | 13 Lateral tibial condyle |
| 4 Superior medial genicular artery | 14 Medial meniscus (anterior horn) |
| 5 Genicular anastomosis | 15 Inferior lateral genicular artery |
| 6 Femur (shaft) | 16 Medial tibial condyle |
| 7 Iliotibial tract | 17 Peroneus (fibularis) longus muscle |
| 8 Medial collateral ligament | 18 Inferior medial genicular artery |
| 9 Lateral femoral condyle | 19 Extensor digitorum longus muscle |
| 10 Medial femoral condyle | 20 Tibia (shaft) |
| | 21 Tibialis anterior muscle |



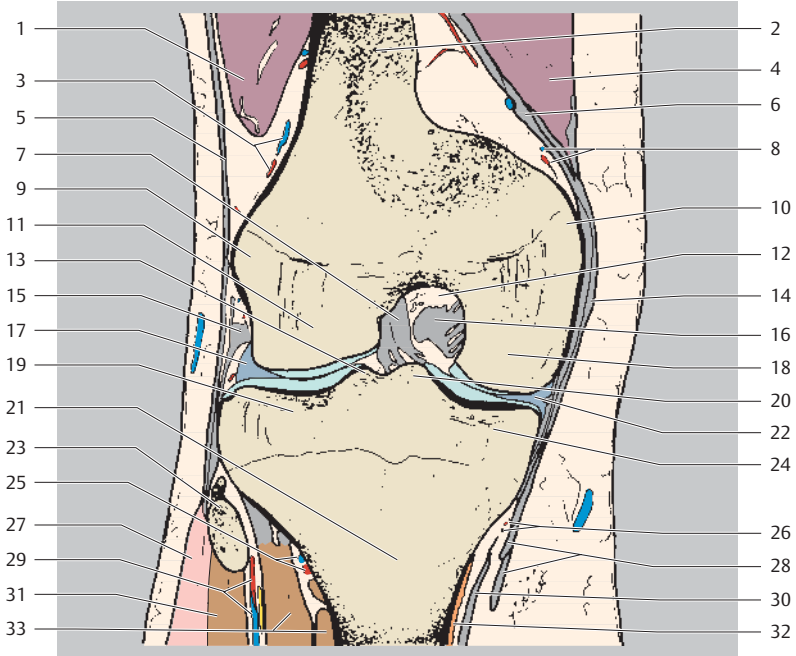
Proximal
Lateral Medial
Distal



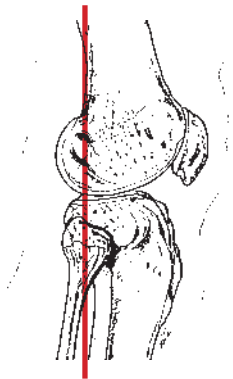
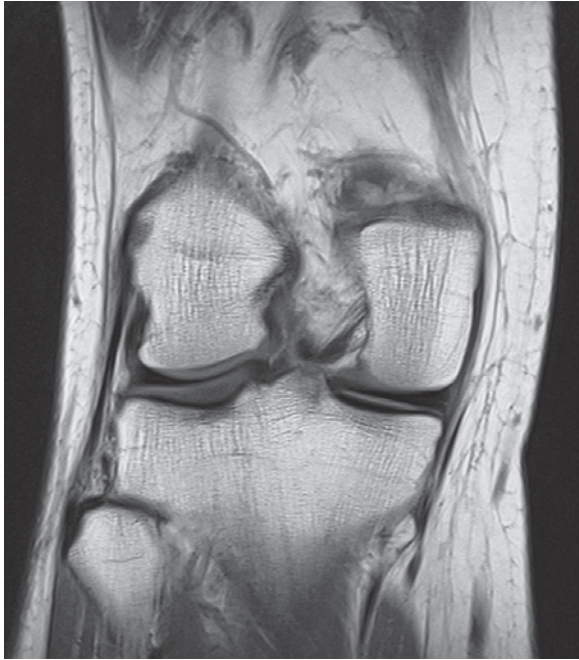- | | |
|--|--|
| 1 Vastus lateralis muscle | 14 Medial femoral condyle |
| 2 Femur (shaft) | 15 Lateral tibial condyle |
| 3 Superior lateral genicular artery | 16 Medial meniscus (intermediate portion) |
| 4 Vastus medialis muscle | 17 Anterior ligament of fibular head |
| 5 Iliotibial tract | 18 Medial intercondylar tubercle |
| 6 Superior medial genicular artery | 19 Peroneus (fibularis) longus muscle |
| 7 Lateral femoral condyle | 20 Medial tibial condyle |
| 8 Medial collateral ligament | 21 Inferior lateral genicular artery |
| 9 Popliteus muscle (tendon) | 22 Inferior medial genicular artery |
| 10 Intercondylar fossa | 23 Extensor digitorum longus muscle |
| 11 Transverse ligament of knee | 24 Pes anserinus (superficial) |
| 12 Anterior cruciate ligament | 25 Anterior tibial recurrent artery and vein |
| 13 Lateral meniscus (intermediate portion) | 26 Tibia (shaft) |
| | 27 Tibialis anterior muscle |



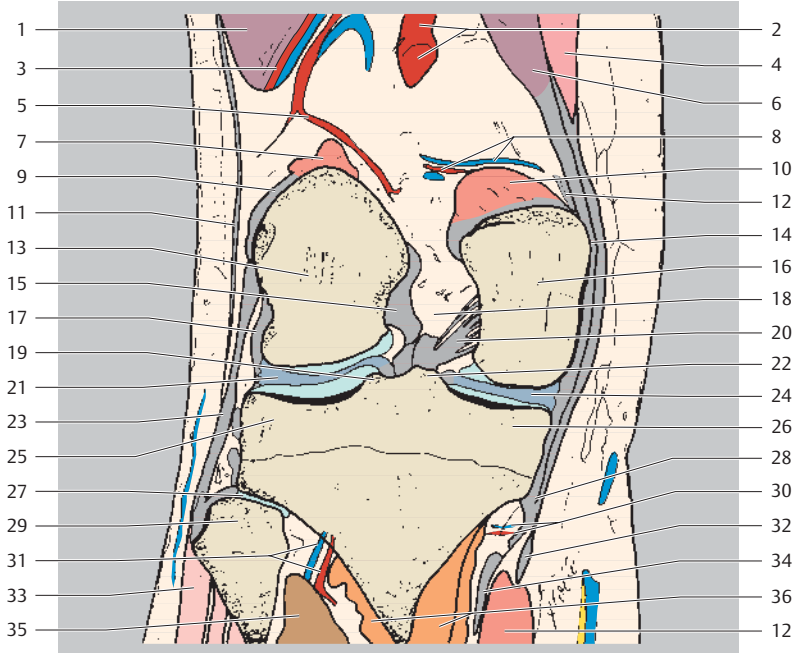
Proximal
Lateral Medial
Distal



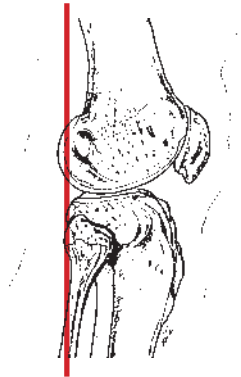
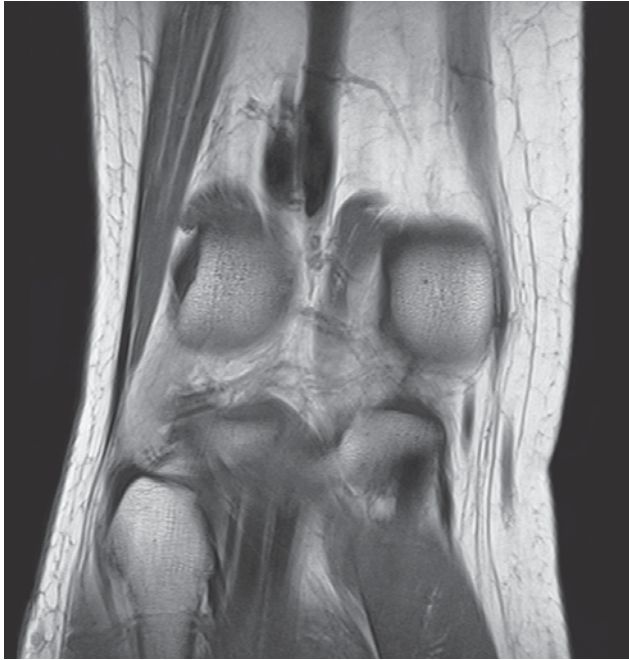- | | |
|--|---|
| 1 Vastus lateralis muscle | 18 Medial femoral condyle |
| 2 Femur (shaft) | 19 Lateral tibial condyle |
| 3 Superior lateral genicular artery | 20 Medial intercondylar tubercle |
| 4 Vastus medialis muscle | 21 Tibia (shaft) |
| 5 Iliotibial tract | 22 Medial meniscus (intermediate portion) |
| 6 Adductor magnus muscle (tendon) | 23 Fibula (head) |
| 7 Anterior cruciate ligament | 24 Medial tibial condyle |
| 8 Superior medial genicular artery | 25 Inferior lateral genicular artery |
| 9 Lateral epicondyle | 26 Inferior medial genicular artery |
| 10 Medial epicondyle | 27 Peroneus (fibularis) longus muscle |
| 11 Lateral femoral condyle | 28 Pes anserinus (superficial) |
| 12 Intercondylar fossa | 29 Anterior tibial recurrent artery and vein |
| 13 Lateral intercondylar tubercle | 30 Semimembranosus muscle (tibial attachment, deep pes anserinus) |
| 14 Medial collateral ligament | 31 Extensor digitorum longus muscle |
| 15 Popliteus muscle (tendon) | 32 Popliteus muscle (tibial attachment) |
| 16 Posterior cruciate ligament | 33 Tibialis anterior muscle |
| 17 Lateral meniscus (intermediate portion) | |



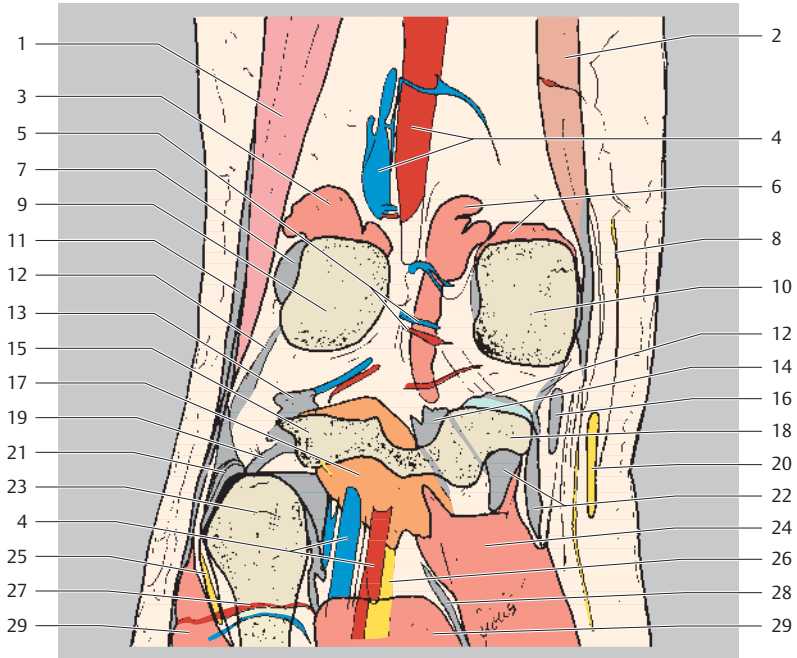
Proximal
Lateral Medial
Distal



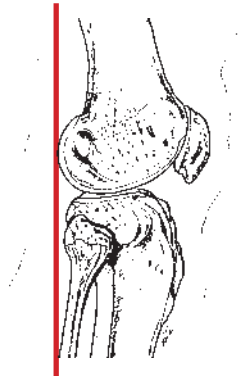
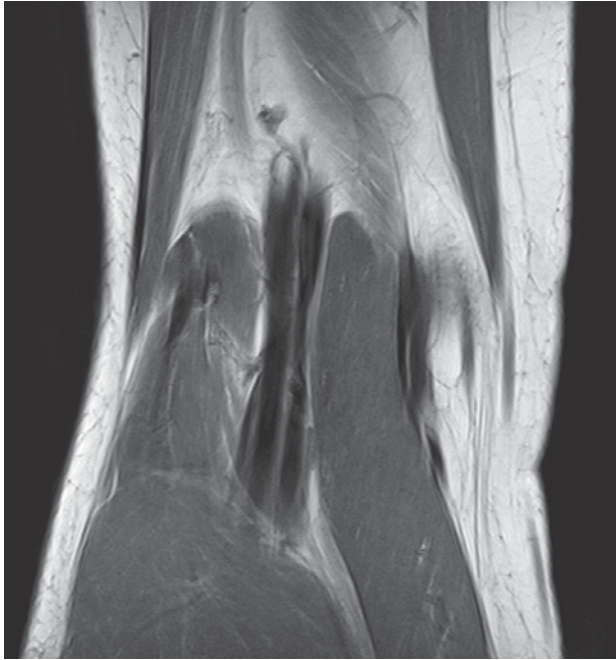
- | | |
|---|---|
| 1 Vastus lateralis muscle | 17 Popliteus muscle (tendon) |
| 2 Popliteal artery | 18 Intercondylar fossa |
| 3 Superior lateral genicular artery | 19 Lateral intercondylar tubercle |
| 4 Sartorius muscle | 20 Posterior cruciate ligament |
| 5 Medial genicular artery | 21 Lateral meniscus (posterior horn) |
| 6 Vastus medialis muscle | 22 Medial intercondylar tubercle |
| 7 Gastrocnemius muscle (lateral head, femoral attachment) | 23 Fibular collateral ligament |
| 8 Superior medial genicular artery | 24 Medial meniscus (posterior horn) |
| 9 Plantaris muscle (tendon) | 25 Lateral tibial condyle |
| 10 Gastrocnemius muscle (medial head) | 26 Medial tibial condyle |
| 11 Iliotibial tract | 27 Tibiofibular joint |
| 12 Adductor magnus muscle (tendon attachment) | 28 Pes anserinus (superficial) |
| 13 Lateral femoral condyle | 29 Fibula (head) |
| 14 Medial collateral ligament | 30 Inferior medial genicular artery |
| 15 Anterior cruciate ligament | 31 Inferior lateral genicular artery |
| 16 Medial femoral condyle | 32 Semitendinosus muscle (tendon) |
| | 33 Peroneus (fibularis) longus muscle |
| | 34 Semimembranosus muscle (tibial attachment, deep pes anserinus) |
| | 35 Tibialis posterior muscle |
| | 36 Popliteus muscle |



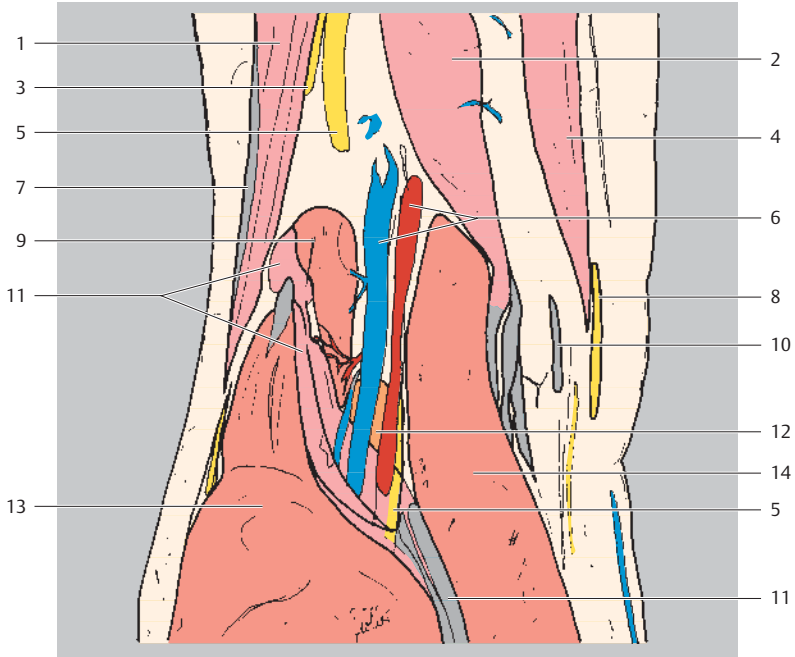
Proximal
Lateral Medial
Distal



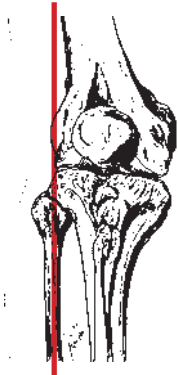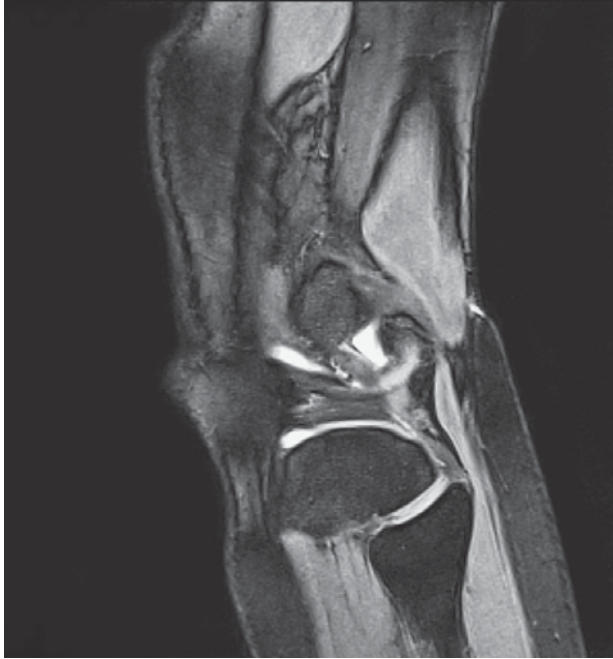- | | |
|--|---|
| 1 Biceps femoris muscle | 15 Lateral tibial condyle |
| 2 Gracilis muscle | 16 Semitendinosus muscle (tendon) |
| 3 Gastrocnemius muscle (lateral head) | 17 Posterior ligament of fibular head |
| 4 Popliteal artery and vein | 18 Medial tibial condyle |
| 5 Sural arteries and veins | 19 Fibular collateral ligament |
| 6 Gastrocnemius muscle (medial head, femoral attachment) | 20 Saphenous nerve |
| 7 Plantaris muscle | 21 Popliteus muscle (tendon) |
| 8 Saphenous nerve (branch) | 22 Semimembranosus muscle (tibial attachment, deep pes anserinus) |
| 9 Lateral femoral condyle | 23 Fibula (head) |
| 10 Medial femoral condyle | 24 Gastrocnemius muscle (medial head) |
| 11 Iliotibial tract | 25 Common fibular (peroneal) nerve |
| 12 Joint capsule | 26 Tibial nerve |
| 13 Arcuate popliteal ligament | 27 Posterior tibial artery (circumflex fibular branch) |
| 14 Oblique popliteal ligament | 28 Plantaris muscle (tendon) |
| | 29 Soleus muscle |



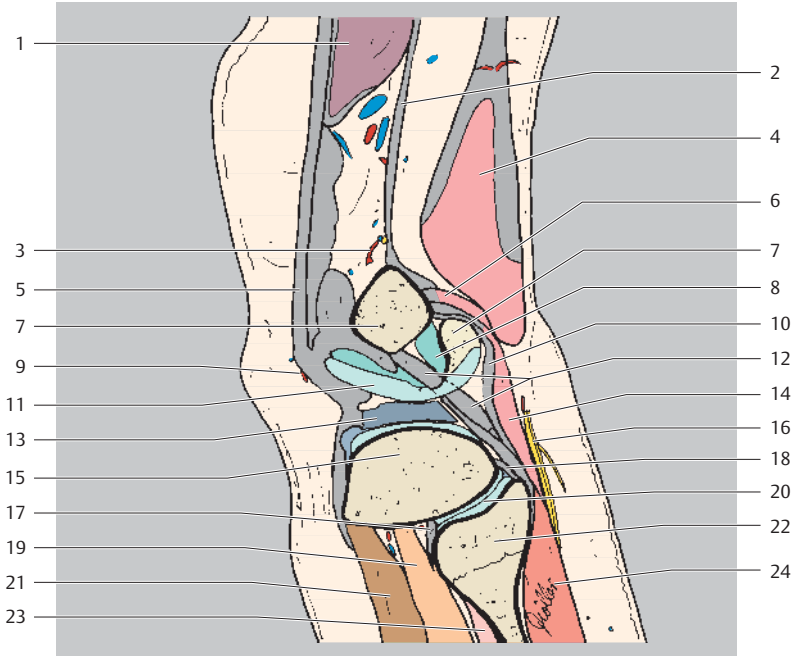
Proximal
Lateral Medial
Distal



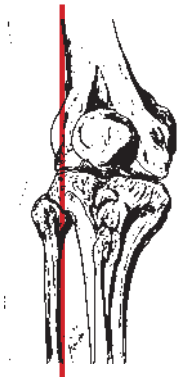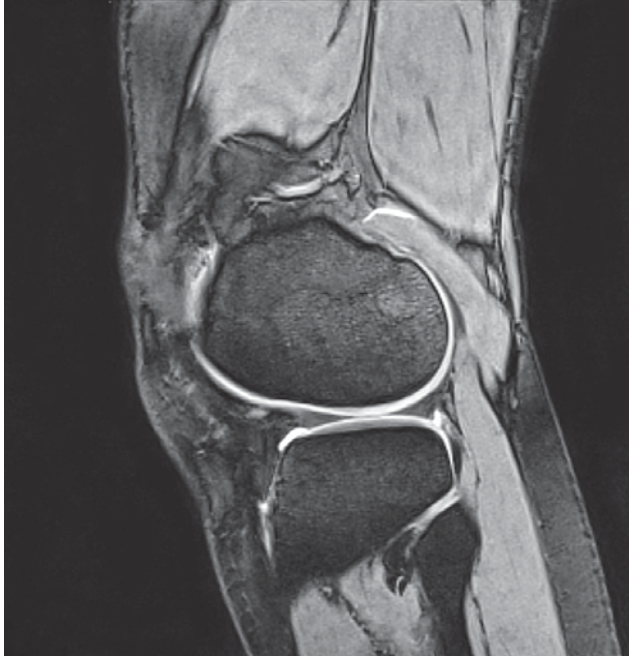
- | | |
|-----------------------------------|---------------------------------------|
| 1 Biceps femoris muscle | 8 Saphenous nerve |
| 2 Semimembranosus muscle | 9 Gastrocnemius muscle (lateral head) |
| 3 Common fibular (peroneal) nerve | 10 Semitendinosus muscle (tendon) |
| 4 Gracilis muscle | 11 Plantaris muscle (+ tendon) |
| 5 Tibial nerve | 12 Popliteus muscle |
| 6 Popliteal artery and vein | 13 Soleus muscle |
| 7 Iliotibial tract | 14 Gastrocnemius muscle (medial head) |



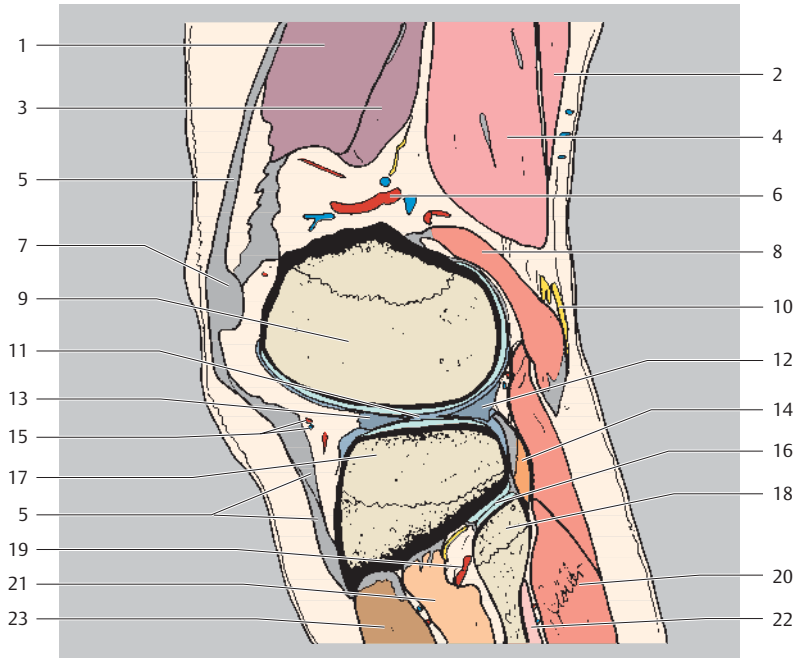
Proximal
Ventral Dorsal
Distal



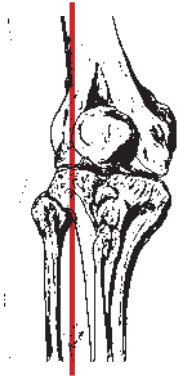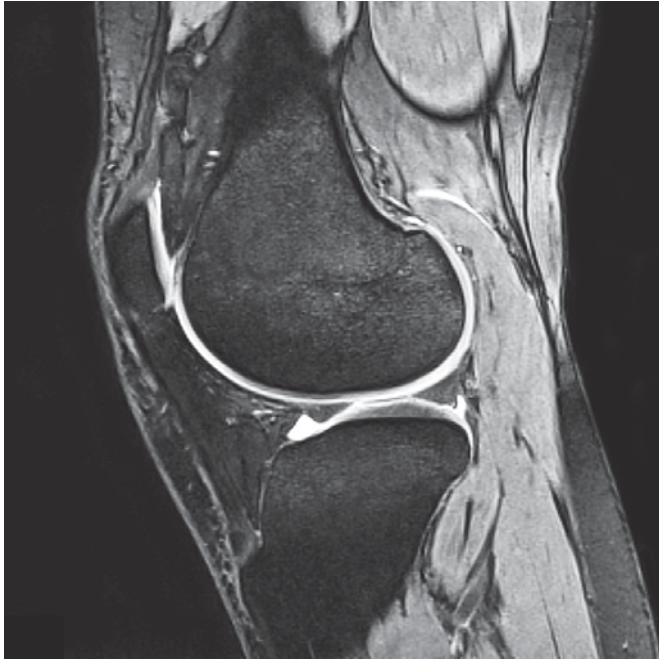
- | | |
|---|---------------------------------------|
| 1 Vastus lateralis muscle | 13 Lateral meniscus |
| 2 Iliotibial tract | (intermediate portion) |
| 3 Blood vessels to genicular anastomosis | 14 Plantaris muscle |
| 4 Biceps femoris muscle | (+ tendon attachment) |
| 5 Lateral patellar retinaculum | 15 Lateral tibial condyle |
| 6 Gastrocnemius muscle (lateral head) | 16 Common fibular (peroneal) nerve |
| 7 Femur (lateral condyle) | 17 Anterior ligament of fibular head |
| 8 Lateral joint recess | 18 Posterior ligament of fibular head |
| 9 Inferior lateral genicular artery | 19 Tibialis posterior muscle |
| 10 Joint capsule | 20 Tibiofibular joint |
| 11 Femur (lateral condyle, joint cartilage) | 21 Tibialis anterior muscle |
| 12 Popliteus muscle (tendon) | 22 Fibula (head) |
| | 23 Peroneus (fibularis) longus muscle |
| | 24 Soleus muscle |



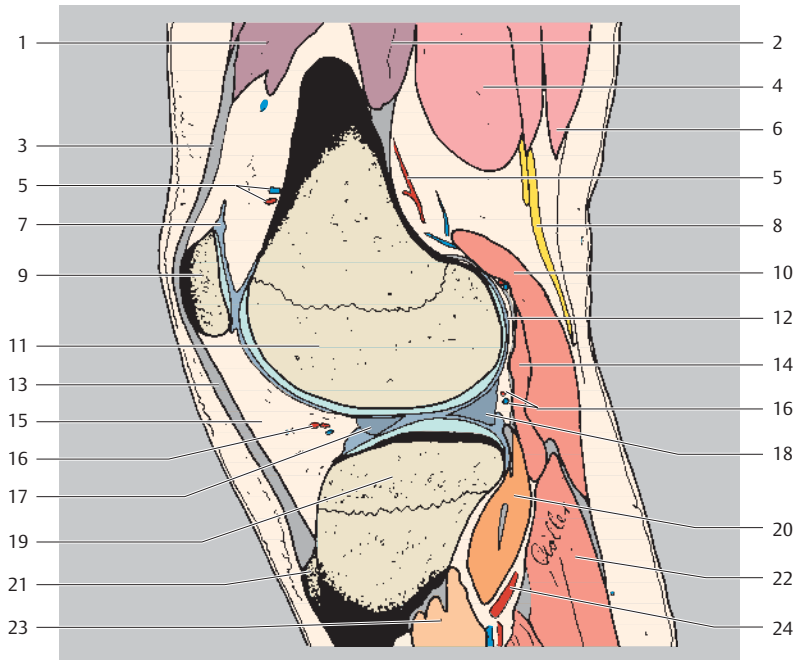
Proximal
Ventral Dorsal
Distal



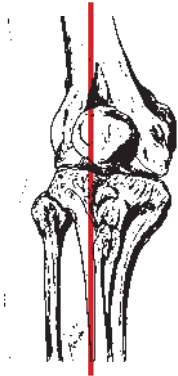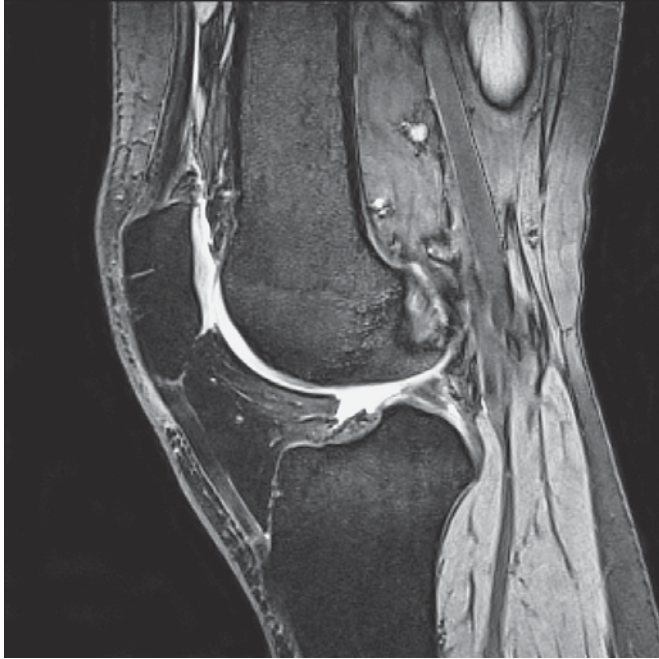
- | | |
|---|---------------------------------------|
| 1 Vastus lateralis muscle | 10 Common fibular (peroneal) nerve |
| 2 Biceps femoris muscle (long head) | 11 Knee joint |
| 3 Vastus intermedius muscle | 12 Lateral meniscus (posterior horn) |
| 4 Biceps femoris muscle (short head) | 13 Lateral meniscus (anterior horn) |
| 5 Lateral patellar retinaculum (longitudinal) | 14 Popliteus muscle (with tendon) |
| 6 Superior lateral genicular artery and vein | 15 Inferior lateral genicular artery |
| 7 Lateral patellar retinaculum (transverse) | 16 Tibiofibular joint (proximal) |
| 8 Gastrocnemius muscle (lateral head) | 17 Lateral tibial condyle |
| 9 Femur (lateral condyle) | 18 Fibula (head) |
| | 19 Anterior tibial artery |
| | 20 Soleus muscle |
| | 21 Tibialis posterior muscle |
| | 22 Peroneus (fibularis) longus muscle |
| | 23 Tibialis anterior muscle |



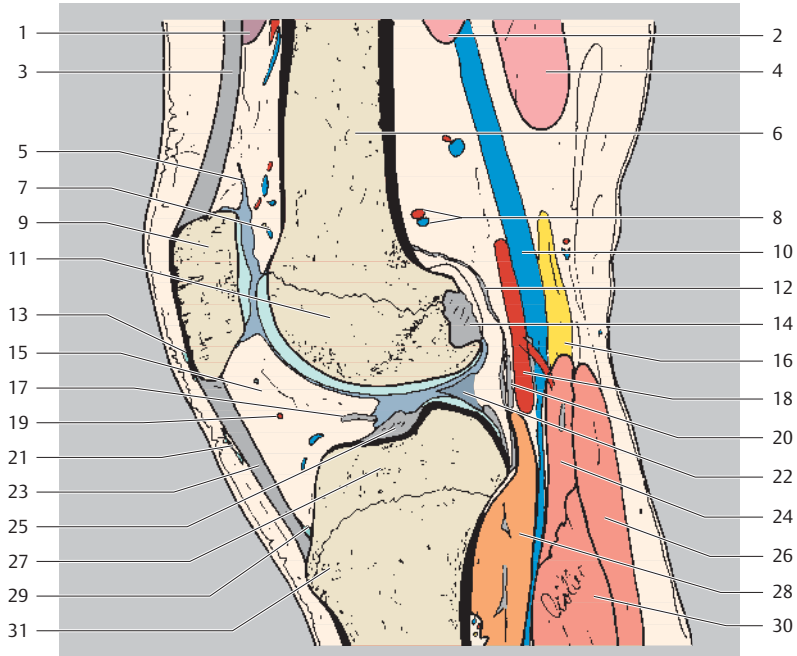
Proximal
Ventral Dorsal
Distal



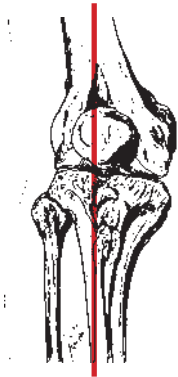
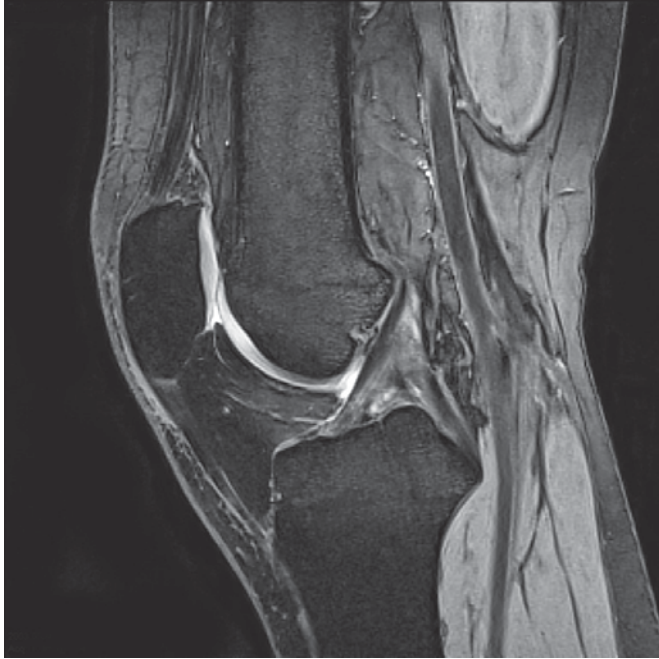- | | |
|--|---|
| 1 Vastus lateralis muscle | 11 Femur (lateral condyle) |
| 2 Vastus intermedius muscle | 12 Joint capsule |
| 3 Quadriceps tendon | 13 Patellar ligament |
| 4 Biceps femoris muscle (short head) | 14 Plantaris muscle |
| 5 Superior lateral genicular artery and vein | 15 Infrapatellar fat pad |
| 6 Biceps femoris muscle (long head) | 16 Inferior lateral genicular artery and vein |
| 7 Suprapatellar bursa | 17 Lateral meniscus (anterior horn) |
| 8 Common fibular (peroneal) nerve | 18 Lateral meniscus (posterior horn) |
| 9 Patella | 19 Lateral condyle of tibia |
| 10 Gastrocnemius muscle (lateral head) | 20 Popliteus muscle |
| | 21 Tibial tuberosity |
| | 22 Soleus muscle |
| | 23 Tibialis posterior muscle |
| | 24 Anterior tibial artery |



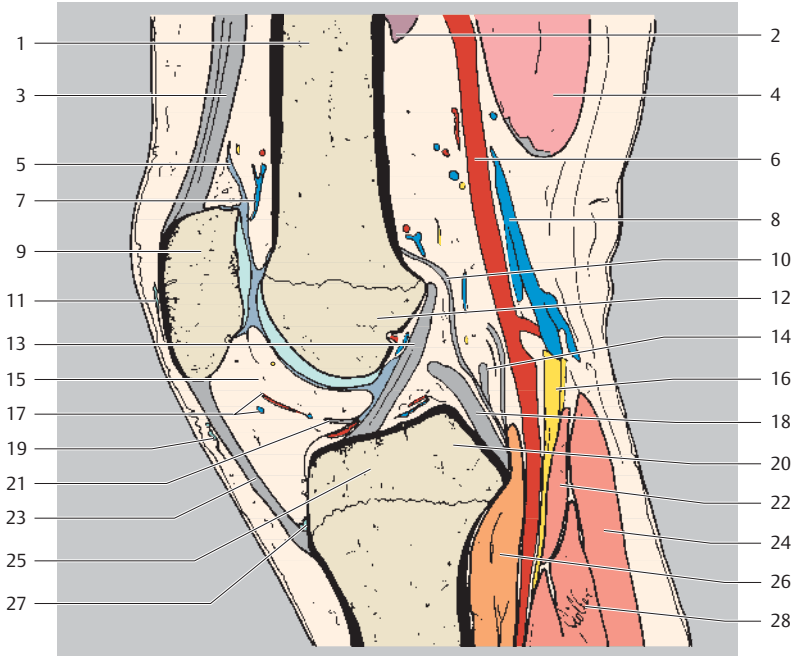
Proximal
Ventral Dorsal
Distal



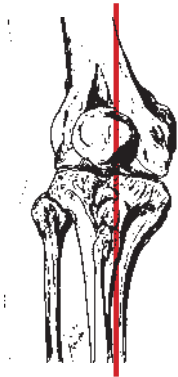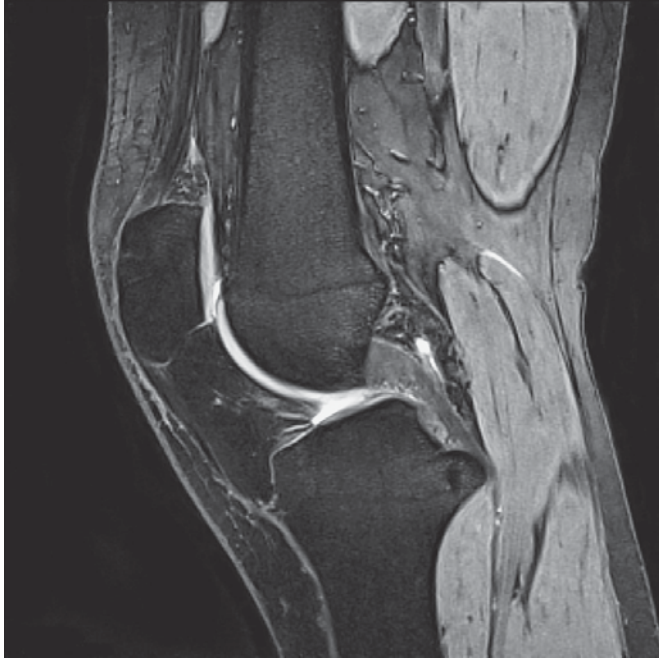- | | |
|--|--|
| 1 Vastus medialis muscle | 17 Transverse ligament of knee |
| 2 Biceps femoris muscle | 18 Popliteal artery |
| 3 Quadriceps tendon | 19 Inferior lateral genicular artery and vein |
| 4 Semimembranosus muscle | 20 Oblique popliteal ligament |
| 5 Suprapatellar bursa | 21 Subcutaneous infrapatellar bursa |
| 6 Femur (shaft) | 22 Lateral meniscus (posterior horn, inner attachment) |
| 7 Patellar anastomosis | 23 Patellar ligament |
| 8 Superior lateral genicular artery and vein | 24 Plantaris muscle |
| 9 Patella | 25 Posterior cruciate ligament (tibial origin) |
| 10 Popliteal vein | 26 Gastrocnemius muscle (lateral head) |
| 11 Femur (lateral condyle) | 27 Head of tibia |
| 12 Joint capsule | 28 Popliteus muscle |
| 13 Subcutaneous prepatellar bursa | 29 Deep infrapatellar bursa |
| 14 Anterior cruciate ligament (femoral attachment) | 30 Soleus muscle |
| 15 Infrapatellar fat pad | 31 Tibial tuberosity |
| 16 Tibial nerve | |



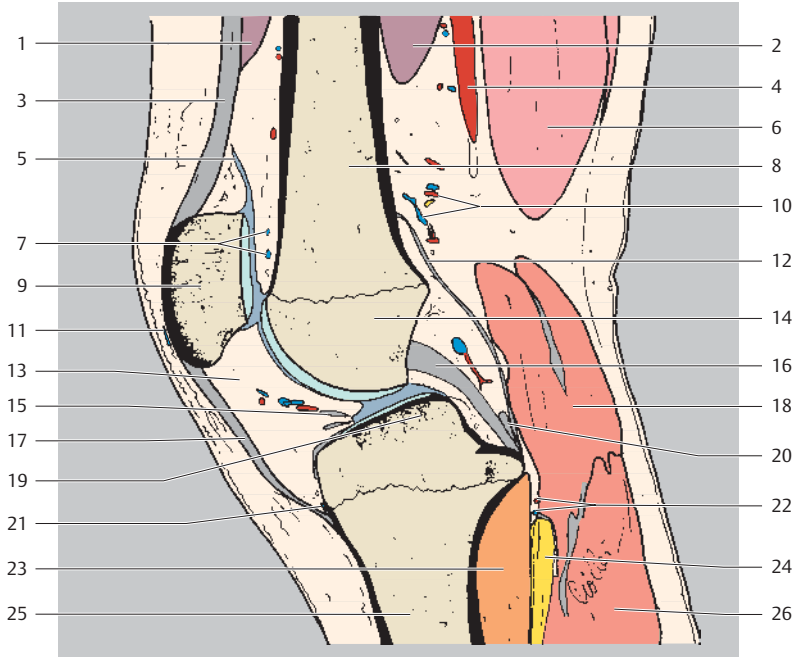
Proximal
Ventral Dorsal
Distal



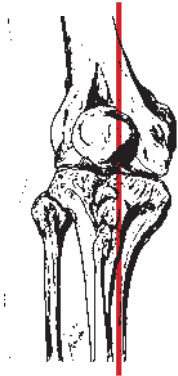
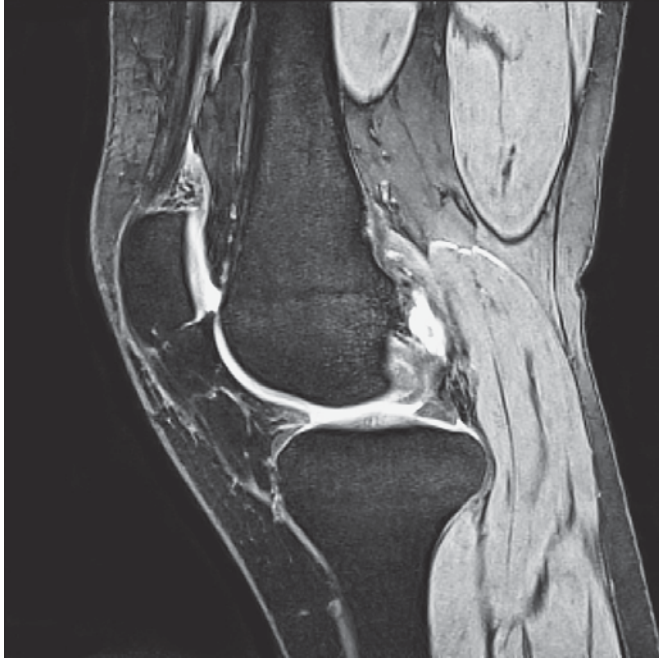- | | |
|-----------------------------------|---|
| 1 Femur (shaft) | 16 Tibial nerve |
| 2 Vastus medialis muscle | 17 Inferior lateral genicular artery and vein |
| 3 Quadriceps muscle | 18 Posterior cruciate ligament |
| 4 Semimembranosus muscle | 19 Subcutaneous infrapatellar bursa |
| 5 Suprapatellar bursa | 20 Medial intercondylar tubercle |
| 6 Popliteal artery | 21 Transverse ligament of knee |
| 7 Patellar anastomosis | 22 Plantaris muscle |
| 8 Popliteal vein | 23 Patellar ligament |
| 9 Patella | 24 Gastrocnemius muscle (lateral head) |
| 10 Joint capsule | 25 Head of tibia |
| 11 Subcutaneous prepatellar bursa | 26 Popliteus muscle |
| 12 Femur (intercondylar part) | 27 Deep infrapatellar bursa |
| 13 Anterior cruciate ligament | 28 Soleus muscle |
| 14 Oblique popliteal ligament | |
| 15 Infrapatellar fat pad | |



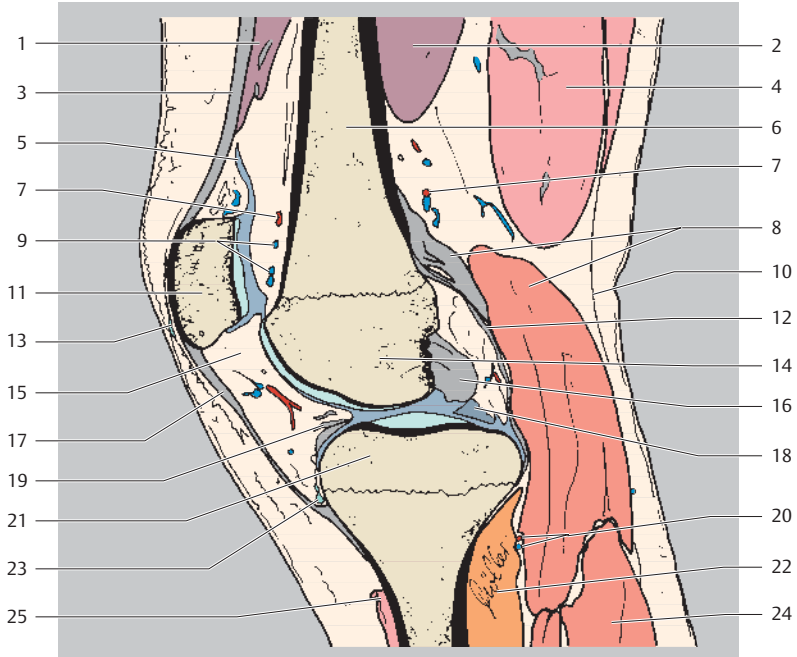
Proximal
Ventral Dorsal
Distal



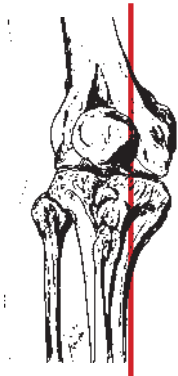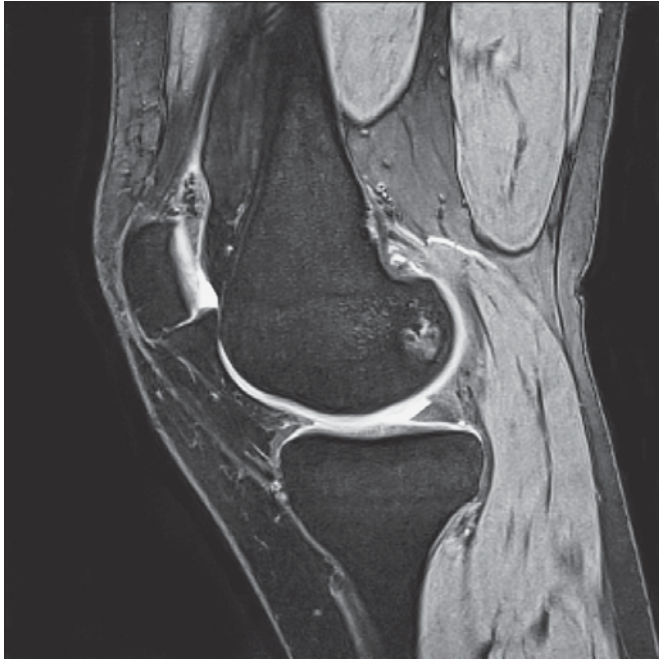- | | |
|--|--|
| 1 Rectus femoris muscle | 15 Transverse ligament of knee |
| 2 Vastus medialis muscle | 16 Posterior cruciate ligament |
| 3 Quadriceps tendon | 17 Patellar ligament |
| 4 Superficial femoral artery | 18 Gastrocnemius muscle (medial head) |
| 5 Suprapatellar bursa | 19 Medial intercondylar tubercle of tibial condyle |
| 6 Semimembranosus muscle | 20 Posterior meniscofemoral ligament (Wrisberg's ligament) |
| 7 Patellar anastomosis | 21 Deep infrapatellar bursa |
| 8 Femur (shaft) | 22 Inferior medial genicular artery and vein |
| 9 Patella | 23 Popliteus muscle |
| 10 Superior medial genicular artery and vein | 24 Tibial nerve |
| 11 Subcutaneous prepatellar bursa | 25 Tibia (shaft) |
| 12 Joint capsule | 26 Gastrocnemius muscle (lateral head) |
| 13 Infrapatellar fat pad | |
| 14 Femur (medial condyle) | |



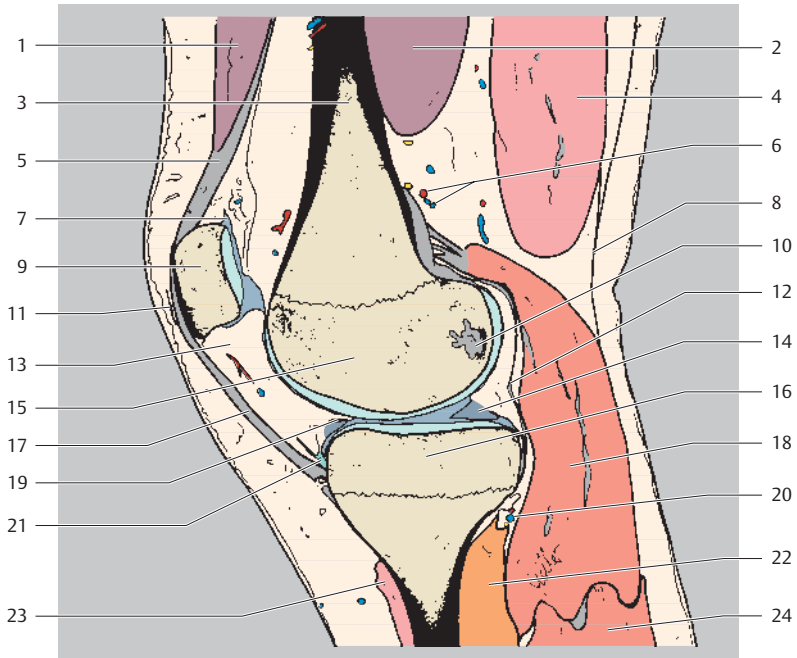
Proximal
Ventral Dorsal
Distal



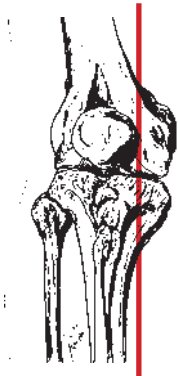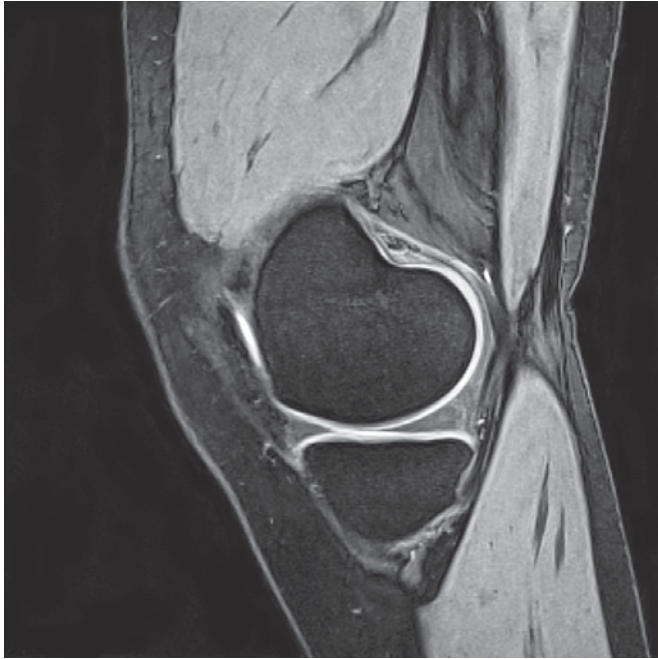
- | | |
|--|---|
| 1 Rectus femoris muscle | 15 Infrapatellar fat pad |
| 2 Vastus medialis muscle | 16 Posterior cruciate ligament (attachment) |
| 3 Quadriceps tendon | 17 Patellar ligament |
| 4 Semimembranosus muscle | 18 Medial meniscus (posterior horn, inner attachment) |
| 5 Suprapatellar bursa | 19 Transverse ligament of knee |
| 6 Femur (shaft) | 20 Inferior medial genicular artery and vein |
| 7 Superior medial genicular artery and vein | 21 Medial tibial condyle |
| 8 Gastrocnemius muscle (medial head + muscle attachment) | 22 Popliteus muscle |
| 9 Patellar anastomosis | 23 Deep infrapatellar bursa |
| 10 Deep fascia of leg | 24 Gastrocnemius muscle (lateral head) |
| 11 Patella | 25 Sartorius muscle (attachment, part of superficial pes anserinus) |
| 12 Joint capsule | |
| 13 Subcutaneous prepatellar bursa | |
| 14 Femur (medial condyle) | |



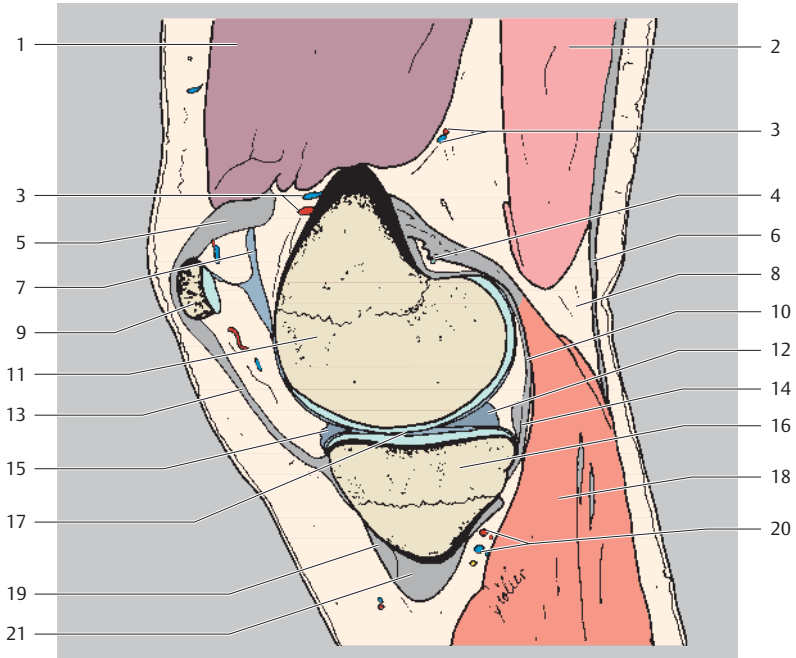
Proximal
Ventral Dorsal
Distal



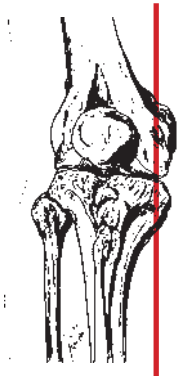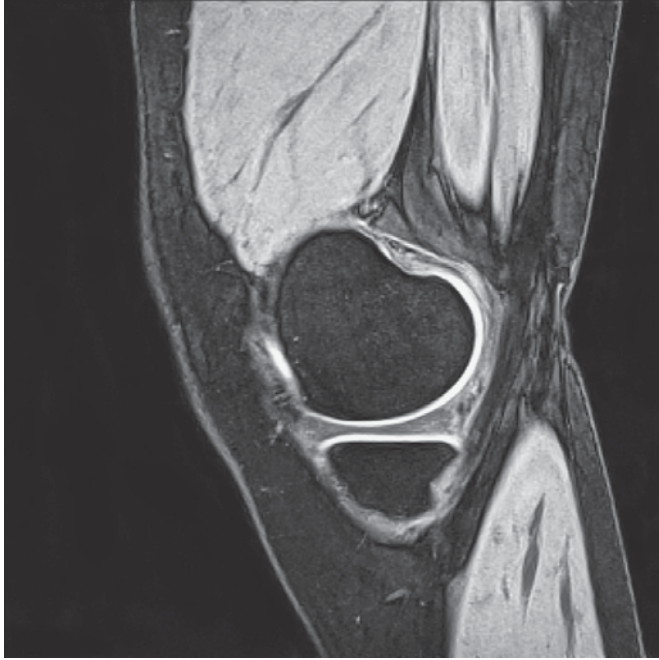
- | | |
|---|---|
| 1 Rectus femoris muscle | 13 Infrapatellar fat pad |
| 2 Vastus medialis muscle | 14 Medial meniscus (posterior horn) |
| 3 Femur (shaft) | 15 Femur (medial condyle) |
| 4 Semimembranosus muscle | 16 Medial condyle of tibia |
| 5 Quadriceps tendon | 17 Patellar ligament |
| 6 Superior medial genicular artery and vein | 18 Gastrocnemius muscle (medial head) |
| 7 Suprapatellar bursa | 19 Transverse ligament of knee |
| 8 Deep fascia of leg | 20 Inferior medial genicular artery and vein |
| 9 Patella | 21 Deep infrapatellar bursa |
| 10 Posterior cruciate ligament (attachment) | 22 Popliteus muscle |
| 11 Subcutaneous prepatellar bursa | 23 Sartorius muscle (attachment, part of superficial pes anserinus) |
| 12 Joint capsule | 24 Gastrocnemius muscle (lateral head) |



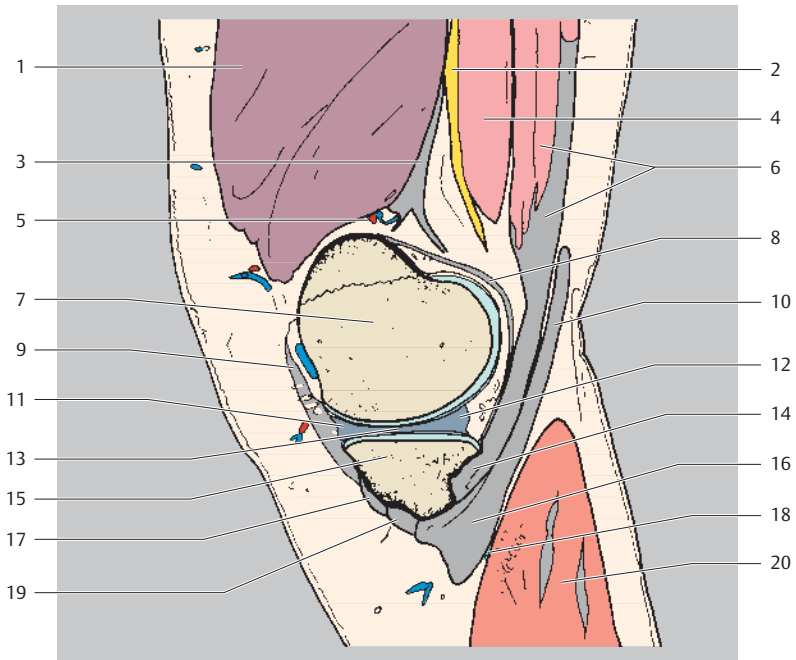
Proximal
Ventral Dorsal
Distal



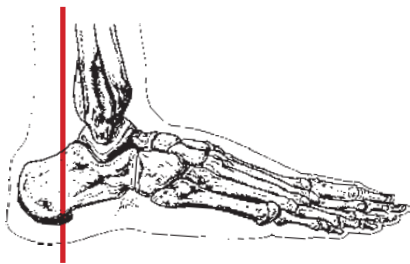
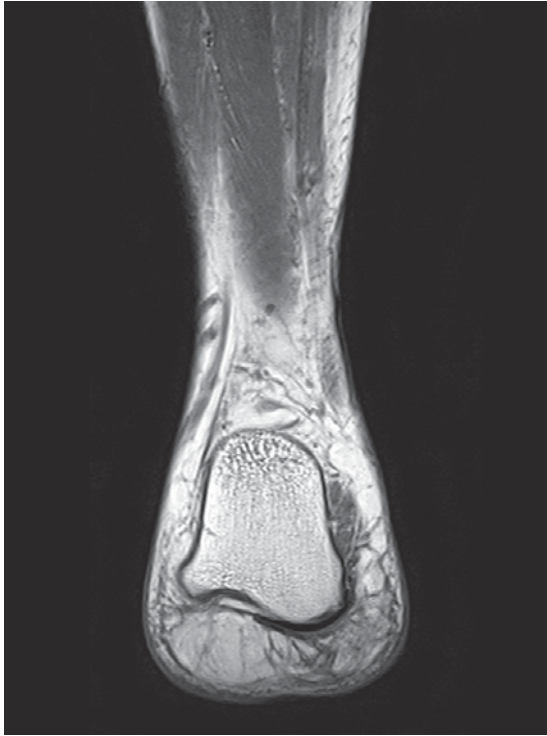
- | | |
|--|---|
| 1 Vastus medialis muscle | 12 Medial meniscus (posterior horn) |
| 2 Semimembranosus muscle | 13 Medial patellar retinaculum |
| 3 Superior medial genicular artery and vein | 14 Oblique popliteal ligament |
| 4 Medial subtendinous bursa of gastrocnemius | 15 Medial meniscus (anterior horn) |
| 5 Medial patellar retinaculum | 16 Medial tibial condyle |
| 6 Deep fascia of leg | 17 Knee joint |
| 7 Suprapatellar bursa | 18 Gastrocnemius muscle (medial head) |
| 8 Popliteal fossa | 19 Sartorius muscle (attachment, part of superficial pes anserinus) |
| 9 Patella | 20 Inferior medial genicular artery and vein |
| 10 Joint capsule | 21 Pes anserinus (superficial part) |
| 11 Femur (medial condyle) | |



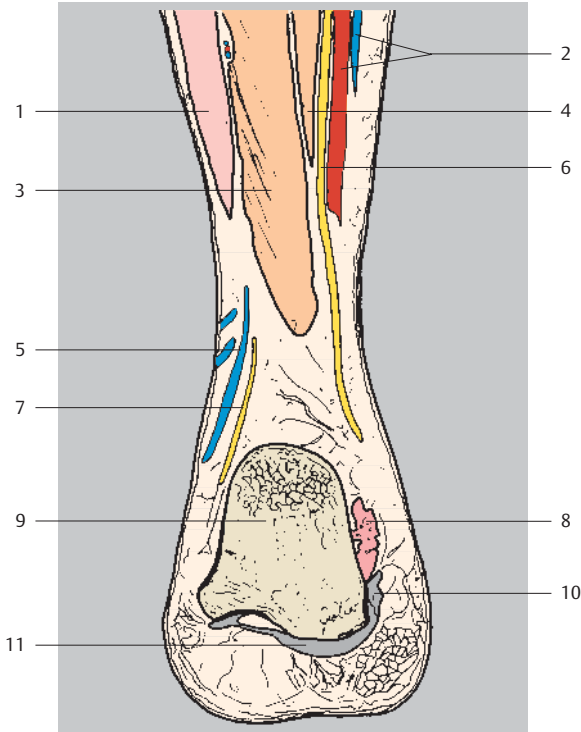
Proximal
Ventral Dorsal
Distal



- | | |
|---|---|
| 1 Vastus medialis muscle | 11 Medial meniscus (anterior horn) |
| 2 Saphenous nerve | 12 Medial meniscus (posterior horn) |
| 3 Adductor magnus muscle (tendon) | 13 Medial meniscus (intermediate portion) |
| 4 Sartorius muscle | 14 Pes anserinus (deep part) |
| 5 Superior medial genicular artery and vein | 15 Medial tibial condyle |
| 6 Semimembranosus muscle (+ tendon) | 16 Pes anserinus (superficial part) |
| 7 Femur (medial condyle) | 17 Sartorius muscle (attachment, part of superficial pes anserinus) |
| 8 Joint capsule | 18 Anserine bursa |
| 9 Medial patellar retinaculum | 19 Gracilis muscle (attachment, part of superficial pes anserinus) |
| 10 Semitendinosus muscle (tendon) | 20 Gastrocnemius muscle (medial head) |

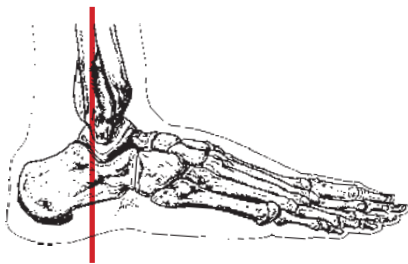
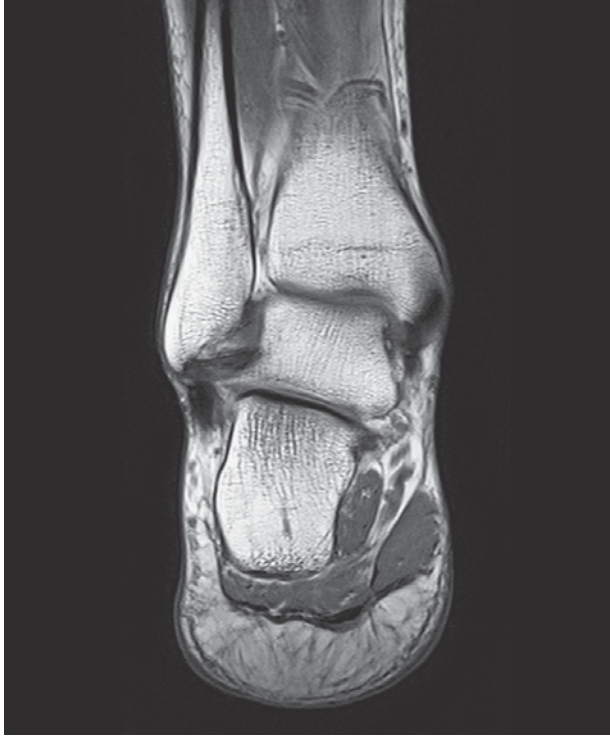

Proximal
Lateral Medial
Plantar

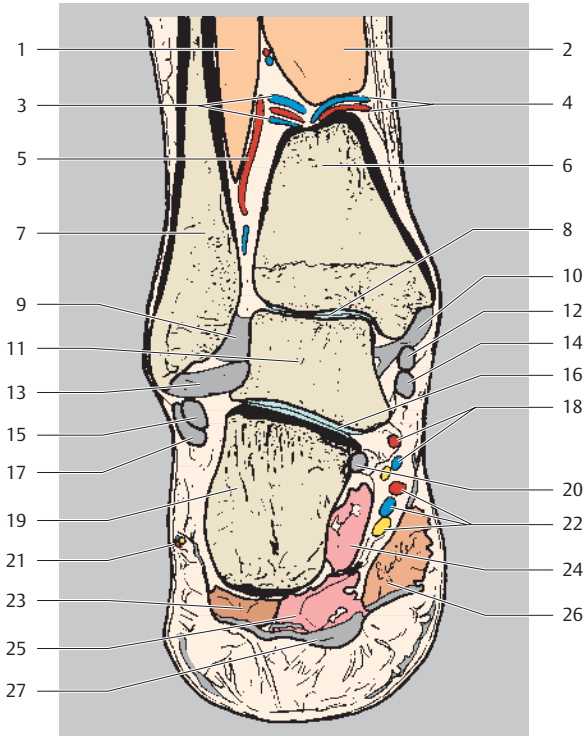


- 1 Peroneus (fibularis) brevis muscle
- 2 Posterior tibial artery and vein
- 3 Flexor hallucis longus muscle
- 4 Flexor digitorum longus muscle
- 5 Small saphenous vein

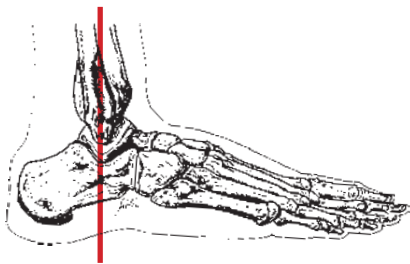
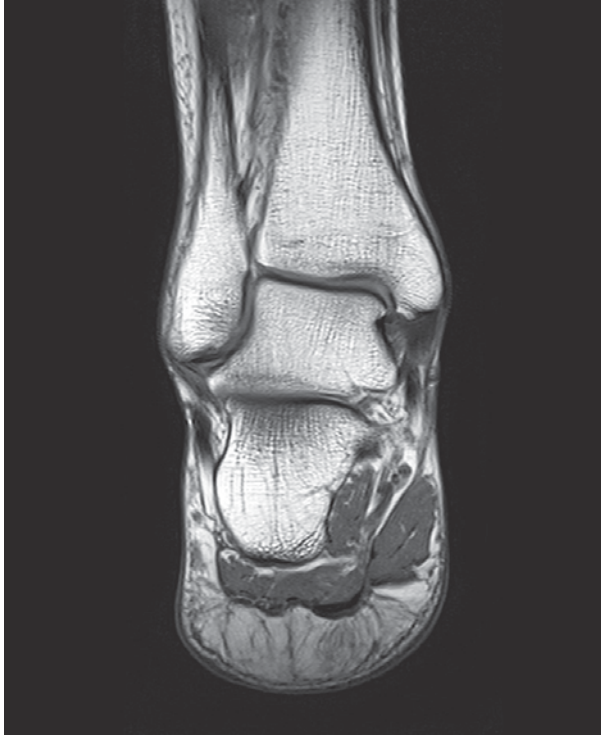- 6 Tibial nerve
- 7 Sural nerve
- 8 Quadratus plantae muscle
- 9 Calcaneus
- 10 Abductor hallucis muscle
- 11 Plantar aponeurosis



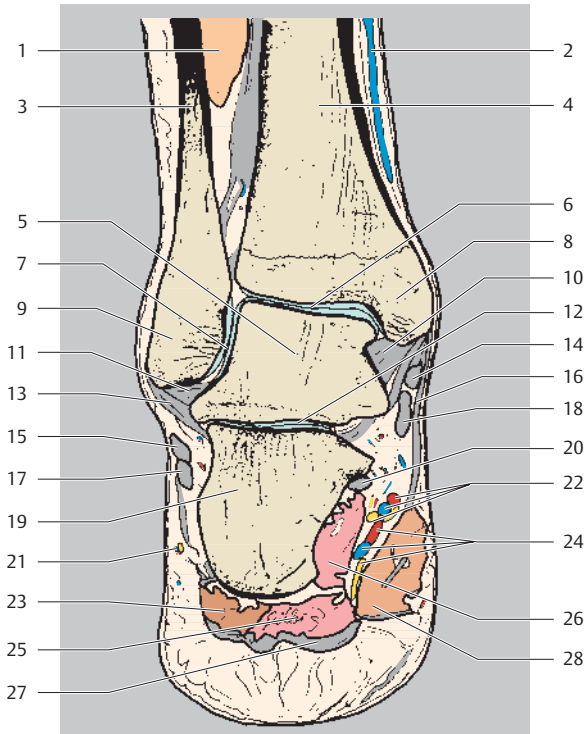
Proximal
Lateral Medial
Plantar



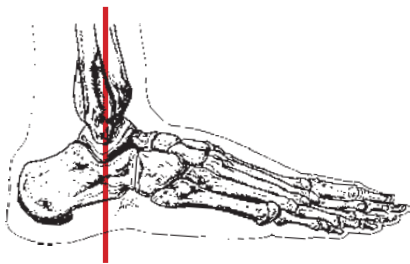
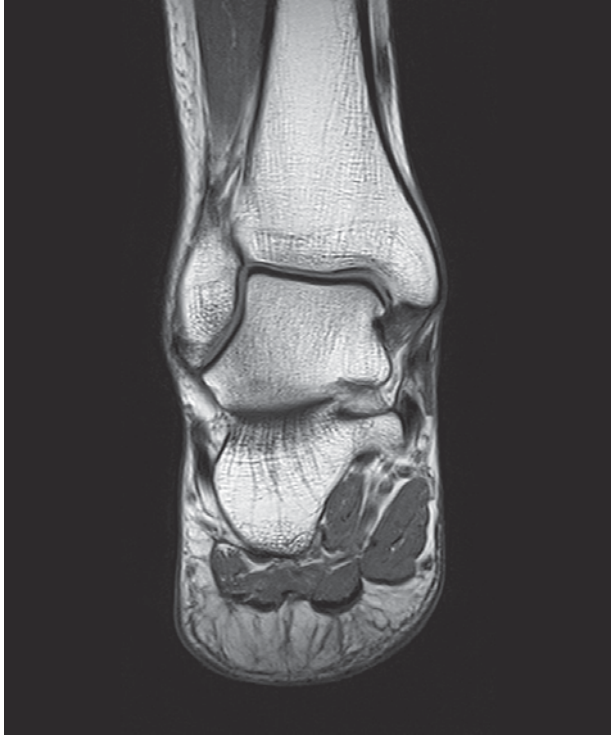- | | |
|--|--|
| 1 Flexor hallucis longus muscle | 15 Peroneus (fibularis) brevis muscle (tendon) |
| 2 Tibialis posterior muscle | 16 Subtalar joint |
| 3 Fibular artery (communicating branch) | 17 Peroneus (fibularis) longus muscle (tendon) |
| 4 Posterior tibial artery (communicating branch) | 18 Medial plantar artery, vein, and nerve |
| 5 Fibular artery | 19 Calcaneus |
| 6 Tibia | 20 Flexor hallucis longus muscle (tendon) |
| 7 Fibula | 21 Sural nerve with accompanying vessels |
| 8 Talocrural joint | 22 Lateral plantar artery, vein, and nerve |
| 9 Dorsal capsule | 23 Abductor digiti minimi muscle |
| 10 Deltoid ligament | 24 Quadratus plantae muscle |
| 11 Talus | 25 Flexor digitorum brevis muscle |
| 12 Tibialis posterior muscle (tendon) | 26 Abductor hallucis muscle |
| 13 Posterior talofibular ligament | 27 Plantar aponeurosis |
| 14 Flexor digitorum longus muscle (tendon) | |



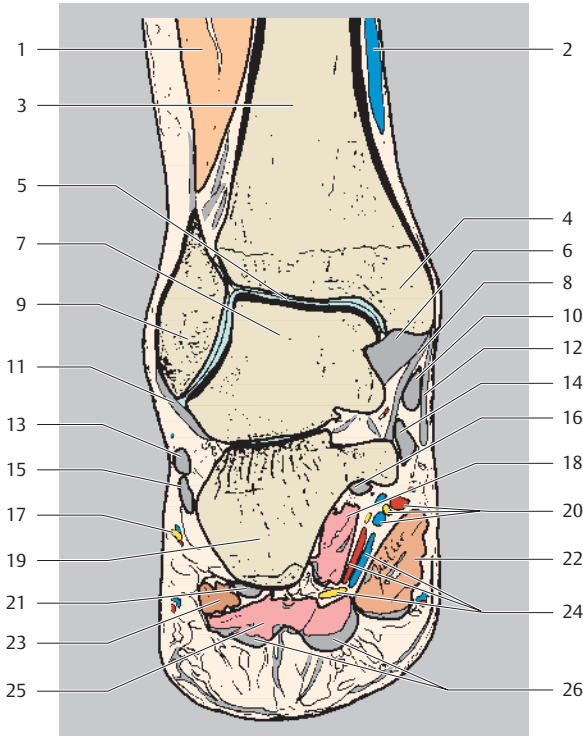
Proximal
Lateral Medial
Plantar



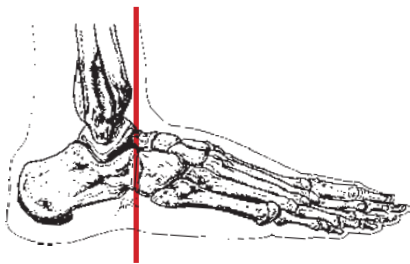
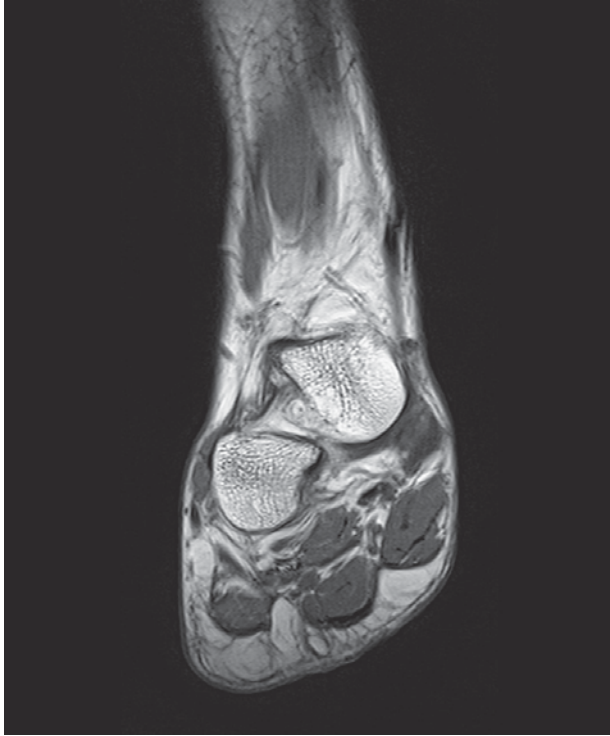- | | |
|---|--|
| 1 Flexor hallucis longus muscle | 16 Flexor retinaculum |
| 2 Great saphenous vein | 17 Peroneus (fibularis) longus muscle (tendon) |
| 3 Fibula | 18 Flexor digitorum longus muscle (tendon) |
| 4 Tibia | 19 Calcaneus |
| 5 Talus | 20 Flexor hallucis longus muscle (tendon) |
| 6 Talocrural joint | 21 Sural nerve with accompanying vessels |
| 7 Talofibular joint | 22 Medial plantar artery, vein, and nerve |
| 8 Medial malleolus | 23 Abductor digiti minimi muscle |
| 9 Lateral malleolus | 24 Lateral plantar artery, vein, and nerve |
| 10 Deltoid ligament (posterior tibiotalar part) | 25 Flexor digitorum brevis muscle |
| 11 Posterior talofibular ligament | 26 Quadratus plantae muscle |
| 12 Subtalar joint | 27 Plantar aponeurosis |
| 13 Calcaneofibular ligament | 28 Abductor hallucis muscle |
| 14 Tibialis posterior muscle (tendon) | |
| 15 Peroneus (fibularis) brevis muscle (tendon) | |



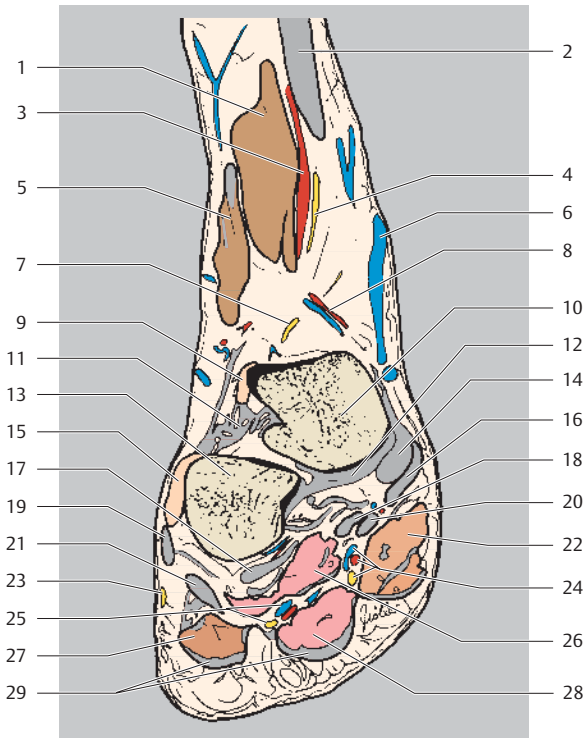
Proximal
Lateral Medial
Plantar



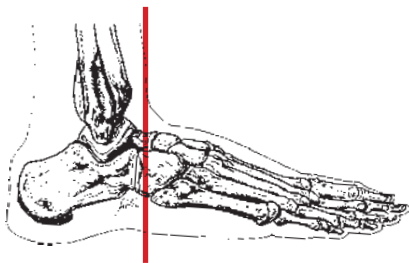
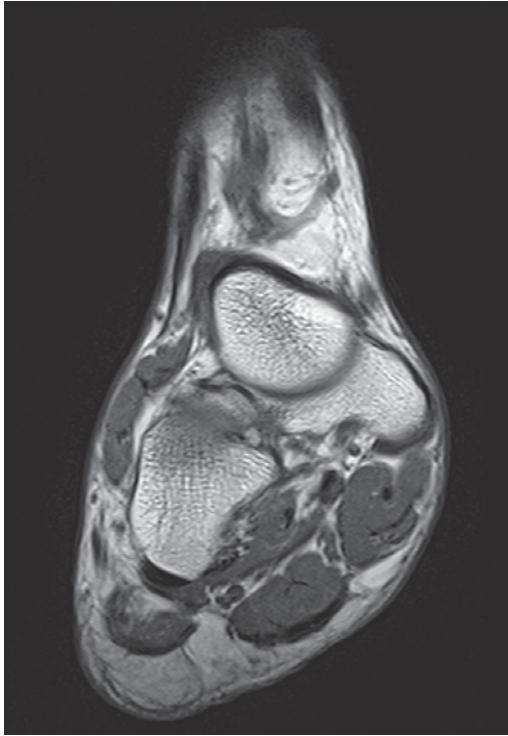
- | | |
|--|--|
| 1 Extensor digitorum longus muscle | 14 Flexor digitorum longus muscle (tendon) |
| 2 Great saphenous vein | 15 Peroneus (fibularis) longus muscle (tendon) |
| 3 Tibia | 16 Flexor hallucis longus muscle (tendon) |
| 4 Medial malleolus | 17 Sural nerve with accompanying vessels |
| 5 Talocrural joint | 18 Quadratus plantae muscle |
| 6 Deltoid ligament (posterior tibiotalar part) | 19 Calcaneus |
| 7 Talus | 20 Medial plantar artery, vein, and nerve |
| 8 Deltoid ligament (tibiocalcaneal part) | 21 Long plantar ligament |
| 9 Fibula (lateral malleolus) | 22 Abductor hallucis muscle |
| 10 Tibialis posterior muscle (tendon) | 23 Abductor digiti minimi muscle |
| 11 Calcaneofibular ligament | 24 Lateral plantar artery, vein, and nerve |
| 12 Flexor retinaculum | 25 Flexor digitorum brevis muscle |
| 13 Peroneus (fibularis) brevis muscle (tendon) | 26 Plantar aponeurosis |



Proximal
Lateral Medial
Plantar

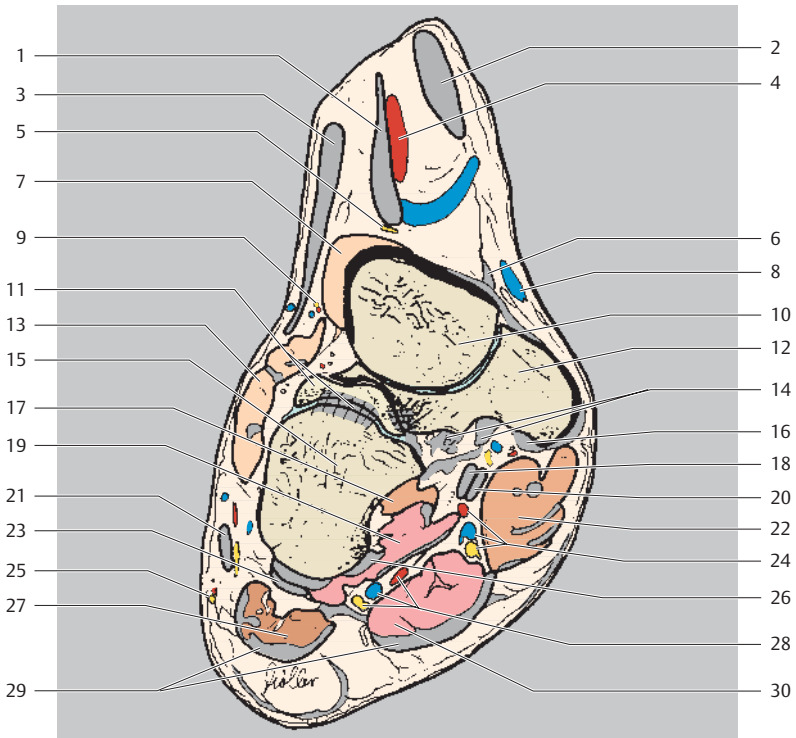


- | | |
|--|--|
| 1 Extensor hallucis longus muscle | 14 Deltoid ligament (tibionavicular part) |
| 2 Tibialis anterior muscle (tendon) | 15 Extensor digitorum brevis muscle |
| 3 Anterior tibial artery | 16 Tibialis posterior muscle (tendon) |
| 4 Deep fibular (peroneal) nerve | 17 Long plantar ligament |
| 5 Extensor digitorum longus muscle | 18 Flexor hallucis longus muscle (tendon) |
| 6 Great saphenous vein | 19 Peroneus (fibularis) brevis muscle |
| 7 Deep fibular (peroneal) nerve (cutaneous branch) | 20 Flexor digitorum longus muscle (tendon) |
| 8 Tarsal artery (medial) | 21 Peroneus (fibularis) longus muscle (tendon) |
| 9 Extensor hallucis brevis muscle (tendon) | 22 Abductor hallucis muscle |
| 10 Talus | 23 Lateral dorsal cutaneous nerve |
| 11 Interosseous talocalcaneal ligament | 24 Medial plantar artery, vein, and nerve |
| 12 Plantar calcaneonavicular ligament | 25 Lateral plantar artery, vein, and nerve |
| 13 Calcaneus | 26 Quadratus plantae muscle |
| | 27 Abductor digiti minimi muscle |
| | 28 Flexor digitorum brevis muscle |
| | 29 Plantar aponeurosis |

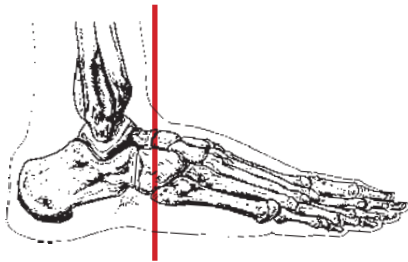
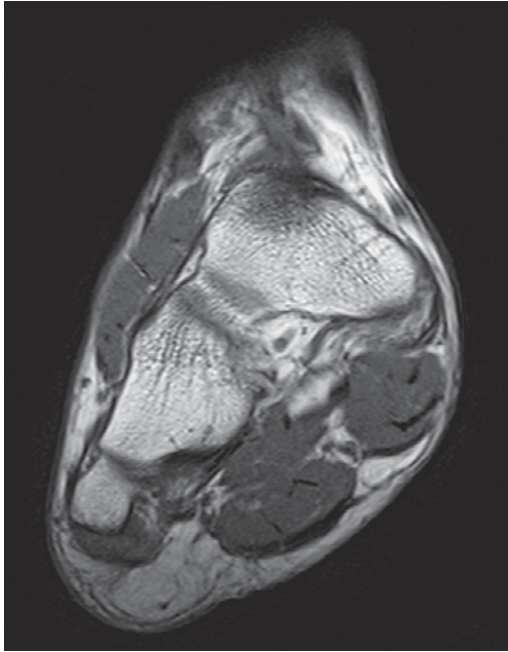


Proximal
Lateral Medial
Plantar

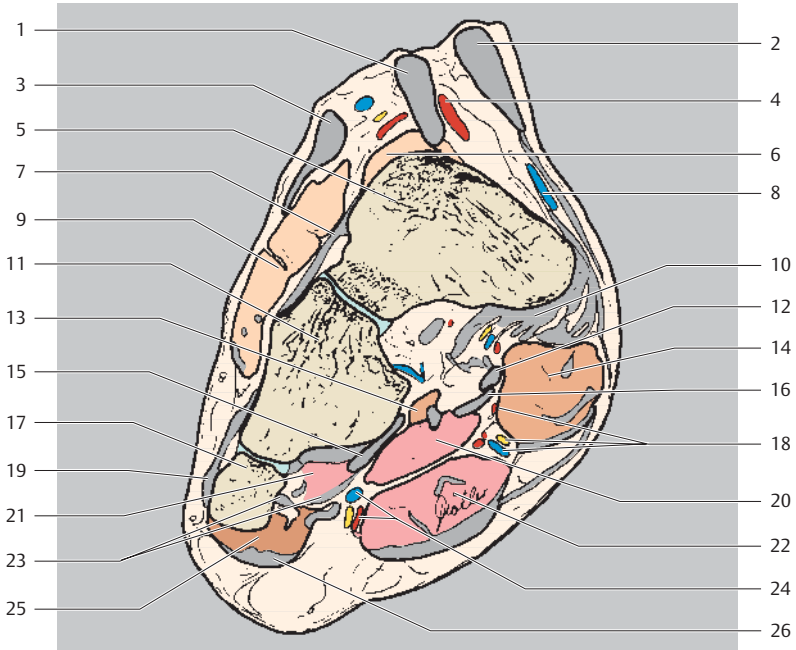
- 1 Extensor hallucis longus muscle (tendon)
- 2 Tibialis anterior muscle (tendon)
- 3 Extensor digitorum longus muscle (tendon)
- 4 Anterior tibial artery



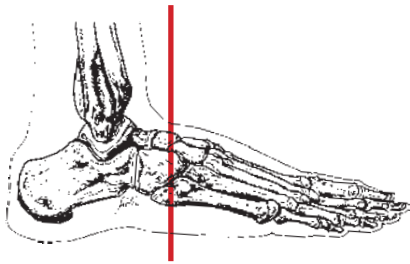
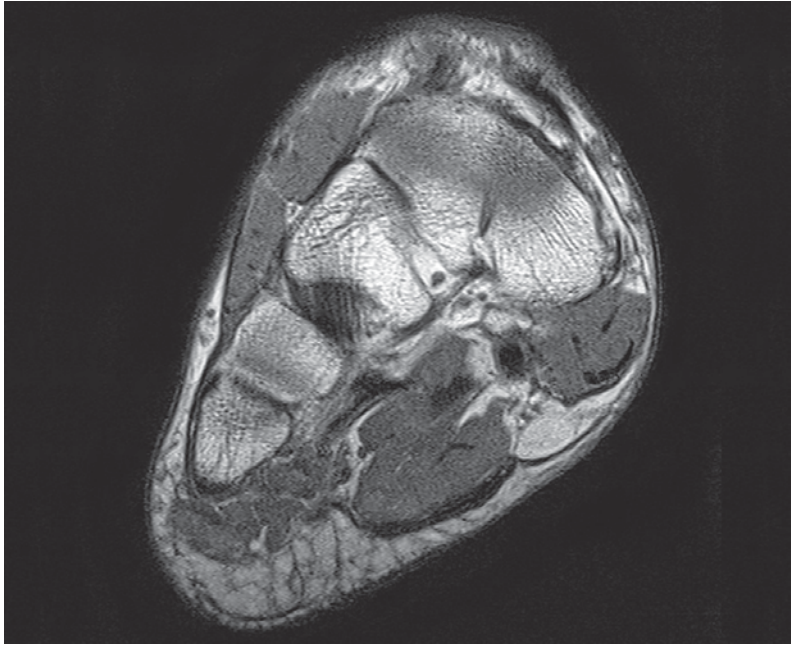
- | | |
|--|--|
| 5 Deep fibular (peroneal) nerve (medial branch) | 17 Adductor hallucis muscle (oblique head) |
| 6 Deltoid ligament (anterior tibiotalar part) | 18 Flexor hallucis longus muscle (tendon) |
| 7 Extensor hallucis brevis muscle | 19 Quadratus plantae muscle |
| 8 Great saphenous vein | 20 Flexor digitorum longus muscle (tendon) |
| 9 Deep fibular (peroneal) nerve (lateral branch) | 21 Peroneus (fibularis) brevis muscle (tendon) |
| 10 Talus | 22 Abductor hallucis muscle |
| 11 Calcaneus and bifurcate ligament | 23 Peroneus (fibularis) longus muscle (tendon) |
| 12 Navicular | 24 Medial plantar artery, vein, and nerve |
| 13 Extensor digitorum brevis muscle | 25 Lateral dorsal cutaneous nerve |
| 14 Plantar calcaneonavicular ligament | 26 Long plantar tendon |
| 15 Cuboid | 27 Abductor digiti minimi muscle |
| 16 Tibialis posterior muscle (tendon) | 28 Lateral plantar artery, vein, and nerve |
| | 29 Plantar aponeurosis |
| | 30 Flexor digitorum brevis muscle |



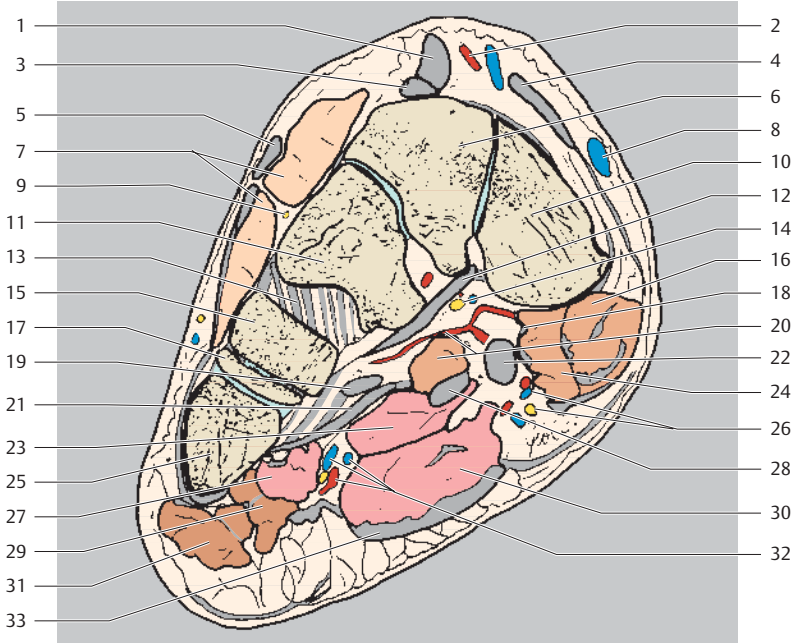
Dorsal
Lateral Medial
Plantar



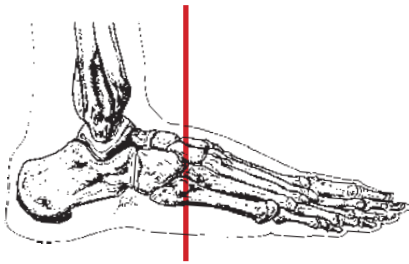
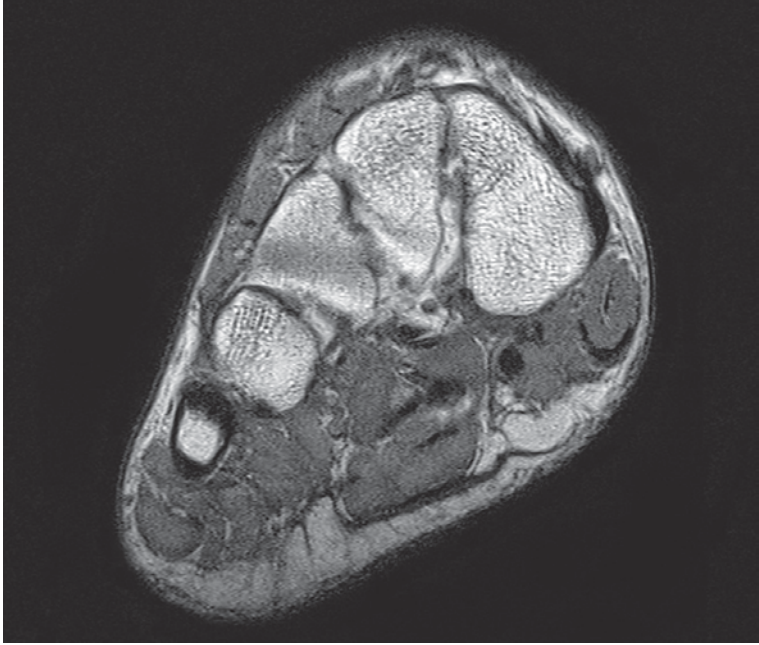
- | | |
|---|--|
| 1 Extensor hallucis longus muscle (tendon) | 13 Adductor hallucis muscle (oblique head) |
| 2 Tibialis anterior muscle (tendon) | 14 Abductor hallucis muscle |
| 3 Extensor digitorum longus muscle (tendon) | 15 Peroneus (fibularis) longus muscle (tendon) |
| 4 Anterior tibial artery | 16 Flexor digitorum longus muscle (tendon) |
| 5 Navicular | 17 Metatarsal V (base) |
| 6 Extensor hallucis brevis muscle | 18 Medial plantar artery, vein, and nerve |
| 7 Dorsal tarsal ligaments | 19 Peroneus (fibularis) brevis muscle (tendon) |
| 8 Great saphenous vein | 20 Quadratus plantae muscle |
| 9 Extensor digitorum brevis muscle | 21 Interosseous muscles |
| 10 Tibialis posterior muscle (tendon) | 22 Flexor digitorum brevis muscle |
| 11 Cuboid | 23 Long plantar ligament |
| 12 Flexor hallucis longus muscle (tendon) | 24 Lateral plantar artery, vein, and nerve |
| | 25 Abductor digiti minimi muscle |
| | 26 Plantar aponeurosis |



Dorsal
Lateral Medial
Plantar

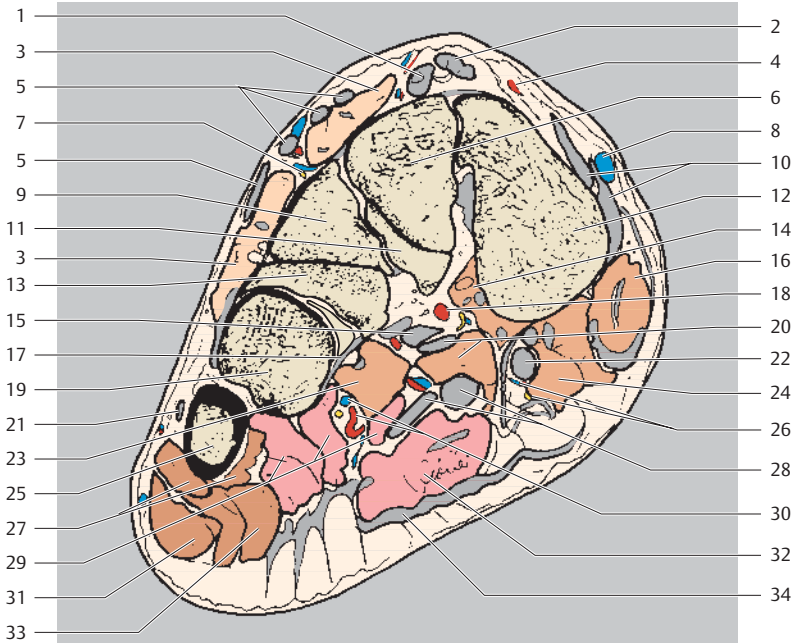


- | | |
|--|--|
| 1 Extensor hallucis longus muscle (tendon) | 16 Abductor hallucis muscle |
| 2 Anterior tibial artery | 17 Metatarsal IV (base) |
| 3 Extensor hallucis brevis muscle (tendon) | 18 Medial plantar septum |
| 4 Tibialis anterior muscle (tendon) | 19 Peroneus (fibularis) longus muscle (tendon) |
| 5 Extensor digitorum longus muscle (tendon) | 20 Adductor hallucis muscle (oblique head) and deep plantar arch |
| 6 Intermediate cuneiform | 21 Long plantar ligament |
| 7 Extensor digitorum brevis muscle | 22 Flexor hallucis longus muscle (tendon) |
| 8 Great saphenous vein | 23 Quadratus plantae muscle |
| 9 Deep fibular (peroneal) nerve (lateral branch) | 24 Flexor hallucis brevis muscle |
| 10 Medial cuneiform | 25 Metatarsal V (base) |
| 11 Lateral cuneiform | 26 Medial plantar artery, vein, and nerve |
| 12 Tibialis posterior muscle (tendon attachment) | 27 Interosseous muscles |
| 13 Dorsal tarsal ligaments | 28 Flexor digitorum longus muscle (tendon) |
| 14 Lateral plantar nerve (deep branch) | 29 Flexor digiti minimi brevis muscle |
| 15 Cuboid | 30 Flexor digitorum brevis muscle |
| | 31 Abductor digiti minimi muscle |
| | 32 Lateral plantar artery, vein, and nerve |
| | 33 Plantar aponeurosis |

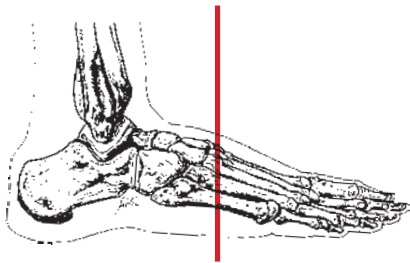
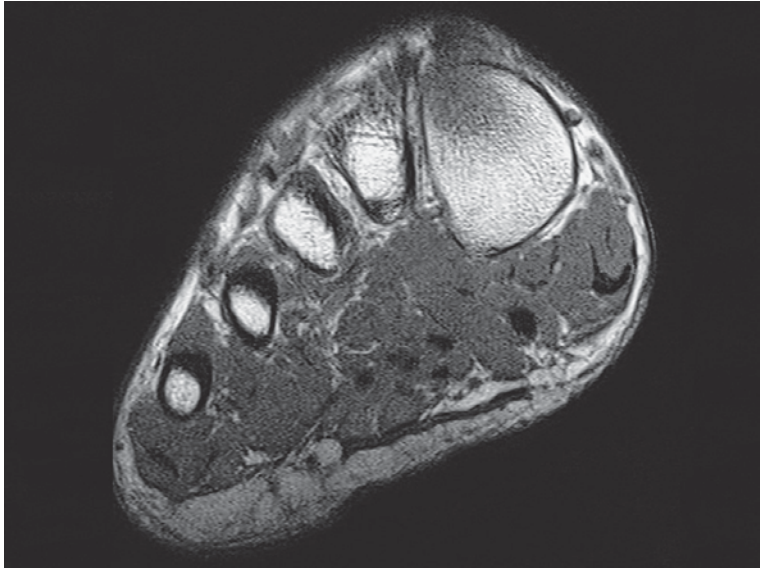


Dorsal
Lateral Medial
Plantar

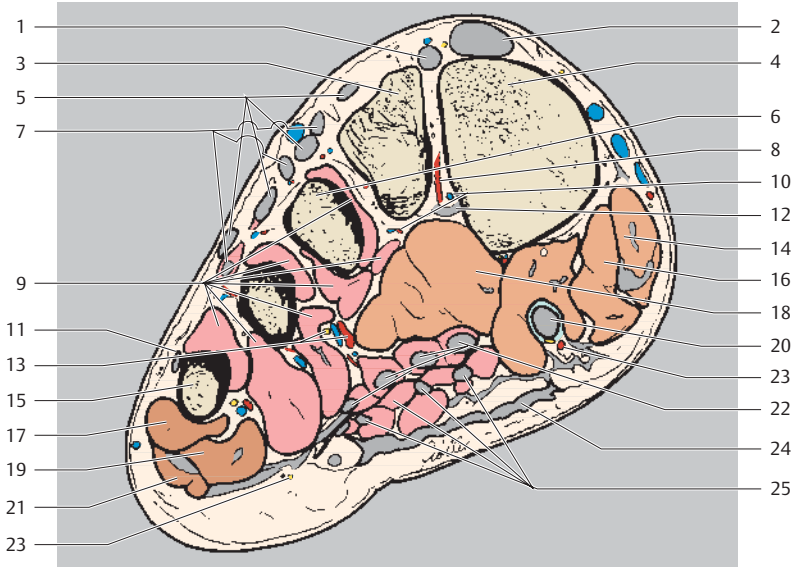
- 1 Extensor hallucis brevis muscle (tendon)
- 2 Extensor hallucis longus muscle (tendon)
- 3 Extensor digitorum brevis muscle
- 4 Anterior tibial artery



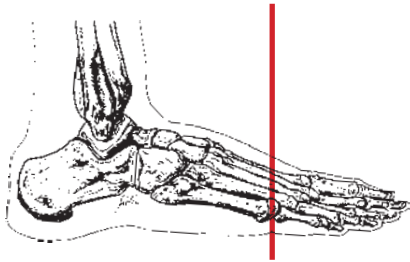
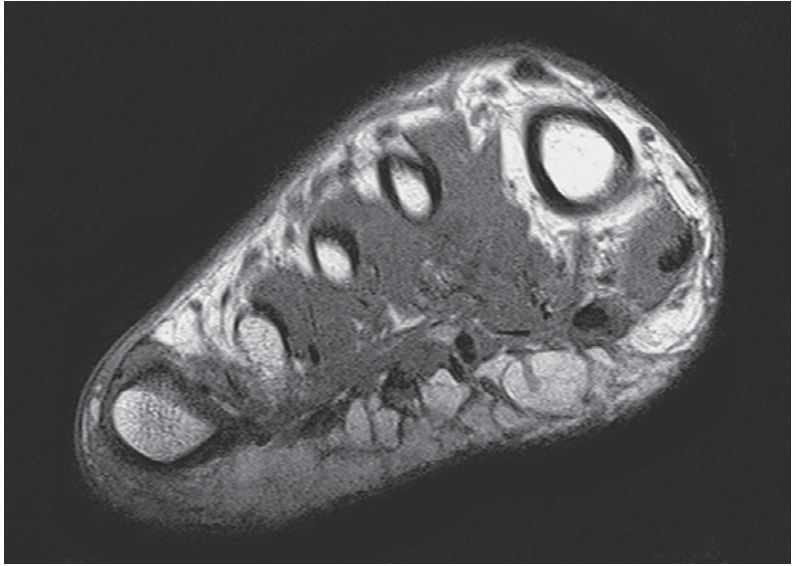
- | | | | |
|----|--|----|---|
| 5 | Extensor digitorum longus muscle (tendons) | 21 | Extensor digiti minimi brevis muscle (tendon) |
| 6 | Intermediate cuneiform | 22 | Flexor hallucis longus muscle (tendon) |
| 7 | Deep fibular (peroneal) nerve (lateral branch) | 23 | Flexor hallucis brevis muscle (lateral head) |
| 8 | Great saphenous vein | 24 | Flexor hallucis brevis muscle (medial head) |
| 9 | Lateral cuneiform | 25 | Metatarsal V (base) |
| 10 | Tibialis anterior muscle (tendon) | 26 | Medial plantar artery, vein, and nerve (superficial branch) |
| 11 | Metatarsal II (base) | 27 | Opponens digiti minimi muscle |
| 12 | Medial cuneiform | 28 | Flexor digitorum longus muscle (tendon) |
| 13 | Metatarsal III (base) | 29 | Interosseous muscles |
| 14 | Flexor hallucis brevis muscle (lateral head) | 30 | Lateral plantar artery, vein, and nerve |
| 15 | Peroneus (fibularis) longus muscle (tendon) | 31 | Abductor digiti minimi muscle |
| 16 | Abductor hallucis muscle | 32 | Flexor digitorum brevis muscle |
| 17 | Long plantar ligament | 33 | Flexor digiti minimi brevis muscle |
| 18 | Deep plantar arch | 34 | Plantar aponeurosis |
| 19 | Metatarsal IV (base) | | |
| 20 | Adductor hallucis muscle (oblique head + tendon) | | |



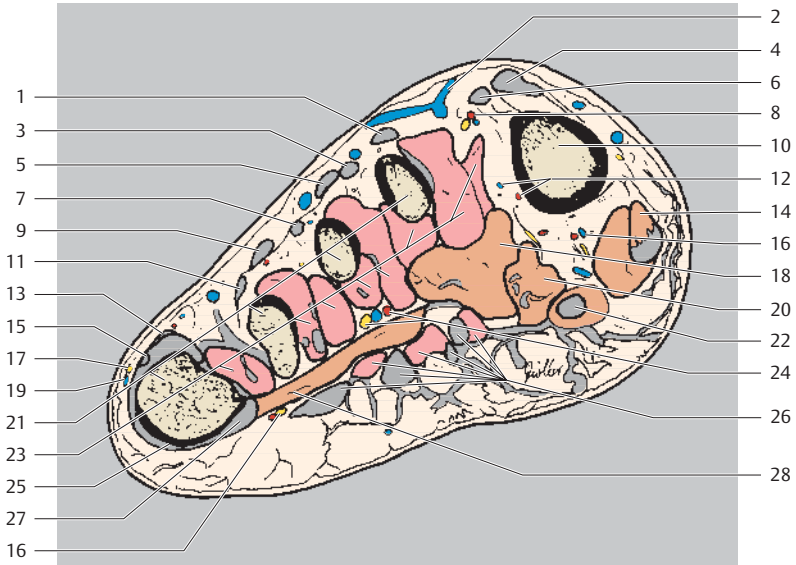
Dorsal
Lateral Medial
Plantar



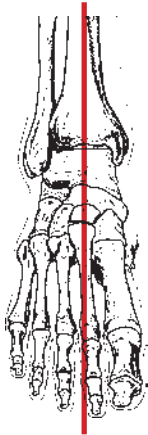
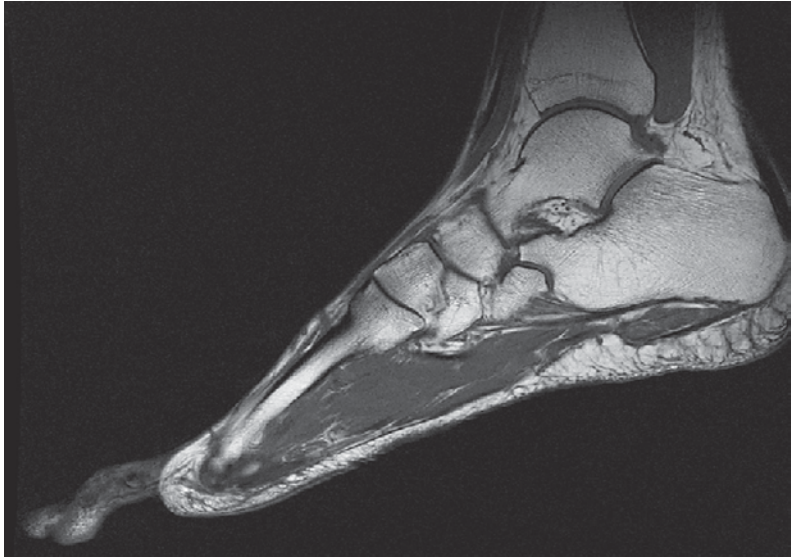
- | | |
|--|--|
| 1 Extensor hallucis brevis muscle (tendon) | 13 Lateral plantar nerve (deep branch) and plantar metatarsal arteries |
| 2 Extensor hallucis longus muscle (tendon) | 14 Abductor hallucis muscle |
| 3 Metatarsal II (base) | 15 Metatarsal V (base) |
| 4 Metatarsal I (base) | 16 Flexor hallucis brevis muscle (lateral head) |
| 5 Extensor digitorum longus muscle (tendons) | 17 Opponens digiti minimi muscle |
| 6 Metatarsal III (base) | 18 Adductor hallucis muscle (oblique head) |
| 7 Extensor digitorum brevis muscle | 19 Flexor digiti minimi brevis muscle |
| 8 Plantar metatarsal arteries | 20 Flexor hallucis longus muscle (tendon) |
| 9 Interosseous muscles | 21 Abductor digiti minimi muscle |
| 10 Perforating veins (of first dorsal interosseous muscle) | 22 Flexor digitorum longus muscle (+ tendon) |
| 11 Extensor digiti minimi brevis muscle (tendon) | 23 Proper plantar digital artery |
| 12 Peroneus (fibularis) longus muscle (attachment) | 24 Plantar aponeurosis |
| | 25 Flexor digitorum brevis muscle (+ tendon) |



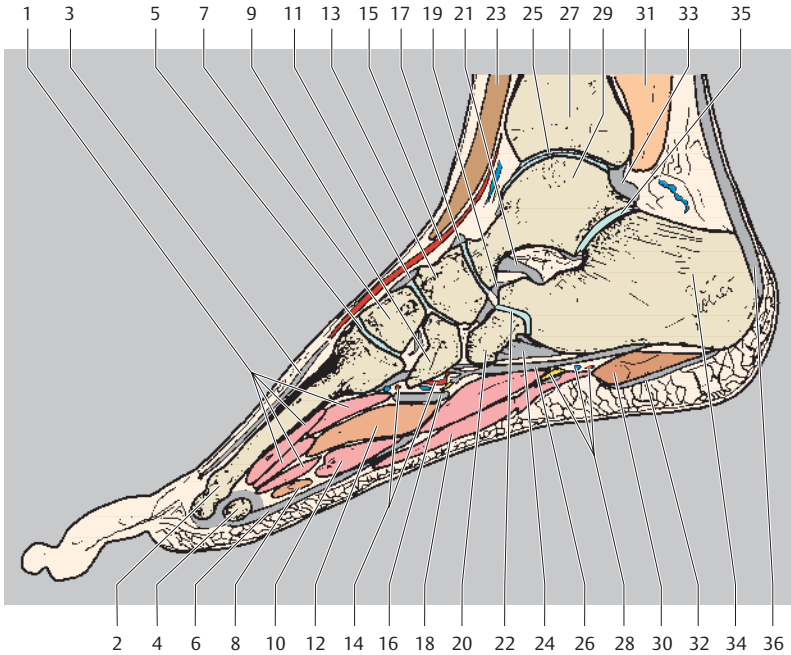
Dorsal
Lateral Medial
Plantar



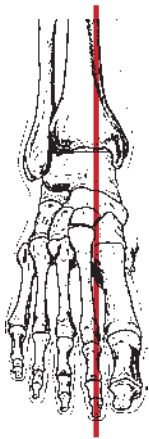
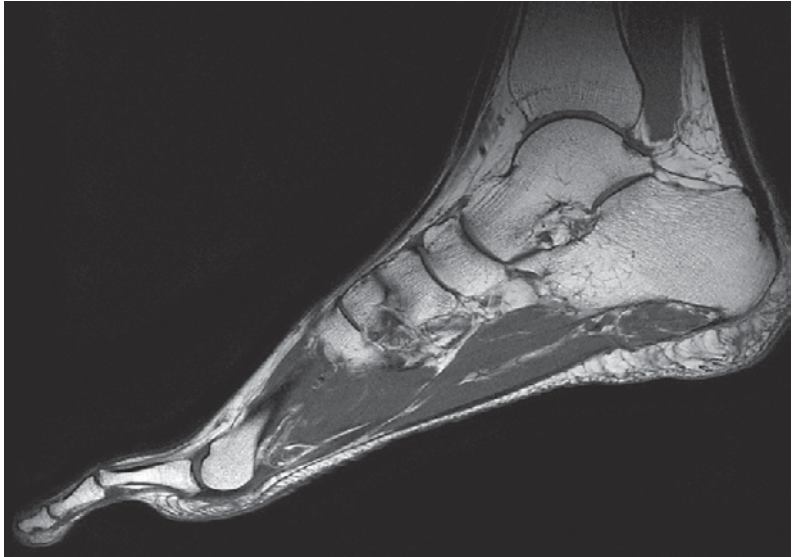
- | | |
|--|--|
| 1 Extensor digitorum longus muscle (tendon) of second toe | 15 Extensor digitorum brevis muscle (tendon) of fifth toe |
| 2 Dorsal venous arch of foot | 16 Proper plantar digital arteries, veins, and nerve |
| 3 Extensor digitorum brevis muscle (tendon) of second toe | 17 Dorsal digital cutaneous nerve of foot |
| 4 Extensor hallucis longus muscle (tendon) | 18 Adductor hallucis muscle (oblique head) |
| 5 Extensor digitorum longus muscle (tendon) of third toe | 19 Small saphenous vein |
| 6 Extensor hallucis brevis muscle (tendon) | 20 Flexor hallucis brevis muscle (lateral head) |
| 7 Extensor digitorum brevis muscle (tendon) of third toe | 21 Metatarsals |
| 8 Dorsal metatarsal arteries and veins | 22 Flexor hallucis longus muscle (tendon) |
| 9 Extensor digitorum brevis muscle (tendon) of fourth toe | 23 Plantar and dorsal interosseous muscles |
| 10 Metatarsal I | 24 Lateral plantar nerve (deep branch) and plantar metatarsal arteries |
| 11 Extensor digitorum brevis muscle (tendon) of fourth toe | 25 Abductor digiti minimi muscle (attachment) |
| 12 Plantar metatarsal artery and vein (perforating branch of first dorsal interosseous muscle) | 26 Flexor digitorum longus and brevis muscles (tendons) |
| 13 Extensor digitorum longus muscle (tendons) of fifth toe | 27 Extensor digiti minimi brevis muscle (tendon) |
| 14 Abductor hallucis muscle | 28 Adductor hallucis muscle (transverse head) |



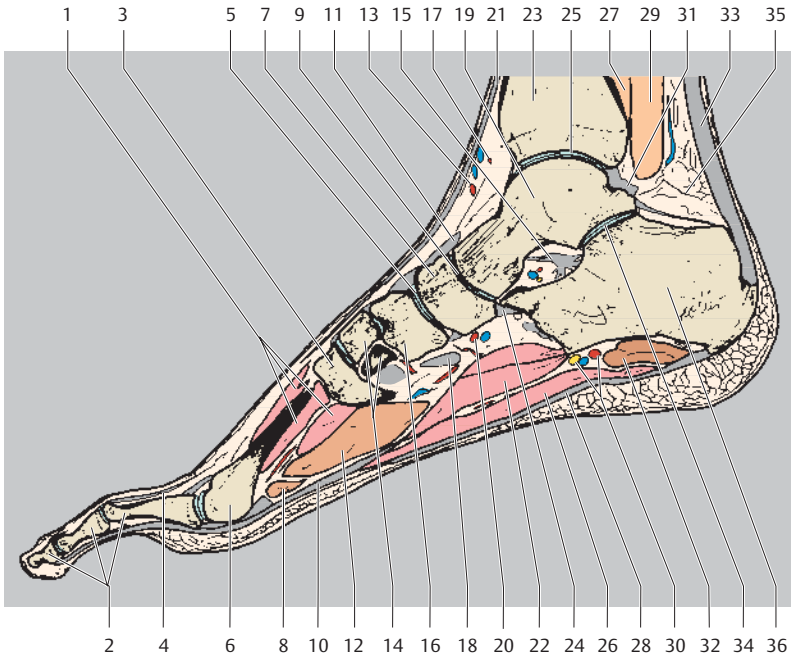
Proximal
Dorsal
Anterior Posterior
Distal
Plantar



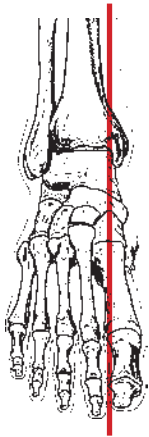
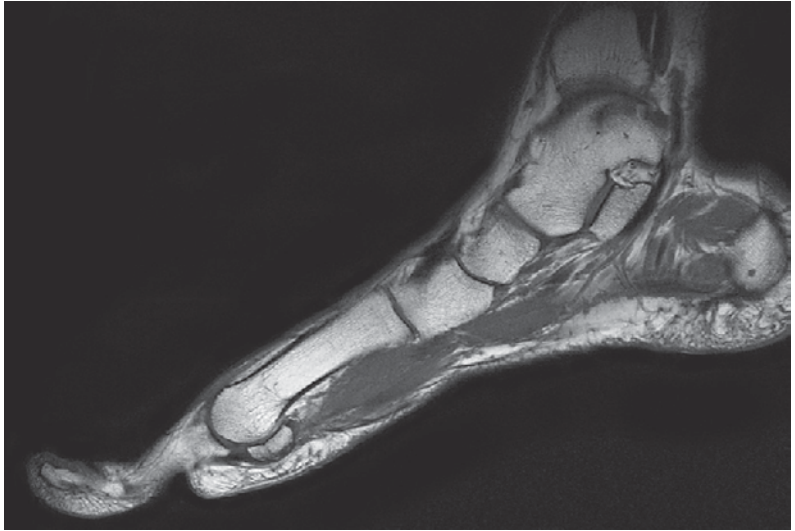
- | | |
|--|---|
| 1 Interosseous muscles | 18 Flexor digitorum brevis muscle |
| 2 Metatarsal II | 19 Bifurcate ligament |
| 3 Extensor digiti II muscle (tendon) | 20 Cuboid |
| 4 Metatarsal II (head) | 21 Talocalcaneal interosseous ligament |
| 5 Tarsometatarsal joint II | 22 Calcaneocuboid joint |
| 6 Flexor digitorum longus muscle (tendon) | 23 Extensor digitorum longus muscle (tendon) |
| 7 Intermediate cuneiform | 24 Spring ligament (plantar calcaneonavicular ligament) |
| 8 Adductor hallucis muscle (transverse head) | 25 Talocrural joint |
| 9 Lateral cuneiform | 26 Long plantar ligament |
| 10 Lumbrical muscle | 27 Tibia |
| 11 Dorsal tarsal ligaments | 28 Lateral plantar artery, vein, and nerve |
| 12 Adductor hallucis muscle (oblique head) | 29 Talus |
| 13 Navicular | 30 Abductor digiti minimi muscle |
| 14 Deep plantar arch | 31 Flexor hallucis longus muscle (tendon) |
| 15 Dorsalis pedis artery | 32 Plantar aponeurosis |
| 16 Peroneus (fibularis) longus muscle (tendon) | 33 Posterior talofibular ligament |
| 17 Dorsal talonavicular ligament | 34 Calcaneus |
| | 35 Subtalar joint |
| | 36 Achilles' tendon (calcaneal tendon) |



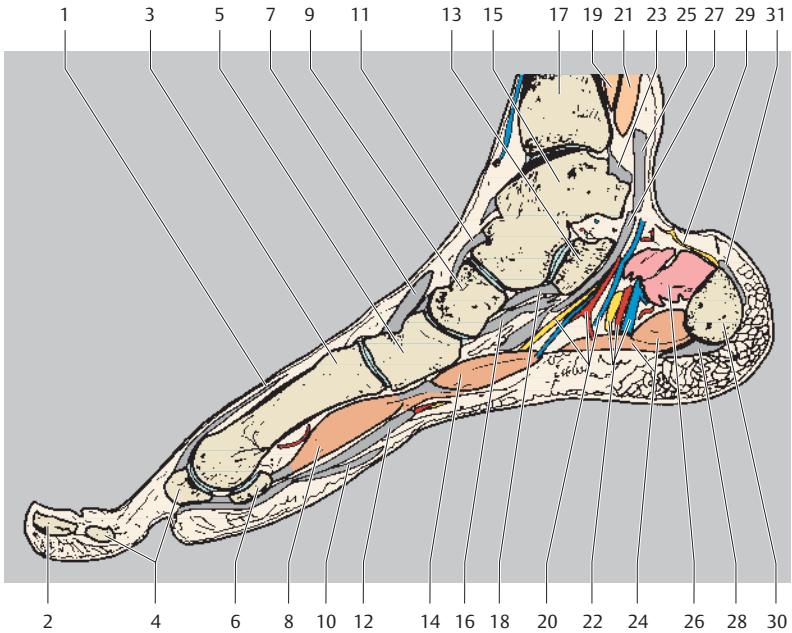
Proximal
Dorsal
Anterior Posterior
Distal
Plantar



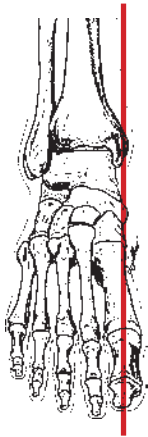
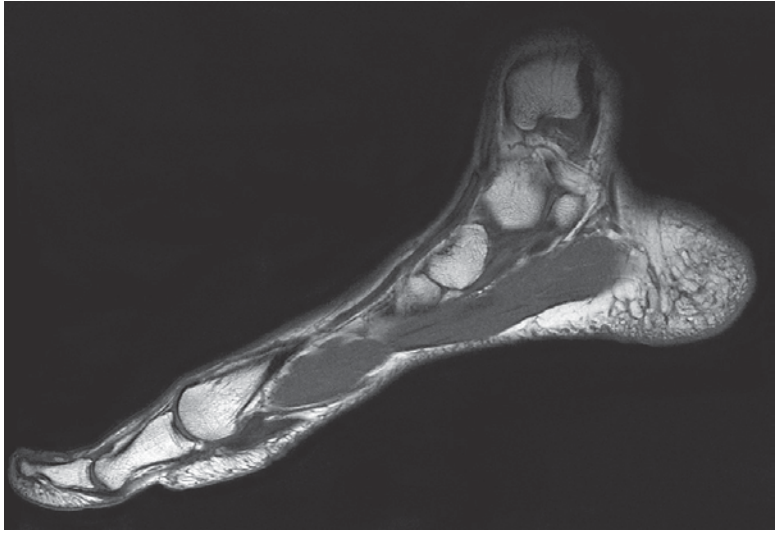
- | | | | |
|----|--|----|---|
| 1 | Interosseous muscle | 17 | Anterior medial malleolar artery |
| 2 | Proximal, middle, and distal phalanx of second toe | 18 | Peroneus (fibularis) longus muscle (tendon) |
| 3 | Metatarsal I (base) | 19 | Talus |
| 4 | Extensor digitorum muscle (tendon) | 20 | Deep plantar arch |
| 5 | Cuneonavicular joint | 21 | Extensor hallucis longus muscle (tendon) |
| 6 | Metatarsal II (head) | 22 | Quadratus plantae muscle |
| 7 | Navicular | 23 | Tibia |
| 8 | Adductor hallucis muscle (transverse head) | 24 | Plantar calcaneonavicular ligament |
| 9 | Talonavicular joint | 25 | Talocrural joint |
| 10 | Flexor digitorum longus muscle (tendon) | 26 | Flexor digitorum brevis muscle |
| 11 | Talonavicular ligament | 27 | Tibialis posterior muscle |
| 12 | Adductor hallucis muscle (oblique head) | 28 | Plantar aponeurosis |
| 13 | Medial tarsal artery | 29 | Flexor hallucis longus muscle |
| 14 | Medial cuneiform | 30 | Lateral plantar artery, vein, and nerve |
| 15 | Talocalcaneal interosseous ligament | 31 | Posterior talofibular ligament |
| 16 | Intermediate cuneiform | 32 | Abductor digiti minimi muscle |
| | | 33 | Achilles' tendon (calcaneal tendon) |
| | | 34 | Subtalar joint |
| | | 35 | Pre-Achilles' fat body |
| | | 36 | Calcaneus |



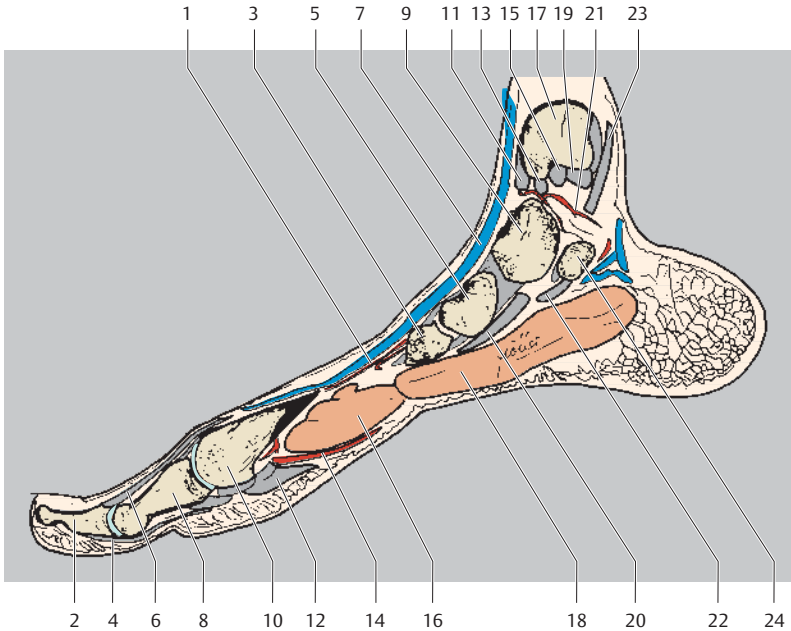Proximal
Dorsal
Anterior Posterior
Distal
Plantar






















- | | |
|--|---|
| 1 Extensor hallucis longus muscle | 17 Tibia |
| 2 Distal phalanx I | 18 Spring ligament (plantar calcaneonavicular ligament) |
| 3 Metatarsal I | 19 Tibialis posterior muscle |
| 4 Proximal phalanx I | 20 Medial plantar artery, vein, and nerve |
| 5 Medial cuneiform | 21 Flexor digitorum longus muscle (tendon) |
| 6 Sesamoid bone | 22 Lateral plantar artery, vein, and nerve |
| 7 Tibialis anterior muscle | 23 Deltoid ligament (posterior tibiotalar part) |
| 8 Flexor hallucis brevis muscle (lateral head) | 24 Abductor hallucis muscle |
| 9 Navicular | 25 Flexor hallucis longus muscle (tendon) |
| 10 Plantar aponeurosis | 26 Quadratus plantae muscle |
| 11 Talonavicular ligament | 27 Flexor digitorum longus muscle (tendon) |
| 12 Flexor hallucis longus muscle (tendon) | 28 Plantar aponeurosis |
| 13 Calcaneus | 29 Calcaneal anastomosis |
| 14 Flexor hallucis brevis muscle (medial head) | 30 Calcaneus (tuber) |
| 15 Talus | 31 Achilles' tendon (calcaneal tendon) |
| 16 Tibialis posterior muscle (tendon) | |






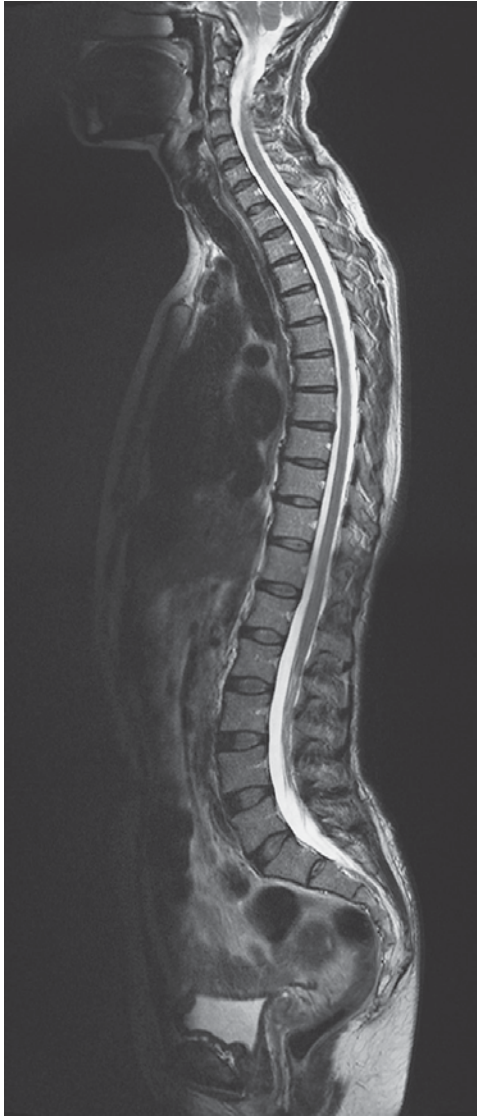Proximal
Dorsal
Anterior Posterior
Distal
Plantar



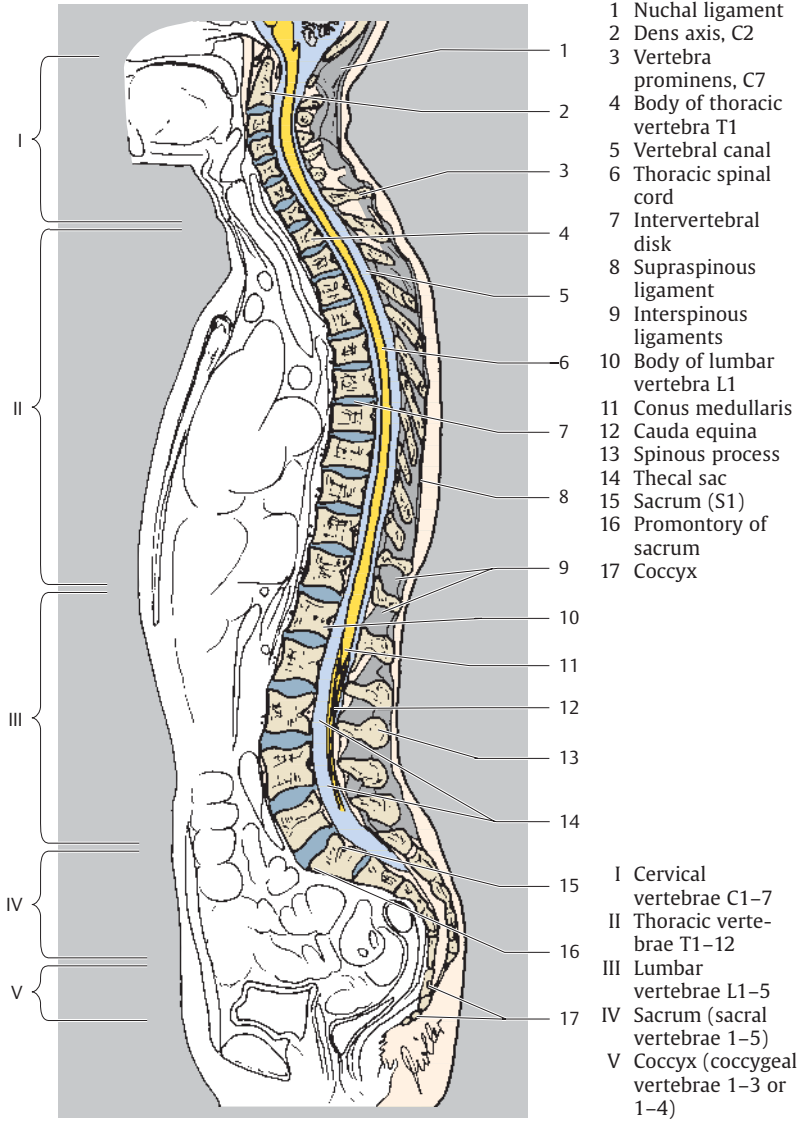
- | | |
|---|---|
| 1 Medial tarsal arteries | 14 Medial plantar artery and nerve (superficial branch) |
| 2 Distal phalanx I | 15 Deltoid ligament (tibiocalcaneal part) |
| 3 Medial cuneiform | 16 Flexor hallucis brevis muscle |
| 4 Flexor hallucis longus muscle (tendon) | 17 Tibia (medial malleolus) |
| 5 Navicular | 18 Abductor hallucis muscle |
| 6 Extensor hallucis longus muscle | 19 Deltoid ligament (posterior tibiotalar part) |
| 7 Dorsalis pedis vein (to great saphenous vein) | 20 Tibialis posterior muscle (tendon) |
| 8 Proximal phalanx I | 21 Posterior tibial artery (medial malleolar branches) |
| 9 Talus | 22 Flexor hallucis longus muscle (tendon) |
| 10 Metatarsal I (head) | 23 Flexor digitorum longus muscle (tendon) |
| 11 Deltoid ligament (anterior tibiotalar part) | 24 Calcaneus |
| 12 Plantar aponeurosis | |
| 13 Deltoid ligament (tibionavicular part) | |

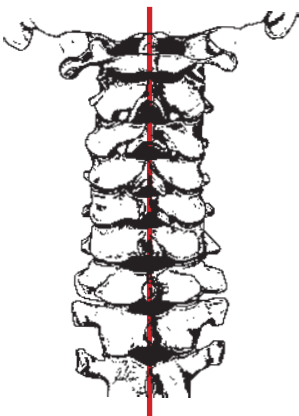
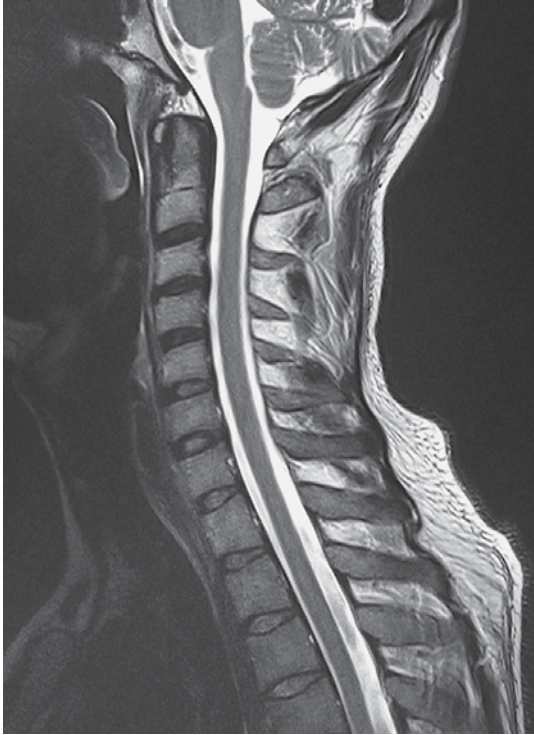	Arteries
	Nerves
	Veins
	Bones
	Fatty tissue
	Cartilage
	Tendon
	Disk, intervertebral cartilage
	Fluid, cerebrospinal fluid
	Lymph nodes
	Esophagus
	Liver, glands
	Air
	Erector Spinae Muscles (Lateral Tract): Iliocostal Longissimus Splenius capitis and splenius cervicis Intertransversarii Levatores costarum
	Erector Spinae Muscles (Medial Tract): Spinal system: interspinous muscles Spinalis thoracis, cervicis, and capitis Transversospinal system: rotatores breves and longi Multifidus lumborum, thoracis, and cervicis Semispinalis thoracis, cervicis, and capitis
	Peroneus
	Short Muscles of Neck and Head Joints: Rectus capitis posterior major and minor Obliquus capitis superior and inferior
	Prevertebral Cervical Muscles: Longus capitis and longus colli Rectus capitis lateralis and anterior
	Muscles of Thoracic Cage: External, internal, and innermost intercostals Transversus thoracis Subcostal Sclenus anterior, medius, minimus, and posterior

	Muscles of the Trunk – Shoulder Girdle – Arm Rhomboideus major and minor Sternocleidomastoid Levator scapulae Serratus anterior Pectoralis major and minor Trapezius
	Muscles of the Trunk – Leg – Abdomen Latissimus dorsi Psoas Quadratus lumborum Quadratus lumborum Piriformis Gluteus medius
	Muscles of Face and Ventral Cervical Muscles: Digastric muscle Stylohyoid Sternohyoid



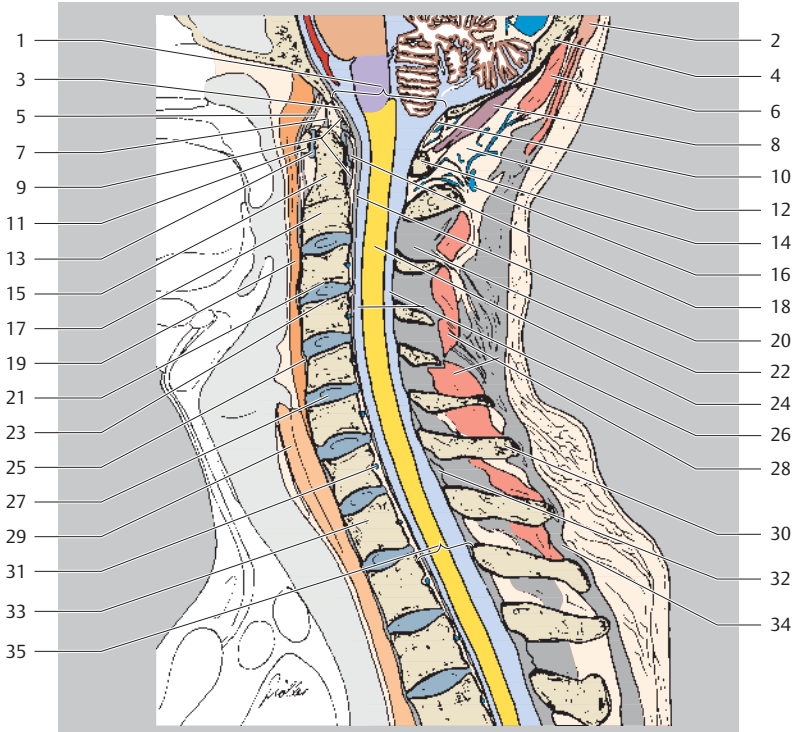
Cranial
Ventral Dorsal
Caudal



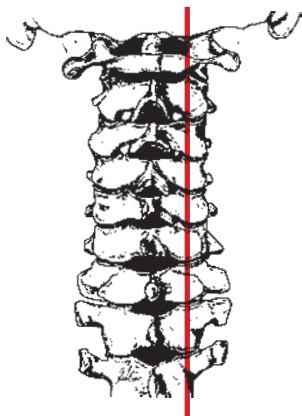
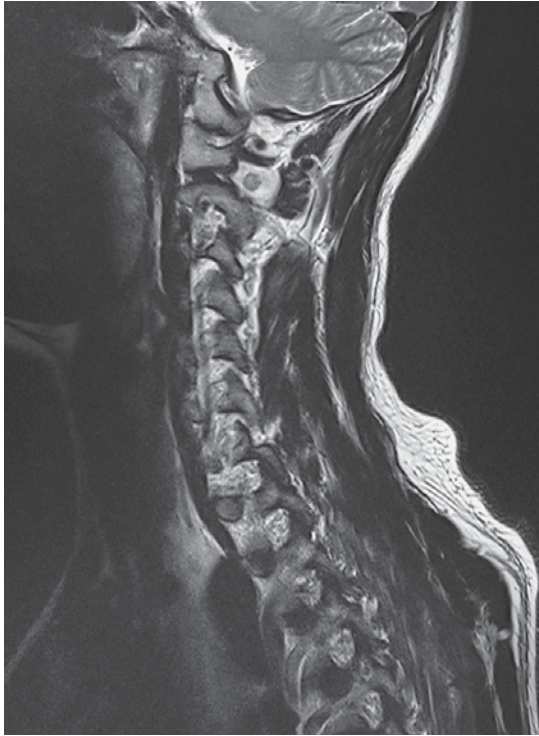

Cranial
Ventral Dorsal
Caudal

- 1 Foramen magnum
- 2 Trapezius muscle (descending part)
- 3 Tectorial membrane
- 4 Occipital bone
(internal occipital protuberance)

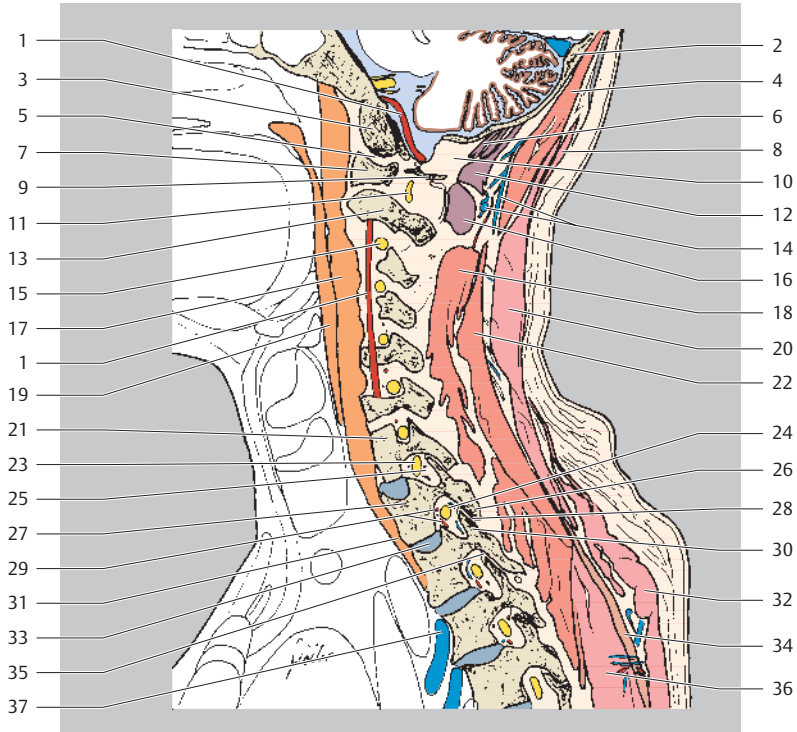

- | | | | |
|----|---------------------------------------|----|---|
| 5 | Anterior atlanto-occipital membrane | 20 | Posterior longitudinal ligament |
| 6 | Semispinalis capitis muscle | 21 | Inferior vertebral endplate C3 |
| 7 | Apical ligament of dens | 22 | Interspinous ligament |
| 8 | Rectus capitis posterior minor muscle | 23 | Superior vertebral endplate C4 |
| 9 | Longitudinal fasciculi | 24 | Cervical spinal cord |
| 10 | Posterior atlanto-occipital membrane | 25 | Anterior longitudinal ligament |
| 11 | Atlas (anterior arch) | 26 | Premedullary and postmedullary subarachnoid space |
| 12 | Suboccipital fatty tissue | 27 | Intervertebral disk |
| 13 | Median atlanto-axial joint | 28 | Interspinales muscles |
| 14 | Atlas (posterior arch) | 29 | Esophagus |
| 15 | Axis (dens) | 30 | Spinous process C7 |
| 16 | Deep cervical veins | 31 | Basivertebral veins |
| 17 | Axis (vertebral body) | 32 | Ligamentum flavum |
| 18 | Transverse ligament of atlas | 33 | Thoracic vertebral body T1 |
| 19 | Longus capitis muscle | 34 | Supraspinous ligament |
| | | 35 | Bony vertebral canal |

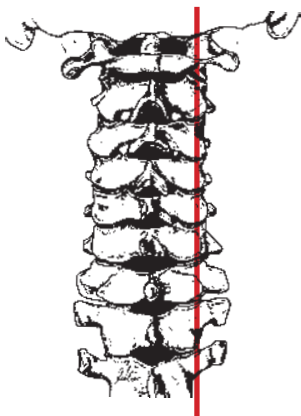
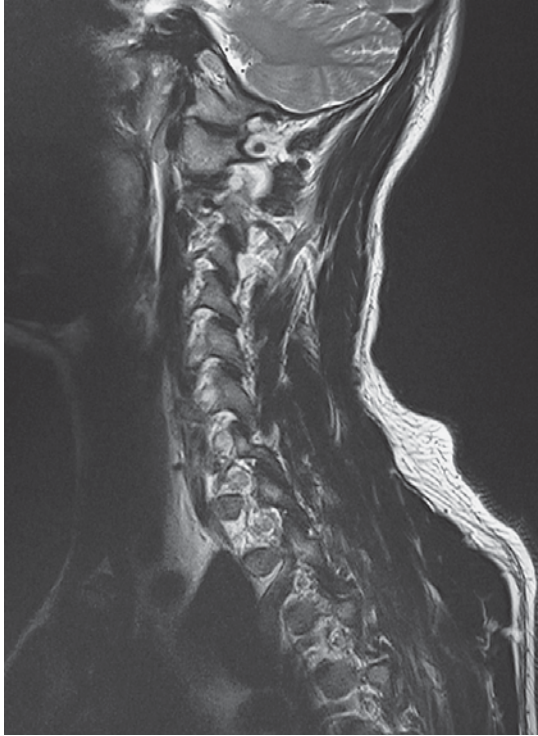

Cranial
Ventral Dorsal
Caudal

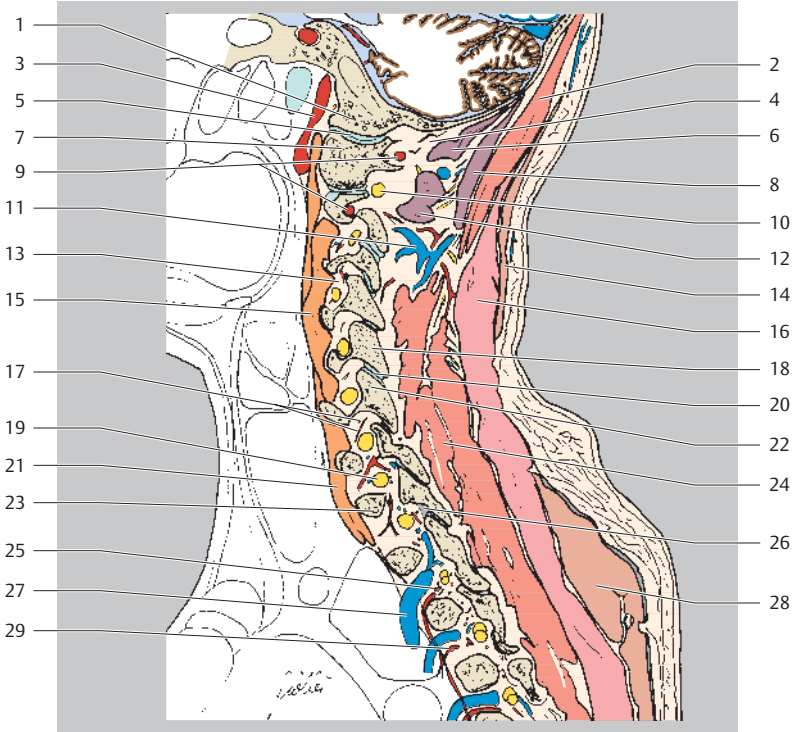
- 1 Vertebral artery
- 2 Occipital bone
- 3 Occipital condyle
- 4 Semispinalis capitis muscle
- 5 Atlanto-occipital joint



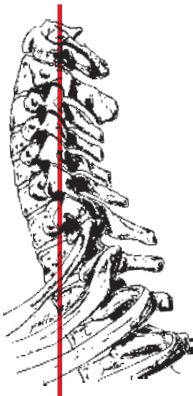
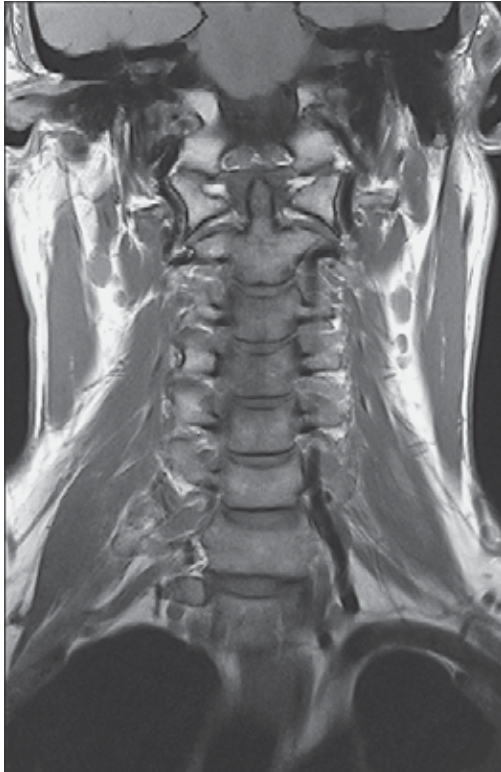- | | |
|---|--|
| 6 Rectus capitis posterior minor muscle | 21 Body of cervical vertebra C7 |
| 7 Atlas (lateral mass) | 22 Semispinalis cervicis muscle |
| 8 Trapezius muscle (descending part) | 23 Spinal ganglion C8 |
| 9 Atlas (posterior arch) | 24 Spinal ganglion T1 |
| 10 Suboccipital fatty tissue | 25 Intervertebral foramen |
| 11 Spinal nerve C2 | 26 Inferior articular process |
| 12 Rectus capitis posterior major muscle | 27 First thoracic vertebral body |
| 13 Axis (body) | 28 Zygapophyseal joint |
| 14 Deep cervical veins | 29 Posterior intercostal artery (spinal and radicular branches of dorsal branch) |
| 15 Spinal ganglion C3 | 30 Superior articular process |
| 16 Obliquus capitis inferior muscle | 31 Longus colli muscle |
| 17 Longus capitis muscle | 32 Trapezius muscle (transverse part) |
| 18 Spinalis cervicis and multifidus muscles | 33 Intervertebral disk |
| 19 Palatopharyngeus muscle | 34 Rhomboid muscle |
| 20 Splenius capitis muscle | 35 Ligamentum flavum |
| | 36 Splenius cervicis muscle |
| | 37 Posterior intercostal vein |



Cranial
Ventral Dorsal
Caudal

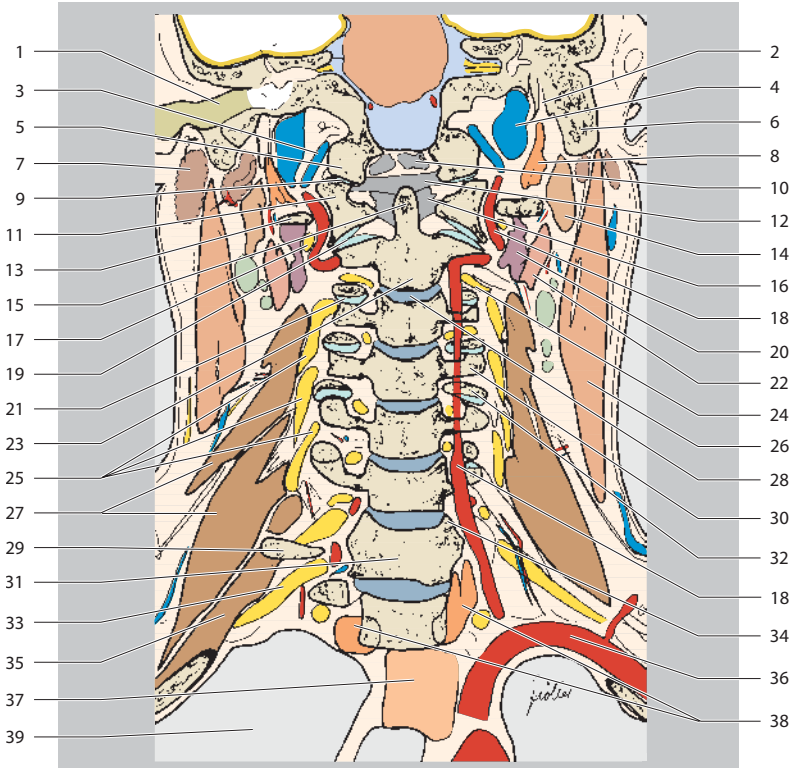


- | | |
|---|--|
| 1 Occipital condyle | 17 Vertebral artery (spinal and radicular branches) |
| 2 Semispinalis capitis muscle | 18 Inferior articular process |
| 3 Internal carotid artery | 19 Spinal ganglion C8 |
| 4 Suboccipital fatty tissue | 20 Zygapophyseal joint |
| 5 Atlanto-occipital joint | 21 Longus colli muscle |
| 6 Rectus capitis posterior minor muscle | 22 Superior articular process |
| 7 Atlas (lateral mass) | 23 First thoracic vertebral body |
| 8 Rectus capitis posterior major muscle | 24 Spinalis cervicis and multifidus muscles |
| 9 Vertebral artery | 25 Posterior intercostal artery (spinal and radicular branches of dorsal branch) |
| 10 Spinal nerve C2 | 26 Ligamentum flavum |
| 11 Deep cervical veins | 27 Posterior intercostal vein |
| 12 Obliquus capitis inferior muscle | 28 Trapezius muscle (transverse part) |
| 13 Intervertebral foramen | 29 Posterior intercostal artery (dorsal branch) |
| 14 Trapezius muscle (descending part) | |
| 15 Longus capitis muscle | |
| 16 Splenius capitis muscle | |

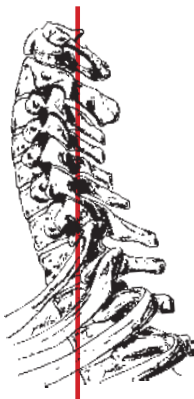
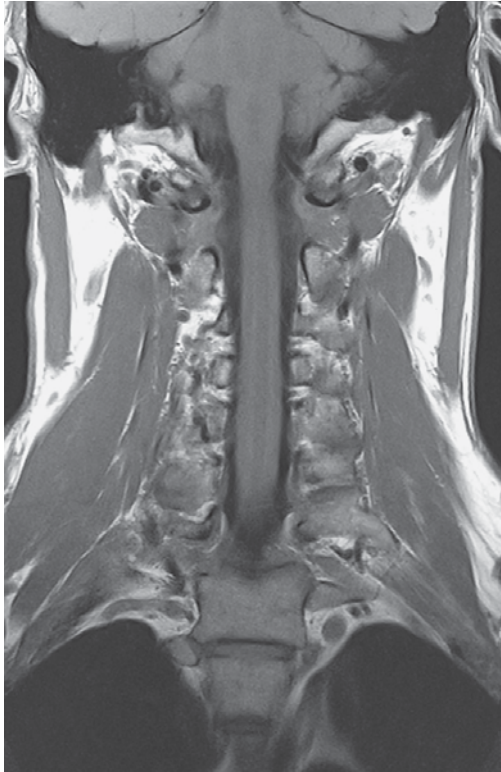

Cranial
Right Left
Caudal

- 1 External auditory canal
- 2 Stylomastoid foramen
- 3 Vertebral vein
- 4 Internal jugular vein
- 5 Occipital condyle
- 6 Mastoid process

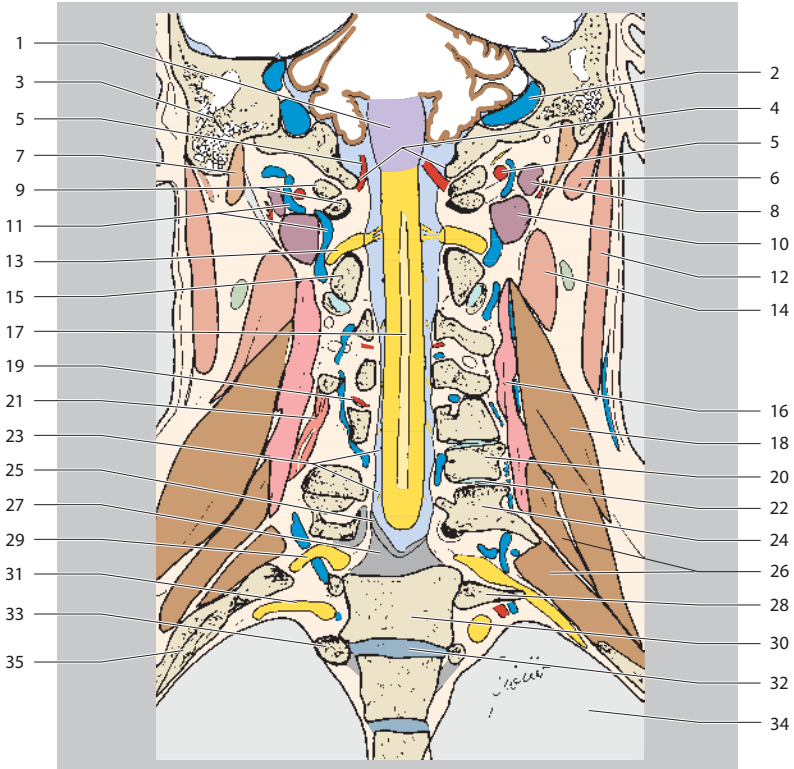


- | | |
|---------------------------------------|----------------------------------|
| 7 Parotid gland | 23 Axis (vertebral body) |
| 8 Rectus capitis lateralis muscle | 24 Spinal ganglion C3 |
| 9 Atlanto-occipital joint | 25 Cervical plexus |
| 10 Tectorial membrane | 26 Sternocleidomastoid muscle |
| 11 Atlas (lateral mass) | 27 Scalenus medius muscle |
| 12 Transverse ligament | 28 Intervertebral disk (C2/C3) |
| 13 Atlas (transverse process) | 29 Transverse process C7 |
| 14 Digastric muscle (posterior belly) | 30 Superior articular process C4 |
| 15 Axis (dens) | 31 Cervical vertebral body C7 |
| 16 Alar ligaments | 32 Inferior articular process |
| 17 Spinal nerve C2 | 33 Spinal nerve C8 |
| 18 Vertebral artery | 34 Uncinate process C7 |
| 19 Lateral atlantoaxial joint | 35 Scalenus posterior muscle |
| 20 Obliquus capitis inferior muscle | 36 Subclavian artery |
| 21 Zygapophyseal joint | 37 Esophagus |
| 22 Levator scapulae muscle | 38 Longus colli muscle |
| | 39 Lung |

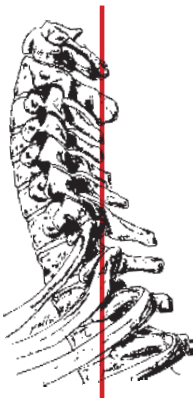
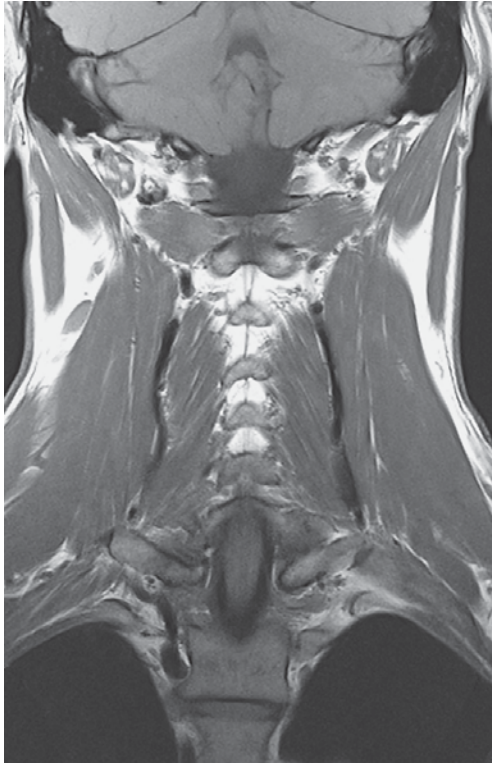

Cranial
 Right Left
 Caudal

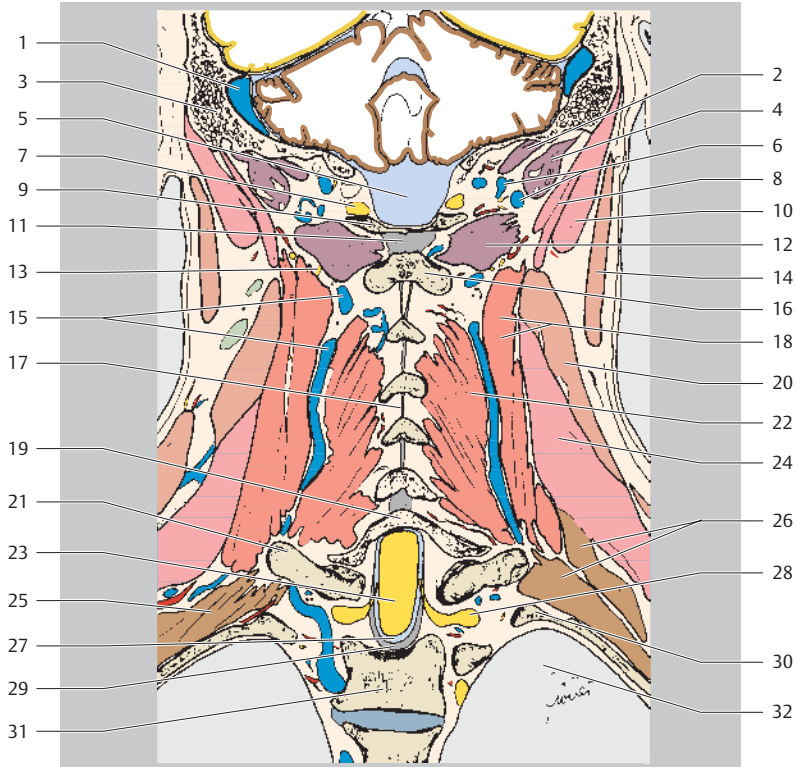
- 1 Medulla oblongata
- 2 Sigmoid sinus
- 3 Mastoid process
- 4 Foramen magnum
- 5 Vertebral artery
- 6 Splenius capitis muscle
- 7 Digastric muscle (posterior belly)



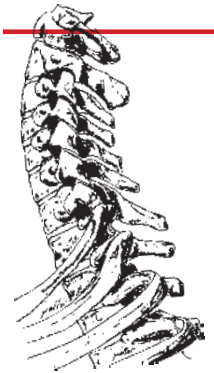
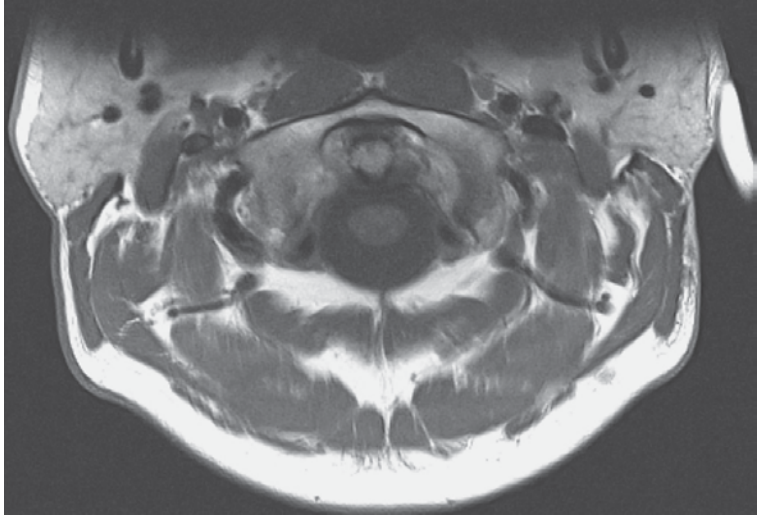
- | | | | |
|----|---|----|-------------------------------------|
| 8 | Obliquus capitis superior muscle | 20 | Inferior articular process C6 |
| 9 | Atlas (posterior arch) | 21 | Semispinalis cervicis muscle |
| 10 | Obliquus capitis inferior muscle | 22 | Zygapophysial joint |
| 11 | Vertebral artery | 23 | Cerebrospinal fluid in spinal canal |
| 12 | Sternocleidomastoid muscle | 24 | Superior articular process C7 |
| 13 | Spinal ganglion C2 | 25 | Spinal dura mater |
| 14 | Levator scapulae muscle | 26 | Scalenus posterior muscle |
| 15 | Axis (vertebral arch) | 27 | Posterior longitudinal ligament |
| 16 | Splenius cervicis muscle | 28 | First rib (neck) |
| 17 | Spinal cord (cervical pulp with central canal) | 29 | Spinal nerve C8 |
| 18 | Scalenus medius muscle | 30 | Thoracic vertebral body T1 |
| 19 | Posterior intercostal artery (spinal and radicular branches of dorsal branch) | 31 | Spinal nerve T1 |
| | | 32 | Intervertebral disk |
| | | 33 | Second rib (head) |
| | | 34 | Left lung |
| | | 35 | First rib (body) |



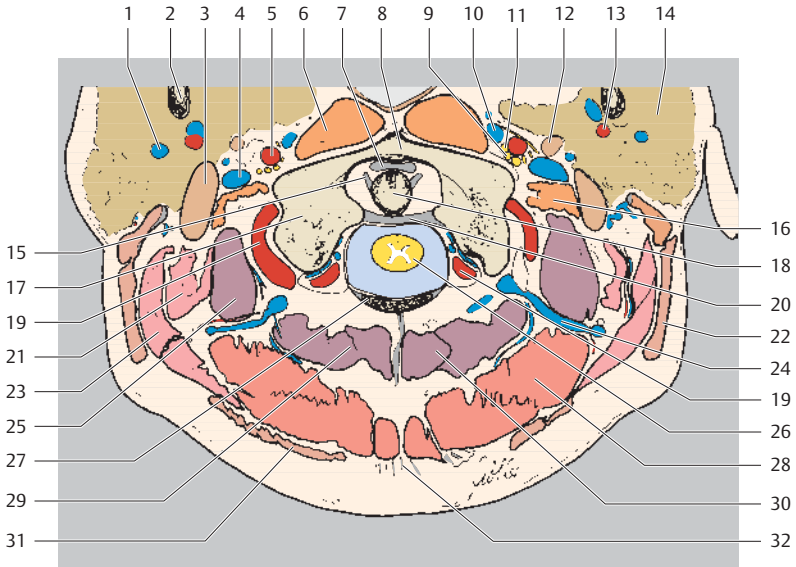
Cranial
Right Left
Caudal



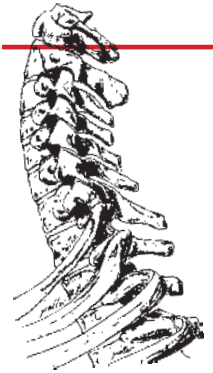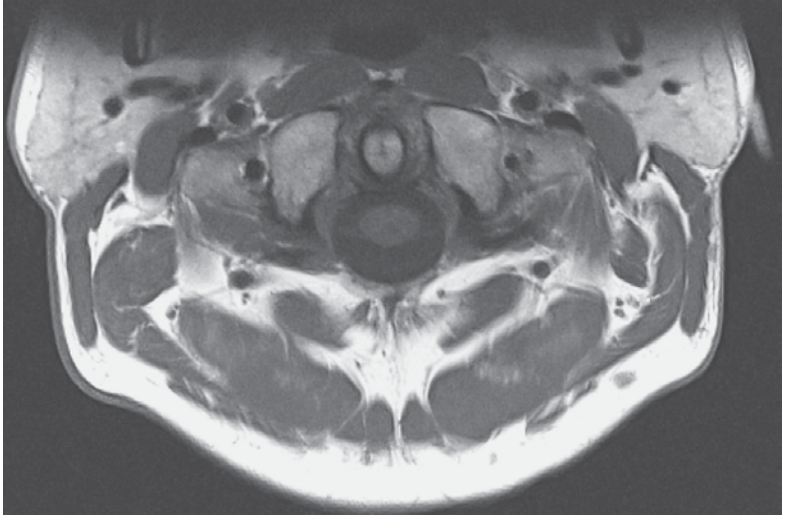
- | | |
|---|--|
| 1 Sigmoid sinus | 17 Interspinous ligament |
| 2 Rectus capitis posterior major muscle | 18 Semispinalis cervicis muscle |
| 3 Mastoid process | 19 Vertebral arch C7 |
| 4 Obliquus capitis superior muscle | 20 Levator scapulae muscle |
| 5 Cisterna magna | 21 First rib (neck and tubercle) |
| 6 Suboccipital venous plexus | 22 Spinalis cervicis and multifidus muscles |
| 7 Suboccipital nerve | 23 Thoracic spinal cord |
| 8 Longissimus capitis muscle | 24 Splenius cervicis muscle |
| 9 Atlas (posterior arch) | 25 Intercostal muscles |
| 10 Splenius capitis muscle | 26 Scalenus posterior muscle |
| 11 Nuchal ligament | 27 Cerebrospinal fluid in vertebral canal |
| 12 Obliquus capitis inferior muscle | 28 Spinal ganglion T1 |
| 13 Major occipital nerve | 29 Spinal dura mater and posterior longitudinal ligament |
| 14 Sternocleidomastoid muscle | 30 Second rib |
| 15 Deep cervical vein | 31 Second thoracic vertebral body |
| 16 Spinous process C2 | 32 Left lung |



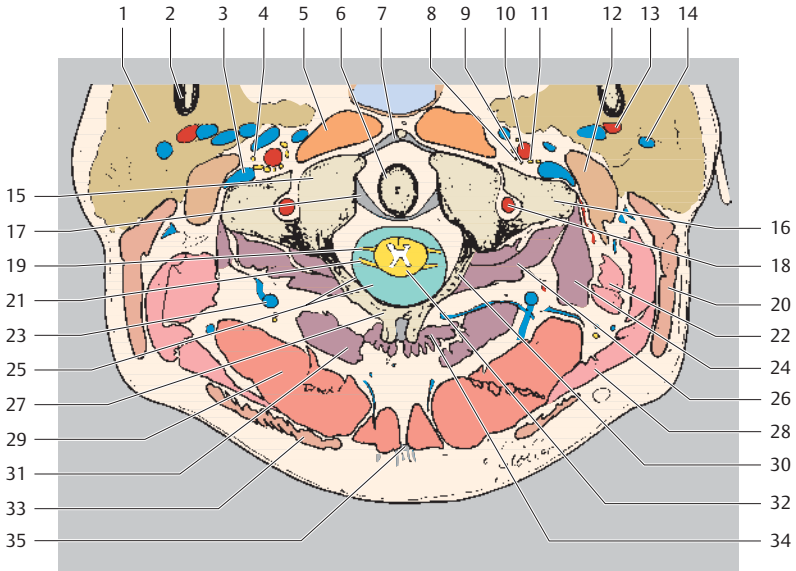
Ventral
Right Left
Dorsal



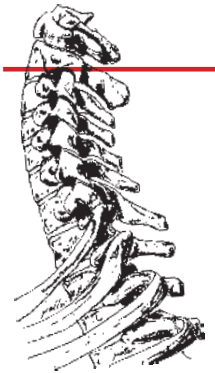
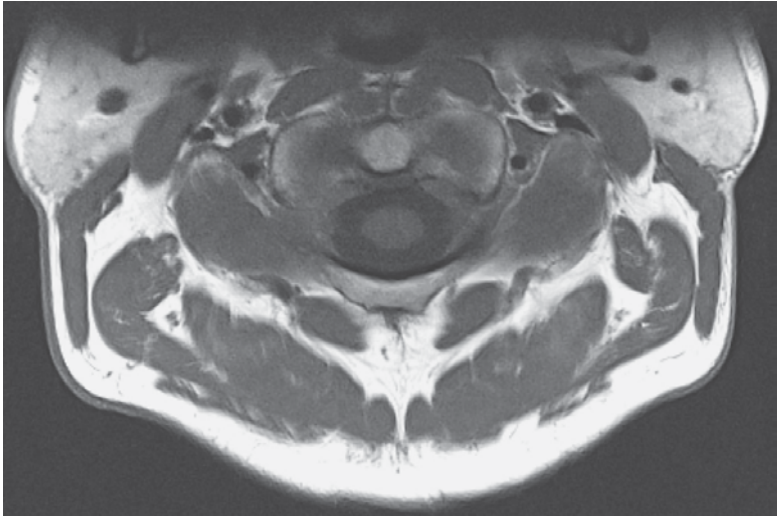
- | | |
|---------------------------------------|---|
| 1 Retromandibular vein | 17 Lateral mass of atlas |
| 2 Mandible | 18 Dens of axis |
| 3 Digastric muscle (posterior belly) | 19 Vertebral artery |
| 4 Internal jugular vein | 20 Cruciate ligament of atlas (Longitudinal bands and transverse ligament of atlas) |
| 5 Internal carotid artery | 21 Longissimus capitis muscle |
| 6 Longus capitis muscle | 22 Sternocleidomastoid muscle |
| 7 Median atlantoaxial joint | 23 Splenius capitis muscle |
| 8 Atlas (anterior arch) | 24 Deep cervical vein |
| 9 Hypoglossal nerve (XII) | 25 Obliquus capitis superior muscle |
| 10 Pterygoid venous plexus | 26 Spinal cord |
| 11 Vagus nerve (X) | 27 Atlas (posterior arch) |
| 12 Stylohyoid muscle | 28 Semispinalis capitis muscle |
| 13 Maxillary artery (mandibular part) | 29 Rectus capitis posterior major muscle |
| 14 Parotid gland | 30 Rectus capitis posterior minor muscle |
| 15 Alar ligaments | 31 Trapezius muscle |
| 16 Rectus capitis lateralis muscle | 32 Nuchal ligament |



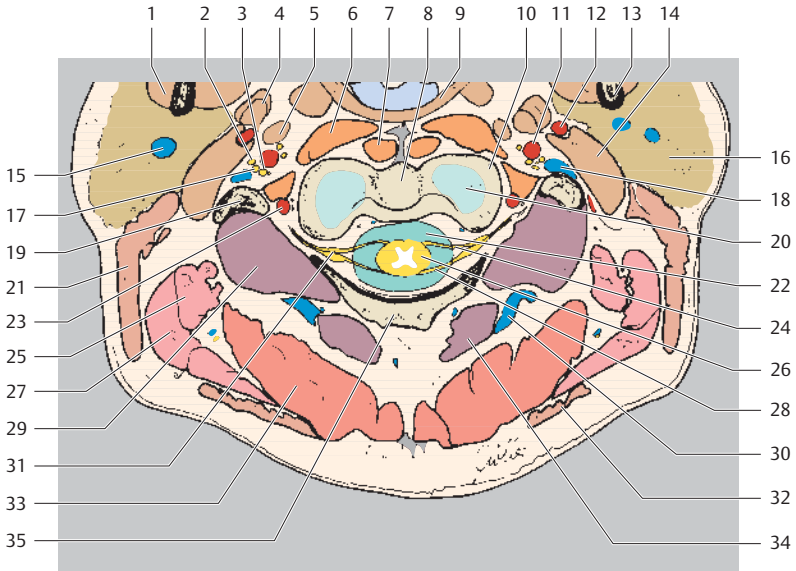
Ventral
Right Left
Dorsal



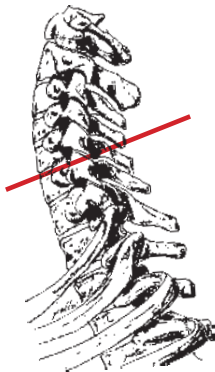
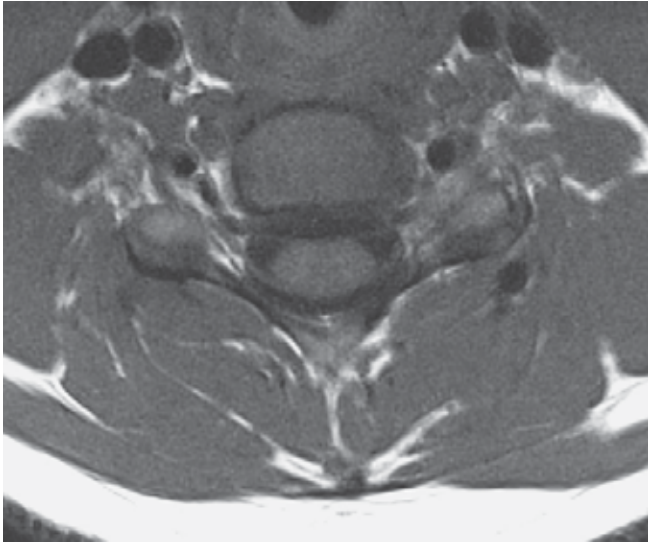
- | | |
|---------------------------------------|--|
| 1 Parotid gland | 19 Ventral root |
| 2 Mandible (ramus) | 20 Sternocleidomastoid muscle |
| 3 Internal jugular vein | 21 Dorsal root |
| 4 Glossopharyngeal nerve (IX) | 22 Longissimus capitis muscle |
| 5 Longus capitis muscle | 23 Deep cervical vein |
| 6 Dens of axis | 24 Obliquus capitis superior muscle |
| 7 Anterior longitudinal ligament | 25 Dura mater and cerebrospinal fluid (subarachnoid space) |
| 8 Vagus nerve (X) | 26 Obliquus capitis inferior muscle |
| 9 Hypoglossal nerve (XII) | 27 Spinous process |
| 10 Internal carotid artery | 28 Splenius capitis muscle |
| 11 Accessory nerve (XI) | 29 Semispinalis capitis muscle |
| 12 Digastric muscle (posterior belly) | 30 Axis (posterior arch) |
| 13 Maxillary artery (mandibular part) | 31 Rectus capitis posterior major muscle |
| 14 Retromandibular vein | 32 Spinal cord |
| 15 Atlas (lateral mass) | 33 Trapezius muscle |
| 16 Atlas (transverse process) | 34 Rectus capitis posterior minor muscle |
| 17 Transverse ligament of atlas | 35 Nuchal ligament |
| 18 Vertebral artery | |



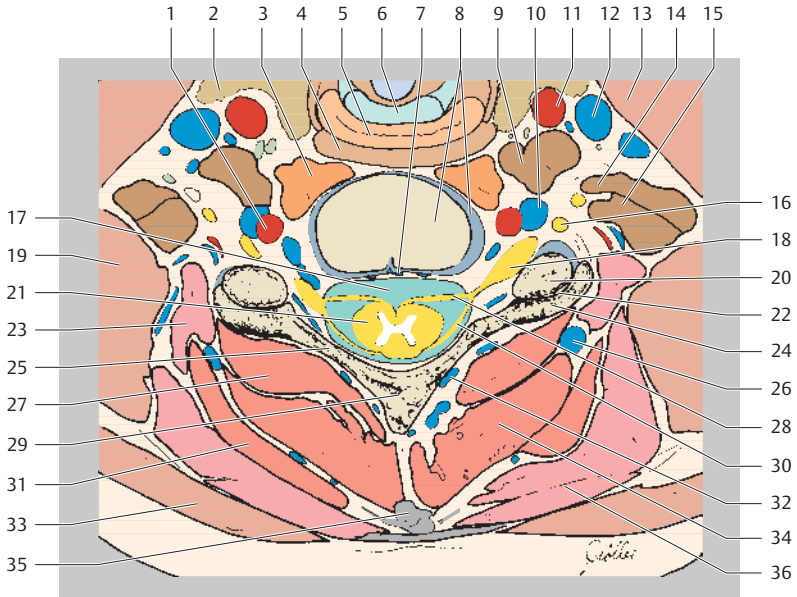
Ventral
Right Left
Dorsal



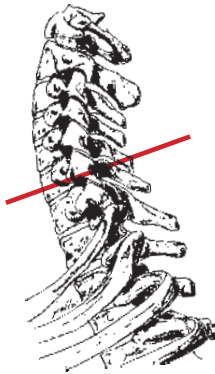
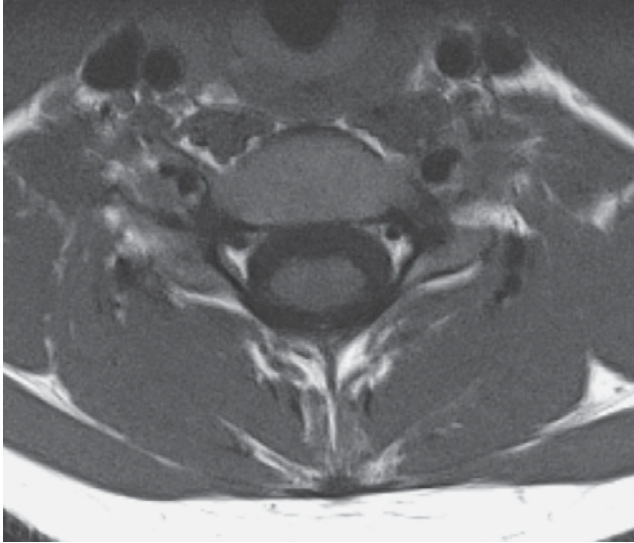
- | | |
|--|---|
| 1 Medial pterygoid muscle | 18 Internal jugular vein |
| 2 Vagus nerve (X) | 19 Atlas (transverse process) |
| 3 Accessory nerve (XI) | 20 Axis (body) |
| 4 Styloglossus muscle | 21 Sternocleidomastoid muscle |
| 5 Stylopharyngeus muscle | 22 Premedullary subarachnoid space |
| 6 Longus capitis muscle | 23 Vertebral artery |
| 7 Longus colli muscle | 24 Ventral root of 2 nd spinal nerve |
| 8 Axis (body) | 25 Longissimus capitis muscle |
| 9 Superior constrictor muscle of pharynx | 26 Spinal cord |
| 10 Atlas (articular process) | 27 Splenius capitis muscle |
| 11 Internal carotid artery | 28 Dorsal root of 2 nd spinal nerve |
| 12 External carotid artery | 29 Obliquus capitis inferior muscle |
| 13 Mandible (ramus) | 30 Deep cervical vein |
| 14 Digastric muscle (posterior belly) | 31 Spinal ganglion (nerve root) |
| 15 Retromandibular vein | 32 Trapezius muscle |
| 16 Parotid gland | 33 Semispinalis capitis muscle |
| 17 Hypoglossal nerve (XII) | 34 Rectus capitis posterior major muscle |
| | 35 Axis (posterior arch) |



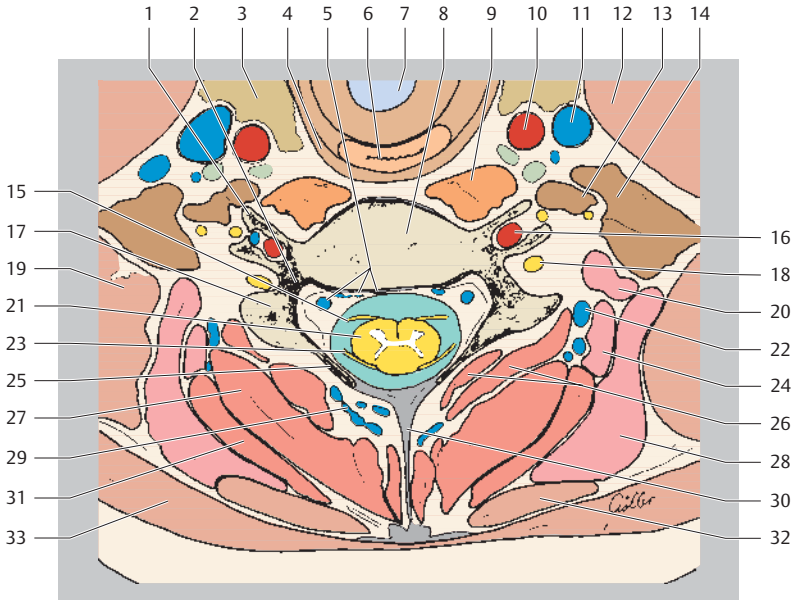
Ventral
Right Left
Dorsal



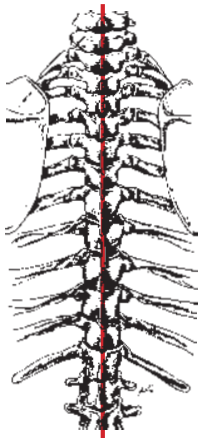
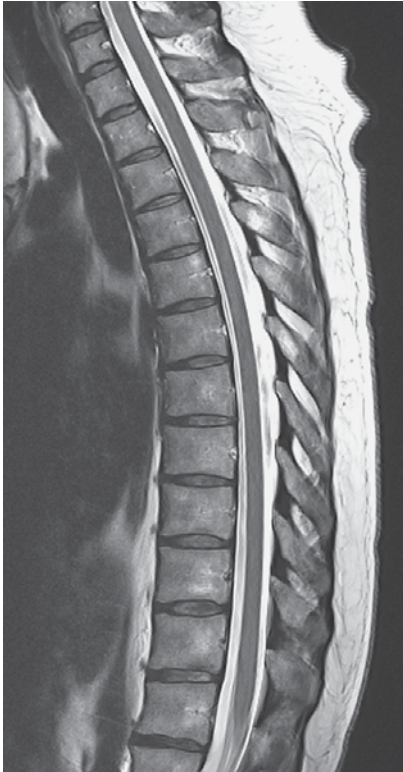- | | | | |
|----|---|----|--|
| 1 | Vertebral artery | 19 | Levator scapulae muscle |
| 2 | Thyroid gland | 20 | Superior articular process |
| 3 | Longus colli muscle | 21 | Spinal cord |
| 4 | Superior constrictor muscle of pharynx | 22 | Zygapophyseal joint |
| 5 | Esophagus | 23 | Longissimus cervicis muscle |
| 6 | Cricoid cartilage | 24 | Inferior articular process |
| 7 | Basivertebral veins | 25 | Posterior vertebral arch C5 (lamina) |
| 8 | Cervical vertebral body C5 and intervertebral space C5/C6 | 26 | Deep cervical vein |
| 9 | Scalenus anterior muscle | 27 | Spinalis cervicis and multifidus muscles |
| 10 | Vertebral vein | 28 | Ventral root C6 |
| 11 | Common carotid artery | 29 | Spinous process |
| 12 | Internal jugular vein | 30 | Dorsal root C6 |
| 13 | Sternocleidomastoid muscle | 31 | Semispinalis capitis muscle |
| 14 | Scalenus medius muscle | 32 | Posterior external vertebral venous plexus |
| 15 | Scalenus posterior muscle | 33 | Trapezius muscle |
| 16 | Spinal nerve C5 | 34 | Semispinalis cervicis muscle |
| 17 | Premedullary subarachnoid space | 35 | Nuchal ligament |
| 18 | Spinal ganglion (nerve root) | 36 | Splenius capitis muscle |



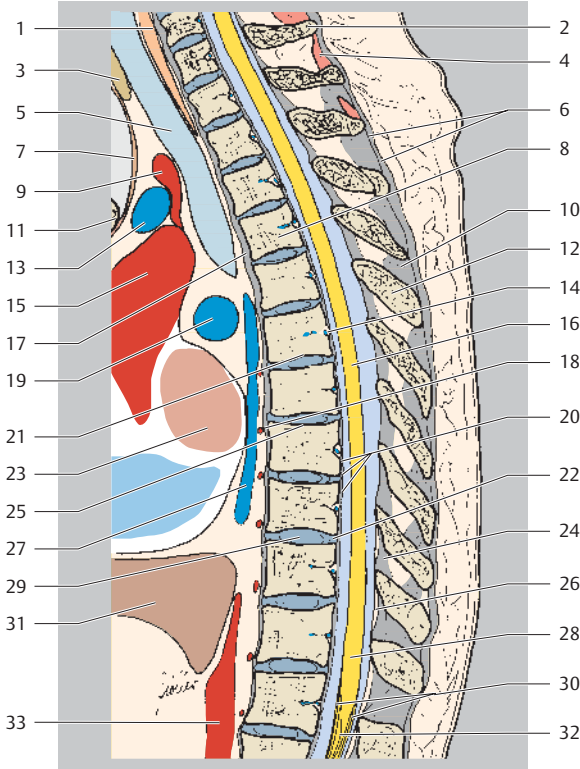
Ventral
Right Left
Dorsal



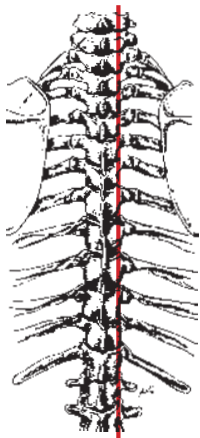
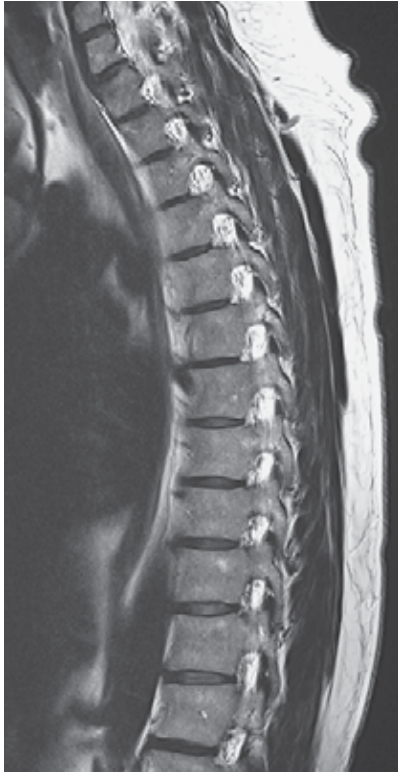- | | |
|---|---|
| 1 Transverse process | 18 Spinal nerve C6 |
| 2 Pedicle of vertebral arch | 19 Levator scapulae muscle |
| 3 Thyroid gland | 20 Longissimus capitis muscle |
| 4 Superior constrictor muscle of pharynx | 21 Spinal cord |
| 5 Anterior internal vertebral venous plexus | 22 Deep cervical vein |
| 6 Esophagus | 23 Dorsal root C7 |
| 7 Larynx | 24 Longissimus cervicis muscle |
| 8 Cervical vertebral body C6 | 25 Posterior vertebral arch C6 (lamina) |
| 9 Longus colli muscle | 26 Spinalis cervicis and multifidus muscles |
| 10 Common carotid artery | 27 Semispinalis cervicis muscle |
| 11 Internal jugular vein | 28 Splenius cervicis muscle |
| 12 Sternocleidomastoid muscle | 29 Posterior external vertebral venous plexus |
| 13 Scalenus anterior muscle | 30 Nuchal ligament |
| 14 Scalenus medius muscle | 31 Splenius capitis muscle |
| 15 Ventral root C7 | 32 Rhomboid minor muscle |
| 16 Vertebral artery | 33 Trapezius muscle |
| 17 Articular process | |



Cranial
Ventral Dorsal
Caudal

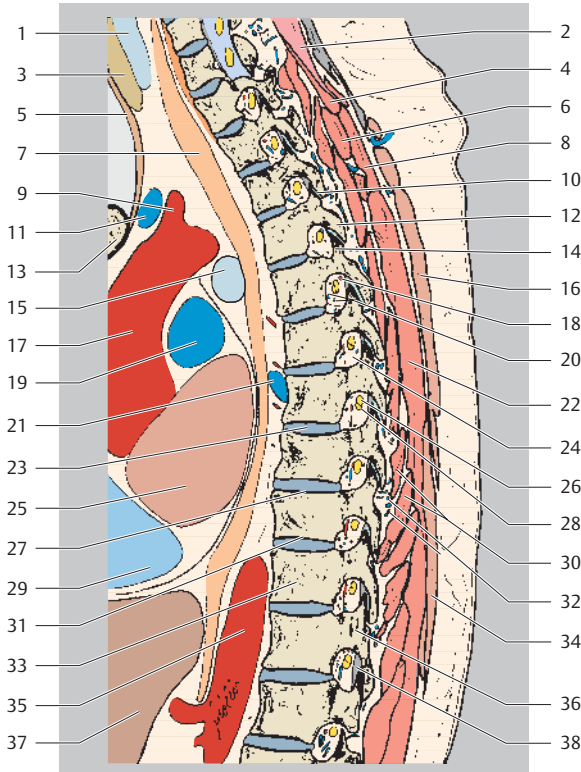


- | | |
|-----------------------------------|--|
| 1 Esophagus | 19 Pulmonary artery |
| 2 Vertebra prominens C7 | 20 Posterior longitudinal ligament |
| 3 Thyroid gland | 21 Inferior vertebral endplate T6 |
| 4 Interspinalis cervicis muscle | 22 Intervertebral disk T9/T10 (anulus fibrosus) |
| 5 Trachea | 23 Left atrium |
| 6 Supraspinous ligament | 24 Ligamentum flavum |
| 7 Sternohyoid muscle | 25 Superior vertebral endplate T7 |
| 8 Thoracic vertebral body T4 | 26 Epidural fatty tissue (retrospinal fat) |
| 9 Brachiocephalic trunk | 27 Azygos vein |
| 10 Interspinous ligament | 28 Conus medullaris |
| 11 Sternum (manubrium) | 29 Intervertebral disk T9/T10 (nucleus pulposus) |
| 12 Spinous process | 30 Cauda equina |
| 13 Left brachiocephalic vein | 31 Liver |
| 14 Basivertebral vein | 32 Filum terminale |
| 15 Ascending aorta | 33 Descending aorta |
| 16 Thoracic spinal cord | |
| 17 Anterior longitudinal ligament | |
| 18 Posterior intercostal artery | |

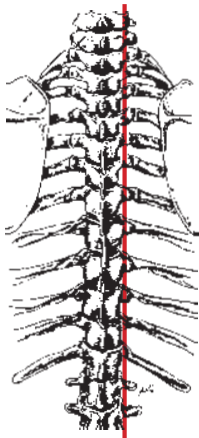
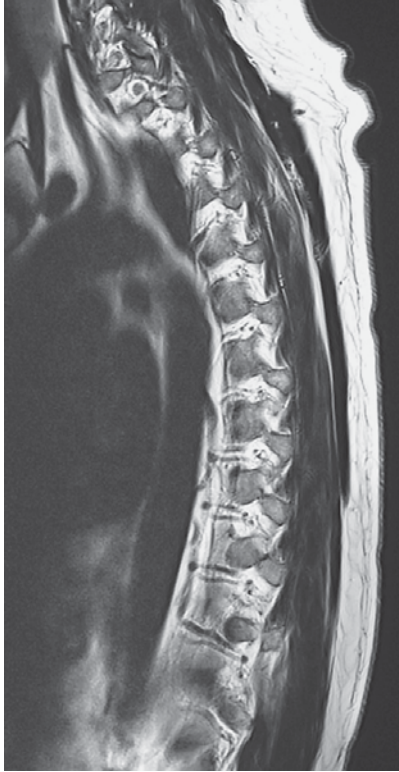

Cranial
Ventral Dorsal
Caudal

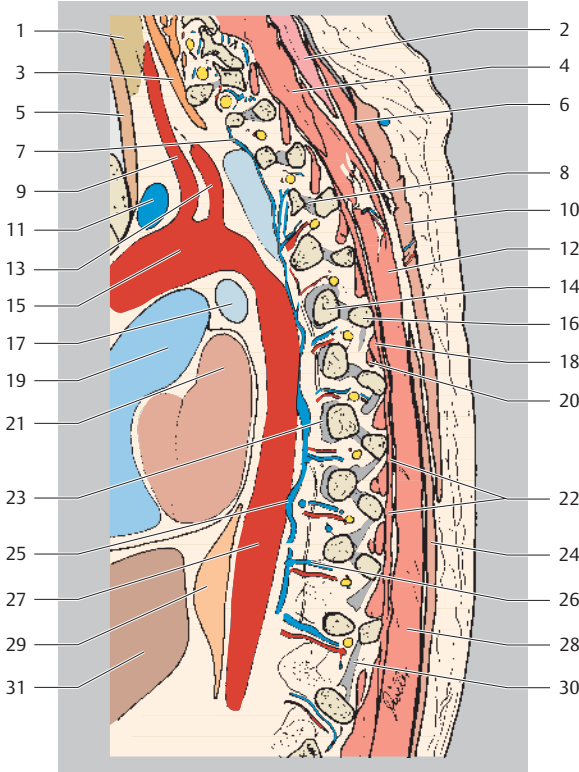
- 1 Trachea
- 2 Splenius cervicis muscle
- 3 Thyroid gland
- 4 Semispinalis capitis muscle
- 5 Sternohyoid muscle
- 6 Serratus posterior superior muscle
- 7 Esophagus
- 8 Rhomboid major muscle
- 9 Brachiocephalic trunk



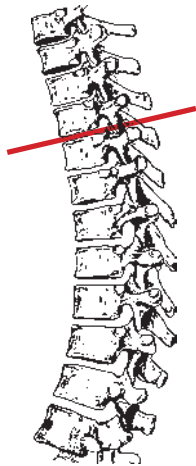
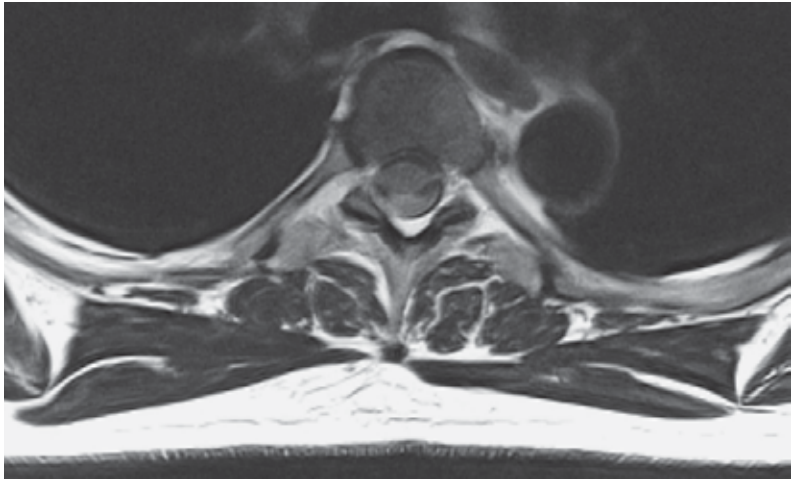
- | | |
|---|---|
| 10 Zygapophyseal joint T3/T4 | 26 Spinal ganglion (dorsal root) |
| 11 Left brachiocephalic vein | 27 Superior vertebral endplate T9 |
| 12 Inferior articular process T4 | 28 Spinal ganglion (ventral root) |
| 13 Sternum (manubrium) | 29 Right atrium |
| 14 Superior articular process T5 | 30 Multifidus and semispinalis thoracis muscles |
| 15 Left main bronchus | 31 Inferior vertebral endplate T9 |
| 16 Trapezius muscle | 32 Posterior external vertebral venous plexus |
| 17 Ascending aorta | 33 Thoracic vertebral body T10 |
| 18 Posterior intercostal artery (spinal branch) | 34 Latissimus dorsi muscle |
| 19 Pulmonary artery | 35 Descending aorta |
| 20 Intervertebral vein | 36 Pedicle of vertebral arch (interarticular portion) |
| 21 Hemiazygos vein | 37 Liver |
| 22 Erector spinae muscle | 38 Ligamentum flavum |
| 23 Intervertebral disk T7/T8 | |
| 24 Intervertebral foramen | |
| 25 Left atrium | |



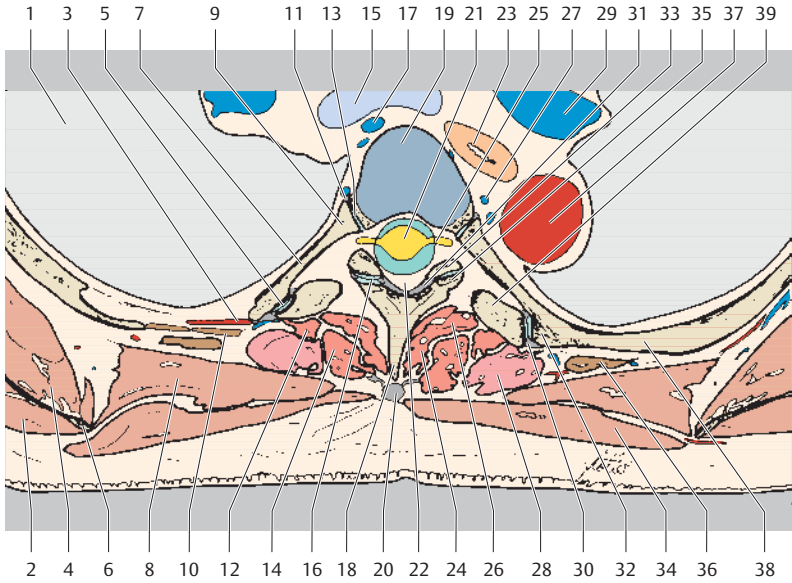
Cranial
Ventral Dorsal
Caudal



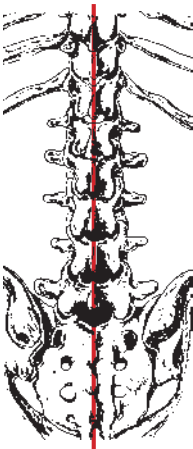
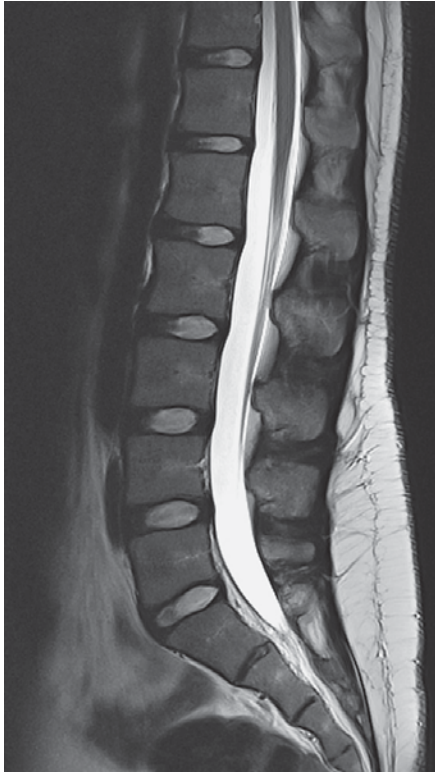
- | | |
|--|--|
| 1 Thyroid gland | 16 Transverse process T6 |
| 2 Splenius cervicis muscle | 17 Left main bronchus |
| 3 Longus capitis muscle | 18 Intertransversarius muscle |
| 4 Spinalis cervicis muscle and multifidus muscle | 19 Pulmonary trunk |
| 5 Sternohyoid muscle | 20 Rotatores muscles |
| 6 Rhomboid major muscle | 21 Left atrium |
| 7 Accessory hemiazygos vein | 22 Multifidus muscle |
| 8 Costotransverse ligament | 23 Radiate ligament of head of rib T8 |
| 9 Common carotid artery | 24 Latissimus dorsi muscle |
| 10 Trapezius muscle | 25 Hemiazygos vein |
| 11 Left brachiocephalic vein | 26 Posterior intercostal artery and vein (dorsal branch) |
| 12 Spinalis thoracis muscle | 27 Descending aorta |
| 13 Subclavian artery | 28 Erector spinae muscle |
| 14 Sixth rib (head) | 29 Esophagus |
| 15 Aortic arch | 31 Liver |



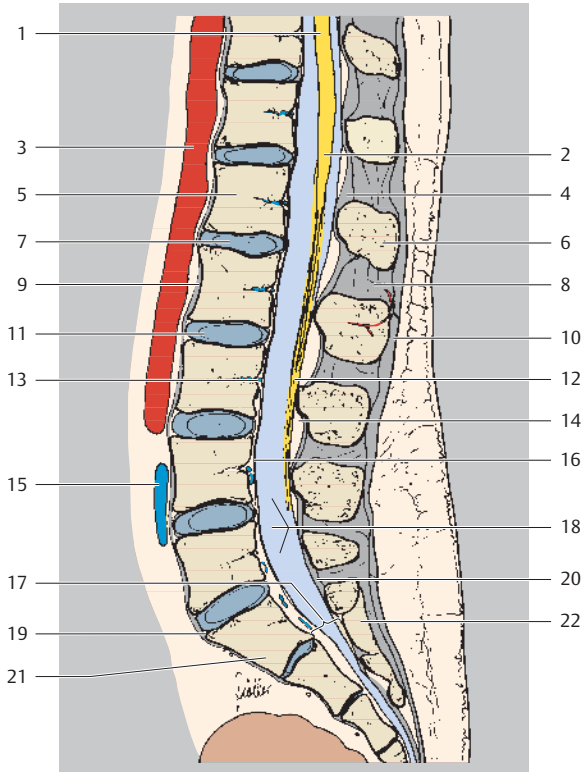
Ventral
Right Left
Dorsal



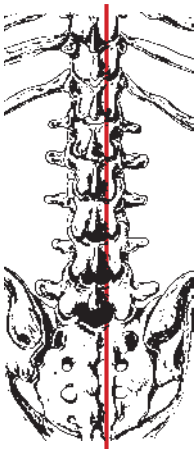
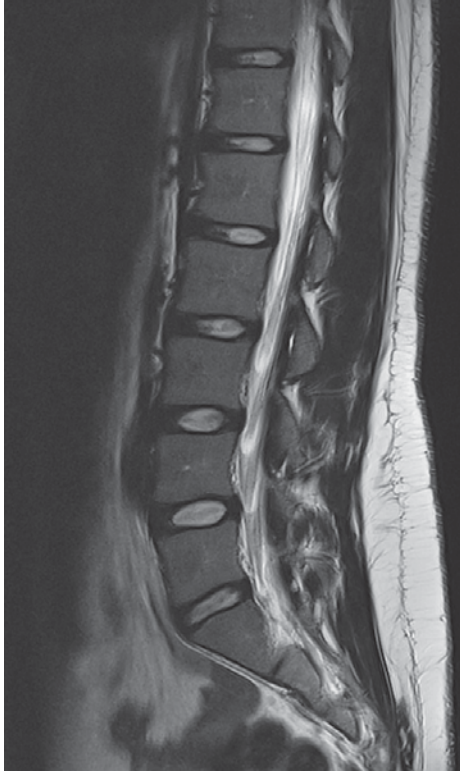- | | |
|------------------------------------|---|
| 1 Right lung | 21 Thoracic spinal cord |
| 2 Infrapinatus muscle | 22 Retrosinal fatty triangle (epidural fat) |
| 3 Intercostal artery | 23 Esophagus |
| 4 Subscapularis muscle | 24 Spinalis thoracis muscle |
| 5 Costotransverse joint | 25 Spinal ganglion |
| 6 Scapula | 26 Multifidus muscle |
| 7 Rib (neck) | 27 Accessory hemiazygos vein |
| 8 Rhomboid major muscle | 28 Longissimus thoracis muscle |
| 9 Fifth rib (head) | 29 Left pulmonary artery |
| 10 Intercostal muscles | 30 Costotransverse ligament (lateral) |
| 11 Radiate ligament of head of rib | 31 Ligamentum flavum |
| 12 Rotatores thoracis muscles | 32 Fifth rib (tubercle) |
| 13 Joint of head of rib | 33 Superior articular process T5 |
| 14 Semispinalis thoracis muscle | 34 Trapezius muscle |
| 15 Trachea (bifurcation) | 35 Inferior articular process T4 |
| 16 Zygapophyseal joint T4/T5 | 36 Iliocostalis thoracis muscle |
| 17 Azygos vein | 37 Descending aorta |
| 18 Spinous process | 38 Fifth rib (body) |
| 19 Intervertebral disk T4/T5 | 39 Transverse process T5 |
| 20 Supraspinous ligament | |



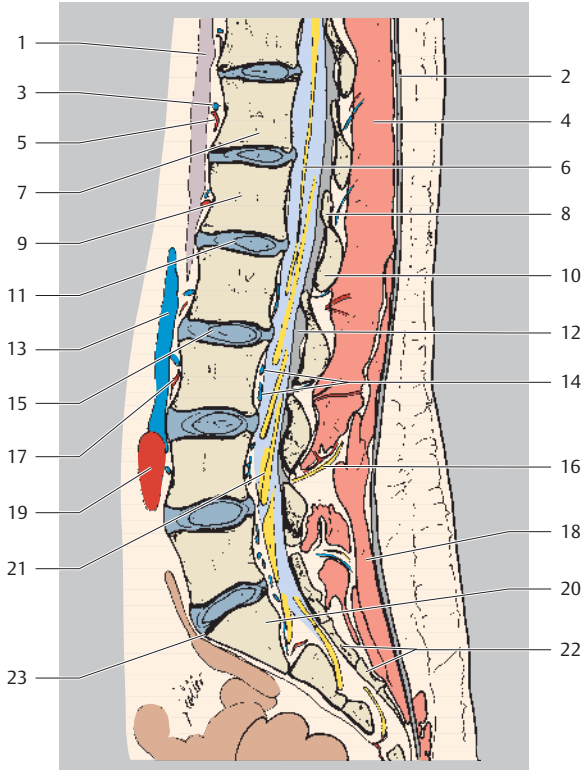
Cranial
Ventral Dorsal
Caudal



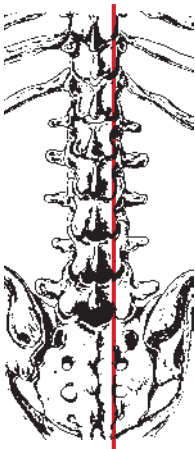
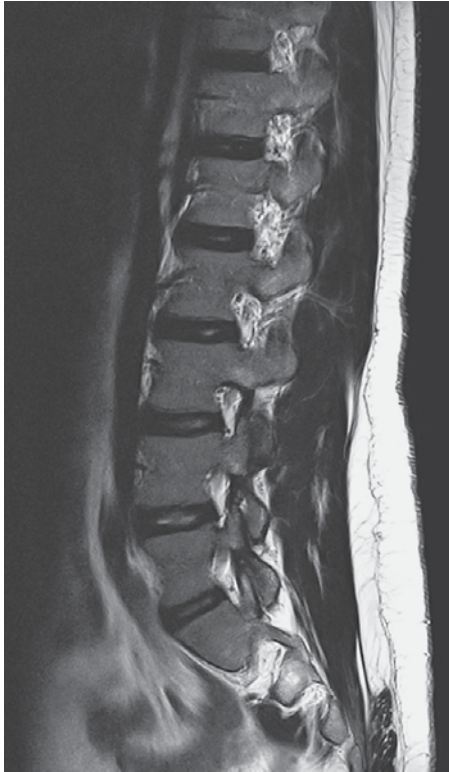- | | |
|--|------------------------------------|
| 1 Spinal cord | 12 Cauda equina |
| 2 Conus medullaris | 13 Basivertebral vein |
| 3 Abdominal aorta | 14 Epidural fatty tissue |
| 4 Ligamentum flavum | 15 Left common iliac vein |
| 5 Lumbar vertebral body L1 | 16 Posterior longitudinal ligament |
| 6 Spinous process L1 | 17 Sacral canal |
| 7 Intervertebral disk L1/L2
(nucleus pulposus) | 18 Thecal sac (lumbar cistern) |
| 8 Interspinous ligament | 19 Promontory of sacrum |
| 9 Anterior longitudinal ligament | 20 Dura mater |
| 10 Supraspinous ligament | 21 Sacrum (S1) |
| 11 Intervertebral disk L2/L3
(annulus fibrosus) | 22 Median sacral crest |



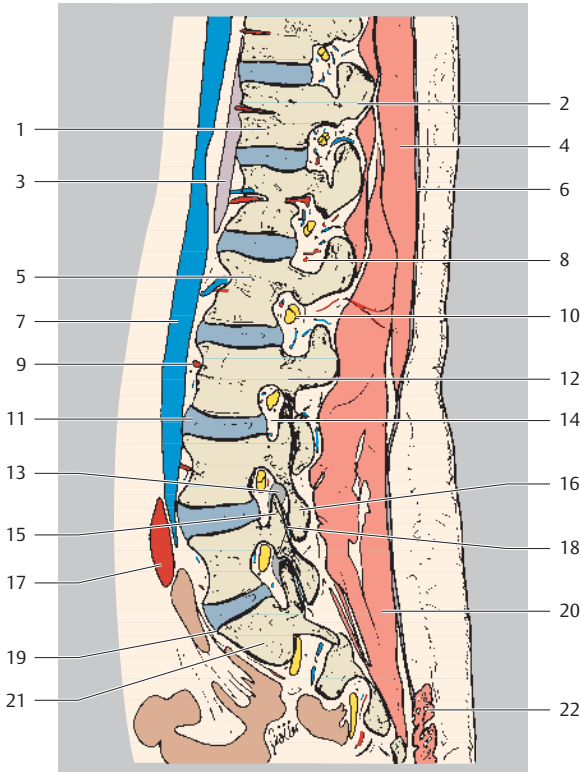
Cranial
Ventral Dorsal
Caudal



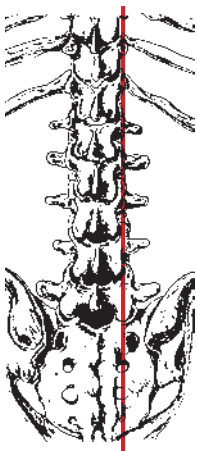
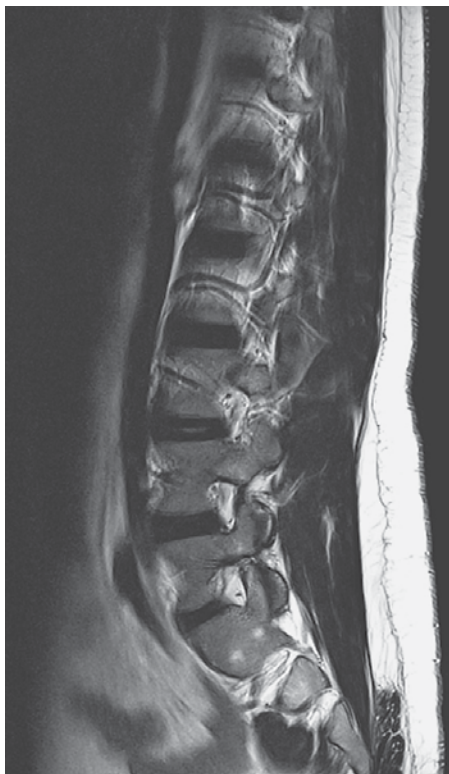- | | |
|---|---|
| 1 Diaphragm (lumbar part) | 12 Ligamentum flavum |
| 2 Thoracolumbar fascia | 13 Inferior vena cava |
| 3 Anterior external vertebral venous plexus | 14 Anterior internal vertebral venous plexus |
| 4 Erector spinae muscle (spinalis muscle) | 15 Intervertebral disk L2/L3 (anulus fibrosus) |
| 5 Posterior intercostal artery | 16 Lumbar artery and nerve (medial cutaneous branch of dorsal branch) |
| 6 Nerve filaments | 17 Lumbar artery |
| 7 Thoracic vertebral body T12 | 18 Multifidus muscle |
| 8 Superior articular process | 19 Common iliac artery |
| 9 Lumbar vertebral body L1 | 20 Sacrum (S1) |
| 10 Posterior vertebral arch (lamina) | 21 Spinal ganglion |
| 11 Intervertebral disk L1/L2 (nucleus pulposus) | 22 Median sacral crest |
| | 23 Promontory of sacrum |



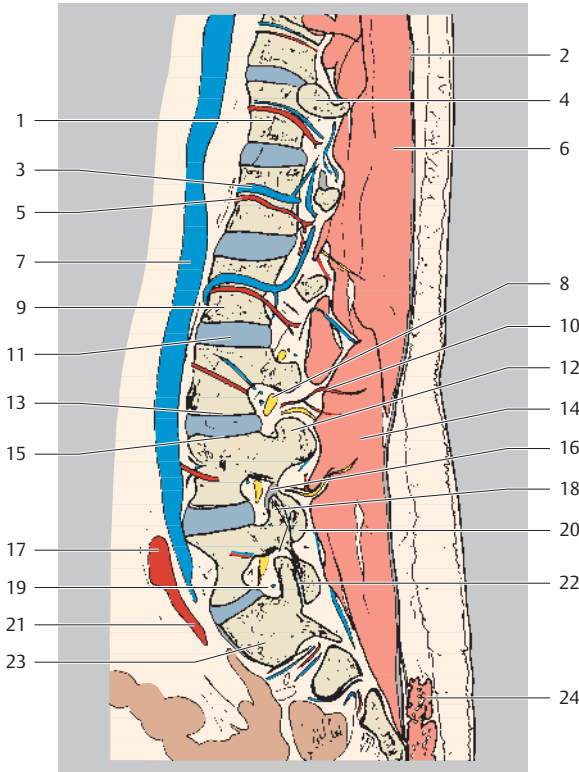
Cranial
Ventral Dorsal
Caudal



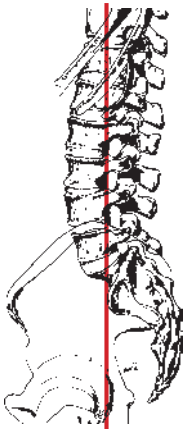
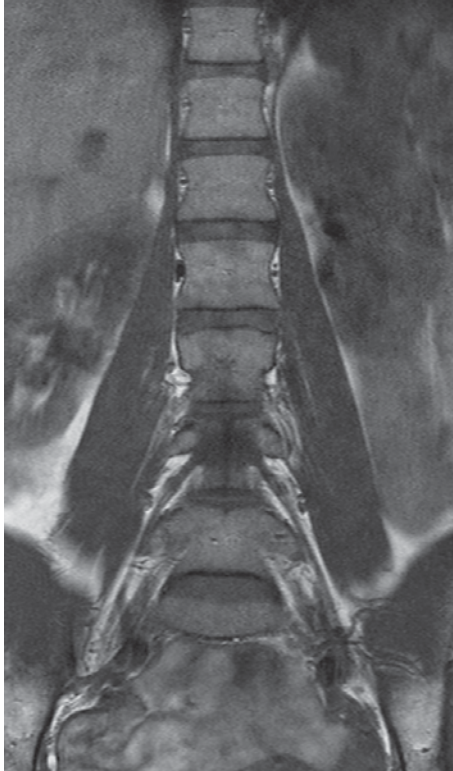- | | |
|--|--------------------------------------|
| 1 Thoracic vertebral body T12 | 12 Posterior vertebral arch (lamina) |
| 2 Mamillary process | 13 Ligamentum flavum |
| 3 Diaphragm (lumbar part) | 14 Intervertebral foramen |
| 4 Erector spinae muscle (spinalis muscle) | 15 Superior articular process |
| 5 Lumbar vertebral body L2 | 16 Inferior articular process |
| 6 Thoracolumbar fascia | 17 Common iliac artery |
| 7 Inferior vena cava | 18 Zygapophyseal joint |
| 8 Spinal branch of lumbar artery (dorsal branch) | 19 Promontory of sacrum |
| 9 Posterior intercostal artery | 20 Multifidus muscle |
| 10 Spinal ganglion L2 | 21 Sacrum (S1) |
| 11 Intervertebral disk L3/L4 (nucleus pulposus) | 22 Gluteus maximus muscle |



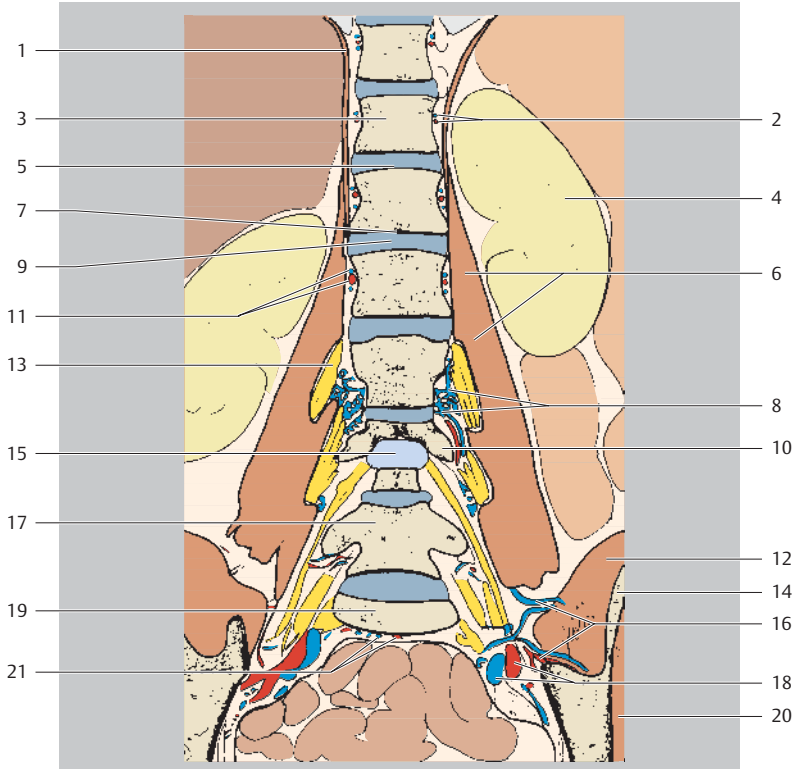
Cranial
Ventral Dorsal
Caudal



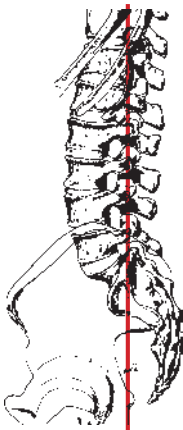
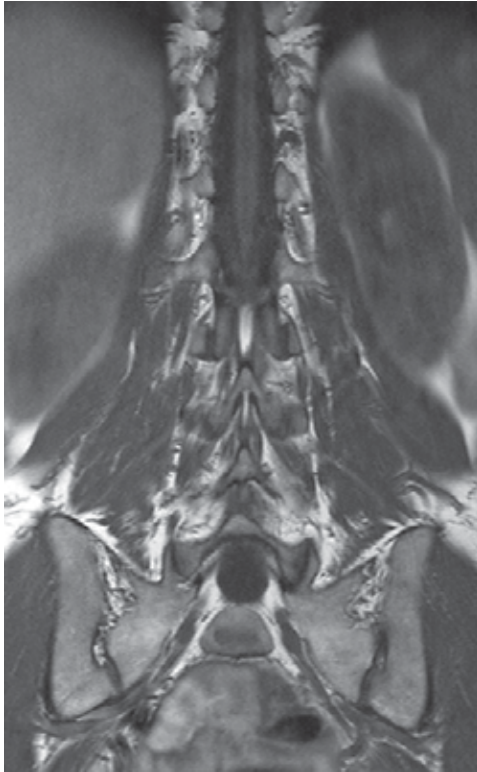
- | | |
|---|--------------------------------|
| 1 Thoracic vertebral body T12 | 13 Inferior vertebral endplate |
| 2 Thoracolumbar fascia | 14 Multifidus muscle |
| 3 Lumbar vein | 15 Superior vertebral endplate |
| 4 Rib (head) | 16 Ligamentum flavum |
| 5 Lumbar artery | 17 Common iliac artery |
| 6 Erector spinae muscle (spinalis muscle) | 18 Superior articular process |
| 7 Inferior vena cava | 19 Intervertebral foramen |
| 8 Spinal nerve L3 | 20 Inferior articular process |
| 9 Lumbar vertebral body L2 | 21 Internal iliac artery |
| 10 Lumbar artery (dorsal branch) | 22 Zygapophyseal joint |
| 11 Intervertebral disk | 23 Sacrum (S1) |
| 12 Transverse process | 24 Gluteus maximus muscle |



Cranial
Right Left
Caudal

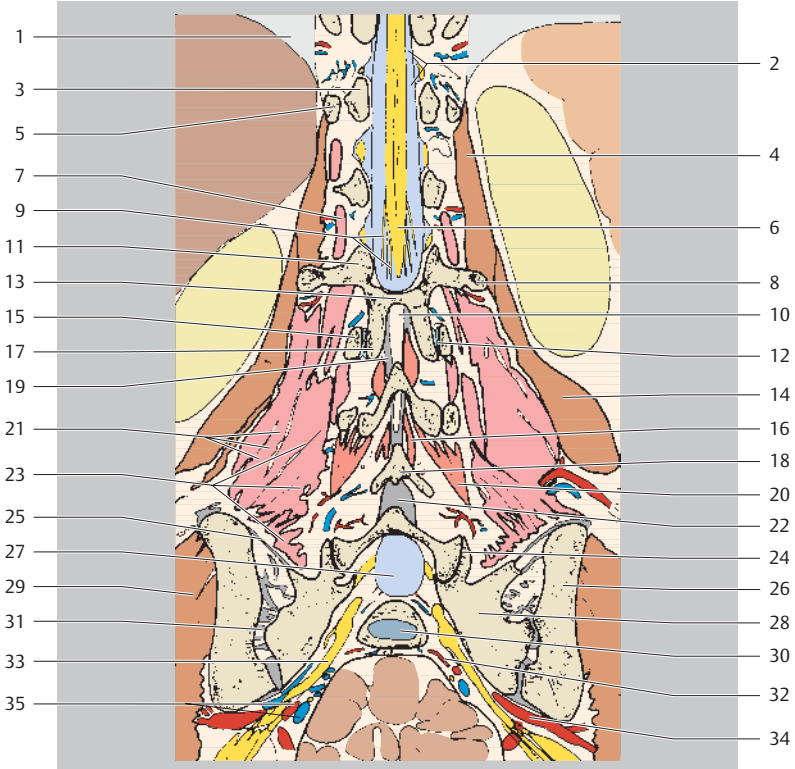


- | | |
|---|-----------------------------------|
| 1 Diaphragm (lumbar part) | 10 Transverse process L4 |
| 2 Posterior intercostal artery and vein | 11 Lumbar artery and vein |
| 3 Thoracic vertebral body T12 | 12 Iliacus muscle |
| 4 Left kidney | 13 Lumbar plexus |
| 5 Superior vertebral endplate L1 | 14 Ilium |
| 6 Psoas major muscle | 15 Thecal sac (lumbar cistern) |
| 7 Inferior vertebral endplate L1 | 16 Iliolumbar artery and vein |
| 8 Anterior external vertebral venous plexus | 17 Lumbar vertebral body L5 |
| 9 Intervertebral disk L1/L2 (anulus fibrosus) | 18 Internal iliac artery and vein |
| | 19 Promontory of sacrum |
| | 20 Gluteus medius muscle |
| | 21 Median sacral artery and vein |

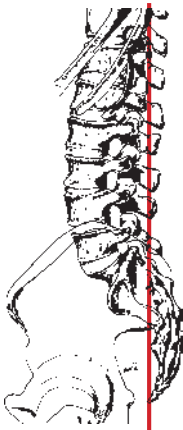
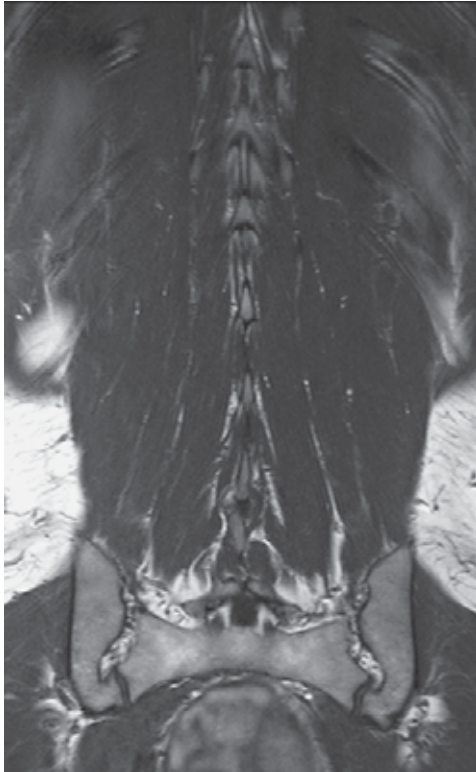


Cranial
Right Left
Caudal

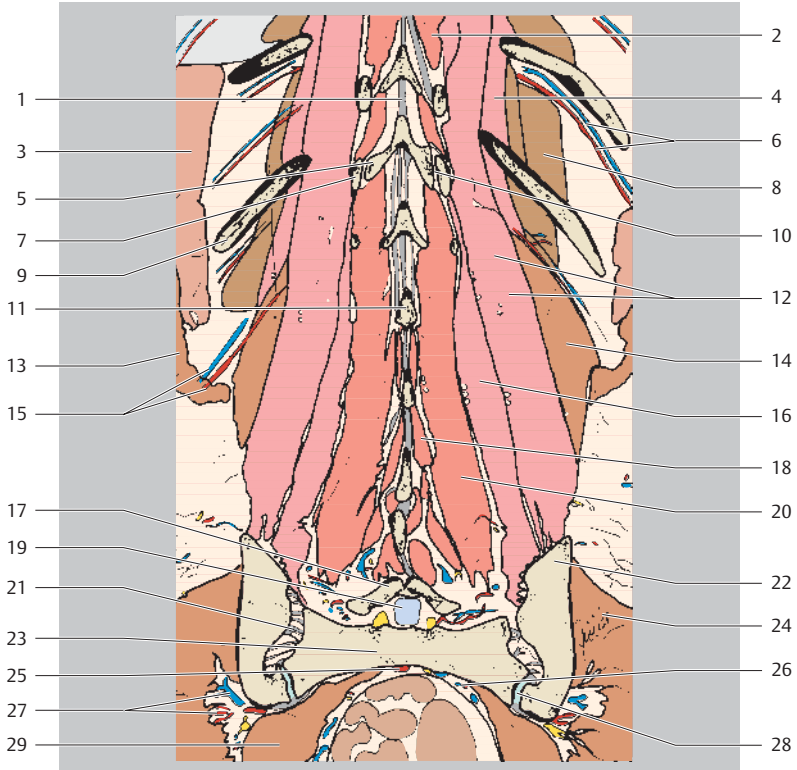
- 1 Right lung
- 2 Cerebrospinal fluid in thecal sac (lumbar cistern)
- 3 Pedicle of vertebral arch T12
- 4 Psoas major muscle
- 5 Twelfth rib (head)



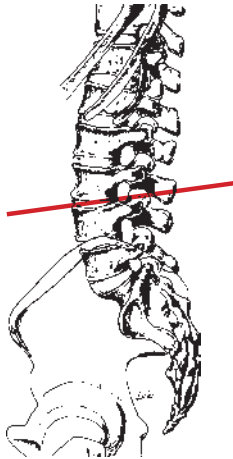
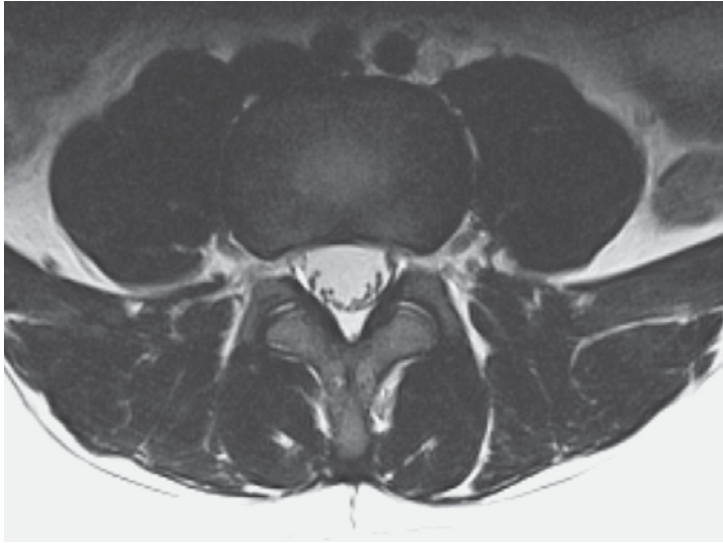
- | | | | |
|----|--|----|---------------------------------------|
| 6 | Conus medullaris | 21 | Iliocostalis lumborum muscle |
| 7 | Intertransversarius muscle | 22 | Interspinous ligament |
| 8 | Transverse process L2 | 23 | Longissimus muscle |
| 9 | Cauda equina | 24 | Lumbosacral zygapophyseal joint L5/S1 |
| 10 | Posterior epidural fat (retrospinal fat, dorsal fat) | 25 | Sacroiliac ligaments |
| 11 | Posterior vertebral arch L2 (lamina) | 26 | Ilium |
| 12 | Zygapophyseal joint | 27 | Thecal sac (lumbar cistern) |
| 13 | Pedicle of vertebral arch L2 | 28 | Sacrum (lateral mass) |
| 14 | Quadratus lumborum muscle | 29 | Gluteus medius muscle |
| 15 | Superior articular process L3 | 30 | Intervertebral space S1/S2 |
| 16 | Interspinalis muscle | 31 | Sacroiliac joint |
| 17 | Inferior articular process L2 | 32 | Lateral sacral artery and vein |
| 18 | Spinous process L4 | 33 | Sacral plexus |
| 19 | Ligamentum flavum | 34 | Superior gluteal artery |
| 20 | Multifidus muscle | 35 | Internal iliac artery and vein |



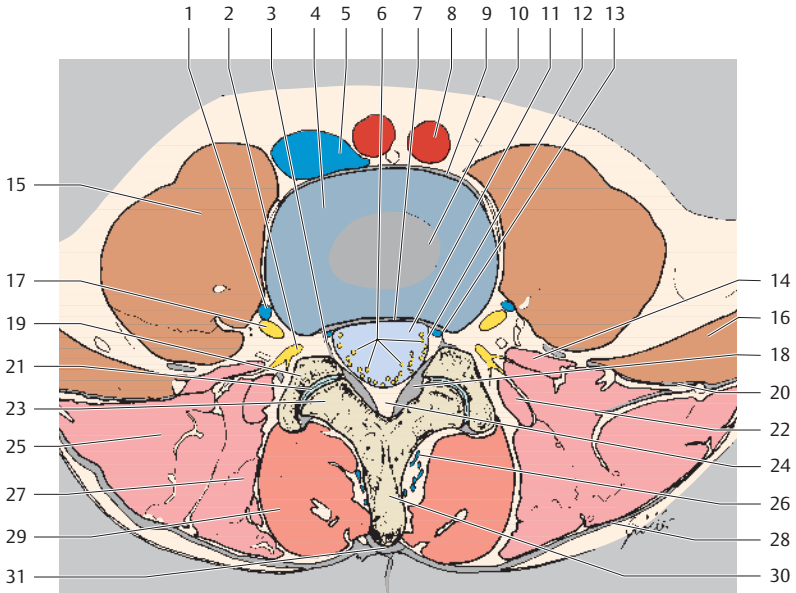
Cranial
Right Left
Caudal



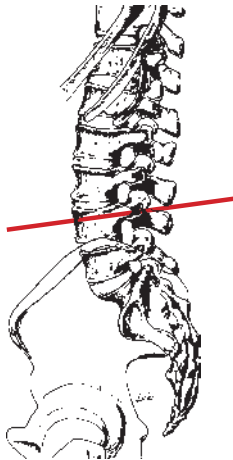
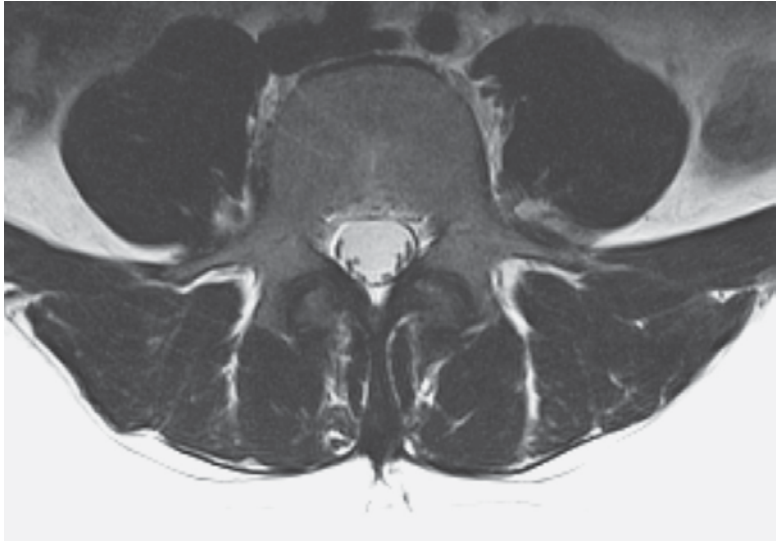
- | | |
|---|---|
| 1 Interspinous ligament | 15 Lumbar artery and vein |
| 2 Spinalis thoracis muscle and rotatores thoracis muscles | 16 Longissimus muscle |
| 3 Serratus anterior muscle | 17 Posterior vertebral arch S1 (lamina) |
| 4 Levatores costarum muscles | 18 Interspinales lumborum muscles |
| 5 Inferior articular process T12 | 19 Cerebrospinal fluid in thecal sac (lumbar cistern) |
| 6 Posterior intercostal artery and vein | 20 Multifidus muscle |
| 7 Superior articular process L1 | 21 Sacroiliac ligaments |
| 8 Intercostal muscles | 22 Ilium |
| 9 Eleventh rib | 23 Sacrum |
| 10 Zygapophyseal joint | 24 Gluteus medius muscle |
| 11 Spinous process L2 | 25 Median sacral artery and vein |
| 12 Iliocostalis lumborum muscle | 26 Lateral sacral artery and vein |
| 13 Latissimus dorsi muscle | 27 Superior gluteal artery and vein |
| 14 Quadratus lumborum muscle | 28 Sacroiliac joint |
| | 29 Piriformis muscle |



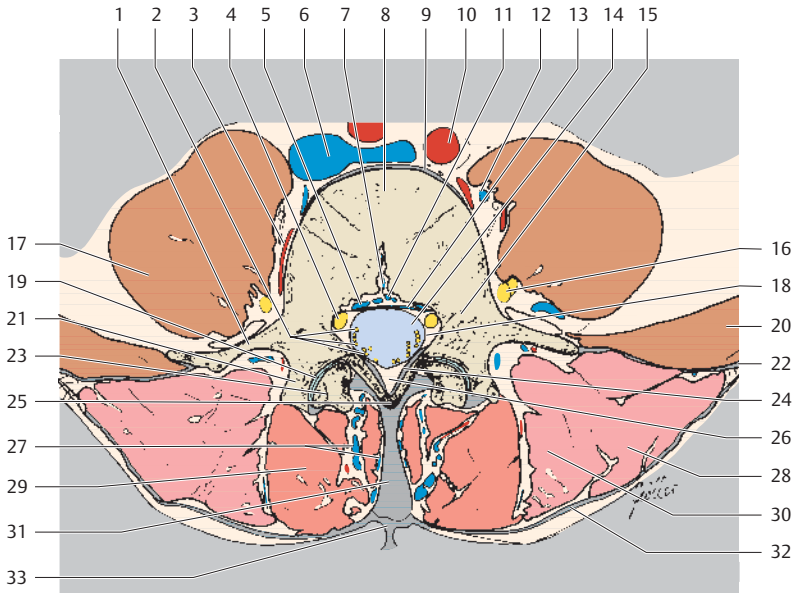
Ventral
Right Left
Dorsal



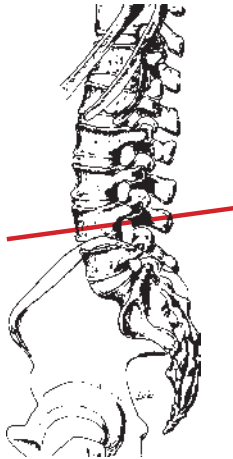
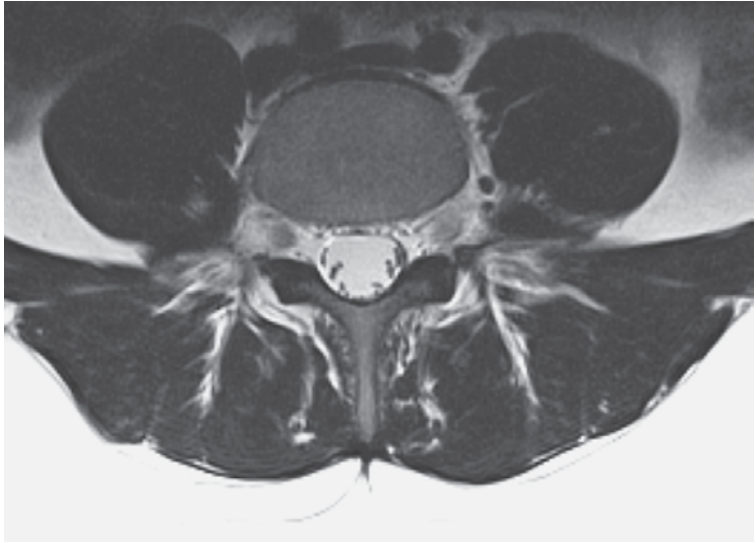
- | | |
|--|---|
| 1 Lumbar vein | 18 Ligamentum flavum |
| 2 Spinal nerve (dorsal ramus) | 19 Inferior articular process |
| 3 Neuroforaminal ligament | 20 Thoracolumbar fascia (anterior layer) |
| 4 Intervertebral disk L3/L4 (anulus fibrosus) | 21 Zygapophyseal joint |
| 5 Inferior vena cava (confluence) | 22 Erector spinae muscle (lateral tract: intertransversarii mediales muscles) |
| 6 Nerve filaments | 23 Superior articular process |
| 7 Posterior longitudinal ligament | 24 Epidural fatty tissue (retrospinal/dorsal fatty triangle) |
| 8 Left common iliac artery | 25 Erector spinae muscle (lateral tract: iliocostalis lumborum muscle) |
| 9 Anterior longitudinal ligament | 26 Posterior external vertebral venous plexus |
| 10 Intervertebral disk L3/L4 (nucleus pulposus) | 27 Erector spinae muscle (lateral tract: longissimus muscle) |
| 11 Thecal sac (lumbar cistern) | 28 Thoracolumbar fascia (posterior layer) |
| 12 Spinal dura mater | 29 Erector spinae muscle (medial tract: multifidus muscle) |
| 13 Internal vertebral venous plexus | 30 Spinous process |
| 14 Erector spinae muscle (lateral tract: intertransversarii laterales muscles) | 31 Supraspinous ligament |
| 15 Psoas major muscle | |
| 16 Quadratus lumborum muscle | |
| 17 Spinal ganglion L3 | |



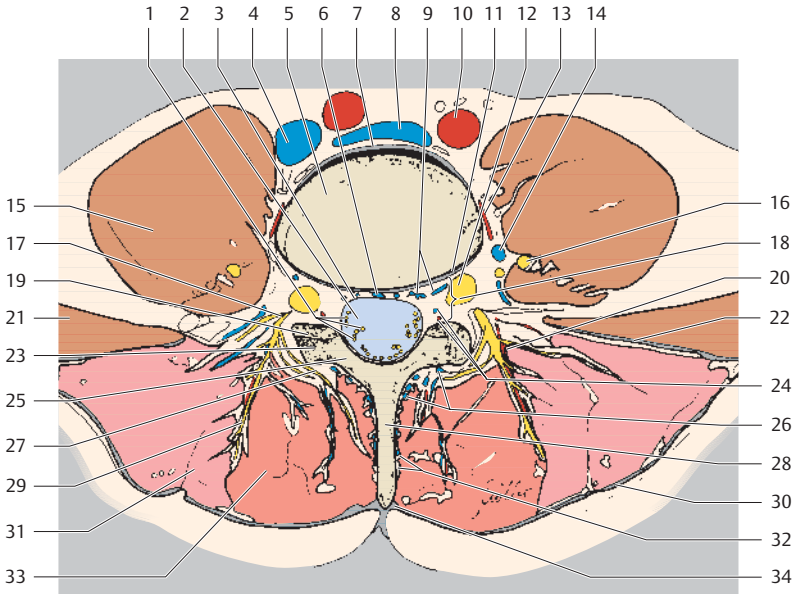
Ventral
Right Left
Dorsal



- | | |
|---|--|
| 1 Costal process | 20 Quadratus lumborum muscle |
| 2 Nerve filaments | 21 Superior articular process |
| 3 Lumbar artery | 22 Thoracolumbar fascia (anterior layer) |
| 4 Spinal ganglion in lateral recess L4 | 23 Inferior articular process |
| 5 Anterior internal vertebral venous plexus | 24 Ligamentum flavum |
| 6 Inferior vena cava (confluence) | 25 Posterior vertebral arch (lamina) |
| 7 Nutrient foramen | 26 Epidural fatty tissue (retrospinal/dorsal fatty triangle) |
| 8 Lumbar vertebral body L4 | 27 Posterior external vertebral venous plexus |
| 9 Anterior longitudinal ligament | 28 Erector spinae muscle (lateral tract: iliocostalis lumborum muscle) |
| 10 Left common iliac artery | 29 Erector spinae muscle (medial tract: multifidus muscle) |
| 11 Basivertebral vein | 30 Erector spinae muscle (lateral tract: longissimus muscle) |
| 12 Ascending lumbar vein | 31 Interspinous ligament |
| 13 Posterior longitudinal ligament | 32 Thoracolumbar fascia (posterior layer) |
| 14 Thecal sac (lumbar cistern) | 33 Supraspinous ligament |
| 15 Interarticular portion L4 | |
| 16 Spinal ganglion L3 | |
| 17 Psoas major muscle | |
| 18 Spinal dura mater | |
| 19 Zygapophyseal joint | |



Ventral
Right Left
Dorsal



- | | |
|--|--|
| 1 Nerve filaments | 21 Quadratus lumborum muscle |
| 2 Thecal sac (lumbar cistern) | 22 Thoracolumbar fascia (anterior layer) |
| 3 Spinal dura mater | 23 Inferior articular process |
| 4 Right common iliac vein | 24 Radicular artery and vein |
| 5 Lumbar vertebral body L4 | 25 Posterior vertebral arch (lamina) |
| 6 Basivertebral vein | 26 Posterior external vertebral venous plexus |
| 7 Anterior longitudinal ligament | 27 Spinal nerve (medial dorsal branch) |
| 8 Left common iliac vein | 28 Spinous process |
| 9 Anterior internal vertebral venous plexus | 29 Spinal nerve (lateral dorsal branch) |
| 10 Left common iliac artery | 30 Thoracolumbar fascia (posterior layer) |
| 11 Posterior longitudinal ligament | 31 Erector spinae muscle (lateral tract: iliocostalis lumborum et longissimus muscles) |
| 12 Spinal ganglion L4 | 32 Paraspinal fatty tissue |
| 13 Lumbar artery | 33 Erector spinae muscle (medial tract: multifidus muscle) |
| 14 Ascending lumbar vein | 34 Supraspinous ligament |
| 15 Psoas major muscle | |
| 16 Spinal ganglion L3 | |
| 17 Spinal nerve (dorsal branch) | |
| 18 Intervertebral foramen | |
| 19 Zygapophyseal joint | |
| 20 Lumbar artery (lateral cutaneous branch of dorsal branch) | |

Bibliography

- Braun H, et al. Direkte MR-Arthrographie des Handgelenkes. *Röfo* 2003;175:1515–24
- Bulling A, Castrop F, Agneskirchner J, et al. *Body Explorer 2.0*. Heidelberg: Springer Electronic Media; 2001
- Burgener FA, Aeyers SP, Tan RK. *Differential Diagnosis in MRI*. Stuttgart: Thieme; 2002
- Cahill DR, Orland MJ, Reading CC. *Atlas of Human Cross-Sectional Anatomy*. New York: Wiley-Liss; 1995
- Chacko AK, Katzberg RW, MacKay A. *MRI Atlas of Normal Anatomy*. New York: McGraw-Hill; 1991
- Clavero JA, et al. MR imaging of ligament and tendon injuries of the fingers. *Radiographics* 2002; 22:237–56
- Clavero JA, et al. Extensor mechanism of the fingers: MR imaging—anatomic correlation. *Radiographics* 2003;23:593–611
- Connell DA, Koulouris G, Thorn DA, Potter HG. Contrast-enhanced MR angiography of the hand. *Radiographics* 2002;22:583–99
- Dauber W. *Pocket Atlas of Human Anatomy*, 5th edn. Stuttgart: Thieme; 2007
- Delfaut EM, et al. Imaging of foot and ankle entrapment syndromes. *Radiographics* 2003;23:613–23
- El-Khoury GY, Bergman RA, Montgomery EJ. *Sectional Anatomy by MRI/CT*. New York: Churchill-Livingstone; 1990
- El-Khoury GY, et al. *Essentials in Musculoskeletal Imaging*. New York: Churchill Livingstone; 2003
- Garcia-Valtuille R, et al. Anatomy and MR imaging appearances of synovial plicae of the knee. *Radiographics* 2002;22:775–84
- Grumme T, Kluge W, Kretzmar K, Roesler A. *Zerebrale und spinale CT*. Berlin: Blackwell; 1998
- Harnsberger R. *Diagnostic imaging. Head and neck*. Salt Lake City, Utah: Amirsys; 2004
- Hosten N, Liebig T. *CT of the head and spine*. Stuttgart: Thieme; 2002
- Huk WJ, Gademann G, Friedmann G. *MRI of Central Nervous System Diseases*. Berlin: Springer; 1990
- Kang MS, Resnick D. *MRI of the Extremities: An Anatomic Atlas*. Philadelphia: Saunders; 2002
- Koritke JG, Sick H. *Atlas of Sectional Human Anatomy*. Baltimore: Urban & Schwarzenberg; 1988
- Kretschmann H-J, Weinrich W. *Cranial Neuroimaging and Clinical Neuroanatomy*. Stuttgart: Thieme; 2003
- Leblanc A. *Encephalo-peripheral Nervous System*. Berlin: Springer; 2001
- Leonhardt H, Tillmann B, Töndury G, Zilles K (eds). *Bewegungsapparat*. (Rauber/Kopsch Anatomie des Menschen. Lehrbuch und Atlas. Vol 1) Stuttgart: Thieme; 1987
- Lustrin ES, et al. *Pediatric Cervical Spine: Normal Anatomy, Variants, and Trauma*. *Radiographics* 2003;23:539–60
- Mayerhöfer ME, Breitenseher MJ. MR-Diagnostik der lateralen Sprunggelenksbänder. *Röfo* 2003;175:670–5
- Mengiardi B, et al. Spring ligament complex: MR imaging—anatomic correlation and findings in asymptomatic subjects. *Radiology* 2005;237:242–9
- Meschan I. *Synopsis of Radiologic Anatomy*. Philadelphia: Saunders; 1978
- Mohana-Borges AV, et al. Lesser metatarsophalangeal joints. *Radiology* 2003;227:175–82
- Moeller TB, Reif E. *MR Atlas of the Musculoskeletal System*. Boston: Blackwell Science; 1994

- Moeller TB, Reif E. Neuroradiologische Schnittbilddiagnostik. Constance: Schnetztor; 2002
- Moeller TB, Reif E. Pocket Atlas of Radiographic Anatomy. Stuttgart: Thieme; 2000
- Morag Y et al. MR Arthrography of rotator interval, long head of the biceps brachii, and biceps pulley of the shoulder. *Radiology* 2005;235:21–30
- Munshi M. et al. Anterior bundle of ulnar collateral ligament: evaluation of anatomic relationship by using MR imaging, MR arthrography, and gross anatomic and histologic analysis. *Radiology* 2004;231:797–803
- Netter FH. Atlas der Anatomie des Menschen, 3rd edn. Stuttgart: Thieme; 2003
- Nowicki BH, Houghton VM. Neural foramina ligament of the lumbar spine: appearance at CT and MR imaging. *Radiology* 1992;183:257–64
- Oae K, et al. Injury of the tibiofibular syndesmosis: value of MR imaging for diagnosis. *Radiology* 2003;227:155–61
- Pech P, Daniels DL, Williams AL, Houghton VM. The cervical neural foramina: correlation of microtomy and CT anatomy. *Radiology* 1985;155:143–6
- Platzer W. Color Atlas and Textbook of Human Anatomy, Vol. 1: Locomotor System, 5th edn. Stuttgart: Thieme; 2003
- Richter E, Feyerabend T. Normal lymph node topography. Berlin: Springer; 1991
- Robinson P, White LM. Soft-tissue and osseous impingement syndromes of the ankle. *Radiographics* 2002;22:1457–71
- Rummeny EJ, Reimer P, Heindel W. Ganzkörper MR-Tomographie, 2nd edn. Stuttgart: Thieme; 2006
- Schäfer FKW, et al. Sport injuries of the extensor mechanism of the knee. *Radiologie* 2002;799–810
- Schmitt R, Lanz U. Bildgebende Diagnostik der Hand. Stuttgart: Thieme; 2004
- Schnitzlein HN, Reed Murtagh F. Imaging Atlas of the Head and Spine. Baltimore: Urban & Schwarzenberg; 1990
- Schünke M, Schulte E, Schumacher U, Voll M, Wesker K. Prometheus—Lernatlas der Anatomie, 3 vols. Stuttgart: Thieme; 2004–2006
- Schuenke M, Schulte E, Ross LM, Lamberti ED. Thieme Atlas of Anatomy. General Anatomy and Musculoskeletal System. Stuttgart: Thieme; 2006
- Stark DD, Bradley WG. Magnetic Resonance Imaging. St. Louis: Mosby; 1999
- Strobel K, Hodler J. MRT des Kniegelenkes. Radiologie up2date. Stuttgart: Thieme; 2003
- Stoller DW. MRI, Arthroscopy, and Surgical Anatomy of the Joints. Philadelphia: Lippincott Williams & Wilkins; 1999
- Stoller DW, Tirman B. Diagnostic imaging: Orthopaedics. Salt Lake City, Utah: Amirsys; 2004
- Theumann NH, et al. MR Imaging of the Metacarpophalangeal Joints of the Fingers. *Radiology* 2002;222:437–45
- Theumann NH, et al. Extrinsic carpal ligaments: Normal MR arthrographic appearance in cadavers. *Radiology* 2003;226:171–9
- Tiedemann K. Anatomy of the Head and Neck. Weinheim: VCH; 1993
- Uhlenbrock D. MR Imaging of the Spine and Spinal Cord. Stuttgart: Thieme; 2004
- Vahlensieck M, Linneborn G, Schild HH, Schmidt HM. MRT der Bursae des Kniegelenk. *Röfo* 2001;173:195–199
- Vahlensieck M. Anatomie der Schulterregion. *Radiologie* 2004;44:556–61
- Vahlensieck M, Reiser M: MRT des Bewegungsapparates. Stuttgart: Thieme; 2001