

## Chapter 117 – Otosclerosis

Barry E. Hirsch

Otosclerosis is a two-stage, metabolic bone-remodeling process of the otic capsule characterized by bone resorption (otospongiosis) and recalcification (otosclerosis). The term *otosclerosis* was ascribed to Politzer in 1894.[1] The etiology is believed to be familial, with inheritance occurring by autosomal dominant transmission with varying penetrance. Konigsmark and Gorlin[2] reported the incidence of clinical otosclerosis to be 3 per 1000 in whites and much less in blacks, although histologic evidence of disease has been reported in as many as 8% of temporal bones.

Investigations over the past few years have focused on other causes of stapes fixation, including viral infections. It is postulated that a systemic viral infection may cause an inflammatory vascular reaction with the subsequent development of otosclerosis. Reverse transcriptase–polymerase chain reaction (RT-PCR) has provided evidence suggesting that a paramyxovirus responsible for measles may be the cause of otosclerosis. An excellent summary of the association of viruses as the cause of otosclerosis was published by Ferlito and colleagues.[3]

Among adults, otosclerosis is the chief cause of conductive hearing loss, which occurs in several well-known patterns. It most frequently begins in young adulthood but may occur from adolescence to old age. Otosclerosis is more common in females by a ratio of 2:1 or 3:1, and the family history is positive in 50% of patients, which implies that the disease develops spontaneously in the remaining 50% of people affected by otosclerosis.

Although conductive hearing loss secondary to stapediaal fixation is the classic manifestation, mixed hearing loss and even pure sensorineural hearing impairment can result from disease in the otic capsule. In addition, it is not uncommon for hearing loss to change in type over time. A sensorineural component may develop in people with conductive loss, and those who start with sensorineural hearing loss can acquire conductive loss as well.

Surgeons have recognized the mechanical impediment to sound transmission caused by otosclerosis since the late 19th century. Since then, surgical procedures for correction of otosclerosis have been modified, abandoned, and then re-established to provide one of otolaryngology's most fascinating stories. Today, a properly selected patient in the hands of an experienced otologic surgeon has a better than 95% chance of hearing restoration, with a low incidence of complications by closure of the air-bone gap. Certainly, these expectations rival those of any surgical procedure and have resulted in stapes surgery for otosclerosis being an extremely successful method of restoring hearing.

### PATIENT EVALUATION AND SELECTION

Patients typically have a complaint of slowly progressive hearing loss in one or both ears identified by themselves or others such as coworkers, friends, and family. Associated complaints may include tinnitus that is occasionally described as “hearing one's heartbeat” in one or both ears. This form of pulsatile tinnitus can occur with otosclerosis, especially when otospongiosis is active. Patients with active disease may describe mild dizziness or motion intolerance. This complaint can be troubling because stapes surgery should be avoided if there are other sources of vestibular dysfunction. Dehiscence of the superior semicircular canal can be manifested as pressure-induced dizziness and conductive hearing loss. This is discussed later in this chapter. If the disequilibrium, lightheadedness, or motion intolerance can be ascribed to otosclerosis, surgery will probably resolve the problem. Patients may have a varied degree of hearing loss once confirmed on audiometric testing. Some people are acutely aware of 10 to 15 dB of hearing difference between the two ears. Others may need to incur greater loss to bring the impairment to their attention. Individual tolerance to hearing impairment varies greatly. For this reason it is not unusual for hearing loss to progress to moderate levels, especially when the patient's hearing needs have not been complex. The patient's subjective assessment of the hearing loss does not always match the physician's objective evaluation.

Physical examination of the ears should identify a healthy ear canal and tympanic membrane with no evidence of middle ear pathology. Tuning fork testing remains an essential factor in helping determine the type and degree of hearing loss. Positive results on the Rinne test (air conduction greater than bone conduction) with 256- and 512-Hz tuning forks suggest that if an air-bone gap is identified on audiometric testing, it is probably less than 15 dB. Such patients are not usually considered candidates for surgical intervention at that time. They are apprised of their hearing levels and advised to be seen again in 6 months to monitor their audiometric and tuning fork results. An audiogram is mandatory in evaluating candidacy for otosclerosis surgery. There should be evidence of a 25-dB

air-bone gap in the involved ear to consider offering surgery for correction of the hearing loss. Conductive hearing loss on audiometric testing should always be confirmed by the tuning fork examination. Mixed hearing loss should prompt the surgeon to consider the phenomenon of Carhart's notch (Fig. 117-1). This will allow as much as 15 dB of "overclosure" at 2000 Hz, 10 dB at 1000 and 3000 Hz, and 5 dB at 500 Hz.




Figure 117-1 Audiogram showing right mixed hearing loss and a sensorineural dip at 2000 Hz indicative of Carhart's notch.

Ideally, successful surgery will restore hearing to normal levels, but many patients are happy with modest improvement that lessens their dependency on amplification. Each patient requires a thoughtful discussion of the realistic expectations for hearing improvement, in addition to counseling about alternative methods. For persons who are not certain about their treatment preference, a trial of amplification should be suggested.

Some clinical situations can present a significant challenge to obtaining accurate audiometric data. First is the presence of a large air-bone gap, particularly when asymmetrical. Correct use of adequate masking in this case is mandatory to avoid errors related to crossover to the other ear. Likewise, unilateral sensorineural impairment can create a "shadow curve" that mimics conductive loss. Tuning fork confirmation of audiometric data will save the physician from being misled.

Profound mixed hearing loss will challenge audiologists and otolaryngologists alike. In this situation, the bone conduction thresholds may exceed the maximum output of the audiometer, and the amount of air-bone gap is difficult to ascertain. Several clues, however, will help make the diagnosis of otosclerosis, including a positive family history of otosclerosis, documentation of progressive loss of hearing, evidence of conductive loss on previous audiograms, and success with amplification beyond that expected from examination of the audiometric thresholds. Reasonable word recognition scores in association with severe to profound sensorineural hearing loss should also heighten the clinician's suspicion of a conductive component. In these patients, surgical restoration of even 20 dB produces a grateful patient. They are in a much better position to successfully use a hearing aid at lower levels of amplification and avoid problems with acoustic feedback.

There are only two relatively hard-and-fast rules in surgery for otosclerosis: the first is never to operate on an only-hearing ear, and the second is always to operate on the poorer-hearing ear. These simple principles have been proved to serve the best interest of the patient. As with any rules, there are rare exceptions. If a person has profound mixed hearing loss in one ear, is anacusis in the other, and is unable to successfully use a hearing aid, the option of attempting partial hearing restoration is reasonable. The only remaining option would be a cochlear

implant. In a similar approach, if a patient who successfully underwent stapes surgery should lose hearing in the contralateral ear and serious complications develop in the operated ear, such as a perilymphatic fistula, surgical intervention is warranted.

### Differential Diagnosis and Concomitant Otologic Disease

Conductive hearing loss does not always guarantee the diagnosis of otosclerosis, especially when only one ear is involved. This is an important principle to be remembered when counseling patients for surgery. The surgeon must always look for and be prepared to manage problems other than stapes fixation when exploring the impaired ear. Congenital middle ear anomalies, tympanosclerosis, and lateral fixation of the ossicular chain are among the other causes of conductive loss.

A new clinical entity has recently been described that provides an explanation for "inner ear conductive hearing loss." Minor noted that patients with dehiscence of the superior semicircular canal present with signs and symptoms indicative of having a third window in the otic capsule, including a positive Tullio phenomenon (sound-induced vertigo); dizziness with a Valsalva maneuver, coughing, belching, or sneezing; pulsatile or thumping tinnitus; and occasionally, conductive hearing loss. Tuning fork testing can still show a negative Rinne test (bone conduction greater than air conduction). Conductive hearing loss coming from the middle ear routinely exhibits absence of elicited acoustic reflexes. In contrast, acoustic reflexes are typically present when the conductive hearing loss is due to dehiscence of the superior semicircular canal.<sup>[4]</sup> Patients suspected of having otosclerosis should undergo testing for acoustic reflexes preoperatively to help avoid performing middle ear surgery when an alternative source of conductive hearing loss may exist.

Concomitant disease must be considered in several instances. Meniere's disease in the involved ear is generally considered to be a contraindication to surgery because of a higher incidence of postoperative cochlear impairment. Active Meniere's disease in the contralateral ear is also a relative contraindication because the final hearing status of that ear is unknown. Tympanic perforations should be repaired before stapes surgery because of the risk of contamination of the middle ear and vestibule by organisms from the external auditory canal. The same strategy is maintained when a ventilation tube is in place. The tube needs to be removed and the tympanic membrane repaired. If needed, a ventilation tube can be placed later in the postoperative period. Osteogenesis imperfecta (van der Hoeve's syndrome) is often associated with conductive hearing loss, but more often it is secondary to erosion of the incus or crura of the stapes. Likewise, patients with Paget's disease may have fixation of the stapes, but long-term results are unfavorable because of the development of sensorineural loss.

### Otosclerosis in the Pediatric Age Group

Children with conductive hearing loss are less likely to have otosclerosis than other problems with the ossicular chain. Fixation of the stapes can be present from birth as a result of congenital fixation or can be acquired from tympanosclerosis or otosclerosis. The outcome after surgery can vary for each condition and may differ from surgeon to surgeon. Welling and coauthors reviewed the literature and reported their experience with pediatric stapes surgery. In general, similar results should be expected after stapes surgery for otosclerosis in children and adults. This implies hearing loss that develops late in the first decade or early teen years and is not associated with a history of recurrent otitis media. Surgical treatment of stapes fixation secondary to tympanosclerosis does not achieve as good or lasting results as treatment of fixation secondary to otosclerosis.<sup>[5]</sup> Computed tomography scanning must be performed in all pediatric patients with conductive hearing loss when surgical exploration is planned. The ear is examined for anomalies of the otic capsule such as a large vestibular aqueduct, cochlear dysplasia such as Mondini's deformity, or a wide internal auditory canal. These findings can be associated with a perilymphatic gusher, which may have disastrous effects on postoperative hearing. We would also recommend directing attention to the course of the facial nerve within the temporal bone to ensure that no anatomic anomalies are present. Such anomalies should temper the surgeon's judgment in favor of the use of amplification.

Selection of the correct ear for surgery is usually straightforward because the ear with the worse hearing is chosen. Word recognition scores are seldom a consideration in otosclerosis, but rarely these and other deficits in cochlear reserve must be factored in when presenting the options and risks to the patient. When hearing thresholds are similar in each ear, it is helpful to ask patients which side is most impaired in their judgment. Again, the worse ear is chosen for initial exploration. If the candidate cannot make a choice, it is useful to consider the side on which the telephone is usually held. Finally, if there is neither sufficient information nor patient preference to pick which side should be done first, the surgeon then has the option. It is easier for a right-handed surgeon to operate on a patient's left ear, especially if the patient has a large chest and short neck. The opposite holds for a left-handed surgeon.

In the past, some physicians have maintained that after successful surgery, the second ear should not undergo surgery. Today, most experienced surgeons believe that elective surgery in the second ear is desirable and carries the same risks as surgery on the first side. The advantages of binaural hearing in eliminating noise and providing sound localization are believed to outweigh the small risk of sensorineural loss. There is no correct period before

which the second ear may undergo surgery, but most surgeons prefer to wait at least 6 months. Certainly, during that period hearing in the operated ear should improve with no signs of complications.

Counseling of a patient considering surgery must always be based on the tenet that these procedures are elective. Some patients will choose no treatment despite what the surgeon and family believe is an obvious need for amelioration. Each individual has the right to make an informed choice, whether seemingly wise or not. No surgeon wishes to be in the position of defending an unfavorable result in a patient who was reluctant to undergo surgery in the first place. This is why unhurried and careful preoperative counseling is so important. A frank discussion of the results expected and potential risks necessarily includes the experience of the surgeon and not merely statistics quoted from the literature.

Although every potential complication cannot be anticipated, it is imperative to discuss those that present the greatest dangers and those that occur with the greatest frequency. Among the specific risks to be addressed are worsening or total hearing loss, possible infection, vertigo, disturbances in taste, perforation of the tympanic membrane, and facial weakness. It is also important to address postoperative restrictions so that patients can properly plan the few weeks after their surgery, including avoiding heavy strenuous work or exercise and keeping the ear dry from water.

## **PREOPERATIVE PLANNING**

A complete medical and drug history is important in each case. Pain in the back or neck or restriction of motion of the head or neck may limit the surgeon's ability to operate, particularly under local anesthesia. Advance knowledge of these potential problems will save a great deal of intraoperative delay. When lateral cervical rotation is restricted, the patient can be carefully strapped to an electric tilting operating table, which should provide adequate access to the ear, although patients with extreme immobility may technically be unable to undergo surgery. Patients who cannot lie flat or require special positioning may do better under general anesthesia. All medications that affect platelet function and coagulation should be discontinued 10 days before the procedure. Maintenance doses of warfarin (Coumadin) require consultation with the patient's primary care physician to discuss possible strategies for discontinuing the medication temporarily. As with any patient, a detailed history of drug allergies and sensitivities is necessary not only for the surgeon but also for the anesthesiologist.

The initial examination should recognize special problems related to the individual's anatomy, including the presence of a narrow external cartilaginous or bony meatus. Admission of a 4.5-mm speculum is generally sufficient for surgery, depending on the configuration of the canal. Constriction of the meatus can easily be alleviated by a 12-o'clock incision in the lateral canal between the helix and tragus. Unusual inclination or overhang of a canal wall should be noted preoperatively. Rarely, limited canal diameter or anterior displacement relative to the middle ear requires a postauricular approach. The presence of a very thin atrophic tympanic membrane, especially in its posterior portion, may alert the surgeon to the potential for a torn tympanic membrane and the need for supplemental tissue grafting of the tympanic membrane.

In the past our method for anesthesia was preoperative sedation and a local infiltration block. Exceptions were children, adults with special pain or positioning problems, and patients who request general anesthesia because of anxiety. We acknowledge the advantage of local anesthesia so that the surgeon can verify whether the patient's hearing is improved while on the operating table. The surgeon can also monitor for the development of vertigo in an awake patient. Complaints of vertigo should alter the surgeon's procedure or technique being taken at that time. Our approach then switched to the use of narcoleptic anesthesia administered intravenously by an anesthesiologist. This form of conscious sedation too often provided varying levels of sedation. The anesthesia would be "too light" or even "too deep," and patients would suddenly startle. They also experienced occasional paradoxical agitation and inability to hold still. Over the past few years we have used general anesthesia. It is our thinking that a motionless patient is less likely to have complications. We are confident in our technical abilities to execute the procedure in the same manner as though the patient were awake or sedated. The ear canal is still infiltrated by local injection via dental carpules containing 2% lidocaine (Xylocaine) with a 1:100,000 solution of epinephrine through a 27-gauge needle.

## **Imaging**

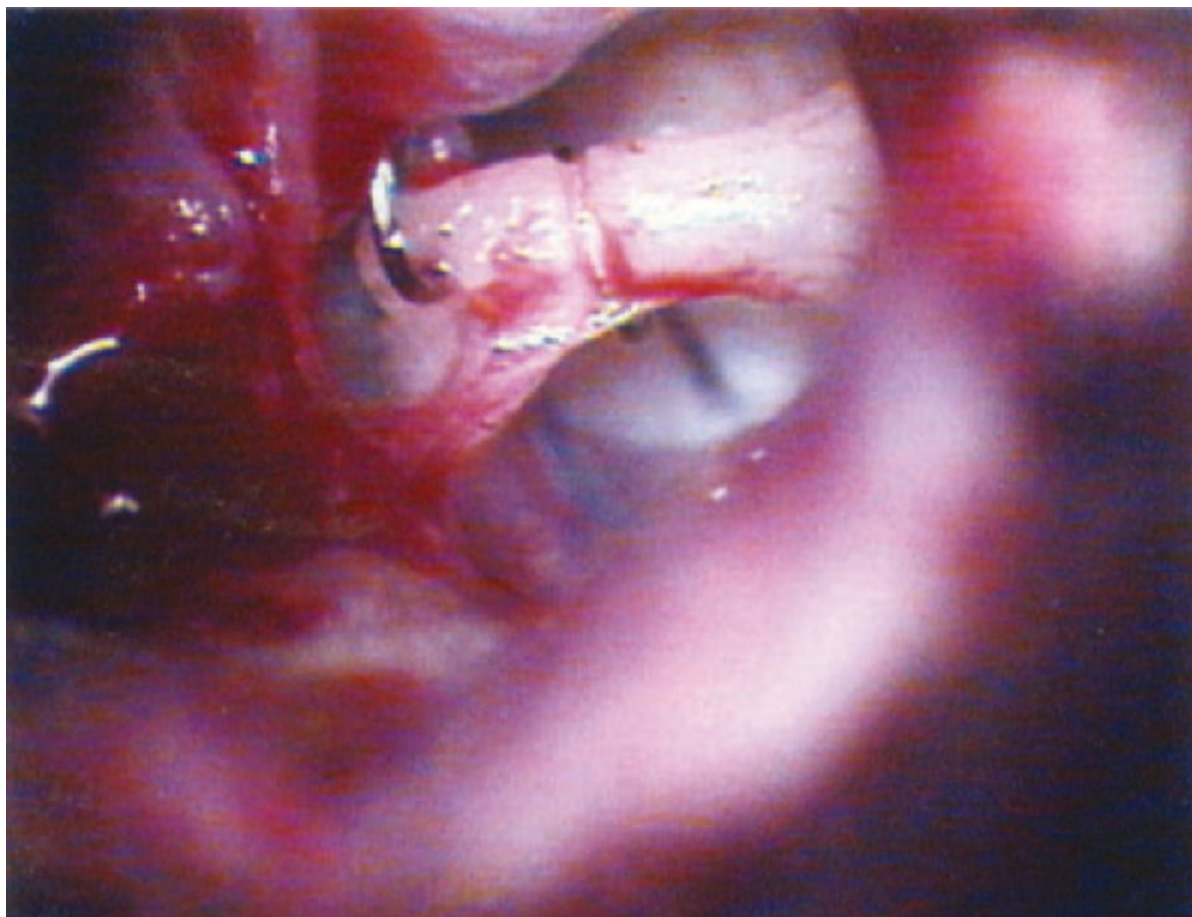
Imaging is rarely necessary in the routine evaluation of otosclerosis if only conductive hearing loss is present. During the active phase of otospongiosis, demineralization may be evident in the anterior aspect of the footplate at the fissula ante fenestram. Patients with sensorineural hearing loss may demonstrate demineralization of the otic capsule by the presence of a double-ring or halo sign. Visualization of the otic capsule with magnetic resonance imaging (MRI) typically reveals a signal void characteristic of bone. Scanning after gadolinium enhancement may demonstrate active foci of otospongiosis. In advanced cases of cochlear otosclerosis, high-resolution, T2-weighted MRI sequences give useful information about the patency of the basal turn of the cochlea when a cochlear implant procedure is being considered.<sup>[6]</sup>



## PROSTHESES AND SURGICAL TECHNIQUES

The intended technique for implantation of stapes prostheses dictates the design and material composition of the device. Small fenestra stapedotomy calls for a narrow piston with a wire extension that is crimped over the distal long process of the incus. It should be relatively firm and lightweight to avoid undue tension on the incus. The hooked portion can be secured over the incus by using crimping forceps to close the loop around the incus. A prosthesis that is too tight around the incus will probably lead to necrosis of the ossicle given the tenuous blood supply along the long process of the incus. A prosthesis that is too loose will also cause traumatic erosion because of the “sawing” action that occurs with reciprocating vibration of the incus against the wire loop. Efforts to avoid this complication of stapes surgery have been made through changes in design and materials. The original round configuration of the wire that is crimped over the incus was modified from the shape of a cylinder to a flat ribbon, which disperses the surface area of contact. The earlier material used in crimp-on prostheses was stainless steel. The ribbon design incorporates platinum, which is softer and more malleable.

The process of crimping the hooked portion around the incus entails a scissors-like action of the fingers to close an instrument with its operating end consisting of slotted jaws that do not close completely. This maneuver may be fraught with minute arcs of hand rotation that make it slightly difficult to remain in the same plane of closure. The mechanical effort of closing the jaws can be delivered with excessive force, thereby crimping the hooked portion too tightly. Similarly, insufficient closure will probably result in the patient complaining of sound distortion and a sense of vibration. If the prosthesis is too loose, erosion of the incus will eventually occur, with return of the conductive hearing loss (Fig. 117-2).



**Figure 117-2** Left ear showing a crimp-on prosthesis that had eroded the long process of the incus.

Numerous investigators have researched outcomes based on the material used for stapes piston prostheses. Massey and coworkers conducted a study to compare the effectiveness of titanium and Teflon wire prostheses for hearing improvement in patients undergoing stapes surgery for otosclerosis. Closure of the air-bone gap to less than 10 dB was achieved in 86% of patients with a Teflon prosthesis versus 71% of those receiving titanium prostheses.<sup>[7]</sup> A smaller number of patients received the titanium prosthesis, which at the time was used when the diameter of the incus was smaller. The design of the prosthesis allows a more circumferential crimp around the incus. A similar study comparing gold and titanium prostheses was reported by Tange and coauthors.<sup>[8]</sup> They found that the heavier gold piston gave more overclosure (gain) than the lighter titanium prosthesis did; however,

they thought that the lighter but stiffer titanium piston provided a higher air-bone gap closure within 10 dB.[8]

Developments in metallurgy over the past few decades have brought new alloys into medicine with applications in otology. Nitinol is a shaped memory alloy composed of nickel and titanium. To remove the forceps from the crimping process, Nitinol is now available in stapes prostheses. The application of heat activates a phase transformation in the metal that causes it to revert to its closed position around the incus. Heat is typically delivered with a laser on low energy settings. The use of this material and technique precludes overcrimping at the attachment to the incus. The piston portion of the device is made of Teflon (Gyrus Corp., Jacksonville, FL). Knox and Reitan published an excellent review of the history, chemical and mechanical properties, and in vitro and in vivo testing of Nitinol stapes prostheses.[9]

There have been minimal changes in the surgical method of treating otosclerosis. In the early years, stapes mobilization was initially successful but routinely succumbed to re-fixation. Over the past 50 years, postoperative results have consistently demonstrated that removal of a portion or the entire stapes footplate (stapedectomy) or bypass of the obstruction with a fenestration piston (stapedotomy) successfully resolves the source of conductive impairment. Silverstein introduced a novel technique for overcoming otosclerosis limited to the anterior portion of the footplate (fissula ante fenestram) when the remainder of the footplate is blue, thin, and without fixation. He described a minimally invasive stapes procedure termed stapedotomy minus prosthesis (STAMP). The anterior crus is vaporized with a hand-held argon laser. The anterior footplate is then vaporized linearly in a superior-to-inferior direction to allow the posterior footplate to be mobile and still be attached by the stapes tendon. The decision whether this procedure could be performed was made during exploration of the middle ear. The preoperative audiogram was not predictive of the degree and location of otosclerosis. Statistical analysis suggested that there was improvement in high-frequency hearing results as compared with conventional laser stapedotomy procedures. The rate of re-fixation was 9%, but revision surgery was not precluded.[10]

### Positioning of the Patient

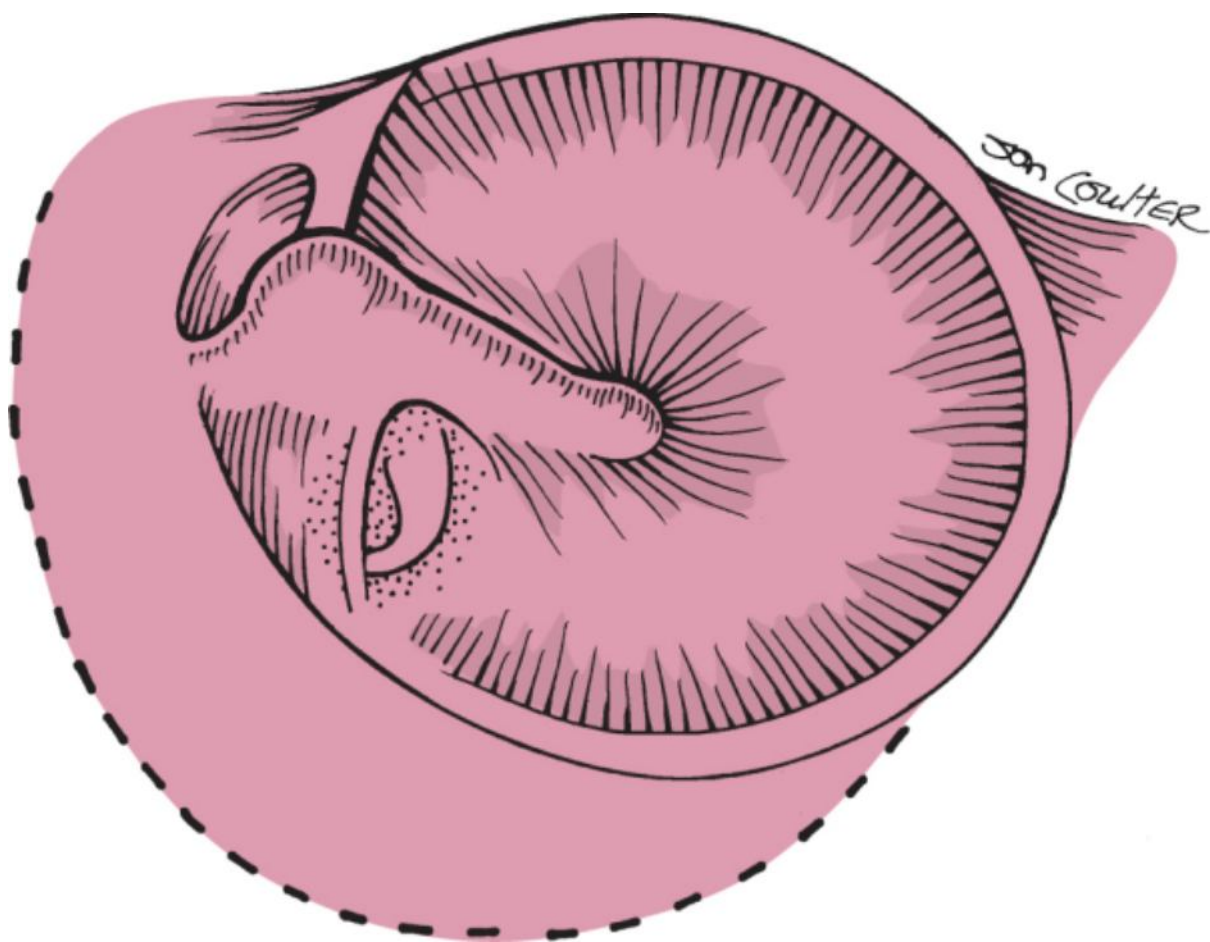
Positioning of the patient on the operating table must be optimal to facilitate proper exposure for the surgeon. The patient should be as close to the surgeon as the table comfortably permits. Elevation of the head should be minimized; in persons with a short neck or a large chest, it may even be helpful to slightly lower the head of the table relative to the horizontal plane of the body. Comfort should be achieved by padding the arms, elevating the knees, or placing support under the lumbar area as necessary. It is not necessary to remove any hair, but it must be secured to allow easy and unobstructed access to the ear canal. The arm opposite the ear undergoing surgery is positioned on an arm board, and an appropriate vein on the dorsum of the hand is identified for use as a tissue graft in the oval window. Preparation is carried out with either alcohol or povidone-iodine (Betadine) solution as the surgeon chooses. After conventional draping for a transcanal procedure, the solution is gently suctioned from the ear canal, and cerumen is removed as necessary.

### Anesthesia

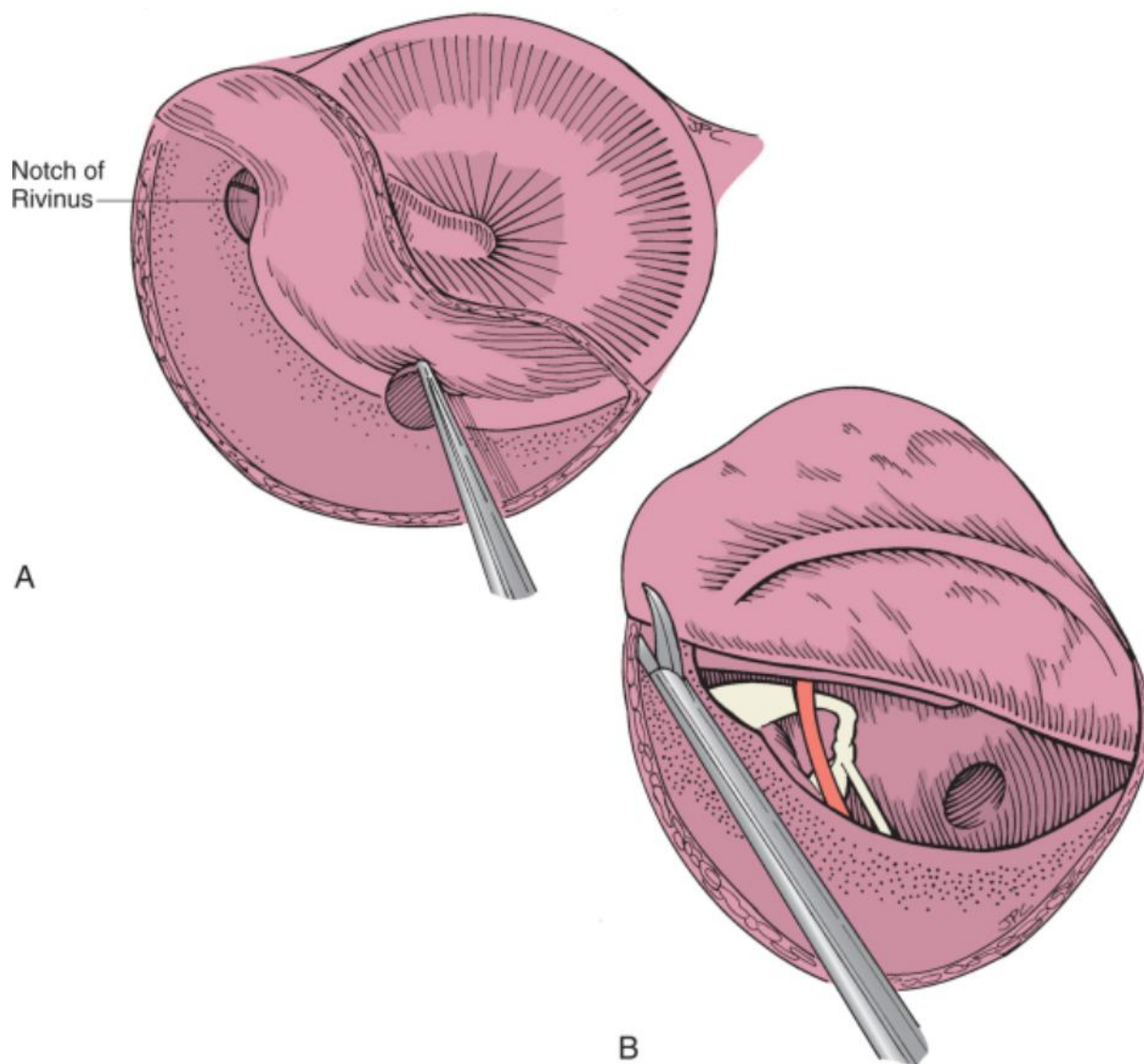
Anesthetic block is achieved with a 27-gauge needle and dental carpules containing 2% lidocaine with a 1:100,000 solution of epinephrine. Injection is begun at the 6-o'clock position in the canal and carried out slowly because of resistance of the skin, which is adherent to cartilage or bone. Gradual blanching of the canal skin signals successful injection. Too rapid an injection may also cause ballooning of the canal skin with a subcutaneous collection of fluid. When this occurs, the ballooned area should be punctured immediately with a needle tip. Gradual progression of the injections then proceeds from the 6-o'clock position in both directions until circumferential anesthesia is complete. Slow injection in this manner usually results in patients feeling only the first injection if they are awake. Care must be taken to inject only a minimum of solution because overzealous injection results in reduction of the size of the meatus and canal. When general anesthesia is administered, the same local agents are injected to provide a bloodless field because of the vasoconstrictive effect of the epinephrine.

### Exposure

Creation of an incision to maximize exposure is important in every operation. When exploring an ear with conductive hearing loss, however, it is wise to anticipate other situations. Discovery of lateral ossicular chain fixation, for example, may necessitate greater removal of bone from the scutum and potentially cause a defect impossible to close with a short tympanomeatal flap. Correct canal incisions are three dimensional and extend from the posteroinferior annulus to a point well superior to Shrapnell's area (Fig. 117-3). The length of the canal flap is 5 to 7 mm, and it is dissected gently to avoid tearing the edges. The flap is elevated until the fibrous annulus is well exposed inferiorly and the notch of Rivinus is seen superiorly (Fig. 117-4). The tympanic membrane is then elevated anteriorly by sharp dissection. Sectioning of the posterior plica (malleal fold) will allow complete reflection of the tympanic membrane. When this does not suffice, the superior incision has generally not been developed far enough anteriorly.



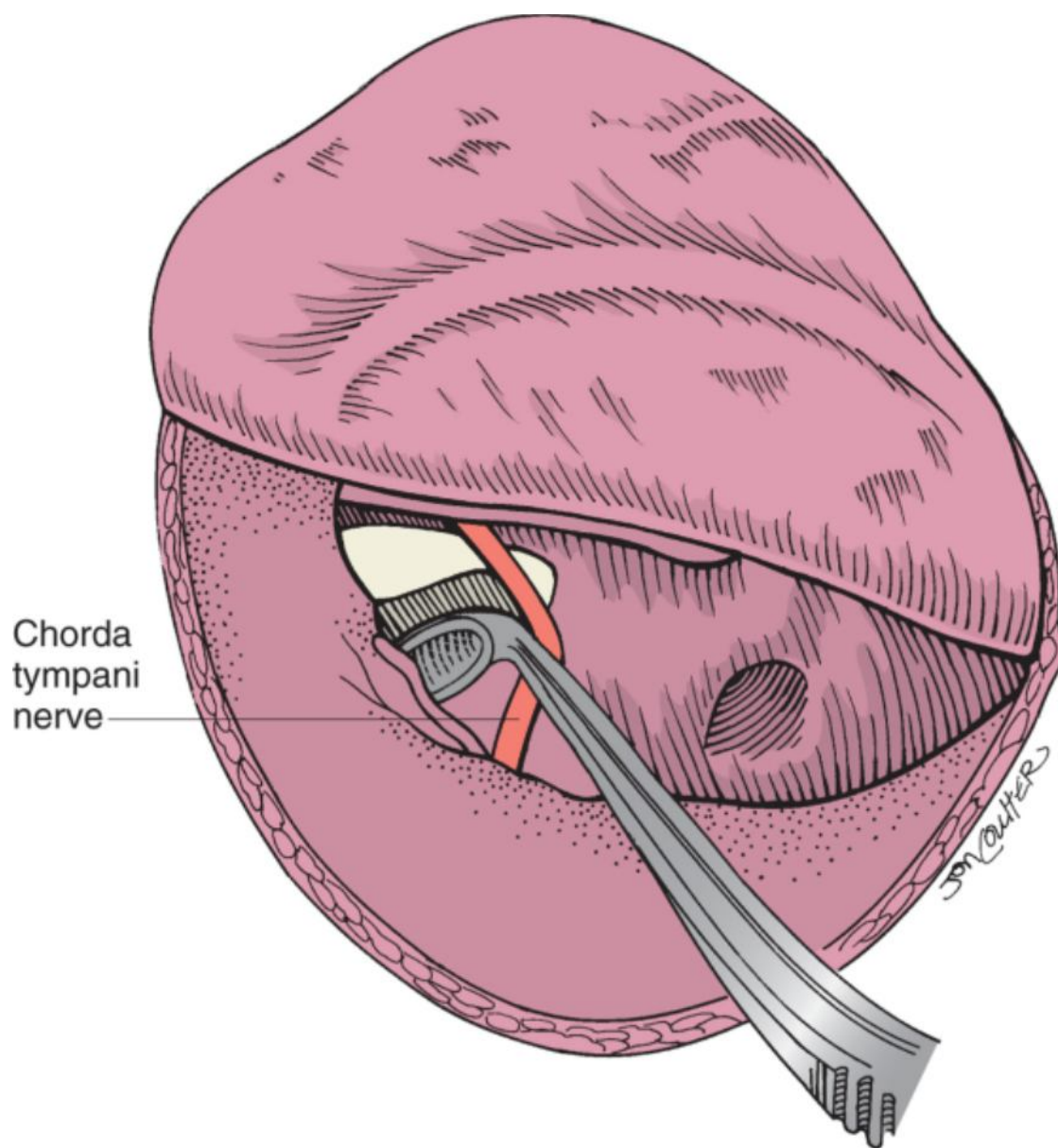
**Figure 117-3** Correct incision in the canal allows adequate removal of bone and exposure of the ossicular chain.



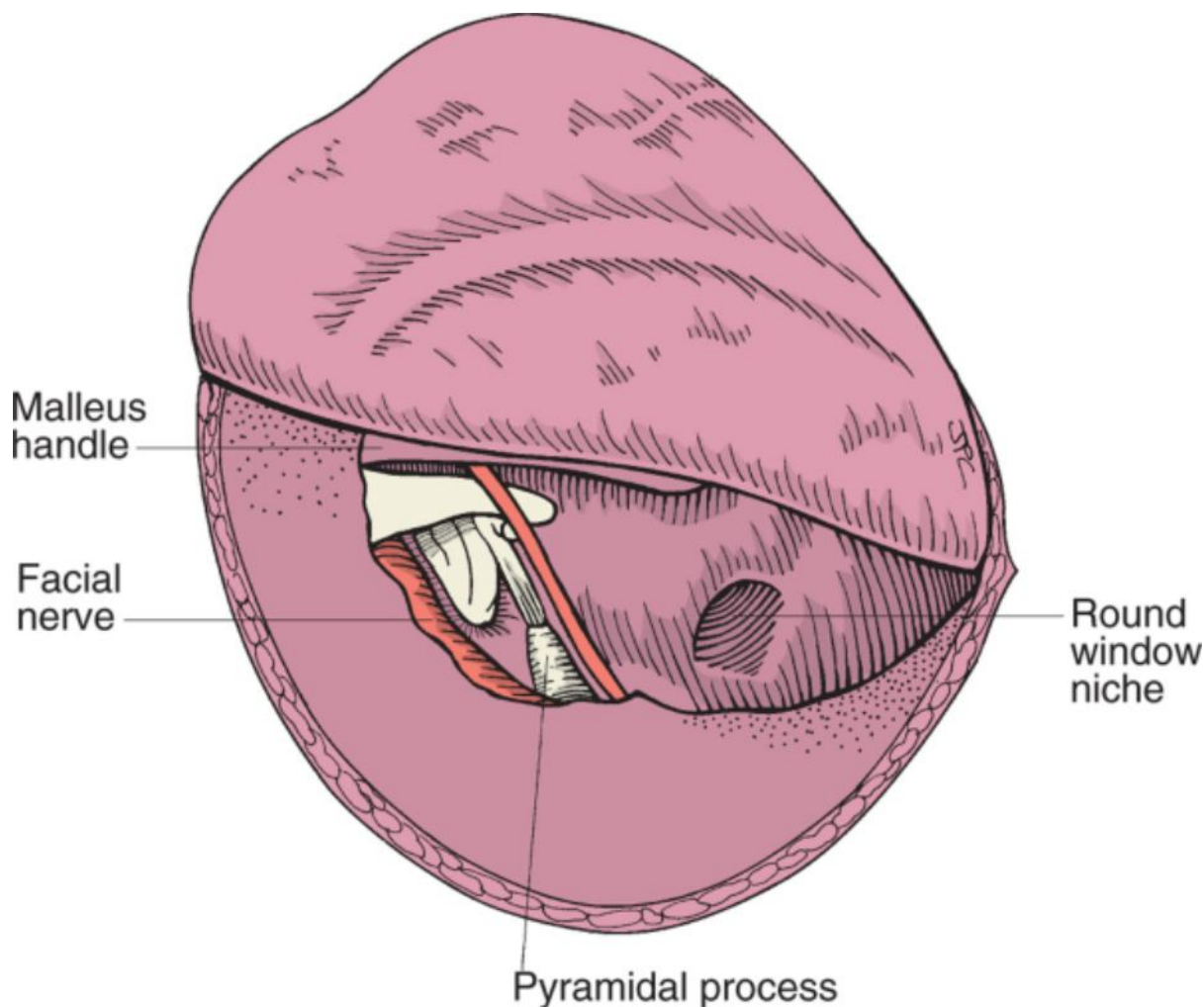
**Figure 117-4** **A**, Elevation of the tympanomeatal flap. **B**, Exposure of the middle ear is enhanced by ensuring adequate anterior development of the flap.

The amount of bone that must be removed from the posterior canal wall for adequate visualization varies considerably. When bone must be removed, curettage should begin at the notch of Rivinus and proceed inferiorly as care is taken to preserve the chorda tympani nerve (Fig. 117-5). When exploring the middle ear for otosclerosis or any conductive hearing impairment, the following landmarks should be visible to the surgeon to ensure adequate exposure (Fig. 117-6):





**Figure 117-5** Curing the posterosuperior bony canal wall with preservation of the chorda tympani nerve.



**Figure 117-6** Demonstrating adequate middle ear exposure for management of any conductive problem encountered.

- Anteriorly—the neck and handle of the malleus
- Inferiorly—the round window
- Posteriorly—the pyramidal process
- Superiorly—the horizontal portion of the facial nerve

Good visualization of these structures will allow surgical correction of any conductive pathology encountered. Bone removal is generally performed with microcurettes but may also be achieved with a small cutting burr. The latter method usually presents a greater risk to the chorda tympani.

The chorda tympani can be preserved in more than 90% of cases. In the event of partial sectioning, the fibers should be reapproximated because good function will typically be restored. Some authors advise complete sectioning of the nerve when partial damage has occurred, but this is not justified in our experience. Even when complete sectioning is necessary, patients rarely complain of taste disturbance for more than a few months.

### Determining Pathology

After adequate exposure, the entire ossicular chain and middle ear should be examined. Foci of otosclerosis may be immediately recognized as chalky white. There may be increased vascularity on the promontory, but recognition of the disease can sometimes be difficult. The ossicular chain is palpated gently with a slightly angled pick. Palpation should begin with the handle of the malleus and proceed medially to the long process of the incus and finally to the superstructure of the stapes. Extreme fixation sometimes precludes determination of the location of pathology. In this situation, the incudostapedial joint should be separated with a right-angled hook or a joint knife. This maneuver will allow separate palpation of the lateral chain and stapes. The site of fixation can then be determined.

In addition to confirming the pathology to be located at the footplate of the stapes, the degree of otosclerotic involvement must be observed. The surgeon must determine whether the footplate is thin enough for easy

penetration or whether obliteration is present. Anatomic difficulties such as a dehiscent or overhanging facial nerve should also be noted at this time. It is always better to recognize potential difficulties before beginning disassembly of the ossicular chain. Failure to see any “blue area” within the central footplate may signal partial or complete oblitative disease. In this situation, the surgeon must judge whether adequate management of all problems that may ensue is possible, such as a floating footplate or the necessity for a drill-out procedure.

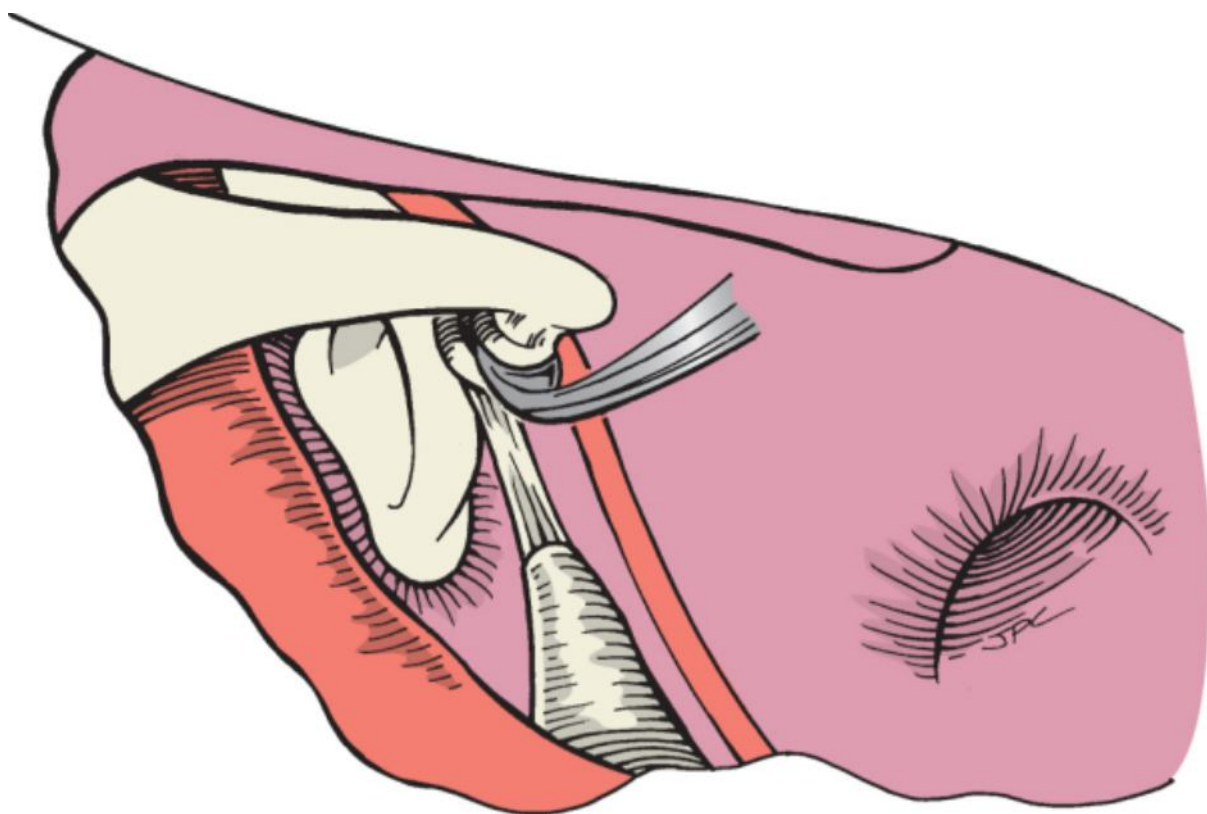
### Philosophy of Footplate Removal

Beginning with the revival of stapes surgery by Dr. John Shea, Jr., in the 1950s, complete removal of the stapes footplate was considered the norm and resulted in satisfactory hearing results in a high percentage of cases. In recent years, the “small fenestra” technique has had a number of proponents because of the perception of improved results, particularly in the higher frequencies of 4 kHz and above. Careful review of the many articles’ pros and cons reveals significant flaws in case study conclusions. In almost all the studies, the cases of more than one surgeon or more than one prosthesis were combined to arrive at conclusions regarding hearing results. A significant article on methodology was authored by Rizer and Lippy,<sup>[11]</sup> who compared results in three groups of patients, all of whom underwent surgery by Lippy. The three groups consisted of total removal of the footplate, partial removal of the footplate, and small fenestra stapedotomy. The Robinson prosthesis and identical tissue grafts were used in all cases. Although not statistically significant, the best hearing results in all frequencies actually occurred in the group with total removal of the footplate. Accordingly, it is safe to conclude that the amount of footplate removal is insignificant in comparison with the skill of the surgeon. With these facts in mind, two techniques for stapes surgery will be described. The first is the standard procedure without use of the laser, and the second embraces the newer laser technology available for otologic surgeons. Both techniques are used by our group, and hearing results have been equivalent.

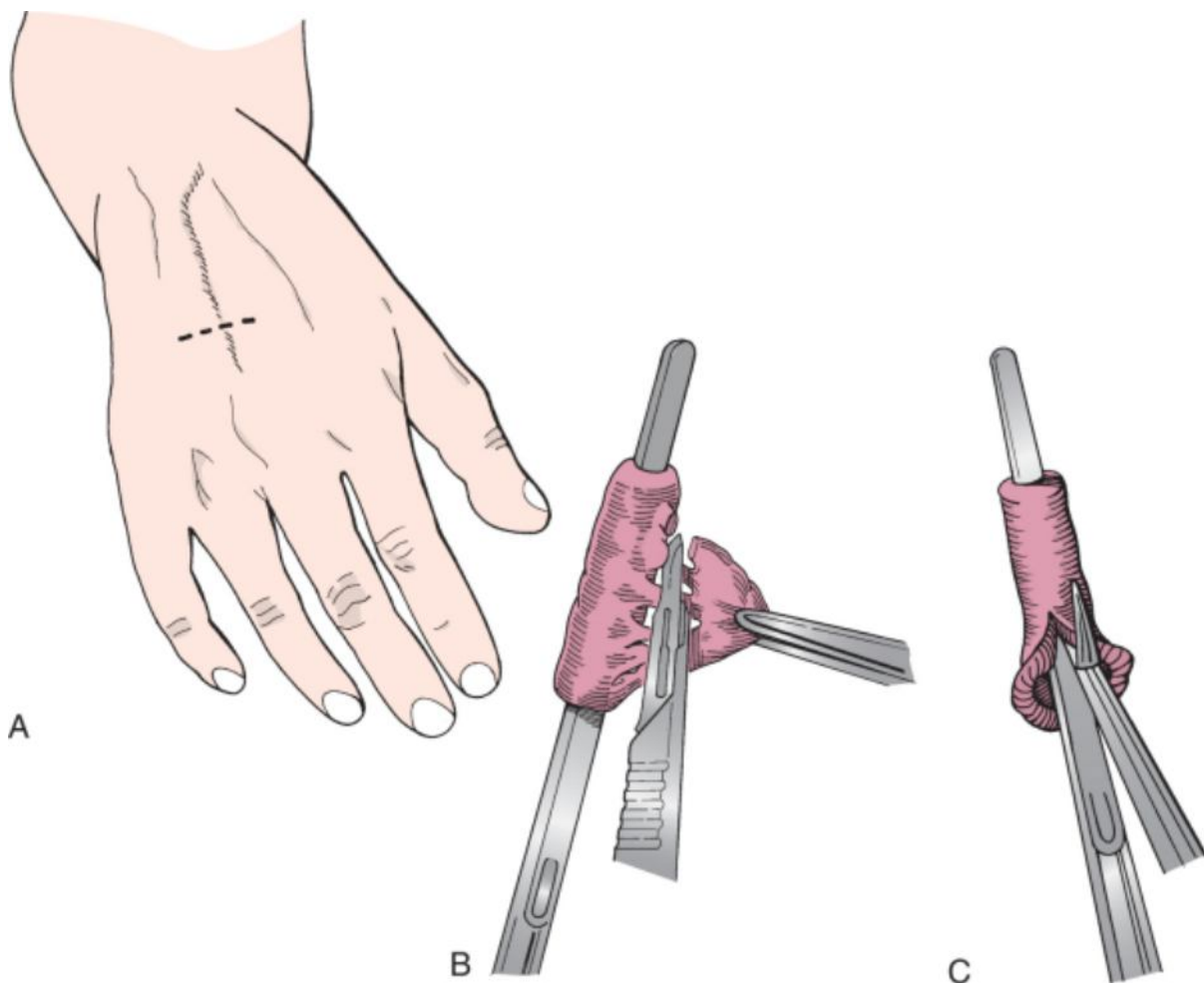
Several general comments can be made. Conventional stapes surgery avoids the risk of high-energy lasers within the middle and inner ear. Laser techniques, on the other hand, better handle bleeding and avoid the potential complication of a floating footplate. Laser surgery is not applicable to oblitative disease.

### Conventional Stapedectomy

After careful assessment of the degree and location of the otosclerosis, the incudostapedial joint is separated (Fig. 117-7). At this time, connective tissue is harvested for use in the oval window. When harvesting tissue, the surgeon may use the tragal perichondrium, areolar tissue, or temporalis fascia because of their proximity to the operative field. An alternative strategy is for an assistant to harvest a vein graft from the dorsum of the hand opposite the ear undergoing surgery (Fig. 117-8) while the otologic surgeon proceeds uninterrupted with the middle ear surgery. The type of connective tissue used for sealing the oval window is unimportant, provided that it is thin. When using vein, either the adventitial or the intimal surface may seal the oval window. Brief drying of the vein graft, as would be done for temporalis fascia, will make the graft easier to handle, thereby facilitating introduction and placement in the oval window. As the tissue graft comes in contact with perilymphatic fluid, it becomes soft and pliable once again. Preparation of the tissue graft should precede opening of the footplate so that the period of exposure of the vestibule is shortened.





**Figure 117-7** Separation of the incudostapedial joint while being careful to preserve the lenticular process of the incus.

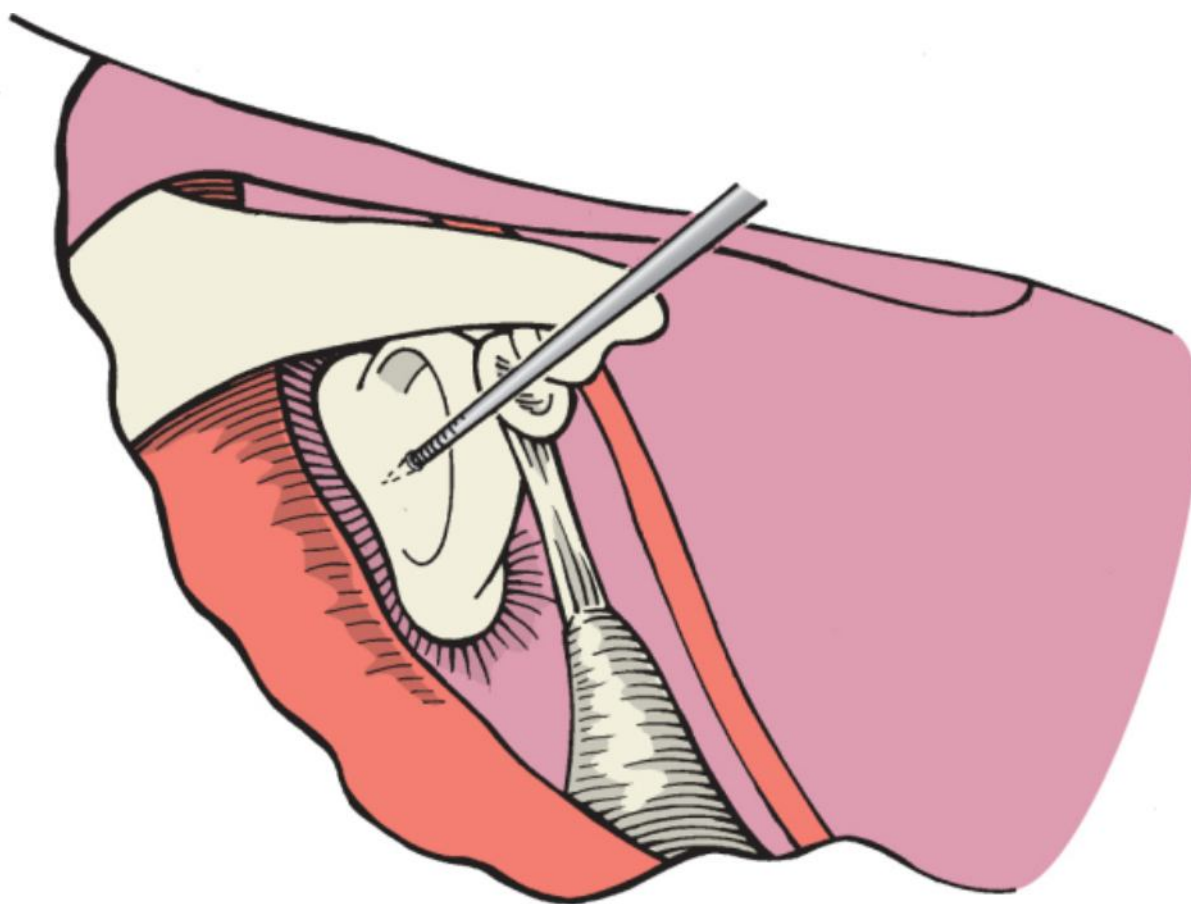




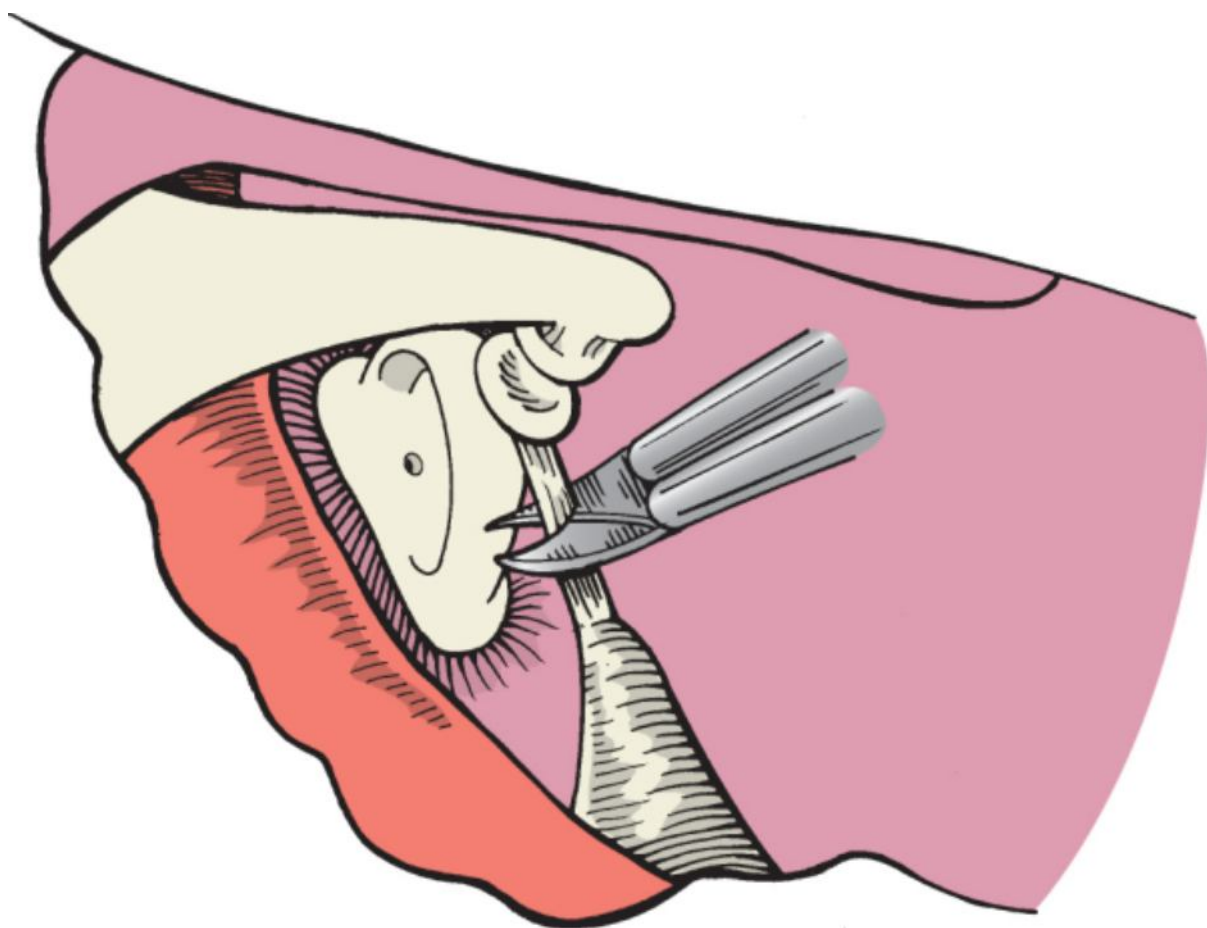
**Figure 117-8** **A**, A 2-cm transverse incision is made on the dorsum of the hand for harvesting the vein graft. **B**, Removal of connective tissue from the vein graft. **C**, Opening the vein graft.

Next, the footplate is fenestrated with a fine, sharp needle (Fig. 117-9). Although fenestration should ideally be performed in the center of the footplate, it may be done wherever the blue color indicates the bone to be thinnest. The stapedius tendon should be kept intact through this step to supply resistance against which to push during the fenestration. If gentle pressure does not perforate the bone, slow to-and-fro rotation of the needle point will generally complete the procedure. Successful fenestration is recognized when the needle point gives way slightly. Perilymph will be seen at the point of entry. Successful creation of the fenestra accomplishes two important purposes. First, the vestibule is already decompressed in the unlikely event of total footplate avulsion on fracture of the superstructure. Second, an area of purchase is now available for instrumentation in the case of footplate flotation. The stapedial tendon is sectioned (Fig. 117-10), and fracture of the stapedial superstructure is next accomplished by quick downward pressure toward the promontory (Fig. 117-11) ([see Video 117-1](#) ).

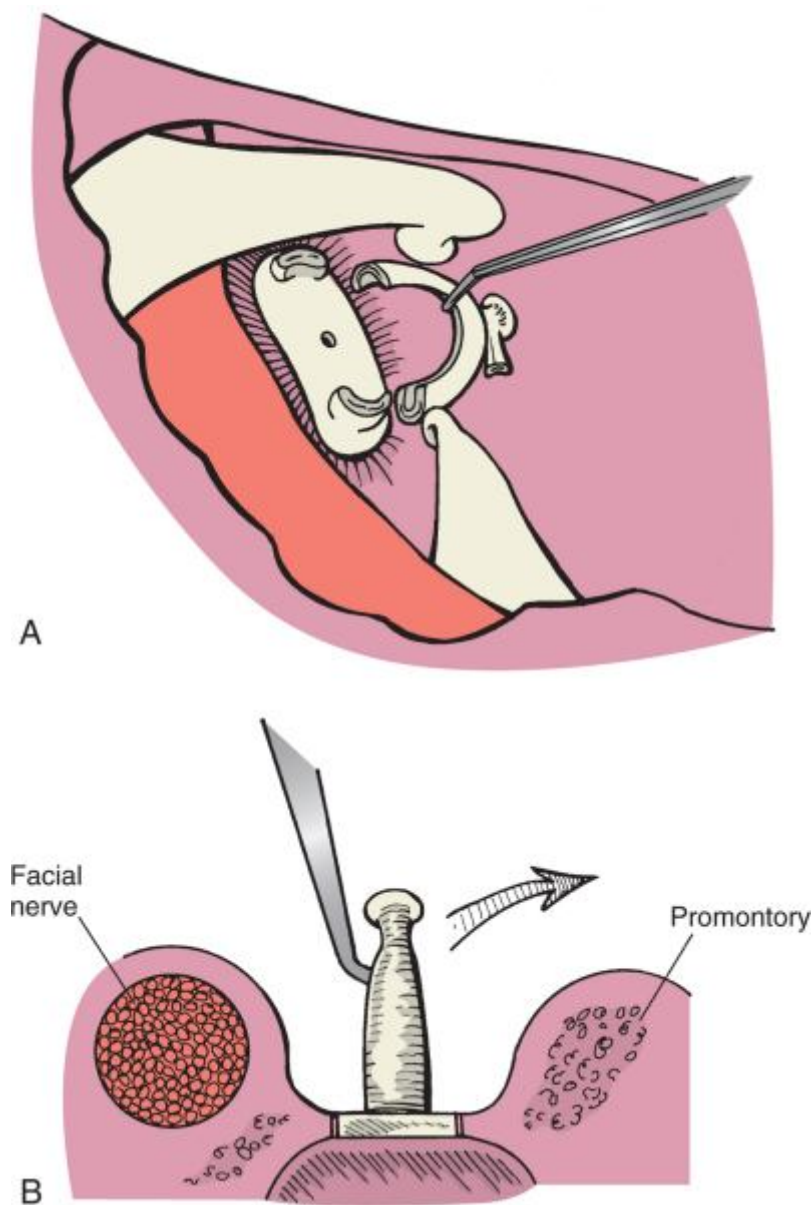
Occasionally,  fixation of the superstructure to the promontory necessitates careful superior fracturing toward the horizontal facial nerve. In either case, the entire stapedial arch is then removed.



**Figure 117-9** Fenestration of the central area of the stapes footplate with a fine needle.

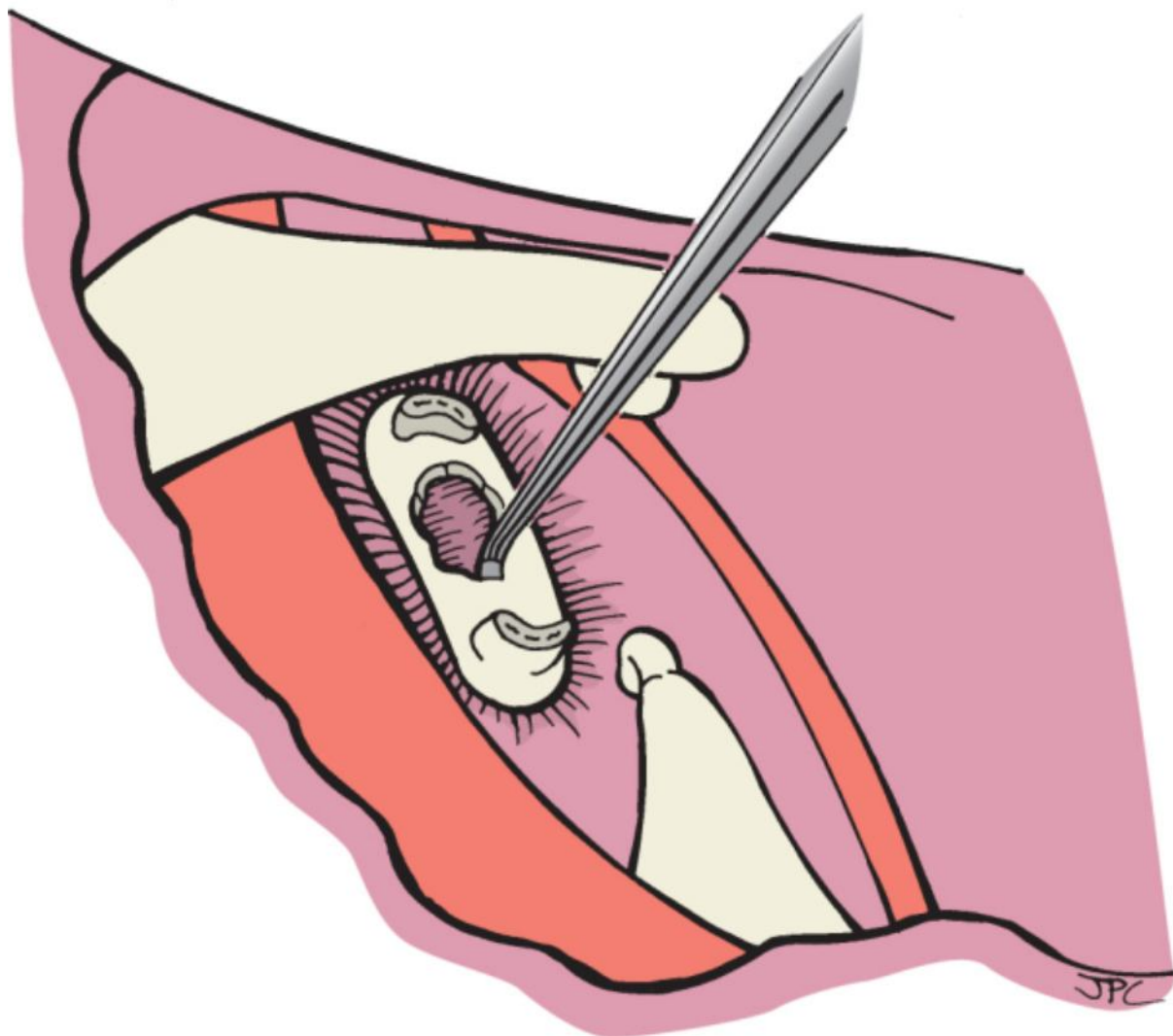


**Figure 117-10** Sectioning of the stapedial tendon.



**Figure 117-11** A and B, Down-fracturing of the stapes superstructure toward the promontory.

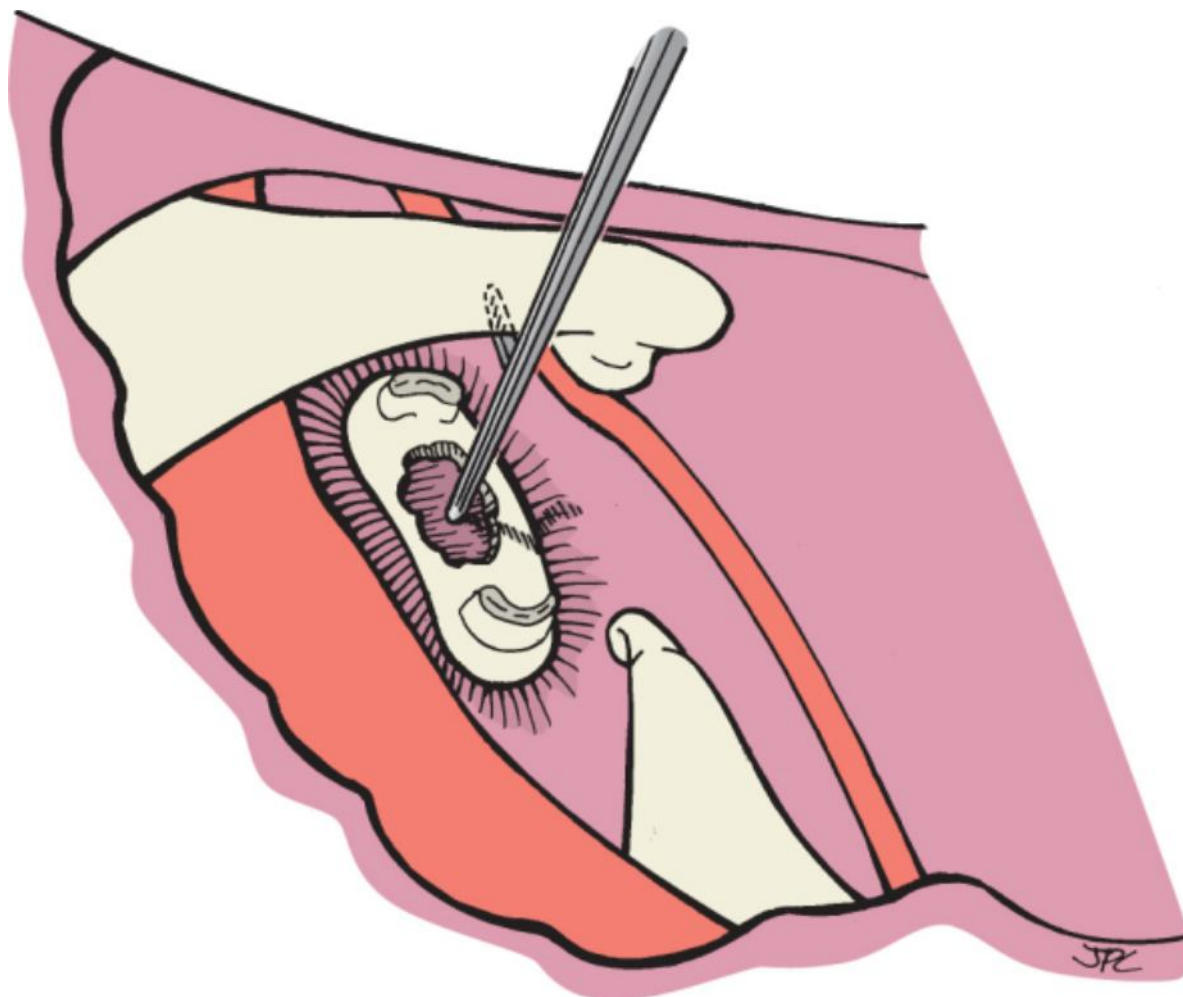
Small angled footplate hooks are next used to remove a sufficient amount of the central area of the footplate for placement of the graft and insertion of the prosthesis (Fig. 117-12). The amount of footplate removed is the portion that can easily be taken out, which usually amounts to approximately one fourth of the surface area of the footplate. Occasionally, larger portions of the footplate become elevated when enlarging the fenestra; in such cases, they may be removed with no fear of complications.



**Figure 117-12** Removal of the central area of the footplate.

The appropriate length for the prosthesis is measured, although 4 mm is almost always the correct size for a bucket-handle prosthesis of the Robinson type (Fig. 117-13). The Robinson prosthesis is favored for several reasons:





**Figure 117-13** Measurement from the vestibule to the undersurface of the incus for the Robinson prosthesis.

1. It is self-centering within the fenestration.
2. Its weight favors good hearing results.
3. Because it is not a “crimped-on” prosthesis, the chance of ischemic pressure necrosis of the incus is negligible.
4. It can be used with minimal footplate removal.

The vein graft is placed over the oval window and gently depressed into the fenestra to identify the location of

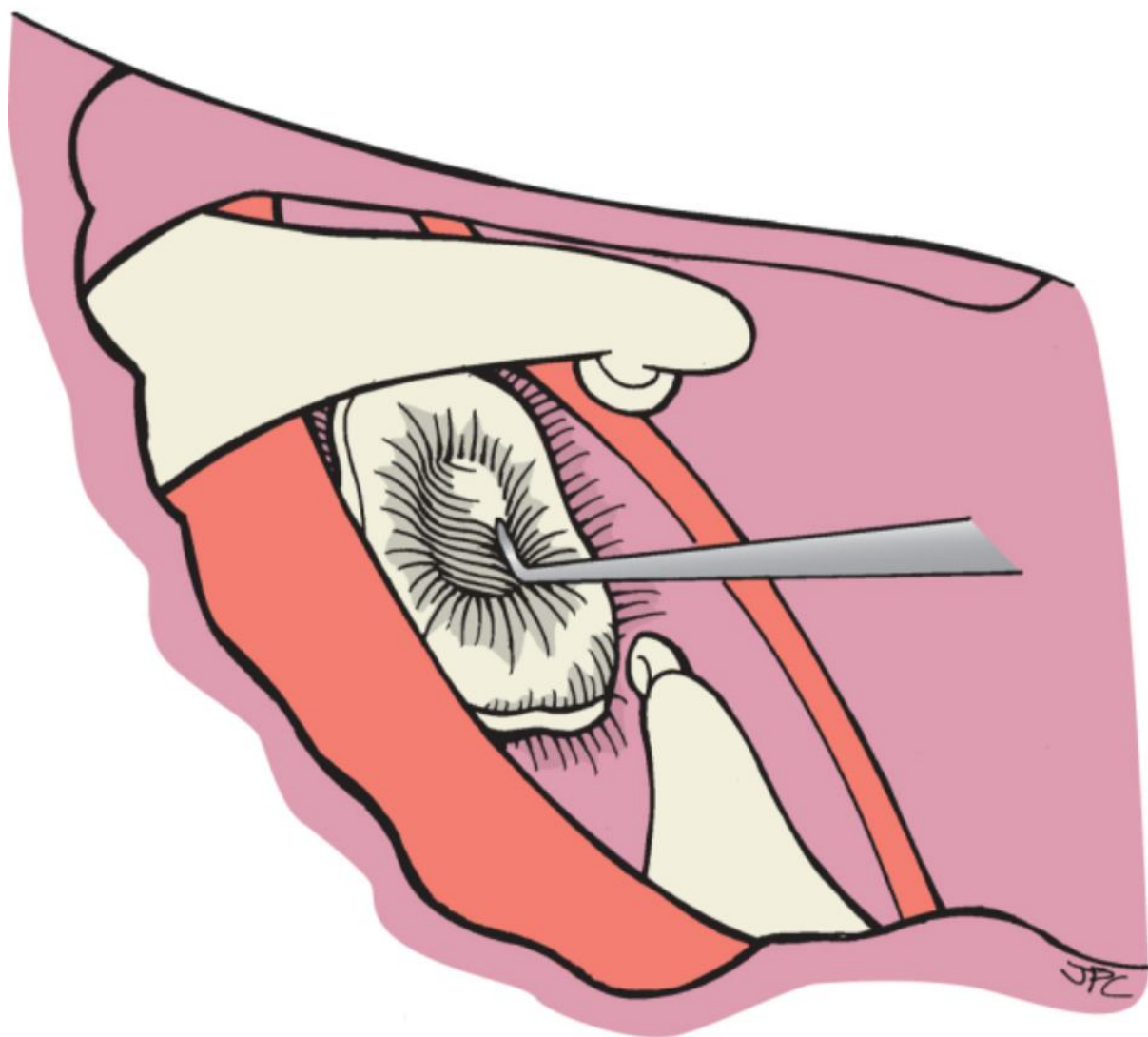
placement for the medial end of the prosthesis (Fig. 117-14) (see Video 117-2). Next, the prosthesis is placed by inserting the device into the fenestra and leaning it against the posterior surface of the

incus, where it will remain standing by capillary attraction (see Video 117-3). A right-angled pick is then used in one hand to lift the long process of the incus while a second pick slides the bucket forward and under the lenticular process (Fig. 117-15). The entire shaft is rotated until the bale or bucket handle becomes aligned with the axis of the incus. The bucket handle is then lifted over the incus and into place (Fig. 117-16). Routine positioning of the prosthesis and swinging the bucket handle over the incus are demonstrated in Video

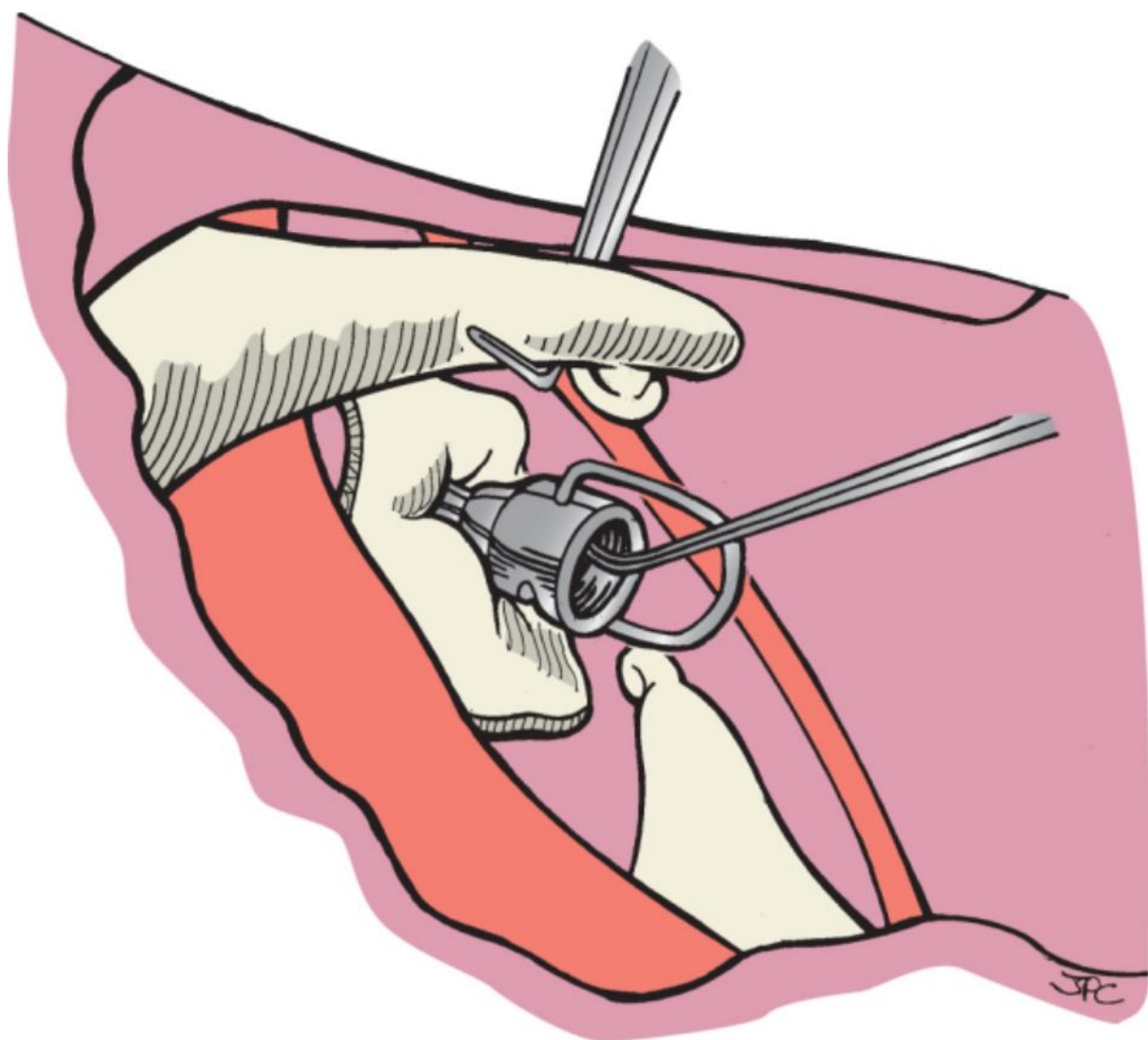
117-4. A few minor maneuvers may be necessary to place the well of the prosthesis beneath

the lenticular process of the incus (see Video 117-5). If the lenticular process is missing from the incus, a Bailey modification of the Robinson prosthesis is used. This modification consists of an elliptical notch in the bucket, which allows one to slide the prosthesis along with its handle superiorly onto the long process until it is well stabilized. If the bucket handle is deemed to be too loose as it rests over the incus, a small piece of tissue graft (residual vein) can be placed to cover it and the distal incus. This provides a “band-aid” to secure the handle

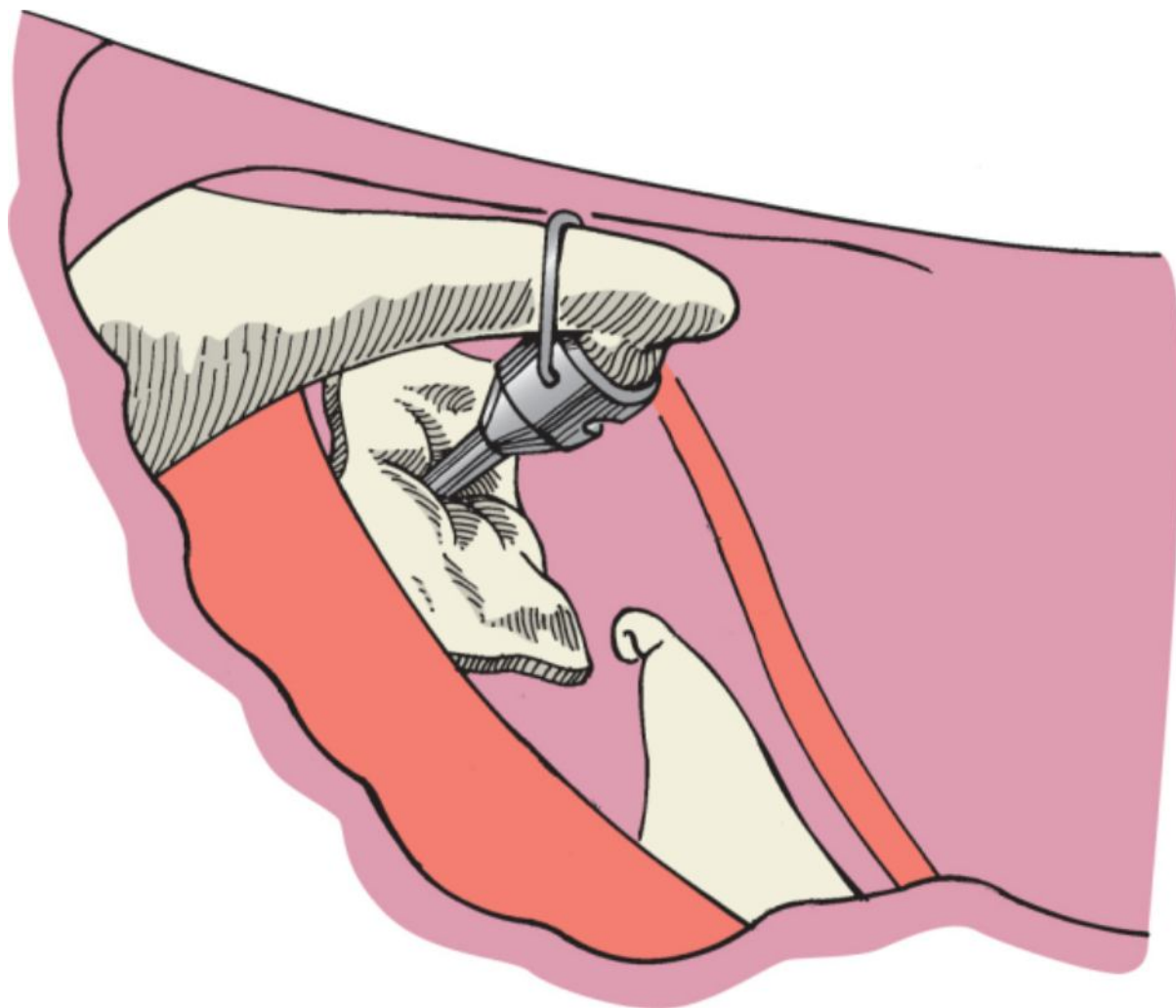
in position (see Video 117-6 ).



**Figure 117-14** Placement of the vein graft over the fenestrated footplate.



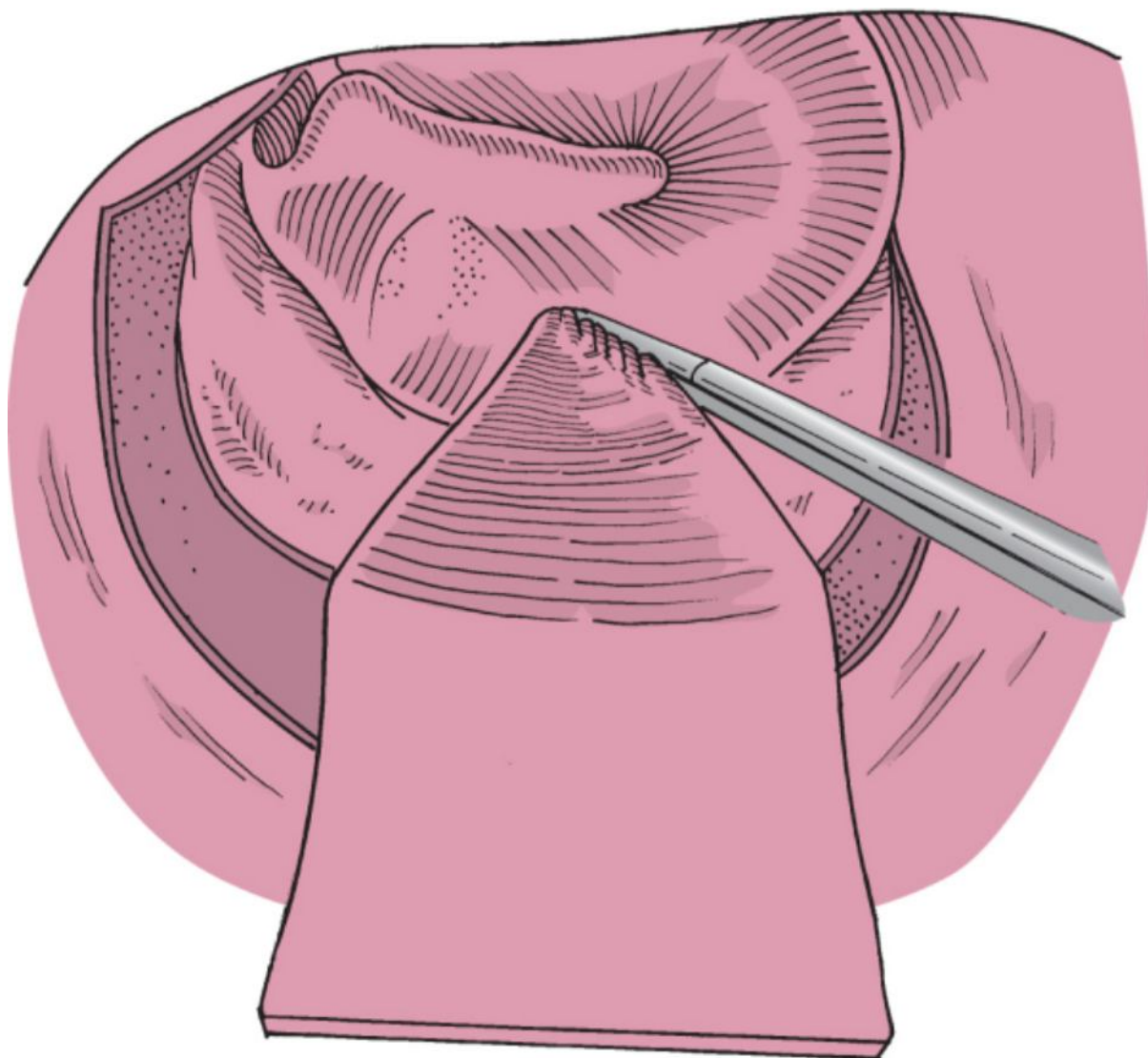
**Figure 117-15** Placement of the Robinson prosthesis via a two-handed technique.



**Figure 117-16** The prosthesis in place with the handle over the incus.

Next, the ossicular chain is palpated at the malleus handle to ensure continuity of the chain; gentle pressure is placed on the incus to ensure good “bounce” of the prosthesis. This maneuver helps center the prosthesis. If this bounce is absent, the medial portion of the strut may not be within the fenestra. Finally, the tympanomeatal flap is reflected to its original position, and the flap is packed with a single silk strip and several small cotton balls impregnated with antibiotic ointment (Fig. 117-17).







**Figure 117-17** Packing of the tympanomeatal flap with a silk sleeve to maintain its position.

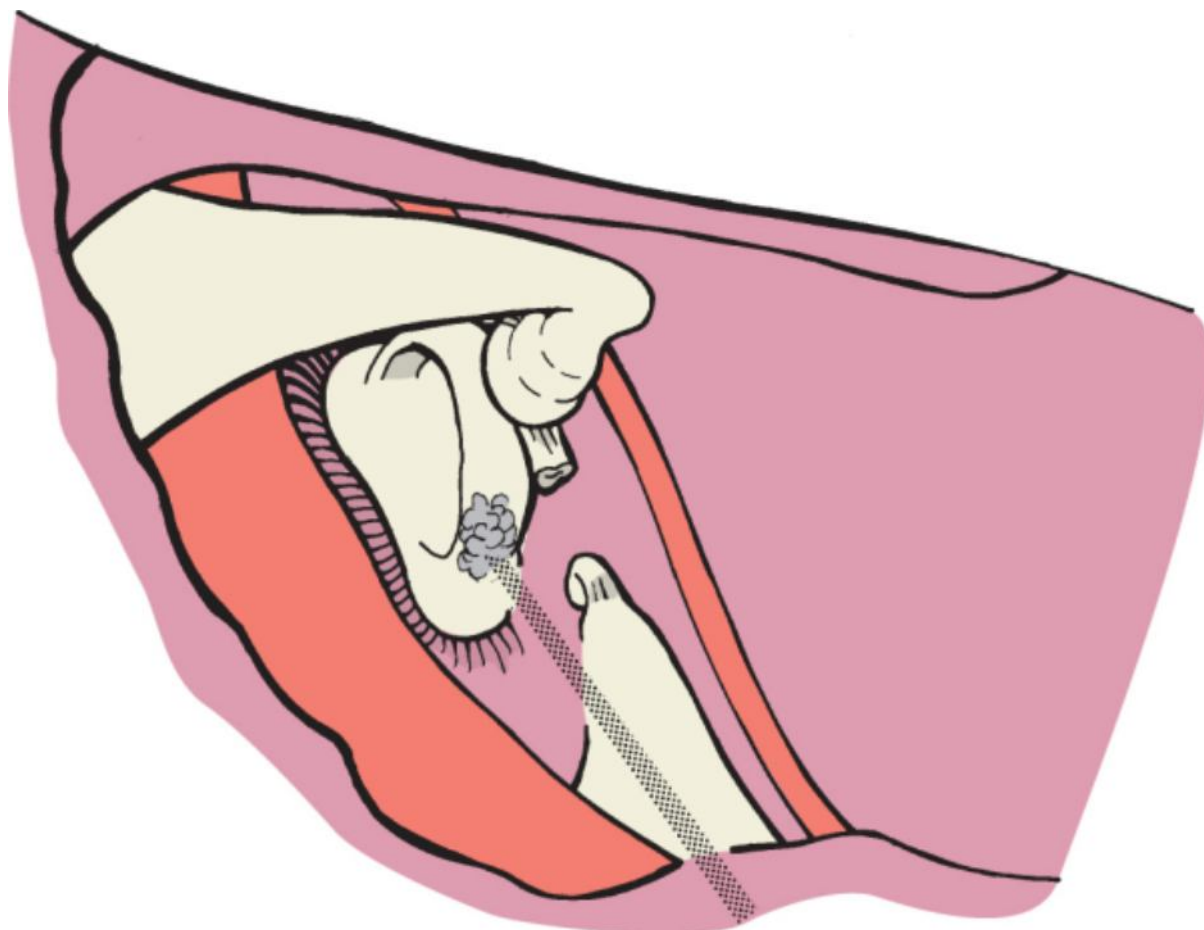
Surgeons should have more than one technique at their disposal when performing stapes surgery because of occasional unanticipated findings. Shortening or absence of the long process of the incus may require a wire-piston device or even the use of a malleus-to-ovalwindow prosthesis. Likewise, lateral chain fixation may necessitate incus interpositioning or the use of a partial ossicular reconstructive/replacement prosthesis.

### *CO<sub>2</sub> Laser-Assisted Stapedotomy*

The laser should be set up with safe energy parameters and test-fired to confirm accuracy of the aiming beam. The HeNe aiming beam can be set on auto-HeNe so that when the foot pedal is depressed, the aiming beam remains off, thereby allowing an undistorted view of the last laser strike. Alcohol should not be used as a preparative solution when the laser is used.

With the CO<sub>2</sub> laser set at a continuous-mode 200-mm spot size, 0.1-second duration, and 1.25 W, a fenestration is made in the superior central area of the footplate. If the oval window niche is narrow or too tight to gain access to the footplate, one should proceed with removing the superstructure by first vaporizing the stapedial tendon. The

video shows initial laser vaporization of the stapedial tendon and the posterior crus and  then fenestration of the footplate ([see Video 117-7](#) ). Suction should be used to evacuate the laser plume. The posterior crus is vaporized as close to the footplate as possible (Fig. 117-18). The bone char that forms along the posterior crus should be removed with a fine pick or suction as it forms. It is not useful to fire the laser into previously carbonized tissue. When dividing the posterior crus, it is important to note that the crus has a horseshoe-arch shape. That is, the superior and inferior aspects of the crus will be much thicker than the midportion of the crus.

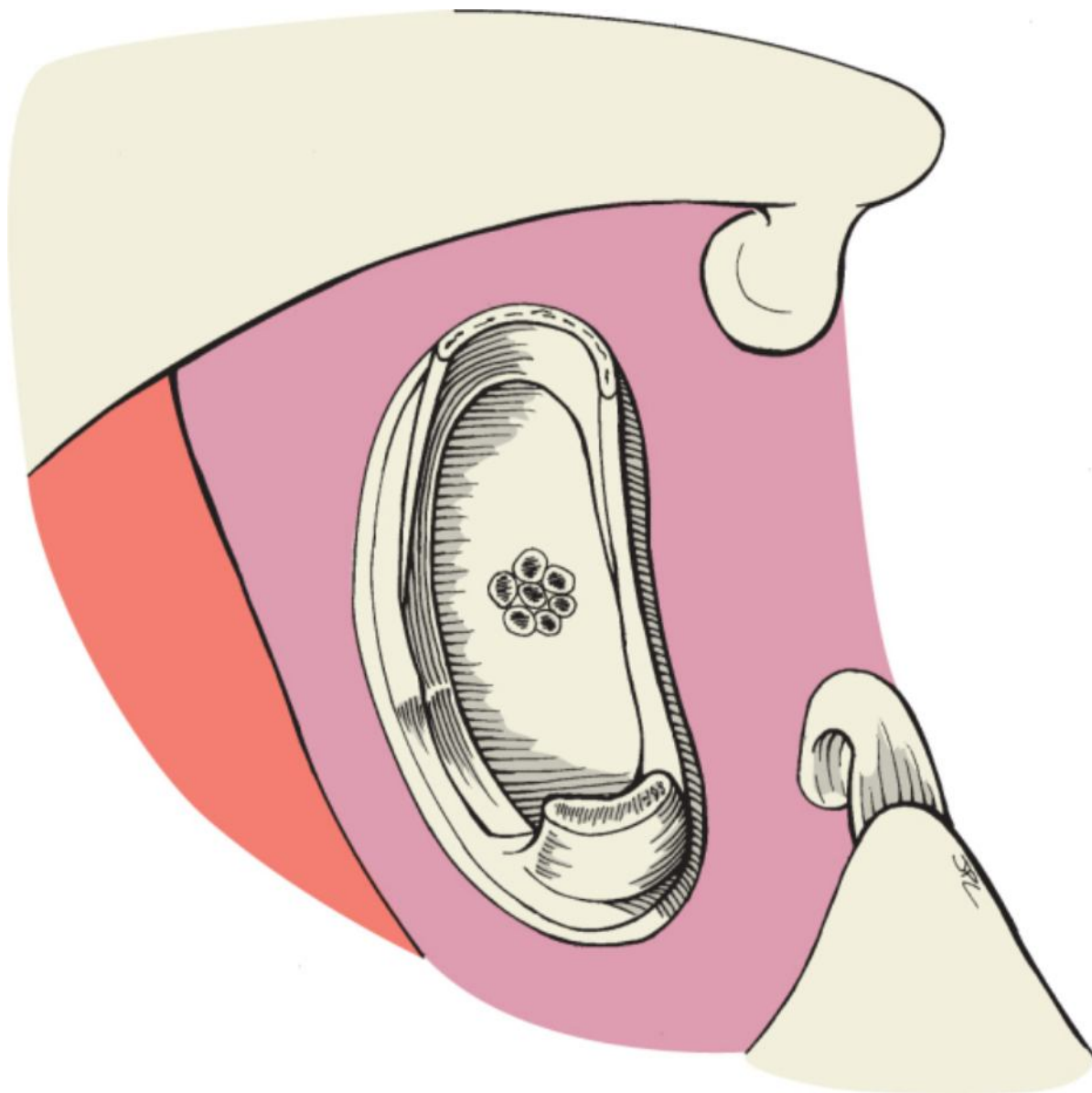


**Figure 117-18** CO<sub>2</sub> laser vaporization of the posterior crus.


Next, the incudostapedial joint is separated with a joint knife, and the stapes superstructure is down-fractured. It has not been necessary to directly divide the anterior crus with the laser because the anterior crus is normally thinner than the posterior crus and otosclerosis usually firmly fixes the anterior footplate. The laser is then focused on the footplate. It is useful to confirm proper depth of focus by using high-power magnification (25 ×) temporarily to focus on the footplate and then return to a comfortable working magnification. Laser strikes are made on the

footplate in a rosette pattern (Fig. 117-19) (see Video 117-8). Six to eight laser strikes are usually required to form a fenestra about 0.8 mm in diameter. The proper size of the fenestra may be confirmed by using a no. 26 suction device that has a 0.6-mm diameter at its tip or estimated by the 200-mm size of the laser strikes. It is easier to form a fenestra that is slightly on the larger side than to increase the size of the fenestra

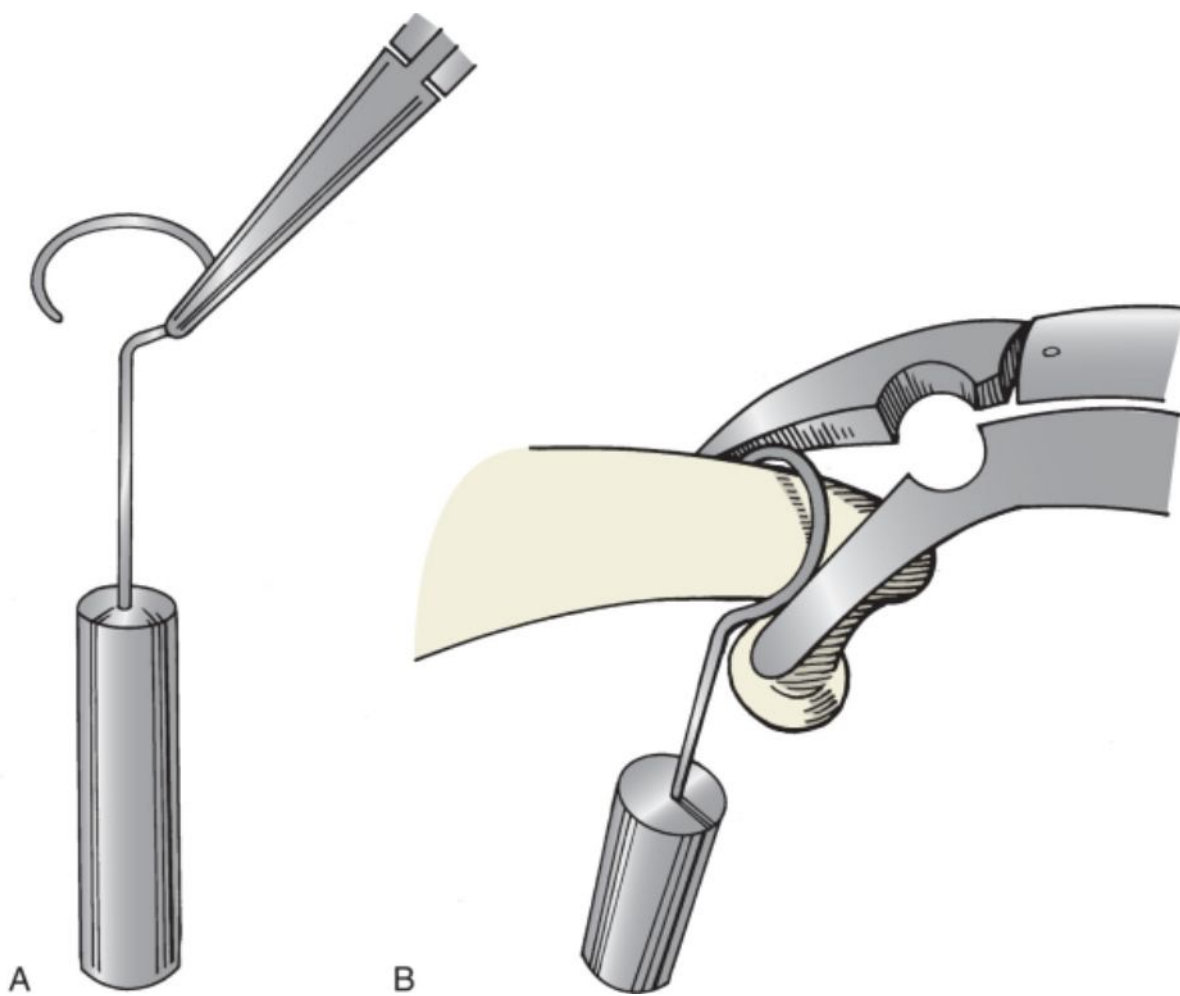
once the vestibule is open. If the stapedotomy is not adequate, it can be enlarged with the laser and footplate instruments (see Video 117-9). It is important to not fire the laser into an open vestibule. Next, a Farrior stapes rasp or a fine 45-degree pick is used to remove the char. The rasp has the shape of a disc (per style) so that small fragments of char may be removed in any direction, which avoids turning or twisting of the instrument as must be done when using angled picks. This instrument comes in two sizes, 0.5 and 0.6 mm, and is manufactured by Gyrus ENT. (Memphis, TN). Once the char is removed, a small fenestra stapedotomy is completed. If the opening in the footplate is irregular, a 6-mm drill set on low speed can be used to optimize the stapedotomy.



**Figure 117-19** Rosette pattern of laser strikes on the central footplate.

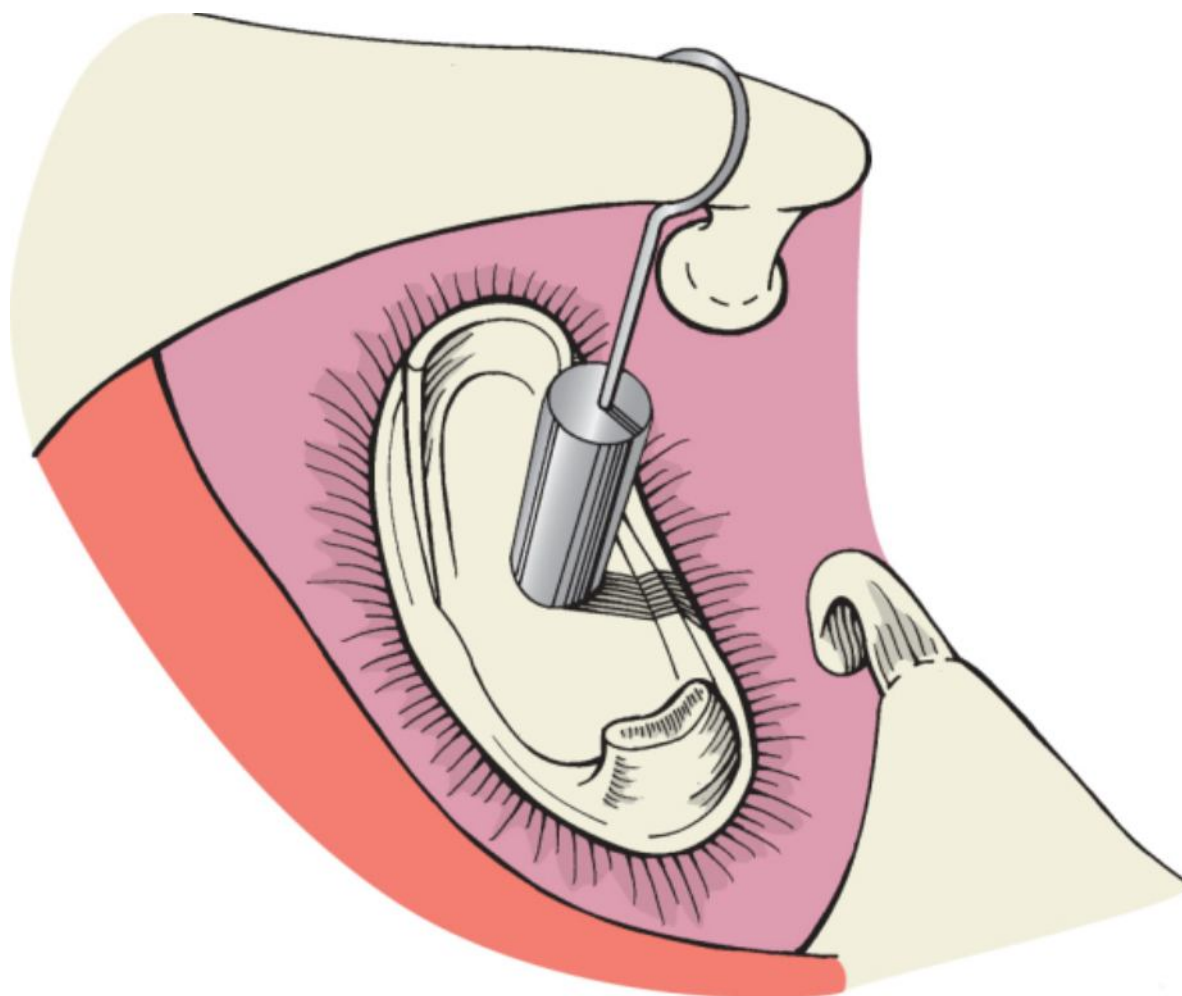
Alternatively, the author still prefers using a Robinson bucket-handle prosthesis over a vein graft for all routine stapedectomy procedures as described earlier. If the surgeon prefers a wire-piston prosthesis, it is placed in the oval window and carefully crimped to the incus (Figs. 117-20 and 117-21). The newer prosthesis does not have to be manually crimped around the incus (Smart; Gyrus ENT). After placing the wire-Teflon prosthesis, the laser is used to heat the hook portion of the prosthesis to secure it around the incus ([see Videos 117-10](#)  and [117-11](#)





**Figure 117-20** **A**, Method of grasping the piston with alligator forceps for insertion onto the incus. **B**, Tightening of the piston onto the long process of the incus.





**Figure 117-21** Piston in place with insertion into the fenestrated footplate.

An alternative to using multiple 200- $\mu$ m laser strikes to form the fenestra is to use one 0.6-mm laser strike in the middle of the footplate. The oval window may be sealed with clotted blood or tissue. The tympanic membrane is then returned to its normal position and secured as described earlier. As mentioned, the laser is not only useful when there is a narrow oval window niche but can also help avoid a floating footplate.

### Revision Stapes Surgery

Revision surgery after stapedectomy or stapedotomy is performed for two reasons. The first indication is for correction of postoperative complications. Such problems typically occur during the first few weeks after the initial procedure. Patients complain of decreased hearing or dizziness, or both. Other complaints may include increased tinnitus, distortion of sound, motion intolerance, and vertigo associated with coughing, straining, sneezing, acute alteration in barometric or middle ear pressure, or change in body position. In the immediate postoperative period this could occur as a result of the formation of a granuloma. In the past, development of a granuloma was ascribed to a complication related to the use of Gelfoam as sealant for the oval window. Synthetic materials are no longer used to cover the vestibule when a stapedectomy is performed. Various autogenous tissues, such as vein, fascia, areolar tissue, perichondrium, periosteum, fat, and blood, are used to seal the opening to the vestibule. Other possible sources include inflammatory tissue formed as a result of reaction to talcum powder on the surgeon's operating room gloves. On rare occasion, people may be allergic to an element included in the metal composition of the prosthesis.

The other urgent indication for surgical intervention is the possibility of a perilymphatic fistula. Similar to the signs and symptoms mentioned earlier, patients can have complaints related to hearing or balance (or both). Hearing loss may be sudden or rapidly progressive and is characteristically sensorineural. Fistula testing (pneumatic otoscopy with recording or observation of eye movements) is not reliable because it can be falsely positive in patients undergoing stapedectomy.

The second indication for revision surgery occurs when conductive hearing loss persists or develops over time. It must be emphasized, similar to the discussion regarding the initial procedure, that this is an elective procedure to



restore hearing. The other alternative is amplification with a hearing aid. The hearing status of the contralateral ear must be defined to determine how best to advise a patient. Given the small but real risk of total hearing loss after revision stapes surgery, absent hearing in the contralateral ear is a contraindication to an elective revision procedure. Possible exceptions to operating on an only-hearing ear are severe complications from the first procedure (progressive hearing loss and dizziness) or a severe to profound mixed hearing loss in which amplification is insufficient and cannot provide adequate gain.

Revisions of this type should be reserved for surgeons with considerable experience because hearing results, even in the best of hands, do not approach those of primary cases. Lesinski reviewed his series of 279 cases of revision stapes surgery performed with a laser. Sources of failure included unrecognized fixation of the lateral ossicular chain, erosion of the incus, displacement of the prosthesis from the oval window, and regrowth of otosclerosis. The most common finding was a displaced or malfunctioning prosthesis (81%), followed by erosion of the incus (30%). It was believed that erosion of the incus was caused by continued vibration of the incus bone against a prosthesis that was immobile at the interface with the otic capsule. Residual fixed stapes footplate was found in the center of the oval window in 14% of patients, and 4% had complete fixation of the malleus.<sup>[12]</sup>

Correction of prosthetic slippage and problems with the incus is statistically more successful than reopening of a bony window closure. The laser has a definite advantage in the presence of middle ear fibrosis or scarring and is invaluable in minimizing trauma to the inner ear associated with removing soft tissue in the oval window niche. The benefits of using the laser for revision stapes procedures were emphasized by Lippy and colleagues. The success rate increased to 80% for closure of the air-bone gap within 10 dB with the use of an argon laser. Hearing results were least successful when the incus could not be used for reconstruction.<sup>[13]</sup>

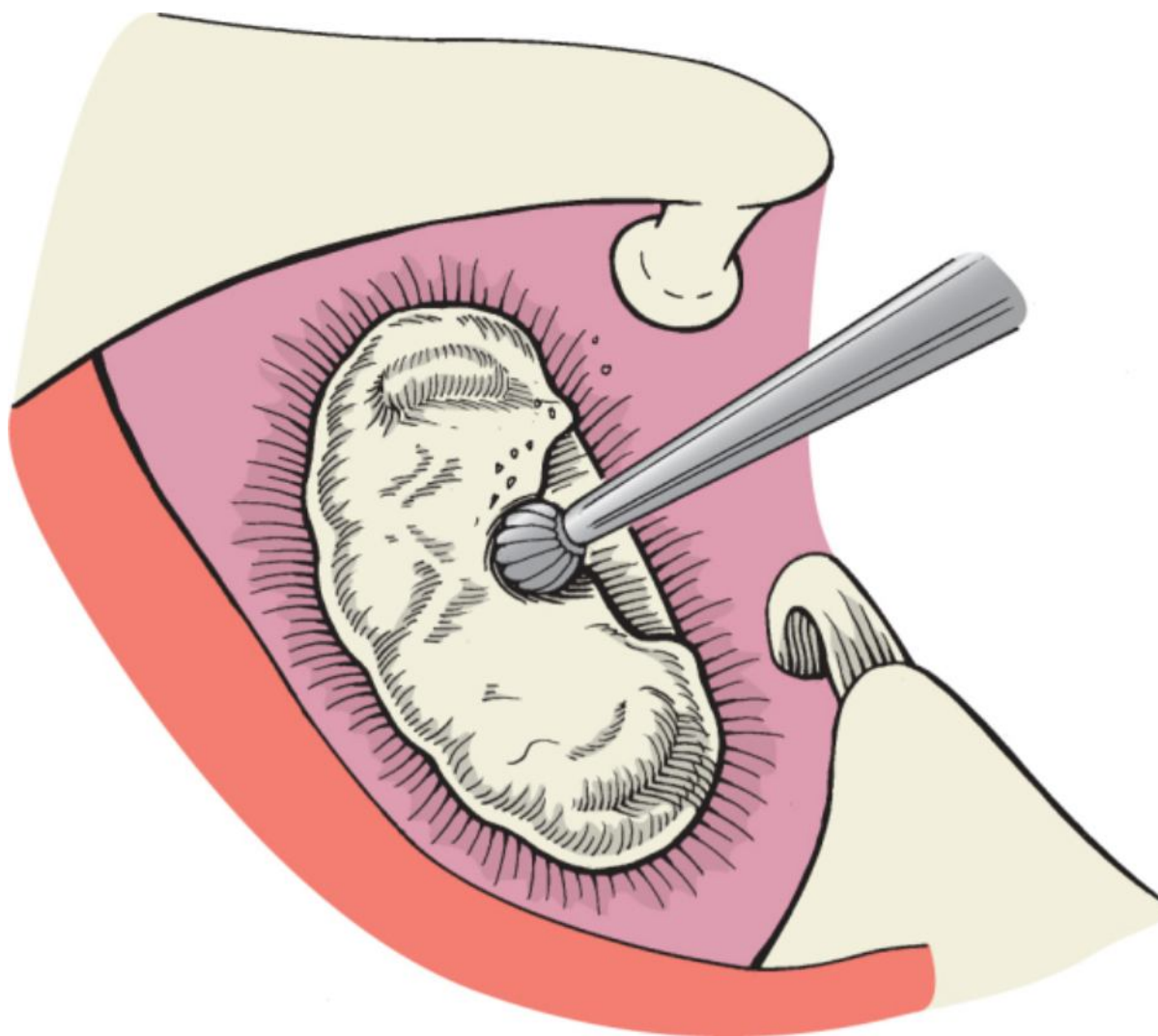
### Obliterative Disease

Replacement of normal footplate anatomy by obliterative otosclerosis presents a greater, but not insurmountable challenge to the surgeon. Forewarning may occur in the form of a positive Schwartz sign, a pinkish blush behind the tympanic membrane indicative of enhanced vascularity. Unfortunately, no typical audiometric pattern suggests this occurrence. Experience in using a microdrill is mandatory for this procedure, and lack thereof requires abandonment of the operation (Fig. 117-22). Visible superstructure is fractured and removed without fear of footplate flotation. A small microdrill with an angled handpiece is used to saucerize the oval window area (Fig. 117-23). Cutting burrs are used initially, and then small diamond burrs are used to remove the remaining focus of

bone until the blue line of perilymph is visualized through the thinned footplate area  (see [Video 117-12](#) ). It is important to keep the saucerization at the same depth throughout the circumference of the drilled-out area. When the site has been sufficiently thinned, fenestration is performed in the usual manner, and surgery proceeds as described earlier. Although drill-out procedures have been associated with a greater risk of sensorineural hearing loss, the risk is small in the hands of an experienced operator.



**Figure 117-22** Micro-ear drills can fit through the ear speculum and still provide good visualization.



**Figure 117-23** Use of a microdrill to saucerize obliterative disease.

### Expected Results

There is no otologic procedure (save perhaps myringotomy) in which hearing improvement will exceed that of stapes surgery. Conservative estimates of at least 90% success in restoration of conductive loss to air-bone gaps of less than 10 dB are realistic and seen in nearly all series reported. Results that differ significantly from these bear investigation for faulty patient selection or surgical technique. Occasional reduction or catastrophic loss of hearing is known to even the most experienced surgeons, but the incidence should be 1% or less. These statistics make surgery an acceptable risk for most patients seeking improvement in hearing. Although otolaryngologists must decide about their own qualifications as stapes surgeons, experience clearly leads to superior hearing results.

### **POSTOPERATIVE MANAGEMENT**

The demands of third-party insurers over the past decade have greatly reduced the length of hospital stay. Today, surgery for otosclerosis is performed as an outpatient procedure regardless of the type of anesthesia provided. Fortunately, most surgeons have discovered that reduction of stay has not altered the outcome in otosclerosis surgery. Nevertheless, each physician must maintain the ability to determine which patients require overnight observation for any of numerous reasons, including age, general health, complicating medical problems, and distance from the hospital. Complications encountered during surgery or symptoms suffered postoperatively should also be sufficient reason for extension of hospital stay.

Patients are allowed to ambulate soon after surgery, but they are advised to not lie on the ear that has undergone

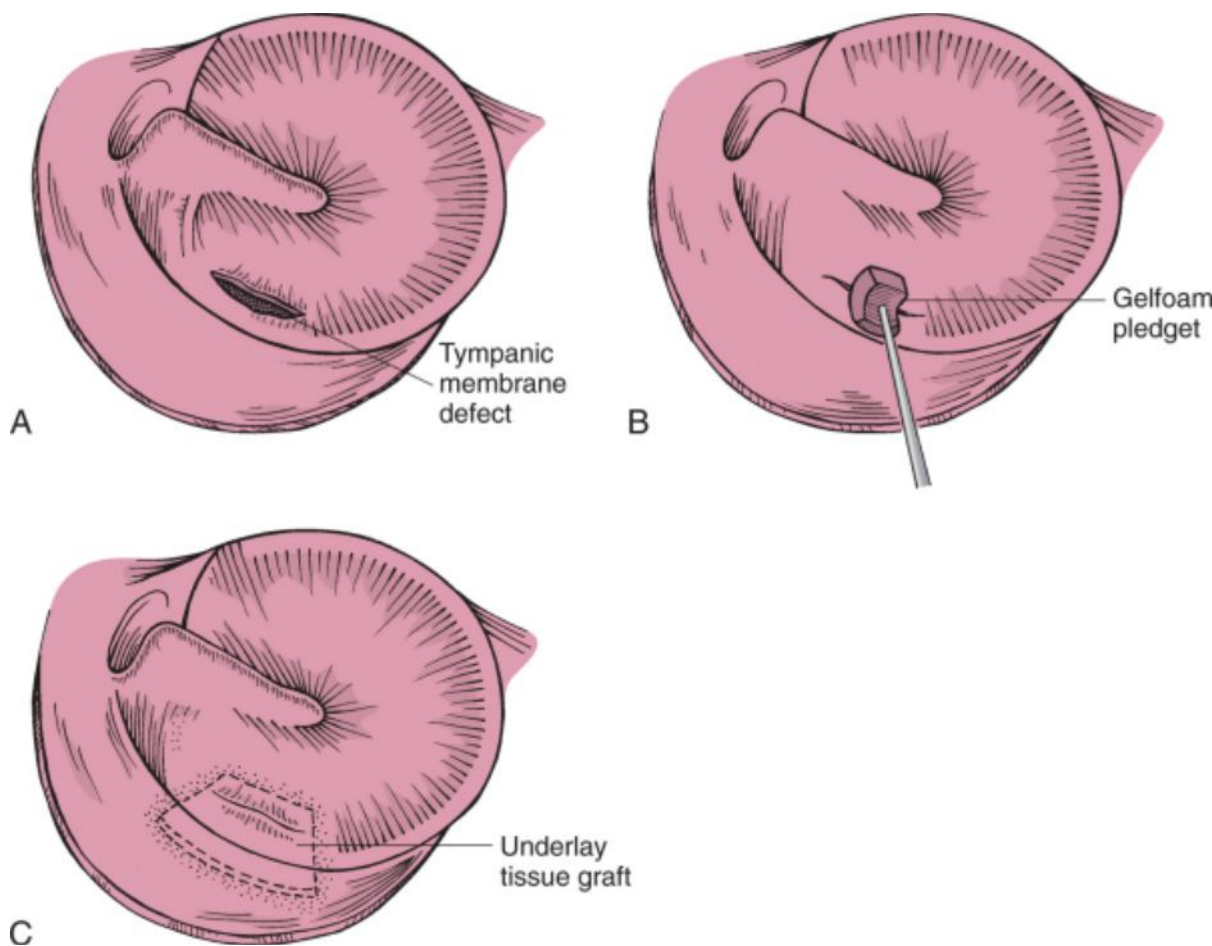
surgery for 24 hours. Precautions are given about sudden head movements to avoid dizziness, and prohibitions are also outlined against nose blowing, straining or lifting, or getting water into the ear that has been repaired. Clean cotton is kept in the external meatus as necessary until the packing is removed in approximately 1 week. Patients are encouraged to report any occurrence of worsening of vertigo, as well as any diminution in hearing. Sedentary work is permitted within 48 hours, but more strenuous occupations are banned for at least 3 weeks. Air travel is discouraged until the middle ear is seen to be well aerated, although this restriction may be impractical for some patients living at great distances. Antibiotics are not prescribed routinely. Analgesics with codeine are given when necessary.

## COMPLICATIONS

Complications encountered during surgery range from the insignificant to those that may require abandonment of the procedure. Even when completion of surgery is not possible, it is of primary importance to preserve auditory nerve function whenever possible. Reliance on a hearing aid as a fall-back position is infinitely preferable to severe loss of cochlear reserve. Complications are considered individually in the following sections.

### Tympanic Membrane Perforations

A tear in the tympanic membrane is most often due to failure to elevate the flap throughout its entire width before separation of the fibrous annulus from its sulcus (Fig. 117-24). A small tear may easily be repaired with tiny pledgets of Gelfoam inserted through the perforation. Larger defects should be reinforced with any remaining harvested tissue as an underlay graft. Occasionally, an extremely atrophic and thinned tympanic membrane is recognized preoperatively, and myringoplasty should be anticipated at the time of surgery. Tympanic membrane problems rarely have an impact on the outcome of surgery.



**Figure 117-24** A, Postoperative defect in the tympanic membrane. B, A moist Gelfoam pledget is inserted through the defect to support it from the medial side. C, Use of an underlay tissue graft for repair of the defect.

### Injuries to the Chorda Tympani Nerve

Careful removal of bone from the posterior canal wall allows preservation of the chorda tympani nerve in approximately 90% of cases. Stretching of the nerve or partial sectioning of less than one half its diameter should



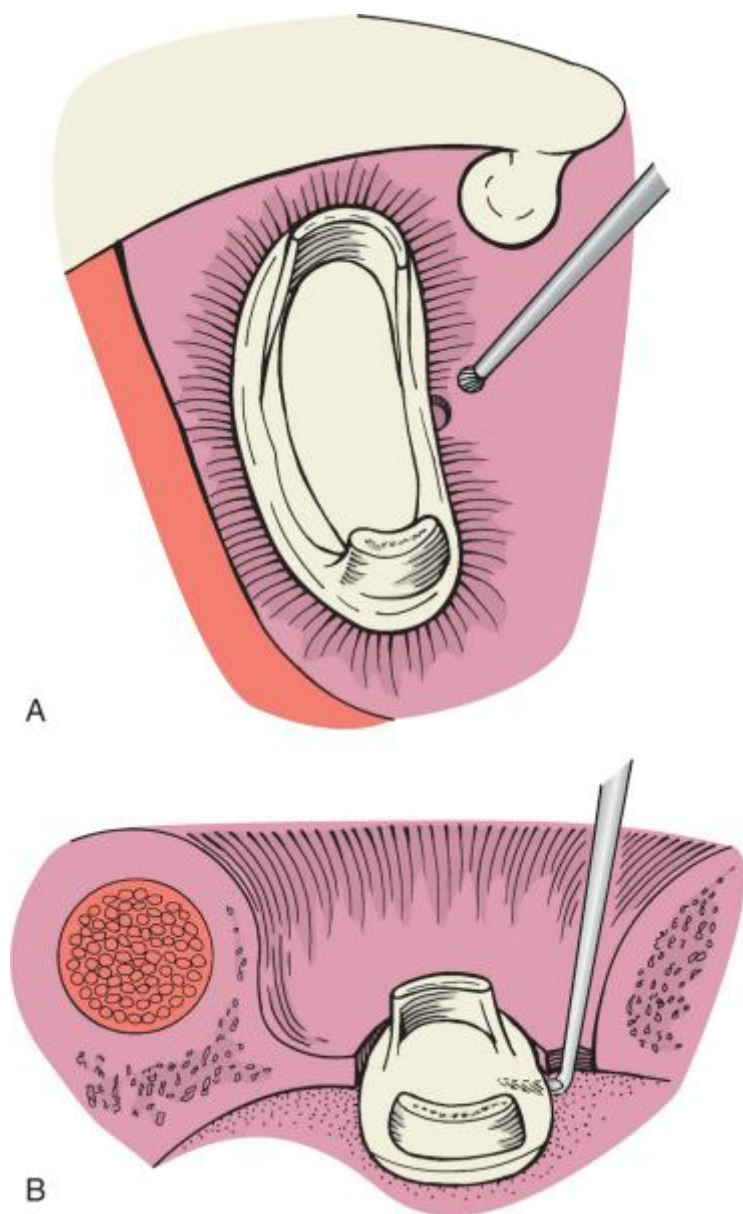
prompt preservation with reapproximation of the fibers as well as possible. Complete or nearly complete sectioning of the nerve is inevitable in a small percentage of cases. Even complete sectioning of the nerve most often results in only temporary dysgeusia. Most patients seem to compensate for taste disturbances within 6 months, although a small number may complain indefinitely. When taste is of utmost importance to the patient and when taste disturbance has resulted from surgery in the opposite ear, amplification for the second ear should be advised.

### Ossicular Dislocation

This unusual complication involves incudomalleal dislocation. It results from inadvertent lateral displacement of the long process of the incus. Careful placement of the incus in its original position will usually give a good hearing result despite somewhat greater difficulty in placing the prosthesis because of instability of the incus.

### Floating Stapedial Footplate

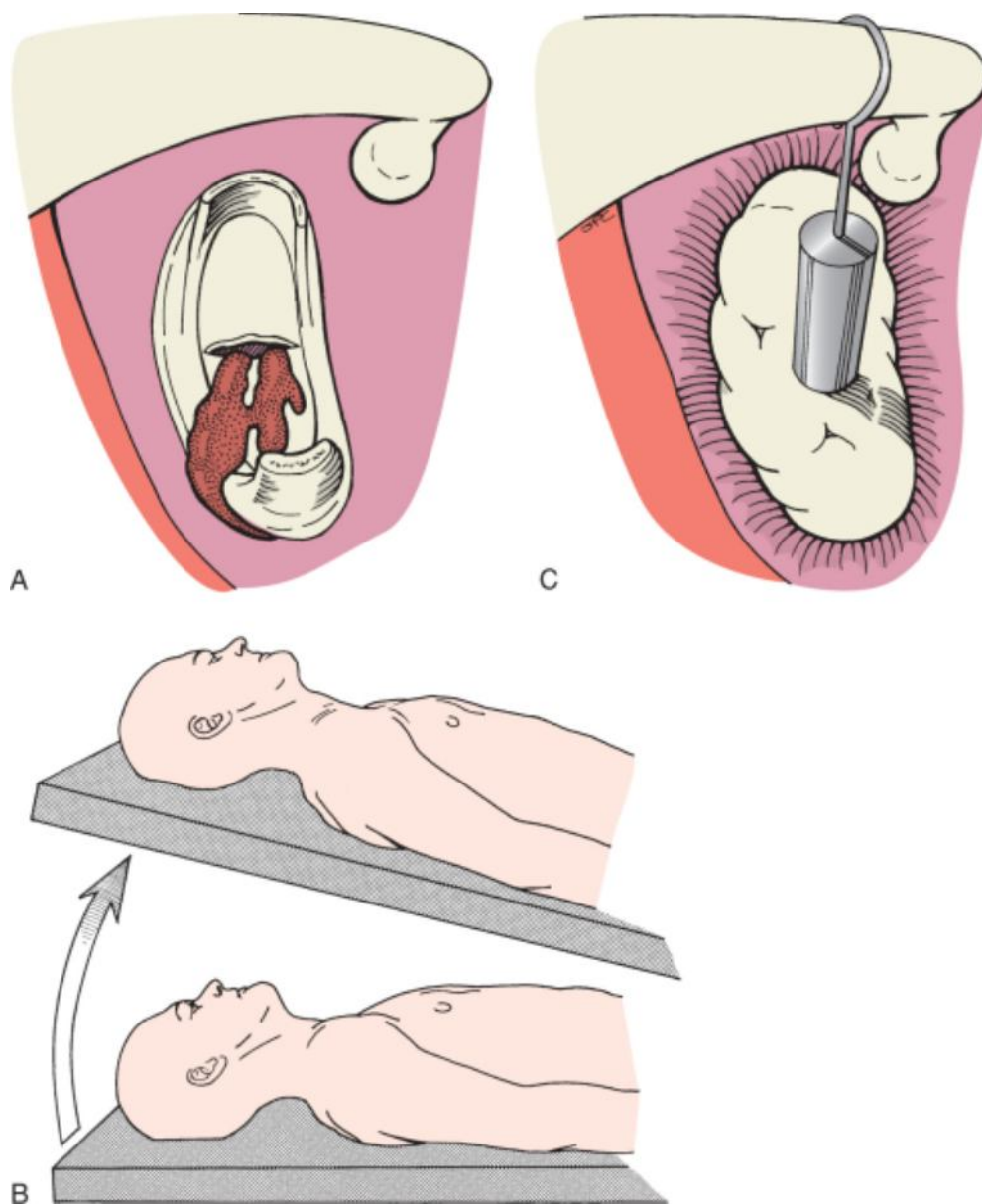
A floating footplate occurs when the superstructure is down-fractured and the entire footplate becomes loosened from the surrounding annular attachment at the oval window. This event is relatively rare and occurs in less than 1% of cases. It is best avoided by awareness of the factors that lead to it. Fracture of the stapedial superstructure before gaining a fenestration or control hole in the footplate may lead to this problem. Excessive pressure exerted on a thickened footplate may also result in circumferential dislodgement of it. It is necessary to get a purchase of the footplate when it is mobilized and floating. If a fenestration was initially performed, a footplate hook can be used to engage the footplate and extract it laterally. When this is not possible, the undersurface of the footplate is best accessed by drilling or curetting a small opening in the promontory side of the footplate until a fine right-angled pick can be inserted under the footplate and turned to complete extraction of it (Fig. 117-25). Another method for removing a large floating fragment is to place a few drops of blood over the window and remove the coapted fragments once a clot has formed. If the footplate becomes subluxated too far medially within the vestibule, attempts at retrieval should not be undertaken to avoid traumatic injury to the inner ear. A wire or bucket-handle prosthesis should be placed over a tissue graft.<sup>[14]</sup> Slight displacement of small fragments should be left alone because they rarely cause hearing loss. Larger fragments may induce persistent postural vertigo.



**Figure 117-25** **A**, Creation of a small "rescue hole" in the vestibule for removal of a floating footplate. **B**, Insertion of a fine right-angled pick through the rescue hole for retrieval of the footplate.

### Perilymph Gushers

Preoperative computed tomography should be performed in children to identify anomalies of the otic capsule and potential gushers. On occasion, perilymph gushers are encountered in adults. The problem consists of excessive perilymphatic flow into the middle ear because of enlargement of the cochlear aqueduct or communication between the medial internal auditory canal (fundus) and the inner ear (Fig. 117-26). Control is best achieved by elevating the head of the table and continuing to suction the perilymph until the reservoir of the cerebellar pontine cistern is exhausted. Fat is harvested from the ear lobule and placed snugly in the oval window after removal of the footplate. The fat is held in place with the stapes prosthesis. Elevation of the head is continued postoperatively and may be supplemented by insertion of a spinal drain. This condition increases the incidence of sensorineural hearing loss.



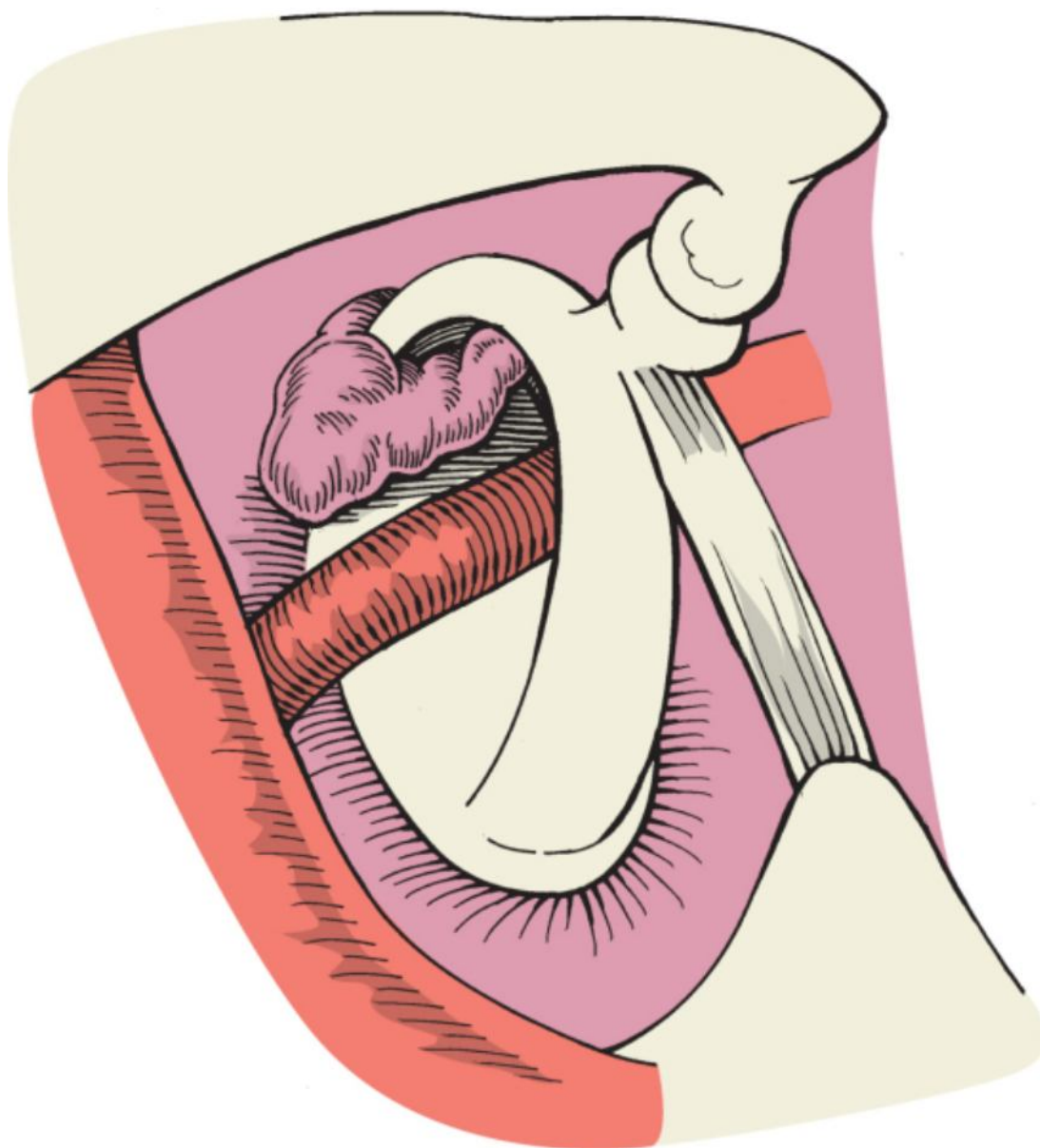
**Figure 117-26** **A**, A gusher of perilymph through the footplate fenestra. **B**, Reverse Trendelenburg position for relief of the perilymphatic gusher. **C**, Use of a piston prosthesis with an adipose tissue graft to seal the perilymphatic gusher.

### Round Window Otosclerosis

Complete obliteration of the round window niche as a result of otosclerosis is rare, although partial narrowing occurs occasionally. The procedure should be abandoned in the case of complete obliteration because drill-out of the round window has been associated with a high rate of sensorineural loss. Surgery may proceed as usual with partial closure.

### Persistent Stapedial Artery

Small remnants of this second branchial arch vessel often course across the stapedial footplate (Fig. 117-27). In a few cases, the artery may be large enough to create potential bleeding problems when disrupted. Even the larger arteries can most often be worked around by fenestration of the footplate and placement of the prosthesis anterior or posterior to the intact vessel. If the obturator foramen is obliterated by the artery, wise judgment may dictate termination of the procedure and the use of amplification with a hearing aid.



**Figure 117-27** Persistent stapedia artery.

### Dehiscence and Displacement of the Facial Nerve

Partial or total dehiscence of the horizontal portion of the facial nerve is a fairly common finding during middle ear surgery. Recognition of this anomaly is usually only important in that it encourages one to avoid instrumentation that could damage the nerve. Much less commonly, the facial nerve may overhang the oval window and, in rare cases, even travel directly across its surface (Fig. 117-28). Stapes surgery can usually be successfully completed in the presence of moderate overhang of the facial nerve, although visualization of the oval window is somewhat more difficult. Gentle retraction of the nerve with the side of a suction tip will ordinarily allow fenestration of the footplate and placement of the prosthesis. When the overhang is more pronounced, a crimp-on prosthesis of tantalum or platinum may be bent to curve around the dehiscence. Nitinol prostheses are also available, but great caution must be taken to ensure that tightening of the metal alloy with the laser does not injure the exposed nerve. The oval window may also be compromised by an overhang of bone from the promontory. This situation may be corrected with a microdrill until visualization is adequate (Fig. 117-29). Extreme situations of nerve displacement with coverage of the footplate dictate abandonment of the surgery.



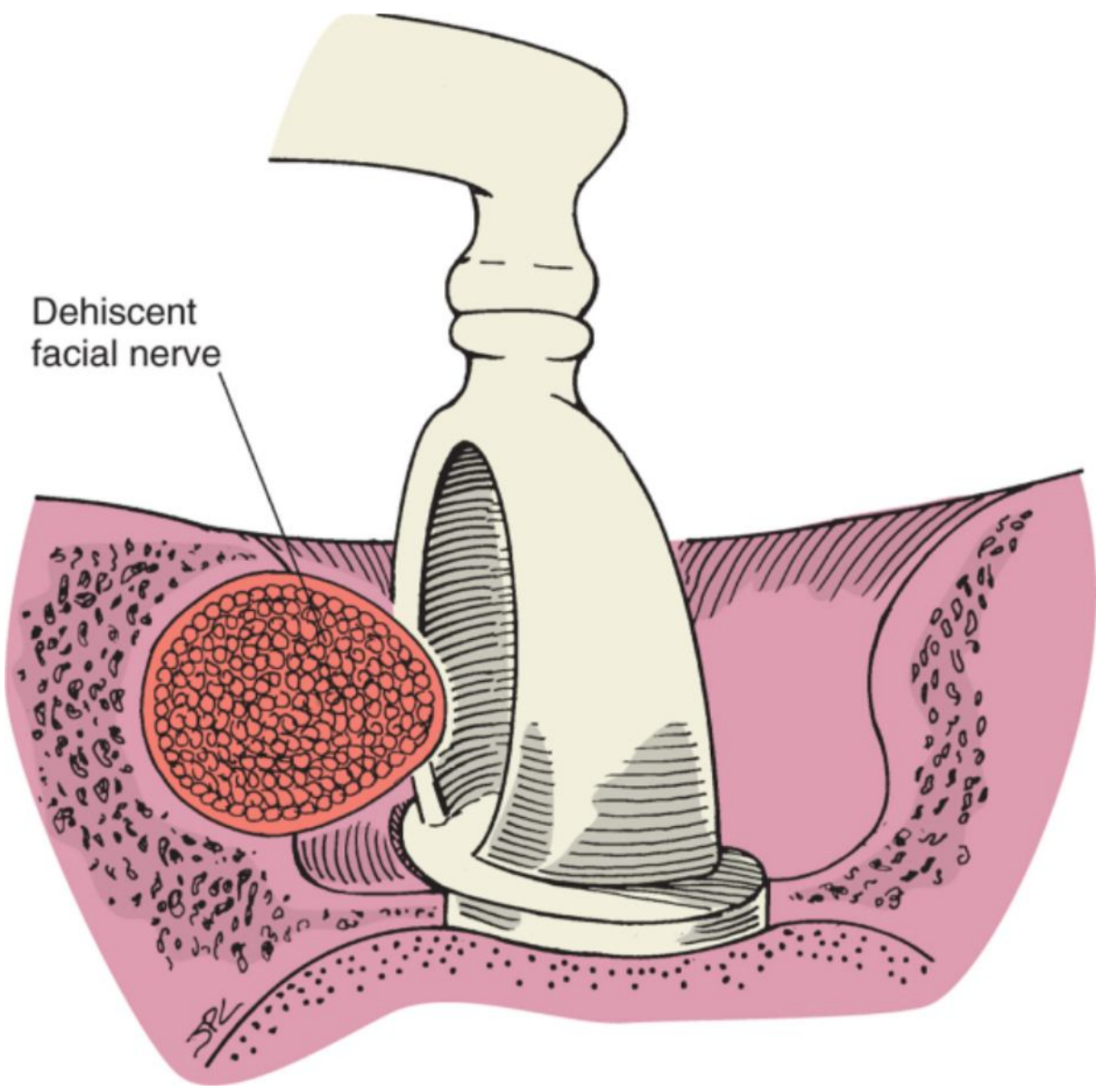
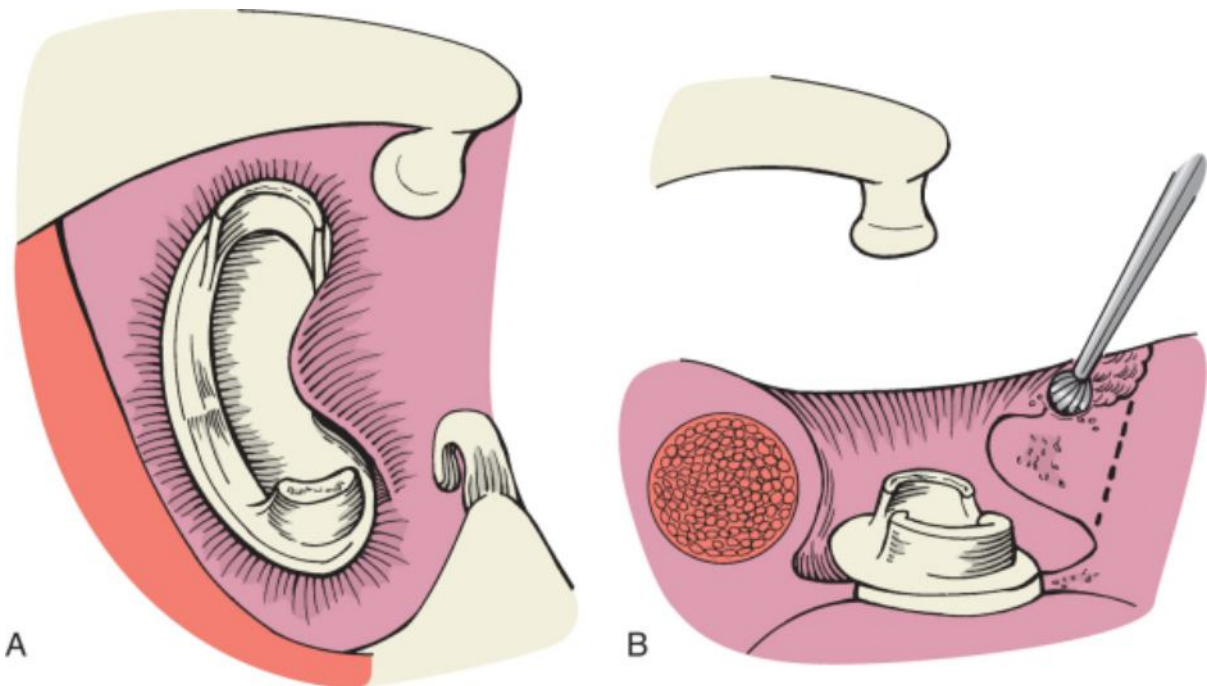


Figure 117-28 Dehiscent and overhanging facial nerve.



**Figure 117-29** A, Promontory focus of otosclerosis. B, Use of a microdrill to remove the promontory overhang.

### Intraoperative Vertigo

The onset of vertigo during surgery is related to stimulation of the labyrinthine receptors, which may occur because of excessive manipulation of the stapes or emptying of the fluid compartment of the vestibule. Local anesthesia permits the surgeon to rely on this symptom as a sign of impending damage to the inner ear. General anesthesia obviates this important signal. Vertigo is often transient or mild, but when it persists, it may imperil the completion of surgery because of associated nausea and vomiting. In this situation, rapid measures must be instituted to relieve symptoms and permit completion of the procedure. Droperidol is the most expeditious drug in this emergency; 1.25 mg is given slowly as a direct intravenous push, and larger doses can be used if necessary. Relief of symptoms is rapid and permits completion of the operation with patient comfort. Intraoperative monitoring is necessary when using this drug because of potential cardiac complications and hypotension. Intravenous ondansetron (4 mg) is also effective in this regard.

The use of general anesthesia does not permit the surgeon to monitor inner ear complications. However, under general anesthesia the patient will not move or become intolerant of minor middle ear stimulation. It is our preference to use general anesthesia rather than local or intravenous sedation for stapes surgery.

### Reparative Granuloma

The formation of reactive granulation tissue in and around the oval window is a catastrophic complication of stapes surgery that is seen less and less commonly today. Some have attributed it to particulate foreign matter from the prosthesis or possibly from the surgeon's gloves, but this hypothesis remains unproved. Possibly, washing of powder from surgical gloves, use of powderless gloves, and rinsing of prosthetics before introduction have reduced the incidence of granuloma. A granuloma typically develops approximately 1 week after surgery. Patients complain of diminished hearing and dizziness after initially exhibiting no significant problems. Examination reveals a violaceous fullness in the posterosuperior quadrant of the tympanic membrane. Audiometric testing confirms sensorineural impairment, which is usually accompanied by reduction in word recognition.

Although some authors have advocated systemic therapy with high-dose steroids, the generally accepted treatment is immediate surgical intervention with removal of the granuloma. This entails removal of the prosthesis and tissue graft and insertion of new material. Rapid recognition of the condition and surgical correction may reverse the hearing loss, but a permanent sensorineural deficit is more likely. In extreme cases or when recognition is delayed, granulomatous tissue has been shown to invade the oval window and fill the vestibule.

### Perilymphatic Fistula

In addition to reparative granuloma, postoperative perilymphatic fistula is the other chief cause of poor hearing results. Although each patient has a temporary fistula after footplate fenestration, the usual manner of healing seals the fluid leak within a short time. Persistence or redevelopment of the fistula after healing may be the result of imperfect tissue graft placement, dislodgment of the prosthesis, or sudden expulsion of fluid because of coughing or sneezing. Symptoms related to perilymphatic leakage are typically fluctuant hearing loss and dizziness. Although physical examination of the ear is unremarkable, audiograms confirm deterioration of cochlear function. When this complication is suspected, immediate exploration is indicated if hearing is to be salvaged. If a fistula is confirmed, tissue grafting and prosthetic placement are repeated.

### Preoperative Problems with the Tympanic Membrane

When the tympanic membrane is extremely thin or atrophic, plans for grafting should be included in the preoperative counseling. Even if such grafting is unnecessary during surgery, it is better to have forewarned the patient. A larger piece of fascia, vein, or perichondrium can be harvested if a tissue graft is used for closure of the oval window. Severe atrophy and atelectasis can be supported with cartilage harvested from the tragus



(see [Video 117-13](#) ).

### Magnetic Resonance Imaging

With few exceptions, almost all middle ear prosthetics in use today are nonferromagnetic. The Robinson prosthesis is included in the group of devices that can be safely subjected to MRI. Patients are instructed in this regard to arm them for future questions about their eligibility for scanning. It is anticipated that magnet strength will increase in the future. The Robinson prosthesis is available in titanium, as well as the original stainless steel configuration.

Titanium is a safe metal in a magnetic field. Prostheses made of nitinol are also safe during MRI.

#### PEARLS

- An appropriate candidate for middle ear exploration to diagnosis otosclerosis is a patient with a normal ear examination, negative Rinne test, conductive hearing loss of 25 dB, absent acoustic reflexes, and an understanding of the risks and benefits of the procedure.
- Offer surgery to the worse-hearing ear and do not undertake elective surgery on an only-hearing ear unless maximum amplification has been tried and deemed unsuccessful.
- Ensure that adequate surgical exposure has been achieved before addressing the status of the stapes.
- Palpate the lateral ossicular chain after the incudostapedial joint has been separated, confirm that the lateral chain is not fixed, and then check the mobility of the stapes.
- Do not apply suction directly to the stapedotomy and vestibule.
- If a floating footplate develops and it sinks into the vestibule, place a tissue graft over the oval window and reconstruct with a wire or bucket-handle prosthesis.

#### PITFALLS

- Proceeding with footplate work before optimizing exposure of the oval window niche may result in prolongation of the procedure and untoward results.
- Attempts at recovering segments of the footplate that fall into the vestibule may result in iatrogenic sensorineural hearing loss.
- Failure to close the air-bone gap after surgery for presumed otosclerosis may be due to fixation of the lateral ossicular chain or dehiscence of the superior semicircular canal.
- Despite closure of the air-bone gap, residual sensorineural hearing greater than a 35-dB speech reception threshold may still require hearing aid amplification.
- In unilateral otosclerosis, the patient's perception of complete success is having the operated ear improve to air conduction scores within 15 dB of the better ear.

Copyright © 2009 [Elsevier](#) Inc. All rights reserved. Read our [Terms and Conditions of Use](#) and our [Privacy Policy](#).  
For problems or suggestions concerning this service, please contact: [online.help@elsevier.com](mailto:online.help@elsevier.com)