

## Chapter 113 – Myringoplasty and Tympanoplasty

Barry E. Hirsch

*Myringoplasty* and *tympanoplasty* are descriptive terms defining surgical procedures that address pathology of the tympanic membrane and the middle ear, respectively. Myringoplasty is an operative procedure used to restore the integrity of a perforated tympanic membrane. This assumes that the middle ear space, its mucosa, and the ossicular chain are free of active disease. Inspection of the middle ear is undertaken through the tympanic membrane. A tympanomeatal flap is not raised and the middle ear is not directly exposed. The only procedure performed is directed at reconstruction of the tympanic membrane. In contrast, tympanoplasty also implies reconstruction of the tympanic membrane but in addition deals with pathology in the middle ear cleft, such as chronic infection, cholesteatoma, or problems with the ossicular chain. Zollner[1] and Wullstein[2] provided a classification of tympanoplasty that focuses on the type of ossicular chain reconstruction needed. This classification is of historical interest because reconstruction of the ossicular chain was not undertaken at that time. It does provide a standardized method for analyzing pathology of the ossicular chain and for reporting outcomes of middle ear reconstruction. The five types of tympanoplasty that these authors described define the status of the ossicular chain as a result of pathologic changes from eustachian tube dysfunction and middle ear disease. Progression from type I to type V describes the status of the remaining ossicular chain. Type I has all ossicles intact and requires reconstruction of only the tympanic membrane. Type V consists of no ossicles and connection to the inner ear through a fenestrated horizontal semicircular canal or the vestibule at the oval window.

A variety of symptoms and signs indicate the need for either myringoplasty or tympanoplasty. Acute tympanic membrane perforation or lacerations may occur as a result of local trauma, such as a hand slap to the ear, from a misdirected cotton-tipped applicator inserted in the external canal, or from barotrauma. Another source of perforation of the tympanic membrane is water compression, which can occur while diving or falling onto a body of water with the ear making direct contact with its surface. It can also occur as a result of a wave hitting the ear while swimming or as a consequence of forceful irrigation of the ear canal during removal of cerumen. Patients with trauma to the tympanic membrane typically complain of a sudden onset of pain with associated hearing loss and occasional bloody otorrhea. The tympanic membrane in such cases may heal spontaneously or might require myringoplasty only. In contrast, patients requiring tympanoplasty more often have a longstanding history of hearing loss, perforation of the tympanic membrane, and chronic otitis media with intermittent otorrhea. Frequent otorrhea often implies chronic mastoid disease, and mastoidectomy may be required.

This chapter focuses on repair of the tympanic membrane. The indications and techniques of ossicular chain reconstruction are covered in Chapter 114. Pathologic processes requiring mastoidectomy, such as chronic otitis media with or without cholesteatoma, are addressed in Chapter 115.

### **PATIENT SELECTION**

Indications for reconstruction of the middle ear and tympanic membrane are to eliminate recurrent disease, provide a dry ear canal and middle ear space with an intact tympanic membrane, and maintain or improve hearing. Achieving an intact tympanic membrane eliminates the precautions that patients must take to avoid potential contamination of the middle ear with water and subsequent otorrhea.

Otologic management is dictated by the patient's symptoms and findings. The status of the tympanic membrane and eustachian tube function greatly influences the alternatives for otologic care. Patients with conductive hearing loss and an intact tympanic membrane who have an aerated middle ear or a clean dry perforation have three options: (1) periodic observation and monitoring of hearing status, (2) surgical reconstruction of the tympanic membrane, and (3) amplification with a hearing aid. Electing no further treatment with a dry tympanic membrane perforation incurs the risk of recurrent otorrhea after an upper respiratory tract infection or contamination with water. Patients should not swim or be exposed to water. If the conductive hearing loss is greater than 30 to 35 dB, the patient is often functionally compromised. Along with reduced hearing in the ipsilateral ear, it may be difficult to localize sound. Patients reluctant to undergo surgery may opt for aural amplification. Although the risks associated with anesthesia and a surgical procedure are avoided, problems inherent with hearing aid use must be accepted, including the need to frequently replace batteries, instrument malfunction, amplification of unwanted background noise, reduced hearing while the hearing aid is out (such as during sleep), and occasionally noisy feedback.

Perforation of the tympanic membrane does not necessarily have to be accompanied by conductive hearing loss. Small perforations, such as those seen after extrusion of a myringotomy tube, may be associated with normal

hearing, whereas a patient with a nearly total perforation may have conductive hearing loss of 35 to 40 dB. A similar loss in the setting of a small perforation raises concern that the ossicular chain may not be intact or may be fixed. The surgeon must anticipate the potential need for reconstruction of the ossicular chain and have appropriate surgical instruments and prostheses available at the time of surgery.

The presence of a mixed loss of hearing may alter the advice given by the surgeon. Although surgical correction of conductive loss may close the air-bone gap, a sensorineural component may still require amplification. In this situation, surgery may not be in the patient's best interest. However, if severe mixed loss precludes adequate gain and comfort from an ear-level aid, surgical correction of the conductive component would better facilitate aural rehabilitation. The diagnosis of otosclerosis must be considered when there is a history of slowly progressive hearing loss, bilateral disease is present, and the family history is positive. Surgical management of fixation of the stapes footplate is addressed in Chapter 117.

Examination of patients with a perforated tympanic membrane via the microscope is helpful in revealing the nature of the pathology. Inspection of the canal and middle ear space may provide evidence of recurrent or chronic otorrhea. The location of the defect in the tympanic membrane may raise the surgeon's suspicion of cholesteatoma. Marginal perforations with thin keratin migrating laterally from the edge ("trail sign") suggests squamous epithelium or cholesteatoma in the middle ear. These findings, along with hypertrophied mucosa or extensive granulation tissue, suggest the need for tympanoplasty with mastoidectomy. Tympanoplasty without mastoidectomy would be considered if recurrent drainage is infrequent.

The role of mastoidectomy in improving the success rate of tympanic membrane grafting is controversial. This issue was examined in a recent study. Similar success was achieved in two groups of patients undergoing tympanoplasty in which the only variable was whether mastoidectomy was performed at the time of tympanoplasty. Neither group had (1) active infection (active otorrhea, abnormal middle ear mucosa, or granulation tissue), (2) ossicular abnormalities (ossicular fixation, ossicular discontinuity, ossicular malformation, or absence of an ossicle), (3) cholesteatoma, or (4) previous attempt at tympanic membrane repair (previous tympanoplasty or mastoidectomy). The authors noted that the need for subsequent revision surgery was diminished in those undergoing mastoidectomy at the initial procedure.<sup>[3]</sup> It is our opinion that tympanoplasty alone, without mastoidectomy, is indicated in patients with normal-appearing mucosa in the middle ear. Despite a well-organized preoperative plan, the surgeon must be prepared to modify the surgical approach and technique based on the intraoperative findings.

Other issues can influence whether surgical intervention is offered. The nature of the patient's disease and desire for intervention typically dictate the type of rehabilitation recommended. An audiogram is always obtained and typically repeated if the patient has not been seen in the office within 6 months. Along with the physical examination, the hearing status of the contralateral ear also influences the method of aural rehabilitation. A patient with mixed or conductive hearing loss and a contralateral anacusis ear is offered a hearing aid unless the hearing ear has significant active disease unresponsive to medical management.

Collecting additional information and identifying other findings on physical examination may influence the decision for or against surgical intervention. The issue of timing of tympanoplasty, especially in children, remains controversial. The status of the contralateral ear may provide caution or reassurance that the eustachian tube is functioning normally in the involved ear. A recent study in children noted that a dry perforation or the presence of a myringotomy tube in the contralateral ear did not negatively affect successful tympanic membrane repair in the ipsilateral ear. Poor prognostic findings included more objective evidence of ongoing contralateral eustachian tube dysfunction, as evidenced by otitis media with effusion or negative middle ear pressure (atelectasis). Surgery in these children less often resulted in an intact tympanic membrane and a normal middle ear space.<sup>[4]</sup>

Operative reports of previous otologic procedures performed on either ear should be reviewed. This may provide insight into the status of eustachian tube function, because patients with tympanic membrane perforation who have undergone repeated tympanoplasty procedures usually have poor tubal function. In addition, evaluating the status of contralateral middle ear aeration and tubal function may predict the probable success of yet another tympanoplasty.

Other physical findings and symptoms may affect the decision to surgically address the tympanic membrane and middle ear. Patients with cleft palate deformities are prone to recurrent and chronic middle ear infection. Symptoms such as vertigo should be investigated to avoid operating on an ear that may have ongoing vestibulopathy. If a patient has an actively draining ear, every effort should be made to dry the ear with topical drops or possibly systemic antibiotics, or both. A dry ear before surgery increases the likelihood of success. It is also important for the physician to know whether the patient will be compliant and return for follow-up care.

The risks and benefits of the planned operative procedure must be explained. Potential complications, although rare, include worsening of hearing or complete hearing loss, vertigo, change in taste on the ipsilateral side of the tongue, and failure of the graft to heal. Taste disturbance results when the chorda tympani nerve is stretched,

desiccated, or divided. Patients may remain symptomatic for 4 to 6 months. In some cases this results in permanent dysfunction. Patients undergoing a postauricular approach should be told that the top of the pinna often feels numb or there may be a sense of “pins and needles” along the midhelix. Sensation usually returns in approximately 3 months.

## PREOPERATIVE PLANNING

Imaging studies are not generally obtained before routine myringoplasty or tympanoplasty procedures. If readily available, the operative notes should be reviewed if previous procedures were performed on the involved ear. However, previous operative reports may not reflect the current situation in the middle ear and mastoid. After numerous otologic procedures, local tissue for grafting may not be readily available. If this is the case, alternative sources such as perichondrium, periosteum, or even areolar tissue or fascia from the contralateral side should be considered. The integrity of the skin and patency of the canal should be assessed. A split-thickness skin graft may be necessary if canal atresia or stenosis is present after previous procedures. Before surgical intervention, informed consent must be obtained.

## ANESTHESIA

Tympanoplasty for reconstruction of the tympanic membrane and correction of conductive hearing loss is typically performed through a postauricular approach, especially in patients with large or anterior perforations and revision operations. Most of the procedures that we perform entail lateral grafting techniques, usually performed under general endotracheal anesthesia. Adult patients who are reluctant to undergo general anesthesia may be given a local anesthetic and regional block supplemented with monitored intravenous sedation. In cases of conductive hearing loss with an intact tympanic membrane or a small perforation in which a medial graft is anticipated, a transcanal approach is used. In this case either local or general anesthesia may be considered. However, intravenous sedation with local anesthesia is preferred and typically well tolerated by the patient. A sedated but awake patient with additional local anesthesia presents distinct advantages during ossicular reconstruction procedures. The surgeon can assess the patient's hearing result during the procedure and detect any untoward symptoms, such as dizziness. Antibiotic prophylaxis is not given for routine myringoplasty and tympanoplasty procedures.

## SURGICAL TECHNIQUES


Medial and lateral grafting are probably equally successful in the hands of experienced surgeons. Nevertheless, we typically choose lateral grafting because of our consistent results, which are in part due to the greater exposure provided by this approach. A graft is placed medially when the patient has an infrequent history of otorrhea; when the perforation in the tympanic membrane is small, not marginal, and located in the posterior half of the tympanic membrane, or when there is minimal evidence of middle ear disease. Myringoplasty by definition addresses only the tympanic membrane in patients in whom the ossicular chain is assumed to be intact. Tympanoplasty techniques incorporate inspection of the middle ear and reconstruction of the ossicular chain when necessary.

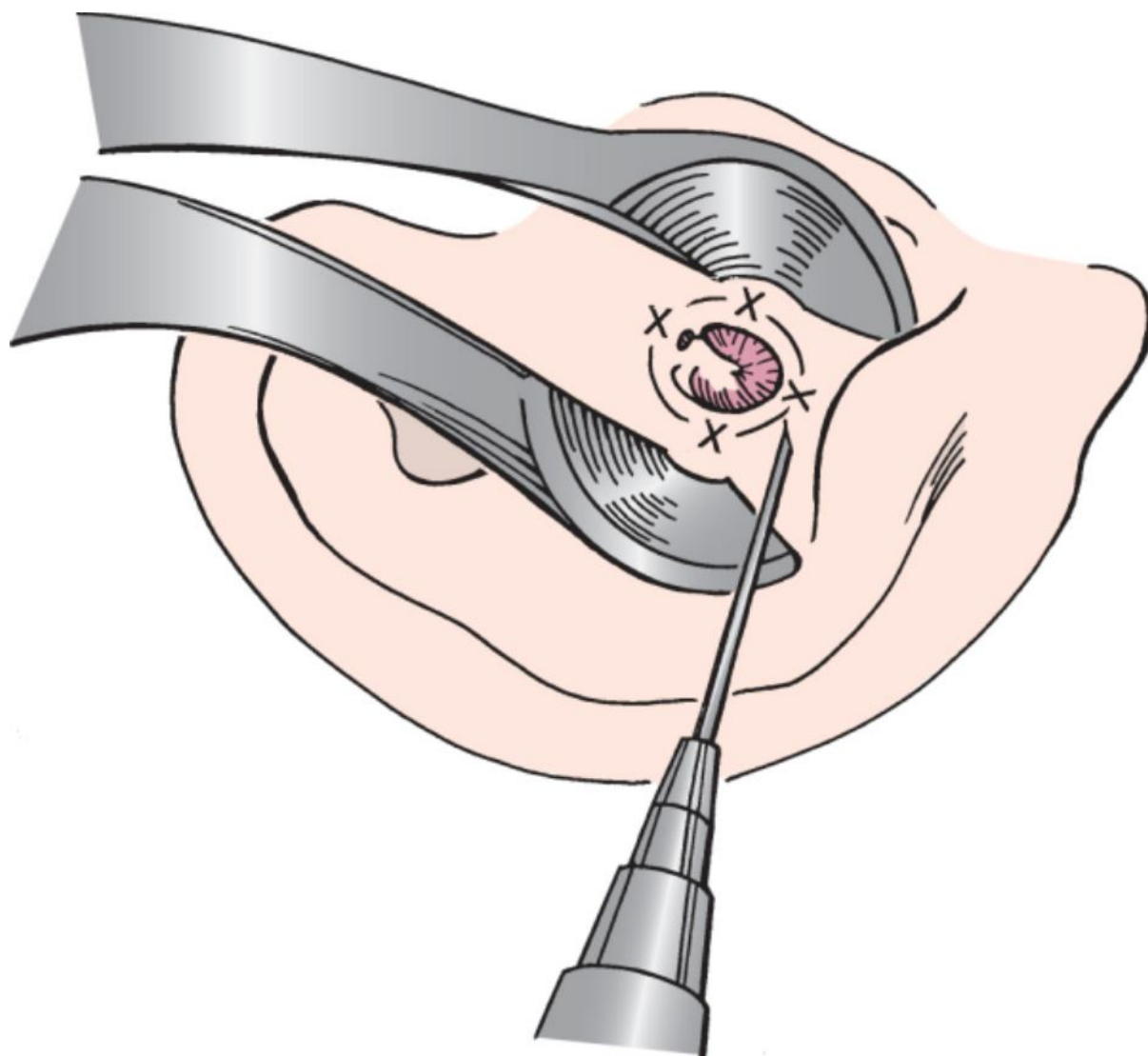
An operative approach recently described for difficult or failed tympanoplasty procedures involves the use of a palisading technique of cartilage and perichondrium. It may be indicated in patients with severe atelectasis, in those with high-risk perforations and an intact ossicular chain, and in association with ossiculoplasty when the malleus is present. High-risk perforation is defined as a tympanic membrane perforation that persists after unsuccessful attempts at surgical repair, a perforation anterior to the malleus, a perforation larger than 50%, or a bilateral perforation.<sup>[5]</sup> Our preference is not to use cartilage because inspection of the middle ear to monitor for the recurrence or development of cholesteatomas may be compromised. Cartilage is necessary when the scutum is eroded or removed to access the epitympanum for mucosal disease and cholesteatoma. Cartilage harvested from the tragus, including an island of perichondrium, can help secure the graft in its desired position.

## Myringoplasty

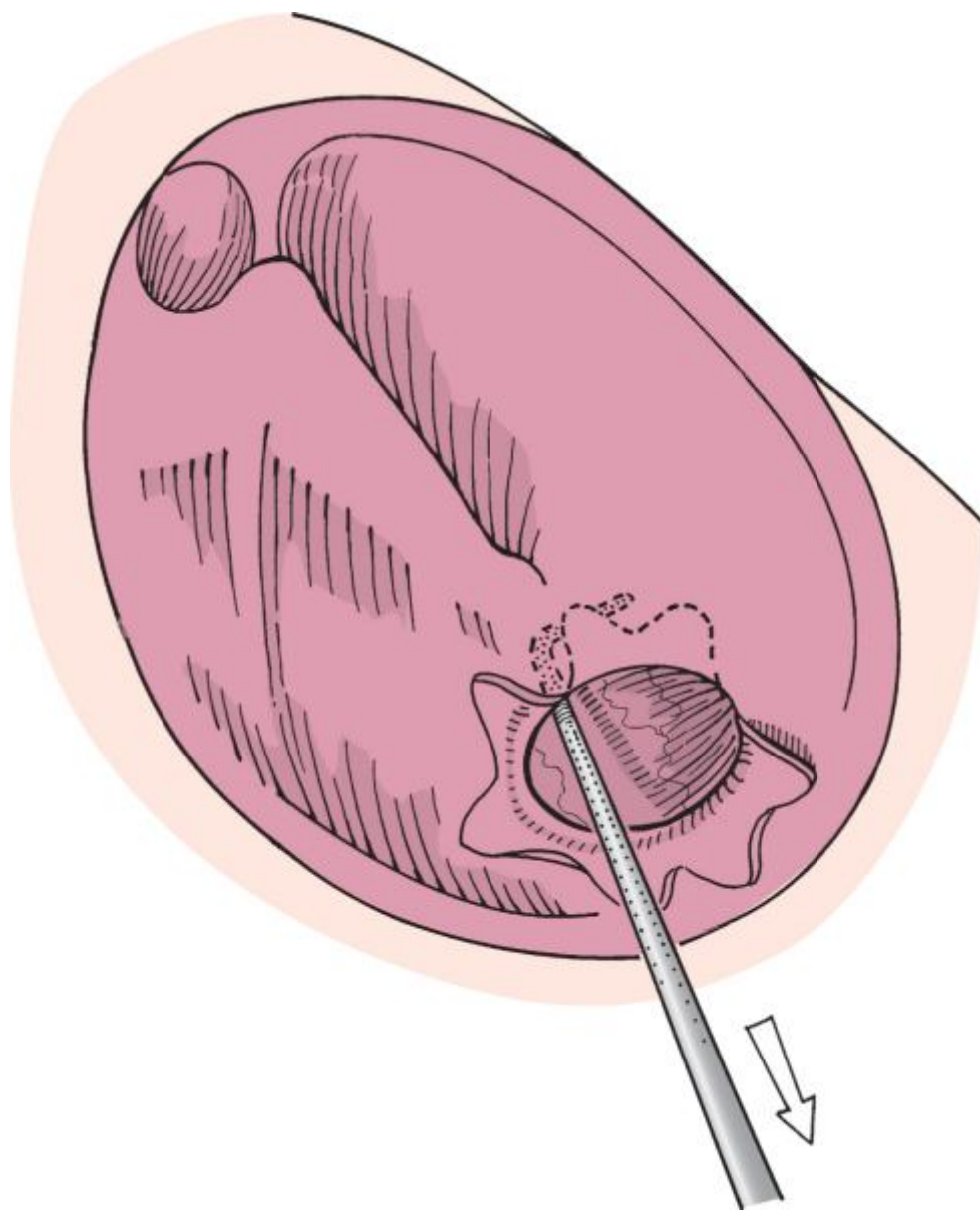
Myringoplasty is performed for small or acute traumatic perforations of the tympanic membrane. Acute traumatic tympanic membrane lacerations or perforations require that the edges of the drum be unfolded to remove squamous epithelium from the medial surface of the tympanic membrane. Analgesia is often necessary and is provided by a four-quadrant external canal block applied just lateral to the cartilaginous-bony junction with 2% lidocaine (Xylocaine) with 1:100,000 epinephrine through a 27-gauge dental needle (Fig. 113-1) ([see Video 113-1](#)



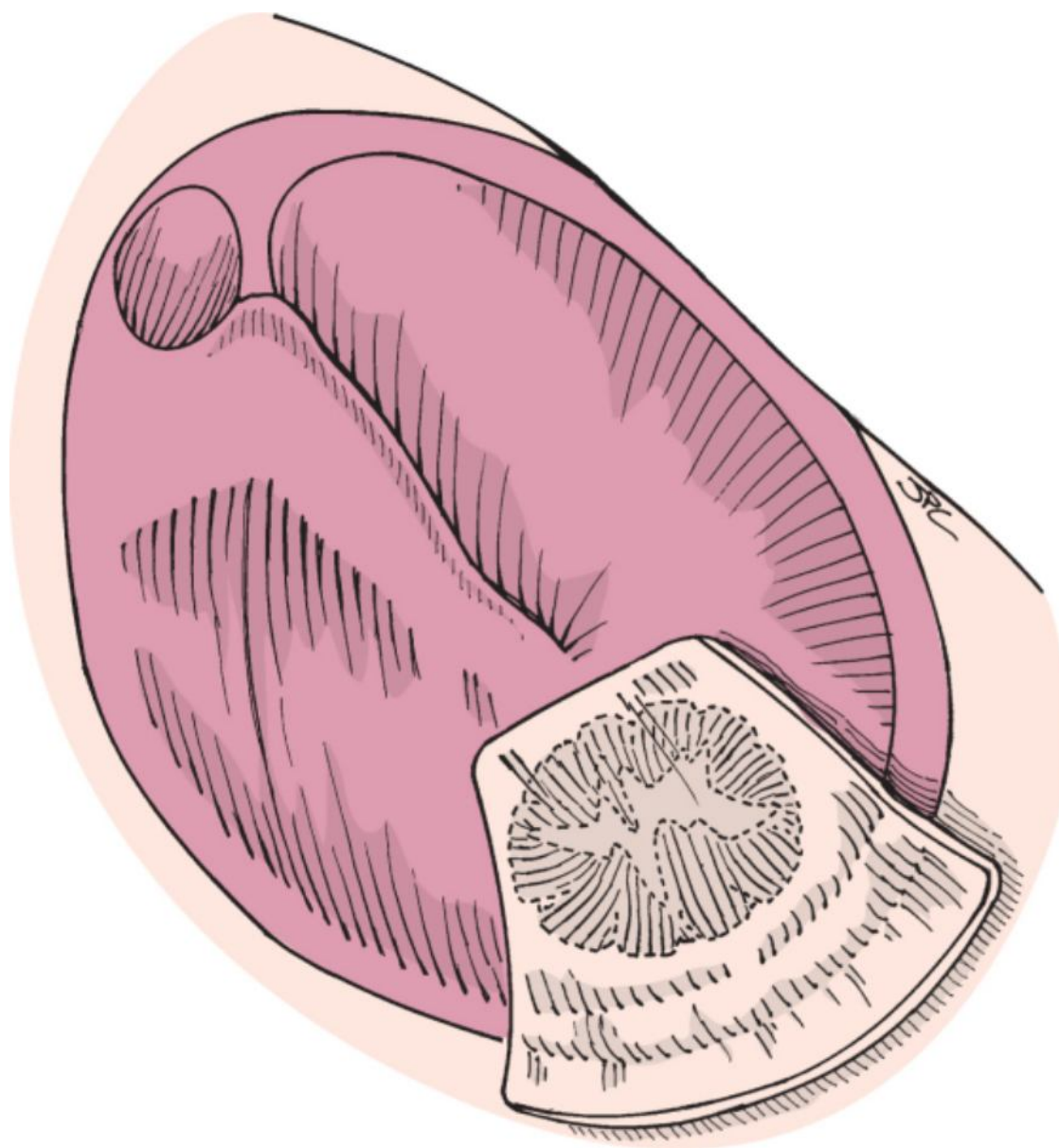
). The edges of the tympanic membrane  perforation are unfolded so that not all squamous epithelium is removed from the middle ear (Fig. 113-2). Often, approximation is not precise, and small pieces of Gelfoam impregnated with a suspension of ciprofloxacin and hydrocortisone (Ciprodex) or plain ciprofloxacin solution (Floxin) is placed medial to the laceration or perforation. A cigarette paper patch, Steri-Strip, or silk patch is applied to the lateral surface of the tympanic membrane (Fig. 113-3).



**Figure 113-1** With a Lempert speculum, local anesthetic is injected in a four-quadrant fashion into the external auditory meatus. The needle tip is placed just lateral to the bone-cartilage junction, and the solution is infiltrated until the skin blanches. (Redrawn from Bluestone CD, Stool S: *Atlas of Pediatric Otolaryngology*, 3rd ed. Philadelphia, WB Saunders, 1996.)

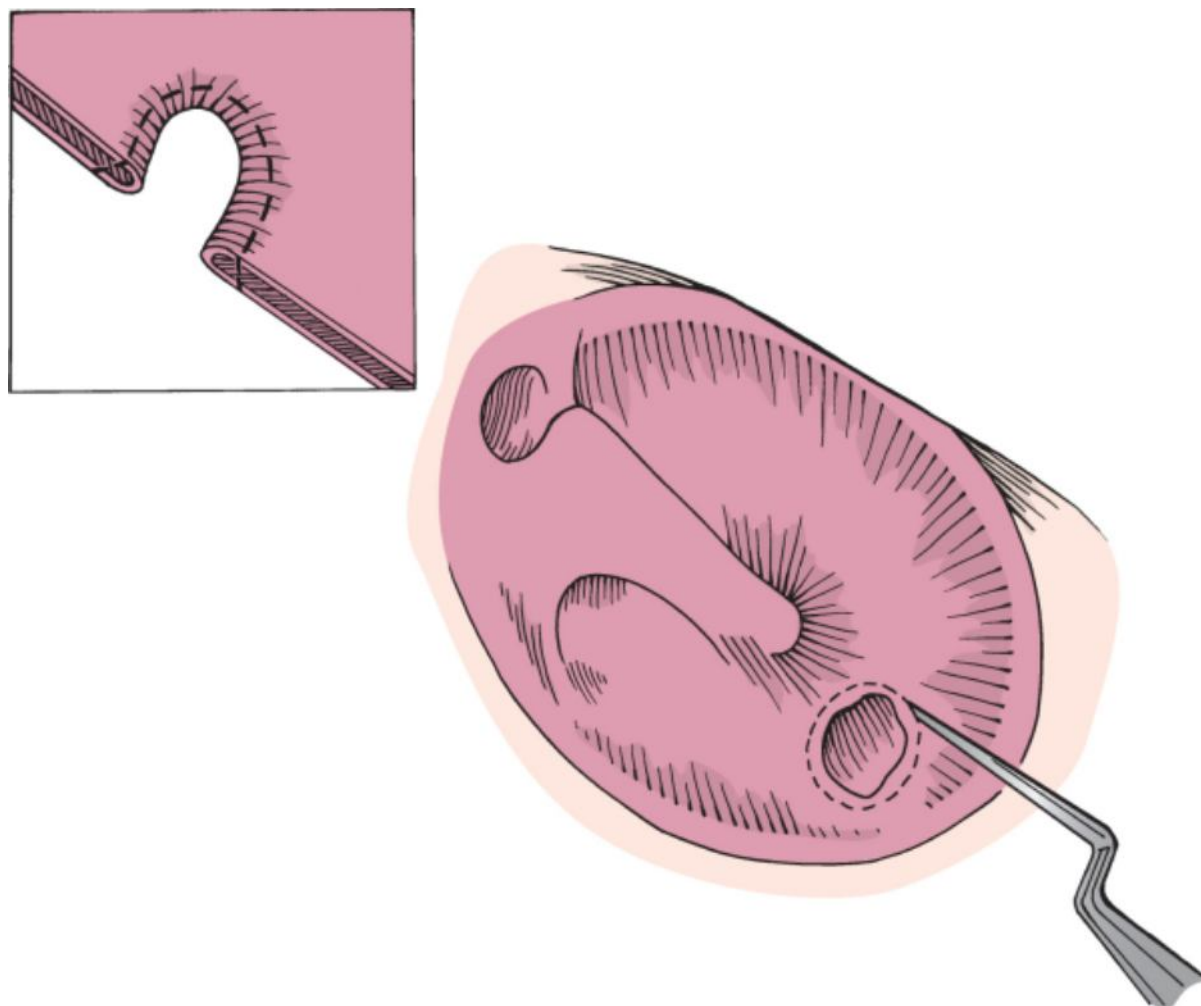


**Figure 113-2** The edges of a fresh stellate perforation are everted from the medial surface of the tympanic membrane. When squamous epithelium is no longer present in the middle ear, the edges are reapproximated.  
(Redrawn from Naumann HH: *Head and Neck Surgery*, vol 3: *Ear*. Stuttgart, Germany, Georg Thieme, 1982.)



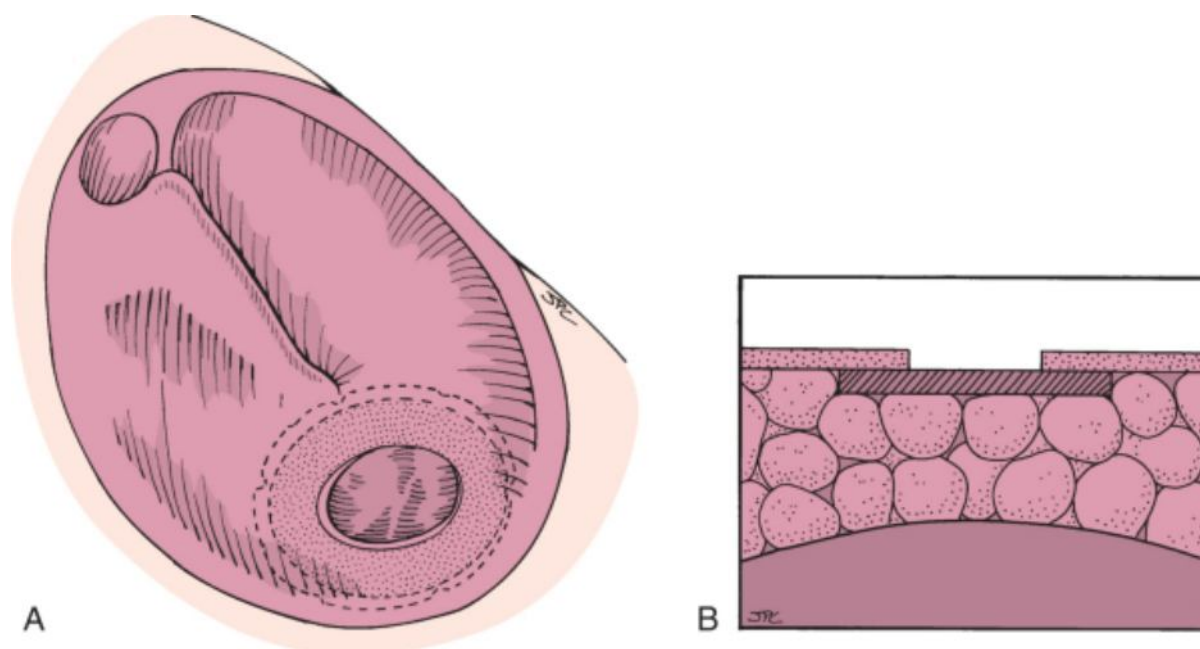
**Figure 113-3** The edges of the stellate perforation are approximated and supported with a cigarette paper patch or a Steri-Strip.

Small chronic perforations may also be treated by lateral patching techniques. In this situation, topical phenol or trichloroacetic acid is applied to the edges of the perforation with a wisp of cotton on an applicator. A sharp pick is then used to freshen the margins of the tympanic membrane perforation to allow removal of the edges of the perforation. This technique removes any squamous epithelium that may have migrated under the medial surface of the tympanic membrane at the edge of the perforation and stimulates bleeding and healing from the local vascular supply (Fig. 113-4). If the perforation is small and the edges are well defined, Gelfoam is not needed in the middle ear. A paper patch is applied to the lateral surface of the tympanic membrane.



**Figure 113-4** The edge of the perforation is circumferentially freshened to remove epithelium from the medial margin and promote local bleeding. The *inset* emphasizes that the medial edge of the perforation must be removed to eliminate squamous epithelium from the middle ear. (Redrawn from Naumann HH: *Head and Neck Surgery*, vol 3: *Ear*. Stuttgart, Germany, Georg Thieme, 1982.)

Small central perforations may be reconstructed with an autogenous tissue graft if paper patching is unsuccessful. This technique requires similar preparation of the tympanic membrane while ensuring that no squamous epithelium has migrated to the medial surface of the edges of the perforation. Depending on the age of the patient, myringoplasty with placement of the graft medially can be performed in the operating room under local anesthesia. Fat from the earlobe or areolar tissue from the postauricular area is harvested, compressed, and allowed to dry. After the edges of the tympanic membrane perforation are freshened, Gelfoam is placed through the perforation into the middle ear space. A properly sized tissue graft is placed through the perforation and sandwiched between the medial surface of the tympanic membrane and the Gelfoam (Fig. 113-5). In the absence of significant conductive hearing loss, this technique can be used to reconstruct such small defects without elevating a tympanomeatal flap. A small piece of Surgicel placed lateral to the grafted perforation may be used to further secure the graft. Gelfoam soaked in antibiotic solution is placed lateral to the tympanic membrane to fill the medial external canal.





**Figure 113-5** **A**, Myringoplasty of the right tympanic membrane with a posteroinferior perforation. The edges of the perforation are freshened, Gelfoam is placed in the middle ear, and an areolar or compressed fat graft (*stippled area*) is placed through the perforation, positioned medial to the tympanic membrane, and supported by the Gelfoam. **B**, Gelfoam supports the graft on the medial surface of the tympanic membrane.

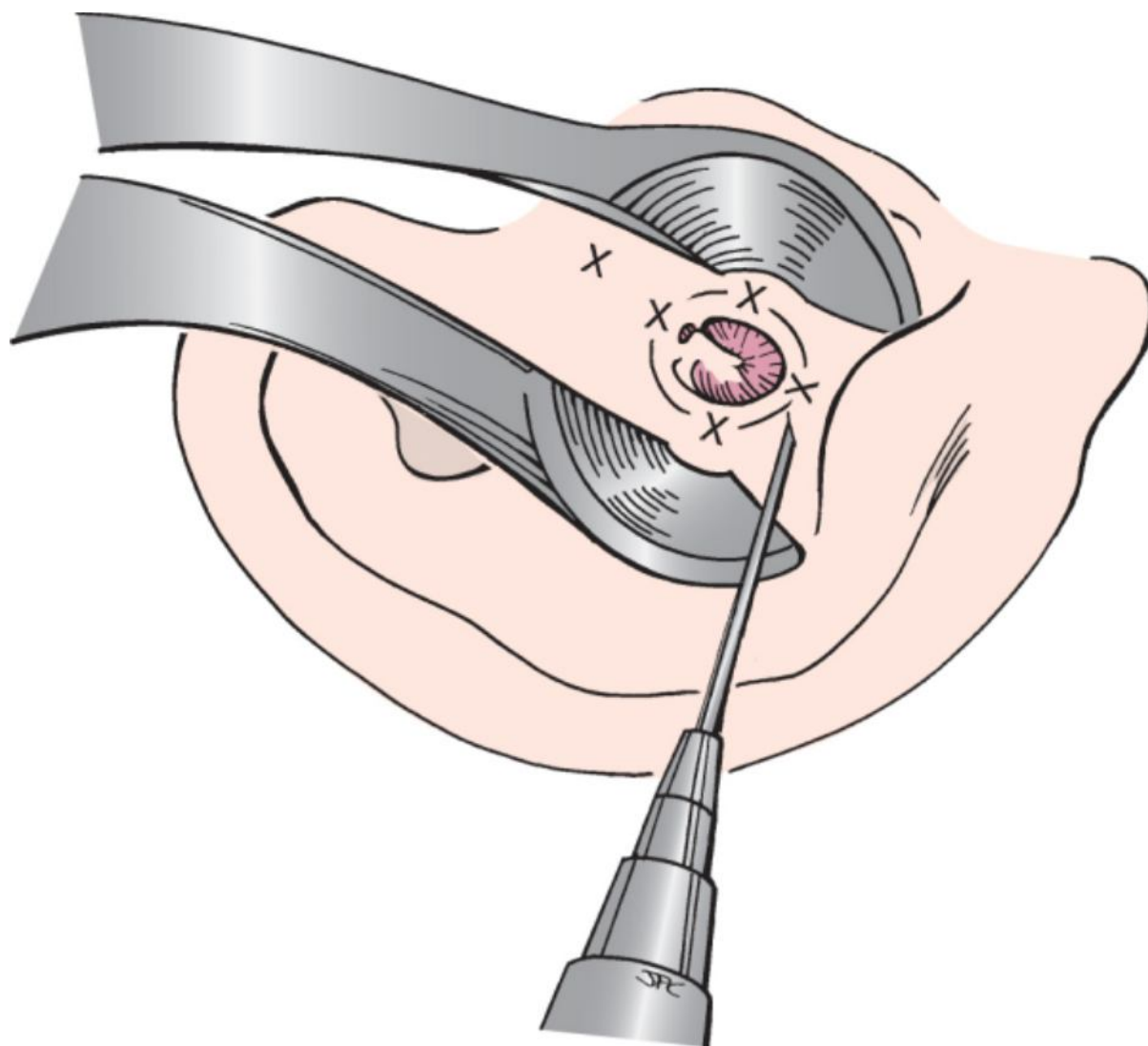
## Tympanoplasty

### Lateral Grafting Technique

The patient's head is turned toward the contralateral side, and the hair is shaved superior and posterior to the pinna to provide approximately 1 to 2 cm of hairless skin. After adequate general anesthesia has been obtained and the operative field has been prepared and draped, 2% lidocaine with 1:100,000 epinephrine is injected into the external canal with a dental syringe and a 27-gauge needle. This is done in at least four quadrants by placing the needle just at the medial margin of the cartilaginous canal and injecting approximately 1 mL. Additional infiltration

is placed at the 12-o'clock position at the incisura down to  the root of the zygoma (Fig. 113-6) (see [Video 113-1](#) ). The same anesthetic is also injected into the postauricular area a few millimeters posterior to the postauricular crease.



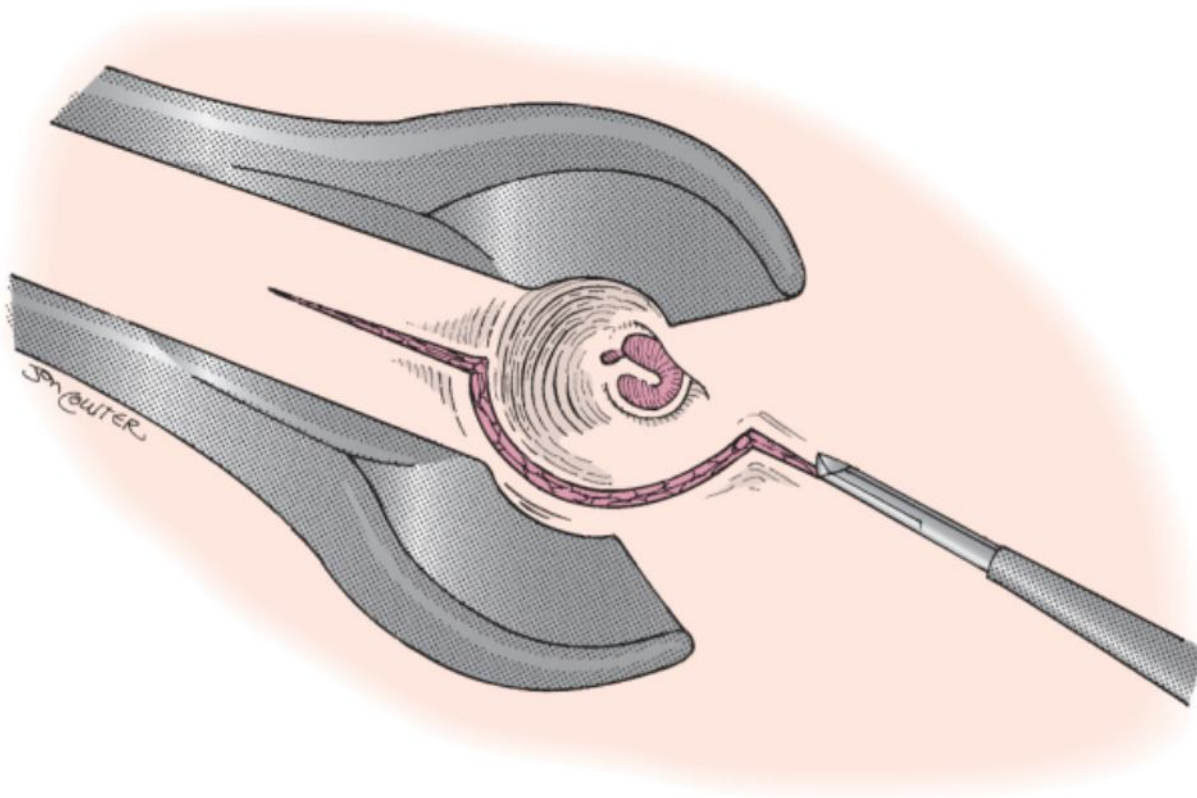


**Figure 113-6** Local anesthetic is injected in a four-quadrant fashion into the external auditory meatus and incisura.

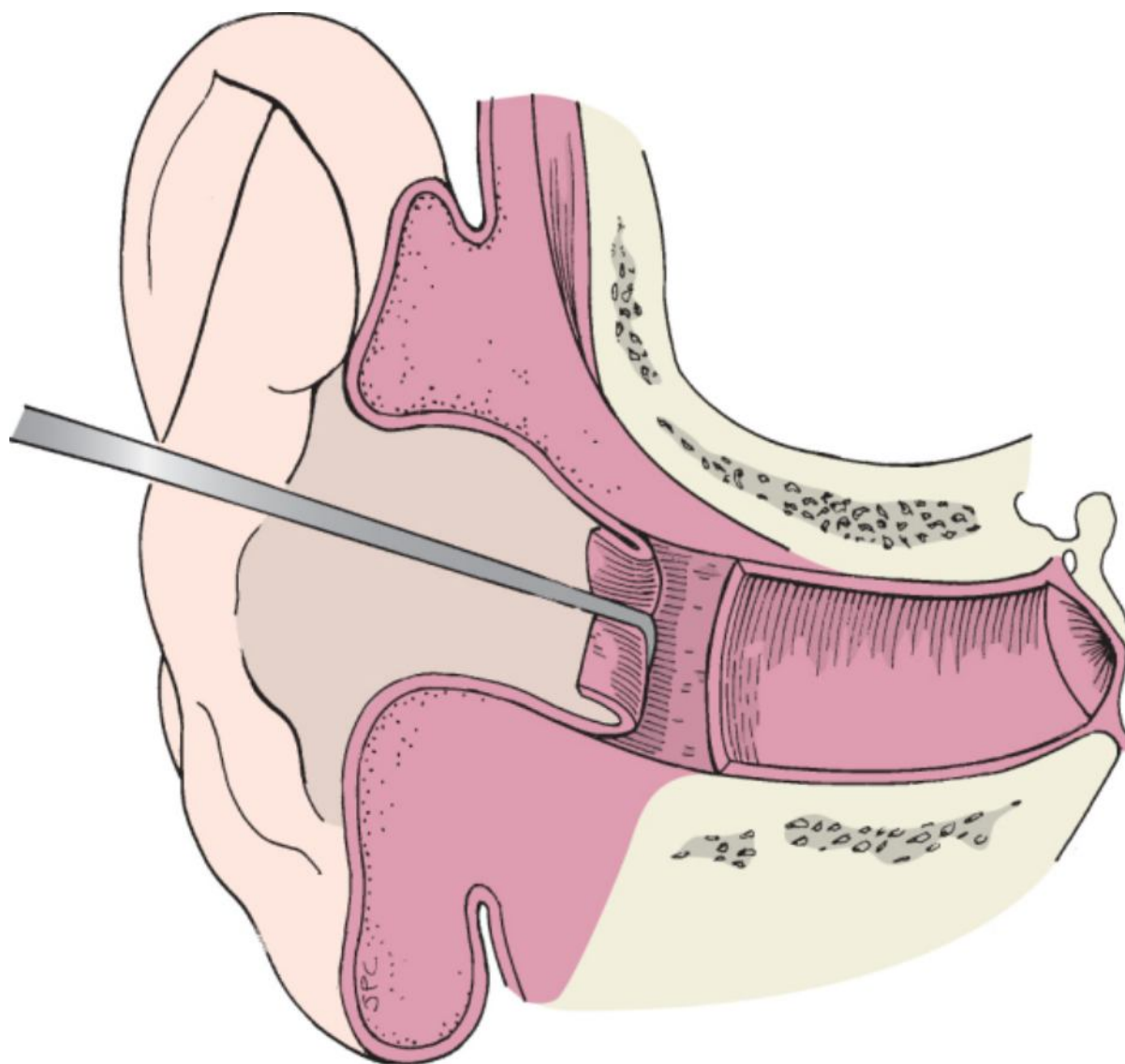
Using the operating microscope, incisions are made in the skin of the external meatus at 12 o'clock and 6 o'clock with a no. 64 Beaver blade. An endaural Lempert speculum is used to facilitate exposure of these incisions. The 12-o'clock incision begins approximately 1 cm lateral to the lateral process of the malleus and extends to the tragal

incisura. The 6-o'clock incision is a short incision in the bony canal down to the junction of the bone and cartilage (see [Video 113-2](#)). These two incisions are then connected vertically along the posterior bony canal wall, about 3 mm medial to the bony-cartilaginous junction, to create a conchal flap (Fig. 113-7). Through this

endaural approach the conchal flap dissection is initiated by back-elevating the canal skin (Fig. 113-8) (see [Video 113-3](#)). The 12-o'clock corner of the flap must be completely dissected and mobilized to facilitate elevation of the skin from the postauricular approach.



**Figure 113-7** With a Lempert speculum and a no. 64 Beaver blade, 12- and 6-o'clock incisions are connected with a posterior canal wall incision, just medial to the conchal cartilage.

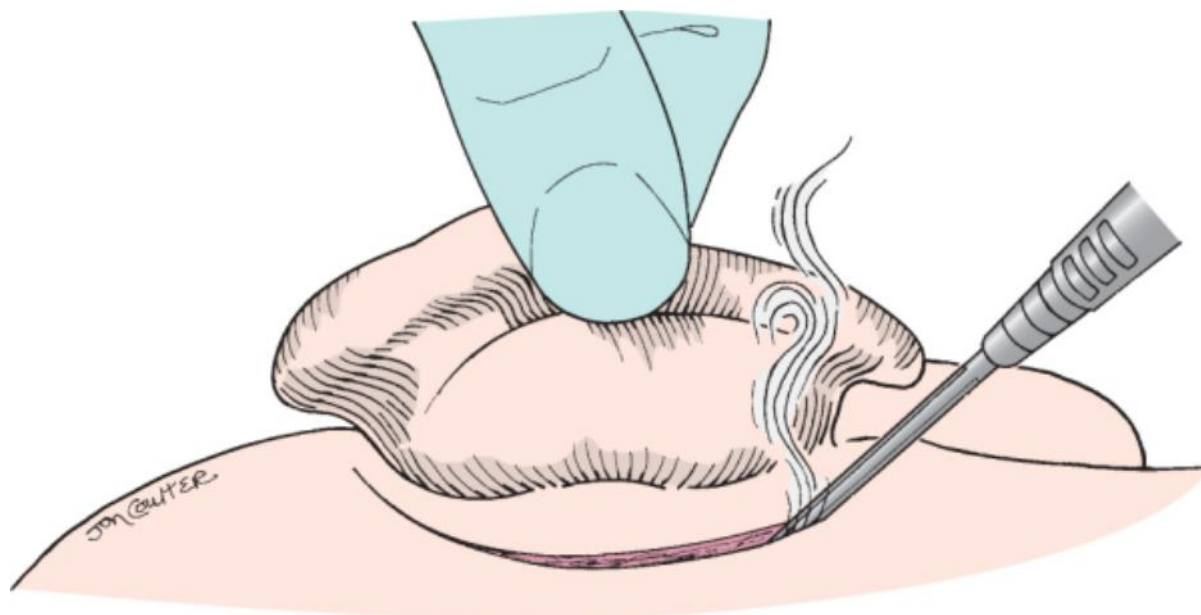


**Figure 113-8** A large duckbill dissector is used to back-elevate the conchal flap to facilitate subsequent mobilization.

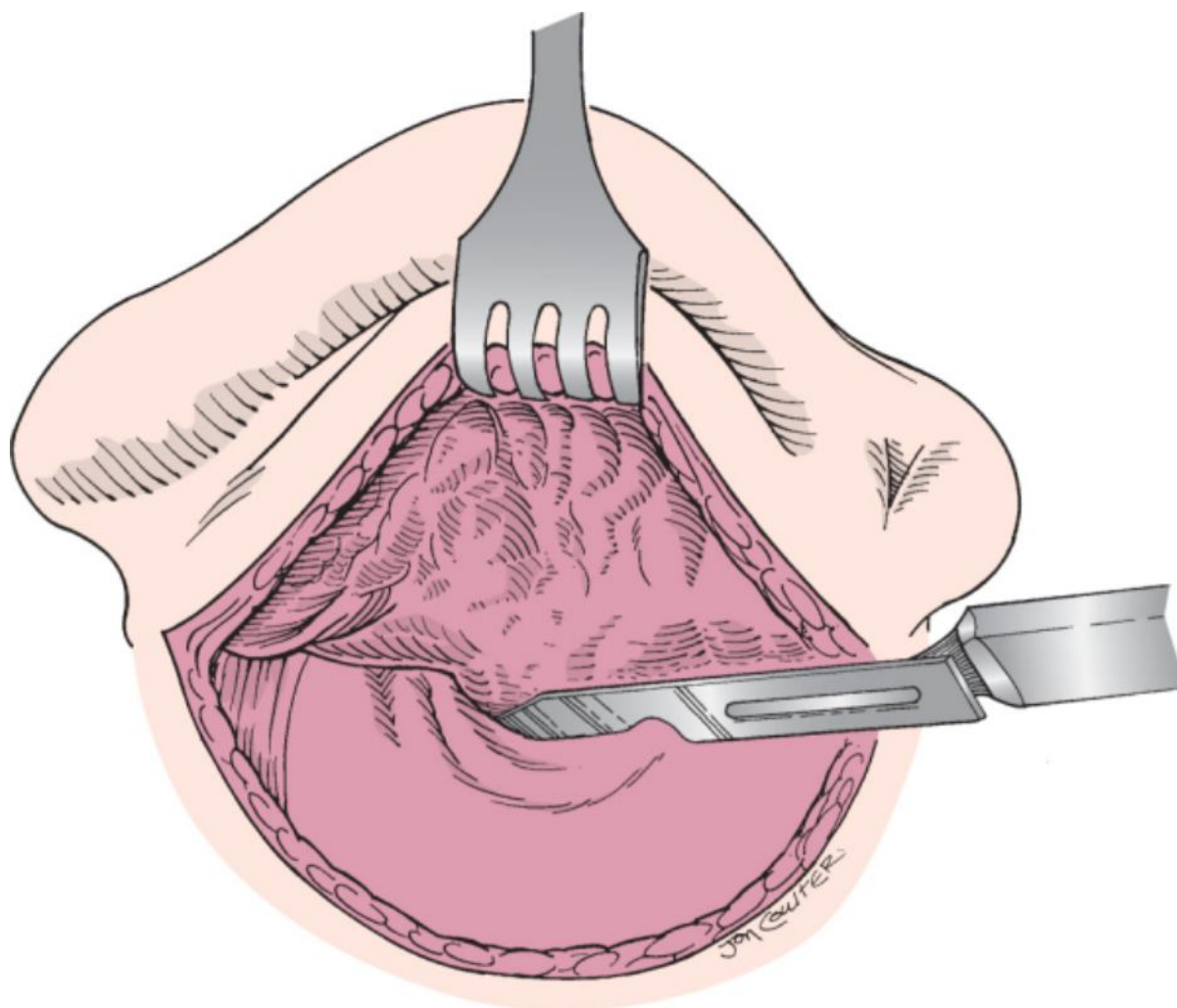
Hatch marks are placed in the postauricular area over the planned postauricular incision and the skin is incised a few millimeters posterior to the sulcus. The skin is initially incised with a no. 15 blade. The incision can be continued through subcutaneous tissue and the postauricular muscle with a knife or electrocautery (Fig. 113-9). Subcutaneous dissection is performed along the posterior aspect of the conchal cartilage to define the posteriorly based conchal flap. The skin of the external auditory canal is elevated from the postauricular approach and

dissected toward the previously made endaural incisions (see Video 113-4). A prominent spine of Henle may be encountered and requires more vigorous soft tissue dissection. The endaural 12-o'clock incision is connected with the postauricular incision by placing a no. 15 blade through the subcutaneous tissue at the zygomatic root. From the postauricular approach, the knife is beveled toward the bony canal wall, and the conchal cartilage flap is further defined (Fig. 113-10). The flap is then elevated off the posterior canal wall via the original vertical conchal flap incision made endaurally. When the two incisions are connected, the conchal flap is retracted with either a tracheostomy tape and a self-retaining retractor or a Perkins retractor alone (Fig. 113-11) (see Video

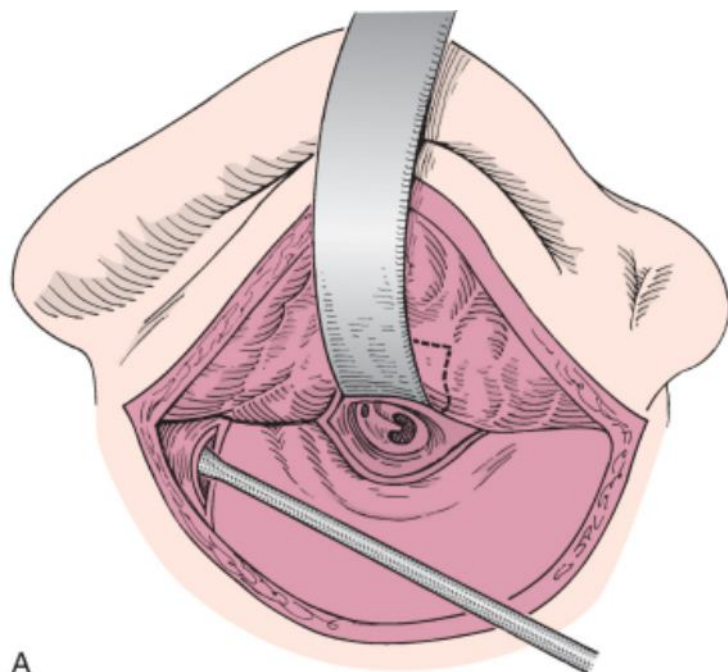
113-5). Incision into and exposure of the cartilage of the external canal may result in pain and possibly chondritis. This complication is more likely if the 6-o'clock incision is carried too far laterally or with extension of the postauricular dissection toward the posterior inferior aspect of the conchal cartilage.



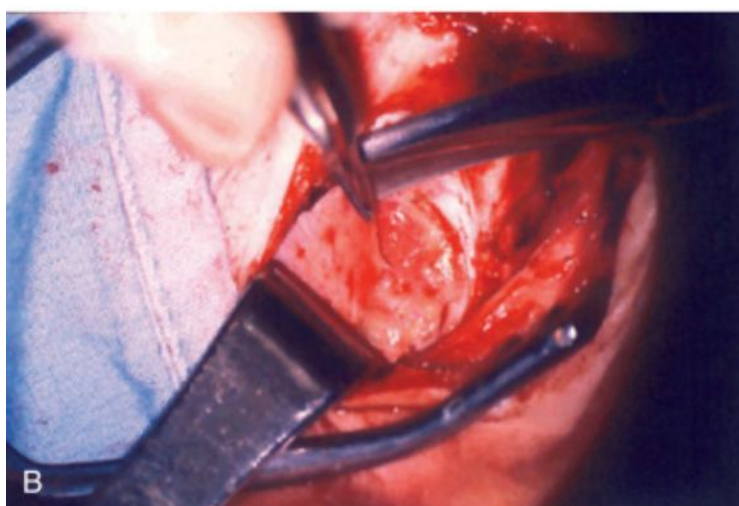**Figure 113-9** An incision with a no. 15 blade is made posterior to the postauricular sulcus. Electrocautery is used to continue the incision and maintain hemostasis.



**Figure 113-10** Through the postauricular incision, a knife is used to dissect the skin from the bony wall of the posterior canal. The blade is directed toward the bony canal wall to avoid laceration of the skin of the canal.



A




B

**Figure 113-11** **A**, The conchal flap has been dissected and inverted toward the external auditory meatus (*dotted lines*). A tracheostomy tape maintains retraction on the soft tissue of the canal. This is then secured with a self-retaining retractor. A Freer dissector is used to harvest areolar tissue or temporalis fascia. **B**, The skin is retracted with an Army-Navy retractor. Temporalis fascia is removed from the temporalis muscle.

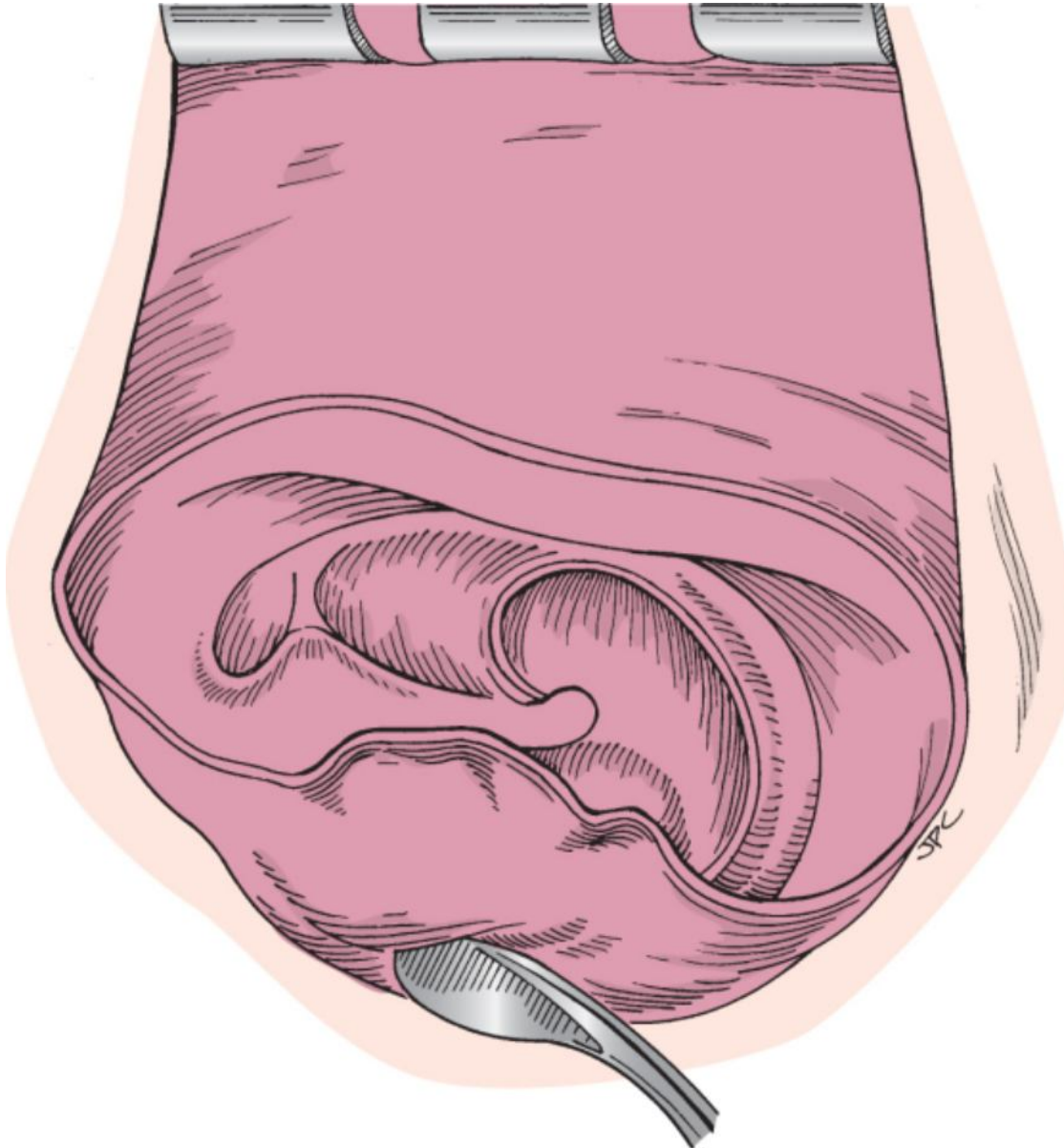
If the areolar tissue (fool's fascia) obtained from the lateral surface of the fascia covering the temporalis muscle is hearty and well defined, this tissue layer is chosen for grafting. The area over the temporalis muscle is exposed and a self-retaining retractor is placed. An Army-Navy retractor may be needed to lift the temporal skin to facilitate better exposure. A no. 15 Bard-Parker blade is used to superficially incise the areolar tissue layer, and a plane is developed between this layer and underlying fascia with a Freer dissector (Fig. 113-11A). Scissors are used to remove a 2 by 2-cm section. If this proves to be too thin or is deemed to be inadequate, true temporalis fascia is harvested in a similar manner (see Fig. 113-11B). Hemostasis may be necessary for regional vessels. The graft is spread on a cutting block, cleaned of attached muscle fibers or adipose tissue with the side of the knife blade, and allowed to dry.

The medial aspect of the canal skin is then removed by circumferentially incising the anterior canal wall at the bulge

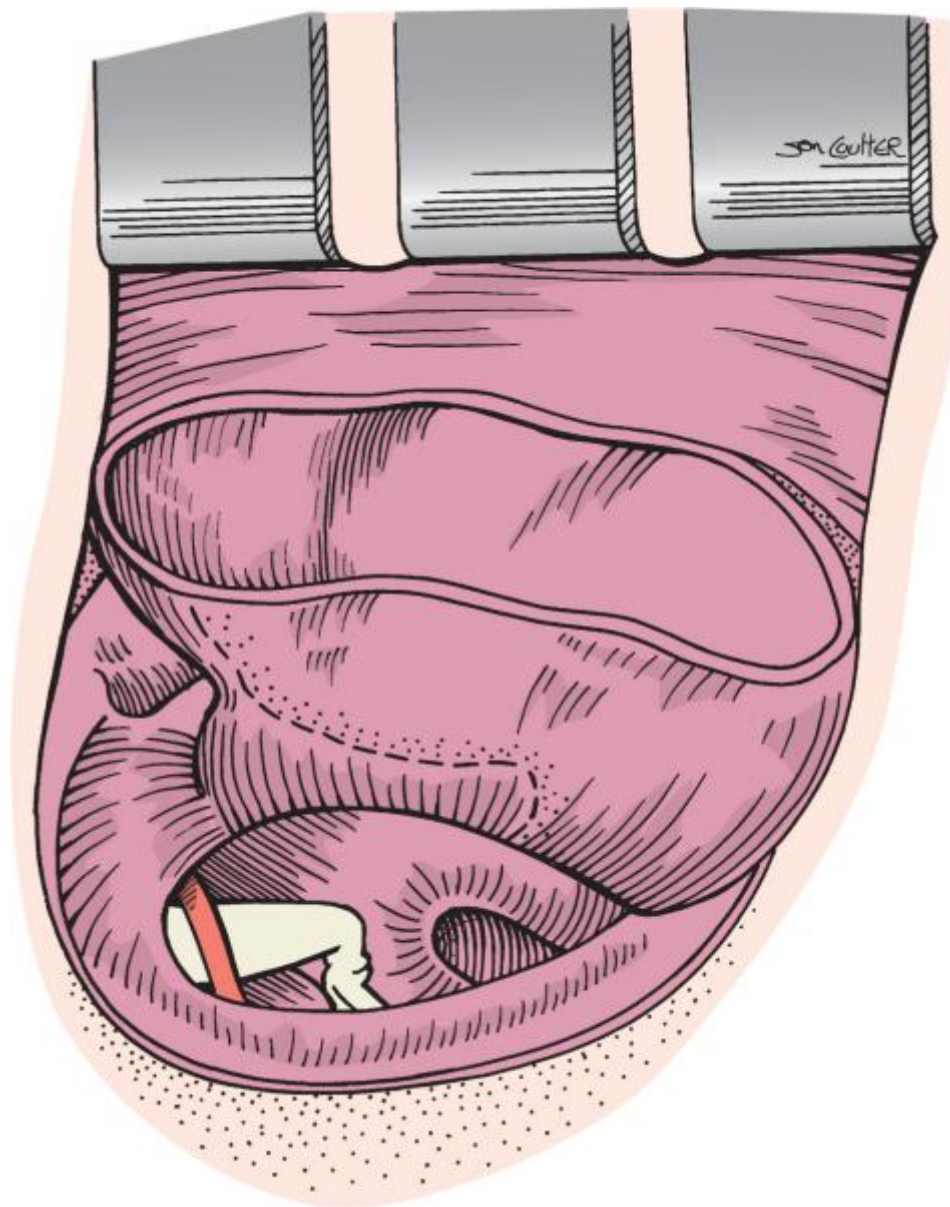
(see [Video 113-6](#) ). The skin remaining in the  canal medial to the incision is then sequentially elevated toward the fibrous tympanic annulus with duckbill elevators or an oval knife (Fig. 113-12) (see [Video](#)

[113-7](#) ).  Dissection extends medially to remove the canal skin and epithelium over the tympanic membrane as an intact sleeve. The easiest area to obtain a clean dissection plane is at the posterior inferior medial canal and annulus, which is at the 8-o'clock position in the demonstrated right ear (Fig. 113-12) (see [Video](#)

[113-8](#) ). Care is taken to elevate all the squamous epithelium off the remaining tympanic membrane. This dissection is facilitated superiorly, where the pars flaccida can be stripped off the lateral process of the malleus in a downward fashion with cup forceps, and posteriorly at the inferior fibrous annulus, where anterior dissection can be easily performed parallel to the plane of the fibrous annulus (Fig. 113-13) ([see Video 113-9](#)). Often, a small perforation of the tympanic membrane is made larger by removing this epithelial layer because of the underlying fibrous layer defect.



**Figure 113-12** With a duckbill elevator, the skin of the bony external meatus is elevated in a medial direction until the bony annulus is encountered. Dissection follows the circumference of the collagenous fibrous layer of the tympanic membrane.



**Figure 113-13** Most of the epithelial layer of the tympanic membrane has been elevated off the anterior and posterior canal walls and fibrous tympanic membrane. It remains pedicled along the handle of the malleus and can be stripped off readily with cup forceps.

A prominent anterior canal wall may obstruct the view of the anterior annulus. The anterior canal wall skin is back-elevated in a medial-to-lateral direction to provide access to the bony anterior canal wall ([see Video 113-10](#)



). This area of bone of the anterior canal may have to be removed with a drill to provide unobstructed exposure of the anterior canal. This reduces the incidence of blunting of the angle between the anterior canal wall and tympanic membrane and facilitates postoperative examination and cleaning ([see Video](#)



[113-11](#) ). If the bony overhang prohibited visualization of the anterior sulcus, the improved



exposure facilitates performance of this step in the procedure ([see Video 113-12](#) ). Epithelial remnants may remain in the anterior and inferior sulcus. Retention of this skin would result in the development of a middle ear or intratympanic cholesteatoma. If there is concern that all the skin was not removed, an angled curette

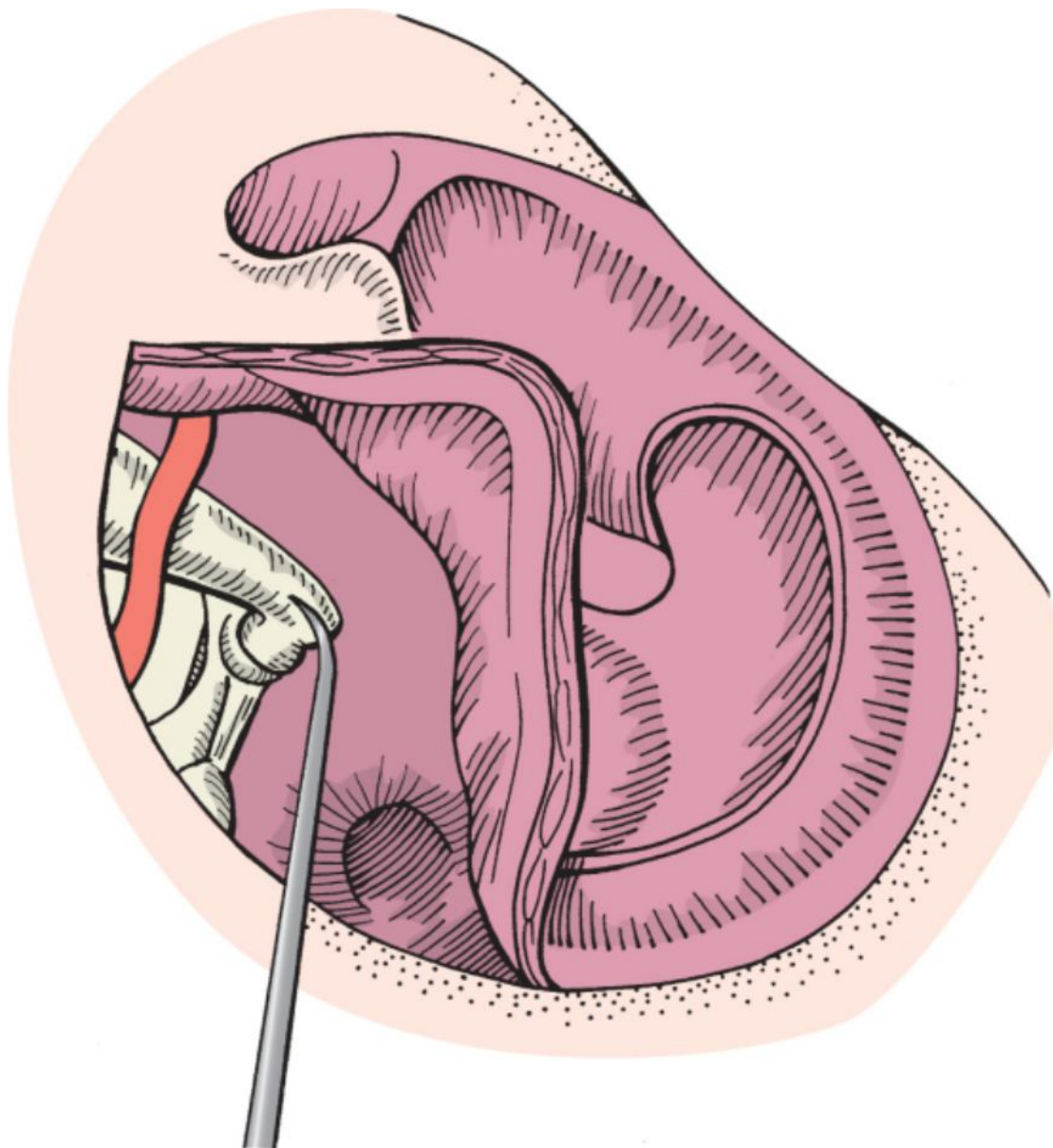
is used to further dissect the anterior and inferior sulcus just lateral to the annulus ([see Video 113-13](#) ).



Tympanoplasty requires inspection of the middle ear space and reconstruction of the ossicles, when necessary. A sickle knife or curved pick (Rosen needle) is used to elevate the posterior fibrous annulus while taking care to

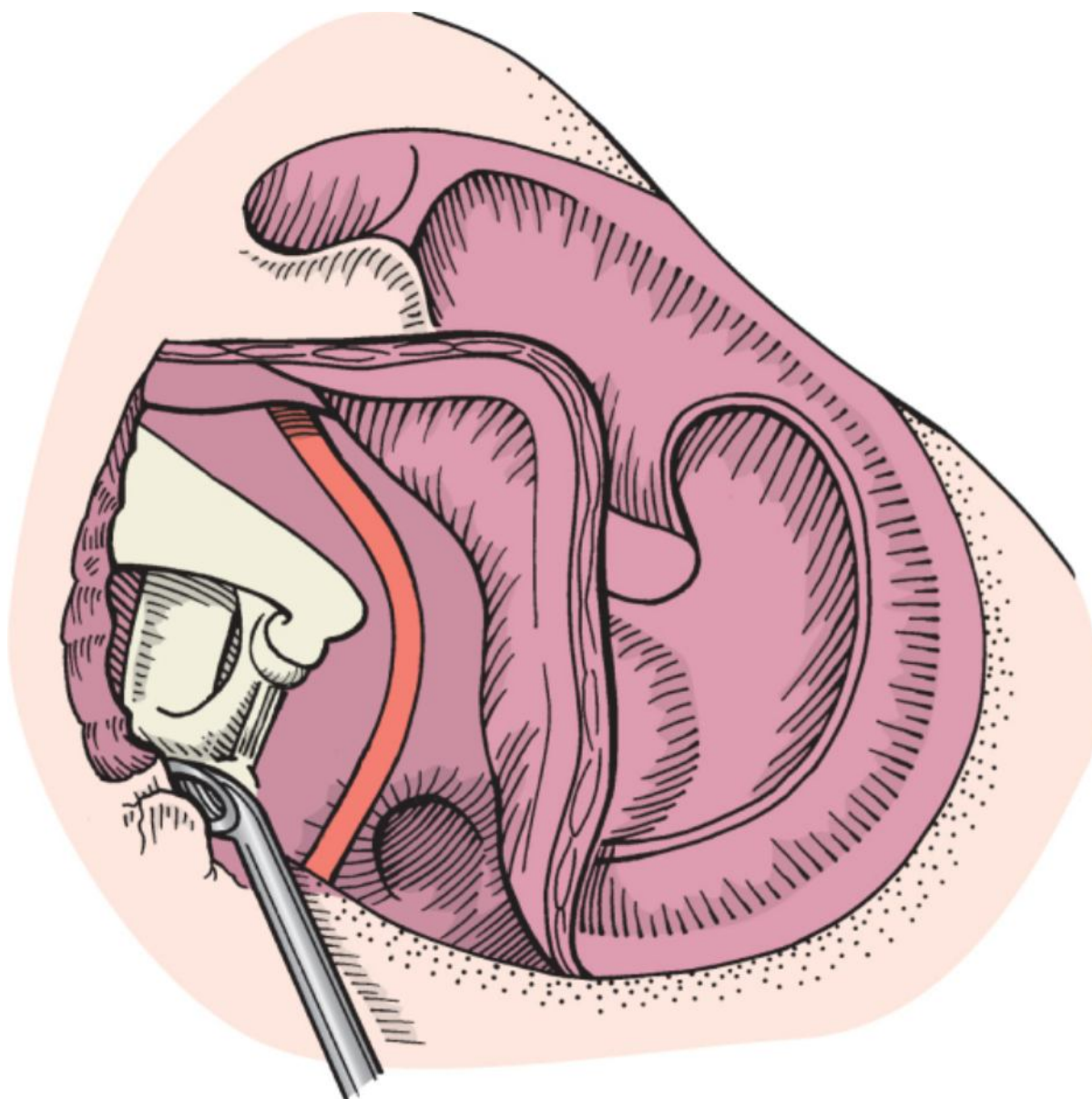
preserve the chorda tympani nerve. The ossicular chain must be completely inspected and palpated (Fig. 113-14). If visualization of the incudostapedial joint and stapes footplate is not adequate, bone of the posterior superior bony canal wall may be removed with a curette or drill (Fig. 113-15). The status of the ossicular chain is assessed by palpation. Limited mobility of the lateral chain (malleus-incus) and fixation of the incus-stapes complex will require separation of the incudostapedial joint. If a cholesteatoma is present in the middle ear, the incus may need

to be removed to evaluate the integrity of the stapes (see Videos 113-14 and 113-15 ).  
Repair of the ossicular chain is reviewed in Chapter 114.



**Figure 113-14** The posterior fibrous annulus has been elevated to inspect the middle ear space and the integrity of the ossicular chain. (Redrawn from Naumann HH: *Head and Neck Surgery*, vol 3: *Ear*. Stuttgart, Germany, Georg Thieme, 1982.)





**Figure 113-15** A curette or small cutting burr is used to remove bone from the posterosuperior tympanic annulus to provide additional exposure of the incudostapedial joint and the footplate of the stapes.

(Redrawn from Naumann HH: *Head and Neck Surgery*, vol 3: *Ear*. Stuttgart, Germany, Georg Thieme, 1982.)

### Middle Ear Disease

Common pathologic processes found in the middle ear include granulation tissue, hyperplastic mucosa, cholesteatoma, and tympanosclerosis. Each is managed in a different way.

Granulation tissue and mucosal hyperplasia require reconstruction of an aerated middle ear space. Early assessment of eustachian tube patency directs one's decision regarding reconstruction. Failure of tympanoplasty is likely if irreversible mucosal disease or eustachian tube obliteration is present. Deciding that a eustachian tube will never function normally is difficult because judgment depends largely on one's surgical experience. If the lining of the middle ear and eustachian tube is hyperplastic and the eustachian tube is patent, removal of the thickened mucosa usually warrants an intervention that would avoid the development of adhesions from the denuded promontory to the tympanic membrane graft and malleus umbo. A thin Silastic disc (0.005 to 0.01 inch) is placed on the promontory in the mesotympanum and can remain indefinitely. More extensive disease extending into the epitympanum may require mastoidectomy. Thicker Silastic sheeting (0.02 to 0.04 inch) is used if it is believed that ossicular reconstruction will be more likely to succeed once the middle ear space is aerated. The decision to stage the procedure and return in 4 to 9 months for subsequent reconstruction is generally made at the time of surgery.

Staging is undertaken if there is concern for incomplete removal or residual cholesteatoma. The incus is usually removed to facilitate elimination of middle ear disease, regardless of whether it is cholesteatoma, granulation tissue, or hyperplastic mucosa. Extensive cholesteatoma around the stapes footplate may be easier to remove

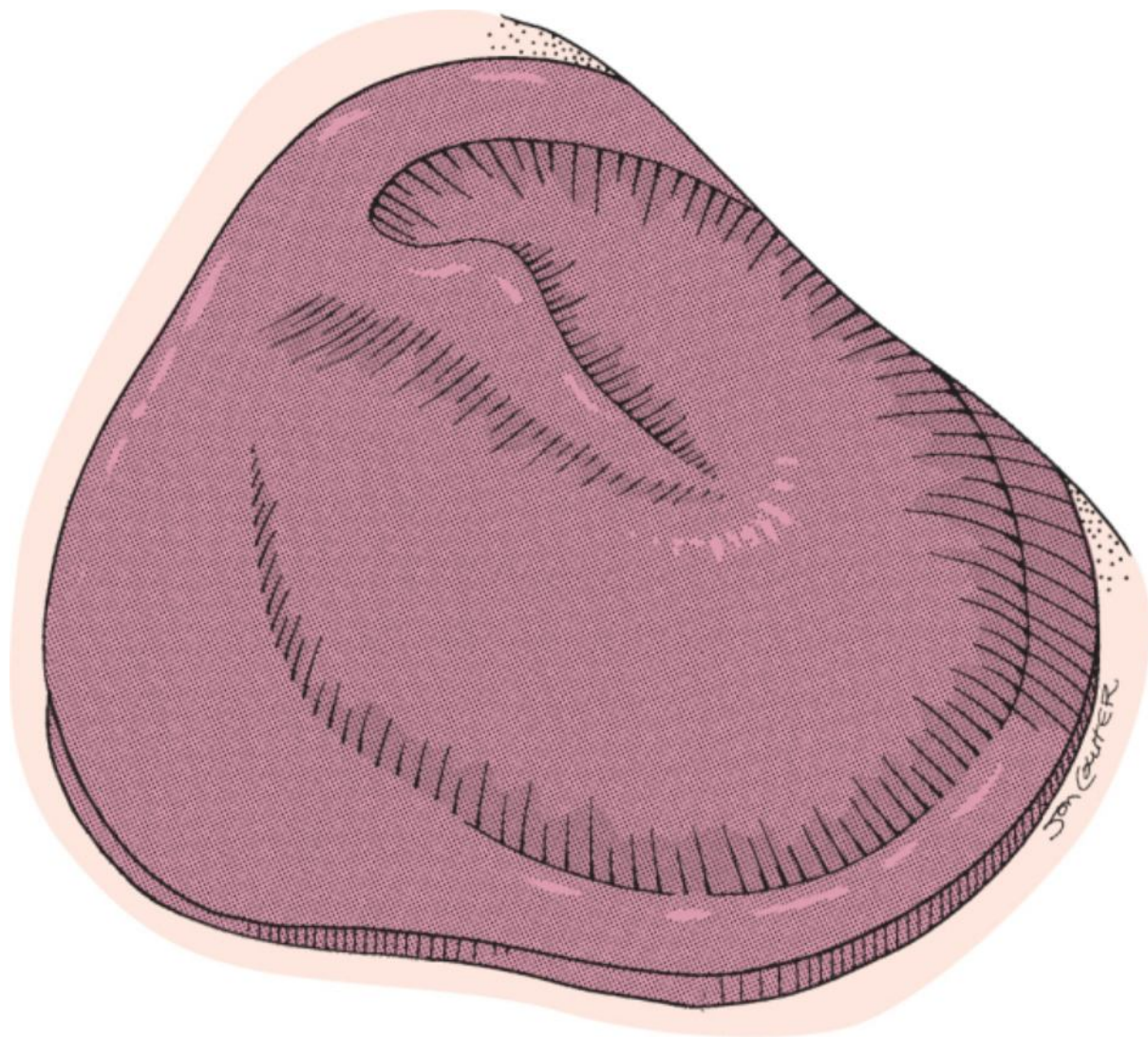
after the inflammatory response has subsided. Cholesteatoma may become more focally organized into a ball or "pearl" and thus facilitate complete removal during a subsequent procedure. Silastic sheeting can maintain a middle ear space between the promontory and tympanic membrane graft. The Silastic sheet is contoured to have a pointed end extend toward the meatus of the eustachian tube and the superior end layover the facial nerve into the epitympanum. Nearly complete closure of the conductive component of the hearing loss may result if Silastic is placed over an intact stapes superstructure.

Cholesteatoma must be totally eradicated. Cholesteatoma pearls or a localized matrix is easily removed. Layered epithelium covering the stapes superstructure or footplate or extending into the sinus tympani must be meticulously removed. Extension of disease into the epitympanum generally requires access and inspection of the attic through a transcortical mastoidectomy approach (see Chapter 115). Recently, the use of endoscopes has proved to be most helpful in closely inspecting the epitympanum.<sup>[6]</sup>

Tympanosclerosis is a unique reparative response believed to be secondary to middle ear inflammation. Tympanosclerosis consists of brittle chalk-like plaque that is typically found within the tympanic membrane, affecting the ossicles, and on the medial wall of the middle ear. Reversing the inflammatory process is believed to eliminate the future development of tympanosclerosis. Both fixation and erosion of the ossicles from tympanosclerosis may be seen. The stapes footplate is occasionally found to be fixed. Reconstruction of the tympanic membrane is facilitated by removing the myringosclerotic plaque if it is restricting the mobile portion of the drum to either the annulus or the malleus handle. Stapedioplasty is not performed when the tympanic membrane is perforated. If the stapes is fixed because of tympanosclerosis, manipulation may result in fracture of the footplate or dislodgement of the footplate from the annular ligament. Repair of stapes fixation should be staged and performed only after the tympanic membrane is intact.

The ossicular chain must be adequately visualized and palpated to determine its mobility. Ossicular reconstruction is undertaken when indicated. Specific details regarding these techniques are discussed in Chapter 114.

After inspection and treatment of the middle ear and ossicular chain, the posterior fibrous tympanic membrane and cartilaginous annulus are returned to their original positions. The areolar tissue or fascia is harvested and cut to the proper size, typically an 11- by 13-mm oval disc, although smaller grafts can be used if the perforation is not large. If the posterior annulus is deficient or a large amount of bone from the posterior canal wall has been removed, a longer, more oblong graft is tailored. The longer portion of the graft is laid on the posterior canal wall. The graft is positioned on the annular margin, lateral to the handle of the malleus (Fig. 113-16).

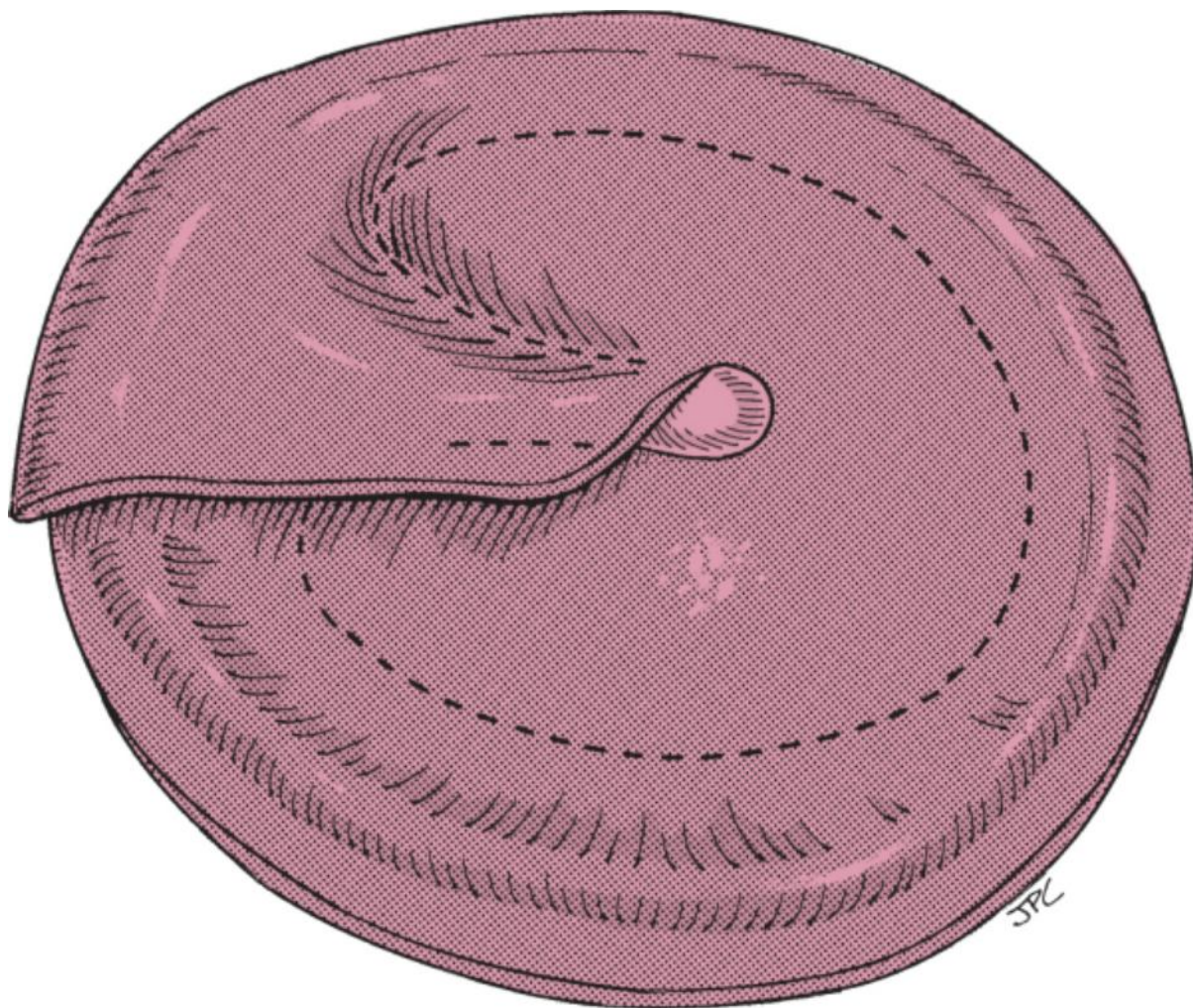


**Figure 113-16** The areolar graft is routinely placed lateral to the annulus, and the remaining fibrous tympanic membrane is draped over the malleus.

When the perforation is nearly total and the malleus is not supported by any remaining fibrous tympanic membrane, the graft can still be positioned lateral to the malleus. However, when the malleus is directed medially, approximating the promontory, the graft should be positioned medial to the umbo of the malleus to prevent lateralization. The graft is then cut radially a few millimeters from the 12-o'clock position and placed medial to the umbo and distal handle of the malleus, with the superior edges of the graft overlapping in the pars flaccida

area (Fig. 113-17) ([see Video 113-16](#) ). The graft must be positioned so that it lies on the cartilaginous annulus and does not extend onto the anterior or inferior bony canal walls. A graft that is too thick, placed beyond the fibrous annulus, and extended onto the anterior inferior canal wall may result in blunting of the angle between the tympanic membrane and the bony canal wall. This problem is avoided by trimming the graft to the appropriate size and shape. When the graft must be wrapped around the medial surface of the malleus, the

superior margins of the incised graft are overlapped over each other ([see Video 113-17](#) ).



**Figure 113-17** If the handle of the malleus is directed medially within the middle ear, the areolar graft is cut vertically at the 12-o'clock position and positioned medial to the malleus handle and lateral to the fibrous tympanic membrane and annulus. The edges of the areolar graft overlap superiorly, lateral to the proximal handle and the short process of the malleus and pars flaccida area.

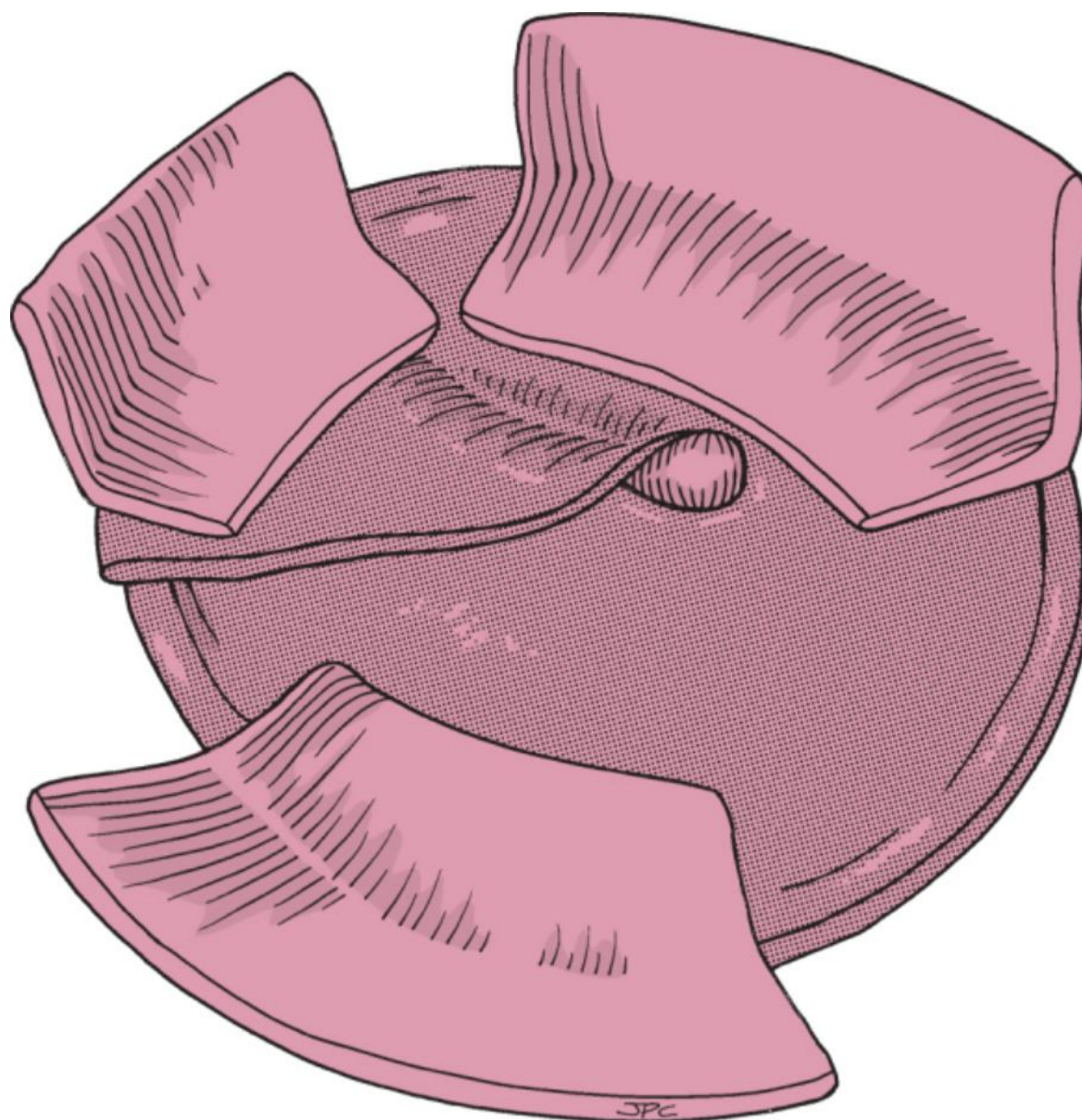
The skin that had been harvested from the external canal is then inspected under the microscope. Scissors are used to open up the sleeve of skin that was obtained from the medial external canal. It is thinned and

subcutaneous tissue is removed if necessary ([see Video 113-18](#)). The separate pieces are placed on a plastic cutting block with the epithelial side up and cut into rectangular shapes. It is necessary to remove extremely thin or irregular edges of the skin to ensure that all of the epithelial surfaces face the ear canal lumen. Preparation and trimming of the skin should be done with use of the microscope to eliminate unfurled edges. An accurately sized graft should be placed so that it is just overlapping the anterior annulus to avoid

blunting ([see Video 113-19](#)).


Each piece of skin is then carefully placed lateral to the areolar (or fascial) graft with the epithelial surface toward the auricle. Attention is directed to the anterior sulcus, where skin is placed on the anterior canal with the thinner edge positioned lateral to the areolar or fascial graft. The skin overlying the graft should be thin. The first piece of skin is placed in this area, and subsequent grafts are placed over the pars flaccida area and, when available,


posteriorly onto the bony canal wall (Fig. 113-18) ([see Video 113-20](#)). If there is insufficient skin to provide coverage of the bony canal, a thin split-thickness skin graft (Thiersch graft) is harvested from the non-hair-bearing postauricular skin with a no. 10 blade.





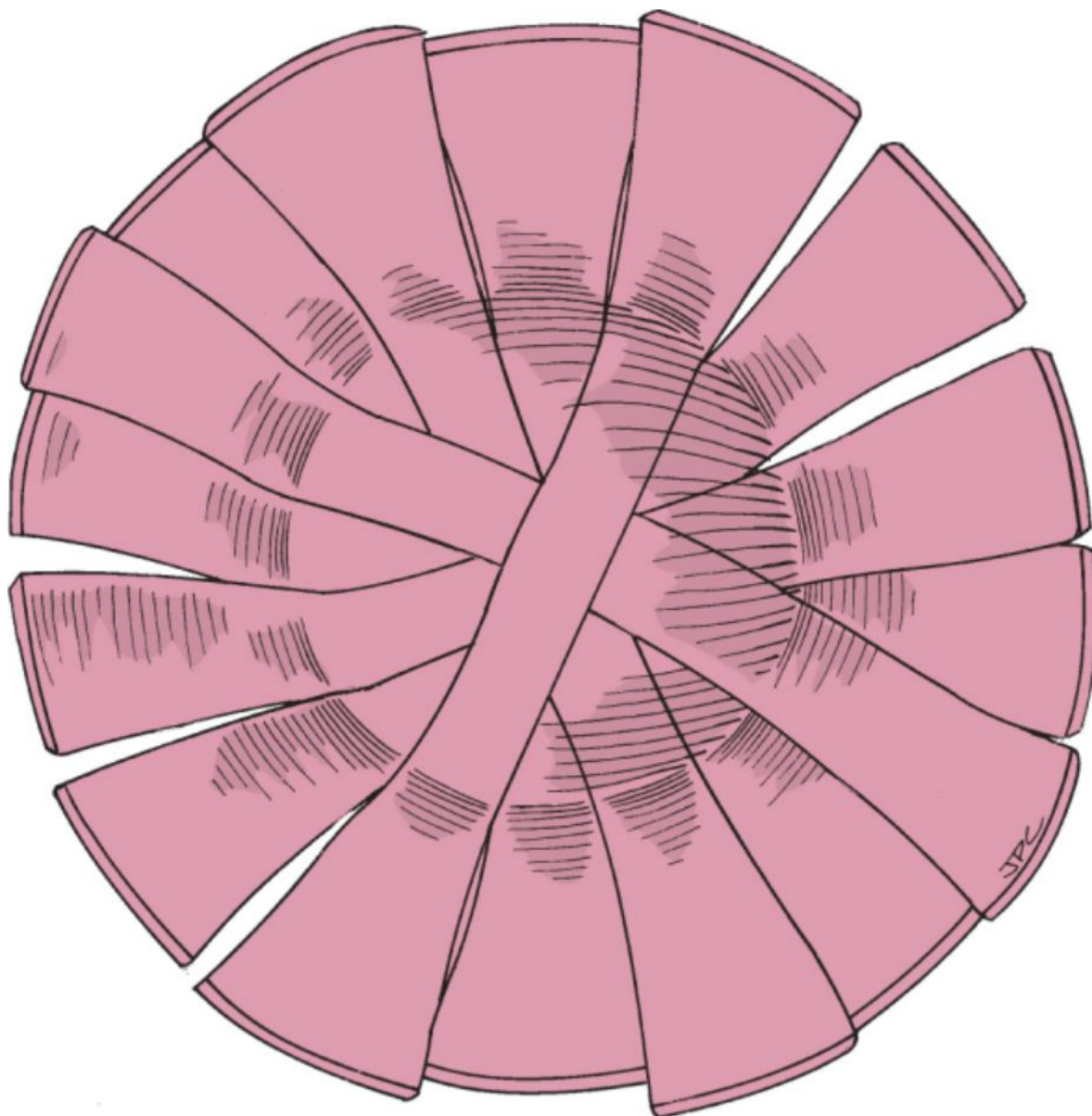
**Figure 113-18** The skin of the medial bony canal wall and lateral tympanic membrane was thinned and cut into rectangular pieces. The thicker part of the skin graft is initially placed on the anterior bony canal wall. The thinner edges overlie the areolar graft. Depending on the availability of skin, multiple pieces are placed.

Packing of the external ear canal is necessary. Packing keeps canal flaps and epithelial grafts in their proper positions, which greatly aids in the healing process. The cylindrical channel of the ear canal is maintained to preclude narrowing from blood products and granulation tissue. The contour and patency are preserved until the packing is removed or dissolves. It is important to prevent blunting of the anterior sulcus with one of the following techniques: Gelfoam, ointment, Merocel sponges, or a silk rosebud pack. We use two methods of packing, depending on the preference of the surgeon. The first consists of Gelfoam soaked in antibiotic suspension. The initial piece is approximately 5 to 7 mm in length and 4 mm in width, compressed, and folded on itself. While firmly holding the anterior canal wall skin graft, the Gelfoam is secured anteriorly to define the anterior tympanomeatal sulcus. The remainder of the ear canal is filled with small to progressively larger pieces of Gelfoam.

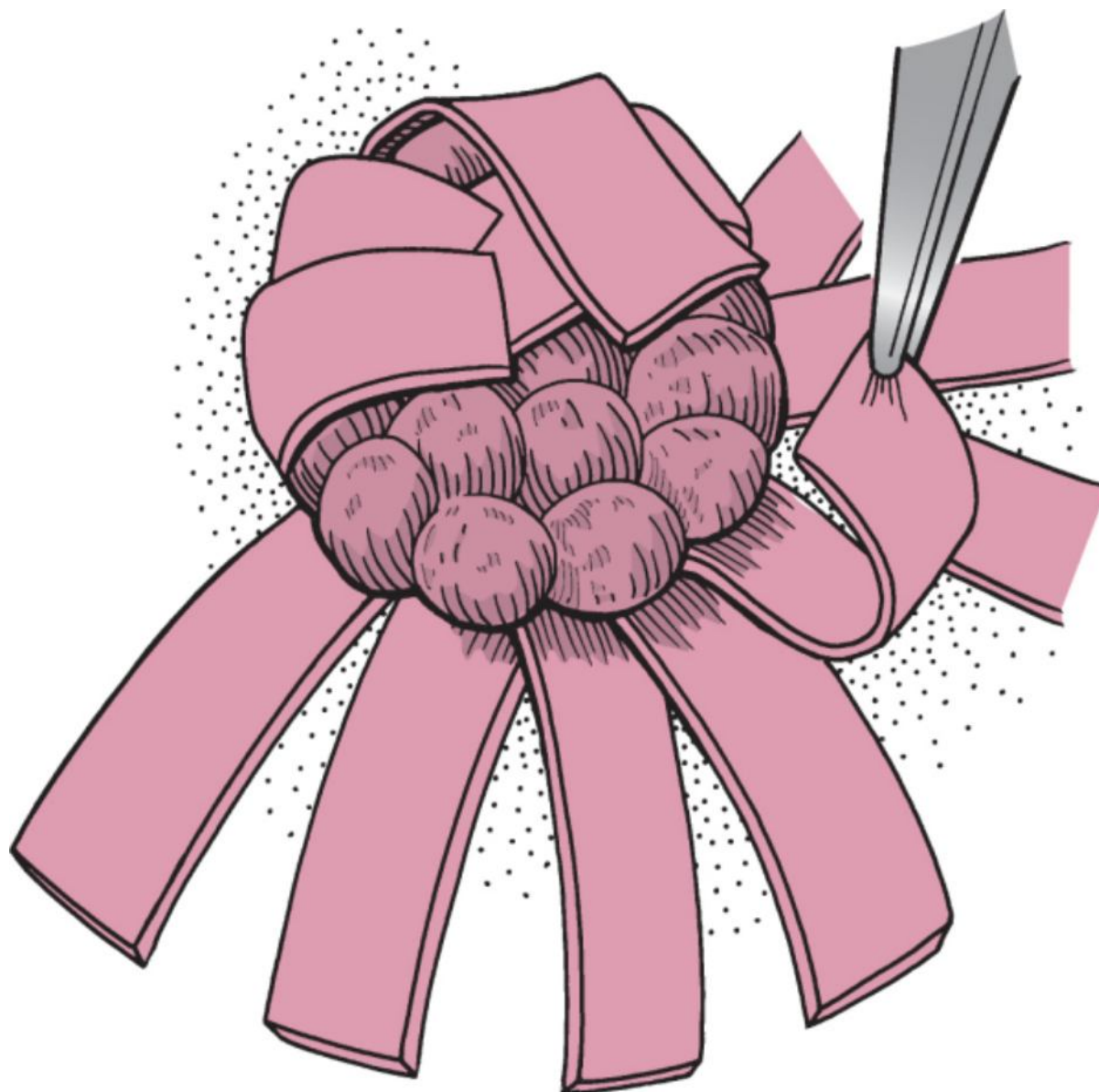
The other packing technique that we use is precise but tedious. It consists of using strips of silk, 4 × 25 mm, placed in rosebud fashion into the medial canal (Fig. 113-19) ([see Video 113-21](#) ). Merocel balls impregnated

 with bacitracin ointment are then placed within the rosebud, and the lateral leaves are folded over one another to create a mold or cast of the medial canal. This accurately defines the anterior sulcus, which will

minimize the risk of anterior blunting and lateralization (Fig. 113-20) ([see Video 113-22](#) ). 



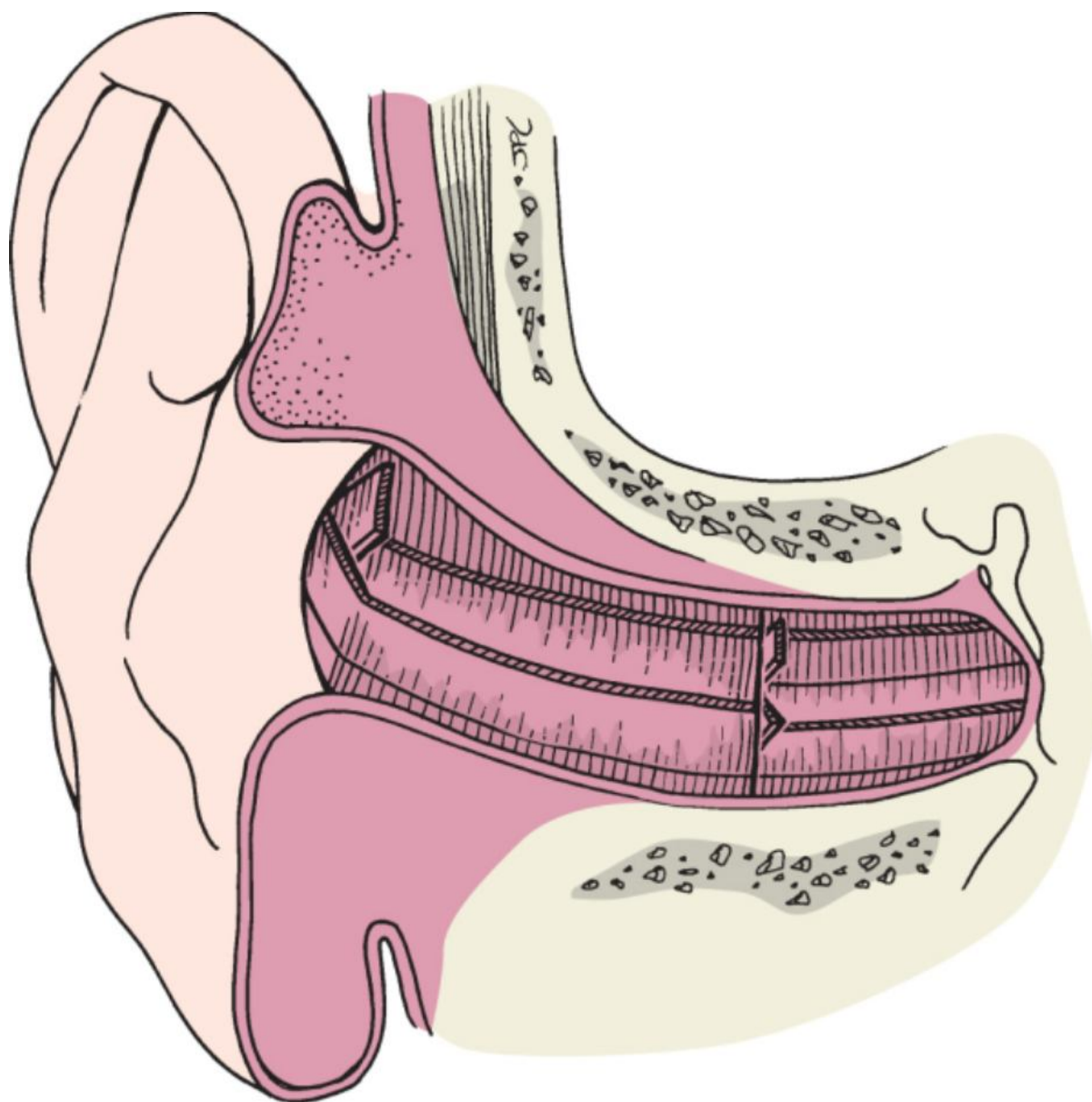
**Figure 113-19** Medial rosebud packing consists of strips of silk that are placed radially to completely cover the areolar graft.



**Figure 113-20** Small cotton or Merocel balls are packed within the rosebud dressing, and the edges are folded over one another.

The tracheostomy tape and self-retaining retractors are then released and the ear is returned to its anatomic position. The conchal flap is thinned if there is too much subcutaneous tissue and returned into the external canal. Lateral rosebud packing consisting of silk strips 7 to 10 mm × 30 to 35 mm is then placed in a similar rosebud

fashion and secured with larger Merocel balls (Fig. 113-21) ([see Video 113-23](#) ). Another method for stenting the lateral canal is with a small-pore Merocel sponge (Schindler ear pack) impregnated with antibiotic otic suspension. The postauricular wound is closed with interrupted 4-0 Monocryl suture and running 5-0 fast-absorbing chromic suture and Steri-Strips. A cotton ball is placed at the external meatus, and a sterile mastoid or Glasscock dressing is applied. Most patients undergo surgery as an outpatient and are discharged the day of the procedure. The mastoid or Glasscock dressing is maintained overnight and removed by the patient or family after 24 hours. The cotton ball placed in the external meatus is removed and replaced every few hours as needed.

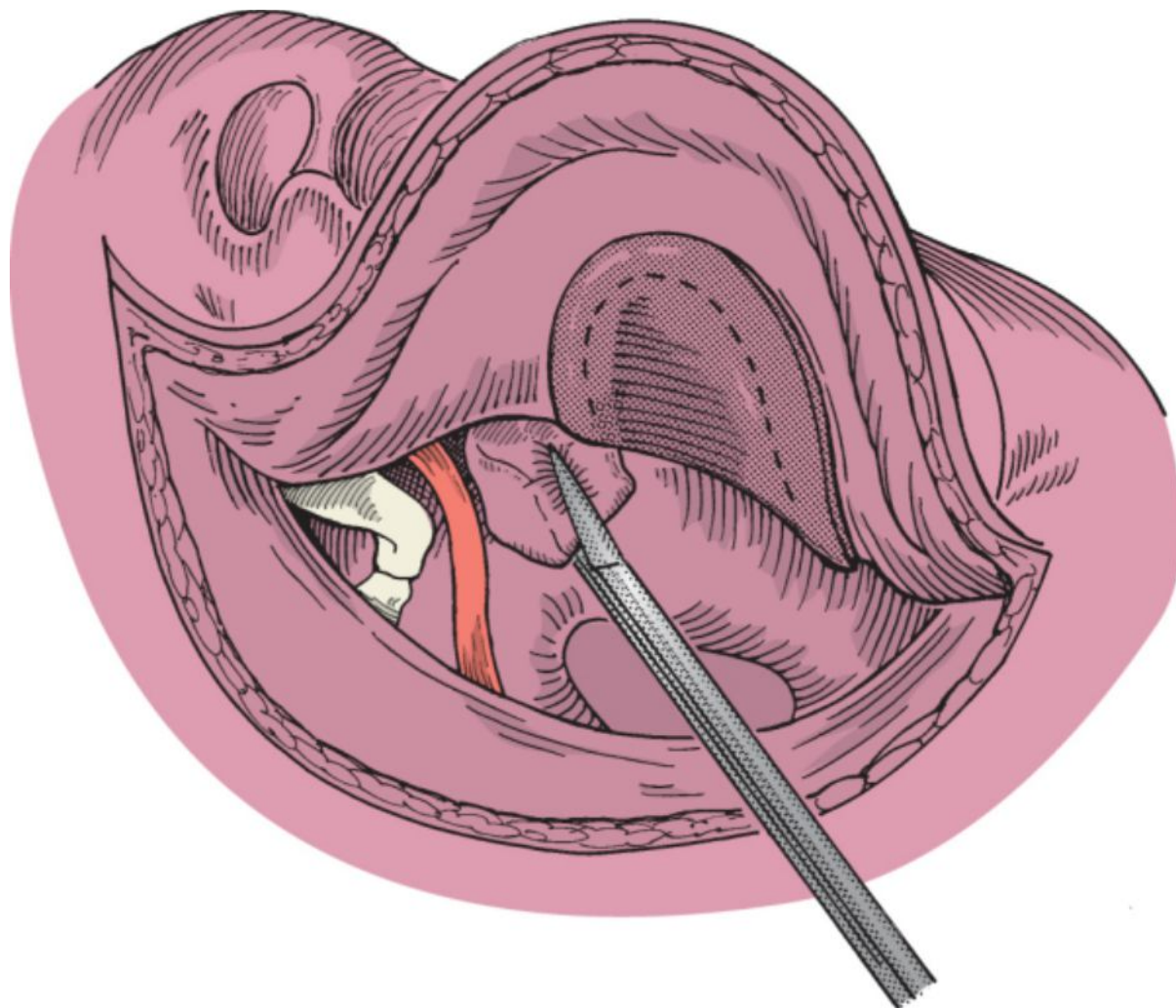


**Figure 113-21** The medial rosebud pack secures the grafted tympanic membrane. The lateral pack stents the lateral canal and conchal flap.

### *Medial Grafting Technique*

The external canal is injected as described earlier. Once anesthesia is adequate, the edges of the perforation are trimmed with a perforating pick or sickle knife (see Fig. 113-4). A graft is then harvested. Small perforations can be repaired with compressed adipose tissue harvested from the earlobe or with areolar tissue from the postauricular area. For larger defects, an incision posterior to the superior aspect of the helix is made over the temporalis area, where areolar tissue or fascia is obtained. (This is incorporated into the postauricular approach if greater exposure of the tympanic membrane is necessary.) A tympanomeatal flap is elevated by incising the medial canal skin over the scutum superior to the lateral process of the malleus. It is extended posteriorly while keeping a distance of 4 to 5 mm from the annulus. The incision is then curved inferiorly, running parallel to the annulus, and is directed toward the 6-o'clock position. The tympanomeatal flap is then elevated along with the annulus. The ossicular chain is next inspected and palpated as mentioned earlier. The graft is then brought into the middle ear, placed up against the medial aspect of the tympanic membrane perforation, and supported with Gelfoam placed within the middle ear space (Fig. 113-22). The flap is then returned to its anatomic position. Packing consists of a strip of silk supported with cotton balls impregnated with bacitracin ointment or Gelfoam to fill the external canal.





**Figure 113-22** Medial grafting technique. After the edges of the tympanic membrane perforation are freshened, a tympanomeatal flap is elevated. A tissue graft (*shaded area*) is positioned medial to the perforation and supported by packing Gelfoam into the middle ear. (Redrawn from Naumann HH: *Head and Neck Surgery, vol 3: Ear. Stuttgart, Germany, Georg Thieme, 1982.*)

## POSTOPERATIVE MANAGEMENT

After myringoplasty for repair of tympanic membrane perforation or lacerations, the packing is removed 7 to 10 days after the procedure. Patients in whom a paper patch has been applied to the lateral surface of the repair are monitored until the paper patch migrates onto the skin of the bony canal wall. This process may take 6 to 12 weeks, during which time the patient is instructed to avoid getting water into the ear.

With the lateral grafting technique, the Glasscock or mastoid dressing is removed on the first postoperative day. Patients are instructed to keep the incision dry for 1 week; they are permitted to shower but should avoid getting the incision and Steri-Strips soaking wet. Topical eardrops are used twice daily for repairs packed with Gelfoam. Lateral packing involving the rosebud technique can remain dry. Topical eardrops are not needed during the first postoperative week. The ointment around the Merocel balls keeps the lateral packing moist. Drainage normally occurs through the external canal, and the cotton ball is changed frequently. Analgesics are provided. The patient is seen 7 to 10 days after surgery, and the postauricular Steri-Strips and the lateral rosebud packing are removed. Antibiotic-steroid drops are prescribed for use twice a day.

One week later, the medial rosebud pack is removed. The canal is cleaned with a thin wisp of cotton on an applicator. The cotton applicator is used to gently wipe or absorb any residual blood that may collect or pool in the inferior or anterior sulcus. Cleaning the medial canal will help avoid the development of granulation tissue, scarring, and blunting. A 3F suction device or cotton on an applicator can be used to remove excessive blood or serum, but caution is needed to avoid accidental removal of the replaced skin. The ear canal may attempt to heal with cicatricial midcanal soft tissue stenosis. If not recognized, it can progress to complete stenosis and give the appearance of a lateralized tympanic membrane. In the immediate postoperative period, most patients have a relatively insensate ear canal that permits office débridement and stenting. Occasionally, the patient must be returned to the operating room for aggressive débridement and repacking. Granulation tissue, if present, is

cauterized with silver nitrate. Excessive granulation tissue can be removed with a curette. Topical 5-fluorouracil can also be used. It may be necessary to place a wick with antibiotic drops for another week to ensure smooth healing of the ear canal.

The tympanic membrane should be intact and mobile. Tuning fork testing is performed and the results compared with those obtained preoperatively. If the middle ear space is incompletely aerated, positive nasal pressure (Valsalva maneuver) is occasionally used to aerate the middle ear space. No additional drops are used if the canal and tympanic membrane are well epithelialized. Otherwise, drops are continued for approximately 2 to 3 weeks. The patient is instructed to continue avoiding getting water in the ear when showering until healing is complete (usually 1 month). Patients are instructed to use Vaseline on a cotton ball for protection from water.

Postoperative care of medial grafts is similar to that for myringoplasty. The lateral packing is removed 7 to 10 days later. Drops are used twice a day, and the patient is instructed to keep the ear dry. For all techniques, the patient returns in approximately 3 to 4 weeks or at a total of 5 to 6 weeks after surgery. If healing is adequate, audiometric testing is performed at that time.

#### PEARLS

- Anticipate and inform patients who may not achieve successful tympanoplasty repair, including those who have failed multiple previous procedures; patients with severe contralateral atelectasis, middle ear effusion, or otorrhea; and those with obvious sources of eustachian tube dysfunction, such as abnormalities of the soft palate.
- Preparation and trimming of the skin should be done under the microscope to ensure that no unfurled edges are present.
- If there is insufficient skin to provide coverage of the bony canal, a thin split-thickness skin graft (Thiersch graft) from the non-hair-bearing postauricular skin is used.
- Place an accurately sized graft that just overlaps the anterior annulus to avoid blunting.
- Once the medial packing is removed from the ear canal, diligent local care of the external canal is necessary to avoid midcanal stenosis.

#### PITFALLS

- Incision into and exposure of the cartilage of the external canal may result in pain and possibly chondritis.
- Leaving remnants of epithelium from the tympanic membrane or on the anterior inferior sulcus when elevating the external canal skin from the medial canal can result in residual drum or canal cholesteatoma.
- Injury to the chorda tympani nerve results in sensation disturbances of the tongue, especially taste.
- The ear canal may attempt to heal with cicatricial midcanal soft tissue stenosis.
- Failure to recognize significant mucosal disease or compromised eustachian tube function will probably result in graft failure.

Copyright © 2009 Elsevier Inc. All rights reserved. Read our Terms and Conditions of Use and our Privacy Policy.  
For problems or suggestions concerning this service, please contact: [online.help@elsevier.com](mailto:online.help@elsevier.com)