

Chapter 102 – Petrosal Approaches

**Trevor Hackman,
Elizabeth H. Toh**

Several surgical approaches can be used to provide access to the petrous apex and lateral skull base for resection of tumors within the middle and posterior cranial fossae. The most common tumors of the skull base include petroclival meningiomas, chordomas, and chondrosarcomas. The most common lesions in the petrous apex include mucocoeles, epidermoids, cholesterol granulomas, and arachnoid cysts. Petroclival meningiomas are the predominant lesions requiring petrosal approaches for surgical resection.

Multiple surgical approaches have been developed over the years to provide access to tumors in the petroclival region. Central to all these approaches is the ability to develop exposure through which the tumor can be visualized and spare important neural and vascular structures within the petroclival region. In the past, morbidity and mortality rates in patients treated surgically for petroclival tumors was high, probably because of lack of knowledge of petrous temporal bone anatomy and therefore a tendency to attempt surgical approaches through the more familiar suboccipital and pterional approaches. Transpetrosal approaches through the lateral skull base offer more direct surgical exposure for resection of tumors in the petroclival region and less risk to neurovascular structures lateral and anterior to the brain stem.

Current transpetrosal approaches encompass a variety of surgical exposures through the petrous portion of the temporal bone to provide access to the cerebellopontine angle, the petroclival region, the basilar artery, and the brain stem (Table 102-1). Abdel Aziz and colleagues in 2000 grouped transpetrosal approaches into anterior and posterior categories and then subclassified them into individual approaches based on the spectrum of bone resection and exposure of the posterior fossa.^[1] The anterior transpetrosal approaches to the posterior fossa, also known as subtemporal approaches, are a continuum of the basic middle fossa approach. The addition of anterior petrosectomy and opening of the temporal lobe dura mater enhances visualization of the posterior fossa. The posterior transpetrosal approaches include the retrolabyrinthine, translabyrinthine, transcochlear, and total petrosectomy approaches, use of which depends on the location and extent of the tumor.

The location and extent of cranial base tumors within the middle and posterior fossae often necessitate a combination of petrosal approaches, such as a subtemporal middle fossa approach along with a transpetrosal approach, to enhance surgical exposure and thereby limit neurovascular morbidity. The extent of temporal bone resection required for adequate exposure is dependent on the approach and tumor location. Anterior, posterior, combined, and complete petrous bone resections must be tailored to each case.

Advantages of transpetrosal approaches include (1) minimal retraction of the cerebellum and temporal lobe; (2) reduced operative distance of the clivus (3 cm shorter than with the suboccipital approach); (3) superior angle of surgical exposure with regard to the anterior and lateral aspects of the brain stem; (4) preservation of the vein of Labbé and the transverse and sigmoid sinuses; (5) anatomic preservation of all critical neural and otologic structures, including the cochlea, vestibule, and facial nerve; (6) availability of multiple angles and routes for tumor resection within the same surgical exposure; and (7) early vascular control of the tumor, thus making subsequent tumor resection easier.^[2-4]

The development of newer microsurgical and skull base surgery techniques, along with improvements in anesthesia, neuroradiology, and monitoring, have significantly reduced surgical morbidity. Recently, newer techniques, including stereotactic radiation therapy and surgical resection through expanded endoscopic nasal approaches, have been used to treat these lesions with relatively low complication rates. Stereotactic radiation therapy offers a nonsurgical option for controlling tumor growth. The expanded endoscopic nasal approach is used for removal of lesions in the middle third of the clivus, petrous internal carotid artery, cavernous sinus, and medial infratemporal fossa, which are located centrally with the surrounding neurovascular structures displaced laterally.^[5]

Table 102-1 -- PETROSAL APPROACHES TO THE CRANIAL BASE

Anterior petrosal approaches (middle fossa)
Classic subtemporal approach
Middle fossa approach to the internal auditory canal
Middle fossa approach to the petrous carotid artery
Petrous apicectomy

Posterior petrosal approaches
Retrolabyrinthine approach
Partial labyrinthine approach
Translabyrinthine approach
Transcochlear approach
Total petrosectomy
Combined anterior and posterior transpetrosal approaches
Expanded endoscopic nasal approaches

PATIENT SELECTION

Factors found to be important in determining selection of the approach for surgery include the size, location, and extent of the tumor; anatomic variations in temporal bone anatomy; location of the sigmoid sinus; and the patient's hearing status. Larger tumors and those with involvement of critical neurovascular structures are more likely to require a combination of approaches for optimal surgical exposure. The approach selected should be tailored to fit the individual patient and maximize access while limiting morbidity. Abdel Aziz and colleagues developed a zoning classification for lateral skull base lesions to guide selection of the surgical approach (Fig. 102-1). Zone I (upper zone) extends from the dorsum sellae to the upper border of the internal auditory canal (IAC) and represents the exposure provided via the anterior petrosal approaches. Zone II (middle zone) extends from the IAC to the upper border of the jugular tubercle and represents the exposure provided via the posterior petrosal approaches. Zone III (lower zone) extends from the upper border of the jugular tubercle to the lower edge of the clivus and represents the exposure provided via a transcondylar approach. Zone III is essentially the anterior lip of the foramen magnum.^[1]

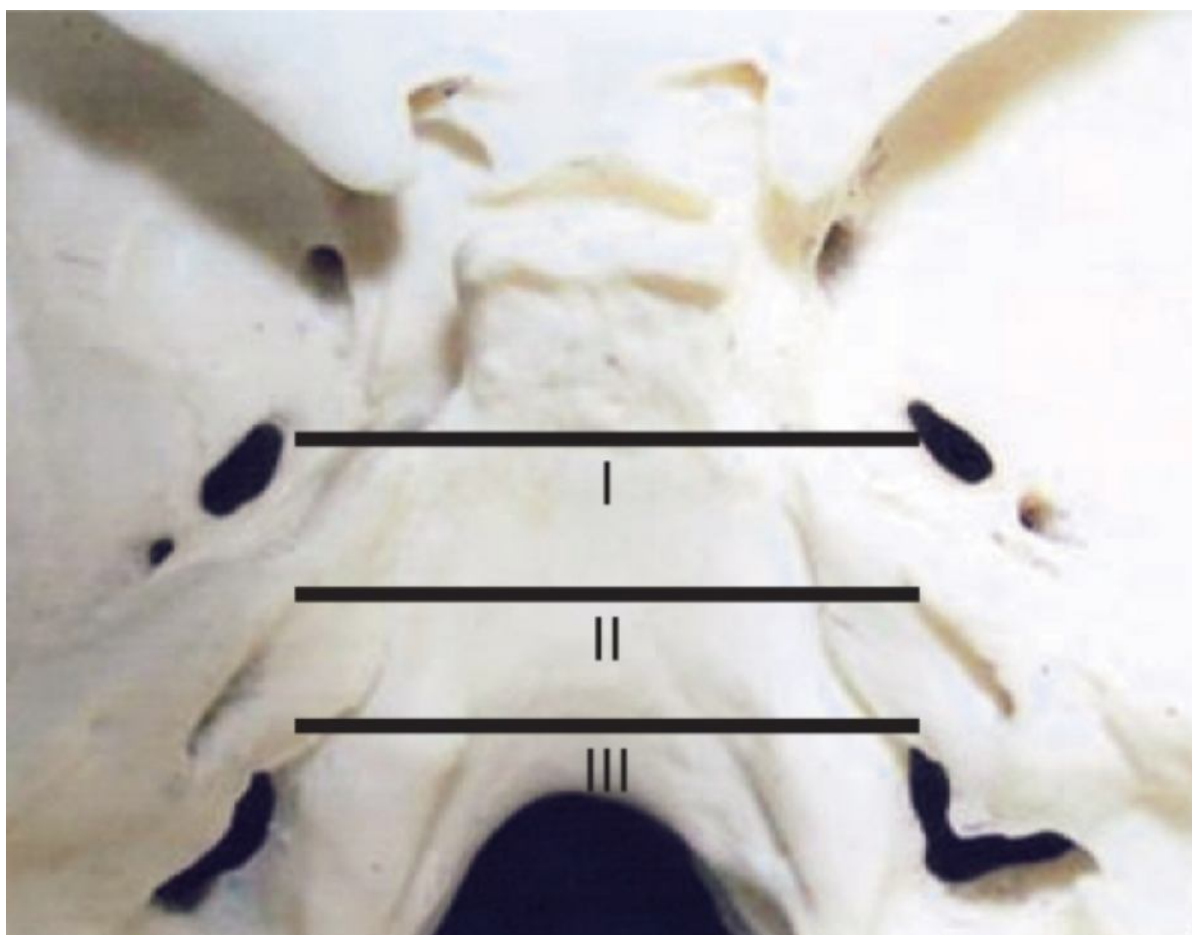


Figure 102-1 Zoning classification of lateral skull base lesions used to select the surgical approach for resection.

Anterior Petrosal Approaches

Based on the standard middle fossa approach, anterior petrosal approaches can provide exposure for resection of zone I lesions extending from the oculomotor nerve anterosuperiorly down to the IAC posteroinferiorly. They also

provide the advantage of optimal exposure and vascular control of the petrous carotid artery and superior visualization of the upper clivus. Their relative disadvantages include the risk of facial nerve injury, necessity for temporal lobe retraction, and limited access to the posterior fossa.

Middle Fossa Approach to the Internal Auditory Canal

Indications for the use of this approach and the surgical technique are described in detail in Chapter 124.

Middle Fossa Approach to the Petrous Carotid Artery

Anatomic identification of the petrous carotid artery is paramount for successful surgical outcomes in skull base surgery, especially when intraoperative hemorrhage is anticipated or when the tumor directly involves the carotid artery or cavernous sinus (or both). Tumors with extensive invasion of the temporal bone, such as squamous cell carcinoma, paraganglioma, and high-grade chondrosarcoma, or tumors of the cranial base, such as meningioma, chondrosarcoma, and chordoma, present such an extirpative dilemma. The middle fossa approach was initially popularized by William House for surgical removal of small acoustic neuromas in patients with aidable hearing in the affected ear. It was subsequently adapted by Glasscock for exposure of the petrous carotid artery and used for surgical removal of skull base tumors in 1975 by Bochenek and Kukwa, who termed the approach the anterior petrosal approach.^[2–4] The approach provides ideal surgical exposure of the horizontal segment, vertical segment, and genu of the petrous carotid artery, as well as for resection of petroclival lesions. With tumors involving the carotid artery, the carotid artery may be mobilized and controlled proximally and distally with this approach to allow improved exposure, more controlled surgical resection, and the ability to repair the carotid artery or perform carotid artery bypass when indicated. Preoperative assessment of these tumors with computed tomography (CT), magnetic resonance imaging (MRI), angiography, and balloon occlusion testing is essential for preoperative planning.

Petrosal Apicectomy

Depending on the size, location, and neurovascular involvement of the tumor, the standard middle fossa approach may need to be expanded to include a petrous apicectomy. When used alone, this approach affords access to the midclivus, anterior cerebellopontine angle, Meckel's cave, the lateral wall of the cavernous sinus, and the petroclival synchondrosis for resection of small meningiomas, chondrosarcomas, and chordomas. The petrous apicectomy approach can also be used to manage aneurysms of the vertebrobasilar junction. The expanded surgical field also allows better vascular control of larger petroclival tumors, thereby leading to more complete and safer resection.

The increased labor associated with more extensive bony resection of the petrous temporal bone in this approach is well balanced by the improved surgical vector and field of exposure afforded to the clivus and even the ventral portion of the posterior fossa. This reduces the need for temporal lobe retraction, thus minimizing the risk for neurologic sequelae caused by prolonged temporal lobe retraction, such as seizures and cerebrovascular events. For larger petroclival tumors extending far into the posterior fossa, additional exposure via a posterior petrosal approach is often needed. In such cases, the anterior and posterior petrosal approaches are used in combination.

Posterior Petrosal (Transpetrosal) Approaches

Posterior petrosal approaches include the retrolabyrinthine, partial labyrinthine, translabyrinthine, transcochlear, and total petrosal approaches, for which a mastoidectomy is the surgical foundation. The progressive degrees of bone resection anteriorly via the retrolabyrinthine, translabyrinthine, and transcochlear approaches, respectively, provide graduated exposure of the posterior fossa within zone II (IAC to the jugular tubercle).^[1] The retrolabyrinthine, translabyrinthine, and transcochlear approaches, when combined with temporal craniotomy and release of the tentorium, are best suited for mid and upper petroclival lesions located in the lateral, anterolateral, and anterior portions of the brain stem, respectively.

Retrolabyrinthine Approach

The retrolabyrinthine approach is ideally suited for patients with good hearing and medium to large tumors of the midclivus and anterior cerebellopontine angle. The approach may be combined with a middle fossa approach for removal of larger lesions lateral to the brain stem and over the clivus, with preservation of hearing and facial nerve function and minimal morbidity. The retrolabyrinthine approach hinges on the ability to mobilize the sigmoid sinus posteriorly for access to the posterior fossa through the presigmoid space. Although the approach can provide lateral exposure from cranial nerve IV to the upper border of the jugular tubercle, the vestibular labyrinth anteriorly limits access to the ventral (anterior) surface of the brain stem and clivus, also known as the paramedian portion of zone II (or the central clival depression).^[1,6] Therefore, tumors with dural attachment in the central clival depression cannot be totally resected with this approach.

The retrolabyrinthine approach is also limited by the variable anatomy of the temporal bone. A contracted mastoid or a far-forward sigmoid sinus can limit the anteroposterior extent of bony exposure provided through this approach. Similarly, a high-riding jugular bulb or low-lying tegmen mastoideum can reduce the superoinferior limits of surgical exposure. Tumor involvement of the cavernous sinus or lower clivus often necessitates additional exposure via a frontotemporal orbital–zygomatic approach or transcondylar approach, respectively. Alternatively, exposure of tumors in the central clival depression may be accomplished via the translabyrinthine or transcochlear approach with posterior mobilization of the facial nerve and sacrifice of hearing in that ear.[1,6]

Partial Labyrinthectomy Approach

The partial labyrinthectomy approach is an extension of the retrolabyrinthine approach that provides additional ventral exposure while preserving hearing in the operated ear. The principle of the partial labyrinthectomy approach involves removal of only a portion of the vestibular labyrinth, thereby attempting to conserve hearing. Specifically, removal of the posterior and superior semicircular canals can provide an additional 6 to 10 mm of posterior exposure and 10 to 15 mm of superior exposure, which significantly reduces temporal lobe retraction and increases the angle of exposure up to 30 degrees. The anterior limit of resection is the IAC. Tumors extending only to the medial half of the IAC can be removed through this exposure. Tumors extending into the lateral portion of the IAC require a translabyrinthine approach if there is no useful hearing or an anterior petrosal approach if hearing preservation is being attempted. The partial labyrinthectomy approach is typically reserved for large neoplastic and vascular lesions in the midportion of the clivus between the trigeminal and vagus nerves.[2]

Translabyrinthine Approach

Patients with poor hearing or those with lesions extending into the IAC are considered suitable candidates for the translabyrinthine approach. Removal of the vestibular labyrinth provides added exposure to the anterolateral aspect of the clivus and brain stem but sacrifices any residual hearing. The anterior limit of the approach is the facial nerve, which is not mobilized with this approach.

Transcochlear Approach

When additional access to the ventral aspect of the clivus and brain stem is required and hearing is poor, the translabyrinthine exposure can be extended into a transcochlear exposure by continuing the bony dissection anteriorly and drilling out the cochlea. The approach provides superior lateral exposure and ventral access to the brain stem, which aids in resection of tumors in the central clival depression. The surgical approach requires posterior mobilization of the facial nerve with resultant facial dysfunction. Therefore, this approach is used primarily for tumors involving the petrous temporal bone, for large petroclival tumors extending to the lateral clivus, for patients with preexisting facial nerve dysfunction, and for those with no serviceable hearing.

Total Petrosectomy

Total petrosectomy provides the widest and most complete field of exposure for the petroclival region. The approach involves extending the transcochlear approach to include exposure and anterior mobilization of the petrous carotid artery. This approach allows complete resection of the petrous temporal bone and clivus when these bones are involved with tumor, as well as removal of giant petroclival tumors with significant involvement of the carotid artery. Total petrosectomy also gives the widest possible access to the mid and upper clivus and the entire zone II.[1–6] Disadvantages of this approach include extended operative time, complete hearing loss in the operated ear, and significant risk of injury to the facial nerve and internal carotid artery. This approach does not provide adequate exposure of zone III and the lower clivus. Small lesions located in these areas may be resected through a retrosigmoid approach, whereas larger lesions will require a transcondylar approach. Upper clival lesions resected through this approach may require retraction of the temporal lobe or partial resection of the inferior gyrus.

Expanded Endoscopic Nasal Approach

Recently, the expanded endoscopic nasal (endonasal) approach has been proposed for removal of centrally based lesions in the middle third of the clivus, petrous internal carotid artery, and cavernous sinus when the neurovascular structures are displaced laterally.[5] The principle of endonasal approaches to the skull base centers around the anatomy of the sphenoid sinus, which provides the gateway to the middle and posterior cranial fossae. Also known as the transsphenoidal approach, the expanded endonasal approach has many advantages over lateral approaches, including improved access and reduced morbidity. Traditional microscopic transsphenoidal surgery was limited by the conical exposure to the skull base and therefore a narrow working field. The advent of endoscopes has revolutionized this approach. Endoscopes provide magnified and unparalleled visualization of key structures, thereby allowing better preservation of uninvolved structures.[7]

When compared with lateral approaches and microscopic approaches, endoscopic approaches provide superior

lighting, the ability to see around corners with angled rigid telescopes, excellent maneuverability, and a magnified, comprehensive view of the surgical field.[4,7] The endoscopic approach also affords expanded visualization in both the transverse and vertical dimensions from the sella turcica to the foramen magnum. The addition of three-dimensional image guidance technology has allowed surgeons to extend approaches into the middle and posterior skull base for resection of tumors previously only approachable via traditional petrosal approaches. From a cosmetic perspective, endonasal approaches have a significantly reduced burden of healing and provide superior cosmesis by eliminating external incisions and soft tissue retraction. From a morbidity standpoint, the endonasal approach avoids complications related to temporal lobe retraction and injury to neurovascular structures typically encountered with lateral approaches, thus decreasing the rate of postoperative lower cranial neuropathy. Finally, the reduced surgical morbidity allows patients with advanced tumors to proceed with adjuvant radiation therapy in timely manner.[5,7]

Endoscopic approaches come with some inherent disadvantages. First and foremost, expanded endonasal approaches require advanced endoscopic surgical skills, which take significant time to acquire. Second, because of the relative infancy of expanded endonasal approaches, only a few centers are using them. Third, the endonasal approach does not usually permit en bloc resection of the tumor. For the most commonly encountered skull base neoplasms, this is not likely to affect the long-term prognosis, especially if surgical decompression is the primary goal of treatment. Conversely, the magnified endoscopic view often provides an enhanced view of tumor margins and attachment of tumor to surrounding normal tissue. If complete tumor resection is the treatment goal, additional tissue margins may be sent for pathologic examination after the tumor has been resected. Fourth, the incidence of cerebrospinal fluid (CSF) leakage is increased, and it may at times be difficult to control endonasally. Finally, control of bleeding during surgery requires considerable technical expertise and careful planning.[5,7]

PREOPERATIVE PLANNING

Preoperative evaluation of patients with petroclival lesions includes an extensive history and physical examination. The history should focus on the onset and duration of symptoms, including visual disturbances, auditory changes, weakness, paresthesias, and voice and swallowing abnormalities. Patients should have a complete head and neck and neurologic examination, including gait testing, cranial nerve examination, otologic evaluation, and sensory and motor testing of the extremities. Ancillary preoperative testing should include a complete audiogram and imaging studies of the skull base. Contrast-enhanced CT of the skull base, including the temporal bone, and gadolinium-enhanced MRI of the brain are essential for determining the extent and location of the lesion and for selecting the appropriate surgical approach or combination of approaches. If symptoms of swallowing dysfunction are detected preoperatively, videofluoroscopic evaluation of swallowing function should be performed. Preoperative cranial nerve function should be carefully documented because the risk for postoperative cranial neuropathy is significant. Patients should be counseled regarding the risk for potential postoperative cranial neuropathy, temporal lobe injury, seizures, CSF leakage, bleeding, and the possible need for additional surgery to address these complications.

SURGICAL APPROACHES

Anterior Petrosal Approaches

Middle Fossa Approach to the Petrous Carotid Artery

The patient is positioned supine with the head turned so that the operated ear is facing up. The ipsilateral shoulder is elevated to decrease tension on the cervical musculature, stretching of the brachial plexus, and torsion of the jugular veins. Intraoperative facial nerve monitoring is established at the beginning of the procedure. Paralytic agents are not used after induction of general anesthesia. Brain stem auditory evoked responses are also monitored routinely because hearing preservation is desired. Perioperative medications administered include broad-spectrum antibiotics with good CSF penetration (ceftriaxone, 2 g); furosemide (Lasix, 20 mg); mannitol, 0.5 mg/kg; and dexamethasone, 10 mg. Bacitracin (50,000 U/L of saline solution) is used in the irrigation fluid. Lumbar drainage is not routinely performed.

When the goal of surgery is complete removal of a petroclival lesion or isolation of the petrous carotid artery, the standard skin incision used for the conventional middle fossa approach (Fig. 102-2) must be adapted to provide increased anterior and inferior exposure (Fig. 102-3). The incision can be combined with a modified Blair incision to allow complete exposure of the petrous carotid artery. The planned incision is marked and then infiltrated with a solution of 1% lidocaine with 1 : 100,000 epinephrine 10 to 15 minutes before elevation of the skin flaps to provide hemostasis. The incision is typically carried down through epidermis and dermis with a scalpel and then continued through subcutaneous tissue with electrocautery. As the skin flap is developed anteriorly, care should be taken to avoid injury to the frontal branch of the facial nerve, which courses over the zygomatic arch in a superficial plane of loose areolar tissue anterior to the temporal hairline. Knowledge of the scalp layers in this region is essential to avoid injury to the facial nerve. The course of the frontal branch of the facial nerve and layers of the scalp are shown in Figures 102-4 and 102-5, respectively.

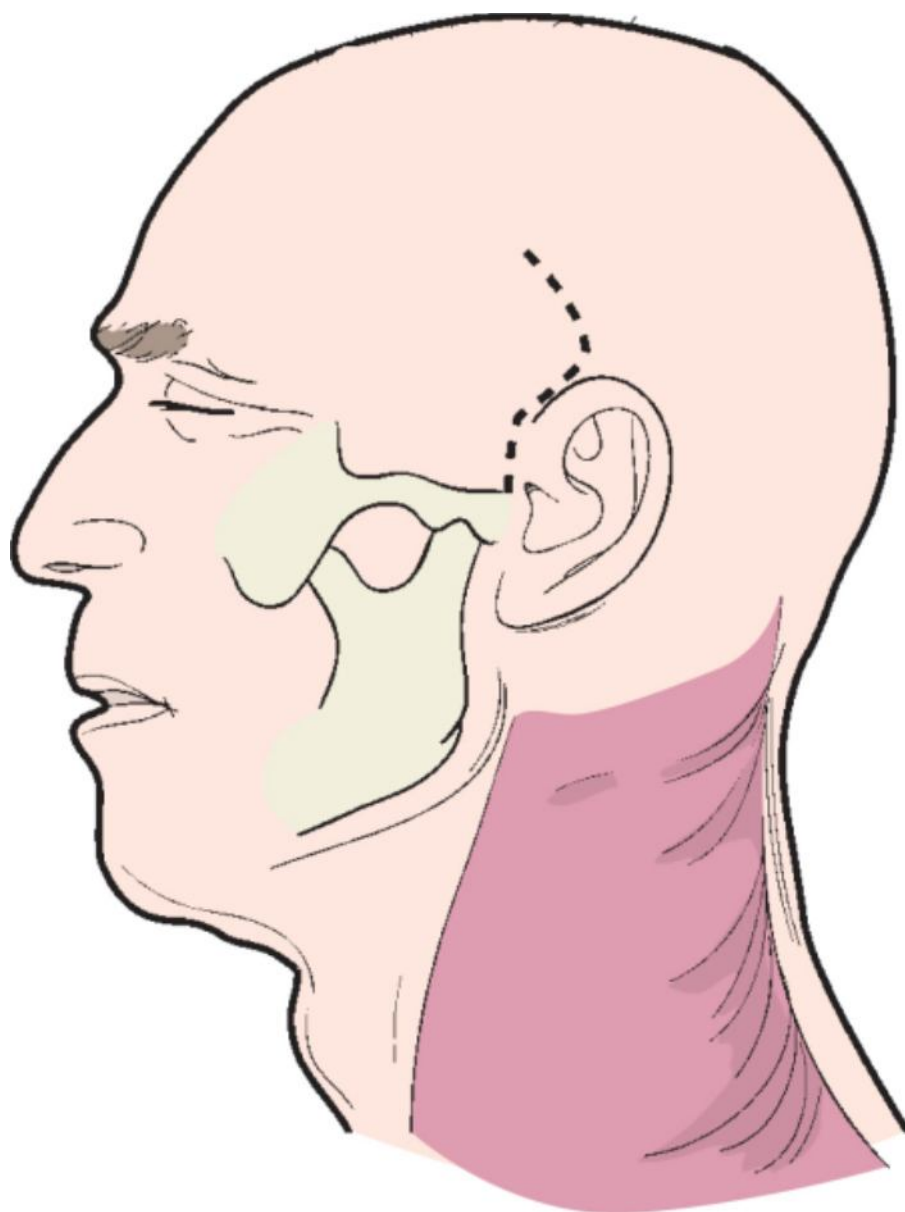


Figure 102-2 Standard skin incision used for the middle fossa approach to the internal auditory canal.

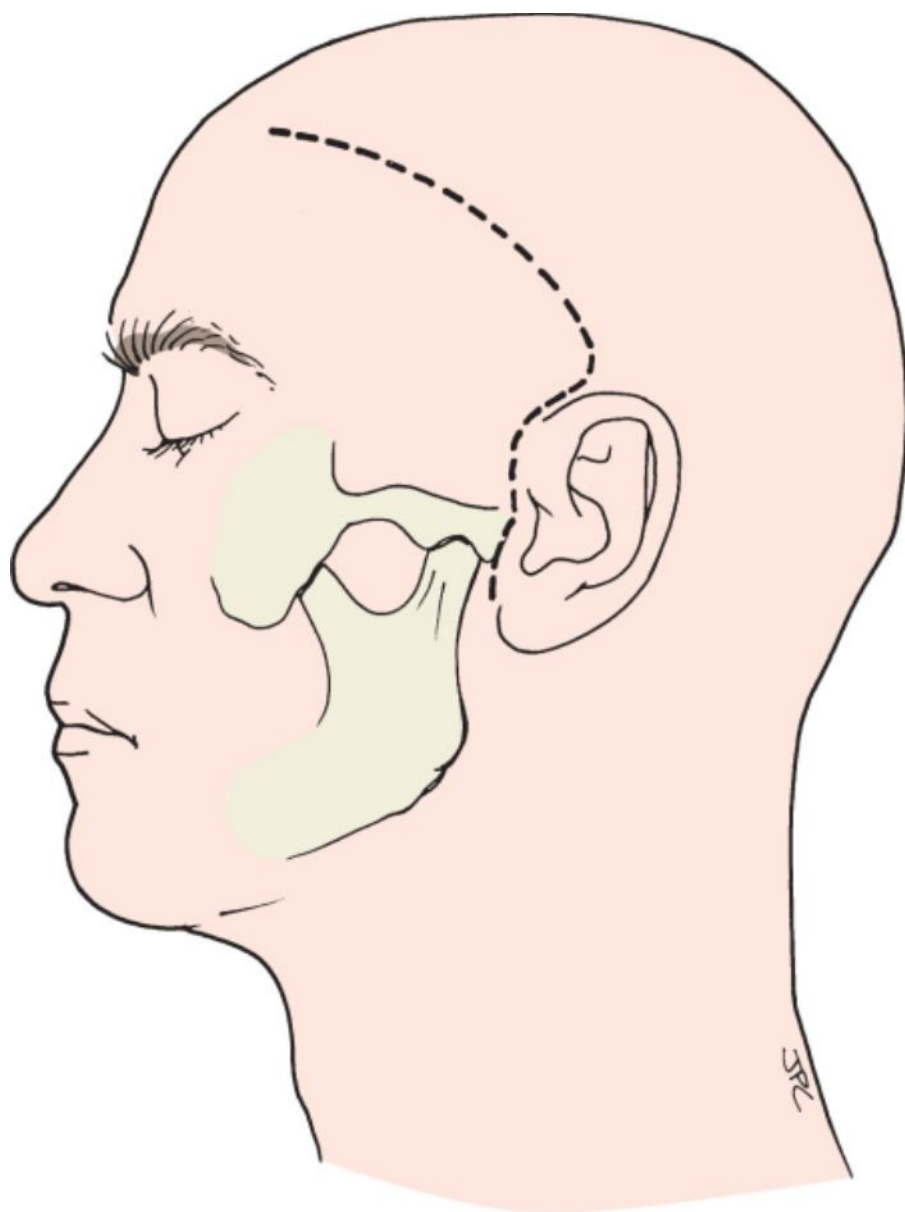


Figure 102-3 Modification of the temporal incision used for exposure of a petrous carotid artery or for petrous apicectomy.

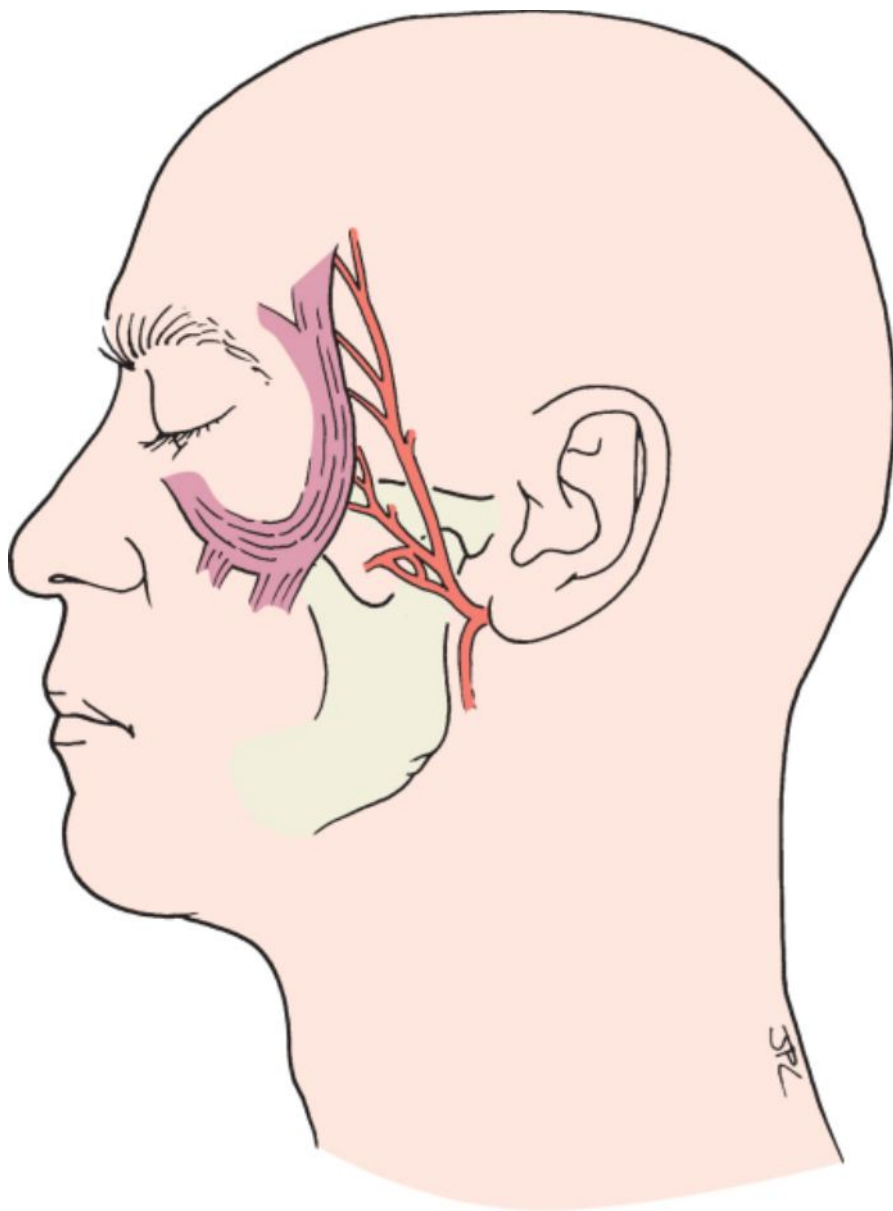


Figure 102-4 Anatomy of the frontal branch of the facial nerve.

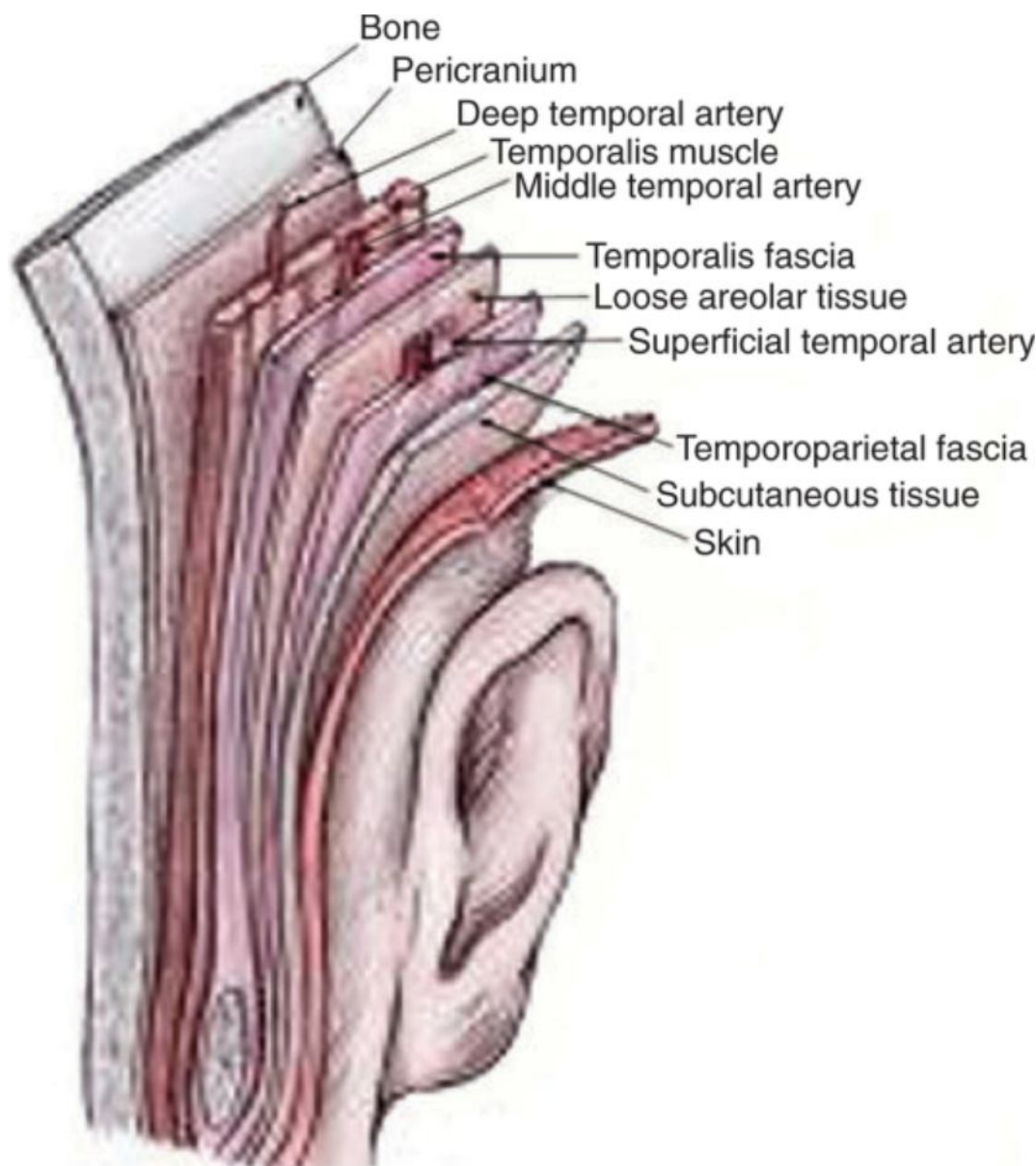


Figure 102-5 Layers of the scalp.

The temporoparietal fascia, considered a continuum of the superficial muscular aponeurosis of the midface, fuses with the superficial layer of the deep temporal fascia approximately 1 cm above the zygoma. The facial nerve, which starts deep to the temporoparietal fascia in the midface, pierces through this fused fascial layer 1 cm above the zygoma and runs superficial to the superficial temporal fascia until its termination on the medial surface of the frontalis muscle. To protect the facial nerve during anterior elevation of the skin flap, the dissection should be performed deep to the superficial layer of the temporal fascia. At the level of the superior brow line, 2 cm above the zygomatic arch, the deep temporal fascia splits into a deep layer and superficial layer to envelop the zygomatic arch, between which the superficial temporal fat pad can be found. At this level the superficial temporal fascia is typically incised (Fig. 102-6), and dissection is extended deep to the superficial temporal fat pad, anteriorly and inferiorly along the surface of the deep temporal fascia to the zygoma, to preserve the facial nerve in the skin flap (Fig. 102-7).

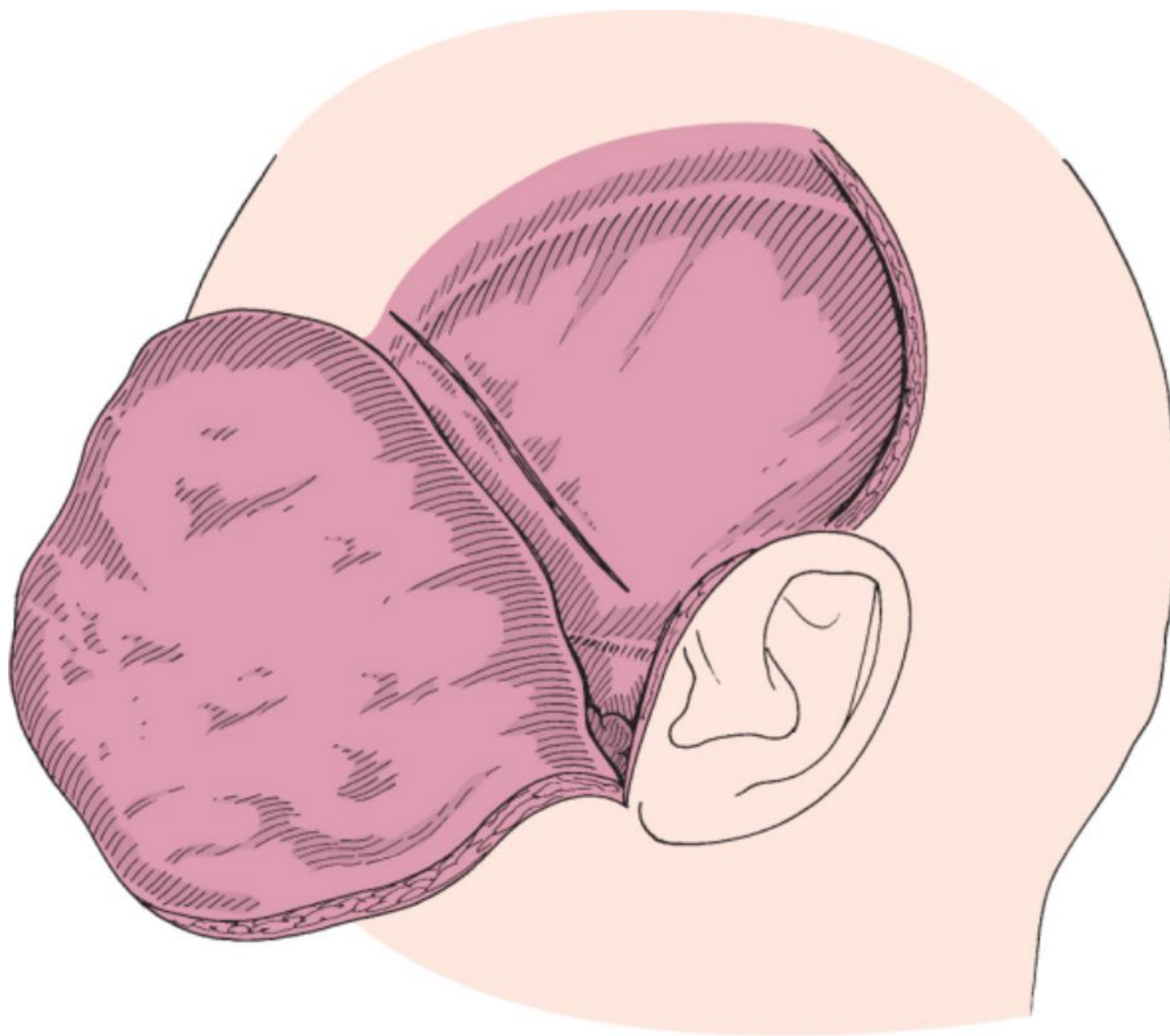


Figure 102-6 Dissection of the superficial layer of the deep temporal fascia to preserve the frontal branch of the facial nerve.

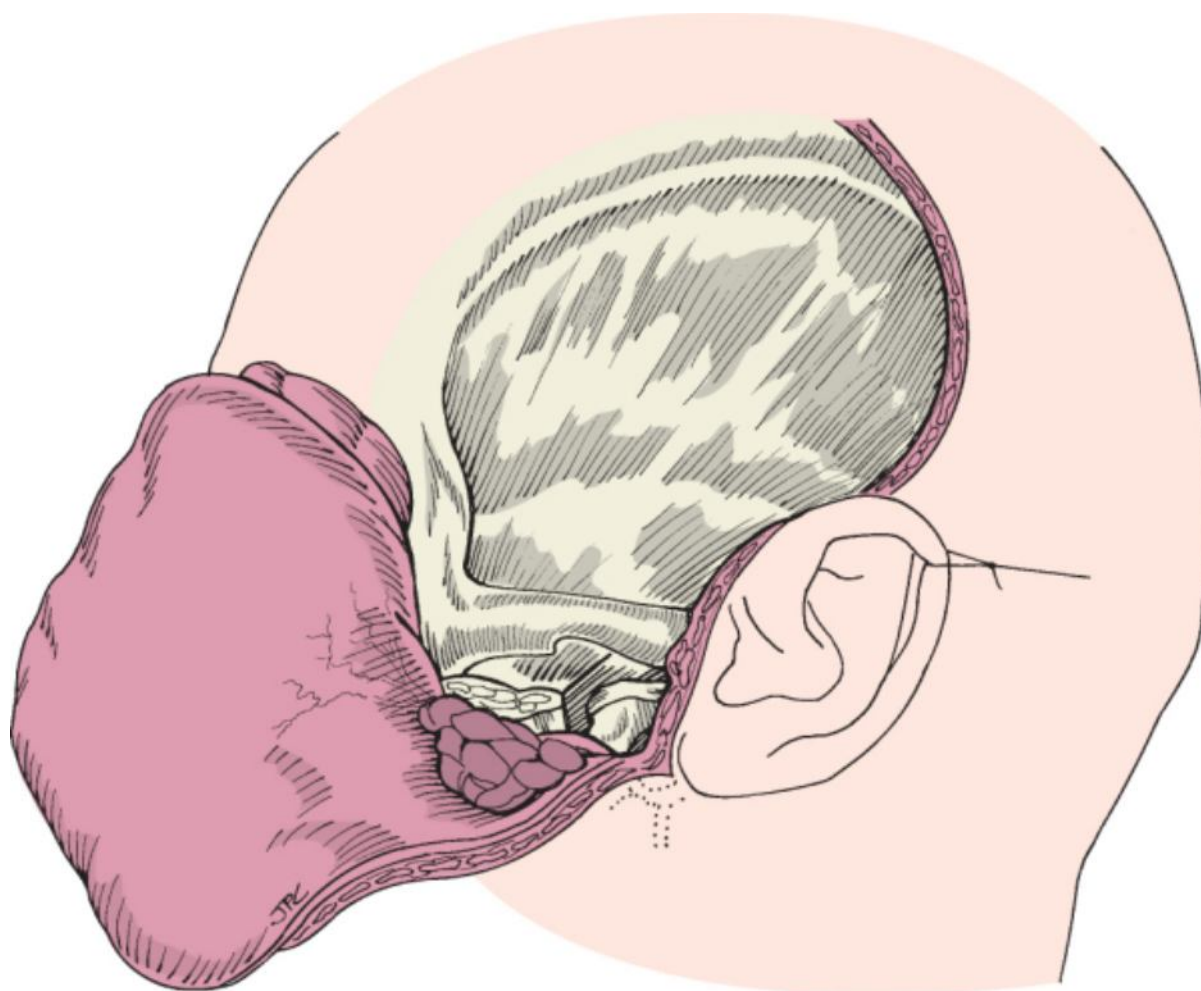


Figure 102-7 The frontal branch of the facial nerve is preserved within the anterior skin flap.

The zygomatic arch, with or without the roof of the glenoid fossa, is then removed via surgical osteotomies to allow elevation of the remaining temporalis muscle inferiorly out of the field of dissection. This lowers the level of the craniotomy to the floor of the middle fossa and provides an improved angle of exposure under the temporal lobe with less retraction of the temporal lobe. The junction of the zygomatic arch and malar eminence is divided via a chevron-shaped osteotomy with an oscillating saw (Fig. 102-8). The glenoid fossa osteotomies are then performed medial to the glenoid fossa to allow removal of the zygomatic arch over the roof of the glenoid fossa.

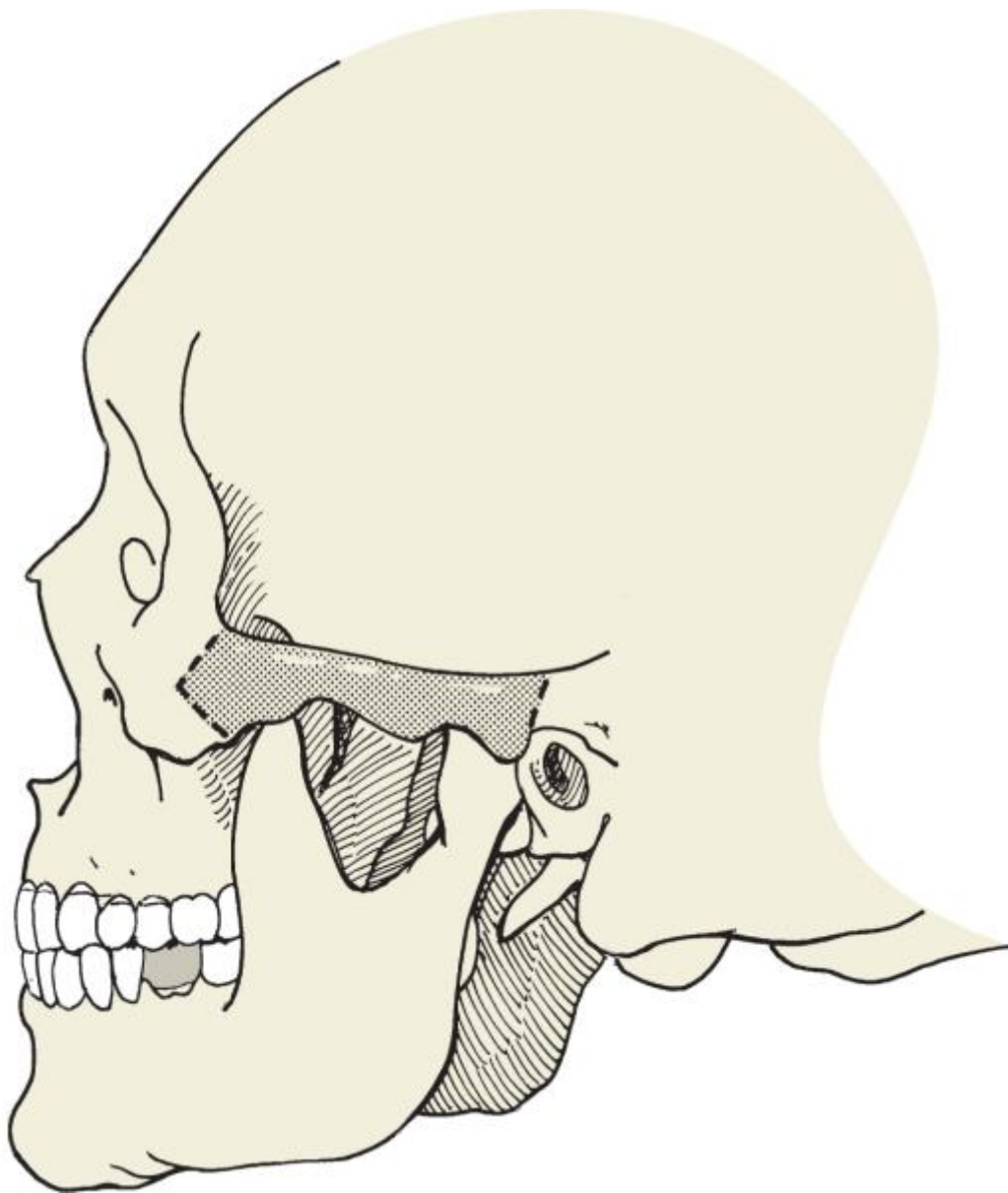


Figure 102-8 Osteotomies used for removal of the zygomatic arch and medial aspect of the glenoid fossa.

An inferiorly based temporalis muscle flap is then created by incising the muscle along the linea temporalis while taking care to leave a superior cuff of muscle attached to its insertion to facilitate subsequent muscle reapproximation. Dissection of the temporalis muscle is carried as inferiorly as possible to permit a low subtemporal approach and placement of self-retaining retractors or stay sutures. In this manner the lateral surface of the skull is exposed (Fig. 102-9). Posteriorly, the root of the zygoma, the glenoid fossa, and the external auditory canal are identified. Anterior dissection has exposed the confluence of the frontal, sphenoidal, and temporal bones in an area known as the pterion. Superiorly, the temporalis muscle has been released from its insertion. The malar eminence and the lateral and superior orbital rim are also exposed.

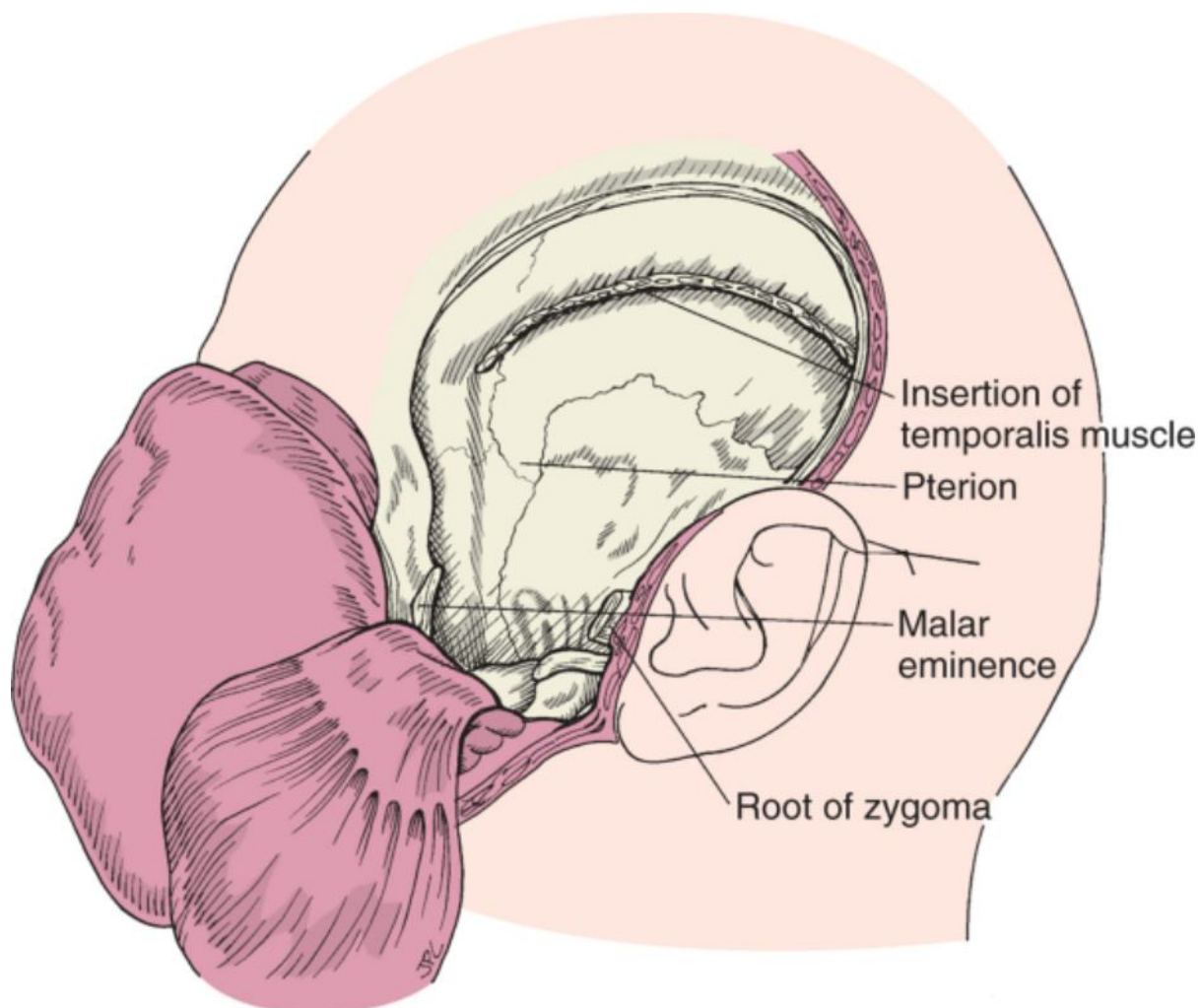


Figure 102-9 Surface anatomy of the lateral skull base.

A low temporal craniotomy is then performed with a cutting burr or craniotome along the floor of the middle fossa from the external auditory canal to the orbital wall, which is possible only after removal of the zygomatic arch. The superior aspect of the craniotomy often extends posterior to the external auditory canal, and burr holes are often made for drilling access when the craniotome is used (Fig. 102-10). Using a dural elevator, the bone flap is carefully elevated off the dura and soaked in saline until completion of the procedure. The completed craniotomy is shown in Figure 102-11. Next, a cutting burr or rongeur is used to lower the inferior border of the craniotomy to the level of the floor of the middle fossa.

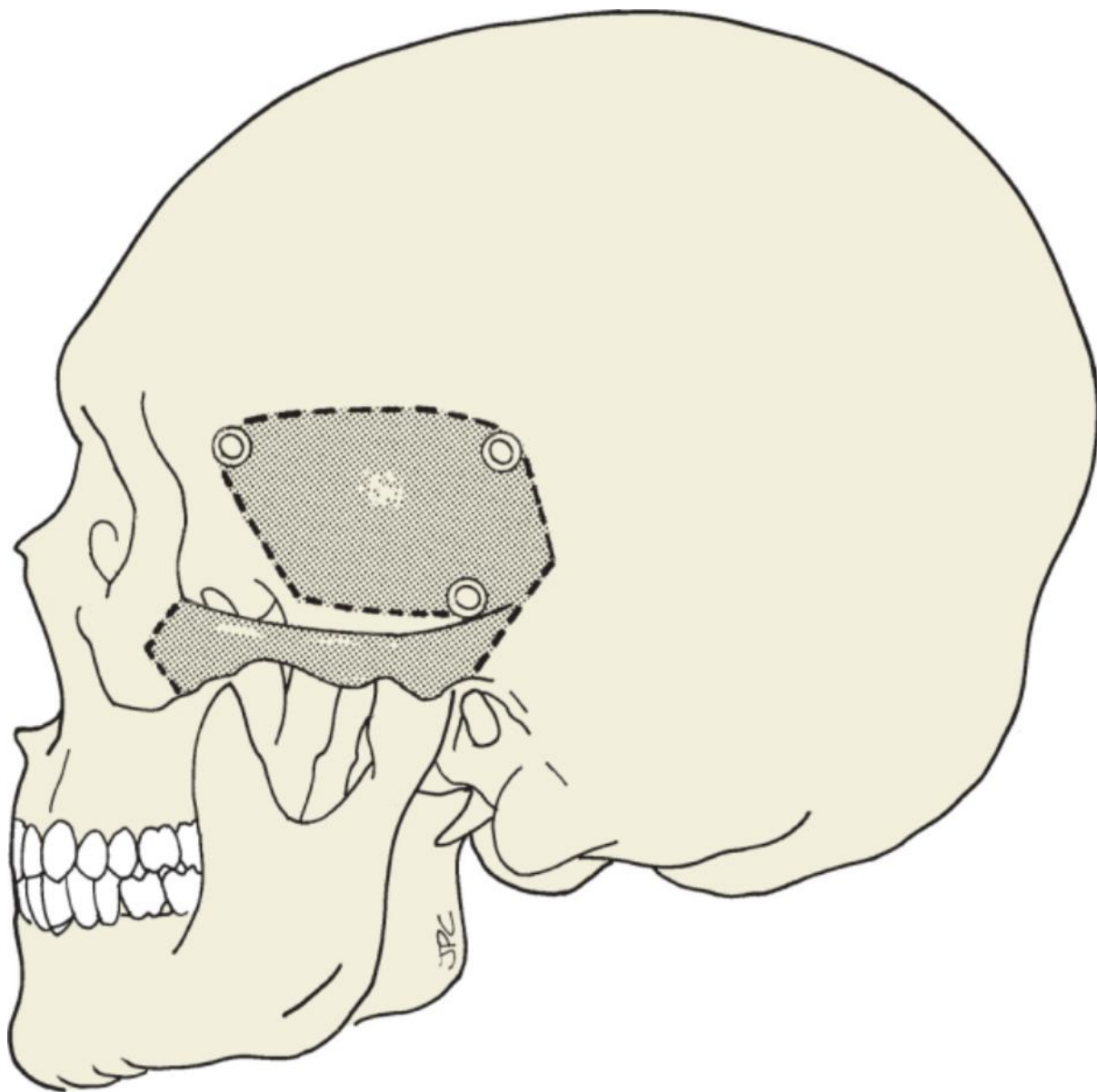


Figure 102-10 Location of the temporal craniotomy and removal of the zygomatic arch.

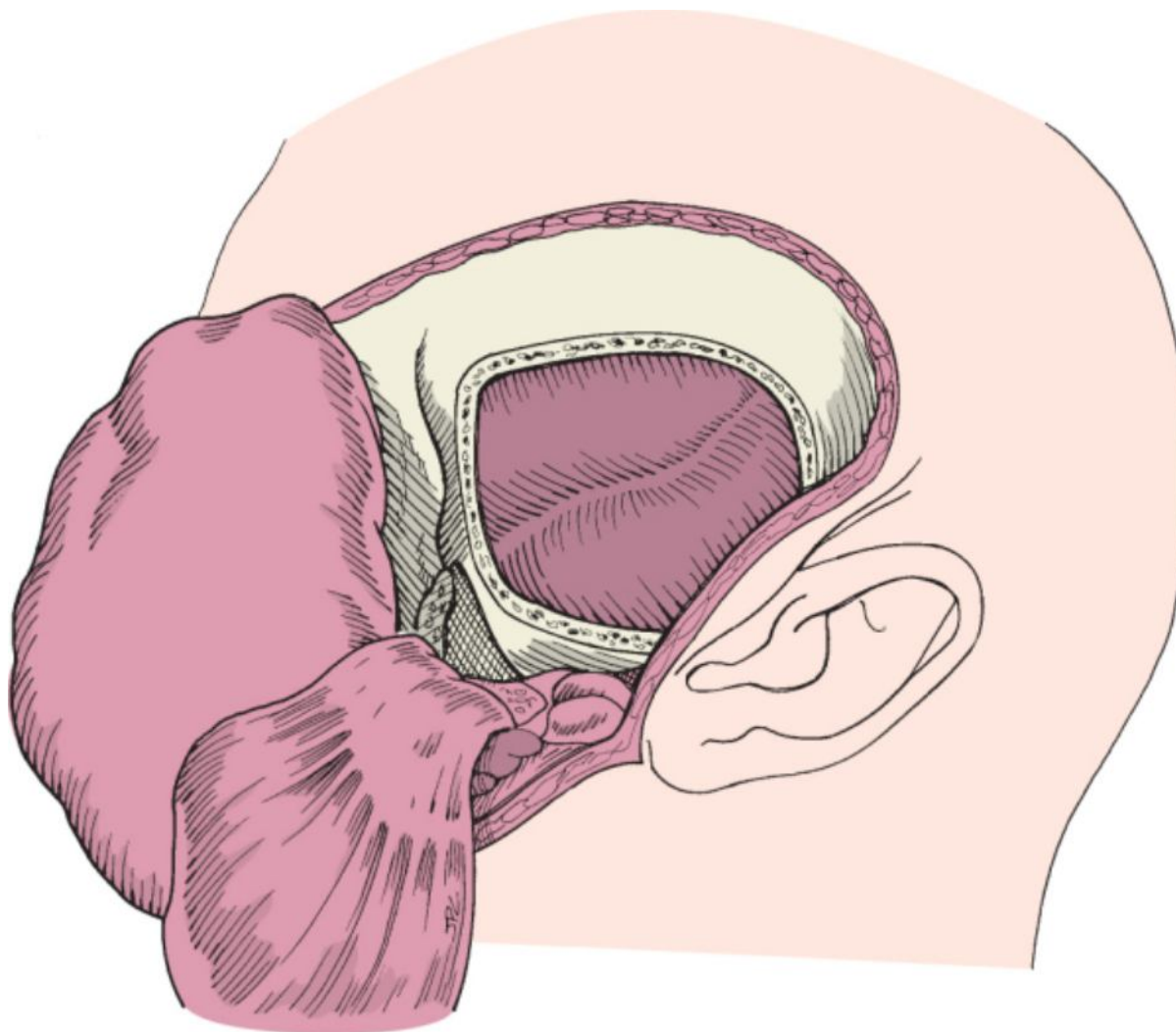


Figure 102-11 Completed craniotomy for petrosal carotid dissection and petrosal apicectomy.

The temporal lobe is then elevated extradurally from the floor of the middle fossa in a posterior-to-anterior direction. Familiarity with the surface anatomy of the floor of the middle fossa is essential (Fig. 102-12). The arcuate eminence, a round elevation of bone overlying the superior semicircular canal (the arcuate eminence may be absent in 15% of patients^[8]), is first identified posteriorly. The sulcus of the superior petrosal sinus forms the medial boundary of the floor of the middle fossa and dural exposure for this approach. Knowledge of the relative locations of the vestibular labyrinth, cochlea, facial nerve, and internal and external auditory canal within the temporal bone is essential for safe bony dissection (Fig. 102-13). As dural elevation is continued anteriorly, the greater superficial petrosal nerve (GSPN) is identified coursing within the sphenopetrosal groove. Posteriorly, the sphenopetrosal groove forms the facial hiatus where the GSPN exits from the geniculate ganglion. This portion of the facial nerve is dehiscent in up to 15% of normal individuals, so gentle dissection and minimal traction on the overlying dura will avoid trauma to the facial nerve. The first landmark in the area overlying the horizontal segment of the petrosal carotid artery is the middle meningeal artery as it emerges from the foramen spinosum anterior and medial to the petrosquamous suture (Fig. 102-14). After cauterizing and transecting this artery (Fig. 102-15), the lesser superficial petrosal nerve, foramen ovale, and third division of the trigeminal nerve are identified. To expose the horizontal petrosal carotid artery, bone must be removed medial to the middle meningeal artery and inferomedial to the GSPN, from the facial hiatus to the sphenopetrosal groove. Attempts should be made to preserve the GSPN whenever possible to avoid postoperative “dry eye” secondary to impaired lacrimation. In rare cases the GSPN may be sacrificed to prevent traction injury to the geniculate ganglion.

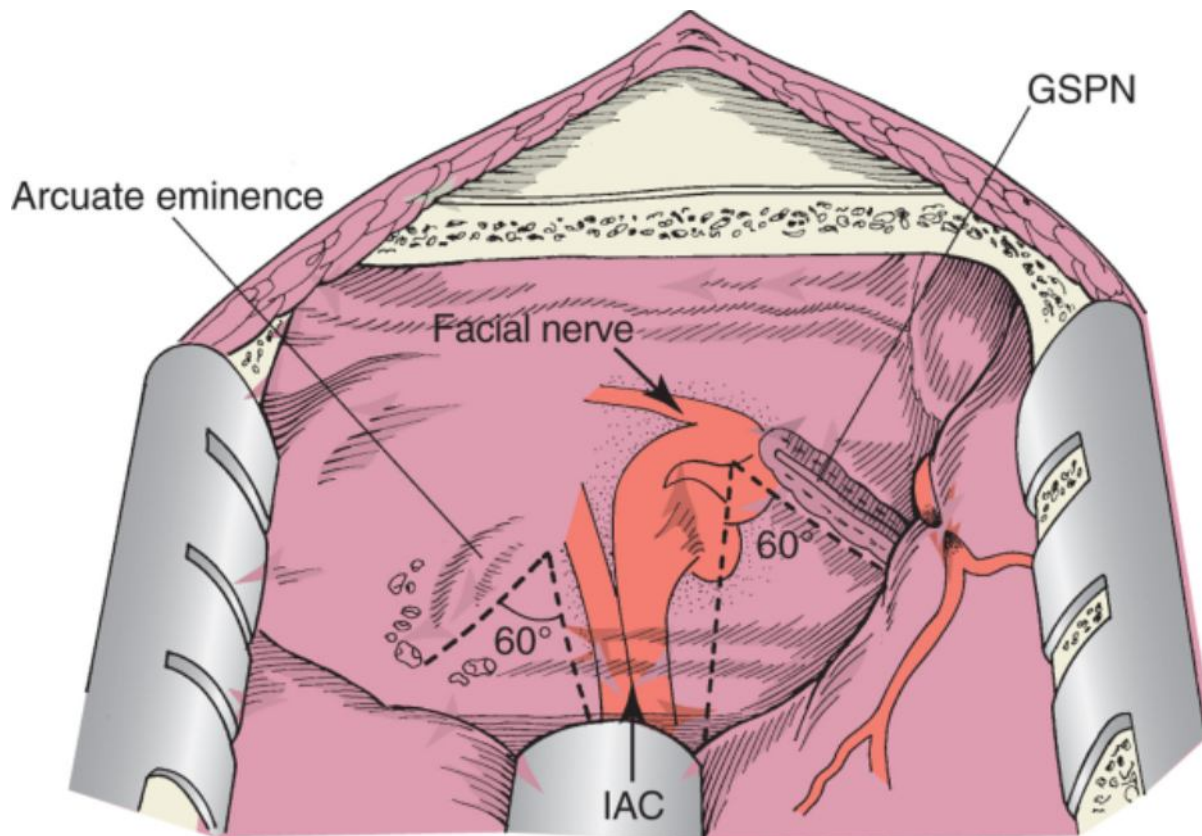


Figure 102-12 Surface anatomy of the middle cranial fossa. GSPN, greater superficial petrosal nerve; IAC, internal auditory canal.

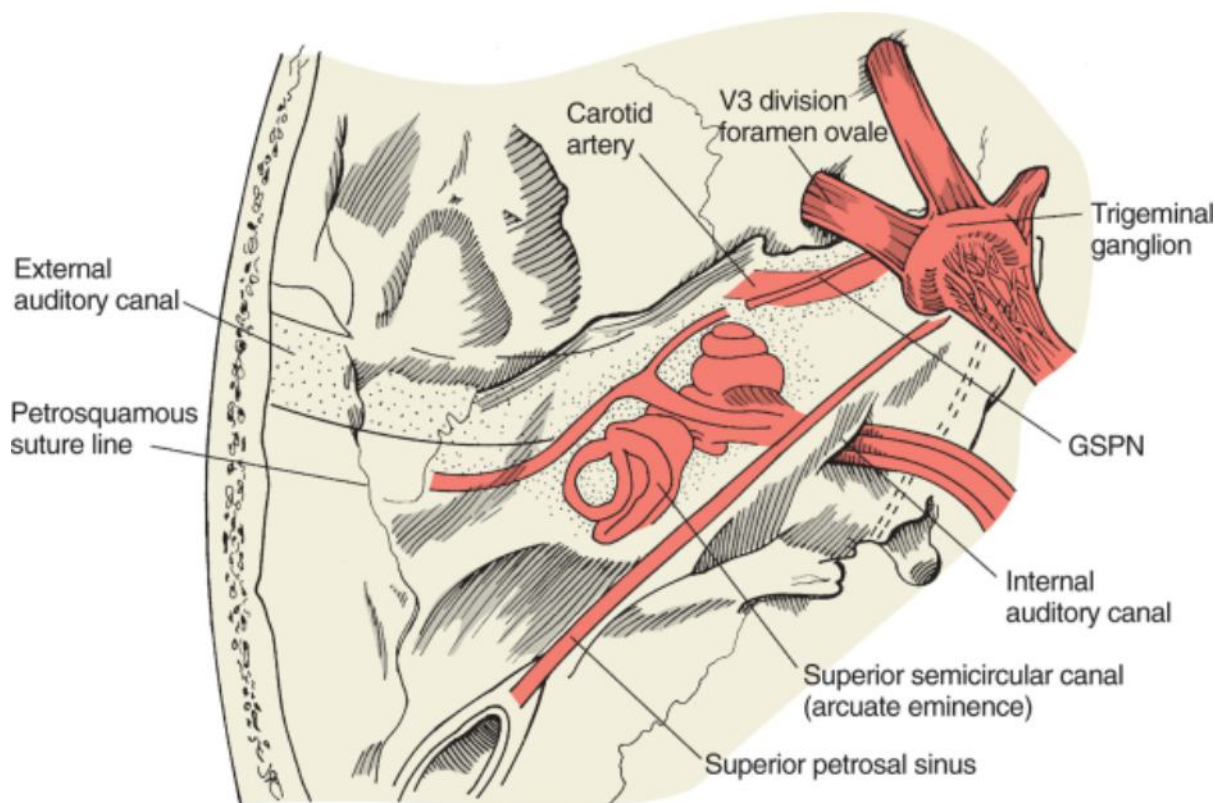


Figure 102-13 Anatomic relationships of the internal auditory canal, labyrinth, carotid artery, facial nerve, and trigeminal nerve. GSPN, greater superficial petrosal nerve.

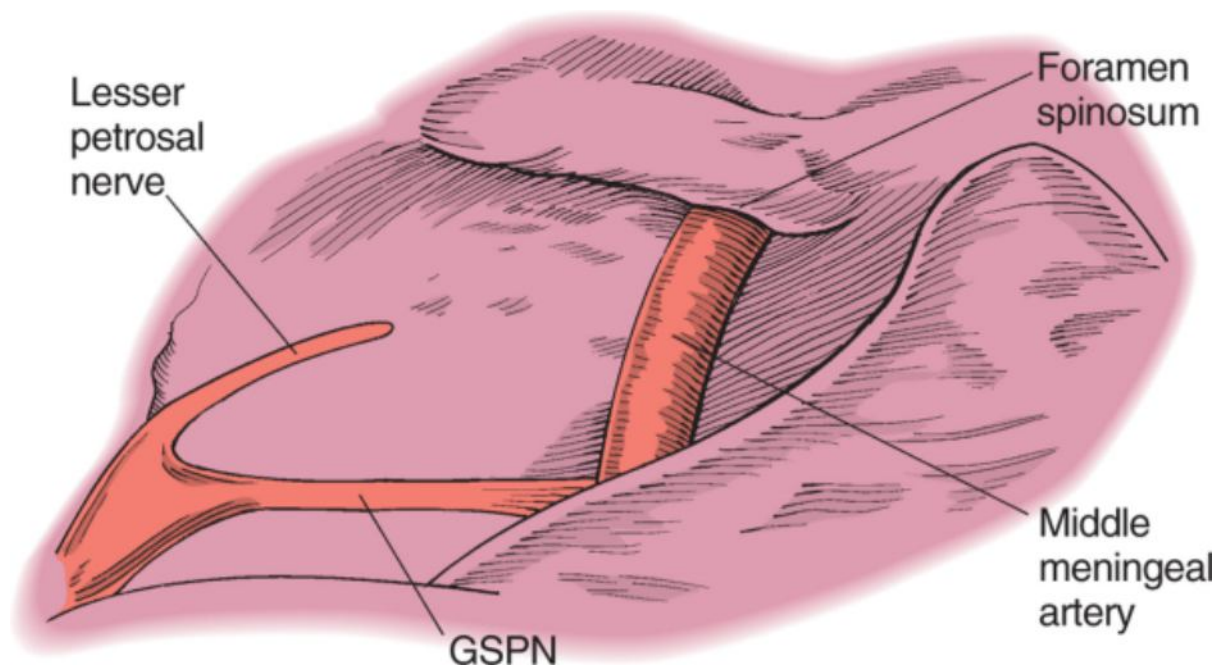


Figure 102-14 Anatomic relationship of the middle meningeal artery to the lesser and greater superficial petrosal nerves. GSPN, greater superficial petrosal nerve.

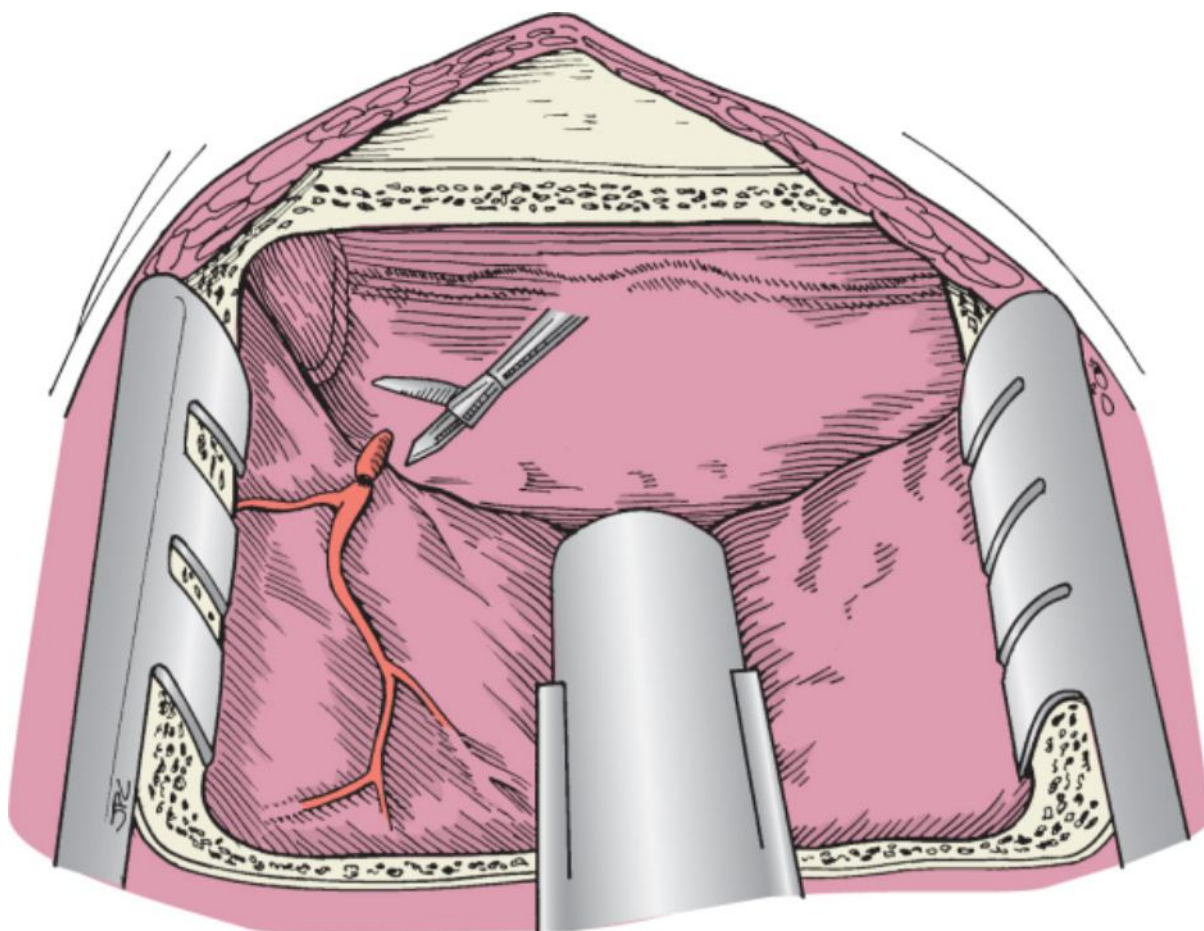


Figure 102-15 The middle meningeal artery is coagulated and divided.

The horizontal segment of the petrous carotid artery lies under the GSPN and runs along an axis approximately 15 degrees medially to the course of the GSPN (Fig. 102-16). A natural bony dehiscence of the carotid canal can often be found immediately posterior to the V3 division of the trigeminal ganglion, and the internal carotid artery may easily be injured in this location. If this natural bony dehiscence is absent, a window of bone over the petrous

carotid artery can be drilled down to eggshell thickness and then carefully elevated off the carotid artery. A blunt elevator is then used to free the carotid artery and its surrounding periosteum from the bony canal. A 2-mm rongeur can be used to complete bone removal around the carotid artery in piecemeal fashion. A 180-degree circumference of the bone of the carotid canal should be removed to provide adequate access for reliable vascular control at the time of tumor removal. Bony dissection can then proceed in a posterolateral direction along the horizontal course of the petrous carotid canal to expose the genu and vertical segments of the carotid artery.

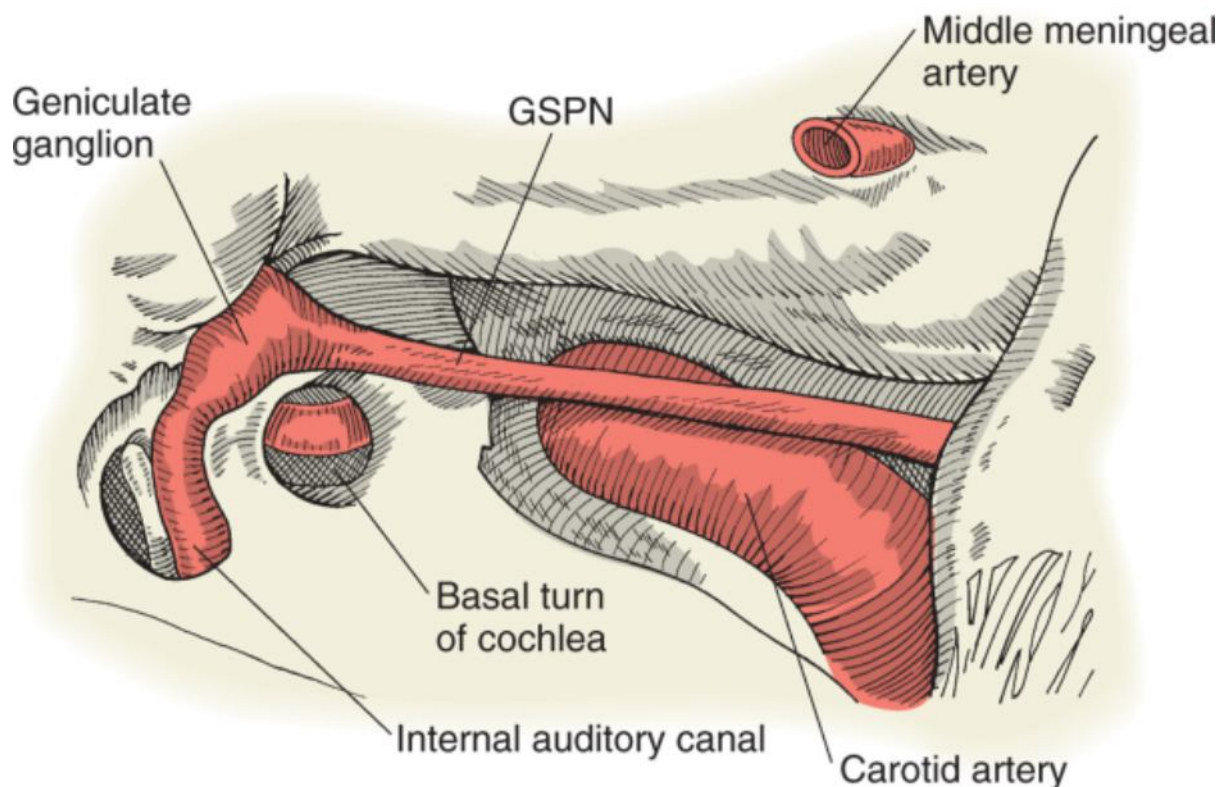


Figure 102-16 Anatomic relationships of the petrous carotid artery. GSPN, greater superficial petrosal nerve.

At the genu of the petrous carotid artery, the eustachian tube and tensor tympani muscle course superolateral to the vertical segment of the carotid artery (Fig. 102-17). When pursuit of a lesion involves exposure of the genu and vertical segment of the petrous carotid artery, the eustachian tube and tensor tympani must be transected, thus compromising middle ear function and increasing the risk for postoperative CSF rhinorrhea. In such cases, the eustachian tube must be clearly identified and oversewn at the conclusion of the procedure.

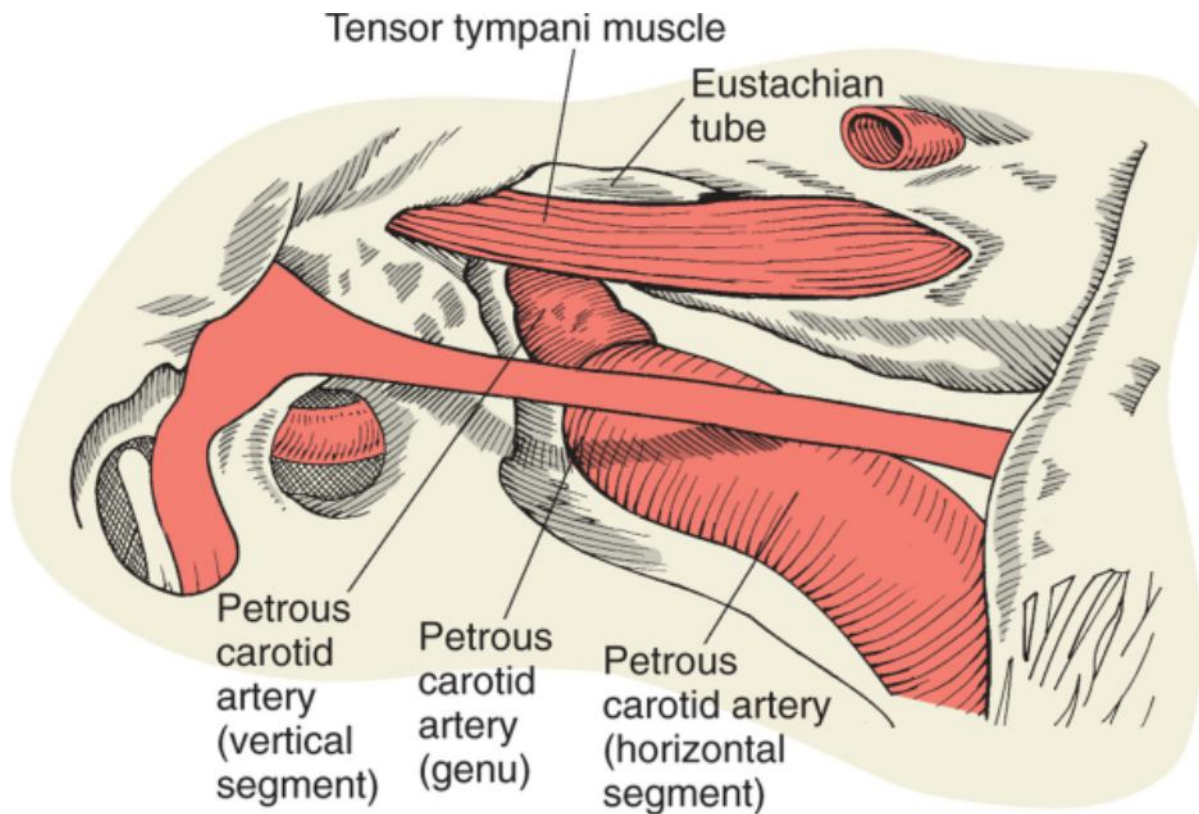


Figure 102-17 Dissection of the carotid artery to the level of the eustachian tube and tensor tympani muscle.

Wound closure is accomplished in layered fashion, beginning with a watertight dural closure. The craniotomy bone plate is replaced and secured with a microplating system. The temporalis muscle is reapproximated and the overlying soft tissues are closed in two layers. A mastoid dressing is then left in place for 72 hours and the patient is observed in the hospital for 4 to 5 days.

Petrosal Apicectomy

The middle fossa approach can be extended to allow further exposure of the petrous apex. This approach may be useful in the management of neoplastic and inflammatory lesions of the petrous apex, including petrous apicitis. The petrous apex is a pyramidal region, also referred to as Kawase's rhomboid, in the anteromedial aspect of the temporal bone with variable degrees of pneumatization. It is bordered superomedially and inferomedially by the superior and inferior petrosal sinuses, respectively^[9]; the trigeminal nerve and ganglion anterosuperiorly; the IAC, cochlea, and geniculate ganglion posteriorly; the GSPN laterally; and the petrous carotid anteriorly and inferolaterally (Fig. 102-18).

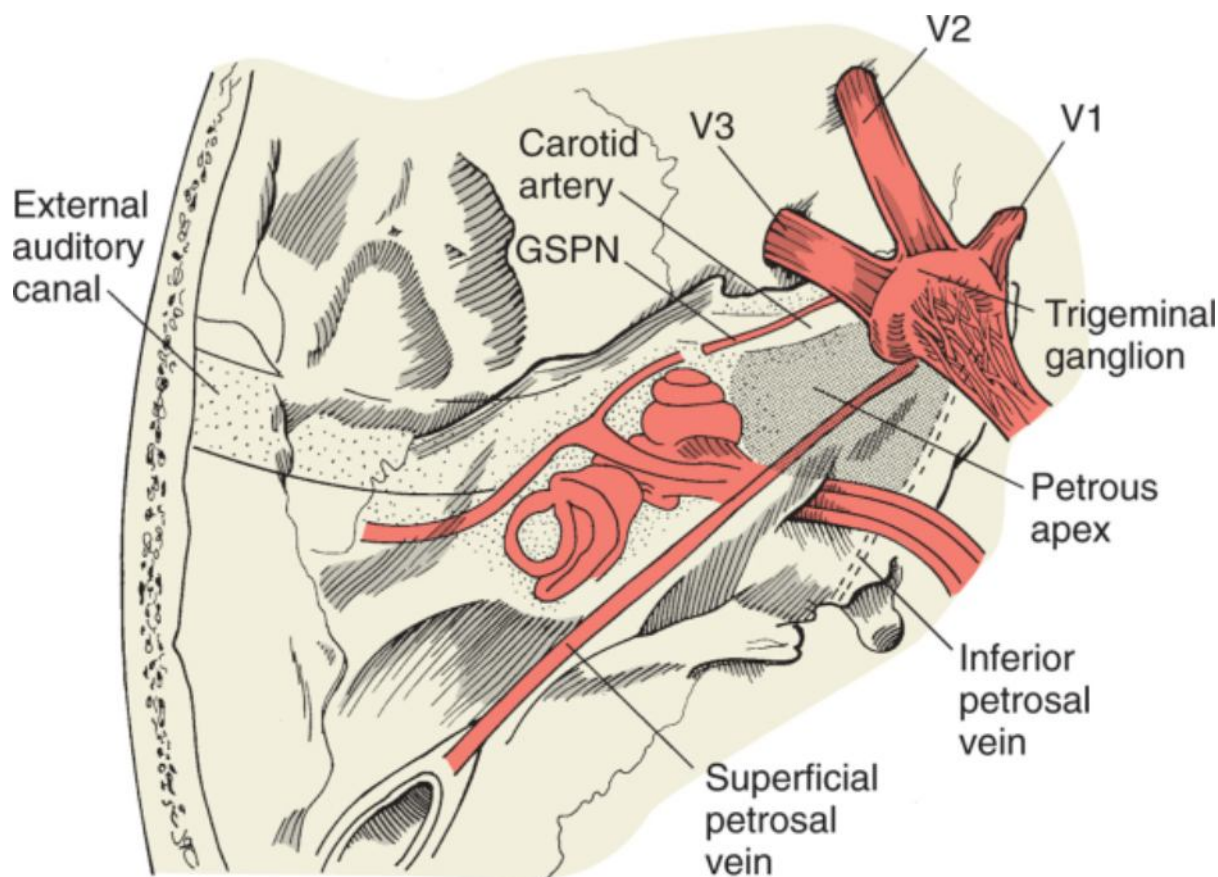


Figure 102-18 Anatomy of the petrous apex. GSPN, greater superficial petrosal nerve.

The key landmarks for the petrous apex are the IAC and the horizontal petrous carotid artery, which define the field of dissection to ensure exposure of the petrous apex and preservation of the cochleovestibular and facial nerves. Several methods have been described to locate the IAC along the floor of the middle cranial fossa. Early approaches describe following the GSPN posteriorly from the facial hiatus to the geniculate ganglion and then along the labyrinthine segment of the facial nerve to the IAC.^[10] This approach places the labyrinthine segment of the facial nerve and the cochlea at risk for injury. A second method proposes using the arcuate eminence (superior semicircular canal) as the major landmark to localize the IAC because the IAC lies along a 60-degree plane from the ampulla of the superior semicircular canal. However, this approach, which involves skeletonizing the superior semicircular canal to view the ampulla, increases the risk of sensorineural hearing loss secondary to violation of the vestibular labyrinth. Our group uses the technique described by Garcia-Ibanez.^[11-14] The IAC is located medially by drilling along the medial border of the petrous temporal bone along a line bisecting the 120-degree angle formed by the arcuate eminence and the GSPN (Fig. 102-19). Bony dissection may be accomplished with a 2- to 3-mm diamond burr until the porus acusticus is identified. Drilling is then continued laterally toward the fundus to unroof the entire length of the IAC. At the fundus, bone resection is limited anteriorly by the basal turn of the cochlea and posteriorly by the ampulla of the superior semicircular canal and the vestibule. The petrous carotid artery is then identified as described earlier.

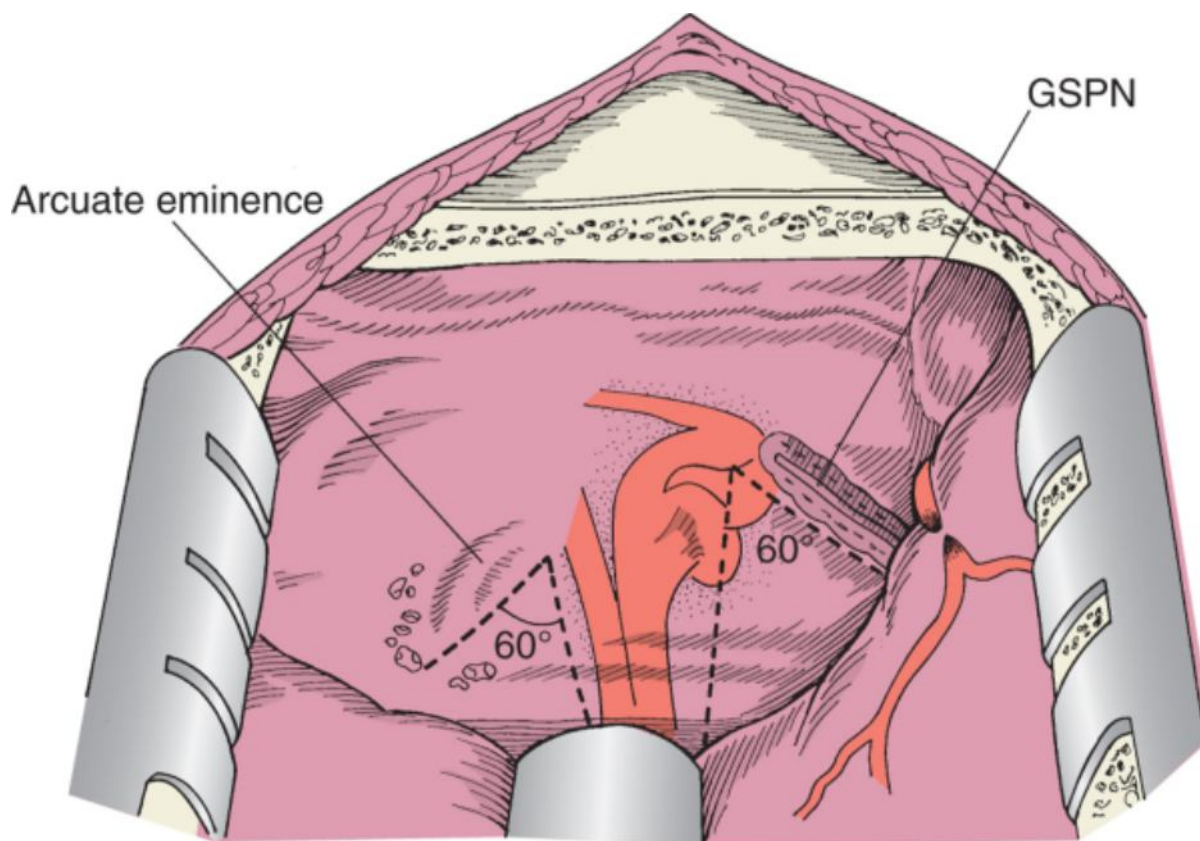


Figure 102-19 Landmarks for the internal auditory canal. GSPN, greater superficial petrosal nerve.

With the IAC and petrous carotid artery skeletonized, the petrous apex can be drilled out to provide exposure of the posterior fossa all the way anterior to the precavernous portion of the ICA and medially to the inferior and superior petrosal sinuses (Fig. 102-20). The final limits of this extended middle fossa exposure are the inferior petrosal sinus inferiorly, the horizontal petrous carotid artery laterally, the gasserian ganglion anteriorly, and the IAC posteriorly. After complete petrous apicectomy, the superior petrosal sinus is ligated to allow opening of the tentorium to the incisura, thereby exposing the contents of the middle and posterior cranial fossae (Fig. 102-21).

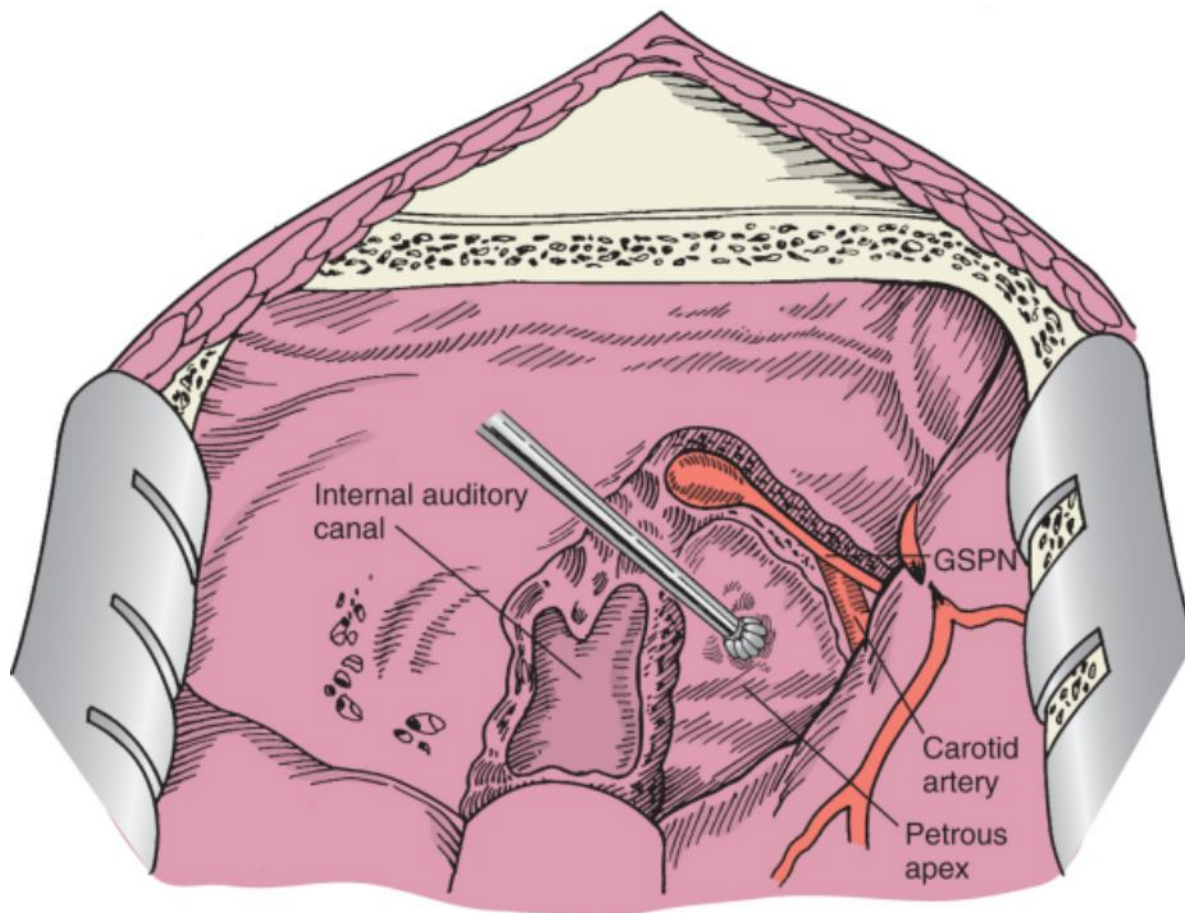


Figure 102-20 Removal of the petrous apex after exposure of the petrous carotid artery and the internal auditory canal. GSPN, greater superficial petrosal nerve.

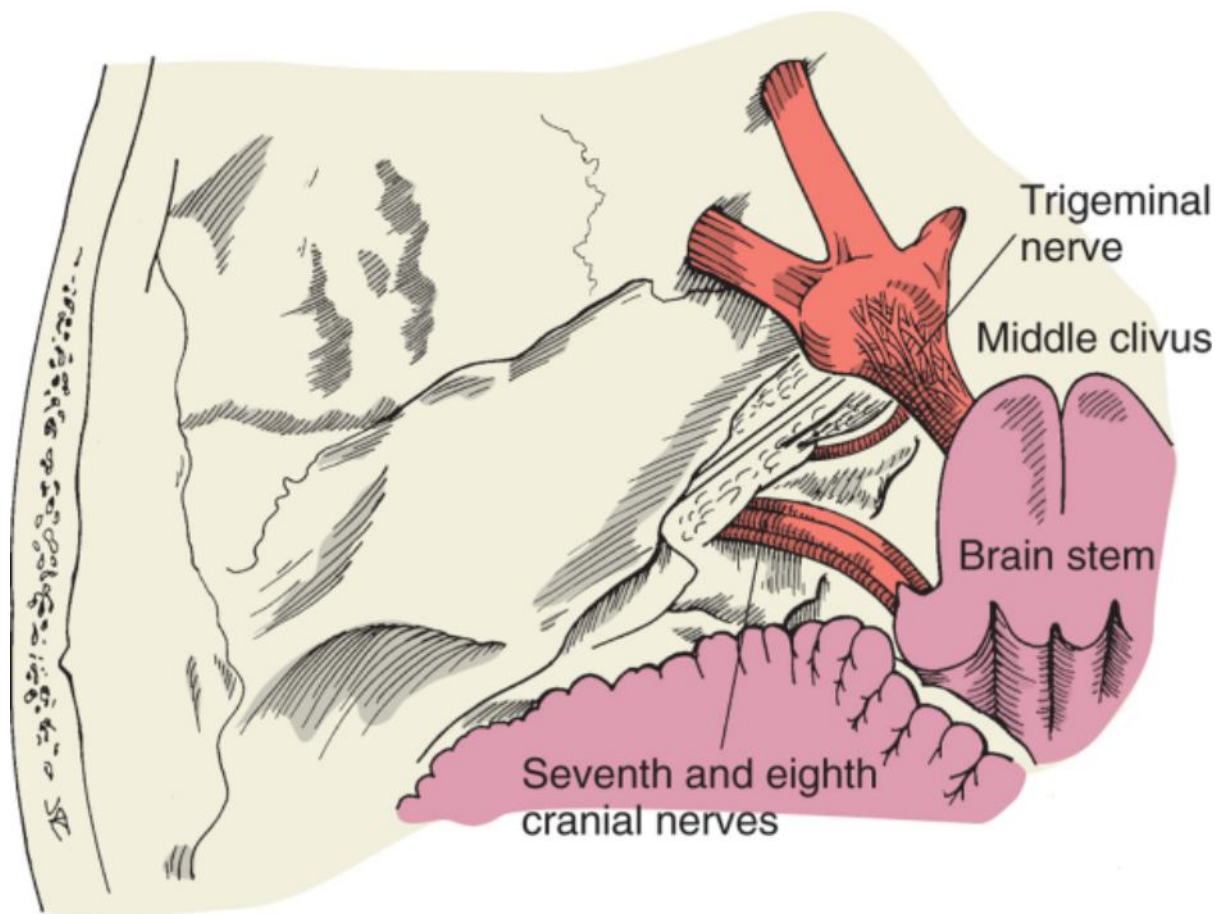


Figure 102-21 Intracranial exposure via a transpetrous apex approach.

Wound closure and postoperative care are as described for the middle fossa approach.

Posterior Petrosal Approaches

Depending on the patient's preoperative hearing status and the need for additional surgical exposure, a retrolabyrinthine, partial labyrinthine, translabyrinthine, transcochlear, or complete petrosectomy approach is chosen. The patient is positioned supine with the head turned to the opposite side and the ipsilateral shoulder raised slightly. Intraoperative facial nerve monitoring is established at the beginning of the procedure. Paralytic agents are not used after induction of general anesthesia. Brain stem auditory evoked responses are also monitored routinely because hearing preservation is desired. Perioperative medications administered include broad-spectrum antibiotics with good CSF penetration (ceftriaxone, 2 g); furosemide (Lasix, 20 mg); mannitol, 0.5 mg/kg; and dexamethasone, 10 mg. Bacitracin (50,000 U/L of saline solution) is used in the irrigation fluid. Lumbar drainage is not routinely performed.

The planned incision is injected with a solution of 1% lidocaine with 1 : 100,000 epinephrine. A large C-shaped postauricular skin incision is made and extended superiorly above the pinna to provide surgical exposure for the temporalis muscle and inferiorly to expose the mastoid tip, as shown in Figure 102-22. This incision may be modified according to the bony exposure required. If hearing is absent, the external auditory canal is transected and oversewn. Anterior and posterior skin flaps are elevated over the temporalis fascia and mastoid periosteum. The frontal branch of the facial nerve is preserved as described earlier. The temporalis muscle is incised along its attachment along linea temporalis. Posteroinferiorly, this incision is extended through the mastoid periosteum to the mastoid tip to develop a large anteroinferiorly based musculoperiosteal flap (Fig. 102-23). Exposure of the lateral surface of the skull is demonstrated in Figure 102-24. Inferiorly, the external auditory canal and glenoid fossa are identified. Anteriorly, the frontal, sphenoid, and temporal bones are exposed at the pterion.

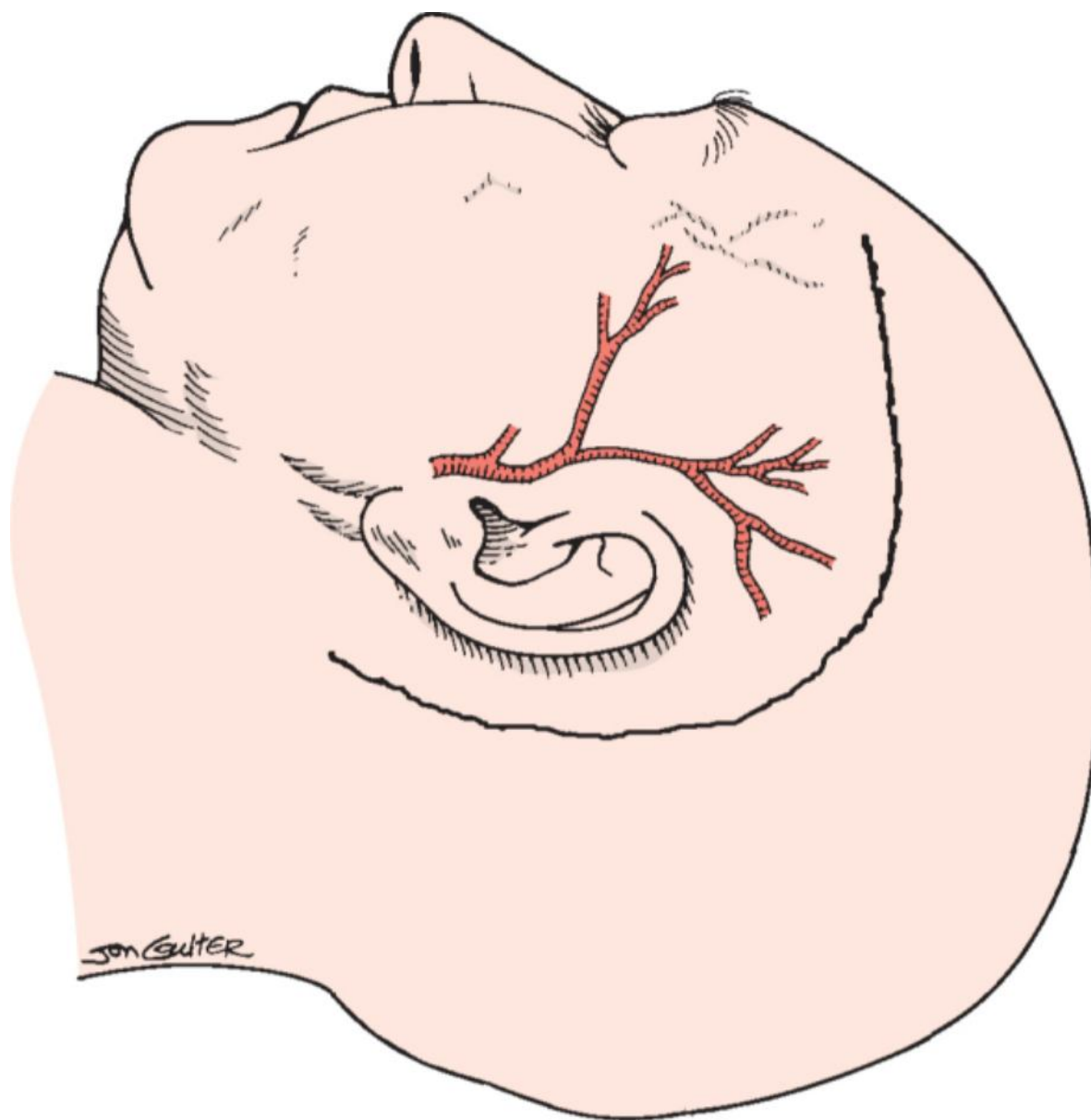


Figure 102-22 Skin incision for a combined anterior and posterior petrosal approach.

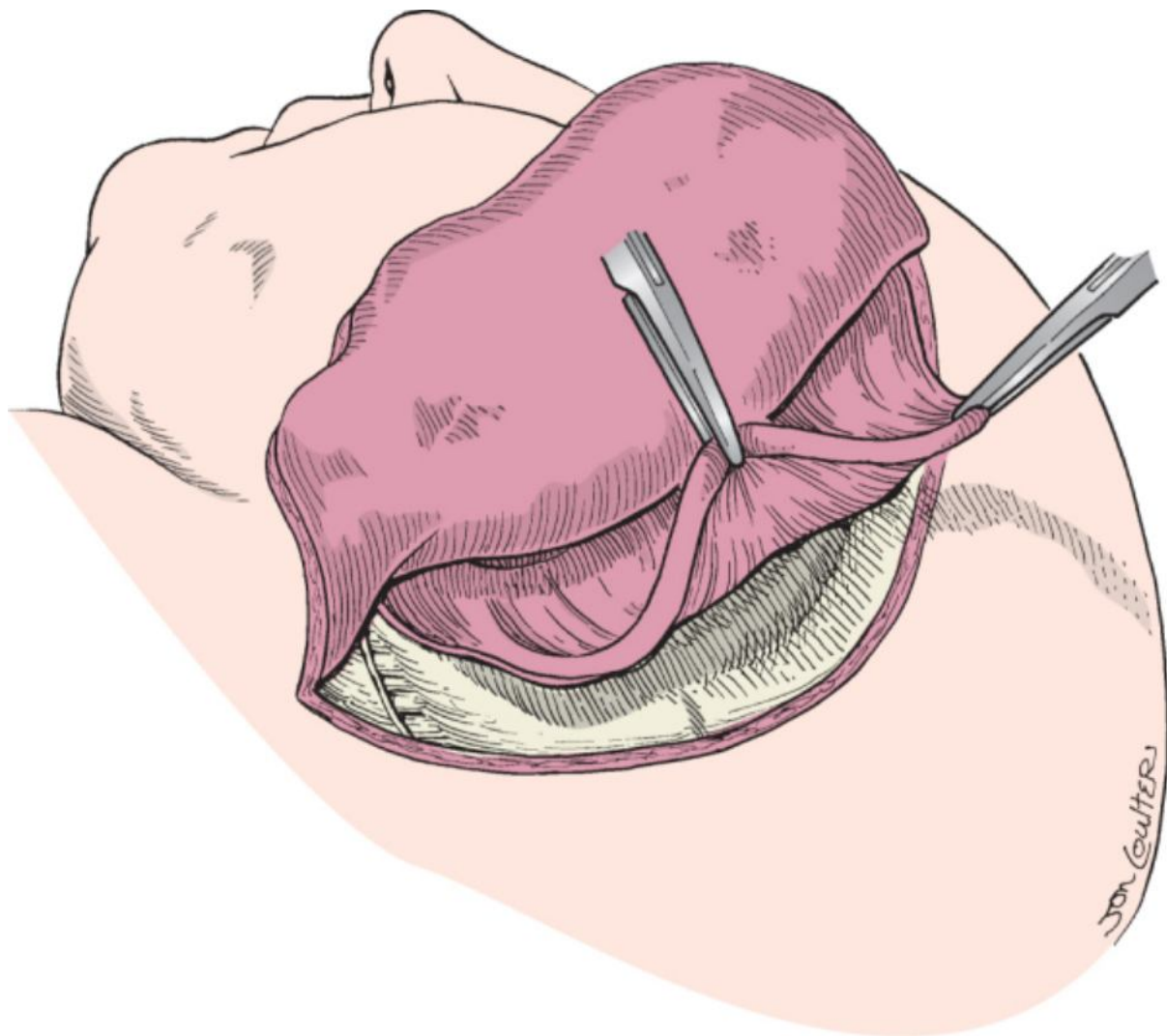


Figure 102-23 Musculo-periosteal flap.

(Redrawn from Cass SP, Sekhar LN, Pomeranz S, et al: Excision of petroclival tumors by a total petrosectomy approach. *Am J Otol* 15:474-484, 1994.)

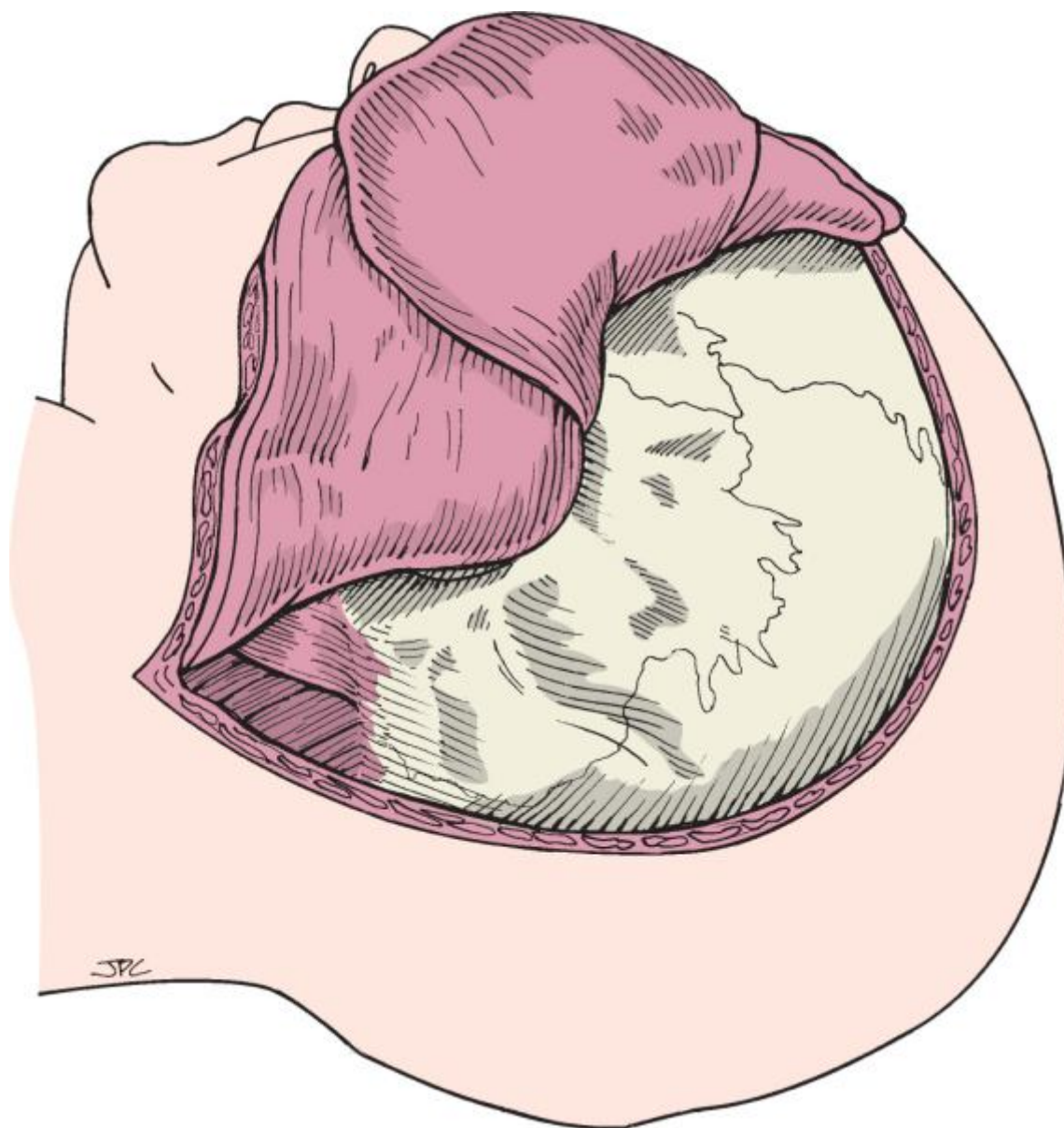


Figure 102-24 Surface anatomy of the exposed cranium.

Osteotomies of the zygoma, a temporal craniotomy, and a mastoidectomy are performed. The size of the temporal craniotomy and the extent of petrosal exposure through the mastoid are determined by the size and location of the tumor. The zygomatic arch and glenoid fossa are removed to improve inferior exposure, and a complete mastoidectomy is performed with variable amounts of additional petrosal bone removal.

We prefer to perform the temporal craniotomy, removal of the zygomatic arch, and mastoidectomy in separate segments (Fig. 102-25). The temporal craniotomy plate and zygomatic arch can then be reattached at closing with a microplating system. It is also possible to perform the bone work in such a manner that the temporal craniotomy and mastoid cortex are removed en bloc with or without the zygomatic arch and glenoid fossa (Fig. 102-26).

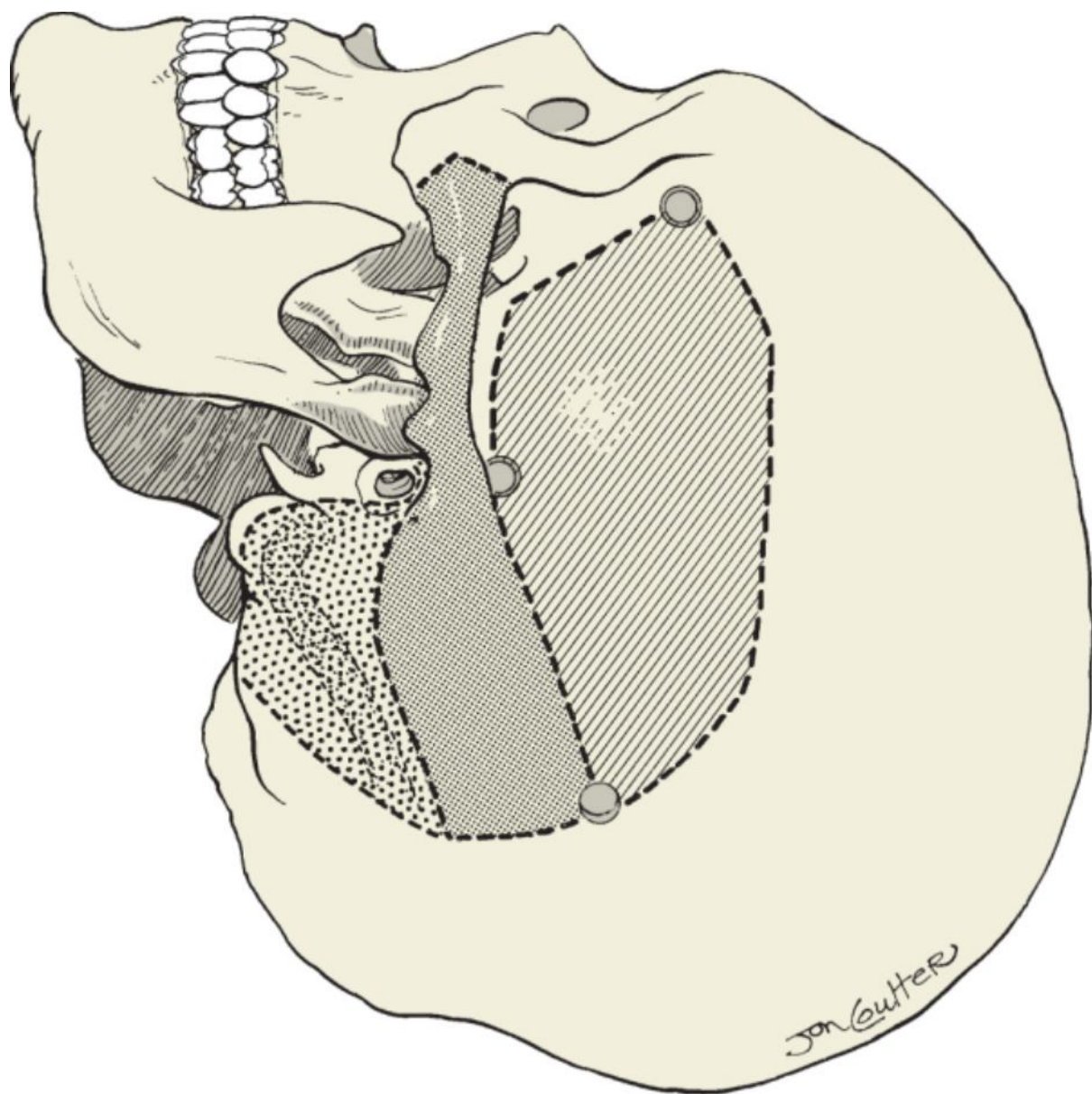


Figure 102-25 Cranial, zygomatic, and mastoid bone work separated into three components.

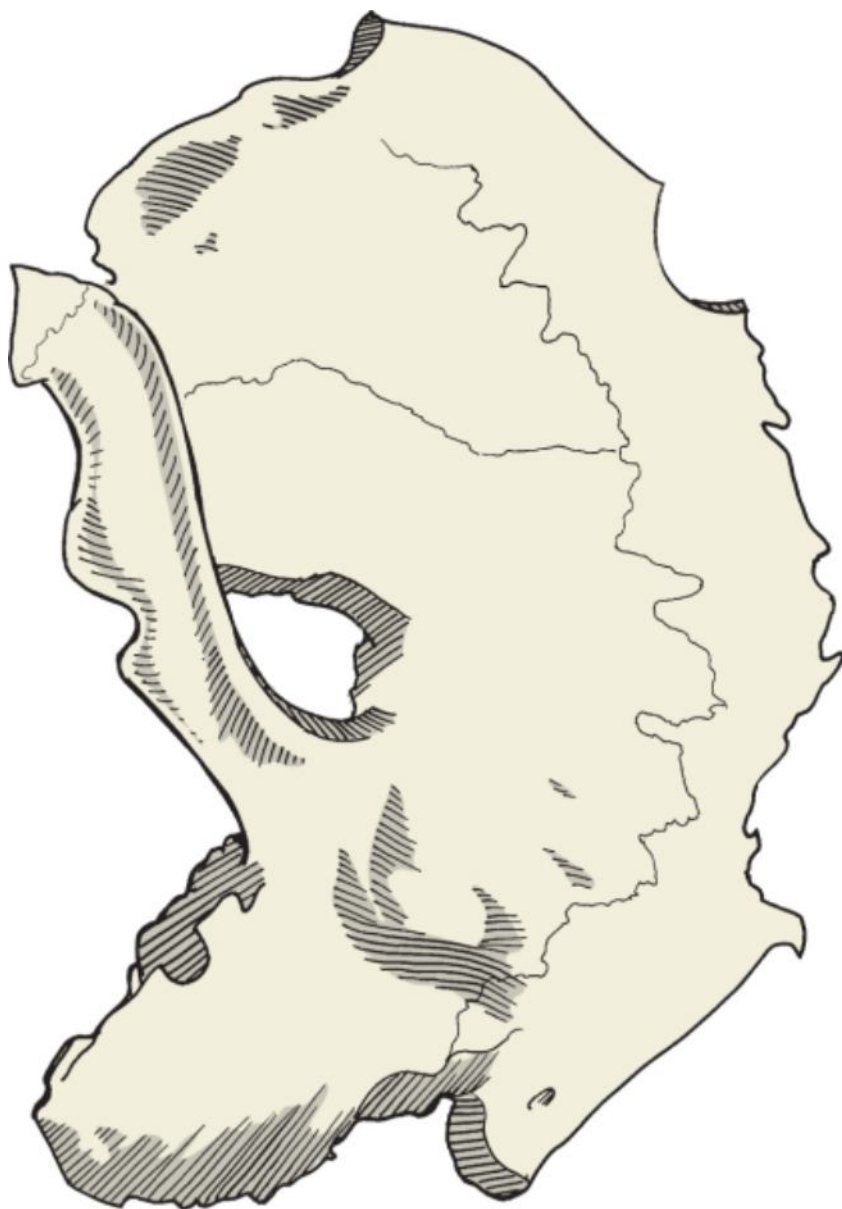


Figure 102-26 Combined temporal craniotomy, osteotomy of the zygoma, and preservation of the mastoid cortex.

To create a bone flap that includes a temporal craniotomy and a large portion of the mastoid cortex, the sigmoid sinus is exposed from the level of the jugular bulb to the confluence of the sigmoid sinus, superior petrosal sinus, and transverse sinus (Fig. 102-27). Approximately 2 cm of bone is removed posteriorly over the transverse sinus. Once the sigmoid and transverse sinuses are exposed, the mastoid cortex is cut with a small cutting burr along the external auditory canal forward into the glenoid fossa. Burr holes are made anteriorly in the temporal fossa, posteriorly above the transverse sinus, and superiorly near the insertion of the temporalis muscle (Fig. 102-28). A footed attachment on a craniotome is used to cut a temporal craniotomy, and the mastoid cortex is freed from the underlying air cells and middle fossa plate with a small cutting burr and chisel.

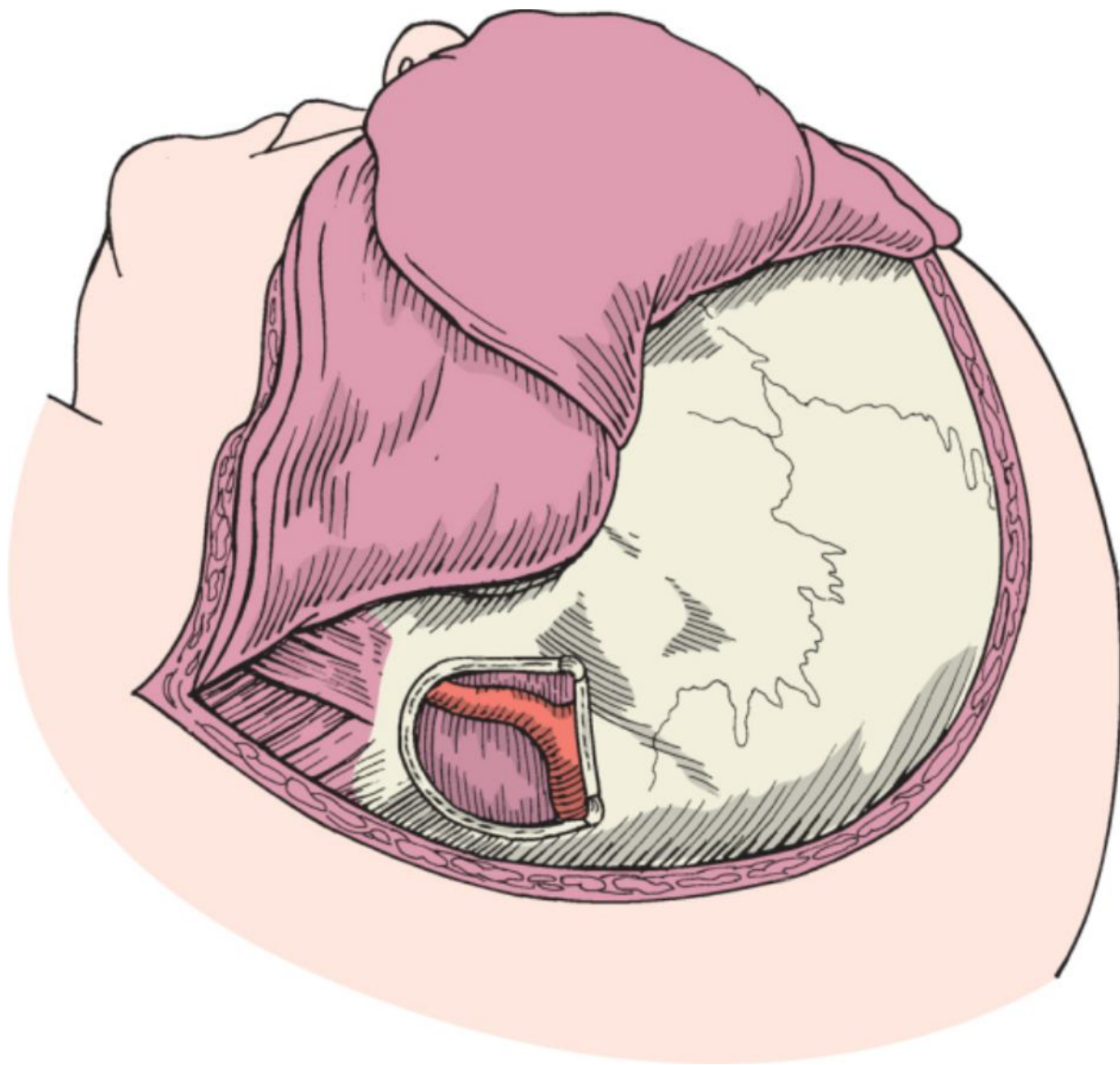


Figure 102-27 Exposure of the sigmoid and transverse sinuses.

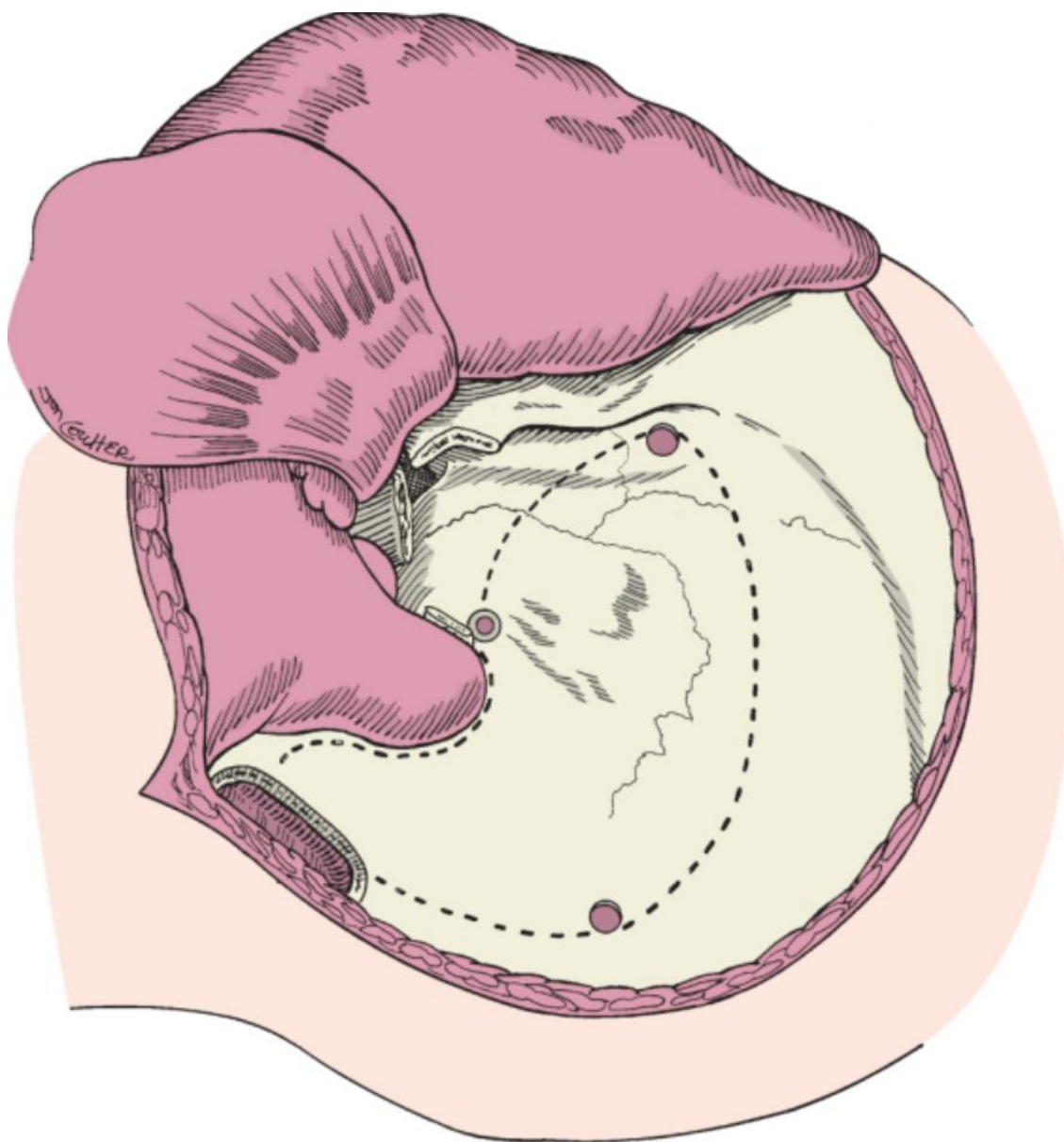


Figure 102-28 Outline of osteotomies within the mastoid and temporal squama.

The zygomatic arch is removed along with the roof of the glenoid fossa by dividing the junction of the zygomatic arch and malar eminence via a chevron-shaped osteotomy with an oscillating saw. The glenoid fossa osteotomies are then performed medial to the glenoid fossa to allow removal of the zygomatic arch along with the roof of the glenoid fossa. Exposure of the middle and posterior fossa dura after completion of the initial bone work is shown in Figure 102-29.

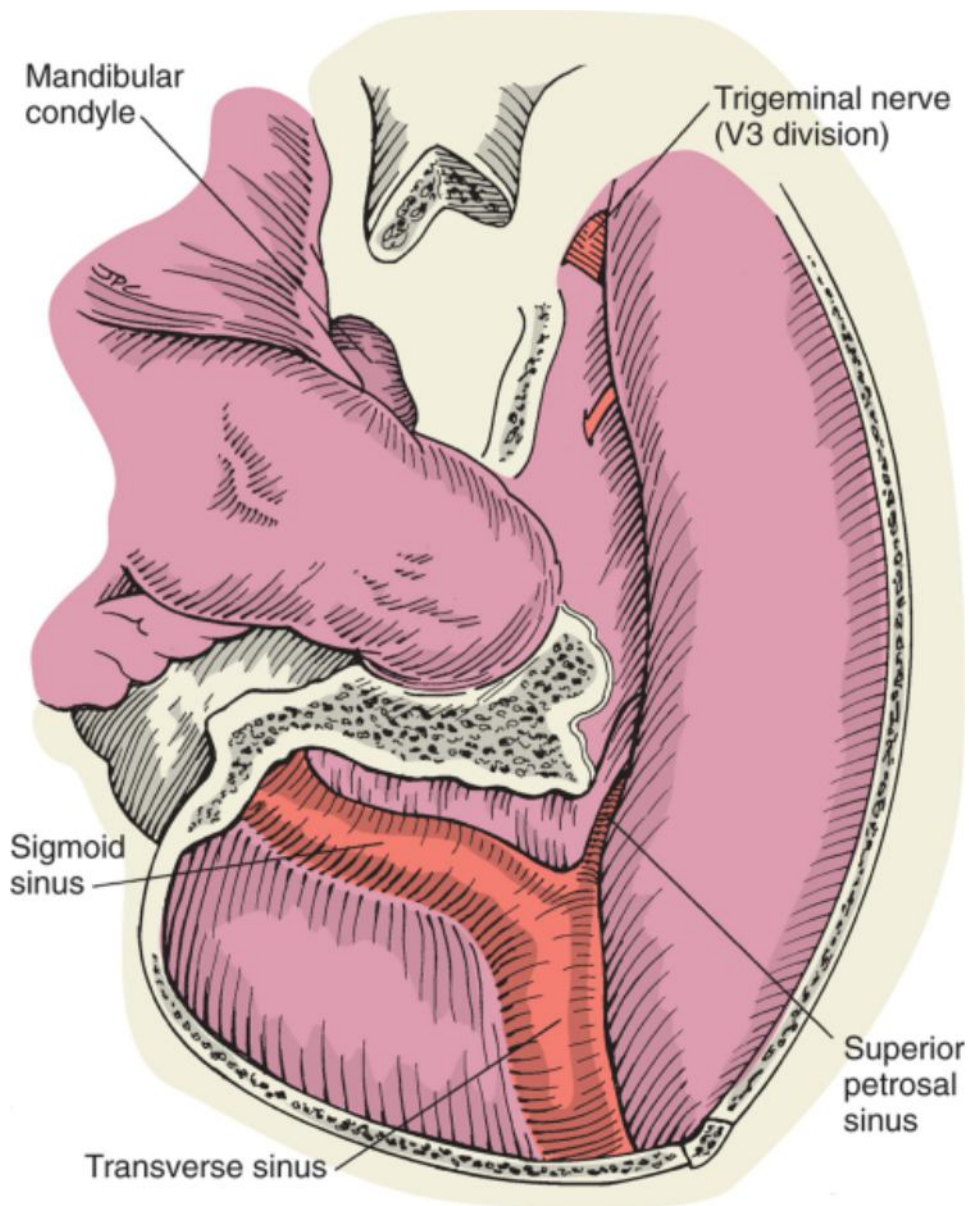


Figure 102-29 Surgical exposure after craniotomy and before transmastoid petrosal bone work.

The dura is opened along the floor of the temporal fossa and in the presigmoid region. Care is taken to locate and protect the vein of Labbé. The superior petrosal sinus is coagulated and ligated. The tentorium is divided parallel to the petrous ridge along the incisura. The fourth cranial nerve should first be isolated and protected. With the posterior temporal lobe elevated superiorly and the sigmoid sinus retracted posteriorly, wide field access to the supratentorial and infratentorial regions of the posterior cranial fossa is obtained.

Retrolabyrinthine Approach

The patient is placed supine with the ipsilateral shoulder elevated and the head turned to the opposite side so that the mastoid process is at the highest point in the field. A complete mastoidectomy is performed with an operating microscope, suction irrigation, and high-speed cutting burr, as described in Chapter 115. Special attention is paid to exposing the sigmoid sinus, jugular bulb, fallopian canal, vestibular labyrinth, superior petrosal sinus, middle fossa dura, and posterior fossa dura (Fig. 102-30). The porus of the IAC is then exposed by further removing bone medial to the superior and posterior semicircular canals. The endolymphatic sac, which lies over the posterior fossa dura between the sigmoid sinus and posterior semicircular canal, is preserved along with the endolymphatic duct. The endolymphatic duct and sac are useful landmarks to help preserve the vestibular labyrinth, but violation of the sac or duct increases the risk for sensorineural hearing loss. The dura over the middle and posterior fossae is then incised to expose the infratentorial portion of the tumor (Fig. 102-31). Once the superior petrosal sinus and tentorium are divided, both the supratentorial and infratentorial portions of the tumor are exposed (Fig. 102-32).

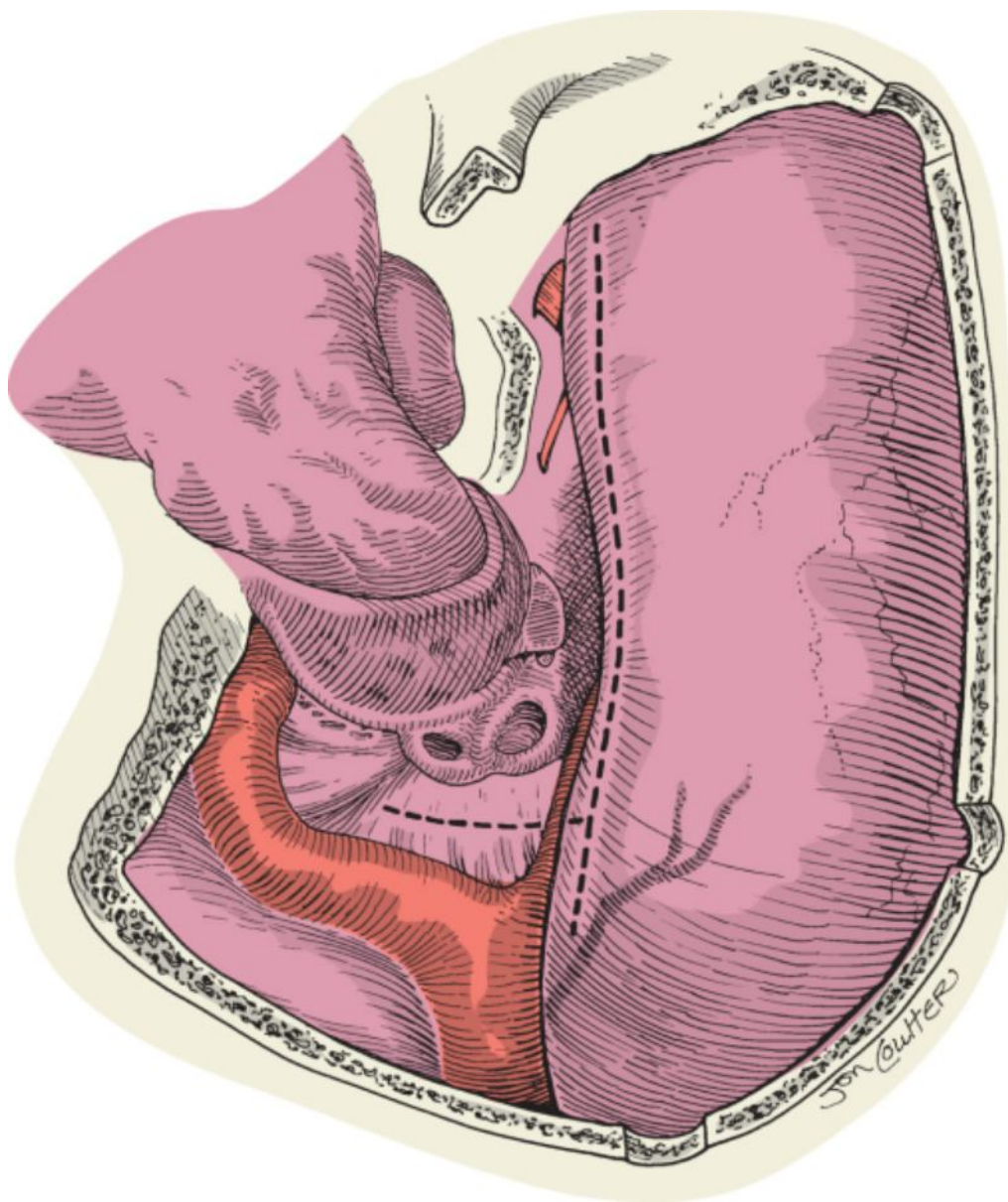


Figure 102-30 Dural exposure after an anterior and retrolabyrinthine petrosal approach and dural incisions.

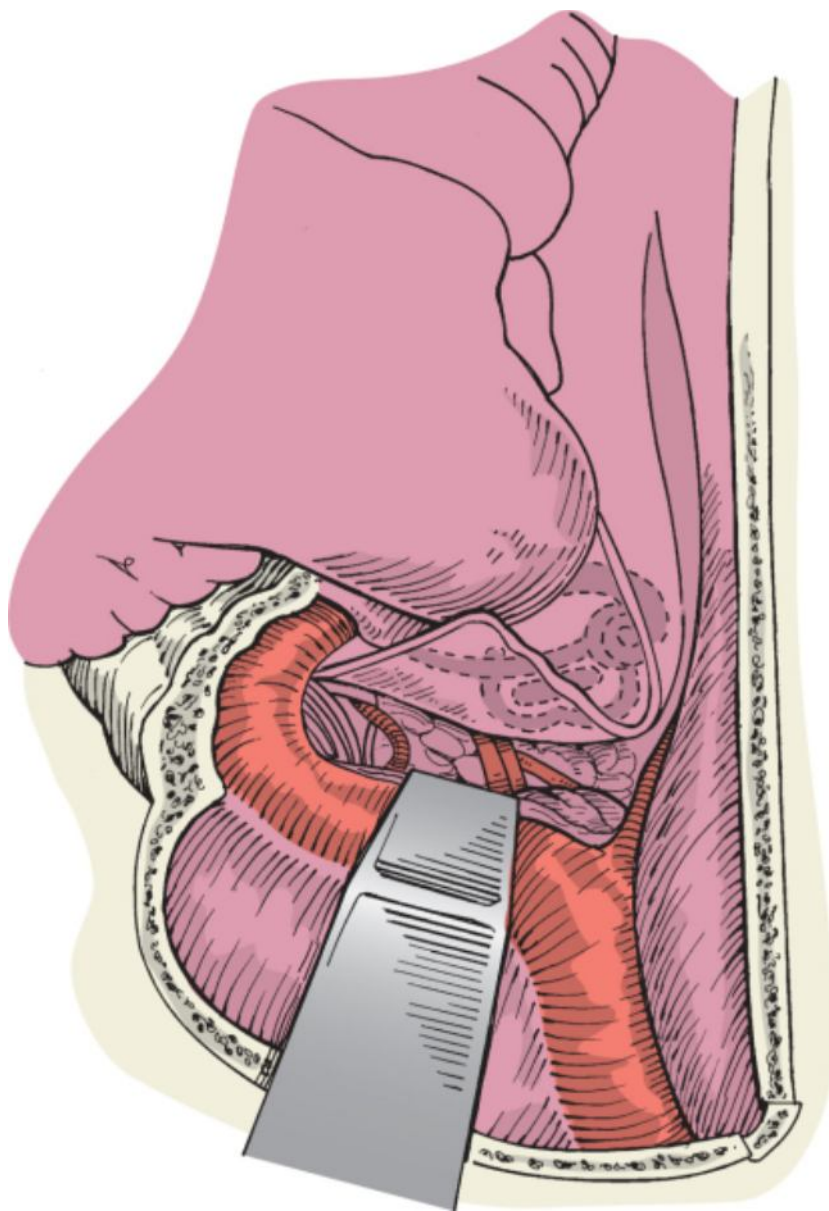


Figure 102-31 The infratentorial portion of the tumor is exposed through the retrolabyrinthine petrosal approach.

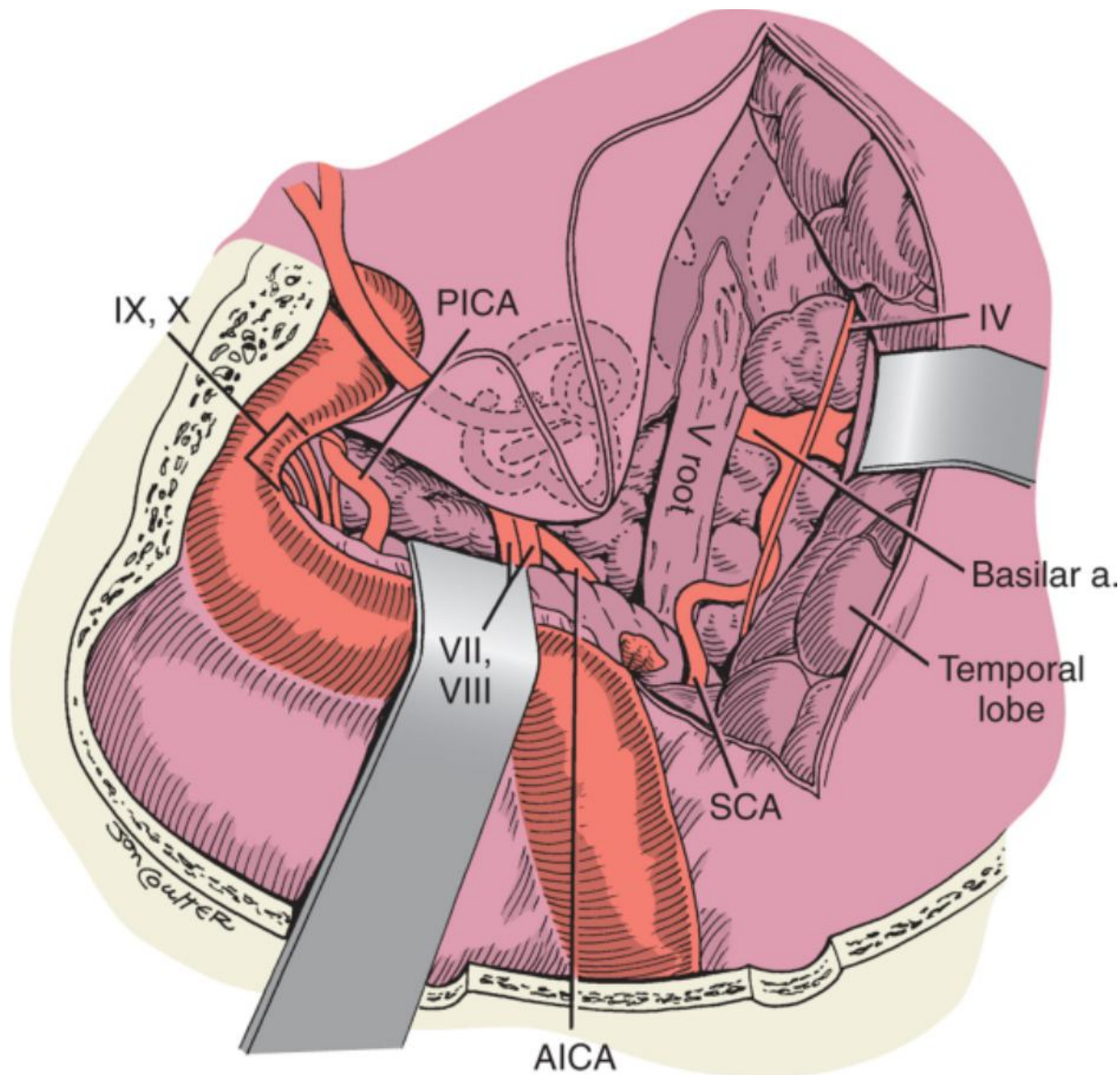


Figure 102-32 Both the supratentorial and the infratentorial portions of the tumor are exposed through the combined anterior and posterior petrosal exposure. AICA, anterior inferior cerebellar artery; PICA, posterior inferior cerebellar artery; SCA, superior cerebellar artery.

This approach alone provides exposure of the cerebellopontine angle but does not offer the surgeon adequate visualization of the anterior brain stem or petroclival region. Adequate exposure of the medial portion of the IAC is possible in most cases, but a high-riding jugular bulb, anteriorly displaced sigmoid sinus, or dominant sigmoid sinus may prevent adequate visualization.

At the completion of the procedure, the dura is reapproximated in watertight fashion. The mastoid cavity is loosely packed with an abdominal fat graft, and the postauricular wound is closed in layers. A firm mastoid dressing is then left over the ear for 72 hours and the patient is observed in the hospital for 4 to 5 days.

Partial Labyrinthectomy Approach

This approach is an extension of the retrolabyrinthine approach. The decision to proceed with a partial labyrinthectomy approach is often an intraoperative decision made when the anatomy of the temporal bone is limited by variations that result in a small presigmoid dural window, such as a high-riding jugular bulb, unfavorable sigmoid sinus location, or contracted mastoid. Partial removal of the posterior and superior semicircular canals will provide additional access to the lateral portion of the IAC, cerebellopontine angle, and petrous apex. After completion of a retrolabyrinthine approach as described earlier, the posterior and superior semicircular canals are carefully skeletonized. The ampullated and nonampullated ends of the posterior and superior semicircular canals are then isolated from the vestibule to allow safe removal of the intervening segments of the semicircular canals.

The technique for fenestration of the semicircular canals is similar to that described for occlusion of the posterior semicircular canal in Chapter 131. A small diamond burr is used to create a small bony window at the common

crus and ampullated ends of both canals (Fig. 102-33). The membranous canal must be preserved to maintain hearing. The membranous canal is then compressed by packing a mixture of bone wax and bone dust into the bony labyrinth (Fig. 102-34). After adequate packing of the semicircular canals in these four locations, the isolated segments of the superior and posterior semicircular canals can be safely drilled away to expose the jugular bulb region, posterior fossa, and IAC (Fig. 102-35). Further anterior and medial dissection of bone above the IAC will lead to the petrous apex. After tumor removal, wound closure and postoperative care are as described for the retrolabyrinthine approach.

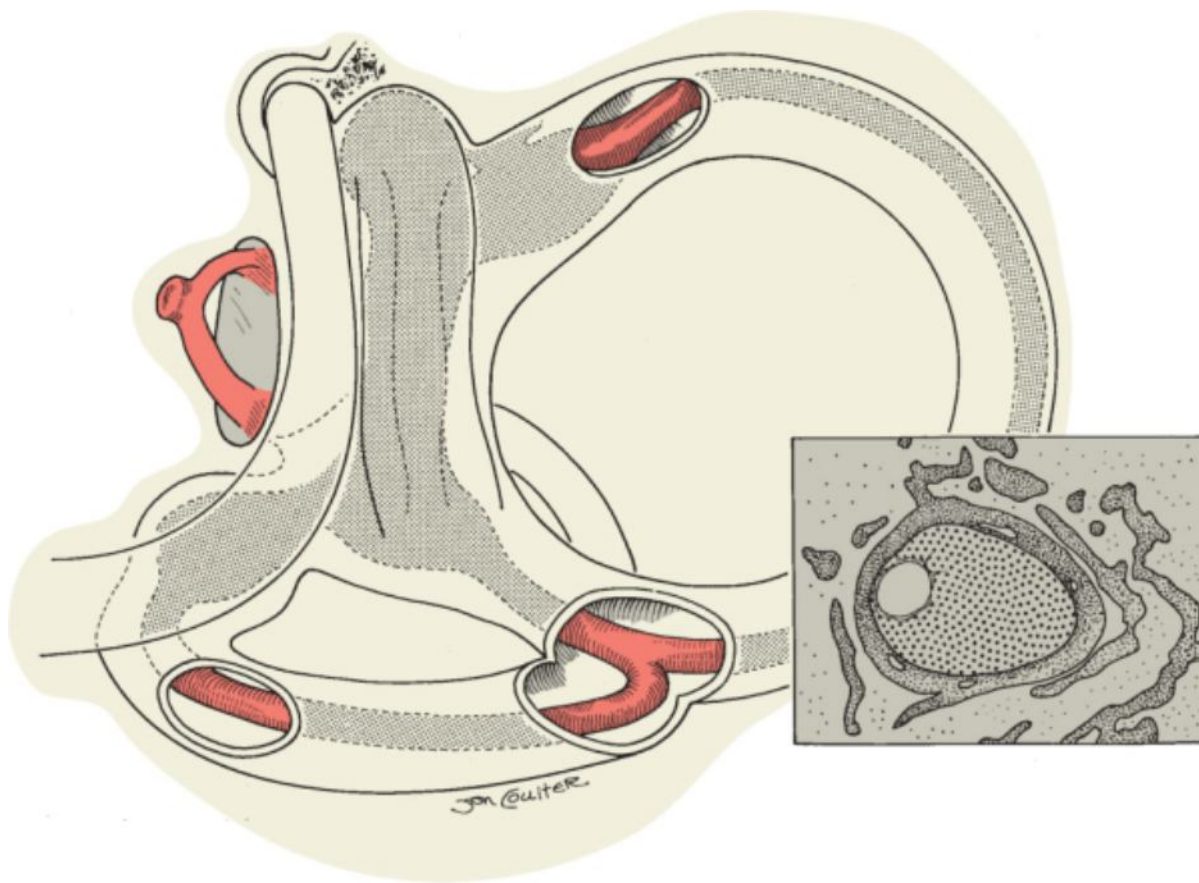


Figure 102-33 Location of the semicircular canal fenestra for partial labyrinthectomy. The *inset* shows the eccentric location of the membranous canal within the bony semicircular canal.

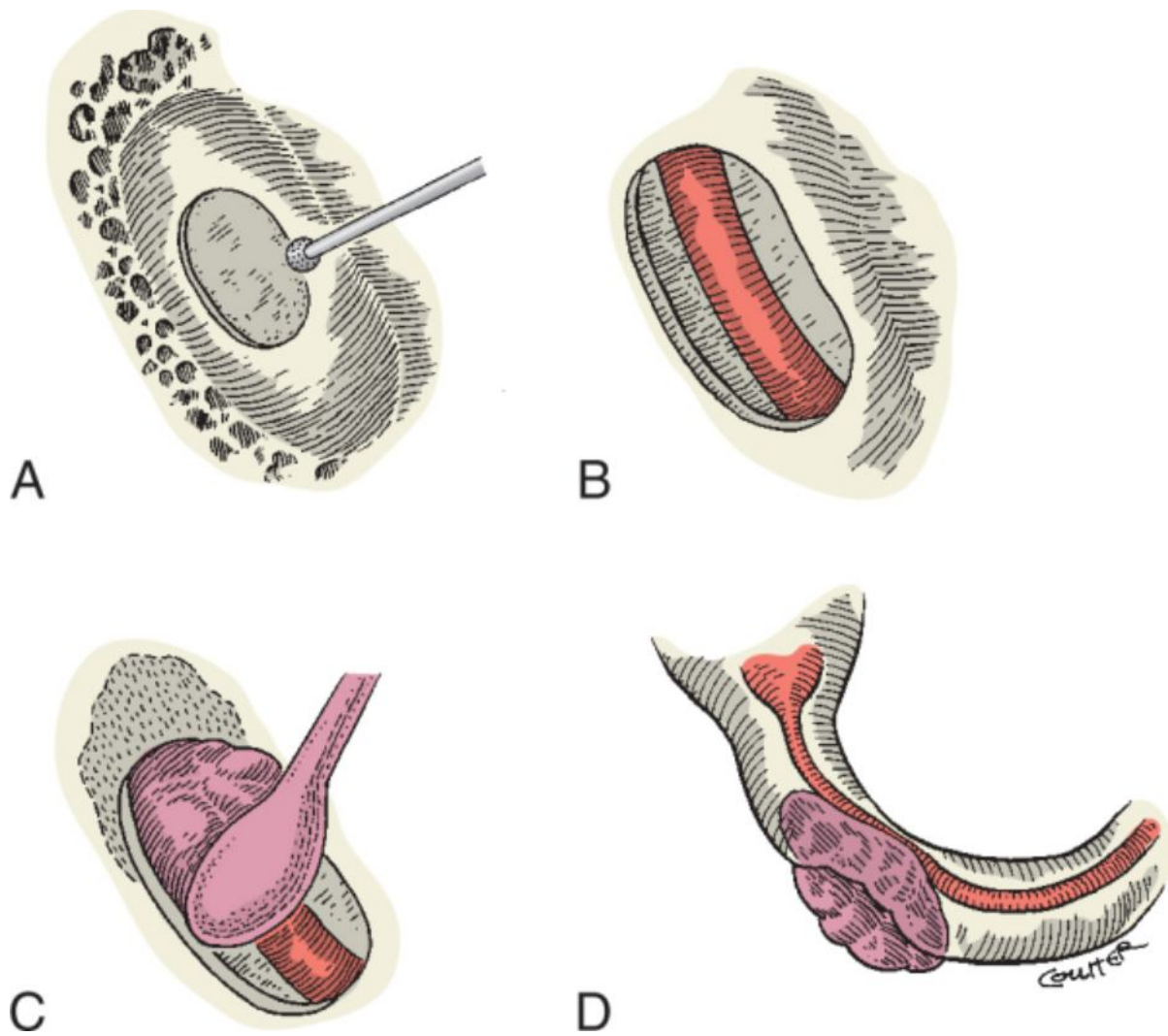


Figure 102-34 Technique for semicircular canal occlusion. **A**, Skeletonization of the semicircular canal with a small diamond burr. **B**, Semicircular canal fenestrated without violating the membranous labyrinth. **C**, Bone wax, bone paste, or soft tissue is applied to the fenestrated portion of the semicircular canal with a duckbill elevator. **D**, The membranous labyrinth is compressed and occluded.

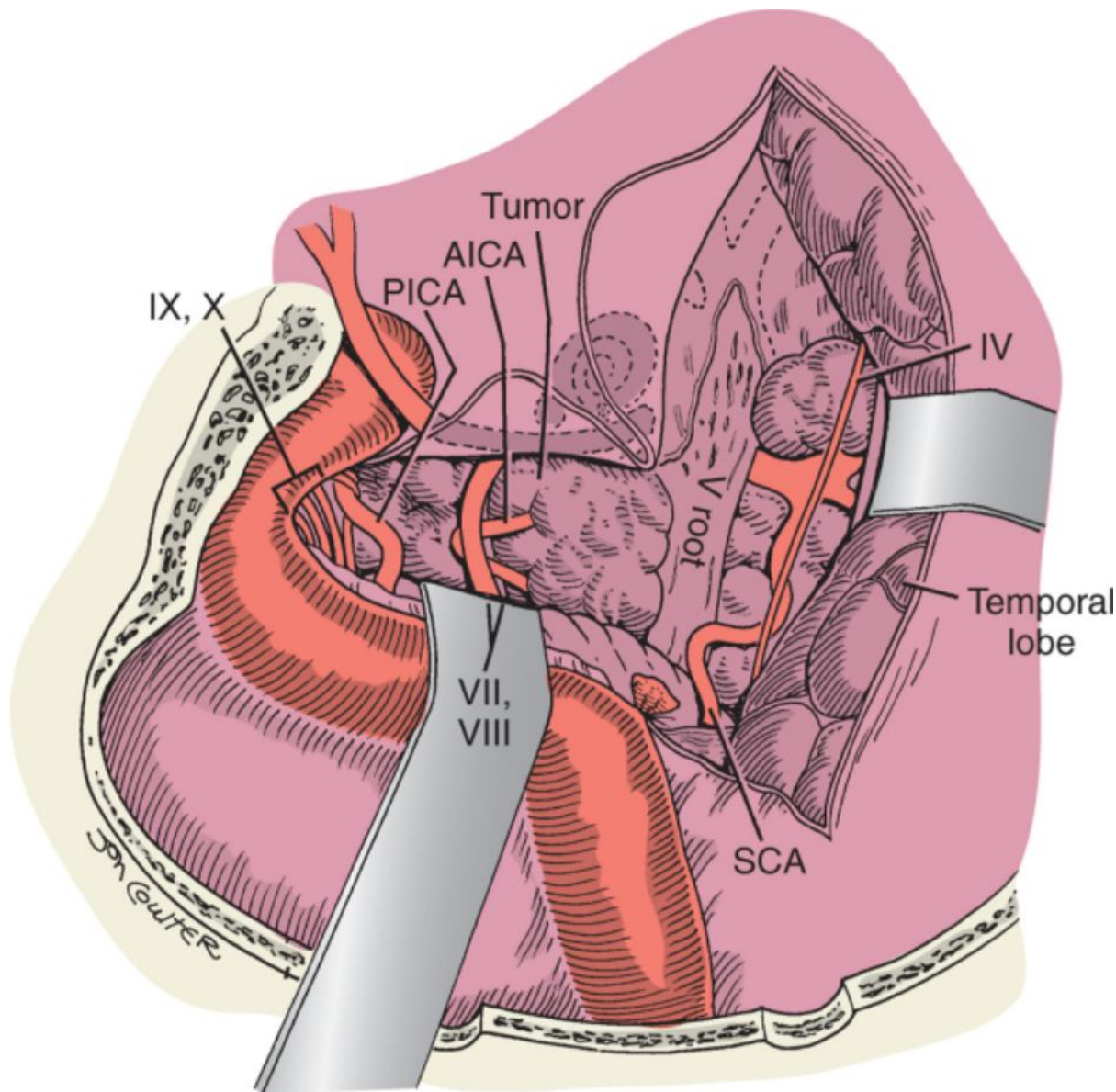


Figure 102-35 Exposure of tumor via a combined partial labyrinthectomy and posterior petrosal approach. AICA, anterior inferior cerebellar artery; PICA, posterior inferior cerebellar artery; SCA, superior cerebellar artery.

Translabyrinthine Approach

When hearing is absent and greater petrosal exposure is required, a translabyrinthine approach can be combined with an anterior petrosal approach. This approach is described in detail in Chapter 124.

Transcochlear Approach and Total Petrosectomy

The transcochlear approach is an anterior extension of the translabyrinthine approach that is used to gain additional exposure to the petrous apex and petroclival region. This approach requires posterior transposition of the facial nerve from the meatal segment to the stylomastoid foramen. The facial nerve remains in the posterior aspect of the surgical field as tumor dissection proceeds anteriorly and medially over the clival region.

In addition to the exposure provided by the translabyrinthine approach, the external auditory canal is transected at the bony-cartilaginous canal and oversewn in two layers to achieve a watertight seal. The facial recess is opened and the facial nerve is skeletonized along the tympanic and mastoid segments, down to the stylomastoid foramen. The incus is removed through the mastoid antrum. The skin of the ear canal is then removed in continuity with the tympanic membrane and malleus, and the canal wall is lowered to the level of the facial nerve in the mastoid segment. Both the chorda tympani and GSPN are sectioned at their origins from the facial nerve to allow posterior transposition of the facial nerve out of the fallopian canal.

Next, the cochlea is drilled out and bone between the basal turn of the cochlea and the horizontal segment of the petrous ICA is removed, including the carotid ridge, to completely expose the jugular bulb and pars nervosa.

Cranial nerves IX, X, and XI will be within the field of dissection as they exit the jugular foramen and are at risk for injury.

To access lesions of the clivus, anteromedial brain stem, infratemporal fossa, and posterior nasopharynx, this approach is combined with a middle fossa approach. The surgical steps are modified accordingly. After transecting and oversewing the external auditory canal, the subtemporal sphenoid bone is removed up to the foramen ovale with a rongeur to completely expose the mandibular nerve (V3) (Fig. 102-36). The petrous carotid is completely unroofed from the precavernous segment to the upper cervical segment while leaving the artery sheathed in periosteum (Fig. 102-37). As mentioned earlier, the middle meningeal artery and GSPN are transected, and the cartilaginous eustachian tube is cauterized, packed with fat, and sutured closed. At this point the cochlea and medial petrous bone are removed through the posterior approach to expose the jugular bulb deep to the facial nerve, including the pars nervosa. Skeletonization of the facial nerve is then completed anteriorly via the middle fossa approach. The facial nerve is completely decompressed and mobilized posteriorly and inferiorly to provide wide surgical exposure for tumor removal. When the facial nerve is mobilized in this manner, the proximal and distal bloodsupply to the nerve from the intracranial vessels and stylomastoid artery, respectively, is preserved.

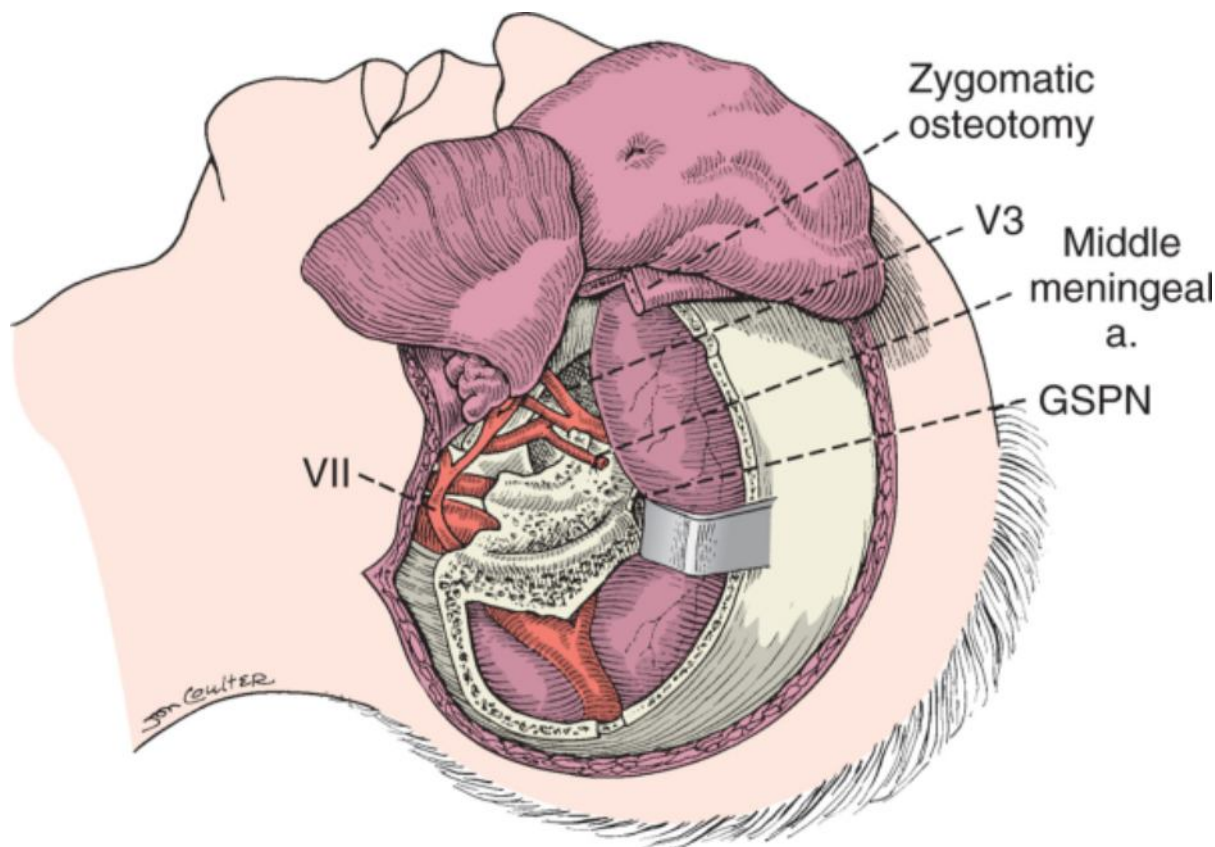


Figure 102-36 Total petrosectomy: radical mastoidectomy with removal of the subtemporal bone to expose V3. The middle meningeal artery is divided. GSPN, greater superficial petrosal nerve.

(Redrawn from Cass SP, Sekhar LN, Pomeranz S, et al: *Excision of petroclival tumors by a total petrosectomy approach. Am J Otol* 15:474-484, 1994.)

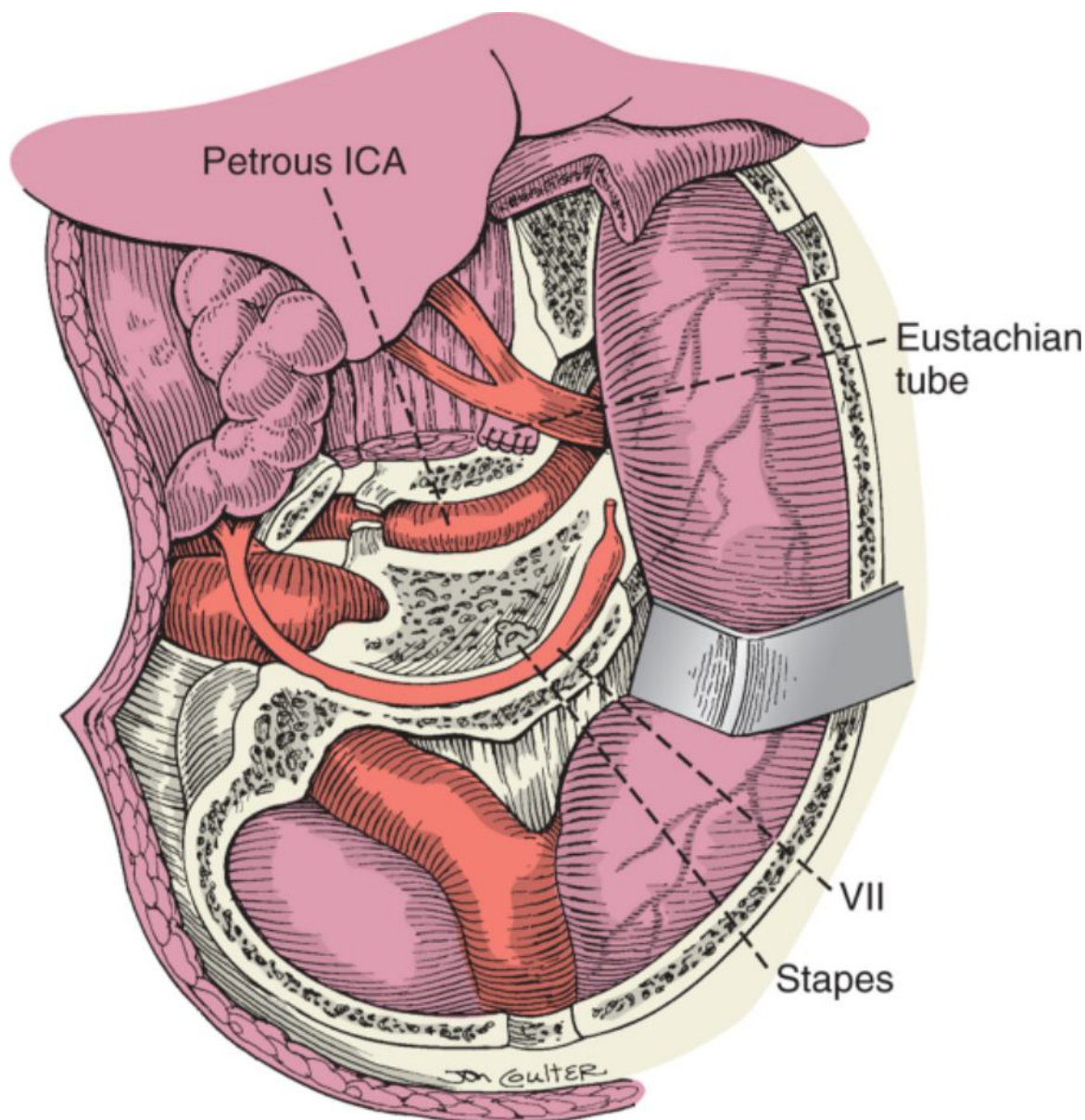


Figure 102-37 Total petrosectomy: exposure of the petrous internal carotid artery (ICA).

(Redrawn from Cass SP, Sekhar LN, Pomeranz S, et al: *Excision of petroclival tumors by a total petrosectomy approach. Am J Otol* 15:474-484, 1994.)

Once the inferior fibrocartilaginous ring surrounding the upper cervical carotid artery is divided, the carotid artery can be mobilized forward without tension and held in place with a suture along the periosteum of the carotid canal. The medial petrous apex clival bone can then be removed to the midline to provide wide exposure with direct views of the midclivus, anterior brain stem, and basilar artery (Fig. 102-38).

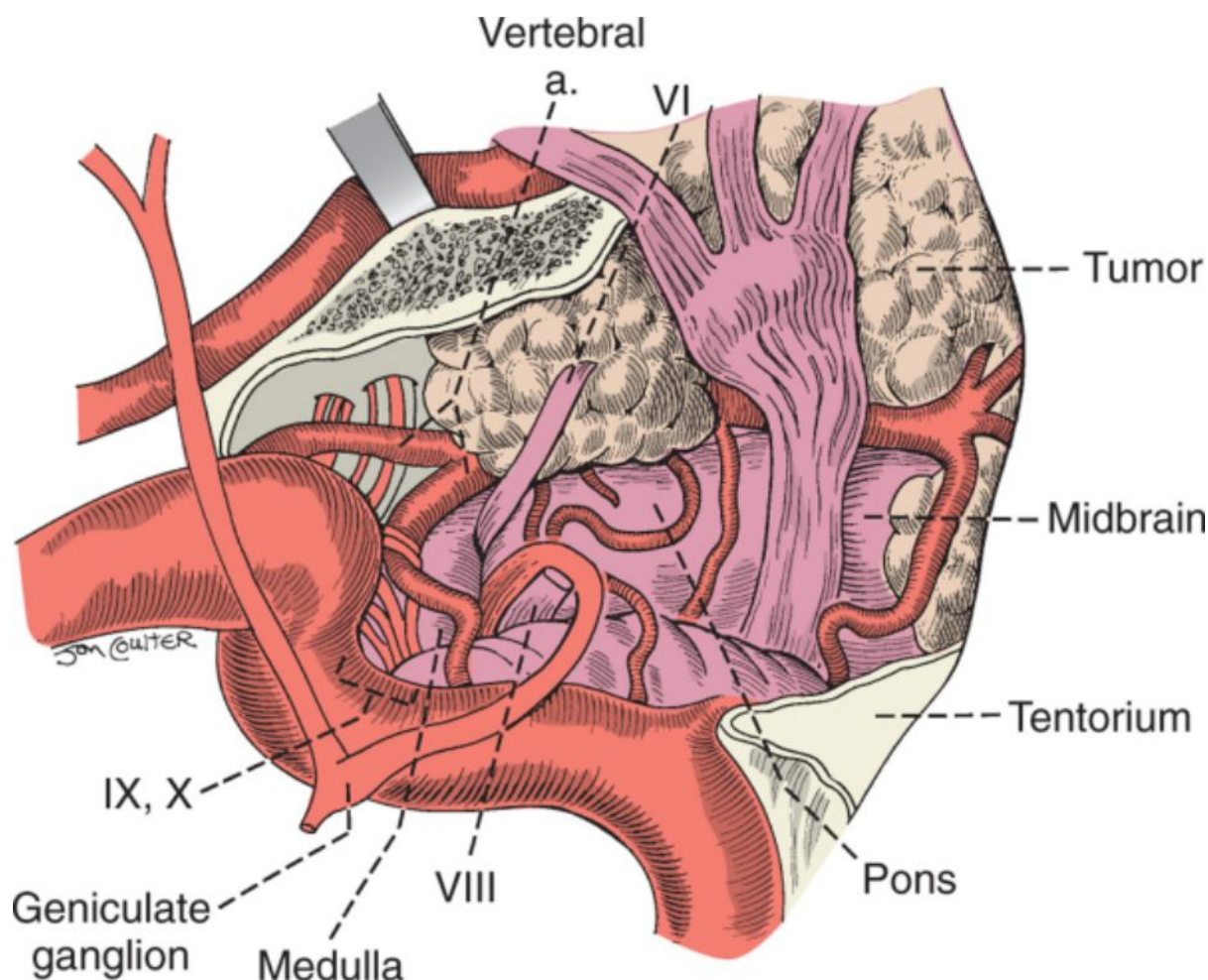


Figure 102-38 Total petrosectomy: exposure of the clivus and tumor after mobilization of the facial nerve and carotid artery. ICA, internal carotid artery; JB, jugular bulb.

(Redrawn from Cass SP, Sekhar LN, Pomeranz S, et al: Excision of petroclival tumors by a total petrosectomy approach. *Am J Otol* 15:474-484, 1994.)

A rarely used variant of the transcochlear approach is the transotic approach, in which the facial nerve is not transposed and tumor resection is performed in front of and behind the facial nerve within the fallopian canal.

Wound closure for the posterior petrosal approaches involves meticulous inspection and obliteration of potential CSF fistulas. Bone wax is used to seal off any remaining air cells within the temporal bone. The middle ear and mastoid cavity are packed with autologous muscle or fat grafts. The wound is closed in layers, including repositioning of the temporalis flap to its superior cuff and application of a pressure dressing and a subgaleal drain. In addition, when the facial nerve is fully exposed, as in a transcochlear or total petrosectomy approach, covering the nerve with Silastic at the time of closure helps aid in identification of the nerve if future surgery is warranted. The extensive operative time needed for the combined approaches and total petrosectomy often necessitates staged surgery 1 week apart.

Expanded Endoscopic Nasal Approach

Kassam and coauthors at the University of Pittsburgh have published landmark papers on the use of endoscopic expanded endonasal approaches for skull base surgery.^[5,15] All patients for endoscopic skull base surgery undergo preoperative imaging, including high-resolution CT angiography and sometimes additional contrast-enhanced MRI of the brain, depending on the tumor type and location. Patients are positioned supine with the head in neutral position and secured with three-point fixation in a Mayfield head frame. Intraoperative frameless stereotactic image guidance is used in every case. When lesions involve or abut critical neurovascular structures, we recommend monitoring the patient intraoperatively with somatosensory evoked potentials, brain stem evoked responses, and electromyography as indicated. The nasal cavities are packed with oxymetazoline-soaked pledgets, and a third- or fourth-generation cephalosporin is administered perioperatively for prophylaxis. We recommend a team surgery approach that includes an otolaryngologist and neurosurgeon, with both nares used simultaneously for surgery. The use of an endoscope holder by an independent surgeon prohibits dynamic intraoperative examination and adaptation.

Surgery begins with the development of a transnasal corridor, which involves rigid nasal endoscopy with a 0-degree endoscope, oftentimes with an irrigating sheath. The right middle turbinate is lateralized. Frequently, the inferior aspect of the right middle turbinate is resected with curved scissors to accommodate the instruments and the endoscope in the right nasal cavity. Suction electrocautery is then used to obtain hemostasis. At this time, if the surgical defect is anticipated to be large or extend intracranially, a posterolaterally pedicled vascularized septonasal mucosa flap based on the posterior nasal branch of the sphenopalatine artery is raised via electrocautery.^[16] The anterior extent of the flap should come to the caudal septum. The width of the flap should be maximized by careful dissection of the superior limit and the inferior extension along the floor of the nasal cavity. The flap is then displaced into the maxillary sinus if an antrostomy is indicated or rotated into the nasopharynx to protect it from trauma during the remainder of the procedure.

A 1- to 2-cm posterior septectomy is performed just anterior to the rostrum of the sphenoid to allow bilateral dissection without contamination of the endoscope. After cauterization of the underlying mucosa, large pituitary forceps are used to remove the rostrum and thereby enter the sphenoid sinus. Wide bilateral sphenoidotomies are created with a Kerrison rongeur and extended laterally and inferiorly to the level of the medial pterygoid plates (pterygoid wedge, where the vidian canal is located). If a septal flap is not used, the posterior septal artery is coagulated and transected as it crosses the inferior aspect of the rostrum to facilitate removal of this portion of the rostrum and the floor of the sphenoid sinus.^[5,15] Within the wide sphenoidotomies, the optic nerve canals, carotid arteries, lateral optic-carotid recesses, planum sphenoidale, and clival indentation or recess are identified. Often the sphenoid sinus is asymmetrically pneumatized and as a result one or both of the intersinus septa lead directly back to the carotid artery. Therefore, these septa should be removed with biting instruments and not pulled off. Occasionally, the optic nerve and carotid artery may be dehiscent within the sphenoid sinus. Finally, the large sphenoidotomy provides room for surgical access and maneuverability.

After the transnasal corridor is established, various approaches can be taken to the skull base. To approach the medial petrous apex, the basopharyngeal fascia is stripped away from the superior nasopharynx, and the sphenoid floor is then drilled until it is flush with the clival recess. As mentioned earlier, if not elevated in a flap, the sphenopalatine and posterior nasal arteries are isolated and ligated. A posterior maxillary antrostomy is performed to identify the key surgical landmark, the medial pterygoid plate. This plate is drilled for about 1 cm along the vidian artery, perpendicular to the clivus, to the anterior genu of the internal carotid artery. The bone is drilled eggshell thin with a coarse 3-mm diamond burr, and the internal carotid artery is exposed. The bone lateral to the internal carotid artery is removed to allow lateral translocation of the vessel without compressing it. Once the internal carotid artery is moved laterally, the underlying petrous apex can be directly accessed and the approach can be extended to the medial anterior margin of the IAC. This approach is ideal for extradural lesions such as cholesterol granulomas and cholesteatomas.

The expanded endonasal approach can also be used for direct access to the medial aspect of the petroclival junction, previously only accessed by conventional lateral skull base approaches, which require a significant degree of petrous bone resection.^[15] The vidian canal is identified at the level of the medial pterygoid plate and followed to its origin from the anterior genu of the internal carotid artery. The bone over the horizontal segment, genu, and parasellar carotid protuberance can be removed with a combination of high-speed drills with extended burr shafts and fine 1-mm Kerrison rongeurs. The medial portion of the clivus at the petroclival junction is drilled to expose the dura and venous plexus. Dorello's canal can be followed superolaterally to the cavernous sinus. The cavernous sinus represents the superior boundary of this exposure and the middle fossa represents the lateral boundary. Venous bleeding from the cavernous sinus and basilar venous plexus is controlled with Avitene microfibrillar collagen packing (Daval, Inc., Cranston, RI). The dura medial to the posterior margin of the cavernous sinus can be opened to provide access to the pontine cistern. This approach has been used for chondrosarcomas, chordomas, and sinonasal lesions of the petroclival space, such as meningiomas, to provide a direct route to the tumor without significant neurovascular manipulation.^[5]

Expanded endoscopic nasal surgery can be further extended to the quadrangular space.^[15] The borders of the quadrangular space include the middle fossa laterally, the horizontal petrous internal carotid artery inferiorly, and the abducens nerve superiorly.^[5] The approach to the quadrangular space involves isolating the maxillary division of the trigeminal nerve, V₂, through a wide maxillary antrostomy. After the vidian canal is followed to the anterior genu of the internal carotid artery, V₂ is isolated and followed superiorly to the foramen rotundum. Care should be taken during bone removal because the space between V₂ and the vidian canal narrows posteriorly. The bone over the horizontal portion of the internal carotid artery is removed, and dissection continues superiorly to the lateral portion of the cavernous sinus, where V₂ disappears into the dura mater. The dura is opened in a medial-to-lateral direction from the genu of the internal carotid artery toward V₂. This approach allows access into Meckel's cave, the petrous bone, and the posterior fossa for tumor resection. The use of angled telescopes enhances the surgical view around corners and in tight areas. By remaining below the abducens nerve and lateral to the internal carotid artery throughout the procedure, the superior portion of the cavernous sinus, where cranial nerves III, IV, V₁, and VI are located, can be avoided, thus reducing the risk for postoperative cranial nerve palsy.

Finally, when tumors invade and thrombose the superior aspect of the cavernous sinus, this region can be

accessed via a dural opening above the quadrangular space in a medial-to-lateral direction over the superior lateral portion of the cavernous sinus.^[15] Initially, bleeding is reduced secondary to tumor-induced thrombosis. The medial margin of the internal carotid artery is identified by opening the sella. With the internal carotid artery protected with a dissector, the tumor can be safely stripped away from the cranial nerves. The incidence of cranial neuropathy is significantly increased when the tumor is adherent to the cranial nerves and when aggressive packing of postresection venous bleeding from the inferior petrosal sinus is necessary. Therefore, this approach should be reserved for tumors that are refractory to medical or radiosurgical management or for tumors with preexisting cranial nerve deficits. Another advantage of the endonasal route is the ability to follow tumor into the pterygopalatine and infratemporal fossae with angled telescopes. Endonasal approaches have been successful in removing tumor as far lateral as the masticator space and pterygoid musculature.

Reconstruction

For open lateral approaches, reconstruction begins with primary dural repair or a dural graft of fascia lata or temporalis fascia, or both repair and a graft, for residual defects or extra support. Abdominal fat is typically used to obliterate the surgically created mastoid or petrous cavities. The bone graft removed at the start of the procedure is reapplied with miniplates and screws. The temporalis muscle is reattached to the superior cuff on the skull so that it reassumes its anatomic position. The skin is closed in dermal and epidermal layers, and a pressure dressing is applied. Depending on the field of dissection, a suction drain may be applied between the musculature and dermal layers.

For the expanded endonasal approach, reconstruction varies from simple packing of the sphenoid defect with duricel or autologous fat grafts for extradural lesions to more involved layered packing with AlloDerm (LifeCell Corporation, Branchburg, NJ) inlay or onlay grafts for repair of the resulting dural defect and subsequent packing of the bony defect with autologous fat, DuraGen (Integra Life Sciences Corporation, Plainsboro, NJ), and a vascularized septal mucosa flap.^[5,15] A temporary balloon catheter positioned in the nasopharynx is filled with saline to reinforce the packing and prevent migration of the grafts. When the cavernous sinus is involved, packing with Avitene for hemostasis plus placement of autograft composed of abdominal or thigh fat is required to protect the exposed internal carotid artery.

POSTOPERATIVE CARE AND COMPLICATIONS

Petrosal approaches expose larger portions of the skull base and thus place the patient at risk for significant complications, including CSF leak, wound infection, meningitis, cranial neuropathy, cerebral edema, pneumocephalus, seizures, temporal lobe hemorrhage, stroke, and pulmonary embolism.

Cerebrospinal Fluid Leak

The key to avoiding postoperative CSF leak is prevention intraoperatively the time of surgery through meticulous repair of dural defects, dural grafting, and restrictions in postoperative activities, such as straining with bowel movements, nose blowing, and weight bearing. CSF usually leaks through the eustachian tube or through the incision. Because primary repair of the surgical wound is not always possible with the more extensive petrosal approaches, closure of the dural defects with free or vascularized grafts and packing of the dead space and the eustachian tube with fat and connective tissue, respectively, are essential. For hearing-preserving posterior petrosal approaches, such as the retrolabyrinthine and partial labyrinthine approaches, the eustachian tube and middle ear are not packed. Instead, only the mastoid antrum and cavity are loosely packed with an abdominal fat graft to minimize the risk of postoperative conductive hearing loss from adhesions involving the ossicular chain. Some postoperative conductive hearing loss is expected for 4 to 6 weeks as a result of hemotympanum. The transcochlear and total petrosectomy approaches require transection and blind sac closure of the external auditory canal and eustachian tube.

As mentioned, the surgical cavities are packed with fat and muscle grafts to limit the risk of CSF leaking through the incision. Additional measures to minimize this risk include oversewing the incision with nonabsorbable suture material, applying a compressive mastoid dressing for up to 72 hours, bed rest with the head elevated 30 to 45 degrees, and occasionally, lumbar drainage. Planning the incisions and dissection preoperatively also helps reduce the risk of leaks. The skin and muscle incisions should be stair-stepped. For larger defects, temporalis muscle flaps can be used to line the defects. When all the aforementioned measures have been attempted and CSF leakage persists, surgical re-exploration should be considered in an otherwise stable patient.

The risk of CSF leakage is increased in expanded endonasal approaches because of limitations with dural closure. The size of the defect, location of the defect, and experience of the surgeon are the most important factors in preventing postoperative leaks. Endoscopic repairs depend on the ability of the brain to settle over the repair and hold the tissues in place over the defect. Thus, excessive lumbar drainage will actually increase the likelihood of repair failure. A multilayered closure is the best way to seal endoscopic approaches. Typically, AlloDerm inlay or onlay grafts (or both) are used to cover the dural defect and are fixed in place with tissue adhesives such as Dura

Seal (Confluent Surgical, Inc., Waltham, MA) and Tisseel VH (Baxter, Deerfield, IL). Abdominal fat grafts are used to fill the extradural surgical defect, and frequently a vascularized nasal septal flap with tissue adhesive is used to cover the surface. To minimize postoperative leaks, a Foley balloon catheter can be left in place for 5 to 7 days. Alternatively, the nasal cavity may be packed with Merocel sponges to secure the flaps in place, with removal after 3 to 5 days. Systemic antibiotics should be administered for the duration that the packing remains in place. If a CSF leak occurs despite these measures, passive lumbar drainage and bed rest are often effective in controlling the leak, and in refractory cases, the defect can typically be repaired endoscopically.

Infections

The majority of infectious complications can be prevented with appropriate perioperative antibiotics, sterile surgical technique, and meticulous wound closure. Localized wound infections, pneumonia, and urinary tract infections are risks associated with any major surgical procedure, and standard postoperative care should be undertaken to prevent these problems, including postoperative incentive spirometry for pulmonary toilet, prompt removal of indwelling lines and catheters, and early ambulation. Specifically for petrosal approaches, the risk of meningitis and epidural abscess is real, and they can be catastrophic. Perioperative antibiotics should be administered for at least 24 hours after surgery and longer if nasal packing was placed. Postoperative fevers or elevated white blood cell counts should be investigated by blood culture, complete blood count, urinalysis, sputum culture, chest radiography, head CT, and lumbar puncture if clinically warranted. Empirical antibiotics with good CSF penetration should be initiated according to Gram stain results or evidence of clinical deterioration.

Cranial Neuropathies and Temporal Lobe Injury

Cranial neuropathies and temporal lobe injuries, including seizure, hemorrhage, stroke, and functional atrophy, are the result of traction injury to the brain during attempts to increase exposure during surgery. Using a combination of anterior and posterior petrosal approaches for larger and anteriorly located tumors within the skull base and lowering the level of the craniotomy to the floor of the middle cranial fossa in anterior petrosal approaches help limit such injuries. With more midline lesions in the petroclival region, endoscopic nasal approaches offer the advantage of direct access to the tumor with less risk for postoperative cranial neuropathy.

If the lower cranial nerves are at risk because of the size or location of the tumor, preoperative or early postoperative assessment of speech and swallowing is essential to limit aspiration and expedite recovery and rehabilitation. If the lower cranial nerves are compromised at the time of surgery, the patient should be treated promptly by tracheostomy, and safe enteral access should be obtained via a nasogastric or gastrostomy tube. If injury is anticipated preoperatively, concurrent medialization thyroplasty may be performed to prevent postoperative voice and swallowing difficulties. When the GSPN is sacrificed, postoperative dry eye syndrome should be anticipated and managed with aggressive eye protection and lubrication. If injury occurs to the main trunk of the facial nerve, eye protection with a moisture chamber, lubrication, and early surgical rehabilitation with an upper eyelid gold weight or palpebral spring should be considered.

Postoperative seizure activity should be controlled with neuroleptic medications, and neurology should be promptly consulted for management. For all anterior petrosal approaches in which the temporal lobe is retracted for prolonged periods, prophylactic anticonvulsants such as phenytoin are indicated.

Pneumocephalus and Cerebral Edema

Pneumocephalus and cerebral edema tend to be early complications that result in focal neurologic deficits and progressive deterioration in mental status, although pneumocephalus can also occur as a late complication secondary to violation of the dural closure with Valsalva maneuvers.

Mild asymptomatic pneumocephalus is commonly seen on early postoperative imaging and is a result of the surgical exposure. It usually resolves within 1 to 2 weeks. However, large or increasing pneumocephalus (tension pneumocephalus), particularly in the setting of mental status changes, should be managed by prompt surgical decompression because the expanding air will result in brain compression and potentially brain herniation. Sources of pneumocephalus are identical to those for CSF leaks and include the nasal cavity, the eustachian tube, and the surgical incision. Imaging studies can be used to localize the defect. Although prevention with meticulous wound closure is essential, avoiding disruption of the repair in the postoperative period is also paramount in preventing pneumocephalus. Excessive lumbar spinal drainage may draw air into the cranial cavity through the nasal cavity, and excessive positive pressure ventilation may displace grafts used to repair nasal defects resulting from endoscopic surgery. Care should therefore be exercised when managing lumbar drains and tracheostomy tubes after surgery.

Cerebral edema can also lead to brain herniation and mortality if not recognized and treated promptly. We routinely perform CT or MRI of the head within 24 hours after surgery to assess for the presence and degree of edema. In the event that clinically significant edema occurs, treatment includes osmotic diuresis with mannitol,

systemic steroids, and hyperventilation to reduce Pco₂. An extraventricular drain may be placed at the bedside to decompress the brain and monitor intracranial pressure. If the cerebral edema is refractory to these measures, the inferior temporal gyrus may have to be partially resected.

Deep Venous Thrombosis and Pulmonary Embolism

Deep venous thrombosis and pulmonary embolism are postoperative complications with high morbidity and mortality that are typically preventable. Prolonged surgery and postoperative immobility drastically increase the risk for thrombotic events. The use of pneumatic compression stockings in the postoperative period dramatically reduces the incidence of such events. Early postoperative ambulation and physical therapy are also helpful. The risk for thromboembolic events is increased in patients with meningiomas and paragangliomas.

Tachycardia and tachypnea are often the first indicators of pulmonary embolism and thus should be thoroughly evaluated in a postoperative patient. Once hypoxia, shortness of breath, chest pain, hypotension, or syncope develop, the prognosis is much poorer because they signify a larger, more hemodynamically compromising clot. Immediate evaluation with a contrast-enhanced spiral CT scan of the chest and intervention are warranted, including thrombectomy, Greenfield filter placement in the inferior vena cava, and in some cases, thrombolytic therapy. Anticoagulation is not routinely used in intracranial surgery because of the risk for intracranial hemorrhage.

PEARLS

- Open petrosal approaches are useful for petroclival lesions within the middle and posterior cranial fossae above the lower third of the clivus. Lower clival tumor extension will require a transcondylar approach.
- Exposure of the central clival depression requires a transcochlear, total petrosectomy, or endonasal approach.
- The petrous carotid artery is the central landmark for anterior petrosal approaches; exposure and isolation of this artery are essential for vascular control.
- In the expanded endonasal approach, the vidian canal is used as a landmark to locate the petrous carotid artery.
- The asymmetrical intrasinus septum in the sphenoid sinus often leads to the vertical petrous carotid artery, and careful removal is necessary to prevent injury to the carotid artery.

PITFALLS

- Surgical dissection should proceed with caution because the carotid artery and optic nerve may be dehiscent on the lateral wall of the sphenoid sinus.
- Tumor extending into the posterior fossa is not accessible through an anterior petrosal approach alone and often necessitates combined anterior and posterior petrosal exposure.
- Surgical exposure through a retrolabyrinthine craniotomy is limited when the sigmoid sinus is located anteriorly and the jugular bulb is high.
- Scalp flap elevation in a plane superficial to the superficial layer of the temporalis fascia places the frontal branch of the facial nerve at risk for injury.
- Excessive spinal fluid drainage through a lumbar drain may produce a counterproductive siphon effect leading to graft displacement and pneumocephalus.