

Chapter 5 – Adenoidectomy

Suman Golla

Adenoid tissue, also known as the pharyngeal tonsils, is lymphatic tissue situated in the nasopharynx. Adenoid tissue rapidly increases in size during the first 6 or 7 years of life and generally atrophies by adolescence. This hypertrophy is physiologic but may also be related to repeated infection. Numerous clinical conditions or symptoms result from hypertrophy of the adenoids, including nasal obstruction, mouth breathing, nasal voice or hyponasality, snoring and restless sleep, mucoid anterior nasal discharge, possible epistaxis, otitis media with effusion, and sinusitis. Adenoid hypertrophy may also be related to obstructive sleep apnea in children.

Abnormal facial development has been attributed to adenoid hypertrophy. This occurs with chronic mouth breathing during times when the facial bones continue to change toward the adult configuration. The open-mouth position leads to certain anatomic abnormalities, including a high arched palate and shortening of the upper lip. The face therefore becomes slightly elongated with the upper teeth often projecting anteriorly. Along with mouth breathing, the previously mentioned changes in facial expression lead to the condition known as adenoid facies. Adenoid obstruction can also cause lateral obstruction of the eustachian tube orifice and contribute to the cause of chronic or recurrent effusions of the middle ear.

The adenoids are located inferior to the sphenoid sinus and anterior to the occiput. Laterally, the adenoids end in a depression known as the fossa of Rosenmüller. This region is medial to the opening of the eustachian tube and torus tubarius. Adenoid tissue forms the bulk of the lymphoid tissue known as Waldeyer's ring. The lingual tonsils form the posterior aspect of this ring, whereas the palatine tonsils form the lateral walls. Smaller aggregates of lymphoid tissue can be found in the mucosa of the posterior wall of the pharynx. These areas appear as submucosal nodules and are often known as "cobblestones." Inferiorly, adenoid tissue extends to the superior margin of the superior constrictor muscle and forms what is known as Passavant's ridge.

The blood supply to adenoid tissue is primarily from the ascending pharyngeal artery. Additional supply occurs through the ascending palatine branch of the facial artery. Venous drainage occurs through the pharyngeal plexus and occasionally the pterygoid plexus. Ultimately, blood drains to the facial veins and internal jugular. Innervation of the pharyngeal tonsils is derived from the lesser palatine nerves, which eventually transmit afferent fibers to the sphenopalatine ganglion. Additional innervation is provided by the lingual nasopharyngeal branch of the glossopharyngeal nerve; this branch often provides the pathway for referred otalgia.

PATIENT SELECTION

Absolute indications for adenoidectomy include adenoid hyperplasia with obstructive sleep apnea. Other indications for adenoidectomy include otitis media with effusion, recurrent otitis media, and adenoid hypertrophy with accompanying symptoms and sinusitis.

In children with recurrent pharyngitis, adenoiditis is a frequent concomitant disease process. Distinguishing adenoiditis from tonsillitis may be difficult because the symptoms are similar. Therefore, patients who undergo tonsillectomy for episodes of recurrent acute tonsillitis generally have adenoidectomy performed at the same time. Patients with adenoiditis, however, often have purulent rhinorrhea, postnasal drainage, fever, otitis media, and nasal obstruction. The occurrence of four or more episodes of acute nasopharyngitis in 1 year, particularly with associated sinus and otologic symptoms, is an indication for adenoidectomy. These symptoms are often difficult to differentiate from chronic rhinosinusitis as well.

Adenoidectomy is characteristically performed in children. Frequently, it is performed in conjunction with tonsillectomy or myringotomy, or both, with the insertion of pressure-equalizing (PE) tubes for chronic serous otitis media. Nasopharyngeal adenoid tissue serves not only as a mechanical obstruction to the eustachian tube orifice, thereby leading to difficulty in ventilation of the middle ear mucosa and space, but also as a reservoir of bacteria, which may contribute to episodes of otitis media.

Adenoidectomy as part of the routine treatment of chronic otitis media with effusion (COME) is controversial. In a 1987 study, Gates and colleagues demonstrated a 50% reduction in the recurrence of COME in patients who had undergone adenoidectomy in conjunction with the insertion of ventilating tubes.^[1] Others have suggested that the addition of adenoidectomy to the insertion of PE tubes increases the risk associated with the surgical procedure by requiring intubation and creating the potential for blood loss. Currently, this debate continues, although most authorities would suggest that adenoidectomy is efficacious in the treatment of patients with otitis media with

effusion and should be considered in cases of recurrent COME or in patients requiring a second insertion of a myringotomy tube for recurrent otitis media. A recent study has indicated that the location of the adenoid tissue may play a role in determining the efficacy of performing adenoidectomy for control of otitis media. Patients with adenoid tissue abutting the torus tubarius seem to benefit more from an adjuvant adenoidectomy in addition to myringotomy and placement of ventilating tubes.^[2]

The efficacy of adenoidectomy for the management of chronic rhinosinusitis in children is controversial. The adenoids are a probable source of obstruction and infection for the paranasal sinuses. Functional endoscopic sinus surgery (FESS) has been well known to improve chronic sinusitis in adults and children. The use of FESS in children, however, has been controversial because of possible growth retardation.^[3] Studies have nonetheless shown that adenoidectomy alone may be beneficial in controlling chronic sinusitis in children.^[4-6] Other studies, though, have shown an improvement in patients who underwent endoscopic sinus surgery as opposed to adenoidectomy for the treatment of chronic sinusitis in the pediatric age group. Further studies have shown an improvement in outcome in patients who have undergone both adenoidectomy and endoscopic sinus surgery.^[7,8] Some surgeons favor adenoidectomy as the first procedure, with endoscopic sinus surgery being performed only if symptoms persist. Other surgeons recommend proceeding with intravenous antibiotics before surgical treatment.^[9] In a survey of pediatric otolaryngologists, the majority (80%) performed adenoidectomy before proceeding with endoscopic sinus surgery.^[10]

Chronic upper airway obstruction in children secondary to hypertrophy of the tonsils and adenoids has long been recognized. Recently, however, increased clinical significance has been attributed to this condition, particularly with regard to sleep disorders resulting from chronic nasopharyngeal and oropharyngeal obstruction. Selection of patients for adenoidectomy and tonsillectomy in this population can be difficult. Various aspects of the history may be useful in decision making. Formal sleep studies can be performed but require an overnight stay and are probably not cost-effective. Audio or video recordings made of the child during sleep may provide helpful clues; however, such recordings require a significant investment of time by a trained observer to identify chronic obstructive sleep patterns.

The patient's parent or guardian will usually provide accurate information that generally correlates with a formal sleep study or video evaluation of sleep patterns. A history of obstructive sleep patterns and loud snoring may often provide an adequate indication for selection of patients for tonsillectomy and adenoidectomy.^[11] As opposed to adults, children merely require a history of sleep-disordered breathing for the diagnosis of obstructive sleep apnea.^[11] Positive findings on polysomnography are not required.

Radiologic evaluation of the nasopharynx with soft tissue lateral radiographs may provide additional medical evidence of adenoid hypertrophy and make case selection more objective (Fig. 5-1). Computed tomography is not usually required or indicated in these patients. Occasionally, patients older than 4 years may be cooperative enough to undergo nasopharyngeal examination in the office, either with rigid endoscopy or with flexible fiberoptic laryngoscopy (or with both) after adequate anesthesia of the nasal cavity. An enlarged adenoid pad visualized in this manner would be a clear indication for adenoidectomy in a patient who exhibits symptoms of adenoid hypertrophy or adenoiditis.

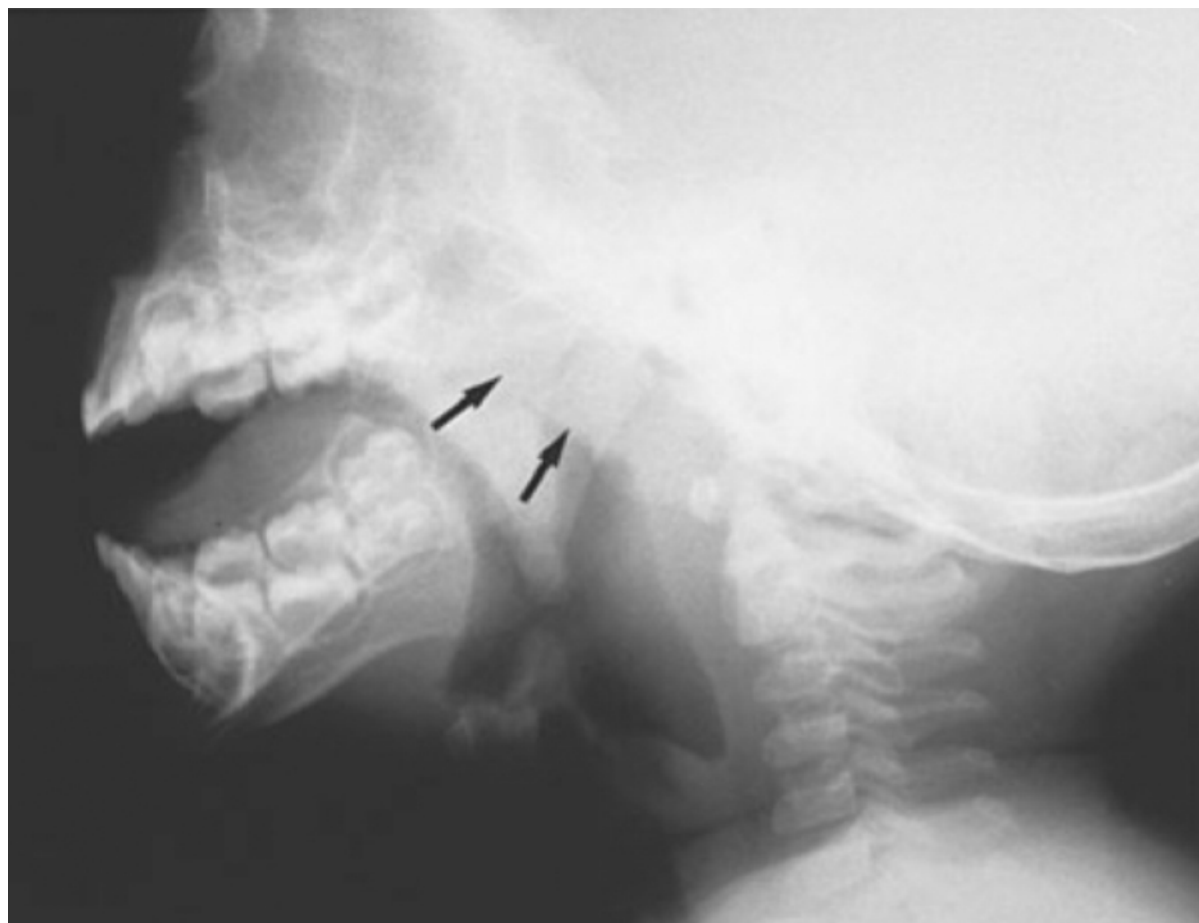


Figure 5-1 Lateral soft tissue radiograph of the nasopharynx demonstrating an enlarged adenoid pad (*arrows*).

PREOPERATIVE EVALUATION

Evaluation for potential bleeding disorders is controversial, although most surgeons would not obtain blood work. In the absence of a family or personal history suggesting a coagulopathy, preoperative hematologic evaluation is not cost-effective, thus obviating the need for blood work.^[12] In patients with a history of a bleeding disorder, evaluation with a prothrombin time and a bleeding time may be necessary, especially to exclude the common diagnosis of von Willebrand's disease. If this condition is diagnosed, patients may need desmopressin (DDAVP) preoperatively and postoperatively.

Adenoidectomy may be performed on an outpatient basis, although some authorities would suggest that if tonsillectomy is included in a patient who is younger than 2 years, the patient should be hospitalized. In this situation the patient may need to be observed for fluid administration or for the potential for postoperative hemorrhage, or for both.

Although perioperative antibiotics are not required, some studies suggest that the use of postoperative antibiotics after tonsillectomy results in decreased odor and reduced pain.^[13] The majority of otolaryngologists prescribe antibiotics for this reason in patients who undergo adenoidectomy and tonsillectomy.^[14,15]

Before performing an adenoidectomy with the patient under general anesthesia, it is necessary to palpate the palate to rule out the possibility of a submucous cleft. This defect can be identified by the presence of a deep V that can be palpated on the posterior edge of the hard palate (Fig. 5-2). The presence of a submucous cleft is associated with a shorter than normal soft palate. Frequently, these patients are able to approximate their velum to the posterior pharyngeal wall only when the adenoids are enlarged. If the enlarged adenoids are removed, velopharyngeal insufficiency may result in hypernasal speech and nasal regurgitation of liquids. Adenoidectomy should not be performed in patients who have a cleft palate or who have previously undergone cleft palate repair because velopharyngeal insufficiency will probably result or become worse.

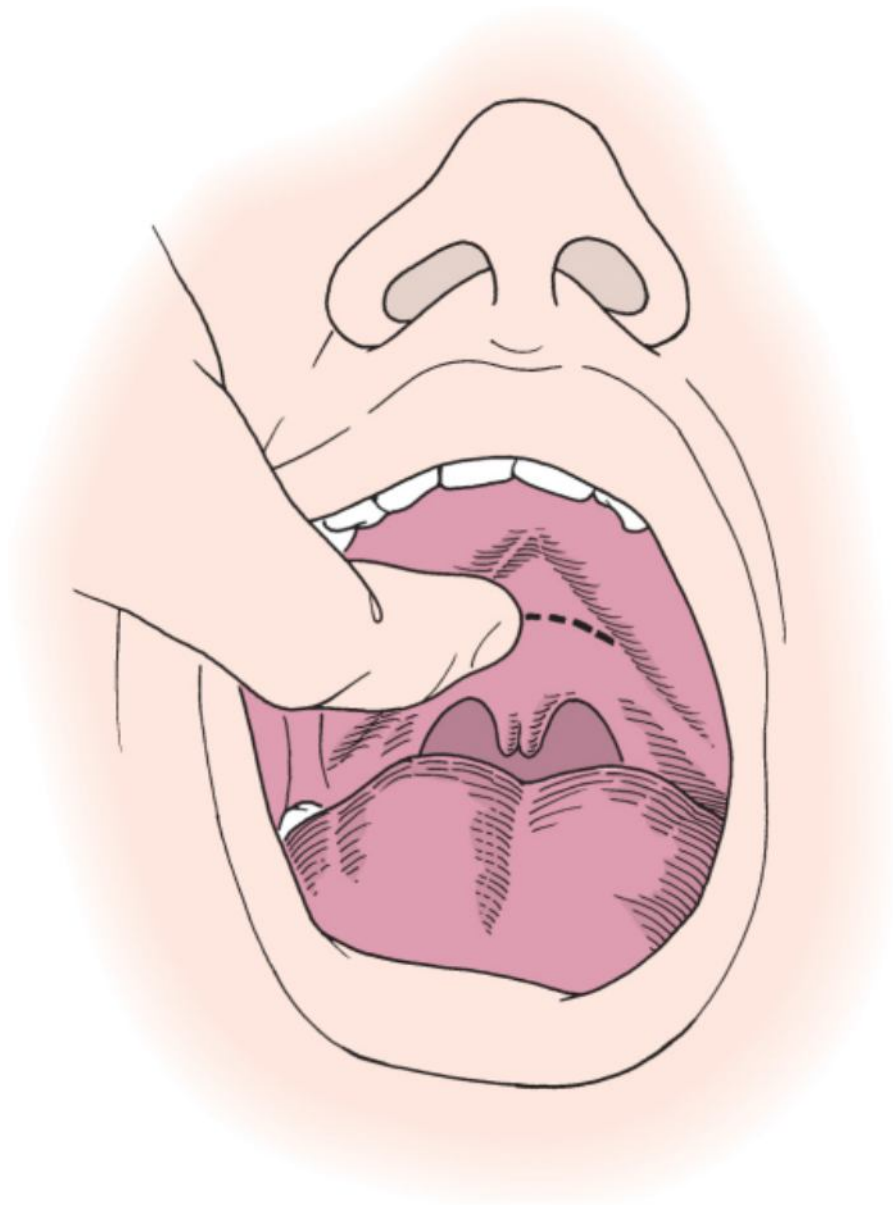


Figure 5-2 Palpation of the palate before adenoidectomy to rule out a submucous cleft.

TECHNIQUE

Adenoidectomy is performed with the patient under general anesthesia. The patient is usually placed in the Rose position with a McIvor mouth gag in position to provide oropharyngeal exposure, depress the tongue, and secure the endotracheal tube (Fig. 5-3). Visualization may be either indirect through the oral cavity or direct through the nose with a nasal endoscope (Fig. 5-4).

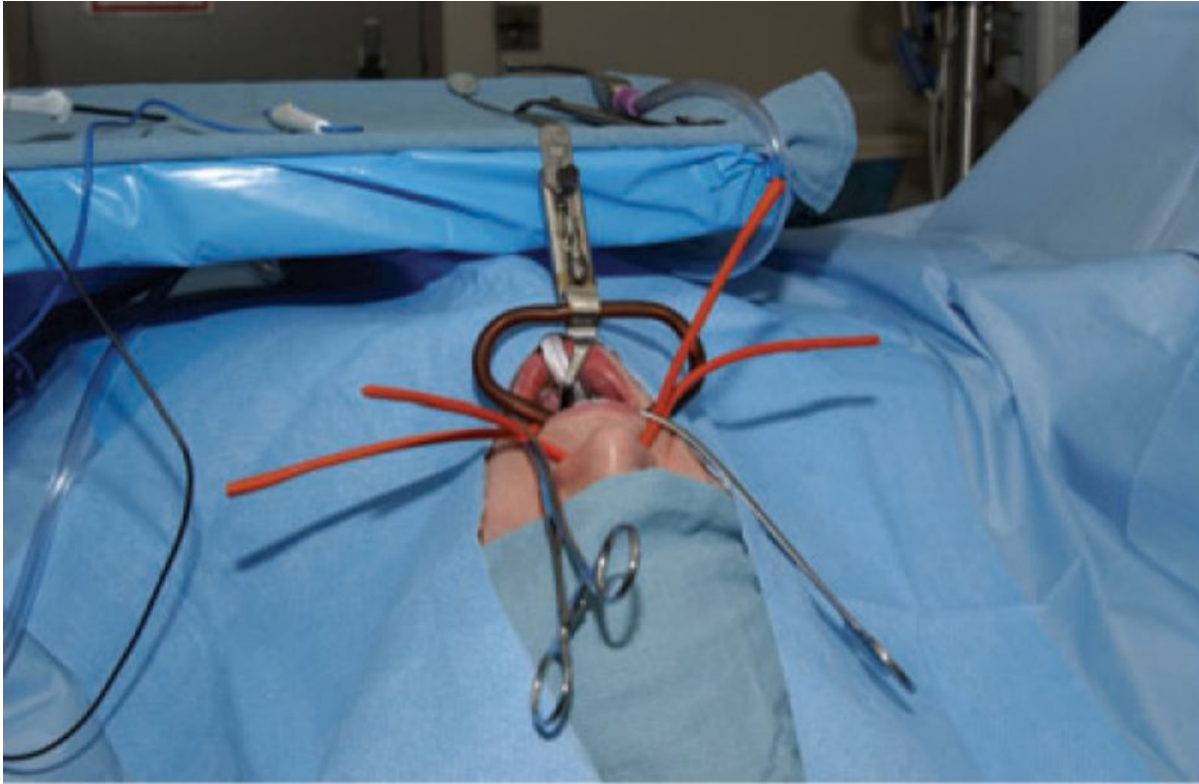


Figure 5-3 Patient positioning for adenoidectomy.



Figure 5-4 Mirrors for obtaining an indirect view of the nasopharynx.

Red rubber catheters are used for retraction of the soft palate, after which a laryngeal mirror is used to reflect the beam of light from the surgeon's headlight for visualization of the nasopharynx. An adenotome or an adenoid curette may be used to perform the adenoidectomy (Fig. 5-5). The mirror is used to ensure adequate placement of the curette against the posterior edge of the vomer. To prevent troublesome bleeding, care must be taken to avoid contact between the curette and the posterior end of the inferior turbinate. The curette should also be distanced from the eustachian tube orifice and torus tubarius. The curette is depressed against the vomer edge, and with the thumb used as a fulcrum, the blade is pushed over the posterior nasopharyngeal wall. More than one pass may be necessary to completely remove the adenoid tissue. A slight rocking motion may also be needed to complete the adenoidectomy. Remnants of adenoid tissue that are bleeding may be removed with small St. Clair Thompson forceps or with electrocautery after the majority of the choana is free of adenoid tissue (Fig. 5-6). An adenotome may also be used rather than a curette when dissecting the adenoid. The basket of the adenotome engages the central adenoid mass and is pressed against the nasopharyngeal wall. Closure of the blade allows removal of the nasopharyngeal adenoid mass. After the adenotome removes most of the central adenoid tissue, additional adenoid tissue may be removed with a curette, St. Clair Thompson forceps, or electrocautery.

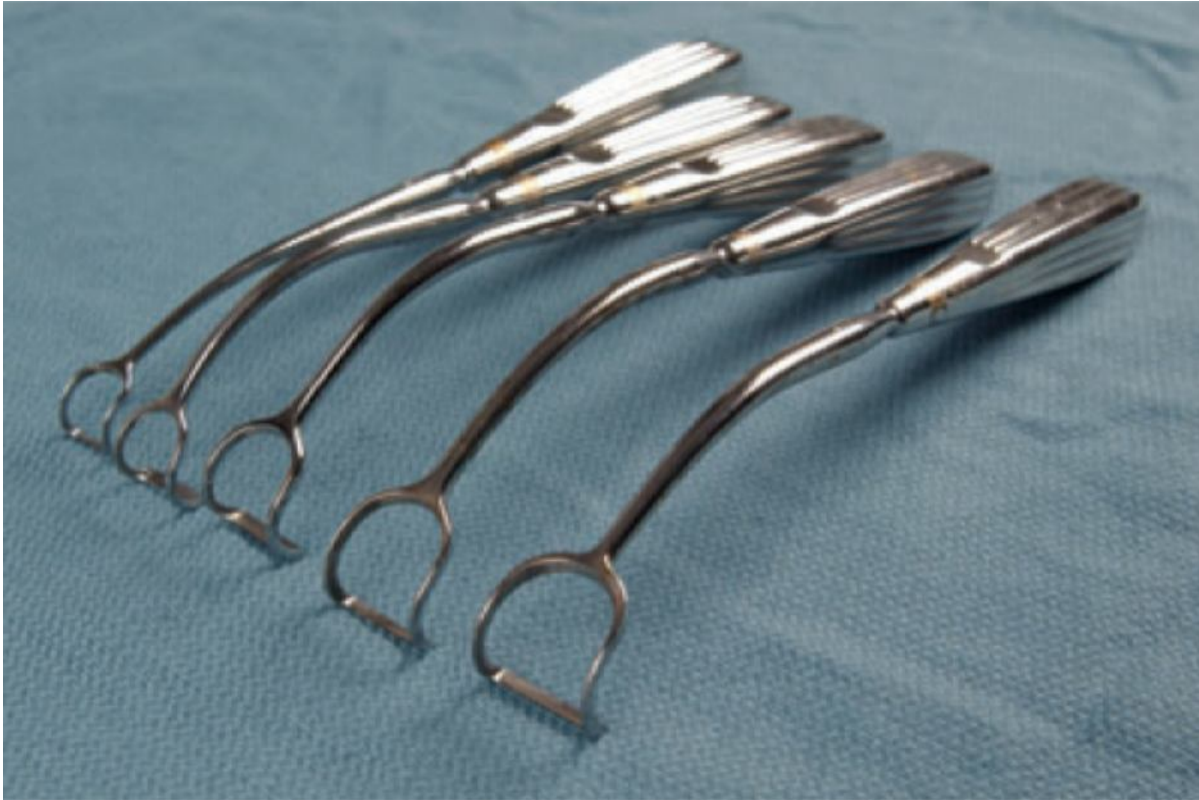

Figure 5-5 Various sizes of adenoid curettes are used to remove the adenoids from the nasopharynx.

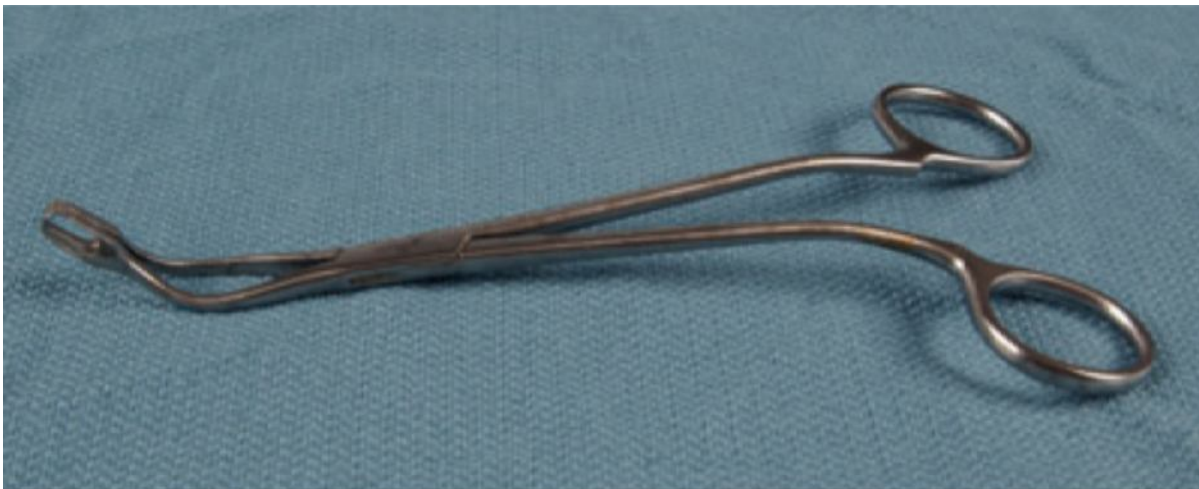

Figure 5-6 St. Clair Thompson forceps are helpful in removing adenoid tissue, especially in the choanae.

The nasopharynx is packed with moist tonsil or adenoid sponges. The use of electrocautery has come into favor as a common means of controlling bleeding (Fig. 5-7). Persistent bleeding is generally a result of retained fragments of adenoid tissue. Removal of the remaining tissue is usually all that is required to stop such bleeding. If bleeding persists, additional techniques may be necessary, including the use of nasopharyngeal packing or the application of a hemostatic agent. This is particularly common in older children and adolescents because the adenoids in these patients are less friable and more difficult to remove with adenoid curettes. In this instance it is often preferable to resort to cautery of the remnants of residual adenoid tissue.

Recently, many otolaryngologists have been using suction and electrocautery as the sole technique for performing adenoidectomy. The initial setup is similar to that for the adenoid curette technique. However, rather than using the adenoid curette, suction electrocautery is used under direct visualization to cauterize adenoid tissue, as well as to control bleeding. In addition to the adenoid curette and suction cautery, other techniques are available for the performance of adenoidectomy. Use of the microdébrider has been described for the performance of adenoidectomy, with low complication rates being reported.^[16,17] Electrocautery has been compared with

curettage and power-assisted methods. In this study the electrocautery technique led to decreased blood loss and shorter operating times than achieved with the conventional curettage technique. In this same study, power-assisted adenoidectomy offered shorter operating times; however, this technique was thought to require expensive equipment, as well as more experience, and therefore was not as favored as the traditional electrocautery technique.[18]

Surveys from otolaryngologists have indicated that of the various techniques available for adenoidectomy, the most popular is curettage followed by cautery. Electrocautery alone, however, has been gaining favor as the technique of choice, with decreased blood loss being the reason cited.

Likewise, adenoidectomy should not be performed in association with uvulopalatopharyngoplasty because nasopharyngeal stenosis may ensue.

POSTOPERATIVE MANAGEMENT

Minimal postoperative care is required. Any residual bleeding will generally stop once the patient awakens and the pharyngeal muscles begin to contract. Patients may be discharged once they are awake. No dietary restrictions are necessary unless tonsillectomy has been performed concurrently.

COMPLICATIONS

A serious problem is an inability to recognize a cleft palate, submucous cleft, or a short soft palate before performing this surgery. Removal of the adenoids may result in an inability of the soft palate to contact the posterior pharyngeal wall, thereby resulting in velopharyngeal insufficiency with characteristic hypernasal speech. This problem can be corrected by means of a pharyngeal flap or palatal push-back. However, it is far better to prevent the problem than to treat it.

Postoperative bleeding is unusual after adenoidectomy; nevertheless, bleeding can result during the procedure and prolong the operation. Occasionally, it is necessary to place a posterior pack to control bleeding during performance of the operation. This pack can generally be removed in the recovery room.

Injury to the posterior tips of the inferior turbinates often results in troublesome bleeding and can be avoided by direct visualization at the time of placement of the adenoid curette. Injury to the eustachian tube orifice by inadvertently placing the lateral aspect of the curette anterior to the torus tubarius is a serious complication. It can often be immediately recognized by the appearance of cartilage in the adenoid specimen. Direct visualization while the adenoid curette is placed is an ideal means of preventing this complication as well.

PEARLS

- Adenoid hypertrophy and sleep-disordered breathing may be diagnosed by history in children without a formal sleep study.
- Most surgeons recommend that adenoidectomy be performed in association with insertion of a PE tube if the otitis media is recurrent.
- Placement of the curette under direct visualization will reduce the likelihood of injury to adjacent structures such as the torus tubarius and inferior turbinate.

PITFALLS

- Adenoidectomy should not be performed in patients with a short palate, cleft palate, or submucous cleft.
- Adenoidectomy should not be performed in association with an uvulopalatopharyngoplasty to avoid nasopharyngeal stenosis.
- Persistent bleeding is usually due to retained fragments of adenoid tissue.